Second Edition

Essential Techniques of Alveolar Bone Augmentation in Implant Dentistry

A Surgical Manual

with website

Edited by **Len Tolstunov**

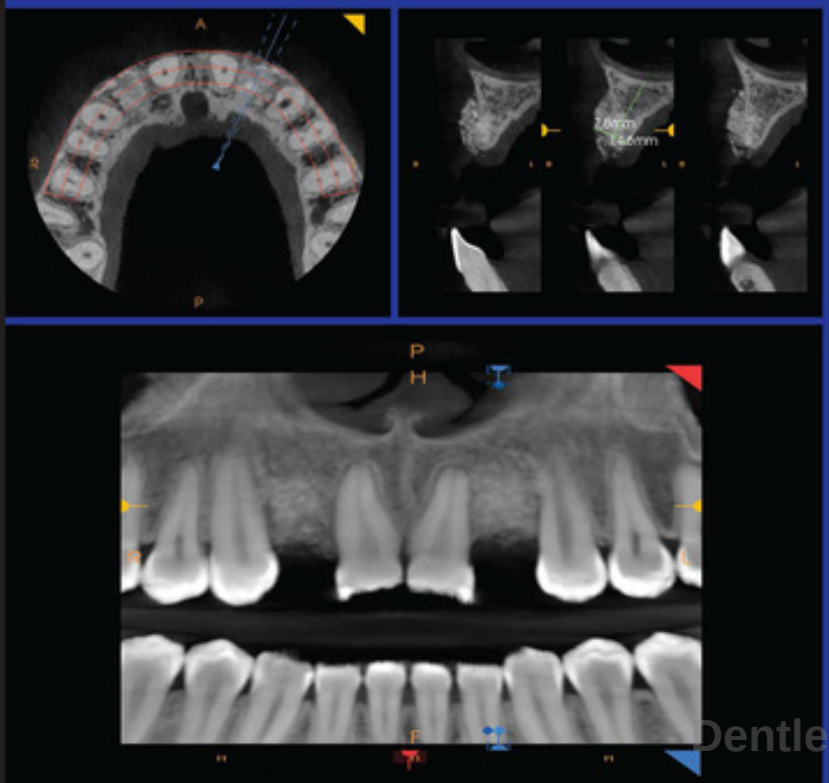

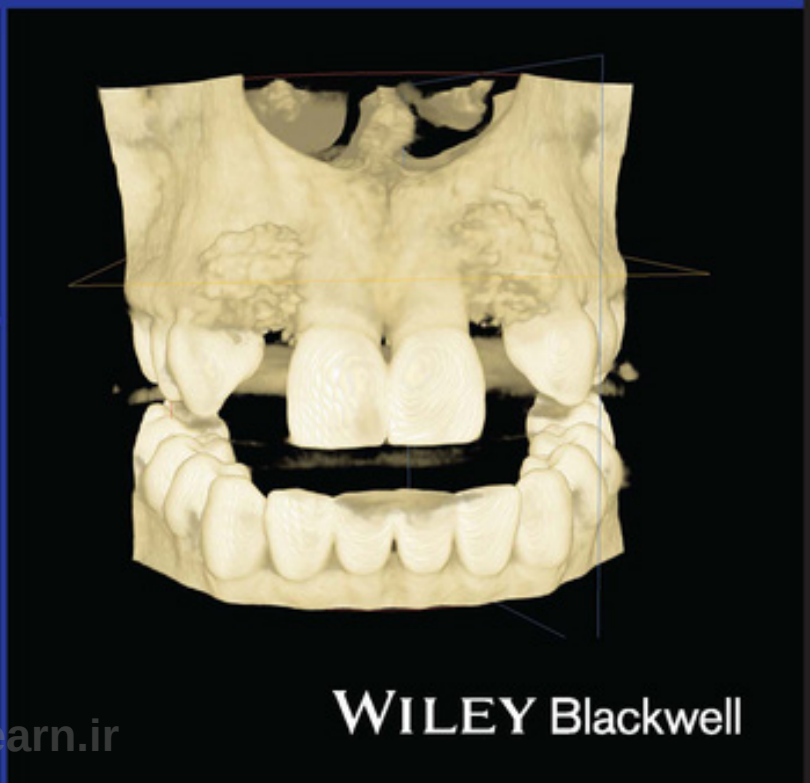

Dentlearn.ir

WILEY Blackwell

Dentlearn.ir

Essential Techniques of Alveolar Bone Augmentation in Implant Dentistry

Dentlearn.ir

This book is dedicated to my mother, Bella Tolstunov, who always made sacrifices for the sake of her children. She wanted to see me become a happy and successful man. All her life she has been a vital and enduring source of genuine love and support, who kept on giving without asking anything in return. Every day I hope to live up to her expectations and return her love. At the time of this writing, my mom is 92 years young.

Dentlearn.ir

Essential Techniques of Alveolar Bone Augmentation in Implant Dentistry

SECOND EDITION

A Surgical Manual

Edited by

Len Tolstunov

Associate Clinical Professor, Department of Oral and Maxillofacial Surgery, University of California San Francisco (UCSF) School of Dentistry, CA, USA

Associate Clinical Professor, Department of Oral and Maxillofacial Surgery, University of the Pacific, Arthur A. Dugoni School of Dentistry, San Francisco, CA, USA

Private OMFS Practice, San Francisco, CA, USA

WILEY Blackwell

Dentlearn.ir

This second edition first published 2023
© 2023 John Wiley & Sons, Inc.

Edition History
John Wiley & Sons, Inc. (1e, Horizontal Augmentation of the Alveolar Ridge in Implant Dentistry, 9781119019886 (2016); and Vertical Augmentation of the Alveolar Ridge in Implant Dentistry, 9781119082590 (2016))

All rights reserved. No part of this publication may be reproduced, stored in a retrieval system, or transmitted, in any form or by any means, electronic, mechanical, photocopying, recording or otherwise, except as permitted by law. Advice on how to obtain permission to reuse material from this title is available at http://www.wiley.com/go/permissions.

The right of Len Tolstunov to be identified as the author of the editorial material in this work has been asserted in accordance with law.

Registered Office
John Wiley & Sons, Inc., 111 River Street, Hoboken, NJ 07030, USA

Editorial Office
111 River Street, Hoboken, NJ 07030, USA

For details of our global editorial offices, customer services, and more information about Wiley products visit us at www.wiley.com.

Wiley also publishes its books in a variety of electronic formats and by print-on-demand. Some content that appears in standard print versions of this book may not be available in other formats.

Limit of Liability/Disclaimer of Warranty
The contents of this work are intended to further general scientific research, understanding, and discussion only and are not intended and should not be relied upon as recommending or promoting scientific method, diagnosis, or treatment by physicians for any particular patient. In view of ongoing research, equipment modifications, changes in governmental regulations, and the constant flow of information relating to the use of medicines, equipment, and devices, the reader is urged to review and evaluate the information provided in the package insert or instructions for each medicine, equipment, or device for, among other things, any changes in the instructions or indication of usage and for added warnings and precautions. While the publisher and authors have used their best efforts in preparing this work, they make no representations or warranties with respect to the accuracy or completeness of the contents of this work and specifically disclaim all warranties, including without limitation any implied warranties of merchantability or fitness for a particular purpose. No warranty may be created or extended by sales representatives, written sales materials or promotional statements for this work. The fact that an organization, website, or product is referred to in this work as a citation and/or potential source of further information does not mean that the publisher and authors endorse the information or services the organization, website, or product may provide or recommendations it may make. This work is sold with the understanding that the publisher is not engaged in rendering professional services. The advice and strategies contained herein may not be suitable for your situation. You should consult with a specialist where appropriate. Further, readers should be aware that websites listed in this work may have changed or disappeared between when this work was written and when it is read. Neither the publisher nor authors shall be liable for any loss of profit or any other commercial damages, including but not limited to special, incidental, consequential, or other damages.

Library of Congress Cataloging-in-Publication Data

Names: Tolstunov, Len, editor.
Title: Essential techniques of alveolar bone augmentation in implant dentistry : a surgical manual / edited by Len Tolstunov.
Other titles: Vertical alveolar ridge augmentation in implant dentistry.
Description: Second edition. | Hoboken, NJ : Wiley, 2023. | Merger of Vertical alveolar ridge augmentation in implant dentistry : a surgical manual / edited by Len Tolstunov. 2016; and Horizontal alveolar ridge augmentation in implant dentistry : a surgical manual / edited by Len Tolstunov. 2016. | Includes bibliographical references and index.
Identifiers: LCCN 2022032872 (print) | LCCN 2022032873 (ebook) | ISBN 9781119827320 (hardback) | ISBN 9781119827337 (adobe pdf) | ISBN 9781119827344 (epub)
Subjects: MESH: Alveolar Ridge Augmentation–methods | Bone Transplantation | Dental Implantation–methods
Classification: LCC RK667.I45 (print) | LCC RK667.I45 (ebook) | NLM WU 600 | DDC 617.6/93–dc23/eng/20220822
LC record available at https://lccn.loc.gov/2022032872
LC ebook record available at https://lccn.loc.gov/2022032873

Cover Design: Wiley
Cover Images: Courtesy of Len Tolstunov

Set in 9.5/12 STIXTwoText by Straive, Chennai, India

Dentlearn.ir

Contents

Preface xxiii

Acknowledgments xxvii

About the Author and the Editor xxix

Contributors xxxi

About the Companion Website xxxv

SECTION I Introduction: Essential Clinical Knowledge 1

1 Bone Biology and Wound Healing 3

1.1 Bone Biology 4
Claudia Dellavia, Gaia Pellegrini, and Luiz Guilherme Fiorin

Bone Tissue Anatomical Aspects *4*
- Main Cellular Components, *4*
- Composition, *5*
- Structure, *6*

Bone Remodeling and Healing, *6*
- Bone Remodeling, *6*
- Bone Healing, *7*
- What Can Compromise Bone Healing?, *7*
- Bone Angiogenesis, *8*

Biomaterials for Bone Regeneration, *9*
- Bone Grafts, *10*
- Synthetic Hydroxyapatite-Based Biomaterials, *10*
- Polymers, *10*
- Bone Morphogenetic Protein-2, *11*
- Platelet Concentrates, *11*

Osseointegration, *12*
- Phases of Osseointegration, *12*

Bone Loading, *14*
- Threshold Strain, *14*

References, *15*

Dentlearn.ir

1.2 Wound Healing **18**
Andrea Pilloni
Overview of the Wound Healing Process, *18*
Phases of Wound Healing, *18*
Which Factors Can Lead To Impaired Healing?, *19*
Main Types of Wound Healing, *19*
Oral Soft Tissue Wound Healing, *20*
Oral Soft Tissue Special Features: Intrinsic Differences Between Oral Mucosa and Skin, *20*
Scar and Scarless Wound Healing in Oral Soft Tissues, *20*
Early Wound Healing Score: A Method To Assess Primary Intention Wound Healing, *21*
References, *22*

2 Applied Surgical Anatomy of the Jaws **24**
Mohamed Sharawy
Maxilla: Surgical Anatomy, *24*
Surgical Access To the Maxillary Sinus, *27*
Muscles Attached To the Maxilla of Surgical Importance, *28*
Sensory Innervation of the Maxilla, *29*
Arterial Supply To the Maxilla, *30*
Venous Drainage From the Maxilla, *31*
Lymphatic Drainage From the Maxilla, *31*
Mandible: Surgical Anatomy, *31*
Muscle Attachment To the Mandible of Surgical Importance To Oral Implantologists, *32*
Innervation of the Lower Jaw and Associated Structures, *34*
Blood Supply to the Mandible, *36*
Summary and Conclusions, *37*
Acknowledgments, *37*
References, *38*

3 Radiographic Evaluation of the Alveolar Ridge in Implant Dentistry: CBCT Technology **40**
Shikha Rathi and David Hatcher
The Role of Radiography in Implant Dentistry, *40*
Periapical Radiography, *40*
Panoramic Radiography, *40*
Occlusal Radiography, *42*
Cone Beam Computed Tomography, *42*
Anatomical and Architectural Considerations for Treatment Planning, *42*
Anterior Maxilla, *42*

Dentlearn.ir

Nasopalatine (Incisive) Canal, *42*
Canalis Sinuosus, *42*
Anterior Nasal Spine and Nasal Floor, *43*
Pattern of Ridge Atrophy in the Anterior Maxilla, *43*
Posterior Maxilla, *44*
Maxillary Sinus, *44*
Greater Palatine foramen, *46*
Pattern of Ridge Atrophy in the Posterior Maxilla, *47*
Anterior Mandible, *47*
Mandibular Incisive Canal, *47*
Lingual Foramen and Lateral Canals, *47*
Genial Tubercles, *48*
Pattern of Ridge Atrophy in the Anterior Mandible, *48*
Posterior Mandible, *48*
Inferior Alveolar (Mandibular) Canal, *48*
Mental foramen, *48*
Submandibular and Sublingual Fossae, *49*
Lingual Nerve, *49*
Pattern of Ridge Atrophy in the Posterior Mandible, *50*
Imaging Considerations for CBCT Utilization, *50*
Technical Considerations, *50*
Bone Quality and Bone Density Assessment, *51*
Pathology Detection, *51*
Radiation Dose, *51*
Interactive Implant Treatment Planning, *51*
Surgical Guides, *54*
Newer Technological Advances, *56*
References, *59*

4 Prosthetic Comprehensive Oral Evaluation in Implant Dentistry 62
Gary A. Morris

Initial Evaluation, *62*
Diagnostic Work-Up, *62*
Diagnosis and Treatment Plan, *63*
Smile Evaluation, *63*
Diagnostic Casts and Wax-Up, *66*
Radiographic Implant Guide, *67*
Clinical Applications, *76*
Prosthetic Evaluation and Treatment Planning of Partially Edentulous Patients in the Esthetic Zone, *76*

Dentlearn.ir

Prosthetic Evaluation and Treatment Planning of Partially Edentulous Patients in the Posterior Dentition, *80*

Prosthetic Evaluation and Treatment Planning of the Completely Edentulous Patient, *83*

Conclusion, *89*

References, *89*

5 Alveolar Ridge Defects and Bone Augmentation Techniques: Surgical Algorithm 92

Len Tolstunov

Ridge Preservation and Ridge Augmentation, *92*

Ridge Preservation, *92*

Ridge Augmentation, *93*

Bone Defects, Bone Grafts, and Bone Grafting Techniques, *94*

Extraosseous Versus Intraosseous Alveolar Bone Defects, *94*

Onlay Versus Inlay Alveolar Bone Grafts, *94*

Static Versus Dynamic Surgical Techniques, *94*

Risk Factors in Bone Augmentation Procedures in Implant Dentistry, *95*

Main Surgical Techniques of Bone Augmentation in Implant Dentistry, *95*

Guided Bone Regeneration, *96*

Block Bone Grafting, *96*

Ridge-Split Expansion Procedure, *96*

Distraction Osteogenesis, *96*

Alternative Surgical Techniques, *97*

Graft Healing and Vascularization, *97*

Alveolar Bone Augmentation Decision Tree Algorithm, *97*

Alveolar Bone Classification By Deficiency (Abcd) – the Tolstunov Classification, *98*

Examples of the Tolstunov Classification, *98*

Conclusion, *101*

References, *102*

6 Incision Design, Soft Tissue Flaps, and Wound Closure in Alveolar Bone Augmentation Surgeries in Implant Dentistry 106

Tetsu Takahashi and Kensuke Yamauchi

Incision Design in Alveolar Bone Augmentation Surgeries, *106*

Soft Tissue Flaps in Alveolar Bone Augmentation Surgeries, *106*

Vascularity Patterns, *106*

Flap Designs, *106*

Reflection of the Mucoperiosteum, *108*

Dentlearn.ir

Preparing for Wound Closure, *109*
Tension Release Incisions, *109*
Wound Closure in Alveolar Bone Augmentation Surgeries, *110*
Principles of Suturing, *110*
Types of Sutures, *111*
Complications, *112*
Nerve Injury, *112*
Bleeding, *112*
Wound Dehiscence, *112*
Conclusion, *113*
References, *113*

7 Biological Rationale of the Surgical Procedure: Bone Augmentation 116
Len Tolstunov

Graft Revascularization Sources, *117*
Conclusion, *123*
Acknowledgment, *124*
References, *124*

SECTION II Ridge Preservation 127

8 Bone Grafting Materials for Bone Preservation and Augmentation in Implant Dentistry: Surgical Algorithm 130
Hanieh Nokhbatolfoghahaei and Arash Khojasteh

Autogenous Bone Grafts, *131*
Allografts, *133*
Xenografts, *134*
Alloplasts, *135*
Calcium Phosphates, *136*
Tricalcium Phosphate, *136*
Hydroxyapatite, *137*
Conclusion, *137*
References, *137*

9 Guided Bone Regeneration for Extraction Sockets: Ridge Preservation 142
Waldemar D. Polido

Review of the Literature, *142*
Surgical Technique, *143*

Dentlearn.ir

Case Reports, *144*
Case 1, *144*
Case 2, *147*
Discussion, *150*
Conclusion, *151*
Acknowledgment, *151*
References, *151*

10 Platelet-Rich Fibrin for Bone Augmentation in Implant Dentistry 154
Richard J. Miron and Michael A. Pikos

The Evolution (History) of Platelet-Rich Fibrin, *154*
Leukocyte and Platelet-Rich Fibrin, *155*
Protocols to Produce Platelet-Rich Fibrin Via Horizontal Centrifugation, *156*
Clinical Uses of Platelet-Rich Fibrin in Bone Augmentation, *157*
Use of Platelet-Rich Fibrin in Extraction Site Management, *157*
Platelet-Rich Fibrin for Guided Bone Regeneration, *160*
Platelet-Rich Fibrin for Sinus Grafting Procedures, *164*
Advantages of the Use of Platelet-Rich Fibrin, *166*
Discussion and Future Research, *167*
Conclusion, *171*
References, *172*

SECTION III Ridge Augmentation: Horizontal 175

11 Guided Bone Regeneration with Resorbable and Non-Resorbable Membranes for (Mainly) Horizontal Alveolar Bone Augmentation in Implant Dentistry 178
John F. Hamrick and Trenton F. Jensen

Applied Surgical Anatomy, *178*
Indications and Contraindications, *179*
Indications, *179*
Contraindications, *179*
Basic Principles of Guided Bone Regeneration, *179*
Primary Wound Closure, *179*
Angiogenesis, *179*
Space Maintenance, *179*
Wound Stability, *179*
Description of Surgical Technique, *180*
Incisions and Flap Design, *180*
Flap Elevation and Site Preparation, *180*
Buccal Flap Release, *180*

Dentlearn.ir

Harvesting of Bone, *180*
Flap Closure Technique, *180*
Case Reports, *181*
Case 1, *181*
Case 2, *183*
Case 3, *184*
Case 4, *187*
Case 5, *189*
Case 6, *191*
Post-Operative Care, *192*
Complications, *192*
Discussion, *193*
Conclusion, *193*
References, *193*

12 Autogenous Block Bone Graft for Horizontal Ridge Augmentation in Implant Dentistry 196
Arash Khojasteh and Farshid Bastami

Recipient Site Analysis, *196*
Block Bone Augmentation Techniques, *197*
Onlay Bone Grafting, *197*
Guided Bone Regeneration and Onlay Bone Block Grafting, *197*
Cortical Autogenous Tenting, *198*
Regenerative Techniques in Bone Grafting, *199*
Platelet Derivatives, *199*
Mesenchymal Stem Cells, *199*
Case Presentations, *200*
Case 1, *200*
Case 2, *201*
Case 3, *201*
Case 4, *203*
Case 5, *204*
Conclusion, *205*
References, *206*

13 Allogenic Block Graft as an Alternative To Autogenous Block Graft for Augmentation of Horizontal Alveolar Bone Defects in Implant Dentistry 210
Shankar Iyer

Indications for Allogenic Block Grafts, *211*
Distinguishing Features of Irradiated Allogenic Block Grafts, *214*

Dentlearn.ir

Materials and Methods, *214*
Patient Selection Criteria, *214*
Pre-Operative Considerations, *214*
Technique of Allogenic Block Graft for A Single Anterior Tooth, *214*
Flap Design, *214*
Preparation of the Recipient Bone Bed for Decortication and Periosteal Release Incision (Scoring), *214*
Conforming the Block, *217*
Fixation of the Block, *218*
Management of Voids and Coverage, *219*
Re-Entry for Implant Placement, *219*
Technique of Allogenic Block Graft for Anterior Sextant, *221*
Pre-Operative Planning, *221*
Surgical Procedure, *221*
Preparation of the Recipient Bed and Adaptation of the Allogenic Block, *222*
Post-Operative Assessment and Surgical Re-Entry, *224*
Biopsy Interpretation, *224*
Implant Placement and Completion of Prosthetic Rehabilitation, *227*
Technique of Allogenic Block Graft for Posterior Sextant, *228*
Pre-Operative Planning, *228*
Surgical Procedure, *229*
Preparation of the Recipient Bed and Adaptation of the Allogenic Block, *229*
Post-Operative Assessment and Surgical Re-Entry, *229*
Biopsy Interpretation, *230*
Implant Placement and Completion of Prosthetic Rehabilitation, *232*
Discussion, *234*
Conclusion, *235*
Acknowledgment, *235*
References, *235*

14 Ridge-Split Expansion Procedure for Horizontal Bone Augmentation in Implant Dentistry 239

14.1 Diagnosis and Treatment Planning 240
Len Tolstunov

History, *240*
Diagnosis and Treatment Planning, *240*
Patient (Host) Selection, *240*
Alveolar Ridge Defect Analysis and Classification, *241*
Diagnostic Work-Up, *243*
Cone Beam Computed Tomography, *244*
Surgical Stent, *245*
Instrumentation, *245*
References, *247*

Dentlearn.ir

14.2 Surgical Principles of the Ridge-Split Expansion Procedure 249
Len Tolstunov

The Maxilla Is Not An Upside-Down Mandible, *249*
Vascularization: Vascular Periosteal Flap, *249*
Secondary Intention and Wound Healing: Ridge-Split Expansion Procedure and Guided Bone Regeneration, *250*
Osteo-Condensation of Surrounding Bone, *252*
Osteo-Mobilization of the Buccal Bone Fragment, *253*
Conclusion, *253*
References, *253*

14.3 Mandibular Two-Stage Alveolar Ridge-Split Expansion Procedure 254
Len Tolstunov

Surgical Procedure: Mandibular Ridge Split, *254*
Stage 1: Corticotomy, *254*
A Common Question, *256*
Stage 2: Split Expansion Graft, *256*
Case Report, *258*
References, *260*

14.4 Maxillary Single-Stage Alveolar Ridge-Split Expansion Procedure 261
Len Tolstunov

Case Report of A Maxillary Single-Stage Alveolar Split Procedure with Simultaneous Implant Placement, *263*
References, *265*

14.5 Advanced Ridge-Split Expansion Techniques for an Experienced Practitioner 266
Len Tolstunov

Single-Stage Mandibular Alveolar Split with A Closed Flap (Closed Mand C-SEG), *266*
Single-Stage Alveolar Split and Immediate Implant with A Closed Flap (Closed C-SEG-I) (Figures 14.5.1–14.5.4), *266*
Single-Stage Alveolar Split with An Open Flap (Open C-SEG), *267*
Single-Stage Alveolar Split and Immediate Implant with An Open Flap (Open C-SEG-I) (Figure 14.5.5), *267*
Spreader-Driven Ridge Expansion Approach (With Or Without Implant) (Figures 14.5.6 and 14.5.7), *268*
Case Report of Alveolar Split with Conical Progressive Osteotomes, *269*
Conclusion, *271*
References, *271*

14.6 Complications of the Ridge-Split Expansion Procedure and Conclusion 272
Len Tolstunov

Conclusion: “10 Commandments” for the Alveolar Split, *275*
References, *276*

Dentlearn.ir

15 Ridge-Split Expansion Procedure Utilizing Piezoelectric Surgery for Horizontal Bone Augmentation in Implant Dentistry 278
Dong-Seok Sohn and Jeong-Uk Heo

Instruments To Split the Alveolar Ridge, *278*
Fissure Bur, *278*
Rotary Disk/Micro-Saw, *278*
Reciprocation Saw, *279*
Case Report: Ridge-Split Expansion Procedure Using A Reciprocation Saw, *280*
Lasers (Er:yag, ER,CR:YSGG), *280*
Piezoelectric Bone Surgery, *280*
Ridge Expanders To Expand the Split Alveolar Ridge, *282*
Manual Osteotome/Chisel, *282*
Rotary Expander/Osseodensification Bur, *283*
Ridge-Split Expansion Procedure with Simultaneous Implant Placement, *283*
Case Report: Ridge-Split Expansion Procedure with Simultaneous Implant Placement in the Posterior Maxilla, *283*
Case Report: Ridge-Split Expansion Procedure with Simultaneous Implant Placement in the Posterior Mandible, *285*
Ridge-Split Expansion Procedure with Delayed Implant Placement (Two-Stage Ridge-Split Expansion), *285*
Case Report: Staged Ridge-Split Expansion Procedure with Split and Expansion/Fracture of the Buccal Segment, *287*
Case Report: Staged Ridge-Split Expansion Procedure with Reposition of Greenstick-Fractured Buccal Segment, *289*
Management of Fractured Buccal Segment, *291*
Conclusion, *291*
References, *292*

16 Minimally Invasive Combined Technique for Vertical and Horizontal Bone Augmentation in the Posterior Maxilla: Alveolar Split with Crestal Sinus Lift 294
Len Tolstunov

Ridge-Split Expansion Procedure for Width-Deficient Alveolar Ridge, *294*
Crestal Sinus Elevation for Height-Deficient Alveolar Ridge in the Posterior Maxilla, *295*
Minimally Invasive Surgical Techniques: Esli Sequence, *296*
Volumetric (Three-Dimensional) Alveolar Bone Augmentation in the Posterior Maxilla, *296*
Biological Rationale of the Alveolar Split and Crestal Sinus Elevation Procedures, *297*

Dentlearn.ir

Revascularization of the Osteotomized Bone Segment, *297*
Revascularization of the Interpositional Bone Graft, *297*
Re-Establishment of Alveolar Anatomy, *297*
Osteocondensation, *298*
Case Reports, *298*
Ridge Expansion and Crestal Sinus Floor Intrusion in the Posterior Maxilla, *298*
Ridge Expansion and Crestal Sinus Floor Elevation with Simultaneous Implant Placement in the Posterior Maxilla, *300*
Conclusion, *302*
References, *302*

SECTION IV Ridge Augmentation: Vertical 305

17 Protected Bone Regeneration with Titanium Mesh for (Mainly) Vertical Alveolar Ridge Augmentation in Implant Dentistry 308
Matteo Chiapasco and Grazia Tommasato

Indications, *308*
Contraindications, *309*
Pre-Operative Planning (T0), *309*
Grafting Materials, *309*
Donor Sites, *310*
Pre-Operative Preparation of Patients, *311*
Surgical Procedure (T1), *311*
Preparation of the Surgical Field, *311*
Type of Anesthesia, *311*
Bone Harvesting Procedure, *311*
Regeneration with A Titanium Mesh, *312*
Surgery: Flap Design, Recipient Site, and Incisions (T1), *312*
Titanium Mesh Removal and Implant Placement (T2), *316*
Implant Re-Opening and Prosthetic Phase (T3 and T4), *316*
Clinical Cases, *317*
Case 1, *317*
Case 2, *317*
Complications, *317*
Early Exposure of the Mesh with Or Without Evident Signs of Inflammation/Suppuration, *321*
Late Exposure of the Mesh with Or Without Evident Signs of Inflammation/Suppuration, *322*

Dentlearn.ir

Discussion, *322*
Vertical Bone Gain, *322*
Complications, *322*
Bone Gain Modifications Before Implant Placement, *322*
Bone Gain Modifications After Implant Placement (Peri-Implant Bone Resorption), *322*
Survival Rate of Implants, *323*
Conclusion, *323*
References, *323*

18 Autogenous Block Bone Graft for (Mainly) Vertical Ridge Augmentation in Implant Dentistry 326
Arash Khojasteh and Vishtasb Broumand

Recipient Site Classification and Defect Analysis, *326*
Donor Sites for Block Bone, *327*
Intraoral Harvest, *327*
Augmentation Techniques, *332*
Onlay Block Bone Grafting, *332*
Cortical Autogenous Block Tenting, *334*
Anatomical Transpositioning, *334*
Inlay (Interpositional) Bone Grafting (Sandwich Technique), *336*
Inferior Alveolar Nerve Lateralization, *337*
Pedicle Segmental Rotation, *337*
Discussion, *338*
Conclusion, *339*
References, *339*

19 Pedicled Vascularized Segmental Osteotomy with Interpositional Bone Grafting for Vertical Ridge Augmentation: Posterior Sandwich Osteotomy 344
Ole T. Jensen

Posterior Maxilla, *344*
Technique, *344*
Clinical Applications, *347*
Posterior Maxilla, *347*
Posterior Mandible, *350*
Discussion, *351*
Conclusion, *353*
References, *353*

Dentlearn.ir

20 Khoury Split Bone Block Grafting Technique: Biological Alveolar Bone Augmentation with Autogenous Bone 356
Fouad Khoury and Charles Khoury

Biology of Bone Regeneration, *356*
Augmentation Techniques, *359*
Bony Lid Technique, *359*
Augmentation of Small Bone Defects: Bone Core Technique, *360*
Augmentation of Large Bony Defects/Severe Bone Atrophy, *362*
Conclusion, *365*
References, *365*

21 Alveolar Distraction Osteogenesis for Bone Augmentation in Implant Dentistry 368
Dekel Shilo and Adi Rachmiel

Surgical Procedure, *369*
Indications for Alveolar Distraction Osteogenesis, *373*
Advantages and Disadvantages, *374*
Complications, *374*
Case Reports, *375*
Case 1: Alveolar Distraction Osteogenesis in the Anterior Maxilla, *375*
Case 2: Alveolar Distraction Osteogenesis in the Posterior Mandible, *376*
Conclusion and Suggestions for A Surgeon, *376*
References, *379*

22 Orthodontic Therapy: Orthodontic Extrusion for Vertical Ridge Enhancement 382
Ugo Macca, Agatino Davide Mirabella, and Francesco Amato

What Is Orthodontic forced Eruption?, *382*
Description of the Technique, *382*
Posterior Teeth, *385*
Three-Dimensional Bone Remodeling, *388*
Lateral Implant Site Development, *388*
Multidirectional Movement, *391*
Discussion, *392*
Results, *392*
Contraindications, *392*
Limitations, *399*
Advantages, *399*
Conclusion, *399*
References, *401*

Dentlearn.ir

23 Reconstruction of Three-Dimensional Alveolar Ridge Defects Utilizing Screws and Implant Abutments for the Tent-Pole Grafting Technique 404
Dong-Seok Sohn

Ridge Augmentation Using the Tent-Pole Screw Technique, *405*
Three-Dimensional Ridge Augmentation Utilizing A Titanium Screw As A Tent-Pole Screw: Case Report, *405*
Augmentation of A Three-Dimensional Alveolar Defect Utilizing A Low-Profile Healing Abutment As A Tent-Pole Abutment, *406*
Case Report, *407*
Description of Tent-Pole Abutment (Santa), *409*
Surgical Procedure of Santa-1–Assisted Horizontal Ridge Augmentation, *410*
Case Report: Horizontal Ridge Augmenting Using A Tent-Pole Abutment (Santa-1), *410*
Three-Dimensional Ridge Augmentation Using A Tent-Pole Abutment (Santa-2), *413*
Case Report: Simplified Three-Dimensional Ridge Augmenting Using A Tent-Pole Abutment (Santa-2), *413*
Conclusion, *416*
References, *417*

24 Lateral Sinus Lift/Bone Graft for Vertical Bone Augmentation in the Posterior Maxilla 420
Tiziano Testori, Riccardo Scaini, and Terry Zaniol

Indications and Contraindications, *420*
Pre-Operative Diagnosis, Planning, and Evaluation of Case Difficulty, *420*
Applied Surgical Anatomy, *422*
Sinus Anatomy, *422*
Sinus Membrane, *422*
Underwood's Septa, *423*
Vascularization, *423*
Innervation, *423*
Surgical Technique, *423*
Anesthesia, *423*
Flap Management (Entry), *423*
Lateral Window Preparation (Antrostomy), *424*
Sinus Membrane Elevation, *430*
Continuing Elevation in the Event of Perforation, *430*
Preparation of Implant Sites for the Simultaneous Approach, *430*

Dentlearn.ir

Insertion of Graft Material and Implant Placement with the Simultaneous Approach, *430*
Graft Materials, *431*
Suturing, *431*
Post-Operative Pharmacological Treatment, *433*
Surgical Technique: Stage Two Surgery, *433*
Conclusion, *434*
References, *434*

25 Crestal Sinus Lift/Bone Graft for Vertical Bone Augmentation in the Posterior Maxilla 438
Hom-Lay Wang, Ann Decker, and Tiziano Testori

Anatomical Structures, *438*
Residual Alveolar Bone Dimensions, *438*
Bone Quality, *439*
Schneiderian Membrane, *439*
Sinus Floor Morphology, *439*
Septa, *440*
Techniques, *440*
Summers' Osteotomy Technique, *440*
Reamers Approach, *443*
Staged Crestal Maxillary Sinus Augmentation, *444*
Hydraulic Pressure Technique, *444*
Osseous Densification, *446*
Grafting Materials Used During the Sinus Augmentation Procedure, *447*
Endoscope-Controlled Maxillary Sinus Elevation, *449*
Implant Length in Osteotome Procedures, *449*
Post-Surgical Considerations, *450*
Complications, *450*
Prevention and Management, *450*
Sinus Membrane Perforation, *450*
Sinusitis and Post-Operative Infection, *450*
Incision Opening/Mucosal Dehiscence, *450*
Rotational Instability/Implant Migration, *452*
Benign Paroxysmal Positional Vertigo, *452*
Conclusion, *453*
References, *453*

Dentlearn.ir

SECTION V Soft Tissue Grafting for Implant Site Development 457

26 Soft Tissue Assessment and Grafting for Alveolar Ridge Enhancement in Implant Dentistry 460
Edgard El Chaar

Techniques, *460*
Techniques To Create Contour and Thickness and Increase the Keratinized Tissue, *460*
Techniques for Papilla Management, *470*
Rotated Pediculated Marginal Tissue (Palacci), *470*
Rotated Pediculated Lingual Marginal Tissue (El Chaar), *470*
Soft Tissue Techniques for Extraction Socket Grafting, *471*
Conclusion, *474*
References, *474*

SECTION VI Alternative (to Bone Grafting) Surgical Techniques 477

27 Short Implants As An Alternative To Bone Augmentation in Implant Dentistry 480
Rolf Ewers and Boyd Tomasetti

Case Presentations, *481*
Case 1, *481*
Case 2, *484*
Case 3, *489*
Considerations and Pitfalls, *493*
Conclusions, *493*
References, *493*

28 Zygomatic and Pterygoid Implants As An Alternative To Bone Augmentation in Implant Dentistry 496
Vishtasb Broumand

Zygomatic Implants, *496*
Pterygoid Implants, *496*
Indications, *498*
Contraindications, *499*
Pre-Operative Planning, *499*
Surgical Procedure, *500*
Surgical Approaches for Zygomatic Implants, *500*
Surgical Approaches for Pterygoid Implants, *503*

Dentlearn.ir

Prosthetic Considerations, *505*
Clinical Cases, *506*
Case 1, *506*
Case 2, *507*
Case 3, *507*
Complications, *508*
Discussion, *510*
Conclusion, *510*
References, *510*

29 Complete-Arch Dental Implant Treatment as an Alternative (to Bone Grafting) Surgical Technique 513

29.1 Complete-Arch Dental Implant Treatment Using Photogrammetry and Delayed Immediate Loading 514
Ole T. Jensen and M. Donald Ross

Complete-Arch Site Classification, *514*
Full-Arch Treatment: Restorative Building Blocks, *517*
Building Block 1: Centric Relation, *517*
Building Block 2: Vertical Dimension of Occlusion, *517*
Building Block 3: Case Planning, *518*
Building Block 4: Surgery, *519*
Building Block 5: Provisionalization, *519*
Building Block 6: Soft Tissue, *522*
Discussion, *523*
Conclusion, *523*
References, *524*

29.2 Maxillary Full-Arch Staged Ceramo-Metal Implant Rehabilitation 525
Len Tolstunov

Case Report, *526*
History, *526*
Examination and Clinical Presentation, *526*
Diagnosis, *527*
Treatment Options, *528*
Final Treatment Plan, *529*
Surgical-Restorative Sequence Performed, *529*
Stage 3 (3 Months Later), *531*
Discussion, *534*
Hybrid Or All-On-Four Full-Arch Implant Prosthesis Design, *534*
Ceramo-Metal Crown-And-Bridge Implant Prosthesis Design, *534*
Conclusion, *534*
References, *535*

Dentlearn.ir

SECTION VII Tissue Bioengineering 537

30 Tissue Bioengineering and Regeneration in Implant Dentistry 540
Tara Aghaloo and Jacob Taylor

Basics of Wound Healing, 540
Bone Biology and Grafting, 540
Guided Bone Regeneration, 542
Soft Tissue Regeneration, 543
Tooth Development and Regeneration, 543
Dental Stem Cells, 544
Bone Marrow Stem Cells, 545
Cells, Scaffolds, and Growth Factors, 545
Conclusion, 546
References, 547

Index 551

Dentlearn.ir

Preface

Education is not a learning of facts but training of the mind to think.

Albert Einstein

Implant dentistry, like any medical or surgical discipline, is a constantly evolving science and practice. Old, complex, and traumatic surgical techniques slowly become obsolete and newer, simplified, less traumatic, and minimally invasive techniques come to the forefront. New medical books and surgical manuals come out to reflect new technological advances and techniques, new materials and methods, with the goal of helping to train a new generation of doctors who will be treating our patients with a higher degree of safety, precision, and efficiency.

The first edition of the book, published in 2016, consisted of two volumes titled *Horizontal Alveolar Ridge Augmentation in Implant Dentistry: A Surgical Manual* and *Vertical Ridge Augmentation in Implant Dentistry: A Surgical Manual*. This is the second edition of the book in a single volume. This second edition is different in two key points:

- As a single volume, it combines the best material from the previous two books with new material and techniques in a concise manner.
- It is geared towards a younger professional audience and written in a more didactic and step-by-step teaching approach. Another words, the material is presented in the easy to follow logical manner, similar to courses that are taught in dental and medical universities and schools. The chapters has plenty of illustrations, tables, photographs and radiographs, providing an ideal learning experience.

This surgical manual is a collaborative effort of more than 40 authors from around the world. They were hand-picked by the editor and, in order to qualify to be contributors, they had to possess three important professional qualities: be an authority in a particular surgical technique; be a full- or part-time professor with long teaching credentials at a university or dental school; and be a clinical scientist with an extensive publishing history (some of the authors have published more than 100 articles and several book chapters). So, the chosen clinical professors, teachers, and scientists from the start had the upper hand in contributing good-quality and high-value material for this book.

There was also another important feature of this multi-contributor approach to writing a professional medical book. Having more than 40 writers from numerous countries automatically gave this book a unique quality – it is *unbiased*. We believe that this impartial ("no agenda") approach of a plurality of material, written by several authors, leads to this book comparing positively to other books written by one or two authors who share a singular, and therefore somewhat partial and subjective, surgical experience.

This book therefore is an international, comprehensive, and balanced source of knowledge presented by experts for a wide audience, including oral surgeons, periodontists, periodontal and oral surgery residents in training, as well as dental students at dental and medical universities and schools around the world. We hope you like it.

BOOK ORGANIZATION

The book has two components: the written (book) version and the web version, which includes video clips prepared by contributors and related to specific chapters. The written text is divided into sections covering different aspects of bone preservation and bone and soft tissue augmentation in implant dentistry. The sections contain chapters demonstrating a variety of surgical techniques. There follows a short description of each section to help readers to orient themselves and choose sections or chapters of interest (see Video 1).

Dentlearn.ir

SECTION I

We had to start the story from the beginning. Section 1 begins with an important chapter on bone biology and wound healing. Chapter 1 should help a reader to develop understanding of the parameters of success of a surgical procedure based on the physiology of the hard and soft tissues of the jaws. This chapter is followed by Chapter 2 on the topographic anatomy of the stomatognathic system and Chapter 3 on radiographic evaluation of a dental patient. "Anatomy is destiny," said Albert Einstein. The physics genius was correct. When you choose a path to become a surgeon, anatomy would and should automatically become the second nature to you. You cannot proceed to and succeed in surgery if you do not know, understand, and respect human anatomy and physiology.

Still in Section I, we continue our journey and in Chapter 4 discuss the prosthetic evaluation of a patient to understand the need for a prosthetically guided approach in alveolar ridge augmentation in implant dentistry. Bone augmentation procedures are not a surgical exercise and only make sense if dental implants can be fully utilized for the function of mastication.

The section continues with Chapter 5 on a surgical classification or algorithm of bone augmentation techniques to demonstrate the decision tree that can help you to arrive at a certain horizontal (H), vertical (V), or both (3D) bone augmentation technique, required in each particular case. Chapter 6 is on key surgical maneuvers: incision designs, soft tissue flaps, and wound closures, imperative knowledge for any successful surgeon. Then comes Chapter 7, which discusses the biological rationale of a surgical procedure to help each surgeon to select a surgical technique with the best possible outcome.

SECTIONS II, III, AND IV

These sections describe the biomechanics of bone augmentation as it relates to implant dentistry, discussing two reconstructive options: ridge preservation and ridge augmentation.

Ridge preservation, the prophylactic approach to bone grafting discussed in Section II, demonstrates surgical techniques of prevention of bone loss after tooth extraction. It proposes bone grafting of a fresh extraction socket to prevent ridge collapse and bone atrophy.

Ridge augmentation, the therapeutic approach to bone grafting discussed in Sections III and IV, will showcase surgical techniques for existing and collapsed edentulous alveolar bone. The resulting bone deficiency, as discussed above, can be horizontal, which is more common and easier to treat; vertical, which is less common and more complex; or both, horizontal and vertical, which is the most difficult to manage. Often, bone loss has both width and height components. Sections III and IV demonstrate the techniques of (mainly) horizontal and (mainly) vertical bone augmentation, respectively.

SECTION V

It has been shown that the quality and quantity of soft tissue envelope covering the bone are another essential factor in implant dentistry. That is why this book presents a separate section, Section V, describing soft tissue grafting techniques for implant site development.

SECTION VI

In some complex cases of severe bone atrophy, a surgeon has to be inventive and think "outside the box." Complicated and traumatic cases can dictate a different approach for implant placement by planning an implant placement without bone grafting in areas where bone is available or using special implant designs. Section VI describes these innovative techniques: the "all-on-four" approach that utilizes a combination of four or more tilted and straight implants to immediately load a full-arch fixed and rigidly connected prosthesis; zygomatic and pterygoid implants that can be placed in less common bone regions, like the zygomatic bone and pterygoid plates of maxillary bone, providing rigid cross-arch support for the maxillary implant prosthesis; and short implants that can be placed in severely atrophic bone regions and prevent nerve injury and sinus complications, providing a viable restorative solution.

Dentlearn.ir

SECTION VII

"The best way to predict your future is to create it," as Abraham Lincoln said. Repair and regeneration of missing human tissue by harnessing patients' growth factors that attract mesenchymal (embryonic) stem cells into the surgical wound are bioengineering methods that are designed today, but lead medical and dental scientists and surgical practitioners into the future. This method is performed through the osteoinductive (bone-forming) process of cell proliferation and differentiation. Section VII is the last in the book, but one that a thoughtful reader should not miss. Chapter 30 on tissue bioengineering will teach the surgeon about these surgical techniques by explaining their biological rationale, encouraging choice of the one that has the highest regenerative value.

This book focuses on key bone reconstructive surgical techniques for deficient alveolar bone in implant dentistry. As an editor and one of more than 40 international contributors of this book, I encourage you to open the first page and start your learning journey, which should benefit both you, as a clinician, and your patients, the fortunate recipients of your acquired knowledge and skills.

Len Tolstunov

with website

To access the videos for this preface section, please go to
www.wiley.com/go/tolstunov/essential

VIDEO 1 Introduction to the Book by the Author and Editor Dr. Len Tolstunov.

Dentlearn.ir

Dentlearn.ir

Acknowledgments

I would like to thank the editorial management team at Wiley for turning this book into reality. These dedicated professionals worked closely with the editor of this book to make it a success. Among many, they are Angela Cohen, Erica Judisch, Susan Engelken, Tanya McMullin, Raghavan Rajamani, and Bhavya Boopathi.

Special appreciation is expressed to all the international contributors for their commitment, time, and dedication in writing their chapters, which will be so essential to the success of this book.

Dentlearn.ir

Dentlearn.ir

About the Author and the Editor

Len Tolstunov, DDS, DMD, is a Diplomate of the American Board of Oral and Maxillofacial Surgery. He is an Associate Clinical Professor in the Department of Oral and Maxillofacial Surgery at the University of the Pacific and University of California, San Francisco, USA. Dr. Tolstunov published more than 40 scientific articles in peer-review journals, founder of the International Bone Symposium in San Francisco, and has lectured nationally and internationally on the topics of oral surgery, bone grafting, and implant dentistry. He published a two-volume book on Bone Augmentation in Implant Dentistry (1st Edition) in 2015. This book is the Second Edition and a single-volume book on Bone Augmentation in Implant Dentistry. Dr. Tolstunov maintains full-time private practice in oral and maxillofacial surgery in San Francisco, CA, USA.

Dentlearn.ir

Dentlearn.ir

Contributors

Tara Aghaloo
Oral and Maxillofacial Surgery
UCLA School of Dentistry
Los Angeles, CA, USA

Francesco Amato
Private Practice
Catania, Italy

Farshid Bastami
Dental Research Center, Research Institute of Dental Sciences
Shahid Beheshti University of Medical Sciences, Tehran, Iran

Vishtasb Broumand
Private Practice, Oral and Maxillofacial Surgery
Desert Ridge Oral Surgery Institute
Phoenix, AZ, USA

Department of Oral and Maxillofacial Surgery
University of Arizona College of Medicine at Banner University
Medical Center
Phoenix, AZ, USA

Matteo Chipasco
Department of Biomedical, Surgical, and Dental Sciences
University of Milan
Milan, Italy

Ann Decker
Department of Periodontics and Oral Medicine
University of Michigan
Ann Arbor, MI, USA

Claudia Dellavia
Thin Section Laboratory
Department of Biomedical, Surgical and Dental Sciences
Università degli Studi di Milano Statale (UNIMI), Milan, Italy

Edgard El Chaar
School of Dental Medicine
University of Pennsylvania
Philadelphia, PA, USA

Rolf Ewers
Department of Crani-Maxillofacial and Oral Surgery
Medical University of Vienna
Vienna, Austria

Luiz Guilherme Fiorin
Department of Diagnosis and Surgery
Division of Periodontics
São Paulo State University "Júlio de Mesquita Filho"
Araçatuba, Brazil

John F. Hamrick
Department of Periodontics
Medical University of South Carolina School of Dentistry
Charleston, SC, USA

Private Practice
Greenville, SC, USA

David Hatcher
Private Practice
Diagnostic Digital Imaging
Sacramento, CA, USA

Jeong-Uk Heo
Private Practice
GoodWill Dental Clinic
Busan, South Korea

Shankar Iyer
Director, Malo Smile USA
Elizabeth, New Jersey, USA

Clinical Assistant Professor, Department of Periodontics & Restorative Dentistry
Rutgers School of Dental Medicine
Newark, New Jersey, USA

Dentlearn.ir

Ole T. Jensen
School of Dentistry
University of Utah
Salt Lake City, UT, USA

Trenton F. Jensen
Private Practice
Greenville, SC, USA

Arash Khojasteh
Department of Oral and Maxillofacial Surgery
Dental Research Center, Research Institute of Dental Sciences
Shahid Beheshti University of Medical Sciences
Tehran, Iran

Faculty of Health and Medicine
University of Antwerp
Antwerp, Belgium

Charles Khoury
Department of Fixed Prosthetics
School of Dentistry, St. Joseph University
Beirut, Lebanon

Fouad Khoury
Privatklinik Schloss Schellenstein
Olsberg, Germany
Department of Oral and Maxillofacial Surgery
University of Muenster
Muenster, Germany

Ugo Macca
CAGS in Prosthodontics
Boston University
Boston, MA, USA

Private Practice
Siracuse, Italy

Agatino Davide Mirabella
Department of Orthodontics
University of Ferrara
Ferrara, Italy

Private Practice
Catania, Italy

Richard J. Miron
Department of Periodontology
School of Dental Medicine, University of Bern
Bern, Switzerland

Gary A. Morris
Department of Graduate Studies
Southern Illinois University, School of Dental Medicine
Alton, IL, USA

Private Practice
Buffalo Grove, IL, USA

Hanieh Nokhbatolfoghahaei
Dental Research Center, Research Institute of Dental Sciences
Shahid Beheshti University of Medical Sciences
Tehran, Iran

Gaia Pellegrini
Thin Section Laboratory
Department of Biomedical, Surgical and Dental Sciences
Università degli Studi di Milano Statale (UNIMI)
Milan, Italy

Michael A. Pikos
The Pikos Institute
Trinity, FL, USA

Andrea Pilloni
Department of Oral and Maxillofacial Sciences
Section of Periodontics
Sapienza University of Rome
Rome, Italy

Waldemar D. Polido
Indiana University School of Dentistry
Indianapolis, IN, USA

Adi Rachmiel
Department of Oral and Maxillofacial Surgery
Rambam Medical Center
Haifa, Israel

Faculty of Medicine
Technion-Israel Technion of Technology
Haifa, Israel

Shikha Rathi
Private Practice
Diagnostic Digital Imaging
Sacramento, CA, USA

Dentlearn.ir

M. Donald Ross
Digital Ape – Full Arch Solutions
Southlake, TX, USA

Riccardo Scaini
IRCCS Orthopedic Institute Galeazzi
Dental Clinic
Section of Implant Dentistry and Oral Rehabilitation, Milan, Italy

Department of Biomedical, Surgical and Dental Sciences
Università degli Studi di Milano
Milan, Italy

Mohamed Sharawy
College of Dental Medicine
Georgia Reagents University
Augusta, GA, USA

Dekel Shilo
Department of Oral and Maxillofacial Surgery
Rambam Medical Center, Haifa, Israel

Faculty of Medicine
Technion-Israel Technion of Technology
Haifa, Israel

Dong-Seok Sohn
Department of Dentistry and Oral and Maxillofacial Surgery
School of Medicine, Daegu Catholic University
Daegu, South Korea

Tetsu Takahashi
Division of Oral & Maxillofacial Surgery
Graduate School of Dentistry
Tohoku University, Miyagi, Japan

Jacob Taylor
Oral and Maxillofacial Surgery
UCLA School of Dentistry
Los Angeles, CA, USA

Tiziano Testori
IRCCS Orthopedic Institute Galeazzi
Dental Clinic
Section of Implant Dentistry and Oral Rehabilitation, Milan, Italy

Department of Biomedical, Surgical and Dental Sciences
Università degli Studi di Milano
Milan, Italy

Department of Periodontics and Oral Medicine
University of Michigan, School of Dentistry
Ann Arbor, MI, USA

Grazia Tommasato
Department of Biomedical, Surgical, and Dental Sciences
University of Milan, Milan, Italy

Len Tolstunov
Associate Clinical Professor, Department of Oral and Maxillofacial Surgery, University of California San Francisco (UCSF) School of Dentistry, San Francisco, CA, USA

Associate Clinical Professor, Department of Oral and Maxillofacial Surgery, University of the Pacific Arthur A. Dugoni School of Dentistry, San Francisco, CA, USA

Private OMFS Practice
San Francisco, CA, USA

Boyd Tomasetti
Oral and Maxillofacial Surgery Residency Program
Denver Health Medical Center
Denver, CO, USA

Hom-Lay Wang
Department of Periodontics and Oral Medicine
University of Michigan School of Dentistry
Ann Arbor, MI, USA

Kensuke Yamauchi
Division of Oral & Maxillofacial Surgery
Graduate School of Dentistry, Tohoku University, Miyagi, Japan

Terry Zaniol
Private Practice
Crocetta del Montello TV, Italy

Dentlearn.ir

Dentlearn.ir

About the Companion Website

This book is accompanied by a companion website:

www.wiley.com/go/tolstunov/essential

The website is featuring with procedural videos.

Dentlearn.ir

Dentlearn.ir

Introduction: Essential Clinical Knowledge

SECTION I

Chapter 1 Bone Biology and Wound Healing 3

Chapter 1.1 Bone Biology 4
Claudia Dellavia, Gaia Pellegrini, and Luiz Guilherme Fiorin

Chapter 1.2 Wound Healing 18
Andrea PIlloni

Chapter 2 Applied Surgical Anatomy of the Jaws 23
Mohamed Sharawy

Chapter 3 Radiographic Evaluation of the Alveolar Ridge in Implant Dentistry: CBCT Technology 39
Shikha Rathi and David Hatcher

Chapter 4 Prosthetic Comprehensive Oral Evaluation in Implant Dentistry 61
Gary A. Morris

Chapter 5 Alveolar Ridge Defects and Bone Augmentation Techniques: Surgical Algorithm 91
Len Tolstunov

Chapter 6 Incision design, soft tissue flaps, and wound closure in alveolar bone augmentation surgeries in implant dentistry 105
Tetsu Takahashi and Kensuke Yamauchi

Chapter 7 Biological Rationale of the Surgical Procedure: Bone Augmentation 115
Len Tolstunov

Dentlearn.ir

Dentlearn.ir

Bone Biology and Wound Healing

Although the bone is a rigid structure with an inert component, it is a living and breathing complex structure that maintains its micro-macroscopic assembly through human life and responds to external stimuli by absorbing or dissipating impacts, healing when fractured or growing. The continuous and adaptive metabolic response of this tissue is accomplished by a specific cellular apparatus that includes osteoblasts, osteoclasts, and osteocytes (see Video 1.1).

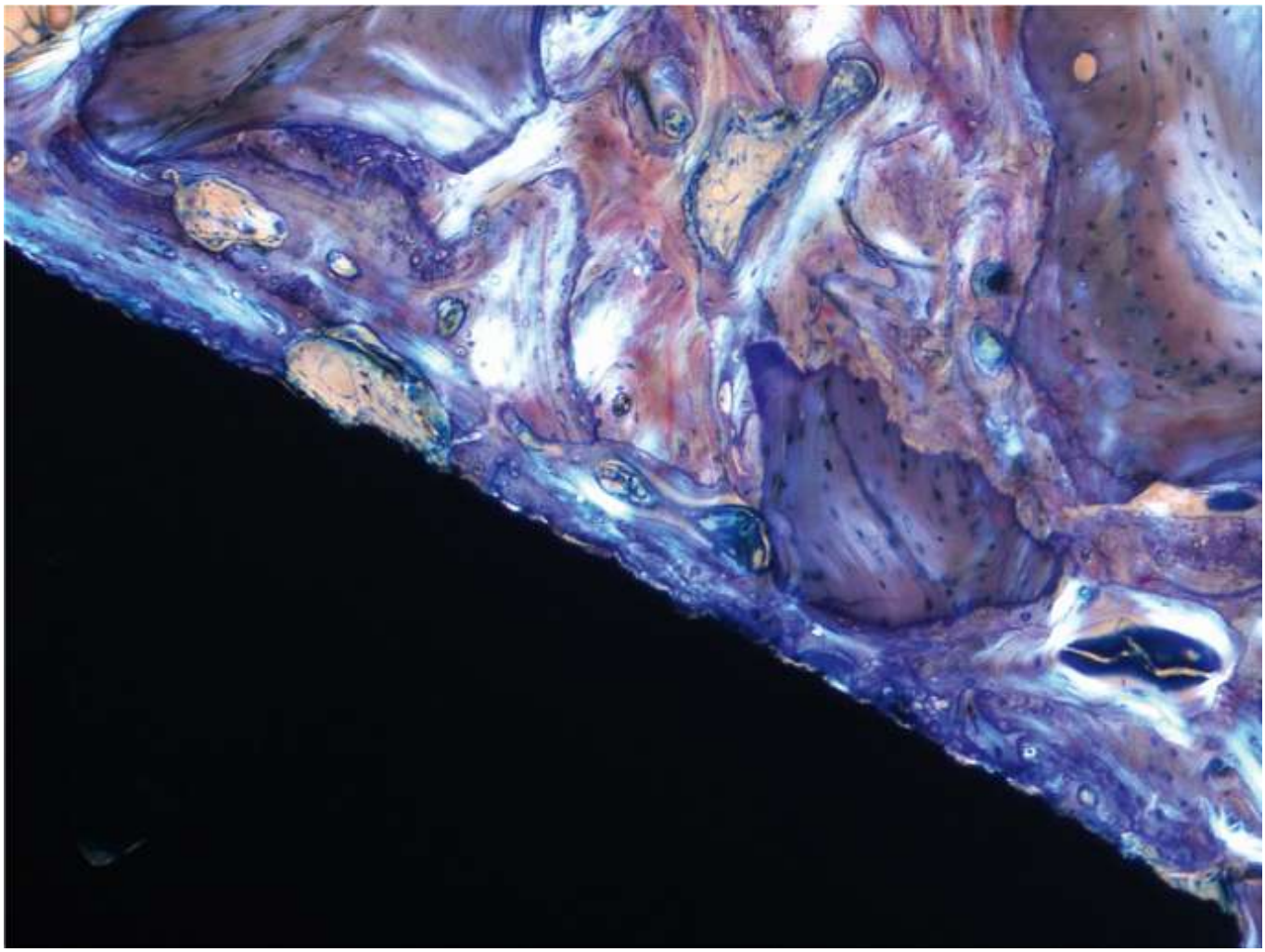

Intimate and functional contact established by the newly formed bone with the implant surface. Toluidine blue and pyronin yellow staining, acquisition by scanner at high resolution, total magnification 100×.

Dentlearn.ir

CHAPTER 1.1

Bone Biology

Claudia Dellavia[1], Gaia Pellegrini[1], and Luiz Guilherme Fiorin[2]

[1]*Department of Biomedical, Surgical and Dental Sciences, Università degli Studi di Milano Statale (UNIMI), Milan, Italy*

[2]*Department of Diagnosis and Surgery, Division of Periodontics, São Paulo State University "Júlio de Mesquita Filho", Araçatuba, Brazil*

BONE TISSUE ANATOMICAL ASPECTS

Bone is a specialized mineralized connective tissue with the functions of protection, mechanical support, insertion of muscles, and reserve of ions for the maintenance of mineral homeostasis in the organism.

Although bone is a rigid structure with an inert component, it is a living complex that maintains its micro-macroscopic structure through the organism's life and responds to external stimuli by absorbing or dissipating impacts, healing when cracked or fractured, and growing. The continuous and adaptative metabolic response of this tissue is performed by a specific cellular apparatus that includes osteoblasts, osteoclasts and osteocytes, and lining cells.

MAIN CELLULAR COMPONENTS

Osteoblasts are bone-forming cells, differentiated from mesenchymal stem cells, that migrate to the local region, secreting proteins in the non-mineralized matrix, called osteoid, that later become mineralized from the accumulation of calcium phosphate as hydroxyapatite. After this process, osteoblasts have different fates: they may become trapped in the bone, remain as cell lining the bone surface, or suffer apoptosis (Figure 1.1.1).

Osteoblasts are responsible for the production of important cytokines including osteocalcin, osteopontin, osteonectin, bone sialoprotein, alkaline phosphatase, and a large amount of type I collagen, insulin-like growth factor I and II, transforming growth factor-beta (TGF-β), and bone morphogenetic proteins (BMPs) that are involved in bone matrix deposition and organization as well as its mineralization. For this reason, some of these proteins, in combination with bone substitute materials [1], cells, or scaffolds, have been proposed with encouraging results to promote bone regeneration when the volume of alveolar crest is insufficient for the correct three-dimensional (3D) implant placement.

Osteocytes are mature osteoblasts entrapped within the matrix; they represent most of the cell population in the bone. During their formation, the cellular body is reduced, organelles are lost, and dendrite-like processes form. These processes are localized in canals filled with fluid, are responsible for communication between other osteocytes, and are able to detect local changes in structure, stress, and microfractures as metabolic changes. These cells act as mechanosensors and release signaling molecules promoting anabolic/catabolic bone activities such as RANKL (receptor activator of nuclear factor kappa-B ligand), responsible for osteoclast recruitment [2, 3]. Furthermore, they assume a specific morphology and align following the collagen fiber orientation, which corresponds to the direction of the tensile strain through the bone tissue [4]. This 3D organization improves the mechanical properties of this tissue when it undergoes masticatory load.

Osteoclasts are multinuclear giant cells formed from the fusion of monocyte/macrophage precursor cells into the bone marrow area adjacent to the bone surface (Figures 1.1.2 and 1.1.3). The osteoclastogenesis is mainly dependent on RANKL, which binds its receptor (RANK) on the surface of the precursor cells, inducing their polarization into the clastic lineage [5].

In periodontal and peri-implant diseases, osteoclast differentiation and activity are stimulated by the presence of bacterial lipopolysaccharides. These molecules increase the secretion of RANKL and pro-inflammatory cytokines by resident cells and the expression of RANK on macrophages, which then upregulates bone resorption activity.

Essential Techniques of Alveolar Bone Augmentation in Implant Dentistry: A Surgical Manual, Second Edition. Edited by Len Tolstunov.
© 2023 John Wiley & Sons, Inc. Published 2023 by John Wiley & Sons, Inc.
Companion website: www.wiley.com/go/tolstunov/essential

Dentlearn.ir

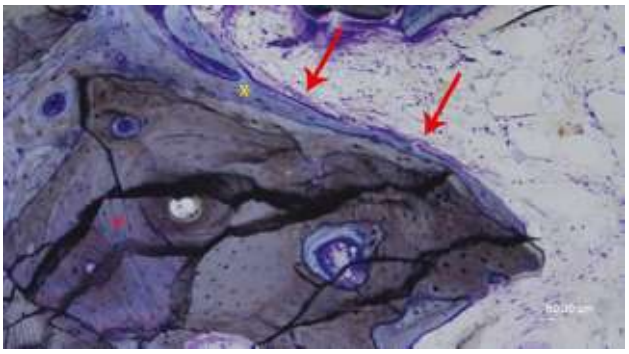

FIGURE 1.1.1 Biomateral particles (red asterisk) surrounded by woven bone (yellow asterisk) and bone lining cells (red arrow). Toluidine blue and pyronin yellow staining, acquisition by scanner at high resolution, total magnification 200×.

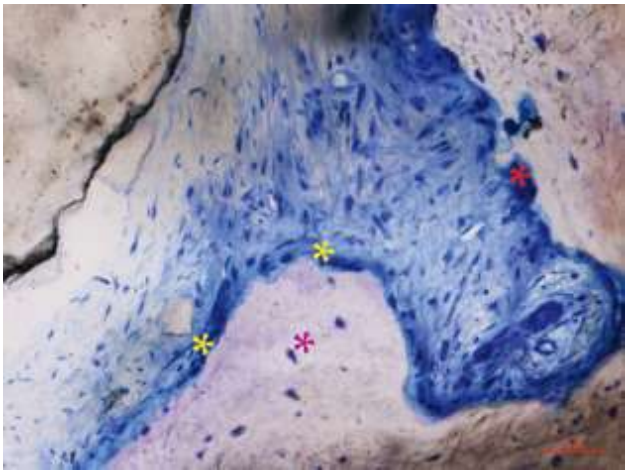

FIGURE 1.1.2 Osteoclast-like cells (red asterisk), osteoblast-like cells (yellow asterisk), and osteocite-like cells (purple asterisk). Toluidine blue and pyronin yellow staining, acquisition by scanner at high resolution, total magnification 400×.

COMPOSITION

The bone tissue is mainly composed of mineral, water, and organic matrix. The mineral part is composed of one analog to hydroxyapatite with a calcium deficiency, with a basic formulation of $Ca_{10}(PO_4)_6OH_2$. Other ions are also found associated with the bone hydroxyapatite, such as phosphorus, potassium, sodium, magnesium, carbonate, chloride, and fluorine. Mineralization begins with the deposit of mineral crystals in the vesicles of the organic matrix, which progressively increases with the maturation of the tissue (Figure 1.1.4).

The organic part is composed of 90% collagen type 1, with mechanical and structural functions being responsible for the elastic stiffness and bending strength. The remaining part is composed of non-collagenous proteins, with structural signaling and mechanical roles.

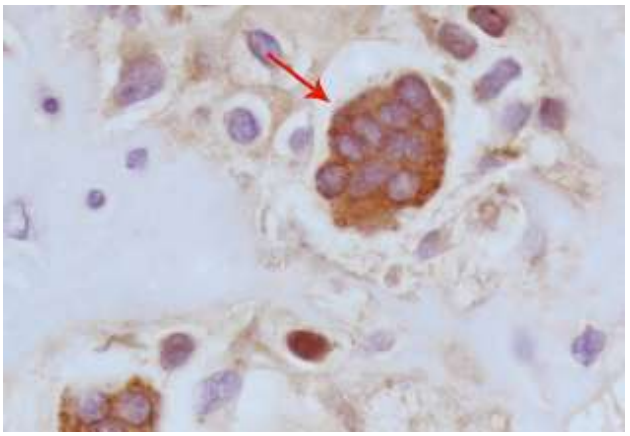

FIGURE 1.1.3 Immunohistological staining for tartrate-resistant acid phosphatase (TRAP) and multinuclear TRAP-positive cells (red arrow). Osteoclasts (red arrow) are responsible for the bone resorption by secreting hydrogen ions and lytic enzymes (including TRAP) that dissolve the mineral content and then degrade the remaining organic structure (red arrow). Light micrography, decalcified sample, Harris hematoxylin counterstaining, total magnification 1000×.



FIGURE 1.1.4 Alveolar bone in post-extraction socket at 4 months of healing: interface between pristine bone characterized by high mineral content (003) and hypomineralized woven bone (001). Dark areas (002) represent the medullary spaces. Sections were observed using a BSE-SEM system without additional fixation and previous coating of carbon film to assess level of mineralization of regenerated tissue.

The intense and constant anabolic and catabolic activity of bone may be altered by age, and by primary or secondary conditions that induce changes to the microstructure, mineralization, and cellular compound. Hypermineralization, changes in composition of the collagen matrix, and accumulation of micro damages affecting the resistance to

Dentlearn.ir

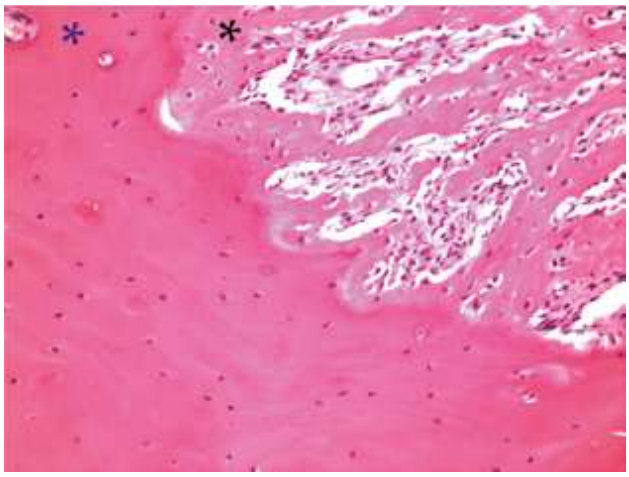

FIGURE 1.1.5 Cancellous (black asterisk) and cortical bone (blue asterisk) structure in rat. Light micrography, decalcified sample, hematoxylin and eosin staining, total magnification 100×.



FIGURE 1.1.6 Osteons of the compact bone. Photomicrograph at polarized light, total magnification 200×.

tensile and compressive strain, as well as the fracture toughness, have been observed in aged cortical bone. Even systemic diseases, including diabetes, osteoporosis, and hematological diseases, and drugs such as anticoagulants, antacids, bisphosphonates, and corticosteroids, profoundly affect bone metabolism and structure [6], although the association between osteoporosis and jawbones is still not well understood [7].

STRUCTURE

Bone has a cancellous or cortical macrostructure; the microstructure includes the Haversian systems, osteons, and trabeculae; the sub-microstructure is the single lamella.

Anatomically, cortical bone is essentially compact and suffers less remodeling than cancellous bone. The latter is formed by trabeculae that define bone marrow spaces: a mesh of rods and plates 3D oriented to sustain stress and mechanical forces [8–10].

Both compact and cancellous bone are constituted by lamellae (Figure 1.1.5); in the compact bone these are organized in concentric rings around the central Haversian canal forming osteons (the structural compound of the bone; Figure 1.1.6). These systems communicate with each other via Volkmann canals.

BONE REMODELING AND HEALING

BONE REMODELING

Bone tissue physiologically undergoes a continuous remodeling process where two opposite activities coexist: tissue degradation and reabsorption by the osteoclasts and deposition of new bone by the osteoblasts (Figures 1.1.7–1.1.9). In this process, the osteoclasts form lacunae, called Howship's lacunae

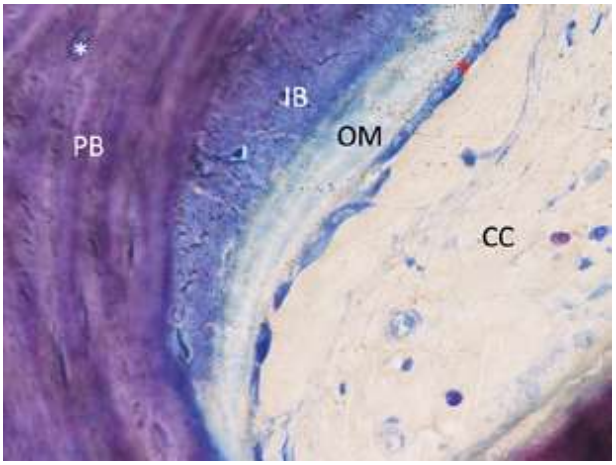

FIGURE 1.1.7 Particular of a cutting bone. White asterisk: osteocyte; red asterisk: osteoblast lining the matrix. Toluidine blue and pyronin yellow staining, acquisition by scanner at high resolution, total magnification 600×. CC, cutting cone; IB, immature bone; OM, osteoid matrix; PB, primitive/pristine bone.

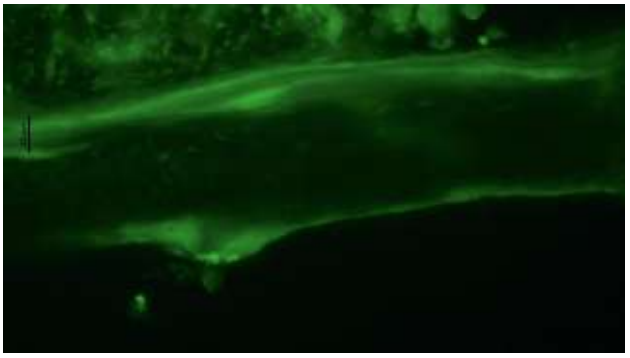

FIGURE 1.1.8 Bone apposition rate detected by tetracycline double labeling technique for the measurement of bone growth *in vivo* assessed at fluorescence microscopy, total magnification 400×.

Dentlearn.ir

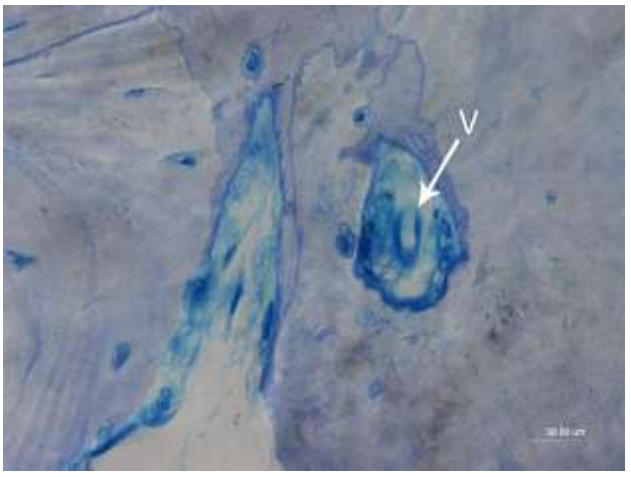

FIGURE 1.1.9 Cutting cones in longitudinal and transversal sections. During the remodeling activity, osteoclasts at the top of the cutting cone are followed by osteoblasts, which depone the osteoid matrix on the walls of the cone, and by newly formed blood vessels in the center of the resorption area. All these components constitute bone multicellular units (BMU). Toluidine blue and pyronin yellow staining, acquisition by scanner at high resolution, total magnification 600×. V, vessel in the center of the cutting cone and surrounded by the resorption cavity.

(Figure 1.1.10), where they pour out the acid ions, and by lowering of the pH the mineral matrix is decalcified, exposing the organic matrix [11]. Then the osteoclasts secrete the collagenases responsible for the degradation of the organic matrix. After completion of the reabsorption, the osteoclast undergoes apoptosis.

But how does the organism know where and when to start the remodeling process? Studies indicate that the osteocyte has a vital function in signaling the start of bone remodeling. Through sensing changes in tissue integrity, associated with microdamage and fatigue load, the cell enter apoptosis. The death of the cells itself does not produce the cytokines responsible for recruiting the osteoclasts, but the neighbor osteocytes that remain viable secrete cytokines as RANKL, directly enhance osteoclast formation, and start the remodeling [12–14]. Not only does the organism have a targeted remodeling process, but the osteocytes are responsible for metabolic signaling. Bone remodeling seems to be triggered also by the presence of metal particles/ions that derive from the degradation of dental implants [15]. This debris may result from corrosion of the implant surface when it is exposed to bacteria from the oral cavity, saliva, and chemical agents from food, mouthwash, and toothpaste, or even when implantoplasty is performed to reduce the surface roughness.

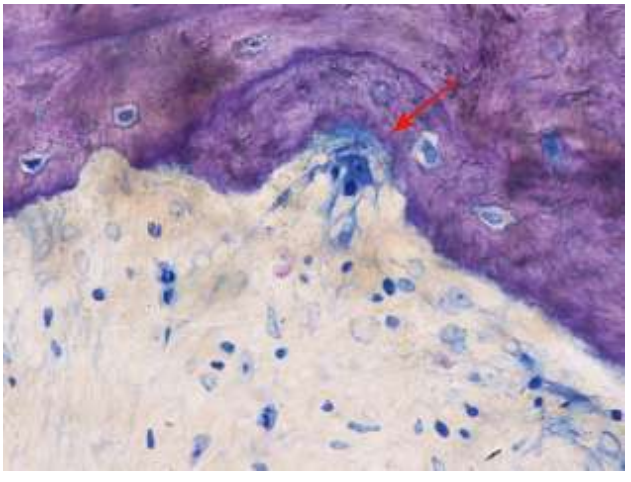

FIGURE 1.1.10 Howship's lacunae (red arrow). An osteoclast-like cell secretes the collagenases responsible for the degradation of the organic matrix. Toluidine blue and pyronin yellow staining, acquisition by scanner at high resolution, total magnification 600×.

BONE HEALING

Bone formation can occur in two ways: via intramembranous ossification, where the bone is formed directly from the connective tissue, and via endochondral ossification, where a skeleton of hyaline cartilage shapes the bone formation. Maxillary and mandibular bone formation and healing proceed via intramembranous osteogenesis, through the deposition of immature woven bone that is remodeled in parallel-fibered and lamellar mature bone [16]. The process of alveolar bone formation that spontaneously occurs within the socket after tooth extraction has been well studied in humans and can be reported as a representative model.

Even though most volume changes occur within a year following the extraction [17], most of the structural changes happen within 180 days. During the first weeks of healing, the blood clot is infiltrated by inflammatory cells and vessels migrating from the walls of the pristine bone and is progressively substituted by a provisional matrix (2–4 weeks; Figure 1.1.11). In the subsequent weeks, cancellous bone with centripetal growth occupies most of the alveolus (6–8 weeks; Figure 1.1.12). Maturation of this bone intensifies in the following days and occurs from the periphery to the center. At 12–24 weeks lamellar bone and medullary spaces can be observed and a bone bridge closes the alveolus coronally (Figure 1.1.13) [18].

In clinical practice, an alveolar socket preservation procedure can be performed to preserve the alveolar bone volume for subsequent implant placement. The effect of the grafted biomaterial on socket healing will be discussed in the section on biomaterials.

WHAT CAN COMPROMISE BONE HEALING?

Several factors can influence bone healing; systemic conditions and drugs are common factors that change the physiology of bone healing, alongside aging. In the elderly, with the

Dentlearn.ir

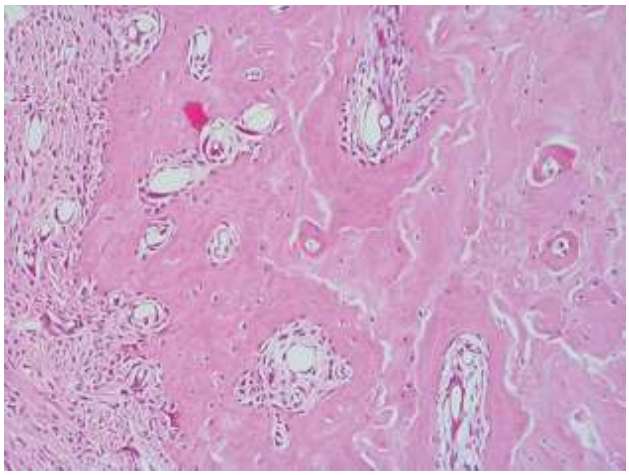

FIGURE 1.1.11 Healing socket after 10 days of extraction (rat). Immature woven bone with newly formed osteons can be observed. Light micrography, decalcified sample, hematoxylin and eosin staining, total magnification 100×. *Source*: Courtesy of Professor Edilson Ervolino, Department of Basic Sciences, School of Dentistry, São Paulo State University (UNESP), Araçatuba, São Paulo, Brazil.



FIGURE 1.1.13 Alveolar socket healing at 4 months after extraction. The highly mineralized pristine bone is lined by newly formed tissue with lower mineral content (red asterisks). Trabecular bone is still visible within the area of the extraction. Photomicrograph at BSE-SEM system without additional fixation and previous coating of carbon film.

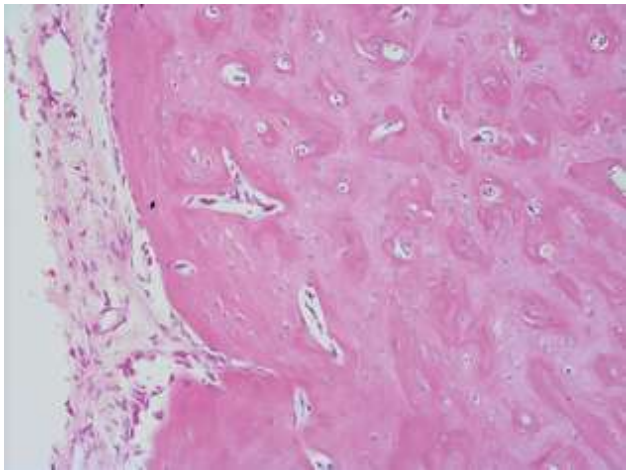

FIGURE 1.1.12 Healing socket after 20 days of extraction (rat). The structure of bone tissue appears more mature as a consequence of the remodeling activity. Light micrography, decalcified sample, hematoxylin and eosin staining, total magnification 100×. *Source*: Courtesy of Professor Edilson Ervolino, Department of Basic Sciences, School of Dentistry, São Paulo State University (UNESP), Araçatuba, São Paulo, Brazil.

decrease of the sex hormones, reabsorption surpasses the formation of new bone, lowering the bone mass and bone strength [19].

Alcohol and smoking habits also impair healing. Alcohol consumption decreases bone remodeling, causing osteopenia by suppression of bone marrow cell differentiation [20]. Smoking leads to lower vascularization, impairing the blood flow essential to bone healing, and also causes damage to the DNA of the cell, leading to somatic changes and increasing the possibility of cancer. Antineoplastic agents are known to exacerbate the inflammation, reducing the expression of osteoblastic lineage cells while increasing osteoclastic expression markers [21, 22].

Diabetes also causes changes in bone strength, leading to deterioration of the organic matrix and accumulation of microdamage, lowering the tensile resistance and elevating its fragility [23].

BONE ANGIOGENESIS

As for all tissues, bone needs a blood supply for its homeostasis and healing activity. The terms angiogenesis and vasculogenesis both refer to the formation of a vascular network, but with a different mechanism. Vasculogenesis is *in situ* differentiation and growth derived from multipotent precursor cells, while angiogenesis is the formation of a vascular network derived from pre-existing endothelial cells. In bone tissue, angiogenesis and osteogenesis are closely related and angiogenesis–osteogenesis coupling activity is referred to. After tooth extraction, bone regenerative procedures, or implant placement, the deposition of immature matrix and its mineralization occur along the newly formed blood vessels that branch out into the granulation tissue [24]. In this chapter, we will focus on factors that influence angiogenesis, stimulating natural bone healing, and that have been most often researched and described.

Compact vs. Cancellous Bone

The blood supply occurs differently in compact/lamellar and cancellous (medullary) bone. In the former, the blood vessels are located in the Haversian and Volkmann canals; in the

Dentlearn.ir

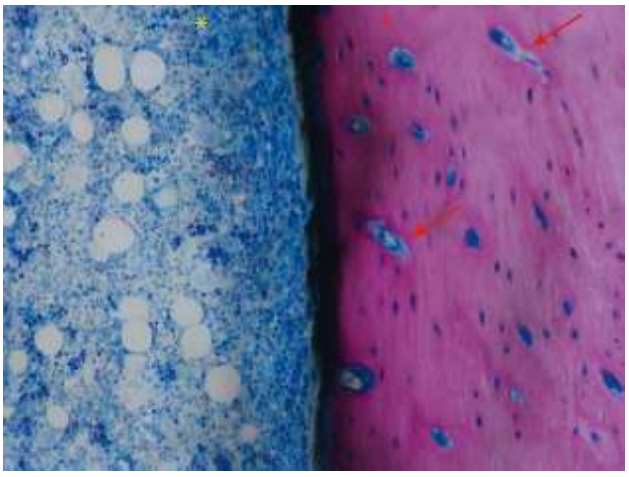

FIGURE 1.1.14 Havers and Volkmann canals (red arrow) in compact/lamellar bone (red asterisk), where the blood vessels are in intimate contact with its walls. Their caliber is limited by the size of the canal. Bone medulla (yellow asterisk) composed mainly of stem cells and adipocytes in rat. Light micrography, calcified sample, Toluidine blue and eosin staining, total magnification 200×. *Source*: Courtesy of Professor Juliano Milanezi de Almeida, Department of Diagnosis and Surgery-Periodontics Division, São Paulo State University (UNESP), Brazil.

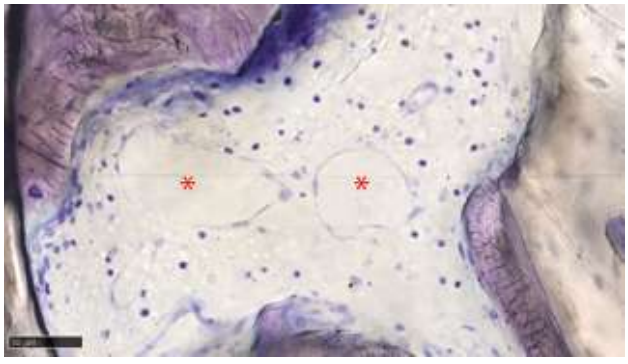

FIGURE 1.1.15 Vessels (red asterisks) running in the center of the medullary area. Compared to the compact bone, the cancellous bone is vascularized by a higher number of vessels with larger caliber located in the bone marrow. Due to these anatomical differences, the angiogenesis that begins in response to a trauma (as implant placement) or to an inflammatory stimulus occurs differently in compact and cancellous bone. Toluidine blue and pyronin yellow staining, acquisition by scanner at high resolution, total magnification 400×.

latter, vessels run within the medullary area surrounded by connective tissue (Figures 1.1.14 and 1.1.15).

Vascular Endothelial Growth Factor

Vascular endothelial growth factor (VEGF) has been extensively studied and is described as affecting endothelial cell proliferation during both vasculogenesis and angiogenesis. It is responsible for coupling angiogenesis with osteogenesis, and also for controlling the differentiation of osteoblasts and osteoclasts. Its isoform VEGF-A, produced by osteoblasts, regulates bone defect regeneration and stimulates the resorptive activity of osteoclasts; the administration of drugs that possess anti-VEGF effects can impair osseointegration and the remodeling of bone [25–27]. In a preclinical model, this protein has been associated with bone morphogenetic protein-2 (BMP-2) to increase the vertical regeneration of alveolar bone around implants, with encouraging results [28].

Hypoxia as an Angiogenetic Determinant

After bone damage or fracture occurs and the blood vessels rupture, blood flow decreases, thus reducing tissue oxygenation. As a consequence, hypoxia induced factor (HIF) is expressed in areas with low oxygen and is responsible for increasing VEGF gene expression.

Type H Vessels

These types of vessels are located along the periosteum and endosteum of the cortical and trabecular bone adjacent to the growth plate. They are highly specialized, since they guide osteogenic activity by expressing proteins that promote the proliferation and differentiation of osteoprogenitors in the tissue such as VEGF and HIF. Osteoprogenitor cells and osteoblasts were found arranged around type H endothelial cells, in which they have high oxygen availability. Furthermore, when hypoxia signaling is activated, these endothelial cells respond, increasing their number [29, 30]. These vessels were also found to promote osteogenesis during alveolar bone remodeling in the healing of post-extraction sockets [31].

BIOMATERIALS FOR BONE REGENERATION

Bone defects may result from tooth extraction, trauma, infection, or genetic problems. Procedures for the replacement of pre-existing or missing bone come from the necessity to remake contour, mainly for implant placement. For this purpose, several biomaterials have been proposed in clinical practice.

Biomaterials are organic or inorganic substances for biomedical use, including in regenerative medicine. They can be classified by their interaction with the surrounding tissues after grafting or by their chemical structure/composition. When taking into consideration the interaction with the surrounding tissues, the biomaterials can be:

- *Biocompatible*: after grafting they do not elicit an adverse immune reaction and are safe for the patient.
- *Bioinert*: when placed in the human body they have little to no interaction with the surrounding tissue.
- *Bioresorbable*: upon placement within the human body they dissolve and are slowly replaced by another tissue.

Dentlearn.ir

Bone grafts and bone substitutes may also be osteoinductive, osteoconductive, and osteogenic. Osteoinductive material induces the recruitment, proliferation, and differentiation of undifferentiated stem cells in the grafted area. Osteoconduction is a process in which the material acts as a scaffold and enhances bone formation. The bone graft is osteogenic when it contains vital osteoblasts that induce bone formation.

Regarding their composition, materials can be divided into bone grafts, synthetic hydroxyapatite-based biomaterials, polymers, ceramics, metals, and composites.

BONE GRAFTS

Bone grafts are largely used in clinical practice and can be classified according to their origin. Bone harvested from the patient, often from the iliac crest or the mandibular ramus, is termed autologous bone. Although this is considered the gold standard in bone grafting due to its osteoinductive, osteoconductive, and osteogenic properties and its biocompatibility and biological safety, autologous bone needs a second surgical area for harvesting and presents a high resorption rate. For this reason, bone grafts harvested from the human cadaver (allogeneic) and from animal sources (xenogeneic) have been proposed. Allogenic bone contains bioactive proteins and presents a 3D structure similar to that of the patient's bone. However, potential immune reaction and disease transmission limit its use in clinical practice. Xenogenic bone grafts are deproteinized, and thus are safer than allografts even if they are less bioactive. These materials are largely used for bone regeneration due to their practicality and manageability. Furthermore, their low resorption rate offers dimensional stability to the regenerated area (Figure 1.1.16) [32].

SYNTHETIC HYDROXYAPATITE-BASED BIOMATERIALS

The need for biomaterials that are even more safe, resorbable, and osteoconductive encouraged research into synthetic substances. Hydroxyapatite (HA) is biocompatible and osteoconductive. For this reason, several HA-based synthetic materials, functionalized and loaded with bioactive molecules and therapeutic agents, have been proposed in the orthopedic and dental fields, such as a nanostructured magnesium (Mg)-enriched HA and a vegetable-originated HA [33, 34], with encouraging data (Figures 1.1.17 and 1.1.18).

POLYMERS

Polymers are materials made by long and repeating chains of natural or synthetic molecules [35]. Natural polymers, such as collagen, chitosan, and hyaluronic acid, are bioactive, biodegradable, and present a biomimetic surface. However, due to their physical and mechanical properties, natural polymers have limited application in bone regeneration.

Synthetic polymers, such as polycaprolactone (PCL), polylactide (PDLA, PLLA), and polylactide-co-glycolide (PLGA), are produced by a range of techniques that determine their 3D spatial and molecular arrangement. These characteristics are useful for the design of tailored scaffold for tissue engineering. Otherwise, synthetic polymers have shown reduced bioactivity, low osteoconductivity, and cellular

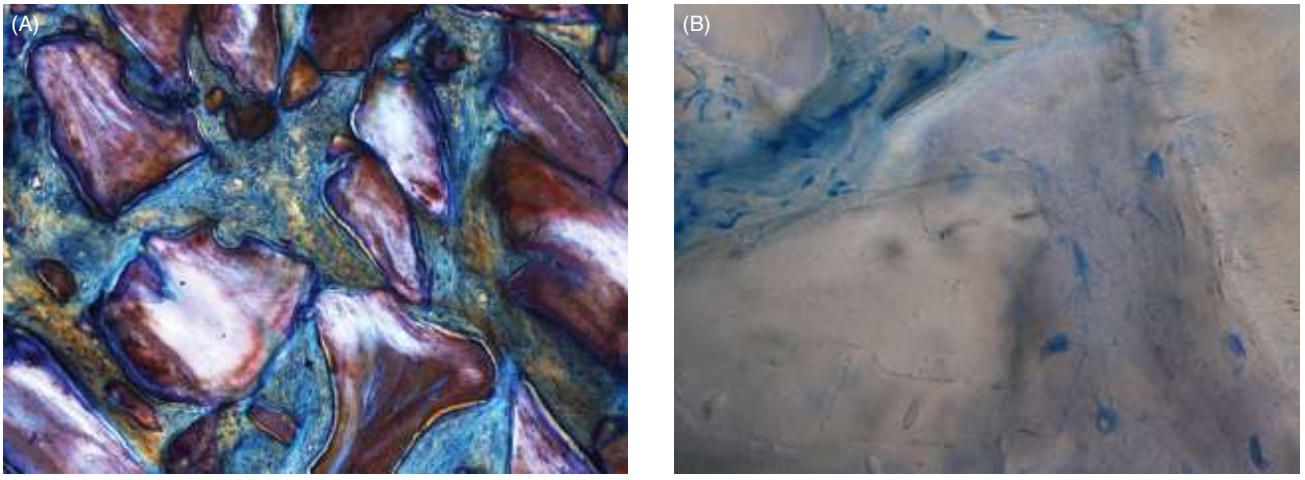

FIGURE 1.1.16 Xenogenic particles at 3 (A) and 9 (B) months of healing in a human extraction socket. The host response after grafting involves the enrollment of inflammatory cells as well as of the overall bone multicellular unit. Despite this activity, the biomaterial remains even after several months of healing. At 3 months, particles appear partially resorbed and embedded in osteoid matrix. At 9 months, remnants of biomaterial are still visible osteointegrated in the newly formed mature bone tissue. Toluidine blue and pyronin yellow staining, photos from an optical microscope (B) equipped with polarized light (A). Total magnification 100× (A), 600× (B).

Dentlearn.ir

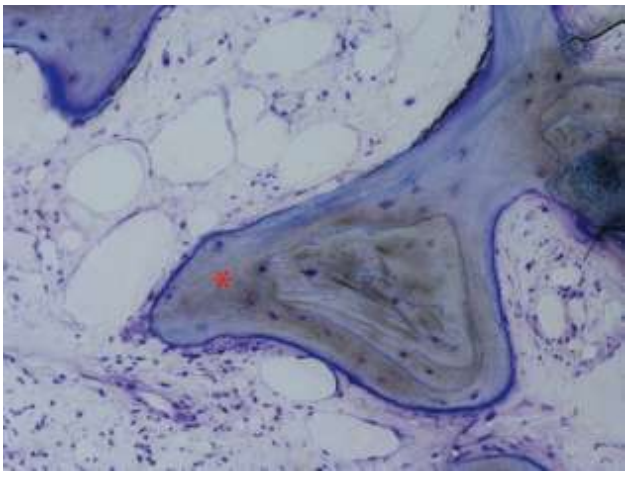

FIGURE 1.1.17 A histological study conducted on humans observed the biocompatibility, osteoconductivity, and resorbable capability of hyaluronic acid (HA)-based biomaterials. In this figure, newly formed bone surrounding the particle of nanostructured magnesium (Mg)-enriched HA (red asterisk) can be observed. This biomaterial presents the partial substitution of HA with Mg for increased solubility. Toluidine blue and pyronin yellow staining, acquisition by scanner at high resolution, total magnification 200×.

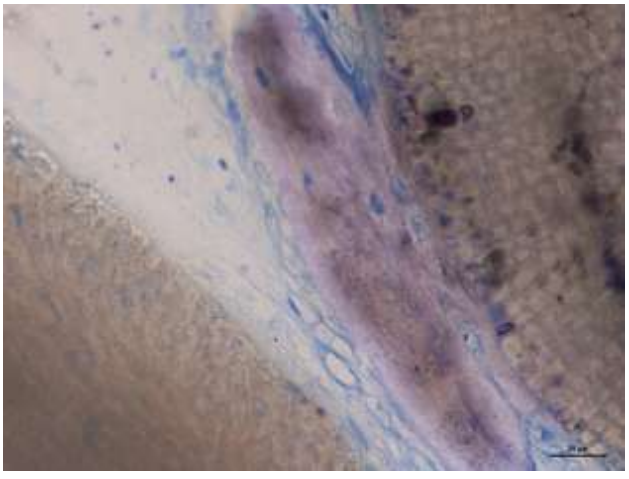

FIGURE 1.1.18 Newly formed bone in tight contact with a particle of vegetable-originated hyaluronic acid. Light microscope, toluidine blue and pyronin yellow staining, total magnification 400×.

adhesion. To overcome these limits, they have been associated with bioceramic particles, forming composite materials with improved biological properties.

BONE MORPHOGENETIC PROTEIN-2

BMPs are growth factors with multiple functions that belong to TGF-β family. Up to 20 different kinds of BMPs have been

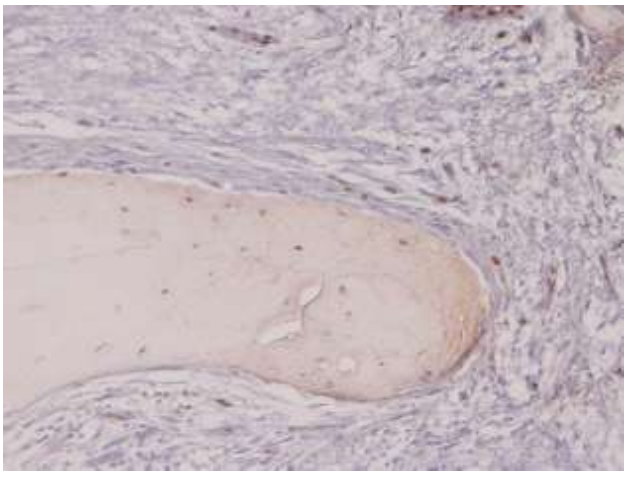

FIGURE 1.1.19 Bone morphogenetic protein (BMP) promotes osteogenesis by inducing the differentiation of mesenchymal cells in osteoblasts, as well as the proliferation of bone mesenchymal stem cells. Immunohistochemical staining with Ab anti-BMP2. Total magnification 200×.

identified and BMP-2 seems to be one of the most important factors in post-natal ossification [36, 37] by inducing the differentiation of mesenchymal cells in osteoblasts, as well as the proliferation of bone mesenchymal stem cells (Figure 1.1.19) [38, 39]. BMP-2 is available for clinical practice through recombinant gene technology [40, 41]. Clinical trials evaluated the association of this protein with metallic and ceramic scaffolds or biomaterials such as absorbable collagen sponges or hydrogels acting as a drug-delivery system, for the treatment of fractures and bone defects, with encouraging results [42]. In dental practice, absorbable collagen sponges embedded with BMP-2 solution have been approved only for sinus augmentation and alveolar ridge preservation by the US Food and Drug Administration, but not by the European Medicines Agency [43, 44].

PLATELET CONCENTRATES

Platelet concentrates consist of autologous blood concentrates containing active molecules, mainly derived from platelets and circulating cells. They include platelet-rich plasma and platelet-rich fibrin and have been introduced in oral surgery because of their potential to stimulate the regeneration of bone tissue as well as oral mucosa. Due to the lack of mechanical properties and space-maintaining activity, these compounds are usually associated with a mixture of particulate autogenous and xenogenous graft when used for vertical and horizontal bone augmentation procedures. However, based on data from clinical and histological studies, the efficacy of these compounds to improve bone regeneration as well as the vitality of the newly formed tissue is still controversial [45–47].

Dentlearn.ir

OSSEOINTEGRATION

Osseointegration is the direct structural and functional connection between live bone tissue and implant, and is considered the primary outcome to determine the success of implants. Molecular and cellular events that occur after the preparation and placement of the implant lead to intimate contact between the newly formed bone and the implant surface. Apposition of the newly formed bone into the implant mimics the pattern of the bone deposited in the healing of bone fractures.

Patient systemic disease or conditions and implant features, including the micro and macro topography of the surface, may affect osseointegration (for factors related to the implant surface, see Table 1.1.1). Conditions such as smoking, non-controlled diabetes, and chemotherapy may impair bone and soft tissue healing or cause loss of peri-implant bone, leading to implant failure [48, 49]. Likewise, periodontally compromised patients are prone to a higher risk of complications and implant loss than periodontally healthy patients [50]. The development of surface treatments aiming at reliable osseointegration and faster healing is a recurrent topic in biomedical research.

PHASES OF OSSEOINTEGRATION

The events of osseointegration are reviewed below as described in animal models [51–53]. The osseointegration phase has a similar pattern in different animal species; however, the healing time changes drastically when considering humans and other animals.

Table 1.1.1 Factors related to the implant surface that can affect osseointegration during implant osseointegration stages.

Healing phases	Implant surface influence on osseointegration
Immediate post-operatory healing and early healing phase	The formation of the titanium oxide, adsorption, adhesion of plasma proteins, and the coagulum suffers the influence of the microtomography and physical-chemical properties of the implant surface. Implant treatment may improve the affinity with the clot, leading to a higher and faster deposition of osteoid matrix.
3–4 days after surgery	Higher number of fibroblast-like cells and an improved tissue metabolism on rough implant surface compared to the machined one. Higher expression of bone-inducing formation and resorption genes was also found when comparing active surfaces with machined implants, while machined implants presented higher expression of pro-inflammatory markers.
1 week after surgery	Fibroblast-like cells observed on machined implants. On active surfaces, cuboid osteoblastic-like cells were observed producing osteoid matrix.
2–4 weeks after surgery	Higher amount of newly formed bone on active titanium surfaces than the machined one.

Immediately after implant installation (0–4 hours) the blood clot forms. Ions (i.e. calcium, Ca) and plasma proteins, like albumin and fibrin, adhere to the implant surface. This protein coat is fundamental to the attachment of inflammatory and tissue-forming cells. After exposure to oxygen in the atmosphere, titanium (Ti) is coated by an oxide layer that plays an important role in biocompatibility and osseointegration [54], since Ca and phosphate (P) ions are gradually included in the Ti oxide layer, forming a 3D structure composed of Ca, P, and oxygen (O) ions, in which the concentration decreases as the Ti ions increase, thus supporting the theory of ingrowth of bone into implant surface nanostructures [55].

During the first days after surgery, the blood clot is progressively organized in granulation tissue through the angiogenesis that comes from the pristine bone. A layer of fibroblast-like cells encircles the implant and elongates through its surface [51–53].

One week after surgery, a thin layer of osteoid matrix begins to be deposited on the implant surface and in the perivascular area (angiogenesis–osteogenesis coupling; Figures 1.1.20 and 1.1.21). Genes related to extracellular matrix formation and organization of collagen fibrils are found to be upregulated in cells in the implant surface [56].

Two weeks after surgery, immature bone is found along the implant surface advancing from the pristine bone. Progressively intramembranous ossification occurs and the provisional matrix with lining osteoblasts is remodeled into lamellar bone. Early signs of bone remodeling appear in the osteons, as a result of osteoclast activity (Figures 1.1.22–1.1.25).

To summarize:

- The formation of bone in the implant surface is a consequence of contact with the old pristine bone, yet the deposition of new bone results from the differentiation of mesenchymal cells into osteoblastic lineage cells.

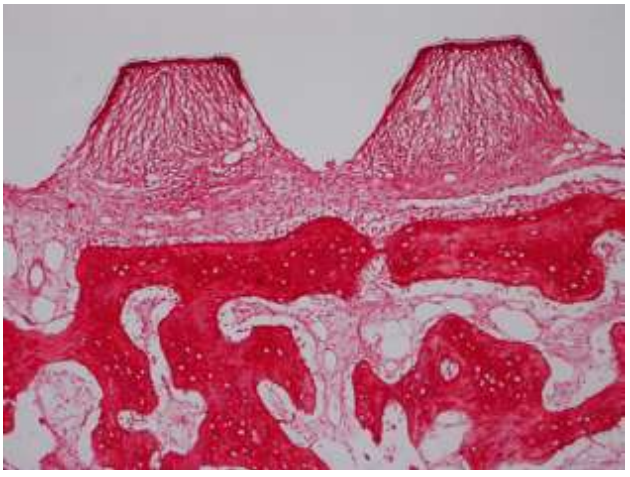

FIGURE 1.1.20 Bone at the implant interface 10 days after surgery (in a dog model). Sample obtained with fracture technique, sirius red staining for collagen fibers, total magnification 100×.

Dentlearn.ir

FIGURE 1.1.21 Bone around an implant thread 7 days after installation (rat). Light micrography, decalcified sample, hematoxylin and eosin staining, total magnification 100×.

FIGURE 1.1.22 Bone around titanium implant threads 90 days after installation (rat). Light micrography, hematoxylin and eosin staining, total magnification 100×.

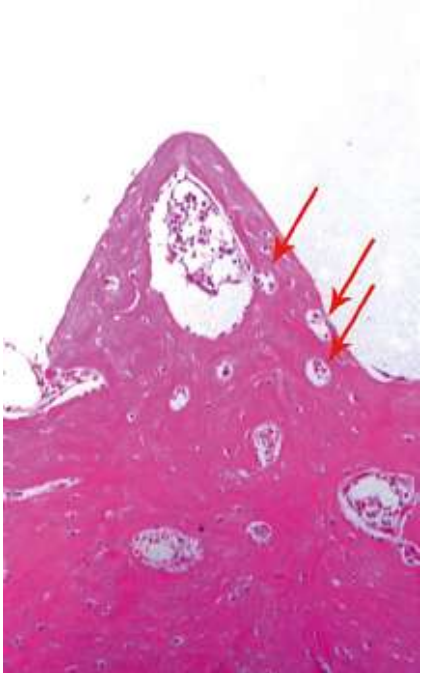

FIGURE 1.1.23 Single implant thread. The arrows indicate blood vessels inside the thread. Light micrography, hematoxylin and eosin staining, total magnification 200×.

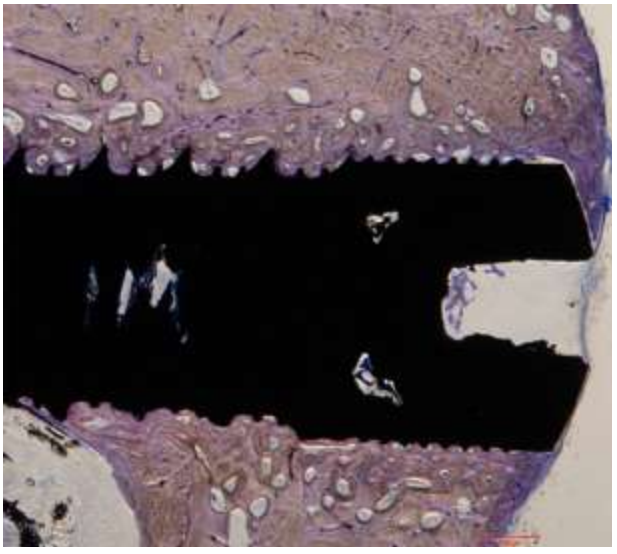

FIGURE 1.1.24 Two weeks after surgery (dog model). Immature bone along the implant surface advancing from the pristine bone. Toluidine blue and pyronin yellow staining, acquisition by scanner at high resolution, total magnification 40×.

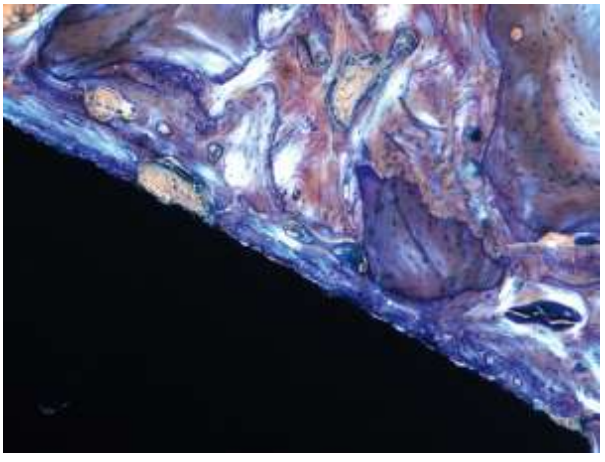

FIGURE 1.1.25 Intimate and functional contact established by the newly formed bone with the implant surface. Toluidine blue and pyronin yellow staining, acquisition by scanner at high resolution, total magnification 100×.

- Properties of the implant surface influence the cellular behavior.
- Treated and rough surfaces appear to osseointegrate faster and at a higher rate by the increased contact with osteogenic cells.
- Ti ions are released from the implant and are incorporated by the bone.

Table 1.1.1 reviews the main factors related to the implant surface that could affect osseointegration during different healing phases.

Dentlearn.ir

BONE LOADING

Considering its biomechanical properties, bone is a natural composite material characterized by viscoelastic features related to strain rate. Bone responds to daily repetitive loads by tissue remodeling in order to counter fatigue, which can lead to a loss of strength and stiffness. When the microdamage occurs at a slow rate, bone has an opportunity to repair, and the response is referred to as "targeted remodeling." Microcracking appears in the interstitial bone tissue in the early stages of fatigue as a result of damage accumulation [57]. It manifests itself as a discontinuity in the calcium-rich matrix, reflecting fissures and fractures in the mineral component, and may become a macrocrack under continued cyclic fatigue testing [58]. Osteons potentially act as barriers to prevent coalescence of the microcracks in order to avoid failure. Indeed, dispersed microcracks exhibit a higher energy absorption potential compared to coalesced microcracks.

The mechanical behavior of compact bone is related to its hierarchical microstructure in terms of the content and direction of fibers and osteons that grow along the loading axis; therefore, the failure pattern changes according to load direction. In experimentally tested bovine femurs, the length and density of microcracks were larger in specimens with loads applied perpendicularly to osteon direction than in those with a longitudinal load, which showed gradual growth until failure. Microcracking serves as a toughening mechanism, but if it is over a critical value it weakens the specimen, leading to failure. When a certain yield of loading rate is reached or an excessive repetitive cycle of load is applied, type I collagen tends to become brittle, thus reducing the energy absorption potential until a critical point [59]. Primary osteons that are more mineralized and less collagen enriched develop more dispersed microcracks than secondary osteons resulting from bone remodeling. The strength, energy absorption, and modulus of elasticity seem to decrease with the percentage area of osteons [60].

At a cellular level, microdamages act as a stimulus for bone remodeling by inducing osteocytes to a programmed death, similar to what happens in the case of hypoxia, immobilization, decrease in estrogen, and release of interleukin (IL)-1 or TNF-α [13, 61]. It has been suggested that under dynamic loading, bone matrix deformation produces an interstitial fluid flow in the lacuno-canalicular system, thus generating shear stress capable of activating osteocytes (Figure 1.1.26) [62]. These cells trigger bone modeling and remodeling, depending on the need to adapt to strain and/or to damage [63].

Alveolar bone presents a faster remodeling rate compared with other bone due to the large stimulation at both cortical (minor changes) and trabecular (major changes) aspects in varying directions. Typically the mandible modifies the orientation, thickness, connectivity, and spacing of its trabeculae according to a plate-like architecture.

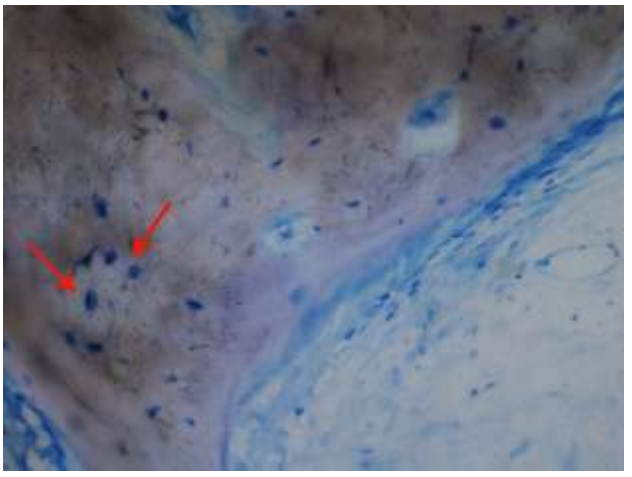

FIGURE 1.1.26 Osteocytes entrapped in mature bone (red arrows). Interstitial fluid flow due to bone matrix deformation generates shear stress capable of activating osteocytes that guide a "targeted remodeling." Toluidine blue and pyronin yellow staining, acquisition by scanner at high resolution, total magnification 200×.

THRESHOLD STRAIN

Bone cells accommodate to routine dynamic loading and drive structural changes only when abnormal stress (applied force) and strain (related deformation) are present. Occlusal forces on oral endosseous implants supporting a prosthesis create a certain level of stress depending on the magnitude of load, cycle number, direction, and frequency, thus affecting the elasticity of bone. In the case of high stress levels, bone cannot adapt and bone remodeling shifts toward peri-implant bone resorption; the more peri-implantar bone loss there is, the more strain occurs in the remaining bone [64]. The threshold is influenced by many variables, such as type of prosthesis, implant design and position, individual genetic profile, and so on [65, 66], thus resulting in the near impossibility of defining a value applicable to all patients. However, it has been hypothesized that osseous density increases after implant placement in order to face the additional stress imposed on the dental prosthesis, but further micro-computer tomography (CT) studies should be performed to verify this concept [58].

When an implant is placed, for several months after surgery bone healing next to the implant surface and to the native damaged bone surface determines a complicated environment, with some weak points localized at the interfacial cement lines between the implant surface and bone for Ti and HA. Since cement lines in normal bone have been identified as weak interfaces, a cement line at a bone–biomaterial interface may also be a weak point. In the case of excessive interfacial micromotion early after implantation, local bone healing is altered and a fibrous tissue interface appears instead of osseointegration; both poor osseointegration and a weak binding force can impair the longevity of an

Dentlearn.ir

implant [67]. Bone tries to adapt to the new loading conditions with different behavior according to the tissue structure (e.g. woven bone, Haversian bone, plexiform bone) and the response modifies with time, together with the environmental modification of the interface [68, 69]. Considering the bone surrounding an implant, the physical properties of the healing bone seem to depend on distance from the implant interface, reflecting the variation of the tissue microstructure. Studies conducted in animal models showed that the elasticity of healing bone, which determines stress and strain distribution around the implant, seems to be low at the interface and to increase at a distance of approximately 150 μm from the implant surface, with a quite wide range according to the histological features [70].

REFERENCES

1. Caballé-Serrano J, Abdeslam-Mohamed Y, Munar-Frau A et al. Adsorption and release kinetics of growth factors on barrier membranes for guided tissue/bone regeneration: A systematic review. *Arch Oral Biol.* 2019;100:57–68.
2. Dallas SL, Prideaux M, Bonewald OF. The osteocyte: an endocrine cell … and more. *Endocr Rev.* 2013;34(5):658–90.
3 de Calais CD, Bordin D, Piattelli A et al. Lateral static overload on immediately restored implants decreases the osteocyte index in peri-implant bone: A secondary analysis of a pre-clinical study in dogs. *Clin Oral Investig.* 2021;25(5):3297–303.
4 Wu V, van Oers RFM, Schulten EAJM et al. Osteocyte morphology and orientation in relation to strain in the jaw bone. *Int J Oral Sci.* 2018;10(1):2.
5. Boyle WJ, Simonet WS, Lacey DL. Osteoclast differentiation and activation. *Nature.* 2003;423(6937):337–42.
6. Goodman SB, Jiranek W, Petrow E, Yasko AW. The effects of medications on bone. *J Am Acad Orthop Surg.* 2007:15(8):450–60.
7. Guiglia R, Di Fede O, Lo Russo L et al. Osteoporosis, jawbones and periodontal disease. *Med Oral Patol Oral Cir Bucal.* 2013;18(1):e93–9.
8. Jee WSS. The skeletal tissues. In L Weiss (ed.), *Histology: cell and tissue biology*, 5th edn. New York: Elsevier Biomedical; 1983, 200–55.
9. Rho JY, Kuhn-Spearing L, Zioupos P. Mechanical properties and the hierarchical structure of bone. *Med Eng Phys.* 1998;20(2):92–102.
10. Patterson-Kane J, Firth E. Tendon, ligament, bone, and cartilage: Anatomy, physiology, and adaptations to exercise and training. In C McGowan, DR Hodgson, K McKeever (eds.), *The Athletic Horse: Principles and Practice of Equine Sports Medicine*, 2nd edn. New York: Elsevier; 2014, 202–42.
11. Teitelbaum SL, Ross FP. Genetic regulation of osteoclast development and function. *Nat Rev Genet.* 2003;4:638–49.
12. Verborgt O, Gibson GJ, Schaffler MB. Loss of osteocyte integrity in association with microdamage and bone remodeling after fatigue in vivo. *J Bone Miner Res.* 2000;15(1):60–67.
13. Kennedy OD, Herman BC, Laudier DM et al. Activation of resorption in fatigue-loaded bone involves both apoptosis and active pro-osteoclastogenic signaling by distinct osteocyte populations. *Bone.* 2012;50(5):1115–22.
14. Kennedy OD, Laudier DM, Majeska RJ et al. Osteocyte apoptosis is required for production of osteoclastogenic signals following bone fatigue in vivo. *Bone.* 2014;64:132–7.
15. Noronha Oliveira M, Schunemann WVH, Mathew MT et al. Can degradation products released from dental implants affect peri-implant tissues? *J Periodontal Res.* 2018;53(1):1–11.
16. Bosshardt DD, Chappuis V, Buser D. Osseointegration of titanium, titanium alloy and zirconia dental implants: Current knowledge and open questions. *Periodontol* 2000. 2017;73(1):22–40.
17. Schropp L, Wenzel A, Kostopoulos L, Karring T. Bone healing and soft tissue contour changes following single-tooth extraction: A clinical and radiographic 12-month prospective study. *Int J Periodontics Restorative Dent.* 2003;23(4):313–23.
18. Trombelli L, Farina R, Marzola A et al. Modeling and remodeling of human extraction sockets. *J Clin Periodontol.* 2008;35(7):630–39.
19. Guo S, DiPietro LA. Factors affecting wound healing. *J Dent Res.* 2010;89(3):219–29.
20. Chakkalakal DA. Alcohol-induced bone loss and deficient bone repair. *Alcohol Clin Exp Res.* 2005;29(12):2077–90.
21. Matheus HR, Ervolino E, Faleiros PL et al. Cisplatin chemotherapy impairs the peri-implant bone repair around titanium implants: An in vivo study in rats. *J Clin Periodontol.* 2018;45(2):241–52.
22. de Almeida JM, Ervolino E, Gusman DJR et al. Antineoplastic agents aggravate the damages caused by nicotine on the peri-implant bone: An in vivo histomorphometric and immunohistochemical study in rats. *Clin Oral Investig.* 2022;26(2):1477–89.
23. Murray CE, Coleman CM. Impact of diabetes mellitus on bone health. *Int J Mol Sci.* 2019;20(19):4873.
24. Patan S. Vasculogenesis and angiogenesis. *Cancer Treat Res.* 2004;117:3–32.
25. Hankenson KD, Dishowitz M, Gray C, Schenker M. Angiogenesis in bone regeneration. *Injury.* 2011;42(6):556–61.
26. Al Subaie AE, Eimar H, Abdallah MN et al. Anti-VEGFs hinder bone healing and implant osseointegration in rat tibiae. *J Clin Periodontol.* 2015;42(7):688–96.
27. Hu K, Olsen BR. Osteoblast-derived VEGF regulates osteoblast differentiation and bone formation during bone repair. *J Clin Investig* 2011;126(2):509–26.
28. Schorn L, Sproll C, Ommerborn M et al. Vertical bone regeneration using rhBMP-2 and VEGF. *Head Face Med.* 2017;13(1):11.
29. Kusumbe AP, Ramasamy SK, Adams RH. Coupling of angiogenesis and osteogenesis by a specific vessel subtype in bone. *Nature.* 2014;507(7492):323–8.
30. Ramasamy SK, Kusumbe AP, Wang L, Adams RH. Endothelial Notch activity promotes angiogenesis and osteogenesis in bone. *Nature.* 2014;507(7492):376–80.
31. Yan ZQ, Wang XK, Zhou Y et al. H-type blood vessels participate in alveolar bone remodeling during murine tooth extraction healing. *Oral Dis.* 2020;26(5):998–1009.

Dentlearn.ir

32. Jayakumar P, Di Silvio L. Cellular response to biocomposites. In L. Ambrosio (ed.), *Biomedical composites*. Boca Raton, FL: CRC Press; 2009;354–84.

33. Garlini G, Redemagni M, Canciani E, Dellavia C. Maxillary sinus floor augmentation with vegetal hydroxyapatite "versus" demineralized bovine bone: a randomized clinical study with a split-mouth design. *J Dental Implant.* 2014;4;118–25.

34. Canullo L, Pellegrini G, Canciani E et al. Alveolar socket preservation technique: Effect of biomaterial on bone regenerative pattern. *Ann Anat.* 2016;206:73–9.

35. Donnaloja F, Jacchetti E, Soncini M, Raimondi MT. Natural and synthetic polymers for bone scaffolds optimization. *Polymers (Basel).* 2020;12(4):905.

36. Milani S, Dal Pozzo L, Rasperini G et al. Deproteinized bovine bone remodeling pattern in alveolar socket: A clinical immunohistological evaluation. *Clin Oral Implants Res.* 2016;27(3):295–302.

37. Ren, Q, Cai M, Zhang K et al. Effects of bone morphogenetic protein-2 (BMP-2) and vascular endothelial growth factor (VEGF) release from polylactide-poly (ethylene glycol)-polylactide (PELA) microcapsule-based scaffolds on bone. *Braz J Med Biol Res.* 2018;51:2.

38. Hu JJ, Liu YW, He MY et al. Proteomic analysis on effectors involved in BMP-2-induced osteogenic differentiation of beagle bone marrow mesenchymal stem cells. *Proteome Sci.* 2014;12(1);13.

39. Qianjun W, Xiaomei X, Zhiqiang K et al. Paeonol prevents IL-1β-induced inflammatory response and degradation of type II collagen in human primary chondrocytes. *Artif Cells Nanomed Biotechnol* 2019;47(1):2139–45.

40. Riley EH, Lane JM, Urist MR et al. Bone morphogenetic protein-2: Biology and applications. *Clin Orthop Relat Res.* 1996;Mar(324):39–46.

41. Chen D, Zhao M, Mundy GR. Bone morphogenetic proteins. *Growth Factors.* 2004;22(4):233–41.

42. Agrawal V, Sinha M. A review on carrier systems for bone morphogenetic protein-2. *J Biomed Mater Res B Appl Biomater.* 2017;105(4):904–25.

43. Poon B, Kha T, Tran S, Dass CR. Bone morphogenetic protein-2 and bone therapy: Successes and pitfalls. *J Pharm Pharmacol.* 2016;68(2):139–47.

44. Sanz M, Dahlin C, Apatzidou D et al. Biomaterials and regenerative technologies used in bone regeneration in the craniomaxillofacial region: Consensus report of group 2 of the 15th European Workshop on Periodontology on Bone Regeneration. *J Clin Periodontol.* 2019;46(21):82–91.

45. Miron RJ, Fujioka-Kobayashi M, Bishara M et al. Platelet-rich fibrin and soft tissue wound healing: A systematic review. *Tissue Eng Part B Rev.* 2017;23(1):83–99.

46. Miron RJ, Moraschini V, Fujioka-Kobayashi M et al. Use of platelet-rich fibrin for the treatment of periodontal intrabony defects: A systematic review and meta-analysis. *Clin Oral Investig.* 2021;25(5):2461–78.

47. Shah R, Gowda TM, Thomas R, Kumar T. Second generation liquid platelet concentrates: A literature review. *Curr Pharm Biotechnol.* 2021;Aug 22. doi: 10.2174/1389201022666210823102618.

48. Diz P, Scully C, Sanz M Dental implants in the medically compromised patient. *J Dent.* 2013;41:195–206.

49. Turri A, Rossetti PH, Canullo L et al. Prevalence of peri-implantitis in medically compromised patients and smokers: A systematic review. *Int J Oral Maxillofac Implants.* 2016;31:111–18.

50. Chrcanovic BR, Albrektsson T, Wennerberg A. Periodontally compromised vs. periodontally healthy patients and dental implants: A systematic review and meta-analysis. *J Dent.* 2014;42:1509–27.

51. Abrahamsson I, Berglundh T, Linder E et al. Early bone formation adjacent to rough and turned endosseous implant surfaces: An experimental study in the dog. *Clin Oral Implants Res.* 2004;15:381–92.

52. Burgos PM, Rasmusson L, Meirelles L et al. Early bone tissue responses to turned and oxidized implants in the rabbit tibia. *Clin Implant Dent Relat Res.* 2008;10:181–90.

53. Orsini E, Salgarello S, Martini D et al. Early healing events around titanium implant devices with different surface microtopography: A pilot study in an in vivo rabbit model. *Sci World J.* 2012;2012:349842.

54. Chung CJ, Su RT, Chu HJ et al. Plasma electrolytic oxidation of titanium and improvement in osseointegration. *J Biomed Mater Res B Appl Biomater.* 2013;101:1023–30.

55. Grandfield K, Gustafsson S, Palmquist A. Where bone meets implant: The characterization of nano-osseointegration. *Nanoscale.* 2013;5:4302–8.

56. Thalji GN, Nares S, Cooper LF. Early molecular assessment of osseointegration in humans. *Clin Oral Implants Res.* 2014;25:1273–85.

57. Liu X, Li W, Cai J et al. Spatiotemporal characterization of microdamage accumulation and its targeted remodeling mechanisms in diabetic fatigued bone. *FASEB J.* 2020;34(2):2579–94.

58. Greenstein G, Cavallaro J, Tarnow D. Assessing bone's adaptive capacity around dental implants: A literature review. *J Am Dent Assoc.* 2013;144:362–8.

59. Hao L, Rui-Xin L, Biao H et al. Effect of athletic fatigue damage and the associated bone targeted remodeling in the rat ulna. *Biomed Eng Online.* 2017;16(1):99.

60. Zhang W, Tekalur SA, Baumann M et al. The effects of damage accumulation on the tensile strength and toughness of compact bovine bone. *J Biomech.* 2013;46:964–72.

61. Rochefort GY, Benhamou CL. Osteocytes are not only mechanoreceptive cells. *Int J Numer Method Biomed Eng.* 2013;29:1082–8.

62. Heino TJ, Kurata K, Higaki H et al. Evidence for the role of osteocytes in the initiation of targeted remodeling. *Technol Health Care.* 2009;17:49–56.

63. Huiskes R, Ruimerman R, van Lenthe GH et al. Effects of mechanical forces on maintenance and adaptation of form in trabecular bone. *Nature.* 2000;405:704–6.

64. Pérez-Pevida E, Chávarri-Prado D, Diéguez-Pereira M et al. Consequences of peri-implant bone loss in the occlusal load transfer to the supporting bone in terms of magnitude of stress, strain, and stress distribution: A finite element analysis. *Biomed Res Int.* 2021;2021:3087071.

Dentlearn.ir

65. Haroun F, Ozan O. Evaluation of stresses on implant, bone, and restorative materials caused by different opposing arch materials in hybrid prosthetic restorations using the all-on-4 technique. *Materials (Basel).* 2021;14(15):4308.

66. Al-Omari FA, Nagasawa M, Suliman M et al. Peri-implant bone alterations under the influence of abutment screw preload stress: A preclinical vivo study. *Clin Oral Implants Res.* 2020;31(12):1232–42.

67. Hou J, Xiao Z, Liu Z et al. An amorphous peri-implant ligament with combined osteointegration and energy-dissipation. *Adv Mater.* 2021;33(45):e2103727.

68. Brand RA, Stanford CM, Swan CC. How do tissues respond and adapt to stresses around a prosthesis? A primer on finite element stress analysis for orthopaedic surgeons. *Iowa Orthop J.* 2003;23:13–22.

69. Brunski JB. in vivo bone response to biomechanical loading at the bone/dental-implant interface. *Adv Dent Res.* 1999;13:99–119.

70. Chang MC, Ko CC, Liu CC et al. Elasticity of alveolar bone near dental implant-bone interfaces after one month's healing. *J Biomech.* 2003;36:1209–14.

Dentlearn.ir

CHAPTER 1.2

Wound Healing

Andrea Pilloni

Department of Oral and Maxillofacial Sciences, Section of Periodontics, Sapienza University of Rome, Rome, Italy

"A wound is an injury, usually involving division of tissue or rupture of the integument or mucous membrane, due to external violence or some mechanical agency rather than disease" [1]. When reading this definition, the reader might rather be impressed by the fact that a wound would normally imply both the concepts of healing and the outcome of a successful cure. However, a wound should be considered many things, but not a disease.

The goal of this chapter is to present an overview of the wound healing process, deepening knowledge in the different patterns of the healing of oral tissues, from a clinical and mostly biological perspective, which definitely make them special and unique when compared to most other tissues of the human body. Moreover, a deep understanding of the intrinsic mechanisms underlying oral soft tissue repair seems more and more to become a useful *passepartout* to open up new scenarios into clinical research aiming at improving the wound healing process in other tissues, toward scarless healing.

OVERVIEW OF THE WOUND HEALING PROCESS

Wound repair represents a controlled sequence of events involving a complex network of cell types and molecular signaling pathways. It is well known that wound healing occurs in four different but partially overlapping phases: hemostasis, inflammation, proliferation, and remodeling.

PHASES OF WOUND HEALING

Hemostasis

Tissue repair mechanisms are initially triggered by damage to the endothelium of the blood vessels exposing extracellular matrix (ECM). So, intrinsic and extrinsic coagulation pathways are activated to prevent blood loss. Local blood vessels constrict and platelets secrete adhesive proteins to form a plug, which is then reinforced by fibrin polymerization, forming a clot at the injury site that provides a temporary seal to the wound, avoiding bacterial infection. The fibrin clot has two important functions in the subsequent phases of the repair process: (i) it is a temporary scaffold for the cell migration into the wound site; and (ii) it is a reserve of growth factors [2, 3].

Inflammation

The inflammatory phase (which reaches its peak at 24–48 h post wounding and lasts for several days) overlaps considerably with initial hemostasis. This phase is aimed at removing debris from the injured site and prevents infection by pathogens. The initial platelet adhesion and degranulation activate a cascade of inflammatory cytokines that attract immune and other cells to the wound site [3, 4]. Neutrophils, monocytes, macrophages, mast cells, and T cells enter the wound bed and drive the immune response against potential pathogenic invaders.

Both infiltrating immune cells and resident cells produce and respond to cytokines. Cytokines have been classified as pro- or anti-inflammatory, or pro- or anti-fibrotic. The inflammatory cytokines released during this phase increase vascular permeability, with a consequent transudate leakage from the capillaries, clinically observed as the classical manifestations of inflammation (redness, warmth, and swelling). Already 4 h after injury, removal of debris starts with resident cells (keratinocytes, fibroblasts, Langerhans cells, and resident macrophages) via phagocytosis.

Neutrophils (polymorphonuclear neutrophils or PMNs), the first inflammatory cells to arrive, play a crucial role in fighting microbial invasion via degranulation and phagocytosis. PMNs secrete matrix metalloproteinases (MMPs), helping to break down ECM components to debride the wound of damaged tissue and facilitate cell migration into the wound site [5]. Furthermore, they release cytokines that recruit monocytes and endothelial cells and stimulate the proliferation of fibroblasts and keratinocytes to initiate re-epithelialization. PMNs are eliminated by apoptosis and phagocytosis when the

Essential Techniques of Alveolar Bone Augmentation in Implant Dentistry: A Surgical Manual, Second Edition. Edited by Len Tolstunov.
© 2023 John Wiley & Sons, Inc. Published 2023 by John Wiley & Sons, Inc.
Companion website: www.wiley.com/go/tolstunov/essential

Dentlearn.ir

wound is cleared of pathogens. In chronic wounds these cells may persist, causing tissue damage by continuous production of MMPs.

Upon arrival, monocytes mature into macrophages, which contribute to phagocytosis of debris and replace the PMN population. This takes approximately 2–4 days after wounding, and macrophages are the predominant cells. Initially the M1 phenotype predominates (which releases pro-inflammatory cytokines and growth factors), and in the later stages the M2 phenotype increases (with an anti-inflammatory and pro-fibrotic function).

Macrophages are a critical source of cytokines such as interleukins 1 and 6, fibroblast growth factor (FGF), epidermal growth factor (EGF), transforming growth factor-β (TGF-β), and platelet-derived growth factor (PDGF) [6]. Signaling by these cytokines stimulates the migration of keratinocytes, fibroblasts, and endothelial precursor cells to initiate the process of proliferative healing.

Proliferation

The aim of the proliferative phase is to reduce the injured area by contraction and fibroplasia, establishing a viable epithelial barrier to activate keratinocytes. This is possible through three closely interconnected events: angiogenesis, re-epithelialization, and granulation tissue formation [3].

The events related to this phase start within the first 48h/4 days (prior to completing the resolution of the inflammation) and continue for about 2 weeks [7].

Angiogenesis Stagnation of the blood flow in the wounded area leads to hypoxia and triggers the angiogenic response. Cells in the hypoxic wound bed stimulate endothelial cell proliferation and migration by the release of pro-angiogenic factors, like hypoxia-inducible factor 1 (HIF-1) and VEGF, which are responsible for the formation of blood vessels necessary for nutrition of the granulation tissue.

Re-epithelialization Re-epithelialization, which begins within hours of injury, is of fundamental importance to restoring the barrier function of the tissues and preventing infections, and is mediated mainly by keratinocytes.

Granulation Tissue Formation The provisional ECM formed by the platelet plug is replaced with new and highly vascularized stroma (granular tissue). The high vascularity of this newly formed tissue increases the further recruitment of immune cells and the oxygenation necessary for collagen crosslinking and wound maturation. The dense fibronectin network at the wound site is essential for the formation of a mature collagen I/III matrix. During the initial stages of wound healing, collagen III is the major collagen type produced, followed by the secretion of collagen I to increase tissue strength and elasticity. Moreover, macrophages provide a continued source of numerous cytokines and growth factors to recruit and activate fibroblasts. Fibroblasts are also attracted to the wound by factors including TGF-β and PDGF from inflammatory cells and platelets. The fibroblasts' transition to an activated myofibroblast phenotype allows the process of wound contraction by extending numerous pseudopods, which attach to the ECM network and are then retracted to promote wound edge approximation.

Remodeling

The maturational or remodeling phase starts around week 3 and can last up to 12 months, resulting in scar tissue that may gradually resolve. The ECM molecules are reorganized and crosslinked by wound fibroblasts, thus gradually strengthening the network of fibers over time.

Macrophages (M2 phenotype) secrete growth factors, MMPs, and tissue inhibitors of metalloproteinases (TIMPs) to stimulate myofibroblast-mediated remodeling of the ECM. The excess collagen is degraded, and the previously highly cellular tissue loses most of its cells as the remaining inflammatory cells and many fibroblasts and endothelial cells undergo apoptosis, leaving a smaller number of fibroblasts and blood vessels. Wound contraction reaches its peak around the third week and occurs to a much greater extent in secondary healing than in primary healing (see the next section).

In this phase, the MMPs/TIMPs balance and myofibroblast differentiation plays an essential role in the final wound repair response.

WHICH FACTORS CAN LEAD TO IMPAIRED HEALING?

The main local factors that can affect the repair process are tissue edema, hypoxia, infection, maceration, and dehydration. Microbial post-surgical infection inhibits the normal tissue healing process [8]. Bacterial biofilm can reduce the oxygen and pH in the wound environments and create a physical barrier, avoiding cell migration. This is an essential aspect, especially with respect to the oral cavity as a reservoir of hundreds of different bacterial species. General factors are related to systemic illness, such as diabetes, and chronic conditions such as malnutrition or habits like smoking can be responsible for bacterial colonization, ischemia, hypoxia, altered cellular response, and collagen synthesis defects.

MAIN TYPES OF WOUND HEALING

Primary intention healing refers to when the wound is properly closed with sutures with no apparent distance of tissue margins. The healing is generally fast and uneventful (Figures 1.2.1 and 1.2.2).

Secondary intention healing is when a wound that cannot be sutured is left with a certain amount of tissue loss.

Dentlearn.ir

FIGURE 1.2.1 Primary intention healing wounds on papilla and attached gingiva.

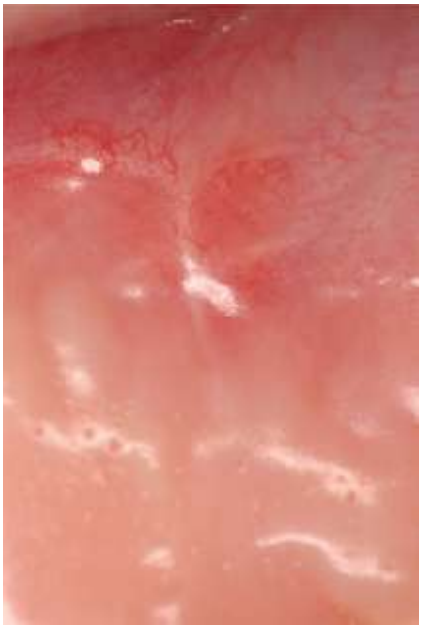

FIGURE 1.2.2 Same area of vertical incision as in Figure 1.2.1 at 20 days.

It is typically seen in the case of donor sites, such as the palate, when tissue grafts are harvested for mucogingival procedures (Figure 1.2.3).

ORAL SOFT TISSUE WOUND HEALING

Most researchers commonly considered that oral wounds can heal better and faster than other wounds such as dermal ones (Figures 1.2.1–1.2.4). When compared to cutaneous healing, mucosal wounds seem to proceed through the same stages as mentioned above [1], although an accelerated healing pattern of mucosal wounds is clearly demonstrated [9, 10]. Moreover, mucosal wounds also generally heal with minimal scar formation and hypertrophic scars are rarely seen in the oral cavity [11]. Until recently, it was reasonable to assume that the basic cell biological and molecular biological events of wound

FIGURE 1.2.3 Palate heals by secondary intention after harvesting of a free gingival graft.

healing would follow the same principles as at the tooth–gingiva interphase, at least at the supracrestal locations [12].

ORAL SOFT TISSUE SPECIAL FEATURES: INTRINSIC DIFFERENCES BETWEEN ORAL MUCOSA AND SKIN

Healthy skin and oral mucosa share many features, but also present several intrinsic histological differences:

- The epidermis is entirely keratinized. Within the oral cavity, there is a difference between the keratinized epithelium of the hard palate and of gingiva (with a major function in resisting mechanical forces during mastication) versus the non-keratinized epithelium of the buccal mucosa that has the flexibility to stretch and withstand compression [13].
- The oral epithelium is generally thicker compared to skin. In particular, palatal and buccal gingiva presents a higher proliferation rate in the basal lamina and more cell layers compared to skin [14].
- More blood vessels are present in the oral mucosa compared to skin [10, 15].
- ECM in oral mucosa contains more elastin compared to skin, hard palate, or gingiva [16, 17].

From a biomolecular standpoint, several studies have clearly demonstrated that the differences between skin and oral mucosa can clearly be seen at only 24 h after wounding and explain the intrinsic and peculiar potential of oral wounds to heal without the necessary tools for the inflammatory response typical in skin wounds (Table 1.2.1) [10, 18].

SCAR AND SCARLESS WOUND HEALING IN ORAL SOFT TISSUES

The oral cavity is lined with what is generally called the "oral mucosa," which, in turn, is made up of the following three types or zones:

Dentlearn.ir

Table 1.2.1 Differences between oral mucosa and skin wound repair.

Re-epithelialization at 24 h	40%	100%
Inflammatory infiltrates		
MPO (U/mg protein) at 24 h	2.82 ± 0.2	1.26 ± 0.2
Mφ (HPF) at 72h	10.8 ± 0.3	6.7 ± 0.4
T cells (HPF) at day 7	15.1 ± 1.5	5.6 ± 0.3
Cytokine/chemokine		
IL-6	↑↑	↑
IL-a	↑↑	↑
IL-1β	↑↑	↑
TNF-α	↑↑	↑
TGF-β1	↑↑	↑
TGF-β3	↑	↑
KC	↑↑	↑
Angiogenesis		
Vessel density compared to normal tissue at day 5 (fold increase)	11.5	3.4
VEGF	↑↑	No marked change
Collagen fibril diameter in wound	Decreased	No marked change

Source: Chen et al. 2010 [19].

- The *masticatory mucosa*, comprising the covering of the hard palate and the gingiva, i.e. the part of the oral mucosa that covers the alveolar processes of both mandible and maxilla and surrounds the cervical part of the teeth.
- The *specialized mucosa*, lining the dorsum of the tongue.
- The *oral mucous membrane*, lining the rest of the oral cavity.

Differential outcomes in terms of scarring between oral mucosa and attached gingiva are a common finding in clinical practice, with gingival repair resulting in a clinically scarless repair (Figure 1.2.4) [20–22]. Larjava et al. [22] reported that palatal wounds heal with minimal scars and rapid resolution of inflammation, showing the main changes in gene expression during the first day after wounding. In 2017, a human comparative study, analyzing biopsies obtained 24 h after injury, showed how, in oral mucosa, characterized by partially fibrotic outcome during repair, the activation of autophagy determined an increase in alpha-smooth muscle actin (αSMA) and collagen Ia1 production.

Conversely, wound healing did not stimulate autophagy in buccal-attached gingiva, and subsequently no increase in myofibroblast differentiation and collagen deposition could be seen, thus justifying the scarless outcome [22]. The same tendency was observed for palatal tissue, showing the faster clinical wound healing response [23].

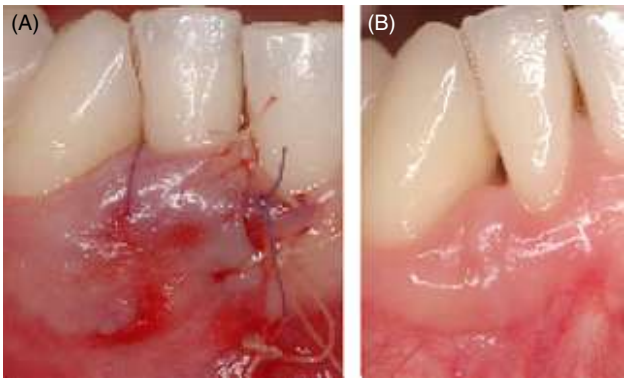

FIGURE 1.2.4 (A) Periodontal flap with vertical releasing incision sutured in place. (B) Scarless healing of the same area at 1 year post op.

EARLY WOUND HEALING SCORE: A METHOD TO ASSESS PRIMARY INTENTION WOUND HEALING

Several qualitative and semi-quantitative assessment methods have been proposed in the last 30 years to evaluate early wound healing of periodontal soft tissues. In 2018, Marini et al. [24] proposed the Early Healing Score (EHS), composed of three parameters: clinical signs of re-epithelialization (CSR), clinical signs of hemostasis (CSH), and clinical signs of inflammation (CSI). To evaluate CSR 0, 3, or 6 points were used, whereas 0, 1, or 2 points were used for both CSH and CSI (Table 1.2.2 and Figure 1.2.5).

Table 1.2.2 The Early Healing Score (EHS).

Parameter	Description	Points
CSR	Merged incision margins	6
	Incision margins in contact	3
	Visible distance between incision margins	0
CSH	Absence of fibrin on the incision margins	2
	Presence of fibrin on the incision margins	1
	Bleeding at the incision margins	0
CSI	Absence of redness along the incision length	2
	Redness involving <50% of the incision length	1
	Redness involving >50% of the incision length and/or pronounced swelling	0
Maximum total score: 10		

EHS: Early Wound Healing Score, CSR: clinical signs of re-epithelialization, CSH: clinical signs of haemostasis, CSI: clinical signs of inflammation.
Source: Marini et al. 2018 [24].

Dentlearn.ir

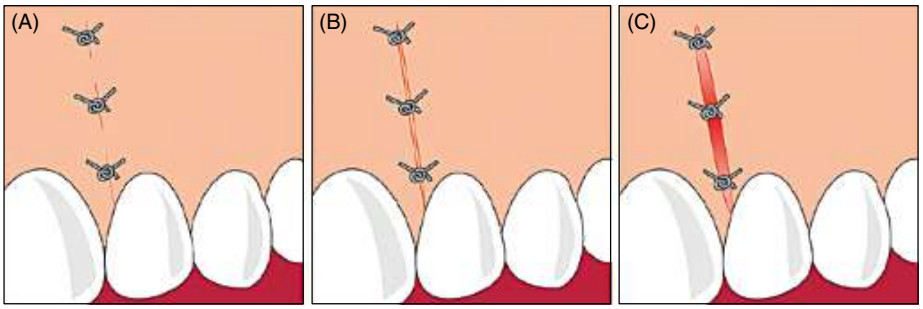

FIGURE 1.2.5 Graphic examples of clinical signs of re-epithelialization (CSR). (A) Incision margins considered "merged" (6 points for CSR); (B) margins in contact (3 points for CSR); (C) distance between incision margins considered "visible" (0 points for CSR). *Source*: Marini et al. 2018 [24].

To access the videos for this chapter, please go to
www.wiley.com/go/tolstunov/essential

VIDEO 1.1 Introduction to Chapters 1.1 and 1.2 by the Authors Drs. Claudia Dellavia, Gaia Pellegrini, Luiz Guilherme Fiorin, and Andrea Pilloni.

REFERENCES

1. Gosain A, DiPietro LA. Aging and wound healing. *World J Surg.* 2004;28(3):321–6.
2. Palta S, Saroa R, Palta A. Overview of the coagulation system. *Indian J Anaesth.* 2014;58(5):515–23.
3. Ellis S, Lin EJ, Tartar D. Immunology of wound healing. *Curr Dermatol Rep.* 2018;7(4):350–58.
4. Eming SA, Martin P, Tomic-Canic M. Wound repair and regeneration: Mechanisms, signaling, and translation. *Sci Transl Med.* 2014;6(265):265sr6.
5. Wilgus TA, Roy S, McDaniel JC. Neutrophils and wound repair: Positive actions and negative reactions. *Adv Wound Care (New Rochelle).* 2013;2(7):379–88.
6. Velnar T, Bailey T, Smrkolj V. The wound healing process: An overview of the cellular and molecular mechanisms. *J Int Med Res.* 2009;37(5):1528–42.
7. Li J, Chen J, Kirsner R. Pathophysiology of acute wound healing. *Clin Dermatol.* 2007;25(1):9–18.
8. Powell LC, Khan S, Chinga-Carrasco G et al. An investigation of Pseudomonas aeruginosa biofilm growth on novel nanocellulose fibre dressings. *Carbohydr Polym.* 2016;137:191–7.
9. Stephens P, Davies KJ, Al-Khateeb T et al. A comparison of the ability of intra-oral and extra-oral fibroblasts to stimulate extracellular matrix reorganization in a model of wound contraction. *J Dent Res.* 1996;75(6):1358–64.
10. Szpaderska AM, DiPietro LA. Inflammation in surgical wound healing: Friend or foe? *Surgery.* 2005;137(5):571–3.
11. Häkkinen L, Uitto VJ, Larjava H. Cell biology of gingival wound healing. *Periodontol* 2000. 2000;24:127–52.
12. Warburton G, Nares S, Angelov N et al. Transcriptional events in a clinical model of oral mucosal tissue injury and repair. *Wound Repair Regen.* 2005;13(1):19–26.
13. Turabelidze A, Guo S, Chung AY et al. Intrinsic differences between oral and skin keratinocytes. *PLoS One.* 2014;9(9):e101480.
14. Gibbs S, Ponec M. Intrinsic regulation of differentiation markers in human epidermis, hard palate and buccal mucosa. *Arch Oral Biol.* 2000;45(2):149–58.
15. Glim JE, Everts V, Niessen FB et al. Extracellular matrix components of oral mucosa differ from skin and resemble that of foetal skin. *Arch Oral Biol.* 2014;59(10):1048–55.
16. Hsieh P-C, Jin Y-T, Chang C-W, Huang CC. Elastin in oral connective tissue modulates the keratinization of overlying epithelium. *J Clin Periodontol.* 2010;37(8):705–11.
17. Glim JE, Beelen RH, Niessen FB et al. The number of immune cells is lower in healthy oral mucosa compared to skin and does not increase after scarring. *Arch Oral Biol.* 2015;60(2):272–81.
18. Szpaderska AM, Zuckerman JD, DiPietro LA. Differential injury responses in oral mucosal and cutaneous wounds. *J Dent Res.* 2003;82(8):621–6.
19. Chen L, Arbieva ZH, Guo S et al. Positional differences in the wound transcriptomeof skin and oral mucosa. *BMC Genomics.* 2010;11:471.
20. Wong JW, Gallant-Behm C, Wiebe C et al. Wound healing in oral mucosa results in reduced scar formation as compared with skin: Evidence from the red Duroc pig model and humans. *Wound Repair Regen.* 2009;17(5):717–29.
21. Larjava H, Wiebe C, Gallant-Behm C et al. Exploring scarless healing of oral soft tissues. *J Can Dent Assoc.* 2011;77:b18.
22. Vescarelli E, Pilloni A, Dominici F et al. Autophagy activation is required for myofibroblast differentiation during healing of oral mucosa. *J Clin Periodontol.* 2017;44(10):1039–50.
23. Rojas MA, Ceccarelli S, Gerini G et al. Gene expression profiles of oral soft tissue-derived fibroblast from healing wounds: Correlation with clinical outcome, autophagy activation and fibrotic markers expression. *J Clin Periodontol.* 2021;48(5):705–20.
24. Marini L, Rojas MA, Sahrmann P et al. Early Wound Healing Score: A system to evaluate the early healing of periodontal soft tissue wounds. *J Periodontal Implant Sci.* 2018;48(5):274–83.

Dentlearn.ir

CHAPTER 2

Applied Surgical Anatomy of the Jaws

Knowledge of the applied surgical anatomy of the maxilla and mandible is the foundation of safe oral surgery. Such knowledge will make the operator aware of the anatomical locations of muscles, nerves, vessels, and sinuses during surgery and, therefore, avoid unnecessary injury to these vital structures and serious consequences such as hemorrhage, paresthesia, and post-operative infection.

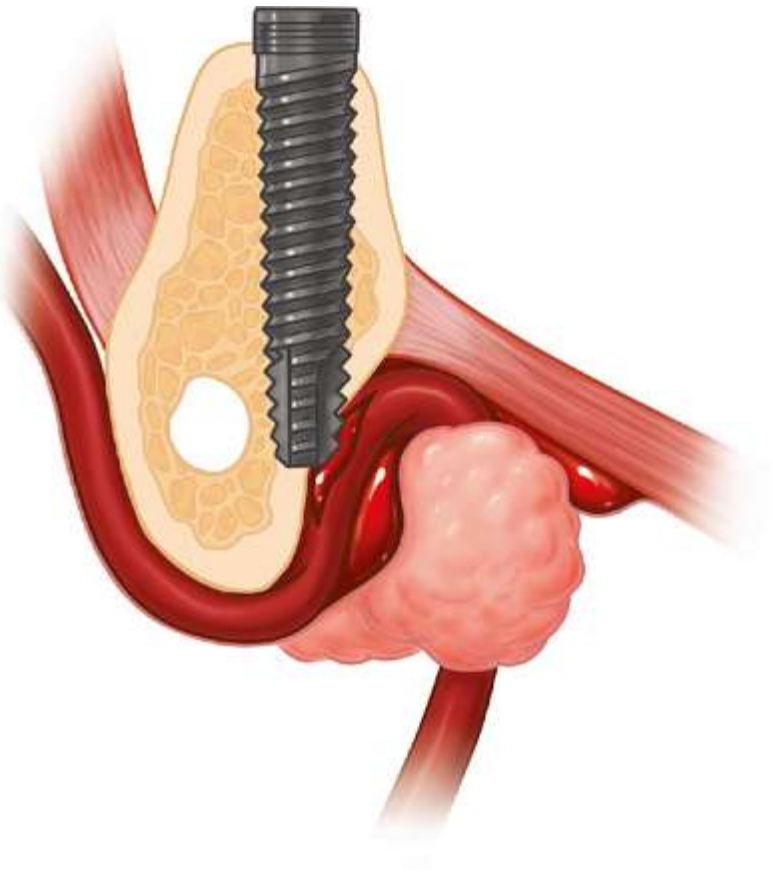

Dentlearn.ir

CHAPTER 2

Applied Surgical Anatomy of the Jaws

Mohamed Sharawy

College of Dental Medicine, Georgia Reagents University, Augusta, Georgia, USA

After extraction of teeth, the alveolar bone sockets heal and create an alveolar ridge. The new alveolar ridge is covered by thin cortex made up of compact bone overlying a core of cancellous bone and bone marrow. A full denture wearer's bite force decreases from 200 psi to 50 psi. In 15 years, denture wearers have a reduced bite force of about 6 psi [1, 2]. As a result, loss of alveolar bone ridge width and height occurs in most patients and the dentures become loose. Many edentulous persons with or without dentures have lost a significant amount or face complete loss of their alveolar bone (Figures 2.1 and 2.2). In some patients the mental neurovascular bundle is abnormally located on the crest of the atrophied jaw, causing pain and numbness of the chin in denture wearers (Figures 2.2 and 2.3) [3–6].

In rare cases, the incisive nerve and vessels are found under the mucosa covering the ridge (Figure 2.4). The loss of alveolar bone in the maxilla is more complicated due to the expansion of the maxillary sinuses in the posterior ridges (Figures 2.1 and 2.5). The facial appearance of these patients is significantly altered due to the reduction of the vertical dimension of the lower one-third of the face. The most recent US health survey has reported that over 40 million people are edentulous. Those with a significant or complete alveolar bone loss have been named dental cripples.

The advances in our knowledge of bone biology and physiology in the past two decades and the results of translational research and clinical trials have led to the development of clinical procedures aimed at bioengineering of the structure and function of the atrophied edentulous ridges using bone grafts and implants. Such clinical procedures involve surgical access to the basal bones of the maxilla, maxillary sinuses, and mandible. Most of the surgical approaches extend beyond the fornices (mucobuccal fold) of the oral cavity and may harm the vital structures in the subcutaneous areas of the head subjected to surgical manipulation from the intraoral approach. To employ such a bioengineering procedure, the dentist and specialists must acquire knowledge of surgical anatomy in order to assure safe access to the jawbone without harming muscles, vessels, and nerves. Such knowledge will also enable the operator to handle unexpected complications such as hemorrhage, airway obstruction, and nerve injury.

In this chapter we will consider the surgical anatomy of the maxilla and mandible as organs. To consider individual bone as organs we will deal with anatomical landmarks of surgical importance, muscle attachments, and arterial supply, with an emphasis on vessels that may be injured during surgery and on veins that may carry and spread infections. Lymphatic drainage from the maxilla and mandible will be discussed. The major sensory and motor innervation will be considered. The anatomy and physiology of the maxillary sinuses will be presented.

MAXILLA: SURGICAL ANATOMY

In gross morphology (Figure 2.6) the maxilla is pyramidal in shape, with the root of the zygoma as its apex [7]. The latter can be palpated in the buccal vestibule of the oral cavity and represents an important surgical landmark; it divides the facial or lateral surface of the maxilla into anterior-lateral and posterior-lateral surfaces. The third surface of the maxilla is the orbital plate, which separates the orbit from the maxillary sinus. Facial trauma may lead to fracture of the orbital plate and drooping of the eye in the direction of the maxillary sinus, resulting in diplopia, a condition known as enophthalmia. The base of the maxilla is the lateral wall of the nose or the medial wall of the maxillary sinus. Puncture of this wall during a sinus lift procedure may lead to an antronasal fistula. The latter heals fast with little or no complications when compared to the oroantral fistula.

The mucobuccal fold, also called the fornix, limits the intraoral part of the maxilla, which is covered by a mucous membrane. Above the fornix is the basal bone of the maxilla, which is covered by the skin and subcutaneous tissue. At the molar region the buccinators' muscle origin acts as a barrier between the buccal vestibule and the subcutaneous tissue of the buccal surgical space. There is no muscle barrier above the mucobuccal fold from canine to canine. The spread of infection from anterior teeth can extend to the facial space and to

Essential Techniques of Alveolar Bone Augmentation in Implant Dentistry: A Surgical Manual, Second Edition. Edited by Len Tolstunov.
© 2023 John Wiley & Sons, Inc. Published 2023 by John Wiley & Sons, Inc.
Companion website: www.wiley.com/go/tolstunov/essential

Dentlearn.ir

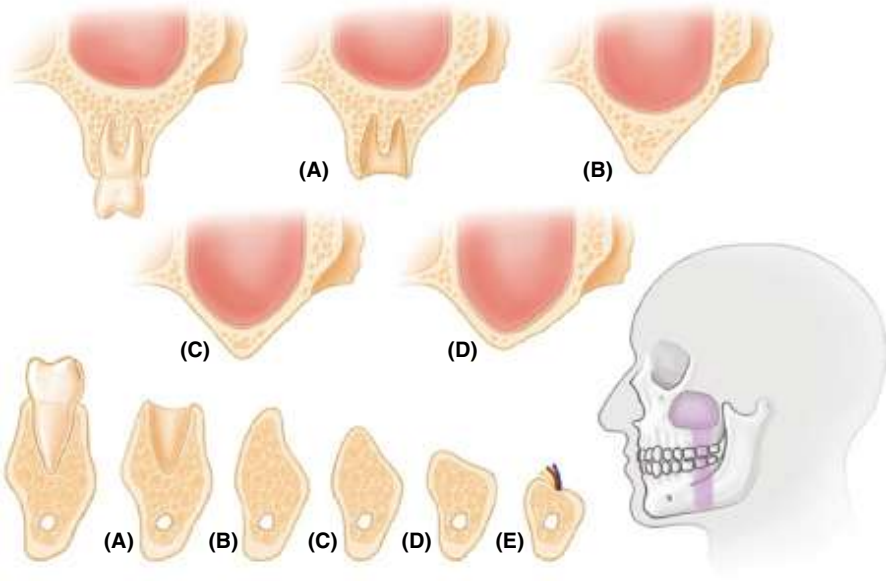

FIGURE 2.1 Bite force of full denture wearers decreases from 200 psi to 50 psi; by 15 years denture wearers have reduced the bite force to 6 psi. The decline in biomechanical force leads to progressive loss of alveolar bone. The maxillary sinus pneumatizes toward the alveolar bone and enhances the loss of alveolar bone in the posterior edentulous area. Progressive loss of alveolar bone of the mandible will bring the mental neurovascular bundle to the crest of the ridge.

FIGURE 2.2 Loss of alveolar bone alters the anatomy of the floor of the mouth. Note the rise of the floor by the mylohyoid muscles, above the posterior ridge. The genial tubercles are abnormally close to the crest of the ridge on the lingual side.

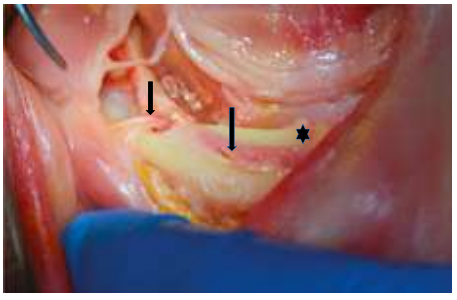

FIGURE 2.4 Morbid anatomy of an atrophied mandible in a cadaver specimen. Note the hypertrophied superior genial tubercles (*), the mental neurovascular bundle at the crest of the ridge (arrow), and the exposure of the incisive neurovascular bundle (arrow).

FIGURE 2.3 Total loss of the alveolar bone has brought the mental neurovascular bundle lingual to the crest of the ridge. Note the loss of buccinators and mylohyoid attachments to the atrophied mandible.

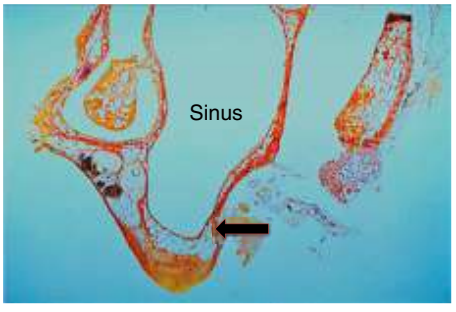

FIGURE 2.5 Expansion of the maxillary sinus into the alveolar process with significant loss of the alveolar bone. This process is called sinus pneumatization.

Dentlearn.ir

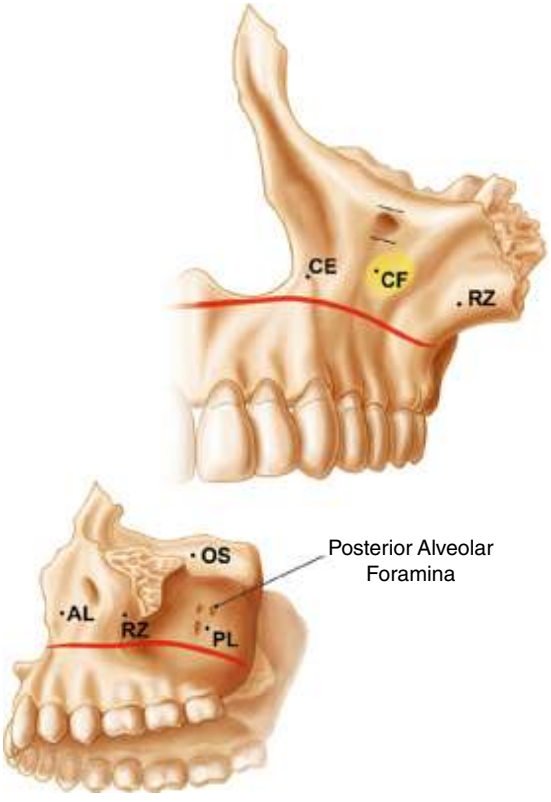

FIGURE 2.6 Anterior and lateral views of the left maxilla. The maxilla is pyramidal in shape, where its apex is the root of zygoma (RZ) and its base forms the lateral wall of the nose. RZ divides the lateral surface into anterior-lateral (AL) and posterior-lateral (PL); the third surface is the orbital (OS). Note the canine eminence (CE) with its apex reaching beyond the fornix into the subcutaneous surface of the AL surface. Between RZ and CE is the canine fossa (CF) or the anterior surface of the maxillary sinus, which reaches superiorly to the infraorbital foramen. The inferior boundary of CF extends intraorally into the alveolar process. Distal to the root of the zygoma is the posterior-lateral surface of the maxilla, divided by the fornix (thick red line) into the intraoral alveolar bone and above the fornix into the infratemporal surface. The arrow points to the posterior alveolar foramina for the transmission of the posterior superior alveolar artery and nerve. Note that the posterior-lateral surface leads superiorly to the infraorbital fissure, which connects the infratemporal fossa to the orbit. The barrier between the intraoral surface and the infratemporal surface is the buccinator muscle origin. Vestibular incision and violation of the buccinator may injure the posterior superior alveolar artery and nerve.

FIGURE 2.7 Facial vestibule. The red line indicates a vestibular incision, where below the line is intraoral and above the line is subcutaneous.

FIGURE 2.8 The buccinator muscle attaches above the line of incision. Above the attachment of the buccinators is the posterior-lateral surface of the maxilla or anterior wall of the infratemporal fossa, where the posterior superior alveolar artery and nerve are found.

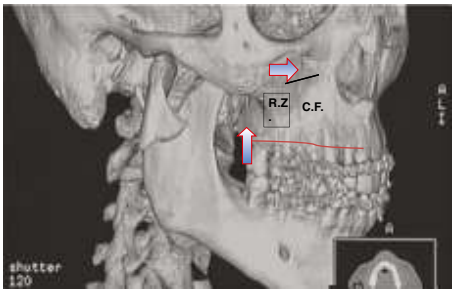

FIGURE 2.9 Computed tomographic (CT) scan showing all the anatomical features of the maxilla discussed in this chapter. You can identify the root of zygoma, canine fossa (surgical access site to maxillary sinus), infraorbital foramen (arrow), origin of caninus muscle (black line), vestibular line or fornix (red line), and the posterior-lateral surface or anterior wall of the infratemporal fossa above the vestibular line (vertical arrow).

the lower and upper eyelids. The buccinators limit the spread of infection to the buccal vestibule. If the infection extends above the origin of the buccinators, it will spread subcutaneously into the buccal surgical space (Figures 2.7–2.9).

The alveolar process of the maxilla related to the anterior-lateral wall carries the incisors, the canines, and the premolars, whereas that of the posterior-lateral wall carries the molars and ends as the maxillary tuberosity. The anterior-lateral surface of the maxilla can be palpated under the skin. At the mid-line the anterior nasal spine projects anteriorly and carries the medial nasal septal cartilage. Excision of this process can lead to drooping of the nasal septum. Intraorally,

Dentlearn.ir

it is possible to palpate the canine eminence and the canine fossa. The latter is located distal to the canine eminence and proximal to the root of the zygoma. It extends superiorly to the infraorbital foramen and inferiorly to the base of the alveolar process.

SURGICAL ACCESS TO THE MAXILLARY SINUS

The canine fossa is the site for facial access to the maxillary sinus (Figures 2.5 and 2.6). A vestibular incision between the canine eminence and the root of the zygoma and reflection of tissue above the fornix should reach the canine fossa subcutaneously and expose the bone, for the purpose of creating a window into the anterior-lateral wall of the sinus. One must be careful not to extend the reflection far superiorly to avoid detaching the levator anguli oris or caninus muscle and injuring the infraorbital neurovascular bundle (Figure 2.10). A vestibular incision at the buccal vestibule will cut the buccinator. Insertion of a periosteal elevator above the vestibular incision should access the posterior-lateral wall of the maxilla, which is also the anterior wall of the infratemporal fossa (Figure 2.6). At this site one should be careful not to sever the posterior superior alveolar nerve and artery. The posterior-lateral wall of the maxilla extends superiorly to the infraorbital fissure and posteriorly to the pterygomaxillary fissure. Surgical manipulation of the posterior-lateral wall to create a window into the maxillary sinus should avoid extending the instruments into these fissures to prevent injury to the maxillary artery and nerve.

The medial wall of the maxilla provides attachment to the inferior nasal concha and to the vertical plate of the palatine bone. The latter is the medial wall of the pterygopalatine fossa. At the superior border of the vertical plate of the palatine bone the sphenopalatine foramen is found, through which the sphenopalatine neurovascular bundle exits from the pterygopalatine fossa to the nasal cavity. Injection of local anesthetic solution into the pterygopalatine fossa for the purpose of blocking the maxillary nerve may pass through the sphenopalatine foramen to the nasal cavity and drip on the upper lip from the nose or reach the oropharynx. The sphenopalatine nerves and vessels supply the walls of the nasal cavity and exit to the palate by passing through the incisive canals, which begin at two foramina located at the floor of the nose above the central incisors. The sphenopalatine neurovascular bundle exits to the palate by passing through the incisive foramen under the incisive papilla.

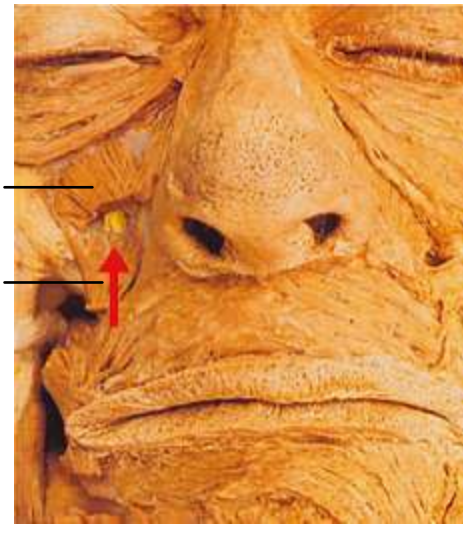

FIGURE 2.10 The infraorbital nerve (red arrow) is sandwiched between the levator labii superior and the caninus muscle. The nerve may be injured during access to the maxillary sinus from an intraoral approach after detaching the caninus muscle.

The opening of the maxillary sinus is actually a canal found in the medial wall of the maxilla, close to the floor of the orbit. The opening is reduced in diameter by the uncinate process of the ethmoid bone. The latter provides the middle and superior nasal conchae. The middle meatus is located between the middle and inferior nasal conchae and is the site of the hiatus semilunaris. The maxillary sinus opens at the hiatus semilunaris. The roof of the maxillary sinus is the orbital plate of the maxilla. The infraorbital canal carries the infraorbital nerve and vessels and forms a bony ridge running along the roof of the sinus cavity.

The sinus space expands into the processes of the maxilla. It expands inferiorly toward the alveolar ridge (50% of all instances) as the alveolar recess, and into the zygoma as the zygomatic recess (41.5%), frontal process (40.4%), and palatine process (1.75%). Palatal perforation leads into the floor of the nose and rarely into the sinus cavity. The sinus cavity is lined by a membrane approximately 1 mm in thickness, known as the Schneiderian membrane. The epithelial component of the membrane is made of pseudostratified ciliate epithelium with goblet mucous-secreting cells. The subepithelial connective tissue layers contain blood vessels from anterior, middle, and posterior alveolar arteries and veins, as well as branches of anterior, middle, and posterior superior alveolar sensory nerves off the maxillary (V2) nerve, autonomic nerves, and seromucous glands. The cilia of the sinus epithelium beat toward the sinus canal and, along with the mucous, carry the foreign particles brought to the sinus by the breathed air toward the sinus opening. Smoking paralyzes the cilia and makes the patient more susceptible to sinusitis.

The bone surfaces at the floor of the sinus show few cells, which appear flat and do not resemble periosteal cells. The floor of the sinus is not flat but is divided into three fossae separated by bony septae. The anterior fossa is related to the premolars, the middle fossa is related to the two molars, and the distal fossa is related to the third molar. The septae may vary in height from 2 mm to 6 mm. They can be detected as radiopaque lines on panoramic radiographs. During the sinus lift procedure for the purpose of augmenting the floor of the

Dentlearn.ir

sinus with bone grafts, the operator should be aware of the presence of the bone septae in order to avoid perforating the sinus membrane.

Possible functions of maxillary sinus:

- Resonance of voice.
- Lightening of skull weight.
- Enhancement of craniofacial resistance to mechanical stress.
- Secretion of bactericidal enzymes, which make the environment of the healthy sinus sterile.
- Warming of inspired air.

Normal sinus function requires patency of the sinus ostium, normal mucociliary function, and normal systemic and local immune function. Imaging of the sinuses using a panoramic view, Water's view, a periapical radiogram, or tomography using computed tomography (CT) or cone beam computed tomography (CBCT), can show a healthy sinus cavity as radiolucent. Any turbidity caused by fluid, polyps, or mucous cysts, thickening of the sinus membrane, and so on should indicate disease. Consulting an ear, nose, and throat (ENT) specialist is highly recommended before proceeding with the sinus lift procedure.

MUSCLES ATTACHED TO THE MAXILLA OF SURGICAL IMPORTANCE

As the maxillary edentulous ridge resorbs, the crest of the atrophied ridge migrates toward the muscles that take their origin from the basal bone of the maxilla (Figures 2.10 and 2.11). Therefore, a vestibular incision or reflection of mucoperiosteal flap may detach these muscles and any surgical manipulation will be subcutaneous rather than intraoral; it therefore has the potential of severing or injuring vital structures such as nerves, vessels, and muscles, as will be described below.

Levator Labii Superioris Muscle

This takes its origin from the infraorbital margin above the infraorbital foramen. The muscle covers the infraorbital neurovascular bundle. The muscle is penetrated during infraorbital nerve block anesthesia from a skin approach. The zygomatic branch of the facial nerve innervates the muscle.

Levator Anguli Oris (Caninus)

This originates in the maxilla below the infraorbital foramen. The infraorbital neurovascular bundle is therefore located between the caninus and levator labii superioris. In the atrophied edentulous maxilla, the infraorbital neurovascular bundle is closer to the crest of the ridge. Reflection of the tissue following a vestibular incision to access the canine fossa, in order to create a lateral window for sinus membrane lift and insertion of bone graft, may detach the caninus muscle and injure the infraorbital neurovascular bundle, leading to hematoma and subsequent parasthesia or anesthesia of the receptive field of the infraorbital nerve (lower eyelid, ala of the nose, skin of the lip, and the gingiva opposite to anterior teeth on the side of the injury). Detached muscles commonly reattach to the periosteum, but heal shorter than their original length and may cause slight elevation of the corner of the mouth. The zygomatic branch of the facial nerve innervates the muscle.

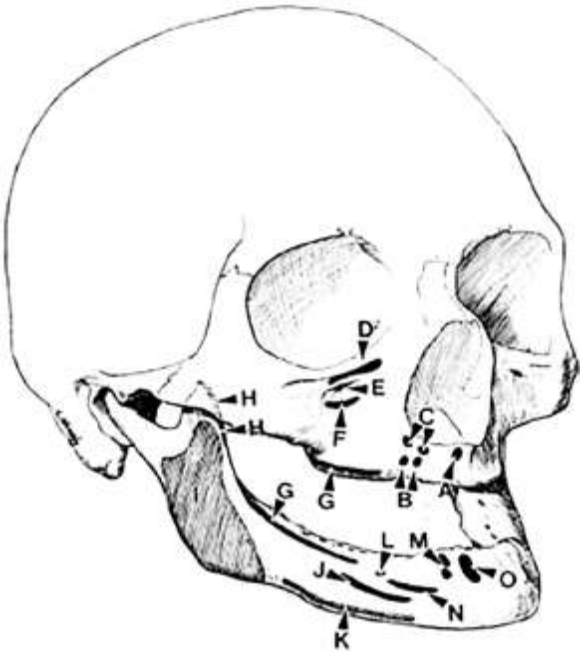

FIGURE 2.11 (A) Origin of the depressor septi muscle; (B) origin of the superior incisivus muscle; (C) origin of the nasalis muscle; (D) origin of the levator labii superioris muscle; (E) infraorbital foramen; (F) origin of the caninus muscle; (G) origin of the buccinator muscle; (H) insertion of the lateral tendon of the temporalis muscle; (I) insertion of the masseter muscle; (J) origin of the triangularis muscle; (K) insertion of the platysma muscle; (L) mental foramen; (M) origin of the inferior incisivus muscle; (N) origin of the depressor labii inferioris muscle; (O) origin of the mentalis muscle.

Incisivus Labii Superior Muscle

This originates from the floor of the incisive fossa of the maxilla, above the eminence of the lateral incisor and deep to the orbicularis oris. To expose the bone of the premaxilla between the canines, a mucoperiosteal flap reflection may detach the incisivus labii superioris. It may also detach the septalis and oblique fibers of the nasalis muscle. The first is attached to the skin of the nasal septum and the latter to the ala of the nose. These small muscles will reattach after placement of the flap. However, if the muscles are damaged, then drooping of the septum and flaring of the ala of the nose may result.

Dentlearn.ir

Buccinator Muscle

This originates from the base of the alveolar process opposite to the first, second, and third molars of both jaws. This muscle also takes its origin from the pterygoid hamulus of the medial pterygoid plate of the sphenoid bone, and therefore bridges the gap between the maxillary tuberosity anteriorly and the hamulus posteriorly. Extension of a subperiosteal frame design into the pterygoid plates may interfere with the fibers of these muscles without adding too much to the retention of the implants. The buccinator muscle crosses the retromolar triangle in order to reach the pterygoid hamulus (a process of the medial pterygoid plate of sphenoid) and pterygomandibular raphe. The latter links the superior constrictor muscle of the pharynx to the buccinator, which runs medial to the medial pterygoid muscle. The long buccal nerve and vessels reach the lateral surface of the buccinators by crossing the retromolar triangle deep to the buccinator muscle fibers. Incision at the retromolar pad that extends along the ramus, in order to access more of the external oblique ridge during harvesting a ramus block for autologous ridge augmentation, may sever the buccinator fibers and also the long buccal nerve and vessels. The buccal branches of the facial nerves innervate the buccinators.

SENSORY INNERVATION OF THE MAXILLA

The maxillary nerve (V2) innervates the maxilla (Figure 2.12). The nerve leaves the maxillary sinus by exiting through the foramen rotundum and crosses the pterygopalatine fossa (pterygopalatine portion). It then exits the fossa through the pterygopalatine fissure and appears at the infratemporal fossa (infratemporal portion). The nerve enters the orbit by passing through the infraorbital fissure and then runs into the infraorbital canal located at the floor of the orbit or the roof of the maxillary sinus (infraorbital portion). It then exits to the face by passing through the infraorbital foramen (facial portion).

Pterygopalatine Portion of the Maxillary Nerve

This portion of the maxillary nerve gives rise to the descending palatine and sphenopalatine nerves. The descending palatine nerves descend through the descending palatine canal and branch into the greater palatine nerve, which supplies the mucosa of the hard palate, and the lesser palatine nerves, which supply the mucosa of the soft palate. These sensory nerves carry autonomic fibers from the sphenopalatine ganglion. Both sympathetic and parasympathetic nerves supply the mucous glands of the palate. The sphenopalatine nerve exits to the nasal cavity by passing through the sphenopalatine foramen. It supplies the nasal mucosa and terminates as the incisive nerve, which supplies the mucosa covering the hard palate opposite the upper six anterior teeth. The sphenopalatine nerve carries autonomic nerves that supply the mucous glands and vessels of the nasal cavity. The infratemporal portion of the maxillary nerve gives rise to the zygomatic branch and posterior superior alveolar nerves. The zygomatic nerve divides into the zygomatico-facial and zygomatico-temporal cutaneous branches. The zygomatic nerve also carries autonomic fibers that supply the lacrimal gland in the orbit. The posterior superior alveolar nerve gives rise to a mucous branch that supplies the gingiva opposite the upper three molars, then enters the posterior wall of the maxillary sinus and contributes to the dental plexus that supplies the third molar, second molar, and the mesio-buccal root of the first molar teeth and the surrounding bone.

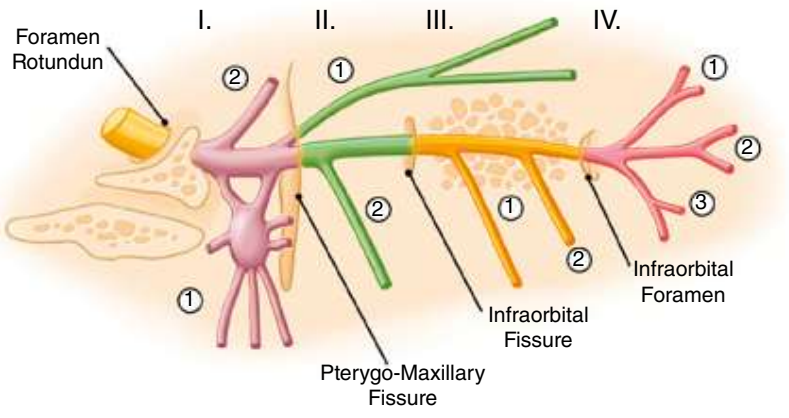

FIGURE 2.12 Maxillary division of the trigeminal nerve as it exits the cranial cavity through the foramen rotundum and appears in the pterygopalatine fossa (I). This part of V2 supplies the descending palatine and sphenopalatine nerves and V2 then exits through the pterygomaxillary fissure to the infratemporal fossa (II). This portion supplies the zygomatic and posterior superior alveolar nerves. Then V2 enters the infraorbital fissure to become the infraorbital portion (III); it supplies the anterior and middle superior alveolar nerves and then V2 exits to the face through the infraorbital foramen (IV) and branches into the labial, nasal, and palpebral nerves.

Dentlearn.ir

After teeth extraction most of the dental nerves degenerate. In some cases, a few dental branches remain within the alveolar ridge. Insertion of implants at this site may impinge on the residual nerves and cause phantom pain that the patient may feel as if the pain is originating from the extracted teeth. In some cases, the severity of the pain may necessitate unscrewing the implant to relieve the pressure, or removal of the implant.

Infraorbital Portion of the Maxillary Nerve

This gives rise to the anterior and middle superior alveolar nerves. These nerves run in bony grooves in the facial wall of the maxillary sinus under the Schneiderian membrane. The nerves supply the sinus wall of the premolars, the canine, lateral, and central incisors on the same side, and also the central incisor at the contralateral side. The infraorbital facial portion of the maxillary nerve exits the infraorbital foramen and supplies cutaneous branches to the lower eyelid, side of the nose, and the upper lip. It also supplies the mucosa lining of the upper lip and the gingivae opposite the incisor and premolar teeth. V2 block anesthesia can be achieved by intraoral routes, either via the descending palatine canal, via the greater palatine foramen, or via the pterygomaxillary fissure into the pterygopalatine fossa, by following the slope of the posterior-lateral surface of the maxilla distal to the root of the zygoma.

ARTERIAL SUPPLY TO THE MAXILLA

The maxillary artery supplies most of the arterial blood to the maxilla (Figure 2.13). It is one of the terminal branches of the external carotid artery. The maxillary artery starts deep to the neck of the mandibular condyle (mandibular portion) and then continues either superficially or deep to the lateral pterygoid muscle in the infratemporal fossa (pterygoid portion). It reaches the pterygomaxillary fissure, where it branches into one artery that enters the pterygopalatine fossa (pterygopalatine portion) and the infraorbital artery, which enters the infraorbital fissure and then proceeds in the infraorbital canal (infraorbital portion) and exits on the face by passing through the infraorbital foramen.

Branches of the maxillary artery are as follows:

- *Mandibular portion*: deep auricular, tympanic, meningeal, and inferior alveolar arteries.
- *Pterygoid portion*: deep temporal, lateral pterygoid, medial pterygoid, and masseteric arteries.
- *Pterygopalatine portion*: posterior superior alveolar artery, descending palatine, and sphenopalatine arteries.
- *Infraorbital portion*: anterior and middle superior alveolar, palpebral, nasal, and labial arteries.

The collateral or supplemental arterial blood supply reaches the maxilla via five arteries: two branches from the cervical portion of the facial artery (ascending palatine and tonsillar), two dorsal lingual arteries from the lingual artery, and the ascending pharyngeal branch from the external carotid artery. These arteries ascend in the head lateral to the lateral wall of the pharynx medial to the mandibular ramus. The operator of surgical osteotomy of the ramus needs to be aware of these parapharyngeal arteries. The latter arteries penetrate the lateral pharyngeal wall of the oropharynx and supply the palatine mucosa and the bone of the maxilla. During orthognathic surgery the surgeon cuts the posterior, middle, and anterior superior alveolar arteries and occasionally the descending

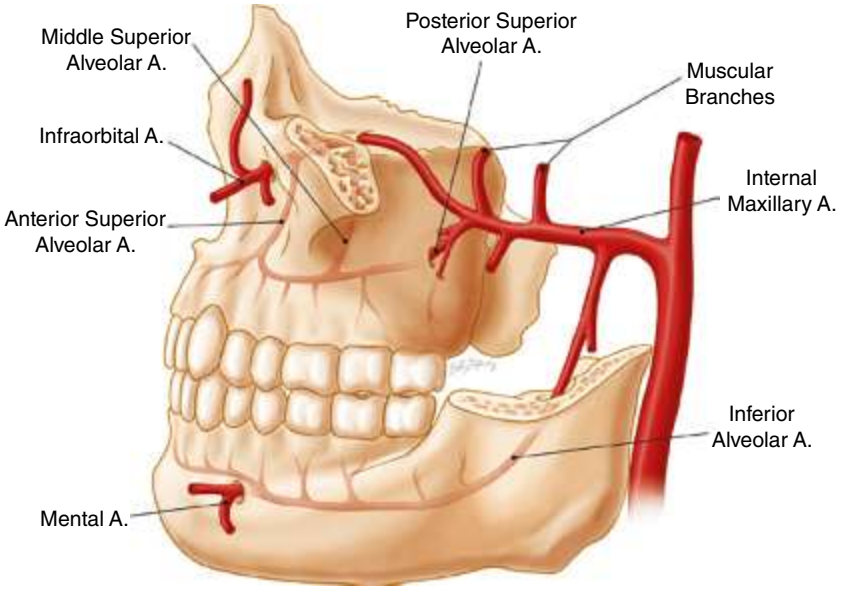

FIGURE 2.13 Arterial supply of the maxilla and mandible.

Dentlearn.ir

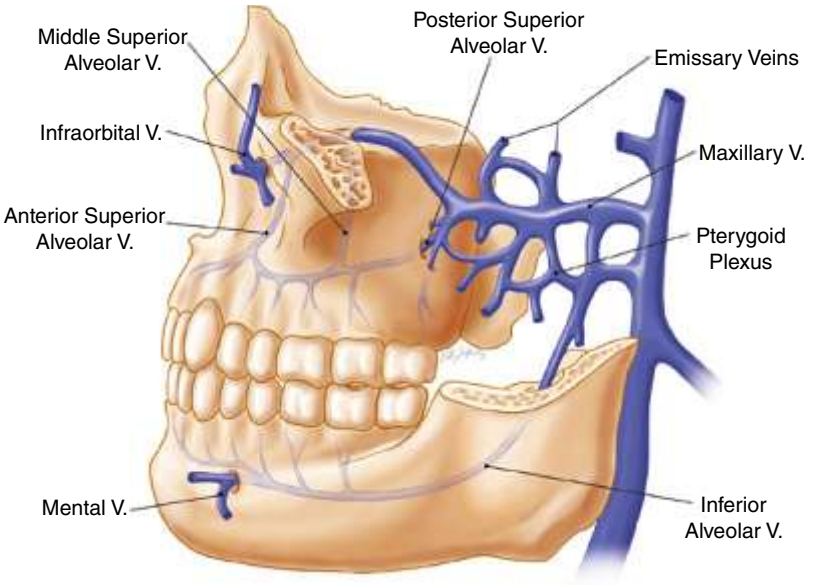

FIGURE 2.14 Venous drainage of the maxilla and mandible.

palatine arteries, without compromising the blood supply to the maxilla because of the presence of the supplemental blood supply from the branches mentioned previously. Reflection of the palatine mucosa and the facial mucosa covering the maxilla during orthognathic surgery is contraindicated, since it can lead to necrosis of the maxilla.

VENOUS DRAINAGE FROM THE MAXILLA

The maxillary vein provides venous drains from the maxilla (Figure 2.14). It is located in the infratemporal fossa and communicates freely with the pterygoid plexus of veins, then joins the superficial temporal vein to form the posterior facial vein within the parotid gland. Infection anywhere in the maxilla may follow the maxillary vein to the pterygoid plexus of veins. The latter communicate to the cavernous sinuses in the middle cranial fossa via emissary veins, causing infected cavernous thrombosis. An adequate arterial blood supply and healthy venous drainage are essential for bone regeneration and remodeling of bone grafts. Bilateral significant blockage of the carotid arteries may compromise the blood supply to the bone of the maxilla and cause a delay of healing after insertion of implants or bone grafting to the area.

LYMPHATIC DRAINAGE FROM THE MAXILLA

The submandibular lymph nodes are the primary nodes that drain the maxilla, including the maxillary sinuses. The most posterior portion of the maxilla drains into the deep facial nodes or retropharyngeal nodes, part of the deep cervical nodes. Normal nodes are not clinically palpable, except the jugulo-digastric or tonsillar nodes and the jugulo-omohyoid or tongue nodes. Pre-operative palpation of lymph nodes is an essential part of physical examination of the head and neck.

MANDIBLE: SURGICAL ANATOMY

The clinician should be familiar with the anatomical landmarks of the dentulous and edentulous mandibles, not only by radiographs but also by clinical examination (Figure 2.15) [7]. The mental eminence, inferior border premasseteric notch, gonial angle, lateral pole of the condyle, and coronoid process are all palpable under the skin. Intraoral palpable features of the mandible from the facial aspect are the external oblique ridge, coronoid process, and the boundaries of the retromolar triangle. The external oblique ridge forms its lateral boundary, the temporal crest forms the medial boundary, the retromolar alveolar bone forms its base, and the coronoid process forms the apex of the triangle. The mental foramen can be palpated at the interpupillary line at the apices of the premolars. In severely atrophied edentulous ridge, the mental foramen along with the mental neurovascular bundle can be palpated at the crest of the ridge. Incision at the crest of the ridge should avoid injury to the mental neurovascular bundle. CBCT imaging is helpful in confirming the location of the mental nerve prior to surgery. Vestibular facial incision at the symphyseal area will expose the mentalis muscles. Mucoperiosteal flap reflection at the molar region beyond the mucobuccal fold may sever the buccinator muscle attachment and periosteal reflection beyond this line will be subcutaneous. The operator needs to be aware of the presence of the facial artery, facial vein, and marginal branch of the facial nerve close to the premasseteric notch of the mandible.

Dentlearn.ir

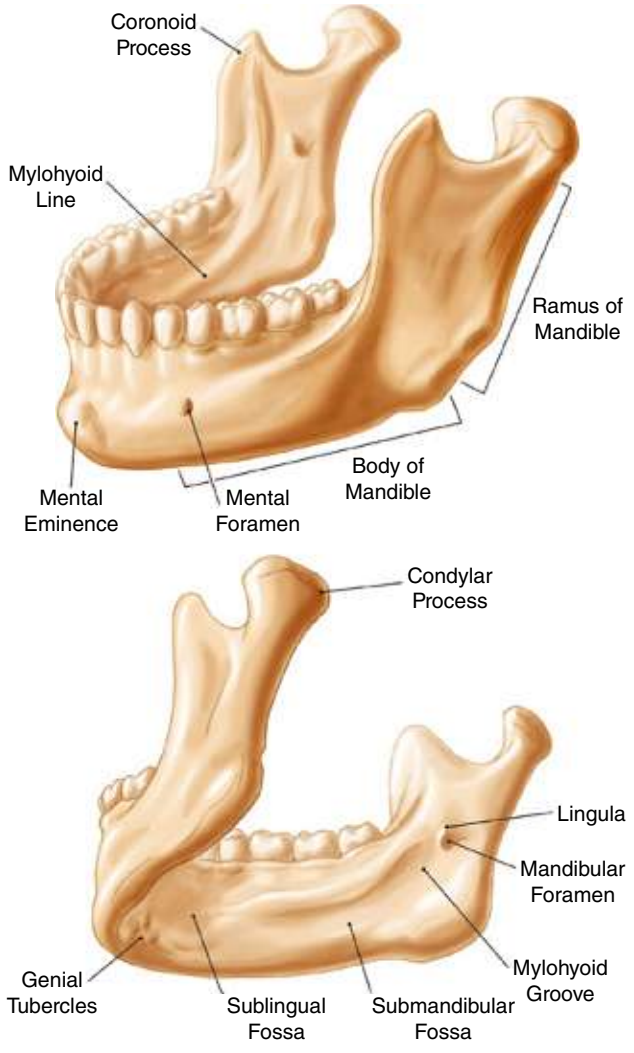

FIGURE 2.15 Anatomical landmarks of the facial and lingual views of the mandible.

Physical examination of the lingual side of the mandible should palpate the internal oblique ridge and the torus mandibularis in the premolar region, the temporal crest (site for insertion of the medial tendon of the temporalis muscle), and coronoid process of the ramus. In some cases of edentulous, severely atrophied mandible, the mylohyoid muscles push the sublingual salivary glands up to cover the crest of the ridge, the buccinators' attachment in the molar regions may also reach the crest of the ridge, and in some cases the muscle loses its attachment to the mandible. An abnormally enlarged superior genial tubercle can be palpated lingually at the midline in a severely atrophied edentulous mandible. The lingual nerve, which has a close relationship to the alveolar bone of the third molar in the dentulous mandible, may run close to the crest of the atrophied edentulous ridge, and in some cases it may be found under the retromolar pad. The operator needs to be aware of the possibility of having the lingual nerve in the line of incision. Retromolar pad incision should be done buccally and in layers rather than down to the bone in order to avoid injury to the lingual nerve.

MUSCLE ATTACHMENT TO THE MANDIBLE OF SURGICAL IMPORTANCE TO ORAL IMPLANTOLOGISTS

Mylohyoid

This muscle takes its origin from the internal oblique ridge bilaterally (Figure 2.16). The most posterior fibers insert into the body of the hyoid bone, while the rest of the fibers meet the mid-line from the mandible to the hyoid bone. The muscle forms the floor of the mouth. The structures above the mylohyoid are intraoral, while the structures below the muscle are subcutaneous, under the skin of the submandibular region. Atrophy of the edentulous mandibular ridge will bring the origin of the muscle close to the crest of the ridge. A cristal incision may injure the muscle and manipulation at this site may cause swelling and ecchymosis above the mylohyoid in the sublingual space, or below the mylohyoid in the submandibular space. The mylohyoid depresses the mandible if the hyoid bone is fixed in position by the infrahyoid muscles and it can also raise the hyoid when the mandible is fixed in centric occlusion during swallowing. The nerves to the mylohyoid branch of V3 innervate the mylohyoid muscle.

Genioglossus Muscle

This muscle takes its origin from the superior genial tubercle and inserts into the tongue from the tongue tip to its tip. Its posterior fibers insert into the body of the hyoid bone. The genioglossi muscles are the main protruders of the tongue. In the edentulous atrophied mandible, the superior genial tubercles may become close to the crest of the ridge, and in some cases are found at the same level as the crest of the anterior ridge (Figure 2.15). Surgical manipulation at this site should avoid severing the tendons of the genioglossi, which may lead to life-threatening fall-back of the tongue and obstruction of the airway. Branches of the hypoglossal nerves innervate the muscles. Paralysis of the genioglossus muscle on one side will lead to deviation of the tongue toward the affected side.

Medial Pterygoid Muscle

The majority of the muscle fibers take their origin from the medial surface of the lateral pterygoid plate of the sphenoid bone. A small slip of the muscle originates from the tuberosity of the maxilla (maxillary head). The muscle inserts on the medial surface of the angle of the mandible. The pterygomandibular surgical space is located between the medial pterygoid and the ramus of the mandible. This space contains the sphenomandibular ligament, inferior alveolar nerve, inferior alveolar artery and vein, and lingual nerve. The pterygomandibular space is entered during inferior alveolar nerve block anesthesia. The spread of dental infection into the space is

Dentlearn.ir

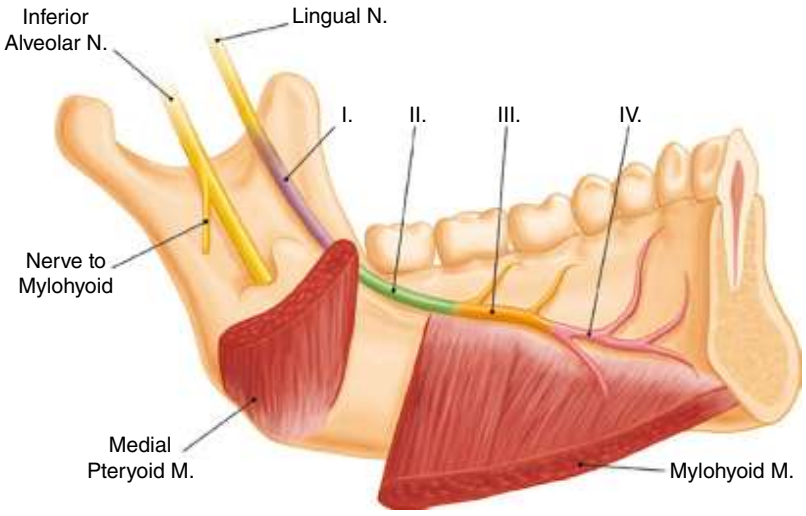

FIGURE 2.16 Lingual view of the mandible showing the lingual nerve at the pterygomandibular space (I) passing to the floor of the mouth at the edge of the mylohyoid muscle (alveolar portion II), then running in the floor of the mouth on the hyoglossus muscle (III) and sending branches to the tongue, lingual gingiva, and mucosa of the floor of the mouth (IV). The pterygomandibular portion is the most injured by the needle during inferior alveolar nerve block anesthesia, while the alveolar portion is most susceptible to injury during complicated surgical removal of an impacted third molar tooth.

dangerous because of its location lateral to the parapharyngeal space in the infratemporal fossa. The latter has no inferior boundary and therefore the infection may descend to the neck surgical spaces and reach the mediastinum. The muscle is a powerful elevator of the mandible and receives innervation from the mandibular nerve (V3).

Lateral Pterygoid Muscle

This muscle is located in the infratemporal fossa. It consists of inferior and superior heads. The superior head originates from the roof of the infratemporal fossa (greater wing of the sphenoid bone), whereas the inferior head originates from the lateral surface of the lateral pterygoid plate of the sphenoid. The superior head inserts on the anterior band of the temporomandibular joint (TMJ) disc (~15% of its fibers) and the remaining fibers insert on the pterygoid fovea on the neck of the condyle. The inferior head inserts on the fovea of the condyle, the median pole of the condyle, and the median collateral ligament of the TMJ disc. Because of the angulation of the lateral pterygoid muscle, it is thought to cause adduction of the mandibular rami during maximum opening or yawning. The phenomenon of mandibular flexure may cause the pain experienced by patients with a full-arch subperiosteal implant. The muscle normally is a protractor and able to shift the mandible from side to side. Branches of the mandibular nerves innervate the muscles.

Temporalis Muscle

This muscle takes its origin from the temporal fossa and descends deep to the zygomatic arch, inserts on the coronoid process, and ends in two tendons. The lateral tendon inserts on the lateral boundary of the retromolar triangle, while the medial tendon inserts on the medial boundary of the retromolar triangle, known as the temporal crest. The long buccal nerve and vessels are closely related to the medial tendon before it crosses the retromolar triangle deep to the buccinator muscle fibers. During ramus bone block harvesting the incision line may extend along the retromolar triangle, and the operator should be aware of the presence of the long buccal neurovascular bundle in order to avoid severing these important vital structures. The temporalis muscles are powerful elevators and retractors of the mandible. Branches of the mandibular nerves supply the muscles.

Mentalis Muscles

The mentalis muscle takes its origin from the mental tubercle and the side of the mental eminence, inserts into the skin of the chin, and superiorly some of its fibers interdigitate with the orbicularis ores muscle (Figure 2.17). The bone of the mental eminence lying between the right and left mentalis muscles is covered by fibroadipose tissue. Vestibular incision from canine to canine will expose the two mentalis muscles. To access the symphyseal bone, the two mentalis muscles should be detached from the periosteum to expose the mental eminence for the purpose of harvesting a bone block graft. The mentalis receives its innervation from the marginal mandibular branch of the facial nerve.

Buccinator Muscle (Mandibular Portion)

The muscle takes part of its origin from the external oblique ridge opposite the lower three molars. It serves as a barrier between the oral vestibule and the subcutaneous tissue. In an

Dentlearn.ir

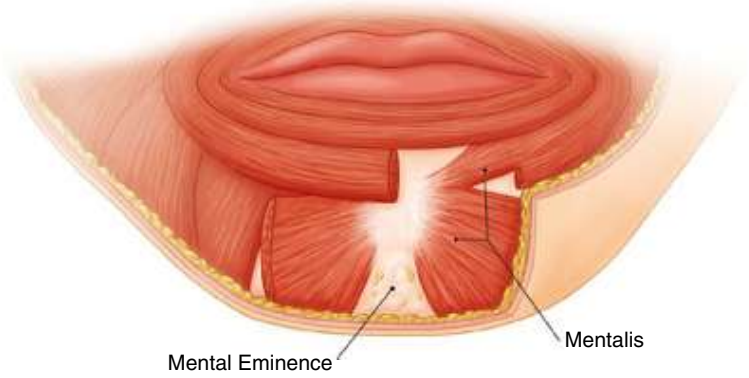

FIGURE 2.17 The mentalis muscle takes its origin from the side of the mental eminence and inserts on the chin skin, where a few fibers interdigitate with the orbicularis oris muscle. Fibroadipose tissue separates the two muscles. Vestibular incision from canine to canine exposes the mentalis muscles.

edentulous atrophied ridge, the reduction in ridge height brings the origin of the buccinators close to or at the crest of the ridge. The buccal mucoperiosteal flap may sever the buccinator and may injure the facial artery, facial vein, and marginal branch of the facial nerve, which are located at the premasseteric notch in the second molar region.

Masseter Muscle

This muscle takes its origin from the zygomatic arch and inserts on the lateral surface of the ramus and the angle of the mandible. Surgical access of the ramus should avoid reflection of the masseter from the zygomatic arch, since it will interfere with the masseteric nerve and masseteric artery, which enter the deep surface of the muscle by passing through the sigmoid notch. A deep masseteric fascia covers the muscle. The space between the muscle and the fascia is a potential surgical space, known as the masseter space, into which an infection may spread causing trismus and myositis.

INNERVATION OF THE LOWER JAW AND ASSOCIATED STRUCTURES

The third division of the trigeminal nerve (V3) exits through the foramen ovale and appears in the infratemporal fossa deep to the lateral pterygoid muscle (Figure 2.18). The main trunk gives off meningeal and medial pterygoid branches. It divides into anterior and posterior divisions. The anterior division gives all motor branches to muscles of mastication and one sensory nerve, called the long buccal nerve. The posterior division gives all sensory branches (auriculotemporal, lingual, and inferior alveolar) and one motor branch (nerve to mylohyoid).

Inferior Alveolar Nerve

This nerve appears at the inferior border of the lateral pterygoid muscle and courses inferiorly toward the mandibular foramen [8, 9]. It gives numerous sensory branches that innervate the mandibular bone. These small nerves are in association with small vessels in neurovascular channels. The inferior dental nerve can run as one unit through the mandibular canal until it reaches the premolar region, where it divides into the mental and the incisive nerves. The mental nerve exits the canal through the mental foramen. The anatomical location of the mental foramen is variable. The foramen may be found at the level corresponding to the apex of the mandibular first premolar, between the apices of the first and second premolars, under the apex of the second premolar, and rarely more distal under the apex of the mesial root of the first molar. Cutright et al. [8] found differences in the location of the submental foramina between white and Black populations. Mandibles of 76 white people showed the anatomical location of the foremen under the first premolar of 6.6%, between apices of the first and second premolars of 31.6%, below the second premolars of 51.1%, and distal to the second premolars of 8%. Of the Black subjects, 78 mandibles were studied. The foramen was located between the apices of the first and second premolars in 14.1%, below the second premolar in 52.6%, between the second premolar and first molar in 32%, and below the mesial root of the first molar in 1.3% of mandibles.

Recent studies using CBCT have revealed an anterior extension of the mental nerve in the mandibular canal before it exits the mental foramen. Such an extension was named the anterior loop of mental nerve. Most of the studies using CBCT reported variability in the presence of the loop and, when it was present, variability of its length. Because of this variation, it is recommended not to use a fixed distance such as 2 mm mesial to the location of the mental foramen for insertion of a lower canine implant. To avoid injury to the mental nerve, it is recommended to use CBCT in every case in order to determine the safe zone for insertion of the implant mesial to the first premolar region without injury to the nerve. Damage of the mental nerve may lead to a permanent numb chin syndrome.

Dentlearn.ir

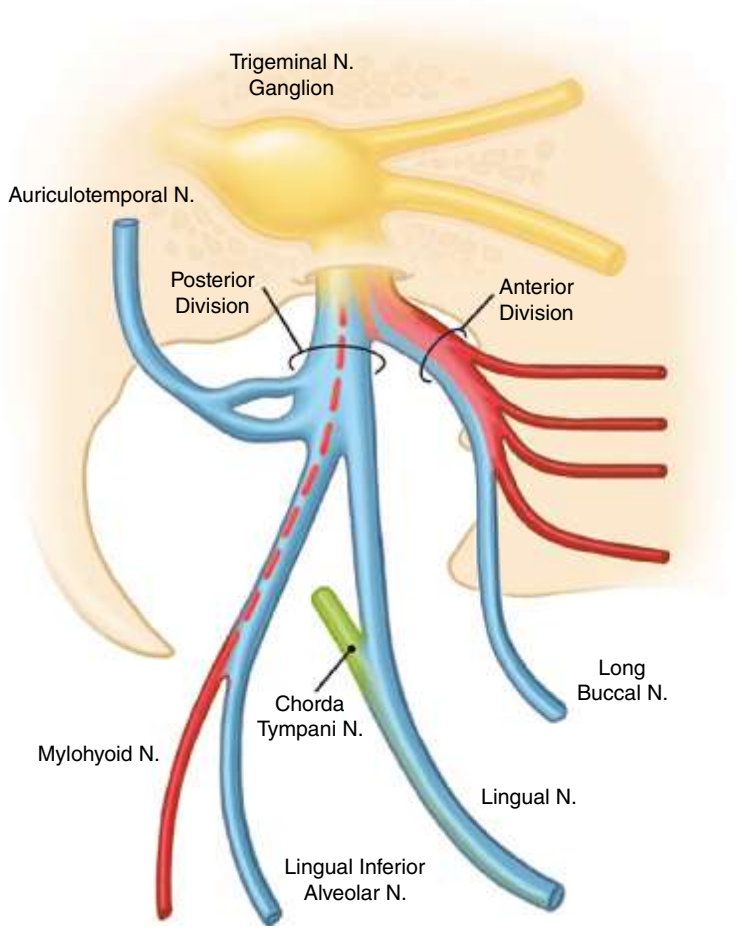

FIGURE 2.18 V3 red (motor) and blue (sensory). The mandibular nerve exits the foramen ovale and appears at the infratemporal fossa, before dividing into an anterior division (all motor to muscles of mastication and one sensory, long buccal nerve). The posterior division is all sensory (auriculotemporal, lingual, inferior alveolar, and one motor nerve to mylohyoid). The chorda tympani nerve, a branch of the facial nerve (green), carries taste fibers and secretomotor parasympathetic fibers and joins the lingual nerve.

In an excessively resorbed ridge, the mental foramen, with its contents of mental nerve and vessels, can be found on the crest of the ridge. When making an incision or reflection of the mucosa in this area, avoid injury to these vital structures. Knowledge of the position of the inferior dental canal in vertical and buccolingual dimensions is of paramount importance during site preparation for implants.

The potential use of reconstruction techniques on CT scans and magnetic resonance imaging may increase clinicians' ability to locate the inferior dental canal precisely within the jawbone. Much less expensive techniques using panoramic cross-sectional tomographic imaging are also available. In some cases, the inferior dental nerve may divide into two or three rami, which occupy separate canals as the nerve travels in the mandible to supply the bone. These variations can be determined by conventional radiographic techniques and the operator should modify the surgical approach and type of implant to avoid injury to the portion of the nerve that exits the foramen. Injury to the portion of the inferior alveolar nerve that remains in the atrophied bone and does not innervate soft tissues is of far less consequence. The nerves in the bone, when in contact with an implant, may account for the rare but occasional observation of tenderness, even though the implant is rigid and appears healthy. In addition, the fibrous tissue around these nerves may cause an increase in the amount of fibrous tissue around an implant that is inserted in contact with these structures.

Lingual Nerve

The lingual nerve (Figure 2.16) is one of the most injured nerves in oral surgery. The dentist needs to learn the details of the course of the nerve and its anatomical location, particularly its relationship to an impacted third molar socket and to the retromolar pad in an edentulous atrophied mandible. The nerve is a branch of the mandibular nerve that is given off in the infratemporal fossa. The nerve is given off the posterior

Dentlearn.ir

division of V3 deep to the inferior belly of the lateral pterygoid muscle. This part of the lingual nerve (pterygoid portion) is rarely injured in dental practice. The next portion of the lingual nerve is found between the medial pterygoid muscle and the ramus of the mandible (pterygomandibular portion). This part is commonly injured during an inferior alveolar nerve block injection, with few or no consequences. The nerve then proceeds from the infratemporal fossa to the oral cavity. It seeks the most posterior portion of the mylohyoid muscle and proceeds on its surface close to the lingual cortex of the third molar tooth (alveolar portion).

The alveolar portion of the lingual nerve is the most injured, particularly during removal of an impacted third molar tooth. The nerve then continues on the surface of the hyoglossus muscle (floor of the mouth portion). The lingual nerve sends its branches to the anterior two-thirds of the tongue, the mucosa of the floor of the mouth, and the lingual gingiva. Severing of the alveolar portion of the lingual nerve will deprive the patient of not only general sensory functions (pain, temperature, pressure, touch), but also taste to the anterior two-thirds of the tongue (fibers of the chorda tympani nerve branch of the facial nerve), and autonomic parasympathetic secretomotor function to the submandibular and sublingual salivary glands (fibers of the chorda tympani nerve carried by the lingual nerve). Some patients also suffer from post-traumatic neuralgia and severe intolerable pain. Incision at the retromolar pad should be done buccally and in layers before reaching bone in order to avoid injury to the lingual nerve.

Mylohyoid Nerve

The mylohyoid nerve is a motor branch of the inferior alveolar nerve given off before the nerve enters the inferior alveolar canal. The nerve follows the path of the submental artery branch of the facial artery in the submandibular triangle, and supplies the anterior belly of digastric and mylohyoid muscles.

Long Buccal Nerve

The long buccal nerve is a branch of the mandibular nerve (V3) given off in the infratemporal fossa. It appears between the superior and inferior heads of the lateral pterygoid muscle and then proceeds by crossing the retromolar triangle close to the medial tendon of the temporalis. The latter guides the nerve to the lateral surface of the buccinators. The nerve supplies the skin of the cheek and runs down to the level of the external oblique ridge, penetrates the buccinators, and branches to supply the mucosa of the cheek and buccal gingivae opposite the lower molar teeth. Implant dentists who extend the incision along the ramus in order to obtain a large ramus block for grafting should be aware of the crossing of the long buccal nerve and vessels at the retromolar triangle area. Unfortunately, the location of the nerve crossing is inconsistent. It may cross high and close to the coronoid process, at the middle, or close to the base of the retromolar triangle.

BLOOD SUPPLY TO THE MANDIBLE

The mandible receives its arterial blood supply from the inferior alveolar artery branch of the internal maxillary artery [10–12]. It also receives a supplemental blood supply from the arteries supplying the muscles attached to its surface. Cadaveric studies after perfusion of the arteries with radiopaque polymer showed clearly that the lingual cortex at the symphyseal area of the mandible receives branches from the sublingual and submental arteries. The lingual artery has two terminal branches. The lingual profunda branch enters the tongue, while the sublingual artery runs on the superior surface of the mylohyoid muscle. The sublingual artery anastomoses with the contralateral artery at the mid-line of the lingual surface of the symphyseal area of the anterior mandible, and gives rise to small arteries that enter the mandible through a median lingual foramen to aid in the arterial supply of the anterior mandible.

Many cadaveric studies have shown that the submental artery branch of the facial artery sends perforating arteries through the mylohyoid muscle, supplements the blood supply to the floor of the mouth, and contributes to the lingual plexus. The microvascular canals that penetrate the lingual cortex of the symphysial area from the lingual plexus of the anterior mandible can be clearly detected by CBCT (Figure 2.19). Lingual perforation during implant surgery may injure these arteries. Hemorrhage in the floor of the mouth from these

FIGURE 2.19 (A, B) Cone beam computed tomography cross-sectional images of the anterior mandible, showing branches of the sublingual artery penetrating the lingual cortex and extending inside the medullary bone compartment. *Source*: Courtesy of Dr. Len Tolstunov.

Dentlearn.ir

FIGURE 2.20 Coronal cut of the mandible at the second molar region, showing the relationship of the facial artery below the mylohyoid muscle to the lingual cortex of the mandible. This area of the mandible is thinner because of the presence of the submandibular fossa. Perforation of the lingual cortex during *implant insertion* may lead to severe hemorrhage at the submandibular region.

arteries under the tongue may lead to hematoma in the sublingual surgical space and a swollen tongue, which may result in airway obstruction. Hemorrhage from the inferior alveolar artery within the bone should be controlled by crushing bone around the vessels or using bone wax. The facial artery passes through the submandibular gland and exits lingual to the mandible under the mylohyoid muscle at the second molar region. Insertion of a dental implant at this region may perforate the mandible and lead to facial artery hemorrhage in the submandibular region (Figure 2.20).

SUMMARY AND CONCLUSIONS

The root of the zygoma is a palpable intraoral bony landmark of surgical importance. It represents the location of the apex of the maxillary sinus. The root of the zygoma divides the lateral wall of the maxilla into anterior-lateral and posterior-lateral walls. Between the root of the zygoma and the canine eminence is the canine fossa or the site of lateral window access to the maxillary sinus. Accessing the canine fossa through the mucoperiosteal flap may detach the caninus muscle and may cause injury to the infraorbital neurovascular bundle. Therefore, clinical location of the infraorbital foramen and marking it on the skin prior to accessing the canine fossa are important safeguards to avoid injury to the infraorbital nerve and vessels.

The vestibular fornix (mucobuccal fold) locates a plane that divides the maxilla into an intraoral part covered by oral mucosa and a subcutaneous part. The facial fornix between the right and left premolars has no muscle barrier, while the posterior fornix at the molars has the buccinators as a barrier. Surgical manipulation at the premaxilla may cause facial swelling that may spread to the lower and upper eyelids. Violation of the attachment of the buccinators opposite the posterior edentulous ridge may injure the superior alveolar artery and nerve at the posterior wall of the maxillary sinus.

Buccal mucoperiosteal flap reflection may violate the buccinators' origin from the external oblique ridge, particularly in cases of partial or complete loss of the alveolar process of the edentulous mandible. Surgical manipulation at this site may injure or sever the marginal mandibular motor nerve, facial artery, and facial vein at the second molar region. On the lingual side of the mandible, the operator must be aware of the location of the superior genial tubercles and the attachment of the genioglossi muscles. Severing of the genioglossi tendons will cause fall-back of the tongue and airway obstruction. Incision at the retromolar pad and/or surgical manipulation lingual to the third molar region may cause injury to the lingual nerve. Extension of a retromolar incision along the anterior border of the mandible may sever the buccinator fibers and the long buccal neurovascular bundle as it crosses the retromolar triangle. Insertion of a dental implant in the mandibular second molar region of an atrophied mandible may perforate the lingual cortex and injure the facial artery, causing a serious hemorrhage in the submandibular region.

A surgical procedure aimed at accessing the symphyseal bone of the mandible for harvesting an autologous bone block graft will expose the mentalis muscles. If the mentalis muscles are detached during surgery, effort should be made to resuture them to the periosteum, or an elastic bandage should be applied to the chin for at least four days. Failure to do this may result in a double chin appearance.

Partial or complete loss of the alveolar bone at the mandibular premolar region may bring the mental neurovascular bundle close to or at the crest of the ridge. Therefore, an incision at the crest of the ridge without pre-operative CBCT imaging may injure or sever the mental nerve and vessels.

Knowledge of the applied surgical anatomy of the maxilla and mandible is the foundation of safe oral surgery. Such knowledge will make the operator aware of the anatomical locations of muscles, nerves, and vessels during surgery and therefore avoid unnecessary injury to these vital structures, which could have serious consequences such as hemorrhage, paresthesia, anesthesia, and post-traumatic neuralgia.

ACKNOWLEDGMENTS

The author wishes to thank Brittany King for her skillful and careful preparation of the original illustrations for this chapter and Linda Cullum for her excellent secretarial assistance.

Dentlearn.ir

REFERENCES

1. Misch CE. Density of bone, its effect on treatment planning surgery, healing, and progressive bone loading. *Int J Oral Implantol.* 1990;6:23–31.
2. Misch CE. Rationale for dental implants. In CE Misch (ed.), *Contemporary Implant Dentistry*, 3rd edn. St. Louis, MO: Elsevier; 2009, 3–25.
3. Atwood DA, Coy WA. Clinical cephalometric and densitometric study of reduction of residual ridges. *J Prosthet Dent.* 1977;26:280–99.
4. Atwood DA. Reduction of residual ridges: A major oral disease entity. *J Prosthet Dent.* 1971;29:266–79.
5. Atwood DA. Some clinical factors related to rate of resorption of residual ridges. *J Prosthet Dent.* 1962;12:441–50.
6. Bays RA. The pathophysiology and anatomy of edentulous bone loss. In RJ Fonseca, WH Davis (eds.), *Reconstructive Pre-Prosthetic Oral and Maxillofacial Surgery*. Philadelphia, PA: WB Saunders; 1986, 1–17.
7. Sharawy M. *Companion of Applied Anatomy*, 6th edn. Augusta, GA: Medical College of Georgia Printing Service; 2015.
8. Cutright B, Quillopa N, Schubert W. An anthropometric analysis of the key foramina for maxillofacial surgery. *J Oral Maxillofac Surg.* 2003;61:354–7.
9. Greenstein G, Marnow D. The mental foramen and nerve: Clinical and anatomical factors related to dental implant placement: A literature review. *J Periodontol.* 2006;77:1933–43.
10. Castelli W. Vascular architecture of the human adult mandible. *J Dent Res.* 1963;42:786–92.
11. Hellem S, Ostrup LT. Normal and retrograde blood supply to the body of the mandible in the dog. II. The role played by periosteo-medullary and symphyseal anastomoses. *Int J Oral Surg.* 1981;10:31–42.
12. Kalpidis CDR, Setayesh RM. Hemorrhaging associated with endosseous implant placement in the anterior mandible: A review of the literature. *J Periodontol.* 2004;75:631–45.

Dentlearn.ir

Radiographic Evaluation of the Alveolar Ridge in Implant Dentistry: CBCT Technology

CHAPTER 3

The goal of imaging is to replicate the anatomical truth (anatomy as it exists in nature) at a resolution that is acceptable for clinical applications. The anatomical truth includes the three-dimensional morphology, the anatomy during function (the fourth dimension), and the interaction of the relevant anatomical components (the fifth dimension).

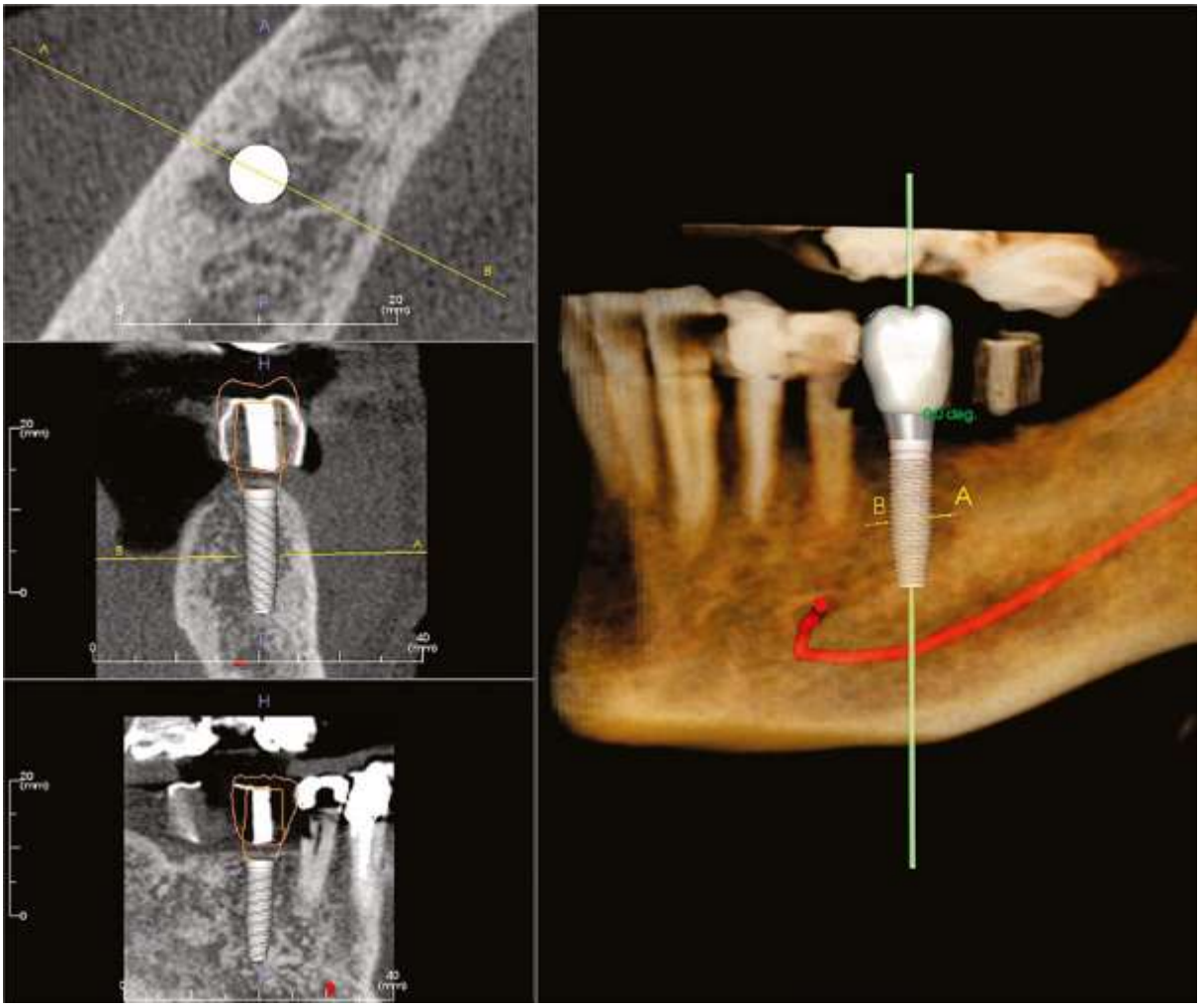

Dentlearn.ir

CHAPTER 3 Radiographic Evaluation of the Alveolar Ridge in Implant Dentistry: CBCT Technology

Shikha Rathi and David Hatcher

Private Practice, Diagnostic Digital Imaging, Sacramento, CA, USA

THE ROLE OF RADIOGRAPHY IN IMPLANT DENTISTRY

Radiography plays a pivotal role in the diagnosis and treatment planning required for the successful placement of an endosseous implant. Implant imaging goals must include determining bone height, width, quality, jaw shape and orientation, identification of anatomical boundaries, and ruling out pathology. Two-dimensional (2D) radiographs, such as panoramic and intraoral periapical x-rays, have been traditionally used for pre-operative implant site assessment. They are widely available, inexpensive, and well tolerated by patients. However, like all plain film radiographs, they are subject to anatomical superimposition and geometrical distortion, and are sensitive to positioning errors. Each examination has specific indications and limitations.

PERIAPICAL RADIOGRAPHY

The paralleling technique for periapical radiographs presents a reliable estimation of the object being examined in the vertical and mesio-distal dimensions. It provides high-resolution images with fine bony detail of the area being examined. The accuracy of linear measurements may be increased by calibration with a radiographic marker or metal grid of known dimensions [1]. The technique, however, permits only a limited area of the dentoalveolar region to be visualized and no cross-sectional (buccal-lingual) information is provided. Superimposition of anatomical structures can sometimes lead to an erroneous interpretation due to lack of information in the third (buccal-lingual) dimension (Figure 3.1A shows a periapical radiograph and Figures 3.1B and 3.1C show cone beam computed tomography (CBCT) images of the corresponding region). Periapical radiographs can be used for preliminary evaluation of an implant site and are indicated in the post-operative assessment of the bone–implant interface to evaluate for a lack of osseointegration or the presence of bone loss due to peri-implantitis.

PANORAMIC RADIOGRAPHY

Panoramic radiography gives a general overview of the jaws and relevant anatomical landmarks and can aid in the identification of gross pathological abnormalities in the jaws (Figure 3.2). They can provide an estimate of the ridge height at a specific location when a radiographic marker of known dimensions is used. However, measurements from panoramic radiographs have limited reliability and accuracy (Figure 3.3). Panoramic radiographs are associated with differential magnification and geometrical distortion, mainly in the horizontal (mesio-distal) direction; this varies in different regions of the jaws and from one piece of equipment to another. Errors may also be associated with patient positioning and discrepancies between the curvature of the dental arch and the focal trough of the machine. Accurate reproduction of the images is difficult and inconsistent. Panoramic radiographs also only provide information of the vertical and mesio-distal dimensions of a region, and do not offer cross-sectional (buccal-lingual) information. In cases of bony undercuts or knife-edged ridges, measurements from these images can be misleading (Figures 3.4 and 3.5). Due to its many inherent limitations, panoramic radiography is considered suboptimal as a single imaging source for pre-operative implant site assessment [2–4].

Essential Techniques of Alveolar Bone Augmentation in Implant Dentistry: A Surgical Manual, Second Edition. Edited by Len Tolstunov.
© 2023 John Wiley & Sons, Inc. Published 2023 by John Wiley & Sons, Inc.
Companion website: www.wiley.com/go/tolstunov/essential

Dentlearn.ir

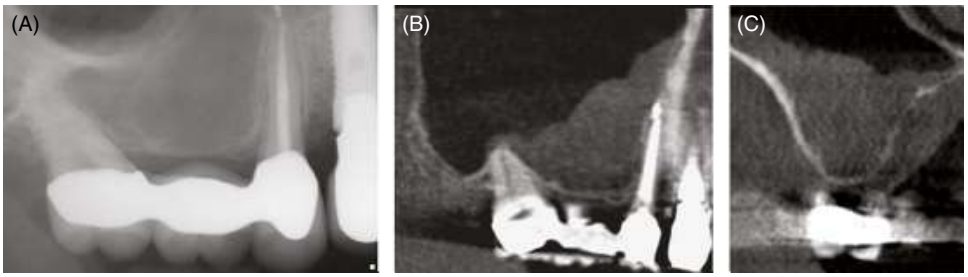

FIGURE 3.1 (A) Periapical radiograph of the right posterior maxilla with indistinct margins of the floor of the maxillary sinus and the alveolar crest in the region of the upper right first molar. (B) Sagittal view CBCT of the region showing marked atrophy of the alveolar ridge and pneumatization of the right maxillary sinus, with soft tissue collection within it. (C) CBCT cross-sectional (bucco-lingual) view of the area showing no residual ridge height and presence of sinus pathology. Superimposition of anatomical structures in conventional two-dimensional radiographs can mask pathology and make interpretation of landmarks difficult.

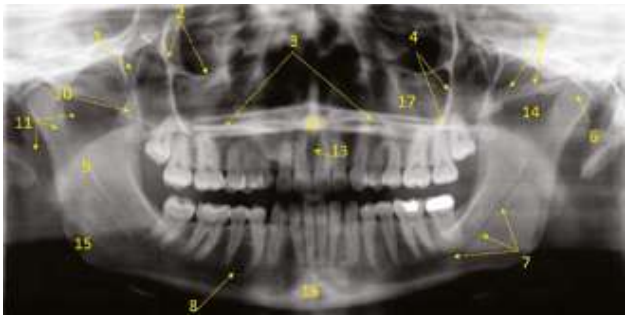

FIGURE 3.2 Panoramic anatomical landmarks: (1) pterygo-maxillary fissure; (2) orbital floor; (3) hard palate; (4) zygomatic process of the maxilla (malar process); (5) zygomatic arch; (6) condyle; (7) mandibular canal; (8) mental foramen; (9) mandibular foramen; (10) coronoid process; (11) pharyngeal air space; (12) anterior nasal spine; (13) incisive canal; (14) mandibular notch; (15) mandibular angle; (16) genial tubercles; (17) maxillary sinus.

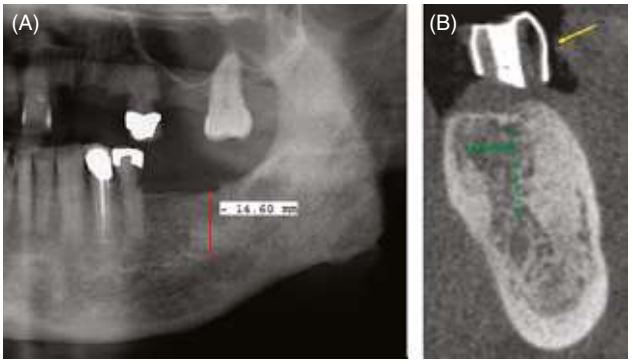

FIGURE 3.3 (A) Cropped panoramic image showing vertical bone measurement (of 14.6 mm) from the alveolar crest to the superior border of the mandibular canal in the region of the lower left second molar. Inconsistent magnification associated with the panoramic techniques makes measurements made on them unreliable. (B) CBCT cross-section of the same region showing a measurement of 12.84 mm. The arrow points to the radiographic marker indicating the position and trajectory of the proposed implant.

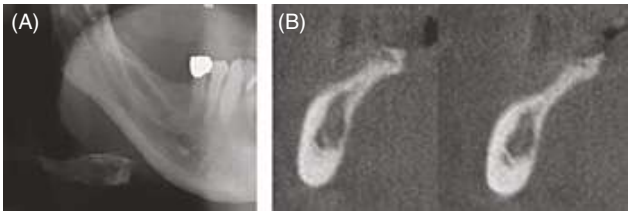

FIGURE 3.4 (A) A cropped panoramic of the right posterior mandible with missing lower right first, second, and third molars. (B) CBCT cross-sections in the region of the lower right first and second molars. Note the lingual projection of the narrowed ridge and large lingual undercut representing the submandibular fossa. The major limitation of panoramic radiography is that bucco-lingual assessments cannot be made.

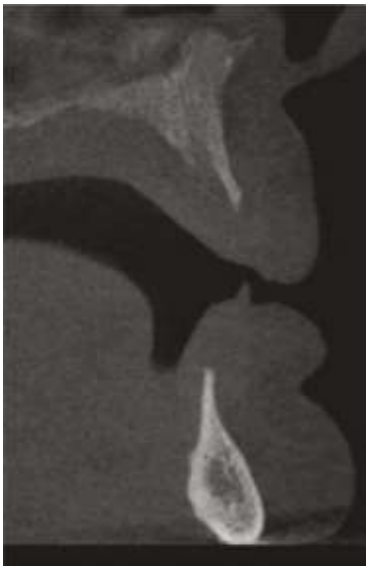

FIGURE 3.5 CBCT cross-section of the anterior maxilla and mandible showing a knife-edged ridge. Panoramic and periapical radiographs only provide information on the bone height but not on bone width.

Dentlearn.ir

OCCLUSAL RADIOGRAPHY

Occlusal radiographs provide information on the general shape of the dental arch and its *maximum* buccal-lingual dimension. However, no information about bone morphology, angulation, or undercuts is provided. Maxillary images are inherently oblique and therefore distorted. Occlusal radiographs may offer limited usefulness in post-operative assessment of implant positioning in the buccal-lingual dimension.

CONE BEAM COMPUTED TOMOGRAPHY

The introduction of CBCT has overcome the shortcomings of conventional radiography and has established a new era of implant imaging [5–8]. The technology has improved diagnostic information and treatment outcomes due to visualization of the anatomy at potential implant sites in three dimensions with sub-millimeter accuracy [9]. Software programs possess versatile reformatting capabilities that allow slicing of the scan to be performed in any plane; this can be done to obtain sectional images in the optimum orientation for implant site assessment. Interactive treatment simulation software also enables virtual implant planning that can be transferred to a surgical guide to be used in executing the treatment plan at surgery. More recently, CBCT data has been integrated with surgical navigation systems to perform computer-guided implant placement without the use of surgical guides. This chapter emphasizes the role and applications of CBCT in the planning and placement of implants.

ANATOMICAL AND ARCHITECTURAL CONSIDERATIONS FOR TREATMENT PLANNING

Pre-operative treatment planning necessitates obtaining thorough knowledge on the anatomical appearance, location, dimensions, and variations of critical structures that are routinely encountered during implant placement. This information is crucial in determining implant length, size, and angulation for long-term implant function and esthetics, and in lowering the risk of complications. In addition to evaluation of internal anatomy, consideration should be given to jaw shape, orientation, and boundaries; this assessment is necessary since the clinical examination may not reveal the underlying osseous contours. The canine fossa on the labial surface of the anterior maxilla and the submandibular fossa on the lingual surface of the posterior mandible are common normal anatomical depressions; however, shallow or deep facial and lingual fossae may be present in any area of the jaws. The vertical long axis of the mandible has a lingual angulation that is more pronounced in the posterior regions (Figure 3B). Atrophy of the alveolar ridge occurs to a greater extent in the mandible than in the maxilla and atrophy reduces bone width more than bone height. Cross-sectional imaging is essential in the visualization of anatomical structures and morphological changes to the residual ridges [5]. Implant placement beyond the anatomical boundaries may result in neurovascular injuries that can lead to inflammation and infection with ultimate loss of implant, compromised or complete loss of sensation, and even life-threatening events. Some of the anatomical structures that are commonly encountered during implant site assessment are discussed here.

ANTERIOR MAXILLA

NASOPALATINE (INCISIVE) CANAL

The nasopalatine canal is located at the anterior mid-line of the maxilla, posterior to the central incisor teeth (Figure 3.6A–D), and is formed by the union of the two palatal processes of the maxilla. The nasopalatine canal transmits the nasopalatine nerve (V2 sensory branch) and the terminal branch of the nasopalatine artery. The canal extends from the nasal floor and emerges on the hard palate through the nasopalatine (incisive) foramen. In this foramen, the orifices of two lateral canals are usually visible; these are the canals of Stensen (Figure 3.6E). Occasionally, two additional minor canals, canals of Scarpa, are seen in the mid-line; they serve as passageways for the nasopalatine nerves.

The diameter of the nasopalatine foramen is typically below 6 mm; when it exceeds 8–10 mm, pathological conditions such as nasopalatine duct cysts should be considered. The average length of the canal is reported to be ~8–10 mm and it is situated ~7.4 mm from the labial surface of an unresorbed ridge [10]. The nasopalatine canal tends to enlarge in all dimensions with increasing age and progressive ridge atrophy after tooth loss in the anterior maxilla [11]. Perforation of the incisive canal by dental implant may happen intraoperatively if the canal is enlarged and is encroaching on the central incisor space (Figure 3.6F). Pre-operative analysis of the CBCT scan prior to surgery helps to avoid this complication.

CANALIS SINUOSUS

The anterior maxillary region also contains the anterior superior alveolar (ASA) nerve and artery in a bony canal named the canalis sinuosus (Figure 3.7A). Along with the nasopalatine nerve and vessels, these supply the incisors and canines, as well as the adjacent soft tissues. The canal is present along the lateral nasal wall and follows the curve of the narial margin. A palatine extension of the canalis sinuosus may sometimes be present in the anterior region of the palate [12]. Figure 3.7B is a para-sagittal view CBCT showing perforation of the posterior superior alveolar (PSA) canal by a dental implant in the left posterior maxilla.

Dentlearn.ir

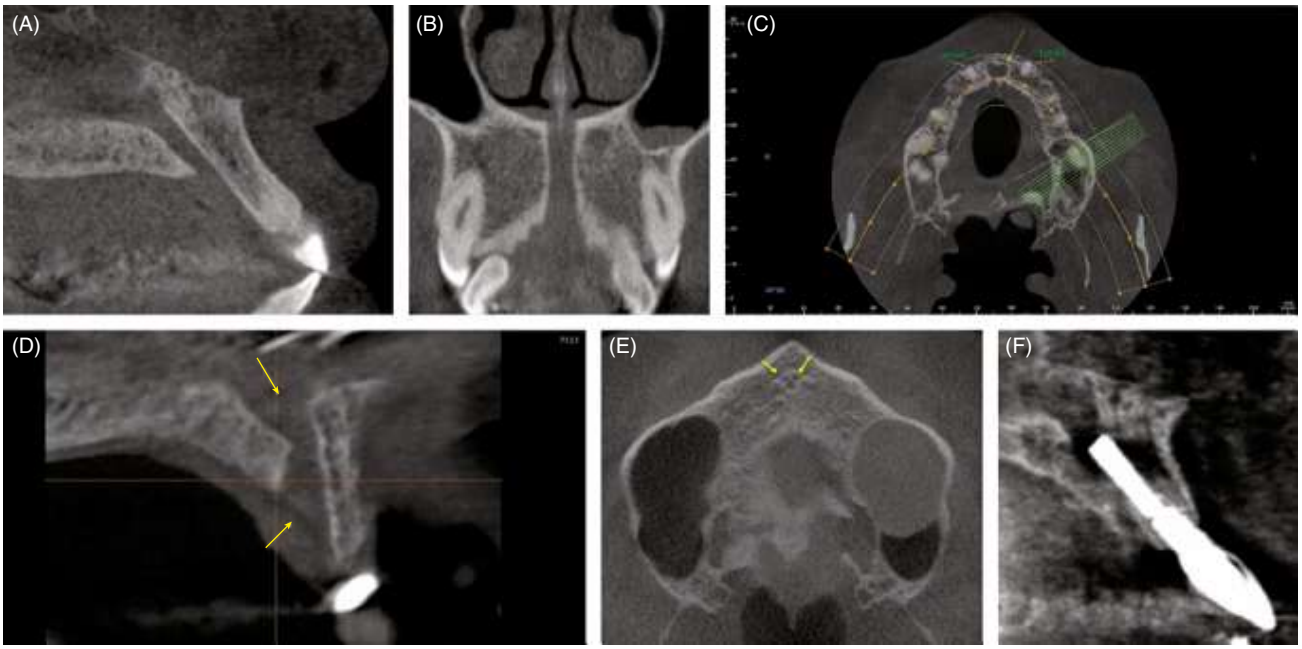

FIGURE 3.6 (A) Mid-sagittal view CBCT showing the incisive canal located palatal to the maxillary central incisors. (B) Coronal view CBCT showing the incisive canal extending from the floor of the nasal cavity to the incisive foramen. (C) Axial view CBCT showing an enlarged nasopalatine canal. (D) Mid-sagittal view CBCT showing an enlarged incisive canal. (E) Two lateral canals within this incisive foramen, on each side of the mid-line (arrows). These represent the foramina of Stensen, which transmit the nasopalatine nerves and the terminal branch of the descending palatine artery. (F) Sagittal view showing perforation of the incisive canal by an implant.

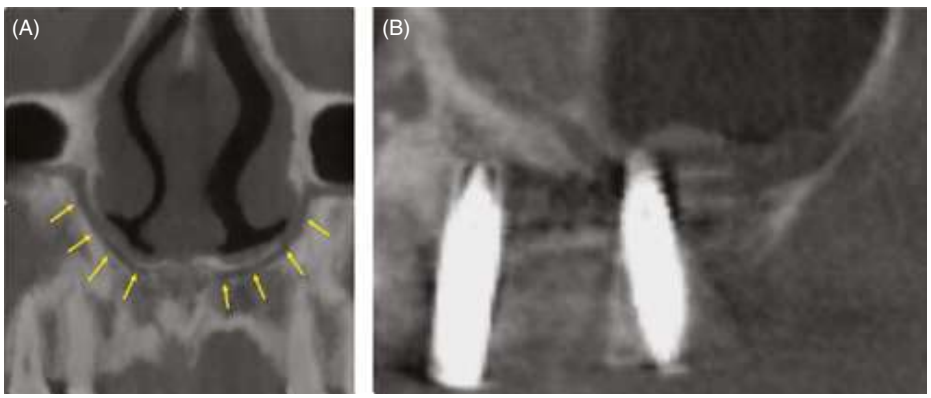

FIGURE 3.7 (A) Coronal view CBCT showing the location of the canalis sinuosus containing the anterior superior alveolar canal (arrows) along the lateral walls of the nasal cavity. (B) Para-sagittal view CBCT showing perforation of the posterior superior alveolar canal by an implant in the left posterior maxilla.

ANTERIOR NASAL SPINE AND NASAL FLOOR

The anterior nasal spine (ANS) is a sharp bony projection formed by the forward elongation of the maxillae in the mid-line at the anterior and inferior aspect of the nasal cavity (Figure 3.8).

The floor of the nasal cavity is a curved bony landmark located apical and palatal to the roots of the maxillary anterior teeth. Perforation of the nasal floor by an implant (Figure 3.9) may cause difficulty in nasal breathing and infection.

PATTERN OF RIDGE ATROPHY IN THE ANTERIOR MAXILLA

Atrophy of the anterior maxilla progresses from initial development of a labial concavity with development of a

Dentlearn.ir

FIGURE 3.8 Mid-sagittal view CBCT showing the anterior nasal spine in the mid-line on the anterior-inferior aspect of the nasal cavity.

bulbous alveolar crest. It proceeds to uniform thinning of the alveolar ridge until the residual ridge crest becomes knife-edged (Figures 3.5 and 3.10A). There is simultaneous progressive loss of bone height until the ridge involves the basal bone. In advanced cases, there may be resorption of the ANS and exposure of the nasopalatine foramen at the residual ridge crest. Buccal cortical plate is typically thin to begin with (Figure 3.10B) and becomes more resorbed with age, history of trauma (bike accidents, etc.), and loss of maxillary incisors and canines. This often leads to the necessity of bone grafting of the anterior maxilla if implant treatment is contemplated. Therefore, severely resorbed maxilla atrophies superiorly and posteriorly and maxillo-mandibular relations with loss of teeth and bone often become class III.

POSTERIOR MAXILLA

MAXILLARY SINUS

The maxillary sinus is the largest of all the paranasal sinuses and is pyramidal in shape. The sinus ostium is the opening of the sinus to the middle meatus of the nose (ostiomeatal complex, OMC) and is located on the medial wall of the superior aspect of the maxillary sinus (Figure 3.11). The mean distance from the most inferior point of the sinus floor to the ostium is 28.5 mm [10]. Evaluation of the patency of the osteo-meatal complex is important during pre-surgical planning for sinus augmentation, since a pre-existing sinusitis with an obstructed ostium (outflow) could increase the likelihood of a flare-up or graft failure after a sinus lift surgery (Figure 3.12). The normal width of the Schneiderian membrane is 0.3–0.8 mm [10]; sinus floor membrane thickening >5 mm has been reported to be associated with progressively increased risk for ostium obstruction. Membrane perforations occur in 10–60% of cases and are usually not significant. The risk for complications increases when the perforation is greater than 2 mm. Implant protrusion into the sinus (Figure 3.13) often does not cause sinus inflammation, but may exacerbate pre-existing sinusitis or result in new infection (Figure 3.14).

The sinus floor may be flat or oblique, and may extend between the roots of the maxillary posterior teeth. Sinus septation may be present on the sinus floor and the sinuses tend to get larger as they proceed medially. A sinus lift surgery should proceed lateral to medial over a partial septum instead of anteriorly to posteriorly to avoid a membrane perforation. When large or multiple longitudinal septa are present, more than one lateral window may be created anterior and posterior to them as part of the antral opening. Mucous retention pseudocysts are commonly found arising from the sinus floor; when small, these are not considered a risk factor for sinus surgery (Figure 3.15A shows a large pseudocyst that can

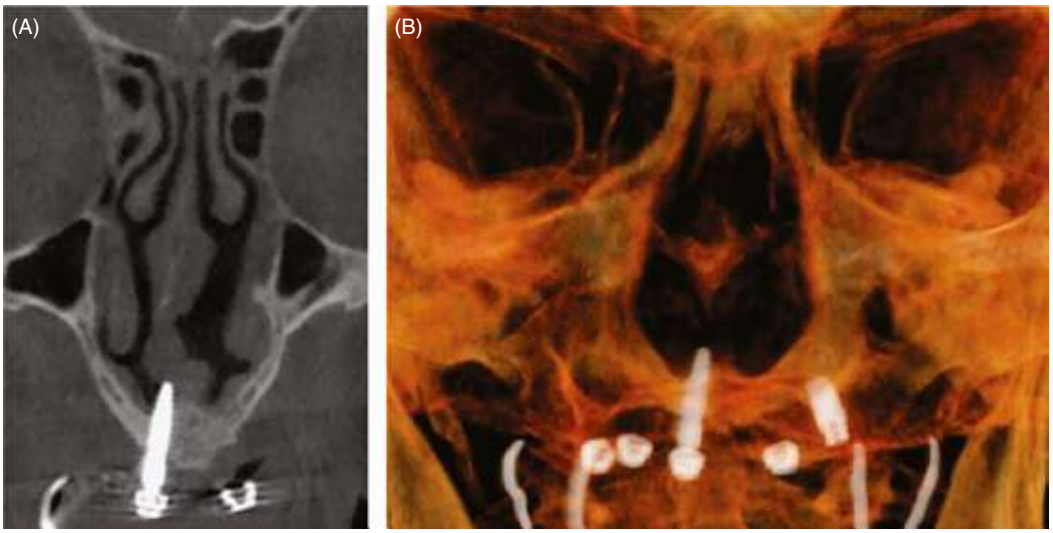

FIGURE 3.9 (A) Coronal view CBCT showing perforation of the floor of the right nasal cavity by an implant. (B) Volume rendered image of the same case.

Dentlearn.ir

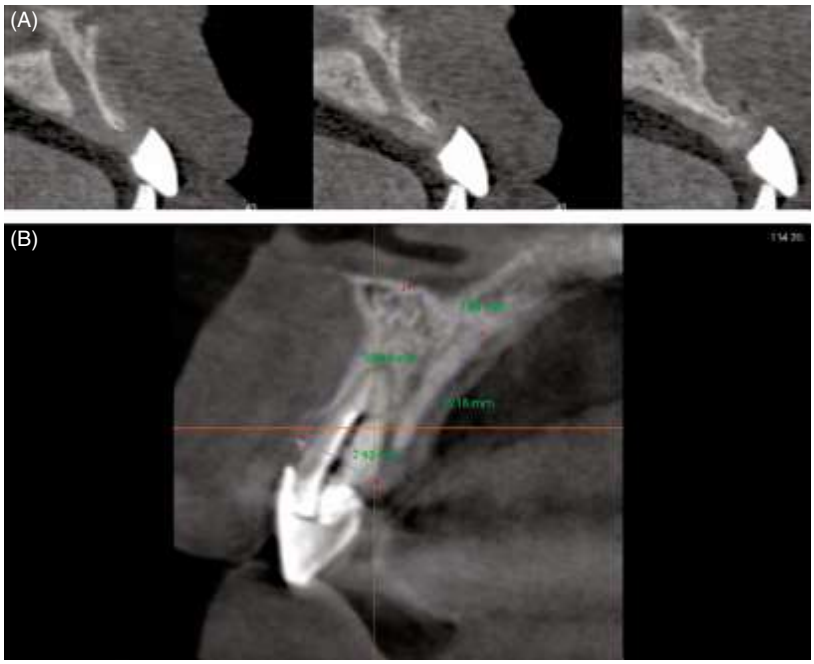

FIGURE 3.10 (A) CBCT cross-sections showing atrophy in the anterior maxilla. Note the marked labial resorption of the ridge with development of a labial undercut and a knife-edged crest. (B) Sagittal CBCT view showing thinning of the buccal cortical plate adjacent to the failing central incisor.

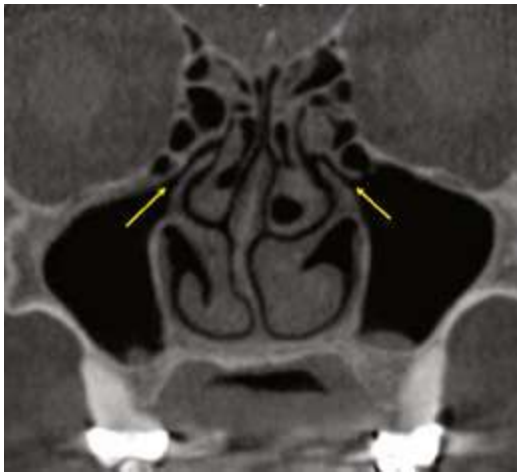

FIGURE 3.11 Coronal view CBCT showing paranasal sinuses with a patent osteo-meatal complex (arrows) on both sides. The complex is located on the superior-medial aspect of the maxillary sinuses and provides a pathway for drainage from the maxillary sinuses to the nasal cavity.

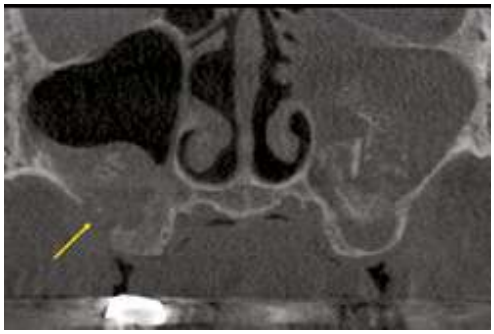

FIGURE 3.12 Coronal view CBCT showing dislodgment of the graft into the maxillary sinuses and resultant sinus infection, more pronounced on the left. Perforation of the sinus floor can be seen on the right side (arrow).

FIGURE 3.13 Sagittal view CBCT showing no sinus reaction in spite of three implants protruding into the maxillary sinus. Implant protrusion into the sinus cavities often does not result in sinus inflammation. The dark areas adjacent to the implants represent beam hardening artifact. The presence of these artifacts limit evaluation of the peri-implant bone on a CBCT.

Dentlearn.ir

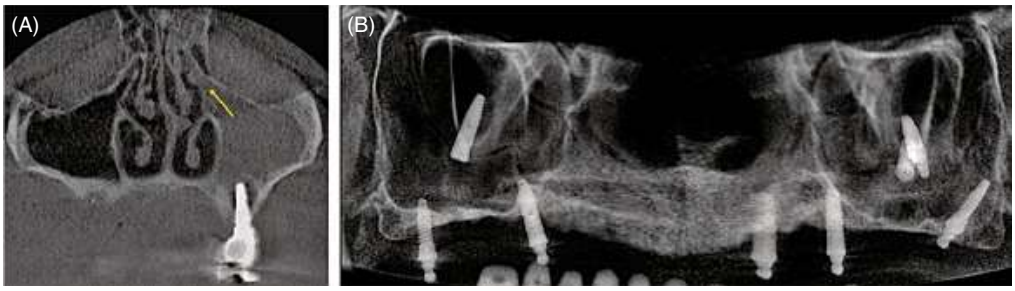

FIGURE 3.14 (A) Coronal view CBCT showing infection of the left maxillary sinus and obstruction of the osteo-meatal complex (arrow) due to implant perforation. (B) CBCT-generated panoramic showing dislodgment of three implants into the maxillary sinuses and perforation of the sinus floor by other implants.

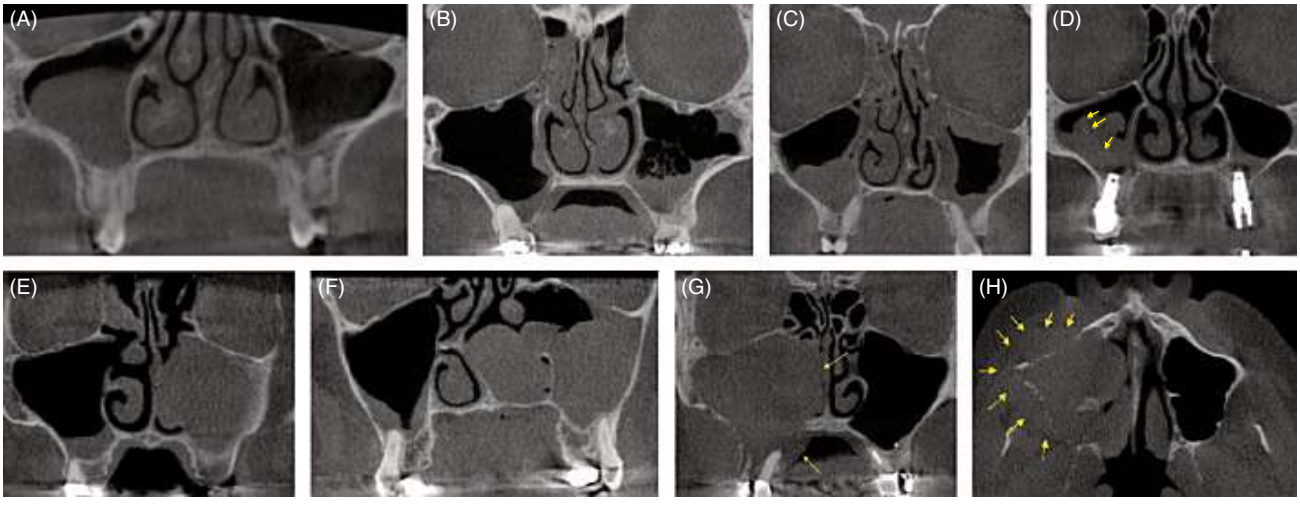

FIGURE 3.15 (A) Coronal view CBCT showing a large mucous retention pseudocyst in the right maxillary sinus. These can be raised to obstruct the osteo-meatal complex during a sinus lift procedure. (B) Coronal view CBCT showing acute rhinosinusitis with air bubbles in the left maxillary sinus. Acute rhinosinusitis presents with air-fluid levels, mucosal thickening, and air bubbles within the sinuses. (C) Coronal view CBCT showing chronic rhinosinusitis with soft tissue collection along the walls of the maxillary sinuses and in the ethmoid air cells. Chronic rhinosinusitis presents with thickened sinus mucosa, opacification, and/or sclerosis of the sinus walls. The degree of mucosal thickening is considered as normal (2–3 mm), mild (3–5 mm), moderate (5–10 mm), or severe (> 10 mm). (D) Coronal view CBCT showing fungal sinusitis in the right maxillary sinus. Fungal sinusitis often presents with polypoid soft tissue mass with diffuse, scattered calcifications within (arrows). Expansion, remodeling, sclerosis, thinning, or erosion of the sinus walls may be present. The osteo-meatal complex of the involved sinuses is almost always present. (E) Coronal view CBCT showing mucocele in the left maxillary sinus that invades into the left nasal cavity. Mucoceles are mucus-containing expansile lesions that are capable of bony destruction and compromise surrounding structures. (F) Coronal view CBCT of a polypoid lesion that extends from the left maxillary sinus into the left nasal cavity (antrochoanal polyp). Sinonasal polyposis demonstrates rounded, polypoid masses causing partial to complete sinus opacification and thickening/remodeling of sinus walls. (G, H) Coronal view and axial view CBCTs of a mucosal melanoma in the right maxillary sinus. Sinus malignancies are associated with destruction of the sinus walls with little or no expansion. Often there is infiltration into the adjacent soft tissues (arrows) through sieve-like penetrations in the sinus walls.

obstruct the OMC during sinus lift surgery). Other sinus pathology that can requires ear, nose, and throat (ENT) evaluation includes acute (Figure 3.15B) and chronic (Figure 3.15C) rhinosinusitis, fungal sinusitis (Figure 3.15D), mucocele (Figure 3.15E), sinonasal polyp (Figure 3.15F), and malignancy (Figure 3.15G, H).

The PSA canal is present within the postero-lateral wall of the maxillary sinus and contains the PSA nerve and blood vessels that supply the maxillary sinuses, alveolar bone, teeth, and surrounding soft tissues. In 20% of patients, the diameter of the PSA canal is >1 mm, large enough to cause bleeding and/or paresthesia if damaged during implant surgery [13] (Figure 3.7B shows perforation of the PSA canal by an implant in the left posterior maxilla).

GREATER PALATINE FORAMEN

The greater palatine foramen is located on the palatal aspect of the third molar, halfway between the alveolar ridge crest and the median palatal raphe (Figure 3.16). The greater palatine artery and nerve emerge from the foramen and traverse the palate anteriorly to reach the incisive canal.

Dentlearn.ir

FIGURE 3.16 Coronal view CBCT showing the greater palatine foramen (arrows) located on the palatal aspect of the third molars.

Severing the palatal artery close to the foramen may retract the artery into the bone, thereby making its ligation during surgery difficult.

PATTERN OF RIDGE ATROPHY IN THE POSTERIOR MAXILLA

Atrophy of the posterior maxilla progresses from the initial loss in bone width from the buccal aspect of the cervical third of the alveolar crest to a loss in ridge height from the alveolar crest and concomitant pneumatization of the maxillary sinus into the alveolar bone (Figure 3.1B). There is a tendency for a decrease in bone height and an increase in bone width from the premolar to the molar regions. With the progression of bone remodeling, there can be complete effacement of the alveolus, with only a thin layer of cortex separating the sinus and the alveolar mucosa (Figure 3.1C). Therefore, severely resorbed maxilla atrophies superiorly and posteriorly and maxillo-mandibular relations with loss of teeth and bone often become class III.

ANTERIOR MANDIBLE

MANDIBULAR INCISIVE CANAL

The incisive canal is present anterior to the mental foramen and typically narrows as it approaches the mid-line, usually terminating apical to the lateral incisor (Figure 3.17). The size of the canal is typically less than 1 mm, and as such it does not pose a risk for osteotomies that penetrate the canal.

LINGUAL FORAMEN AND LATERAL CANALS

Small vascular canals are often present at or near the mid-line of the mandible; a mid-line lingual foramen is present in 99% of cases (Figure 3.18). Sublingual arteries can extend into the anterior mandible, perforating the lingual cortex and providing blood supply for the anterior mandibular bone. Canals larger than 1 mm pose a risk for excessive bleeding during surgery. In addition, accessory foramina may be present in the lingual cortical plate of the anterior mandible, through which branches of the sublingual and submental arteries may enter the mandible. These vascular channels do not have resilient walls, as is common for arteries traveling in the soft tissue. Implant placements into, for example, the anterior mandibular bone that extends far down to these sublingual vessels, or inadvertent penetration into the floor of the mouth through the lingual cortex, can cause arterial trauma, thereby resulting in a sublingual or submandibular hematoma. The development of a hematoma can displace the tongue superiorly and posteriorly, thereby potentially causing an airway obstruction [14, 15].

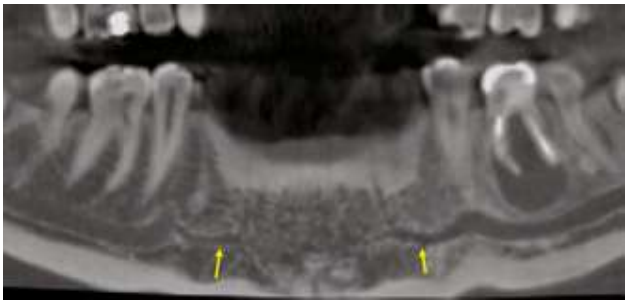

FIGURE 3.17 CBCT-generated panoramic section showing the mandibular incisive canal (arrows) extending anteriorly from the mandibular foramen toward the mid-line.

FIGURE 3.18 (A, B) Sagittal view CBCTs of the anterior mandible demonstrating the lingual canal and foramen (arrow) in the mid-line for sublingual arteries.

Dentlearn.ir

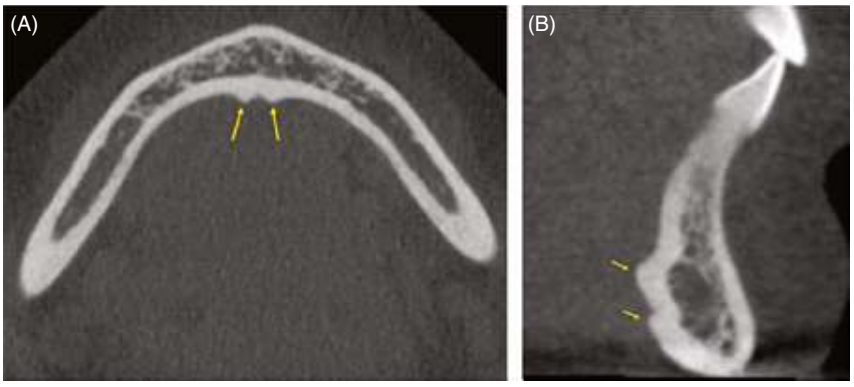

FIGURE 3.19 (A) Axial view CBCT showing two superior genial tubercles on either side of the mid-line in the anterior mandible (arrows). (B) Sagittal view of the anterior mandible demonstrating the superior and inferior genial tubercles (arrows).

GENIAL TUBERCLES

The genial tubercles are small, bony projections on the lingual surface of the inferior aspect of the mandible, on either side of the mid-line (Figure 3.19). There are two superior and two inferior tubercles and they serve as the points of attachment of the genioglossus and the geniohyoid muscles, respectively. The genioglossus muscle should not be completely reflected during flap elevation, because the tongue may retract to the posterior part of the throat and obstruct the airway.

PATTERN OF RIDGE ATROPHY IN THE ANTERIOR MANDIBLE

Bone loss causes progressive thinning of the alveolus labiolingually in the anterior mandible. The alveolar crest may become knife-edged (Figure 3.5) and is typically shifted labially due to the forces exerted by the tongue. Loss in bone height also occurs, with gradual flattening of the crest. In advanced cases, the lingual canal and the superior genial tubercle may become exposed to the ridge crest. Therefore, severely resorbed mandible atrophies inferiorly and anteriorly and maxillo-mandibular relations with loss of teeth and bone often become class III.

POSTERIOR MANDIBLE

INFERIOR ALVEOLAR (MANDIBULAR) CANAL

The inferior alveolar nerve (IAN), a branch of V3, enters the mandibular canal through the mandibular foramen on the medial surface of the ramus and exits through the mental foramen. The canal is ~3.4 mm wide and houses the nerve (~2.2 mm thick) along with an artery, vein, and lymphatic vessels [10]. The IAN crosses from the lingual side of the mandible to the buccal, and is usually located midway buccolingually in the first molar region. Canal bifurcation is seen in ~1% of patients (Figure 3.20) [10]. Injury to the IAN may occur when the canal is compressed or perforated (Figure 3.21) during implant surgery or placement. Complications range from hypoesthesia or paresthesia (reduced sensation) to anesthesia (complete loss of sensation). Painful (unpleasant) sensation can also occur and is called dysesthesia. The IAN terminates in the mental and incisive nerves in the premolar region [16]. The mental nerve exits the mental foramen and the canal continues anteriorly as the incisive canal.

MENTAL FORAMEN

The mental foramen is located on the buccal aspect of the mandible, at the apical region of the second premolar or between the premolars (Figure 3.22). The foramen is usually inferior to the apex of the premolars, but may be present superior to the apex or at its level [17]. It is typically located halfway between the alveolar crest and the lower border of the mandible [18].

The IAN may course anteriorly and inferiorly to the mental foramen and then loop back to emerge from the

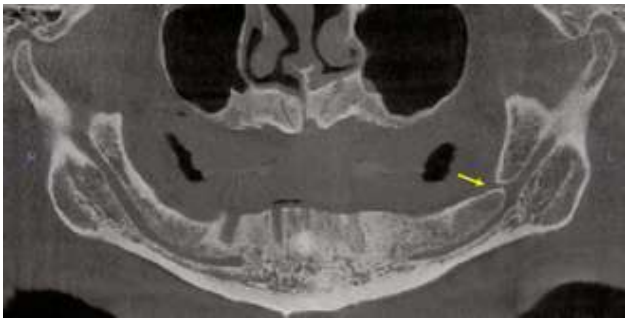

FIGURE 3.20 CBCT-generated panoramic cross-section showing an accessory branch of the mandibular canal (arrow) exiting at the alveolar crest.

Dentlearn.ir

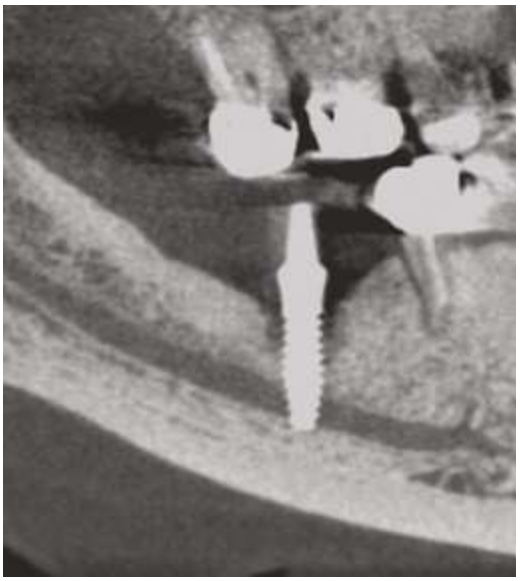

FIGURE 3.21 CBCT showing implant interrupting the superior and inferior borders of the mandibular canal. Perforation of the canal may result in mandibular nerve injury that could cause pain and paresthesia.

foramen. The anterior loop of the canal can be up to 4 mm in length.

SUBMANDIBULAR AND SUBLINGUAL FOSSAE

The submandibular fossa is a medial/lingual depression on the posterior aspect of the mandible and inferior to the mylohyoid line; it houses the submandibular gland (Figures 3.4 and 3.23). The sublingual fossa is a shallow depression in the canine-premolar region superior to the mylohyoid line; it houses the sublingual gland (Figure 3.24). The resultant lingual undercut gets deeper as it progresses distally from the premolar to the second molar region. It poses a risk for perforation of the lingual cortex and resultant hemorrhage during implant surgery.

LINGUAL NERVE

The lingual nerve is a branch of the mandibular nerve (V3) and provides sensory innervation to the mucous membranes of the anterior two-thirds of the tongue and to the lingual tissues. It is usually located 3 mm apical to the alveolar crest and

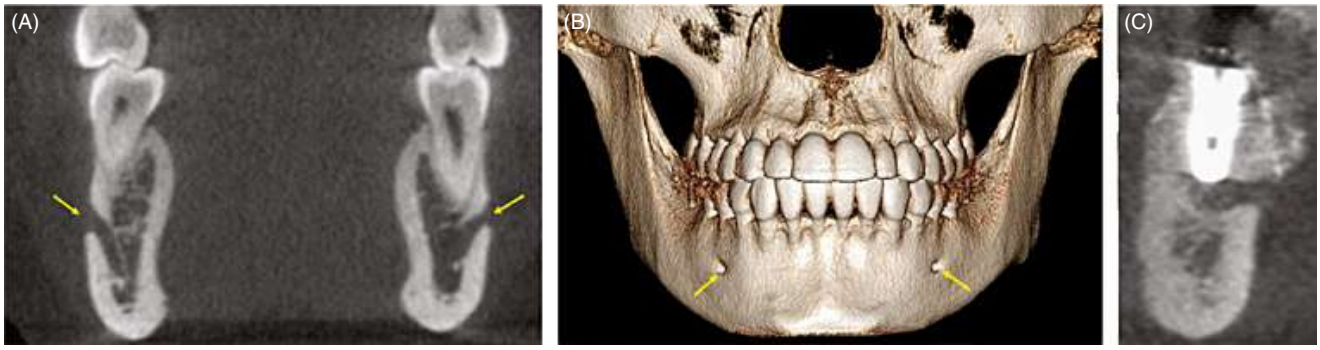

FIGURE 3.22 CBCT of the mental foramen on the apical aspect of the mandibular premolar exiting the bone on the buccal aspect. (A) coronal view. (B) Three-dimensional volume rendered view. (C) CBCT cross-section showing perforation of the superior aspect of the inferior alveolar nerve as it exits the mental foramen.

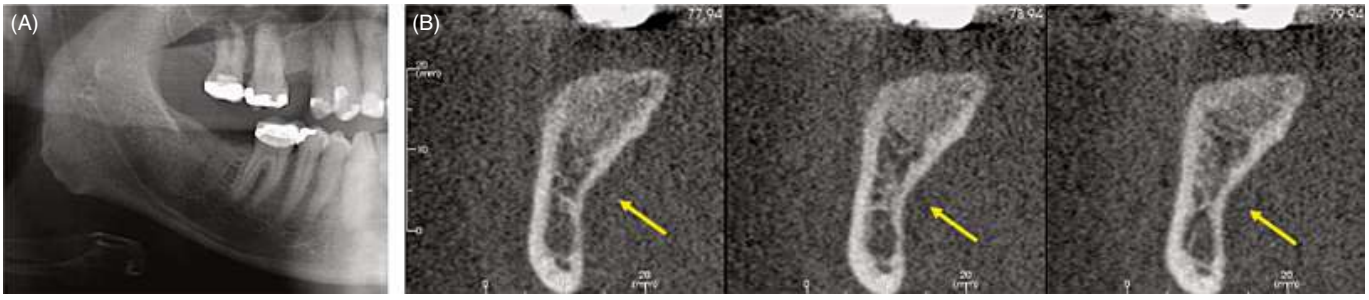

FIGURE 3.23 (A) Panoramic radiograph of the right side and (B) CBCT cross-sections in the region of the lower right second molar showing a lingual undercut (arrows) representing the submandibular gland fossa.

Dentlearn.ir

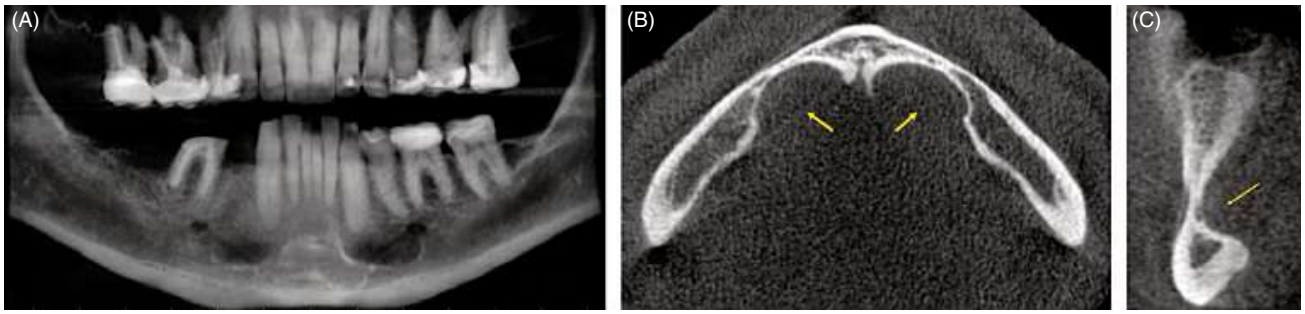

FIGURE 3.24 Bilateral large sublingual salivary gland depressions seen on CBCT. (A) Panoramic reformat. (B) Axial view showing anterior sublingual gland depressions (arrows). (C) Cross-sectional view in the region of the lower right canine showing the lingual depression (arrow).

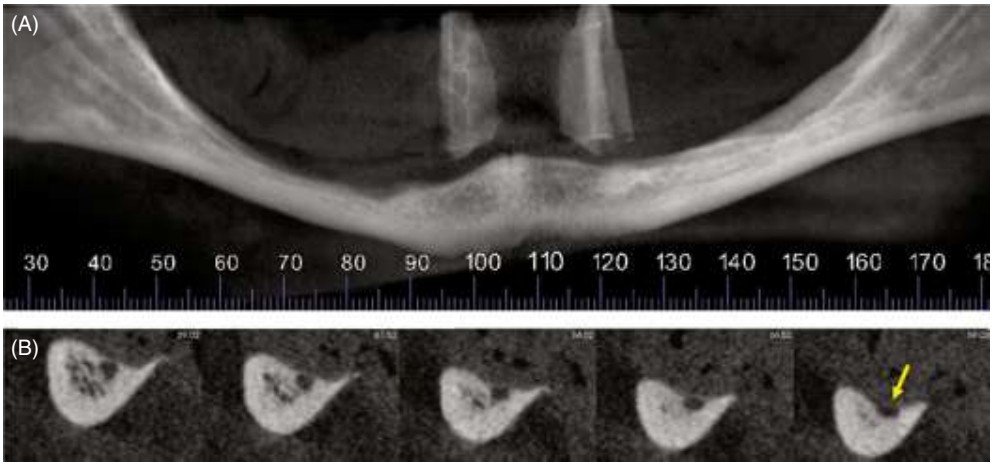

FIGURE 3.25 (A) CBCT panoramic of a severely atrophic mandible. (B) Cross-sections of the right posterior mandible exhibit loss in bone height that extends to the superior cortex of the mandibular canal. Note exposure of the mental foramen at the alveolar crest (arrow).

2 mm medial to the lingual cortical plate. In 15–20% of cases, it may be located at or above the crest lingual to the third molars. In 22% of cases, the lingual nerve may contact the lingual cortical plate [19].

PATTERN OF RIDGE ATROPHY IN THE POSTERIOR MANDIBLE

Bone loss results in thinning of the alveolar ridge in the buccolingual dimension and the ridge may become knife-edged. Lingualization of the crest may also occur, which can become more pronounced if the buccal plate of the alveolar bone is fractured during tooth extraction (Figure 3.4). Atrophic loss in ridge height ensues, which could extend down to the superior border of the mandibular canal and cause an eventual exposure of the mental foramen (Figure 3.25). As a rule, severely resorbed mandible atrophies inferiorly and anteriorly and maxillo-mandibular relations with loss of teeth and bone often become class III.

IMAGING CONSIDERATIONS FOR CBCT UTILIZATION

TECHNICAL CONSIDERATIONS

The *field of view* (FOV) on a CBCT scan for implant imaging should extend beyond the implant site to include adjacent structures that could affect implant surgery. The selection should, however, be limited to the smallest FOV necessary to minimize the radiation dose to the patient [20, 21].

The *voxel size* of a scan is the primary determinant of spatial resolution; the smaller the voxel size, the greater the scan resolution. A low scan resolution can reduce the accuracy of measurement and the visualization of the adjacent anatomical boundaries. Selection of a smaller voxel size is typically associated with an increase in radiation dose due to the increase in mA (tube current) or scan time required to maintain adequate image quality. A voxel size of 0.2–0.3 mm is considered a good compromise between image quality and radiation dose for implant scanning [22].

Dentlearn.ir

All CBCT scans are subject to *artifacts* emerging from dense materials such as implants, cast restorations, and gutta percha that degrade image quality in the affected area. *Beam hardening* artifacts appear as dark bands adjacent to the high-density object. Bone or tooth structures adjacent to the high-density areas may appear "burned out" or missing (Figure 3.13), which may mimic disease [23]. *Streak* artifacts appear as light and lines arising from a dense source object (Figure 3.26). The presence of these metallic artifacts limits the evaluation of trabecular bone in the adjacent region during pre-surgical assessment, and also limits the evaluation of peri-implant bone defects or osseointegration during post-surgical assessment. For this reason, intraoral periapical radiographs should often be utilized for post-operative implant evaluation for osseointegration [24].

BONE QUALITY AND BONE DENSITY ASSESSMENT

Bone quality comprises the thickness of cortical bone as well as the characteristics and patterns of trabecular bones and contributes to the stability of implants [25]. Successful implant integration is dependent upon the type and density of bone at an implant site. The mean bone density is greatest in the anterior mandible, followed by the anterior maxilla, and is least in the posterior maxilla. For implant placement, the most critical area for bone density assessment is the crestal 7–10 mm of bone, since this is the region where stresses are applied to the bone–implant interface. Hounsfield units (HU) are standardized objective measurements in medical CT that represent the relative density of bony tissues according to a calibrated gray-scale level. Density numbers measured in CBCT represent the gray-scale level and do not directly correspond to HU. They are influenced by exposure parameters, image artifacts, and increased level of scatter in CBCT scans; for these reasons, *density measurements are unreliable in CBCT* and evaluation is only subjective [26].

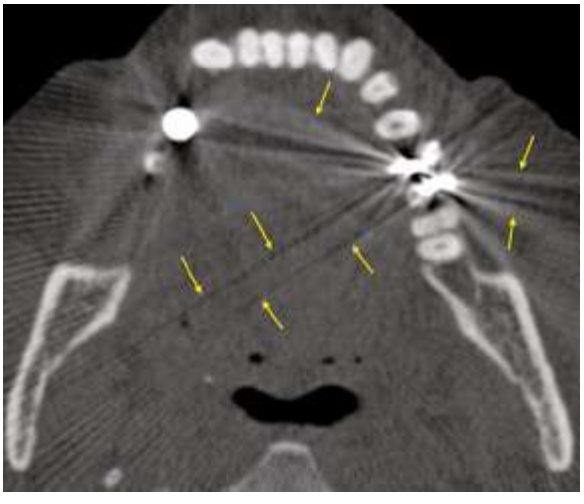

FIGURE 3.26 Axial view CBCT showing metallic streak artifacts that appear as light and dark lines arising from a dense object (arrows).

PATHOLOGY DETECTION

Successful implant placement and retention may be compromised in the presence of a disease process or an abnormal condition involving the implant site. These may include retained root fragments, inflammatory processes, fibro-osseous lesions, cysts, neoplasms, dense bone islands, and systemic conditions causing abnormal bone density. In addition, anomalies involving other significant maxillofacial structures, such as maxillary sinuses and the temporomandibular joint (TMJ), may interfere with or be exacerbated by implant placement. Due to its high accuracy and precision in portraying bony detail, CBCT can identify or rule out the presence of osseous pathology or abnormality at an implant site (Figure 3.15 demonstrates various types of sinus pathology).

RADIATION DOSE

The radiation dose from CBCT scans varies considerably, depending on the scanner used and the imaging protocols selected. With the continuing development of technology, radiation doses are steadily declining. Further dose reduction during a scan can be done by limiting the FOV to the area of interest, or by reducing the mA or scan time. Increasing the voxel size indirectly reduces the radiation dose [27–30]. A careful selection of exposure protocols should be made dependent on patient size, age, and the image quality required. In recent years, the media has highlighted the potential danger of radiation exposure from dental imaging. This has served to remind the community that the ALARA ("As Low As Reasonably Achievable") principle with dose reduction strategies should be applied whenever possible while maintaining diagnostic image quality.

Table 3.1 compares the effective radiation dose from different imaging modalities and background radiation [27–30]. The data includes some of the higher-dose CBCT machines that have been discontinued. It also does not consider the variability in CBCT dose introduced due to technique selection. Limiting the FOV and adjusting the scan protocol for patient size and age can significantly reduce the CBCT dose without a considerable effect on image quality.

INTERACTIVE IMPLANT TREATMENT PLANNING

The concept of implant placement in the area of maximum bone volume over the last 20 years has been replaced by a prosthetically driven (crown-to-bone) approach of implant

Dentlearn.ir

Table 3.1 Effective radiation doses from different imaging modalities and background radiation: comparison.

Examination	Effective dose
CBCT – small and medium volumes (FOV <10 cm)	11–674 μSv (median value 61 μSv)
CBCT – large volumes (FOV >10 cm)	30–1073 μSv (median value 87 μSv)
Panoramic	9–26 μSv
FMX – PSP plates/F-speed film, rectangular collimation	34.6 μSv
FMX – PSP plates/F-speed film, round collimation	170.7 μSv
FMX – D-speed film, round collimation	388 μSv
Medical CT	280–1410 μSv
Daily background radiation in USA	8 μSv

CBCT, cone beam computed tomography; CT, computed tomography; FMX, full-mouth x-rays; FOV, field of view; PSP, photo-stimulable phosphor.

placement in order to incorporate the functional, restorative, and esthetic requirements into overall implant diagnosis and treatment planning. Radiographic guides with markers (constructed from a pre-planned wax-up of the shape of the final restoration on a diagnostic cast) can be used during scan acquisition to transfer the prosthetic plan to the CBCT scan (Figure 3.3B). The marker aids in accurate localization of the desired placement position and angulation of an implant on a CBCT scan and permits assessment of the bone availability and adjacent anatomical boundaries in the area. In this way, the need for bone augmentations or other treatment modifications can be determined presurgically to allow restoratively optimal implant placement and an accurate emergence profile.

The preliminary step in implant planning on a CBCT scan is *proper scan orientation* so as to create accurate cross-sections in the area of implant placement. This is required so that assessment can be performed perpendicular to the long axis of the planned implant. Cross-sections that are not correctly reformatted can lead to erroneous measurements at the proposed implant site [31]. Accurate implant site evaluation requires that scan orientation be based on the following principles:

- The axial and coronal planes of the scan should be aligned with the patient's mid-line.
- The sagittal plane of the scan should be oriented such that the occlusal plane of the implant arch is parallel antero-posteriorly to the horizontal axis (axial plane) (Figures 3.27 and 3.28).
- The sagittal plane should also be adjusted so that the roots of the adjacent teeth are parallel to the long axis of the implant site and to the coronal plane.
- Cross-sections should be created to be perpendicular to the curve of the arch (Figure 3.29).

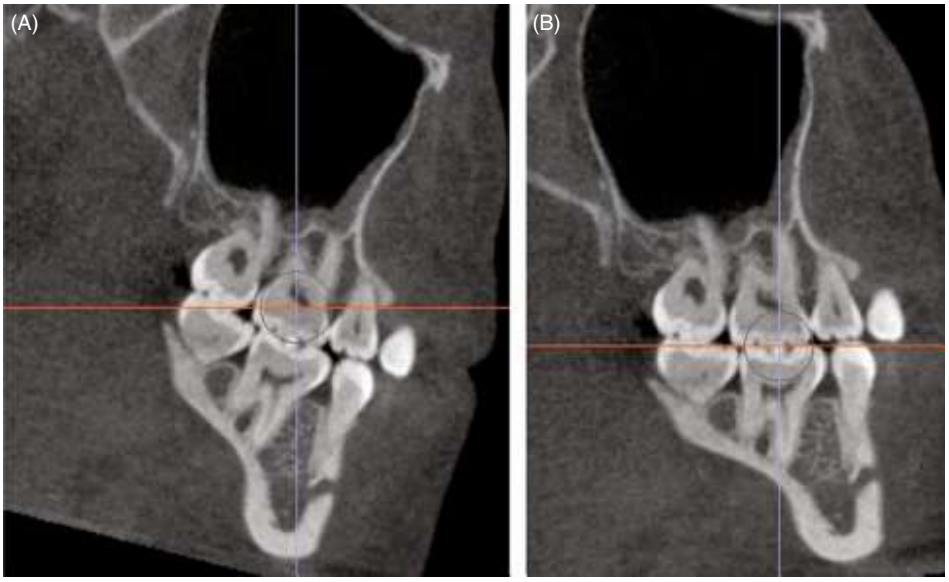

FIGURE 3.27 Orienting the sagittal tilt on a CBCT scan. (A) Sagittal view showing an incorrect scan orientation due to the sagittal tilt tipped forward (chin down), resulting in an occlusal plane that is not parallel to the horizontal axis. (B) Sagittal view showing correct scan orientation with the occlusal plane parallel to the horizontal axis.

Dentlearn.ir

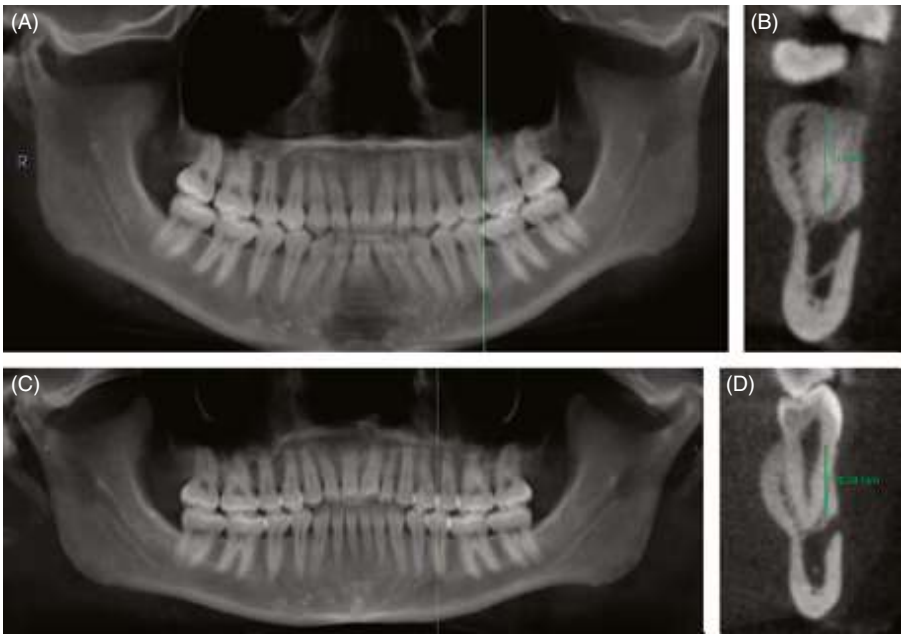

FIGURE 3.28 (A) CBCT-generated panoramic with incorrect sagittal tilt (corresponding to Figure 3.27A) that results in (B) a cross-section in the region of the lower left second premolar to have greater bone height. (C) CBCT-generative panoramic with corrected sagittal tilt (corresponding to Figure 3.27B) that results in (D) a cross-section in the region of the lower left second premolar to have the correct bone height, as it cuts in the same trajectory as the long axis of the tooth in question or of an implant that would be planned in the region.

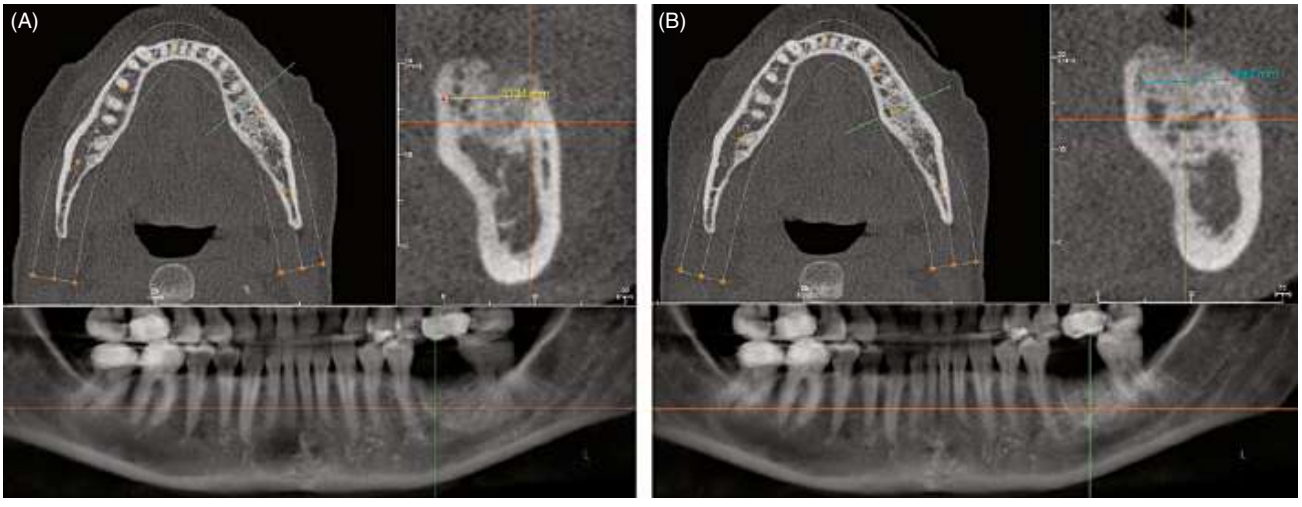

FIGURE 3.29 Cross-sections generated for bone width measurement should be perpendicular to the dental arch. (A) An incorrectly created focal trough on an axial view can give an impression of greater bone width than is present. (B) CBCT images showing a correctly traced focal trough on an axial image resulting in a cross-section that accurately represents bone width at the implant site.

- The cross-section in the center of the interdental space, level with the implant trajectory, should be used for measurements.

The use of a radiographic guide during image acquisition facilitates correct scan orientation and creation of appropriate cross-sections for measurements.

CBCT-reconstructed panoramic images may be distorted since they represent curved three-dimensional (3D) anatomy; hence measurements on these may be incorrect. They can, however, be used to cross-reference the location of a cross-sectional image in the mesio-distal dimension (Figure 3.25).

Dentlearn.ir

3D volume renderings can give misinterpretations of the jaw boundaries and the location of the cortical bone. Improper threshold or brightness settings can cause a false appearance of a periodontal bone defect. 3D renderings can be used as an adjunct to cross-sectional images in order to visualize implant trajectories, bone orientation, and the relationship of the planned implant to adjacent anatomical structures (Figure 3.30).

Current implant planning software offers a variety of tools that further aid in implant treatment planning and surgery. Depending on the specific software capabilities, realistic models of implants can be virtually placed along with the corresponding virtual restorations or prosthetics (Figures 3.30 and 3.31). This can be selected from an implant library in the software that has specifications from popular implant manufacturers, or a generic implant with flexible design parameters may be used. When intraoral optical scans or CBCT scans of stone models are available (to depict the precise locations of crown and soft tissue contours that are often masked in CBCT scans because of metal artifacts), they can be fused with the CBCT scan of the patient to allow for planning of the desired restorative outcome along with the surgical planning (Figure 3.32). Some software permits bone graft planning along with tools for volume measurement, so that the precise location and amount of augmentation material that is required for surgery can be calculated. A ridge reduction planning tool is provided in some software that can aid in the fabrication of ridge reduction guides, which can be used along with surgical guides during implant surgery. A comparison of pre- and post-operative scans can be done by superimposition capabilities that allow the two scans to be overlaid on top of each other so that surgical changes can be assessed.

SURGICAL GUIDES

The transfer of the virtual treatment plan on CBCT software can be facilitated by computer-aided manufacturing (CAM) surgical guides that can be used at the time of the implant surgery (Figure 3.33). These surgical guides are used with implant-specific drilling instruments to place the planned

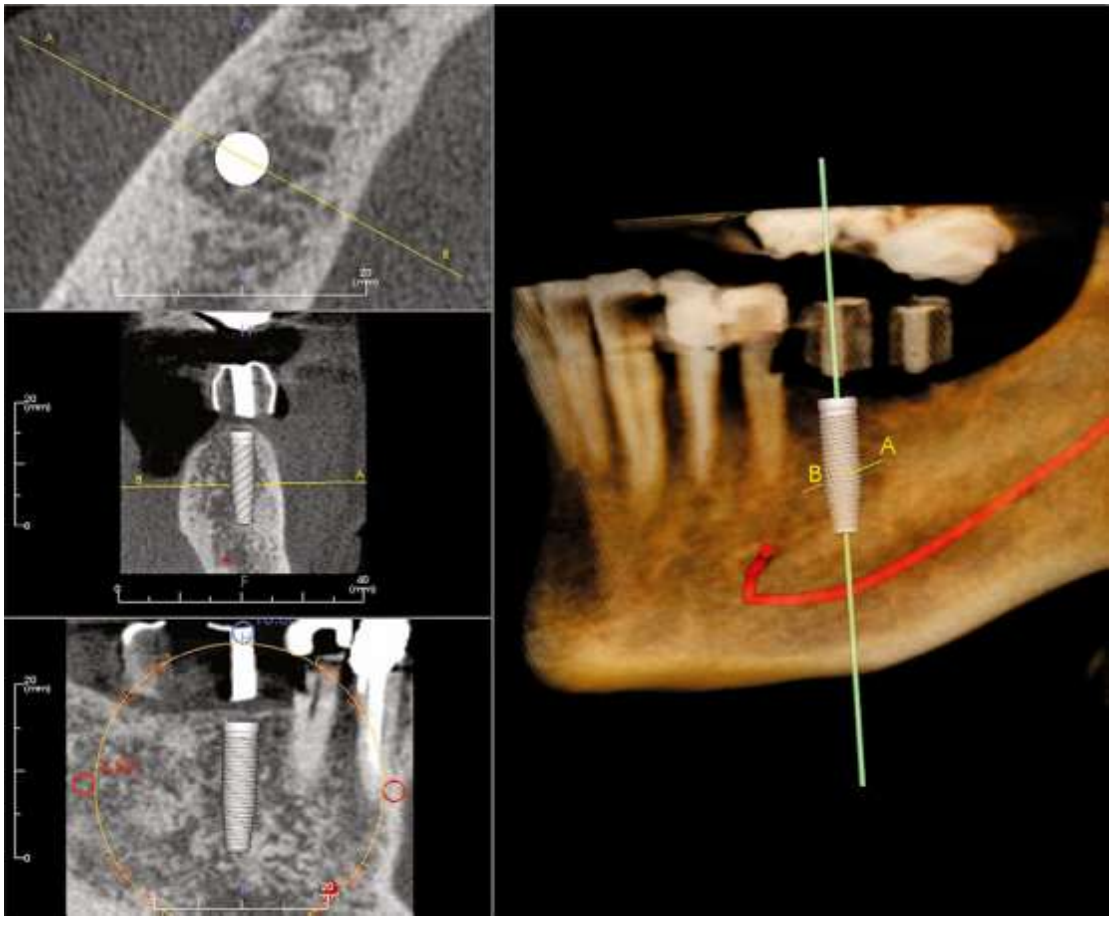

FIGURE 3.30 CBCT multiplanar reformats showing the trajectory of a planned implant. The three-dimensional reformation is used as an adjunct to sectional images and shows the relationship of the planned implant with the adjacent anatomical structures. The course of the mandibular canal is marked in red; note the presence of the anterior loop of the canal.

Dentlearn.ir

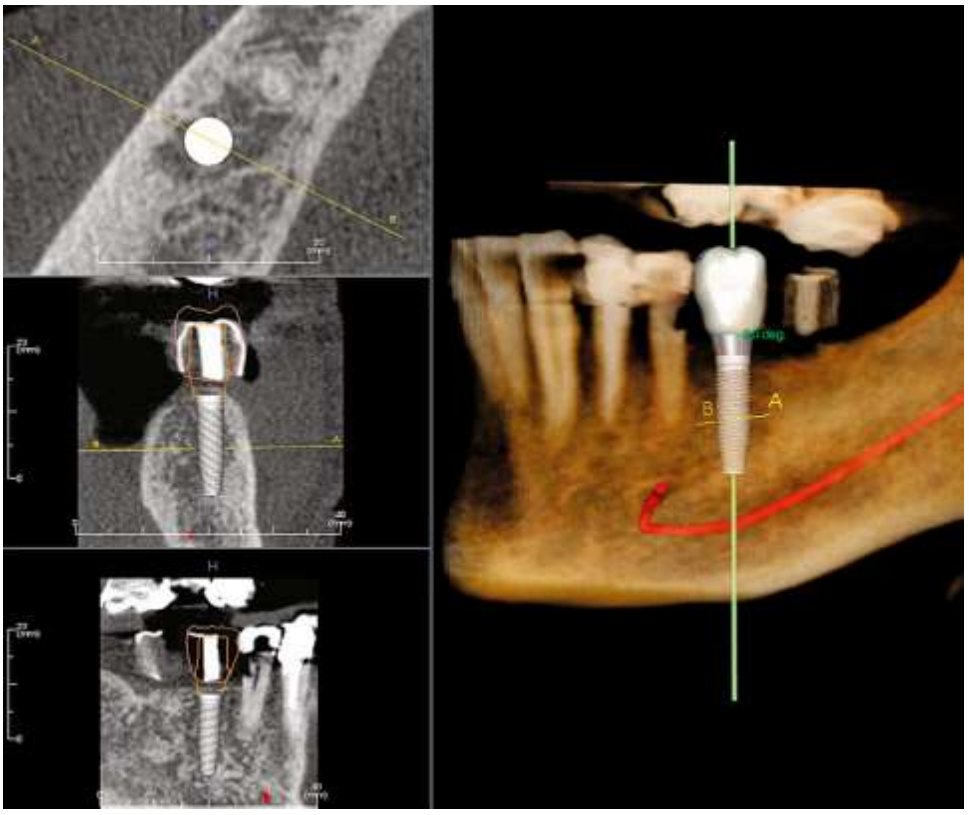

FIGURE 3.31 The same images as Figure 3.30, but showing the placement of a virtual restoration on the planned implant.

FIGURE 3.32 Fusion of an intraoral optical scan with the CBCT scan of the same patient.

implants in the same position, depth, and angulation as the virtual plan. They allow for accurate and predictable implant placement and can significantly reduce surgical time.

Depending on the type of tissue that provides intraoral stability to a surgical guide, the guides may be one of the following:

- *Tooth-borne*. These offer great stability of the surgical guide, but are limited to partially edentulous cases. Periodontally compromised mobile teeth may result in an inaccurate guide position (Figure 3.33).
- *Soft tissue-borne*. These are typically used in completely edentulous cases for flapless implant placement. Anchor pins may be used to increase the stability of the guide.
- *Bone-borne*. These are typically used in completely edentulous cases with full-thickness tissue flaps. Bone modeling for surgical guide fabrication is not a precise technique and therefore these guides may not provide an accurate fit during surgery. Anchor pins may be used to increase the stability of the guide.
- *Combination tooth–bone-borne*. These allow for a portion of the guide to rest on teeth and another portion to rest on the bone above the surgical site with a flap.

Based on the system selected, surgical guides can provide control of the pilot drill, drill sequence, and/or depth control. Certain implant manufacturers require specific protocols and radiographic guides for surgical guide fabrication. Accuracy of the surgical guide fit may be compromised in the presence of patient movement and metallic artifacts. Use of intraoral optical scans or a CBCT of the stone model that is fused with a patient's CBCT scan enables creation of a surgical guide with better accuracy. The guide fit may also be compromised if a change in intraoral tissues (such as extractions, new resto-

Dentlearn.ir

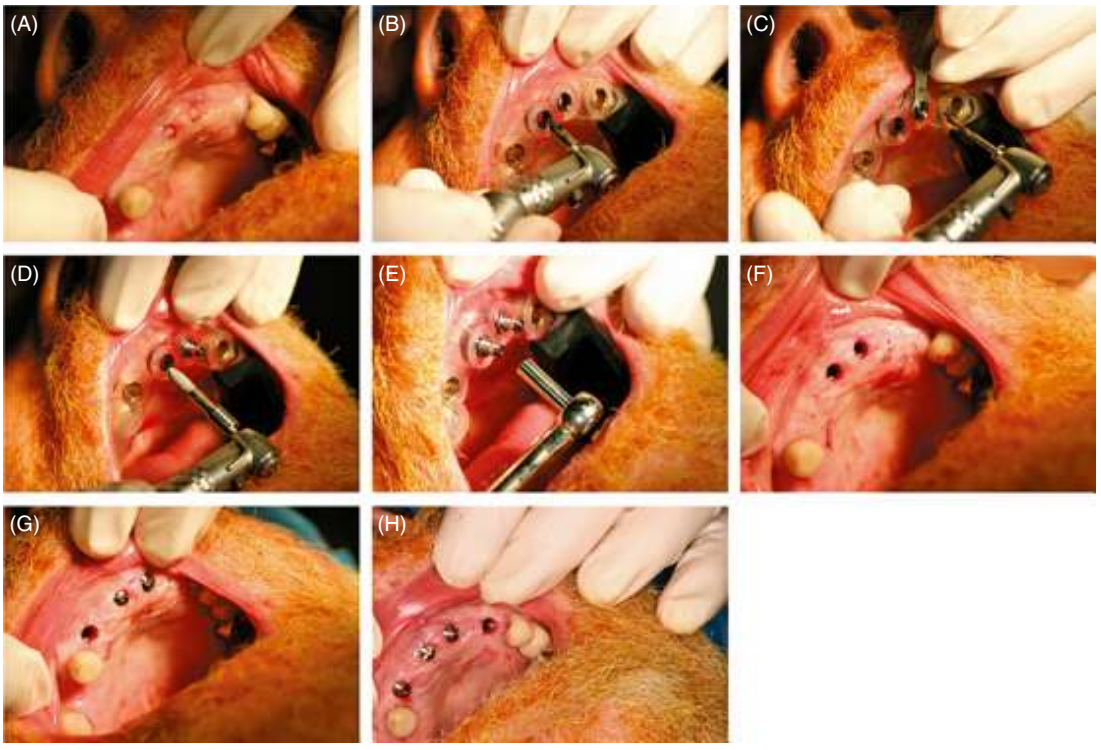

FIGURE 3.33 (A–H) Clinical intra-operative photographs of a surgical guide. The surgical guide transfers the virtual implant planning performed on a CBCT scan and is worn by the patient during surgery.

rations, or displacement of adjacent teeth) occurs between scan capture and surgery.

Implant analogs for pre-made provisional restorations can be used to guide the placement of a restoration with surgical guides.

NEWER TECHNOLOGICAL ADVANCES

The goal of imaging is to replicate the anatomical truth (anatomy as it exists in nature) at a resolution that is acceptable for clinical applications. The anatomical truth includes the 3D morphology, anatomy during function (the fourth dimension), and the interaction of the relevant anatomical components (the fifth dimension). The fourth dimension is a timed sequence of 3D images. The time intervals can be relatively long and portray treatment outcomes or growth and development. They can also be short to portray jaw motion or dynamic tooth contacts. The fifth dimension allows for estimations of biomechanical forces during functional activities between the muscles, teeth, jaws, and TMJ. Currently no single imaging modality can replicate all the desired anatomical elements contained in a human interactive system. The near-term solution is to utilize multiple independent imaging modalities that have been optimized for selected tasks and combine them to reconstruct the anatomical form and function. These independent imaging devices include CBCT for the osseous structures, intraoral scans for the crowns of teeth, visible light 2D and 3D cameras for the facial soft tissues, and laser-based (Vision X, San Francisco, CA, USA) technology for jaw motion, dynamic articulation, and smile visualization. Vision X has a resolution of approximately 20 μm at the tooth level and a frame rate of 30 frames/second. The anatomical reconstruction begins with registering each independent image file on a common Cartesian coordinate system and requires rotation and translation of the image file without scaling. The anatomical model can then be segmented into independent anatomical objects, such as teeth and jaws.

The segmented anatomical model can be used as a platform to aid in diagnosis and treatment simulation and to play a role in the execution of the planned therapy. Four-dimensional computer vision is the key technology that allows both jaw tracking (articulation) and navigation surgery.

Precise and efficient implant placement can occur through the employment of navigation technology (offered by X-Nav Technologies, Lansdale, PA, USA). Dynamic surgical navigation eliminates the need for manufacturing surgical guides, thus permitting reduced time and fewer steps between implant planning and surgery. The workflow is simple and efficient and begins with a CBCT scan, followed by virtual planning of implant placement (and/or bone reduction) and

Dentlearn.ir

execution using dynamic navigation. There are several surgical navigation schemas allowing surgical control of osteotomy position, angle, and depth (Figure 3.34). In general, the navigation process begins with a CBCT scan acquired with a fiducial marker in the mouth and followed by implant planning of one or more implant sites (Figure 3.35). The virtual plan of the proposed implant length, angle, and position is carried to the navigation technology system. The surgical procedure begins with reattaching the fiducial markers in the mouth and then calibrating a surgical headpiece into the surgical field, thus achieving 3D localization of the bur tip and shaft orientation (Figure 3.36). Using computer vision (close-range stereophotogrammetry), the position of the handpiece can be tracked during surgery in real time with six degrees of freedom (x, y, z, yaw, pitch, and roll; Figure 3.37). The surgeon can view the simulated position of the handpiece on a computer monitor that is simultaneously showing the CBCT volume and

FIGURE 3.34 The X-Guide Machine tracks the handpiece in real time during surgery with six degrees of freedom (x, y, z, yaw, pitch, and roll) and provides a real-time, 360-degree view of the simulated implant position, drill movements, and anatomy on a single display. *Source*: X-Nav Technologies, LLC, 1555 Bustard Road, Suite 75, Lansdale, PA 19446, USA.

FIGURE 3.36 Registration of the drill to the X-Guide system to enable real-time tracking.

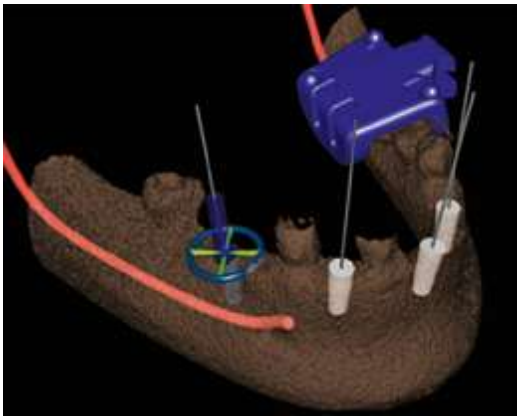

FIGURE 3.35 A virtual plan on the CBCT scan. The mandibular canal is marked for visualization. The X-point in the right mandibular bicuspid region is the target point for placing the drill bit. An X-clip is fastened to the dental arch and is used to calibrate the clinical scene.

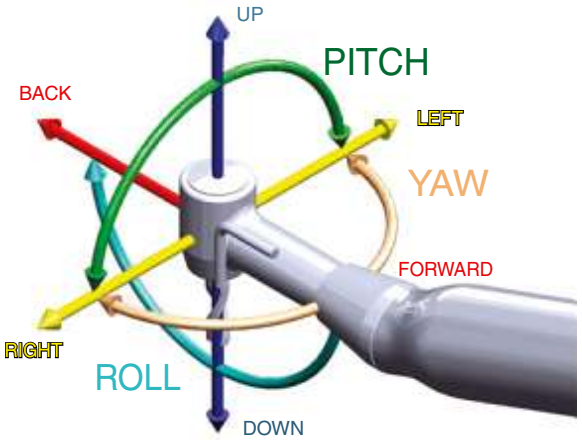

FIGURE 3.37 Graphic illustrating the dimensions of drill bit control with six degrees of freedom (x, y, z, yaw, pitch, and roll).

Dentlearn.ir

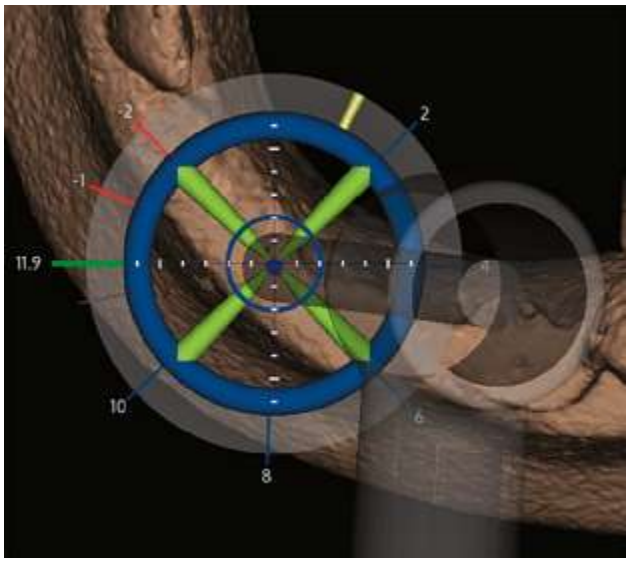

FIGURE 3.38 The tracking system indicates that the drill bit tip is correctly placed on the target point. The partially transparent image of the headpiece attitude in space reminds the clinician to align it.

proposed plan (Figure 3.38). There is feedback incorporated into the display software to inform the surgeon in real time of the position, angle, and depth of the bur relative to the plan (Figures 3.39 and 3.40). Recent advances in navigation surgery technology (by X-Nav) have improved patient registration options, and enabled navigation of bone reduction surgery and of implant placement in edentulous patients.

The goal of implant dentistry is to replace missing teeth with dental implants placed in restoratively and occlusally driven locations. A combination of the modeling platform and navigation surgery can be used to achieve design, manufacturing, and execution to restore the ideal functional occlusion.

Intraoral ultrasonography is a new and emerging noninvasive imaging technology and its potential use for evaluating dental structures is being investigated. Ultrasound imaging can be used to measure mucosa and the thickness of the gingiva, detect periodontal bony defects, identify the cemento-enamel junction, and evaluate alveolar bone levels. Recent improvements in ultrasound image processing and segmentation have been promising for greater utilization of the modality for dento-periodontium applications.

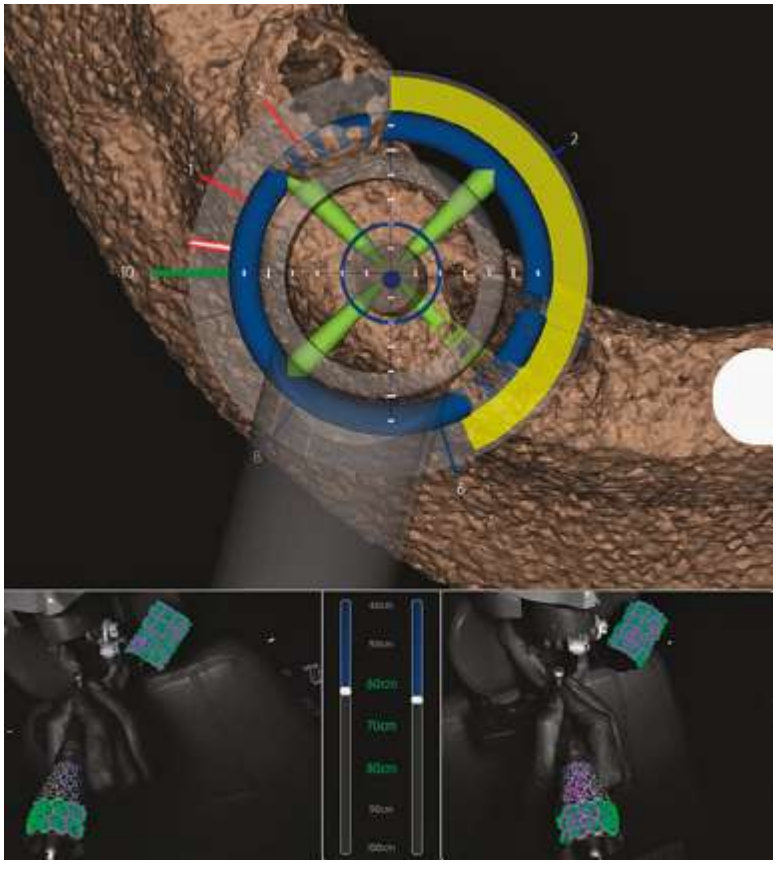

FIGURE 3.39 The handpiece properly aligned. The yellow arch is depth control tracking indicating that nearly 6 mm of drill depth has been completed. The images at the bottom are stereo views of the headpiece in the surgical field along with tracking targets on the headpiece and in the mouth.

Dentlearn.ir

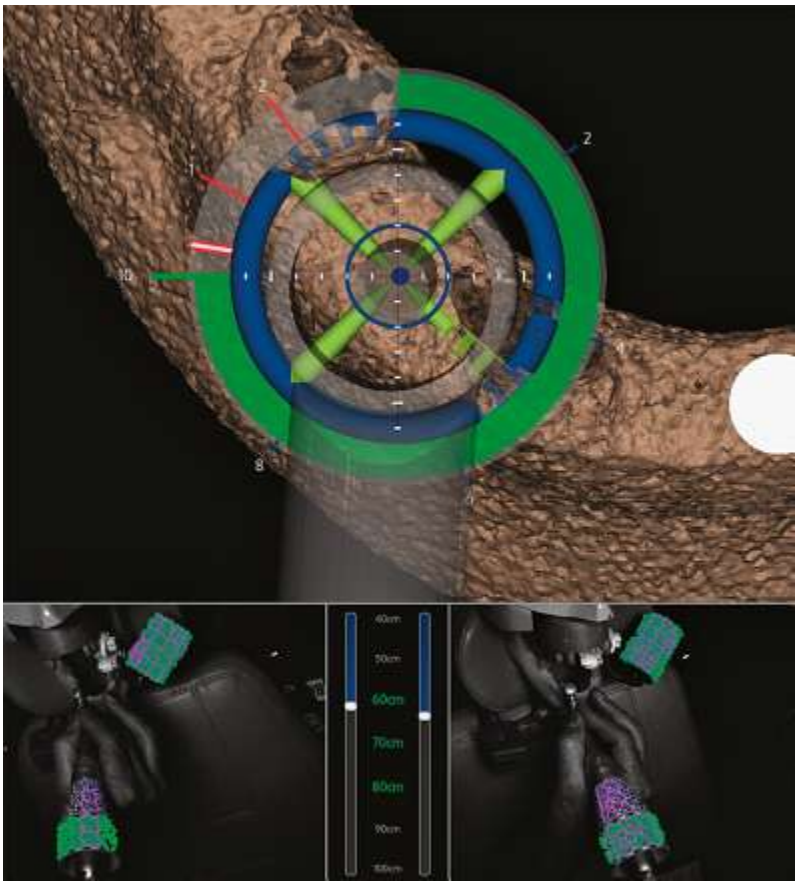

FIGURE 3.40 The same as Figure 3.39, with the green ring indicating that the drill bit tip has reached the planned depth.

REFERENCES

1. Wakoh M, Harada T, Otonari T et al. Reliability of linear distance measurement for dental implant length with standardized periapical radiographs. *Bull Tokyo Dent Coll.* 2006;47:105–15.
2. Angelopoulos C, Thomas SL, Hechler S et al. Comparison between digital panoramic radiography and cone-beam computed tomography for the identification of the mandibular canal as part of presurgical dental implant assessment. *J Oral Maxillofac Surg.* 2008;66:2130–35.
3. Fortin T, Elsa C, Mahdi A et al. Panoramic images versus three-dimensional planning software for oral implant planning in atrophied posterior maxillary: A clinical radiological study. *Clin Implant Dent Relat Res.* 2013;15(2):198–204.
4. Correa L, Ruhland R, Andreas S et al. Planning of dental implant size with digital panoramic radiographs, CBCT-generated panoramic images, and CBCT cross-sectional images. *Clin Oral Implants Res.* 2014;25(6):690–95.
5. Tyndall DA, Price JB, Tetradis S et al. Position statement of the American Academy of Oral and Maxillofacial Radiology on selection criteria for the use of radiology in dental implantology with emphasis on cone beam computed tomography. *Oral Surg Oral Med Oral Pathol Oral Radiol.* 2012;113(6):817–26.
6. Benavides E, Rios HF, Ganz SD et al. Use of cone beam computed tomography in implant dentistry: The International Congress of Oral Implantologists consensus report. *Implant Dent.* 2012;21(2):78–86.
7. Worthington P, Rubenstein J, Hatcher DC. The role of cone-beam computed tomography in the planning and placement of implants. *J Am Dent Assoc.* 2010;141:19–24.
8. American Dental Association Council on Scientific Affairs. The use of cone-beam computed tomography in dentistry: An advisory statement from the American Dental Association Council on Scientific Affairs. *J Am Dent Assoc.* 2012;143(8):899–902.
9. Al-Ekrish AA, Ekram M. A comparative study of the accuracy and reliability of multidetector computed tomography and cone beam computed tomography in the assessment of dental implant site dimensions. *Dentomaxillofacial Radiol.* 2011;40(2):67–75.
10. Greenstein G, Cavallaro J, Tarnow D. Practical application of anatomy for the dental implant surgeon. *J Periodontol.* 2008;79(10):1833–46.
11. Bornstein MM, Balsiger R, Sendi P et al. Morphology of the nasopalatine canal and dental implant surgery: A radiographic analysis of 100 consecutive patients using limited cone-beam computed tomography. *Clin Oral Implants Res.* 2011;22(3):295–301.

Dentlearn.ir

12. Oliveira-Santos C, Rubira-Bullen IR, Monteiro S et al. Neurovascular anatomical variations in the anterior palate observed on CBCT images. *Clin Oral Implants Res.* 2013;24(9):1044–8.

13. Nicolielo LF, Van Dessel J, Jacobs R et al. Presurgical CBCT assessment of maxillary neurovascularization in relation to maxillary sinus augmentation procedures and posterior implant placement. *Surg Radiol Anat.* 2014;36(9):915–24.

14. Woo BM, Al-Bustani S, Ueeck BA. Floor of mouth haemorrhage and life-threatening airway obstruction during immediate implant placement in the anterior mandible. *Int J Oral Maxillofac Surg.* 2006;35(10):961–4.

15. Tarakji B, Nassani MZ. Factors associated with hematoma of the floor of the mouth after placement of dental implants. *Saudi Dent J.* 2012;24(1):11–15.

16. Lofthag-Hansen S, Gröndahl K, Ekestubbe A. Cone-beam CT for preoperative implant planning in the posterior mandible: Visibility of anatomic landmarks. *Clin Implant Dent Related Res.* 2009;11(3):246–55.

17. Greenstein G, Tarnow D. The mental foramen and nerve: Clinical and anatomical factors related to dental implant placement: A literature review. *J Periodontol.* 2006;77(12):1933–43.

18. Jacobs R, Quirynen M, Bornstein MM. Neurovascular disturbances after implant surgery. *Periodontol* 2000. 2014;66(1):188–202.

19. Chan HL, Leong DJ, Fu JH et al. The significance of the lingual nerve during periodontal/implant surgery. *J Periodontol.* 2010;81(3):372–7.

20. Hatcher DC. Operational principles for cone-beam computed tomography. *J Am Dent Assoc.* 2010;141(Suppl 3):3S–6S.

21. Nemtoi A, Haba D, Czink C et al. Cone beam CT: A current overview of devices. *Dentomaxillofacial Radiol.* 2013;42(8):20120443.

22. Waltrick KB, De Abreu J, Nunes MJ et al. Accuracy of linear measurements and visibility of the mandibular canal of cone-beam computed tomography images with different voxel sizes: An in vitro study. *J Periodontol.* 2013;84(1):68–77.

23. Kamburŏglu K, Kolsuz E, Murat S et al. Assessment of buccal marginal alveolar peri-implant and periodontal defects using a cone beam CT system with and without the application of metal artefact reduction mode. *Dentomaxillofacial Radiol.* 2013;42(8):20130176.

24. Dave M, Wilson R, Palmer R et al. A comparison of cone beam computed tomography and conventional periapical radiography at detecting peri-implant bone defects. *Clin Oral Implants Res.* 2013;24(6):671–8.

25. Rozé J, Babu S, Saffarzadeh A et al. Correlating implant stability to bone structure. *Clin Oral Implants Res.* 2009;20:1140–45.

26. Molteni R. Prospects and challenges of rendering tissue density in hounsfield units for cone beam computed tomography. *Oral Surg Oral Med Oral Pathol Oral Radiol.* 2013;116(1):105–19.

27. European Commission. Radiation protection no. 172: Cone beam CT for dental and maxillofacial radiology. Evidence-based guidelines. *A report prepared by the SEDENTEXCT project*. Luxembourg: EC; 2011.

28. Ludlow JB, Walker C. Assessment of phantom dosimetry and image quality of i-CAT FLX cone-beam computed tomography. *Am J Orthod Dentofacial Orthop.* 2013;144(6):802–17.

29. Palomo JM, Rao PS, Hans MG. Influence of CBCT exposure conditions on radiation dose. *Oral Surg Oral Med Oral Pathol Oral Radiol Endod.* 2008;105(6):773–82.

30. Davies, J, Johnson B, Drage N. Effective doses from cone beam CT investigation of the jaws. *Dentomaxillofacial Radiol.* 2012;41(1):30–36.

31. Kourtis S, Skondra E, Roussou I et al. Presurgical planning in implant restorations: Correct interpretation of cone-beam computed tomography for improved imaging. *J Esthet Restor Dent.* 2012;24(5):321–32.

Dentlearn.ir

Prosthetic Comprehensive Oral Evaluation in Implant Dentistry

CHAPTER 4

The restoration of a dental implant patient is a multidisciplinary specialty. Coordination of efforts in diagnosis and treatment planning can be the difference between success and failure on many levels. Long-term predictability, patient satisfaction, and implant-restorative success rely on the communication between the surgical specialist, restorative dentist, and laboratory technician.

Dentlearn.ir

CHAPTER 4 Prosthetic Comprehensive Oral Evaluation in Implant Dentistry

Gary A. Morris[1,2]

[1]*Department of Graduate Studies, Southern Illinois University, School of Dental Medicine, Alton, IL, USA*

[2]*Private Practice, Buffalo Grove, IL, USA*

Dental implant therapy continues to evolve as a restorative and surgical treatment modality. New concepts in facial form and functional design as well as data obtained on joint position and airway patency have changed the way we look at comprehensive, collaborative implant treatment planning [1]. Ultimately our goal continues to be the restoration of the dentition both cosmetically and functionally. This starts with the foundation, hard and soft tissue anatomy, which will allow the restoration to mimic the natural dentition. Replacing missing teeth and contiguous oral structures cannot be accomplished without the newer technologies available to us. These include different grafting techniques, site-specific dental implants, and restorative technologies, both digital and analog. The collaborative application of this therapy continues to require an interdisciplinary team approach to ensure the patient has a predictable and satisfying outcome.

INITIAL EVALUATION

The evaluation of a patient prior to the initiation of dental implant therapy by a prosthodontist or restorative dentist continues to be critical for the ultimate success of a treatment plan. Determination of the diagnostic needs as well as the type of site preservation, site development, provisional restorations, and prosthetic design necessary to accomplish the restorative goal prior to the initiation of therapy remains the difference between success and failure. Communication between the patient's restorative dentist, surgical specialist, and laboratory technician requires an understanding of the goal of therapy [2]. Treatment planning is site specific, dependent on the design of the desired final prosthesis, and can be enhanced with the use of newer technologies and dental implant designs [3, 4]. Not correcting ridge width defects prior to implant placement can cause significant issues for the final prosthesis [5]. The techniques and materials chosen to correct these anatomical challenges may come with difficulties and complications that must be considered [6].

DIAGNOSTIC WORK-UP

The prosthodontic work-up begins with a comprehensive examination and interview of the patient. A thorough review of the patient's medical history, current medications, allergies, habits, and dental history is taken [7, 8]. A review of their chief complaint and the history associated with the concern is recorded. During the patient interview, it is important to determine the patient's desires and to assess whether their expectations are realistic. If not, it is important to educate them as to what they can expect from treatment, result, maintenance requirements, and potential for revision or replacement of their restoration in the future. It is also imperative that alternative treatment options are discussed, including the option of no treatment and the consequences of that. The clinical examination comprises the following examinations.

Radiographic Examination

A thorough radiographic examination is required to determine the patient's candidacy for dental implant therapy. Three-dimensional radiographs such as cone beam computed tomography (CBCT) provide necessary information regarding the ability to place a dental implant in an appropriate position. These radiographs will allow for the determination of hard tissue deficiencies and need for grafting prior to or in conjunction with implant placement [9]. Alternative options such as the use of site-specific implants must be considered. Novel implant designs available today may allow for the avoidance of anatomical limitations that will require grafting to place dental implants [3, 4]. The use of radiographic guides is most helpful, as they will provide the restorative coordinates and emergence-positioning information for the

Essential Techniques of Alveolar Bone Augmentation in Implant Dentistry: A Surgical Manual, Second Edition. Edited by Len Tolstunov.
© 2023 John Wiley & Sons, Inc. Published 2023 by John Wiley & Sons, Inc.
Companion website: www.wiley.com/go/tolstunov/essential

Dentlearn.ir

final restoration based on a diagnostic wax-up. These wax-ups can be virtual as well with intraoral scans and computer-aided design (CAD) software. With the use of implant planning software, the size and angulation of a dental implant can be illustrated in the planning phase. The need for ridge augmentation will be evident and can be planned (Figure 4.1) [10].

Dental Examination

The dental examination consists of an evaluation and charting of the dentition. The presence and condition of the teeth and supporting structures are evaluated and recorded. Clinical evidence of decay, attrition, erosion, and fracture of the teeth is observed. The presence of existing restorations and the condition of the restorations are also evaluated and recorded in the chart. The edentulous spaces are evaluated for the thickness of tissue overlying the site, the presence or absence of keratinized tissue, ridge width dimensions, the presence of undercuts, height irregularities, and the position of muscle attachments, which are examined and recorded.

Periodontal Examination

Complete periodontal probing and charting, including bleeding points and areas with a suppurative discharge, are essential to a complete diagnosis. Charting of recession and mobility as well as gingival attachment levels is diagnostic and provides essential information needed to form a proper diagnosis. Determination of the gingival biotype will help guide the plan with respect to the conversion of biotype through hard tissue grafting, soft tissue grafting, or a combination of both to provide the proper supporting structures for a predictable emergence profile or healthy gingival sulcus surrounding dental implants in the partially edentulous patient.

Occlusal Examination

A thorough occlusal examination is important for several reasons. One is that it relates to the three-dimensional placement of the dental implant to ensure that the platform is appropriately positioned beneath the abutment and occlusal surface of the restoration. This will allow forces to be directed vertically down the long access of the implant in function. The relative placement of the implant may be centered in the ridge, but this is not sufficient to allow for proper force mitigation. Placement of the implant relative to the occlusal plane will determine a dentist's ability to screw-retain the restoration without the use of additional componentry such as angle-correcting abutments. Specialty implants and subcrestal angle correction, which is afforded by newer designs, will also help with these concerns. Skeletal and dental relationships as well as resorption patterns will influence the position of the implant. Adjunctive services such as orthodontic correction of occlusion may be necessary, in addition to site preparation through ridge augmentation to allow for proper dental implant positioning [11].

Root proximity is often an issue, especially in patients with congenitally missing teeth. In some cases, site development benefits from the intrusion or extrusion of teeth prior to extraction and implant placement [12, 13]. Malocclusion needs to be addressed prior to the commencement of restorative and surgical care. It is important to look to the opposing arch to rule out the eruption of teeth that will interfere with implant placement and occlusion. In some cases, this can be corrected with a crown and bridge or orthodontic intrusion [14]. In other cases, it may be corrected with extraction and the placement of additional implants. Included in this is a thorough evaluation and examination of the temporomandibular joint (TMJ).

Intra- and Extraoral Soft Tissue Examination

Examination of the intra- and extraoral soft tissues for pathology is a critical part of the prosthodontic examination. Any lesions of concern should be noted and referred for evaluation by the oral and maxillofacial surgeon. The surgeon should biopsy the lesion if appropriate. Intraoral pre-malignant, malignant, and inflammatory lesions should be treated, and the patient cleared medically prior to the initiation of dental implant therapy [8].

DIAGNOSIS AND TREATMENT PLAN

Presentation to the patient with a diagnosis is an important part of informed consent and an educational opportunity. A thorough diagnosis will not only allow for an open discussion of the restorative plan and recommendations, but will also enable the procedures needed to accomplish this goal to be outlined. A classification system for dental implant patients has been suggested in the literature and is based on several factors, including the size and position of the edentulous site, complicating factors such as the need for grafting, and an assessment of patient factors that may require the modification of expectations [15].

It is the responsibility of the restorative dentist to provide information to the patient along with the risks and benefits of the proposed plan. Alternative plans along with the option of no treatment must be discussed. It is appropriate for the restorative dentist to speak to the patient regarding the need to create the foundation for the restoration with site development and to communicate this need to the oral and maxillofacial surgeon. The surgical specialist can then discuss the type of grafting or site development needed more thoroughly.

SMILE EVALUATION

The smile evaluation largely looks to assess the probability of creating an esthetic restoration. Multiple data points from the

Dentlearn.ir

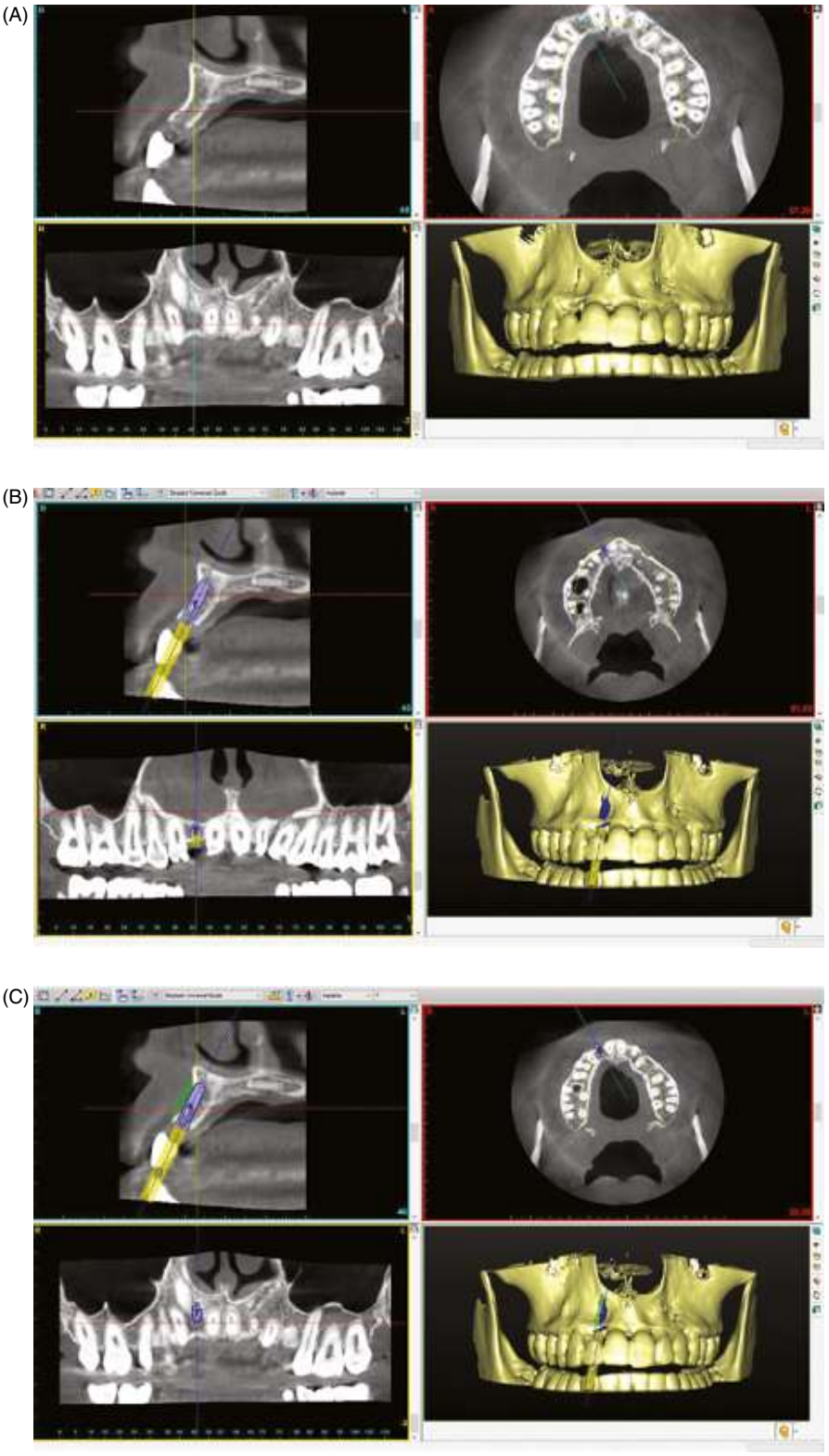

FIGURE 4.1 (A) Cone beam computed tomography scan demonstrating a horizontal defect mid-facial and apically, which will lead to a fenestration when an implant is placed for screw retention. (B) Implant planned, demonstrating the fenestration. (C) Graft volume needed to cover the buccal threads. (D) Planning for a subcrestal angle-correcting implant. (E) 12-degree angle correction noted with the restorative space. (F) Graft volume noted only for support of the emergence profile of the crown.

Dentlearn.ir

(D)

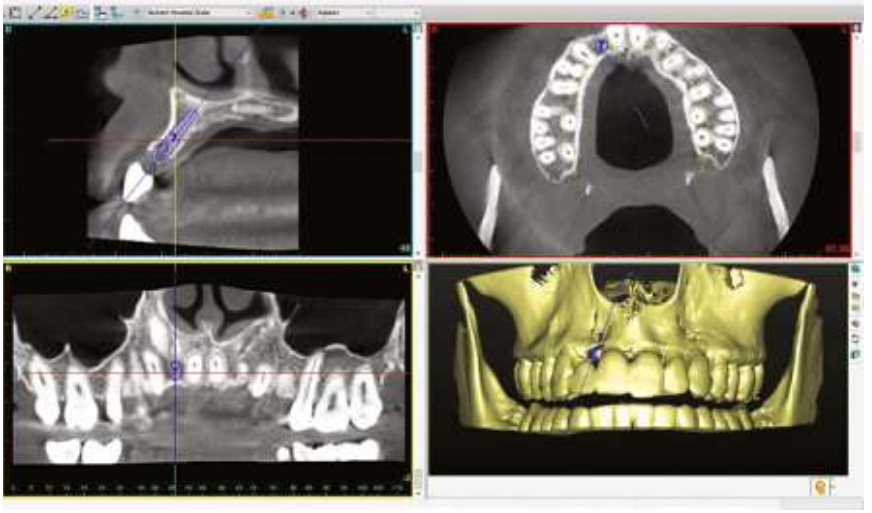

(E)

(F)

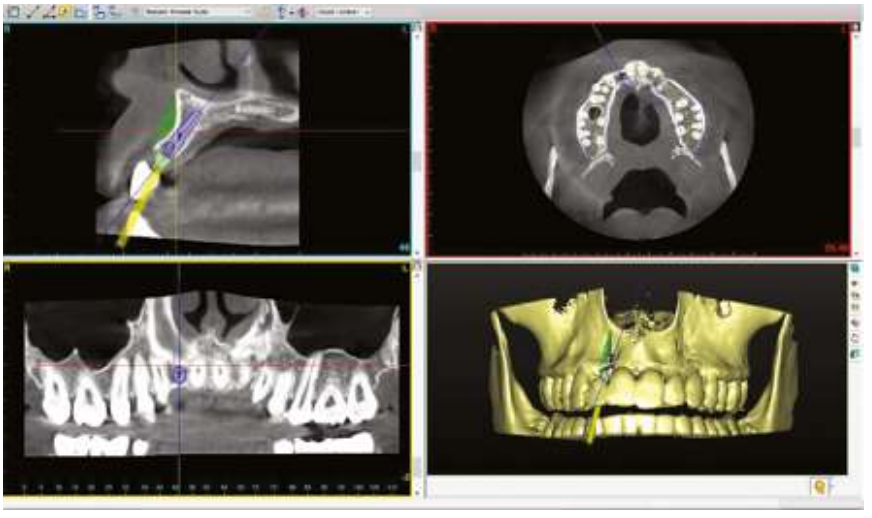

FIGURE 4.1 *(continued)*

Dentlearn.ir

restorative evaluation are considered when determining the probability of achieving this goal. Beyond the dental characteristics below, a thorough review of the patient's habits, including whether they smoke, their hygiene habits, bruxism, as well as patient expectations, can have a dramatic effect on outcome.

The shape and shade of the teeth are evaluated as well as the patient's smile line esthetics. The facial symmetry and lip to incisal edge distance in repose and at high smile are evaluated [16]. The amount of marginal gingiva exposed at high smile, if any, is recorded. A discussion of the patient's perception of their smile and dental health is essential. Examination and recording of the tooth shape and proportion to other teeth are essential for understanding the possibility of creating an esthetic, natural-looking restoration. Papilla generation is more predictable on square teeth and thicker biotype, as the interdental contact is in the gingival third, bringing it closer to the interdental bone. Evidence in the literature suggests that the critical distance is 5 mm from the contact point to the supporting bone on an adjacent tooth [17, 18]. This is more critical in the circumstance of implants placed side by side. Most tissue changes are found to occur in the first year after placement of the restoration, but this can be variable.

Newer technologies allow for the digital trial of a treatment plan before moving forward with the fabrication of provisional restorations. These digital smile blueprints are becoming more useful as the technology evolves (Figures 4.2–4.4) [19].

DIAGNOSTIC CASTS AND WAX-UP

Diagnostic casts and a diagnostic wax-up constitute an important tool allowing for the prediction of the final expected result. Mounted diagnostic casts on the articulator will provide information regarding the shape and position of the proposed restoration, angle of emergence from the ridge, interaction with the opposing dentition, and amount or significance of the soft tissue defect accompanying the loss of the teeth.

FIGURE 4.2 High lip profiles are more esthetically challenging as the gingival emergence profile is evident when the patient smiles. Volume grafting in these instances is often for cosmetic reasons. In some cases the grafts serve both functions, cosmetics and for the adequate housing of bone to support the implant. In this case a specialty subcrestal angle-correcting implant was used.

FIGURE 4.3 Moderate lip profiles are less esthetically challenging as the gingival emergence profile is rarely exposed in the smile. Volume grafting in these instances is more for support of the dental implant and less often for gingival cosmetics. Symmetry is more easily attained, as in this case requiring a veneer to restore the upper right lateral incisor and an implant to restore the upper left lateral incisor.

Dentlearn.ir

FIGURE 4.4 Low lip profiles are esthetically neutral. Grafting in these instances is more for the creation of an adequate bony housing for the dental implant. This interdisciplinary case required orthodontics, grafting, implant placement, and restorative dentistry to complete the restorations.

Duplication of the wax-up and fabrication of a radiographic guide with varying amounts of barium sulfate create a replica of the proposed tooth position on the computed tomography (CT) scan. The wax-up must be to the proper tooth dimensions so that the thickness of tissue can be evaluated. The implant can be sounded to the proper angulation and depth based on the desired result, which allows for quantification of the bone and/or soft tissue grafting needed to achieve success.

An implant placement guide using this information is then fabricated and, where indicated, computer-guided surgery allows the surgical restorative team to provide predictable treatment and achieve the best possible results. It is now possible to wax up virtually by utilizing digital design software programs. Many planning software platforms allow for digital placement of teeth to aid in planning. Cases are planned in reverse, from the prosthetic goal to the foundation (Figure 4.5).

RADIOGRAPHIC IMPLANT GUIDE

A properly fabricated radiographic implant guide is anatomically correct to the proposed design of the final proposed prosthesis. The guides differ based on the area being restored. Radiographic markers are embedded in the guide to ensure that the footprint of the proposed prostheses can be appreciated clearly on the radiograph. These fiduciary markers must be fabricated with a material that will impart a clean, clear image on the radiograph. Many different materials have been used to create the radiopaque image. In some cases, metal spheres of a defined geometrical size and shape have been used to determine the magnification of a panoramic radiograph (Figure 4.6). Other materials such as gutta percha points embedded in the acrylic resin matrix and painted on radio-reflective materials have been used to coat the proposed restorative center or shell of the diagnostic wax-up. These appear as points or a silhouette on the radiograph. More commonly, barium sulfate of varying percentages is mixed into the acrylic resin used to fabricate the guide to identify the different parts of the restoration. This allows the clinician to accurately determine the volume and dimension of graft needed in both hard and soft tissues to appropriately support the restoration [20, 21].

In the partially edentulous patient, the radiographic implant guide is a duplicate of a diagnostic wax-up (Figure 4.7). The guide can be stabilized on the adjacent teeth with solid occlusal land, like the design of an occlusal orthotic appliance. In other instances, the guide can be fabricated and stabilized on the palate or ridges, similarly to a removable partial denture. Clearly, the more the guide relies on non-resilient or non-moving structures, the more accurate it is [22, 23].

A dual-scan technique allows for the diagnostic wax-up to be scanned in a three-dimensional optical scanner (Figure 4.8). The resultant scan can be overlaid in a CT scan to allow for planning of the final restoration digitally without the use of an additional guide. Newer technologies allow for digital wax-up and planning. The combination of the intraoral scan as well as fiduciary markers included in an impression tray worn during the scan allows for the marriage of the intraoral diagnostic scan with the cone beam computed tomography (CBCT). This will allow for more accurate digital planning of the final

Dentlearn.ir

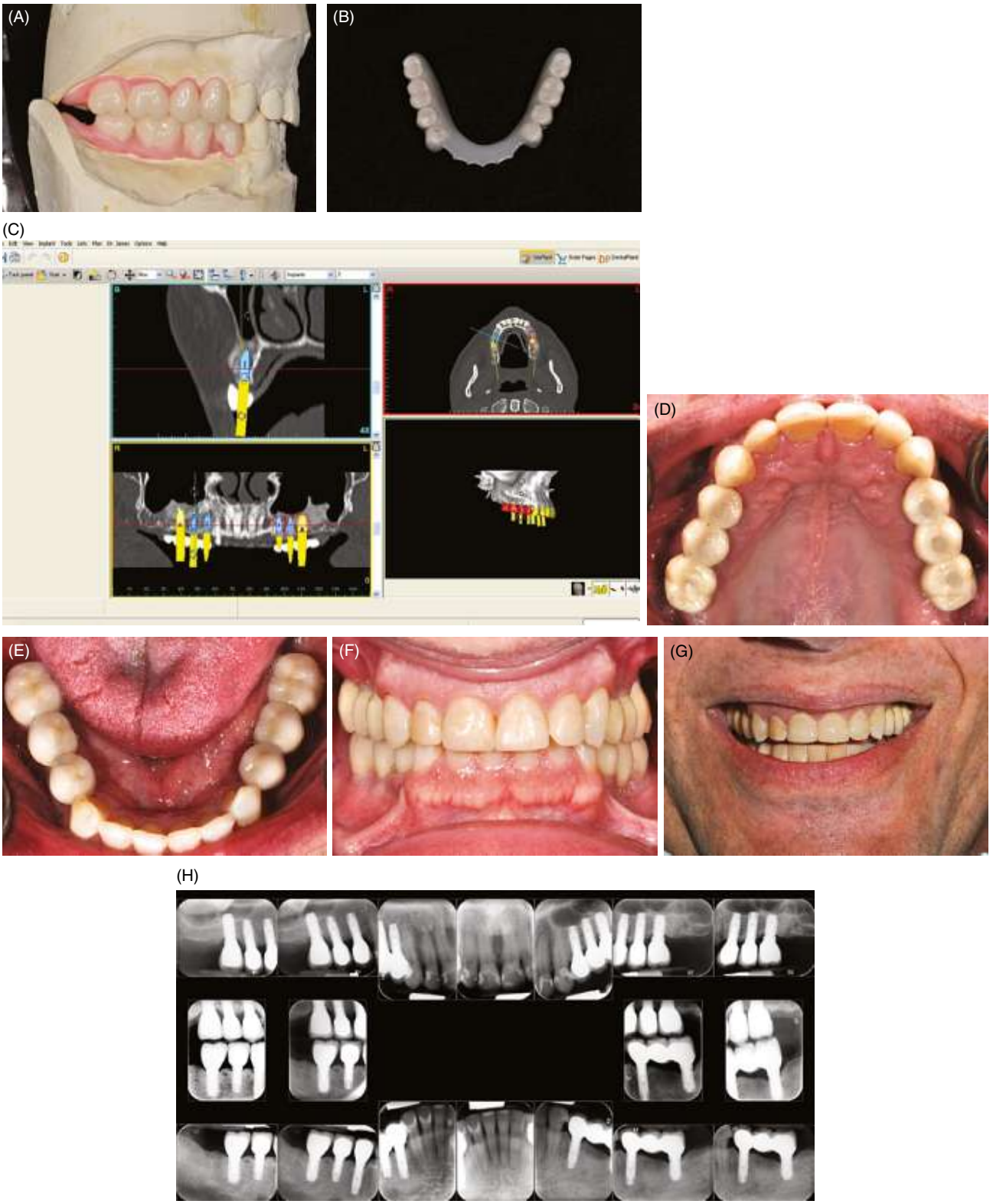

FIGURE 4.5 The diagnostic wax-up can be duplicated in acrylic resin impregnated with a radiographic marker such as barium sulfate after intraoral verification. The radiographic guide is worn during the computed tomography scan and appears as a halo on the radiograph. This is used for the purpose of implant planning. Both the position of the implant as well as the need for grafting to produce a sound housing for the implant can be determined with this technique. A computer-generated implant guide is ordered and used to ensure the plan is followed out accurately.

Dentlearn.ir

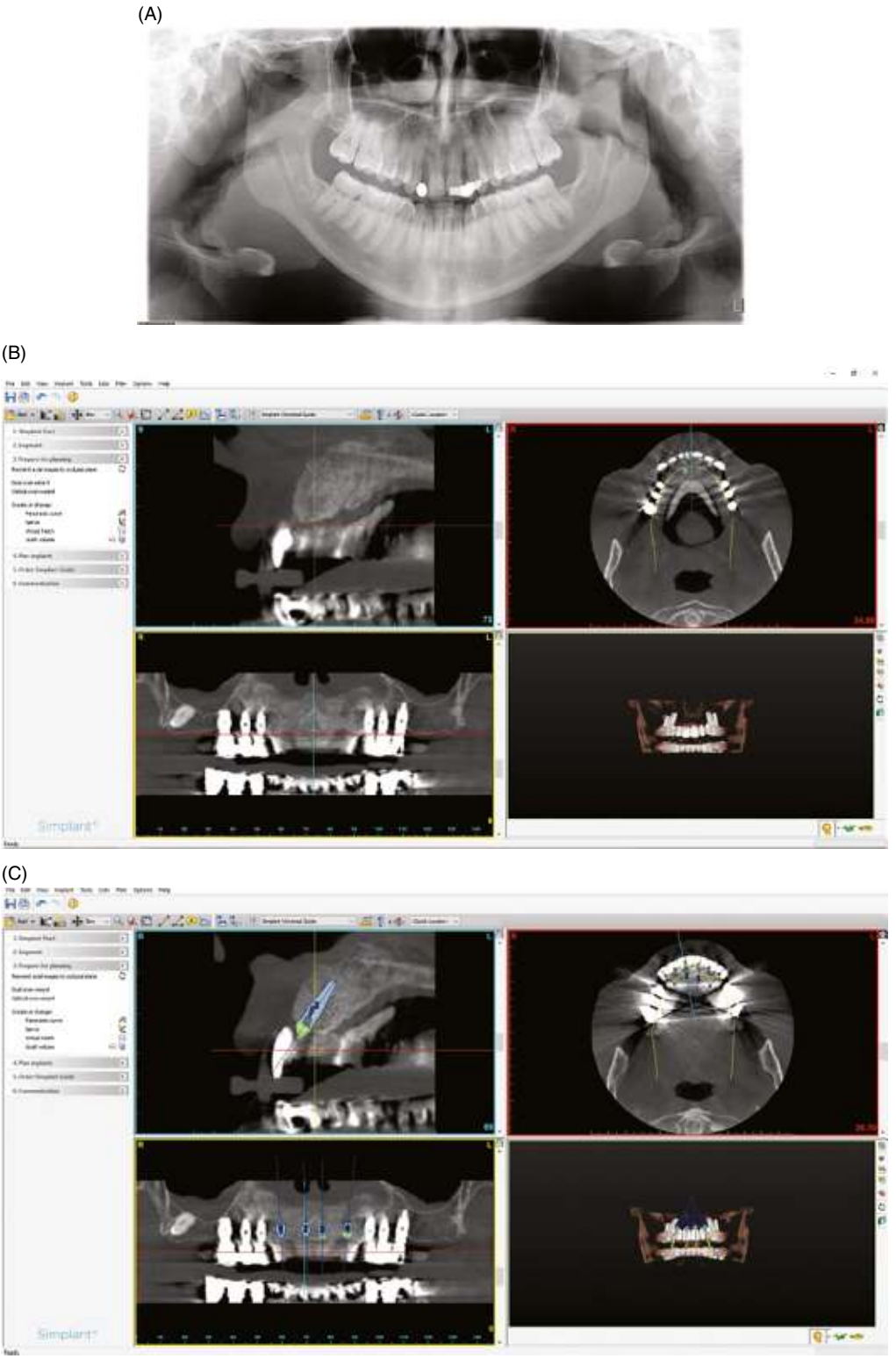

FIGURE 4.6 Examples of fiduciary markers on radiographs. (A) The sphere is of a defined dimension, allowing for determination of the degree of magnification in the radiograph. (B, C) Diagnostic radiographic guide noted on cone beam computed tomography. Note the large-volume veneer graft placed prior to implant placement.

Dentlearn.ir

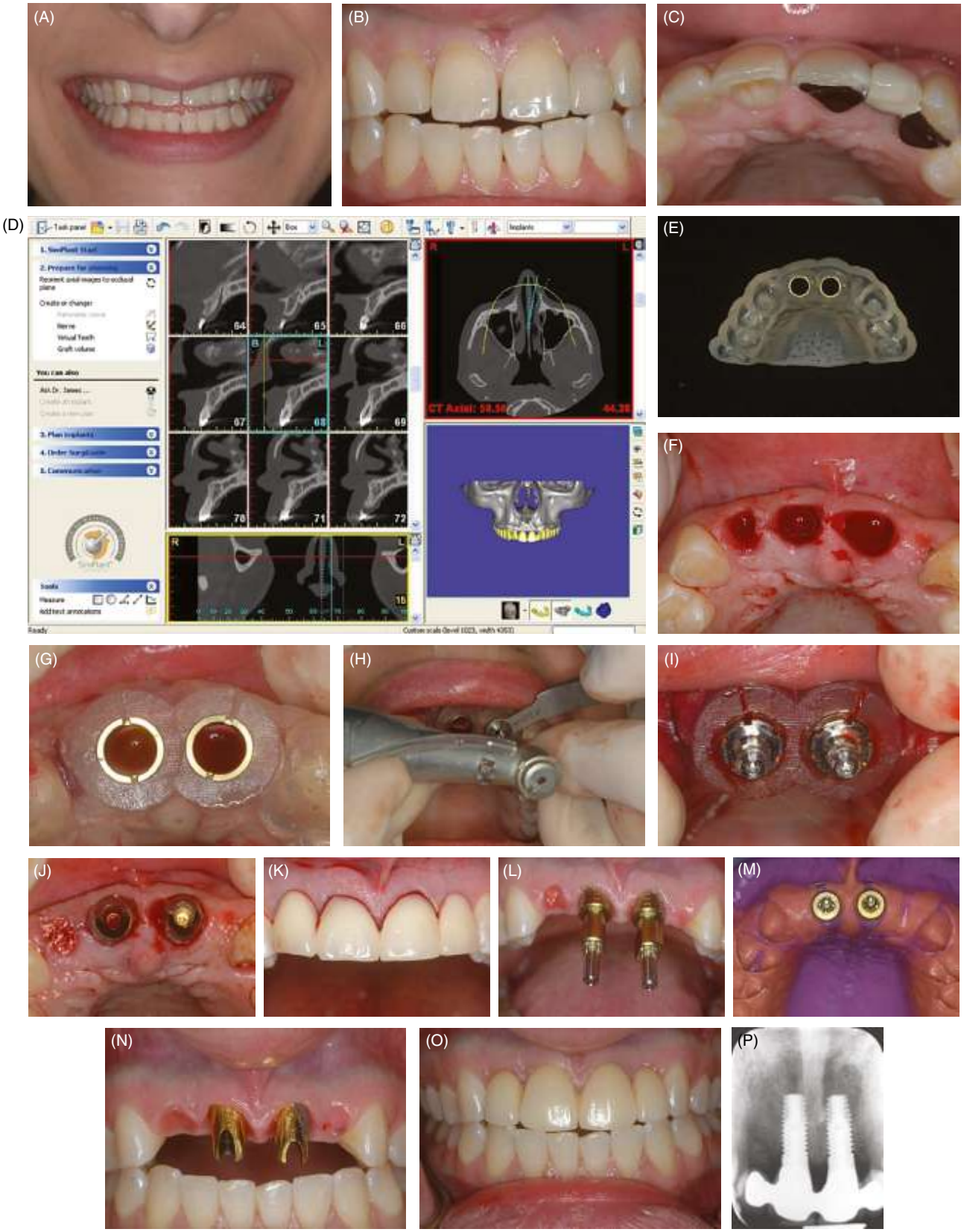

FIGURE 4.7 Computed tomography scan with a SimPlant plan for the placement of central incisor implants with computer-guided surgery. Navigator guide stabilized by the teeth. Dental implants replacing central incisor teeth with pontic to replace teeth adjacent to lateral incisors.

Dentlearn.ir

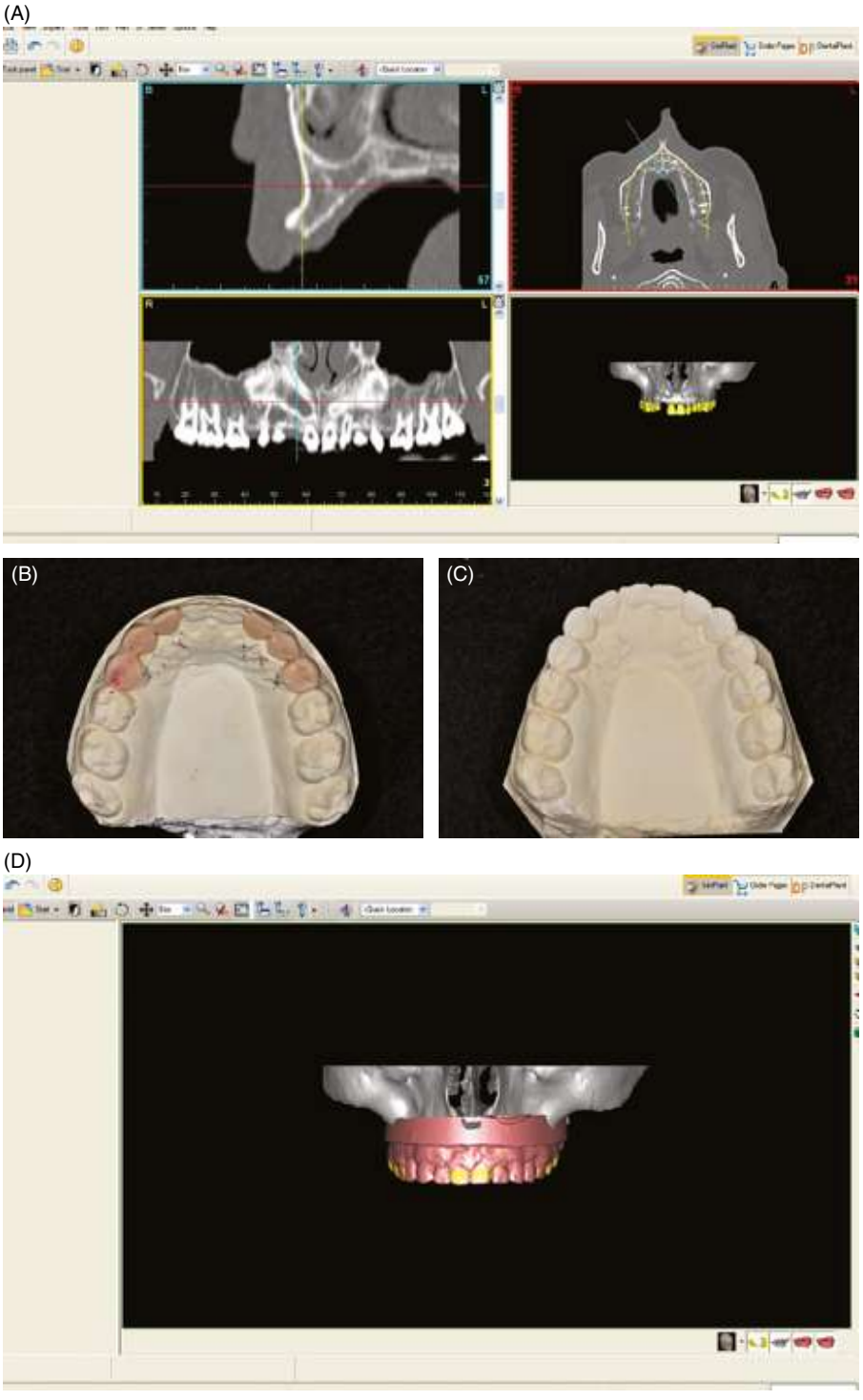

FIGURE 4.8 The dual-scan technique is demonstrated in this figure. The diagnostic wax-up is scanned and overlaid in the patient's computed tomography (CT) scan. Dental implants and grafts are virtually planned, making it possible to predict the outcome. (A) The CT scan without the overlaid wax-up. (B, C) The diagnostic wax-up is duplicated in stone and scanned. (D, E) The scan is shown with the wax-up overlay. (F) The dental implant planned in the software. Implant guides are fabricated based on this plan. (G–I) Final photos and radiograph.

Dentlearn.ir

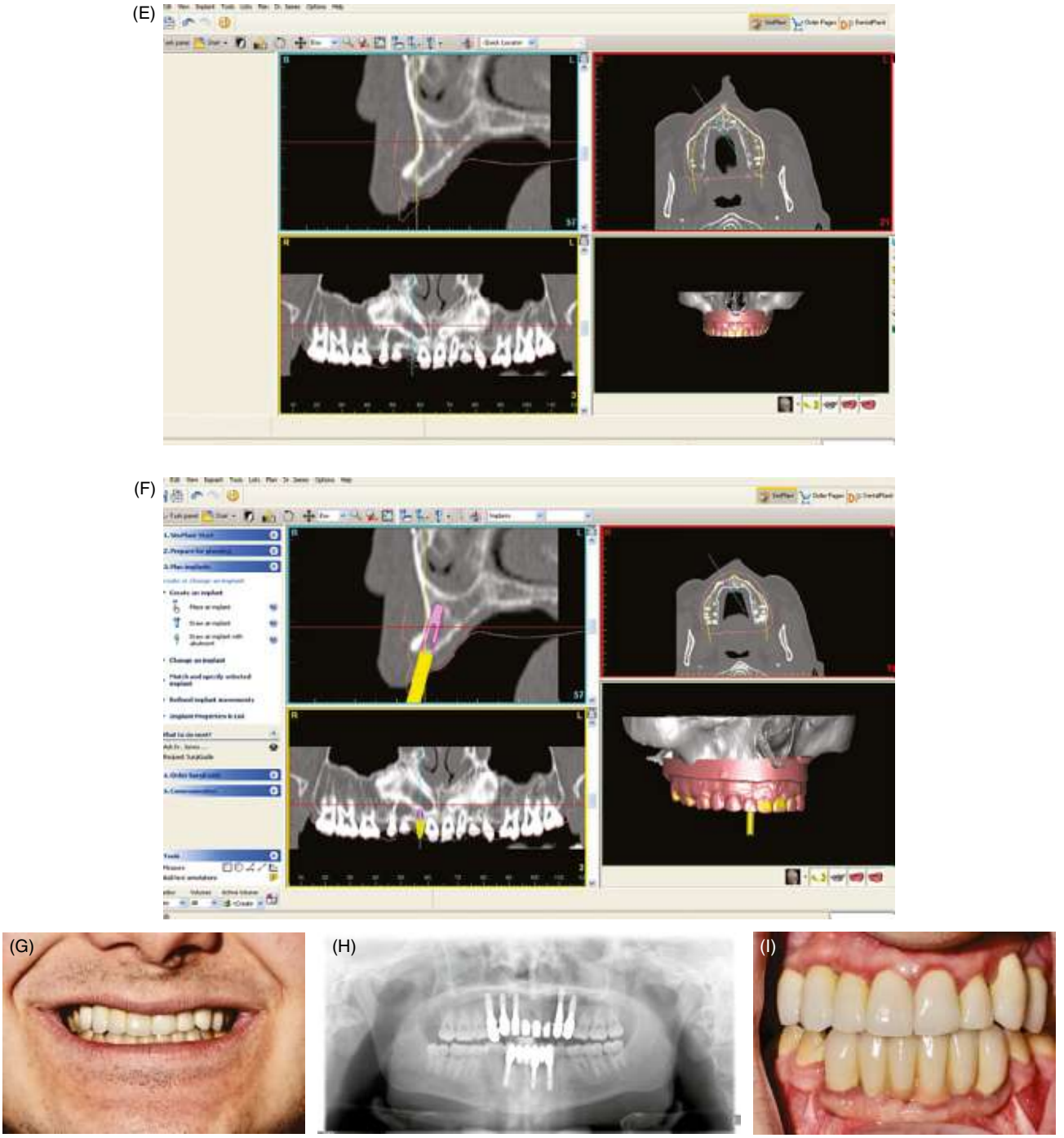

FIGURE 4.8 *(continued)*

restoration. This technology can be used in single, short-span, and full-arch applications. Working from facially driven esthetics and planning from the restoration backward allows another level of precision that was previously not possible.

The edentulous patient brings a new set of considerations for prosthesis design. Depending on the restorative goal, spacing must be considered in developing an implant placement treatment plan. As an example, if a patient desires a bar-supported overdenture, more prosthetic clearance will be needed to accommodate the bar, abutments, and attachments. In these cases, implants are likely to be placed deeper and ridge width augmentation may be necessary to

Dentlearn.ir

accommodate the dental implants. At times this may be accomplished with alveolectomy. In either case, the implant depth and angulation are dependent on the final prosthetic design. Other considerations such as incisal edge to lip distance will require knowledge of the prosthetic design and correlation with the facial anatomy. Often alveolectomy will be necessary to place the dental implants at the appropriate level for the prosthetics. The ridge will have adequate width for dental implants once the procedure is complete. At times the ridge will require horizontal augmentation. In any case, the information gained from the radiographic guide will be the determinant.

In the edentulous patient, a full diagnostic set-up is required to determine the proper placement of the teeth. This wax-up can be duplicated in acrylic resin mixed with barium sulfate of varying density and worn by the patient during the CT scan. A mix recommended is 30% barium sulfate in the teeth and 10% in the tissues. The planning software will allow for each different layer of the guide to be blocked out and used to plan the position of the dental implants relative to the tooth position and amount of soft tissue volume replaced by the flanges. This is more challenging when there are remaining teeth in place. A dual-scan technique is also useful in these instances (Figure 4.9) [24].

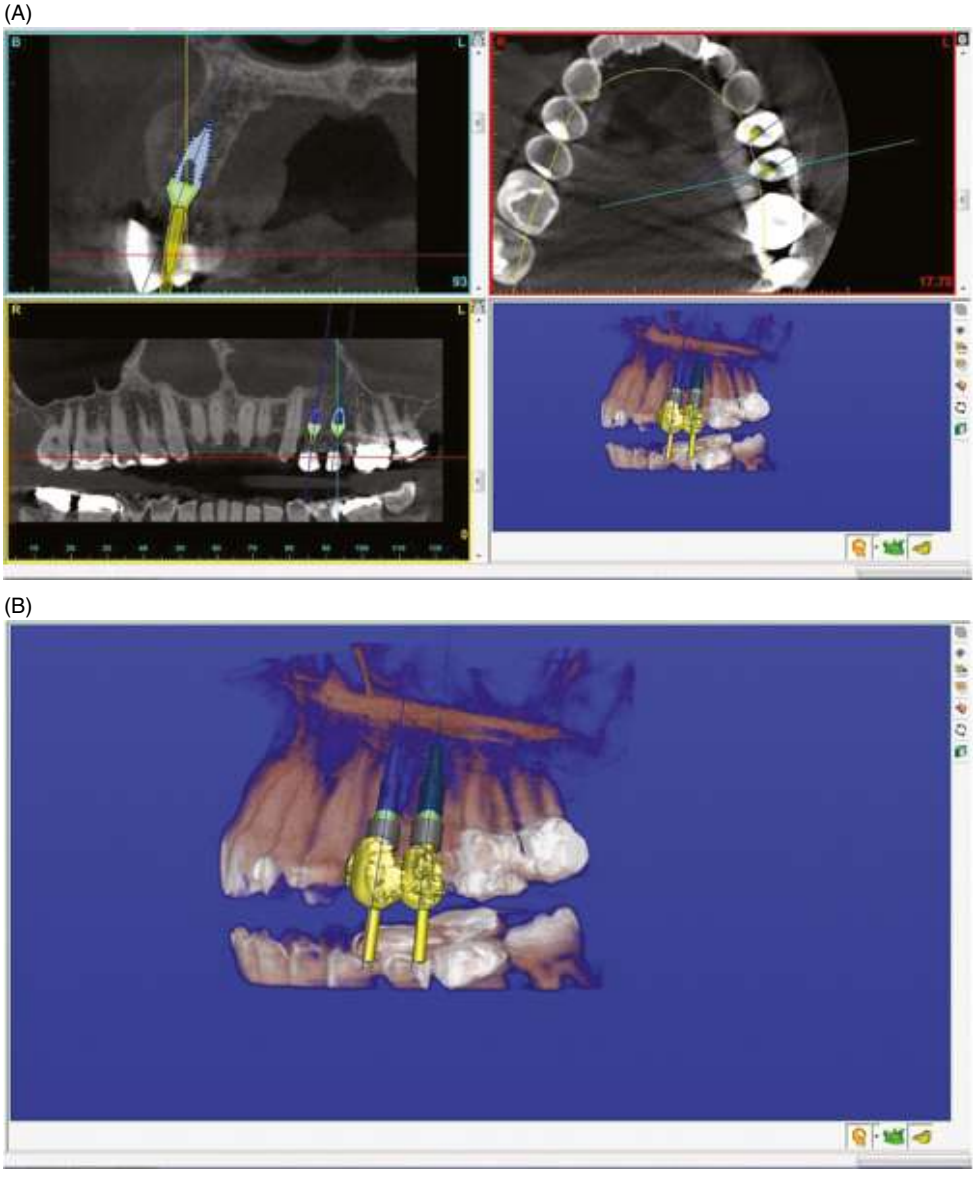

FIGURE 4.9 Examples of a plan and final result for a patient requiring full maxillary and mandibular implant-supported restorations. (A–C) Subcrestal angle correction planned to avoid the need for lateral bone grafting. (D) Placement: implants placed properly in the ridge to take advantage of the alveolar housing and provide direct screw channel access for the restorative dentist to place screw-retained restorations.

Dentlearn.ir

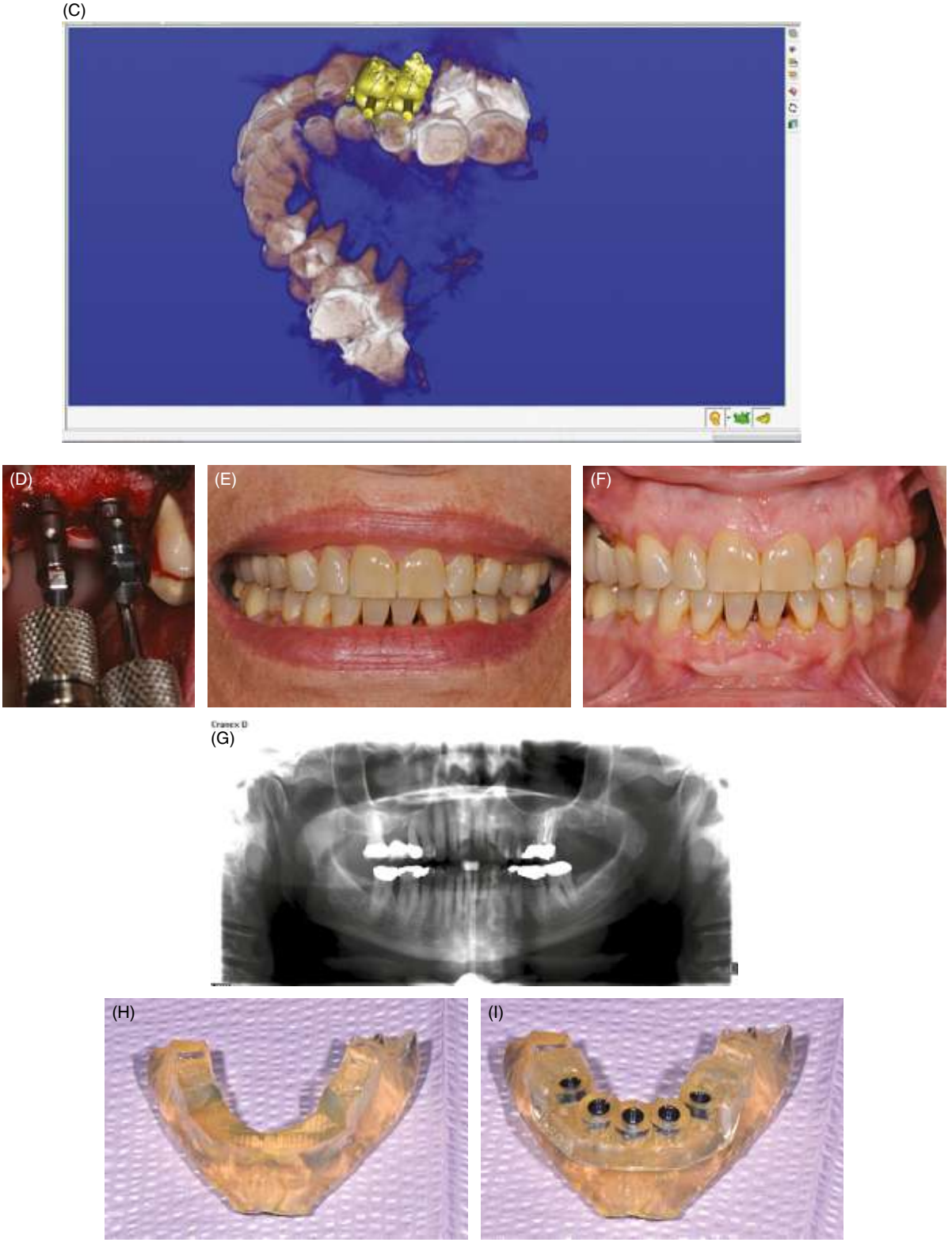

FIGURE 4.9 *(continued)*

Dentlearn.ir

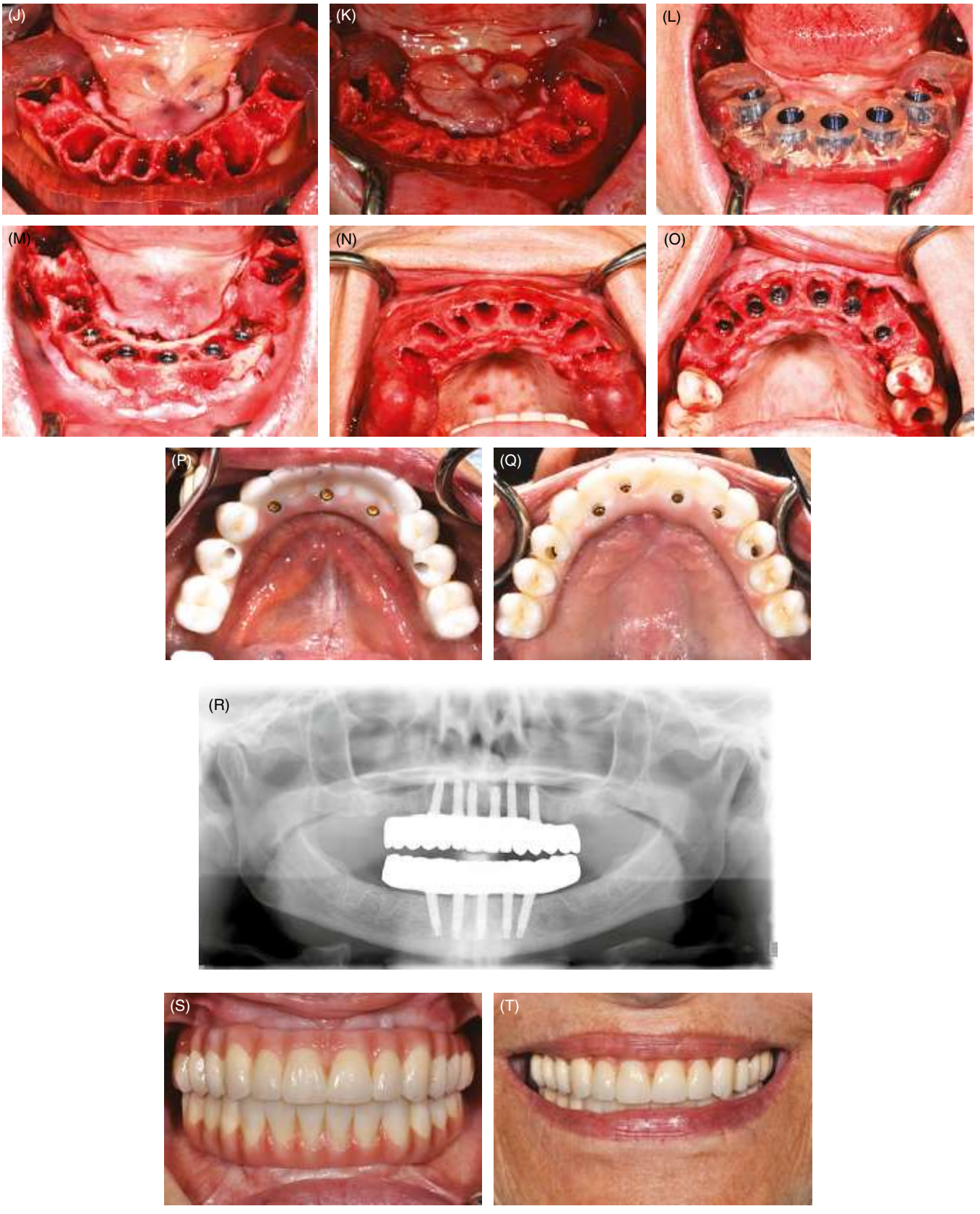

FIGURE 4.9 *(continued)*

Dentlearn.ir

CLINICAL APPLICATIONS

PROSTHETIC EVALUATION AND TREATMENT PLANNING OF PARTIALLY EDENTULOUS PATIENTS IN THE ESTHETIC ZONE

Ridge width defects are very difficult to overcome from a prosthodontist's point of view. When these defects occur in the anterior maxilla, they pose several threats to the ultimate success of a treatment. An insufficient anatomical site can be developed by a traumatic extraction of a failing tooth, causing the buccal plate of bone to be lost (Figure 4.10). Teeth exhibiting endodontic failure with a periapical lesion or previous apicoectomy can cause deficient housing for a dental implant in the mid to apical third (Figure 4.11). This can lead to the need for angulation of the implant to avoid a fenestration of the bone. Thin scalloped biotypes and congenitally missing teeth can also be problematic in allowing an implant to be placed properly for the creation of a natural-looking and esthetic restoration [25]. Implant site development with orthodontics in addition to grafting may be necessary to create an ideal site for the replacement of congenitally missing lateral incisors (Figure 4.12) [26]. In all cases, the width of the ridge needs to be preserved or restored prior to or as part of dental implant placement. Often a staged approach is more predictable than an immediate approach, depending on the anatomy of the defect and position in the mouth. This is especially true in the anterior maxilla [27].

FIGURE 4.10 (A–C) Examples of a failing endodontically treated tooth and subsequent defect left by the extraction.

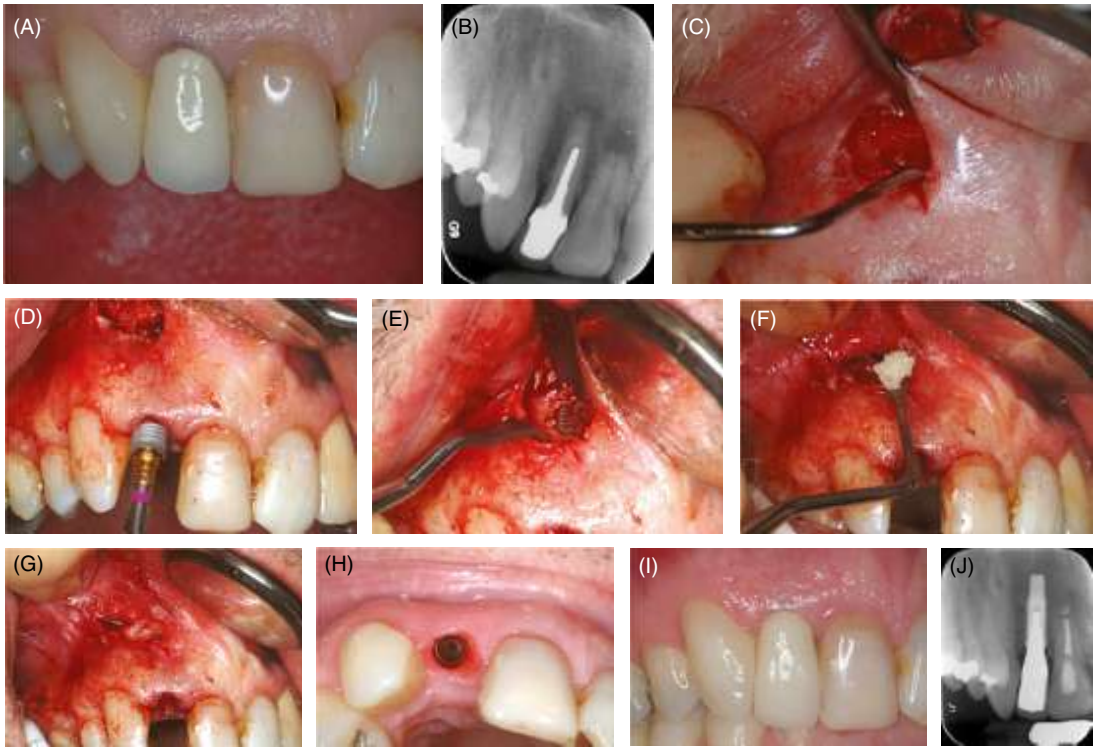

FIGURE 4.11 (A, B) Radiograph and clinical photo of a failing endodontically treated lateral incisor. (C) The tooth is extracted and the apical lesion is debrided with a vestibular approach after verification of the presence of the labial plate after extraction. (D) The dental implant is placed to the proper depth and angulation. (E) The apex of the dental implant is visualized. (F) A graft is placed. (G) A membrane is placed and the site is sutured. (H–J) The dental implant is restored.

Dentlearn.ir

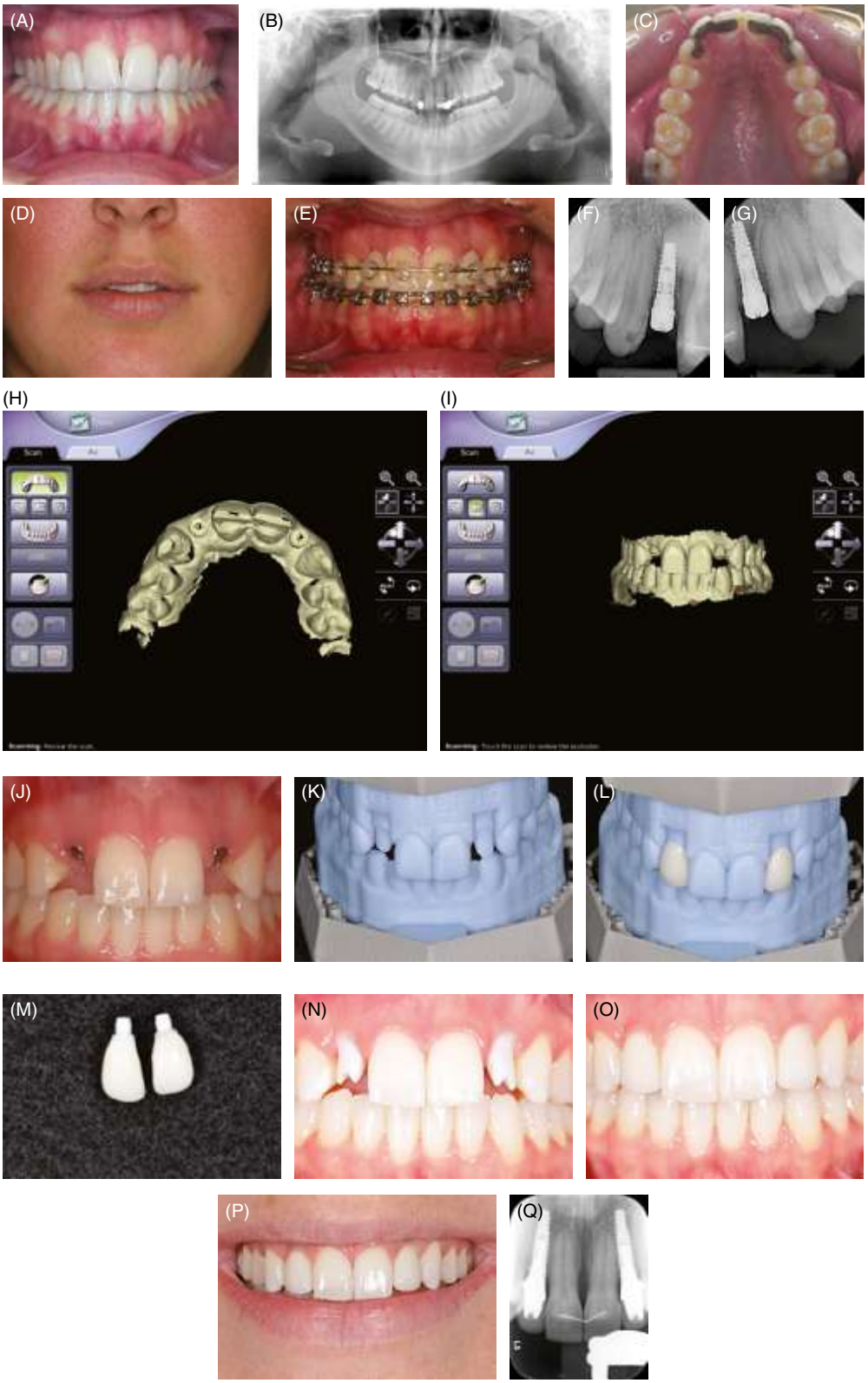

FIGURE 4.12 The replacement of congenitally missing lateral incisors after spacing is corrected orthodontically. There is a panfacial horizontal defect that will affect the emergence of the dental implant. Adequate bone is present to house the implant, but the emergence is not supported. Dental implants are placed in concert with a hard and soft tissue graft. At the restorative phase, the biotype has been altered to support the gingival emergence of the restoration. Intraoral scans of encoded healing abutments facilitated the impression and design process. Ceramic crowns and abutments were used to create the restorations. Final clinical photograph and radiograph represent a four-year follow-up.

Dentlearn.ir

The dental implant position in three dimensions influences the biological width and height of bone and soft tissue. Ultimately, the soft tissue contours are determined by the supporting bone and implant position. This has a direct effect on the final esthetic outcome of the case [27–30]. When dental implants are placed with an angle that is too far to the buccal to avoid a ridge width defect apical to the alveolar crest, labial bone remodeling will result in recession of the facial gingival margin, causing asymmetry between the dental implant and adjacent natural teeth [31, 32]. Thread exposure can occur, causing a change in tissue color relative to the adjacent teeth (Figure 4.13).

Complicating factors such as side-by-side dental implant placement can create other issues that will lead to a compromised result (Figure 4.14). If the dental implants cannot be placed parallel to each other, unpredictable esthetics due to a lack of papilla, dental asymmetry, or improper alignment of the labial surfaces relative to the facial plane are likely results [33, 34].

An additional complicating factor is a palatal width defect (Figure 4.15). These can be missed and cause a great deal of concern. The implant threads can be exposed in this circumstance, causing an implant to fail. Such defects are often overlooked and are best treated in a staged manner.

Mechanical and functional concerns such as angled load generation on the implant abutment interface, inadequate occlusal force distribution, and food trapping will also alter predictability and patient satisfaction. Other complicating factors such as screw loosening can occur due to the off-angle loading of the implant. In circumstances where dental implants are positioned relative to the existing bone and soft tissue anatomy, rather than creating a proper site with hard and soft tissue grafting, long-term results are unpredictable and can cause a variety of complicating issues for the restorative dentist.

Ideal implant placement in the esthetic zone is easy to accomplish. Reverse engineering and design are the key elements. Placement parameters include the following:

- 3 mm of space is needed between dental implants with a platform and abutment to prevent the horizontal aspect of crestal bone remodeling from eliminating the bone between dental implants.
- Less space may be needed between dental implants with a dental implant platform that is wider than the restorative abutment (platform-switching implants).
- 1.5 mm of space is needed between dental implants and natural teeth so as not to compromise the bone supporting the adjacent tooth.
- Screw access is required between the incisal edge and cingulum.
- Platform depth should be 3 mm deep to the zenith of the facial gingival margin.

Ridge augmentation in a horizontal dimension is often necessary to satisfy the placement parameters. When possible, its avoidance can create the ideal implant recipient site (Figure 4.16).

Newer implant designs can obviate the need for ridge width augmentation in some circumstances. The use of site-specific implants that are designed with subcrestal angle

FIGURE 4.13 Maxillary right lateral incisor presents with a gray gingival hue. The thin biotype does not block the color of the abutment supporting the crown. Exposure of the collar of the implant due to the angle of placement is a contributing factor. Changing the abutment to a pressed ceramic UCLA abutment along with a connective tissue graft to convert the biotype corrected the complication.

Dentlearn.ir

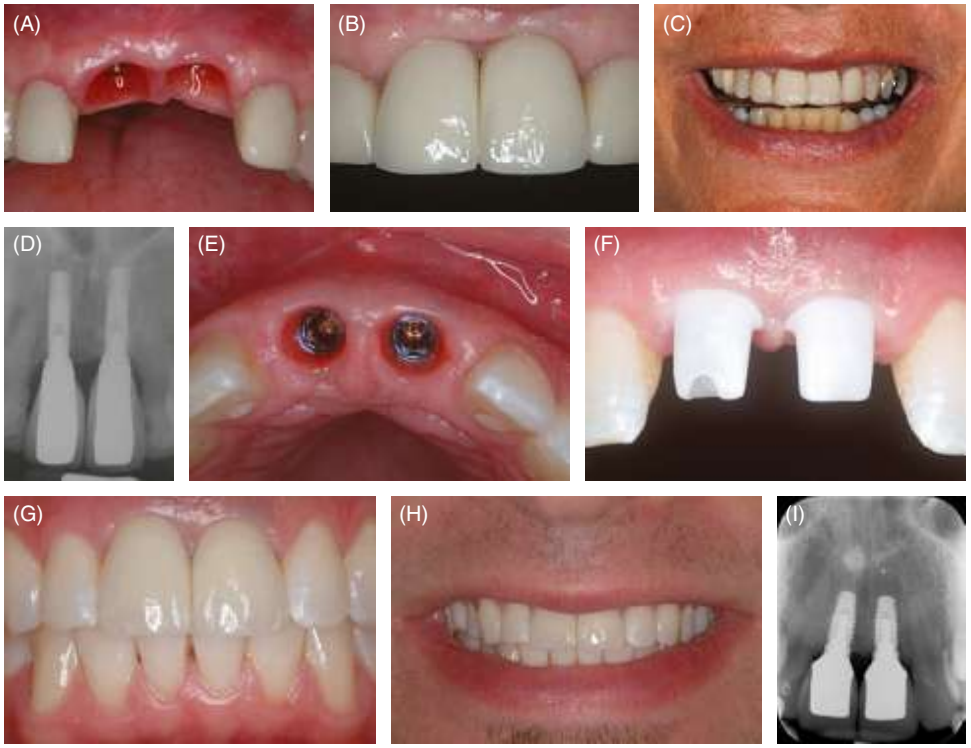

FIGURE 4.14 (A–D) Central incisors replaced with dental implants and screw-retained crowns. Adequate spacing is present between the implants, but the implants were placed without vertical or horizontal augmentation. (E–I) The central incisors were lost to trauma. This patient underwent horizontal ridge augmentation prior to implant placement. Ceramic abutments and crowns were used to restore the dental implants. Grafting allowed for normal dental proportions to be restored.

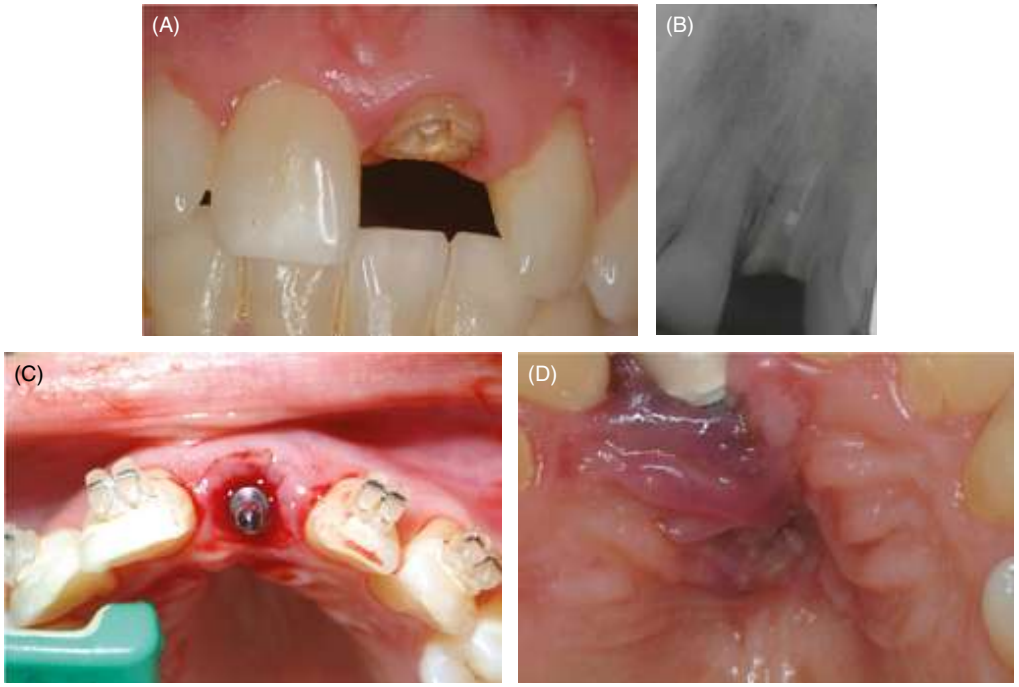

FIGURE 4.15 Palatal defects are often overlooked. In this case the dental implant perforated the palatal plate.

Dentlearn.ir

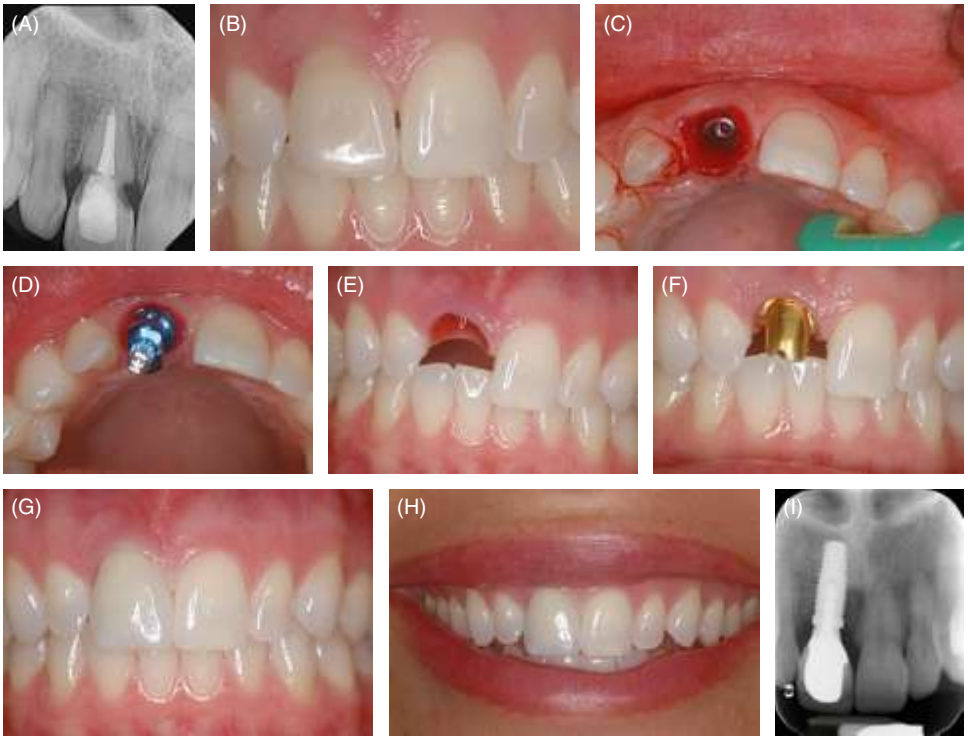

FIGURE 4.16 Extraction and immediate placement of dental implants can prevent the need for grafting for emergence support in some cases. The maxillary right central incisor was extracted, and a dental implant immediately placed. A provisional restoration was immediately loaded out of occlusion. After healing, a custom computer-aided design/manufacturing (CAD/CAM) abutment was placed and restored with porcelain fused to a high noble metal crown. An 18-month follow-up reveals nice gingival symmetry between the dental implant and adjacent natural teeth.

correction can be useful in patients with a severely flared alveolus. These implants allow for sustainment of the gingival emergence profile without the need for advanced augmentation techniques. They also allow for the placement of the platform in a position that will allow for screw retention in most cases. Augmentation of the emergence may still be necessary; however, this can be accomplished in a less invasive manner.

PROSTHETIC EVALUATION AND TREATMENT PLANNING OF PARTIALLY EDENTULOUS PATIENTS IN THE POSTERIOR DENTITION

When ridge width defects occur in the posterior dentition, they influence implant size in terms of diameter and position. Implant placement can have a significant impact on occlusion. As the maxilla recedes, it tends to do so toward the midline, making the palatal vault narrow. If an implant is placed centered in the ridge, the implant will be placed in the crossbite. The same holds true in the mandible. With the resorption pattern being buccal in direction, the same will occur. This can be magnified if the teeth being replaced are concurrently on the same side in opposing jaws. Long-standing tooth loss complicated using removable prosthetics to replace the posterior teeth can create anatomical issues that will be difficult to overcome. Ridge width defects can be created by a traumatic extraction of a failing tooth, causing the buccal plate of bone to be lost. Periodontal disease, dental caries, endodontic failure, and tooth fracture are common causes of posterior tooth loss. One possible prevention of this can be to have a dental implant placed at the time of extraction [35, 36]. Ridge width defects are prevented in this scenario by the preservation of the extraction socket with the dental implant. Sound socket preservation techniques are also useful to prevent the need for grafting [37]. Larger site-specific implants are now available to accommodate larger ridges in terms of width. In their design, these implants are more likely to hold ridge width and further decrease the complications for inadequate occlusal support, as well as further managing food-trapping issues by maintaining ridge width to a greater dimension.

In circumstances requiring grafting to provide adequate width to place an implant with a suitable diameter to support the occlusion, ridge width augmentation is a powerful tool used by the surgical specialist at the time of or prior to implant placement to provide adequate foundation. In most cases the graft is in the coronal third. Anatomical structures such as the

Dentlearn.ir

mental foramen can complicate this. Many different materials and techniques have been described to accomplish it. The advantages are many and include providing a stable base for the abutment and restoration [38]. This can prevent complications such as screw loosening and breakage. Further, food trapping can be an issue around dental implant restorations, as the implant diameter can be significantly narrower than the occlusal table of the restoration. By widening the ridge, a larger-diameter implant can be placed, decreasing the overcontouring of the restoration and preventing food from being directed into the sulcus or to the emergence base of the restoration (Figure 4.17). Implants requiring placement at an angle to the occlusal plane can alter the screw exit, making it difficult to screw-retain a restoration if desired. Congenitally missing premolars can also be problematic in allowing an implant to be placed properly for a natural-looking and esthetic restoration (Figure 4.18). In all cases, the width of the ridge needs to be preserved or restored prior to or as part of dental implant placement.

As previously stated, dental implant position in three dimensions influences the biological width and height of bone and soft tissue. This remains true in the functional zone as well as the esthetic zone. Ultimately, sound treatment planning and site preparation will prevent complications. Similar mechanical and functional concerns from angled load generation on the implant abutment interface, inadequate

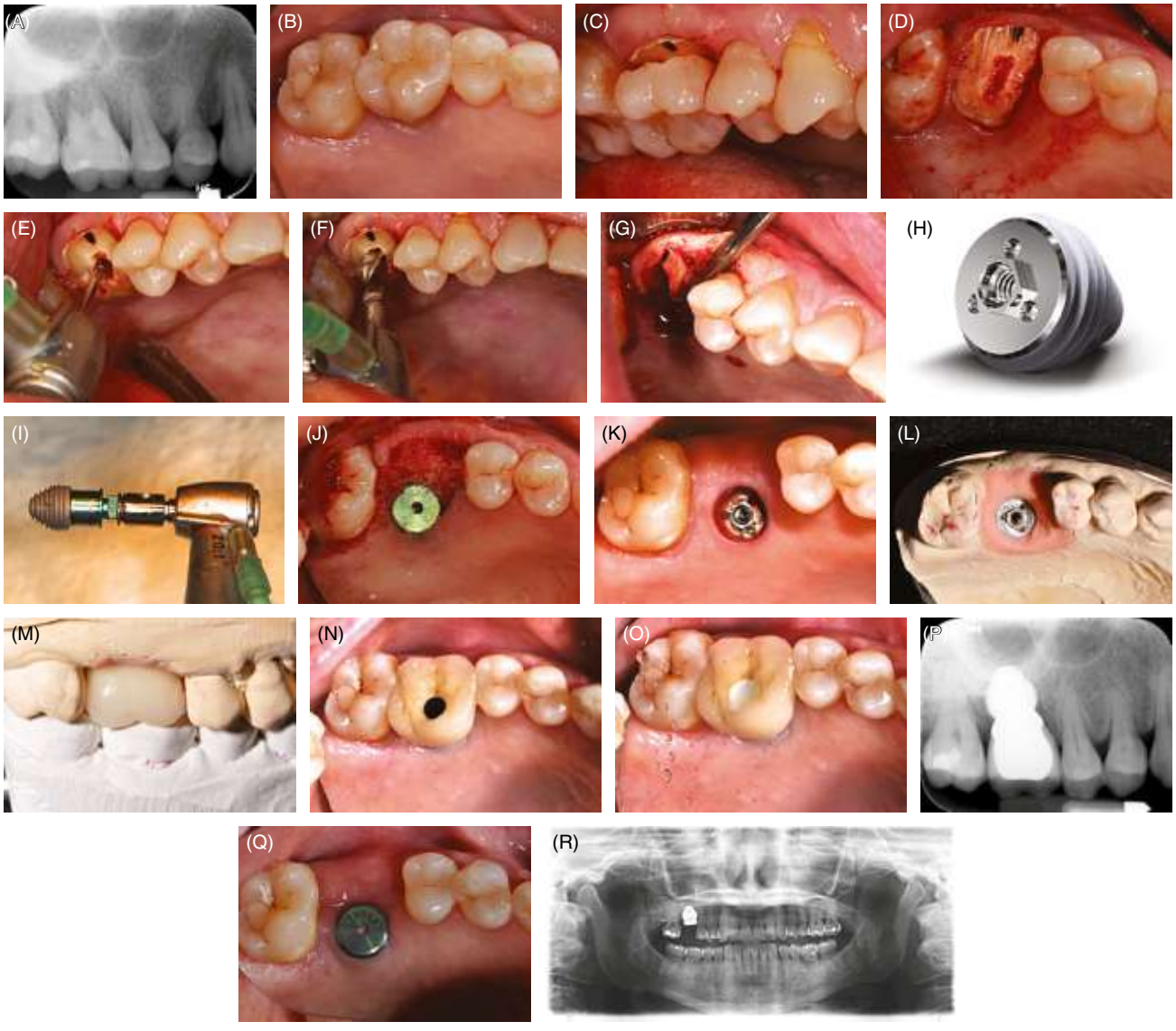

FIGURE 4.17 A 7.0 mm dental implant is used to restore a missing maxillary first molar. This implant was placed beneath the sinus without sinus elevation. The implant is 7.0 mm wide. Ridge width augmentation was avoided by preserving the site with immediate implant placement and gap grafting.

Dentlearn.ir

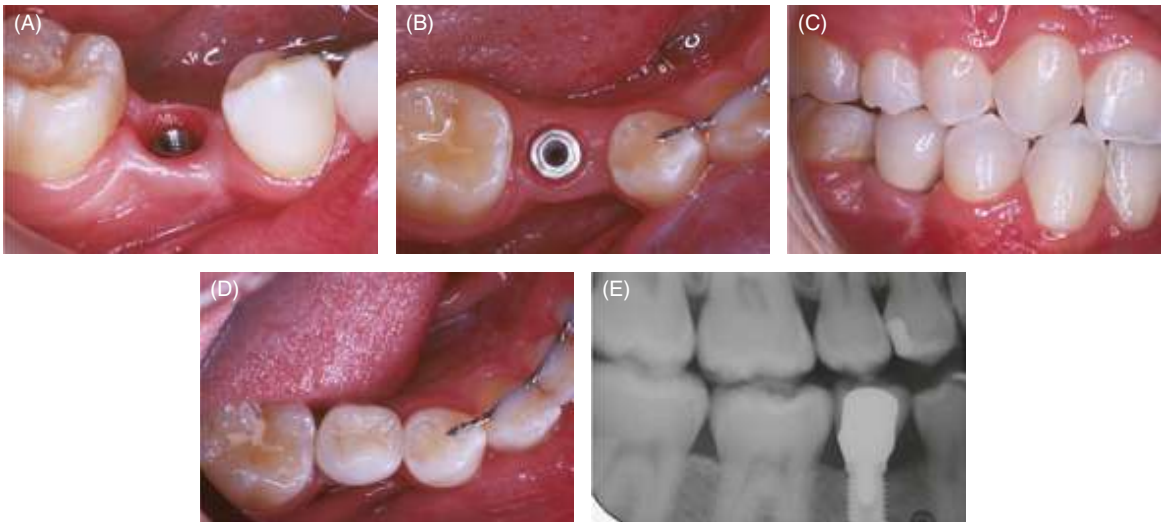

FIGURE 4.18 A mandibular right second premolar is replaced with a dental implant, custom abutment, and crown. The area was not grafted horizontally, leaving a defect relative to the adjacent teeth. The gingival emergence is chronically irritated.

occlusal force distribution, and food trapping will also alter the predictability and patient satisfaction in the posterior maxilla and mandible (Figure 4.19).

Complicating factors such as side-by-side dental implant placement are more tolerable than in the anterior. The loss of papilla is less problematic, as it is not an esthetic concern. In some cases, a patient will benefit from additional implant support in the posterior maxilla and mandible.

Ideal implant placement in the posterior maxilla and mandible can be accomplished by treatment planning from the restoration down (see Figure 4.20). Placement parameters include the following:

- 3 mm of space is needed between dental implants with a matched platform and abutment to prevent the horizontal aspect of crestal bone remodeling from eliminating the bone between dental implants.
- 2.1 mm of space is needed between dental implants with a dental implant platform that is wider than the restorative abutment.

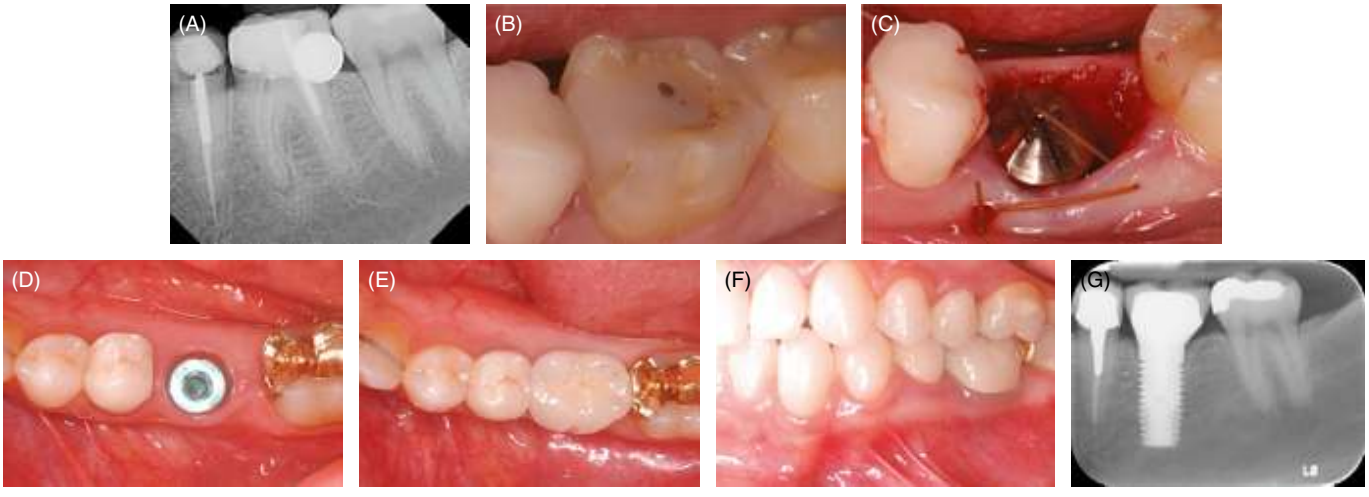

FIGURE 4.19 (A–G) The mandibular left first molar is fractured and not restorable. The tooth was extracted and a dental implant immediately placed. Once integrated, a custom abutment was digitally fabricated, and a porcelain-fused-to-metal crown placed to restore the implant. The need for horizontal ridge augmentation was prevented by the immediate placement of the dental implant. Ideal emergence was achieved with this technique.

Dentlearn.ir

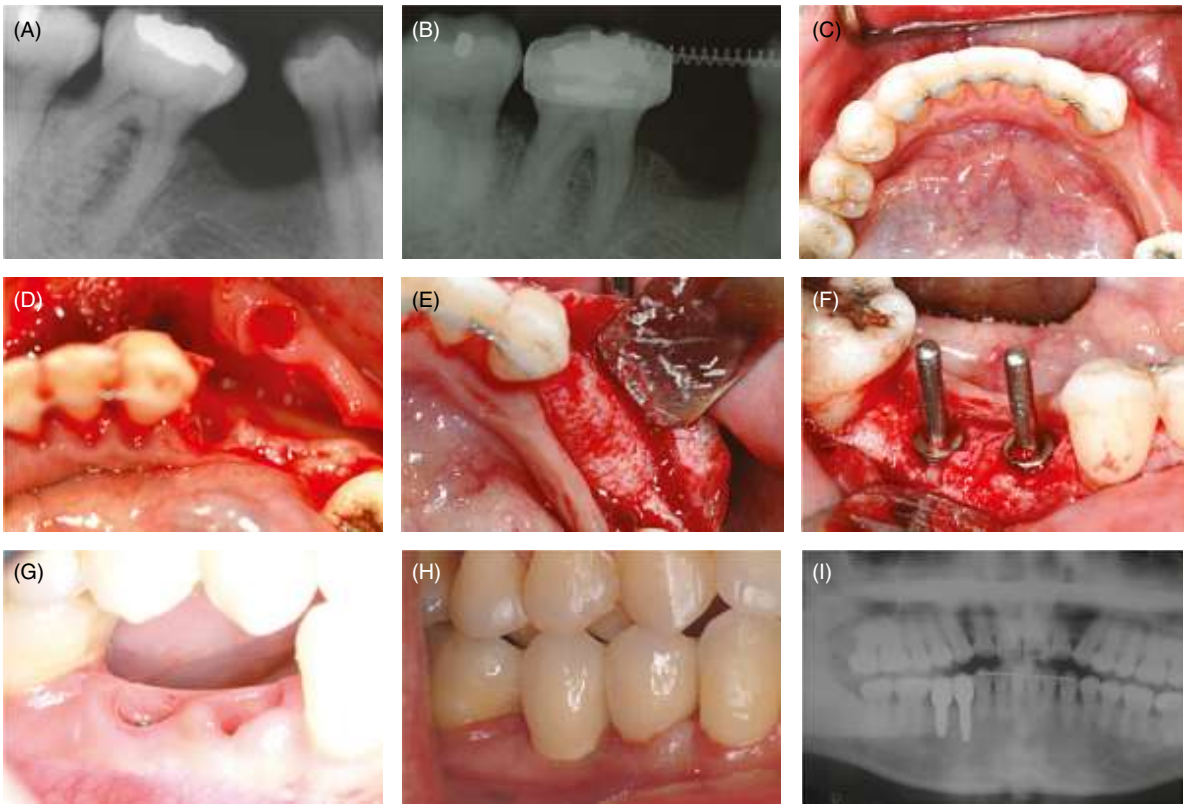

FIGURE 4.20 (A, B) Pre-operative radiograph. (C) Orthodontic site preparation. (D) The ridge is deficient buccally. (E) Ridge augmentation procedure to provide adequate width for dental implant placement. (F, G) Dental implant placement. (H, I) Five-year follow-up clinical photo and radiograph.

- 1.5 mm of space is needed between dental implants and natural teeth so as not to compromise the bone supporting the adjacent tooth.
- Screw access is required in the middle of the occlusal table.
- Platform depth should be 3 mm deep or less to the zenith of the facial gingival margin.
- Plan and place the widest implant possible.

PROSTHETIC EVALUATION AND TREATMENT PLANNING OF THE COMPLETELY EDENTULOUS PATIENT

When a patient presents to the surgeon restorative team for the replacement of their entire dentition in the maxilla, mandible, or both, they often do not have a clear understanding of the options available to them. When asked, many will desire to have a fixed, non-removable dentition. Others will opt for the convenience of a removable overdenture prosthesis supported by a bar from the standpoint of cleansibility, and others may need the additional facial support of a flange. Due to finances, some may choose freestanding dental implants with stud attachments. The joint decision on how to accomplish this goal is based ultimately on their desire to replace their teeth and their clinical needs. The patient wishes to replace their teeth in a predictable manner. They want the teeth to look natural and function as if they are their own. The type of restoration chosen will determine the proposed position of dental implants.

Recommendations for the placement of dental implants to support fixed crown and bridge restorations on six implants, whether it be with sinus elevation and vertical bone augmentation to accommodate the position of the dental implants or the use of angled implants, have been well described in the literature. The need to graft horizontally is determined by the design of the restoration and implant position necessary to provide adequate support [38, 39].

Crown and Bridge Restoration

Edentulous patients who desire a crown and bridge restoration often lack the support needed both vertically and horizontally. In these cases, a staged approach typically works best (Figure 4.21). Working from the restoration to the apex, the

Dentlearn.ir

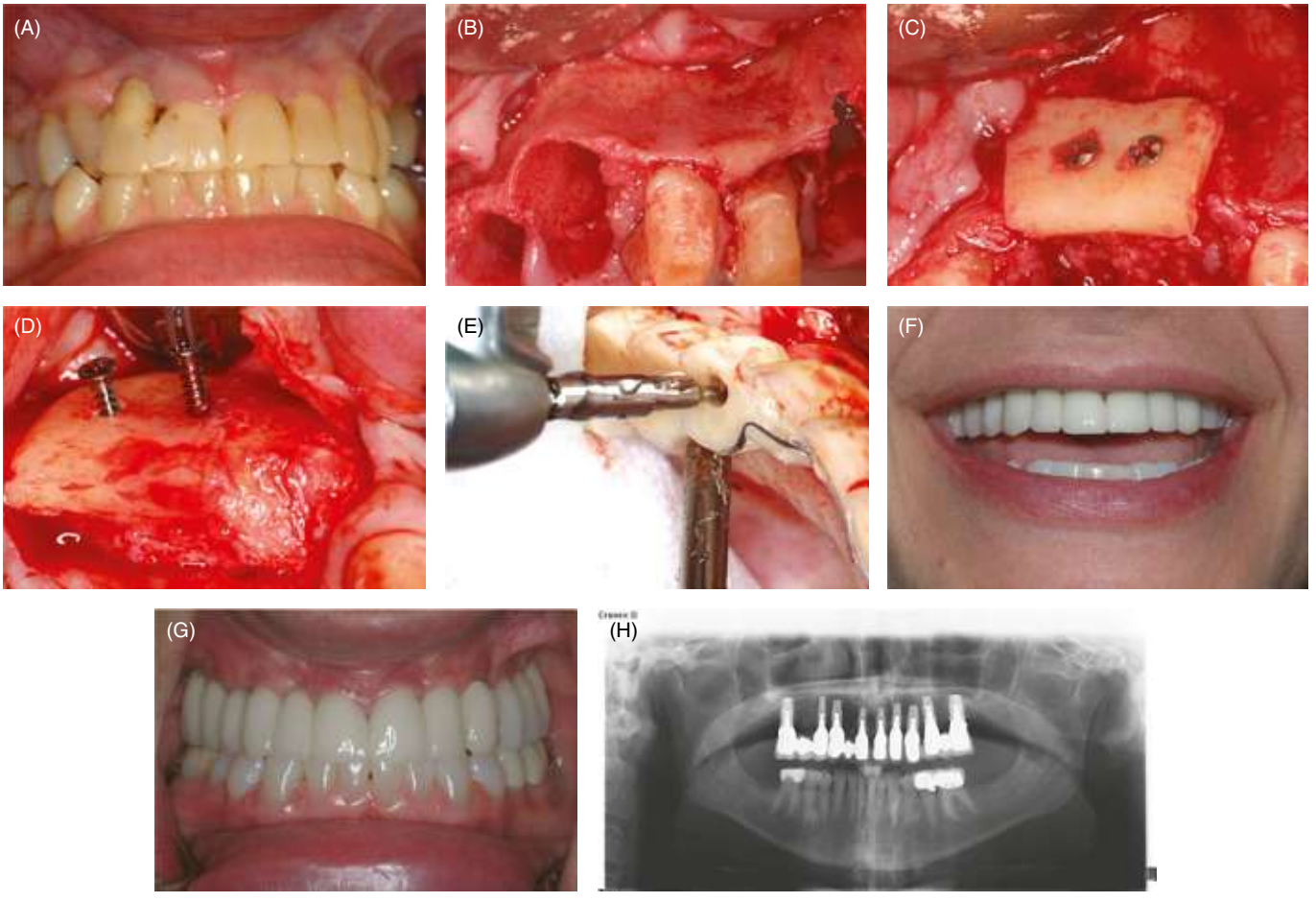

FIGURE 4.21 (A) Pre-treatment clinical photographs of a failing maxillary dentition. (B, C) Extracting and block bone grafting. (D, E) Dental implant placement. (F–H) 24-month follow-up.

implant prosthetic platform should be 9–11 mm from the incisal edge. The platform needs to be of adequate width to properly support the occlusion. The bone must be able to accommodate the appropriate platform diameter. Ridge width augmentation is needed to allow for the labial/facial surfaces of the restoration to be in the proper orientation to the facial plane. Without that, a small ridge lap may be needed to create the proper facial plan parallelism.

If the vertical bone support calls for artificial gingiva to create teeth of a proper dimension, ridge width augmentation may be needed in conjunction to implant placement to allow for proper implant support beneath the restoration. This can be done in a staged approach (Figure 4.22). Great concern must be given to the design of the provisional denture. The flanges must be short of the vestibule and allow for adequate relief on the buccal surface so as not to pressure the healing graft.

Implant-Supported Overdentures and Implant-Supported Fixed Complete Dentures

In the case where a patient requires a hybrid or overdenture, ridge width augmentation is often a subtraction of the thin part of the alveolar ridge to create an adequate housing for the implants (Figure 4.23). This is especially true in the anterior mandible. Although fixed implant restorations supported by four dental implants are successful, studies show greater prosthetic success when hybrid prostheses are restored on five or six dental implants [40, 41].

Implants set more posteriorly in the maxilla allow for a more stable anterior–posterior spread and enable avoidance of the bar crossing the anterior maxilla, keeping the prosthesis thinner, increasing comfort, and improving speech by decreasing the horizontal thickness of the restoration in this area. Studies suggest equal success rates when bars are split on six

Dentlearn.ir

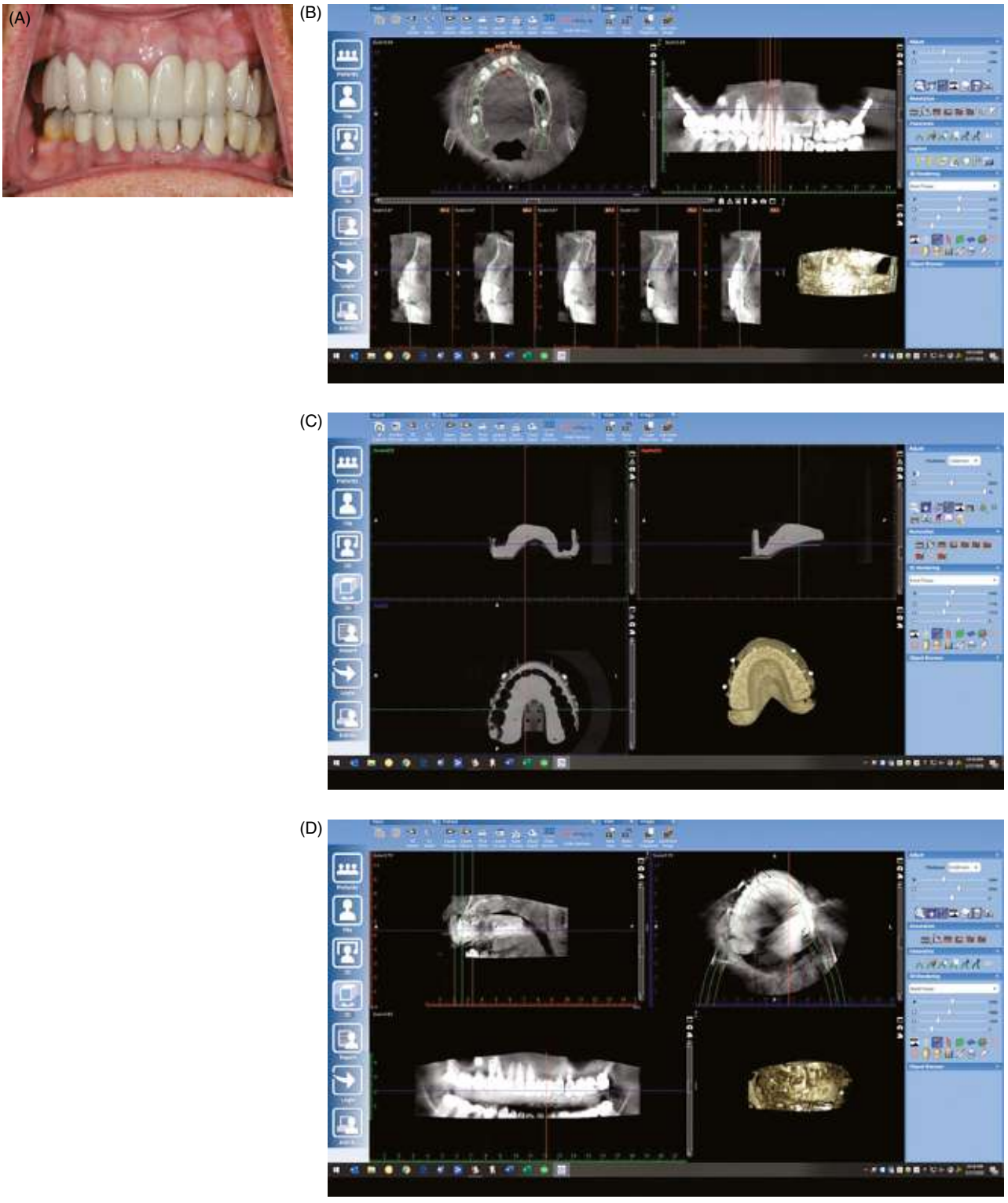

FIGURE 4.22 This patient presents with a failing maxillary and mandibular dentition. She had previous posterior implant restorations. The anterior teeth are failing. In addition, the mandibular left fixed partial denture is failing, and mandibular right first premolar is fractured. The maxillary dentition is replaced with a fully digital protocol. The ridge width is gained by a subtraction technique. In this case, 12 mm of alveolectomy was necessary to place the implants in the proper restorative position.

Dentlearn.ir

(E)

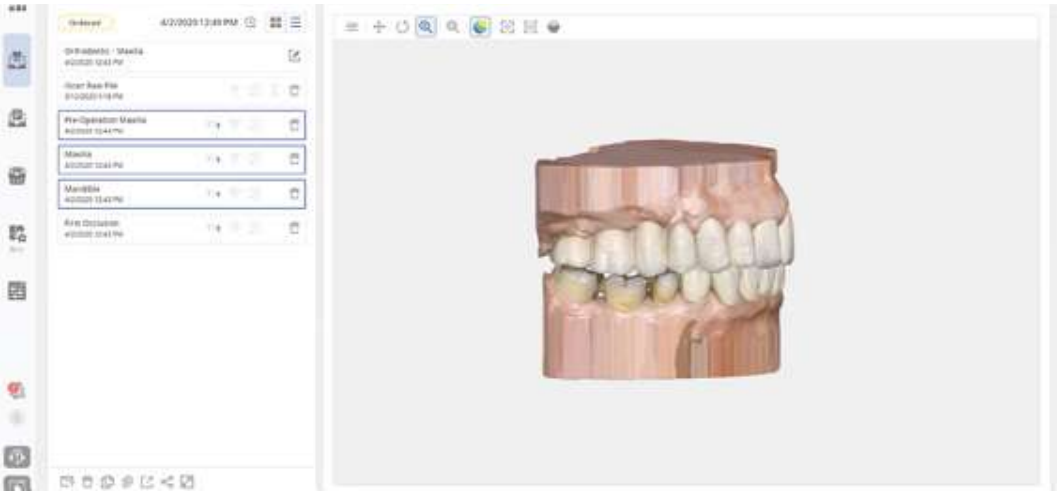

(F)

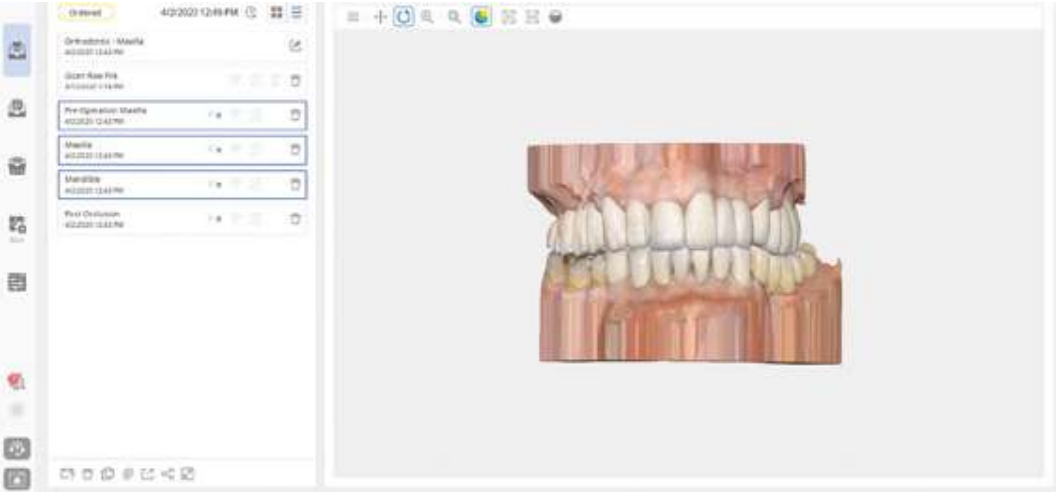

(G)

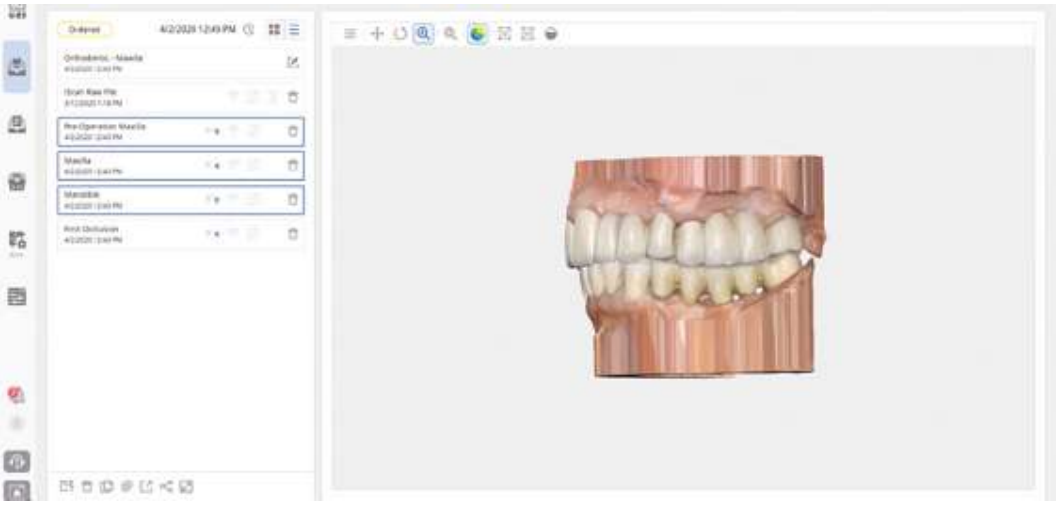

FIGURE 4.22 *(continued)*

Dentlearn.ir

FIGURE 4.22 *(continued)*

Dentlearn.ir

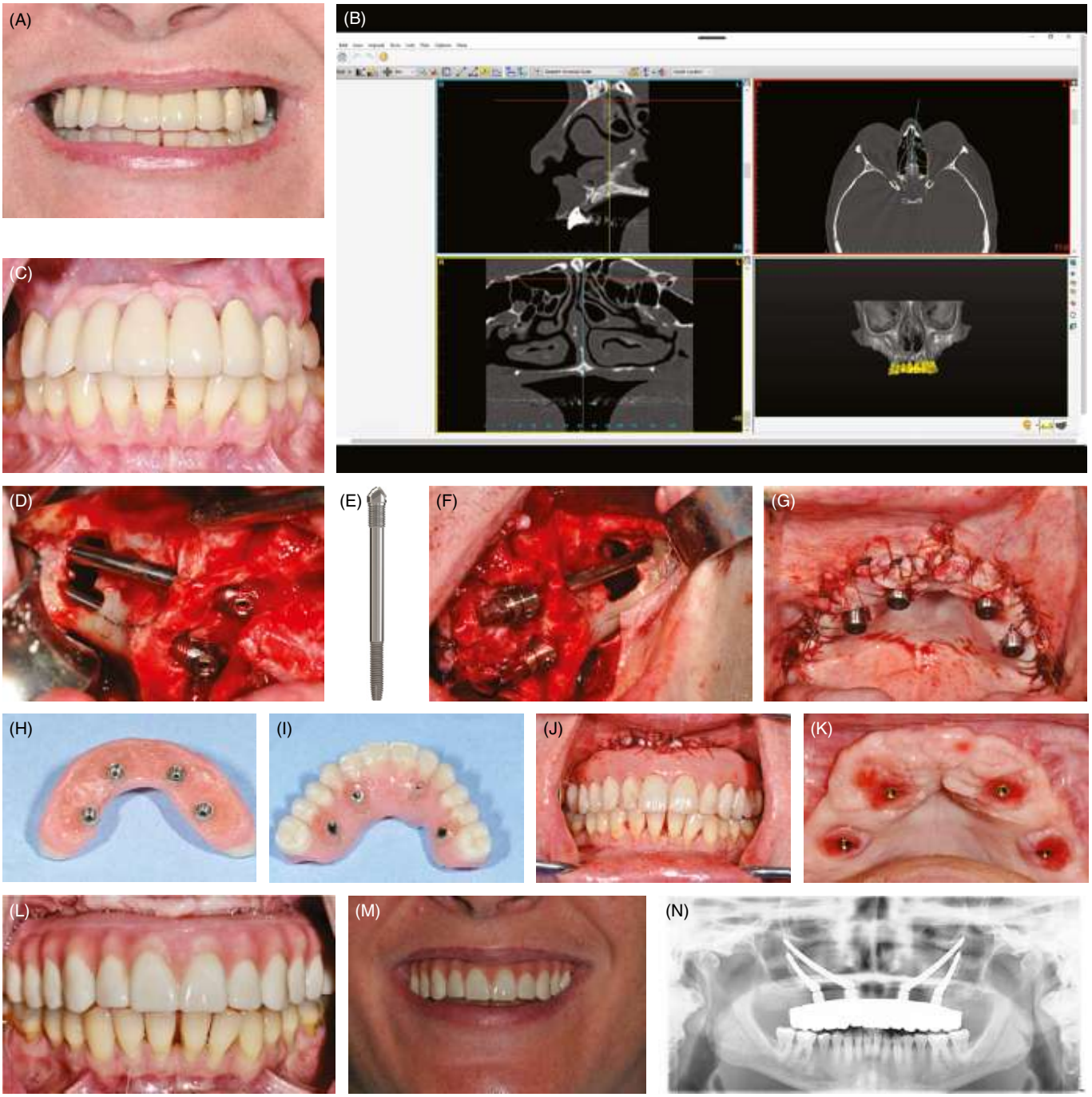

FIGURE 4.23 When all else fails in the maxilla, zygomatic implants are an appropriate and viable approach to implant reconstruction. This case depicts a severely atrophic maxilla requiring both horizontal and vertical augmentation. Quad zygomatic implants were chosen as an alternative therapy, with great success. Note the design of the zygomatic implant. It is threaded at the apex and collar. The middle of the implant is polished and can be placed intra- or extra-sinus cavity.

Dentlearn.ir

implants set more posteriorly or when four dental implants are placed between the maxillary sinuses [3].

Site-specific implants are useful in the full-arch restoration. Zygomatic implants for patients with advanced atrophy in combination with subcrestal angle correction allow for very predictable full-arch restoration. Short/wide implants can be used subantrally in the posterior maxilla if width allows, supporting the restoration from an occlusal and maintenance standpoint. In the posterior mandible, often they can be placed distal to the mental foramen. The net effect on the restoration is one that eliminates cantilevers and food traps.

CONCLUSION

The restoration of a dental implant patient is a multidisciplinary specialty. Coordination of efforts in diagnosis and treatment planning can be the difference between success and failure on many levels. Long-term predictability, patient satisfaction, and implant-restorative success rely on the communication between the surgical specialist, restorative dentist, and laboratory technician. Coordination of diagnostic information, goals of restoration, implementation of procedures, and delivery of prosthetics, as well as long-term maintenance, must be outlined prior to initiation of treatment so that patients have an understanding of their commitment to the treatment plan.

REFERENCES

1. Coachman C, Calamita M. Virtual smile design. *J Cosmet Dent.* 2014:29(4):102–16.
2. Spear FM. Forming an interdisciplinary team: A key element in practicing with confidence and efficiency. *J Am Dent Assoc.* 2005;135(10):1463–4.
3. Krennmair G, Krainhofner M, Piehslinger E. Implant-supported maxillary overdentures retained with milled bars: Maxillary anterior versus maxillary posterior concept – a retrospective study. *Int J Oral Maxillofac Implants.* 2008;23:343–52.
4. Chu S, Ostman P, Nicolopoulos C et al. Prospective multicenter clinical cohort study of a novel macro hybrid implant in maxillary anterior postextraction sockets: 1-year results. *Int J Periodontics Restorative Dent.* 2018;38(suppl):s17–s27.
5. Hattingh AC, De Bruyn H, Ackermann A, Vandeweghw S. Immediate placement of ultrawide-diameter implants in molar sockets: Description of a recommended technique. *Int J Periodontics Restorative Dent.* 2018;38:17–23.
6. Lizio G, Corinaldesi G, Marchetti C. Alveolar ridge reconstruction with titanium mesh: A three-dimensional evaluation of factors affecting bone augmentation. *Int J Oralmaxillofac Implants.* 2014;29:1354–63.
7. Borenstein M, Cionca N, Mombelli A. Systemic conditions and treatments as risks for implant therapy. *Int J Oralmaxillofac Implants.* 2009;24(suppl):12–27.
8. Sugarman P, Barber M. Patient selection for endosseous dental implants: Oral and systemic considerations. *Int J Oralmaxillofac Implants.* 2002;17:101–201.
9. Borenstein M, Al-Nawas B, Kuchler U. Consensus statement and recommended clinical procedures regarding contemporary surgical and radiographic techniques in implant dentistry. *Int J Oralmaxillofac Implants.* 2014;29(suppl):79–82.
10. DeKok I, Thalji G, Bryington M, Cooper L. Radiographic stents integrating treatment planning and implant placement. *Dent Clin N Am.* 2014;58:181–92.
11. Kokich V, Kinzer G, Janakievski J. Congenitally missing lateral incisors: Restorative replacement. *Am J Orthod Dentofacial Orthop.* 2011;139:434–5.
12. Celenza F. The development of forced eruption as a modality for implant site enhacement. *Alpha Omegan.* 1997;90(2):40–43.
13. Korayem M, Flores-Mir C, Nassar U, Olfert K. Implant site development by orthodontic extrusion. *Angle Orthodontist.* 2008;78(4):752–60.
14. Chel-Park Y, Seung-Yeon L, Doo-Hyung K, Sung-Hoon J. Intrusion of posterior teeth using mini-screw implants. *Am J Orthod Dentofacial Orthop.* 2003;123(6):690–94.
15. Davidoff S, Steinberg M. A prosthodontic-based implant patient classification system. *J Prosthod.* 1993;2(1):44–50.
16. Pannosian A, Block M. Evaluation of the smile: Facial and dental considerations. *J Oralmaxillofac Surg.* 2010;68:547–54.
17. Choquet V, Hermans M, Adriaenssens P et al. Clinical and radiographic evaluation of the papilla level adjacent to single-tooth dental implants: A retrospective study in the maxillary anterior region. *J Periodontol.* 2001;72:1364–71.
18. Priest G. Predictability of soft tissue form around single-tooth implant restorations. *Int J Periodontics Restorative Dent.* 2003;23:19–27.
19. Coachman C, Calamita M, Sesma N. Dynamic documentation of the smile and the 2D/3D digital smile design process. *Int J Periodontics Restorative Dent.* 2017;37:183–93.
20. Mandelaris G, Rosenfeld A. Bone anatomy. In M Sonick, D Hwang, A Saddoun (eds.), *Implant Site Development*. Oxford: Wiley-Blackwell; 2001, 14–34.
21. Ganz S. CT/CBCT diagnosis and treatment planning concepts for bone grafting applications. In M Sonick, D Hwang, A Saddoun (eds,), *Implant Site Development*. Oxford: Wiley-Blackwell; 2001, 101–20.
22. Lal K, White G, Morea D, Wright R. Use of steriolithographic templates for surgical and prosthodontic implant planning. *Part I. The concept. J Prosthodont.* 2006;15:51–8.
23. Sclar A, Kannikal J, Fortes Ferreira C et al. Treatment planning and surgical considerations in therapy for patients with agenesis, oligodontia, and extodermal dysplasia: Review and case presentation. *J Oral Maxillofac Surg.* 2009;67(suppl 3):2–12.
24. Annibali S, La Monaca G, Tantardini M, Cristalli MP. The role of the template in prosthetically guided implantology. *J Prosthodont.* 2009;18:177–83.

Dentlearn.ir

25. Levine R, Huynh-Ba G, Cochran D. Soft tissue augmentation procedures for mucogingival defects in esthetic sites. *Int J Oral Maxillofac Implants.* 2014;29(suppl):155–85.

26. Kokich V. Maxillary lateral incisor implants: Planning with the aid of orthodontics. *J Oral Maxillofac Surg.* 2004;62(suppl 2):48–56.

27. Kuchler U, von Arx T. Horizontal ridge augmentation in conjunction with or prior to implant placement in the anterior maxilla: A systematic review. *Int J Oral Maxillofac Implants.* 2014;29(suppl):14–24.

28. Priest G. The esthetic challenge of adjacent implants. *Int J Oral Maxillofac Implants.* 2007;65(suppl):2–12.

29. Buser D, Martin W, Belser U. Optimizing esthetics for implant restorations in the anterior maxilla: Anatomic and surgical considerations. *Int J Oral Maxillofac Implants.* 2004;19(suppl):43–61.

30. Saadoun A, Touati B. Soft tissue recession around implants: Is it still avoidable? *Part I. Pract Proced Aesthet Dent.* 2007;19:55–62.

31. Bouri A, Bissada N, Al-Zahrani M et al. Width of keratinized gingival and the health status of the supporting tissues around dental implants. *Int J Oral Maxillofac Implants.* 2008;23:323–6.

32. Small P, Tarnow D. Gingival recession around implants: A 1-year longitudinal prospective study. *Int J Oral Maxillofac Implants.* 2000;15:527–32.

33. Tarnow D, Elian E, Fletcher P et al. Vertical distance from the crest of bone to the height of the interproximal papilla between adjacent implants. *J Periodontol.* 2003;74:1785–8.

34. Tarnow D, Magner A, Fletcher P. The effect of the distance from the contact point to the crest of bone on the presence or absence of the interproximal dental papilla. *J Periodontol.* 1992;63:995–6.

35. Walker L, Morris G, Novotny P. Implant insertional torque values predict outcomes. *J Oral Maxillofac Surg.* 2011;69:1344–9.

36. Block M. Placement of implants into fresh molar sites: Results of 35 cases. *J Oral Maxillofac Surg.* 2011;69(1):170–74.

37. Pagni G, Pellegrini G, Giannobile W, Rasperini G. Post extraction alveolar ridge preservation: Biological basis and treatments. *Int J Dent.* 2012;2012:151030.

38. Tolstunov L. 13–23–30 anatomic approach for maxillary full-arch implant reconstruction: A case report and surgical-prosthetic considerations. *J Oral Maxillofac Surg.* 2010;68:818–24.

39. Krennmair G, Seemann R, Weinlander M et al. Clinical outcome and peri-implant findings of four-implant-supported distal cantilevered fixed mandibular prostheses: Five-year results. *Int J Oral Maxillofac Implants.* 2013;28:831–40.

40. Silva G, Mendonca J, Lopes L, Landre J Jr. Stress patterns on implants in prostheses supported by four or six implants: A three-dimensional finite element analysis. *Int J Oral Maxillofac Implants.* 2010;25:239–46.

41. Testori T, Del Fabbro M, Szmukler-Moncler S et al. Immediate occlusal loading of osseotite implants in the completely edentulous mandible. *Int J Oral Maxillofac Implants.* 2003;18:544–51.

Dentlearn.ir

Alveolar Ridge Defects and Bone Augmentation Techniques: Surgical Algorithm

CHAPTER 5

Objective evaluation of bone and soft tissue defects with comprehensive clinical and radiographic three-dimensional examination should guide a surgeon into making a proper diagnosis and targeted treatment plan. Knowledge of alveolar bone augmentation techniques is extremely important, and the surgeon's skills and experience ultimately determine the selection of a surgical technique. A team approach with both restorative and surgical specialists working side by side can assure the success of the overall implant treatment, with optimal implant prosthetic outcome (see Video 5.1).

ALVEOLAR BONE CLASSIFICATION BY DEFICIENCY (ABCD TOLSTUNOV CLASSIFICATION): DECISION TREE ALGORITHM

- Most type I (mild) horizontal or vertical ridge defects can be successfully treated with guided bone regeneration (GBR).
- Type II–III (moderate to severe) horizontal bone defects with a sufficient vertical bone stock should be treated based on the surgeon's comfort zone:
  - *Onlay autogenous block bone graft* is an excellent choice for localized 2–3 edentulous space horizontal concave defects. Remember: donor site morbidity and recipient site block graft adaptation, fixation, and good primary wound closure.
  - *Ridge-split expansion procedure* is an excellent choice for a flat 4–5 mm width ridge (one-stage technique for maxillary and two-stage technique for mandibular bony defects). Remember: technique sensitive – proper bone split between cortical plates and second surgical procedure may be required.
  - *GBR* procedure is an excellent choice for any horizontally deficient ridges. Remember: use of resorbable or non-resorbable membranes and good adaptation of soft tissue margins.
- Type II–III (moderate to severe) vertical bone defects with a sufficient horizontal bone stock should be treated based on the surgeon's comfort zone by an experienced surgeon:
  - *Distraction osteogenesis* is a good choice for a large vertical bone deficiency. Remember: technique sensitive – proper osteotomy and placement of a distractor, tendency for a lingual vector of distraction, patient's compliance, need for a second surgery [61].
  - *Autogenous (or allogenic) extraoral (onlay) or intraoral (inlay) block graft* is a good choice for a large, localized, 2–3 edentulous space, vertical concave bone defects [61]. Remember: technique sensitive – recipient site block graft adaptation, fixation, and good primary wound closure, donor site morbidity.
  - *Segmental sandwich osteotomy* is a good choice for a large, localized, vertical or three-dimensional concave or flat bone defect. Remember: technique sensitive – proper osteotomy and fixation of the osteotomized segment, good soft tissue primary closure, possible second bone grafting surgery.
  - *GBR* procedure is a good choice for most vertically deficient ridges, with increasing difficulty as the vertical defect gets larger. Remember: technique sensitive – use of a non-resorbable titanium (Ti)-reinforced membrane or Ti-mesh, staging of procedures, possible soft tissue grafting before bone grafting, good primary wound closure [62].
- Type II–III (moderate to severe) combined bone defects with both horizontal and vertical components should be treated by an experienced surgeon, considering the soft tissue envelope and staging of bone reconstruction for a successful surgical-prosthetic implant rehabilitation.

Dentlearn.ir

CHAPTER 5 Alveolar Ridge Defects and Bone Augmentation Techniques: Surgical Algorithm

Len Tolstunov[1,2,3]

[1]*Associate Clinical Professor, Department of Oral and Maxillofacial Surgery, University of California San Francisco (UCSF) School of Dentistry, San Francisco, CA, USA*

[2]*Associate Clinical Professor, Department of Oral and Maxillofacial Surgery, University of the Pacific Arthur A. Dugoni School of Dentistry, San Francisco, CA, USA*

[3]*Private OMFS practice, San Francisco, CA, USA*

To instruct is *not* to fill the bucket but to ignite the fire.

WB Yeats

Loss of alveolar bone quality and quantity in the stomatognathic system appears to be an inevitable part of life. Events that lead to jawbone loss, in addition to tooth loss, are infection (of periodontal or endodontic origin), wearing of removable dentures, sinus pneumatization, pathology, and oral and facial trauma [1]. The most common traumatic event, like loss of teeth and associated loss of function of mastication, is the most common reason for slow and progressive bone atrophy that starts with resorption of the bundle bone (part of the alveolar bone proper – alveolar ridge) that surrounds the teeth [2–8]. The horizontal component of the alveolar ridge loss in most post-extraction situations predominates, but vertical bone loss is also present [4–7]. Most of these adverse conditions (except physical trauma and pathological lesions) are directly or indirectly related to loss of teeth. Wolff's law, commonly used in orthopedics, is often applied to describe bone remodeling changes following tooth loss and the inter-relationships between the anatomy and function of the musculoskeletal system when a change of function (post extraction) leads to alveolar bone loss due to non-use atrophy [9, 10].

Implant dentistry targets the replacement of missing teeth and associated loss of masticatory function, esthetics, and comfort, with dental implants that are intended be placed in occlusally and restoratively driven position to accomplish these important goals. Loss of teeth and following loss of the alveolar supporting bone lead to a compromise of this premise. Ridge preservation and bone augmentation techniques are designed to help to accomplish these goals.

RIDGE PRESERVATION AND RIDGE AUGMENTATION

Ridge preservation and ridge augmentation are two prevailing bone grafting strategies in implant dentistry. Two questions help to distingue each method and understand their differences in relationship to tooth extraction: *when* (timing of grafting relative to the tooth loss) and *how* (specifics of grafting) [11].

RIDGE PRESERVATION

Ridge preservation (RP; prophylactic treatment) consists of hard and soft tissue grafting procedures that intend to preserve the existing ridge volume *within* its bony envelope [12, 13]. These surgical procedures are usually performed at the time of tooth extraction, with the goal of minimizing surrounding tissue loss after the tooth loss. RP techniques are usually done in an immediate fashion (simultaneously with a tooth extraction), in an attempt to preserve the alveolar ridge and prevent the collapse of socket walls [14–17]. This surgical approach tends to involve the guided bone regeneration (GBR) principle, utilizing a particulate (particulated) bone grafting material (bone substitute and/or autogenous bone chips) placed in an internal or *inlay* fashion between the socket bony walls (interpositional graft) [14, 15, 18, 19].

Guided tissue regeneration (GTR) membranes, resorbable and non-resorbable, are often used simultaneously with a

Essential Techniques of Alveolar Bone Augmentation in Implant Dentistry: A Surgical Manual, Second Edition. Edited by Len Tolstunov.
© 2023 John Wiley & Sons, Inc. Published 2023 by John Wiley & Sons, Inc.
Companion website: www.wiley.com/go/tolstunov/essential

Dentlearn.ir

FIGURE 5.1 Guided bone regeneration procedure with a particulate bone grafting material and dense polytetrafluoroethylene (d-PTFE) membrane for a ridge preservation (post-extraction socket grafting) of the upper right first molar.

particulate graft (described in more detail later in this chapter) in an attempt to encourage the growth of certain tissue cells, like slower-growing osteoblasts, into the bony defect while shielding others, like fast-growing epithelium and connective tissue cells, regulating the bone formation process [20–22].

A particulate graft can be used as a single grafting material, a mixed (composite) graft of different bone materials, or in a layered manner (sandwich approach) of one material (for instance, xenograft) on top of another (for example, autogenous bone). Advanced periodontal bone loss around failing tooth or teeth may require a larger amount of a particulate graft material. The RP approach is intended to decrease or eliminate the need for larger bone augmentation procedures later, although an additional bone grafting is sometimes needed again, prior to or with an implant placement. Section II of this book is devoted to RP (Figure 5.1).

RIDGE AUGMENTATION

Ridge augmentation (RA; therapeutic approach) consists of hard and soft tissue grafting procedures that intend to increase (augment) the alveolar ridge volume *beyond* the existing deficient skeletal envelope [11, 23, 24]. These surgical procedures are usually performed at the edentulous state of a variety of bone defects (BDs). These bone defects or deficiencies can be horizontal (HBD), vertical (VBD), or volumetric or 3D (3DBD). Most of the alveolar bone deficiencies have some degree of both directional components, with a prevalence of one. The correctional surgical bone augmentation (BA) techniques therefore tend to be either horizontal (HBA), or vertical (VBA), or both (3DBA). Sections III and IV describe multiple surgical procedures related to HBA and VBA in detail (Figures 5.2 and 5.3).

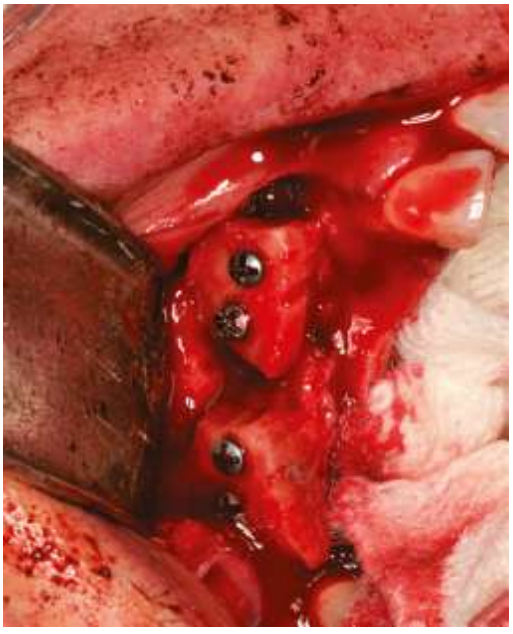

FIGURE 5.2 Autogenous block bone graft procedure: two symphyseal (chin) bone blocks were harvested and fixated to the horizontally deficient maxillary right alveolar ridge with titanium screws.

FIGURE 5.3 Collagen membrane can be used to cover the block graft prior to primary closure of the wound.

Dentlearn.ir

BONE DEFECTS, BONE GRAFTS, AND BONE GRAFTING TECHNIQUES

EXTRAOSSEOUS VERSUS INTRAOSSEOUS ALVEOLAR BONE DEFECTS

Alveolar bone defects can be classified as *extraosseous* (extrabony), which are usually diagnosed in edentulous cases of atrophied or vertically collapsed alveolar ridge with only one or two osseous walls remaining (1- or 2-wall defect), and *intraosseous* (intrabony), which are typically seen in extraction socket cases with 3 or 4 natural bony walls present (3- or 4-wall defects) in horizontally or vertically deficient ridges. The regenerative ability (potential) of extrabony vertical defects is lower and successful augmentation is more difficult to achieve than in cases of intraosseous defects that are surrounded by osteoconductive walls, a vital source of bone regeneration (Figures 5.4 and 5.5) [25, 26].

ONLAY VERSUS INLAY ALVEOLAR BONE GRAFTS

Biological regenerative materials (grafts, membranes) for the alveolar ridge defect repair can be inserted in an *onlay* (external or veneer) or *inlay* (internal or interpositional) manner, when they are respectively positioned either on top of the collapsed cortical plate of the atrophied alveolar ridge as an onlay graft or inserted internally (inside) a fresh extraction socket or osteotomized bony segment into the medullary (trabecular) bone compartment between cortical plates as an inlay graft (Figures 5.2 and 5.6) [27, 28].

Another modification of graft positioning can be called a "tent-pole" grafting technique, sometimes used for the reconstruction of large vertical alveolar ridge defects. In this situation, the surgeon chooses a *tenting* device (titanium screws or dental implants) fixated into the atrophied bone, expanding or stretching the soft tissue matrix, with a particulate bone graft placed in inlay fashion between the top of the screw(s) or implant abutment and the deficient bone. This technique is more successful in concave alveolar ridges [29, 30].

STATIC VERSUS DYNAMIC SURGICAL TECHNIQUES

Most BA procedures are *static*, meaning they can be done in one (block graft) or two (ridge-split) stages to a definitive bone expansion goal by the end of the surgery. If a BA procedure is done in a dynamic mode, it means that a pilot (preliminary) procedure is done first, followed by an incremental *process* of actual augmentation that is accomplished over time (dynamically or incrementally). Orthodontic extrusion of

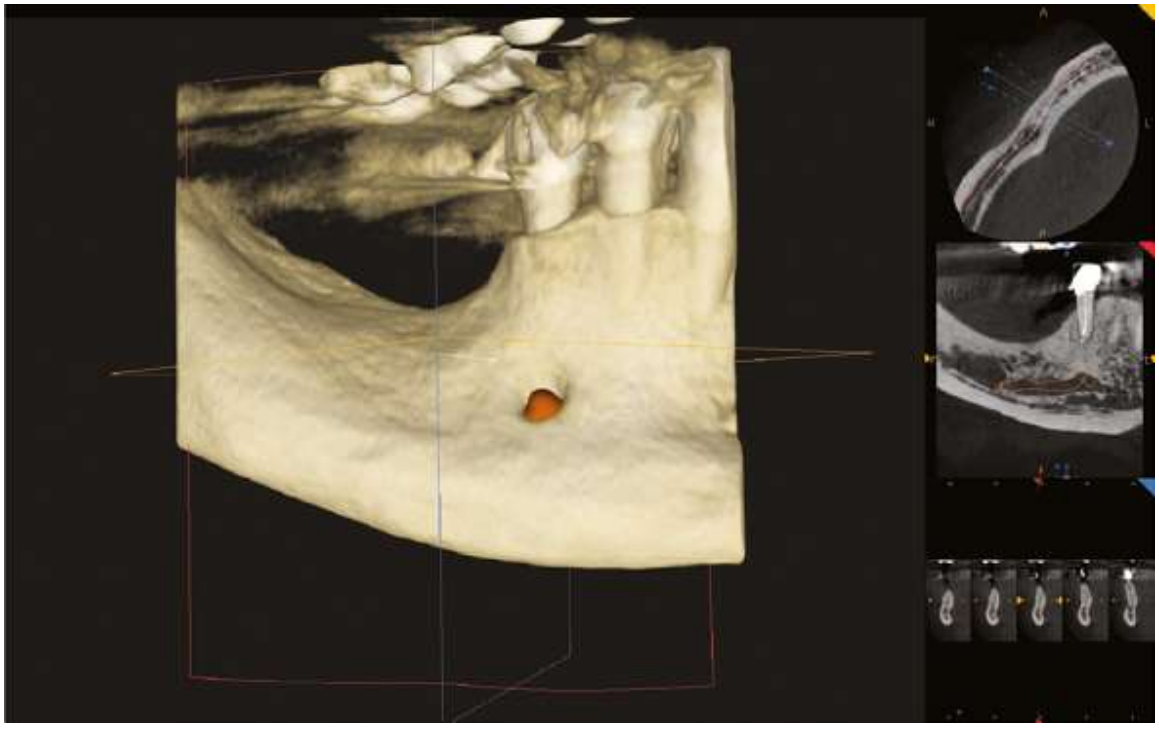

FIGURE 5.4 Large vertical extraosseous bone atrophy can be seen on a cone beam computed tomography scan of the right posterior mandible as a collapsed concave bone defect. The proximity of the mental foramen can also be visualized.

Dentlearn.ir

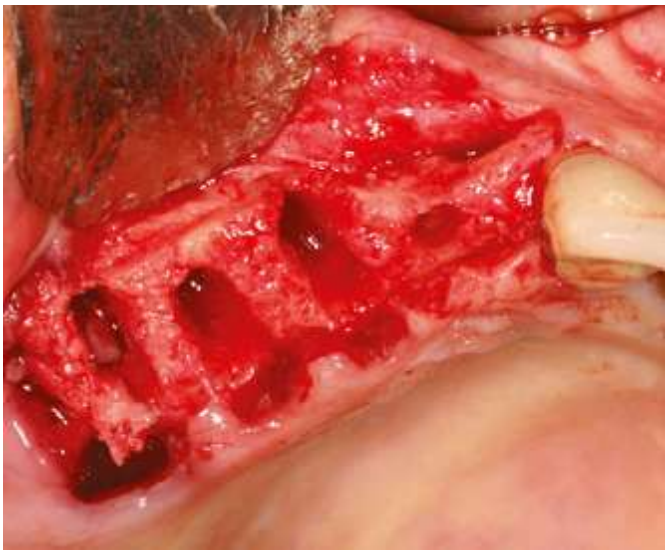

FIGURE 5.5 Intraosseous post-extraction bone deficiency and sockets in the anterior maxilla can be seen prior to immediate implant placement and bone grafting procedure.

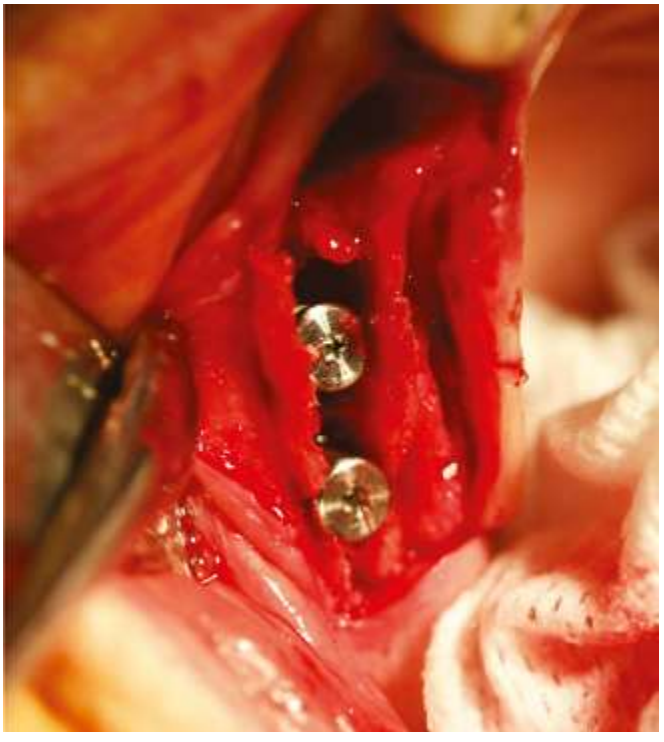

FIGURE 5.6 Ridge-split expansion procedure: two implants are positioned inside the split in the trabecular bone compartment between cortical plates in this posterior maxillary bone deficiency case.

tooth, periosteal expansion osteogenesis, or distraction osteogenesis of bone are good examples of dynamic BA methods when bone expansion and growth *progress* over time in an incremental fashion using tensile stress (forces) to a final planned outcome [31–34]. Chapters 21 and 22 in Section IV are dedicated to this topic.

RISK FACTORS IN BONE AUGMENTATION PROCEDURES IN IMPLANT DENTISTRY

Among many systemic (e.g. uncontrolled diabetes mellitus) and local (e.g. cigarette smoking) factors [35, 36] that can have an adverse effect on the success of any BA procedure, there are two that we would like to emphasize here that can complicate successful HBA and, especially, VBA in implant dentistry.

One is the function of mastication, which naturally has a vertical component (chewing strokes) working against bone-building grafting techniques, mainly in VBA [24, 37]. Creation of vertical space and shielding of a bone graft with scaffolding devices, like metal (titanium) mesh (Ti-mesh) or Ti-reinforced non-resorbable membranes, are necessary to protect grafting material during the healing stage. These are complex and challenging surgical techniques that have a higher failure rate.

The second is a bacterial contamination factor. If general or orthopedic elective surgeries are mostly done in a sterile environment, oral surgical procedures are not sterile and often not even "clean," and therefore are under the constant danger of graft contamination from aerobic and anaerobic bacteria that might be present in the oral environment [38, 39]. Ongoing food intake (mechanical and bacterial factors) and salivary flow in the post-operative period can contribute to graft contamination, wound dehiscence, infection, and graft loss. Effective tension-free and water-tight primary wound closure and GTR membranes are usually utilized in most cases to protect the grafting material from these unfavorable sources of contamination and infection.

Based on local surgical risk factors, HBA techniques tend to be less challenging and more predictable and VBA procedures are often more complex, require a higher level of surgical expertise, and are less predictable.

MAIN SURGICAL TECHNIQUES OF BONE AUGMENTATION IN IMPLANT DENTISTRY

Among many, there are four main surgical bone grafting techniques in implant dentistry for HBD, VBD, or 3DBA. These are guided bone regeneration (GBR), the autogenous block bone graft (BBG), the ridge-split expansion procedure (RSEP), and the distraction osteogenesis (DO) procedure. In this book, chapters in Sections III and IV describe these surgical techniques in detail.

Dentlearn.ir

GUIDED BONE REGENERATION

The GBR technique employs a particulate grafting material in inlay or onlay fashion for intraosseous or extraosseous bone defects for HBA, VBA, or both. Historically, the GBR technique was derived in the last 20 years from the existing guided *tissue* regeneration (GTR) technique for restoration of compromised tooth periodontium [40, 41]. The *guided* principle implies a surgical use of occlusive membranes that selectively block non-osteogenic tissue cells (e.g. epithelial and connective tissue) from repopulating the bone defect and grafting environment, while encouraging the growth and regeneration of osteogenic tissue cells into the bone defect [42].

GBR techniques have flourished with and parallel to developments in implant dentistry for the purpose of correcting the deficiency of bone prior to implant placement or bone defect around an existing dental implant, as well as for repair of a compromised periodontal apparatus around a natural tooth. Both guided regenerative approaches, GTR and GBR, are now usually used together (graft and membrane) in implant dentistry for bone grafting and are often simply called the GBR technique (Figures 5.1 and 5.7). This technique utilizes different particulate grafting materials, including autogenous bone (chips), xenograft, allograft, alloplast, or mixed graft, usually in conjunction with GTR resorbable or non-resorbable membranes. Non-resorbable options include dense polytetrafluoroethylene (d-PTFE) and Ti-reinforced membranes for space maintenance and rigidity, and tacks and screws for membrane fixation [25]. Not truly cell *guided*, augmentation procedures with a metal scaffolding device, like Ti-mesh, should more properly be called "protective bone regeneration" [25]. Nevertheless, they are often grouped into the same category of GBR grafting techniques.

FIGURE 5.7 Clinical example of guided bone regeneration technique in the left posterior maxilla after extraction of three teeth: the ridge preservation procedure consisted of a particulate graft placed into three sockets and protected by a resorbable collagen membrane. The wound was approximated (secondary intention) with silk sutures.

Biomimetics known for high osteogenic potential and release of growth factors, like recombinant bone morphogenetic protein (rhBMP-2), platelet-rich plasma (PRP), platelet-rich fibrin (PRF), platelet-derived growth factor (PDGF), and vascular endothelial growth factor (VEGF), can be used in combination with the GBR for cases of extensive VBA [43]. Recently, GBR techniques have gained in popularity. Complications of this technique, among many, include collapse of the membrane, graft infection, and delayed healing.

BLOCK BONE GRAFTING

The BBG technique (autogenous or non-autogenous, intraoral or extraoral) requires a free (fully separated) bone block harvested from a patient's donor site (in the case of an autogenous bone) and fixated as an onlay or inlay cortical (ramus) or cortico-cancellous (chin or symphyseal, anterior or posterior iliac crest) graft with stabilizing screws to the recipient site for both HBA and VBA (Figure 5.2). Addition of a particulate bone substitute (with GBR membrane) next to a block graft can also be used in some cases [24]. In the process of harvesting the block graft becomes devascularized (fully separated from the blood supply) and then needs to be revascularized from the recipient site for consolidation. Interruption of vascularization might contribute to the degree of bone resorption known with autogenous block bone grafts [44]. Other complications include donor site morbidity and infection.

RIDGE-SPLIT EXPANSION PROCEDURE

The RSEP, based on a pedicled (pedunculated) osteo-periosteal vascularized flap, is accomplished by splitting (osteotomizing) the alveolar ridge horizontally (ridge-split) or vertically (segmental sandwich osteotomy, SSO) with (usually) a particulate grafting material placed as an inlay (interpositional) graft in the trabecular bone compartment (where the split occurred) between cortical bony plates (Figure 5.6) [24]. Limitations of these techniques include very thin horizontal or vertical ridges (less than 3 mm) that are technically difficult to split and relapse.

DISTRACTION OSTEOGENESIS

The DO technique is mainly used for large (≥5 mm) VBD cases with a distractor that is applied to an osteotomized bone segment. This technique is done in an incremental (dynamic) way (usually at a rate of 1 mm a day for a 1–2-week period), eventually leading to progressive expansion (distraction) of the medullary bone compartment [24]. The distraction process involves not only alveolar bone but a simultaneously ex-

Dentlearn.ir

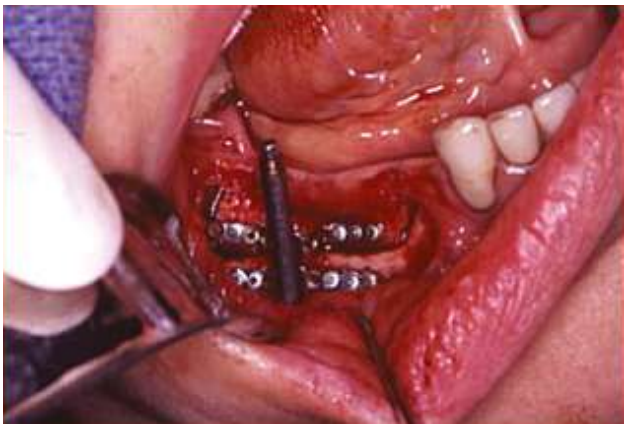

FIGURE 5.8 Distraction osteogenesis procedure in the posterior mandible (right side): the osteotomized bone segment is fixated and a distractor is placed.

panding soft tissue envelope with blood vessels. Distracted and separated bony fragments then need to be stabilized in the new position for a period of 3–4 months to allow formation of bone and implant placement (Figure 5.8). An orthodontic tooth extrusion (OE; rapid or slow) or forced eruption is similarly intended for 3–5 mm of vertical gain with tensile forces applied to the tooth [45]. Periosteal expansion is a modification of the DO technique [33]. Disadvantages of the technique include the need for a second surgery, infection, the lingual vector of distraction, dehiscence, and others.

ALTERNATIVE SURGICAL TECHNIQUES

Alternative (to BA) surgical techniques (ASTs) in implant dentistry can be used in advanced or complex bone atrophy cases. These techniques do not utilize bone grafting but instead, and due to the complexity of the bone defect, employ other, alternative methods, like the placement of short or angled implants, or the insertion of long collateral implants into pterygoid plates or zygomatic bone. These techniques are described in Section VI.

GRAFT HEALING AND VASCULARIZATION

The healing (consolidation) time for a successful bone graft is similar but not identical in different BA techniques and usually ranges between 4 and 9 months, with a longer time required for VBA cases and larger and complex grafting procedures. In smaller bone defects, dental implant placement can often be done simultaneously with grafting [25].

The vascularization requirements of each grafting technique dictate the success or failure of the graft consolidation and the eventual success of the BA technique. This principle can be called the *biological rationale* of a surgical procedure [46] and is described in more detail in Chapter 7.

ALVEOLAR BONE AUGMENTATION DECISION TREE ALGORITHM

The four main surgical augmentation techniques described above can be used at the surgeon's discretion for HBA, VBA, or 3DBA, separately or in conjunction with each other. They are effective if used by a trained operator for a proper bone defect [1]. Correct diagnosis of the failing tooth (teeth) and/or edentulous condition of the alveolar ridge is important for making a proper treatment decision. The surgeon's familiarity with most bone grafting techniques helps in the surgical decision tree and in selecting an effective bone grafting technique prior to or with implant placement.

For most implant protocols, 10×10 mm^2 bone stock (width and height) is ideal in any alveolar quadrant of the maxillary or mandibular jaws. That is how much alveolar bone is usually needed to place a successful implant of 4–5 mm in diameter and 10 mm in length. For placing a narrower or shorter implant, 8×10 mm^2 or 8×8 mm^2 bone stock is suggested. Less bone (width and/or height), such as 6×8 mm^2 or 6×6 mm^2 bone stock, encourages bone grafting or ASTs. It is generally agreed that short implants should be at least wider (e.g. 6×6 mm) and small-diameter implants should be longer (e.g. 3×12 mm). Two-dimensional (horizonal or vertical) bone defects can often be treated with a single surgery, while 3DBD can frequently be addressed in a staged fashion. These procedures are described in Sections III and IV.

There are many classifications of partially edentulous arches and related decision tree algorithms of alveolar BA in implant dentistry, designed to help surgeons to choose the proper technique for a particular defect [11, 25, 37, 42, 47–56). Some classifications appear biased, leaning toward one technique that is favored by the author of the publication. Other classifications concentrate too much on bone that is present and on size in mm rather than what is missing for a successful implant placement. It is known that narrow-diameter implants as well as short implants can be successfully placed in many situations of suboptimal ridge dimensions [57, 58]. Overall, it is impossible to be fully objective and find an ideal classification and decision tree for all bone circumstances. Ultimately, the decision is based on the surgeon's preference (training, skills, and comfort zone).

Recently, there has been a trend toward the GBR grafting technique as favorable, utilizing a particulate graft with resorbable or non-resorbable membranes or Ti-mesh [59]. This tendency can be explained by many factors, among them the apparent simplicity of the technique, no need for a donor site and its associated morbidity, lack of special and expensive devices (e.g. a DO device), the established

Dentlearn.ir

success record of particulated grafting materials, high biological rationale based on graft vascularization, lower rate of complications, good bone consolidation for successful implant osseointegration [25, 26, 37, 50, 60].

ALVEOLAR BONE CLASSIFICATION BY DEFICIENCY (ABCD) – THE TOLSTUNOV CLASSIFICATION

The Tolstunov classification [11] of alveolar bone deficiency of edentulous conditions could be used to choose an effective grafting technique for immediate or delayed implant placement of a standard implant size, 4 mm in diameter and 10 mm in length (see Tables 5.1 and 5.2). The edentulous alveolar length space (A–P distance between teeth along the arch on both sides of the edentulous span or space) is known to be about 7 mm for a single 4 mm diameter implant [54].

This decision tree algorithm proposes four types of edentulous arches, with type O being no or minimal bone deficiency and types I, II and III a progressive degree of either bone height or width deficiency. It is based on how much bone is present, how much is missing, choices of surgical techniques, and estimated success. Measurements (in mm) are derived from clinical evaluation and cone beam computed tomography (CBCT) scans. There are more details in Box 5.1.

EXAMPLES OF THE TOLSTUNOV CLASSIFICATION

In these examples of ABCD, the first Roman numeral indicates the grade of HBD (bone width, BW) and the second the extent of VBD (bone height, BH), with suggestions for surgical corrections. It is always better to address both deficiencies in

Table 5.1 Horizontal bone deficiency decision tree.

Type of HBD	HBD	BW present (CBCT)	Implant of 4 mm diameter Readiness	HBA	Success
0 (No)	0–1 mm	≥9 mm	Insert	Not needed	High
I (Mild)	2–3 mm	7–8 mm	Insert and graft or narrow implant	GBR	High
II (Moderate)	4–5 mm	5–6 mm	Graft, then insert (2 stages), or narrow implant and graft	GBR ± R, BBG, RSEP	Good
III (Severe)	≥6 mm	≤4 mm (50% + loss of BW)	Graft, then insert ± graft again (2–3 stages)	GBR + R, BBG, DO	Modest

BBG, bone block grafting; BW, bone width; CBCT, cone beam computed tomography; DO, distraction osteogenesis; GBR, guided bone regeneration; HBA, horizontal bone augmentation; HBD, horizontal bone deficiency; R, reinforcement with dense polytetrafluoroethylene (d-PTFE) membrane, titanium (Ti)-reinforced membrane, or Ti-mesh; RSEP, ridge-split expansion procedure.

Table 5.2 Vertical bone deficiency decision tree.

Type of VBD	VBD	BH present (CBCT)	Implant of 10 mm length Readiness	VBA	Success
0 (No)	0–1 mm	≥9 mm	Insert	None	High
I (Mild)	2–3 mm	7–8 mm	Insert and graft, or short implant	GBR, OE	High
II (Moderate)	4–5 mm	5–6 mm	Graft, then insert (2 stages), CSL (1 stage), or short implant and graft	GBR ± R, SSO, BBG, OE/DO, CSL, AST	Good
III (Severe)	≥6 mm	≤4 mm (50% + loss of BH)	Graft, then insert and graft again (2–3 stages), LSL (2 stages)	GBR + R, DO, BBG, AST	Modest

AST, alternative surgical techniques, like "All-on-4," pterygoid, or zygomatic implants; BBG, bone block grafting; BH, bone height; CBCT, cone beam computed tomography; CSL, crestal sinus lift procedure with particulate graft; DO, distraction osteogenesis; GBR, guided bone regeneration; LSL, lateral sinus lift procedure with particulate graft; OE, orthodontic extrusion; R, reinforcement with dense polytetrafluoroethylene (d-PTFE) membrane, titanium (Ti)-reinforced membrane, or Ti-mesh; SSO, segmental sandwich osteotomy; VBA, vertical bone augmentation; VBD, vertical bone deficiency.

Dentlearn.ir

BOX 5.1 ALVEOLAR BONE CLASSIFICATION BY DEFICIENCY (ABCD TOLSTUNOV CLASSIFICATION): DECISION TREE ALGORITHM

- Most type I (mild) horizontal or vertical ridge defects can be successfully treated with guided bone regeneration (GBR).
- Type II–III (moderate to severe) horizontal bone defects with a sufficient vertical bone stock should be treated based on the surgeon's comfort zone:
  - *Onlay autogenous block bone graft* is an excellent choice for localized 2–3 edentulous space horizontal concave defects. Remember: donor site morbidity and recipient site block graft adaptation, fixation, and good primary wound closure.
  - *Ridge-split expansion procedure* is an excellent choice for a flat 4–5 mm width ridge (one-stage technique for maxillary and two-stage technique for mandibular bony defects). Remember: technique sensitive – proper bone split between cortical plates and second surgical procedure may be required.
  - *GBR* procedure is an excellent choice for any horizontally deficient ridges. Remember: use of resorbable or non-resorbable membranes and good adaptation of soft tissue margins.
- Type II–III (moderate to severe) vertical bone defects with a sufficient horizontal bone stock should be treated based on the surgeon's comfort zone by an experienced surgeon:
  - *Distraction osteogenesis* is a good choice for a large vertical bone deficiency. Remember: technique sensitive – proper osteotomy and placement of a distractor, tendency for a lingual vector of distraction, patient's compliance, need for a second surgery [61].
  - *Autogenous (or allogenic) extraoral (onlay) or intraoral (inlay) block graft* is a good choice for a large, localized, 2–3 edentulous space, vertical concave bone defects [61]. Remember: technique sensitive – recipient site block graft adaptation, fixation, and good primary wound closure, donor site morbidity.
  - *Segmental sandwich osteotomy* is a good choice for a large, localized, vertical or three-dimensional concave or flat bone defect. Remember: technique sensitive – proper osteotomy and fixation of the osteotomized segment, good soft tissue primary closure, possible second bone grafting surgery.
  - *GBR* procedure is a good choice for most vertically deficient ridges, with increasing difficulty as the vertical defect gets larger. Remember: technique sensitive – use of a non-resorbable titanium (Ti)-reinforced membrane or Ti-mesh, staging of procedures, possible soft tissue grafting before bone grafting, good primary wound closure [62].
- Type II–III (moderate to severe) combined bone defects with both horizontal and vertical components should be treated by an experienced surgeon, considering the soft tissue envelope and staging of bone reconstruction for a successful surgical-prosthetic implant rehabilitation.

one step, or if that is not possible to target the larger bone defect first. A soft tissue graft, in some cases, should be done prior to a bone graft (discussed in Section V).

ABCD: 0/I (Figures 5.9 and 5.10)

- No bone width deficiency (0–1 mm missing, ≥9 mm present).
- Mild bone height defect (2–3 mm missing, 7–8 mm present):
  - Posterior maxilla or posterior mandible: immediate or delayed implantation with GBR for bone height defect (2–3 mm of vertical correction for vital structures; preservation of vertical dimension of occlusion).
  - Posterior maxilla or posterior mandible: short implants ± GBR (2–3 mm of vertical correction for vital structures, like inferior alveolar nerve and mental foramen).
  - Anterior maxilla and anterior mandible: immediate or delayed implantation with GBR for bone height defect (consider staging in the esthetic zone).
  - Anterior maxilla and anterior mandible: orthodontic extrusion, followed by extraction and immediate implantation.

FIGURE 5.9 Alveolar bone classification by deficiency (ABCD) type 0/I. Clinical example of anterior maxilla: normal bone width and mild bone height defect.

Dentlearn.ir

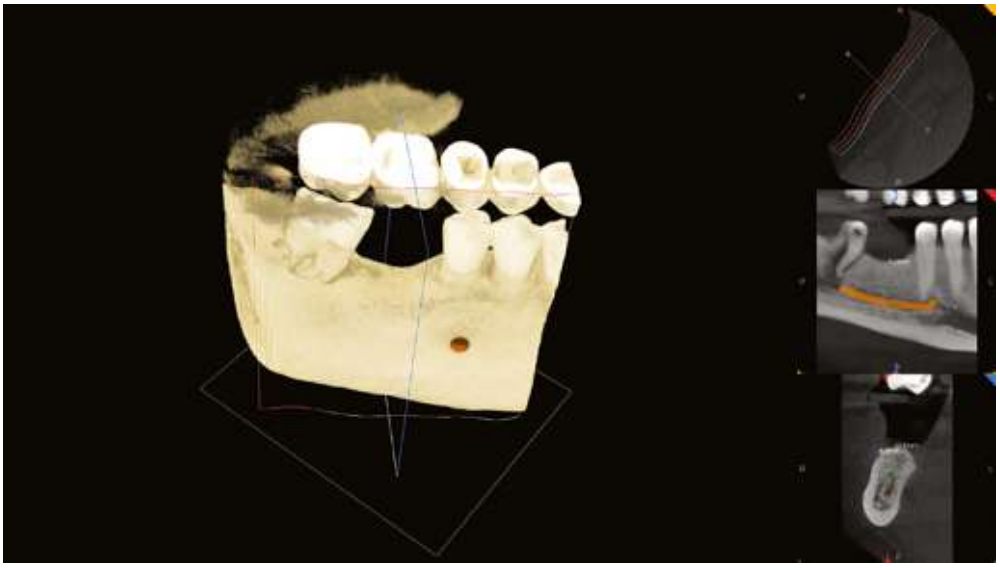

FIGURE 5.10 Alveolar bone classification by deficiency (ABCD) type 0/I. Cone beam computed tomography scan (three-dimensional image) example of posterior mandible: normal bone width and mild bone height defect.

ABCD: II/I (Figures 5.11 and 5.12)

- Moderate bone width defect (4–5 mm missing, 5–6 mm present).
- Mild bone height defect (2–3 mm missing, 7–8 mm present):
  - GBR with resorbable or Ti-reinforced membrane for correction of BW and BH, delayed implantation.
  - Block bone graft for correction of BW and BH, delayed implantation.
  - RSEP (one- or two-stage technique) to correct width, delayed implantation with additional GBR for BH.
  - Posterior maxilla: 3.5–4 mm immediate implant with crestal sinus lift to augment 2–3 mm of BH and buccal GBR with non-resorbable membrane to augment 4–5 mm of BW.

FIGURE 5.11 Alveolar bone classification by deficiency (ABCD) type II/I. Clinical example of right posterior maxilla: moderate bone width defect and mild bone height deficiency.

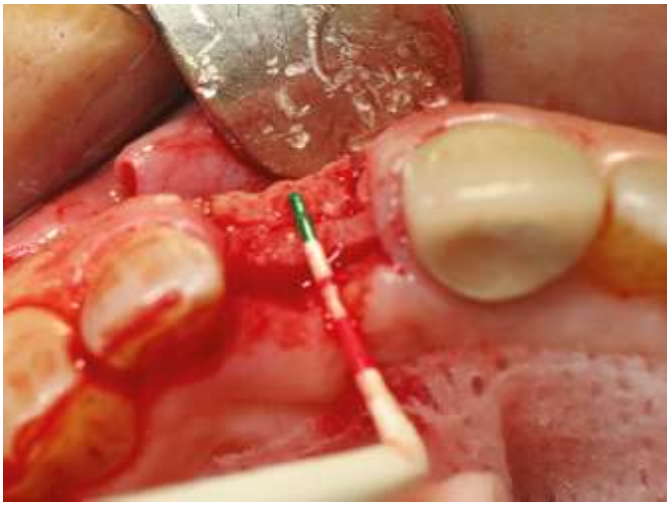

FIGURE 5.12 Alveolar bone classification by deficiency (ABCD) type II/I. Clinical example of anterior maxilla: moderate bone width defect (5 mm) and mild bone height deficiency.

Dentlearn.ir

ABCD: II/III (Figures 5.13 and 5.14)

- Moderate bone width defect (4–5 mm missing, 5–6 mm present).
- Severe bone height defect (≥6 mm missing or 50%+ loss of BH, 3–4 mm bone present):
  - GBR with Ti-mesh or Ti-reinforced membrane for correction of BH and BW, delayed implantation.
  - DO procedure for correction of BH and BW, delayed implantation, additional buccal GBR may be required.
  - BBGs (vertical and horizontal) for correction of BH and BW, delayed implantation.
  - AST with placement of angled, pterygoid, or zygomatic implants.

FIGURE 5.13 Alveolar bone classification by deficiency (ABCD) type II/III. Clinical example of anterior maxilla: moderate bone width defect and severe bone height deficiency (≥6 mm).

CONCLUSION

The rationale for a particular bone augmentation procedure in implant dentistry originates from the very beginning – the patient consultation – using clinical and radiographic data, including CBCT. The patient's wishes are important and may significantly modify the proposed treatment plan. The patient's medical status can alter an ideal treatment plan and suggest a palliative approach. Objective data on bone and soft tissue defects should guide a surgeon into making a proper diagnosis and formulating a targeted treatment plan. The surgeon's skills and expertise can ultimately help to select an appropriate surgical technique. A team approach with both restorative and surgical specialists working side by side not only helps to choose a particular bone augmentation technique, but assures the success of the overall implant treatment, with adequate restoratively driven implant placement and the final prosthetic outcome.

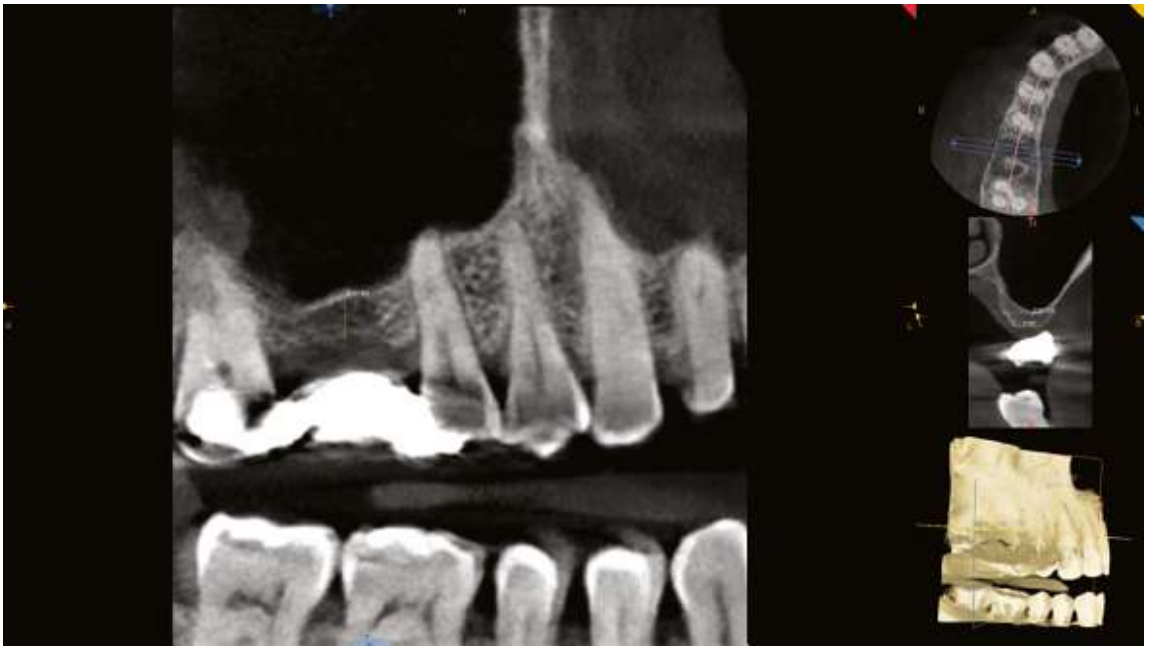

FIGURE 5.14 Alveolar bone classification by deficiency (ABCD) type II/III. Cone beam computed tomography scan (reconstructed panoramic image) example of posterior maxilla: severe vertical bone height deficiency with sinus floor pneumatization and 3.5 mm proximity to the alveolar crest.

Dentlearn.ir

To access the videos for this chapter, please go to
www.wiley.com/go/tolstunov/essential

VIDEO 5.1 Introduction to the chapter by the Author and Book Editor Dr. Len Tolstunov.

REFERENCES

1. McAllister BS, Haghighat K. Bone augmentation techniques. *J Periodontol.* 2007;78(3):377–96.
2. Pietrokovski J, Massler M. Alveolar ridge resorption following tooth extraction. *J Prosthet Dent.* 1967;17(1):21–7.
3. Hsieh YD, Devlin H, Roberts C. Early alveolar ridge osteogenesis following tooth extraction in the rat. *Arch Oral Biol.* 1994;39(5):425–8.
4. Araujo MG, Lindhe J. Ridge alterations following tooth extraction with and without flap elevation: An experimental study in the dog. *Clin Oral Implants Res.* 2009;20(6):545–9.
5. Cardaropoli G, Araujo M, Lindhe J. Dynamics of bone tissue formation in tooth extraction sites: An experimental study in dogs. *J Clin Periodontol.* 2003;30(9):809–18.
6. Chappuis V, Araujo MG, Buser D. Clinical relevance of dimensional bone and soft tissue alterations post-extraction in esthetic sites. *Periodontol 2000*. 2017;73(1):73–83.
7. Misawa M, Lindhe J, Araujo MG. The alveolar process following single-tooth extraction: A study of maxillary incisor and premolar sites in man. *Clin Oral Implants Res.* 2016;27(7):884–9.
8. Van der Weijden F, Dell'Acqua F, Slot DE. Alveolar bone dimensional changes of post-extraction sockets in humans: A systematic review. *J Clin Periodontol.* 2009;36(12):1048–58.
9. Frost HM. Wolff's law and bone's structural adaptations to mechanical usage: An overview for clinicians. *Angle Orthod.* 1994;64(3):175–88.
10. Rowe P, Koller A, Sharma S. Physiology, bone remodeling. *StatPearls*. Treasure Island, FL: StatPearls Publishing; 2021.
11. Tolstunov L. Surgical restorative decision algorithm for edentulous condition in implant dentistry with emphasis on bone augmentation. *J Oral Implantol.* 2019;45(5):421–4.
12. Iyer S, Haribabu PK, Xing Y. Part II. Minimizing alveolar bone loss during and after extractions. Protocol and techniques for alveolar bone preservation. *Alpha Omegan.* 2014;107(1):14–25.
13. Horowitz R, Holtzclaw D, Rosen PS. A review on alveolar ridge preservation following tooth extraction. *J Evid Based Dent Pract.* 2012;12(3 suppl):149–60.
14. Avila-Ortiz G, Chambrone L, Vignoletti F. Effect of alveolar ridge preservation interventions following tooth extraction: A systematic review and meta-analysis. *J Clin Periodontol.* 2019;46(suppl 21):195–223.
15. Avila-Ortiz G, Elangovan S, Kramer KW et al. Effect of alveolar ridge preservation after tooth extraction: A systematic review and meta-analysis. *J Dent Res.* 2014;93(10):950–58.
16. Jung RE, Ioannidis A, Hammerle CHF, Thoma DS. Alveolar ridge preservation in the esthetic zone. *Periodontol 2000*. 2018;77(1):165–75.
17. Jung RE, Sapata VM, Hammerle CHF et al. Combined use of xenogeneic bone substitute material covered with a native bilayer collagen membrane for alveolar ridge preservation: A randomized controlled clinical trial. *Clin Oral Implants Res.* 2018;29(5):522–9.
18. Avila-Ortiz G, Gubler M, Romero-Bustillos M et al. Efficacy of alveolar ridge preservation: A randomized controlled trial. *J Dent Res.* 2020;99(4):402–9.
19. Bassir SH, Alhareky M, Wangsrimongkol B et al. Systematic review and meta-analysis of hard tissue outcomes of alveolar ridge preservation. *Int J Oral Maxillofac Implants.* 2018;33(5):979–94.
20. Cosyn J, De Bruyn H. [Guided bone regeneration: general survey]. *Rev Belge Med Dent (1984)*. 2009;64(4):160–72.
21. Hermann JS, Buser D. Guided bone regeneration for dental implants. *Curr Opin Periodontol.* 1996;3:168–77.
22. Wang RE, Lang NP. Ridge preservation after tooth extraction. *Clin Oral Implants Res.* 2012;23(suppl 6):147–56.
23. Tolstunov L. Surgical algorithm for alveolar bone augmentation in implant dentistry. *Oral Maxillofac Surg Clin North Am.* 2019;31(2):155–61.
24. Tolstunov L, Hamrick JFE, Broumand V et al. Bone augmentation techniques for horizontal and vertical alveolar ridge deficiency in oral implantology. *Oral Maxillofac Surg Clin North Am.* 2019;31(2):163–91.
25. Misch CM, Basma H, Misch-Haring MA, Wang HL. An updated decision tree for vertical bone augmentation. *Int J Periodontics Restorative Dent.* 2021;41(1):11–21.
26. Aghaloo TL, Misch C, Lin GH et al. Bone augmentation of the edentulous maxilla for implant placement: A systematic review. *Int J Oral Maxillofac Implants.* 2016;31(suppl):s19–s30.
27. El Zahwy M, Taha S, Mounir R, Mounir M. Assessment of vertical ridge augmentation and marginal bone loss using autogenous onlay vs inlay grafting techniques with simultaneous implant placement in the anterior maxillary esthetic zone: A randomized clinical trial. *Clin Implant Dent Relat Res.* 2019;21(6):1140–47.
28. Aloy-Prosper A, Penarrocha-Oltra D, Penarrocha-Diago M, Penarrocha-Diago M. The outcome of intraoral onlay block bone grafts on alveolar ridge augmentations: A systematic review. *Med Oral Patol Oral Cir Bucal.* 2015;20(2):e251–e258.
29. Daga D, Mehrotra D, Mohammad S et al. Tentpole technique for bone regeneration in vertically deficient alveolar ridges: A prospective study. *J Oral Biol Craniofac Res.* 2018;8(1):20–24.
30. Guillen GA, Araujo ALD, Macedo FGC et al. Evaluation of the screw tent-pole technique for the repair of anterior maxilla width defects:

Dentlearn.ir

A prospective, randomized, split-mouth study. *Int J Oral Maxillofac Surg.* 2021;50(6):801–7.

31. Conserva E, Fadda M, Ferrari V, Consolo U. Predictability of a new orthodontic extrusion technique for implant site development: A retrospective consecutive case-series study. *Scientific World Journal.* 2020;2020:4576748.
32. Lethaus B, Tudor C, Bumiller L et al. Guided bone regeneration: Dynamic procedures versus static shielding in an animal model. *J Biomed Mater Res B Appl Biomater.* 2010;95(1):126–30.
33. Kessler P, Bumiller L, Schlegel A et al. Dynamic periosteal elevation. *Br J Oral Maxillofac Surg.* 2007;45(4):284–7.
34. Somoza-Martin JM, Vazquez-Casal A, Suarez-Cunqueiro M et al. A new morphologic classification of the alveolar ridge after distraction osteogenesis in human patients: A 17 years retrospective case series study. *Med Oral Patol Oral Cir Bucal.* 2021;26(3):e304–e313.
35. French D, Ofec R, Levin L. Long term clinical performance of 10 871 dental implants with up to 22 years of follow-up: A cohort study in 4247 patients. *Clin Implant Dent Relat Res.* 2021;23(3):289–97.
36. Moy PK, Aghaloo T. Risk factors in bone augmentation procedures. *Periodontol 2000.* 2019;81(1):76–90.
37. Urban IA, Jovanovic SA, Lozada JL. Vertical ridge augmentation using guided bone regeneration (GBR) in three clinical scenarios prior to implant placement: A retrospective study of 35 patients 12 to 72 months after loading. *Int J Oral Maxillofac Implants.* 2009;24(3):502–10.
38. Takamoto M, Takechi M, Ohta K et al. Risk of bacterial contamination of bone harvesting devices used for autogenous bone graft in implant surgery. *Head Face Med.* 2013;9:3.
39. Purcz NM, Birkenfeld F, Oetke M et al. Increased infection rates of sinus floor elevations after the use of a bone filter. *Clin Oral Investig.* 2015;19(5):1115–19.
40. Mellonig JT, Triplett RG. Guided tissue regeneration and endosseous dental implants. *Int J Periodontics Restorative Dent.* 1993;13(2):108–19.
41. Mellonig JT, Nevins M. Guided bone regeneration of bone defects associated with implants: An evidence-based outcome assessment. *Int J Periodontics Restorative Dent.* 1995;15(2):168–85.
42. Retzepi M, Donos N. Guided bone regeneration: Biological principle and therapeutic applications. *Clin Oral Implants Res.* 2010;21(6):567–76.
43. Schorn L, Sproll C, Ommerborn M et al. Vertical bone regeneration using rhBMP-2 and VEGF. *Head Face Med.* 2017;13(1):11.
44. Cansiz E, Haq J, Manisali M et al. Long-term evaluation of three-dimensional volumetric changes of augmented severely atrophic maxilla by anterior iliac crest bone grafting. *J Stomatol Oral Maxillofac Surg.* 2020;121(6):665–71.
45. Gonzalez-Martin O, Solano-Hernandez B, Gonzalez-Martin A, Avila-Ortiz G. Orthodontic extrusion: Guidelines for contemporary clinical practice. *Int J Periodontics Restorative Dent.* 2020;40(5):667–76.
46. Tolstunov L. Biologic rationale of a surgical procedure: Bone augmentation. *J Oral Maxillofac Surg.* 2018;76(5):914–16.
47. Fu JH, Wang HL. Horizontal bone augmentation: The decision tree. *Int J Periodontics Restorative Dent.* 2011;31(4):429–36.
48. Smiler D, Soltan M. The bone-grafting decision tree: A systematic methodology for achieving new bone. *Implant Dent.* 2006;15(2):122–8.
49. Stacchi C, Spinato S, Lombardi T et al. Minimally invasive management of implant-supported rehabilitation in the posterior maxilla. Part II. Surgical techniques and decision tree. *Int J Periodontics Restorative Dent.* 2020;40(3):e95–e102.
50. Plonka AB, Urban IA, Wang HL. Decision tree for vertical ridge augmentation. *Int J Periodontics Restorative Dent.* 2018;38(2):269–75.
51. Felice P, Pistilli R, Zucchelli G et al. Decision criteria proposed for the treatment of vertical bone atrophies in the posterior mandible. *Int J Periodontics Restorative Dent.* 2021;41(1):71–7.
52. Esposito M, Grusovin MG, Coulthard P, Worthington HV. The efficacy of various bone augmentation procedures for dental implants: A Cochrane systematic review of randomized controlled clinical trials. *Int J Oral Maxillofac Implants.* 2006;21(5):696–710.
53. Aghaloo TL, Moy PK. Which hard tissue augmentation techniques are the most successful in furnishing bony support for implant placement? *Int J Oral Maxillofac Implants.* 2007;22(suppl):49–70.
54. Misch CE, Judy KW. Classification of partially edentulous arches for implant dentistry. *Int J Oral Implantol.* 1987;4(2):7–13.
55. Chiapasco M, Casentini P. Horizontal bone-augmentation procedures in implant dentistry: Prosthetically guided regeneration. *Periodontol 2000.* 2018;77(1):213–40.
56. Chiapasco M, Casentini P, Zaniboni M. Bone augmentation procedures in implant dentistry. *Int J Oral Maxillofac Implants.* 2009;24(suppl):237–59.
57. Carosi P, Lorenzi C, Laureti M et al. Short dental implants (</= 6 mm) to rehabilitate severe mandibular atrophy: A systematic review. *Int J Oral Maxillofac Implants.* 2021;36(1):30–37.
58. Ma M, Qi M, Zhang D, Liu H. The clinical performance of narrow diameter implants versus regular diameter implants: A meta-analysis. *J Oral Implantol.* 2019;45(6):503–8.
59. Khojasteh A, Kheiri L, Motamedian SR, Khoshkam V. Guided bone regeneration for the reconstruction of alveolar bone defects. *Ann Maxillofac Surg.* 2017;7(2):263–77.
60. Misch CM, Jensen OT, Pikos MA, Malmquist JP. Vertical bone augmentation using recombinant bone morphogenetic protein, mineralized bone allograft, and titanium mesh: A retrospective cone beam computed tomography study. *Int J Oral Maxillofac Implants.* 2015;30(1):202–7.
61. Elnayef B, Monje A, Gargallo-Albiol J et al. Vertical ridge augmentation in the atrophic mandible: A systematic review and meta-analysis. *Int J Oral Maxillofac Implants.* 2017;32(2):291–312.
62. Urban IA, Monje A, Wang HL. Vertical ridge augmentation and soft tissue reconstruction of the anterior atrophic maxillae: A case series. *Int J Periodontics Restorative Dent.* 2015;35(5):613–23.

Dentlearn.ir

Dentlearn.ir

Incision Design, Soft Tissue Flaps, and Wound Closure in Alveolar Bone Augmentation Surgeries in Implant Dentistry

CHAPTER 6

Regenerative procedures in conjunction with or before implant installation require undisturbed wound healing guaranteed by primary wound closure. To ensure complication-free healing, it is important that tension-free adaptation of the flap margins results in primary wound closure that is maintained throughout the healing phase. Proper closure and stabilization of wound margins in their desired position are critical to the success of bone augmentation surgeries in implant dentistry.

Dentlearn.ir

CHAPTER 6

Incision Design, Soft Tissue Flaps, and Wound Closure in Alveolar Bone Augmentation Surgeries in Implant Dentistry

Tetsu Takahashi and Kensuke Yamauchi

Division of Oral & Maxillofacial Surgery, Graduate School of Dentistry, Tohoku University, Miyagi, Japan

INCISION DESIGN IN ALVEOLAR BONE AUGMENTATION SURGERIES

The placement of incisions and flaps in the oral cavity is determined primarily by convenience, access, and local anatomy [1–3]. The incisions should be made in the areas adjacent to the surgical site, so that the flap remains supported by normal tissue and the revascularization potential is preserved. The maintenance of an adequate blood supply is of prime importance. This is accomplished by making the incisions parallel to major vessels, minimizing the number of side cuts, and designing the flap with a base as wide as, or wider than, the apex.

Incisions should not be made in areas of thin mucosa, such as exostoses or other bony prominences, because the blood supply is compromised, suturing is difficult, and there is a high risk of dehiscence. Incisions should be made far enough away from the surgical area to ensure that wound margins are over sound bone, even when unexpected extensions are necessary. This prevents the collapse of the flap into the bony defect. The size of the incision does not affect the rate of healing, so a flap of adequate size should be developed to ensure visibility and circulation without overexposure of the bone.

For mucoperiosteal flaps the incision should be made directly to bone in a single stroke, and the entire flap should be elevated without tearing the periosteum. Sharp instruments should be used to avoid tearing the mucoperiosteum. A common error is not using the point of the blade, which facilitates incision over bone contours and irregularities. There should be no sharp angles in the flap. Any changes in direction should follow a gentle curve, as sharp corners tend to slough because of poor circulation, which results in excessive scarring.

SOFT TISSUE FLAPS IN ALVEOLAR BONE AUGMENTATION SURGERIES

Vascularization is paramount for soft tissue flaps. There are different patterns of soft tissue flaps based on their blood supply.

VASCULARITY PATTERNS

See Figure 6.1.

Random Pattern Flaps

These flaps are dependent on the local subdermal or submucosal plexus for blood supply and are susceptible to distal ischemia. Most of the gingival flaps belong to this type.

Axial Pattern Flaps

These flaps are based on an anatomically defined configuration of vessels. The palatal mucoperiosteal flap, used for the closure of oroantral communications, includes the vessels that emerge from the corresponding greater palatine foramen.

FLAP DESIGNS

Trapezoidal Flap

This flap is formed by a horizontal incision parallel to the gingival margin and two oblique vertical incisions extending to the buccal vestibule (Figure 6.2). The vertical incisions always extend to the interdental papillae and never to the center of the labial or buccal surface of the tooth. This avoids root exposure due to the contraction of the wound margins. An

Essential Techniques of Alveolar Bone Augmentation in Implant Dentistry: A Surgical Manual, Second Edition. Edited by Len Tolstunov.
© 2023 John Wiley & Sons, Inc. Published 2023 by John Wiley & Sons, Inc.
Companion website: www.wiley.com/go/tolstunov/essential

Dentlearn.ir

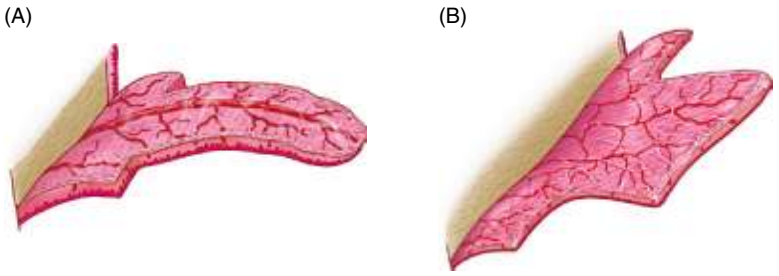

FIGURE 6.1 Flap pattern from vascularity: (A) random pattern; (B) axial pattern.

FIGURE 6.2 A clinical case of trapezoidal flap. (A) Flap design and decortication; (B) augmentation bone graft material and titanium mesh; (C) flap closure.

adequate surgical field requires an incision that extends at least one or two teeth on either side of the surgical area. The base of the flap is broader than its free gingival margin to ensure adequate blood supply (Figure 6.3). This type of flap provides excellent access, allows easy re-approximation, and hastens the healing process.

Triangular Flap

The triangular flap is the result of an L-shaped incision, which consists of a horizontal incision along the gingival sulcus and a vertical or oblique incision (Figure 6.4). The vertical incision begins at the vestibular fold and extends to the interdental papilla. The triangular flap is used in esthetic areas to avoid gingival recession and scar formation at the frenulum.

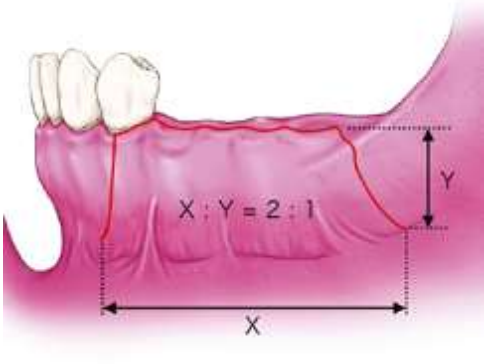

FIGURE 6.3 The design of the trapezoidal flap. The base of the flap should have enough width to acquire an adequate blood supply. X should be > Y. Ideally, Y : Y = 2:1.

Envelope Flap

This type of flap is the result of an extended horizontal incision along the cervical lines of the teeth. The incision is made in the gingival sulcus and extends along four or five teeth. The tissue attached to the cervical lines of the teeth and the interdental papillae are mobilized. An envelope flap avoids vertical incisions and is easy to reposition. However, it provides limited access, and access to the apical area places the flap under tension, which may lead to tearing.

Semilunar Flap

This flap is the result of a curved incision, which begins just beneath the vestibular fold and follows a bow-shaped course, with the convex side toward the gingiva. The lowest point of the incision must be at least 5 mm from the gingival margin to ensure adequate blood supply. The incision should be made 3–5 mm away from the bony defect (Figure 6.5).

Other Types of Flaps

A flap with crestal or gingival sulcus incisions is advantageous in terms of the blood supply. However, sometimes a facially or palatally (lingually) placed incision is required to minimize the possibility of implant exposure due to wound dehiscence

Dentlearn.ir

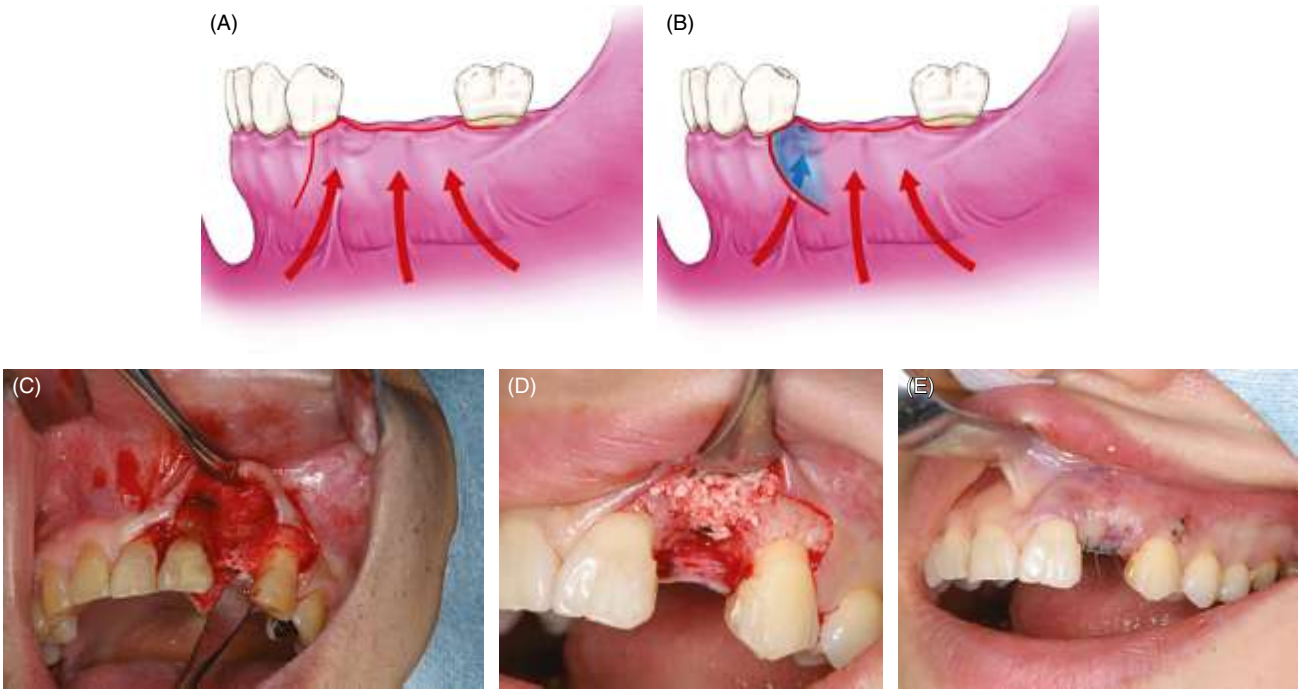

FIGURE 6.4 The triangular flap. (A) Vertical incision must be designed considering uninterrupted blood supply to the flap. (B) Acute angle of the vertical incision may cause necrosis of the tip of the flap. (C–E) A clinical case of triangular flap for implant insertion and guided bone regeneration. Note that the vertical incision began at the distal angle of the left upper incisor (C), bone graft materials were put in place (D), and flap closure performed (E).



FIGURE 6.5 The incision should be made 3–5 mm away from the bony defect or grafted block bone.

(Figure 6.6). Care must be taken not to damage the attached gingiva while elevating the flap. The vestibular incision leads to decreased vestibular soft tissue depth after healing, and future soft tissue procedures may be required for correction. This type of flap is useful in cases of a previous scar at the alveolar process with poor vascularity, for example in cleft patients, previous trauma, or edentulous atrophic mandible (Figure 6.7).

REFLECTION OF THE MUCOPERIOSTEUM

Reflection is performed to detach the mucoperiosteal flap from the underlying bone. An elevator is placed in direct contact with bone and reflection starts at the incision, usually at an angle or in the gingival sulcus. Reflection is completed with gentle, steady strokes toward the labial or buccal vestibule, taking care not to damage the tissues (Figure 6.8).

Dentlearn.ir

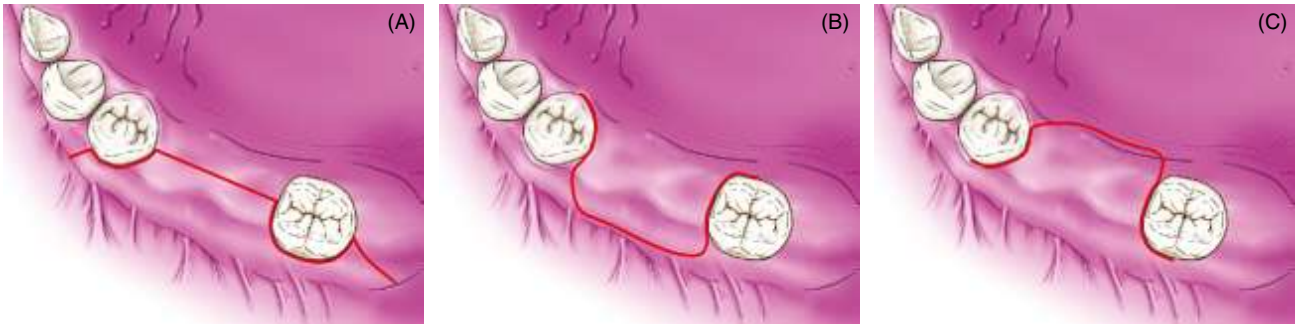

FIGURE 6.6 Variations of acceptable flap patterns: (A) crestal incisions as standard design; (B) flap based on lingual or palatal tissue; (C) buccally based flap.

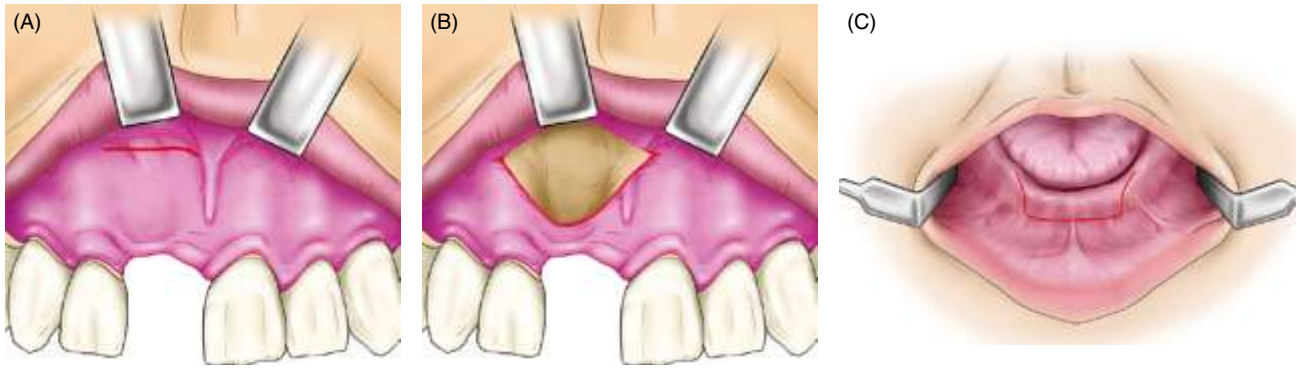

FIGURE 6.7 A vestibular incision is applied for cases with poor vascularity at the crestal region. This type of flap is useful in case of a previous scar at the alveolar process with poor vascularity in cleft patients. (A) Note a visible scar. (B) An incision was made using the previous scar. (C) This incision is useful for an edentulous atrophic mandible.

FIGURE 6.8 Reflection of the mucoperiosteum. (A) Flap design. (B) The elevator is in direct contact with bone and reflection starts at the incision, usually at an angle or gingival sulcus. (C) Reflection was completed with gentle, steady strokes toward the labial or buccal vestibule.

In case of a strong attachment between the bone and periosteum, scissors or surgical blades may be used.

PREPARING FOR WOUND CLOSURE

TENSION RELEASE INCISIONS

In cases of alveolar bone augmentation, the key to success is to close the incision without any tension. A tension release incision is an important technique to achieve a tension-free closure. The releasing incisions are usually made at a 45-degree angle to the horizontal incision. The technique involves a releasing incision made through the periosteum to allow advancement of the flap for proper closure. It is important to place the flap under tension while the periosteum is incised. For even greater advancement, the incision at the periosteum is widened using scissors or an elevator, taking care not to damage the tissues, so as not to cause bleeding and compromise the blood supply of the flap (Figures 6.9 and 6.10). After a tension release incision, the anchor sutures to track the

Dentlearn.ir

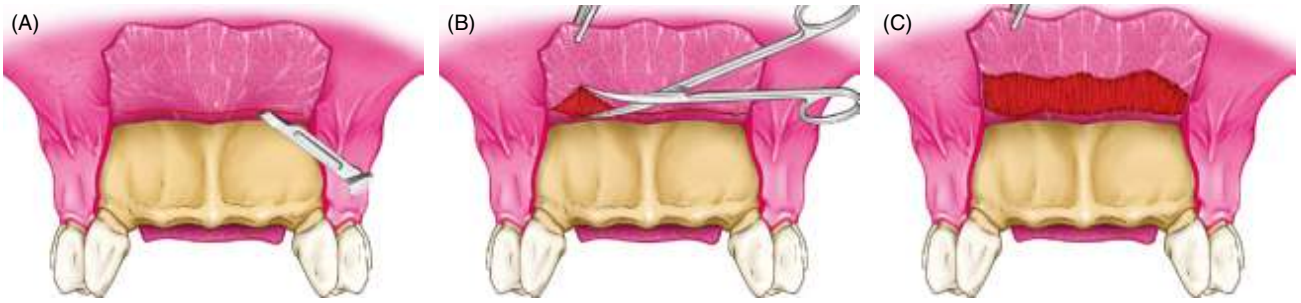

FIGURE 6.9 Tension release incision. (A) The red line shows the place of a release incision. (B) A releasing incision should ideally be made with a single stroke through the depth of the periosteum. (C) The flap height was extended (released) using the releasing incision. An alternative approach to releasing the full-thickness flap is to make a small vertical incision through the periosteum and then use sharp scissors to make a horizontal cut through the length of the flap periosteum.

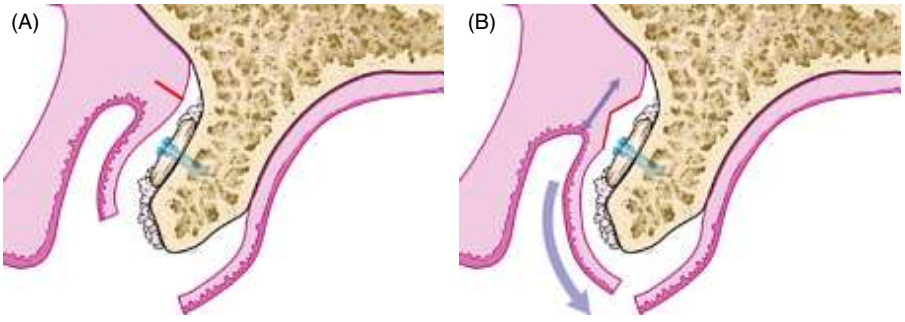

FIGURE 6.10 Tension-releasing incision and closure at the site of the alveolar bone graft. (A) The red line shows the point where the releasing incision should be made. The incision line should be above the gingival cheek transition toward the cheek. (B) Extension of the mucoperiosteal flap after the releasing incision.

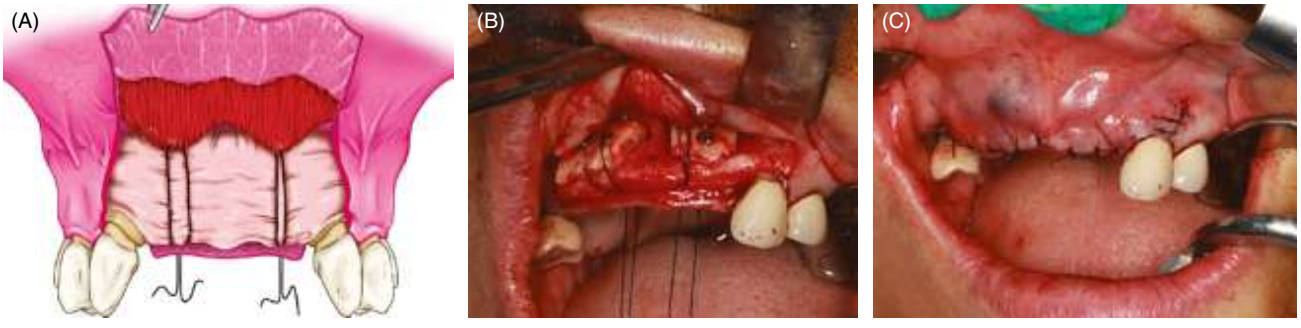

FIGURE 6.11 Anchoring sutures for periosteum traction after a tension release incision. (A) Diagram of the anchoring suture. (B, C) Clinical photos of wound closure at a block bone graft.

periosteum are effective to decrease the tension to the edge of the flaps (Figure 6.11).

WOUND CLOSURE IN ALVEOLAR BONE AUGMENTATION SURGERIES

Wound closure is one of the most important steps of the surgical procedure.

PRINCIPLES OF SUTURING

- The needle holder should grasp the needle at approximately three-quarters of the distance from the tip. Grasping the needle end would result in at least a bent needle, if not a broken one.
- The needle should enter the tissue perpendicular to the surface.

Dentlearn.ir

- The suture should be placed at an equal distance (2–3 mm) and depth on both sides of the incision.
- If one tissue side is free and the other is fixed, the needle should pass from the free to the fixed side.
- If one tissue side is thinner than the other, then the needle should be passed from the thinner to the thicker side.
- The tissues should never be closed under tension, as this may lead to either a tear or necrosis around the suture. If tissues are under tension, then they should be undermined, or tension-releasing incisions should be made to relieve the tension.
- The knot should never be placed over the incision line.
- Sutures should be placed approximately 3–4 mm apart.

TYPES OF SUTURES

See Figure 6.12.

Interrupted Sutures

This is the simplest and most frequently used type of suture and may be employed in any intraoral surgery. Each suture is independent of the others, and the distance between the sutures, and between the sutures and the incision line, can be varied. This type of suture is strong, and each successive suture can be placed according to the specific situation. The loosening of one suture has no effect on the remaining sutures.

Continuous Sutures

Continuous suturing is a rapid technique for closure. Another advantage is the even distribution of tension over the entire suture line. In case of swelling of a specific area, the remaining sutured area can provide a degree of slack to relieve pressure. However, continuous sutures should not be used in areas of existing tension, because if one suture is inadvertently cut or loosened, all the sutures become loose.

Locking Continuous Sutures

This type of suturing incorporates loops, which make up parts of a chain along the incision. These loops are positioned on the buccal side of the wound after being tightened. The suture aligns perpendicular to the incision and the locking feature forgoes the need for continuous tightening of the suture as wound closure progresses. However, care must be taken not to excessively tighten the locks, because doing so may prevent distribution of tension over the suture line as tissue swelling occurs.

Mattress Sutures

The main purpose of the mattress suture is to provide more tissue eversion than simple interrupted sutures (Figure 6.13). It also may be used in areas where wound contraction could cause dehiscence or a broad scar. There are two types: horizontal and vertical. The vertical mattress suture is useful for deep incisions, while the horizontal mattress suture is useful for soft tissue closure over osseous cavities. The main disadvantage of mattress sutures is that they constrict the blood

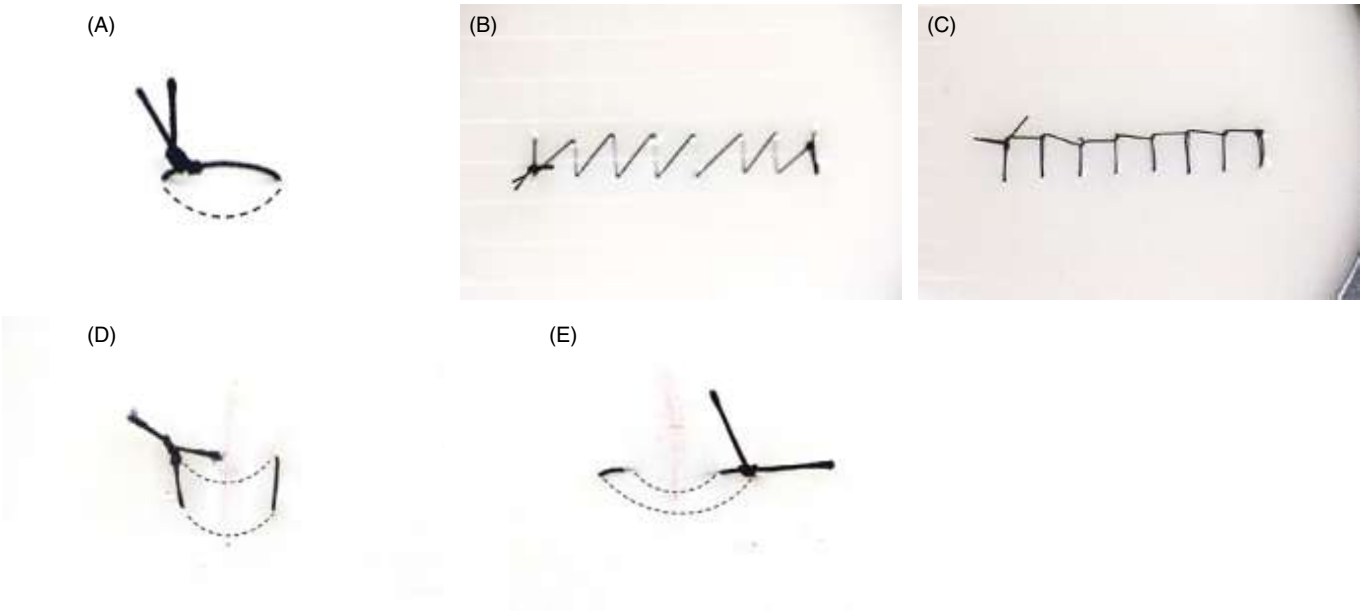

FIGURE 6.12 Type of sutures: (A) Interrupted suture; (B) continuous suture; (C) locking continuous suture; (D) horizontal mattress suture; (E) vertical mattress suture.

Dentlearn.ir

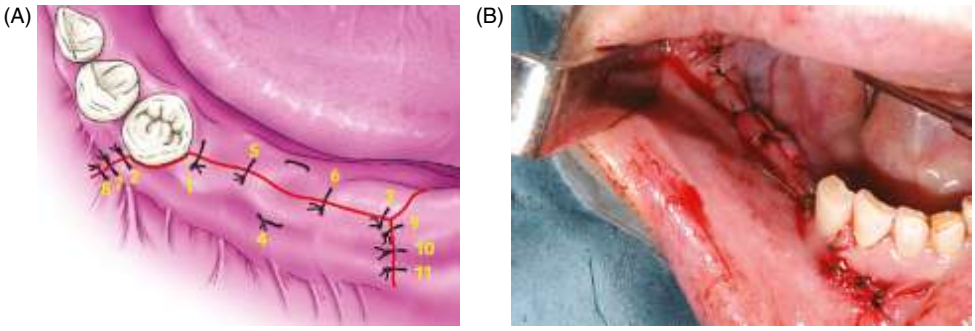

FIGURE 6.13 Diagram and intraoral photo of sutures for a crestal incision. (A) Yellow figures show the sequence of the sutures. (B) A horizontal mattress suture was performed at the center of the edentulous space with simple interrupted sutures.

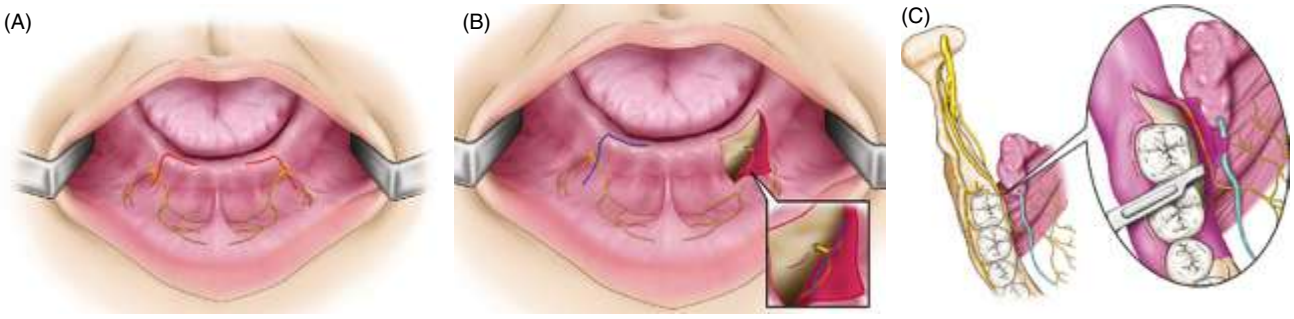

FIGURE 6.14 The risks of nerve damage: (A) incisions for edentulous mandible; (B) tension release incision around mental foramen; (C) releasing incisions from the lingual mandibular flap. Note that the lingual nerve runs very close to the lingual periosteum of the mandible.

supply to the edge of the incision. If improperly used, they may cause necrosis and dehiscence.

COMPLICATIONS

NERVE INJURY

The most common nerve injuries in implant dentistry are of the inferior alveolar, mental, and lingual nerves [4, 5]. Nerve trauma may cause sensory disturbances (anesthesia, hypesthesia, paresthesia, and dysesthesia) in the innervated area. Nerve injury may occur in the following cases (Figure 6.14):

- While creating an incision that extends to the region of the mental foramen and the lingual vestibular fold.
- While releasing incisions from the lingual mandibular flap to obtain elasticity by raising the mylohyoid muscle that extends toward the origin of hyoglossus muscle.
- While creating a crestal incision at the alveolar ridge of an edentulous patient, whose mental foramen, due to bone sorption, is localized superficially.
- In the case of compression and strangulation of a nerve, after inadvertent suturing of the nerve during the suturing of a flap.

BLEEDING

Bleeding or hemorrhage is a common complication in oral surgery due to the injury or severance of the inferior alveolar vessels or palatal artery (Figure 6.15). During bone augmentation surgery, complications in the lingual area are not limited to sensory disturbances or trauma of sublingual and submental arteries, with consequential hematoma in the submandibular and sublingual spaces [5]. It is important to protect this anatomical area because the lingual nerve, the branches of the lingual artery, and the sublingual gland could be damaged, requiring emergency care to stop bleeding. These unfortunate events could result in hematoma followed by swelling, which has occasionally been reported as life-threatening due to respiratory obstruction (Figure 6.16) [6]. Another dangerous area for bleeding is the palatal region around the greater palatine foramen. However, it less frequently causes respiratory obstruction compared to the mandibular lingual side.

WOUND DEHISCENCE

Wound dehiscence is a commonly encountered complication in regenerative procedures of the jaw (Figure 6.17). When dehiscence occurs, the amount of bone regeneration might be limited, corresponding to only 40–60% of the original defect

Dentlearn.ir

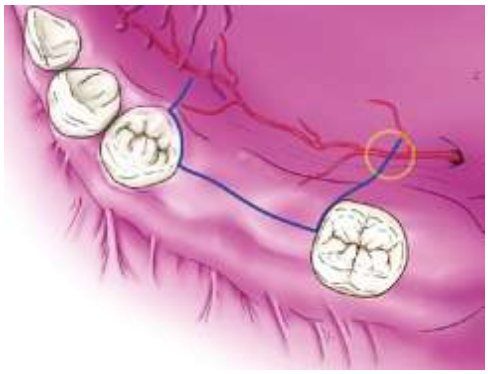

FIGURE 6.15 Diagram of an inadequate incision that induces damage to the palatal artery.

FIGURE 6.16 Intraoral photograph of a hematoma followed by swelling inducing respiratory obstruction.

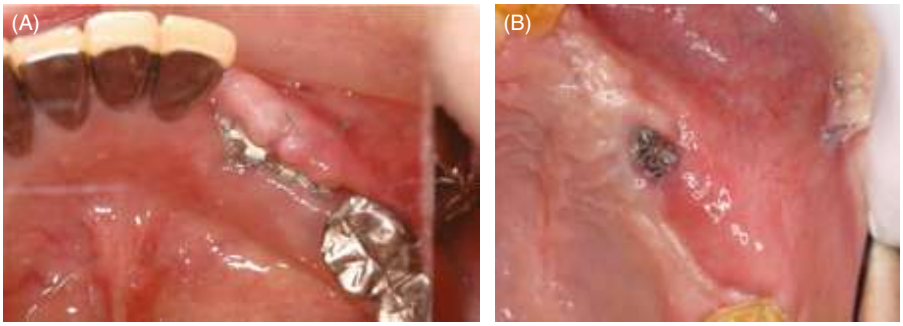

FIGURE 6.17 Wound dehiscence. (A) Two weeks post-operative from bone graft with titanium mesh. (B) Titanium mesh exposure during consolidation phase.

size without the presence of infection. It is worth noting that wound dehiscence may be detrimental to the bone augmentation outcome, as flap tension plays a primary role in post-operative closure, and thus in undisturbed wound healing. As such, closing forces >0.1 N may substantially increase the rate of wound dehiscence (>40%) [7]. To obtain stable wound closure, both the tension applied to the wound margins during suturing and the thickness and mobilization of the flaps may be determining factors.

CONCLUSION

Regenerative procedures in conjunction with or before implant installation require undisturbed wound healing guaranteed by primary wound closure. To ensure complication-free healing, it is important that tension-free adaptation of the flap margins results in primary wound closure that is maintained throughout the healing phase. Proper closure and stabilization of wound margins in their desired position are critical to the success of bone augmentation surgeries in implant dentistry.

REFERENCES

1. Burkhardt R, Lang NP. Role of flap tension in primary wound closure of mucoperiosteal flaps: A prospective cohort study. *Clin Oral Implants Res.* 2010;21:50–54.
2. Camargo IB, Van Sickels JE. Surgical complications after implant placemen. *Dent Clin North Am.* 2015;59:57–72.
3. Davis WH, Hochwald DA, Marshall M. Surgical procedures for screw/cylinder implants. In J Reynord, W Fonseca, H Davis (eds.), *Reconstructive preprosthetic oral and maxillofacial surgery*, 2nd edn. Philadelphia, PA: Saunders; 1995, 341–82.
4. Gerstein H. Surgical endodontics. In DM Laskin (ed.), *Oral and maxillofacial surgery*. St. Louis, MO: Mosby; 1985, 143–56.
5. Fragiskos F. Principles of surgery. In F Fragiskos (ed.), *Oral surgery*. New York: Springer; 2007, 33–42.
6. Kalpidis CD, Setayesh RM. Hemorrhaging associated with endosseous implant placement in the anterior mandible: A review of literature. *J Periodontol.* 2004;75:631–45.
7. Urban IA, Monje A, Wang HL, Gerber G. Mandibular regional anatomical landmarks and clinical implications for ridge augmentation. *Int J Periodontics Restorative Dent.* 2017;37:347–53.

Dentlearn.ir

Dentlearn.ir

Biological Rationale of the Surgical Procedure: Bone Augmentation

CHAPTER 7

Surgical practitioners should always try to select the alveolar bone augmentation procedure with the highest biological rationale. This will ensure an ideal environment for bone and soft tissue graft revascularization and healing. A bone grafting procedure with optimal angiogenesis will undoubtably bring long-lasting surgical success, and both surgeon's and patient's satisfaction (see Video 7.1).

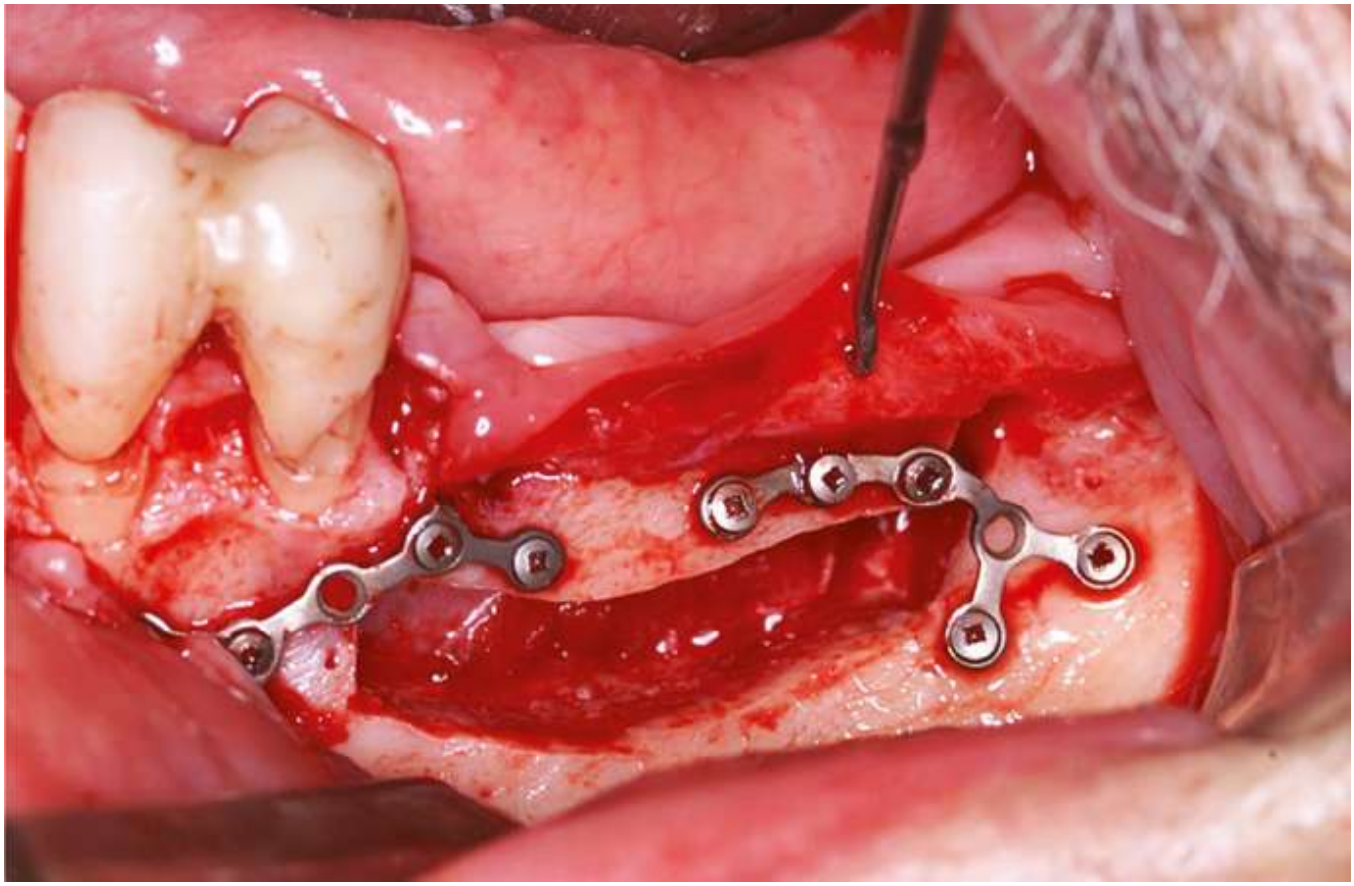

Dentlearn.ir

CHAPTER 7 Biological Rationale of the Surgical Procedure: Bone Augmentation

Len Tolstunov[1,2,3]

[1]*Associate Clinical Professor, Department of Oral and Maxillofacial Surgery, University of California San Francisco (UCSF) School of Dentistry, San Francisco, CA, USA*

[2]*Associate Clinical Professor, Department of Oral and Maxillofacial Surgery, University of the Pacific Arthur A. Dugoni School of Dentistry, San Francisco, CA, USA*

[3]*Private OMFS practice, San Francisco, CA, USA*

Merriam-Webster's definition of the word rationale is "an explanation of controlling principles of opinion, belief, practice, or phenomena," "an underlying reason." The word is based on the Latin *ratio*, which means *reason*; something must have a reason, make sense, or be based on fundamental principles. An analogous semantic explanation can be found in the word "self-evident," as in self-evident truth ("All men are created equal," Thomas Jefferson), something that does not necessarily need to be explained and should be accepted as truth, based on the history of humankind, science, and ethics [1].

In medicine and surgery, the definition of the word "rationale" is not given, but it often implies that a particular surgical technique with a (true) "biological rationale" must be *naturally* driven or physiologically self-evident (it follows the natural laws of biology), or it should have a biological *reason* to be successful in the majority of cases under similar circumstances. Scientifically, we can infer that it should be based on a high level of scientific evidence (randomized controlled studies, systematic reviews, or meta-analyses).

The success of a surgical procedure is defined by subjective and objective components. Subjective factors include the surgeon (skills, knowledge, and expertise) and the patient (medical status, immune competence, age, compliance, wishes, etc.). Objective considerations include the procedure itself: the overall success of a chosen surgical procedure, its risks, complications, benefits, and technical considerations. Some surgical procedures tend to have a higher success rate than others.

In this chapter we will discuss which surgical techniques can be more physiologically driven than others. What procedures can ensure lasting success on a consistent basis? Discussing bone augmentation techniques in implant dentistry, among many fundamental biological principles of surgery, we focus on blood supply or *angiogenesis*.

Alexis Carrel, a French surgeon in the twentieth century and a Nobel Prize winner, is known as the father of organ transplantation. Among many contributions, he described the end-to-end suturing technique in vascular anastomosis, a method still in use today, and a key surgical biological principle necessary for success in vascular surgery [2].

In oral and maxillofacial surgery, studies by Dr. William Bell on segmental maxillary and mandibular osteotomies [3–7] in the 1960s and 1970s demonstrated that the success of an orthognathic or maxillofacial procedure depends on the establishment of adequate vascularization of the osteotomized segments. Bone or wound healing can be successful if an adequate blood supply or revascularization is being established or confirmed by the end of the surgery. According to Bell, this was the underlying biological basis of a successful bone surgical procedure [4].

Among many others, Dr. P.I. Brånemark, the father of implant dentistry and implant osseointegration, in his initial research in the early 1960s stumbled on the unusual integration of metal scaffolding devices and discovered the "intra-osseous anchorage of dental prostheses." This amazing discovery was published only *after* his extensive research on the revascularization of different organs and tissues (bone marrow, knee joints, connective tissue, skin grafts) in animals [8]. Brånemark understood that vascularization was an essential component of integration in living tissues.

Wang and Boyapati [9] indicated four major biological principles (i.e. PASS) that should be present for predictable bone regeneration: **P**rimary wound closure, **A**ngiogenesis, **S**pace maintenance, and **S**tability. Primary wound closure is important for undisturbed wound healing in many bone augmentation procedures (block grafting, titanium-mesh cases, distraction osteogenesis), but in some surgical

Essential Techniques of Alveolar Bone Augmentation in Implant Dentistry: A Surgical Manual, Second Edition. Edited by Len Tolstunov.
© 2023 John Wiley & Sons, Inc. Published 2023 by John Wiley & Sons, Inc.
Companion website: www.wiley.com/go/tolstunov/essential

Dentlearn.ir

techniques, like ridge-split expansion or ridge preservation procedures, secondary wound closure can be as predictable and successful as primary and, in fact, is more preferred for the preservation of vestibule and attached soft tissue. Other two factors, space maintenance to "facilitate adequate space for bone ingrowth" and wound stability "to induce blood clot formation and uneventful healing," are important principles of bone augmentation [9]. Nevertheless, in many successful bone augmentation cases, like lateral sinus lift, the Schneiderian membrane is tented by only an implant without a particulate graft (just a blood clot). Non-grafted dental sockets (no ridge preservation) also demonstrate that unprotected or partially stabilized wounds without wound stabilizing or space maintenance factors, like a bone graft, membrane, or metal device, can still successfully heal with a good bone fill [10–12].

Although the three factors described (primary wound closure, space maintenance, and stability) are very important in bone augmentation cases, they are not always absolutely essential for every case. The same cannot be said about the last, key factor: angiogenesis. Angiogenesis for proper wound healing and bone graft consolidation, as well as implant osseointegration, appears to be the truly essential biological principle. Ingrowth of new capillaries into the bone graft provides the essential and indispensable vitality of bone segments, and seems to be the one major biological principle that wounds cannot live without. Any maxillofacial surgical procedures, like orthognathic, temporomandibular joint, craniofacial trauma and deformities, dentoalveolar surgery, pathology, ridge augmentation/oral implantology, or cosmetic surgery, can only be successful (heal properly) if the blood supply (oxygen, nutrients, growth factors) to the organs and tissues, osteotomies, and surgical wounds is not interrupted or is in fact established during a surgical procedure and successful revascularization is achieved.

Bone augmentation in implant dentistry can be a good example of maxillofacial procedures that can be examined for angiogenesis as the fundamental biological principle of surgical success. Bone regeneration and bone grafting procedures must assume consistent bone healing that is determined by uninterrupted vascularization. Research demonstrates that "angiogenesis is known to be a critical and closely regulated step during bone formation . . . driven by a complex interaction of various cytokines" [13] and "revascularization is a prerequisite for successful regenerative healing in bone" [14]. Angiogenesis and bone formation are "coupled during skeletal development and fracture healing" [15] and interrupted oxygen delivery (hypoxia) in the process of bone healing can detrimentally influence the "subsequent generation of angiogenic factors that have been shown to be critical in achieving successful bone regeneration" [15]. Therefore, timely restoration of blood flow is extremely important in bone healing and bone regeneration procedures for adequate oxygen and nutrient delivery to the site of bone repair [16]. Thus, consistent (quality) vascularization during and after a bone augmentation procedure determines its biological rationale.

We will use this biological principle – biological rationale – to classify bone augmentation surgical procedures [17]. We will examine vascularization sources in different bone augmentation procedures and stratify them as having a higher or lower biological rationale based on the level of continuous and uninterrupted vascularization to bone fragments and bone grafts.

GRAFT REVASCULARIZATION SOURCES

After bone or soft tissue grafting, graft revascularization starts with angiogenesis (development of new blood vessels) and the formation of small vascular channels (sprouts) or capillaries from the peripheral tissues (*sprouting angiogenesis*) that grow toward and penetrate the graft periphery, replacing the interrupted donor site vasculature with endothelial cells from the recipient site [18, 19]. That is why the condition of the alveolar ridge (recipient site) that receives the grafting material is important. Vascularization of the alveolar ridge that is being grafted can determine the quality of angiogenesis of the graft and influence the success of the grafting procedure [20, 21], as well as future implant osseointegration [22].

Revascularization of bone and soft tissue grafts can come from either central (endosteal) or peripheral (periosteal) sources:

- *Endosteal vascularization* can also be called central, centromedullary, or centrifugal when blood supply to the graft is being re-established through the vascularized medullary and cortical bone compartments adjacent to the graft (sprouting angiogenesis) [18, 19, 23].
- *Periosteal vascularization* can also be called peripheral or centripetal and, as the name implies, relies on the functional (undamaged) periosteum as a significant source of progenitor cells (osteoblasts and osteoclasts) for bone repair and remodeling, graft healing, and vascularization [23–27]. Chanavaz called the periosteum the "umbilical cord" of bone, emphasizing the need for "impeccable soft tissue and periosteum managements" at the time of surgery [27].
- *Microvascular (surgical) anastomosis* provides the best and most immediate source of blood supply. Vascularized bone free flaps with hard and soft tissue transfer, like fibula free osteocutaneous flap, rely on the creation of surgical anastomoses with a local central source (facial artery and vein). Complete and adequate revascularization is established via this route from the very beginning, providing an ample source of blood supply, i.e. oxygen, nutrients, and regenerative cells, for the vitality of the bone and soft tissue flaps, and eventual tissue healing and bone consolidation.

Dentlearn.ir

Vascularized bone free flap surgery is a bone augmentation procedure with instant revascularization of tissues by means of a microvascular anastomosis. Among many distant bone free flaps, reconstruction of large mandibular defects with a free fibular osteocutaneous flap is often selected for cancer patients. Establishment of a central anastomosis with a recipient artery leads to full reperfusion of transferred bone and soft tissues. Vascularized bone free flap surgery has the highest biological rationale (5/5) due to the surgical establishment of microvascular anastomosis for excellent vitality of the graft as an essential part of the procedure (Table 7.1 and Figures 7.1–7.3).

Distraction osteogenesis (DO) is performed for mostly vertically deficient alveolar ridges. The vitality of the osteotomized (transport) bone segment is preserved from two vascular sources: endosteal (through the slow separation of fragments at a distraction rate of about 1 mm a day) and peripheral (through the intact and slow-stretching mucoperiosteal flaps). This technique provides an uninterrupted vascular supply important for bone healing that starts with woven (embryonic) bone formation and progresses to lamellar (mature) bone. The DO procedure has very high biological rationale (4/5) due to both centrifugal and centripetal sources of vascularization established for satisfactory vitality of the graft (Table 7.1 and Figure 7.4).

FIGURE 7.1 The entire fibula is free and the tourniquet is released with excellent perfusion of the fibula, muscle, and skin paddle.

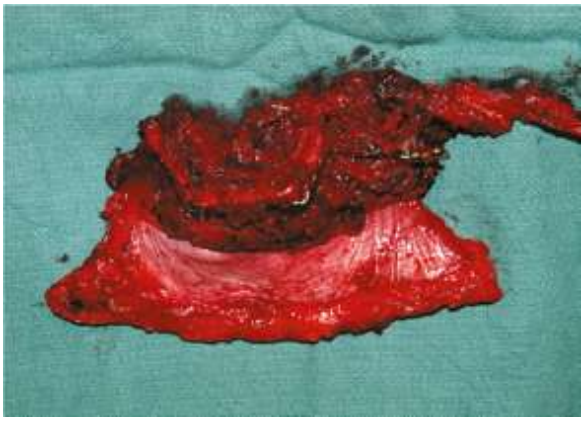

FIGURE 7.2 Fibula osteocutaneous free flap after three closing wedge osteotomies and rigid fixation with titanium reconstruction plates.

FIGURE 7.3 Inset of the fibula osteocutaneous free flap to restore the bilateral maxillary defect. The skin paddle of the free flap is used to close the oral cavity defect.

The *ridge-split expansion procedure* (RSEP), *sagittal sandwich osteotomy* (SSO), and *guided bone regeneration* (GBR) are horizontal and vertical ridge augmentation procedures with optimal vascularization that is preserved throughout the procedure. RSEP with formation of an osteo-periosteal flap is based on a particulate graft placed in inlay fashion after the bone split into the bony gap (gap osteotomy). The internally placed particulate graft is surrounded by spongy (medullary or trabecular) bone and is vascularized by both endosteal (from inside out) and periosteal (from outside in) reperfusion sources from the very beginning [29–32]. The same type of dual vascularization is provided in the majority of GBR cases that employ resorbable or non-resorbable membranes. Although some delay of endosteal vascularity is anticipated in osteotomized (fractured) bone segments in RSEP or SSO procedures, it is usually well compensated by the periosteal source [4, 30]. RSEP/SSO/GBR procedures have a high biological rationale (3/5) due to both continuous and ample endosteal and periosteal sources of vascularization necessary for the adequate vitality of the bone graft. Sinus lift procedures utilize inlay particulate graft and are similarly well vascularized with both endosteal and periosteal sources, and therefore have a comparably good biological rationale (Table 7.1 and Figures 7.5–7.7).

An *autogenous block bone* (ABB) graft (extra- or intraoral) is performed for horizontally and vertically deficient alveolar ridges as onlay or inlay bone blocks. During surgery these free grafts are separated from the original source of vascularization (donor site) and transferred/juxtaposed to an

Dentlearn.ir

Table 7.1 Stratification of bone augmentation procedures by their biological rationale (BR; based on vascularization).

Surgical techniques	Biological rationale	Revascularization (sources of blood supply to the graft)
Free bone–soft tissue flap transfer	*****	Central microvascular anastomosis Optimal to transferred bone and soft tissue flap
Distraction osteogenesis	****	Periosteal and endosteal sources Optimal, dual, and uninterrupted
Ridge-split expansion, pedicled sandwich osteotomy, guided bone regeneration, sinus lift	***	Periosteal source for mobilized bone segment and endosteal for inlay bone graft Delay of endosteal vascularity to fractured bone segments in ridge-split expansion/sandwich osteotomy
Block bone graft	**	Delayed vascularization from both endosteal and periosteal sources
Cortical tenting block	*	Single initial source of blood supply – periosteal It is also delayed, leaving tented cortical block devascularized for weeks Endosseous blood supply is delayed

***** Outstanding vascularization is realized during and after the surgical procedure; BR = 5
**** Excellent vascularization is achieved during and after the surgical procedure; BR = 4
*** Good vascularization is attained during and after the surgical procedure; BR = 3
** Marginal vascularization is realized during and after the surgical procedure; BR = 2
* Poor vascularization is achieved during and after the surgical procedure; BR = 1
Source: Reprinted with modifications from Tolstunov L. Biologic rationale of a surgical procedure: Bone augmentation. *J Oral Maxillofac Surg*. 2018;76(5):914–16, with permission of Elsevier [1].

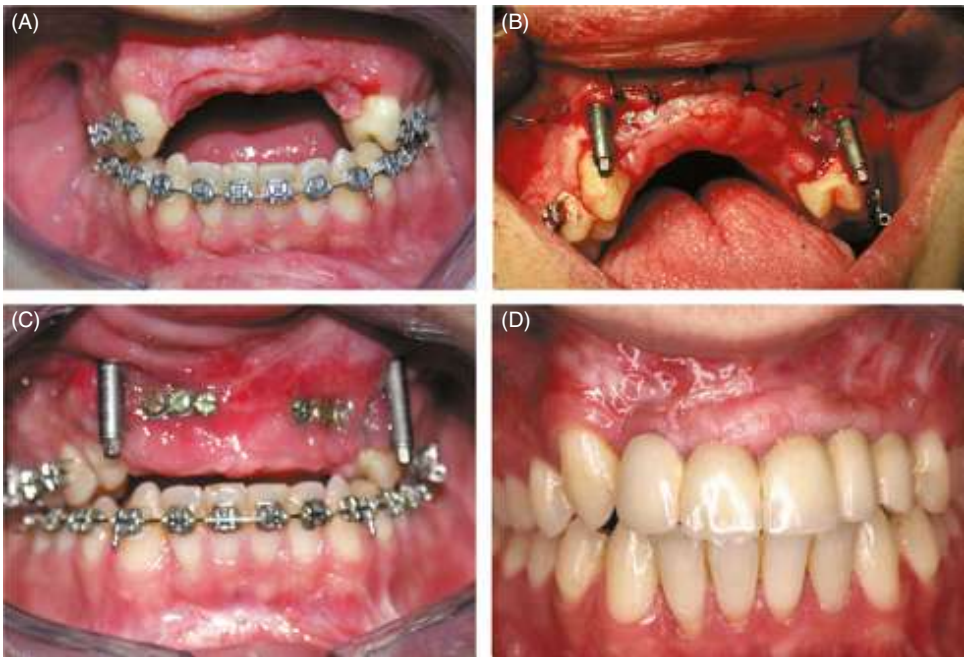

FIGURE 7.4 Clinical photos showing vertical alveolar distraction of the anterior maxilla in a trauma patient and rehabilitation. A 29-year-old patient presents with previous maxillofacial trauma resulting in avulsion of pre-maxillary bone and teeth. (A) Pre-operative maxillary vertical bone deficiency. (B) Placement of two distraction devices following a trapezoid osteotomy. (C) Vertical bone elongation after completion of alveolar distraction. (D) Distraction devices were removed, implants were placed, and the prosthetic rehabilitation can be observed. *Source*: Reproduced with permission from Elsevier. Aizenbud D et al. Combined orthodontic temporary anchorage devices and surgical management of the alveolar ridge augmentation using distraction osteogenesis. J Oral Maxillofac Surg. 2012;70(8):1815–26 [28].

Dentlearn.ir

FIGURE 7.5 The buccal fragment of bone is being subfractured and then slowly displaced (repositioned) laterally with a sharp chisel osteotome.

FIGURE 7.6 Two implants are positioned inside the split ridge according to the prosthetic and occlusal considerations. *Source*: Tolstunov 2013 and 2014 [33, 34]. Reproduced with permission of Douglas P Sinn, DDS. Editor in Chief, SROMS.

atrophic alveolar ridge on top of or between recipient bone. Thus, the vitality of a free graft is temporarily interrupted and is restored slowly with time, after fixation to the recipient site from the endosteal source (host bone) by plasmatic imbibition and ingrowth of capillaries (sprouting angiogenesis) and a delayed peripheral source of vascularization (reattached periosteum) [18, 19, 23].

A cancellous free bone graft is faster to revascularize by the mechanism of creeping substitution [35]. Free block grafts show a slower revascularization rate. With tight approximation of the stable (no mobility) block graft over the perforated recipient bone, 2–3 weeks are required in most cases for the initial revascularization to take effect, and thicker block grafts require more time [19–21]. Complete bone graft

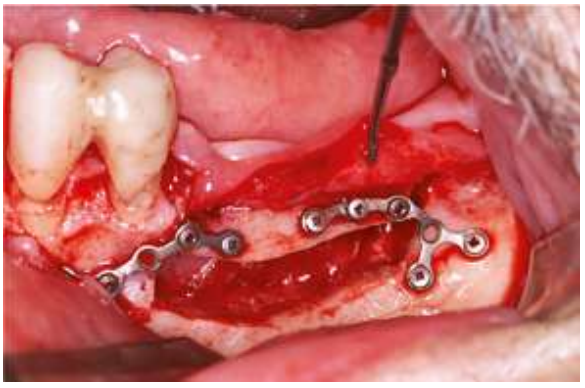

FIGURE 7.7 Condition after fixation of the osteotomized bone segment moved vertically by approximately 9 mm and with a lingual periosteal–soft tissue pedicle fixed with two micro-osteosynthesis plates.

integration into the recipient bone takes four months or longer. Inlay or interpositional block grafts have a double endosteal source of revascularization from both recipient bone surfaces and are therefore expected to revascularize faster. Onlay block grafts have one endosteal source and a periosteal source. Both take weeks to revascularize the onlay block graft. The secondary bone resorption common with autogenous free bone block grafts can be linked to a temporary loss of blood supply to the grafted bone in the process of revascularization (angiogenesis) [36].

Khoury's split block technique is a modification of onlay block grafting [37]. Interruption of vascularization to the free block graft in the process of graft transfer and delayed revascularization from the endosteal or periosteal sources at the recipient site might contribute to the bone resorption known with ABB grafts [38]. Therefore, the free autogenous block bone graft procedure has an average to good biological rationale (2/5), due to the interruption of all sources of blood supply temporarily and then delayed revascularization necessary for graft vitality through the endosteal and periosteal sources (Table 7.1 and Figures 7.8–7.14).

Tent-pole bone augmentation procedures include the use of different tenting devices, like metal screws, dental implants with abutments, and cortical autogenous tenting (CAT) block grafts. A CAT block in a cortical tenting grafting technique works by placing a cortical block at a distance from the recipient bone, creating a space for the particulate graft in between (Figure 7.15) [39–41]. Tenting of the periosteum and soft tissue in the form of a tent provides space for the particulate graft underneath and appears to work at the initial stage in larger three-dimensional reconstruction cases [41–43].

If a typical onlay block graft starts to receive revascularization through sprouting angiogenesis from the endosteal source right after the block graft transfer (instant angiogenesis, as discussed above, is extremely important for the vitality of the graft and its survival [13]), a CAT block graft, suspended

Dentlearn.ir

FIGURE 7.8 Clinical photograph of soft tissue dehiscence following inlay block bone graft with micro-titanium plate in posterior mandible: compromised post-operative vascularization to the graft. *Source*: Courtesy of Dr. Arash Khojasteh.

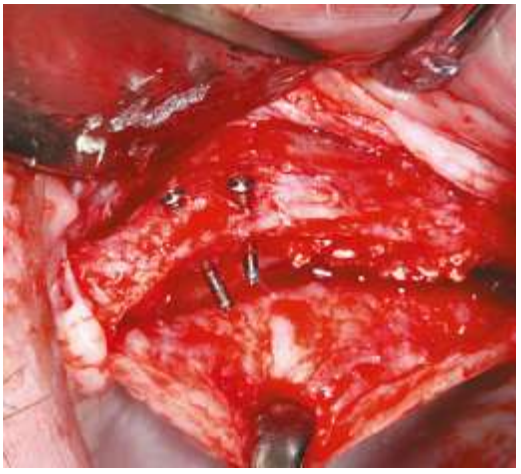

FIGURE 7.9 Clinical photograph depicting resorption of maxillary tuberosity block bone graft five months following surgery. *Source*: Courtesy of Dr. Arash Khojasteh.

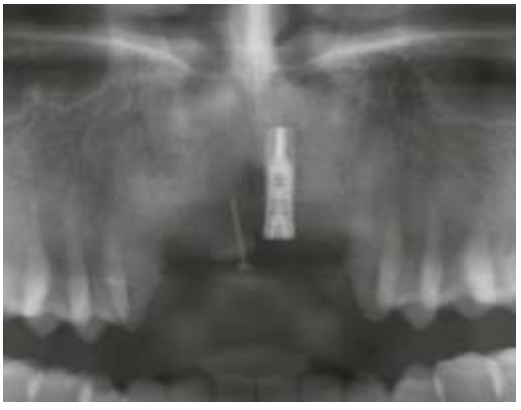

FIGURE 7.10 Panoramic radiograph demonstrating block bone graft for vertical ridge augmentation fixated with a screw in the anterior maxilla: devascularization and failure.

FIGURE 7.11 Clinical photograph showing block bone graft for vertical ridge augmentation fixated with a screw in the anterior maxilla: devascularization and failure.

FIGURE 7.12 Clinical photograph depicting failed block bone graft fixated with a screw in the anterior maxilla that was removed: it was completely devascularized and demonstrated resorption.

FIGURE 7.13 Clinical photograph showing failed block bone graft in the anterior maxilla: devascularized graft with resorption protruding through the soft tissue.

Dentlearn.ir

FIGURE 7.14 Cone beam computed tomography scan showing failed block bone graft in the anterior maxilla: partially resorbed block bone graft fixated with a screw and radiolucency of bone between the graft and native bone.

FIGURE 7.15 Cortical tenting with 3–4 mm distance.

above the particulate graft and physically separated from the recipient bone, initially has very little vascularization. Although a particulate graft, sandwiched in the middle, is at a better position for revascularization from the adjacent bone underneath, the cortical tenting graft does not seem to have these vascular benefits at an early stage. Weeks later, re-established endosteal and periosteal vascularization starts to provide vascular support to the cortical tenting graft. Due to its poor initial reperfusion, a cortical tenting block graft has a higher risk of early resorption and necrosis [44]. From this point of view, the cortical tenting bone block technique appears to have a low (initial) biological rationale (1/5) (Table 7.1 and Figures 7.16 and 7.17).

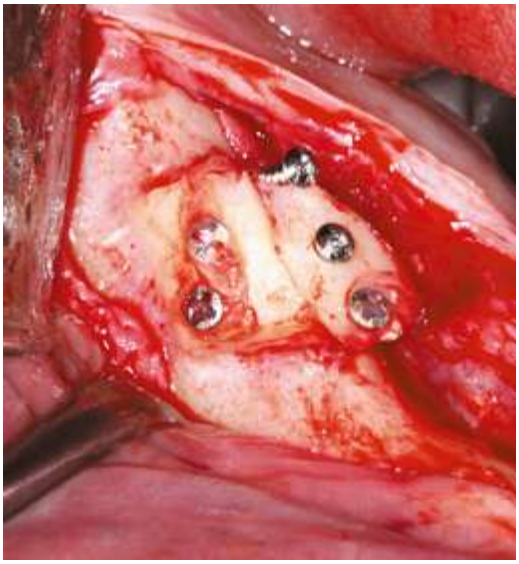

FIGURE 7.16 Clinical photograph demonstrating disintegration of cortical autogenous tenting block bone graft: compromised post-operative vascularization to the graft. Courtesy of Dr. Arash Khojasteh.

The same principle of immediate or delayed vascularization can be applied to *soft tissue grafts* (STG). Figures 7.18–7.20 demonstrate failure of a connective tissue graft (CTG). Particulate bone graft was placed to correct the bone deficiency next to an implant. It was covered with a collagen membrane. A CTG then was placed on top of the collagen membrane, and

Dentlearn.ir

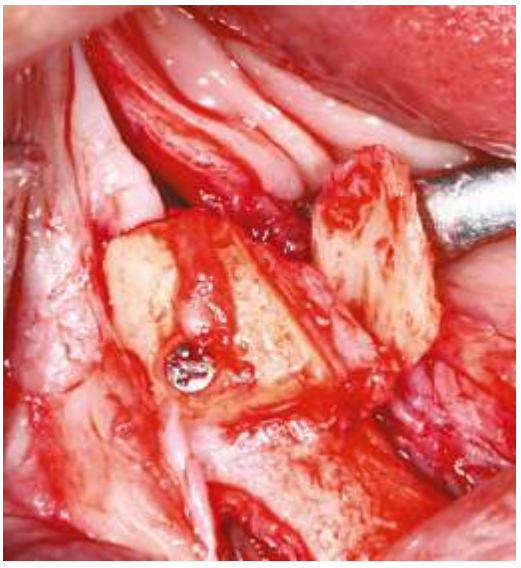

FIGURE 7.17 Clinical photograph showing disintegration of cortical autogenous tenting block bone graft: compromised graft revascularization. Courtesy of Dr. Arash Khojasteh.

FIGURE 7.18 Clinical photograph depicting failure of a connective tissue graft: particulate bone graft was placed on top of the horizontally deficient alveolar ridge in the anterior maxilla.

the wound was closed. The source of blood supply for the free STG was limited. It takes weeks to establish periosteal (peripheral) vascularization for the STG. Due to physical separation of the CTG from the endosseous source of vitality, coming from the particulate bone graft below, by the collagen membrane, in the initial stages of healing the CTG had barely any blood supply. Eventually, devascularization caused infection and graft failure. This surgical procedure was not planned and executed correctly – the biological principle of vascularization for the CTG was not followed. The biological rationale of the procedure was low, and the surgical outcome was compromised.

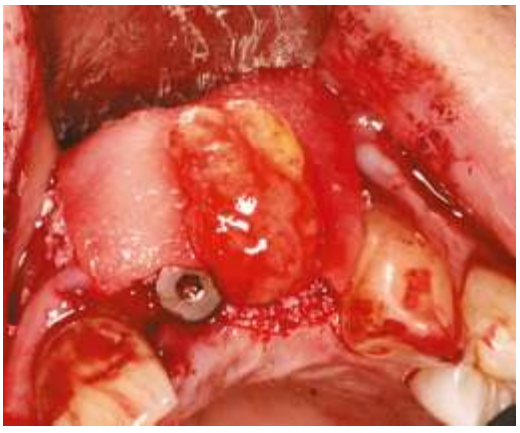

FIGURE 7.19 Clinical photograph showing failure of a connective tissue graft: particulate bone graft was covered with a collagen membrane. Free soft tissue graft was placed on top, not stabilized, and was lacking the source of blood supply that was blocked by a membrane from the bone graft below.

FIGURE 7.20 Clinical photograph showing failure of a connective tissue graft (CTG): 2-week post-operative appointment demonstrating devascularized, "extruded," and failed CTG.

CONCLUSION

Many factors are important for the success of bone augmentation in implant dentistry. As mentioned in this chapter, these factors can be classified as objective and subjective. Objective factors related to a surgical procedure include primary wound closure, space maintenance, wound stability, angiogenesis [9], adequate site preparation [45], complexity of the procedure [46], and the specific location of the jaw where surgery is performed [46, 47]. Subjective factors include the surgeon's experience and skills [48], and the patient's compliance, oral hygiene, smoking, and overall health [45]. All these factors, including proper case selection, accurate diagnosis, and a targeted treatment plan, play an important role in surgical success.

Dentlearn.ir

There is no question that excellent execution of a surgical procedure following all other surgical and biological principles can compensate for the lack of optimal vascularization, and the surgical outcome can still be acceptable. An example of good execution of a free intraoral block graft surgery would be adhering to the following concepts:

- A quick surgical procedure with a prepared recipient site for a block graft transfer to minimize the time of interruption of the blood supply to the graft.
- Perforation of the recipient bone to improve angiogenesis and osteogenesis.
- Tight and uniform approximation of the harvested block graft to the recipient bone bed to avoid gaps between two bony surfaces, and avoid protrusion of the graft above the alveolar crest or beyond the prepared osseous bed.
- Adding a supplementary particulate graft above and on the periphery of the block graft to encourage faster vascularization.
- Covering the grafted bone with a resorbable collagen membrane, like collagen tape, for protection.
- Good primary soft tissue closure of the grafted site with no tension to prevent wound dehiscence.
- Protection of the grafted site in the early post-operative period from the forces of mastication, and maintaining good oral hygiene.
- Host control (poor results in immunocompromised patients).
- Antibiotics prior to and after the surgery, disinfectant rinse.
- Surgical expertise.

Although these factors can help to achieve good results, a surgical technique with better inherent angiogenesis can accomplish them faster and/or better.

Surgical practitioners should be encouraged to select a bone augmentation procedure with a higher potential for optimal angiogenesis. This approach of selecting the procedure with the highest biological rationale can produce an optimal environment for graft revascularization, osteogenesis, and uninterrupted healing. A bone grafting procedure with an ideal and timely angiogenesis will undoubtably bring optimal and long-lasting surgical success, and both surgeon's and patient's satisfaction.

ACKNOWLEDGMENT

This chapter is reprinted with modifications from Tolstunov L, Biologic rationale of a surgical procedure: Bone augmentation. *J Oral Maxillofac Surg.* 2018;76(5):914–16, with the permission of Elsevier.

To access the videos for this chapter, please go to
www.wiley.com/go/tolstunov/essential

VIDEO 7.1 Introduction to the chapter by the Author and Book Editor Dr. Len Tolstunov.

REFERENCES

1. Tolstunov L. Biologic rationale of a surgical procedure: Bone augmentation. *J Oral Maxillofac Surg.* 2018;76(5):914–16.
2. Aida L. Alexis Carrel (1873–1944): Visionary vascular surgeon and pioneer in organ transplantation. *J Med Biogr.* 2014;22(3):172–5.
3. Bell WH. Revascularization and bone healing after anterior maxillary osteotomy: A study using adult rhesus monkeys. *J Oral Surg.* 1969;27(4):249–55.
4. Bell WH. Biologic basis for maxillary osteotomies. *Am J Phys Anthropol.* 1973;38(2):279–89.
5. Bell WH, Levy BM. Revascularization and bone healing after anterior mandibular osteotomy. *J Oral Surg.* 1970;28(3):196–203.
6. Bell WH, Levy BM. Revascularization and bone healing after posterior maxillary osteotomy. *J Oral Surg.* 1971;29(5):313–20.
7. Bell WH, You ZH, Finn RA, Fields RT. Wound healing after multisegmental Le Fort I osteotomy and transection of the descending palatine vessels. *J Oral Maxillofac Surg.* 1995;53(12):1425–33; discussion 33–4.
8. Lindstrom J, Branemark PI. Capillary circulation in the joint capsule of the rabbit's knee: A vital microscopic study. *Arthritis Rheum.* 1962;5:226–36.
9. Wang HL, Boyapati L. "PASS" principles for predictable bone regeneration. *Implant Dent.* 2006;15(1):8–17.
10. Avila-Ortiz G, Elangovan S, Kramer KW et al. Effect of alveolar ridge preservation after tooth extraction: A systematic review and meta-analysis. *J Dent Res.* 2014;93(10):950–8.
11. Silva LD, de Lima VN, Faverani LP et al. Maxillary sinus lift surgery—with or without graft material? A systematic review. *Int J Oral Maxillofac Surg.* 2016;45(12):1570–76.

Dentlearn.ir

12. Zenobio EG, Cardoso LD, Oliveira LJ et al. Blood clot stability and bone formation following maxillary sinus membrane elevation and space maintenance by means of immediate implant placement in humans: A computed tomography study. *J Craniomaxillofac Surg.* 2019;47(11):1803–8.

13. Weiss S, Zimmermann G, Pufe T et al. The systemic angiogenic response during bone healing. *Arch Orthop Trauma Surg.* 2009;129(7):989–97.

14. Schmidt-Bleek K, Schell H, Lienau J et al. Initial immune reaction and angiogenesis in bone healing. *J Tissue Eng Regen Med.* 2014;8(2):120–30.

15. Portal-Nunez S, Lozano D, Esbrit P. Role of angiogenesis on bone formation. *Histol Histopathol.* 2012;27(5):559–66.

16. Carlier A, Geris L, van Gastel N et al. Oxygen as a critical determinant of bone fracture healing—a multiscale model. *J Theor Biol.* 2015;365:247–64.

17. Ewers R, Tomasetti B, Ghali G, Jensen O. *A new biologic classification of bone augmentation. The osteoperiosteal flap: A simplified approach to alveolar bone reconstruction*. Chicago, IL: Quintessence; 2010, 19–42.

18. Capla JM, Ceradini DJ, Tepper OM et al. Skin graft vascularization involves precisely regulated regression and replacement of endothelial cells through both angiogenesis and vasculogenesis. *Plast Reconstr Surg.* 2006;117(3):836–44.

19. De Marco AC, Jardini MA, Lima LP. Revascularization of autogenous block grafts with or without an e-PTFE membrane. *Int J Oral Maxillofac Implants.* 2005;20(6):867–74.

20. Saghiri MA, Asatourian A, Garcia-Godoy F, Sheibani N. The role of angiogenesis in implant dentistry. Part I: Review of titanium alloys, surface characteristics and treatments. *Med Oral Patol Oral Cir Bucal.* 2016;21(4):e514–e525.

21. Saghiri MA, Asatourian A, Garcia-Godoy F, Sheibani N. The role of angiogenesis in implant dentistry. Part II: The effect of bone-grafting and barrier membrane materials on angiogenesis. *Med Oral Patol Oral Cir Bucal.* 2016;21(4):e526–e537.

22. Drago CJ. Rates of osseointegration of dental implants with regard to anatomical location. *J Prosthodont.* 1992;1(1):29–31.

23. Chanavaz M. Anatomy and histophysiology of the periosteum: Quantification of the periosteal blood supply to the adjacent bone with 85Sr and gamma spectrometry. *J Oral Implantol.* 1995;21(3):214–19.

24. Shahbazi A, Feigl G, Sculean A et al. Vascular survey of the maxillary vestibule and gingiva—clinical impact on incision and flap design in periodontal and implant surgeries. *Clin Oral Investig.* 2021;25(2):539–46.

25. Syed-Picard FN, Shah GA, Costello BJ, Sfeir C. Regeneration of periosteum by human bone marrow stromal cell sheets. *J Oral Maxillofac Surg.* 2014;72(6):1078–83.

26. Soltan M, Smiler D, Soltan C. The inverted periosteal flap: A source of stem cells enhancing bone regeneration. *Implant Dent.* 2009;18(5):373–9.

27. Chanavaz M. [The periosteum: The "umbilical cord" of bone. Quantification of the blood supply of cortical bone of periosteal origin]. *Rev Stomatol Chir Maxillofac.* 1995;96(4):262–7.

28. Aizenbud D, Hazan-Molina H, Cohen M, Rachmiel A. Combined orthodontic temporary anchorage devices and surgical management of the alveolar ridge augmentation using distraction osteogenesis. *J Oral Maxillofac Surg.* 2012;70(8):1815–26.

29. Jensen OT, Ellis E. The book flap: A technical note. *J Oral Maxillofac Surg.* 2008;66(5):1010–14.

30. Jensen OT, Mogyoros R, Owen Z et al. Island osteoperiosteal flap for alveolar bone reconstruction. *J Oral Maxillofac Surg.* 2010;68(3):539–46.

31. Jensen OT, Bell W, Cottam J. Osteoperiosteal flaps and local osteotomies for alveolar reconstruction. *Oral Maxillofac Surg Clin North Am.* 2010;22(3):331–46, vi.

32. Casap N, Brand M, Mogyros R et al. Island osteoperiosteal flaps with interpositional bone grafting in rabbit tibia: Preliminary study for development of new bone augmentation technique. *J Oral Maxillofac Surg.* 2011;69(12):3045–51.

33. Tolstunov L. Ridge-split procedure for horizontal augmentation of the alveolar ridge in implant dentistry. *SROMS.* 2013;21 (1 April):1–53.

34. Tolstunov L. Classification of the alveolar ridge width: Implant-driven treatment considerations for the horizontally deficient alveolar ridges. *J Oral Implantol.* 2014;40:365–70.

35. Donos N, Mardas N, Chadha V. Clinical outcomes of implants following lateral bone augmentation: Systematic assessment of available options (barrier membranes, bone grafts, split osteotomy). *J Clin Periodontol.* 2008;35(8 suppl):173–202.

36. Baker RD, Terry BC, Davis WH, Connole PW. Long-term results of alveolar ridge augmentation. *J Oral Surg.* 1979;37(7):486–9.

37. Khoury F, Hanser T. Mandibular bone block harvesting from the retromolar region: A 10-year prospective clinical study. *Int J Oral Maxillofac Implants.* 2015;30(3):688–97.

38. Cansiz E, Haq J, Manisali M et al. Long-term evaluation of three-dimensional volumetric changes of augmented severely atrophic maxilla by anterior iliac crest bone grafting. *J Stomatol Oral Maxillofac Surg.* 2020;121(6):665–71.

39. Khojasteh A, Behnia H, Shayesteh YS et al. Localized bone augmentation with cortical bone blocks tented over different particulate bone substitutes: A retrospective study. *Int J Oral Maxillofac Implants.* 2012;27(6):1481–93.

40. Morad G, Khojasteh A. Cortical tenting technique versus onlay layered technique for vertical augmentation of atrophic posterior mandibles: A split-mouth pilot study. *Implant Dent.* 2013;22(6):566–71.

41. Le B, Burstein J, Sedghizadeh PP. Cortical tenting grafting technique in the severely atrophic alveolar ridge for implant site preparation. *Implant Dent.* 2008;17(1):40–50.

Dentlearn.ir

42. Yu H, Chen L, Zhu Y, Qiu L. Bilamina cortical tenting grafting technique for three-dimensional reconstruction of severely atrophic alveolar ridges in anterior maxillae: A 6-year prospective study. *J Craniomaxillofac Surg.* 2016;44(7):868–75.

43. Pourdanesh F, Esmaeelinejad M, Aghdashi F. Clinical outcomes of dental implants after use of tenting for bony augmentation: A systematic review. *Br J Oral Maxillofac Surg.* 2017;55(10):999–1007.

44. Novy LFS, Aguiar EG, de Arruda JAA et al. Linear and volumetric gain after vertical bone augmentation in the posterior mandible using an autologous cortical tenting method. *Int J Oral Maxillofac Surg.* 2019;48(11):1485–91.

45. Waldrop TC, Semba SE. Closure of oroantral communication using guided tissue regeneration and an absorbable gelatin membrane. *J Periodontol.* 1993;64(11):1061–6.

46. Urban IA, Monje A, Lozada J, Wang HL. Principles for vertical ridge augmentation in the atrophic posterior mandible: A technical review. *Int J Periodontics Restorative Dent.* 2017;37(5):639–45.

47. Tolstunov L. Implant zones of the jaws: Implant location and related success rate. *J Oral Implantol.* 2007;33(4):211–20.

48. Jerjes W, Hopper C. Surgical experience, workload and learning curve vs postoperative outcome. *Eur J Oral Implantol.* 2018;11 (suppl 1):S167–S178.

Dentlearn.ir

Ridge Preservation

SECTION II

Chapter 8 Bone Grafting Materials for Bone Preservation and Augmentation in Implant Dentistry: Surgical Algorithm 129
Hanieh Nokhbatolfoghahaei and Arash Khojasteh

Chapter 9 Guided Bone Regeneration for Extraction Sockets: Ridge Preservation 141
Waldemar D. Polido

Chapter 10 Platelet-Rich Fibrin for Bone Augmentation in Implant Dentistry 153
Richard J. Miron and Michael A. Pikos

Dentlearn.ir

Dentlearn.ir

Bone Grafting Materials for Bone Preservation and Augmentation in Implant Dentistry: Surgical Algorithm

CHAPTER 8

Selection of a bone grafting material in implant dentistry is driven by many factors, including the size of the defect and the host's immunocompetency. Bone grafting with bone substitutes can result in significant augmentative outcomes that are often comparable to autogenous grafts. The result of using bone graft materials prior to or simultaneous with implant insertion demonstrates that successful bone gain is reported with different graft materials, and that non-autogenous bone grafts can become feasible alternatives to autografts, when chosen in accordance with the recipient's conditions.

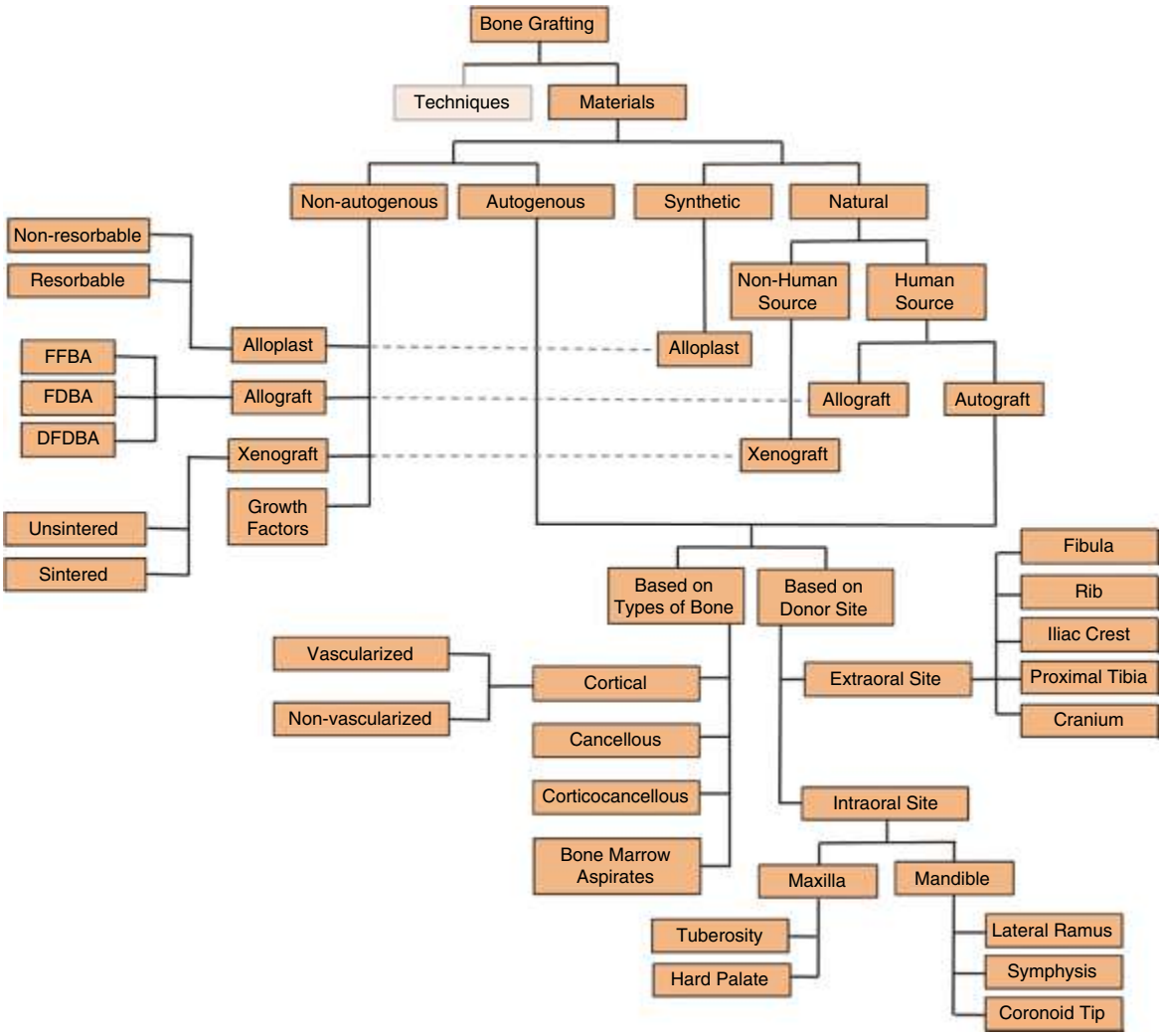

Dentlearn.ir

CHAPTER 8 Bone Grafting Materials for Bone Preservation and Augmentation in Implant Dentistry: Surgical Algorithm

Hanieh Nokhbatolfoghahaei[1] and Arash Khojasteh[1,2]

[1]*Dental Research Center, Research Institute of Dental Sciences, Shahid Beheshti University of Medical Sciences, Tehran, Iran*

[2]*Faculty of Health and Medicine, University of Antwerp, Antwerp, Belgium*

The presence of teeth and their attachment apparatus contribute to the preservation of the surrounding alveolar bone tissues. Following tooth loss, due to the absence of periodontal ligaments, periodic force application is not provided and, consequently, the alveolar bone is significantly impacted. Over time, the overall dimensions of edentulous alveolar ridge tend to diminish at varying rates. The first 3 months post extraction show the highest amount of dimensional alternations of the alveolar process [1]. In general, the alveolar ridge resorbs at an average rate of 1.5–2 mm per 6 months vertically and 40–50% of the horizontal dimension over 6 months [2–4]. If neither post-extraction immediate prophylactic procedures nor restoring treatments are performed, bone loss occurs at the aforementioned rate and loss of up to 40–60% of the ridge volume in 2–3 years is expected [2, 5-7]. The gradual resorption of edentulous alveolar ridge necessitates compromising or therapeutic interventions in order to restore the functional and esthetic properties of the bone, and prevent the emergence of additional complications [5].

After the concept of osteoconduction in the oral and maxillofacial region emerged in the early years of the twentieth century, a variety of materials have been introduced [5]. The materials have been gradually developed and have adopted osteoinductive properties, leading to significantly improved bone quality prior to implant placement [8–10]. Various bone regenerative substitutes are available, including the patient's own bone from a secondary location (autografts), organic and/or inorganic materials from either another patient (allografts) or animal species (xenografts), artificially made substitutes (synthetic alloplastic biomaterials), and osteoactive agents [2, 5, 11–17]. These bone substitutes can be generally categorized as either autogenous and non-autogenous or natural and synthetic. Moreover, bone grafts can be implemented as blocks or particulates [5].

Bone grafting materials should have four characteristics to be clinically applicable: osseointegration, osteoconduction, osteoinduction, and osteogenesis. *Osteointegration* is the capacity of the grafting material to chemically bond to the surface of the recipient bed without scarring. *Osteoconduction* is attributed to the matrix the graft provides for new bone to form and supports bone growth. An osteoconductive substitute promotes cell–matrix interactions, cell adhesion, and deposition of extracellular matrix (ECM). *Osteoinduction* means that the grafting material is capable of inducing the differentiation of pluripotent stem cells in the surrounding tissues toward an osteoblastic lineage, and therefore results in induced bone formation. *Osteogenesis* refers to the presence of osteoblastic cells within the graft material that directly generate new bone [17].

The properties of native bone tissue are shown in Figure 8.1. Factors of importance that allow physical properties of the native bone to be mimicked include the bone's chemical composition, calcium/phosphate ratio, carbonate content, crystalline homogeneity, degree of porosity, pore size, specific surface area, and others.

For instance, xenografts with a processing temperature beyond 600 °C tend to have reduced carbonate amount, calcium/phosphate ratio, porosity, and specific surface area. Moreover, the crystals are formed in a more homogeneous fashion, resulting in prolonged degradation of the material [18]. Other examples of late degradability, mineralized allografts, hydroxyapatites, and sintered tricalcium phosphate blocks, are late degradable substitutes [19, 20]. Early degradable materials can be used in ridge preservation, ridge

Essential Techniques of Alveolar Bone Augmentation in Implant Dentistry: A Surgical Manual, Second Edition. Edited by Len Tolstunov.
© 2023 John Wiley & Sons, Inc. Published 2023 by John Wiley & Sons, Inc.
Companion website: www.wiley.com/go/tolstunov/essential

Dentlearn.ir

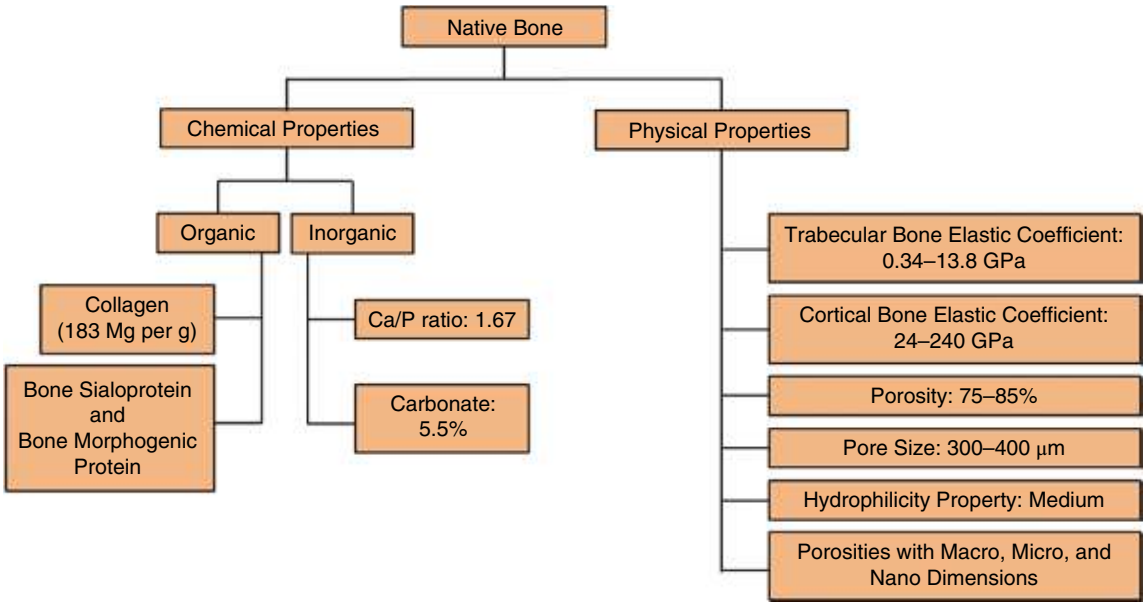

FIGURE 8.1 The characteristics of normal bone (native bone). Ca, calcium; P, phosphate.

reconstruction, and also guided bone regeneration cases in which accelerated bone regeneration is required. The physical and chemical properties of the grafting material play a significant role. Substitute selection depends on the biological activity that is expected for the feasible rate of new bone formation, space maintenance capacity, the material's resorption rate, and the patient's psychological and religious beliefs [21].

Based upon their origin, five types of bone graft materials exist: autografts, allografts, xenografts, alloplasts, and growth factors (Figure 8.2) [17].

AUTOGENOUS BONE GRAFTS

Among all types of materials proposed for ridge augmentation, autogenous bone grafts, namely grafts obtained from the same patient, are often favored over non-autogenous grafts [17]. Autologous bone grafts are the only bone grafts to possess all the four desired properties of a bone graft: they are osteoconductive, osteoinductive, osteogenic, and osseointegrative [5,17,22]. Autologous grafts mechanically support the vessels and cellular elements that surround the grafting site, stimulate bone formation, and contain mature cellular elements that produce new bone tissue [17]. They are biocompatible and do not initiate immunogenic responses [12]. The inorganic component of the autogenous bone, namely hydroxyapatite (HA), contributes to the rigidity of the graft, while the organic component, the collagen bundles, provides strength, durability, and stability [17].

Autogenous bone grafts are currently considered the gold standard material for intraoral bone grafting procedures [5, 17, 23–26]. The rationale behind this is that notwithstanding the ischemia during the grafting process, living osteogenic cells and the mesenchymal stem cells (MSCs) retained within the bone marrow tend to have a higher viability [26]. The bone-harvesting technique performed is said to impact the viability of MSCs and their ability to release growth factors [21, 27]. Using bone mills or bone scrapers has demonstrated better cell performance within the harvested graft, compared to drills or piezoelectric devices [27, 28].

Regarding the drawback of autogenous bone grafts, several studies have reported apoptosis of endogenous cells within the autogenous bone and, subsequently, tissue necrosis during the grafting procedure [26, 28–30]. Flow cytometry analyses have demonstrated the proportion of viable and apoptotic cells within maxillary-collected bone chips to be <5% and >95%, respectively [28]. These results have been shown to be regardless of the type of graft harvesting instrument. Moreover, up to 80% of the osteocyte lacunae were either empty or packed with debris at the end of the grafting procedure [29]. In addition, harvesting autogenous bone grafts is associated with a risk of donor site morbidity [17, 23, 26, 31]. Therefore, certain complications may arise, including extended healing periods, additional postoperative discomfort, bone fracture, infection, and trauma to the adjacent anatomical structures such as nerves and blood vessels that can result in neurosensory and vascular impairment [5, 32].

Dentlearn.ir

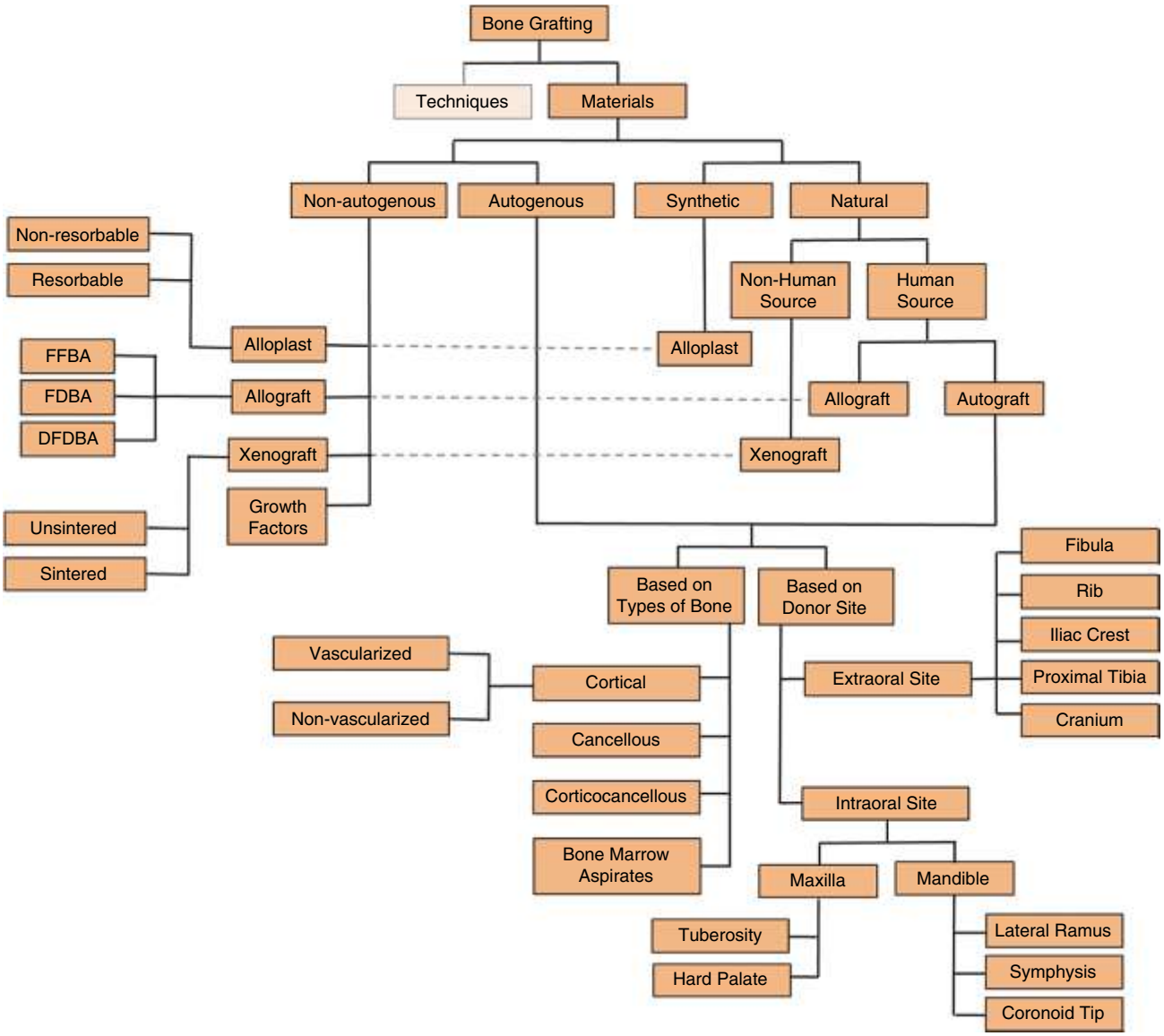

FIGURE 8.2 Different types of bone grafts. DFDBA, demineralized freeze-dried bone allografts; FDBA, freeze-dried bone allografts; FFBA, fresh-frozen bone allografts. *Source:* [17] / Elsevier.

The most commonly used autologous bone grafts are the cancellous type [33]. The cancellous grafts have porous trabeculae lined with functional osteoblasts that allow easy revascularization. Despite its impaired initial mechanical support, the graft material gradually incorporates into the recipient bed and achieves strength equivalent to that of a cortical graft over a 6–12 month period [5, 33]. After the graft implantation process, viable donor osteocytes remain within the graft tissue. With regard to this, the local cytokines and graft porosity can promote angiogenesis and recruitment of host MSCs. The graft has the potential to be fully vascularized within 2 days [5]. Moreover, the recruited MSCs can be directed to differentiate into osteoblasts. New bone formation is expected within a few weeks and remodeling mechanisms are typically observed at the 8th week post operation. Eventually, complete graft turnover is expected within 1 year. The turnover phenomenon is attributed to the process of "creeping substitution," namely the simultaneous deposition of new osteoid by concomitant osteoblasts and the resorption of necrotic trabeculae by osteoclasts [5].

Cortical bone grafts serve as highly osteoconductive materials, despite their hindered osteoinductive and

Dentlearn.ir

osteogenic properties [34]. The dense cortical matrix contributes to the restrained and slow rates of graft revascularization and incorporation. Moreover, the constrained perfusion and the scarce number of donor osteocytes manifest as impeded resorption that prevents occupation of the space provided with new bony deposits [17]. Non-vascularized cortical grafts provide immediate structural support, but over a period of 6 weeks after the procedure the graft is debilitated due to ongoing tissue resorption and revascularization [5]. The cortical grafts offer immediate strength that diminishes over time. Up to 6 months post operation, cortical grafts tend to become 40–50% weaker than native bone tissues [2, 35].

Cortico-cancellous bone grafts offer the advantages of both cortical and cancellous tissues: the cortical component provides an osteoconductive medium with immediate structural stability, whereas the cancellous component serves as an osteoinductive and osteogenic material [36]. On the other hand, bone marrow aspirates contain bone marrow–derived stem cells that manifest as high osteoblastic capacities of the graft. Injecting autogenous bone marrow aspirates results in improving the osteoinductive and osteogenic properties of harvested bone grafts. This is due to the high number of secreted cytokines and growth factors present within the aspirate. Revascularization of these grafts is initiated at around the 5th day post operation. The survival of osteocytes depends on the presence of vascular supply within a distance of 0.1 mm [37].

ALLOGRAFTS

Allogenic bone grafts, also referred to as allografts, are non-vital osseous tissues that are harvested from one individual and transferred to another member of the species that is genetically non-identical [38, 39]. These grafts are harvested from individuals with a well-documented medical history and devoid of infectious diseases, under sterile conditions [17]. Allografts may be either fresh-frozen bone allografts (FFBA), freeze-dried bone allografts (FDBA), or demineralized freeze-dried bone allografts (DFDBA) [39–42]. Fresh-frozen allografts have demonstrated higher osteoinductive and strength compared to freeze-dried grafts [43].

In comparison with FDBAs and DFDBAs, FFBAs tend to induce a stronger immunological response. Immunogenic responses, and delayed capillary infiltration, retard the rate of new bone growth, incorporation, and bone remodeling [44]. The literature indicates that the more aggressive the processing is, the less intense immunological responses are expected. Moreover, a risk of disease transmission exists with the use of allografts, albeit at a much lower rate compared to blood-derived products. In this light, unlike freeze-dried allografts, transmission of human immunodeficiency virus (HIV) has been reported following the application of fresh-frozen allografts [43]. Thus, the clinical application of fresh-frozen allografts has ended [43].

FDBAs and DFDBAs are the outcome of freeze-drying, demineralizing, irradiating, and ethylene oxide treatment, in order to minimize the chances of disease transmission and immunological reactions [5]. However, the mechanical properties of FDBAs are reported to become compromised through these processes [2, 45]. Moreover, these grafts come in a variety of shapes and sizes. Each of the allograft types is available in cortical chips, cortical granules, cortical wedges, or even cancellous powdered grafts [46, 47]. These materials are frequently coupled with osteoinductive autogenous bone or bone substitutes [2]. Allografts contain no viable cells, but the risk of disease transmission still exists. The use of tissue-banked bone substitutes has alleviated the need to perform surgeries on secondary sites. Thus, the concerns regarding donor site morbidity have been eliminated.

Of note is that freeze-dried allografts have been indicated to render little to no osteoinductivity. Growth factors bound within the bony matrix cannot be released from cortical and cancellous allografts. Along with that, even if they were quantifiably released, according to several studies stating that these materials show minimal osteoinductivity in cell-contact free assay, no osteoinductivity would be expected [48]. In addition, chemical disinfecting procedures can omit viable bone cells and denaturing osteoconductive and osteoinductive proteins that are present within the graft, while the number of growth and differentiation factors, especially bone morphogenetic protein-2 (BMP-2), in the DFDBA also has been reported to be insufficient to induce bone formation [49, 50]. This moreover draws significant attention to revitalizing allograft strategies, namely loading crucial growth factors onto the processed allograft [50].

Cortical FDBAs offer a higher volume of bone matrix that leads to increased resorption time, higher inductive potential due to accumulation of growth factors, and lower overall antigenicity [2]. FDBAs are considered osteoconductive due to their ability to maintain space. Moreover, in order to boost their osteoinductive potential, autogenous grafts can be mixed with FDBAs [51]. DFDBAs are frequently implemented, either alone or in combination with FDBAs or autografts. Among all types of allografts, DFDBAs have demonstrated the most rapid resorption rates and the lowest mechanical stability, due to their demineralization processing [52]. The bioactivity of DFDBAs is highly dependent on the donor's age: grafts harvested from younger individuals tend to have higher osteogenic potential than those harvested from older individuals [53, 54].

Limitations of these grafts are restricted success in large vertical defects, the amount of resorption, and the lack of osteoinduction. The preparation process of an allograft (i.e. freeze-drying and irradiation) leads to compromised integrity and osteogenic potential. Moreover, immunological reactions may result in impaired incorporation of the graft. The chemical and physical properties of allograft materials are depicted in Figure 8.3.

Dentlearn.ir

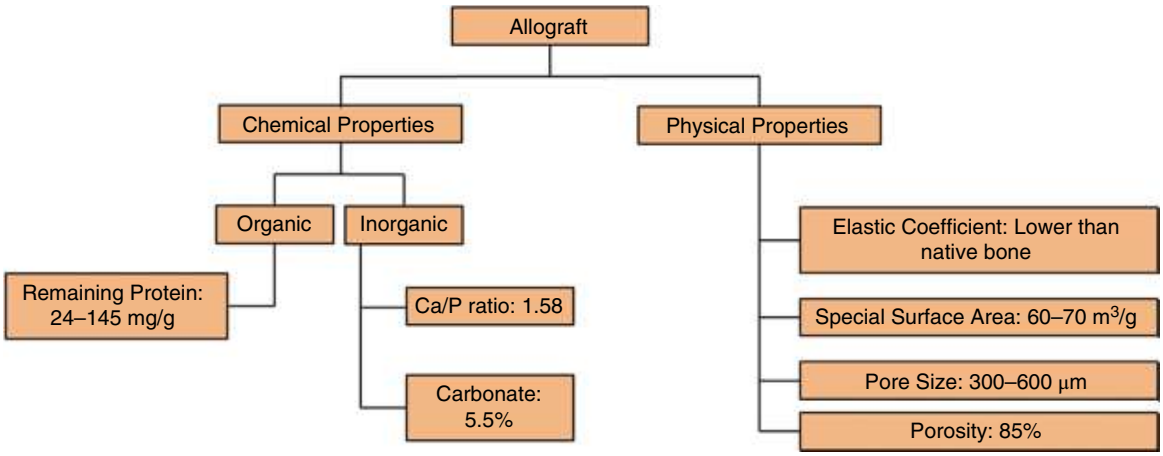

FIGURE 8.3 The characteristics of allograft bone. Ca, calcium; P, phosphate.

XENOGRAFTS

Xenografts are derived from non-human species. They are composed of naturally derived deproteinized cancellous bone tissues from either animals, such as cows, horses, or swine, or bone-like minerals that are derived from corals or algae, including calcium carbonate [5, 17, 25]. Implantation of xenografts has presented a number of biological challenges, which include disease transmission (e.g. prions and retroviruses), host immunological reactions, a scarcity of viable cells, and impeded osteoinduction following their manufacturing process [55, 56].

Xenograft materials resorb and allow the gradual formation of new bone at the recipient sites [57]. However, the materials are inert and resorb at a relatively slow rate [58]. The existing micro- and macropores within the material promote clot stability and creeping of new bone inward to the graft structure [59]. Xenografts can be used either alone or in combination with autogenous grafts, in order to enhance the osteoinductive capacity of the material.

Porites, a genus of stony coral, is primarily composed of aragonite (>98% calcium carbonate, $CaCO_3$) and provides coralline calcium carbonate [60]. Coralline calcium carbonate matrices have not only pores of 100–200 μm diameter, but also a calcium/phosphate ratio of 1.6, which both resemble the characteristics of native cancellous bone [2, 60]. Their relatively high porosity of ~45% provides a wide surface area, contributing to enhanced graft resorption and subsequent replacement of the graft with new bone [61]. HA is also obtained from porites through heat conversion processes. However, unlike calcium carbonate, HA has been demonstrated to be non-resorbable *in vivo* [2]. In terms of periodontal regenerative applications, coralline calcium carbonate has been associated with significant periodontal clinical attachment gain, reduction of probing depths, and feasible defect fill.

The most used xenograft material is deproteinized bovine bone mineral, such as Bio-Oss® (Geistlich Biomaterials, Wolhusen, Switzerland) and OsteoGraf/N® (Dentsply Friadent Ceramed, Lakewood, CO, USA) [62–64]. Bovine xenografts play a major role in using xenografts for craniomaxillofacial regenerative applications.

Despite the paucity of bibliographical data regarding clinical complications and long-term safety following the application of xenografts, the risk of bovine spongiform encephalopathy (BSE) or transmissible spongiform encephalopathies (TSE) remains worthy of consideration [65]. The constrained ability to screen prions within the animal genome, coupled with a prolonged latency period prior to manifestation of the disease (from 1 to over 50 years), necessitates established frameworks for discussing the long-term risks of the widely used xenografts in dental procedures [66].

Bio-Oss has properties similar to human cancellous bone, regarding its macrostructure, crystalline content, and physical properties, including pore sizes ranging from 300 to 1500 μm, 70–75% porosity, an internal surface of 97 m^2/g, 6.9% carbonate content, 1.6 Ca/P ratio, and heterogenous nanocrystals within the range of 50–100 nm [67–70]. The Bio-Oss material has the ability to migrate into the connective tissue during the healing process. Although Bio-Oss is purely mineral and osteoconductive, it still resorbs at a critical rate, resulting in limited applications [5].

Bovine bone undergoes deproteinization, namely extraction of proteins, in order to prevent immunological rejection of the implanted graft [5, 17]. However, the deproteinization process eliminates the osteoinductive capacity, and generates a solely osteoconductive scaffold. Improved blood clot stability has been reported following the application of deproteinized bovine bone minerals with a membrane [5]. Both particulates and blocks of bovine bone grafts have been

Dentlearn.ir

indicated to effectively contribute to the treatment of human intrabony defects. With low-heat treatment and chemical extraction of organic components of the bovine bone, inorganic bone substitutes remain that are composed of an HA skeleton that retains the micro- and macroporous structure of the cancellous and cortical bone [5].

The sintering temperature highly impacts the mechanical properties of naturally obtained HAs, and in particular bovine-derived HA. The most prominent variable is the temperature in which the purification process of precursor bone tissue of a xenogeneic origin takes place. For instance, Cerabone® (Botiss Biomaterials, Zossen, Germany), also known as a sintered xenograft, is treated at temperatures of up to 1250 °C [71]. OsteoGraf N is sintered at 1100 °C, during which the bone crystals are fused and matrix porosity is diminished [17]. On the other hand, Bio-Oss, also known as an unsintered xenograft, undergoes low-heat treatments at 300 °C, resulting in preservation of trabecular architecture and higher porosity [17]. At lower temperatures, such as the temperature at which Bio-Oss is processed, the natural crystalline structure of the matrix is retained. This contributes to the remodeling potential of the graft in the long run. Thereafter, the grafts are sterilized and antigens are eliminated. Physiochemical properties of xenografts, based on their sintering temperature, are depicted in Figure 8.4.

Various xenograft formulations are available on the market, but not all of them provide for easy adaptation. Moreover, xenogeneic bone blocks that are used for vertical augmentation purposes are brittle and provide impeded toughness.

ALLOPLASTS

Alloplastic bone grafts are inert, biocompatible, and inorganic synthetic materials [5, 72]. Alloplastic grafts are composed of non-biological materials that can be utilized for defect augmentation, such as polymers or ceramics (e.g. polycaprolactone [PCL], polylactic acid [PLA, PDLA, PLLA], polylactic-co-glycolic acid [PLGA], or calcium-based biomaterials) [73, 74]. The polymer or ceramic components can be used as fillers within a composite, and through gradual degradation, within 18–24 months, become replaced by the newly formed bone tissue.

Alloplasts can be manufactured in various formulations and with varying physicochemical properties. They are available in resorbable and non-resorbable forms, with customized levels of porosity and pore size [75]. Synthetic resorbable materials are intended as inexpensive substitutes for bone regeneration purposes. The relatively rough structure and large particle sizes of alloplasts have been proven to allow adequate bone ingrowth. Their pore size is a reliable determinant of their capacity to form new bone. For instance, pore size diameters below 100 μm are less likely to permit cellular and capillary invasion, resulting in impeded induction of bone formation. However, pore size diameters greater than 300 μm provide efficient matrices for capillaries to form and invade into the graft and promote new bone formation. However, most of the current commercially available materials do not exhibit any pores [76, 77].

The most used ceramic alloplasts are dicalcium phosphates, tricalcium phosphates (TCP), bioactive glasses, and

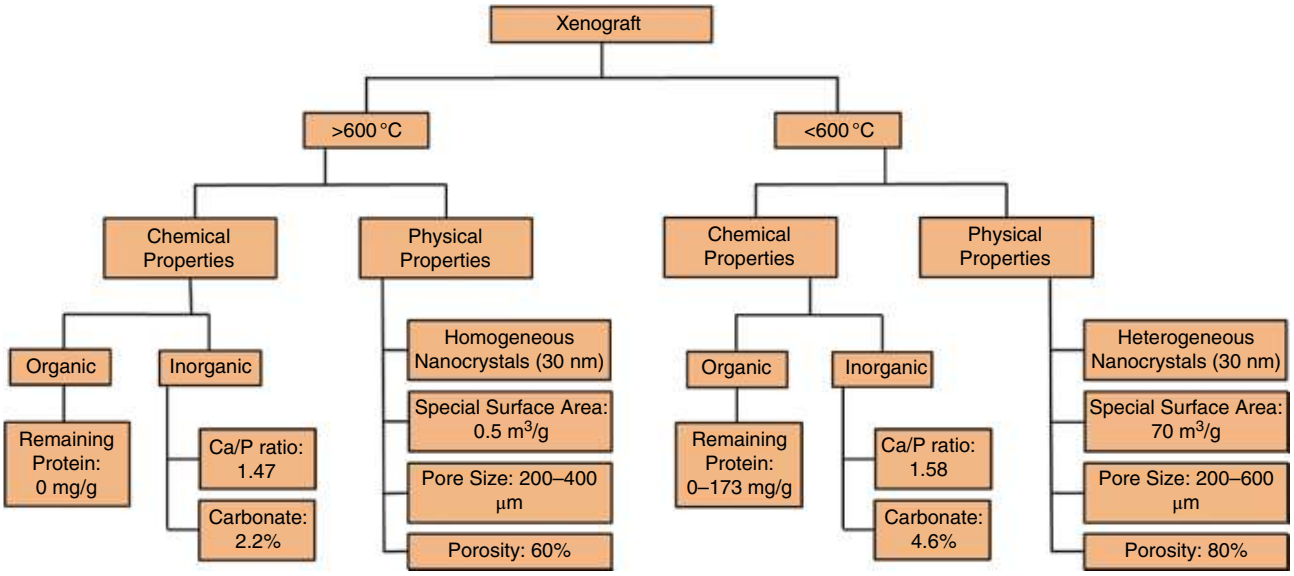

FIGURE 8.4 The characteristics of xenograft bone. Ca, calcium; P, phosphate.

Dentlearn.ir

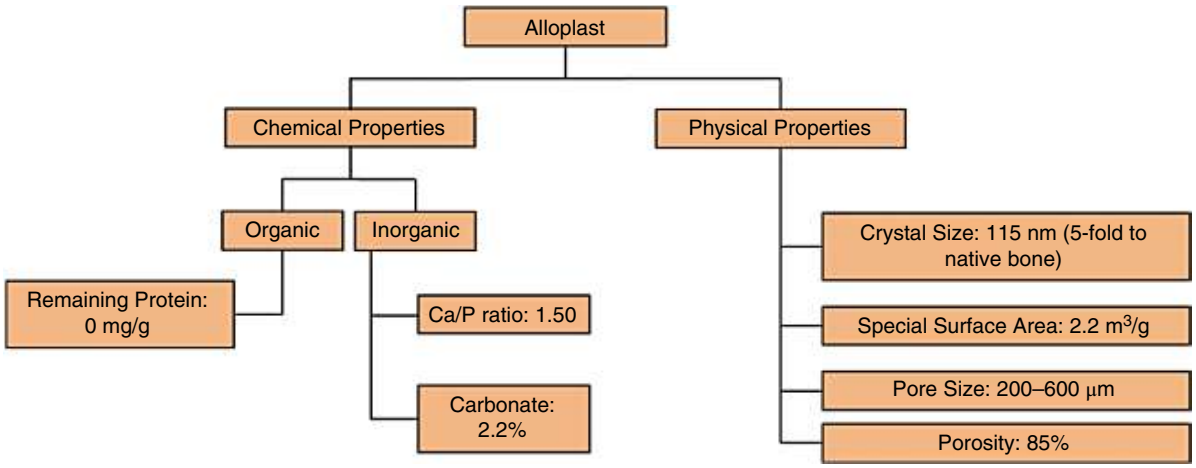

FIGURE 8.5 The characteristics of alloplasts. Ca, calcium; P, phosphate.

hydroxyapatite and its compositions with collagen, sulfated glycosaminoglycans such as keratin and chrondroitin sulfate. Moreover, these materials can be combined with auto- or allografts [5,10,78].

Their major advantages include their abundance, nonexistent risk of disease transmission, and low antigenicity. Alloplasts are mainly osteoconductive and lack the intrinsic potential for osteoinduction and osteogenesis. Hence, their application is mostly restricted to smaller and less challenging defects. Moreover, their osteoconductive ability is highly dependent on the material's resorption rate. Physiochemical properties of alloplastic materials are depicted in Figure 8.5.

CALCIUM PHOSPHATES

The calcium phosphate family has been reported to demonstrate both osteoconductive and osteointegrative characteristics. They have indicated an excellent record of biocompatibility, with no reports of systemic toxicity or foreign body reactions. Their clinical use was first established in the 1980s [5]. Regarding their chemical composition, calcium phosphates are categorized as HA, TCP, and their composites.

TRICALCIUM PHOSPHATE

TCP is a porous form of calcium phosphate. It has two crystallographic forms, α-TCP and β-TCP. The latter is the most commonly used TCP and is implemented as a partially resorbable filler that allows bone formation respective to its resorption rate. The literature states that TCP granules undergo fibrous encapsulation and may result in inadequate bone growth stimulation [2]. Variable results have been reported following vertical and horizontal ridge augmentation with α- and/or β-TCP [79]. β-TCP, in particular, is one of the earliest calcium phosphate materials used for bone augmentation. In 1920, Albee and Morrison reported improved bone union due to injection of β-TCP into the existing gap in a segmental bone defect [5]. It also facilitates adhesion, proliferation, migration, and phenotypic expression of the osteogenic cells, manifesting as apposition bone formation on the graft surface.

Despite the advantageous biological properties of β-TCP, like most calcium phosphates the material has poor mechanical durability and critically slow *in vivo* resorption rates [80]. This has resulted in limited application of β-TCP in aesthetically sensitive defects and areas. Additionally, β-TCP is brittle and performs weakly under tension and shear stresses. However, it shows notable resistance to compressive loads [81]. The resorption of β-TCP occurs via dissolution and fragmentation over a 6–18-month period [5]. However, even as it resorbs, the β-TCP graft is not equitably replaced, resulting in less bone volume formed to replace the β-TCP graft. β-TCP is available in both porous and intact forms, such as granules or blocks. The porous β-TCP resembles the compressive and tensile strength of the cancellous bone.

Of note is that alloplasts can be combined with stem cells and growth factors to enhance bone regeneration. Bastami et al. [81] demonstrated that a gelatin-coated TCP scaffold with the rhBMP-2 delivery system provides a mechanically and biologically compatible framework that supports cell viability and cell adhesion. It also serves as a osteoinductive material through providing a sustained release of rhBMP-2 for inducing osteogenic differentiation of human buccal fat pad–derived stem cells (hBFPSCs). Khojasteh et al. [82] have reported that 8 weeks after implantation of cell/PCL/TCP scaffolds in critical-sized defects, a higher amount of lamellar bone tissue was inspected at the histomorphometric analysis, compared to the control side (pure PCL/TCP). Also, Baghaban et al. [74] have shown that the percentage of newly formed

Dentlearn.ir

bone for cell-loaded HA/TCP scaffolds was 29.12±6.01%, compared to 23.55±4.99% with cell-free implants ($p < 0.05$). Furthermore, formation of lamellar mature bone was only inspected in cells/scaffold groups [74].

HYDROXYAPATITE

Hydroxyapatite ($Ca_{10}(PO_4)_6(OH)_2$) is the principal mineral of the bone, with osteoconductive and osteophilic properties; however, it lacks osteogenecity and osteoinduction. Synthetic HAs come in porous and solid (i.e. solid granules or blocks) ceramics or non-ceramics. The term "ceramic" denotes that the material has a highly crystalline structure following its sintering at temperatures between 700 °C and 1300 °C [83]. Ceramic HAs are resistant to *in vivo* resorption, whereas non-ceramic HAs are more readily resorbable. Synthetic HAs have demonstrated good compressive strength, although they perform weakly under tension and shear stresses [5, 84]. Solid forms of synthetic HAs are difficult to carve into different shapes, and possess a critically higher modulus of elasticity compared to bone. Moreover, they do not allow fibro-osseous ingrowth to take place.

The resorbability of HAs hinges on the temperature at which they are processed. Higher processing temperatures result in the production of dense, non-porous, and non-resorbable matrices with relatively larger crystal sizes [57]. Dense HA grafts are provided with osteoconductive and osteophilic properties and primarily act as biocompatible fillers. On the other hand, processing of HAs at low temperature leads to the fabrication of resorbable particulate or porous scaffolds. As mentioned earlier, this type of HAs is non-sintered (i.e. non-ceramic) and consists of 300–400 μm particles [85]. Non-sintered HAs are suggested to act as mineral reservoirs that encourage bone formation via osteoconduction.

The resorbability of synthetic HA depends on the temperature at which the material is prepared. For instance, when prepared at high temperatures, a non-resorbable, non-porous, dense HA-based material is achieved and applied as a filler. The granulate form of porous ceramics that are implanted into defects can result in osteogenic differentiation of seeded cells within the scaffold and extensive growth of connective tissue. For filling of voids, porous granular HAs can be used both alone or in combination with auto- and allografts.

CONCLUSION

Selection of bone substitute materials, with respect to the size of the defect, can result in significant augmentative outcomes that are, at times, comparable to the implantation of autogenous bone grafts. Considering the complications associated with autogenous grafting procedures, bone substitutes can be alternatives of value. The outcome of using bone graft materials prior to or simultaneous with implant insertion demonstrates that no significant difference in ultimate bone gain is reported with different graft materials. The literature concludes that non-autogenous bone grafts can become feasible alternatives to autografts, when chosen in accordance with the recipient's conditions. Aiming for improved decision-making regarding material selection for the effective treatment of large defects, standardized studies are required to determine the clinical efficacy and limitations associated with different graft types.

REFERENCES

1. Schropp L, Wenzel A, Kostopoulos L, Karring T. Bone healing and soft tissue contour changes following single-tooth extraction: A clinical and radiographic 12-month prospective study. *Int J Periodontics Restorative Dent.* 2003;23(4):313–23.
2. Sheikh Z, Sima C, Glogauer M. Bone replacement materials and techniques used for achieving vertical alveolar bone augmentation. *Materials.* 2015;8(6):2953–93.
3. Liu J, Kerns DG. Suppl 1: Mechanisms of guided bone regeneration: A review. *Open Dent J.* 2014;8:56.
4. Van der Weijden F, Dell'Acqua F, Slot DE. Alveolar bone dimensional changes of post-extraction sockets in humans: A systematic review. *J Clin Periodontol.* 2009;36(12):1048–58.
5. Dimova C, Evrosimovska B, Zlatanovska K, Zarkova J. Alveolar augmentation using different bone substitutes. In I Antoniac (ed.), *Handbook of bioceramics and biocomposites.* Cham: Springer; 2015. doi 10.1007/978-3-319-09230-0_51-1.
6. Bernstein S, Cooke J, Fotek P, Wang H-L. Vertical bone augmentation: Where are we now? *Implant Dent.* 2006;15(3):219–28.
7. Carlsson G, Thilander H, Hedegård B. Histologic changes in the upper alveolar process after extractions with or without insertion of an immediate full denture. *Acta Odontol Scand.* 1967;25(1):21–43.
8. Khojasteh A, Behnia H, Morad G et al. Healing of extraction sockets and augmented alveolar defects following 1-year treatment with bisphosphonate. *J Craniofacial Surg.* 2013;24(1):e68–e73.
9. Khojasteh A, Safiaghdam H, Farajpour H. Pedicled segmental rotation techniques for posterior mandible augmentation: A preliminary study. *Int J Oral Maxillofac Surg.* 2019;48(12):1584–93.
10. Khojasteh A, Behnia H, Hosseini FS et al. The effect of PCL-TCP scaffold loaded with mesenchymal stem cells on vertical bone augmentation in dog mandible: A preliminary report. *J Biomed Mat Res Part B: Appl Biomat.* 2013;101(5):848–54.
11. Yuce M, Adali E, Turk G et al. Three-dimensional bone grafting in dental implantology using autogenous bone ring transplant: Clinical outcomes of a one-stage technique. *Niger J Clin Pract.* 2019;22(7):977.
12. Chatelet M, Afota F, Savoldelli C. Review of bone graft and implant survival rate: A comparison between autogenous bone block versus

Dentlearn.ir

guided bone regeneration. *J Stomatol Oral Maxillofac Surg.* 2021;Apr 27;S2468-7855(21)00085-9.

13. Park YH, Choi SH, Cho KS, Lee JS. Dimensional alterations following vertical ridge augmentation using collagen membrane and three types of bone grafting materials: A retrospective observational study. *Clin Implant Dent Relat Res.* 2017;19(4):742–9.
14. Tal H, Artzi Z, Kolerman R et al. Augmentation and preservation of the alveolar process and alveolar ridge of bone. In H Tal (ed.), *Bone Regeneration*. London: IntechOpen; 2012, 139–84.
15. Tolstunov L. Surgical algorithm for alveolar bone augmentation dentistry in implant dentistry. Part I: Reconstruction. *Oral Maxillofac Surg Clin N A.* 2019;31(2):155–61.
16. Chiapasco M, Casentini P, Zaniboni M. Bone augmentation procedures in implant dentistry. *Int J Oral Maxillofac Implants.* 2009;24(suppl):237–59.
17. Herford AS, Stoffella E, Stanford CM. Bone grafts and bone substitute materials. In M Torabinejad, MA Sabeti, CJ Goodacre (eds.), *Principles and practice of single implant and restorations*. St. Louis, MO: Elsevier; 2014, 75–86.
18. Ramírez Fernández MP, Gehrke SA, Pérez Albacete Martinez C et al. SEM-EDX study of the degradation process of two xenograft materials used in sinus lift procedures. *Materials.* 2017;10(5):542.
19. Wood RA, Mealey BL. Histologic comparison of healing after tooth extraction with ridge preservation using mineralized versus demineralized freeze-dried bone allograft. *J Periodontol.* 2012;83(3):329–36.
20. Goto T, Kojima T, Iijima T et al. Resorption of synthetic porous hydroxyapatite and replacement by newly formed bone. *J Orthop Sci.* 2001;6(5):444–7.
21. Moy PK, Aghaloo T. Risk factors in bone augmentation procedures. *Periodontol* 2000. 2019;81(1):76–90.
22. Palmer RM, Howe LC, Palmer PJ. *Implants in clinical dentistry*. Boca Raton, FL: CRC Press; 2011.
23. Jensen SS, Terheyden H. *Bone augmentation procedures in localized defects in the alveolar ridge: Clinical results with different bone grafts and bone-substitute materials. In Database of Abstracts of Reviews of Effects (DARE): Quality-assessed reviews*. York: Centre for Reviews and Dissemination; 2009, https://www.ncbi.nlm.nih.gov/books/NBK77628.
24. Raghoebar GM, Batenburg RH, Vissink A, Reintsema H. Augmentation of localized defects of the anterior maxillary ridge with autogenous bone before insertion of implants. *J Oral Maxillofac Surg.* 1996;54(10):1180–85.
25. Shamsoddin E, Houshmand B, Golabgiran M. Biomaterial selection for bone augmentation in implant dentistry: A systematic review. *J Adv Pharm Technol Res.* 2019;10(2):46.
26. Yamada M, Egusa H. Current bone substitutes for implant dentistry. *J Prosthodont Res.* 2018;62(2):152–61.
27. Miron RJ, Gruber R, Hedbom E et al. Impact of bone harvesting techniques on cell viability and the release of growth factors of autografts. *Clin Implant Dent Relat Res.* 2013;15(4):481–9.
28. Atari M, Chatakun P, Ortiz O et al. Viability of maxillary bone harvesting by using different osteotomy techniques: A pilot study. *Histol Histopathol.* 2011;26(12):1575–83.
29. Guillaume B, Gaudin C, Georgeault S et al. Viability of osteocytes in bone autografts harvested for dental implantology. *Biomed Mat.* 2008;4(1):015012.
30. Kamijou T, Nakajima T, Ozawa H. Effects of osteocytes on osteoinduction in the autogenous rib graft in the rat mandible. *Bone.* 1994;15(6):629–37.
31. Clavero J, Lundgren S. Ramus or chin grafts for maxillary sinus inlay and local onlay augmentation: Comparison of donor site morbidity and complications. *Clin Implant Dent Relat Res.* 2003;5(3):154–60.
32. Dinçel YM. Bone graft types. In R Kummoona (ed.), *Bone grafting – recent advances with special references to cranio-maxillofacial surgery*. London: IntechOpen; 2018, doi 10.5772/intechopen.73956.
33. Roberts TT, Rosenbaum AJ. Bone grafts, bone substitutes and orthobiologics: The bridge between basic science and clinical advancements in fracture healing. *Organogenesis.* 2012;8(4):114–24.
34. Wang W, Yeung KWK. Bone grafts and biomaterials substitutes for bone defect repair: A review. *Bioact Mater.* 2017;2(4):224–47.
35. Miloro M, Larsen PE, Ghali GE, Waite P. *Peterson's principles of oral and maxillofacial surgery*, 2nd edn. London: BC Decker; 2004.
36. Titsinides S, Agrogiannis G, Karatzas T. Bone grafting materials in dentoalveolar reconstruction: A comprehensive review. *Jpn Dent Sci Rev.* 2019;55(1):26–32.
37. Hallman M, Thor A. Bone substitutes and growth factors as an alternative/complement to autogenous bone for grafting in implant dentistry. *Periodontol* 2000. 2008;47:172–92.
38. Kumar P, Vinitha B, Fathima G. Bone grafts in dentistry. *J Pharm Bioallied Sci.* 2013;5(suppl 1):S125–7.
39. Schwartz Z, Goldstein M, Raviv E et al. Clinical evaluation of demineralized bone allograft in a hyaluronic acid carrier for sinus lift augmentation in humans: A computed tomography and histomorphometric study. *Clin Oral Implants Res.* 2007;18(2):204–11.
40. Moest T, Frabschka J, Kesting MR et al. Osseous ingrowth in allogeneic bone blocks applied for vertical bone augmentation: A preclinical randomised controlled study. *Clin Oral Investig.* 2020;24(8):2867–79.
41. Nazirkar G, Singh S, Dole V, Nikam A. Effortless effort in bone regeneration: A review. *J Int Oral Health.* 2014;6(3):120–24.
42. Broumand V, Khojasteh A, Marshall Green J III. Vertical alveolar ridge augmentation with autogenous block grafts in implant dentistry. In L Tolstunov (ed.), *Vertical alveolar ridge augmentation in implant dentistry: A surgical manual*. Chichester: Wiley-Blackwell; 2016, 274.
43. Giannoudis PV, Dinopoulos H, Tsiridis E. Bone substitutes: An update. *Injury.* 2005;36(3):S20–S27.
44. Ehrler DM, Vaccaro AR. The use of allograft bone in lumbar spine surgery. *Clin Orthop Rel Res.* 2000;371:38–45.
45. Mellonig JT. Freeze-dried bone allografts in periodontal reconstructive surgery. *Dent Clin North Am.* 1991;35(3):505–20.
46. Al Ruhaimi KA. Bone graft substitutes: A comparative qualitative histologic review of current osteoconductive grafting materials. *Int J Oral Maxillofac Implants.* 2001;16(1):105–14.
47. Zhao R, Yang R, Cooper PR et al. Bone grafts and substitutes in dentistry: A review of current trends and developments. *Molecules.* 2021;26(10):3007.

Dentlearn.ir

48. Bormann N, Pruss A, Schmidmaier G, Wildemann B. in vitro testing of the osteoinductive potential of different bony allograft preparations. *Arch Orthop Trauma Surg.* 2010;130(1):143–9.
49. Sharmin F, O'Sullivan M, Malinowski S et al. Large scale segmental bone defect healing through the combined delivery of VEGF and BMP-2 from biofunctionalized cortical allografts. *J Biomed Mat Res Part B: Appl Biomat.* 2019;107(4):1002–10.
50. Shuang Y, Yizhen L, Zhang Y et al. in vitro characterization of an osteoinductive biphasic calcium phosphate in combination with recombinant BMP2. *BMC Oral Health.* 2017;17(1):1–10.
51. MeIIonig JT. Human histologic evaluation of a bovine-derived bone xenograft in the treatment of periodontal osseous defects. *Int J Periodontics Restorative Dent.* 2000;20(1):19–29.
52. Bolander ME, Balian G. The use of demineralized bone matrix in the repair of segmental defects: Augmentation with extracted matrix proteins and a comparison with autologous grafts. *J Bone Joint Surg.* 1986;68(8):1264–74.
53. Jergesen HE, Chua J, Kao RT, Kaban LB. Age effects on bone induction by demineralized bone powder. *Clin Orthop Relat Res.* 1991(268):253–9.
54. Dodson SA, Bernard GW, Kenney EB, Carranza FA. in vitro comparison of aged and young osteogenic and hemopoietic bone marrow stem cells and their derivative colonies. *J Periodontol.* 1996;67(3):184–96.
55. Naenni N, Lim HC, Papageorgiou SN, Hämmerle CH. Efficacy of lateral bone augmentation prior to implant placement: A systematic review and meta-analysis. *J Clin Periodontol.* 2019;46:287–306.
56. Schroeder JE, Mosheiff R. Tissue engineering approaches for bone repair: Concepts and evidence. *Injury.* 2011;42(6):609–13.
57. AlGhamdi AS, Shibly O, Ciancio SG. Osseous grafting part II: Xenografts and alloplasts for periodontal regeneration—a literature review. *J Int Acad Periodontol.* 2010;12(2):39–44.
58. Maiorana C, Santoro F, Rabagliati M, Salina S. Evaluation of the use of iliac cancellous bone and anorganic bovine bone in the reconstruction of the atrophic maxilla with titanium mesh: A clinical and histologic investigation. *Int J Oral Maxillofac Implants.* 2001;16(3):427–32.
59. Hämmerle CH, Chiantella GC, Karring T, Lang NP. The effect of a deproteinized bovine bone mineral on bone regeneration around titanium dental implants. *Clin Oral Implants Res.* 1998;9(3):151–62.
60. Guillemin G, Patat JL, Fournie J, Chetail M. The use of coral as a bone graft substitute. *J Biomed Mat Res.* 1987;21(5):557–67.
61. Yukna RA. Clinical evaluation of coralline calcium carbonate as a bone replacement graft material in human periodontal osseous defects. *J Periodontol.* 1994;65(2):177–85.
62. Aludden H, Mordenfeld A, Hallman M et al. Lateral ridge augmentation with Bio-Oss alone or Bio-Oss mixed with particulate autogenous bone graft: A systematic review. *Int J Oral Maxillofac Surg.* 2017;46(8):1030–38.
63. de Carvalho Moreira A, Silva JR, de Paula Samico R et al. Application of Bio-Oss in tissue regenerative treatment prior to implant installation: Literature review. *Braz Dent Sci.* 2019;22(2):147–54.
64. Urban IA, Ravidà A, Saleh MH et al. Long-term crestal bone changes in implants placed in augmented sinuses with minimal or moderate remaining alveolar bone: A 10-year retrospective case-series study. *Clin Oral Implants Res.* 2021;32(1):60–74.
65. Rodriguez AE, Nowzari H. The long-term risks and complications of bovine-derived xenografts: A case series. *J Ind Soc Periodontol.* 2019;23(5):487.
66. Kim Y, Rodriguez AE, Nowzari H. The risk of prion infection through bovine grafting materials. *Clin Implant Dent Relat Res.* 2016;18(6):1095–102.
67. Fan Y-P, Lu J-F, Xu A-T, He F-M. Physiochemical characterization and biological effect of anorganic bovine bone matrix and organic-containing bovine bone matrix in comparison with Bio-Oss in rabbits. *J Biomat Appl.* 2018;33(4):566–75.
68. Benke D, Olah A, Möhler H. Protein-chemical analysis of Bio-Oss bone substitute and evidence on its carbonate content. *Biomaterials.* 2001;22(9):1005–12.
69. Fujisawa K, Akita K, Fukuda N et al. Compositional and histological comparison of carbonate apatite fabricated by dissolution–precipitation reaction and Bio-Oss®. *J Mater Sci Mater Med.* 2018;29(8):121.
70. Lee DS, Pai Y, Chang S. Physicochemical characterization of InterOss® and Bio-Oss® anorganic bovine bone grafting material for oral surgery—a comparative study. *Mater Chem Phys.* 2014;146(1–2):99–104.
71. Herliansyah MK, Hamdi M, Ide-Ektessabi A et al. The influence of sintering temperature on the properties of compacted bovine hydroxyapatite. *Mater Sci Eng C.* 2009;29(5):1674–80.
72. Bran S, Baciut G, Baciut M et al. The opportunity of using alloplastic bone augmentation materials in the maxillofacial region—literature review. *Part Sci Technol.* 2019;37(8):916–26.
73. Khojasteh A, Fahimipour F, Eslaminejad MB et al. Development of PLGA-coated β-TCP scaffolds containing VEGF for bone tissue engineering. *Mat Sci Eng C.* 2016;69:780–88.
74. Baghaban EM, Mohammad J, Khojasteh A et al. in vivo bone formation by canine mesenchymal stem cells loaded onto HA/TCP scaffolds: Qualitative and quantitative analysis. *Cell J.* 2008;10(3):205–12.
75. Leventis M, Tsetsenekou E, Kalyvas D. Treatment of osseous defects after mandibular third molar removal with a resorbable alloplastic grafting material: A case series with 1- to 2-year follow-up. *Materials (Basel).* 2020;13(20):4688.
76. Fukuba S, Okada M, Nohara K, Iwata T. Alloplastic bone substitutes for periodontal and bone regeneration in dentistry: Current status and prospects. *Materials.* 2021;14(5):1096.
77. Prasadh S, Suresh S, Hong KL et al. Biomechanics of alloplastic mandible reconstruction using biomaterials: The effect of implant design on stress concentration influences choice of material. *J Mech Behav Biomed Mater.* 2020;1(103):103548.
78. Ghayor C, Bhattacharya I, Weber FE. The optimal microarchitecture of 3D-printed β-TCP bone substitutes for vertical bone augmentation differs from that for osteoconduction. *Mater Design.* 2021;1(204):109650.
79. Carrel JP, Wiskott A, Moussa M et al. A 3D printed TCP/HA structure as a new osteoconductive scaffold for vertical bone augmentation. *Clin Oral Implants Res.* 2016;27(1):55–62.
80. Bohner M, Santoni BLG, Döbelin N. β-tricalcium phosphate for bone substitution: Synthesis and properties. *Acta Biomater.* 2020;1(113):23–41.

Dentlearn.ir

81. Bastami F, Paknejad Z, Jafari M et al. Fabrication of a three-dimensional β-tricalcium-phosphate/gelatin containing chitosan-based nanoparticles for sustained release of bone morphogenetic protein-2: Implication for bone tissue engineering. *Mater Sci Eng C.* 2017;1(72):481–91.

82. Khojasteh A, Behnia H, Hosseini FS et al. The effect of PCL-TCP scaffold loaded with mesenchymal stem cells on vertical bone augmentation in dog mandible: A preliminary report. *J Biomed Mater Res B Appl Biomater.* 2013;101(5):848–54.

83. Muralithran G, Ramesh S. The effects of sintering temperature on the properties of hydroxyapatite. *Ceram.* 2000;26(2):221–30.

84. Dutta SR, Passi D, Singh P, Bhuibhar A. Ceramic and non-ceramic hydroxyapatite as a bone graft material: A brief review. *Ir J Med Sci.* 2015;184(1):101–6.

85. Wagner JR. Clinical and histological case study using resorbable hydroxylapatite for the repair of osseous defects prior to endosseous implant surgery. *J Oral Implantol.* 1989;15(3):186–92.

Dentlearn.ir

Guided Bone Regeneration for Extraction Sockets: Ridge Preservation

CHAPTER 9

Ridge preservation and ridge augmentation are two prevailing bone grafting strategies in implant dentistry. Ridge preservation (prophylactic treatment) is hard and soft tissue grafting procedures that intend to preserve the existing ridge volume *within* its bony envelope, and it is usually done at the time of tooth extraction, with the goal to minimize surrounding tissue loss after the tooth loss. Ridge augmentation (therapeutic approach) is hard and soft tissue grafting procedures that intend to increase (augment) the alveolar ridge volume *beyond* the existing deficient skeletal envelope, and it is usually performed at the edentulous state of horizontally, vertically, or volumetrically deficient alveolar ridges. This chapter will review the indications and surgical technique for grafting the socket at the time of extraction, the ridge preservation technique.

Dentlearn.ir

CHAPTER 9 Guided Bone Regeneration for Extraction Sockets: Ridge Preservation

Waldemar D. Polido

Indiana University School of Dentistry, Indianapolis, IN, USA

REVIEW OF THE LITERATURE

Bone and soft tissue loss are often unavoidable, even after atraumatic tooth extraction. Certain surgical steps then must be taken to prevent the tissue loss [1].

Timing for implant placement and bone graft after an extraction has been extensively discussed in the literature. According to Chen and Buser [2], recession of the mid-facial mucosa is a risk with immediate (type 1) placement in the esthetic zone, leading to less than optimal outcomes. In their systematic review, immediate implant placement was shown to be associated with a greater variability in outcomes and a higher frequency of recession greater than 1 mm of the mid-facial mucosa (eight studies; range 9–41% and median 26% of sites, 1–3 years after placement) compared to early (type 2 and type 3) implant placement (2 studies; no sites with recession >1 mm). In two retrospective studies of immediate implant placement with bone graft, the facial bone wall was not detectable on cone beam computed tomography (CBCT) in 36% and 57% of sites. These sites had more recession of the mid-facial mucosa compared to sites with detectable facial bone. Immediate implant placement also requires grafting of the gap between the implant and the buccal wall, with autogenous bone, bone substitute, and/or soft tissues, to achieve a better result [1]. An immediate provisional restoration, with an adequate contour, is also a key factor, as well as the perfect three-dimensional position of the implant, ideally performed in a flapless approach. Presence of soft tissue recession, infection, or lack of available bone to anchor the implant in the ideal restoratively driven position are also factors that need to be analyzed before the extraction, to consider immediate placement. Still, in the hands of experienced clinicians, and when all conditions are favorable, immediate implant placement is considered the preferred approach.

Buser and colleagues [3] have proposed an early approach, placing the implant 6–8 weeks after the extraction. This time allows for complete soft tissue healing after extraction, increasing soft tissue thickness, but accompanied by flattening of the alveolar bone in the most coronal portion of the socket. Then, with an open flap procedure, a perfect three-dimensional implant placement and simultaneous reconstruction of the alveolar volume can be achieved, by simultaneous contour augmentation using a guided bone regeneration (GBR) procedure with autogenous bone chips combined with a low-substitution bone filler and a resorbable collagen membrane. These procedures are necessary in most cases, especially to improve the horizontal dimension, since thin facial bone wall phenotypes have shown progressive vertical bone loss of 7.5 mm in the facial aspect after 8 weeks [1, 4]. Although this procedure has proven to have an excellent and stable outcome over time [5], it carries three important aspects: need for two separate procedures, need for an open flap, and need for a GBR reconstruction. These are procedures that require more time until the final restoration is placed. Also, they are more invasive and require a clinician with an expertise level able to manage advanced to complex situations. In cases where soft tissue recession and infection are present, but with enough remaining bone to stabilize the implant, an early approach allows for safe and ideal implant placement and reconstruction.

Both immediate and early implant placement require a similar condition: enough remaining alveolar bone that allows good primary stability of the implant that must be placed at a restoratively driven position. Both techniques also require a bone graft (or filler) to compensate for the alveolar bone remodeling that occurs after extraction and support the adjacent soft tissues.

Four important aspects distinguish differences for single and partially edentulous situations: implant placement, graft placement, soft tissue management, and implant loading.

Placing the implant with an open flap allows the clinician to visualize where the implant is going, whereas in a flapless approach it may be more difficult to achieve the ideal position and visualize where the implant is being anchored. Guided surgery and experience may improve outcomes. With an open flap (early) one can visualize exactly where the *graft needs to be placed*, use a larger amount of graft material, and visualize and secure a membrane, if needed. In an immediate

Essential Techniques of Alveolar Bone Augmentation in Implant Dentistry: A Surgical Manual, Second Edition. Edited by Len Tolstunov.
© 2023 John Wiley & Sons, Inc. Published 2023 by John Wiley & Sons, Inc.
Companion website: www.wiley.com/go/tolstunov/essential

Dentlearn.ir

and flapless approach, it is more difficult to place the graft (or fill the gap) and use a membrane. A larger graft can be utilized in an early approach, and complete closure is less difficult to obtain.

In an early approach, more *soft tissue* is formed, and therefore this technique is preferred in situations with soft tissue recession. Soft tissue thickness may be increased by making the incision more palatal and bringing the connective tissue being formed inside the socket to the buccal area [3]. Soft tissue substitutes can be more easily placed and stabilized. In an immediate placement with a flapless approach, it may be technically challenging and less predictable to increase the soft tissue thickness, if necessary. Immediate implant placement can be performed with an open flap approach, allowing for same visualization achieved with the early approach. However, in case of a need for complete (primary) closure, flap mobilization must be achieved, and this may lead to a non-optimal esthetic soft tissue profile due to mobilization of the buccal soft tissue that is brought coronally. This can compromise the attached gingival layer and depth of vestibule, and may require an additional and separate procedure to correct the soft tissue deficiency later.

In an immediate placement with a flapless approach, there are advantages if one can use a custom healing abutment or an immediate provisional, to preserve the original soft tissue contour before the extraction. If an early approach is used, an immediate provisional is not impossible, but it is not as well documented in the literature as the immediate placement approach [6]. *Loading* conditions have mostly to do with the primary stability of the implant, which can be achieved in both approaches, but also have a soft tissue component, once a provisional will support the soft tissues and seal the socket, protecting the graft placed [7].

However, when there is not adequate bone to stabilize the implant (apical available bone <5 mm) and/or the clinician does not want to risk an immediate placement, placing a bone graft into the socket after extraction to reduce alveolar bone remodeling and support the soft tissues may be the ideal approach. Cardaropoli and colleagues [8], in a recent classification, called this situation a class II post-extraction site (intact extraction with partially favorable anatomical conditions).

Alveolar ridge preservation is a technique that is aimed to minimize horizontal and vertical remodeling after tooth extraction. Recent studies indicate that with alveolar ridge preservation procedures, horizontal resorption of just over 1 mm will still occur with relative preservation of the vertical bone, whereas a lack of alveolar ridge preservation will generally result in more than 3 mm of horizontal loss and at least 1 mm or more of vertical loss [9]. Usually, implant surgery can be performed after 4–6 months, with results like those achieved with implants inserted in the native bone [10].

Compared to the immediate and early techniques, ridge preservation is an easier procedure that can be performed in a flapless approach in a consistent manner, even with less experienced clinicians. It helps to improve soft tissues, once it allows for a spontaneous closure, but also allowing for the use of soft tissue sealing using autogenous or xenograft materials [11]. As a disadvantage, it requires two separate procedures (one to extract the tooth and graft, and another to place the implant) and more time to heal (usually 4–6 months, depending on the material utilized and on how healing progresses). But in most instances, the implant site after healing can be treated as a healed ridge. A flap or flapless approach can be used, an additional soft tissue graft can be placed if indicated, and implants can be immediately loaded when placed. The *SAC Classification in Implant Dentistry* book and tool [12] highlights anatomical and clinical factors that must be observed in defining the best technique for a specific situation and serves as a checklist to assist the clinician.

SURGICAL TECHNIQUE

Planning for timing of implant placement and need for a graft, including an indication for socket preservation, is initiated when the decision to extract the tooth is planned. A CBCT scan taken prior to extraction is advised to assess the alveolar bone and the space occupied by the tooth. Adequate visualization of the future implant position is performed, and the surgeon needs to assess if an implant can be anchored in the ideal restoratively driven position in the remaining alveolar bone. Using segmentation tools in digital planning software, a virtual extraction can be performed, and visualization of the area's available bone and virtual positioning of the implant can be performed. A virtual wax-up can also be used to assess the ideal implant position.

If minimal or no bone is available apically and palatally to anchor the implant (<5 mm), a ridge preservation procedure is indicated.

Clinically, soft tissues need to be evaluated from the buccal and occlusal views. If recession is present, the decision must be also taken of whether a soft tissue graft is needed, with a socket sealing approach.

If an acute infection is present, antibiotics should be prescribed starting 3–4 days before the surgical procedure, for a total course of 7–10 days. Amoxicillin is the preferred indication for non-allergic patients. Pain control is usually achieved with non-steroidal anti-inflammatory drugs and/or acetaminophen 500 mg.

The procedure can be performed under local anesthesia, using the clinician's anesthetic of preference. We highly recommend wiping the gingival and teeth region using a gauze moistened with chlorhexidine gluconate 0.12%, just before the extraction. Plaque control should be done prior to the extraction and bone graft, to reduce the chances of contamination and loss of the graft.

Dentlearn.ir

The first surgical step involves a *minimally traumatic extraction*, using a flapless approach. There is no need for soft tissue reflection. A periotome can be used to section the periodontal ligament. Delicate instruments such as a periotome or a #1 or #3 SDI Luxator® (Directa, Upplands Väsby, Sweden) are utilized to luxate the tooth, to avoid any rotation and rupture of the buccal plate and adjacent soft tissues. Vertical extraction devices such as the Benex® (Benex-Dent, Lucerne, Switzerland) can also be used in single-rooted teeth if there are no vertical fractures. There is usually the need for sectioning teeth for an easier and less traumatic extraction, in a flapless manner, especially in multirooted teeth. The surgical handpiece of preference can be utilized. The author prefers a multiplier high-torque NSK contra-angle (Nakanishi Inc., Tochigi, Japan), adapted to the electric drilling equipment, with a 702 L bur. Small forceps, such as root tip forceps, special minimally invasive forceps, and even pediatric forceps, are used to finally extract the tooth.

After careful removal of the affected tooth, curettage and irrigation of the socket are performed to clean the region. Any granular tissue and/or existing periapical lesions are removed. *Probing of the buccal plate* is undertaken, to define the presence or absence of buccal alveolar bone. clinical and useful tip to define the *soft* tissue thickness is to use a periodontal probe inside the socket and check if it is visible under transparency through the soft tissues. If it is, a soft tissue graft may be indicated. If it is not, the soft tissue is usually thick enough.

In case of absent or extremely thin buccal bone (visualized also on a CBCT examination), we recommend the use of a resorbable non–cross-linked porcine-derived collagen membrane (BioGide®, Geistlich, Wolhusen, Switzerland) internally in the alveolar socket, with a "socket repair" technique, as suggested by Elian et al. [13]. The round part is left outside of the socket, to close over the resorbable biomaterial placed inside the socket. Then, a bone substitute (the authors prefer demineralized bovine bone mineral with 10% collagen; Bio-Oss® Collagen, Geistlich) is placed into the alveolar socket, wet with blood, to completely fill it. Packing the bone using an oval or round plugger is important, as leaving loose material inside the socket may not hold the volume adequately. The remaining (occlusal) part of the membrane is rotated to cover the occlusal opening and tucked underneath the palatal (lingual) gingiva.

When the buccal plate is present, like in posterior teeth or with minimal loss, there is normally no need to use a membrane. The socket is filled with the bone substitute and sealed. There is rarely a need to obtain primary closure. According to Horowitz et al. [9], there is no strong evidence that supports the use of a soft tissue graft or even of primary closure over the alveolar socket.

The socket may be sealed to protect the graft using different techniques, depending on the clinical situation. If a fixed provisional is placed, bonded, or cemented to adjacent teeth, the pontic must be prepared in an ovoid shape and light pressure applied on the extraction socket. A simple and low-cost collagen plug may be placed to protect the graft, especially in maxillary molars, where a figure-eight suture may also assist in holding the graft in place.

A soft tissue graft may be used as a socket sealing material, autogenous (usually harvested from the tuberosity) or a soft tissue substitute, with a specific design for sealing the socket.

The provisional is adapted, if any is used, which should avoid pressure on the grafted socket. After initial soft tissue healing, an ovoid pontic can progressively be used to start conditioning the tissue in the correct emergency profile of the future restoration, assisting in defining the implant position.

After a healing period of 5–6 months, a new CBCT is obtained, and bone volume and quality are assessed. In many situations a flapless implant placement can be performed, due to the excellent condition of bone and soft tissues. If an additional graft is needed, a flap is designed as per the clinician's preference. The implant is placed in the usual manner.

Occasionally a softer bone may be encountered, but this usually happens when a poor bone grafting material was used, material was not correctly packed into the socket, or the time from socket grafting to implant placement was too short.

CASE REPORTS

CASE 1

A 40-year-old male presents to the clinic with an esthetic concern. At the clinical examination, it was noticed that the left maxillary canine was missing and the first premolar had migrated mesially, occupying that space. There was mucosal recession, showing a dark root on the premolar. Additionally, all anterior teeth (maxillary canine to canine) needed new restorations (Figures 9.1 and 9.2).

After radiographic examination, it was concluded that the first premolar needed to be extracted. Consideration was

FIGURE 9.1 Initial clinical view, buccal. Note recession on left maxillary first premolar in place of a missing canine.

Dentlearn.ir

FIGURE 9.2 Close-up of clinical view, buccal, left maxillary first premolar.

given to an immediate implant placement, but the esthetic risk was high according to the esthetic risk assessment [12].

The decision was taken to do a flapless extraction and a ridge preservation procedure, to avoid significant bone loss and improve the soft tissue quality. After a complete esthetic smile design involving the adjacent teeth, an implant would be placed to replace the missing left maxillary canine.

The extraction was performed with the use of a periotome and an SDI Luxator #3. Care was taken not to disrupt the papillae on the mesial and distal of the premolar (Figures 9.3 and 9.4). Probing the socket immediately after extraction showed missing buccal plate, confirming the radiographic findings.

Materials selected for the ridge preservation procedure were a bone graft substitute (90% demineralized bovine bone matrix and 10% porcine collagen), a bilayer porcine collagen resorbable membrane, and a soft tissue substitute (porcine collagen) (Figure 9.5). The membrane was trimmed according to the technique described by Elian et al. [13], where one part is placed inside the socket on the buccal and a round portion stays out, to be folded over the graft material and seal the socket (Figures 9.6 and 9.7). The bilayer membrane prevents premature ingrowth of soft tissue, supporting bone and soft tissue regeneration.

FIGURE 9.3 Buccal view immediately after extraction.

FIGURE 9.4 Occlusal view immediately after extraction.

FIGURE 9.5 Materials utilized.

After careful placement of the membrane, the bone substitute graft was placed wet with blood, completely filling the socket (Figures 9.8 and 9.9). The remaining portion of the membrane was folded over the socket opening and tucked under the palatal mucosa, sealing the socket (Figure 9.10). The soft tissue substitute was then positioned over the membrane and sutured to the soft tissue margins, using a 5-0 Vicryl suture (Figures 9.11 and 9.12).

Five months after the procedure the socket was fully healed, with adequate soft tissue contours. A small concavity was noticed on the buccal aspect, due to excessive pressure of the provisional restoration during the healing phase (Figure 9.13).

The implant was placed and restored with a conventional loading protocol (3 months after placement). A good contour before placing the restoration can be noticed

Dentlearn.ir

FIGURE 9.6 Membrane trimmed and positioned under the periosteum on the buccal aspect. A round portion is left outside and will be folded over the graft, after its placement.

FIGURE 9.9 Occlusal view, graft material placed, and membrane open toward buccal.

FIGURE 9.7 Occlusal view, showing the membrane placed under the periosteum on the buccal, and socket prepared to receive the graft.

FIGURE 9.10 Occlusal view, membrane folded over socket entrance, tucked into palatal mucosa, protecting the graft material.

FIGURE 9.8 Bone graft material wet with blood, in a conical shape to fit the socket anatomy, ready to be placed inside socket.

FIGURE 9.11 Soft tissue substitute positioned to seal the socket.

Dentlearn.ir

FIGURE 9.12 Soft tissue substitute sutured over the socket with 5-0 Monocryl suture.

FIGURE 9.13 Clinical aspect 5 months after ridge preservation, at moment of implant placement.

(Figure 9.14). Final restorations were placed and an improved esthetic outcome was achieved (Figure 9.15).

CASE 2

A 38-year-old female patient presented with the chief complaint of mobility on the left maxillary central incisor. She also had multiple adjacent restorations, with deficient contour and poor esthetic outcome (Figures 9.16 and 9.17).

A CBCT showed a longitudinal fracture of the left maxillary central incisor, with a periapical radiolucency. A thin buccal plate was present, and there was not enough apical bone to anchor an immediate implant (Figure 9.18). Additionally, a complete esthetic assessment needed to be done before placing an implant to replace the left central incisor. According to the esthetic risk assessment, the risk was considered to be high. The decision to do a ridge preservation procedure was taken.

FIGURE 9.14 Clinical aspect 3 months after implant placement.

FIGURE 9.15 Final restorations placed.

FIGURE 9.16 Buccal view, showing esthetic imbalance on anterior teeth. Left maxillary central incisor is fractured and extraction is indicated.

Dentlearn.ir

FIGURE 9.17 Occlusal view, before extraction of left maxillary central incisor.

FIGURE 9.18 Cone beam computed tomography showing longitudinal fracture of left maxillary central incisor with a periapical radiolucency.

One of the disadvantages of a ridge preservation procedure is the long wait until a final implant-supported restoration can be delivered. Hence, all efforts must be made to create a stable provisional restoration to be used during the healing period, especially in the esthetic zone. Restorations on adjacent teeth were removed, new preparations were done, and a provisional restoration cemented on the right central incisor and on the left lateral incisor was constructed, preparing for the extraction of the left central incisor.

Extraction was performed under local anesthesia, using a periotome and an SDI #3 Luxator. Care was taken to be as untraumatic as possible, preserving the adjacent papillae (Figures 9.19 and 9.20). Probing the socket after extraction showed that there was an intact buccal plate with a thick soft

FIGURE 9.19 Occlusal view immediately after minimally traumatic extraction.

FIGURE 9.20 Buccal view immediately after extraction. Note adjacent teeth prepared to receive a cemented provisional.

tissue phenotype. Therefore there was no need to use a membrane on the buccal or a soft tissue graft.

A bone substitute grafting material (90% demineralized bovine bone matrix and 10% porcine collagen), wet with blood, was placed and packed inside the socket using a plugger (Figures 9.21–9.24).

The provisional restoration with a pontic prepared in an ovoid shape was delivered, applying light pressure, and sealing the socket after grafting (Figure 9.25).

Five months after healing, a flapless implant placement was planned, with a connective tissue graft to improve the buccal concavity, secondary to horizontal remodeling (Figure 9.26). CBCT showed excellent bone volume (Figure 9.27).

When performing ridge preservation procedures, an additional soft tissue graft may be indicated at the time of implant placement, to compensate for horizontal remodeling. Autogenous or soft tissue substitutes can be used for it.

The implant was placed under local anesthesia. After the implant placement in a flapless manner, through a punch incision, a small pocket was prepared on the buccal aspect, to create space for an autogenous soft tissue graft (Figure 9.28).

An autogenous connective tissue graft harvested from the tuberosity was trimmed, positioned in the buccal pouch subperiosteally, and sutured in place with 6-0 nylon sutures (Figure 9.29).

Since excellent primary stability was achieved, a customized healing abutment was utilized, to start shaping the

Dentlearn.ir

FIGURE 9.21 Grafting material wet with blood, ready to be placed.

FIGURE 9.22 Graft material being positioned into the socket.

FIGURE 9.23 Graft material being gently pushed into the socket with the use of a plugger/condenser instrument.

FIGURE 9.24 Occlusal view, graft material positioned and covered with collagen sponge.

FIGURE 9.25 Provisional restoration with a pontic prepared in an ovoid shape to apply light pressure and seal the socket after grafting.

FIGURE 9.26 Clinical aspect, occlusal view, 5 months after grafting, prior to implant placement.

Dentlearn.ir

FIGURE 9.27 Cone beam computed tomography showing complete healing of graft material, 5 months after grafting.

FIGURE 9.28 Connective tissue graft harvested from the tuberosity is sutured with a 5-0 nylon suture on the buccal aspect.

FIGURE 9.29 Occlusal intraoperative view of implant placement.

FIGURE 9.30 Occlusal view, immediately after implant placement and soft tissue graft, custom healing abutment.

soft tissue contour during healing (Figure 9.30). An implant-supported immediate provisional prosthesis could also have been an option, but since the patient already had a stable provisional, the decision was taken not to risk an immediate loading protocol, in favor of the most predictable conventional healing. Final restorations were delivered three months after implant placement, achieving an improved esthetic and functional outcome (Figure 9.31).

FIGURE 9.31 Final restorations, 3 months after implant placement.

DISCUSSION

The indication for a ridge preservation technique is broad. Even in cases where an immediate implant can be placed, the decision to graft the socket and wait, and place the implant in a second procedure, may be a viable and more predictable option. The longer healing time (4–5 months) prior to implant placement, plus 2–3 months for osseointegration, are disadvantages, as well as the lack of uniform healing. Some patients heal differently than others and each socket has a different anatomy, influencing the outcome. Choice of materials can also influence healing and final bone quality and volume [14].

The need to use a membrane has also been discussed. The larger the defect, the greater the need to use a membrane, even in a flapless technique [15]. Kalsi et al. [16], Al Yafi et al. [17], and Cardaropoli et al. [8] defined a clinical classification of

Dentlearn.ir

extraction sockets and proposed similar algorithms to define the surgical technique to be used with a particular defect.

Performing ridge preservation with a flapless technique seems to be the preferred technique by most authors. However, there is no clear evidence regarding a superior result with different bone graft materials, use of membranes, and use of a socket seal material [18, 19].

There may be a need for an additional bone and/or soft tissue augmentation procedure at the time of implant placement. However, in most instances an implant can be placed. One other consideration is that if a non-successful preservation of the alveolar volume happens, one still would have the chance for a simultaneous GBR procedure at the time of implant placement.

Another major advantage of a ridge preservation technique is to avoid a staged graft. When the tooth is extracted and there is no available bone for an immediate implant, if the socket is left to heal without any intervention significant bone resorption may occur, making it difficult to place an implant. A staged GBR or block graft can be indicated, leading to a more invasive procedure, more risks, more cost, and more time until the final restoration is delivered.

CONCLUSION

The ridge preservation technique is a relatively straightforward procedure, which can be safely performed by most trained clinicians, providing successful long-term outcomes [20]. Careful surgical technique and material selection are important aspects that can influence the outcome. It must be understood by both the clinician and the patient that the use of ridge preservation (socket grafting) delays implant placement from 3 to 6 months. At the same time, it usually brings a more predictable bone and soft tissue volume and improves the chances of an ideal implant placement.

ACKNOWLEDGMENTS

The author would like to acknowledge prosthodontists who restored the cases presented here: Case 1, Dr. Priscila Meneghetti, DDS, MS, from Brazil, currently a Clinical Instructor, Department of Biological and Materials Sciences & Prosthodontics, University of Michigan School of Dentistry; Case 2, Dr. Joao Emilio Roehe Neto, DDS, currently in private practice in Porto Alegre, Brazil.

REFERENCES

1. Araújo MG, Silva CO, Misawa M, Sukekava F. Alveolar socket healing: What can we learn? *Periodontol* 2000. 2015;68(1):122–34.
2. Chen S, Buser D. Esthetic outcomes following immediate and early implant placement in the anterior maxilla—a systematic review. *Int J Oral Maxillofac Implants.* 2014;29(suppl):186–215.
3. Buser D, Bornstein MM, Weber H-P et al. Early implant placement with simultaneous guided bone regeneration following single-tooth extraction in the esthetic zone: A cross-sectional, retrospective study in 45 subjects with a 2- to 4-year follow-up. *J Periodontol.* 2008;79(9):1773–81.
4. Chappuis V, Engel O, Reyes M et al. Ridge alterations post-extraction in the esthetic zone: A 3D analysis with CBCT. *J Dent Res.* 2013;92(12 suppl):195S–201S.
5. Buser D, Chappuis V, Bornstein MM et al. Long-term stability of contour augmentation with early implant placement following single tooth extraction in the esthetic zone: A prospective, cross-sectional study in 41 patients with a 5- to 9-year follow-up. *J Periodontol.* 2013;84(11):1517–27.
6. Gallucci GO, Hamilton A, Zhou W et al. Implant placement and loading protocols in partially edentulous patients: A systematic review. *Clin Oral Implan Res.* 2018;29(suppl 16): 106–34.
7. Finelle G, Lee SJ. Guided immediate implant placement with wound closure by computer-aided design/computer-assisted manufacture sealing socket abutment: Case report. *Int J Oral Maxillofac Implants.* 2017;32:e63–e67.
8. Cardaropoli D, Nevins M, Casentini P. A clinical classification system for the treatment of postextraction sites. *Int J Periodont Restorative Dent.* 2021;41(2):227–32.
9. Horowitz R, Holtzclaw D, Rosen PS. A review on alveolar ridge preservation following tooth extraction. *J Evid Based Dent Pract.* 2012;12(3):149–60.
10. Cardaropoli D, Tamagnone L, Roffredo A, Gaveglio L. Evaluation of dental implants placed in preserved and non-preserved postextraction ridges: A 12-month post loading study. *Int J Periodontics Restorative Dent.* 2015;35:677–85.
11. Jung RE, Ioannidis A, Hämmerle CHF, Thoma DS. Alveolar ridge preservation in the esthetic zone. *Periodontol* 2000. 2018;77(1):165–75.
12. Dawson A, Martin W, Polido W. *The SAC Classification in Implant Dentistry*, 2nd edn. Berlin: Quintessence; 2022.
13. Elian N, Cho S-C, Froum S et al. A simplified socket classification and repair technique. *Pract Proced Aesthet Dent.* 2007;19(2):99–104.
14. Yafi FA, Alchawaf B, Nelson K. What is the optimum for alveolar ridge preservation? *Dent Clin N Am.* 2019;63:399–418.
15. Faria-Almeida R, Astramskaite-Januseviciene I, Puisys A, Correia F. Extraction socket preservation with or without membranes, soft tissue influence on post extraction alveolar ridge preservation: A systematic review. *J Oral Maxillofac Res.* 2019;10(3):e5.

Dentlearn.ir

16. Kalsi AS, Kalsi JS, Bassi S. Alveolar ridge preservation: Why, when and how. *Brit Dent J.* 2019;227(4):264–74.

17. Al Yafi F, Alchawaf B, Nelson K. What is the optimum for alveolar ridge preservation? *Dent Clin N Am.* 2019;63(3):399–418.

18. MacBeth N, Trullenque-Eriksson A, Donos N, Mardas N. Hard and soft tissue changes following alveolar ridge preservation: A systematic review. *Clin Oral Implants Res.* 2017;28(8):982–1004.

19. Aribau-Gumà C, Jorba-García A, Sánchez-Torres A, Sànchez-Garcés MÀ. Alveolar ridge preservation: An overview of systematic reviews. *Int J Oral Maxillofac Surg.* 2022;51(2):234–42.

20. Roberto C, Paolo T, Giovanni C et al. Bone remodeling around implants placed after socket preservation: A 10-year retrospective radiological study. *Int J Implant Dent.* 2021;7:74.

Dentlearn.ir

Platelet-Rich Fibrin for Bone Augmentation in Implant Dentistry

CHAPTER 10

This chapter highlights the growing use of natural regenerative therapy with platelet-rich fibrin (PRF) and its use in bone augmentation procedures in implant dentistry. Today, PRF is one of the most frequently utilized growth factors in dentistry. It is easy to obtain, low cost, and readily available. Future research will continue studying natural regenerative strategies for clinical applications in bone regeneration and implant dentistry.

Dentlearn.ir

CHAPTER 10

Platelet-Rich Fibrin for Bone Augmentation in Implant Dentistry

Richard J. Miron[1] and Michael A. Pikos[2]

[1]*Department of Periodontology, School of Dental Medicine, University of Bern, Bern, Switzerland*

[2]*The Pikos Institute, Trinity, FL, USA*

Platelet concentrates have been utilized in medicine for over two decades owing to their ability to rapidly secrete autologous growth factors and ultimately speed wound healing. They have gained tremendous momentum as a regenerative agent derived from autologous sources capable of stimulating tissue regeneration in a number of medical fields [1–3]. Many years ago, it was proposed that by concentrating platelets utilizing a centrifugation device, growth factors derived from blood could be collected from a platelet-rich plasma layer, and later utilized in surgical sites to promote local wound healing [2, 3]. Today, it has been well established that platelet concentrates act as a potent mitogen capable of (Figure 10.1):

- Speeding the revascularization of tissues (angiogenesis).
- Acting as a potent recruitment agent of various cells, including stem cells.
- Inducing the prompt multiplication of various cell types found in the human body (proliferation).

Specifically in dentistry, platelet concentrates were introduced over 20 years ago by Marx and colleagues with the aim of concentrating blood proteins as a natural source of growth factors that would stimulate vascularization (angiogenesis) and tissue ingrowth, based on the fact that blood supply is pivotal for tissue regeneration of all tissues [4]. Wound healing has been described as a four-step process: hemostasis, inflammation, proliferation, and maturation [5–7].

THE EVOLUTION (HISTORY) OF PLATELET-RICH FIBRIN

It is interesting to point out that the use of platelet concentrates has slowly and gradually gained in popularity, with a dramatic increase being observed in the past 5–10 years (QR code 1; see Video 10.1). Platelet-rich plasma (PRP), as its name implies, was designed to accumulate platelets in supraphysiological doses within the plasma layer following centrifugation. The main aim of PRP was to isolate and further concentrate the highest quantify of platelets and their associated growth factors for regenerative purposes, and thereafter to re-implant this specialized supraconcentrate at sites of local injury [1].

SCAN ME

Initial protocols typically ranged in duration from 30 minutes to 1 hour, based on the centrifugation/collection systems and protocols utilized. Since lengthy protocols were utilized, anticoagulants were added to blood collection tubes. These typically were either various forms of concentrated bovine thrombin or calcium chloride.

Despite its growing success and continued use, several reported limitations existed with respect to reaching the full healing potential of PRP. Mainly, the use of anticoagulants was shown to limit wound healing from reaching its maximum potential. Simply put, when injury is created following an open wound, a blood clot is one of the first steps that occurs for healing to take place. Shortly thereafter, cells and growth factors get trapped within this newly formed extracellular matrix and the wound healing process/cascade begins. By limiting the body's ability to form a clot-stable tissue, wound healing is delayed. Several studies have now demonstrated the superior outcomes of PRF when compared to PRP simply by removing anticoagulants from their formulations [1].

Essential Techniques of Alveolar Bone Augmentation in Implant Dentistry: A Surgical Manual, Second Edition. Edited by Len Tolstunov.
© 2023 John Wiley & Sons, Inc. Published 2023 by John Wiley & Sons, Inc.
Companion website: www.wiley.com/go/tolstunov/essential

Dentlearn.ir

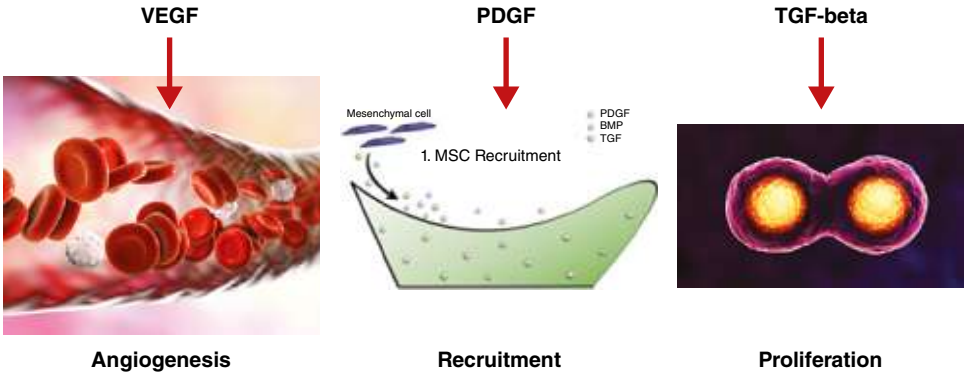

FIGURE 10.1 The three main growth factors that are released from platelet rich fibrin are vascular endothelial growth factor (VEGF), a known inducer of angiogenesis; platelet-derived growth factor (PDGF), a known inducer of cell recruitment; and transforming growth factor-beta1 (TGF-β1), a known stimulator of cell proliferation. *Source*: Kateryna_Kon and fusebulb / Adobe Stock.

Another drawback of PRP was the fact it remained liquid by nature (use of anticoagulants) and therefore when it was typically combined with biomaterials. PRP demonstrates a quick initial burst of growth factors being released, whereas PRF demonstrates a more slow and gradual release of growth factors over an extended period, which has since been shown to significantly improve cell growth and tissue regeneration [8, 9].

LEUKOCYTE AND PLATELET-RICH FIBRIN

Owing to the main drawback that the anticoagulants utilized in PRP prevented clotting, platelet-rich fibrin (PRF) was developed, with the main aim of simply removing anticoagulants [10]. In doing so, a much quicker working time was needed and the practitioner absolutely required centrifugation to begin shortly after blood draw (otherwise the blood would naturally clot). The main advantage of this fibrin matrix was the ability for it to release growth factors over an extended period of time while the fibrin clot was being degraded (as opposed to PRP, which remained in liquid form and had a much faster growth factor release profile) [11]. Over the years, PRF has also been termed L-PRF (for leukocyte and platelet-rich fibrin) owing to the discovery that several leukocytes remained incorporated in PRF.

Recently, a series of basic laboratory experiments revealed better means to optimize the production of PRF using horizontal centrifugation. Simply put, horizontal centrifuges are routinely utilized in high-end research laboratories as well as in medical hospitals owing to their greater ability to separate layers based on density (Figure 10.2). Unlike a fixed-angle centrifugation system where the tubes are inserted on a ~45-degree angle, horizontal centrifugation (often referred to as swing-out bucket centrifugation) can have the tubes swing out to 90 degrees once they are in rotation (QR code 2; see Video 10.2). This technology leads to up to four times greater cell content

FIGURE 10.2 Clinical photo of a Bio-PRF centrifuge demonstrating the horizontal centrifugation concept. When tubes are inserted vertically (up and down), once the device begins to rotate the tubes swing out completely horizontally. This favors better blood cell layer separation with higher platelet and growth factor concentrations. *Source*: Bio-PRF.

SCAN ME

Dentlearn.ir

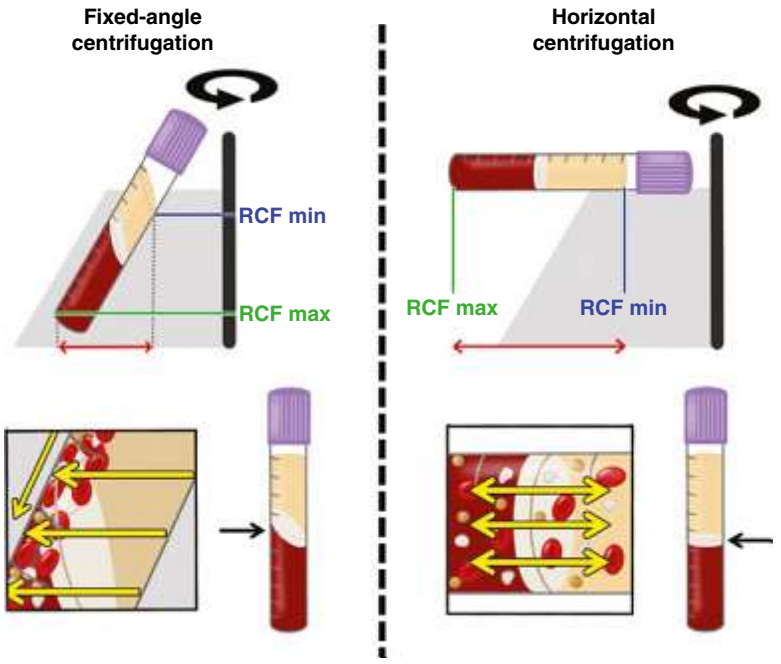

FIGURE 10.3 Illustrations comparing fixed-angle and horizontal centrifuges. With horizontal centrifugation, a greater separation of blood layers based on density is achieved owing to the greater difference in relative centrifugal force – RCF min and RCF max. Following centrifugation on fixed-angle centrifuges, blood layers do not separate evenly, and as a result an angled blood separation is observed. In contrast, horizontal centrifugation produces even separation. Owing to the large RCF values (~200–700 g), the cells are pushed toward the outside and downward. On a fixed-angle centrifuge, cells are pushed toward the back of centrifugation tubes and then downward/upward based on cell density. These g-forces produce additional shear stress on cells as they separate based on density along the back walls of centrifugation tubes. In contrast, horizontal centrifugation allows for the free movement of cells to separate into their appropriate layers based on density, enabling better cell separation as well as less trauma/shear stress on cells. Modified from Miron et al. 2019 [12].

when compared to fixed-angle centrifugation (Figure 10.3) [12]. The major disadvantage of fixed-angle centrifugation is that during the spin cycles, cells are typically driven along the back wall of centrifugation tubes at high g-forces, making them relatively difficult to separate properly according to their cell density. This also exposes cells to higher compressive forces against the back wall, and cells must then separate by traveling either up or down the inclined centrifugation slope based on their respective cell density differences. Since red blood cells are larger and heavier than platelets and leukocytes, they travel downward, whereas lighter platelets travel toward the top of the tube where PRF is collected. This makes it relatively difficult for the small cell types such as platelets and leukocytes to reach the upper level, especially given that red blood cells (RBCs) outnumber white blood cells (WBCs) by typically as much as 1000-fold. Therefore, and in summary, by utilizing a fixed-angle centrifuge it is not possible to reach an optimal accumulation of platelets or leukocytes as a result of the fixed-angle system design (QR code 3; see Video 10.3).

PROTOCOLS TO PRODUCE PLATELET-RICH FIBRIN VIA HORIZONTAL CENTRIFUGATION

In general, three protocols are necessary for basic PRF therapy (QR code 4; see Video 10.4). The first is the standard solid-PRF protocol to produce PRF membranes in which a high yield of platelets and leukocytes are harvested with an even distribution of cells within the upper 4–5 mL PRF layers. This is best achieved using a horizontal centrifugation system (700 relative centrifugal force [RCF] for 8 minutes). The second protocol is a liquid PRF formulation capable of concentrating platelets and leukocytes within the upper 1 mL layer (previously known as injectable-PRF or i-PRF). By utilizing a horizontal centrifugation system, higher concentrations are ensured (a smaller volume though a higher concentration of cells). This protocol is achieved utilizing a protocol of 300 RCF for 5 minutes. The final and third protocol is concentrated-PRF (C-PRF), where cells are purposefully accumulated specifically toward the buffy coat layer using faster spin protocols. This is best achieved using a protocol of 2000 RCF for

SCAN ME

SCAN ME

Dentlearn.ir

FIGURE 10.4 Three centrifugation protocols needed for the production of platelet-rich fibrin. *Source*: Quintessence Publishing Co., Inc.

8 minutes. The resulting 0.3–0.5 mL cell-rich zone may be collected exactly within the buffy coat (Figure 10.4).

In dentistry, most procedures are done utilizing the 700 RCF for 8 minutes protocol. Specific to guided bone regeneration (GBR), the "sticky bone" protocol utilizes this spin rate when both liquid PRF (blue or white) and solid-PRF (red) tubes are drawn simultaneously and centrifuged at the same time (Figure 10.5). Always remember to draw liquid PRF tubes first (QR Code 5; see Video 10.5).

SCAN ME

FIGURE 10.5 Clinical photo of a fabricated "sticky bone" by using particulate allograft mixed with solid-PRF (platelet-rich fibrin) fragments (cut up PRF membranes) with the addition of liquid-PRF. *Source*: Quintessence Publishing Co., Inc.

It is especially noteworthy that recently more patients are taking vitamins that delay clotting as a result of recommendations from the US Centers for Disease Control (CDC) to prevent COVID-related complications. For these patients, clotting of PRF is also delayed. For such patients, a protocol of 950 RCF for 12 minutes is recommended. It is also recommended to have patients avoid taking vitamins 24–72 hours prior to surgery, as clotting variability has been encountered.

CLINICAL USES OF PLATELET-RICH FIBRIN IN BONE AUGMENTATION

The aim of this chapter is to cover the use of PRF in bone augmentation procedures, including extraction site management, GBR procedures, and sinus grafting. It is noteworthy that an entire textbook has been written on this topic with chapters dedicated to each of these clinical indications [1]. Furthermore, several hundreds of articles have been gathered into systematic reviews with meta-analysis on each of these topics. A summary is provided here describing how PRF is utilized for the treatment of each of these areas to improve clinical outcomes.

USE OF PLATELET-RICH FIBRIN IN EXTRACTION SITE MANAGEMENT

In the United States alone, over 36 million people are completely edentulous and 120 million people are missing at least one tooth [13]. It is now well understood that following tooth loss, marked alterations in the dimensions of the bone–alveolar structure also occur [14, 15]. While numerous advancements and research articles over the years have attempted to preserve ridge dimensions following tooth loss, to date no single therapy has been shown to effectively/entirely preserve the ridge post extraction, with the majority of studies demonstrating a 2.0–2.5 mm reduction in the horizontal and/or 0.5–1.5 mm vertical directions following a 2–6-month healing period [1]. A great deal research utilizing bone grafts, different types of barrier membranes, as well as biological agents and growth factors is continuing to investigate the minimization of dimensional changes post extraction [1].

The most common biomaterial utilized to limit dimensional changes post extraction has been the use of a bone grafting (BG) material. Yet to date, many alternative strategies have been employed, either alone or in combination with BGs, with the aim of minimizing dimensional changes post extraction.

A recent systematic review with meta-analysis was conducted to investigate the use of PRF for alveolar ridge preservation after tooth extraction [16]. As a primary outcome, PRF was investigated for its ability to limit dimensional changes post extraction (i) when compared to natural wound healing; (ii) when compared to a BG; and (iii) when utilized in combination with a BG. Additionally, the effects of PRF on

Dentlearn.ir

soft tissue healing and patient report pain scores were assessed as secondary outcomes. In total, 16 RCTs [17–32] were incorporated, including 12 investigating the use of PRF versus natural wound healing, 4 investigating the use of PRF versus a BG material, as well as 3 studies (3 overlapping studies) investigating BG versus BG + PRF.

Platelet-Rich Fibrin versus Natural Wound Healing

In total, 12 studies have now reported the effects of PRF versus natural wound healing [17–28]. Hauser and coworkers were the first to show that PRF was capable of inducing new bone formation in extraction sockets when compared to controls [21]. Analysis by microcomputed tomography showed better bone healing with improvements in the microarchitecture in the group treated with PRF. It was also shown that PRF had a significant effect on intrinsic bone tissue quality and preservation of the alveolar width. Interestingly, an invasive surgical procedure with a mucosal flap appeared to completely neutralize the advantages of PRF [21]. For these reasons, it is strongly recommended to avoid raising flaps during routine tooth extraction, as others have also shown in similar studies.

Suttapreyasri and colleagues then demonstrated that PRF showed better early healing of soft tissue covering socket orifices in the first 4 weeks [24]. However, neither better alveolar ridge preservation nor enhanced bone formation in the PRF group was observed [24].

Temmerman and colleagues demonstrated that the use of PRF as a socket filling material to achieve preservation of horizontal and vertical ridge dimension at 3 months after tooth extraction is beneficial [25]. In that study, the ridge width at 1 mm below the crest was better maintained when PRF was utilized (23% loss) compared to control (52% loss) [25].

Du Toit and colleagues investigated histologically in a split-mouth human bone biopsy specimens from extraction sockets treated with PRF versus natural healing at 3 months [27]. At the time of implant placement, a trephined bone core was retrieved and processed for histological evaluation. The findings resulted in a 9.9%±5.9% gain in newly formed osteoid in the PRF group versus 4.0%±2.1% for specimens derived from the control sites. Due to the low sample size, this was not deemed significant ($p = .089$) [27].

Alzahrani and colleagues investigated the ridge width assessed using cast analysis with the help of acrylic stent and a pair of calipers [17]. Radiographic analysis of socket surface area was performed using graphics software at 1, 4, and 8 weeks. It was concluded that the mean residual bone fill was significantly higher in the PRF group compared to the control group at all time intervals [17].

Clark and colleagues found that the ridge height was significantly lower in the blood clot group (3.8±2.0 mm) compared to the PRF (1.8±2.1 mm) group ($p < 0.05$) [28]. Significantly more vital bone was also present in the PRF group [28].

Zhang and colleagues performed cone beam computed tomography (CBCT) and investigated alveolar ridge height, width, bone mineral density, and histomorphometry at 3 months [26]. Histological analysis of new bone formation confirmed that PRF increased the quality and enhanced the rate of bone formation, despite the effect of PRF not being significant in reducing alveolar bone resorption in the extraction socket alone [26].

Srinivas and colleagues investigated in a split-mouth study bone height and density using PRF versus natural wound healing [23]. Patients in the PRF group had a better healing index compared to without PRF and also showed comparable improvements in bone density [23].

Areewong and colleagues compared new bone formation using PRF versus normal healing via histomorphometric analysis [18]. It may be concluded that the use of PRF did not statistically significantly enhance new bone formation after tooth extraction compared to normal wound healing [18].

Canellas and colleagues performed CBCT immediately after tooth extraction and at 3 months after tooth extraction, prior to implant surgery, and compared bone density [19]. There was a higher percentage of new bone formation in the PRF group compared with the control group [19].

Furthermore, in total three studies investigated the effects of PRF on soft tissue healing compared to controls [20, 22, 25]. In each of these studies, PRF improved post-operative pain, promoted the soft tissue healing process, and reduced the early adverse effects of inflammation [20,22,25].

In summary, seven of ten studies showed a significant advantage of using PRF to either limit dimensional changes post extraction or improve new bone formation, with three of ten studies demonstrating no advantage. Furthermore, 100% of the studies showed some benefit for soft tissue wound healing.

Platelet-Rich Fibrin versus a Bone Grafting Material

A total of four randomized controlled trials (RCTs) have investigated the use of PRF versus a BG for extraction site management [28–31]. Das and colleagues investigated the use of PRF in comparison to beta-tricalcium phosphate with collagen (β-TCP-Cl) in preserving extraction sockets at 6 months [29]. It was found that the use of either autologous PRF or β-TCP-Cl was effective in socket preservation. It was reported that the results obtained from PRF were almost like β-TCP-Cl, though there was significantly greater vertical bone loss in the coronal one-third in the PRF group. Thus, it was concluded that the use of this synthetic bone graft was slightly superior to PRF [29].

Clark and colleagues performed one of the largest studies on the topic in which four groups –natural wound healing, PRF, freeze-dried bone allograft, and FDBA + PRF – were evaluated for vital bone formation and alveolar dimensional stability

Dentlearn.ir

during ridge preservation at 15 weeks [28]. It was concluded that significantly greater loss of ridge height was noted in the blood clot group (3.8±2.0 mm) compared to PRF (1.8±2.1 mm) [28]. The combination approach utilizing PRF and FDBA demonstrated the best ability to limit both horizontal and vertical bone dimensions post extraction [28].

In a study by de Angelis and colleagues, three groups were compared at 6 months: PRF, xenograft, and xenograft + PRF [30]. It was concluded that the PRF group experienced significantly greater horizontal and vertical bone resorption compared to the xenograft group, which demonstrated less vertical and horizontal bone resorption. Better post-operative pain and wound healing were observed in the PRF group [30].

Mendoza-Azpur and colleagues investigated β-TCP compared to PRF following 4 months of healing [31]. It was concluded once again that PRF accelerated wound healing in post-extraction sockets in terms of the new mineralized tissue component; however, the use of β-TCP biomaterial was superior at maintaining the bucco-lingual volume and the final position of the muco-gingival junction [31].

In conclusion, it was found that the use of a bone grafting material in three of four studies demonstrated a better ability to maintain ridge dimension compared to PRF alone, whereas PRF alone was better able to speed wound healing and mineralization toward bone (the bone graft is typically not fully resorbed yet and remains within the site at the time of analysis).

Bone Graft versus Bone Graft + Platelet-Rich Fibrin

In total, three RCTs investigated the use of BG versus BG + PRF [28,30,32]. A study by Thakkar and colleagues investigated *demineralized freeze-dried bone allograft* (DFDBA) with and without PRF for extraction site management at 3 and 6 months [32]. In conclusion, it was observed that the addition of PRF to DFDBA favored the maintenance of ridge width, though the improvements were not statistically significant among the groups [32].

In the study by Clark and colleagues [28], it was found that the ridge was better maintained with the PRF + freeze-dried bone allograft (FDBA) (1.0±2.3 mm) group compared to the FDBA alone group (1.8±2.1 mm). The addition of PRF to FDBA also favored significantly greater new vital bone [28].

In the previously reported study by de Angelis and colleagues [30], while the PRF group did experience significantly greater horizontal and vertical bone resorption compared to xenograft, the combination of BG + PRF demonstrated significantly less vertical and horizontal bone resorption than the xenograft alone group. PRF also reduced patient-reported post-operative pain [30].

In conclusion, two of three studies demonstrated significant advantages for the combination of BG + PRF, including its ability to further limit dimensional changes and/or improve new vital bone post extraction compared to BG alone.

Discussion on Using Platelet-Rich Fibrin for Extraction Site Management

Today, it is well known from various systematic reviews that on average, dimensional changes post extraction are in the 0.5–1.0 mm range when bone grafting materials are utilized [16]. Most RCTs investigating the use of PRF alone fall more frequently into the 1.0–2.5 mm range. Thus, even in well-conducted studies on the topic, PRF was shown to lead to a greater loss of the ridge compared to a BG, both when compared to previous systematic reviews as well in comparative RCTs. This important finding highlights the need for considering the use of a BG material for all extraction sockets, especially when the buccal and/or lingual plate is compromised.

Another important finding was that the reported clinical outcomes for utilizing PRF alone for alveolar ridge preservation demonstrated more pronounced and significant variability in reported clinical outcomes [16], with some studies even demonstrating no advantage at all. In light of these findings and in parallel with the considerable variations in patients (genetics, medication taken, etc.), clinicians should consider that not all sockets resorb equally, not all patients are genetically predisposed to resorb equally, and PRF may contribute to greater differences in ridge preservation/loss between sites and patients. For instance, a study by Chappuis et al. showed convincingly that facial bone thickness in the esthetic zone was a critical factor affecting dimensional changes post extraction [33]. These differences may be more pronounced when sites are grafted with PRF compared to BGs owing to their faster degradation rates (one of the limitations of PRF is that it typically resorbs within a 2-week period).

One noted benefit of socket grafting with PRF was the reported improvements in soft tissue wound healing in all studies. Together with previous findings from systematic reviews investigating the use of PRF during gingival recession coverage and periodontal regeneration [34–36], it becomes increasingly clear that PRF favors soft tissue healing. When it is utilized either in combination with BGs or as an outer PRF membrane to promote soft tissue healing, studies have now demonstrated that it led to faster rates of soft tissue healing, less post-operative reported patient pain, as well as fewer analgesics taken by patients.

Clinical Bottom Line: Use of Platelet-Rich Fibrin and Extraction Site Management

- The use of PRF alone has been shown to limit dimensional changes compared to natural healing.
- The use of a BG material has been more frequently shown to better limit dimensional changes compared to PRF.

Dentlearn.ir

When considering bone graft versus PRF, it is important to note that more horizontal bone loss will occur in the PRF alone group.

- The use of PRF in combination with a BG material has been shown to favor significantly more vital bone formation compared to BG alone. Thus, there may potentially be advantages of combining BGs with PRF, though data remains inconclusive.
- The use of PRF has been shown to favor better soft tissue healing when utilized as an outer barrier membrane with improvements in visual analog scale (VAS) scores, reported patient pain scores, as well as fewer analgesics taken.
- Several studies have now shown that PRF significantly lowers the rate of dry sockets and post-operative discomfort following third molar tooth extraction.

Clinical Procedure for Using Platelet-Rich Fibrin for Extraction Site Management

Based on the evidence from the literature, it is known that the use of PRF alone for extraction site management will limit the dimensional changes. Therefore, its use has been shown to better maintain ridge dimensions compared to natural healing. Typically for such procedures, compressed PRF plugs are formed and placed within the extraction site (not demonstrated here since it is not the gold standard). Ideally as many PRF plugs as possible are used. Following their incorporation into the extraction site, a typical cross-suture is utilized. PRF may be left exposed to the oral cavity without difficulty. Within a 3–4-month period, implant placement is then advised.

For extraction sites that are later planned to be treated with a dental implant, maximum ridge width maintenance is a primary objective. Data from a number of randomized clinical studies now points to the fact that the use of a BG material better maintains the dimensional stability of the ridge post extraction. Therefore, it is highly advised to use a BG material for such cases, with a bone allograft being the preferred choice [37]. In such cases, the use of PRF can be mixed with a bone allograft (Figure 10.6) in a "sticky bone"–type consistency. Thereafter, a PRF membrane that has been flatted can be utilized over the top of the extraction site to improve soft tissue healing.

PLATELET-RICH FIBRIN FOR GUIDED BONE REGENERATION

The concept of GBR and the use of barrier membranes were first introduced to the field of periodontology and implant dentistry roughly 30 years ago [38, 39]. These concepts were derived from the fact that different rates of cell growth and migration properties were observed between alveolar soft tissues compared to underlying hard tissues [38]. Thus, the concept originally attempted to hamper faster-growing non-functional epithelial cells from infiltrating into bone defects to allow for the unimpaired healing of slower-growing bone cells [40]. Over the years, a variety of additional parameters, including space maintenance, ability to form a blood clot, mechanical stabilization, cellular infiltration potential, biocompatibility, and resorption properties, have been investigated to achieve more favorable bone tissue healing [41].

Overall, GBR has seen extremely highly predictable results, with well-established and well-documented protocols leading to high implant survival rates of over 90% even 10 years post surgery [42]. One key concept described often in the literature is that sufficient primary wound closure is mandatory to prevent soft tissue ingrowth, bacterial contamination, early membrane degradation, soft tissue dehiscence, and potential graft exposure. This concept will be discussed with respect to PRF. A recent systematic review addressed this topic along with its use for sinus grafting, and is presented later in this chapter [43].

Clinical Evidence for Using Platelet-Rich Fibrin during Guided Bone Regeneration

Despite PRF being utilized for over two decades in clinical practice, to date only two RCTs have been performed investigating its use in GBR procedures. In both RCTs [44, 45] the authors investigated the impact of PRF in GBR procedures as a replacement option for collagen. No single study has yet compared the addition of PRF into a BG material in a comparative study (BG + PRF versus BG alone) and therefore it remains impossible to determine whether PRF influences new bone formation in GBR procedures.

In a study by Moussa et al., lateral augmentation was performed with bone blocks either covered with PRF or left uncovered [44]. There was a statistically significant increase in the bucco-palatal bone width in both groups measured by CBCT as well as the manual caliper, with no differences reported between the groups. The PRF group did however show statistically significantly lower mean graft resorption compared to the control group (PRF, 0.8±0.6 mm; control, 1.6±0.9 mm; $p = .006$) [44]. In a second study by Hartvel et al., a staged lateral ridge augmentation was performed with an autogenous bone block covered with either PRF or an absorbable collagen membrane [45]. A total of 27 partially edentulous patients (test $n = 14$, control $n = 13$) were included. CBCT assessment was performed prior to grafting and 2 weeks and 6 months after grafting. It was determined that no difference in mean bone volumetric loss was reported between the PRF group (14.7±8.9%), and the collagen membrane group (17.8±13.3%) at 6 months [45].

Discussion on Using Platelet-Rich Fibrin for Guided Bone Regeneration Procedures

The use of PRF has gained tremendous momentum as a low-cost biological scaffold capable of improving tissue healing.

Dentlearn.ir

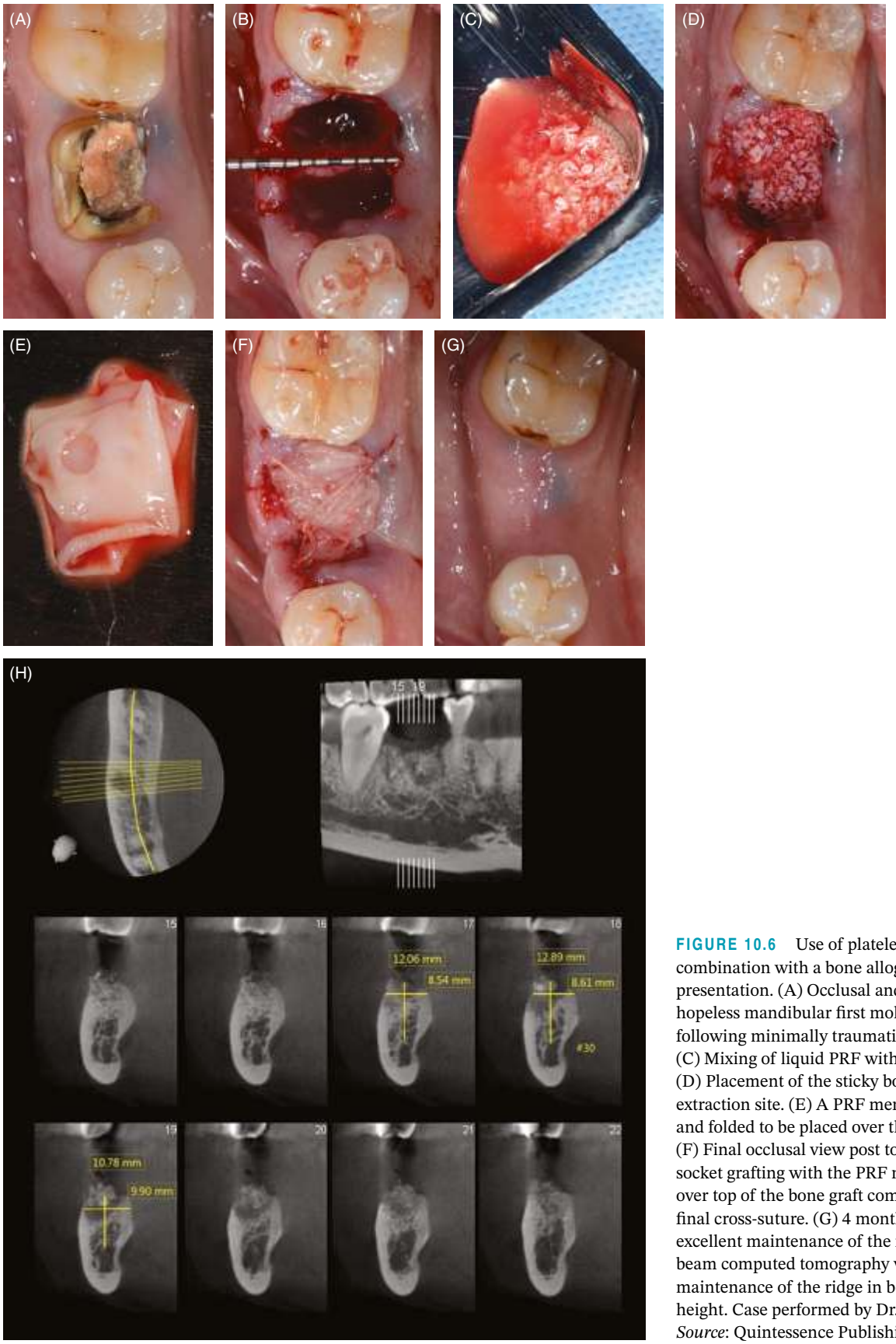

FIGURE 10.6 Use of platelet-rich fibrin (PRF) in combination with a bone allograft for ridge presentation. (A) Occlusal and buccal view of a hopeless mandibular first molar. (B) Occlusal view following minimally traumatic tooth extraction. (C) Mixing of liquid PRF with a bone allograft. (D) Placement of the sticky bone complex into the extraction site. (E) A PRF membrane was created and folded to be placed over the extraction socket. (F) Final occlusal view post tooth extraction and socket grafting with the PRF membrane placed over top of the bone graft complex followed by a final cross-suture. (G) 4 months post-op, note the excellent maintenance of the ridge. (H) Cone beam computed tomography visualization of the maintenance of the ridge in both width and height. Case performed by Dr. Alphonso Gil. *Source*: Quintessence Publishing Co., Inc.

Dentlearn.ir

However, to date limited data exists supporting additional bone growth when PRF is utilized in combination with BGs for GBR procedures and studies remain lacking. Overall, studies do demonstrate that use of PRF favors rapid angiogenesis of tissues, an area highly relevant to bone regeneration. Additionally, the handling properties of BGs may be improved when combining PRF with bone particles (sticky bone concept).

Studies to date have demonstrated clearly that PRF improves soft tissue wound healing, enhances gingival recession coverage, and promotes intrabony defect regeneration [36, 46–48]; however, limited data in comparison is available investigating its impact on bone formation during GBR procedures. Therefore, the use of PRF as a barrier membrane is hypothesized to contribute to soft tissue healing and/or regeneration in GBR procedures, yet no study to date has characterized its regenerative potential on bone formation in a well-conducted RCT. These missing studies are therefore crucial.

While initially PRF was utilized for a variety of biological procedures in dentistry, it became clear that its main effects on soft tissues led to the hypothesis that PRF could potentially serve as a barrier membrane in GBR procedures. It is now well understood that PRF can accomplish both soft tissue regeneration of overlaying tissue, protect the underlying bone tissues from incoming pathogens (due to its accumulation of host defense immune cells such as leukocytes), and facilitate angiogenesis to the underlying bone structure. For these reasons, PRF is typically utilized as an outer barrier membrane on top of either collagen or titanium membranes, and further combined with BG material particles to improve their handling, as reviewed in all presented cases. In this way, collagen barrier membranes are additionally protected from membrane exposure, leading to a potential reduction in the risk of infection. This is especially important in medically compromised patients (diabetes, smokers, immuno-compromised, advanced age, etc.).

Clinical Bottom Line: Using Platelet-Rich Fibrin during Guided Bone Regeneration

- Limited data in general exist from comparative RCTs evaluating PRF for GBR procedures. Therefore, at present it is not possible to substantiate the claim that PRF improves new bone formation owing to a lack of well-conducted studies.
- Animal studies, much like extraction socket management, demonstrate variability when evaluating new bone formation when PRF is combined with a BG material.
- PRF was shown to increase the early vascularization of bone tissues, important for new bone formation.
- When utilizing PRF as a barrier membrane, it should be applied *over* collagen barrier membranes in contact with soft tissues.

Clinical Procedure for Using Platelet-Rich Fibrin during Guided Bone Regeneration

Several important discussion points must first be considered prior to reviewing the surgical application of PRF during GBR procedures. First, PRF's advantage when combined with a BG material is mainly owing to its improved handling properties, as well as its ability to increase the vascularization of bony tissues. To date limited data exists on the topic demonstrating its ability to convincingly promote new bone formation.

It is also important to note that all cases utilize some form of barrier membrane (whether it be collagen or titanium) whether in order to exclude the faster-growing soft tissue from infiltrating the planned bone augmentation area or owing to its superior mechanical strength (titanium). PRF does not act to minimize soft tissue infiltration since it generally will be fully resorbed within 2–3 weeks and has extremely limited mechanical strength. Therefore, larger augmentation procedures (vertical augmentations) are typically achieved with either a titanium mesh or titanium-reinforced polytetrafluoroethylene (PTFE) membrane.

Figure 10.7 demonstrates a horizontal ridge augmentation procedure grafted with a combination of autogenous bone and a xenograft (Bio-Oss®, Geistlich Pharma, Wolhusen, Switzerland) mixed in a 1:1 ratio. Note in Figure 10.7C that a collagen barrier membrane was utilized with overlapping layers of PRF membranes (Figure 10.7D). Following 5 months of healing, note the excellent bone formation all around.

Figure 10.8 represents how both horizontal and vertical deficiencies in the anterior maxilla require substantial bone volume prior to implant placement. In this case, a titanium mesh membrane was utilized to favor the mechanical stability of the grafted area. The grafting procedure was performed using a combination of allograft and xenograft particulate bone with PRF. An accompanying Video 10.6 is provided demonstrating this grafted case using rhBMP-2 and PRF with a bone grafting material complex compared of allograft/xenograft for a large lingual and buccal bone deficiency in the anterior maxilla. Note the improvements in bone graft handling when PRF was incorporated into the bone graft complex (QR Code 6; see Video 10.7).

SCAN ME

Dentlearn.ir

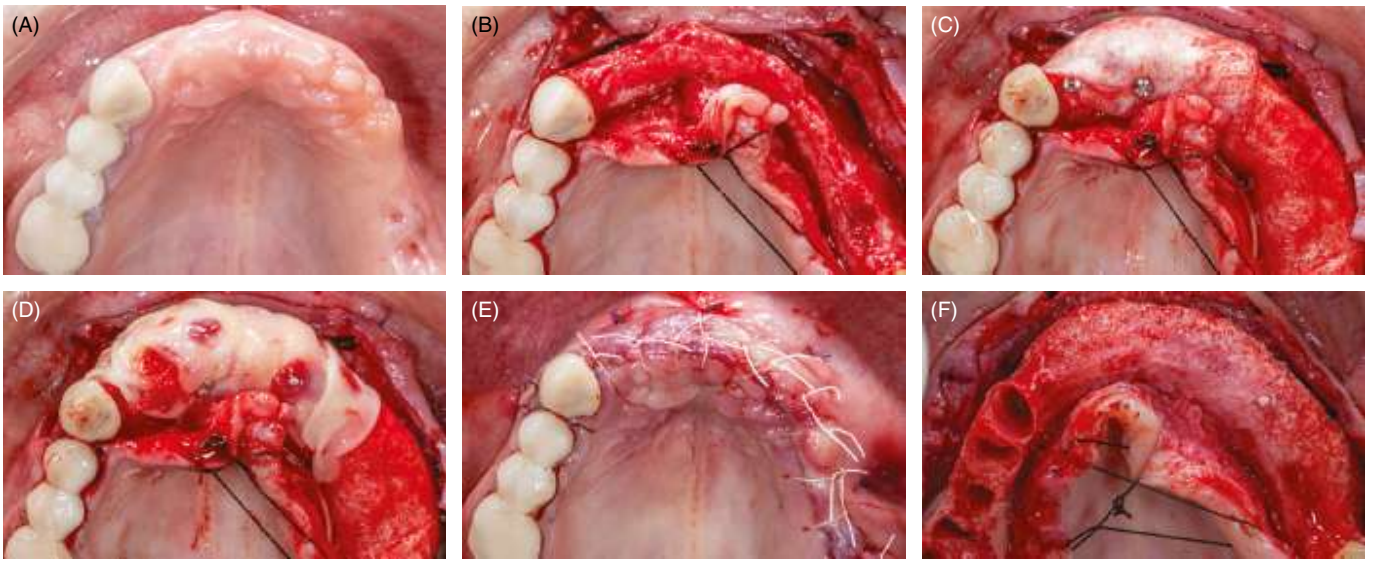

FIGURE 10.7 Case regenerated using autogenous bone with deproteinized bovine bone matrix (DBBM) and platelet-rich fibrin (PRF) viathe "sausage technique." (A) Occlusal view of a thin ridge extending about two-thirds of the maxillary arch in a systemically and periodontally healthy non-smoker female patient. (B) Occlusal view of the combined horizontal and sinus graft area. Autogenous bone chips were collected using bone scrapers and bone collector drills (Bonesier, Jeil Medical, Seoul, South Korea) and mixed with DBBM in a 40/60% mixture. A sticky composite bone was packed under the membrane. (C) Collagen membrane was fixed and stretched in place using multiple titanium pins. (D) Due to the extensive grafted area, only the anterior region of the graft was covered with three layers of PRF membranes. (E) Tension-free flap closure by blunt instruments and apical mattress sutures to minimize trauma to flap blood supply. (F) Occlusal view of the grafted area 5 months post-op. Case performed by Dr. Omid Moghaddas. *Source*: Quintessence Publishing Co., Inc.

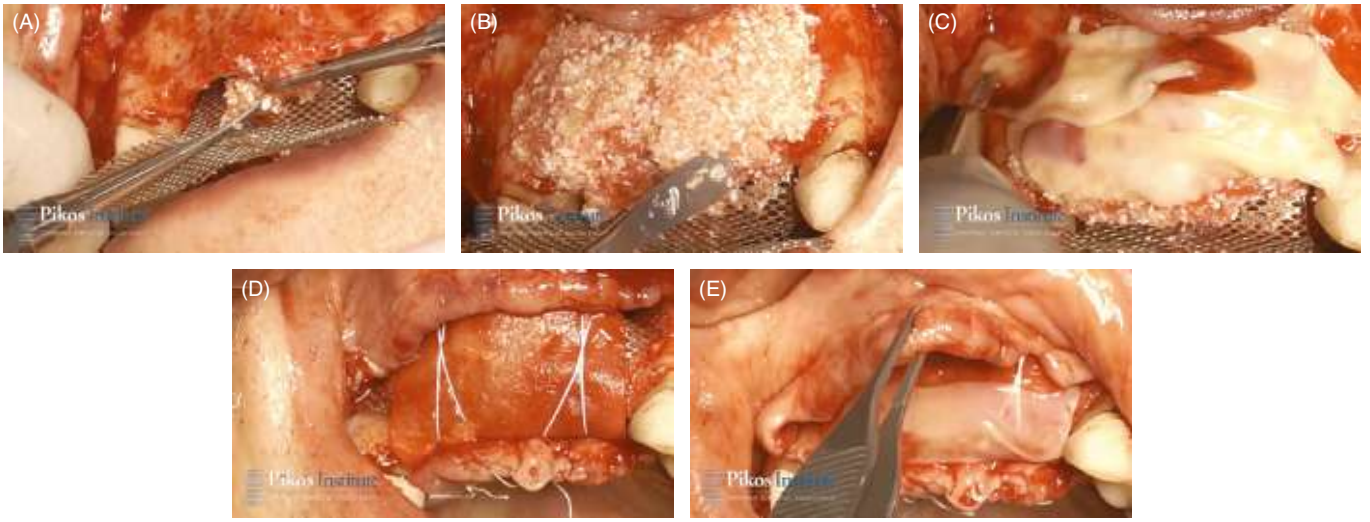

FIGURE 10.8 Large guided bone regeneration requiring both lingual and buccal bone regeneration. Clinical image demonstrating a bone grafting material complex composed of rhBMP-2, platelet-rich fibrin (PRF), bone allograft, and a xenograft grafting the (A) lingual and (B) buccal surfaces. (C) PRF membranes were then placed adjacent to the bony defect. (D) Following screw fixation of the titanium mesh, a collagen membrane was utilized to cover the titanium mesh and minimize the risk of mesh exposure followed by (E) coverage with PRF membranes. Case performed by Dr. Michael A Pikos (QR code 7; see Video 10.8).

Dentlearn.ir

PLATELET-RICH FIBRIN FOR SINUS GRAFTING PROCEDURES

It is well known that the edentulous maxillae demonstrate decreasing vascularity as bone resorption progresses [49]. As a result, bone augmentation procedures specifically in the sinus have generally been associated with longer healing times and higher failure rates [50–52]. Not only is the rate of new bone formation within the area slower (standard sinus augmentation protocols are nearly double [6–8 months] that of extraction site grafting [3–4 months], for instance), but generally higher infection rates and/or post-operative complications are observed [53, 54].

Due to the biological advantages of PRF, it has frequently been utilized for sinus augmentation procedures, both as a sole grafting material as well as in combination with bone grafts [55, 56]. While it is known that PRF alone can be utilized as a grafting material during sinus augmentation procedures with simultaneous implant placement, this section discusses the biological and dimensional properties of the sinus cavity to facilitate when and how to use PRF alone versus in combination with a BG material for sinus augmentation procedures.

Evaluation of Clinical Studies Using Platelet-Rich Fibrin as a Sole Grafting Material

In a total of 12 studies evaluating PRF in a case series [55,57–66], 10 studies evaluated PRF as a sole grafting material, whereas the studies by Meyer et al. [63] and Inchingolo et al. [59] evaluated the use of PRF in combination with ß-TCP and Bio-Oss, respectively (a case series with no controls). Of the remaining 10 studies, 5 studies investigated the use of PRF as a sole grafting material utilizing a crestal/osteotome approach, 3 studies utilized exclusively a lateral approach, and 2 studies utilized a combination of either a crestal or a lateral approach, depending on the clinical situation. In each of these studies, only PRF was utilized as a sole grafting material. Thus, it may be concluded that PRF may be utilized as a sole grafting material, with various success rates observed.

Key parameters discussed for utilizing PRF as a sole grafting material include the following:

- It is an absolute requirement that implant placement be performed simultaneously. This is because the use of an implant by itself will act as a space creator (i.e. tenting) to provide needed space for bone ingrowth. Thus far, studies have supported the notion that implants can be placed alone, with no use of biomaterials or PRF, if a stable blood clot is formed around the implant surface. New bone formation will then follow.
- While several authors have demonstrated that PRF alone may be utilized to promote sinus grafting with vertical bone height gain, with bone gains sometimes being more than 7.5 mm from the sinus floor to the surrounding bone at the apex of the implant, such cases were typically limited to bone increases ranging in height from 3 to 4 mm, as well as results that particularly favored narrower sinuses, as discussed later in this chapter. Thus, in wider sinuses and sinuses requiring greater bone gain, a BG material is favored.

Evaluation of Clinical Studies Using Platelet-Rich Fibrin in Combination with a Bone Graft

More commonly, PRF has been utilized with a BG material using the sticky bone concept for improved clinical handling, as well as to obtain the many advantages that PRF possesses. A recent systematic review compared the use of BG material alone versus in combination with PRF for sinus augmentation procedures [56,67–75]. In total ten clinical trials were investigated, with seven studies investigating the use of a bone graft with/without PRF [56,67,69,72–75], two studies evaluating the use of PRF as a membrane for lateral wall closure [68, 70], and one study evaluating the use of PRF in early pain management and post-operative swelling [71].

Of the seven studies evaluating bone formation, five studies demonstrated no significant improvement in bone formation as evaluated histologically when PRF was added to a bone grafting material [67,69,72,74,75], with two studies demonstrating favorable results with respect to being capable of placing implants earlier in PRF-grafted sites (with BGs) [56, 73].

Platelet-Rich Fibrin as a Sole Material for the Repair of Schneiderian Membrane Perforations

Another frequent use of PRF has been for the repair of Schneiderian membrane perforations (Figure 10.9). While major advancements have been made with respect to surgical techniques, tools, and instruments to decrease the rate of membrane perforation, typical frequencies of tears have generally been reported in the 20% range [76, 77]. While over the years absorbable collagen membranes have most commonly been utilized, more recently attempts have been made to cover perforations with PRF (Figure 10.9). Owing to the general "sticky" consistency of PRF, this 100% natural fibrin scaffold may be utilized as a low-cost replacement to standard collagen

Dentlearn.ir

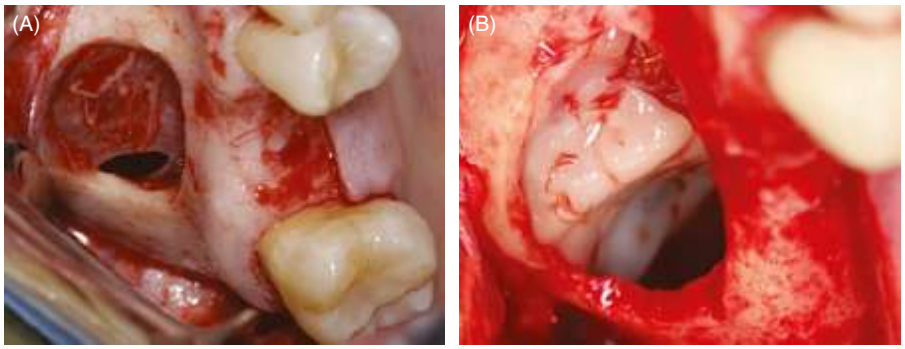

FIGURE 10.9 (A) Small Schneiderian membrane perforation during a standard lateral approach. (B) Schneiderian membrane tear covered with a platelet-rich fibrin membrane. *Source*: Quintessence Publishing Co., Inc.

membranes. Considering its natural properties, it is known that PRF, unlike a collagen barrier membrane, will not induce a foreign-body reaction.

Figure 10.9 demonstrates a small tear that was covered with PRF alone. A recent consensus report recommended that tears larger than 5 mm be treated with a standard approach utilizing a collagen membrane [37, 52]. Nevertheless, the advantage of utilizing PRF for perforations smaller than or equal to 5 mm in diameter is that the reparative process may take place with better handling properties owing to the sticky consistency of PRF without potentially inducing a foreign-body reaction. As a rule of thumb, multiple layers may be utilized for larger tears, at relatively no additional cost. It is noteworthy that resorption periods are typically 10–14 days and for this reason it is advised to utilize PRF in a double layer to assure complete coverage. Larger tears greater than 5 mm should be covered with a collagen membrane.

Clinical Bottom Line: Platelet-Rich Fibrin in Sinus Grafting Procedures

- PRF has been utilized as a sole grafting material in nearly a dozen studies. While favorable results have been observed, it is generally recommended to favor this approach for narrow sinuses and/or those requiring small (3–4 mm) sinus bumps.
- PRF has more commonly been utilized in combination with a BG material. In such cases, it has generally only been demonstrated that PRF may favor slightly shorter healing periods prior to implant placement, with no significant advantages in new bone formation compared to bone graft alone.
- PRF may also have been utilized to cover the lateral window. In both controlled studies, implant stability quotient (ISQ) values were equivalent between sites grafted with PRF versus a collagen barrier membrane.
- PRF has also been utilized to repair Schneiderian membrane perforations. Results from a recent consensus report generally recommended its use in smaller tears (limited to 5 mm or less), with larger tears being more favorably covered with a collagen barrier membrane.
- PRF has also been demonstrated in one clinical study to favor a significant reduction in patient-reported postoperative pain and swelling. This is likely owing to improvements in soft tissue wound healing/closure following grafting procedures when placed in contact with soft tissues.

Clinical Procedure for Utilizing Platelet-Rich Fibrin in Sinus Grafting

Based on the above-mentioned conclusions, sinus grafting procedures are generally performed combining BG materials with PRF. The following clinical procedure and recommendations are a small excerpt from a recent textbook detailing sinus grafting procedures [37].

Briefly, the role of bone allografts is generally to provide a more osteoinductive bone graft with the ability to facilitate bone formation, while the xenograft is typically utilized owing to its space-maintenance ability (generally considerable nonresorbable). For these reasons, bone allografts are mixed with xenografts in a 1:1 ratio for sinus grafting procedures in order to take advantage of both grafting properties [37]. To this, a few PRF membranes are cut into PRF fragments and mixed with the BG complex. Thereafter, the grafting material is coated with liquid PRF to create "sticky bone."

When a lateral approach is performed, typically hand instruments and/or a Piezo surgery device are utilized to create the lateral window and minimize trauma to the Schneiderian membrane (Figure 10.10; see Video 10.9). Following its reflection, two PRF membranes may be introduced into the sinus to minimize potential Schneiderian membrane damage during/following grafting. Alternatively, a small collagen membrane may also be utilized. When larger or complete tears/perforations are encountered, a large collagen barrier membrane is recommended, with external fixation when needed. For further clinical protocols, the reader is encouraged to view the detailed protocols in a recent textbook on the topic [37].

Dentlearn.ir

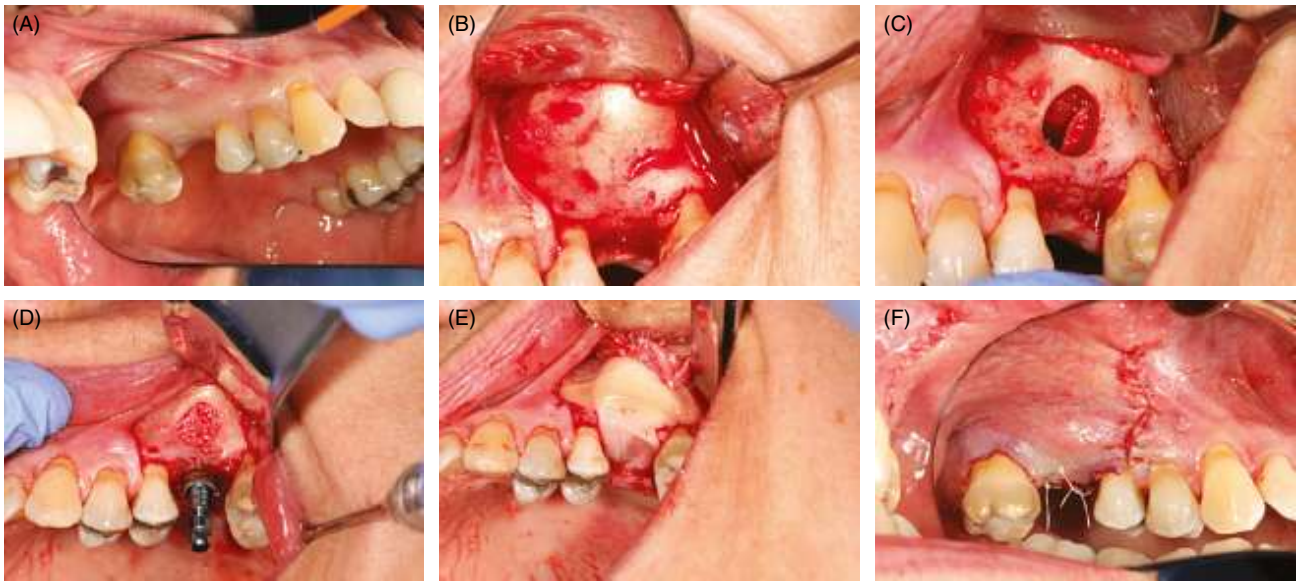

FIGURE 10.10 Lateral sinus floor elevation and platelet-rich fibrin (PRF) membrane with implant placement. (A) Facial view of the area of the upper left first molar. (B) Full-thickness flap has been elevated showing the area where the lateral window will be prepared. (C, D) Sinus floor elevation is completed, osteotomy has been prepared, and upper left first molar implant has been placed. (E) Collagen membrane has been positioned over the lateral window access and multiple PRF membranes positioned over the underlying defect. (F) Surgical wound sutured with PTFE monofilament sutures in the edentulous area and vertical releasing incisions closed with chronic gut sutures. Case performed by Dr. Michael A Pikos. *Source*: Quintessence Publishing Co., Inc.

Once the Schneiderian membrane is covered with PRF/collagen membrane, the sticky bone may then be entered within the sinus cavity. The general sticky consistency favors graft material handling and placement. At this stage, it is generally recommended to ascertain that all bony walls are covered with grafting particles and moderately condensed. Simultaneous implant placement may also be performed at this time, with the osteotomy created prior to BG material placement into the sinus. In such cases, protocols typically follow the following sequence:

1. Lateral window creation and Schneiderian membrane elevation.
2. Implant osteotomy preparation.
3. Placement of the BG material complex into the sinus.
4. Implant placement.
5. Final grafting around the implant.
6. Soft tissue closure with PRF membrane use (Figure 10.10, QR Code 8; see Video 10.10) [37].

If implant placement is done prior to bone grafting, it is generally much more difficult to enter the grafting material in and around the implant within the sinus cavity, with potentially voided/non-grafted areas.

ADVANTAGES OF THE USE OF PLATELET-RICH FIBRIN

- It favors better BG material handling.
- It often requires less BG material, since several PRF membranes/fragments are utilized to hold volume (thereby slightly lowering grafting material costs).
- It may facilitate earlier implant placement compared to bone grafted sites alone, as demonstrated in two controlled studies (though no long-term bone gain has been shown).
- It may be utilized to further support better soft tissue healing at incision lines as well as around implant healing sites.
- It reduces pain and swelling post grafting, as demonstrated in one controlled clinical study.

Dentlearn.ir

DISCUSSION AND FUTURE RESEARCH

Regeneration of a pneumatized sinus following tooth loss is a frequently performed surgical procedure requiring longer treatment healing times and higher potential complication rates compared to other grafting procedures such as extraction sites. As a result, the use of PRF has been increasingly popular to speed angiogenesis to the defective tissues and favor improve soft tissue healing. The purpose of this chapter was not to discuss the surgical concepts for sinus augmentation procedures (e.g. when to perform a sinus augmentation immediately versus utilizing a delayed approach, or when to utilize a lateral window versus crestal approach for sinus augmentation procedures). Discussion of these surgical topics and regenerative approaches is extensive and they are covered in much greater depth elsewhere in this textbook. Instead, the focus of this chapter was to highlight when, where, and how to utilize PRF in the above-mentioned clinical scenarios, either alone or in combination with a BG material or barrier membrane. A flow chart is provided in Figure 10.11, which is covered in much greater detail in a previous study by the authors [52].

When a delayed approach for implant placement is necessary, PRF should be combined with a BG material due to the fast resorption time of PRF scaffolds. PRF should not be utilized alone without a BG material or an implant. When implant placement is performed simultaneously with sinus augmentation, the factor most predictive of when to utilize PRF alone versus in combination with a BG material is the bucco-palatal width of the sinus cavity. When sinuses are larger than 10 mm, it is generally recommended to combine PRF with a BG material, while for narrower sinuses (10 mm or less), PRF may be utilized predictably as a sole grafting material. Similarly, when a perforation of the sinus is encountered, PRF may be utilized alone when the Schneiderian membrane tear is considered small (5 mm or less), whereas a collagen barrier membrane is more often recommended when perforations are larger.

Similarly, PRF may be utilized following a crestal sinus grafting procedure, especially when no grafting material is envisioned, simply to minimize potential damage to the Schneiderian membrane. Interestingly and as reviewed in this chapter, PRF has been shown to reduce post-operative pain

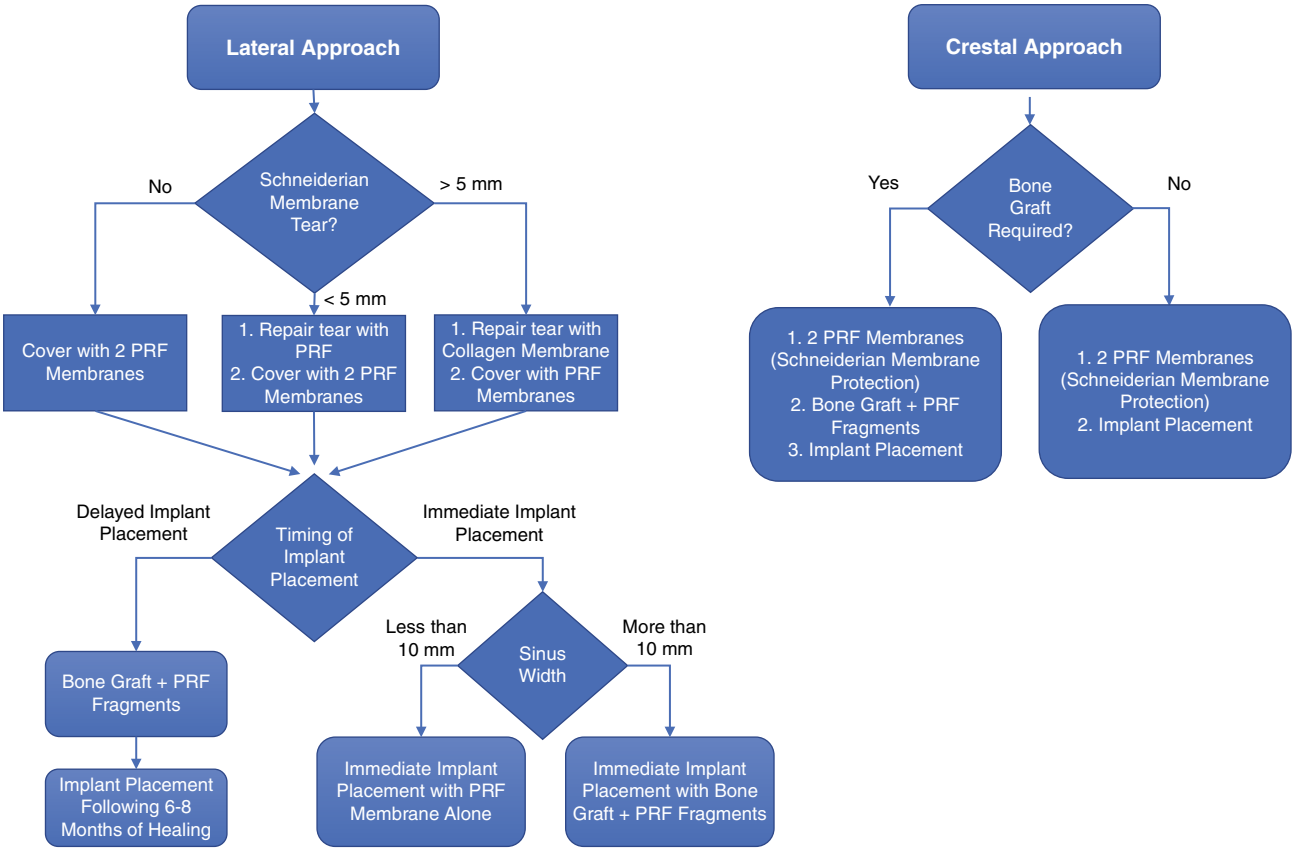

FIGURE 10.11 Decision-making flow chart describing the use of platelet-rich fibrin (PRF) for either a lateral or crestal sinus augmentation procedure.

Dentlearn.ir

and lower infections of third molars by threefold owing to the antimicrobial qualities of the leukocytes present in PRF that can defend the wound site against infection and regulate the healing process [78, 79]. This may be one of the reasons why patients report less post-operative pain/swelling, not only in the study reported in bone grafting but also in other procedures such as gingival grafting or palatal graft harvesting, as well as post extraction. It remains relatively unknown to what extent supraphysiological doses of leukocytes may favor lower infection rates in sinus grafting procedures, as this topic has never been addressed in a large clinical study.

One area that has gained recent awareness in the clinical research community is the ability to extend the resorption properties of PRF by utilizing a simple heating process (Bio-Heat technology, Bio-PRF, Venice, FL, USA). Simply stated, by heating and denaturing albumin, a modification in the secondary structure after heating transforms the matter into a tridimensional structure. During this heating process, new hydrogen and disulfide ligations in the enzymes are created, which favor a larger tridimensional structure with drastic changes in its resorption properties and improve its stability over time. In accordance with US Food and Drug Administration (FDA) standard 10993 to evaluate biomaterial resorption rates, it was found that this 100% natural biomaterial dramatically extended the resorption properties of PRF from 2–3 weeks up to 4–6 months (Figure 10.12; QR Code 9; see Video 10.11).

SCAN ME

While this change in protocol adds approximately 10 minutes to standard PRF membranes, it presents clear clinical benefits. It therefore becomes possible to create a true "barrier" or "filler" biomaterial derived from 100% autologous whole blood with drastically extended resorption properties. This has been utilized for various clinical indications, such as recession coverage cases as a membrane (Figure 10.13). It has also been injected for black triangles to improve papilla volume, with five-year data now showing stable results (Figure 10.14).

In 2019, a Bio-Heat tray was developed with the aim of specifically customizing the shapes of e-PRF to create specific geometries for extraction sockets (smaller, circular), membranes (square, rectangular), or diabetic foot ulcers (larger, circular). This allows for the easy fabrication of a customized kit that is autoclavable (Figure 10.15; QR Code 10; see Video 10.12). This technology has been utilized in medicine as a superior form of platelet concentrates for joint injections, and is even utilized today by top

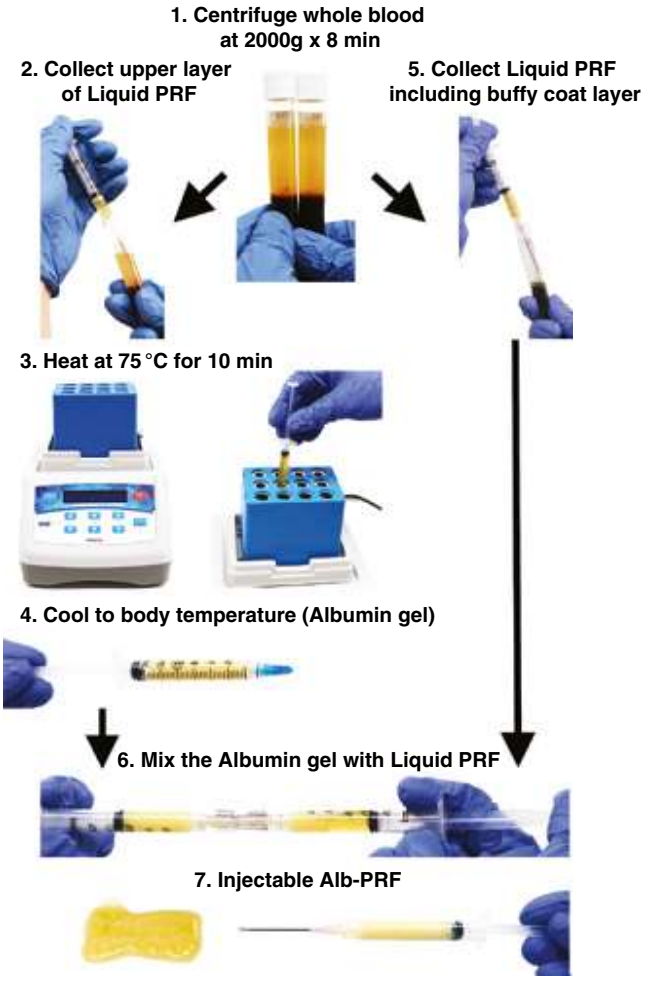

FIGURE 10.12 Step-by-step clinical demonstration of the production of e-PRF (extended platelet-rich fibrin). (1) Centrifugation of blood. (2) Following centrifugation, collection of the serum plus plasma poor in platelets (PPP). (3) Introduction of the PPP to the Bio-Heat at 75 °C (10 minutes). (4) Cooling the denatured albumin gel to room temperature. (5) After 10 minutes, collection of the liquid PRF + buffy coat zone. (6) A Luer Lock mixer device is attached to both the liquid PRF and albumin gel and mixing of the liquid PRF and albumin gel back and forth occurs to create e-PRF. (7) e-PRF ready for use. Note the ability to inject out of a syringe following adequate mixing. *Source*: Davies C, Miron RJ. Platelet rich fibrin in facial esthetics. Chicago, IL: Quintessence; 2020. Reproduced with permission of Quintessence Publishing Co., Inc.

Dentlearn.ir

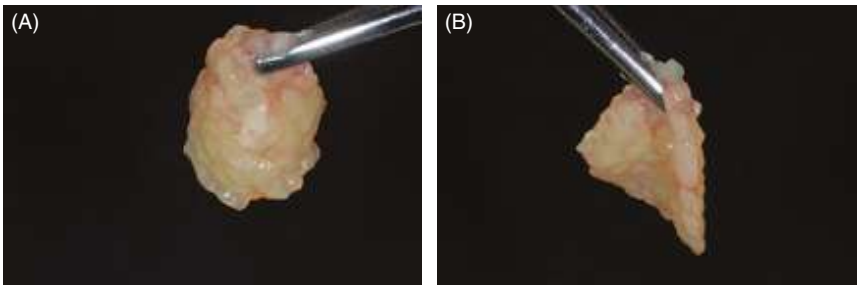

FIGURE 10.13 (A, B) Clinical photos of an e-PRF (extended platelet-rich fibrin) membrane utilized for recession coverage. *Source*: Davies C, Miron RJ. Platelet rich fibrin in facial esthetics. Chicago, IL: Quintessence; 2020. Reproduced with permission of Quintessence Publishing Co., Inc.

FIGURE 10.14 (A) Clinical photo demonstrating maxillary anterior teeth with multiple black triangles. (B) Final clinical photos post injections. Case performed by Dr. Ezio Gheno. *Source*: Quintessence Publishing Co., Inc.

FIGURE 10.15 Custom Bio-Heat trays are available to fabricate custom squares, rectangles, or circles of various sizes depending on the clinical application. *Source*: Quintessence Publishing Co., Inc.

SCAN ME

SCAN ME

orthopedic surgeons for spine injections, often avoiding the need for spinal surgery (QR Code 11; see Video 10.13).

In dentistry, the technology is currently being heavily investigated as a replacement to collagen membranes owing to its longer resorption periods like collagen. Figure 10.16 demonstrates a full-arch zygomatic implant case where extended-PRF membranes were utilized as a substitute for collagen to cover exposed implants. Future research in this field is ongoing, with much future potential regarding its clinical benefits. One further growing use of this technology is as an injectable biological filler material in facial esthetics (Figure 10.17). These clinical indications highlight the start of a growing field whereby the resorption of PRF can be dramatically extended, and therefore many novel clinical indications will ensue in the coming years.

Dentlearn.ir

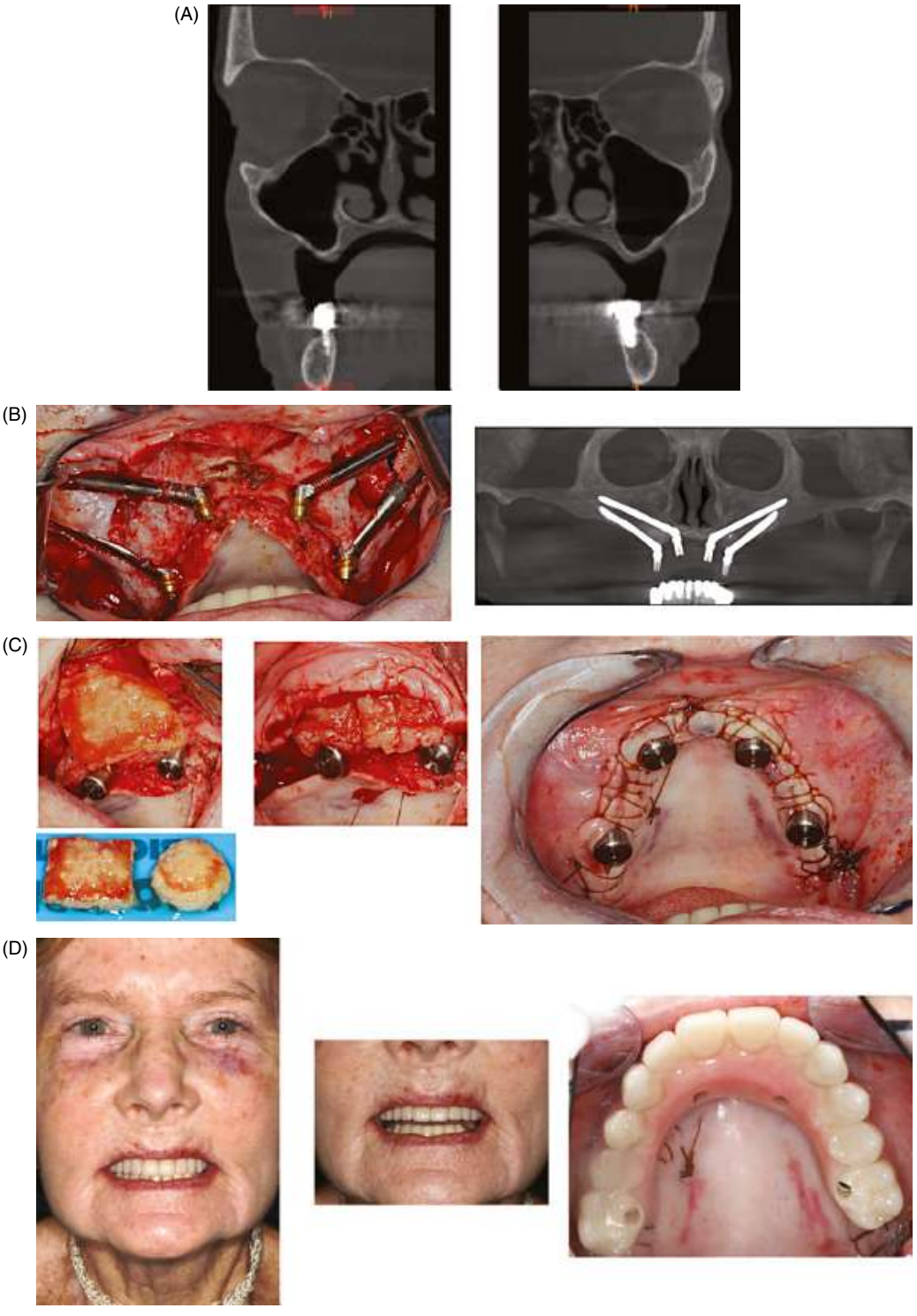

FIGURE 10.16 Use of extended platelet-rich fibrin (e-PRF) membranes during a full-arch zygomatic implant case. (A) Cone beam computed tomography images demonstrating fully pneumatized sinuses with minimal residual bone height. (B) Placement of four zygomatic implants with significant exposure of implants. (C) Fabrication of various e-PRF membranes utilized to cover the implants. (D) 1 week post-op demonstrating excellent healing and low post-op inflammation owing to the natural autologous consistency of the material. These cases are currently being followed 1-year post-op with excellent clinical success thus far, without the need for use of a collagen barrier membrane. Case performed by Dr. Michael A Pikos.

Dentlearn.ir

FIGURE 10.17 (A) Mid-40-year-old female patient with pronounced Mariotte lines, deep nasolabial folds, and an overall aged facial appearance. (B) Final outcome following three treatments with 100% natural approaches, including laser therapy (Smoothlase®, Fotona, Dallas, TX, USA), microneedling with platelet-rich fibrin (PRF), and extended PRF injections. Case performed by Dr. Scott Delboccio. *Source*: Davies C, Miron RJ. Platelet rich fibrin in facial esthetics. Chicago, IL: Quintessence; 2020. Reproduced with permission of Quintessence Publishing Co., Inc.

CONCLUSION

This chapter highlights the growing use of natural regenerative therapy with PRF and its use in bone augmentation procedures in implant dentistry. Today, PRF is one of the most frequently utilized growth factors in dentistry. It is easy to obtain, low cost, and readily available. Its use has been investigated in several randomized clinical studies where various advantages have been reported highlighting its use. Future research will continue, primarily focused on the novel heated albumin-PRF membranes, where an array of clinical indications is being continuously studied and developed with the aim of utilizing more natural regenerative strategies for future clinical applications.

with website

To access the videos for this chapter, please go to
www.wiley.com/go/tolstunov/essential

VIDEO 10.1 Evolution of PRF by the author Dr. Richard Miron.

VIDEO 10.2 Horizontal centrifugation by the author Dr. Richard Miron.

VIDEO 10.3 Demo fixed-angle vs horizontal centrifuges by the author Dr. Richard Miron.

VIDEO 10.4 Protocols for PRF by the author Dr. Richard Miron.

VIDEO 10.5 Making sticky bone by the author Dr. Richard Miron.

VIDEO 10.6 Protected bone regeneration with titanium mesh and PRF.

VIDEO 10.7 Drawing C-PRF by the author Dr. Richard Miron.

VIDEO 10.8 Large bone augmentation procedure using Ti-Mesh, rhBMP2, PRF and bone allograft by the author Dr. Richard Miron.

VIDEO 10.9 Lateral sinus lift, bone graft with PRF.

VIDEO 10.10 Lateral sinus grafting procedure utilizing PRF, bone allografts and xenografts by the author Dr. Richard Miron.

VIDEO 10.11 Scientific basis of extended-PRF (e-PRF) by the author Dr. Richard Miron.

VIDEO 10.12 Making a bio-bone by the author Dr. Richard Miron.

VIDEO 10.13 Spinal injection using extended-PRF by the author Dr. Richard Miron.

Dentlearn.ir

REFERENCES

1. Miron RJ. *Understanding platelet rich fibrin*. Batavia, IL: Quintessence; 2021.
2. Anfossi G, Trovati M, Mularoni E et al. Influence of propranolol on platelet aggregation and thromboxane B2 production from platelet-rich plasma and whole blood. *Prostaglandins Leukot Essent Fatty Acids.* 1989;36:1–7.
3. Fijnheer R, Pietersz RN, de Korte D et al. Platelet activation during preparation of platelet concentrates: A comparison of the platelet-rich plasma and the buffy coat methods. *Transfusion.* 1990;30:634–8.
4. Upputuri PK, Sivasubramanian K, Mark CS, Pramanik M. Recent developments in vascular imaging techniques in tissue engineering and regenerative medicine. *Biomed Res Int.* 2015;2015:783983.
5. Gosain A, DiPietro LA. Aging and wound healing. *World J Surg.* 2004;28:321–6.
6. Eming SA, Brachvogel B, Odorisio T, Koch M. Regulation of angiogenesis: Wound healing as a model. *Prog Histochem Cytochem.* 2007;42:115–70.
7. Eming SA, Kaufmann J, Lohrer R, Krieg T. [Chronic wounds. Novel approaches in research and therapy]. Hautarzt 2007;58:939–44.
8. Lucarelli E, Beretta R, Dozza B et al. A recently developed bifacial platelet-rich fibrin matrix. *Eur Cell Mater.* 2010;20:13–23.
9. Saluja H, Dehane V, Mahindra U. Platelet-rich fibrin: A second generation platelet concentrate and a new friend of oral and maxillofacial surgeons. *Ann Maxillofac Surg.* 2011;1:53–7.
10. Choukroun J, Adda F, Schoeffler C, Vervelle A. Une opportunité en paro-implantologie: le PRF. *Implantodontie.* 2001;42:e62.
11. Dohan Ehrenfest DM, Del Corso M, Diss A et al. Three-dimensional architecture and cell composition of a Choukroun's platelet-rich fibrin clot and membrane. *J Periodontol.* 2010;81:546–55.
12. Miron RJ, Chai J, Zheng S et al. A novel method for evaluating and quantifying cell types in platelet rich fibrin and an introduction to horizontal centrifugation. *J Biomed Mater Res Part A.* 2019;107:2257–71.
13. Dye BA, Thornton-Evans G, Li X, Iafolla T. Dental caries and tooth loss in adults in the United States, 2011–2012. NCHS Data Brief. 2015;May:197.
14. Schropp L, Kostopoulos L, Wenzel A. Bone healing following immediate versus delayed placement of titanium implants into extraction sockets: A prospective clinical study. *Int J Oral Maxillofac Implants.* 2003;18:189–99.
15. Botticelli D, Persson LG, Lindhe J, Berglundh T. Bone tissue formation adjacent to implants placed in fresh extraction sockets: An experimental study in dogs. *Clin Oral Implants Res.* 2006;17:351–8.
16. Miron RJ, Fujioka-Kobayashi M, Moraschini V et al. Efficacy of platelet-rich fibrin on bone formation, part 1: Alveolar ridge preservation. *Int J Oral Implantol (Berl).* 2021;14:181–94.
17. Alzahrani AA, Murriky A, Shafik S. Influence of platelet rich fibrin on post-extraction socket healing: A clinical and radiographic study. *Saudi Dent J.* 2017;29:149–55.
18. Areewong K, Chantaramungkorn M, Khongkhunthian P. Platelet-rich fibrin to preserve alveolar bone sockets following tooth extraction: A randomized controlled trial. *Clin Implant Dent Relat Res.* 2019;21:1156–63.
19. Canellas J, da Costa RC, Breves RC et al. Tomographic and histomorphometric evaluation of socket healing after tooth extraction using leukocyte- and platelet-rich fibrin: A randomized, single-blind, controlled clinical trial. *J Craniomaxillofac Surg.* 2020;48:24–32.
20. de Almeida Barros Mourão CF, de Mello-Machado RC, Javid K, Moraschini V. The use of leukocyte- and platelet-rich fibrin in the management of soft tissue healing and pain in post-extraction sockets: A randomized clinical trial. *J Craniomaxillofac Surg.* 2020;48:452–7.
21. Hauser F, Gaydarov N, Badoud I et al. Clinical and histological evaluation of postextraction platelet-rich fibrin socket filling: A prospective randomized controlled study. *Implant Dent.* 2013;22:295–303.
22. Marenzi G, Riccitiello F, Tia M et al. Influence of leukocyte- and platelet-rich fibrin (L-PRF) in the healing of simple postextraction sockets: A split-mouth study. *Biomed Res Int.* 2015;2015:369273.
23. Srinivas B, Das P, Rana MM et al. Wound healing and bone regeneration in postextraction sockets with and without platelet-rich fibrin. *Ann Maxillofac Surg.* 2018;8:28–34.
24. Suttapreyasri S, Leepong N. Influence of platelet-rich fibrin on alveolar ridge preservation. *J Craniofac Surg.* 2013;24:1088–94.
25. Temmerman A, Vandessel J, Castro A et al. The use of leucocyte and platelet-rich fibrin in socket management and ridge preservation: A split-mouth, randomized, controlled clinical trial. *J Clin Periodontol.* 2016;43:990–99.
26. Zhang Y, Ruan Z, Shen M et al. Clinical effect of platelet-rich fibrin on the preservation of the alveolar ridge following tooth extraction. *Exp Ther Med.* 2018;15:2277–86.
27. Du Toit J, Siebold A, Dreyer A, Gluckman H. Choukroun platelet-rich fibrin as an autogenous graft biomaterial in preimplant surgery: Results of a preliminary randomized, human histomorphometric, split-mouth study. *Int J Periodontics Restorative Dent.* 2016;36(suppl):s75–s86.
28. Clark D, Rajendran Y, Paydar S et al. Advanced platelet-rich fibrin and freeze-dried bone allograft for ridge preservation: A randomized controlled clinical trial. *J Periodontol.* 2018;89:379–87.
29. Das S, Jhingran R, Bains VK et al. Socket preservation by beta-tricalcium phosphate with collagen compared to platelet-rich fibrin: A clinico-radiographic study. *Eur J Dent.* 2016;10:264–76.
30. De Angelis P, De Angelis S, Passarelli PC et al. Hard and soft tissue evaluation of different socket preservation procedures using leukocyte and platelet-rich fibrin: A retrospective clinical and volumetric analysis. *J Oral Maxillofac Surg.* 2019;77:1807–15.
31. Mendoza-Azpur G, Olaechea A, Padial-Molina M et al. Composite alloplastic biomaterial vs. autologous platelet-rich fibrin in ridge preservation. *J Clin Med.* 2019;8(2):223.
32. Thakkar DJ, Deshpande NC, Dave DH, Narayankar SD. A comparative evaluation of extraction socket preservation with demineralized freeze-dried bone allograft alone and along with platelet-rich fibrin: A clinical and radiographic study. *Contemp Clin Dent.* 2016;7:371–6.

Dentlearn.ir

33. Chappuis V, Engel O, Reyes M et al. Ridge alterations post-extraction in the esthetic zone: A 3D analysis with CBCT. *J Dent Res.* 2013;92:195s–201s.

34. Castro AB, Meschi N, Temmerman A et al. Regenerative potential of leucocyte-and platelet-rich fibrin. Part B: Sinus floor elevation, alveolar ridge preservation and implant therapy. A systematic review. *J Clin Periodontol.* 2017;44:225–34.

35. Castro AB, Meschi N, Temmerman A et al. Regenerative potential of leucocyte-and platelet-rich fibrin. Part A: Intra-bony defects, furcation defects and periodontal plastic surgery. A systematic review and meta-analysis. *J Clin Periodontol.* 2017;44:67–82.

36. Miron RJ, Zucchelli G, Pikos MA et al. Use of platelet-rich fibrin in regenerative dentistry: A systematic review. *Clin Oral Investig.* 2017;21:1913–27.

37. Pikos MA, Miron RJ. *Bone augmentation in implant dentistry*. Batavia, IL: Quintessence; 2019.

38. Dahlin C, Linde A, Gottlow J, Nyman S. Healing of bone defects by guided tissue regeneration. *Plast Reconstr Surg.* 1988;81:672–6.

39. Buser D, Dula K, Belser U et al. Localized ridge augmentation using guided bone regeneration. 1. Surgical procedure in the maxilla. *Int J Periodontics Restorative Dent.* 1993;13:29–45.

40. Fujihara K, Kotaki M, Ramakrishna S. Guided bone regeneration membrane made of polycaprolactone/calcium carbonate composite nano-fibers. *Biomaterials.* 2005;26:4139–47.

41. Toffler M. Guided bone regeneration (GBR) using cortical bone pins in combination with leukocyte-and platelet-rich fibrin (L-PRF). *Compend Contin Educ Dent.* 2014;35:192–8.

42. Jung RE, Fenner N, Hammerle CH, Zitzmann NU. Long-term outcome of implants placed with guided bone regeneration (GBR) using resorbable and non-resorbable membranes after 12–14 years. *Clin Oral Implants Res.* 2013;24:1065–73.

43. Fujioka-Kobayashi M, Miron RJ, Moraschini V et al. Efficacy of platelet-rich fibrin on bone formation, Part 2: Guided bone regeneration, sinus elevation and implant therapy. *Int J Oral Implantol (Berl).* 2021;14:285–302.

44. Moussa M, El-Dahab OA, El Nahass H. Anterior maxilla augmentation using palatal bone block with platelet-rich fibrin: A controlled trial. *Int J Oral Maxillofac Implants.* 2016;31:708–15.

45. Hartlev J, Spin-Neto R, Schou S et al. Cone beam computed tomography evaluation of staged lateral ridge augmentation using platelet-rich fibrin or resorbable collagen membranes in a randomized controlled clinical trial. *Clin Oral Implants Res.* 2019;30:277–84.

46. Miron RJ, Moraschini V, Fujioka-Kobayashi M et al. Use of platelet-rich fibrin for the treatment of periodontal intrabony defects: A systematic review and meta-analysis. *Clin Oral Investig.* 2021;25:2461–78.

47. Miron RJ, Moraschini V, Del Fabbro M et al. Use of platelet-rich fibrin for the treatment of gingival recessions: A systematic review and meta-analysis. *Clin Oral Investig.* 2020;24:2543–57.

48. Miron RJ, Fujioka-Kobayashi M, Bishara M et al. Platelet-rich fibrin and soft tissue wound healing: A systematic review. *Tissue Eng Part B Rev.* 2017;23:83–99.

49. Solar P, Geyerhofer U, Traxler H et al. Blood supply to the maxillary sinus relevant to sinus floor elevation procedures. *Clin Oral Implants Res.* 1999;10:34–44.

50. Wallace SS, Froum SJ. Effect of maxillary sinus augmentation on the survival of endosseous dental implants: A systematic review. *Ann Periodontol.* 2003;8:328–43.

51. Chambrone L, Preshaw PM, Ferreira JD et al. Effects of tobacco smoking on the survival rate of dental implants placed in areas of maxillary sinus floor augmentation: A systematic review. *Clin Oral Implants Res.* 2014;25:408–16.

52. Miron RJ, Pikos MA. Sinus augmentation using platelet-rich fibrin with or without a bone graft: What is the consensus? *Compend Contin Educ Dent.* 2018;39:355–61; quiz 362.

53. Kozuma A, Sasaki M, Seki K et al. Preoperative chronic sinusitis as significant cause of postoperative infection and implant loss after sinus augmentation from a lateral approach. *Oral Maxillofac Surg.* 2017;21(2):193–200.

54. Ghasemi S, Fotouhi A, Moslemi N et al. Intra- and postoperative complications of lateral maxillary sinus augmentation in smokers vs nonsmokers: A systematic review and meta-analysis. *Int J Oral Maxillofac Implants.* 2017;32(4):759–67.

55. Simonpieri A, Choukroun J, Del Corso M et al. Simultaneous sinus-lift and implantation using microthreaded implants and leukocyte- and platelet-rich fibrin as sole grafting material: A six-year experience. *Implant Dent.* 2011;20:2–12.

56. Choukroun J, Diss A, Simonpieri A et al. Platelet-rich fibrin (PRF): A second-generation platelet concentrate. Part V: Histologic evaluations of PRF effects on bone allograft maturation in sinus lift. *Oral Surg Oral Med Oral Pathol Oral Radiol Endod.* 2006;101:299–303.

57. Aoki N, Maeda M, Kurata M et al. Sinus floor elevation with platelet-rich fibrin alone: A clinical retrospective study of 1–7 years. *J Clin Exp Dent.* 2018;10:e984–e991.

58. Diss A, Dohan DM, Mouhyi J, Mahler P. Osteotome sinus floor elevation using Choukroun's platelet-rich fibrin as grafting material: A 1-year prospective pilot study with microthreaded implants. *Oral Surg Oral Med Oral Pathol Oral Radiol Endod.* 2008;105:572–9.

59. Inchingolo F, Tatullo M, Marrelli M et al. Trial with platelet-rich fibrin and Bio-Oss used as grafting materials in the treatment of the severe maxillar bone atrophy: Clinical and radiological evaluations. *Eur Rev Med Pharmacol Sci.* 2010;14:1075–84.

60. Kanayama T, Horii K, Senga Y, Shibuya Y. Crestal approach to sinus floor elevation for atrophic maxilla using platelet-rich fibrin as the only grafting material: A 1-year prospective study. *Implant Dent.* 2016;25:32–8.

61. Kumar M, Chopra S, Das D et al. Direct maxillary sinus floor augmentation for simultaneous dental implant placement. *Ann Maxillofac Surg.* 2018;8:188–92.

62. Mazor Z, Horowitz RA, Del Corso M et al. Sinus floor augmentation with simultaneous implant placement using Choukroun's platelet-rich fibrin as the sole grafting material: A radiologic and histologic study at 6 months. *J Periodontol.* 2009;80:2056–64.

63. Meyer C, Chatelain B, Benarroch M et al. [Massive sinus-lift procedures with beta-tricalcium phosphate: Long-term results]. *Rev Stomatol Chir Maxillofac.* 2009;110:69–75.

Dentlearn.ir

64. Molemans B, Cortellini S, Jacobs R et al. Simultaneous sinus floor elevation and implant placement using leukocyte- and platelet-rich fibrin as a sole graft material. *Int J Oral Maxillofac Implants.* 2019;34:1195–201.

65. Tajima N, Ohba S, Sawase T, Asahina I. Evaluation of sinus floor augmentation with simultaneous implant placement using platelet-rich fibrin as sole grafting material. *Int J Oral Maxillofac Implants.* 2013;28:77–83.

66. Toffler M, Toscano N, Holtzclaw D. Osteotome-mediated sinus floor elevation using only platelet-rich fibrin: An early report on 110 patients. *Implant Dent.* 2010;19:447–56.

67. Bolukbasi N, Ersanlı S, Keklikoglu N et al. Sinus augmentation with platelet-rich fibrin in combination with bovine bone graft versus bovine bone graft in combination with collagen membrane. *J Oral Implantol.* 2015;41:586–95.

68. Bosshardt DD, Bornstein MM, Carrel JP et al. Maxillary sinus grafting with a synthetic, nanocrystalline hydroxyapatite-silica gel in humans: Histologic and histomorphometric results. *Int J Periodontics Restorative Dent.* 2014;34:259–67.

69. Cömert Kılıç S, Güngörmüş M, Parlak SN. Histologic and histomorphometric assessment of sinus-floor augmentation with beta-tricalcium phosphate alone or in combination with pure-platelet-rich plasma or platelet-rich fibrin: A randomized clinical trial. *Clin Implant Dent Relat Res.* 2017;19:959–67.

70. Gassling V, Purcz N, Braesen JH et al. Comparison of two different absorbable membranes for the coverage of lateral osteotomy sites in maxillary sinus augmentation: A preliminary study. *J Craniomaxillofac Surg.* 2013;41:76–82.

71. Gurler G, Delilbasi C. Effects of leukocyte-platelet rich fibrin on postoperative complications of direct sinus lifting. *Minerva Stomatol.* 2016;65:207–12.

72. Nizam N, Eren G, Akcalı A, Donos N. Maxillary sinus augmentation with leukocyte and platelet-rich fibrin and deproteinized bovine bone mineral: A split-mouth histological and histomorphometric study. *Clin Oral Implants Res.* 2018;29:67–75.

73. Pichotano EC, de Molon RS, de Souza RV et al. Evaluation of L-PRF combined with deproteinized bovine bone mineral for early implant placement after maxillary sinus augmentation: A randomized clinical trial. *Clin Implant Dent Relat Res.* 2019;21:253–62.

74. Tatullo M, Marrelli M, Cassetta M et al. Platelet rich fibrin (P.R.F.) in reconstructive surgery of atrophied maxillary bones: Clinical and histological evaluations. *Int J Med Sci.* 2012;9:872–80.

75. Zhang Y, Tangl S, Huber CD et al. Effects of Choukroun's platelet-rich fibrin on bone regeneration in combination with deproteinized bovine bone mineral in maxillary sinus augmentation: A histological and histomorphometric study. *J Craniomaxillofac Surg.* 2012;40:321–8.

76. Hernández-Alfaro F, Torradeflot MM, Marti C. Prevalence and management of Schneiderian membrane perforations during sinus-lift procedures. *Clinical Oral Implants Res.* 2008;19:91–8.

77. Schwartz-Arad D, Herzberg R, Dolev E. The prevalence of surgical complications of the sinus graft procedure and their impact on implant survival. *J Periodontol* 2004;75:511–16.

78. Everts P, Overdevest EP, Jakimowicz JJ et al. The use of autologous platelet–leukocyte gels to enhance the healing process in surgery, a review. *Surg Endosc.* 2007;21:2063–8.

79. Hoaglin DR, Lines GK. Prevention of localized osteitis in mandibular third-molar sites using platelet-rich fibrin. *Int J Dent.* 2013;2013:875380.

Dentlearn.ir

Ridge Augmentation: Horizontal

SECTION III

Chapter 11 Guided Bone Regeneration with Resorbable and Non-resorbable Membranes for (Mainly) Horizontal Alveolar Bone Augmentation in Implant Dentistry 177
John F. Hamrick and Trenton F. Jensen

Chapter 12 Autogenous Block Bone Graft for Horizontal Ridge Augmentation in Implant Dentistry 195
Arash Khojasteh and Farshid Bastami

Chapter 13 Allogeneic Block Graft as an Alternative to Autogenous Block Graft for Augmentation of Horizontal Alveolar Bone Defects in Implant Dentistry 209
Shankar Iyer

Chapter 14 Ridge-Split Expansion Procedure for Horizontal Bone Augmentation in Implant Dentistry 239
Len Tolstunov

Chapter 14.1 Diagnosis and Treatment Planning 240
Len Tolstunov

Chapter 14.2 Surgical Principles of the Ridge-Split Expansion Procedure 249
Len Tolstunov

Chapter 14.3 Mandibular Two-Stage Alveolar Ridge-Split Expansion Procedure 254
Len Tolstunov

Chapter 14.4 Maxillary Single-Stage Alveolar Ridge-Split Expansion Procedure: Corticotomy-Split Expansion Graft 261
Len Tolstunov

Chapter 14.5 Advanced Ridge-Split Expansion Techniques for an Experienced Practitioner 266
Len Tolstunov

Chapter 14.6 Complications of the Ridge-Split Expansion Procedure and Conclusion 272
Len Tolstunov

Chapter 15 Ridge-Split Expansion Procedure Utilizing Piezoelectric Surgery for Horizontal Bone Augmentation in Implant Dentistry 277
Dong-Seok Sohn and Jeong-Uk Heo

Chapter 16 Minimally Invasive Combination Techniques for Vertical and Horizontal Bone Augmentation in the Posterior Maxilla: Alveolar Split with Crestal Sinus Lift 293
Len Tolstunov

Dentlearn.ir

Dentlearn.ir

Guided Bone Regeneration with Resorbable and Non-resorbable Membranes for (Mainly) Horizontal Alveolar Bone Augmentation in Implant Dentistry

CHAPTER 11

Horizontal bone augmentation with guided bone regeneration (GBR) is a useful and important technique for alveolar ridge augmentation for patients needing implant therapy. The primary goal in GBR is isolating and developing alveolar bone as the selected tissue for regeneration. The basic principles of GBR are foundational to predictable and successful implant therapy. These principles include primary wound closure, angiogenesis, space maintenance, and wound stability.

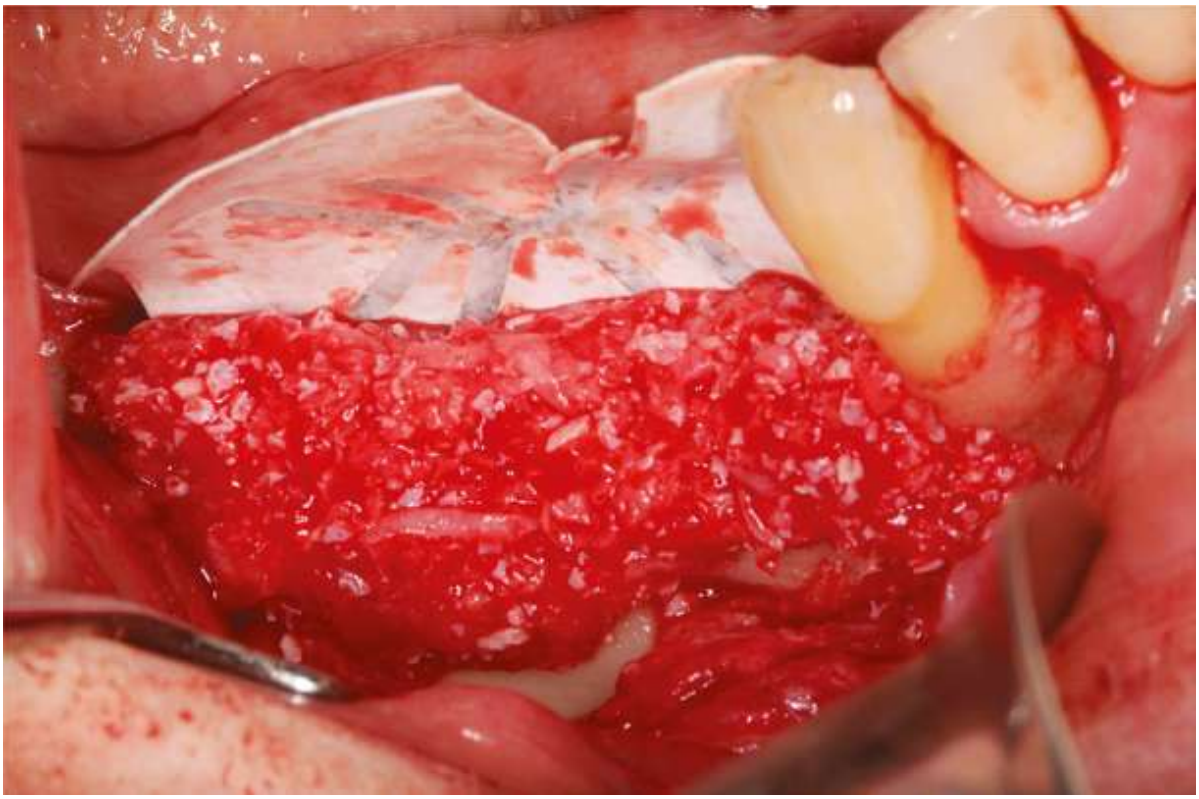

Dentlearn.ir

CHAPTER 11

Guided Bone Regeneration with Resorbable and Non-resorbable Membranes for (Mainly) Horizontal Alveolar Bone Augmentation in Implant Dentistry

John F. Hamrick[1,2] and Trenton F. Jensen[2]

[1]*Department of Periodontics, Medical University of South Carolina School of Dentistry, Charleston, SC, USA*

[2]*Private Practice, Greenville, SC, USA*

The primary goal in guided bone regeneration (GBR) is isolating and developing alveolar bone as the selected tissue for regeneration. GBR to aid in the development of an adequate alveolar ridge form and volume for proper implant placement has been successfully accomplished with various techniques and materials over the past 30 years in implant dentistry. Prior research in periodontal regeneration around teeth by Nyman, Karing, and others [1] with the use of membranes to exclude unfavorable tissues to assist in the development of a fully functional periodontal ligament (PDL) and periodontal attachment led to the development of GBR, as described by Buser [2]. In this chapter, we will discuss in detail various techniques commonly utilized to regenerate bone in deficient sites for implant placement.

The two basic membrane types for GBR include resorbable and non-resorbable materials. For resorbable membranes, we will present how to use them and which alveolar defects are suitable for their use. The resorbable membranes will include those manufactured with porcine collagen and ribose cross-linked membranes.

The non-resorbable membranes to be reviewed will include both titanium mesh and dense polytetrafluoroethylene (PTFE), with and without reinforced titanium. Most cases presented will demonstrate the use of dense PTFE, as the authors feel this material is more user friendly, and in our hands provides a more predictable GBR result.

APPLIED SURGICAL ANATOMY

A thorough understanding of vital anatomical structures that make up the oral cavity is vital to accomplishing successful GBR with minimal surgical and post-surgical complications. Some of these structures (not all) include the inferior alveolar nerve, lingual nerve, mental foramen and nerve, greater palatine nerves, incisive canal and nerve, infraorbital nerve, mandibular incisive canal and nerve, buccal artery, lingual and sublingual arteries, mylohyoid muscle and artery, facial artery, posterior superior alveolar artery, and maxillary sinus.

In posterior mandibular GBR cases, the limiting anatomical structure when releasing the lingual flap is the location of the mylohyoid muscle. A detailed discussion of the management of the lingual flap release will be included in the surgical technique section.

During GBR procedures in the posterior mandible, avoiding trauma and rupture of the lingual artery is of paramount importance. Damage to this artery, which arises from the carotid artery superior to the hyoid bone (second branch of the carotid artery), can quickly lead to life-threatening sequelae, including tongue elevation and airway obstruction. Besides learning how to carefully release lingual flaps without injuring the lingual artery, understanding and developing the skills to manage a lingual arterial bleed are also critical. This will be discussed in the complications section.

Essential Techniques of Alveolar Bone Augmentation in Implant Dentistry: A Surgical Manual, Second Edition. Edited by Len Tolstunov.
© 2023 John Wiley & Sons, Inc. Published 2023 by John Wiley & Sons, Inc.
Companion website: www.wiley.com/go/tolstunov/essential

Dentlearn.ir

INDICATIONS AND CONTRAINDICATIONS

INDICATIONS

The primary indication for GBR is for development of sufficient alveolar bone height and width for dental implant placement. The regeneration of bone is critical for precise implant placement, such that implants are placed in a prosthetically favorable positions to aid the restorative dentist in constructing a prosthesis that is both esthetic and functional. Adequate alveolar bone and accurate implant placement are also fundamental in the management of occlusal forces applied to the implants. This is critical in preventing occlusal overload and implant failure, and failure of the prosthesis (screw loosening, prosthetic fracture, etc.).

CONTRAINDICATIONS

The primary contraindications for treating a patient with GBR are related to compromised systemic health conditions that may lead to poor wound healing and graft failure. The list of common contraindications includes:

- Poorly controlled diabetes (A1C >7.5).
- Autoimmune disease that requires the use of daily steroids and other immune-modifying medications.
- During the active phase of chemotherapy for various cancers and during radiation therapy.
- Irradiated bone to the maxilla or mandible.
- Patients taking infusion bisphosphonate or monoclonal antibody medications for the treatment of osteoporosis. This is not an absolute contraindication; consultation with the treating physician may be required to temporarily discontinue the medication during treatment.
- Patients with untreated periodontitis. Periodontal disease should be treated and stabilized prior to initiating guided bone procedures.
- Non-compliant patients. This includes patients with poor compliance to reasonable plaque control, and also patients who lack motivation to keep appointments, especially postoperative appointments.
- Moderate to heavy use of nicotine-containing products, including smoking, vaping, and the use of smokeless tobacco. These products can contribute to delayed wound healing, resulting in graft failure.

BASIC PRINCIPLES OF GUIDED BONE REGENERATION

The basic principles of GBR are foundational to predictable and successful implant therapy. These principles are important regardless of the type of exclusive membrane being used. As described by Sonick and Hwang [3], these principles include primary wound closure, angiogenesis, space maintenance, and wound stability.

PRIMARY WOUND CLOSURE

Tension-free closure is essential in successful GBR with both resorbable and non-resorbable barriers. Careful flap release, and tension-free closure of the flaps over the GBR site, must be mastered by clinicians for predictable results. Meticulous periosteal releasing incisions of the buccal flaps and the use of vertical releasing incisions where necessary are of greater value in allowing for flap closure without tension [4]. Releasing the lingual mucoperiosteal flap off the mylohyoid muscle dramatically helps achieve primary closure in the posterior mandible. It also can help prevent distortion of the mucogingival junction.

ANGIOGENESIS

Angiogenesis in GBR is accomplished by way of cortical penetrations, opening vascular channels to allow for the delivery of both angioblasts and stem cells to the graft. Cortical penetrations are an important step to aid in graft healing and are particularly important in regions where thick and dense portions of cortical bone are present. One primary goal of cortical perforations is to initiate the regional acceleratory phenomenon (RAP) [5], resulting in rapid angiogenesis to the graft site [6].

SPACE MAINTENANCE

Space maintenance occurs by way of the morphological shape of some of the ridge defects. In natural concavities, the graft itself combined with the occlusive barrier may be all that is required for successful GBR. In defects that are not conducive to space maintenance, the use of a tenting device with titanium mesh, or titanium incorporated in the membrane itself (ti-reinforced PTFE), will provide for the necessary space and resist against collapse of the graft during membrane closure. Tenting devices can be used with resorbable barriers, but with less predictable GBR results. Long-term space maintenance is critical in providing predictable GBR success [7].

WOUND STABILITY

Wound stability is also an essential prerequisite in performing GBR. Any trauma that causes disruption of the initial fibrin clot will lead to graft failure, resulting in the formation of unwanted granulation tissue. Selection of appropriate temporary tooth replacement devices is critical. This will often include the use of Essex retainers instead of classic temporary removable partials, to avoid compression of the graft. When

Dentlearn.ir

possible, a fixed temporary prosthesis can be extremely helpful in protecting the healing GBR site. Careful written and verbal post-operative instructions are also important in preventing trauma and disturbance of the grafted area. These instructions include important dietary modifications, and specific recommendations regarding how to accomplish home care without disruption of the surgical site.

DESCRIPTION OF SURGICAL TECHNIQUE

INCISIONS AND FLAP DESIGN

Surgical technique is paramount regardless of the type of exclusive barrier, but particularly when utilizing non-resorbable membranes in GBR. If membrane exposure occurs after GBR, wound closure can occur with resorbable membranes following membrane degradation. When using non-resorbable membranes, wound closure will not occur. The incisions and flap design must begin with the end in mind. In the mandible, a mid-crestal incision is performed with the flap extending two teeth from the edentulous site if possible. For the maxillary arch, the crestal incision should be made slightly to the facial to properly evert the flap upon closure. Vertical releasing incisions are then completed and full-thickness flaps buccally and lingually are completed.

FLAP ELEVATION AND SITE PREPARATION

Adequate reflection is imperative to visualize the entire defect and anatomical structures while allowing for proper release and fixation of the membrane. Careful manipulation of the flaps around important anatomical structures, i.e. the mental and infraorbital foramina and their respective nerves and blood vessels, must be observed [8]. Once the entire defect is visualized, the clinician can inspect the defect and add cortical perforations and/or tenting screws for space maintenance. Decortication through the existing cortical bone into the bone marrow is accomplished, initiating the RAP as previously described. This step is accomplished using a small round bur or a small-diameter carbide end-cutting bur [9]. Copious irrigation can be used to be sure the site is free from debris or soft tissue.

BUCCAL FLAP RELEASE

Once proper flap reflection has been completed, periosteal release is performed on the buccal aspect. Flap release generally results in increased bleeding and such bleeding should be controlled prior to proceeding with graft and membrane placement. The incision is completed with a new 15 or 15c blade and is made near the base of the flap in a distal to mesial direction. Theis incision should be through the periosteum and only slightly into the underlying connective tissue. Metzenbaum scissors are then inserted 1–2 mm into the wound, opening the beaks of the scissors in a direction parallel to the releasing incision [10]. Care should be taken so as not to perforate the flap, nor to sever a portion of the mental nerve bundle during the periosteal release in the premolar region of the mandible. On the lingual aspect, release of the lingual flap from the mylohyoid muscle is also crucial for larger defects. Similarly, the crestal portion of the flap is held with Adson tissue forceps providing slight tension. Then, digital pressure or the smooth aspect of a larger periosteal elevator is used to gently release the lingual flap from the mylohyoid muscle. Great care should be taken not to perforate the flap or damage the lingual nerve. Lingual release is essential for larger GBR grafts and can also prevent distortion of the mucogingival junction. This technique is fundamental to any type of alveolar bone graft procedure where maintaining primary closure is paramount. This is particularly true of GBR grafts where non-resorbable membranes are to be used. Early exposure and infection of non-resorbable membranes often require removal of the barriers, frequently resulting in significantly less bone regeneration [11].

HARVESTING OF BONE

After buccal and lingual releases have been completed, site preparation and autogenous bone harvesting take place. Cortical perforations are placed wherever bone augmentation is needed. This is often achieved by utilizing a high-speed handpiece and a carbide bur penetrating through cortical bone and into medullary bone. Harvesting autogenous bone can then take place from either the ramus of the mandible or the chin area. Trephines, piezo bone saw, carbide fissured bur with handpiece, or autogenous safe scrapers can all be used to harvest bone. If a safe scraper is not used, the bone block will need to be morselized prior to placing it in the recipient bed.

Once harvested or morselized into chips, the autogenous bone is mixed with either allograft bone or xenograft bone. This is then placed within the defect and covered with a non-resorbable membrane. The membrane should be appropriately trimmed to fit the defect before the grafted bone has been placed. Although minimal adjustments to the membrane can be made afterward, most of the trimming should take place prior to bone graft placement. After placing the graft, the membrane is then placed and fixated using either screws or tacks, preferably on both the buccal and lingual aspects. Stabilization and immobility of the non-resorbable membrane are vital to GBR success. Lack of stability and resulting movement at the GBR site impares bone healing and regeneration [12]. The membrane should not be in direct contact with any tooth to avoid bacterial contamination and/or early failure of the graft during initial healing. Instead, the membrane should be 1–2 mm away from any tooth.

FLAP CLOSURE TECHNIQUE

The vertical releasing incisions on either side of the surgical site are closed with single interrupted sutures. The mid-crestal

Dentlearn.ir

incision over the grafted site is closed in two layers. The first layer closure involves the use of horizontal mattress sutures, which will evert the flap, resulting in an intimate approximation of the connective tissue of the buccal and lingual flaps. Afterward, single interrupted loop sutures are then placed between the horizontal mattress sutures to complete the final layer of wound closure. To close the mid-crestal incision 5.0 Gortex PTFE suture is used, and a combination of 5.0 Gortex suture and 5.0 gut suture is used to close the vertical incisions. Gortex suture is often utilized to close the gingiva, while gut suture is used to close the mucosa. Primary closure (Figure 11.4) is necessary for successful GBR.

Most cases presented by the author with titanium-reinforced PTFE™ membranes (Osteogenics Inc., Lubbock, TX, USA) involve the use of particulate allograft, bovine xenograft and autogenous bone. Figures 11.1–11.4 illustrate the surgical technique in the treatment of a horizontal alveolar ridge defect with titanium-reinforced Cytoplast.

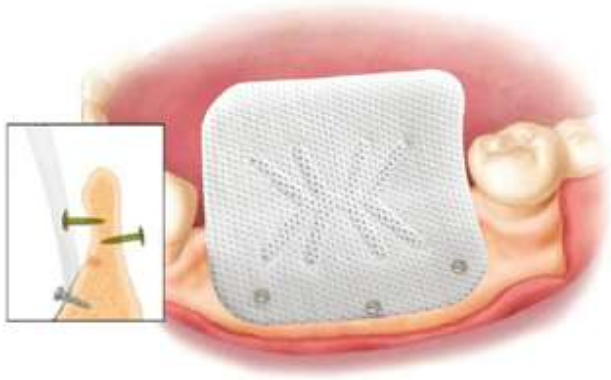

FIGURE 11.1 The membrane has been trimmed and initial fixation of the membrane on the buccal aspect in preparation for bone grafting.

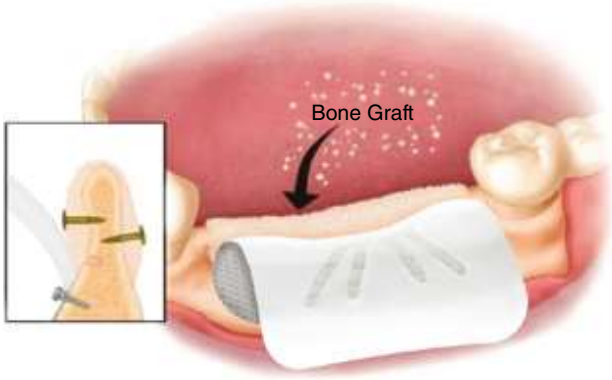

FIGURE 11.2 A combination of autogenous bone with allograft and/or xenograft has been placed beneath the membrane.

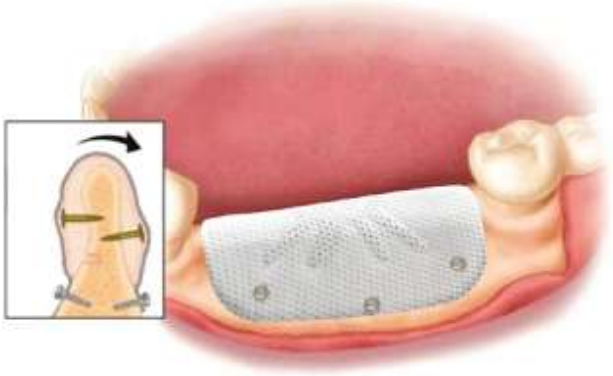

FIGURE 11.3 Final fixation of the lingual with fixation screws.

FIGURE 11.4 Flap release has been accomplished and primary closure achieved with both horizontal mattress sutures and single interrupted loop sutures.

CASE REPORTS

CASE 1

Case 1 involves the treatment of a missing mandibular left first molar. The resulting alveolar ridge defect occurred following a traumatic extraction (Figures 11.5 and 11.6). The defect was treated with a composite graft material consisting of autogenous particulate and freeze-dried bone allograft (Puros®, Zimmer, Inc. Warsaw, IN, USA; Figure 11.7). The autogenous bone was harvested in particulate form using an Ebner bone scraper. A resorbable porcine collagen membrane (BioGide, Osteohealth) membrane (Datum Dental, Lod, Israel) was used as a barrier with a tenting screw to assist in space maintenance (Figure 11.8). Upon graft re-entry and implant placement, excellent GBR and guided tissue regeneration (GTR) were noted (Figure 11.9). The healing abutment was placed (Figure 11.10A) and the implant was restored with a cement-retained implant crown four months after placement (Figure 11.10B, C).

Dentlearn.ir

FIGURE 11.5 Representative case of a significant alveolar ridge defect and tent screw in place.

FIGURE 11.8 The porcine collagen membrane over the bone graft is well adapted.

FIGURE 11.6 Composite graft consisting of autogenous bone and freeze-dried bone allograft.

FIGURE 11.9 The healed guided bone regeneration site after four months of healing. Guided tissue regeneration also noted on adjacent root surface of the mandibular left second molar.

FIGURE 11.7 Particulated composite graft hydrated with platelet-rich plasma. Note good consolidation of the graft.

Dentlearn.ir

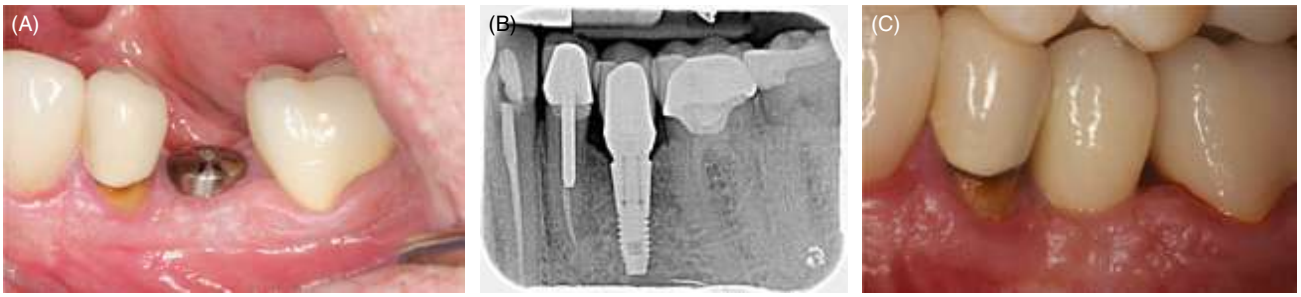

FIGURE 11.10 (A) Healing abutment placed. (B, C) Final radiograph and clinical intraoral photograph of the restored implant one month post loading.

CASE 2

Case 2 presented initially to our practice with a failing endosseous implant replacing the mandibular right central incisor (Figure 11.11). The implant failure was likely due to a lack of sufficient bone during prior placement. The implant was placed too far buccally and exhibited issues related to a lack of keratinized gingiva (Figure 11.12). The initial surgery involved atraumatic removal of the implant (Figure 11.13), debridement of the osseous defect, and grafting with a bone allograft and porcine collagen membrane (Figure 11.14). Ten weeks later, a free gingival graft was completed to augment the keratinized tissue on the buccal side of the defect (Figure 11.15). Four months after the GBR was completed, the site was reentered and the implant was placed in the mandibular left central incisor site (Figures 11.16–11.18). After four months of healing, a final restoration was placed utilizing a cantilever pontic to replace the mandibular right central incisor (Figures 11.19 and 11.20). This prosthetic treatment plan was chosen due to inadequate space for an additional implant.

FIGURE 11.11 Radiographic evidence consistent with severe peri-implant bone loss.

FIGURE 11.12 Exposed crestal aspect of implant showing bone and soft tissue loss.

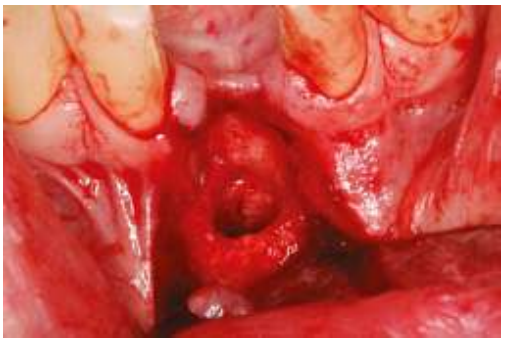

FIGURE 11.13 The implant was atraumatically removed, revealing the resulting defect.

Dentlearn.ir

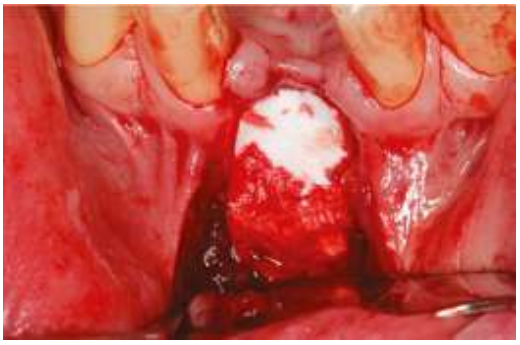

FIGURE 11.14 Freeze-dried bone allograft was used in conjunction with a resorbable membrane.

FIGURE 11.15 Post-operative healing of the tissue graft.

FIGURE 11.16 Post-operative healing of the newly regenerated osseous defect.

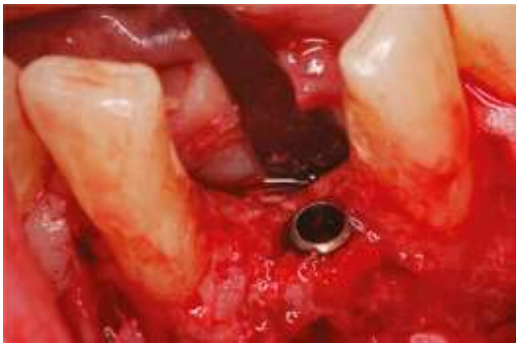

FIGURE 11.17 An implant placed in Site 24 to support a cantilever crown.

FIGURE 11.18 The implant has been uncovered with a healing abutment placed.

FIGURE 11.19 Periapical radiograph taken after one month of loading.

FIGURE 11.20 Final implant restoration and keratinized tissue showing peri-implant stability.

CASE 3

Case 3 involved the use of titanium-reinforced dPTFE barrier membrane in the treatment of an advanced horizontal alveolar bone defect in the anterior maxilla, as described by Jovanovic and Nevins [13]. The patient presented to our practice

Dentlearn.ir

with the chief complaint of his bonded bridge loosening on abutment teeth, which include the maxillary right central incisor and canine (Figures 11.21 and 11.22). Both maxillary lateral incisors were discovered to be congenitally missing. Mesial to distal space was sufficient for implant placement in the maxillary right lateral incisor site. Due to root angulation issues on the maxillary left central incisor and canine, there was insufficient space for implant placement noted in the maxillary left lateral incisor site. Orthodontics was recommended to correct the problem, but the patient declined treatment. Figures 11.23 and 11.24 illustrate the severe buccal concavity in the maxillary right lateral incisor site. During GBR augmentation, freeze-dried bone allograft hydrated with autogenous platelet-rich plasma was placed (Figure 11.25). A titanium-reinforced dPTFE membrane was trimmed and shaped to cover the grafted site. The membrane was fixated with three small bone screws. Prior to primary flap closure, a BioXclude® membrane (Snoasis, Golden, CO, USA) was placed over the dPTFE membrane to aid in accelerated soft

FIGURE 11.21 Periapical radiograph depicting a failing bonded bridge.

FIGURE 11.22 Pre-operative clinical photo of failing bonded bridge.

FIGURE 11.23 Clinical photo showing the buccal ridge defect of the edentulous site.

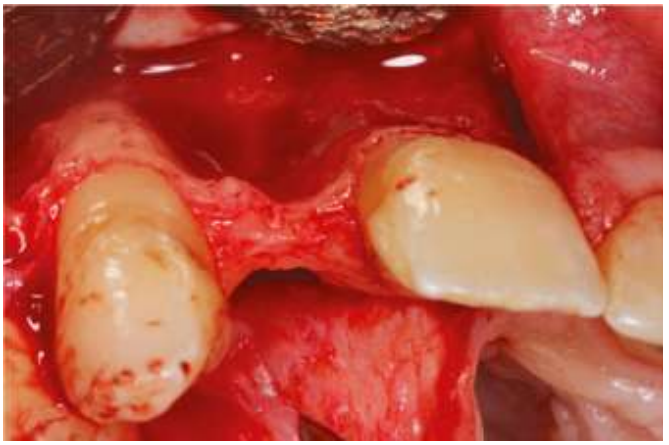

FIGURE 11.24 Clinical photo showing the severely atrophic buccal ridge defect.

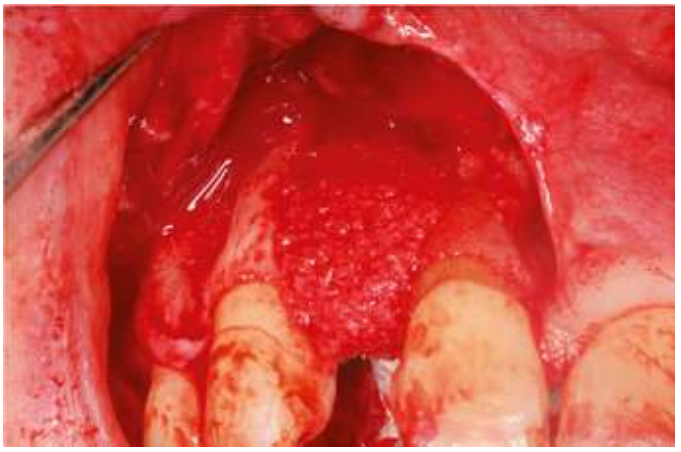

FIGURE 11.25 The severe buccal concavity has been grafted with a combination of autogenous bone and freeze-dried bone allograft.

Dentlearn.ir

tissue healing (Figure 11.26). After five months of wound healing (Figure 11.27), the site was re-entered, the membrane removed, and an Astra TX 3.0 mm implant (Dentsply Sirona, York, PA, USA) placed (Figures 11.28 and 11.29). After placing a provisional restoration to develop natural soft tissue contours, the final restoration was placed (Figure 11.30). A final radiograph was taken post loading for three months (Figure 11.31).

FIGURE 11.26 The Cytoplast membrane has been fixated and covered with a BioXclude membrane.

FIGURE 11.27 Post-operative healing of the ridge defect after 4–5 months.

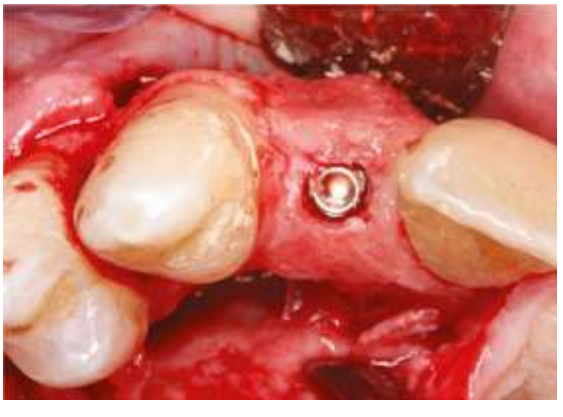

FIGURE 11.28 Newly regenerated bone showing excellent ridge width and placement of an Astra TX 3.0 diameter implant.

FIGURE 11.29 Recently placed Astra implant in the newly regenerated alveolar ridge.

FIGURE 11.30 Final restoration was placed following provisionalization of 6–8 weeks.

FIGURE 11.31 Final periapical radiograph approximately one month post loading.

Dentlearn.ir

CASE 4

Case 4 involves a patient who presented to our office as an emergency following trauma from a fall. The trauma resulted in significant horizontal and vertical fractures of the anterior maxilla, leading to tissue sloughing, loss of labial alveolar bone, and exposure of a small segment of crestal bone in the mid-line area. Both maxillary central incisors and the maxillary left lateral incisor were avulsed, and the maxillary right canine had a severe horizontal fracture (Figure 11.32). The initial surgery involved flap debridement, stabilization of the exposed crestal bone with a fixation screw, extraction of the maxillary right canine with completion of a socket graft with allograft and a porcine absorbable membrane, and initial bone grafting in the anterior maxilla with allograft and an autogenous platelet-rich fibrin membrane (Figures 11.33 and 11.34). After four months of healing, the maxillary right canine site was re-entered and an implant placed. During the same surgery, a maxillary anterior frenectomy and free gingival graft were completed (Figure 11.35 and 11.36). When closing the flaps over a larger GBR site, it is advantageous to have keratinized tissue to work with in achieving primary flap closure [14]. Following four months of healing, mucoperiosteal flaps were reflected, the buccal aspect of the ridge was decorticated, and a composite bone graft was placed consisting of 50% autogenous bone and 25% each of freeze-dried bone allograft and bovine particulate (Bio-Oss®, Geistlich, Wolhusen, Switzerland; Figure 11.37). The graft was then covered with a dPTFE titanium-reinforced membrane and fixated both buccally and palatally with 2 mm bone screws. A porcine collagen membrane was additionally placed to cover the central incisor sites (Figures 11.38

FIGURE 11.32 Initial photograph of trauma resulting in avulsion of teeth and alveolar fracture.

FIGURE 11.33 Fixation screw securing fractured alveolus.

FIGURE 11.34 Initial bone grafting at time of placement of fixation screw.

FIGURE 11.35 Excellent healing of previously fractured alveolus. Fixation screw has been removed.

FIGURE 11.36 Tissue graft completed prior to completing second guided bone regeneration.

Dentlearn.ir

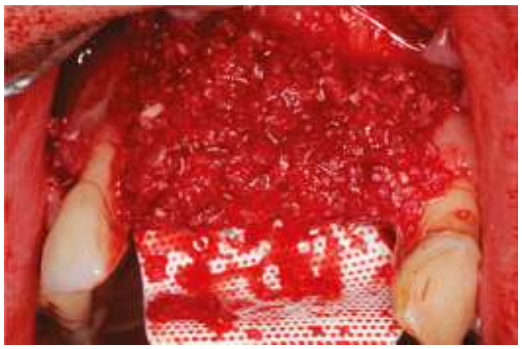

FIGURE 11.37 Secondary bone graft placed utilizing a composite graft of autogenous bone, xenograft, and allograft.

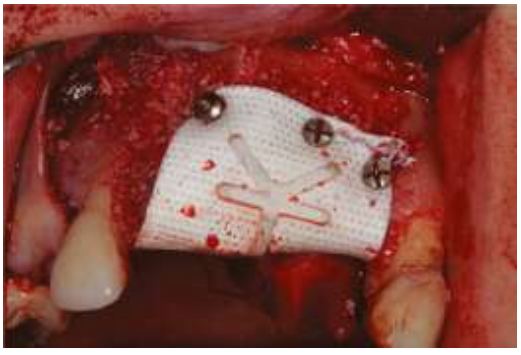

FIGURE 11.38 dPTFE membrane secured on both palatal and buccal aspects.

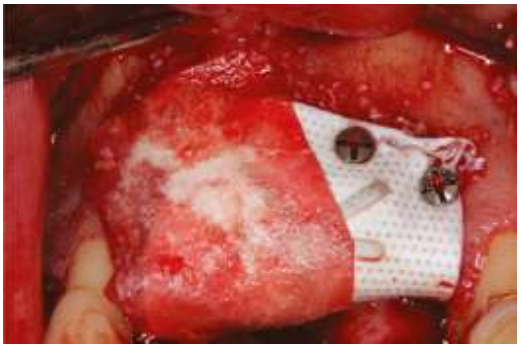

FIGURE 11.39 A resorbable membrane was added to the 8 and 9 sites to provide additional protection and coverage.

and 11.39). After six months of healing (Figure 11.40), the maxillary anterior site was re-entered, and the non-resorbable membrane was removed (Figure 11.41). Significant horizontal and vertical bone augmentation was noted. Endosseous titanium implants were placed in the maxillary right central incisor and left lateral incisor sites with cover screws and flaps were closed with a two-stage layered primary closure (Figure 11.42). After five months of healing, implants were uncovered with healing abutments (Figure 11.41). Three weeks later, provisional restorations were placed to encourage soft tissue remodeling, which remained in place for four months (Figure 11.42). The final screw-retained, fixed ceramic restoration was delivered (Figure 11.43). A screw-retained provisional restoration was placed to aid in soft tissue contours and remodeling (Figure 11.44). The final restoration was delivered following 4 months of provisionalization (Figure 11.45). The last radiograph was taken following delivery and loading of the screw-retained final restoration (Figure 11.46).

FIGURE 11.40 Healing after six months.

FIGURE 11.41 Buccal view of guided bone regeneration. Excellent vertical and horizontal regeneration noted.

FIGURE 11.42 Implants were uncovered in second-stage procedure. Note adequate keratinized tissue on the facial.

Dentlearn.ir

FIGURE 11.43 Screw-retained provisional restoration was fabricated.

FIGURE 11.44 Screw-retained provisional was placed to aid in soft tissue contours and remodeling.

FIGURE 11.45 Final restoration delivered following four months of provisionalization.

FIGURE 11.46 Final radiograph one month following delivery and loading of the screw-retained final restoration.

CASE 5

Case 5 involved GBR to regenerate the extensive loss of both horizontal and vertical alveolar bone secondary to peri-implantitis and implant failure in the mandibular right posterior quadrant (Figure 11.47). The implants were removed by reverse torque in a flapless manner. The resulting healed ridge was exposed with flap reflection, both buccally and lingually, with vertical incisions being made on the mesio-buccal of the mandibular right canine, and a disto-buccal incision slightly buccal to the retromolar pad, up the ascending ramus. A mid-crestal incision, bisecting the crestal keratinized incision, connected the vertical incisions. Note the vertical and horizontal bone loss from the implant failure (Figure 11.48). Prior to initiating GBR, both buccal and lingual flaps were released, as described in the surgical technique

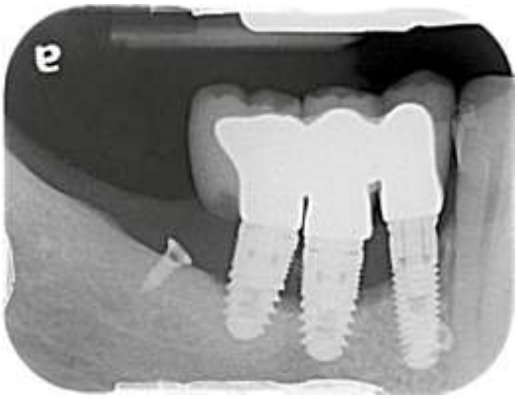

FIGURE 11.47 Periapical radiograph depicting extensive bone loss of failing implants.

Dentlearn.ir

section. Autogenous bone was then harvested from the ramus buccal shelf and mixed with freeze-dried bone allograft and bovine particulate in a 50/50 mix. The composite graft was hydrated with autogenous platelet-rich plasma. A titanium-reinforced dPTFE (Cytoplast) was trimmed and shaped and initially fixated lingually with bone tacks. The bone graft was then placed to augment both the crest and buccal aspect of the ridge (Figure 11.49) prior to fixating the membrane buccally, and the membrane was trimmed to avoid pressure on the mental nerve (Figure 11.50). After eight months of healing, the same incisions were made and the membrane was exposed and removed. Three titanium implants were then placed in sites 28, 29, and 30, with the assistance of a surgical guide (Figures 11.51 and 11.52). After four months of healing in a submerged environment, the implants were carefully exposed and healing abutments were placed. One month later, individual screw-retained crowns were delivered (Figures 11.53 and 11.54).

FIGURE 11.50 The membrane was trimmed so as not to impinge on the inferior alveolar nerve bundle and then was fixated using bone tacks.

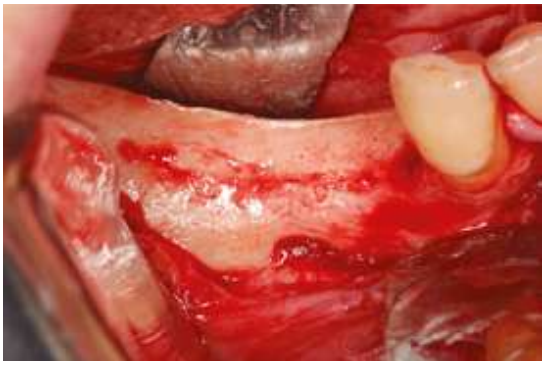

FIGURE 11.48 Horizontal and vertical ridge defect following removal of failing dental implants.

FIGURE 11.51 Healing of eight months revealed a fully regenerated ridge regaining height and width.

FIGURE 11.49 A dPTFE membrane was fixated on the lingual and a composite graft utilized for the defect.

FIGURE 11.52 A surgical guide was utilized to place three implants.

Dentlearn.ir

FIGURE 11.53 Implants were placed in the first and second premolar and first molar positions. The implants healed in a submerged state and then uncovered after 4 months of healing.

FIGURE 11.54 Individual screw-retained crowns were utilized.

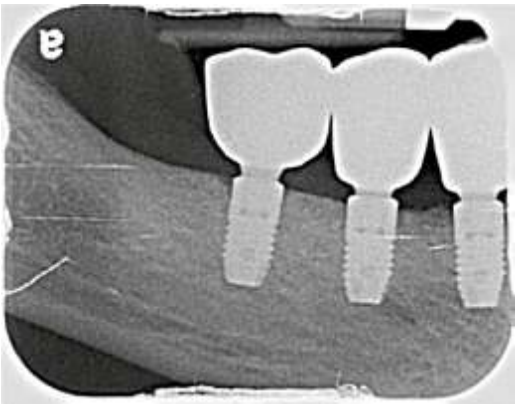

FIGURE 11.55 Periapical radiograph taken following one month of loading.

CASE 6

Case 6 presented with a failing four-unit fixed partial denture in the lower right quadrant, with the distal abutment developing subgingival caries (Figure 11.55). Following flap reflection and extraction of the mandibular right second molar, a buccal ridge defect was present in the second premolar and first molar sites (Figure 11.56). Cortical perforations were made (Figure 11.57) and autogenous bone was harvested from the right ramus and mixed with freeze-dried bone allograft. This was covered with a resorbable collagen membrane that was secured with bone tacks to aid in graft stabilization (Figure 11.58). A periosteal releasing incision was made on the buccal flap and the lingual flap was released from the mylohyoid muscle. Primary closure could then be achieved. After

FIGURE 11.56 Clinical photograph of failing four-unit bridge.

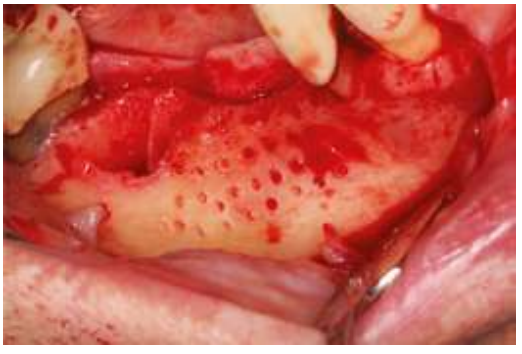

FIGURE 11.57 Buccal ridge defect at sites 29 and 30 with cortical perforations.

FIGURE 11.58 Composite graft consisting of autogenous bone and freeze-dried bone allograft placed within buccal ridge defect and extraction site.

Dentlearn.ir

approximately five months of healing, the site was re-entered and three endosseous implants placed in the mandibular right quadrant. After an additional four months of healing and implant integration, the implants were then uncovered and subsequently restored with three single-unit screw-retained restorations (Figures 11.59 and 11.60). A periapical radiograph was taken after 1 month of loading (Figure 11.61).

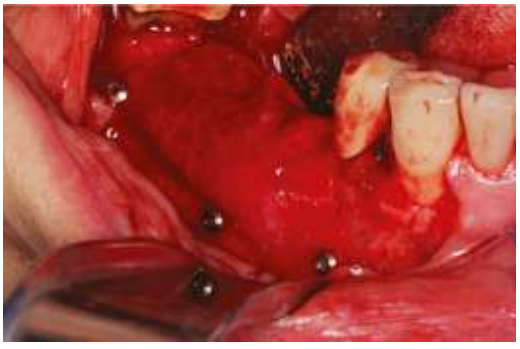

FIGURE 11.59 Collagen membrane covers composite graft and is secured with several bone tacks for graft stability throughout healing.

FIGURE 11.60 Implants were restored with individual screw-retained crowns.

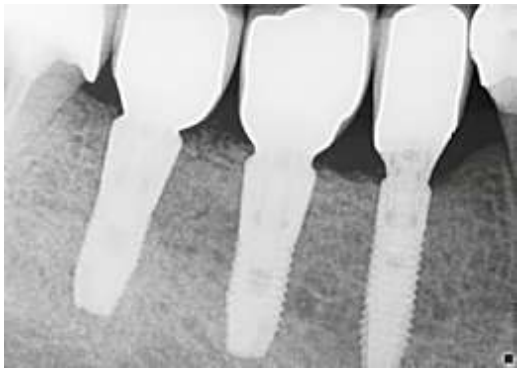

FIGURE 11.61 Periapical radiograph taken one month after loading.

POST-OPERATIVE CARE

Utilizing non-resorbable membranes for ridge augmentation requires more frequent post-operative follow-up appointments, particularly for the first four weeks. Exposure of these barriers may lead to bacterial contamination, infection, and loss of the graft. With early graft exposure, the patient should be followed on a weekly basis for signs of infection [15]. Two days prior to membrane removal, the patient begins the antibiotic regimen prior to the surgery and continues for eight days. A 0.12% chlorhexidine rinse twice per day is administered until soft tissue closure is confirmed. At the first post-operative visit at approximately seven days, if slight incision line separation is noted, the use of GEM 21S® growth-factor enhanced matrix (Osteohealth, Shirley, NJ, USA) over the area may encourage more rapid revascularization and soft tissue bridging. The author has used this adjunctive biologic in numerous cases involving non-resorbable membranes with good success. The key is early recognition and supportive use of the biologic in the early stage of wound healing. The patient is routinely seen every two weeks for the first three appointments and, once documented wound healing over the incision line is noted, monthly post-operative visits are maintained until the appointment for implant placement several months later.

COMPLICATIONS

Like any surgical procedure, complications can arise in GBR procedures. Following the PASS (**P**rimary closure, **A**ngiogenesis, **S**pace maintenance, **S**tability) principle for GBR procedures is vital for success and avoiding complications.

One of the most common complications when using a non-resorbable membrane is post-surgical membrane exposure. This may occur early or late in healing and is often associated with inadequate release of the tissue preventing primary closure, non-compliance from the patient during healing, tissue pressure from a temporary prosthesis, poor adaptation of the membrane and/or fixation screws, and so on. The membrane should not be in contact with an adjacent tooth, but instead the clinician should allow for 1 mm distance between the membrane and any tooth. Following fixation, the membrane can easily be trimmed/relieved around teeth with a 15 blade. Adequate release of the mucoperiosteal flaps and proper eversion of the flaps are paramount to achieving success utilizing this technique. This is perhaps the most frequent cause of exposure. In certain circumstances, an early membrane exposure may be "nursed" along until 4–6 weeks post surgery before it must be removed. If so, this may prevent complete loss of the bone graft. Various studies report a range in non-resorbable membrane exposure of 9–18% [16–17].

Dentlearn.ir

Another complication that arises during GBR procedures is infection. It is important to scale the teeth near the surgical site to debride the area of visible plaque and calculus. It is also recommended to rinse with 0.12% chlorhexidine gluconate for at least 30 seconds prior to surgical entry. Improper handling of the flap, membrane, bone materials, and armamentarium may result in post-surgical infection.

DISCUSSION

In the treatment of alveolar bone defects in preparation for implant placement, when GBR is being utilized there are several important factors to consider:

- Morphology of the defect (i.e. the presence or absence of bridge concavities, vertical and horizontal bone loss, or a combination defect).
- Size of the ridge defect, and length of healing time anticipated for successful augmentation.
- Systemic health of the patient.
- Experience of the clinician.

In deciding on what type of occlusive barrier to use in a GBR case, resorbable or non-resorbable, bio-resorbable membranes have fewer complications, are generally easier to adapt, and successful in morphological defects that are conducive morphological defects are conducive to space maintenance and require no fixation. In a clinician's early learning curve with GBR, the use of resorbable membranes are recommended, treating defects that are primarily horizontal in nature.

In larger alveolar ridge defects, especially those with both vertical and horizontal bone loss, use of a non-resorbable barrier is often required. Although this chapter primarily focuses on the treatment of horizontal bone defects, in cases where both vertical and horizontal defects are treated simultaneously, using a more rigid barrier to maintain a three-dimensional space is more predictably accomplished with these types of space-maintaining devices [18, 19]. The two primary non-resorbable barriers are titanium mesh and dPTFE. As a result of extensive experience with both barriers, the authors' choice in most cases is dPTFE reinforced with titanium (Cytoplast). When using any non-resorbable barrier, achieving tension-free flap closure is extremely important to keep the barrier completely covered during the entire regeneration period. Because the primary complication with the use of non-resorbable barriers is membrane exposure, titanium mesh and perforated dPTFE membranes generally become infected much earlier due to bacterial invasion through the barrier, resulting in graft failure. dPTFE's small pore size prevents bacterial invasion, allowing an exposed membrane to remain functional as a GBR barrier for at least 4–6 additional weeks, sometimes longer. This is a significant advantage of dPTFE over the other barriers. In some cases when using a titanium-reinforced Cytoplast membrane where biologics are planned to be used, utilizing its perforated membrane may be advantageous. The perforations allow easy access of the growth factors to the graft site, while the membrane itself still functions as an occlusive barrier. However, the risk of this type of barrier is that if it becomes exposed early on during the healing process, microorganisms can easily go through the pores and rapidly infect the graft. This type of barrier should only be used when the clinician has had some degree of experience with the dPTFE membrane.

As mentioned earlier, resorbable membranes are often chosen with treating smaller, less challenging defects. Although early exposure generally does not lead to infection, it does accelerate resorption of the membrane and less bone regeneration. It is still important to complete adequate flap release to provide primary flap closure with these membranes.

In the authors' experience, the Ossix Plus membrane may rival non-resorbable barriers when augmenting large buccal-lingual ridge defects. This membrane remains intact as a barrier out to 25 weeks, is well tolerated, and has been used extensively in horizontal GBR cases by the author with predictable results. If sufficient tenting is combined with primary flap closure, some limited vertical augmentation is often achieved. In cases where vertical augmentation of more than 2–3 mm is necessary, non-resorbable membranes prove to be superior to resorbable membranes [19, 20].

CONCLUSION

Horizontal bone augmentation with GBR will continue to be a useful technique for alveolar ridge augmentation for patients needing implant therapy. As tissue engineering with biologics continues to evolve, this technique will continue to improve clinical outcomes. Despite new advances, the basic surgical techniques in GBR will remain critical for predictable clinical results.

REFERENCES

1. Nyman S, Lindhe J, Karring T, Rylander H. New attachment following surgical treatment of human periodontal disease. *J Clinical Periodontol.* 1982;9(4):290–96.
2. Buser D, Bragger U, Lang NP, Nyman S. Regeneration and enlargement of jawbone using guided tissue regeneration. *Clin Oral Implants Res.* 1990;1(1):22–32.

Dentlearn.ir

3. Sonick M, Hwang D. Guided bone regeneration: concepts and materials. In M Sonick, D Hwang (eds.), *Implant Site Development*. Chichester: Wiley; 2012, 153–4.

4. Greenstein G, Greenstein B, Cavallaro J et al. Flap advancement: Practical techniques to attain tension-free primary closure. *J Periodontol.* 2009;80(1):4–15.

5. Nishimura I, Shimizu Y, Ooya K. Effects of cortical bone perforation: An experimental guided bone regeneration. *Clin Oral Implants Res.* 2004;15:293–300.

6. Frost H. The regional acceleratory phenomenon: A review. *Henry Ford Hosp Med J.* 1983;31:3–9.

7. Becker W, Becker BE, McGuire MK. Localized ridge augmentation using absorbable pins and e-PTFE barrier membranes: A new surgical technique. Case reports. Int J Periodont *Restorative Dent.* 1994;14(1):48–61.

8. Mormann W, Ciancio SG. Blood supply of human gingiva following periodontal surgery: A fluorescein angiographic study. *J Periodontol.* 1977;48(11):681–92.

9. Greenstein G, Greenstein B, Cavallaro J, Tarnow D. The role of bone decortication in enhancing the results of guided bone regeneration: A literature review. *J Periodontol.* 2009;80(2):175–89.

10. Silverstein L, Kurtzman D, Shatz P. *Principles of hard tissue regeneration and implant therapy: A complete step-by-step guide*, vol. 7A(1). Newtown, PA: Aegis Communications; 2010, 249–50.

11. Machtei EE. The effect of membrane exposure on the outcome of regenerative procedures in humans: A meta-analysis. *J Periodontol.* 2001;72(4):512–16.

12. Fontana F, Santoro F, Maiorana C et al. Clinical and histologic evaluation of allogenic bone matrix versus autogenous bone chips associated with titanium reinforced e-PTFE membrane for vertical ridge augmentation: A prospective pilot study. *Int J Oral Maxillofac Implants.* 2008;23:1003–12.

13. Jovanovic SA, Nevins M. Bone formation utilizing titanium reinforced barrier membranes. *Int J Periodont Restorative Dent.* 1995;15:57–69.

14. Buser D, Dula K, Belser U et al. Localized ridge augmentation using guided bone regeneration. 1. Surgical procedure in the maxilla. Int J Periodont *Restorative Dent.* 1993;13(1):29–45.

15. Simion M, Baldoni M, Rossi P et al. A comparative study of the effectiveness of e-PTFE membranes with and without early exposure during the healing period. *Int J Periodont Restorative Dent.* 1994;14:166–80.

16. Merli M, Migani M, Bernardelli F, Esposito M. Vertical augmentation with dental implant placement: Efficacy and complications associated with 2 different techniques. A retrospective cohort study. *Int J Oral Maxillofac Implants.* 2006; 21(4):600–6.

17. Machtei E. The effect of membrane exposure on the outcome of regenerative procedures in humans: A meta-analysis. *J Periodontol.* 2001;72(4):512–16.

18. Strietzel FP, Khongkhunthian P, Khattiya R et al. Healing pattern of bone defects covered by different membrane types – a histologic study in the porcine mandible. *J Biomed Mater Res B Appl Biomater.* 2006;78(1):35–46.

19. Tinti C, Parma-Benfenati S, Polizzi G. Vertical ridge augmentation: What is the limit? *Int J Periodont Restorative Dent.* 1996;16(3):220–29.

20. Simion M, Jovanovic SA, Tinti C, Benfenati SP. Long-term evaluation of osseointegrated implants inserted at the time or after vertical augmentation: A retrospective study on 123 implants with 1–5 year follow up. *Clin Oral Implants Res.* 2001;12(1):35–45.

Dentlearn.ir

Autogenous Block Bone Graft for Horizontal Ridge Augmentation in Implant Dentistry

CHAPTER 12

This chapter will review non-vascular autogenous block bone grafts in oral and maxillofacial bone grafting for horizontal-type bone defects. Several cases of horizontal ridge augmentation in different locations with various sizes will be presented with favorable outcomes. The most effective surgical plan, regenerative technique, and type and amount of bone graft can be ultimately determined by the restoratively driven implant treatment plan.

Dentlearn.ir

CHAPTER 12

Autogenous Block Bone Graft for Horizontal Ridge Augmentation in Implant Dentistry

Arash Khojasteh[1,2] and Farshid Bastami[1]

[1]*Department of Oral and Maxillofacial Surgery, Dental Research Center, Research Institute of Dental Sciences, Shahid Beheshti University of Medical Sciences, Tehran, Iran*

[2]*Faculty of Health and Medicine, University of Antwerp, Belgium*

Implant-supported prosthesis in age-related jawbone atrophy following tooth extraction is a great challenge for oral and maxillofacial surgeons. Selection of appropriate donor site, surgical experience with augmentation technique, and most importantly analyzing the recipient sites have made decision-making complex [1,2]. The goal for treatment of atrophied bone is to achieve normal anatomical shape and size for a prosthetic-driven dental implant placement [3]. Jawbone atrophy presents from a small, localized defect to an extensive large-span edentulous area with horizontal or vertical bone loss [4]. In this chapter we will focus on pre-prosthetic horizontal augmentation of maxillomandibular bone. Autogenous bone has been suggested as the gold standard for bone augmentation due to its having osteogenic cells, morphogenetic proteins, and native mechanical bone structure. Recent advancements in the knowledge of bone physiology have led to the introduction of regenerative techniques whose outcomes are comparable with autogenous bone grafts. Guided bone regeneration (GBR) with the aid of various bone substitutes, membranes, and inductive molecules helps to augment atrophied ridges with more conservative techniques [5–8].

Alternative approaches, such as anatomical transpositioning (sinus lifting in the posterior maxilla and nerve lateralization in the posterior mandible) [9,10], zygomatic implants in the maxilla [11], and three-dimensional printed subperiosteal implants [12], can bypass autogenous bone grafting to rehabilitate edentulous patients. On the other hand, the combination of regenerative techniques with local donor sites lessens the use of extraoral donor sites in larger defects and decreases the rate of hospitalization and costs in atrophic ridge augmentation. The use of proper technique to harvest bone from intraoral donor sites, and appropriate preparation in either cortical or particulate form, can provide a stable 4–6 mm increase in the width/height of new regenerate bone [13]. Extensive or large atrophy still needs a larger amount of bone that should be harvested from extraoral donor sites.

Although free non-vascular block bone grafts showed lower survival with late bone resorption, adding regenerative techniques increases the outcome following dental implant placement. Anterior and posterior ilium, cranium, and rib are the common extraoral donor sites used for block bone augmentation (BBA) [14]. Block bone traditionally was fixed over the recipient site as an overlying bone, termed onlay bone grafting (OBG). With the advent of GBR, autogenous cortical plate could be tented over the recipient site, termed cortical autogenous tenting (CAT), to increase the width or height of the protected healing space [15,16]. Bone tissue engineering concepts such as RhBMP-2, platelet concentrations [17], mesenchymal stem cells [18], and bio-printed scaffolds [19] might change the future of BBA to be more conservative and cost-effective for patients.

RECIPIENT SITE ANALYSIS

The type of defects in the recipient site can affect the outcomes of regeneration protocols [2], which can be defined by the location, morphology, and size of the defect. Anterior and posterior parts of the maxilla and mandible represent dissimilar bone qualities. This categorization is based on the location of the bone defects (anterior, posterior, and the combination of both locations) and their size (small, medium, and large). This classification is briefly called the LMS system: **L**ocation, **M**orphology, and **S**ize of the defect [20,21]. The cortical and

Essential Techniques of Alveolar Bone Augmentation in Implant Dentistry: A Surgical Manual, Second Edition. Edited by Len Tolstunov.
© 2023 John Wiley & Sons, Inc. Published 2023 by John Wiley & Sons, Inc.
Companion website: www.wiley.com/go/tolstunov/essential

Dentlearn.ir

cancellous nature of the bone [22] and the difference in bone quality can affect donor site selection. Recipient and donor bone from the same niche match better during the grafting procedure and lessen the time of the operation [23]. Moreover, proximity to important anatomical structures such as the inferior alveolar nerve in the posterior mandible and the maxillary sinuses in the posterior maxilla must be considered in treatment planning [10].

Alveolar bone defects can also be classified as peri-implant defects [24], extraction sockets [25], defects of sinus pneumatization in the posterior maxilla [26], and vertical and horizontal bone atrophy [27]. It is obvious that reconstruction strategies vary due to the anatomical and biological features of defects. The lower the number of bony walls, the more difficult it would be to maintain the space for bone regeneration [28]. The recipient site surface area in contact with the bone graft is an important factor in the revascularization stage that can simplify the proliferation and differentiation of osteogenic cells [29,30]. In the regeneration process in the sinus cavity, socket preservation, fenestration and dehiscence-type defects, a repair can be successfully performed with bone-substitute materials alone because of the multiwall recipient bone. Horizontal- and vertical-type defects with complicated morphologies need the use of complex techniques to succeed, mostly with autogenous bone.

In horizontal-type defects, the available bone width can provide a favorable space for ridge augmentation and GBR. Augmentation of larger defects is more challenging and they are often reconstructed by extraoral bone blocks [2]. However, intraoral donor sites and new regenerative techniques, using bone blocks and bone substitutes simultaneously, have reduced the need for autogenous bone obtained from extraoral sources [7].

Reconstruction of alveolar defects in the anterior mandible is like in the anterior maxilla, except for the presence of thin periodontal tissue and interdental dehiscence, which make the surgery more sensitive in this region. For instance, the surgery can loosen the adjacent teeth in the anterior mandible and avoiding trauma to the teeth adjacent to this region has been suggested during reconstructive surgery.

Free autogenous bone graft can be obtained in three forms: cortical, cancellous, and cortico-cancellous. Cortical autogenous bone graft can withstand premature and early forces, but needs more time for revascularization.

The common sites of cortical bone graft are the cranium, iliac crest, ribs, mandibular symphysis, and lateral ramus. A cancellous autogenous bone graft can significantly increase new bone formation, but its disadvantages are the inability to provide mechanical stability and more resorption than cortical grafts [31]. The common sites of cancellous bone graft are the anterior and posterior iliac crests [13]. Cortico-cancellous bone grafts, obtained from the ribs, iliac crest, and calvarium, not only provide mechanical stability, but also increase osteogenesis. However, their osteogenesis is lower than for cancellous bone grafts due to their cortical layer.

FIGURE 12.1 Schematic picture of onlay bone graft for horizontal augmentation of atrophic ridge.

BLOCK BONE AUGMENTATION TECHNIQUES

ONLAY BONE GRAFTING

Three-dimensional reconstruction of atrophied ridges can be achieved by block bone grafting harvested from extra- or intraoral donor sites. OBG follows the same biological rules as the other regeneration techniques. A schematic image of OBG for horizontal augmentation of an atrophic ridge is provided in Figure 12.1. Adequate primary stability of the graft on the recipient site is essential, and can be obtained by insertion of micro-screws or even dental implants [32]. During the healing period, grafted block bone is gently replaced by newly formed bone. This process depends on revascularization from the recipient site [33]. Hence, it is suggested that the recipient site should be perforated to improve angiogenesis and prepare osteogenic cells [34]. Donor site morbidity is the major downside of autogenous OBG [35]. The other major disadvantage of OBG is the limited availability of autogenous block bone. OBG is a technique-sensitive procedure due to the long treatment time, risk of graft failure, and donor site complications. Simultaneous implant insertion may be considered to shorten the treatment time, even though bone graft complications, including exposure of the graft, infection, and graft failure, can lead to dental implant failure [13]. The survival of dental implants inserted in autogenous block bone was 73.8–100% and 72.8–100%, and in allogenic block bone 95.3–100% and 93.7–100% [36].

GUIDED BONE REGENERATION AND ONLAY BONE BLOCK GRAFTING

Covering OBG by a barrier membrane can decrease the postoperative resorption [37]. The barrier membranes used in GBR

Dentlearn.ir

should have certain features, including biocompatibility, preventing cell penetration, integrity with the host tissue, simple clinical management, and ability for space maintenance [38].

Bone blocks can preserve adequate space under the membrane, so collapse of the membrane can be prevented. Nonetheless, using resorbable membranes is more common than non-resorbable ones due to their soft tissue complications [39]. An important point that should be noted in the GBR technique is the stability of the membrane: the less the membrane stability, the less new bone formation there is. In addition, exposure of membrane to the oral cavity can negatively affect new bone formation [40]. In fact, resorbable membranes in combination with cortical blocks can act as a titanium membrane to preserve the space with less soft tissue exposure.

In simultaneous use of OBG and GBR, bone-substitute materials fill the spaces between the onlay block and recipient site, and are finally covered by a barrier membrane [37]. In fact, the resorption of onlay bone block is compensated by bone-substitute materials. In the anterior maxilla, using bovine bone mineral block combined with autogenous particulate bone showed an optimal horizontal gain of about 8.73±0.82, with a resorption rate of 7.03%, six months postoperatively [41]. Fixation of bone blocks harvested from either the symphysis or retromolar regions covered by xenograft bone particulates and a collagen membrane showed a minor resorption of 0.36 mm during a mean healing period of 5.8 months [37]. Barone and Covani harvested bone block from ilium and xenograft particles to vertically or horizontally augment atrophied maxillary ridges [42]. They demonstrated that the mean marginal bone loss around dental implants placed 4–5 months after bone grafting was 0.05 mm in both anterior and posterior defects less than 5 mm. Boronat et al. reported that the mean marginal bone loss was about 0.64 mm one year after implant loading in only horizontal defects using autogenous bone with an intraoral source [43]. A noticeable complication reported in this technique is a fistula through the non-integrated bovine blocks on the buccal sides of the augmented area six years after dental implant loading [41].

CORTICAL AUTOGENOUS TENTING

A thin autogenous bone block from intraoral sources tented over the recipient site can act as an alternative to a covering membrane, in order to create a protective space for bone particles [44]. This technique has also been termed cortical autogenous tenting. A schematic picture of CAT for horizontal ridge augmentation is provided in Figure 12.2. In this technique, cortical bone acts as an osteogenic membrane, provide a protective roof for the healing space. Moreover, the pressure of soft tissue is removed from the underneath bone particles by the bone block [45]. Lateral ramus and symphyseal cortical bone grafts can be used for the CAT technique with desirable outcomes [13].

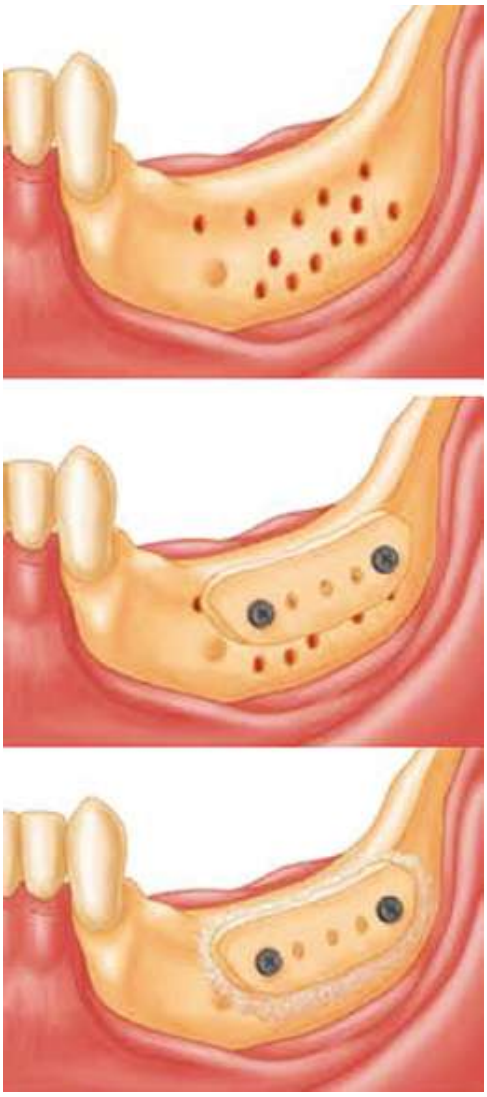

FIGURE 12.2 Schematic picture of horizontal bone augmentation using the cortical autogenous tenting technique,

For this procedure, multiple cortical perforations are made on the recipient site surface to improve revascularization and induce the rapid acceleration phenomenon during the healing process. In horizontal augmentation, cortical bone graft is fixed on the recipient site surface with a distance of 3–4 mm. The cortical bone can be divided by a reciprocating saw into two thinner segments, and each segment can be fixed on either the buccal or the lingual side. The protective space made between the cortical bone and the surface of the recipient site is filled by bone-substitute materials such as allografts, xenografts, or synthetic bone materials, alone or in combination with autogenous bone particles in a 1:1 ratio. When the cortical bone has a thickness more than 2 mm, it can be made thinner by a bone scraper, during which autogenous particles are also obtained. Osteogenic cells in the region are derived

Dentlearn.ir

from stem cells on the recipient site surface, osteoblasts and osteocytes in the bone graft, and mesenchymal stem cells in the inner layer of the periosteum under the gingiva.

The multiple CAT or bilateral CAT technique has been introduced for reconstruction of larger bone defects such as type B and C defects in the ABC classification [2]. A large cortical bone is harvested from the lateral ramus and divided into two or three parts, then fixed on each side of the atrophic ridge.

Khojasteh et al. demonstrated that vertical and horizontal ridge augmentations by the CAT technique were reported at about 3.6 mm and 3.85 mm, respectively, which showed no significant difference to the results of the OBG technique reported by other studies [13]. To illustrate, less need for autogenous bone is the advantage of the CAT technique over OBG, using bone-substitute materials, which leads to simple and fast surgery.

REGENERATIVE TECHNIQUES IN BONE GRAFTING

PLATELET DERIVATIVES

In 1988, Marx introduced the application of platelet-rich plasma (PRP) for bone regeneration [46]. Eskan et al. have investigated the effects of the addition of PRP to cancellous allograft for horizontal ridge augmentation using GBR, and demonstrated a significant increase in both the crestal ridge width and the percentage of vital bone in comparison to the control group. The rate of resorption after augmentation decreased from 34%±17% to 28%±17% when PRP was added [47].

In a retrospective study, Lorenzetti et al. demonstrated the management of atrophic knife-edge ridges with Cawood-Howell class IV using xenograft bone particulates, plasma rich in growth factors (PRGF), and a resorbable membrane [48]. They observed mature lamellar bone with no signs of inflammation or necrosis after 1 and 5 years of bone grafting. In horizontal bone augmentation, Moussa et al. evaluated the addition of platelet-rich fibrin (PRF) to autogenous palatal bone blocks in the anterior maxillary ridge of less than 4.5 mm, and compared it with using bone blocks only [49]. They demonstrated a significant increase in the width of the ridge in both groups after 4 months, even though the test group indicated less graft resorption compared to the control group, 0.8±0.6 mm versus 1.6±0.9 mm. Furthermore, using a combination of injectable PRF/L-PRF (leucocyte- and platelet-rich fibrin) and bone-substitute materials during GBR demonstrated favorable horizontal and vertical augmentation in atrophied ridges of the posterior mandible [50].

MESENCHYMAL STEM CELLS

The most used stem cells for regeneration of bone tissue are adult stem cells derived from bone marrow – bone marrow stem cells (BMSCs). Their ability to differentiate into osteoblasts *in vitro* and the formation of engineered bone *in vivo* have been demonstrated [51,52]. Khojasteh and Sadeghi reported greater bone formation using iliac bone graft in combination with buccal fat pad–derived cells (BFPSCs) compared to using iliac bone graft alone in a horizontal bone block (Figure 12.3) [6]. Multiple factors can influence the results of bone regeneration, including methods of cell delivery, incubation period, possible use of growth factor, using adhesive agents, genetic modifications, and the size of the defect, which is the most important factor. In our studies, synthetic scaffolds demonstrated better outcomes in bone regeneration with the same cell delivery methods [27,53–62]. The combination of MSCs with PRGF as an adhesive agent with biphasic calcium phosphate scaffold can enhance the amount of bone formation in the alveolar cleft by up to 52% [57].

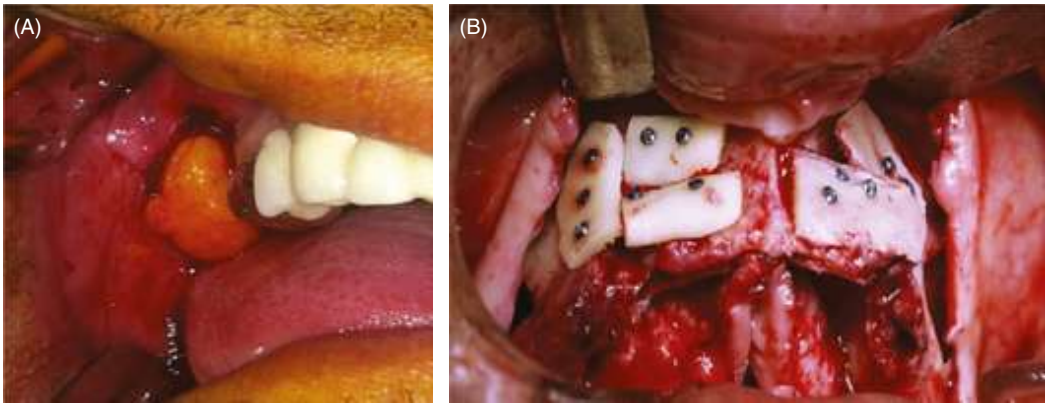

FIGURE 12.3 Horizontal bone augmentation using buccal fat pad–derived cells (BFPSCs). (A) Buccal fat pad exposure from a lateral vestibular incision; sufficient buccal fat pad (3–4 mL) for the culture of stem cells can be harvested. (B) Fixation of bone blocks harvested from the anterior iliac crest on the alveolar buccal side. (C) Filling the spaces by allograft particles loaded with BFPSCs. (D) Using collagen membrane for protection of the healing space. (E) Cone beam computed tomography evaluation of the augmented bone at the time of implant insertion.

Dentlearn.ir

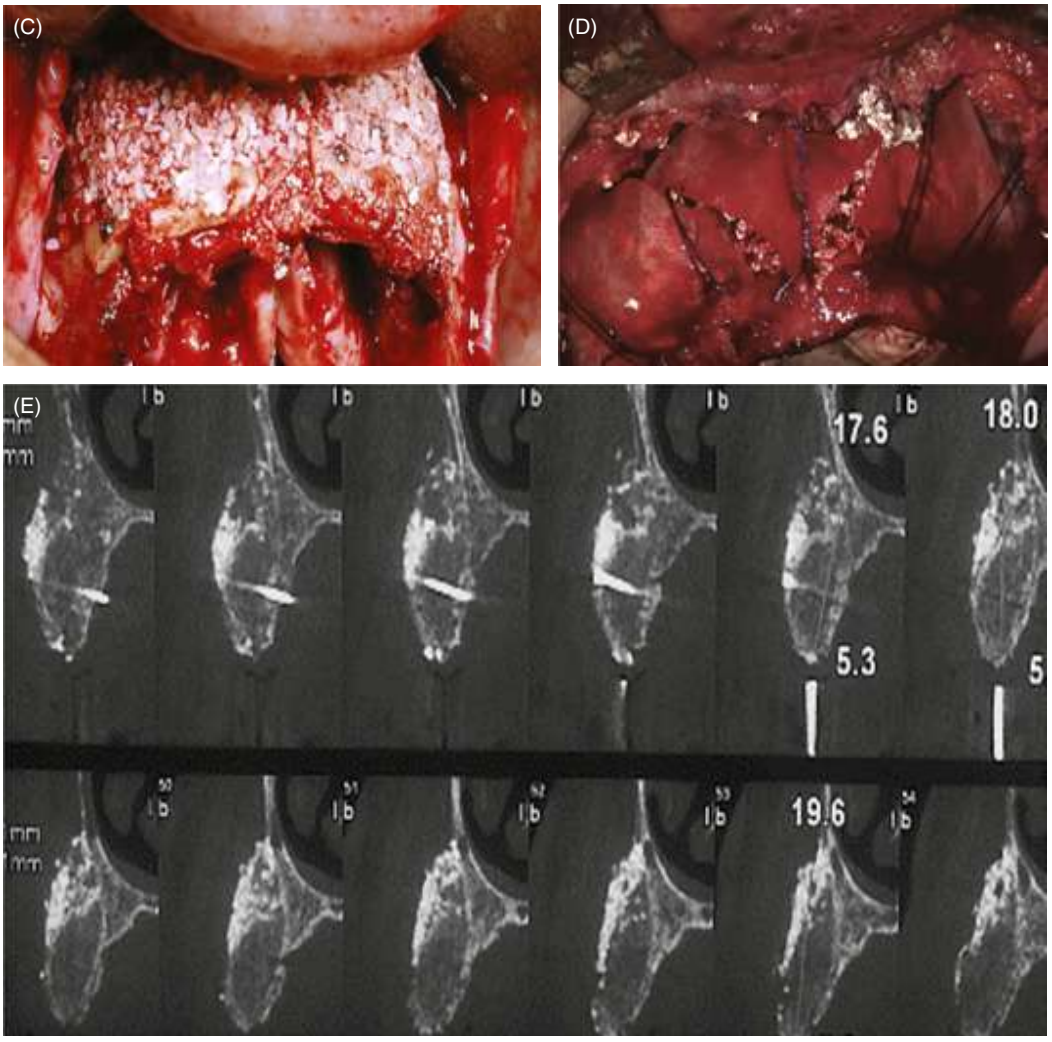

FIGURE 12.3 (*Continued*)

CASE PRESENTATIONS

CASE 1

- Location: Anterior maxilla
- Morphology: Horizontal defect
- Length 10 mm, width <3 mm
- Technique: Onlay bone grafting (tunneling technique)
- Donor site: Lateral ramus

A small horizontal defect (limited to a single tooth) can be treated by autogenous block bone with a predictable outcome. In the esthetic zone where a large incision can affect the esthetic outcome, two small (5–10 mm) vertical incisions may be sufficient for surgical access (Figure 12.4A). Subperiosteal tunnel dissection to the nasal floor provides enough access for the bone block fixation. It is better to retract the labial tissue with a vascular tape or lacrimal probe elastic band to prevent soft tissue injury during bone graft preparation and fixation (Figure 12.4B). In the presented case, bone block was fixed with two micro-screws and L-PRF was applied over the grafted block (Figure 12.4C, D). Soft tissue healing was even and little or no scar could be seen (Figure 12.4E, 2 weeks post-op; Figure 12.4F, 4 months post-op). Surgical re-entry at five months post operation revealed complete bone integration (Figure 12.4G).

Dentlearn.ir

FIGURE 12.4 (A) Short vertical incision design in the anterior maxilla for block bone augmentation. (B) Subperiosteal dissection through the nasal floor could be done by tunneling between two vertical incisions. (C) Lateral ramus cortical bone plate (LRCP) fixed with micro-screw with careful retraction of soft tissue pedicle. (D) Application of leucocyte- and platelet-rich fibrin (L-PRF) to enhance soft tissue healing. (E) Soft tissue healing two weeks following surgery. (F) Minimum scar was evident four months following augmentation. (G) Appropriate integration of block bone to recipient site.

CASE 2

Location: Anterior maxilla

- Morphology: Horizontal defect
- Length 12 mm, width 3.5 mm
- Technique: Bilateral cortical autogenous tenting
- Donor site: Lateral ramus

The length of the edentulous ridge was about 10 mm. A lateral ramus cortical plate was fixed with the bilateral CAT technique (Figure 12.5A, B). The cortical bone was divided into two parts and fixed to the labial and palatal sides of the ridge. After 5 months, new bone regeneration was favored for dental implant placement (Figure 12.5C, D).

CASE 3

- Location: Anterior mandible
- Morphology: Horizontal defect
- Technique: Bilateral cortical autogenous tenting
- Donor site: Symphysis

In this case the length of the edentulous ridge was like in Case 2, so successful reconstruction was obtained using the bilateral CAT technique (Figure 12.6). The symphysis was selected as the donor site due to the proximity to the reconstruction area. L-PRF was used to cover the augmented tissue. After 5 months, successful horizontal bone augmentation was observed after flap elevation. Evaluation of the crestal bone level at the neighboring teeth also revealed successful periodontal attachment regeneration.

Dentlearn.ir

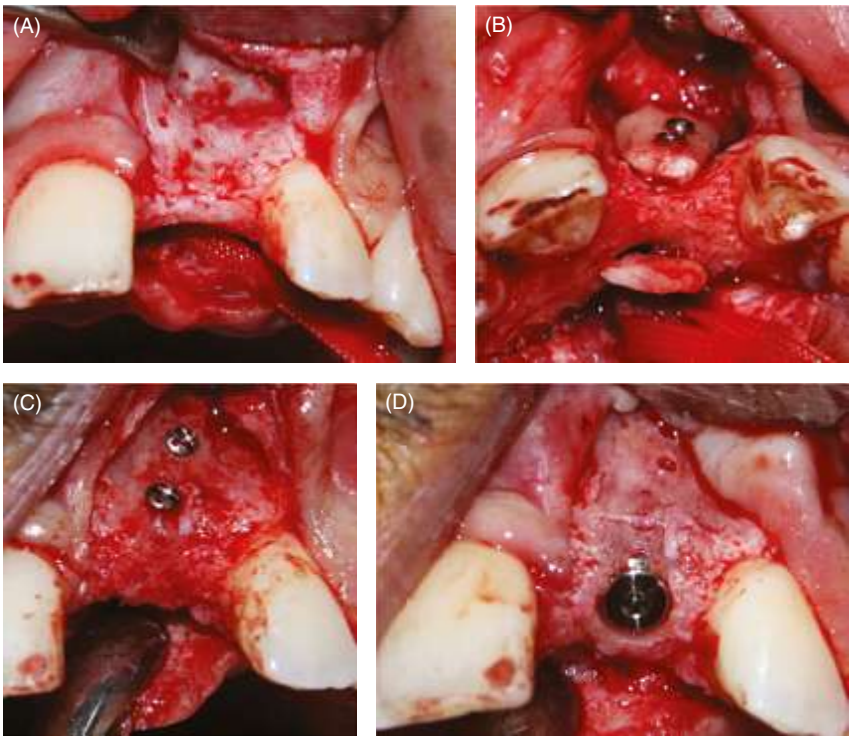

FIGURE 12.5 (A–D) A bilateral cortical autogenous tenting technique in horizontal bone augmentation of the anterior maxilla with labial and palatal simultaneous width augmentation.

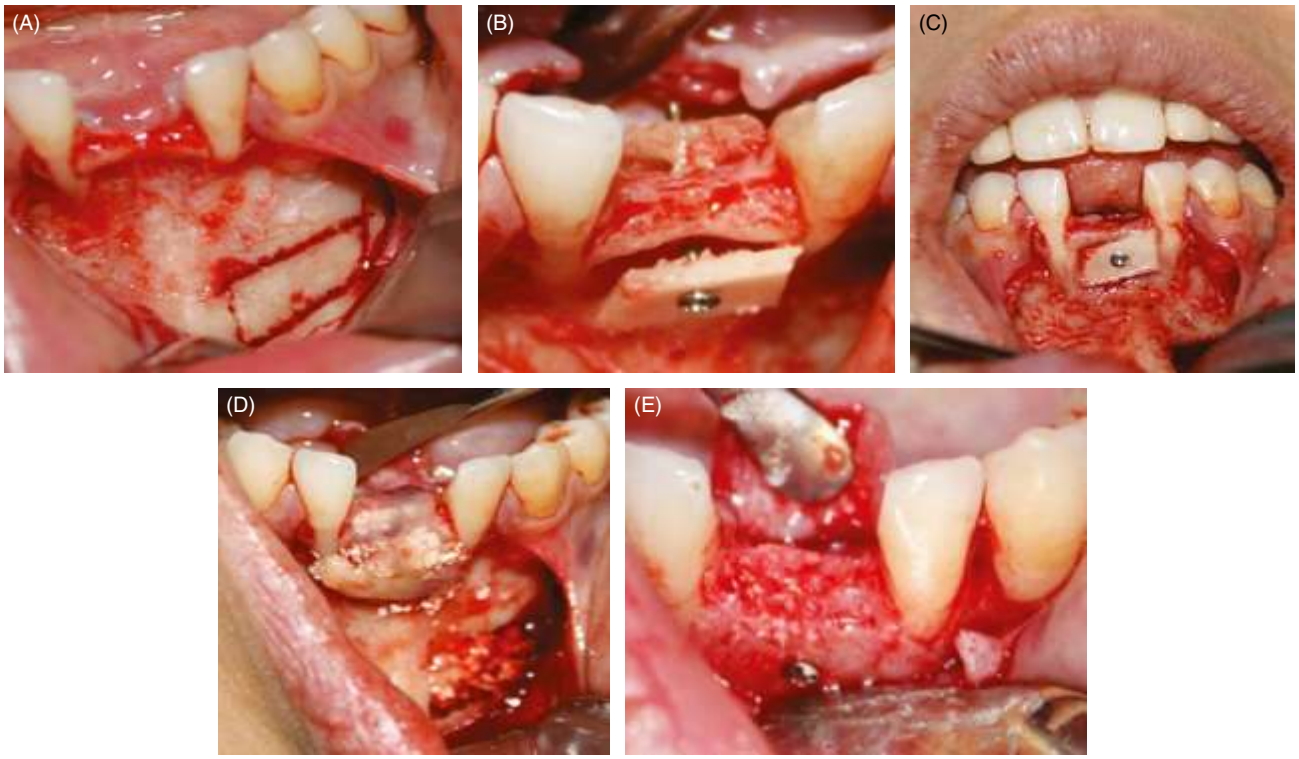

FIGURE 12.6 (A–C) Bilateral cortical autogenous tenting with chin block in horizontal augmentation of the anterior mandible. (D) Application of leucocyte- and platelet-rich fibrin (L-PRF) over the augmented bone. (E) Five-month post-operative healing showing an appropriate bone dimension in defect site and regeneration of new periodontal apparatus in the adjacent teeth.

Dentlearn.ir

CASE 4

- Location: Anterior maxilla
- Morphology: Horizontal defect
- Length 30 mm, width <2.5 mm
- Technique: Onlay bone graft + bilateral cortical autogenous tenting
- Donor site: Lateral ramus of the mandible

The edentulous span was 4 cm in length and the width was less than 3 mm in the mesial part and less than 2 mm in the distal part of the defect (Figure 12.7A). For BBA, more cortical bone should be harvested. A cortical bone plate with a length of 40 mm was harvested from the lateral ramus (Figure 12.7B), divided into two equal parts. The bilateral CAT technique was used for horizontal augmentation in the distal part of the defect and an OBG was chosen for the mesial part (Figure 12.7C). L-PRF was prepared in two forms of solid and liquid from 20 cc autogenous patient blood (Figure 12.7D). A combination of

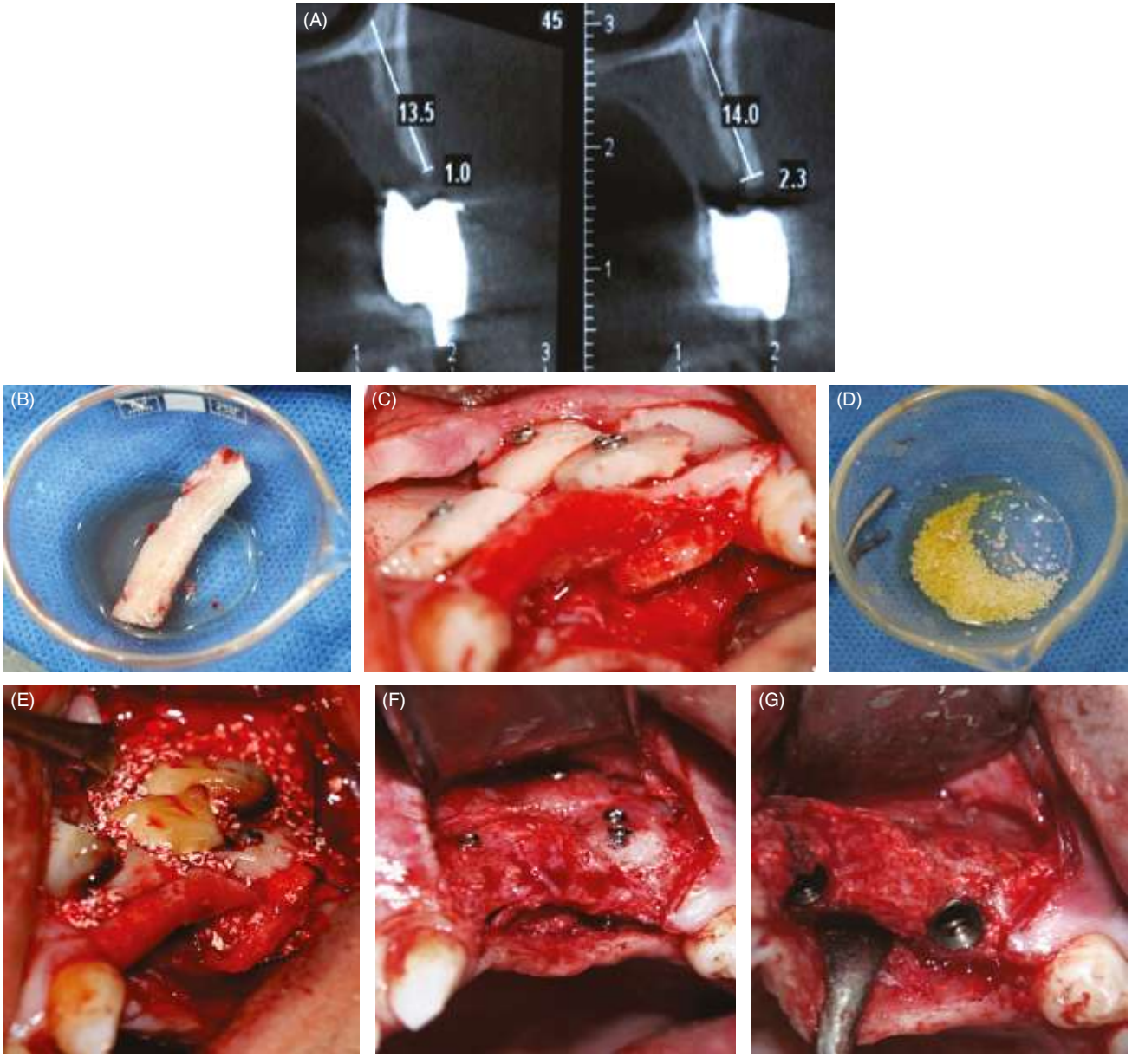

FIGURE 12.7 (A) A horizontal defect in the anterior maxilla with a length of 3 cm. The defect had A2 morphology on the mesial side and A3 morphology on the distal side. (B) 4 cm of lateral ramus cortical bone plate (LRCP) was harvested. (C) The block has been cut into three pieces and fixed with the onlay bone graft technique on the mesial side (A2) and bilateral cortical autogenous tenting on the distal side (A3). (D) Bovine bone mineral was mixed with liquid platelet-rich fibrin (PRF). (E) Solid PRF was applied over the augmented site. (F–G)After five months, the whole of the defect showed favorable new bone formation, even in the middle part filled by the bone substitute alone. Two dental implants have been installed successfully.

Dentlearn.ir

bovine bone mineral and liquid L-PRF was used to fill the gaps between the cortical bone and recipient site, and solid L-PRF was used to cover the augmented site (Figure 12.7E). After 5 months, the whole defect showed favorable new bone formation, even in the middle part filled by the bone substitute alone (Figure 12.7F, G). To illustrate, lateral ramus cortical bones placed in anterior and posterior parts can act as new bone walls, which minimize the defect size in the middle part.

CASE 5

- Location: Anterior maxilla
- Morphology: Horizontal defect
- Length 60 mm, width <3 mm
- Technique: Onlay bone graft (left side) + guided bone regeneration (right side)
- Donor site: Lateral ramus

In the presented case there is an extensive horizontal bone defect in the anterior maxilla (Figure 12.8A) of more than 6 cm. A large harvested ramus cortical bone (4 cm) was not sufficient for the bone augmentation. Clinicians face a great dilemma in situations like this patient, between harvesting bone grafts from extraoral sources and alternative techniques such as zygomatic dental implants. However, in this case we harvested a large cortical bone from both right and left lateral ramus (Figure 12.8B). One cortical plate was milled to form a particulate bone graft and mixed with liquid L-PRF (Figure 12.8C). Then, the left side was treated by the OBG technique, and the other side was augmented only by a GBR approach (Figure 12.8D–H). On the left side, the cortical bone was fixed by micro-screws on the buccal side, but on the right side some micro-screws (diameter 1.5 mm, height 10 mm) were placed to fix the covering collagen membrane (Figure 12.8I). It is recommended that the micro-screws are placed in a divergent direction to provide more stability for the healing space. Soft tissue closure was done free of tension with continuous vertical mattress sutures. After 6 months, cone beam computed tomography evaluation demonstrated adequate horizontal augmentation on both sides (Figure 12.8J). Soft tissue healing followed and was found to be normal (Figure 12.8K). Surgical exposure showed enough new viable bone for dental implant placement (Figure 12.8L, M).

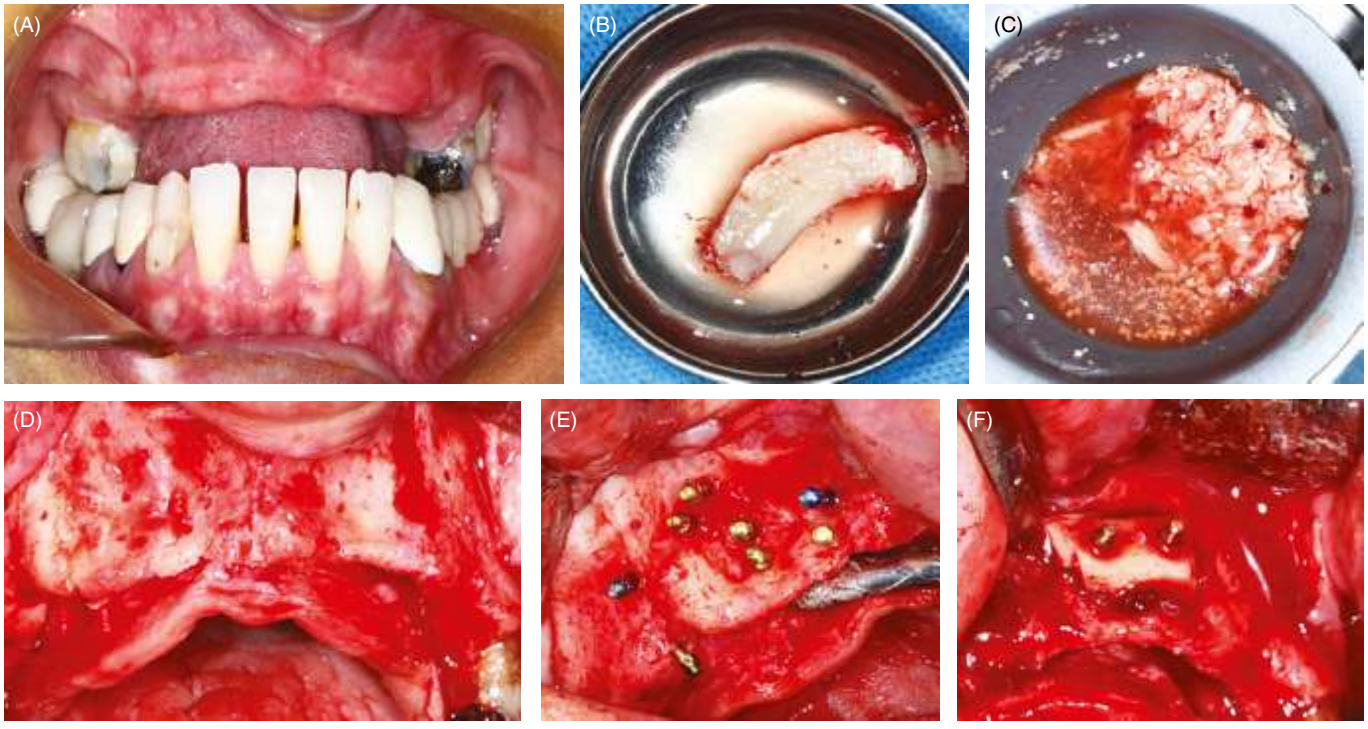

FIGURE 12.8 (A) An extensive defect in the anterior maxilla (>6 cm). (B) Lateral ramus cortical bone plate (2-LRCP) was harvested from the right and left sides. (C) One side was used to make particulate bone with bone mill and mixed with bovine bone mineral and liquid platelet-rich fibrin. (D–I) The cortical bone is fixed as an onlay graft on the left side, whereas the paucity of intraoral donor caused the technique to be changed to guided bone regeneration on the right side. The tenting screws were installed in a divergent manner to provide maximum stability for the covering membrane. (J–M) Six months post operation showed an appropriate amount of new bone formation on both sides and the possibility of an intraoral donor site for a large defect in the anterior maxilla.

Dentlearn.ir

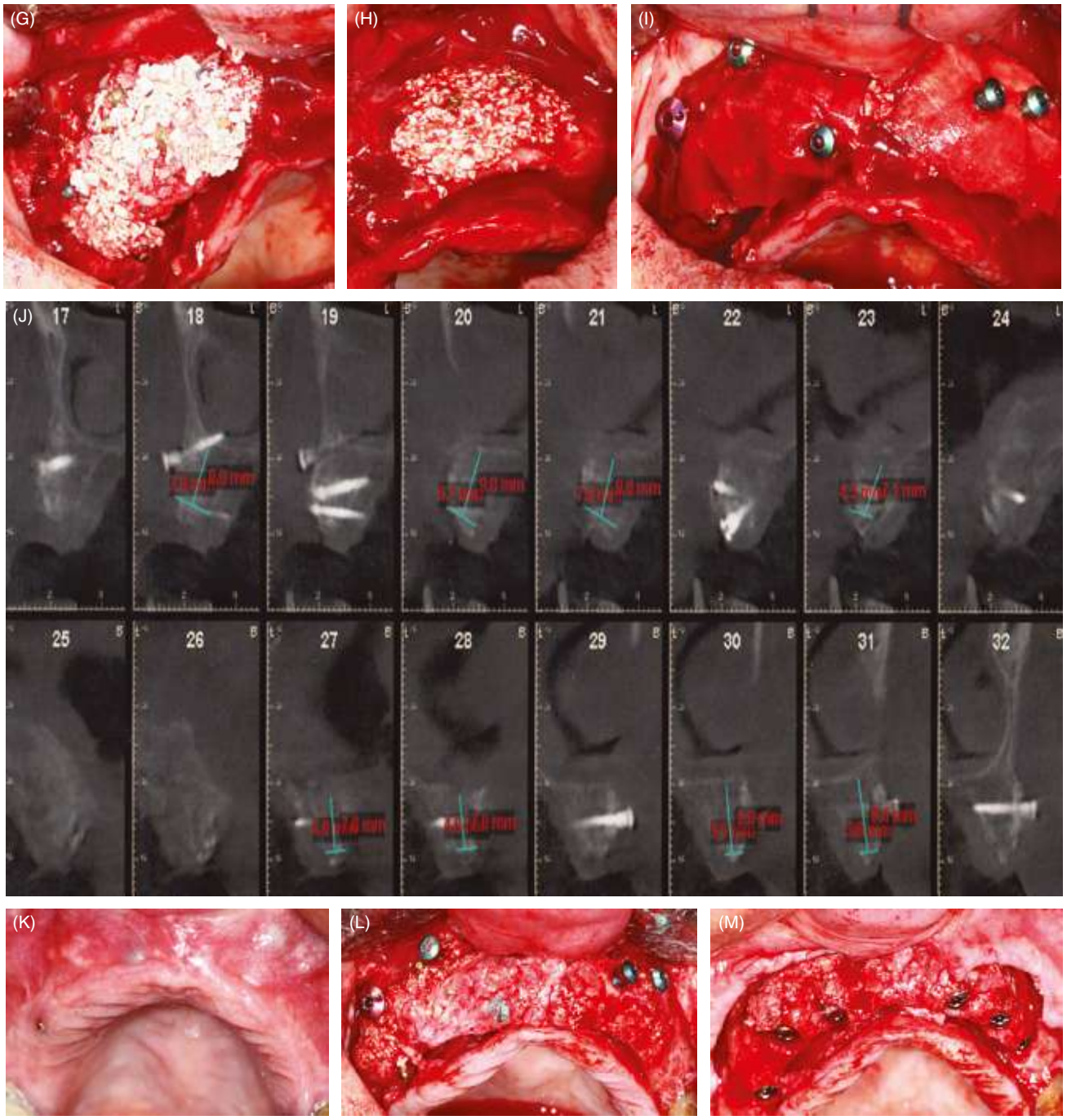

FIGURE 12.8 *(continued)*

CONCLUSION

This chapter has reviewed the more common types of techniques using non-vascular autogenous block bone grafts employed in oral and maxillofacial bone grafting for horizontal-type defects, according to the clinical expertise of the authors. The LMS system was represented to properly define the horizontal defect and achieve a predictable regenerative technique according to well-established evidence. Furthermore, several cases of horizontal ridge augmentation in different locations with various sizes have been presented with favorable outcomes. The most effective surgical plan, regenerative technique, and type and amount of bone graft can be ultimately determined with the help of prosthetic implant treatment.

Dentlearn.ir

REFERENCES

1. Khojasteh A, Motamedian SR, Sharifzadeh N, Zadeh HHJ. The influence of initial alveolar ridge defect morphology on the outcome of implants in augmented atrophic posterior mandible: An exploratory retrospective study. *Clin Oral Implants Res.* 2017;28:e208–e217.
2. Khojasteh A, Morad G, Behnia H. Clinical importance of recipient site characteristics for vertical ridge augmentation: A systematic review of literature and proposal of a classification. *J Oral Implantol* 2013;39:386–98.
3. Nevins M, Mellonig JT. Enhancement of the damaged edentulous ridge to receive dental implants: A combination of allograft and the GORE-TEX membrane. *Int J Periodont Restorative Dent.* 1992;12(2):96–111.
4. Araujo MG, Wennström JL, Lindhe J. Modeling of the buccal and lingual bone walls of fresh extraction sites following implant installation. *Clin Oral Implants Res.* 2006;17:606–14.
5. Khojasteh A, Soheilifar S, Mohajerani H, Nowzari H. The effectiveness of barrier membranes on bone regeneration in localized bony defects: A systematic review. *Int J Oral Maxillofac Implants.* 2013;28(4):1076–89.
6. Khojasteh A, Sadeghi N. Application of buccal fat pad-derived stem cells in combination with autogenous iliac bone graft in the treatment of maxillomandibular atrophy: A preliminary human study. *Int J Oral Maxillofac Surg.* 2016;45:864–71.
7. Khojasteh A, Hosseinpour S. Challenges in the rehabilitation handling of large and localized oral and maxillofacial defects. In L Tayebi (ed.), *Applications of biomedical engineering in dentistry*. Cham: Springer; 2020, 239–62.
8. Khojasteh A, Hosseinpour S, Rad MR, Alikhasi M. Buccal fat pad–derived stem cells in three-dimensional rehabilitation of large alveolar defects: A report of two cases. *J Oral Implantol.* 2019;45:45–54.
9. Correia F, Pozza DH, Gouveia S et al. Advantages of porcine xenograft over autograft in sinus lift: A randomised clinical trial. *Materials.* 2021;14:3439.
10. Khojasteh A, Azizi S. Inferior alveolar nerve repositioning with simultaneous iliac bone autogenous graft for treatment of atrophic posterior mandibular ridge. *J Craniomaxillofac Res.* 2021;7(4):222–7.
11. Aparicio C, Manresa C, Francisco K et al. Zygomatic implants: Indications, techniques and outcomes, and the zygomatic success code. *Periodontology.* 2014;66:41–58.
12. Mangano C, Bianchi A, Mangano FG et al. Custom-made 3D printed subperiosteal titanium implants for the prosthetic restoration of the atrophic posterior mandible of elderly patients: A case series. *3D Print Med.* 2020;6:1–14.
13. Khojasteh A, Behnia H, Soleymani Shayesteh Y et al. Localized bone augmentation with cortical bone blocks tented over different particulate bone substitutes: A retrospective study. *Int J Oral Maxillofac Implants.* 2012;27(6):1481–93.
14. Yates DM, Brockhoff HC II, Finn R, Phillips C. Comparison of intraoral harvest sites for corticocancellous bone grafts. *J Oral Maxillofac Surg.* 2013;71:497–504.
15. Jensen OT. Alveolar segmental "sandwich" osteotomies for posterior edentulous mandibular sites for dental implants. *J Oral Maxillofac Surg.* 2006;64:471–5.
16. Jensen OT, Block MJ. Alveolar modification by distraction osteogenesis. *Atlas Oral Maxillofac Surg Clin N Am.* 2008;16:185–214.
17. Bastami F, Khojasteh A. Use of leukocyte- and platelet-rich fibrin for bone regeneration: A systematic review. *Regen Reconstr Restor.* 2016;1:47–68,
18. Ueda M, Sumi Y, Mizuno H et al. Tissue engineering: Applications for maxillofacial surgery. *Mat Sci Eng C Biomimetic Mat Sensor Sys.* 2000;13:7–14.
19. Bari E, Scocozza F, Perteghella S et al. 3D bioprinted scaffolds containing mesenchymal stem/stromal lyosecretome: Next generation controlled release device for bone regenerative medicine. *Pharmaceutics.* 2021;13:515.
20. Aghaloo TL, Moy PK. Which hard tissue augmentation techniques are the most successful in furnishing bony support for implant placement? *Int J Oral Maxillofac Implants.* 2007;22(suppl):49–70.
21. Broumand V, Khojasteh A, Green JM III. Vertical alveolar ridge augmentation with autogenous block grafts in implant dentistry. In L Tolstunov (ed.), *Vertical alveolar ridge augmentation in implant dentistry*. Hoboken, NJ: Wiley-Blackwell; 2016, 245–72.
22. Misch C, Judy K. Classification of partially edentulous arches for implant dentistry. *Int J Oral implantol.* 1987;4:7.
23. Hassani A, Khojasteh A, Shamsabad AN. The anterior palate as a donor site in maxillofacial bone grafting: A quantitative anatomic study. *J Oral Maxillofac Surg.* 2005;63:1196–200.
24. Bogaerde LV. A proposal for the classification of bony defects adjacent to dental implants. *Int J Periodont Restorative Dent.* 2004;24(3):264–71.
25. Caplanis N, Lozada JL, Kan JY. Extraction defect assessment, classification, and management. *J Calif Dent Assoc.* 2005;33(11):853–63.
26. Wang H-L, Katranji A. ABC sinus augmentation classification. *Int J Periodont Restorative Dent.* 2008;28(4):383–9.
27. Khojasteh A, Eslaminejad MB, Nazarian H et al. Vertical bone augmentation with simultaneous implant placement using particulate mineralized bone and mesenchymal stem cells: A preliminary study in rabbit. *J Oral Implantol.* 2013;39:3–13.
28. Wang H-L, Boyapati L. "PASS" principles for predictable bone regeneration. *Implant Dent.* 2006;15:8–17.
29. Einhorn TA, Lee CA. Bone regeneration: New findings and potential clinical applications. *J Am Acad Orthop Surg.* 2001;9:157–65.
30. Kim E-S, Kim J-J, Park E-J. Angiogenic factor-enriched platelet-rich plasma enhances in vivo bone formation around alloplastic graft material. *J Adv Prosthodont.* 2010;2:7–13.
31. Carlson ER, Marx RE. Mandibular reconstruction using cancellous cellular bone grafts. *J Oral Maxillofac Surg.* 1996;54:889–97.
32. Özkan Y, Özcan M, Varol A et al. Resonance frequency analysis assessment of implant stability in labial onlay grafted posterior mandibles: A pilot clinical study. *Int J Oral Maxillofac Implants.* 2007;22(2):235–42.
33. Burchardt H, Enneking W. Transplantation of bone. *Surg Clin N Am.*1978; 58:403–27.
34. Pikos MA. Block autografts for localized ridge augmentation: Part II. *The posterior mandible. Implant Dent.* 2000;9:67–75.

Dentlearn.ir

35. Scheerlinck LME, Muradin MSM, van der Bilt A et al. Donor site complications in bone grafting: Comparison of iliac crest, calvarial, and mandibular ramus bone. *Int J Oral Maxillofac Implants.* 2013;28(1):222–7.

36. Motamedian SR, Khojaste M, Khojasteh A. Success rate of implants placed in autogenous bone blocks versus allogenic bone blocks: A systematic literature review. *Ann Maxillofac Surg.* 2016;6:78.

37. Von Arx T, Buser D. Horizontal ridge augmentation using autogenous block grafts and the guided bone regeneration technique with collagen membranes: A clinical study with 42 patients. *Clin Oral Implants Res.* 2006;17:359–66.

38. Karring T, Nyman S, Gottlow J, Laurell LJP. Development of the biological concept of guided tissue regeneration—animal and human studies. *Periodontology.* 1993;1:26–35.

39. Urban IA, Nagursky H, Lozada JL, Nagy K. Horizontal ridge augmentation with a collagen membrane and a combination of particulated autogenous bone and anorganic bovine bone-derived mineral: A prospective case series in 25 patients. *Int J Periodont Restorative Dent.* 2013;33(3):299–307.

40. Beitlitum I, Artzi Z, Nemcovsky CE. Clinical evaluation of particulate allogeneic with and without autogenous bone grafts and resorbable collagen membranes for bone augmentation of atrophic alveolar ridges. *Clin Oral Implants Res.* 2010;21:1242–50.

41. Qiu L, Yu H. Onlay grafting with bovine bone mineral block for horizontal reconstruction of severely atrophic alveolar ridges in anterior maxillae: A 6-year prospective study. *J Craniomaxillofac Surg.* 2018;46:1199–204.

42. Barone A, Covani U. Maxillary alveolar ridge reconstruction with nonvascularized autogenous block bone: Clinical results. *J Oral Maxillofac Surg.* 2007;65:2039–46.

43. Boronat A, Carrillo C, Peñarrocha M, Peñarrocha M. Dental implants placed simultaneously with bone grafts in horizontal defects: A clinical retrospective study with 37 patients. *Int J Oral Maxillofac Implants.* 2010;25(1):189–96.

44. Khoury F, Khoury C. Mandibular bone block grafts: Diagnosis, instrumentation, harvesting techniques and surgical procedures. In F Khoury, H Antoun, P Missika (eds.), *Bone augmentation in oral implantology*. Berlin: Quintessence; 2007, 435.

45. Khojasteh A, Hassani A, Motamedian SR et al. Cortical bone augmentation versus nerve lateralization for treatment of atrophic posterior mandible: A retrospective study and review of literature. *Clin Implant Dent Relat Res.* 2016;18:342–59.

46. Marx RE, Carlson ER, Eichstaedt RM et al. Platelet-rich plasma: Growth factor enhancement for bone grafts. *Oral Surg Oral Med Oral Pathol Oral Radiol Endod.* 1998;85:638–46.

47. Eskan MA, Greenwell H, Hill M et al. Platelet-rich plasma–assisted guided bone regeneration for ridge augmentation: A randomized, controlled clinical trial. *J Periodontol.* 2014;85:661–8.

48. Lorenzetti M, Vono M, Lorenzetti V. A retrospective tomographic and histologic analysis of horizontal bone augmentation in maxillary atrophic ridges using resorbable membrane with anorganic bovine bone-derived mineral and plasma rich in growth factors. *Int J Periodont Restorative Dent.* 2019;39(3):399–406.

49. Moussa M, El-Dahab OA, El Nahass H. Anterior maxilla augmentation using palatal bone block with platelet-rich fibrin: A controlled trial. *Int J Oral Maxillofac Implants.* 2016;31(3):708–15.

50. Thanasrisuebwong P, Kiattavorncharoen S, Deeb GR, Bencharit S. Implant site preparation application of injectable platelet-rich fibrin for vertical and horizontal bone regeneration: A clinical report. *J Oral Implantol.* 2020;Dec 3:doi: 10.1563/aaid-joi-D-20-00031.

51. Farré-Guasch E, Martí-Pagès C, Hernández-Alfaro F et al. Buccal fat pad, an oral access source of human adipose stem cells with potential for osteochondral tissue engineering: An in vitro study. *Tissue Eng C Methods.* 2010;16:1083–94.

52. Shiraishi T, Sumita Y, Wakamastu Y et al. Formation of engineered bone with adipose stromal cells from buccal fat pad. *J Dent Res.* 2012;91:592–7.

53. Khojasteh A, Eslaminejad MB, Nazarian HJOS. Mesenchymal stem cells enhance bone regeneration in rat calvarial critical size defects more than platelet-rich plasma. *Oral Surg Oral Med Oral Pathol Oral Radiol Endod.* 2008;106:356–62.

54. Khojasteh A, Behnia H, Hosseini FS et al. The effect of PCL-TCP scaffold loaded with mesenchymal stem cells on vertical bone augmentation in dog mandible: A preliminary report. *J Biomed Mat Res B Appl Biomat.* 2013;101:848–54.

55. Shayesteh YS, Khojasteh A, Soleimani M et al. Sinus augmentation using human mesenchymal stem cells loaded into a β-tricalcium phosphate/hydroxyapatite scaffold. *Oral Surg Oral Med Oral Pathol Oral Radiol Endod.* 2008;106:203–9.

56. Behnia H, Khojasteh A, Soleimani M et al. Secondary repair of alveolar clefts using human mesenchymal stem cells. *Oral Surg Oral Med Oral Pathol Oral Radiol Endod.* 2009;108:e1–e6.

57. Behnia H, Khojasteh A, Soleimani M et al. Repair of alveolar cleft defect with mesenchymal stem cells and platelet derived growth factors: A preliminary report. *J Craniomaxillofac Surg.* 2012;40:2–7.

58. Khojasteh A, Dashti SG, Dehghan MM et al. The osteoregenerative effects of platelet-derived growth factor BB cotransplanted with mesenchymal stem cells, loaded on freeze-dried mineral bone block: A pilot study in dog mandible. *J Biomed Mat Res B Appl Biomat.* 2014;102:1771–8.

59. Jafarian M, Eslaminejad MB, Khojasteh A et al. Marrow-derived mesenchymal stem cells-directed bone regeneration in the dog mandible: A comparison between biphasic calcium phosphate and natural bone mineral. *Oral Surg Oral Med Oral Pathol Oral Radiol Endod.* 2008;105:e14–e24.

60. Baghban EM, Jafarian M, Khojasteh A et al. in vivo bone formation by canine mesenchymal stem cells loaded onto HA/TCP scaffolds: Qualitative and quantitative analysis. *Cell J.* 2008;10(3):205–12.

61. Behnia H, Khoshzaban A, Zarinfar M, Khojasteh A. Histological evaluation of regeneration in rabbit calvarial bone defects using demineralized bone matrix, mesenchymal stem cells and platelet rich in growth factors. *J Dent Sch.* 2012;30:143–54.

62. Behnia H, Khojasteh A, Kiani MT et al. Bone regeneration with a combination of nanocrystalline hydroxyapatite silica gel, platelet-rich growth factor, and mesenchymal stem cells: A histologic study in rabbit calvaria. *Oral Surg Oral Med Oral Pathol Oral Radiol.* 2013;115:e7–e15.

Dentlearn.ir

Dentlearn.ir

Allogenic Block Graft as an Alternative to Autogenous Block Graft for Augmentation of Horizontal Alveolar Bone Defects in Implant Dentistry

CHAPTER 13

The problem of alveolar ridge resorption is of great concern when bone deficiency is present horizontally, as it jeopardizes optimal implant position. This chapter will introduce the use of irradiated allogenic block grafts as an alternate to autogenous block graft in cases with horizontal bone defects. The safety and effectiveness of augmentation of bone by use of these grafts will be made evident in the chapter through numerous clinical scenarios, the radiographic findings, as well as histological evidence. The chapter shall also enumerate the specific indications for use of these grafts, together with the advantages it has to offer when compared with the autogenous bone. The chapter highlights the use of these grafts that enable placement of implant in restoratively optimal position within augmented, neo regenerated bone, thereby fulfilling the objectives of esthetics, function, and longevity of treatment.

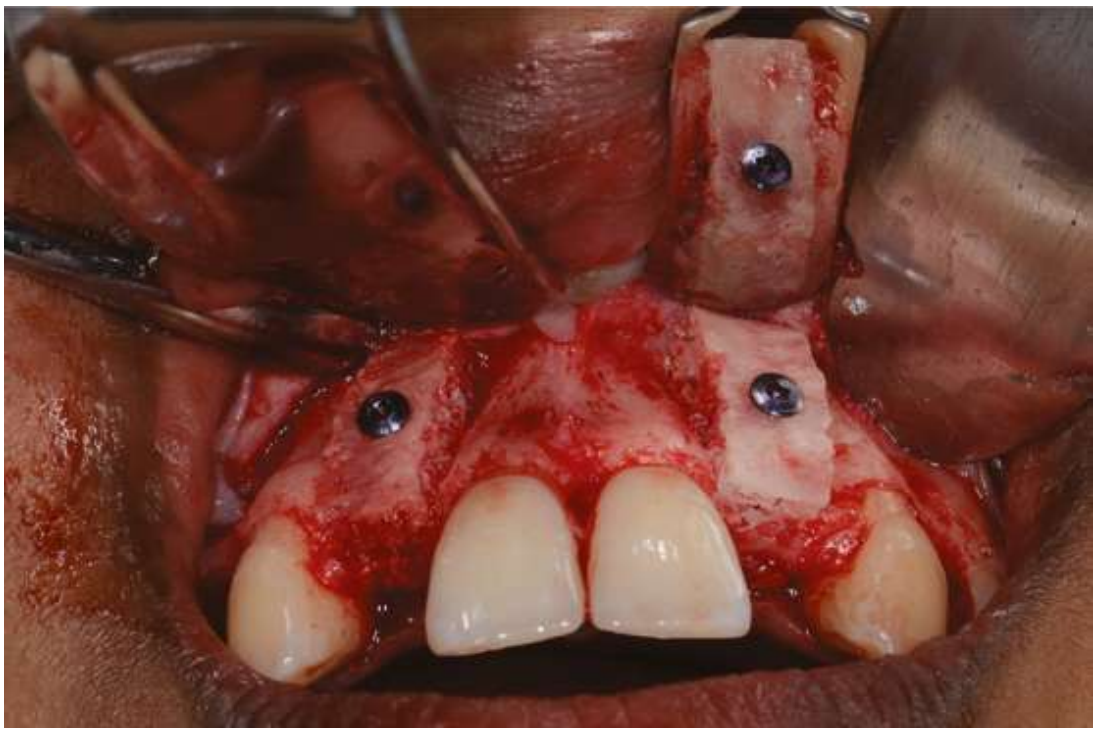

Dentlearn.ir

CHAPTER 13

Allogenic Block Graft as an Alternative to Autogenous Block Graft for Augmentation of Horizontal Alveolar Bone Defects in Implant Dentistry

Shankar Iyer[1,2]

[1]*Director, Malo Smile USA, Elizabeth, New Jersey, USA*

[2]*Clinical Assistant Professor, Department of Periodontics & Restorative Dentistry, Rutgers School of Dental Medicine, Newark, New Jersey, USA*

The phenomenon of alveolar ridge resorption as a consequence of physiological changes has been studied extensively. Numerous factors including biomechanics, local and systemic factors, and the use of prostheses have been considered to explain the irreversible progressive process of alveolar ridge resorption [1–4]. Regardless of the cause of resorption, the deficiency of available bone due to the inevitability of resorption greatly affects the bucco-coronal aspect [1, 4–7], and may preclude placement of an implant in an optimal position, thereby forfeiting the accomplishment of satisfactory function, esthetics, and longevity of the treatment [8]. When the deficiency is present horizontally, it leads to the choice of a less than ideal diameter for the implant or the implant being placed at an unfavorable angle [7, 9–14].

A variety of alveolar ridge preservation (ARP) procedures with a combination of bone substitutes and membranes have been successfully utilized following extractions in order to circumvent this challenge of a horizontal alveolar bone defect [1–38]. Despite the introduction of bone graft substitutes, the incidence of atrophic ridges is still very high, as ARP methods are relatively recent and associated with high variability of the products and the technique of use [30, 39]. The clinical predictability of ridge preservation by these substitutes is also challenging in situations where the buccal plate thickness of the remaining alveolar ridge is inadequate [3, 6, 30, 39].

Autogenous bone in general has been considered to be the gold standard for site development to manage deficient alveolar bone [1, 3, 9, 15, 16, 23, 40–49]. There are several intraoral and extraoral sites from where autogenous bone can be harvested for horizontal and vertical bone defects for implant placement. Autogenous bone provides several advantages such as promotion of healing through osteogenesis, faster incorporation of the augmented bone, and almost no possibility of rejection. However, such augmentation is not free from morbidity and there are numerous factors modulating the success of an autogenous graft, including embryological origin, microarchitecture, and size of the graft [16, 17]. As a result, its advantages must be carefully considered [3]. The variable graft resorption rate that can jeopardize the outcome of the procedure, donor site morbidity, paresthesia, devitalization, and a prolonged post-operative recovery period are some debilitating complications associated with autogenous grafts [1, 3, 9, 16, 30, 42, 50–52]. The technique of harvesting autogenous bone blocks from intraoral sources like the symphysis and ramus involves the use of special instrumentation like saws, carbide burs, and piezo surgery. The extent of the harvest with respect to the thickness is, however, often arbitrary, and based on the thickness of the cortical plate, depth of the marrow space, and the proximity to vital structures. After harvesting, conforming the block to the recipient site can be a challenge, as the blocks are not that easy to manipulate.

To reduce donor site morbidity and facilitate the availability of larger block grafts, allogenic block grafts were introduced in the late 1990s [21]. These grafts consist of scaffolds derived from human cadavers (genetically non-identical donors of the same species) and are processed subsequently to maintain architecture and extracellular proteins very similar to native bone [7, 8, 21, 30, 53–62]. The allogenic grafts can be available either as blocks (cortico-cancellous) or as particulate (chips or granules) [7]. There are also allogenic blocks that are obtained from live donors (femoral heads) and these are

Essential Techniques of Alveolar Bone Augmentation in Implant Dentistry: A Surgical Manual, Second Edition. Edited by Len Tolstunov.
© 2023 John Wiley & Sons, Inc. Published 2023 by John Wiley & Sons, Inc.
Companion website: www.wiley.com/go/tolstunov/essential

Dentlearn.ir

denser than the cortico-cancellous blocks. Some of the allogenic blocks are popularly known as "J" blocks and typically have a larger cortical component than cancellous structure. In a generic way, the allogenic grafts need to be sterilized and then processed either by freeze drying (FDA), demineralizing and freeze drying (DFDA), or by being fresh frozen (FFA) [7, 8, 53].

Processing of the allogenic blocks by the patented Tutoplast® protocol (RTI Biologics, Inc., Alachua, FL, USA) – solvent dehydration by using osmotic oxidative and alkaline treatments, as used by Zimmer Dental (Munich, Germany) for Puros® [27, 56] – and the Allowash® technique – chemical processing, ultrasonication, and centrifugation, as used by Readigraft® from LifeNet Health (Virginia Beach, VA, USA) to remove 99% of marrow, lipids, and blood elements from the internal matrix of bone, thereby eliminating enveloped and non-enveloped viruses and providing effective bacterial inactivation – have been shown to be reliable and optimal methods, thereby making allogenic block grafts potential replacements for autogenous block grafts.

After these processes the allogenic grafts are devoid of any matrix or collagen [53, 57–60]. Varying the number and duration of freeze cycles results in elimination of the cellular component of tissue, thereby reducing the risk of disease transmission or immune response [2, 27, 30, 61]. It also alters the surface protein characteristics, and the mechanical stability that imparts to the graft characteristic osteoconductive and varying degrees of osteoinductive properties [30, 61, 62]. These grafts have to be rehydrated adequately prior to being used.

The potential for autoinduction and osteoconduction of allogenic grafts depends on the processing technique [1]. At the very least, all allogenic grafts are osteoconductive, as they provide a scaffold around which a functional skeletal network is developed by the host cells within the graft, to eventually replace the graft by creeping substitution [1, 24].

Mineralized freeze-dried bone allograft (FDBA) has osteoconductive properties when compared to demineralized freeze-dried bone allograft (DFDBA), which has osteoinductive properties due to the expression of bone morphogenic proteins, but in implant dentistry use of DFDBA is often limited as it resorbs faster than FDBA [53].

This chapter will review the techniques for predictable augmentation by using irradiated allogenic block graft for three clinical scenarios: single anterior tooth, posterior quadrant, and anterior sextant rehabilitation of extremely atrophic alveolar ridges. In a generic way, to attain a satisfactory outcome, Wang's PASS principles (**P**rimary wound coverage for undisturbed wound healing, **A**ngiogenesis promotion for blood supply and undifferentiated mesenchymal cells, **S**pace maintenance to ensure bone ingrowth, and **S**tability of graft to induce blood clot and promote uneventful healing), along with a tension-free approximation, should be followed to ensure graft uptake [63]. Also, to maximize the favorable outcome, a two-stage approach is preferred, where the first surgery is block grafting, and following the uptake of the graft the implants are placed [53]. The graft that will be discussed in depth is irradiated cancellous bone (Rocky Mountain Tissue Bank, Denver, CO, USA), obtained from the human vertebra and irradiated with radiation between 2.5 and 3.8 Mrad. It has been found to be most similar to autogenous bone when compared to autologous bone [54, 55].

INDICATIONS FOR ALLOGENIC BLOCK GRAFTS

In a generic manner, allogenic block grafts are indicated for a predictable increase in horizontal alveolar ridge width (Table 13.1).

Table 13.1 Indications for the allogenic block graft.

Cases that have 1–3 mm of remaining alveolar bone that precludes the possibility of ridge expansion (Figure 13.1)

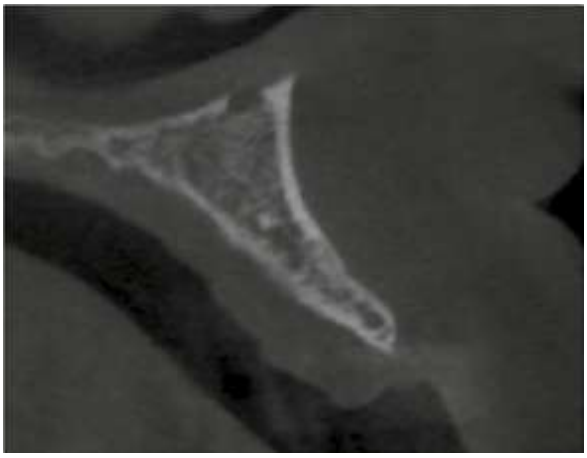

FIGURE 13.1 Extremely reduced remaining alveolar bone that precludes ridge expansion.

(continued)

Dentlearn.ir

Table 13.1 *(continued)*

Alveolar ridges that are extremely angulated (Figure 13.2)

FIGURE 13.2 Extremely angulated alveolar ridges.

Atrophic ridges that produce skeletal discrepancies (class I patients with a class III ridge relationship) (Figure 13.3)

FIGURE 13.3 Severe skeletal discrepancy due to alveolar bone resorption.

To replace flange support of removable prosthesis that provides support to lips with osseous build-up for implant restorations (Figure 13.4)

FIGURE 13.4 Elimination of the flange of the removable prosthesis for an implant restoration.

Dentlearn.ir

Table 13.1 *(continued)*

Prosthetic convenience is attained by minimizing the angulated abutments in the esthetic zone and promote screw retained (Figure 13.5)

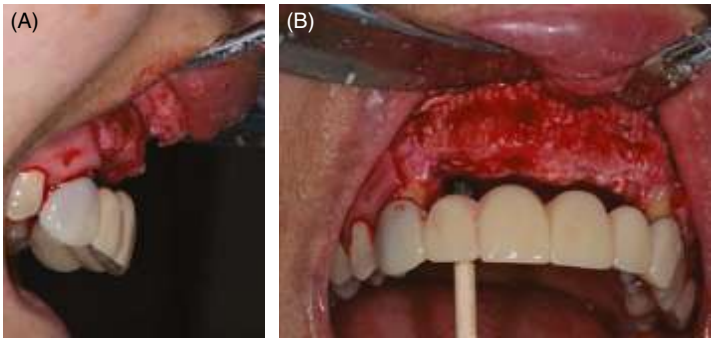

FIGURE 13.5 Allogenic block graft helps to provide bone bed for appropriate three-dimensional orientation of the implant circumventing the need for angulated abutments. (A) Lateral view; (B) Frontal view.

Extreme alveolar atrophy with minimal marrow space (Figure 13.6)

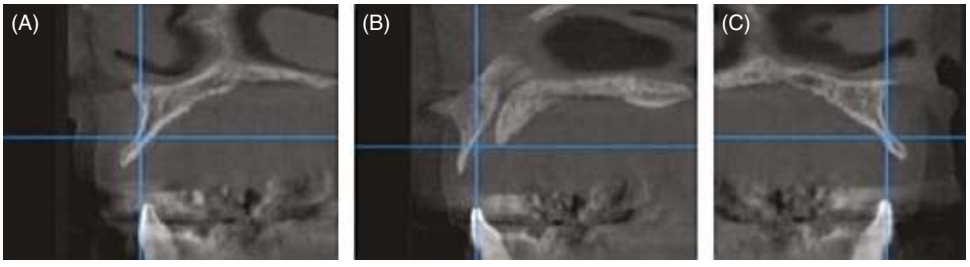

FIGURE 13.6 Minimal marrow space in atrophic ridge.

Table 13.2 Unique features of the irradiated allogenic block graft.

A distinct cortical and cancellous architecture can be created to restore the original, native form of the alveolus
The stability of the graft due to close proximity to the recipient bone is a major asset in limiting any micro-movement of the graft in the recipient site
The solid block allows for space-maintaining properties and does not require any tenting support with screws or reinforced membranes that can still cause some collapse
The porosities of the block allow for vasculature to grow through and these porosities aid in turnover of the non-vital bone into vital bone rapidly
Ease of adapting an allogenic block into the defect due to ease of sculpting the graft
Ability to conform the block intimately to the mortise preparation due to the compressibility of the cancellous portion of the block

Dentlearn.ir

DISTINGUISHING FEATURES OF IRRADIATED ALLOGENIC BLOCK GRAFTS

Irradiated allogenic block grafts offer numerous favorable features that make them a promising alternative to the other options for augmentation. These have been enumerated in Table 13.2.

MATERIALS AND METHODS

The allogenic block grafts (Rocky Mountain Tissue Bank) are harvested from the vertebral bone of human cadaveric donors. The cadaveric grafts are treated through thorough debridement to ensure removal of any soft tissues, and then irradiated thorough gamma radiation to completely denature the allelic properties of the allograft. This bone is different from allografts derived through lyophilization, in that these grafts maintain the matrix content of the donor and are dispensed in a hydrated form.

A list of items used for graft fixation is provided in Table 13.3.

Table 13.3 List of items used for graft fixation.

Bone graft	Rocky Mountain Tissue Bank, Denver, CO, USA
Titanium screws	Salvin Dental Specialties, Charlotte, NC, USA
Type I collagen membrane	Ossix® membrane, OraPharma, Bridgewater, NJ, USA
Trephine bur	Salvin Dental Specialties

PATIENT SELECTION CRITERIA

The patients for allogenic block grafts are chosen based on the criteria in Table 13.4.

Table 13.4 Patient selection criteria for allogenic block graft.

Healthy patients with no medically complex conditions
Non-smokers
Patients who could have been treated through bone manipulation, but needed bone augmentation for prosthetic convenience
Patients with a minimum of 2 mm of available bone
Patients whose available bone could not be manipulated through ridge expansion
Edentulous patients who do not mind wearing their dentures for four months, and those who do not mind having the flanges removed in their removable partial dentures

PRE-OPERATIVE CONSIDERATIONS

In order to ensure a satisfactory surgical outcome, the features that must be assessed specifically for allogenic block graft augmentation prior to surgery have been shown in Table 13.5.

Table 13.5 Features to be assessed prior to surgery.

Presence of a minimum of 3–4 mm of keratinized gingiva over the site to be augmented
Evaluation of available bone through bone sounding and confirmed with cone beam computed tomography scans
Evaluation of periapical status of the teeth adjacent to the edentulous segment
Patients should have undergone thorough prophylaxis within the two weeks prior to the surgery
All patients covered with pre-operative antibiotics with either 2 g of amoxycillin 1 h prior to procedure or 600 mg of clindamycin (in case of allergy to penicillin)

TECHNIQUE OF ALLOGENIC BLOCK GRAFT FOR A SINGLE ANTERIOR TOOTH

The ideal way to begin one's competency in allogenic block graft augmentation is to develop a single-tooth atrophic site that may not be ideal for traditional guided bone regeneration (GBR) techniques. Clinical assessment (Figure 13.7) and radiographic assessment (Figure 13.8) are completed.

FLAP DESIGN

Under local infiltration anesthesia, an incision along the palatal aspect of the mid-crest of the ridge is made. This is followed by sulcular incision extending over a tooth on each side (Figures 13.9 and 13.10). A full-thickness muco-periosteal flap is reflected [1]. If the flap elevation does not permit full access to the defect, two vertical release incisions are made distal to adjacent teeth that include the papillae. The vertical releasing incision should be located at least 10 mm from the allogeneic block graft site to make flap exposure less likely during closure [53]. The extent of the defect is assessed occluso-gingivally and mesio-distally (Figure 13.10).

A $5 \times 10 \times 10$ or $5 \times 10 \times 15$ block is chosen depending on the desired vertical length occluso-apically. The block is supplied hydrated in distilled water and double pouched. The outer sachet is removed and the inner sterile pouch that contains the graft and the solution is carefully cut, and the block is transferred to a sterile bowl. It is noteworthy that the technique sensitivity of retrieving, saving, and handling the graft is markedly reduced.

PREPARATION OF THE RECIPIENT BONE BED FOR DECORTICATION AND PERIOSTEAL RELEASE INCISION (SCORING)

The recipient bone bed is prepared to allow the graft to be mortised into position for graft stability and to allow maximum bone-to-graft contact (Figures 13.11 and 13.12) [1].

Dentlearn.ir

FIGURE 13.7 Pre-operative view of missing maxillary right and left lateral incisors with severe horizontal alveolar ridge deficiency on labial aspect. (A) Pre-operative frontal view during smile. (B) Pre-operative frontal view (intraoral during occlusion). (C) Pre-operative frontal view of maxillary arch revealing defect on labial aspect. (D) Occlusal view of maxillary arch showing the horizontal alveolar ridge defect.

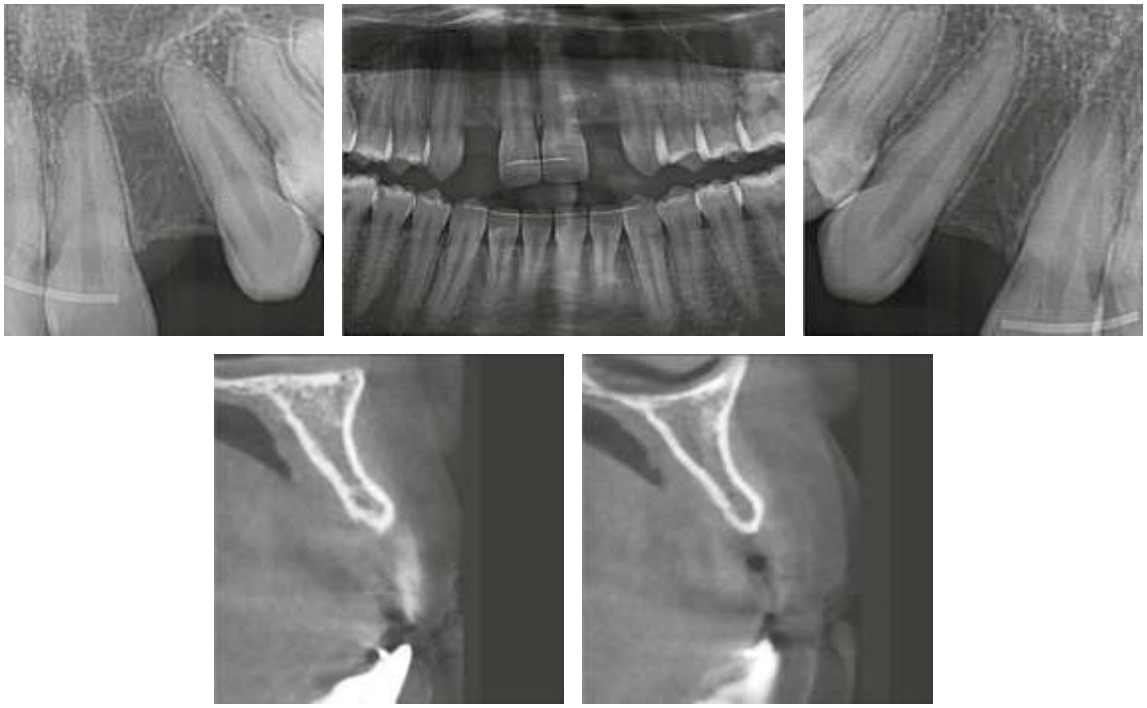

FIGURE 13.8 Pre-operative radiography. The cone beam computed tomography images depict extreme atrophy with minimal marrow space.

Dentlearn.ir

Utilizing an electric handpiece with a 5:1 ratio, a 700XXL carbide bur is used to create demarcating borders, including slight ridge osteoplasty (mortise preparation) to establish graft recipient bed and graft adaptation, and decortications by creating micro-perforations through the cortical plates to encourage bleeding points by using a fissure carbide bur. Some authors who use autogenous grafts have demonstrated that decortication is not necessary, but the same may not be true for allogenic blocks [48]. The blocks need to be perfused with the patient's blood and should ideally appear to be fully soaked prior to fixating the block. Hence the decortication promotes hemorrhage and activates the regional acceleratory phenomenon (RAP) by increasing blood supply and stimulating growth factors and migration of the mesenchymal cells, as proposed by Frost [1, 53, 64]. Care should be taken not to compromise the root elevations for the adjacent teeth during the mortise preparation. If the roots are exposed, then one should avoid having the interface of the block against any roots. Creating a ledge during mortise preparation, if the anatomy permits, would be ideal to provide a positive seat for the block, and will help position the block during the osteotomy preparation for fixating the block. In addition, a block holder can help secure it in place during drilling through the block into the native recipient bone.

Passive tension-free closure requires an incision that ensures re-approximation of periosteum and keratinized gingival over the allogenic bone graft completely [7, 29, 31, 65–67]. Periosteal release incision or scoring of the perios-

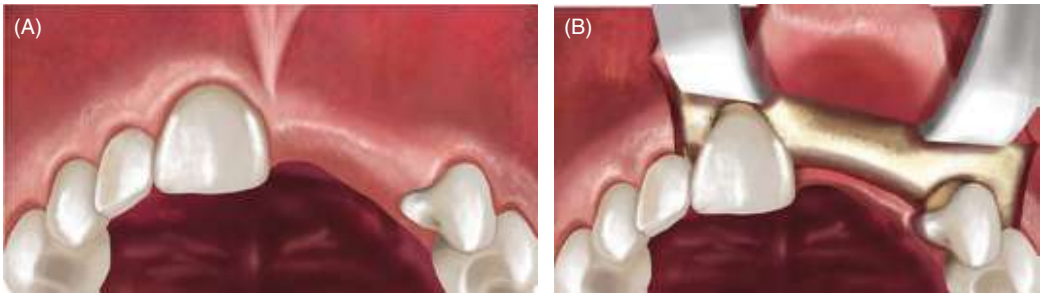

FIGURE 13.9 (A) Illustration of a labial defect in the maxillary anterior region. (B) Incision palatal to mid-crest and sulcular incision followed by elevation of a full-thickness mucoperiosteal flap.

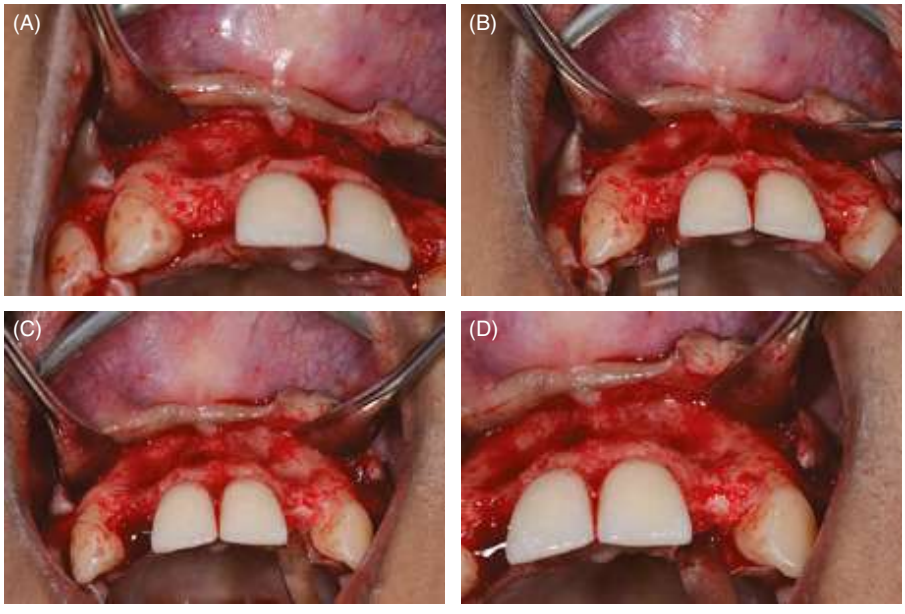

FIGURE 13.10 Evaluation of recipient site prior to preparation of the bed. (A) Occlusal view shows extent of horizontal defect at the maxillary right lateral incisor site. (B) Superior–inferior extent of horizontal defect can be appreciated at the maxillary right lateral incisor site. (C) Extent of horizontal defect on labial aspect of the maxillary right and left lateral incisor sites. (D) Extent of defect at the maxillary left lateral incisor site.

Dentlearn.ir

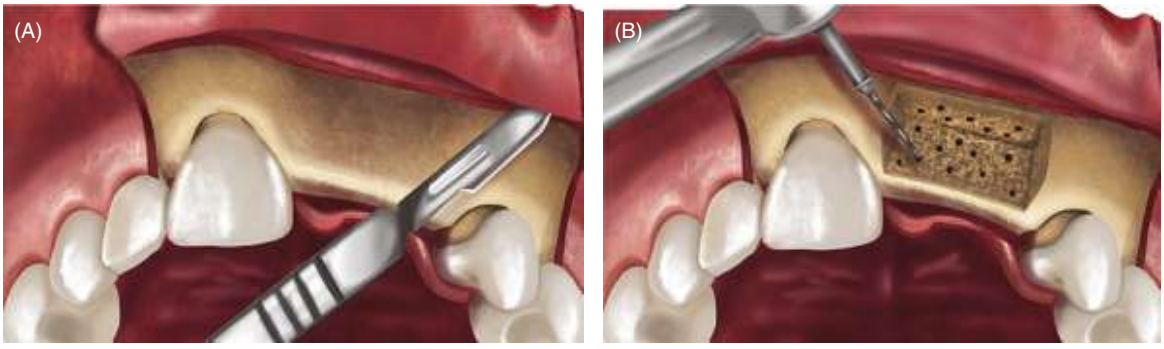

FIGURE 13.11 (A) Periosteal release incision in advance of block placement. (B) Mortise preparation and decortication.

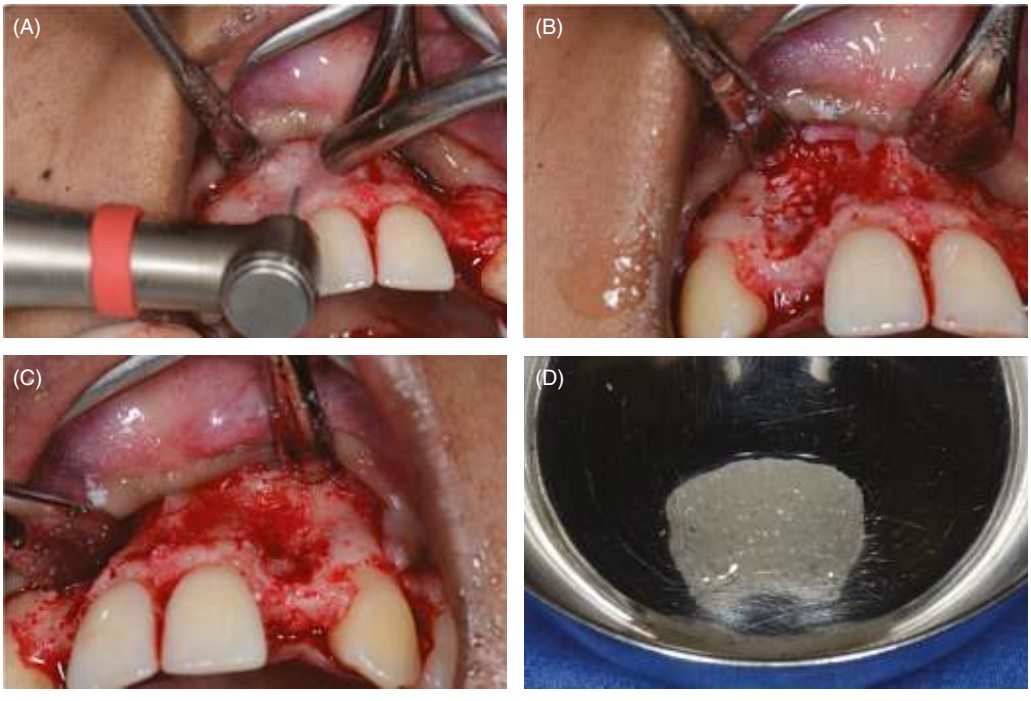

FIGURE 13.12 (A) Decortication to create definitive borders of mortise preparation. (B) Creation of bleeding points. (C) Definitive mortise preparation. (D) The allogenic graft is hydrated.

teum releases the taught collagen fibers of periosteum to allow for re-approximation of the flap over the bulk of allogenic graft that will be placed (Figure 13.11). This is done in advance of the block fixation to avoid performing this step after the block is affixed, which sometimes can be a challenge.

CONFORMING THE BLOCK

One of the critical aspects of achieving success in an allogenic block graft is the ability to approximate the cancellous portion of the block as closely as possible to the prepared host bone. Any space intervening between the two could lead to healing by secondary intention, which increases the chances of fibrous tissue incorporation or delamination of the block during implant placement. To facilitate the block's positioning, the borders need to be trimmed with either a scalpel (since the block is not hard) or a rongeur (Figure 13.13). The blocks are rectangular in configuration and hence the cancellous portion needs to be reduced according to the concave shape of the prepared site in the bone. The excess that is removed should be saved and can be crushed in a bone mill and used to fill the voids along the borders.

Dentlearn.ir



FIGURE 13.13 Contouring of the allogenic block graft to fit into the defect snugly, as closely as possible. (A) Contouring with Bard Parker blade. (B) Adjusting the size and shape of the graft to be well received in the mortise preparation.

FIXATION OF THE BLOCK

The block is positioned within the confines of the mortise preparation and should ideally be restricted when it is slid left to right, or from top to bottom. Once it is stable, a block holder or tissue forceps can be used to hold the block (Figure 13.14).

A 1.2 mm drill is used to drill through the block into the host bone. The depth of drilling should exceed the length of the screw that is being planned to fix the graft. The length of the screw is calculated by measuring the width of the block and the thickness of the palatal or lingual plate of the host bone. It is not uncommon to drill through and through the palatal plate, but drilling should not be through the soft tissue covering the palatal bone plate. Smooth, self-tapping titanium screws that have a definite locking interface between the driver and the screw head are paramount, as the torquing forces should not strip the hex or the cross-hatch on the heads. If the conformed block has been manipulated a lot, it needs to be carefully fixated. Larger blocks tend to maintain their integrity, but when reduced and trimmed the block may lose its volume and could disintegrate. The fixation screws need to be made of titanium and machined in texture so as to avoid integrating with the block. The screw head should ideally be flush with the block and not stick out of the contours more than the thickness of the screw head (Figure 13.14). The block should not be countersunk to accommodate the screw head. The screw will enter the block with ease and then will begin to get firmer as it enters the host bone. At least 2–3 mm of the screw should engage the host bone. As the screw becomes tighter to insert, the block gets approximated more intimately. Care must be taken not to overcompress the block, as this may propagate a crack.

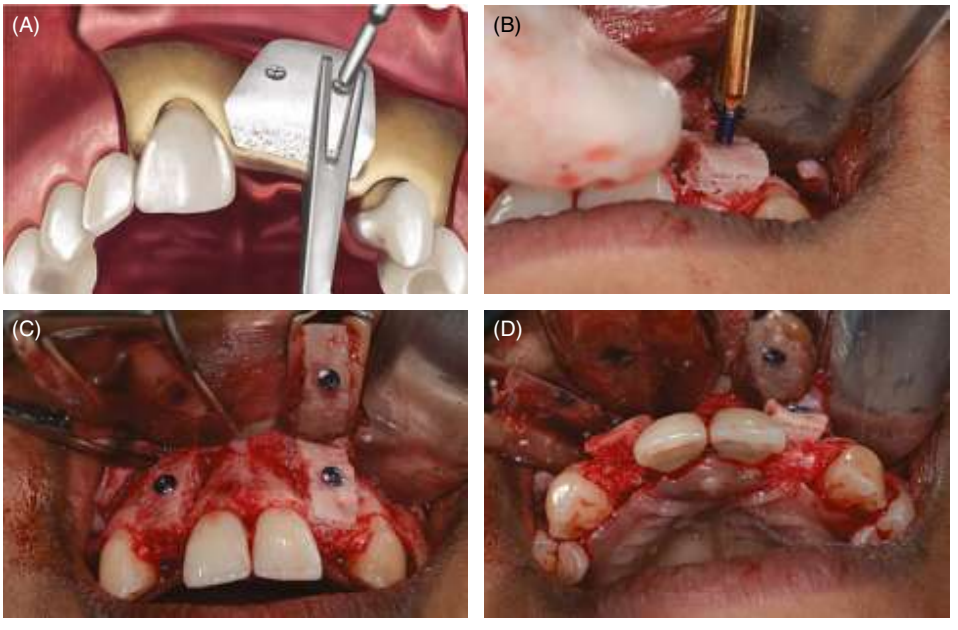

FIGURE 13.14 Graft stabilized and implant screw tightened. Fixation of the block with screws. (B) Tightening the titanium screw to stabilize the graft. (C) Firmly secured graft (frontal view). (D) Firmly secured graft (occlusal view).

Dentlearn.ir

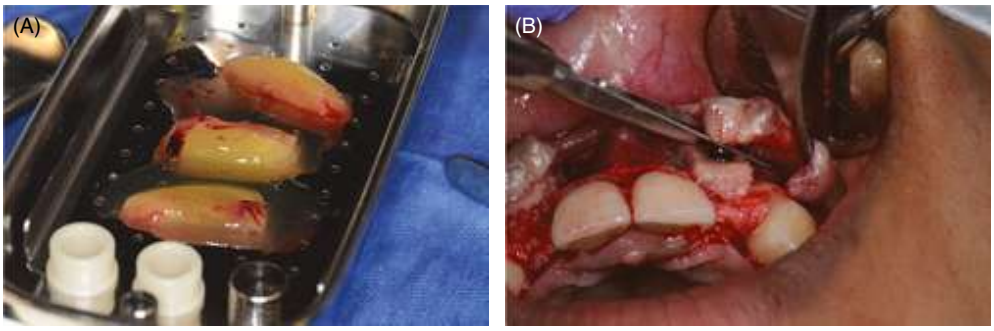

FIGURE 13.15 (A) Preparation of platelet-rich fibrin. (B) Scoring of periosteum to ensure complete closure of the flap over the bulk of the graft.

FIGURE 13.16 (A) Coverage of the allogenic block with platelet-rich fibrin. (B) Covering the augmented site with collagen membrane. (C) Closure of surgical site by suturing.

MANAGEMENT OF VOIDS AND COVERAGE

Voids between block edges from the adjoining bone or between two blocks should be filled with particulate graft material, either from the excess that was trimmed and then ground, or with some particulate allograft after hydration. The block should be covered either with a combination of platelet-rich fibrin (PRF) and resorbable type I collagen membrane (which has a long resorption time; Figures 13.15 and 13.16) or with a large piece of collagen membrane that does not possess any memory, to protect the particulate bone and isolate the healing graft by the cell occlusion properties of keeping out the unwanted epithelial cells.

It is noteworthy that use of a collagen membrane has been documented to minimize graft resorption [68–71]. Non-resorbable membranes such as expanded polytetrafluoroethylene (ePTFE) are not preferred, as they require a second surgical intervention for membrane removal and are prone to membrane exposure and wound infection [72]. The periosteum manipulated by scoring the undersurface of the flap that was performed prior can be advanced to obtain primary closure (Figure 13.15). The utmost caution is to be exercised not to leave the flap unapproximated [73]. Most failures occur on account of inadequate tension-free closure of the flaps. The upper lip should be pulled forward and upward to ensure that the facial flap does not move with the lip. Closure is obtained by first coapting the flaps with a horizontal mattress suture, followed by interrupted 4-0 Vicryl sutures (Figure 13.16).

RE-ENTRY FOR IMPLANT PLACEMENT

The blocks take an average of about 4 months (16 weeks) to mature and get incorporated when left undisturbed without any pressure from an overlying prosthesis in an otherwise healthy patient (Figure 13.17).

A flap is raised along the original incision that was made to ensure an intact flap architecture. In the case of a single-tooth site, a remote incision can be made and the fixation screw can be removed. In cases of a larger site, a full-thickness flap needs to be elevated to expose the fixation screws and remove them atraumatically. A surgical guide is used to locate the sites of the implant placement and the sequence of osteotomy is aided by using paralleling pins (Figure 13.18).

The author recommends the use of osseodensification burs for osteotomies to avoid any chatter of the twist drills that could potentially cause the graft to become unstable. It is

Dentlearn.ir

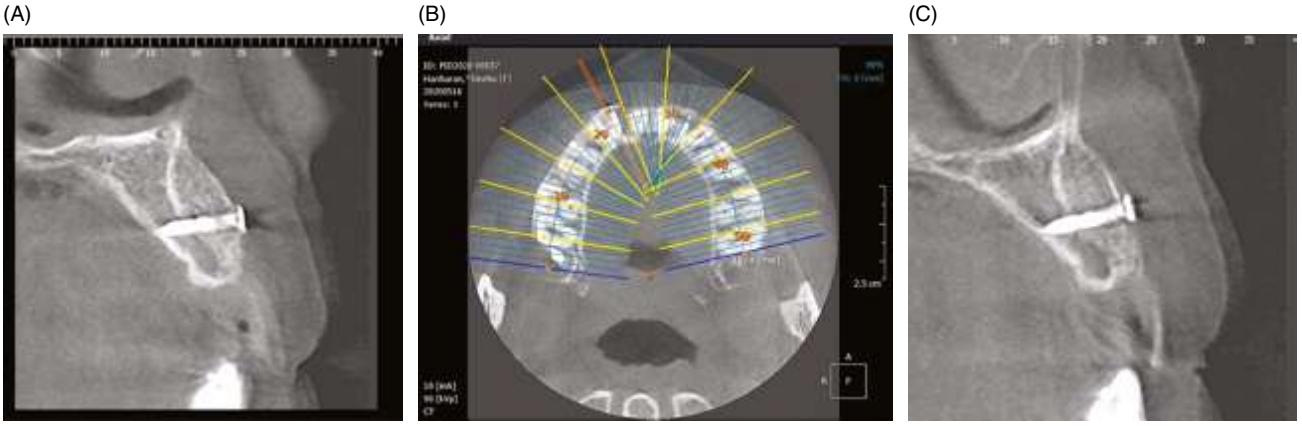

FIGURE 13.17 Post-operative cone beam computed tomography revealing augmentation of the previously present horizontal alveolar defect. (A) Cross-section of site corresponding to missing maxillary right lateral incisor tooth. (B) Transverse view. (C) Cross-section of site corresponding to missing maxillary left lateral incisor tooth.

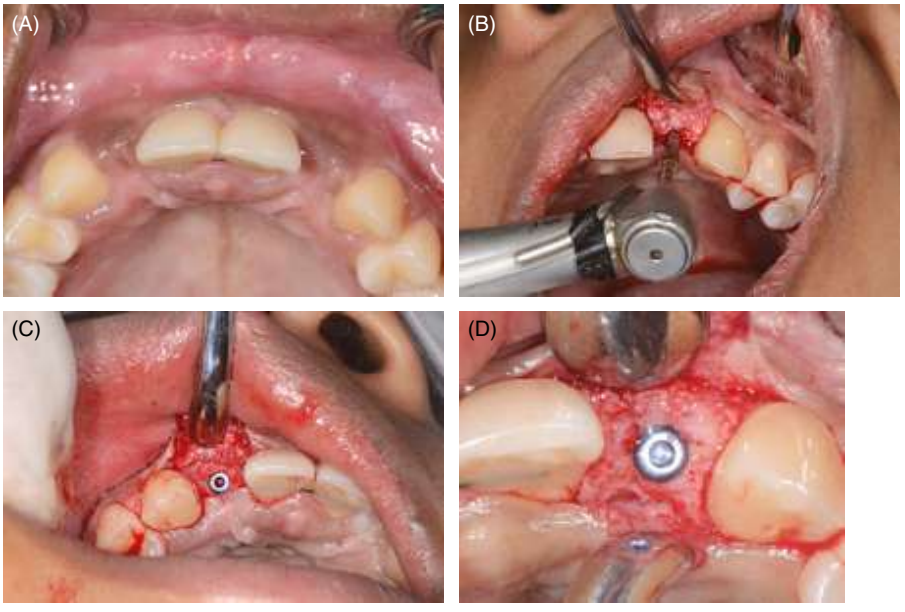

FIGURE 13.18 (A) Post-operative increase in horizontal alveolar width can be appreciated. (B) Use of osseodensification burs for the osteotomy. (C, D) Placement of implant in augmented bone.

pertinent to note that drilling of the grafted bone for implant causes bleeding, which is suggestive of neo-vascularization at the grafted site as well as implying the probability of new bone formation. This has been confirmed from histological observations subsequently as well as in previous literature [28]. It has been observed that torque values close to 35 Ncm can be routinely achieved in such allogenic block grafts. The post-operative implant placement within adequate facial bone can be appreciated in Figures 13.19 and 13.20. The completion of rehabilitation can be appreciated in Figures 13.20 and 13.21.

Dentlearn.ir

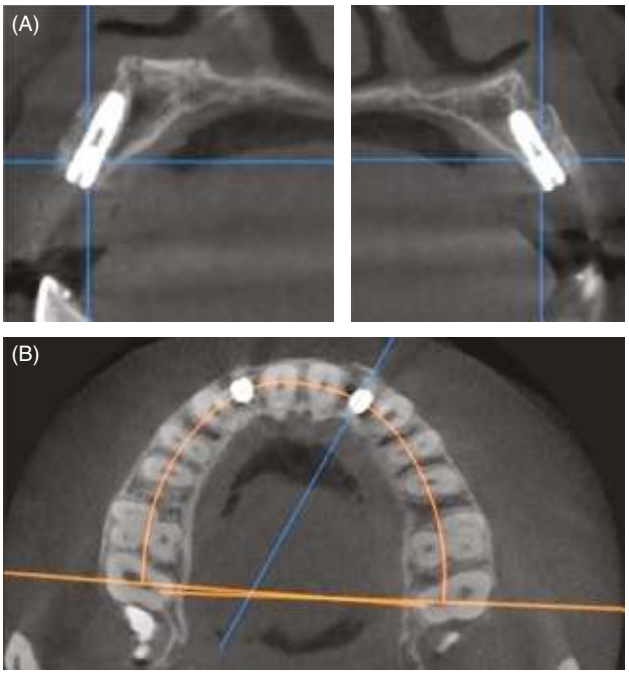

FIGURE 13.19 Post-operative implant placement within adequate bone augmented by allogenic block graft. (A) Cross-section; (B) occlusal view.

TECHNIQUE OF ALLOGENIC BLOCK GRAFT FOR ANTERIOR SEXTANT

The elementary difference between an allogenic block graft for an anterior single tooth and for the anterior sextant is the extent of the span. For the anterior sextant the span covers four or more teeth and a longer block is conventionally chosen (of about 10 × 10 × 30 mm). The anatomical considerations of an allogenic block graft in the anterior sextant have been shown in Table 13.6.

PRE-OPERATIVE PLANNING

A pre-operative orthopantograph (Figure 13.22) and a cone beam computed tomography (CBCT) scan would be a prerequisite to diagnosing the case for an allogenic block graft (Figure 13.23).

The clinical factors that should be considered include the presence of adequate keratinized gingiva, prosthetic space, and a class III ridge relationship, or being close to an edge to edge with the lower anterior teeth (Figure 13.24).

SURGICAL PROCEDURE

An incision is made palatal to the mid-crest along the thin ridge and continued to the adjacent teeth with a sulcular incision. Two vertical release incisions are made distal to one tooth on either side of the edentulous site. A full-thickness flap is raised to expose the entire ridge and to explore the

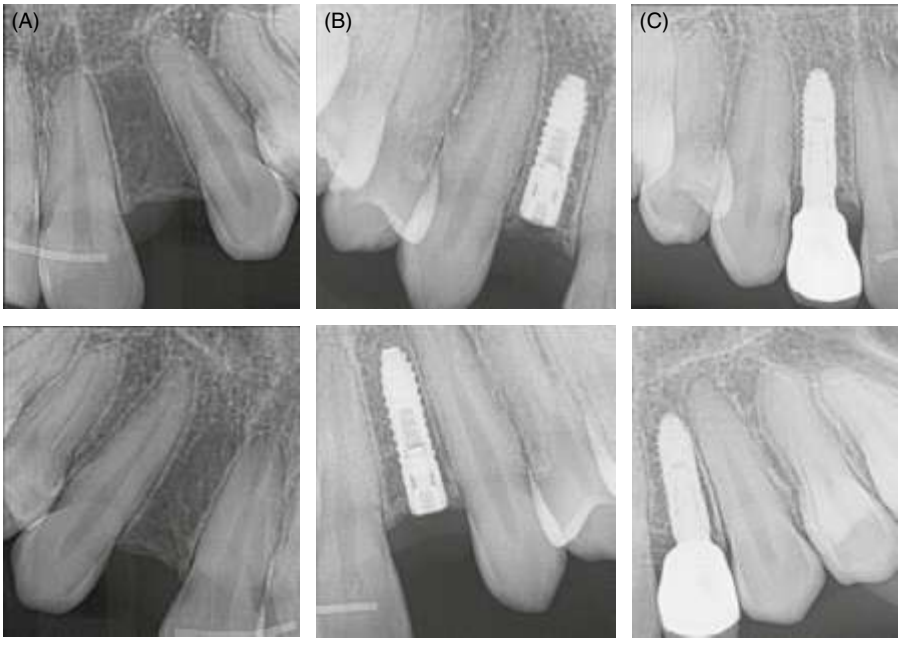

FIGURE 13.20 Sequential radiographs before and after rehabilitation. (A) Before implant placement. (B) After implant placement. (C) After prosthetic rehabilitation.

Dentlearn.ir

FIGURE 13.21 (A–C) Completion of rehabilitation and restoration of smile.

Table 13.6 Anatomical considerations for allogenic block grafts in anterior sextant region.

Segment of anterior teeth is extracted (maxillary lateral incisors or cuspid sites), extensive atrophy, and obtaining a large volume of autograft can be a challenge
Incisive canal is too wide and gets in the way of proposed implant placement
Anterior nasal spine produces a protuberance that creates obstruction for the blocks to be adapted intimately
Curvature of host bone will necessitate extensive recontouring of allogenic freeze-dried dense monocortical blocks or dense autogenous bone derived from the symphyseal region
Shape of the allogenic block derived from the vertebral column has a natural curvature that can adapt to the curved anterior sextant and one can avoid using multiple strips of blocks, which is often necessary to negotiate a curve

incisive foramen. Often the fibrous tissue and other associated soft tissues emanating from the foramen are severed and the contents scooped out to permit augmentation of the defect, since an implant may come to the proximity of the canal for prosthodontic reasons (Figure 13.25).

PREPARATION OF THE RECIPIENT BED AND ADAPTATION OF THE ALLOGENIC BLOCK

When the thickness of the residual alveolar bone is deficient, decortication and the mortise preparation are kept to a minimum. The ascending buttress of the anterior nasal spine may have to be reduced to accommodate the intaglio portion of the block apically (Figure 13.26). Alternatively, a notch can be made within the block to fit snugly against the anterior nasal spine. It is recommended that a definitive mortise preparation is made at the apical termination of the bony interface of the block. (A 700XXL surgical carbide bur is commended for this preparation.) A 10 × 10 × 30 mm pre-curved block is further shaped to fit the contours of the atrophic alveolar bone.

FIGURE 13.22 Pre-operative orthopantograph.

After adaptation, three to four 1.5 × 10 mm titanium screws (Salvin Dental Specialties, Charlotte, NC, USA) are used to fixate the block (Figure 13.26). If additional length is desired, then a smaller 10 × 10 × 10 mm block can be added to fill the defect. The interface between the two blocks should be as small as possible and any voids should be filled with particulate graft. Finally, a resorbable, crosslinked, type I

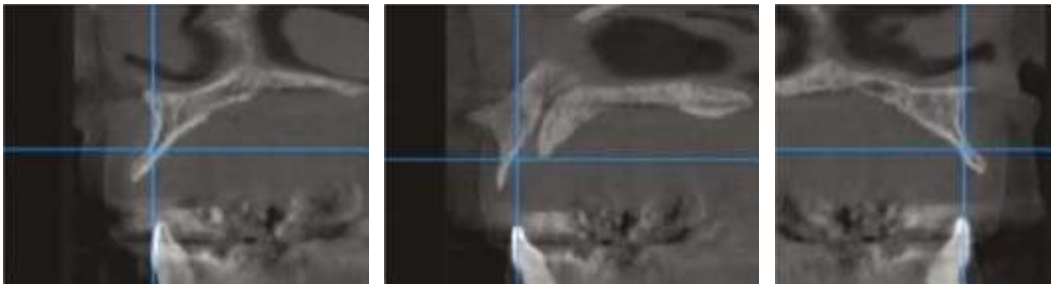

FIGURE 13.23 Pre-operative cone beam computed tomography scan.

Dentlearn.ir

FIGURE 13.24 Clinical evaluation of the patient planned for anterior sextant augmentation. (A) Frontal view with removal of partial denture. (B) Frontal view without removal of partial denture. (C) Lateral view with removal of partial denture. (D) Lateral view without removal of partial denture.

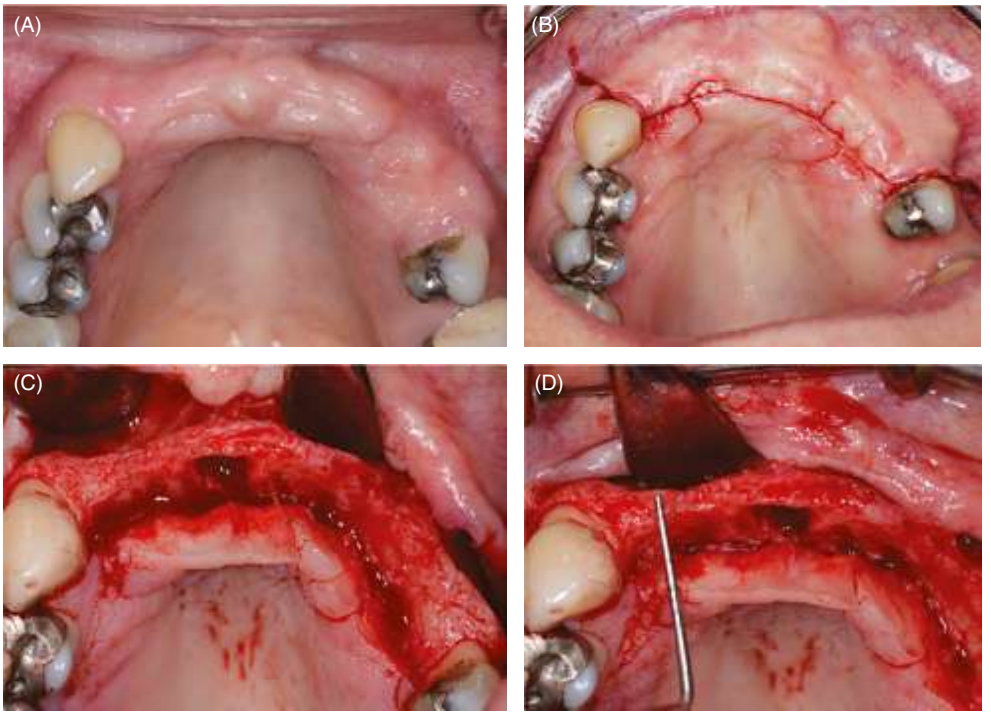

FIGURE 13.25 Palatal to mid-crest incision and reflection of full-thickness flap. Atrophic ridge in anterior sextant region is evident. (A) Pre-operative view. (B) Incision line. (C) Assessment of the existing ridge. (D) Measurement of the existing ridge.

Dentlearn.ir

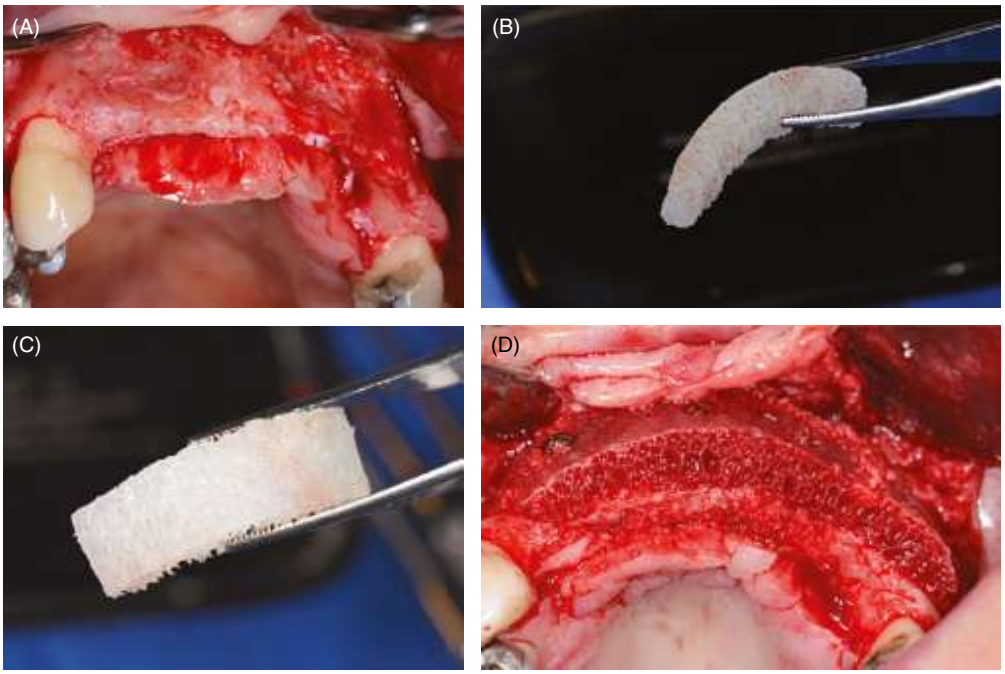

FIGURE 13.26 Recipient bed preparation and adaptation of the large segment of allogenic block graft. (A) Recipient bed after flap reflection. (B) Allogenic block graft before contouring. (C) Allogenic block graft after contouring. (D) Adaptation of pre-shaped graft on recipient bone.

collagen membrane that does not possess any memory (so fixation is required) and that has a long resorption time is utilized to cover the allogenic block graft completely (Figure 13.27).

POST-OPERATIVE ASSESSMENT AND SURGICAL RE-ENTRY

The patient was reviewed after four months of augmentation surgery. In Figures 13.28 and 13.29 the extent of horizontal augmentation can be appreciated.

A full-thickness flap is reflected to expose the fixation screws and remove them atraumatically. Confluence of the bone formed at the grafted site with the native bone is evident in Figures 13.30 and 13.31. The bulk of bone support created ensures ideal prosthetic support (Figure 13.32).

BIOPSY INTERPRETATION

A cylindrical biopsy specimen was taken for histological assessment from the grafted site by using a 2 mm trephine bur, sparing the region of prospective implant osteotomies (Figure 13.33).

The biopsy specimen was routinely fixed, dehydrated, embedded in paraffin, and sectioned, followed by staining with hematoxylin and eosin (H&E) for observation under light microscope and under polarized light. The core consisted

FIGURE 13.27 Fixation of the allogenic block graft with titanium screws. (A) The intimate approximation and the porous nature of the block can be appreciated. (B) Particulate allograft is used to fill in the voids and alongside the ledges. (C) A resorbable collagen membrane is placed over the entire graft.

Dentlearn.ir

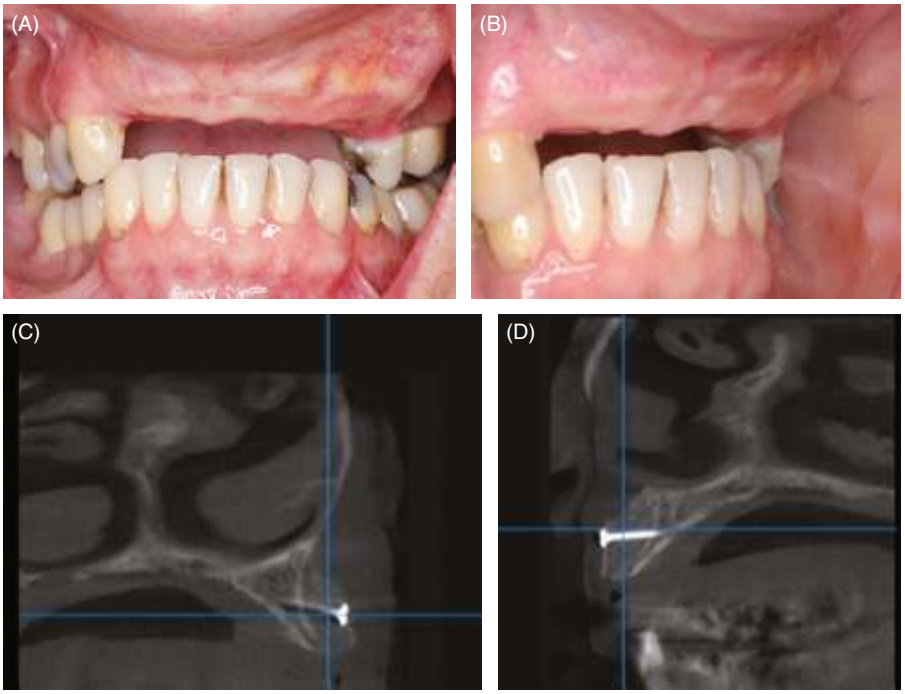

FIGURE 13.28 (A) Post-operative outcome after four months of augmentation surgery. (B) The extent of horizontal augmentation is appreciable. (C) Post-operative cone beam computed tomography (CBCT). (D) Post-operative CBCT.

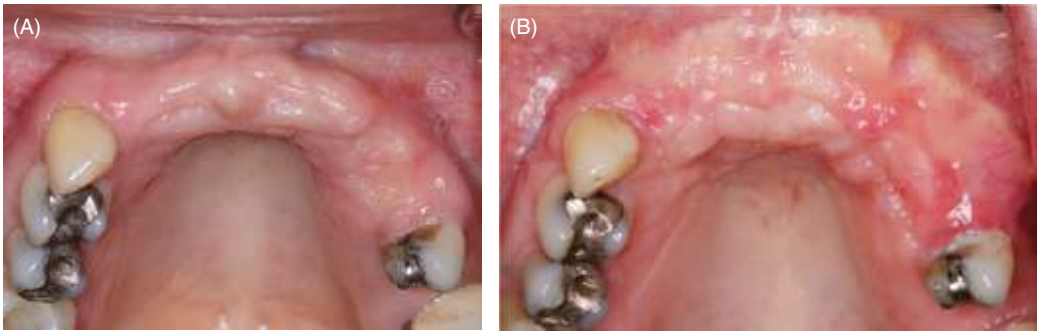

FIGURE 13.29 Comparison of pre-operative and post-operative clinical presentation. The gain in anterior ridge with can be appreciated. (A) Pre-operative; (B) post-operative.

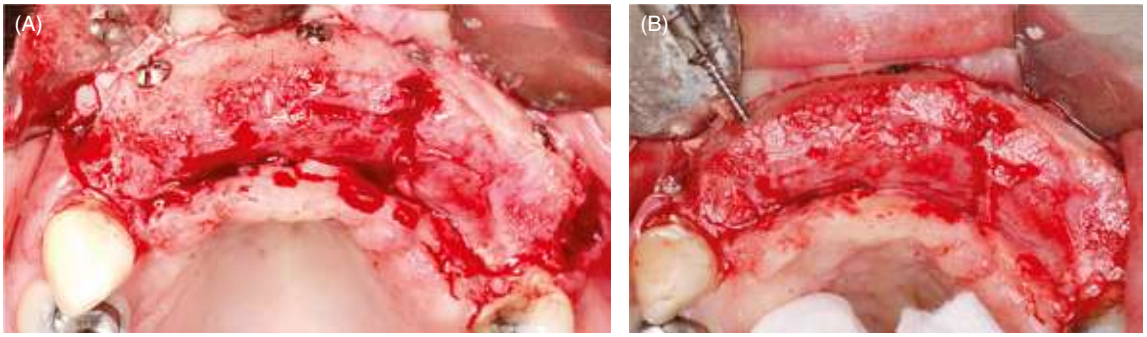

FIGURE 13.30 (A, B) Removal of the titanium screws from the grafted site after reflection of a full-thickness flap. Absence of any porosities or demarcation of the block and host site is appreciable.

Dentlearn.ir

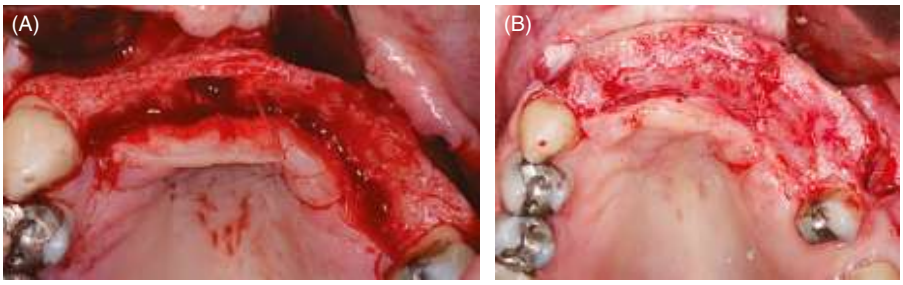

FIGURE 13.31 Comparison of ridge presentation before and after allogenic block graft procedure. (A) Pre-operative view; (B) post-operative view.

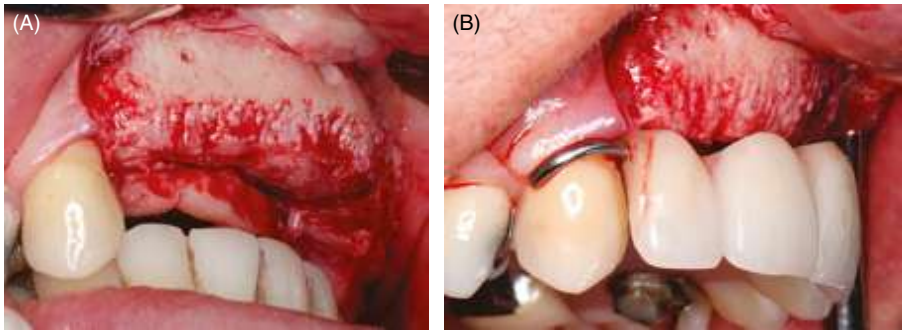

FIGURE 13.32 (A, B) Ideal bone contours created by the allogenic graft ensure proper prosthetic support.

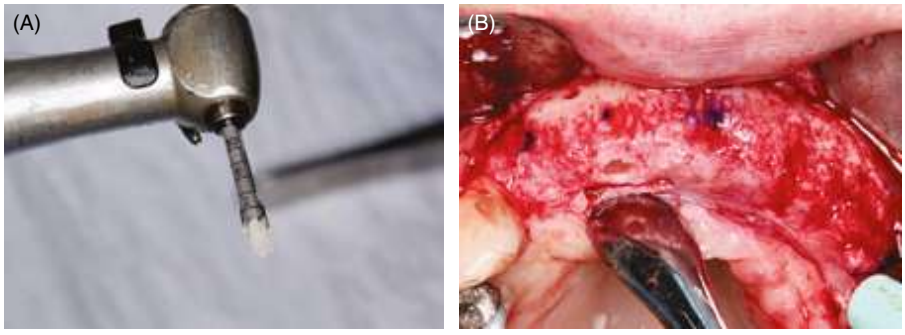

FIGURE 13.33 Harvesting a core biopsy for histomorphometric study. (A) Harvested bone from augmented site in the trephine. (B) Prospective implant placement positions.

of 27% bone, of which 86% was vital bone (new bone) and 14% was the remaining allogenic graft material. Thus, a distinction between non-vital (remaining allograft) and vital bone (neo-bone) replacing the graft was evident. The low- and medium-power images show well-formed trabeculae that have quite good connectivity, suggestive of a very good cancellous bone pattern (Figure 13.34).

There is evidence of vital osteocytes or osteoblasts (blue nuclei evident in H&E–stained section) within lacunae in unorganized woven bone or mature lamellar bone, together with active remodeling areas in the new bone (Figure 13.35).

The different staining qualities reflect the varying maturity levels of the different areas of the bone, with darker red-staining bone representing less mature (woven) bone than the lighter-staining mature (lamellar) bone (Figure 13.35). In the polarized view, remodeling is evident from the differentiated reddish color of the remaining allograft and the contrasting bluish color of the active new bone formation due to the osteoid, within which the high density of osteocytes can be

Dentlearn.ir

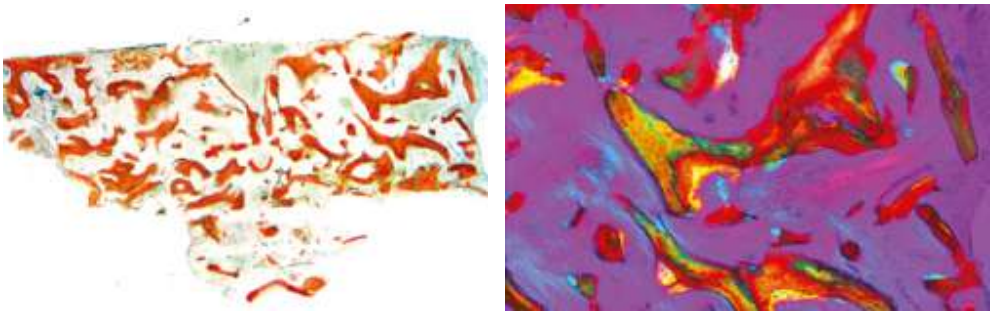

FIGURE 13.34 Histomorphometric analysis revealing almost complete bone turnover.

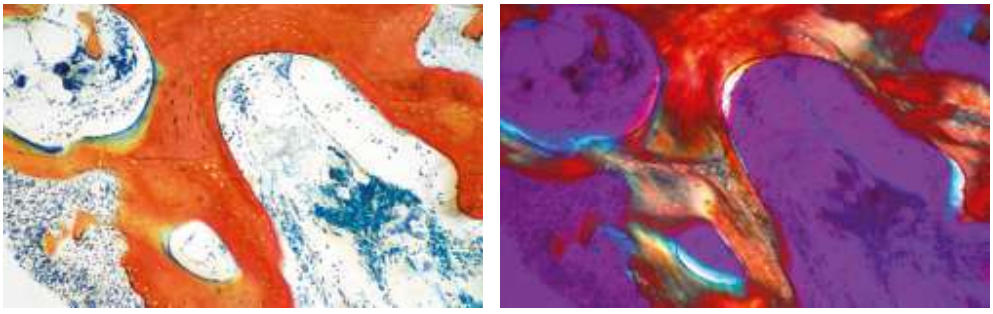

FIGURE 13.35 Histomorphometric analysis revealing evidence of vital osteocytes and active remodeling areas.

appreciated. Further investigation of the core shows good cancellous bone formation, well-formed and even trabeculae, marrow space, and connective tissue accounting for nearly 73%. The low- and medium-power images show a fair core with thick trabeculae demonstrating partial connectivity. Abundant new bone formation, which is associated with allograft particles (pale color in the H&E–stained section and purple colored in polarized light) is appreciated in all the high-power views (Figure 13.35). The high-power images show a very delicate, totally non-inflamed marrow and very dense connective tissue, together with very newly formed bone with osteocytes in it (Figure 13.35).

IMPLANT PLACEMENT AND COMPLETION OF PROSTHETIC REHABILITATION

The conventional protocol for using a surgical guide for implant placement is implemented. Sequential osteotomy by osseodensification burs is completed. Adequate volume of augmented new bone enables vertical implant placement to be accommodated without any need for angulation correction, as is seen in Figure 13.36. Restoratively driven implant placement is accomplished due to the augmentation achieved by the allogenic block graft, promising esthetic and functional outcomes together with longevity (Figure 13.36).

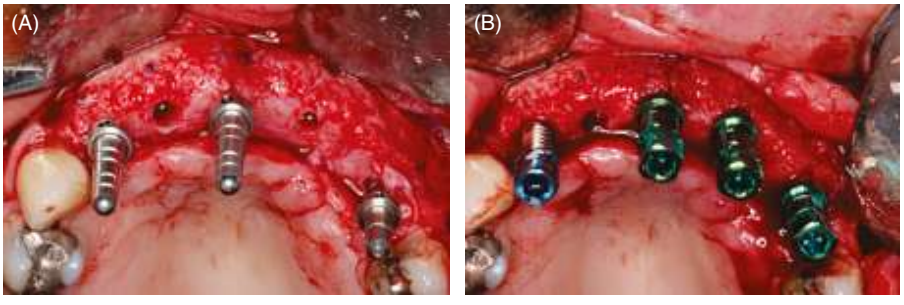

FIGURE 13.36 Implant placement by osseodensification. (A) Use of parallel pins. (B) Adequate volume to accommodate vertical implant placement without any need for angulation correction.

Dentlearn.ir

TECHNIQUE OF ALLOGENIC BLOCK GRAFT FOR POSTERIOR SEXTANT

The elementary difference between allogenic block grafts for anterior teeth and the posterior sites is the role of occlusion in determining the outcome. Occlusal contacts in centric and eccentric occlusion together with the relation of the edentulous ridge to the opposing arch, the occlusal forces, and the crown-to-implant ratio are important prosthetic considerations. Use of allogenic grafts expands the possibilities to provide support for implants in a more axial relationship with the opposing arch and to permit wider-diameter implants. The surgical considerations for allogenic block grafts in the posterior region have been shown in Table 13.7.

PRE-OPERATIVE PLANNING

A pre-operative orthopantograph (Figure 13.37) and a CBCT scan would be a prerequisite (Figure 13.38). It is extremely useful to obtain CBCT images that depict the relation of the remaining posterior alveolar ridge to the prospective position of the definitive prosthesis. For this a radiographic template can be fabricated that is aligned with the occlusion of the opposing arch. The template is layered with a radio-opaque marker to permit its interpretation (Figure 13.38).

The clinical factors that should be considered include the presence of adequate keratinized gingiva, absence of high frenum attachment, available prosthetic space, and occlusion relation with the opposing arch, as determined by the radiographic template (Figure 13.39).

Table 13.7 Surgical considerations for allogenic block grafts in posterior region.

Proximity to the inferior alveolar nerve (IAN) has to be considered – a minimum of 8 mm of height of bone is needed between the crest of the existing alveolar ridge and the IAN to accommodate the block graft
A prominent basal bone if available is better for the outcome
A minimal amount of marrow space is needed for an effective outcome
3.–4 mm thick keratinized tissue (attached gingiva)
The crest of the ridge should be lingual or palatal to the occlusal contour (Figure 13.38)

FIGURE 13.37 Pre-operative orthopantograph.

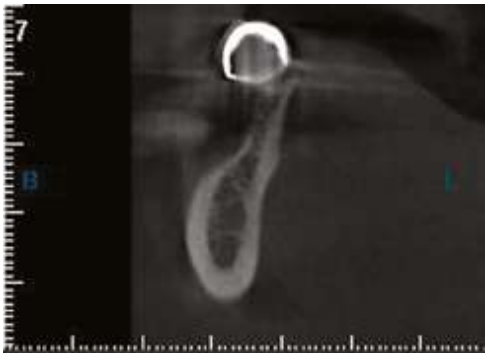

FIGURE 13.38 Pre-operative cone beam computed tomography scan.

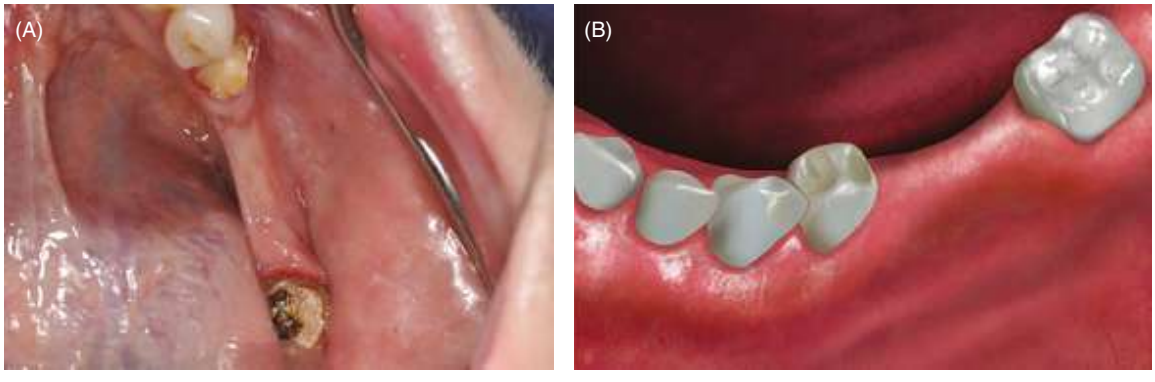

FIGURE 13.39 (A) Clinical evaluation of the patient planned for posterior horizontal alveolar ridge defect. (B) Diagrammatic illustration of the horizontal alveolar defect in the posterior region.

Dentlearn.ir

SURGICAL PROCEDURE

An incision is made slightly lingual to the mid-crest along the ridge. A sulcular incision on the teeth adjacent to the edentulous ridge and two vertical release incisions are made distal to one tooth on either side of the edentulous site. A full-thickness flap is raised to expose the entire ridge (Figures 13.40 and 13.41). Scoring or release of periosteal fibers (Figure 13.40) ensures flap approximation after placement of the allogenic graft.

FIGURE 13.40 Incision is made lingual to mid-crest and full-thickness flap is reflected. Release of periosteal fibers or scoring is done in order to enable flap approximation after placement of allogenic graft. Horizontal alveolar bone defect is evident after flap reflection.

PREPARATION OF THE RECIPIENT BED AND ADAPTATION OF THE ALLOGENIC BLOCK

Decortication and mortise preparation are done to accommodate the intaglio portion of the block (Figure 13.42). A definitive mortise preparation ensures secure placement of the graft block and fit over the basal bone to provide the desired contour.

The allogenic block graft is dispensed from its sterile water–hydrated packing into a bowl. The graft is adapted over the defect by contouring with a rongeur (Figure 13.43).

After adaptation, 1.5 × 10 mm titanium screws (Salvin Dental Specialties) are used to fixate the block. A block holder can be used through which the screws can be inserted to stabilize the block of graft. Care should be taken to ensure close approximation of the graft to the recipient bone (Figure 13.44). Any voids should be filled with particulate graft. Resorbable, crosslinked, type I collagen membrane is used to cover the allogenic block graft completely. Complete approximation of the flap is accomplished, followed by suturing (Figure 13.44).

POST-OPERATIVE ASSESSMENT AND SURGICAL RE-ENTRY

The re-entry should be planned four months after the augmentation surgery. Clinical evaluation of the augmented site, confirmatory othopantograph, and CBCT are required

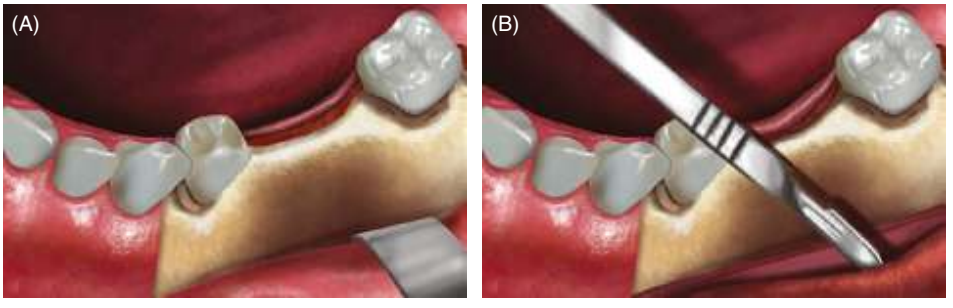

FIGURE 13.41 (A) Illustration of reflection of full-thickness flap. (B) Periosteal scoring to enable flap re-approximation after graft fixation.

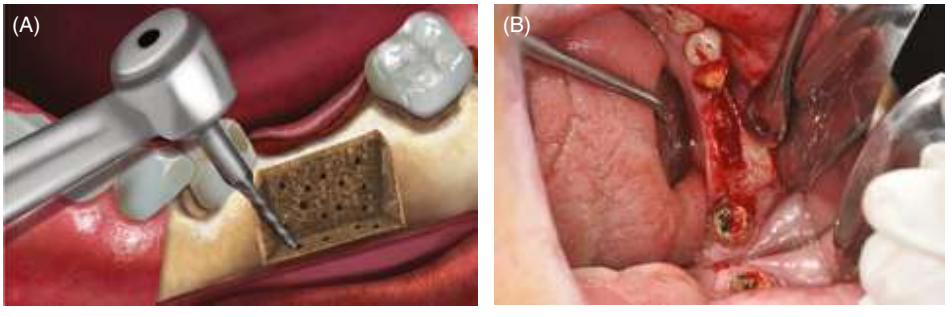

FIGURE 13.42 (A) Recipient bed preparation and decortication. (B) Definitive mortise preparation to ensure secure placement of graft.

Dentlearn.ir

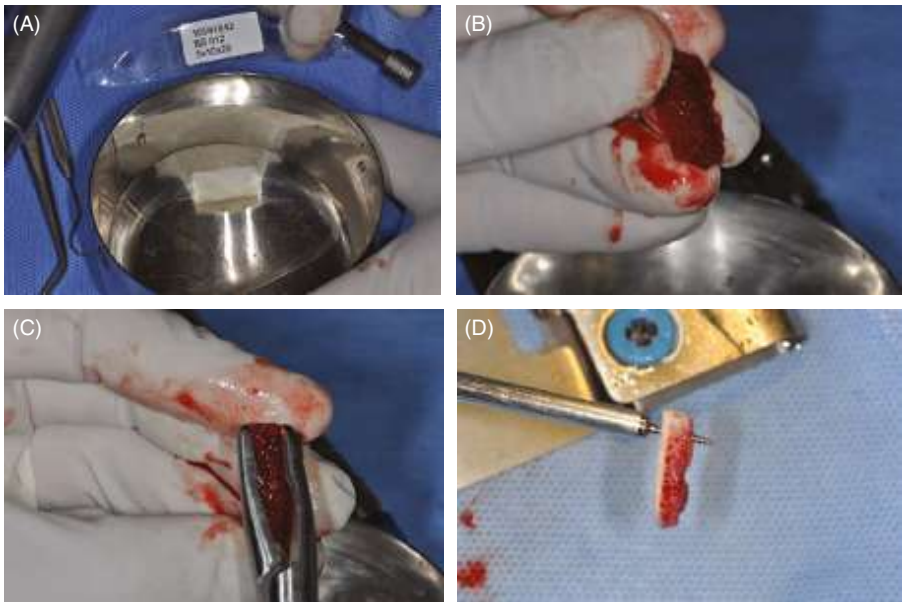

FIGURE 13.43 (A) Hydrated graft is dispensed into a bowl. (B) Block graft soaked in patient's blood. (C) Contouring of the graft with rongeur. (D) Fixation screw transgressing through the contoured block graft.

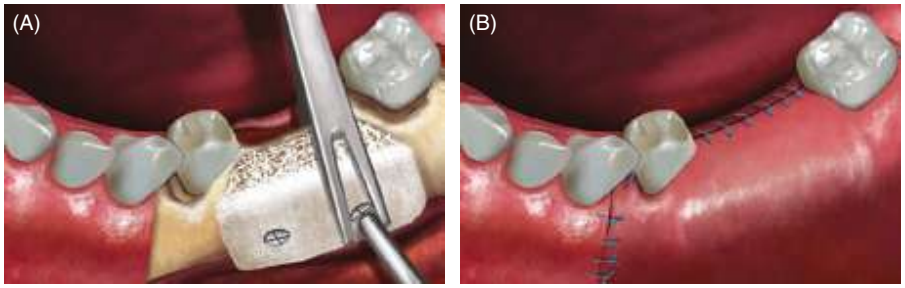

FIGURE 13.44 (A) Illustration of fixation of the allogenic block graft with titanium screws through the block holder in the posterior mandible. (B) Illustration of flap approximation followed by suturing.

(Figures 13.45 and 13.46). A full-thickness flap is reflected to expose and remove the fixation screws atraumatically.

BIOPSY INTERPRETATION

A cylindrical biopsy specimen from the grafted site was obtained by using a 2 mm trephine (Figure 13.47).

The core specimen was treated according to routine protocol and stained with H&E for further observation and interpretation (Figure 13.48). The grafted site showed both vital, new bone with osteocytes and osteoblasts and non-vital, remaining allogenic graft (Figure 13.49). The ongoing remodeling process can be well appreciated in the specimen.

The core consisted of 50.5% vital bone (new bone), 49.3% bone marrow, and 0.3% remaining allogenic graft (Figure 13.50).

FIGURE 13.45 Clinical evaluation of horizontal augmentation. The increase in bone width can be appreciated.

Dentlearn.ir

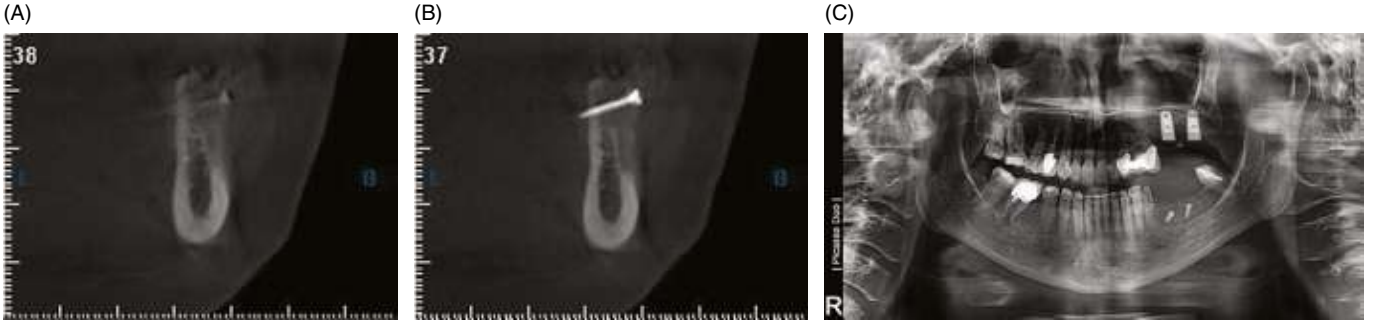

FIGURE 13.46 (A, B) Radiographic evaluation of horizontal augmentation can be appreciated in post-operative cone beam computed tomography. (C) Post-operative panoramic view.

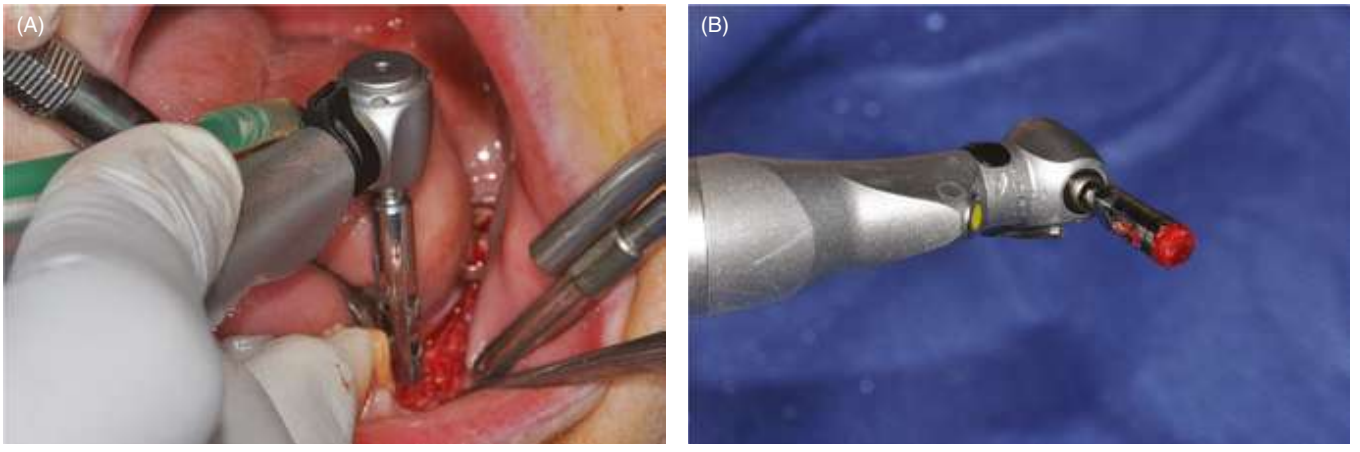

FIGURE 13.47 (A) Harvesting a core of graft for histomorphometric study. (B) Harvested graft in the trephine bur.

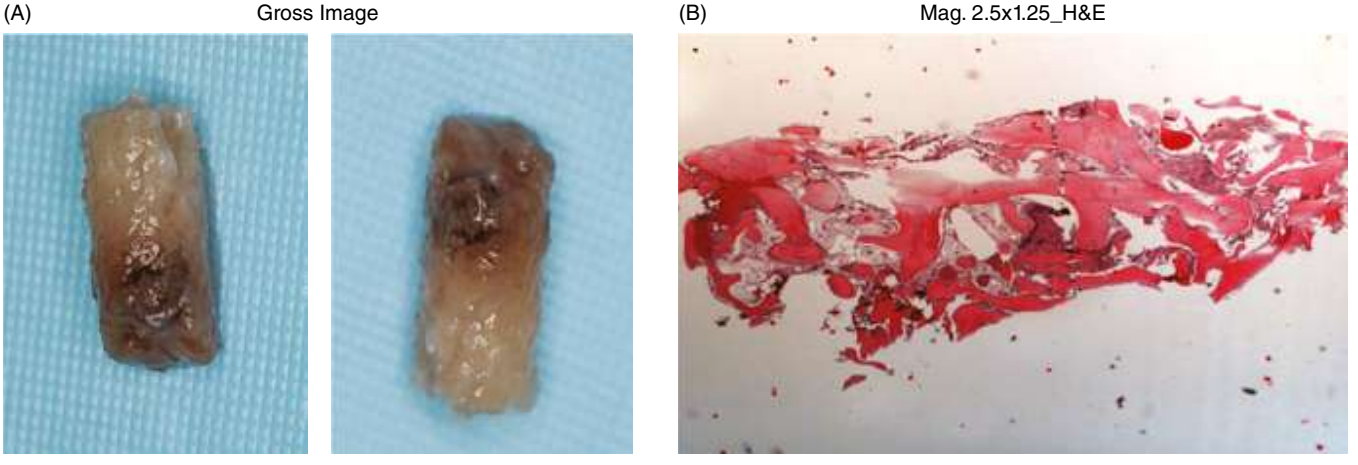

FIGURE 13.48 (A) Gross view of core of grafted site collected by trephine bur four months after augmentation. (B) Hematoxylin and eosin (H&E) staining was done for further evaluation.

Dentlearn.ir

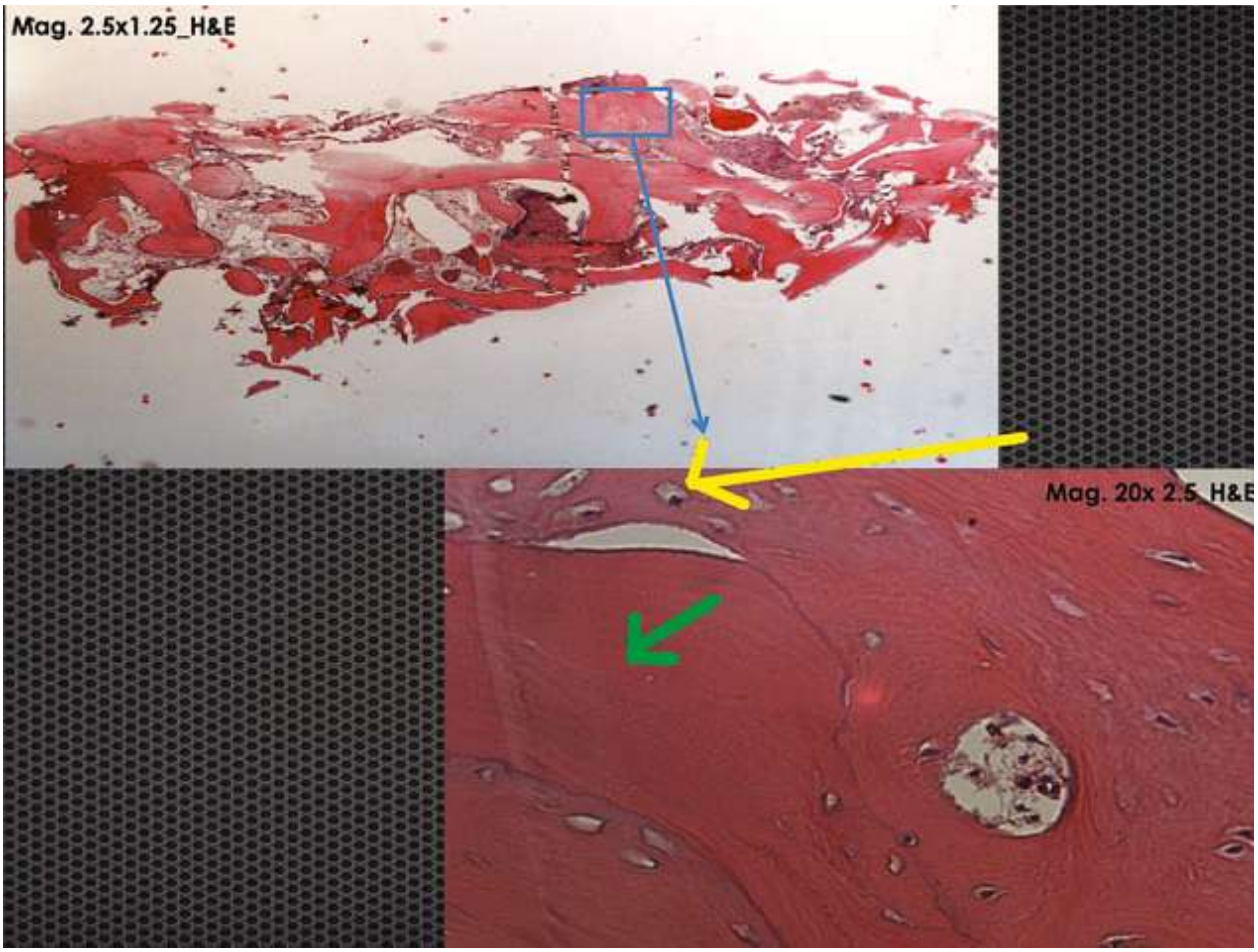

FIGURE 13.49 The grafted site shows vital bone (with osteocytes and osteoblasts), as depicted by yellow arrows, replacing the remaining allogenic block graft, as depicted by the green arrow.

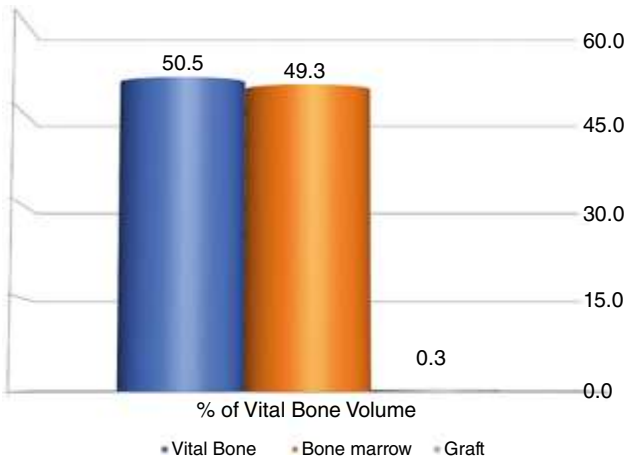

FIGURE 13.50 Composition of the specimen studied.

IMPLANT PLACEMENT AND COMPLETION OF PROSTHETIC REHABILITATION

For implant placement, osseodensification is performed and a restoratively driven implant placement in horizontally augmented alveolar bone was attained (Figure 13.51).

The extent of increase in horizontal alveolar bone dimensions is evident in Figure 13.52. The placement of a wide-diameter implant ideal for the current clinical scenario has been accomplished in the augmented alveolar bone. The same would have been unattainable in the pre-augmented status.

Satisfactory radiographic and clinical implant placement can be observed (Figures 13.53 and 13.54).

Dentlearn.ir

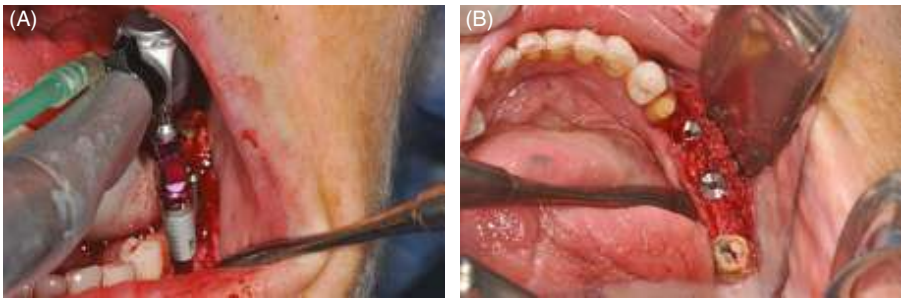

FIGURE 13.51 (A) Osseodensification and restoratively driven implant placement. (B) Implants placed in new bone at augmented site.

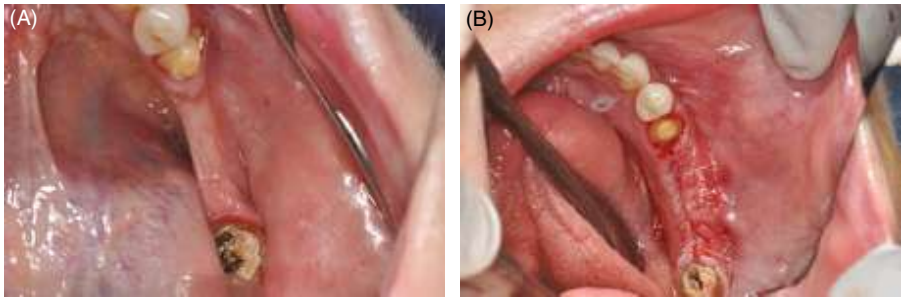

FIGURE 13.52 Comparison of pre-operative and post-operative changes in bone width. (A) Pre-operative view; (B) post-operative view.

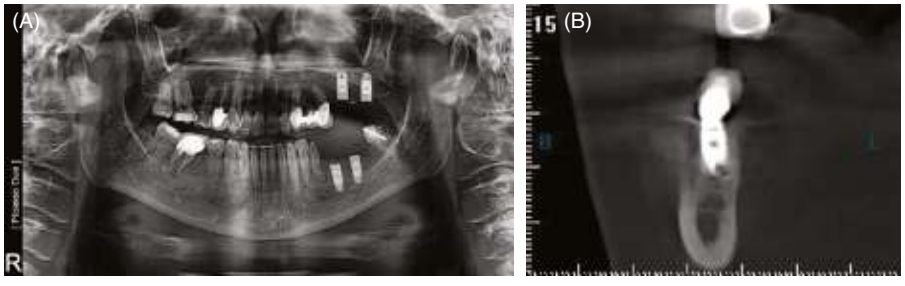

FIGURE 13.53 (A) Radiographic confirmation of the implant placed. (B) The implant occupies a spatial position within the augmented site in the new bone formed. Alignment with the opposing arch can also be appreciated.

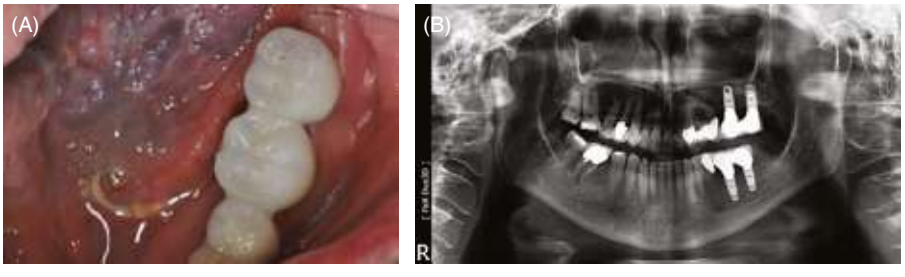

FIGURE 13.54 (A) Completion of prosthetic treatment. (B) Radiographic verification of completion of treatment.

Dentlearn.ir

DISCUSSION

To minimize the biological and mechanical complications of implant prosthesis rehabilitation, horizontal alveolar ridge augmentation may be required for optimal execution of the surgical placement of the implant. The benefits of ARP are most noticeable in the horizontal dimension and are compelling with allogenic bone substitute [4].

The unlimited source of graft material that is available off the shelf (compared with autogenous block graft) [31], the ease of handling [28], the ability to be self-contained in the defect space (compared with particulate graft) [28], complete elimination of donor site–associated morbidity, ideal biocompatibility, low block graft failure rates [29, 74, 75], minimal resorption and high volume stability [7, 13, 26, 29, 31, 76], and high survival rates of implants [7, 75, 77, 78] are factors supporting allograft augmentation as a successful treatment alternative to an autogenous block graft, despite autogenous bone block grafts being considered a reference to date.

The rigorous processing guidelines for allogenic grafts have also practically eliminated the risk of immune reactions and cross-contamination by diminishing the microbial load, making them a safe alternative for the augmentation of deficient bone [24,79–81]. It has been reported that the volumetric reduction of the horizontal area augmented by using an allogenic block graft was 4.4% and 5.3% with an autogenous block graft after 6 months. After 12 months, the volumetric reduction was 4.8% with an allogenic block graft and 6.3% with an autogenous block graft. This study also suggests that overcontouring the alveolar ridge when using allogenic block grafts should be no different from the overcontouring performed with autogenous grafts, as there is no difference in the mean shrinkage rate of the grafts after 12 months (12.5%±7.8% for autogenous grafts and 14.4±9.8% for allogenic grafts). This, together with the fact that there is no associated donor site morbidity, makes allogenic block grafts a feasible alternate for rebuilding horizontal alveolar ridge defects [26]. In fact, in a clinical trial it was reported that augmentation with allograft remains stable even 5 years after surgery and has a 100% implant survival rate for the same duration [75].

In another systematic review comparing implant success and survival rate in autogenous bone graft with allogenic bone graft, a favorable outcome was observed with the allograft material. The range of implant survival and success rates in autogenous bone grafts was from 73.8% to 100% and 72.8% to 100%, respectively. The corresponding numbers for allogenic bone grafts were 95.3–100% and 93.7–100%, respectively [20].

Key concerns during the surgical procedure include a close adaptation of the graft to the host tissue bed, permitting rapid vascularization and bony integration [28, 29, 82]. Avoidance of dehiscence and membrane exposure due to watertight yet tension-free wound closure during healing is imperative for promising outcomes. This requires an incision that ensures re-approximation of periosteum and keratinized gingival completely over the allogenic bone graft [7, 29, 31, 65–67, 83–85]. It is noteworthy that the incidence of incision line opening has been documented to be 80% [83] and soft tissue dehiscence reported is 27–74% [75, 84, 85]. To avoid this complication, scoring of the periosteum is imperative, as the collagen fibers of the periosteum will not stretch and scoring will allow the elastic fibers of submucosa to lengthen [25].

Another complication that operators must be aware of is loosening of the osteosynthesis screws [31, 74]. Here it must be ensured that the selected screws are self-tapping and smooth surfaced. They must also have a definitive locking interface between the driver and the screw head so as to enable insertion without slippage. The additional consideration is that the threads should not strip while screwing the block.

Rehydration of the allogenic block graft is necessary as it results in increasing the breaking strength and flexibility [31, 86]. The irradiated graft is advantageous in this aspect as it is supplied in hydrated form in a sterile pouch and does not require any special preparation.

The histological outcome of sites augmented by irradiated allogenic block graft is suggestive of the excellent remodeling capacity of the material, resulting in stable, viable neobone formation. This concurs with the clinically favorable outcome as well. This has been supported previously in the literature [8, 21, 28, 84, 87–91]. It has been reported that neobone formation accounts for 42.9–70.5% (mean of 47.6%) and residual allograft comprises 29.5–57.1% (mean of 52.4%) in a histological specimen. This again implies that allografts provide a predicable way to support new bone formation in deficient ridges prior to implant placement [92].

The intense remodeling can be attributed to the corticocancellous nature of the block allograft. While the cortical part of the graft provides mechanical stability at the graft site, the cancellous component provides the vascularization to support the bone tissue remodeling [21, 28]. The role of collagen membrane is emphasized, as it separates the healing site from the epithelial cells and minimizes the resorption of graft, thus achieving a favorable histological response [28]. A close scrutiny of the reports on immunohistochemical findings yields positive results for three biomarkers along the osteoblast nuclei, which are found parallel to the border of the allogenic bone to newly formed mature bone, or in osteoblast nuclei within the marrow. The three biomarkers documented are bone morphogenic protein (BMP-2), osteocalcin (OCN), and alkaline phosphatase (ALP), and they imply an active bone formation process.

Benefits specific to the irradiated allogenic block grafts are numerous and outweigh those of the other augmentation options. The storage, transportation, and handling of these grafts are easy, not requiring any special equipment. The grafts are supplied in hydrated form and do not need any special diluting or reconstitution of liquids. They can also be stored at

Dentlearn.ir

room temperature. The fuss-free handling makes these grafts a popular choice where control of ambient climatic conditions is difficult.

The graft blocks are available in numerous size options, making them versatile in numerous clinical conditions, as has been illustrated in this chapter. This distinguishing feature sets the irradiated allogenic grafts apart from the autogenous grafts, as the available volume of autogenous grafts is anatomically restricted.

Being derivative of vertebral bone, the grafts are also available in a form with inherent curvature, which permits convenient adaptation of the graft in different regions of the arch. The high cancellous nature of the graft makes it easy to contour and adapt intimately over the recipient bone, with minimal instrumentation. Hydration of the graft further enhances the process of adjusting the graft to the recipient site.

The rapid replacement of the graft by new bone and consistent establishment of a reasonable ratio of new bone provides histological predictability. The formation of the new bone and placement of implants in this bone accomplish the treatment goals in terms of function, esthetics, and longevity.

Clinical, histological, and radiographic outcomes are suggestive that irradiated allogenic block graft is an effective and viable method of horizontal augmentation of alveolar bone defects and has the potential to replace autogenous procedures for the challenging clinical situation. Future directions can explore the options of applying computer-aided design/manufacturing (CAD/CAM) technology to customize the grafts such that they are characterized by impeccable accuracy in the defect geometry, further reducing the operatory times [27, 29, 88, 89, 93, 94].

CONCLUSION

The procedural details of allogenic block grafts have been demonstrated through three distinct case illustrations, which represent exceedingly challenging clinical situations. The safety and effectiveness of this horizontal alveolar bone augmentation procedure are evident through the clinical outcomes. The procedure circumvents the drawbacks of the autogenous block graft procedure and enables placement of the implant in neo-regenerated bone. The radiographic and histological findings concur with the clinical outcome and are suggestive of substantial bone formation at the site grafted by the allograft.

ACKNOWLEDGMENT

The author wishes to acknowledge the tireless efforts of Dr. Aditi Nanda, Assistant Professor, All India Institute of Medical Sciences, New Delhi, India, for her contributions in helping prepare the manuscript, bibliography, and organization of the images for the chapter.

REFERENCES

1. Leonetti JA, Koup R. Localized maxillary ridge augmentation with a block allograft for dental implant placement: Case reports. *Implant Dent.* 2003;12:217–26.
2. Shahmohammadi R, Moeintaghavi A, Radvar M et al. Clinical and histological evaluation of increase in the residual ridge width using mineralized corticocancellous block allografts: A pilot study. *J Dent Res Dent Clin Dent Prospects.* 2017;11:229–35.
3. Sakkas A, Wilde F, Heufelder M et al. Autogenous bone grafts in oral implantology—is it still a "gold standard"? A consecutive review of 279 patients with 456 clinical procedures. *Int J Implant Dent.* 2017;3(1):23.
4. Avila-Ortiz G, Chambrone L, Vignoletti F. Effect of alveolar ridge preservation interventions following tooth extraction: A systematic review and meta-analysis. *J Clin Periodontol.* 2019;46:195–223.
5. Tan WL, Wong TL, Wong MC, Lang NP. A systematic review of post-extractional alveolar hard and soft tissue dimensional changes in humans. *Clin Oral Implants Res.* 2012;23:1–21.
6. Van der Weijden F, Dell'Acqua F, Slot DE. Alveolar bone dimensional changes of post-extraction sockets in humans: A systematic review. *J Clin Periodontol.* 2009;36:1048–58.
7. Starch-Jensen T, Deluiz D, Tinoco EMB. Horizontal alveolar ridge augmentation with allogeneic bone block graft compared with autogenous bone block graft: A systematic review. *J Oral Maxillofac Res.* 2020;11:e1.
8. Andrade MG, Moreira DC, Dantas DB et al. Pattern of osteogenesis during onlay bone graft healing. *Oral Surg Oral Med Oral Pathol Oral Radiol Endod.* 2010;110:713–19.
9. Zaki J, Alnawawy M, Yussif N, Elkhadem A. The effect of membrane coverage on the resorption of autogenous intraoral block grafts in horizontal ridge augmentation: A systematic review of literature and meta-analysis: Inevitability or an iatrogenic vulnerability? *J Evid Based Dent Pract.* 2018;18:275–89.
10. Tolstunov L. Classification of the alveolar ridge width: Implant-driven treatment considerations for the horizontally deficient alveolar ridges. *J Oral Implantol.* 2014;40:365–70.
11. Wang HL, Al-Shammari K. HVC ridge deficiency classification: A therapeutically oriented classification. *Int J Periodontics Restorative Dent.* 2002;22:335–43.
12. Aludden HC, Mordenfeld A, Hallman M et al. Lateral ridge augmentation with Bio-Oss alone or Bio-Oss mixed with particulate autogenous bone graft: A systematic review. *Int J Oral Maxillofac Surg.* 2017;46:1030–38.
13. Troeltzsch M, Troeltzsch M, Kauffmann P et al. Clinical efficacy of grafting materials in alveolar ridge augmentation: A systematic review. *J Craniomaxillofac Surg.* 2016;44(10): 1618–29.
14. Sanz-Sánchez I, Ortiz-Vigón A, Sanz-Martín I et al. Effectiveness of lateral bone augmentation on the alveolar crest dimension: A systematic review and meta-analysis. *J Dent Res.* 2015;94:128S–142S.

Dentlearn.ir

15. Lampert RC, Braidy HF, Zweig BE et al. Intraoral autogenous vs allogeneic block grafts in preparation for dental implants placement: A retrospective cohort study. Oral abstract track 3. *J Oral Maxillofac Surg.* 2015;73:E30–E31.

16. Chappuis V, Cavusoglu Y, Buser D, von Arx T. Lateral ridge augmentation using autogenous block grafts and guided bone regeneration: A 10-year prospective case series study. *Clin Implant Dent Relat Res.* 2017;19:85–96.

17. Restoy-Lozano A, Dominguez-Mompell JL, Infante-Cossio P et al. Reconstruction of mandibular vertical defects for dental implants with autogenous bone block grafts using a tunnel approach: Clinical study of 50 cases. *Int J Oral Maxillofac Surg.* 2015;44:1416–22.

18. Slotte C, Nannmark U. Augmentation of severely resorbed alveolar crests with bovine bone blocks: A human histology pilot study. *Clin Implant Dent Relat Res.* 2017;19:581–5.

19. Leong DJ, Oh TJ, Benavides E et al. Comparison between sandwich bone augmentation and allogenic block graft for vertical ridge augmentation in the posterior mandible. *Implant Dent.* 2015;24:4–12.

20. Motamedian SR, Khojaste M, Khojasteh A. Success rate of implants placed in autogenous bone blocks versus allogenic bone blocks: A systematic literature review. *Ann Maxillofac Surg.* 2016;6:78–90.

21. Peleg M, Sawatari Y, Marx RN et al. Use of corticocancellous allogeneic bone blocks for augmentation of alveolar bone defects. *Int J Oral Maxillofac Implants.* 2010;25:153–62.

22. Petrungaro PS, Amar S. Localized ridge augmentation with allogenic block grafts prior to implant placement: Case reports and histologic evaluations. *Implant Dent.* 2005;14:139–48.

23. Fretwurst T, Nack C, Al-Ghrairi M et al. Long-term retrospective evaluation of the peri-implant bone level in onlay grafted patients with iliac bone from the anterior superior iliac crest. *J Craniomaxillofac Surg.* 2015;43:956–60.

24. Spin-Neto R, Stavropoulos A, Coletti FL et al. Remodeling of cortical and corticocancellous fresh-frozen allogeneic block bone grafts—a radiographic and histomorphometric comparison to autologous bone grafts. *Clin Oral Implants Res.* 2015;26:747–52.

25. Keller EE, Tolman DE, Eckert S. Surgical-prosthodontic reconstruction of advanced maxillary bone compromise with autogenous onlay block bone grafts and osseointegrated endosseous implants: A 12-year study of 32 consecutive patients. *Int J Oral Maxillofac Implants.* 1999;14:197–209.

26. Kloss FR, Offermanns V, Kloss-Brandstätter A. Comparison of allogeneic and autogenous bone grafts for augmentation of alveolar ridge defects—a 12-month retrospective radiographic evaluation. *Clin Oral Implants Res.* 2018;29:1163–75.

27. Schlee M, Rothamel D. Ridge augmentation using customized allogenic bone blocks: proof of concept and histological findings. *Implant Dent.* 2013;22:212–18.

28. Jun CM, Yun JH. Three-dimensional bone regeneration of alveolar ridge defects using corticocancellous allogeneic block grafts: Histologic and immunohistochemical analysis. *Int J Periodontics Restorative Dent.* 2016;36:75–81.

29. Blume O, Back M, Born T, Donkiewicz P. Reconstruction of a unilateral alveolar cleft using a customized allogenic bone block and subsequent dental implant placement in an adult patient. *J Oral Maxillofac Surg.* 2019;77:2127.e1-2127.e11.

30. Bow A, Anderson DE, Dhar M. Commercially available bone graft substitutes: The impact of origin and processing on graft functionality. *Drug Metab Rev.* 2019;51:533–44.

31. Tunkel J, de Stavola L, Kloss-Brandstätter A. Alveolar ridge augmentation using the shell technique with allogeneic and autogenous bone plates in a split-mouth design—a retrospective case report from five patients. *Clin Case Rep.* 2020;9:947–59.

32. Misch CM. Comparison of intraoral donor sites for onlay grafting prior to implant placement. *Int J Oral Maxillofac Implants.* 1997;12:767–76.

33. Garg AK, Morales MJ, Navarro I, Duarte F. Autogenous mandibular bone grafts in the treatment of the resorbed maxillary anterior alveolar ridge: Rationale and approach. *Implant Dent.* 1998;7:169–76.

34. Bedrossian E, Tawfilis A, Alijanian A. Veneer grafting: A technique for augmentation of the resorbed alveolus prior to implant placement. A clinical report. *Int J Oral Maxillofac Implants.* 2000;15:853–8.

35. Antonious M, Couso-Queiruga E, Barwacz C et al. Evaluation of a minimally invasive alveolar ridge reconstruction approach in postextraction dehiscence defects: A case series. *Int J Periodontics Restorative Dent.* 2021;41:335–45.

36. Atieh MA, Alsabeeha NH, Payne AG et al. Interventions for replacing missing teeth: Alveolar ridge preservation techniques for dental implant site development. *Cochrane Database Syst Rev.* 2021;4:CD010176. doi: 10.1002/14651858.CD010176.pub2.

37. Roca-Millan E, Jané-Salas E, Estrugo-Devesa A, López-López J. Evaluation of bone gain and complication rates after guided bone regeneration with titanium foils: A systematic review. *Materials (Basel).* 2020;13:5346.

38. Soni R, Priya A, Agrawal R et al. Evaluation of efficacy of platelet-rich fibrin membrane and bone graft in coverage of immediate dental implant in esthetic zone: An in vivo study. *Natl J Maxillofac Surg.* 2020;11:67–75.

39. Lee DW, Pi SH, Lee SK, Kim EC. Comparative histomorophometric analysis of extraction sockets healing implanted with bovine xenografts, irradiated cancellous allografts and solvent dehydrated allografts in humans. *Int J Oral Maxillofac Implants.* 2009;24:609–15.

40. Jensen SS, Terheyden H. Bone augmentation procedures in localized defects in the alveolar ridge: Clinical results with different bone grafts and bone-substitute materials. *Int J Oral Maxillofac Implants.* 2009;24:218–36.

41. Sanz-Sanchez I, Ortiz-Vigon A, Sanz-Martin I et al. Effectiveness of lateral bone augmentation on the alveolar crest dimension: A systematic review and meta-analysis. *J Dent Res.* 2015;94:128s–142s.

42. Chiapasco M, Casentini P, Zaniboni M. Bone augmentation procedures in implant dentistry. *Int J Oral Maxillofac Implants.* 2009;24:237–59.

43. Meijndert CM, Raghoebar GM, Meijndert L et al. Single implants in the aesthetic region preceded by local ridge augmentation: A 10-year randomized controlled trial. *Clin Oral Implants Res.* 2017;28:388–95.

44. Verdugo F, Uribarri A, D'Addona A. Autogenous bone block grafting provides facial implant tissue stability long-term. *Clin Implant Dent Relat Res.* 2017;19:478–85.

45. Fuglsig JMCES, Thorn JJ, Ingerslev J et al. Long term follow-up of titanium implants installed in block-grafted areas: A systematic review. *Clin Implant Dent Relat Res.* 2018;20:1036–46.

Dentlearn.ir

46. Esposito M, Grusovin MG, Felice P et al. The efficacy of horizontal and vertical bone augmentation procedures for dental implants – a Cochrane systematic review. *Eur J Oral Implantol.* 2009;2:167–84.
47. Milinkovic I, Cordaro L. Are there specific indications for the different alveolar bone augmentation procedures for implant placement? A systematic review. *Int Journal Oral Maxillofac Surg.* 2014;43:606–25.
48. Khoury F, Hanser T. Mandibular bone block harvesting from the retromolar region: A 10-year prospective clinical study. *Int J Oral Maxillofac Implants.* 2015;30:688–97.
49. von Arx T, Buser D. Horizontal ridge augmentation using autogenous block grafts and the guided bone regeneration technique with collagen membranes: A clinical study with 42 patients. *Clin Oral Implants Res.* 2006;17:359–66.
50. Nkenke E, Neukam FW. Autogenous bone harvesting and grafting in advanced jaw resorption: Morbidity, resorption and implant survival. *Eur J Oral Implantol.* 2014;7:S203–S217.
51. Jensen T, Schou S, Svendsen PA et al. Volumetric changes of the graft after maxillary sinus floor augmentation with Bio-Oss and autogenous bone in different ratios: A radiographic study in minipigs. *Clin Oral Implants Res.* 2012;23:902–10.
52. Cricchio G, Lundgren S. Donor site morbidity in two different approaches to anterior iliac crest bone harvesting. *Clin Implant Dent Relat Res.* 2003;5:161–9.
53. Morelli T, Neiva R, Wang HL. Human histology of allogeneic block grafts for alveolar ridge augmentation: Case report. *Int J Periodontics Restorative Dent.* 2009;29:649–56.
54. Tatum OH Jr. Osseous grafts in intra-oral sites. *J Oral Implantol.* 1996;22:51–2.
55. Tatum OH Jr, Lebowitz MS, Tatum CA, Borgner RA. Sinus augmentation: Rationale, development, long-term results. *N Y State Dent J.* 1993;59:43-8.
56. Schoepf C. Allograft safety: Efficacy of the Tutoplast! process. *Int J Oral Implantol.* 2006;7:10–15.
57. Tsao YP, Neiva R, Al-Shammari K et al. Effects of a mineralized human cancellous bone allograft in regeneration of mandibular Class II furcation defects. *J Periodontol.* 2006;77:416–25.
58. Wang HL, Tsao YP. Histologic evaluation of socket augmentation with mineralized human allograft. *Int J Periodontics Restorative Dent.* 2008;28:231–7.
59. Wang HL, Tsao YP. Mineralized bone allograft-plug socket augmentation: Rationale and technique. *Implant Dent.* 2007;16:33–41.
60. Block MS, Degen M. Horizontal ridge augmentation using human mineralized particulate bone: Preliminary results. *J Oral Maxillofac Surg.* 2004;62:67–72.
61. Kadam A, Millhouse PW, Kepler CK et al. Bone substitutes and expanders in spine surgery: A review of their fusion efficacies. *Int J Spine Surg.* 2016;10:33.
62. Drosos GI, Touzopoulos P, Ververidis A et al. Use of demineralized bone matrix in the extremities. *World J Orthop.* 2015:6;269–77.
63. Wang HL, Boyapati L. "PASS" principles for predictable bone regeneration. *Implant Dent.* 2006;15:8–17.
64. Frost HM. The regional acceleratory phenomenon: A review. *Henry Ford Hosp Med J.* 1983;31:3–9.
65. Kleinheinz J, Büchter A, Kruse-Lösler B et al. Incision design in implant dentistry based on vascularization of the mucosa. *Clin Oral Implants Res.* 2005;16:518–23.
66. Chaushu G, Mardinger O, Peleg M et al. Analysis of complications following augmentation with cancellous block allografts. *J Periodontol.* 2010;81:1759–64.
67. Keith JD Jr, Petrungaro P, Leonetti JA et al. Clinical and histologic evaluation of a mineralized block allograft: Results from the developmental period (2001–2004). *Int J Periodontics Restorative Dent.* 2006;26:321–7.
68. Jardini MA, De Marco AC, Lima LA. Early healing pattern of autogenous bone grafts with and without e-PTFE membranes: A histomorphometric study in rats. *Oral Surg Oral Med Oral Pathol Oral Radiol Endod.* 2005;100:666–73.
69. Jensen OT, Greer RO Jr, Johnson L, Kassebaum D. Vertical guided bone-graft augmentation in a new canine mandibular model. *Int J Oral Maxillofac Implants.* 1995;10:335–44.
70. Elgali I, Omar O, Dahlin C, Thomsen P. Guided bone regeneration: Materials and biological mechanisms revisited. *Eur J Oral Sci.* 2017;125:315–37.
71. Omar O, Elgali I, Dahlin C, Thomsen P. Barrier membranes: More than the barrier effect? *J Clin Periodontol.* 2019;46:103–23.
72. Machtei EE. The effect of membrane exposure on the outcome of regenerative procedures in humans: A meta-analysis. *J Periodontol.* 2001;72:512–16.
73. Park SH, Wang HL. Clinical significance of incision location on guided bone regeneration: Human study. *J Periodontol.* 2007;78:47–51.
74. Monje A, Pikos MA, Chan HL et al. On the feasibility of utilizing allogeneic bone blocks for atrophic maxillary augmentation. *Biomed Res Int.* 2014;2014:814578.
75. Novell J, Novell-Costa F, Ivorra C et al. Five-year results of implants inserted into freeze-dried block allografts. *Implant Dent.* 2012;21:129–35.
76. Kloss FR, Offermanns V, Donkiewicz P, Kloss-Brandstätter A. Customized allogeneic bone grafts for maxillary horizontal augmentation: A 5-year follow-up radiographic and histologic evaluation. *Clin Case Rep.* 2020;8:886–93.
77. Nissan J, Marilena V, Gross O et al. Histomorphometric analysis following augmentation of the posterior mandible using cancellous bone-block allograft. *J Biomed Mater Res A.* 2011;97(4):509–13.
78. Park YH, Choi SH, Cho KS, Lee JS. Dimensional alterations following vertical ridge augmentation using collagen membrane and three types of bone grafting materials: A retrospective observational study. *Clin Implant Dent Relat Res.* 2017:19;742–49.
79. Waasdorp J, Reynolds MA. Allogeneic bone onlay grafts for alveolar ridge augmentation: A systematic review. *Int J Oral Maxillofac Implants.* 2010:25;525–31.
80. Salvucci JT. Bone tissue, lyophilized and stored at room temperature for 15 days or more, is not capable of transmitting HIV, *HCV or HBV. Cell Tissue Bank.* 2011;12:99–104.
81. Hinsenkamp M, Muylle L, Eastlund T et al. Adverse reactions and events related to musculoskeletal allografts: Reviewed by the World Health Organisation Project NOTIFY. *Int Orthop.* 2012;36:633–41.

Dentlearn.ir

82. Eskow AJ, Mealey BL. Evaluation of healing following tooth extraction with ridge preservation using cortical versus cancellous freeze-dried bone allograft. *J Periodontol.* 2014;85:514–24.

83. Chaushu L, Chaushu G, Kolerman R et al. Anterior atrophic mandible restoration using cancellous bone block allograft. *Clin Implant Dent Relat Res.* 2019;21:903–9.

84. Nissan J, Marilena V, Gross O et al. Histomorphometric analysis following augmentation of the anterior atrophic maxilla with cancellous bone block allograft. *Int J Oral Maxillofac Implants.* 2012;27:84–9.

85. Chiapasco M, Colletti G, Coggiola A et al. Clinical outcome of the use of fresh frozen allogeneic bone grafts for the reconstruction of severely resorbed alveolar ridges: Preliminary results of a prospective study. *Int J Oral Maxillofac Implants.* 2015;30:450–60.

86. Pabst A, Ackermann M, Thiem D, Kämmerer P. Influence of different rehydration protocols on biomechanical properties of allogeneic cortical bone plates: A combined in-vitro/in-vivo study. *J Invest Surg.* 2021;34:1158–64.

87. Jacotti M, Wang HL, Fu JH et al. Ridge augmentation with mineralized block allografts: Clinical and histological evaluation of 8 cases treated with the 3-dimensional block technique. *Implant Dent.* 2012;21:444–8.

88. Blume O, Hoffmann L, Donkiewicz P et al. Treatment of severely resorbed maxilla due to peri-implantitis by guided bone regeneration using a customized allogenic bone block: A case report. *Materials (Basel).* 2017;10:1213.

89. Blume O, Donkiewicz P, Back M, Born T. Bilateral maxillary augmentation using CAD/CAM manufactured allogenic bone blocks for restoration of congenitally missing teeth: A case report. *J Esthet Restor Dent.* 2019;31:171–8.

90. Al-Abedalla K, Torres J, Cortes AR et al. Bone augmented with allograft onlays for implant placement could be comparable with native bone. *J Oral Maxillofac Surg.* 2015;73:2108–22.

91. Schmitt CM, Doering H, Schmidt T et al. Histological results after maxillary sinus augmentation with Straumann® BoneCeramic, Bio-Oss®, Puros®, and autologous bone: A randomized controlled clinical trial. *Clin Oral Implants Res.* 2013;24:576–85.

92. Feuille F, Knapp CI, Brunsvold MA, Mellonig JT. Clinical and histologic evaluation of bone-replacement grafts in the treatment of localized alveolar ridge defects. Part 1: Mineralized freeze-dried bone allograft. *Int J Periodontics Restorative Dent.* 2003;23:29–35.

93. Otto S, Kleye C, Burian E et al. Custom-milled individual allogeneic bone grafts for alveolar cleft osteoplasty—a technical note. *J Craniomaxillofac Surg.* 2017;45:1955–61.

94. Jacotti M, Barausse C, Felice P. Posterior atrophic mandible rehabilitation with onlay allograft created with CAD-CAM procedure: A case report. *Implant Dent.* 2014;23:22–8.

Dentlearn.ir

Ridge-Split Expansion Procedure for Horizontal Bone Augmentation in Implant Dentistry

CHAPTERS 14.1–14.6

This chapter will discuss diagnosis, classification, treatment planning, and surgical principles of the ridge-split expansion procedure (RSEP), one of the commonly used horizontal bone augmentation techniques in implant dentistry. Clinical and radiographic evaluation, including cone beam computed tomography scans, will be presented. A traditional two-stage approach for the mandibular alveolar RSEP and single-stage maxillary RSEP will be discussed with case reports, benefits, alternatives, and complications. A learning curve must be considered for a novice surgeon interested in mastering the RSEP (see Video 14.1).

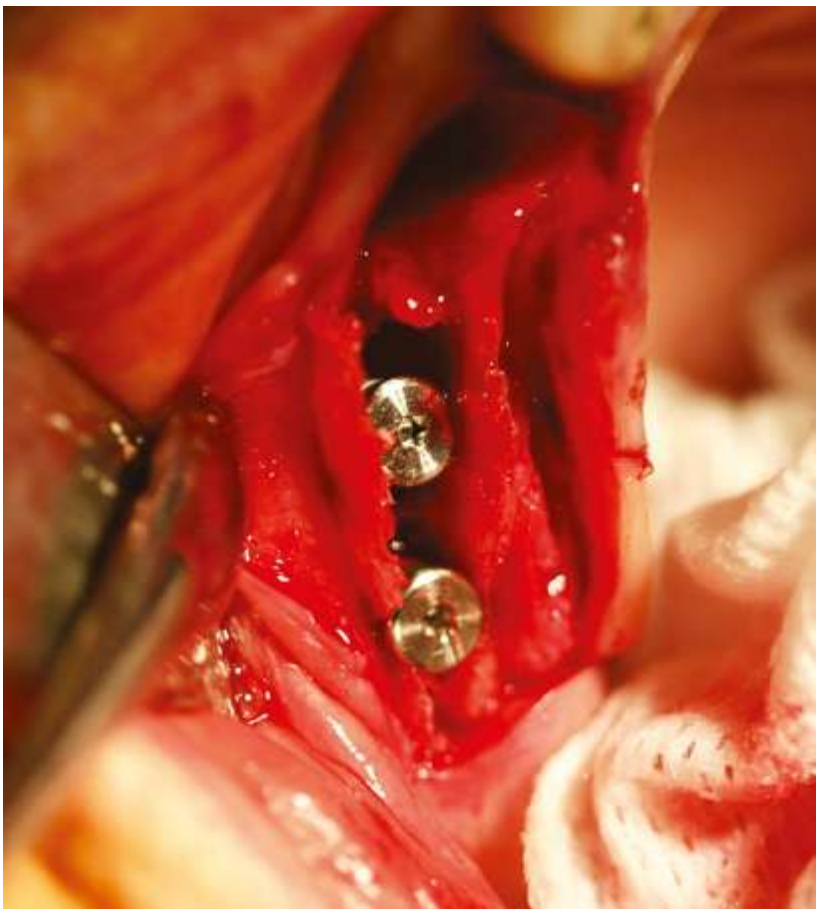

Dentlearn.ir

CHAPTER 14.1

Diagnosis and Treatment Planning

Len Tolstunov[1,2,3]

[1]*Associate Clinical Professor, Department of Oral and Maxillofacial Surgery, University of California San Francisco (UCSF) School of Dentistry, San Francisco, CA, USA*

[2]*Associate Clinical Professor, Department of Oral and Maxillofacial Surgery, University of the Pacific Arthur A. Dugoni School of Dentistry, San Francisco, CA, USA*

[3]*Private OMFS practice, San Francisco, CA, USA*

HISTORY

The seminal works of William H. Bell's animal and clinical studies in the late 1960s–early 1970s on bone vascularization, bone healing, and pulp vitality [1–5] helped to establish the biological rationale for segmental and total (Le Fort I) jawbone osteotomies in orthognathic surgery. Bell demonstrated that the vitality of the segment of a jaw to be osteotomized would be preserved if the soft tissue pedicle were kept intact. This principle of preservation of bone vascularization after its complete osteotomy through the *intact* periosteal (soft tissue) pedicle was adapted from Bell's segmental maxillary osteotomies by subsequent researchers, who explored the possibilities of *alveolar* ridge osteotomies.

In 1992, an Italian group led by Simion [6] published an article called "Jawbone enlargement using immediate implant placement associated with a split-crest technique and guided tissue regeneration." The surgical technique involved a longitudinal split of the alveolar ridge "in two parts, provoking a green-stick fracture," and introduced a concept of the immediate insertion of dental implants.

In 1994, another Italian group led by Scipioni [7] published an article entitled "The edentulous ridge expansion technique: A five-year study." In this work, 329 implants were placed in 170 patients after the single-stage edentulous ridge expansion (ERE). The authors commented that "The essential feature of ERE technique is the partial-thickness flap with preservation of its buccal blood supply" as well as that "the integrity of the periosteum must be maintained."

In 2000, Smiler [8] described the "sandwich" split cortical graft for implant placement with a bone replacement graft that is "placed within the cancellous compartment and is contained by the autogenous cortical block harvested from the recipient bed." In a report the same year, Vercellotti [9] presented a new piezoelectric ridge expansion technique with implants placed in a single-stage surgery. At three months, the ridge thickness increased and all implants successfully osseointegrated. By 2007, Bravi et al. [10] had gathered a large amount of data over a period of 10 years on 1715 implants placed with the ERE technique by a group of experienced surgeons, and demonstrated an overall implant success rate of 95.7%. In 2010, Sohn et al. [11] described differences in immediate and delayed lateral ridge expansion techniques in the atrophic posterior mandibular ridge on 32 patients (84 implants were placed). The authors concluded that the delayed approach (9 patients) was safer and more predictable in patients with a denser bone and thick cortex (typical for the mandibular ridges). In 2014, Ella et al. [12], in a prospective three-year study in 32 patients, concluded that "a lack of bone substitute resulted in significant resorption," with the recommendation to consider a bone graft during the ridge-split expansion procedure (RSEP) to prevent ridge resorption and relapse later.

DIAGNOSIS AND TREATMENT PLANNING

PATIENT (HOST) SELECTION

An ideal candidate for the RSEP is a non-smoking patient with good oral hygiene, healthy, and committed to quality dental treatment.

Essential Techniques of Alveolar Bone Augmentation in Implant Dentistry: A Surgical Manual, Second Edition. Edited by Len Tolstunov.
© 2023 John Wiley & Sons, Inc. Published 2023 by John Wiley & Sons, Inc.
Companion website: www.wiley.com/go/tolstunov/essential

Dentlearn.ir

ALVEOLAR RIDGE DEFECT ANALYSIS AND CLASSIFICATION

After extraction of single or multiple teeth, the alveolar ridge undergoes slow and progressive three-dimensional (3D) bone resorption. The RSEP works best in mild to moderate horizontal bone resorption cases, with the width of the alveolar ridge between 3 and 5 mm and a largely preserved alveolar height (Figures 14.1.1 and 14.1.2). Clinical and radiographic examination with a cone beam computed tomography (CBCT) scan helps to determine if the bone deficiency is two-dimensional (2D) or 3D (Figures 14.1.3 and 14.1.4).

There are different classifications of partial edentulism for implant applications based on missing teeth and morphology of the edentulous alveolar ridge. The Misch–Judy classification adapted the Kennedy–Applegate classification of partial edentulism (class I through IV) to implant dentistry by adding divisions A through D, which describe the anatomy of the edentulous region [13]. Cawood and Howell suggested an anatomical classification of the edentulous jaws for the pre-prosthetic surgery [14]. Six classes were proposed. Cawood and Howell observed early that, as resorption progresses after tooth loss, the width diminishes first and then the height is eventually affected. Jensen proposed an implant-derived site classification by bone quality and quantity and proximity to vital structures [15]. Wang and Al-Shammari described a practical (therapeutically oriented) classification of alveolar ridge defects – horizontal, vertical, and combination (HVC) – proposing the ERE for the horizontal and combination defects [16].

FIGURE 14.1.1 Intraoral photograph of a moderate horizontal alveolar bone loss with a largely preserved alveolar height: typical indication for the ridge-split expansion procedure.

FIGURE 14.1.2 Panoramic radiograph of a moderate horizontal alveolar bone loss with a largely preserved alveolar height: typical indication for the ridge-split expansion procedure.

FIGURE 14.1.3 Intraoral photograph of a volumetric bone loss with an alveolar bone width and height deficiency: a case that is not typically suitable for a ridge-split expansion procedure alone.

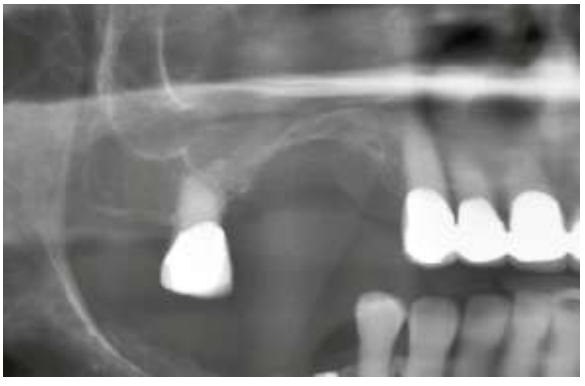

FIGURE 14.1.4 Panoramic radiograph of a volumetric bone loss with an alveolar bone width and height deficiency: a case that is not typically suitable for a ridge-split expansion procedure alone.

In this book, the author would like to offer a clinically and surgically relevant anatomical classification of horizontal alveolar ridge deficiency that might help in cases where the implant-related RSEP is contemplated. This classification (shown in Table 14.1.1) was first published in the *Journal of Oral Implantology* in 2014 [17].

This classification is based on the true computed tomography (CT)-derived measurements of the width of the alveolar ridge for the placement of endosseous dental implants. Table 14.1.1 demonstrates the classification of a progressive horizontal alveolar bone loss where an alveolar

Dentlearn.ir

Table 14.1.1 Classification of the alveolar ridge width (Tolstunov).

Alveolar ridge width (based on CBCT scan)	>10 mm	8–10 mm	6–8 mm	4–6 mm	2–4 mm	<2 mm
Alveolar ridge deficiency	No deficiency	Minimal	Mild	Moderate	Severe	Extreme
Class	**0**	**I**	**II**	**III**	**IV**	**V**
Schematic diagram	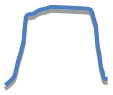	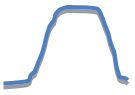	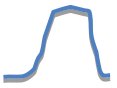	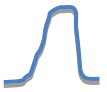		
Indications for surgery	Bone graft is not indicated Occasionally, alveolar width (buccal projection) can be improved with soft tissue graft for esthetic reasons	Bone graft is rarely indicated Occasionally, alveolar width can be improved with GBR or soft tissue graft for esthetic and prosthetic reasons	GBR or RSEP could be indicated to improve buccal bone projection for restoratively driven implant position	An ideal width for RSEP (one- or two-stage) Block graft and GBR can also be indicated	Block bone graft or protective Ti GBR is preferred RSEP can be difficult (surgeon's preference)	Large block graft or protective Ti GBR is preferred Alternative: 2–3 grafting procedures
Immediate implant insertion	Yes	Yes	Yes/no Depends on presence of apical bone for primary implant stability	Yes/no Depends on presence of apical bone for primary implant stability	No	No
Operator experience	Basic	Basic	Basic	Basic to advanced	Advanced	Advanced

Alveolar ridge width (based on CBCT scan)	6–10/2–4 mm	2–4/6–10 mm
Alveolar ridge deficiency	"Hourglass" (undercut)	"Bottleneck"
Class	**VI**	**VII**
Schematic drawing		
Comments	GBR at the mid-ridge Alternative: block graft	Ridge reshaping or GBR Alternative: subcrestal implant placement
Immediate implant insertion at the time of the split	Yes/no, depends on the severity of the undercut	Usually yes, depends on morphology of the ridge crest
Operator experience	Basic	Basic

CBCT, cone beam computed tomography; GBR, guided bone regeneration; RSEP, ridge-split expansion procedure; Ti, titanium.
Source: With permission from Quintessence.

Dentlearn.ir

ridge has an assigned class (from 0 to VII), accompanied with a schematic diagram, indications for surgery (RSEP or block bone grafting), the possibility of an immediate implant placement, and suggested operator experience.

The most common alveolar thickness chosen for the RSEP is 3–5 mm. A 3 mm alveolar bone forms an "alveolar sandwich" consisting of about 1 mm of a (collapsed) buccal cortical plate, 1 mm of medullary bone, and 1 mm of (intact) palatal/lingual cortical plate. CBCT studies demonstrated that the average buccal plate thickness could vary from 0.75 to 1.75 mm with the palatal plate that is slightly thicker [18, 19]. In experienced hands, 3 mm and even 2.5 mm alveolar ridges could be divided. A 2–2.5 mm alveolar ridge in practice represents two adhered cortical plates with little or no medullary bone in between. It becomes a surgical challenge to separate two cortical plates (without medullary layer) successfully during the RSEP. The medullary (trabecular or spongy) layer is the layer where an actual split occurs. The wider this layer, the easier it is to divide the cortical plates. For the novice surgeon, the author recommends choosing an alveolar ridge of 4–5 mm width that has an observable (2–3 mm) medullary layer (Figure 14.1.5). The clinically relevant classification of the alveolar ridge width deficiency can be studied in Table 14.1.1, which demonstrates the classification of a progressive horizontal alveolar bone loss with classes from 0 to VII.

It is important to consider that the morphology of a collapsed alveolar ridge often resembles an "iceberg," with its thinner portion at its crestal region and slowly widening at the base (Figure 14.1.6). On occasion, it might be acceptable to lower the top (crestal) portion of the ridge slightly (about 1–2 mm) to get a wider ridge that can be acceptable for implant insertion without grafting. If this leads to a vertical discrepancy with the adjacent teeth, then the taller permanent abutments might need to be used (occlusal requirements still must be met). This approach would be called a prosthetic correction and may not be acceptable in every case. A patient's refusal of an operation can be one of the reasons for the prosthetic correction. Surgical correction methods without lowering the top of the ridge but using some type of ridge augmentation instead are described elsewhere in this book.

FIGURE 14.1.5 Cone beam computed tomography scan (transaxial slice) of an ideal case that can be treated with a ridge-split expansion procedure: 3–5 mm of the remaining width of the ridge with a 2–3 mm of the trabecular (spongy) bone, the layer where the split occurs.

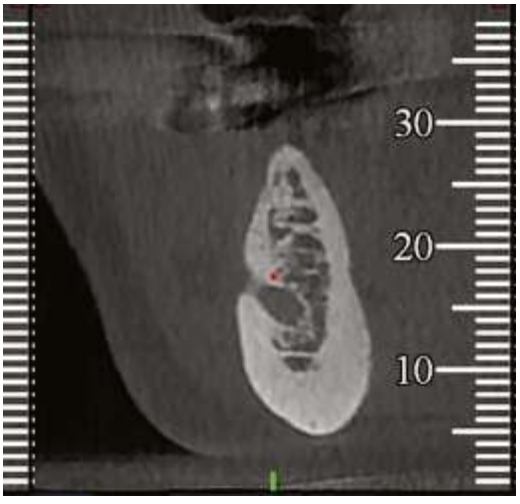

FIGURE 14.1.6 Cone beam computed tomography scan (transaxial slice) of a common pattern of alveolar width loss, an "iceberg" cross-sectional configuration of the ridge, with significant width loss at the top of the ridge and enlargement of the ridge width toward the basal bone.

It is also important to note that some alveolar ridges appear to have an appropriate width for an implant placement from a surgical perspective (6–7 mm of bone width), but esthetically or prosthetically still show insufficient buccal projection of the alveolar crest, and thus can still be considered for a ridge-widening procedure, like RSEP. A team approach can help to identify these cases. From an esthetic point of view for cases in the anterior maxilla, this means that although the ridge might have 6–7 mm alveolar width and an implant can be inserted, there is still some degree of labial collapse present for a patient with a high smile line (gingival exposure). This patient might still benefit from surgical correction via RSEP or a soft tissue graft (Figure 14.1.7) to recreate a more convex and esthetically pleasing buccal ridge profile. If this is a mild esthetic issue, soft tissue augmentation is usually adequate.

From the prosthetic point of view, although a ridge might have a surgically appropriate width for an implant placement, it still can be width deficient restoratively or occlusally, and an implant might emerge more lingually or palatally than the occlusion calls for. This can also be a consideration to "move" the ridge more buccally, possibly utilizing an RSEP (Figure 14.1.8).

DIAGNOSTIC WORK-UP

The diagnostic work-up for the RSEP consists of a thorough clinical examination, appropriate radiographic imaging, and

Dentlearn.ir

FIGURE 14.1.7 Intraoral view of horizontally deficient alveolar ridge in the anterior maxilla that can potentially be restored with an implant without the ridge-widening procedure, although esthetically it could produce a suboptimal result.

FIGURE 14.1.8 Intraoral view of horizontally deficient alveolar ridge in the posterior mandible that can potentially be restored with an implant without the ridge-widening procedure, although prosthetically (occlusally) it would create a suboptimal result.

diagnostic laboratory work. A pre-operative clinical examination helps to determine the right candidate for the procedure. It is important for the full team to evaluate the occlusal, prosthetic, esthetic, and periodontal status of the patient, and assess the edentulous ridge. Digital palpation of the ridge with two fingers sliding along the alveolar crest helps to develop a tactile sense of the ridge "thinness" and presence of bone undercuts (can be crucial at surgery), plate perforations and irregularities, bone defects, and soft tissue thickness (Figure 14.1.9). A sufficient thickness of soft tissue can camouflage true alveolar ridge deficiency. The length of the implant fixture and position of the inferior alveolar canal or mental foramen (in the posterior mandible) determine the vertical dimension of the split.

At the clinical evaluation stage, different calipers and gauges can help to measure the ridge width (Figure 14.1.10). A ridge mapping with sharp gauges (Boley gauge, for example) that penetrate the soft tissue requires local anesthetic for the

FIGURE 14.1.9 Intraoral photograph of the collapsed alveolar ridge: digital palpation of the ridge can help to assess the ridge "thinness" and presence of bone undercuts, plate perforations and irregularities, bone defects, and soft tissue thickness.

FIGURE 14.1.10 Instrumentation: calipers and gauges that can help to measure the ridge width and perform ridge mapping. *Source*: Tolstunov L. Ridge-split procedure for horizontal augmentation of the alveolar ridge in implant dentistry. SROMS. 2013;21(1):1–53. Reproduced with permission of Douglas P. Sinn, DDS. Editor in Chief, SROMS.

proper evaluation of bone thickness. The radiographic value of 2D imaging (panoramic, periapical radiographs) is limited. These radiographs can show only height, not the width that is the key component in the RSEP evaluation. Occlusal radiographs are also suboptimal. CBCT significantly enhances 3D bone evaluation and appreciation of width of the alveolar ridges.

CONE BEAM COMPUTED TOMOGRAPHY

A CBCT scan (Figure 14.1.11) can show the thickness of the buccal and lingual cortical plates, thickness of the medullary layer of bone, width of the alveolar ridge along the edentulous region, presence of bone undercuts and irregularities, and

Dentlearn.ir

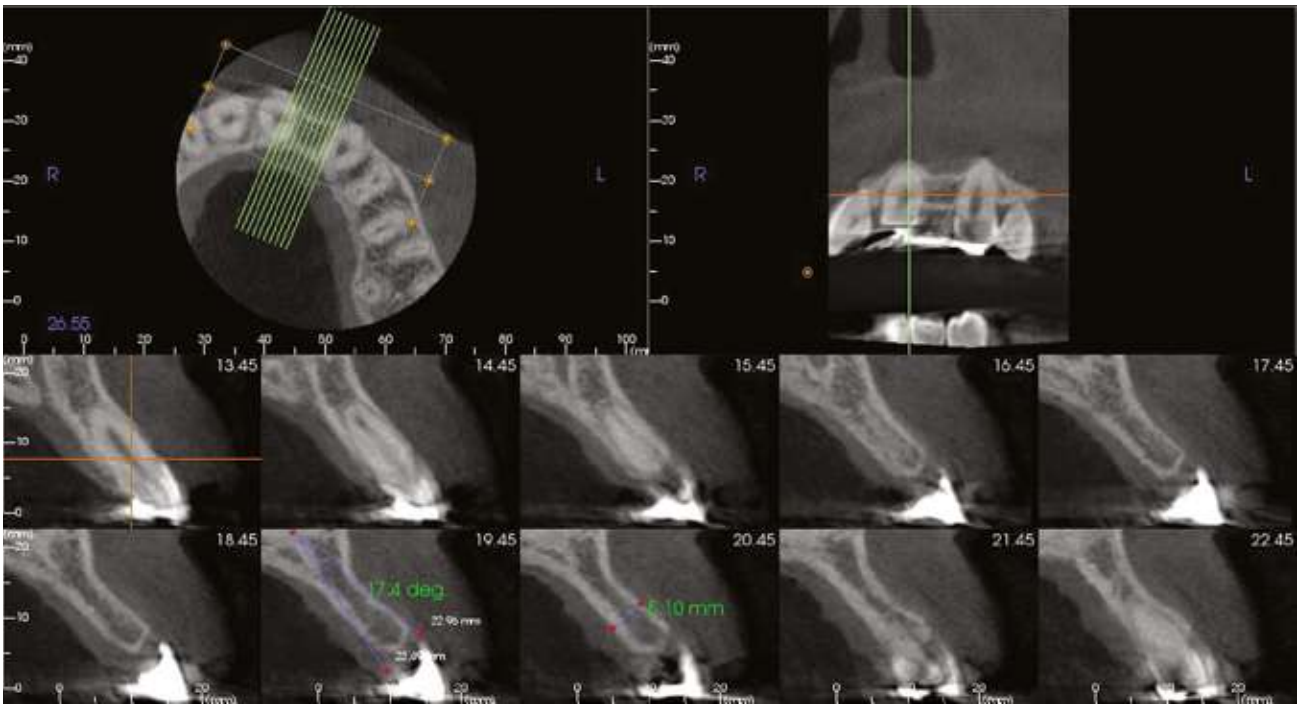

FIGURE 14.1.11 Cross-sectional (transaxial) slices of cone beam computed tomography scan that show thickness of the buccal and lingual cortical plates, thickness of the trabecular layer of bone, and width of the alveolar ridge in the edentulous region. *Source*: Tolstunov L. Ridge-split procedure for horizontal augmentation of the alveolar ridge in implant dentistry. SROMS. 2013;21(1):1–53. Reproduced with permission of Douglas P. Sinn, DDS. Editor in Chief, SROMS.

proximity of the mental foramen, inferior alveolar nerve (IAN), maxillary sinus, and inferior border of the mandible. All these can help in diagnosis and treatment planning of the procedure. Sometimes, CBCT scans taken pre-operatively and post-operatively can help to compare the results of a bone augmentation procedure and evaluate the bone for implant placement (Figure 14.1.12).

SURGICAL STENT

An important part of the diagnostic work-up for the bone augmentation procedure prior to implant placement also consists of diagnostic models, wax-up, and a surgical stent (Figures 14.1.13 and 14.1.14). More about this is described in Chapter 2. Although a surgical stent is often utilized at implant insertion, it can also be helpful at the bone augmentation stage. A surgical stent helps to ensure proper planning for the widening of the ridge (proper buccal plate expansion or lateralization) necessary for the future restoratively driven implant placement. At the implant insertion stage, the same surgical stent can also be utilized.

INSTRUMENTATION

Instrumentation is a matter of preference or availability. The author would like to suggest some general instruments that can be used for the RSEP. Instruments that can be used for bone osteotomy or corticotomy include a thin fissure bur (e.g. 701 bur); small round burs; piezoelectric cutting tips; small oral surgical saws with oscillating, reciprocal, and sagittal movements; diamond disks, and lasers (e.g. erbium:yttrium-aluminum-garnet). Instruments that are helpful for bone splitting include no. 15 (or 15C) scalpel blades; progressive (incremental) chisels, osteotomes, or ridge-splitting/expanding chisels; ridge spreaders; and mallets. Our RSEP set (Figure 14.1.15) consists of the following instruments: scalpel (no. 15), ridge-splitting/expanding chisels (3 and 5 mm with markings at 6, 8, 10, and 12 mm), mallet, Tatum "D" spreader, and periotomes.

The key instrument for the RSEP is a chisel or osteotome, sometimes called a chisel osteotome or splitting (expanding) chisel. When a surgeon selects a comfortable set for the practice, he/she should consider the following. Razor-sharp bone chisels are important for the RSEP to be successful. Chisel osteotomes should have a relatively small size, should have a comfortable handle that fits nicely in your hand, and should have a tip/blade with a sharp edge for engaging and splitting thin ridges. An important feature of a good splitting and expanding chisel is the design of the blade, which should have a flat palatal (lingual) side (to prevent movement and ensure stability of the lingual or palatal cortical plate) and a curved buccal or expanding side, like a

Dentlearn.ir

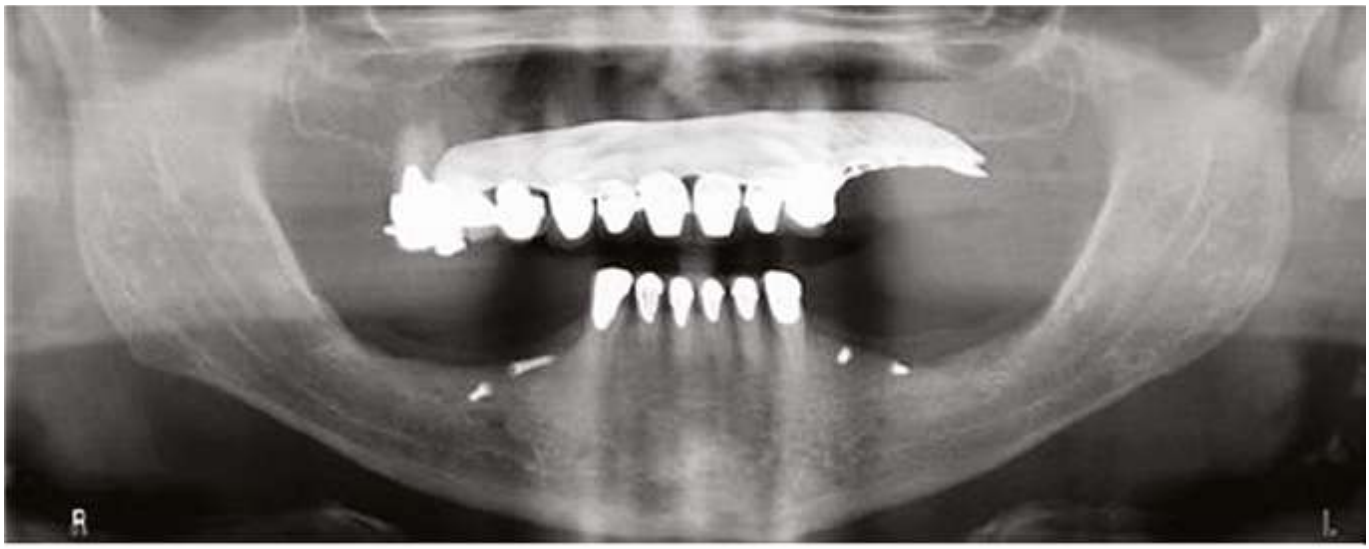

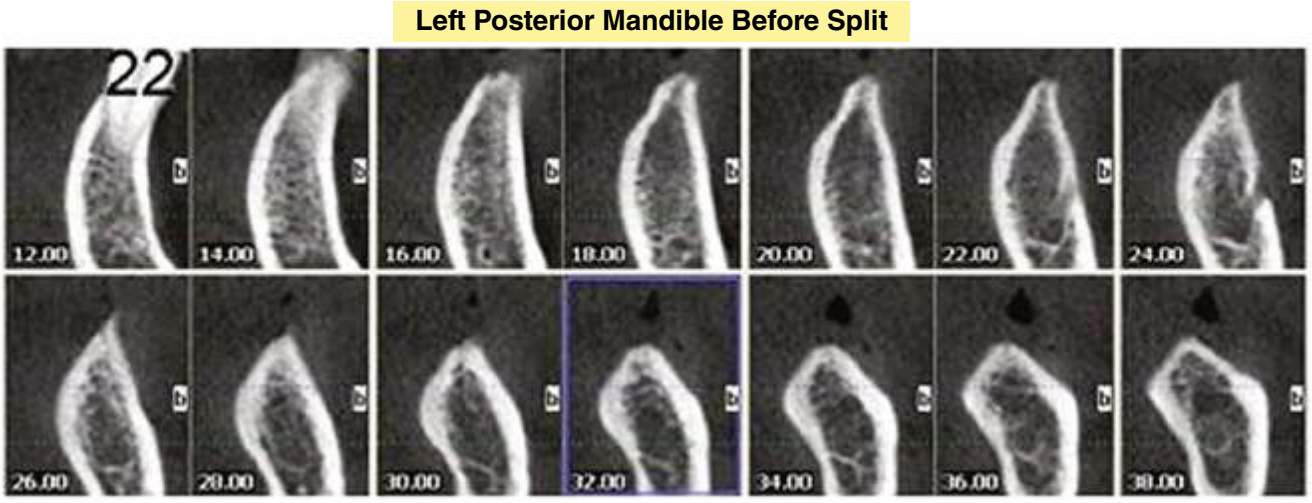

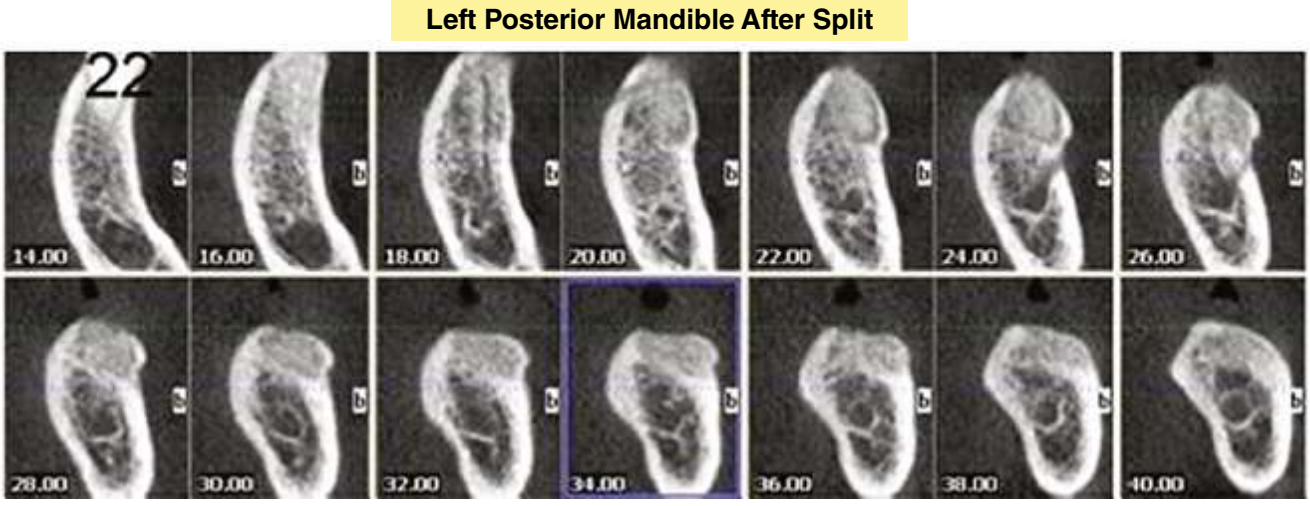

FIGURE 14.1.12 A cone beam computed tomography scan, taken pre-operatively and post-operatively, can help to compare results of bone augmentation and evaluate bone for implant placement. Courtesy of Dr. Bruce Hicke.

Dentlearn.ir

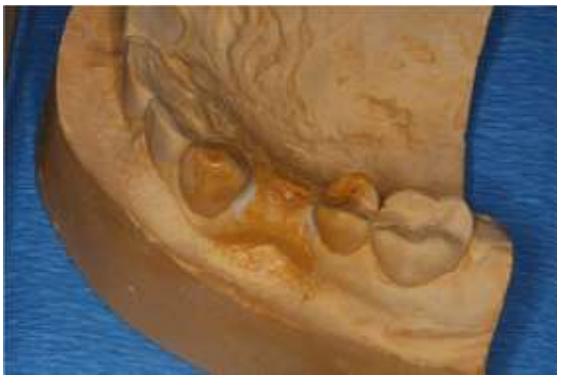

FIGURE 14.1.13 Diagnostic model as part of a pre-operative diagnostic work-up for the ridge-split expansion procedure. *Source*: Tolstunov L. Ridge-split procedure for horizontal augmentation of the alveolar ridge in implant dentistry. SROMS. 2013;21(1):1–53. Reproduced with permission of Douglas P. Sinn, DDS. Editor in Chief, SROMS.

FIGURE 14.1.14 A surgical stent as part of a pre-operative diagnostic work-up for the ridge-split expansion procedure. *Source*: Tolstunov L. Ridge-split procedure for horizontal augmentation of the alveolar ridge in implant dentistry. SROMS. 2013;21(1):1–53. Reproduced with permission of Douglas P. Sinn, DDS. Editor in Chief, SROMS.

FIGURE 14.1.15 Example of surgical instrumentation for the ridge-split expansion procedure.

D- (Tatum) osteotome. A comfortable surgical mallet needs to be chosen for gentle and precise blows to the chisels or osteotomes. Companies such as Salvin Dental Specialties (Charlotte, NC, USA) and many others offer sets of ridge-splitting chisels, expanding osteotomes, and bone spreaders with directional gauges. Meisinger kits (Jacksonville, FL, USA) have a few sets of instruments for osteotomy, ridge splitting, spreading, implant placement, and bone grafting. Another way to approach the RSEP is by utilizing piezoelectric instrumentation. Although slightly slower, it is an accurate way to perform bone cuts. This technique is descried in Chapter 15.

REFERENCES

1. Bell WH. Revascularization and bone healing after anterior maxillary osteotomy: A study using adult rhesus monkey. *J Oral Surg.* 1969;27:249–55.
2. Bell WH, Levy BM. Revascularization and bone regeneration following anterior mandibular osteotomy. *J Oral Surg.* 1970;28:196–203.
3. Bell WH. Biologic basis for maxillary osteotomies. *Am J Phys Anthropol.* 1973;38:279–89.
4. Bell WH, Levy BM. Revascularization and bone healing after posterior maxillary osteotomy. *J Oral Surg.* 1971;29:313–20.
5. Bell WH, You ZH, Finn RA, Fields RT. Wound healing after multisegmental Le Fort I osteotomy and transaction of the descending palatine vessels. *J Oral Maxillofac Surg.* 1995;53(12):1425–33.
6. Simion M, Baldoni M, Zaffe D. Jawbone enlargement using immediate implant placement associated with a split-crest technique and guided tissue regeneration. *Int J Periodontics Restorative Dent.* 1992;12:462–73.
7. Scipioni A, Bruschi GB, Calesini G. The edentulous ridge expansion technique: A five-year study. *Int J Periodontics Restorative Dent.* 1994;14:451–9.
8. Smiler DG. Advances in endosseous implants: The “sandwich” split cortical graft for dental implant placement. *Dent Implantol Update.* 2000;11:49–53.
9. Vercellotti T. Piezoelectric surgery in implantology: A case report—a new piezoelectric ridge expansion technique. *Int J Periodontics Restorative Dent.* 2000;20:359–65.

Dentlearn.ir

10. Bravi F, Bruschi GB, Ferrini F. A 10-year multicenter retrospective clinical study of 1715 implants placed with the edentulous ridge expansion technique. *Int J Periodontics Restorative Dent.* 2007;27(6):557–65.

11. Sohn DS, Lee HJ, Heo JU et al. Immediate and delayed lateral ridge expansion technique in the atrophic posterior mandibular ridge. *J Oral and Maxillofac Surg.* 2010;68:2283–90.

12. Ella B, Laurentjoye M, Sedarat C et al. Mandibular ridge expansion using a horizontal bone-splitting technique and synthetic bone substitute: An alternative to bone block grafting? *Int J Oral Maxillofac Implants.* 2014;29(1):135–40.

13. Misch CE, Judy KW. Classification of partially edentulous arches for implant dentistry. *Int J Oral Implantol.* 1987;4(2):7–13.

14. Cawood JI, Howell RA. A classification of the edentulous jaws. *Int J Oral Maxillofac Surg.* 1988;17:232–6.

15. Jensen O. Site classification for the osseointegrated implant. *J Prosthet Dent.* 1989;61(2):228–34.

16. Wang HL, Al-Shammari K. HVC ridge deficiency classification: A therapeutic oriented classification. *Int J Periodontics Restorative Dent.* 2002;22(4):335–43.

17. Tolstunov L. Classification of the alveolar ridge width: Implant-driven treatment considerations for the horizontally deficient alveolar ridges. *J Oral Implantol.* 2014;40(spec):365–70.

18. Flanagan D: A comparison of facial and lingual cortical thickness in edentulous maxillary and mandibular sites measured on computerized tomograms. *J Oral Implantol.* 2008;34(5):256–8.

19. La Rocca AP, Alemany AS, Levi P Jr et al. Anterior maxillary and mandibular biotype: Relationship between gingival thickness and width with respect to underlying bone thickness. *Implant Dent.* 2012;21(6):507–15.

Dentlearn.ir

Surgical Principles of the Ridge-Split Expansion Procedure

CHAPTER 14.2

Len Tolstunov[1,2,3]

[1]*Associate Clinical Professor, Department of Oral and Maxillofacial Surgery, University of California San Francisco (UCSF) School of Dentistry, San Francisco, CA, USA*

[2]*Associate Clinical Professor, Department of Oral and Maxillofacial Surgery, University of the Pacific Arthur A. Dugoni School of Dentistry, San Francisco, CA, USA*

[3]*Private OMFS practice, San Francisco, CA, USA*

There is some variability of surgical approaches to accomplishing an alveolar ridge split in implant dentistry. Most of the techniques are based on the controlled force of an operating surgeon in the process of mobilization of a thin facial (buccal or labial) bony fragment, utilizing an open- or closed-flap approach. This is a technique-sensitive procedure that relies on the tactile sense of a surgeon and requires practice and time to master.

For anyone interested in learning this technique, and often even for an experienced practitioner, it is important to consider adhering to certain surgical principles or rules of the procedure to increase success, prevent complications, and avoid disappointments and frustration.

Among many surgical principles, there are five that are important in a ridge-split expansion procedure (RSEP):

- Understanding the variability between *bone density* in the maxilla and mandible: this often leads to choosing a different surgical approach in RSEP.
- Understanding the biological rationale of RSEP: *vascularization* from the periosteal vascular bone flap must be respected (Chapter 7).
- Understanding that healing by *secondary intention* is common in RSEP. This is similar to the guided bone regeneration (GBR) procedure for post-extraction socket grafting.
- Understanding the *osteo-condensation* technique that is common in maxillary RSEP cases.
- Understanding the *osteo-mobilization* technique that is common in maxillary and mandibular cases.

This chapter contains a detailed discussion of each surgical principle.

THE MAXILLA IS NOT AN UPSIDE-DOWN MANDIBLE

It is well known in the profession that quality of mandibular and maxillary bone is not the same and that the mandible is not an "upside-down maxilla." Lekholm and Zarb published an alveolar bone qualitative classification in relation to implant insertion and initial (primary) implant stability [1]. In their classification, four types of jawbone were distinguished: types I and II, a denser compact/cortical bone, often found in the mandible; and types III and IV, a softer and less dense bone, often found in the maxilla. These differences in bone density are important in bone manipulation during the RSEP. Due to this density factor, a single-stage surgical procedure (osteotomy, split, expansion, and grafting, ± implant) can be done in most maxillary alveolar splits. In contrast, mandibular alveolar splits are frequently performed in a staged manner, with bone osteotomies done at the initial (preparatory) stage and split and graft at a separate stage weeks later (see below).

VASCULARIZATION: VASCULAR PERIOSTEAL FLAP

Vascularization of the osteotomized and mobilized segment of jawbone plays a dominant role in preservation of its vitality and the success of bone transplantation. Bell's pivotal work on bone vascularization and bone healing helped to establish the biological rationale for jawbone osteotomies in orthognathic surgery [2–4]. Bell demonstrated that the vitality of the segment of jaw that was osteotomized would be preserved if the soft tissue pedicle were kept intact.

During an RSEP, a greenstick fracture with the periosteum attached to the buccal bone fragment is created. The

Essential Techniques of Alveolar Bone Augmentation in Implant Dentistry: A Surgical Manual, Second Edition. Edited by Len Tolstunov.

© 2023 John Wiley & Sons, Inc. Published 2023 by John Wiley & Sons, Inc.

Companion website: www.wiley.com/go/tolstunov/essential

Dentlearn.ir

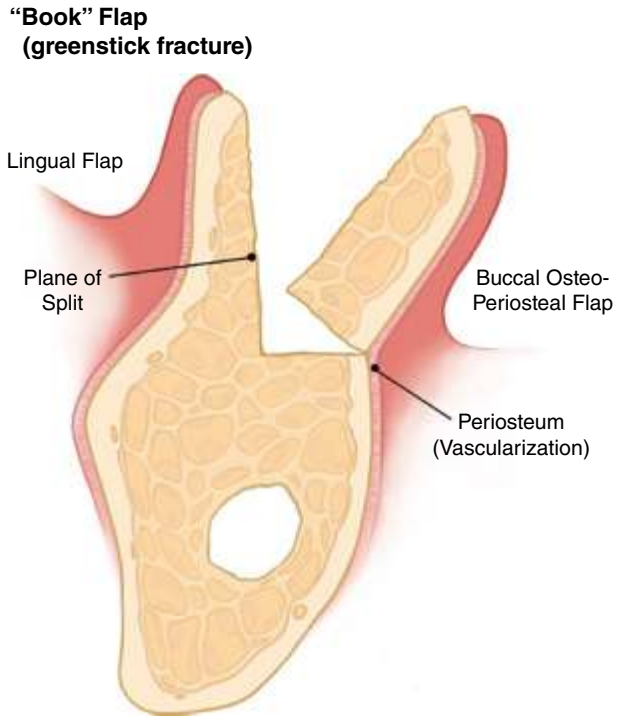

FIGURE 14.2.1 Illustration of a vascularized hard–soft tissue (osteoperiosteal) buccal flap during the ridge-split expansion procedure in the manner of a book flap [5] rotating about its base (binder) in a hinged manner (still connected to its base, like a greenstick fracture).

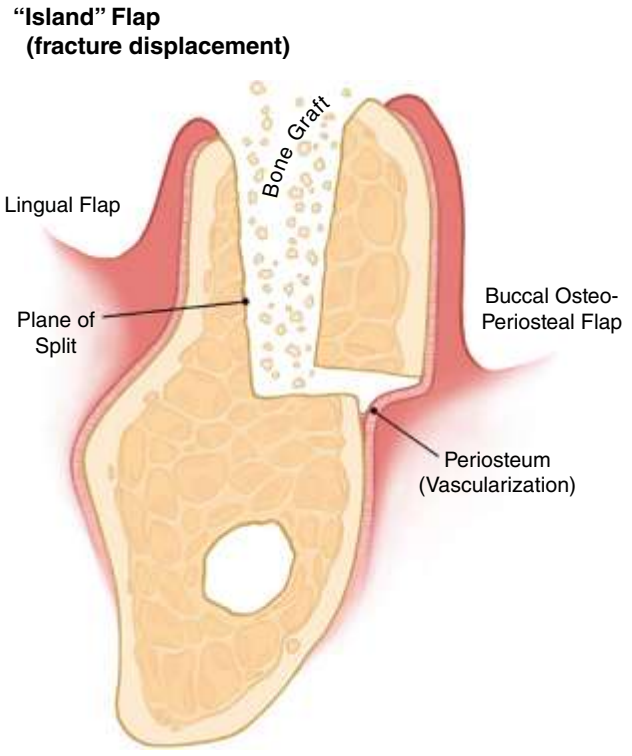

FIGURE 14.2.2 Illustration of a vascularized hard–soft tissue (osteoperiosteal) buccal flap during the ridge-split expansion procedure in a manner of an island flap [6] being displaced laterally with a complete separation from its bony base (free floating), but still connected by soft tissue with preserved periosteum (like a displaced fracture).

buccal full-thickness flap (FTF) consists of all the soft tissues on the buccal (facial) side (attached periosteum and gingivo-mucosal complex) plus a subfractured and mobilized buccal bony fragment. The soft tissue flap provides vascularity to the attached bone (the vascular bone flap). To prevent the risk of bone devascularization (a known complication), most of the mandibular alveolar splits are done in stages (see below) and most maxillary splits are done in a single stage (see below) with a limited FTF or partial-thickness flap (PTF). Meticulous tissue manipulation preserving the periosteum and peripheral (periosteal) vascularization is important.

A vascularized tissue flap can be developed in different ways based on the attachment of bone to its base. It can either be open like a book rotating about its base (binder) in a hinged manner (still connected to its base, like a greenstick fracture), called a "book flap" (Figure 14.2.1) [5], or be fully separated from its bony base (free floating) but still connected to the soft tissue, called an "island flap" (Figure 14.2.2) [6, 7]. The biological rationale in both types of bone flap development is the maintenance of the periosteal blood supply (intact soft tissue flap) to the osteotomized buccal bony fragment in the process of alveolar split [5]. The combined hard–soft tissue buccal flap (book flap or island flap) is often called a vascularized osteoperiosteal or muco-osteoperiosteal flap that has preserved periosteal (peripheral) blood supply to all its components. The differences in the two flaps are based on the degree of osteo-mobilization needed. Obviously, an island flap can be displaced laterally to a larger degree than a book flap and can be repositioned vertically, potentially correcting not only horizontal but some vertical bone deficiency.

SECONDARY INTENTION AND WOUND HEALING: RIDGE-SPLIT EXPANSION PROCEDURE AND GUIDED BONE REGENERATION

As the name implies, during the ridge-split expansion or ridge-widening procedure the bony fragments of the alveolar ridge are separated, the ridge is expanded laterally, and an *internal* bone space (gap) is formed. When bone grafting is done, it is done "internally" as an interpositional, inlay, or "sandwich" grafting [8, 9], in a similar fashion to the socket bone grafting in the ridge preservation procedure following tooth extraction. In both cases, the particulate bone grafting material (replacement graft) is placed internally as an inlay

Dentlearn.ir

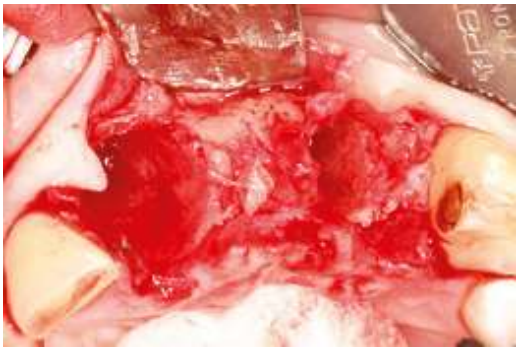

FIGURE 14.2.3 Intraoperative view of the ridge preservation procedure: reflected flap and extraction sockets. *Source*: Tolstunov L. Ridge-split procedure for horizontal augmentation of the alveolar ridge in implant dentistry. SROMS. 2013;21(1):1–53. Reproduced with permission of Douglas P. Sinn, DDS. Editor in Chief, SROMS.

FIGURE 14.2.4 Particular graft was placed into extraction sockets. *Source*: Tolstunov L. Ridge-split procedure for horizontal augmentation of the alveolar ridge in implant dentistry. SROMS. 2013;21(1):1–53. Reproduced with permission of Douglas P. Sinn, DDS. Editor in Chief, SROMS.

FIGURE 14.2.5 Bone graft was covered with resorbable CollaTape membrane, and closed with sutures for healing by secondary intention. *Source*: Tolstunov L. Ridge-split procedure for horizontal augmentation of the alveolar ridge in implant dentistry. SROMS. 2013;21(1):1–53. Reproduced with permission of Douglas P. Sinn, DDS. Editor in Chief, SROMS.

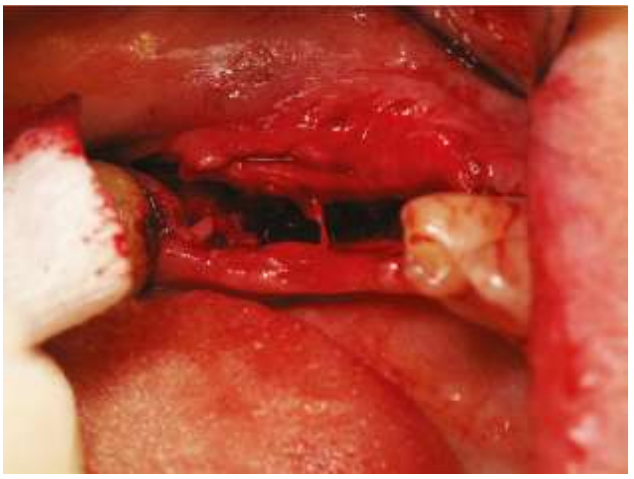

FIGURE 14.2.6 Intraoperative view of the ridge-split expansion procedure: subfracture and full lateral repositioning of the buccal fragment of bone (expansion).

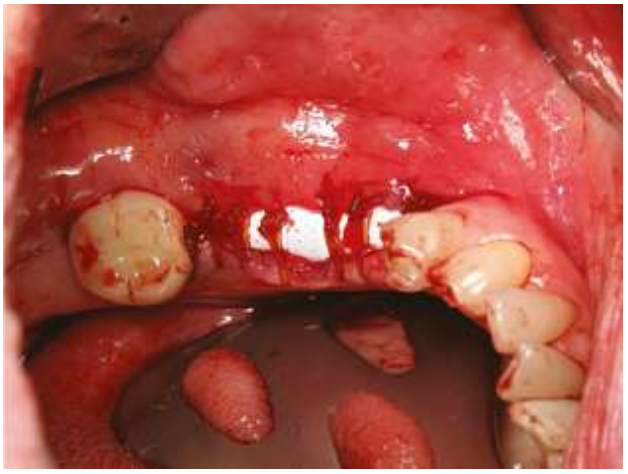

FIGURE 14.2.7 Interpositional grafting: alveolar gap is filled with a particulate bone grafting material, covered with a non-resorbable Teflon guided tissue regeneration membrane, and closed with sutures for healing by secondary intention.

(Figures 14.2.3–14.2.7) [10, 11]. The "horizontal space maintenance" concept allows grafting of ridge-split gaps like extraction sockets [12]. A guided tissue regeneration (GTR) membrane is placed on top of the particulate graft to protect, contain, and guide osteogenic cells for proper healing in both RSEP and GBR. In the majority of cases, the alveolar split is done in the edentulous region of a thin (width-deficient) ridge. On occasion, it is possible to plan and execute an immediate socket split right after the extraction of the tooth (or teeth).

Primary closure of the surgical wound results in a full approximation of its edges. Secondary closure (closure or

Dentlearn.ir

FIGURE 14.2.8 Healing by secondary intention that is recommended in many ridge-split expansion procedure cases. "Side benefits" is the gain of tissue and preservation of vestibule and attached gingiva. Courtesy of Dr. Bruce Hicke.

FIGURE 14.2.9 Healing by secondary intention: 2.5 months after the surgery. The attached gingiva and vestibule are preserved. Courtesy of Dr. Bruce Hicke.

healing by secondary intention) leaves the surgical wound open and relies on the potential of the wound edges to grow and the wound to eventually heal (close) with a scar formation. Many RSEP and ridge preservation (socket grafting) wounds (expanded/widened bone or sockets) can heal successfully by secondary intention.

Healing by secondary intention has several advantages (Figures 14.2.5 and 14.2.7). It preserves the soft tissue architecture around the surgical site. The buccal attached gingival soft tissue is not detached from its bony foundation and is not forced onto the alveolar crest to achieve the primary closure. This ensures the presence of the gingival attached and keratinized tissue on the facial side of an implant, and provides proper maintenance and hygiene years after completion of the procedure. The vestibular depth is also preserved. There is a frequent gain of tissue that can be seen in wounds healed by secondary intention. This can be shown in Figures 14.2.8 and 14.2.9, which were taken two months apart. Complete gingival healing of the wound treated by secondary intention is usually seen within 6–8 weeks.

OSTEO-CONDENSATION OF SURROUNDING BONE

In the process of bone manipulation during the RSEP, the adjacent fragments of bone are slightly compressed or condensed. This is more apparent in the maxilla due to lower bone density. In 1994 Summers introduced his osteotome technique for the soft maxillary bone as an alternative to bone drilling [13]. Many implant practitioners since have noticed some degree of horizontal bone compression that occurs with the hydraulic vertical osteotome technique, which likely helps in primary implant stability. Nishioka and Kojima described a screw-spreading/crest-expansion technique as an alternative to Summers's osteotome approach, commenting on a controlled and standardized dilation of the bone horizontally and

FIGURE 14.2.10 Intraoperative photograph of maxillary book osteo-periosteal flap in progress.

FIGURE 14.2.11 Intraoperative photograph of maxillary island osteoperiosteal flap in progress. *Source*: Tolstunov L. Ridge-split procedure for horizontal augmentation of the alveolar ridge in implant dentistry. SROMS. 2013;21(1):1–53. Reproduced with permission of Douglas P. Sinn, DDS. Editor in Chief, SROMS.

Dentlearn.ir

an enhancement of the dental implant site due to compression of the medullary bone against the cortical wall that allows for greater initial implant stability [14]. It is postulated that an increase in density of bone through a moderate degree of compression might be helpful in implant osseointegration due to an increase in primary implant stability and in the early loading protocols [15]. Another common way to increase bone density is to place an implant into the undersized osteotomy.

OSTEO-MOBILIZATION OF THE BUCCAL BONE FRAGMENT

As the name of the technique implies, during ridge expansion the buccal cortical plate is separated from the underlying medullary or spongy bone and is moved buccally (labially, in anterior cases). As mentioned above, the buccal cortical bone fragment is attached to the periosteum, and is thus vascularized. This partially or fully detached fragment of the buccal portion of the alveolar ridge is repositioned laterally as a book flap (Figures 14.2.1 and 14.2.10) or an island flap (Figures 14.2.2 and 14.2.11).

CONCLUSION

Alveolar bone augmentation should accomplish a bone reconstruction goal of achieving the quality and quantity of bone that were present before the bone loss occurred. To accomplish this goal, a variety of surgical techniques can be offered that, in principle, differ from each other by the way the graft is attained. RSEP is one of the inlay particulate bone grafting techniques with cortical bone repositioning and periosteal vascularization. The key surgical principles described here should be followed for a successful outcome of this surgical technique.

REFERENCES

1. Lekholm U, Zarb GA. Patient selection and preparation. In P-I Branemark, GA Zarb, T Albrektsson (eds.), Tissue-integrated prostheses osseointegration in clinical dentistry. Chicago, IL: Quintessence; 1985, 199–209.
2. Bell WH. Revascularization and bone healing after anterior maxillary osteotomy: A study using adult rhesus monkeys. *J Oral Surg.* 1969;27:249.
3. Bell WH, Levy BM. Revascularization and bone regeneration following anterior mandibular osteotomy. *J Oral Surg.* 1970;28:196–203.
4. Bell WH. Biologic basis for maxillary osteotomies. *Am J Phys Anthropol.* 1973;38:279–89.
5. Jensen OT, Ellis E. The book flap: A technical note. *J Oral Maxillofac Surg.* 2008;65(5):1010–14.
6. Jensen OT, Mogyoros R, Owen Z et al. Island osteoperiosteal flap for alveolar bone reconstruction. *J Oral Maxillofac Surg.* 2010;68(3):539–46.
7. Casap N, Brand M, Mogyros R et al. Island osteoperiosteal flaps with interpositional bone grafting in rabbit tibia: Preliminary study for development of new bone augmentation technique. *J Oral Maxillofac Surg.* 2011;69(12):3045–51.
8. Schettler D. Sandwich technique with cartilage transplant for raising the alveolar process in the lower jaw. Fortschr Kiefer Gesichtschir. 1976;20:61–3.
9. Schettler D, Holtermann W. Clinical and experimental results of a sandwich technique for mandibular alveolar ridge augmentation. *J Maxillofac Surg.* 1977;5:199.
10. Buser D, Brägger U, Lang NP et al. Regeneration and enlargement of jaw bone using guided tissue regeneration. *Clin Oral Implants Res.* 1990;1(1):22–32.
11. Annibali S, Bignozzi I, Sammartino G et al. Horizontal and vertical ridge augmentation in localized alveolar deficient sites: A retrospective case series. *Implant Dent.* 2012;21(3):175–85.
12. Levin BP. Horizontal alveolar ridge augmentation: The importance of space maintenance. *Compend Contin Educ Dent.* 2011;32(8):12–21.
13. Summers RB. A new concept in maxillary implant surgery: The osteotome technique. *Compendium.* 1994;15(2):152–8.
14. Nishioka RS, Kojima AN. Screw spreading: Technical considerations and case report. *Int J Periodontics Restorative Dent.* 2011;31(2):141–7.
15. Nevins M, Nevins ML, Schupback P et al. The impact of bone compression on bone-to-implant contact of an osseointegrated implant: A cohort study. *In J Periodontics Restorative Dent.* 2012;32(6):637–45.

Dentlearn.ir

CHAPTER 14.3

Mandibular Two-Stage Alveolar Ridge-Split Expansion Procedure

Len Tolstunov[1,2,3]

[1]*Associate Clinical Professor, Department of Oral and Maxillofacial Surgery, University of California San Francisco (UCSF) School of Dentistry, San Francisco, CA, USA*

[2]*Associate Clinical Professor, Department of Oral and Maxillofacial Surgery, University of the Pacific Arthur A. Dugoni School of Dentistry, San Francisco, CA, USA*

[3]*Private OMFS practice, San Francisco, CA, USA*

Due to variations in bone density, the ridge-split expansion procedure (RSEP) is often performed differently in the maxilla and the mandible. A staged alveolar RSEP is often performed in the mandible due to the high density of the bone and is described in this chapter, where stage 1 is called corticotomy and stage 2 split expansion grafting (SEG).

Corticotomy is a superficial osteotomy when the motorized drill or piezo tip is cutting only through the dense portion of bone-cortical layer (cortex) without touching the medullary and softer portion of bone. The goal of corticotomy is to weaken the dense mineralized rigid cortical layer of bone in the designated areas. Seaming or creating a trough through the cortical bone prior to the split is particularly important in the mandible, where the bony cortex appears to be especially dense. Figure 14.3.1 illustrates a cross-section of the mandibular bone with the segment of bone that would be eventually split and moved laterally (plane of split). Attention to detail and the atraumatic performance of this initial stage is important and determines the success of the final bone expansion.

Corticotomy is done as a bony window (like a lateral sinus lift procedure) with usually four (occasionally three) bony cuts shaped in the form of a rectangle: crestal, apical, anterior, and posterior (Figures 14.3.2 and 14.2.3). The distance between crestal and apical (horizontal) corticotomies (*osteotomy height*) is determined by the implant fixture (its length; generally 10–12 mm). Rarely, there is a need to widen the bone and extend the apical cut beyond 12 mm from the crest due to the natural widening of the alveolar bone (an "iceberg effect") toward its base. Also, anatomical limitations, like the presence of the inferior alveolar nerve (IAN), mental foramen, or maxillary sinus, are important to consider. It is also essential to remember that in atrophic edentulous mandibles (the elderly population) the height of the bony window should not extend beyond 70% of the total bone height to prevent significant weakening of the mandible and mandible fracture. In some cases of softer bone, apical corticotomy is not needed to accomplish the split.

The distance between anterior and posterior (vertical) corticotomies (*osteotomy length*) depends on the length of the edentulous area to be widened. RSEP can be done for a single edentulous and collapsed ridge (Figure 14.3.4) or a full edentulous arch (Figure 14.3.5), but is most successful in the 2–3-tooth edentulous region or 10–20 mm distance. The procedure performed on a length shorter than 7 mm might be challenging and compromise the periodontal health of adjacent teeth.

Finally, the *osteotomy width* is the width of expansion after the split and is determined by the size of the dental implant to be placed in this region at the time of the split or weeks to months later. A standard 4–5 mm diameter implant requires at least 7–8 mm of eventual alveolar width, preferrable 10 mm. This takes into consideration at least 1.5 mm of bone that is expected to be present on both the lingual and especially the buccal side of an implant. Overcorrection with widening of the ridge closer to 9–10 mm is better (bone stock of 10×10 mm^2) and takes into consideration some degree of long-term relapse that is seen in some cases; 10–12 mm is also the normal width of a dentate alveolar process.

SURGICAL PROCEDURE: MANDIBULAR RIDGE SPLIT

STAGE 1: CORTICOTOMY

The surgery can be done under local anesthesia or intravenous (IV) sedation. Good oral hygiene is important and chlorhexidine 0.12% rinse perioperatively should be considered. Antibiotic is given the morning of surgery (1 h preoperatively: amoxicillin 2 g or clindamycin 600 mg, or another antibiotic of choice).

Essential Techniques of Alveolar Bone Augmentation in Implant Dentistry: A Surgical Manual, Second Edition. Edited by Len Tolstunov.
© 2023 John Wiley & Sons, Inc. Published 2023 by John Wiley & Sons, Inc.
Companion website: www.wiley.com/go/tolstunov/essential

Dentlearn.ir

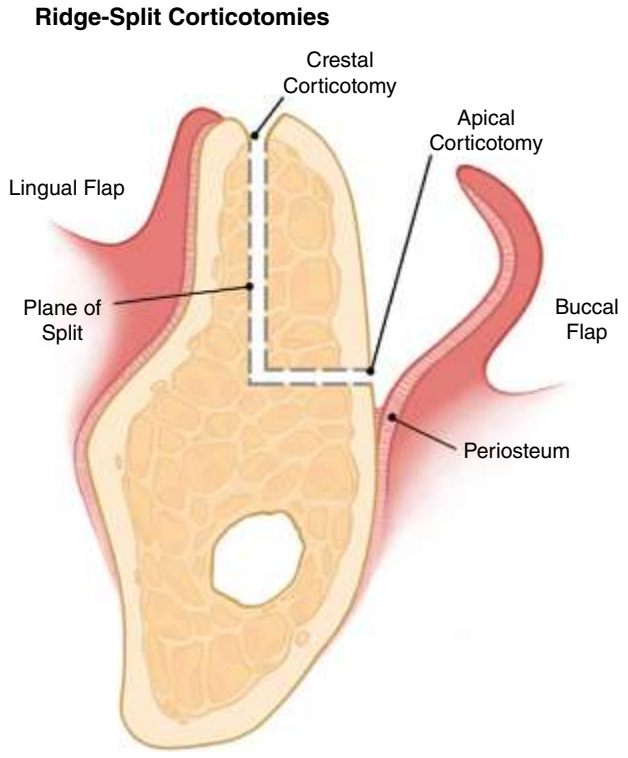

FIGURE 14.3.1 Schematic illustration of a cross-section of mandibular bone demonstrating a plane of split of buccal fragment of bone during the preparatory stage (stage 1) of a ridge-split expansion procedure: four bone cuts (corticotomies) are needed (two are shown in the illustration – crestal and apical).

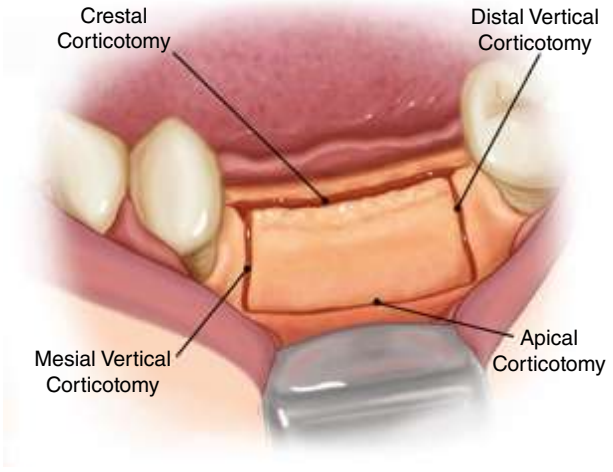

FIGURE 14.3.2 Illustration of four corticotomies at the initial (preparatory) stage 1 of a ridge-split expansion procedure in the mandible: crestal, apical, mesial vertical, and distal vertical.

FIGURE 14.3.3 Clinical photograph of four corticotomies at the initial (preparatory) stage 1 of a ridge-split expansion procedure in the mandible. Courtesy of Dr. Bruce Hicke.

FIGURE 14.3.4 A single edentulous area with a width-deficient alveolar ridge suitable for a segmental ridge-split expansion procedure.

FIGURE 14.3.5 A full edentulous arch with horizontal width deficiency that may be suitable for a full-arch ridge-split expansion procedure. *Source*: Tolstunov L. Ridge-split procedure for horizontal augmentation of the alveolar ridge in implant dentistry. SROMS. 2013;21(1):1–53. Reproduced with permission of Douglas P. Sinn, DDS. Editor in Chief, SROMS.

Dentlearn.ir

- The surgery starts with reflection of a *buccal full-thickness muco-periosteal flap* (FTMPF) consisting of crestal and two vertical releasing incisions. The crestal incision should be slightly off center and more toward the lingual side. The vertical releasing incisions should start at 90 degrees from the adjacent teeth (mesial line angle) and diverge slightly toward the depth of the vestibule. Attention to the position of the mental foramen when working in the mandibular premolar region is crucial to avoid post-operative neurosensory complications. The reflected flap should expose buccal bone of sufficient height (12–15 mm). The soft tissue flap should always be about 2 mm wider than the osteotomy window.
- After the buccal bone exposure, corticotomies are done, as discussed above, outlining the bony window. The four corticotomies (two horizontal and two vertical) should be performed with a thin fissure bur (e.g. surgical 701) or with the help of piezoelectric tips in a uniform, interconnected, and continuous trough fashion. Crestal corticotomy is scored on the alveolar crest of the edentulous segment and apical corticotomy is placed parallel to the crestal and 10–12 mm apically on the buccal cortex. Two vertical corticotomies connect the horizontal ones, forming a bone window ("trapdoor") that resembles a rectangle. Due to a slight divergence of the two vertical corticotomies in many cases, the actual geometric shape of the bone window is reminiscent of a trapezoid (Figures 14.3.2 and 14.3.6). Crestal corticotomy is crucial: it is the only area that will be "revisited" or reopened and used for initiation of the split at the following surgical stage. It is recommended to position the crestal corticotomy at mid-crest or slightly toward the lingual side to increase the thickness of the buccal plate that will become fractured and moved laterally at the following stage. If the buccal plate is not thick enough, it can develop comminuted fractures and will not be able to be repositioned laterally in one unit. The corticotomies are extended through the cortical layer evenly into the medullary bone (Figures 14.3.2 and 14.3.6). While performing this surgical stage, the operator can then run a perio probe along the trough and experience a feeling of "drop" into the spongious bone, as confirmation of even perforation of the cortical layer (a proper corticotomy depth of 2–3 mm) along the whole osteotomy window. Bleeding is another visual confirmation of exposure of the medullary bone. It is better if all four corticotomies are interconnected with slightly rounded corners, paying particular attention to the two apical corners.
- The buccal flap is repositioned, and the wound is closed with 4-0 or 5-0 chromic gut sutures.

FIGURE 14.3.6 Intraoperative photograph of two vertical corticotomies connecting two horizontal ones and forming a bone window ("trapdoor") that resembles a rectangle at stage 1 of the ridge-split expansion procedure. Note the full-thickness buccal flap and bone cuts that are extended evenly into the medullary layer of bone. *Source*: Tolstunov L. Ridge-split procedure for horizontal augmentation of the alveolar ridge in implant dentistry. SROMS. 2013;21(1):1–53. Reproduced with permission of Douglas P. Sinn, DDS. Editor in Chief, SROMS.

Post-operative discomfort is usually minimal, and the patient may require only non-steroidal anti-inflammatory drugs (NSAIDS), such as ibuprofen. Icepack and pressure dressing on the cheek are recommended on the day of surgery. The patient is seen 4–5 weeks later for stage 2.

A COMMON QUESTION

Why was the flap closed and surgery not progressed further to the actual split? In some advanced cases, it is possible to do this. The main requirement for the split to happen at this stage is preservation of the periosteal attachment to the buccal surface (Figures 14.3.1, 14.3.3, and 14.3.6). In the majority of cases, the author recommends a two-stage approach for the mandibular alveolar split. If the buccal surface of bone is fully uncovered and a split is done at this stage, the buccal fragment of the denuded and devascularized bone would be fractured off from its base, which is a complication for RSEP (it is a goal for the block bone graft). That is why repositioning of the buccal mucosal-periosteal flap and closure of the wound is important to re-establish the blood supply to the buccal segment of bone. At the next stage, the actual split will occur, with the buccal soft tissue flap attached to the buccal fragment of bone.

This is entirely opposite to block grafting, where a monocortical block of buccal bone is purposefully removed from one (donor) site and attached to the other (recipient) site. In the RSEP, the donor and recipient sites are one.

STAGE 2: SPLIT-EXPANSION-GRAFT

The second stage of the RSEP is usually done 4–5 weeks after stage 1. This stage can also be done under local anesthesia or IV sedation. IV sedation can be beneficial at this stage due to some discomfort from the use of mallet and chisel osteotomes. An antibiotic is given on the morning of surgery (1 h preoperatively: amoxicillin 2 g or clindamycin 600 mg, or another antibiotic of choice). The procedure is as follows:

- This stage starts with a *semi-open (limited) FTF* through the crestal and two short vertical releasing incisions

Dentlearn.ir

(Figure 14.3.7). The goal is to open the crestal corticotomy only to keep periosteal vascularization intact. An alternative approach is to use a split- or partial-thickness flap [1–4], leaving the periosteum attached to the buccal surface of the alveolar ridge and reflecting only the supraperiosteal soft tissue (mucosal and submucosal layers). Elian et al. advocated a *combination* flap that consists of an "FTF at the crest of the ridge, which is then transitioned into a split-thickness flap along the buccal plate" [5]. Kang et al. also advocated the FTF with no vertical bone incisions [6]. According to both sets of authors, an FTF at the crest of the ridge *only* helps in visualization of the split and expansion if it is done at the same stage without an inadvertent risk of buccal cortical bone fracture with no soft tissue attachment. An operator ultimately determines the choice of flap. Both flap techniques (limited open FTF or PTF) are intended to preserve the necessary vascularization for the bone at the time of split and graft.

- The *bone split* that follows should be initiated with osteotomes at the center of the crest and progress deep inside as the split widens (Figure 14.3.8). The split starts with 15-blade pressure into the crestal corticotomy, followed by tapping the spatula or chisel osteotomes into the crestal cut to initiate the split. Continued gentle tapping with larger (wider) progressive sharp chisels (osteotomes), accompanied by a controlled lateral force, will first create a greenstick fracture of the buccal segment of bone. This is followed by a gradual widening of the split (Figures 14.3.7 and 14.3.8), with a soft tissue flap still attached to the buccal bone (muco-osteoperiosteal flap). The buccal bony fragment is subfractured and pushed laterally in one unit with the attached soft tissue, preserving the periosteal blood supply to the buccal bone either as a book (greenstick fracture) or island (full fracture with separation) flap [7, 8]. An I-flap (island osteoperiosteal flap; [8, 9]) forms a free-floating osteoperiosteal flap. The preferred thickness of the buccal cortical plate (fragment) in an I-flap is at least 2 mm [10]. A facial plate with a thickness less than 2 mm appears to have a higher risk of subsequent resorption in any bone grafting or implant procedures.

There are many sets of progressive chisel osteotomes specifically designed for the RSEP. Figure 14.3.9 demonstrates example instruments, including osteotomes that can be used for this stage. This set includes scalpel, ridge-splitting/expanding chisels (3 and 5 mm), Tatum "D" spreader protecting the lingual plate and expanding the buccal, periotomes, and other instruments.

FIGURE 14.3.7 Stage 2 of the mandibular ridge-split expansion procedure through the limited full-thickness flap: the buccal fragment of bone is split.

FIGURE 14.3.8 The buccal fragment of bone is displaced laterally with sharp progressive chisel osteotomes.

FIGURE 14.3.9 Example of a surgical tray with instruments for the ridge-split expansion procedure. *Source*: Tolstunov L. Ridge-split procedure for horizontal augmentation of the alveolar ridge in implant dentistry. SROMS. 2013;21(1):1–53. Reproduced with permission of Douglas P. Sinn, DDS. Editor in Chief, SROMS.

Dentlearn.ir

FIGURE 14.3.10 Intraoperative view of the bone grafting step of a ridge-split expansion procedure: particulate graft is packed into the gap.

FIGURE 14.3.11 Particulate graft is covered with the protective membrane of choice and sutures are placed for healing by secondary intention.

FIGURE 14.3.12 Clinical view of a self-tapping mini-screw that can be used to stabilize cortical plates in some cases prior to grafting. Courtesy of Dr. Bruce Hicke.

FIGURE 14.3.13 Clinical photograph of the alveolar ridge at the implant stage: this demonstrates the quality of bone that can be achieved after the ridge-split expansion procedure.

- After split and expansion are accomplished, the following step is *particulate bone grafting* using autogenous bone and/or a bone graft substitute of the surgeon's choice that is packed from the bottom up into the created gap osteotomy, similar to the ridge preservation procedure (Figure 14.3.10). The author often uses either human allograft (cortico-cancellous) or bovine xenograft, or both (composite graft). These grafts provide osteoconductive qualities as well as creating the "body" needed to maintain the dimension (volume) of the widened ridge in the initial stage of healing. To isolate the graft from the oral environment and encourage osteogenic cell migration, guided tissue regeneration (GTR) resorbable or non-resorbable membrane can be used and gently tacked into the reflected lingual flap very lightly – the buccal flap (Figure 14.3.11). Then 4-0 or 5-0 chromic gut or silk sutures can be used for wound closure by secondary intention in figure-eight, vertical mattress, and interrupted fashions. If vertical incisions are made, sutures are placed there too. On occasion and prior to grafting, a self-tapping mini-screw(s) (10–12 mm in length and 1.0–1.5 mm in diameter) can be used to stabilize a displaced buccal plate (Figure 14.3.12). Figure 14.3.13 demonstrates the quality of bone that can be achieved after the RSEP. If a non-resorbable membrane is used, it needs to be removed 3–4 weeks following the surgery. Post-operative instructions are the same and include antibiotic use for a period of 5–7 days.

CASE REPORT

A 60-year-old healthy female presented to the oral surgery office with a retained non-restorable lower left first premolar root. A 3 mm narrow mandibular alveolar ridge was measured clinically in the second premolar to first molar region. RSEP treatment was scheduled and included removal of the retained

Dentlearn.ir

first premolar root, exposure of the buccal cortex, and a staged RSEP in the premolar-molar region. During the first surgery (stage 1), the premolar root was removed atraumatically, and the corticotomies were placed as described above from the canine to the second molar, forming a bony window (Figures 14.3.14 and 14.3.15). The flap was then repositioned and sutured. Stage 2 of the RSEP was done 4 weeks later with a limited flap. Crestal osteotomy was identified and sequential chisel osteotomes were used in a progressive manner by tapping into the depth of the split. The buccal plate was carefully subfractured and the fully mobilized island muco-osteoperiosteal flap was repositioned laterally (Figure 14.3.16). In this case, Puros® cortical and cancellous allograft 1:1 was utilized as the graft material of choice (Zimmer Dental Inc., Carlsbad, CA, USA). Teflon non-resorbable GTR membrane (Kendall Curity™, Tyco Healthcare, Mansfield, MA, USA) was tucked a few millimeters

FIGURE 14.3.14 Intraoperative photograph of a case report demonstrating a thin posterior mandibular ridge and typical mandibular corticotomies at stage 1 of the ridge-split expansion procedure: a non-restorable premolar was removed at the same time. Lateral view. Courtesy of Dr. Bruce Hicke.

FIGURE 14.3.15 Intraoperative photograph of a case report demonstrating a thin posterior mandibular ridge and typical mandibular corticotomies at stage 1 of the ridge-split expansion procedure: a non-restorable premolar was removed at the same time. Occlusal view. Courtesy of Dr. Bruce Hicke.

FIGURE 14.3.16 Intraoperative photograph of a case report showing subfracture and full lateral repositioning of the buccal fragment of bone as an island muco-osteoperiosteal flap. Courtesy of Dr. Bruce Hicke.

FIGURE 14.3.17 Intraoperative photograph of a case report showing interpositional grafting after the split and displacement of the buccal bone flap (Puros grafting material, Teflon membrane, sutures). Courtesy of Dr. Bruce Hicke.

FIGURE 14.3.18 Clinical view of the implant stage 2, 6 months after the surgery. *Source*: Dr. Bruce Hicke.

Dentlearn.ir

FIGURE 14.3.19 Clinical photograph of the restorative stage demonstrating three porcelain-fused-to-metal crowns at the completion of the case. Courtesy of Dr. Bruce Hicke.

FIGURE 14.3.20 Clinical panoramic radiograph of the restorative stage demonstrating three separate crowns at the completion of the case. Courtesy of Dr. Bruce Hicke.

under the reflected lingual FTF. The membrane was then wrapped around and tucked under the limited buccal flap. The flaps were closed with 4-0 chromic gut sutures (Figure 14.3.17). Three Replace Select™ implants (Nobel BioCare, Yorba Linda, CA, USA) were placed 6 months later in the positions of the second and first molars and the second premolar (Figure 14.3.18). All implants were allowed to osseointegrate. They were restored 6 months later (Figures 14.3.19 and 14.3.20).

REFERENCES

1. Pikos M. Bucco-lingual expansion of the maxillary ridge. *Dental Implantol Update.* 1992;3:85–7.
2. Scipioni A, Bruschi GB, Calesini G. The edentulous ridge expansion technique: A five-year study. *Int J Periodontics Restorative Dent.* 1994;14:451–9.
3. Bruschi GB, Scipioni A, Calesini G et al. Localized management of sinus floor with simultaneous implant placement: A clinical report. *Int J Oral Maxillofac Implants.* 1998;13:219–26.
4. Sethi A, Kaus T. Maxillary ridge expansion with simultaneous implant placement: 5-year results of an ongoing clinical study. *Int J Oral Maxillofac Implant.* 2000;15:491–9.
5. Elian N, Jalbout Z, Ehrlich B et al. A two-stage full-arch ridge expansion technique: Review of the literature and clinical guidelines. *Implant Dent.* 2008;17(1):16–23.
6. Kang T, Flen M, Gober D et al. A modified ridge expansion technique in the maxilla. *Compend Contin Educ Dent.* 2012;33(4):250–56.
7. Jensen OT, Ellis E. The book flap: A technical note. *J Oral Maxillofac Surg.* 2008;65(5):1010–14.
8. Jensen OT, Mogyoros R, Owen Z et al. Island osteoperiosteal flap for alveolar bone reconstruction. *J Oral Maxillofac Surg.* 2010;68(3):539–46.
9. Casap N, Brand M, Mogyros R et al. Island osteoperiosteal flaps with interpositional bone grafting in rabbit tibia: Preliminary study for development of new bone augmentation technique. *J Oral Maxillofac Surg.* 2011;69(12):3045–51.
10. Qahash M, Susin C, Polimeni G et al. Bone healing dynamics at buccal peri-implant sites. *Clin Oral Implants Res.* 2008;19(2):166–72.

Dentlearn.ir

Maxillary Single-Stage Alveolar Ridge-Split Expansion Procedure

CHAPTER 14.4

Len Tolstunov[1,2,3]

[1]*Associate Clinical Professor, Department of Oral and Maxillofacial Surgery, University of California San Francisco (UCSF) School of Dentistry, San Francisco, CA, USA*

[2]*Associate Clinical Professor, Department of Oral and Maxillofacial Surgery, University of the Pacific Arthur A. Dugoni School of Dentistry, San Francisco, CA, USA*

[3]*Private OMFS practice, San Francisco, CA, USA*

Although the maxillary ridge-split expansion procedure (RSEP) can be performed in an identical way to that in the mandibular, discussed previously, due to the elasticity or "softness" of maxillary bone (type 3 and 4 bone) [1] in the majority of cases the maxillary alveolar split is done in a single stage. The typical single-stage maxillary alveolar split consists of corticotomy (C), split (S), expansion (E), and grafting (G) done in one surgery. In some cases, an implant (I) can also be placed inside the split. We will discuss this below in detail.

The ridge selection criteria are the same. In the maxillary alveolar ridge split, there is *usually* no need for four interconnected corticotomies as well as a preparatory stage. Stage 2 (see Chapter 14.3) is done right away in a single stage, with crestal corticotomy and short vertical cuts through a limited full-thickness flap (FTF) or split-thickness flap followed by bone split and grafting (Figure 14.4.1). The buccal flap is reflected just enough to visualize the top of the alveolar crest. Positioning of the crestal incision slightly more to the palatal side helps to better visualize the alveolar crest. The crestal corticotomy can be initiated with a 15 blade, or very sharp chisel, small fissure bur (701), or piezoelectric tip.

The surgeon must be careful when making the crestal trough and entering the medullary bone layer. Having good visualization of the alveolar crest and side vertical corticotomies helps to make a slow and incrementally progressive split and expansion to avoid unfavorable fractures of the buccal cortex and comminuted bone fragments. The goal is even progression into a depth of about 10 mm in the medial bone compartment and between both cortices (buccal and palatal), preserving the cortical plates intact and developing a uniform bony split. Chisel osteotomes are carefully tapped into the depth of bone to widen the split by continuing displacement of the buccal plate laterally, forming the gap (Figure 14.4.2). Remember to move the buccal plate away from the palatal: the buccal cortex is collapsed and needs to be repositioned back to increase the bone width. It is helpful to stay parallel and close to the palatal cortical plate, which can serve as an orientation plane for the split as it progresses deeper, to prevent buccal tipping and buccal plate thinning and its unfavorable comminuted fracture.

After completion of the alveolar split, the mobilized buccal muco-osteoperiosteal flap (MOPF) consists of the following layers: fractured buccal (cortical and medullary) bone fragment; periosteum; and mucosa. This flap has its own peripheral (muscular-periosteal) vascularization. There are variations of the displacement of this flap. It can be called a book flap, if it is still attached to the basal bone on the hinge, or an I (island) flap, if it is fully detached and freely floating, according to Jensen [2, 3]. The specifics of the flap design depend on the amount of expansion needed and the operator's experience. The goal is to drive the collapsed buccal plate facially (laterally or buccally) and away from the palatal plate without compromising flap integrity.

It is also important to allow time for the bone expansion/manipulation, especially in the maxilla. During ridge expansion, the bone has to "breathe", expand on its own accord, after each session of tapping and lateral displacement. Dual-finger guidance (holding the expanding alveolar crest on both sides with a thumb and second finger) helps to "mold" and properly position the buccal fragment of bone. In some cases of a longer alveolar ridge that undergoes a maxillary RSEP, fixation pins or ligature wire can be used to hold the mobilized buccal portion of bone to the non-mobile palatal portion of bone (Figures 14.4.3 and 14.4.4). An internal bony gap can be grafted (similar to the guided bone regeneration procedure) with a particulated graft of choice and covered

Essential Techniques of Alveolar Bone Augmentation in Implant Dentistry: A Surgical Manual, Second Edition. Edited by Len Tolstunov.
© 2023 John Wiley & Sons, Inc. Published 2023 by John Wiley & Sons, Inc.
Companion website: www.wiley.com/go/tolstunov/essential

Dentlearn.ir

FIGURE 14.4.1 Illustration of a maxillary single-stage ridge-split expansion procedure showing a partial full-thickness flap with a crestal and two limited vertical corticotomies (osteotomies).

FIGURE 14.4.3 Intraoperative view of the displaced maxillary bone that required fixation with a screw for stabilization. *Source*: Tolstunov L. Ridge-split procedure for horizontal augmentation of the alveolar ridge in implant dentistry. SROMS. 2013;21(1):1–53. Reproduced with permission of Douglas P. Sinn, DDS. Editor in Chief, SROMS.

FIGURE 14.4.2 Intraoperative photograph demonstrating slow and careful expansion of the maxillary ridge by lateral displacement of the buccal bone segment, forming a gap (opening). *Source*: Courtesy of Dr. Bruce Hicke.

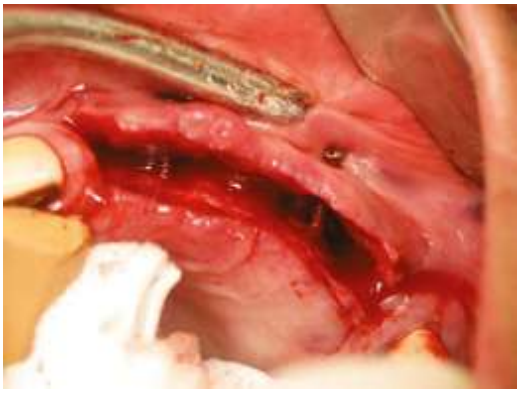

FIGURE 14.4.4 Intraoperative view of the displaced maxillary bone that required fixation with screws for stabilization. *Source*: Tolstunov L. Ridge-split procedure for horizontal augmentation of the alveolar ridge in implant dentistry (see Video 14.4.1). SROMS. 2013;21(1):1–53. Reproduced with permission of Douglas P. Sinn, DDS. Editor in Chief, SROMS.

with a membrane [4]. As with ridge preservation, secondary closure is recommended in the majority of cases (Figure 14.4.5). Piezo surgery can also be utilized for a local or full-arch narrow ridge in the maxilla. In many cases, the piezo surgical approach for the RSEP is more precise and effective [5]. In some cases, after expansion implants can be placed immediately, if primary implant stability (engaging the apical, peri-split bone) is possible. Otherwise, implant or implants can be placed 4–6 months later. There are reports describing earlier placement of implants [6].

After RSEP, it is recommended to avoid an immediate denture placement for 4–5 days during the time of tissue swelling. A denture with a narrow buccal flange will compress the expanded ridge post-operatively and compromise the results. A good surgical-restorative team and precise treatment plan are important at each stage. The described surgical technique can be successfully used for the anterior or posterior maxilla, or a full maxillary arch. An immediate implant insertion at the time of the split can only be done in experienced hands.

Dentlearn.ir

FIGURE 14.4.5 The ridge-split expansion procedure at its completion: split and internal grafting with a membrane were done. The wound was closed with secondary intention. *Source*: Tolstunov L. Ridge-split procedure for horizontal augmentation of the alveolar ridge in implant dentistry (see Video 14.4.2). SROMS. 2013;21(1): 1–53. Reproduced with permission of Douglas P. Sinn, DDS. Editor in Chief, SROMS.

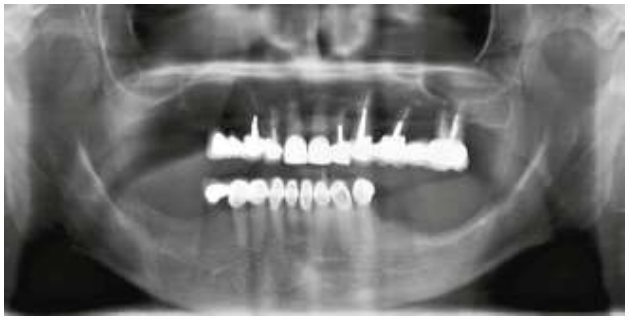

FIGURE 14.4.6 Panoramic radiograph demonstrating missing teeth (molars and premolars) in the upper right alveolar quadrant and fractured root of an upper right canine that had a two-unit cantilevered bridge extending posteriorly, where severe bone width deficiency was present. *Source*: Tolstunov L. Ridge-split procedure for horizontal augmentation of the alveolar ridge in implant dentistry. SROMS. 2013;21(1):1–53. Reproduced with permission of Douglas P. Sinn, DDS. Editor in Chief, SROMS.

CASE REPORT OF A MAXILLARY SINGLE-STAGE ALVEOLAR SPLIT PROCEDURE WITH SIMULTANEOUS IMPLANT PLACEMENT

An 82-year-old woman with a fractured upper right canine and severe alveolar ridge width deficiency in the upper right posterior quadrant presented for an implant evaluation. The patient's medical history was unremarkable. Her clinical and radiographic examination was consistent with missing teeth (molars and premolars) in the upper right alveolar quadrant and the fractured root of an upper right canine that had a two-unit cantilevered bridge extending posteriorly (Figure 14.4.6). The patient had advanced horizontal bone loss in the maxillary right premolar region. She also had mandibular anterior teeth with a partial lower denture extending to the first molar region in a class I occlusion with maxillary teeth. The patient asked, if possible, to place implants in the edentulous maxillary region at the same time as her ridge augmentation procedure.

FIGURE 14.4.7 Intraoperative photograph demonstrating careful division (split) of two thin cortical plates during the ridge-split expansion procedure. *Source*: Tolstunov L. Ridge-split procedure for horizontal augmentation of the alveolar ridge in implant dentistry. SROMS. 2013;21(1):1–53. Reproduced with permission of Douglas P. Sinn, DDS. Editor in Chief, SROMS.

The following plan was proposed and accepted by the patient: sectioning of the bridge between the lateral incisor and canine, atraumatic extraction of the fractured upper right canine, RSEP in the premolar-molar region of the upper right quadrant, and simultaneous two-implant placement. The canine tooth was first removed atraumatically. A direct visualization of the edentulous ridge intraoperatively demonstrated a thin alveolar ridge of about 2.5 mm that consisted of two interconnected cortical plates with a minimum trabecular layer of bone in between. A careful division of two cortical plates was accomplished with a 15 scalpel blade and thin osteotome (Figure 14.4.7). The surgeon's digital sense (two-finger control) was used to prevent the buccal plate from fracture and ensure a controlled split. Two implant osteotomies, engaging the apical (basal) bone, were drilled atraumatically, paying special attention to protection of the fragile and thin buccal plate. Two Biomet 3i 4 mm internal hex "Certain" implants (Biomet 3i, Palm Beach Gardens, FL, USA) were placed with a primary stability of 20 Ncm between the two thin cortical plates (Figures 14.4.8 and 14.4.9). The gap between both implants and the socket of the removed canine tooth was filled with cancellous granules of Bio-Oss® xenograft (300–500 particle size; Geistlich, Wolhusen, Switzerland) (Figure 14.4.10). A layer of CollaTape® membrane (Zimmer Dental, Carlsbad, CA, USA) was placed on top of the graft and the wound was closed with 4-0 chromic gut sutures (primary closure was achieved; Figure 14.4.11). The implants were allowed to heal for a period of 9 months.

Dentlearn.ir

FIGURE 14.4.8 Intraoperative photograph demonstrating placement of two paralleling pins into osteotomies after the split. *Source*: Tolstunov L. Ridge-split procedure for horizontal augmentation of the alveolar ridge in implant dentistry. SROMS. 2013;21(1):1–53. Reproduced with permission of Douglas P. Sinn, DDS. Editor in Chief, SROMS.

FIGURE 14.4.10 Intraoperative photographs demonstrating placement of two implants and interpositional bone grafting at the end of the ridge-split expansion procedure. *Source*: Tolstunov L. Ridge-split procedure for horizontal augmentation of the alveolar ridge in implant dentistry. SROMS. 2013;21(1):1–53. Reproduced with permission of Douglas P. Sinn, DDS. Editor in Chief, SROMS.

FIGURE 14.4.9 Intraoperative photographs demonstrating placement of two implants after the split during the ridge-split expansion procedure. *Source*: Tolstunov L. Ridge-split procedure for horizontal augmentation of the alveolar ridge in implant dentistry. SROMS. 2013;21(1):1–53. Reproduced with permission of Douglas P. Sinn, DDS. Editor in Chief, SROMS.

FIGURE 14.4.11 Intraoperative photograph demonstrating primary closure after the ridge-split expansion procedure, which consisted of split, expansion, grafting, and immediate implants. *Source*: Tolstunov L. Ridge-split procedure for horizontal augmentation of the alveolar ridge in implant dentistry. SROMS. 2013;21(1):1–53. Reproduced with permission of Douglas P. Sinn, DDS. Editor in Chief, SROMS.

Surgical stage 2 was done with the placement of two healing abutments into well-osseointegrated implants (Figure 14.4.12). The restorative stage was completed two months later and consisted of a splinted porcelain-fused-to-metal implant-supported bridge connecting both implants and extending as a small cantilever to the canine region (Figure 14.4.13). The patient was very satisfied with the final restoration: its function, esthetics, and comfort (Figure 14.4.14).

Dentlearn.ir

FIGURE 14.4.12 View of the implant stage 2 that was done nine months after the ridge-split expansion procedure. *Source*: Tolstunov L. Ridge-split procedure for horizontal augmentation of the alveolar ridge in implant dentistry. SROMS. 2013;21(1):1–53. Reproduced with permission of Douglas P. Sinn, DDS. Editor in Chief, SROMS.

This maxillary case demonstrates an advance alveolar width deficiency. A single stage of alveolar split, expansion, graft, and implants was done in this case. An immediate implant placement in these advanced cases is not routinely recommended, especially for a novice surgeon.

The author's two video clips on the RSEP demonstrate the maxillary alveolar split technique for single and larger maxillary edentulous spaces.

FIGURE 14.4.13 Panoramic radiograph of completion of the restorative stage: implant-supported bridge connecting both implants and extending as a small cantilever to the canine region. *Source*: Tolstunov L. Ridge-split procedure for horizontal augmentation of the alveolar ridge in implant dentistry. SROMS. 2013;21(1):1–53. Reproduced with permission of Douglas P. Sinn, DDS. Editor in Chief, SROMS.

FIGURE 14.4.14 Intraoral photograph of completion of the restorative stage: implant-supported bridge connecting both implants and extending as a small cantilever to the canine region. *Source*: Tolstunov L. Ridge-split procedure for horizontal augmentation of the alveolar ridge in implant dentistry. SROMS. 2013;21(1):1–53. Reproduced with permission of Douglas P. Sinn, DDS. Editor in Chief, SROMS.

with website

To access the videos for this chapter, please go to
www.wiley.com/go/tolstunov/essential

VIDEO 14.1 Introduction to the Chapter 14 by the Author and Book Editor Dr. Len Tolstunov.

VIDEO 14.4.1 Ridge-Split Expansion Procedure, Anterior Maxilla.

VIDEO 14.4.2 Ridge-Split Expansion Procedure, Anterior Maxilla.

REFERENCES

1. Lekholm U, Zarb GA. Patient selection and preparation. In P-I Branemark, GA Zarb, T Albrektsson (eds.), Tissue-integrated prostheses osseointegration in clinical dentistry. Chicago, IL: Quintessence; 1985, 199–209.
2. Jensen OT, Mogyoros R, Owen Z et al. Island osteoperiosteal flap for alveolar bone reconstruction. *J Oral Maxillofac Surg.* 2010;68(3):539–46.
3. Jensen OT, Ellis E. The book flap: A technical note. *J Oral Maxillofac Surg.* 2008;65(5):1010–14.
4. Tang Y-L, Yuan J, Song Y-L et al. Ridge expansion alone or in combination with guided bone regeneration to facilitate implant placement in narrow alveolar ridges: A retrospective study. *Clin Oral Implants Res.* 2015;26(2):204–11.
5. Shahakbari R, Eshghpour M, Mianbandi V et al. The comparison of utilizing piezotome and surgical disc in ridge splitting of atrophic edentulous maxillary ridge. *J Oral Maxillofac Surg.* 2020;19(3):374–9.
6. Demetriades N, Park J, Lascarides C. Alternative bone expansion technique for implant placement in atrophic edentulous maxilla and mandible, J Oral Implantol. 11;37(4):463–71.

Dentlearn.ir

CHAPTER 14.5 Advanced Ridge-Split Expansion Techniques for an Experienced Practitioner

Len Tolstunov[1,2,3]

[1]*Associate Clinical Professor, Department of Oral and Maxillofacial Surgery, University of California San Francisco (UCSF) School of Dentistry, San Francisco, CA, USA*

[2]*Associate Clinical Professor, Department of Oral and Maxillofacial Surgery, University of the Pacific Arthur A. Dugoni School of Dentistry, San Francisco, CA, USA*

[3]*Private OMFS practice, San Francisco, CA, USA*

It is reasonable to describe the complexity of a surgical procedure at three levels: standard, intermediate, and complex. Familiarity with a surgical technique and experience can help a surgeon learning the technique to progress from a procedure with mild complexity (standard) to one that is complicated or difficult (complex).

This chapter consists of a few examples of advanced alveolar split procedures (complexity levels 2 and 3) for an experienced operator.

SINGLE-STAGE MANDIBULAR ALVEOLAR SPLIT WITH A CLOSED FLAP (CLOSED MAND C-SEG)

This procedure is common for the maxilla (softer bone) and difficult to perform in the mandible. In the mandible, two stages are usually required to prepare the bone by four interconnected corticotomies, followed by the actual split and grafting four weeks later. In this case, corticotomies (C), split (S), expansion (E), and graft (G) are performed at the same time in a single-stage surgery through a closed or semi-open (limited open) flap in the mandibular edentulous region (mand C-SEG). Only crestal and small lateral corticotomies are done through the limited opening, which helps to preserve periosteal blood supply but makes surgery difficult in the dense mandibular bone. Placement of an implant is performed at a separate stage weeks or months later.

- *Technical difficulty* (level 2): dense mandibular bone is difficult to split without previous osteotomies, and a very careful split and bone expansion are required through crestal corticotomy with a limited view of the fracturing buccal plate and interpositional grafting.
- *Pros*: the limited flap helps to preserve vascularization to the buccal cortical bone; single surgery.
- *Cons*: potentially suboptimal propagation of fracture with a "bad split" or comminuted fracture of the dense buccal cortical plate not amenable to bone grafting; delayed implant placement.

SINGLE-STAGE ALVEOLAR SPLIT AND IMMEDIATE IMPLANT WITH A CLOSED FLAP (CLOSED C-SEG-I) (FIGURES 14.5.1–14.5.4)

Corticotomies (C), split (S), expansion (E), and graft (G) are performed at the same time in a single-stage surgery through a closed or semi-open (limited open) flap in the maxillary or mandibular edentulous regions. Only crestal and occasionally lateral corticotomies can be done through the limited opening, which helps to preserve the periosteal blood supply. Placement of an implant is performed at the same time (immediate implantation).

- *Technical difficulty* (maxilla level 2, mandible level 3): very careful split and bone expansion are required based on often single crestal corticotomy with limited view of the fractured buccal plate, followed by implant placement again with a restricted view, and then interpositional grafting and closure.
- *Pros*: limited flap helps to preserve vascularization to the buccal cortical bone; single surgery for both bone augmentation and implant placement.
- *Cons*: potentially suboptimal propagation of fracture with a "bad split" or comminuted fracture of the buccal cortical plate not amenable for implant placement; poor implant position with compromised osseointegration.

Essential Techniques of Alveolar Bone Augmentation in Implant Dentistry: A Surgical Manual, Second Edition. Edited by Len Tolstunov.
© 2023 John Wiley & Sons, Inc. Published 2023 by John Wiley & Sons, Inc.
Companion website: www.wiley.com/go/tolstunov/essential

Dentlearn.ir

FIGURE 14.5.1 Clinical photograph of a ridge-split expansion procedure at the expansion stage.

FIGURE 14.5.2 Clinical photograph of a ridge-split expansion procedure at the implant osteotomy preparation stage, which is done right after the split and expansion of the alveolar ridge.

FIGURE 14.5.3 Clinical photograph of the implant placement stage, which is done right after the ridge-split expansion procedure.

FIGURE 14.5.4 Clinical photograph of the placed implant in the expanded alveolar ridge.

SINGLE-STAGE ALVEOLAR SPLIT WITH AN OPEN FLAP (OPEN C-SEG)

Corticotomies (C), split (S), expansion (E), and graft (G) are performed at the same time in a single-stage surgery through an open flap in the maxillary or mandibular edentulous region. The buccal bone is exposed (devascularized) during this approach. Split and expansion are done openly, with the risk of full fracture of devascularized bone. Placement of an implant is performed at a separate stage months later.

- *Technical difficulty* (maxilla level 2, mandible level 3): very careful split and bone expansion are required based on usually three interconnected corticotomies, with opening/expansion of a "trapdoor" segment of the buccal cortical plate in one piece, still attached to the basal bone, followed by interpositional grafting and primary closure.
- *Pros*: open flap helps to visualize the region and improve surgical access; single surgery that can prepare the ridge for the future implant.
- *Cons*: this technique can potentially lead to a "bad split" or comminuted fracture of the buccal cortical plate that can be fully disconnected from the basal alveolar bone and its vascular supply.

SINGLE-STAGE ALVEOLAR SPLIT AND IMMEDIATE IMPLANT WITH AN OPEN FLAP (OPEN C-SEG-I) (FIGURE 14.5.5)

Corticotomies (C), split (S), expansion (E), and graft (G) are performed at the same time in a single-stage surgery through the open flap in the mandibular or maxillary edentulous region. The buccal bone is exposed (devascularized) during this approach. Split and expansion are done openly, with the risk of full fracture of devascularized bone. Placement of an implant (I) is performed at the same time (immediate implantation).

Dentlearn.ir

FIGURE 14.5.5 Clinical photograph of ab open-flap alveolar split with immediate implants, complicated with fracture of the buccal cortical plate, which was fixated with mini-screws.

- *Technical difficulty* (level 3): very careful split and bone expansion are required based on three interconnected corticotomies, with opening/expansion of a "trapdoor" segment of the buccal cortical plate in one piece, still attached to the basal bone, followed by an immediate implant, placed through the split into the peri-split (apical) bone, followed by interpositional grafting of the space between the cortical plates and around the implant, and then primary closure.
- *Pros*: open flap helps to visualize the region and improve surgical access; single surgery with bone augmentation and implant placement.
- *Cons*: this technique can potentially lead to a "bad split" or comminuted fracture of the buccal cortical plate, which can be fully disconnected from the basal alveolar bone and its vascular supply; poor implant placement with a compromised primary stability and osseointegration.

SPREADER-DRIVEN RIDGE EXPANSION APPROACH (WITH OR WITHOUT IMPLANT) (FIGURES 14.5.6 AND 14.5.7)

This is based on the Meisinger bone spreading and condensing system (Meisinger USA, Centennial, CO, USA). In the maxilla, it is usually performed with a split-control kit. In the mandible, it is usually performed with a crest-control kit.

FIGURE 14.5.6 Clinical view of the crest-control bone splitting device inserted into the crestal osteotomy and being activated; two bone distractors were positioned.

FIGURE 14.5.7 Clinical view of an immediate implant placement into the expanded alveolar ridge.

- *Technical difficulty* (maxilla level 2, mandible level 3): very careful split and bone expansion are required.
- *Cons*: "bad split"; devascularization of the fractured buccal bone fragment (usually in the mandible); lack of bone expansion (especially in the mandible); poor implant placement with compromised primary stability and osseointegration.

In all cases, when a ridge split is combined with an immediate implant placement, an engagement of the apical bone beyond the split must be achieved for primary stability and successful osseointegration. An implant of 12+ mm in length should be ideal in the majority of cases when the apical portion of the implant is engaged into the solid native bone beyond the split, and its coronal part is inside the split and surrounded by bone graft material. The implant diameter should also be chosen carefully to ensure that no significant pressure is applied to a mobilized segment of bone. An implant of 3–4 mm in diameter, preferably with a tapered design, should work well. In the

Dentlearn.ir

mandible, the position of the inferior alveolar nerve and mental foramen should be considered, leaving 2–3 mm of safety margin above the vital structures to prevent neurosensory complications.

CASE REPORT OF ALVEOLAR SPLIT WITH CONICAL PROGRESSIVE OSTEOTOMES

A 22-year-old healthy female with a history of a bike accident and loss of lateral incisor as a child presented for an implant evaluation (Figure 14.5.8). Clinical and radiographic evaluation with cone beam computed tomography (CBCT) scans (Figures 14.5.8–14.5.10) and a study model (Figure 14.5.11) confirmed the diagnosis of alveolar width deficiency of 2 mm/alveolar width of 5 mm present (Tolstunov classification class III). The surgery consisted of a ridge-widening procedure with conical osteotomes and simultaneous implant placement. A limited full-thickness flap was elevated and an initial indentation into the alveolar crest was done with a 15 blade scoring the cortical layer of bone along the ridge (Figure 14.5.12). Then an initial 2 mm drill was used to a depth of 5 mm in the middle of the scored corticotomy (Figure 14.5.13). After that, sequential conical (cylindrical) osteotomes were used to tap into the bone to the predetermined length based on the chosen implant (Figures 14.5.14 and 14.5.15). Due to the circumferential expansion created by progressive osteotomes, bone widening and some degree of bone compression were expected. A conical tunnel osteotomy with a diameter at the cortex of 3.5 mm was achieved (Figure 14.5.16). A 4.0 mm diameter/13 mm length implant was placed into the

FIGURE 14.5.8 Clinical photograph of a single edentulous space in the area of the lateral incisor, showing collapse of the alveolar ridge with ridge width deficiency after a history of a bike accident.

FIGURE 14.5.9 Panoramic radiograph of the case: missing lateral incisor.

FIGURE 14.5.10 Cone beam computed tomography radiograph showing moderate horizontal ridge deficiency and need for additional 3–4 mm of buccal bone projection.

FIGURE 14.5.11 Diagnostic model confirming the diagnosis of horizontal alveolar ridge deficiency.

FIGURE 14.5.12 Intraoperative photographs of the initial stage of the ridge-split expansion procedure using a 15 blade to identify the middle of the ridge prior to ridge expansion.

Dentlearn.ir

FIGURE 14.5.13 Intraoperative photograph of the initial stage of the ridge-split expansion procedure using a 2 mm drill to identify the middle of the ridge, perforate the cortex, and enter the trabecular layer of bone prior to ridge expansion.

FIGURE 14.5.14 Intraoperative photograph of the ridge split in progress utilizing conical (cylindrical) osteotomes that were tapped into the trabecular bone to the predetermined depth (based on the implant length) and performing slow and progressive ridge expansion.

FIGURE 14.5.15 Intraoperative photograph of the ridge split in progress utilizing conical (cylindrical) osteotomes that were tapped into the trabecular bone to the predetermined depth (based on the implant length) and performing slow and progressive ridge expansion.

FIGURE 14.5.16 Clinical view of the implant osteotomy after expansion of the ridge, which had a slightly smaller diameter than the implant.

FIGURE 14.5.17 Intraoperative views of a dental implant that was prepared to be placed into the osteotomy after the ridge-split expansion procedure.

FIGURE 14.5.18 Intraoperative views of a dental implant that was placed into the osteotomy after the ridge-split expansion procedure with insertion torque of 35 Ncm.

Dentlearn.ir

FIGURE 14.5.19 Intraoperative view of a dental implant that was placed into the osteotomy after the ridge-split expansion procedure, followed by placement of a healing abutment.

osteotomized tunnel to the predetermined depth (crestal placement) with a torque of 35 Ncm (Figures 14.5.17 and 14.5.18). A stage 2 healing abutment was also placed (Figure 14.5.19). The implant was successfully restored 6 months later (Figure 14.5.20).

FIGURE 14.5.20 Periapical radiograph of the successfully restored implant 6 months later.

CONCLUSION

There are many modifications of the ridge-split expansion procedure (RSEP) that have been suggested in the literature. Scipioni et al. proposed a graftless "morphogenic bone splitting" technique done through a partial-thickness flap, when the bone-mucosa-gingival complex is displaced laterally in its entirety to eliminate the facially inclined hinge displacement often seen with a traditional alveolar split [1]. Coatoam and Mariotti proposed a modification of a traditional segmental RSEP with the use of lyophilized bone allograft [2]. Implants were placed simultaneously, and cortical plates were braced with a ligature wire. An induced osteogenesis by periosteal distraction and guided bone regeneration by dynamic periosteal elevation are other modifications of ridge widening. Here, the actual split is not done, but the periosteum is tented to promote bone regeneration and widening [3, 4]. Distraction osteogenesis principles can also be used for horizontal ridge widening, employing titanium mesh [5] or a crest-widening/horizontal distraction device [6]. These advanced techniques of ridge widening are outside the scope of this chapter.

A staged surgical approach with a delayed placement of implants after completion of bone augmentation and consolidation of the graft appears to be a more predictable technique with fewer complications.

REFERENCES

1. Scipioni A, Calesini G, Micarelli C et al. Morphogenic bone splitting: Description of an original technique and its application in esthetically significant areas. *Int J Prosthodont.* 2008;21:389–97.
2. Coatoam GW, Mariotti A. The segmental ridge-split procedure. *J Periodontol.* 2003;74(5):757.
3. Schmidt BL, Kung L, Jones C et al. Induced osteogenesis by periosteal distraction. *J Oral Maxillofac Surg.* 2002;60:1170–75.
4. Lethaus B, Tudor C, Bumiller L et al. Guided bone regeneration: Dynamic procedures versus static shielding in an animal model. *J Biomed Mater Res B Appl Biomater.* 2010;95:126–30.
5. Funaki K, Takahashi T, Yamuchi K. Horizontal alveolar ridge augmentation using distraction osteogenesis: Comparison with a bone splitting method in a dog model. *Oral Surg Oral Med Oral Pathol Oral Radiol Endod.* 2009;107:350–58.
6. Laster Z, Rachmiel A, Jensen OT. Alveolar width distraction osteogenesis for early implant placement. *J Oral Maxillofac Surg.* 2005;63:1724–30.

Dentlearn.ir

CHAPTER 14.6 Complications of the Ridge-Split Expansion Procedure and Conclusion

Len Tolstunov[1,2,3]

[1]*Associate Clinical Professor, Department of Oral and Maxillofacial Surgery, University of California San Francisco (UCSF) School of Dentistry, San Francisco, CA, USA*

[2]*Associate Clinical Professor, Department of Oral and Maxillofacial Surgery, University of the Pacific Arthur A. Dugoni School of Dentistry, San Francisco, CA, USA*

[3]*Private OMFS practice, San Francisco, CA, USA*

The alveolar ridge can be too thin and therefore too difficult to split (Figures 14.6.1 and 14.6.2). Among the complications of the ridge-split expansion procedure (RSEP), a ridge "mistreatment" with *fracture of the displaced buccal cortex* is the most common. This can happen during the RSEP, when the thin and often fragile buccal cortex can fracture and the fracture can spread (propagate) unfavorably. As a result, only part of the buccal cortical bone (the occlusal or crestal portion) may expand buccally. The other *apical* portion of bone may still be attached to the remaining basal bone. A surgeon may not realize this complication in a closed-flap environment and progress to the next stage of bone grafting. This particulate graft then can be placed on the buccal side of the bone instead of being placed between cortical plates internally. This can compromise the results of bone grafting and implant treatment (Figures 14.6.3 and 14.6.4).

Scipioni et al. discuss the need to maintain an adequate thickness of about 1.5+ mm of the buccal cortical bone during the split [1]. The whole buccal plate (which was subfractured) must be evenly moved or repositioned during the procedure. The thicker the buccal plate (the layer to be mobilized), the more easily this can be accomplished without complications. Staying parallel and close to the palatal (or lingual) cortical plate as well as use of piezoelectric instrumentation during the split help to maintain buccal cortex integrity. Dual-finger guidance (holding the expanding alveolar crest on both sides with a thumb and second finger) helps to "mold" and properly position the buccal fragment of bone. If the buccal plate appears too loose at the time of the split, a horizontal fixation screw can be placed to brace both plates together. An interpositional bone graft, if considered, should be placed internally, into the gap between the cortical plates.

The other common complication is a complete exposure of the buccal surface of bone at the time of the split, developing a full-thickness flap (FTF) instead of a partial-thickness or limited FTF. If an alveolar split is carried out in this circumstance, there could be a high risk of a complete fracture of the buccal bone with the formation of a *detached and devascularized buccal bone fragment* (Figure 14.6.5) [2, 3]. A free buccal bone fragment then needs to be fixated to the alveolar ridge with osteosynthesis screws (Figure 14.6.6). If this is not done, the fragment will become necrotic and will need to be removed (Figure 14.6.7). After a waiting period of 4–6 months, the procedure can be redone. A lingual (palatal) plate fracture is rare and can be prevented by positioning chisel osteotomes parallel and not angled to the lingual plate.

Soft tissue complications can happen at the time of flap reflection and include tear of the buccal flap mucosa and periosteal perforation or dehiscence. Atraumatic surgery and attention to detail should hopefully help to reduce these issues. Often the soft tissue flap is not fully reflected, but remains connected to the bone and is raised together with a buccal portion of bone as an osteoperiosteal vascularized flap.

The use of mallet and chisel osteotomes in the craniofacial region must be gentle and controlled. Ridge splitting and expansion utilizing these instruments might be unpleasant to patients. Panarrocha et al. described *benign (paroxysmal) positional vertigo* (BPV or BPPV) as a complication of osteotome expansion of the maxillary alveolar ridge for implant placement [4]. Saker and Ogle presented a case of BPV after an indirect (crestal) sinus lift as a complication of intervention with osteotome and mallet [5]. Symptoms of BPV (BPPV) include a feeling of spinning or tilting (vertigo) during head movement resulting from inner ear "stones" dislocation. If the condition does not improve, the ear, nose, and throat doctor might need to perform Epley maneuver (head exercises) to "reposition" the stones.

Position of the mental foramen and inferior alveolar nerve must be determined pre-operatively on cone beam computed tomography (CBCT) radiographs and monitored

Essential Techniques of Alveolar Bone Augmentation in Implant Dentistry: A Surgical Manual, Second Edition. Edited by Len Tolstunov.
© 2023 John Wiley & Sons, Inc. Published 2023 by John Wiley & Sons, Inc.
Companion website: www.wiley.com/go/tolstunov/essential

Dentlearn.ir

FIGURE 14.6.1 Clinical photograph showing severe width deficiency of the alveolar ridge.

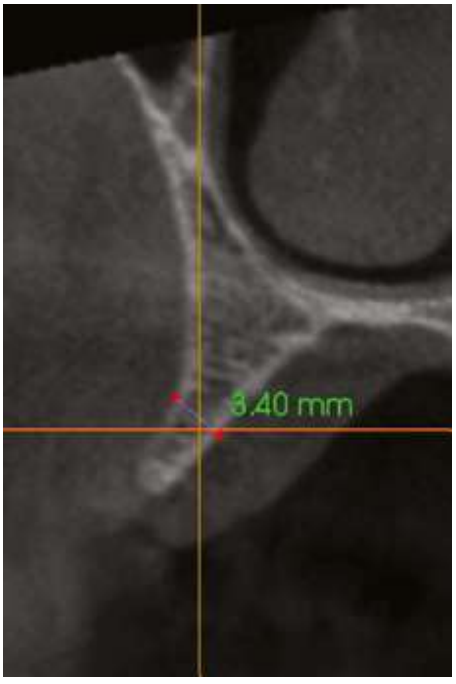

FIGURE 14.6.2 Cone beam computed tomography radiograph showing severe width deficiency of the alveolar ridge.

intraoperatively to prevent *neuro-sensory complications* during a mandibular RSEP in the premolar region. Other complications, like post-operative infection and extensive bleeding, are rare and can be managed with debridement, antibiotics, and local hemostatic agents.

Implant-related complications are also known. If an immediate implant was placed incorrectly or with poor primary implant stability, or if a delayed implant was placed too early (less than 3 months) after stage 1 of the split, an implant has a higher risk of non-integration and failure. The implant diameter must correspond to the expanded ridge. Having 1.5–2 mm of bone on both buccal and palatal (lingual) sides is

FIGURE 14.6.3 Clinical photograph demonstrating complication that resulted from the accidental fracture of the crestal portion of the buccal plate during the ridge-split expansion procedure. *Source*: Tolstunov L. Ridge-split procedure for horizontal augmentation of the alveolar ridge in implant dentistry. SROMS. 2013;21(1):1–53. Reproduced with permission of Douglas P. Sinn, DDS. Editor in Chief, SROMS.

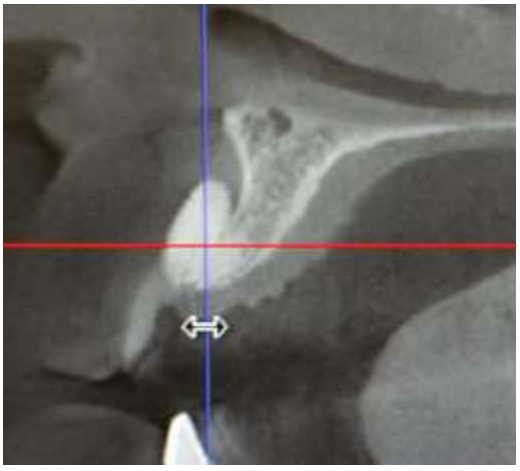

FIGURE 14.6.4 Cone beam computed tomography radiograph demonstrating a complication that resulted from the accidental fracture of the coronal portion of the buccal plate during the ridge-split expansion procedure and inadvertent bone grafting on the labial side in front of the buccal plate and next to the soft tissue (instead of inside the split). *Source*: Tolstunov L. Ridge-split procedure for horizontal augmentation of the alveolar ridge in implant dentistry. SROMS. 2013;21(1):1–53. Reproduced with permission of Douglas P. Sinn, DDS. Editor in Chief, SROMS.

important for long-term implant success (lasting osseointegration). Tapered long and narrow implants tend to do better in a ridge-split environment. Immediate implants should always be longer than the depth of the split to engage the apical bone and achieve primary implant stability intraoperatively. If an implant is too wide at the time of split and immediate implantation, it may "dehisce" through the buccal plate and get exposed to the buccal soft tissue (Figures 14.6.8 and 14.6.9).

Dentlearn.ir

FIGURE 14.6.5 Intraoperative photograph of a complication of the ridge-split expansion procedure when the whole buccal cortical plate fractured off and was fully detached from the reflected buccal soft tissue. *Source*: Reproduced from [3] with permission from Elsevier.

FIGURE 14.6.6 Intraoperative photograph of a complication of the ridge-split expansion procedure when the detached and devascularized buccal cortical plate was fixated back with mini-screws. Implants were inserted at the same time. *Source*: Reproduced from [3] with permission from Elsevier.

FIGURE 14.6.7 A complication of the ridge-split expansion procedure when the detached and devascularized buccal cortical plate became necrotic (became a bone sequester). *Source*: Reproduced from [4] with permission from Elsevier.

FIGURE 14.6.8 Clinical photograph of a post-operative complication of the ridge-split expansion procedure showing the placement of inappropriately wide diameter implants that were inserted into a thin ridge at the time of the split, resulting in the protrusion of implant bodies (threads) into the buccal soft tissue months later. Courtesy of Dr. Albert Zickmann.

Dentlearn.ir

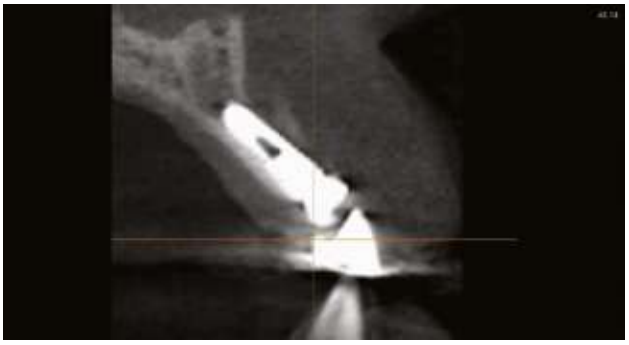

FIGURE 14.6.9 Cone beam computed tomography radiograph showing a wide diameter implant that was placed into the thin ridge at the time of the split, resulting in buccal plate resorption and protrusion of implant threads into the soft tissue months later.

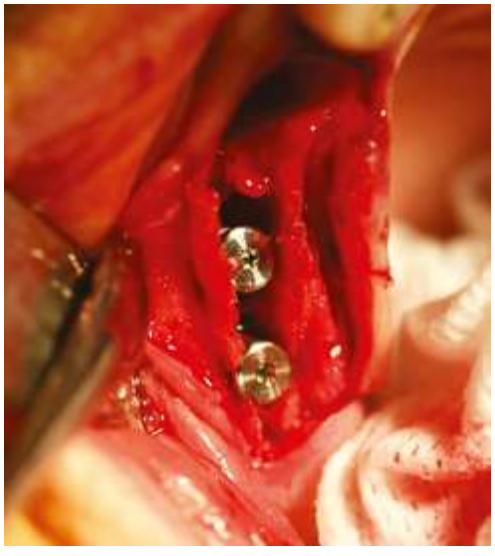

FIGURE 14.6.10 Clinical photograph of a buccal plate that was too thin at the time of the alveolar split, which could potentially result in bone resorption and protrusion of the implant into the soft tissue months or years later. *Source*: Tolstunov L. Ridge-split procedure for horizontal augmentation of the alveolar ridge in implant dentistry. SROMS. 2013;21(1):1–53. Reproduced with permission of Douglas P. Sinn, DDS. Editor in Chief, SROMS.

The same can happen if the buccal plate is too thin at the time of the alveolar split (Figure 14.6.10). This may go unnoticed if the buccal flap was not reflected or a post-operative CBCT scan was not ordered. When diagnosed, secondary buccal bone grafting with guided bone regeneration might be needed to attempt to regenerate the buccal bone on top of exposed implant threads (Figure 14.6.11). A staged approach to the alveolar split seems to reduce the risk of buccal ridge dehiscence, as well as crestal bone loss, soft tissue recession, and other complications [6].

FIGURE 14.6.11 Treatment of complication of implant thread exposure with delayed guided bone regeneration. Courtesy of Dr. Albert Zickmann.

A learning curve must be considered for a novice surgeon interested in mastering the RSEP. A surgical practitioner, skilled in a variety of hard tissue augmentation techniques, may have faster and accelerated learning of the technique described. Many surgeons skilled in the open full-thickness flap approach needed for an autogenous block bone graft initially may have difficulty learning the closed full-thickness or split-thickness flap common for the RSEP.

CONCLUSION: "10 COMMANDMENTS" FOR THE ALVEOLAR SPLIT

The author would like to conclude this chapter with 10 principles of success when contemplating and performing the RSEP. These principles are derived from the author's experience as well a literature review on the subject [3, 7–16].

1. Smokers have a higher rate of failure with bone augmentation and implant osseointegration.
2. Due to poor bone quality, the posterior maxilla is the least successful region for bone augmentation and implant osseointegration.
3. Secondary wound closure is commonly used in RSEP.
4. 1.5 mm+ of bone on the buccal side of the placed implant after the RSEP is preferable for long-term implant success.
5. The most reliable timing for delayed implant placement after the RSEP is 4–6 months.
6. Tapered implants placed simultaneously with the RSEP tend to better accommodate to the expanded ridge than parallel-wall (straight) implants and have less risk of buccal bone perforation.

Dentlearn.ir

7. The ideal diameter and length for an implant immediately placed into the ridge after the RSEP are 3–3.5 mm in diameter and 12+ mm in length. Implants that are too wide will require more expansion and lead to more buccal bone resorption. Implants that are too short may not have enough length beyond the split for primary implant stability.
8. A staged approach (versus a single stage) with the RSEP seems to improve surgical control and reduce the risks and complications related to both split and implant.
9. The presence of adequate keratinized (attached) tissue on the buccal/labial gingiva and sufficient depth of the vestibule after the split and implant placement and restoration will improve the long-term maintenance and implant hygiene of the area.
10. Bone augmentation through the RSEP appears to be effective and have stable and lasting success. If the implant fails, the stability of the expanded alveolar ridge usually remains and replacement of an implant in the same area can be done at a later time.

REFERENCES

1. Scipioni A, Bruschi GB, Calesini G. The edentulous ridge expansion technique: A five-year study. *Int J Periodontics Restorative Dent.* 1994;14:451–9.
2. Piccinini M. Mandibular bone expansion technique in conjunction with root form implants: A case report. *J Oral Maxillofac Surg.* 2009;67:1931–6.
3. Sohn DS, Lee HJ, Heo JU et al. Immediate and delayed lateral ridge expansion technique in the atrophic posterior mandibular ridge. *J Oral and Maxillofac Surg.* 2010;68:2283–90.
4. Penarrocha M, Perez H, Gargia A. Benign paroxysmal positional vertigo as a complication of osteotome expansion of the maxillary alveolar ridge. *J Oral Maxillofac Surg.* 2001;59:106–7.
5. Saker M, Ogle O. Benign paroxysmal positional vertigo subsequent to sinus lift via closed technique. *J Oral Maxillofac Surg.* 2005;63(9):1385–7.
6. Elian N, Jalbout Z, Ehrlich B et al. A two-stage full-arch ridge expansion technique: Review of the literature and clinical guidelines. *Implant Dent.* 2008;17(1):16–23.
7. Testori T, Weinstein RL, Taschieri S et al. Risk factor analysis following maxillary sinus augmentation: A retrospective multicenter study. *Int J Oral Maxillofac Implants.* 2012;27(5):1170–76.
8. Abt E. Smoking increases dental implant failures and complications. *Evid Based Dent.* 2009;10(3):79–80.
9. Bravi F, Bruschi GB, Ferrini F. A 10-year multicenter retrospective clinical study of 1715 implants placed with the edentulous ridge expansion technique. *Int J Periodontics Restorative Dent.* 2007;27(6):557–65.
10. Carr AB. Implant location and radiotherapy are the only factors linked to 2-year implant failure. J Evid Based Dent Pract. 201;12(3 suppl):217–19.
11. Tolstunov L. Implant zones of the jaws: Implant location and related success rate. *J Oral Implantol.* 2007;33(4):211–20.
12. Alves CC, Neves M. Tapered implants: From indications to advantages. *Int J Periodontics Restorative Dent.* 2009;29(2):161–7.
13. Kang T, Flen M, Gober D et al. A modified ridge expansion technique in the maxilla. *Compend Contin Educ Dent.* 2012;33(4):250–56.
14. Schultze-Mosgau S, Keweloh M, Wiltfang J et al. Histomorphometric and densitometric changes in bone volume and structure after avascular bone grafting in the extremely atrophic maxilla. *Br J Oral Maxillofac Surg.* 2001;39(6):439–47.
15. Elian N, Jalbout Z, Ehrlich B et al. A two-stage full-arch ridge expansion technique: Review of the literature and clinical guidelines. *Implant Dent.* 2008;17(1):16–23.
16. Tolstunov L, Hicke B. Horizontal augmentation through the ridge-split procedure: A predictable surgical modality in implant reconstruction. *J Oral Implantol.* 2013;39(1):59–68.

Dentlearn.ir

Ridge-Split Expansion Procedure Utilizing Piezoelectric Surgery for Horizontal Bone Augmentation in Implant Dentistry

CHAPTER 15

The ridge-split expansion procedure (RSEP) is very effective for horizontal augmentations in severely atrophic posterior mandibular ridges. There is an advantage when implants are placed inside the expanded bony envelope between cortical plates, like natural teeth. Ultrasonic piezoelectric instruments utilize micro-vibrations that allow clean and fast bone cutting, which is also safe around soft tissues such as oral mucosa and vital organs.

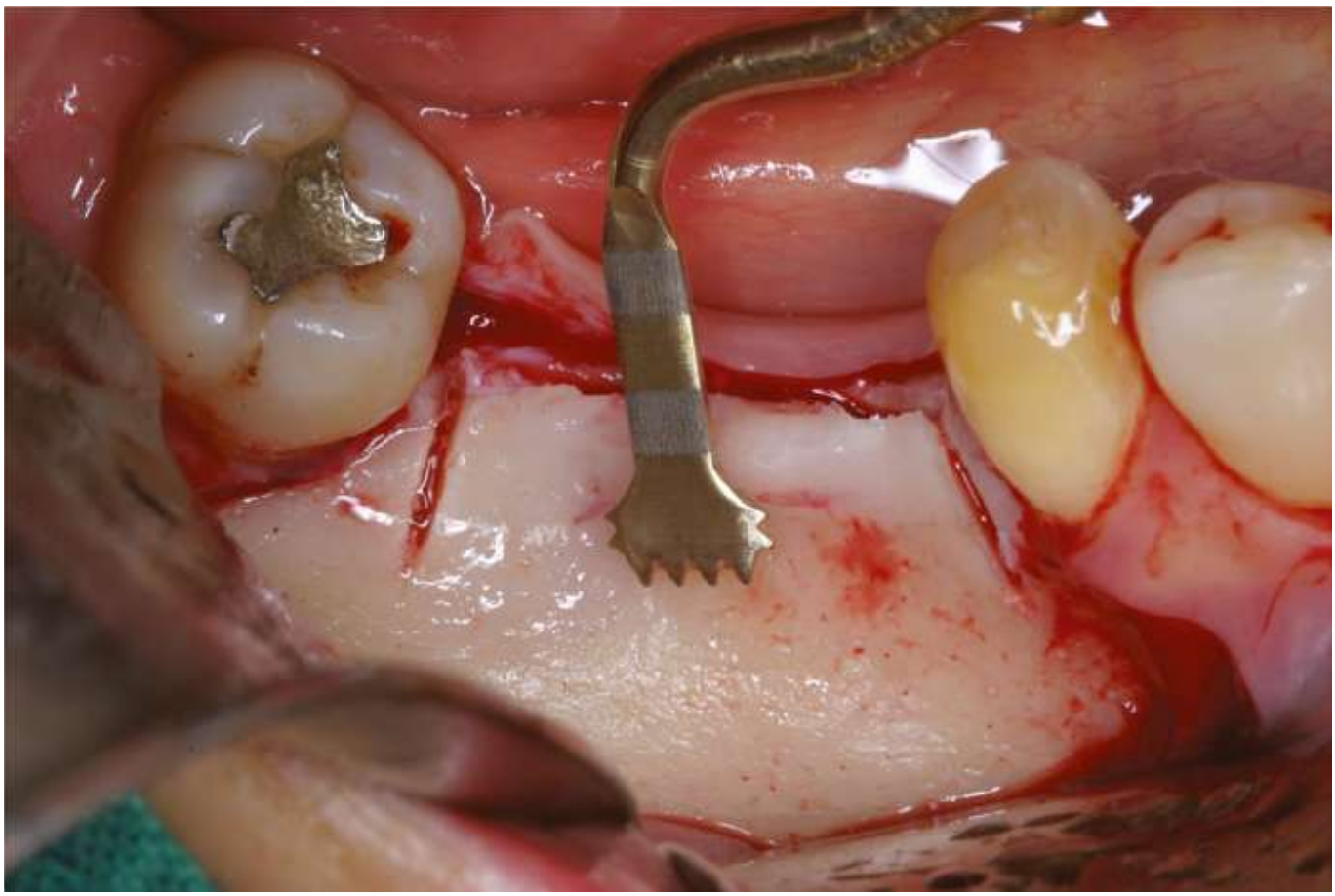

Dentlearn.ir

CHAPTER 15

Ridge-Split Expansion Procedure Utilizing Piezoelectric Surgery for Horizontal Bone Augmentation in Implant Dentistry

Dong-Seok Sohn[1] and Jeong-Uk Heo[2]

[1]*Department of Dentistry and Oral and Maxillofacial Surgery, School of Medicine, Daegu Catholic University, Daegu, South Korea*

[2]*Private Practice, GoodWill Dental Clinic, Busan, South Korea*

Missing dentition over a long period of time results in ridge atrophy in width and height. Numerous surgical techniques have been described for augmentation of the atrophic mandibular alveolar ridge. Strategies used to overcome this include onlay block bone grafting [1, 2], guided bone regeneration with barrier membranes [3–5], distraction osteogenesis [6], and the ridge-split expansion procedure (RSEP) [7–10]. RSEP is indicated when the available bone height is favorable but the bone width is not sufficient. The lateral ridge expansion technique aims at the creation of a new implant bed by longitudinal osteotomy of the alveolar bone. RSEP involves splitting of the buccal cortical bone to expand the ridge and place the implant in the expanded bony ridge. Compared to block bone grafting, this technique is simple because it does not require a donor site. RSEP is usually performed simultaneously with implant placement and significantly shortens the healing time. RSEP is more suitable to the maxilla than the mandible due to thinner cortical plates and softer medullary bone [11]. In the mandible, the risk of malfracture of the osteomized buccal segment is higher because of less flexibility and thicker cortical plates. A staged approach to avoid malfracture in the mandible can be used. The space between the expanded buccal and lingual cortical plates is usually grafted with various biomaterials [12–14].

This chapter presents RSEP with the immediate and delayed lateral expansion technique. There are instruments that can be used to split the alveolar ridge and instruments that are used to expand it after.

INSTRUMENTS TO SPLIT THE ALVEOLAR RIDGE

Various instruments for osteotomy to split a thin alveolar ridge have been utilized.

FISSURE BUR

A rotary fissure bur has the advantage of fast bone cutting. However, compared to a micro-saw or piezoelectric bone surgery, it can cause irregular osteotomy and loss of a large amount of bone during osteotomy. Therefore, a fissure bur is not recommended to split a thin alveolar ridge (2 mm or less thick ridge) in RSEP. A rotary bur is also prone to soft tissue damage while cutting intraorally. The heat generated by friction around the shank can cause burn on the lip or facial tissue. When in contact with soft tissue or vital organs adjacent to the cutting surface, it can cause serious complications (Figure 15.1).

ROTARY DISK/MICRO-SAW

A rotary disk is effective for doing osteotomy. However, access to the posterior mandible and maxilla is difficult and such instruments can cause serious complications in soft tissue (Figures 15.2 and 15.3). Therefore it requires constant caution during osteotomy. In addition, these instruments have limited precise depth control in crestal osteotomy.

Essential Techniques of Alveolar Bone Augmentation in Implant Dentistry: A Surgical Manual, Second Edition. Edited by Len Tolstunov.
© 2023 John Wiley & Sons, Inc. Published 2023 by John Wiley & Sons, Inc.
Companion website: www.wiley.com/go/tolstunov/essential

Dentlearn.ir

FIGURE 15.1 Note damaged vessel during osteotomy using a rotary bur. While cutting the bone, adjacent buccal mucosa was caught in the bur and the artery was severed, causing serious hemorrhage and facial swelling. The patient was hospitalized for the following three days, during which blood transfusion was done to restore the lost blood.

FIGURE 15.2 Rotary disk.

FIGURE 15.3 Note severe damage to oral mucosa during osteotomy in ridge split using a rotary disk. It caused severe bleeding. Courtesy of Dr. Qing Lan Peter.

RECIPROCATION SAW

This employs macro-vibrations that allow fast bone cutting. It allows for precise osteotomy. Therefore it can split a thin alveolar ridge similar to piezoelectric bone surgery. However, this produces unfavorable vibrations and noise that can cause stress in patients. The saw also requires caution to prevent soft tissue damage (Figures 15.4 and 15.5). This saw has limited access in the posterior mandible and maxilla.

FIGURE 15.4 Micro-saw.

FIGURE 15.5 Note damage on lower lip due to improper use of micro-saw.

Dentlearn.ir

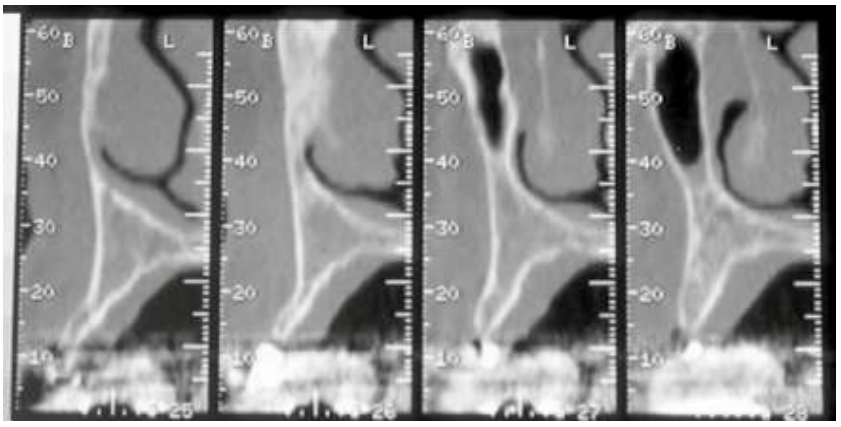

FIGURE 15.6 Pre-operative computed tomography indicating 1–3 mm of bone width.

CASE REPORT: RIDGE-SPLIT EXPANSION PROCEDURE USING A RECIPROCATION SAW

A 70-year-old female with missing maxillary left first and second premolars and first molar visited our department for implant-supported prosthesis. Pre-operative computed tomography showed a ridge width of 1–3 mm at the edentulous site (Figure 15.6). A full-thickness flap was retracted to expose the alveolar bone after administration of local anesthesia. A micro-saw was used to make crestal and anterior vertical osteotomies to split the ridge. A manual chisel was inserted into the osteotomy to expand the ridge. Three implants (Frialit®-2, Dentsply, Hessen, Germany) were placed at the same time. The buccal bone was green-stick fractured after implant placement. Xenograft (Algipore®, Dentsply) was mixed with platelet-rich plasma to make gel-conditioned bone and placed around the expanded ridge. A collagen barrier was not placed over the bone graft. Primary tension-free suture was achieved (Figures 15.7–15.10). Exposure was done after 6 months of healing. Successful ridge augmentation was achieved (Figures 15.11–15.13).

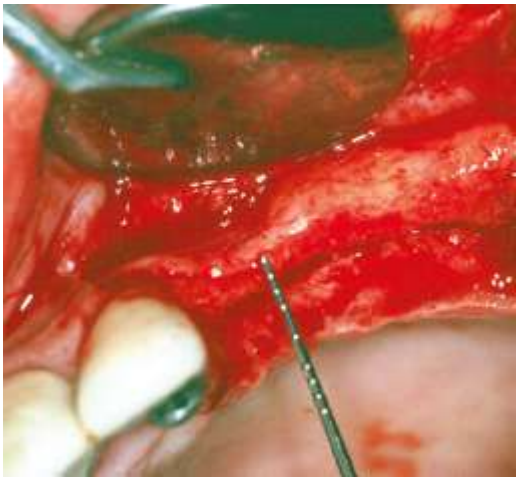

FIGURE 15.7 Intraoral image indicating very narrow edentulous alveolar ridge and buccal bony concavity on the sites of premolars.

LASERS (Er:YAG, Er,Cr:YSGG)

The laser allows increased hemostasis, improved visibility during surgery, and reduced infection and discomfort of the patient post-operatively when it is applied to soft and hard tissue. However, compared to other rotary devices and piezoelectric surgery, it takes longer to do the osteotomy with a laser [15].

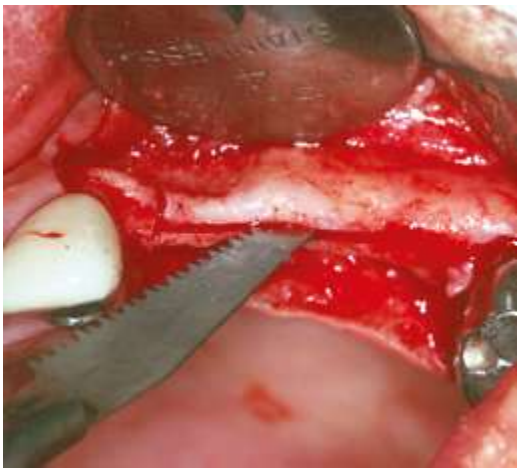

FIGURE 15.8 Crestal osteotomy was done without perforating the buccal concavity, and anterior vertical osteotomies were prepared with a micro-saw. Note the precise crestal and vertical osteotomy.

PIEZOELECTRIC BONE SURGERY

Ultrasonic piezoelectric instruments utilize micro-vibrations that allow clean and fast bone cutting. Because cutting power is specific only to hard tissues, it is safe to

Dentlearn.ir

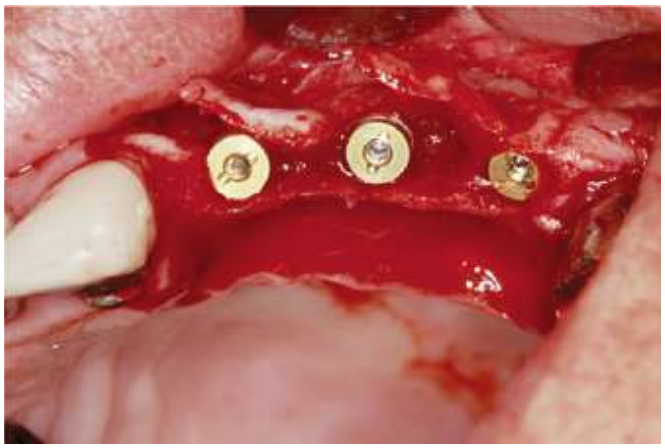

FIGURE 15.9 Note expanded ridge after implant placement.

FIGURE 15.10 Xenograft (Algipore) mixed with platelet-rich plasma was grafted in the gap between the expanded buccal cortex and basal bone and outside the expanded buccal ridge.

FIGURE 15.11 Exposure after 6 months of healing revealed favorable ridge augmentation.

FIGURE 15.12 A periapical radiograph after cementation of a final restoration.

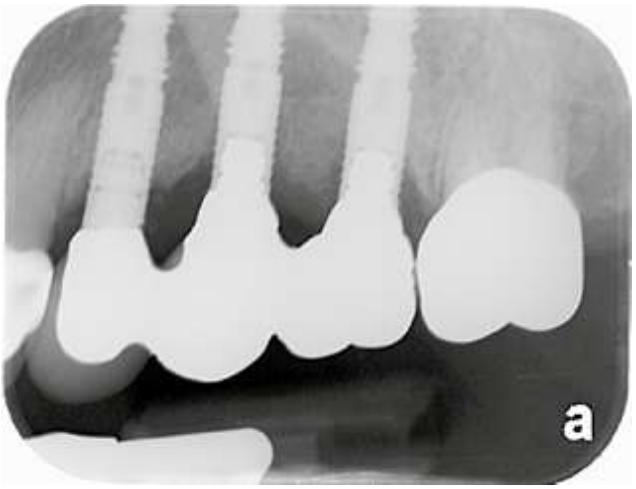

FIGURE 15.13 A periapical radiograph after 11 years in function. Slight marginal bone resorption is seen in the second premolar implant.

operate around soft tissues such as oral mucosa and vital organs. The micrometric cuts of piezoelectric bone surgery ensure precise bone cutting and conserve bone [16, 17]. Therefore it allows for splitting alveolar bone with less than 2 mm of width. The small handpiece can access any surgical sites in the small oral cavity. Various piezoelectric inserts (tips) can be used to do osteotomy. However, a thin saw tip with cutting edges on all sides shows the fastest osteotomy (Figure 15.14). Unlike a rotary bur or laser, an ultrasonic device can be used in ridge splitting of a ridge that is as narrow as 2 mm or less without bony perforation (Figures 15.15–15.17). In addition, the insignificant noise and vibrations, compared to those from a rotary bur or saw, provide better comfort to patients.

Dentlearn.ir

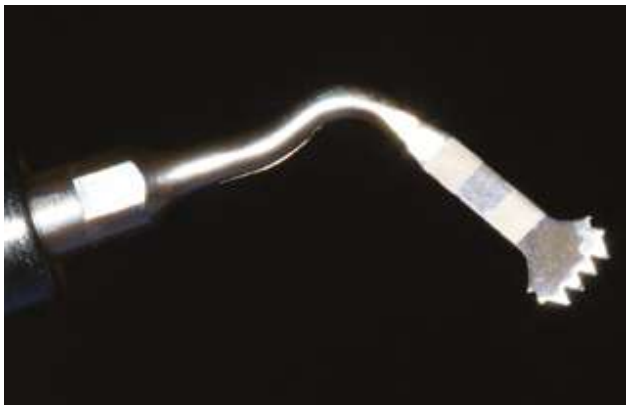

FIGURE 15.14 Saw tip with cutting blade on all sides (S-Saw, BukBu Dental, Daegu, Korea) makes it quick to do osteotomy inside the alveolar bone.

FIGURE 15.15 Intraoral image indicating 2–3 mm of bone width. Note the buccal concavity under the alveolar crest.

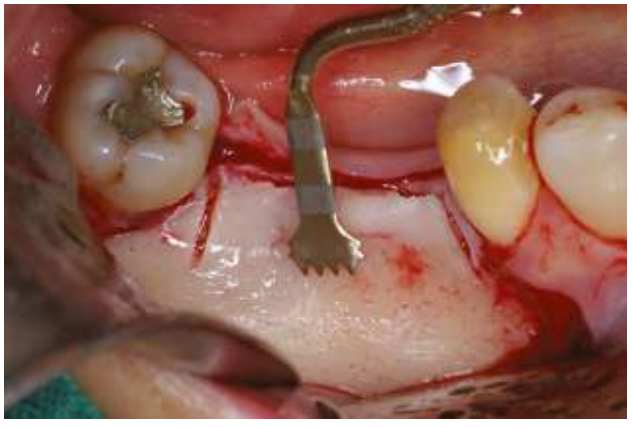

FIGURE 15.16 Ridge splitting using a saw insert. A saw insert allows fast osteotomy and precise osteotomy in a narrow ridge. The length of the vertical osteotomy should be long enough to avoid unintentional malfracture of the buccal plate in the posterior mandible with dense bone quality.

FIGURE 15.17 Note the expanded ridge after placing an implant in the bony envelope.

RIDGE EXPANDERS TO EXPAND THE SPLIT ALVEOLAR RIDGE

MANUAL OSTEOTOME/CHISEL

To expand the split ridge, a manual osteotome or chisel is inserted into the osteotomy and advanced to the desired depth to place implants using light tapping with a surgical mallet. A gentle striking force to osteotome should be used, because striking a mallet with heavy force can cause benign paroxysmal positional vertigo (Figures 15.18 and 15.19) [18].

FIGURE 15.18 Osteotomes of variable diameters.

FIGURE 15.19 Mono-beveled chisels of various thicknesses.

Dentlearn.ir

ROTARY EXPANDER/OSSEODENSIFICATION BUR

The direct force of the surgical mallet to chisel or osteotome is unpleasant and traumatic to patients and is not well tolerated. Therefore, a rotary expander has been introduced to expand the split ridge, and is recommended [19]. The expander can expand the split ridge without removing the alveolar bone (Figures 15.20–15.22).

FIGURE 15.20 A rotary expander not only to expand the split ridge, but to improve bone quality at implant sites.

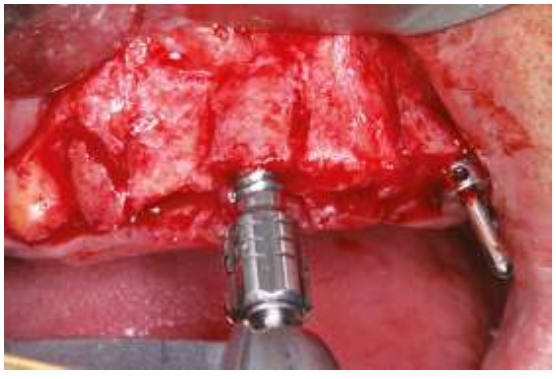

FIGURE 15.21 Ridge expansion using a rotary expander in forward rotation at 50 rpm. The expander compacts cancellous alveolar bone during expansion.

FIGURE 15.22 Expanded ridge using an osseodensification bur in reverse mode at 50 rpm.

RIDGE-SPLIT EXPANSION PROCEDURE WITH SIMULTANEOUS IMPLANT PLACEMENT

RSEP with simultaneous implant placement is indicated in a narrow alveolar ridge with less bone density. It usually applies in the posterior maxillary ridge with a thinner cortex and less bone density. However, it can also be performed in a mandibular ridge with type II bone quality when the ridge is thin from the alveolar crest to the base of alveolar bone. Staged RSEP is recommended when malfracture of the buccal segment is expected in the mandibular alveolar ridge with thick and dense basal bone.

CASE REPORT: RIDGE-SPLIT EXPANSION PROCEDURE WITH SIMULTANEOUS IMPLANT PLACEMENT IN THE POSTERIOR MAXILLA

A 55-year-old female patient presented to our department for restoration of the missing upper right first and second molars. Prophylactic oral antibiotics, cefditoren pivoxil (Meiact®, Boryung Parm., Seoul, South Korea) were given to her, beginning one day prior to the procedure and continuing for five days. Following local anesthesia, a crestal incision and vertical incisions were made, and a full-thickness mucoperiosteal flap was elevated to expose the buccal aspect of the alveolar ridge. An approximately 2–3 mm wide edentulous ridge was measured. A crestal horizontal osteotomy was made using the piezoelectric saw connected with ultrasonic piezoelectric surgery (SurgyBone®, Silfradent, Sofia, Italy). The osteotomy was started 1–2 mm away from the adjacent tooth. The length of the horizontal cut was extended to the site of the second molar and the depth of the osteotomy was approximately two-thirds the length of the implant that was to be placed. Two parallel vertical corticotomies were created on the buccal cortical plate. Their extension (height) was based on the planned implant length. All osteotomies' lengths were performed to reach the lingual plate. A rotary expander (MIS Implants, Or Yehudah, Israel) with the smallest diameter, connected with a handpiece, was placed into the osteotomy and rotated in a forward direction at 50 rpm without coolant to expand the split buccal plate. Sequentially, a wider expander was used to widen the ridge. Implants 4.3 mm wide × 12 mm long (Dentis Implants, Deagu, South Korea) were placed simultaneously without preparation of the implant sites using an implant drill. Mineral allograft (Allotis, Biotis, Busan, South Korea) was mixed with gel-conditioned allograft (Orthoblast® II, IsoTis Orthobiologics, Irvine, CA, USA) and grafted around the expanded ridge. Concentrated growth factor (CGF) membranes were covered over the bone graft to accelerate wound healing. Tension-free primary wound closure was achieved. After 5 months of healing, the implants were exposed (Figure 15.23–15.31).

Dentlearn.ir

FIGURE 15.23 Note the precise crestal and vertical osteotomies prepared with a piezoelectric saw insert.

FIGURE 15.24 A ridge expander was advanced in a forward direction at 50 rpm. A rotary expander was inserted 1 mm deeper than the length of the implant that was to be placed.

FIGURE 15.25 Note the expanded ridge after placing implants in the bony envelope.

FIGURE 15.26 Bone graft over expanded ridge.

FIGURE 15.27 Concentrated growth factor membrane was used to cover the bone graft instead of using a collagen barrier.

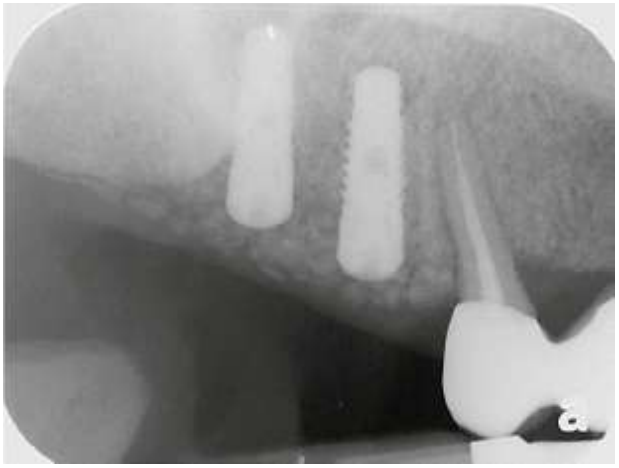

FIGURE 15.28 A postoperative periapical radiograph.

Dentlearn.ir

FIGURE 15.29 An intraoral image indicating favorable ridge augmentation after 5 months of healing.

FIGURE 15.30 An intraoral image after 10 years in function.

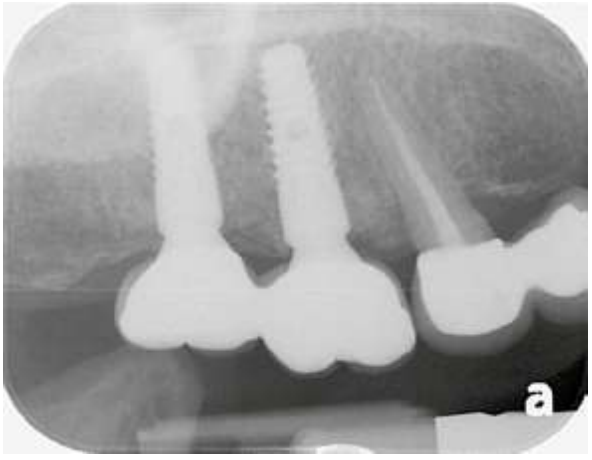

FIGURE 15.31 A periapical radiograph indicating stability of marginal bone around implants after 10 years loading.

CASE REPORT: RIDGE-SPLIT EXPANSION PROCEDURE WITH SIMULTANEOUS IMPLANT PLACEMENT IN THE POSTERIOR MANDIBLE

A 44-year-old female presented at our department with missing lower right first and second molars. The patient had no significant medical history. Surgery was performed under local anesthesia. First a muco-periosteal flap was prepared to uncover the alveolar bone. An approximately 2 mm wide alveolar ridge was revealed and the base of alveolar bone was not thick. Therefore, RSEP and immediate implant placement were planned. The vertical deficiency was not significant. To expand the ridge, a crestal osteotomy was prepared with a piezoelectric saw insert. Anterior and posterior osteotomies were prepared and connected with the crestal horizontal osteotomy. The split was expanded gradually with a rotary expander at 50 rpm, as even the alveolar bone was dense. A rotary expander was advanced 1 mm deeper to the length of the implant that was to be placed. Two implants (Alpha-Bio Tec, Petah Tikva, Israel) were placed simultaneously without preparation of the implant sites with implant drills. The patient's extracted first molar was prepared with decalcified osteoinductive particulate and block graft using a vacuum-ultrasonic machine (VacuaSonic system, Cosmo BioMedicare, Seoul, South Korea) one day prior to surgery. The patient's venous blood was taken from the forearm to make autologous fibrin glue (AFG) and CGF membrane to prepare sticky bone, as described first by Sohn et al. [20]. The sticky tooth bone was grafted on the expanded ridge and a collagen barrier was covered over the bone graft. CGF membranes were placed over the collagen membrane to aid in wound healing. Tension-free primary wound closure was done. Favorable horizontal augmentation was revealed after 5 months of healing (Figures 15.32–15.42).

RIDGE-SPLIT EXPANSION PROCEDURE WITH DELAYED IMPLANT PLACEMENT (TWO-STAGE RIDGE-SPLIT EXPANSION)

RSEP with delayed implant placement is applied to the ridge with a dense and thick cortex, because the expansion could cause the fracture of the expanded buccal segment [21, 22]. Although a two-stage approach increases the time, it allows for subsequent evaluation of the expanded ridge and avoidance of malfracture of the buccal segment. With this approach, the location of the greenstick fracture is predetermined, and the perfusion for the buccal segment remains intact [9]. Staged RSEP can be performed with two different methods. The first method is to do the split and expansion at the same time and intentionally fracture the buccal plate after the split, with biomaterials placed in the gap between the fractured segment and basal bone using the guided bone regeneration principle. Implants will be placed after bone healing 4–6 months later. The second method is to do the split/greenstick fracture only

Dentlearn.ir

FIGURE 15.32 Note the 2 mm wide alveolar crest.

FIGURE 15.33 Crestal osteotomy and vertical osteotomies were prepared with a piezoelectric saw insert. Precise osteotomies were verified. An anterior vertical osteotomy was prepared 1–2 mm away from the adjacent second premolar. The length of the vertical osteotomy should be two-thirds of the implant length to avoid malfracture of the buccal segment in the alveolar crest.

FIGURE 15.34 Careful expansion of the buccal plate was performed when expanding the spit ridge with a rotary expander to avoid malfracture of the buccal plate. The expander should be advanced 1 mm deeper than the implant length.

FIGURE 15.35 Note the expanded ridge after placement of implants.

FIGURE 15.36 Intraoral image showing approximately 2 mm expansion in the occlusal view.

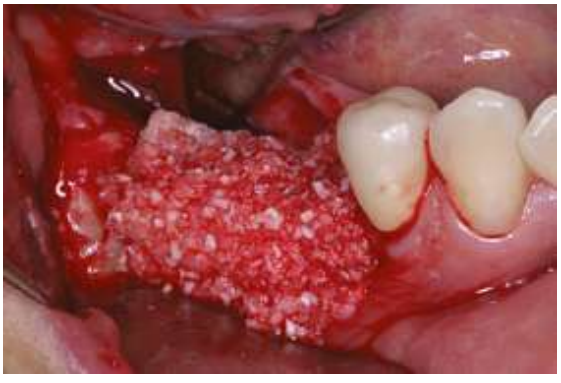

FIGURE 15.37 Sticky tooth bone was grafted on the expanded ridge.

Dentlearn.ir

FIGURE 15.38 A collagen barrier was placed on top of the bone graft.

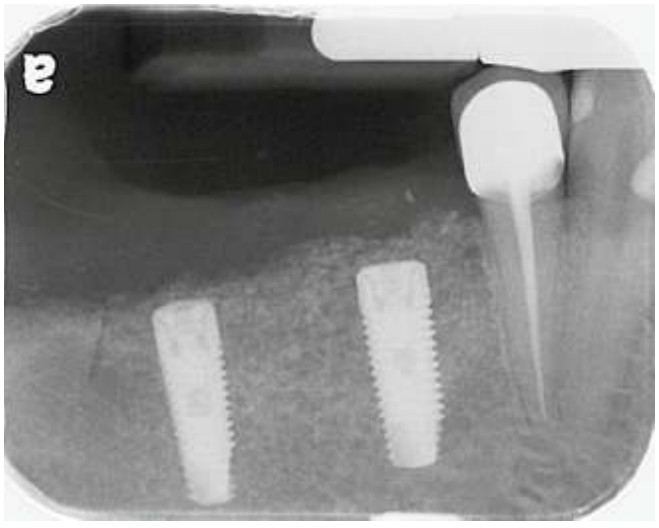

FIGURE 15.39 A postoperative radiograph.

FIGURE 15.40 Exposure showed favorable ridge augmentation after 5 months of healing.

FIGURE 15.41 An intraoral image after the delivery of the final restoration.

FIGURE 15.42 A plain radiograph indicating stable marginal bone after 2 years in function.

and close the wound. Further ridge expansion and possible implant placement will be performed when the buccal bony segment and attached soft tissue have healed, after about a month [11].

CASE REPORT: STAGED RIDGE-SPLIT EXPANSION PROCEDURE WITH SPLIT AND EXPANSION/FRACTURE OF THE BUCCAL SEGMENT

A 23-year-old female visited our department to replace missing lower right first and second molars with implant-supported fixed restoration. The surgical procedure was performed under local anesthesia, an incision was made along the ridge crest slightly toward the lingual, and two vertical incisions were made. A full thickness of muco-periosteal flap was elevated to expose the buccal aspect of the mandibular alveolar ridge. The crestal bone was thin but the basal bone was dense and thick. Therefore, staged RSEP was performed. After completing rectangular corticotomies with an Er:YAG laser (Dual laser®, Lambda Scientifica, Brendola, Italy), the buccal segment was fractured and expanded with the osteotome. Bone graft (Cerasorb®, Curason, Bad Schwartau, Germany) was placed in the gap between the buccal segment and the lingual

Dentlearn.ir

plate and over the buccal segment. Primary wound closure was performed. Implants were placed after 5 months of healing (Figure 15.43–15.48).

FIGURE 15.43 An intraoral image indicating a very thin alveolar crest.

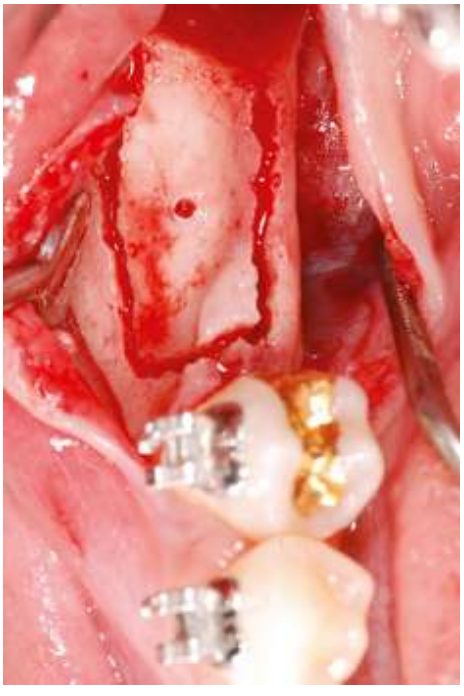

FIGURE 15.44 Complete rectangular osteotomies were prepared to expand the buccal segment.

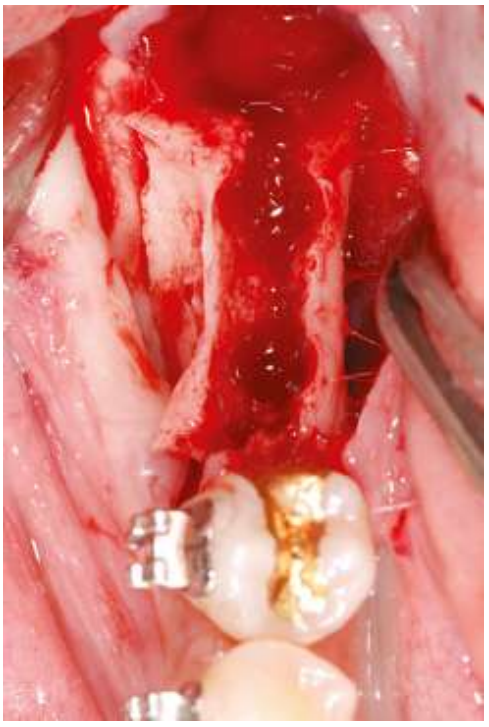

FIGURE 15.45 The buccal segment was fractured and expanded to place a bone graft in the gap between the mobile buccal segment and the lingual plate.

FIGURE 15.46 Alloplast mixed with whole blood was grafted over the mobile buccal plate. The buccal plate was not stabilized with micro-screws.

Dentlearn.ir

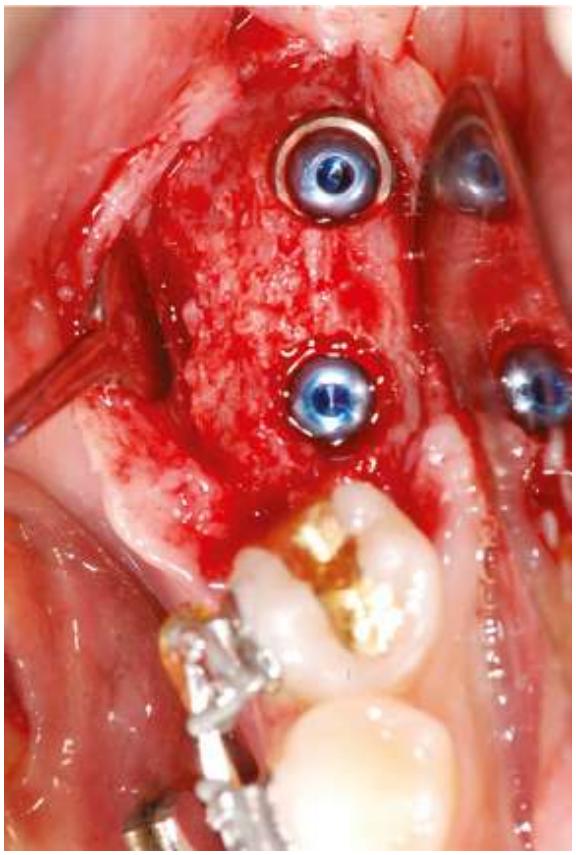

FIGURE 15.47 Implants were placed after 5 months of healing. Note the widened alveolar ridge.

FIGURE 15.48 A panoramic radiograph indication stability of crestal bone around the implant after 3 years in function.

CASE REPORT: STAGED RIDGE-SPLIT EXPANSION PROCEDURE WITH REPOSITION OF GREENSTICK-FRACTURED BUCCAL SEGMENT

A 55-year-old female patient presented with missing lower left first and second molars. Following local anesthesia, a full-thickness muco-periosteal flap was elevated to expose the edentulous alveolar ridge. An Er:YAG laser was utilized to make rectangular osteotomies, including crestal, vertical, and basal osteotomies in the buccal aspect of the alveolar bone. The prepared buccal segments were greenstick fractured with osteotomes. Implant sites were prepared with a 3 mm wide implant drill. The greenstick-fractured buccal segments were repositioned and the muco-periosteal flap was sutured. The second-stage surgery to expand the ridge was performed three weeks later. A crestal incision to expose the crestal cut was performed. The buccal flap was minimally reflected to preserve the blood supply for the buccal segment. A small chisel was advanced into the crestal osteotomy to carefully separate and mobilize the buccal segment, provoking a greenstick fracture. After the final preparation of implant sites to accommodate the implants was done, the implants were placed. Mineral allograft (Puros®, Zimmer Biomet, Warsaw, IN, USA) mixed with whole blood was placed on the expanded ridge. After 4 months of healing, the implants were exposed to deliver a restoration (Figures 15.49–15.54).

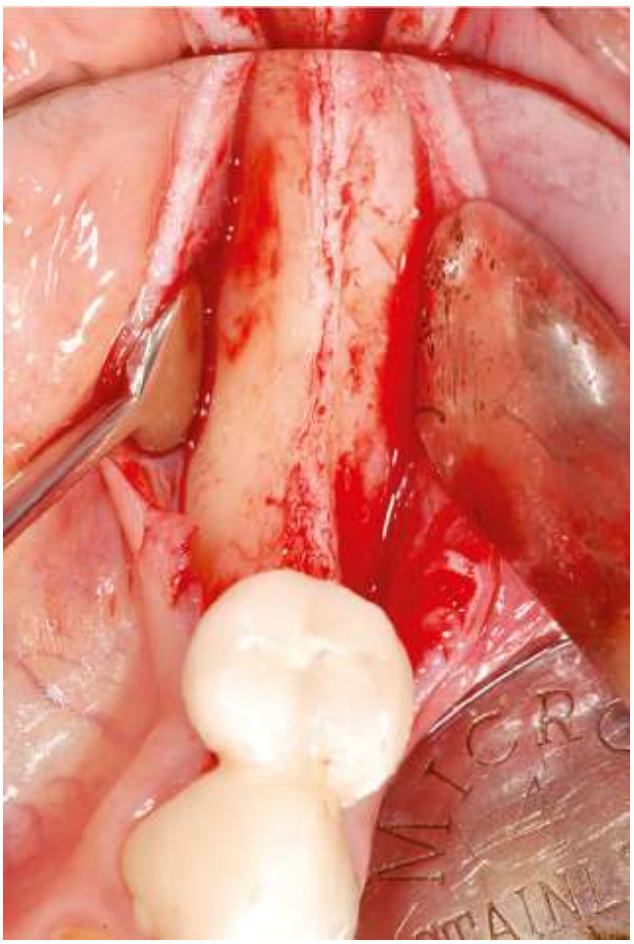

FIGURE 15.49 Note the narrow alveolar crest and thick basal bone.

Dentlearn.ir

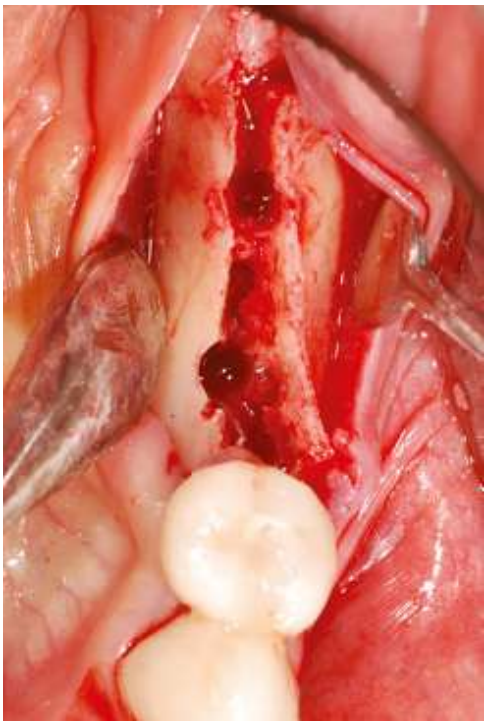

FIGURE 15.50 Following rectangular osteotomies using an Er:YAG laser in the buccal cortex, the buccal segment was green-stick fractured with an osteotome. The fractured segment was repositioned, and primary wound closure was done.

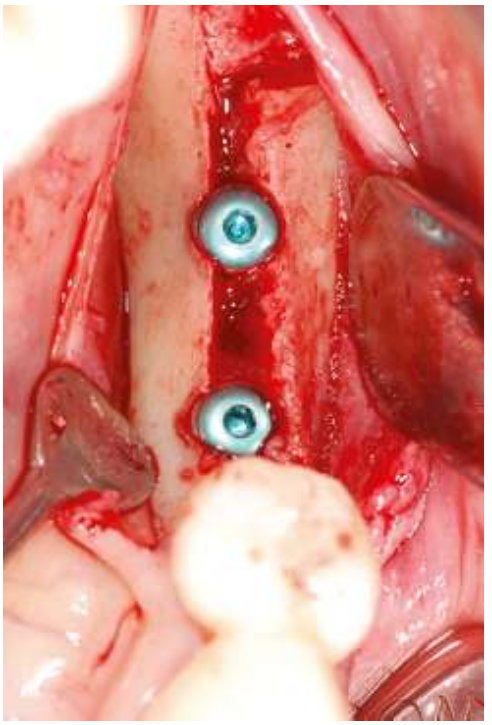

FIGURE 15.52 Implants were placed after expanding the ridge with a chisel.

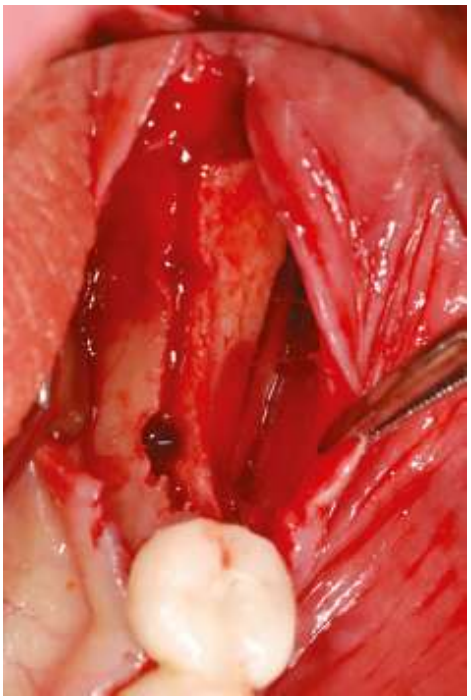

FIGURE 15.51 The ridge was re-exposed after 3 weeks of healing. The buccal segment was flexible because it was healed by collagenous fibers.

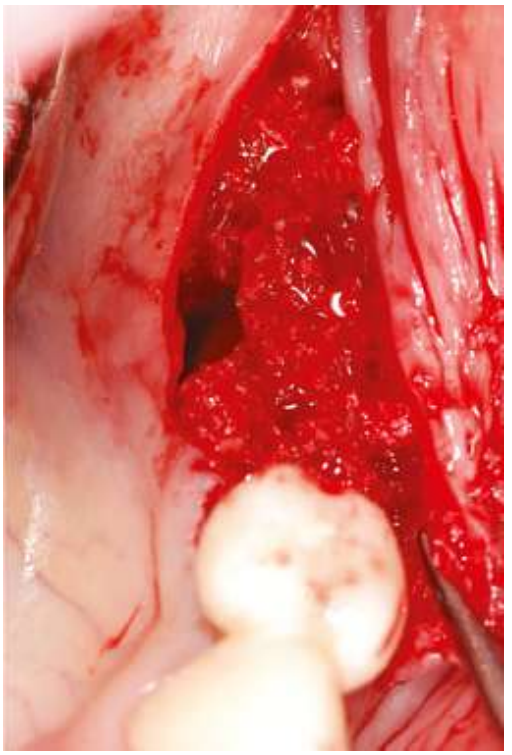

FIGURE 15.53 Allograft mixed with whole blood was grafted on the expanded ridge. Exposure was done after 4 months of healing.

Dentlearn.ir

FIGURE 15.54 A panoramic radiograph after 7 years in function.

MANAGEMENT OF FRACTURED BUCCAL SEGMENT

Even when RSEP is achieved favorably with a ridge expander, an expanded buccal plate can be fractured after implant placement. A small fractured segment can be stabilized with a sticky bone graft, but a large bony segment should be stabilized with micro-screws (Figures 15.55–15.57).

FIGURE 15.55 Note the fractured buccal segment after implant placement. Stabilization using micro-screws is not possible.

FIGURE 15.56 The fractured segment was stabilized with sticky bovine bone.

FIGURE 15.57 (A) Postoperative radiograph. (B) Periapical radiograph indicating stability of the augmented ridge after 4 years in function.

CONCLUSION

RSEP is very effective for horizontal augmentation in severely atrophic posterior mandibular ridges. In addition, there is an advantage when implants are placed inside the expanded bony envelope and positioned between cortical plates like natural teeth. In alveolar ridges with low bone quality and a thin cortex, RSEP with immediate lateral ridge expansion is recommended to shorten the healing time. Delayed RSEP is indicated in patients who have high bone quality, a thick cortex, and narrower ridges (mandible) to avoid unintentional fracture of buccal bone segments.

Dentlearn.ir

REFERENCES

1. Vermeeren JI, Wismeijer D, van Waas MA. One-step reconstruction of the severely resorbed mandible with onlay bone grafts and endosteal implants: A 5-year follow-up. *Int J Oral Maxillofac Surg.* 1996;25(2):112–15.
2. Cordaro L, Amadé DS, Cordaro M. Clinical results of alveolar ridge augmentation with mandibular block bone grafts in partially edentulous patients prior to implant placement. *Clin Oral Implants Res.* 2002;13(1):103–11.
3. Buser D, Brägger U, Lang NP, Nyman S. Regeneration and enlargement of jaw bone using guided tissue regeneration. *Clin Oral Implants Res.* 1990;1(1):22–32.
4. Nowzari H, Slots J. Microbiologic and clinical study of polytetrafluoroethylene membranes for guided bone regeneration around implants. *Int J Oral Maxillofac Implants.* 1995;10(1):67–73.
5. Woo RH, Kim HG, Kim G et al. Simplified 3-dimensional ridge augmentation using a tenting abutment. *Adv Dent Oral Health.* 2020;12(2):185–205.
6. Laster Z, Rachmiel A, Jensen OT. Alveolar width distraction osteogenesis for early implant placement. J Oral Maxillofac Surg. 2005;63(12):1724–30. Erratum: *J Oral Maxillofac Surg.* 2006;64(3):566.
7. Simion M, Baldoni M, Zaffe D. Jawbone enlargement using immediate implant placement associated with a split-crest technique and guided tissue regeneration. *Int J Periodontics Restorative Dent.* 1992;12(6):462–73.
8. Scipioni A, Bruschi GB, Calesini G. The edentulous ridge expansion technique: A five-year study. *Int J Periodontics Restorative Dent.* 1994;14(5):451–9.
9. Sohn DS, Lee HJ, Heo JU et al. Immediate and delayed lateral ridge expansion technique in the atrophic posterior mandibular ridge. *J Oral Maxillofac Surg.* 2010;68(9):2283–90.
10. Demetriades N, Park JI, Laskarides C. Alternative bone expansion technique for implant placement in atrophic edentulous maxilla and mandible. *J Oral Implantol.* 2011;37(4):463–71.
11. Misch CM. Implant site development using ridge splitting techniques. *Oral Maxillofacial Surg Clin N Am.* 2004;16:65.
12. Lustmann J, Lewinstein I. Interpositional bone grafting technique to widen narrow maxillary ridge. *Int J Oral Maxillofac Implants.* 1995;10:568.
13. Duncan JM, Westwood M. Ridge widening for the thin maxilla: A clinical report. *Int J Oral Maxillofac Implants.* 1997;12:224.
14. Basa S, Varol A, Turker N. Alternative bone expansion technique for immediate placement of implants in the edentulous posterior mandibular ridge: A clinical report. *Int J Oral Maxillofac Implants.* 2004;19:554.
15. Sohn DS, An KM, Lee JS et al. Erbium, chromium:yttrium-scandium-gallium-garnet laser-assisted sinus graft procedure. *Lasers Med Sci.* 2009;24:673.
16. Vercellotti T. Piezoelectric surgery in implantology: A case report—a new piezoelectric ridge expansion technique. *Int J Periodontics Restorative Dent.* 2000;20:358.
17. Sohn DS. *Color atlas:* Clinical applications of piezoelectric bone surgery. Seoul, Kunja Publishing; 2008.
18. Peñarrocha M, Garcia A. Benign paroxysmal positional vertigo as a complication of interventions with osteotome and mallet. *J Oral Maxillofac Surg.* 2006;64(8):1324.
19. Mazzocco F, Nart J, Cheung WS, Griffin TJ. Prospective evaluation of the use of motorized ridge expanders in guided bone regeneration for future implant sites. *Int J Periodontics Restorative Dent.* 2011;31(5):547–54.
20. Sohn DS, Huang B, Kim J et al. Utilization of autologous concentrated growth factors (CGF) enriched bone graft matrix (Sticky Bone) and CGF-enriched fibrin membrane in implant dentistry. *J Implant Adv Clin Dent.* 2015;7(10):11–29.
21. Enislidis G, Wittwer G, Ewers R. Preliminary report on a staged ridge splitting technique for implant placement in the mandible: A technical note. *Int J Oral Maxillofac Implants.* 2006;21(3):445–9.
22. Scipioni A, Bruschi GB, Giargia M, et al. Healing at implants with and without primary bone contact. *Clin Oral Implants Res* 8:39, 1997.

Dentlearn.ir

Minimally Invasive Combined Technique for Vertical and Horizontal Bone Augmentation in the Posterior Maxilla: Alveolar Split with Crestal Sinus Lift

CHAPTER 16

Both the ridge-split expansion procedure and the crestal sinus lift can be called minimally invasive surgical techniques that can be used simultaneously to improve bone volume and bone density. The combination procedure for correction of three-dimensional bone deficiency in the posterior maxilla often consists of atraumatic extraction, ridge-split expansion, transcrestal sinus floor lift, and, in some cases, immediate implant placement.

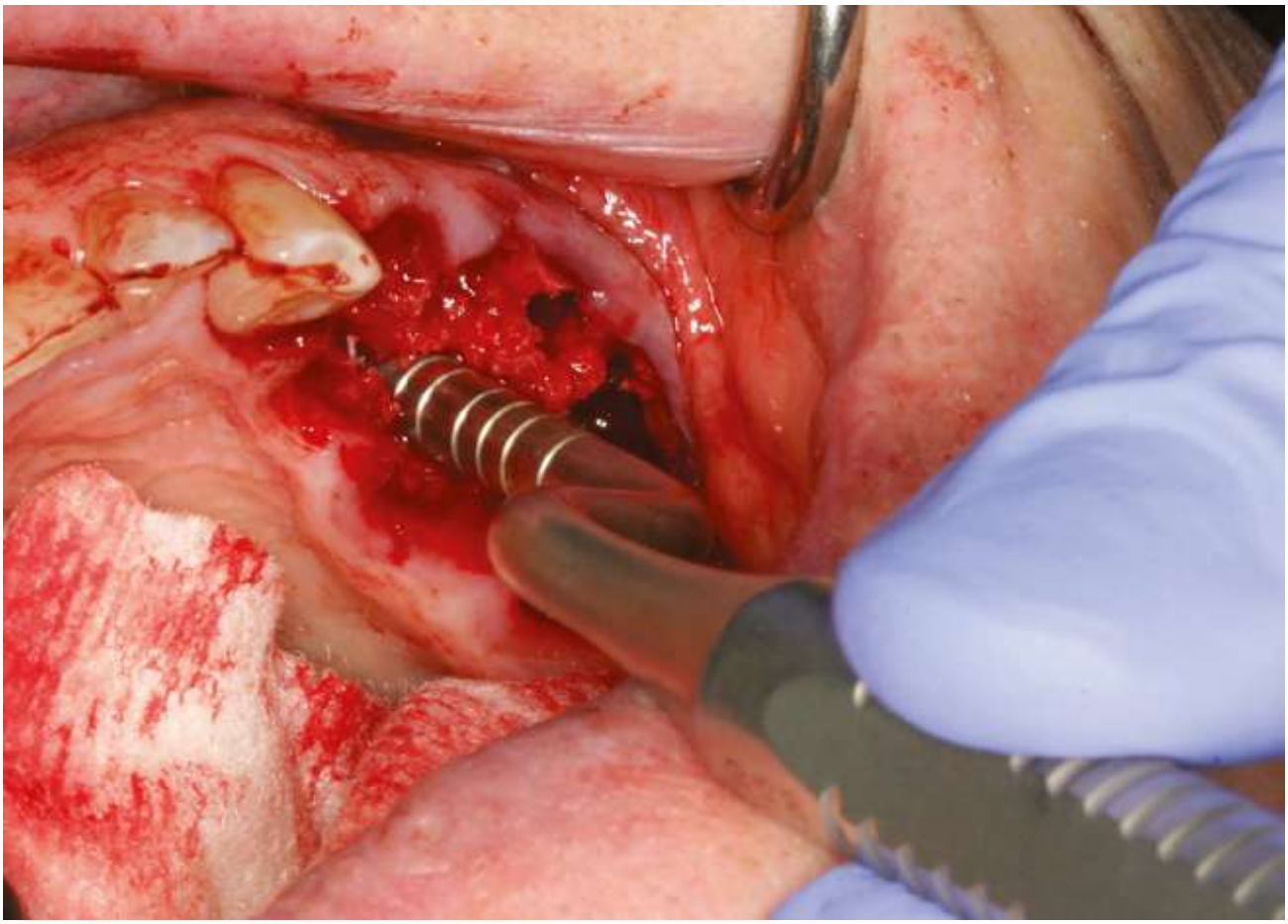

Dentlearn.ir

CHAPTER 16

Minimally Invasive Combined Technique for Vertical and Horizontal Bone Augmentation in the Posterior Maxilla: Alveolar Split with Crestal Sinus Lift

Len Tolstunov[1,2,3]

[1]*Associate Clinical Professor, Department of Oral and Maxillofacial Surgery, University of California San Francisco (UCSF) School of Dentistry, San Francisco, CA, USA*

[2]*Associate Clinical Professor, Department of Oral and Maxillofacial Surgery, University of the Pacific Arthur A. Dugoni School of Dentistry, San Francisco, CA, USA*

[3]*Private OMFS practice, San Francisco, CA, USA*

Implant treatment in the posterior maxilla is often complicated by poor bone volume and insufficient bone density. Lack of both bone width due to buccal bone collapse and bone height due to sinus pneumatization in the posterior maxilla makes placement of immediate or delayed dental implants difficult [1–5].

There are a few surgical techniques that can accomplish both: improve bone volume and attempt to improve bone density. These surgical techniques are the ridge-split expansion procedure (alveolar split; RSEP) and the crestal sinus lift (sinus floor intrusion; CSL). The goal of the first technique is to enlarge bone in a horizontal direction; the goal of the second to increase bone stock in a vertical direction and improve bone density [6].

In this chapter we will discuss the synchronized application of both techniques or a combination of them (horizontal expansion followed by vertical elevation) in the posterior maxilla with delayed or immediate placement of dental implants. Both techniques can be viewed as minimally invasive surgical techniques for reasons explained below. It is important to demonstrate the essential concepts related to each technique.

RIDGE-SPLIT EXPANSION PROCEDURE FOR WIDTH-DEFICIENT ALVEOLAR RIDGE

When a tooth is removed, the alveolar ridge undergoes bone atrophy through the process of resorption due to loss of function (non-use atrophy) and loss of mechanical strain (Wolff's law) [7, 8]. Bone atrophy is mainly horizontal, resulting in narrowing of the alveolar ridge in the buccal-palatal (buccal-lingual) direction, with the resulting bone collapse from a normal 10–12 mm to often 3–5 mm of alveolar ridge width [9–12]. The ridge-split expansion (alveolar split) technique is designed for these width-deficient ridges, with the goal to improve the horizontal dimension of the collapsed alveolar ridge for restoratively driven implant placement.

The objective for RSEP is to reposition the collapsed buccal cortical plate. RSEP does not utilize the bone from outside of the surgical area (no donor site, like with an autogenous block bone graft) and does not rely on external sources of vascularization (like with microvascular free bone flaps). During the alveolar split, the buccal plate is outfractured and repositioned facially (buccally) and a particulate graft is placed internally into the created bony gap. Positioning of the particulate graft as an inlay (interpositional) graft has the important advantage of keeping the grating zone surrounded by the vascularized structures, like bone plates, soft tissue, and periosteum on both sides. The split interface retains vascularity through the preserved osteoperiosteal flaps. In fact, both bony split modifications – book flap (attached, greenstick fracture) and i-flap (detached, separated, full fracture), described in previous chapters – appear to preserve vitality and participate in particulate graft consolidation (Figures 16.1–16.4) [13–15]. Dental implants can be placed immediately or in a delayed fashion, depending on the presence of apical solid bone for primary implant stability.

Essential Techniques of Alveolar Bone Augmentation in Implant Dentistry: A Surgical Manual, Second Edition. Edited by Len Tolstunov.
© 2023 John Wiley & Sons, Inc. Published 2023 by John Wiley & Sons, Inc.
Companion website: www.wiley.com/go/tolstunov/essential

Dentlearn.ir

FIGURE 16.1 Book flap (Jensen): clinical photograph of the hinged modification of the ridge-split procedure.

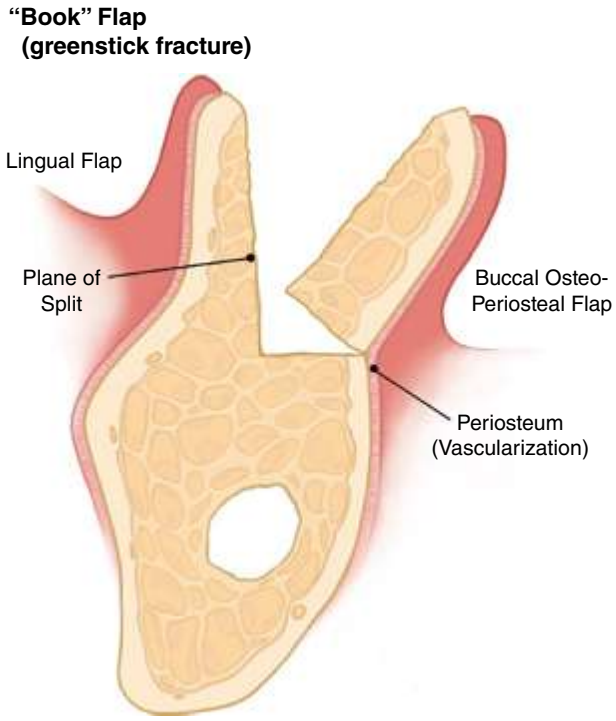

FIGURE 16.2 Book flap (Jensen): schematic illustration of the hinged modification of the ridge-split procedure.

FIGURE 16.3 Island flap (Jensen): clinical photograph of the displaced (island) modification of the ridge-split procedure. *Source*: Tolstunov L. Classification of the alveolar ridge width: implant-driven treatment considerations for the horizontally deficient alveolar ridges. J Oral Implantol. 2014;40:365–70.

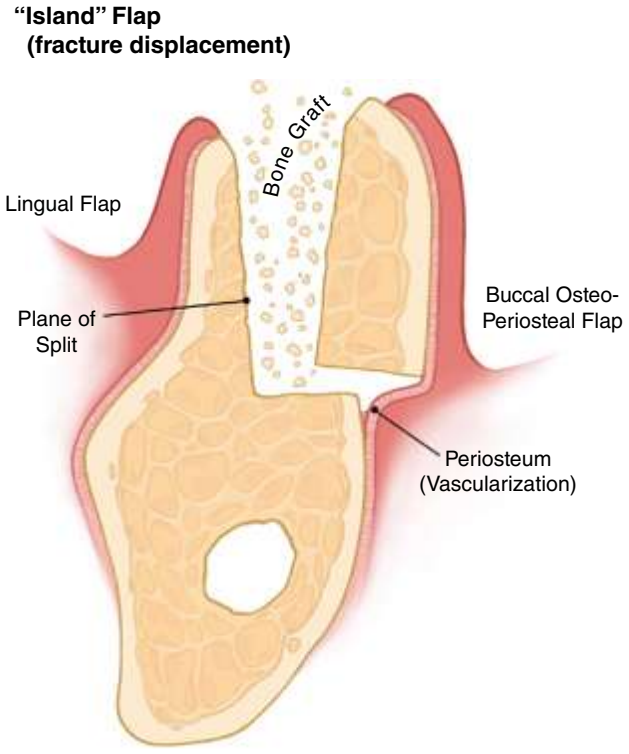

FIGURE 16.4 Island flap (Jensen): schematic illustration of the displaced (island) modification of the ridge-split procedure.

CRESTAL SINUS ELEVATION FOR HEIGHT-DEFICIENT ALVEOLAR RIDGE IN THE POSTERIOR MAXILLA

Pneumatization of the maxillary sinus after loss of maxillary posterior teeth can occur in the first and second molar region, but can extend as far as the first premolar and even canine tooth. Lowering of the sinus floor can lead to a significant deficiency of bone height in the alveolar process of the posterior maxilla.

There are two main surgical approaches to the pneumatized sinus in implant dentistry for bone height augmentation: lateral or direct through the modified Caldwell–Luc approach introduced by Tatum [16]; and crestal or indirect (transalveo-

Dentlearn.ir

lar), which uses special osteotomes developed by Summers [17]. It is accepted that the residual bone height of 4–5 mm is a borderline height to choose one technique over the other [18]. Less than this amount (1–3 mm) in cases of severe sinus pneumatization is the most common indication for a lateral sinus elevation technique, usually with a bone graft and delayed implant placement. If there is 4–8 mm of vertical bone remaining, a mild to moderate sinus pneumatization case, this is an indication for a crestal sinus floor elevation (intrusion), which is commonly accompanied by simultaneous implant placement. In both approaches to the maxillary sinus, lateral (direct) or crestal (indirect), the goal remains the same: to carefully elevate the Schneiderian membrane off the sinus floor and add bone grafting material into the created sinus pocket. Placement of a transalveolar implant at the same time is usually done with a crestal approach. More than 8 mm of bone height in the posterior maxilla usually does not require sinus elevation and an implant of 9–10 mm length can be placed immediately.

Summers's osteotome technique for the crestal approach to sinus elevation in the posterior maxilla (Figures 16.5 and 16.6) [6, 17, 19] can be considered a minimally invasive surgical technique in implant dentistry and has many advantages. These include lack of donor site, decreased risk of sinus membrane perforation, shortness of the procedure, bone condensation for improved bone density, and immediate implantation [6, 19, 20]. At the time of transcrestal sinus floor intrusion, bone manipulation with osteotomes allows compression or condensation of soft trabecular bone. Summers observed that "osteotomes conserve osseous tissue and may improve bone density around the implant" [17]. Mild bone compression may improve primary implant stability and early implant loading [21–23].

FIGURE 16.5 An osteotome crestal sinus floor elevation technique.

FIGURE 16.6 Radiographic image of a transcrestally elevated sinus floor on a follow up radiograph 6 months after the surgery.

MINIMALLY INVASIVE SURGICAL TECHNIQUES: ESLI SEQUENCE

Minimally invasive surgical procedures are atraumatic by nature and assume the patient's positive and uncomplicated experience in both intraoperative and post-operative periods. Little surgical morbidity and easy recovery are part of this experience.

An atraumatic extraction (E), careful ridge split (S), cautious crestal sinus lift (L), and precise implant insertion (I) can be considered a minimally invasive combined surgical technique with this ESLI sequence. The reasons for this are many and include atraumatic internal ridge techniques "from within" with little bone or soft tissue manipulation, no donor site morbidity, often no flap reflection, and guided bone regeneration (GBR) with a particulate graft (not always necessary) [24]. These procedures are usually associated with an easy recovery with little post-operative discomfort or swelling, and a shortened treatment time.

VOLUMETRIC (THREE-DIMENSIONAL) ALVEOLAR BONE AUGMENTATION IN THE POSTERIOR MAXILLA

Combining both techniques – alveolar split and crestal sinus floor intrusion with osteotomes – is a valuable treatment option for three-dimensional (3D) bone augmentation in the posterior maxilla. Horizontal bone (ridge width) between 3 and 5 mm and vertical bone (ridge height) between 4 and 8 mm are the ideal amount of bone stock for this combined procedure, which starts with the alveolar split, progresses with the osteotome-driven sinus intrusion (lift), and ends with the immediate implant insertion (Figures 16.7 and 16.8). A few articles on this topic, including extraction of teeth with immediate alveolar split and CSL, have been published [24–26]. When extraction of teeth is done with horizontal alveolar split and CSL, implant placement is possible in some cases or can be delayed for 4–6 months. When this combination procedure is done for the edentulous maxillary posterior ridge, implants can be placed simultaneously, assuming primary implant stability is achieved. In ESLI cases, an immediate implant can be inserted simultaneously with extraction, split, and lift, if primary implant stability can be achieved. Case

Dentlearn.ir

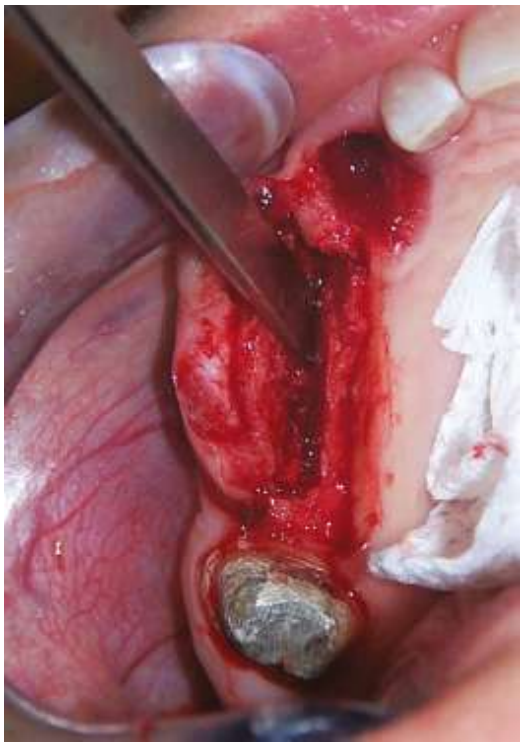

FIGURE 16.7 Widening of the ridge by alveolar split for horizontal bone augmentation (step 1). With permission from Quintessence.

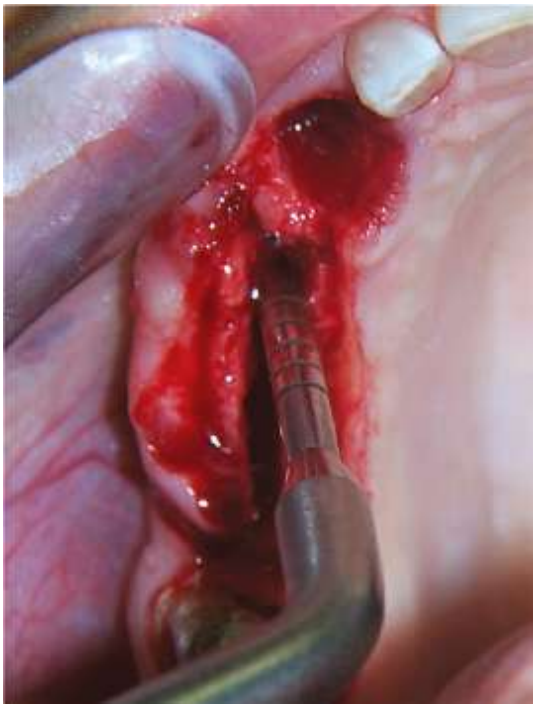

FIGURE 16.8 Vertical bone expansion by transcrestal sinus intrusion for immediate implant placement (step 2). With permission from Quintessence.

reports of variations of this technique with or without simultaneous implant insertion are described below.

BIOLOGICAL RATIONALE OF THE ALVEOLAR SPLIT AND CRESTAL SINUS ELEVATION PROCEDURES

REVASCULARIZATION OF THE OSTEOTOMIZED BONE SEGMENT

Vascularization of osteotomized bone segments during RSEP is an important factor. Scipioni et al. commented that "The essential feature of edentulous ridge expansion technique is the partial-thickness flap with preservation of its buccal blood supply," pointing to the importance of preservation of the integrity of the periosteum for vascularization of osteotomized bone segments [27].

Jensen also described three cases of segmental split combined with extraction and osteotome sinus floor intrusion on the posterior maxilla using BMP-2 with allograft [26]. Both Bruschi [28] and Jensen [26] demonstrated that interpositional bone augmentation techniques, like RSEP and CSL, have a similar biological basis that determines their success, i.e. preservation of collateral blood supply during the procedure and early post-operative period of bone healing.

REVASCULARIZATION OF THE INTERPOSITIONAL BONE GRAFT

In a systematic review, Aghaloo and Moy [24, 29] noted that a GBR procedure based on particulate bone grafting is the only well-documented surgical technique that is used for localized ridge augmentation. Creating a well-vascularized (from the soft tissue and periosteum) and protected environment with an interpositional particulate graft in both alveolar split and CSL procedures is important for the long-lasting success and osseointegration of dental implants placed in an immediate or delayed fashion.

The middle intercortical portion of bone during the alveolar split – trabecular or spongy bone – is a source of blood supply that is mandatory for proper healing and heavily dependent on oxygen and nutrients. This is the place where an endosseous implant is inserted in the process of the alveolar split and where osseointegration occurs [30, 31].

RE-ESTABLISHMENT OF ALVEOLAR ANATOMY

Atrophy of the alveolar ridge after extraction consists of resorption of both trabecular and cortical bone compartments, resulting in progressive loss of alveolar width. The goal of the alveolar split is to reposition the collapsed buccal cortical plate back to where it was prior to extraction and expand the intercortical marrow space with a bone graft, restoring the original anatomical form and function horizontally. CSL utilizes a

Dentlearn.ir

similar concept of lifting the fractured cortical fragment of the sinus floor and grafting underneath, also restoring the original anatomical form and function vertically.

OSTEOCONDENSATION

In the process of bone manipulation during the alveolar split, the adjacent fragments of bone are slightly compressed or condensed [32]. It is more apparent in the maxilla due to lesser bone density. In the process of bone manipulation during the CSL, Summers observed that "osteotomes conserve osseous tissue and may improve bone density around the implant" [17]. Therefore, mild bone compression can improve primary implant stability and early implant loading [21–23].

CASE REPORTS

RIDGE EXPANSION AND CRESTAL SINUS FLOOR INTRUSION IN THE POSTERIOR MAXILLA

A 63-year-old male, interested in implant treatment, presented for extraction of failing root canal–treated upper left first and second molars (Figure 16.9). A panoramic radiograph showed the close proximity of the sinus floor to the apices of the roots of both molars (Figure 16.10). Knowing the potential for post-extraction collapse of the sinus floor (sinus pneumatization), the first surgical goal was to lift the sinus floor through both sockets and graft the vertically "enlarged socket" to maintain its height dimension. Due to known collapse of the buccal plate after extraction, the second surgical goal was to also expand both molar sockets horizontally through the alveolar split to be able to maintain and improve the width of the alveolar ridge. Both intersocket alveolar split and trans-socket sinus floor intrusion could help volumetrically (3D) augment the alveolar ridge beyond its existing dimensions, as a preparation for the delayed placement of two implants in 4–6 months.

FIGURE 16.10 Pre-operative radiograph of failing first and second molars. With permission from Quintessence.

After atraumatic extraction of both molars (sectioning the crowns off and separation of all three roots; Figure 16.11), chisel osteotomes of progressive width were used by gently tapping into the middle portion of each socket (Figures 16.12–16.14). These splitting–expanding chisels were wedged inside the bone only 4–5 mm in depth (due to proximity of the sinus floor) and were used to luxate, subfracture, and expand the buccal wall of both sockets laterally as one muco-osteoperiosteal unit or osteoperiosteal flap (Jensen). Figure 16.15 demonstrates the split gap of about 6–7 mm between palatal and fractured buccal portions of the sockets, as well as the intact

FIGURE 16.9 Pre-operative clinical photograph of failing first and second molars. With permission from Quintessence.

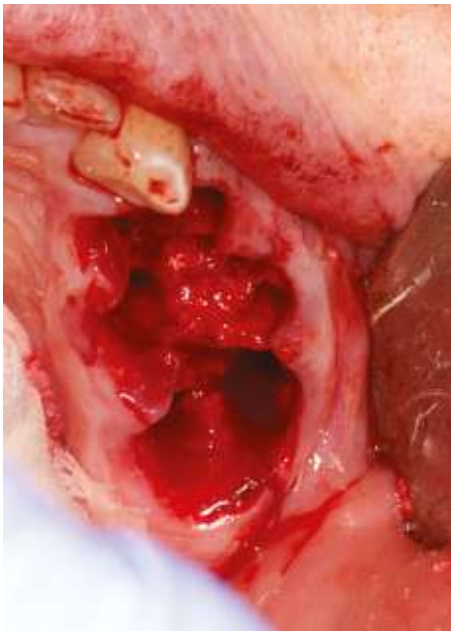

FIGURE 16.11 Immediate post-extraction intraoral photograph. With permission from Quintessence.

Dentlearn.ir

FIGURE 16.12 Fracture of the buccal segment of both sockets and its facial displacement at the initial stage of the ridge-split expansion procedure. With permission from Quintessence.

FIGURE 16.13 Fracture of the buccal segment of both sockets and its facial displacement in the process of the ridge-split expansion procedure. With permission from Quintessence.

FIGURE 16.14 Fracture of the buccal segment of both sockets and its facial displacement at the end of the ridge-split expansion procedure. With permission from Quintessence.

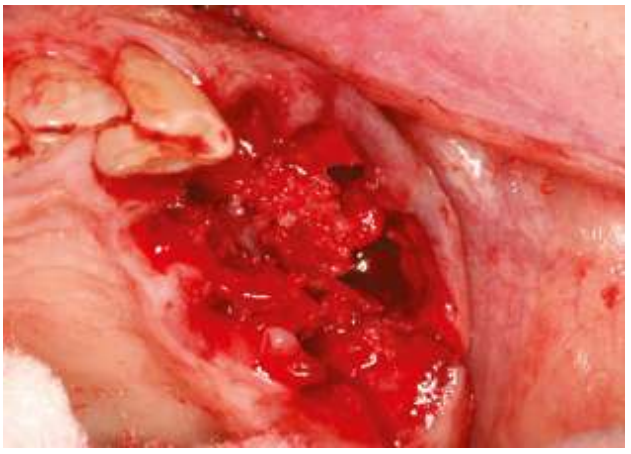

FIGURE 16.15 Sockets of the first and second molars after the ridge-widening procedure. The sinus membrane can be seen at the bottom of both sockets. With permission from Quintessence.

Schneiderian membrane that can be seen at the bottom of the split. Then, the sinus osteotomes were used for sinus lift. Offset round sinus osteotomes were gently tapped vertically to intrude and lift the sinus floor, using a fractured portion of bone at the bottom of the socket as a driving upward vehicle (Figures 16.16 and 16.17). It is important to have a segment of bone for safe vertical intrusion. Light gentle tapping is the only required force to atraumatically intrude the sinus floor 4–5 mm.

After sockets were both vertically and horizontally expanded (subfractured and widened), they were grafted from the bottom up with a particulate graft material (0.5 g of Bio-Oss® particulate xenograft, Geistlich, Wolhusen, Switzerland). Ossix® Volumax resorbable collagen membrane (Datum Dental, Lod, Israel) was then used in this case to cover-isolate the graft (Figure 16.18), and 4-0 silk sutures were placed on top for secondary closure (Figure 16.19). Primary closure is not mandatory in these cases.

FIGURE 16.16 Sinus osteotomes were used for the trans-socket sinus elevation. With permission from Quintessence.

Dentlearn.ir

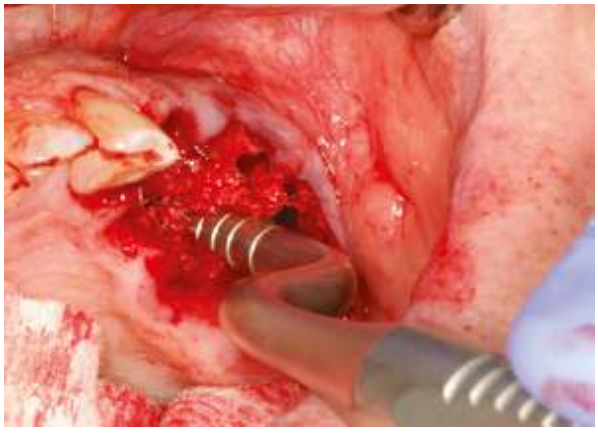

FIGURE 16.17 Sinus osteotomes were used for the crestal sinus intrusion. With permission from Quintessence.

FIGURE 16.18 Particulate bone grafting material was placed into the expanded (in width and height) sockets of both molars. With permission from Quintessence.

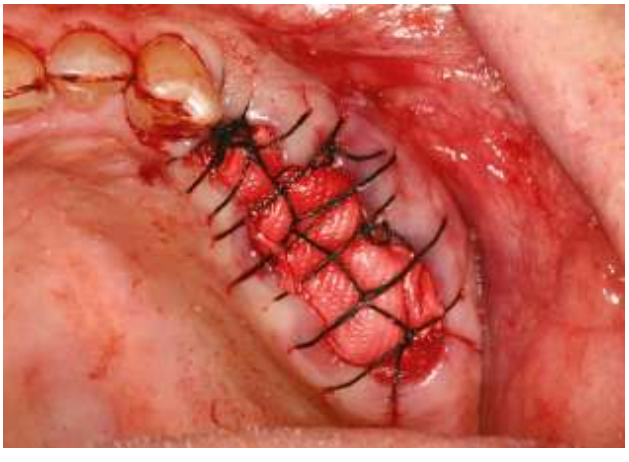

FIGURE 16.19 A resorbable membrane was placed to isolate and protect the grafting material. Secondary closure was achieved with 4-0 chromic gut sutures. With permission from Quintessence.

RIDGE EXPANSION AND CRESTAL SINUS FLOOR ELEVATION WITH SIMULTANEOUS IMPLANT PLACEMENT IN THE POSTERIOR MAXILLA

This 55-year-old female presented with an edentulous left maxillary molar region, desiring implant reconstruction at the first molar site. The edentulous area demonstrated horizontal alveolar deficiency and inadequate vertical height to the sinus floor due to sinus pneumatization seen on panoramic radiograph (Figure 16.20). A buccal-based palatal incised flap was developed posterior to the tuberosity for planned apical positioning. Bone osteotomies (crestal and anterior vertical) were completed with piezosurgical OT7S4 inserts at the palatal final implant margin from anterior to posterior and beveled posteriorly and laterally at the tuberosity region (Figure 16.21). Custom-designed chisels and tapered osteotomes were used to expand the crestal alveolus below the sinus floor (Figure 16.22).

FIGURE 16.20 Pre-operative radiograph demonstrating bone and sinus dimensions. With permission from Quintessence.

FIGURE 16.21 Intraoperative view of the edentulous first molar area at the initiation of the ridge-split expansion procedure. Crestal osteotomy can be seen. With permission from Quintessence.

Dentlearn.ir

The sinus osteotomes were then used to up-fracture the floor to allow insertion of a 5.8 × 9.0 mm tapered implant (Tapered Plus, BioHorizons, Birmingham, AL, USA), which was advanced into position showing 3–4 mm of ridge expansion (Figure 16.23). Intraoperative periapical radiographs were used to confirm trial length and implant position.

FIGURE 16.22 Intraoperative view of final osteotome for expansion and floor elevation, showing expansion next to the anterior vertical osteotomy. With permission from Quintessence.

FIGURE 16.23 Intraoperative view of the first molar implant placed at the corner of crestal and anterior vertical osteotomies, right after ridge expansion and transcrestal sinus elevation. With permission from Quintessence.

The site was over-grafted mostly to the distal to enhance and preserve long-term bony contours, with apical flap positioning followed by a mesial-based finger flap that was created for primary closure around the healing cap (Figure 16.24). The immediate post-operative cone beam computed tomography radiograph (Figure 16.25) showed good implant position after the 3–4 mm of ridge expansion and sinus floor elevation of 3 mm. The 2-year post-operative results can be seen in Figures 16.26 and 16.27, demonstrating implant and crown with surrounding excellent bone and soft tissue contours.

FIGURE 16.24 Immediate post-operative result demonstrating use of a mesially based finger flap for primary closure and transgingival healing. With permission from Quintessence.

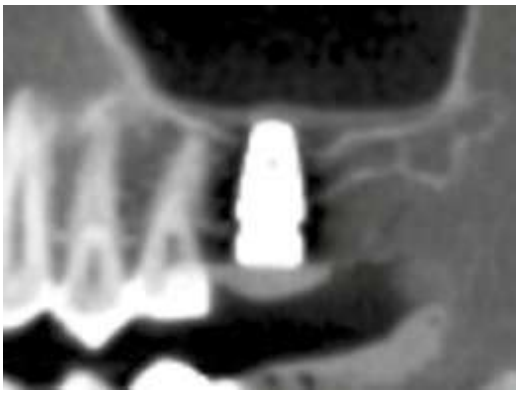

FIGURE 16.25 Post-operative cone beam computed tomography of the first molar implant placed immediately after ridge expansion with simultaneous transcrestal sinus elevation. With permission from Quintessence.

Dentlearn.ir

FIGURE 16.26 The 2-year post-restoration clinical photograph demonstrating excellent bone and soft tissue contours. With permission from Quintessence.

Ridge expansion with implant placement is most predictable with thick bone flaps and over-grafting, if a full-thickness flap is utilized. The advantages of this application are a single-stage procedure, optimized keratinized tissue, and long-term stability, as well as minimal post-operative discomfort [33–36].

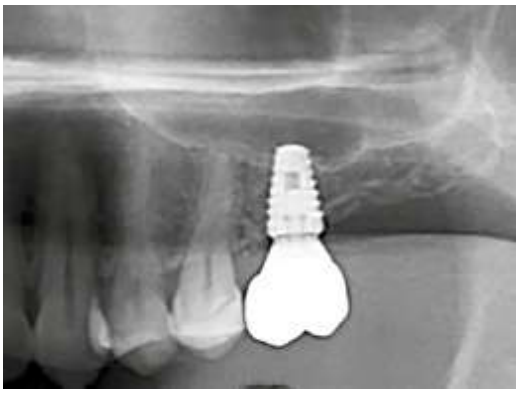

FIGURE 16.27 The 2-year post-restoration radiograph showing excellent bone level. With permission from Quintessence.

CONCLUSION

Both ridge-split expansion and transcrestal sinus floor intrusion procedures are alveolar ridge osteoplasties that are unique from the biological standpoint. Both procedures ensure vascularization of the osteotomized bone segment and internal grafting site. The combined procedure that includes atraumatic extraction, horizontal split, and vertical transcrestal sinus lift leads to a volumetric socket enlargement and, in some cases, immediate implant placement. Endosseous implant placement into a vascularized trabecular bone environment is highly favorable in this setting. This combined technique is minimally invasive, has little morbidity, uneventful recovery, and shortened treatment time.

REFERENCES

1. Morand M, Irinakis T. The challenge of implant therapy in the posterior maxilla: Providing a rationale for the use of short implants. *J Oral Implantol.* 2007;33(5):257–66.
2. Tolstunov L. Implant zones of the jaws: Implant location and related success rate. *J Oral Implantol.* 2007;33(4):211–20.
3. He J, Zhao B, Deng C et al. Assessment of implant cumulative survival rates in sites with different bone density and related prognostic factors: An 8-year retrospective study of 2,684 implants. *Int J Oral Maxillofac Implants.* 2015;30(2):360–71.
4. Truhlar RS, Orenstein IH, Morris HF, Ochi S. Distribution of bone quality in patients receiving endosseous dental implants. *J Oral Maxillofac Surg.* 1997;55(12 suppl):538–45.
5. Farre-Pages N, Auge-Castro ML, Alaejos-Algarra F et al. Relation between bone density and primary implant stability. *Med Oral Patol Oral Cir Bucal.* 2011;16(1):e62–e67.
6. Summers RB. The osteotome technique: Part 4—Future site development. *Compend Contin Educ Dent.* 1995;16(11):1090–98, quiz 1099.
7. Mihalko WM, May TC, Kay JF, Krause WR. Finite element analysis of interface geometry effects on the crestal bone surrounding a dental implant. *Implant Dent.* 1992;1(3):212–17.
8. Cornette R, Tresset A, Herrel A. The shrew tamed by Wolff's law: Do functional constraints shape the skull through muscle and bone covariation? *J Morphol.* 2015;276(3):301–9.
9. Pietrokovski J, Massler M. Alveolar ridge resorption following tooth extraction. *J Prosthet Dent.* 1967;17(1):21–7.
10. Pietrokovski J, Starinsky R, Arensburg B, Kaffe I. Morphologic characteristics of bony edentulous jaws. *J Prosthodont.* 2007;16(2):141–7.
11. Schropp L, Kostopoulos L, Wenzel A. Bone healing following immediate versus delayed placement of titanium implants into extraction sockets: A prospective clinical study. *Int J Oral Maxillofac Implants.* 2003;18(2):189–99.
12. Carlsson GE, Persson G. Morphologic changes of the mandible after extraction and wearing of dentures: A longitudinal, clinical, and x-ray cephalometric study covering 5 years. *Odontol Revy.* 1967;18(1):27–54.
13. Casap N, Brand M, Mogyros R et al. Island osteoperiosteal flaps with interpositional bone grafting in rabbit tibia: Preliminary study for development of new bone augmentation technique. *J Oral Maxillofac Surg.* 2011;69(12):3045–51.
14. Jensen OT, Ellis E. The book flap: A technical note. *J Oral Maxillofac Surg.* 2008;66(5):1010–14.

Dentlearn.ir

15. Jensen OT, Mogyoros R, Owen Z et al. Island osteoperiosteal flap for alveolar bone reconstruction. *J Oral Maxillofac Surg.* 2010;68(3):539–46.

16. Tatum H Jr. Maxillary and sinus implant reconstructions. *Dent Clin North Am.* 1986;30(2):207–29.

17. Summers RB. A new concept in maxillary implant surgery: The osteotome technique. *Compendium.* 1994;15(2):152–8; quiz 162.

18. Mazor Z, Peleg M, Garg AK, Chaushu G. The use of hydroxyapatite bone cement for sinus floor augmentation with simultaneous implant placement in the atrophic maxilla: A report of 10 cases. *J Periodontol.* 2000;71(7):1187–94.

19. Summers RB. The osteotome technique: Part 3—Less invasive methods of elevating the sinus floor. *Compendium.* 1994;15(6):698–704; quiz 710.

20. Pjetursson BE, Rast C, Bragger U et al. Maxillary sinus floor elevation using the (transalveolar) osteotome technique with or without grafting material. Part I: Implant survival and patients' perception. *Clin Oral Implants Res.* 2009;20(7):667–76.

21. Nishioka RS, Kojima AN. Screw spreading: Technical considerations and case report. *Int J Periodontics Restorative Dent.* 2011;31(2):141–7.

22. Khayat PG, Arnal HM, Tourbah BI, Sennerby L. Clinical outcome of dental implants placed with high insertion torques (up to 176 Ncm). *Clin Implant Dent Relat Res.* 2013;15(2):227–33.

23. Nevins M, Nevins ML, Schupbach P et al. The impact of bone compression on bone-to-implant contact of an osseointegrated implant: A canine study. *Int J Periodontics Restorative Dent.* 2012;32(6):637–45.

24. Jensen OT, Kuhlke KL, Leopardi A et al. BMP-2/ACS/allograft for combined maxillary alveolar split/sinus floor grafting with and without simultaneous dental implant placement: Report of 21 implants placed into 7 alveolar split sites followed for up to 3 years. *Int J Oral Maxillofac Implants.* 2014;29(1):e81–e94.

25. AlGhamdi AS. Management of combined ridge defect and osteotome sinus floor elevation with simultaneous implant placement—a 36-month follow-up case report. *J Oral Implantol.* 2009;35(5):225–31.

26. Jensen OT. Segmental alveolar split combined with dental extractions and osteotome sinus floor intrusion in posterior maxilla using BMP-2/ACS allograft for alveolar reconstruction: Technical note and report of three cases. *J Oral Maxillofac Surg.* 2013;71(12):2040–47.

27. Scipioni A, Bruschi GB, Calesini G. The edentulous ridge expansion technique: A five-year study. *Int J Periodontics Restorative Dent.* 1994;14(5):451–9.

28. Bruschi GB, Scipioni A, Calesini G, Bruschi E. Localized management of sinus floor with simultaneous implant placement: A clinical report. *Int J Oral Maxillofac Implants.* 1998;13(2):219–26.

29. Aghaloo TL, Moy PK. Which hard tissue augmentation techniques are the most successful in furnishing bony support for implant placement? *Int J Oral Maxillofac Implants.* 2007;22(suppl):49–70.

30. Adell R, Lekholm U, Rockler B, Branemark PI. A 15-year study of osseointegrated implants in the treatment of the edentulous jaw. *Int J Oral Surg.* 1981;10(6):387–416.

31. Ohta K. [SEM-studies on the osseous healing and changes of the microvascular architecture in supporting tissues of endosseous implants]. *Nihon Hotetsu Shika Gakkai Zasshi.* 1990;34(2):294–308.

32. Scipioni A, Bruschi GB, Calesini G,et al. Bone regeneration in the edentulous ridge expansion technique: Histologic and ultrastructural study of 20 clinical cases. *Int J Periodontics Restorative Dent.* 1999;19(3):269–77.

33. Cullum DR, Jensen OT. Trans-alveolar sinus elevation combined with ridge expansion. In OT Jensen (ed.), *The sinus bone graft*, 2nd edn. Chicago, IL: Quintessence; 2006, 251–62.

34. Cullum DR. Advances in bone manipulation techniques: Part 1: Minimally invasive sinus elevation. *Sel Read Oral Maxillofac Surg.* 2010;18:4.

35. Cullum DR. Advances in bone manipulation techniques: Part 2: Ridge expansion and splitting. *Sel Read Oral Maxillofac Surg.* 2010;18:5.

36. Cullum DR. Ridge expansion and trans-alveolar sinus elevation. In DR Cullum, D Deporter (eds.), Minimally invasive dental implant surgery. Hoboken, NJ: Wiley; 2016, 311–33.

Dentlearn.ir

Dentlearn.ir

Ridge Augmentation: Vertical

SECTION IV

Chapter 17 Protected Bone Regeneration with Titanium Mesh for (Mainly) Vertical Alveolar Ridge Augmentation in Implant Dentistry 307
Matteo Chiapasco and Grazia Tommasato

Chapter 18 Autogenous Block Bone Graft for (Mainly) Vertical Ridge Augmentation in Implant Dentistry 325
Arash Khojasteh and Vishtasb Broumand

Chapter 19 Pedicled Vascularized Segmental Osteotomy with Interpositional Grafting for Vertical Ridge Augmentation: Posterior Sandwich Osteotomy 343
Ole T. Jensen

Chapter 20 Khoury Split Bone Block Grafting Technique: Biological Alveolar Bone Augmentation with Autogenous Bone 355
Fouad Khoury and Charles Khoury

Chapter 21 Alveolar Distraction Osteogenesis for Bone Augmentation in Implant Dentistry 367
Dekel Shilo and Adi Rachmiel

Chapter 22 Orthodontic Therapy: Orthodontic Extrusion for Vertical Ridge Enhancement 381
Ugo Macca, Agatino Davide Mirabella, and Francesco Amato

Chapter 23 Reconstruction of Three-Dimensional Alveolar Ridge Defects Utilizing Screws and Implant Abutments for the Tent-Pole Grafting Technique 403
Dong-Seok Sohn

Chapter 24 Lateral Sinus Lift/Bone Graft for Vertical Bone Augmentation in the Posterior Maxilla 419
Tiziano Testori, Riccardo Scaini, and Terry Zaniol

Chapter 25 Crestal Sinus Lift/Bone Graft for Vertical Bone Augmentation in the Posterior Maxilla 437
Hom-Lay Wang, Ann Decker, and Tiziano Testori

Dentlearn.ir

Dentlearn.ir

Protected Bone Regeneration with Titanium Mesh for (Mainly) Vertical Alveolar Ridge Augmentation in Implant Dentistry

CHAPTER 17

Protected bone regeneration with titanium meshes in association with particulate bone grafts represents a very reliable procedure. It appears that protected regeneration with titanium meshes (both non-customized and customized) in association with mixtures of autogenous bone and xenografts may represent a reliable technique for bone augmentation of atrophic edentulous sites. The aim of this chapter is to present indications, contraindications, advantages, and limits of this reconstructive procedure (see Video 17.1).

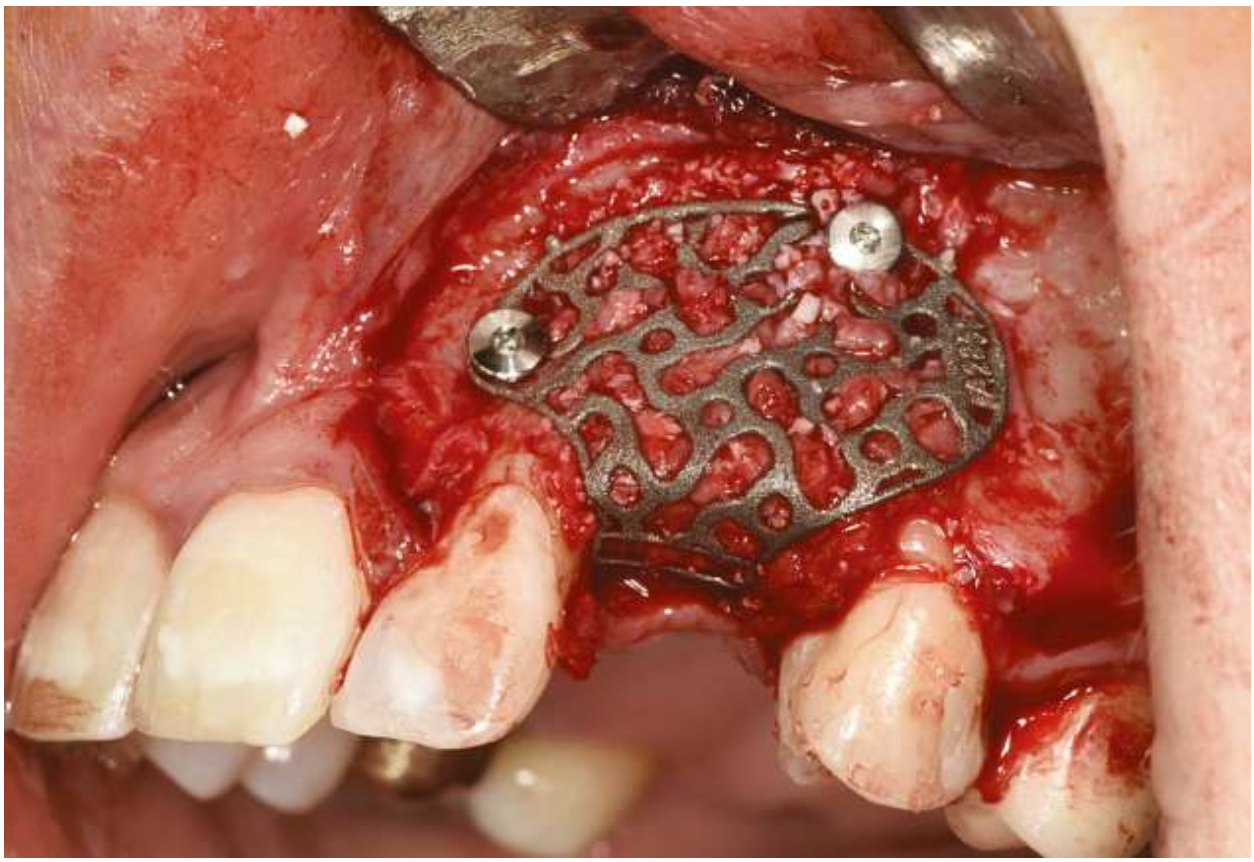

Dentlearn.ir

CHAPTER 17

Protected Bone Regeneration with Titanium Mesh for (Mainly) Vertical Alveolar Ridge Augmentation in Implant Dentistry

Matteo Chiapasco and Grazia Tommasato

Department of Biomedical, Surgical, Dental Sciences, University of Milan, Milan, Italy

Vertical deficits of edentulous alveolar ridges (often associated with a variable degree of horizontal bone resorption) still represent a challenge for oral surgeons and prosthodontists whenever patients request an implant-supported restoration. Bone defects create the following problems:

- The lack of sufficient bone volume not only may render implant placement difficult or impossible, but also impedes implant placement in a prosthetically guided way.
- An increased interarch distance creates unfavorable intermaxillary relationships.
- There is a risk of damaging anatomical structures such as the inferior alveolar nerve, the sublingual vessels, the floor of the nose, and the maxillary sinus, even if short implants are used.
- There may be poor results from both a functional and an aesthetic point of view (long prosthetic suprastructures, necessity of pink porcelain components).

To summarize, implant placement may be impossible or not compatible with an acceptable prosthetic outcome from a functional and/or aesthetic point of view.

Many surgical procedures have been proposed over the years not only to re-create more favorable conditions in terms of bone volume, but also to allow implant placement in an appropriate, prosthetically guided way. Among these, guided bone regeneration (GBR) with particulate xenografts, allografts, autografts, or a combination of these, in association with resorbable or non-resorbable membranes [1–5], allogeneic or autogenous inlay, or onlay bone block reconstructions [2, 6–10], and distraction osteogenesis [11, 12] have been proposed, with favorable results for all of them. However, no consensus has been found yet as to which the most reliable technique.

As an alternative, "protected" bone regeneration with particulate bone and non-customized [13–19] or customized titanium meshes [19–23] has been demonstrated to be another effective solution (see Video 17.2).

The aim of this chapter is to describe in detail indications, contraindications, advantages, disadvantages, and medium- to long-term clinical outcome of alveolar ridge augmentation by means of non-customized (conventional) or the new generation of computer-aided design/manufacturing (CAD/CAM) customized titanium meshes.

INDICATIONS

Larger size of vertical alveolar bone defect (often in association with a horizontal bone loss), from a single-tooth gap to a full edentulous arch, can be an indication for bone regeneration with a titanium mesh. In these extensive alveolar bone deficiency cases, a restoratively driven functional and esthetic implant placement would be deemed impossible without need for an extensive bone grafting. Protective vertical or three-dimensional bone regeneration where a particulate bone grafting material is protected by a rigid structure, a Ti mesh, can provide an effective solution in these cases.

Relevant deficits of the alveolar ridges may be the consequence of (i) tooth loss because of periodontal disease; (ii) trauma causing teeth and surrounding bone loss; (iii) resections because of tumors involving primarily or secondarily the maxillo-mandibular complex; and finally (iv) defects following implant loss because of untreatable peri-implant infection or necessity of removal because of malpractice (malposition, lesion of important anatomical structures, etc.). This latter aspect is unfortunately an increasing phenomenon, due to the enormous quantity of implants placed, not always in a proper way.

Essential Techniques of Alveolar Bone Augmentation in Implant Dentistry: A Surgical Manual, Second Edition. Edited by Len Tolstunov.
© 2023 John Wiley & Sons, Inc. Published 2023 by John Wiley & Sons, Inc.
Companion website: www.wiley.com/go/tolstunov/essential

Dentlearn.ir

There are no specific limits as regards the amount of horizontal and vertical bone increase with titanium meshes: more than 10 mm in vertical and horizontal augmentation can be obtained [23]. However, the regeneration potential of horizontal and, in particular, vertical defects is generally inversely proportional to the quantity of vertical bone gain requested [24]. Troeltzsch et al. stated: "Horizontal and vertical gain by 3.7 mm on average can be achieved using particulate materials. This can be increased by using titanium meshes. Substantial vertical gains beyond this dimension require the use of extraoral bone block grafts" [24].

We have arbitrarily divided augmentations with titanium meshes as follows:

- Limited: <3 mm.
- Intermediate: 3–6 mm.
- Relevant: >6 mm.

The basic principle of protected regeneration is that particulate bone placed in a deficient area will be rigidly stabilized by a metal grid (the titanium mesh) during the integration and consolidation of the graft in the recipient bed, which eventually will acquire characteristics similar to the pristine alveolar/basal bone [13]. Without this protection, particulate bone might be subjected, in the early post-operative phases, to micro/macro-movements, displacement, or compression caused by the overlying soft tissues. These events may lead to non-integration, resorption, and/or transformation into fibrous tissue.

CONTRAINDICATIONS

Contraindications for the therapy can be classified as systemic, local, and behavioral. Systemic contraindications include organ failure (heart, lungs, kidney, liver, thyroid), congenital and acquired immunodeficiency, uncontrolled type I diabetes, advanced cancer and related chemotherapy, bisphosphonate chemotherapy in progress, and medication-related osteonecrosis of the jaws, as well as other severe, unstable systemic conditions. Local contraindications include severe periodontal disease and poor oral hygiene, advanced oral gingival/mucosal disease (such as lichen planus), and head and neck radiation. Behavioral contraindications include alcohol and tobacco abuse, non-compliance, and lack of commitment, motivation, and/or comprehension.

PRE-OPERATIVE PLANNING (T0)

The first visit will include evaluation of (i) residual dentition (if any) in terms of periodontal situation, including the periodontal indexes, such as bleeding index, probing depth, plaque index; (ii) the quality of restorations of the neighboring dentition; and (iii) the type of occlusion. A panoramic radiograph and a complete series of intraoral radiographs are fundamental for the initial evaluation of the patient.

In order to obtain a favorable outcome of an oral rehabilitation supported by implants, the initial planning must start from accurate prosthetic planning with traditional impressions or, more recently, with digital intraoral scanners. The main objective is to know and understand the final position of the prosthetic crowns in order to properly integrate them with adjacent dentition (if any) and with the opposing arch, following the well-known principle of a prosthetically guided regeneration (PGR) [25].

A wax-up of the ideal dentition and a clear understanding of the final prosthetic outcome are fundamental for a reliable and accurate result. Once an ideal wax-up has been obtained either analogically or digitally, it will be possible to produce a diagnostic template including radio-opaque reference points (such as barium-enriched resin teeth, which will be worn by patients at the time of cone beam computed tomography, CBCT).

The analysis of the digital files of the CBCT will make it possible to correlate the position of the future prosthetic crowns and the profile of the actual residual alveolar crest. In this way it will be possible to know the entity of the bone defect in relation to the final prosthetic crown position, and to evaluate the distances between the more coronal margin of the residual crest and anatomical structures such as the inferior alveolar nerve, the floor of the maxillary sinus, and the nasal floor.

In the case of customized titanium meshes, the digital files obtained by the CBCT will be used to create with CAD/CAM technology a three-dimensional model reproducing both the edentulous and the neighboring dentate areas. On this model, it will be possible to produce a precise three-dimensional titanium scaffold, generally by means of laser sintering or melting techniques (Figure 17.1).

GRAFTING MATERIALS

A titanium mesh is not able *per se* to regenerate bone in a defect area: grafting materials are therefore necessary. At present, no ideal material in terms of osteo-genetic, osteo-inductive, and osteo-conductive potential has yet been found. However, according to the present literature, in particular in the case of relevant vertical augmentations, autogenous bone is still considered the gold standard to which all other grafting materials should be compared [6, 7, 24, 26, 27]. Particulate autogenous bone chips can be used as a single grafting material or, more frequently, by combining autogenous bone with allografts, xenografts, or alloplastic materials, such as bovine bone mineral (BBM), hydroxyapatites, and tricalcium phosphate/sulfate. Although it is difficult to extrapolate from the literature the ideal ratio between autogenous bone and non-autogenous materials, it appears that a minimum of 50% autogenous bone is recommended [23, 28, 29].

Dentlearn.ir

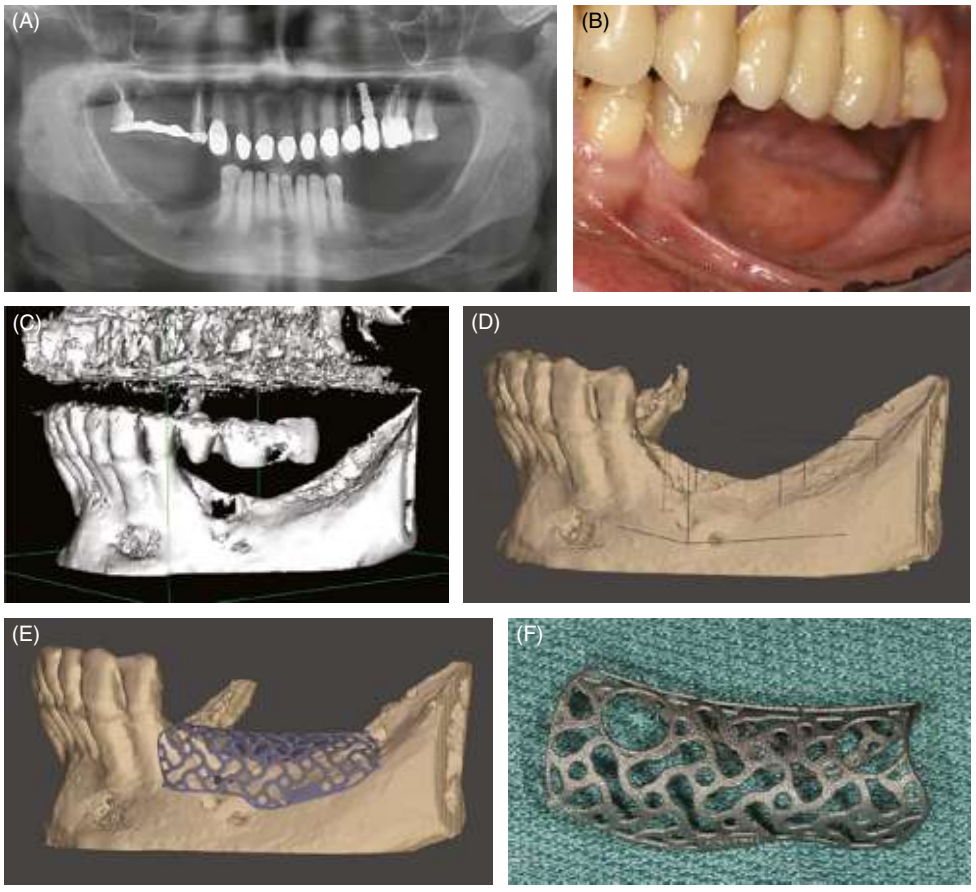

FIGURE 17.1 (A) bilateral edentulism in the premolar and molar area of the mandible with intermediate (3–6 mm) vertical atrophy of the residual alveolar ridge. (B) Initial clinical situation on the left side. (C) Cone beam computed tomography (CBCT) is done with the patient wearing a diagnostic template with radio-opaque teeth: the vertical deficit is evident. (D, E) DICOM files of the CBCT are used to construct a three-dimensional model on which the titanium mesh is designed with computer-aided design/manufacturing (CAD/CAM) technology. (F) The customized titanium mesh ready to be used.

Titanium meshes have also been used in association with bone morphogenetic proteins, in particular rhBMP-2, and carriers such as collagen sponges, mineralized bone allograft, anorganic bovine bone, crushed cancellous freeze-dried allogeneic bone, and demineralized frozen human cortical bone (all used in particulate form), as reported in a recent systematic review [30].

Autogenous bone can be harvested either in blocks that will be particulated with dedicated bone microtomes (mills) or, more simply, directly in the form of particulate bone using bone scrapers (generally disposable). This latter method is nowadays the most frequently used. Once collected, the bone chips are mixed with a non-autogenous material in a 1:1 ratio, approximately [28, 29, 31, 32].

In all cases treated by the authors, the non-autogenous material was represented by BBM (Bio-Oss®, Geistlich, Wolhusen, Switzerland) with a particle size between 250 and 1000 μm [23].

DONOR SITES

Donor sites are represented by two main categories:

- Intraoral donor sites, mainly represented by the body and the ramus of the mandible, and the mental symphysis. Other sites such as the maxillary tuberosity, nasal spine, or the zygomatic buttress are rarely used, as they provide limited bone quantities.
- Extraoral sites are mainly represented by the anterior iliac crest and the calvarium, and, to a lesser extent, the tibia.

The choice of donor sites is mainly related to the quantity of autogenous bone necessary for the correction of the defect. As a general rule, intraoral sites are sufficient to regenerate defects in partially edentulous patients (1–8 missing teeth). In the case of multiple edentulous sites (for instance, bilateral edentulism of the posterior mandible in association with edentulism of the upper arch or vice versa, or in fully edentu-

Dentlearn.ir

lous atrophic arches), extraoral donor sites might be necessary, despite the volume augmentation obtained with the aid of non-autogenous grafting materials.

PRE-OPERATIVE PREPARATION OF PATIENTS

According to the authors' protocol, patients are prepared for both the regeneration procedure (T1) and the second-stage implant surgery (T2) according to the following protocol:

- Professional oral hygiene (1–2 weeks prior to T1–T2).
- Local antisepsis with 0.2% chlorhexidine mouthwashes starting 3 days before T1–T2.
- Anti-edema medication such as bromelain to be taken 3 days before T1–T2 (3 tabs per day).
- Antibiotic prophylaxis, consisting of oral administration of amoxicillin and clavulanate (2 g), 1 hour before T1–T2. In the case of intravenous sedation or general anesthesia, antibiotics are infused at the time of induction. In the case of allergy or intolerance, amoxicillin is substituted by macrolides or cephalosporins.
- At the beginning of the surgical procedure, 8 mg dexamethasone is injected intravenously in the case of sedation or general anesthesia, or intramuscularly in the oral cavity in the case of local anesthesia. This single shot of steroids reduces post-operative edema.

SURGICAL PROCEDURE (T1)

PREPARATION OF THE SURGICAL FIELD

The regeneration procedure with titanium meshes must be performed under sterile conditions. The skin of the face must be prepared with antiseptic solutions such as iodine and the patient must be covered with sterile drapes, just leaving the mouth and nose area exposed. In the case of extraoral bone harvesting, the skin surrounding the surgical field must be prepared as well with antiseptic solutions (no need to cut hair if harvesting from the calvarium). For extraoral donor sites, bone harvesting will represent the first phase of surgery, as the oral cavity is the more contaminated area.

TYPE OF ANESTHESIA

Regeneration procedures with titanium meshes can be done under local anesthesia with or without intravenous sedation or under general anesthesia with naso-tracheal intubation. The choice among different modalities is mainly related to the extent of the defect (and consequently the extent of autogenous bone harvesting), the compliance of patients, and the duration of the surgical procedure. Of course, the experience of the surgeon may play a relevant role in the duration and invasiveness of the surgery.

Generally speaking, limited edentulous spans can be treated under local anesthesia, while extended edentulous spans may require intravenous sedation or general anesthesia. The latter will also allow control of blood pressure (controlled hypotension), with a consequent reduction of intra- and post-operative bleeding, and thus better control of the surgical field, reduction of surgical times, and eventually reduction of swelling/hematoma.

BONE HARVESTING PROCEDURE

Mandibular Body and Ramus

If the site to be regenerated is in an area close to the mandibular ramus (donor site), one single incision associated with releasing incisions will make it possible to access both the harvesting and the recipient sites.

A full-thickness flap is elevated, the posterior mandible and the ascending ramus exposed, and bone chips are collected with a scraper, taking care to respect important anatomical structures such as the mental and the lingual nerve. With a dedicated bone scraper, bone chips are collected from the posterior mandible and the ascending ramus, generally distal to the second molar area.

If the area to be regenerated is different, a single, linear incision following the linea obliqua externa of the posterior mandible and the ascending ramus is made and a full-thickness flap is elevated. The rest of the procedure is similar to that previously described.

If scrapers are not available, a cortico-cancellous block can be harvested with fine chisels and a mallet, after having outlined the block either with a fissure bur or diamond disks assembled on a handpiece, or with oscillating/reciprocating micro-saws, or finally with piezoelectric instruments. Care must be taken to respect the integrity of the inferior alveolar nerve, thanks to an appropriate interpretation of pre-operative CBCTs and appropriate surgical maneuvers (Figure 17.2).

Mental Symphysis

If the area to be regenerated is adjacent to the mental symphysis, a single flap giving access to both the donor site and the area to be reconstructed can be obtained with a single incision in association with two vertical releasing incisions.

If the edentulous area is different, a curved incision between the two cuspids is generally performed in the buccal mucosa and access to the mental symphysis is obtained after sharp incision of the two mental muscles, taking care to leave the more coronal insertions of these muscles intact, in order to simplify the final suture.

Then, a full-thickness flap is raised and the mental symphysis exposed. As for the ramus, bone can be harvested with

Dentlearn.ir

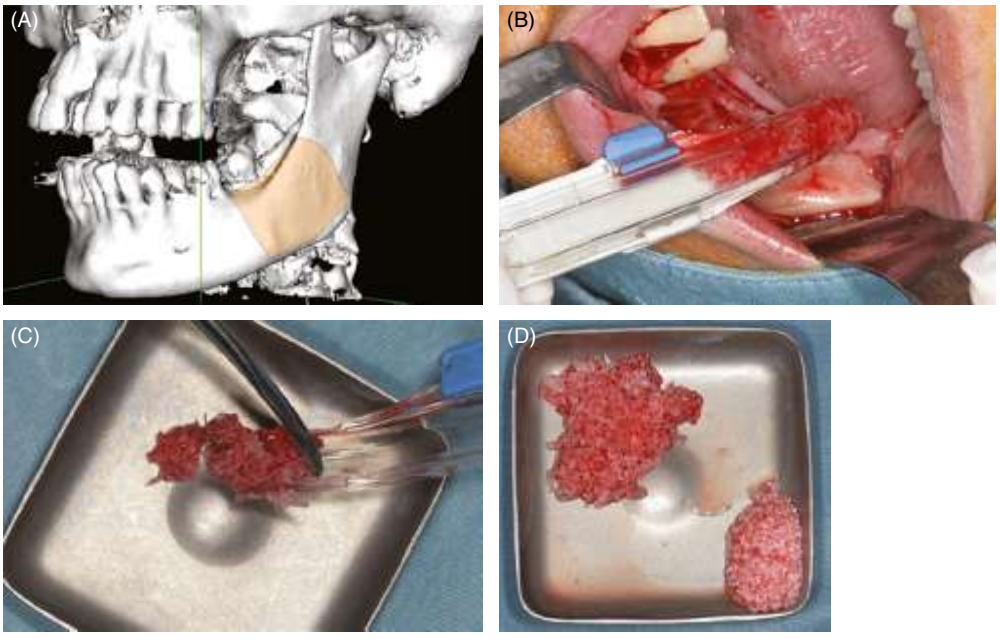

FIGURE 17.2 (A) Bone harvesting area from the ramus and molar area of the mandible. (B) Particulate bone is harvested from the mandibular ramus with a bone scraper. (C, D) The particulate bone is removed from the scraper and mixed in a 60:40 ratio with bovine bone mineral granules, to increase the available quantity of grafting material and take advantage of the osteoinductive properties of autogenous bone and the osteoconductive properties of the xenograft.

a bone scraper (first choice) or as a block that must be then particulated with a bone mill (Figure 17.3).

Anterior Iliac Crest

Access to the anterior iliac crest is obtained with a full-thickness straight incision starting at least 1 cm posterior to the anterior iliac spine backward along the crest. Once the crest has been exposed, bone is harvested either with scrapers or with dedicated trephines and surgical spoons. Surgical access is closed with a multilayered suture (Figure 17.4).

Calvarium

Access to the parietal bone of the skull is obtained with a straight incision, either horizontal along a parasagittal plane or with a hemi-coronal incision through skin, subcutaneous tissue, galea capitis, and periosteum. After the incision, the two sides are retracted and the periosteum elevated.

With a bone scraper it is possible to collect in a very safe way a relevant quantity of bone chips from the outer cortex of the parietal bone.

If bone scrapers are not available, piezo surgery instruments, oscillating reciprocating saws, a fine chisel, and a mallet can be used. Once blocks are collected, they must be particulated with a bone mill.

After accurate hemostasis, the surgical access is closed with a multilayered suture (generally one subcutaneous and one cutaneous layer; Figure 17.5).

REGENERATION WITH A TITANIUM MESH

The main surgical steps, for both conventional, non-customized titanium meshes and CAD/CAM customized meshes, are similar and will be described only once. The differences are related only to the fact that conventional titanium meshes must be bended, modeled, and trimmed starting from a square or rectangular "flat" titanium foil, once the flap has been elevated and the recipient site prepared. Of course, there is also the possibility of pre-modeling non-customized titanium meshes by creating pre-operatively a three-dimensional model of the maxilla or the mandible, although this procedure is seldom used.

In contrast, customized titanium meshes are ready to be used without modeling/trimming because they are produced on a three-dimensional resin model obtained by a digital printer on the base of the DICOM files obtained from a CBCT.

SURGERY: FLAP DESIGN, RECIPIENT SITE, AND INCISIONS (T1)

A mid-crestal incision with mesial and distal releasing incisions at least 1 cm from the area to be augmented and the elevation of a full-thickness flap are performed to expose the edentulous area. As already mentioned, if the area to be regenerated is adjacent to the bone harvesting area, the incision lines can be modified in order to include in one single

Dentlearn.ir

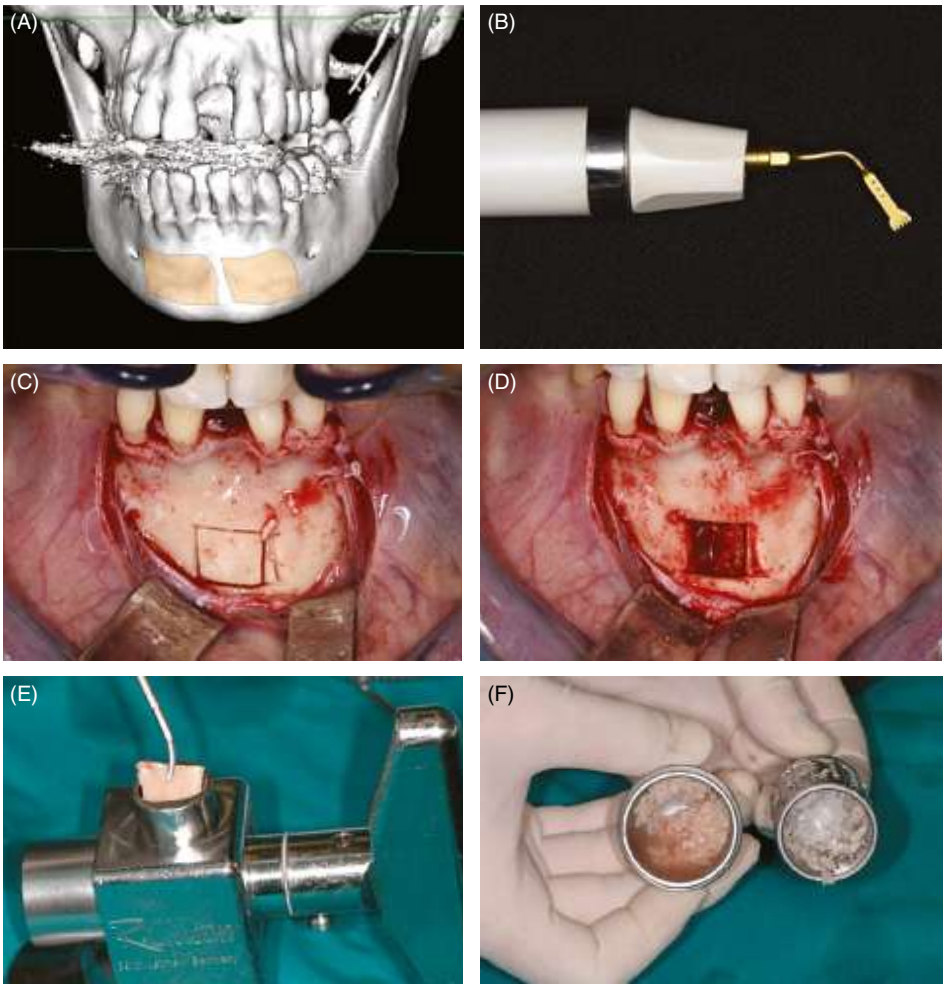

FIGURE 17.3 (A) Bone harvesting area from the mental symphysis. (B–D) With the aid of an osteotomy tip assembled on a piezoelectric handpiece, it is possible to outline a bone block that is harvested with the aid of a fine chisel. (E, F) The bone block is particulated with a bone microtome (mill).

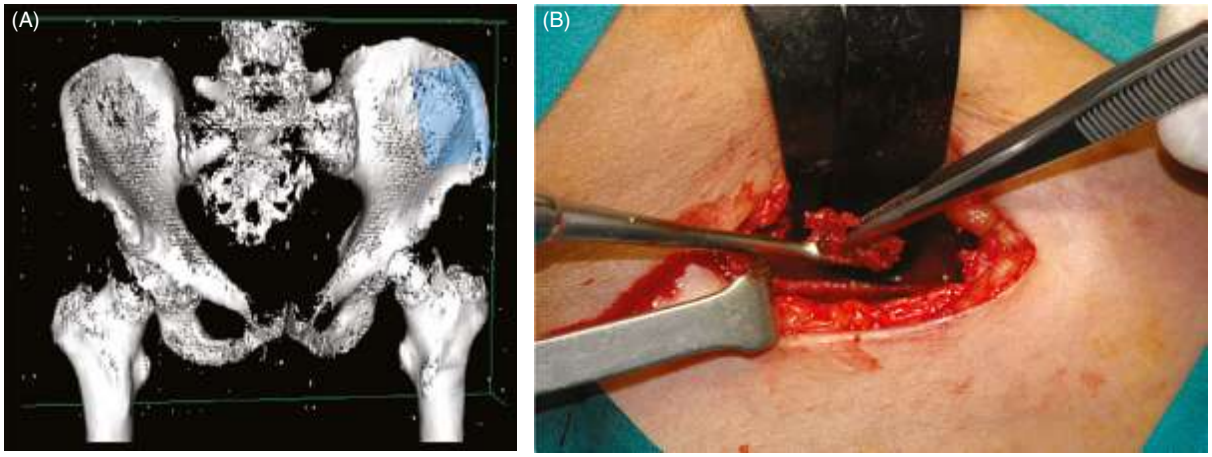

FIGURE 17.4 (A) Bone harvesting area from the anterior iliac crest. (B) A 2 cm, full-thickness incision allows access to the anterior iliac crest and harvesting of larger quantities of bone with a surgical spoon.

Dentlearn.ir

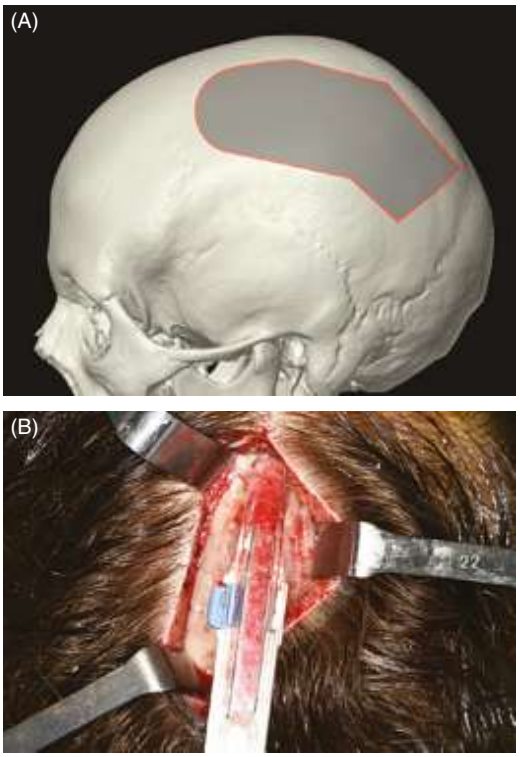

FIGURE 17.5 (A) Bone harvesting area from the parietal calvarium. (B) Access to the cranial vault is obtained with a single, full-thickness straight incision in the parietal area. Large quantities of particulate bone can be collected with a bone scraper from the outer cortex.

flap both the donor and recipient sites. Any residual soft tissues over the residual crest are accurately removed to avoid interposition of connective tissue between the recipient site and the grafting material.

As a relevant augmentation is expected at the end of surgery, periosteal releasing incisions on the buccal and lingual sides are performed in the mandible and only on the buccal side in the maxilla, as the palate cannot be released. Further release can be obtained by means of blunt dissection of the submucosal layer from the muscle layer beyond the periosteum.

During the releasing procedures, care must be taken not to damage important anatomical structures (i.e. the mental nerve and its branches, as well as the branches of the facial artery and the ascending ramus of the submental artery during the release in the buccal aspect of the mandible; the sublingual artery, the submandibular ducts, and the sublingual gland during release on the lingual side of the anterior mandible; the mylohyoid artery and the lingual nerve during release on the lingual side of the posterior mandible; or branches of the infraorbital nerve and parotid duct during release of the posterior/lateral maxilla).

Adaptation and Fixation of the Mesh to Recipient Site

Once the defect has been exposed, the non-customized mesh must be trimmed, bent, and adapted in order to cover completely the area to be augmented, following the same maneuvers used for titanium-reinforced polytetrafluoroethylene (PTFE) membranes. As a general rule, the mesh must be wider than the area to be regenerated in order to appropriately contain the graft to be fixed outside the regenerated area. The titanium mesh must be checked to control adequacy of shape and fitting to the atrophic site.

The previously harvested bone chips are now mixed with the non-autogenous bone graft, with the aim of taking advantage of the osteogenic/osteoinductive potential of autogenous bone and the osteoconductive and volume-maintaining potential of a slowly resorbable material such as particulate BBM. According to the surgeon's preference, there are two main methods to manage the grafting material: the graft can be packed in the defect area and then covered by the mesh; or the mesh can be filled with the graft outside the patient's oral cavity and then placed in the defect area.

Stabilization of the mesh is obtained with dedicated titanium micro-screws (1.3–1.5 mm in diameter and 5–13 mm long), according to surgical need.

If a customized titanium mesh is used, there is no need for modeling, as the mesh is already fabricated on a three-dimensional model by the manufacturer, is generally very precise, and adapts perfectly to the defect. However, before grafting, it is a good rule to double-check the adaptability and precision of the mesh. In all cases treated by the authors, the mesh was packed with the mixture of autogenous bone and BBM in a 1:1 ratio outside of the oral cavity and then placed and fixed with titanium screws, as previously described.

Patients presenting with bone atrophy of the posterior maxilla requiring sinus grafting in addition to bone augmentation received a sinus lift with BBM via a lateral approach in association with the ridge augmentation with the titanium mesh.

A collagen membrane can be applied over the mesh to reduce the risk of soft tissue ingrowth through the mesh during the early phases of healing [23]. Autogenous platelet-rich fibrin (PRF) membranes obtained at the time of surgery can be used to cover the titanium mesh surfaces and reduce the risk of mesh exposures.

Flap Tension and Sutures

At the end of the augmentation procedure, it is fundamental to check whether the flaps have been adequately released. In the mandible, both flaps must move freely and without any tension over the mesh. In the maxilla, the buccal flap must cover the palatine mucosa, by-passing easily the incision line, as the palatine mucosa is not easy to release.

The surgical procedure is concluded with a watertight and tension-free closure, generally with 5-0 sutures (polyglactin), alternating horizontal mattress and single sutures (Figure 17.6A–I).

Dentlearn.ir

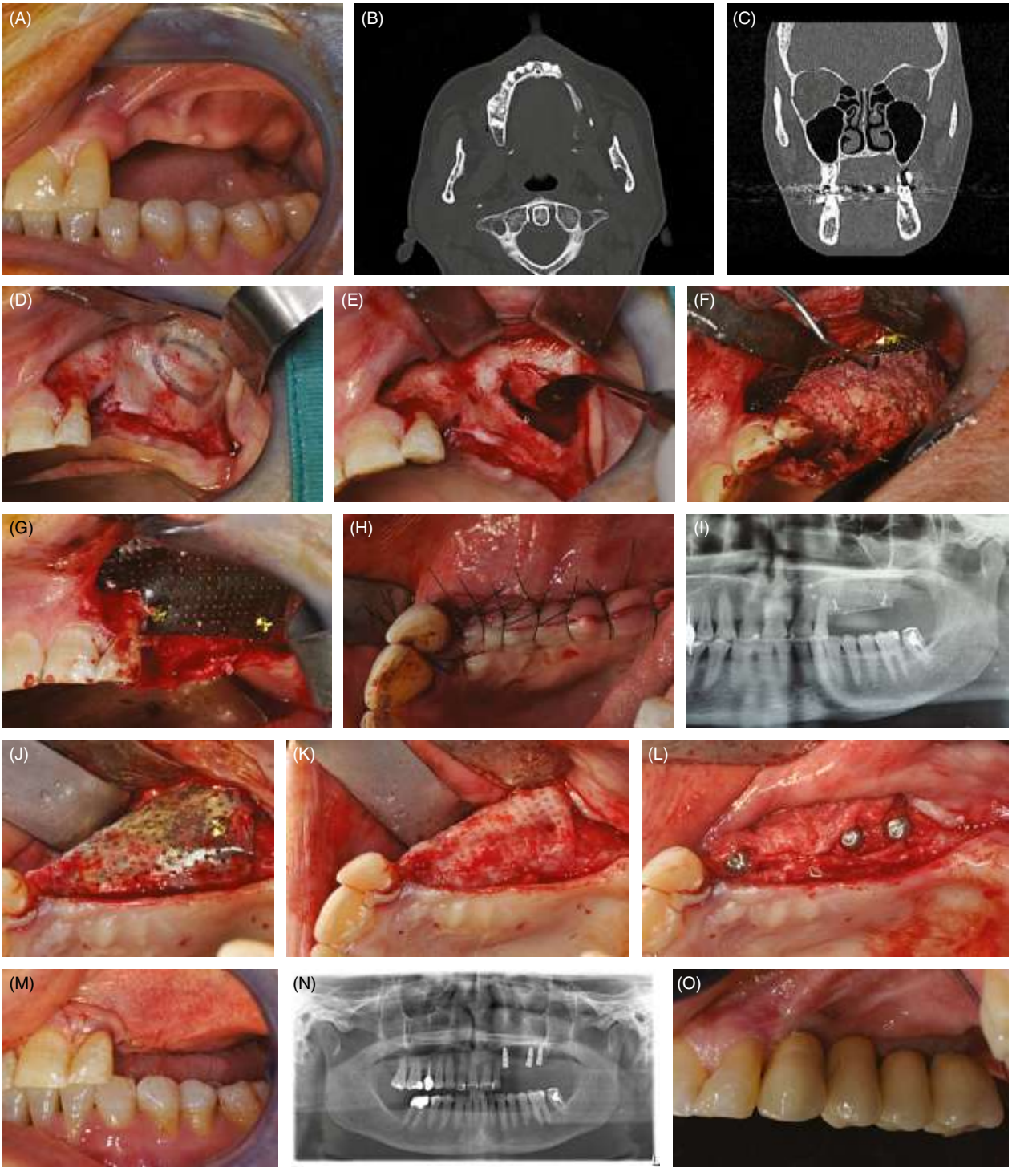

FIGURE 17.6 (A–C) Initial clinical situation of a horizontally and vertically atrophied left edentulous maxillary ridge, as demonstrated by cone beam computed tomography sections. (D, E) Sinus floor elevation through a lateral approach is performed. (F) First, a conventional titanium mesh is modeled and trimmed according to the defect; secondly, it is stabilized on the apical margin of the defect and the particulate bone is used to fill the sinus and to augment the alveolar ridge, both vertically and horizontally. (G, H) The mesh is fixed with titanium micro-screws on both the buccal and palatal sides and, after releasing incisions, the flaps are sutured without tension. (I) Radiographic control immediately after surgery. (J, K) Nine months later the mesh is removed and a relevant increase is evident; a thin layer of pseudo-periosteum is covering the regenerated bone. (L) Three implants are placed in the regenerated area and partially covered with the pseudo-periosteum left in place. (M) The suture of the flap shows clearly the appropriate vertical intermaxillary relationships. (N) Radiographic control immediately after implant placement. (O) Final prosthetic result.

Dentlearn.ir

Post-operative Follow-Up

The following post-surgical instructions are recommended:

- Application of ice packs for 6–8 hours after surgery.
- Oral antibiotics – amoxicillin and clavulanate (3 g per day for 6 days) or macrolids/cephalosporins in case of allergy.
- Non-steroidal anti-inflammatory drugs (NSAIDs) or paracetamol for 3–5 days after surgery.
- Anti-edema medications such as bromelain (3 tabs per day for 10 days).
- Cold and liquid diet for the first 2 days after surgery and a soft diet until suture removal.
- 0.2% chlorhexidine mouth rinses, twice per day for 14–21 days, combined with normal oral hygiene maneuvers on the remaining dentition (if present).

When a concomitant maxillary sinus floor elevation is performed, patients are instructed to avoid any pressure peak in the upper respiratory tract for at least 15 days, so as not to potentially damage the Schneiderian membrane (i.e. sneezing with the mouth closed, blowing the nose, flying in the post-operative days, etc.). Furthermore, patients are not allowed to wear removable prostheses that may traumatize the reconstructed area for at least 6 weeks. Vacuform retainers including resin teeth, Maryland bridges, or conventional bridges are fabricated to provide a purely cosmetic restoration and to avoid any compression on the operated area.

In the case of fully edentulous maxillae, it is possible to insert a short implant (4 mm long) just behind the nasopalatine canal. Six weeks later a ball attachment or locator can be screwed to this implant, which can offer an anchorage to a denture, therefore improving the stability of a temporary denture without loading the buccal side of the regenerated area.

TITANIUM MESH REMOVAL AND IMPLANT PLACEMENT (T2)

After a waiting time ranging from 6 to 9 months, patients are generally ready for stage 2 surgery, which is removal of titanium meshes and implant placement. These waiting times are necessary to obtain a good integration of the graft, and are also on the basis of the available literature [2, 6, 7, 15, 20–23, 28].

Patients should be re-evaluated both clinically and radiographically with a new CBCT performed with the aid of the same radiological templates used at the time of the pre-operative CBCTs, to check the bone volumes of the regenerated tissues and to plan implant placement according to a prosthetically guided project.

Removal of a mesh and implant placement are performed under local anasthesia, sedation, or general anesthesia, according to patients' compliance and the extent of the surgery. Access is obtained following the previous incisions. Titanium meshes and fixation screws are exposed and removed, surgical templates applied, and implant site preparation started. It must be underlined that dissection of the flaps overlying the mesh and removal of the titanium meshes are, in the majority of cases, more demanding and time consuming compared to removal of other non-resorbable membranes, such as PTFE membranes, for a series of reasons.

Firstly, the soft tissues of the flaps may penetrate through the "open spaces" of the meshes and may strongly adhere to the mesh. Particular care must be taken during the dissection on the lingual side of mandibular meshes, where the soft tissues are often very thin, also because of the releasing incisions performed during the first surgery.

Secondly, sometimes the newly generated bone grows over the titanium mesh, which may as a result be embedded (often only partly) in the newly formed bone. In this case the removal of the mesh can be demanding. In such cases parts of the mesh can be left *in situ*, if they do not interfere with implant placement, to avoid elimination of useful bone tissue.

In two recent publications, histomorphometric results of the regenerated tissue were reported [23, 33]. It was demonstrated that, in uneventful healing, no signs of necrosis, fibrosis, or inflammation of the regenerated tissue were present. The hard tissue below the meshes was completely calcified or in the phase of mineralization with the following proportions: 35.88%±13.53% new lamellar bone, 16.42%±6.41% woven bone, 10.88%±6.41% osteoid matrix, and 14.10%±7.54% grafted remnants. The 22.72%±9.72% of the regenerated area was occupied by medullary spaces. In all sites no signs of necrosis, fibrosis, and ectopic infiltration of fatty cells were observed. Only a few inflammatory cells were detected in the samples.

Interestingly enough, new vessels were spread over the whole section of all specimens. Histomorphometric analysis revealed that the regenerated areas were occupied 4.06±1.26% by blood vessels (Figure 17.6J–N).

IMPLANT RE-OPENING AND PROSTHETIC PHASE (T3 AND T4)

After the waiting time necessary for implant osseointegration, implants are uncovered and the prosthetic phase is started. At this time, the quality and quantity of peri-implant soft tissues must be evaluated.

Following the regeneration procedure, relevant releasing incisions are necessary, and this is frequently followed by modification of the position of the residual band of the keratinized mucosa and reduction of the buccal sulcus. If the latter are judged inadequate to guarantee a sufficient seal around implant abutments, a vestibuloplasty in association with a free gingival graft harvested from the palate is recommended.

Dentlearn.ir

In patients presenting with adequate keratinized mucosa, but with insufficient thickness of peri-implant soft tissues, it may be indicated to thicken the soft tissues with autogenous connective tissue taken from the palate or with porcine-derived collagen matrices.

A series of publications have demonstrated that the thickness of peri-implant soft tissues can play a relevant role in the long-term survival of implants, irrespective of whether the latter have been inserted in native or regenerated bone [34–37].

Generally, provisional restorations are delivered first and, after adequate conditioning of peri-implant soft tissues, the final prostheses (screw-retained or cemented) are delivered.

After the start of prosthetic loading, patients are generally recalled 6 and 12 months later, and annually thereafter, to assess peri-implant hard and soft tissue condition, the stability of the reconstructed bone, and the onset of implant-related complications, with both clinical and radiographic controls (Figure 17.6O, Figure 17.7, and Table 17.1).

Table 17.1 Main advantages and disadvantages of protected regeneration with both conventional and customized titanium meshes.

Advantages of protected regeneration with titanium meshes	Disadvantages of protected regeneration with titanium meshes
Precision of titanium mesh and easy adaptation to site to be reconstructed	Removal of mesh more complex because of: • Bone overgrowth over the mesh • Penetration of periosteum/muscle fibers into the mesh • "Thinning" of overlying soft tissue during integration • Higher risk of exposure and need for early removal in case of infection
Elimination of trimming/modeling phases	
Grafting phase done directly into the mesh	
Easy stabilization of the mesh	
Shortening of surgical times of regeneration phases	
Possibility of regeneration of fully edentulous arches presenting with severe vertical/horizontal atrophy	

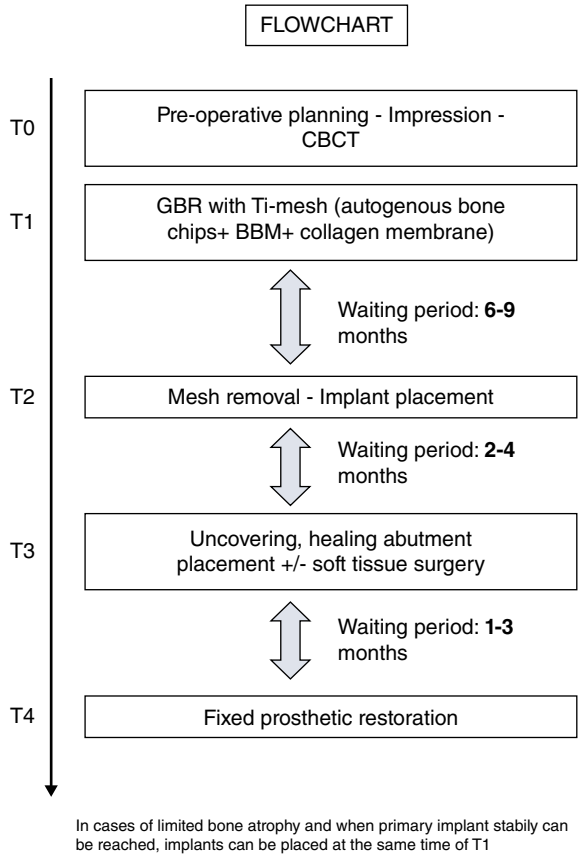

FIGURE 17.7 Flowchart summarizing the different phases of rehabilitation by means of titanium meshes, implants, and prosthetic restoration. BBG, bone block graft; BBM, bovine bone mineral; CBCT, cone beam computed tomography; Ti, titanium.

CLINICAL CASES

CASE 1

See Figure 17.8.

CASE 2

See Figure 17.9.

COMPLICATIONS

Besides common complications following any type of vertical bone regeneration performed with different techniques (hematomas, edema, transient paresthesia, etc.), the main complication associated with the use of titanium meshes is the exposure of the titanium surface, with or without clinically evident infection. This event may occur despite a tension-free and hermetic suture done by an expert surgeon. These exposures can be the consequence of an early dehiscence of the surgical wound (within 2–3 weeks after surgery) or of a late breakdown of the soft tissues surrounding the mesh (after more than 3 weeks after surgery), frequently in areas not connected to the initial incisions. A recent systematic review by Zhou et al. [38] reported that the overall rate of exposure, including both customized and non-customized titanium meshes (combined value), was 44%. The combined value of exposures was 31% and 51%, for customized and non-customized meshes, respectively. This data demonstrated that, although the rate of exposure of customized meshes is lower than that of conventional ones, the breakdown of soft

Dentlearn.ir

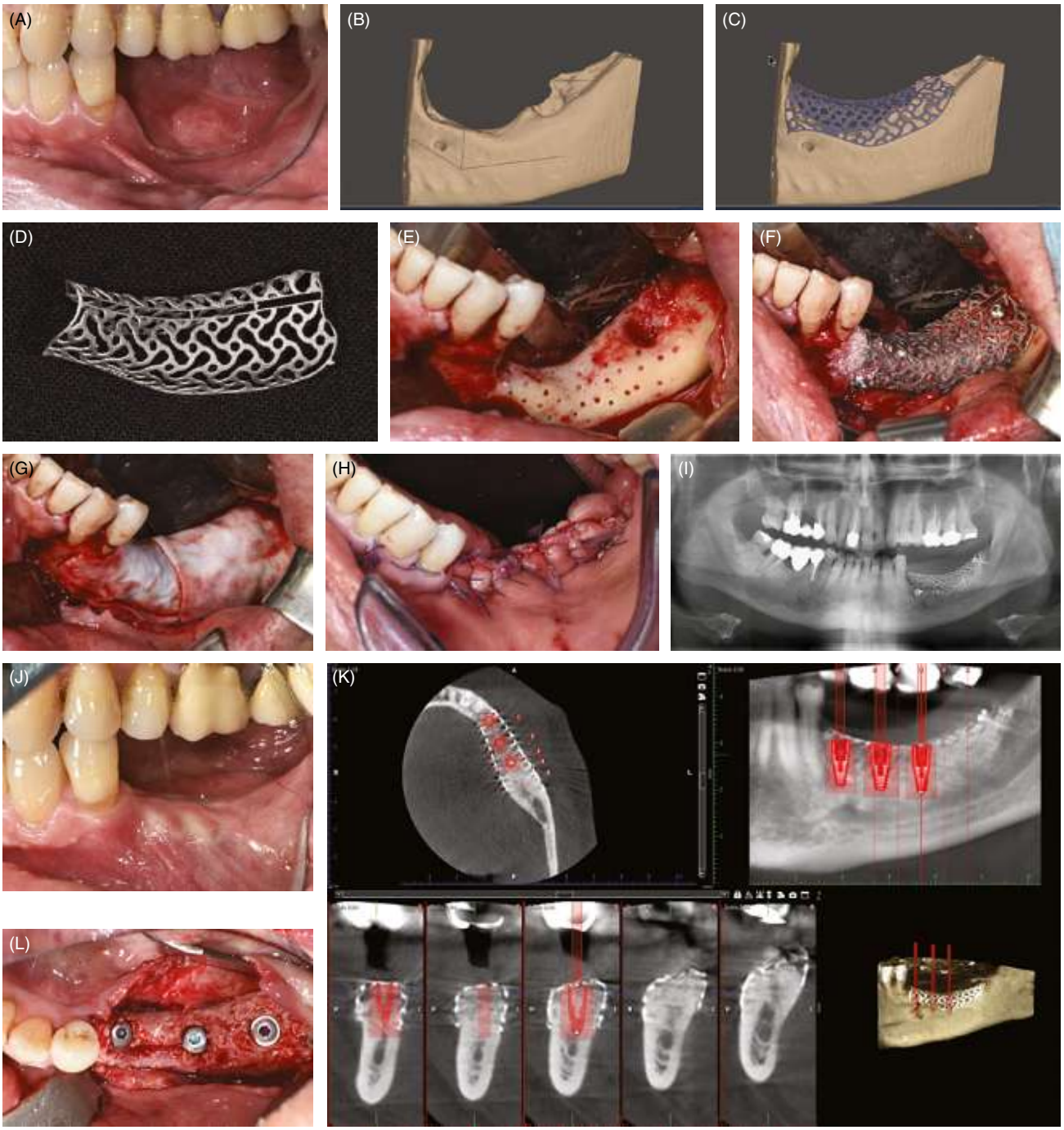

FIGURE 17.8 (A, B) Initial situation showing severe vertical deficit of the left mandibular alveolar ridge with unfavorable intermaxillary relationships and insufficient distance between the crest and the inferior alveolar nerve (approximately 3–4 mm). (C) A three-dimensional model is created on the basis of DICOM files of the cone beam computed tomography (CBCT) and the titanium mesh is designed and produced with computer-aided design/manufacturing (CAD/CAM) technology. (D) The titanium mesh after production and ready to be used. (E) The recipient site is exposed and the cortical layer is perforated with a round bur to promote bleeding from the cancellous compartment of the mandible. (F) The customized mesh is filled with a mixture of autogenous bone and xenograft particles and fixed with titanium micro-screws. (G, H) The mesh is covered with collagen membranes and the flaps sutured without tension after adequate releasing incisions. (I) Radiographic control immediately after surgery. (J) Clinical control 6 months after the regeneration procedure showing the correction of the initial defect. (K) The CBCT taken after 6 months shows the bone augmentation obtained and planning of implant placement with three implants, 4.1 mm in diameter and 10 mm long. (L, M) After mesh removal, three implants are placed according to the initial plan. (N, O) Final prosthetic result. (P) Radiographic control performed 2.5 years after the completion of the prosthetic rehabilitation showing stability of initial vertical bone gain with extremely limited peri-implant bone resorption.

Dentlearn.ir

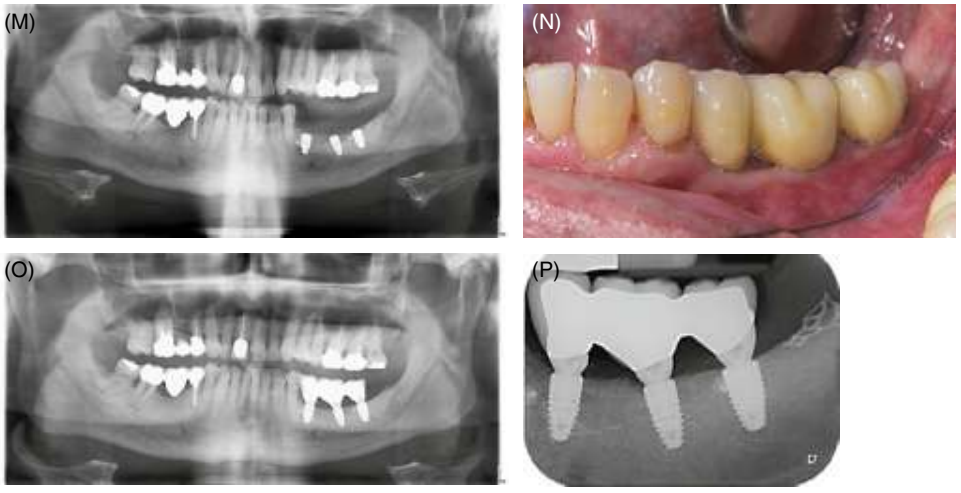

FIGURE 17.8 *(continued)*

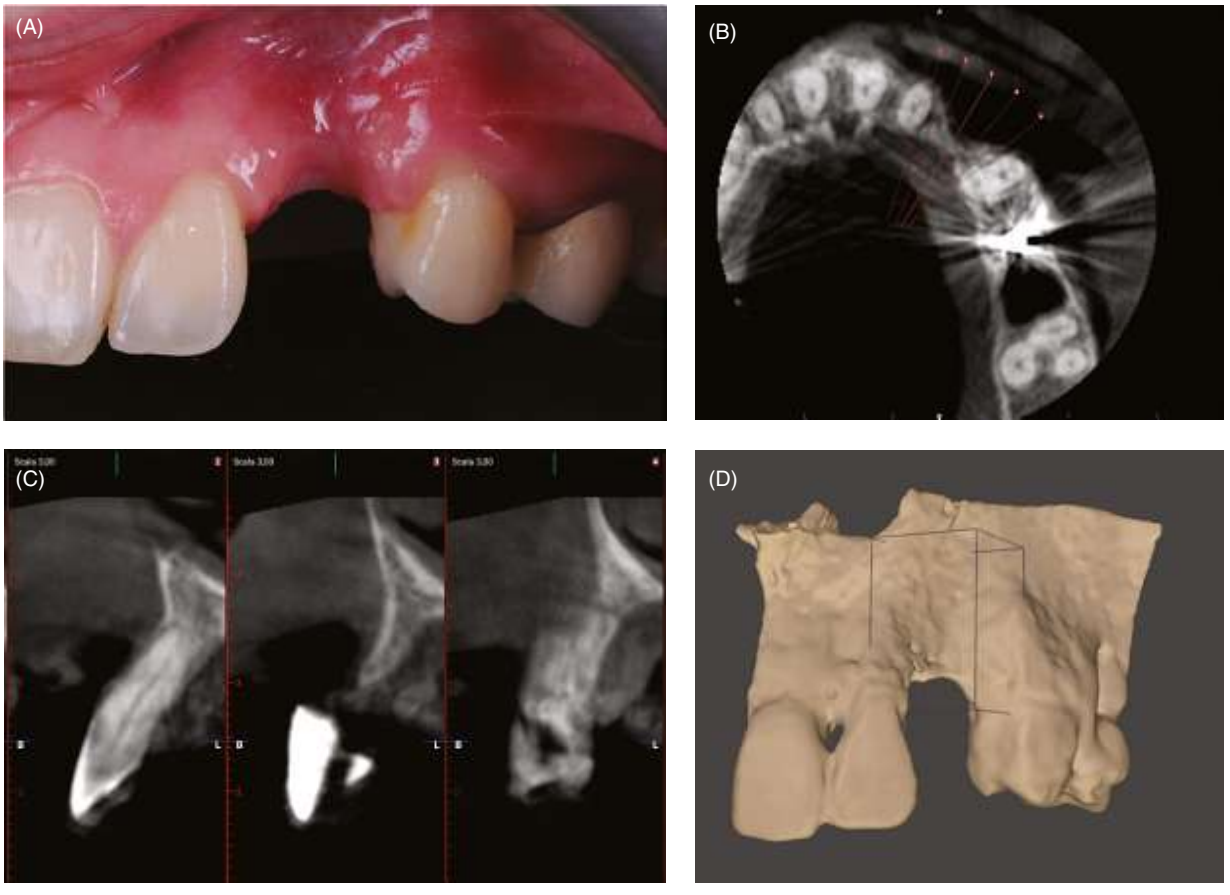

FIGURE 17.9 (A) Initial situation showing vertical and horizontal deficit of the alveolar ridge in the left maxillary cuspid area. (B, C) Cone beam computed tomography (CBCT), done with the patient wearing a diagnostic template, confirms atrophy and an unfavorable relationship between the prosthetic crown and the residual ridge. (D–F) On the basis of the DICOM files of the CBCT, a three-dimensional model is created and the titanium mesh designed and produced with computer-aided design/manufacturing (CAD/CAM) technology. (G) The customized mesh is filled with a mixture of autogenous bone and xenograft particles and fixed with titanium micro-screws. (H) The flaps are sutured without tension after adequate releasing incisions. (I, J) CBCT taken after 6 months shows the bone augmentation obtained and implant planning with one implant, 3.3 mm in diameter and 12 mm long. (K, L) After mesh removal, the implant is placed in the proper position with the aid of a surgical template. (M) Clinical control before final restoration showing the relevant augmentation obtained. (N, O) Final prosthetic result.

Dentlearn.ir

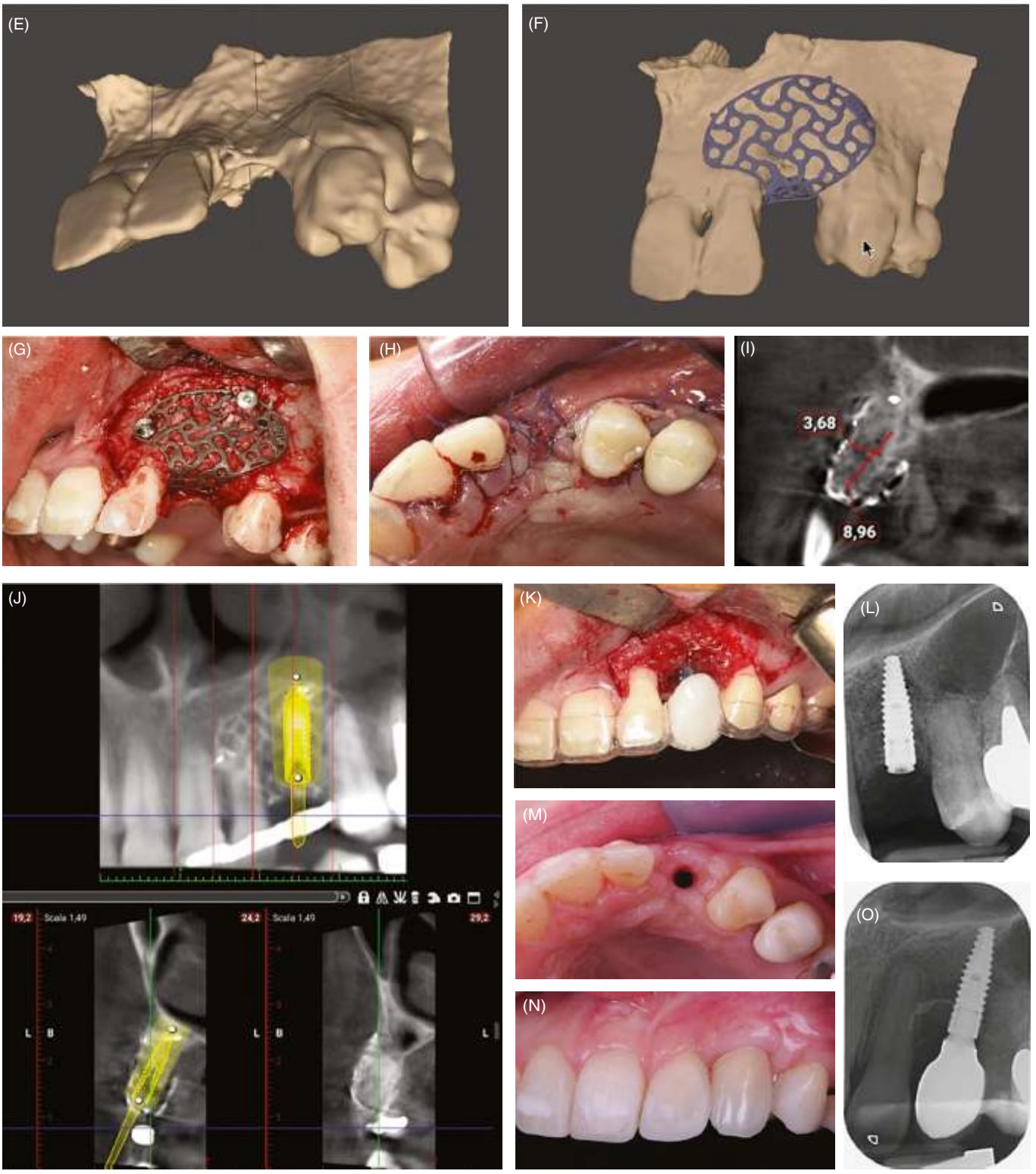

FIGURE 17.9 *(continued)*

Dentlearn.ir

tissues overlying the meshes, either early or late, is still the major drawback of this type of regenerative technique. In a recent publication by the authors of this chapter [23], the overall rate of exposure of a customized titanium mesh was 20.75%.

If we exclude a surgical mistake at the time of surgery (i.e. insufficient release and/or inappropriate suturing technique), which is generally followed by very early dehiscence along the incision line, the etiology of titanium mesh exposures, which may range from minimal to very large, is still unclear, but may include the following:

- Contamination of the surgical site during or immediately after the procedure.
- Mechanical trauma over the flap by removable prostheses.
- Mechanical trauma on the flaps caused by the rigidity of the titanium mesh.
- Reduced vascularization of the flaps because of excessive release, in particular in patients with a thin phenotype.
- Association of two or more of the above.

Although there is no consensus in the literature on the definition of timing and extent of a mesh exposure, we have arbitrarily divided the timing of exposures into:

- Early: within 3 weeks after surgery.
- Late: more than 3 weeks after surgery.

As far as the extent of exposures is concerned, we have arbitrarily divided this into:

- Limited: <10% of the mesh surface.
- Intermediate: 10–30% of the mesh surface.
- Large: >30% of the mesh surface.

We think that an evaluation, although approximate, of the percentage of surface exposure is more appropriate compared to a measurement in square mm or cm (as an example, 1 cm^2 can represent 90% of a small mesh or less than 10% of a large mesh; the clinical implications are evident).

Mesh exposures can be associated with the absence or presence of clinically detectable infection. Sumida et al. [22], in a comparative study, reported an infection rate of 7.7% and 23.1% for customized and non-customized meshes, respectively. In a recent publication on customized titanium meshes [23], clinically detectable suppuration occurred in only 1 site out of 53 (1.9%).

Irrespective of the extent of the exposure, clinical scenarios can be very different and are summarized as follows:

- Early exposure of the mesh with or without evident signs of inflammation/suppuration.
- Late exposure of the mesh with or without evident signs of inflammation/suppuration.

EARLY EXPOSURE OF THE MESH WITH OR WITHOUT EVIDENT SIGNS OF INFLAMMATION/SUPPURATION

An early exposure is generally followed by the expulsion of a variable quantity of grafting material (from minimal to relevant). If a clinically evident infection is absent, it is possible to keep the patient under very strict follow-up by means of daily irrigations with sterile saline, chlorhexidine mouth rinses, and application of chlorhexidine gel over the exposed area. No attempt must be done to resuture the flap over the mesh; this procedure is useless and may also worsen the natural evolution of healing by secondary intention. In fact, once the dehiscence has occurred, the margins are contaminated and a new suture will trap bacteria below the flap, creating an excellent pabulum for bacteria proliferation.

Exposure might be followed by the formation of granulation tissue and eventually re-epithelization just below the inner part of the mesh, providing natural protection to the grafted material. In such a way, there is a chance to obtain integration of the graft with minimal or limited volume loss.

If this process is slow or absent, it is more likely that a higher quantity of the grafted material will be lost, and the volume of initial bone gain will be lower.

In favorable cases, the exposed mesh can be left *in situ* following the standard waiting time (6–9 months). If the bone loss is minimal and compatible with the initial implant plan, the mesh is removed, implants placed, and prosthetic restoration completed, with no changes to the initial plan.

In the case of more relevant bone loss, the clinician and the patient may accept a compromise solution using the available bone with shorter/narrower implants. If the residual gain is judged insufficient to allow an acceptable prosthetic outcome, a new grafting procedure might be proposed. Patients' compliance, elongation of treatment times, and costs are all factors to be taken into consideration [23].

In the case of early exposure and suppuration, irrespective of the extent of the mesh exposure, there are limited chances to rescue the graft and the mesh, despite the use of local and systemic antibiotics. In this circumstance, it is recommended to remove the mesh and the infected bone particles and to let it heal by secondary intention. Some of the graft might be saved, but in the majority of the cases the final outcome will be a clinical situation very similar to the pre-operative one. As already described, patient and clinician will decide either to perform a new regeneration procedure (after a suitable healing time) or to change the prosthetic plan.

Dentlearn.ir

LATE EXPOSURE OF THE MESH WITH OR WITHOUT EVIDENT SIGNS OF INFLAMMATION/ SUPPURATION

A late exposure without clinical evidence of infection/suppuration is generally associated with the formation of granulation tissue and eventually of a layer of epithelium that forms below the inner part of the exposed mesh. In these cases there is a higher chance that, at the time of mesh removal and implant placement, the grafted bone will be consolidated and integrated and can receive implants according to the original, prosthetically guided plan.

In the presence of infection/suppuration not responding to medical therapy, the only solution, as for early exposures, is to remove the mesh. The main difference, compared with early infection/suppuration, is that the grafted bone has, at different levels according to when this adverse event has occurred, a higher chance of surviving and guaranteeing adequate bone volumes to conclude the implant prosthetic plan.

DISCUSSION

Protected regeneration of relevant vertical and/or horizontal bone defects of edentulous ridges with titanium meshes can be considered an alternative to other regeneration procedures, such as GBR or reconstruction with autogenous bone blocks [5, 13, 15, 23, 24, 38].

However, the advantages and disadvantages of protected (mainly) vertical regeneration with titanium meshes must be analyzed and compared with the advantages and disadvantages of the other augmentation procedures. In particular, the following issues must be discussed and compared with the outcomes of GBR and autogenous bone blocks:

- Vertical bone gain.
- Complications, mostly represented by titanium mesh exposure.
- Stability of initial bone gain over time and peri-implant bone resorption.
- Implant survival rates.

VERTICAL BONE GAIN

The literature analysis has demonstrated that relevant vertical bone gains can be obtained with titanium meshes (up to 10 mm), with the majority of articles reporting an average of 4–5 mm [17, 18, 20, 23]. These results are consistent with those obtained with vertical GBR and autogenous bone blocks [2, 5, 10, 24].

COMPLICATIONS

Exposure is still the major drawback of bone regeneration with both conventional and customized titanium meshes. Zhou et al. [38], in a systematic review, reported a mean exposure rate of 44% (conventional = 51%; customized = 31%). In a recent publication by the authors of this chapter, the exposure rate was 20.75% [23]. On the other hand, in a systematic review by Milinkovic and Cordaro [2], the rate of exposure following vertical GBR with non-resorbable membranes ranged from 6.95% to 13.1%.

As regards autogenous bone blocks used for vertical augmentation, the mean exposure rate reported in a systematic review by Chiapasco et al. [7] was 3.3%. In two recent publications by the authors of this chapter, the exposure rate of intraoral (mandibular ramus) and extraoral (calvarium) autogenous bone blocks was 4% and 8.33%, respectively [9, 10].

Although these results are difficult to compare, because of the heterogeneity of the studies, it appears that the exposure rate of titanium meshes is quite high and still represents an unsolved drawback of this regeneration technique.

However, it must be underlined that, despite the relevant percentage of titanium mesh exposures, bone regeneration can be obtained in any case thanks to the low rate of infection and the spontaneous formation of granulation tissue below the exposed mesh. This phenomenon may create a natural barrier protecting the graft and thus make it possible for efficient bone regeneration to occur [20–23].

BONE GAIN MODIFICATIONS BEFORE IMPLANT PLACEMENT

As regards bone gain modifications between the time of protected regeneration with titanium meshes and the time of implant placement, very limited information is available. In the previously cited article by Chiapasco [23] it is observed that, in the majority of cases (with the exclusion of patients with early exposure and high rate of infection), the contraction of the initial vertical bone augmentation was very limited (–0.39±0.64 mm; range –3.1 to +0.80 mm). It is worth noting that in some patients the meshes were partly covered by newly formed bone, demonstrating the efficacy of this type of bone regeneration. This phenomenon was not observed in cases of bone augmentation with GBR or autogenous bone blocks [2, 5–7, 9, 10].

BONE GAIN MODIFICATIONS AFTER IMPLANT PLACEMENT (PERI-IMPLANT BONE RESORPTION)

There is a paucity of data in the available literature regarding peri-implant bone resorption after vertical regeneration with titanium meshes. Chiapasco et al. [23], on a sample of 36 patients and 90 implants placed, reported a peri-implant bone

Dentlearn.ir

loss <1.5 mm after a mean follow-up of 10.6±6.5 months after the start of prosthetic loading.

As regards peri-implant bone resorption after (mainly) vertical regeneration with PTFE membranes, it was shown that marginal bone loss continued over time (–1 mm between 1 and 5 years; –1.7 mm between 5 and 10 years; –2 mm after more than 10 years after the regeneration procedure) [5].

The mean peri-implant bone resorption for intraoral (ramus) and extraoral (calvarium) and grafts were 1.06±1.19 mm (range 0.00–5.05 mm) and 1.11±1.14 mm (range 0.00–4.87 mm), respectively, after a mean observation period of 10 years [9, 10]. These results are also consistent with those reported in other publications [2, 39–42].

SURVIVAL RATE OF IMPLANTS

The survival rate of implants placed in areas treated with protected regeneration with titanium meshes was on average very high, ranging from 98.3% to 100% [18, 20, 23, 43]. Similar results were obtained with vertical regeneration using non-resorbable membranes or with autogenous bone blocks [2, 6–8].

CONCLUSION

According to data available in the literature, it appears that protected regeneration with titanium meshes (both non-customized and customized) in association with mixtures of autogenous bone and xenografts may represent a reliable technique for bone augmentation of atrophic edentulous sites. Compared to conventional titanium meshes, the customized ones present the following advantages: (i) no need for modeling and trimming *in situ*; (ii) increased precision; and (iii) shortened surgical times. Survival rates of implants placed in regenerated areas with titanium meshes are consistent with those obtained with other augmentation procedures, such as GBR or autogenous bone blocks.

However, exposure of the meshes, which occurs at higher percentages as compared to non-resorbable membranes and autogenous bone blocks, as well as the complexity of their removal at the time of implant placement, because of the frequent penetration of soft tissues below the titanium mesh surface, still represent the biggest drawbacks of this procedure.

with website

To access the videos for this chapter, please go to
www.wiley.com/go/tolstunov/essential

VIDEO 17.1 Introduction to Chapter 17 by Authors Drs. Matteo Chiapasco and Grazia Tommasato.

VIDEO 17.2 Guided bone regeneration (GBR) with a customized titanium mesh by Author Dr. Matteo Chiapasco.

REFERENCES

1. Lang NP, Hämmerle CH, Brägger U et al. Guided tissue regeneration in jawbone defects prior to implant placement. *Clin Oral Implants Res.* 1994;5(2):92–7.
2. Milinkovic I, Cordaro L. Are there specific indications for the different alveolar bone augmentation procedures for implant placement? A systematic review. *Int J Oral Maxillofac Implants.* 2014;43:606–25.
3. Benic GI, Hämmerle CH. Horizontal bone augmentation by means of guided bone regeneration. *Periodontol* 2000. 2014;66(1):13–40.
4. Wessing B, Lettner S, Zechner W. Guided bone regeneration with collagen membranes and particulate graft materials: A systematic review and meta-analysis. *Int J Oral Maxillofac Implants.* 2018;33(1):87–100.
5. Urban IA, Montero E, Monje A, Sanz-Sánchez I. Effectiveness of vertical ridge augmentation interventions: A systematic review and meta-analysis. *J Clin Periodontol.* 2019;46(suppl 21):319–39.
6. Chiapasco M, Zaniboni M, Boisco M. Augmentation procedures for the rehabilitation of deficient edentulous ridges with oral implants. *Clin Oral Implants Res.* 2006;17(suppl 2):136–59.
7. Chiapasco M, Casentini P, Zaniboni M. Bone augmentation procedures in implant dentistry. *Int J Oral Maxillofac Implants.* 2009;24:237–59.
8. Aghaloo TL, Misch C, Lin GH et al. Bone augmentation of the edentulous maxilla for implant placement: A systematic review. *Int J Oral Maxillofac Implants.* 2016;31(suppl):s19–s30.
9. Chiapasco M, Tommasato G, Palombo D et al. Dental implants placed in severely atrophic jaws reconstructed with autogenous calvarium, bovine bone mineral, and collagen membranes: A 3- to 19-year retrospective follow-up study. *Clin Oral Implants Res.* 2018;29(7):725–40.
10. Chiapasco M, Tommasato G, Palombo D, Del Fabbro M. A retrospective 10-year mean follow-up of implants placed in ridges grafted using autogenous mandibular blocks covered with bovine bone mineral and collagen membrane. *Clin Oral Implants Res.* 2020;31(4):328–40.
11. Chin M, Toth BA. Distraction osteogenesis in maxillofacial surgery using internal devices: Review of five cases. *J Oral Maxillofac Surg.* 1996;54(1):45–53; discussion 54.
12. Chiapasco M, Consolo U, Bianchi A, Ronchi P. Alveolar distraction osteogenesis for the correction of vertically deficient edentu-

Dentlearn.ir

lous ridges: A multicenter prospective study on humans. *Int J Oral Maxillofac Implants.* 2004;19:399–407.

13. Gongloff RK, Cole M, Whitlow W, Boyne PJ. Titanium mesh and particulate cancellous bone and marrow grafts to augment the maxillary alveolar ridge. *J Oral Maxillofac Surg.* 1986;15(3):263–8.
14. Proussaefs P, Lozada J, Kleinman A et al. The use of titanium mesh in conjunction with autogenous bone graft and inorganic bovine bone mineral (Bio-Oss) for localized alveolar ridge augmentation: A human study. *Int J Periodontics Restorative Dent.* 2003;23(2):185–95.
15. Roccuzzo M, Ramieri G, Bunino M, Berrone S. Autogenous bone graft alone or associated with titanium mesh for vertical alveolar ridge augmentation: A controlled clinical trial. *Clin Oral Implants Res.* 2007;18(3):286–94.
16. Her S, Kang T, Fien MJ. Titanium mesh as an alternative to a membrane for ridge augmentation. *J Oral Maxillofac Surg.* 2012;70:803–10.
17. Miyamoto I, Funaki K, Yamauchi K et al. Alveolar ridge reconstruction with titanium mesh and autogenous particulate bone graft: Computed tomography-based evaluations of augmented bone quality and quantity. *Clin Implant Dent Rel Res.* 2012;14(2):304–11.
18. Briguglio F, Falcomatà D, Marconcini S et al. The use of titanium mesh in guided bone regeneration: A systematic review. *Int J Dent.* 2019;2019:9065423.
19. Xie Y, Li S, Zhang T et al. Titanium mesh for bone augmentation in oral implantology: Current application and progress. *Int J Oral Sci.* 2020;12(1):37.
20. Sagheb K, Schiegnitz E, Moergel M et al. Clinical outcome of alveolar ridge augmentation with individualized CAD-CAM-produced titanium mesh. *Int J Implant Dent.* 2017;3(1):36.
21. Seiler M, Peetz M, Hartmann A, Witkowski R. Individualized CAD/CAM-produced titanium scaffolds for alveolar bone augmentation: A retrospective analysis of dehiscence events in relation to demographic and surgical parameters. *J Oral Sci Rehab.* 2018;4(1):38–46.
22. Sumida T, Otawa N, Kamata YU et al. Custom-made titanium devices as membranes for bone augmentation in implant treatment: Clinical application and the comparison with conventional titanium mesh. *J Craniomaxillofac Surg.* 2015;43(10):2183–8.
23. Chiapasco M, Casentini P, Tommasato G et al. Customized CAD/CAM titanium meshes for the guided bone regeneration of severe alveolar ridge defects: Preliminary results of a retrospective clinical study in humans. *Clin Oral Implants Res.* 2021;32(4):498–510.
24. Troeltzsch M, Troeltzsch M, Kauffmann P et al. Clinical efficacy of grafting materials in alveolar ridge augmentation: A systematic review. *J Craniomaxillofac Surg.* 2016;44(10):1618–29.
25. Chiapasco M, Casentini P. Horizontal bone-augmentation procedures in implant dentistry: Prosthetically guided regeneration. *Periodontol* 2000. 2018;77(1):213–40.
26. Urist MR, Silverman BF, Büring K et al. The bone induction principle. *Clin Orthop Relat Res.* 1967;53:243–83.
27. Precheur H. Bone grafts materials. *Dent Clin N Am.* 2007;51:729–46.
28. Proussaefs P, Lozada J. Use of titanium mesh for staged localized alveolar ridge augmentation: Clinical and histologic-histomorphometric evaluation. *J Oral Implantol.* 2006;32(5):237–47.
29. Pieri F, Corinaldesi G, Fini M et al. Alveolar ridge augmentation with titanium mesh and a combination of autogenous bone and anorganic bovine bone: A 2-year prospective study. *J Periodontol.* 2008;79(11):2093–103.
30. Trento GS, Carvalho PHA, Macedo DV et al. Titanium mesh associated with rhBMP-2 in alveolar ridge reconstruction. *Int J Oral Maxillofac Surg.* 2019;48(4):546–53.
31. Carini F, Longoni S, Amosso E et al. Bone augmentation with TiMesh autologous bone versus autologous bone and bone substitutes. *A systematic review. Ann Stomatol (Roma).* 2014;5(suppl 2):27–36.
32. Titsinides S, Agrogiannis G, Karatzas T. Bone grafting materials in dentoalveolar reconstruction: A comprehensive review. *Jpn Dent Sci Rev.* 2019;55(1):26–32.
33. Dellavia C, Canciani E, Pellegrini G et al. Histological assessment of mandibular bone tissue after guided bone regeneration with customized computer-aided design/computer-assisted manufacture titanium mesh in humans: A cohort study. *Clin Implant Dent Relat Res.* 2021;23(4):600–11.
34. Martin W, Lewis E, Nicol A. Local risk factors for implant therapy. *Int J Oral Maxillofac Implants.* 2009;24(suppl):28–38.
35. Puisys A, Linkevicius T. The influence of mucosal tissue thickening on crestal bone stability around bone-level implants: A prospective controlled clinical trial. *Clin Oral Implants Res.* 2015;26(2):123–9.
36. Thoma DS, Buranawat B, Hämmerle CHF et al. Efficacy of soft tissue augmentation around dental implants and in partially edentulous areas: A systematic review. *J Clin Periodontol.* 2014;41:S77–S91.
37. Gargallo-Albiol J, Barootchi S, Tavelli L, Wang H-L. Efficacy of xenogeneic collagen matrix to augment peri-implant soft tissue thickness compared with autogenous connective tissue graft: A systematic review and meta-analysis. *Int J Oral Maxillofac Implants.* 2019;34(5):1059–69.
38. Zhou L, Su Y, Wang J et al. Effect of exposure rates with customized versus conventional titanium mesh on guided bone regeneration: A systematic review and meta-analysis. *J Oral Implantol.* 2021;Jun 5. doi: 10.1563/aaid-joi-D-20-00200.
39. Quiles JC, Souza FA, Bassi AP et al. Survival rate of osseointegrated implants in atrophic maxillae grafted with calvarial bone: A retrospective study. *Int J Oral Maxillofac Surg.* 2015;44:239–44.
40. Restoy-Lozano A, Dominguez-Mompell JL, Infante-Cossio P et al. Calvarial bone grafting for three-dimensional reconstruction of severe maxillary defects: A case series. *Int J Oral Maxillofac Implants.* 2015;30:880–90.
41. Mertens C, Decker C, Seeberger R et al. Early bone resorption after vertical bone augmentation: A comparison of calvarial and iliac grafts. *Clin Oral Implants Res.* 2013;24: 820–25.
42. Mertens C, Freier K, Engel M et al. Reconstruction of the severely atrophic edentulous maxillae with calvarial bone grafts. *Clin Oral Implants Res.* 2017;28:749–56.
43. Rasia-dal Polo M, Poli PP, Rancitelli D et al. Alveolar ridge reconstruction with titanium meshes: A systematic review of the literature. *Med Oral Patol Oral Cir Bucal.* 2014;19(6):e639–e646.

Dentlearn.ir

Autogenous Block Bone Graft for (Mainly) Vertical Ridge Augmentation in Implant Dentistry

CHAPTER 18

Vertical ridge augmentation has always posed a challenge, even to the skilled surgeon. In this chapter, the authors review non-vascularized autogenous block bone grafting techniques for vertical alveolar bone augmentation. The chapter discusses indications, contraindications, advantages, and limits of this reconstructive procedure.

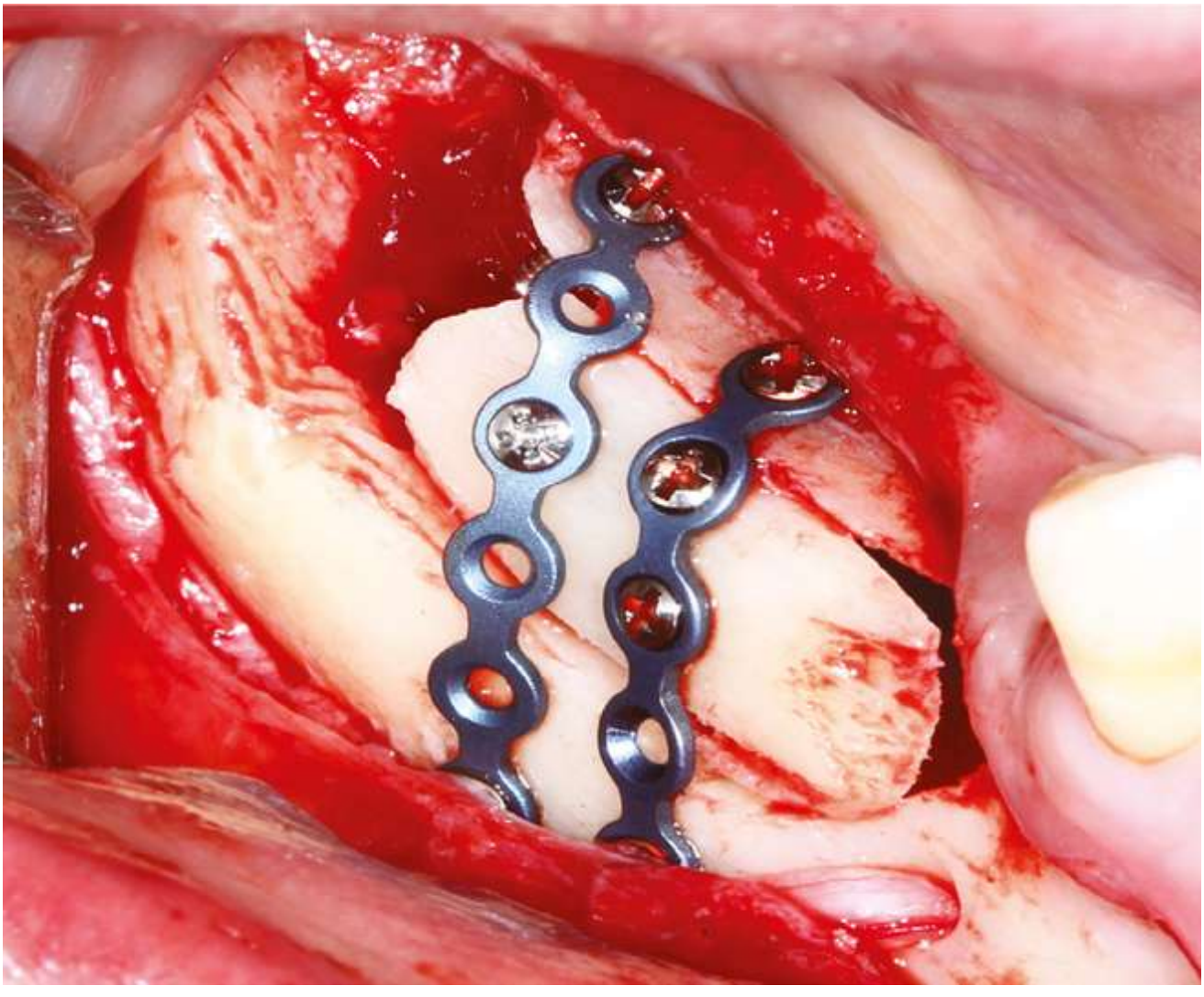

Dentlearn.ir

CHAPTER 18

Autogenous Block Bone Graft for (Mainly) Vertical Ridge Augmentation in Implant Dentistry

Arash Khojasteh[1,2] and Vishtasb Broumand[3,4]

[1]*Oral and Maxillofacial Surgery Department, Dental Research Center, Research Institute of Dental Sciences, Shahid Beheshti University of Medical Sciences, Tehran, Iran*

[2]*Faculty of Health and Medicine, University of Antwerp, Antwerp, Belgium*

[3]*Private Practice, Oral and Maxillofacial Surgery, Desert Ridge Oral Surgery Institute, Phoenix, AZ, USA*

[4]*Department of Oral and Maxillofacial Surgery, University of Arizona College of Medicine at Banner University Medical Center, Phoenix, AZ, USA*

Osseous defects of the maxillofacial region, prompting the investigation of autogenous bone harvest sites and advancement of grafting techniques, have long been a driving force in the clinical practice of surgeons focused on the head and neck region. More specifically, the return of the maxilla and mandible to near-anatomical shape and size for dental rehabilitation with endosseous implants is constantly an area of interest. Defects of the maxilla and mandible often range from those associated with continuity defects to smaller, localized losses of the alveolar bone proper. These osseous defects frequently are the result of head and neck cancer, oral pathological processes, facial trauma, dental infection, or due to loss of teeth and aging because of poor dental health. To narrow the scope of discussion, focus will be given here only to the vertical augmentation of the maxillary and mandibular ridges [1].

The history of bone grafting is intertwined with conflict, as many of the publications and advancements associated with this topic have been the direct result of armed conflicts such as World Wars I and II. While many of the techniques previously developed such as the block tibial harvest have fallen from use, these early pioneers paved the way out of an era where facial osseous defects often went unconstructed to today, when bone grafts have developed into much more of a science. In this field, autogenous bone has long proved to be the gold standard, but rapid developments in the understanding of bone physiology and growth have led to near-equal if not superior results with no autogenous harvest required. While many of the alternatives to autogenous bone grafting have proven to be quite technique sensitive, the tried-and-true methods of block graft harvesting and subsequent vertical ridge augmentation within the scope of the oral and maxillofacial surgeon will be covered here in detail. The optimal donor site depends on the volume and type of regenerated bone needed for the specific case. The common sites for nonvascular block bone harvests, techniques for bone grafting, indications, contraindications, and caveats and various pitfalls will be discussed.

RECIPIENT SITE CLASSIFICATION AND DEFECT ANALYSIS

The focus of bone grafting studies has been mainly on improving the techniques and introducing novel augmentation materials to provide more promising outcomes. However, the variation among studies does not allow for a generalized conclusion on the effectiveness of the suggested protocols. This inconsistency may be partly due to imprecise consideration of the properties of recipient sites within the study designs [2]. Khojasteh et al. presented their classification based on the importance of the vertical bone walls and width of the recipient site [2]. When the recipient site has two vertical walls it is class A, whereas with one vertical wall it is class B, and without walls it is class C.

The second feature considered in the current classification is the width of the defect's base. The width is divided into three groups: I, more than 5 mm; II, between 3 and 5 mm; III, less than 3 mm (Figure 18.1). Another potential factor affecting bone regeneration is the length of the

Essential Techniques of Alveolar Bone Augmentation in Implant Dentistry: A Surgical Manual, Second Edition. Edited by Len Tolstunov.
© 2023 John Wiley & Sons, Inc. Published 2023 by John Wiley & Sons, Inc.
Companion website: www.wiley.com/go/tolstunov/essential

Dentlearn.ir

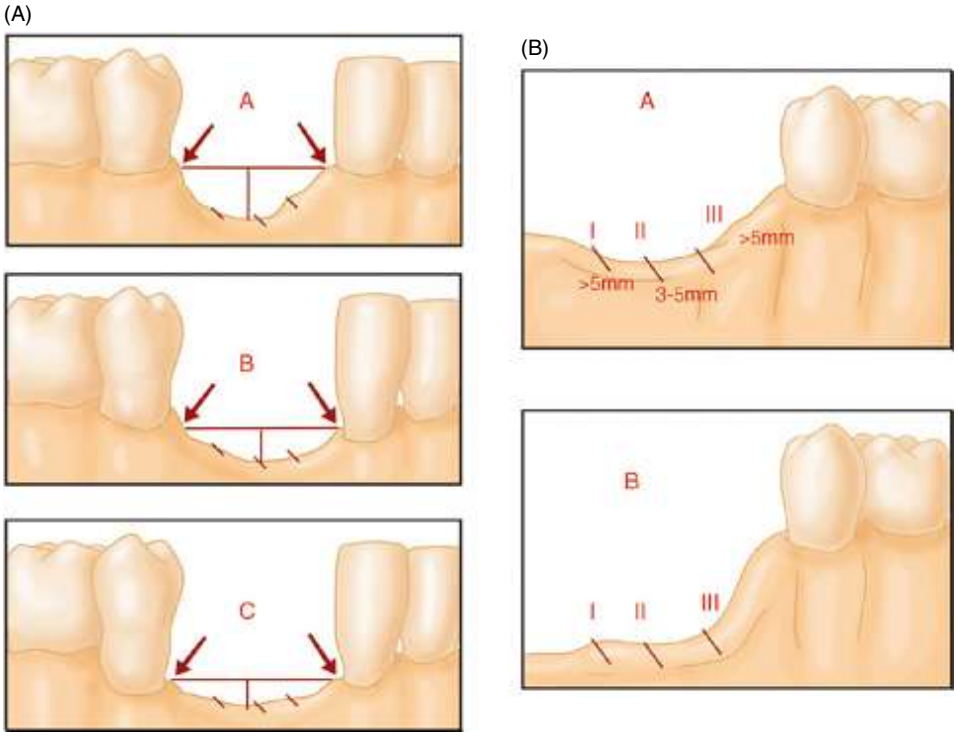

FIGURE 18.1 (A) Class A: two-wall defect; Class B: one-wall defect; Class C: defect with no surrounding bony walls. (B) Width of the defect's base: Class I: >5 mm; Class II: between 3 mm and 5 mm; Class III: <3 mm.

edentulous span, which alters the surface area of a defect, hence influencing the degree of vascularization. Various studies have demarcated this factor by using terms such as localized or extensive ridge augmentation, though these have not been explicitly defined. Localized defects seem to pertain to missing teeth areas within a range of 1–6 teeth [1], while extensive augmentations often indicate a fully edentulous jaw [3]. Location of the defect in the maxilla or mandible and proximity to the vital structure also affect the selection of either donor site or augmentation technique. The anatomical location of the alveolar bone defect might affect the outcome of bone healing. Anterior and posterior parts of the maxilla and mandible represent dissimilar bone qualities. This categorization is based on the location of the bone defects (anterior, posterior, and the combination of both locations) and the size of defects (small, medium, and large) (Figure 18.2) [4].

DONOR SITES FOR BLOCK BONE

INTRAORAL HARVEST

Short and narrow dental implants with a bioactive surface showed higher survival and decreased pre-prosthetic procedures before dental implant placement. This paradigm shift put the intraoral donor sites as the main choice for treatment of localized atrophied jaw defects.

Mandibular Donor Sites

Ramus-External Oblique Ridge The lateral mandibular surface area is the most popular source providing blocks for bone augmentation. The external oblique ridge distal to the lower second molar represents the main anatomical area of this donor site. Horizontal and vertical defects up to 3–5 mm thickness and 20 mm length can be augmented with this donor site [5]. The dimensions of ramus cortical bone blocks are 4 mm (thickness) × 15–45 mm (length) × 10–15 mm (height), depending on the regional anatomy. The bone has a 100% cortical nature. The lateral ramus as an intraoral donor site showed 17.4% of bone resorption after 4–6 months of block bone grafting. It showed a 5.75 mm increase in initial height [6]. The lateral ramus cortical bone (LRCB) can be sectioned into 3–4 pieces and milled to particulate form (Figure 18.3). Block harvesting can proceed in two different ways: vestibular or sulcular. Osteotomy lines should be confined to cortical bone to avoid inferior alveolar nerve (IAN) injury. The anterior vertical osteotomy line can be drawn where the external oblique ridge fades to the mandibular body (usually at the location of the lower second molar). The distal vertical line can be extended to the coronoid notch, depending on the length of the cortical bone needed (up to 4 cm). Two vertical lines connect with the horizontal osteotomy line in the lateral third of the anterior border of the ramus. The inferior horizontal osteotomy is 10–15 mm away from the superior

Dentlearn.ir

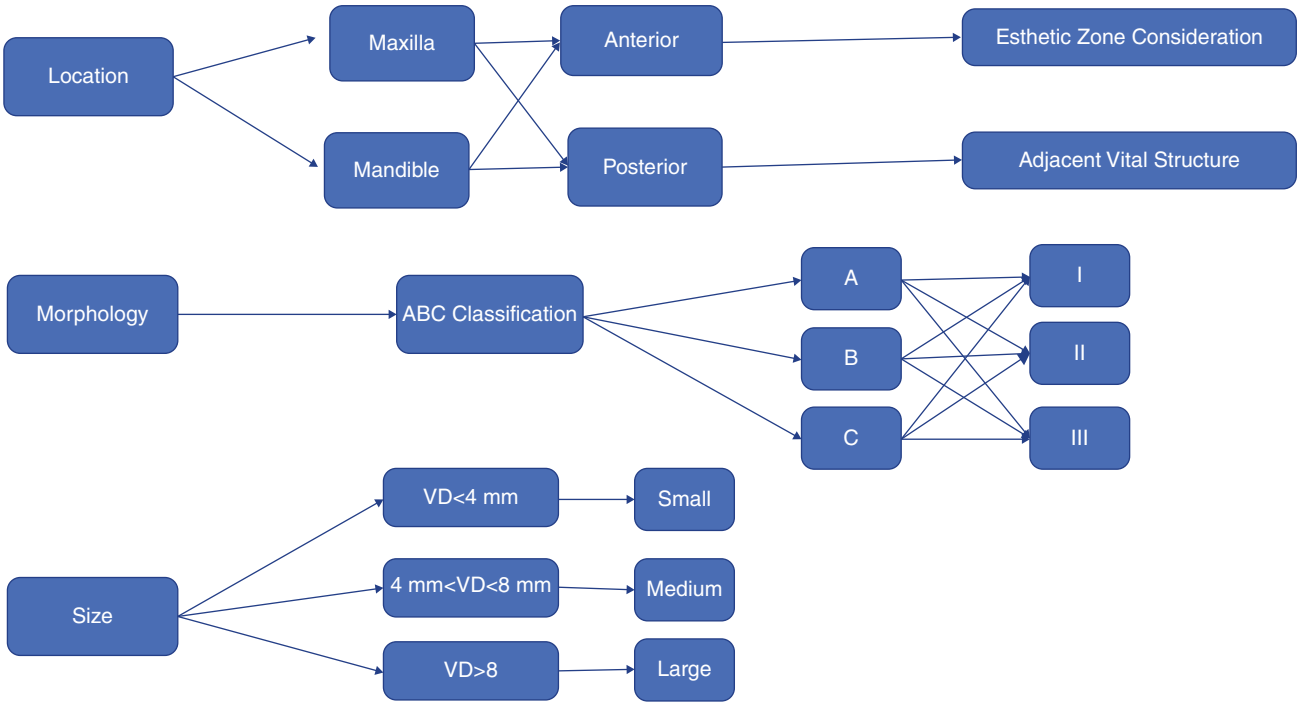

FIGURE 18.2 Recipient site analysis in vertical defect according to the **L**ocation, **S**ize, and **M**orphology of the defect (LMS system). VD: vertical defect.

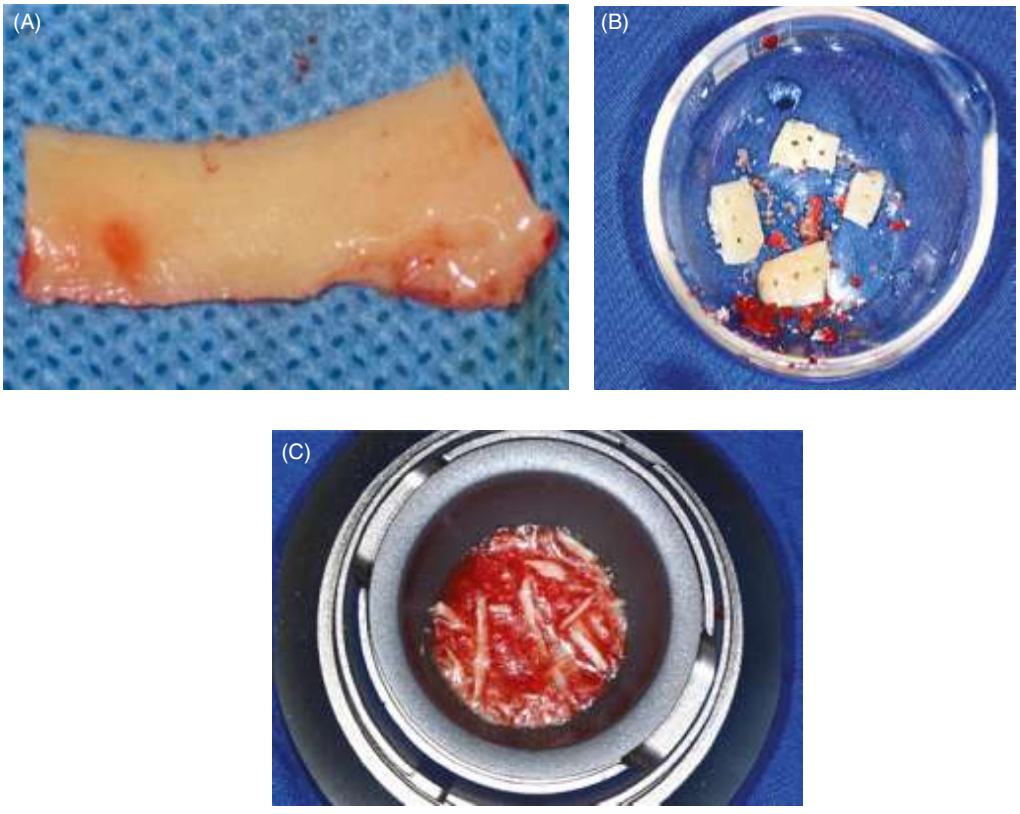

FIGURE 18.3 Lateral ramus cortical plate. (A) Up to 3 cm could be harvested. (B) Cutting the cortical plate into four pieces. (C) Milling the cortical plate to particulate bone.

Dentlearn.ir

line. A gentle tap with an 8 mm osteotome or a chisel helps to outfracture the lateral cortical plate. The proximity of the graft harvest site is an opportunity for posterior mandibular block augmentation. A low rate of post-operative complication and acquaintance with the regional anatomy are advantages of this donor site [7]. In contrast, the limited amount of available bone for large defects and the cortical nature of the bone are the disadvantages. The risk of neuro-sensory disturbance, mandibular angle fracture, bleeding, and trismus can be avoided with the correct method of bone harvesting.

Chin (Symphysis) A cortical or cortico-cancellous block graft up to 4 cm can be harvested from the mandibular symphysis area. The mandibular symphysis as a donor site has been documented to provide sufficient bone to reconstruct alveolar ridge defects 15 mm in horizontal and up to 4 mm in vertical dimensions, and can cover a span up to three teeth in length [8]. The dimension of block bone from this site is 10 mm (height) × 15–17 mm (width) × 6 mm (thickness) and can provide 50% larger graft volume in comparison to the lateral ramus region [9]. The density of the chin bone is between D1 and D2 and consists of 65% cortical bone and 36% cancellous bone [10]. There are three basic approaches to access the mandibular symphysis for bone graft harvesting: sulcular, attached gingiva, or vestibular. The advantages of the sulcular and attached gingiva approaches are reductions in wound dehiscence and bleeding compared to the vestibular approach. Use of the sulcular approach is not advocated in pre-existing periodontal disease or crown margins [11]. It is suggested that at least 5 mm bone is maintained below the teeth apexes, in the mandibular inferior border and bilaterally anterior to the mental foramen. When the aim is to harvest a large bone block, do not violate the anterior-most portion of the symphysis, the mental protuberance. If it is necessary to harvest two graft blocks from each side, leave a 3 mm mid-line connection to maintain support for the chin profile (Figure 18.4) [12]. A fine osteotome or chisel can be used to reflect the block bone graft from its bed. After block removal, a hemostatic agent can be used in the bone harvested site. Some clinicians prefer to graft the site with allogenic or xenogeneic bone substitute, especially when a large block has been harvested. In the vestibular approach, in the closing stage a resorbable suture is first used to attach the mentalis muscle to the 3 mm periosteal muscle layer left on the bone side.

Maxillary Donor Sites

Anterior Palate This area is used as a donor site usually for anterior maxillary reconstruction surgeries, especially when an impacted canine is imbedded in this region. A cortico-cancellous block and cancellous or crescent-shaped grafts could be harvested from this site. The average amount of bone in this area in dentate patients is 2 cc and 2.4 cc in edentulous patients (Figure 18.5) [13].

Maxillary Tuberosity This region is typically used for harvesting cancellous bone to fill defect cavities, especially for sinus lifting procedures. Existence of the third molar in this site decreases the available bone for harvesting. Other anatomical limitations for using it include the maxillary sinus, pterygoid plates, and the greater palatine canal. Tolstunov [14] proposes harvesting of tuberosity block for vertical augmentation of a localized upper jaw defect. The quality of tuberosity bone usually falls within D3–D4 quality and the bone marrow in that region falls within the cancellous bone with fatty degeneration, so a particulate mixture of the bone with xenograft is recommended in many studies. Khojasteh and Tolstunov [15] introduced the tubero-alveolar block (TAB) as a donor site for block bone augmentation. With the absence of the upper third molar and distal pneumatization of the maxillary sinus, the osteotomy design could be extended to the alveolar bone crest

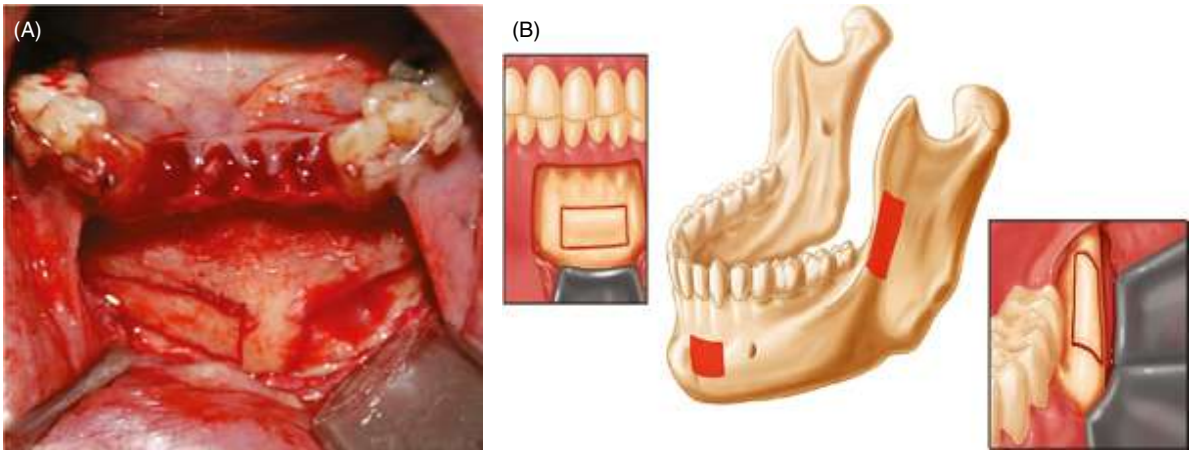

FIGURE 18.4 (A) Drawing an osteotomy line in the symphysis area. Pay attention to preserving the anterior portion of the chin. (B) Schematic image of the mandibular lateral ramus donor site and symphysis bone.

Dentlearn.ir

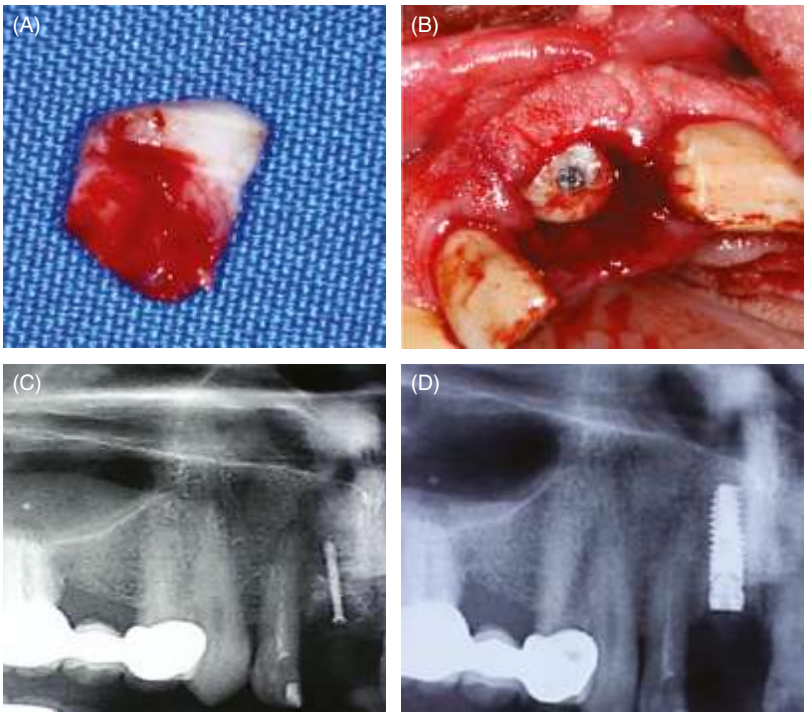

FIGURE 18.5 (A) Harvesting anterior palate block graft. (B) Graft fixation with micro-screw. (C) Radiographic evaluation showed cortical block stability after 4 months. (D) Radiograph of the dental implant in the anterior maxillary block–augmented site.

and increase both the quantity and quality of the harvested bone. The harvested bone can be sectioned and fixed with micro-screws. The main indication for the use of tuberosity block is vertical block augmentation in the posterior maxilla, because of proximity of the recipient site (Figure 18.6).

Extraoral Donor Sites

Extraoral donor sites that have mainly been used for the treatment of extensive atrophied jawbone defects are the anterior and posterior iliac crest (PIC), calvaria, and anterior tibia bone. This serves as a non-vascularized free piece of cortico-cancellous bone in onlay or inlay techniques.

Posterior Iliac Crest The PIC has been demonstrated to have 100–150 mL of cortico-cancellous bone [16]. The bone stock available in the posterior ilium has been found to be highly osteogenic, osteoinductive, and osteoconductive. Severely osteoporotic individuals, previous hip replacements, and retained hardware from a previous femur fracture are relative contraindications for PIC [17]. The most commonly reported complication is formation of a seroma, which is treated by aspiration and a pressure dressing. As mentioned, nerve injury to the superior or middle cluneal nerves can cause dyesthesia and paresthesia of the buttocks, but this is rarely a complaint of the patient in the authors' experience. Also, while damage

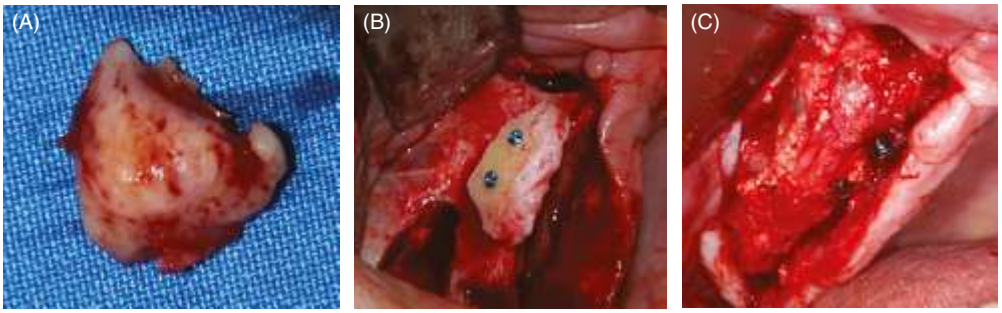

FIGURE 18.6 (A) Tubero-alveolar block harvesting. (B) Micro-screw fixation of harvested block. (C) Dental implant placement in the block-augmented site that has been mixed with bone substitute at the time of augmentation.

Dentlearn.ir

to the sciatic nerve with associated lower-extremity motor function compromise is possible, an overaggressive dissection of more than 6–8 cm from the PIC would most likely be the cause. There is a representation of PIC harvesting and important anatomical landmarks in Figure 18.7.

Anterior Iliac Crest A source of cortical bone of up to 5 × 5 cm and 30–50 mL of uncompressed cancellous marrow can be harvested from the anterior iliac crest (AIC) [18]. The anterior ilium has a plethora of osteoprogenitor cells, which allows for favorable bone growth as well as rapid revascularization. The most common complications associated with AIC bone graft harvest are seroma formation, bruising, and gait disturbance associated with disturbance of the tensor fascia latae. As mentioned, major complications have been reported in small numbers to include fracture of the ilium, perforation of the peritoneum and/or bowel, infection, and sensory nerve damage [19]. One must maintain the cartilaginous cap in children, therefore during the harvest the surgeon must either split or maintain it. The AIC showed a resorption range between 20% and 92% in 10-year follow-up [20]. A representation of AIC harvesting and important anatomical landmarks is given in Figure 18.8.

Calvarium Cortical block is harvested from the parietal region, posterior to the pinna, where the calvarium is thickest, and a full-thickness graft on average can yield 7–8 mm of width [21]. A split-thickness harvest, however, can safely provide excellent bone stock from this region. The bone from this region has shown exceptional resistance to resorption once reimplanted compared to other autogenous sources [22]. In split-thickness harvest the area of interest should be outlined

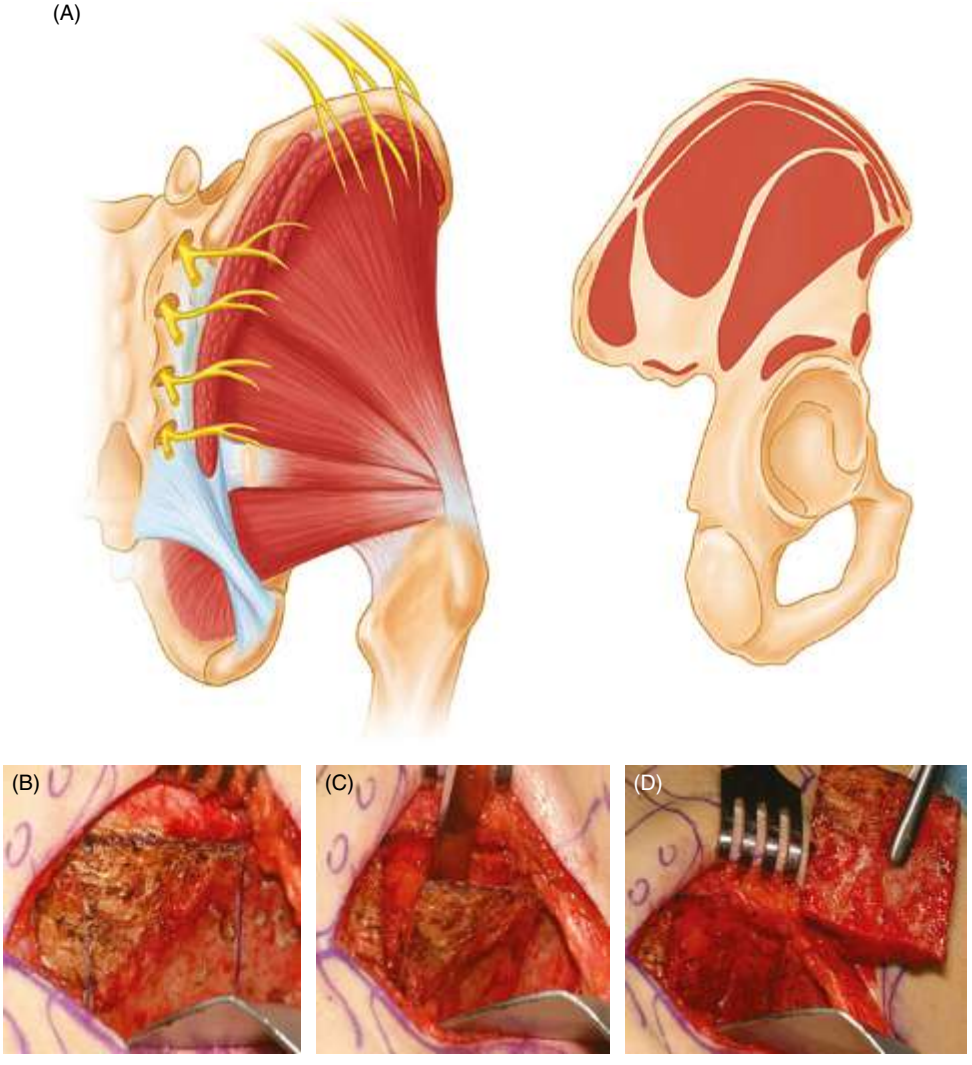

FIGURE 18.7 (A) Anatomical landmark for harvesting posterior iliac bone. (B–D) Dissection and bone harvesting of cortico-cancellous block.

Dentlearn.ir

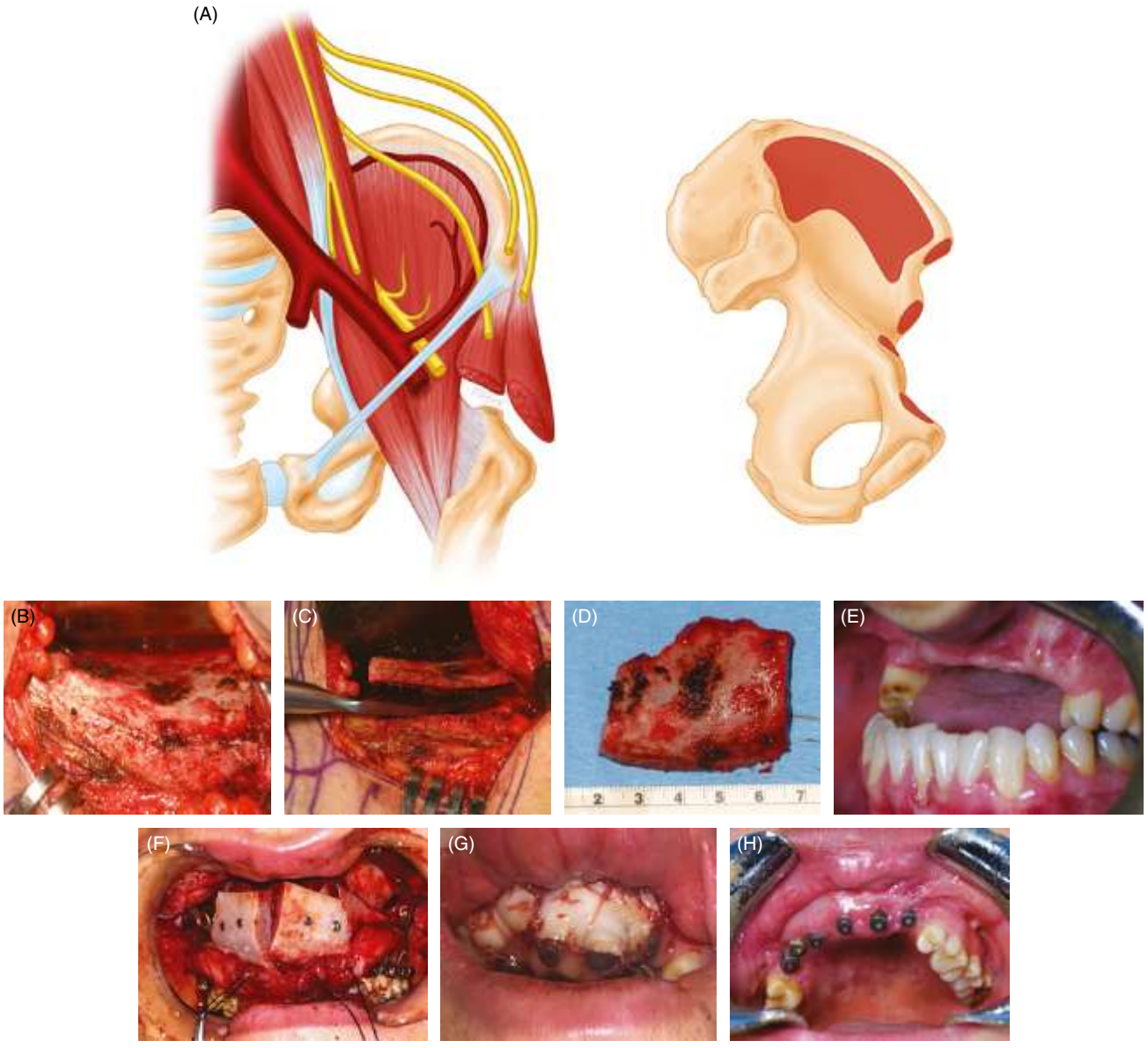

FIGURE 18.8 (A–D) Anatomical landmarks and harvesting technique for anterior iliac crest. (E–H) Representative case of anterior maxillary reconstruction with anterior hip cortico-cancellous block.

with a fissure bur into the diploe. The use of an acrylic or barrel bur can aid in beveling the peripheral bone around the graft to facilitate the insertion of osteotomes. Curved osteotomes can then be used in a circumferential fashion, taking care not to elevate with the chisel, as this carries a risk of fracturing the inner table. Complications associated with the procedure are rare and usually minor in nature, although they can be devastating. The more common complications include alopecia near the incision and hematoma formation. Other complications, while rare, may present when the inner table is perforated, including cerebrospinal fluid leak, extradural hematoma, and direct intracerebral trauma. A representation of cranial bone harvesting and important anatomical landmarks is given in Figure 18.9.

AUGMENTATION TECHNIQUES

ONLAY BLOCK BONE GRAFTING

Block bone grafting by harvesting a piece of bone from either extraoral or intraoral donor sites allows three-dimensional reconstruction of defects with complicated morphology. The block bone graft should be stabilized on the recipient bed by

Dentlearn.ir

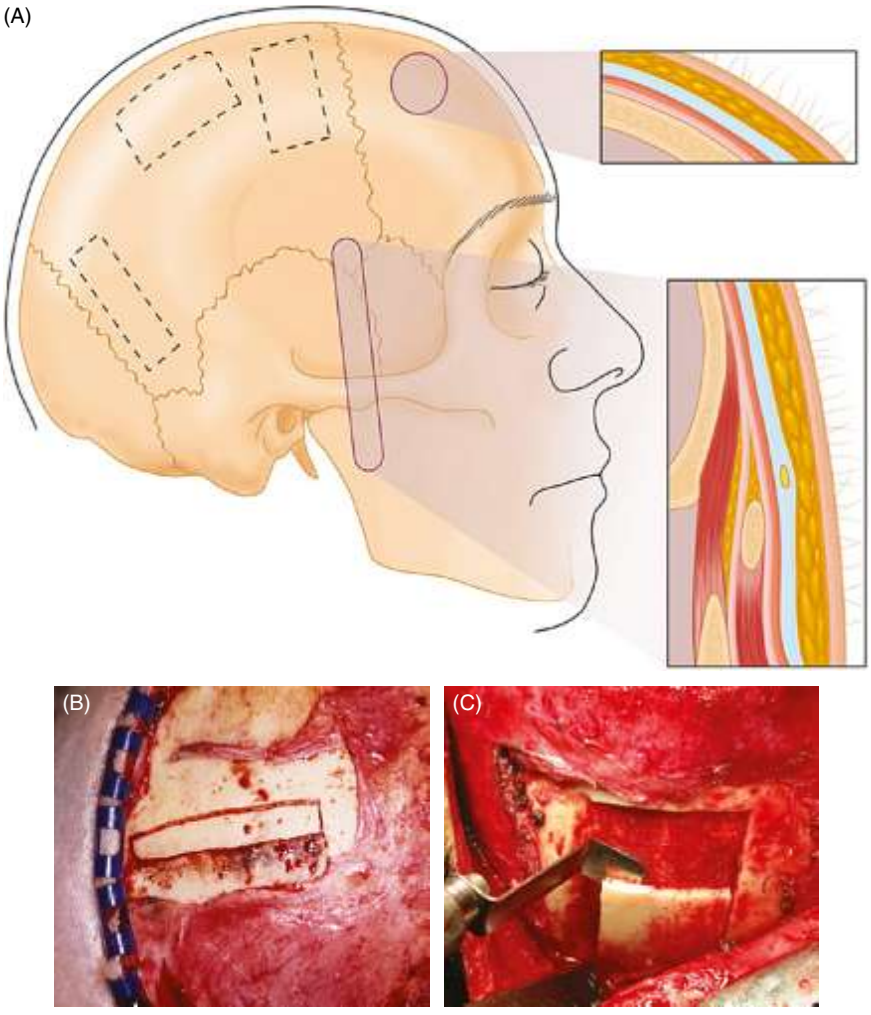

FIGURE 18.9 (A–C) Anatomical landmark and cortical block harvesting technique from calvarial bone.

fixation with micro/mini-screws or plates. During the healing period, the grafted bone is gradually replaced by new regenerate and depends on revascularization from the recipient site [23]. The proliferative phase and revascularization are initiated as soon as the graft is placed, but capillary buds first appear and penetrate the graft by day 3. Complete vascularization of the graft occurs by the end of the second week. Although revascularization is usually complete by days 10–14, it is dependent upon graft size/thickness and the vascularity of the local tissue bed. Therefore, perforation of the recipient site is recommended to enhance angiogenesis and provide osteogenic cells [24]. By 4 months, bone graft integration is complete.

Cortical grafts are able to withstand early mechanical forces; however, they require more time to revascularize. Common donor sites include cranium, iliac crest, ribs, mandibular symphysis, and the external oblique ridge [25]. The advantage of cancellous grafts is an apparent increase in healing rate. The most abundant supply can be harvested from the AIC or PIC. The only apparent disadvantage of autogenous cancellous grafts is their inability to provide mechanical stability, and in general they tend to undergo more resorption [26].

Cancellous bone revascularizes better and is strengthened by creeping substitution in comparison to cortical bone [27]. The main disadvantage of autogenous onlay bone grafting (OBG) is donor site morbidity [28]. Based on a retrospective study by Schwartz-Arad et al. focused on the surgical success of intraoral autogenous onlay block for alveolar ridge augmentation, the average vertical gain was approximately 5.6 mm from the bottom of the vertical defect prior to grafting to the top of the onlay block. In this study there was no relationship between complications or failure rates and type of bone source, length of recipient site, and recipient site areas [7]. Secondary bone resorption is the main challenge in autogenous block grafting. The AIC showed a resorption

Dentlearn.ir

range between 20% to 92% in 10-year follow-up [20, 29]. The lateral ramus as an intraoral donor site showed 17.4% of bone resorption after 4–6 months of bone grafting [3]. Merging with various concepts of guided bone regeneration (GBR) modifies OBG. For instance, after fixing block bone to the recipient site, bovine bone mineral or human mineral bone is applied to fill the gap, or creating a large protected healing space with the tent-pole technique helps to increase the amount of vertical bone augmentation (Figure 18.10) [30]. The application of resorbable or non-resorbable membrane showed better results in the amount of bone gain when used in vertical defects [31].

CORTICAL AUTOGENOUS BLOCK TENTING

The three-dimensional reconstruction technique successfully applied the concept of exploiting high-strength cortical bone blocks for the protection of particulate bone [32]. The efficacy of this concept was subsequently proved with the cortical tenting technique, in which cortical blocks were tented over the particulate material to increase the ridge width [25]. In fact, thin cortical bone in this condition acts as an osteogenic membrane that provides a roof for a protected healing space. The lateral ramus and chin cortical bone are well adapted for cortical autogenous tenting (CAT; Figure 18.11). The bone block(s) were placed at least 3–4 mm from the vertically deficient site or buccal to the lateral surface of the horizontally deficient ridge. Fixation micro-screws were tightened while a periosteal elevator was placed between the bone block and the recipient site to maintain the desired distance. Particulate bone substitute materials were used to fill the gap between the graft and the recipient site (Figure 18.12). When the cortical bone has a thickness of more than 2 mm, a bone scraper is used to thin the bone. By gentle use of a wheel saw, the cortical piece may provide two thinned cortical layers and be used on both labial and lingual sides [25]. In larger defects such as "B" or "C" defects, multiple cortical autogenous tenting (mCAT) or bilateral CAT (biCAT) can help in proper implant position. In this way a large piece of LRCB is harvested, cut into 2–3 pieces, and tented on both facial and lingual sides (Figure 18.13). Prolonged treatment time, soft tissue complications, graft failure, and donor site morbidity cause block bone tenting to be a technique-sensitive procedure. Simultaneous placement of implants might be considered a way to shorten the treatment period (Figure 18.14), While using a graft prior to implant therapy, complications such as graft exposure, infection, and failure may result in implant failure [25].

ANATOMICAL TRANSPOSITIONING

Onlay techniques have several limitations in vertical bone augmentation. The amount of new regenerated bone, related soft tissue complications, donor site morbidity, and the patient's medical condition narrow our decision in treating patients with jaw atrophy. Vital structure repositioning such

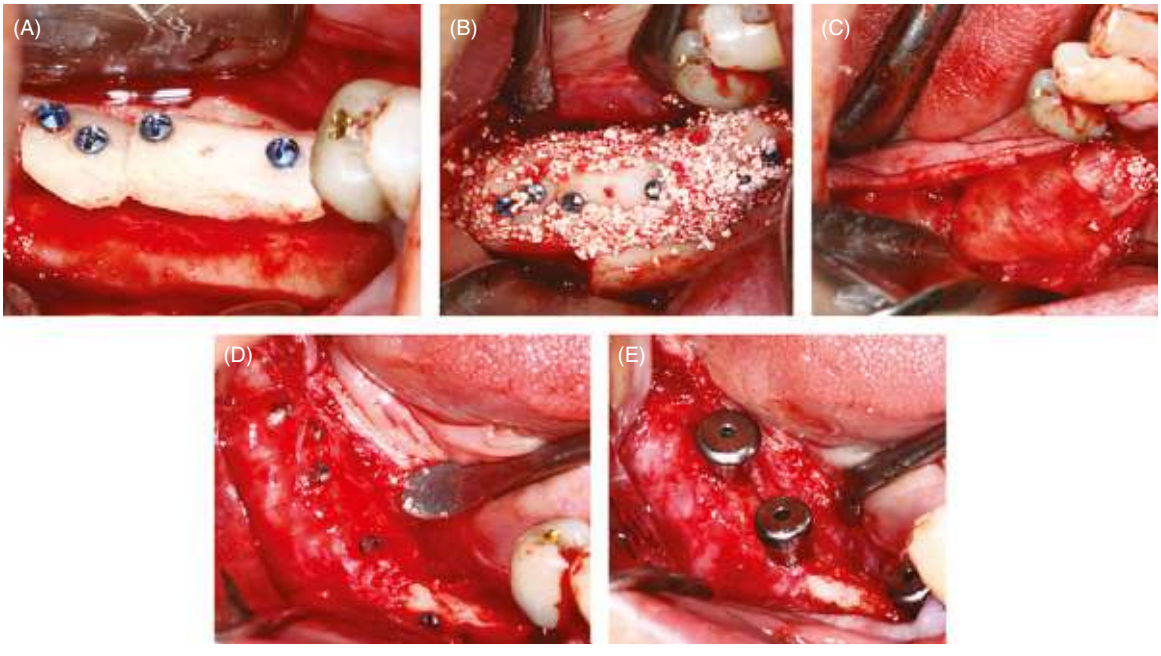

FIGURE 18.10 (A) Onlay bone grafting with lateral ramus cortical plate. (B) Covering the block bone with bovine bone mineral. (C) Covering with collagen membrane. (D) Five months re-entry showed successful vertical bone regeneration. (E) Dental implant placement in the grafted site.

Dentlearn.ir

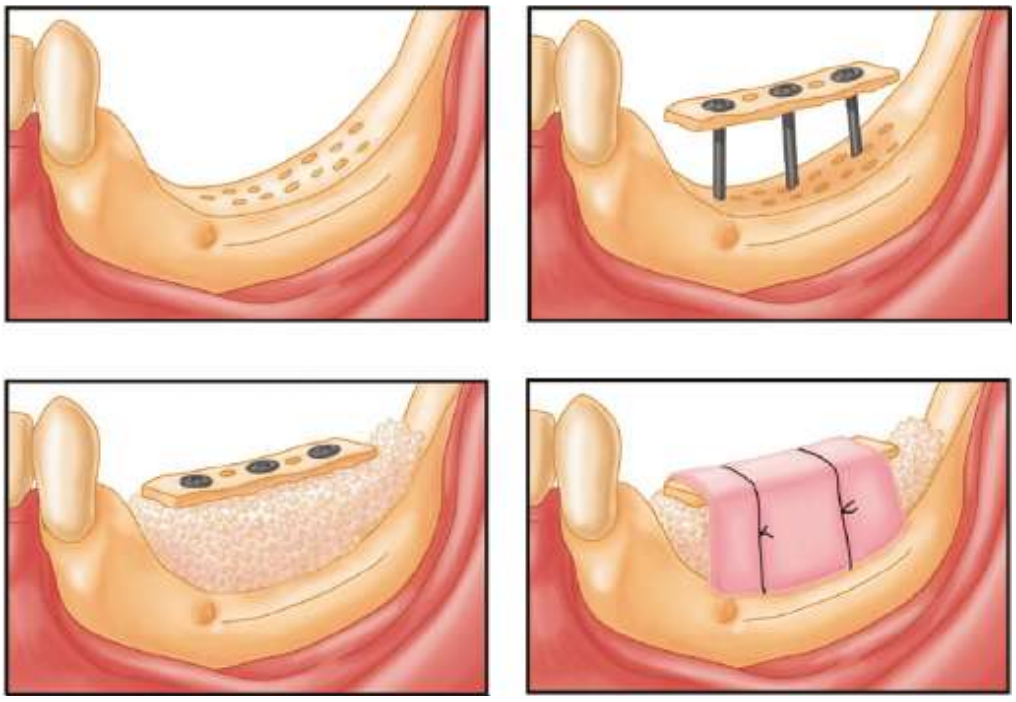

FIGURE 18.11 Schematic drawing presenting the principle of the cortical autogenous tenting (CAT) technique.

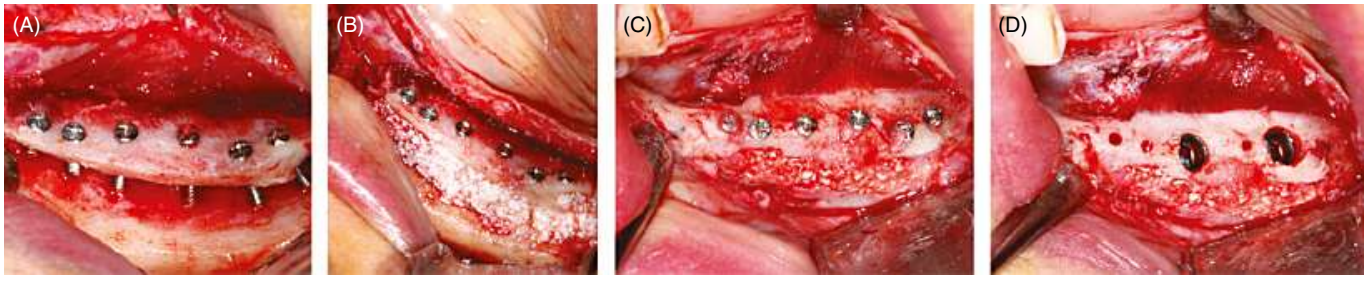

FIGURE 18.12 Cortical autogenous tenting (CAT) in the posterior mandible "C" defect. (A) Harvesting a large piece of lateral ramus cortical bone. (B) Cortical tenting with 4–5 mm distance. (C) Filling the space with natural bovine bone mineral. (D) Dental implant placement in grafted site.

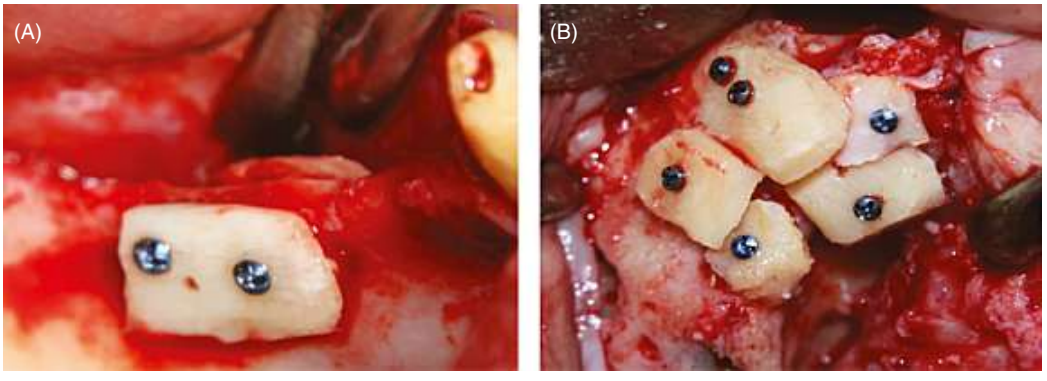

FIGURE 18.13 (A) Bilateral cortical autogenous tenting (CAT) in the posterior mandible. (B) Multiple CAT in the posterior maxilla.

Dentlearn.ir

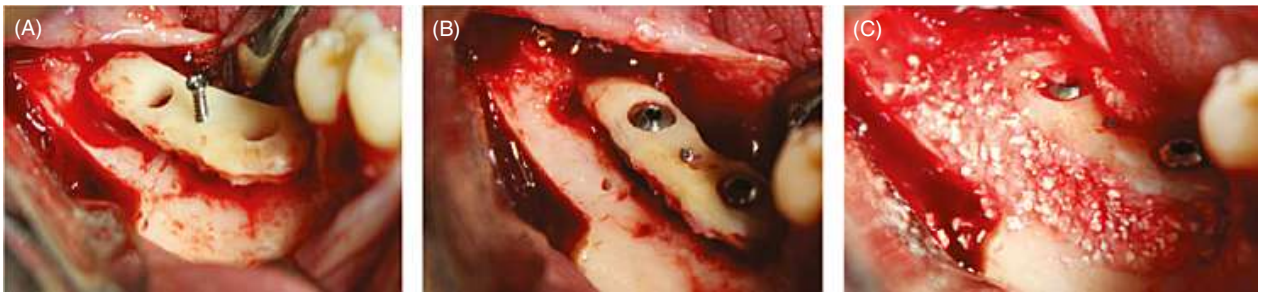

FIGURE 18.14 Simultaneous implant placement with cortical autogenous tenting (CAT). (A) Pre-drilled lateral ramus cortical bone. (B) CAT. (C) Simultaneous implant placement. Filling the gap with allograft.

as sinus floor augmentation in the posterior maxilla and IAN lateralization in the posterior mandible showed successful results in patient rehabilitation. Displacing of the recipient site bone in inlay bone grafting (IBG) or gradual distraction (distraction osteogenesis) of the osteotomized bone also revealed promising results.

INLAY (INTERPOSITIONAL) BONE GRAFTING (SANDWICH TECHNIQUE)

Horizontal osteotomy with interposition of bone in the form of a sandwich, also known as an "inlay," was described by Schettler [33]. Felice et al. showed that autogenous block, heterogenous block, or particulate bone in the sandwich gap would have the same result [34]. A three-wall trapezoid-like osteotomy line is drawn in the atrophic area with a thin fissure bur or piezo surgical blade. The wider side of the trapezoid should face toward the crestal part of the alveolar bone to prevent possible impingement of the side wall during the transposition. The transposed segment can be fixed with mini-screws or mini-plates. The crestal bone level in adjacent teeth and the available interarch space were considered as a vertical limit for transposition of the osteotomized segment. Bone graft (block or particulate) fills the gap, which will be replaced with new bone by remodeling during the healing period (Figure 18.15).

The horizontal osteotomy, which is most difficult part of the procedure, should have a 2 mm safe margin with the adjacent vital structure, which can be the nasal floor, maxillary sinus, or IAN. IBG with the xenogeneic block showed a

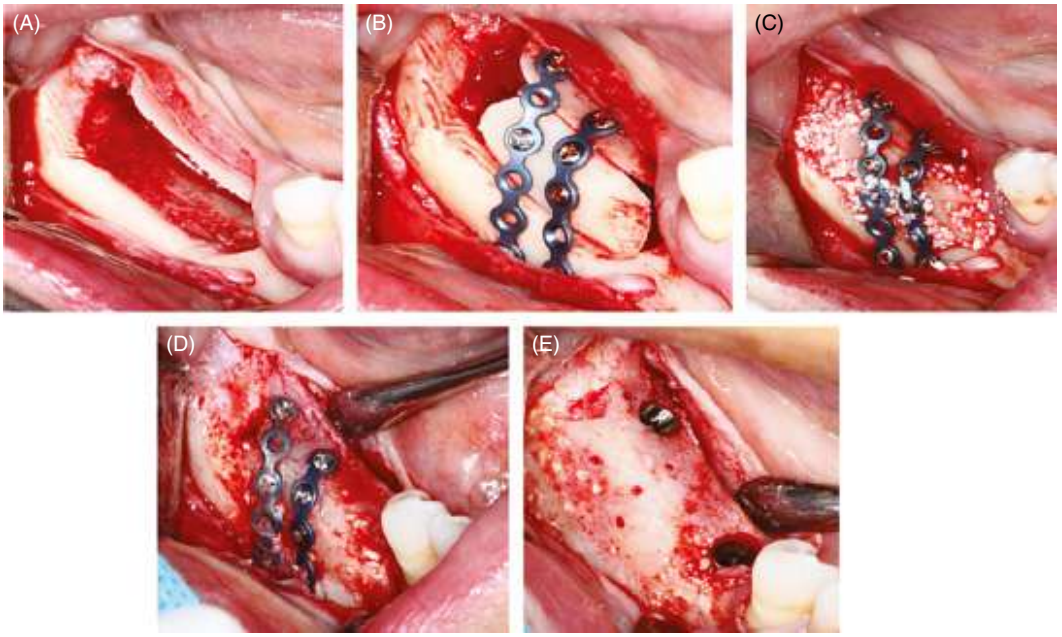

FIGURE 18.15 (A) Trapezoid osteotomy for posterior mandible augmentation. (B) Fixation of transposed segment with microplate. Note the lateral ramus cortical plate that could help in better stabilization of the osteotomized segment. (C) Filling the gap with the particulate bone substitute. (D) Complete bone healing was evident in the gap, 5 months after re-entry. (E) Dental implant placement in the grafted site.

Dentlearn.ir

comparable result to titanium mesh GBR in vertical augmentation of the anterior maxilla [35]. Both labial and palatal approaches can be used to draw osteotomy lines in the anterior maxilla [36]. A cortico-cancellous iliac onlay block bone graft in the posterior mandible gains 7 mm in vertical length, whereas IBG revealed 6 mm in a retrospective radiomorphometric study [37]. Short-term follow-up studies show more than 90% implant survival in atrophic posterior mandibles treated with the IBG technique [34]. As the vitality of the superior bone segment is supported with the periosteal blood supply from the lingual soft tissue pedicle, less bone resorption occurs following IBG compared to OBG, giving IBG more predictable results [38]. Apart from minor graft-related complications such as graft exposure and infection as well as soft tissue dehiscence, IBG might be associated with major complications, including a transported segment fracture and IAN paresthesia. A minimum of 4 mm of bone above the IAN is required to avoid major complications. The IBG procedure has high technical sensitivity and cannot be performed in defects with complicated morphology [39].

INFERIOR ALVEOLAR NERVE LATERALIZATION

A safety zone of 2 mm from the mandibular canal to prevent nerve damage is not always achievable in patients with atrophic bone, and implant placement may cause sensory dysfunction. Short implants (<8.5 mm) seem to have successful outcomes (98.3% biological success) in short-term follow-up. In many clinical conditions, the amount of available bone over the IAN is not sufficient to place short implants [40]. On the other hand, IAN lateralization allows insertion of dental implants of standard length when the bone volume above the IAN is less than 2–4 mm. In IAN lateralization the nerve is freed from the IAN canal and is retracted laterally and placed on the lateral surface of the implants. IAN transpositioning was first reported in 1987 [41]. Transposition of the IAN allows simultaneous implant placement with longer length and high primary stability. However, it is a very technique-sensitive procedure and sensory dysfunction might occur [42]. In cases with ridge atrophy and a large interarch space, without an augmentative procedure, the length of the occluso-lingual crown inevitably remained inevitably large and a good emergence profile could not be obtained [43]. However, a narrow basal bone or the presence of a jaw defect needs simultaneous augmentation (Figure 18.16) [44, 45].

PEDICLE SEGMENTAL ROTATION

A modification of the segmental sandwich osteotomy, called the pedicle segmental rotation (PSR), is reported by Khojasteh et al. to treat vertical defects of the posterior mandible. This involves a horizontal osteotomy, then flipping the segment through 90 degrees and supporting it with particulate bone materials. The aim of this method is to expand bone both

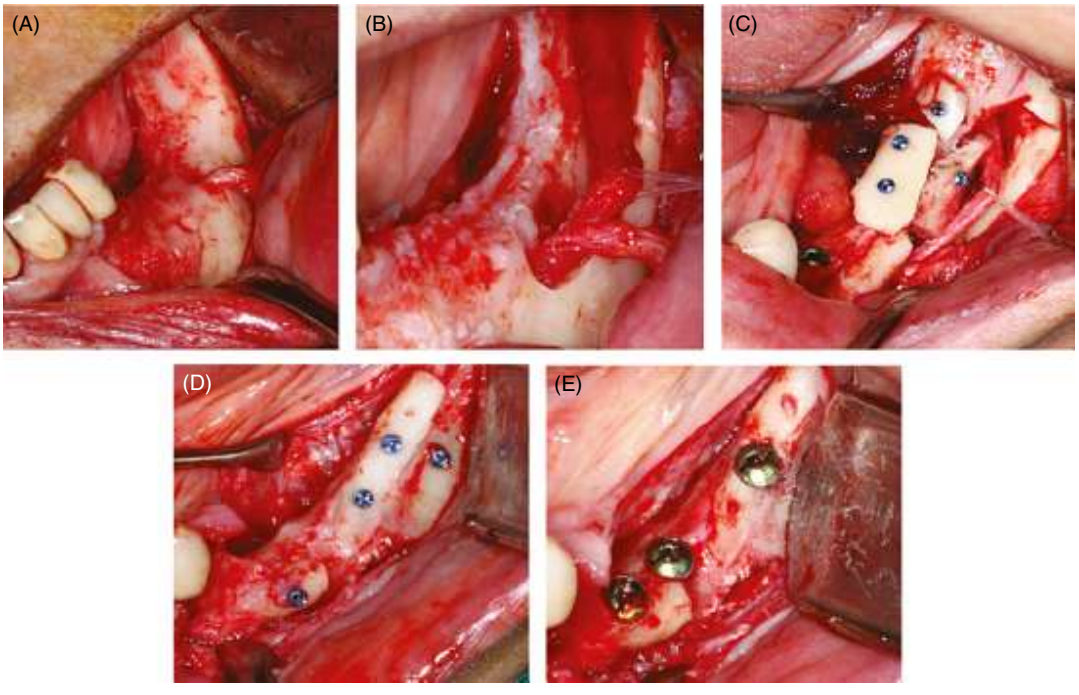

FIGURE 18.16 (A) Vertical defect type "C" in posterior mandible. (B) Nerve exposure with extreme care to protect the nerve. (C) Simultaneous block bone augmentation from lateral ramus to reconstruct the horizontal dimension of the bone. (D) Appropriate healing of the bone 6 months following surgery. (E) Dental implant placement in grafted and nerve lateralized bone.

Dentlearn.ir

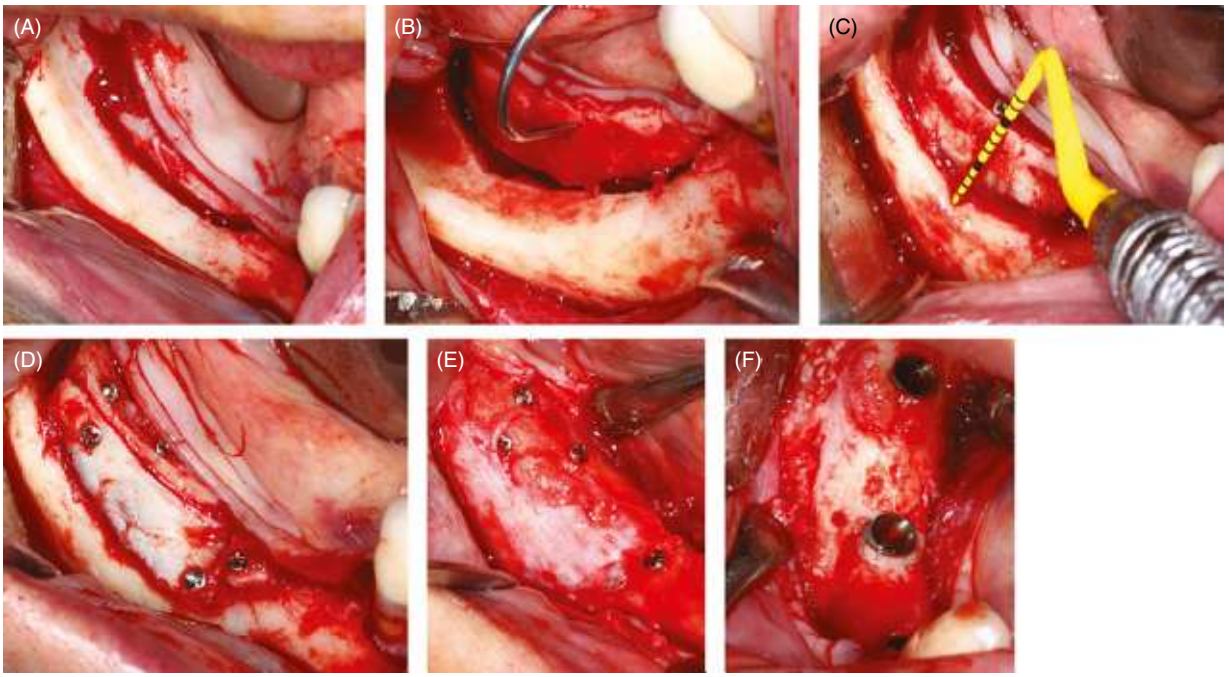

FIGURE 18.17 Pedicle segmental rotation technique in vertical augmentation of the posterior mandible. (A) Trapezoid sandwich osteotomy such as inlay bone grafting technique. (B) 90-degree rogation of the segment. (C) Fixation of the rotated segment with micro-screws. (D) Lateral ramus block also harvested and fixed to the rotated segment to increase the horizontal dimension. (E, F) Uncovering and dental implant placement in the augmented posterior mandible 6 months later.

vertically and horizontally while maintaining the vascular supply [46]. The osteotomy lines were the same as interpositional bone grafting in the posterior mandible (IBG). The osteotomized segment was up-fractured superiorly after all bone cuts were completed and then flipped through 90 degrees to a vertical position. Care was taken to maintain the soft tissue pedicled on the lingual surface. Next, the rotated segment was fixed with three 12 mm endosteal micro-screws. The periphery was filled with a mixture of particulate inorganic bovine bone mineral and particulate autogenous bone graft. In the case of a combination horizontal and vertical defect in the posterior mandible, simultaneous onlay block augmentation with a lateral ramus cortical plate or alveolar nerve medialization could be done to increase the bone dimension for dental implant placement (Figure 18.17).

DISCUSSION

Autogenous block bone from the different sites described in this chapter can be used as indicated based on the desired graft size and consistency. When the decision has been made to avoid autogenous harvest, multiple other options exist, such as recombinant human bone morphogenetic protein-2 (rhBMP-2), mesenchymal stem cells (MSCs), allogeneic bone, xenogeneic bone, and alloplastic bone substitutes. RhBMP-2 in combination with an absorbable collagen sponge (ACS) is the most commonly used recombinant protein in human bone regeneration studies [47]. Composite graft consisting of rhBMP-2/ACS and particulate mineralized bone allograft with titanium mesh showed an average of 8.53 mm vertical bone gain [48]. Platelets play a fundamental role in hemostasis and are a natural source of growth factors, such as platelet-derived growth factor (PDGF), transforming growth factor beta (TGF-β), insulin-like growth factor (IGF), and vascular endothelial growth factors (VEGF) [49]. These derivates have not demonstrated a significant benefit in vertical bone regeneration [50]. MSCs derived from bone marrow aspirates have been frequently used as a cell source in bone tissue engineering. As such, MSCs showed promising results in posterior maxillary sinus augmentation [51]. Buccal fat pad–derived cells, cultured over bovine bone mineral and protected with titanium mesh, showed $164.91 \pm 3.74\,mm^2$ of new bone surface after horizontal and vertical defect reconstruction in the posterior mandible [52]. Particulated demineralized freeze-dried bone allograft with non-absorbable membranes revealed a 4.1 mm increase in height in the posterior mandible [53]. Allograft block showed less than 50% long-term success in severe atrophic jaw reconstruction [54]. In human trials, xeno-blocks

Dentlearn.ir

have been most often used with inlay techniques for posterior mandibular rehabilitation. The results showed a similar success rate in comparison with autogenous bone (mean height gain = 5.48 mm) [34].

The average vertical gain was approximately 5.6 mm from the bottom of the vertical defect prior to grafting to the top of the onlay block vertical bone augmentation [55]. Urban et al.'s recently published systematic review showed mean clinical vertical bone gain and complications for OBG were estimated to be 3.46 mm and 23.9% for bone block [56]. The main disadvantages of autogenous OBG are donor site morbidity, the risk of graft exposure, and delay in graft resorption. With the advent of new techniques and merging the GBR concept with block bone vertical augmentation, the outcome may increase and solve the pre-prosthetic vertical problem in patients.

CONCLUSION

When considering the options for reconstruction of the partially or completely edentulous patient with inadequate bone, the surgeon must establish a plan to take the patient from his/her current state to a fully functional restoration in a restoratively driven (pre-prosthetic) manner. The focus and purpose of this chapter are to remind the practitioner that there are many surgical ways and varieties of surgical techniques to obtain an ideal result. The issue to consider when formulating a proper surgical plan and appropriate donor site to reconstruct maxillofacial defects is the recognition that there is both a horizontal and vertical deficiency of bone. Traditionally, vertical ridge augmentation has posed a clinical challenge that can be overcome by topics reviewed by the authors in this chapter.

REFERENCES

1. Jensen O, Pikos MA, Simion M, Vercellotti T. In M Miloro, GE Ghali, PE Larsen, P Waite (eds.), Peterson's principles of oral and maxillofacial surgery, 2nd edn. Hamilton: BC Decker; 2004, 1(2):223–4.
2. Khojasteh A, Morad G, Behnia H. Clinical importance of recipient site characteristics for vertical ridge augmentation: A systematic review of literature and proposal of a classification. *J Oral Implantol.* 2013;39(3):386–98.
3. Proussaefs P, Lozada J, Kleinman A, Rohrer MD. The use of ramus autogenous block grafts for vertical alveolar ridge augmentation and implant placement: A pilot study. *Int J Oral Maxillofac. Implants.* 2002;17(2):238–48.
4. Khojasteh A, Hosseinpour S. Challenges in the rehabilitation handling of large and localized oral and maxillofacial defects. In L Tayebi (ed.), *Applications of Biomedical Engineering in Dentistry*. Cham: Springer; 2020, 239–62.
5. Pikos MA. Block autografts for localized ridge augmentation: Part I. *The posterior maxilla. Implant Dent.* 1999;8(3):279–85.
6. Proussaefs P, Lozada J. The use of intraorally harvested autogenous block grafts for vertical alveolar ridge augmentation: A human study. *Int J Periodontics Restorative Dent.* 2005;25(4):351–63.
7. Schwartz-Arad D, Levin L, Sigal L. Surgical success of intraoral autogenous block onlay bone grafting for alveolar ridge augmentation. *Implant Dent.* 2005;14(2):131–8.
8. Pikos MA. Mandibular block autografts for alveolar ridge augmentation. *Atlas Oral Maxillofac Surg Clin N Am.* 2005;13(2):91–107.
9. Misch C. Comparison of intraoral donor sites for onlay grafting prior to implant placement. *Int J Oral Maxillofac Implants.* 1997;12(6):767–76.
10. Neiva RF, Gapski R, Wang H-L. Morphometric analysis of implant-related anatomy in Caucasian skulls. *J Periodontol.* 2004;75(8):1061–7.
11. Gapski R, Wang H, Misch CE. Symphysis graft procedures: A review of incision bone grafts. *J Oral Implantol.* 2001;XXVII:7–11.
12. Toscano NJ, Shumaker ND, Holtzclaw D. The art of block grafting: A review of the surgical protocol for reconstruction of alveolar ridge deficiency. *J Implant Adv Clin Dent.* 2010;2(2):45.
13. Hassani A, Khojasteh A, Shamsabad AN. The anterior palate as a donor site in maxillofacial bone grafting: A quantitative anatomic study. *J Oral Maxillofac Surg.* 2005;63(8):1196–200.
14. Tolstunov L. Maxillary tuberosity block bone graft: Innovative technique and case report. *J Oral Maxillofac Surg.* 2009;67(8):1723–9.
15. Khojasteh A, Nazeman P, Tolstunov L. Tuberosity-alveolar block as a donor site for localised augmentation of the maxilla: A retrospective clinical study. *Br J Oral Maxillofac Surg.* 2016;54(8):950–55.
16. Xu R, Ebraheim NA, Yeasting RA, Jackson WT. Anatomic considerations for posterior iliac bone harvesting. Spine (Phila Pa 1976). 1996;21(9):1017–20.
17. Kolomvos N, Iatrou I, Theologie-Lygidakis N et al. Iliac crest morbidity following maxillofacial bone grafting in children: A clinical and radiographic prospective study. *J Craniomaxillofac Surg.* 2010;38(4):293–302.
18. Ahlmann E, Patzakis M, Roidis N et al. Comparison of anterior and posterior iliac crest bone grafts in terms of harvest-site morbidity and functional outcomes. *J Bone Joint Surg Am.* 2002;84(5):716–20.
19. Bauer TW, Muschler GF. Bone graft materials: An overview of the basic science. *Clin Orthop Relat Res.* 2000;371:10–27.
20. Baker RD, Terry BC, Davis WH, Connole PW. Long-term results of alveolar ridge augmentation. *J Oral Surg.* 1979;37(7):486–9.
21. Bruno BJ, Gustafson PA. Cranial bone harvest, grafting: A choice for maxillofacial reconstruction. *AORN J.* 1994;59(1):242–51.
22. Iizuka T, Smolka W, Hallermann W, Mericske-Stern R. Extensive augmentation of the alveolar ridge using autogenous calvarial split bone grafts for dental rehabilitation. *Clin Oral Implants Res.* 2004;15(5):607–15.

Dentlearn.ir

23. Burchardt H, Enneking WF. Transplantation of bone. *Surg Clin N Am.* 1978;58(2):403–27.

24. Pikos MA. Block autografts for localized ridge augmentation: Part II. *The posterior mandible. Implant Dent.* 2000;9(1):67–75.

25. Khojasteh A, Behnia H, Shayesteh YS et al. Localized bone augmentation with cortical bone blocks tented over different particulate bone substitutes: A retrospective study. *Int J Oral Maxillofac Implants.* 2012;27(6):1481–93.

26. Carlson ER, Marx RE. Part II. Mandibular reconstruction using cancellous cellular bone grafts. *J Oral Maxillofac Surg.* 1996;54(7):889–97.

27. Donos N, Mardas N, Chadha V. Clinical outcomes of implants following lateral bone augmentation: Systematic assessment of available options (barrier membranes, bone grafts, split osteotomy). *J Clin Periodontol.* 2008;35(suppl 8):173–202.

28. Scheerlinck LME, Muradin MSM, van der Bilt A et al. Donor site complications in bone grafting: Comparison of iliac crest, calvarial, and mandibular ramus bone. *Int J Oral Maxillofac Implants.* 2013;28(1):222–7.

29. Sbordone C, Toti P, Guidetti F et al. Volume changes of iliac crest autogenous bone grafts after vertical and horizontal alveolar ridge augmentation of atrophic maxillas and mandibles: A 6-year computerized tomographic follow-up. *J Oral Maxillofac Surg.* 2012;70(11):2559–65.

30. von Arx T, Buser D. Horizontal ridge augmentation using autogenous block grafts and the guided bone regeneration technique with collagen membranes: A clinical study with 42 patients. *Clin Oral Implants Res.* 2006;17(4):359–66.

31. Khojasteh A, Soheilifar S, Mohajerani H, Nowzari H. The effectiveness of barrier membranes on bone regeneration in localized bony defects: A systematic review. *Int J Oral Maxillofac Implants.* 2013;28(4):1076–89.

32. Khoury F, Antoun H, Missika P, Bessade J. *Bone augmentation in oral implantology*. Batavia, IL: Quintessence; 2007.

33. Schettler D, Holtermann W. Clinical and experimental results of a sandwich-technique for mandibular alveolar ridge augmentation. *J Maxillofac Surg.* 1977;5(3):199–202.

34. Felice P, Barausse C, Barone A et al. Interpositional augmentation technique in the treatment of posterior mandibular atrophies: A retrospective study comparing 129 autogenous and heterologous bone blocks with 2 to 7 years follow-up. *Int J Periodontics Restorative Dent.* 2017;37(4):469–80.

35. Mounir M, Mounir S, Abou-Elfetouh A, Shaker MA. Assessment of vertical ridge augmentation in anterior aesthetic zone using onlay xenografts with titanium mesh versus the inlay bone grafting technique: A randomized clinical trial. *Int J Oral Maxillofac Surg.* 2017;46(11):1458–65.

36. El Hadidy MS, Mounir M, Abou-Elfetouh A, Barakat A. Assessment of vertical ridge augmentation and labial prominence using buccal versus palatal approaches for maxillary segmental sandwich osteotomy (inlay technique): A randomized clinical trial. *Clin Implant Dent Relat Res.* 2018;20(5):722–8.

37. Barone A, Toti P, Menchini-Fabris GB et al. Early volumetric changes after vertical augmentation of the atrophic posterior mandible with interpositional block graft versus onlay bone graft: A retrospective radiological study. *J Craniomaxillofac Surg.* 2017;45(9):1438–47.

38. Roccuzzo A, Marchese S, Worsaae N, Jensen SS. The sandwich osteotomy technique to treat vertical alveolar bone defects prior to implant placement: A systematic review. *Clin Oral Investig.* 2020;24(3):1073–89.

39. Felice P, Checchi C, Pistilli R et al. Bone augmentation versus 5-mm dental implants in posterior atrophic jaws: Four-month postloading results from a randomised controlled clinical trial. *Eur J Oral Implantol.* 2009;2(4):267–81.

40. Atieh MA, Zadeh H, Stanford CM, Cooper LF. Survival of short dental implants for treatment of posterior partial edentulism: A systematic review. *Int J Oral Maxillofac Implants.* 2012;27(6):1323–31.

41. Jensen O, Nock D. Inferior alveolar nerve repositioning in conjunction with placement of osseointegrated implants: A case report. *Oral Surg Oral Med Oral Pathol.* 1987;63(3):263–8.

42. Lorean A, Kablan F, Mazor Z et al. Inferior alveolar nerve transposition and reposition for dental implant placement in edentulous or partially edentulous mandibles: A multicenter retrospective study. *Int J Oral Maxillofac Surg.* 2013;42(5):656–9.

43. Norton MR. Multiple single-tooth implant restorations in the posterior jaws: Maintenance of marginal bone levels with reference to the implant-abutment microgap. *Int J Oral Maxillofac Implants.* 2006;21(5):777–84.

44. Khojasteh A, Hassani A, Motamedian SR et al. Cortical bone augmentation versus nerve lateralization for treatment of atrophic posterior mandible: A retrospective study and review of literature. *Clin Implant Dent Relat Res.* 2016;18(2):342–59.

45. Khojasteh A, Hosseinpour S, Nazeman P, Dehghan MM. The effect of a platelet-rich fibrin conduit on neurosensory recovery following inferior alveolar nerve lateralization: A preliminary clinical study. *Int J Oral Maxillofac Surg.* 2016;45(10):1303–8.

46. Khojasteh A, Safiaghdam H, Farajpour H. Pedicled segmental rotation techniques for posterior mandible augmentation: A preliminary study. *Int J Oral Maxillofac Surg.* 2019;48(12):1584–93.

47. Khojasteh A, Behnia H, Naghdi N et al. Effects of different growth factors and carriers on bone regeneration: A systematic review. *Oral Surg Oral Med Oral Pathol Oral Radiol.* 2013;116(6):e405–e423.

48. Misch C, Jensen O, Pikos M, Malmquist J. Vertical bone augmentation using recombinant bone morphogenetic protein, mineralized bone allograft, and titanium mesh: A retrospective cone beam computed tomography study. *Int J Oral Maxillofac Implants.* 2015;30(1):202–7.

49. Anitua E, Andia I, Ardanza B et al. Autologous platelets as a source of proteins for healing and tissue regeneration. *Thromb Haemost.* 2004;91(1):4–15.

50. Plachokova AS, Nikolidakis D, Mulder J et al. Effect of platelet-rich plasma on bone regeneration in dentistry: A systematic review. *Clin Oral Implants Res.* 2008;19(6):539–45.

51. Shayesteh Y, Khojasteh A, Soleimani M et al. Sinus augmentation using human mesenchymal stem cells loaded into a [beta]-tricalcium phosphate/hydroxyapatite scaffold. *Oral Surg Oral Med Oral Pathol Oral Radiol Endod.* 2008;106(2):203–9.

Dentlearn.ir

52. Khojasteh A, Hosseinpour S, Rezai Rad M et al. Buccal fat pad-derived stem cells with anorganic bovine bone mineral scaffold for augmentation of atrophic posterior mandible: An exploratory prospective clinical study. *Clin Implant Dent Relat Res.* 2019;21(2):292–300.

53. Fontana F, Santoro F, Maiorana C et al. Clinical and histologic evaluation of allogeneic bone matrix versus autogenous bone chips associated with titanium-reinforced e-PTFE membrane for vertical ridge augmentation: A prospective pilot study. *Int J Oral Maxillofac Implants.* 2008;23(6):1003–12.

54. Motamedian S, Khojaste M, Khojasteh A. Success rate of implants placed in autogenous bone blocks versus allogenic bone blocks: A systematic literature review. *Ann Maxillofac Surg.* 2016;6(1):78.

55. Schwartz-Arad D, Levin L. Intraoral autogenous block onlay bone grafting for extensive reconstruction of atrophic maxillary alveolar ridges. *J Periodontol.* 2005;76(4):636–41.

56. Urban IA, Montero E, Monje A, Sanz-Sánchez I. Effectiveness of vertical ridge augmentation interventions: A systematic review and meta-analysis. *J Clin Periodontol.* 2019;46(S21):319–39.

Dentlearn.ir

Dentlearn.ir

Pedicled Vascularized Segmental Osteotomy with Interpositional Bone Grafting for Vertical Ridge Augmentation: Posterior Sandwich Osteotomy

CHAPTER 19

The use of a pedicled vascularized sandwich osteotomy in the posterior jaws can be difficult and is done in complex bony atrophy settings despite sinus and nerve proximity. This chapter will discuss this procedure, which can increase bone stock up to 10 mm vertically to satisfy successful implant placement for dental restorative alveolar reconstruction.

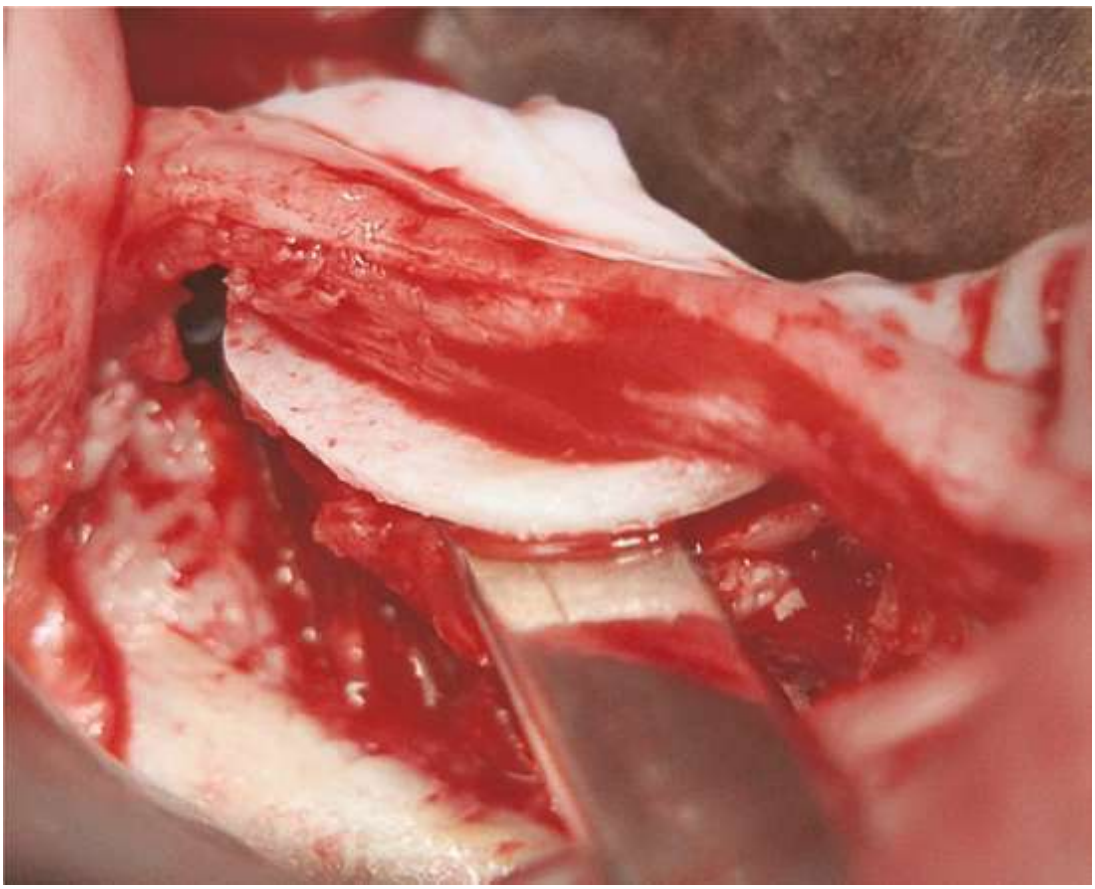

Dentlearn.ir

CHAPTER 19

Pedicled Vascularized Segmental Osteotomy with Interpositional Bone Grafting for Vertical Ridge Augmentation: Posterior Sandwich Osteotomy

Ole T. Jensen

School of Dentistry, University of Utah, Salt Lake City, UT, USA

Vascularized osteotomies can be used to treat vertical alveolar deficiency in the oral cavity in all areas of both jaws. However, the posterior maxilla and the posterior mandible are less commonly treated in this way. This chapter will address the two most challenging areas for vertical augmentation grafting: first, alveolar ablation in the posterior maxilla in the partially edentulous patient; and second, the atrophic posterior mandible in the partially edentulous patient. Osteotomies in these locations are complicated by proximate vital structures, the sinus cavity, and the inferior alveolar nerve.

POSTERIOR MAXILLA

The posterior maxilla in a state of atrophy with a prominent sinus cavity can be treated with combined alveolar and sinus floor augmentation to gain enough bone stock for dental implant restoration [1, 2]. One way to augment the alveolus to avoid a vertical onlay graft, which is often challenging for the posterior maxilla, is to perform a sandwich osteotomy with an interpositional bone graft, essentially a vertically extended sinus floor graft [3, 4].

The biological rationale of the posterior segmental osteotomy, as described by Wunderer, was confirmed in the laboratory by Bell [5–7]. When this procedure is done with a sinus membrane elevation for sinus floor grafting (that is, it also has a well-founded biological basis), the combined procedure for the posterior segment of the maxilla appears to be an optimal strategy for implant reconstruction [8, 9]. The problem, however, is a technical one, and is therefore seldom attempted. For this reason, the technical aspect of this procedure will be presented here with clinical correlations.

TECHNIQUE

Models are made and a mock surgery is planned and completed on the models, as it is done in an orthognathic surgery work-up. The technique for the posterior sandwich osteotomy is shown in Figure 19.1 [2]. One of the most important aspects to plan is the anterior–posterior extent of the segment, as well as the location of the vertical cuts to the crest of the alveolus away from the dental roots. Vertical cuts should be 2 mm away from dental elements [10]. Following administration of intravenous anesthesia and local anesthesia, a lateral approach is made to the sinus cavity for a lateral antrostomy [11]. This is done through a vestibular incision carried down to bone, reflecting mostly superiorly to maintain mucosal drape on the residual alveolar process. Once the lateral wall of the maxilla is identified, a lateral window osteotomy is made, about 10 mm vertical × 15 mm horizontal, that does not extend to the vertical segmental osteotomy cuts that have been planned. The sinus membrane is then elevated and reflected anterior and posterior to clear room for the segmental osteotomies, which will pass through the sinus cavity.

Next, a frown-shaped cut extends from the sinus osteotomy window forward, curving to the alveolar crest to about 2 mm posteriorly from the most distal tooth. The posterior cut extends posterior to the tuberosity region in front of the pterygoid plate. The cut then curves down to the alveolar

Essential Techniques of Alveolar Bone Augmentation in Implant Dentistry: A Surgical Manual, Second Edition. Edited by Len Tolstunov.
© 2023 John Wiley & Sons, Inc. Published 2023 by John Wiley & Sons, Inc.
Companion website: www.wiley.com/go/tolstunov/essential

Dentlearn.ir

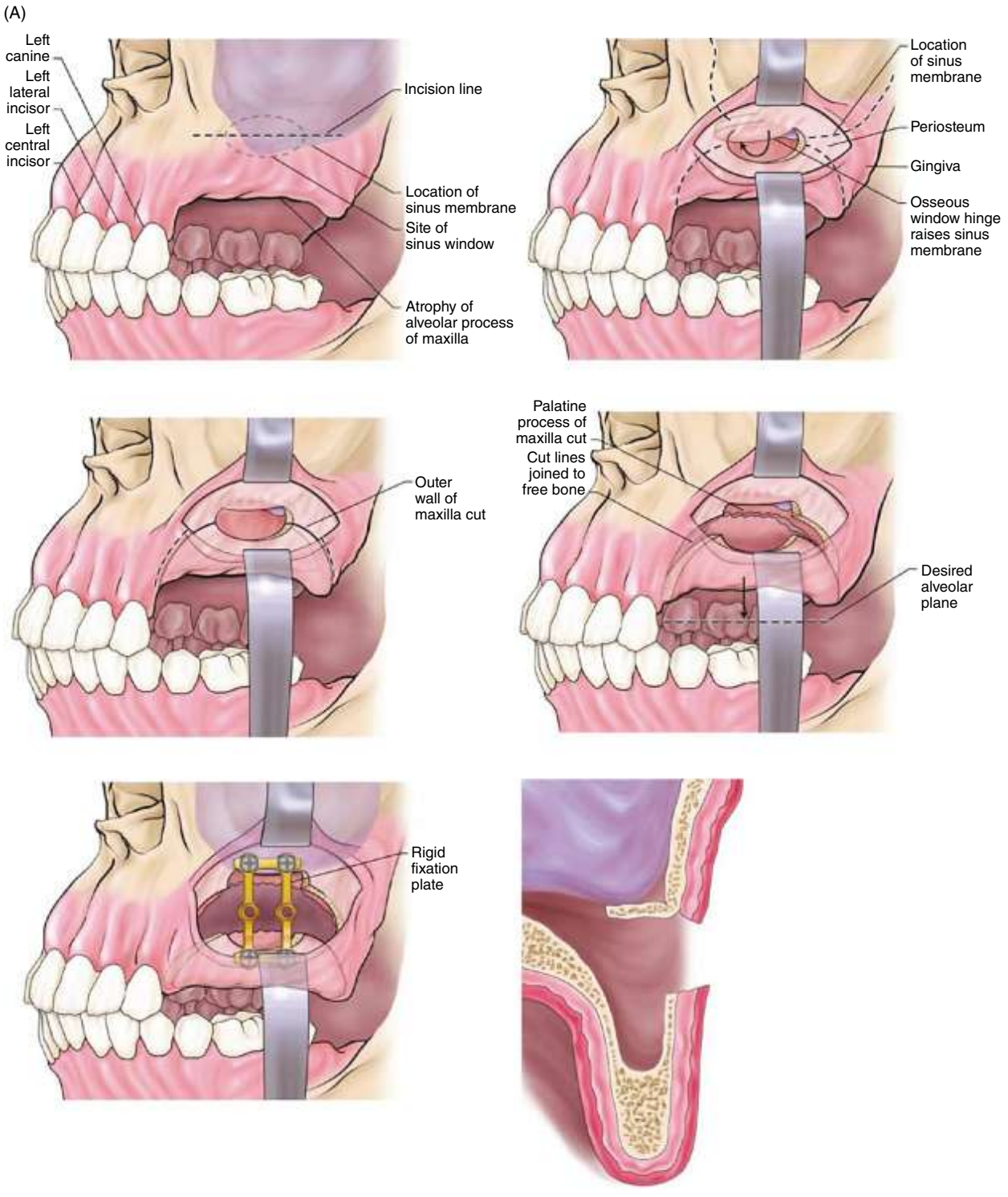

FIGURE 19.1 (A) Vertically deficient maxilla approached via vestibular incision. The sinus window is made to elevate the sinus membrane. Lateral osteotomy is made using piezo surgery from the window anterior and posterior, curving down to the alveolar crest. (B) Palatal osteotomy is done trans-sinus, curving down toward the alveolar crest using piezo surgery. Segment is freed with osteotomes and down-fractured. Segment is fixed with bone plate and interpositionally grafted. Vestibular wound is closed primarily. *Source*: Jensen 2010. Reproduced with permission from Quintessence Publishing Inc.

Dentlearn.ir

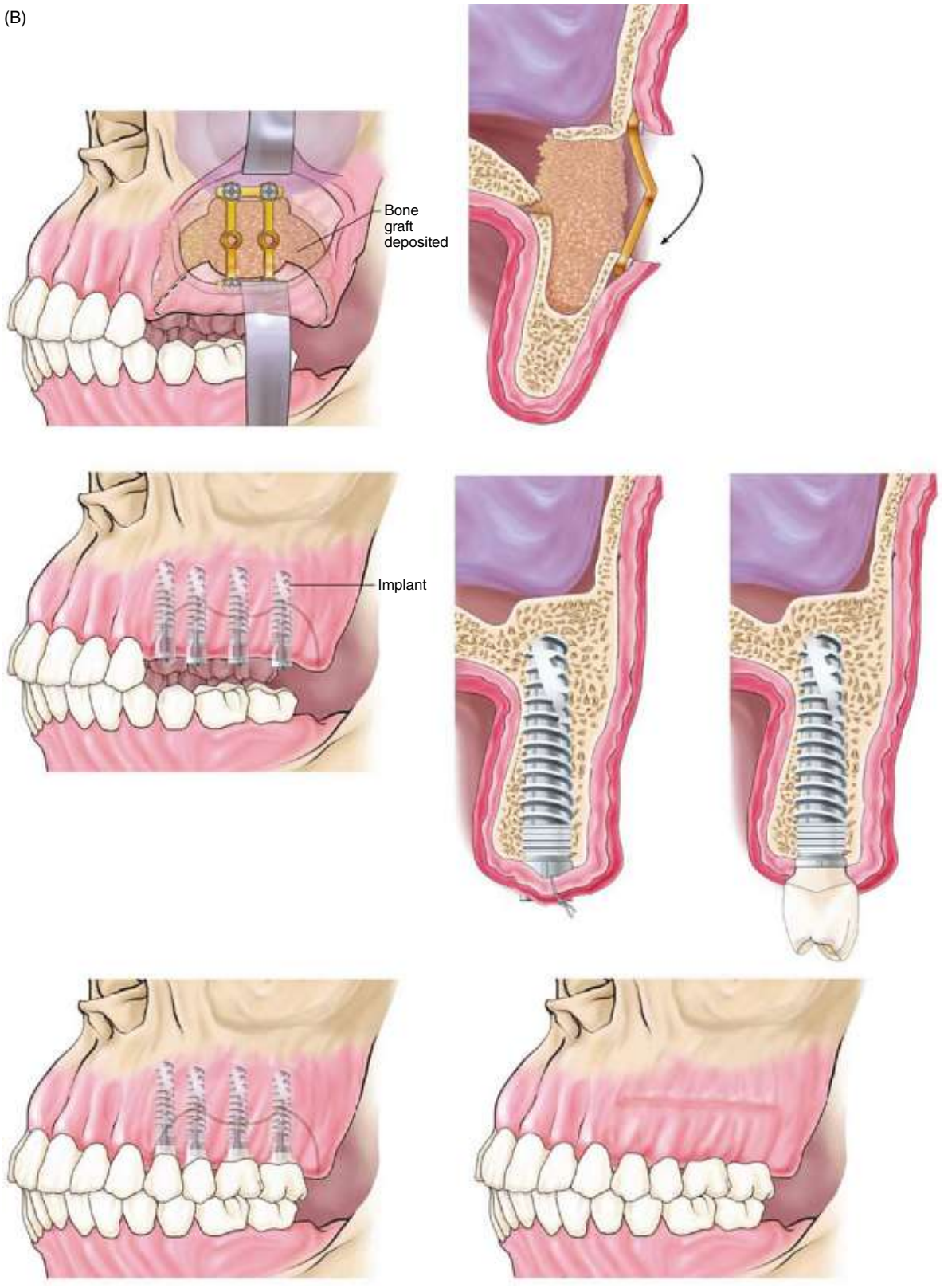

FIGURE 19.1 *(continued)*

Dentlearn.ir

crest. These cuts are made without reflecting mucosa – easily done with a piezo knife submucosally [12]. Once the lateral cuts are complete, a similar cut is made trans-sinus of the palatal bone. This usually requires a combination of piezo surgery and hand osteotomies to free the segment. A curved oscillating sagittal saw can also aid in making this cut. The palatal cut needs not be complete in most cases (creating a greenstick fracture is enough), as the palatal wall is usually quite thin. The segment is then down-fractured, rotating the segment medially. The palatal mucosa is not released. The segment can be brought down about 10 mm maximum, but usually 6–8 mm is sufficient to greatly improve the alveolar dimension vertically. The alveolar crest will end up slightly palatal, which can be corrected at the time of implant placements about 5–6 months later. This is usually done by soft tissue transfer and additional alveolar facial bone grafting using guided bone regeneration (GBR) [1].

CLINICAL APPLICATIONS

POSTERIOR MAXILLA

A 30-year-old female presented with an impacted decayed bicuspid tooth that required removal of almost all the remaining alveolus in the presence of a prominent sinus cavity (Figure 19.2). Socket bone grafting was done at the time of tooth removal using allograft and autograft particles. Following 3 months' healing from the tooth removal, the patient returned for reconstruction of the left posterior maxilla (Figure 19.3). A vestibular incision was made and curved osteotomies were performed laterally, followed by sinus membrane elevation and trans-sinus palatal osteotomy (Figure 19.4A). The segment was down-fractured (Figure 19.4B). A fixation plate was placed (Figure 19.5A). Interpositional grafting combined with sinus floor grafting were done using bone morphogenetic protein (BMP)-2/allograft in a

FIGURE 19.2 Pre-operative panoramic image showing impacted tooth in left sinus with very little residual bone.

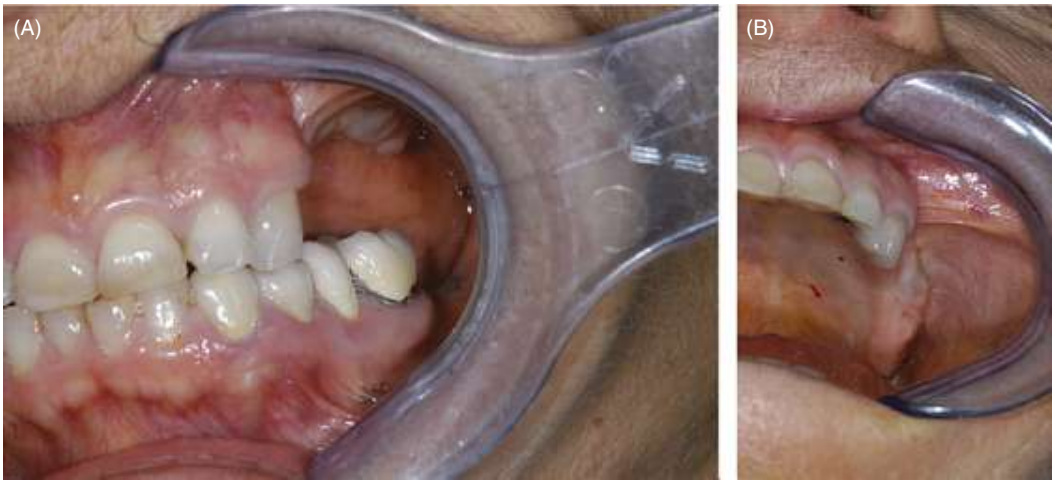

FIGURE 19.3 (A) Pre-operative lateral view (intraoral photograph). (B) Pre-operative occlusal view (intraoral photograph).

Dentlearn.ir

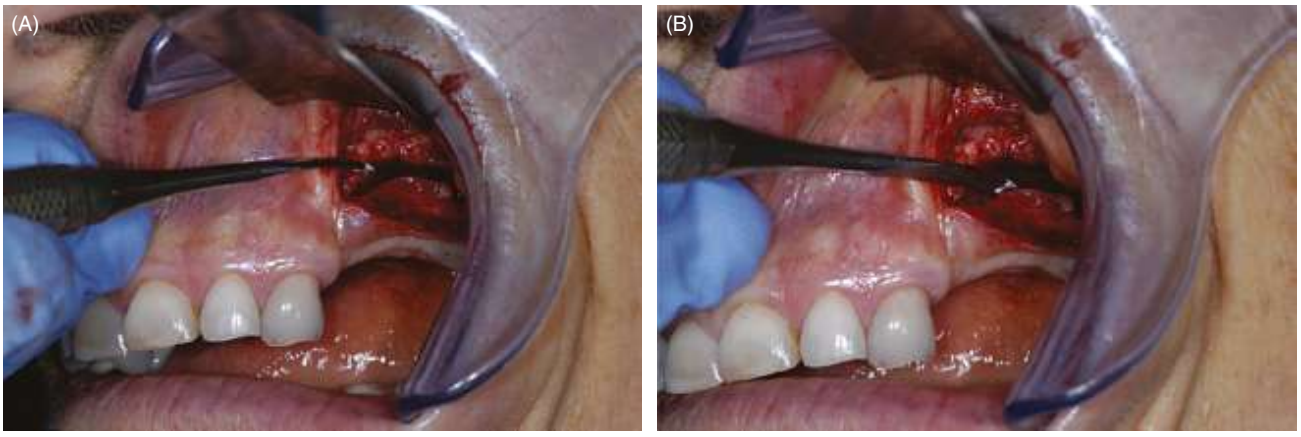

FIGURE 19.4 (A) Intraoperative photograph showing curved lateral osteotomy of the buccal wall that is followed by a trans-sinus palatal vault osteotomy. (B) Intraoperative photograph demonstrating a bone segment down-fracture to increase the vertical height of the vertically deficient posterior maxilla.

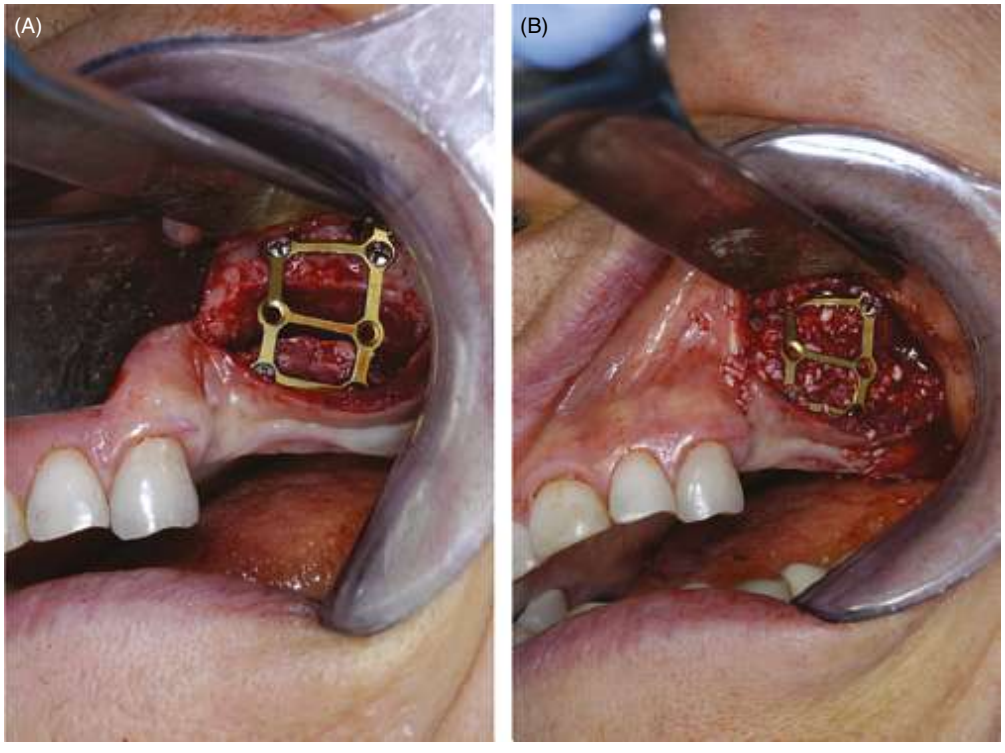

FIGURE 19.5 (A) Intraoperative photograph depicting a segment of bone that was fixated with a bone plate at an appropriate vertical height. (B) Intraoperative photograph showing an interpositional grafting.

50:50 ratio, using bovine collagen sponge as a carrier for the BMP-2 (Figure 19.5B) [13]. The wound was closed and the observable improved alveolar height was demonstrated (Figure 19.6). Five months later, cone beam computed tomography (CBCT) scan images showed bone graft consolidation (Figure 19.7). At this stage, through a slightly palatally positioned crestal incision, the fixation plate was removed, revealing a well-ossified bone (Figure 19.8). Three implants were placed (Figure 19.9) and an additional bone xenograft was added laterally to improve the buccal projection of the alveolar ridge (Figure 19.10). Post-operative radiographs demonstrated two implants in the grafted bone (Figure 19.11). Final restoration as a splinted three-unit bridge was done 4 months later and depicted in the photograph after 1 year in function (Figure 19.12).

Dentlearn.ir

FIGURE 19.6 Intraoperative photograph of the wound closure.

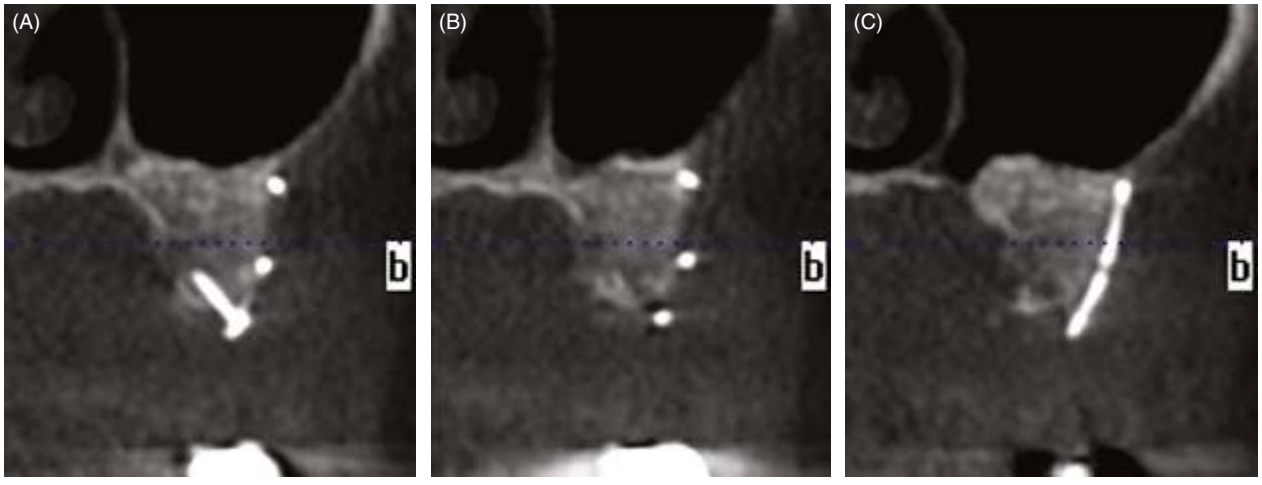

FIGURE 19.7 Cross-sectional (coronal) cone beam computed tomography slices of bone consolidation 4 months after surgery.

FIGURE 19.8 Intraoperative photograph of removal of hardware and exposure of the healed alveolar process.

FIGURE 19.9 Intraoperative photograph demonstrating placement of three endosseous implants.

Dentlearn.ir

FIGURE 19.10 Intraoperative photograph of secondary buccal grafting with xenograft to improve buccal projection of the alveolar ridge.

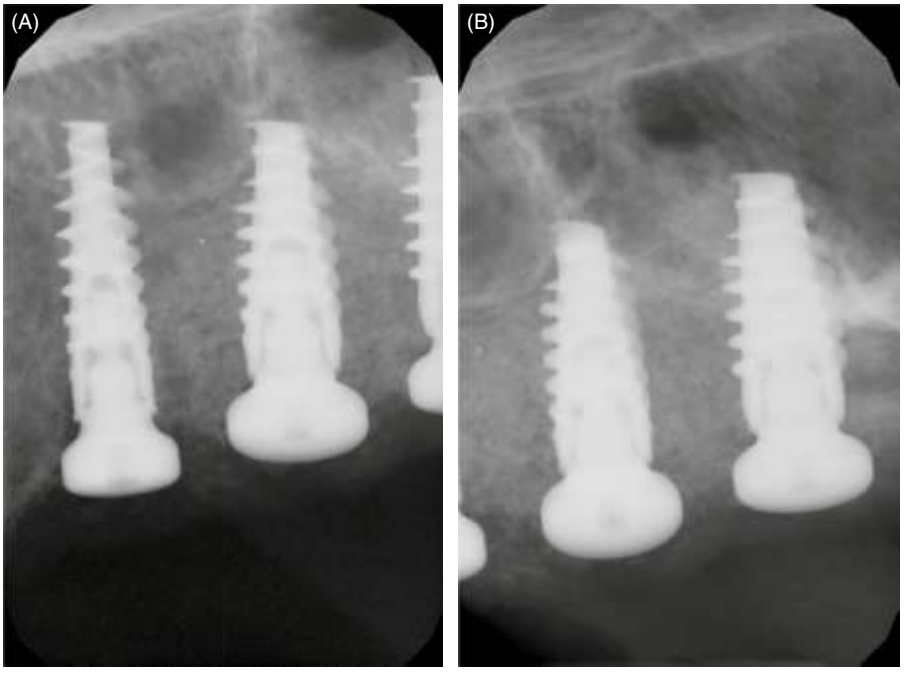

FIGURE 19.11 Post-operative periapical radiographs of placed dental implants.

POSTERIOR MANDIBLE

In cases of severe vertical bone deficiency, the posterior mandible can be treated with a variety of interpositional (inlay) block bone grafts: autogenous, like the iliac crest bone graft, allogeneic blocks, or xenogeneic anorganic bovine bone blocks [14]. There are many surgical techniques for interpositional block bone grafting. The posterior mandible can be treated using the so-called smile osteotomy, which employs a curved osteotomy path that follows the route of the nerve, as shown in Figure 19.13 [15]. The osteotomy can approach the nerve to as close as 2 mm, but the segment must minimally be 4–5 mm in height, such that a reasonable amount of bone above the nerve should be at least 6 mm to successfully proceed with the surgery.

The technique for the smile osteotomy is illustrated in Figures 19.13–19.15. The vestibular incision is not reflected superiorly, allowing a piezo knife or sagittal saw to osteotomize the segment laterally. Once the bone segment above the osteotomy is free, it can be easily lifted and interpersonally grafted. Bone plates can be used to stabilize the bone segment and control the segment vector. A clinical case is illustrated in Figures 19.16–19.19 showing the osteotomy and grafting method.

Dentlearn.ir

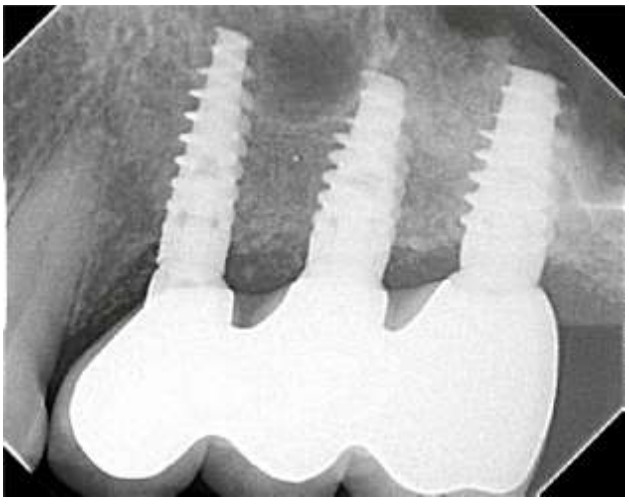

FIGURE 19.12 Periapical radiograph indicating a final restoration (three-unit bridge) after 1 year in function.

FIGURE 19.14 A smile-shaped osteotomy is used to minimize proximity to the nerve. The segment once freed is easily lifted 10 mm and is not difficult to position into alveolar alignment. The use of interpositional block grafting has become a preferred method for grafting, sometimes used without bone plating.

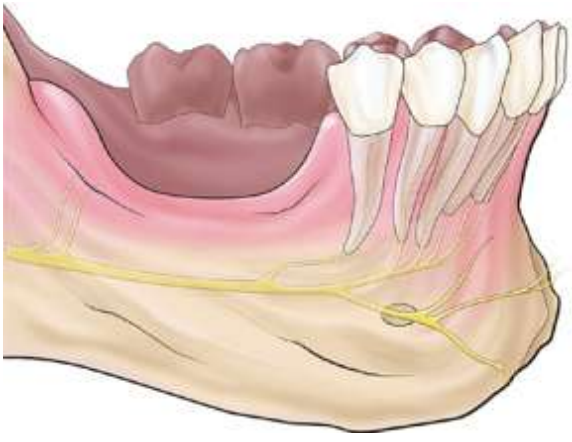

FIGURE 19.13 The indication for vertical osteotomy of the posterior mandible is 6–10 mm of vertical loss with enough bone present above the nerve to perform the osteotomy.

FIGURE 19.15 Alveolar restoration vertically to the alveolar plane allows for standard-size implants and dental crowns, the restoration more conventional than the use of short implants or a cantilever bridge. The procedure is indicated in settings where the arch form is otherwise relatively ideal.

The amount of bone is often adequate for an extra-short implant, so the surgeon must weigh the risk–benefit ratio of performing the smile osteotomy instead of placing 5 or 6 mm implants without bone augmentation (Figure 19.20) [16, 17]. The complication rate of smile osteotomy is greater than short implant placement, though both procedures can injure the nerve [18].

The advantage of raising the alveolus level to the alveolar plane is to reduce prosthesis vertical cantilever, improve function of mastication, improve anatomy for oral hygiene access, and increase implant length for support of a prosthesis [19]. Disadvantages include nerve injury as well as bone resorption from vascular compromise of the pedicled segment. One major technical complication is perforation of the vascular pedicle. When this occurs, the entire segment becomes devitalized and can be lost [20].

DISCUSSION

The use of the interpositional graft method is one element of a vast number of augmentation procedures available to the surgeon. What is interesting about the interpositional graft is that the vertical amplitude is easier to achieve than with any other method. For example, the LeFort I interpositional graft can easily achieve a stable vertical increase of 10 mm, whereas the use of onlay grafting and other methods struggle to achieve and

Dentlearn.ir

FIGURE 19.16 An atrophic posterior mandible with a vertical loss of about 10 mm. *Source*: William Hartman at Quintessence with permission.

FIGURE 19.17 The smile osteotomy made below unreflected mucosa to allow vertical displacement of the segment. *Source*: William Hartman at Quintessence with permission.

FIGURE 19.18 Elevation of the segment is easily done, but care must be taken not to perforate the vascular supply from the lingual pedicle. *Source*: William Hartman at Quintessence with permission.

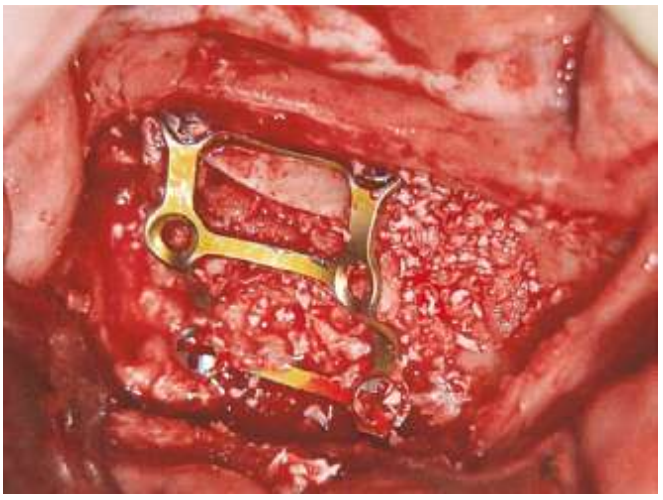

FIGURE 19.19 Interpositional grafting is done with a small block graft harvested in the adjacent ramus and particulate graft is also added, as needed. Sometimes bone morphogenetic protein (BMP)-2 is used. The use of bone plate helps to ensure stability of the graft during healing. *Source*: William Hartman at Quintessence with permission.

FIGURE 19.20 The interpositional graft and later placement of an implant, here illustrated using a relatively short implant (7 mm Ditron Implant, Ditron Ltd., Ashkelon, Israel). It can alternatively be done using placement of an ultra-short 5 mm implant inserted *without grafting*, making treatment less invasive and less prone to complications. *Source*: William Hartman at Quintessence with permission.

maintain a 10 mm increase. Likewise, segmental alveolar osteotomies easily achieve 5+ mm of vertical augmentation, which is difficult or impossible to achieve alternatively with GBR.

What makes the posterior maxilla so difficult in the face of a large vertical defect is the combined nature of limited alveolar bone stock and pneumatization of maxillary sinuses. The osteotomy procedure, better than any other approach, can address both bone deficiencies. Other procedures may not provide the same success. For example, the use of iliac block grafts has been shown to have a high incidence of bone resorption in this location, whereas the osteotomy interpositional

Dentlearn.ir

graft has proven to be much more stable [20]. The use of sinus grafting alone can be done in a flattened posterior maxilla, but this does not correct the alveolar height and leads to an increase in the crown–implant ratio [21]. Other approaches, like titanium mesh or GBR with barrier membranes, are helpful for a modest amount of vertical correction, but should probably be limited to smaller-defect cases [22, 23]. In addition, with GBR or mesh there is a higher incidence of infection, dehiscence, or risk of mesh exposure. These complications leading to early graft exposure are not observed as often in the sandwich osteotomy technique [24, 25].

BMP-2 is sometimes recommended in these cases, because the interpositional graft defect tends to be quite large and the use of a particulate xenograft alone, for example, may not be sufficient in forming bone as an osteoconductive additive. BMP-2 grafts are well suited for consolidation and healing of compromised segments, as is iliac particulate graft material, whereas alloplast, allograft, or xenograft alone does not do as well.

One advantage of the osteotomy approach is that secondary, definitive alveolar grafting can be done at the time of implant placement. This will shape the alveolus in what is volumetrically a much less extensive grafting procedure than would be required otherwise. Therefore, this modest though definitive peri-implant grafting is more likely to avoid complications [1].

The main disadvantage of the interpositional graft is lack of expertise by surgeons unfamiliar with the principles of common orthognathic surgery. Any surgeon familiar with Le-Fort osteotomy procedures and alveolar segmental surgeries can easily learn the vascularized pedicle procedures, which can be done in the ambulatory setting.

If it was not for the success of short and ultra-short implants in the posterior mandible, the smile osteotomy would become much more commonly used today. Still, the reconstruction to a verticalized alveolus leads to orthoalveolar form, a more ideal prosthetic restoration with greater self-cleanability during mastication.

CONCLUSION

Pedicled vascularized posterior alveolar osteotomies in both jaws can be done in complex bony atrophy settings despite sinus and nerve proximity. In general, bone stock can be increased up to 10 mm vertically to satisfy successful implant placement for dental restorative alveolar reconstruction.

REFERENCES

1. Jensen OT, Cottam J. Posterior maxillary sandwich osteotomy combined with sinus grafting with bone morphogenetic protein-2 for alveolar reconstruction for dental implants: report of four cases. *Int J Oral Maxillofac Implants.* 2013;28(6):e14–e23.
2. Jensen OT, Cottam JR. Sinus graft combined with osteoperiosteal flaps. In OT Jensen (ed.), *The osteo periosteal flap*. Chicago, IL: Quintessence; 2011, 189–202.
3. Cordaro L, Torsello F, Accorsi Ribeiro C et al. Inlay-onlay grafting for three-dimensional reconstruction of the posterior atrophic maxilla with mandibular bone. *IntJ Oral Maxillofac Surg.* 2010;39(4):350–57.
4. Dasmah A, Thor A, Ekestubbe A et al. Particulate vs. block bone grafts: Three-dimensional changes in graft volume after reconstruction of the atrophic maxilla, a 2-year radiographic follow-up. *J Craniomaxillofac Surg.* 2012;40(8):654–9.
5. Wunderer S. Die Prognathieopertion mittels frontal gestltem maxillafragment. *Osterr A Stomatol.* 1962;59:98–102.
6. Quejada JG, Kawamura H, Finn RA, Bell WH. Wound healing associated with segmental total maxillary osteotomy. *J Oral Maxillofac Surg.* 1986;44(5):366–77.
7. Bell WH, Levy BM. Revascularization and bone healing after posterior maxillary osteotomy. *J Oral Surg.* 1971;29:313–20.
8. Nevins M, Kirker-Head C, Nevins M et al. Bone formation in the goat maxillary sinus induced by absorbable collagen sponge implants impregnated with recombinant human bone morphogenetic protein-2. *Int J Periodontics Restorative Dent.* 1996;16(1):8–19.
9. Boyne PJ, Lilly LC, Marx RE et al. De novo bone formation by recombinant human bone morphogenetic protein-2 (rhBMP-2) in maxillary sinus floor augmentation. *J Oral Maxillofac Surg.* 2005;63(12):1693–707.
10. Ho MW, Boyle MA, Cooper JC et al. Surgical complications of segmental Lefort I osteotomy. *Br J Oral Maxillofac Surg.* 2011;49(7):562–6.
11. Kim JM, Sohn DS, Heo JU et al. Benefit of the replaceable bony window in lateral maxillary sinus augmentation: Clinical and histological study. *Implant Dent.* 2014;23(3):277–82.
12. Pavlikova G, Foltan R, Horka M et al. Piezosurgery in oral and maxillofacial surgery. *Int J Oral Maxilofac Surg.* 2011;40(5):451–7.
13. Jensen OT, Lehman H, Ringeman JL, Casap N. Fabrication of printed titanium shells for containment of BMP-2 composite graft materials for alveolar bone reconstruction. *Int J Oral Maxillofac Implants.* 2014;29(1):e103–e105.
14. Felice P, Marchetti C, Piattelli A et al. Vertical ridge augmentation of the atrophic posterior mandible with interpositional block grafts: Bone from the iliac crest versus bovine and organic bone. *Eur J Oral Implantol.* 2008;1(3):183–98.
15. Jensen OT. Alveolar segmental "sandwich" osteotomies for posterior edentulous mandibular sites for dental implants. *J Oral Maxillofac Surg.* 2006;64(3):471–5.
16. Laviv A, Jensen OT, Tarazi E, Casap N. Alveolar sandwich osteotomy in resorbed alveolar ridge for dental implants: A 4-year prospective study. *J Oral Maxillofac Surg.* 2014;72(2):292–303.

Dentlearn.ir

17. Amato F, Polara G, Spedicato GA. Immediate loading of fixed partial dental prostheses on extra-short and short implants in patients with severe atrophy of the posterior maxilla and mandible: An up to 4-year clinical study. *Int J Oral Maxillofac Implants.* 2020;35(3):607–15.

18. Jensen OT, Ringeman JL, Cottam JR, Casap N. Orthognathic and osteoperiosteal flap augmentation strategies for maxillary dental implant reconstruction. *Oral Maxillofac Surg Clin N Am.* 2011;23(2):301–19.

19. Felice P, Canizzaro G, Checchi V et al. Vertical bone augmentation versus 7mm long implants in the posterior atrophic mandibles: Results of a randomized controlled clinical trial of up to 4 months after loading. *Eur J Oral Implantol.* 2009;2(1):7–20.

20. Jensen OT, Ellis E III, Glick P. Book bone flap. In OT Jensen (ed.), *The osteoperiosteal flap*. Chicago, IL: Quintessence; 2010, 87–99.

21. Antua E, Alkhraust MH, Pinas L et al. Implant survival and crestal bone loss around extra short implants supporting a fixed denture: The effect of crown height space, crown-to-implant ratio, and offset placement of the prosthesis. *Int J Oral Maxillofac Implants.* 2014;23(3):682–9.

22. Her S, Kang T, Fien MJ. Titanium mesh as an alternative to membrane for ridge augmentation. *J Oral Maxillofac Surg.* 2012;70(4):803–10.

23. Roccuzzo M, Ramieri G, Bunino M, Berrone S. Autogenous bone graft alone or associated with titanium mesh for vertical alveolar ridge augmentation: A controlled clinical trial. *Clin Oral Implants Res.* 2007;18(3):286–94.

24. Khojasteh A, Scheilifar S, Mohajerani H, Nowzari H. The effectiveness of barrier membranes on bone regeneration in localized bony defects: A systematic review. *Int J Oral Maxillofac Implants.* 2013;28(4):1076–89.

25. Nazirkar G, Singh S, Dole V, Nikam A. Effortless effort in bone regeneration: A review. *J Int Oral Health.* 2014;6(3):120–24.

Dentlearn.ir

Khoury Split Bone Block Grafting Technique: Biological Alveolar Bone Augmentation with Autogenous Bone

CHAPTER 20

This chapter demonstrates the use of autogenous bone grafts harvested from intraoral sites. Autogenous bone grafts are still the gold standard for bone augmentation. Autogenous bone presents essential biological qualities and properties, offering possibilities to reconstruct all kind of bone defects. This chapter describes the split bone block (Khoury) grafting technique that demonstrates reproducible and stable, long-term results for horizontal and vertical alveolar bone augmentation.

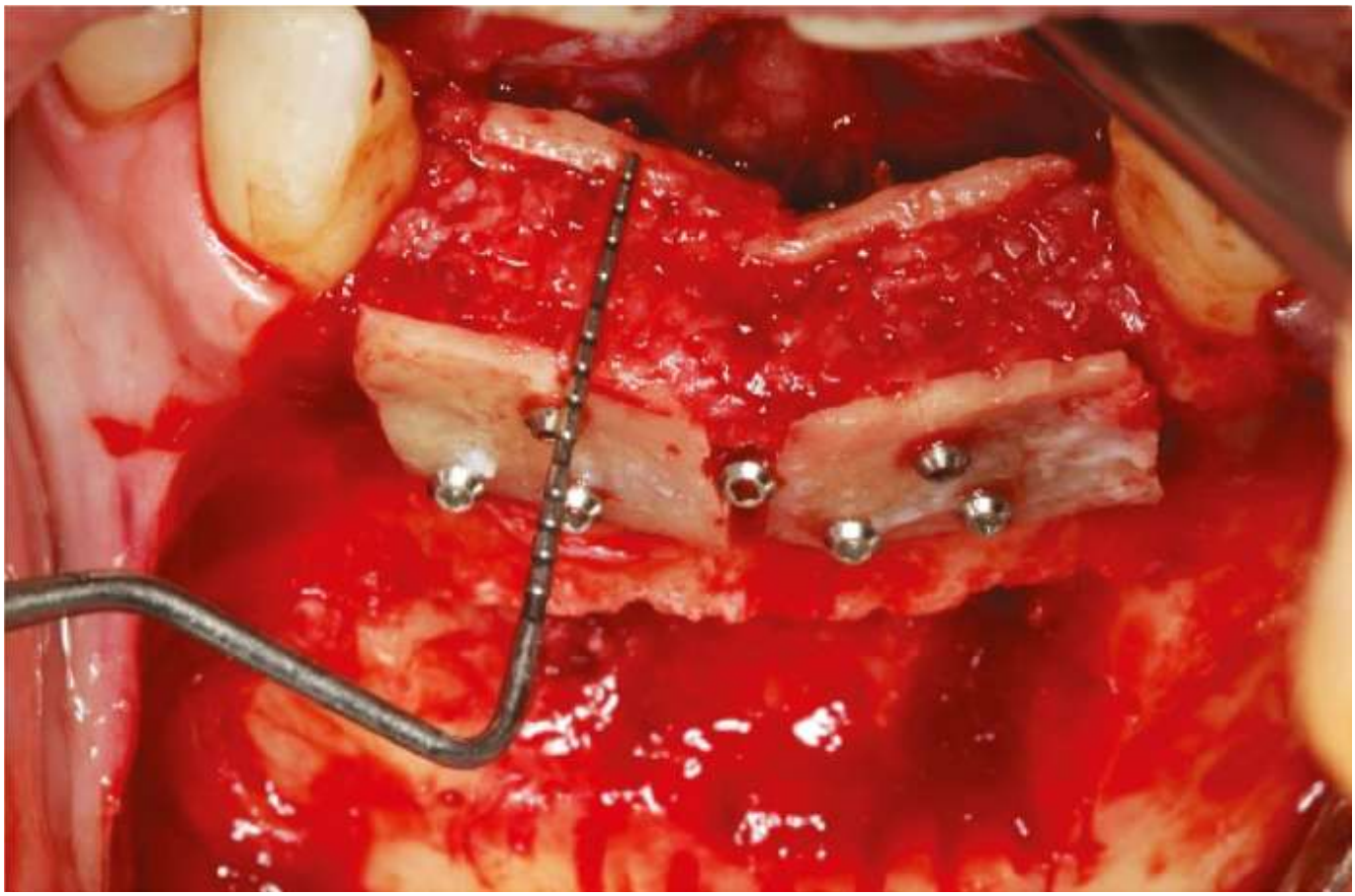

Dentlearn.ir

CHAPTER 20

Khoury Split Bone Block Grafting Technique: Biological Alveolar Bone Augmentation with Autogenous Bone

Fouad Khoury[1,2] and Charles Khoury[3]

[1]*Privatklinik Schloss Schellenstein, Olsberg, Germany*

[2]*Department of Oral and Maxillofacial Surgery, University of Muenster, Muenster, Germany*

[3]*Department of Fixed Prosthetics, School of Dentistry, St. Joseph University, Beirut, Lebanon*

The objective of dental implant treatment is to achieve optimal esthetics, and functional and long-term stable results. Adequate hard and soft tissue availability, appropriate implant position, and surgical and prosthetic skills are essential to reach this goal [1]. When these three features are available, the implant placement is adjusted to the site. However, an edentulous ridge with a deficiency of hard and soft tissues may interfere or pose a significant challenge, if not prohibit the insertion of implants of adequate length and in the correct position with an appropriate inclination. In these situations, the site should be adjusted for the implant insertion.

Several publications have attempted to classify the alveolar hard and soft tissue deficiency [2–4]. This deficit could be vertical, horizontal, three-dimensional (3D), antral (sinus), and/or a combination. In the literature various treatment options for alveolar reconstruction are available: guided bone regeneration (GBR) using xenografts or allografts with or without autogenous bone particles covered with resorbable or non-resorbable membranes [5, 6]; autogenous block grafting with intra- or extra-oral harvested bone in the form of thick or thin blocks in combination with autogenous bone chips; sinus lift procedures with different techniques and materials [5, 6]; alveolar distraction osteogenesis [7]; inferior alveolar nerve lateralization [8]; and others. Every technique has its advantages and success rates, but also its limitations.

Although different augmentation materials have been described in all these techniques with variable success rates [9–11], autogenous grafts are still superior to all others due to their clear osteogenic, osteoconduction, and osteoinduction characteristics. In many situations it is possible today to harvest bone locally close to the recipient site with a minimally invasive approach. But the reconstruction of severe bony defects or atrophies requires a second surgical site for the harvesting of bone block grafts. The literature describes the mandibular retromolar area (external oblique ridge) as the main intraoral bone harvesting site with the lowest morbidity and complication rates [12]. Since bone harvested from this area is mostly cortical with limited revascularization properties and regeneration quality, the technique of grafting procedures with this bone has been modified to improve the revascularization and regeneration potential (split bone block or SBB technique), allowing different options for bone reconstruction procedures, especially for the reconstruction of severe 3D bony defects with stable long-term results [13–15].

This chapter details a minimally invasive approach with locally harvested bone grafts (bone core technique) for the reconstruction of limited bony defects, as well as the protocol for a safe and secure bone harvesting technique from the mandibular retromolar area and the biological SBB technique for the reconstruction of severe bony defects with intraoral harvested bone grafts.

BIOLOGY OF BONE REGENERATION

The success and long-term stability of the grafted bone depend mainly on the amount of revascularization. The prognosis for the reconstructed area is determined by the quality and intensity of revascularization, the regeneration potential of the recipient site, and the quality of the regenerated area.

In orthopedic surgery, bone grafting procedure have long-term success if infection control rules are respected and the grafted area remains closed and protected by thick muscles [16, 17]. In contrast, a bone grafting procedure in the oral cavity occurs in an uncontrollable area contaminated by saliva and oral flora. Moreover, after the healing period, the regenerated area is reopened for the implant insertion and

Essential Techniques of Alveolar Bone Augmentation in Implant Dentistry: A Surgical Manual, Second Edition. Edited by Len Tolstunov.
© 2023 John Wiley & Sons, Inc. Published 2023 by John Wiley & Sons, Inc.
Companion website: www.wiley.com/go/tolstunov/essential

Dentlearn.ir

again at the time of implant exposure. Furthermore, after the prosthetic restoration of the implants, the peri-implant tissue will be in permanent contact with the oral flora. In these conditions, peri-implant regenerated bone with poor vascularization is not able to offer either appropriate implant osseointegration or acceptable defense against oral flora during its permanent contact through the peri-implant sulcus after prosthetic restoration. In addition, when future problems arise, such as peri-implantitis and bone loss, the treatment outcome is uncontrollable in a case of poor vascularization of the regenerated peri-implant tissue [18].

The goal of bone grafting for dental implant insertion is to reconstruct a new crestal bone similar in shape and quality to the original native bone. This is generally possible by using autogenous bone, especially in particulate form, allowing quick revascularization and helping a certain number of grafted bone cells to survive [19, 20]. Usually, the majority of the grafted bone cells (e.g. osteocytes) will not survive the grafting procedure by the time the vascular supply reaches them through neo-vascularization [21, 22]. But on the other hand, the dying process of the cells leads to an additional expression of bone morphogenetic proteins (BMPs), which will transform the pluripotent cells into osteoblasts. Osteoblasts will form new bone like the original one. However, this kind of osteoinduction is limited to bony recipient sites, probably through the influence of genetics. In addition, cell death activates the osteoclasts to remove dead materials, as well as activating a neo-angiogenesis in the form of inflammation for bone remodeling [22, 23]. This is one of the reasons why autogenous bone grafts are still the gold standard of augmentation materials, since all other bone substitutes do not possess cells and cannot induce the expression of their own growth proteins and factors.

In summary, the gold standard is achieved through the three functions of the autogenous bone graft:

- *Osteogenesis*: new bone formation through the surviving bone cells [24].
- *Osteoconduction*: the bone mineral presents a scaffold for attachment of the osteoid layers [25].
- *Osteoinduction*: new bone formation over the scaffold through expression of BMPs [26].

Autogenous bone grafts can be harvested from extra- or intraoral sites. Harvesting of bone grafts from an extraoral site is usually reserved for extreme atrophy of the jaw or severe bony defects, e.g. after tumor surgeries or severe trauma. Bone grafts harvested from intraoral sites are more appropriate to everyday work, since they can cover most of the grafting indications to allow implant insertion. In addition, the surgery can be done under local anesthesia without hospitalization [12].

Bone grafts from an intraoral site can be harvested in the form of bone chips, bone core, or bone block. Since bone chips and bone core are usually harvested from the implant bed, bone blocks are mostly harvested from the mandibular retromolar area (external oblique line). A 10-year prospective study on more than 3800 harvested bone blocks from this area confirmed the high security of this technique following the MicroSaw® protocol (Dentsply Sirona, Philadelphia, PA, USA; Figure 20.1A, B) [15].

Bone grafts harvested from the mandibular retromolar area are mostly cortical and difficult to revascularize. Thick cortical mandibular bone block grafts usually remain unaltered; even after they have become fully incorporated with the neighboring structures, they can still contain a large number of dead cells for years, due to a lack of vascular supply [17]. This situation will have a negative influence on the prognosis and stability of the grafted area, making it more vulnerable to infection when exposed to the oral flora after the prosthetic restoration. The SBB technique was developed to avoid such a situation and to improve the regeneration potential of the grafted bone.

The SBB technique is based on splitting longitudinally the thick cortical bone block harvested from the mandibular retromolar or chin area into two or more thin bone blocks by using the MicroSaw® disk (Figure 20.1C). The resulting two bone blocks, which usually have the same dimensions but with less thickness (Figure 20.1D), are then thinned to a width of about 1 mm by using a bone scraper, producing at the same time an important volume of bone chips. The thin bone blocks are then stabilized at a distance to the recipient site by microscrews (Figure 20.1E), leaving a space that will be filled with the autogenous bone chips (Figure 20.1F). After a healing time of 3–4 months, implants are placed in the vascularized graft (Figure 20.1G). In a case of reconstruction of a vertical bony defect, the two thin bone blocks are used to prepare a box that will be filled with the bone chips (Figure 20.1H–J). Also in this situation implants are inserted after a healing period of 3–4 months (Figure 20.1K, L).

This modification of the grafting procedure first improves biological healing: scraping cortical bone into bone chips increases exponentially the surface of the grafted bone, leading to more new bone formation through osteoconduction. In addition, it also increases the amount of revascularization: it is much easier and quicker for the vascular channels to pass through the thin bone block or bone chips than to traverse a thick cortical block [20]. The SBB technique (also known as the "shell technique") offers a biological improvement over the cortical block bone graft and presents the following advantages:

- Possibility of reconstructing large areas in different forms: splitting the thick blocks into two or more thin blocks with the same surface area increases the number of bone blocks.
- Better adaptation to the recipient site: thin bone blocks can be better adapted to different forms of atrophic crest than thick blocks.

Dentlearn.ir

- Individual determination of the width of the grafted site: with this technique, the surgeon can decide during the surgery the future width of the alveolar crest.
- More possibilities for vertical and 3D bone augmentation: with the use of two or more thin bone blocks, it is easy to build the bone vertically in the form of a box up to 15 mm. This is possible in all regions without any exceptions. The thin bone blocks are used as a biological membrane to give the form of the future alveolar crest; therefore, there is no need for additional membranes.
- Biological reconstruction of the donor site: sometimes, one thin block can be enough to achieve bone augmentation. In this situation, the second bone block can be replaced in its original site over the remaining bone chips or collagen chips, reconstructing the external oblique line and offering the possibility of reharvesting a bone block from the same area after a period of 6 months.
- Easier to save the grafted area in case of graft exposure: early graft exposure is a serious complication that often leads to graft failure. With the SBB technique, the grafting occurs in many layers, where bone chips are protected by thin bone blocks. In case of graft exposure, thin cortical bone plates will continue to protect the particulate bone graft (chips), where revascularization has already started, from getting infected. After the removal of the exposed part of the bone block, good vascularization and stability of the underlying bone chips can be observed [27].

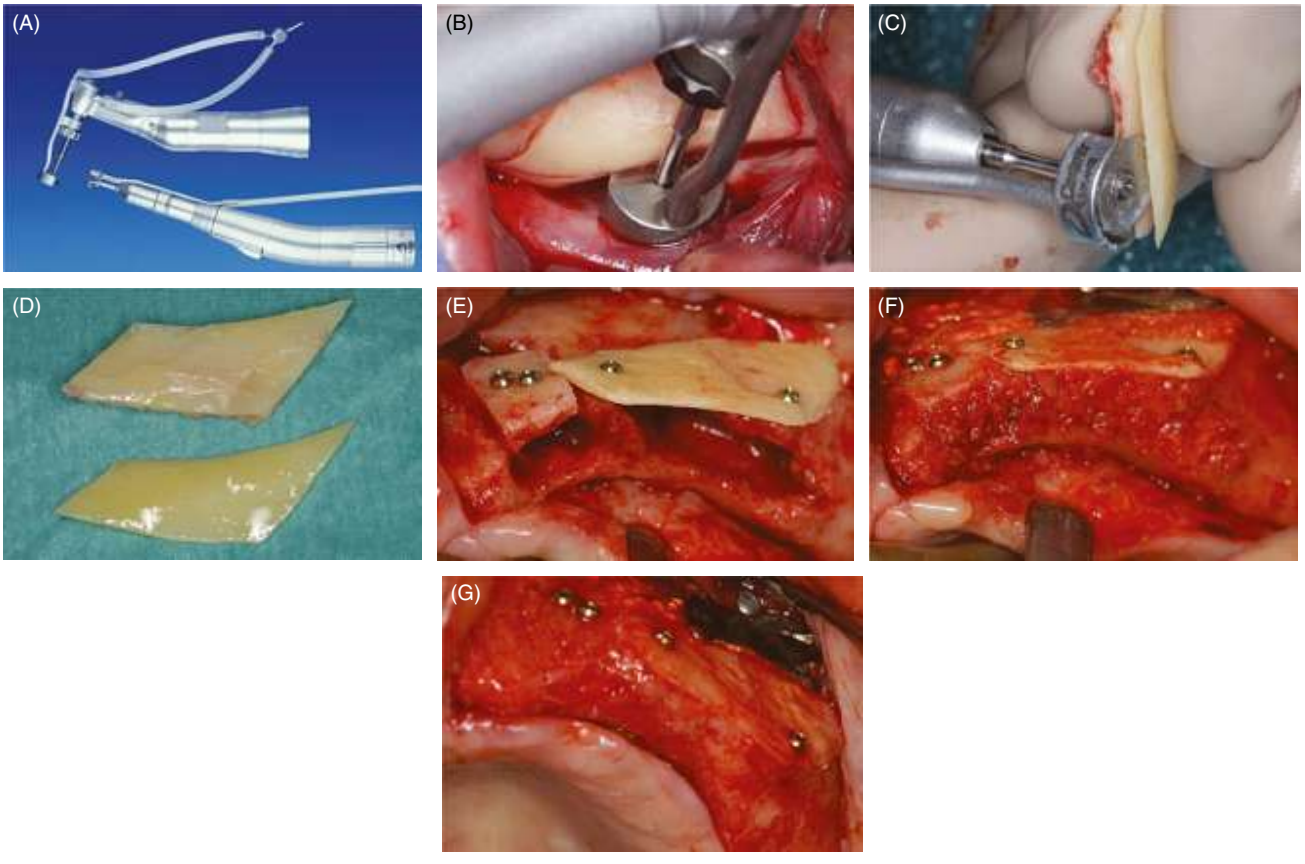

FIGURE 20.1 (A) MicroSaw devices. (B) Bone block harvesting from the mandibular external oblique line with the MicroSaw. (C) The bone block is split longitudinally with the thin diamond disk. (D) The resulting two blocks after the splitting. (E) The thin bone blocks are stabilized with micro-screws to reconstruct the buccal bone wall. (F) The gap is filled with autogenous bone chips. (G) Clinical aspect 3 months after the bone grafting. The titanium membrane was used to close the sinus window after the additional sinus floor elevation. (H) Severe bony defect after failed guided bone regeneration with bovine material in the front tooth area. (I) Three-dimensional reconstruction with two thin bone blocks stabilized with micro-screws for the reconstruction of the vestibular and palatal missing bone. (J) The created box is filled with autogenous bone chips. (K) Clinical aspect 3 months after bone grafting: the removed bone core shows the quality of the regenerated bone. (L) Insertion of two implants in the well-vascularized and regenerated bone.

Dentlearn.ir

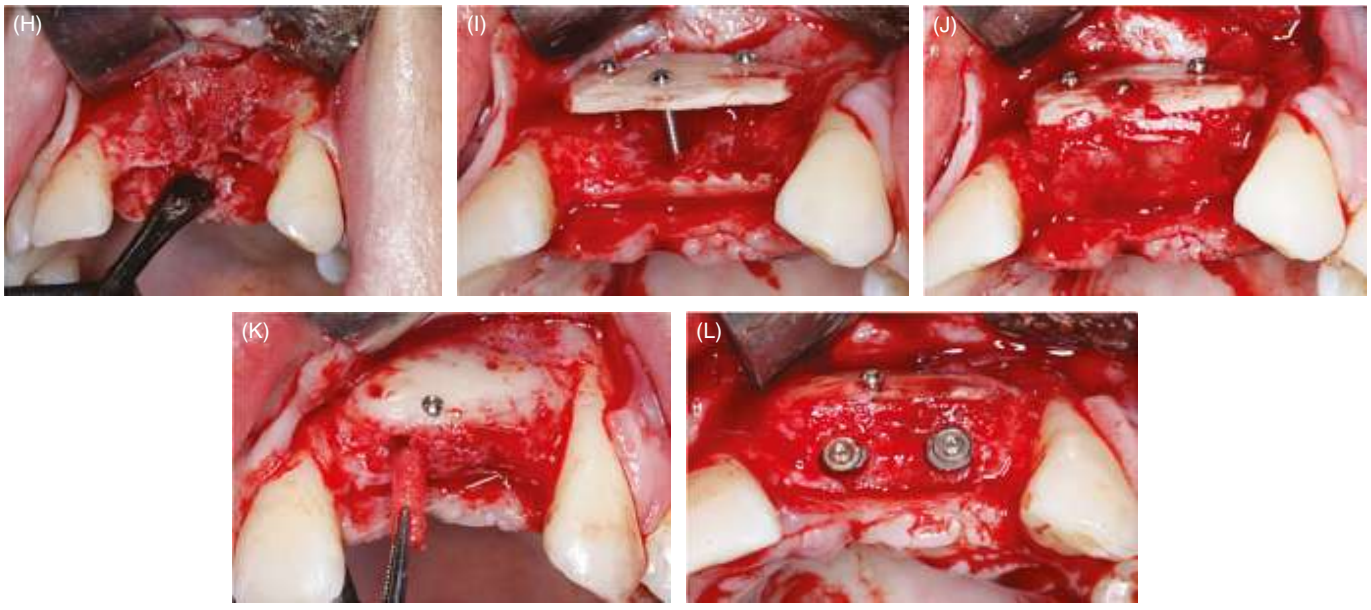

FIGURE 20.1 (*Continued*)

The SBB technique shows good long-term results in periodontally compromised patients. In a retrospective study of up to 13 years on lateral bone augmentation following the SBB protocol with a total of 241 implants inserted in grafted bone, two implants were lost (0.83%) due to peri-implantitis after 10–11 years of loading [28].

A 10-year prospective study on the SBB technique for 3D vertical alveolar ridge augmentation in the posterior maxilla using a tunnel approach in combination with sinus floor elevation showed a stable average of crestal vertical augmentation of 7.2±2.1 mm. A total of 306 implants were inserted in the vertically grafted bone. After a control period of between 10 and 14 years, three implants were lost (<1%) due to peri-implantitis [29].

AUGMENTATION TECHNIQUES

The treatment strategy for every bone augmentation, especially in the esthetic area, is to start with the proper diagnosis concerning the quality of the neighboring teeth, the quality and biotype of the soft tissue, the smile line, and the occlusion, as well as the demands of the patient. Very often it is recommended, in cases of scar tissue and poor soft tissue quality, to augment the soft tissue first. This soft tissue grafting is performed as a security measure to avoid a later tissue necrosis with exposure of the grafted bone [30]. The bone augmentation can be performed 2–3 months after the soft tissue grafting. Implant insertion in the grafted bone occurs after another 3 months. The implant exposure, performed after a following 3 months, is usually combined in the esthetic area with soft tissue management and connective tissue grafting. Methods for bone preservation and bone augmentation are presented in detail below.

BONY LID TECHNIQUE

The bony lid technique, as a bone-saving method, has been described in the literature for various treatments [31]. It is indicated to save bone every time where bone must be removed for different reasons, for example for the removal of impacted teeth, foreign bodies, cystectomies, deeply fractured roots, or implants.

The buccal bone wall over the surgical site can be cut precisely with the MicroSaw in the form of a bone window exposing the impacted tooth or the foreign body. At the end of the surgery, this bony lid is replanted, replacing the bony defect in this area. With the application of this technique, the

Dentlearn.ir

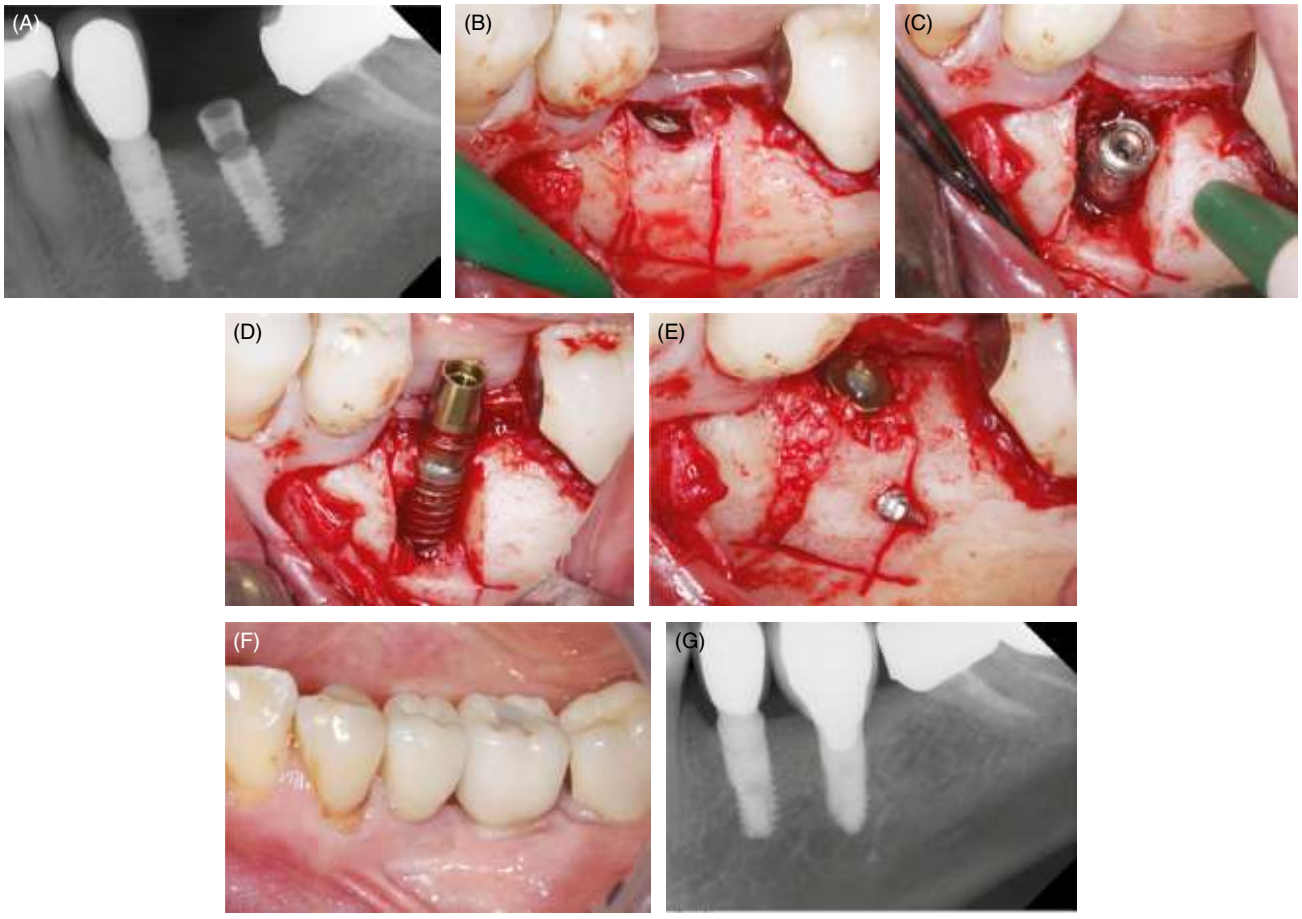

FIGURE 20.2 (A) Fracture of an implant. (B) A bony lid is cut with the MicroSaw on the vestibular bone wall. (C) Lateral removal of the fractured implant after dislocation of the bony lid. (D) A new and wider implant is inserted at the same place. (E) The bony lid is used as a graft after covering the implant threads with bone chips harvested from the bony lid with a bone scraper. (F) Clinical situation after the prosthetic restoration. (G) Control radiograph 7 years post operative.

original bony contours can be preserved in pre-implant and implant surgery by replacing the luxated buccal bone wall. The precise replantation of the bony lid, which usually needs no additional screw fixation, positively influences bone regeneration without connective tissue ingrowth [32]. In some situations it is possible to directly insert a new implant and use the removed bony lid as a bone graft (Figure 20.2).

AUGMENTATION OF SMALL BONE DEFECTS: BONE CORE TECHNIQUE

Small bone defects can also be grafted with locally harvested autogenous bone. An augmentation with simultaneous implant placement is recommended only if it is possible to insert and stabilize an implant inside of the bony contour [32]. In this situation, both important requirements for success can be fulfilled: optimal healing of the bone graft and good osseointegration of the implant through sufficient vascular supply and primary stabilization of graft and implant. Graft healing and osseointegration of the implant require good vascular supply and immobility [33]. In cases where an implant insertion inside the bony contour is not possible, it is recommended first to reconstruct the bone and then to insert the implant later (two-stage procedure) after the healing of the graft.

The bone core technique (Carota technique) is a minimally invasive augmentation method based on the use of a stable bone core, harvested from the implant site during implant bed preparation with a trephine, as augmentation material. This bone core is stabilized through retention between two bone walls or through compression with microscrews. This avoids the use of biomaterials and membrane and makes unnecessary the harvesting of bone grafts from other sites. This technique is indicated in cases where parts of the vestibular and/or palatal/lingual bone wall are missing, especially where a wide crest/socket platform exists, allowing implant insertion inside the bony contour [33].

Dentlearn.ir

FIGURE 20.3 (A) The trephine kit. (B) Two-piece trephine. (C) Pre-trephines with different diameters.

The surgery is generally performed under local anesthesia. Pre-operative antibiotic is administered (penicillin G, 1×10^6 IU) and must be continued after surgery for 7 days. After the exposure of the bone and exploration of the defect, a decision can be taken about the choice of the trephine diameter. A special kit has been developed (Meisinger USA, Centennial, CO, USA) with four different trephine diameters that can be adapted to different implant systems (Fig.20.3A). The trephines are designed as a two-piece instrument, allowing simple removal of the bone core in case of retention of the core inside the trephine bur (Figure 20.3B). In addition, for every trephine the kit contains a pre-trephine (Figure 20.3C). The pre-trephine prepares a retention in the harvesting area, allowing controlled and stable drilling with the trephine. After the removal of the bone core, the implant bed preparation can be continued with the standard burs of the implant system until the appropriate planned implant length and diameter are reached. Bone chips can be collected during this procedure. Care should be taken during implant insertion to keep the implant threads, especially on the crestal side of the socket, at least 1 mm inside the bony contours to assure good vascular supply to the grafted bone (Figure 20.4A–C). The bone core is then adjusted to the defect on the buccal or palatal (or both) sides and stabilized through compression with the head of micro-screws (Meisinger USA) inserted into local bone near the core (Figure 20.4D, E). The remaining exposed threads under the core can be covered with bone chips. In case of a wide implant thread exposure, a second bone core can be used in the same manner. The remaining gaps are filled with autogenous bone chips and so there is no need to use any biomaterials or membranes. At the end of the surgery, and after releasing incisions in the basal periosteum, the flap is repositioned tension free and sutured over the grafted area hermetically with resorbable 6-0 monofilament sutures. Exposure of the implant is performed after 3 months due to the high regeneration potential of the autogenous bone core (Figure 20.4F, G). Bone cores harvested from the middle part of the alveolar crest with a trephine bur are composed of both thin cortical and large cancellous bone and are rich in cell growth factors and osteoinductive proteins [34, 35].

A 5-year prospective study with this minimally invasive technique on 186 consecutively treated patients and 223 grafted sites documented minor primary healing complications (1.4%). The average width of the reconstructed area at the end of the grafting procedure was 2.4±0.8 mm, and at re-entry it was 2.1±0.6 mm. Partial resorption was observed on the cores grafted partially outside the bony contours. After 3 months of healing, all the 223 implants healed and primary osseointegra-

Dentlearn.ir

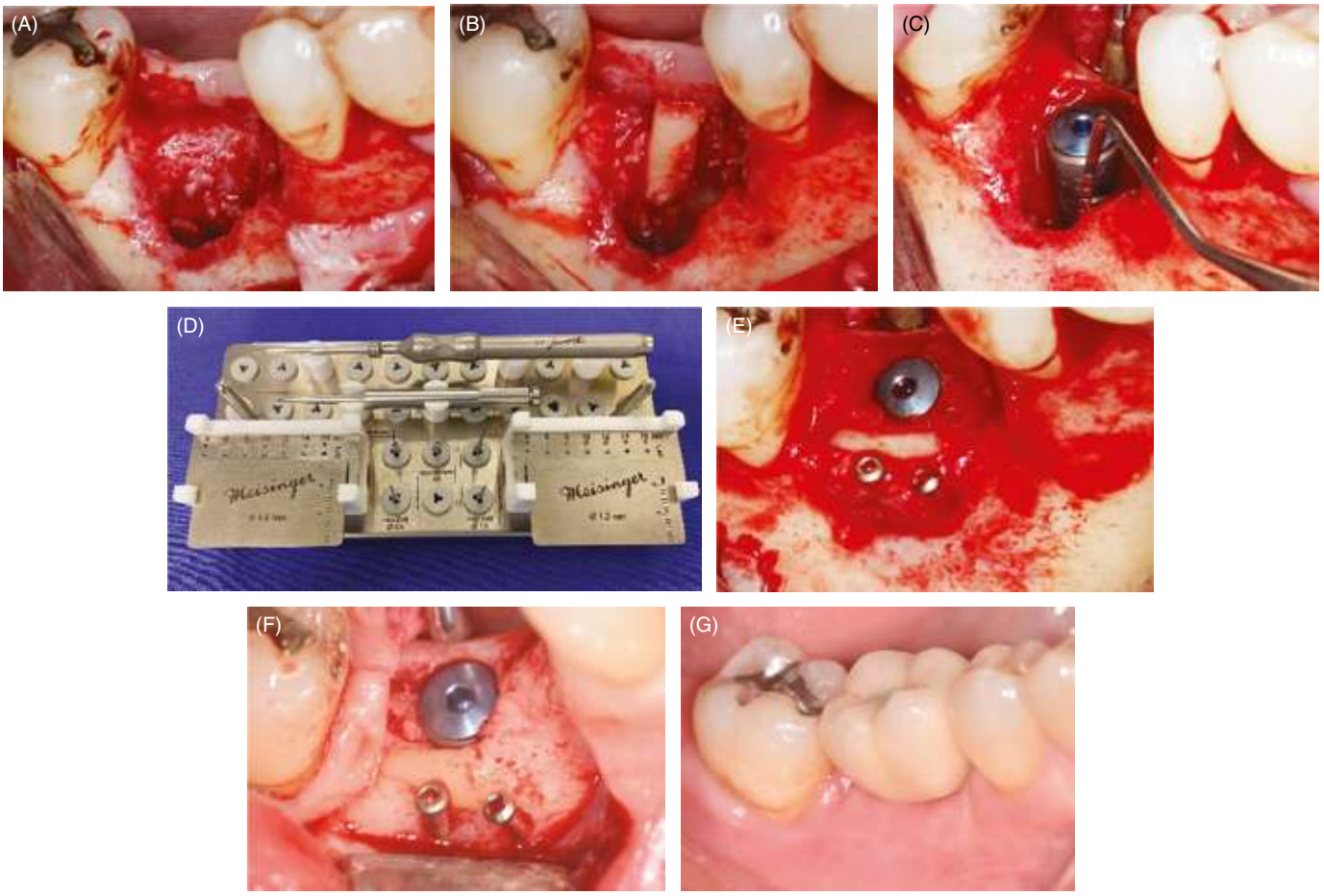

FIGURE 20.4 (A) Bony defect in the area of the mandibular first molar. (B) Bone core harvested from the socket. (C) Insertion of an Astra implant (Dentsply Sirona, Philadelphia, PA, USA) with a diameter of 4.8 mm. The depth of the pocket and the missing bone on the buccal site is approximately 12 mm. (D) The MicroScrew kit. (E) The bony defect is filled with autogenous bone chips harvested during implant bed preparation. The bone core is stabilized with two micro-screws to reconstruct the crestal border of the vestibular bony wall. (F) Clinical situation 3 months after the bone grafting, documenting excellent bone regeneration. (G) Clinical aspect after the prosthetic restoration.

tion took place. The implants were restored after an average time of 4 months. No implant failed during the control period [36].

AUGMENTATION OF LARGE BONY DEFECTS/ SEVERE BONE ATROPHY

In cases of severe bone atrophy or large defects in the horizontal or vertical dimension or both (3D defects), bone blocks are required to reconstruct the missing bone, allowing implants to be inserted in a prosthetically correct position. The decision of whether simultaneous implant insertion at the time of bone augmentation is possible depends on the same condition presented previously in the bone core technique: an augmentation with simultaneous implant placement is recommended only if it is possible to insert and stabilize an implant within the bony contours [32]. In cases where an implant insertion inside the bony contour is not possible, it is recommended first to reconstruct the bone and then insert the implant later (two-stage procedure) after the healing of the bone graft. This is mostly the situation in cases of 3D bony defects.

Horizontally atrophied alveolar bone with minimum width of 3 mm can be modified and expanded by splitting/ spreading the crest to allow implant insertion inside of the bony contours [13, 32]. Care should be taken to insert the implant inside of the teeth contours to prevent later soft tissue recession, especially in the esthetic zone.

A removable prosthesis should be avoided in cases of bone augmentation procedures: loading of the grafted bone with an uncontrolled removable prosthesis will lead to failure, with possible loss of the graft. The temporary restoration must be planned, preferably as a fixed bridge. In cases of atrophied edentulous jaw, provisional (mini) implants inserted in the

Dentlearn.ir

bone before or during bone augmentation can allow the patient to receive a fixed temporary (provisional) restoration stabilized on the temporary implants [32, 37].

Bone blocks can be harvested from different areas of the mandible and the maxilla. The main area to harvest bone blocks is the mandibular retromolar area. A prospective study with more than 3800 harvested bone blocks from this area following the MicroSaw protocol demonstrate high security with a very low number of complications [15]. Bone block grafts can be also harvested from the chin (symphyseal) area (Figure 20.5). It is preferable to do this in the *edentulous* symphyseal region to avoid sensory disturbance of the lower front teeth [38, 39]. In addition, small bone block grafts can be harvested from every mandibular edentulous area, mostly behind the mental nerve [39].

The harvested bone blocks are prepared as previously described according to the SBB technique. After splitting the cortical bone into two blocks, autogenous bone chips are collected through thinning the bone blocks with a bone scraper. The thin bone blocks can then be adapted to the bone defect in a different manner and stabilized with micro-screws at a distance to the atrophied crest to reach a bone width of about 7–8 mm. The gaps between the bone blocks and the remaining alveolar bone are filled with the autogenous bone chips, recreating a new alveolar crest. A tension-free watertight soft tissue closure is required for a complication-free healing. The implants can be inserted into the grafted area after a healing period of 3 months. In cases of simultaneous implant insertion, implant exposure in combination with soft tissue management is also performed after the 3-month period of healing.

In cases of vertical bony defects, two bone walls are reconstructed with the thin bone blocks, also stabilized with micro-screws forming a bone box (Figure 20.6). The thin blocks usually reconstruct the vestibular and palatal/lingual bone walls. Sometimes, especially when the surgery is performed through the tunnel approach in the posterior maxilla or mandible, the two thin blocks reconstruct the crestal and vestibular bone wall (Figure 20.7). The bone box created is filled at the end of surgery with autogenous bone chips. The stabilization of the bone chips with platelet-rich fibrin (PRF) to get what is called "sticky bone" is useful in facilitating the filling of the bone box with stable bone chips. Covering the grafted area with PRF membranes can positively influence healing [40]. No other materials or membranes are used. Tension-free watertight primary flap closure is very important to avoid any dehiscence or tissue necrosis with graft exposure. Implants are usually inserted into the grafted area after the healing period of 3 months.

The highest-risk area for vertical bone grafting is the posterior mandible due to difficult access, thin lingual soft tissue, and strong muscle activity. The risk of graft exposure through soft tissue dehiscence or necrosis can be reduced through a tunnel or lateral approach (Figure 20.8A, B).

Soft tissue management and soft tissue augmentation represent a very important factor for success in all types of bone augmentation. Poor soft tissue quality and quantity, mostly after failures of implants or bone augmentation

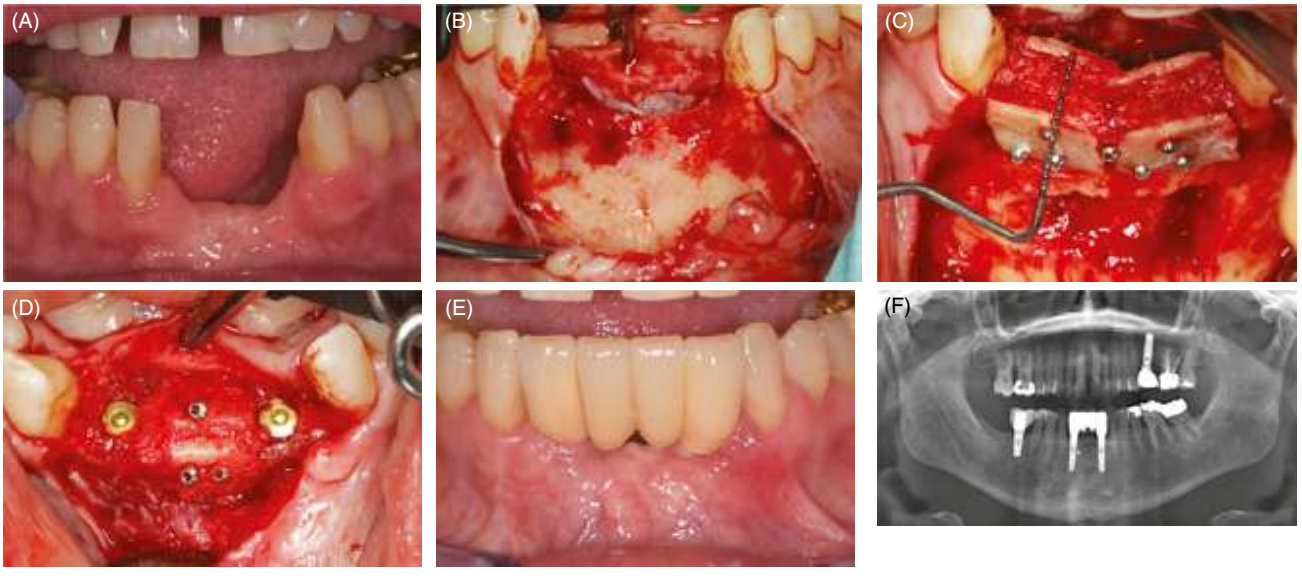

FIGURE 20.5 (A) Clinical situation after failed grafting with allograft blocks. (B) The remaining alveolar crest demonstrates a severe bony defect: the right central incisor was removed due to lack of bony support. (C) Three-dimensional reconstruction with bone blocks harvested from the apical part of the chin. (D) Two implants are inserted in the healed graft 3 months after the grafting. The removed bone cores from the implant site were used for additional grafting in the pontic area. (E) Clinical situation 2 years after bone grafting. (F) Control radiograph 4 years after bone grafting.

Dentlearn.ir

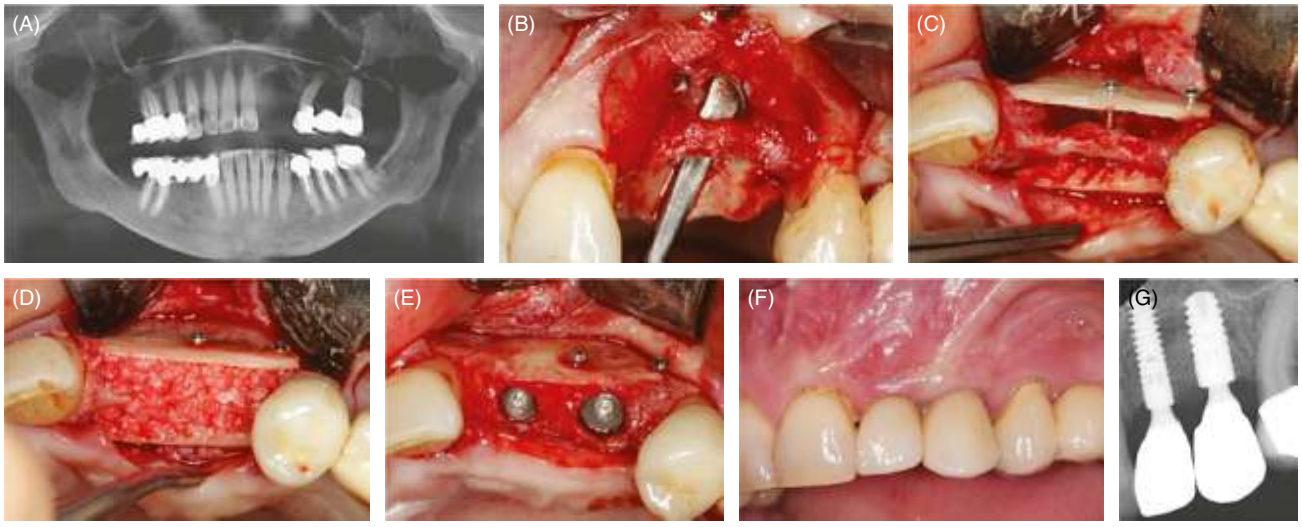

FIGURE 20.6 (A) Severe bony defect in the anterior left maxilla. (B) Clinical situation of the missing bone. (C) Reconstruction of the buccal and palatal bone wall with two thin bone blocks stabilized with micro-screws. (D) The box is filled with autogenous bone chips. (E) Insertion of two implants in the well-regenerated bone 3 months after surgery. (F) Clinical aspect after the prosthetic restoration. (G) Control radiograph 3 years after the grafting procedure.

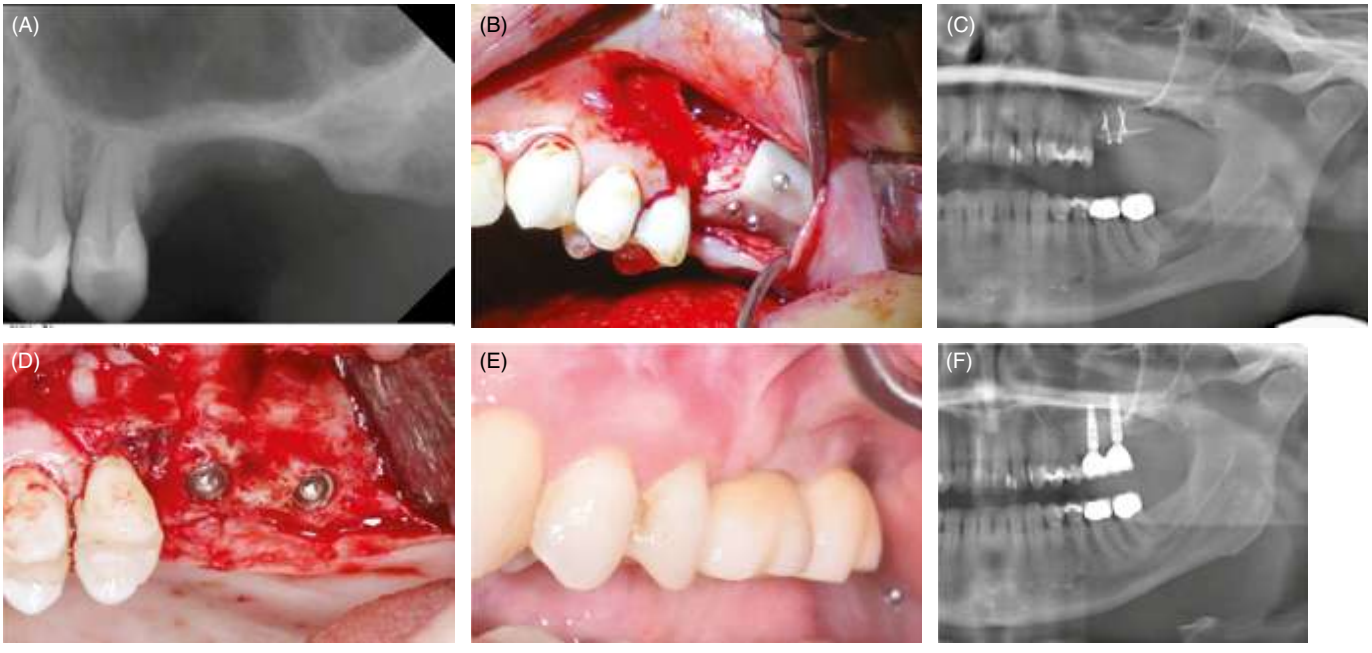

FIGURE 20.7 (A) Large three-dimensional bony defect in the left posterior maxilla. (B) Three-dimensional bone reconstruction with autogenous bone through a tunnel approach. (C) Post-operative radiograph: bone block was harvested from the mandibular left retromolar area. (D) Insertion of two implants in the grafted and regenerated area. (E) Clinical situation 3 years after prosthetic restoration. (F) Control radiograph 7 years after the bone grafting procedure.

with biomaterials, as well as poor soft tissue biotype, represent a high risk for every bone augmentation procedure [41, 42]. For this reason, it is recommended in such cases to improve soft tissue quality and quantity *prior to* bone augmentation with, for example, a pedicle palatal connective tissue flap in the maxilla and connective tissue graft in the mandible [32, 43]. Soft tissue management with or without soft tissue grafting is an extremely important factor for the

Dentlearn.ir

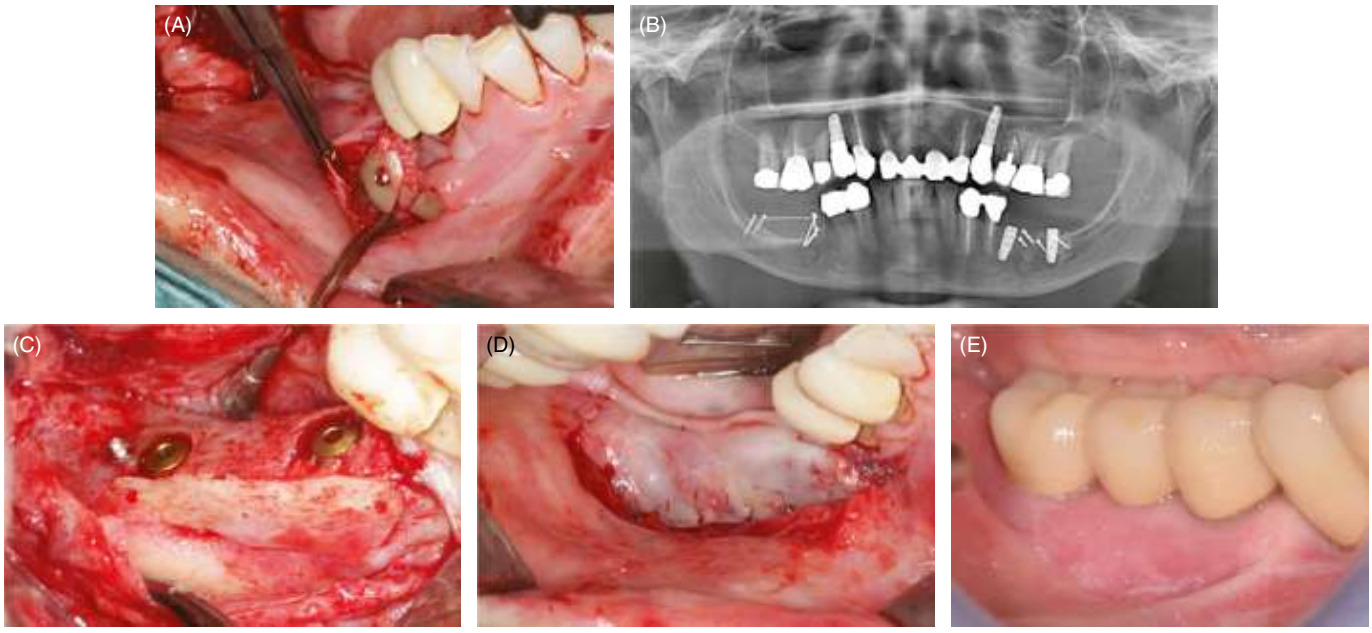

FIGURE 20.8 (A) Three-dimensional grafting of the right posterior mandible through a tunnel approach. (B) Post-operative radiograph documenting the amount of the vertical grafting in the posterior right mandible. (C) Two implants are inserted in the grafted and regenerated bone 3 months after the bone grafting. (D) Wound closure and vestibuloplasty according to the Kazanjian technique. (E) Clinical situation documenting stable and fixed soft tissue around the restored implants.

long-term success and stability of an implant treatment. Different techniques of soft tissue surgeries, for example the Kazanjian vestibuloplasty (Figure 20.8C–E) [44] or free gingival graft, are important for a stable peri-implant soft tissue profile without muscle activity. Other soft tissue techniques, such as apical repositioning flaps with or without connective tissue graft, roll flaps, or papilla reconstruction techniques, are important for esthetics and soft tissue stability around dental implants [32].

CONCLUSION

This chapter demonstrates the use of autogenous bone grafts harvested from intraoral sites by using safe techniques for the reconstruction of different bone defects, starting from a small bony deficit to complex 3D bone augmentation. The use of autogenous bone grafts following the SBB technique has demonstrated reproducible and stable long-term results. The technique offers possibilities to reconstruct large horizontal and vertical bony defects up to 15 mm.

REFERENCES

1. Farronato D, Pasini PM, Orsina AA et al. Correlation between buccal bone thickness at implant placement in healed sites and buccal soft tissue maturation pattern: A prospective three-year study. *Materials (Basel).* 2020;13(3):511.
2. Cawood JI, Howell RA. A classification of the edentulous jaws. *Int J Oral Maxillofac Surg.* 1988;17:232–6.
3. Chiapasco M, Zaniboni M, Rimondini L. Dental implants placed in grafted maxillary sinuses: A retrospective analysis of clinical outcome according to the initial clinical situation and a proposal of defect classification. *Clin Oral Implants Res.* 2008;19:416–28.
4. Misch CM, Chiapasco M, Jensen OT. Indications for and classification of sinus bone grafts. In OT Jensen (ed.), *The sinus graft*. New York: Academic Press; 2006, 43.
5. Jensen SS, Broggini N, Hjørting-Hansen E et al. Bone healing and graft resorption of autograft, anorganic bovine bone and b-tricalcium phosphate: A histologic and histomorphometric study in the mandibles of minipigs. *Clin Oral Impl Res.* 2006;17:237–43.
6. Urban IA, Monje A. Guided bone regeneration in alveolar bone reconstruction. *Oral Maxillofac Surg Clin N Am.* 2019;31:331–8.
7. Toledano-Serrabona J, Sánchez-Garcés MÁ, Sánchez-Torres A, Gay-Escoda C. Alveolar distraction osteogenesis for dental implant treatments of the vertical bone atrophy: A systematic review. *C Med Oral Pathol Oral Cir Bucal.* 2019;24(1):e70–e75.
8. Atef M, Mounir M. Computer-guided inferior alveolar nerve lateralization with simultaneous implant placement: A preliminary report. *J Oral Implantol.* 2018;44:192–7.
9. Simion M, Jovanovic SA, Tinti C, Benfenati SP. Long-term evaluation of osseointegrated implants inserted at the time or after vertical ridge augmentation: A retrospective study on 123 implants with 1–5 year follow-up. *Clin Oral Implants Res.* 2001;12:35–45.

Dentlearn.ir

10. Lee HJ, Choi BH, Jung JH et al. Vertical alveolar ridge augmentation using autogenous bone grafts and platelet-enriched fibrin glue with simultaneous implant placement. *Oral Surg Oral Med Oral Pathol Oral Radiol Endod.* 2008;105:27–31.
11. Elnayef B, Monje A, Gargallo-Albiol J et al. Vertical ridge augmentation in the atrophic mandible: A systematic review and meta-analysis. *Int J Oral Maxillofac Implants.* 2017;32:291–312.
12. Sittitavornwong S, Ashley D, Denson D, Cruz Walma DA. Integrity of human mandibular angle after block graft harvested from mandibular body. *Int J Oral Maxillofac Implants.* 2019;34:692–7.
13. Khoury F. [Surgical aspects and results for improvement of alveolar bone prior to implant therapy]. *Z Zahnärztl Implantol.* 1994;3:237–45.
14. Günzl H-J, Khoury F. Morphologische Untersuchungen von Knochenbiopsien nach autogener Alveolar-Extensionsplastik am unentkalkten, kunststoffeingebetteten Schliffpräparat. In Gesellschaft für orale Implantologie (ed.), Jahrbuch für oral Implantologie. Quintessence; 1993, 153.
15. Khoury F, Hanser T. Mandibular bone block harvesting from the retromolar region: A 10-year prospective clinical study. *Int J Oral Maxillofac Implants.* 2015;30:688–97.
16. Chen NT, Glowacki J, Bucky LP et al. The roles of revascularization and resorption on endurance of craniofacial onlay bone grafts in the rabbit. *Plast Reconstr Surg.* 1994;93(4):714–22.
17. Ozaki W, Buchman SR. Volume maintenance of onlay bone grafts in the craniofacial skeleton: Micro-architecture versus embryologic origin. *Plast Reconstr Surg.* 1998;102(2):291–9.
18. Scarano A, Kelekis CA, Piatelli A. Histologic evaluation of the sinus grafting materials after peri-implantitis-induced failure: A case series. *Int J Oral Maxillofac Implants.* 2017;32:e69–e75.
19. Lorenzetti M, Mozzati M, Campanino PP, Valente G. Bone augmentation of the inferior floor of the maxillary sinus with autogenous bone or composite bone grafts: A histologic-histomorphometric preliminary report. *Int J Oral Maxillofac Implants.* 1998;13:69.
20. Pallesen L, Schou S, Aabie M et al. Influence of particle size of autogenous bone grafts on the early stages of bone regeneration: A histologic and stereologic study in rabbit calcavrium. *Int J Oral Maxillofac Implants.* 2002;17:498–506.
21. Oppenheimer AJ, Tong L, Buchman SR. Craniofacial bone grafting: Wolff's law revisited. *Craniomaxillofac Trauma Reconstr.* 2008;1:49–62.
22. Mulliken JB, Kaban LB, Glowacki J. Induced osteogenesis: The biological principle and clinical applications. *J Surg Res.* 1984;37:487–96.
23. Burchardt H. The biology of bone graft repair. *Clin Orthop Relat Res.* 1983;178:28–42.
24. Wolff J. *Das Gesetz der Transformation der Knochen*. Berlin: Hirschwald; 1892.
25. Barth A. Ueber histologische Befunde nach Knochen-implantationen. Jena: Fischer; 1893.
26. Boyne PJ. Osseous reconstruction of the maxilla and the mandible: Surgical techniques using titanium mesh and bone mineral. Chicago, IL: Quintessence; 1997.
27. Khoury F, Ponte A, Happe A. The 3-dimensional reconstruction of the alveolar crest with mandibular bone block: A clinical study. *Int J Oral Maxillofac Implants.* 2004;19:765–6.
28. Keeve P, Khoury F. Long-term results of peri-implant conditions in periodontally compromised patients following lateral bone augmentation. *Int J Oral Maxillofac Implants.* 2017;32(1):137–46.
29. Khoury F, Hanser T. Three-dimensional vertical alveolar ridge augmentation in the posterior maxilla: A 10-year clinical study. *Int J Oral Maxillofac Implants.* 2019;34(2):471–80.
30. Khoury F, Happe A. Soft tissue management in oral implantology: A review of surgical techniques for shaping an esthetic and functional peri-implant soft tissue structure. *Quintessence Int.* 2003;31:483–99.
31. Khoury F. The bony lid approach in pre-implant and implant surgery: A prospective study. *Eur J Oral Implantol.* 2013;6:375–84.
32. Khoury F. Bone and soft tissue augmentation in implantology. Berlin: Quintessence; 2021.
33. Khoury F, Hidaja H. Secure and effective stabilization of different sized autogenous bone grafts. *JOS.* 2011;2:1–6.
34. Miron RJ, Gruber R, Hedbom E et al. Impact of bone harvesting techniques on cell viability and the release of growth factors. *Clin Implant Dent Rel Res.* 2013;15(4):481–9.
35. Maridati P, Dellavia C, Pelligrini G et al. Histologic and radiographic comparison of bone scraper and trephine bur for autologous bone harvesting in maxillary sinus augmentation. *Int J Oral Maxillofac Implants.* 2015;30(5):1128–36.
36. Khoury F, Doliveux R. The bone core technique for the augmentation of limited bony defects: Five-year prospective study with a new minimally invasive technique. *Int J Periodontics Restorative Dent.* 2018;38(2):199–207.
37. Khoury F, Happe A. Temporäre Implantate bei ausgedehnten Kieferaugmentationen – Ergebnisse einer klinischen Studie. *Implantologie.* 2001;4:375–87.
38. Khoury F, Happe A. Zur Diagnostik und Methodik von intraoralen Knochenentnahmen. *Z Zahnärztl Implantol.* 1999;15:167–76.
39. Khoury F, Khoury C. Mandibular bone block graft: Instrumentation, harvesting technique and application. *J Parodontol Implantol Orale.* 2006;25:15–34.
40. Miron RJ, Zucchelli G, Pikos MA et al. Use of platelet-rich fibrin in regenerative dentistry: A systematic review. *Clin Oral Investig.* 2017;21:1913–27.
41. Khoury F, Happe A. [Soft tissue management in oral implantology: A review of surgical techniques for shaping an esthetic and functional peri-implant soft tissue structure I]. *Quintessence Int.* 1998;49:861–8.
42. Khoury F, Happe A. [Soft tissue management in oral implantology: A review of surgical techniques for shaping an esthetic and functional peri-implant soft tissue structure II]. *Quintessence Int.* 1998;49:969–77.
43. Khoury F, Happe A. The palatal subepithelial connective tissue flap method for soft tissue management to cover maxillary defects: A clinical report. *Int J Oral Maxillofac Implants.* 2000;15:415–18.
44. Kazandjian VH. Surgical operations as related to satisfactory dentures. *Dental Cosmos.* 1924;66:387–95.

Dentlearn.ir

Alveolar Distraction Osteogenesis for Bone Augmentation in Implant Dentistry

CHAPTER 21

Distraction osteogenesis's greatest advantage is the large amount of newly created bone and simultaneous formation of soft tissue. Vascularization of the bone–soft tissue flap is important to avoid necrosis, as well as the rate of distraction: not too slow to avoid premature ossification and not too fast to avoid improper ossification. This surgical technique is very effective if used correctly and should be part of the toolbox of any oral surgeon.

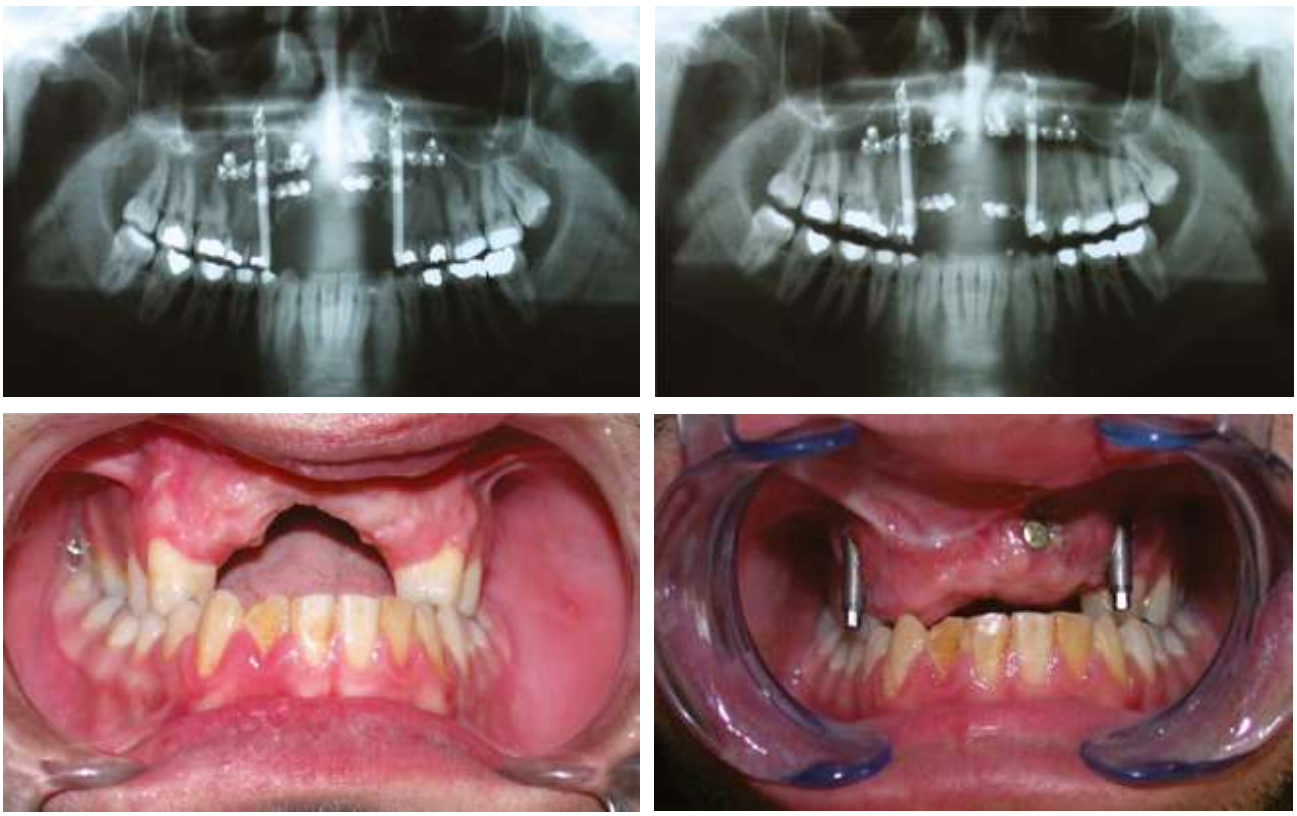

Dentlearn.ir

CHAPTER 21

Alveolar Distraction Osteogenesis for Bone Augmentation in Implant Dentistry

Dekel Shilo[1,2] and Adi Rachmiel[1,2]

[1]*Department of Oral and Maxillofacial Surgery, Rambam Medical Center, Haifa, Israel*

[2]*Faculty of Medicine, Technion-Israel Technion of Technology, Haifa, Israel*

In an era in which dental implants and fixed prosthetic restorations have become common practice, patients with atrophic or avulsed alveolar bone expect a treatment plan for complete restoration of the bone and dentition. Loss of teeth may be a result of periodontal/caries disease, trauma, or marginal resection due to tumors or aggressive cysts. Following teeth loss, resorption of the alveolar bone commences. Resorption is most prominent in the first year post extraction and is accelerated by the use of dentures [1, 2]. The long-term stability of dental implants and their many advantages are well established [3–5]. Different regions in the jaws pose different challenges for implant placement and augmentation. In the posterior mandible, limited by the mental foramen anteriorly, it is not uncommon to find extensive bone deficiency and a caudally placed inferior alveolar nerve (IAN). In the anterior regions of the maxilla and mandible, a knife-edge bone appearance is commonly observed [6].

Deficient atrophic bone impairs the proper placement of dental implants with the required bone support both horizontally for long-term stability and vertically for a desirable crown-to-root ratio. In these cases, bone augmentation is recommended for improving bone support. Restoring proper bone volume allows for proper interarch relations, an adequate crown-to-root ratio, and thus superior prosthetic results. Mild bone deficiencies can be treated using several reconstructive and regenerative methods. These modalities include autogenous onlay bone grafting [7–9], interpositional bone graft [10, 11], guided bone regeneration (GBR) [12, 13], and IAN lateralization [14]. Each of these augmentation techniques presents advantages and disadvantages. Autogenous onlay bone graft may exhibit substantial resorption, resulting in reduction of the graft and thus unpredictable outcomes [15]. Donor site morbidity is also an issue when autologous bone graft is used and different graft harvest locations result in different morbidity outcomes [16]. GBR is an augmentation technique that is easy to master and is well documented in the literature [12, 13]. It is frequently used for minor deficiencies, yet it is limited in producing significant bone height [12, 13].

IAN lateralization for the placement of dental implants was first described in 1987 [17]. This method allows for implant placement at the same surgical procedure as the nerve lateralization, without donor site morbidity, and thus is very tempting for both the patient and the clinician. The main risk of IAN lateralization is damage to the IAN, resulting in neuro-sensory disturbances in the distribution of the mental nerve. The most common neuro-sensory complications are hypoesthesia, paresthesia, and hyperesthesia [17, 18]. It is important to remember that although this method allows for placement of dental implants, the lack of vertical augmentation results in am unfavorable crown-to-implant ratio.

When encountering a case with severe bone deficiency, these techniques will not suffice for achieving adequate augmentation in both hard and soft tissue. As a result, the use of distraction osteogenesis (DO) for alveolar bone augmentation has increased gradually during the past two decades [19–21]. The DO technique is based on the ability to create new bone by slow traction. Following an osteotomy, gradual expansion of the segments induces bone formation in the created gap [22, 23]. Ilizarov described the tension-stress effect on bone and soft tissue, and discussed the need for loading and blood perfusion in the contouring of bones [22, 23]. Complications were reduced by maintaining the blood supply through preserving the surrounding periosteum and soft tissue. Ilizarov also encouraged maintaining the stability rather than rigidity

Essential Techniques of Alveolar Bone Augmentation in Implant Dentistry: A Surgical Manual, Second Edition. Edited by Len Tolstunov.
© 2023 John Wiley & Sons, Inc. Published 2023 by John Wiley & Sons, Inc.
Companion website: www.wiley.com/go/tolstunov/essential

Dentlearn.ir

of the distraction device. He stressed the importance of controlling the vector of distraction.

DO is different to other augmentation methods, especially by the simultaneous elongation of the soft tissue envelope, resulting in better stabilization of the newly created bone. This is crucial in intraoral augmentation, where lack of soft tissue is a major factor in failure of the bone graft.

In alveolar distraction osteogenesis (ADO) we use Ilizarov's principles but create a transport segment. We maintain the integrity of the periosteum and soft tissue attached to the transport segment in the palatal/lingual aspect and in the crestal region to prevent resorption.

The first clinical application of DO in the craniofacial complex was performed by McCarthy [24]. Following McCarthy, other groups showed their experience, concluding that progressive elongation of two bone fragments in the facial bony complex resulted in new bone formation at the newly created gap [25–27]. DO for alveolar bone elongation in humans was described in 1996 [28]. Since then the use of DO for alveolar bone has been popularized and used for both vertical and horizontal augmentation.

ADO devices can be categorized into extraosseous devices, which are the most prevalent, intraosseous devices, which include central application devices, and distraction by implants [28–30].

In this chapter, we will describe the use of ADO prior to dental implant placement. The distraction protocol, special indications, tips based on our experience, and complications are discussed in detail.

SURGICAL PROCEDURE

Pre-operative imaging is essential in ADO. Currently, cone beam computed tomography (CBCT) is easily available and thus the gold standard prior to surgical treatment planning (Figure 21.1).

ADO requires a minimum of bone height. We recommend a minimum of 5–6 mm for the transport segment. This is important for the viability of the transport segment and for proper fixation of the distraction device without fracturing the segment (Figure 21.2). Following initial assessment and given the patient is a candidate for alveolar distraction, planning of the procedure is commenced. There are different devices for different situations, which are detailed in the "indications" section of this chapter. For the surgical incision, we recommend performing a vestibular muco-periosteal incision, just below the attached mucosa (Figure 21.3).

It is crucial to leave the attached mucosa and the lingual/palatal mucosa intact, which allows for appropriate blood supply to the transport segment. Next, a trapezoid osteotomy is performed with the larger base placed on the crest (Figure 21.4). This allows for vertical elongation without the risk of bony interferences. We suggest using a piezoelectric device for the osteotomy to preserve the lingual/palatal blood supply. In the mandible, always remember to be aware of the location of the IAN and maintain 1–2 mm above it. In addition, remember the mandible is under strong masticatory forces and thus one should maintain enough vertical height of basal bone to avoid fractures of the jaw.

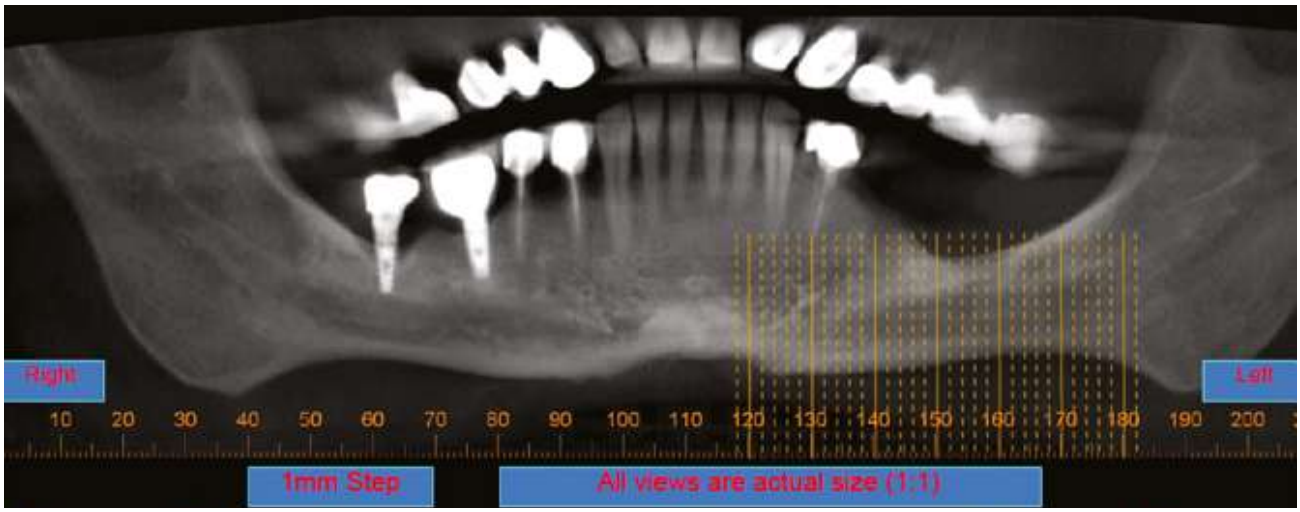

FIGURE 21.1 Cone beam computed tomography exhibiting an atrophic posterior mandible.

Dentlearn.ir

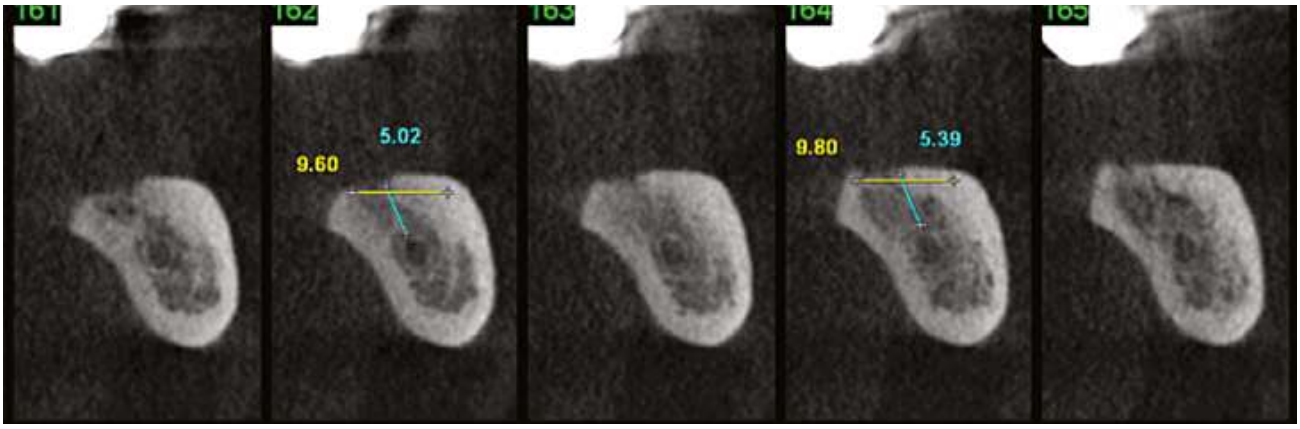

FIGURE 21.2 Sections of the cone beam computed tomography in Figure 21.1 demonstrating the amount of bone above the inferior alveolar nerve. This bone represents the potential height for a transport segment.

FIGURE 21.3 Clinical photograph demonstrating the vestibular incision performed for approaching the alveolar bone. Note that the attached mucosa is intact and is left attached to the crestal bone.

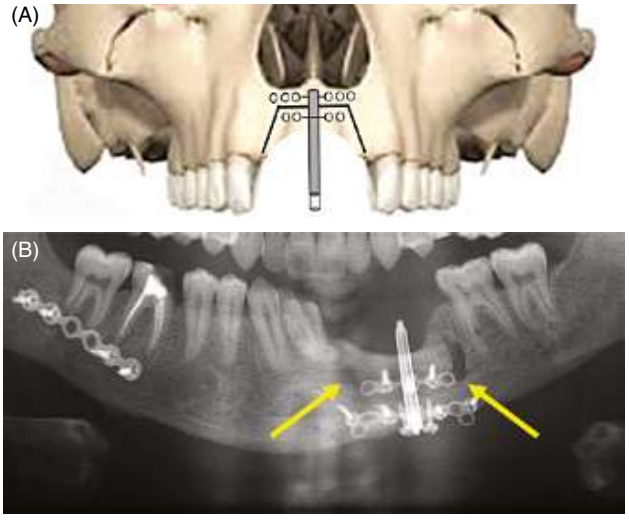

FIGURE 21.4 The trapezoid osteotomy performed in alveolar distraction osteogenesis (ADO). (A) An illustration of the osteotomy and ADO device in the anterior maxilla. *Source*: Adapted from Rachmiel A. et al. Two-stage reconstruction of the severely deficient alveolar ridge: bone graft followed by alveolar distraction osteogenesis. *International journal of oral and maxillofacial surgery* 2018;47:117–124. (B) A panoramic radiograph of the osteotomy and an ADO device in the left mandible. *Source*: Adapted from Rachmiel A. et al. Vertical alveolar distraction osteogenesis of the atrophic posterior mandible before dental implant insertion. J Oral Maxillofac Surg. 2017;75:1164–75 with permission of Elsevier.

At this stage the distraction device is fixed to the basal and transport bony structures (Figure 21.5). If two devices are used, one on each side, remember to remove the distal part of the fixation plate in the device on the transport segment (Figure 21.6). Use mini-screws to assure proper fixation during the activation and retention periods. Suture the surgical incision using VICRYL® sutures (Ethicon, Somerville, NJ, USA; Figure 21.7). The latency period in mature patients undergoing ADO should be approximately 4 days. Following the latency period, activation should commence and should be performed at a rate of 0.5 mm per day (Figure 21.8). It is important to see patients at least twice a week while in the activation period, as it is during this phase that most complications occur. One must emphasize numerous times the correct orientation for activating the device, as opposite turning of the activation rod is not a rare complication. In addition, make sure the elongation is symmetric on both sides of the device and the vector of elongation is as planned. The elongation should be performed in excess, as a slight relapse is expected due to masticatory forces (Figure 21.9). It is not uncommon for slight device exposure (Figure 21.10) and, if this is not accompanied by infection, no action is indicated. Use of chlorhexidine rinse is recommended.

Dentlearn.ir

FIGURE 21.5 Photograph of an alveolar distraction osteogenesis device connected to the transport segment and the basal bone in the mandible.

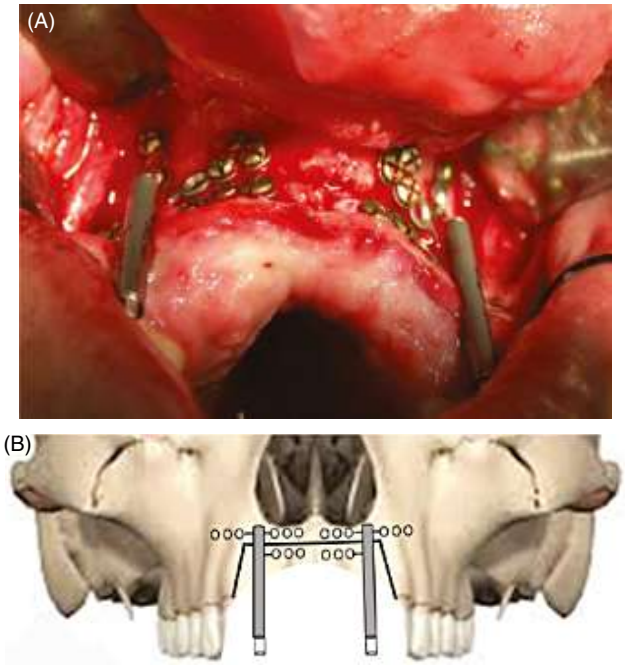

FIGURE 21.6 Using two devices for a large span. (A) Clinical photo of two alveolar distraction osteogenesis devices connected on each side of a maxillary segment. (B) Illustration of a similar case to that in (A). Note the removal of the fixation plate in the distal part of the transport segment. *Source*: Adapted from Rachmiel A et al. Three-dimensional reconstruction of post-traumatic deficient anterior maxilla. J Oral Maxillofac Surg. 2017;75:2689–700 with permission of Elsevier.

FIGURE 21.7 Suturing of the surgical incision in the maxillary vestibulum using absorbable VICRYL sutures.

It is important to note that in large vertical elongation procedures there is a risk for palatal/lingual collapse of the transport segment, due to forces from traction of the lingual/palatal periosteum and additional masticatory forces. Thus, it is possible to use elastics from the activation rod to an orthodontic device or to temporary anchored devices (screws) inserted in the jaw (Figure 21.11). During the activation phase panoramic radiographs should be taken prior to elongation, at a time point in the middle of the activation phase, and when the expected elongation is presumably reached (Figure 21.12).

When the desired elongation is achieved, the retention period begins. We recommend a 4-month period for retention. At times, the period needs to be shortened due to patient compliance or infection from device exposure. During this period, if a temporary restoration is applied to restore the dentition, it is important to make sure the restoration does not apply pressure on the transport segment.

At the end of the retention period, the devices should be removed. This can be performed under local anesthesia with or without sedation, according to the preference of the patient and the surgeon. It is possible to insert dental implants concomitantly with the device removal or as a second stage. We recommend waiting 1–2 months before inserting dental implants for two reasons: the incision for device removal is different than the one for implant placement; and to allow for additional healing of the bone and soft tissue following device removal. It should be noted that the dental implant itself helps preserve the newly formed bone (Figure 21.13).

An important situation that should be discussed is a scenario in which the vector of elongation was not controlled well enough and was severely offset. In these cases, during device removal the newly created bone segment can be fractured, repositioned, and fixated using a miniplate (Figure 21.14). This of course delays the rehabilitation by approximately 4 months.

Dentlearn.ir

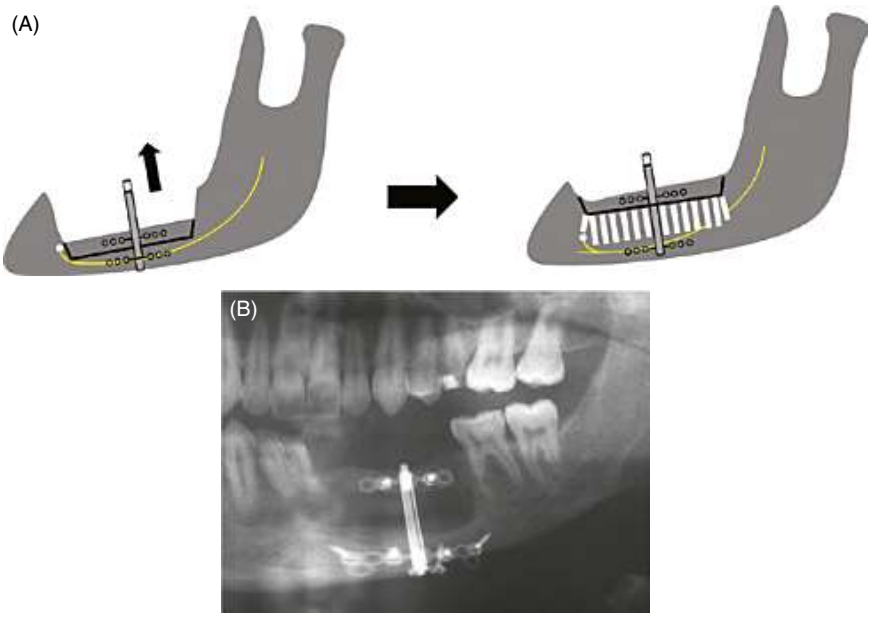

FIGURE 21.8 Activation phase. (A) Illustration of the activation process of an alveolar distraction osteogenesis device (ADO) in the mandible. Upon activation, new bone is created in the space between the bone segments. (B) Panoramic radiograph following the activation process using an ADO device. *Source*: Rachmiel A. et al. Vertical alveolar distraction osteogenesis of the atrophic posterior mandible before dental implant insertion. J Oral Maxillofac Surg. 2017;75:1164–75 with permission of Elsevier.

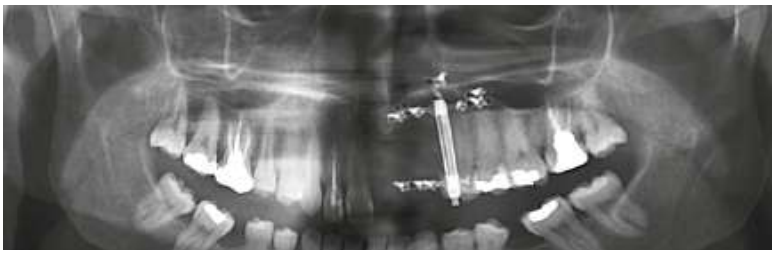

FIGURE 21.9 Panoramic radiograph following maxillary alveolar distraction osteogenesis in the left anterior maxilla. Note the overcorrection observed by the height of the crestal bone compared to adjacent teeth. If the overcorrected bone is not absorbed during the retention phase, the excess bone can be removed during dental implant placement. *Source*: Rachmiel A. et al. Two-stage reconstruction of the severely deficient alveolar ridge: Bone graft followed by alveolar distraction osteogenesis. Int J Oral Maxillofac Surg. 2018;47:117–24 with permission of Elsevier.

FIGURE 21.10 Clinical photograph exhibiting exposure of the fixation plates and screws of maxillary alveolar distraction osteogenesis devices.

FIGURE 21.11 Clinical photograph showing elastics and orthodontic devices used for controlling the vector of elongation during alveolar distraction osteogenesis in the mandible.

Dentlearn.ir

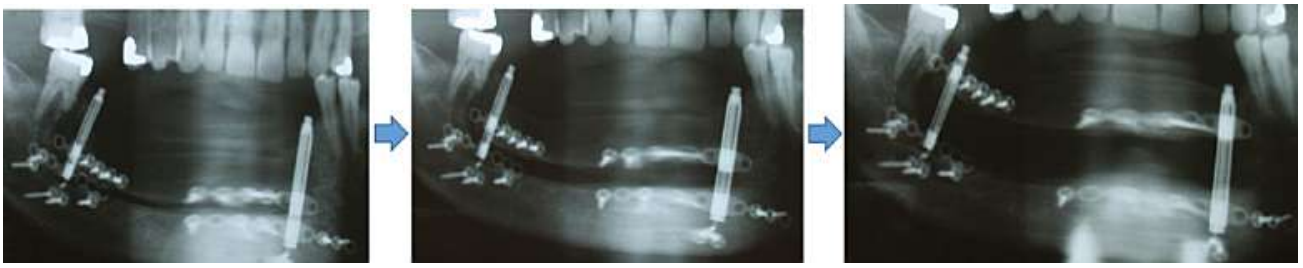

FIGURE 21.12 Panoramic radiographs performed following device fixation and prior to activation, during the activation phase and at the end of the activation process. *Source*: Rachmiel A. et al. Two-stage reconstruction of the severely deficient alveolar ridge: Bone graft followed by alveolar distraction osteogenesis. Int J Oral Maxillofac Surg. 2018;47:117–24 with permission of Elsevier.

FIGURE 21.13 Panoramic radiograph performed following dental implant placement in the newly created bone.

INDICATIONS FOR ALVEOLAR DISTRACTION OSTEOGENESIS

ADO is a very useful technique for bone elongation in cases of moderate to severe bone deficiency. In cases of mild to moderate alveolar bone loss, up to 6 mm, several one-stage procedures exhibiting less discomfort are available. These procedures include onlay bone grafts, interpositional bone grafts [11, 31, 32], and in minor cases guided bone regeneration [12, 13]. In onlay and inlay, when autogenous bone graft is used, donor site morbidity is unavoidable. In addition, some resorption of the autogenous grafted bone occurs, resulting in an unpredictable outcome (Figure 21.15).

It should be mentioned that although unidirectional devices are the most frequent, there are also two other types of devices: bidirectional devices, which elongate simultaneously in vertical and buccal directions [33]; and horizontal devices, which apply forces in a buccal direction [34, 35].

When observing the application of ADO in the upper and lower jaws, it is apparent that in the maxilla ADO is most frequently applied in the anterior region [29, 36], while in the mandible it is more frequent in the posterior region to improve the crown-to-implant ratio and avoid nerve injury [37, 38]. ADO can also be applied in the anterior mandibular region in order to allow for inter-foraminal implant placement in a correct crown-to-implant ratio [39, 40]. A large span (more than four teeth) may require a large device in the middle of the transport segment (Figure 21.16) or two smaller devices, one on each side of the segment (Figure 21.6).

In cases where there is not enough vertical bone for a proper transport segment, an onlay bone graft procedure can precede the distraction surgery (Figure 21.17) [41]. The second surgery should be performed at least 6 months following

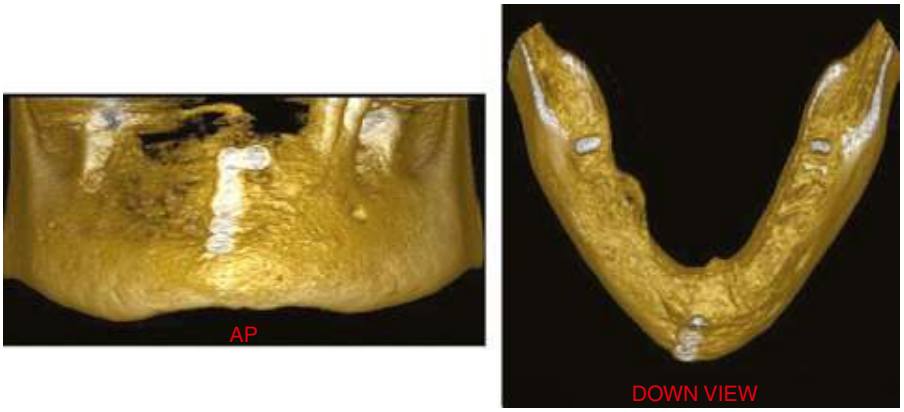

FIGURE 21.14 Three-dimensional reconstruction of cone beam computed tomography performed following alveolar distraction osteogenesis in the anterior mandible and repositioning of the newly created bone during device removal for correct buccolingual orientation. Note the miniplate used to fixate the alveolar segment following the osteotomy and repositioning. *Source*: Adapted from Rachmiel A. et al. Two-stage reconstruction of the severely deficient alveolar ridge: Bone graft followed by alveolar distraction osteogenesis. Int J Oral Maxillofac Surg. 2018;47:117–24 with permission of Elsevier.

Dentlearn.ir

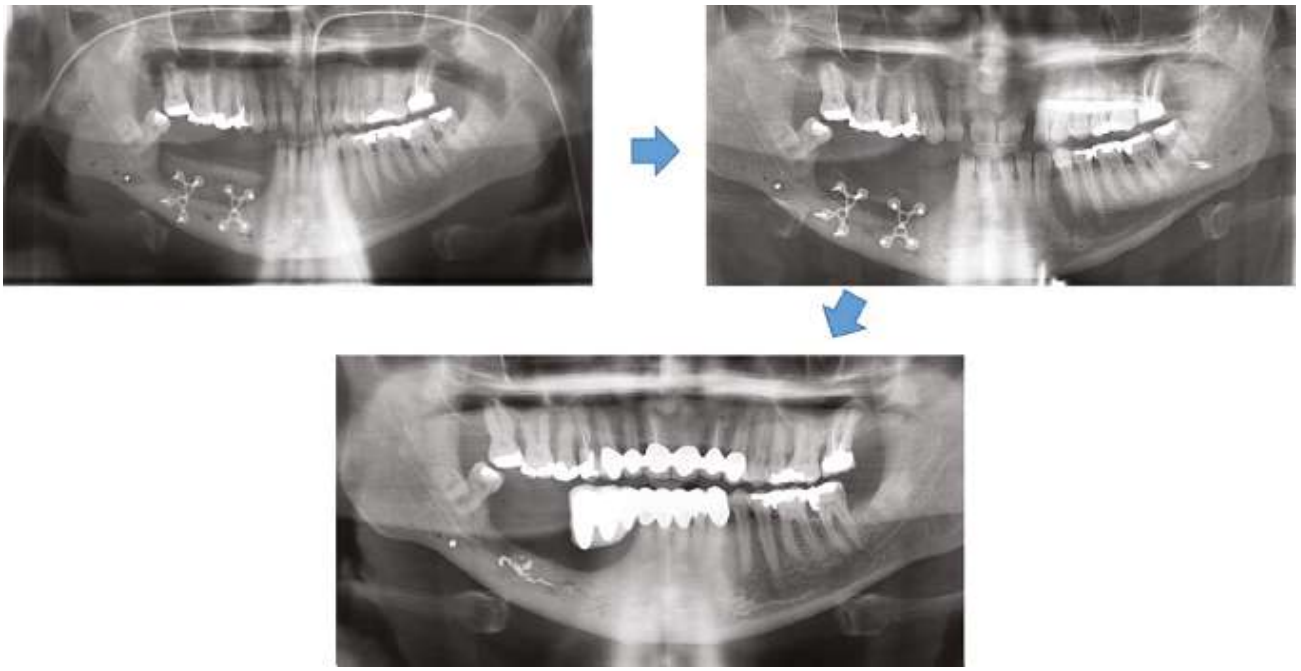

FIGURE 21.15 Panoramic radiographs exhibiting a case of deficient posterior alveolar bone in the right mandible with an etiology of trauma. The case was treated using only autogenous bone graft fixated with two miniplates. Note the resorption of the bone graft and finally the removal of the miniplates with a poor outcome.

the first surgery. CBCT can be used to assess proper bone remodeling prior to the distraction phase.

ADVANTAGES AND DISADVANTAGES

Perhaps the greatest advantage of ADO is the ability to simultaneous expand bone and soft tissues. This contrasts with onlay bone graft, which requires extensive flap release and thus shortening of the vestibulum, which in turn requires a second operation for vestibuloplasty. Another advantage includes the quality of the bone at the alveolar crest, which remains as cortical and mature bone. In addition, there is no donor site morbidity, as opposed to autogenous block bone grafts, and greater bone lengthening than other methods, with less relapse [19, 36, 38].

Disadvantages include the long overall time required for the different stages of the procedure; the need for a second operation for device removal; the possibility of device exposure and infection; discomfort for the patient; and the need for controlling the vector of elongation.

COMPLICATIONS

Surgeons often learn the most from their complications. Understanding of the possible complications helps to avoid them. The important guidelines about the ADO procedure can be suggested here:

- Always remember that blood supply is critical for the success of the procedure. If it is not maintained, resorption of

FIGURE 21.16 Panoramic radiograph exhibiting the application of a large alveolar distraction osteogenesis device due to the large span of deficient alveolar bone.

Dentlearn.ir

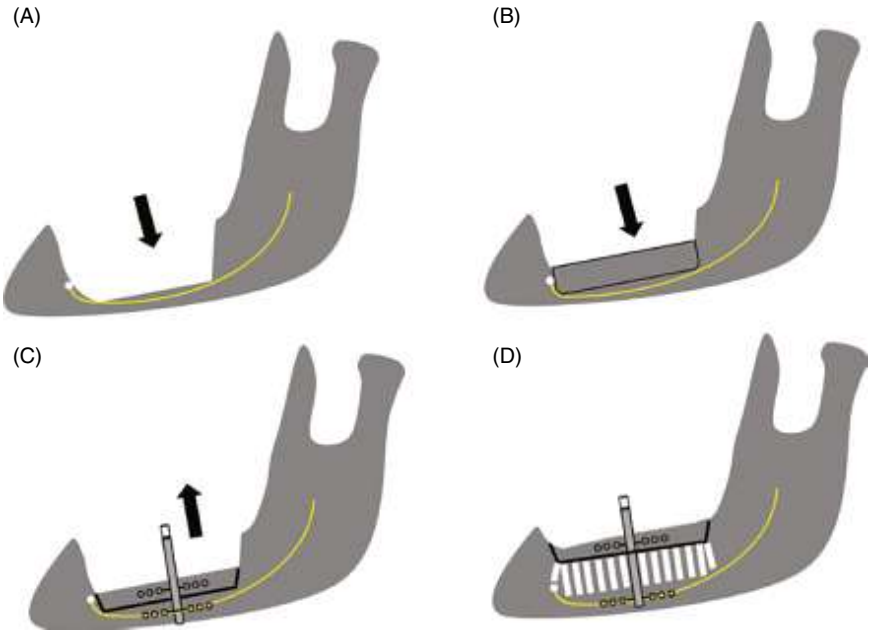

FIGURE 21.17 Onlay bone graft prior to alveolar distraction osteogenesis (ADO). In cases of severely deficient bone, not allowing for a proper transport segment, the option of onlay bone graft as the first stage is encouraged. (A) Illustration of a severely atrophic posterior mandible without enough vertical bone above the inferior alveolar nerve (IAN). (B) Onlay bone graft placed in the deficient mandible. (C) ADO device is fixated following a trapezoid osteotomy above the IAN. (D) The newly created bone following the activation phase. *Source*: Adapted from Rachmiel A. et al. Two-stage reconstruction of the severely deficient alveolar ridge: Bone graft followed by alveolar distraction osteogenesis. Int J Oral Maxillofac Surg. 2018;47:117–24 with permission of Elsevier.

the transport segment is possible. To avoid this, take care to maintain the palatal/lingual blood supply. We advise using a piezoelectric device for minimizing the risk of unintended soft tissue impairment.

- Device fracture. In this case a second surgery to replace the fractured device should be performed as soon as possible.
- Premature ossification. This may happen if the latency period is too long, the activation rate is too slow, or there is a malfunction in the device. In this case, refracture is required and if the device malfunctioned it should be replaced.
- Device exposure and local infection that prevents bone formation. In this case, immediate device removal is indicated. If possible, fixation of the segment in the final position should be performed using a miniplate.
- Improper direction of elongation. If this is identified early enough, the use of elastics may reposition the segment in the correct vector. If it is identified at a late stage, fracturing of the segment should be performed during device removal and fixation done in the correct position using miniplates and screws.
- Sensory deficits. This may happen during the osteotomy from injury to the IAN or from the fixation screws into the mandibular canal. One should try to avoid this by meticulous planning based on the CBCT. Nowadays the use of three-dimensional technology to create surgical guides for the osteotomy and screw placement may help avoid this complication.
- Bony fractures. Both the transport segment and the basal bone may undergo fractures. This can be avoided by maintaining a proper size for the transport segment and preserving enough height of basal bone. In case the transported segment is large, a proper device with a large enough base fixation plate should be used to stabilize the remaining basal bone instead of two devices, one on each side.

CASE REPORTS

CASE 1: ALVEOLAR DISTRACTION OSTEOGENESIS IN THE ANTERIOR MAXILLA

A 22-year-old male presented to our institute with a history of an injury to the anterior maxilla. The injury resulted in avulsion of a dentoalveolar segment spanning from canine to canine (Figure 21.18). The missing teeth and alveolar bone resulted in a posterior position of the premaxilla and upper lip, leading to an appearance of old age.

ADO was chosen as the treatment plan. A vestibular mucoperiosteal incision, just below the attached mucosa, was performed. A trapezoid osteotomy was carried out using a microsaw (Figure 22.19A) and two distraction devices were fixated on both sides of the segment (Figure 22.19B). Two devices were used due to the large span of the deficiency for superior control over the vector of elongation. Fixation plates on the lateral aspect of the transported segment were removed due to the placement of the devices on the edges of the segment. Following a latency period of 4 days, activation was commenced. Devices were activated to the maximal length (Figure 21.20).

At this stage, alveolar bone in the anterior maxilla was regenerated to normal height, yet a proper anteroposterior intermaxillary relationship was not yet addressed. To change this relationship, a LeFort I maxillary advancement was performed during distraction device removal. The maxilla was placed into angle class II relations for aesthetic and stable results (Figure 21.21).

Next, four dental implants were placed in the anterior maxilla, and prosthetic restoration was performed (Figure 21.22A, B). Proper teeth exposure was achieved (Figure 21.22C). The intermaxillary relation was corrected and a normal profile facial convexity exhibiting a youthful appearance was achieved (Figure 21.23).

Dentlearn.ir

FIGURE 21.18 Case presentation of a 22-year-old male with severe deficiency in the anterior maxilla. (A, B) Extraoral clinical photographs of the deficiency. Anterior view and profile exhibiting the posterior location of the upper lip. (C, D) Intraoral clinical photos of the deficiency.

CASE 2: ALVEOLAR DISTRACTION OSTEOGENESIS IN THE POSTERIOR MANDIBLE

A 25-year-old male presented following a traumatic injury to the left mandible. On presentation he suffered from a major deficiency of the alveolar bone spanning from the lower central incisor to the premolar region (Figure 21.24A). After discussing alternative treatment plans, the patient decided to go ahead with ADO.

Following a vestibular incision under the attached mucosa, a trapezoid osteotomy was performed, and an ADO device was fixated to the transport segment and the basal bone (Figure 21.24B). Activation was commenced 4 days following the fixation. Lengthening was performed to the planned height (Figure 21.25). Exposure of the fixation plate on the transported segment can be observed, yet no infection was evident.

The device was removed without complications three months later. Two months following the removal, three dental implants were placed. Three months later, prosthetic restoration was performed (Figure 21.26).

CONCLUSION AND SUGGESTIONS FOR A SURGEON

It is important to choose cases wisely. Remember the advantages of the DO method, but also remember the disadvantages. The DO method requires a high level of cooperation from the patient and is not suitable for any patient.

DO's greatest advantage is the large amount of newly created bone and simultaneous formation of soft tissue. Remember to maintain the palatal/lingual blood supply to avoid necrosis.

Make sure the transport segment is larger than the minimal size to avoid resorption.

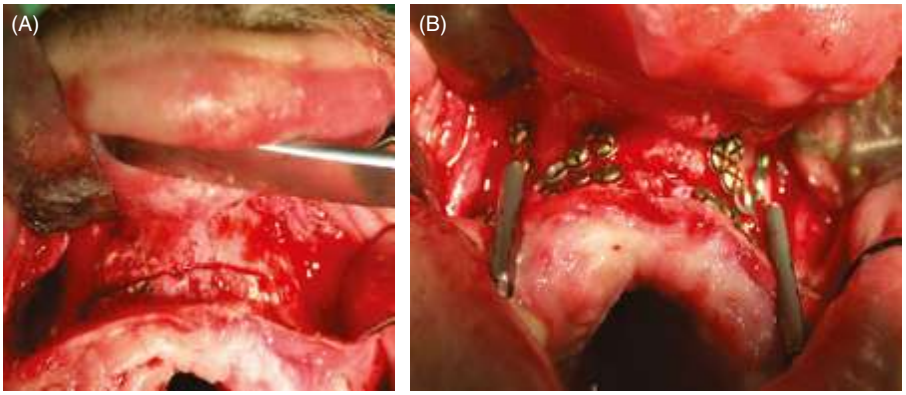

FIGURE 21.19 Intraoperative clinical photographs of the patient presented in Figure 21.18. (A) Following the trapezoid osteotomy. (B) Following the placement and fixation of two alveolar distraction osteogenesis devices, one on each side of the transport segment.

Dentlearn.ir

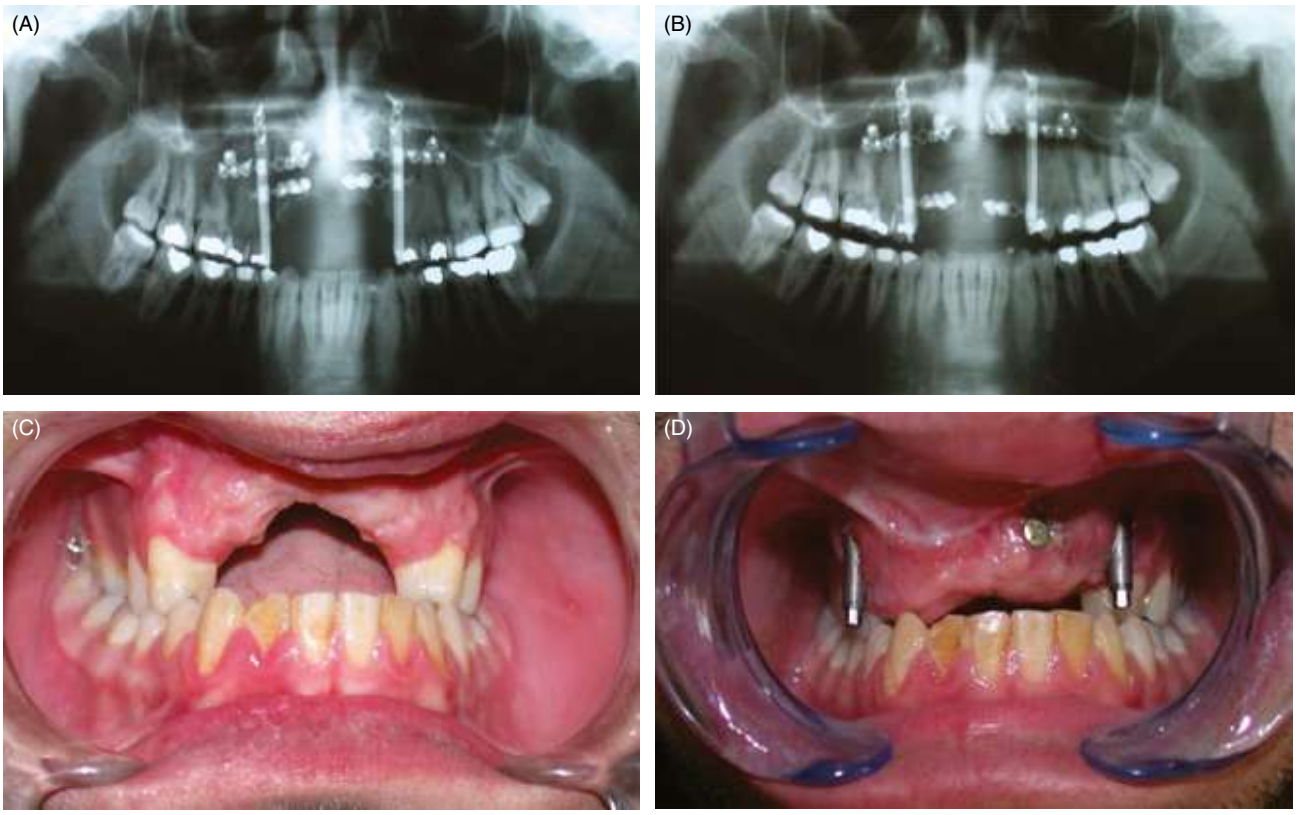

FIGURE 21.20 Panoramic radiographs and clinical photographs prior to and post the activation phase in the patient described in Figure 21.19. (A) Panoramic radiograph following the placement of two alveolar distraction osteogenesis (ADO) devices. (B) Panoramic radiograph following the activation phase. (C) Clinical photograph prior to the placement of the ADO device. (D) Clinical photograph following the activation phase.

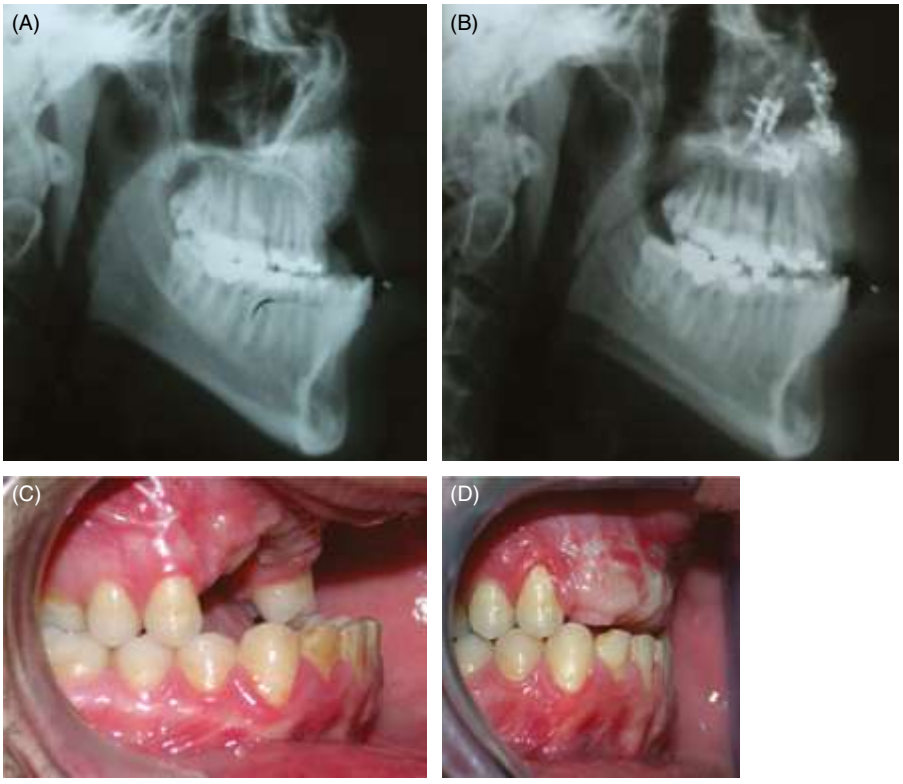

FIGURE 21.21 Pre and post treatment of the case described in Figure 21.20. (A) Lateral cephalometric radiograph prior to the treatment of the patient. Note the posterior location of the maxilla and the alveolar deficiency in the anterior maxilla. (B) Lateral cephalometric radiograph following alveolar distraction osteogenesis (ADO) of the anterior maxilla in the first stage and LeFort I advancement in the second stage. (C) Clinical photograph prior to the treatment of the patient. (D) Clinical photograph following ADO of the anterior maxilla in the first stage and LeFort I advancement in the second stage. Note the height of the alveolar bone in the anterior maxilla and the anteroposterior location of the maxilla following the LeFort I advancement.

Dentlearn.ir

FIGURE 21.22 Clinical and radiographic outcomes following the treatment of the patient described in Figure 21.21. (A) Panoramic radiograph following the placement of dental implants in the newly created bone of the anterior maxilla. (B, C) Clinical photographs of the outcome following the prosthetic restoration on top of the dental implants.

FIGURE 21.23 Profile photographs of the patient described in Figure 21.22. (A) Prior to treatment. (B) Following alveolar distraction osteogenesis to the anterior maxilla followed by LeFort I advancement, placement of dental implants, and final prosthetic restoration. Note the deficient maxilla and upper lip in (A) and the proper maxillo–mandibular relation surgically created and exhibited in (B).

FIGURE 21.24 Case presentation of a 25-year-old male with severe deficiency in the alveolar mandibular bone. (A) Intraoral clinical photograph of the deficiency. (B) Trapezoid osteotomy with fixation of the alveolar distraction osteogenesis device. *Source*: Adapted from Rachmiel A et al. Vertical alveolar distraction osteogenesis of the atrophic posterior mandible before dental implant insertion. J Oral Maxillofac Surg. 2017;75:1164–75 with permission of Elsevier.

Dentlearn.ir

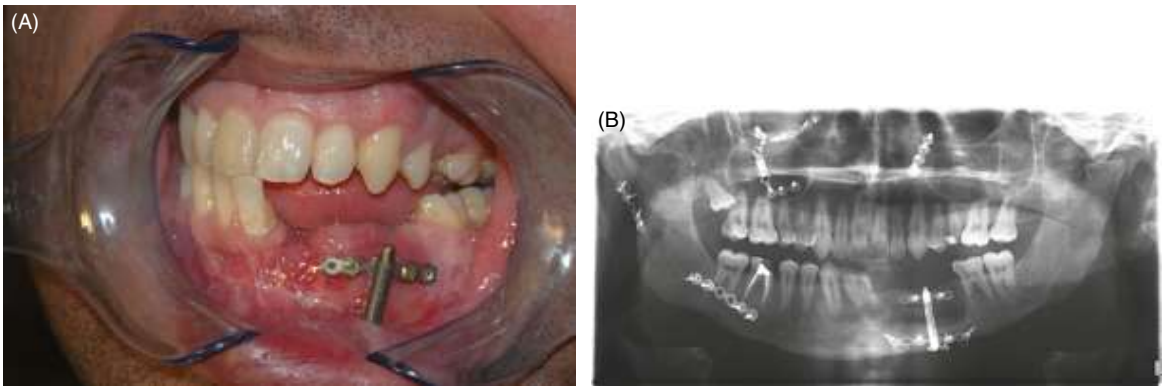

FIGURE 21.25 Following activation of the alveolar distraction osteogenesis (ADO) device in the patient described in Figure 21.24. (A) Clinical photograph following activation of the ADO device. Note the exposure of the fixation plate in the transport segment. (B) Panoramic radiograph following the activation phase. *Source*: Adapted from Rachmiel A et al. Vertical alveolar distraction osteogenesis of the atrophic posterior mandible before dental implant insertion. J Oral Maxillofac Surg. 2017;75:1164–75.

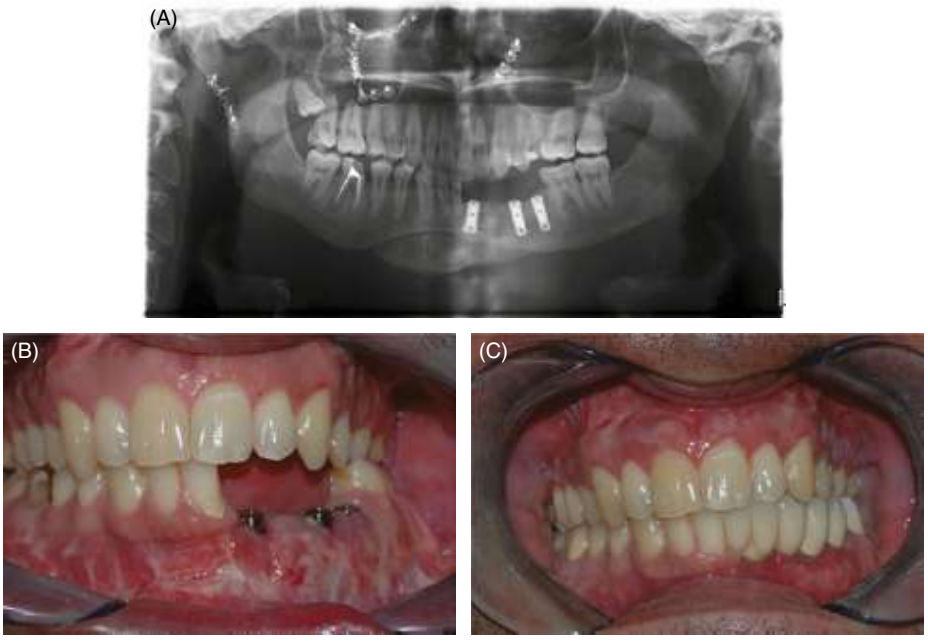

FIGURE 21.26 Dental implant placement and prosthetic rehabilitation of the patient described in Figure 21.25. (A, B) Panoramic and clinical photographs following the placement of dental implants in the newly created bone. (C) Following prosthetic rehabilitation. *Source*: Adapted from Rachmiel A. et al. Vertical alveolar distraction osteogenesis of the atrophic posterior mandible before dental implant insertion. J Oral Maxillofac Surg. 2017;75:1164–75 with permission of Elsevier.

Close follow-up is essential. Request that the patient visit the office at least twice weekly during the activation phase, as early identification of complications is critical.

Respect the principles of bone biology: make sure the rate of distraction is correct, not too slow to avoid premature ossification and not too fast to avoid improper ossification. This surgical technique is very effective if used correctly and should be part of the toolbox of any oral surgeon.

REFERENCES

1. Bell R, Blakey G, White R et al. Staged reconstruction of the severely atrophic mandible with autogenous bone graft and endosteal implants. *J Oral Maxillofac Surg*. 2002;60:1135–41.
2. Tallgren A. The continuing reduction of the residual alveolar ridges in complete denture wearers: A mixed-longitudinal study covering 25 years. *J Prosthet Dent.* 1972;27:120–32.

Dentlearn.ir

3. Alberktsson T, Dahl E, Enbom L et al. Osseointegrated oral implants: A Swedish multicenter study of 8139 consecutively inserted Nobelpharma implants. *J Periodontol.* 1988;59:287–96.
4. Tomasi C, Wennström J, Berglundh T. Longevity of teeth and implants – a systematic review. *J Oral Rehabil.* 2008;35:23–32.
5. Jung RE, Pjetursson BE, Glauser R et al. A systematic review of the 5-year survival and complication rates of implant-supported single crowns. *Clin Oral Implants Res.* 2008;19:119–30.
6. Pietrokovski J, Starinsky R, Arensburg B, Kaffe I. Morphologic characteristics of bony edentulous jaws. *J Prosthodont.* 2007;16:141–7.
7. Nystrom E, Kahnberg KE, Gunne J. Bone grafts and Branemark implants in the treatment of the severely resorbed maxilla: A 2-year longitudinal study. *Int J Oral Maxillofac Implants.* 1993;8:45–53.
8. Satow S, Slagter AP, Stoelinga PJ, Habets LL. Interposed bone grafts to accommodate endosteal implants for retaining mandibular overdentures: A 1–7 year follow-up study. *Int J Oral Maxillofac Surg.* 1997;26:358–64.
9. Triplett RG, Schow SR. Autologous bone grafts and endosseous implants: Complementary techniques. *J Oral Maxillofac Surg.* 1996;54:486–94.
10. Block MS, Haggerty CJ. Interpositional osteotomy for posterior mandible ridge augmentation. *J Oral Maxillofac Surg.* 2009;67:31–9.
11. Jensen O. Alveolar segmental "sandwich" osteotomies for posterior edentulous mandibular sites for dental implants. *J Oral Maxillofac Surg.* 2006;64:471–5.
12. Caplanis N, Sigurdsson TJ, Rohrer MD, Wikesjo UM. Effect of allogeneic, freeze-dried, demineralized bone matrix on guided bone regeneration in supra-alveolar peri-implant defects in dogs. *Int J Oral Maxillofac Implants.* 1997;12:634–42.
13. Jensen OT, Greer RO Jr, Johnson L, Kassebaum D. Vertical guided bone-graft augmentation in a new canine mandibular model. *Int J Oral Maxillofac Implants.* 1995;10:335–44.
14. Lorean A, Kablan F, Mazor Z et al. Inferior alveolar nerve transposition and reposition for dental implant placement in edentulous or partially edentulous mandibles: A multicenter retrospective study. *Int J Oral Maxillofac Surg.* 2013;42:656–9.
15. von Arx T, Hardt N, Wallkamm B. The TIME technique: A new method for localized alveolar ridge augmentation prior to placement of dental implants. *Int J Oral Maxillofac Implants.* 1996;11:387–94.
16. Laurie SW, Kaban LB, Mulliken JB, Murray JE. Donor-site morbidity after harvesting rib and iliac bone. *Plastic Reconstr Surg.* 1984;73:933–8.
17. Jensen O, Nock D. Inferior alveolar nerve repositioning in conjunction with placement of osseointegrated implants: A case report. *Oral Surg Oral Med Oral Pathol.* 1987;63:263–8.
18. Morrison A, Chiarot M, Kirby S. Mental nerve function after inferior alveolar nerve transposition for placement of dental implants. *Can Dent Assoc.* 2002;68:46–50.
19. Rachmiel A, Srouji S, Peled M. Alveolar ridge augmentation by distraction osteogenesis. *Int J Oral Maxillofac Surg.* 2001;30:510–17.
20. Shilo D, Emodi O, Aizenbud D, Rachmiel A. [Distraction osteogenesis of deficient alveolar bone prior to dental rehabilitation]. *Refuat Hapeh Vehashinayim* (1993). 2015;32:38–42, 69.
21. Aizenbud D, Hazan-Molina H, Cohen M, Rachmiel A. Combined orthodontic temporary anchorage devices and surgical management of the alveolar ridge augmentation using distraction osteogenesis. *J Oral Maxillofac Surg.* 2012;70:1815–26.
22. Ilizarov G. The tension-stress effect on the genesis and growth of tissues: Part I. The influence of stability of fixation and soft-tissue preservation. *Clin Orthop Relat Res.* 1989;238:249–81.
23. Ilizarov G. The tension-stress effect on the genesis and growth of tissues: Part II. The influence of the rate and frequency of distraction. *Clin Orthop Relat Res.* 1989;239:263–85.
24. McCarthy J, Schreiber J, Karp N et al. Lengthening the human mandible by gradual distraction. *Plastic Reconstr Surg.* 1992;89:1–10.
25 Rachmiel A, Laufer D, Jackson I, Lewinson D. Midface membranous bone lengthening: A one-year histological and morphological follow-up of distraction osteogenesis. *Calcif Tissue Int.* 1998;62:370–76.
26. Rachmiel A, Potparic Z, Jackson I et al. Midface advancement by gradual distraction. *Br J Plast Surg.* 1993;46:201–7.
27 Rachmiel A, Rozen N, Peled M, Lewinson D. Characterization of midface maxillary membranous bone formation during distraction osteogenesis. *Plastic Reconstr Surg.* 2002;109:1611–20.
28. Chin M, Toth B. Distraction osteogenesis in maxillofacial surgery using internal devices: Review of five cases. *J Oral Maxillofac Surg.* 1996;54:45–53.
29 Jensen O, Cockrell R, Kuhike L, Reed C. Anterior maxillary alveolar distraction osteogenesis: A prospective 5-year clinical study. *Int J Oral Maxillofac Implants.* 2002;17:52–68.
30. Hidding J, Lazar F, Zöller J. Initial outcome of vertical distraction osteogenesis of the atrophic alveolar ridge. *Mund Kiefer Gesichtschir.* 1999;3:S79–S83.
31. Jensen O, Kuhlke L, Bedard J, White D. Alveolar segmental sandwich osteotomy for anterior maxillary vertical augmentation prior to implant placement. *J Oral Maxillofac Surg.* 2006;64:290–96.
32 Rachmiel A, Emodi O, Rachmiel D et al. Sandwich osteotomy for the reconstruction of deficient alveolar bone. *Int J Oral Maxillofac Surg.* 2018;47:1350–7.
33. Jensen O, Ueda M, Laster Z et al. Alveolar distraction osteogenesis. *Sel Read Oral Maxillofac Surg.* 2002;10:1–48.
34. Laster Z, Rachmiel A, Jensen O. Alveolar width distraction osteogenesis for early implant placement. *J Oral Maxillofac Surg.* 2005;63:1724–30.
35. Laster Z, Reem Y, Nagler R. Horizontal alveolar ridge distraction in an edentulous patient. *J Oral Maxillofac Surg.* 2011;69:502–6.
36. Rachmiel A, Shilo D, Aizenbud D et al. Three-dimensional reconstruction of post-traumatic deficient anterior maxilla. *J Oral Maxillofac Surg.* 2017;75:2689–700.
37. Garcia-Garcia A, Somoza-Martin M, Gandara-Vila P et al. Alveolar distraction before insertion of dental implants in the posterior mandible. *Br J Oral Maxillofac Surg.* 2003;41:376–9.
38. Rachmiel A, Shilo D, Aizenbud D, Emodi O. Vertical alveolar distraction osteogenesis of the atrophic posterior mandible before dental implant insertion. *J Oral Maxillofac Surg.* 2017;75:1164–75.
39. Feichtinger M, Gaggl A, Schultes G, Karcher H. Evaluation of distraction implants for prosthetic treatment after vertical alveolar ridge distraction: A clinical investigation. *Int J Prosthodont.* 2003;16:19–24.
40. Krenkel C, Grunert I. The Endo-Distractor for preimplant mandibular regeneration. *Rev Stomatol Chir Maxillofac.* 2009;110:17–26.
41. Rachmiel A, Emodi O, Aizenbud D et al. Two-stage reconstruction of the severely deficient alveolar ridge: Bone graft followed by alveolar distraction osteogenesis. *Int J Oral Maxillofac Surg.* 2018;47:117–24.

Dentlearn.ir

Orthodontic Therapy: Orthodontic Extrusion for Vertical Ridge Enhancement

CHAPTER 22

Orthodontic implant site development uses the phenomenal potential of forced extrusion to move the alveolar apparatus, including teeth with a large attachment loss, occlusally, making it an excellent alternative treatment to surgical methods of bone augmentation. Forced eruption can help to improve the quality and quantity of hard and soft tissue of an edentulous area and develop an adequate site for immediate implant placement, with a highly esthetic restorative outcome that can stand the test of time.

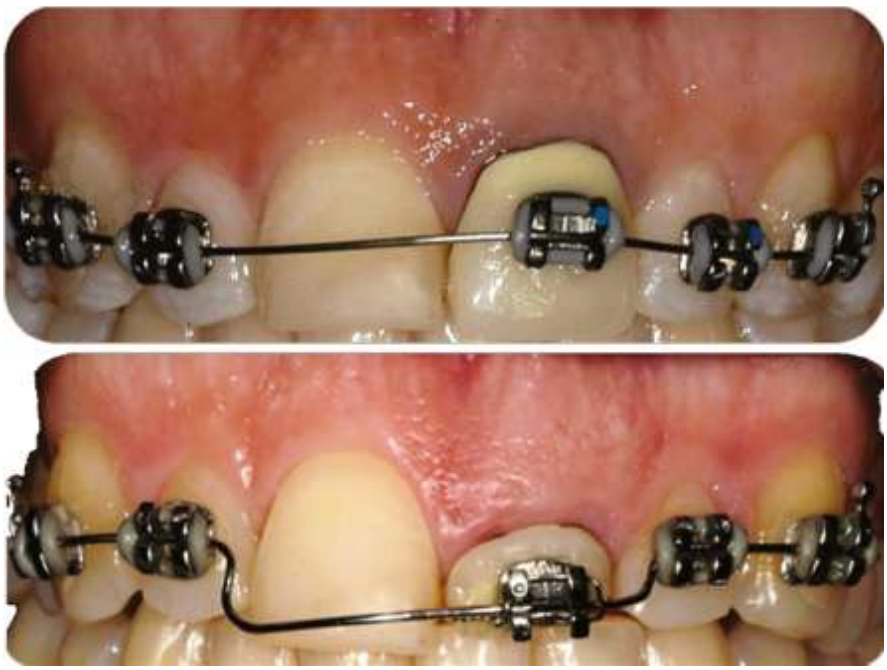

Dentlearn.ir

CHAPTER 22

Orthodontic Therapy: Orthodontic Extrusion for Vertical Ridge Enhancement

Ugo Macca[1,2], Agatino Davide Mirabella[3,4], and Francesco Amato[4]

[1] *CAGS in Prosthodontics, Boston University, Boston, MA, USA*

[2] *Private Practice, Siracuse, Italy*

[3] *Department of Orthodontics, University of Ferrara, Ferrara, Italy*

[4] *Private Practice, Catania, Italy*

In contemporary interdisciplinary treatment planning, forced eruption [1–3] is a valid therapeutic option [4] to correct osseous and gingival levels in a compromised environment and to prevent post-extraction ridge deficiency [5]. Forced eruption of single-rooted teeth is considered predictable, even in those cases when active periodontal disease is present [6]. As far as multirooted teeth are concerned, though this area is not sufficiently reported in the literature, our experience is highly positive. The outcome of pre-extractive orthodontic therapy is a more favorable ridge for dental implant placement and for the pontic area as well [7, 8]. Hopeless but not "useless" [5] teeth can be used to fill bone defects, extend gingival surfaces, and improve the extraction site, overbuilding it to compensate for post-extraction remodeling (Figure 22.1).

Several times an implant can be effective from an osseointegration standpoint (Figure 22.2), but a failure from an esthetic point of view (Figure 22.3). Most of the time, what makes the difference is the lack or the presence of adequate tissue surrounding the crown.

How can we prevent this kind of failure? First, through surgical options; and secondly, through orthodontic implant site development (OISD) (Figure 22.4).

WHAT IS ORTHODONTIC FORCED ERUPTION?

It is the therapeutic induction of a natural phenomenon, starting with the appearance of permanent teeth in the mouth until a stable occlusal contact is established, and continuing through life to compensate for grinding and occlusal abrasion. Light and uniform [9] extrusive forces stretch gingival fibers during eruption, so that a tension is applied to the bone surrounding the tooth, stimulating bone apposition at the alveolar crest. The entire alveolar bone housing follows the tooth in its movement [10].

Orthodontic treatment can also treat some clinical difficulties that cannot be solved by surgery alone, improving the whole scenario around the implant site: the mesiodistal dimension of the edentulous space, root proximity, positions and periodontal topography of the teeth adjacent to the edentulous area, and the occlusal scheme [4].

DESCRIPTION OF THE TECHNIQUE

The treatment protocol is as follows (Figures 22.5–22.14) [11]:

- Diagnosis of the defect (Figure 22.6).
- Endodontic treatment (Figure 22.7).
- Periodontal therapy (Figure 22.8).
- Orthodontic appliance application (Figure 22.9).
- Two weeks of periodontal and occlusal checks (Figure 22.10).
- Two/three months of stabilization (Figure 22.11).
- Immediate implant placement flapless (Figures 22.12 and 22.13).
- Immediate provisional crown insertion (Figure 22.14).

Essential Techniques of Alveolar Bone Augmentation in Implant Dentistry: A Surgical Manual, Second Edition. Edited by Len Tolstunov.
© 2023 John Wiley & Sons, Inc. Published 2023 by John Wiley & Sons, Inc.
Companion website: www.wiley.com/go/tolstunov/essential

Dentlearn.ir

FIGURE 22.1 Pre-extractive orthodontic extrusion improves the future implant site. Overbuilding is necessary to compensate for post-extraction remodeling.

FIGURE 22.2 Osseointegration is obtained.

The treatment starts by collecting clinical data (x-rays, probing chart, pictures, and stone models) in order to make a diagnosis of a hopeless tooth suitable for orthodontic extrusion. The first step is root canal therapy to eliminate any sensitivity following periodontal treatment or occlusal reduction. Teeth with pocket depths ranging between 1 and 5 mm are treated with scaling and root planning in combination with topical antibacterial treatment (chlorhexidine 0.2% rinse three times daily). In the case of teeth with pockets that are 5 mm or deeper, the treatment is followed 1 month later by an open-flap debridement (modified Widman flap) in combination with topical antibacterial treatment (chlorhexidine 0.2% three times daily for 2 weeks). Immediately after periodontal treatment, orthodontic brackets are applied, and tooth alignment, if needed, is obtained with a 0.016 in. heat-activated nickel-titanium archwire.

The OISD technique is defined as a slow-rate biological technique. It starts with the initial periodontal activation [12] and then a 0.018 in. stainless steel archwire is placed. A vertical-forward step of 1 mm is bent to obtain 1 mm of extrusion along the tooth's long axis and is increased by the same amount monthly. Therefore a very light force (interrupted continuous forces) [12] will produce bone apposition in accordance with the same rate of 1 mm per month described in the literature.

Alternatively, a 0.019 × 0.025 in. beta-titanium archwire with a 1 mm vertical step and palatal root torque can be used. The bends are deepened at each appointment at 1-month intervals.

FIGURE 22.3 Esthetic failure due to inadequate hard and soft tissue.

FIGURE 22.4 Orthodontic role to improve implant sites: (A) soft tissue profile improvement; (B) hard tissue volume increase; (C) space distribution.

Dentlearn.ir

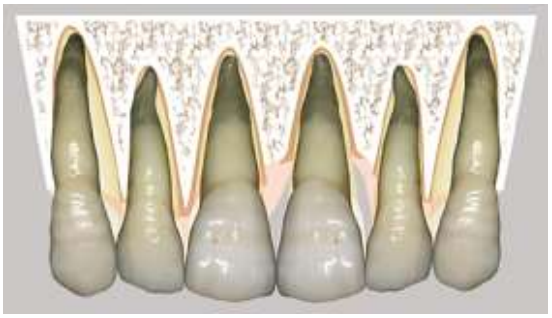

FIGURE 22.5 Treatment protocol.

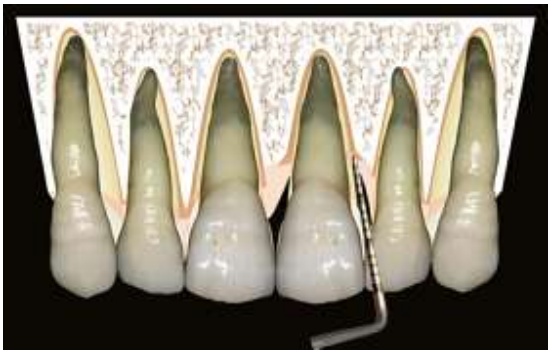

FIGURE 22.6 Diagnosis of the defect.

FIGURE 22.7 Endodontic treatment.

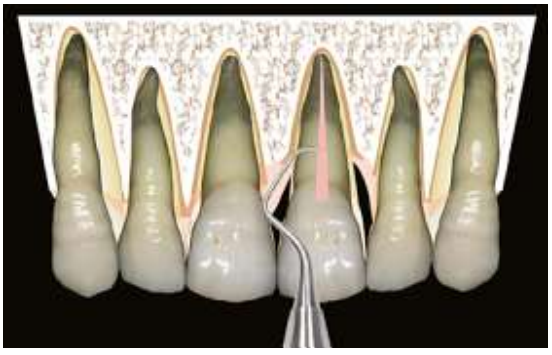

FIGURE 22.8 Periodontal therapy.

FIGURE 22.9 Orthodontic application.

FIGURE 22.10 2 weeks of periodontal and occlusal monitoring.

FIGURE 22.11 2 months of stabilization.

FIGURE 22.12 Tooth extraction.

Dentlearn.ir

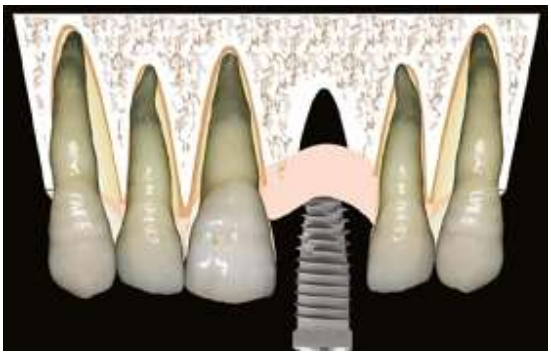

FIGURE 22.13 Immediate implant placement (flapless if possible).

FIGURE 22.14 Immediate temporary crown placement.

The very key to treatment success can be compressed in this statement: during its movement the tooth must follow its long axis (Figure 22.15) [11]. This can be achieved putting a step down and forward in the orthodontic arch, in order to keep the root away from the buccal cortical plate. It is important to point out that strong contact between the root and the buccal cortical plate could cause bone dehiscence. In that respect, it is the authors' conviction that most failures in obtaining bone augmentation are likely to be related to improper biomechanics.

It is assumed that the amount of extrusion would be equal to the total millimeters of activation; at each visit, the incisal edge and any occlusal contact area of the extruding tooth are ground with a diamond bur (1 or 2 mm each time), and the amount of shortening should also correspond to the tooth extrusion.

Patients are monitored every other week to ensure that the extruded tooth is kept out of occlusion and to confirm good hygienic conditions in the area to prevent inflammation.

The alveolar bone coronal movement is monitored by periodic periapical radiographs. The goal is to exceed by at least 2 mm the bone level of the contralateral tooth, which acts as a reference. At this point, extrusion is ended and a period of 2–3 months of orthodontic stabilization is allowed to enable mineralization of the newly formed bone matrix. Two days before implant placement a final, rapid extrusion is applied. This helps to widen the periodontal ligament space and makes extraction easier and less traumatic.

The patient is prescribed antibiotic prophylaxis (amoxicillin tablets, 1 g every 12 h) and antibacterial mouth rinse (chlorhexidine 0.2%) starting 24 h before surgery. The implants are inserted, preferably flapless, the provisional abutments are connected, and the screw-retained provisional crowns must be placed out of occlusion. Although there is ample evidence that insertion of an implant into a fresh extraction socket does not prevent alveolar bone resorption [13–15], regardless of whether a crown is placed immediately or after a delay [16], the immediate placement and provisionalization help in supporting and maintaining soft tissues, especially papillae [17].

POSTERIOR TEETH

OISD is effective on molars and premolars too (Figure 22.16–18). As described for the anterior teeth, it is possible to improve bone width and height with a thicker and higher attached gingiva. On multirooted teeth a guided bone regenerative effect is shown (Figure 22.19), since not only does the attachment apparatus follow the root in its eruptive movement, but also the inter-rooted area is filled with newly formed bone that makes implant positioning easy and safe.

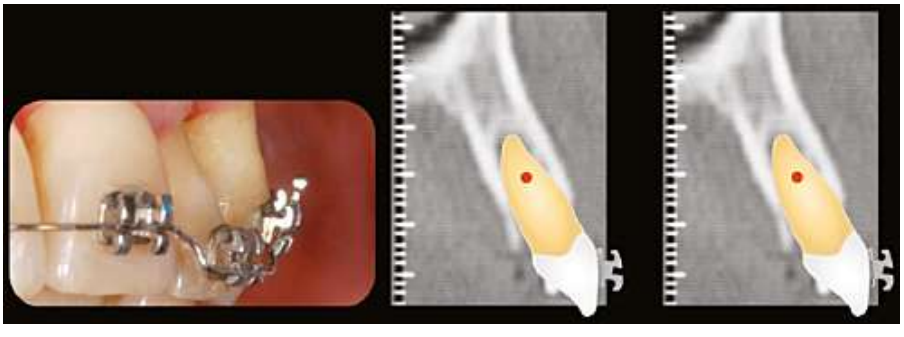

FIGURE 22.15 Extrusion must occur along the tooth's long axis.

Dentlearn.ir

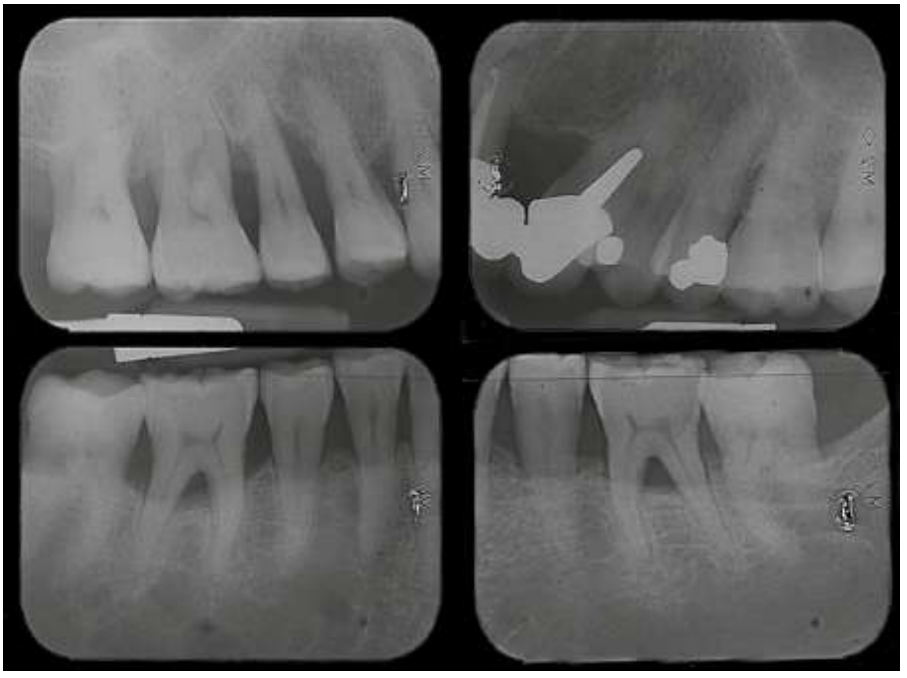

FIGURE 22.16 Pre-treatment x-rays.

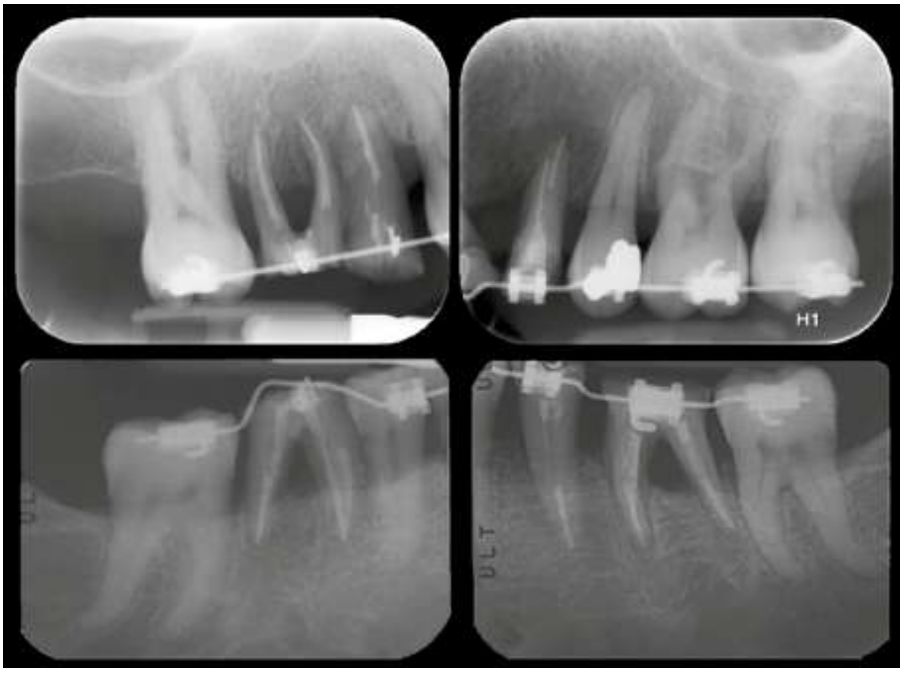

FIGURE 22.17 Post-orthodontics x-rays.

Dentlearn.ir

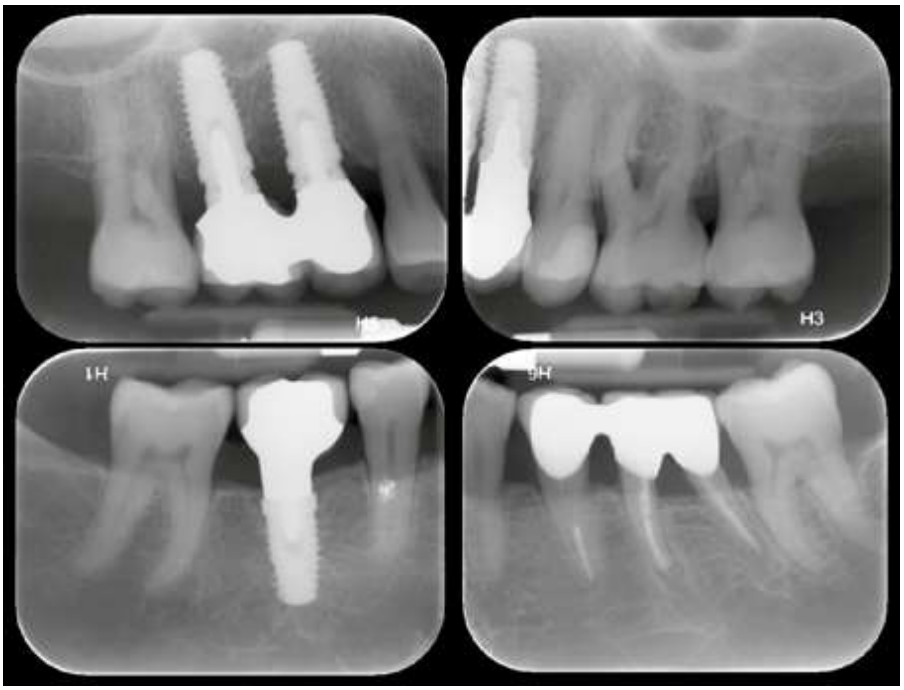

FIGURE 22.18 Post-treatment x-rays.

FIGURE 22.19 Orthodontic guided bone regenerative effect in inter-radicular area.

Dentlearn.ir

THREE-DIMENSIONAL BONE REMODELING

In a very advanced case where the buccal bone crest is completely gone and a deep pocket (>8 mm) is present, it is still possible to utilize OISD effectively, utilizing medial, distal, and especially palatal bone to fill up the defect completely (Figure 22.20–22.28) [18]. The first steps in the treatment are the usual extrusion protocol previously described, but open-flap debridement is chosen to treat the active pocket (Figure 22.29).

FIGURE 22.20 Pre-treatment clinical situation.

When forced extrusion is complete, a buccal root torque is activated, using a 0.019 × 0.025 in. beta-titanium wire, to pursue the filling of the alveolus thanks to the residual palatal bone (Figure 22.30).

LATERAL IMPLANT SITE DEVELOPMENT

In orthodontic therapy, horizontal tooth movement has been traditionally used to close post-extraction spaces (Figure 22.31) in patients with well-preserved alveolar bone and good periodontal health. However, some authors [4, 12] have advocated that horizontal tooth movement may be an effective therapy to solve the lack of alveolar bone in cases of narrow or vertically resorbed alveolar ridges.

Following tooth extraction, 20–25% bone loss may be expected within the first year [19]. This process will be more relevant when a thin cortical buccal wall is present [20], a full-thickness flap is opened [21], or the extracted tooth is severely periodontally compromised. An atrophic alveolar ridge is also usually found in patients with congenitally missing teeth as a consequence of either early exfoliation of the baby tooth or to the smaller root size of the deciduous tooth compared to the permanent one.

Lindskog et al. [22, 23] suggested that the key points for achieving bone regeneration through orthodontic horizontal tooth movement were the presence of bone covering the root surface facing the edentulous area; accurate orthodontic biomechanics; and good periodontal health. When such conditions are respected, the final result consists in a

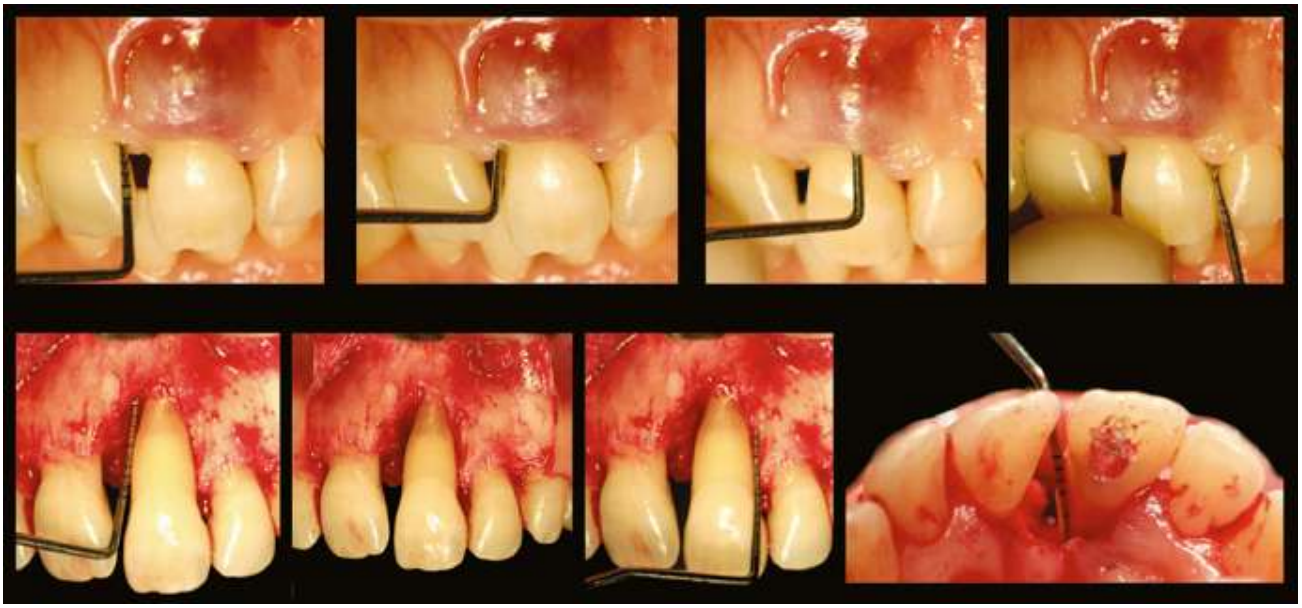

FIGURE 22.21 Probing >10 mm and the buccal bone is completely missing up to the apex. A flap is raised, and an accurate debridement is accomplished before orthodontics.

Dentlearn.ir

FIGURE 22.22 The extrusive movement of the left central incisor fills the bone defect vertically.

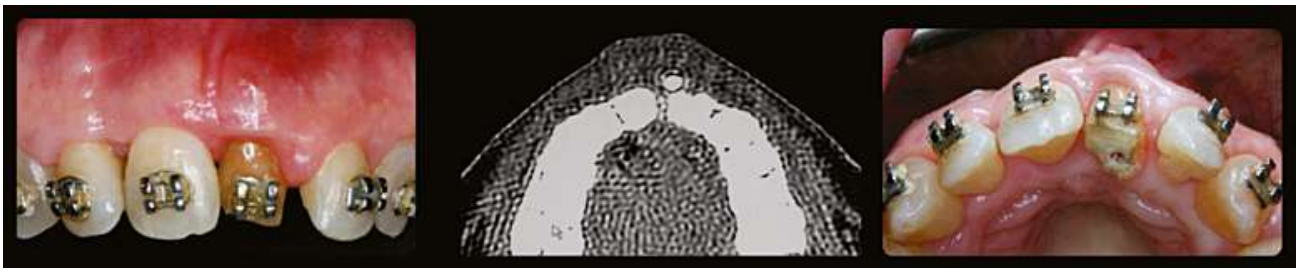

FIGURE 22.23 The movement is completed with a buccal root torque that fills the defect horizontally. The root apex is so buccal to perforate the soft tissue and to appear in front of the buccal crest in the computed tomography scan.



FIGURE 22.24 Computed tomography scan slice shows the amount of newly formed bone palatal to root apex.

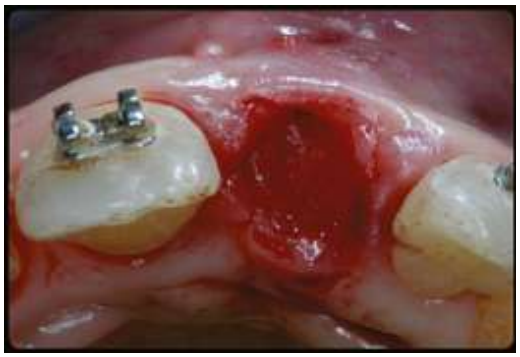

FIGURE 22.25 Post-extractive alveolus is almost non-existent: ideal for implant placement.

FIGURE 22.26 Immediate temporary emergence profile is achieved out of the mouth to determine soft tissue shape.

Dentlearn.ir

FIGURE 22.27 Temporary crown is inserted the same day as implant placement (flapless) to maintain or improve soft tissue contour.

FIGURE 22.28 Final crown placement.

natural-looking appearance and a harmonious gingival height of contour.

Horizontal bodily movement using routine fixed orthodontic appliances to move a tooth distally or mesially into an edentulous area that is too thin, labiolingually, is an excellent way to regenerate new alveolar bone before the insertion of osseointegrated implants. When a tooth is moved through the alveolar process, new bone is formed back around it, building up the alveolar process and thereby providing, in a biological manner, optimal space for implants [24].

When the edentulous area presents a thin alveolar ridge (Figures 22.32 and 22.33), implant positioning could be difficult or impossible without bone augmentation. A major surgical treatment, such as guided bone regeneration, is an available solution. Orthodontic therapy can also give a great contribution through horizontal movement for lateral implant site development.

Teeth are moved into the gap carrying the surrounding hard and soft tissue (Figure 22.34). They fill the space in a thin/low crest case, maintaining their regular bone–gingival contour and avoiding collapse in a freshly edentulous site. Simultaneously, on the opposite side of the moving tooth, a new gap full of bone and attached gingiva is created, perfectly suitable for implant positioning. After mesial movement of the lateral incisor, there is ample bone for insertion of a single-tooth titanium implant in the position previously occupied by the moved tooth. The new site will be ideal both horizontally and vertically (Figure 22.35).

Another important advantage is switching the case from a two-unit implant to a double single-unit case (Figure 22.36). As is well described in the literature [25], it is very difficult to maintain bone peaks and papillae between close implants compared with an implant next to a tooth or between two teeth (Figure 22.37) [26]. There are technical difficulties [27] and biological problems. The discriminant inter-implant distance is considered to be 3 mm. In the single-implant case scenario, the presence of a regular bone peak on the tooth side allows the presence of a full papilla even in a case of a deeply inserted implant (Figure 22.38).

As far as orthodontic biomechanics is concerned, it has been strongly pointed out that bodily tooth movement should be performed in order to fill in the space. The authors recommend placing a stainless steel rectangular archwire and applying a light force until teeth reach a sound interproximal contact. We recommend using a nickel-titanium (NiTi SE) coil spring or an elastic chain to be renovated at 1-month intervals (Figure 22.39).

After the removal of the orthodontic appliance, the treatment will be finalized restoratively with two zirconia crowns on implants in the lateral position and two ceramic laminates on the new central incisors (Figure 22.40).

The good teeth alignment together with a regular gingival contour favor oral hygiene maintenance. Moreover, when the edentulous alveolar ridge has been created by the orthodontic separation of two teeth, little resorption change will occur over time (less than 1% over 4 years) [28]. A good long-term prognosis is accordingly predictable.

Dentlearn.ir

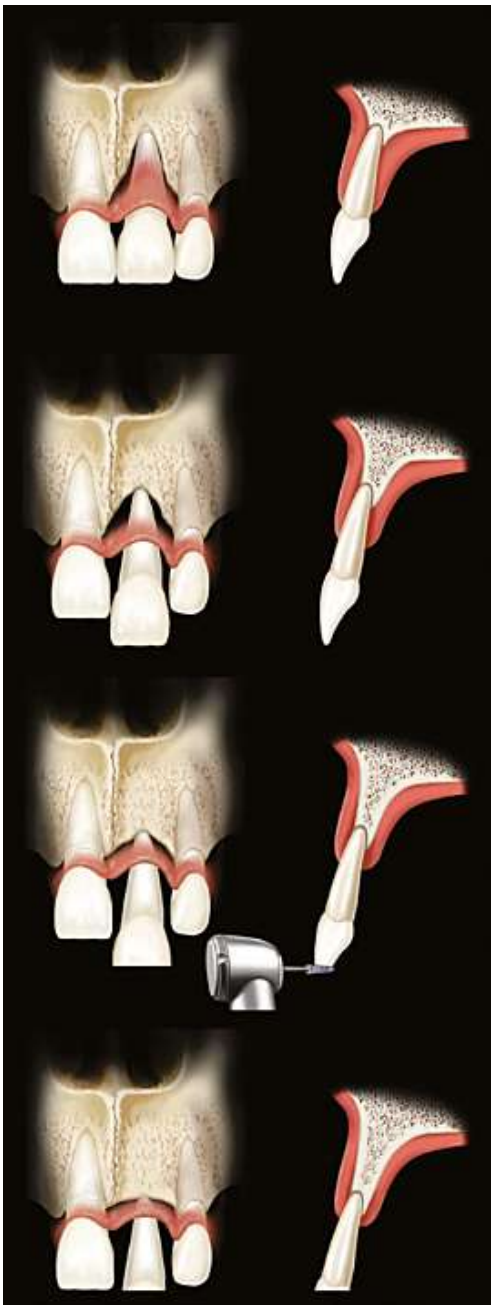

FIGURE 22.29 The first orthodontic phase consists of extrusive movement. The tooth must be shortened in advance to avoid traumatic contacts.

MULTIDIRECTIONAL MOVEMENT

In daily practice tooth movements can be combined to reach the best result (Figure 22.41). In the anterior area, a correct implant position on three planes is essential for a nice smile appearance. When the case starts with a severe deficiency in bone and gingival level on a tooth to be extracted, it is useful to move it orthodontically to relocate these levels vertically, bucco-palatally, and mesio-distally (Figures 22.42–22.44). When a tooth is broadly destroyed, a good temporary is essential to connect the orthodontic appliance and maintain a decent esthetic appearance throughout the treatment.

A round 0.016 in. heat-activated nickel-titanium (HANT) archwire was used in the initial phase of the orthodontic treatment to align the dentition and to achieve some initial tooth extrusion of the teeth to be extracted (Figures 22.45 and 22.46). Following the alignment and leveling stages, 1 mm extrusion bends were placed on a rectangular 0.019 × 0.025 beta-titanium archwire. Orthodontic extrusion generated new bone tissue along the vertical plane and, in particular (Figure 22.47), brought the medial bone peak of the tooth more coronally.

When the extrusion movement was almost complete, a compressed NiTi SE coil spring was placed on the stainless steel rectangular archwire to move the upper left canine toward the edentulous site of the upper left lateral incisor (Figures 22.48 and 22.49). Additional extrusion, which improves bone peak and papilla volume, was achieved by pulling tooth remnants with an elastic chain stretched from the archwire.

After 2 months of post-orthodontic stabilization, implants were inserted flapless at extraction time and a temporary resin bridge was screwed immediately on top to condition tissue healing (Figure 22.50). Chlorhexidine daily rinses were prescribed. The restorative treatment was completed 6 months later (Figure 22.51–22.53). In the areas where OISD had been accomplished, the tissue level showed extraordinary stability over time (Figure 22.54).

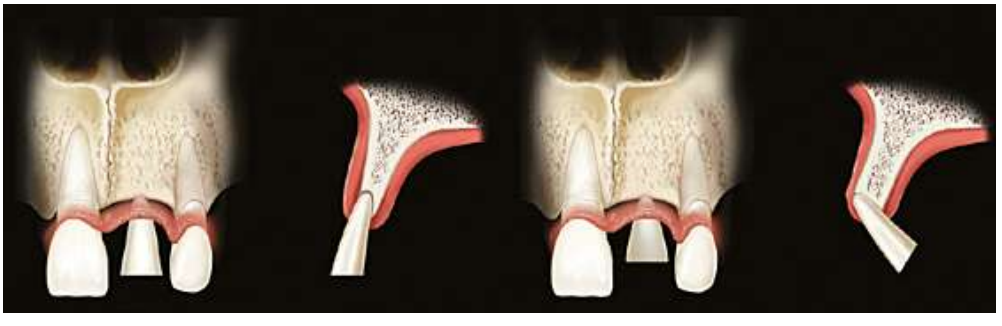

FIGURE 22.30 The second phase consists of buccal root torque.

Dentlearn.ir

FIGURE 22.31 Horizontal tooth movement used to close post-extraction spaces in a case with horizontal and vertical bone defect and soft tissue shortage.

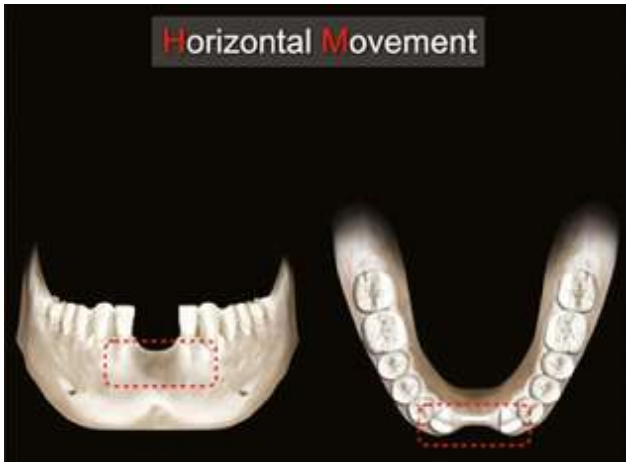

FIGURE 22.32 A thin alveolar ridge represents an unfavorable area for implant positioning.

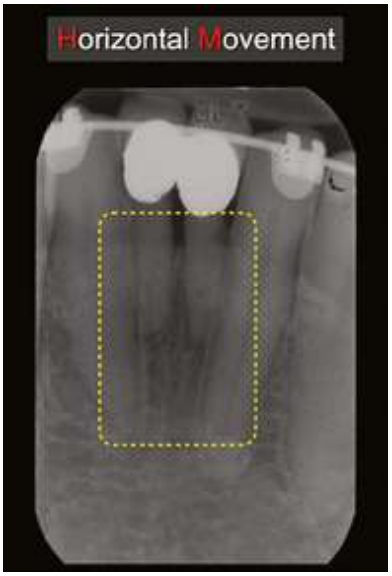

FIGURE 22.33 Clinical case showing deciduous central lower incisors in an adult patient with agenetic permanent ones.

DISCUSSION

RESULTS

In interdisciplinary treatment plans, orthodontics plays an effective role in achieving success and the desired esthetic outcome. Concerning implant site development by orthodontic forced extraction, the early clinical results are highly promising (Table 22.1 and 22.2). A significant increase in the quantity and quality of hard and soft tissue is possible to achieve, provided that the operator uses the proper technique, and is aware of the contraindications and limitations.

CONTRAINDICATIONS

During the whole extrusive movement, the tooth must avoid any occlusal contact against the opposite tooth, both static

FIGURE 22.34 Teeth are moved into the gap carrying the surrounding hard and soft tissue.

Dentlearn.ir

FIGURE 22.35 An ideal implant site is created on the opposite side of the moving tooth full of bone and attached gingiva. The new site is implemented both horizontally and vertically.

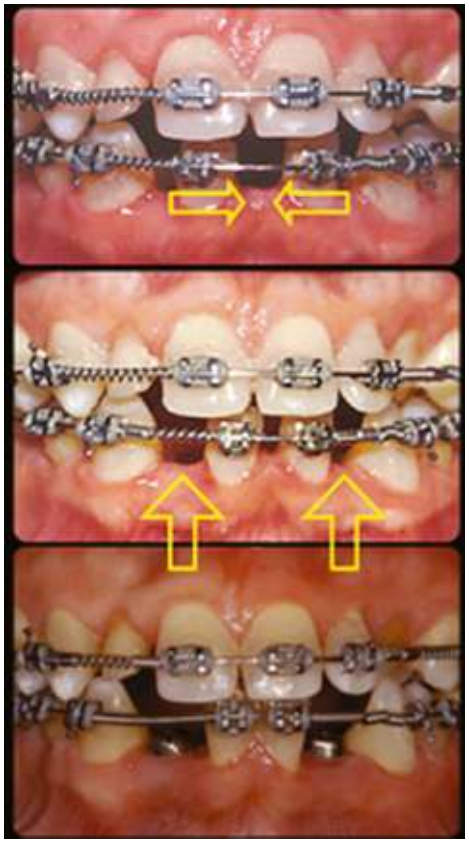

FIGURE 22.36 The teeth are moved mesially through the alveolar process, moving hard and soft tissue and avoiding collapse in a freshly edentulous site situation. The case is switched from a two-unit implant case to a double single-unit case.

FIGURE 22.37 The presence of the papilla depends on the distance between the bone peak and the point of contact. It changes if it is adjacent to a tooth, an implant, or an edentulous area.

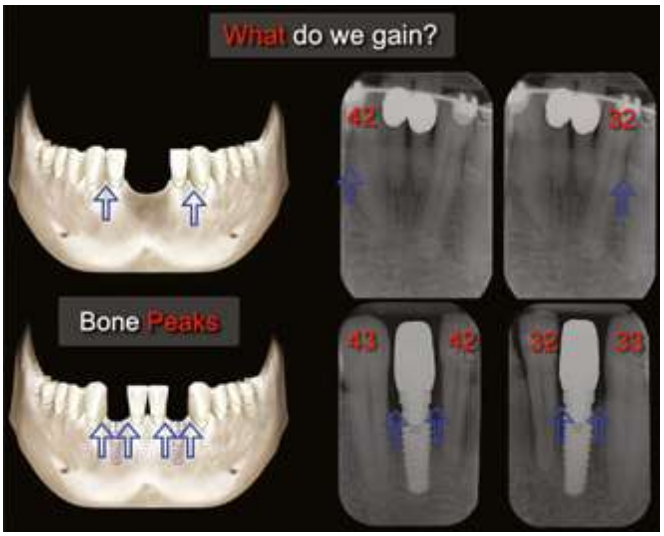

FIGURE 22.38 In the single-implant case scenario, the presence of a regular bone peak on the tooth side allows the presence of a full papilla even in a case of a deeply inserted implant, on both sides of the crown.

and dynamic (Figure 22.55). This kind of traumatic contact, contrary to tooth movement, would prevent the new apposition of bone that usually occurs during extrusive movements. To prevent any contact, the extruding tooth will be shortened by 1 mm incisally and at the cingulum at every appointment.

When a periapical endodontic lesion is present, the extrusion of the affected tooth will enlarge it dramatically. Still, on the coronal side, there will be gingival and bone augmentation with esthetic improvement, even in the presence of a wider periodical lesion that may be completely filled spontaneously after the extraction. If possible, endodontic treatment or pre-treatment or, if necessary, apicectomy is the treatment of choice before starting orthodontics.

Dentlearn.ir

FIGURE 22.39 A bodily tooth movement is performed by placing a stainless steel rectangular archwire (0.19 × 0.25 SS) and applying a light force (NiTi SE coil spring) until the teeth reach a sound interproximal contact.

FIGURE 22.40 The final restoration consists of two ceramo-zirconia crowns on implants in the lateral position and two ceramic laminates on the new central incisors.

FIGURE 22.41 Bone regenerated by a combination of horizontal and vertical movements.

FIGURE 22.42 Initial severe esthetic defect.

Dentlearn.ir

FIGURE 22.43 Severe bone loss around upper left central incisor, canine, and first bicuspid.

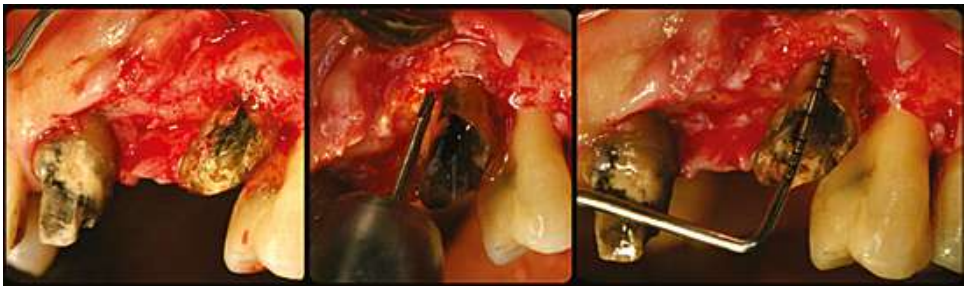

FIGURE 22.44 The cuspid was considered hopeless, but a crown lengthening was performed to expose enough root surface to receive a temporary crown.

FIGURE 22.45 Initial alignment and extrusion using a round 0.016 in. HANT archwire.

Dentlearn.ir

FIGURE 22.46 Initial tooth extrusion of the cuspid separated from the pontic.

FIGURE 22.47 Orthodontic extrusion generates new bone tissue along the vertical plane and there is no pocket probing.

FIGURE 22.48 The mesial bone peak of the upper left cuspid is moved more coronally and mesially and a conspicuous amount of bone is left distally.

Dentlearn.ir

FIGURE 22.49 A compressed nickel-titanium (NiTi SE) coil spring placed on the stainless steel rectangular archwire to move the upper left canine toward the edentulous site of the upper left lateral incisor. The soft tissue is implemented as well.

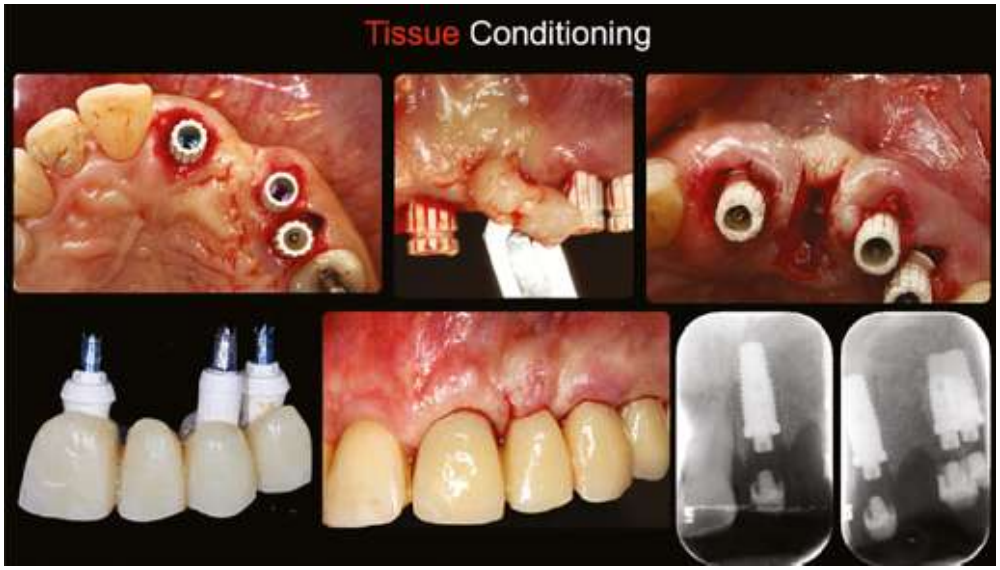

FIGURE 22.50 Immediate insertion of three implants. A roll flap improves the pontic site buccal volume. A temporary resin bridge is positioned immediately to support the soft tissue and especially the papillae.

FIGURE 22.51 After 6 months tissue conditioning is complete.

FIGURE 22.52 The final restoration consists of a four-unit ceramo-metal crown cemented on implants (left central, lateral, cuspid, and bicuspid) and two ceramic veneers (right central and lateral). The patient refused any treatment on the right cuspid and bicuspid.

Dentlearn.ir

FIGURE 22.53 Post orthodontics: both soft and hard tissue levels are adequate.

FIGURE 22.54 Tissue levels are stable over time (9-year follow-up).

Table 22.1 Implant site development by orthodontic forced extraction: a preliminary study. Source: Based on [11].

Characteristics of study	Results
• 5 years	• Orthodontic extrusion 6.2±1.4 mm
• 13 patients consecutively treated	• Bone augmentation 4±1.4 mm
• 32 orthodontically extracted teeth	• Gingival augmentation 3.9±1.5 mm
• 27 implant sites, 5 pontic sites	• Mucogingival junction movement 2.1±1.3 mm
• Evaluation of hard and soft tissue	• Keratinized gingiva augmentation 1.8±
	• Recession 1.8±1.2 mm
	• Pocket depth reduction 1.8±0.9 mm
	• Gingival thickness augmentation 0.7±0.4 mm
	• Bone augmentation/orthodontic eruption 68.9±17.3%
	• Gingival augmentation/orthodontic eruption 65.2±19.9%

Table 22.2 Mean clinical parameters after orthodontic implant site development in all patients (complete study data). Source: Based on [11].

Measurement	Mean	SD	Range
OE	6.2	1.4	3–10
BA	4	1.4	0.6–8
KGA	1.8	1.1	–1.5–3.8
MGJM	2.1	1.3	0.4–5.0
GA	3.9	1.5	1.7–7.7
R	1.8	1.2	0.2–5.7
GTA	0.7	0.4	0.2–1.7
PDR	1.8	0.9	0–4
BA/OE%	68.9	17.3	10–97
GA/OE%	65.2	19.9	28–100
BA/GA%	115.3	50.0	22.2–285.7

BA, bone augmentation; BA/GA%, bone augmentation/gingival margin ratio; BA/OE%, bone augmentation/amount of orthodontic movement ratio (efficacy); GA, gingival augmentation; GA/OE%, gingival augmentation/amount of orthodontic movement ratio (efficacy); GTA, gingival thickness augmentation on the facial side; KGA, keratinized gingival augmentation; MGJM, mucogingival junction movement; OE, orthodontic extrusion; PDR, pocket depth reduction; SD, standard deviation.

Dentlearn.ir

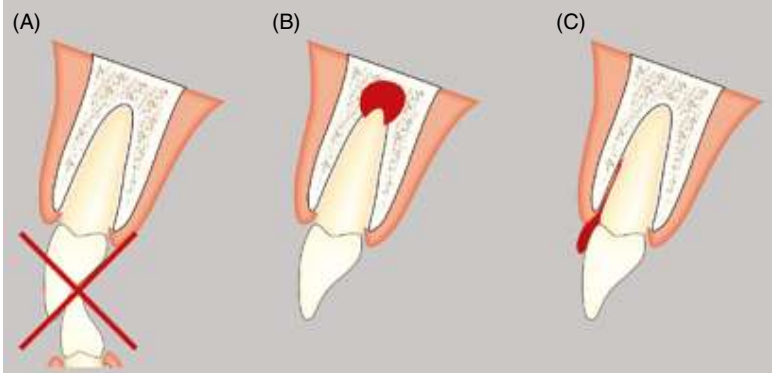

FIGURE 22.55 Contraindications to extrusive movement: (A) occlusal traumatic contacts avoid bone apposition; (B) periapical lesions can widen; (C) active pocket must be treated before starting orthodontic treatment.

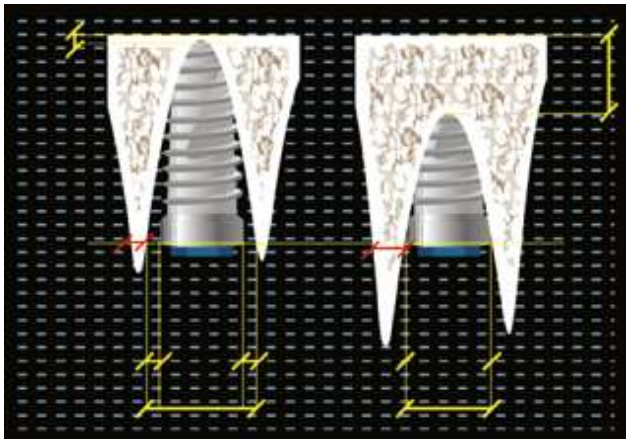

FIGURE 22.56 The main mechanical advantages of an orthodontically developed site are a greater amount of basal bone useful for primary stability; a reduced implant–alveolar gap at the head of the implant; and increased buccal ridge thickness to avoid complete post-extractive resorption.

Table 22.3 Main biological, esthetic, and mechanical advantages of the orthodontic implant site development technique.

Advantages		
Biological	**Esthetic**	**Mechanical**
• Coronal movement of crestal bone • Coronal movement of gingival margin • Increase of keratinized gingiva	• Vertical increase of papillae dimension • Increase of gingival thickness • Increase of buccal bone thickness at implant head	• Easier tooth extraction (bone preservation) • Increase of basal bone • Reduced implant–alveolar gap • Alveolar diameter reduction

Periodontal lesions should not be active (no bleeding, no suppuration). Plaque control is recommended. Mobility is not a factor, except for patient discomfort. Control of inflammation is accomplished immediately prior to beginning the orthodontic treatment, by means of surgical or non-surgical debridement.

LIMITATIONS

OISD allows a favorable pre-implant edentulous site to be obtained eventually, but the positive result is definitely technique sensitive. Plaque control has to be constantly perceived. The treatment protocol must be followed carefully, consisting of multiple visits and frequent monitoring, so patient compliance is needed. The overall treatment before implant placement can be long (6–9 months). Some minor toothache can be present, as in any adult orthodontic treatment. The within-treatment esthetic-compromising aspect, due to progressive shortening of the tooth and enhancing of pink tissue, is the main discomfort.

ADVANTAGES

As described by other authors [10], there are many good reasons to utilize OISD (Table 22.3 and Figure 22.56).

CONCLUSION

In selected cases and using the proper technique, forced extrusion represents a valid alternative to a surgical approach. The results obtained show stability over the years (Figures 22.57–22.60). Although a few questions remain open (bone quality and its stability over time, which orthodontic extrusion rate assures more predictable results, which is the best timing for implant placement after orthodontic treatment), OISD might be a valuable treatment option to regenerate tissues for implant site development in patients in need of conventional orthodontic therapy.

Dentlearn.ir

FIGURE 22.57 The left central incisor is not restorable and must be extracted. The orthodontic implant site development (OISD) technique is performed to improve hard and soft tissue in anticipation of post-extractive remodeling.

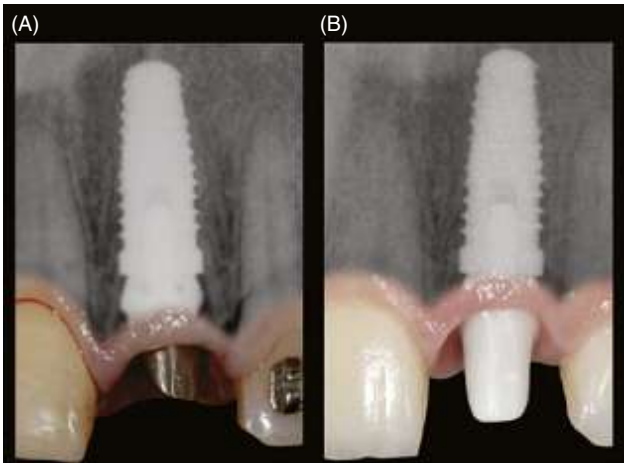

FIGURE 22.58 Osseointegration is complete and platform switching helps in maintaining bone level. (A) Day of insertion: a temporary abutment is used. (B) Six months later: the gingival contour is established and a zirconia abutment is chosen.

FIGURE 22.59 Final restoration: a ceramo-zirconia crown is cemented on the zirconia abutment on the implant and a laminate is cemented on the other central incisor.

FIGURE 22.60 The result is stable over time. Gingival and bone level are the same at the initial placement, 3 years later, and 7 years post insertion.

Dentlearn.ir

REFERENCES

1. Ingber JS. Forced eruption: Part I. *J Periodontol.* 1974;45:199–206.
2. Ingber JS. Forced eruption: Part II. *J Periodontol.* 1976;47:203–16.
3. Ingber JS. Forced eruption: Alteration of soft tissue cosmetic deformities. *Int J Periodont Restorative Dent.* 1989;9:417–25.
4. Spear FM, Kokich VG, Mathews DP. Interdisciplinary management of anterior dental esthetics. *J Am Dent Assoc.* 2006;137:160–69.
5. Salama H, Salama M. The role of orthodontic extrusive remodeling in the enhancement of soft and hard tissue profiles prior to implant placement. Int J Periodont *Restorative Dent.* 1993;13:312 1993;13:312-333.
6. Van Venrooy JR, Yukna RA. Orthodontic extrusion of single rooted teeth affected with advanced periodontal disease. *Am J Orthod.* 1985;87:67–74.
7. Mantzikos T, Shamus I. Forced eruption and implant site development: Soft tissue response. *Am J Orthod Dentofac Orthop.* 1997;112:596–606.
8. Kois JC. Esthetic extraction site development: The biologic variables. *Contemp Esthet Restor Pract.* 1998;2:10–17.
9. Reitan K. Clinical and histologic observation on tooth movement during and after orthodontic movement. *Am J Orthod.* 1967;53:721–45.
10. Oppenheim A. Artificial elongation of the teeth. *Am J Orthod Oral Surg.* 1940;926:931.
11. Amato F, Mirabella AD, Macca U, Tarnow D. Implant side development by orthodontic forced extraction: A preliminary study. *Int J Oral Maxillofac Implants.* 2012;27:411–20.
12. Zachrisson BU. Alveolar bone augmentation for implants by orthodontic extrusion. *World J Orthod.* 2003;4(2):168–73.
13. Araujo MG, Wennstrom JL, Lindhe J. Modeling of the buccal and lingual bone walls of fresh extraction sites following implant installation. *Clin Oral Implants Res.* 2006;17:606–14.
14. Botticelli D, Persson LG, Lindhe J, Berglundh T. Bone tissue formation adjacent to implants placed in fresh extraction socket: An experimental study in dogs. *Clin Oral Implants Res.* 2006;17:351–8.
15. Botticelli D, Berglundh T, Lindhe J. Hard tissue alterations following immediate implant placement in fresh extraction sites. *Clin Oral Implants Res.* 2006;17:606–14.
16. Wohrle PS. Single tooth replacement in the aesthetic zone with immediate provisionalization: Fourteen consecutive case reports. *Prac Periodontics Aesthet Dent.* 1998;10:1107–14.
17. Kan YK, Rungcharassaeng K, Lozada J. Immediate placement and provisonalization of maxillary single implants: 1-year prospective study. *Int J Oral Maxillofac Implants.* 2003;18:31–9.
18. Zuccati G. Bocchieri A. Implant site development by orthodontic extrusion of teeth with poor prognosis. *J Clin Orthod.* 2003;37(6):307–11.
19. Schropp L, Wenzel A, Kostopoulos L, Karring T. Bone healing and soft tissue contour changes following single-tooth extraction: A clinical and radiographic 12-month prospective study. *Int J Periodontics Restorative Dent.* 2003;23:313–23.
20. Nevins M, Camelo M, De Paoli S et al. A study of the fate of the buccal wall of extraction sockets of teeth with prominent roots. *Int J Periodontics Restorative Dent.* 2006;26:19–29.
21. Spear FM, Matthews DM, KokichVG. Interdisciplinary management of single tooth implants. *Semin Orthodont.* 1997;3(1):45–72.
22. Lindskog-Stokland B, Wennström JL, Nyman S, Thilander B. Orthodontic tooth movement into edentulous areas with reduced bone height: An experimental study in dogs. *Eur J Orthod.* 1993;15:89–96.
23. Lindskog-Stokland B, Hansen K, Ekestubbe A, Wennström JL. Orthodontic tooth movement into edentulous ridge areas—a case series. *Eur J Orthod.* 2013;35:277–85.
24. Zachrisson BU. Implant site development by horizontal tooth movement. *World J Orthod.* 2003;4:266–72.
25. Tarnow DP, Cho SC, Wallace SS. The effect of inter-implant distance on the height of the inter-implant bone crest. *J Periodontol.* 2000;71:546–9.
26. Tarnow DP, Elian N, Fletcher P et al. Vertical distance from the crest of bone to the height of the interproximal papilla between adjacent implants. *J Period.* 2003;74(12):1785–8.
27. Michalakis KX, Kalpidis CDR, Kang K, Hirayama H. A simple impression technique for dental implants placed in close proximity or adverse angulations. *J Prosthet Dent.* 2005;94(3):293–5.
28. Spear M, Mathews D, Kokich VG. Interdisciplinary management of single tooth implants. *Semin Orthodont.* 1997;3(1):45–72.

Dentlearn.ir

Dentlearn.ir

Reconstruction of Three-Dimensional Alveolar Ridge Defects Utilizing Screws and Implant Abutments for the Tent-Pole Grafting Technique

CHAPTER 23

This chapter will discuss the tent-pole abutment technique with the guided bone regeneration procedure, which is intended to prevent collapse of the space produced by the bone graft and minimize resorption of the grafting material in horizontal and vertical ridge augmentation procedures. This technique is technically easy and offers minor complications, shortens the healing period, and reduces the frequency of surgeries required.

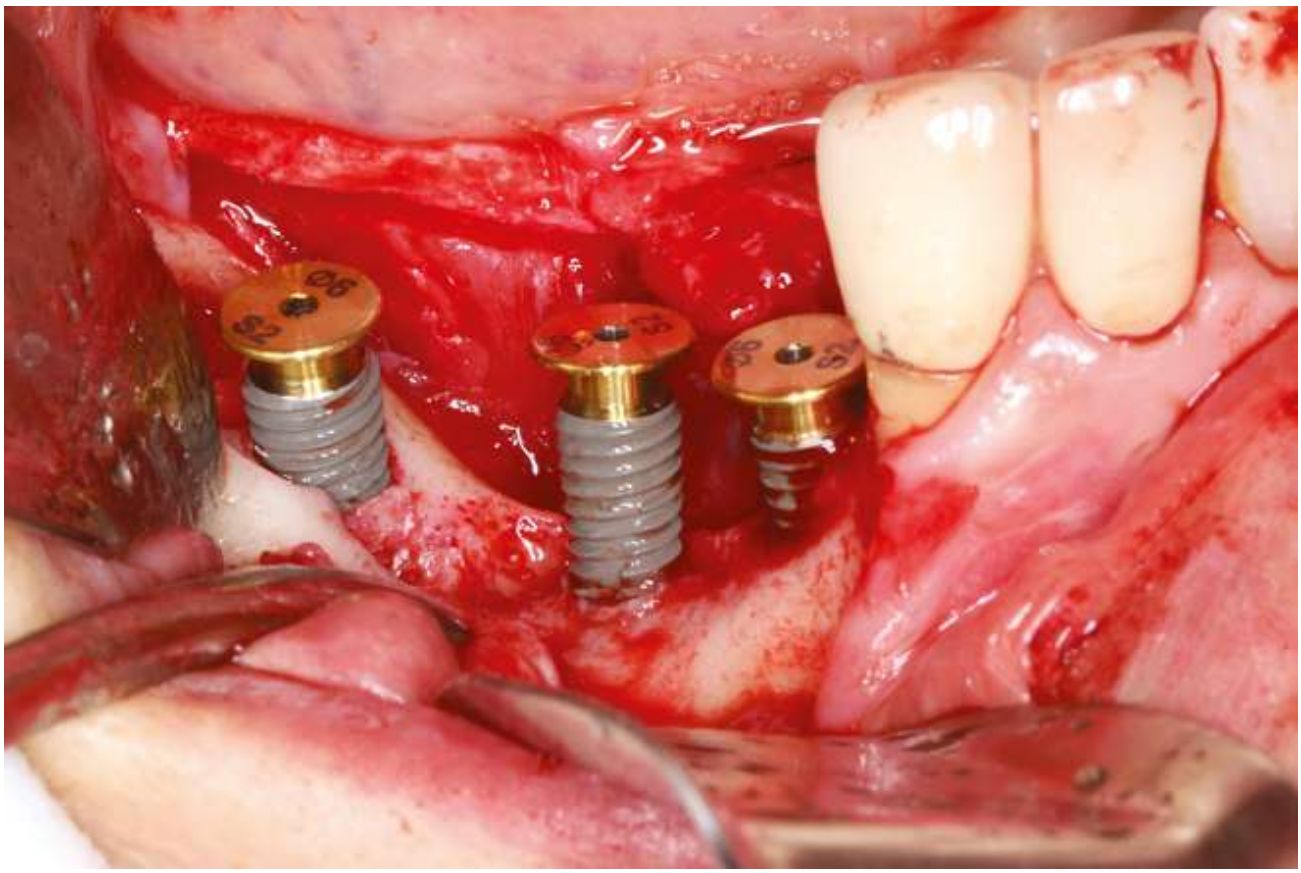

Dentlearn.ir

CHAPTER 23

Reconstruction of Three-Dimensional Alveolar Ridge Defects Utilizing Screws and Implant Abutments for the Tent-Pole Grafting Technique

Dong-Seok Sohn

Department of Dentistry and Oral and Maxillofacial Surgery, School of Medicine, Daegu Catholic University, South Korea

Dental implant-supported oral rehabilitation is commonly utilized to restore an edentulous ridge in modern dentistry. However, the placement of dental implants on an atrophic alveolar ridge with severe bone resorption is still considered a challenging procedure. To augment an atrophic alveolar ridge, diverse surgical methods have been advocated to provide implant-supported restoration with predictable functional and esthetic outcomes.

Autologous block bone grafting using an intraosseous or extraosseous bone block is always considered the gold standard for the reconstruction of an atrophic alveolar ridge [1–4]. However, grafting of intraoral and extraoral autoblock bone is known to cause complications. Wound dehiscence at the recipient site is the primary complication that causes graft failure. Hematoma and inflammation at the donor and recipient sites are the most common complications associated with the harvesting procedure for intraoral autoblock grafts [5]. Other complications have also been reported, including unpredictable resorption of block bone after healing, fracture of the mandible during harvesting of autogenous block bone, neuro-sensory disturbances at recipient and donor sites, long surgical time and edentulous period, prolonged post-operative pain and significant morbidity, and high risk of iliac bone fracture after harvesting of iliac bone at the donor site [6–10].

As an alternative to the harvesting of autogenous block bone, allogenic block grafting has been widely utilized because it is known to have several advantages, such as biocompatibility, no donor site morbidity, and unlimited volume in quantity [11, 12]. However, allogenic block bone is known to have unpredictable resorption, cracking of the bone graft, and poor integration of grafts [12–15].

To overcome the drawbacks of block bone grafting, distraction osteogenesis, sandwich osteotomy with an interposition bone graft, and the ramus split bone technique have been utilized to manage vertical bone deficiency [16–19]. They can be technically challenging procedures. Because these techniques have the disadvantage of being technically difficult and face complications, guided bone regeneration (GBR) using a barrier membrane or titanium mesh is widely accepted for vertical augmentation of an atrophic alveolar ridge [20, 21]. Due to the poor stiffness of resorbable collagen membranes, non-resorbable barriers such as dense polytetrafluoroethylene (d-PTFE), expanded polytetrafluoroethylene (e-PTFE), and titanium mesh are utilized to achieve more favorable vertical support in three-dimensional ridge augmentation [22–25]. However, the main disadvantage of a non-resorbable barrier membrane is early exposure, which can cause unfavorable bone generation [26]. Another disadvantage of non-resorbable barrier–supported GBR are technical difficulties when placing it over the bone graft and when removing it after the healing period. To stabilize these barriers over the bone graft placed on the bony defect, several bone tacks should be placed on the edge of the barrier membrane to stabilize it. In addition, over-grafting is essential when performing GBR with a non-resorbable barrier or titanium mesh, because a 1–2 mm thick soft tissue layer is always regenerated under a non-resorbable barrier and remodeling bone resorption is revealed over time [27]. In order to overcome the disadvantages of these complicated surgeries, a tent-pole screw in conjunction with a resorbable collagen barrier has been utilized to augment a large vertical alveolar defect [28].

Essential Techniques of Alveolar Bone Augmentation in Implant Dentistry: A Surgical Manual, Second Edition. Edited by Len Tolstunov.
© 2023 John Wiley & Sons, Inc. Published 2023 by John Wiley & Sons, Inc.
Companion website: www.wiley.com/go/tolstunov/essential

Dentlearn.ir

RIDGE AUGMENTATION USING THE TENT-POLE SCREW TECHNIQUE

The tent-pole screw technique in conjunction with a resorbable collagen membrane was introduced to prevent collapse of biomaterials grafted on the defect for horizontal ridge augmentation by Fugazzotto et al. [29, 30]. In these reports, a non-resorbable e-PTFE membrane, which can cause early exposure, was covered over biomaterials to exclude soft tissue ingrowth. The tent-pole screw technique in conjunction with a resorbable collagen membrane resulted in predictable functional and esthetic reconstruction of large vertical defects [29, 31–33]. The placement of titanium screws on large vertical defects as tent poles prevents collapse of the bone graft and bio-resorbable barrier membrane, with favorable tissue compatibility in three-dimensional ridge augmentation. The tent-pole screw technique is technically simple, compared to complicated augmentation using block bone, which requires a distant donor site or non-resorbable titanium-reinforced membranes or titanium meshes, the shape of which needs to be customized and stabilized using membrane tacks over the bone graft [32]. Tenting of the periosteum and soft tissue matrix maintains space and enhances the effectiveness of the bone graft. In addition, the tent-pole screw technique offers minor complications compared to GBR using a non-resorbable barrier.

THREE-DIMENSIONAL RIDGE AUGMENTATION UTILIZING A TITANIUM SCREW AS A TENT-POLE SCREW: CASE REPORT

A 46-year-old female was referred after ridge augmentation using the GBR principle failed. Implants were exposed and a severe vertical defect was revealed in the sites of the left upper canine and first premolar. The implants were removed easily with a ratchet under local anesthesia. The patient had a second bone augmentation with autologous block bone graft in the edentulous left area after 2 months of healing in our oral and maxillofacial surgery (OMFS) department. The surgical procedure was performed under local anesthesia. Severe vertical (6 mm) and horizontal defects were revealed after elevation of a full-thickness mucoperiosteal flap. A vestibular incision was made to expose the mandibular symphysis. Two horizontal and vertical osteotomies were performed using the piezoelectric saw (Surgybone®, Silfradent, Sofia, Italy) to harvest thick cortico-cancellous block bone. The block bone was fixed with two mini-screws (Jeil Corp., Seoul, South Korea) at the atrophic recipient site. Using a piezoelectric scalpel connected to the piezoelectric handpiece, autogenous bone chips were collected in the cortex of the chin above the superior osteotomy and filled in the gap between recipient bone and grafted block. Allogenic fibrin adhesive (Tisseel, Baxter, Deerfield, IL, USA) was injected to stabilize particulate autologous bone and control bleeding in the recipient site. Tension-free suture was applied.

FIGURE 23.1 Two 12 mm long micro-screws were placed on the recipient site. Note the 6 mm of tenting screw above the crestal bone.

FIGURE 23.2 Grafting of mineral allograft soaked with antibiotics.

The bone block was found to be exposed after 2 months of healing. The failed block bone was removed with granulation tissue. Two 12 mm long micro-screws were placed simultaneously as space makers. Approximately 6 mm of the screw was exposed above the edentulous defect. Mineralized allograft (Tutoplast® Cancellous Microchips, Tutogen Medical, Neunkirchem am Brad, Germany) mixed with antibiotics (tetracycline HCl) was grafted in the defect until the cover surface of the screws was completely invisible. Then, a bioabsorbable barrier membrane (Tutoplast Pericardium) that had been rehydrated in sterile saline was covered over the bone graft without placing membrane tacks. After performing tension-free suture, a free gingival graft was done at the same time to make an attached keratinized gingiva on the buccal mucosa. Healing was uneventful. The mini-screws were removed after 4 months of healing. Favorable ridge augmentation was revealed. The patient visited the OMFS clinic to place implants in the sites of the left upper canine and first premolar and receive a final restoration (Figures 23.1–23.5).

Dentlearn.ir

FIGURE 23.3 The uncovering procedure revealed favorable three-dimensional ridge augmentation after 4 months of healing.

FIGURE 23.4 Intraoral image after 11 years in function.

FIGURE 23.5 A periapical radiogram after 11 years in function reveals favorable maintenance of the bone graft.

AUGMENTATION OF A THREE-DIMENSIONAL ALVEOLAR DEFECT UTILIZING A LOW-PROFILE HEALING ABUTMENT AS A TENT-POLE ABUTMENT

The tent-pole screws technique requires a long edentulous period and an increased number of surgeries, because implants cannot be placed at the same time. Marx et al. first described the surgical approach using dental implants as an alternative to tent-pole screws combined with autologous bone grafting to augment a severely resorbed fully edentulous mandible using an extraoral approach under general anesthesia [34]. Implants placed in the severely resorbed mandible created a tenting effect to maintain space for the predictable long-term reconstruction of the severely resorbed, completely edentulous mandible. This approach is performed under general anesthesia and requires hospitalization due to the harvest of autologous bone from the ilium or cranium [35, 36]. Therefore the approach is not appropriate for the augmentation of a partially edentulous atrophic ridge. A GBR procedure with a barrier membrane is known to form 1–2 mm of thick, soft tissue under a barrier membrane [27]. In addition, the augmented ridge in a GBR procedure often undergoes bone resorption of 13–15% at 6 months after bone grafting [37, 38]. Therefore, overcorrection with a graft is essential when placing implants simultaneously in an atrophic ridge performing GBR with a barrier membrane.

To compensate for the early resorption of biomaterial grafted in the severely resorbed partially edentulous ridge, the tent-pole abutment technique in conjunction with simultaneous implant placement as an alternative to the tent-pole screw was described first by the author [39]. A low-profile healing abutment (2–3 mm high) or a specially designed tent-pole abutment (SANTA®, Biotem Implant, Seoul, South Korea) is placed on the platform of the implant. In contrast to the tent-pole screw technique, which requires a staged procedure, a tenting abutment technique is performed when placing implants simultaneously on the bony defect. Therefore the number of surgeries is reduced, and the edentulous healing period is shortened. In addition, a tenting abutment prevents vertical and horizontal collapse of the bone graft, because the tenting abutment resists the compression from the overlying periosteum and oral mucosa during the healing period. It also compensates for the remodeling bone resorption that can occur over time because of the overgrowth of bone that can be observed over an implant platform [40]. Tension-free primary wound closure is essential to achieve favorable vertical and horizontal augmentation. Also, surgeons should ensure about a 2 mm interocclusal space to prevent early wound exposure from contact of the opposing dentition to the closed wound during healing.

Dentlearn.ir

CASE REPORT

A 44-year-old male was referred to our OMFS department for oral rehabilitation with implant-supported fixed restorations in the maxillary and mandibular jaws. The patient's maxillary and mandibular dentition revealed severe periodontitis. An implant-supported lower anterior restoration also showed severe bone resorption (Figure 23.6). All non-restorable teeth and failed implants were removed, and upper and immediate lower dentures were delivered on the same day. The extracted teeth were prepared as decalcified osteoinductive particulate and block graft using a vacuum-ultrasonic machine (VacuaSonic System, Cosmo BioMedicare, Seoul, South Korea) one day prior to surgery. Implant placement in conjunction with ridge augmentation in the fully edentulous mandible was performed after 6 weeks of healing. A pre-operative radiograph and cone beam computed tomography scan indicated severe horizontal and vertical bone deficiency in the edentulous ridge. The patient's venous blood was taken from the forearm to make autologous fibrin glue (AFG) and concentrated growth factor (CGF) membrane to prepare sticky bone, as described first by Sohn et al. [40].

The surgical procedure was performed under local anesthesia after intravenous (IV) administration of pre-operative antibiotics (flomoxef, Flumarin®, Ildong Pharm, Seoul, South Korea). A full-thickness mucoperiosteal flap was elevated, and the inflammatory tissue was removed completely with a bony scraper tip connected to the piezoelectric handpiece (Surgybone; Figures 23.7 and 23.8). Four implants (Tapered Screw-Vent®, Zimmer Dental, Carlsbad, CA, USA) were placed in each posterior mandible. Approximately 6 mm of implants placed on the site of the left first and second molars were exposed.

The tooth bone block preparation consisted of the following technique. The root of the patient's extracted canine was dissected along its axis with a disk and micro-holes were prepared with a small round bur to allow blood infiltration. The perforated dentinal block was sterilized with sterilization reagent (peracetic acid ethanol solution) in a device to undergo vacuum compression and ultrasonic vibration. After sterilization of the perforated dentin block, it was demineralized for 30 minutes using 0.6N hydrochloride under vacuum compression and ultrasonic vibration in a vacuum-ultrasonic device. The prepared demineralized tooth bone block was grafted from the thin buccal bony wall around canine and premolar for horizontal ridge augmentation. Then 2 mm high healing abutments as tent-pole abutments were placed on the platform of the first and second molar implants. Sticky tooth bone was grafted and a resorbable collagen barrier (Remaix™, Matricel, Herzogenrath, Germany) was placed over the bone graft. Sticky tooth bone graft was also grafted on the right posterior mandible after placement of implants. A resorbable collagen barrier was placed over the bone graft. Three mini-implants were placed at the same time to deliver immediate temporary fixed restoration. Tension-free sutures were placed (Figures 23.9–23.14).

Uncovering was done after 6 months of healing. Vertical bone regeneration was shown beyond the platform of the implants. After 3 years in loading, there was favorable maintenance of the augmented ridge (Figures 23.15–23.19).

FIGURE 23.6 Intraoral image before extraction of hopeless teeth and implant-supported restorations.

FIGURE 23.7 Pre-operative panoramic view after extraction of all teeth: vertical defect can be seen on lower left and right posterior mandible.

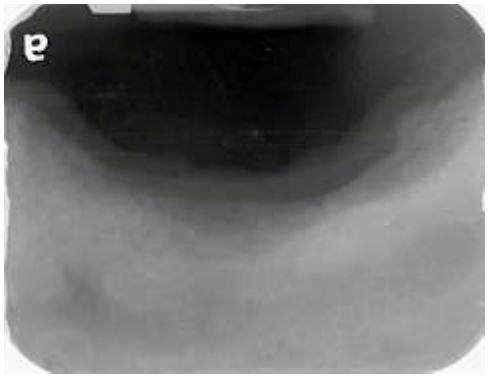

FIGURE 23.8 Periapical radiograph revealed severe vertical deficiency of the lower left posterior mandible.

Dentlearn.ir

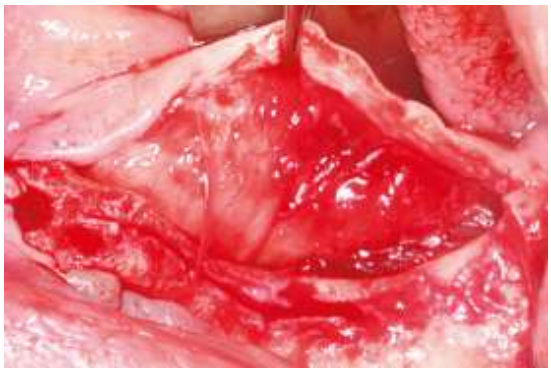

FIGURE 23.9 Note the severe vertical defect after elevation of a full-thickness flap.

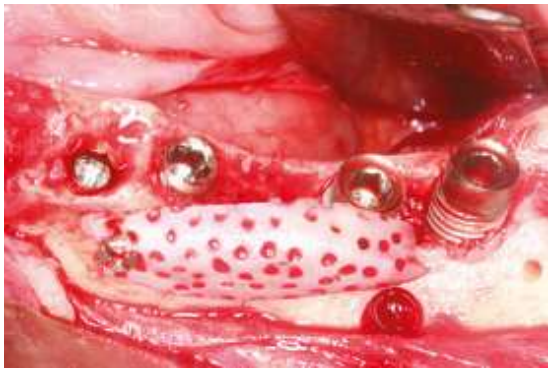

FIGURE 23.10 Note the 6 mm high exposure of the implant surface placed on the site of first and second molars. Demineralized tooth block bone was grafted for horizontal ridge augmentation around implants placed on the site of premolars.

FIGURE 23.11 Tent-pole healing abutments were placed on each implant platform to house bone graft around the implants.

FIGURE 23.12 Sticky demineralized osteoinductive tooth bone graft was placed in the defect around the implants. A collagen barrier was placed over the bone graft.

FIGURE 23.13 Post-operative panoramic image after implant placement. Three mini-implants were placed simultaneously to deliver immediate fixed restoration in the mandible.

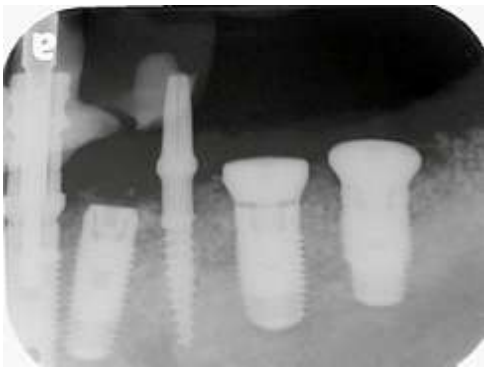

FIGURE 23.14 Note the bone graft placed over the implant platform.

Dentlearn.ir

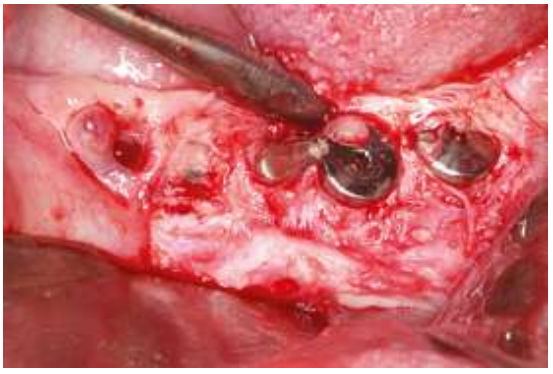

FIGURE 23.15 Intraoral view indicating favorable ridge augmentation after 6 months of healing.

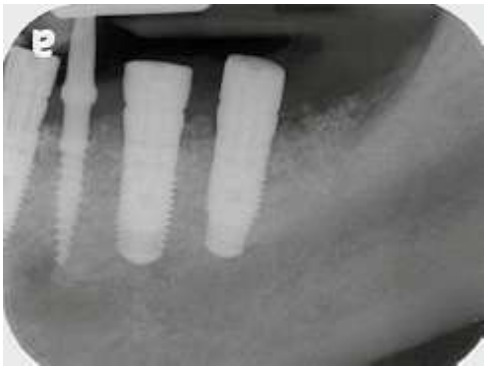

FIGURE 23.16 Periapical radiograph showing favorable ridge augmentation over implant platform after 6 months of healing.

FIGURE 23.17 Intraoral image after delivery of upper and lower implant-supported fixed restorations.

FIGURE 23.18 Panoramic image after delivery of zirconia-based fixed restoration.

FIGURE 23.19 A plain radiograph indicating stable marginal bone over the implant platform in 3-year loading.

DESCRIPTION OF TENT-POLE ABUTMENT (SANTA)

SANTA is a specially designed tent-pole abutment to assist in horizontal and vertical ridge augmentation procedures. It is placed on the platform of the implant inserted into the bony defect. This special abutment prevents the periosteum and overlying mucosa from compressing the bone graft. Therefore, it helps to house bone graft materials around the bony defect and exposed surface of implants, improving stabilization of the bone graft, which is an essential requirement for the GBR procedure. In addition, more bone graft materials can be laid around implants when using SANTA compared to normal healing abutments, due to the design of the narrower neck. The diameter of the SANTA cover head is 6 mm and the cuff height is available in two sizes: 1 mm (SANTA-1) and 2 mm (SANTA-2). SANTA-1 is indicated for horizontal augmentation and SANTA-2 is indicated for vertical and three-dimensional ridge augmentation (Figure 23.20).

Dentlearn.ir



FIGURE 23.20 (A) SANTA-1 has a 1 mm cuff height and is indicated for horizontal ridge augmentation. (B) SANTA-2 has a 2 mm cuff height and is indicated for vertical ridge augmentation.

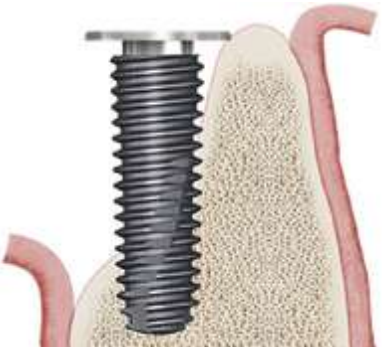

FIGURE 23.22 SANTA-1 is placed on the implant platform and tightened to 10 Ncm.

SURGICAL PROCEDURE OF SANTA-1–ASSISTED HORIZONTAL RIDGE AUGMENTATION

After elevation of a full-thickness muco-periosteal flap, under-osteotomy is performed to achieve initial stability of the implant. The implant is placed 1 mm deeper than the lingual crest bone. SANTA-1 is placed on the implant and tightened to 10 Ncm. Biomaterials are grafted along the implant and over the head of the SANTA. A collagen barrier is covered over the bone graft without placing membrane tacks. Primary tension-free closure is required (Figures 23.21–23.23).

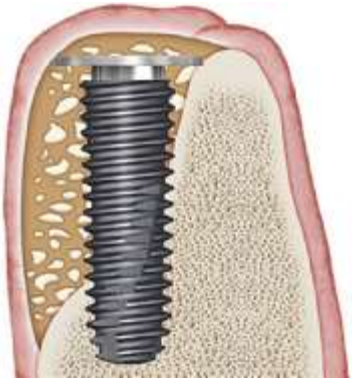

FIGURE 23.23 Biomaterials are placed on the bony defect around the implant and over SANTA-1.

CASE REPORT: HORIZONTAL RIDGE AUGMENTING USING A TENT-POLE ABUTMENT (SANTA-1)

A 65-year-old female presented with loss of the upper left lateral incisor. Severe horizontal bone resorption was shown on the edentulous ridge (Figures 23.24 and 23.25).

FIGURE 23.21 The implant is placed 1 mm deep to the lingual crest.

FIGURE 23.24 Pre-operative intraoral image showing horizontal alveolar deficiency.

Dentlearn.ir

FIGURE 23.25 Occlusal view indicating significant horizonal bone resorption.

FIGURE 23.27 Note the large exposure of the implant surface.

The surgical procedure was performed under local anesthesia after IV administration of pre-operative antibiotics (Flumarin). A full-thickness flap was retracted to expose the alveolar bone. Under-osteotomy was performed to ensure initial stability of the implant. A 13 mm long × 4 mm wide implant (Biotem Implant) was placed with favorable initial stability. A tent-pole abutment with a 1 mm high cuff (SANTA-1) was placed on the implant platform to maintain the volume of the tooth bone graft during the healing period. Putty bovine bone (S1, Medpark, Busan, South Korea) was grafted around the exposed implant surface and a tent-pole abutment. Two layers of CGF membrane were placed over the bone graft to accelerate wound healing (Figures 23.26–23.31). The augmented ridge was exposed after 11 weeks of healing. The bone graft was well maintained around a tenting abutment. A temporary restoration was delivered on the same day. A final zirconia restoration was cemented after 4 months' use of a temporary crown. After 1 year in loading, there was favorable maintenance of the augmented ridge (Figures 23.32–23.36).

FIGURE 23.28 Placement of SANTA-1 abutment to allow over-grafting of the bone graft.

FIGURE 23.26 Note the severe bony defect.

FIGURE 23.29 Grafting of biomaterial on the defect.

Dentlearn.ir

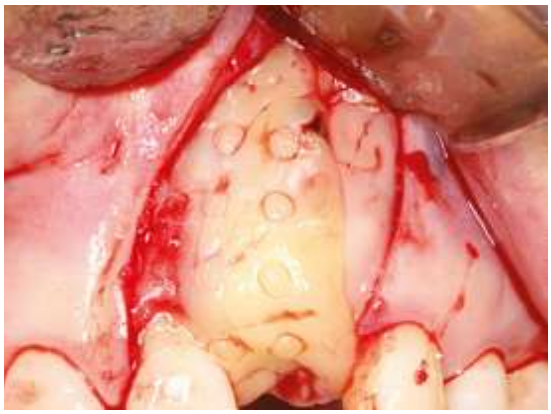

FIGURE 23.30 Concentrated growth factor membranes placed over the bone graft.

FIGURE 23.31 Post-operative periapical radiograph.

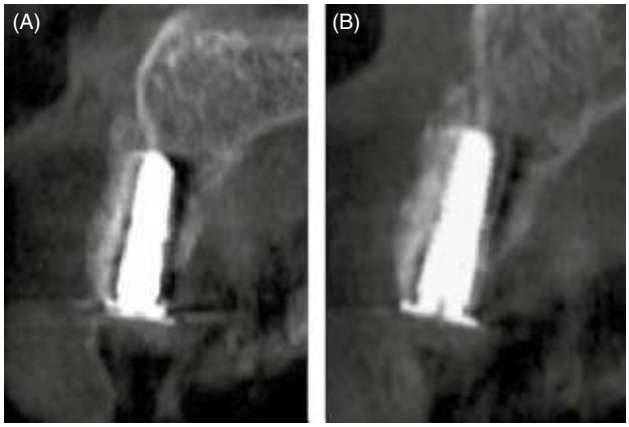

FIGURE 23.32 (A) Post-operative cone beam computed tomography (CBCT) image indicating bone graft around the implant. (B) CBCT image indicating stability of the bone graft after 11 weeks of healing.

FIGURE 23.33 Intraoral image showing favorable ridge augmentation after 11 weeks of healing.

FIGURE 23.34 Note the well-maintained bone graft around SANTA-1 and the implant after 11 weeks of healing.

FIGURE 23.35 Intraoral image in 1-year loading revealed esthetic outcomes.

Dentlearn.ir

FIGURE 23.36 Periapical radiograph indicting stable bone graft over the implant platform.

THREE-DIMENSIONAL RIDGE AUGMENTATION USING A TENT-POLE ABUTMENT (SANTA-2)

A full-thickness mucoperiosteal flap is elevated and the inflammatory tissue is removed completely. Under-osteotomy is applied to obtain initial stability of the implant. Implant platforms are placed 2 mm subcrestally to the adjacent proximal bone height. SANTA-2 is applied on the implants to allow over-grafting of biomaterials for three-dimensional ridge augmentation. Biomaterials are grafted on the defect and over the head of SANTA-2. A bioresorbable collagen barrier is placed over the bone graft. No membrane tacks or membrane stabilization suture are necessary. Tension-free wound closure is performed (Figures 23.37–23.39). Surgeons must ensure about a 2 mm interocclusal space in order to prevent early wound exposure from contact of the opposing dentition into the closured wound during healing.

FIGURE 23.37 The implant is placed 2 mm subcrestally to the proximal bony crest.

FIGURE 23.38 Placement of SANTA-2 on the implant platform to house the bone graft on the defect around the implant.

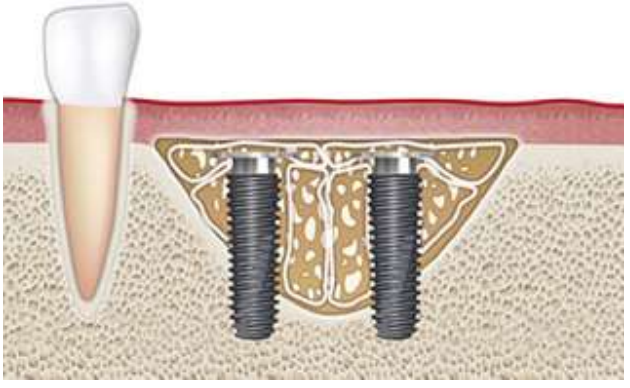

FIGURE 23.39 Over-grafting of biomaterial over the implant platform.

CASE REPORT: SIMPLIFIED THREE-DIMENSIONAL RIDGE AUGMENTING USING A TENT-POLE ABUTMENT (SANTA-2)

A 64-year-old female was referred with a complaint of pain and mucosal swelling on the mandibular left posterior area. She mentioned that the wound had not healed after removal of an implant-supported restoration about 2 months previously at another clinic. A full-thickness flap was elevated, piezoelectric curettage was performed to remove necrotic bone and inflammatory tissue, and three CGF blocks were placed on the defect to accelerate wound healing and reduce post-operative healing. A primary soft tissue closure was performed. Wound healing was uneventful (Figures 23.40–23.42).

The patient came back to have implants placed in the edentulous ridge after 11 months of healing. The pre-operative radiogram showed a severe three-dimensional bony defect on the mandibular right side. All surgical procedures were performed under local anesthesia after IV administration of pre-operative antibiotics (Flumarin). A full-thickness mucoperiosteal flap was elevated to expose the bony defect. Harvesting of

Dentlearn.ir

FIGURE 23.40 Note the suppuration and mucosal swelling due to improper healing after removal of failed implants.

FIGURE 23.41 Piezoelectric curettage was done to remove necrotic bone and inflammatory tissue.

FIGURE 23.42 Concentrated growth factor blocks were placed in the defect to aid in wound healing.

FIGURE 23.43 Panoramic radiograph indicating severe three-dimensional ridge deficiency on the right posterior mandible.

FIGURE 23.44 Note the significant bony defect after elevation of a full-thickness flap.

FIGURE 23.45 Harvesting autogenous bone chips from the retromolar area.

autogenous bone chips using a bone collector (ACM, Neobiotech, Seoul, Korea) was performed. A 4 mm wide × 10 mm long, a 4.5 mm wide × 10 mm long, and a 5 mm wide × 10 mm long implant (Biotem Implant) were placed on the lower first premolar, the first molar, and the second molar, respectively, with good initial stability after preparation of the under-osteotomy. Approximately 5–8 mm of implants were exposed and SANTA-2 was placed on the top of each implant. Sticky autogenous bone was grafted as the first layer around exposed implant surfaces and sticky porcine bone (Bone XP, Medpark) was grafted over the auto bone graft with the purpose of space maintaining. A resorbable collagen membrane (Colla-D®, Medpark) was used to cover the bone graft, and two CGF membranes were placed over the barrier membrane to accelerate wound healing. After making a periosteal-releasing incision, tension-free wound closure was done. Healing was uneventful (Figures 23.43–23.51).

Uncovering was done after 18 weeks. The bone graft remained stable, as it was when the first operation was performed. To widen the attached keratinized gingiva around the implants, a free gingival graft was performed. A superficial

Dentlearn.ir

FIGURE 23.46 Note 5–8 mm exposure of implants. SANTA-2 abutments were connected on each implant to house the bone graft.

FIGURE 23.47 Grafting of sticky autogenous bone graft along the exposed implant surface.

FIGURE 23.48 Grafting of sticky porcine bone as a space maintainer.

FIGURE 23.49 A collagen barrier was placed over the bone graft without membrane tacks.

FIGURE 23.50 Tension-free primary closure.

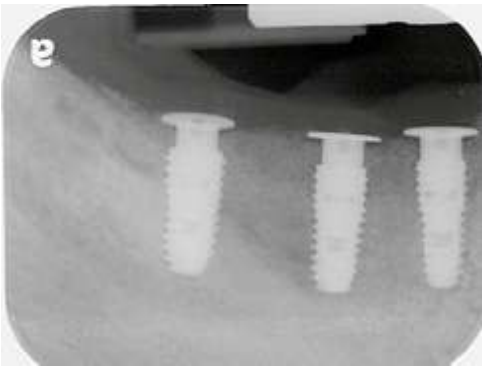

FIGURE 23.51 Post-operative periapical radiograph indicating implants and bone graft.

horizontal incision was made at the muco-gingival junction using a 15c blade. Two superficial vertical incisions were made at the end of the horizontal incision and extended into the vestibule. The recipient bed was then prepared by split-thickness free graft. Free gingival tissue harvested from the palate was grafted on the recipient site and stabilized with tissue cyanoacrylate (N-butyl-2-cyanoacrylate, Histoacryl®, B. Braun Surgical, Barcelona, Spain). Tissue cyanoacrylate was also applied immediately on the donor site for hemostasis. A progressive restoration was delivered after 1 month. A final zirconia-based restoration was cemented on the implants after 2 months of loading of the progressive restoration (Figures 23.52–23.56).

Dentlearn.ir

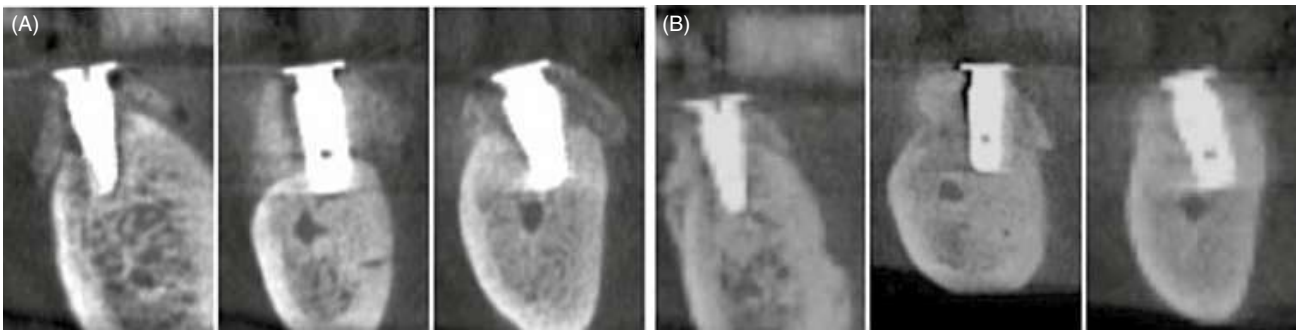

FIGURE 23.52 (A) Post-operative cone beam computed tomography (CBCT) image. (B) CBCT image after 14 weeks of healing. Note the stable ridge augmentation on the defect.

FIGURE 23.53 Periapical radiograph after the uncovering procedure. Note the well-maintained bone graft over the implant platforms.

FIGURE 23.54 To widen the zone of attached keratinized gingiva, a free gingival graft was performed after preparation of the recipient bed using an apically repositioned flap on the day of uncovering.

FIGURE 23.55 Free gingival graft was stabilized with tissue cyanoacrylate (no sutures).

FIGURE 23.56 Periapical radiograph after completion of final restoration.

CONCLUSION

The tent-pole abutment technique with the GBR procedure prevents collapse of the space produced by the bone graft and minimizes resorption of the grafting material in horizontal and vertical ridge augmentation procedures. This technique is technically easier and offers minor complications compared to other complex augmentation techniques, including block bone grafting and mesh-assisted ridge augmentation. This procedure shortens the healing period and reduces the frequency of surgeries required.

Dentlearn.ir

REFERENCES

1. Misch CM, Misch CE, Resnik RR, Ismail YH. Reconstruction of maxillary alveolar defects with mandibular symphysis grafts for dental implants: A preliminary procedural report. *Int J Oral Maxillofac Implants.* 1992;7:360–66.
2. Aloy-Prósper A, Peñarrocha-Oltra D, Peñarrocha-Diago M, Peñarrocha-Diago M. The outcome of intraoral onlay block bone grafts on alveolar ridge augmentations: A systematic review. *Med Oral Patol Oral Cir Bucal.* 2015;20:e251–e258.
3. Sakkas A, Wilde F, Heufelder M et al. Autogenous bone grafts in oral implantology—is it still a "gold standard"? A consecutive review of 279 patients with 456 clinical procedures. *Int J Implant Dent.* 2017;3(1):23.
4. Sohn DS, Ahn MR, Lee WH et al. Piezoelectric osteotomy for intraoral harvesting of bone blocks. *Int J Periodontics Restorative Dent.* 2007;27(2):127–31.
5. Francis CS, Mobin SS, Lypka MA et al. Localized bone augmentation with cortical bone blocks tented over different particulate bone substitutes: A retrospective study. *Int J Oral Maxillofac Implants.* 2012;27(6):1481–93.
6. Nkenke E, Neukam FW. Autogenous bone harvesting and grafting in advanced jaw resorption: Morbidity, resorption and implant survival. *Eur J Oral Implantol.* 2014;7(suppl 2):S203–S217.
7. Sakkas A, Schramm A, Winter K, Wilde F. Risk factors for postoperative complications after procedures for autologous bone augmentation from different donor sites. *J Craniomaxillofac Surg.* 2018;46(2):312–22.
8. Dimitriou R, Mataliotakis GI, Angoules AG et al. Complications following autologous bone graft harvesting from the iliac crest and using the RIA: A systematic review. *Injury.* 2011;42(suppl 2):S3–15.
9. Seiler JG 3rd, Johnson J. Iliac crest autogenous bone grafting: Donor site complications. *J South Orthop Assoc.* 2000;9(2):91–7.
10. Nocini PF, Bedogni A, Valsecchi S et al. Fractures of the iliac crest following anterior and posterior bone graft harvesting: Review of the literature and case presentation. *Minerva Stomatol.* 2003;52(10):441–44.
11. Novell J, Novell-Costa F, Ivorra C et al. Five-year results of implants inserted into freeze-dried block allografts. *Implant Dent.* 2012;21(2):129–35.
12. Motamedian SR, Khojaste M, Khojasteh A. Success rate of implants placed in autogenous bone blocks versus allogenic bone blocks: A systematic literature review. *Ann Maxillofac Surg.* 2016;6(1):78–90.
13. Spin-Neto R, Stavropoulos A, Dias Pereira LA et al. Fate of autologous and fresh-frozen allogeneic block bone grafts used for ridge augmentation: A CBCT-based analysis. *Clin Oral Implants Res.* 2013;24:167–73.
14. Pelker RR, Friedlaender GE. Biomechanical aspects of bone autografts and allografts. *Orthop Clin North Am.* 1987;18:235–9.
15. Acocella A, Bertolai R, Ellis E 3rd et al. Maxillary alveolar ridge reconstruction with monocortical fresh-frozen bone blocks: A clinical, histological and histomorphometric study. *J Craniomaxillofac Surg.* 2012;40:525–33.
16. Lee HJ, Ahn MR, Sohn DS. Piezoelectric distraction osteogenesis in the atrophic maxillary anterior area: A case report. *Implant Dent.* 2007;16(3):227–34.
17. Jensen OT. Alveolar segmental "sandwich" osteotomies for posterior edentulous mandibular sites for dental implants. *J Oral Maxillofac Surg.* 2006;64:471–5.
18. Khoury F, Hanser T. Three-dimensional vertical alveolar ridge augmentation in the posterior maxilla: A 10-year clinical study. *Int J Oral Maxillofac Implants.* 2019;34(2):471–80.
19. Esenlik E, DeMitchell-Rodriguez EM. Alveolar distraction. *Clin Plast Surg.* 2021;48(3):419–29.
20. Urban IA, Lozada JL, Wessing B et al. Vertical bone grafting and periosteal vertical mattress suture for the fixation of resorbable membranes and stabilization of particulate grafts in horizontal guided bone regeneration to achieve more predictable results: A technical report. *Int J Periodontics Restorative Dent.* 2016;36(2):153–9.
21. Hameed MH, Gul M, Ghafoor R, Khan FR. Vertical ridge gain with various bone augmentation techniques: A systematic review and meta-analysis. *J Prosthodont.* 2019;28(4):421–7.
22. Rakhmatia YD, Ayukawa Y, Furuhashi A, Koyano K. Current barrier membranes: Titanium mesh and other membranes for guided bone regeneration in dental applications. *J Prosthodont Res.* 2013;57(1):3–14.
23. Urban IA, Saleh MHA, Ravidà A et al. Vertical bone augmentation utilizing a titanium-reinforced PTFE mesh: A multi-variate analysis of influencing factors. *Clin Oral Implants Res.* 2021;32(7):828–39.
24. Ronda M, Rebaudi A, Torelli L, Stacchi C. Expanded vs. dense polytetrafluoroethylene membranes in vertical ridge augmentation around dental implants: A prospective randomized controlled clinical trial. *Clin Oral Implants Res.* 2014;25(7):859–66.
25. Windisch P, Orban K, Salvi GE et al. Vertical-guided bone regeneration with a titanium-reinforced d-PTFE membrane utilizing a novel split-thickness flap design: A prospective case series. *Clin Oral Investig.* 2021;25(5):2969–80.
26. Soldatos NK, Stylianou P, Koidou VP et al. Limitations and options using resorbable versus nonresorbable membranes for successful guided bone regeneration. *Quintessence Int.* 2017;48(2):131–47.
27. Her S, Kang T, Fien MJ. Titanium mesh as an alternative to a membrane for ridge augmentation. *J Oral Maxillofac Surg.* 2012;70(4):803–10.
28. Le B, Rohrer MD, Prasad HS. Screw "tent-pole" grafting technique for reconstruction of large vertical alveolar ridge defects using human mineralized allograft for implant site preparation. *J Oral Maxillofac Surg.* 2010;68(2):428–35.
29. Fugazzotto PA. Ridge augmentation with titanium screws and guided tissue regeneration: Technique and report of a case. *Int J Oral Maxillofac Implants.* 1993;8(3):335–9.
30. Hempton TJ, Fugazzotto PA. Ridge augmentation utilizing guided tissue regeneration, titanium screws, freeze-dried bone, and tricalcium phosphate: Clinical report. *Implant Dent.* 1994;3(1):35–7.
31. Daga D, Mehrotra D, Mohammad S et al. Tentpole technique for bone regeneration in vertically deficient alveolar ridges: A review. *J Oral Biol Craniofac Res.* 2015;5(2):92–7.
32. Deeb GR, Tran D, Carrico CK et al. How effective is the tent screw pole technique compared to other forms of horizontal ridge augmentation? *J Oral Maxillofac Surg.* 2017;75(10):2093–8.

Dentlearn.ir

33. Daga D, Mehrotra D, Mohammad S et al. Tentpole technique for bone regeneration in vertically deficient alveolar ridges: A prospective study. *J Oral Biol Craniofac Res.* 2018;8(1):20–24.

34. Marx RE, Shellenberger T, Wimsatt J, Correa P. Severely resorbed mandible: Predictable reconstruction with soft tissue matrix expansion (tent pole) grafts. *J Oral Maxillofac Surg.* 2002;60(8):878–88; discussion 888–9.

35. Fenton CC, Nish IA, Carmichael RP, Sàndor GK. Metastatic mandibular retinoblastoma in a child reconstructed with soft tissue matrix expansion grafting: A preliminary report. *J Oral Maxillofac Surg.* 2007;65(11):2329–35.

36. Manfro R, Batassini F, Bortoluzzi MC. Severely resorbed mandible treated by soft tissue matrix expansion (tent pole) grafts: Case report. *Implant Dent.* 2008;17(4):408–13.

37. Proussaefs P, Lozada J. Use of titanium mesh for staged localized alveolar ridge augmentation: Clinical and histologic-histomorphometric evaluation. *J Oral Implantol.* 2006;32(5):237–47.

38. Roccuzzo M, Ramieri G, Bunino M, Berrone S. Autogenous bone graft alone or associated with titanium mesh for vertical alveolar ridge augmentation: A controlled clinical trial. *Clin Oral Implants Res.* 2007;18(3):286–94.

39. Woo RH, Kim HG, Kim G et al. Simplified 3-dimensional ridge augmentation using a tenting abutment. *Adv Dent Oral Health.* 2020;12(2):185–205.

40. Sohn DS, Huang B, Kim J et al. Utilization of autologous concentrated growth factors (CGF) enriched bone graft matrix (Sticky Bone) and CGF-enriched fibrin membrane in implant dentistry. *J Implant Adv Clin Dent.* 2015;7(10):11–29.

Dentlearn.ir

Lateral Sinus Lift/Bone Graft for Vertical Bone Augmentation in the Posterior Maxilla

CHAPTER 24

The maxillary sinus elevation procedure using a lateral window approach has been shown to be one of the most successful bone augmentation procedures. This chapter will illustrate step by step the surgical lateral approach to maxillary sinus elevation and soft tissue management at the second-stage surgery to improve the longevity of implant restorations.

Dentlearn.ir

CHAPTER 24

Lateral Sinus Lift/Bone Graft for Vertical Bone Augmentation in the Posterior Maxilla

Tiziano Testori[1,2,3], Riccardo Scaini[1,2], and Terry Zaniol[4]

[1] *IRCCS Orthopedic Institute Galeazzi, Dental Clinic, Section of Implant Dentistry and Oral Rehabilitation, Milan, Italy*

[2] *Department of Biomedical, Surgical and Dental Sciences, Università degli Studi di Milano, Milan, Italy*

[3] *Department of Periodontics and Oral Medicine, University of Michigan, School of Dentistry, Ann Arbor, MI, USA*

[4] *Private Practice, Crocetta del Montello TV, Italy*

The physiological resorption of alveolar process in the craniocaudal and vestibulo-palatal direction following tooth loss often does not allow placement of osseointegrated implants in the posterior upper jaw without adequate bone reconstruction. The functional load on the residual crest transforms into compression load, leading to bone resorption in the centripetal and craniocaudal direction [1], with a consequent reduction in the size of the alveolar process associated with progressive pneumatization of the maxillary sinus. Among pre-implant surgery procedures to restore lost bone volume, maxillary sinus surgery has been shown to have a high clinical predictability [2–9]. The lateral approach is adopted in the presence of bone atrophy with residual crestal bone below 4 mm, without an overall bone deficit that may compromise the construction of appropriate prosthesis. If any other, lateral and/or horizontal bone deficit is encountered, a three-dimensional (3D) reconstruction of the crestal bone is indicated. In the planning stage it is mandatory to identify all possible ear, nose, and throat (ENT) diseases and to consult an ENT specialist if necessary.

INDICATIONS AND CONTRAINDICATIONS

The health of the maxillary sinus is assured by a properly functioning mechanism that produces and transports sinus secretions, and proper oxygenation of the epithelium that lines the sinus cavity. Drainage of sinus secretions produced by serous and mucous glands (muco-ciliary clearance) is a complex function depending on the quality and quantity of mucus produced, the efficiency of the ciliar transport, and unobstructed communication between the sinus and nasal cavity.

Sinus ventilation, facilitated by the ostia, allows normal functioning of the clearance mechanism. According to research findings, it takes 5 minutes to renew 90% of the air in the sinus. Appropriate mucus production, also in terms of quality, efficient muco-ciliary transport, unobstructed drainage, and adequate sinus ventilation assures optimal nose–sinus homeostasis, since an healthy sinus, from both anatomical and functional points of view, has a good probability of restoring homeostasis (high compliance) without developing sinusitis also in a case of membrane perforation during surgery. The evaluation of the health of the maxillary sinus from an otolaryngological point of view is therefore fundamental in order to guarantee high success rates of the surgical procedure [10–12].

PRE-OPERATIVE DIAGNOSIS, PLANNING, AND EVALUATION OF CASE DIFFICULTY

During the diagnosis phase, an important parameter to assess is the degree of resorption in the alveolar crest. This variable must be evaluated in the apico-coronal, vestibulo-palatal, and residual crestal directions with respect to the occlusal plane (interarch distance). The classic indication for sinus elevation is moderate atrophy in the upper jaw without skeletal alteration. In these cases, it is possible to carry out an implant-prosthetic rehabilitation with normal-sized teeth [2, 6]. A 3D

Essential Techniques of Alveolar Bone Augmentation in Implant Dentistry: A Surgical Manual, Second Edition. Edited by Len Tolstunov.
© 2023 John Wiley & Sons, Inc. Published 2023 by John Wiley & Sons, Inc.
Companion website: www.wiley.com/go/tolstunov/essential

Dentlearn.ir

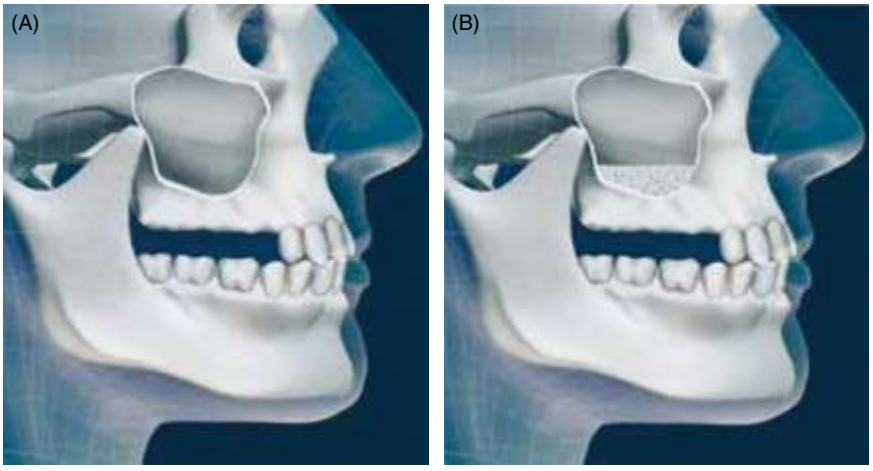

FIGURE 24.1 (A, B) Classic indication for sinus elevation moderate atrophy in the upper jaw without skeletal alteration. *Source*: Reprinted with permission of ACME (Viterbo).

analysis of the edentulous ridge will determine the type of surgery needed to restore vertical and/or horizontal bone volume (Figure 24.1) [13].

In clinical cases with an increased interarch distance and/or an alveolar ridge with a thickness of less than 6 mm in the vestibulo-palatal direction, the ideal treatment would be by reconstructive surgery (Figure 24.2). The quantity of crestal bone available in the apico-coronal direction can influence the choice of surgical approach. Many clinicians would accept 4 mm as the limit determining whether to carry out maxillary sinus elevation with a crestal or lateral approach. An analysis of the quality/quantity of available bone is a useful parameter to predict the primary stability of the proposed implant. Such considerations determine the choice between sinus surgery with implant placement (simultaneous protocol) and sinus surgery with implant placement at a later stage (delayed protocol).

Although it is technically possible to stabilize implants with residual crestal bone heights of 2 mm or less, the risk of early implant failure is high if implants are spontaneously exposed before graft material consolidation. In the case of exposure, the physiological process establishing the supracrestal tissue height begins, with consequent crestal bone resorption of about 2 mm. This phenomenon may result in micromotion or outright mobility of the implant due to loss of the only bone–implant contact present prior to graft consolidation. Premature exposure of implants is more likely to occur when soft tissues are thin (under 1–1.5 mm), or it can be caused by compression from improperly conditioned removable prostheses. In cases with residual crestal bone of 3 mm or less, it is advisable to plan a delayed approach, after graft consolidation.

Prosthetic crowns, in a case of maxillary sinus elevation, are usually longer in the apico-coronal direction to compensate for the bone resorption that has taken place. Future prosthetic rehabilitation must be planned with a diagnostic wax-up to evaluate function, esthetics, and maintenance with normal homecare hygiene procedures. On the transversal plane, the clinician's aim is to obtain an interarch ratio that assures a proper distribution of functional and occlusal load.

FIGURE 24.2 (A–C) In clinical cases with vertical and/or horizontal bone atrophy, the ideal treatment would be done by reconstructive surgery.

Dentlearn.ir

On the sagittal plane, especially in a fully edentulous patient, an intraoral examination analyzing the state of and support available from perioral soft tissues in association with skeletal class assessment is fundamental.

Modest atrophy of the crest can usually be treated in a manner that avoids invasive reconstruction procedures by compensating for the bone resorption with longer crowns along with adequate treatment of peri-implant tissues, hence obtaining a good compromise from an esthetic–functional point of view.

Following clinical parameters can be evaluated pre-operatively: emergence profile of prosthetic restoration, adequate quantity of peri-implant keratinized mucosa, and sufficient arch depth. Pre-operative radiological examinations recommended include cone beam computed tomography (CBCT) extended to the osteomeatal complex (OMC) for the assessment of ostium patency and investigating the possible presence of disease in the paranasal sinuses. This examination allows for an accurate ENT diagnosis in the case of sinus disease. When compared to a bi-dimensional examination (orthopantomography), CBCT allows for an accurate assessment of septal anatomy, the diameter and course of blood vessels, possible bone dehiscence, and sinus disease [14]. Using dedicated software, graft volume can be determined and surgical guides for the antrostromy and implant positioning can be fabricated.

Once a thorough pre-operative evaluation and surgical diagnosis is completed, it is possible to assess the surgical risk and determine the level of experience/expertise that is necessary to achieve a positive outcome. To achieve such an outcome a Maxillary Sinus Elevation Difficulty Score has been developed [15].

APPLIED SURGICAL ANATOMY

SINUS ANATOMY

The maxillary sinus is the largest of the paranasal cavities, which include ethmoidal, frontal, and sphenoid sinuses and occupy most of the maxilla [16]. The maxillary sinus is a pneumatic, quadrangular pyramid-shaped cavity with the following walls:

- Medial wall facing the nasal cavity.
- Posterior wall facing the maxillary tuberosity.
- Vestibular (or lateral) wall that joins the mesial (or anterior) wall, which appears concave due to the canine fossa; the angle between the vestibular and the medial wall varies widely from individual to individual.
- Superior wall serving as the orbital floor.
- Inferior wall corresponding to the alveolar process functioning as the sinus floor.

The sinus communicates with the homolateral nasal cavity via a natural ostium anterosuperior to the medial wall. Mucus is discharged by ciliary activity through the natural ostium, ethmoidal infundibulum, and semilunar hiatus (which constitute the OMC) toward the middle meatus of the nasal cavity. The patency of the nasal cavity is a determining factor in the maintenance of normal sinus physiology.

The natural sinus ostium is usually oval shaped (7–11 mm × 2–6 mm). It is connected to the nasal cavity indirectly via a narrow, subtle vestibule termed the ethmoidal infundibulum. All paranasal sinuses communicate with nasal cavities and therefore indirectly with each other.

SINUS MEMBRANE

The internal walls of the sinus are lined with a mucous membrane (the sinus membrane) consisting of three layers with a thickness of 80–100 μm in a healthy patient:

- The first layer is a superficial layer corresponding to the respiratory epithelium (cylindrical, ciliated, pseudostratified), composed of basal cell units, columnar ciliates, and calciform cells (the so-called goblet cells attached to the basal membrane).
- The second layer is a middle layer corresponding to lax connective tissue that can become edematous (lamina propria) in reaction to inflammation. It is separated from the overlying basal membrane epithelium and entirely permeated by a dense network of blood vessels that ensure abundant nourishment of the mucosa. The lamina propria houses the serous mucous glands, which are very abundant at the level of the sinus ostium.
- The third deep layer, corresponding to the periosteum, separates the connective tissue from the bony walls of the sinus.

The epithelium that lines the sinus continues into nasal mucosa that tends to be thicker, around 1 mm. The apical ciliated cells consist of 50–200 cilia, whereas non-ciliated cells possess microvilli that increase the surface area. The mucus film lining the sinus mucosa consists of two overlapping layers: a deeper serous layer (*sol phase*), inside which the ciliary movement takes place; and a more superficial, denser layer (*gel phase*). In the absence of sinus disease, this mechanism keeps the nasal cavity sterile. Under normal conditions, the muco-ciliary transport mechanism allows the renewal of the antral mucous film in 20–30 minutes with a flow rate of around 1 cm per minute. The quality and quantity of the mucus depend on hydration, environmental humidity, and consumption of drugs (i.e. atropine and similar substances). The ciliary apparatus under normal conditions has a beat rate of between 8 and 20 cycles per second; the inhaled air temperature directly influences such action (ideally 33 °C; reduced activity is observed under 18 °C and over 40 °C; no activity is

Dentlearn.ir

detected under 12 °C and over 43 °C) as well as the pH (optimal between 7 and 8), oxygenation, osmotic pressure, metabolism, humidity, and hydration. Maxillary endoscopy shows that ciliary movement stops during sinus elevation, the duration and extent of which are currently unknown.

UNDERWOOD'S SEPTA

The sinus normally extends in the anteroposterior direction from the premolar to the molar area, even though often the two sinuses are asymmetric. Within the sinus cavity it is not unusual to encounter septa originating from the sinus floor that can extend to variable heights on the lateral wall. These septa, also called Underwood's septa, can be traced to the first molar and premolar zone and consist of cortical bone. The incidence of septa varies between 16% and 58%, with an average of around 30% [17, 18].

VASCULARIZATION

The vascular network in the maxilla is particularly extensive and is supplied by three arteries:

- Infraorbital artery.
- Major palatine artery.
- Alveolar antral artery originating from the internal maxillary artery.

The alveolar antral artery often sprouts an intraosseous anastomosis, with the infraorbital artery running inside the lateral wall of sinus to an average distance of 19 mm from crestal bone [19]. Solar showed how the anastomotic branch of the posterior superior alveolar artery is present in 100% of samples [20]. Elian et al. showed that this artery may be situated in the lateral wall and is visible in computed tomography (CT) scans in 52% of sinuses [21]. In addition, in 20% of cases the artery is found in the projection area of the antrostomy. CBCT studies demonstrated that the artery is present in the lateral wall; Mardinger et al. reported it in 55% of cases [22], Temmermann et al. in 49.5% [23], and Rosano et al. in 47.5% of cases [19]. Furthermore, Rosano et al. found that the artery may run entirely externally (extraosseous, subperiosteal), run entirely internally (extraosseous maintaining contact with the membrane), or have a mixed course [19]. In cases where the artery path is intraosseous, 3D imaging such as CT or CBCT reveals a circumferential radiotransparent area in the bone wall visible in the paraxial sections. This anastomosis ensures blood supply to the sinus membrane and the periosteal tissues. It is important to take note of the anastomosis preoperatively to avoid intraoperative hemorrhaging when this artery branch is sectioned during antrostomy. Venous return from the sinus is facilitated by the facial vein, sphenopalatine vein, and pterygoid plexus. It is important to note that veins can spread infection from the sinus to the surrounding tissues.

INNERVATION

Innervation of the sinus derives directly from the maxillary nerve, the second branch of the fifth cranial nerve (trigeminal nerve). This nerve with its posterior middle and superior alveolar ramifications innervates the sinus floor in the posterior region, the ipsilateral molar and premolar teeth. The anterior superior alveolar branch originating from the infraorbital nerve at the infraorbital foramen level reaches the anterior sinus wall and teeth in the maxilla, running below the sinus membrane.

SURGICAL TECHNIQUE

ANESTHESIA

An ideal local anesthetic for the surgical procedure would be one with a short onset and long duration. In a study comparing lidocaine 2% with 1:100 000 epinephrine to articaine 4% with either 1:100 000 or 1:200 000 epinephrine, the shortest onset and longest duration were recorded with articaine 4% with 1:100 000 epinephrine (1.4 min onset, 66.3 min duration). This long duration is appropriate for the projected length of a sinus elevation procedure. Two carpules should be sufficient for this procedure. In addition to the facial and palatal infiltration anesthesia, a block through the greater palatine foramen will give more profound anesthesia to the medial sinus wall.

FLAP MANAGEMENT (ENTRY)

Access for a lateral window antrostomy is accomplished via a full-thickness mucoperiosteal flap. Flap design must keep in mind the principles of atraumatic flap management, adequate blood supply, access to the antrostomy site, post-operative protection of the surgical site (window and accompanying barrier membrane), and effective primary closure.

The flap design should include broad-based vertical incisions for adequate vascular supply. The crestal incision should be made in keratinized gingiva for more stable suturing. Generally, the incision would be made mid-crestal, if possible, or in a position that would best favor positioning the flap around immediately placed implants. If the window will be close to the crest due to the presence of only a minimal amount of crestal bone, the incision should be moved somewhat toward the palate.

When making the anterior releasing incision, keep in mind the position of the infraorbital nerve and its branches. In cases with severe alveolar loss or a short facial profile, these branches may be quite close to the window location. The vertical releasing incision should be performed by preserving the papilla with a beveled incision in keratinized tissue and in mucosa. In this manner, the incision can be moved medially in the cuspid/lateral area, avoiding the infraorbital nerve

Dentlearn.ir

branches. The split-thickness incision at the level of the papilla and the bevels avoids the formation of unsightly scar tissue.

Depending upon the window location (generally toward the anterior sinus wall), the distal releasing incision may be shortened. The distal releasing incision should be made at the level of the tuberosity if bone quality in the tuberosity is of at least type 3 and bone harvesting is desired. Furthermore, consider that longer horizontal incisions and shorter vertical releasing incisions may be less traumatic than the constant trauma of overzealous flap retraction. The longer the horizontal incision, the greater the flap retraction that can be achieved.

If the adjacent natural teeth have root recession, the flap design could be modified and a coronally advanced flap utilized to simultaneously address the recession via a root coverage procedure.

LATERAL WINDOW PREPARATION (ANTROSTOMY)

The lateral antrostomy should provide access to the sinus cavity in the best possible location to allow for the successful elevation of the Schneiderian membrane in the location of the proposed graft. Factors that should be considered are the following: the thickness of the lateral wall, the location of the posterior superior alveolar (PSA) artery, location of the sinus floor and anterior sinus wall, the internal sinus anatomy (septa number and location, medio-lateral sinus width), and the proposed anteroposterior graft dimension. The discussion that follows focuses on window size, window location, and window design.

Window Size

A relatively large window (on average 20 mm mesio-distal and 10 mm apico-coronal dimensions) will provide better access for the elevation of the Schneiderian membrane. The presence of anatomical obstacles such as septa will be easier to instrument if the window is sufficiently large to allow direct visual access to both sides of the septum. It should also be apparent that the removal of large amounts of the lateral sinus wall may reduce the vascular supply to the graft that originates from the sinus wall microvasculature. This will influence the percentage of vital bone formed in the sinus in each period. Avila Ortiz et al. have shown that there is an inverse relationship between window size and vital bone production [24].

Window Location

The location of the window should be dictated by a desire to gain access and perform the membrane elevation while limiting the incidence of the intraoperative complications of bleeding and membrane perforation (Figure 24.3). It has been shown that membrane perforations are more likely to occur in the narrow anterior portion of the sinus [25]. An acute angle between the medial and lateral walls at the sinus floor results in the need for significantly greater manipulations of sinus curettes in a narrow, restricted-access area. Making the window in an anterior location both provides direct visual access and requires significantly less manipulation. Likewise, making the window close to the sinus floor reduces the coronal movements required to reach the sinus floor. The authors have therefore chosen to make the window 3 mm distal to the anterior sinus wall and 2–3 mm coronal to the sinus floor.

The size of the window is then determined by the internal sinus anatomy and the size of the proposed graft. The presence of a septum should influence the anteroposterior location of the window. It is best to have the window straddle the septum so that sinus curettes can be utilized in a lateral to medial direction on both the anterior and posterior aspects of the septum, this being far safer than trying to elevate in an anteroposterior direction over a sharp septal spine. Modifications were frequently made with rotary window techniques to protect the integrity of the PSA artery. This is less of a problem with the advent of piezoelectric techniques, which protect the integrity of the vasculature, even while carefully working directly over it.

Window Design

There have been many lateral window designs proposed over the years. The choice may be that of the operator, although certain designs do offer advantages. Among the designs are the elevated hinge, elevated island, island removed, complete osteotomy via osteoplasty, crestal approach, palatal approach, the simplified antrostomy design (SAD), and the low window technique [26, 27].

Simplified Antrostomy Design SAD (Figure 24.3) presents a systematic approach that positions the antrostomy in an ideal location, thereby minimizing the risk for membrane perforation by creating the most favorable access for sinus membrane elevation [28].

It has been the experience of the authors that less experienced clinicians tend to make the antrostomy in a less than ideal location. Specifically, this unfavorable antrostomy is made too far superior and too far toward the distal. As the anterior extension of the sinus is generally narrow, and has a report of high perforation rates, membrane elevation will be simplified if the window starts from the mesial sinus wall and there is direct visualization of the membrane, so the clinician does not work in a blind area.

SAD utilizes the best available CBCT scan slices and clinical measurements and is accomplished in a four-step procedure:

- Make a small window 3 mm high × 6 mm long, just distal to where you envision the location of the anterior sinus wall.

Dentlearn.ir

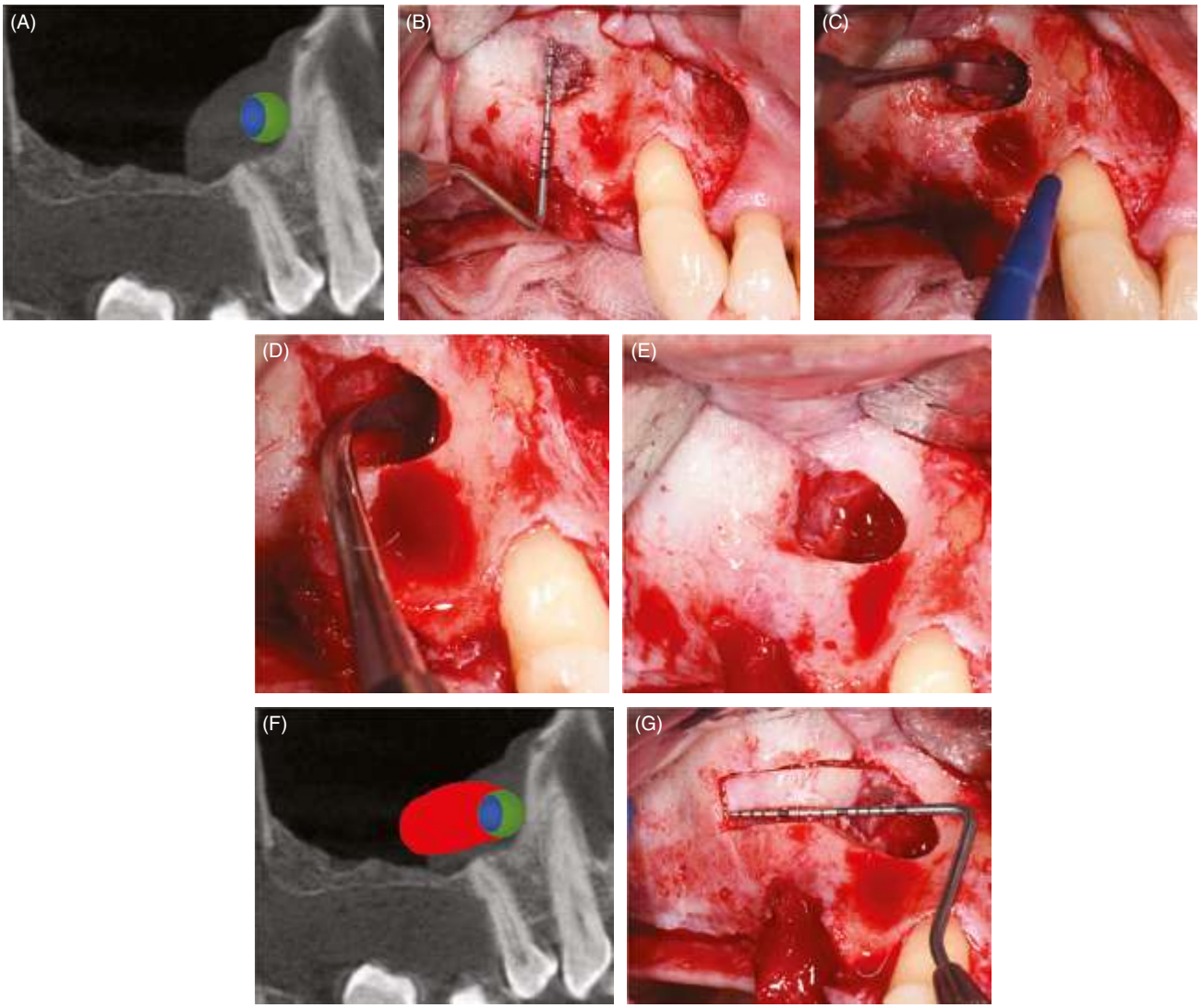

FIGURE 24.3 (A, B) Micro-antrostomy is performed to find the sinus membrane, then is enlarged to reach the anterior wall. (C–E) The detachment starts flush to the sinus anterior wall. (F, G) The antrostomy is enlarged to the desired size to meet case requirements.

- Extend the window in the anterior (mesial) direction to locate the anterior sinus wall.
- Enlarge the antrostomy distally as required by the internal anatomy (septa) and the number of implants to be placed.
- Extend the antrostomy down to 2–3 mm from the sinus floor and roughly 10 mm in the antero-posterior direction.

This simple and predictable antrostomy approach provides multiple benefits for routine lateral window sinus elevations in addition to the trans-sinus technique. These include:

- Providing the ideal antrostomy location for preventing membrane perforations (narrow anterior sinus) by providing the best visual and tactile access for membrane elevation.
- Guaranteeing that the anterior sinus compartment will be reached and fully grafted.
- Allowing for the creation of a smaller antrostomy, thus preserving the lateral wall blood supply.
- Reducing morbidity by requiring a less invasive flap reflection.

Low Window Technique The low window antrostomy design is a further modification of the SAD technique (Figure 24.4) [29]. The window is placed as low and mesially as possible. The lower osteotomy line is placed flush with the sinus floor, and the mesial line is always flush with the sinus anterior wall. Additionally, the window never exceeds 6 mm in height [30], to avoid intraosseous anastomosis. The distal osteotomy is positioned to correspond to the most distally planned implant.

Dentlearn.ir

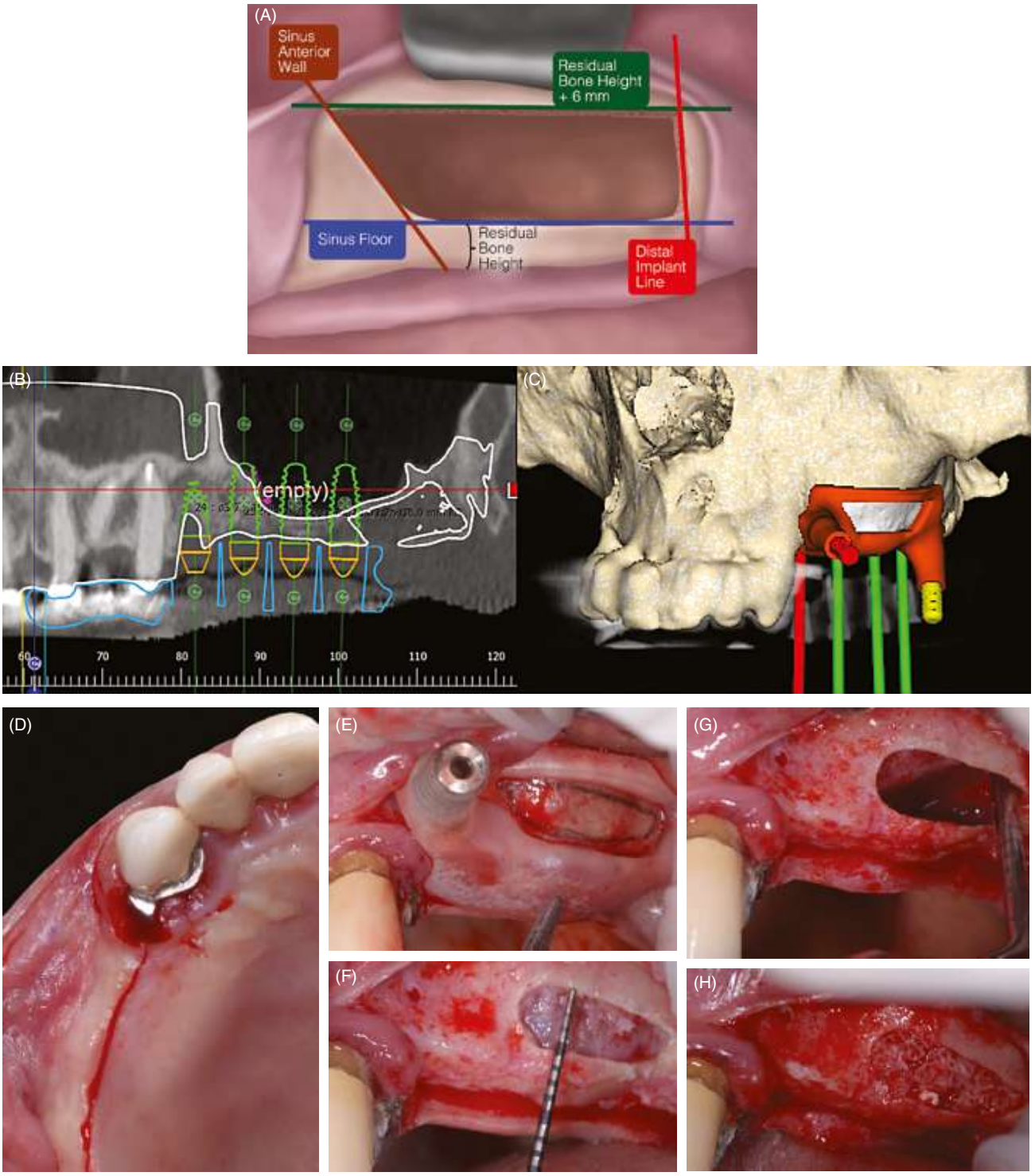

FIGURE 24.4 (A) The low window sinus lift antrostomy. The lower osteotomy line (blue) is positioned flush with the sinus floor. The upper one (green) is 6 mm higher; that is, it is placed at a distance from the ridge equal to the residual bone height plus 6 mm. The mesial line (brown) is flush with the sinus anterior wall. The distal one (red) should be placed to correspond to the position of the most distal implant. (B, C) The case is first studied on cone beam computed tomography scans. The implant position is planned, and a surgical guide, incorporating a template to guide the surgeon during the antrostomy, is designed. The guide will later be fabricated with stereolithography. (D) A muco-periosteal flap is elevated. The flap is limited to a linear incision, preserving the attached gingiva of the most distal residual element present. Release incisions are not performed. (E) The antrostomy is carried out with the help of the surgical guide. (F) The window height is 6 mm. (G) The membrane is lifted, and the sinus is grafted. (H) Before suturing. (I) A collagen membrane is placed to protect the antrostomy. (J) Finally, suturing is carried out. (K) The radiograph shows the extent of filling performed.

Dentlearn.ir

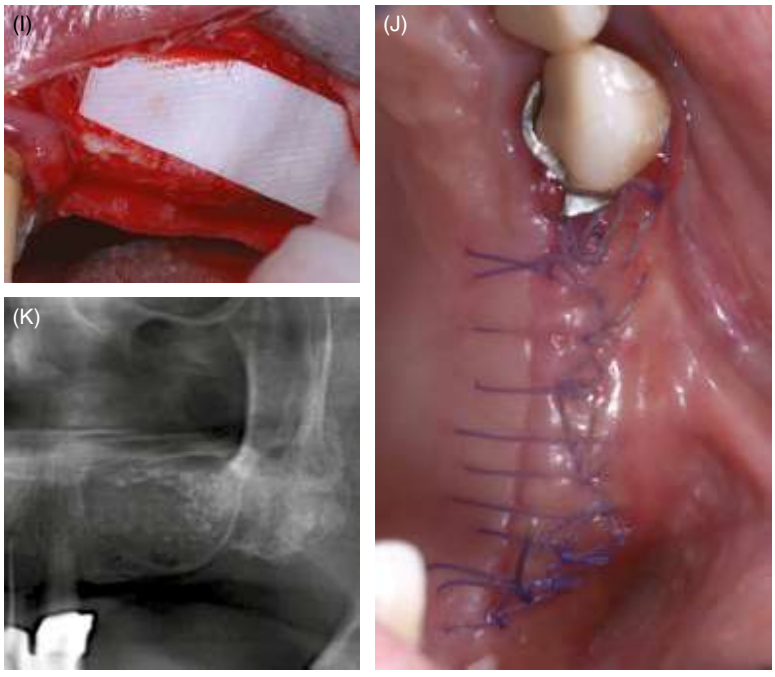

FIGURE 24.4 *(continued)*

The position of this osteotomy design provides specific surgical advantages. Placement of the lower horizontal osteotomy flush with the sinus floor eliminates any residual bone wall that could hinder detachment of the sinus membrane and there are no more "blind spots." The position of the distal osteotomy line is optimized according to the position of the most distal implant; extending it more distally than that provides no advantage and may result in elevation of a wider mucoperiosteal flap. The low window design may reduce the risk of sinus membrane perforation even in the anterior narrow sinus recess.

Rotary Window Preparation

In 1980 Boyne published a case of maxillary sinus elevation with window preparation utilizing a laboratory-sized carbide bur [26]. The profession modified this technique over the years, first utilizing low-speed implant motors outlining the window with round carbide or diamond burs of various sizes, and later modified by using a high-speed contra-angle handpiece.

While rotary instrumentation with carbide or diamond burs has been used successfully for many years, there are inherent complications associated with this technique. Intraoperative complication rates of bleeding (2–4%) and membrane perforation (20–25%) are relatively high with this technique, due to the inability of a rotary instrument to differentiate between hard and soft tissues. All discrimination is left to the diligence of the operator. One of the greatest innovations in maxillary sinus elevation was the introduction of a piezoelectric device for window preparation and membrane elevation. The advent of more sophisticated techniques that are more respectful of soft tissues has dramatically reduced the incidence of the above complications.

Piezoelectric Window Preparation

Piezoelectric techniques (Figure 24.5) have been very well documented in the literature [30, 31]. In oral surgery it has been found to be especially useful in maxillary sinus elevation, where the integrity of both the internal branch of the PSA artery and the Schneiderian membrane can be predictably maintained [32]. Perforation rates with piezoelectric surgery reported in the literature range from 3.6% to 8% [33–36]. This compares favorably to the frequently documented perforation rates averaging 20–25% with the earlier rotary techniques. This safety factor is in part because ultrasonic vibration does not produce the "drag" or tearing effect that is produced by traditional rotary instrumentation. Furthermore, the technique introduced a unique ultrasonic (trumpet-shaped) elevator that can provide an approximate 2 mm of circumferential internal membrane release, which then allows hand instruments to be safely introduced to the sinus without accidently stretching and tearing the Schneiderian membrane. The cavitation effect of piezo surgery devices maintains a blood-free operating field, which further enhances instrument control and procedural safety.

There are two distinct protocols for performing a piezoelectric antrostomy: an osteotomy (outlining) technique and an osteoplasty (grinding) technique. The outlining technique should be restricted to cases where the lateral wall is 1 mm or less in thickness, as this technique can be quite time-consuming when the wall is thick, and additionally will quickly wear out the diamond osteotomy inserts. The

Dentlearn.ir

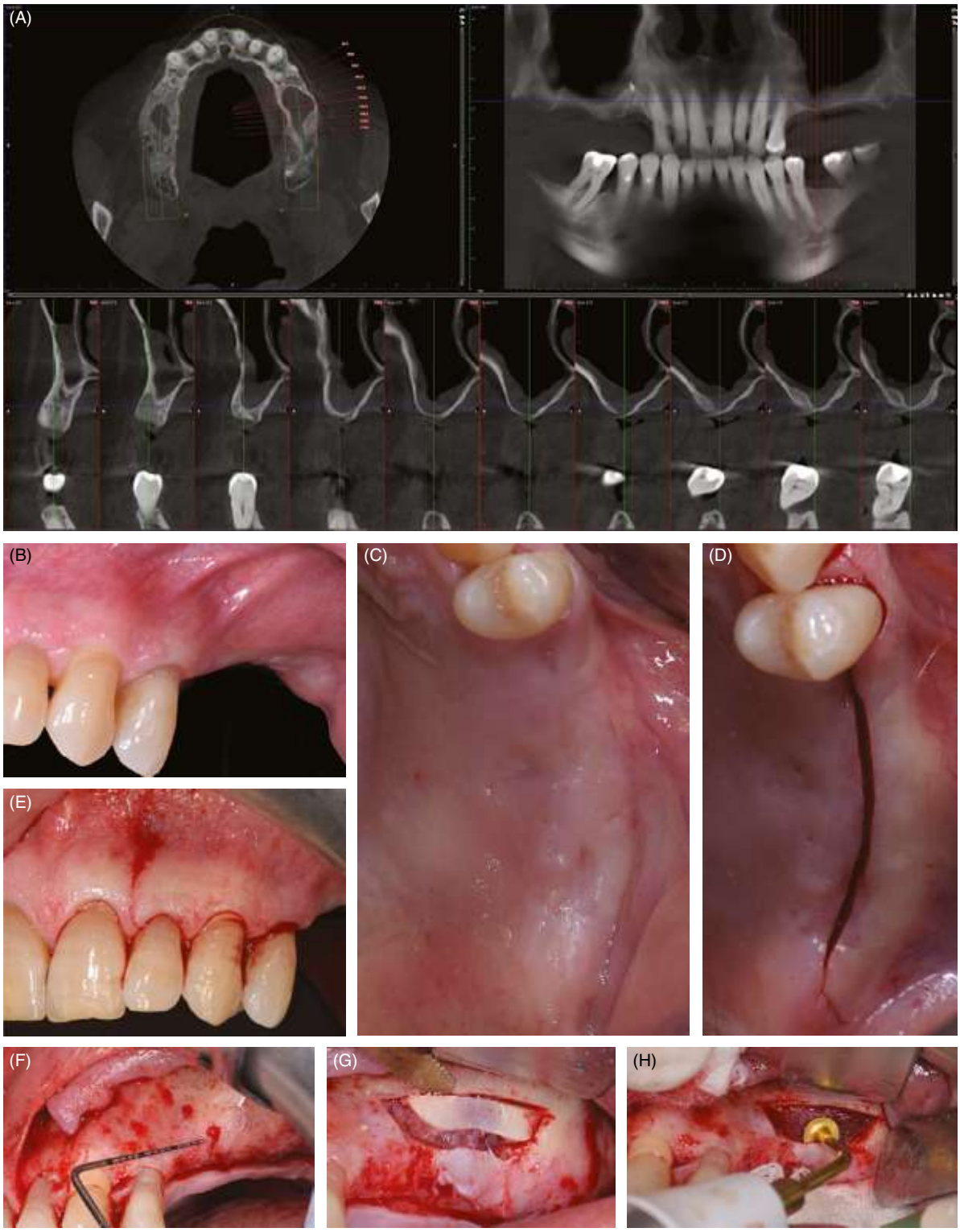

FIGURE 24.5 (A) Pre-operative cone beam computed tomography (CBCT) examination. (B, C) Lateral and occlusal intraoral views. (D) Horizontal incision with distal releasing incision. (E) Mesial releasing incision extended to the alveolar mucosa. (F) A full-thickness flap is raised, and a periodontal probe is used in order to identify the anterior wall of the maxillary sinus. (G) A piezoelectric device is used to perform a selective cut of the bony wall of the sinus. (H) A trumpet-like insert is used to detach the sinus membrane from the bony walls of the sinus. (I) The detachment is carried out via manual elevators. (J) The dimension of the antrostomy is related to the anatomy of the maxillary sinus and to the dimension of the surgical instruments. (K) A bone graft is carried out using a sterile carrier. (L) When the sinus is completely grafted a resorbable collagen membrane is placed over the antrostomy. (M) The thickness of the bone wall is filled with bone particles. (N, O) The flap is sutured with absorbable VICRYL 5-0 sutures. (P, Q) Post-operative CBCT. (R) Final prosthetic restoration. (S) 1 year follow x-ray.

Dentlearn.ir

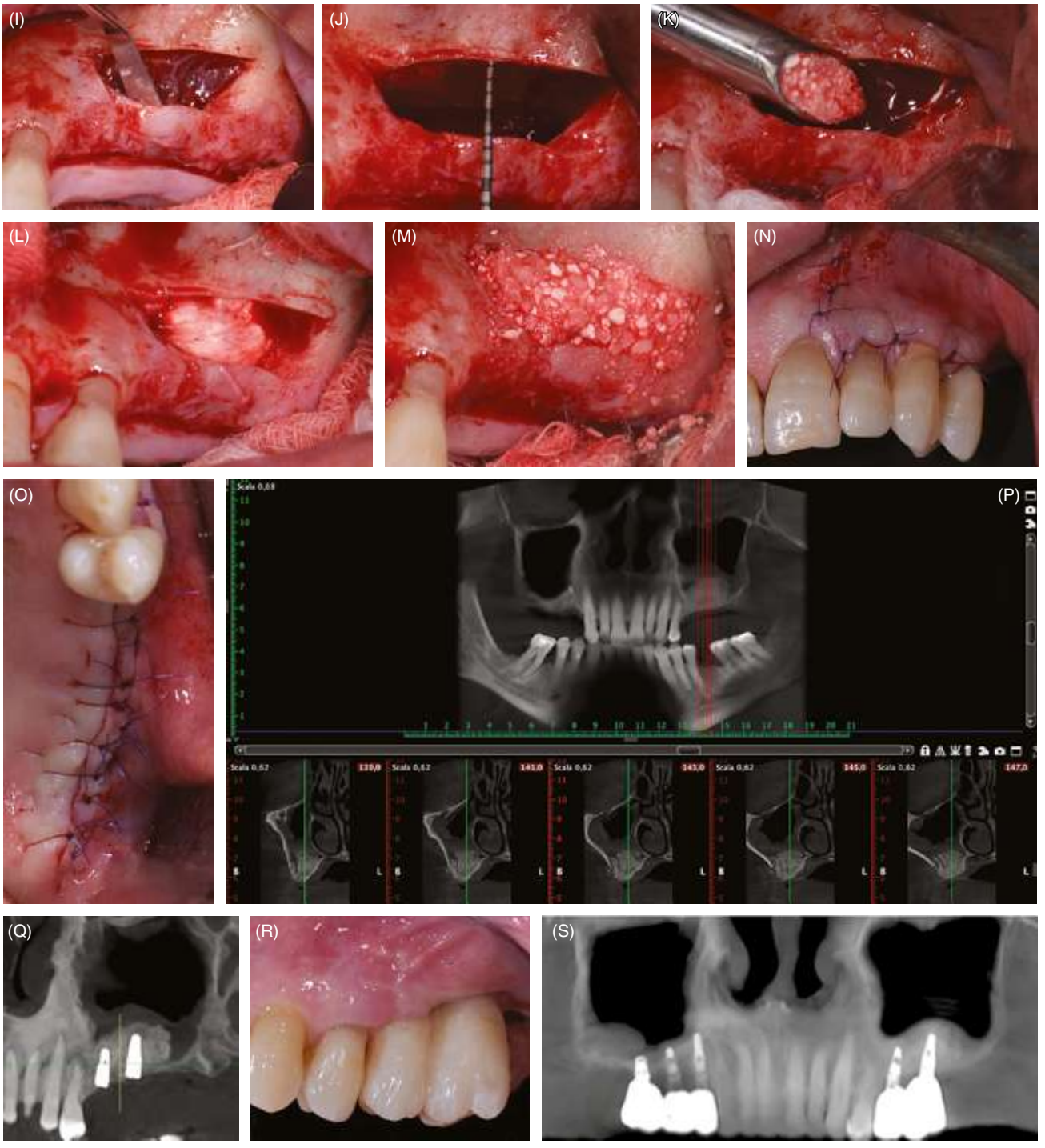

FIGURE 24.5 *(continued)*

Dentlearn.ir

osteotomy technique is accomplished with blade-like or round diamond-covered inserts.

Osteoplasty is accomplished with a spoon-shaped metal insert and more efficient when a thicker lateral wall is present. In cases where the wall is very thick, such as in the area of the malar eminence, it is appropriate to consider reduction of the bulk of the thickness with rotary instrumentation prior to completing window preparation with piezo osteoplasty and/or osteotomy inserts. A study by Stacchi et al. shows that the osteoplasty technique has the lowest perforation rate [37].

SINUS MEMBRANE ELEVATION

In cases where piezoelectric surgery is used, once the antrostomy has been completed, a dedicated insert is employed in the first cleavage plane between the bone plane and periosteal side of the sinus membrane along the antrostomy margins. Detachment is carried out with manual elevators that are more ergonomic and practical than piezoelectric instruments. Elevators must be maintained in constant contact with bone, exercising a continuous force to elevate the sinus membrane, thereby avoiding membrane perforation. In case of resistance to detachment, it is advisable to keep direct contact with the underlying bone and sever the tissue adherence with a sharp tool. Blunt tools have a higher probability of causing perforations when the membrane is very adherent to the bone.

The mucosa must be detached until the medial wall of the sinus cavity (i.e. the lateral wall of the nose) is revealed to the height of the expected graft material placement. Failure to release the membrane to this height creates a potential void near the medial wall. Increases in intra-sinus pressure can then re-pneumatize this space, displacing the graft material laterally and, possibly, out of the sinus window. Detachment from the medial wall also allows the exposure a significantly greater bone surface, which favors better graft neo-vascularization and additionally a more favorable implant placement for prosthetic rehabilitation [38].

Elevation must be performed with dedicated instruments and not with graft material, which must be placed passively into the volume created without further membrane detachment. The prior passive creation of volume is a fundamental prerequisite for a predictable maxillary sinus elevation, preventing accidental perforations by the graft material that may remain undetected, causing dispersion of graft material in the sinus cavity.

Schneiderian membrane perforation is considered the most common intraoperative complication, ranging from 0% to 58.3%, with an average of 19.5% [39]. The wide perforation range reported in the literature may be explained by the different surgical techniques utilized and, importantly, the anatomy of the operated sinus. Several anatomical variations can increase the perforation risk during sinus floor elevation. These include membrane thickness, presence of septa, an acute angle between lateral and medial sinus walls, location of the alveolar antral artery, and so on [39, 40].

CONTINUING ELEVATION IN THE EVENT OF PERFORATION

In the event of a perforation, one can proceed cautiously to continue the elevation. The direct area of the perforation should be avoided as it is a weak spot, with the perforation likely to expand if disturbed. Further membrane elevation should take place at a distance from the perforation, possibly going completely around it. You will likely notice the perforation getting smaller as tension on the membrane is relieved by this further release, and as a precaution at the end of the membrane elevation phase a collagen membrane should be utilized to seal the perforation.

PREPARATION OF IMPLANT SITES FOR THE SIMULTANEOUS APPROACH

The simultaneous approach is indicated when there is a minimum of 3–4 mm of crestal bone remaining. As specified in pre-surgical planning, there are biological limits and technical difficulties for implant placement when the quantity of crestal bone is reduced. Preparation of implant sites is carried out following standard surgical protocols, with under-preparation of the osteotomy. When at least 3–4 mm of crestal bone is present, primary stability can typically be achieved. With less than 3–4 mm of crestal bone present, it is inadvisable to under-prepare the osteotomy sites, as partial or total fracture of the crestal bone may occur due to the pressure created with implant insertion. This is especially true in cases with multiple implant placements. Another precaution that should be adopted is that of protection of the sinus membrane with an elevator (Prichard type) when preparing the implant osteotomy.

INSERTION OF GRAFT MATERIAL AND IMPLANT PLACEMENT WITH THE SIMULTANEOUS APPROACH

In the absence of perforations, it is advisable to insert a non-cross-linked resorbable membrane, especially when employing grafts of 1–2 mm diameter granules, to avoid micro-perforations of the membrane during graft compacting. Currently it is not known whether these micro-perforations are clinically relevant; nevertheless, it seems reasonable to preserve the anatomical–functional integrity of the sinus membrane. A recent histological study showed that the percentage of vital bone is greater when deproteinized bovine bone of large particle size (1–2 mm) is utilized when compared with small particle size (0.5–1.0 mm) [41].

Graft material, in both the simultaneous and delayed approaches, must be inserted starting from less accessible areas (i.e. the anterior and posterior recesses and then along the medial sinus wall), placing the graft in contact with the bone walls to facilitate neo-vascularization. If simultaneous placement of implants has been planned, it is advisable to

Dentlearn.ir

pack two-thirds of the volume, place the implants, and finalize the graft. This sequence will prevent any further elevation of the sinus membrane, since the implants do not create any additional volume inside the graft, thereby preventing late perforations.

An excessive compaction of graft material reduces the space between biomaterial particles, preventing vascularization; this is particularly evident when slow-absorbing materials are employed. Placement of implants with a rough surface statistically increases bone-to-implant contact, and the survival rate is higher than with smooth-surface implants. Once the sinus cavity has been filled, a resorbable membrane is placed on the vestibular bone wall over the antrostomy. Many clinical studies suggest that placement of a resorbable membrane over the antrostomy results in a higher percentage of vital bone and a higher implant success rate compared with sites that do not employ a membrane [42, 43]. A recent paper reported conflicting data stating that there is no significant statistical difference in terms of vital bone percentage between use and non-use of a membrane [44].

GRAFT MATERIALS

Autogenous graft material has historically been considered the gold standard of graft materials due to its osteogenic, osteoinductive, and osteoconductive pathways for bone formation, and was therefore recommended during the developmental period of the sinus augmentation technique. Current studies have found no statistical difference between biomaterials and autogenous bone in terms of implant survival [45]. Regarding bone replacement grafts, xenografts account for the greatest number of clinical trials. Their successful outcomes have been attributed to three factors:

- Osteoconductivity of the biomaterial results in approximately 25% of vital bone formation after 6–8 months of grafting maturation time.
- Residual graft material adds a further 25% of mineral content to the implant site.
- Histological results show that there is no direct contact between the residual non-vital biomaterial and the implant surface, thereby not interfering with osseointegration [45].

Clinical data and histological studies suggest that biomaterials may currently be the gold standard in sinus elevation surgery. This is due to the achievement of similar results with significantly less morbidity than when utilizing autogenous bone grafts. It must also be stated that similar results have been achieved with certain alloplastic materials, although the level of evidence is currently lower [45].

Alternative techniques have been reported in cases of simultaneous implant placement where only a blood clot, collagen, or homologous growth factors are inserted under the sinus membrane [46–48].

The rationale behind this approach is that the implants create a tenting effect to support the membrane and thus favor new bone formation in the interimplant zone. In cases where no filling material is used, bone formation is limited to the implant apex or slightly more coronal to it, leaving the last threads protruding above the newly formed bone, but covered by the sinus membrane.

Many authors have suggested placing a barrier membrane over the antrostomy, following the traditional biological rationale for guided bone regeneration resulting in an increase in vital bone formation. This membrane would prevent the invagination of connective tissue cells from the periosteum into the grafted space, as well as acting to contain the graft material within the sinus cavity [42, 43, 45, 49].

A reported post-operative complication is the loss of graft material through the access window as a result of displacement of a non-stabilized collagen barrier membrane. The loss of graft material can be related to the increased intrasinus pressure caused by post-operative inflammation, bleeding from within the sinus, and patient sneezing or nose blowing [50, 51].

To reduce graft displacement after sinus surgery, a novel technique for placing a collagen barrier membrane (cross-linked or non-cross-linked) just within the antrostomy is presented. After the graft is placed into the sinus, the access window is measured mesiodistally and apicocoronally. The planned collagen membrane should be at least 3 mm larger than the size of the antrostomy. The membrane is then placed over the window and its borders gently tucked between the inner side of the bony wall. It is the experience of the authors that this procedure prevents graft dislodgment caused by post-operative inflammation, bleeding from within the sinus, and sneezing or nose blowing, without the need to stabilize the barrier membrane with tacks or sutures.

If the clinical case presents a thick lateral wall, the clinician can place an extra layer of graft material covered by another membrane to accurately re-establish the contour of the wall.

SUTURING

It is beneficial to suture the vertical releasing incisions starting from the apical end. This will allow the clinician to suture the papillary area in a more passive manner. When suturing a coronally advanced flap, it is beneficial to approximate the tissues with a 45-degree bevel to achieve a smooth interface.

The flap must be sutured without tension. In cases of simultaneous horizontal or vertical augmentation of the atrophic crest, periosteal releasing incisions are suggested to mobilize the flap coronally. At the crestal level, horizontal mattress sutures may be used in association with single or continuous sutures. In keratinized gingiva, non-resorbable monofilament sutures are advisable, whereas in the alveolar mucosa resorbable sutures are indicated.

Dentlearn.ir

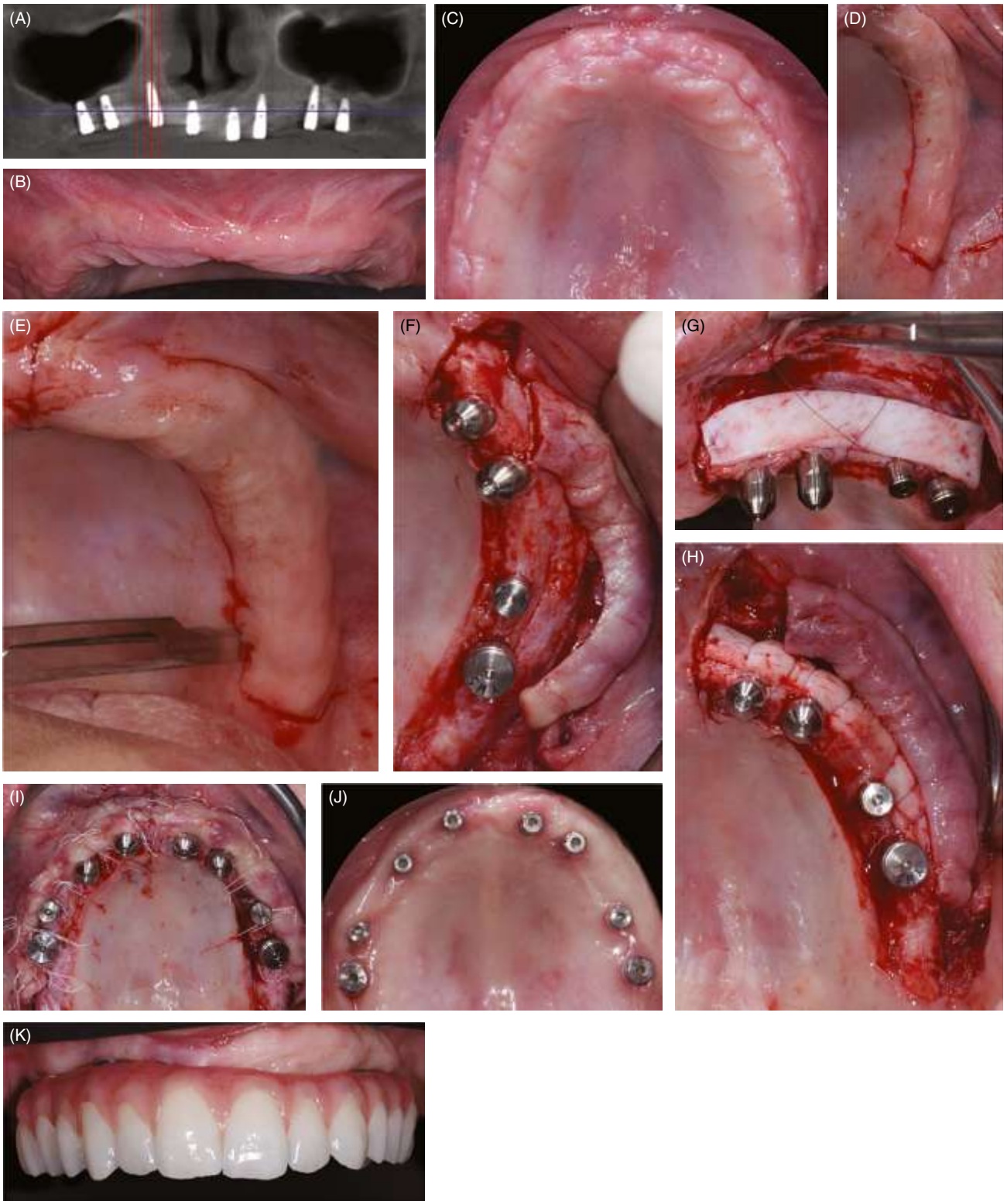

FIGURE 24.6 (A) Post-operative x-ray showing maxillary sinus graft integration and implants position. (B, C) Intraoral clinical views of surgical procedures carried out in the first-stage surgery leading to a reduced fornix depth. (D) The palatal incision allows for 5–6 mm of keratinized tissue to be buccally displaced. The longitudinal incision was carried out up to the tuberosity and a medial buccal and distal release incision was performed. (E) The split-thickness flap is performed orienting the 15c blade or a Goldman-Fox #7 periodontal knife perpendicular to the palate. (F) The flap is raised and buccally displaced. (G, H) A dermal matrix is sutured to the periosteum with absorbable VICRYL 5-0 sutures. (I) Flaps are sutured by horizontal mattress sutures, and at least 5–6 mm keratinized tissue is buccally displaced. (J) Post-operative healing at 3 weeks. (K) Final restoration in place.

Dentlearn.ir

POST-OPERATIVE PHARMACOLOGICAL TREATMENT

Standard post-operative pharmacological treatment consists of a wide-spectrum antibiotic, an analgesic/anti-inflammatory drug, and a mouth rinse with chlorhexidine to control dental plaque. Treatment with non-steroidal anti-inflammatory drugs (NSAIDs) begins immediately after surgery and continues for the next 2 days; subsequently they should be taken only if necessary. Application of ice is recommended during the first day after surgery to limit swelling and bleeding. Plaque is kept under control via daily rinsing with 0.2% chlorhexidine until the sutures are removed. Employment of cortisone spray to limit post-operative swelling in the infundibulum meatus of the nasal mucosa is controversial. It may favor the blockage of the ostium (in case of reduced diameter), with consequent alteration of sinus homeostasis and increased risk of infection.

SURGICAL TECHNIQUE: STAGE TWO SURGERY

The aims of second-stage surgery are:

- To re-establish the correct fornix depth.
- To increase the radius of the maxillary buccal arch.
- To create adequate quantity and thickness of soft tissue on the buccal side.

The buccally displaced palatal flap (BDP-flap) design calls for a longitudinal palatal incision along the entire length of the maxilla (Figures 24.6 and 24.7) [52]. The incision's position depends on the quantity of keratinized tissue present on the buccal side; most of the time, the palatal incision allows for 5–6 mm of keratinized tissue to be buccally displaced. The longitudinal incision is carried out up to the tuberosity independently by the number of the implants placed to optimize the upper-arch morphology. To obtain mobilization of the flap, a medial buccal and a distal release incision should be performed.

The thickness of the flap varies depending on the thickness of tissues, but should never be <1.5 mm to avoid flap necrosis [53]. Once the buccal area is exposed, apical deepening in the fornix is carried out until the correct fornix depth is achieved (empirically to allow the insertion of a rotary electric toothbrush or a small manual toothbrush). Muscle attachments must be adequately freed from their deep insertion to obtain a periosteal bed, which can be used to anchor connective tissue grafts/soft tissue substitutes during the final graft secured stage.

If the clinician judges the need to increase the soft tissue width, a connective tissue graft (CTG) or soft tissue substitutes are sutured to the periosteum with absorbable sutures. Leukocyte-enriched platelet-rich fibrin (L-PRF) membranes can be added to speed up soft tissue healing and reduce post-operative discomfort (Figures 24.6 and 24.7).

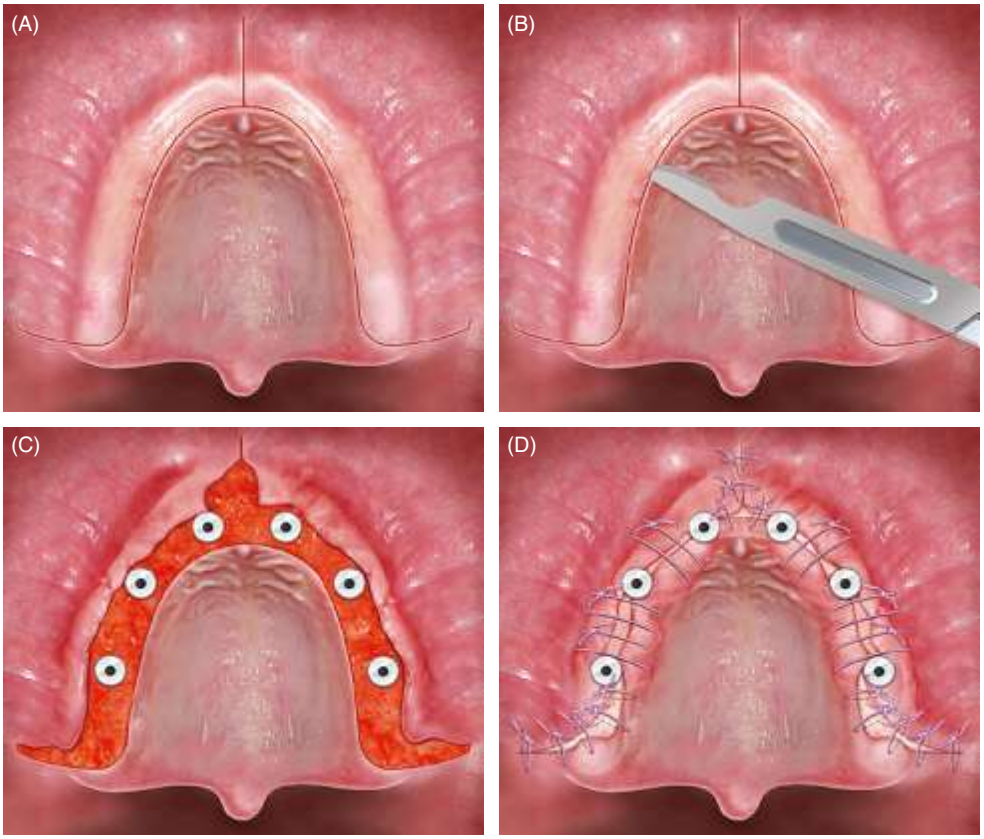

FIGURE 24.7 (A) The surgical procedure starts by identifying where to place the main incisions and the cut-backs. (B) Then a split-thickness flap is performed orienting the 15c blade perpendicular to the palate. (C) Healing abutments are placed. (D) The buccally displaced palatal flaps are then sutured with horizontal mattress resorbable sutures.

Dentlearn.ir

CONCLUSION

The maxillary sinus elevation procedure using a lateral window approach has been shown to be one of the most successful bone augmentation approaches that is performed as a preprosthetic procedure, usually prior to implant placement. Complications of the procedure are minimal.

REFERENCES

1. Cawood JI, Howell RA. A classification of the edentulous jaws. *Int J Oral Maxillofac Surg.* 1988;17:232–6.
2. Wallace SS, Froum SJ. Effect of sinus augmentation on the survival of endosseous dental implants: A systematic review. *Ann Periodontol.* 2003;8:328–43.
3. Del Fabbro M, Testori T, Francetti L, Weinstein R. Systematic review of survival rates for implants placed in the grafted sinus. *Int J Periodontics Restorative Dent.* 2004;24:565–77.
4. Del Fabbro M, Rosano G, Taschieri S. Implant survival rates after sinus augmentation. *Eur J Oral Sci.* 2008;116:497–506.
5. Del Fabbro M, Corbella S, Weinstein T et al. Implant survival rates after osteotome-mediated sinus augmentation: A systematic review. *Clin Implant Dent Relat Res.* 2012;14(suppl 1):e159–e168.
6. Del Fabbro M, Bortolin M, Taschieri S, Weinstein RL. Effect of autologous growth factors in sinus augmentation: A systematic review. *Clin Implant Dent Relat Res.* 2013;15:205–16.
7. Del Fabbro M, Wallace SS, Testori T. Long-term implant survival in the grafted sinus: A systematic review. *Int J Periodontics Restorative Dent.* 2013;33:773–83.
8. Pjetursson BE, Tan WC, Zwahlen M, Lang NP. A systematic review of the success of sinus floor elevation and survival of implants inserted in combination with sinus floor elevation. *Part I: Lateral approach. J Periodontol.* 2008;35:216–40.
9. Testori T, Weinstein RL, Taschieri S, Del Fabbro M. Risk factor analysis following sinus augmentation: A retrospective multicenter study. *Int J Oral Maxillofac Implants.* 2012;27:1170–76.
10. Pignataro L, Mantovani M, Torretta S et al. ENT assessment in the integrated management of candidate for (maxillary) sinus lift. *Acta Otorhinolaryngol Ital.* 2008;28:110–19.
11. Torretta S, Mantovani M, Testori T et al. Importance of ENT assessment in stratifying candidates for sinus floor elevation: A prospective clinical study. Clin Oral Implants Res. 2013;24(suppl A100):57–62.
12. Mantovani M. Otorhinolaryngological contraindications in augmentation of the sinus. In T Testori, M Del Fabbro, R Weinstein, SS Wallace (eds.), Sinus surgery and alternatives in treatment. Chicago, IL: Quintessence; 2009, 23–33.
13. Testori T, Weinstein RL, Wallace SS. Sinus surgery and alternatives in treatment. Chicago, IL: Quintessence; 2009.
14. Harris D, Horner K, Gröndahl K et al. E.A.O. guidelines for the use of diagnostic imaging in implant dentistry 2011. A consensus workshop organized by the European Association for Osseointegration at the Medical University of Warsaw. *Clin Oral Implants Res.* 2012;23:1243–53.
15. Testori T, Tavelli L, Yu SH et al. Maxillary Sinus Elevation Difficulty Score with lateral wall technique. *Int J Oral Maxillofac Implants.* 2020;35(3):631–8.
16. Del Fabbro M, Testori T. Anatomy of the sinus. In T Testori, M Del Fabbro, R Weinstein, SS Wallace (eds.), Sinus surgery and alternatives in treatment. Chicago, IL: Quintessence, 2009, 7–21.
17. Underwood AS. An inquiry into the anatomy and pathology of the sinus. *J Anat Physiol.* 1910;44(Pt 4):354–69.
18. Rosano G, Taschieri S, Gaudy JF et al. Sinus septa: A cadaveric study. *J Oral Maxillofac Surg.* 2010;68:1360–64.
19. Rosano G, Taschieri S, Gaudy JF et al. Sinus vascular anatomy and its relation to sinus lift surgery. *Clin Oral Implants Res.* 2011;22:711–15.
20. Solar P, Geyerhofer U, Traxler H et al. Blood supply to the sinus relevant to sinus floor elevation procedures. *Clin Oral Implants Res.* 1999;10:34–44.
21. Elian N, Wallace S, Cho SC et al. Distribution of the maxillary artery as it relates to sinus floor augmentation. *Int J Oral Maxillofac Implants.* 2005;20:784–7.
22. Mardinger O, Abba M, Hirshberg A, Schwartz-Arad D. Prevalence, diameter and course of the maxillary intraosseous vascular canal with relation to sinus augmentation procedure: A radiographic study. *Int J Oral Maxillofac Surg.* 2007;36:735–8.
23. Temmerman A, Hertelé S, Teughels W et al. Are panoramic images reliable in planning sinus augmentation procedures? *Clin Oral Implants Res.* 2011;22:189–94.
24. Avila-Ortiz G, Wang HL, Galindo-Moreno P et al. Influence of lateral window dimensions on vital bone formation following maxillary sinus augmentation. *Int J Oral Maxillofac Implants.* 2012;27:1230–38.
25. Cho SC, Wallace SS, Froum SJ, Tarnow DP. Influence of anatomy on Schneiderian membrane perforations during sinus elevation surgery: Three-dimensional analysis. *Pract Proced Aesthet Dent.* 2001;13:160–63.
26 Boyne PJ, James RA. Grafting the floor of the maxillary sinus with autogenous marrow and bone. *J Oral Surg.* 1980;38:613–16.
27. Wood RM, Moore DL. Grafting of the maxillary sinus with intraorally harvested autogenous bone prior to implant placement. *Int J Oral Maxillofac Implants.* 1988;3:209–14.
28 Testori T, Scaini R, Deflorian M et al. Lateral window surgical techniques for sinus elevation. In OT Jensen (ed.), The sinus bone graft, 3rd edn. Chicago, IL: Quintessence; 2019, 48–65.
29. Zaniol T, Zaniol A, Tedesco A, Ravazzolo S. The low window sinus lift: A CAD-CAM-Guided surgical technique for lateral sinus augmentation: A retrospective case series. *Implant Dent.* 2018;27(4):512–20.
30 Guerrero JS, Al-Jandan BA. Lateral wall sinus floor elevation for implant placement: Revisiting fundamentals and the surgical technique. *J Calif Dent Assoc.* 2013;41:185–95.
31. Vercellotti T. Technological characteristics and clinical indications of piezoelectric bone surgery. *Minerva Stomatol.* 2004;53:207–14.

Dentlearn.ir

32. Vercellotti T, De Paoli S, Nevins M. The piezoelectric bony window osteotomy and sinus membrane elevation: Introduction of a new technique for simplification of the sinus augmentation procedure. *Int J Periodontics Restorative Dent.* 2001;21:561–7.

33. Wallace SS, Mazor Z, Froum SJ et al. Schneiderian membrane perforation rate during sinus elevation using piezosurgery: Clinical results of 100 consecutive cases. *Int J Periodontics Restorative Dent.* 2007;27:413–19.

34. Blus C, Szmukler-Moncler S, Salama M et al. Sinus bone grafting procedures using ultrasonic bone surgery: 5-year experience. *Int J Periodontics Restorative Dent.* 2008;28:221–9.

35. Toscano NJ, Holtzclaw D, Rosen PS. The effect of piezoelectric use on open sinus lift perforation: A retrospective evaluation of 56 consecutively treated cases from private practices. *J Periodontol.* 2010;81:167–71.

36. Jordi C, Mukaddam K, Lambrecht JT, Kühl S. Membrane perforation rate in lateral maxillary sinus floor augmentation using conventional rotating instruments and piezoelectric device—a meta-analysis. *Int J Implant Dent.* 2018;4(1):3.

37. Stacchi C, Vercellotti T, Toschetti A et al. Intraoperative complications during sinus floor ele-vation using two different ultrasonic approaches: A two-center, randomized, controlled clinical trial. *Clin Implant Dent Relat Res.* 2015;17:e117–e125.

38. Margolin MD, Cogan AG, Taylor M et al. Sinus augmentation in the non-human primate: A comparative radiographic and histologic study between recombinant human osteogenic protein-1 and natural bone mineral. *J Periodontol.* 1998;69:911–19.

39. Pjetursson BE, Tan WC, Zwahlen M, Lang NP. A systematic review of the success of sinus floor elevation and survival of implants inserted in combination with sinus floor elevation. *J Clin Periodontol.* 2008;35:216–40.

40. Lum AG, Ogata Y, Pagni SE, Hur Y. Association between sinus membrane thickness and membrane perforation in lateral window sinus augmentation: A retrospective study. *J Periodontol.* 2017;88:543–9.

41. Testori T, Wallace SS, Trisi P et al. Effect of xenograft (ABBM) particle size on vital bone formation following sinus augmentation: A multicenter, randomized, controlled, clinical histomorphometric trial. *Int J Periodontics Restorative Dent.* 2013;33:467–75.

42. Tarnow DP, Wallace SS, Froum SJ et al. Histologic and clinical comparison of bilateral sinus floor elevations with and without barrier membrane placement in 12 patients: Part 3 of an ongoing prospective study. *Int J Periodontics Restorative Dent.* 2000;20:117–25.

43. Tawil G, Mawla M. Sinus floor elevation using a bovine bone mineral (Bio-Oss) with or without the concomitant use of a bilayered collagen barrier (Bio-Gide): A clinical report of immediate and delayed implant placement. *Int J Oral Maxillofac Implants.* 2001;16:713–21.

44. Barone A, Ricci M, Grassi RF et al. A 6-month histological analysis on sinus augmentation with and without use of collagen membranes over the osteotomy window: Randomized clinical trial. *Clin Oral Implants Res.* 2013;24:1–6.

45. Wallace SS, Tarnow DP, Froum SJ et al. Sinus elevation by lateral window approach: Evolution of technology and technique. *J Evid Based Dent Pract.* 2012;12(3 suppl):161–71.

46. Mazor Z, Horowitz RA, Del Corso M et al. Sinus floor augmentation with simultaneous implant placement using Choukroun's platelet-rich fibrin as the sole grafting material: A radiologic and histologic study at 6 months. *J Periodontol.* 2009;80:2056–64.

47. Lundgren S, Andersson S, Gualini F, Sennerby L. Bone reformation with sinus membrane elevation: A new surgical technique for sinus floor augmentation. *Clin Implant Dent Relat Res.* 2004;6:165–73.

48. Cricchio G, Palma VC, Faria PE et al. Histological outcomes on the development of new space-making devices for sinus floor augmentation. *Clin Implant Dent Relat Res.* 2011;13:224–30.

49. Wallace SS, Froum SJ, Cho SC et al. Sinus augmentation utilizing anorganic bovine bone (Bio-Oss) with absorbable and non-absorbable membrane placed over the lateral window: Histomorphometric and clinical analyses. *Int J Periodontics Restorative Dent.* 2005;25:551–59.

50. Testori T. Complications: Diagnosis and management. In T Testori (ed.), *Maxillary sinus surgery and alternatives in treatment*. Chicago, IL: Quintessence; 2009, 311–24.

51. Rosen P. Complications with the bone-added osteotome sinus floor elevation: Etiology, prevention and treatment. In SJ Froum (ed.), Dental implant complications: Etiology, prevention, and treatment. Chichester: Wiley-Blackwell; 2010, 310–24.

52. Testori T, Deflorian MA, Scaini R et al. The buccally displaced palatal flap (BDP-flap) to increase quantity and thickness of peri-implant soft tissue: A case series. *Submitted to Int J Periodontics Restorative Dent.*

53. Burkhardt R, Lang NP. Fundamental principles in periodontal plastic surgery and mucosal augmentation—a narrative review. *J Clin Periodontol.* 2014;41(suppl 15):S98–S107.

Dentlearn.ir

Dentlearn.ir

Crestal Sinus Lift/Bone Graft for Vertical Bone Augmentation in the Posterior Maxilla

CHAPTER 25

Maxillary sinus floor elevation can be performed either from a lateral or transcrestal approach. The transcrestal sinus floor elevation approach, discussed in this chapter, is a minimally invasive technique that is time efficient, and has minimal adverse effects and high success rates. This chapter will highlight important anatomical considerations, techniques for modification, postsurgical considerations, and complications with management strategies.

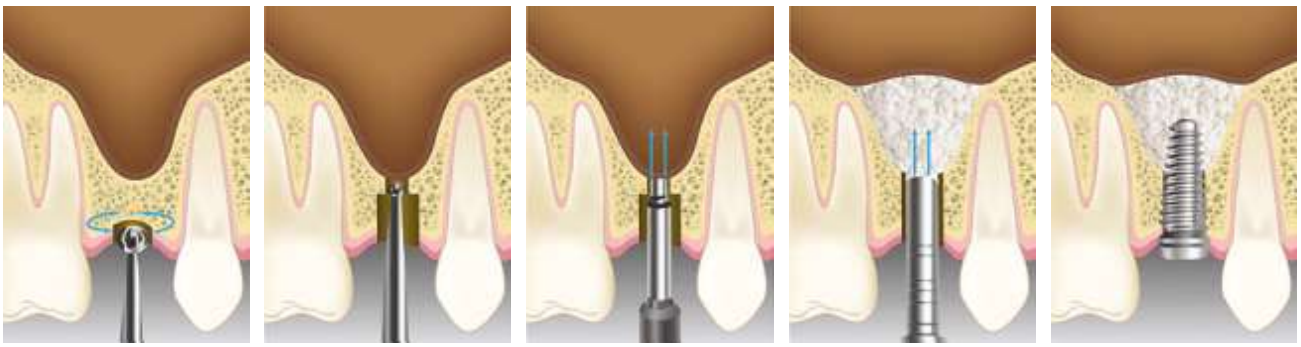

Dentlearn.ir

CHAPTER 25

Crestal Sinus Lift/Bone Graft for Vertical Bone Augmentation in the Posterior Maxilla

Hom-Lay Wang[1], Ann Decker[1], and Tiziano Testori[1,2,3]

[1] *Department of Periodontics and Oral Medicine, University of Michigan School of Dentistry, Ann Arbor, MI, USA*

[2] *IRCCS Orthopedic Institute Galeazzi, Dental Clinic, Section of Implant Dentistry and Oral Rehabilitation, Milan, Italy*

[3] *Department of Biomedical, Surgical and Dental Sciences, Università degli Studi di Milano, Milan, Italy*

Maxillary sinus floor elevation is a surgical procedure performed to vertically augment bone. Bone augmentation in the posterior maxilla is often indicated for the placement of implants with adequate length and position. Sinus floor elevation may be completed either from a lateral approach with a "window" through the lateral wall of the alveolar ridge, or a transcrestal/transalveolar approach with access to the inferior border of the sinus through the edentulous bone crest. The maxillary transcrestal sinus floor elevation (tSFE) approach was introduced in the 1980s, and later modified by Summers [1–3] as an alternative to the lateral window sinus floor elevation. The tSFE technique is often indicated in areas with residual bone height of ≥4 mm and sufficient bone width (≥5 mm); however, as implant technology advances, these values are subject to modification (see the section on anatomical structures). The tSFE procedure utilizes preparation of the implant bed with osteotomes of increasing diameters and subsequent in-fracture of the sinus floor [3]. In addition, condensation of the trabecular alveolar bone increases bone density at the implant site [4], which has been demonstrated to positively influence primary implant stability [5, 6]. This chapter will discuss important anatomical considerations, techniques/modifications, post-surgical considerations, and complications with management strategies.

ANATOMICAL STRUCTURES

RESIDUAL ALVEOLAR BONE DIMENSIONS

Following dentition loss, the alveolar bone in the posterior maxilla undergoes atrophy in both vertical and horizontal dimensions [7]. In cases with concomitant sinus pneumatization, bone atrophy following tooth loss frequently results in deficient vertical height for prosthetic-driven solutions with implants or implant-retained prostheses [8, 9]. A classification system is often used to reliably plan implant treatment in the posterior maxilla based on residual bone height (Table 25.1) [10]. According to the ABC sinus augmentation classification, tSFE is often used in class B (barely sufficient group), where the residual bone height is between 6 and 9 mm, based upon the placement of a minimum 10 mm implant length.

However, the residual bone height constraints for osteotome procedures fundamentally and biologically rely on two considerations: implant length and a reliable bone augmentation distance. Recent literature suggests that predictable osseointegration can reliably be achieved using surface-coating technology with 8 mm length implants [11–13]. Furthermore, reliable bone augmentation distances of 5 mm with 1–2 mm

Essential Techniques of Alveolar Bone Augmentation in Implant Dentistry: A Surgical Manual, Second Edition. Edited by Len Tolstunov.
© 2023 John Wiley & Sons, Inc. Published 2023 by John Wiley & Sons, Inc.
Companion website: www.wiley.com/go/tolstunov/essential

Dentlearn.ir

Table 25.1 Original ABC residual alveolar height classification for sinus augmentation procedures, and the placement of an implant with a minimum length of 10 mm.

Classification	Residual bone height (mm)	Clinical treatment options
A: Adequate	≥10	Implant placement without intervention
B: Barely sufficient	6–9	Osteotome/lateral window + simultaneous or delayed implant placement
C: Compromised	≤5	Lateral window + delayed implant placement

post-operative bone remodeling can be readily achieved in a patient without compromising host response/wound healing considerations [14, 15]. Thus, using these updated clinical parameters we have modified the ABC classification to have extended parameters of use for osteotome procedures for ridge dimensions ≥4 mm and <8 mm when 8 mm implants are selected/indicated (Table 25.2).

BONE QUALITY

A fundamental element in achieving primary implant stability and subsequent osseointegration in implant therapeutics depends on the quality/wound healing properties of the alveolar bone at the therapeutic site. Alveolar bone density is a gradient that can be classified into four subtypes: I, II, III, and IV. The four-subtype gradient spans between type I bone that is dense/cortical and type IV that is porous/cancellous [16]. These subtypes can be further delineated to include location, composition, and density reported by computed tomography (CT) [17].

Inherently, the posterior maxilla is considered D3–D4 (porous bone), characterized by a thin layer of cortical bone surrounding a core of fine trabecular bone [17]. The bone volume is low in maxillary molar areas with a value of 23.4% for males and 17.1% for females, and a positive correlation between bone volume and bone height [18, 19]. Important to the goal of achieving primary implant stability, type III and IV bone can be densified using osteotomes of increasing diameters or osseodensification techniques with specialty burs.

Table 25.2 Modification of the ABC residual alveolar height classification for sinus augmentation procedures, based on the placement of an implant with a minimum length of 8 mm and net gain of 4 mm from bone regeneration.

Classification	Residual bone height (mm)	Clinical treatment options
A: Adequate	≥8	Implant placement without intervention
B: Barely sufficient	≥4, <8	Osteotome/lateral window + simultaneous or delayed implant placement
C: Compromised	<4	Lateral window + delayed implant placement

SCHNEIDERIAN MEMBRANE

The Schneiderian membrane is the bordering tissue structure of the sinus that is elevated during sinus lift procedures. It comprises two main components: (i) pseudostratified, ciliated, columnar epithelium (i.e. respiratory mucosa); and (ii) an underlying connective tissue (i.e. mucoperiosteal tissue) that fixes the sinus membrane to the alveolar bone. Schneiderian membrane thickness has been characterized by both histology and cone beam computed tomography (CBCT). Assessment of cadaver specimens using histology reported mean membrane thickness of 0.4 mm with additional thickening at sites of chronic inflammation or sinusitis. In contrast, membrane thickness assessed by CBCT produced a mean value of 1.8 mm [20]. Comparatively, CBCT measurements of membrane thickness were found to be 2.6 times greater than the histological examination [21, 22]. Interestingly, one study has positively correlated sinus membrane thickness with gingival architecture, suggesting that thick gingival architecture might suggest thicker sinus membrane measurements [23].

Histologically, basal cells, goblet cells, and ciliated cells comprise the main cellular components of the sinus membrane [22]. Osteoprogenitor cells that are required for successful sinus lift/bone augmentation procedures may be associated with pericytes located either within the Schneiderian membrane microvascular walls or in the alveolar bone marrow [24]. As such, these progenitor cells (isolated from human maxillary Schneiderian sinus membrane) may have significant osteogenic potential for bone regeneration in sinus lift procedures under adequate osteogenic conditions.

SINUS FLOOR MORPHOLOGY

Sinus floor morphology can influence the likelihood of membrane perforation during surgery [25], hence clinicians should check the pre-surgical two-dimensional and three-dimensional images with care. Three-dimensional images are extremely important for this type of procedure, since they provide a more precise anatomical diagram of the surgical location/volume and anatomical nuances of the space involved. The osteotome technique, rather than reamer or balloon approach, is generally recommended when the sinus floor is curved, to minimize the potential for perforation. An average of 2 mm bone reduction/shrinkage occurs after sinus elevation, so compensation for this shrinkage must be incorporated into the calculation of vertical height augmentation required within the context of limitations for residual bone height parameters [26].

Dentlearn.ir

Furthermore, sinus floor morphology impacts grafted bone height dimensional stability following tSFE [27]. Sinus configuration can be classified into three categories according to the sinus floor profile at the implant site: concave, angled, and flat. A flat sinus floor has a greater reduction in grafted bone height than the corresponding concave morphology. All graft materials placed in the maxillary sinus after the tSFE undergo remodeling and shrinkage (average 2.4 mm) [27]; however, the outcome of the procedure is more predictable in sinuses with a concave floor when compared to other sinus morphologies (e.g. angled or flat) [28–30]. This implies that if or when tSFE is performed in a flat sinus floor, an additional 2 mm bone graft may be needed compared to concave sinus floor morphology.

SEPTA

Septa are intra-sinus bony variations that divide the sinus into multiple compartments. Implants cannot be placed in or partially in these bony structures. The incidence of antral septa varies between 20 and 67% [31], with higher prevalence in atrophic/edentulous segments compared to dentate segments [32]. Primary septa are embryological features of the maxilla, whereas secondary septa arise from pneumatization of the sinus floor following tooth loss [33–35].

Frequency, morphology, and locations of maxillary sinus septa can be evaluated using CBCT [36]. Incidence of septa was found in 66.5% of patients and 56.5% of sinuses [36]. The most common orientation of the septa was coronal (61.8%) and most were located on the floor of the maxillary sinus (58.6%) in the location of the first and second molars (60.7%) [36].

A classification for the management of antral septa during maxillary sinus augmentation has been proposed to minimize sinus perforations in septa cases [31]. The proposed classification consists of three categories – easy (E), moderate (M), and difficult (D) – based on the number, orientation, size, and location of the antral septa. The proposed treatment options include a combination of multiple lateral window procedures or a combination of transcrestal and lateral window procedures in some anterior/posterior to zygomatic septa larger than 6 mm [31]. The only clinical scenario in which tSFE will be indicated is when the septum is in an anteroposterior orientation (Category D, subclass b), one window from the crestal approach with the wall-gone technique [37,38].

TECHNIQUES

Regardless of the approach, tSFE is a safe and predictable procedure when the necessary anatomical and biological considerations are appropriately assessed. A central theme to the tSFE strategy is the use of bone densification strategies for subsequent implant placement immediately following sinus lift, using osteotomes of increasing diameters or osseodensification techniques with specialty burs. Different osteotome instrument shapes have different indications (Table 25.3). Firm resistance during osteotome use requires pilot preparation with drills to widen the cortex first; notably, most resistance is caused by a cortical ring that prevents passage of the osteotome [39]. Excessive use of force while using the osteotomes may lead to a labyrinthine concussion or other side effects such as benign paroxysmal positional vertigo (BPPV) [40], discussed in greater detail at the conclusion of this chapter. Most clinical studies [41–45] report mean sinus elevation between 4 and 6 mm with this approach [15].

Table 25.3 Osteotome shape and indication.

Shape	Description
Convex	Initial drilling and bone compression
Concave	Bone collection and compression at the apical aspect
Bladed	Ridge spit and cortex fracture
Pointed	Advance or widen the osteotomy sites in porous bone (type III/IV)
Flat	Bone compression and increase bone density

Clinical methods include Summers' osteotome technique, the reamer approach, the balloon technique, a hydraulic pressure approach (using piezo instruments or saline pressure), and osseodensification using specialty burs. We have consolidated these approaches into four broad technique-based categories, summarized in Table 25.4. Each tSFE technique has benefits and limitations. Importantly, the patient's anatomy, medical history, and requirements should be evaluated to discern the appropriate technique to be employed.

SUMMERS' OSTEOTOMY TECHNIQUE

The most commonly utilized tSFE method is Summers' osteotomy technique (osteotome sinus floor elevation, OSFE; Figure 25.1) [3, 46]. Summers used a series of conical osteotomes for two reasons: (i) to increase the density of the maxillary soft bone (type III and IV) through lateral condensation, resulting in bone compression stiffness and achieving a better primary stability of implants; and (ii) to elevate the sinus to the proper height (approximately 10 mm) without sinus membrane perforation. These maneuvers specifically avoid the use of drills to preserve bone and increase lateral bone density. Originally this technique was indicated for 5–6 mm of residual bone height and low-density bone using 10 mm implants.

There follows a brief description of the Summers technique and clinical depiction (Figure 25.2):

- A mid-crestal incision with full-thickness flap reflection is often performed (however, recently due to the advancement of digital planning, some clinicians have adopted the flapless approach for this approach also).

Dentlearn.ir

Table 25.4 Transcrestal sinus floor elevation technique: options, benefits, and limitations.

Technique	Benefits	Limitations	Sources
Osteotome	Minimally invasive compared to lateral window	• Significant force applied • Pressure points/high risk of perforation • Patient discomfort • Risk of vertigo/benign paroxysmal positional vertigo (BPPV)	Boyne and James (1980) Summers (1994)
Drill + osteotome	Drill used within 1–2 mm of the sinus to minimize mallet forces	• Significant force applied • Pressure points/risk of perforation • Patient discomfort • Risk of vertigo/BPPV • Loss of alveolar bone during drilling sequence	Davarpanah et al. (2001)
Trephine + osteotome	Trephine used within 1–2 mm of the sinus to minimize mallet forces	• Significant force applied • Pressure points/risk of perforation • Patient discomfort • Risk of vertigo/BPPV	Fugazzotto et al. (1999, 2022)
Balloon	Minimized risk of perforation Distributed force application	• Many parts complicate sequence • Small components could be lost in the sinus	Soltan and Smiler (2005)
Hydraulic	Minimized risk of perforation	• Significant complications reported • Small components could be lost in the sinus	Sotirakis and Gonshor (2005)
Crestal bone trap	Allows simultaneous, multiple implant placement Simultaneous horizontal bone augmentation optional	• Invasive • Primary stability is technique sensitive	Soardi and Wang (2012)
Osseous densification	Preserves elastic spring-back nature of cortical bone to enhance primary stability Minimal instrumentation Increased bone density	• Invasive • Crestal bone necrosis • Lack of long-term data • Limited elevation height (3 mm)	Huwais et al. (2017, 2018)
Reamer approach	Minimized risk of perforation No excessive mallet forces Low risk of complications	• Many steps	Michigan Group/ Gargallo-Albiol et al. (2019)

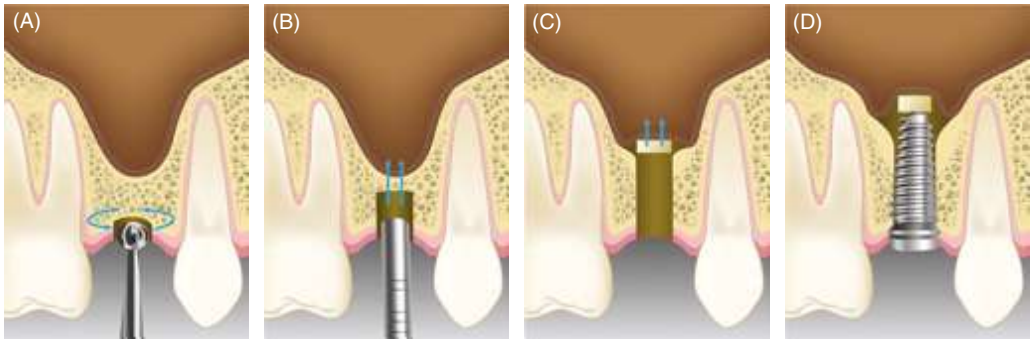

FIGURE 25.1 General pictorial depiction of the Summers osteotome transcrestal sinus floor elevation technique. (A) Round bur used to create the osteotomy. (B) Osteotomes selected to up-fracture the sinus. (C) Residual bone used a graft to create space between the implant and the sinus. (D) Implant can be placed.

Dentlearn.ir

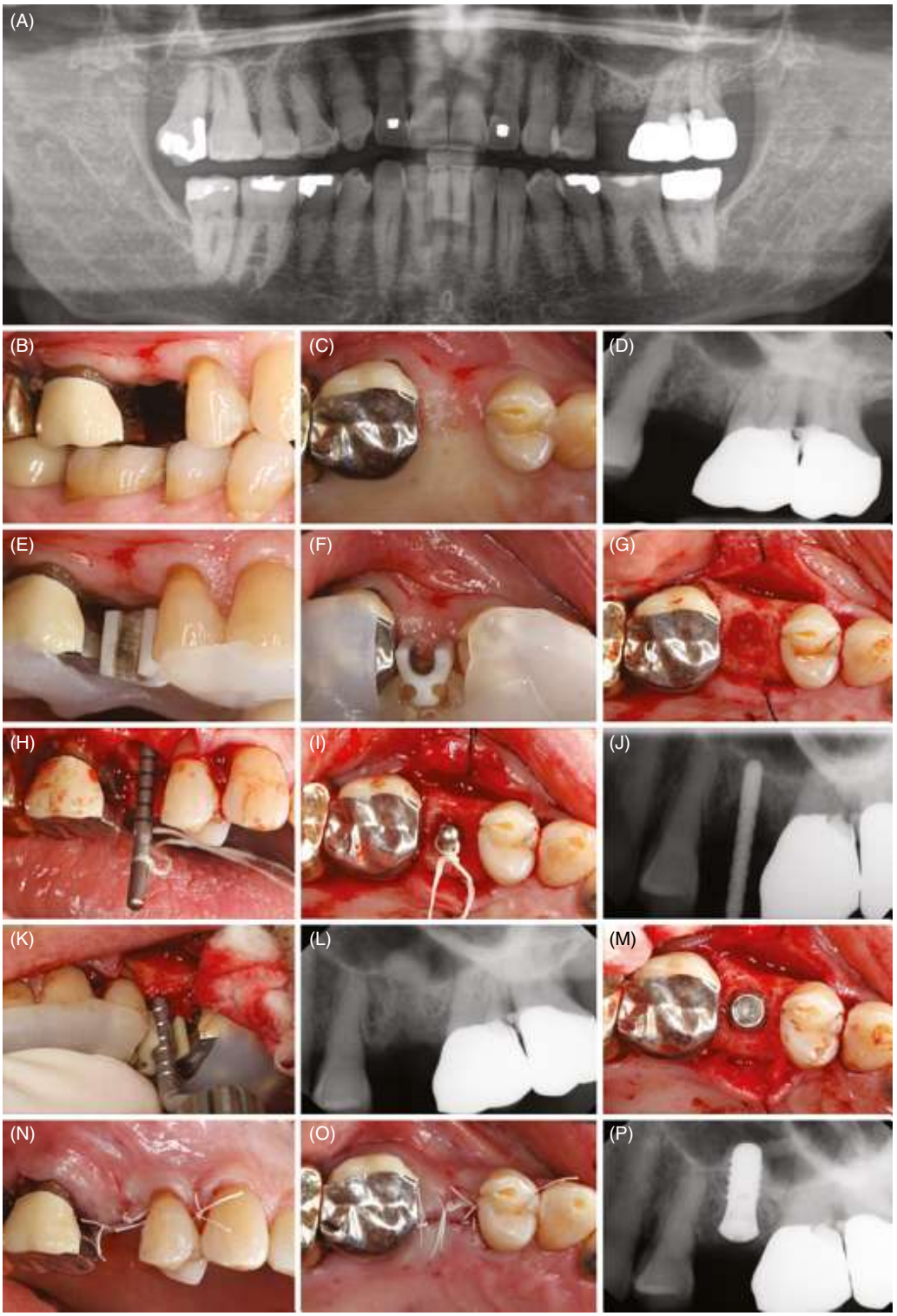

FIGURE 25.2 Clinical case depicting the transcrestal sinus floor elevation technique using osteotomes. (A–D) Pre-operative radiographs and clinical presentation depicting minimal residual ridge height at the site of the upper left second premolar. (E, F) Clinical photograph depicting appropriate placement of the guide. (G) Initial osteotomy drilled to a diameter of 2.3 mm. (H–J) Guide pin placed to demonstrate accurate angulation and initial osteotome up-fracture. (K, L) Bone graft is added to the osteotomy and progressively increased diameters of osteotomes used to laterally condense the preparation to a diameter of 3.4 mm. Radiograph depicts appropriate angulation and sinus elevation prior to implant placement. (M) 3.7 mm diameter implant is placed. (N–P) 6-0 polytetrafluoroethylene (PTFE) mattress sutures placed to achieve flap closure and final radiograph taken.

Dentlearn.ir

- Implant sites are prepped with a 2.0 mm round bur drill and stopped around 0.5–1.5 mm below the sinus floor.
- Sequential and progressive osteotomes with different diameters are used to expand the implant osteotomy sites as well as the vertical extent of the preparation, achieving sinus up-fracture, but any osteotome instrument itself should never enter the sinus.
- Sinus elevation should be delayed until the osteotome with the final apical diameter is used at the desired working depth. Once the largest osteotome has expanded the implant site, the sinus floor is fractured with the final osteotome.
- Expansion of the osteotomy is completed by concave-tipped osteotomes with increasing diameters.
- Greenstick fractured bone is elevated further by an additional 2–3 mm of bone graft.
- The osteotome should advance 1 mm with each mallet tap. If the osteotome does not advance, the surgeon should go back to a smaller osteotome, or use a drill or even a reamer.

In additional modifications to the technique, the osteotome can be used to further develop the site by creating a "bone plug" with a trephine bur and displacing the bone superiorly with the use of a broad osteotome [1, 3].

REAMERS APPROACH

A sinus crest augmentation kit (SCA kit, Neobiotech, Seoul, South Korea) was developed to facilitate osteotomies and avoid trauma or perforation to the Schneiderian membrane (Figure 25.3). Similar instrument sets have also been developed by many commercial companies using the same principles. One of the unique features of this approach is the use of reamers, which only cuts bone without causing soft tissue laceration under gentle force. Reamers are used during the osteotomy approaches to the sinus membrane, thereby eliminating harsh pressure/percussion from the original tSFE approach. To this end, a precise analysis of available remaining bone height is important. Hence, pre-surgery planning using CBCT technology is often recommended to accurately calculate the residual ridge height, drill sequence approach, and sinus floor morphology.

There follows a short description of the technique and clinical case depiction (Figure 25.4):

- A mid-crestal incision is often made followed by full-thickness flap reflection. To assist in flap reflection, single sling sutures held by the needle holder can be done to assist flap reflection on both the buccal and palatal sides. (However, recently due to the advancement of digital planning, some clinicians have adopted the flapless approach for this approach also.)

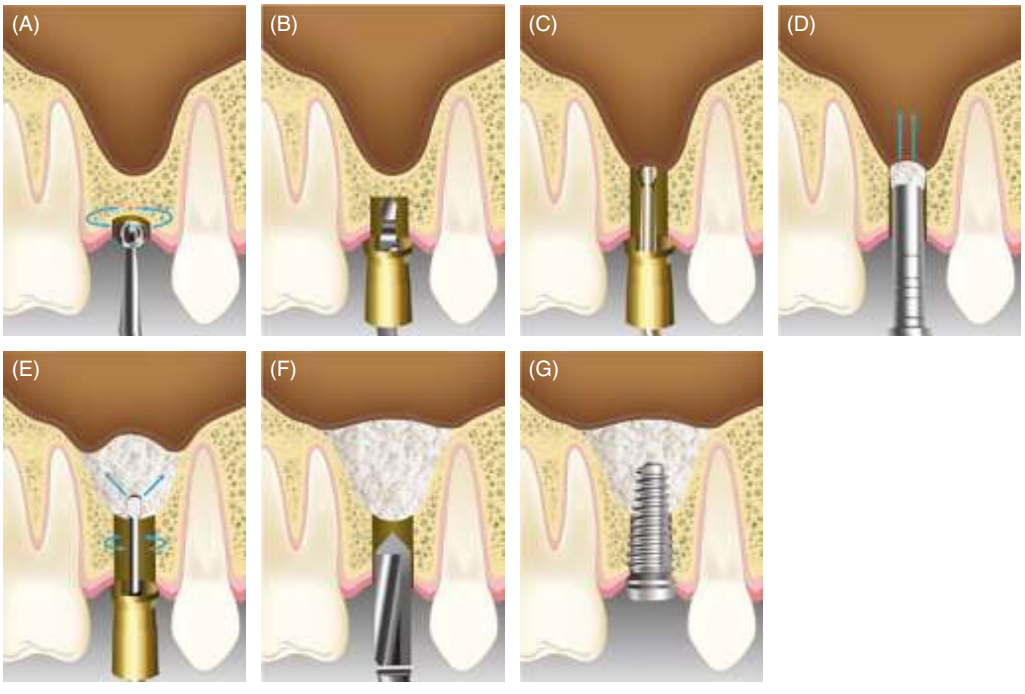

FIGURE 25.3 General pictorial depiction of the Michigan reamer transcrestal sinus floor elevation technique. (A) Round bur used to create the initial osteotomy through the cortical bone. (B) Drill sequence using the drill guide sleeve to limit vertical ascent within 0.5–1 mm of the sinus floor. (C) The remaining distance to the sinus is prepared using the non-end-cutting reamer. (D) Osteotome used to elevate the bone graft and create vertical sinus elevation. (E) Bone spreader used to create horizontal release of the sinus. (F) Osteotomy can be increased in diameter with subsequent drill series. (G) Implant placement can be achieved during the same procedure with primary stability.

Dentlearn.ir

- Implant sites are marked with a 2.0 mm round bur drill and drilled to a depth of 1.0 mm from the sinus floor with the first two osteotome drills (up to 2.8 mm wide).
- A 2.8 mm reamer (SCA kit) should be inserted with different lengths of stopper until the sinus membrane wall is felt to be fractured.
- After the sinus membrane wall is fractured, a gauge is applied to check the sinus wall surrounding to ensure the membrane is somehow lifted from the sinus wall.
- Subsequently, bone graft (either human allograft or xenograft, small particle, 250–850 μm) is inserted into the osteotome sites, then these materials are slowly tapped into the sinus floor either by a bone inserter/spreader (SCA kit) or an osteotome instrument by a mallet. It is important to remember that these instruments should not enter the sinus cavity.
- Generally, the sinus floor should be elevated to at least 2 mm height and longer than the desired implant length due to bone shrinkage that occurs after healing [26].
- Implant osteotome drills are used to drill the osteotome site to the final diameter according to the manufacturer's guideline, but only to the level of remaining bone height. Again, the instruments should not enter the sinus cavity to avoid any potential perforation.
- The implant is inserted into the prepared hole:
  - If the implant has stability (torque to >35 Ncm), then a healing abutment can be placed.
  - If clinicians feel the implant needs more protection, as in the case of smokers, osteoporosis patient, type III or IV bone quality, then a healing cap will be placed with primary wound closure to ensure undisturbed healing.
- The implant is loaded after 5–6 months' healing, depending upon the bone density.

Notably, the reamer method has been recently assessed for incidence of perforation and elevation height compared to the conventional Summers osteotome technique using endoscopy in a randomized *ex vivo* cadaver study [47]. A significantly lower incidence of perforation ($p = 0.007$) and vertical elevation height ($p < 0.001$) was noted while using the reamer method compared to the conventional osteotome technique [47]. Thus, the reamer method may demonstrate superior osteotomy preparation and membrane capabilities over other techniques, as ridge height and vertical elevation height are risk-determinant factors in sinus elevation procedures.

STAGED CRESTAL MAXILLARY SINUS AUGMENTATION

In cases of residual bone height of 2–4 mm, where the sinus membrane must be elevated at least 6–8 mm without membrane perforation, the lateral window approach or sequential staged crestal sinus augmentation approach may be employed. The sequential staged crestal sinus augmentation approach is a two-stage crestal sinus augmentation technique, whereby an initial site preparation/sinus lift is achieved using a reamer or osteotome approach (described above) and 0.3 mL of graft material is inserted [48]. This surgery is followed by a healing period of 6–8 weeks. A second surgery is then completed to achieve the final sinus augmentation height, with an additional placement of 0.2 mL or 0.3 mL graft material with simultaneous implant placement [48].

HYDRAULIC PRESSURE TECHNIQUE

Another modification of the original Summers technique includes use of hydraulic pressure [49, 50] to lift the sinus membrane (Figure 25.5). There follows a brief discussion of the technique:

- Diamond/carbide burs are used to create an osteotomy 1 mm below the floor of the sinus.
- The 2 mm and/or 2.8 mm sinus bur (or piezo instrument) is/are used to create osteotome sites that are 1 mm below the sinus floor with a conical shape.
- Hydraulic pressure using saline solution is introduced to the surgical site at this stage, providing enough force to begin atraumatically dissecting the membrane from the sinus floor. The water pressure is allowed to enter the hole slowly, before the bur/piezo instrument is tapped all the way through. A delicate touch at this stage safeguards against membrane perforation.
- The bone graft is then added to gain the dimension of the sinus membrane lift.
- The osteotomy is then widened using a manufacturer-designed implant drill.
- More bone graft is added, with a wider condenser if needed.
- The osteotomy is then completed to the appropriate diameter for implant placement.
- The implant is placed. (It is recommended to use implants with close threads to have a better engagement.)

Transcrestal maxillary sinus augmentation can also be done with the help of water pressure. The Sinus Physiolift® (Mectron, Garasco, Italy) utilizes a piezoelectric handpiece and a specially designed tip with controlled hydrodynamic pressure that is applied after the initial osteotomy preparation. A 3 mL saline syringe is used to elevate the Schneiderian membrane with this method. Later on, the Intralift technique [51] was developed as a minimally invasive technique for lifting the maxillary sinus floor employing piezoelectric surgery, using a specific set of tips for the application of ultrasound. In this study, the authors compared the results of pneumatic pressure and hydraulic pressure applied to elevate the sinus during sinus lifting procedures in sheep [51]. Using the hydraulic

Dentlearn.ir

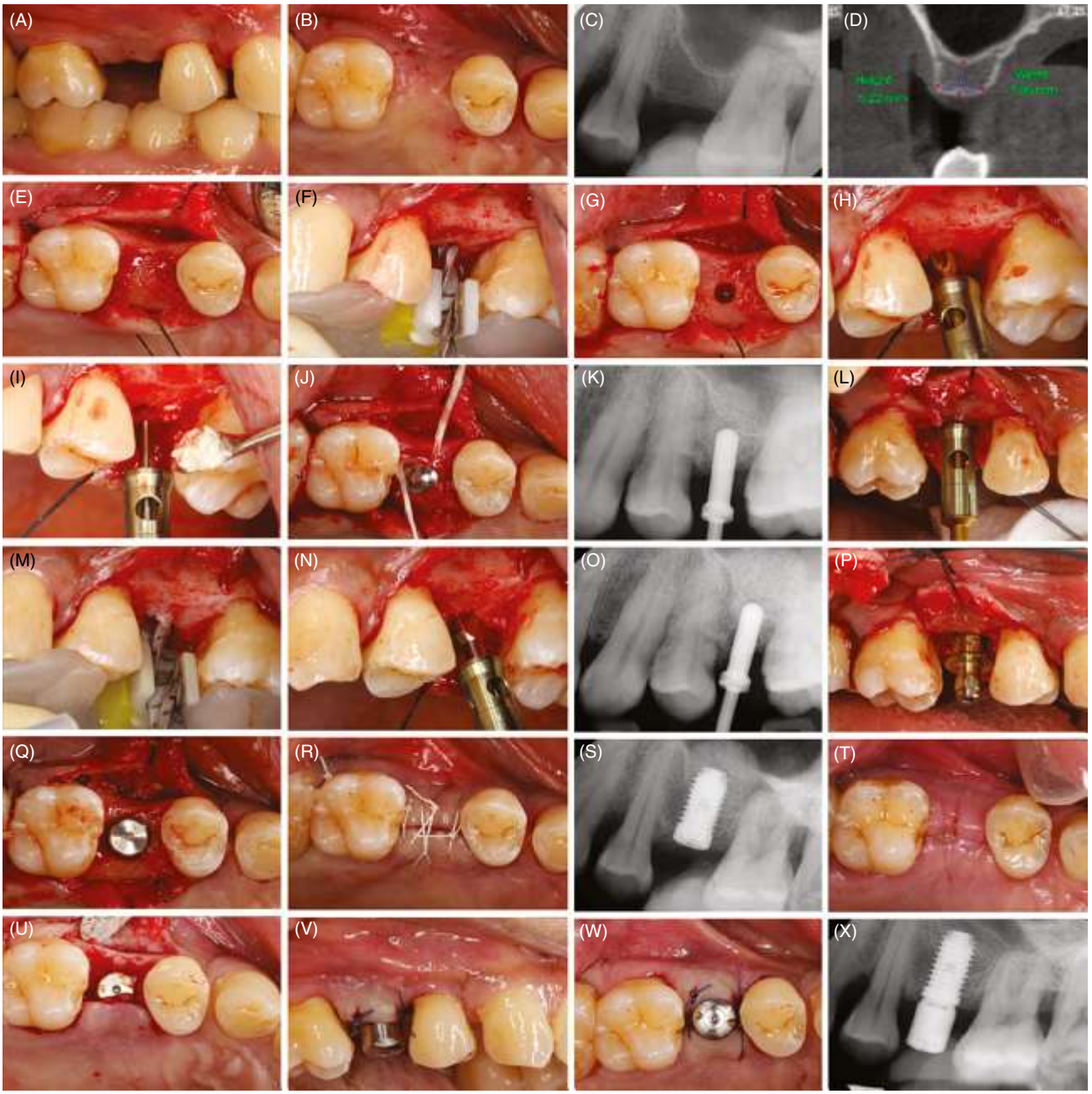

FIGURE 25.4 Clinical case depicting the transcrestal sinus floor elevation (tSFE) technique using the Michigan reamer technique at the site of the maxillary left second premolar. (A–D) Initial clinical, radiographic, cone beam computed tomography presentation. (E) Crestal incisions are made to expose the underlying alveolar bone and reflected with silk suture for visualization. (F, G) Initial drill sequence taken to 1 mm from the sinus. (H) Clinical photo of the non-end-cutting reamer and use of the reamer with the stopper sleeve. (I, J) Following extravasation of the remaining alveolar bone to the sinus, a sinus depth gauge can be used to ensure the membrane is circumferentially lifted and bone graft can be subsequently placed. (K) Radiograph depicting the first measure after bone graft placement to observe sinus membrane integrity and initial ballooning of the sinus. (L) Clinical photo of the non-end-cutting reamer and use of the reamer with the stopper sleeve inserted to the full length of the osteotomy. (M) Osteotomy can be expanded if needed using the guide and implant drill. (N) Osteotome and bone spreader used with bone graft to elevate the sinus floor. (O) Orientation and diameter of the osteotomy were checked prior to implant placement. (P, Q) Implant placed. (R, S) Sutures placed and implant radiograph taken prior to dismissal of the patient. (T) Clinical photograph and radiograph at 2-week follow-up. (U–X) Stage II clinical photos and radiograph at 5 months after tSFE using the Michigan reamer technique.

Dentlearn.ir

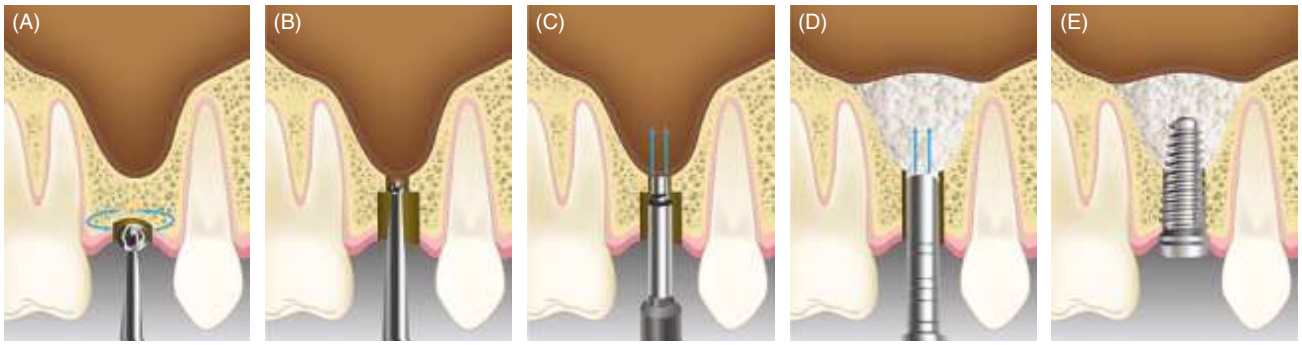

FIGURE 25.5 General pictorial depiction of the hydraulic transcrestal sinus floor elevation technique. (A) Initial preparation made with a round bur to within 1 mm of the sinus. (B) Smaller round bur used to make the final preparation of the sinus. (C) Shape of the osteotomy is essential to creating the pressure needed from the hydraulic syringe. Pressure created and sinus is lifted using a number of different methods described in the text. (D) Bone graft added to maintain sinus elevation through use of the osteotome technique (previously described). (E) Simultaneous implant placement can be completed.

technique, 19.8 Mbar of pressure was used at a flow of 60 mL/min, creating 5.58 mL of volumetric increase and no rupture of the sinus membrane [51]. The authors concluded from these experiments that hydrodynamic ultrasound could be used as an alternative method for sinus floor elevation with 3 mm diameter transcrestal access [51].

The field of tSFE is growing quickly. There are many more modifications to these basic techniques to lift the sinus transcrestally, such as the use of balloon catheters [52], drill sequences with the use of bone graft [53], and the crestal bone–impacted trap technique that uses a rectangular-shaped osteotomy [54]. These techniques are modifications of the three broad categories. However, one of the modified techniques applies tSFE at the time of maxillary molar extraction [55, 56], and will be briefly discussed here.

Fugazzotto et al. [55,56] described a technique for accomplishing both localized tSFE and guided bone regeneration at the time of maxillary molar extraction through the following procedure:

- An atraumatic maxillary molar tooth extraction is undertaken without removing interradicular bone.
- A trephine bur with an internal diameter dimension is used to encompass both the interradicular septum and around 50% of the extraction sockets.
- The osteotome site is prepared with a trephine bur to within 1 mm of the sinus. If the bone core comes out inside the trephine bur, it is carefully pulled out of the trephine and replaced in the alveolar bone preparation.
- Osteotome preparation is continued using different diameters of trephines.
- If guided bone regeneration (GBR) is required, the extraction site is filled with bone graft and a membrane placed over the socket.
- If an immediate implant placement is indicated, a bone tap is used at the crestal one-third and the implant placed.

OSSEOUS DENSIFICATION

Osseous densification is a non-excavating drilling technique that was developed with specialty burs that increase bone density through compaction autographing (Figure 25.6) [57, 58]. The specialty burs are manufactured with a tapered geometry and flutes to progressively expand the osteotomy while compacting bone into its walls and apex [57, 58]. This compaction creates a twofold benefit: (i) an elastic spring-back effect within the conical osteotomy site for enhanced implant primary stability; and (ii) expedited bone formation due to the creation of residual bone chips that act as osteoinductive nucleation sites [59].

This technique has been applied to general implant placement as well as the tSFE technique. The osseous densification drilling process to elevate the sinus floor without sinus membrane perforation is based on the fact that densifying burs are capable of bone instrumentation in a counterclockwise motion [57]. In a multicenter retrospective case series, this technique was reported using a mean residual bone height of 5.4 mm at baseline, significant vertical increases to a mean value of 7 mm following sinus augmentation, and an implant survival rate of 97% at 64-month follow-up.

The surgical steps for osseous densification are described below for alveolar ridge dimensions with a residual vertical height of ≥5–6 mm (Figure 25.7):

- A pilot drill with 1.7 mm diameter is taken to a depth within 1–2 mm of the sinus floor.
- Osseous densification is performed using specialized burs according to the manufacturer's protocols.

Dentlearn.ir

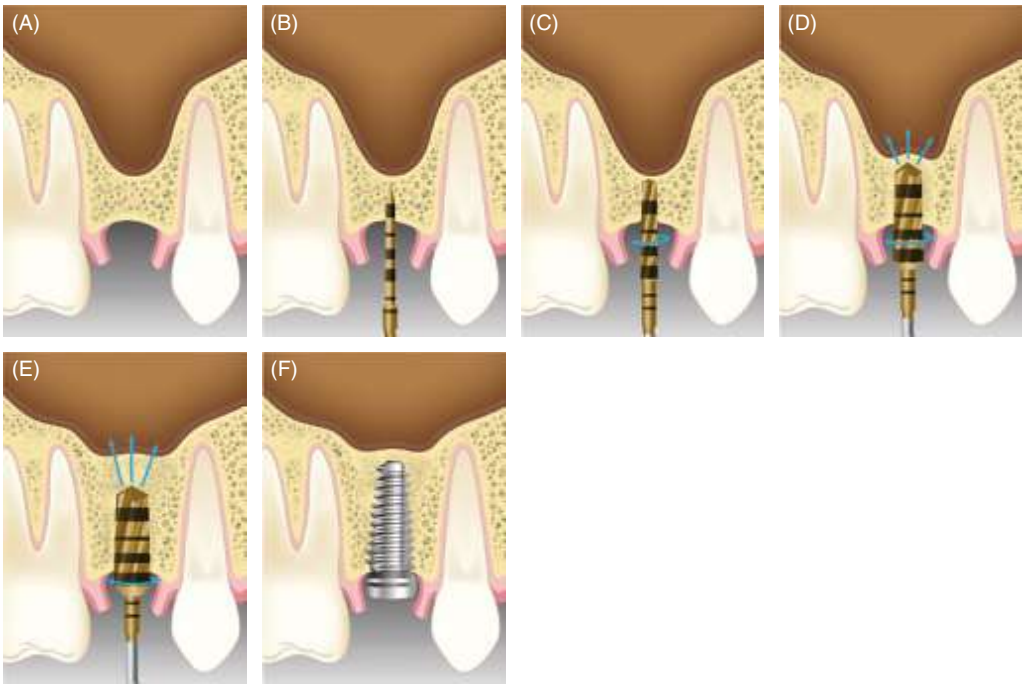

FIGURE 25.6 Osseous densification approach. (A) Initial incisions are made and full-thickness gingival tissue is elevated. (B) The initial pilot bur is used to create an osteotomy. (C–E) Progressively larger osseous densification burs are used to expand the site and create sinus elevation of 1–2 mm. (F) Final implant may be placed.

- The narrowest bur is run in a counterclockwise direction at 1200 rpm with irrigation in a modulating fashion until the dense sinus floor is reached.
- A wider bur (up to 3 mm diameter) is advanced further to a limit of 3 mm beyond the sinus floor in 1 mm increments.
- Radiographs are taken consistently throughout the procedure to evaluate depths.
- After completing the osteotomy, the selected implant is inserted.

It is critical to note that this technique alone can only provide sinus expansion up to 3 mm. In cases requiring greater than 3 mm of vertical sinus augmentation (i.e. residual ridge <5 mm), the above steps can be repeated with expansion of the osteotomy diameter, placement of particulate bone graft substitute, and then use of a final densifying bur at 100–200 rpm in a counterclockwise rotation to propel the allograft apically for additional vertical and lateral membrane elevation [57]. This additional step may be repeated with additional bone grafting material until the desired vertical augmentation is achieved. To minimize the development of compression necrosis on cortical bone [60], using a round bur or implant osteotome drills first to prepare the site is highly advised prior to the use of osseodensification burs.

GRAFTING MATERIALS USED DURING THE SINUS AUGMENTATION PROCEDURE

A variety of bone replacement graft materials as well as biological agents have been used in sinus floor elevation procedures to fill the elevated space created after lifting the Schneiderian membrane. Autogenous bone has been considered to be the gold standard; however, it is not commonly used in tSFE because of limited intraoral site harvest and donor site morbidity. Other bone replacement graft materials and biological agents are often a better choice.

Autogenous particulate bone grafts are prone to volumetric changes over time, with a decrease of 23% at 6 months and 39.2% at 6 years when Intralift hydraulic sinus lifting was used [61]. Autogenous bone blocks performed better, with a 21.5% reduction after 6 years. When autogenous particulate bone graft was mixed with hydroxyapatite in a 20:80 ratio, the volume reduction was 25.8% [62].

To increase the stability of the graft over time, demineralized bovine bone was added in a ratio of 60:40 Bio-Oss® (Geistlich, Wolhusen, Switzerland) to platelet-rich fibrin (PRF), which showed a 1.4 times increase in new bone formation [63]. This result was attributed to patient-dependent factors (number of teeth, anatomy, etc.).

Some clinicians advocate the use of blood clots in place of bone substitutes in sinus floor elevation. In a review of 22 clinical studies (864 implants) that used a graft-free sinus lifting technique, a mean residual bone height of 5.7±1.7 mm was reported [64]. The average bone gain using blood clot alone was 3.80±0.35 mm [59]. The vertical bone gain was found to be greater for the lateral window approach than for the tSFE. Mean implant survival was 97.9% [64]. Interestingly, the marginal bone loss measured at these sites was 0.9 mm after a follow-up of 41.9 months, which was lower than sites reported around implants placed in grafted sites and pristine maxillary posterior sites [64]. Another

Dentlearn.ir

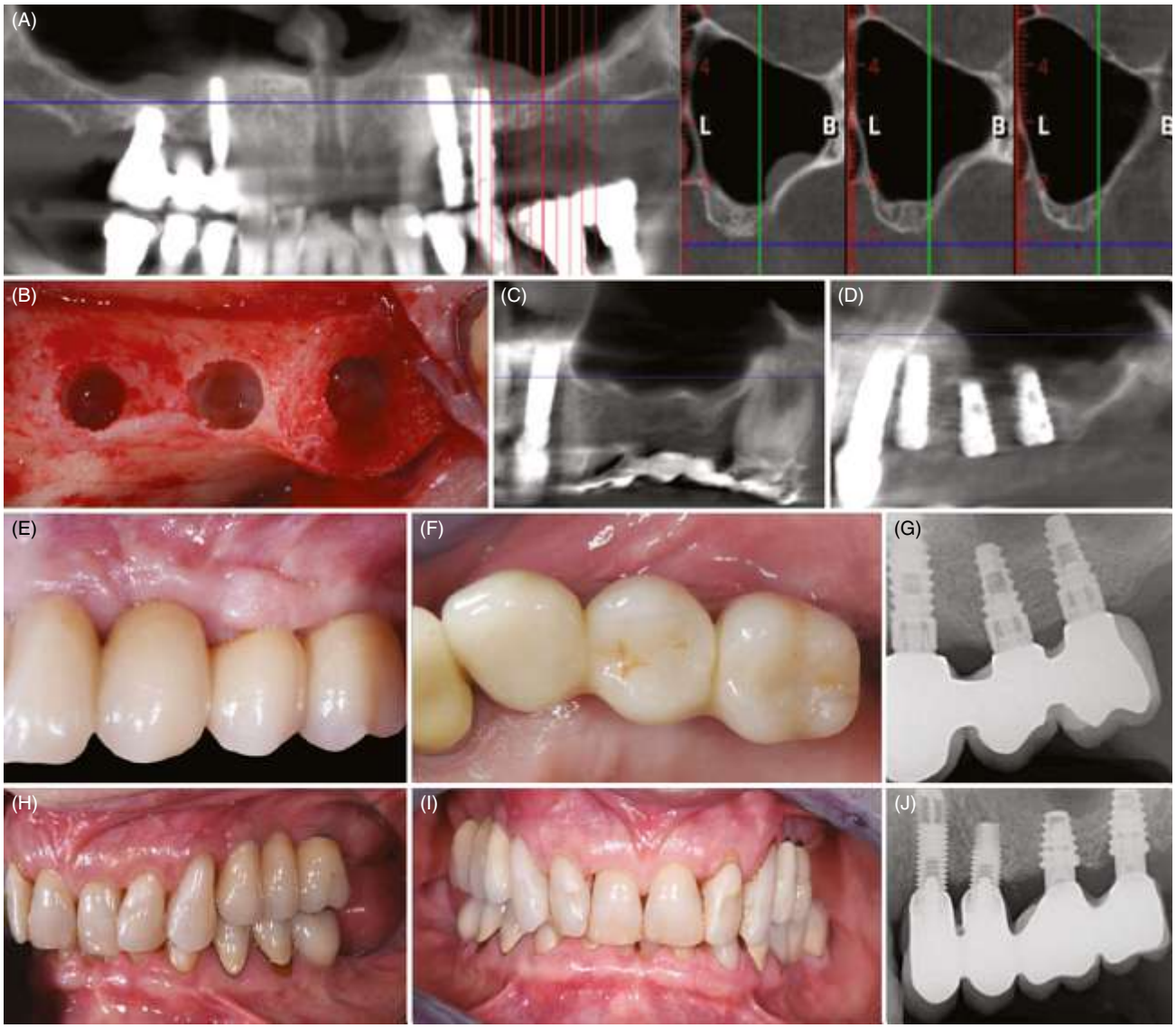

FIGURE 25.7 Clinical case depicting the osseous densification approach. (A) Pre-operative cone beam computed tomography delineates sinus anatomy and minimal bone height at the upper left canine, first premolar, and first molar teeth. (B) Osseous densification burs used in sequence to create mature osteotomy preparations. (C) Intraoperative radiograph depicts sinus elevation and appropriate osteotomy angulation. (D) Final implants placed with cover screws. (E–G) At 6 months post-operatively, the stage two procedure was completed and final restorative crowns were placed. (H–J) 5 years post-operative clinical photos and radiographs depict maintenance of crestal bone levels and sinus elevation.

systematic review/meta-analysis reported no statistical significance between the reported survival of implants (follow-up time of 1 year) in tSFE with and without grafting [65]. Membrane perforation rates ranging from 0 to 10.8% [65]. The literature on this topic includes significant heterogeneity and the vertical bone dimension is often reported using different measurement techniques (panoramic and periapical x-rays). Despite the reported limitations of this emerging technique, graft-free sinus elevation with simultaneous implant placement may achieve a satisfactory mean survival outcome.

It is the authors' experience that a bone graft should be placed if a >2 mm elevation height is required, since the physical properties of space maintenance are needed for bone growth achieving the requirements of the PASS principles (see the section on complications and Figure 25.8) [66]. If only a minor elevation height is required, then blood clot may be sufficient.

Outside the discussion of bone grafting type, another question remains: How much bone graft should be added to the site? One study evaluated 34 subjects (16 female, 18 male) with 61 crestal sinus elevation sites to discern the relationship

Dentlearn.ir

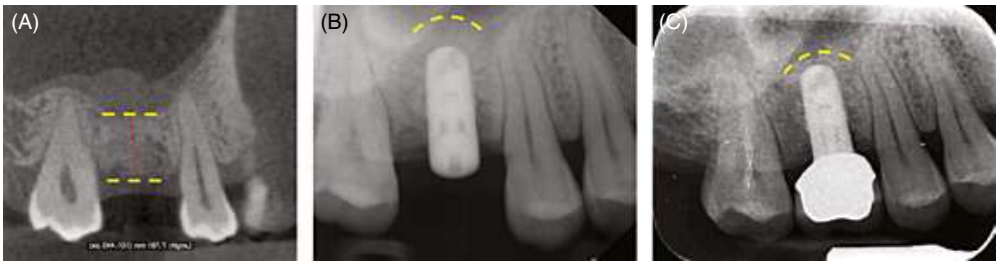

FIGURE 25.8 Graft resorption may spontaneously occur during the remodeling period. (A) Initial radiograph depicts limited alveolar bone present at site the site of the upper left first molar. (B) Transcrestal sinus floor elevation procedure completed with 2 mm bone fill, as shown by the yellow dashed line. (C) Radiograph depicting 1 mm of bone resorption occurred during the 1-year remodeling period.

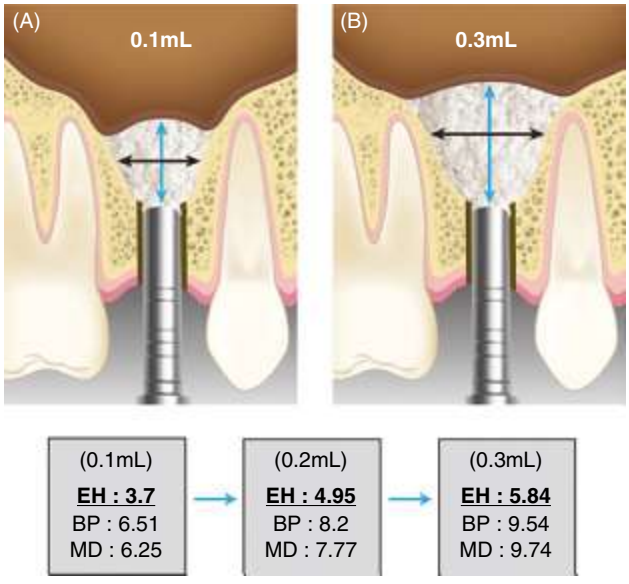

FIGURE 25.9 Graft volume relates to elevation height. (A) 0.1 cc of bone graft corresponded to a vertical gain of 3.7 mm. (B) 0.3 cc of bone graft corresponded to a vertical gain of 5.84 mm. (C) Depiction of graft volume and corresponding dimensions of transcrestal sinus floor elevation. BP, bucco-palatal dimension elevation; EH, elevation height; MD, mesio-distal dimension elevation.

between bone volume utilized during tSFE and vertical sinus elevation [67]. It found that 1 cc of bone graft corresponded to a vertical elevation height of 3.5 mm, while 0.2 cc resulted in 5 mm, and 0.3 cc corresponded to 6 mm of vertical elevation (Figure 25.9) [67]. To avoid sinus perforation, the ratio of vertical sinus elevation to mesiodistal or buccopalatal elevation should be kept under 0.8 [67].

ENDOSCOPE-CONTROLLED MAXILLARY SINUS ELEVATION

Among the most common complications in sinus elevation procedures is Schneiderian membrane perforation. If left untreated, sinus perforation can result in bacterial contamination and infection of the grafting material or implant/implant site, as discussed in the section on post-surgical considerations. One recent technological advancement to detect and treat sinus perforations in tSFE is the use of endoscopes placed into the sinus cavity, which allows direct visualization of the maxillary sinus membrane [68]. The techniques that have been developed for endoscope-controlled sinus lift procedures generally have one of two insertion methods: insertion via the subantral space or through the alveolar ridge crest osteotomy site [69, 70]. Using the osteotomy site provides information on the quality of bone density around the implant in addition to information about sinus integrity [70]. However, the distinct limitation of the transalveolar method for endoscope evaluation remains that it is not possible to evaluate the integrity of the maxillary sinus membranes pre-operatively or remove obstructing cystic lesions concomitant with the procedure [70, 71].

IMPLANT LENGTH IN OSTEOTOME PROCEDURES

With the development of implant surface modification, short implants are sometimes utilized in the posterior maxilla, either to avoid sinus lift procedures or in conjunction with them. The definition of short implants can vary by author; however, we define short implants as less than 8 mm (<8 mm) and extra-short implants as less than or equal to 6 mm (≤6 mm) in length. Thus, following this nomenclature, a recent systematic review and meta-analysis assessed survival during both the healing period and 3-year loading periods [72]. There was no evidence that the survival rate of short implants combined with tSFE was different than that of conventional-length implants combined with tSFE [72]. Survival rates at 1-year and 3-year periods were not significantly different [72]; however, long-term studies with 10+ years of follow-up are needed to understand the long-term stability of short implants versus longer implants (≥8 mm) with tSFE.

Dentlearn.ir

POST-SURGICAL CONSIDERATIONS

Following the tSFE procedure, patients are often prescribed antibiotics for 10 days to prevent bacterial infection from either oral or sinus contamination. Chlorohexidine mouthwash (0.12–2%, 2× daily, 30 s) for 10 days can also be prescribed to minimize the oral bacterial load. Dexamethasone (8 mg 1 hour prior to surgery, 4 mg on second and third days, and 2 mg total on fourth day) can also be prescribed to decrease the inflammatory burden of the site. The patient must be provided with verbal and written instructions to avoid physical stress and blowing the nose or sneezing with a closed mouth for 2 weeks following the procedure, just in case there is an unnoticed membrane perforation. A post-operative appointment should be scheduled 2 weeks following the procedure to evaluate healing and suture removal. Monthly post-operative appointments should be scheduled until the final restorative appointment to monitor healing of the site.

COMPLICATIONS

PREVENTION AND MANAGEMENT

All of the tSFE techniques described have been shown to be safe and predictably to increase vertical bone height by at least 3 mm. Despite the high success rate of this procedure, some associated complications may occur [73]. Complications include but are not limited to BPPV due to extensive malleting [40,74], bleeding (low incidence, but can happen), infection, implant migration [75, 76], and loss of primary implant stability (lack of initial bone height, poor bone quality, overpreparation, and premature loading). Other complications that may occur include post-operative hemorrhage, nasal bleeding, blocked nose, hematoma, loosening of cover screws, and migration of dental implants into the sinus (Table 25.5) [77].

SINUS MEMBRANE PERFORATION

Sinus membrane perforation is the most encountered intraoperative complication, which can cause termination of the tSFE surgery. The membrane perforation rate with tSFE has been reported to be on average 3.8–56% [78]. However, due to the limited accessibility for checking membrane integrity, this incidence rate could be underestimated. In an attempt to address this shortcoming, endoscopic studies have been performed and reported that the sinus floor could be elevated up to 5 mm without perforation of the membrane [14, 15]. Risk of Schneiderian membrane perforation is heightened with the presence of maxillary sinus septa and root apices penetrating into the sinus. Small perforations may be closed through the transalveolar preparation using fibrin glue. If a perforation does occur and repair of the sinus membrane cannot be achieved through the osteotomy created during the tSFE, the procedure cannot proceed further, and the repair must be completed using a lateral window approach. If the perforation occurs before any grafting material is placed, a collagen membrane may be placed followed by a shorter implant without the addition of bone graft [79]. In situations of perforation, the operator should always consider closure, with a new attempt after 6–9 months [80].

The incidence of Schneiderian membrane perforation during tSFE significantly affects the overall intra- and post-operative complication rate. Not only will perforations significantly increase many related complications such as graft infection and/or failure, reduced bone formation, or sinus infection/sinusitis [81], but they also reduce implant survival rate [82]. Hence, clinicians should learn how to protect the Schneiderian membrane integrity during tSFE to avoid these potential complications [83].

SINUSITIS AND POST-OPERATIVE INFECTION

Post-operative infection and sinusitis are other complications reported with tSFE. Post-operative infection for tSFE was on average 0.8%, with a range from 0 to 2.5% [78]. When preforming tSFE, the clinician should be mindful to minimize the bacterial burden pre-, intra-, and post-operatively. Prior to the tSFE procedure, patients should be screened/treated for active endodontic infections, periodontal disease, and sinus diseases. Patients with a history of chronic sinus diseases should be free of active symptoms and have established sinus health before the tSFE to minimize post-surgical complications or compromised results [84, 85]. Post-surgical sinus infection or overpacking of bone replacement grafts can result in ostium obstruction, which can be alleviated by referral to an otolaryngologist and subsequent endoscopy. Risk of obstruction is more common (74%) in patients that present with a flat or semi-aspherical membrane thickening of >10 mm [86]. The sinus membrane status, morphology, and thickness can be evaluated by CBCT and endoscopy prior to tSFE.

To minimize bacterial infection during bone grafting or implant placement for tSFE, all debris should be removed and good oral hygiene established. In addition, the patient can rinse with chlorohexidene for 30 s prior to surgical incisions. If infection occurs, the first line of treatment is prescription of a bacteriocidal antibiotic such as amoxicillin/clavulanic acid (875 mg/125 mg oral 2×/day for 7 days) [87]. If the patient fails to respond to systemic antibiotics, it is possible that the bone graft is compromised and requires removal. This might entail lateral access or removal of the implant.

INCISION OPENING/MUCOSAL DEHISCENCE

Soft tissue management guidelines are essential to the success of tSFE procedures. Healing of the augmented sinus follows the temporal sequence of hemostasis, inflammation,

Dentlearn.ir

Table 25.5 Transcrestal sinus floor elevation: complications.

Complication	Etiology	Prevention	Management
Perforation of the sinus membrane			
• **During preparation of the osteotomy**	Lack of controlled force upon the last 1 mm of the osteotomy	• Know measurements using cone beam computed tomography prior to and radiographs during site preparation • Use sharp/effective instruments	*Microlesion* (<2 mm): Collagen plug/membrane with no bone graft or short implant *Macrolesion* (>2 mm): (1) Revert to lateral window osteotomy to repair defect (2) Abort and repeat the procedure after 3 months
• **During membrane elevation**	Pressure/abrasion during elevation of the sinus	• Be cautious • Use low-force approaches • Understand local anatomical variants	*Microlesion* (<2 mm): Collagen plug/membrane with no bone graft or short implant *Macrolesion* (>2 mm): (1) Revert to lateral window osteotomy to repair defect (2) Abort and repeat the procedure after 3 months
• **During grafting**	Pressure/abrasion during elevation of the sinus	• Be cautious • Do not overfill • Do not use large graft particles with sharp edges	*Microlesion* (<2 mm): Collagen plug/membrane with no bone graft or short implant *Macrolesion* (>2 mm): (1) Revert to lateral window osteotomy to repair defect (2) Abort and repeat the procedure after 3 months
• **During implant site preparation**	Pressure/abrasion during elevation of the sinus	• Be cautious • Know dimensions of the site fill using radiographs	(1) Monitor for symptoms (2) Consider removal of graft or endoscopic surgery (ear, nose, and throat, ENT)
Excessive bleeding	Anatomical structure or medical history	• Updated medications and medical history • Pre-op location of local vessels	• Apply pressure • Bone wax application
Infection	Graft contamination, residual pathology (i.e. sinusitis, endodontic infection)	• Define and eliminate pathology prior to surgery	Systemic antibiotics. If infection persists for more than 4 weeks, remove graft and attempt again in 3–6 months
Incision opening, mucosal dehiscence	Tension-free primary closure not achieved	• Achieve tension-free closure, soft tissue grafting prior to surgery	• Systemic antibiotics • Resuture if needed
Sinusitis, cystic formation, polyp formation	Microbial, viral, allergy-induced inflammation of the sinus membranes	• Define pathology prior to surgery	• Systemic antibiotics • Surgical intervention/referral to ENT
Anatomical alterations/sinus radiopacities (deformity, post-traumatic, tumor)	Stenosis of drainage ventilation pathways in the maxillary sinus	• Define pathology prior to surgery	• Surgical intervention/referral to ENT

(Continued)

Dentlearn.ir

Table 25.5 (Continued)

Complication	Etiology	Prevention	Management
Loss of bone graft particles	Primary closure not achieved	• Achieve tension-free closure, use of connective tissue graft/ membrane as needed	• Do nothing, allow to heal for 3 months, and radiographically evaluate
Rotational instability of implant	Poor osteotomy diameter control	• Determine bone quality during pilot drill. Underprepare type III and type IV bone	• Prolonged (4–5 months) submerged healing with insertion torque <25 Ncm • Wider implant if residual buccopalatal bone present is >1 mm at each dimension • Remove implant, graft, bioabsorbable membrane, re-enter at 4–6 months
Implant migration into sinus	Poor primary stability (<15 Ncm insertion torque)	• Ensure primary stability	• Remove implant, graft, and bioabsorbable membrane, and re-enter at 4–6 months
Benign paroxysmal positional vertigo (BPPV)	Canalith displacement	• Avoid significant mallet use	• Epley maneuver to reposition canaliths • Prescription of benzodiazepines and antihistamines can reduce motion sickness symptoms

proliferation, and maturation/remodeling [88]. Fundamentals described in the PASS principle of GBR are required to promote this healing sequence: **P**rimary wound closure, **A**ngiogenesis, **S**pace maintenance, and wound **S**tability [66]. Space and wound stability are crucial for mesenchymal stem cell and osteoprogenitor populations to undergo proliferation/differentiation in the sinus and surrounding the implant post-operatively [89]. Furthermore, flap stability for a one-stage approach and primary wound closure for a two-stage approach is guided by tension-free flap design and releasing incisions [22, 90–92]. If these tenets are not followed, flap sloughing, incision opening, or mucosal dehiscence can result, exposing the underlying graft/implant site. As such, antibiotics can be prescribed to minimize infection outcomes or re-suturing can be completed if the exposure is severe.

ROTATIONAL INSTABILITY/IMPLANT MIGRATION

Primary implant stability is essential for predictable osseointegration in tSFE with simultaneous implant placement. Inability to achieve primary stability could result in implant mobility due to failed osseointegration, fibrous encapsulation, or implant migration into the sinus post-operatively [93]. To prevent implant rotational instability, undersized drilling should be considered, primarily in softer posterior trabecular bone (types III and IV) or osteoporosis patients to maximize bone-to-implant contact [94, 95]. Using the reamer approach, the clinician can underprepare the tSFE site diameter prior to the osteotome/sinus augmentation steps. Following sinus elevation and addition of the bone graft, the site can then be further prepared to an adequate diameter that also provides primary stability. Osteotomes and bone condensation are techniques that can be used to increase the bone density at the site of preparation.

Residual bone height has also been used as valuable predictor of primary stability. Earlier studies on tSFE emphasized the requirement of ≥5 mm of residual bone height prior to surgery [96, 97]. Less than 5 mm of residual bone height resulted in a 5–20% reduction in the success rate [96, 97]. Though some tSFE technique publications have demonstrated success with <5 mm residual bone height [98–101], the prognosis for implant success is still more favorable when residual ridge height is ≥5 mm [102]. If <5 mm residual bone height is observed prior to surgery, a staged trancrestal approach using the reamer technique or lateral window may be employed.

If primary stability is not achieved after placement, implant displacement into the maxillary sinus can become a serious post-operative complication and occurs at a rate of 3.8–6.28% [102]. Implant displacement can occur as an intra-operative event or within the days following the surgical procedure [75, 76]. Severe displacement of the implant into the maxillary sinus can occur if there is a combination of osseointegration failure, membrane perforation, and intrusive forces on the implant toward the sinus [103–105]. In the event that an implant migrates into the sinus, a lateral window is needed to extract the implant body [75, 76].

BENIGN PAROXYSMAL POSITIONAL VERTIGO

BPPV is one of the most common form of vertigo associated with dentistry, characterized by brief spinning sensations

Dentlearn.ir

with/without nausea following a change in head position and lasting less than 1 minute. The lifetime prevalence of BPPV in the general population not associated with dental treatment is 2.4% [106]. The peak onset is between 50 to 60 years of age and there is a female to male ratio of 2:1 to 3:1 [107,108]. BPPV is diagnosed on the basis of nystagmus trending in an upward and torsional direction, as observed when the patient is lying on one side during the Dix–Hallpike maneuver [109]. Treatment to reposition a canalith can be completed using the Epley maneuver, involving a number of head positions held for a minimum of 30 seconds until the nystagmus and vertigo resolve. Each head position in the Epley maneuver aims to move the otolithic debris closer to the common crus, and eventually cause the debris to fall into the vestibule through the common crus, eliminating the etiology of BPPV [109].

The complication of BPPV and/or headaches can occur following use of osteotomes for sinus augmentation procedures [39, 98, 110]. The incidence of post-operative BPPV was reported in the literature to be around 3% [111]. These complications can arise due to excessive force of malleting during the procedure [39, 98, 110]. This outcome can be minimized through use of drills to within a working distance from the sinus of 0.5–1 mm, or use of the reamer technique in which non-end cutting drill series or osseous densifying burs are used to complete the final millimeter of osteotomy. The osteotome technique is generally used preferentially to increase primary stability in type III and IV bone; however, this technique was not superior to use of conventional drill sequences after 3 months of follow-up [112]. If an osteotome technique is selected to in-fracture the sinus floor or displace grafting materials, the patient's head should be well supported by a headrest (preventing neck hyperextension) and firm pressure placed at the forehead to stabilize the patient from movement during percussion.

CONCLUSION

Many tools and techniques (i.e. piezo surgery, balloon catheters, hydraulic pressure, reamers, instruments, endoscopes, osseous densifying burs) have been developed to overcome the concern of membrane perforation during tSFE; however, the most common and widely accepted approach is still a combination of the osteotome instrument and bone graft to elevate the sinus membrane. In an attempt to minimize sinus membrane perforation, it is essential to know the anatomy, technique-sensitive details, integrity of the sinus membrane, how much bone graft to use, and what kind of bone graft to use.

Factors to be considered during the tSFE procedure include but are not limited to bone quantity (both horizontal and vertical dimensions), sinus floor morphology (straight, curved, or irregular), bone quality, Schneiderian membrane characteristics, and septa presence. Generally, 4–8 mm of residual alveolar bone height is needed to achieve implant primary stability. If implant stability is not obtained, then simultaneous implant placement cannot not be recommended with predictable success. If the bone is soft (type III or IV bone quality [16] or patients with osteoporosis), undersized preparation or osteotome or osseous densification may be needed to improve bone density and implant stability.

Other factors to consider include tissue thickness and amount of keratinized mucosa, which have been discussed in other chapters. Briefly, we would like to see at least 2 mm soft tissue thickness and at least 2 mm of keratinized mucosa. The transalveolar method is becoming a very commonplace surgical procedure, because it remains less invasive and thus there is less post-operative morbidity, and it avoids the disruption of vascularization [113]. A comprehensive understanding of the patient's anatomy, medical history, the available armamentarium, and post-operative complications/management strategies are all essential to the completion of a successful tSFE approach for implant placement in the posterior maxilla.

REFERENCES

1. Summers R. The osteotome technique: Part 4—Future site development. Compend Cont Educ *Dent.* 1995;16(11):1090–98, quiz 1099.
2. Summers RB. The osteotome technique: Part 3—Less invasive methods of elevating the sinus floor. *Compendium.* 1994;15(6): 698–704; quiz 710.
3. Summers RB. A new concept in maxillary implant surgery: The osteotome technique. *Compendium.* 1994;15(2):152–58; quiz 162.
4. Krafft T, Graef F, Winter W et al. Use of osteotomes for implant bed preparation – effect on material properties of bone and primary implant stability. *J Oral Implantol.* 2013;39:241–7.
5. Gomes de Oliveira RC, Leles CR, Lindh C, Ribeiro-Rotta RF. Bone tissue microarchitectural characteristics at dental implant sites. Part 1: Identification of clinical-related parameters. *Clin Oral Implants Res.* 2012;23(8):981–6.
6. Marquezan M, Osorio A, Sant'Anna E et al. Does bone mineral density influence the primary stability of dental implants? A systematic review. *Clin Oral Implants Res.* 2012;23(7):767–74.
7. Araújo MG, Lindhe J. Dimensional ridge alterations following tooth extraction: An experimental study in the dog. *J Clin Periodontol.* 2005;32(2):212–18.
8. Johnson K. A study of the dimensional changes occurring in the maxilla following tooth extraction. *Aust Dent J.* 1969;14(4):241–44.
9. Schropp L, Wenzel A, Kostopoulos L, Karring T. Bone healing and soft tissue contour changes following single-tooth extraction: A clinical and radiographic 12-month prospective study. *Int J Periodont Restorative Dent.* 2003;23(4):313–23.
10. Wang HL, Katranji A. ABC sinus augmentation classification. *Int J Periodont Restorative Dent.* 2008;28(4):383–9.

Dentlearn.ir

11. Pommer B, Frantal S, Willer J et al. Impact of dental implant length on early failure rates: A meta-analysis of observational studies. *J Clin Periodontol.* 2011;38(9):856–63.
12. Annibali S, Cristalli M, Dell'Aquila D et al. Short dental implants: A systematic review. *J Dent Res.* 2012;91(1):25–32.
13. Neldam CA, Pinholt EM. State of the art of short dental implants: A systematic review of the literature. *Clin Implant Dent Relat Res.* 2012;14(4):622–32.
14. Engelke WG, Diederichs CG, Jacobs HG, Deckwer I. Alveolar reconstruction with splitting osteotomy and microfixation of implants. *Int J Oral Maxillofac Implants.* 1997;12(3):310–18.
15. Chan HL, Oh TJ, Fu JH et al. Sinus augmentation via transcrestal approach: A comparison between the balloon and osteotome technique in a cadaver study. *Clin Oral Implants Res.* 2013;24(9):985–90.
16. Lekholm U, Zarb G, Albrektsson T. Patient selection and preparation: Tissue integrated protheses. *J Prosthet Dent.* 1985;85(5):199–209.
17 Misch C. Bone classification, training keys to implant success. *Dent Today.* 1989;8(4):39.
18. Ulm C, Kneissel M, Schedle A et al. Characteristic features of trabecular bone in edentulous maxillae. *Clin Oral Implants Res.* 1999;10(6):459–67.
19. Monje A, Monje F, González-García R et al. Influence of atrophic posterior maxilla ridge height on bone density and microarchitecture. *Clin Implant Dent Relat Res.* 2015;17(1):111–19.
20. Wen SC, Lin YH, Yang YC, Wang HL. The influence of sinus membrane thickness upon membrane perforation during transcrestal sinus lift procedure. *Clin Oral Implants Res.* 2015;26(10):1158–64.
21. Insua A, Monje A, Chan HL et al. Accuracy of Schneiderian membrane thickness: A cone-beam computed tomography analysis with histological validation. *Clin Oral Implants Res.* 2017;28(6):654–61.
22. Insua A, Monje A, Urban I et al. The sinus membrane–maxillary lateral wall complex: Histologic description and clinical implications for maxillary sinus floor elevation. *Int J Periodont Restorative Dent.* 2017;37(6):e326–e338.
23. Aimetti M, Massei G, Morra M et al. Correlation between gingival phenotype and Schneiderian membrane thickness. *Int J Oral Maxillofac Implants.* 2008;23(6):1128–32.
24. Berbéri A, Al-Nemer F, Hamade E et al. Mesenchymal stem cells with osteogenic potential in human maxillary sinus membrane: An in vitro study. *Clin Oral Invest.* 2017;21(5):1599–609.
25. Chan HL, Monje A, Suarez F et al. Palatonasal recess on medial wall of the maxillary sinus and clinical implications for sinus augmentation via lateral window approach. *J Periodontol.* 2013;84(8):1087–93.
26. Brägger U, Gerber C, Joss A et al. Patterns of tissue remodeling after placement of ITI® dental implants using an osteotome technique: A longitudinal radiographic case cohort study. *Clin Oral Implants Res.* 2004;15(2):158–66.
27. Chen HH, Lin YC, Lee SY et al. Influence of sinus floor configuration on grafted bone remodeling after osteotome sinus floor elevation. *Journal Periodontol.* 2017;88(1):10–16.
28. Galindo-Moreno P, Ávila G, Fernández-Barbero JE et al. Evaluation of sinus floor elevation using a composite bone graft mixture. *Clin Oral Implants Res.* 2007;18(3):376–82.
29. Galindo-Moreno P, Ávila G, Fernández-Barbero JE et al. Clinical and histologic comparison of two different composite grafts for sinus augmentation: A pilot clinical trial. *Clin Oral Implants Res.* 2008;19(8):755–9.
30. Galindo-Moreno P, Moreno-Riestra I, Ávila G et al. Histomorphometric comparison of maxillary pristine bone and composite bone graft biopsies obtained after sinus augmentation. *Clin Oral Implants Res.* 2010;21(1):122–8.
31. Wen S-C, Chan H-L, Wang H-L. Classification and management of antral septa for maxillary sinus augmentation. *Int J Periodont Restorative Dent.* 2013;33(4):509–17.
32. Kim M-J, Jung U-W, Kim C-S et al. Maxillary sinus septa: Prevalence, height, location, and morphology. A reformatted computed tomography scan analysis. *J Periodontol.* 2006;77(5):903–8.
33. Krennmair G, Ulm C, Lugmayr H. Maxillary sinus septa: Incidence, morphology and clinical implications. *J Craniomaxillofac Surg.* 1997;25(5):261–5.
34. Krennmair G, Ulm CW, Lugmayr H, Solar P. The incidence, location, and height of maxillary sinus septa in the edentulous and dentate maxilla. *J Oral Maxillofac Surg.* 1999;57(6):667–71.
35. Neivert H. Symposium on maxillary sinus: Surgical anatomy of the maxillary sinus. *Laryngoscope.* 1930;40(1):1–4.
36. Bornstein MM, Seiffert C, Maestre-Ferrín L et al. An analysis of frequency, morphology, and locations of maxillary sinus septa using cone beam computed tomography. *Int J Oral Maxillofac Implants.* 2016;31(2):280–87.
37. Soardi CM, Soardi B, Wang H-L. Crestal window sinus elevation and its long-term clinical outcomes. *Int J Periodont Restorative Dent.* 2020;40(5):757–64.
38. Soardi CM, Wang HL. New crestal approach for lifting sinus in the extremely atrophic upper maxillae. *Clin Adv Periodont.* 2012;2(3):179–85.
39. Flanagan D. Labyrinthine concussion and positional vertigo after osteotome site preparation. *Implant Dent.* 2004;13(2):129–32.
40. Vernamonte S, Mauro V, Messina A. An unusual complication of osteotome sinus floor elevation: Benign paroxysmal positional vertigo. *Int J Oral Maxillofac Surg.* 2011;40(2):216–18.
41. Cavicchia F, Bravi F, Petrelli G. Localized augmentation of the maxillary sinus floor through a coronal approach for the placement of implants. *Int J Periodont Restorative Dent.* 2001;21(5):475–85.
42. Ferrigno N, Laureti M, Fanali S. Dental implants placement in conjunction with osteotome sinus floor elevation: A 12-year life-table analysis from a prospective study on 588 ITI implants. *Clin Oral Implants Res.* 2006;17(2):194–205.
43. Leblebicioglu B, Ersanli S, Karabuda C et al. Radiographic evaluation of dental implants placed using an osteotome technique. *J Periodontol.* 2005;76(3):385–90.
44. Nedir R, Bischof M, Vazquez L et al. Osteotome sinus floor elevation without grafting material: A 1-year prospective pilot study with ITI implants. *Clin Oral Implants Res.* 2006;17(6):679–86.
45. Pjetursson BE, Ignjatovic D, Matuliene G et al. Transalveolar maxillary sinus floor elevation using osteotomes with or without grafting material. Part II: Radiographic tissue remodeling. *Clin Oral Implants Res.* 2009;20(7):677–83.

Dentlearn.ir

46. Summers RB. Sinus floor elevation with osteotomes. *J Esthet Restor Dent.* 1998;10(3):164–71.
47. Gargallo-Albiol J, Tattan M, Sinjab KH et al. Schneiderian membrane perforation via transcrestal sinus floor elevation: A randomized ex vivo study with endoscopic validation. *Clin Oral Implants Rese.* 2019;30(1):11–19.
48. Sonoda T, Yamamichi K, Harada T, Yamamichi N. Effect of staged crestal maxillary sinus augmentation: A case series. *J Periodontol.* 2020;91(2):194–201.
49. Chen L, Cha J. An 8-year retrospective study: 1,100 patients receiving 1,557 implants using the minimally invasive hydraulic sinus condensing technique. *J Periodontol.* 2005;76(3):482–91.
50. Sotirakis EG, Gonshor A. Elevation of the maxillary sinus floor with hydraulic pressure. *J Oral Implantol.* 2005;31(4):197–204.
51. Troedhan AC, Kurrek A, Wainwright M, Jank S. Hydrodynamic ultrasonic sinus floor elevation—an experimental study in sheep. *J Oral Maxillofac Surg.* 2010;68(5):1125–30.
52. Soltan M, Smiler DG. Antral membrane balloon elevation. *J Oral Implantol.* 2005;31(2):85–90.
53. Davarpanah M, Martinez H, Tecucianu J-F et al. The modified osteotome technique. *Int J Periodont Restorative Dent.* 2001;21(6):599–607.
54. Fugazzotto PA, Vlassis J. Long-term success of sinus augmentation using various surgical approaches and grafting materials. *Int J Oral Maxillofac Implants.* 1998;13(1):52–8.
55. Fugazzotto PA. Immediate implant placement following a modified trephine/osteotome approach: Success rates of 116 implants to 4 years in function. *Int J Oral Maxillofac Implants.* 2002;17(1):113–20.
56. Fugazzotto PA. Sinus floor augmentation at the time of maxillary molar extraction: Technique and report of preliminary results. *Int J Oral Maxillofac Implants.* 1999;14(4):536–42.
57. Huwais S, Mazor Z, Ioannou AL et al. A multicenter retrospective clinical study with up-to-5-year follow-up utilizing a method that enhances bone density and allows for transcrestal sinus augmentation through compaction grafting. *Int J Oral Maxillofac Implants.* 2018;33(6):1305–11.
58. Huwais S, Meyer EG. A novel osseous densification approach in implant osteotomy preparation to increase biomechanical primary stability, bone mineral density, and bone-to-implant contact. *Int J Oral Maxillofac Implants.* 2017;32(1):27–36.
59. Trisi P, Berardini M, Falco A, Vulpiani MP. New osseodensification implant site preparation method to increase bone density in low-density bone: in vivo evaluation in sheep. *Implant Dent.* 2016;25(1):24.
60. Bashutski JD, D'Silva NJ, Wang HL. Implant compression necrosis: Current understanding and case report. *J Periodontol.* 2009;80(4):700–4.
61. Sbordone C, Toti P, Guidetti F et al. Volume changes of autogenous bone after sinus lifting and grafting procedures: A 6-year computerized tomographic follow-up. *J Craniomaxillofac Surg.* 2013;41(3):235–41.
62. Browaeys H, Bouvry P, De Bruyn H. A literature review on biomaterials in sinus augmentation procedures. Clin Implant Dent Relat Res. 2007;9(3):166–77.
63. Temmerman A, Vandessel J, Cortellini S et al. Volumetric changes of grafted volumes and the Schneiderian membrane after transcrestal and lateral sinus floor elevation procedures: A clinical, pilot study. *J Clin Periodontol.* 2017;44(6):660–71.
64. Duan DH, Fu JH, Qi W et al. Graft-free maxillary sinus floor elevation: A systematic review and meta-analysis. *J Periodontol.* 2017;88(6):550–64.
65. Chen MH, Shi JY. Clinical and radiological outcomes of implants in osteotome sinus floor elevation with and without grafting: A systematic review and a meta-analysis. *J Prosthodont.* 2018;27(5):394–401.
66. Wang H-L, Boyapati L. "PASS" principles for predictable bone regeneration. *Implant Dent.* 2006;15(1):8–17.
67. Sonoda T, Harada T, Yamamichi N et al. Association between bone graft volume and maxillary sinus membrane elevation height. *Int J Oral Maxillofac Implants.* 2017;32(4):735–40.
68. Engelke W, Deckwer I. Endoscopically controlled sinus floor augmentation: A preliminary report. *Clin Oral Implants Res.* 1997;8(6):527–31.
69. Engelke W, Schwarzwäller W, Behnsen A, Jacobs HG. Subantroscopic laterobasal sinus floor augmentation (SALSA): An up-to-5-year clinical study. *Int J Oral Maxillofac Implants.* 2003;18(1):135–43.
70. Yu X, Ye G, Zhao F et al. Endoscopic-controlled maxillary sinus floor elevation: A review of the literature. *Br J Oral Maxillofac Surg.* 2021;Apr 12:S0266-4356(21)00154-6.
71. Nkenke E, Schlegel A, Schultze-Mosgau S et al. The endoscopically controlled osteotome sinus floor elevation: A preliminary prospective study. *Int J Oral Maxillofac Implants.* 2002;17(4):557–66.
72. Lin Z-Z, Jiao Y-Q, Ye Z-Y et al. The survival rate of transcrestal sinus floor elevation combined with short implants: A systematic review and meta-analysis of observational studies. *Int J Implant Dent.* 2021;7(1):1–11.
73. Stacchi C, Andolsek F, Berton F et al. Intraoperative complications during sinus floor elevation with lateral approach: A systematic review. *Int J Oral Maxillofac Implants.* 2017;32(3):e107–e118.
74. Trombelli L, Franceschetti G, Trisi P, Farina R. Incremental, transcrestal sinus floor elevation with a minimally invasive technique in the rehabilitation of severe maxillary atrophy: Clinical and histological findings from a proof-of-concept case series. *J Oral Maxillofac Surg.* 2015;73(5):861–88.
75. Galindo-Moreno P, Padial-Molina M, Avila G et al. Complications associated with implant migration into the maxillary sinus cavity. *Clin Oral Implants Res.* 2012;23(10):1152–60.
76. Galindo-Moreno P, Padial-Molina M, Sánchez-Fernández E et al. Dental implant migration in grafted maxillary sinus. *Implant Dent.* 2011;20(6):400–5.
77. Bakhshalian N, Sim YC, Nowzari H et al. Accidental migration of a dental implant into the ethmoid sinus following a transalveolar sinus elevation procedure. *Clin Implant Dent Relat Res.* 2015;17(2):360–64.
78. Tan WC, Lang NP, Zwahlen M, Pjetursson BE. A systematic review of the success of sinus floor elevation and survival of implants inserted in combination with sinus floor elevation. Part II: Transalveolar technique. *J Clin Periodontol.* 2008;35(s8):241–54.

Dentlearn.ir

79. Tavelli L, Enrico Borgonovo A, Saleh MH et al. Classification of sinus membrane perforations occurring during transcrestal sinus floor elevation and related treatment. *Int J Periodont Restorative Dent.* 2020;40(1):111–18.

80. Bergh J, Bruggenkate CM, Disch FJ, Tuinzing DB. Anatomical aspects of sinus floor elevations. *Clin Oral Implants Res.* 2000;11(3):256–65.

81. Ding X, Zhu X-H, Wang H-M, Zhang X-H. Effect of sinus membrane perforation on the survival of implants placed in combination with osteotome sinus floor elevation. *J Craniofac Surg.* 2013;24(2):e102–e104.

82. Proussaefs P, Lozada J, Kim J, Rohrer MD. Repair of the perforated sinus membrane with a resorbable collagen membrane: A human study. *Int J Oral Maxillofac Implants.* 2004;19(3):413–20.

83. Schwartz-Arad D, Levin L, Sigal L. Surgical success of intraoral autogenous block onlay bone grafting for alveolar ridge augmentation. *Implant Dent.* 2005;14(2):131–8.

84. Anavi Y, Allon DM, Avishai G, Calderon S. Complications of maxillary sinus augmentations in a selective series of patients. *Oral Surg Oral Med Oral Pathol Oral Radiol Endod.* 2008;106(1):34–8.

85. Timmenga NM, Raghoebar GM, Liem RS et al. Effects of maxillary sinus floor elevation surgery on maxillary sinus physiology. *Eur J Oral Sci.* 2003;111(3):189–97.

86. Carmeli G, Artzi Z, Kozlovsky A et al. Antral computerized tomography pre-operative evaluation: Relationship between mucosal thickening and maxillary sinus function. *Clin Oral Implants Res.* 2011;22(1):78–82.

87. Shakibaie B. Microscope-controlled internal sinus floor elevation (MI-SFE): A new technique to evaluate the sinus membrane during transcrestal lifting. *Int J Microdent.* 2013;4:12–19.

88. Lambert F, Léonard A, Drion P et al. Influence of space-filling materials in subantral bone augmentation: Blood clot vs. autogenous bone chips vs. bovine hydroxyapatite. *Clin Oral Implants Res.* 2011;22(5):538–45.

89. Frank V, Kaufmann S, Wright R et al. Frequent mechanical stress suppresses proliferation of mesenchymal stem cells from human bone marrow without loss of multipotency. *Sci Rep.* 2016;6:24264.

90. Urban IA, Lozada JL, Jovanovic SA, Nagy K. Horizontal guided bone regeneration in the posterior maxilla using recombinant human platelet-derived growth factor: A case report. *Int J Periodont Restorative Dent.* 2013;33(4):421–5.

91. Urban IA, Monje A, Lozada J, Wang H-L. Principles for vertical ridge augmentation in the atrophic posterior mandible: A technical review. *Int J Periodont Restorative Dent.* 2017;37(5):639–45.

92. Urban IA, Monje A, Lozada JL, Wang HL. Long-term evaluation of peri-implant bone level after reconstruction of severely atrophic edentulous maxilla via vertical and horizontal guided bone regeneration in combination with sinus augmentation: A case series with 1 to 15 years of loading. *Clin Implant Dent Relat Res.* 2017;19(1):46–55.

93. Lioubavina-Hack N, Lang NP, Karring T. Significance of primary stability for osseointegration of dental implants. *Clin Oral Implants Res.* 2006;17(3):244–50.

94. Tabassum A, Meijer GJ, Frank Walboomers X, Jansen JA. Biological limits of the undersized surgical technique: A study in goats. *Clin Oral Implants Res.* 2011;22(2):129–34.

95. Al-Marshood MM, Junker R, Al-Rasheed A et al. Study of the osseointegration of dental implants placed with an adapted surgical technique. *Clin Oral Implants Res.* 2011;22(7):753–9.

96. Cavicchia F, Bravi F, Petrelli G. Localized augmentation of the maxillary sinus floor through a coronal approach for the placement of implants. *Int J Periodont Restorative Dent.* 2001;21(5):475–85.

97. Toffler M. Osteotome-mediated sinus floor elevation: A clinical report. *Int J Oral Maxillofac Implants.* 2004;19(2):266–73.

98. Jung J-H, Choi S-H, Cho K-S, Kim C-S. Bone-added osteotome sinus floor elevation with simultaneous placement of non-submerged sand blasted with large grit and acid etched implants: A 5-year radiographic evaluation. *J Periodontol Implant Sci.* 2010;40(2):69–75.

99. Lai HC, Zhuang LF, Lv XF et al. Osteotome sinus floor elevation with or without grafting: A preliminary clinical trial. *Clin Oral Implants Res.* 2010;21(5):520–26.

100. Bernardello F, Righi D, Cosci F et al. Crestal sinus lift with sequential drills and simultaneous implant placement in sites with <5 mm of native bone: A multicenter retrospective study. *Implant Dent.* 2011;20(6):439–44.

101. Kim DY, Itoh Y, Kang TH. Evaluation of the effectiveness of a water lift system in the sinus membrane-lifting operation as a sinus surgical instrument. *Clin Implant Dent Relat Res.* 2012;14(4):585–94.

102. Del Fabbro M, Corbella S, Weinstein T et al. Implant survival rates after osteotome-mediated maxillary sinus augmentation: A systematic review. *Clin Implant Dent Relat Res.* 2012;14(suppl 1):e159–e168.

103. Kluppel LE, Santos SE, Olate S et al. Implant migration into maxillary sinus: Description of two asymptomatic cases. *Oral Maxillofac Surg.* 2010;14(1):63–6.

104. Chappuis V, Suter VG, Bornstein MM. Displacement of a dental implant into the maxillary sinus: Report of an unusual complication when performing staged sinus floor elevation procedures. *Int J Periodont Restorative Dent* 2009;29(1):81–7.

105. Iida S, Tanaka N, Kogo M, Matsuya T. Migration of a dental implant into the maxillary sinus. *Int J Oral Maxillofac Surg.* 2000;29(5):358–9.

106. Bhattacharyya N, Baugh RF, Orvidas L et al. Clinical practice guideline: Benign paroxysmal positional vertigo. *Otolaryngol Head Neck Surg.* 2008;139(5 suppl):47–81.

107. Von Brevern M, Radtke A, Lezius F et al. Epidemiology of benign paroxysmal positional vertigo: A population based study. *J Neurol Neurosurg Psychiatr.* 2007;78(7):710–15.

108. Baloh RW, Honrubia V, Jacobson K. Benign positional vertigo: Clinical and oculographic features in 240 cases. *Neurology* 1987;37(3):371.

109. Kim J-S, Zee DS. Benign paroxysmal positional vertigo. *N Engl J Med.* 2014;370(12):1138–47.

110. Penarrocha-Diago M, Rambla-Ferrer J, Perez V, Perez-Garrigues H. Benign paroxysmal vertigo secondary to placement of maxillary implants using the alveolar expansion technique with osteotomes: A study of 4 cases. *Int J Oral Maxillofac Implants.* 2008;23(1):129–32.

111. Călin C, Petre A, Drafta S. Osteotome-mediated sinus floor elevation: A systematic review and meta-analysis. *Int J Oral Maxillofac Implants.* 2014;29(3):558–76.

112. Shayesteh YS, Khojasteh A, Siadat H et al. A comparative study of crestal bone loss and implant stability between osteotome and conventional implant insertion techniques: A randomized controlled clinical trial study. *Clin Implant Dent Relat Res.* 2013;15(3):350–57.

113. Emmerich D, Att W, Stappert C. Sinus floor elevation using osteotomes: A systematic review and meta-analysis. *J Periodontol.* 2005;76(8):1237–51.

Dentlearn.ir

Soft Tissue Grafting for Implant Site Development

SECTION V

Chapter 26 Soft Tissue Assessment and Grafting for Alveolar Ridge Enhancement in Implant Dentistry 459
Edgard El Chaar

Dentlearn.ir

Dentlearn.ir

Soft Tissue Assessment and Grafting for Alveolar Ridge Enhancement in Implant Dentistry

CHAPTER 26

Before a dental implant is placed and from the moment of treatment planning, the clinician must assess both the hard and soft tissue. Keratinized tissue around a dental implant is described as the phenotype and it is as important as around a natural tooth. Today, it is essential for clinicians to understand biology, functionality, and esthetics when treatment planning and executing implants. Quality of soft tissue around dental implants is of paramount significance in modern implantology.

Dentlearn.ir

CHAPTER 26

Soft Tissue Assessment and Grafting for Alveolar Ridge Enhancement in Implant Dentistry

Edgard El Chaar

School of Dental Medicine, University of Pennsylvania, Philadelphia, PA, USA

With the advent of implant surface technology, the need to have keratinized tissue (KT) became an important point in having a sustainable, healthy dental implant. In the World Workshop on periodontics [1], it was stated that a minimum of 2 mm appears to be the important number to achieve this goal. Before a dental implant is placed and from the moment of treatment planning, the clinician must assess both the hard and soft tissue. The parameters to place a dental implant have been set and well established for three-dimensional implant placement [2] in relation to the amount of bone facial to the placed implant and its relation to the adjacent teeth, especially in partially edentulous patients. Now we will need to add to the agreed amount of KT. That is now known as the phenotype as it would be around a natural tooth, a site to be extracted, or a site for implant placement. Clinicians today must balance biology, functionality, and esthetics when treatment planning and executing implants.

In most instances, these procedures will be used to correct an esthetic or functional failure of placed implants. Failures that compromise the health of an implant fixture are inflammatory in nature and include peri-implantitis and peri-implant mucositis. While the result of these pathological changes is often unesthetic, the underlying cause of the disease must first be addressed before steps can be made to restore the esthetics. When an implant is healthy, but the result of the surgical and prosthetic placement is unsatisfactory to both patient and clinician, immediate steps can be taken to achieve a more desirable esthetic result. As with all dental treatment, the disease process and pathology must be eliminated or controlled before steps can be taken to repair the damage that it has caused. It is best to take measures to prevent both infectious and esthetic implant failures through proper planning and surgical execution.

Some common esthetic failures are loss of interdental papilla, "black triangles," mid-facial gingival recession, a non-harmonious gingival margin, buccal concavities, and translucency of the implant body or prosthetic margins. There are steps that can be taken to avoid these failures during the planning and surgical execution of implant placement, including augmentation prior to implant placement, flap design during placement, and soft tissue management during the second stage. The fundamental point is to assess the hard and soft tissue prior to implant placement in order to determine if there is a need for augmentation prior to the placement. Bone height and thickness are major determinants of soft tissue contours that will affect the implant placement and subsequently will dictate the tooth morphology, which will determine the contact point from the crest of the bone, and finally this will lead to the tissue quality and quantity important for the long-term success of the dental implant.

This chapter will discuss manipulation and/or augmentation of existing soft tissue, rather than prosthetic gingiva, in combination with implant-supported crowns, to achieve an ideal esthetic result.

TECHNIQUES

TECHNIQUES TO CREATE CONTOUR AND THICKNESS AND INCREASE THE KERATINIZED TISSUE

Flap Management

Over the years we all have been faced with the concept of flapless versus flap and many designs have been promoted for the latter. The clinician has to always remember that we are replacing a lost dental organ, which is our ultimate goal. By setting that goal we need to start thinking from it backward, which I often quote as "set your goal and walk your way back." Whether it is an anterior or posterior tooth, it has a specific

Essential Techniques of Alveolar Bone Augmentation in Implant Dentistry: A Surgical Manual, Second Edition. Edited by Len Tolstunov.
© 2023 John Wiley & Sons, Inc. Published 2023 by John Wiley & Sons, Inc.
Companion website: www.wiley.com/go/tolstunov/essential

Dentlearn.ir

shape at its coronal level. A central maxillary incisor is triangular, a canine is oval, and transitioning from the premolars to the molars it becomes a rectangle; yet the coronal part of the implant is a circle regardless of that implant diameter. All of that takes place at the flap level.

Gomez-Roman [3] showed that even if there is adequate crestal bone height prior to implant placement, the flap design can affect the amount of crestal bone resorption following placement. By preserving the proximal tissue of the adjacent teeth in a limited flap design, 0.29 mm bone was noted versus 0.79 mm with a "widely mobilized flap procedure" that includes the proximal tissue. Another advantage of preserving that tissue is giving the clinician a visual marker to keep the 1.5 mm from adjacent teeth during the placement [2, 4].

For years periodontal surgeons used the H design, in which they would evaluate the position of an adequate amount of KT and initiate crestal incision followed by two cross-arches on the buccal and lingual, extending up to the muco-gingival line (MGL) on the buccal side and enough on the lingual to allow exposure of the crestal bone. On the buccal side, it can extend past the MGL in case where an apical repositioning is needed. Although it covers all the criteria cited above, suturing the flap and controlling the level of it either coronally or apically becomes a challenge, since we have a raised flap on the lingual and we need to suture together the buccal and lingual components. To avoid this difficulty, the author designed a flap that he called the U shape, where the crestal incision is made depending on the adequate KT that the clinician judges is necessary coupled with two buccal-only crestal incisions extending up to the MGL. The lingual portion at the crestal level is elevated without being mobilized. The major advantage of this design is that the clinician can control the positioning of the flap either coronally or apically, depending on the esthetic assessment done during the treatment planning, namely the pink esthetic score, assessment of papilla height, and pink and white esthetic score in gingival display (Figures 26.1–26.5).

As a technically important side note, to position the flap coronally a surgeon needs to position the flap at the level needed and place the first suture coronally on both sides. It is important that the two cross-arch incisions on the buccal are parallel and not widened at the apical part, to avoid shrinkage of the coronal part of the flap. If that occurs, it will be difficult to have enough width to cover the buccal aspect. For the apical position it is the opposite: the surgeon needs to place the flap in the desired place and suture the apical part first, followed by the coronal.

FIGURE 26.1 Occlusal view showing the muco-gingival junction and limited buccal keratinized tissue (about 1 mm).

FIGURE 26.2 The U-shape incision to the buccal with parallel vertical incisions.

Roll Technique

A roll flap procedure was developed by Abrams in 1980 as a means of correcting small Seibert class I ridge defects that result in a buccal concavity. This technique is useful in correcting a ridge defect at a future site for a pontic, or a small buccal concavity present in the area where an implant has been placed. If there is an implant present in the site, this

Dentlearn.ir

FIGURE 26.3 Full-thickness flap elevated, exposing the implant.

FIGURE 26.4 Flap sutured at the needed coronal level matching the adjacent margins.

technique can be used in combination with the uncovering procedure. The technique employs a pedicle connective tissue graft that is harvested from the palate and then folded under into a pouch created on the buccal. The augmentation provided by the pedicle is meant to match the root eminences of the adjacent teeth, therefore if the edentulous span is greater than one tooth multiple pedicle grafts may be prepared.

The roll technique presented here is a *modification* to the roll technique introduced by Scharf and Tarnow in 1992 [5] and will be illustrated in a series of figures

FIGURE 26.5 6 weeks' healing revealing a good band of keratinized tissue with buccal contour continuous with the adjacent teeth and coronal levels of tissue similar to the adjacent as well.

FIGURE 26.6 Buccal view showing the soft tissue buccal discrepancy.

(Figures 26.6–26.11). The main modifications are that there are no vertical incisions on both sides and the shape of the harvested connective tissue is trapezoidal, not rectangular as designed by Scharf and Tarnow. It begins with making three measurements. First measure from the crest of the ridge or the anticipated gingival margin of the future crown to the most apical extent of the concavity; second measure the apical

Dentlearn.ir

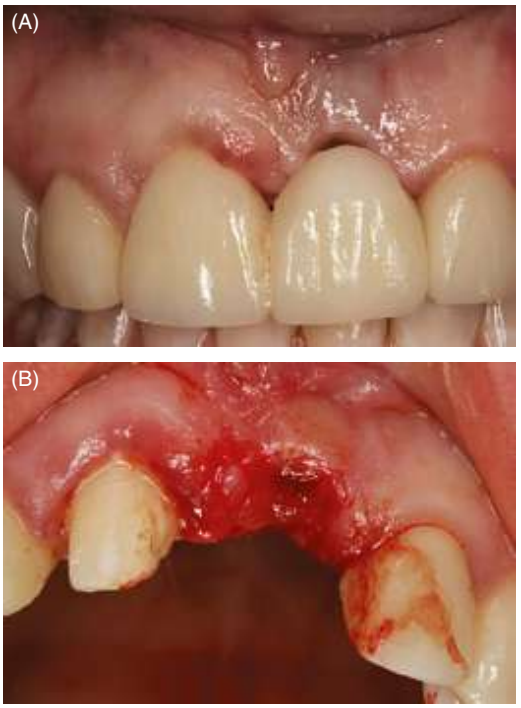

FIGURE 26.7 The implant was disconnected (A) to let the tissue grow over it and bury it (B).

FIGURE 26.8 The trapezoidal-shaped incision was made on the palatal side to reflect the palatal flap needed to gain keratinized tissue on the buccal side: the full-thickness palatal flap was de-epithelized.

FIGURE 26.9 Tissue was rolled under the pouch, made buccal, and part of it was kept coronal to match the adjacent tooth. A narrow healing abutment was placed to support the tissue.

FIGURE 26.10 8 weeks' healing of the rolled tissue. (A) Buccal view; (B) Palatal view showing the fill of the donor site and the placed healing abutment.

width 1 mm from the mesial side of each adjacent apex of the adjacent teeth; and third measure the interproximal distance between the adjacent teeth coronally, accounting for the papillary-like tissue to be left on the side of each tooth. Those lines of measurements will form a trapezoid shape. The measurements will determine the size of the pedicle that needs to be harvested from the palatal area. The buccal limit of the donor site is the mid-crest of the pontic site preparation or above the middle of the cover screw for implants. This delineates the donor site, with incisions extending to the underlying bone in all areas except the crestal limit, which will serve as the base of the pedicle. Once the site is delineated, de-epithelialize that area and sharply elevate the

Dentlearn.ir

FIGURE 26.11 Final prosthesis in place with marginal tissue matching the adjacent tooth.

connective tissue pedicle to full thickness, leaving exposed bone on the palate.

Some authors suggest dissecting the pedicle graft leaving behind the periosteum, but doing so risks severing the supra-periosteal capillary bed that may lead to flap necrosis and jeopardize the end result. Full-thickness elevation also reduces the risk of perforation of the pedicle flap, allows for a thicker graft, and maintains the supra-periosteal blood supply to the graft. Once the pedicle is elevated to the buccal transition area, create a full-thickness pouch in the area of the defect on the buccal, following the planned trapezoidal architecture. After elevation of the pouch, roll the pedicle graft into the area of the buccal defect. At this time the pedicle may be trimmed and adjusted to fit. Once the graft is in place, place two stabilizing sutures coronally on either side of the trapezoid. At this point, the healing abutment can be placed and any periosteum or osseous structure over the implant cover screw should be removed.

Autograft Subepithelial Connective Tissue, Free Gingival Graft, Allograft Dermis, and Tunnel Technique

If there is a lack of KT surrounding the implant fixture or there is not enough tissue present to be displaced apically or rolled buccally, one may employ a free gingival graft (FGG), connective tissue autograft (CTG), or allograft dermis.

CTG can be used to increase tissue thickness and/or to increase attached KT in areas of esthetic concern. FGG can also be used to increase the zone of KT, but will heal with a more blanched-looking tissue, and it is not advised in areas of esthetic concern. Alternatively, and for the same reason, an allograft dermis can be used to increase KT.

The main advantage of using a CTG is the color match with the surrounding tissue compared with the FGG. These techniques are easiest to perform at the time of the second-stage surgery or implant placement, but can be done with a prosthesis in place if necessary, although that will require a more diligent and refined execution.

Free Gingival Graft This technique is mainly used to increase the amount of KT while preserving the marginal gingiva. A submarginal incision is made down to the bone in the case of an implant that is already exposed or submarginal to the existent KT in a healed ridge. The extent of the incision depends on the extent of the area to be treated. At the margins of this area, extend the incisions curved apically. A full-thickness flap is reflected.

In case the implants are not uncovered, an incision is made at the MGL and a full-thickness flap is reflected to expose the previously placed implant. In both instances, the flap is apically positioned and stabilized with tacks to establish the new vestibule. Once the flap is secured, measure the recipient area to determine the amount of tissue that needs to be harvested from the palate. Next, harvest a full-thickness graft from the palate to place in the area of deficient tissue. The donor tissue should be taken at least 2 mm from the palatal gingival margin, as tissue contraction occurs during healing and recession may occur as a result of the wound edge being too close to teeth. The shape of the donor tissue is outlined with a scalpel at a right angle to the palate at the desired depth, which can be gauged by the bevel on a #15C scalpel blade (approximately 1 mm). The blade is then turned parallel to the palate and a graft of the desired uniform thickness is removed by sharp dissection from the palate. The donor tissue is transferred to the recipient site to check the fit and modified if needed. Suturing techniques vary widely, but stabilization of the graft is the most important principle and can be accomplished using stabilizing structures adjacent to the surgical site. Reducing graft mobility and dead spaces between tissues will improve graft success, and after an average of 8 weeks the donor and recipient sites are healed. This technique does give a high level of discomfort at the palate site, which is reported by most patients regardless of which kind of cover is used over the donor site, and does not provide a highly esthetic result due to the color mismatch.

Connective Tissue Grafts Following the development and use of FGG, Langer and Calagna in 1980 described the subepithelial connective tissue graft for root coverage and ridge augmentation as the second major type of free soft tissue autograft [6]. The esthetic advantages, healing period, and superior color match of CTG versus FGG make CTG the most widely used soft tissue autograft technique in periodontal plastic surgery [7]. A connective tissue graft used under a pedicle flap yields a mean root coverage of 89.3% around natural teeth [8]. When the palatal masticatory mucosa is used as autogenous donor material for a CTG, it is important to control the thickness of the graft harvested. Harvesting a thick graft helps in vascularity and ease of manipulation of the donor tissue, but delays the healing period, while use of a thin graft decreases the healing time but often results in graft shrinkage or early necrosis [9, 10].

Dentlearn.ir

Histological analysis of the mucosa by Yu et al. showed that the thickness of the lamina propria decreased toward the posterior palatal area and mid-palatal suture, while that of the submucosa increased [11]. Yu's results suggest that the most appropriate donor site for it is the region 3 mm below the cemento-enamel junction (CEJ), between the distal surface of the canine and the mid-line surface of the first molar. When harvesting from this area, also keep in mind the anatomical landmarks of the palate. The greater and lesser palatine vessels and nerves lie in a bony groove, the greater palatine groove, which traverses the palate anteriorly at the junction of the horizontal and vertical palates. It is important to avoid the nerves and vessels located along this neurovascular line. The location of this line relative to the CEJ varies with palatal vault depth. In shallow palatal vaults the average distance between the neurovascular line and the CEJ is 7 mm, whereas in high vaults the maximum average distance is 17 mm. In an average vault there is a distance of about 12 mm from the neurovascular line to the CEJ [12, 13].

Major problems can occur when the surgeon violates the neurovascular area, such as paresthesia and excessive bleeding. Paresthesia of the anterior palate is more noticeable to the patient during speech due to the phonetic impact of an absence of feeling in this area. This paresthesia is generally temporary and often dissipates over the span of 6–12 months due to regeneration of nerve fibers. Bleeding can be a major problem in the palate, but most bleeding can be controlled by pressure, increasing the number of sutures, and the use of chemical or electrical coagulants. Taking to account that the incision starts 2–3 mm from the free gingival margin and ends 2 mm prior to the neurovascular line, then the maximum width of donor tissue needed will vary from 3 mm to 9 mm. Harvesting a graft from an individual with a shallow palatal vault may not be adequate and doing so could risk neurovascular damage. In these cases, the clinician should consider allogenic grafting as the best treatment option.

A connective tissue autograft can be used in two different ways. One is to increase the bulk of tissue in the area of a small concavity or thin mucosa, and the other is to increase the zone of KT. If the intention is to increase the zone of KT, one should employ a free CTG, while if tissue thickness needs to be increased, a classic CTG procedure should be applied. These two CTG techniques will be presented separately.

A Free Connective Tissue Graft A free CTG is performed in the same manner as a FGG at the recipient site and the harvesting from the palate is performed by dissecting the connective tissue rather than harvesting a full-thickness graft. When harvesting connective tissue from the palate, begin by doing a single horizontal incision 2 mm apical to the gingival margins, especially at the first molar, without vertical incisions, then elevate a full-thickness envelope flap from which connective tissue is dissected out. The remaining flap epithelium cover is left attached to the remaining palatal tissue. Once the graft has been removed, the remaining flap will be sutured to the adjacent immobile palatal tissue.

The recipient site will be denuded in a full-thickness manner by making a horizontal incision, which is submarginal to the intended zone of width augmentation (Figures 26.12 and 26.13). The mobilized mucosa needs to be stabilized apically, and I recommend tacking it using titanium tacks, one on each corner and one in the middle (Figure 26.13). At this point the harvested connective tissue (Figure 26.14) is placed over the prepared site and sutured coronally with interrupted sutures (Figure 26.15). The advantage of using a free CTG is the color match, avoiding the very bulky keloid white tissue that results from using an FGG (Figure 26.16).

FIGURE 26.12 The focus in this case is the implant in the position of the upper left canine, where there is an aberrant frenum with loss of keratinized tissue and recession on the abutment buccally.

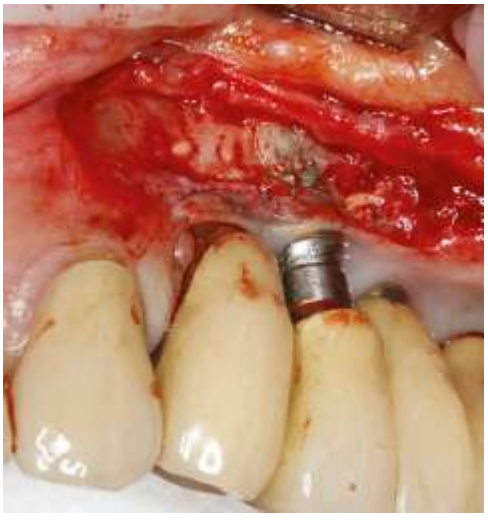

FIGURE 26.13 A full-thickness bed was made in the area of the recipient site and the apically repositioned mucosa was tacked apically.

Dentlearn.ir

FIGURE 26.14 A thick connective tissue graft was harvested from the palate for placement over the defect.

FIGURE 26.15 The free connective tissue was secured coronally to the recipient site and one tack was used to affix it at the apical side.

FIGURE 26.16 6 months' healing showing the keratinized tissue gained, which blends in color with the adjacent tissue.

FIGURE 26.17 Purulent exudate and a lack of keratinized tissue with recession on the buccal of the implant in the position of the lower right canine and first premolar, to be treated with implant decontamination and connective tissue graft.

Covered Connective Tissue Graft A conventional CTG is useful in areas where one needs to increase the thickness of the buccal tissue around an implant, or in areas where it is necessary to improve the quality of the tissue [14]. In a covered CTG the flap created at the donor site is placed over the graft and positioned coronally, called a coronally advanced flap (CAF). The CAF increases the graft survival by increasing the necessary blood supply as well as the thickness [15, 16]. We will describe the CAF with the connective tissue in a case of peri-implantitis treatment to make it more exciting (Figure 26.17).

- Begin with preparation of the recipient bed: lay a full-thickness envelope flap exposing the bone in the area that needs augmentation. Use intra-sulcular incisions on the coronal portion of the flap in areas of surrounding natural teeth and the same in the area of the implant. All

Dentlearn.ir

FIGURE 26.18 The procedure began with debridement and elevation of a full-thickness flap.

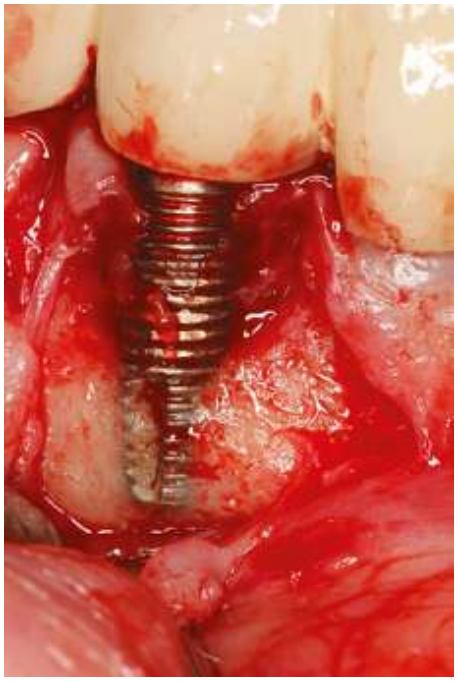

FIGURE 26.19 Once the flap was elevated, it was confirmed that the implant was placed outside of the bony housing. Note the intrabony defects present on both the mesial and lingual of the implant. The area was debrided and prepped for implantoplasty.

interproximal papillae should be sliced (de-epithelized), exposing the underlying connective tissue and leaving the base intact and attached to the underlying bone. If any elements of the implant fixture are exposed following flap elevation, these areas should be disinfected following the clinician's chosen protocol (Figures 26.18–21).

- As done in previous techniques, measure the area of the defect and harvest a CTG from the palate (Figure 26.22).

FIGURE 26.20 High-speed handpiece and irrigation were used to perform implantoplasty on all exposed areas of the implant. Following implantoplasty, the implant surface was treated with phosphoric etch solution and then thoroughly irrigated with saline.

FIGURE 26.21 A cancellous mineralized allograft bone graft was placed in the intrabony defect on the mesial and distal. Note the wicking of the blood into the area between the bone particles and the creation of an overall red tone to the otherwise white graft material.

- Place the CTG into the opened flap and suture it to the interproximal non-elevated tissue with interrupted sutures using VICRYL® P-3 5.0 sutures (Ethicon, Somerville, NJ, USA). In this case, mineralized cancellous allograft was placed in the interproximal two-wall defects (Figure 26.21).

Dentlearn.ir

FIGURE 26.22 A thick connective tissue graft was harvested from the palate for placement over the defect.

FIGURE 26.24 8-year follow-up shows thick, firm pink healthy tissue surrounding the implant.

FIGURE 26.23 The flap was elevated over the donor tissue and both the flap and graft were sutured into place.

- Stretch the elevated flap and cover the now stabilized graft. Affix the overlaying flap using a single sling with 5.0 VICRYL P3 sutures (Figure 26.23).
- If the overlying tissue is mainly from mucosa, another step may be done following healing where the mucosa is split to expose the underlying matured tissue (Figure 26.24).

Allograft Dermis

While autografts such as CTG and FGG have been considered the gold standard for soft tissue grafting, improvement in processing mechanisms and development of soft tissue allografts have made them a predicable alternative to autografts [17, 18]. There are many different acellular dermises available on the market, each type differing in processing and sterilization techniques, but all serve as a sterile acellular collagen matrix, which acts a scaffold for the ingrowth of surrounding tissue [18, 19]. The current processing technique involves complete removal of the epithelium by uncoupling the bond with the dermis, ensuring no damage to the dermal structure and maintaining the basement membrane. This process renders the dermal matrix free from cellular components, while the graft still contains blood vessel channels, collagen, elastin, and proteoglycans. The acellular dermal matrix allograft is in the thin to medium range of graft thickness (0.75–1.4 mm) [17].

The use of acellular dermal matrix is technique sensitive in the case of KT augmentation around implants. Allograft dermis does not provide a predictable outcome used as a free graft, due to the rate of necrosis and delay in vascularization when not covered by a flap, yet studies demonstrated that acellular dermal matrix (ADM) was a compatible graft material to increase keratinized tissue around implants [20–22].

To increase its predictability, we introduced a new procedure based mainly on stabilizing the dermis to the recipient site using tacks [22]. The surgical steps of this technique are described as follows:

- An incision following the muco-gingival junction is made.
- A full-thickness flap is reflected to expose the previous placed implant.
- The flap is apically positioned and stabilized with tacks to establish a new vestibule.
- Tacks are used to stabilize the ADM as well. No sutures are used.

Dentlearn.ir

We compared an FGG where the flap was sutured apically (control) and the contralateral flap where the ADM was used and stabilized with tacks [22]. We can see the dramatic effect that immobilization has had compared with the contralateral side where sutures were used. The basement membrane side of the ADM facing the oral cavity did slough partially due to lack of complete vascularization, but was repopulated by epithelium at 4–6 weeks. The tacks covered by tissue can be maintained submerged if no irritation is reported. Otherwise, it can be easily removed with topical anesthetic. We believe that stabilization of the ADM with tacks increases the chance of a plasmatic fluid phase in the first 3–4 days to populate the dermis and allow the neovascularization to take place, which is essential in any graft survivability [21]. Secondly, stabilizing the flap of the recipient site with tacks apically also allows, both in cases of FGG as described previously and in this case, for inhibiting the disengagement of the flap from the sutures and the coronal creep of the flap, which limits the chances of the graft maturing.

Tunnel Technique

The tunnel technique allows for placement of a CTG or an allograft dermis without reflection of a conventional flap. A tunnel flap is in essence an alteration of a pedicle flap, as it maintains blood supply from the papillary and the mucogingival aspects. This increase in blood supply compared to a conventional flap aids in graft stability and circulation [12]. A full-thickness dissection prepares the donor site to receive the CTG. This style of flap is difficult and time-consuming compared to a conventional flap. This technique of reflection should only be undertaken after many conventional flaps have been reflected and a working knowledge of the anatomy has been learned. This technique has many advantages, as it allows for increased blood supply and more rapid healing, but it lacks good stability of the graft [24–26]. Keep in mind that these techniques are mainly described for natural teeth.

In a tunnel technique, the recipient bed is a tunneled full-thickness pouch spanning the area of the defect. Elevate the tissue with a tunnel technique in the area of the defect without opening the flap at the gingival crest. Ensure the instrument tip is resting on the underlying osseous structure and with a gentle back-and-forth pushing motion develop and dissect a full-thickness pouch under the tissue. Extend the plane of dissection close to but not breaking the free gingival margin. Harvest a CTG from the palate as previously described or use an allograft dermis. In this case, a surgeon can thread the suture through the created pouch, grab the allograft, and pull it through the pouch. Once the graft is satisfactorily placed into the area, suture it into place through the flap while coronally elevating the flap using multiple interrupted sling sutures. Particularly when using an allograft dermis, the latter should be completely covered by the patient's tissue for successful results and the overlying flap needs to be at least 1 mm in thickness (Figures 26.25–26.27) [27, 28].

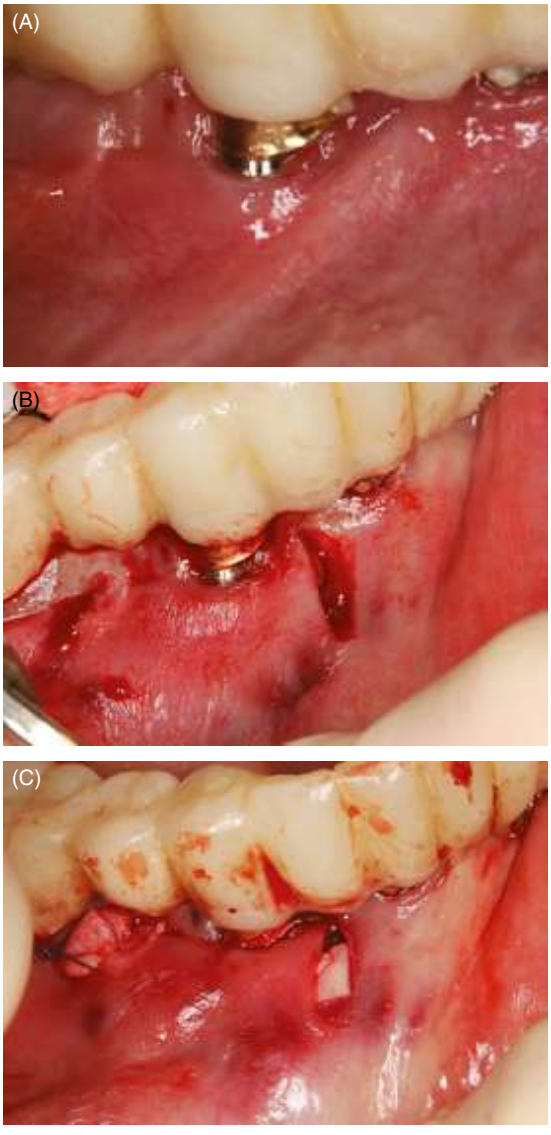

FIGURE 26.25 (a) There was thin tissue and a shallow vestibule in the area of this mandibular implant. A tunnel technique to place allograft dermis was used to thicken the tissue and deepen the vestibule. (B) Two vertical incisions were made and a full-thickness tunnel flap was elevated. (C) The allograft dermis was sutured on one end to aid in pulling the allograft dermis through the tunnel and passing it inside.

Dentlearn.ir

FIGURE 26.26 The allograft dermis was sutured in place and the vertical incisions were closed.

FIGURE 26.27 The area healed and providing a good vestibule for good plaque control.

TECHNIQUES FOR PAPILLA MANAGEMENT

Second-stage surgery or soft tissue augmentation in sites with multiple implants in a row presents a very specific challenge: managing the interproximal implant tissue. When using the roll technique, apically repositioned flaps, FGG, or CTG during the second stage around multiple implants, the interproximal areas are left exposed to heal through secondary intention. This type of healing can lead to inter-implant crestal bone loss and the formation of flat or even inverted inter-implant papilla tissue. All of these outcomes are of extreme esthetic detriment and prevent adequate embrasure space fill following final restoration. Fortunately, there are techniques to manage soft tissue in a way to correct or minimize this setback.

ROTATED PEDICULATED MARGINAL TISSUE (PALACCI)

In 1995 Palacci described a technique to create a papilla-like formation. The attached gingiva is displaced buccally, beginning with a crestal incision in line with the palatal or lingual limits of the implant cover screws, with two vertical releasing incisions and a full-thickness flap. The flap is elevated and pushed buccally, while the healing abutments are placed to hold the flap buccally. The excess buccal tissue is dissected into pedicles that are then rotated into the interproximal spaces. Dissection and rotation are done with semi-lunar incisions starting from the distal and rotation of the pedicle 90 degrees in the palatal direction. The pedicles should be sutured without tension or engagement of the pedicles; a figure-eight suture is suggested to hold them in place [29]. The drawback of this suturing approach is that the peak of the rotated papilla is not attached fully to have an adequate blood supply in the early phases of healing, considering that the lingual flap does not have a great blood supply to begin with after the tooth loss.

ROTATED PEDICULATED LINGUAL MARGINAL TISSUE (EL CHAAR)

A major modification to the Palacci technique takes advantage of the abundance of soft tissue on the palate, while reducing the risk of buccal gingival recession and the early necrosis of the rotated papilla that can be caused by use of the buccal as a donor site. In this modification, the attached gingiva is displaced buccally, beginning by using the U-shaped flap described earlier, by having the crestal incision over the center of the cover screws. The elevated flap is displaced buccally and is secured at the level intended either coronally or apically.

Contrary to the Palacci technique, the pedicle is created from the palatal tissue. That is, it is laying over half of the cover screws and rotated forward rather than from the buccal. This is advantageous, because no buccal KT is sacrificed. The rotated pediculated papilla-like tissue is sutured to the buccal flap using a horizontal mattress suture. The sutures start from the buccal flap, allowing the pediculated papilla to cover the interproximal bone and lay passively in the interproximal space, which is a very important variant to the Palacci technique, securing the rotated pedicle more and accelerating the revascularization between the two joining tissues.

This technique can be utilized anywhere, including in the anterior. In cases where both right and left sides are involved, one might end up having two rotated papillae in the mid-line or inter-implant in positions of the upper right and left central incisors. Before committing the two sides, one has to measure the inter-implant space. If the mid-line interproximal space is 3 mm, then one side's (right or left) rotated pedicle should fill up the space. If that space exceeds 4 mm, then the two pedicles from both sides, right and left, should be rotated to fill up the space. If needed, those two pedicles can be affixed together via 6.0 polypropylene sutures (Figure 26.28–26.31).

Dentlearn.ir

FIGURE 26.28 Maxillary posterior prior to placement of two adjacent implants and closure using the rotated pediculated lingual marginal tissue El Chaar technique. This technique can be used at the time of single-stage implant placement or during implant uncovering of adjacent implants. Note the inadequate keratinized tissue on the buccal.

FIGURE 26.29 A U-shape flap as described previously is made with full-thickness flap elevation. Two Straumann® TLX implants (Institut Straumann, Basel, Switzerland) were placed in a previously grafted maxillary sinus.

FIGURE 26.30 After the healing abutments were placed and the flap secured at the coronal level, a pedicle was dissected out of the lingual tissue and rotated to the interproximal and sutured to the buccal flap with a horizontal mattress suture.

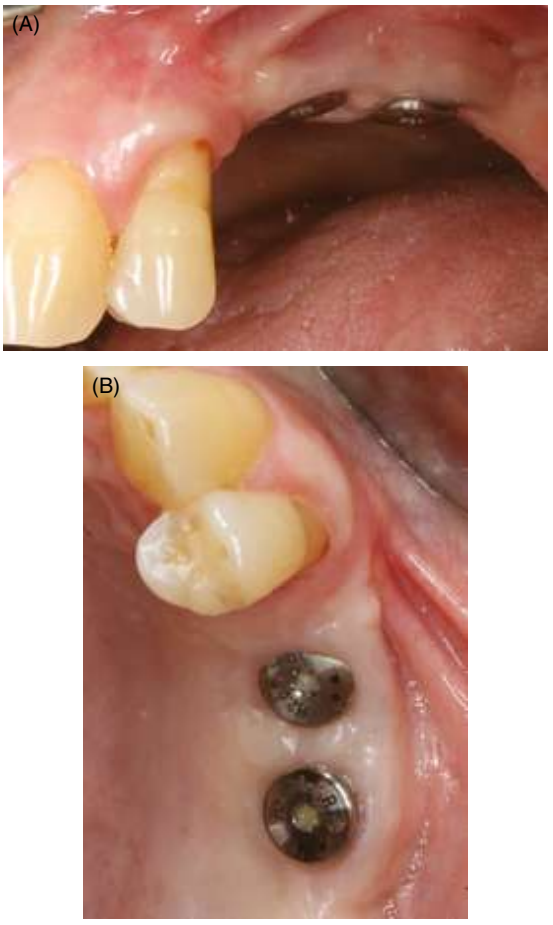

FIGURE 26.31 (A) Note the abundant keratinized soft tissue height and papilla-like structure present between the two healing abutments, most visible in the buccal view. (B) Palatal view showing the thickness achieved and the continuous contour with the adjacent teeth.

SOFT TISSUE TECHNIQUES FOR EXTRACTION SOCKET GRAFTING

It has been well established that after extraction of a tooth, the alveolus undergoes a volumetric change [30] and the thinner the phenotype, the more volumetric change will take place [31] by means of losing buccal bone. This has a vast effect on the esthetics due to the flattening of the gingival scallop, which is the critical part of the esthetics. This becomes more of an issue when we have loss of interproximal bone, which will lead to proximal attachment loss on the adjacent teeth, mainly the papilla. El Chaar [32] suggested soft tissue coverage at the time of socket grafting in a single-rooted maxillary tooth. Without altering the gingival scallop, in 2012 El Chaar introduced an original technique for posterior maxillary extraction teeth and a modification for maxillary anterior teeth, using a rotated

Dentlearn.ir

pedicle graft from the palate to seal the socket, which allows the gingival scallop to be preserved intact at the time of hard tissue grafting [33, 34]. In 4–6 months, implant placement can be done flapless, especially with the advent of digital dentistry, increasing the accuracy and allowing for accurate temporization to maximize the esthetic outcome (Figures 26.32–26.40) [35].

FIGURE 26.32 A 24-year-old female presented with composite restored centrals with a very pronounced gingival scallop (A) and fractured roots, with a history of endodontic treatment and reimplantation when she was 11 years old due to a bike accident (B).

FIGURE 26.33 An atraumatic extraction was done.

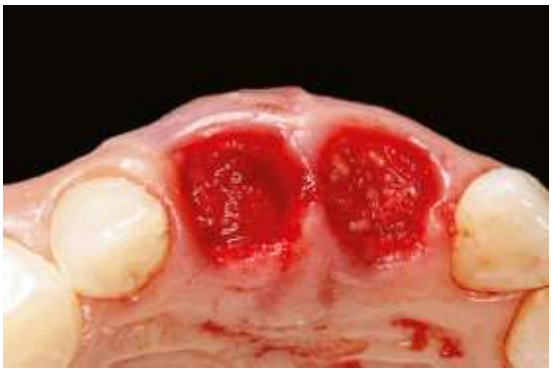

FIGURE 26.34 The socket was grafted with a layered cancellous, cortical mineralized allograft.

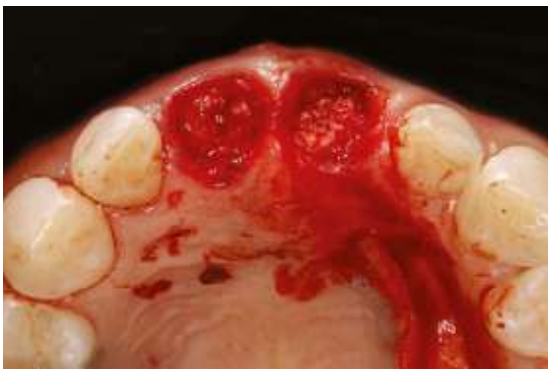

FIGURE 26.35 Harvesting of the connective tissue starts from the disto-lingual angle of the canine, leaving it pediculated anteriorly. The de-epithelization of the palatal tissue will be done from that point to the lingual gingival margins of the extracted central on both sides.

Dentlearn.ir

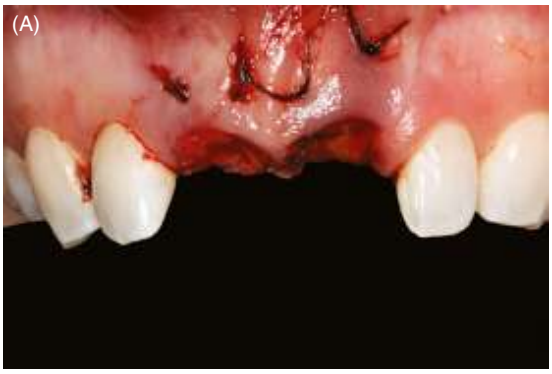

FIGURE 26.36 (A, B) The pediculated rotated subepithelial connective tissue graft is rolled over the socket and laid inside of it in the coronal part, and secured by three horizontal mattresses from the buccal side.

FIGURE 26.37 6 months' healing (A) buccal and (B) palatal views of the site prior to implant placement.

FIGURE 26.38 A three-dimensional printed digital guide for implant placement is inserted.

FIGURE 26.39 The two implants placed flaplessly to the needed depth.

FIGURE 26.40 Facial view of the temporary in place, 4 months post placement.

Dentlearn.ir

CONCLUSION

The need for adequate soft tissue around dental implants is mandatory not only for adequate plaque control, but also for long-term implant health. In the initial treatment planning, the clinician should assess the presence of KT and explore means of correction if it is missing or inadequate. Clinicians should educate the patient about the soft tissue correction procedure if it is needed. With the advent of digital technology, the integration of soft tissue in cone beam tomography treatment planning, by compiling/stitching the two files together, can guide the clinician on being ideally prepared for comprehensive implant planning and treatment.

REFERENCES

1. Berglundh T, Armitage G, Araujo MG et al. Peri-implant diseases and conditions: Consensus report of workgroup 4 of the 2017 World Workshop on the Classification of Periodontal and Peri-Implant Diseases and Conditions. *J Periodontol.* 2018;89:S313–S318.
2. Buser D, Martin W, Belser UC. Optimizing esthetics for implant restorations in the anterior maxilla: Anatomic and surgical considerations. *Int J Oral Maxillofac Implants.* 2004;19(7):43–61.
3. Gomez-Roman G. Influence of flap design on peri-implant interproximal crestal bone loss around single-tooth implants. *Int J Oral Maxillofac Implants.* 2001;16:61–7.
4. Esposito M, Ekestubbe A, Gröndahl K. Radiological evaluation of marginal bone loss at tooth surfaces facing single Brånemark implants. *Clin Oral Implants Res.* 1993;4(3):151–7.
5. Scharf DR, Tarnow DP. Modified roll technique for localized alveolar ridge augmentation. *Int J Periodontics Restorative Dent.* 1992;12:415–25.
6. Langer B, Calagna L. The subepithelial connective tissue graft. *J Prosthet Dent.* 1980;44:363.
7. Langer B, Calagna L. The subepithelial connective tissue graft: A new approach to the enhancement of anterior cosmetics. *Int J Periodontics Restorative Dent.* 1982;2:22–33.
8. Langer L, Langer B. The subepithelial connective tissue graft for treatment of gingival recession. *Dent Clin North Am.* 1993;37:243–64.
9. Mörmann W, Schaer F, Firestone AR. The relationship between success of free gingival grafts and transplant thickness. Revascularization and shrinkage: A one-year clinical study. *J Periodontol.* 1981;52:74–80.
10. Sullivan HC, Atkins JH. Free autogenous gingival grafts. *I. Principles of successful grafting. Periodontics.* 1968;6:121–9.
11. Yu S-K, Lee M-H, Kim CS et al. Thickness of the palatal masticatory mucosa with reference to autogenous grafting: A cadaveric and histologic study. *Int J Periodontics Restorative Dent.* 2014;34:115–21.
12. Rose LF. Periodontics: Medicine, surgery, and implants. St. Louis, MO: Mosby; 2004.
13. Reiser G, Bruno J, Mahan P, Larkin L. The subepithelial connective tissue graft palatal donor site: Anatomic considerations for surgeons. *Int J Periodontics Restorative Dent.* 1996;16:131–7.
14. Tal H, Moses O, Zohar R et al. Root coverage of advanced gingival recession: A comparative study between acellular dermal matrix allograft and sub-epithelial connective tissue grafts. *J Periodontol.* 2002;73:1404–11.
15. Goaslind G, Roberston P, Mahan C et al. Thickness of facial gingiva. *J Periodontol.* 1977;48:768–71.
16. El Chaar ES, Oshman S, Danesh-Sani SA. et al. Increasing contact between soft tissue graft and blood supply. *J Cosmet Dent.* 2016;32(3):52–66.
17. Paolantonio M, Dolci M, Esposito P et al. Subpedicle acellular dermal matrix graft and autogenous connective tissue graft in the treatment of gingival recessions: A comparative 1-year clinical study. *J Periodontol.* 2002;73:1299–307.
18. Hirsch A, Goldstein M, Goultschin J, Boyan BD. A 2 year follow-up of root coverage using subpedicle acellular dermal matrix allografts and subepithelial connective tissue allografts. *J Periodontol.* 2005;76:1323–28.
19. Schlee M, Esposito M. Human dermis graft versus autogenous connective tissue grafts for thickening soft tissue and covering multiple gingival recessions: 6 months results from a preference clinical trial. *Eur J Implantol.* 2011;4(2):119–25.
20. Wei PC, Laurell L, Geivelis M et al. Acellular dermal matrix allografts to achieve increased attached gingiva. Part 1. A clinical study. *J Periodontol.* 2000;71:1297–305.
21. Park JB. Increasing the width of keratinized mucosa around endosseous implant using acellular dermal matrix allograft. *Implant Dent.* 2006;15:275–81.
22. Yan JJ, Tsai AY, Wong MY, Hou LT. Comparison of acellular dermal graft and palatal autograft in the reconstruction of keratinized gingiva around dental implants: A case report. *Int J Periodontics Restorative Dent.* 2006;26:287–92.
23. Shi Y, Segelnick SL, El Chaar ES. A modified technique of tacking acellular dermal matrix to increase keratinized mucosa around dental implants as an alternative to a free gingival graft: A case report. *Clin Adv Periodont.* 2020;10(4):175–80.
24. Zabalequi I, Sicilia A, Cambra J et al. Treatment of multiple adjacent gingival recessions with the tunnel subepithelial connective tissue graft: A clinical report. *Int J Periodontics Restorative Dent.* 1999;19:199–206.
25. Blanes RJ, Allen EP. The bilateral pedicle flap-tunnel technique: A new approach to cover connective tissue grafts. *Int J Periodontics Restorative Dent.* 1999;19(5):471–9.
26. Allen AL. Use of the supraperiosteal envelope in soft tissue grafting for root coverage. I. Rationale and technique. *Int J Periodontics Restorative Dent.* 1994;14:217–27.
27. Stefanini M, Zucchelli G, Marzadori M, de Sanctis M. Coronally advanced flap with site-specific application of connective tissue graft for the treatment of multiple adjacent gingival recessions: A 3-Year follow-up case series. *Int J Periodontics Restorative Dent.* 2018;38(1):25–33.

Dentlearn.ir

28. Cairo F, Cortellini P, Pilloni A et al. Clinical efficacy of coronally advanced flap with or without connective tissue graft for the treatment of multiple adjacent gingival recessions in the aesthetic area: A randomized controlled clinical trial. *J Clin Periodontol.* 2016;43(10):849–56.

29. Palacci P. Peri-implant soft tissue management: Papilla regeneration technique. In P Palacci, I Ericcson, P Engstrand, B Rangert (eds.), Optimal implant positioning and soft tissue management for the Brånemark system. Chicago, IL: Quintessence; 1995, 59–70.

30. Schropp L, Wenzel A, Kostopoulos L, Karring T. Bone healing and soft tissue contour changes following single-tooth extraction: A clinical and radiographic 12-month prospective study. *Int J Periodontics Restorative Dent.* 2003;23(4):313–23.

31. Chappuis V, Engel O, Reyes M et al. Ridge alterations post-extraction in the esthetic zone: A 3D analysis with CBCT. *J Dent Res.* 2013;92 (12 suppl):195S–201S.

32. El Chaar E, Oshman S. Single-rooted extraction sockets: Classification and treatment protocol. *Compend Cont Educ Dent.* 2016;37(8): 537–41.

33. El Chaar ES. Soft tissue closure of grafted extraction sockets in the posterior maxilla: The rotated pedicle palatal connective tissue flap technique. *Implant Dent.* 2010;19(5):370–77.

34. El Chaar E, Oshman S, Cicero G et al. Soft tissue closure of grafted extraction sockets in the anterior maxilla: A modified palatal pedicle connective tissue flap technique. *Int J Periodontics Restorative Dent.* 2017;37(1):99–107.

35. El Chaar E, White C, Salama T et al. Quantifying the emergence profile contour for immediate provisionalization: A proposed mathematical model. *J Oral Implantol.* 2021;47:191–8.

Dentlearn.ir

Dentlearn.ir

Alternative (to Bone Grafting) Surgical Techniques

SECTION VI

Chapter 27 Short Implants as an Alternative to Bone Augmentation in Implant Dentistry 479
Rolf Ewers and Boyd Tomasetti

Chapter 28 Zygomatic and Pterygoid Implants as an Alternative to Bone Augmentation in Implant Dentistry 495
Vishtasb Broumand

Chapter 29 Complete-Arch Dental Implant Treatment as an Alternative (to Bone Grafting) Surgical Technique 513

Chapter 29.1 Complete-Arch Dental Implant Treatment Using Photogrammetry and Delayed Immediate Loading 514
Ole T. Jensen and M. Donald Ross

Chapter 29.2 Maxillary Full-Arch Staged Ceramo-Metal Implant Rehabilitation 525
Len Tolstunov

Dentlearn.ir

Dentlearn.ir

Short Implants as an Alternative to Bone Augmentation in Implant Dentistry

CHAPTER 27

Short and ultra-short implants are an excellent alternative to bone augmentations. Their use will allow the surgeon to place implants when they would otherwise need to perform an additional surgical procedure. By having short and ultra-short implants as part of their armamentarium, surgeons will expose their patients to less risk and reduce the treatment cost (see Video 27.1).

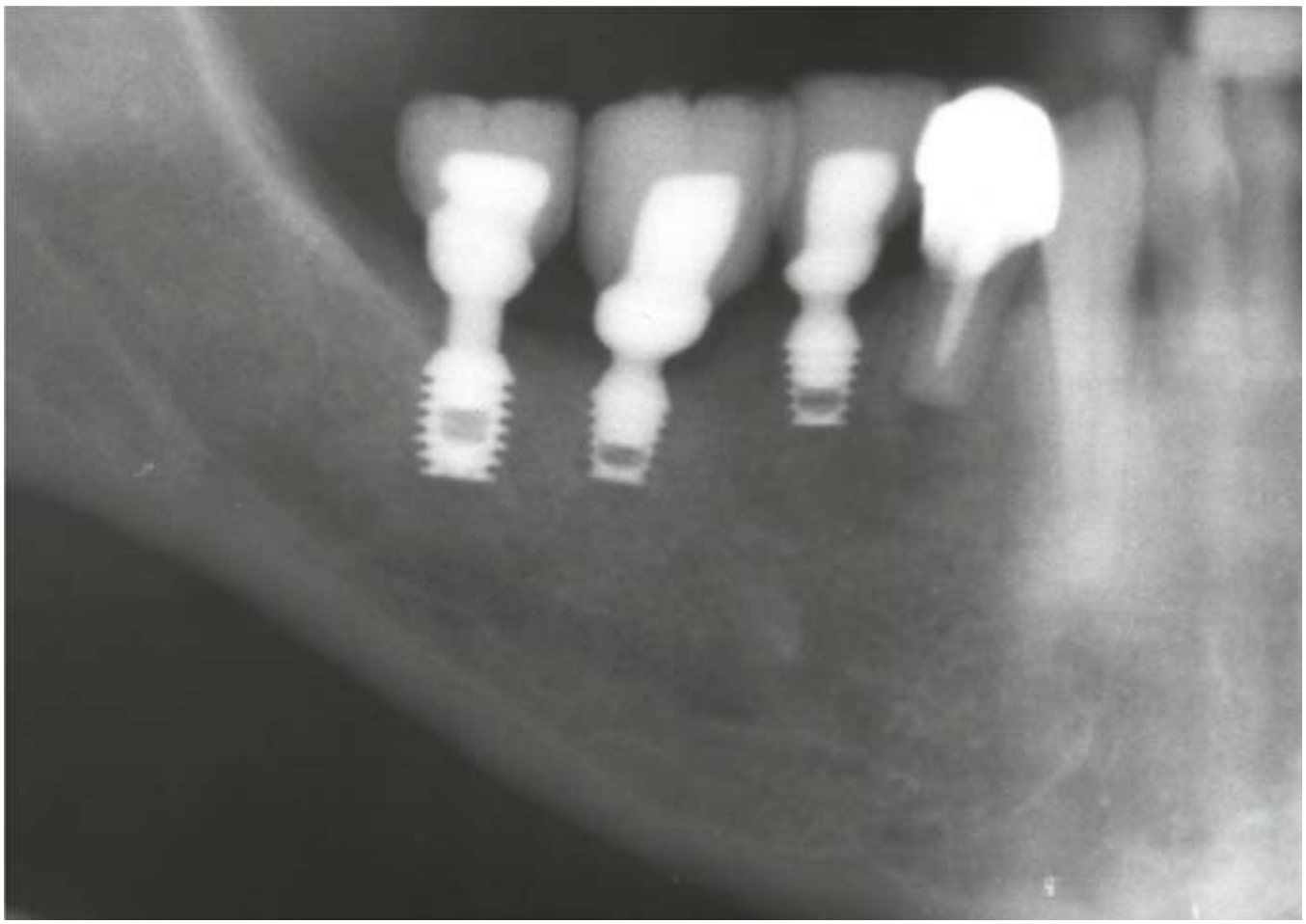

Dentlearn.ir

CHAPTER 27

Short Implants as an Alternative to Bone Augmentation in Implant Dentistry

Rolf Ewers[1] and Boyd Tomasetti[2]

[1]*Department of Cranio-Maxillofacial and Oral Surgery, Medical University of Vienna, Austria*

[2]*Oral and Maxillofacial Surgery Residency Program, Denver Health Medical Center, Denver, CO, USA*

The atrophic maxilla and mandible have been a problem for implant surgeons and restorative dentists since before the introduction of the osseointegrated implant. With the development of the modern osseointegrated implant, the need for a method to deal with these atrophic jaws came to the forefront. This was especially important as the initial implants had a length of 12–16 mm.

In 1963, Atwood introduced a classification for the post-extraction mandible [1]. The atrophic maxilla was introduced in the 1970s [2]. In 1988, Cawood and Howell developed a classification for the atrophic maxilla and mandible that was based on radiographic findings [3]. The Cawood–Howell classification of atrophic jaws is still in use today. It is based on the amount of residual bone that is available: I, dentate alveolar ridge; II, early edentulous ridge; III, high well-rounded ridge; IV, knife-edged ridge; V, low well-rounded ridge; and VI, low depressed ridge.

Initially, most of the attention was directed toward the atrophic posterior maxillary ridge, where a pneumatized maxillary sinus made it difficult to place implants. In 1974, Tatum developed the original sinus lift procedure and did *not* use any graft material – his findings were presented at the Alabama Implant Congress in 1976 [4]. It was not long after this that Boyne and James described a lateral approach sinus graft using autogenous bone as the graft material [5]. Sinus grafting soon became the recognized standard of care for dealing with the atrophic posterior maxilla. With the development of more sophisticated surgical techniques, allografts and xenografts replaced autogenous bone as the choice for graft materials. Consensus Conferences held by the American Association of Oral and Maxillofacial Surgeons (AAOMS) and the Academy of Osseointegration (AO) attested to the efficacy of the lateral approach to sinus grafting using an appropriate graft material [6–8]. Ewers in 2005 published a seminal article on the efficacy of the lateral approach sinus graft using an allograft [9].

The advent of short and ultra-short implants gave surgeons an option to avoid grafting sites in both the maxilla and mandible. These implants now allow the surgeon to avoid extensive grafting of both vertical and transverse dimensions in highly atrophic areas. The success rate for short and ultra-short implants is like that of traditional-length implants [10].

Some of the areas where short implants can be placed without grafting are as follows:

- A single-tooth defect where the residual bone is 8 mm or less.
- A very thin maxillary or mandibular ridge where narrow short and ultra-short implants can be used in conjunction with a ridge split.
- Areas where grafting or distraction would be needed prior to implant placement to avoid the inferior alveolar nerve.
- Maxillary tuberosity areas.
- A minimally invasive crestal sinus lift.
- Full-arch fixed hybrid prosthesis on four or occasionally three implants in cases of severely atrophic maxillary or mandibular alveolar ridges.

In this chapter we will describe the techniques for using short implants as an alternative to bone augmentation. The cases will give examples of how to select the appropriate patient and illustrate the surgical approaches we have used in our surgeries. All our cases involve the use of the Bicon SHORT® and ultra-short implants (Bicon, Boston, MA, USA). In cases of full-mouth rehabilitation, we have used the TRINIA® prosthesis (Bicon).

Traditionally, the implant-supported fixed prosthesis was screw-retained on a framework that was cast, milled, or laser welded. By the mid 2000s the fixed prosthesis was being fabricated in all ceramics. Some years later, fiber-reinforced

Essential Techniques of Alveolar Bone Augmentation in Implant Dentistry: A Surgical Manual, Second Edition. Edited by Len Tolstunov.
© 2023 John Wiley & Sons, Inc. Published 2023 by John Wiley & Sons, Inc.
Companion website: www.wiley.com/go/tolstunov/essential

Dentlearn.ir

composite (FRC) material was being used. The FRC material and computer-aided design/manufacturing (CAD/CAM) technology allowed for the development of a metal-free fixed prosthesis. This has resulted in a lower-cost prosthesis that can be used in severely atrophic jaws in conjunction with short implants.

TRINIA is a CAD/CAM-reinforced polymer used as a framework in non-metallic prosthetic restorations. The material consists of a glass fiber network and multilayer polymer held together by an epoxy resin. This combination replaces the metallic framework of a traditional dental prosthesis. Perhaps TRINIA's greatest attribute is its high flex strength along with great compressive strength. The TRINIA material also comes in a tooth-like color, thus enhancing the esthetics of the prosthesis. All these attributes combine to make TRINIA the ideal material for the full-arch prosthesis that will be used on four or fewer short and ultra-short implants.

CASE PRESENTATIONS

CASE 1

Thin alveolar ridges with a Cawood–Howell atrophy class IV–V are often treated after ridge-splitting methods before inserting standard long implants [11, 12]. As an alternative, we are using narrow 3.0 × 8.0 mm short Bicon implants without widening or splitting the alveolar crest (see Video 27.2).

This case shows a 45-year-old female with a very thin and steep alveolar crest in the premolar region (Figures 27.1 and 27.2). As the alveolar crest is sometimes very steep on the buccal side, there will be a discrepancy in the position of the implant on the lingual and buccal sides (Figures 27.3 and 27.4). Performing slow-motion osteotomy at 50 rpm without irrigation, the surgeon can collect autogenous bone chips for later augmentation (Figure 27.5) [13]. After finishing the 3 mm wide osteotomy and cleaning the lower part of the osteotomy with an excavator instrument (Figure 27.6), the 3.0 × 8.0 mm short Bicon implant with the black healing plug in place is inserted with low pressure into the osteotomy (Figure 27.7). With the seating tip on a straight handle, the implant is then pushed gently into its final position

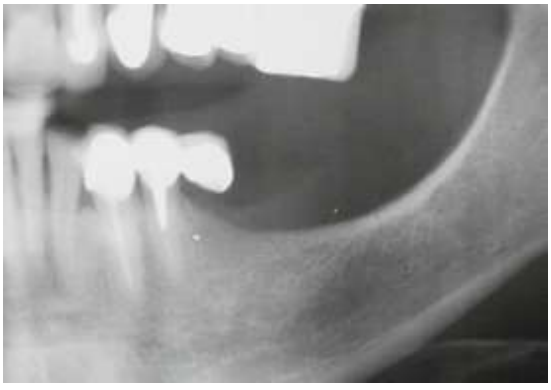

FIGURE 27.1 Section of panoramic radiograph of a 45-year-old female with vertical and horizontal atrophy of the premolar and molar region class IV–V.

FIGURE 27.2 Cone beam computed tomography of left premolar region with very thin alveolar crest.

FIGURE 27.3 Positioning of a paralleling pin after osteotomy with the pilot drill in the mandibular left canine area.

Dentlearn.ir

FIGURE 27.4 Situation without paralleling pin. Note the difficult situation with the steep alveolar crest.

FIGURE 27.5 50 rpm osteotomy with the 3 mm latch reamer and not using irrigation, collecting autogenous bone chips for later augmentation.

(Figure 27.8). Note that the implant, due to the steep alveolar ridge on the lingual side, is about 6 mm subcrestal on the buccal and on the lingual side about 3 mm supracrestal. The second seated implant is an ultra-short Bicon implant, size 4.0 × 5.0 mm, and is positioned about 3 mm subcrestally.

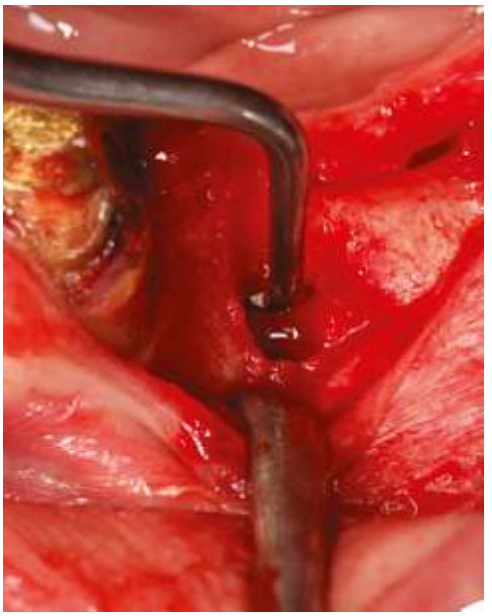

FIGURE 27.6 Removing autogenous bone chips out of the lower part of the osteotomy with an excavator instrument.

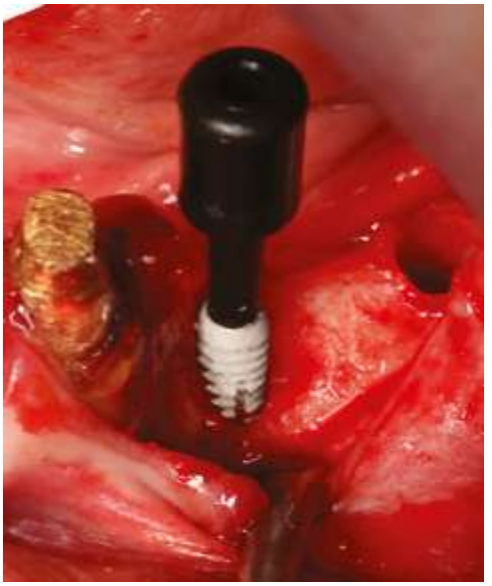

FIGURE 27.7 Inserting the 3.0 × 8.0 mm short Bicon implant with the black healing plug.

This implant is very close to the inferior alveolar nerve (Figure 27.9). The two implants are covered with the collected autogenous bone chips (Figure 27.10) before suturing (Figure 27.11). The post-operative panoramic radiograph

Dentlearn.ir

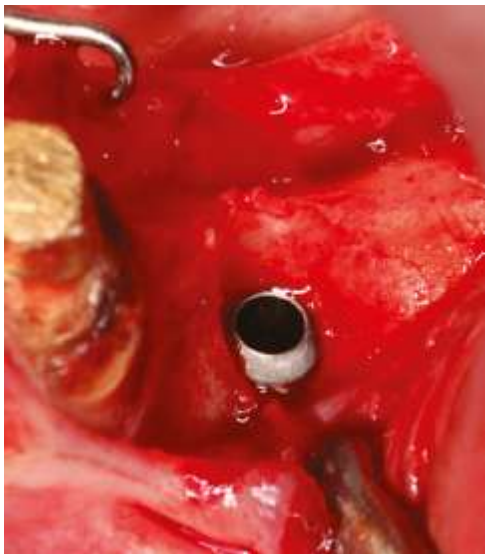

FIGURE 27.8 Final insertion position of the 3.0 × 8.0 mm short Bicon implant. Note that the implant is due to the steep alveolar ridge on the lingual side about 6 mm subcrestal and on the lingual side about 3 mm supracrestal.

FIGURE 27.9 Situation after also inserting the 4.0 × 5.0 mm ultra-short Bicon implant in the mandibular left first molar and covering both with the healing plug. Note the 3 mm subcrestal position of the implant.

reveals the adequate position of the two sort and ultra-short Bicon implants (Figure 27.12).

After an osseointegration time of 3 months, the implants are uncovered, and the single loaded integrated abutment crowns (IACs) will be placed (Figures 27.13 and 27.14) [14, 15]. Figures 27.15 and 27.16 show the 11-year recall with a

FIGURE 27.10 Situation after covering both implants with the freshly collected autogenous bone chips during the 50 rpm osteotomy.

FIGURE 27.11 Situation after continuous suturing with 5/0 Supramid® suture (S. Jackson, Inc., Alexandria, VA, USA).

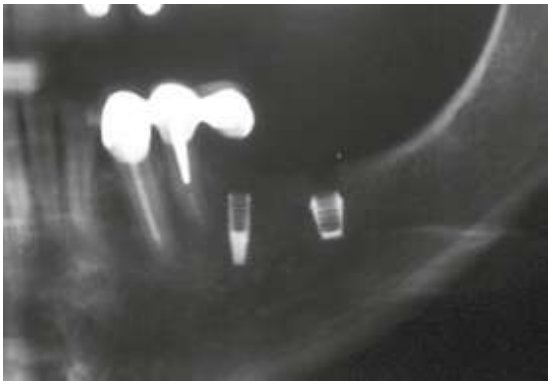

FIGURE 27.12 Section of panoramic radiograph after inserting a 3.0 × 8.0 mm short and a 4.0 × 5.0 mm ultra-short Bicon implant.

Dentlearn.ir

FIGURE 27.13 Section of panoramic radiograph after inserting two cemented integrated abutment crowns.

FIGURE 27.14 Clinical situation after incorporating the two cemented integrated abutment crowns.

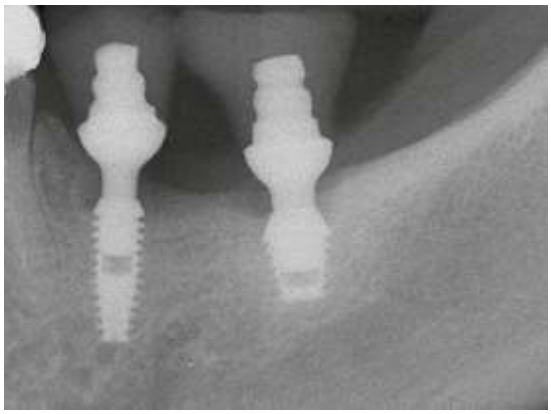

FIGURE 27.15 Section of panoramic radiograph at 11-year recall.

very satisfying result. There was a very thin alveolar crest in the premolar region, and we were able to insert a 3.0 × 8.0 mm short implant. There was no marginal bone loss, and the peri-implant mucosa situation was excellent.

FIGURE 27.16 Clinical situation at 11-year recall.

CASE 2

After extraction, placing an immediate implant with primary wound closure can be a very successful procedure. This case demonstrates a 47-year-old male who had the maxillary right second molar removed (Figure 27.17; see Video 27.3). Following removal of the tooth, a trapeze-like vestibular mucoperiosteal flap is raised from the mesial of the third molar to the distal of the first molar. The periosteum is then incised vertically on the mesial side. To prevent perforating through the mucosa, it is advisable to hold the blade at a 45-degree angle. Only the periosteum is incised, therefore the underlying tissue will not be harmed (Figure 27.18). Using rounded curved scissors, a tunnel is created between the periosteum and the mucosal layer (Figure 27.19). The next cut is made vertically at an angle of 45 degrees along the distal aspect of the periosteum, allowing the tip of the scissors to penetrate the second vertical periosteal cut and completing the tunnel (Figure 27.20). The final step is a high horizontal periosteal cut until the periosteal tissue is loose (Figure 27.21) and the tissue can be separated

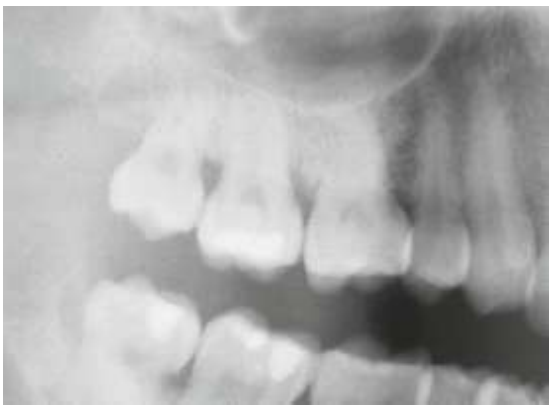

FIGURE 27.17 A panoramic radiograph of a 47-year-old male before extraction of the maxillary right second molar.

Dentlearn.ir

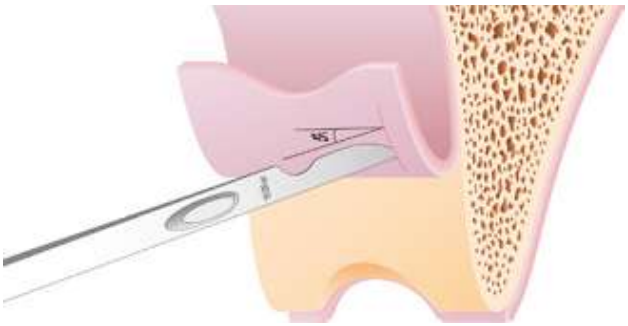

FIGURE 27.18 Schematic demonstrating the safest way to cut the periosteum without perforating the mucosa by holding the blade at a 45-degree angle.

FIGURE 27.19 Intraoperative photograph demonstrating preparation of the tunnel with slightly curved scissors.

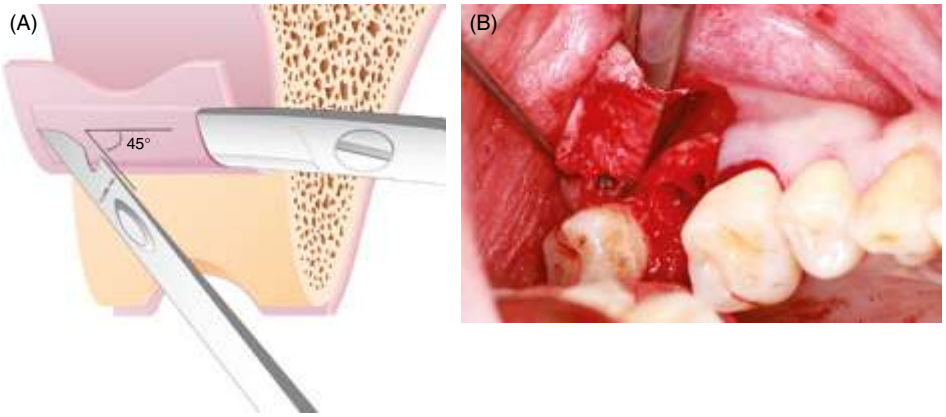

FIGURE 27.20 (A) Schematic showing the second vertical cut at an angle of 45 degree toward the tip of the scissors. As soon as the periosteum is perforated, the tunnel will be finished. (B) Intraoperative photograph showing perforation of the second vertical periosteum cut in the dorsal region of the flap.

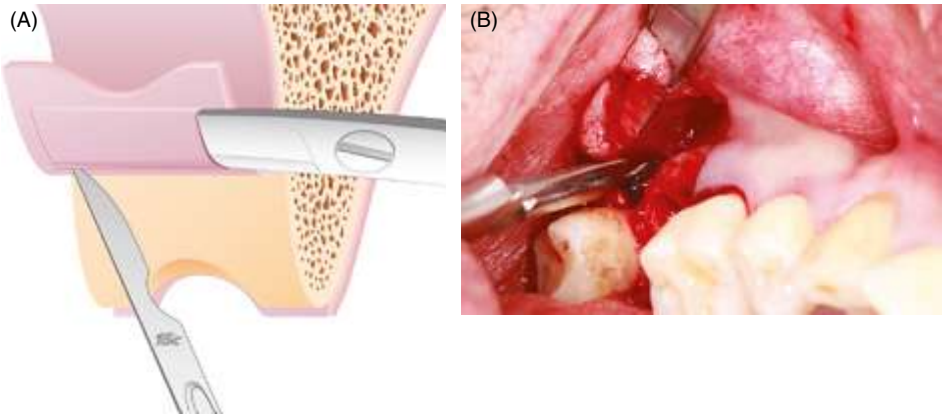

FIGURE 27.21 (A) Schematic demonstrating the horizontal periosteum incision in the upper vestibule with scissors in place. (B) Photograph of the surgical site showing the incised periosteum.

completely from the underlying mucosal tissue with a blunt Freer instrument (Figure 27.22A). The loose periosteal flap may now be stretched over the extraction defect. It is important to ensure that the length of the flap will allow for tension-free primary closure of the extraction defect (Figure 27.22B).

After careful curettage of the three root sockets, implant site drilling begins with a pilot drill in the palatal socket. The osteotomy is enlarged to the desired width with latch or hand reamers. All drilling is done at 50 rpm or less without irrigation, allowing collection of autogenous bone

Dentlearn.ir

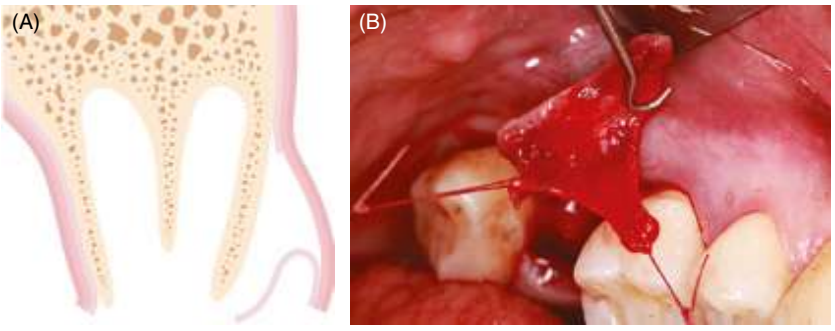

FIGURE 27.22 (A) The periosteal tissue is completely separated from the underlying mucosal tissue (transverse view). (B) Intraoperative photograph showing the loose periosteal flap pulled over the defect, to demonstrate whether the length will be enough for a primary closure of the extraction defect.

FIGURE 27.23 Widening of the osteotomy to the desired width with latch- or hand reamers. Drilling is done at 50 rpm or less without irrigation, in order to collect autogenous bone chips for later coverage of the implants.

FIGURE 27.24 Intraoperative photograph showing insertion of a 5.0 × 6.0 mm ultra-short Bicon implant into the palatal root socket.

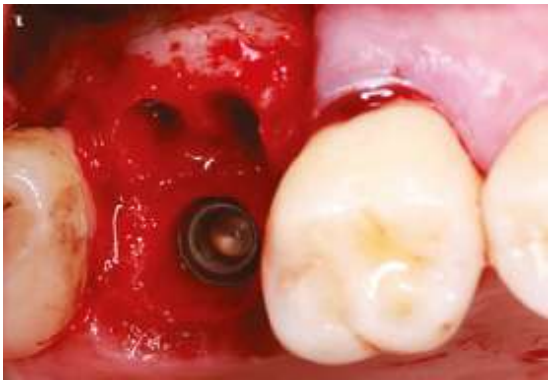

FIGURE 27.25 The seated 5.0 × 6.0 mm ultra-short Bicon implant. Note that the insertion depth is about 3 mm subcrestal.

FIGURE 27.26 Intraoperative site before closing the wound, showing application of the collected autogenous bone chips to cover the implant and the rest of the socket defects.

chips for later coverage of the implants (Figure 27.23). Some augmentation material may, at the surgeon's discretion, be placed into the bottom of the socket. A 5.0 × 6.0 mm ultra-short Bicon implant was inserted into the palatal root socket (Figure 27.24). Figure 27.25 shows the seated implant without a healing plug, which will be inserted as the next step. Note that the insertion depth always should be at least 2 mm, and better 3 mm, subcrestal. Before closing, the previously collected autogenous bone chips are used to cover the implant and the remaining socket defects (Figure 27.26). The final step is the wound closure with the periosteal flap (Figure 27.27A). First, we undermine the periosteum on the palatal side and secure the periosteum flap under the palatal periosteum with at least two double mattress sutures (Figure 27.27B). Successful preparation of the envelope, allowing it to be both loose and flexible, will enable us to

Dentlearn.ir

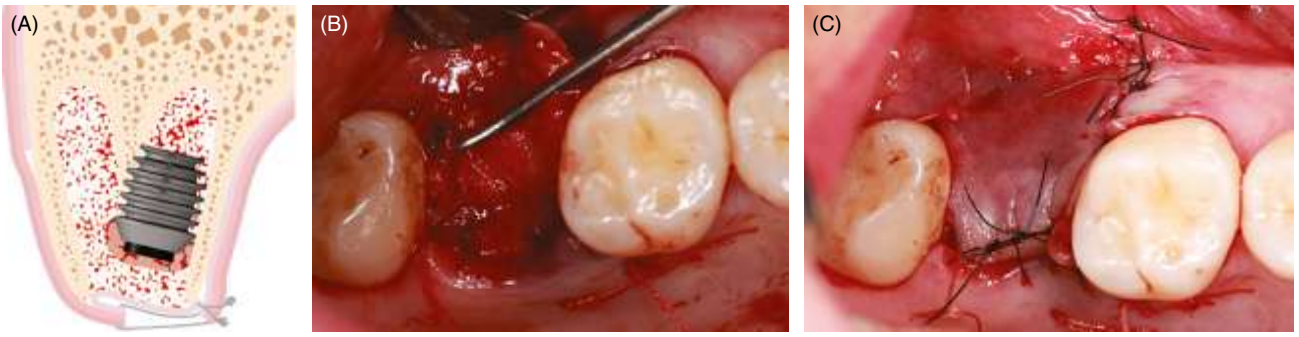

FIGURE 27.27 (A) Schematic showing the last operating step of closing the wound with the periosteal flap. (B) Intraoperative site demonstrating undermining the periosteum on the palatal side and pulling the periosteal flap under the palatal periosteum. Note that two double mattress sutures are used to pull the flap. (C) Intraoperative site of a successful preparation of the envelope, as in this operation the mucosa was so loose and flexible that the mucosa layer could be pulled to the palatal mucosa to perform with single-knot sutures a primary double-layer closure.

FIGURE 27.28 A panoramic radiograph taken after inserting the 5.0 × 6.0 mm ultra-short Bicon implant. Note the 3 mm subcrestal positioning.

easily pull the mucosa layer to the palatal mucosa and perform a primary double-layer closure (Figure 27.27C).

The post-operative radiograph shows an excellent position of the implant (Figure 27.28). The post-operative implant and wound healing were uneventful (Figure 27.29A) and 6 months later (Figure 27.29B) the implant was uncovered. Due to the collected autogenous bone placed at the original surgery, the implant and surrounding area were completely covered with new bone (Figure 27.30). With a round bur, the bone was carefully removed (Figure 27.31). Figure 27.32 shows the implant after the excess bone had been removed. Note the 3 mm subcrestal position of the implant. After removing the healing plug, inserting the impression post, suturing the surrounding mucosa, and inserting the impression sleeve (Figure 27.33), an implant-level impression for an IAC was taken. The clinical view after inserting the IAC crown is seen in Figure 27.34. Figures 27.35 and 27.36 show the images of the IAC crown and implant in the maxillary right second molar region.

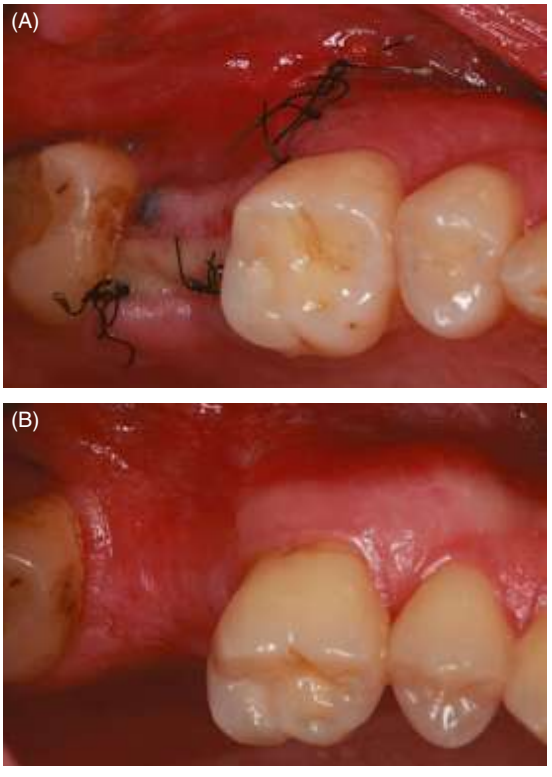

FIGURE 27.29 (A) Immediate post-operative implant placement and closure. (B) Six months post surgery, immediately prior to uncovering the implants.

Dentlearn.ir

FIGURE 27.30 Intraoperative site showing complete bone coverage of implant and surrounding areas that were covered with autogenous bone.

FIGURE 27.31 Removing the extra bone with a round bur.

FIGURE 27.32 Photograph showing the implant after bone was removed. Note the 3 mm subcrestal position.

FIGURE 27.33 Implant with the impression post and impression sleeve in place and ready for an implant-level impression.

FIGURE 27.34 Clinical view after inserting the integrated abutment crown.

FIGURE 27.35 Radiograph after inserting the integrated abutment crown into the implant well. Note the subcrestal position of the implant and the bone surrounding the abutment shaft.

Dentlearn.ir

FIGURE 27.36 Section of a panoramic radiograph after inserting the integrated abutment crown into the well of the implant.

FIGURE 27.37 Clinical view at the 6.5-year recall showing good peri-implant mucosa.

The clinical (Figure 27.37) and radiological (Figures 27.38A and B) results at the 6.5-year recall show good peri-implant mucosa and implant bone level. The radiographs show very active mineralization around the implant. Note that due to the 3 mm subcrestal positioning of the implant, there is some crestal bone growth.

CASE 3

This patient is a 51-year-old female with a loose mandibular right first molar implant and a loose root canal–treated mandibular right second premolar with a periapical infection (Figure 27.39; see Video 27.4). The patient did not want the

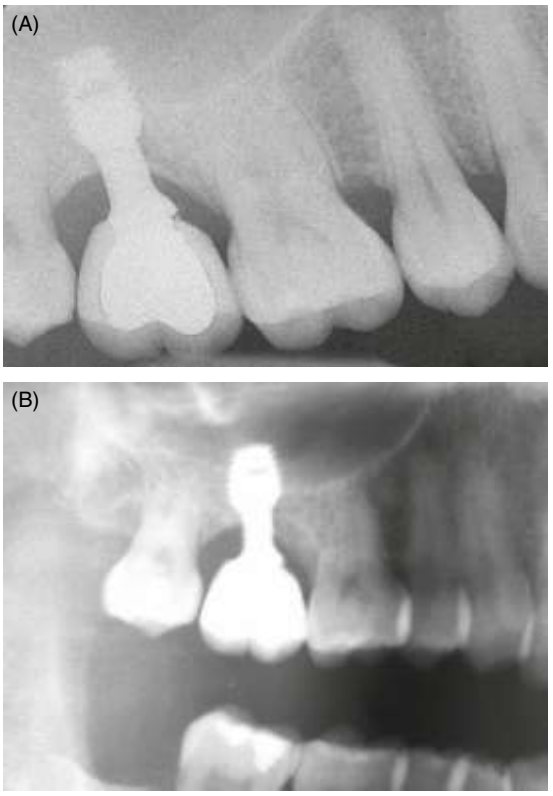

FIGURE 27.38 (A) Radiograph at the 6.5-year recall. Note the bone level over the implant and around the shaft of the abutment. (B) Section of a panoramic radiograph at the 6.5-year recall, again showing good crestal bone level.

FIGURE 27.39 Section of panoramic radiograph of a 51-year-old female with an implant region of the mandibular right first molar and a mandibular right second premolar with periapical infection.

Dentlearn.ir

mandibular right first premolar tooth removed. After removing the mandibular right first molar implant and the second premolar tooth (Figure 27.40), we waited for 8 weeks before inserting the implants. Figure 27.41 shows the intraoperative situation after raising the mucoperiosteal flap. After beginning drilling of the three implant sites with the pilot drill, paralleling pins were inserted to check the desired position and angulation of the implants (Figure 27.42). The three osteotomies were completed with ascending latch reamers (Figure 27.43). The drilling was done at less than 50 rpm without irrigation, and autogenous bone chips were collected.

Three ultra-short Bicon implants were placed: the mandibular second premolar and first molar regions received 4.0 × 5.0 mm implants and the mandibular second molar region a 4.5 × 5.0 mm implant. Guide pins were used to recheck the implant angulation to the neighboring teeth (Figure 27.44). In Figure 27.45 the subcrestal positions of the implants can be seen. The implant insertion procedure was completed by inserting the shortened healing plugs (Figure 27.46). Prior to closing the mucosa, the three implants were covered with the previously collected autogenous bone chips (Figures 27.47 and 27.48). The muco-periosteal flap was closed with 5-0 non-resorbable interrupted sutures (Figure 27.49).

FIGURE 27.40 Section of panoramic radiograph after removing implant in the mandibular right first molar region and the mandibular right second premolar with root canal and periapical infection.

FIGURE 27.41 Intraoperative situation after raising the muco-periosteal flap.

FIGURE 27.42 Situation after drilling the three bone cavities with the pilot drill and inserting the paralleling pins to check the desired position and angulation of the implants.

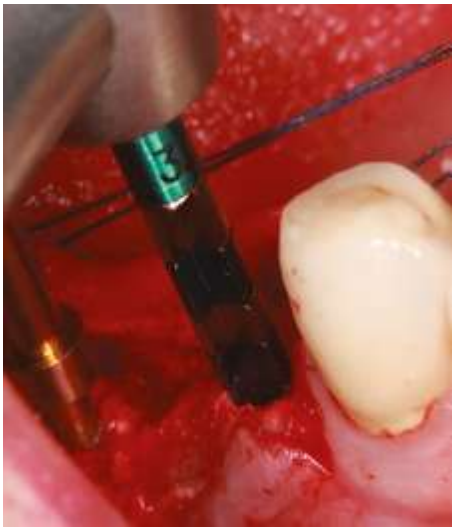

FIGURE 27.43 Step by step performing the three osteotomies with the ascending latch reamers.

Dentlearn.ir

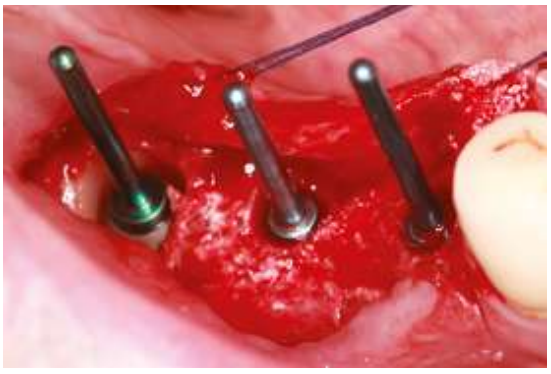

FIGURE 27.44 Inserting the guide pins to recheck the implant angulation to the neighboring teeth.

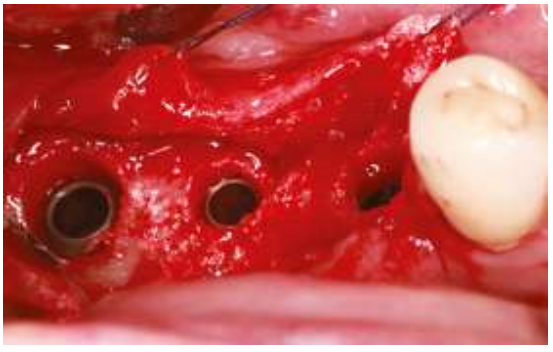

FIGURE 27.45 Situation after inserting three ultra-short Bicon implants. Note the subcrestal positions of the implants.

FIGURE 27.46 Situation after inserting the three shortened healing plugs.

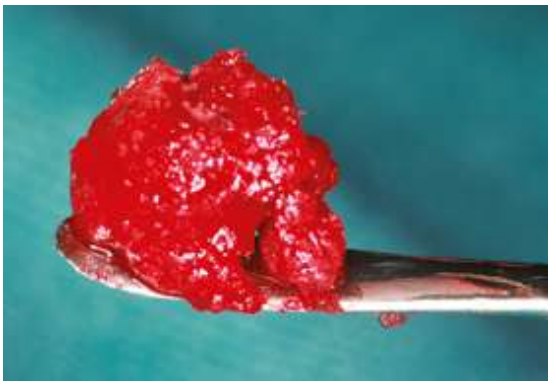

FIGURE 27.47 Collected autogenous bone chips.

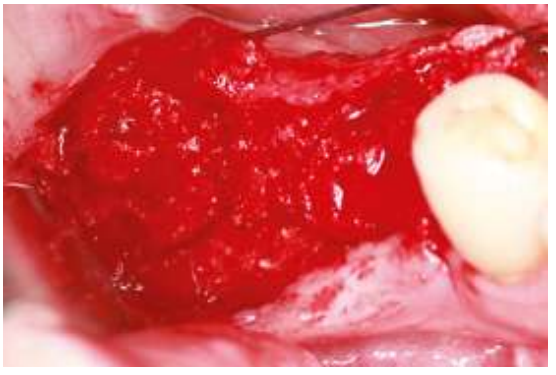

FIGURE 27.48 Situation after covering the three implants with collected autogenous bone chips.

FIGURE 27.49 Situation after covering the muco-periosteal flap with 5/0 non-resorbable interrupted sutures.

Dentlearn.ir

The post-operative panoramic radiograph reveals a very satisfactory position of the three implants (Figure 27.50). The implant in the mandibular right second molar area is far away from the alveolar neve. The uncovering procedure of the implants in the mandible took place after 3 months. After impression taking in the same session as the uncovering, we inserted temporary abutments to assisting in forming the peri-implant mucosa (Figure 27.51). The final three single IACs were inserted 10 days later (Figure 27.52). Figure 27.53 shows the three single IACs and Figure 27.54 is the panoramic radiograph at initial loading. The clinical and radiological result at the 8.5-year recall session revealed an excellent result. The mucosa around the crowns and abutments showed no inflammation and, in the radiograph, the crestal bone showed no resorption (Figures 27.55 and 27.56).

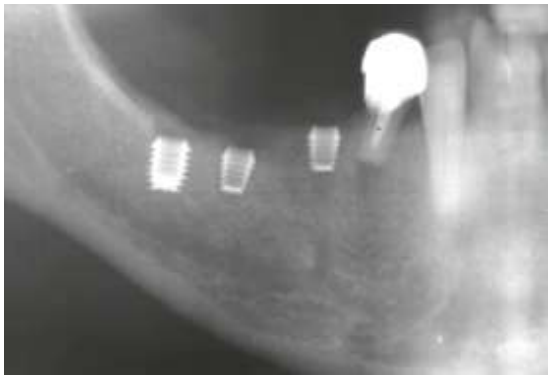

FIGURE 27.50 Section of panoramic radiograph after inserting three ultra-short Bicon implants: 4.0 × 5.0 mm for the mandibular right second premolar and first molar region and 4.5 × 5.0 mm for the mandibular right second molar region.

FIGURE 27.51 After inserting temporary abutments to form the peri-implant mucosa.

FIGURE 27.52 Finalized three single integrated abutment crowns for insertion into the implants in a stone model mounted to an articulator.

FIGURE 27.53 Clinical situation after inserting the three single integrated abutment crowns.

FIGURE 27.54 Section of panoramic radiograph at initial loading.

Dentlearn.ir

FIGURE 27.55 Clinical result at 8.5-year recall reveals an excellent result with infection-free peri-implant mucosa.

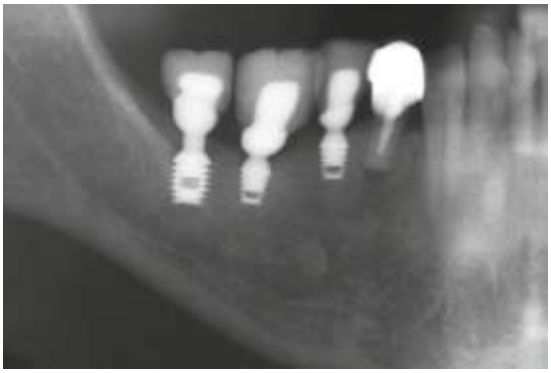

FIGURE 27.56 Section of panoramic radiograph at 8.5-year recall reveals a very satisfactory crestal bone situation without any bone loss.

CONSIDERATIONS AND PITFALLS

The technique for placing short and ultra-short implants is considerably different than when placing traditional implants. It is sometimes said that both the surgeon and restoring dentist must rethink their previous implant training. This is particularly true when placing the Bicon short and ultra-short implants, where the drilling process is done under very low speed – 50 rpm – and no irrigation is used. These implants are not threaded, so they are not the implant of choice for immediate loading. The crown-to-implant ratio is also much greater than the "standard" 2:1. One often sees a ratio of 4–5:1 when ultra-short implants are being used. Historical concerns with a large crown-to-implant ratio have not been shown to be a clinical issue. It is also advisable, whenever possible, to place the implant 2–3 mm below the alveolar crest.

There are no more complications with short and ultra-short implants than with traditional implants. However, when there is crestal bone loss around one of these implants, it can easily become a very difficult situation. A 1–2 mm loss of crestal bone can be 25+% of the total implant length.

CONCLUSIONS

Short and ultra-short implants are a good alternative to bone augmentation. Their use will allow the surgeon to place implants when they would otherwise need to perform an additional surgical procedure. By having short and ultra-short implants as part of their armamentarium, surgeons will expose their patients to less risk and reduce the treatment cost.

with website

To access the videos for this chapter, please go to
www.wiley.com/go/tolstunov/essential

VIDEO 27.1 Introduction to Chapter 27 by the Author Dr. Boyd Tomasetti.

VIDEO 27.2 Narrow implants by the author Dr. Rolf Ewers, Case 1.

VIDEO 27.3 Immediate implants by the Author Dr. Rolf Ewers, Case 2.

VIDEO 27.4 Short implants by the Author Dr. Rolf Ewers, Case 3.

REFERENCES

1. Atwood DA. Post extraction changes in the adult mandible as illustrated by microradiographs of midsagittal sections and cephalometric roentgenograms. *J Prosthetic Dent* 1963;13:810–24.
2. Atwood DA. Reduction of residual ridges: A major oral disease entity. *J Prosthetic Dent.* 1973;17:747–54.
3. Cawood JL, Howell RA. A classification of the edentulous jaws. *Int J Oral Maxillofac Surg.* 1988;17:232–6.
4. Tatum H. *Lecture to Alabama Implant Congress*, 1976.
5. Boyne PJ, James RA. Grafting of the maxillary sinus floor with autogenous marrow and bone. *J Oral Surg.* 1980;38(8):613–16.
6. AAOMS *Consensus Conference on Sinus Lifts*, 1996.
7. AO Consensus Conference on Sinus Lifts, 2000.
8. European Consensus Conference on Short, Angulated and Diameter Reduced Implants, 2017.

Dentlearn.ir

9. Ewers R. Maxilla sinus grafting with marine algae derived bone forming material: A clinical report of long-term results. *J Oral Maxillofac Surg.* 2005;63(12):1712–23.

10. Urdaneta RA, Daher S, Leary J et al. The survival of ultrashort locking taper implants. *Int J Oral Maxillofac Implants.* 2012;27:644–54.

11. Cawood JL, Howell RA. A classification of the edentulous jaws. *Int J Oral Maxillofac Surg.* 1988;17:232–6.

12. Demetriades N, Park JI, Laskarides C. Alternative bone expansion technique for implant placement in atrophic edentulous maxilla and mandible. *J Oral Implantol.* 2011;37(4):463–71.

13. Bernabeu-Mira JC, Soto-Peñaloza D, Peñarrocha-Diago M et al. Low-speed drilling without irrigation versus conventional drilling for dental implant osteotomy preparation: A systematic review. *Clin Oral Investig* 2021;25(7):4251–67.

14. Urdaneta RA, Marincola M. The integrated abutment crown, a screwless and cementless restoration for single-tooth implants: A report on a new technique. *J Prosthodont.* 2007;16(4):311–18.

15. Poggio CE, Ercoli C, Rispoli L et al. Metal-free materials for fixed prosthodontic restorations *Cochrane Database Syst Rev.* 2017;12(12): CD009606. doi: 10.1002/14651858.CD009606.pub2.

Dentlearn.ir

Zygomatic and Pterygoid Implants as an Alternative to Bone Augmentation in Implant Dentistry

CHAPTER 28

Treatment concepts with zygomatic and pterygoid implants have evolved as an alternative for challenging bone augmentation procedures. A combination of conventional implants and zygomatic or pterygoid implants has been used successfully for restoration of the moderately atrophic maxilla. Placement of anterior conventional implants without large grafting procedures will be extremely difficult in the severely atrophic premaxilla. In such situations, quadruple zygomatic implants with or without pterygoid implants can be used for the dental rehabilitation of the edentulous maxilla.

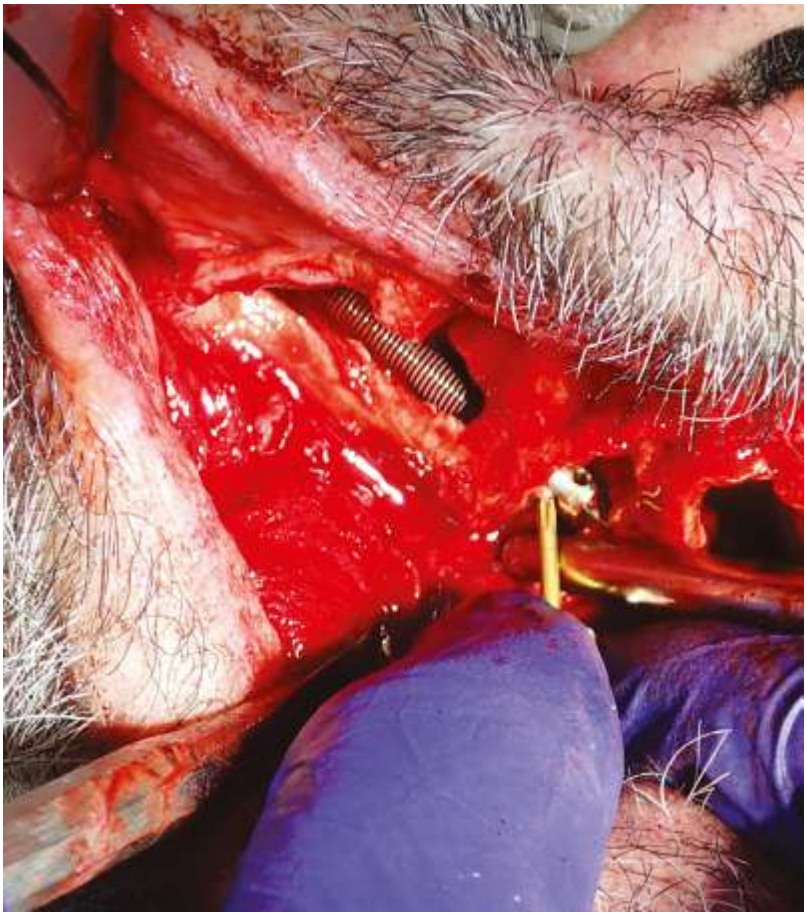

Dentlearn.ir

CHAPTER 28

Zygomatic and Pterygoid Implants as an Alternative to Bone Augmentation in Implant Dentistry

Vishtasb Broumand[1,2]

[1]*Private Practice, Oral and Maxillofacial Surgery, Desert Ridge Oral Surgery Institute, Phoenix, AZ, USA*

[2]*Department of Oral and Maxillofacial Surgery, University of Arizona College of Medicine at Banner University Medical Center, Phoenix, AZ, USA*

ZYGOMATIC IMPLANTS

Zygomatic implants were designed by Dr. Per-Ingvar Brånemark in the late 1980s for patients who could not wear a full maxillary denture due to inadequate retention and stability and could not have conventional dental implants due to lack of maxillary bony support [1]. The goal was to allow an implant-supported fixed prosthetic rehabilitation in these challenging cases.

Placement of dental implants in patients with tumor- or trauma-related defects, or with vertical and horizontal deficiency of the maxilla, is often limited by the extensive pneumatization of the sinus cavities and furthermore by poor quality and inadequate amounts of remaining bone. Many surgical procedures have been developed to rebuild the atrophic maxilla in order to subsequently place dental implants, such as allogeneic bone grafting with mesh, autogenous iliac crest block grafting, LeFort I osteotomies with interpositional grafts, and sinus augmentation procedures. None of these procedures yields immediate results and complications and failures are common.

In more contemporary literature, in order to avoid extensive bone grafting procedures, angled implants with or without single zygomatic implants have been recommended for the dental rehabilitation and reconstruction of this group of patients; however, the palatal and posterior resorptive pattern of the edentulous maxillae may also limit the horizontal bony volume necessary to successfully place angled endosseous implants (Figure 28.1) [2–4]. Severe atrophy of the maxilla can be due to various factors, such as tumor resection, generalized aggressive periodontitis, genetic disorders, or syndromes. Fabrication of a prosthesis with adequate retention and stability for patients with an atrophic edentulous maxilla presents a significant challenge for even the most skilled surgeon. Treatment concepts with zygomatic implants have evolved as an alternative for bone augmentation procedures, although initially conceived only as a treatment for the victims of traumas or maxillary resection with significant loss of maxillary structure. Following maxillectomy, many patients retain anchorage regions only in the body of the zygoma or in the frontal extension of the zygomatic bone, as do many patients who suffer from extreme maxillary atrophy [5, 6].

PTERYGOID IMPLANTS

Placement of an implant through the maxillary tuberosity and into the pterygoid plate at the pterygomaxillary junction is called a tubero-pterygoid or more commonly a pterygoid implant, which is not the same as a tuberosity implant. Pterygoid implants were first placed by Tulasne in 1985 [7] as an alternative to rehabilitate the atrophic maxilla, avoiding the need for further surgeries, such as sinus lifts or alternative ridge augmentation with bone grafting [8, 9]. In 1992, Tulasne initially described a success rate of 80%; he later reported a success rate of 92% in 1999. Nonetheless, during the past years several studies have reported a much higher success rate, ranging from 90.7% to 99% success by Balshi in 2005 [10–14].

Dental implant placement in the posterior maxilla poses a challenge due to the quality and quantity of bone, the

Essential Techniques of Alveolar Bone Augmentation in Implant Dentistry: A Surgical Manual, Second Edition. Edited by Len Tolstunov.
© 2023 John Wiley & Sons, Inc. Published 2023 by John Wiley & Sons, Inc.
Companion website: www.wiley.com/go/tolstunov/essential

Dentlearn.ir

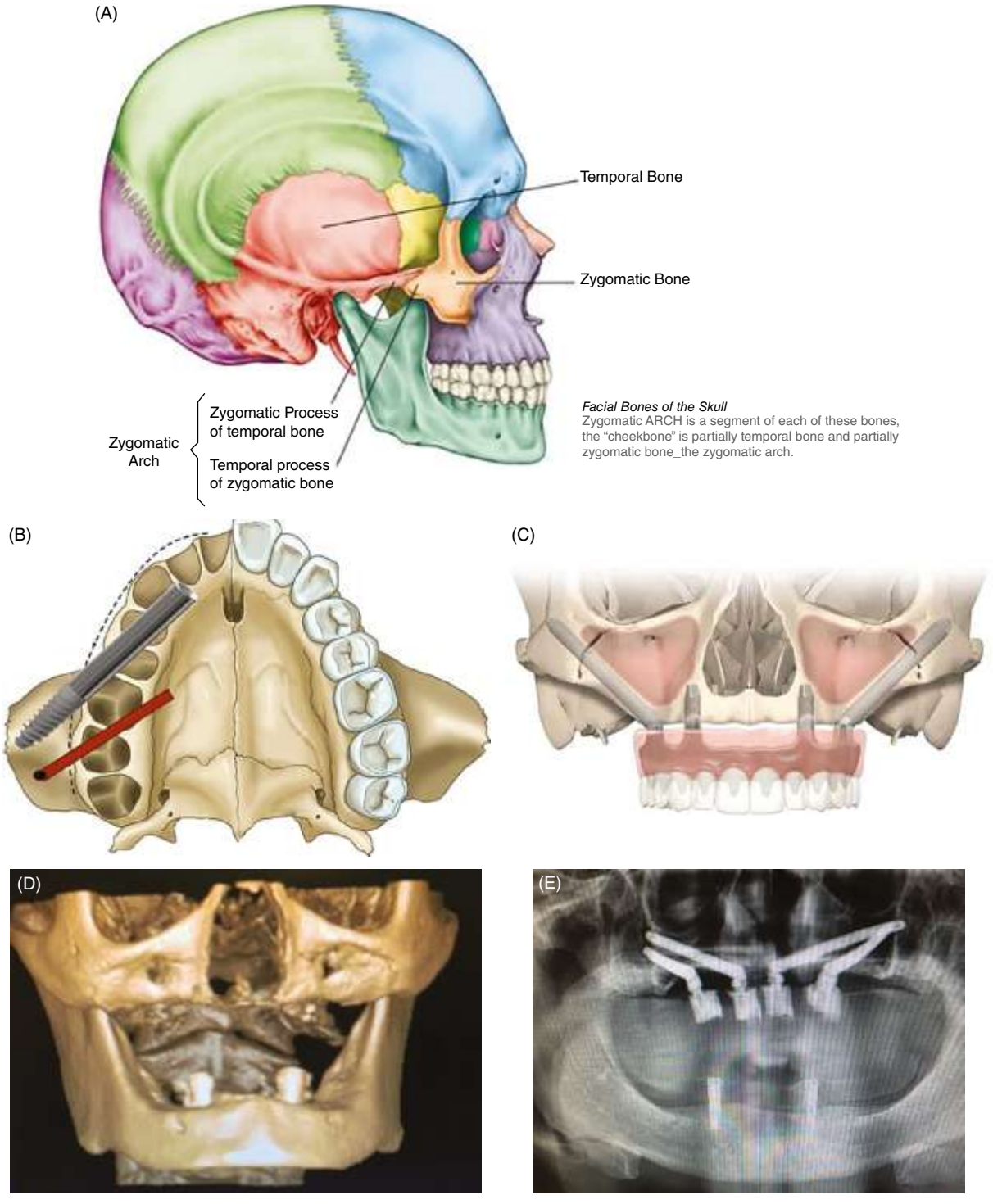

FIGURE 28.1 In more contemporary literature, in order to avoid extensive bone grafting procedures, angled implants with or without single zygomatic implants have been recommended for the dental rehabilitation and reconstruction of the atrophic maxilla. (A) Zygomatic implants are placed in the body of the zygoma, not within the zygomatic arch itself. (B) When placing zygomatic implants always plan for placing quads anatomically, even only if only placing single zygomatic implants on either side. (C) Single zygomatic implants on either side with anterior maxillary implants are commonly called a zygoma hybrid. (D) Extreme atrophy of the maxilla lends itself to placement of (E) quadruple zygomatic implants.

Dentlearn.ir

anatomy of the maxillary sinus, and difficulty in access. To overcome these challenges, several surgical procedures such as sinus lifts, ridge augmentation, tilted implants, short implants, and zygomatic implants have been used by many clinicians, although not all patients are candidates for such techniques. All these procedures have their own limitations. The pterygomaxillary junction provides us with an excellent source of D1 cortical bone for the placement of implants and rehabilitation of the posterior maxilla [15]. Pterygoid implants serve to reduce the anterior–posterior (AP) cantilever and are commonly used as rescue implants in cases of failed hybrid four-implant-supported cases.

Placement of pterygoid implants involves an osteotomy starting in the tuberosity region, with a mesio-cranial oblique trajectory proceeding posteriorly toward the pyramidal process of the palatine bone. It is subsequently directed superiorly between both the medial and lateral pterygoid wings of the pterygoid processes, destined for the pterygoid or scaphoid fossa of the sphenoid bone.

Placement of pterygoid implants can present some challenges, as it is a blind procedure compared to conventional dental implants. Surgical access is limited, and serious injuries can occur if, unintentionally, the descending palatine artery or maxillary artery is severed if the implant is too far apical, or an implant can invade the pterygomaxillary fossa and the pterygoid plexus of veins [16]. The pterygoid plexus is a valve-free venous plexus located in the infratemporal fossa. It is continuous with the cavernous sinus, and eventually becomes the maxillary vein as it drains inferiorly. There is only a risk of bleeding to the plexus if during surgery the implant extends too far laterally, as the pterygoid plexus is lateral to the implant area (Figure 28.2).

It is imperative to have a thorough knowledge of the regional anatomy, because nearby vital structures can be injured during the blind placement. The pterygomaxillary fissure connects the infratemporal fossa to the pterygopalatine fossa and is a conduit for the internal maxillary artery, which is in the pterygomaxillary fissure and crosses at 18.7 mm above the pterygomaxillary suture (according to Uchida) [17, 18].

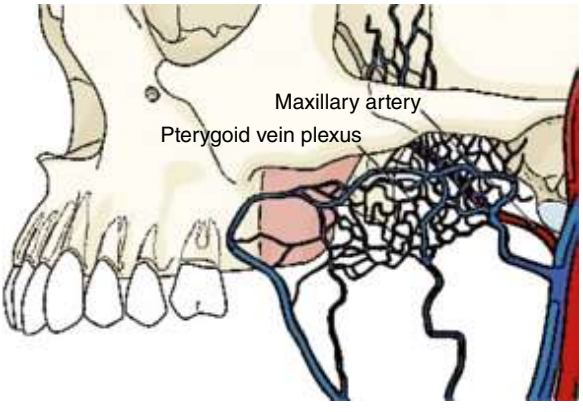

FIGURE 28.2 When placing pterygoid implants, there is only a risk of bleeding to the plexus if during surgery the implant extends too far laterally, as the pterygoid plexus is lateral to the implant area.

When placing a pterygoid implant, it is essential to pay attention to its proximity to the greater palatine canal and nerve, as it also houses the descending palatine artery, one of the terminal branches of the maxillary artery [19]. The location of the greater palatine foramen is quite variable: 16.3% at the second maxillary molar site, 6.8% between the second and third molars, 63.9% at the third molar, and 2.2% distal to the third molar site [20].

INDICATIONS

Treatment concepts with *zygomatic implants* have evolved as an alternative for challenging bone augmentation procedures. A combination of conventional implants and zygomatic implants, namely a "hybrid zygoma," has been used successfully for restoration of the moderately atrophic maxilla [21–27]. Placement of anterior conventional implants without large grafting procedures will be extremely difficult in the severely atrophic premaxilla. In such situations, quadruple zygomatic implants can be used for the dental rehabilitation of the edentulous maxilla in combination with the use of pterygoid plate implants [28–31].

Quadruple zygomatic implant placement procedures that do not require any adjunctive procedures such as grafting have become a logical choice for dental rehabilitation of the severely atrophic maxilla, especially in patients with previous conventional implant or grafting failures. Quadruple zygomatic implant-supported dental rehabilitation can immediately restore oral function, based on implant osseointegration achieved through the zygomatic and malar process rather than the alveolar process of the maxilla [1].

Ideally, a single or multiple standard implants inserted in the premaxilla can counteract the long lever arm of zygomatic implants and prevent prosthetic screw loosening, as well as increasing the odds of long-term success of the zygomatic implants. When successfully placed in combination with pterygoid implants, the posterior prosthetic cantilever can be diminished significantly.

One of the most important reasons and advantages for the use of *pterygoid implants* is the elimination of the need to perform sinus lift surgeries or bone grafts, therefore decreasing the morbidity and shortening the treatment time, as these implants can be used for immediate loading with a fixed prosthesis. Unlike maxillary tuberosity implants, pterygoid implants anchor in cortical bone, allowing better primary stabilization, which is known to be a critical factor for long-term success [13, 32, 33].

Dentlearn.ir

CONTRAINDICATIONS

Contraindications to the placement of zygomatic implants include untreated acute sinus infection, maxillary or zygoma pathology, or recent pterygomaxillary or zygomatic arch fracture. Relative contraindications include chronic infectious sinusitis and heavy smoking [11]. Any pathology of the maxillary sinus should preferably be treated before placement of the zygomatic implant (Figure 28.3). Contraindications to the placement of pterygoid implants are limited mouth opening that leads to decreased access, lack of a maxillary tuberosity, and presence of impacted maxillary third molars.

PRE-OPERATIVE PLANNING

A through clinical examination, although mandatory, is incomplete without a proper radiological evaluation and three-dimensional assessment must be considered. In order to properly evaluate a patient for zygomatic and pterygoid implants, a panoramic radiograph gives distorted and incomplete information, as one must be able to thoroughly evaluate the size and shape of the maxillary sinuses, the health of the sinuses, the height of the maxillary tuberosity and the pterygomaxillary process, the width of the pterygomaxillary process, the mediolateral thickness and anterior posterior length, as well as the density of the body of the zygoma and the position of the nasal floor [34]. The examination of choice is

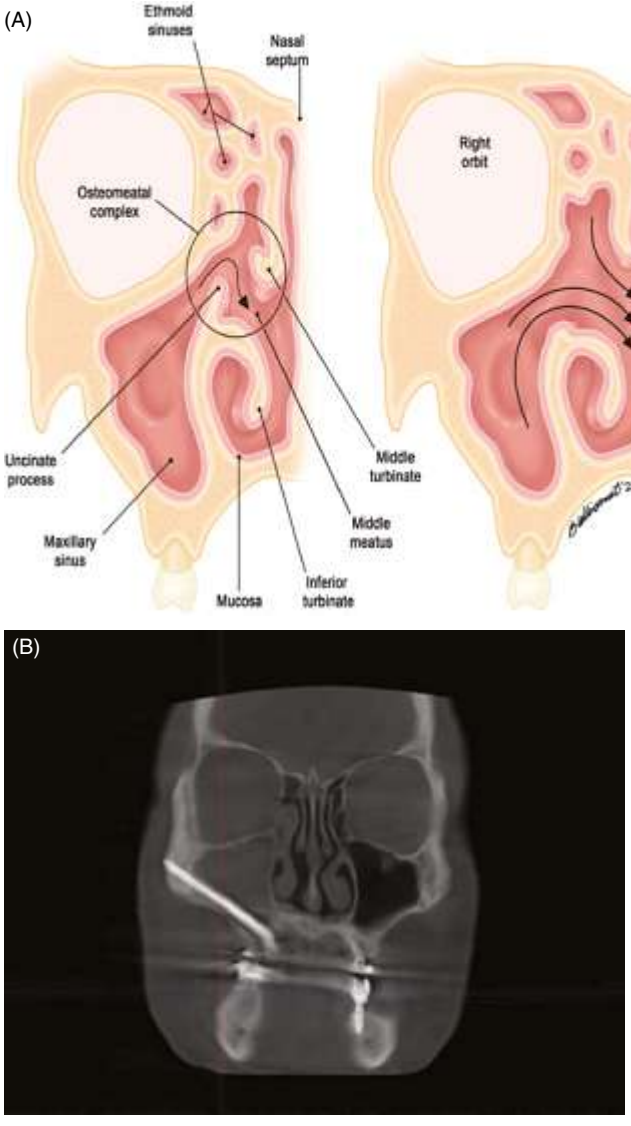

FIGURE 28.3 Pathology or infection of the maxillary sinus or (A) closed osteum should be treated before placement of zygomatic implants to avoid (B) chronic sinusitis by placing a zygomatic implant in a diseased sinus.

Dentlearn.ir

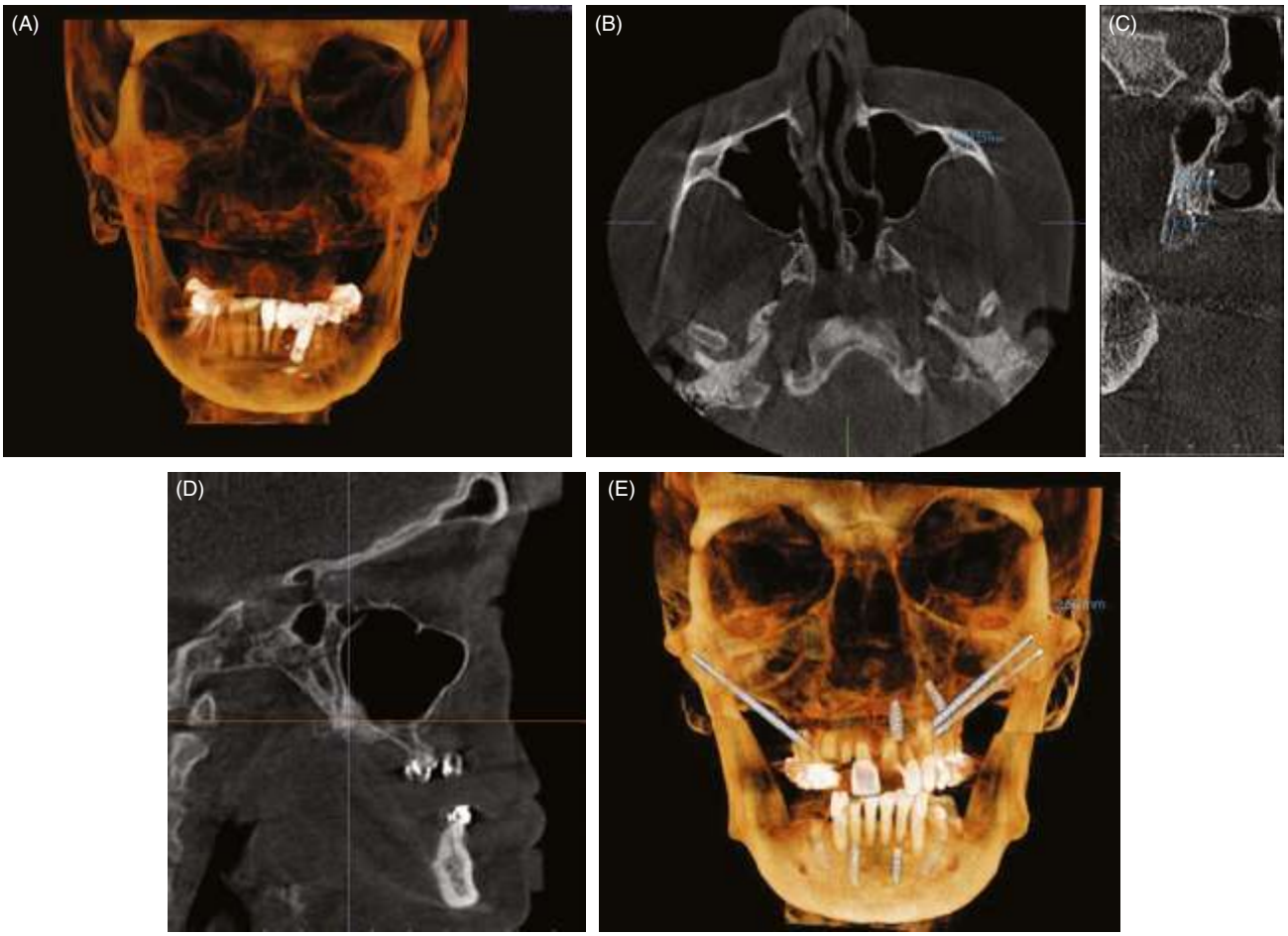

FIGURE 28.4 A three-dimensional computed tomography (CT) scan is needed in order to assess and thoroughly evaluate the size and shape of the maxillary sinuses, health of the sinuses; (A) the anterior posterior length and (B) the mediolateral thickness as well as density of the body of the zygoma; (C) the height of the maxillary tuberosity and the pterygomaxillary process; (D) the width of the pterygomaxillary process and the position of the nasal floor. (E) The CT scans also allow for prior planning and construction of surgical guides, as well as stereolithographic models to facilitate the orientation of pterygoid and zygomatic implants during surgery.

three-dimensional computed tomography (CT) scans, which also allow for the construction of surgical guides as well as stereolithographic models to facilitate the orientation of pterygoid and zygomatic implants during the surgery (Figure 28.4) [35].

SURGICAL PROCEDURE

SURGICAL APPROACHES FOR ZYGOMATIC IMPLANTS

Classic Approach

The classic approach was proposed by Brånemark with the patient under general anesthesia. Pre-operative measurement of the lower half of the face (nasion to pogonion) is done prior to making an incision. The classic sinus window technique consists of exposing the fronto-lateral face of the zygomatic bone and creating a 10 × 5 mm window in the sinus to visualize the implant trajectory. After administration of local anesthesia, a standard LeFort I–type incision is used for exposure of the entire maxillary crest, which ensures future coverage of the implant by the periosteum and a wide wound area to minimize the risk of dehiscence during healing. It is recommended to make vertical incisions along the infra-zygomatic crest region and to continue the incisions in a downward direction, thereby facilitating the exposure of the maxilla and the zygomatic bone and protecting the parotid gland duct [36].

The lateral surface of the maxilla is exposed, and the infraorbital foramen identified for anatomical orientation of the area. Soft tissue dissection is extended along the inferior and frontal and lateral surfaces of the zygoma;

Dentlearn.ir

special care is taken to avoid invading the orbit or sectioning the insertion of the masseter muscles to excess to avoid bleeding. A specialized Broumand zygomatic notch retractor is then placed in the zygomatic notch. This always allows visualization of the end of the drill and implant apex. The retractor placement is an added precaution to avoid injuries to the floor of the orbit (Brånemark System Zygoma TiUnite implants, Nobel Biocare, Kloten, Switzerland; Figure 28.5).

A 10 × 5 mm window is made on the lateral wall of the sinus close to the infra-zygomatic crest [37]. The sinus Schneiderian membrane should be kept intact during this process. Carefully lift the sinus mucosa away from the area where the implant will pass through the sinus, from the floor of the sinus to the roof, trying not to penetrate the mucosa. Prior to completing osteotomies, the palatal mucosa is then detached, visualizing the insertion trajectory from the zone of the second premolar/first molar to reach the zygomatic bone traversing the maxillary sinus. In quad zygoma surgeries the posterior implant is placed first. The zygomatic bone implant bed is prepared using the standard implant drilling protocol for zygoma implants. Make an entrance mark in the posterior superior roof of the sinus with a round drill, penetrating at palatine level. The drilling sequence is continued using a 2.9 mm twist drill before penetrating the outer cortical layer of the zygomatic bone at the incisura. The trajectory through the maxillary sinus should be followed, allowing visual control of the drill through the infra-zygomatic window, with insertion in the zygomatic bone until the superior cortical layer is perforated (Figure 28.6A–F).



FIGURE 28.5 A specialized Broumand zygomatic notch retractor is placed in the zygomatic notch, which allows visualization of the end of the drill and implant when placing zygomatic implants; the retractor placement is an added precaution to avoid injuries to the floor of the orbit.

Next, the straight depth indicator is used to determine the desired length of zygoma implant to be used. Then a helicoid 3.5 mm drill is used to create a shallow osteotomy within the zygomatic bone, which stabilizes the 3.5 mm final drill. The 3.5 mm final drill is used to widen and complete the osteotomy both at the maxillary crest and at the body of the zygomatic bone successively. With the larger 3.5 mm final drill aimed at the zygomatic notch retractor, which is held at a 90 degree angle to the zygoma, the osteotomy is safely completed (Zygoma TiUnite implants; Figure 28.6G–L).

The surgeon must verify the depth of the prepared bone site with the angled depth indicator to ensure that the selected implant length can be fully seated without apical bone interference or cutaneous perforation. Next, by using the slow speed on the drilling unit or by use of a hand driver while engaging the implant apex in the prepared bone site, implants are sequentially placed. The correct insertion angle of the implant is confirmed while continuing through the sinus until the implant apex engages the zygomatic bone. The process is repeated for the anterior implant. An insertion torque of more than 35 Ncm must be achieved for the four zygomatic implants.

Extramaxillary (Extrasinus) Approach to Zygomatic Implants

The extrasinus placement of the zygomatic implant was proposed by Migliorança et al. and Aparatio et al. [22, 38–40]. This modification was intended to simplify surgical procedures and improve prosthetic outcomes. The success rate obtained was 98.7%. The extrasinus technique for the placement of zygomatic implants is simpler than both the original technique proposed by Brånemark, and the slot technique proposed by Stella and Warner [41, 42]. The extrasinus approach eliminates the need for a large maxillary antrostomy, sinus elevation, or the creation of a slot that perforates the sinus membrane. It also results in the emergence of the zygomatic implant next to or on the top of the alveolar ridge crest in a more buccal position, thereby improving oral hygiene, prosthesis design, speech, and biomechanics. In contrast, the palatal implant emergence that is typically seen with classic intrasinus techniques increases the risk of occlusal overload and makes oral hygiene more difficult

Dentlearn.ir

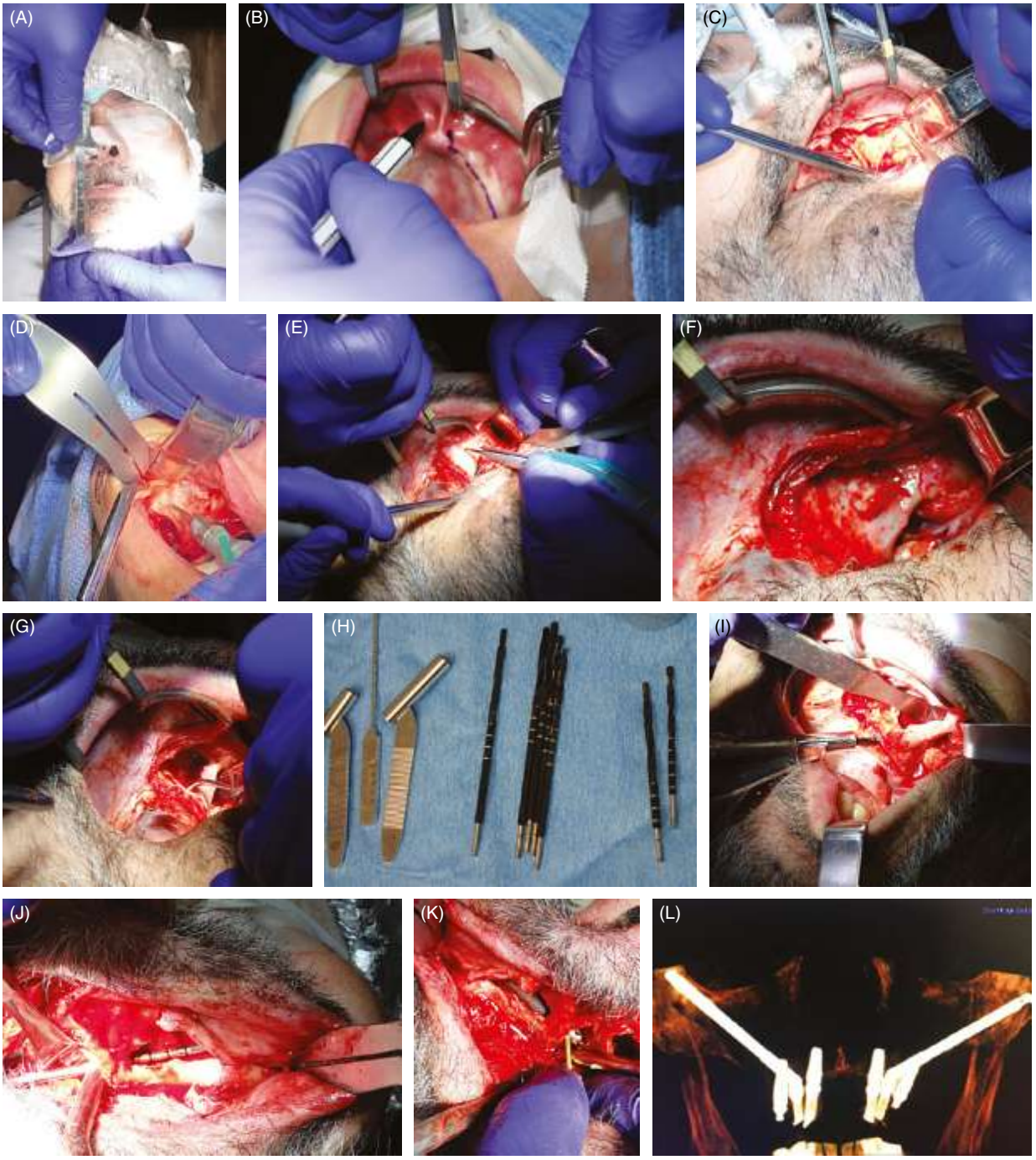

FIGURE 28.6 (A) Placement of zygomatic implants is preceded by pre-operative measurement of the lower half of the face (nasion to pogonion) made prior to making the incision. (B) The incision is a hemi-LeFort type, sparing the maxillary incisive papilla. (C) Vertical incisions are made along the infra-zygomatic crest in a downward direction, facilitating the exposure of the maxilla and the zygomatic bone. (D) The lateral surface of the maxilla is exposed, and the infraorbital foramen identified for the anatomical orientation of the area. (E, F) With use of a round marking bur, an initial osteotomy is made and eventually a 10 × 5 mm window is made on the lateral wall of the sinus close to the infra-zygomatic crest. An entrance mark is made in the posterior superior roof of the sinus with a round drill penetrating at palatine level. The drilling sequence is continued using a 2.9 mm twist drill before penetrating the outer cortical layer of the zygomatic bone at the incisura. (G, H) A straight depth indicator is used to determine the desired length of implant. A helicoid 3.5 mm drill is used to create a shallow osteotomy within the zygomatic bone, which stabilizes the 3.5 mm final drill. The 3.5 mm final drill is used to widen and complete the osteotomy, both at the maxillary crest and at the body of the zygomatic bone. (I–L) With the larger 3.5 mm final drill aimed at the Broumand retractor held at a 90-degree angle to the zygoma, the osteotomy is completed, the implant is placed by hand after copious irrigation with the appropriate multiunit abutment, and the implants are temporized, as seen on the radiograph.

Dentlearn.ir

A standard LeFort 1–type incision is used to expose the maxillary crest, yet this technique attempts to spare the maxillary incisive papilla and the incision is palatally deviated by 5 mm. The larger incision is used for adequate exposure, which ensures future coverage of the implant by the periosteum and a wide wound area to minimize the risk of dehiscence during healing. It is recommended to make vertical incisions along the infra-zygomatic crest region and to continue the incisions in a downward direction, thereby facilitating the exposure of the maxilla and the zygomatic bone and protecting the parotid gland duct [36].

The lateral surface of the maxilla is exposed, and the infraorbital foramen identified for anatomical orientation of the area. Soft tissue dissection is extended along the inferior and frontal, superior and lateral surfaces of the zygoma; special care is taken to avoid invading the orbit or sectioning the insertion of the masseter muscles in excess to avoid bleeding. A specialized Broumand zygomatic notch retractor is then placed in the zygomatic notch, which always allows visualization of the end of the drills and the implant apex. The retractor placement is an added precaution taken to avoid injuries to the floor of the orbit and always allow visualization of the implant and drill apices (Figure 28.7A–C).

Two points are planned in order to determine the correct zygomatic implant angulation. The first is the prosthetic connection level of the zygomatic implant, planned to emerge at the position of the canine and the second premolar for a quad zygoma in proximity to the alveolar ridge. The second is the extraoral penetration points of the zygomatic implants into the base of the zygomatic bone, located as posterior as possible. Using a round or marking bur, the shallow marking hole should be at the site of the osteotomy in the zygomatic bone (Figure 28.7B) [43].

Orientation grooves are created in the lateral maxillary wall to determine the direction of drilling into the zygomatic bone and future implant placement. The grooves are accomplished with a diamond cylindrical drill with a standard diameter identical to the implant, preserving and slightly detaching the sinus membrane. The starting diamond bur is coarsely gritted to allow for the corticotomy, and a groove is completed with a fine diamond ball bur. Following the inclination predisposed by the marking hole, the zygomatic implant beds in the form of grooves are prepared under visual control, using progressive gritted burs from coarse to fine. When the tip of each diamond bur is positioned in the marking hole, it serves as a fulcrum in placing the burs in the correct position. The bur is lowered toward the maxilla and a groove is shaped in the form of the outer diameter of the implant. Next a 2.0 mm twist drill is directed through the groove from the alveolar ridge through the zygomatic bone. Then the depth indicator should be used to determine the desired length of zygoma implant to be used.

The drilling sequence is continued using a 2.8 mm twist drill to its entire length, followed by a 3.5 mm twist drill to only half of the measured length, unless the bone is extremely dense. The implant is preferably placed by hand, with a minimal torque value of 30 Ncm for immediate loading. With this technique the goal is insertion of implants in the frontal portion of zygomatic bone and using the residual alveolar-basal bone as anchorage of a standard implant anteriorly [44, 45]. Following placement of all the implants and immediate conversion to a fixed temporary hybrid denture in order to decrease the risk of implant dehiscence and gingival adherence to the sinus membrane, a membrane can be placed over the exposed cylinders, or a buccal fat pad graft can be performed (Figure 28.7C–J).

SURGICAL APPROACHES FOR PTERYGOID IMPLANTS

After local anesthetic administration, a full-thickness flap extending to the posterior border of the tuberosity is developed. A small amount of bone reduction is performed with a large-head bone rongeur, followed by a straight handpiece flame-shape tungsten bur in order to (i) achieve an optimal platform for implant placement; (ii) create a flat bone surface; and (iii) create prosthetic space for the future screw-retained hybrid prosthesis. Pterygoid implant positioning should be carefully studied using a helical or a cone beam computer tomography (CBCT) scan of the patient. Careful planning is important, as these implants require bucco-palatal and medial-distal angulation [46, 47].

Clinically, the anatomy of the tuberosity, the length from the planned starting point to the end of the tuberosity, and the relative position of the sinus are used as landmarks for the starting drill. Operator's experience and haptic awareness are extremely important in this step, as the placement of pterygoid implants allows no direct vision of the end point. Implant placement follows standard procedures, but some techniques are used to increase primary stability, in particular underpreparation, osseodensification, and bi-corticalization.

For the pterygoid implants, implant bed preparation follows the following sequence. The first needle-type drill and the second 2.0 mm diameter pilot drill from a standard implant kit are used clockwise, full length, until perforation of the pterygoid process is achieved, allowing the bi-corticalization of the implants. The three following drills used (2.3 mm, 3.0 mm, and 3.3 mm) are Densah® Bur osseodensification drills (Versah, Jackson, MI, USA), with counterclockwise rotation, in order to increase the bone density of the tuberosity. Together, these two

Dentlearn.ir

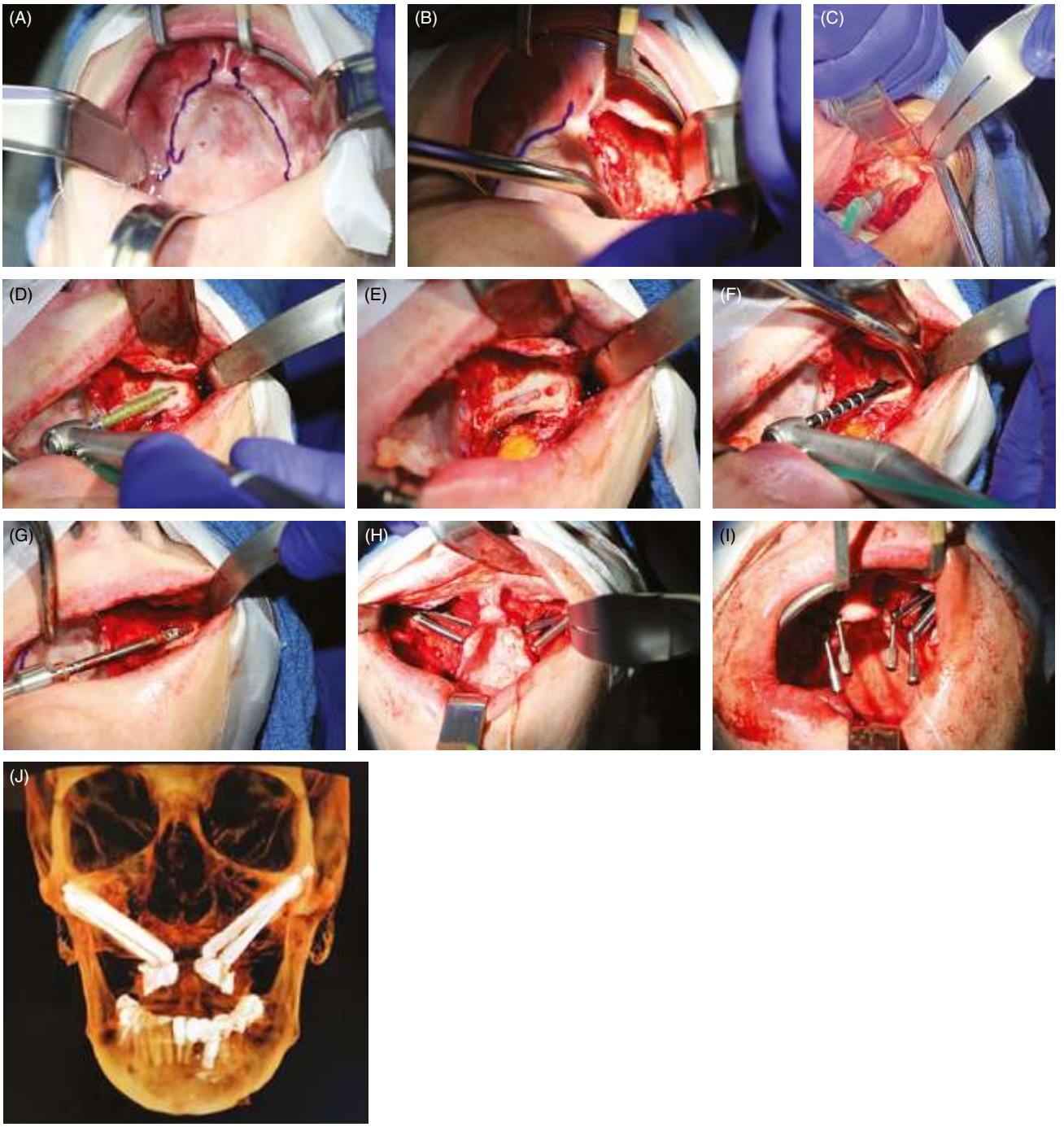

FIGURE 28.7 (A) In the extramaxillary approach the incision is a hemi-Lefort type, sparing the maxillary incisive papilla. (B) Vertical incisions are made along the infra-zygomatic crest in a downward direction, facilitating the exposure of the maxilla and the zygomatic bone. (C) The lateral surface of the maxilla is exposed, and the infraorbital foramen identified for the anatomical orientation of the area. Using a round or marking bur, a shallow marking hole should be at the site of the osteotomy in the zygomatic bone. (D, E) Orientation grooves are accomplished with a diamond cylindrical drill with a standard diameter identical to the implant, preserving and slightly detaching the sinus membrane. (F) The drilling sequence is continued using a 2.8 mm twist drill to its entire length, followed by a 3.5 mm twist drill to only half of the measured length, unless the bone is extremely dense. (G) The implant is preferably placed by hand with a minimal torque value of 30 Ncm for immediate loading. (H) With this technique the goal is insertion of quadruple implants in the frontal portion of the zygomatic bone. (I, J) Following placement of all the implants and immediate conversion to a fixed temporary hybrid denture in order to decrease the risk of implant dehiscence and gingival adherence to the sinus membrane, a membrane can be placed over the exposed cylinders, or a buccal fat pad graft can be performed.

Dentlearn.ir

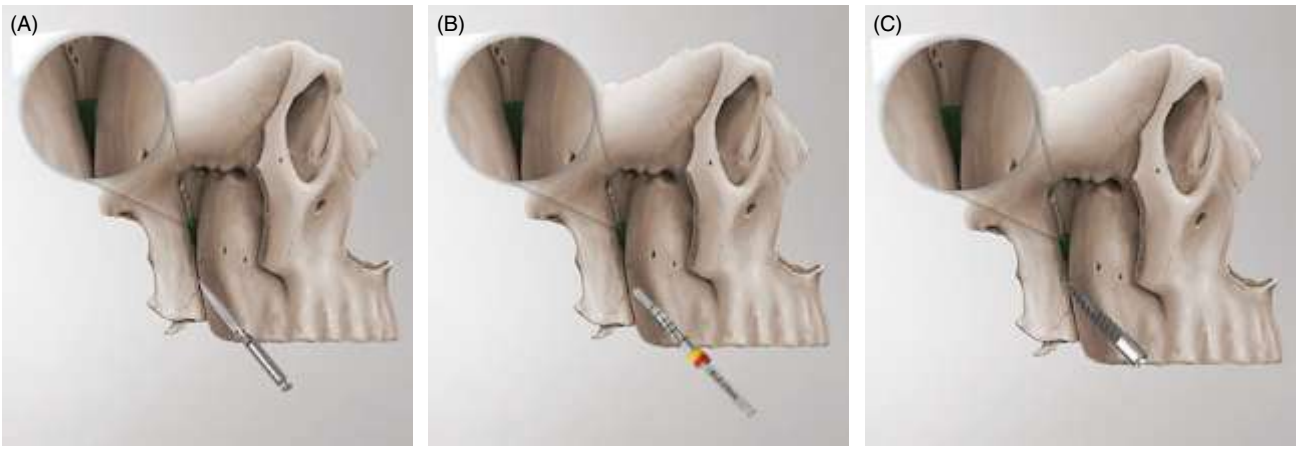

FIGURE 28.8 (A) For placement of pterygoid implants, the first needle-type drill and the second 2.0 mm diameter pilot drill from a standard implant kit are used clockwise, full length, until perforation of the pterygoid process is achieved, allowing the bi-corticalization of the implants. (B) The three following drills if used (2.3 mm, 3.0 mm, and 3.3 mm) are Densah Bur osseodensification drills with counterclockwise rotation, in order to increase the bone density of the tuberosity. (C) The 3.3 mm bur is rarely used to the full depth, as the implant has a 4.2 mm diameter.

techniques result in high primary stability in the pterygoid implants (Figure 28.8).

The implant enters the region of the former maxillary first or second molar and follows an oblique mesio-cranial direction, proceeding posteriorly toward the pyramidal process. It subsequently proceeds upward between both wings of the pterygoid processes and finds its encroachment in the pterygoid or scaphoid fossa of the sphenoid bone [46, 47]. All pterygoid implants should anchor with 50+ Ncm torque and the most common length is 18 mm. After implant placement, a multiunit-type abutment is placed on each implant, generally angled 17–30 degrees in the pterygoid implants, and the flap is sutured in place, as described by de Sousa [48]. A previous removable provisional denture can be converted to a fixed, screw-retained, full acrylic FP-3 prosthesis following the denture conversion technique described by Misch [49].

PROSTHETIC CONSIDERATIONS

In most cases we consider an immediate-load protocol, although a delayed-load protocol is also possible [50–52]. The immediate one-stage protocol requires the immediate cross-arch splinting of the zygomatic and or pterygoid implants at the time of surgery. The patient's existing or new denture is converted to a hybrid bridge. The denture is altered to accommodate the multiunit abutments with temporary cylinders, in order to splint the zygomatic or pterygoid implants with or without any premaxillary implants by conversion of the patient's existing denture into a fixed provisional bridge, using the same direct or indirect conversion technique described for the conversion protocol used when immediate loading is considered. During the first month of the healing stage, the patient is seen every week to adjust the occlusion, as it must remain equally balanced across the entire arch. After healing of the bone and soft tissues, abutment-level final impressions of the zygomatic or pterygoid implants are taken for the fabrication of a definitive fixed hybrid with a titanium bar, approximately 6 months later [53–55].

Once the final restorations are delivered, it is recommended to use a Waterpik® water flosser (Water Pik, Fort Collins, CO, USA) twice daily, especially at bedtime. It is also recommended to brush twice daily with a soft manual toothbrush using a non-abrasive, non-whitening toothpaste. Recall appointments are advised at 3 months, 6 months, and 1 year after delivery of the final appliance. At the yearly appointment, the appliance is removed to clean the underside of the hybrid restoration and the multiunit abutments, especially for patients who have difficulty maintaining hygiene. Periapical and panoramic radiographs are taken each year at the recall appointment for 3 years following insert, and then once every 3 years or as deemed necessary thereafter.

From a prosthetic standpoint, pterygoid implants minimize the time to rehabilitation by avoiding secondary grafting, bypass the need for a distal cantilever, and make it possible to place second molars in the final full-arch prosthesis. Even though they are placed in the pterygomaxillary region at an angle, once osseointegrated these pterygomaxillary implants resist all axial and non-axial forces better than any other implants placed in the maxilla. As illustrated in our cases, patients tolerate the distal position of the implant, and show no difficulty in speech or swallowing. They also demonstrate no difficulty in maintenance of oral hygiene. The success rate of these implants is highest when they meet criteria for an immediate prosthetic load, with adequate vertical restorative space to avoid prosthetic or screw fracture [56].

Dentlearn.ir

CLINICAL CASES

CASE 1

The case shown in Figure 28.9 illustrates full-mouth rehabilitation using a combination of zygomatic implants and implant-retained lower hybrid zirconia bridges, with five dental implants utilizing an immediate-load protocol, in a 70-year-old female who had been fully edentulous in the maxilla for 40 years. Additionally, she was told she was not a candidate for maxillary dental implants due to severe maxillary hypoplasia. She underwent restoration of the maxillary dentition using four zygomatic implants, commonly known as the *quad zygomatic* implant technique, and a mandibular all-on X protocol utilizing a combination of Noris Medical (Nesher, Israel) maxillary and Nobel Biocare mandibular implants. No complications were encountered during the procedure.

FIGURE 28.9 (A–I) The case is of a patient with terminal dentition in the mandible and severely atrophic maxilla. It illustrates full-mouth rehabilitation using a combination of four zygomatic implants and implant-retained lower hybrid zirconia bridges with five dental implants, utilizing an immediate-load protocol in a 70-year-old female who had been fully edentulous in the maxilla for 40 years. Additionally, she was told she was not a candidate for maxillary dental implants due to severe maxillary hypoplasia. She underwent restoration of the maxillary dentition using four zygomatic implants, commonly known as the quad zygomatic implant technique, and a mandibular all-on-X protocol utilizing a combination of Noris Medical maxillary and Nobel Biocare mandibular implants.

Dentlearn.ir

CASE 2

The case shown in Figure 28.10 illustrates full-mouth rehabilitation using a combination of zygomatic and pterygoid implants and implant-retained lower hybrid zirconia bridges with five dental implants utilizing an immediate-load protocol, in a 50-year-old female who had been fully edentulous in the maxilla for 4 years. Additionally, she was told she was not a candidate for maxillary dental implants due to severe maxillary hypoplasia. She underwent restoration of the maxillary dentition using four zygomatic and two pterygoid implants, commonly known as the *quad zygomatic plus pterygoid* implant technique, and a mandibular all-on X protocol, utilizing a combination of Noris Medical maxillary and Noris Medical Tuff™ mandibular implants. No complications were encountered during the procedure.

CASE 3

The case shown in Figure 28.11 illustrates full-mouth rehabilitation using a combination of zygomatic and pterygoid implants and implant-retained lower hybrid zirconia bridges with five dental implants utilizing an immediate-load protocol, in a 40-year-old dentate female who had

FIGURE 28.10 (A–I) The case illustrates full-mouth rehabilitation using a combination of four zygomatic and two pterygoid implants in the maxilla and implant-retained lower hybrid zirconia bridges with five dental implants utilizing an immediate-load protocol, in a 50-year-old female who had been fully edentulous in the maxilla for 4 years. Additionally, she was told she was not a candidate for maxillary dental implants due to severe maxillary hypoplasia. She underwent restoration of the maxillary dentition using four zygomatic implants, commonly known as the quad zygomatic plus pterygoids implant technique, and a mandibular all-on X protocol utilizing a combination of Noris Medical maxillary and Noris Medical Tuff mandibular implants.

Dentlearn.ir

FIGURE 28.11 (A–G) The case illustrates full-mouth rehabilitation using a combination of four zygomatic and two pterygoid implants in the maxilla and implant-retained lower hybrid zirconia bridges with five dental implants utilizing an immediate-load protocol, in a 40-year-old female who had been fully edentulous in the maxilla for 4 years. Additionally, she was told she was not a candidate for maxillary dental implants due to severe maxillary hypoplasia. She underwent restoration of the maxillary dentition using four zygomatic implants, commonly known as the quad zygomatic plus pterygoids implant technique, and a mandibular all-on-X protocol utilizing a combination of Noris Medical maxillary and Noris Medical Tuff mandibular implants.

had terminal maxillary and mandibular dentition for over 4 years. Additionally, she was told she was not a candidate for maxillary dental implants due to severe maxillary vertical and horizontal hypoplasia. She underwent restoration of the maxillary dentition using four zygomatic and two pterygoid implants, commonly known as the quad zygomatic plus pterygoid implant technique, and a mandibular all-on X protocol utilizing a combination of Noris Medical maxillary and Noris Medical Tuff mandibular implants. No complications were encountered during the procedure.

COMPLICATIONS

The overall frequency of complications with zygomatic implants has been studied by retrospective analyses and has been reported to be as high as 9.9% [56, 57]. Intraoral complications accounted for 1.2% of all complications and included oro-sinusal fistula (0.4%), vestibular cortical fenestration (0.4%), and implant loss (0.4%) [58]. Extraoral complications represented 8.7% of all complications and included sinusitis (7.5%), subcutaneous malar emphysema and rarely cutaneous fistula (0.8%), infraorbital nerve paresthesia (0.4%), and rarely orbital penetration [59].

Dentlearn.ir

Almost all cases of subcutaneous malar emphysema resolve spontaneously; however, cases of vestibular cortical fenestration and oro-sinusal fistula are usually treated with rotational local flaps, and in some cases multiple attempts at closure are required to succeed. Cutaneous fistulas may require implant apicoectomy and fistulectomy for definitive resolution [56].

It is important to note that in accordance with the literature, placement of zygomatic implants does not yet seem to be associated with severe rhinosinusitis complications [59]. However, in a considerable number of patients, asymptomatic radiological alterations of the paranasal sinuses were observed [56]. In some cases, middle meatal antrostomy has been shown to cause shrinkage of the osteomeatal complex, which plays a fundamental role in the onset of sino-nasal pathological features after zygomatic implant placement [60]. It is important for the surgeon to have a clear knowledge of the intricate anatomy of the maxilla and the zygoma before undertaking surgery for the placement of zygomatic implants (Figure 28.12) [58, 59].

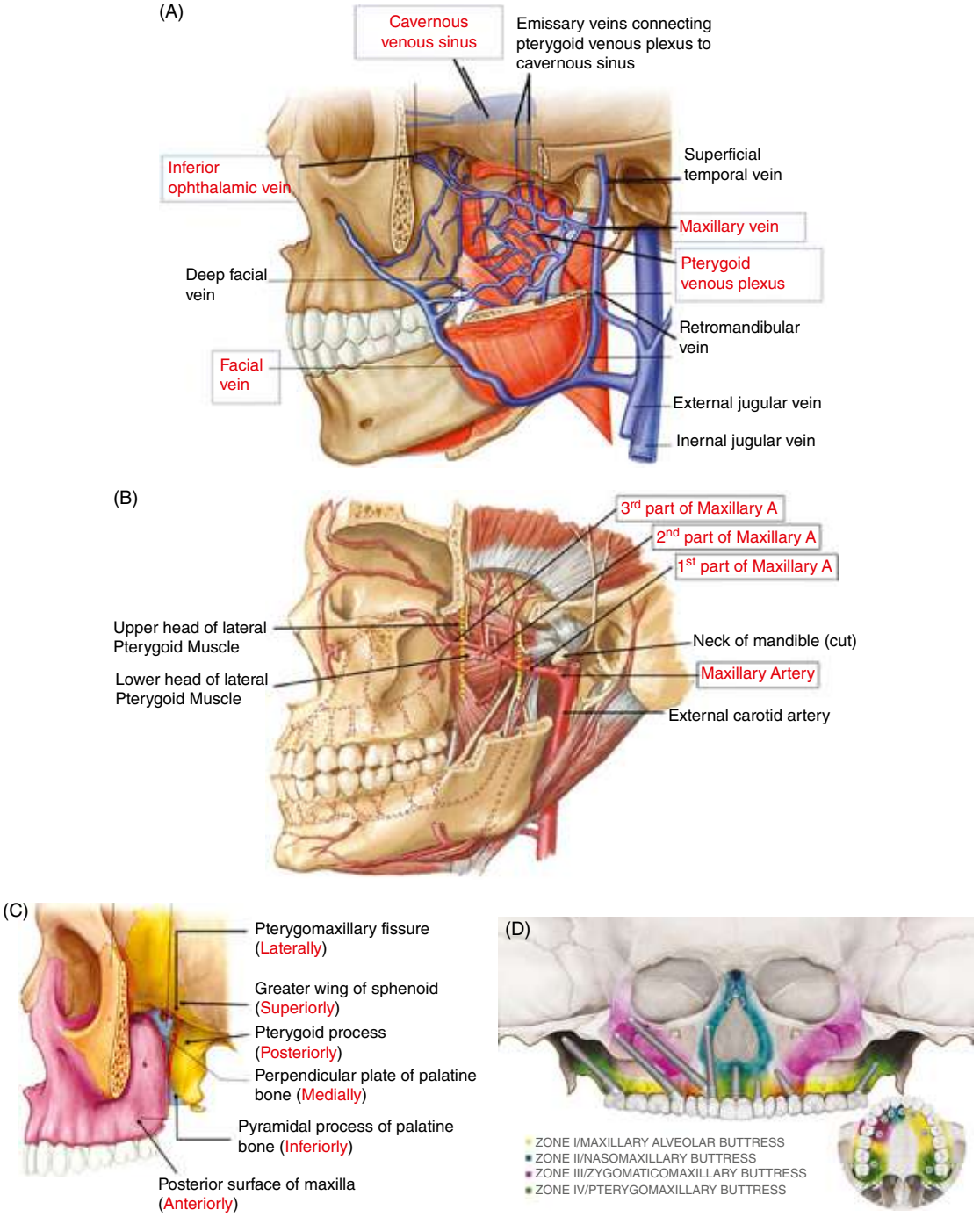

FIGURE 28.12 It is important for surgeon to have a clear knowledge of the intricate anatomy of the maxilla and the zygoma, especially (A) the pterygoid plexus and venous drainage; (B) maxillary and descending palatine artery; (C) the pterygomaxillary complex; and (D) the maxillary buttresses, before undertaking surgery for the placement of zygomatic implants.

Dentlearn.ir

The overall frequency of complications with pterygoid implants is variable and includes implant failure, hemorrhage, trismus, tuberosity or pterygoid complex fracture, and displacement into the infratemporal fossa.

DISCUSSION

Dental implant placement in the posterior maxilla poses a challenge due to the quality and quantity of bone, the anatomy of the maxillary sinus, and difficulty in access. To overcome these challenges, several surgical procedures such as sinus lifts, ridge augmentation, tilted implants, short implants, and zygomatic implants have been used by many clinicians, although not all patients are candidates for such techniques. All these procedures have their own limitations and the pterygomaxillary junction provides us with an excellent source of D1 cortical bone for the placement of implants and rehabilitation of the posterior maxilla [16, 61]. Pterygoid implants serve to reduce the AP cantilever significantly and are commonly used as rescue implants in cases of failed hybrids.

Treatment concepts with zygomatic and pterygoid implants have evolved as an alternative for challenging bone augmentation procedures. A combination of conventional implants and zygomatic or pterygoid implants has been used successfully for restoration of the moderately atrophic maxilla [21–27]. Placement of anterior conventional implants without large grafting procedures will be extremely difficult in the severely atrophic premaxilla. In such situations, quadruple zygomatic implants with or without pterygoid implants can be used for the dental rehabilitation of the edentulous maxilla [28–31, 62].

CONCLUSION

Quadruple zygomatic implant placement procedures, which do not require any adjunctive procedures such as bone grafting, have become a logical choice for dental rehabilitation of the severely atrophic maxilla. These procedures are especially needed in patients with previous conventional implant or grafting failures [8, 9].

Quadruple zygomatic implant-supported dental rehabilitation can immediately restore oral function, based on implant osseointegration achieved through the zygomatic and malar process rather than the alveolar process of the maxilla [1, 62, 63]. Ideally, a single or multiple standard implants inserted in the premaxilla can counteract the long lever arm of zygomatic implants and prevent prosthetic screw loosening, as well as increasing the odds of long-term success of the zygomatic implants. Additionally, when anterior implants are not feasible, the addition of pterygoid implants seems to be a valid solution for the full-arch rehabilitation with immediate loading of the atrophic maxilla, avoiding more invasive and time-consuming procedures like sinus lifts and large bone grafts. In some cases, quadruple zygomatic implants can be avoided if adequate pterygoid anchorage is obtained.

Numerous companies have designed and market zygomatic implants worldwide. The implants mostly used in the United States are available in different lengths between 30 and 57.5 mm in 2.5 mm increments, depending on the manufacturer [13]. In planning patients with the zygoma implant, a systematic pre-operative evaluation protocol is required before the surgical treatment [32]. Both surgical and prosthetic needs must be considered before initiation of the surgical treatment to allow for a predictable outcome. The overall frequency of complications with zygomatic implants has been studied by retrospective analyses and has been reported to be as high as 9.9% [57]. Intraoral complications accounted for 1.2% of all complications and include oro-sinus fistula (0.4%), vestibular cortical fenestration (0.4%), and implant loss (0.4%) [58]. Extraoral complications represented 8.7% of all complications and include sinusitis (7.5%), subcutaneous malar emphysema and rarely cutaneous fistula (0.8%), infraorbital nerve paresthesia (0.4%), and rarely orbital penetration [57, 59].

REFERENCES

1. Brånemark PI, Gröndahl K, Ohrnell L-O et al. Zygoma fixture in the management of advanced atrophy of the maxilla: Technique and long-term results. *Scand J Plast Reconstr Surg Hand Surg.* 2004;38: 70–85.
2. Fortin Y, Sullivan RM, Rangert BR. The Marius implant bridge: Surgical and prosthetic rehabilitation for the completely edentulous upper jaw with moderate to severe resorption: A 5-year retrospective clinical study. *Clin Implant Dent Relat Res.* 2002;4:69–77.
3. Krekmanov L, Kahn M, Rangert B, Lindström H. Tilting of posterior mandibular and maxillary implants for improved prosthesis support. *Int J Oral Maxillofac Implants.* 2000;15:405–14.
4. Aparicio C, Perales P, Rangert B. Tilted implants as an alternative to maxillary sinus grafting: A clinical, radiologic, and periotest study. *Clin Implant Dent Relat Res.* 2001;3(1):39–49.
5. Jensen OT, Brownd C, Blacker J. Nasofacial prostheses supported by osseointegrated implants. *Int J Oral Maxillofac Implants.* 1992;7:203–11.
6. Weischer T, Schettler D, Mohr C. Titanium implants in the zygoma as retaining elements after hemimaxillectomy. *Int J Oral Maxillofac Implants.* 1997;12:211–14.
7. Tulasne JF. Implant treatment of missing posterior dentition. In T Albrektson, G Zarb (eds.), *The Branemark osseointegrated implant*. Chicago, IL: Quintessence; 1989, 103–15.
8. Fuh L-J, Huang H-L, Chen C-S et al. Variations in bone density at dental implant sites in diferent regions of the jawbone. *J Oral Rehabil.* 2010;37:346–51.
9. Candel E, Peñarrocha D, Peñarrocha M. Rehabilitation of the atrophic posterior maxilla with pterygoid implants: A review. *J Oral Implantol.* 2012;38:461–6.

Dentlearn.ir

10. Balshi SF, Wolfnger GJ, Balshi TJ. Analysis of 164 titanium oxide-surface implants in completely edentulous arches for fixed prosthesis anchorage using the pterygomaxillary region. *Int J Oral Maxillofac Implants.* 2005;20, 946–52.
11. Suzuki M, Omine Y, Shimoo Y et al. Regional anatomical observation of morphology of greater palatine canal and surrounding structures. *Bull Tokyo Dent Coll.* 2016;57:223–31.
12. Kato Y, Kizu Y, Tonogi M, Yamane GY. Internal structure of zygomatic bone related to zygomatic fixture. *J Oral Maxillofac Surg.* 2005;63:1325–9.
13. Peñarrocha M, Carrillo C, Boronat A, Peñarrocha M. Retrospective study of 68 implants placed in the pterygomaxillary region using drills and osteotomes. *Int J Oral Maxillofac Implant.* 2009;24: 720–26.
14. Valerón JF, Valerón PF. Long-term results in placement of screw-type implants in the pterygomaxillary-pyramidal region. *Int J Oral Maxillofac Implant.* 2007;22:195–200.
15. Parsa A, Ibrahim N, Hassan B et al. Bone quality evaluation at dental implant site using multislice CT, micro-CT, and cone beam CT. *Clin Oral Implants Res.* 2013;26:e1–e7.
16. Rodríguez X, Rambla F, De Marcos Lopez L et al. Anatomical study of the pterygomaxillary area for implant placement: Cone beam computed tomographic scanning in 100 patients. *Int J Oral Maxillofac Implants.* 2014;29:1049–52.
17. Uchida Y, Yamashita Y, Danjo A et al. Computed tomography and anatomical measurements of critical sites for endosseous implants in the pterygomaxillary region: A cadaveric study. *Int J Oral Maxillofac Surg.* 2017;46:798–804.
18. Lee SP, Paik KS, Kim MK. Anatomical study of the pyramidal process of the palatine bone in relation to implant placement in the posterior maxilla. *J Oral Rehabil.* 2001;28:125–32.
19. Balaji VR, Lambodharan R, Manikandan D, Deenadayalan S. Pterygoid implant for atrophic posterior maxilla. *J Pharm Bioallied Sci.* 2017;9:S261–S263.
20. Balshi TJ, Lee HY, Hernandez RE. The use of pterygomaxillary implants in the partially edentulous patient: A preliminary report. *Int J Oral Maxillofac Implants.* 1995;10:89–98.
21. Malevez C, Abarca M, Durdu F, Daelemans P. Clinical outcome of 103 consecutive zygomatic implants: A 6–48-month follow-up study. *Clin Oral Implants Res.* 2004;15:18–22.
22. Bedrossian E. Rehabilitation of the edentulous maxilla with the zygoma concept: A 7-year prospective study. *Int J Oral Maxillofac Implants.* 2010;25:1213–21.
23. Aparicio C, Manresa C, Francisco K et al. The long-term use of zygomatic implants: A 10-year clinical and radiographic report. *Clin Implant Dent Relat Res.* 2014;16:447–59.
24. Miglioranca RM, Sotto-Maior BS, Senna PM et al. Immediate occlusal loading of extrasinus zygomatic implants: A prospective cohort study with a follow-up period of 8 years. *Int J Oral Maxillofac Surg.* 2012;41:1072–6.
25. Farzad P, Andersson L, Gunnarsson S, Johansson B. Rehabilitation of severely resorbed maxillae with zygomatic implants: An evaluation of implant stability, tissue conditions, and patients' opinion before and after treatment. *Int J Oral Maxillofac Implants.* 2006;21:399–404.
26. Adell R, Eriksson B, Lekholm U et al. A long-term follow-up study of osseointegrated implants in the treatment of totally edentulous jaws. *Int J Oral Maxillofac Implants.* 1990;5:347–59.
27. Bedrossian E, Stumpel L 3rd, Beckely ML, Indresano T. The zygomatic implant: Preliminary data on treatment of severely resorbed maxillae. A clinical report. *Int J Oral Maxillofac Implants.* 2002;17:861–5.
28. Davo R, Pons O. Prostheses supported by four immediately loaded zygomatic implants: A 3-year prospective study. *Eur J Oral Implantol.* 2013;6:263–9.
29. Padovan LE, Ribeiro-Junior PD, Sartori IA et al. Multiple zygomatic implants as an alternative for rehabilitation of extremely atrophic maxilla: A case letter with 55 months of follow-up. *J Oral Implantol.* 2015;41(1):97–100.
30. Rajan G, Natarajarathinam G, Saravanakumar M, Ashok Y. Full mouth implant rehabilitation of patients with severely atrophic maxilla: Quad zygomatic implants approach. *J Dent Implants.* 2014;4(2):182–6.
31. Vega L, Louis PJ. Zygomatic implants. In CJ Haggerty, RM Laughlin (eds.), *Atlas of operative oral and maxillofacial surgery*. Hoboken, NJ: Wiley; 2015, 42–7.
32. Penarrocha M, Vina JA, Carrillo C, Penarrocha M. Rehabilitation of reabsorbed maxillae with implants in buttresses in patients with combination syndrome. *J Oral Maxillofac Surg.* 2012;70:e322–e330.
33. Park YJ, Cho SM. Retrospective chart analysis on survival rate of fixtures installed at the tuberosity bone for cases with missing unilateral upper molars: A study of 7 cases. *J Oral Maxillofac Surg.* 2010;68:e1338–e1344.
34. Rodrıguez X, Lucas-Taule E, Elnayef B et al. Anatomical and radiological approach to pterygoid implants: A cross-sectional study of 202 cone beam computed tomography examinations. *Int J Oral Maxillofac Surg.* 2015;45(5):e636–e640.
35. Grecchi F, Stefanelli LV, Grivetto F et al. A novel guided zygomatic and pterygoid implant surgery system: A human cadaver study on accuracy. *Int J Environ Res Public Health.* 2021;18:6142.
36. Siddiqui AS, Narayanraopeta S, Chittaranjan B et al. Zygomatic implants: A boon for the depleted maxilla. *Ind J Dent Adv.* 2014;6(3):1613.
37. Brånemark P-I. *Surgery and fixture installation: Zygomaticus fixture clinical procedures*. Goteborg: Nobel Biocare AB; 1998, 1.
38. Aparicio C. Extrasinus zygomatic implants: Three year experience from a new surgical approach for patients with pronounced buccal concavities in the edentulous maxilla. *Clin Implant Dent Relat Res.* 2010;12(1):1–7.
39. Hinze M, Vreilinck L, Thalmair T et al. Zygomatic implant placement in conjunction with sinus bone grafting: The "extended sinus elevation technique." A case-cohort study. Oral Craniofac *Tissue Eng.* 2011;1:188–97.
40. Chow J, Hui E, Lee PKM, Li W. Zygomatic implants—protocol for immediate loading: A preliminary report. *J Oral Maxillofac Surg.* 2006;64:804–11.
41. Penarrocha M. Zygomatic implants using the sinus slot technique. *J Oral Maxillofac.* 2005;20:788–92.
42. Stella JP, Warner MR. Sinus slot technique for simplification and improved orientation of zygomaticus dental implants: A technical note. *Int J Oral Maxillofac Implants.* 2000;15: 889–93.

Dentlearn.ir

43. Balan I, Di Girolamo M, Lauritano D, Carinci F. Treatment of severe atrophic maxilla with zygomatic implants: A case series. *Oral Implantol.* 2017;10(3):317–24.

44. Duarte LR, Filho HN, Francischone CE et al. The establishment of a protocol for the total rehabilitation of atrophic maxillae employing four zygomatic fixtures in an immediate loading system – a 30-month clinical and radiographic follow-up. *Clin Implant Dent Relat Res.* 2007;9:186–96.

45. Balshi TJ, Wolfinger GJ, Petropoulos VC. Quadruple zygomatic implant support for retreatment of resorbed iliac crest bone graft transplant. *Implant Dent.* 2003;12:47–53.

46. Graves SL. The pterygoid plate implant: A solution for restoring the posterior maxilla. *Int J Periodontics Restorative Dent.* 1994;14:512–23.

47. Tulasne J. Osseointegrated fixtures in the pterygoid region. In P Worthington, PI Branemark (eds.), *Advanced osseointegration surgery: Applications in the maxillofacial region*. Chicago, IL: Quintessence; 1992, 182.

48. Nunes de Sousa BL, Leitão de Almeida B. Pterygoid implants for the immediate rehabilitation of the atrophic maxilla: A case report of a full arch on 4 implants. *Oral Maxillofac Surg Cases.* 2020;6(4):100192.

49. Misch CM. Immediate loading of definitive implants in the edentulous mandible using a fixed provisional prosthesis: The denture conversion technique. *J Oral Maxillofac Surg.* 2004;62:106–15.

50. Bedrossian E, Sullivan RM, Fortin Y et al. Fixed prosthetic implant restoration of the edentulous maxilla: A systematic pretreatment evaluation method. *J Oral Maxillofac Surg.* 2008;66:112–22.

51. Uchida Y, Goto M, Katsuki T, Akiyoshi T. Measurement of the maxilla and zygoma as an aid in installing zygomatic implants. *J Oral Maxillofac Surg.* 2001;59:1193–8.

52. Aparicio C. A proposed classification for zygomatic implant patient based on the zygoma anatomy guided approach (ZAGA): A cross-sectional survey. *Eur J Oral Implantol.* 2011;4(3):269–75.

53. Bedrossian E, Rangert B, Stumpel L, Indresano T. Immediate function with the zygomatic implant—a graftless solution for the patient with mild to advanced atrophy of the maxilla. *Int J Oral Maxillofac Surg.* 2006;21:1–6.

54. Zhao Y, Skalak R, Branemark PI. Analysis of a dental prosthesis supported by zygomatic fixtures. Gothenberg: Institute for Applied Biotechnology.

55. Balshi TJ. The Biotes conversion prosthesis: A provisional fixed prosthesis supported by osseointegrated titanium fixtures for restoration of the edentulous jaws. *Quintessence Int.* 1985;16:667–77.

56. Bedrossian E, Stumpel LJ. Immediate stabilization at stage II of zygomatic implants: Rationale and technique. *J Prosthet Dent.* 2001;86(1):10–14.

57. Chrcanovic BR, Albrektsson T, Wennerberg A. Survival and complications of zygomatic implants: An updated systematic review. *J Oral Maxillofac Surg.* 2016;74(10):1949–64.

58. Fernández H, Gómez-Delgado A, Trujillo-Saldarriaga S et al. Zygomatic implants for the management of the severely atrophied maxilla: A retrospective analysis of 244 implants. *J Oral Maxillofac Surg.* 2014;72(5):887–91.

59. Aboul-Hosn Centenero S, Lázaro A, Giralt-Hernando M, Hernández-Alfaro F. Zygoma quad compared with 2 zygomatic implants: A systematic review and meta-analysis. *Implant Dent.* 2018;27(2):246–53.

60. D'Agostino A, Trevisiol L, Favero V et al. Are zygomatic implants associated with maxillary sinusitis? *J Oral Maxillofac Surg.* 2016;74(8):1562–73.

61. D'Agostino A, Favero V, Nocini R et al. Does middle meatal antrostomy prevent the onset of maxillary sinusitis after zygomatic implant placement? *J Oral Maxillofac Surg.* 2019;77(12):2475–82.

62. Yates JM, Brook IM, Patel RR et al. Treatment of the edentulous atrophic maxilla using zygomatic implants: Evaluation of survival rates over 5–10 years. *Int J Oral Maxillofac Surg.* 2014;43:237–42.

63. Malo P, de Araujo Nobre M, Lopes A et al. Extramaxillary surgical technique: Clinical outcome of 352 patients rehabilitated with 747 zygomatic implants with a follow-up between 6 months and 7 years. *Clin Implant Dent Relat Res.* 2015;17(suppl 1):e153–e162.

Dentlearn.ir

Complete-Arch Dental Implant Treatment as an Alternative (to Bone Grafting) Surgical Technique

CHAPTERS 29.1 & 29.2

Multiple failing teeth of the full maxillary or mandibular arches can be replaced with implants in many ways, with a removable or fixed implant approach, in an immediate or delayed fashion. This chapter describes a maxillary and mandibular digital full arch workflow (Part 1; see Video 29.1.1) and metal-ceramic (Part 2 ; See Video 29.2.1) implant rehabilitation. Both surgical-restorative fixed implant-supported techniques are considered the most challenging in implant dentistry. It is an obligation of the whole implant team to listen to each patient with terminal dentition and use clinical skills and expertise to choose one implant design versus another.

Dentlearn.ir

CHAPTER 29.1

Complete-Arch Dental Implant Treatment Using Photogrammetry and Delayed Immediate Loading

Ole T. Jensen[1] and M. Donald Ross[2]

[1]*School of Dentistry, University of Utah, Salt Lake City, UT, USA*

[2]*OnXX Digital – Automated Prosthodontix, Dallas, TX, USA*

The treatment of the edentulous or the soon to be edentulous arch is challenged by anatomical variability, technical difficultly with implant insertion, and the desire for immediate function. The use of four well-distributed implants placed into immediate function has been shown to be optimal in most settings [1–3]. Despite this, there continues to be modification in treatment approaches, including the use of delayed immediate loading. One significant basis for delaying immediate function is based on the new surgical-prosthetic technology of photogrammetry [4, 5].

Photogrammetry enables a new approach to surgery, albeit indirectly. The idea is for in-office patient treatment time to be as brief as possible. Instead of "teeth" being placed the same day as implant placement, with photogrammetry digital images are made and the patient dismissed from the office for later insertion of the prosthesis. *Delayed immediate function* occurs a few days to a week later in the restorative dentist's office [6, 7]. Immediately after surgery a patient is not placed into recovery for some hours to allow for onsite laboratory manufacture of a provisional for "same-day" treatment. Instead, the patient is sent home to return postoperatively to the restorative dentist, who receives delivery of the prosthesis from an off-site central or regional laboratory. Therefore, there need not be an inhouse laboratory facility. The surgical theater can remain a surgical theater and is not clogged by a combined surgical-prosthetic protocol.

In addition, photogrammetry and soft tissue scanning can be performed by auxiliary personnel within a 20–30-minute timeframe and do not require the surgeon or restorative dentist's expertise [8]. Once digitally captured. the data is sent *by email* to the laboratory for processing. Prosthesis manufacture, because of the accuracy of photogrammetry, can elucidate both the interim and final prosthesis concurrently, and therefore are inserted 2 to 6 months apart, depending on the healing requirement of the implant sites [9].

The surgical importance of this is that surgeons are not required to import laboratory personnel or even create an onsite laboratory to do complete-arch treatment. This is a great advantage to most dental surgical clinics throughout the world. It enables the surgeon in these settings to concentrate on surgical case management, especially in cases of complex computer-guided implant surgery [11], and not bifurcate focus in performing complete immediate restorative dental arch treatment. This allows for greater surgical productivity in surgical centers, as well as greater prosthetic productivity in restorative dental clinics [11]. The need for patients to seek treatment at "same-day" implant centers for immediate function is reduced, as the accuracy and simplicity of photogrammetry for delayed immediate function tend to equalize the two treatment options.

The purpose of this chapter is to suggest the use of two simplifying protocols to perform complete-arch implant treatment: first, the use of the *Jensen all-on-four site classification* to help determine the best surgical approach for available bone; and second, the use of delayed immediate function using the almost entirely digital approach of photogrammetry [12, 13].

COMPLETE-ARCH SITE CLASSIFICATION

The purpose and importance of a site classification are to crystallize thinking about anatomical variability that can confound clear decision-making. Classifying jawbone structure into types of morphology forecasts implant placement strategy to be both minimally invasive (efficient) and biomechanically sufficient [14]. The *sine qua non* is to do the *least* needed but

Essential Techniques of Alveolar Bone Augmentation in Implant Dentistry: A Surgical Manual, Second Edition. Edited by Len Tolstunov.
© 2023 John Wiley & Sons, Inc. Published 2023 by John Wiley & Sons, Inc.
Companion website: www.wiley.com/go/tolstunov/essential

Dentlearn.ir

with *optimal* load-bearing capacity, nothing more. For example, if there is sufficient vertical bone one need not angle implants, or one might also consider the use of short implants [15]. In a sense the question is: Is the proposed treatment plan *medically necessary*? The classification concept then becomes the first step in an approach to treatment planning to answer the question: *What is both efficient and sufficient?*

One treatment controversy is the number of implants required to sustain a complete-arch restoration. In a small, highly resorbed mandible, three implants are efficient/sufficient, but doctors most often prefer four [16]. In the maxilla, four implants are efficient/sufficient, but doctors frequently prescribe six as a failsafe measure [17]. Also, one should consider the medical necessity of a particular implant length given the improvement in modern implant technology, as a reduced length requirement in the range of 8 mm is now considered the "optimal" length for an implant (Figure 29.1.1A) [18]. Implants of 6 mm length or less can also be considered as part of a complete-arch implant scheme when bone height is limited [19]. However, clinical judgment and experience should override any classification protocol. There are always exceptional situations. Nevertheless, classification of jawbone morphology is very much a baseline starting point and the final treatment plan is suggested by classification for most patients.

For single-implant sites, optimal classification becomes 8 mm or more of vertical height. In the maxilla, vertical implants are used if there is 8 mm of bone available; however, a 6 mm implant may serve well, as is shown in Figure 29.1.1A. In the mandible, vertical loss of bone categorizes jawbone structure into three basic single-site categories (Figure 29.1.1A–C), as shown in Figure 29.1.1B. When there is good vertical bone above the nerve posterior to the foramen, a vertical implant can be placed as far posterior as the mesial of the first molar, deriving an excellent anterior–posterior spread. When vertical is lost, and implants cannot be placed posterior to the foramen, an angled implant is recommended to help gain spread, as shown in Figure 29.1.2. Types of vertical atrophy and suggested treatment schemes are shown in Figures 29.1.3–29.1.6. Importantly, when severe bone loss occurs and the inter-foramen distance is reduced, three implants are recommended and adequate, as shown in Figure 29.6.

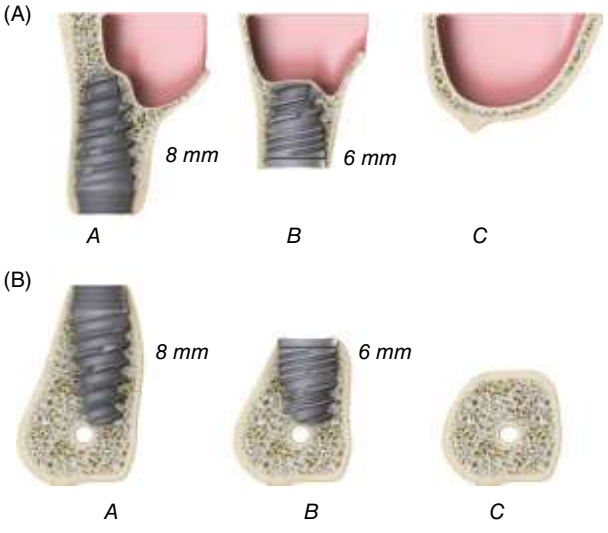

FIGURE 29.1.1 (A, B) A site classification for dental implants is now one of less length. An 8 mm length implant is now considered optimal and a 6 mm implant is considered a satisfactory-length implant, which impacts each implant site on a single-implant basis and therefore effects complete-arch treatment accordingly. Implants illustrated are from Ditron Dental Implants, Ashkelon, Israel.

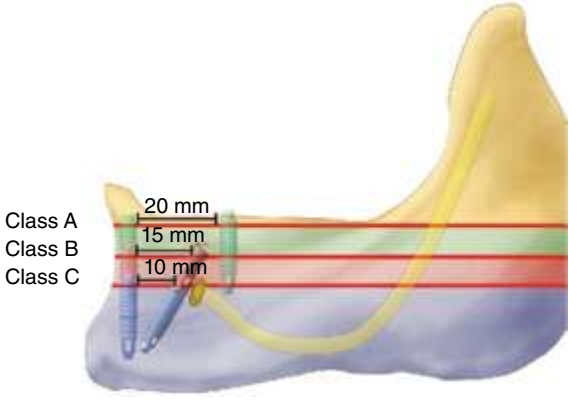

FIGURE 29.1.2 A schematic of the mandible with three classes of atrophy according to loss of vertical bone.

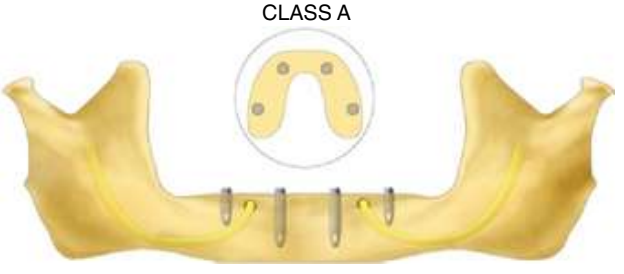

FIGURE 29.1.3 When there is little atrophy, vertical implants can be placed posteriorly as shown.

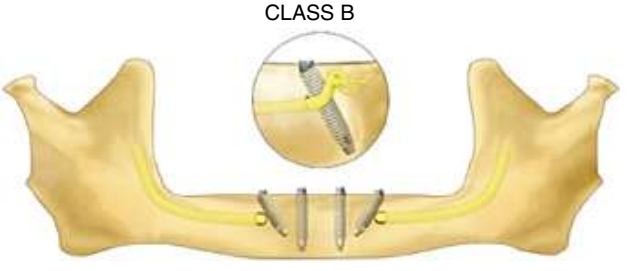

FIGURE 29.1.4 A typical setting for the edentulous mandible is inadequate vertical bone posteriorly, but it is still often amenable to angled implant placement.

Dentlearn.ir

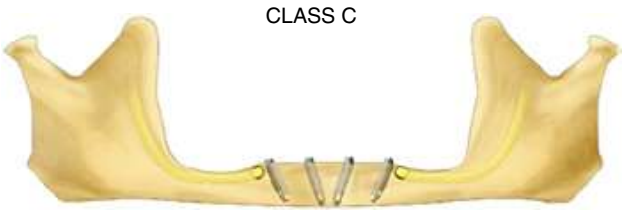

FIGURE 29.1.5 With greater vertical loss four implants can be used, but cannot be angled posterior to the mental foramen.

FIGURE 29.1.6 Severe atrophy suggests a three-implant scheme for the mandible.

The maxilla can be treated with four implants most of the time, despite vertical atrophy, as illustrated in Figure 29.1.7 [20]. Like in the mandible, vertical bone loss determines the treatment plan, which generally falls into four classes. When there is vertical bone posteriorly, vertical implants can be placed. Common practice is to place six implants, as shown in Figure 29.1.8, but four implants serve just as well. When atrophy brings the sinus floor into prominence, then angled implants are used to gain anterior–posterior spread (Figure 29.1.9). This treatment plan is done more than 80% of the time [21]. Angled placement includes the use of trans-sinus placement with and without bone grafting (Figure 29.1.10) [22]. Severe atrophy may eliminate maxillary structural bone to such an extent that treatment options of sinus floor grafting or the use of extraosseous sites such as the zygomatic and pterygoid are employed (Figure 29.1.11 and 29.1.12) [23].

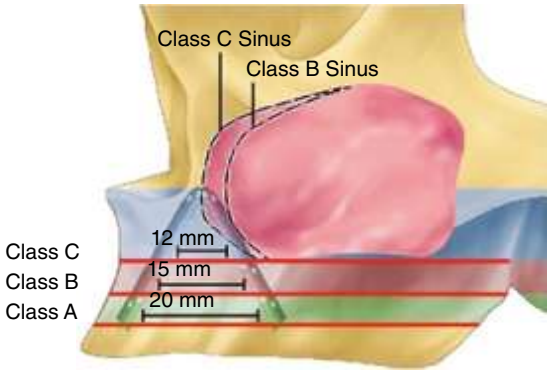

FIGURE 29.1.7 As maxillary atrophy progresses, vertically optimal implant site options contract, leading to a much-reduced anterior–posterior spread. Class A sites can be treated vertically as there is room beneath the sinus for at least an 8 mm vertical implant.

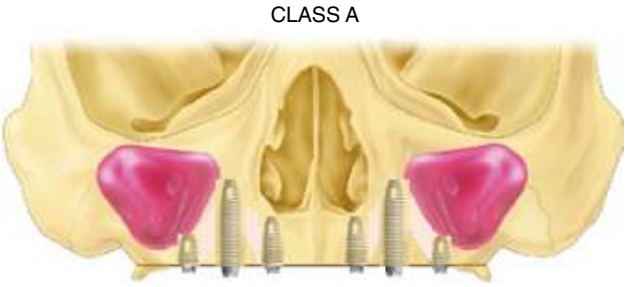

FIGURE 29.1.8 An example of a class A site in which vertical implants can be placed; usually only four implants are required.

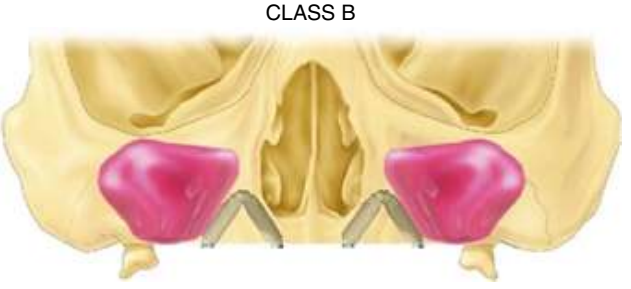

FIGURE 29.1.9 The most common presentation is inadequate bone posterior but adequate bone anteriorly excellent for the M-4 method, as shown in this example of a class B.

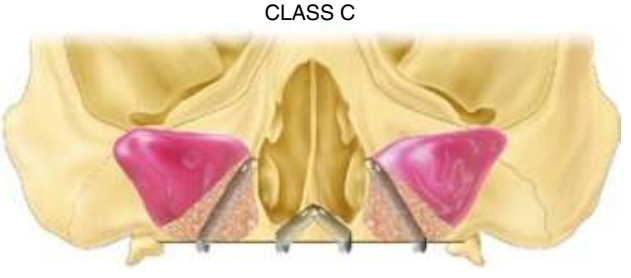

FIGURE 29.1.10 The class C maxilla requires sinus floor grafting with simultaneous or delayed trans-sinus implants, as shown here.

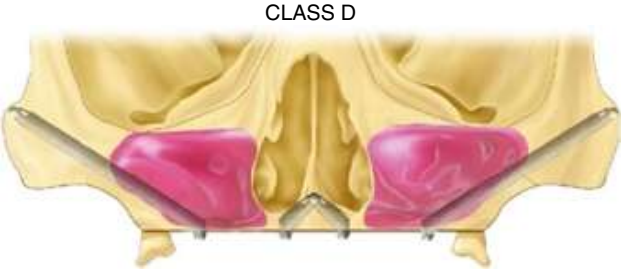

FIGURE 29.1.11 The flat, severely atrophic maxilla can often be managed with zygomatics, and two anterior nasal crest–directed implants.

Dentlearn.ir

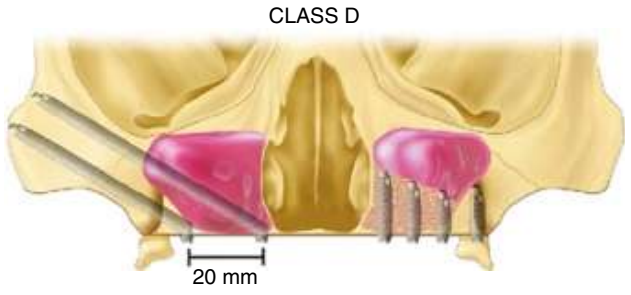

FIGURE 29.1.12 The class D maxilla may also require a delayed placement method, with sinus grafts or a quad zygomatic approach if immediate function is preferred, the two options shown here.

FULL-ARCH TREATMENT: RESTORATIVE BUILDING BLOCKS

The key to success for any production process involves the identification, understanding, and control of key components of that process. Failure to do so will result in chaos, unpredictability, and variability of outcome, as well as an over-expenditure of both time and resources. To achieve success with full-arch implant treatment is no different. A systematic and sequential process that identifies foundational and key components of full-arch treatment is required.

Identification and control of key clinical processes and the removal of all non-essential items from the process lead to a clear understanding of where to focus efforts when providing complete-arch treatment. Removing variability through standardization removes clinical barriers, allowing more clinicians to predictably provide full-arch care for their patients.

The goal of full-arch implant treatment is to efficiently and predictably execute on the key surgical and restorative clinical requirements needed for success. Moving from point A (exam) to point B (surgery) to point C (final restoration) should be as efficient as possible, with minimal waste in time or resources. Enabling technology such as photogrammetry, when properly used, can improve accuracy and efficiencies in these variables, which can save a significant amount of time and effort.

Presented here is an introduction of six key components of full-arch dental implant treatment that any clinician can use. Think of each component as a *building block* of data, with each block building onto the other in a prescribed order. The proper sequence of each building block is the key to predictability and, when followed, serves to more easily identify problems and remedy complications during treatment.

BUILDING BLOCK 1: CENTRIC RELATION

Goal: To establish and record a repeatable mandibular position and then to use this position as the foundational position (block) for everything moving forward.

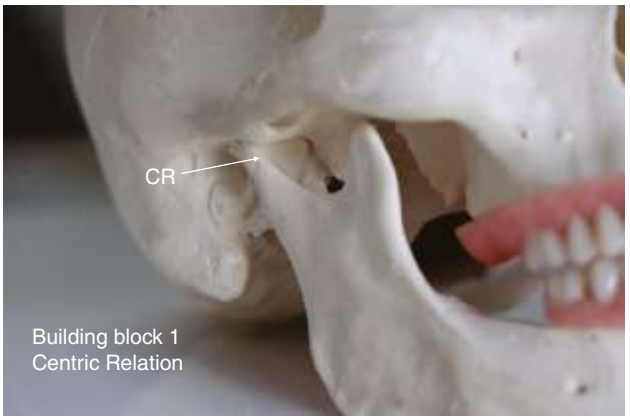

FIGURE 29.1.13 Centric relation (CR) is needed to produce a reproducible occlusion.

Centric relation (CR; Figure 29.1.13) is extremely useful and worthy of our effort. For predictable clinical outcomes there is a CR spectrum that clinicians should fall within when providing full-arch treatment. At minimum, the surgeon have a practical understanding and appreciation of its importance and usefulness. At maximum, a clinician should possess the ability to consistently obtain a CR record from a patient.

The CR is the standard starting point used by prosthodontists, because it is a reproducible mandibular position that is the most reliable reference point obtainable in an edentulous patient for accurately recording the relationship between the mandible and the maxilla, and ultimately for controlling the occlusal contact pattern.

Once a patient is edentulous, a CR position must be obtained as the reliable starting point to build upon. Reconstructing a dentition outside of the CR position will at best be unpredictable and arbitrary about esthetics or occlusion. Therefore, CR becomes the foundational building block for all subsequent building blocks in the process. It is important to state here that *there is no workflow or technology that replaces the need for the CR record*.

Once CR is obtained, we are ready to add the next building block: vertical dimension of occlusion (VDO).

BUILDING BLOCK 2: VERTICAL DIMENSION OF OCCLUSION

Goal: To determine and record the proper vertical distance between the mandible and the maxilla while in CR.

Once CR is obtained, the second position to establish is the VDO. It is important to note that VDO needs to be established while the mandible is in CR (Figure 29.1.14). While in CR, the mandible is rotated on the arc of closure to a position where the correct distance between the mandible and the maxilla is established and recorded for the patient. If the correct VDO is established but the mandible is not in the CR position, then variability in outcome is introduced. Therefore,

Dentlearn.ir

FIGURE 29.1.14 Proper vertical dimension is determined.

VDO is always the second building block to CR. Positioning the mandible in CR at the correct VDO establishes the proper boundaries, framework, and borders for the next building block: case planning.

BUILDING BLOCK 3: CASE PLANNING

Goal: To set or position teeth within the prescribed borders of CR and VDO with ideal esthetics and occlusion in mind. To perform a virtual surgery that follows the restorative plan.

The next step is to design a smile by positioning teeth within the established borders of CR and VDO. The smile design should follow important principles pertaining to esthetics and occlusion. Items to consider are tooth mold, shade, incisal position, occlusal planes, arch form, occlusal relationships, and contacts. The restorative plan can follow an analog wax set-up (Figure 29.1.15A) or digital design workflow (Figure 29.1.15B, C). It is only after the restorative plan is completed that the surgical plan can be designed (Figure 29.1.15D, E). Surgical planning includes bone reduction, implant placement according to all-on-four site classification principles, and abutment positioning, all done digitally. For predictable results implant placement planning should never

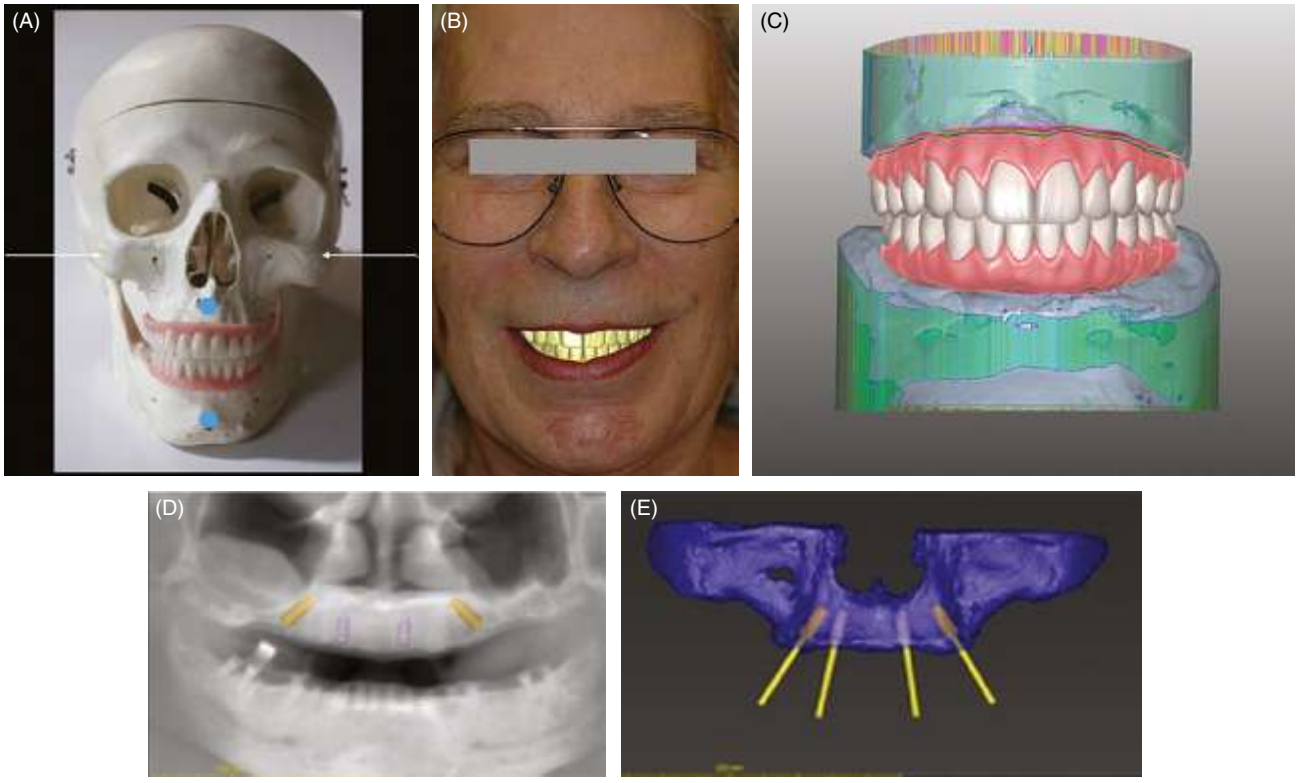

FIGURE 29.1.15 (A) Wax-up with tooth placement plan at proper vertical dimension and centric relation. (B) Digital plan for tooth position at centric relation and correct vertical dimension. (C) Digital tooth set-up. (D) Virtual surgical plan for implant placement. (E) Digital surgical plan angulating implants within the prosthesis.

Dentlearn.ir

be done prior to the establishment of CR, VDO, and restorative planning and design.

Proper restorative and surgical planning done preoperatively can set up treatment perfectly for the next building block: surgery.

BUILDING BLOCK 4: SURGERY

Goal: To execute surgery following the restorative and surgical plans.

Key items for a successful execution of surgery provide for adequate bone reduction. Ideally, this will be approximately 15 mm of prosthetic space per arch. Bone reduction verification can be done with or without a guide, as shown in Figure 29.1.16A–D.

Current methods of implant placement for complete-arch care include freehand placement, guided surgery, and robotics. Key items to aim for during implant placement are primary stability, anterior–posterior spread, proper angulation, and orientation. Abutment selection follows, done by the surgeon at the time of implant placement to include bone profiling for abutment seat, proper abutment height and angle, and abutment torque. Successful implant and abutment placement will be predictable when the surgery follows a prosthetic plan (Figure 29.1.16E).

Once bone reduction, implant placement, and abutment selection are completed, and the wound closed, the clinician is set up for the next building block: provisionalization and digital duplication.

BUILDING BLOCK 5: PROVISIONALIZATION

Goal: To fabricate and deliver a provisional prosthesis with optimal esthetics and occlusion that fits passively onto the implant abutments while maintaining CR and VDO.

This is one of the most important steps of the restorative phase of full-arch treatment. Fabrication of a provisional that maintains all of the critical items will give the patient the best chance to accept the provisional. Patient acceptance of the provisional is a key predictor as to whether going to final restoration will be simple or difficult. If changes to the provisional are requested, more restorative appointments will be needed to correct esthetics, occlusal, VDO, and CR issues.

If provisionalization is done correctly, the provisional prosthesis will possess all critical information needed to move toward final restoration, including CR, VDO, esthetics, occlusion, and implant position. Careful records allow for digital duplication of all this data in preparation for making the final restoration. Restorative efficiency toward making the final restoration relies completely on accurately capturing of all this information at the time of surgery.

The three most common processes to fabricate a provisional and capture data for a final prosthesis are denture conversion, guided surgery with prefabricated provisional,

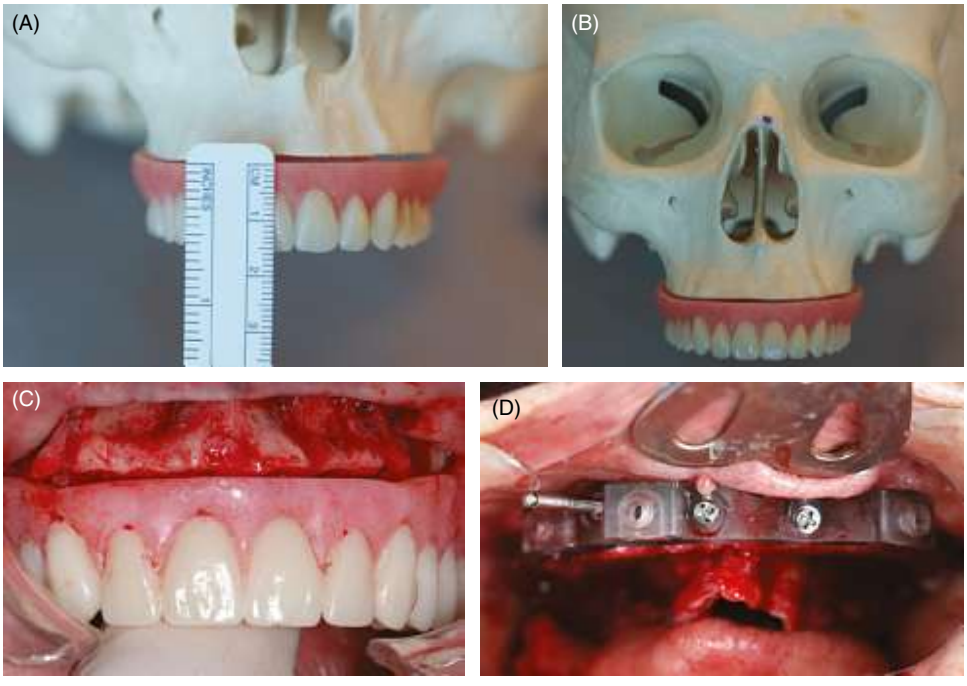

FIGURE 29.1.16 (A) Interocclusal space required by vertical bone reduction for the fixed-denture prosthesis is 15 mm. (B) The bone reduction mock-up with tooth position plan. (C) Intraoperative prosthesis vertical position following bone relief. (D) The bone reduction guide enables in a more exact way than freehand a bone shelf parallel to the Frankfort horizontal.

Dentlearn.ir

and digital production of a provisional using photogrammetry. Each method is described here, elucidating the advantages and disadvantages for both conversion and patient data duplication.

Denture Conversion

This commonly used technique requires the fabrication of a removable denture prosthesis prior to surgery. On the day of surgery, the removable prosthesis is converted to a fixed-detachable prosthesis (hybrid; Figure 29.1.17). If done correctly, the provisional will maintain esthetics, occlusion, VDO, and CR. Because this method is technique sensitive, both provisional fabrication and patient data duplication require much more time, effort, and laboratory expertise when compared to other techniques.

There are advantages and disadvantages to using the denture conversion method of which the surgeon should become more conscious. The main advantages are that it is commonly done, and dentists and laboratory technicians are familiar with the technique. But there are many disadvantages, including high costs and high incidence of prosthetic complications, including breaking of the provisional during function, necessitating repairs. These prosthetic complications toggle implants due to loose fit and can sometimes lead to early loss of implants from lateral moment of force loading, impacting the surgeon's practice. The denture conversion technique ties the clinician into a long restorative timeline with multiple appointments. Appointments can be long, and overall treatment time can extend to longer than a year. The method is highly inaccurate, relying quite heavily on the surgeon's skill to reduce adequate bone and place implants properly, leading to variability of outcomes that relate back to inadequate CR and VDO. With this method the surgical theatre becomes a prosthodontic and laboratory facility where extended chair time and prolonged patient waiting time are required.

Guided Surgery Provisional

Guided surgery is a common technique used for complete-arch case planning, including surgical bone reduction and implant placement. This workflow method standardizes bone reduction and can lead to more ideal placement of dental implants and abutments. However, most surgeons abandon guided surgery, as freehand placement is more tactile and allows for slight changes in placement pattern to be done. Also, guides sometimes do not replicate anatomy well or if aligned inaccurately lead to implant insertion difficulties. But where this type of treatment can go wrong is prosthetically, leading to suboptimal provisional outcomes.

If CR and VDO (blocks 1 and 2) were properly obtained during the patient exam, then the virtual esthetic design, implant placement, and abutment selection should be accomplished within the correct parameters. A prefabricated provisional (Figure 29.1.18) is then finished and attached with a high chance of having proper esthetics and occlusion. If the virtual smile design is done without satisfactory CR and VDO input, then it is highly likely that the provisional will need significant occlusal adjustments when delivered. This complicates the restorative process post surgery and therefore affects the surgeon's time. When a provisional is fabricated outside of CR and VDO, it takes considerable skill and effort to course-correct and re-establish CR, VDO, esthetics, and occlusion prior going to final restoration. To do this once again requires laboratory support, extended surgical theatre chair time, and prolonged patient waiting time.

There are great advantages to the guided method when it works well, including more predictable bone reduction, implant positioning, abutment placement, and accurate placement of a provisional prosthesis. If this always happened, then the surgeon would demand to use this method invariably. But this is often not the case, as the main disadvan-

FIGURE 29.1.17 Abutment selection is most commonly done by the surgeon. Early step of previsualization: "conversion" of the prosthesis using a guided implant placement method.

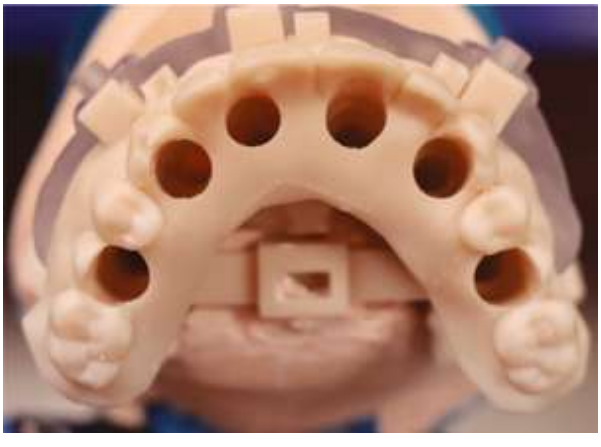

FIGURE 29.1.18 The denture conversion finalized in the laboratory on the same day as the surgery.

Dentlearn.ir

tage is provisional unpredictability, leading to a bail-out denture conversion method being required. So, the considerable added cost of the guided method may not be justified if it is not consistently working, particularly if laboratory support is a necessity.

Provisionalization Using Photogrammetry

Photogrammetry is a proven technology that enables a clinician or dental auxiliary to quickly and easily capture the precise implant abutment position after implant placement, regardless of the number of implants placed (Figure 29.1.19). The surgeon and his/her staff now take on the role of photogrammetry, often done prior to wound closure, instead of the prosthodontist performing an analog impression.

Historically, the accurate capture of implant position and the reproduction of the patient record post implant placement have been difficult due to the limitations of dental materials. Prior to photogrammetry, capturing implant position on a full arch required a complex, time-consuming, and technique-sensitive impression technique. Expansion/contraction of dental stone, impression compounds, and resin materials always adds variability and a degree of unpredictability in accuracy.

FIGURE 29.1.19 Accurate implant abutment capture using photogrammetry.

Because photogrammetry is the most accurate method of obtaining implant position, and because this photographic method can be done in minutes, it opens the door like no other method for complete disruption of all previous workflows. Indeed, photogrammetry opens the "digital door" for complete-arch treatment. And the surgeon is the one opening this door in the surgical theatre.

Photogrammetry is faster, more predictable, and more precise when capturing the position of dental implants on an arch. This, in turn, saves time and precious resources for everyone involved. Once obtained, the photogram (Figure 29.1.20) can be combined with data captured and digitized from the denture or provisional (CR, VDO, esthetics/occlusion; Figure 29.1.21), to fabricate a provisional via milling or printing production methods (Figure 29.1.22). There are many advantages, including reproducibility, precision, lack of porosity, and optimal esthetics, but perhaps most important to the surgeon is the increased strength and dependability of the interim prostheses to support implant healing during immediate function.

If all building blocks have been successfully established up to this point (CR, VDO, esthetics, and occlusion) and proper surgical execution was done within these parameters, then photogrammetric capture of the implant abutment positions becomes the next building block added to this stack of information. By capturing and adding the exact implant position after surgery to an ideal esthetic and occlusal plan that is built within the boundaries of the correct VDO and CR, a provisional can be fabricated that will have a high likelihood of being accepted by the patient. More importantly, this digital data can be used to easily and quickly correct any complication that may arise during healing, such as provisional breakage or implant failure.

For the first time a consistently accurate implant position data set is added to all of the previous building blocks.

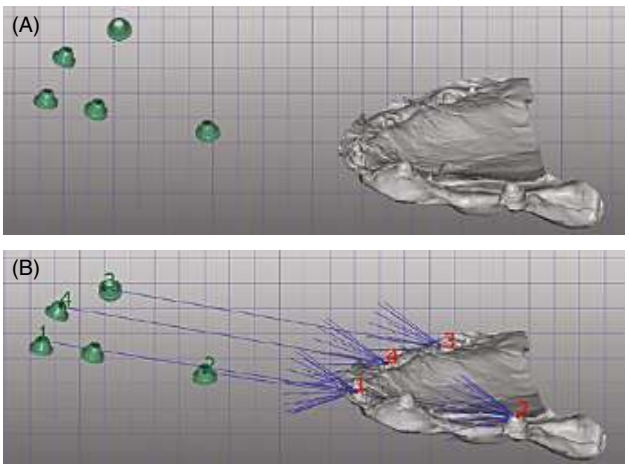

FIGURE 29.1.20 (A) Floating scan from photogrammetry of prosthesis with scan markers. (B) Matching of the scans.

Dentlearn.ir

FIGURE 29.1.21 A scan of soft tissue or an alginate impression is made if a scanner is not available.

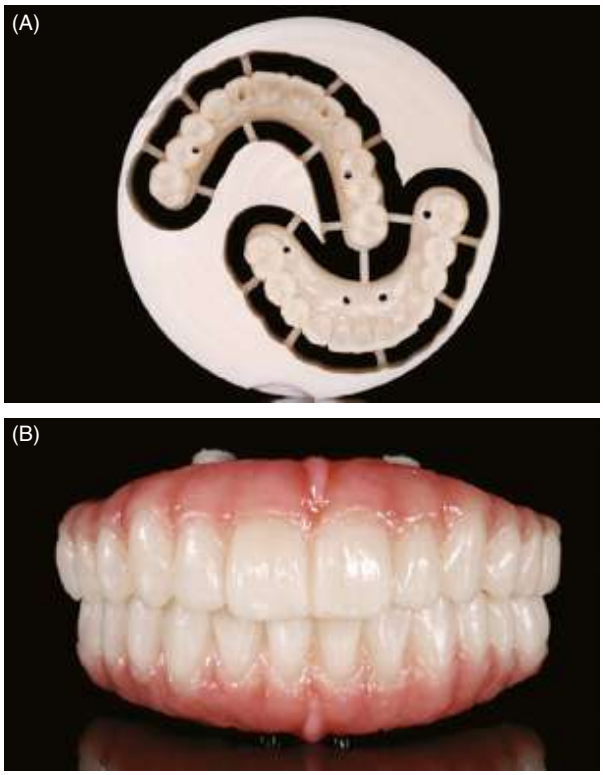

FIGURE 29.1.22 (A) Photogrammetry-derived digital prosthesis is made and then colorized and personalized in the laboratory. (B) The final photogrammetry-derived prosthesis.

With the digitization of CR, VDO, esthetics, occlusion, and implant position, the clinician for the first time has full control of the case from the day of surgery. Up to now, this information had to be acquired through numerous lengthy appointments over the course of up to a year or more.

Photogrammetry does have both advantages and disadvantages that must be weighed by the treatment team. An advantage that must be understood clearly in terms of the last four decades of complete-arch restoration is the unparalleled passive fit of the prosthesis. This has been a historical difficulty, leading to hundreds of publications on methods to obtain what seemed impossible. Photogrammetry appears to solve this. The second advantage alluded to above is near-entire digitation of the complete-arch treatment process, with attendant minimization of laboratory time and skill requirement, including ease of repair or remakes for lost implants. This one, call it the laboratory advantage, is about to inspire a massive paradigm shift in implant dentistry.

One advantage to emphasize from a surgeon's point of view is the efficiencies, not just of outcome, but of how patients come and go in the office and what complicating factors will or will not impact the surgeon's workflow. Since photogrammetry is a camera system that auxiliary personnel can easily be trained to perform, the surgeon can complete surgery and photogrammetry can be done immediately thereafter in less than 30 minutes. The patient is then dismissed to return home, freeing up the operating theater, the waiting room, and dramatically reducing patient waiting time. The prosthodontist's digital control of the case from start to finish also impacts the surgeon's control of the case from his/her perspective. Increased predictability, accuracy, and efficiency for the prosthodontist and the laboratory also greatly affect the surgeon as well.

The disadvantages of photogrammetry are all related to its being a relatively new technology. The present cost of the camera is expensive. Laboratory expertise in photogrammetry is highly limited. But the major disadvantage is *delayed immediate function* requiring the use of an outside laboratory with milling, printing, and finalization capability from photogrammetric images. One option to avoid delayed delivery of the provisional is for the surgeon to invest and being the production equipment and personnel inhouse to replicate the capabilities of the laboratory.

BUILDING BLOCK 6: SOFT TISSUE

Goal: To capture and digitize fully healed soft tissue and add this data block to all previous data blocks prior to the fabrication of the final prosthesis.

The last building block needed prior to going to final restoration is the capture of fully healed soft tissue. Once the soft tissue has healed, a simple polyvinyl siloxane (PVS) or alginate impression can be taken, or an intraoral scan of the soft tissue can be performed. This information can be digitized

Dentlearn.ir

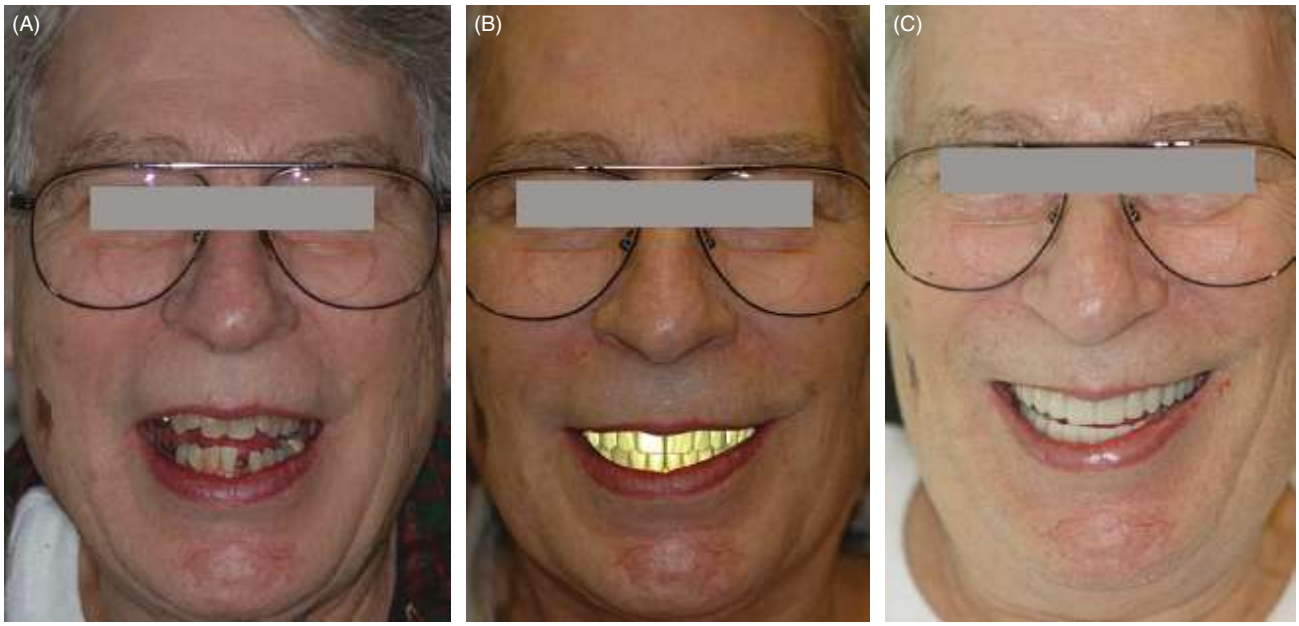

FIGURE 29.1.23 (A) Pre-operative findings with terminal dentition. (B) The digitally derived smile. (C) The final photogrammetry-derived smile, the most digital method available to conduct surgical-prosthetic treatment to minimize laboratory work.

and added to the other data in the chain. Once this is captured, all of the necessary information is ready to be used to fabricate the final prosthesis.

In the end, the benefit of this workflow is that it gathers all necessary information in a digital format early in the process. If this information is accurate, then moving to final restoration can be done much sooner and with accurate and esthetic results (Figure 29.1.23). Previous workflows required the gathering of this data through a series of many appointments over a long span of time, which delayed the final prosthesis. Longer treatment times open the door for increased complications, which lead to increased frustrations, added costs, and poor patient experience. By using photogrammetry, one shortens the time, effort, and complexities needed to move toward a final prosthesis.

DISCUSSION

Complete-arch treatment planning, now second nature to dentists, is based on structural jawbone morphology and follows a simple classification scheme. Once adopted, a classification mindset allows for a minimally invasive approach for the optimal use of available bone, leading to consistent immediate function. The unnecessary number and length of implants are curtailed. The unnecessary use of sinus bone grafting, nerve transposition, zygomatic implants, or other more invasive procedures is reduced in incidence by adhering to classification principles.

There are many factors to consider in decision-making for complete-arch treatment, not the least of which is the wishes of the patient. The *patient factor* can generally be formulated into four factors: a desire for the least invasive procedure, rapid treatment time, immediate function if possible, and financial consideration.

The all-on-four protocol manages to address all four of these issues by avoiding complex grafting procedures, having a relatively rapid treatment time, leading to immediate function, and having significantly reduced cost when compared to bone graft reconstruction such as sinus floor grafting.

Photogrammetry also impacts the patient factor favorably, in that it is less invasive than traditional analog methods, has a shorter treatment time including less in-office waiting time, can lead to immediate or nearly immediate function, and further reduces patient cost. The viewpoints of the patient, the surgeon, and the restorative dentist on photogrammetry are all favorable, but there are both advantages and disadvantages when compared to same-day treatment regimes.

CONCLUSION

The use of four implants for complete-arch immediate function becomes more efficient, simplified, and precise using anatomical site classification and photogrammetry. Once site classification is fully embraced and understood, surgery becomes more efficient and less invasive. Photogrammetry also leads to efficient delivery of care, permitting complete-arch treatment to be done at non-centralized and more accessible care sites, where onsite laboratory function is not required or is reduced in importance due to digitization of the prosthetic laboratory process.

Dentlearn.ir

To access the videos for this chapter, please go to
www.wiley.com/go/tolstunov/essential

VIDEO 29.1.1 Introduction to Chapter 29.1, by the Authors Drs. Ole T. Jensen and M. Donald Ross.

REFERENCES

1. Graves S, Mahler BA, Javid B et al. Maxillary all-on-four therapy using angled implants: A 16-month clinical study of 1110 implants in 276 jaws. *Dent Clin North Am.* 2011;55(4):779–94.
2. Butura CC, Galindo DF, Jensen OT. Mandibular all-on-four therapy using angled implants: A three-year clinical study of 857 implants in 219 jaws. *Dent Clin North Am.* 2011;55(4):795–811.
3. Mitsias M, Siormpas K, Pistilli V et al. Immediate, early (6 weeks) and delayed loading (3 months) of single, partial and full fixed implant supported prostheses: 1-year post-loading data from a multicenter randomized controlled trial. *Eur J Oral Implantol.* 2018:11(1):63–75.
4. Fischer K, Stenberg T, Hedin M, Sennerby L. Five-year results from a randomized, controlled trial on early and delayed loading of implants supporting full-arch prosthesis in the edentulous maxilla. *Clin Oral Implants Res.* 2008;19(5):433–41.
5. Sanchez-Monescillo A, Hernanz-Martin J, Gonzalez-Serrano C et al. All-on-four rehabilitation using photogrammetric impression technique. *Quintessence Int.* 2019;50(4):288–93.
6. Sanchez-Monescillo A, Sanchez-Turrion A, Vellon-Domarco E et al. Photogrammetry impression technique: A case history report. *J Prosthodont.* 2016;29(1):71–3.
7. Revilla-Leon M, Att W, Ozcan M, Rubinstein J. Comparison of conventional photogrammetry and intraoral scanning accuracy of complete-arch implant impression procedures evaluated with a coordinate measuring machine. *J Prosthet Dent.* 2021;125(3):470–78.
8. Molinero-Mourelle P, Lam W, Cascos-Sanchez R et al. Photogrammetric and intraoral digital impression technique for the rehabilitation of multiple unfavorably positioned dental implants: A clinical report. *J Oral Implantol.* 2019;45(5):398–402.
9. Penarrocha-Oltra D, Agustin-Panadero R, Bagan L et al. Impression of multiple implants using photogrammetry description of technique and case presentation. *Patol Oral Cir Bucal.* 2014;19(4):e366–e371.
10. D'haese J, Ackhurst J, Wismeijer D et al. Current state of the art of computer-guided implant surgery. *Peridontol* 2000. 2017;73(1):121–33.
11. Jensen OT. Complete arch site classification for all-on-four immediate function. *J Prosthet Dent.* 2014;112(4):741–51.
12. Tannyhill RJ, Jensen OT. Computer simulation and maxillary all on four surgery. *Oral Maxillofac Surg Clin of North Am.* 2019;31(3):497–504.
13. Jensen OT, Ringeman JL, Adams MW, Gregory N. Reduced arch length as a factor for 4-implant immediate function in the maxilla: A technical note and report of 39 patients followed for 5 years. *J Oral Maxillofac Surg.* 2016;74(12):2379–84.
14. Polak D, Shapira L. From maximally to minimally invasive surgery for sinus floor augmentation. *Compend Contin Educ Dent.* 2013;34(spec):19–24.
15. Felice P, Barausse C, Pistilli R et al. Short implants versus longer implants in vertically augmented posterior mandibles: Results at 8 years after loading from a randomized controlled trial. *J Oral Implantol.* 2018;11(4):385–95.
16. Malo P, Rangert B, Nobre M. All-on-four immediate function concept with Branemark system implants for completely edentulous mandibles: A retrospective clinical study. *Implant Dent Relat Res.* 2003;5(suppl 1):2–9.
17. Daudt Polido W, Aghaloo T, Emmett TW et al. Number of implants placed for complete-arch fixed prostheses: A systematic review and meta-analysis. *Clin Oral Implants Res.* 2018;29(suppl 16):154–83.
18. Nielsen HB, Schou S, Isidor F et al. Short implants (8mm) compared to standard length implants (>8mm) in conjunction with maxillary sinus floor augmentation: A systemic review and meta-analysis. *Int J Oral Maxillofac Surg.* 2019;48(2):239–49.
19. Naenni N, Sahrmann P, Schmidlin PR et al. Five-year survival of short single tooth implants (6mm): A randomized controlled clinical trial. *J Dent Res.* 2018;97(8):887–92.
20. Jensen OT, Adams MW, Butura C, Galindo DF. Maxillary V-4: Four implant treatment for maxillary atrophy with dental implants fixed apically at the vomer-nasal crest, lateral pyriform rim and zygoma for immediate function. Report of 44 patients followed from 1–3 years. *J Prosthet Dent.* 2015;114(6):810–17.
21. Malo, P, de Araujo Nobre M, Lopes A et al. All on 4 immediate function concept for completely edentulous maxillae: A clinical report on the medium (3 years) and long term (5 years) outcomes. *Implant Dent Relat Res.* 2012;14(suppl 1):e139–e150.
22. Jensen OT, Cottam J, Ringeman J, Adams M. Trans-sinus dental implants, bone morphogenetic protein 2 and immediate function for all on four treatment of severe maxillary atrophy. *J Oral Maxillofac Surg.* 2012;70(1):141–8.
23. Jensen OT, Adams MW. Anterior sinus grafts for angled implant placement for severe maxillary atrophy as an alternative to zygomatic implants for full arch fixed restoration: Technique and report of five cases. *J Oral Maxillofac Surg.* 2014;72(7):1268–80.

Dentlearn.ir

Maxillary Full-Arch Staged Ceramo-metal Implant Rehabilitation

CHAPTER 29.2

Len Tolstunov[1,2,3]

[1]*Associate Clinical Professor, Department of Oral and Maxillofacial Surgery, University of California San Francisco (UCSF) School of Dentistry, San Francisco, CA, USA*

[2]*Associate Clinical Professor, Department of Oral and Maxillofacial Surgery, University of the Pacific Arthur A. Dugoni School of Dentistry, San Francisco, CA, USA*

[3]*Private OMFS practice, San Francisco, CA, USA*

Failing dentition presents complex challenges in full-mouth implant rehabilitation cases. Psychologically, it is often hard for patients to accept the reality of deteriorating dentition and losing not just one or two teeth, but the whole set of upper, lower, or all teeth at the same time [1]. Often, an extensive explanation is needed for a patient to accept that most of his/her teeth are severely decayed or periodontally involved and, even if one or two teeth are in a repairable condition, it would be better overall for the patient to consider full-arch implant reconstruction in the long term [2, 3]. Patients with fixed dentition, even if it is in a poor state, often have a difficult time agreeing to a removable denture treatment plan, even if it is offered for a short period of time. Implant reconstruction of a single or double dental arches can also be expensive. The patient's oral hygiene is often suboptimal in these severely decayed cases, and the patient's willingness to change and improve with a new "implant dentition," especially in a fixed implant strategy, can be unrealistic. In general, maxillary implant-supported fixed prosthetic options are successful and improve the patient's function and comfort [4].

This chapter discusses full-arch implant treatment of failing maxillary dentition. In the majority of maxillary full-arch cases where teeth cannot be restored, there are four main treatment strategies:

- Extraction of all remaining teeth, alveoloplasty, and full maxillary denture.
- Extraction of all remaining teeth, minor bone reduction, and placement of four dental implants for a maxillary implant overdenture.
- Extraction of all remaining teeth, major bone reduction, and placement of 4–6 implants for a fixed implant-supported metal-resin (hybrid) prosthesis (in immediate or delayed fashion), often known as an all-on-four design.
- Extraction of all remaining teeth, minor bone remodeling, and ideal placement of 6–10 implants for a fixed implant-supported metal-ceramic prosthesis (implant crown-bridge).

What helps the clinician to determine full-arch implant treatment choices often depends on the patient's previous history of wearing removable prostheses, oral hygiene habits, financial reasons, and others. All full-arch maxillary implant rehabilitation treatment options (removable or fixed, splinted or not, immediate or delayed, on 4 or 6+ implants) provide significant improvement of the patient's mastication, esthetics, satisfaction, and comfort relative to the diseased and failing (due to extensive teeth decay and/or advanced periodontal condition) natural dentition [5, 6].

It is generally agreed that full-arch fixed implant rehabilitation with ceramo-metal crown-and-bridge restorations after extraction of all remaining teeth is one of the most challenging implant approaches from the functional and esthetic point of view [7–9]. Immediate implantation (into fresh sockets), including full-arch cases after removal of periodontally involved teeth, has been shown to be a predictable surgical approach with a success rate approximating that of delayed implantation [10, 11]. It has been shown that the success rate of immediate implantation is higher in the posterior mandible than in the posterior maxilla [12].

When selecting a full-arch metal-ceramic surgical-restorative implant approach, it is also important to consider future complications, like screw loosening, porcelain fracture, de-cementation of cementable restorations, fracture of any part of the metal-ceramic prosthesis, or peri-implantitis and implant failure, which can be difficult and expensive to correct [9, 13, 14].

In some cases, due to the patient's objection to wearing a removable prosthesis at any time during the implant rehabil-

Essential Techniques of Alveolar Bone Augmentation in Implant Dentistry: A Surgical Manual, Second Edition. Edited by Len Tolstunov.
© 2023 John Wiley & Sons, Inc. Published 2023 by John Wiley & Sons, Inc.
Companion website: www.wiley.com/go/tolstunov/essential

Dentlearn.ir

itation process, transition from a failing dentition to a full-arch implant prosthesis can be challenging. A hybrid all-on-four approach can eliminate the need to wear a removable prosthesis by having an immediate conversion to a transitional (temporary) one-piece prosthesis.

The ceramo-metal multi-unit approach uses a different tactic for this transition. It is usually done through a staged extraction method with temporary fixed bridges (tooth supported and/or implant supported). This surgical-restorative technique has been documented as a successful and patient-tailored approach [15–17]. The following case presents this treatment approach. It consisted of a maxillary full-arch metal-ceramic implant reconstruction that was done in stages to avoid a removable prosthesis throughout the patient's overall implant rehabilitation.

CASE REPORT

HISTORY

A 73-year-old African American male, a semi-retired doctor, presented to our oral and maxillofacial surgery clinic for evaluation of his failing upper dentition. For many years the patient had been uncomfortable with his upper teeth. He had difficulty chewing, poor esthetics, on-and-off pain, teeth mobility, occasional swelling, and pus discharge. Prior to his presentation, the patient had taken several courses of antibiotics for his advanced periodontal condition. His medical history was significant for controlled type II diabetes and hypertension.

EXAMINATION AND CLINICAL PRESENTATION

On presentation, the patient had features typical of a long face syndrome with dolichocephalic (excessive vertical) skeletal type (Figure 29.2.1). His facial and stomatognathic examination demonstrated a long lower face height and vertical dimension of occlusion (VDO; nose–chin distance) of 86 mm (normal 60–80 mm), a high smile line of up to 8–10 mm with gingival exposure (often called a transitional zone, between animated upper lip and cemento-enamel junction of maxillary anterior teeth; Figures 29.1.2 and 29.1.3). The patient's remaining maxillary dentition from the right second premolar to the left second premolar was in poor repair and showed advanced periodontal disease, with teeth mobility and exposure of roots.

The exposed maxillary gingival display (Figures 29.1.2 and 29.1.3) during smile and even normal talk was a typical feature of this patient. He, his immediate family, and friends, who knew about his forthcoming implant treatment, did not want to have it eliminated (they were used to it), but consented only to some degree of reduction in his gum exposure.

Diagnostic radiographic images (periapical, panoramic, and cone beam computed tomography scan) demonstrated that the patient's remaining maxillary dentition was in a state

FIGURE 29.2.1 On presentation, the patient had features typical of a long face syndrome with dolichocephalic (vertical excess) skeletal type.

FIGURE 29.2.2 Extraoral photograph of the exposed maxillary gingival display at smile.

FIGURE 29.2.3 Extraoral photograph of the exposed maxillary gingival showing high smile line.

Dentlearn.ir

of advanced periodontal disease, with 50+% periodontal bone loss but adequate basal bone stock between pneumatized maxillary sinuses for maxillary implant treatment (Figures 29.2.4–29.2.9).

The patient had little posterior function due to missing maxillary molars and was chewing mostly with his anterior teeth and premolars. His mandibular dentition had a mild to moderate degree of generalized bone loss, but was stable (Figure 29.2.6).

DIAGNOSIS

The patient's stomatognathic assessment was consistent with class I skeletal and dental malocclusion of a patient with long

FIGURE 29.2.5 Periapical radiograph of the patient's maxillary anterior dentition showing the state of severe periodontal disease.

FIGURES 29.2.4 Periapical radiographs of the patient's maxillary dentition showing the state of advanced periodontal disease with 50+% of bone loss.

FIGURE 29.2.6 Panoramic radiograph of the patient's maxillary anterior dentition showing advanced periodontal disease with severe bone loss.

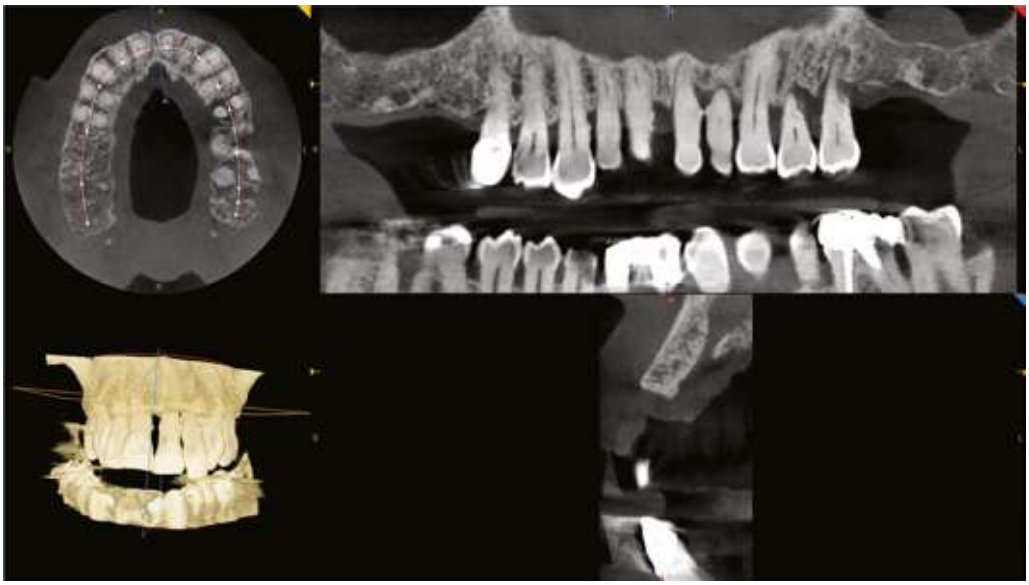

FIGURE 29.2.7 Cone beam computed tomography scan of the patient's maxillary dentition showing the state of advanced periodontal disease.

Dentlearn.ir

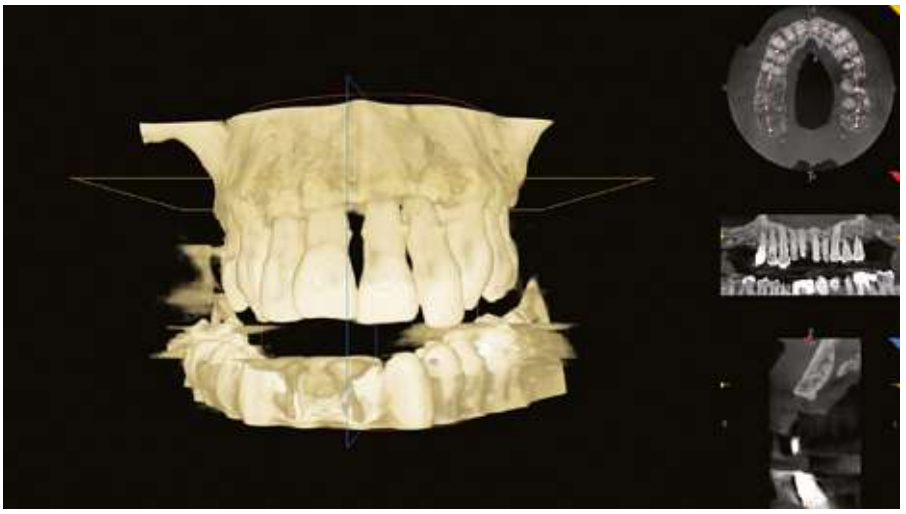

FIGURE 29.2.8 Cone beam computed tomography scan of the patient's maxillary dentition showing the state of advanced periodontal disease.

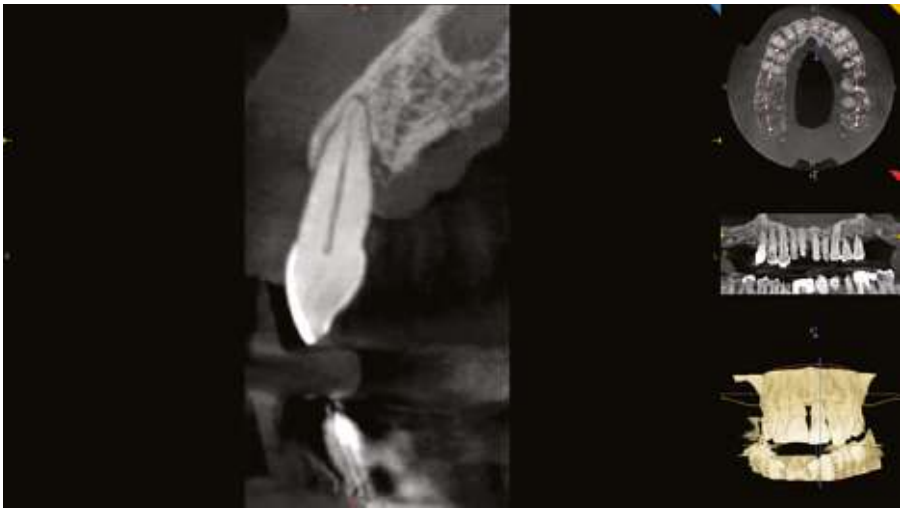

FIGURE 29.2.9 Cone beam computed tomography scan of the patient's maxillary dentition showing the state of advanced periodontal disease.

face syndrome, vertical maxillary access, and extreme gingival display, severe maxillary generalized periodontitis, and advanced bone loss around maxillary teeth with non-restorable (failing) maxillary dentition, and deficiency of function of mastication, esthetics, and comfort (Figures 29.2.3, 29.2.6, and 29.28).

TREATMENT OPTIONS

The patient was interested in replacement of his full upper dentition with an implant-supported fixed prosthesis. He rejected implant treatment options that would result in a removable prosthesis. The patient had never had a removable denture and was not interested in having one with his new implant treatment. Due to his line of work (doctor and teacher), he also asked, if possible, to avoid a transitional removable implant option in the process of his implant rehabilitation.

Therefore, only two satisfactory immediate implant treatment options remained and were presented to the patient following extraction of the non-restorable maxillary dentition. They were:

- *Immediate approach*: extraction of all teeth, bone reduction, placement of 4–6 implants with intraoperative conversion to a temporary fixed full-arch implant-supported hybrid

Dentlearn.ir

prosthesis (all-on-four) for immediate function [18–20]. Definitive treatment: metal-acrylic (or metal-ceramic) fixed bridge 6 months later (this approach is presented in Part 1 of this chapter).

- *Staged approach*: selective extraction and placement of 6–8 implants with transitional fixed tooth-supported and later implant-supported bridges. Definitive treatment: crown-and-bridge porcelain-fused-to-metal (PFM) full-arch implant restorations [10, 15].

FINAL TREATMENT PLAN

The patient selected the second treatment plan: ceramometal implant crown-and-bridge restorations. His rejection of a hybrid implant treatment plan was associated with the large amount of maxillary bone reduction (up to 15 mm) that would be required due to his extreme vertical maxillary overgrowth. This would be necessary to hide his fixed temporary and later definitive implant prostheses under his upper lip. The patient reasonably stated that the removal of up to 15 mm of maxillary alveolar bone would significantly change his facial features and his gummy smile, which he and his family wanted to preserve to some degree (Figure 29.2.3).

Therefore, the emphasis of this treatment plan was on two factors: (i) avoiding removable prostheses at any stage of the maxillary implant reconstruction; and (ii) decreasing vertical maxillary excess and gummy smile, but retaining some of the patient's physical facial and dental characteristics that he and his family were accustomed to. This approach included:

- Staged extraction of selected teeth with severe periodontal disease and immediate placement of several implants, making sure that patient had fixed temporary tooth-supported or implant-supported bridges after each surgical procedure.
- Intentionally, all dental implants were placed deep, 4–5 mm subcrestally. This required judicious bone reduction of the maxillary alveolar crest, with the goal of decreasing (but not eliminating) the patient's gingival exposure by at least 50% (from 8–10 to 4–5 mm).

SURGICAL-RESTORATIVE SEQUENCE PERFORMED

Stage 1

Restorative Diagnostic models and maxillary surgical stent were prepared for the surgery.

- Teeth to be temporarily preserved as abutments for a temporary full-arch maxillary bridge were identified. These teeth were upper right second premolar, upper right lateral incisor, upper left canine, and upper left first premolar. The prefabricated provisional resin prosthesis on four temporarily retained teeth was made.

Surgical #1 Under general anesthesia, the patient underwent extraction of severe periodontally involved maxillary teeth with the worst prognosis and inability to be used as transitional abutments for temporary bridges. All teeth, except the four indicated, were removed.

- Immediate placement of eight implants (Straumann BLT North America, Andover, MA, USA) was done according to the plan. The implants were placed 4–5 mm deep, subcrestally, with a torque of 40+ Ncm, and had long (4–6 mm) healing abutments attached that slightly protruded through the gingiva. These eight implants were upper right first molar, upper right first premolar, upper right canine, upper right central incisor, upper left central and lateral incisors, upper left first premolar, and upper left first molar (Figures 29.2.10–29.2.14).
- Provisional prosthesis on four remaining teeth was delivered by the restorative team at the end of the surgery (Figures 29.2.12–29.2.14).
- The restorative team also took an intraoperative impression of inserted implants for a second temporary implant bridge to be based on four implants (upper right first molar

FIGURE 29.2.10 Intraoperative photograph demonstrating immediate post-extraction and subcrestal placement of eight maxillary implants. *Source*: Institut Straumann AG.

Dentlearn.ir

FIGURE 29.2.11 Post-operative panoramic radiograph demonstrating immediate placement of eight maxillary implants.

FIGURE 29.2.12 Frontal photograph showing remaining maxillary teeth that were left temporarily for support of a tooth-supported provisional restoration.

FIGURE 29.2.13 Provisional fixed prosthesis on four remaining teeth that was delivered by the restorative team at the end of the surgery.

FIGURE 29.2.14 Provisional fixed prosthesis on four remaining teeth: maxillary alveolar ridge is shown after bone reduction.

and canine, and upper left lateral incisor and second premolar). This implant-supported bridge was planned to be delivered at the next surgical procedure (Figures 29.2.15 and 29.2.16).

The patient left the surgical office very satisfied with the procedure and immediate fixed temporary upper prosthesis.

FIGURE 29.2.15 Laboratory photographs showing models and an implant-supported bridge that was scheduled to be delivered at the next surgical stage.

Dentlearn.ir

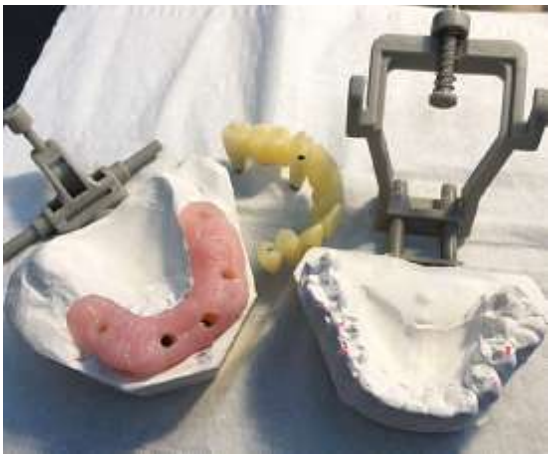

FIGURE 29.2.16 Laboratory photograph showing mounted models and an implant-supported bridge that was scheduled to be delivered at the next surgical stage.

Stage 2 (6 Months Later)

Surgical #2 Under general anesthesia, the patient underwent extraction of the five remaining maxillary teeth as well as the lower right second molar. All sockets were grafted (Figure 29.2.17).

- Alveoloplasty with bone reduction was performed around all eight maxillary implants to assure the planned 5–6 mm of maxillary alveolar ridge reduction (Figures 29.2.18 and 29.2.19).
- Healing abutments that were intentionally long and protruding through the thick layer of bone and soft tissue were then removed and replaced with shorter ones (Figure 29.2.19).

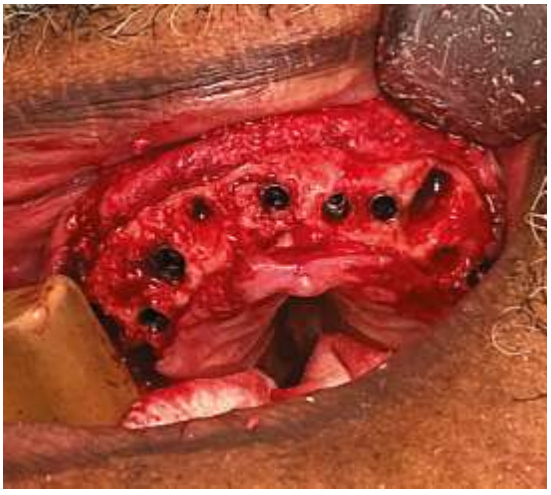

FIGURE 29.2.17 Intraoperative photograph of the second surgical procedure that shows extraction of remaining five maxillary teeth and exposure of eight integrated subcrestally placed implants.

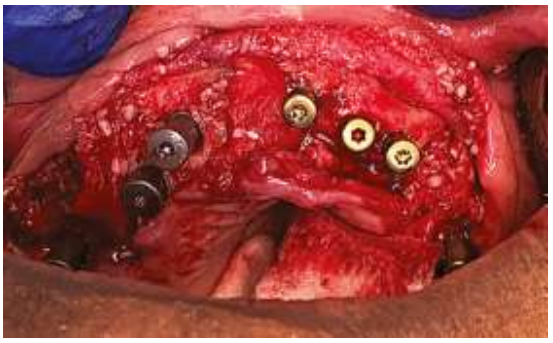

FIGURE 29.2.18 Intraoperative photograph of the alveoloplasty/bone reduction that was performed above and around eight maxillary implants to assure the planned 5–6 mm maxillary alveolar ridge reduction. Healing abutments were placed at the end of the procedure and the wound was closed with 4-0 chromic gut sutures.

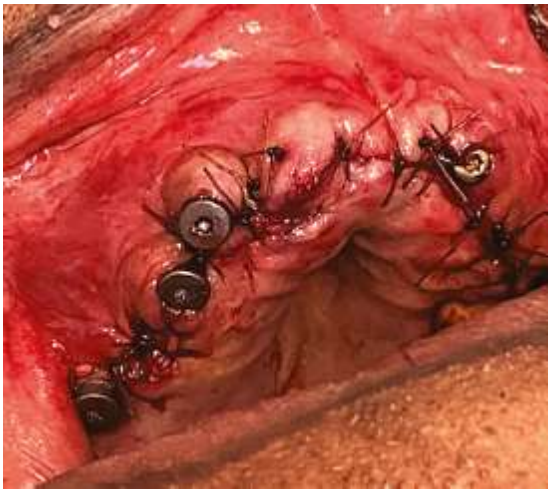

FIGURE 29.2.19 Intraoperative photograph of the healing abutments that were placed at the end of the procedure: the wound was closed with 4-0 chromic gut sutures around protruding healing abutments.

- The restorative team then placed a second temporary implant-supported bridge on four implants at the end of the surgery (upper right first molar and canine, upper left lateral incisor and second premolar; Figures 20.2.20 and 29.2.21).

The patient again left the surgical office very pleased with an immediate fixed temporary prosthesis.

STAGE 3 (3 MONTHS LATER)

Restorative The restorative team delivered the definitive maxillary implant-supported crown-and-bridge restorations. These PFM implant restorations consisted of upper right first molar to first premolar screw-retained bridge, upper right

Dentlearn.ir

FIGURE 29.2.20 Second temporary implant-supported bridge on four implants that was secured at the end of the second surgical procedure around protruding implant healing abutments.

FIGURE 29.2.21 Second temporary implant-supported bridge on four implants that was secured at the end of the second surgical procedure.

FIGURE 29.2.22 Laboratory procedure of constructing the definitive ceramo-metal crown-and-bridge maxillary full-arch implant-supported prosthesis (screw-retained posterior components and cementable anterior).

canine to central incisor cementable bridge, upper left single central incisor cementable crown, upper left lateral incisor to second premolar cementable bridge, and first upper left molar screw-retained implant crown (Figures 29.2.22–29.2.26).

The patient was extremely happy with the overall surgical-restorative implant outcome: function, esthetics, comfort, having fixed restorations throughout the reconstruction process of his dental implant treatment, as well as the team's attention to his wishes and preservation of his facial features (Figures 29.2.27–29.2.30).

FIGURE 29.2.23 Laboratory procedure of constructing the definitive ceramo-metal crown-and-bridge maxillary full-arch implant-supported prosthesis (screw-retained – posterior components; and cementable – anterior): frontal view.

FIGURE 29.2.24 Laboratory procedure of constructing the definitive ceramo-metal crown-and-bridge maxillary full-arch implant-supported prosthesis (screw-retained – posterior components; and cementable – anterior): occlusal view.

Dentlearn.ir

FIGURE 29.2.25 Definitive ceramo-metal crown-and-bridge maxillary full-arch implant-supported prosthesis: models mounted in articulator (check of vertical dimension of occlusion).

FIGURE 29.2.26 Laboratory procedure of constructing the definitive ceramo-metal crown-and-bridge maxillary full-arch implant-supported prosthesis (screw-retained – posterior components; and cementable – anterior): pink porcelain in the anterior region.

FIGURE 29.2.27 Intraoral and extraoral photographs demonstrating the final restorative outcome: ceramo-metal full-arch maxillary crown-and-bridge implant-supported restorations.

FIGURE 29.2.28 Clinical photograph demonstrating maxillary ceramo-metal crown-and-bridge restoration and passive lip position.

FIGURE 29.2.29 Extraoral photograph of the smiling patient after placement of a final ceramo-metal full-arch maxillary implant bridge prosthesis.

Dentlearn.ir

FIGURE 29.2.30 Extraoral facial photograph of the happy patient with excellent esthetic and functional outcome of the definitive implant-supported restoration.

DISCUSSION

Maxillary full-arch implant-supported fixed rehabilitation options for replacing terminal maxillary dentition can be the most complex and, at the same time, the most rewarding in implant dentistry. The literature [4, 18, 21–23] supports the following general "rules" regarding maxillary full-arch implant rehabilitation:

- Avoidance of mini-implant treatment.
- Placement of at least four implants for successful removable or fixed implant prosthesis.
- Four implants (two anterior straight, and two posterior tilted) splinted together can provide good and lasting support of a single-piece fixed metal-resin hybrid implant-supported prosthesis (all-on-four).
- Six to eight axial implants evenly and bilaterally distributed throughout the anterior and posterior alveolar regions can provide good function and lasting support of the crown-and-bridge (unitary) fixed metal-ceramic implant-supported prosthesis.
- Immediate placement combined with immediate or early loading for a fixed implant prosthesis, specifically in the maxilla, although successful, can potentially lead to peri-implantitis and increase implant failure rate.

Maxillary fixed all-on-four full-arch hybrid bridge or ceramo-metal restorations are both acceptable surgical-restorative implant options for replacement of failing maxillary dentition and can have their benefits and drawbacks. These include the following.

HYBRID OR ALL-ON-FOUR FULL-ARCH IMPLANT PROSTHESIS DESIGN

- *Benefits*: immediate conversion (placement and loading) to a fixed cross-arch temporary acrylic prosthesis with delivery of a predictable definitive prosthesis 6 months later.
- *Drawbacks*: requires 15–17 mm of prosthetic space and smile design that often requires significant maxillary alveolar bone reduction to provide a functional and esthetically pleasing prosthesis. It is often considered the "end of the line" implant solution.

CERAMO-METAL CROWN-AND-BRIDGE IMPLANT PROSTHESIS DESIGN

- *Benefits*: immediate fixed temporary restorations can be possible with staged extraction of teeth, without major bone reduction or alteration of the patient's facial features.
- *Drawbacks*: staging of multiple surgical and restorative procedures and time of final reconstruction that could take a year or more to complete, esthetic and functional concerns, future complications that could be difficult and expensive to correct.

In the described case, due to the patient's vertical maxillary excess and high smile line with excessive gingival display, a conventional removable full upper denture or implant-supported overdenture would have been better prosthetic choices to hide the transitional zone of exposed maxillary gingiva with a denture flange [24]. Better esthetics with smiling and easier hygiene of the removable prosthesis could also have been beneficial for this patient.

The patient (and his family) requested a fixed maxillary implant ceramo-metal reconstruction option that would provide a fixed prosthesis throughout the treatment time and preserve some of the patient's facial features. This implant reconstruction was difficult but successful.

CONCLUSION

This chapter has described a successful and complex staged maxillary full-arch implant-supported ceramo-metal rehabilitation case. It taught both the surgical and the restorative team to listen to the patient's wishes and concerns, needs and wants, and to attempt to address them with a team approach of surgical and restorative clinicians equipped with implant knowledge and skills.

Dentlearn.ir

To access the videos for this chapter, please go to
www.wiley.com/go/tolstunov/essential

VIDEO 29.2.1 Introduction to Chapter 29.2, by the Author and Book Editor Dr. Len Tolstunov.

REFERENCES

1. Berman CL, Berman LG. The psychological implications of tooth loss. *Dent Clin North Am.* 1969;13(4):961–6.
2. Craddock HL. Consequences of tooth loss (part 1): The patient perspective—aesthetic and functional implications. *SADJ.* 2010;65(6):242–5.
3. Craddock HL. Consequences of tooth loss (part 2): Dentist considerations—restorative problems and implications. *SADJ.* 2010;65(7):292–6.
4. Gallucci GO, Avrampou M, Taylor JC et al. Maxillary implant-supported fixed prosthesis: A survey of reviews and key variables for treatment planning. *Int J Oral Maxillofac Implants.* 2016;31(suppl):s192–s197.
5. Di Francesco F, De Marco G, Capcha EB et al. Patient satisfaction and survival of maxillary overdentures supported by four or six splinted implants: A systematic review with meta-analysis. *BMC Oral Health.* 2021;21(1):247.
6. Di Francesco F, De Marco G, Sommella A, Lanza A. Splinting vs not splinting four implants supporting a maxillary overdenture: A systematic review. *Int J Prosthodont.* 2019;32(6):509–18.
7. Ali K, Kay EJ. What are the long-term survival and complication rates of complete-arch fixed implant rehabilitation in edentulous patients? *Evid Based Dent.* 2019;20(3):97–8.
8. Chaushu G, Schwartz-Arad D. Full-arch restoration of the jaw with fixed ceramo-metal prosthesis: Late implant placement. *J Periodontol.* 1999;70(1):90–94.
9. Papaspyridakos P, Bordin TB, Kim YJ et al. Technical complications and prosthesis survival rates with implant-supported fixed complete dental prostheses: A retrospective study with 1- to 12-year follow-up. *J Prosthodont.* 2020;29(1):3–11.
10. Schwartz-Arad D, Chaushu G. Full-arch restoration of the jaw with fixed ceramometal prosthesis. *Int J Oral Maxillofac Implants.* 1998;13(6):819–25.
11. Schwartz-Arad D, Gulayev N, Chaushu G. Immediate versus non-immediate implantation for full-arch fixed reconstruction following extraction of all residual teeth: A retrospective comparative study. *J Periodontol.* 2000;71(6):923–8.
12. Schwartz-Arad D, Grossman Y, Chaushu G. The clinical effectiveness of implants placed immediately into fresh extraction sites of molar teeth. *J Periodontol.* 2000;71(5):839–44.
13. Gonzalez-Gonzalez I, deLlanos-Lanchares H, Brizuela-Velasco A et al. Complications of fixed full-arch implant-supported metal-ceramic prostheses. *Int J Environ Res Public Health.* 2020;17(12):4250.
14. Pieralli S, Kohal RJ, Rabel K et al. Clinical outcomes of partial and full-arch all-ceramic implant-supported fixed dental prostheses: A systematic review and meta-analysis. *Clin Oral Implants Res.* 2018;29(suppl 18):224–36.
15. Greenstein G, Cavallaro J Jr. Serial extraction protocol: Transitioning a hopeless dentition to a full-arch reconstruction. *Compend Contin Educ Dent.* 2008;29(9):526–34; quiz 35–6.
16. Mijiritsky E, Mazor Z, Lorean A et al. Transition from hopeless dentition to full-arch fixed-implant-supported rehabilitation by a staged extraction approach: Rationale and technique. *J Craniofac Surg.* 2014;25(3):847–50.
17. Papaspyridakos P, Chronopoulos V. Transition from failing dentition to complete-arch implant rehabilitation with a staged approach: A 3-year clinical report. *J Prosthet Dent.* 2014;112(3):423–8.
18. Capelli M, Zuffetti F, Del Fabbro M, Testori T. Immediate rehabilitation of the completely edentulous jaw with fixed prostheses supported by either upright or tilted implants: A multicenter clinical study. *Int J Oral Maxillofac Implants.* 2007;22(4):639–44.
19. Tealdo T, Bevilacqua M, Pera F et al. Immediate function with fixed implant-supported maxillary dentures: A 12-month pilot study. *J Prosthet Dent.* 2008;99(5):351–60.
20. Chiapasco M. Early and immediate restoration and loading of implants in completely edentulous patients. *Int J Oral Maxillofac Implants.* 2004;19(suppl):76–91.
21. Messias A, Nicolau P, Guerra F. Different interventions for rehabilitation of the edentulous maxilla with implant-supported prostheses: An overview of systematic reviews. *Int J Prosthodont.* 2021;34:s63–s84.
22. Testori T, Zuffetti F, Capelli M et al. Immediate versus conventional loading of post-extraction implants in the edentulous jaws. *Clin Implant Dent Relat Res.* 2014;16(6):926–35.
23. Covani U, Orlando B, D'Ambrosio A et al. Immediate rehabilitation of completely edentulous jaws with fixed prostheses supported by implants placed into fresh extraction sockets and in healed sites: A 4-year clinical evaluation. *Implant Dent.* 2012;21(4):272–9.
24. Sadowsky SJ, Zitzmann NU. Protocols for the maxillary implant overdenture: A systematic review. *Int J Oral Maxillofac Implants.* 2016;31(suppl):s182–s191.

Dentlearn.ir

Dentlearn.ir

Tissue Bioengineering

SECTION VII

Chapter 30 Tissue Bioengineering and Regeneration in Implant Dentistry 539
Tara Aghaloo and Jacob Taylor

Dentlearn.ir

Dentlearn.ir

Tissue Bioengineering and Regeneration in Implant Dentistry

CHAPTER 30

Tissue engineering and regenerative medicine is an ever-evolving field with many applications, including in the field of dentistry and oral and maxillofacial surgery. The goal of this chapter is to explore bone grafting materials and the current understanding of growth factors used for tissue engineering in implant dentistry.

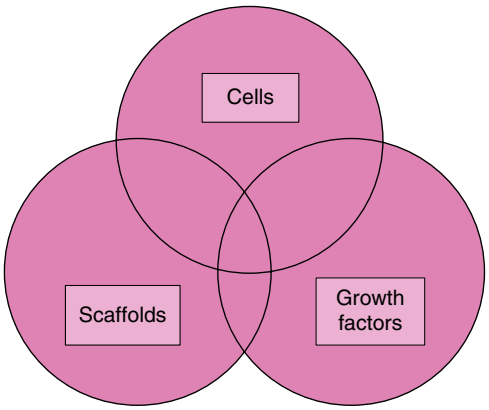

Dentlearn.ir

CHAPTER 30

Tissue Bioengineering and Regeneration in Implant Dentistry

Tara Aghaloo and Jacob Taylor

Oral and Maxillofacial Surgery, UCLA School of Dentistry, Los Angeles, CA, USA

In the setting of injury to tissues, the body has natural healing cascades in place to regenerate and repair the sites of injury. The field of study that looks at enhancing this regeneration, repair, and restoration of normal function is known as regenerative medicine. The term "regenerative medicine," coined by William Haseltine in 1999, can be described as replacement or regeneration of human cells, tissues, or organs, to restore or establish normal function [1]. Under the umbrella of regenerative medicine is tissue engineering. Langer and Vacanti defined tissue engineering as "an interdisciplinary field that applies the principles of engineering and life sciences toward the development of biological substitutes that restore, maintain, or improve tissue function or a whole organ" [2]. Tissue engineering and regenerative medicine (TERM) is an ever-evolving field with many applications, including within the field of dentistry and oral and maxillofacial surgery. Resorption of the alveolar bone can be caused by many things, including trauma, post-extraction resorption, pathology, periodontal disease, congenital deformities, ill-fitting prostheses, or disuse atrophy from long-term edentulism [3]. Resorption of the alveolar ridge presents a unique problem when deciding to restore the area, especially when it involves implant placement. The goal of this chapter is to briefly explore bone grafting materials and current clinical trends with implant placement, as well as the current understanding of growth factors used for tissue engineering in implant dentistry.

BASICS OF WOUND HEALING

To fully understand TERM in implant dentistry, one first must understand general principles of wound healing. The three phases of wound healing include inflammation (4–6 days), proliferation (days to weeks), and maturation (weeks to months) [4, 5]. After initial injury, there is a complicated interaction between cytokines, growth factors, and proteases that are closely involved with completing the process of wound repair, starting with the inflammatory phase with release of IL-1, IL-6, and other interleukins in addition to tumor necrosis factor-alpha (TNF-α) [6]. Circulating platelets also arrive to assist in hemostasis and attach to exposed subendothelial collagen and form a fibrin matrix, resulting in a platelet plug that then acts as a scaffold for further inflammatory cells [7]. The platelet plug that is formed also acts as a reservoir for release of growth factors such as transforming growth factor-beta (TGF-β), platelet-derived growth factor (PDGF), vascular endothelial growth factor (VEGF), epidermal growth factor (EGF), fibroblast growth factor (FGF), and several chemokines [6, 7]. Chemokines are essentially signals that help recruit other cells to the site of injury, in this case lymphocytes, neutrophils, and monocytes [8]. Neutrophils act to clear debris and bacteria in the area, while monocytes become macrophages and play a key role in angiogenesis, fibroplasia, and nitric oxide production, as well producing numerous enzymes, cytokines, and growth factors that help transition to the proliferative phase of wound healing [5]. It is important to understand relevant growth factors and cells of origin involved in healing as new strategies to improve wound healing are developed (Table 30.1).

The proliferative phase consists of fibroplasia with extracellular matrix (ECM) deposition, re-epithelialization, angiogenesis, and peripheral nerve repair [9]. Macrophages play a key role in the inflammatory, proliferative, and remodeling phases of wound healing [10–12]. The remodeling and maturation phase consists of remodeling of collagen and ECM to resemble those of healthy surrounding tissue, vascular regression, as well as contraction of the wound [13]. The three stages of wound healing are a model for repair for other tissues as well, including bone.

BONE BIOLOGY AND GRAFTING

Bones form by either intramembranous (direct or primary) ossification or endochondral (indirect or secondary) ossification [17]. Bone fractures generally heal with a combination of both intramembranous and endochondral ossification with a

Essential Techniques of Alveolar Bone Augmentation in Implant Dentistry: A Surgical Manual, Second Edition. Edited by Len Tolstunov.
© 2023 John Wiley & Sons, Inc. Published 2023 by John Wiley & Sons, Inc.
Companion website: www.wiley.com/go/tolstunov/essential

Dentlearn.ir

Table 30.1 Summary of growth factors and biological function in wound healing.

Growth factor	Sources	Target cells	Biological function
TGF-β	Platelets Macrophages Endothelial cells Keratinocytes Lymphocytes Fibroblasts Osteoblasts Osteoclasts Chondrocytes	Endothelial cells	Cell chemotaxis stimulates angiogenesis and fibroplasia
PDGF	Platelets Macrophages Endothelial cells Fibroblasts	Endothelial cells	Cell chemotaxis, mitogenic for fibroblasts, stimulates angiogenesis, stimulates wound contraction
FGF	Macrophages Mast cells Lymphocytes Endothelial cells Fibroblasts	Endothelial cells	Chemotactic and mitogenic for fibroblasts and keratinocytes, stimulates angiogenesis
VEGF	Platelets Macrophages	Endothelial cells Osteoblasts	Stimulates angiogenesis, cartilage and bone growth and repair
EGF	Platelets Macrophages Epithelial cells	Endothelial cells	Mitogenic for keratinocytes and fibroblasts, stimulates keratinocyte migration
BMP	Osteoblasts Osteoclasts Chondrocytes	Mesenchymal cells	Bone and cartilage growth and repair
BMP-2, BMP-4	Epithelial cells	Endothelial cells	Stimulates angiogenesis
IGF-1	Fibroblasts Endothelial cells	Endothelial cells	Stimulates angiogenesis and bone growth

BMP, bone morphogenic protein; EGF, epidermal growth factor; FGF, fibroblast growth factor; IGF-1, insulin-like growth factor; PDGF, platelet-derived growth factor; TGF-β, transforming growth factor; VEGF, vascular endothelial growth factor.
Source: Adapted from [5, 9, 14–16].

cartilage callus in a similar three-phase sequence of repair: inflammation, proliferation, and maturation or latency [17, 18]. Bone is in a constant state of remodeling, with osteoblasts responsible for new bone formation and osteoclasts in charge of bone resorption [19, 20]. As with soft tissue, there are many growth factors, cytokines, and cells involved with fracture healing and remodeling, including bone morphogenetic protein (BMP-2), FGF, PDGF, insulin-like growth factor (IGF-1), TGF-β, and VEGF [14]. Often in maxillofacial surgery and implant dentistry, bone grafting is commonly performed to augment the quality and quantity of bone to enable reconstruction and rehabilitation. To date, autologous bone is still considered to be the gold standard bone grafting material, as it combines all properties required in an ideal grafting material: osteoinduction, osteogenesis, and osteoconduction [21]. Osteoinduction is the ability of a bone graft material with chemotactic properties to bring osteoprogenitor cells to the recipient site and stimulate osteoblastic differentiation and bone formation, such as with growth factors BMP-2, -4, and -7. Osteoconduction refers to the ability of a material to allow ingrowth of new bone cells and vascularity and act as a scaffold [22, 23]. Osteogenesis refers to the presence of bone forming cells that, when transplanted, are live cells that can form bone in their new location [23]. Even though autogenous bone is the gold standard, it has significant drawbacks, including donor site morbidity, limited supply, and resorption over time [24, 25].

In cases where autogenous bone grafts are less ideal, bone graft substitute materials (BSMs) such as allografts, xenografts, and alloplasts, continue to be investigated as an alternative to attempt to retain favorable aspects of autogenous grafts without the donor site morbidity or restriction on the amount needed for grafting [22, 23]. In addition to natural bone substitutes, investigation of synthetic materials such as bioactive glass, beta-tricalcium phosphate ceramics, as well as materials impregnated with osteogenic cells or different growth factors are being studied (Figure 30.1) [26]. Not all BSMs exhibit the same level of osteoconduction, osteoinduction, or osteogenesis, and therefore the search for an ideal substitute that fits all three categories continues. The material must also have the ability to support implant osseointegration, or essentially the direct contact between living bone and an implant at a microscopic level [27].

As clinicians and researchers search for the ideal bone graft material, properties of all materials are favorable. The slow or minimal resorption of a xenograft or hydroxyapatite-based alloplast will keep the structure and support soft tissues. The osteogenic properties of autogenous bone are desirable, but autografts remodel more quickly to possess properties identical to native bone. However, they can also resorb quickly, and ultimately lose their structural support and ability to maintain the surrounding soft tissue contours. To combat the shortcomings of individual materials, composite grafts that utilize combinations of autologous graft revascularization and

Dentlearn.ir

FIGURE 30.1 Brief classification of bone graft and substitute materials alone and in combination, as utilized in implant dentistry.

remodeling with slow resorption and support of xenografts, or the faster resorption of allografts with xenografts, are now both commercially available and combined by clinicians in practice to capitalize on the advantages of each individual material. In addition, constructs including viable mesenchymal stem cells (MSCs) and osteoprogenitor cells, or growth factors on calcified or collagen-based scaffolds, are in demand to enhance bone formation and vascularity or shorten healing times for challenging defects and compromised patients (Figure 30.1).

GUIDED BONE REGENERATION

Guided bone regeneration (GBR), first described in the late 1970s, is the idea of preventing the migration of unwanted cells to a reconstructed site by using a barrier membrane, which provides stability of the bone graft, prevents collapse of soft tissue, prevents infiltration of unwanted non-osteogenic cells, and accumulates growth factors [28]. These membranes can be broken down grossly into two different groups: non-resorbable, such as polytetrafluoroethylene (PTFE), and resorbable, such as those that are collagen based. Wang and Boyapati described four principles that can be followed to achieve predictable bone regeneration: primary wound closure for undisturbed wound healing, angiogenesis, space maintenance to facilitate bone ingrowth, and stability of wound and implant to induce blood clot formation [29]. Urban and Monje explained that GBR is indicated for many bone defects, including sites of dehiscence and fenestrations, vertical and horizontal defects, two- and three-wall peri-implant defects, and extraction sites with and without immediate implant placement.

Notable contraindications to GBR include smoking, uncontrolled systemic disorders, poor plaque control, and inability to obtain primary wound closure and stability of the site [30]. Other types of bone grafts that can be used include free bone grafts, particulate cancellous bone marrow grafts, pedicled composite grafts, synthetic bone grafts, allogeneic/xenogeneic bone grafts, and distraction osteogenesis [31]. Being able to understand the interplay between GBR, implant placement, and the growth factors involved is the key to advancements in bone healing and regeneration to improve our current grafting techniques. The addition of growth factors and stem cells into grafting with GBR techniques is also a field of current research. The details of GBR are discussed in detail in Chapters 8 and 10.

Dentlearn.ir

SOFT TISSUE REGENERATION

As with GBR, soft tissue regeneration is an ever-evolving field with the ultimate goal of creating autologous tissue harvesting. Soft tissue regeneration can be used as grafts, pedicles, or flaps, with the goal of restoring form and function for skin, nerves, and muscle [32]. Autologous options for soft tissue replacement have been the workhorse inside the oral cavity, including connective tissue grafts (CTG) and free gingival grafts (FGG) for soft tissue replacement around dental implants, soft tissue thickening, ridge preservation, soft tissue ridge augmentation, and papilla reconstruction [33]. Increasing the level of keratinized tissue and tissue thickness around dental implants is vital to their biological functionality as well as maintaining peri-implant soft tissue health [34]. The soft tissue thickness is important to minimize show-through and the "translucency" of the implant through soft tissues in patients with baseline thicker biotypes (>2.5 mm in thickness), where soft tissue substitutes may have comparable results to autologous grafts [35]. Although CTGs are generally considered the gold standard for soft tissue augmentation around implants, recent studies demonstrate minimal to no difference in outcomes of tissue thickness between autologous CTGs and soft tissue substitutes (both xenogeneic collagen matrices and acellular dermal matrices) [35]. Soft tissue regeneration is discussed in detail in Chapter 24.

TOOTH DEVELOPMENT AND REGENERATION

Significant research in the field of tooth regeneration has been evolving over the past 20 years and it may be a viable option for tooth replacement. To fully understand tooth regeneration, one must understand the process of how teeth form (Figure 30.2) [36].

Humans have two sets of teeth (diphyodonts): deciduous teeth or primary teeth are replaced with permanent teeth. Unlike some vertebrates who can replace their teeth continuously when lost (polyphyodonts), humans do not have that ability after their permanent teeth are lost. When permanent teeth are lost, the edentulous site left behind has to then be replaced with something fixed, such as an implant crown or fixed partial denture, or something removable, such as a removable partial denture. Tooth development relies on the interaction between epithelium and MSCs that lead to the different stages (placode, bud, cap, and bell) of tooth formation (Figure 30.2). This odontogenic development and interplay of epithelium and mesenchymal cells, like other ectodermal tissues, are determined by conserved signaling pathways such as Wnt, FGF, BMP, and sonic hedgehog [36]. The production of enamel and dentin starts at the interface of the epithelial and mesenchyme, and after the tooth crown is formed, the roots develop [37]. Dentin and enamel are mineralized tissues produced at the late bell stage of tooth development by cells specific to teeth: odontoblasts, derived from mesenchyme, that produce dentin, and ameloblasts, derived from epithelium, that produce enamel [38]. In addition, in the bell stage the enamel organ consists of two basal cell layers: (i) the inner enamel epithelium, which encloses the dental papilla and gives rise to odontoblasts (dentin) and pulp cells; and (ii) the outer enamel epithelium, which faces the dental follicle and later gives rise to cementoblasts (cementum) and periodontal ligament [38]. Once the cell layers of enamel, dentin, and cementum are laid down, as the ameloblasts, odontoblasts, and cementoblasts, respectively, have finished their jobs, they lose their regenerative capacity as they are now considered "cell free," thus leading to poor repair and healing if the teeth are damaged or have caries.

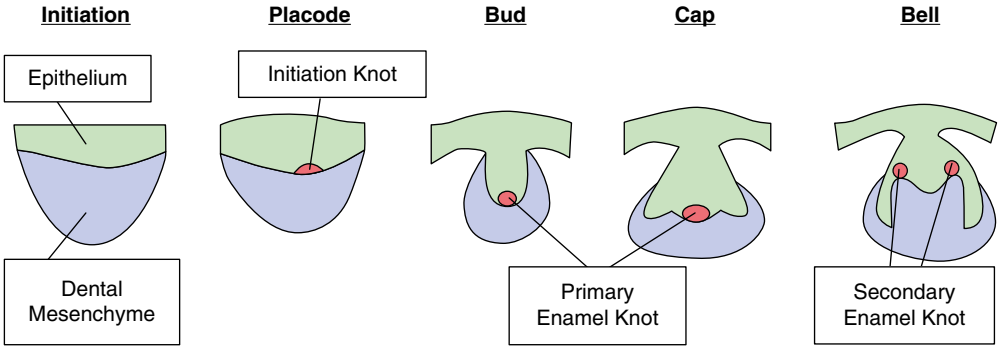

FIGURE 30.2 Schematic representation of tooth development. Teeth are initiated from the dental lamina, which is a thickening of the epithelium (called competent epithelium) in the jaws. The shape and morphogenesis of the epithelium happen through three signaling centers, as indicated in the illustration. The initiation knot in the placode stage begins with a condensation of neural crest–derived mesenchymal cells, the primary enamel knot assists in folding in the bud and cap stages, and the secondary enamel knot leads to fine-tuning of the crown and cusps.

Dentlearn.ir

DENTAL STEM CELLS

The potential for regenerating teeth starts with understanding stem cells. Stem cells are undifferentiated cells present in embryonic, fetal, and adult tissues and are the building blocks of tissue and organs. They are characterized by their ability to extensively proliferate (self-renewal), arise from a single cell (clonal), and differentiate into different types of tissue and cells (potent) [39]. Stem cells can be categorized by where they come from and what they can become. Pluripotent stem cells, or embryonic stem cells, can differentiate into cells in any of the three germ layers (endoderm, mesoderm, ectoderm), whereas multipotent stem cells can differentiate into tissue derived from a single germ layer, such as MSCs forming bone or cartilage [39]. There are other types of stem cells; however, details of these will not be discussed in this chapter.

When regenerating tooth structures that arise from the mesenchymal and epithelial interaction, stem cells play an integral role (Figure 30.3) [40]. In 2003, Miura and colleagues were looking into sources of post-natal stem cells, and they were able to isolate stem cells from human exfoliated deciduous teeth (SHEDs) [41]. SHEDs were identified to be highly proliferative and capable of differentiating into a variety of cells *in vitro*, including neural cells, adipocytes, and odontoblasts, and, after *in vivo* transplantation, were able to induce bone formation, generate dentin, and survive in the mouse brain [41]. The future goal is to utilize these stem cells that have similar qualities to other multipotent stem cells to be able to generate other cell lines, and eventually regenerate multiple tissue types.

SHEDs originate from embryonic neural crest cells as ectodermal MSCs, and they have the same cell markers as embryonic stem cells, which has a large impact on how they can be used [42]. SHEDs and dental pulp stem cells (DPSCs), which are derived from the pulp of permanent teeth, have been shown to have similar activity to pericytes, which are vital in the proper functioning of blood vessels and play a role in vascular engineering [43]. Fuloria et al. further explain that with the current available evidence, SHEDs may differentiate into endothelial cells, neurons, odontoblasts, beta cells of the pancreas, hepatocytes, renal cells, fibroblasts, osteoblasts, and other tissues as well [44]. The origin for dental-derived stem cells, as well as the potential for differentiation of these cell types into tooth-forming cells, can drive the field of tooth regeneration forward, providing another option to replace missing teeth in addition to dental implants (Table 30.2) [45].

As seen in Table 30.2, stem cells can be derived from many sources in and around the teeth and jaws, including the apical papilla, periodontal ligament (PDL), deciduous teeth, permanent teeth, dental follicle of third molars, and gingiva [45]. It is important to understand that these stem cells must express specific markers to have the potential to differentiate into other cell types, the details of which will not be discussed in this chapter. Though dental MSCs can be derived from all the above sources, SHEDs and DPSCs are the most easily obtained and have the fewest comorbidities. SHEDs have been shown to have better differentiation capabilities than DPSCs, as DPSCs have a strong predilection toward neurological diseases [45, 46], even though SHEDs have been shown to play a role in facial nerve regeneration [47]. Stem cells from apical papillae have similar properties to DPSCs, but with stronger potential for root formation [48]. In addition, PDL stem cells are currently being investigated in a guided tissue regeneration clinical study for patients with periodontitis and alveolar bone loss, demonstrating an increase in alveolar bone height after the stem cell therapy [48]. Further studies are ongoing utilizing gingival mesenchymal stem cells (GMSCs) in combination with hydrogels to treat peri-implantitis [49]. These publications demonstrate the potential of stem cells from the dental–pulp–follicle complex. However, significant research must be continued in both basic science and translational studies before they can become validated and acceptable for use in patient care.

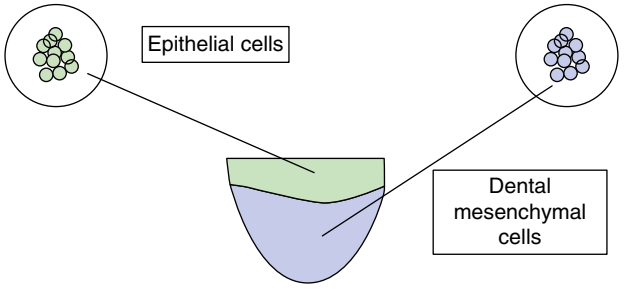

FIGURE 30.3 Epithelial and mesenchymal interplay and potential for tooth regeneration. When able to combine epithelial and mesenchymal stem cells *in vitro*, there is the potential to essentially bioengineer a tooth bud that can then move forward in tooth formation. *Source*: Adapted from [40].

Table 30.2 Stem cells from selected areas in dental–dentin–pulp complex.

Stem cell	Origin
Dental follicle precursor cells (DFPCs)	Dental follicle
Gingiva-derived mesenchymal stem cells (GMSCs)	Gingiva
Dental pulp stem cells (DPSCs)	Dental pulp of permanent teeth
Periodontal ligament stem cells (PDLSCs)	Periodontal ligament
Stem cell from apical papilla (SCAP)	Apical papilla in a forming tooth
Stem cells from human exfoliated deciduous teeth (SHED)	Dental pulp of deciduous teeth
Bone marrow-derived mesenchymal stem cells (BMSCs)	Bone marrow

Dentlearn.ir

BONE MARROW STEM CELLS

Bone marrow stem cells, now also termed stromal stem cells or MSCs, are able to differentiate into multiple distinct tissues, and were first described 40 years ago by Friedenstein [50]. MSCs are currently being studied in stroke [51], hepatology [51], epilepsy [52], pancreatic cancer [53], diabetes [51, 54], tendon repair [55], myocardial infarction and insufficiency [51, 56], prostate cancer [57], orthopedic trauma [58], Alzheimer's disease [59], and systemic sclerosis [60]. There are also many studies using MSCs in the orofacial region for craniofacial defects [61].

MSCs are intimately involved in bone development, bone repair, and bone regeneration [62]. There are several studies evaluating the use of MSCs in the bones of the orofacial region. Kaigler et al.'s phase I/II trial studied transplantation of tissue repair cells from bone marrow into jawbone defects of 24 patients versus traditional GBR. After one year, the transplantation of the tissue repair cells showed accelerated alveolar bone regeneration [63]. Bone marrow MSCs have been used in combination with autogenous bone grafts to augment alveolar bone defects [31], as well as in combination with stem cell-–based allogeneic grafts [64]. However, the technique of extracting and adding bone marrow stem cells to autogenous bone grafts (e.g. iliac crest) for placement can be labor intensive, involving multiple steps [31]. Obtaining the bone marrow aspirate concentrate (BMAC) requires centrifuging out platelets, myeloid precursors, granulocytes, and red blood cells, leaving only a small percentage of BMAC that can then be combined with an autogenous bone graft as a scaffold to aid in successful delivery of MSCs [31].

This challenging and complex autologous process has resulted in the availability of alternative constructs that utilize an allograft where stem cell aspirates can be added. A recent randomized controlled trial showed a head-to-head comparison of an allograft/stem cell aspirate construct versus conventional cortico-cancellous graft in 18 posterior maxillary edentulous sites in need of sinus augmentation. The results demonstrated a statistically significant difference ($p = 0.03$) between the test and control groups in posterior sites where the allograft/stem cell product showed thicker bone on histomorphometry [64]. Another MSC allograft showed bone union and formation in 21 of 23 patients who received revision ankle surgery [65]. Currently, second- and third-generation MSC–allograft constructs are also available, with potential osteoconductive, osteoinductive, and osteogenic properties, and viable MSCs and osteoprogenitor cells such as osteoblasts [66]. These stem cell allografts are approved for use in musculoskeletal defects and may also be a viable option for the orofacial region. Although there is great potential for stem cell use in dentistry, controlled clinical studies are needed to evaluate these new MSC constructs, including their ability to regenerate alveolar bone and to support implant osseointegration and long-term stability.

CELLS, SCAFFOLDS, AND GROWTH FACTORS

Bone and tissue engineering techniques are based on three main components: cells, growth factors, and carriers/scaffolds (Figure 30.4) [67].

Scaffolds, carriers, and matrices are terms often used when discussing tissue engineering and can be employed interchangeably. Scaffolds are defined as supporting matrices that aid in the delivery of substances or matrices to facilitate migration, adhesion, or transport of cells or bioactive molecules that are used for replacement, repair, or regeneration of lost tissues [68]. Scaffolds can be used as a support device in which cells are laid down *in vitro* and then be encouraged to lay down matrix to produce the foundations of a tissue. Scaffolds can be used as a growth factor/drug delivery in which the scaffold is combined with growth factors so upon implantation, cells from around the body are recruited to the scaffold site to form tissue on and throughout the matrix [69]. In other words, scaffolds can be viewed as bioactive agent delivery systems. Growth factors that play roles in wound and bone healing (refer to Table 30.1) are also important in bone regeneration among other functions, and are generally combined with or seeded on scaffolds to allow for controlled release to maximize effects.

Growth factors have many functions, including binding to receptors on cell membranes, aiding in cell growth and proliferation, metabolic functions, and mediating regulatory functions [70]. Of the growth factors listed in Table 30.1, VEGF, IGF, FGF, and BMPs are the most widely studied in the field of bone regeneration [70]. Because of the osteoinductive functions of growth factors such as BMP-2, -4, and -7, both orthopedics and dental/oral and maxillofacial indications are at the forefront of clinical interest [71–73]. Specifically, recombinant human (rh)BMP-2 on an absorbable collagen

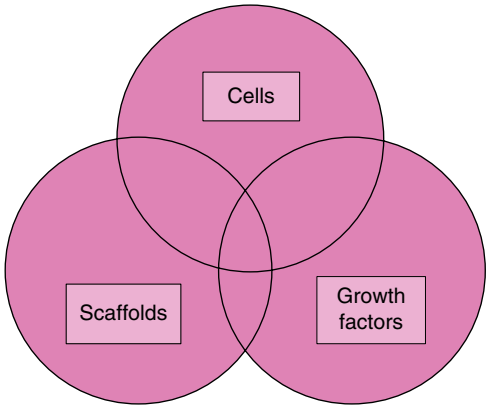

FIGURE 30.4 Keys to bone and tissue engineering. The interplay between cells (e.g. osteoblasts), scaffolds (e.g. hydrogels, poly(lactic-co-glycolic) acid (PLGA), allograft), and growth factors are necessary for successful bone and tissue engineering. *Source*: Adapted from [67].

Dentlearn.ir

sponge (ACS) is US Food and Drug Administration (FDA) approved for use in orthopedics for spinal fusion and non-union tibia fractures, and in dentistry for local alveolar ridge defects associated with extraction sockets and sinus augmentation [74–76]. Since rhBMP-2 is chemotactic for MSCs and promotes their differentiation to osteoprogenitor cells such as osteoblasts, it can form bone in small and large alveolar ridge defects [77, 78]. However, scaffolds or carriers with compression-resistant structure and that can deliver growth factors in a controlled-release manner are better for optimal tissue engineering [79, 80]. Much research is now focusing on the release of combinations of growth factors and stem cells from scaffolds in clinical, animal, and *in vitro* settings.

A meta-analysis by Shanbhag et al. analyzed clinical and pre-clinical studies that compared the addition of stem cells from bone marrow (BMAC) and other sites, such as dental pulp, to various scaffolds and compared the bone growth and regeneration to a control with the scaffold alone [81]. When stem cells were added to scaffolds, such as allograft, xenograft, gelfoam, collagen membrane, platelet-rich fibrin, poly(lactic-co-glycolic) acid (PLGA), or beta-tricalcium phosphate (β-TCP), there was superior bone regeneration compared to scaffolds alone in both sinus augmentation and horizontal ridge augmentation [81]. Chitosan, a natural polysaccharide, can be used as a hydrogel, sponge, or film and has been widely studied as a scaffold to deliver growth factors and cells [82, 83]. PLGA scaffolds have even been studied in delivering drug therapies in orthopedic surgery with titanium implants [84]. Targeted drug delivery on titanium implants could play a major role in loss of bone, and in tackling one of the major complications in implant dentistry, peri-implantitis. BMPs have also been coated onto PLGA scaffolds for delivery and shown positive results in certain bone pathologies [85], as an addition to β-TCP hydrogels for vertical bone growth around implants [86], and in mandibular defects in rabbit models [87]. Growth factor combination studies using VEGF and BMP-2 on a matrix for vertical bone loss around existing dental implants in mini-pig jaws have shown increased vertical bone growth [88]. However, these combination studies in humans are needed to further expand the clinical relevance of these materials before they can be considered for use in patient care.

It is important to understand that there are many types of scaffolds that are naturally occurring or synthetic that can carry stem cells, growth factors, and even medications added to them to be delivered. However, much current research is attempting to find the perfect material that combines all of these things. See Figure 30.5 [89] for the factors that may be included to create the perfect bone graft for regeneration. At this time, there is no one perfect scaffold/combination of materials for bone regeneration. In the future, studies focusing on timed release of specific growth factors in a certain sequence or with sustained release will provide great insight to the field [90], since this is a more natural pathway of bone healing and regeneration. Another factor to consider is the ideal pore size in a membrane or scaffold for more vascular ingrowth, since vascularity is essential to bone formation and remodeling [91]. The field of tissue regeneration has great potential for growth in the field of implant dentistry, and, given the volume of research that has been performed and that will continue, new materials and strategies are guaranteed to change how clinicians practice and how patients receive care.

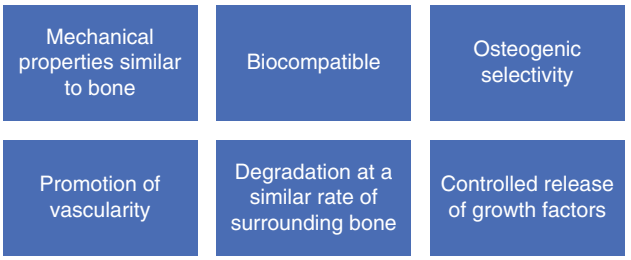

FIGURE 30.5 Potential characteristics of the "perfect" bone graft material: mechanical properties like those of bone, such as osteogenesis, osteoinduction, and osteoconduction; compatibility with surrounding tissue and support from surrounding tissue; ability to allow adequate angiogenesis; similar build-up and breakdown of graft as with natural bone; and controlled release of growth factors, timing the same way as it would be with physiological wound healing. *Source*: Adapted from [89].

CONCLUSION

After more than 30 years of GBR and even longer since implant dentistry was introduced, tissue engineering for bone regeneration is still in its infancy. While significant strides have been taken to ensure that our materials are biocompatible, possess favorable mechanical properties, and support bone remodeling and regeneration, the "perfect" bone grafting material has not yet been developed. Whether the future might be a combination of existing materials, grafts containing growth factors or live cellular constructs, or a complete innovation, there is still much work to be done. As patients become more medically compromised and the defects more challenging, available materials must be able to predictably regenerate missing bone that can support implant osseointegration and sustain implant success over the long term. Although soft tissue substitutes are newer and more recently available, researchers and clinicians already have significant knowledge in the field that will guarantee meaningful innovation and progress in the next 30 years.

Dentlearn.ir

REFERENCES

1. Sampogna G, Guraya SY, Forgione A. Regenerative medicine: Historical roots and potential strategies in modern medicine. *J Microsc Ultrastruct.* 2015;3(3):101–7.
2. Langer R, Vacanti JP. Tissue engineering. *Science.* 1993;260(5110): 920–26.
3. Aghaloo TL, Misch C, Lin G-H et al. Bone augmentation of the edentulous maxilla for implant placement: A systematic review. *Int J Oral Maxillofac Implants.* 2016;31(suppl):s19–s30.
4. Lindley LE, Stojadinovic O, Pastar I, Marjana Tomic-Canic M. Biology and biomarkers for wound healing. *Plast Reconstr Surg.* 2016;138 (3 suppl):18S–28S.
5. Broughton G 2nd, Janis JE, Attinger CE. Wound healing: An overview. Plast Reconstr Surg, 2006;117(7 suppl):1e-S–32e-S.
6. Kondo T, Ishida Y. Molecular pathology of wound healing. *Forensic Sci Int.* 2010;203(1–3):93–8.
7. Miloro M, Peterson LJ. *Peterson's principles of oral and maxillofacial surgery*. Shelton, CT: People's Medical Publication House; 2012.
8. Wang P-H, Huang B-S, Horng H-C et al. Wound healing. *J Chin Med Assoc.* 2018;81(2):94–101.
9. Canedo-Dorantes L, Canedo-Ayala M. Skin acute wound healing: A comprehensive review. *Int J Inflam.* 2019;2019:3706315.
10. Smigiel KS, Parks WC. Macrophages, wound healing, and fibrosis: Recent insights. *Curr Rheumatol Rep.* 2018;20(4):17.
11. Snyder RJ, Lanter J, Kirsner RS et al. Macrophages: A review of their role in wound healing and their therapeutic use. *Wound Repair Regen.* 2016;24(4):613–29.
12. Kim SY, Nair MG. Macrophages in wound healing: Activation and plasticity. *Immunol Cell Biol.* 2019;97(3):258–67.
13. Guo S, Dipietro LA. Factors affecting wound healing. *J Dent Res.* 2010;89(3):219–29.
14. Aghaloo TL, Le AD. Growth factors in implant site development. *Oral Maxillofac Surg Clin N Am.* 2004;16(1):111–25.
15. Henry G, Garner WL. Inflammatory mediators in wound healing. *Surg Clin N Am.* 2003;83(3):483–507.
16. Barrientos S, Stojadinovic O, Golinko MS et al. Growth factors and cytokines in wound healing. *Wound Repair Regen.* 2008;16(5): 585–601.
17. Oryan A, Monazzah S, Bigham-Sadegh A. Bone injury and fracture healing biology. *Biomed Environ Sci.* 2015;28(1):57–71.
18. Sathyendra V, Darowish M. Basic science of bone healing. *Hand Clin.* 2013;29(4):473–81.
19. Chen X, Wang Z, Duan N et al. Osteoblast-osteoclast interactions. *Connect Tissue Res.* 2018;59(2):99–107.
20. Caetano-Lopes J, Canhão H, Fonseca JE. Osteoblasts and bone formation. *Acta Reumatol Port.* 2007;32(2):103–10.
21. Dimitriou R, Jones E, McGonagle D, Giannoudis PV. Bone regeneration: Current concepts and future directions. *BMC Med.* 2011; 9:66.
22. Moy P, Pozzi A, Beumer J. *Fundamentals of implant dentistry: Surgical principles*. Vol. 2. Chicago, IL: Quintessence; 2016.
23. Aghaloo TL, Hadaya D. Basic principles of bioengineering and regeneration. *Oral Maxillofac Surg Clin N Am.* 2017;29(1):1–7.
24. Janicki P, Schmidmaier G. What should be the characteristics of the ideal bone graft substitute? Combining scaffolds with growth factors and/or stem cells. *Injury.* 2011;42:S77–S81.
25. Chiapasco M, Zaniboni M. Failures in jaw reconstructive surgery with autogenous onlay bone grafts for pre-implant purposes: Incidence, prevention and management of complications. *Oral Maxillofac Surg Clin N Am.* 2011;23(1):1–15.
26. Zhao R, Yang R, Cooper PR et al. Bone grafts and substitutes in dentistry: A review of current trends and developments. *Molecules.* 2021;26(10):3007.
27. Albrektsson T, Johansson C. Osteoinduction, osteoconduction and osseointegration. *Eur Spine J.* 2001;10(suppl 2):S96–S101.
28. Schenk RK, Buser D, Hardwick WR, Dahlin C. Healing pattern of bone regeneration in membrane-protected defects: A histologic study in the canine mandible. *Int J Oral Maxillofac Implants.* 1994;9(1): 13–29.
29. Wang, HL, Boyapati L. "PASS" principles for predictable bone regeneration. *Implant Dent.* 2006;15(1):8–17.
30. Urban IA, Monje A. Guided bone regeneration in alveolar bone reconstruction. *Oral Maxillofac Surg Clin N Am.* 2019;31(2):331–8.
31. Panicker PP, Mohan SP, Nallusamy J et al. Reconstruction of craniofacial bone defects with autologous human bone marrow stem cells and autogenous bone grafts: A case report with review of literature. *J Pharm Bioallied Sci.* 2020;12(suppl 1):S394–S398.
32. Kim RY, Bae SS, Feinberg SE. Soft tissue engineering. *Oral Maxillofac Surg Clin N Am.* 2017;29(1):89–104.
33. Zuhr O, Baumer D, Hurzeler M. The addition of soft tissue replacement grafts in plastic periodontal and implant surgery: Critical elements in design and execution. *J Clin Periodontol.* 2014;41(suppl 15):S123–S142.
34. Thoma DS, Buranawat B, Hämmerle CHF et al. Efficacy of soft tissue augmentation around dental implants and in partially edentulous areas: A systematic review. *J Clin Periodontol.* 2014;41:S77–S91.
35. Lissek M, Boeker M, Happe A. How thick is the oral mucosa around implants after augmentation with different materials: A systematic review of the effectiveness of substitute matrices in comparison to connective tissue grafts. *Int J Mol Sci.* 2020;21:5043.
36. Balic A. Biology explaining tooth repair and regeneration: A mini-review. *Gerontology.* 2018;64(4):382–8.
37. Thesleff I. From understanding tooth development to bioengineering of teeth. *Eur J Oral Sci.* 2018;126(suppl 1):67–71.
38. Balic A, Thesleff I. Tissue interactions regulating tooth development and renewal. *Curr Top Dev Biol.* 2015;115:157–86.
39. Kolios G, Moodley Y. Introduction to stem cells and regenerative medicine. *Respiration.* 2013;85(1):3–10.

Dentlearn.ir

40. Volponi AA, Zaugg LK, Neves V. et al. Tooth repair and regeneration. *Curr Oral Health Rep.* 2018;5(4):295–303.

41. Miura M, Gronthos S, Zhao M et al. SHED: Stem cells from human exfoliated deciduous teeth. *Proc Natl Acad Sci U S A.* 2003;100(10): 5807–12.

42. Ko CS, Chen JH, Su WT. Stem cells from human exfoliated deciduous teeth: A concise review. *Curr Stem Cell Res Ther.* 2020;15(1): 61–76.

43. Zhu SY, Yuan CY, Lin YF et al. Stem cells from human exfoliated deciduous teeth (SHEDs) and dental pulp stem cells (DPSCs) display a similar profile with pericytes. *Stem Cells Int.* 2021;2021:8859902.

44. Fuloria S, Jain A, Singh S et al. Regenerative potential of stem cells derived from human exfoliated deciduous (SHED) teeth during engineering of human body tissues. *Curr Stem Cell Res Ther.* 2021;16(5):507–17.

45. Shi X, Mao J, Liu Y. Pulp stem cells derived from human permanent and deciduous teeth: Biological characteristics and therapeutic applications. *Stem Cells Transl Med.* 2020;9(4):445–64.

46. Anoop M, Datta I. Stem cells derived from human exfoliated deciduous teeth (SHED) in neuronal disorders: A review. *Curr Stem Cell Res Ther.* 2021;16(5):535–50.

47. Pereira LV, Bento RF, Cruz DB et al. Stem cells from human exfoliated deciduous teeth (SHED) differentiate in vivo and promote facial nerve regeneration. *Cell Transplant.* 2019;28(1):55–64.

48. Zhang W, Yelick PC. Tooth repair and regeneration: Potential of dental stem cells. *Trends Mol Med.* 2021;27(5):501–11.

49. Diniz IMA, Chen C, Ansari S et al. Gingival mesenchymal stem cell (GMSC) delivery system based on RGD-coupled alginate hydrogel with antimicrobial properties: A novel treatment modality for peri-implantitis. *J Prosthodont.* 2016;25(2):105–15.

50. Vaananen HK. Mesenchymal stem cells. *Ann Med.* 2005;37(7): 469–79.

51. Stoltz JF, de Isla N, Li YP et al. Stem cells and regenerative medicine: Myth or reality of the 21th century. *Stem Cells Int.* 2015;2015:734731.

52. Agadi S, Shetty SK. Concise review: Prospects of bone marrow mononuclear cells and mesenchymal stem cells for treating status epilepticus and chronic epilepsy. *Stem Cells.* 2015;33(7):2093–103.

53. Blogowski W, Bodnarczuk T, Starzynska T. Concise review: Pancreatic cancer and bone marrow-derived stem cells. *Stem Cells Transl Med.* 2016;5(7):938–45.

54. Cao Y, Gang X, Sun C, Wang G. Mesenchymal stem cells improve healing of diabetic foot ulcer. *J Diabetes Res.* 2017;2017:9328347.

55. Costa-Almeida R, Calejo I, Gomes ME. Mesenchymal stem cells empowering tendon regenerative therapies. *Int J Mol Sci.* 2019; 20(12):3002.

56. Miao C, Lei M, Hu W et al. A brief review: The therapeutic potential of bone marrow mesenchymal stem cells in myocardial infarction. *Stem Cell Res Ther.* 2017;8(1):242.

57. Noh J, Yu J, Kim W et al. Bone marrow-derived mesenchymal stem cells migrate toward hormone-insensitive prostate tumor cells expressing TGF-beta via N-cadherin. *Biomedicines.* 2021;9(11):1572.

58. Pastides PS, Welck MJ, Khan WS. Use of bone marrow derived stem cells in trauma and orthopaedics: A review of current concepts. *World J Orthop.* 2015;6(6):462–8.

59. Qin C, Lu Y, Wang K et al. Transplantation of bone marrow mesenchymal stem cells improves cognitive deficits and alleviates neuropathology in animal models of Alzheimer's disease: A meta-analytic review on potential mechanisms. *Transl Neurodegener.* 2020;9(1):20.

60. Rozier P, Maria A, Goulabchand R et al. Mesenchymal stem cells in systemic sclerosis: Allogenic or autologous approaches for therapeutic use? *Front Immunol.* 2018;9:2938.

61. Ansari S, Seagroves JT, Chen C et al. Dental and orofacial mesenchymal stem cells in craniofacial regeneration: The prosthodontist's point of view. *J Prosthet Dent.* 2017;118(4):455–61.

62. Bruder SP, Fink DJ, Caplan AI. Mesenchymal stem cells in bone development, bone repair, and skeletal regeneration therapy. *J Cell Biochem.* 1994;56(3):283–94.

63. Kaigler D, Pagni G, Park CH et al. Stem cell therapy for craniofacial bone regeneration: A randomized, controlled feasibility trial. *Cell Transplant.* 2013;22(5):767–77.

64. Whitt J, Al-Sabbagh M, Dawson D et al. Efficacy of stem cell allograft in maxillary sinus bone regeneration: A randomized controlled clinical and blinded histomorphometric study. *Int J Implant Dent.* 2020;6(1):25.

65. Rush SM, Hamilton GA, Ackerson LM. Mesenchymal stem cell allograft in revision foot and ankle surgery: A clinical and radiographic analysis. *J Foot Ankle Surg.* 2009;48(2):163–9.

66. Johnstone B, Zhang N, Waldorff EI et al. A comparative evaluation of commercially available cell-based allografts in a rat spinal fusion model. *Int J Spine Surg.* 2020;14(2):213–21.

67. Costello BJ, Kumta P, Sfeir CS. Regenerative technologies for craniomaxillofacial surgery. *J Oral Maxillofac Surg.* 2015;73(12):S116–S125.

68. Grumezescu AM. *Nanobiomaterials in hard tissue engineering: Applications of nanobiomaterials*. Amsterdam: Elsevier; 2016.

69. Howard D, Buttery LD, Shakesheff KM, Roberts SJ. Tissue engineering: Strategies, stem cells and scaffolds. *J Anat.* 2008;213(1):66–72.

70. Toosi S, Behravan J. Osteogenesis and bone remodeling: A focus on growth factors and bioactive peptides. *BioFactors.* 2020;46(3):326–40.

71. Sampath TK, Reddi AH. Discovery of bone morphogenetic proteins – a historical perspective. *Bone.* 2020;140:115548.

72. Davies SD, Ochs MW. Bone morphogenetic proteins in craniomaxillofacial surgery. *Oral Maxillofac Surg Clin North Am.* 2010;22(1):17–31.

73. Aghaloo TL, Tencati E, Hadaya D. Biomimetic enhancement of bone graft reconstruction. *Oral Maxillofac Surg Clin North Am.* 2019;31(2):193–205.

74. Gillman CE, Jayasuriya AC. FDA-approved bone grafts and bone graft substitute devices in bone regeneration. *Mater Sci Eng C Mater Biol Appl.* 2021;130:112466.

75. Triplett RG, Nevins M, Marx RE et al. Pivotal, randomized, parallel evaluation of recombinant human bone morphogenetic protein-2/absorbable collagen sponge and autogenous bone graft for maxillary sinus floor augmentation. *J Oral Maxillofac Surg.* 2009;67(9):1947–60.

76. Freitas RM, Spin-Neto R, Marcantonio E Jr et al., Alveolar ridge and maxillary sinus augmentation using rhBMP-2: A systematic review. *Clin Implant Dent Relat Res.* 2015;17(suppl 1):e192–e201.

77. Trento GS, Carvalho PHA, Macedo DV et al. Titanium mesh associated with rhBMP-2 in alveolar ridge reconstruction. *Int J Oral Maxillofac Surg.* 2019;48(4):546–53.

Dentlearn.ir

78. Herford AS, Lowe I, Jung P. Titanium mesh grafting combined with recombinant human bone morphogenetic protein 2 for alveolar reconstruction. *Oral Maxillofac Surg Clin North Am.* 2019;31(2):309–15.

79. Chen X, Tan B, Bao Z et al. Enhanced bone regeneration via spatiotemporal and controlled delivery of a genetically engineered BMP-2 in a composite hydrogel. *Biomaterials.* 2021;277:121117.

80. Cheng G, Yin C, Tu H et al. Controlled co-delivery of growth factors through layer-by-layer assembly of core-shell nanofibers for improving bone regeneration. *ACS Nano.* 2019;13(6):6372–82.

81. Shanbhag S, Suliman S, Pandis N et al. Cell therapy for orofacial bone regeneration: A systematic review and meta-analysis. *J Clin Periodontol.* 2019;46(suppl 21):162–82.

82. Saravanan S, Vimalraj S, Thanikaivelan P et al. A review on injectable chitosan/beta glycerophosphate hydrogels for bone tissue regeneration. *Int J Biol Macromol.* 2019;121:38–54.

83. Oryan A, Sahvieh S. Effectiveness of chitosan scaffold in skin, bone and cartilage healing. *Int J Biol Macromol.* 2017;104(Pt A):1003–11.

84. Barik A, Chakravorty N. Targeted drug delivery from titanium implants: A review of challenges and approaches. *Adv Exp Med Biol.* 2020;1251:1–17.

85. Carreira ACO, Zambuzzi WF, Rossi MC et al. Bone Morphogenetic Proteins: Promising molecules for bone healing, bioengineering, and regenerative medicine. *Vitam Horm.* 2015;99:293–322.

86. Lee JH, Ryu MY, Baek H-R et al. Generation of an rhBMP-2-loaded beta-tricalcium phosphate/hydrogel composite and evaluation of its efficacy on peri-implant bone formation. *Biomed Mater.* 2014;9(5):055002.

87. Deng N, Sun J, Li Y et al. Experimental study of rhBMP-2 chitosan nano-sustained release carrier-loaded PLGA/nHA scaffolds to construct mandibular tissue-engineered bone. *Arch Oral Biol.* 2019; 102:16–25.

88. Schorn L, Sproll C, Ommerborn M et al. Vertical bone regeneration using rhBMP-2 and VEGF. *Head Face Med.* 2017;13(1):11.

89. Block MS, Kent JN. Sinus augmentation for dental implants: The use of autogenous bone. *J Oral Maxillofac Surg.* 1997;55(11):1281–6.

90. Kim S, Kim J, Gajendiran M et al. Enhanced skull bone regeneration by sustained release of BMP-2 in interpenetrating composite hydrogels. *Biomacromolecules.* 2018;19(11):4239–49.

91. Valtanen RS, Yang YP, Gurtner GC et al. Synthetic and bone tissue engineering graft substitutes: What is the future? *Injury.* 2021;52 (suppl 2):S72–S77.

Dentlearn.ir

Dentlearn.ir

Index

Page locators in **bold** indicate tables. Page locators in *italics* indicate figures. This index uses letter-by-letter alphabetization.

A

ABB *see* autogenous block bone
ABCD *see* alveolar bone classification by deficiency
ABC sinus augmentation classification, 438–439, **439**
absorbable collagen sponge (ACS), 338
abutments
  allogenic block bone graft, *213*
  complete-arch dental implants, 519, 521, *521*, 531, *531*
  guided bone regeneration, 150, *150*, *184*, 188, *188*
  orthodontic implant site development, *400*
  prosthetic evaluation in implant dentistry, *77–79*, 78
  ridge-split expansion procedure, 265, *265*
  short and ultra-short implants, 483–484, *484*, 487, *488–489*, 492, *492–493*
  tent-pole abutment technique, 403–418
acellular dermal matrix (ADM), 468–469
ACS *see* absorbable collagen sponge
ADM *see* acellular dermal matrix
ADO *see* alveolar distraction osteogenesis
AFG *see* autologous fibrin glue
AIC *see* anterior iliac crest
ALARA principle, 51, **52**
alcohol, bone biology, 8
alginate impressions, 522–523, *522*
alkaline phosphatase (ALP), 234
allogenic block bone graft
  anterior sextant, 221–227, *222–227*, **222**
  autogenous block bone graft, 210–211
  biopsy interpretation, 224–227, *226–227*, 230, *231–232*
  complications, 404
  concepts and definitions, 210–211
  conforming/contouring the block, 217, *218*, 222–224, *224*, 229, *229–230*
  discussion, 234–235
  features of irradiated allogenic block grafts, 213, **213**
  fixation of the block, 218, *218*
  horizontal ridge augmentation, 209–238
  implant placement and prosthetic rehabilitation, 219–220, *219–222*, 227, *227*, 232, *233*
  incision and flap design, 214–217, *216–217*, 221–222, *223*, 229, *229*
  indications, 211, *211–213*, **211–213**
  management of voids and coverage, 219, *219*
  materials and methods, 214, **214**
  patient selection criteria, 214, **214**
  posterior sextant, 228–232, *228–233*, **228**
  post-operative assessment and surgical re-entry, 224, *225–226*, 229–230, *230–231*
  pre-operative considerations, 214, **214**, 221, *222–223*, **223**, 228, *228*, **228**
  single anterior tooth, 214–220, *215–222*
allograft dermis, 468–469, *469–470*
allografts
  bone grafting materials, 130, 133, *134*
  guided bone regeneration, 180, *181*
  tissue engineering and regenerative medicine, 541
alloplasts
  bone grafting materials, 135–136, *136*
  tissue engineering and regenerative medicine, 541
ALP *see* alkaline phosphatase
alternative surgical techniques (AST), 97
alveolar bone classification by deficiency (ABCD), 91–103
  alternative surgical techniques, 97
  decision tree algorithm, 91, 97–101, **98**, *99–101*
  extraosseous versus intraosseous alveolar bone defects, 94, *94–95*
  graft healing and vascularization, 97
  main surgical techniques, 95–97, *96–97*
  onlay versus inlay alveolar bone grafts, 94, *95*
  ridge preservation and ridge augmentation, 92–93, *93*
  risk factors, 95
  static versus dynamic surgical techniques, 94–95
  type 0/I, 99, *99–100*
  type II/I, 100, *100*
  type III/II, 101, *101*
alveolar distraction osteogenesis (ADO)
  advantages and disadvantages, 374
  anterior maxilla, 375, *376–378*
  case reports, 375–379, *376–379*
  complications, 374–375
  conclusion and recommendations, 376–379

Essential Techniques of Alveolar Bone Augmentation in Implant Dentistry: A Surgical Manual, Second Edition. Edited by Len Tolstunov.

© 2023 John Wiley & Sons, Inc. Published 2023 by John Wiley & Sons, Inc.

Companion website: www.wiley.com/go/tolstunov/essential

Dentlearn.ir

alveolar distraction osteogenesis (ADO) (*Continued*)
indications, 373–374, *374–375*
posterior mandible, 376, *378–379*
surgical procedure, 369–371, *369–373*
vertical ridge augmentation, 367–380
alveoloplasty, 531, *531*
anatomical transpositioning, 334–336
anchoring sutures, 109–110, *110*
angiogenesis
biological rationale for surgical procedure, 116–117, 120–122
bone biology, 8–9, *9*
guided bone regeneration, 179
platelet-rich fibrin, *155*
wound healing, 19
angulated alveolar ridge, *212*
ANS *see* anterior nasal spine
anterior iliac crest (AIC)
autogenous block bone graft, 331, *332*, 333
titanium mesh, 312, *313*
anterior mandible, 47–48, *47–48*
anterior maxilla, 42–44, *43–45*
anterior nasal spine (ANS), 43, *44*
anterior palate, 329, *330*
anterior superior alveolar (ASA) canal, 42, *43*
anterior superior alveolar nerve, 30
antibiotics
guided bone regeneration, 143
maxillary sinus elevation using lateral window approach, 433
orthodontic implant site development, 385
tent-pole abutment technique, 405
titanium mesh, 311, 321
antral septa, 440
antrostomy, 424–430, *425–429*
applied surgical jaw anatomy, 23–38, *23*
bone biology, 24
guided bone regeneration, 178
mandible, *30–37*, 31–37
maxilla, 24–31, *26–31*
maxillary sinus elevation using lateral window approach, 422–423
maxillary sinus elevation using transcrestal sinus floor elevation, 438–440, **439**
artifacts, 51, *51*
ASA *see* anterior superior alveolar
AST *see* alternative surgical techniques
autogenous block bone (ABB) graft
allogenic block bone graft, 210–211
alveolar bone classification by deficiency, *93*, 95, 96
anatomical transpositioning, 334–336
augmentation techniques, 332–338
biological rationale for surgical procedure, 118–120, *122–123*
case presentations, 199–205
complications, 404
concepts and definitions, 196
cortical autogenous block tenting, 334, *335–336*
cortical autogenous tenting, 196, 198–204, *198*, *202–203*
discussion, 338–339
donor sites for block bone, 327–332, *328–333*
guided bone regeneration, 196, 197–198, 204–205, *204–205*
horizontal ridge augmentation, 195–206
inferior alveolar nerve lateralization, 337, *337*
inlay bone grafting, 336–337, *336*
onlay block bone grafting, 332–334, *334*, 337, 339
onlay bone grafting, 196, 197–198, 199, 201–205, *201*, *203–205*
pedicle segmental rotation, 337–338, *338*
recipient site analysis, 196–197, *197*
recipient site classification and defect analysis, 326–327, *327–328*
regenerative techniques in bone grafting, 199, *200*
techniques, 197–199
vertical ridge augmentation, 325–341
see also Khoury split bone block grafting technique
autogenous bone grafts
short and ultra-short implants, 481, *482*, *486*, 490, *491*
tissue engineering and regenerative medicine, 540–541
titanium mesh, 309–310
autoinduction, 211
autologous fibrin glue (AFG), 285, 407
axial pattern flaps, 106

B

bacterial contamination, 95
BBG *see* block bone graft
BBM *see* bovine bone mineral
BDP-flap *see* buccally displaced palatal flap
beam hardening artifacts, 51
Bell, William H., 240
benign (paroxysmal) positional vertigo (BPV/BPPV), 272, 440, 452–453
beta-titanium archwire, 383, 388, 391
BFPSC *see* buccal fat pad-derived stem cells
biCAT *see* bilateral cortical autogenous tenting
Bicon implants *see* short and ultra-short implants
bilateral cortical autogenous tenting (biCAT), 334, *335*
biofilm, 19
Bio-Heat trays, 168–169, *168–169*
biological rationale for surgical procedure, 116–125
angiogenesis, 116–117, 120–122
conclusion and recommendations, 123–124
graft revascularization sources, 117–123, *118–123*, **119**
Khoury split bone block grafting technique, 120, *121–122*, 356
posterior sandwich osteotomy, 344
ridge-split expansion procedure/crestal sinus lift, 297–298
biomimetics, 96
Bio-Oss, 134–135
biopsy, 224–227, *226–227*, 230, *231–232*
bleeding/hemorrhage

Dentlearn.ir

guided bone regeneration, 180
wound closure and healing, 112, *113*
block bone graft (BBG)
alveolar bone classification by deficiency, *93*, 95, 96
biological rationale for surgical procedure, 118–122, *121–123*
see also allogenic block bone graft; autogenous block bone graft
BMP *see* bone morphogenetic protein
BMSC *see* bone marrow stem cells
bone biology, 3–17, *3*
anatomical aspects, 4–6, *5–6*
angiogenesis, 8–9, *9*
applied surgical jaw anatomy, 24
biomaterials for bone regeneration, 9–11, *10–11*
loading, 14–15, *14*
osseointegration, 12–13, *12–13*, **12**
remodeling and healing, 6–9, *6–9*
bone-borne guides, 55
bone core technique, 359–361, *361–362*
bone density, 51
bone grafting materials, 130–140
allografts, 130, 133, *134*
alloplasts, 135–136, *136*
autogenous bone grafts, 131–133
characteristics of normal bone, 130, *131*
guided bone regeneration, 180, *181*
maxillary sinus elevation using lateral window approach, 431
maxillary sinus elevation using transcrestal sinus floor elevation, 447–449, *449*
platelet-rich fibrin, 158–159
tissue engineering and regenerative medicine, 540–542, *542*
titanium mesh, 309–310
types of bone grafts, 130–131, *132*
xenografts, 130–131, 134–135, *135*
bone harvesting
autogenous block bone graft, 327–332, *328–333*
guided bone regeneration, 180
Khoury split bone block grafting technique, 357, *358*, 361–362, *363*
short and ultra-short implants, 481, *482*, *486*, 490, *491*
tent-pole abutment technique, *414*
titanium mesh, 311–312, *312–314*
bone loss
applied surgical jaw anatomy, 24, *25*, 37
complete-arch dental implants, 527, *527*
maxillary sinus elevation using transcrestal sinus floor elevation, 447–448
orthodontic implant site development, 388, *395*
bone marrow stem cells (BMSC), 199, 545–546
bone morphogenetic protein (BMP)
allogenic block bone graft, 234
bone biology, 4, 9, 11, *11*
bone grafting materials, 133
Khoury split bone block grafting technique, 357
posterior sandwich osteotomy, 347–348, 353
tissue engineering and regenerative medicine, 541, 545–546
bone quality, 51, 439
bone split, 257
bony fractures, 375
bony lid technique, 359, *360*
book flap, 250, *250*, *252*, 289, *290–291*, 294, *295*
bovine bone mineral (BBM), *163*, 309–310
bovine spongiform encephalopathy (BSE), 134
BPV/BPPV *see* benign (paroxysmal) positional vertigo
bridges
complete-arch dental implants, 529–532, *530–534*
prosthetic evaluation in implant dentistry, 83–84, *84–87*
ridge-split expansion procedure, 265, *265*
zygomatic and pterygoid implants, *507–508*
Broumand zygomatic notch retractor, 501, *501*
BSE *see* bovine spongiform encephalopathy
buccal fat pad-derived stem cells (BFPSC), 199, *200*
buccal flap release, 180, *181*
buccally displaced palatal flap (BDP-flap), *432–433*, 433
buccinator muscle, 26, *26*, 29, 31, 33–34

C

CAD/CAM
allogenic block bone graft, 235
complete-arch dental implants, 518–519, *518*
cone beam computed tomography, 54–58, *56–59*
prosthetic evaluation in implant dentistry, 63, *80*
short and ultra-short implants, 481
titanium mesh, 308, 309, *318–320*
CAF *see* coronally advanced flap
calvarium
autogenous block bone graft, 331–332, *333*
titanium mesh, 312, *314*
canalis sinuosus, 42, *43*
cancellous bone grafts
autogenous block bone graft, 197, 333–334
biological rationale for surgical procedure, 120
bone biology, *6*, 8–9, *9*
bone grafting materials, 132
canine fossa, 42
Carota technique, 359–361, *361–362*
CAT *see* cortical autogenous tenting
Cawood–Howell classification, 480, 481
CBCT *see* cone beam computed tomography
CEJ *see* cemento-enamel junction
cell proliferation, *155*
cell recruitment, *155*
cemento-enamel junction (CEJ), 465
centric relation (CR), 517–522, *517*
CGF *see* concentrated growth factor
chin
autogenous block bone graft, 329, *329*
Khoury split bone block grafting technique, 361–362, *363*

Dentlearn.ir

chlorhexidine, 391, 433
collagen membranes
alveolar bone classification by deficiency, *93*
guided bone regeneration, 145, *145*
platelet-rich fibrin, 169
combination tooth–bone-borne guides, 55
compact bone, 6, *6*, 8–9, *9*, 14
complete-arch dental implants, 513–535
metal-resin implant with delayed immediate loading, 514–524
case planning, 518–519, *518*
centric relation, 517–522, *517*
discussion and conclusion, 523
photogrammetry, 521–522, *521–522*
provisionalization, 519–522, *520–522*
restorative building blocks, 517–523, *517–523*
site classification, 514–516, *515–517*
soft tissue, 522–523, *523*
surgical procedures, 519, *519*
vertical dimension of occlusion, 517–522, *518*
platelet-rich fibrin, 169, *170*
staged ceramo-metal implant rehabilitation, 525–535
case report, 526–534, *526–534*
diagnosis, 527–528
discussion and conclusion, 534
examination and clinical presentation, 526–527, *526–528*
failing/deteriorating dentition, 525–526
final treatment plan, 529
patient history, 526
provisionalization, 529–531, *530–532*
surgical-restorative sequence performed, 529–532, *529–534*
treatment options, 528–529
compliance, 179
computed tomography (CT)
allogenic block bone graft, *213*
applied surgical jaw anatomy, *26*, 27, 35
maxillary sinus elevation using lateral window approach, 423
maxillary sinus elevation using transcrestal sinus floor elevation, 439
orthodontic implant site development, *385*, *389*
prosthetic evaluation in implant dentistry, 67–72, *68–72*, *77*, *85*
ridge-split expansion procedure, 280
zygomatic and pterygoid implants, *499–500*, 500
see also cone beam computed tomography
computer-guided surgery, *70*
concentrated growth factor (CGF)
ridge-split expansion procedure, 285
tent-pole abutment technique, 407, 411, *412*, 413–414
cone beam computed tomography (CBCT)
allogenic block bone graft, *215*, *220–222*, *225*, *228*, *231*, *233*
alveolar bone classification by deficiency, *94*, *100–101*
anterior mandible, 47–48, *47–48*
anterior maxilla, 42–44, *43–45*
applied surgical jaw anatomy, 28, 31, 34–36, *35*
autogenous block bone graft, *200*, *203*, *205*
biological rationale for surgical procedure, *122*
complete-arch dental implants, 526–527, *527–528*
considerations for treatment planning, 42
distraction osteogenesis, 369, *369–370*, 374–375
evaluation of the alveolar ridge, 39–60
guided bone regeneration, 142, 144, 147, *148*
imaging considerations, 50–51, *51*, **52**
interactive implant treatment planning, 51–54, *52–55*
maxillary sinus elevation using lateral window approach, 422–424, *426*, *428–429*
maxillary sinus elevation using transcrestal sinus floor elevation, 439, 443, *448*
platelet-rich fibrin, 158, *161*, *170*
posterior mandible, 48–50, *48–50*
posterior maxilla, 44–47, *45–47*
posterior sandwich osteotomy, 348, *349*
prosthetic evaluation in implant dentistry, 62–63, *64–65*, 67–72, *69*
ridge-split expansion procedure, 241–245, **242**, *243*, *245–246*, *269*, 272–275, *273*, *275*
role of radiography in implant dentistry, 40–42, *41*
scan orientation, 52, *52–53*
short and ultra-short implants, *481*
surgical guides, 54–56, *56*
technological advances, 56–58, *57–59*
tent-pole abutment technique, *412*, *416*
titanium mesh, 309, *310*, *315*, *318–320*
zygomatic and pterygoid implants, 503, *504*, *506–508*
conical progressive osteotomies, 269–271, *269–271*
connective tissue grafts (CTG), 464–468
biological rationale for surgical procedure, 122–123, *123*
covered connective tissue graft, 466–468, *466–468*
free connective tissue graft, 465, *465–466*
guided bone regeneration, 150
maxillary sinus elevation using lateral window approach, 433
tissue engineering and regenerative medicine, 543
continuous sutures, 111, *111*
coronally advanced flap (CAF), 466–468, *466–468*
cortical autogenous tenting (CAT), 196, 198–204, *198*, *202–203*, 334, *335–336*
cortical bone grafts
autogenous block bone graft, 197, 331–333, *333*
bone biology, 6, *6*
bone grafting materials, 132–133
Khoury split bone block grafting technique, 357, *358*
cortico-cancellous bone grafts
autogenous block bone graft, 197, 330–331, *331–332*
bone grafting materials, 133
corticotomy *see* ridge-split expansion procedure
CR *see* centric relation
crestal corticotomy, 256
crestal incisions, 107, *109*, *112*

Dentlearn.ir

crestal osteotomy, 259, *280*
crestal sinus lift (CSL)
biological rationale for surgical procedure, 297–298
case reports, 298–302, *298–302*
ESLI sequence, 296
platelet-rich fibrin, 167–168, *167*
ridge-split expansion procedure, 294–303
vertical ridge augmentation, 295–296, *296*
volumetric bone augmentation in posterior maxilla, 296–302, *297–302*
see also transcrestal sinus floor elevation
crowns
complete-arch dental implants, 532, *532–534*
maxillary sinus elevation using lateral window approach, 421
orthodontic implant site development, 382, 385, *385*, *390*, *394–395*, *397*, *400*
prosthetic evaluation in implant dentistry, *77*, *79*, 83–84, *84–87*
ridge-split expansion procedure, *260*
short and ultra-short implants, 483–484, *484*, 487, *488–489*, 492, *492–493*
titanium mesh, 309
Cr:YSGG lasers, 280
CSL *see* crestal sinus lift
CT *see* computed tomography
CTG *see* connective tissue graft
cutaneous fistula, 508–509
cytokines, 18–19

D

DBBM *see* deproteinized bovine bone matrix
decortication, 214–217, *217*
demineralized freeze-dried bone allografts (DFDBA), 133
allogenic block bone graft, 211
platelet-rich fibrin, 159
demineralized tooth bone block, 407, *408*
dense polytetrafluoroethylene (d-PTFE) membranes
alveolar bone classification by deficiency, *93*, 96
guided bone regeneration, 178, 184–190, *185–191*, 193
volumetric ridge augmentation, 404
dental examination, 63
dental pulp stem cells (DPSC), 544
dental stem cells, 544, *544*, **544**
dentures
applied surgical jaw anatomy, 24, *25*
complete-arch dental implants, 520, *520*, 525
partial dentures, 190–191, *191–192*
prosthetic evaluation in implant dentistry, 84–89, *88*
deproteinized bovine bone matrix (DBBM), *163*
detached/devascularized buccal bone fragment, 272, *274*
DFDBA *see* demineralized freeze-dried bone allografts
diabetes mellitus, 8
diagnostic casts/wax-ups
complete-arch dental implants, 518–519, *518*, 529–530, *530–533*
guided bone regeneration, 143
prosthetic evaluation in implant dentistry, 63, 66–67, *68*, *71–72*, 73
ridge-split expansion procedure, 245, *247*
titanium mesh, 309
distraction osteogenesis (DO)
advantages and disadvantages, 374
alveolar bone classification by deficiency, 95, 96–97, *97*
anterior maxilla, 375, *376–378*
biological rationale for surgical procedure, 118, *119*
case reports, 375–379, *376–379*
complications, 374–375
conclusion and recommendations, 376–379
indications, 373–374, *374–375*
posterior mandible, 376, *378–379*
surgical procedure, 369–371, *369–373*
vertical ridge augmentation, 367–380
DPSC *see* dental pulp stem cells
d-PTFE *see* dense polytetrafluoroethylene
dual-scan techniques, 67–73, *71–75*
dynamic surgical techniques, 94–95

E

Early Healing Score (EHS), 21, **21**, *22*
ECM *see* extracellular matrix
edentulous patient
prosthetic evaluation in implant dentistry, 72–73, *73–75*, 83–89, *84–88*
zygomatic and pterygoid implants, 496, *497*, 506–508, *506–508*
edentulous ridge expansion (ERE), 240
EHS *see* Early Healing Score
El Chaar technique, 470, *471*
endochondral ossification, 7
endodontics, 382, *384*
endoscope-controlled maxillary sinus elevation, 449
endosteal revascularization, 117
envelope flaps, 107
e-PRF *see* extended platelet-rich fibrin
e-PTFE *see* expanded polytetrafluoroethylene
ERE *see* edentulous ridge expansion
Er:YAG lasers, 280
ESLI sequence, 296
esthetics
gingival display, 526, *526*
gingival hue, 78, *78*
orthodontic implant site development, 382, *383*
prosthetic evaluation in implant dentistry, 76–80, *76–80*
soft tissue grafts, 460
expanded polytetrafluoroethylene (e-PTFE), 404
extended platelet-rich fibrin (e-PRF), 168–169, *168–171*
external oblique ridge, 31
extracellular matrix (ECM), 18–19, 540

Dentlearn.ir

extractions
alveolar bone classification by deficiency, 92
applied surgical jaw anatomy, 24, 30
complete-arch dental implants, 525, 528–529
cone beam computed tomography, 50
guided bone regeneration, 144–145, *145*, 147–148, *148*, 181, *182–183*
orthodontic implant site development, 382, *383*, *384*, 388
platelet-rich fibrin, 157–160, *161*
prosthetic evaluation in implant dentistry, 76, *76*
short and ultra-short implants, 484–489, *484–489*
soft tissue grafts, 471–472, *472–473*
extraoral harvest, 330–332, *331–333*
extraoral soft tissue examination, 63
extraosseous alveolar bone defects, 94, *94*
extrasinus surgical approach, 501–503, *504*

F

facial esthetics, 169, *171*
FDBA *see* freeze-dried bone allografts
FFBA *see* fresh-frozen bone allografts
FGF *see* fibroblast growth factor
FGG *see* free gingival graft
fiber-reinforced composite (FRC), 480–481
fibroblast growth factor (FGF), 540–541, 545–546
fiduciary markers, *69*
field of view (FOV), 50
fissure bur, 278, *279*
fixed prosthesis
prosthetic evaluation in implant dentistry, 84–89, *88*
short and ultra-short implants, 480–481
zygomatic and pterygoid implants, 498, 505
flap design, 106–108, *107–109*
allogenic block bone graft, 214, *216*, 221–222, *223*, 229, *229*
guided bone regeneration, 180
maxillary sinus elevation using lateral window approach, 423–424, *432–433*, 433
ridge-split expansion procedure, 249–250, *250*, 256–257, *257*, 261
short and ultra-short implants, 484–486, *485–487*, 490, *490*
soft tissue grafts, 460–461, *461–462*, 464–469, *465–470*
tent-pole abutment technique, 407, 413–414
titanium mesh, 312–314
flapless extraction, 145, *145*, 151
forced eruption, 381–382
FOV *see* field of view
fracture displacement *see* island flap
fractured teeth, 147–150, *147–151*
FRC *see* fiber-reinforced composite
free connective tissue graft, 465, *465–466*
free gingival graft (FGG), 464, 543
freeze-dried bone allografts (FDBA)
allogenic block bone graft, 211
bone grafting materials, 133
platelet-rich fibrin, 158–159
fresh-frozen bone allografts (FFBA), 133
FTF *see* full-thickness flap
full-arch dental implants *see* complete-arch dental implants
full-thickness flap (FTF), 250, 256–257, *257*, 261, 272

G

GBR *see* guided bone regeneration
general anesthesia, 311
genial tubercles, 48, *48*
genioglossus muscle, 32
gingival display, 526, *526*
gingival hue, 78, *78*
gingival mesenchymal stem cells (GMSC), 544
granulation tissue, 19
greater palatine foramen, 46–47, *47*
greenstick-fracture *see* book flap
GTR *see* guided tissue regeneration
guided bone regeneration (GBR)
alveolar bone classification by deficiency, 92, *93*, 95–96, *96*
applied surgical anatomy, 178
autogenous block bone graft, 196, 197–198, 204–205, *204–205*, 334, 339
basic principles, 179–180
biological rationale for surgical procedure, 118, *120*
bone loss due to peri-implantitis, 189–190, *189–191*
case reports, 144–150, *144–151*, 181–191
complications, 192
conclusion and recommendations, 151
discussion, 150–151, 193
distraction osteogenesis, 368
failing endosseous implant, 182–184, *183–184*
failing partial denture, 190–191, *191–192*
fractured maxillary incisor, 147–150, *147–151*
horizontal ridge augmentation, 177–194
indications and contraindications, 179
literature review, 142–143
orthodontic implant site development, *387*
platelet-rich fibrin, 157, *157*, 160–163, *163*
posterior sandwich osteotomy, 347, 352–353
post-operative care, 192
ridge preservation, 141–152
ridge-split expansion procedure, 250–252, *251–252*, 275, *275*
soft tissue grafts, 144–147, *145–147*
surgical technique, 143–144, 180–181, *181*
tent-pole abutment technique, 403–418
tissue engineering and regenerative medicine, 542
titanium mesh, 308
titanium-reinforced dPTFE membranes, 178, 184–190, *185–191*, 193
traumatic mandibular molar extraction, 181, *182–183*
traumatic tooth loss, 185–189, *187–189*
volumetric ridge augmentation, 404

Dentlearn.ir

guided surgery, *70*, 520–521, *520*
guided tissue regeneration (GTR)
alveolar bone classification by deficiency, 92–93, 96
horizontal ridge augmentation, 181, *182*
ridge-split expansion procedure, 251, 258

H

HA *see* hyaluronic acid
HANT *see* heat-activated nickel-titanium
Haversian canal, 8–9, *9*
heat-activated nickel-titanium (HANT) archwire, 391, *395–396*
hematoma, 112, *113*
hemostasis, 18, 21, **21**
HIF *see* hypoxia inducible factor
histomorphometric analysis, 226–227, *227*, *231*
HIV/AIDS, 133
horizontal ridge augmentation
allogenic block bone graft, 209–238
alveolar bone classification by deficiency, 93, *93*, 95–96, **98**
autogenous block bone graft, 195–206
guided bone regeneration, 177–194
prosthetic evaluation in implant dentistry, 78–80, *80*
ridge-split expansion procedure, 239–276, 277–292
ridge-split expansion procedure/crestal sinus lift, 294–303
tent-pole abutment technique, 410–411, *410–413*
Howship's lacunae, 6–7, *7*
hyaluronic acid (HA), 10, *11*
hydraulic pressure technique, 444–446, *446*
hydroxyapatite (HA)
bone biology, 5, 10, *11*
bone grafting materials, 131, 134–135, 137
hypermineralization, 5–6
hypomineralization, *5*
hypoxia inducible factor (HIF), 9

I

IAC *see* integrated abutment crowns
IAN *see* inferior alveolar nerve
IBG *see* inlay bone grafting
IGF *see* insulin-like growth factor
implant migration, 452
implant-related complications, 273–275, *274–275*
implant stability quotient (ISQ), 165
implant-supported bridges
complete-arch dental implants, 529–532, *530–534*
prosthetic evaluation in implant dentistry, 83–84, *84–87*
ridge-split expansion procedure, 265, *265*
zygomatic and pterygoid implants, *507–508*
incision design, 106
allogenic block bone graft, 214–217, *217*, 221–222, *223*, 229, *229*
guided bone regeneration, 180
maxillary sinus elevation using lateral window approach, 423–424
titanium mesh, 312–314
incisive canal, 47, *47*
incisivus labii superioris muscle, 28
inferior alveolar nerve (IAN)
applied surgical jaw anatomy, 34–35, *35*
autogenous block bone graft, 327, 337, *337*
cone beam computed tomography, 48, *48–49*
distraction osteogenesis, 368–369, *370*, *375*
inflammation/infection
cone beam computed tomography, 44–46, *46*
distraction osteogenesis, 375
maxillary sinus elevation using transcrestal sinus floor elevation, 450
orthodontic implant site development, 385
tissue engineering and regenerative medicine, 540
titanium mesh, 321–322
wound healing, 18–19, 21, **21**
informed consent, 63
infraorbital nerve, 423
infraorbital neurovascular bundle, 27, *27*
infratemporal fossa, 27, 31
inlay bone grafting (IBG)
alveolar bone classification by deficiency, 94, *95*
autogenous block bone graft, 336–337, *336*
biological rationale for surgical procedure, 344
clinical applications, 347–351, *347–352*
discussion, 351–353
posterior mandible, 350–351, *351–353*
posterior maxilla, 344–348, *345–351*
posterior sandwich osteotomy, 343–354
technique, 344–346, *345–346*
insulin-like growth factor (IGF), 338, 541, 545–546
integrated abutment crowns (IAC), 483–484, *484*, 487, *488–489*, 492, *492–493*
internal oblique ridge, 32
interrupted sutures, 111, *111*
intramembranous ossification, 7
intramembranous osteogenesis, 7
intraoral harvest, 327–330, *328–330*
intraoral soft tissue examination, 63
intraoral ultrasonography, 58
intraosseous alveolar bone defects, 94, *95*
island flap, 250, *250*, *252*, *259*, 272, *273*, 287–289, *288–291*, 291, 294, *295*
ISQ *see* implant stability quotient

J

Jensen all-on-four site classification, 514–516, *515–517*

K

Kazanjian vestibuloplasty, *364*, 365
keratinization
allogenic block bone graft, 234
guided bone regeneration, 182–184, *183–184*, *188*
ridge-split expansion procedure, 276
soft tissue grafts, 459–474

Dentlearn.ir

Khoury split bone block grafting technique, 355–366
augmentation techniques, 359–365
biological rationale for surgical procedure, 120, *121–122*, 356
biology of bone regeneration, 356–359, *358*
bone core technique, 359–361, *361–362*
bony lid technique, 359, *360*
large bony defects/severe bone atrophy, 361–365, *363–364*
knife-edged crest, 44, *45*

L

large bony defects, 361–365, *363–364*
lateral canal, 47, *47*
lateral cephalometric radiography, *377*
lateral implant site development, 388–390, *392–394*
lateral pterygoid muscle, 33
lateral ramus cortical bone (LRCB), 327, 334, *334*
lateral sinus lift/bone graft
anesthesia, 423
applied surgical anatomy, 422–423
flap management/entry, 423–424
indications and contraindications, 420
insertion of graft material and implant placement, 430–431
maxillary sinus elevation, 419–435
perforation, 430
post-operative considerations, 433
pre-operative diagnosis, planning, and case difficulty, 420–422, *421*
preparation of implant sites, 430
sinus membrane elevation, 430
stage two surgery, *432–433*, 433
window preparation/antrostomy, 424–430, *425–429*
leukocyte- and platelet-rich fibrin (L-PRF), 155–156, *155–156*
autogenous block bone graft, 201, *201–202*
maxillary sinus elevation using lateral window approach, 433
levator anguli oris muscle, 28
levator labii superioris muscle, 28
lingual foramen, 47, *47*
lingual nerve, *33*, 35–36, 49–50
LMS classification, 196–197, *197*, *328*
loading
bone biology, 14–15, *14*
guided bone regeneration, 143, 145
local anesthesia
guided bone regeneration, 143, 148
maxillary sinus elevation using lateral window approach, 423
titanium mesh, 311
locking continuous sutures, 111, *111*
long buccal nerve, 36
long face syndrome, 526–534, *526–534*
low window technique, 425–427
L-PRF *see* leukocyte- and platelet-rich fibrin
LRCB *see* lateral ramus cortical bone
lymph nodes, 31

M

macrophages, 19
mandible
applied surgical jaw anatomy, *30–37*, 31–37
blood supply, *30–31*, 36–37, *36–37*
cone beam computed tomography, 42, 47–50, *47–50*
innervation of lower jaw and associated structures, *33*, 34–35, *35*
muscles of surgical importance, 32–34, *33–34*
mandibular body/ramus
autogenous block bone graft, 327–329, *328*
titanium mesh, 311, *312*
mandibular symphysis, 329, *329*, 361–362, *363*
manual osteotome/chisel, 282, *282*, 439–440, **440**
masseter muscle, 34
mastication, 92, 95
matrix metalloproteinases (MMP), 18–19
mattress sutures, 111–112, *111–112*
maxilla
applied surgical jaw anatomy, 24–31, *26–31*
arterial supply, 30–31, *30*
cone beam computed tomography, 42–47, *43–47*
lymphatic drainage, 31
muscles of surgical importance, 28–29, *29*
sensory innervation, 29–30, *29*
surgical access to maxillary sinus, 27–28, *27–28*
venous drainage, 31, *31*
maxillary full-arch dental implants *see* complete-arch dental implants
maxillary nerve, 423
maxillary sinus elevation
anesthesia, 423
applied surgical anatomy, 422–423, 438–440, **439**
complications, 450–453, **451–452**
conclusion and recommendations, 453
endoscope-controlled maxillary sinus elevation, 449
flap management/entry, 423–424
hydraulic pressure technique, 444–446, *446*
implant length in osteotome procedures, 449
indications and contraindications, 420
insertion of graft material and implant placement, 430–431, 447–449, *449*
instrumentation and techniques, 440–449, **440–441**
lateral sinus lift/bone graft, 419–435
osseodensification burs, 439–440, 446–447, *447–448*
perforation, 430
post-operative considerations, 433, 450
pre-operative diagnosis, planning, and case difficulty, 420–422, *421*
preparation of implant sites, 430
reamers approach, 443–444, *443*, *445*
sinus membrane elevation, 430
staged crestal maxillary sinus augmentation, 444
stage two surgery, *432–433*, 433
Summers' osteotomy technique, 440–443
transcrestal sinus floor elevation, 437–456

Dentlearn.ir

window preparation/antrostomy, 424–430, *425–429*
maxillary tuberosity
autogenous block bone graft, 329–330, *330*
guided bone regeneration, 150, *150*
zygomatic and pterygoid implants, 496, 499–500, *500*, 504
mCAT *see* multiple cortical autogenous tenting
MDT *see* multidisciplinary team
medial pterygoid muscle, 32–33
membrane perforation
cone beam computed tomography, 44, *45–46*
maxillary sinus elevation using lateral window approach, 430
maxillary sinus elevation using transcrestal sinus floor elevation, 448–449, 450
platelet-rich fibrin, 164–166, *165*
mental foramen
applied surgical jaw anatomy, 31, 35
cone beam computed tomography, 48–49, *49*
mentalis muscle, 33, *34*
mental neurovascular bundle, 31
mental symphysis, 311–312, *313*
mesenchymal stem cells (MSC)
autogenous block bone graft, 199, 338
bone grafting materials, 131
tissue engineering and regenerative medicine, 542, 544–545
MGL *see* muco-gingival line
micro-saw, 278, *279*, 357–359, *358*
microvascular anastomosis, 117
middle superior alveolar nerve, 30
MMP *see* matrix metalloproteinases
MOPF *see* muco-osteoperiosteal flap
MSC *see* mesenchymal stem cells
muco-gingival line (MGL), 461, *461–462*, 464
muco-osteoperiosteal flap (MOPF), 261
mucoperiosteal flap
allogenic block bone graft, *216*
applied surgical jaw anatomy, 31, 37
guided bone regeneration, 180, 190–191
incision design, 106
ridge-split expansion procedure, 256
short and ultra-short implants, 484–486, *485–487*, 490, *490*
tent-pole abutment technique, 407, 413–414
wound closure and healing, 108–109, *109*
multidirectional orthodontic movement, 391, *394–397*
multidisciplinary team (MDT), 62
multiple cortical autogenous tenting (mCAT), 334, *335*
mylohyoid muscle, 32, *33*
mylohyoid nerve, 36

N

nasal floor, 43, *44*
nasopalatine canal, 42, *43*
nasopalatine foramen, 42
nerve injury, 112, *112*
neurosensory complications, 273
nickel-titanium (NiTi SE) coil spring, 390–391, *394*, *396–397*
nonsteroidal anti-inflammatory drugs (NSAID), 433

O

OBG *see* onlay bone grafting
occlusal examination, 63
occlusal radiography, 42
OISD *see* orthodontic implant site development
OMC *see* osteomeatal complex
onlay bone grafting (OBG)
alveolar bone classification by deficiency, 94, *95*
autogenous block bone graft, 196, 197–198, 199, 201–205, *201*, *203–205*, 332–334, *334*, 337, 339
distraction osteogenesis, 373–374, *375*
oral mucosa, 20–21, *21–22*, **21**
oral soft tissue, 20–21, *21–22*, **21**
oro-sinusal fistula, 508–509
orthodontic implant site development (OISD)
advantages, 399, *399*, **399**
conclusion and recommendations, 399, *400*
contraindications, 392–399, *399*
discussion, 392–399, **398–399**, *399*
distraction osteogenesis, 371, *372*, 375
forced eruption, 381–382
lateral implant site development, 388–390, *392–394*
limitations, 399
multidirectional movement, 391, *394–397*
posterior teeth, 385, *386–387*
prosthetic evaluation in implant dentistry, *67*, *77*
technique, 382–385, *383–385*
three-dimensional bone remodeling, 388, *388–391*
vertical ridge augmentation, 381–401
orthognathic surgery, 30–31
orthopantograph *see* panoramic radiography
orthopedics, 92
osseodensification
allogenic block bone graft, 227, *227*, 232
maxillary sinus elevation using transcrestal sinus floor elevation, 439–440, 446–447, *447–448*
ridge-split expansion procedure, 283, *283*
osseointegration
bone biology, 12–13, *12–13*, **12**
bone grafting materials, 130
maxillary sinus elevation using lateral window approach, 431
orthodontic implant site development, 382, *383*, *400*
ridge-split expansion procedure, 275
short and ultra-short implants, 483
zygomatic and pterygoid implants, 498
ossification, 7, 11
osteoblasts, 4, *5*, 6–7, *6–7*
osteocalcin, 234
osteoclasts, 4, *5*, 6–7, *7*

Dentlearn.ir

osteocondensation, 298
osteoconduction
allogenic block bone graft, 211
bone grafting materials, 130, 132–133
Khoury split bone block grafting technique, 357
maxillary sinus elevation using lateral window approach, 431
ridge-split expansion procedure, 252–253
tissue engineering and regenerative medicine, 541
osteocytes, 4, *14*
osteogenesis
autogenous block bone graft, 197
bone biology, 7, *11*
bone grafting materials, 130
Khoury split bone block grafting technique, 357
tissue engineering and regenerative medicine, 541
osteoinduction
bone grafting materials, 130, 132–133
Khoury split bone block grafting technique, 357
tissue engineering and regenerative medicine, 541
osteomeatal complex (OMC), 44–46, *45–46*, 422
osteomobilization, *252*, 253
osteons, 6, *6*
osteoperiosteal flap, 249–252, *250*, *252*
osteoporosis, 179
osteosynthesis screws, 272, *274*
overdentures, 84–89, *88*

P

Palacci technique, 470
palatal defects, 78, *79*
palatal incisions, 107, *109*
panoramic radiography
allogenic block bone graft, *215*, *222*, *228*, *231*, *233*
biological rationale for surgical procedure, *121*
complete-arch dental implants, 526–527, *527*, *530*
distraction osteogenesis, *370*, 371, *372–374*, *377–379*
evaluation of the alveolar ridge, 40, *41*, *49–50*, 53, *53*
Khoury split bone block grafting technique, *363–364*
maxillary sinus elevation using lateral window approach, *432*
maxillary sinus elevation using transcrestal sinus floor elevation, *442*
orthodontic implant site development, *397*
posterior sandwich osteotomy, *347*
prosthetic evaluation in implant dentistry, *69*, *72–75*, *77*, *81*, *83–84*, *87–88*
ridge-split expansion procedure, *241*, *260*, *263*, *265*, *269*, *289*, *291*
short and ultra-short implants, *481*, *483–484*, *487–490*, *492–493*
tent-pole abutment technique, *407–409*, *414*
titanium mesh, *315*, *318–319*
zygomatic and pterygoid implants, *497*, *508*
papilla management, 470, *471*
paralleling pins, *481*, *490–491*
partial dentures, 190–191, *191–192*
partially edentulous patient, 67–72, *70–72*, 76–83, *76–83*
partial-thickness flap (PTF), 250
particulate bone grafts
autogenous block bone graft, *328*
ridge-split expansion procedure, 258, *258*
PASS principles, 211
PDGF *see* platelet-derived growth factor
pedicled vascularized segmental osteotomy, 343–354
biological rationale for surgical procedure, 344
clinical applications, 347–351, *347–352*
discussion, 351–353
posterior mandible, 350–351, *351–353*
posterior maxilla, 344–348, *345–351*
technique, 344–346, *345–346*
pedicle segmental rotation (PSR), 337–338, *338*
periapical radiography
allogenic block bone graft, *215*, *221*
complete-arch dental implants, 526–527, *527*
evaluation of the alveolar ridge, 40, *41*
guided bone regeneration, *183–186*, *189*, *191–192*
Khoury split bone block grafting technique, *360*, *363–364*
maxillary sinus elevation using lateral window approach, *425*, *427*, *429*
maxillary sinus elevation using transcrestal sinus floor elevation, *442*, *445*, *448–449*
orthodontic implant site development, *383*, *386–387*, *392–398*, *400*
posterior sandwich osteotomy, *350–351*
prosthetic evaluation in implant dentistry, *66*, *68*, *76–77*, *79–83*
ridge-split expansion procedure, *271*, *281*, *284–285*, *287*, *291*
ridge-split expansion procedure/crestal sinus lift, *296*, *298*, *300–302*
soft tissue grafts, *472*
tent-pole abutment technique, *406–409*, *412–413*, *415–416*
titanium mesh, *319–320*
peri-implant bone resorption, 322–323
peri-implantitis
bone biology, 4
complete-arch dental implants, 525
guided bone regeneration, 189–190, *189–191*
soft tissue grafts, 466–468, *466–468*
periodontal disease
bone biology, 4
complete-arch dental implants, 526–528, *526–528*
guided bone regeneration, 179
periodontal examination, 63
periodontal therapy, 382, *384*
periosteal release incision, 214–217, *217*, *229*
periosteal revascularization, 117
PGR *see* prosthetically guided regeneration
photogrammetry, 521–522, *521–522*
PIC *see* posterior iliac crest
piezoelectric surgery
maxillary sinus elevation using lateral window approach, 427–430, *428–429*

Dentlearn.ir

ridge-split expansion procedure, 280–281, *282*
platelet concentrates, 11
platelet-derived growth factor (PDGF)
alveolar bone classification by deficiency, 96
autogenous block bone graft, 338
platelet-rich fibrin, *155*
tissue engineering and regenerative medicine, 540–541, 545–546
platelet-rich fibrin (PRF), 153–174
advantages, 166
allogenic block bone graft, 219, *219*
alveolar bone classification by deficiency, 96
autogenous block bone graft, 199, 201, *201–203*
bone graft versus bone graft + PRF, 159
centrifugation protocols, 155–157, *155–157*
clinical uses, 157–166
discussion and future research, 167–171, *167–171*
extended platelet-rich fibrin, 168–169, *168–171*
extraction site management, 157–160, *161*
facial esthetics, 169, *171*
growth factors, 154, *155*
guided bone regeneration, 157, *157*, 160–163, *163*
historical development, 154–155
Khoury split bone block grafting technique, 362–363
leukocyte- and platelet-rich fibrin, 155–156, *155–156*, 201, *201–202*
maxillary sinus elevation using lateral window approach, 433
maxillary sinus elevation using transcrestal sinus floor elevation, 447
Schneiderian membrane perforations, 164–166, *165*
sinus grafting procedures, 164–168, *165–167*
titanium mesh, 314
versus bone grafting material, 158–159
wound closure and healing, 158
platelet-rich plasma (PRP), 96, 199
PLGA *see* poly(lactic-co-glycolic) acid
PMN *see* polymorphonuclear neutrophils
poly(lactic-co-glycolic) acid (PLGA), 546
polymers, 10–11
polymorphonuclear neutrophils (PMN), 18–19
polytetrafluoroethylene (PTFE) membranes
alveolar bone classification by deficiency, *93*, 96
guided bone regeneration, 178, 181, *181*, 184–190, *185–191*, 193
volumetric ridge augmentation, 404
pontics
guided bone regeneration, 148, *149*, 182–184, *183–184*
orthodontic implant site development, *396–397*
posterior iliac crest (PIC), 330–331, *331*, 333
posterior mandible, 48–50, *48–50*
posterior maxilla, 44–47, *45–47*
posterior sandwich osteotomy, 343–354
biological rationale for surgical procedure, 344
clinical applications, 347–351, *347–352*
discussion, 351–353
posterior mandible, 350–351, *351–353*
posterior maxilla, 344–348, *345–351*
technique, 344–346, *345–346*
posterior superior alveolar (PSA) artery, 424
posterior superior alveolar (PSA) canal, 42, *43*, 46
posterior superior alveolar (PSA) nerve, 29
premature ossification, 375, 379
PRF *see* platelet-rich fibrin
proliferation, 19
prosthetically guided regeneration (PGR), 309
prosthetic evaluation in implant dentistry, 61–90
clinical applications, 76–89
completely edentulous patient, 83–89, *84–88*
crown and bridge restoration, 83–84, *84–87*
overdentures and fixed complete dentures, 84–89, *88*
partially edentulous patient in esthetic zone, 76–80, *76–80*
partially edentulous patient in posterior dentition, 80–83, *81–83*
cone beam computed tomography, 54, *54–55*
diagnosis and treatment plan, 63
diagnostic casts and wax-ups, 66–67, *68*
diagnostic work-up, 62–63, *64–65*
initial evaluation, 62–73
radiographic guides, 62–63, 67–73, *69–75*
smile evaluation, 63–66, *66–67*
provisionalization, 519–522, *520–522*, 529–531, *530–532*
PRP *see* platelet-rich plasma
PSA *see* posterior superior alveolar
pseudocysts, 44–45, *46*
PSR *see* pedicle segmental rotation
pterygoid implants, 495–512
clinical cases, 507–508, *507–508*
complete-arch dental implants, 516, *516–517*
complications, 507–510, *509*
contraindications, 499, *499*
discussion and conclusion, 510
historical development, 496
indications, 498
pre-operative planning, 499–500, *500*
prosthetic considerations, 505
surgical approaches, 503–505, *505*
treatment concepts, 496–498, *498*
pterygomandibular space, 32–33, *33*
pterygomaxillary process, 498–500, *500*
pterygopalatine fossa, 27, 29–30
PTF *see* partial-thickness flap
PTFE *see* polytetrafluoroethylene

R

radiation dose, 51, **52**
radiographic guides, 62–63, 67–73, *69–75*
random pattern flaps, 106
RANK/RANKL, 4
RAP *see* regional acceleratory phenomenon

Dentlearn.ir

RBC *see* red blood cells
reamers approach, 443–444, *443*, *445*
reciprocation saw, 279–280, *279–281*
recombinant bone morphogenetic protein (rhBMP-2)
  alveolar bone classification by deficiency, 96
  autogenous block bone graft, 338
  platelet-rich fibrin, *163*
  tissue engineering and regenerative medicine, 545–546
  titanium mesh, 310
red blood cells (RBC), 156
re-epithelialization, 19, 21, **21**, *22*
regional acceleratory phenomenon (RAP), 216
remodeling process
  bone biology, 6–9, *6–9*, 14
  wound healing, 19
residual alveolar height classification, 438–439, **439**
retention, 371, *372*
revascularization
  biological rationale for surgical procedure, 117–123, *118–123*, **119**
  bone grafting materials, 132–133
  Khoury split bone block grafting technique, 357
  ridge-split expansion procedure/crestal sinus lift, 297
rhBMP-2 *see* recombinant bone morphogenetic protein
rhinosinusitis, 509
ridge atrophy/hypoplasia
  allogenic block bone graft, *212–213*
  complete-arch dental implants, 514–516, *515–517*
  cone beam computed tomography, 42, 43–44, *45*, 47–48, 50, *50*
  Khoury split bone block grafting technique, 361–365, *363–364*
  ridge-split expansion procedure, 272, *273*
  zygomatic and pterygoid implants, 496, 498, 506–508, *506–508*
ridge expanders, 282–283, *282–284*
ridge preservation (RP)
  alveolar bone classification by deficiency, 92–93, *93*
  bone grafting materials, 130–140
  guided bone regeneration, 141–152
  platelet-rich fibrin, 153–174
ridge-split expansion procedure (RSEP)
  advanced techniques for experienced practitioners, 266–271
  alveolar bone classification by deficiency, 94–95, *95*, 96
  alveolar split with conical progressive osteotomies, 269–271, *269–271*
  anatomic difference of maxilla and mandible, 249
  biological rationale for surgical procedure, 118, *120*, 297–298
  case reports, 258–260, *259–260*, 263–265, *263–265*, 269–271, *269–271*, 280, *280–281*, 283–289, *284–291*, 298–302, *298–302*
  complications, 272–275, *273–275*
  conclusion and recommendations, 275–276
  cone beam computed tomography, 241–245, **242**, *243*, *245–246*
  crestal sinus lift, 294–303
  diagnosis and treatment planning, 240–248
  diagnostic work-up, 243–244, *244*
  ESLI sequence, 296
  guided bone regeneration, 250–252, *251–252*, 275, *275*
  historical development, 240
  horizontal ridge augmentation, 239–276, 277–292, 294, *295*
  instrumentation, *244*, 245–247, *247*, 257, *257*, 278–283, *279–283*
  management of fractured buccal segment, 291, *291*
  osteoconduction of surrounding bone, 252–253
  osteomobilization of buccal bone fragment, *252*, 253
  patient (host) selection, 240
  piezoelectric surgery, 280–281, *282*
  ridge defect analysis and classification, 241–243, *241*, **242**, *243*
  ridge expanders, 282–283, *282–284*
  secondary intention and wound healing, 250–252, *251–252*
  single-stage alveolar split/immediate implant/closed flap, 266, *267*
  single-stage alveolar split/immediate implant/open flap, 267–268, *268*
  single-stage alveolar split/open flap, 267
  single-stage mandibular alveolar split/closed flap, 266
  single-stage mandibular alveolar split/simultaneous implant, 285, *286–287*
  single-stage maxillary alveolar split, 261–265
  single-stage maxillary alveolar split/simultaneous implant, 283, *284–285*
  spreader-driven ridge expansion, 268–269, *268*
  staged RSEP/fracture of the buccal segment, 287–288, *288–289*
  staged RSEP/reposition of greenstick-fractured buccal segment, 289, *290–291*
  surgical principles, 249–253
  surgical stent, 245, *247*
  two-stage mandibular alveolar split, 254–260
  two-stage ridge-split expansion, 285–287
  vascularization, 249–250, *250*
  vertical ridge augmentation, 294–303
  volumetric bone augmentation in posterior maxilla, 296–302, *297–302*
ridge width augmentation, 80–81, *81–82*
roll technique, 461–464, *462–464*
rotary disk, 278, *279*
rotary expanders, 283, *283*
rotary window preparation, 427
rotated pediculated lingual marginal tissue, 470, *471*
rotated pediculated marginal tissue, 470
rotational stability, 452
RP *see* ridge preservation
RSEP *see* ridge-split expansion procedure

S

SAD *see* simplified antrostomy design
sagittal sandwich osteotomy (SSO), 118, *120*
sandwich split cortical graft, 240
sandwich technique, 336–337, *336*
SANTA tent-pole abutments, 406, 409–415, *410–416*
SBB *see* Khoury split bone block grafting technique
scaffolds, 545–546, *545–546*
SCA kit *see* sinus crest augmentation kit
scar tissue, 20–21, *21*, *109*

Dentlearn.ir

Schneiderian membrane, 44, 439
screw-retained restorations, 188–189, *189*
segmental sandwich osteotomy (SSO), 96
segmentation tools, 143
semilunar flaps, 107
septa, 440
SHED *see* stem cells from human exfoliated deciduous teeth
short and ultra-short implants, 479–493
  case presentations, 481–492
  considerations and pitfalls, 493
  extracted maxillary right second molar, 484–489, *484–489*
  historical development, 480–481
  loose mandibular molar implant and premolar, 489–492, *489–493*
  thin alveolar ridge/steep crest, 481–484, *481–484*
side-by-side implant placement, 78, *79*
simplified antrostomy design (SAD), 424–425
sinus crest augmentation kit (SCA kit), 443–444, *443*
sinus floor, 44–46, *45–46*
sinus grafting procedures, 164–168, *165–167*
sinusitis
  maxillary sinus elevation using transcrestal sinus floor elevation, 450
  zygomatic and pterygoid implants, 499, *499*, 508
sinus membrane, 422–423
skeletal discrepancies, *212*
skin, 20, **21**
slow-motion osteotomy, 481, *482*, 485–486, *486*
smile evaluation, 63–66, *66–67*
smoking and nicotine products
  bone biology, 8
  guided bone regeneration, 179
  ridge-split expansion procedure, 240, 275
  zygomatic and pterygoid implants, 499
sockets
  applied surgical jaw anatomy, 24
  guided bone regeneration, 144
  soft tissue grafts, 471–472, *472–473*
  see also wound closure and healing
soft-tissue borne guides, 55
soft tissue complications, 272, 317–321
soft tissue flaps
  flap designs, 106–108, *107–109*
  vascularization, 106, *107*
soft tissue grafts (STG), 457–475
  allograft dermis, 468–469, *469–470*
  autograft subepithelial connective tissue, 464–468, *465–468*
  biological rationale for surgical procedure, 122–123, *123*
  extraction socket grafting, 471–472, *472–473*
  flap management, 460–461, *461–462*
  free gingival graft, 464
  guided bone regeneration, 144–147, *145–147*
  papilla management, 470, *471*
  roll technique, 461–464, *462–464*
  tissue engineering and regenerative medicine, 543
  tunnel technique, 469, *469–470*
sphenopalatine neurovascular bundle, 27, 29
split bone block (SBB) *see* Khoury split bone block grafting technique
split expansion graft (SEG) *see* ridge-split expansion procedure
spreader-driven ridge expansion, 268–269, *268*
SSO *see* segmental sandwich osteotomy
staged crestal maxillary sinus augmentation, 444
stainless steel archwire, 383, 390–391, *394*, *397*
static surgical techniques, 94–95
stem cells from human exfoliated deciduous teeth (SHED), 544
STG *see* soft tissue grafts
sticky bone protocol
  Khoury split bone block grafting technique, 362–363
  platelet-rich fibrin, 157, *157*, 165–166
  tent-pole abutment technique, 407, *408*, 414, *415*
streak artifacts, 51, *51*
subcutaneous malar emphysema, 508–509
sublingual fossa, 42, 49, *50*
submandibular fossa, 42, 49, *49*
Summers' osteotomy technique, 440–443, *441–442*
suppuration, 321–322
surgical guides, 54–56, *56*, *190*
surgical stent, 245, *247*
sutures *see* wound closure and healing
synthetic biomaterials, 10, *11*

T

TAB *see* tubero-alveolar block
tartrate-resistant acid phosphatase (TRAP), *5*
TCP *see* tricalcium phosphate
temporalis muscle, 33
temporomandibular joint (TMJ), 33, 51
tension release incisions, 109–110, *110*
tent-pole abutment technique, 403–418
  advantages over other techniques, 404
  alveolar bone classification by deficiency, 94
  biological rationale for surgical procedure, 120, *122–123*
  horizontal ridge augmentation, 410–411, *410–413*
  SANTA tent-pole abutments, 406, 409–415, *410–416*
  utilizing low-profile healing abutment, 406–407, *407–409*
  utilizing titanium screw, 405, *405–406*
  volumetric ridge augmentation, 405–407, *405–409*, 413–415, *413–416*
TERM *see* tissue engineering and regenerative medicine
TGF *see* transforming growth factor
three-dimensional bone remodeling, 388, *388–391*
three-dimensional cone beam computed tomography, 53–54, *54*
three-dimensional ridge augmentation *see* volumetric ridge augmentation
threshold strain, 14–15
TIMP *see* tissue inhibitors of metalloproteinases
tissue cyanoacrylate, 415, *416*

Dentlearn.ir

tissue engineering and regenerative medicine (TERM), 539–549
basics of wound healing, 540, **541**
bone biology and grafting, 540–542, *542*
bone marrow stem cells, 545–546
cells, scaffolds, and growth factors, 545–546, *545–546*
concepts and definitions, 540
conclusion and recommendations, 546
dental stem cells, 544, *544*, **544**
guided bone regeneration, 542
soft tissue regeneration, 543
tooth development and regeneration, 543, *543*
tissue inhibitors of metalloproteinases (TIMP), 19
titanium implants, 12, *13*
titanium mesh
adaption and fixation to recipient site, 314
anesthesia, 311
bone grafting materials, 309–310
bone harvesting procedure, 311–312, *312–314*
clinical cases, 317, *318–320*
complications, 317–322
contraindications, 309
discussion, 322–323
donor sites, 310–311
flap tension and sutures, 314, *315*
guided bone regeneration, 178
implant re-opening and prosthetic phase, 316–317, *317*, **317**
indications, 308–309
patient preparation, 311
peri-implant bone resorption, 322–323
post-operative follow-up, 316
pre-operative planning, 309–311, *310*
preparation of surgical field, 311
regeneration with, 312–316, *313–315*
removal and implant placement, 316
surgical procedures, 311–312, *312*
survival rate of implants, 323
vertical ridge augmentation, 307–324
volumetric ridge augmentation, 404
wound closure and healing, *113*
titanium-reinforced PTFE membranes, 178, 181, *181*, 184–190, *185–191*, 193
TMJ *see* temporomandibular joint
Tolstunov classification *see* alveolar bone classification by deficiency
tooth-borne guides, 55
tooth development and regeneration, 543, *543*
transcrestal sinus floor elevation (tSFE)
applied surgical anatomy, 438–440, **439**
complications, 450–453, **451–452**
conclusion and recommendations, 453
endoscope-controlled maxillary sinus elevation, 449
hydraulic pressure technique, 444–446, *446*
implant length in osteotome procedures, 449
insertion of graft material and implant placement, 447–449, *449*
instrumentation and techniques, 440–449, **440–441**
maxillary sinus elevation, 437–456
osseodensification burs, 439–440, 446–447, *447–448*
post-operative considerations, 450
reamers approach, 443–444, *443*, *445*
staged crestal maxillary sinus augmentation, 444
Summers' osteotomy technique, 440–443
transforming growth factor (TGF)
autogenous block bone graft, 338
platelet-rich fibrin, *155*
tissue engineering and regenerative medicine, 540–541, 545–546
transmissible spongiform encephalopathies (TSE), 134
TRAP *see* tartrate-resistant acid phosphatase
trapezoidal flaps, 106–107, *107*
trapezoid osteotomy
autogenous block bone graft, 336, *336*
distraction osteogenesis, *370*, *378*
traumatic tooth loss, 92, 185–189, *187–189*
trephine kits, 359–360, *361*
triangular flaps, 107, *108*
tricalcium phosphate (TCP)
bone grafting materials, 130, 135–137
platelet-rich fibrin, 158–159
tissue engineering and regenerative medicine, 546
trigeminal nerve, 29–30, *29*, 34
TRINIA, 481
TSE *see* transmissible spongiform encephalopathies
tSFE *see* transcrestal sinus floor elevation
tubero-alveolar block (TAB), 329, *330*
tunnel technique, 469, *469–470*
type H vessels, bone biology, 9

U

ultra-short implants *see* short and ultra-short implants
Underwood's septa, 423

V

VAS *see* visual analog score
vascular endothelial growth factor (VEGF)
alveolar bone classification by deficiency, 96
autogenous block bone graft, 338
bone biology, 9
platelet-rich fibrin, *155*
tissue engineering and regenerative medicine, 540–541, 545–546
vascularization
allogenic block bone graft, 234
alveolar bone classification by deficiency, 97
autogenous block bone graft, 327
biological rationale for surgical procedure, 118, *118*
maxillary sinus elevation using lateral window approach, 423

Dentlearn.ir

posterior sandwich osteotomy, 343–354
ridge-split expansion procedure, 249–250, *250*, 272
soft tissue flaps, 106, *107*
VDO *see* vertical dimension of occlusion
VEGF *see* vascular endothelial growth factor
veneers, *394*, *397*
vertical dimension of occlusion (VDO), 517–522, *518*
vertical ridge augmentation
alveolar bone classification by deficiency, 93, *93*, 95–96, **98**
autogenous block bone graft, 325–341
distraction osteogenesis, 367–380
Khoury split bone block grafting technique, 355–366
maxillary sinus elevation using lateral window approach, 419–435
maxillary sinus elevation using transcrestal sinus floor elevation, 437–456
orthodontic implant site development, 381–401
posterior sandwich osteotomy, 343–354
ridge-split expansion procedure/crestal sinus lift, 294–303
tent-pole abutment technique, 403–418
titanium mesh, 307–324
vestibular cortical fenestration, 508–509
vestibular fornix, 37
vestibular incisions, 108, *109*
vestibule, 26, *26*
virtual restorations, 54, *54–55*
visual analog score (VAS), 160
Volkmann canal, 8–9, *9*
volumetric ridge augmentation
alveolar bone classification by deficiency, 93, *93*
guided bone regeneration, 404
ridge-split expansion procedure/crestal sinus lift, 296–302, *297–302*
tent-pole abutment technique, 405–407, *405–409*, 413–415, *413–416*
voxel size, 50

W

white blood cells (WBC), 156
Wolff's law, 92
wound closure and healing, 3, 18–22, 105–113
allogenic block bone graft, 219
alveolar bone classification by deficiency, *93*, 97
bone biology, 7–8, *8*
complications, 112–113, *112–113*
distraction osteogenesis, 370, *371*
factors leading to impaired healing, 19
guided bone regeneration, 179–180
incision design, 106
main types, 19–20, *20*
maxillary sinus elevation using lateral window approach, *427*, *429*, 431
oral soft tissue, 20–21, *21–22*, **21**
phases of wound healing, 18–19
platelet-rich fibrin, 158
posterior sandwich osteotomy, 348, *349*
preparing for wound closure, 109–110, *110*
primary/secondary intention healing, 19–20, *20*
principles of suturing, 110–112, *111–112*
reflection of the mucoperiosteum, 108–109, *109*
ridge-split expansion procedure, 250–252, *251–252*, 256
short and ultra-short implants, *483*, *487*, *491*
soft tissue flaps, 106–108, *107–109*
soft tissue grafts, *463*, 467–468, *468*, *470*
tension release incisions, 109–110, *110*
tent-pole abutment technique, 414, *414–415*
tissue engineering and regenerative medicine, 540, **541**
titanium mesh, 314, *315*
types of sutures, 111–112, *111–112*
wound dehiscence
autologous block bone grafting, 404
biological rationale for surgical procedure, *121*
maxillary sinus elevation using transcrestal sinus floor elevation, 450–452
wound closure and healing, 107–108, 112–113, *113*

X

xenografts
bone grafting materials, 130–131, 134–135, *135*
guided bone regeneration, 180, *181*
posterior sandwich osteotomy, 348, *350*, 353
tissue engineering and regenerative medicine, 541
X-Guide Machine, 56–58, *57–59*

Z

zirconia-based restorations
tent-pole abutment technique, *409*, 411, 415, *416*
zygomatic and pterygoid implants, 506–508, *506–508*
zygomatic implants, 495–512
clinical cases, 506–508, *506–508*
complete-arch dental implants, 516, *516–517*
complications, 507–510, *509*
contraindications, 499, *499*
discussion and conclusion, 510
historical development, 496
indications, 498
instrumentation, 501, *501*
platelet-rich fibrin, 169, *170*
pre-operative planning, 499–500, *500*
prosthetic considerations, 505
prosthetic evaluation in implant dentistry, *88*, 89
surgical approaches, 500–503, *501–504*
treatment concepts, 496, *497*
zygomatic nerve, 29

Dentlearn.ir

WILEY END USER LICENSE AGREEMENT

Go to www.wiley.com/go/eula to access Wiley's ebook EULA.

Dentlearn.ir