Gottfried Schmalz
Dorthe Arenholt-Bindslev

Biocompatibility of Dental Materials

Springer

Dentlearn.ir

Gottfried Schmalz
Dorthe Arenholt-Bindslev

Biocompatibility of Dental Materials

Dentlearn.ir

Gottfried Schmalz
Dorthe Arenholt-Bindslev

Biocompatibility of Dental Materials

With 302 Figures and 82 Tables

Springer

Dentlearn.ir

Gottfried Schmalz, D.D.S., Dr. med. dent., Ph.D.
Professor and Chairman
Department of Operative Dentistry
and Periodontology, University of Regensburg,
93042 Regensburg, Germany
gottfried.schmalz@klinik.uni-regensburg.de

Dorthe Arenholt-Bindslev, D.D.S., Ph.D., Certif. Orthod.
Professor and consultant orthodontist
School of Dentistry, Århus University
Århus, Denmark
dbindslev@odont.au.dk

ISBN 978-3-540-77781-6 e-ISBN 978-3-540-77782-3

DOI 10.1007/978-3-540-77782-3

Library of Congress Control Number: 2008925341

© 2009 Springer-Verlag Berlin Heidelberg

This work is subject to copyright. All rights are reserved, whether the whole or part of the material is concerned, specifically the rights of translation, reprinting, reuse of illustrations, recitation, broadcasting, reproduction on microfilm or in any other way, and storage in data banks. Duplication of this publication or parts thereof is permitted only under the provisions of the German Copyright Law of September 9, 1965, in its current version, and permission for use must always be obtained from Springer. Violations are liable to prosecution under the German Copyright Law.

The use of general descriptive names, registered names, trademarks, etc. in this publication does not imply, even in the absence of a specific statement, that such names are exempt from the relevant protective laws and regulations and therefore free for general use.

Product liability: the publishers cannot guarantee the accuracy of any information about dosage and application contained in this book. In every individual case the user must check such information by consulting the relevant literature.

Cover design: Frido Steinen-Broo, eStudio Calamar, Spain
Production & Typesetting: le-tex publishing services oHG, Leipzig, Germany

Printed on acid-free paper

9 8 7 6 5 4 3 2 1

springer.com

Dentlearn.ir

Preface

The question of whether and to what extent dental materials may be hazardous to patients, the environment, and dental personnel has become of increasing public concern. The very emotional discussion in the public media about amalgam has significantly contributed to this dispute. In addition, reports about potential health risks in relation to other dental materials, such as resins and dental alloys, have generated an increased public and professional interest in this topic. One consequence of this tendency is that dental materials are now the subject of special regulations and directives in almost all countries of the world, intended to guarantee efficiency, safety, and quality and to make sure that only biocompatible materials are brought on the market. Basically, manufacturers are responsible for the safety and quality of their medical devices. It is, however, the responsibility of the dentist to fulfill distinct assignments in this context: The dentist is thus responsible for choosing the most suitable material for each specific indication in an individual patient. Furthermore, the dentist is the primary contact person for patients who have questions about the biocompatibility of the applied materials and is therefore an important part of the market surveillance system, with the responsibility to report adverse effects to the relevant authorities.

For the practicing dentist, it is therefore highly germane to be familiar with the field of biocompatibility of dental materials, which tightly interconnects modern dentistry with other medical disciplines, biology, chemistry, and physics. The first part of the book (Chaps. 1–3) reviews relevant background information on biocompatibility (definitions, determination of biocompatibility, and regulations and standards) in order to qualify the dentist to critically review data and information provided by the manufacturers and marketing companies. The biocompatibility aspects are reviewed in the second part of the book (Chaps. 4–11), structured by groups of materials. The third part of the book (Chaps. 12–14) is devoted to special topics that are of particular clinical and current relevance (environment, occupational hazards, diagnosis of side effects). To ensure the readability of each individual chapter, some aspects are approached from different scopes, and some topics are thus mentioned in more than one chapter, although with different approaches.

The editors are grateful to the publisher for providing the possibility of including a great number of colourful illustrations and clinical pictures. To further enhance the readability of the book *Key Notes* and *Clinical Practice Advices* have been highlighted all through the texts, and at the end of each chapter a comprehensive summary of key points have been underlined in *Conclusions for the Dental Practitioner.*

The guiding theme of all parts of the book was to provide a scientifically based background that should be helpful for the practicing dentist in his or her daily routine and not least form an objective basis for information and discussions with patients presenting individual needs and concerns. The editors of this book recognize that the field of dental biomaterial science is subject to permanent and partly very rapid development and supplementation. Considering this, the authors have intended to present data and concepts of biocompatibility that are currently available. We would like to thank all authors for their diligent work in preparing their texts and for their patience in adjusting the manuscripts.

For the editors and a number of authors of this book, English is not their mother language. The editors are therefore very grateful to Prof. Dr. Werner Geurtsen for his substantial input in providing an English text version of most chapters. The authors thank the publisher, especially Ms. Schröder, Ms. Himberger and Ms. Kaschubowski, for the efficient language editing process and for the important and helpful assistance during the publishing process. Furthermore, the editors would like to thank all those persons who contributed with their professional advice (Dr. H. Claus, Prof. Dr. S. Halbach, Dr. H.-P. Keller, attorney R. Krousky, Prof. Dr. M. Landthaler, Prof. L. Magos, Dr. A. Petermann, Prof. Dr. H. v.

Dentlearn.ir

Philipsborn, Dr. C. Schorn, Prof. Dr. H. Schweikl) or corrected the text (Ms. B. Bey, Dr. T. Bimmerle). Our thanks are also due to our secretaries, in particular Ms. B. Nothaas, K. Eichinger, and K. Roeder. We would like to also thank those colleagues who provided illustrations, which make many aspects of the text more descriptive. Last but not least, we would like to thank the publisher and their editors, whose persistent requests and helpful editorial hints made this book possible.

February 2008

Gottfried Schmalz
Dorthe Arenholt-Bindslev

Dentlearn.ir

Contents

1 Basic Aspects 1
G. Schmalz and D. Arenholt-Bindslev

1.1 Introduction 1
1.2 Health Effects 2
1.2.1 Systemic Toxicity 3
1.2.2 Local Reactions 3
1.2.3 Allergies 3
1.2.4 Other Effects 4
1.3 Risk 5
1.3.1 Risk Analysis 6
1.3.2 Risk Evaluation/Risk Perception . . . 6
1.3.3 Risk Management 7
1.3.4 Threshold Values 7
1.4 Effective Dose/Concentration 7
1.4.1 Principle of Dose 7
1.4.2 Effective Versus Applied Dose 8
1.4.3 Low-Level Dose Range 8
1.4.4 Placebo/Nocebo Effect 9
1.5 Interdisciplinary Collaboration 10
Conclusions for the Dental Practitioner 10
Appendix 10
References 11

2 Determination of Biocompatibility 13
G. Schmalz

2.1 Introduction 13
2.2 Evaluation of Materials 13
2.2.1 Principles of Biocompatibility Testing 13
2.2.1.1 Overview of Test Methods 13
2.2.1.2 Phenomena and Mechanisms 14
2.2.1.3 Strategies for Evaluating Biocompatibility 14
2.2.2 Test Materials 15
2.2.3 Systemic Toxicity 16
2.2.4 Local Toxicity and Tissue Compatibility 16
2.2.4.1 Cell Cultures 17
2.2.4.2 Implantation Tests 19
2.2.4.3 Pulp Damage and the Pulp/Dentin Test 20
2.2.4.4 Mucosal Damage and Mucosa Usage Tests 23
2.2.4.5 Periapical Tissue Damage and Endodontic Usage Test 23
2.2.4.6 Intraosseous Implant Test 24
2.2.5 Allergenic Properties 24
2.2.6 Other Reactions 25
2.2.6.1 Mutagenicity 25
2.2.6.2 Teratogenic Effects and Influence on Reproduction 26
2.2.7 Clinical Studies 26
2.3 Diagnostic Tests on Patients 27
2.3.1 Allergy Tests 28
2.3.1.1 Patch Test 28
2.3.1.2 Prick Test 30
2.3.1.3 Radioallergosorbent Test (RAST) . . 32
2.3.1.4 Immunotoxicological Test Methods 32
2.3.2 Measurement of Intraoral Voltage . . 32
2.3.3 Evaluation of Pulp Sensitivity 33
2.3.4 Analysis of Intraoral Alloys 34
2.3.5 Analysis of Metals in Saliva and Biopsies 34
2.3.6 Test Methods of "Alternative Medicine" 36
Appendix 39
Conclusions for the Dental Practitioner 39
References 40

3 Regulations and Standards 45
G. Schmalz and P. L. Fan

3.1 Introduction 45
3.2 Legal Regulations in the European Union 45
3.2.1 Medical Device Directive 45
3.2.1.1 Area of Jurisdiction and Definitions 46

Dentlearn.ir

3.2.1.2 Essential Requirements 46
3.2.1.3 Classification of Medical Devices . . 46
3.2.1.4 Conformity Assessment 46
3.2.1.5 Responsibilities and Liability 48
3.2.2 European Chemical Legislation (REACH) 48
3.3 Legal Regulations in the United States 49
3.3.1 Food, Drug, and Cosmetic Act and Medical Device Amendments 49
3.3.2 Classification of Devices 49
3.3.3 Premarket Notification and FDA Review 50
3.3.4 Records and Reports on Devices . . . 50
3.4 Legal Regulations in Australia 50
3.5 Legal Regulations in Japan 51
3.5.1 Classification and Marketing Authorization 51
3.5.2 Marketing and Manufacturing Licenses 52
3.5.3 Marketing Authorization 52
3.6 Labeling 52
3.7 Standards 54
3.7.1 Harmonized Standards 54
3.7.2 OECD Guidelines 54
3.7.3 Relevant Standards 55
3.8 Surveillance and Reporting Systems 56
Conclusions for the Dental Practitioner 57
References 57

4 Dental Amalgam 59
D. Arenholt-Bindslev and P. Hørsted-Bindslev

4.1 Introduction 59
4.2 Composition and Setting Reaction 60
4.2.1 Mercury-Based Amalgams 60
4.2.1.1 Setting Reaction 60
4.2.1.2 Mercury Emission and Corrosion Products 60
4.2.1.3 New Alloys 63
4.2.2 Mercury-Free Amalgams 63
4.3 Systemic Toxicity 64
4.3.1 Metabolism, Distribution, and Excretion of Mercury 64
4.3.1.1 Release and Uptake 64
4.3.1.2 Proposed Threshold Values 65
4.3.1.3 Deposition in Organs 66
4.3.1.4 Mercury Concentrations in Blood, Feces, and Urine 67
4.3.1.5 Mercury in Saliva 69
4.3.1.6 Mercury in Scalp Hair 70
4.3.1.7 Transplacental Distribution of Mercury from Dental Amalgam 70
4.3.1.8 Mercury in Breast Milk 71
4.3.2 Immunotoxicity 72
4.3.3 Neurotoxicity 73
4.3.4 Fertility Dysfunction and Teratogenicity 74
4.4 Local Toxic Reactions 76
4.4.1 Cytotoxicity and Implantation Studies 76
4.4.2 Pulp Reactions 76
4.4.3 Reactions of the Oral Mucosa 77
4.4.3.1 Mercury 77
4.4.3.2 Amalgam 78
4.5 Allergies 80
4.6 Carcinogenicity 85
4.7 Clinical Studies 85
4.7.1 Relationships Among Symptoms, General Diseases, and Amalgam Fillings 85
4.7.2 Removal of Amalgam Restorations 88
4.7.2.1 Effect on Health Improvement 88
4.7.2.2 Mercury Burden in Relation to Removal of Amalgam Fillings . . 88
4.8 Public Discussion 89
Conclusions for the Dental Practitioner 90
References 91

5 Resin-Based Composites 99
G. Schmalz

5.1 Introduction 99
5.2 Basic Material Properties 99
5.2.1 Composition 99
5.2.2 Setting Reaction 104
5.2.3 Release of Substances 105
5.2.4 Biodegradation of Monomers 107
5.3 Systemic Toxicity 108
5.3.1 Preclinical Studies 108
5.3.2 Estrogenicity 108
5.3.3 Clinical Symptoms and Complaints 109
5.4 Local Toxicity and Tissue Compatibility 110
5.4.1 Cytotoxicity 110
5.4.2 Influence on Cell Metabolism 112

Dentlearn.ir

5.4.3 Antimicrobial Properties 112
5.4.4 Implantation Tests 114
5.4.5 Pulp Reactions 114
5.4.5.1 Diffusion Through Dentin 114
5.4.5.2 Usage Tests 115
5.4.5.3 Bacteria at the Cavity Floor 117
5.4.5.4 Direct Pulp Capping with Dentin Adhesives 117
5.4.5.5 Thermal Effects of Light-Curing Units 119
5.4.5.6 Postoperative Sensitivity and Clinical Studies 119
5.4.6 Hazards for Eyes 120
5.4.7 Inhalation of Resin-Based Composite Particles 121
5.4.8 Reactions of Gingiva and Oral Mucosa 121
5.5 Allergies 121
5.5.1 Prevalence 122
5.5.2 Preclinical Studies 123
5.5.3 Allergic Reactions in Patients 124
5.5.4 Allergic Reactions in Dental Personnel 125
5.6 Mutagenicity and Carcinogenicity 127
5.7 Public Discussion 127
Conclusions for the Dental Practitioner 128
Appendix 129
References 130

6 Cements and Ceramics 139
6.1 Introduction 139
G. Schmalz

References 140

6.2 Zinc Phosphate Cements 141
H. Stanley †

6.2.1 Basic Material Properties 141
6.2.1.1 Composition and Setting Reaction 141
6.2.1.2 Release and Degradation 142
6.2.2 Systemic Toxicity and Allergies ... 142
6.2.3 Local Toxicity and Tissue Compatibility 143
6.2.3.1 Cytotoxicity 143
6.2.3.2 Implantation Studies 143
6.2.3.3 Pulp Reactions – Histopathology .. 143
6.2.3.4 Pulp Reactions – Clinical Observations 145
6.2.3.5 Microgaps (“Microleakage”) 146
6.2.3.6 Gingival Reactions 146
6.2.4 Mutagenicity and Carcinogenicity 147
Conclusions for the Dental Practitioner 147
References 147

6.3 Glass Ionomer Cements 149
G. Schmalz

6.3.1 Basic Material Properties 149
6.3.1.1 Composition 149
6.3.1.2 Setting Reaction 149
6.3.1.3 Release and Degradation 150
6.3.2 Systemic Toxicity and Allergies ... 151
6.3.3 Local Toxicity and Tissue Compatibility 151
6.3.3.1 Cytotoxicity 151
6.3.3.2 Antimicrobial Properties 152
6.3.3.3 Implantation Studies 153
6.3.3.4 Pulp Reactions 154
6.3.3.5 Reactions of Gingiva and Oral Mucosa 155
6.3.4 Mutagenicity and Carcinogenicity 156
Conclusions for the Dental Practitioner 156
References 156

6.4 Zinc Oxide and Eugenol Cements 160
G. Schmalz and B. Thonemann

6.4.1 Basic Material Properties 160
6.4.1.1 Composition and Setting Reaction 160
6.4.1.2 Release and Degradation 160
6.4.2 Systemic Toxicity and Allergies ... 160
6.4.2.1 Preclinical Allergy Studies 160
6.4.2.2 Allergic Reactions of Patients 160
6.4.2.3 Allergic Reactions of Dental Personnel 161
6.4.3 Local Toxicity and Tissue Compatibility 162
6.4.3.1 Cytotoxicity 162
6.4.3.2 Antimicrobial Properties 162
6.4.3.3 Implantation Studies 162
6.4.3.4 Pulp Reactions 162
6.4.4 Mutagenicity and Carcinogenicity 163
Conclusions for the Dental Practitioner 163
References 164

6.5 Calcium Hydroxide Cements 166
H. Stanley (†) and B. Thonemann

6.5.1 Basic Material Properties 166

Dentlearn.ir

6.5.1.1 Composition and Setting Reaction 166
6.5.1.2 Release and Degradation 167
6.5.2 Systemic Toxicity and Allergies . . . 168
6.5.2.1 Calcium Hydroxide 168
6.5.2.2 Alternatives to Calcium Hydroxide 168
6.5.3 Local Toxicity and Tissue Compatibility 169
6.5.3.1 Cell Cultures 169
6.5.3.2 Antimicrobial Properties 169
6.5.3.3 Pulp Reactions 169
6.5.4 Mutagenicity and Carcinogenicity 173
Conclusions for the Dental Practitioner 173
References 174

6.6 Dental Ceramics 177
G. Schmalz

6.6.1 Basic Material Properties 177
6.6.1.1 Composition 177
6.6.1.2 Release and Degradation 179
6.6.2 Systemic Toxicity and Allergies . . . 180
6.6.3 Local Toxicity and Tissue Compatibility 180
6.6.3.1 Cell Cultures 180
6.6.3.2 Implantation Studies 181
6.6.3.3 Pulp Reactions 182
6.6.3.4 Gingival Reactions 182
6.6.3.5 Periapical Area 183
6.6.3.6 Implants 183
6.6.4 Mutagenicity and Carcinogenicity 183
Conclusions for the Dental Practitioner 184
References 185

7 Root Canal Filling Materials 187
G. Schmalz

7.1 Introduction 187
7.1.1 Classification 187
7.1.2 Requirements 188
7.1.3 Clinical Data and Biocompatibility 189
7.1.4 Mandibular Nerve Injuries 189
7.1.5 Rubber Dam 190
7.2 Gutta-Percha 191
7.2.1 Composition 191
7.2.2 Release and Degradation 191
7.2.3 Systemic Toxicity and Allergies . . . 191
7.2.4 Local Toxicity and Tissue Compatibility 192
7.2.5 Antimicrobial Properties 194
7.2.6 Clinical Data and Mandibular Nerve Injuries 194
7.3 Root Canal Sealers 195
7.3.1 Overview 195
7.3.2 Zinc Oxide Eugenol Sealers 195
7.3.2.1 Composition 195
7.3.2.2 Setting Reaction and Release of Substances 196
7.3.2.3 Systemic Toxicity and Allergies . . . 196
7.3.2.4 Local Toxicity and Tissue Compatibility 196
7.3.2.5 Aspergillosis 198
7.3.2.6 Antimicrobial Properties 199
7.3.2.7 Clinical Data and Mandibular Nerve Injuries 199
7.3.3 Polyketone-Based Sealers 200
7.3.3.1 Composition, Setting Reaction, and Release of Substances 200
7.3.3.2 Systemic Toxicity and Allergies . . . 200
7.3.3.3 Local Toxicity 200
7.3.4 Epoxy-Based Sealers 201
7.3.4.1 Setting Reaction and Release of Substances 201
7.3.4.2 Systemic Toxicity and Allergies . . . 201
7.3.4.3 Local Toxicity 202
7.3.4.4 Mutagenicity 202
7.3.4.5 Antimicrobial Properties 203
7.3.4.6 Clinical Studies and Mandibular Nerve Injuries 203
7.3.5 Calcium-Hydroxide-Based Sealers 203
7.3.5.1 Composition 203
7.3.5.2 Setting Reaction and Release of Substances 203
7.3.5.3 Systemic Toxicity and Allergies . . . 203
7.3.5.4 Local Toxicity and Tissue Compatibility 204
7.3.5.5 Antimicrobial Properties 205
7.3.5.6 Clinical Data and Mandibular Nerve Injury 205
7.3.6 Mineral Trioxide Aggregate 205
7.3.6.1 Composition and Setting Reaction 206
7.3.6.2 Release of Substances 206
7.3.6.3 Systemic Toxicity and Allergy 206
7.3.6.4 Local Toxicity and Tissue Compatibility 206
7.3.6.5 Antimicrobial Properties 207
7.3.6.6 Mutagenicity 207
7.3.7 Calcium Phosphate Cement 207
7.3.8 Silicones 208

Dentlearn.ir

7.3.8.1 Composition 208
7.3.8.2 Systemic Toxicity and Allergy 208
7.3.8.3 Local Toxicity and Tissue Compatibility 208
7.3.8.4 Antimicrobial Properties 208
7.3.9 Resin-Based Sealers 208
7.3.9.1 Composition and Setting Reactions 208
7.3.9.2 Degradation and Release of Substances 208
7.3.9.3 Local Toxicity and Tissue Compatibility 208
7.3.9.4 Antimicrobial Properties 210
7.3.9.5 Clinical Data 210
7.4 Materials for Retrograde Root Canal Fillings 210
7.4.1 Composition and Setting Reaction 211
7.4.2 Systemic Toxicity and Allergies . . . 211
7.4.3 Local Toxicity and Tissue Compatibility 211
7.4.4 Clinical Data 212
Conclusions for the Dental Practitioner 213
References 213

8 Dental Alloys 221
J. C. Wataha and G. Schmalz

8.1 Introduction 221
8.2 Basic Material Properties 221
8.2.1 Composition 221
8.2.1.1 Elements 221
8.2.1.2 Weight Percentage vs. Atomic Percentage 222
8.2.1.3 Phases 223
8.2.1.4 Analysis of Dental Alloys 223
8.2.2 Corrosion and Release of Elements 224
8.2.2.1 Fundamentals 224
8.2.2.2 Implanted Dental Alloys 227
8.2.2.3 Nonimplanted Dental Alloys 227
8.3 Systemic Toxicity 228
8.3.1 Absorption, Distribution, and Excretion 229
8.3.2 Implanted Dental Alloys 230
8.3.3 Nonimplanted Dental Alloys 231
8.3.4 Clinical Symptoms and Complaints 232
8.4 Local Toxicity and Tissue Compatibility 232
8.4.1 Corrosion and Local Toxicity 232
8.4.2 Implanted Dental Alloys 233
8.4.3 Nonimplanted Dental Alloys 234
8.4.3.1 Cell Cultures 234
8.4.3.2 Adhesion of Bacteria 236
8.4.3.3 Implantation Tests 237
8.4.4 Local Clinical Symptoms and Complaints 237
8.4.4.1 Subjective Complaints 237
8.4.4.2 Gingival Inflammation 238
8.4.4.3 Alterations of the Tongue 239
8.4.4.4 Palatal Erythema 239
8.4.4.5 Lichenoid Reactions 239
8.5 Allergies 240
8.5.1 Mechanisms 240
8.5.2 Diagnosis and Frequency of Allergies to Metal Ions 241
8.5.3 Clinical Symptoms 242
8.6 Mutagenicity, Carcinogenicity, and Teratogenicity 242
8.7 Public Concerns and Controversies 244
8.7.1 Palladium in Dental Alloys 246
8.7.2 Nickel in Dental Alloys 246
Conclusions for the Dental Practitioner 248
Appendix 249
References 250

9 Polymethylmethacrylate Resins 255
W. Geurtsen

9.1 Introduction 255
9.2 Basic Material Properties 255
9.2.1 Composition and Setting Reaction 255
9.2.2 Release of Substances and Degradation 256
9.3 Systemic Toxicity 258
9.4 Local Toxicity and Tissue Compatibility 259
9.4.1 Cytotoxicity 259
9.4.2 Microbial Effects 261
9.4.3 Implantation Studies 262
9.4.4 Pulp Reactions 262
9.4.5 Reactions of the Gingiva and Oral Mucosa 262
9.4.6 Burning Mouth Syndrome 263
9.5 Allergies 264
9.6 Mutagenicity and Carcinogenicity 265
Conclusions for the Dental Practitioner 266
References 267

Dentlearn.ir

10 Oral Hygiene Products 271
A. Richards

10.1 Introduction 271
10.2 Toothpastes and Mouthwashes 271
10.2.1 Systemic Toxicity 272
10.2.1.1 Acute Systemic Toxicity 272
10.2.1.2 Chronic Systemic Toxicity 274
10.2.2 Local Toxicity and Biocompatibility 276
10.2.2.1 Mechanical Abrasion 276
10.2.2.2 Hard Tissue Erosion 277
10.2.2.3 Soft Tissue Reaction 277
10.2.2.4 Detergents 278
10.2.2.5 Alcohol 279
10.2.2.6 Chlorhexidine 279
10.2.3 Allergies 279
10.2.3.1 Prevalence 279
10.2.3.2 Allergy Testing 280
10.2.3.3 Allergens 280
10.2.4 Mutagenicity, Carcinogenicity, and Teratogenicity 282
10.3 Tooth Bleaching Agents 284
10.3.1 Carbamide Peroxide 284
10.3.2 Systemic Toxicity 284
10.3.3 Local Toxicity and Tissue Compatibility 285
10.4 Fluoride Varnishes and Gels 286
10.4.1 Gels 286
10.4.2 Varnishes 287
10.4.3 Vehicle Substances 287
Conclusions for the Dental Practitioner 288
References 289

11 Materials for Short-Term Application in the Oral Cavity .. 293
G. Schmalz

11.1 Introduction 293
11.2 Impression Materials 294
11.2.1 Basic Material Properties 294
11.2.1.1 Composition 294
11.2.1.2 Setting Reaction, Release, and Degradation 295
11.2.2 Systemic Toxicity 295
11.2.3 Local Toxicity and Tissue Compatibility 295
11.2.3.1 Cytotoxicity 295
11.2.3.2 Implantation Tests 296
11.2.3.3 Periodontal and Pulpal Damage .. 297
11.2.4 Allergies 299
11.2.5 Mutagenicity 299
11.3 Periodontal Dressings 299
11.3.1 Basic Material Properties 300
11.3.1.1 Composition 300
11.3.1.2 Setting Reaction and Release of Substances 300
11.3.2 Systemic Toxicity 300
11.3.3 Local Toxicity and Tissue Compatibility 301
11.3.3.1 Cytotoxicity 301
11.3.3.2 Implantation Tests 301
11.3.3.3 Local Reactions in the Oral Cavity 301
11.3.3.4 Antimicrobial Properties 302
11.3.4 Allergies 302
11.3.5 Mutagenicity 302
11.4 Suture Materials 303
11.4.1 Basic Material Properties 303
11.4.1.1 Composition 303
11.4.1.2 Degradation 303
11.4.2 Systemic Toxicity 303
11.4.3 Local Toxicity and Tissue Compatibility 303
11.4.3.1 Reactions at the Suture Site 304
11.4.3.2 Bacterial Colonization 304
11.4.4 Allergies 305
11.4.5 Mutagenicity 306
Conclusions for the Dental Practitioner 306
Appendix 307
References 307

12 Occupational Exposures 311
A. Hensten and N. Jacobsen

12.1 General Aspects 311
12.1.1 Introduction 311
12.1.2 Exposure Modalities 312
12.1.3 Absorption Routes 312
12.1.4 Nature of Reactions 312
12.2 Clinical Symptoms and Related Materials 313
12.2.1 Historic Aspects 313
12.2.2 Nondermal Reactions 313
12.2.2.1 Amalgam-Related and Mercury-Related Hazards 313
12.2.2.2 Methylmethacrylate-Related Reactions 314
12.2.2.3 Reactions Related to Grinding Dusts and Fumes 314
12.2.2.4 Other Nondermal Reactions 315
12.2.3 Dermal Reactions 315

Dentlearn.ir

12.2.4 Relevant Substances and Materials 316
12.2.4.1 Metals 316
12.2.4.2 Polymer-Associated Substances . . 317
12.2.4.3 Miscellaneous 317
12.2.4.4 Rubber Chemicals 317
12.3 Prophylactic Measures and Safety Precautions 318
12.3.1 General Considerations 318
12.3.2 Handling of Dental Materials 319
12.3.2.1 "No-Touch" Technique for Resin-Based Materials 319
12.3.2.2 Amalgam and Mercury Precautions 319
12.3.2.3 Barrier Equipment 320
Appendix 321
Conclusions for the Dental Practitioner 321
References 322

13 Environmental Aspects 325
D. Arenholt-Bindslev

13.1 Introduction 325
13.2 Environmental Aspects of Dental Amalgam 325
13.2.1 Mercury in the External Environment 325
13.2.2 Environmental Mercury Burden Related to the Use of Amalgam in Dentistry 327
13.2.3 Amalgam Separating Devices – Regulations and Recommendations 330
13.2.4 Interment and Cremation 331
13.3 Environmental Aspects of Composite Dental Filling Materials 332
Conclusions for the Dental Practitioner 332
References 332

14 Diagnosis of Side Effects of Dental Materials, with Special Emphasis on Delayed and Immediate Allergic Reactions 335
D. Arenholt-Bindslev, R. Jolanki and L. Kanerva

14.1 General Diagnostic Aspects and Irritant/Allergic Stomatitis . . . 335
14.2 Delayed Allergic Reactions (Cell Mediated) 338
14.2.1 Clinical Picture 338
14.2.2 Verified Contact Allergic Reactions to Dental Materials and Substances Released by Dental Materials 340
14.2.2.1 Dental Metals 340
14.2.2.2 Rare Metals 345
14.2.2.3 Acrylate-Based Materials 345
14.2.2.4 Activators and Inhibitors 349
14.2.2.5 Epoxy Compounds 349
14.2.2.6 UV Absorbers 350
14.2.2.7 Root Canal Sealers and Cavity Liners 350
14.2.2.8 Antimicrobials 351
14.2.2.9 Other Disinfectants 352
14.2.2.10 Fragrances and Colophony 352
14.2.3 Epicutaneous Test (Patch Test) 353
14.3 Immediate Allergic Reactions (IgE Mediated) 353
14.3.1 Clinical Picture 353
14.3.2 Verified Immediate Allergic Reactions to Dental Materials 354
14.3.3 Chemicals with Low Molecular Weight 356
14.3.3.1 Metals 356
14.3.3.2 Antimicrobials 356
14.3.3.3 Fragrances and Flavorings 356
14.3.3.4 Medicaments 356
14.3.4 Skin Test with Low Molecular Weight Compounds 357
14.3.5 Management of Acute Allergic Reactions 357
14.4 Diagnosis of Side Effects Caused by Dental Materials 357
14.4.1 Anamnesis 357
14.4.2 Local Irritative Reactions 358
14.4.3 General Symptoms 358
14.4.4 Allergy 359
14.4.4.1 Delayed Allergic Reactions (Type IV) 359
14.4.4.2 Evaluation of Patch Test Results . . . 360
14.4.4.3 Immediate Allergic Reactions 361
14.4.5 Defining the Causative Agent(s) . . 361
14.4.6 The Importance of Communication 361
References 361

Subject Index 367

Dentlearn.ir

Contributors

Gottfried Schmalz, D.D.S., Dr. med. dent., Ph.D.
Professor and Chairman
Department of Operative Dentistry
and Periodontology
University of Regensburg
93042 Regensburg, Germany
gottfried.schmalz@klinik.uni-regensburg.de

Dorthe Arenholt-Bindslev, D.D.S., Ph.D., Certif. Orthod.
Professor and consultant orthodontist
School of Dentistry
Århus University
Århus, Denmark
dbindslev@odont.au.dk

P. L. Fan, Ph.D.
431 South Reuter Drive
Arlington Heights, IL 60005-2231, USA
fanpl@umich.edu

Werner Geurtsen, D.D.S., Dr. med. dent., Ph.D.
Professor and Chairman
Department of Operative Dentistry
and Periodontology
Medical University of Hannover
Carl-Neuberg-Straße 1
30625 Hannover, Germany
Geurtsen.werner@mh-hannover.de

Arne Hensten, D.D.S., Ph.D., Dr. Odont., Odont. Dr. h.c (Lund)
Professor and Chairman
University of Tromsø
Tromsø, Norway
arne.hensten@fagmed.uit.no

Preben Hørsted-Bindslev, D.D.S.
Professor and Head of School of Dentistry
School of Dentistry
Århus University
Århus, Denmark
ph-b@odont.au.dk

Nils Jacobsen, Ph.D., Dr. Odont.
Professor emeritus
Dental Faculty
University of Oslo
Oslo, Norway
&
Nordic Institute of Dental Materials (NIOM)
Haslum, Norway
njj@niom.no

Riitta Jolanki, Ph.D. (Chem.Tech.)
Senior Research Scientist
Finnish Institute of Occupational Health
Helsinki, Finland
riitta.jolanki@ttl.fi

Lasse Kanerva, M.D., Ph.D.
Dermatologist
Finnish Institute of Occupational Health
Helsinki, Finland
faina.kanerva@focusmed.fi

Alan Richards, B.D.S, Ph.D.
Professor
School of Dentistry
Århus University
Århus, Denmark
arichards@odont.au.dk

* The contributors of this book derive from different parts of the world with different academic traditions. The academic titles used in this list are translations and adaptations to an internationally accepted nomenclature (and it does not imply any legal recognition).

Dentlearn.ir

H. Stanley, D.D.S. B.S., M.S. (†)
Formerly Professor emeritus
College of Dentistry
University of Florida
Gainesville, FL, USA

Birger Thonemann, D.D.S., Dr. med. dent., Ph.D.
Professor
Luegplatz 3, 40545 Düsseldorf, Germany
zahnaerzte@oberkassel.de
&
Department of Operative Dentistry
and Periodontology
University of Regensburg,
93042 Regensburg, Germany

John C. Wataha, D.D.S., Ph.D.
Professor and Chairman
Department of Restorative Dentistry
University of Washington
Box 357456, 1959 NE Pacific St.
Seattle, WA 98195-7456, USA
jwataha@u.washington.edu

Dentlearn.ir

1 Basic Aspects

G. Schmalz and D. Arenholt-Bindslev

Contents

1.1	Introduction	1
1.2	Health Effects	2
1.2.1	Systemic Toxicity	3
1.2.2	Local Reactions	3
1.2.3	Allergies	3
1.2.4	Other Effects	4
1.3	Risk	5
1.3.1	Risk Analysis	6
1.3.2	Risk Evaluation/Risk Perception	6
1.3.3	Risk Management	7
1.3.4	Threshold Values	7
1.4	Effective Dose/Concentration	7
1.4.1	Principle of Dose	7
1.4.2	Effective Versus Applied Dose	8
1.4.3	Low-Level Dose Range	8
1.4.4	Placebo/Nocebo Effect	9
1.5	Interdisciplinary Collaboration	10
	Conclusions for the Dental Practitioner	10
	Appendix	10
	References	11

1.1 Introduction

During the past few years, the biocompatibility of dental materials has evolved into a comprehensive, complex, and independent discipline of dental materials science. Consequently, a number of terms have been developed or were adopted from toxicology. Some of these terms may be familiar to patients and dentists from daily life – for example, the term "safety." Their exact definitions within the framework of biocompatibility are, however, not always well understood. To avoid misunderstandings and to allow discussions between dentists, manufacturers, and patients at an objective and scientific level, certain knowledge of some fundamental terms and aspects of biocompatibility is necessary. This chapter is an introduction to the field.

Like many other disciplines, the field of biocompatibility has been trying to agree on generally accepted definitions of terms. However, this has not always been successful. Thus, the following definitions are based on general concepts of biocompatibility as they are frequently used in the literature and in standards [1, 8–11].

Biomaterial refers to any nonvital material intended to interact with biological systems within or on the human body. Dental materials inserted into the oral cavity therefore belong to the group of biomaterials. As such, they are subject to specific legal regulations, a situation that in turn has a direct influence on daily dental practice (see Chap. 3). Worldwide, most countries allow the use of only those dental materials that have successfully passed a special certification process (Fig. 1.1).

Biocompatibility (or tissue compatibility) describes the ability of a material to perform with an appropriate host response when applied as intended. A biocompatible material may not be completely "inert"; in fact, the appropriateness of the host response is decisive. This adequacy is generally assessed by various experts according to specific guidelines in which a comparison with products that are already on the market plays an important role. Because there is always a possible range associated with these assessments, evaluations may not generate identical results. It is thus the dentist's obligation to not rely on these assessments blindly but rather to question them critically.

Besides this classic concept of biocompatibility (inert/tolerable biomaterial), the targeted influence of a biomaterial on the metabolism of adjacent cells has gained an increasingly important function (**bioactive materials**). Surfaces of materials can be specifically pretreated ("biofunctionalized"), such as by coating a titanium surface with signaling proteins (e.g., bone morphogenetic protein to improve the attachment of bone tissue). Regarding bone regeneration, the

Dentlearn.ir

term "osteoconductive material" is used for materials serving as scaffolds for the ingrowth of preosteoblasts, whereas osteoinductive materials induce formation of new bone by the differentiation of pluripotent local connective tissue cells into bone-forming cells.

The biocompatibility of a material is mainly determined by its release of substances through solubility or corrosion. These substances may damage cells, or, by stimulating cellular synthesis of certain proteins (e.g., pro-inflammatory mediators such as interleukin-1 and interleukin-6), induce inflammation. Likewise, the surface absorption or accumulation of proteins, or the interaction of a material with the extracellular matrix, is important for the biological behavior of a material (for example, the attachment of cells/bacteria on material surfaces). The adhesion of proteins (e.g., the formation of a pellicle by saliva proteins) is influenced by a material's chemical properties as well as its physical characteristics (e.g., wettability, surface energy).

Tissue engineering is a comparatively new area of biomaterial application. It is the science of design and manufacture of new tissues for the functional restoration of tissues and organs (regenerative medicine/dentistry). Nondegradable and (mainly) degradable biomaterials serve as scaffolds for signaling molecules or cells, or both, and they are designed to actively interfere with adjacent body cells.

Safety in relation to the evaluation of (dental) biomaterials means freedom from unacceptable risks. Thus, safety does not stand for a complete lack of risks. As with the definition of the term "biocompatibility", adequacy has an important function with respect to safety.

Side effects of a biomaterial are defined as those effects that, besides the intended main function, are also characteristic for this biomaterial but are not wanted. A synonymously used term is "adverse effects."

Toxicity of a material describes the ability to damage a biological system by chemical means. In higher organisms (animals, human beings), local toxicity – that is, adverse reactions emerging at the application site – is differentiated from systemic toxicity, in which adverse reaction appear in an area distant from the application site. In dentistry, local reactions primarily occur in the pulp, the periapical periodontium, and the gingiva/oral mucosa.

Immunotoxicity of a material describes adverse effects on the structure and function of the immune system, for instance on relevant cells such as monocytes. These effects impair the host defense (e.g., against infection) or may cause tissue damage, such as by chronic inflammation.

1.2 Health Effects

Key Note

Dental materials may cause adverse health effects. In dental patients, the frequency of these effects lies within the range of one-tenth of a percent and is thus very low [12, 20]. For comparison, an epidemiologic survey in the United Kingdom in 2004 revealed that 23% of women and 13.8% of men experience some sort of adverse reaction to a personal care product (such as cosmetics) over the course of a year [18]. The incidence of occupational health complaints in dental personnel is considerably higher. Among dental personnel, 40–50% report work-related health problems, primarily related to latex gloves, followed by acrylates (see Chap. 12).

Health effects can be subdivided into the following:

- Systemic toxicity
- Local reactions
- Allergic reactions
- Other reactions

Fig. 1.1 Only those biomaterials (medical devices) that are labeled "CE" may be used in dental practice in the European Union

Dentlearn.ir

1.2.1 Systemic Toxicity

Almost all dental materials release substances into the oral cavity, from where they may enter the human body through different routes, including swallowing of saliva and inhalation, with subsequent passage of the epithelial barriers in the gastrointestinal tract or the lungs. These substances may, via the blood circulation, be transported to different organs. The application site may thus be in a different location from the effect. At the location of the effect, there may be interference with the function of the specific organ if the concentration is sufficiently high (systemic toxicity). According to the time frame, acute (up to an exposure period of 24 h), subacute (up to 3 months), and chronic toxicity are differentiated. A considerable number of single case reports published in the literature, in particular in the lay press, have claimed to present mainly chronic side effects of dental materials. Examples of such materials are amalgams, resin-based composites, and dental alloys. However, scientifically based literature reviews clearly show that a causal relation between chronic general health complaints and exposure to dental materials has very rarely been found (see Chaps. 4–9). Patients may thus feel a need for thorough information about safety aspects, so dentists need to be familiar with this topic to be able to supply their patients with correct and adequate information.

1.2.2 Local Reactions

Substances released from dental materials may generate a reaction (e.g., inflammation or necrosis) in adjacent tissues (local toxicity), such as oral mucosa/gingiva (Fig. 1.2), pulp (Fig. 1.3), or alveolar bone. Cytotoxicity refers to damage to individual cells, for example in cell cultures. Cells can die because of necrosis or apoptosis (programmed cell death). Furthermore, if cell metabolism is influenced, the release of pro-inflammatory mediators may be the consequence.

However, factors other than substances released from dental materials may cause a local tissue reaction. Of these, the presence of bacteria that accumulate at the surface, at the margin, or under a material is the most important factor (Fig. 1.4). Numerous studies and reports in the scientific literature address these mechanisms. Mechanical/physical irritation, such as pressure caused by dentures, can also cause local tissue reactions. Local reactions are quite often seen in dental practice, and a correct diagnosis is thus of great importance.

1.2.3 Allergies

An allergic reaction to a substance can be triggered if the organism was previously sensitized to this compound. Four different types of allergic reactions are differentiated (Table 1.1). Types I, II, and III are mediated by antibodies (IgE, IgG), whereas type IV is primarily imparted by cells. Dental materials may cause allergies of type I (immediate reaction) and type IV (delayed reaction). The concentrations that elicit a reaction in a previously sensitized person vary between subjects. The dose levels causing allergic reactions are generally significantly lower than those causing toxic reactions. Substances may be released from dental

Fig. 1.2 Inflammation of the gingiva in contact with a porcelain-fused-to-metal crown

Fig. 1.3 Pulp necrosis after application of resin fillings

Dentlearn.ir

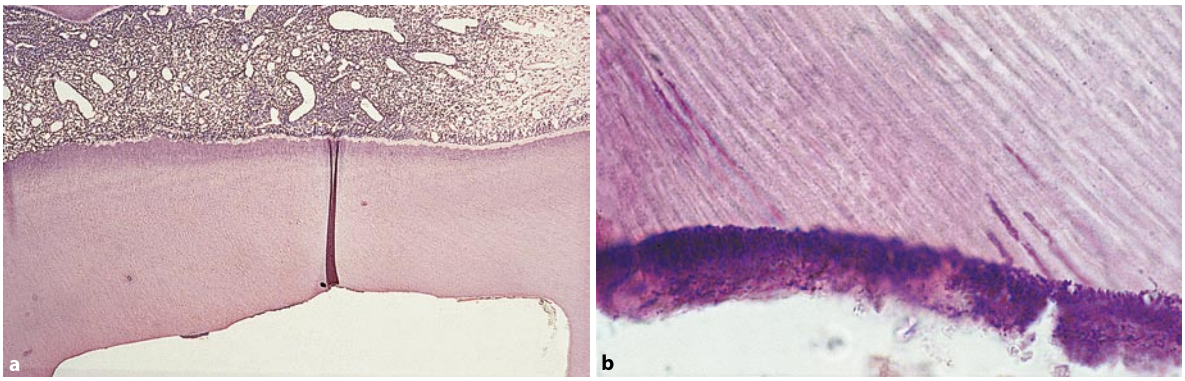

Fig. 1.4 **a** Pulp damage caused by bacteria on the cavity floor: pronounced pulp reaction. (magnification ×80) **b** Bacteria on the cavity floor and in dentin tubules, which may be the cause of a pulp reaction (magnification ×400)

materials into the oral cavity at dose levels sufficiently high to elicit allergic reactions in previously sensitized individuals. Allergic reactions elicited by dental materials can occur intraorally or as remote reactions extraorally, such as reactions associated with nickel exposure (Figs. 1.5–1.7).

Allergies to various substances can occur simultaneously. A **cross-sensitivity** is assumed if allergies to chemically-related substances occur in a patient. Examples are nickel and palladium, which belong to the same main group in the periodic table of elements. Patients who suffer from an allergy to nickel are very often also allergic to palladium [5]. This must be kept in mind if palladium-containing alloys are used for restorative purposes. Cross-reactivity to chemically-related methacrylates is also known (see Chap. 14).

A **concurrent sensitization** is generated by two allergens that are frequently present at the same time in the environment or in a material and thus by parallel exposure may sensitize an individual and/or elicit positive reactions in allergy testing.

Numerous reports and studies about the allergenic properties of dental materials have been published in the scientific literature (see also Chap. 14). Allergies that are associated with dental materials are of increasing importance, not least due to the marketing of new resin monomers. Reactions in patients and particularly in dental personnel may have an allergenic origin.

A position paper on chemicals and contact allergens was recently published by a German health authority [13]. Accordingly, contact allergy is classified into three categories:

- A: Important contact allergens
- B: Suspected contact allergens in humans
- C: Unimportant contact allergens

A number of substances that are components of dental materials belong to category A, including Peru balm, bisphenol A diglycidyl ether (BADGE), certain methacrylates, formaldehyde, and glutaraldehyde (see Chap. 14).

1.2.4 Other Effects

This group includes mutagenic, carcinogenic, and teratogenic effects. Substances released from materials can cause alterations of the genome DNA (genotoxicity). Cells possess a number of mechanisms to repair genotoxic damages. Alternatively, a transfer of these genetic damages to subsequent generations of cells can be avoided by programmed cell death (apoptosis). Nonetheless, if these genetic damages are passed on to the next generation, this effect is called mutagenicity. Some materials or substances released from them may also basically promote the generation of malignant

Table 1.1 Types of allergic reactions

Immediate reaction, anaphylactic (Type I)
Cytotoxic reaction (Type II)
Formation of immune complexes (Type III)
Delayed reaction (Type IV)

Dentlearn.ir

Fig. 1.5 Allergic contact dermatitis on the fingertip of a dentist after contact with resin-based composite

Fig. 1.7 Allergic reaction of type IV (reaction on the hands, distant from the exposure site) after exposure to nickel during an orthodontic treatment (Courtesy of N. Veien, Aalborg, Denmark)

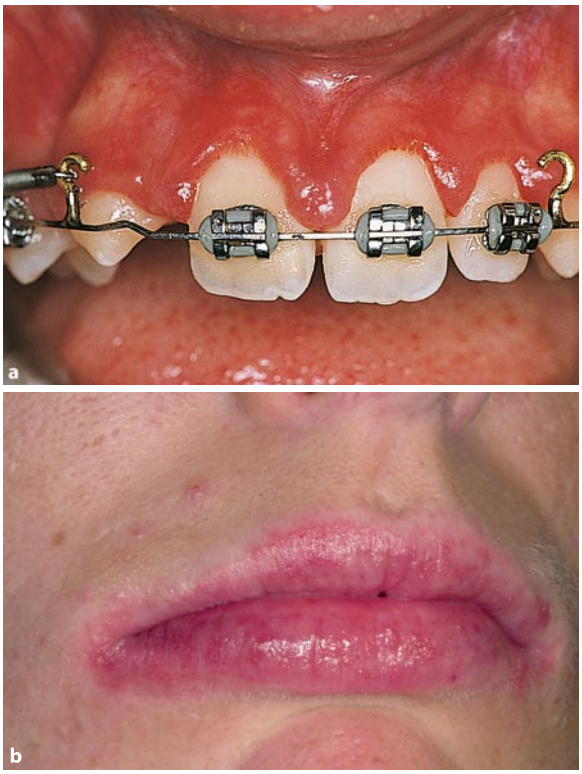

Fig. 1.6 **a** Pronounced gingivitis of an orthodontic patient (nickel-containing device) who revealed a positive reaction in a patch test. The most important differential diagnosis would be "plaque-associated" inflammation. **b** Persisting perioral and labial eczema of an orthodontic patient (copper–nickel–titanium wires). The patient had no intraoral symptoms, and there was complete regression after replacement with titanium wires

tumors; in other words, they have a carcinogenic effect. Mutagenicity can be assessed as an indicator of possible carcinogenicity of substances that directly attack DNA.

It is known that certain substances (thalidomide, for example) may cause malformations during embryonic development (teratogenicity). Thus, substances leaching from materials should be evaluated for their potential risk of causing a teratogenic effect (see Sect. 1.3.2). This also applies regarding a possible influence on reproductive ability.

In relation to dental materials, the aforementioned health effects belonging to this group are generally more theoretical, since up to now no such damages have been clinically observed subsequent to the application of dental materials.

1.3 Risk

According to EU regulations the intended use and the duration of the intended exposure period determine the extent of biological assessment prior to marketing, for which the manufacturer is responsible. This information is the basis for the manufacturer's information to the dentist, who is responsible for passing the relevant information on to the staff as well as to the patients. The degree or extent of possible health damage is described by the term "risk."

Dentlearn.ir

1

Key Note

In the context of biocompatibility, risk means the combination of the probability of occurrence of harm (side effect) and the severity of that harm. An important basis for evaluating a risk is the detailed knowledge about the composition of a material, including possible contaminants.

The following factors need to be considered in the risk assessment of a material: the exposure route, the duration of the intended contact with vital tissues, the hazards potentially associated with the application, and the character of the leaching substances.

1.3.1 Risk Analysis

Risk can be evaluated according to methods that are recommended by standard guidelines (e.g., ISO 14971) [3, 10]. The first step is risk analysis, which comprises the systematic use of available information to identify hazards and to estimate the risk. Risk analysis is subdivided into different segments (Fig. 1.8) and includes identification and evaluation of possible damages considering the effective exposure. The aim of risk analysis is to assess or predict the probability and the degree of effects of a material on human health and to create guidelines for its use, if necessary.

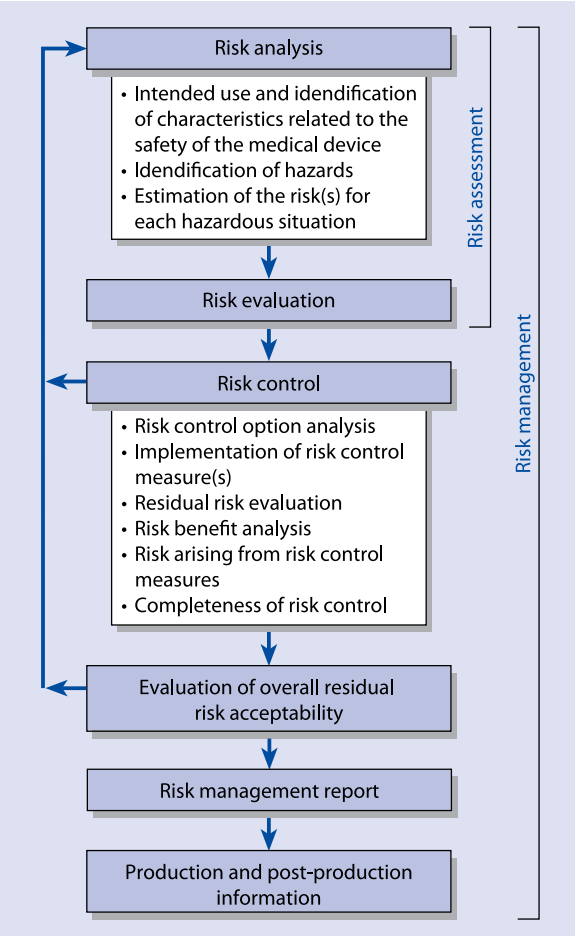

Fig. 1.8 Schematic representation of the risk management process [10]

1.3.2 Risk Evaluation/Risk Perception

Risk evaluation must be distinguished from risk analysis (see Fig. 1.8). Risk evaluation addresses the question of whether a risk can be accepted or not by comparing the estimated risks against given risk criteria. An important factor, besides the results of the risk analysis, is the expected benefit. Risk evaluation also incorporates socioeconomic factors of the specific society. Both, risk analysis and risk evaluation are summarized as risk assessment. This risk assessment – based on statistical data (probability calculation) – must be differentiated from the perception of a risk in the general population. Tables 1.2 and 1.3 summarize the risks of daily life and the risks when using various drugs. It is obvious that the general population currently accepts various risks even though they are associated with comparably high death rates, such as riding a motorbike. Some risks are even connected with a positive image, for instance in terms of challenging one's strength ("No risk – no fun").

The public perception of risk is intuitive. In particular, in cases of uncertainty, objectively low risks are frequently overestimated. Thus, a balanced "risk communication" between dentist and patient is of high importance. An important goal is that the discrepancy between objective risk assessment and intuitive risk perception is clearly demonstrated by precise examples.

Dentlearn.ir

Key Note

It is important for the clinician to be aware that in most cases, a conspicuous discrepancy exists between the patient's risk perception and the scientifically assessed risk. The current public discussion about dental materials is an excellent example of this discrepancy. Thus, an important step toward objectifying the patient's consultation may be to refer to this gap and to the risks of daily life; this can make it easier for the patient to realize and estimate the risk posed by dental materials.

1.3.3 Risk Management

Risk management includes all steps of risk analysis, risk evaluation, and risk control (see Fig. 1.8). Warning notices about particular risks in the user's information (for instance, "allergenic") may reduce the risk, since the frequency of unwanted side effects may be minimized by precautionary measures such as nonapplication in cases of supposed allergy. Such warning notices can be found as symbols printed on the wrapping of dental materials (see also Chap. 3).

Table 1.2 Risks of daily life [14]

Risk	Incidence: one fatality per *x* number of persons
Bee sting	5 million
Strike of lightning	2 million
Food poisoning	0.8 million
Air travel	0.8 million
Cycling	54,000
Pedestrian	26,000
Active soccer player	6,000
Driving a car	5,700
Motor biking	1,000
Smoking	200

1.3.4 Threshold Values

Threshold values are defined by national and international boards and are intended to serve as points of reference. Frequently, specific threshold values are used for assessing biocompatibility (NOEL, NOEAL, LOEL, LOAEL). Furthermore, threshold values are also defined for administrative purposes (TI, TDI, TWI, STEL). In dentistry, these values mainly apply to systemic toxic reactions. Definitions of important threshold values are summarized in the appendix of this chapter.

1.4 Effective Dose/Concentration

1.4.1 Principle of Dose

Key Note

Paracelsus pointed out as early as the 16th century that toxic reactions are dependent on the dose (*"Dosis facit venenum"*). This principle still applies. The concentrations necessary to trigger an allergic reaction are individually different and are much lower than those that elicit toxic reactions.

For dental materials, "dose" means the amount of substance that is released from a specific material. The dependence of the toxic reaction on the dose is exemplarily illustrated in Fig. 1.9, regarding nickel ions that were added to cell cultures. There is obviously a dose–

Table 1.3 Real risks of drug-associated side effects [2]

Drug	Fatalities	Treated patients
Digoxin	5	6,612
Heparin	2	2,102
Potassium chloride	1	8,764
Streptokinase	1	7
Allopurinol	1	1,331
Cosyntropin	1	68
Meperidine	1	2,852

Dentlearn.ir

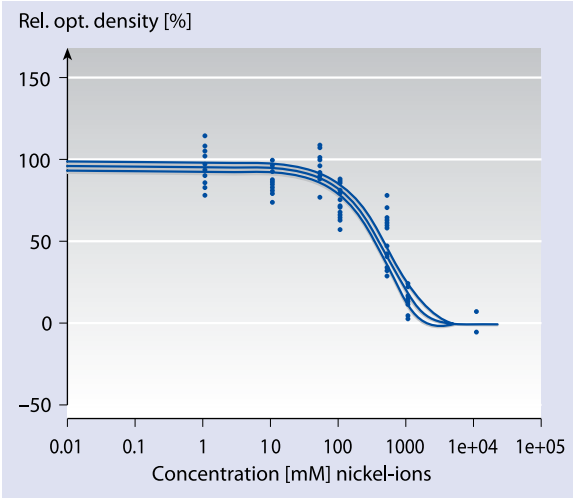

Fig. 1.9 Typical dose–response curve: influence of nickel ions on a cell culture. Single measurements are shown in combination with a mathematical calculation of the dose–response curve and a 95% confidence interval

reaction curve, meaning an elevated toxicity with increasing concentration: 0% on the *y*-axis means that all cells are dead, and 100% means that all cells are viable. Below a certain dose, no reaction occurs; this is the "threshold dose." This principle, which is known from toxicology, means that there might be no toxic reaction if the amount of substances released from a material is very low. However, alterations of the genome (DNA) are exceptions to this principle because up to now no threshold dose can be documented for these damages.

1.4.2 Effective Versus Applied Dose

One needs to differentiate between effective dose and applied dose. The effective dose is available at the target organ, but is different from that at the application site, because absorption, transportation, and metabolism will take place between both locations. For instance, only 7% of the Hg^{++} ions that are released from amalgam into saliva will, in fact, be absorbed in the gastrointestinal tract, subsequently distributed via the blood circulation, and then transported to the target organs (such as the kidneys). Thus, the orally applied dose (that is, the concentration in saliva) is significantly different from the effective levels at the target organs. Absorption, transportation, and metabolism of various substances are very different. Another example is that the effective concentration of a substance released from a restorative material (eugenol, for instance) is significantly lower in the pulp than at the cavity floor. Therefore, zinc oxide and eugenol cements clearly have an antimicrobial action (are toxic to bacteria) at the cavity floor, but pulp cells will not be damaged if the dentin is not perforated.

Key Note

For the clinician, it is very important to differentiate between applied and effective dose. For instance, readings of salivary metal concentrations are of little significance because these values represent only the applied dose, which can be considerably different from the effective dose.

1.4.3 Low-Level Dose Range

Long-term and low-level dose exposure is of special interest in the current public discussion about chronic toxicity. This subject is well known from public debate about environmental issues, and similar concern has been raised about dental restorative materials such as composite resins and amalgam. Currently, new analytic methods are being developed that allow the detection of minute amounts of a chemical substance, specifically of metals, with highly sensitive analyses.

Key Note

The presence of a substance in tissue is not equivalent to a toxic effect, but the dose is decisive.

It is not possible to extrapolate from biological reactions caused by high doses and short exposure times to effects associated with low concentrations and long-term exposure. The principle of threshold dose also applies for chronic exposure: Substances do not cause a reaction below a certain dose [16]. This principle is valid for all effects, except for some carcinogens that react directly with DNA. Further, it has to be considered that small quantities of a chemical substance may be beneficial rather than detrimental. For instance, low amounts of methacrylates can significantly promote proliferation of certain bacteria [4, 7, 19]. The clinical consequence of this growth promotion is an

Dentlearn.ir



Fig. 1.10 Accumulation of bacteria on the surface of a luting composite

accumulation of bacteria, for instance at the surface of composite resins (Fig. 1.10). Hence, the risk associated with a substance has to be carefully assessed for each clinically relevant exposure before a recommendation can be given.

1.4.4 Placebo/Nocebo Effect

The placebo effect means that an effect will be observed without the application of an active ingredient. This phenomenon is well known in pharmacology. This placebo effect may be due to an extrinsic effect or to an autosuggestion [16]. Equivalently, adverse effects may occur even if no active ingredient is applied; this is known as the nocebo effect. Translated into biocompatibility, this means that belief in the harmfulness of

Table 1.4 Examples of the frequency of unwanted placebo/nocebo effects in clinical studies [16]

Nocebo effect	Percentage of incidence of unwanted effects		
	Placebo (P)	Active drug (A)	Difference (A – P)
Headache	32	56	+24
Drowsiness	21	29	+8
Fatigue	30	32	+2
Faintness	6	13	+7
Dizziness	24	50	+26
Nausea	20	30	+10
Vomiting	9	8	–1
Loss of appetite	15	23	+8
Diarrhea	19	15	–4
Abdominal pain	8	17	+9
Anxiety state	25	33	+8
Impaired vision	18	20	+2
Eczema	4	16	+12
Itching	10	16	+6

Dentlearn.ir

a material may cause the symptoms of disorders. Frequently, symptoms associated with the testing of drugs are characterized by a disturbed existential orientation (psychosomatic disturbances; see Table 1.4).

Interestingly, patients who claim dental materials to be the reason for their disorders reveal similar symptoms as those mentioned above. Nocebo effects can be triggered or enhanced in anxious patients because of the suggestive genesis, by fearful imaginations, and also by reports in the media [16]. The dentist should, therefore, thwart these fears by providing correct information.

1.5 Interdisciplinary Collaboration

A close collaboration of different medical disciplines is required to evaluate biocompatibility and to handle patients who allege assumed or real adverse effects to dental materials. The dentist has an important function in this team, including providing information about the composition of a material or of specific circumstances in a patient's oral cavity (such as bruxism) and establishing differential diagnoses. The treatment of patients who claim a material-related health problem should always begin with a comprehensive dental examination and treatment. A dermatologist must be consulted in a case of suspected allergy, but the dentist is responsible for providing the necessary information (case history, symptoms, composition of the suspected material, and so on). Furthermore, to avoid unnecessary allergy tests, the dentist has to be familiar with the problems associated with them. Patients who claim material-associated damage frequently specify various disorders for which the reported symptoms are very general and may also be caused by internal diseases or drug therapy. A close collaboration with the family doctor, a specialist in internal medicine, or another medical specialist is necessary in these cases.

A possible psychiatric disorder must be also considered, even though most patients will perceive this possibility very negatively. A number of scientific studies have clearly shown that patients with claimed material-related disease may also suffer from a mental disturbance [6].

Last but not least, it has to be accepted that in some cases, no cause may be found for symptoms or disturbances of existential orientation. Unfortunately, this fact is often not accepted in traditional dentistry, with its mainly mechanistic focus compared to general medicine (and also due to expectations of the patients). But some patients are indeed relieved to hear that their symptoms are not the sign of a malignant disease or tumor.

Close collaboration among various disciplines is possible in specialized medical centers. Treatment of patients with a claimed material-related disorder is extremely time-consuming; a comprehensive dental and medical examination will often take several hours.

Conclusions for the Dental Practitioner

1. Dental materials are biomaterials and, therefore, are subject to specific legal regulations and standards.
2. Dental materials may cause various side effects. The frequency in patients, however, is very low (in the range of tenths of a percent) but is significantly higher in dental personnel. Local reactions and allergies represent the most important side effects.
3. Patients' risk perception is often very different from the scientifically based risk (risk analysis/risk evaluation). In this context, the dentist should provide objective information. A correlation to other risks of daily life may be very helpful for many patients to enable them to rank risks more objectively and realistically.
4. Treatment of patients with claimed or real side effects caused by dental materials will often be successful only if specialists of various medical disciplines collaborate very closely. Severe cases are rare, but the treatment of each individual patient requires much time and experience.

Appendix

LOEL: Lowest Observed Effect Level. Lowest concentration or amount of a substance, found by experiment or observation, that causes any alteration in morphology, functional capacity, growth, development, or life span of target organisms distinguishable from normal (control) organisms of the same species and strain under the same defined conditions of exposure [17].

Dentlearn.ir

LOAEL: Lowest Observed Adverse Effect Level. Lowest concentration or amount of a substance, found by experiment or observation, that causes an adverse alteration of morphology, functional capacity, growth, development, or life span of target organisms distinguishable from normal (control) organisms of the same species and strain under defined conditions of exposure [17].

NOEL: No Observed Effect Level. Greatest concentration or amount of a substance, found by experiment or observation, that causes no alterations of morphology, functional capacity, growth, development, or life span of the target organism distinguishable from those observed in normal (control) organisms of the same species and strain under the same defined conditions of exposure [17].

NOAEL: No Observed Adverse Effect Level. Greatest concentration or amount of a substance, found by experiment or observation, that causes no detectable adverse alteration of morphology, functional capacity, growth, development, or life span of the target organism under defined conditions of exposure [17].

The following threshold values have been defined for administrative purposes based on risk assessments:

STEL: Short-Term Exposure Level. Concentration to which workers can be exposed continuously for a short period of time without suffering from irritation, chronic or irreversible tissue damage, narcosis of sufficient degree to increase the likelihood of accidental injury, impaired self-rescue, or materially reduced work efficiency.

TI: Tolerable Intake. Maximum amount of a xenobiotic (in correlation to body weight) that can be ingested over time by the human organism without causing damage, usually indicated in mg/kg/time unit.

TDI: Tolerable Daily Intake. Daily tolerable intake.

TWI: Tolerable Weekly Intake. Weekly tolerable intake.

References

1. Amdur, M. O., Doull. J., Klaasen, C. D. (eds): Casarett and Doull's Toxicology: The Basic Science of Poison. McGraw-Hill, New York 1996.
2. Bundesverband der Pharmazeutischen Industrie e.V. Arzneimittel: Chancen und Risiken. [Chances and Risks] Pharma, Frankfurt 1985.
3. Christ, O.P.: ISO/IEC 14971 soll Harmonisierte Europäische Norm werden. [ISO/IEC 14871 shall become a Harmonized European Standard] Medizinprodukte Journal, 7, 7–8 (2000).
4. Friedl, K.-H., Schmalz, G., Hiller, K.-A.: Flüssigkeitskulturen zur Prüfung der Wirkung zahnärztlicher Werkstoffe auf das Bakterienwachstum. [Liquid cultures for testing the antibacterial effect of dental materials] Dtsch Zahnärztl Z 47, 826–831 (1992).
5. Garhammer, P., Schmalz, G., Hiller, K.-A., Reitinger, T., Stolz, W.: Patients with local adverse effects from dental alloys: frequency, complaints, symptoms, allergy. Clin Oral Investig 5, 240–249 (2001).
6. Gottwald, B., Kupfer, J., Traenckner, I., Ganss, C., Gieler, U.: Psychological, allergic, and toxicological aspects of patients with amalgam-related complaints. Psychother Psychosom 71, 223–232 (2002).
7. Hansel, C., Leyhausen, G., Mai, U.E., Geurtsen, W.: Effects of various resin composite (co)monomers and extracts caries-associated micro-organisms in vitro. J Dent Res 77, 60–67 (1998).
8. International Electrotechnical Commission: IEC 60601-1-4, Medical electrical equipment. Part 1: general requirements for safety. 4. Collateral standard: programmable electrical medical systems. International Electrotechnical Commission, Geneva 1996.
9. International Organization for Standardization: ISO 10993-1: Biological evaluation of medical devices. Part 1: evaluation and testing. International Organization for Standardization, Geneva 1992.
10. International Organization for Standardization: ISO 14971: Medical devices – application of risk analysis to medical devices. International Organization for Standardization, Geneva 2000.
11. International Organization for Standardization: ISO 10993-17: Biological evaluation of medical devices. Part 17: establishment of allowable limits for leachable substances. International Organization for Standardization, Geneva 2002.
12. Kallus, T., Mjör, I.A.: Incidence of adverse effects of dental materials. Scand J Dent Res 99, 236–240 (1991).
13. Kayser, D., Schlede, E. (eds): Chemikalien und Kontaktallergien. [Chemicals and contact allergies] Bundesinstitut für gesundheitlichen Verbraucherschutz und Veterinärmedizin. Urban & Vogel, München 2001.
14. van Leeuwen, C.J., Hermens, J.L.M.: Risk Assessment of Chemicals. An Introduction. Kluwer Academic, Dordrecht 1995.
15. Levinson, W., Jawath, E.: Medical Microbiology & Immunology. Prentice Hall International, London 1996.
16. Marquardt, H., Schäfer, S. G. (eds): Lehrbuch der Toxikologie. [Textbook on Toxicology] Spektrum Akad., Heidelberg 1997.
17. Nordberg, M., Duffus, J., Templeton, D.M.: Glossary of terms used in toxicokinetics (IUPAC Recommendations 2003). Pure Appl Chem 76, 1033–1082 (2004).
18. Orton, D.I., Wilkinson, J.D.: Cosmetic allergy: incidence, diagnosis, and management. Am J Clin Dermatol 5, 327–337 (2004).

Dentlearn.ir

19. Schmalz, G.: Der Einfluß verschiedener Frontzahnfüllungsmaterialien auf das In-vitro-Wachstum von *Streptococcus mutans*. [The effect of various front tooth filling materials on the in vitro growth of *Streptococcus mutans*] Dtsch Zahnärztl Z 32, 575–579 (1977).

20. Schmalz, G., Garhammer, P.: Biological interactions of dental cast alloys with oral tissues. Dent Mater 18, 396–406 (2002).

Dentlearn.ir

2 Determination of Biocompatibility

G. Schmalz

Contents

2.1	Introduction	13
2.2	Evaluation of Materials	13
2.2.1	Principles of Biocompatibility Testing	13
2.2.2	Test Materials	15
2.2.3	Systemic Toxicity	16
2.2.4	Local Toxicity and Tissue Compatibility	16
2.2.5	Allergenic Properties	24
2.2.6	Other Reactions	25
2.2.7	Clinical Studies	26
2.3	Diagnostic Tests on Patients	27
2.3.1	Allergy Tests	28
2.3.2	Measurement of Intraoral Voltage	32
2.3.3	Evaluation of Pulp Sensitivity	33
2.3.4	Analysis of Intraoral Alloys	34
2.3.5	Analysis of Metals in Saliva and Biopsies	34
2.3.6	Test Methods of "Alternative Medicine"	36
	Conclusions for the Dental Practitioner	39
	Appendix	39
	References	40

2.1 Introduction

Dental materials may result in damage to various tissues. Therefore, a great variety of different test methods are applied to evaluate the risk of such damage to ensure material compatibility prior to market launch. However, the results of such evaluations are dependent not only on the tested material but also on the test method used. The findings of these studies and the resulting claims of the manufacturers should be critically challenged by the dentist, so dentists need to be familiar with the principles and, in particular, with the problems of these test methods. This chapter describes and assesses the fundamental and frequently used methods for evaluating the biocompatibility of dental materials (see Sect. 2.2).

Even if the risk of damage caused by a new material is considered to be acceptable, it has to be kept in mind, not least due to the frequently high number of subjects who will come into contact with this material, that some patients may reveal problems based on specific circumstances – in other words, the problem of individual compatibility. This problem is addressed by certain test methods applied on individual patients, such as allergy tests. These diagnostic tests will be discussed in the second part of this chapter (Sect. 2.3).

2.2 Evaluation of Materials

2.2.1 Principles of Biocompatibility Testing

2.2.1.1 Overview of Test Methods

Evaluation of the biocompatibility of dental materials is a complex and comprehensive area because unwanted tissue reactions may occur in a great variety of types. An overview of common test methods is given in Table 2.1. Any single test method is applicable only for investigating one type of unwanted reaction out of a great variety of possible reactions. For instance, the so-called pulp/dentin test can be applied to determine the pulpal compatibility of a new material (local reaction), but it cannot be used to determine its allergenic potency.

Moreover, individual test methods are usually adequate only to describe or document a single aspect of a certain type of unwanted reactions. For example, cell culture tests will detect only the influence of a material on isolated cells. These findings cannot be transferred to patients without limitation. An alloy that does not cause a reaction in cell cultures may very well result in problems in patients because there may be a lower pH value below plaque or in crevices (e.g., telescope crowns) in the oral cavity. This lower pH value may result in a more pronounced corrosion of the alloy in vivo compared to the neutral conditions in cell cultures. However, cell culture findings may help explain the mechanisms of an unwanted reaction in a patient, for instance, an inflammation of the gingiva.

Dentlearn.ir

2

Table 2.1 Selection of usual test methods for assessing the compatibility of dental materials

	Systemic reactions	Local reactions	Allergic reactions	Other reactions
In vitro	(Cell cultures can be used for specific problems)	Cell cultures – Agar overlay – MTT test – Dentin-barrier test	(Cell culture models are currently being developed)	Mutagenicity – Ames test – Micronucleus test – HPRT test – Mouse lymphoma test
Animal experiments	Acute LD_{50} (e.g., oral application) Chronic LD_{50} (e.g., oral application)	Implantation tests Usage tests – Pulp/dentin test – Endodontic test – Implantation test	Maximization test with modifications Local lymph node assay	Micronucleus test (rodents) Teratogenicity (rodents) Reproductive toxicity (rodents)
Patient	← Clinical studies →			
Others	← (Occupational exposure, poisoning)[a] →			

[a] No real test methods but may be helpful for assessment

Key Note

Biocompatibility of a material cannot be evaluated by using a single test rather than a group of various techniques.

2.2.1.2 Phenomena and Mechanisms

Dentists and patients are primarily those who ask whether a material may be harmful for the patient or dental personnel, how this possible damage would become manifest, how it could be prevented, and what countermeasures are available. These questions can be answered by clinical investigations and observations as well as by animal studies, mainly on larger animals such as primates or dogs. These animal models are adequate for the best possible simulation of a material's application on patients (usage tests). The focus of these animal studies is the observed phenomenon and its transfer to the patient. However, for the further development (improvement) of dental materials and their overall assessment, the answer to the question of *why* a certain unwanted reaction occurs is decisive. Therefore, it is necessary to clarify the mechanism of an observed phenomenon – that is, the unwanted reaction. For this purpose, studies with smaller experimental animals (e.g., rats or guinea pigs) or cell cultures are performed.

2.2.1.3 Strategies for Evaluating Biocompatibility

The common approach and principle when testing the biological behavior of materials is to start with simple in vitro tests mostly based on cell cultures, as is generally done in toxicology. If these experiments and investigations of a material's efficiency deliver promising findings, then more comprehensive studies on experimental animals and usage tests (in vivo evaluation) will be performed. Clinical studies are the final step of this evaluation process.

However, some materials (e.g., zinc oxide and eugenol cements) have caused toxic reactions in cell cultures whereas no damage was induced in patients (in this case, no pulp reactions); indeed, valuable therapeutic properties such as pain relief were revealed. Thus, the aforementioned more schematic approach is increasingly being abandoned. Today's focus is an initial risk assessment by an expert. In this process, data already available about physical, chemical, and biological characteristics are evaluated, and a decision is made regarding whether further studies are necessary at all. If a material that has already been applied in practice was only slightly modified, then its harmlessness (i.e., acceptable risk) can be certified, for example, based on the chemical analysis of extracts (see below). If, however, further biological tests are necessary – for instance, because the formulation has considerably

Dentlearn.ir

changed or new components are used – then in vitro tests will be performed first. Subsequently, the risk will be reassessed, followed by more tests if needed (Fig. 2.1). The formal approach is regulated by standards. This policy, which appears rather complicated at first glance, has the advantage that each material will be individually assessed. This may save unnecessary animal experiments and allow a faster market launch of materials. But it must be emphasized that the assessing experts and the manufacturers have to bear a particular responsibility [86] (see also Chap. 3).

Key Note

It is important for the clinician to realize that experiences with premarket evaluation and certification systems, even those based on legal regulations, have revealed that assessment results must be critically questioned. For instance, filling materials that had successfully passed such a test system were introduced on the market without previous clinical studies. In daily practice, however, these materials generated severe side effects including pain and tooth fracture (refer to Sect. 2.2.7: Figs. 2.15 and 2.16) [12].

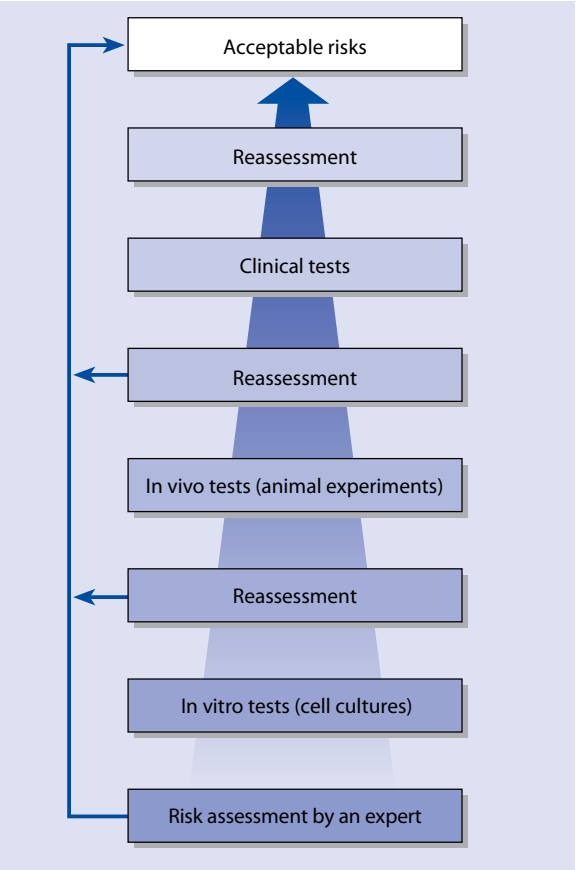

Fig. 2.1 Strategy for selecting necessary test methods based on risk assessment/management

2.2.2 Test Materials

The biocompatibility of a material can be determined directly or by using an "extract." In the first case, tissue will be directly exposed to the material, whereas in the second case, the material will be stored under specific conditions (e.g., defined by standards) for a certain time (e.g., 24 h) at a specified temperature (e.g., 37°C) in a liquid. Subsequently, this "loaded" liquid, known as extract or eluate, will be used for further tests. A chemical analysis of these extracts may already provide valuable information regarding the "leaching behavior" of materials. Hydrophilic liquids (e.g., saline solution) or lipophilic fluids (e.g., dimethyl sulfoxide, or DMSO) are used for extractions. Mixtures (ethanol/water) are also used as extraction fluids [27, 34].

Interestingly, almost all materials release the major share of their releasable components when they are not set or shortly after mixing. This is exemplified in Fig. 2.2, which demonstrates the release of fluoride from filling materials. An important conclusion from these findings is that dental personnel, who may have intensive contact with unset materials, may be exposed

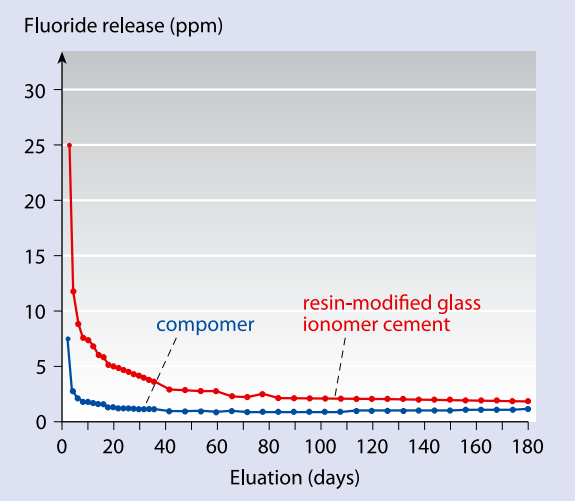

Fig. 2.2 Release of substances from setting materials, exemplarily demonstrated by the fluoride release from two filling materials [30]

Dentlearn.ir

to very high concentrations of released substances and thus should be considered a risk group (Fig. 2.3).

2.2.3 Systemic Toxicity

Experimental animals are usually used to determine systemic toxicity. The test substances can be administered in various ways. In dentistry, most substances or materials are administered orally (feeding of an extract or of the test material, mostly finely ground). Previously, the acute LD_{50} (see Appendix) was determined as routine. Today, other methods that are more sparing of animals are used, such as the so-called limit test (administration of a fixed dose, e.g., 2,000 mg/kg body weight). If this concentration is not high enough to reach the LD_{50}, then generally no further tests will be done, and the material will not be placed in the categories of "very toxic" to "minor toxic," according to Table 2.2 [76].

The chronic systemic toxicity will be determined by administering the material or extract over several months. Tests are sometimes extended over the lifetimes of the experimental animals. At the end of these studies, survival rates of the animals and pathohistological alterations of the main organs will be determined.

Fig. 2.3 Contaminations, such as at the outer surface of a bottle containing pit and fissure sealant, can cause direct skin contact with high amounts of resin monomers

Besides these classic systemic toxicity tests, additional methods may have to be used to answer special questions, such as those regarding genetically modified animal strains. Further information regarding chronic toxicity is obtained from accidents (high exposure level) and based on observations of occupationally exposed subjects (e.g., dental personnel) who are often in contact with the "active" unset material. Substances can be classified in various toxicity categories according to relevant guidelines (Table 2.2).

Assessment: In the past, data about acute systemic toxicity were routinely presented to assess a material according to relevant legal regulations and standards. Unfortunately, this information is often not published and thus is not accessible for scientific discussion [109]. Available data regarding acute LD_{50} (Tables 2.3 and 2.4) indicate, however, that dental materials are characterized by a low acute systemic toxicity in general [87].

Only rare findings are available regarding systemic toxicity of dental materials due to chronic exposure. Dental amalgam represents an exception: Comprehensive data about many different aspects after chronic exposure have been published, specifically addressing mercury toxicology (see Chap. 4). Today, the significance of the aforementioned preclinical tests to evaluate the systemic toxicity of dental materials is generally considered low. At least, it no longer seems appropriate to determine a classic LD_{50} [109].

Key Note

Findings from preclinical tests to determine the systemic toxicity of dental materials are usually of little clinical relevance for the dentist. Such tests are applied for assessing new materials before they are introduced on the market in order to fulfill legal requirements. Of special importance, however, is the analysis of risk groups, such as dental personnel.

2.2.4 Local Toxicity and Tissue Compatibility

Local toxicity must be differentiated from local tissue compatibility. Local toxicity is based on the chemical interaction of a toxic substance with biologically relevant molecules. Tissue compatibility, however, may also be dependent on causes other than material toxic-

Dentlearn.ir

Table 2.2 Classification of toxicity grades based on the acute LD_{50} (rat) [58]

Category	Oral LD_{50} (rat; mg/kg body weight)
Very toxic	≤ 25
Toxic	25–200
Less toxic	200–2,000
Not classified	> 2,000

Table 2.3 Acute systemic toxicity of orally applied composite resin compounds [15, 87]

Substance	LD_{50} (rat; mg/kg body weight)
Bis-GMA	> 5,000
UDMA	> 5,000
TEGDMA	10,837
Bisphenol A	3,250
Glycidyl methacrylate	597
Methyl methacrylate	8,000
2-hydroxyethyl methacrylate	5,050
Compare: nicotine	1

Table 2.4 Acute systemic toxicity of orally applied filling materials [87]

Material	LD_{50} (rat; mg/kg body weight)
Polymethyl methacrylate	8,000
Silicate cement (powder)	> 8,000
Silicate cement (liquid)	5.7 ml/kg
Eugenol	4,000
Zinc phosphate cement (powder)	> 8,000
Zinc phosphate cement (liquid)	5.7 ml/kg
Temporary cement (Provilink)	> 5,000

ity, including accumulation of bacteria below or at fillings and other restorations/dentures or the temperature rise generated by setting autopolymerizing resins (Fig. 2.4).

Local toxic features are determined by a great variety of different tests. Relatively simple test methods (cell cultures, implantation tests) will not represent the target tissues after application of the material in the patient's oral cavity; therefore, the data from such tests inform about the unspecific toxicity of a material. By contrast, in so-called usage tests, the experimental materials are used in animals or, in exceptional cases, on humans equivalent to the subsequent application on patients.

2.2.4.1 Cell Cultures

Many claims about the biocompatibility of products made by manufacturers are based on data from cell culture studies. Isolated cells derived from animal or human tissues are grown in culture plates and then are used for these tests [46, 56]. Today, mainly permanently growing cells (permanent cell lines) are used for this purpose because these cells can be easily amplified and their behavior is well known, relatively consistent, and constant [83]. Frequently, permanent mouse fibroblasts (L-929, 3T3) or human epithelial cells (HeLa) are used. However, other cells directly grown from explants (biopsies) of target tissues are applied, too, like gingival or pulp fibroblasts. These cells are called primary cultures [2]. Recently, primary cells were "immortalized" by transfection with certain virus particles (oncogenes), in order to maintain characteristics of the original tissue (gene expression pattern) but to be able to keep them for a long (theoretically unlimited) time in culture [85, 94]. Cells can be also grown in vitro three-dimensionally, which allows better in vivo simulation [98].

These cell cultures are treated ("incubated") with the materials or their extracts. Subsequently, a series of various parameters will be measured, for example, the number of "surviving" cells, protein synthesis, enzyme activity, or synthesis of inflammatory mediators [85]. One of the first methods for the evaluation of cell damage due to materials was based on the dye "neutral red" (Fig. 2.5). This dye stains vital cells, whereas cells with membrane damage will not be stained. Another method, which is often applied today, is to determine the activity of mitochondrial enzymes photometrically via a color change reaction (MTT assay).

Dentlearn.ir

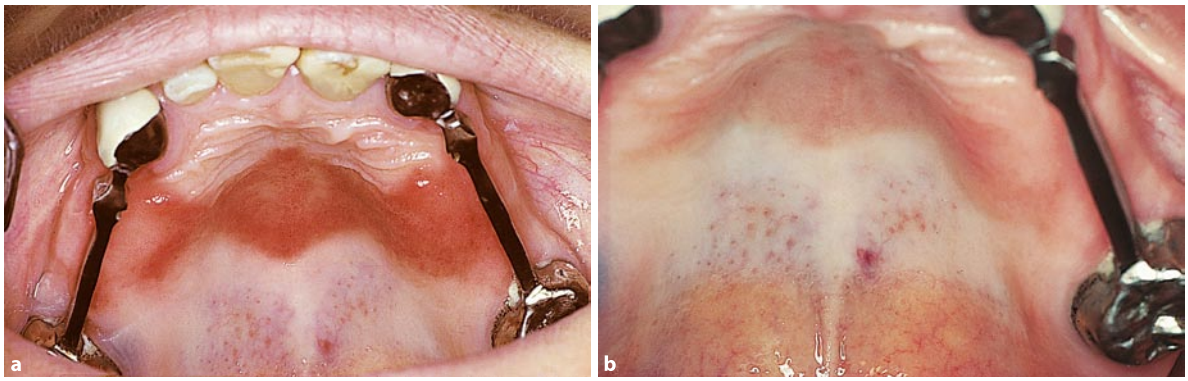

Fig. 2.4a,b Inflammation of the palatal mucosa. **a** Reaction beneath a denture. **b** Healing of the inflammation after hygiene instructions and rinsing with 0.1% chlorhexidine digluconate

More recent techniques are dentin-barrier tests, which simulate the tooth conditions by placing a dentin disc between target cells and test material. Three-dimensional cultures consisting of immortalized pulpal fibroblasts can be used as target cells. Cultures are permanently perfused with growth medium, which will keep the cultures vital for up to several weeks. That way, animal experiments will be unnecessary in certain cases [94, 95, 98] (Fig. 2.6).

Molecular toxicology methods have also been introduced. For example, fluorescence-activated cell sorting (FACS) and Western blotting (a method for detecting specific proteins by gel electrophoresis, transfer to a membrane such as nitrocellulose, and detecting by antibodies) are applied to detect the influence of a biomaterial on cell metabolism, especially upon signaling pathways within the cell. This may include the determination of radical oxygen species, apoptosis rate, DNA damage and repair, changes of the cell

Fig. 2.5a,b Cell culture. **a** The size of the zone of neutral red decolorization around the sample is indicative of cell damage (*left*). **b** The cell morphology (e.g., rounding, disintegration) indicates the extent of damage (*right*)



Fig. 2.6 Dentin-barrier test: a dentin disk is placed between the test material and the target cells (three-dimensional cell culture)

Dentlearn.ir

cycle, or synthesis of specific inflammation mediators [104]. Gene expression analysis using microarray test systems (e.g., Affymetrix) reveals information on the genes involved in the cellular stress response [105].

Assessment: Cell culture studies are comparatively quick and simple to perform, and findings are largely reproducible. But results depend on the selected test conditions. Therefore, it is always necessary to test and assess a material in comparison with similar materials whose clinical behavior is known (relative toxicity analysis) [85].

The major problem associated with cell cultures is the question of possible extrapolation of the results to patients. There are, in fact, situations in which this extrapolation is possible. For instance, most materials damage cells immediately after setting but not in the set state. Equivalently, pulpal alterations can be observed after the application of fillings in deep cavities; these alternations usually disappear after a few weeks if the pulp is sound and reveals a sufficient regenerative capacity. These reactions may be due to the initial toxicity of filling materials, eventually combined with cavity preparation trauma.

On the other hand, discrepancies between cell culture data and patient reactions have been documented. Zinc oxide and eugenol cement (ZOE) is, for instance, highly toxic in cell cultures but almost nontoxic for the pulp in those cavities where the dentin has not been perforated [85]. Thus, an evaluation of ZOE based only on cytotoxicity tests would result in a wrong assessment of a material, which is important in dentistry.

In the future, these problems will be solved by a best possible simulation of clinical conditions in cell culture, as is already possible, for instance, in the dentin-barrier test [94]. But currently, only limited experiences are available for this method.

Key Note

It is important for the clinician to realize that cell culture data cannot be *a priori* transferred to the patient. In fact, such studies indicate only whether potentially incompatible substances are released from a material at all. Further studies are then necessary to investigate compatibility with the target tissues of the oral cavity. But cell cultures are an excellent tool to study the mechanisms of incompatibility reactions.

2.2.4.2 Implantation Tests

For implantation tests, materials are implanted subcutaneously, intramuscularly, or in the bone of an experimental animal (rats, rabbits, etc.). After different periods of implantation of the material in the tissues (between 1 week and several months), the adjacent tissue is investigated macroscopically and microscopically (Fig. 2.7). After a short implantation time (1–2 weeks), degrees of inflammation surrounding the implant will primarily be assessed. In the case of an extended implantation period, the nature and quantity of the connective encapsulation will be evaluated, too.

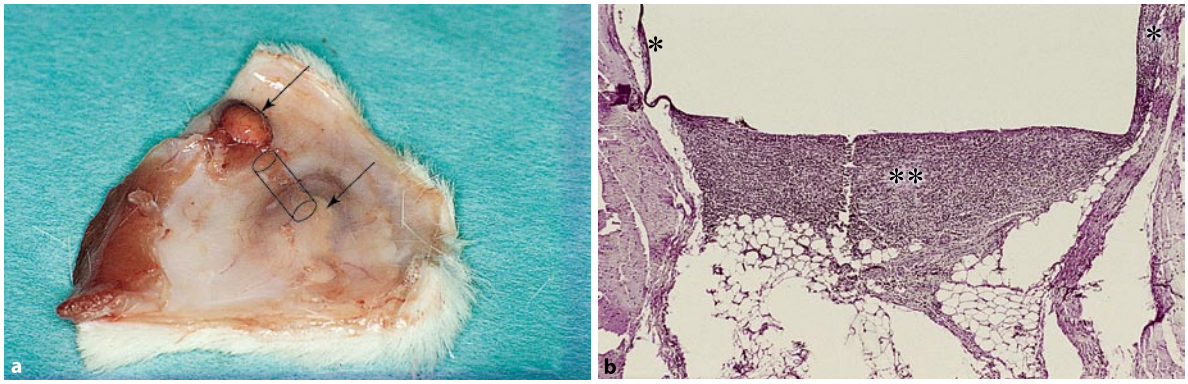

Fig. 2.7a,b Implantation test. **a** Formation of an abscess at the interface between material and connective tissue (*arrows* mark the location of the open ends of the Teflon tube containing the test material, which was implanted into the tissue). **b** The histologic slide reveals severe inflammation at the interface between the material and connective tissue (**), but no reaction at the contact area with Teflon (*) (magnification ×80)

Dentlearn.ir

Assessment: In contrast to cell culture tests, implantation studies also provide information about the removal of toxic substances from the tissue (open system) and about the defense reaction of the entire organism, such as via an inflammatory reaction. Thus, this type of study is closer to the patients than cell culture experiments are. However, a good correlation was found between cell culture data and findings from implantation tests regarding certain dental filling materials [84]. For instance, ZOE provokes a pronounced tissue reaction in implantation tests, as it does in cell culture experiments. When testing alloys by means of implantation, an extended implantation period of tissue contact of more than 4 weeks is necessary.

2.2.4.3 Pulp Damage and the Pulp/Dentin Test

Pulp compatibility of dental materials is naturally of great importance for the dentist. To generate better understanding of the processes of pulp reaction during evaluation of a material as well as daily treatment of patients, this topic will be discussed in more detail. Pulp compatibility of a material is investigated on teeth of experimental animals or on human teeth that have to be extracted for orthodontic reasons (pulp/dentin test) [43]. In both cases, class V cavities are prepared as atraumatically as possible and are then filled with the test material. This approach is equivalent to the future mode of application on patients. After a period of days to several months, the teeth are removed and histologically prepared, and the pulps are microscopically evaluated for signs of acute or chronic inflammation and odontoblast reaction (including dentin neogenesis; Fig. 2.8). In addition, the space between test material and the cavity wall is investigated for bacterial penetration [47].

These methods can be modified in such a way that the pulp is exposed or part of the pulp is removed before the material is applied. In this way, materials and methods intended for direct (vital) pulp cappings or pulpotomies can be assessed.

Assessment: The most important causes of pulp damage resulting from a restorative procedure (in addition to cavity preparation) are the following:

- Toxic substances released from the material
- Bacteria and their toxins between the material and the cavity

The pulp can react to these irritations in the following ways:

- Inflammation, which, based on the degree of irritation, may be reversible (with subsequent healing) or irreversible (with the formation of pulp abscesses and subsequent necrosis)
- Tertiary dentin formation; minor irritations can stimulate present odontoblasts to form tertiary dentin ("reactive dentin") in the pulp combined with an obliteration of dentin tubules (dentinal sclerosis). More pronounced stimuli will result in degeneration of the original odontoblasts, which

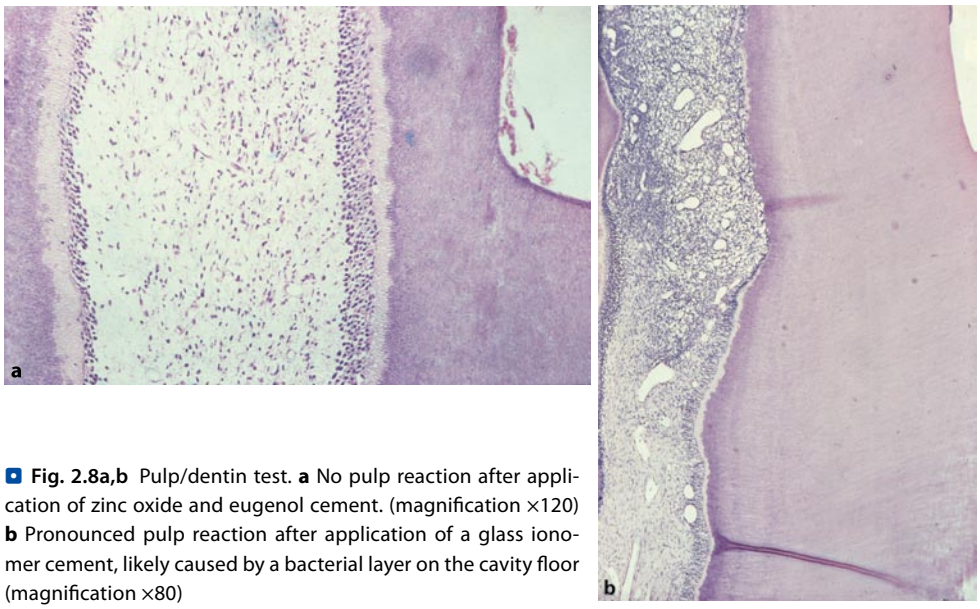

Fig. 2.8a,b Pulp/dentin test. **a** No pulp reaction after application of zinc oxide and eugenol cement. (magnification ×120) **b** Pronounced pulp reaction after application of a glass ionomer cement, likely caused by a bacterial layer on the cavity floor (magnification ×80)

Dentlearn.ir

will be replaced by "secondary" odontoblasts due to differentiation of pulp (stem/progenitor) cells. Secondary odontoblasts can also form tertiary, or regenerative, dentin, but it may reveal a more irregular structure and voids (tunnel defects) [114].

Toxic substances, bacteria, and bacterial toxins may only evoke a pulp reaction if they can diffuse through dentin tubules toward the pulp. At the same time, dentin exerts a certain barrier function despite dentin tubules. This barrier function is increased by a smear layer that is generated during preparation (Fig. 2.9) [78, 92]. In addition, some substances, including zinc ions and eugenol, will be bound to dentin. An additional barrier factor is the obliteration of dentin below a carious lesion (dentinal sclerosis; Fig. 2.10), which may further reduce diffusion of substances [106].

The barrier function of dentin may be reduced by acids, which may particularly remove the smear layer and extend the orifices of the dentin tubules [21, 79]. On the other hand, acids are neutralized when coming into contact with dentin, which may potentially abolish their toxicity [66].

However, the barrier function of dentin does not mean that the transport of substances through dentin is completely inhibited. First, permeability of dentin depends on the topography: Distant from the pulp, permeability is lower than close to the pulp due

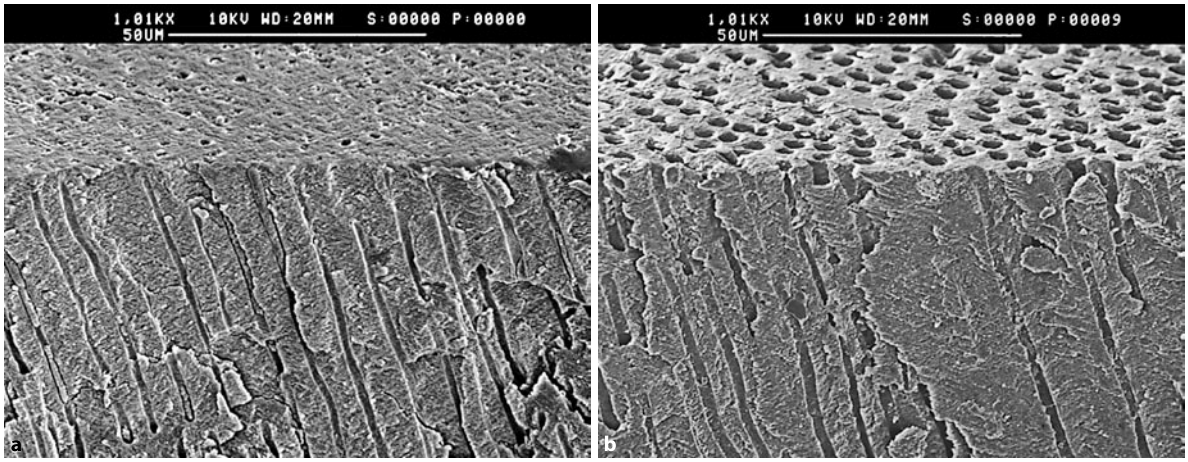

Fig. 2.9 Scanning electron microscopic image of dentin with (**a**) and without (**b**) smear layer



Fig. 2.10a,b Dentin tubules of the same tooth. **a** Obliterated beneath a caries lesion (sclerotic dentin). **b** Not obliterated in the vicinity of the pulp

Dentlearn.ir



Fig. 2.11 Number and diameter of dentin tubules of the same tooth are much higher close to the pulp (**a**) than distant from the pulp (**b**)

to the lower number and the smaller volume of dentin tubules in the dentin periphery (Fig. 2.11) [79]. The barrier function is also dependent on the dentin thickness; permeability increases exponentially with decreasing dentin thickness (see also Chap. 5) [92]. Apparently, at a remaining dentin thickness of less than 0.5 mm, defense mechanisms of the pulp are increasingly stimulated [72]. These factors may explain why reactions observed in deep cavities are different from those in medium-deep or shallow cavities. Dentin sclerosis reduces the dentin's permeability, but low-molecular substances may diffuse even through sclerotic dentin [37].

This (limited) barrier function of dentin applies for substances released from filling materials and for bacterial toxins as well [65, 66]. The concentration of toxic substances leaching from filling materials generally decreases with the setting of materials and with increasing time (Fig. 2.2); if bacteria can penetrate below a filling, then the synthesis of toxins will increase with increasing time. This may explain the pronounced pulp reaction that has been observed in these cases [11, 93] (see also Chaps. 5 and 6).

Extensive experiences are available with the pulp/dentin test. It was found that some filling materials, including silicate cements and composite resins without a cavity base and applied without adhesive techniques, cause severe inflammatory reactions in this test. These materials have also resulted in pulp necrosis/gangrene in patients. ZOE, however, triggers no or only slight pulpal reactions in the pulp/dentin test and in patients as well, as long as the dentin layer is intact and not perforated [47]. A high degree of conformity of data from these studies and clinical experience has been documented over the years.

However, sound teeth, mostly without obliterated dentin, are used in pulp/dentin tests. Thus, there may be a discrepancy between the clinical situation (below a carious lesion with dentinal sclerosis) and the usage test with filling materials. The diffusion of potentially damaging substances through sclerotic dentin toward the pulp may be reduced. On the other hand, similar situations are given if a tooth was prepared for a crown and sound dentin was extensively exposed.

In addition, the target organ of the pulp/dentin test is the pulp of sound (test) teeth and not the "predamaged" pulp, as is frequently the case in patients. A chronic inflammation in the patient's tooth pulp may impair the defensive capacity of the pulp, rendering it more susceptible to toxic material components.

Furthermore, recent studies addressing direct pulp capping with dentin adhesives revealed that no or little reactions were triggered in experimental animals, especially primates, whereas inflammatory alterations up to necrosis were generated in humans (see also Chap. 5). The pulps of experimental animals, especially primates, seem to be much more resistant to chemicals – but less resistant to bacteria and bacterial toxins. Another problem is the use of (mainly large) experimental animals, such as primates, dogs, and miniature pigs, which is not only rather costly but also increasingly questioned by the public. Certain cell culture tests (e.g., dentin-barrier test) could partly replace these animal experiments.

Dentlearn.ir

Key Note

It is important for the clinician to know that data from pulp/dentin tests exhibit a comparably good transferability to the clinical situation (patient) because this method simulates the following clinical application in the best possible way. But since these methods also reveal a number of disadvantages, data always need to be assessed together with findings from other tests, such as cell culture experiments and clinical studies.

2.2.4.4 Mucosal Damage and Mucosa Usage Tests

Various cell cultures and animal models have been described in the literature for testing mucosal compatibility (oral mucosa test) [47, 96, 116]. A relatively new model consists of in vitro grown skin equivalents and is already being applied for test purposes in the cosmetics industry [88]. For instance, in vitro co-cultures are grown that consist of skin fibroblasts and keratinocytes [88]. Partially or completely differentiated, multilayered, epithelial-like cells are being used in other models [96], and a number of new skin/mucosa models are currently being developed [26, 69].

Assessment: Because of their technical limitations, oral mucosa tests are not considered in most national and international standards, so the number of relevant publications is comparatively small. Alternatively, other test methods (cell cultures, implantation tests) can be used to determine potential damage of the mucosa. Based on the experience of the cosmetics industry, in vitro grown mucosa equivalents may offer an interesting perspective, but experiences with dental materials are still minor.

Key Note

It is important for the clinician that no optimal preclinical test system for assessing mucosa compatibility is available. As alternatives, data from cytotoxicity tests, implantation studies, or, more recently, cell culture models (in vitro mucosa equivalents) need to be used for evaluation.

2.2.4.5 Periapical Tissue Damage and Endodontic Usage Test

The literature includes descriptions of animal models (e.g., primates, dogs) that allow the application of a given material into the root canal according to endodontic techniques after a usual root canal preparation. Compatibility is assessed by histologic evaluation of the periapical tissues. It is also possible to induce pulp gangrene as a disease model in the experimental animal and to perform an appropriate treatment [28].

Assessment: The classic endodontic usage test is very elaborate and includes the same technical and ethical problems as the pulp/dentin test using large experimental animals. Relatively few studies using this test method are available in the literature. The presented findings, however, document a good correlation with clinical observations. In particular, stimulating effects on special cells can be determined, such as the influence of calcium hydroxide compounds on periapical cementoblasts [110]. Otherwise, implantation tests, in which Teflon tubes are filled with the experimental material and subsequently implanted, may be used as alternatives (Fig. 2.12).

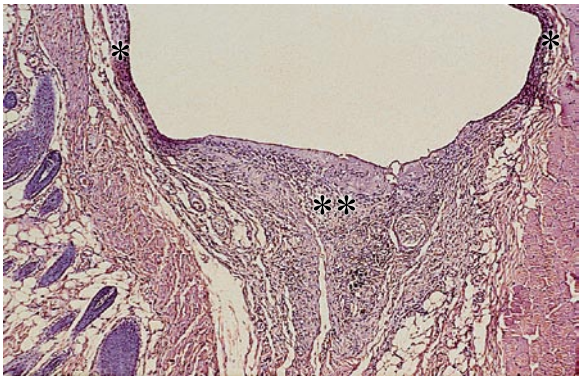

Fig. 2.12 Implantation test of a root canal sealer filled into a Teflon tube. Inflammatory reactions at the interface of the material (containing paraformaldehyde) and the connective tissue indicate an incompatibility (**); no inflammatory reactions in the contact area with Teflon (*) (magnification ×80)

Dentlearn.ir

2

Key Note

The clinician should know that data from endodontic tests can be "translated" into the patient under consideration of the mentioned technical problems. Such tests are especially useful when assessing the claimed bioactive effects of test materials. But it should be emphasized that appropriate and modified implantation tests generate data that allow assessment of toxic properties of root canal filling materials and are well transferable to the clinical situation.

2.2.4.6 Intraosseous Implant Test

Materials used for dental implants are inserted into the jaw of test animals (intraosseous implants). For this, penetration of the epithelial barrier, equivalent to the treatment of patients, is simulated on experimental animals. Appropriate animals are, among others, primates, dogs, miniature pigs, guinea pigs, and rats. Tissue reaction is assessed histologically, with the tissue in contact with the implant being of particular interest [19].

Assessment: Available data from these animal studies show that implants based on titanium or ceramics, for example, are generally well tolerated by the surrounding tissue. A good correlation of these findings with patients' situations can be expected.

Key Note

Many factors, including surgical technique, biomechanics, anatomical conditions, and oral hygiene, play an extremely important role in the clinical success of implant materials. Preclinical intraosseous implant tests are a prerequisite for the use of dental implants. Clinically, however, a variety of additional factors must be considered (as for other materials) in order to secure biocompatible behavior of the implants.

2.2.5 Allergenic Properties

In general, allergenic properties (type IV reaction) of dental materials are currently preclinically tested on experimental animals. According to OECD Guideline 406 (see also Chap. 3), two test methods are recommended using guinea pigs: the maximization test and the Buehler test [6, 29, 55].

For the maximization test, the investigated substance is at first injected intradermally into the experimental animal, together with Freud's Complete Adjuvans (FCA). Seven days later, the same substance is applied topically at the same site for 2 days. It is intended to amplify the immunological effect by FCA and, thus, to increase the sensitivity of the test. Fourteen days after this induction period, the test substance is applied on a different area of the skin. Subsequently, the skin reaction is assessed after an appropriate exposure time (Fig. 2.13). It is important that the substances be applied at a concentration that does not evoke primarily toxic (irritating) skin reactions.

The Buehler test is similarly executed on guinea pigs but without the application of FCA. Therefore, the Buehler test is considered to be more protective for the animals than the maximization test. The local lymph node assay (LLNA) on mice and the mouse ear swelling test (MEST) are of increasing importance. In addition, in vitro methods are being developed.

Assessment: Extensive data are available with these test methods because they are part of various international standards. Therefore, many materials that are certified according to national or international legal requirement must be subjected to these tests [6, 29, 55]. There is some indication that the Buehler test is less sensitive than the maximization test [29]. Some

Fig. 2.13 Allergy test on a guinea pig; the redness of the back skin is typical of an allergenic material (Courtesy of A. Hensten, Tromsø, Norway)

Dentlearn.ir

resin-filling materials (e.g., acrylates), cements (e.g., eugenol-containing compounds), and metals (nickel, palladium) have caused positive reactions in the maximization test. A higher incidence of allergic reactions to these materials has also been documented in patients. This applies specifically for dental personnel (see also Chaps. 12 and 14).

Cases have been reported, however, in which a material that was inert in this preclinical test resulted in allergic reactions in some patients. This may be because dental materials are used in a very high number of patients. Thus, the probability is much higher that an accordingly disposed patient is exposed to the material, compared with preclinical experiments with a limited number of test animals.

Key Note

It is important for the clinician to know that preclinical data derived from allergy tests are transferable to the patient. This applies specifically to positive findings. Dentists need to know about corresponding test results of those materials that are used in their practice; this information must be considered before application on patients.

2.2.6 Other Reactions

2.2.6.1 Mutagenicity

A variety of different methods, mainly in vitro techniques, are described in relevant standards. Basically, the influence of a material on the genome (DNA) of bacteria or of mammalian cells is investigated. The Ames test is the most famous in vitro method [57]. Genetically altered bacteria are used as test organisms. These bacteria cannot grow and form colonies on a special culture agar, which is histidine-deficient. But as soon as they come into contact with a mutagenic substance, they begin to grow. The number of forming colonies is a criterion for the mutagenicity. The result indicates that the genome has been changed and was passed on to the next generation of bacteria (mutagenicity).

With other methods, DNA damage is determined without demonstrating that the damage was transferred to the next generation (genotoxicity). In vitro test systems based on cells include (among others) the HPRT test [99], in which an alteration of the gene is detected that encodes for the enzyme HPRT, and the in vitro micronucleus test, in which direct morphological alterations of the chromosomes are identified (formation of micronuclei). Genotoxicity can be also documented on lower animals such as clams, but these tests are primarily used in environmental toxicology (e.g., water pollution) [39].

Mitchell investigated the carcinogenicity of a number of dental materials by implanting them in rodents for an extended period of time, the life span of the animals. None of the tested materials caused a tumor. The authors concluded that this technique would be appropriate for detecting carcinogenic properties of dental materials [67].

Assessment: The number of (published) studies addressing the mutagenicity of dental materials is comparatively low. Mostly in vitro data about root canal sealers, composite resins/adhesives and some cements have been reported [39, 99–103]. For some materials, e.g. glutaraldehyde-containing dentin adhesives, specific epoxy-based root canal sealers and for some acrylic materials, in particular when unset, mutagenic effects have been reported [39, 50, 100, 101, 103]. The number of animal studies about mutagenicity and carcinogenicity is even lower.

The assessment of the results of mutagenicity tests is very difficult. The evaluation of a series of 300 chemicals by means of the Ames test revealed that approximately 90% of the tested carcinogenic substances were mutagenic and 87% of the noncarcinogenic chemicals were nonmutagenic [61]. More recent studies differentiate between carcinogenic substances, which react directly with DNA, and those that do not. More than 80% of the carcinogens reacting directly with DNA were positive in the Ames test, but less than 10% of the other group (not directly with DNA-reacting chemicals) [3].

So far, no clinical reports have been published that document a carcinogenic effect of certain dental materials in the oral cavity. The long exposure time that is necessary for the emergence of a malignant tumor is a very aggravating factor for clinical assessment of potential carcinogenic properties. Therefore, it is only possible to draw indirect conclusions from other areas (e.g., occupational exposure to chemicals) to a possible carcinogenic effect.

Today it is generally accepted that results from single mutation tests do not allow conclusions about a possible mutagenic or carcinogenic effect of a material in patients. Rather, positive findings from three

Dentlearn.ir

different test systems, at least two in mammalian cells, are necessary [42]. Then, animal experiments (e.g., in rats) have to be performed if the carcinogenicity of a material is to be disproved.

Clinical Practice Advice

It is important for the clinician to request data about mutagenicity and carcinogenicity of a material from the producer. If suspicion has been raised that a material may be mutagenic when unset, then the dental personnel should avoid repeated skin contact ("no-touch" technique). It should be kept in mind that some substances can penetrate protective gloves (see also Chaps. 5 and 12). If a material caused positive results in different mutagenicity tests, specifically when set, then caution should be exercised.

2.2.6.2 Teratogenic Effects and Influence on Reproduction

To assess these types of damage, the test substance will be applied to animals, such as rodents, before mating (males and females) or after mating (only females). At the end of the study, female animals and fetuses/newborns are macroscopically and microscopically evaluated for malformations. This trial may possibly be extended to the next generation. The indication of these extensive studies is considered with great reservation in relevant standards regarding dental materials (ISO 10993-3) [42]. So far, no clinical case with a suspicion of such effects deriving from exposure to a dental material has been published.

2.2.7 Clinical Studies

The vast majority of clinical studies address the efficiency of new materials, for instance, wear, formation of marginal gaps, or longevity. The examination of the biocompatibility of dental materials is a part of clinical studies but not their main focus. For example, if filling materials are investigated, pulp sensitivity, postoperative pain, and other potential problems (hot-cold sensitivity, etc.) are also examined, but more detailed investigations, such as by means of histology, are rarely executed.

Clinical studies have to be approved by ethical committees, mainly based on the Helsinki Declaration (see Chap. 3). Drugs are frequently examined in blind studies; that is, patients are not informed whether they receive the tested drug or a control substance, which might be an older drug or a placebo. In double-blind studies, the treating physician is also unaware which drug he or she is going to administer in each individual case. This approach is frequently not possible for dental material testing, since handling and appearance are often completely different between the test and control materials.

In a controlled clinical study, test and control materials are examined at the same time. Controlled clinical studies possess a higher level of significance/evidence compared with studies in which only one material is investigated. In studies with a so-called split-mouth design, both materials (test and control material) are applied in the same patient on similar teeth (e.g., in different quadrants). The assignment of test material/control material to individual teeth/cavities should be randomized, similar to a rolling of the dice [70].

Assessment: Biocompatibility data from clinical studies are naturally of special interest for the dentist, since the examination was done on the target group of this material (patients). But this should not conceal the fact that clinical studies reveal limitations, too. An uncritical transfer of such results to patients in daily practice may result in problems, for instance, if data are not based on a blinded study. Therefore, at least treatment and subsequent assessment should be done by different persons. In addition, the clinical diagnosis of pulp damage is afflicted with significant uncertainty. For instance, pathologic processes in the pulp may proceed without clinical symptoms [113]. This was observed in the past with silicate cements [47], but also nowadays with dentin adhesives (in very deep cavities) [38] (Fig. 2.14).

Many unwanted reactions appear only after chronic exposure. But clinical studies – in particular those with new materials – are frequently limited to comparatively short periods of time (some only 6 months). In addition, only a small and often strictly selected group of patients is included in the study, for instance in a university hospital. In one clinical study, tooth fractures occurred more than 6 months after the application of a new filling material [12] (Figs. 2.15 and 2.16). Another problem with today's clinical studies is the very low rate of side effects. It could be

Dentlearn.ir

Fig. 2.14 Tooth discoloration indicating a pulp necrosis, often occurring with no pain symptoms

demonstrated that for a side effect frequency of 0.1%, it is necessary to have a test group of 3,750 patients in order to be able to document such effects [32, 44]. Because such high numbers of patients are usually not available for clinical studies, unwanted side effects may not completely be identified. It is, therefore, of outstanding importance to monitor the market through an observation and reporting system that is critically dependent on participation of the practicing dentists (see also Chap. 3).

Key Note

It is important for the clinician to keep in mind that clinical studies, although of high significance, are also characterized by certain disadvantages and therefore have to be critically questioned in each single case. An overall picture of the biocompatibility of a material requires preclinical compatibility tests and clinical studies as well.

2.3 Diagnostic Tests on Patients

Contrary to the test methods that are used to characterize a (new) material and which have been described so far, diagnostic tests on patients are used to more deeply analyze claimed or real unwanted side effects in individual subjects (individual compatibility). This branch of biocompatibility studies has become very important during recent years, since many materials do not cause clinically manifest reactions in the vast

Fig. 2.15a–c Tooth fracture 2 years after application of a (modified) composite resin: crack of the lingual cusp (*arrow*) (Courtesy of N. Krämer, Erlangen, Germany)

Dentlearn.ir

Fig. 2.16a–d Tooth fracture 2 years after application of a (modified) resin-based composite: complete fracture of the mesial-lingual cusp [12] (Courtesy of N. Krämer, Erlangen, Germany)

majority of the population but may generate claimed or real disease symptoms linked to materials in single cases. The assumption of an **individual compatibility** for dental materials is based on these observations. Thus, examination of the individual compatibility of various materials has been attempted by means of one or more test methods in order to find a feasible explanation for certain symptoms, to perform a causal treatment, or, if possible, to avoid such symptoms by a preceding examination.

A variety of methods have been described, some of which are accepted by the scientific community and some that have not yet been scientifically approved. The most important methods will be discussed and critically evaluated in the following sections. Other methods, such as the analysis of blood or urine to determine exposure to heavy metals, are part of general toxicology or occupational medicine. The metal concentration of whole blood, blood plasma, or 24-h urine can be analyzed by common chemical procedures (e.g., atomic absorption spectrometry). These methods are explained in detail in textbooks of toxicology or occupational medicine.

2.3.1 Allergy Tests

The patch test, originally developed and described by Jadassohn [16], is the most important allergy test regarding dental materials. This test can be applied to identify delayed type hypersensitivity (type IV reactions) as the cause for an allergic contact dermatitis [16]. Immediate reactions (type I reaction, such as asthma) can be diagnosed by the prick test. The radioallergosorbent test (RAST) may be used as an alternative or supplement to the prick test (see below). Further immunological tests are offered in the current literature and will be mentioned for the sake of completeness, but based on previous experience, these tests should not yet be used for routine diagnosis.

2.3.1.1 Patch Test

Adhesive tapes containing the potential allergens at concentrations that are just high enough to trigger the allergic reaction (but which are nonirritating) are adhered to the clinically sound skin of the patient's back

Dentlearn.ir

(Fig. 2.17) [48] (see also Chap. 14). The most important allergens are combined in so-called standard series at ready-made concentrations and are commercially available. Special series include dental materials. The patient should avoid excessive sweating or exposure to sun as well as scratching of the back, and should not have a shower or bath. During the following days, after the tape has been removed, the skin is evaluated for test reactions: redness, itching, blisters, etc. Skin reactions are assessed after 2 and 3 days (Fig. 2.17), but later checks (after 5 and 7 days) are also necessary to detect late reactions, since immunocompetent T lymphocytes occasionally require several days before they cause a visible allergic reaction.

Assessment: The patch test is the primary method for the detection of a delayed-type hypersensitivity (type IV reaction) allergy to dental materials. Although many attempts have been made, cell cultures are not yet generally accepted for diagnosing a type IV hypersensitivity (see below). Skin and oral mucosa react similarly in the case of an allergy, as in many other diseases, too. The skin is, therefore, an adequate organ for the appropriate allergy tests. The basic requirement for the stimulating effect on T lymphocytes is that the allergen is released from the material in sufficiently high quantities and then penetrates the skin.

It was recommended, as an alternative to the patch test, to assess the allergy at the actual tissue of target, the oral mucosa (epimucosal test). However, this approach is much more difficult to perform, and results are considered to be less meaningful. Saliva will dilute the allergens, and the oral mucosa may have a different immunological reaction, for instance, with a lower increase in the numbers of Langerhans cells after allergen exposure compared with the skin [75]. Thus, higher allergen concentrations are necessary to trigger positive test reactions. Altogether, this means a lower reactivity of the oral mucosa compared with the skin of the back. Also, some patients who reveal a positive reaction to a substance (e.g., nickel) on the skin of their back may not show clinical symptoms to nickel-containing alloys in their mouth. The intraoral situation, however, may change due to, for instance, a reduction of salivary flow because of disease or to drug therapy. Thus, the more sensitive patch test should be preferred. The patch test is recommended by a number of national and international contact allergy associations for diagnosing type IV hypersensitivity [8, 10, 14].

Clinical Practice Advice

Questions about existing allergies should always be part of the first medical examination of the patient. In addition, the patient should be asked at regular intervals to report newly developed allergies; thus, the general medical history should periodically be updated.

Fig. 2.17 Assessment of allergic reactions in the patch test. **a** Applied tapes. **b** Skin reactions indicating a type IV hypersensitivity

Dentlearn.ir

It is important for the clinician to know when patch tests are indicated because the dentist is the patient's primary contact person. It must be kept in mind that patch tests should be performed only if there is a well-founded suspicion of a type IV hypersensitivity, *since the test itself may cause sensitization*. Therefore, a general patch testing of patients with no clinical symptoms prior to a dental treatment ("prophetic test") is disapproved of. Even in the case of a negative result of the patch test, the possibility that the patient will develop an allergy to the applied material in the future cannot be excluded. Likewise, tests should not be performed with undiluted substances (e.g., acrylates) because this may increase the risk of sensitization by the test itself.

Anamnestic details that are reported by the patient, such as allergies to jewelry (rings, studs) combined with claimed reactions to dental alloys, may be indications of an allergy. This information may be supplemented by clinical intraoral signs of inflammation (redness, swelling, bleeding) or blisters, which may be chronologically associated with an exposure to a certain material. Additional information may be obtained by a positive elimination test and/or a provocation test. These tests are possible only with removable restorations, such as dentures. If the dentures are removed (elimination test), complaints may decrease and may reappear after reinsertion (provocation test). Additional manifestations of an allergy are extraoral symptoms, like eczema on hands or face (Fig. 2.18). Purely subjective extraoral complaints, such as itching, that are chronologically linked to a material exposure, represent a limited indication for a patch test.

It is important that the clinician is passing relevant information on to the allergologist/dermatologist. These include anamnestic information, specifically with respect to a chronological association between exposure and symptoms. Finally, the dermatologist will need data about the composition of the material that might be causative for the symptoms, in order to execute a targeted test. For this, the dentist has to rely on the manufacturer's information. Data provided by the package information sheet are generally not sufficient for this purpose. Therefore, in these cases the dentist should directly contact the manufacturer. When testing for possible allergies to alloys, the use of test discs (consisting of the cast alloy) for the patch test proved to be of little help. It was found in a number of cases that the results of the patch test indicated an allergy to the relevant metal salts (in accordance with the clinical symptoms), whereas the alloy discs provoked no reaction in the patch test [32].

Fig. 2.18 Contact allergy after patient contact with the dentist's latex gloves (cause: the additive thiuram)

Key Note

Diagnosis of a material-linked type IV hypersensitivity is possible only if the clinical signs of an allergy can be associated with the presence of the positively tested (patch test) allergen that is present in the oral cavity.

2.3.1.2 Prick Test

This test is used to detect "immediate-type" allergies (type I reactions) [48]. The allergen is applied as a drop to the skin, and then the skin is "pricked" through the drop [48]. Test substances/extracts (e.g., containing natural latex) are offered by various manufacturers. After 5–30 min, the skin reaction is assessed (redness, formation of weals, etc.: Fig. 2.19). Although the risk of provoking an immediate allergic reaction by the test itself is very minor, it cannot be completely excluded. Therefore, this test should be executed only by qualified personnel. The risk of sensitization of a patient by the prick test is considered low [48].

Key Note

It is important for the clinician to know that immediate-type reactions to dental materials are very rare (e.g., pit and fissure sealants). Much more frequent, however, are immediate allergic reactions to latex (Fig. 2.20).

Dentlearn.ir

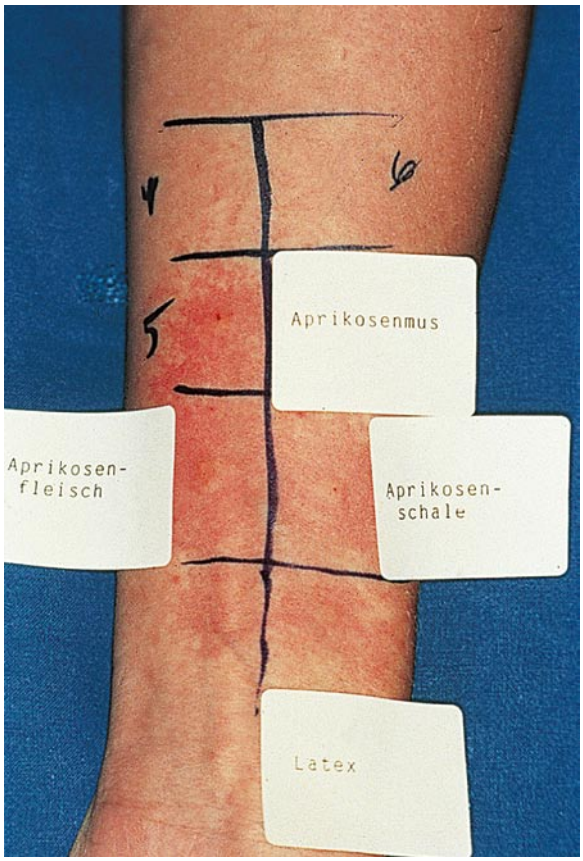

Fig. 2.19 Prick test on the forearm; persons suffering from a latex allergy frequently show cross-reactions with various fruits, such as apricots, peaches, avocados, and bananas. (Courtesy of M. Landthaler, Regensburg, Germany)

Fig. 2.20a–d Allergic reaction, immediate type (type I), to latex gloves. **a** Local: urticaria. **b** Allergic edema. **c** Conjunctivitis. **d** Allergic shock (Courtesy of A. Heese, Bayreuth, Germany)

Dentlearn.ir

2.3.1.3 Radioallergosorbent Test (RAST)

The RAST belongs to the group of in vitro tests for diagnosing an allergy. It is used to diagnose immediate-type allergies (IgE mediated) by identifying an allergen-specific IgE in the patient's blood [48]. Because the RAST is an in vitro test, the patient will not be exposed to the risk of sensitization by the test itself. However, with atopic patients or through other circulating antibodies, this test may render results that are inconsistent with clinical findings.

Key Note

This test can be used for diagnosing suspected allergies to medication or latex, potentially in combination with the prick test. But indication, execution, and assessment need to be done by an experienced allergologist through an allergy laboratory.

2.3.1.4 Immunotoxicological Test Methods

Recently, immunotoxicological test methods for determining the biocompatibility of dental materials (mainly metals) have been discussed. These techniques are used to identify the influence of a substance or material on one or several components of the immune system. Components may be the triggering of specific sensitizations (see above), the induction of autoimmune reactions or the inhibition (or promotion) of the cellular immune defense [9]. A number of studies thus aim to further characterize the influence of materials on the immune system [96].

A completely different approach, however, is followed by other immunotoxicological methods in which the patient is characterized corresponding to his or her specific reaction to a material. One of these tests is the lymphocyte transformation test (LTT) [9]. For the LTT, a blood sample is taken from the patient with suspected allergy, and then the proliferation of T-lymphocytes in the presence of the allergen is determined. This test has been claimed to detect sensitization to metals, for instance. The memory lymphocyte immunostimulation assay (MELISA) is a modification of the LTT. Monocytes derived from the patient's blood are used for the MELISA.

Assessment: Although immunotoxicological testing of materials is a widely accepted procedure, the testing of the specific reactions of patients using the LTT and MELISA tests is still under scientific evaluation [9]. Associations with clinical signs and symptoms have been sporadically reported, but are not consistent. In particular, the function of genetic factors has not been clarified so far. Thus, these methods have not yet been scientifically approved as routine tests [9, 51]. For instance, mercury-associated local lichenoid reactions of the oral mucosa (contact lesions), which are mainly allergic in nature, provoked no different lymphocyte stimulation in blood of patients compared to subjects without clinical symptoms (control group) in the LTT [51].

Key Note

Immunotoxicological test methods that have been described so far to evaluate patients are not yet scientifically approved and should not be considered for routine clinical application. National and international contact allergy groups recommend the patch test as standard procedure [8, 10, 13, 14].

2.3.2 Measurement of Intraoral Voltage

All metals in the oral cavity are exposed to an aqueous environment. They corrode (more or less) and at the same time release different positively charged ions. The metal surface thereby becomes negatively charged, which will then cause the attachment of positively charged ions from saliva (Ca^{2+}, Na^{+}, or K^{+}). Voltage differences can be found against a reference electrode or between two metals in the oral cavity (e.g., between two equivalent gold alloys) [45]. If there is a conductive contact between the two metals (e.g., direct contact or through wires), then ionic electricity can circulate (ion shift) in the tissue/saliva. The electric current or the current density per cross-sectional tissue area cannot be directly measured. Various authors have reported that measuring intraoral electrical phenomena and comparing the results with threshold values for tolerance may allow determination of the individual compatibility of a patient for materials, particularly metals.

A number of measurement devices are available on the market that can be used for determining intraoral voltages between different restorations. These devices require a high internal resistance (at least 20 megaohms). Certain techniques measure a "current." But it

Dentlearn.ir

should be kept in mind that this does not represent a current (electricity) in tissue or in saliva, but a discharge via an instrument-specific internal resistance, although it is sometimes referred to as measurement of intraoral current [59]. Change of electric current by time (e.g., per second) can be measured by means of appropriate computer programs. Some techniques even claim to be able to measure currents between resins.

Assessment: Local electrical phenomena can occasionally generate perceivable reactions in patients. This may be caused by short circuits, for instance, if a new amalgam filling is placed in direct proximal or occlusal contact with a high gold alloy [63]. The consequence may be a metallic taste. In general, however, an insulating oxide layer will soon be formed on the amalgam, which will act as high electrical resistance, and thus the sensations will disappear after a few days [73]. Another example is electric current peaks, which are generated by the insertion of tinfoil into the oral cavity. This may result in pain sensation. Voltages without current discharge may cause sensations (e.g., metallic taste), if they exceed a certain level, which is 1,000 mV, according to Kappert [45]. A maximum electrode voltage of 600 mV will occur between an amalgam filling and a high gold alloy. In a few patients, the threshold may be much lower, for example 200 mV. This may cause local sensations [63], which can be eliminated by exchanging the restorative material, for example [63].

General symptoms, including headache, gastrointestinal irritation, circulation discomfort, psychovegetative and central nervous alterations, and sleep disturbances, have also been linked to intraoral voltages/currents and are referred to as pathological/oral galvanism or "oral battery" [59]. A previous review of the literature regarding the influence of voltage on biological systems is the basis of the following information. Cells migrate if they are exposed to an electrical field of at least 500 mV/cm². But no cell damage has been documented. An electrical field of 5,000 mV/cm² caused increased proliferation of tumor spheroids (three-dimensionally growing cells derived from tumor tissue), but cell death was observed only at field strengths of 20,000 mV/cm². This and other studies do not provide evidence that electric effects due to intraoral metallic restorations may damage nerval and nonnerval biological structures or tissues [24].

Furthermore, it was reported in the literature that patients who associated their (mainly general) symptoms with intraoral electric phenomena (oral galvanism) revealed no correlation between their complaints and the level of the measured intraoral electric values [1, 20, 97, 115]. The "experimental" readings were not different from measurements in the control group (subjects without symptoms/complaints) [1, 64]. Interestingly, various authors who are in favor of this method specify different tolerance threshold values [59]. Evidence that this technique is of diagnostic value for assessing general symptoms is still missing [63].

2.3.3 Evaluation of Pulp Sensitivity

The sensibility test of the pulp may demonstrate functional nerval structures. This method is used for pulp diagnosis and is mainly based on the application of cold and of electric current [17, 31]. The threshold of pulp nerves regarding electric current varies between 20 and 100 μA, whereas this value for periodontal structures ranges between 176 and 250 μA [60]. Thus, it is possible to differentiate between an irritation of nerves in the pulp and in the periodontium [60]. Thermal examination is performed with sticks of ice, CO_2-snow (– 78.5 °C), or cold sprays, which, for instance, contain propane, butane or similar substances (– 22 to – 50 °C). Dichlorine–difluorine–methane, which has been used previously, has been discontinued for environmental reasons. All substances will cause a similar temperature decrease in the pulp [31].

Assessment: These tests are frequently applied in biocompatibility tests to determine material-associated pulp damages in clinical studies. However, a decisive limitation of sensibility tests is that they only indicate the presence of functioning nerval structures. But these tests cannot be used to prove vitality or specific inflammatory reactions of the pulp. For example, a histologic control showed that, despite positive sensibility reactions, up to 40% of the evaluated cases revealed partly pronounced pulp necroses [40]. It was found that the nerval structures of the pulp belong to the most resistant tissues [71]. The probability that a negative sensibility test in fact indicates a nonvital pulp exceeds 90% [40]. On the other hand, the probability that a positive sensibility test documents a vital pulp is much lower. Altogether, sensibility tests tend to draw a picture that is too optimistic [40]. Sensibility tests are not likely to cause damage in patients, such as an electric pulp tester current in patients with a pacemaker, or enamel

Dentlearn.ir

cracks due to application of cold [53, 80]. Lack of pulp damage by cold application was documented in animal experiments [41]. Some authors found enamel cracks or an enlargement of preexisting cracks after an extended application of cold [4, 52], but this was not confirmed by other studies [80].

Key Note

Sensibility tests are an essential part of any kind of pulp diagnosis, but it must be kept in mind that a number of pulp damages will not be diagnosed by these methods. Some substances, such as propane and butane, are easily flammable. Cold should be applied only briefly in order to prevent (possible) formation of enamel cracks.

2.3.4 Analysis of Intraoral Alloys

Knowledge about the exact composition of materials in patients' oral cavities is an important prerequisite for subsequent clinical tests, such as allergy tests. But so far, appropriate techniques are available only for the routine analysis of metals. For removable restorations and dentures, processing and corrosive alterations can be examined by means of modern analytical methods (polished metallic micrograph sections in combination with energy dispersive x-ray analysis, or EDX). However, clinical evaluation is much more difficult if restorations such as crowns, inlays, or bridges are fixed in the oral cavity and thus cannot be removed for identification of the alloy and the structure in the laboratory [118].

In these cases, the composition of an intraoral alloy can be identified using the chip test. A small amount of alloy particles (chips) is produced intraorally using a silicon carbide stone or a tungsten carbide bur. The alloy particles are collected on a small, circular, self-adhesive graphite plate. This self-adhesive carrier conducts electricity. Subsequently, the collected alloy particles can be identified quantitatively and qualitatively by means of EDX analysis (Fig. 2.21).

Assessment: Our own experiments revealed that this analytical method (chip test) is easy to perform and generates reliable data. Naturally, it is not possible to identify a specific brand, since too many almost identical alloys are on the market. Also minor element shifts due to processing of the alloy are always possible, e.g. warm transformation of alloys. Nevertheless, the analytical accuracy is ± 1% for individual alloy components.

Key Note

It is important for the clinician to know that the composition of intraoral alloys can be analyzed with an accuracy of ±1% using the chip test. Exact knowledge about the composition of intraoral materials is an important prerequisite for a specifically designed allergy test. However, the chip test is not able to examine a correct processing of the alloys, which must be considered a disadvantage of this test because a correct processing is of decisive influence on corrosion and, thus, also on tissue compatibility.

2.3.5 Analysis of Metals in Saliva and Biopsies

So far, examination of saliva to diagnose material-linked side effects concentrates on the detection of metals, although most recently, resin components were also identified in saliva (see Chap. 5). A defined amount of "morning saliva" (before any food or drink intake or oral hygiene measures) is collected and, after chemical pulping, is analyzed, such as by atomic absorption spectrometry (AAS) [89]. Biopsies, for instance from the gingiva adjacent to metal restorations, were also used to determine the metal content. Metal concentrations in biopsies are usually analyzed by AAS after chemical pulping [118].

Assessment: There is a certain correlation between salivary metal content and the composition of intraoral alloys: Metals that are part of dental restoration can be usually found in saliva, too. But the salivary metal content reveals great variations, even if sample collection is standardized [33, 91]. For instance, the metal content is considerably dependent on the nutrition and parafunctions [111]. Repeated collection of saliva from the same subjects within a few days and using generally identical conditions revealed a variation of the metal concentration of several orders of magnitude [33, 91]. Therefore, it must be concluded that it is methodologically extremely difficult to set a reproducible value for each patient. Further, it is not possible to differentiate between the oxidation levels of the single metals, which is decisive for absorption

Dentlearn.ir

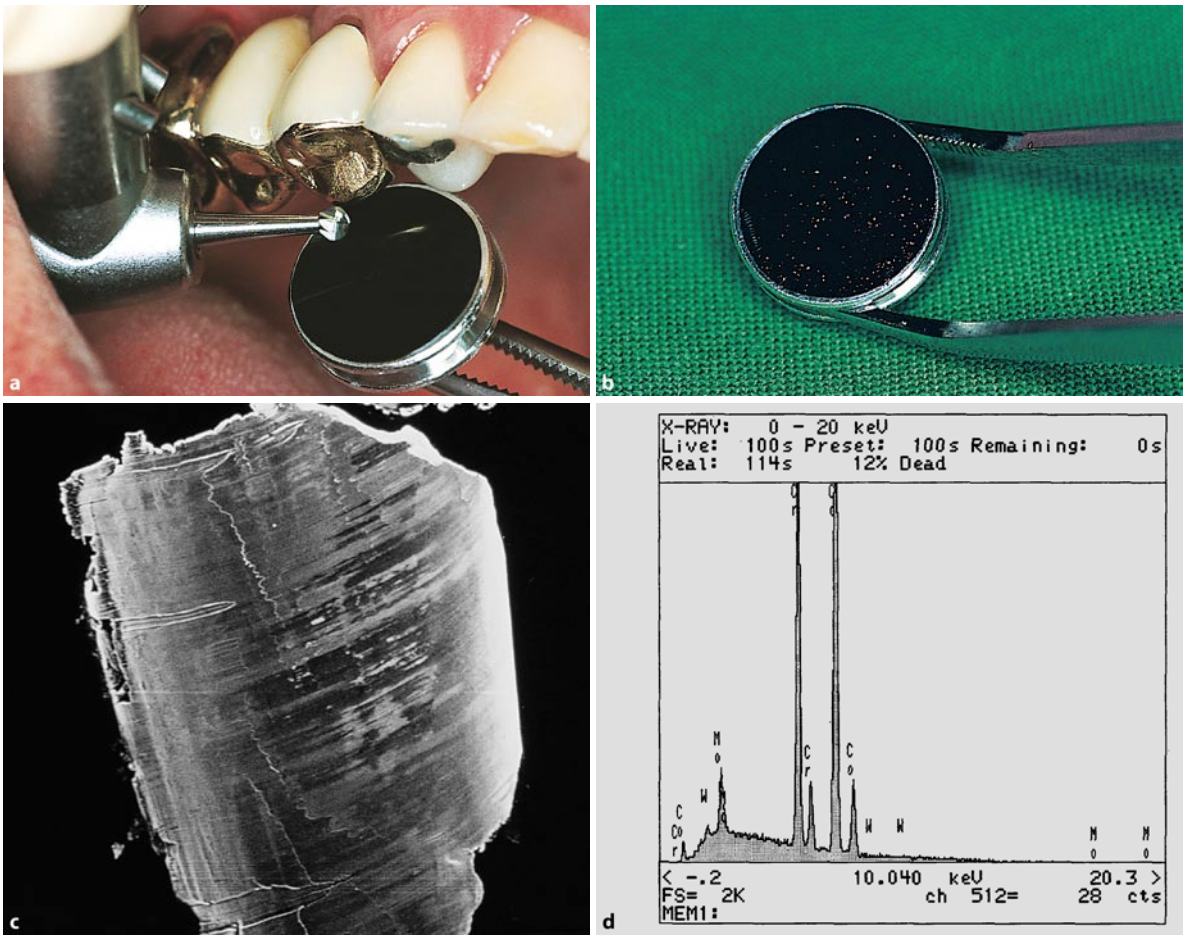

Fig. 2.21a–d Analysis of intraoral fixed alloys. **a** Collection of alloy particles/chips. **b** Alloy chips attached to self-adhesive graphite disk. **c** Scanning electron microscopic image of an alloy chip. **d** Results of energy dispersive x-ray analysis; peaks indicate the identified elements

in the gastrointestinal tract, and for toxicity. Thus, the salivary metal content is an imprecise indicator for the applied dose and provides no information about the effective dose of a substance (see also Chap. 1).

So far, the metal content of the gingiva adjacent to dental alloys has only been analyzed by a few researchers. Cases have been reported that revealed a significantly elevated metal concentration (determined by AAS) in the severely inflamed but plaque-free gingiva next to a metal restoration compared to sound tissue [117]. However, in other studies, metals were also detected in clinically sound gingiva, which supposedly originated from adjacent restorations [81]. Of all analyzed gingiva samples, 73% revealed alloy compounds, to some extent in the form of particles [81]. Our own investigations have shown that there is a good correlation between the metal content of biopsies and the adjacent alloy [89, 90].

However, metal analysis of gingival biopsies is also associated with some problems. First of all, it is not possible to differentiate between the oxidation levels of the single metals. In particular, tiny metal chips, which are generated by finishing of the alloy or the removal of old restorations and which are then transported in the proximate tissue, will significantly increase the metal content of a biopsy. But these metallic particles are considerably less biologically active than metal ions. Finally, it is not yet possible to define threshold concentrations below which no tissue reaction due to metals is to be expected.

Dentlearn.ir

Key Note

It is important for the clinician that in general, metal analyses of single saliva samples are not helpful for the diagnosis of side effects. The examination of the metal content of the gingiva is also of little diagnostic value for dental practice.

2.3.6 Test Methods of "Alternative Medicine"

Under this heading, a large number of very heterogeneous diagnostic methods will be summarized, which have not yet been scientifically approved, since they do not fulfill the usual requirements of reproducibility, verifiability, and diagnostic quality [18]. Some methods, for instance using the pendulum, even obviously and crassly contradict current trusted knowledge. Often, these methods are called "complementary" methods, which gives the impression of supplementation of or even a further advantage to scientifically accepted test methods. Altogether, these methods claim to be able to be a valuable tool for the diagnosis and treatment of the individual incompatibility/compatibility of (dental) materials.

Procedures of alternative medicine have to be distinguished from classic methods of naturopathic treatment or medical practices of other cultures [107]. Naturopathic treatment applies natural impulses like motion/exercise, warmth, cold, etc. in order to stimulate the regeneration of the organism. Classic methods of naturopathic medicine with proven efficacy are accepted and practiced by science-based medicine. Medical practices of other cultures include traditional Chinese medicine, for instance. Although some of these hypotheses and models have been disproved, other techniques have been found to be effective, such as traditional Chinese medicine acupuncture. These methods can be also used in dentistry, e.g. to reduce choking and pain.

Procedures of alternative medicine are receiving more and more public attention [22, 23], and many patients ask their dentist about these methods. In addition, "diagnostic" findings based on these tests are frequently the reason for very invasive therapeutic procedures, like removal of fillings, extraction of teeth or even the resection of entire segments of the jaw (Fig. 2.22) [107]. Therefore, some of the methods will be briefly described and assessed.

Electroacupuncture according to Voll (EAV) supposedly allows for the diagnosis of degenerative, inflammatory, toxic, or allergic tissue alterations of single organs by measuring the skin resistance at different sites (acupuncture sites) [77]. EAV also includes a drug test, which supposedly permits determination of the compatibility of materials in individual patients. Small, closed glass bottles contain the materials, which are placed in a measurement comb. This measurement comb consists of a brass block with appropriate cavities. The electric current is conducted through these cavities to read the skin resistance. Certain changes in the patient's skin resistance are supposed to indicate a material incompatibility. The basic concept of this method is that each substance irradiates "informative energy with a characteristic mode of vibration," which causes defined alterations in the organism [59]. The early diagnosis, which means identifying incompatibilities before clinical symptoms emerge, is considered a special advantage. Based on EAV, other techniques are using the "distribution of charge density on the skin surface" or "electromagnetic oscillations" as well as the "measurement of ultrafine body energies" to determine individual compatibility.

In contrast, applied kinesiology (AK) is breaking different ground. Changes of posture, muscle movement, and, above all others, muscle tone, are considered to be leading signs of a disease or a material incompatibility [35, 36, 59]. The diagnosis is based mainly on manual exploration of the patient's muscle tone.

Key Note

Alternative methods are not scientifically proven and thus cannot be used as rationale for diagnosing and treating oral or systemic diseases. But it is important to know the basics of such alternative concepts in medicine and dentistry in order to competently inform patients about them.

Assessment: Alternative diagnostic and therapeutic methods have been assessed in detail in the literature and by scientific associations [18, 62, 74, 77, 82, 107, 112]. The most important problems are as follows:

1. **Misleading terminology:** These methods are frequently called holistic and are associated with naturopathic medicine. Followers of such methods postulate that with these methods, the patient is diagnosed and treated in his or her entirety, whereas scientifically based methods envisage only single organs. However, the methods of scientifically-ori-

Dentlearn.ir

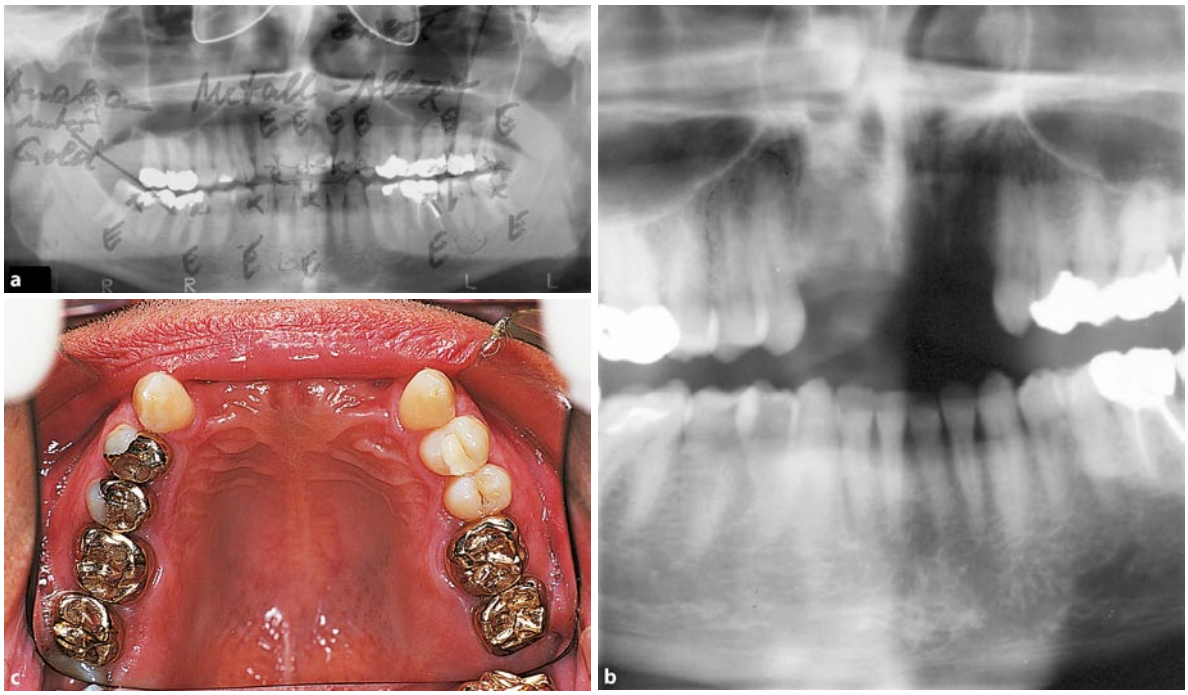

Fig. 2.22a–c A 40-year-old patient who complained of sciatic pain and insomnia. **a** Elsewhere, an allergy to metals was diagnosed based on the radiograph; the glutathione-S-transferase test was positive; and the saliva analysis revealed elevated levels of Au, Pd, Pt, Ag, Sn, and Hg. **b** Extraction of anterior teeth elsewhere; bone was resected twice. **c** Patient 9 months later, with no recovery of complaints but with a large bone defect

ented medicine and dentistry also incorporate the entire patient; this is also true for biocompatibility testing of dental materials (see Chap. 1.5 on interdisciplinary collaboration). "Holistic" is, therefore, also characteristic for scientifically based methods and not specific to "alternative" procedures. Also, psychological and psychosomatic aspects are currently included in a scientifically based diagnostic approach. Naturopathic methods (for example, a balanced lifestyle, healthy diet, and adequate body hygiene) are well accepted today and are intensely covered by medical and dental education.

2. **Contradiction of current knowledge of natural sciences:** As described above, a number of these alternative methods are based on concepts like "information energy" or "bioenergy" of a material. However, these phenomena cannot be physically described as can, for instance, an electron volt or a product of mass and the square of the speed of light [62]. The drug test using EAV simply ignores physical laws because the sample is completely isolated by glass. Of course, the possibility exists that current knowledge may be found to be false in the future. But many of the alternative concepts are so far beyond the current state of knowledge that their truth is extremely unlikely [62]. Furthermore, originators of new concepts should prove that their hypotheses are true. This becomes very problematic if natural science as such is fundamentally challenged and called into question. However, the patient should then be clearly informed that such methods are in opposition to natural science. In any case, these methods are speculative in nature and based on belief. "It is the unavoidable risk of believing operators that they may get into the sphere of charlatanry" [62].
3. **Missing reproducibility of the test results:** This is even conceded by advocates of these methods [5, 107].
4. **Missing proof of diagnostic validity:** Advocates of these methods mainly refer to single case reports describing the successful use of their methods in patients who could not be successfully treated by scientifically based methods. However, the success of a

Dentlearn.ir

procedure demonstrated in single case reports is no proof for the diagnostic validity or the correctness of the acclaimed mechanism behind those alternative diagnostic methods. The result may be due to a placebo effect (or a suggestive effect; see also Chap. 1), especially because the advocates of this direction always refer to a close interaction between operator and patient as a decisive precondition for these test methods [59]. It would be very easy to prove the diagnostic value of EAV because materials could be blind-tested in the comb. Such a joint study between EAV supporters and a scientific laboratory was rejected by leading EAV representatives in 2001.

Recently, applied kinesiology was tested in a double-blind study evaluating the individual compatibility of a number of patients towards two different resin-based composites [108]. The testing was performed by advocates of this method. It was, however, found that the reliability of applied kinesiology in diagnosing compatibility/incompatibility of the two different products did not exceed random chance. The authors further stated that any method that fails to be reliable cannot be valid [108].

5. **Differentiation between electroacupuncture and classic acupuncture:** While classic acupuncture results in accepted effects (pain elimination, prevention of choking, and so on) [107], EAV is based on completely different, unaccepted hypotheses (such as information energy).
6. **Speculative assessment:** Real physical parameters are measured by some alternative medical procedures, for instance by EAV. But there is no scientific basis for assessing the measurement results. Therefore, the nature of the interpretation of these results, such as regarding an incompatibility to materials, is speculative.
7. **Potential for misuse:** The aforementioned procedures, used in the sense of a final attempt, are frequently offered as supplementation ("complementary methods") with the reference that the classic, science-based (test) methods were unsuccessful in some patients. Often, the methods are also designated as harmless and noninvasive. However, the situation becomes problematic if an extensively invasive therapy is recommended based on a non-science-based diagnosis, for instance, removal of intact fillings, extraction of teeth, and even resecting of entire segments of the jaw (Fig. 2.22) [107]. It is necessary to countervail the success due a placebo effect against possible failures. Reproducible data are missing here.

Another case illustrates the problem: A 12-year-old girl suffering from insulin-dependent diabetes was subjected to alternative methods ("bioresonance therapy"), resulting in the diagnosis that amalgam was the reason for the diabetes. Amalgam removal and the cessation of insulin intake were recommended. Six weeks later the girl lost consciousness and died despite emergency treatment [25].

Dentlearn.ir

Conclusions for the Dental Practitioner

1. The biocompatibility of dental materials can be only characterized based on a battery of different test methods. Statements about biocompatibility based on one test method only, have to be assessed very critically.
2. Materials release substances specifically before setting and immediately after mixing, which may cause side effects. Therefore, dental personnel represent a risk group for these materials.
3. Cell culture data are frequently used for advertizing statements, since these tests can be quickly performed and they are cost-effective. But extrapolation of such findings to the patients is often questionable. The development of new methods may solve this problem in the future. Today, these tests are very important during the development of a material and the detection of causes of tissue reactions.
4. The extrapolation of findings from *in vitro* mutagenicity tests to the patient requires caution, in particular, if the material was only mutagenic when freshly mixed. A no-touch technique is recommended for dental personnel.
5. Usage tests (e.g., pulp/dentin test) and allergy tests on experimental animals generate results that better represent the clinical situation. However, even these tests have certain limitations, and they always have to be evaluated together with the results from in vitro and clinical tests.
6. Clinical studies are decisive for the final assessment of a material and should always be requested from the manufacturer. However, regarding the biocompatibility there may be problems, since some damages, e.g., of the pulp, may occur without clinical symptoms. Therefore, clinical studies always need to be evaluated together with pre-clinical tests.
7. The patch test plays the most important role in the determination of the individual compatibility. However, it is only indicated in cases with a reasonable suspicion of a type IV hypersensitivity. Knowledge of the composition of the potentially causative material is essential for a specific test. The chip test can be used to analyze unknown, fixed intraoral metallic restorations or devices.
8. The measurement of intraoral voltage between various materials may reveal a lower threshold value in individual cases. But these findings cannot be linked to general symptoms. Metal analysis of saliva is associated with many basic and technical problems. They are usually assessed as being unreliable. Metal analyses of gingival biopsies reflect the adjacent alloy. But they are of little value for therapeutic decision making because, among other reasons, no threshold concentrations are known.
9. Different alternative medical test methods have been described to determine individual compatibility. They do not fulfill the basic requirements of a scientifically accepted method, e.g. reproducibility, validity, and specific efficiency. On the other hand, these procedures, which by themselves may not be invasive, may be the basis for very invasive treatments. Therefore, their application is discouraged.

Appendix

LD_{50}: Median lethal dose. Calculated dose of a chemical substance that causes death of 50% of the experimental population (i.e., experimental animals). Formerly the standard procedure for the determination of acute toxicity for all types of application except inhalation.

LC_{50}: Median lethal concentration. Calculated concentration of a chemical substance, either dissolved or in air, that is expected to cause death of 50% of a defined experimental group (cells or animals), exposed to the substance for a specific period of time.

TC_{50}: Median toxic concentration. Calculated concentration of a chemical substance, either dissolved or in air, which causes an expected 50% reduction of a specific biological function in a defined experimental group (cells or animals) exposed to the substance for specific period of time.

Dentlearn.ir

References

1. American Dental Association: ADA status report on the occurrence of galvanic corrosion in the mouth and its potential effects. J Am Dent Assoc 115, 783–787 (1987).
2. Arenholt-Bindslev, D., Bleeg, H.: Characterization of two types of human oral fibroblasts with a potential application to cellular toxicity studies: tooth pulp fibroblasts and buccal mucosa fibroblasts. Int Endod J 23, 84–91 (1990).
3. Ashby, J., Tennant, R.W.: Definitive relationship among chemical structure, carcinogenicity and mutagenicity for 301 chemicals tested by the US NTP. Mutat Res 257, 229–306 (1991).
4. Bachmann, A., Lutz, F.: Schmelzsprünge durch die Sensibilitätsprüfung mit CO_2 Schnee und Dichlor-difluormethan – Eine vergleichende in vivo Untersuchung. [Cracks in the dental enamel caused by sensitivity testing with CO_2 snow and dichlorodifluoromethane – a comparative in vivo study] Schweiz Mschr Zahnheilk 86, 1042–1059 (1976).
5. Banis, R.: Energetische Testverfahren und angewandte Kinesiologie – ein kritischer Überblick. [Energetic test methods and applied kinesiology – a critical review] Erfahrungsheilkunde 45, 245–250 (1996).
6. Basketter, D.A., Selbie, E., Scholes, E.W., Lees, D., Kimber, I., Botham, P.A.: Results with OECD recommended positive control sensitizer in the maximization, Buehler and local lymph node assays. Food Chem Toxicol 31, 63–67 (1993).
7. Bender, I.B., Freedland, J.B.: Clinical considerations in the diagnosis and treatment of intra-alveolar root fractures. J Am Dent Assoc 107, 595–600 (1983).
8. Beltrani, V. S., Bernstein, I. L., Cohen, D. E., Fonacier, L.: Contact dermatitis: a practice parameter. Ann Allergy Asthma Immunol 97 (3, suppl 2), 1–38 (2006).
9. Bieger, W.P.: Immuntoxikologie der Metalle. Labordiagnostik der Quecksilber- und Dentalmetall-Sensibilisierung. [Immunotoxicology of metals. Laboratory diagnosis of mercury and dental alloy sensitization] Clin Lab 42, 243–255 (1996).
10. Bourke, J., Coulson, I., English, J.: Guidelines for care of contact dermatitis. Br J Dermatol 145, 877–885 (2001).
11. Brannström, M., Mattson, B., Torstenson, B.: Material techniques for lining composite resin restorations: a critical approach. J Dent 19, 71–79 (1991).
12. Braun, A.-R., Frankenberger, R., Krämer, N.: Clinical performance and margin analysis of Ariston pHc versus Solitaire I as posterior restorations after 1 year. Clin Oral Investig 5, 139–147 (2001).
13. Brehler, R., Becker, D., Merk, H.: MELISA – In-vitro-Test zum Nachweis einer Kontaktallergie? Eine Stellungnahme der Deutschen Kontaktallergie-Gruppe. [In-vitro test for detection of a contact allergy? Statement of the German Group for Contact Allergy] Der Hautarzt 5, 418–419 (1998).
14. Bruze, M., Conde-Salazar, L., Goossens, A., Kanerva, L., White, I.R.: Thoughts on sensitizers in a standard patch test series. The European Society of Contact Dermatitis. Contact Dermatitis 41 (5), 241–250 (1999).
15. Casarett and Doull's Toxicology: The Basic Science of Poisons, 3rd edn. McMillan, London 1986.
16. Cohen, D.E.: Contact dermatitis: a quarter-century perspective. J Am Acad Dermatol 51 (1), 60–61 (2004).
17. Cooley, R.L., Stilley, J., Lubow, R.M.: Evaluation of a digital pulp tester. Oral Surg 58, 437–442 (1984).
18. Deutsche Gesellschaft für Zahn-, Mund- und Kieferheilkunde: „Komplementäre Verfahren" in der Zahnheilkunde. Stellungnahme der DGZMK. [The so-called Complementary Methods in dentistry. Statement of the German Scientific Society for Dentistry] Dtsch Zahnärztl Z 52, 564–566 (1997).
19. Donath, K.: The diagnostic value of the new method for the study of undecalcified bones and teeth with attached soft tissue [Säge-Schliff (sawing and grinding) technique]. Pathol Res Pract 179, 631–633 (1985).
20. Drews, M., Geurtsen, W.: Experimentell-klinische Überprüfung der Korrelation zwischen Mundstrommessungen und subjektiven Beschwerden. [Experimental and clinical evaluation of the correlation between oral current measurements and subjective symptoms] Dtsch Zahnärztl Z 48, 704–706 (1993).
21. Dumsha, T., Sydiskis, R.: Cytotoxicity testing of a dentin bonding system. Oral Surg Oral Med Oral Pathol 59, 637–641 (1985).
22. Eisenberg, D. M., Kessler, R.C., Foster, C., Norlock, F.E., Calkins, D.R., Delbanco, T.L.: Unconventional medicine in the United States – prevalence, costs, and patterns of use. N Engl J Med 328, 246–252 (1993).
23. Eisenberg, D. M., Davis, R. B., Ettner, S. L., Appel, S., Wilkey, S., Van Rompay, M., et al.: Trends in alternative medicine use in the United States, 1990-1997: results of a follow up national survey. J Am Dent Assoc 280, 1569–1575 (1998).
24. Elger, C.E.: Statement. In: Institut der Deutschen Zahnärzte (Hrsg.): Amalgam – Pro and Contra. Deutscher Ärzte-Verlag, Köln 1992, pp 169–172.
25. Federspiel, K., Herbst, V.: Handbuch: Die andere Medizin: "Alternative" Heilmethoden für Sie bewertet. [Handbook on the Other Medicine: Alternative Treatment Methods Evaluated] Stiftung Warentest in Zusammenarbeit mit dem Verein für Konsumenteninformation. Stiftung Warentest, Berlin 2005, p 333.
26. Fentem, J. H., Botham, P. A.: ECVAM's activities in validating alternative tests for skin corrosion and irritation. Altern Lab Anim 30, 61–67 (2002).
27. Ferracane, J.L.: Elution of leachable components from composites. J Oral Rehabil 21, 441–452 (1994).
28. Fouad, A.F., Walton, R.E., Rittman, B.R.: Healing of induced periapical lesions in ferret canines. J Endod 19, 123–129 (1993).
29. Frankild, S., Volund, A., Wahlberg, J.E., Andersen, K.E.: Comparison of the sensitivities of the Buehler test and the guinea pig maximization test for predictive testing of contact allergy. Acta Derm Venereol 80, 256–262 (2000).
30. Friedl, K.-H., Schmalz, G., Hiller, K.-A., Shams, M.: Resin-modified glass ionomer cements: fluoride release and influence on *Streptococcus mutans* growth. Eur J Oral Sci 105, 81–85 (1997).
31. Fuss, Z., Trowbridge, H., Bender, I.B., Rickoff, B., Sorin, S.: Assessment of reliability of electrical and thermal pulp testing agents. J Endod 12, 301–305 (1986).
32. Garhammer, P., Schmalz, G., Hiller, K.-A., Reitinger, T., Stolz, W.: Patients with local adverse effects from dental alloys: frequency, complaints, symptoms, allergy. Clin Oral Investig 5, 240–249 (2001).
33. Garhammer, P., Hiller, K.-A., Reitinger, T., Schmalz, G.: Metal content of saliva of patients with and without metal restorations. Clin Oral Investig 8, 238–242 (2004).
34. Geurtsen, W.: Substances released from dental resin composites and glass ionomer cements. Eur J Oral Sci 106, 687–695 (1998).
35. Goodheart, G.: Applied kinesiology in dysfunction of the temporomandibular joint. Dent Clin North Am 27, 613–630 (1983).

Dentlearn.ir

36. Goodheart, G.: Applied kinesiology and dentistry. Basal Facts 9, 69–73 (1987).
37. Hamid, A., Hume, W.R.: Diffusion of resin monomers through human carious dentin in vitro. Endod Dent Traumatol 13, 1–5 (1997).
38. Hebling, J., Giro, E.M., Costa, C.A.: Biocompatibility of an adhesive system applied to the human dental pulp. J Endod 25, 676–682 (1999).
39. Heil, J., Reifferscheid, G., Waldmann, P., Leyhausen, G., Geurtsen, W.: Genotoxicity of dental material. Mutat Res 368, 181–194 (1996).
40. Hyman, J.J., Doblecki, W.: Computerized endodontic diagnosis. J Am Dent Assoc 107, 755–758 (1983).
41. Ingram, T.A., Peters, D.D.: Evaluation of the effects of carbon dioxide used as a pulpal test. Part 2. In vivo effect on canine enamel and pulpal tissues. J Endod 9, 296–303 (1983).
42. International Organization for Standardization: ISO 10993-3: Biological evaluation of medical devices. Part 3: Tests for genotoxicity, carcinogenicity and reproductive toxicity. International Organization for Standardization, Geneva 1992.
43. International Organization for Standardization: ISO 7405: Dentistry – preclinical evaluation of biocompatibility of medical devices used in dentistry. Test methods for dental materials. International Organization for Standardization, Geneva 2008.
44. Kallus, T., Mjör, I.A.: Incidence of adverse effects of dental materials. Scand J Dent Res 99, 236–240 (1991).
45. Kappert, H.F.: Oraler Galvanismus unter besonderer Berücksichtigung des Amalgams. [Oral galvanism related to amalgam] Phillip J 7, 233–240 (1990).
46. Kawahara, H., Shiota, M., Yamakawa, Y.: Studies on the effects of dental metals upon the mesenchymal cells in tissue culture. J Osaka Odontol Soc 18, 343–348 (1955).
47. Klötzer, W.T., Langeland, K.: Tierexperimentelle Prüfung von Materialien und Methoden der Kronen- und Brückenprothetik. [Testing of materials and methods for crown and bridge prosthesis on animals] Schweiz Monatsschr Zahnheilkd 83, 163–244 (1973).
48. Korting, H.C., Sterry, W.: Diagnostische Verfahren in der Dermatologie. [Diagnostic Methods in Dermatology] Blackwell Wissenschafts-Verlag, Berlin 1997.
49. Langer, H.: Das Schleimhautbrennen beim Tragen von Acrylatplatten. [Burning mucosa after insertion of acrylic plates] Dtsch Zahnärztl Z 11, 1321–1326 (1956).
50. Leyhausen, G., Heil, J., Reifferscheid, G., Waldmann, P., Geurtsen, W.: Genotoxicity and cytotoxicity of the epoxy resin-based root canal sealer AH plus. J Endod 25, 109–113 (1999).
51. Loftenius, A., Skoglund, A., Ekstrand, J., Hovmark, A., Möller, E.: No evidence for specific in vitro lymphocyte reactivity to $HgCl_2$ in patients with dental amalgam related contact lesions. J Oral Pathol Med 28, 364–370 (1999).
52. Lutz, F., Mörmann, W., Lutz, T.: Schmelzsprünge durch die Vitalitätsprüfung mit Kohlensäureschnee? [Enamel cracks by carbon dioxide snow for pulp vitality testing] Schweiz Monatsschr Zahnheilk 84, 709–725 (1974).
53. Machtens, E.: Die zahnärztliche Behandlung von Patienten mit Herzschrittmachern. [Dental treatment of patients with cardiac pacemakers] Dtsch Zahnärztl Z 38, 1048–1052 (1983).
54. Macintyre, J.E.: Dictionary of Inorganic Compounds, vol. 1–7. Chapman & Hall, London 1992.
55. Magnusson, B., Kligman, A.M.: The identification of contact allergen by animal assay. The guinea pig maximization test. J Invest Dermatol 52, 268–276 (1969).
56. Maizumi, H., Sauerwein, E.: Die Wirkung verschiedener Vitalerhaltungs- und Wurzelfüllmittel auf Gewebekulturen. [Effect of various endodontic materials on cell cultures] Dtsch Zahnärztl Z 17, 1628–1634 (1962).
57. Maron, D.M., Ames, B.N.: Revised method for the Salmonella mutagenicity test. Mutat Res 113, 173–215 (1983).
58. Marquardt, H.: Lehrbuch der Toxikologie. [Textbook on Toxicology] Spektrum Akademischer Verlag, Heidelberg 1997.
59. Mastalier, O.: Ganzheitliche Zahn-, Mund- und Kieferheilkunde. Regulations- und Komplementärmethoden. [Holostic Dentistry. Regulation and Complementary Methods] Urban & Schwarzenberg, München 1995.
60. Matthews, B., Searle B.N.: Some observations on pulp testers. Br Dent J 137, 307–312 (1974).
61. McCann, J., Choi E., Yamasai E., Ames B.N.: Detection of carcinogens as mutagens in the Salmonella/microsome test: assay of 300 chemicals. Proc Natl Acad Sci USA 72, 5135–5139 (1975).
62. Meiners, H.: Alternative Methoden in der Medizin. [Alternative methods in medicine] Dtsch Zahnärztl Z 52, 318–322 (1997).
63. Meiners, H.: Elektrische Erscheinungen an metallischen zahnärztlichen Restaurationen (oraler Galvinismus). [Electrical phenomena related to dental restorations (oral galvanism)] In: Institut der Deutschen Zahnärzte (Hrsg.): Amalgam im Spiegel kritischer Auseinandersetzungen. Interdisziplinäre Stellungnahmen zum „Kieler Amalgamgutachten". Deutscher Ärzte-Verlag, Köln 1999, pp 57–62.
64. Meiners, H., Marxkors, R.: Bewertung elektrischer Vorgänge in der Mundhöhle. [Assessment of electrical processes in the oral cavity] In: Akademie Praxis und Wissenschaft in der DGZMK (Hrsg.): Pro und Contra – Alternative Heilmethoden in der Zahn-, Mund- und Kieferheilkunde. Hanser, München 1992, pp 71–81.
65. Meryon, S.D., Jakeman, K.J.: Uptake of zinc and fluoride by several dentin components. J Biomat Res 21, 127–135 (1987).
66. Meryon, S.D., Tobias, R.S., Johnson, S.G.: Penetration of dentin by different conditioners in vitro: a quantitative study. Endod Dent Traumatol 4, 118–121 (1988).
67. Mitchell, D.F., Shankwalker, G.B., Shazer, S.: Determining the tumorgenicity of dental materials. J Dent Res 39, 1023–1028 (1960).
68. Mjör, I.A.: Problems and benefits associated with restorative materials: side-effects and long-term cost. Adv Dent Res 6, 7–16 (1992).
69. Moharamzadeh, K., Brook, I. M., Van Noort, R., Scutt, A. M., Thornhill, M. H.: Tissue-engineered oral mucosa: a review of scientific literature. J Dent Res 86 (2), 115–124 (2007).
70. Moher, D., Schulz, K.F., Altmann, G.: The CONSORT statement: revised recommendations for improving the quality of reports of parallel-group randomised trials. Lancet 357, 1191–1194 (2001).
71. Montgomery, S., Ferguson, C.D.: Endodontics – diagnostics, treatment planning, and prognostic considerations. Dent Clin North Am 30, 533–548 (1986).
72. Murray, P. E., About, I., Lumley, P. J., Franquin, J. C., Remusat, M., Smith, A. J.: Cavity remaining dentin thickness and pulpal activity. Am J Dent 15, 41–46 (2002).
73. Nilner, K., Glantz, P.O., Zoger, B.: On interoral potential- and polarization-measurements of metallic restorations. Acta Odont Scand 40, 275–281 (1982).
74. Oepen, I., Federspiel, K., Sarma, A.: Lexikon der Parawissenschaften. [Enzyclopedia of Parasciences] Literaturverlag, Münster 1999.

Dentlearn.ir

75. Okamura, T., Morimoto, M., Yamane, G., Takahashi, S.: Langerhans' cells in the murine oral mucosa in the inductive phase of delayed type hypersensitivity with 1-chloro-2,4-dinitrobenzene. Clin Exp Immunol 134, 188–194 (2003).
76. Organisation for Economic Co-operation and Development: Guidelines for the Testing of Chemicals, vol. 2. Organisation for Economic Co-operation and Development, Paris 1993.
77. Ostendorf, G.M.: Die Bedeutung von Naturheilverfahren und alternativen Methoden für die Zahnheilkunde. [The relevance of natural medicine and alternative methods for dentistry] Dtsch Zahnärztl Z 52, 329–331 (1997).
78. Pashley, D.H.: Smear layer: physiological considerations. Oper Dent 3, 513–529 (1984).
79. Pashley, D.H., Derkson, G.D., Tao, L., Derkson, M., Kalathoor, S.: The effects of a multi-step dentin bonding system on dentin permeability. Dent Mater 4, 60–63 (1988).
80. Peters, D.D., Mader, C.L., Donnelly, J.C.: Evaluation of the effects of carbon dioxide used as a pulpal test. 3. In vivo effect of human enamel. J Endod 12, 13–20 (1996).
81. Rechmann, P.: Nachweis metallischer Restaurationsmaterialien in klinisch unauffälliger Gingiva. [The detection of metallic restorative materials in clinically sound gingiva] Dtsch Zahnärztl Z 48, 270–275 (1993).
82. Schissl, M. J., Dodes, J. E.: Dentistry and alternative therapy. NY State Dent J 63, 32–37 (1997).
83. Schmalz, G.: Die Gewebeverträglichkeit zahnärztlicher Materialien – Möglichkeiten einer standardisierten Prüfung in der Zellkultur. [Biocompatibility of Dental Materials – Possibilities of a Standardized Test Using Cell Cultures] Thieme, Stuttgart 1981.
84. Schmalz, G.: Korrelationsanalysen zwischen Zellkulturen und Tierversuch. [Correlation analyses between cell cultures and animal experiments] Dtsch Zahnärztl Z 37, 184–186 (1982).
85. Schmalz, G.: The use of cell cultures for toxicity testing of dental materials – advantages and limitations. J Dent 22 (suppl. 2), 6–11 (1994).
86. Schmalz, G.: Concepts in biocompatibility testing of dental restorative materials. Clin Oral Investig 1, 154–162 (1997).
87. Schmalz, G.: The biocompatibility of nonamalgam dental filling materials. Eur J Oral Sci 106, 696–706 (1998).
88. Schmalz, G., Arenholt-Bindslev, D., Hiller, K.-A., Schweikl, H.: Epithelium-fibroblast co-culture for assessing the mucosal irritancy of metals used in dentistry. Eur J Oral Sci 105, 86–91 (1997).
89. Schmalz, G., Garhammer, P.: Biological interactions of dental cast alloys with oral tissues. Dent Mater 18, 396–406 (2002).
90. Schmalz, G., Garhammer, P., Hiller, K.-A., Reitinger, T.: Metal content of biopsies from the neighborhood of casting alloys. J Dent Res (abstract) 78, 236 (1999).
91. Schmalz, G., Hiller, K.-A., Garhammer, P., Reitinger, T.: Metal content of saliva from patients with and without metal restorations. J Dent Res (abstract) 80, 1254 (2001).
92. Schmalz, G., Hiller, K.-A., Nunez, L.J., Stoll, J., Weis, K.: Permeability characteristics of bovine and human dentin under different pretreatment conditions. J Endod 27, 23–30 (2001).
93. Schmalz, G., Schmalz, C., Rotgans, J.: Die Pulpaverträglichkeit eines Glasionomer- und Zinkphosphat-Zements. Dtsch Zahnärztl Z 41, 806–812 (1986).
94. Schmalz, G., Schuster, U., Nützel, K., Schweikl, H.: An in vitro pulp chamber with three-dimensional cell cultures. J Endod 25, 24–29 (1999).
95. Schmalz, G., Schweikl, H.: Characterization of an in vitro dentin barrier test using a standard toxicant. J Endod 20, 592–594 (1994).
96. Schmalz, G., Schweikl, H., Hiller, K.-A.: Release of prostaglandin E_2, IL-6 and IL-8 from human oral epithelial culture models after exposure to compounds of dental materials. Eur J Oral Sci 108, 442–448 (2000).
97. Schriever, W., Diamond, L.E.: Electromotive forces and electric currents caused by metallic dental fillings. J Dent Res 31, 205–229 (1952).
98. Schuster, U., Schmalz, G., Thonemann, B., Mendel, N., Metzl, C.: Cytotoxicity testing with three-dimensional cultures of transfected pulp-derived cells. J Endod 27, 259–265 (2001).
99. Schweikl, H., Schmalz, G.: Triethylene glycol dimethacrylate induces large deletions in the hprt gene of V79 cells. Mutat Res 438, 71–78 (1999).
100. Schweikl, H., Schmalz, G., Federlin, M.: Mutagenicity of the root canal sealer AH Plus in the Ames test. Clin Oral Investig 2, 125–129 (1998).
101. Schweikl, H., Schmalz, G., Göttke, C.: The mutagenic activity of various dentin bonding agents. Biomaterials 17, 1451–1456 (1996).
102. Schweikl, H., Schmalz, G., Rackebrandt, K.: The mutagenic activity of unpolymerized resin monomers in *Salmonella typhimurium* and V79 cells. Mutat Res 415, 119–130 (1998).
103. Schweikl, H., Schmalz, G., Stimmelmayr, H., Bey, B.: Mutagenicity of AH26 in an in vitro mammalian cell mutation assay. J Endod 21, 407–410 (1995).
104. Schweikl, H., Spagnuolo, G., Schmalz, G.: Genetic and cellular toxicology of dental resin monomers. J Dent Res 85, 870–877 (2006).
105. Schweikl, H., Hiller, K.-A., Eckhardt, A., Bolay, C., Spagnuolo, G., Stempfl, T., Schmalz, G.: Differential gene expression involved in oxidative stress response caused by triethylene glycol dimethacrylate. Biomaterials 29,1377–1387 (2008).
106. Silverstone, L.M., Mjör, I.A.: Dental caries. In: Hørsted-Bindslev P., Mjör I. A. (eds): Modern Concepts in Operative Dentistry. Munksgaard, Copenhagen 1988, pp 16–58.
107. Staehle, H.J.: „Komplementäre Verfahren" in der Zahnheilkunde. [Complementary methods in dentistry] Dtsch Zahnärztl Z 52, 323–328 (1997).
108. Staehle, H. J., Koch, M. J., Pioch, T.: Double-blind study on materials testing with applied kinesiology. J Dent Res 84, 1066–1069 (2005).
109. Svendsen, O., Garthoff, B., Spielmann, H., Hensten-Pettersen, A., Jensen, J.C., Kuijpers, M.R., Leimgruber, R., Liebsch, M., Müller-Lierheim, W.G.K., Rydhög, G., Sauer, U.G., Schmalz, G., Sim, B., Stea, S.: Alternatives to the animal testing of medical devices. ECVAM workshop report 17. ATLA 24, 659–669 (1996).
110. Tagger, M., Tagger, E.: Periapical reactions to calcium hydroxide-containing sealers and AH26 in monkeys. Endod Dent Traumatol 5, 139–146 (1989).
111. Takaku, S.: Studies on mercury concentration in saliva with particular reference to mercury dissolution from dental amalgam into saliva. Shikwa Dakuho 82, 385–406 (1982).
112. Teuber, S. S., Porch-Curren, C.: Unproved diagnostic and therapeutic approaches to food allergy and intolerance. Curr Opin Allergy Clin Immunol 3, 217–221 (2003).
113. Trowbridge, H.O.: Review of dental pain – histology and physiology. J Endod 12, 445–452 (1986).

Dentlearn.ir

114. Tziafas, D., Smith, A. J., Lesot, H.: Designing new treatment strategies in vital pulp therapy. J Dent 28, 77–92 (2000).
115. Vanherle, G.: Tandheelkundige verzorging met zilveramalgam. Ver K Acad Geneeskd Belg 58, 587–634 (1996).
116. Wirthlin, M.R., Armitage, G.C., Rao, S., Fritzinger, B., Phillips, S., Heller, J.: A mucosal irritancy test device for intraoral use in dogs. J Periodontol 68, 746–749 (1997).
117. Wirz, J.: Schädigung des Parodonts durch zahnärztliche Werkstoffe. [Damage of the periodontium by dental materials] Zahnärztl Welt/Reform 102, 146–162 (1993).
118. Wirz, J., Vock, M., Schmidli, F.: Splittertest – ein zuverlässiges Diagnosehilfsmittel bei Abklärungen von Metallunverträglichkeit. [The particle test – a reliable diagnostic tool for detection of a metal incompatibility] Quintessenz 47, 1373–1384 (1996).

Dentlearn.ir

3 Regulations and Standards

G. Schmalz and P. L. Fan

Contents

3.1 Introduction 45
3.2. Legal Regulations in the European Union . 45
3.2.1 Medical Device Directive 45
3.2.2 European Chemical Legislation (REACH) . 48
3.3 Legal Regulations in the United States 49
3.3.1 Food, Drug, and Cosmetic Act and Medical Device Amendments 49
3.3.2 Classification of Devices 49
3.3.3 Premarket Notification and FDA Review . . 50
3.3.4 Records and Reports on Devices 50
3.4 Legal Regulations in Australia 50
3.5 Legal Regulations in Japan 51
3.5.1 Classification and Marketing Authorization 51
3.5.2 Marketing and Manufacturing Licenses . . . 52
3.5.3 Marketing Authorization 52
3.6 Labeling 52
3.7 Standards 54
3.7.1 Harmonized Standards 54
3.7.2 OECD Guidelines 54
3.7.3 Relevant Standards 55
3.8. Surveillance and Reporting Systems 56
Conclusions for the Dental Practitioner . . . 57
References 57

3.1 Introduction

Dental materials and devices are subject to legal regulations in most countries. In this chapter such legal regulations in different parts of the world are reviewed. The Global Harmonization Task Force (GHTF), which is an international group of medical device regulators and industry representatives from the United States, Canada, Europe, Japan, and Australia, is working toward a global regulatory system for medical devices by developing broad principles for the regulation of medical devices that can be implemented by individual jurisdictions. All these regulations address safety (including biocompatibility) and effectiveness of the materials and devices. Dentists should know about the regulations and their responsibilities required by the regulations (for example, adverse effect reporting). Manufacturers should be knowledgeable about regulations in countries in which their products are to be marketed. These include meeting the requirements for medical device directives, product requirements, and record keeping and reporting, as well as postmarket surveillance. There are also regulations concerning waste disposal, environmental protection, and occupational safety. These subjects will be reviewed in Chaps. 12 and 13. Only the name of original versions of regulations and standards will be cited in this review, but the actual effective version is always meant.

3.2 Legal Regulations in the European Union

In the European Union (EU), a number of regulations apply and must be followed for materials and devices used in dental practice. The most important regulations are the Medical Device Directive (MDD) [8] and the European Chemical Regulation for Registration, Evaluation, Authorization, and Restriction of Chemicals (REACH) [13]. Besides the EU directive for medical devices, other directives are also applicable, including the following:

- Cosmetics (76/768/EEC), which comprises, among other things, oral hygiene products [6]
- Drugs (65/65/EEC), now included in directive 01/83/EEC [4, 10]
- Active, implantable medical devices (AIMD; 90/385/EEC) such as heart pacemakers, which are currently not significantly applicable to dentistry [7]
- In vitro diagnostics (98/79/EEC) [9]

3.2.1 Medical Device Directive

The directive 93/42/EEC on medical devices (MDD) was adopted on 14 June 1993 [8]. Directives of the EU

Dentlearn.ir

are equivalent to laws and must be turned into national legislation within the given time limit by all member countries of the EU. Directives, like laws, are periodically amended. The MDD was most recently amended in 2007.

Key Note

The directive 93/42 EEC for medical devices is the legal basis for the market launch of dental materials within the European Economic Area and thus also regulates the field of biocompatibility. Furthermore, additional legal regulations of the EU, such as REACH, have to be considered for market launches of medical devices.

3.2.1.1 Area of Jurisdiction and Definitions

The MDD applies in the area of the countries of the European Economic Area (EU countries, Norway, Iceland, Liechtenstein, and Switzerland). The term "medical device" is defined in the MDD. Accordingly, a medical device is applied, among other reasons, for diagnosis, prevention, monitoring, treatment, or alleviation of disease. It does not achieve its principal intended action in or on the human body by pharmacological, immunological, or metabolic means, but it may be assisted in its function by such means. Because the intended main function of dental materials is generally to replace lost tissue, these materials fall by definition into the jurisdiction of the MDD.

3.2.1.2 Essential Requirements

Key Note

The basic idea behind the MDD is that the so-called essential requirements must be fulfilled by each medical device that is intended to be marketed. These essential requirements are related to safety, performance, and quality. To meet these requirements, the general condition and outlines are defined in the directive.

The MDD does not describe in detail how these essential requirements have to be fulfilled. One possibility is the fulfillment of appropriate "harmonized standards" (see Sect. 3.7.1). But it is left to the manufacturer to use other test methods as well, if they correspond with the state of the art. However, available standards (such as those of the International Organization for Standardization, or ISO) are used in most cases. Thus, available standards are presently of high importance for fulfilling the essential requirements. But even if harmonized standards are applied, the essential requirements and the state of the art are always (legally) decisive.

3.2.1.3 Classification of Medical Devices

The MDD applies to a great variety of more than 400,000 different medical devices [29]. Therefore, a classification system is necessary. This classification into four classes is based on the intended application of the products and the risk potential associated with each individual product (Table 3.1). In general, class I is associated with low health risk, and class III devices carry the highest risk.

The type of testing and the extent of individual requirements depend on the classification of the medical device. For instance, in contrast to class IIb devices, no clinical tests are mandatory for class IIa devices (see Sect. 3.2.1.4); clinical testing of class IIa devices is required only when clinical assessment cannot provide the necessary information [43]. Dental materials are usually classified under class IIa; exceptions include dental implants (class IIb) and root canal filling materials containing active pharmaceutical ingredients (class III). Recently, a bioactive dental bonding material containing an antibacterial monomer [19] was registered as a class III product. This category of materials must fulfill the relevant requirements of the drug directive.

3.2.1.4 Conformity Assessment

A medical device that is in compliance (conformity) with the essential requirements of the MDD receives the CE label (Fig. 3.1) and can be launched on the market within the area of MDD jurisdiction. The respective process is therefore called conformity assessment. Various possibilities for such a conformity assessment are described in the MDD, depending on the class to which the individual medical device belongs.

Conformity assessment for class I devices: Devices of class I can be assessed for conformity by the manu-

Dentlearn.ir

Table 3.1 Classification of medical devices according to Medical Devices Directive 93/42 EEC [8]

Class	Definition and examples
Class I	Noninvasive products, such as adhesive bandages for small wounds Invasive products (for transient contact with the body, such as impression materials and materials for bite registration) Reusable surgical instruments
Class IIa	Surgically invasive products (for longer than transient contact with the body), such as pit and fissure sealants and filling materials and syringes and needles for dental anesthetic cartridges Active therapeutic products without potential risk, such as dental hand pieces Active diagnostic products, such as appliances for determining pulp vitality
Class IIb	Dental implants Contraceptives; condoms Active therapeutic appliances with potential risk, such as electrosurgical devices Ionizing radiation
Class III	Products for life-maintaining functions Products with druglike effect

facturers themselves. This applies, for instance, to impression materials. The manufacturer, however, needs to have all information available for a clinical assessment of its devices.

Conformity assessment for class II and class III devices: Medical devices of classes II and III must be assessed together with an external authority ("notified body"). Class II and class III devices are assessed for conformity by different processes. The manufacturer always uses the CE label at its own responsibility when all essential requirements are met and the stipulated conformity assessments have been successfully performed.

In the case of class IIa products, either the manufacturer or one of its products can be certified by the notified body. If a manufacturer has been certified (complete quality assurance system), then the manufacturer can place the CE label on the devices it manufactures with no further involvement of a notified body. This policy is preferred by most manufacturers of dental materials of class II (e.g., restorative materials and alloys). For medical devices that contain pharmaceutically active agents (class III), a statement by the legal authority responsible for drugs is necessary during the conformity assessment.

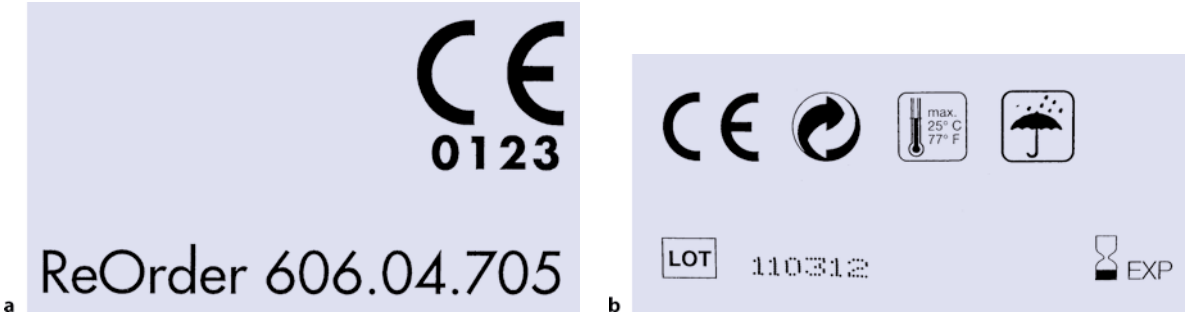

Fig. 3.1a,b The CE label on the wrapping of a dental material indicates that this product was brought on the market according to the Directive for Medical Devices based on all appropriate European legal requirements. **a** The number below the CE label shows which notified body was in charge (products of classes II and III); the name of notified body can be identified by this number in the internet. **b** If no number is shown below the CE label, the product belongs to class I

Dentlearn.ir

Key Note

Conformity assessment of a medical device is based on a clinical assessment, which either can be done by a review of the appropriate literature or can be based on clinical and other studies (Appendix X of the MDD [43]). Devices with a higher risk (classes IIb and III) are always subject to individual clinical studies. However, it is the view of scientific associations that for dental materials with fundamentally new compositions (even if they "only" belong to class IIa), clinical studies are always necessary. Thus, it is recommended that the dentist requests clinical data from the manufacturers of such materials.

The execution of clinical studies is regulated in a specific paragraph of the MDD. Each clinical study has to be registered with the appropriate agency, and a number of requirements (such as approval by an ethics committee) have to be met before such a study can be initiated. These regulations are meant to protect patients who participate in these studies (see also Sect. 3.7 on standards).

3.2.1.5 Responsibilities and Liability

3.2.1.5.1 Manufacturer/Importer

According to the MDD, the responsibility for performance, safety, and quality of a medical device – that is, fulfillment of the essential requirements – always lies with the manufacturer. Importers may be responsible for products imported from countries outside the European Economic Area. In general, the manufacturers define the indications for use of their medical devices.

3.2.1.5.2 Dentist

The legal regulations of the MDD do not release dentists from their responsibility to inform patients independent of the manufacturer's interest and to define the indications for each individual case within the scope of the specifications set by the manufacturer. Furthermore, a patient will most likely contact the dentist first if he or she has a problem with a material. In addition, it has been found in the past that various filling materials were labeled with CE (without clinical examination) but subsequently caused problems in patients (pain, tooth fractures; refer to Figs. 2.15 and 2.16). Therefore, if any doubt exists, one should not just rely on the CE label but should critically question the statements associated with the material's label.

If a medical device is not applied by the dentist according to the manufacturer's specifications (for example, use of an expired product or application of a product outside the range of indications), then this qualifies as malpractice. In this case, the injured person can claim compensation.

3.2.2 European Chemical Legislation (REACH)

Since 1 June 2007, the new European regulation on registration, evaluation, and authorization of chemicals (REACH) has been in force [13]. The main purpose of this legislation is a high level of protection of human health for consumers, workers, and the environment. It is directed at chemical elements and their compounds, preparations (mixtures or solutions composed of two or more substances), and articles (objects of special design) that mainly determines their functions. The responsibility for safe use lies with the manufacturer of the substances.

Manufacturers and importers of chemicals have until 2018 to use a stepwise approach to register with the European Chemicals Agency (ECHA) in Helsinki all new and currently available (presently, approximately 30,000 marketed substances) chemicals that have a production volume of >1 ton (1,000 kg) per year. Particularly dangerous substances must pass an authorization procedure.

REACH replaces about 40 different pieces of legislation with a streamlined and improved regulation. Related legislation (such as that regarding product safety, construction products, and the health and safety of workers who handle chemicals) and other legislation that regulates chemicals (such as in cosmetics and detergents) are not replaced by REACH and will continue to apply. REACH has been designed not to overlap or conflict with other chemical legislation [15].

Dentists, dental manufacturers, and dental laboratories belong mainly to the group of "downstream users" as long as they do not synthesize chemicals themselves. For them, it is important that scenarios of chemical exposure in dentistry be addressed in the basic documents for the substances. Therefore, the

Dentlearn.ir

manufacturers of such substances must declare that, for these substances, the exposure scenarios in dentistry have been taken into account. Information for the downstream user is provided by information such as the safety data sheet. It is stipulated that the structure of this data sheet must provide a clear format with all necessary information.

Key Note

Safety data sheets are an important source of information on the safety of substances. They are also required for dental materials (material safety data sheets), and they can be requested from the manufacturer or obtained from the Internet (refer to the manufacturer's Web site). These data sheets (see Table 3.2) are an important source of information concerning the components of a material and its biocompatibility. However, because this is a shortcut standard information format, other information sources, such as the scientific literature, are still necessary.

3.3 Legal Regulations in the United States

The United States Food and Drug Administration (FDA) Center for Devices and Radiological Health regulates the dental materials and devices marketed in the United States.

3.3.1 Food, Drug, and Cosmetic Act and Medical Device Amendments

The Federal Food, Drug, and Cosmetic (FD&C) Act was enacted in 1938. This act was supplemented by the Medical Device Amendments in May 1976, with subsequent amendments. The current document is updated to December 2004 [31]. The document puts on record that the FDA has regulations for premarket notification of an intent to market a medical (including dental) device and for the classification of all marketed medical devices in one of three classes (I, II, and III) in consideration of safety and effectiveness [32]. This means that the class to which a medical device is allocated defines the requirements necessary for marketing that device.

Table 3.2 Information provided in a material safety data sheet

1.	Product and company identification (USA) Identification of the substance/preparation (EU)
2.	Ingredients (USA) Composition/information on ingredients (EU)
3.	Hazard identification
4.	First-aid measures
5.	Firefighting measures
6.	Accidental release measures
7.	Handling and storage
8.	Exposure controls/personal protection
9.	Physical and chemical properties
10.	Stability and reactivity
11.	Toxicological information
12.	Ecological information
13.	Disposal considerations
14.	Transport information
15.	Regulatory information
16.	Other information

3.3.2 Classification of Devices

Class I devices are subject to general controls as defined by the FDA. For dental devices, the controls identified by section 510k [32, 33] of the FD&C Act require manufacturers to provide the FDA with premarket notification, along with information that the device is "substantially equivalent" compared with a predicate device and has the same intended use [34]. Class I devices are not purported or represented to be used for supporting or sustaining human life. In addition, they are not intended for a use that is of substantial importance in preventing impairment of human life, and they do not present an unreasonable potential risk of illness or injury. Examples of class I devices are denture adhesives and preformed crowns [35].

Dentlearn.ir

Class II devices are subject to special controls where there is sufficient information to establish controls, such as performance standards or guidelines. The FDA has recognized a number of international standards developed by the ISO Technical Committee 106 for dentistry, as well as standards developed by the American Dental Association Standard Committee on Dental Products, which operates under the auspices of the American National Standards Institute [35, 36, 37]. Examples of class II devices are tooth shade resin materials and endosseous implants [35].

Class III devices are subject to premarket approval in which the manufacturer is required to provide information on safety and effectiveness, possibly including clinical data on the device. For these devices, there is insufficient existing information to determine that general controls are sufficient or that special controls would provide reasonable assurance of safety and effectiveness. The device is purported or represented for use in supporting or sustaining human health or presents a potential unreasonable risk of illness or injury. Examples of class III devices are total temporomandibular joint prostheses and interarticular disc prostheses [35].

3.3.3 Premarket Notification and FDA Review

The FDA conducts reviews of premarket notification submitted by device manufacturers intending to market medical and dental devices. The FDA could conduct its own reviews of the submissions. It also has a third-party review process through its Accredited Persons Program [38, 39]. Under this program, the FDA has accredited third parties (accredited persons) who are authorized to conduct the primary review of premarket notification submissions based on claims of "substantial equivalency" (often referred to as 510k) for eligible devices [33]. The accredited person conducts the primary review and forwards the submission, review, and recommendation to the FDA, which makes the final determination on the submission.

Information on the Federal FD&C Act and steps to obtain marketing clearance for devices from the FDA Center for Devices and Radiological Health is available from the FDA's Web site [40]. Because regulations are subject to change, it is imperative to obtain current information from the FDA.

3.3.4 Records and Reports on Devices

A manufacturer or importer of a medical/dental device is required to maintain records to assure the safety and effectiveness of the device [41]. The manufacturer or importer is also required to report to the FDA any information that reasonably suggests that the device may have caused or contributed to death or serious injury. User facilities are also required to report to the FDA any information that reasonably suggests that the device may have caused or contributed to death, and if the device's identity is known, the information is to be reported to the manufacturer or importer.

When a health professional or consumer encounters a serious problem with a device, he or she can report it to the FDA Safety Informational and Adverse Event Reporting Program known as MedWatch [42]. Health professionals and consumers can report serious adverse events and product quality problems. Health professionals can also report errors in product use (see also Sect. 3.8 on surveillance and reporting). The FDA has a data base for clinical adverse effects, which can be visited under http://www.accessdata.fda.gov/scripts/cdrh/cfdocs/cfMAUDE/search.CFM

3.4 Legal Regulations in Australia

The Australian Therapeutic Goods Act of 1989 provides the legislative basis for controls over therapeutic goods, including dental products such as dental materials and equipment [1]. Under this umbrella, the new Australian regulatory system for medical devices came into force in 2002. It was created in line with the principles developed by the Global Harmonization Task Force (GHTF) for regulating medical devices.

Therapeutic goods supplied in Australia must be included in the Australian Register of Therapeutic Goods [2]. The Australian medical device regulatory system is in line with the GHTF principles, and the system is based on classifying devices according to risks and essential principles of safety and performance.

The Australian Therapeutic Goods Administration classifies medical devices into five categories:

- Class I (low risk) – examples are dental impression material and curing lights
- Class IIa (low-medium risk) – examples are dental filling materials and dental alloys
- Class IIb (medium-high risk) – examples are non-absorbable suture and permanent implants

Dentlearn.ir

- Class III (high risk) – examples are absorbable suture and absorbable implants
- Active implantable medical devices (high risk)

Conformity assessment procedures are used to demonstrate that medical devices conform to essential principles. Australian standards for dental materials and devices may be used for assessment. Manufacturers of medical devices and the Therapeutic Goods Administration are responsible for postmarket monitoring. Medical device users can report adverse events, or suspected problems that may present a health hazard, to the Therapeutic Goods Administration [3].

Key Note

The legal regulations in Australia closely resemble those in the EU. In the EU, active implantable medical devices are regulated under a separate directive (directive 90/385/EEC).

3.5 Legal Regulations in Japan[1]

In Japan, dental materials are listed as a category of medical devices and are regulated by the Pharmaceutical Affairs Law (PAL) and its ordinances. The Ministry of Health, Labour and Welfare (MHLW) revised the former PAL with the intention to adopt the GHTF rules and issued the new PAL, which came into effect on 1 April 2005. Besides the medical device regulations, a variety of chemical laws regarding the evaluation, regulation, and control of chemical substances and preparations must be considered in view of health and environmental protection (e.g., the necessity of safety data sheets). Further information on the Japanese legal regulations is available from various sources [16–18, 26–28].

3.5.1 Classification and Marketing Authorization

The Japanese Medical Device Nomenclature (JMDN) has been adjusted to the Global Medical Device Nomenclature (GMDN), although some terms for dental materials have been added and some definitions modified. The PAL classification for medical devices is close, but not identical, to the international GHTF classification. Medical devices are classified into four groups (Table 3.3). For class IV and class III devices (high and high-moderate risk), marketing approval has to be obtained before marketing. "Controlled medical devices" of class II, which belong to the low-moderate GHTF risk class, also need a marketing approval unless they fulfill the requirements of the specified standards for "designated controlled medical devices." In such cases, a marketing certification by a Registered Certification Body (RCB) is sufficient. "General medical devices" of class I (low-risk GHTF class) require only a notification. With the exception of most class I medical devices, for all other medical devices a Quality Management System survey is required, depending on the manufacturer's classification and location (domestic or foreign), by the Pharmaceutical and Medical Devices Agency (PMDA), the Prefectural Government, or an RCB.

Table 3.3 Japanese medical device classification

Class	Marketing authorization
General medical devices (class I), such as x-ray film	Notification
Designated controlled medical devices (class II), such as silicone-based impression material	Certification
Controlled medical devices (class II), such as dentin adhesives	Approval
Specially controlled medical devices (class III), such as calcium-hydroxide-containing root canal filling material	Approval
Specially controlled medical devices (class IV), such as absorbable bone regeneration material	Approval

1 The text for the legal regulations in Japan has kindly been provided by Dr. Barbara Wagner-Schuh, R•A•C Regulatory Affairs Consulting, www.R-A-C.de, Germany.

Dentlearn.ir

3.5.2 Marketing and Manufacturing Licenses

A person who places a medical device on the market in Japan needs to obtain a marketing license, depending on the device's classification. The Marketing License Holder (MLH) has to fulfill the requirements of standards for Good Quality Assurance Practice (GQP), Good Vigilance Practice (GVP) and Good Postmarketing Surveillance Practice (GPSP). When a foreign manufacturer intends to get a marketing approval or certificate, he needs to assign an MLH located in Japan as his appointed "Marketing Approval Holder" (MAH). The MAH is required to obtain the appropriate type of marketing license. He also has to fulfill the relevant standards. The MAH is responsible for the medical device, just as the manufacturer or authorized representative is according to the European MDD. However, if an MLH imports medical devices from foreign manufacturers and places them on the market under his own responsibility, the foreign manufacturers do not need to appoint an MAH.

Each manufacturing site must obtain a special manufacturing license (valid for 5 years) issued by the Prefectural Government for the category of manufacturing processes being used. Also, foreign manufacturers need a category-related special accreditation from the PMDA for each manufacturing site.

3.5.3 Marketing Authorization

To obtain a marketing approval or certification or to submit a notification, the applicant should have the appropriate business licenses (see Sect. 3.5.2). He must provide the complete documentation for the approval, certification, or notification basically in Japanese language.

The certification process for designated controlled medical devices shows some analogies to the certification system of the MDD in Europe according to international standards (essential requirements, conformity standards, and so on). To get the marketing approval/certification, and in connection with the notification of certain designated devices, a Quality Management System survey of all involved manufacturing sites is also required. This audit has to be renewed after 5 years. After review of the application documents and completed audit(s) for every application, the marketing approval/certification will be issued.

3.6 Labeling

Labeling of a substance, preparation, or medical device (including dental materials) serves as a tool for risk communication from the manufacturer to the user. So far, no worldwide accepted system for labeling is available; therefore, the dentist should request information from his or her national dental association. Within the EU, a labeling system for chemicals is laid down in directives 67/548/EEC (substances) [5] and 1999/45/EC (preparations) [12]. The latter regulation is obligatory in some EU countries (e.g., in Scandinavia) to be used for dental materials; in others, it is used by certain manufacturers. A central aspect of these regulations is the use of specific symbols to visualize risks. These symbols are placed on the device together with "R-phrases" to further specify the risk (see Table 3.4, Fig. 3.2, Fig. 3.3). "S-phrases" describe safety advices for the material. The formulations of these sentences are standardized and have to be selected by the manufacturer according to the directive's defined procedure.

Key Note

If a dental material includes a danger label, the dentist should consult the safety data sheet for further information, especially concerning safety advice. These data sheets can be obtained from the manufacturer, the Internet, or the supplier.

After about 10 years of effort, a new regulatory body was developed by the United Nations and adopted in 2003: the Globally Harmonized System of Classification and Labeling of Chemicals (GHS). The GHS will enter in the EU into force in 2008. It includes criteria for classifying health, physical, and environmental hazards, and it furthermore specifies which information should be included on labels of hazardous chemicals and on safety data sheets. The GHS is intended to be utilized globally as a harmonized system for managing chemical substances. The symbols used in the GHS are partially new and partially modified compared to those currently used in the EU, for example. Up to now, it has not been clear whether this system will apply to medical devices or only to substances (chemicals). GHS classifies chemicals into 27 categories according to physical properties and health and environmental hazards and indicates their hazard level

Dentlearn.ir

Table 3.4 Selection of symbols, R-phrases (risk phrases indicating the nature of the special risk and definitions), and definition of terms with relevance for dental materials (EU directive 1999/45/EEC) [12]

R-phrases	Hazard symbols/R-phrases
F: Highly flammable Substances and preparations which may become hot and finally catch fire in contact with air at ambient temperature without any application of energy, or Solid substances and preparations which may readily catch fire after brief contact with a source of ignition and which continue to burn or to be consumed after removal of the source of ignition, or Liquid substances and preparations having a very low flash point, or Substances and preparations which, in contact with water or damp air, evolve extremely flammable gases in dangerous quantities	 Highly flammable
Xn: Harmful Substances and preparations which may cause death or acute or chronic damage to health when inhaled, swallowed or absorbed via the skin	 Harmful
T: Toxic Substances and preparations which in low quantities cause death or acute or chronic damage to health when inhaled, swallowed or absorbed via the skin	 Toxic
C: Corrosive Substances and preparations which may, on contact with living tissues, destroy them	 Corrosive
Xi: Irritant Noncorrosive substances and preparations which, through immediate, prolonged or repeated contact with the skin or mucous membrane, may cause inflammation (the same symbol is used for sensitizers)	 Irritant
N: Dangerous for the environment Substances and preparations which, where they enter the environment, would or could present an immediate or delayed danger for one or more components of the environment	 Dangerous for the environment

Dentlearn.ir

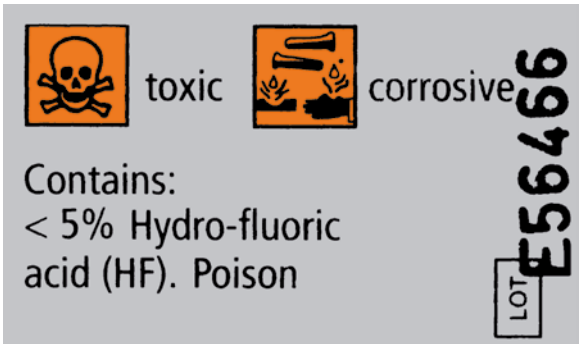

Fig. 3.2 Reference to a toxic and caustic substance (acid for ceramic etching)

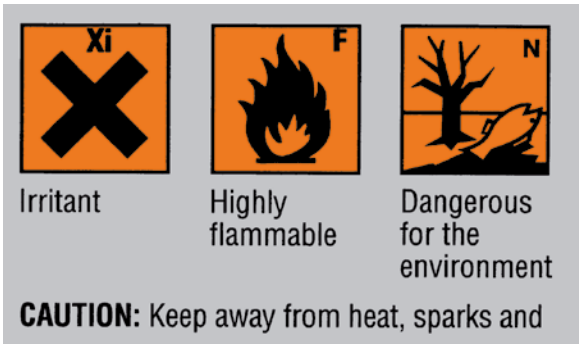

Fig. 3.3 Reference to an irritating, highly flammable, and environmentally hazardous substance (adhesive for an impression material)

in nine pictographs. The system also makes it easy to know their harmfulness and danger with mandatory labeling of signal words (danger, warning) and phrases ("may cause cancer," etc.).

3.7 Standards

Standards play an important role as tools for organizing daily life. Standardization, which is done by interested groups, is the planned unification of material and immaterial matters for the benefit of the general public. Standards are jointly defined by manufacturers, traders, users, and scientists, based on set rules. One of the aims of standards is to determine minimum requirements for the quality of products, such as dental materials. Standards are intended to provide protection (e.g., of the consumers and the environment) and save costs by means of standardized elements. Standards are regularly revised to adjust them to the newest technological standards. It is the general philosophy of the International Organization for Standardization (ISO) that international standards contribute to making the development, manufacturing, and supply of products and services safer, cleaner, and more efficient. They also make trade between countries easier and fairer [25].

However, based on general experience, the generation of standards is a very time-consuming process and may take several years in some cases. Therefore, newer technological developments might not be reflected by some standards. Furthermore, standards can be regarded as the least common denominator of the interests of the various participants. Overall, however, standards have proved to be valuable for quality assurance in all dental areas (and in other areas as well) for more than 80 years.

3.7.1 Harmonized Standards

"Harmonized" standards play a special role in the EU. These are standards that are requested by the European Commission based on a specified procedure; they have been generated on a European level, and their titles are published in the official journal of the EU. Most standards for dental materials have been harmonized through a so-called cumulative standard (EN 1641) [11]. This cumulative standard has been generated to simplify matters; it summarizes a variety of different individual standards, including ISO 7405 for dentistry [21]. Standards that are not harmonized in terms of the MDD are characterized by a lesser obligation; this may play a role in cases of liability or legal conflicts.

Key Note

Harmonized standards are of high importance within the framework of European legislation on medical devices. The wording of the law explicitly calls them a possibility to specify the essential requirements that have to be met by a medical device regarding performance, safety, and quality.

3.7.2 OECD Guidelines

Besides standards, other test guidelines exist in toxicology, such as the Organization for Economic Cooperation and Development (OECD) guidelines for testing of chemicals. These comprise a series of accepted test methods including testing for acute and chronic toxicity, sensitization, and teratogenicity as well as for

Dentlearn.ir

mutagenic and carcinogenic properties. In the standard series ISO 10993, reference is made in some areas to appropriate tests within the OECD guidelines [20].

3.7.3 Relevant Standards

A variety of different standards have been generated that specify composition, processing, or physical/chemical properties of dental materials. This paragraph will review only standards for the assessment of biocompatibility. Distinctions have been drawn between the following:

- Horizontal standards
- Semihorizontal standards
- Vertical standards

Horizontal standards are valid for all medical devices; semihorizontal standards are valid for groups of products (such as dental materials); and vertical standards are valid for individual materials such as amalgam. For reasons of simplicity, only ISO terms will be used in the following. In general, ISO standards are adopted by the Comité Européen de Normalisation (CEN) and receive the EN ISO prefix. Harmonized standards used for the European MDD are always EN standards.

ISO 10993: Biological Evaluation of Medical Devices [20]

Under this name, a series of standards is summarized that is, in most cases, jointly issued by ISO and CEN. It is effective (for the major part) for the entire area of medical devices (horizontal standard). Part I of this series contains guidelines for selecting appropriate test methods, and the following parts describe various methods for evaluating different aspects of biocompatibility (for details, see Table 3.5).

ISO 7405 (2008): Preclinical Evaluation of Biocompatibility of Medical Devices Used in Dentistry – Test Methods for Dental Materials [21]

This standard applies specifically to dental materials (semihorizontal standard) and supplements the mentioned series of horizontal standards, ISO 10993. The focus of ISO 7405 is test methods that are not or are only cursory described in the horizontal standard ISO 10993 (see Table 3.6) and for which special needs and special experiences exist in dentistry.

Table 3.5 Standards of the ISO 10993 series (all standards adopted by the Comité Européen de Normalisation)

ISO Standard	Title
ISO 10993-1: 2003	Evaluation and testing
ISO 10993-2: 2006	Animal welfare requirements
ISO 10993-3: 2003	Tests for genotoxicity, carcinogenicity, and reproductive toxicity
ISO 10993-4: 2002	Selection of tests for interactions with blood
ISO 10993-5: 1999	Tests for in vitro cytotoxicity
ISO 10993-6: 2007	Tests for local effects after implantation
ISO 10993-7: 1995	Ethylene oxide sterilization residuals
ISO 10993-9: 1999	Framework for identification and quantification of potential degradation products
ISO 10993-10: 2002	Tests for irritation and delayed-type hypersensitivity
ISO 10993-11: 2006	Tests for systemic toxicity
ISO 10993-12: 2002	Sample preparation and reference materials
ISO 10993-13: 1998	Identification and quantification of degradation products from polymeric medical devices
ISO 10993-14: 2001	Identification and quantification of degradation products from ceramics
ISO 10993-15: 2000	Identification and quantification of degradation products from metals and alloys
ISO 10993-16: 1997	Toxicokinetic study design for degradation products and leachables
ISO 10993-17: 2002	Establishment of allowable limits for leachable substances
ISO 10993-18: 2005	Chemical characterization of materials
ISO/TS* 10993-19: 2006	Physicochemical, morphological, and topographical characterization of materials
ISO/TS* 10993-20: 2006	Principles and methods for immunotoxicological testing of medical devices

*TS = Technical specification only, no ISO-standard

Dentlearn.ir

Table 3.6 Test methods according to ISO 7405 [21] that are not explicitly defined in series ISO 10993 [20]

Cell cultures	Usage tests
Agar-overlay test	Pulp/dentin test
Filter test	Pulp-capping test
Dentin-barrier test	Endodontic usage test Implant usage test

ISO 14971: Medical Devices – Application of Risk Management to Medical Devices [22]

Risk analysis and risk assessment are the basis for the justification of a risk (see also Chap. 1). This standard summarizes the guidelines for the general procedure of risk management (including risk analysis). In doing so, the intended application of each material as well as its composition, solubility, and damaging potential are evaluated. The result of a risk analysis is either a determination of tests that still have to be done (test profile) or, if all necessary data are available, the decision of whether a risk is acceptable and/or under which limitations (for example, a special indication) it would be acceptable. This evaluation requires reference to products that are already available on the market.

ISO 14155-1: Clinical Investigation of Medical Devices for Human Subjects – Part 1: General Requirements [23]

This standard conceives clinical investigations as each systemic evaluation on test subjects and is intended to evaluate the safety and performance of a certain medical device under normal conditions of application. Standard ISO 14155-1 describes the competences, responsibilities, and principle process of a clinical evaluation. A clinical investigation is essentially based on the prerequisites of the Declaration of Helsinki for the protection of test subjects (the current version can be downloaded from http://www.fda.gov/oc/health/helsinki). All levied data and information are confidential, and the investigation must be approved by an ethics committee. The test subjects have to be informed in an appropriate manner; their consent must be given in writing and include the right to end their participation in the clinical investigation at any time without justification. The investigation itself has to be described in a detailed test protocol (ISO 14155-2) [24]. Dental materials of class IIa must undergo a "clinical assessment." Approval for marketing is not necessarily linked to a clinical evaluation according to ISO 14155.

3.8 Surveillance and Reporting Systems

Experience has shown that even the most meticulous risk analysis/risk assessment cannot avoid cases in which a material does cause reactions in patients during the time of application. This fact has also been considered in legal regulations that dictate postmarket surveillance and reporting systems for medical devices. Details are regulated, such as in a safety plan for medical devices in the EU [30]. As mentioned above (see information on U.S. regulations), such reports in the United States must be directed to the FDA. Similar systems exist in other countries.

Side effects caused by medical devices are generally first detected by the treating dentist, who is responsible and obligated to transfer this information to the authority in charge. The modalities of this feedback differ among countries, and dentists must check their national legislation regarding the stipulations for their country.

Some countries, including Norway, have central national report registers for side effects due to dental materials. These central agencies are not dictated by law within the EU, since side effects caused by dental materials are generally not severe (compared with fatal consequences) [14]. Because the frequency of side effects of dental materials is low, central registers have the advantage that scientific and clinical experiences regarding diagnosis, therapy, and, eventually, prevention of these effects can be gathered on a broad basis.

Dentlearn.ir

Conclusions for the Dental Practitioner

1. A multiplicity of laws, standards, and recommendations regulate the marketing of medical devices, generating the impression that the dentist can rely exclusively on them (e.g., CE labeling). Most laws and directives, however, are of newer date. Therefore, experiences are more limited. Thus, insecurities may exist in single cases during their application, such as for classification and the requirement for clinical evaluations. Therefore, legal regulations do not release the dentist from the responsibility to gather as much information as possible about the products used or to request this information from the manufacturer. The dentist should use only those medical devices for which appropriate information is available.
2. Within the European Economic Area, the dentist has to consider the following (according to the MDD):
   - Only materials labeled with "CE" may be used.
   - All materials that are used in patients have to be documented.
   - Dental lab work (end products) usually consists of medical devices. The dentist, as the operator of a dental laboratory, is therefore a producer in terms of the MDD.
   - Information about the responsibilities associated with the MDD is available in detail from the respective countries' dental associations.
3. In the United States, the FDA regulates dental materials and devices. It defines the requirements for products to demonstrate safety and effectiveness in order to obtain clearance to market.
4. Japan and Australia have adopted the principles of the GHTF with some modifications. The classifications are similar to those in the EU and the United States.
5. Safety data sheets for medical devices can be downloaded from the Internet. They are an important source of information about the biocompatibility of dental materials as they were investigated by the manufacturers. Appropriate safety labels on the wrappings should be considered.
6. The manufacturer/importer is responsible for its products and is potentially liable for damages. The dentist is responsible for correct application of the medical device; this also applies to correct use by the dentist's personnel. Liability claims may be made in terms of damage compensation as well as compensation for pain and suffering.

References

1. Australian Government Department of Health and Ageing, Therapeutic Goods Administration. http://www.tga.gov.au/docs/html/dentalreg.htm. Cited 27 Aug 2007.
2. Australian Government Department of Health and Ageing, Therapeutic Goods Administration: Australian register of therapeutic goods. http://www.tga.gov.au/docs/html/artg.htm. Cited 27 Aug 2007.
3. Australian Government Department of Health and Ageing, Therapeutic Goods Administration: Medical device adverse event reporting by medical device users. http://www.tga.gov.au/docs/html/forms/iris_udir.htm. Cited 27 Aug 2007.
4. Council of the European Communities: Council Directive 65/65 EEC on the approximation of provisions laid down by law, regulation or administrative action relating to proprietary medicinal products. Official Journal of the European Communities P22, 369–373 (1965).
5. Council of the European Communities: Council Directive 67/548 EEC on the approximation of laws, regulations and administrative provisions relating to the classification, packaging and labelling of dangerous substances. Official Journal of the European Communities P 196, 1–98 (1967).
6. Council of the European Communities: Council Directive 76/768/EEC of 27 July 1976 on the approximation of the laws of the Member States relating to cosmetic products. Official Journal of the European Communities L 262, 169–200 (1976).
7. Council of the European Communities: Council Directive 90/385/EEC of 20 June 1990 of the approximation of the laws of the Member States relating to active implantable medical devices. Official Journal of the European Communities L 189, 17–36 (1990).
8. Council of the European Communities: Council Directive 93/42/EEC of 14 June 1993 concerning medical devices. Official Journal of the European Communities L 169, 1–43 (1993), Directive 2007/47 EC-OJ L 247/21.9.2007.

Dentlearn.ir

9. Council of the European Communities: Council Directive 98/79/EC of the European Parliament and of the Council of 27 October 1998 on in vitro diagnostic medical devices. Official Journal of the European Communities L 331, 1–37 (1998).
10. Council of the European Communities: Council Directive 01/83 EEC on the community code relating to medicinal products for human use. Official Journal of the European Communities L 311, 67–128 (2001).
11. European Committee for Standardization: EN 1641 Dentistry – Medical devices for dentistry: materials. European Committee for Standardization, Brussels 1996.
12. European Parliament and the Council: Directive 1999/45/EC concerning the approximation of the laws, regulations and administrative provisions of the Member States relating to the classification, packaging and labelling of dangerous preparations. Official Journal of the European Communities L 200/1 (1999).
13. European Parliament and the Council of the European Union: Regulation (EC) No 1907/2006 of the European Parliament and of the Council concerning the Registration, Evaluation, Authorisation and Restriction of Chemicals (REACH). Official Journal of the European Union L 396/1 (2006).
14. Fuller, J., Parmentier, C.: Dental device-associated problems. An analysis of FDA postmarket surveillance data. J Am Dent Assoc 132, 1540 (2001).
15. European Chemical Agency (2007): REACH guidance. http://reach.jrc.it./about_reach_en.htm. Cited Aug/Sept 2007.
16. Japan Pharmaceutical Manufacturers Association (2007). http://www.jpma.or.jp/english. Cited Aug/Sept 2007.
17. Pharmaceuticals and Medical Devices Agency (2007). http://www.pmda.go.jp/english/operations.html. Cited Aug/Sept 2007.
18. [Japanese legal regulations] http://kanpou.npb.go.jp. Cited Aug/Sept 2007.
19. Imazato, S., Tay, F.R., Kaneshiro, A.V., Takahashi, Y., Ebisu, S.: An in vivo evaluation of bonding ability of comprehensive antibacterial adhesive system incorporating MDPB. Dent Mater 23, 170–176 (2007).
20. International Organization for Standardization: ISO 10993: Biological evaluation of medical devices. International Organization for Standardization, Geneva.
21. International Organization for Standardization: ISO 7405: Dentistry – Preclinical evaluation of the biocompatibility of medical devices used in dentistry: test methods for dental materials. International Organization for Standardization, Geneva 2008.
22. International Organization for Standardization: ISO 14971: Medical devices – application of risk management to medical devices. International Organization for Standardization, Geneva 2000.
23. International Organization for Standardization: ISO 14155-1: Clinical investigation of medical devices for human subjects. Part 1: General requirements. International Organization for Standardization, Geneva 2002.
24. International Organization for Standardization: ISO 14155-2: Clinical investigations of medical devices for human subjects. Part 2: Clinical investigation plan. International Organization for Standardization, Geneva 2002.
25. International Organization for Standardization: Overview of the ISO system. http://www.iso.org/iso/en/aboutiso/introduction/index.html#one. Cited Aug/Sept 2007.
26. Ministry of Health, Labour and Welfare [Japan]: Ministerial Ordinance No. 2, 1961 (amended 2004). Regulations for buildings and facilities of pharmacies etc.
27. Ministry of Health, Labour and Welfare [Japan]: Ministerial Ordinances 38, 135, 136, 169.
28. The Pharmaceuticals Affairs Law. Yakuji Nippo, ISBN4-8408-0773-6.
29. Schmalz, G.: Biological evaluation of medical devices: A review of EU regulations, with emphasis on in vitro screening for biocompatibility. ATLA 23, 469 (1995).
30. Schorn, G., Baumann, H.G.: MPG Medizinprodukte-Recht. Recht – Materialien und Kommentar [Medical device legislation – materials and comments], 2nd edn. Wissenschaftliche Verlagsgesellschaft, Stuttgart 2002
31. United States Food and Drug Administration: Federal Food, Drug, and Cosmetic Act (as amended through 31 December 2004). http://www.fda.gov/opacom/laws/fdcact/fdctoc.htm. Cited 24 Aug 2007.
32. United States Food and Drug Administration: Federal Food, Drug, and Cosmetic Act, Sec. 513, Classification of devices intended for human use. Device Classes. http://www.fda.gov/opacom/laws/fdcact/fdcact5a2.htm. Cited 24 Aug 2007.
33. United States Food and Drug Administration: 510(k) overview. http://www.fda.gov/cdrh/510k.html. Cited 24 Aug 2007.
34. United States Food and Drug Administration: Federal Food, Drug, and Cosmetic Act, Sec 513i: Substantial Equivalence. http://www.fda.gov/opacom/laws/fdcact/fdcact5a2.htm. Cited 24 Aug 2007.
35. United States Code of Federal Regulations: Title 21 Food and Drugs, chapter 1. Food and Drug Administration, Department of Health and Human Services. Subchapter H, medical devices. Part 872, dental devices. http://www.accessdata.fda.gov/cdrh/cfdocs/cfcfr/CFRSearch.cfm?CFRPart=872. Cited 24 Aug 2007.
36. United States Food and Drug Administration: Federal Food, Drug, and Cosmetic Act. Sec 514c: Recognition of a standard. http://www.fda.gov/opacom/laws/fdcact/fdcact5a2.htm. Cited 24 Aug 2007.
37. United States Food and Drug Administration, Center for Devices and Radiological Health: Standards. http://www.accessdata.fda.gov/scripts/cdrh/cfdocs/cfStandards/Results.CFM. Cited 24 Aug 2007.
38. United States Food and Drug Administration, Center for Devices and Radiological Health. What is third party review? http://www.accessdata.fda.gov/scripts/cdrh/cfdocs/cfThirdParty/current.cfm?panel=DE. Cited 24 Aug 2007.
39. United States Food and Drug Administration, Center for Devices and Radiological Health. List of devices for third party review under the FDA Modernization Act of 1997. Database update 7 Feb 2002. http://www.accessdata.fda.gov/scripts/cdrh/cfdocs/cfThirdParty/current.cfm?panel=DE. Cited 24 Aug 2007.
40. United States Food and Drug Administration, Center for Devices and Radiological Health. www.fda.gov/cdrh. Cited 24 Aug 2007.
41. United States Food and Drug Administration: Federal Food, Drug, and Cosmetic Act. Sec 519: Records and Reports on Devices. http://www.fda.gov/opacom/laws/fdcact/fdcact5a2.htm. Cited 24 Aug 2007.
42. United States Food and Drug Administration: MedWatch. http://www.fda.gov/medwatch. Cited 24 Aug 2007.
43. Wachenhausen, H.: Rechtliche Voraussetzungen für klinische Prüfungen. [Legal requirements for clinical testing] Medizinprodukte Journal 9, 80 (2002).

Dentlearn.ir

4 Dental Amalgam

D. Arenholt-Bindslev and P. Hørsted-Bindslev

Contents

4.1 Introduction 59
4.2 Composition and Setting Reaction 60
4.2.1 Mercury-Based Amalgams 60
4.2.2 Mercury-Free Amalgams 63
4.3 Systemic Toxicity 64
4.3.1 Metabolism, Distribution, and Excretion of Mercury 64
4.3.2 Immunotoxicity 72
4.3.3 Neurotoxicity 73
4.3.4 Fertility Dysfunction and Teratogenicity .. 74
4.4 Local Toxic Reactions 76
4.4.1 Cytotoxicity and Implantation Studies 76
4.4.2 Pulp Reactions 76
4.4.3 Reactions of the Oral Mucosa 77
4.5 Allergies 80
4.6 Carcinogenicity 85
4.7 Clinical Studies 85
4.7.1 Relationships Among Symptoms, General Diseases, and Amalgam Fillings 85
4.7.2 Removal of Amalgam Restorations 88
4.8 Public Discussion 89
Conclusions for the Dental Practitioner ... 90
References 91

4.1 Introduction

Silver amalgam has been the most important restorative material in the history of dentistry. The material has been widely used for almost two centuries, although the composition has changed during this period. In many countries, silver amalgam is still of great importance for restoring decayed teeth. For example, in England and Wales, out of a population of 38 million people (those age 18 years and over), approximately 17 million amalgam fillings were placed each year in the early 1990s (Dental Practice Board, United Kingdom, 2002). However, the overall use of amalgam in Western countries is decreasing; for example, in Denmark, with a population of 5.5 million, the number of amalgam fillings dropped from about 3.5 million in 1980 to about 700,000 in 2006. The material is relative cheap, and when handled correctly, the durability of amalgam fillings exceeds that of alternative direct restorative materials [24, 161, 225, 247] (Fig. 4.1). Acceptable durability can be obtained even under difficult operative circumstances, in contrast to analogous materials, which are more technique-sensitive (Fig. 4.2). On the other hand, silver amalgam has been and still is a matter of concern for patients and

Fig. 4.1 A 19-year-old intact amalgam filling

Dentlearn.ir

Fig. 4.2 Extended amalgam restorations on an upper molar and premolar tooth. Indirect restorations would have been the treatment of choice for these severely decayed teeth, but patients' individual situations may require more inexpensive solutions, such as large amalgam fillings

the dental profession due to its content of toxic substances, mercury in particular.

4.2 Composition and Setting Reaction

4.2.1 Mercury-Based Amalgams

The word "amalgam" is derived from the Arabic "al-malgham" and the Greek "malagma," which refer to a soft substance or mass. Silver amalgams are primarily composed of metallic mixtures whose main component is mercury. The alloy powder of modern high-copper amalgams comprises silver, tin, copper, and zinc (Table 4.1).

Table 4.1 Composition of alloy powders for γ2-free amalgam (*wt.%* weight percent)

Silver	45–70 wt.%
Tin	12–30 wt.%
Copper	15–30 wt.%
Zinc	0–2 wt.%

4.2.1.1 Setting Reaction

The setting mechanisms of amalgam are very complex (Fig. 4.3). The following description, therefore, represents a simplification of these reactions.

The particles of the alloy powder are moistened with mercury during the trituration of alloy powder and mercury, which diffuses into the particles. As a result, the amalgam sets through dissolution and subsequent crystallization, forming a solid mass. Depending on the manufacturing type of the alloy particles and their shape, two possible reactions will take place in high-copper amalgams. These two types of amalgam are called non-γ2 amalgams. In one type of reaction, a γ2 phase is initially formed, which subsequently transforms into a γ1 phase and an η' phase within 1 year (Fig. 4.3a). In the other type of reaction, no initial γ2 phase is generated (Fig. 4.3b).

Key Note

The γ2 phase is of special interest for toxicological reasons because this phase – in contrast to the γ1 phase and the η' phase – reveals the highest susceptibility to corrosion.

Low-copper amalgams, with less than 5% copper, were primarily used from the end of the 19th century until around 1970. These amalgams essentially form a continuous γ2-phase network throughout the restoration, which facilitates a corrosive deterioration specifically of insufficiently condensed fillings (Fig. 4.3c). No transformation to γ1 occurs in these amalgams, and they are often called γ2 amalgams. During corrosion of the γ2 phase, mercury is released and may react with unreacted γ phase or evaporate. However, non-γ2 amalgams have almost completely ousted these amalgams due to their improved resistance to corrosion, reduced "creep," and better clinical performance [139, 155].

4.2.1.2 Mercury Emission and Corrosion Products

The chemical reactions in the oral cavity are very complex and depend on numerous varied factors. Several reactions may contribute to the release of mercury from amalgam:

Dentlearn.ir

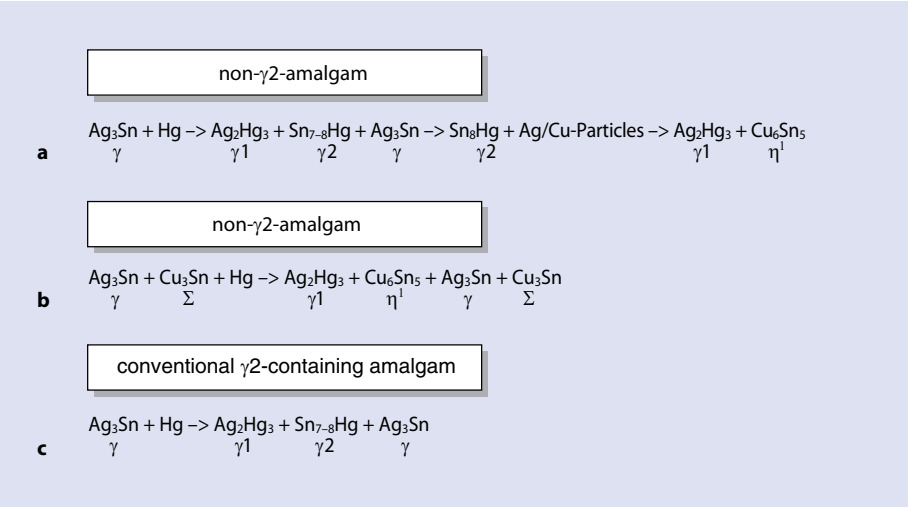

Fig. 4.3 Setting reactions of non-γ2 (**a**,**b**) and γ2-containing (**c**) amalgams

- Free (unbound) mercury can be detected in the superficial layer of fresh amalgam specimens [165].
- Mercury is released in the oral cavity because of the low melting point of the γ1 phase (127°C) over the course of time.
- Mercury can evaporate from the surface in contact with air because of its relatively high vapor pressure in equilibrium with the γ1 phase [156].
- Further, it has been found that after placement of amalgam restorations, the γ1 phase is, over a number of years, gradually transformed to a phase with lower mercury content, leaving free mercury to be released.
- An increased emission of mercury from amalgams with a very low silver content but high copper content may occur under adverse circumstances. This has been ascribed to the risk of either a surplus of unreacted mercury or a mercury-rich γ1 phase in the set material [112].

In the case of electrochemical corrosion, all constituents of amalgam may be released from the restoration. Saliva acts as an electrolyte. The heterogeneous structure of high-copper amalgam favors the corrosive dissolution of the most electrochemically susceptible phases, for instance, the ŋ' phase in non-γ2 amalgams, whereas the least electropositive γ phase and γ1 phase corrode less [141]. The corrosion products of modern non-γ2 amalgams usually contain zinc, tin, and copper [188]. Corrosion products may be detected in the surface of the material, in adhering plaque, in microgaps between restoration and dental hard tissue, and in adjacent soft tissues. Corrosion occurs primarily in a very porous amalgam when fresh amalgam is added to old amalgam or when amalgam is placed in contact with material of lower electrochemical activity, such as gold alloys.

Electrochemical activity may be perceived by the patient as a minor electric shock immediately after placement of an amalgam filling, when the new restoration is brought into a short conducting contact with an existing gold restoration. The symptoms are usually short-lasting and disappear after a few days because a protective layer consisting of peroxides and corrosion products is formed on the surface of the amalgam. This layer causes a "passivation."

The release of mercury from the filling is gradually reduced by formation of the passivation layer. This protective layer is generated by the deposition of corrosion products at the surface of the amalgam restoration, in microgaps between filling and dental hard tissue, or in the contact area with gold alloy.

The passivation layer can be temporarily removed either mechanically, due to intense brushing or mastication, or by dissolving when pH in the adjacent environment is low. Both events facilitate the emission of mercury.

Dentlearn.ir

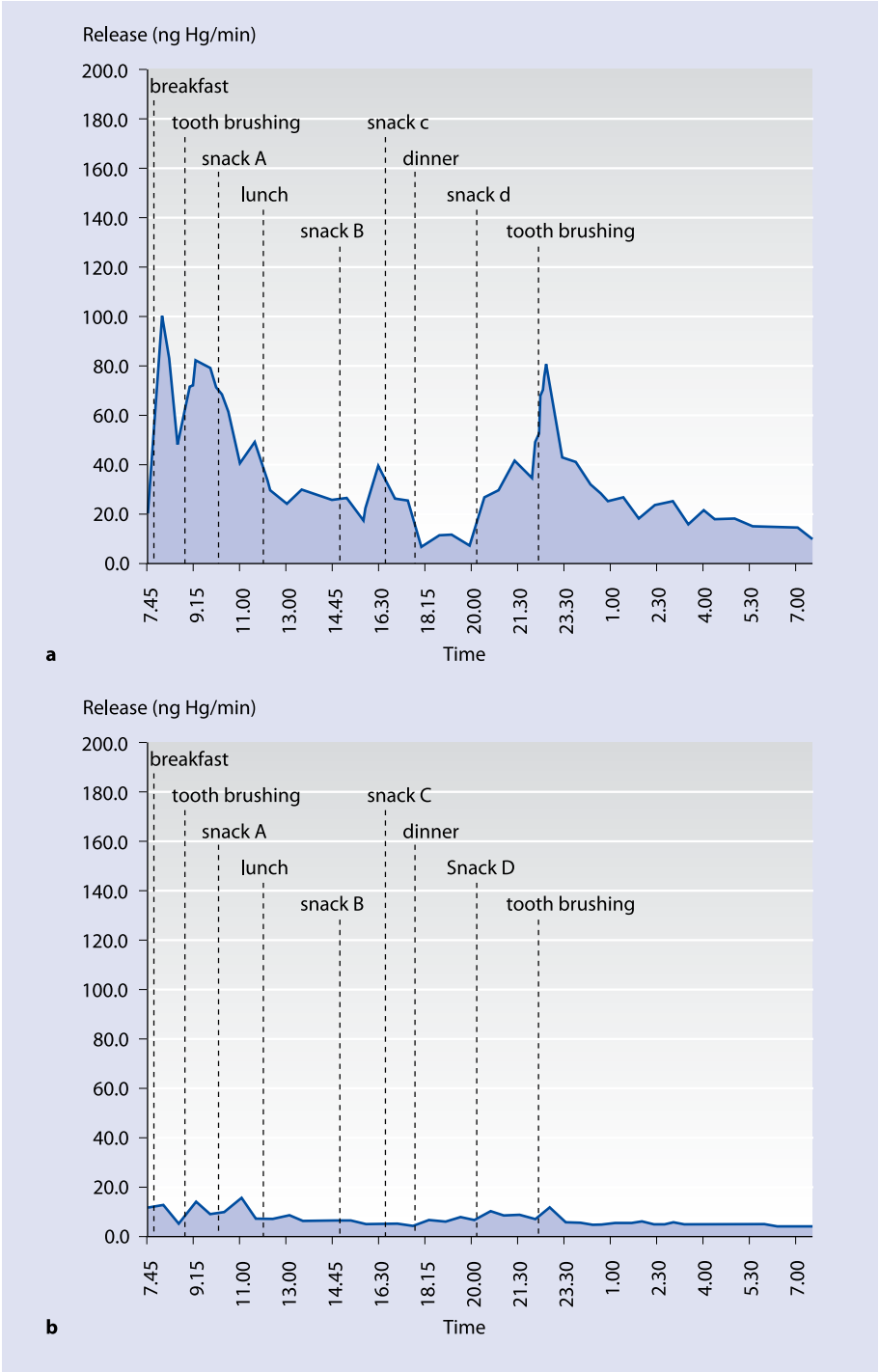

Fig. 4.4 Influence of meals and toothbrushing on the release of mercury from amalgam fillings. Readings during 24 h on test subjects with a total of 36 (**a**) and 18 (**b**) amalgam surfaces [152] (Courtesy of J. R. Mackert, Augusta, Georgia, USA, and A. Berglund, Umeå, Sweden)

Dentlearn.ir

A temperature rise at the surface of amalgam – due to contact with hot coffee, for instance – slightly increases the vapor pressure and thus the release of mercury [152]. The emission of mercury vapor is elevated during toothbrushing, the intake of hot beverages, and, particularly, gum chewing, whereas intake of other foodstuffs apparently has little effect on mercury release (Fig. 4.4) [152]. On the other hand, formation of corrosion products on the amalgam surface and in microspaces tends to reduce the release of mercury from the restoration over time. Chemicals such as carbamide peroxide used for bleaching and mouth rinses used for controlling plaque have no or only a slight effect on the release of metal ions from amalgam [5, 251].

4.2.1.3 New Alloys

Several attempts have been made to improve the resistance of amalgam to corrosion and emission of mercury. One direction has been to change the relationship between metals in the alloy. Modern amalgams contain 40–54% mercury, and another approach has been to substitute some of the mercury with gallium (see also Sect. 4.2.2).

- A small quantity of palladium (0.5–0.7%) has been added to reduce the release of mercury and increase resistance to corrosion [43, 157]. Clinical studies have shown some advantages of these amalgams compared with non-γ2 amalgams regarding surface gloss but not in terms of marginal fractures [157, 240].
- Another example is the addition of platinum or indium to the alloy powder or the liquid mercury. The intention of this approach was to reduce the quantity of free mercury in the set amalgam, to create a more efficient superficial oxide layer, and thus to reduce the vapor pressure of the mercury-releasing phase [187, 264]. But in vitro studies have not unambiguously shown a reduced release of mercury from these amalgams compared with conventional non-γ2 amalgams [81, 156, 187]. A reduced long-term release of mercury from indium-containing amalgams has especially been questioned [74].
- The ratio of tin in the set amalgam also influences the degree of mercury release. In vitro studies revealed that a high amount of tin in the Ag-Hg phase causes a reduced vapor pressure of mercury, a complete oxide layer, and consequently a reduced emission of mercury [156].

Clinical Practice Advice

Appropriate amalgams, for instance, non-γ2 amalgams, should be selected to minimize the risk of release of mercury from amalgam fillings. The ratio between alloy powder and mercury should be adjusted carefully according to the manufacturer's instructions. Preferably, capsulated amalgams should be used. Mixed amalgam has to be carefully condensed in the cavity and subsequently contoured. The surface must be carved accurately to avoid fractures of the fillings and/or a subsequent heavy grinding on the filling (see Sect. 4.3.1). The filling should be polished a few days after placement in order to minimize corrosion. Finish (and removal of amalgam fillings as well) should be performed with sufficient water rinsing/cooling and aspiration of the resulting water mist to reduce exposure to mercury vapor. The use of a rubber dam in relation to removal and insertion of amalgam restorations may be considered (see also Sect. 4.7.2).

4.2.2 Mercury-Free Amalgams

The best way to prevent a release of mercury would be to completely replace this element. Therefore, the replacement of mercury by gallium has been attempted. Gallium is a silver-white metal whose melting point is slightly higher than that of mercury. It also has a lower vapor pressure. Alloy powders, similar to those used for conventional amalgam, are triturated with liquid gallium, whose melting point is further reduced by adding indium and tin.

- The commercially available formulations contain 50–60% Ag, 25–28% Sn, 11–15% Cu, 2–9% Pd, and, eventually 0.3% Zn and 0.05% Pt.
- The liquid contains 62–65% Ga, 19–25% In, 13–16% Sn, and 0.05% Bi.
- The materials set by creating various phases similar to those of conventional amalgams.

The technical properties, such as expansion during setting, creep, and compressive strength, are equal or slightly inferior to amalgam that contains mercury. Condensation is very difficult, and increased porosity and inferior marginal adaptation have been shown in vitro [221]. Manufacturers' instructions state that moisture must be avoided during condensation and for several hours thereafter in order to prevent unwanted

Dentlearn.ir

expansion of the restoration. Furthermore, corrosion is a major problem, especially for the Cu–Ga phase and the Sn phase, the latter being very susceptible to corrosion in an acidic environment. Clinical studies have shown marginal deterioration, tarnish, fracture of hard tooth substance, and postoperative sensitivity to be up to twice as high as for mercury-containing amalgam fillings [59, 122, 181, 190]. It may be concluded that the presently available gallium alloys have clinical properties inferior to those of conventional mercury-containing amalgam. In 1990 the Japanese government approved gallium alloys as dental restorative materials. A product that was approved in the European Union has since been taken from the market.

Key Note

There have been several attempts to change the composition of amalgam in order to reduce the release of mercury. To date, the success of these attempts is only fair, since technical and clinical properties of these alternative materials have been shown to be inferior to those of conventional amalgams.

4.3 Systemic Toxicity

Dental amalgams consist of metals that may cause concerns about the risk of systemic toxic reactions if released in sufficiently high quantities. Before discussing this risk, it should be emphasized that amalgam restorations belong to the most durable type of direct restorative materials. If the release of substances from amalgam were high, the durability of the restoration would be short due to material disintegration. As discussed previously in this chapter, the release of mercury has especially caught public and professional attention, although other constituents of amalgam may also leach. The most important question is whether mercury or other released metals pose a health hazard for individuals with amalgam restorations or for their offspring.

4.3.1 Metabolism, Distribution, and Excretion of Mercury

4.3.1.1 Release and Uptake

The main part of mercury released from restorations is found as mercury vapor in the intraoral air or dissolved in saliva. Corrosion products and microparticles of amalgam may also be found in saliva. Mercury concentrations in the intraoral air and saliva of persons with amalgam fillings are significantly higher than in individuals without amalgam restorations. A qualified estimate of the mean daily intake via the lungs and the gastrointestinal tract indicates values between 2 and 5 µg in persons with 20–40 amalgam surfaces [20, 87, 152, 189], but there are great individual differences. Persons with a high number of amalgam fillings or an overall extensive amalgam surface may reveal a release of very little mercury, whereas individuals who suffer from bruxism or use chewing gum for several hours per day may liberate much higher quantities than the aforementioned amounts (e.g., [205]).

The published data regarding the release of mercury from amalgam restorations and its subsequent resorption vary significantly [152]. This is due to variables such as different reading techniques, uncertainty regarding analytical quality control, the frequency of measurements, the ratio of oral-to-nasal breathing, and whether the collected air was exhaled or sampled in the oral cavity or the trachea. Furthermore, there is also uncertainty about the amount of mercury swallowed. Evidence exists that toothbrushing and specifically the use of chewing gum will increase the release of mercury. However, chewing of other foodstuffs as part of the regular diet or as snacks will not increase the liberation of mercury and may even cause a decrease of its release (Fig. 4.4). A hypothesized increased release of mercury following exposure to low-frequency magnetic fields has not been verified [22].

Mercury uptake from amalgam fillings occurs primarily via the respiratory tract, specifically the lungs, where approximately 80% of the inhaled mercury vapor diffuses from the pulmonary alveoli to the alveolar capillaries. Uptake from the gastrointestinal tract of mercury dissolved in swallowed saliva is normally considered to be 5–10%. Resorption of liquid elemental mercury is extremely low (about 0.01%) [153, 255].

Within minutes, catalase and hydrogen peroxide oxidize most of the absorbed mercury to ionic mercury in red blood cells and tissues ($Hg^0 \rightarrow Hg_2^{2+} \rightarrow Hg^{2+}$) [153]. Before oxidation, circulating elemental mercury is able to penetrate cell membranes and thus the blood–brain and placental barriers. Oxidation significantly reduces the lipid solubility of mercury. Consequently, the ability of oxidized mercury to pass cell membranes is reduced, which leads to an accumulation of this element in the tissues in question [47, 255].

Gastrointestinal uptake via bacterial methylation of elemental mercury by microorganisms of the oral

Dentlearn.ir

cavity and the gut is negligible [65]. But if this biotransformation should occur at all, it would happen only on a minimal scale in mammalian tissues [13, 45, 47, 255].

The body's burden of methylmercury originates primarily from fish consumption, especially from fish ranking high in the food chain, for instance, halibut, tuna and marine mammals (salt water) or pike and trout (fresh water). About 90% of organic methylmercury is absorbed in the gastrointestinal tract. In contrast to elemental mercury, methylmercury is lipid soluble and readily penetrates the blood–brain or placental barrier by means of a rather complex reaction [47]. The brain and the entire central nervous system are the primary tissues targeted, and the clinical symptoms of chronic intoxication are paresthesia, ataxia, tunnel vision (constricted field of vision), and impaired hearing [153, 154]. The elevated exposure of certain populations (for example, around the North Atlantic) to organic mercury via intake of fish and marine mammals with high levels of methylmercury has been known for decades (see also Chap. 13). Large epidemiological studies performed during the 1990s investigated the possible influence of prenatal organic mercury exposure (the mother's ingestion of fish and/or marine mammals) on cognitive abilities in children in New Zealand, the Faroe Islands, and the Seychelles (for review, see [47, 85]). The available data seem to suggest that the nutritional benefits of breastfeeding and fish consumption outweigh the potential adverse effects of methylmercury in infancy and early childhood [47]. It is, however, yet to be elucidated whether potential adverse affects may become more prominent at adolescence [85, 175].

A possible uptake of mercury via the oral mucosa has been discussed in the literature. One study reported elevated mean mercury concentrations in oral mucosal biopsies of symptom-free subjects with amalgam fillings compared with persons without amalgam restorations [260]. It was suggested that the oral mucosa might be a reservoir of mercury derived from amalgam [27, 260]. But Bolewska and colleagues, who used a very sensitive histochemical autometallographic method, found only minute traces of mercury in biopsies of normal mucosa that was in contact with amalgam fillings [31]. Further, no traces of mercury could be detected in desquamated oral epithelial cells of subjects with amalgam restorations contacting the oral mucosa [7].

In animal studies, mercury has been found in dentin tubules and occasionally in dental pulps and pulpal nerves of teeth with amalgam restorations [105, 106]. In a study on rats, amalgam was directly applied to the dental pulp. Traces of mercury were identified in the trigeminal ganglia of only about half of the animals by means of the aforementioned autometallographic analysis [8]. Histologic sections from the brain stem revealed no mercury deposits in neurons, axons, or the parenchyma.

Key Note

Approximately 80% of the mercury vapor will be absorbed in the lungs, and 5–10% of the inorganic mercury (saliva) will be resorbed in the gastrointestinal tract. The hypothesized intake of mercury via oral mucosa or dental pulp, however, seems to be negligible.

4.3.1.2 Proposed Threshold Values

The World Health Organization (WHO) confirmed in 1999 a provisional tolerable weekly intake (PTWI) value of 5 μg/kg body for total mercury intake, the same level as was recommended in the 1980s [256]. Not more than 3.3 μg/kg body weight of the PTWI value should consist of methylmercury (MeHg) [257]. In 2003 the joint Food and Agriculture Organization of the United Nations (FAO)/WHO Expert Committee on Food Additives arrived at a reduced PTWI of 1.6 μg MeHg/kg body weight, which is considered sufficient to protect the developing fetus, the subgroup of the population most sensitive to mercury [113]. Various public agencies have also in recent years reduced the recommended threshold value of the dose rate of organic mercury (primarily derived from the diet) that can be absorbed lifelong without a significant risk of adverse effects [46]. For instance, the following threshold values have been recommended:

- U.S. Environmental Protection Agency [243]: 0.1μg MeHg/kg body weight/day
- U.S. Food and Drug Administration [244]: 0.5μg MeHg/kg body weight/day
- U.S. Agency for Toxic Substances and Disease Registry [1]: 0.3 μg MeHg/ kg body weight/day
- European Food Safety Authority [237] 1.6 μg MeHg/kg body weight/week
- U.S. National Research Council [180]: 0.7 μg MeHg/kg body weight/week

The estimated intake of mercury in Europe varies by country, depending on the amount and type of fish

Dentlearn.ir

consumed. Exposure to methylmercury from fish and seafood varies between 1.3 and 97.3 µg/week, corresponding to < 0.1 to 1.6 µg/kg body weight in a person weighing 60 kg [66]. Thus, the highest average intake is just at the latest PTWI recommended by FAO/WHO and adapted by EFSA.

U.S. and European agencies have recommended a threshold value of 0.05 µg Hg/m^3 air for the mean annual exposure of the general population. At the same time, the typical daily dose rate for an adult would be 0.6–0.8 µg Hg [69]. WHO declares an occupational threshold limit value (TLV) of 50 µg Hg/m^3 as the maximum concentration of exposure based on a 40-h working week. The calculated mean dose rate of mercury, however, varies between 300 and 500 µg Hg depending on physical activity and the minute volume [20]. Meanwhile, several countries have introduced lower concentrations (25 or 35 µg Hg/m^3) as the upper limit.

From time to time, national and international agencies publish recommended threshold values regarding exposure of the general population and specific occupational groups to chemicals, contaminants in food, and environmental pollution. As aforementioned, these threshold values are, in general, administratively determined, such as by decreasing a LOAEL value (lowest observed adverse effect level) by 10–1,000 times (see also Chap. 1). These values, however, do not consider a substance's benefit. For instance, concerns were expressed about the extent to which the continuous decrease of threshold values regarding uptake of organic mercury will challenge the traditional diet with its manifold benefits in countries with a customarily high consumption of fish and marine mammals.

Key Note

Despite the reduction of recommended threshold values for mercury during the past decades, the responsible agencies do not assume a health risk caused by amalgam for the general population:
"… There are no scientific studies that show that having dental amalgams is harmful, or that removing your amalgam fillings will improve your health." (U.S. Food and Drug Administration, consumer information, October 2006)"It has been determined that … dental amalgam fillings do not pose a health risk, although they do account for some mercury exposure to those having such fillings" and "The practice of having all your dental amalgam fillings replaced with non-mercury filling materials just to remove the possibility of mercury exposure is not recommended by the ATSDR." (Agency for Toxic Substances and Disease Registry, USA, September 2003)
"It is concluded that no risk of adverse systemic effects exist and the current use of dental amalgam does not pose a risk of systemic disease" (EU-Commission: Scientific Committee on Emerging and Newly Identified Health Risks. SCENIHR) [69a].

4.3.1.3 Deposition in Organs

The kidney is the main depository of mercury after administration of elemental mercury vapor [47, 255]. In guinea pigs and ewes, mercury has also been found in the thalamus and cortex a few days after placement of amalgam restorations [75, 86, 250]. In primates and minipigs, mercury originating from amalgam fillings was determined in kidneys, pituitary and adrenal glands, pancreas, liver, lungs, and gastrointestinal tract following observation periods of 1–2 years, but no mercury was found in the central nervous system [52, 108]. Studies on human cadavers have given some indication of a positive correlation between the number of amalgam restorations and the mercury level in the brain and kidneys [55, 150]. However, mercury concentrations in pituitary glands did not correlate with the number of dental amalgam fillings, and, contrary to studies in rodents, it was concluded that the hypothesis of a flow of mercury vapor from dental amalgam fillings to the cranial cavity by a direct oronasal route in humans could not be supported [150]. In contrast to controlled studies in animal models, human studies are hampered by many confounders from a complex lifetime experience. The biological half-life varies in different tissues and over time in relation to exposure. The half-life ranges from a few days or weeks for most absorbed mercury to years for fractions of mercury stored in kidney, brain, and pituitary. The form of mercury responsible for a long biological half-life may be biochemically inactive mercury selenide [255].

The mechanism of mercury toxicity is not yet fully understood, although mercury is one of the most extensively investigated of metals. An interference with the cells' enzymatic processes and a binding of the divalent mercury ion to SH, OH, NH_2, and Cl groups of structural proteins is very likely of primary importance, but additional detrimental mechanisms may also occur.

The target organ of prime concern is the central nervous system. Tremor and psychological distur-

Dentlearn.ir

bances (erethism) are classical symptoms of a chronic mercury intoxication caused by extensive occupational exposure. Erethism is characterized by acute irritability, abnormal shyness, timidity, and overreaction to criticism. Disturbance of memory, loss of appetite, depression, fatigue, and weakness may also occur. Further symptoms of chronic intoxication with inorganic mercury are decreased nerve conduction velocity and gastrointestinal disturbances [45, 153]. Oral symptoms, including metallic taste, swollen salivary glands, disturbed salivation, severe gingivitis, mucosal ulcerations, necroses, and even tooth loss have also been reported (Table 4.2, Fig. 4.5) [71, 160]. A so-called bluish mercury line along the gingiva, equivalent to a Burtonian or lead line caused by lead intoxication, has been observed in some cases. In these cases, the blue mercury line was described as a leading symptom [71].

Mercury accumulates in the kidneys. Animal experiments have revealed that 50–90% of the body's burden of mercury is stored there [47, 255]. If the dose exceeds the capacity limit, direct toxic damage of the proximal renal tubules (e.g., impaired filtration rate of the nephritic glomeruli) or as yet poorly understood immunotoxic reactions (for review, see [67]) may occur. Proteinurea is the most prominent symptom of renal damage. Almost two decades ago, an experiment in which amalgam restorations were placed in sheep generated public interest because the released mercury was supposed to cause kidney damage [32]. The selected animal model as well as the research design was subsequently intensely debated in the literature (for review, see [152]). Subsequent human studies did not corroborate the data from this trial with sheep; no signs or symptoms were found that might be indicative of renal dysfunction in humans due to released mercury from amalgam fillings (e.g., [15, 98, 99, 210]; see also Sect. 4.3.2 on immunotoxicity).

4.3.1.4 Mercury Concentrations in Blood, Feces, and Urine

Organic mercury is primarily bound to erythrocytes, whereas most inorganic mercury is in plasma. A correlation between mercury levels in plasma and amalgam surfaces has been shown in quite a number of animal as well as human studies [47, 152]. Mercury concentrations in plasma reveal relatively little variation as-

Table 4.2 Clinical symptoms of mercury poisoning that may be found in heavily exposed persons (according to Magos [153])

Poisoning	Symptoms
Acute inhalation exposure to mercury vapor	Chest pains
	Dyspnoea
	Coughing
	Hemoptysis
	Pulmonary inflammation
Chronic mercury vapor poisoning	Fine tremor (initially involving the hands)
	Erethism (≅ irritability)
	Gingivitis, salivation, metallic taste
	Proteinuria
Methylmercury poisoning (organic)	Paresthesia
	Ataxia (impaired coordination)
	Constricted field of vision
	Impaired hearing

Dentlearn.ir

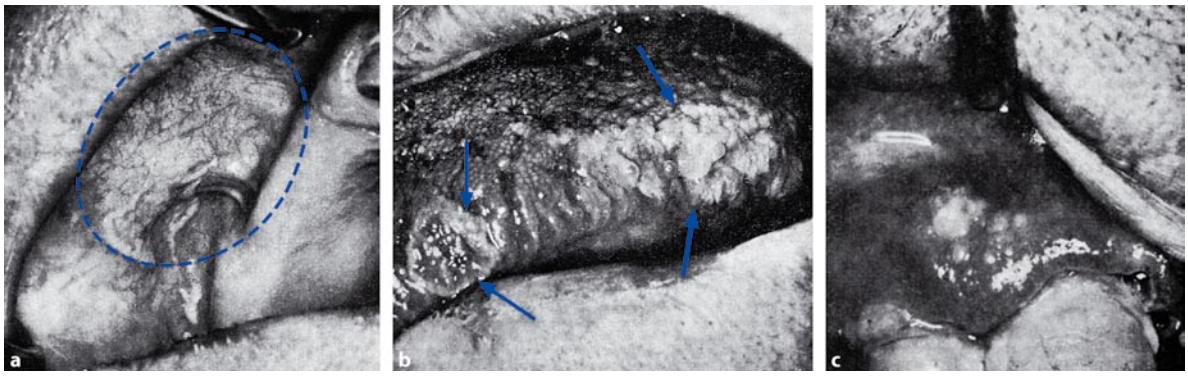

Fig. 4.5a,b A 48-year-old worker in the chloralkali industry suffering from acute mercury poisoning. The urine concentration of mercury was 11,000 mg/l immediately after arrival at the hospital. **a** Epithelial desquamation at the upper vestibule. **b** Epithelial desquamation at the left margin of the tongue. **c** Necrosis of the marginal and interdental gingiva [203] (Courtesy of Danish Dental Journal)

sociated with diet. Thus, mercury levels in plasma and urine have been the markers most often used to assess the body burden of mercury released from dental amalgam. In the literature, urinary mercury excretion is frequently related to creatinine excretion in order to correct for dilution effect, since the quantity of excreted creatinine per day is constant. By contrast, the urinary mercury concentration may vary considerably during the course of the day because of a varying amount of generated urine ("dilution effect").

The main route of excretion after short-term exposure of inorganic mercury is fecal (50%), followed by exhalatory (37%) and urinary (13%) [153]. After long-term exposure, urinary excretion is the principal pathway [47]. By contrast, methylmercury is primarily eliminated via feces, and to a minor extent through urine (10%). Urinary exposure is the most frequently used biological indicator of inorganic mercury exposure. Several studies have revealed a correlation between the number or surface area of amalgam restorations and mercury concentrations in urine (for review, see, e.g., [47, 61, 105, 118, 120, 218]).

A rapid increase and slow decrease of Hg/U and Hg/B has been found following placement and removal of amalgam restorations, respectively. The half-life of elevated plasma concentrations of mercury after removal of amalgam fillings was 3.5–13 days [88, 209]. Due to a slow mobilization of mercury from deposits in organs, periods of 1–3 years have been observed before plasma levels were similar to those found in subjects without amalgam restorations [18, 173, 209].

The median half-life of urine concentrations after removal of amalgam fillings is about 46 days [209]. Urinary excretion of mercury in subjects without amalgam fillings who are not occupationally exposed to inorganic mercury ranges between 0.2 and 2 µg/day [70]. WHO has described an average mercury level for the general population of 4 µg/l [255]. However, the trend in the general population of the European countries, notably Germany and Sweden, has been a gradual decrease in urinary concentration of mercury during the period 1990–1998 [17, 253]. A recommended TLV for mercury vapor of 25 µgHg/m^3 corresponds to about 33 µg Hg/g creatinine (=20 nmol/mmol creatinine). At a urinary mercury level over 100 µg Hg/g creatinine, the probability of developing classical neurological signs of mercury intoxication (tremor, erethism) and proteinuria is high [255]. Levels between 25 and 100 µg Hg/g creatinine may be associated with early symptoms in particularly sensitive subjects, including psychomotor alterations, tremor, impaired nerve conduction velocity, and subjective symptoms such as fatigue, elevated irritability, and loss of appetite, but the relationship is poor [255]. Therefore, a level of approximately 50 µgHg/g creatinine may not cause any objective or subjective signs and symptoms of mercury intoxication [47]. Recent studies on urinary mercury concentrations and amalgam fillings have estimated that 10 amalgam surfaces may increase the urine level by about 1 µg Hg/l [61, 120]. Based on several investigations, Mackert and Berglund [152] estimated that some 450–530 amalgam surfaces would

Dentlearn.ir

be necessary to reach a level of 30 μgHg/g creatinine (18 nmolHg/mmol creatinine)! However, it has been demonstrated that persons with only a tenth of this number of surfaces who chew chewing gum for several hours per day, especially combined with bruxism, may reveal mercury concentrations in the aforementioned order of magnitude. These values are high above the mean levels found in the general population [14].

Animal studies suggest that the absorption of inorganic mercury in the gastrointestinal tract is less than 10%. Human studies that quantified the share of mercury excretion via feces before and after removal of amalgam restorations indicated that fecal mercury levels temporarily increase by a significant amount subsequent to the removal of amalgam fillings [27]. The major part of the amalgam-derived mercury in feces consists of solid particles, and the uptake therefore is very low [27]. Due to many interfering factors, such as the mercury burden in the diet, fecal excretion of total mercury is not a valuable or reliable indicator of systemic exposure to mercury caused by amalgam fillings.

Methylmercury can be converted to inorganic mercury, especially in the intestinal tract [47]. Thus, consumption of fish may add to the burden of inorganic mercury [14]. On the other hand, methylation of inorganic mercury does not appear to take place to any significant extent in human tissues [47].

Animal studies on monkeys demonstrated a marked increase in the proportion of aerobic, mercury-resistant bacteria in the intestinal microflora after placement or removal of amalgam restorations [233]. Subsequent human studies did not confirm these data [64, 193]. Thus, no significant amalgam-associated changes of the human intestinal microflora were found. One of these studies, however, suggested that a transient increase of mercury resistance and antimicrobial resistance of the human microflora in the gut cannot be excluded during the intestinal passage of amalgam particles after the removal of fillings [64]. But then, no selection of antibiotic-resistant strains in patients with amalgam fillings was found in the first systematic analysis of more than 800 bacterial isolates (*Streptococcus mutans*) from more than 200 patients [137]. Further, it was recently demonstrated that mercury-resistant bacteria are frequently present in the dental plaque of children who have no amalgam fillings [199]. Other factors than amalgam thus seem to play an important role regarding the generation of mercury-resistant bacteria in the gastrointestinal tract.

Key Note

Kidneys are the primary storage organ for inorganic mercury derived from amalgam fillings. The creatinine-adjusted excretion of mercury in urine is presently considered the best parameter to assess the body's burden of inorganic mercury.

4.3.1.5 Mercury in Saliva

A linear correlation exists between surface area and exposure time and mercury release from amalgam specimens incubated in vitro with a mixture of light paraffin oil and saline solution [87]. Salivary mercury content in patients consists of amalgam microparticles, mercury ions, and dissolved mercury vapor. The majority of studies on the contribution of dental amalgam to the salivary mercury content reported a total mercury amount without specifying the chemical form of the available mercury. This factor, however, would be of great importance for its bioavailability. Mercury bound in abraded particles of set amalgam will be absorbed at a significantly lesser quantity than dissolved mercury ions. The uptake of inorganic (ionic) mercury in the gastrointestinal tract is not very high and should not exceed 5–10%, according to general estimates [255]. A Norwegian study demonstrated that a considerable share of mercury and silver in samples of stimulated and nonstimulated saliva was in fact bound in amalgam particles [149] (stimulated saliva is that directly collected after intense mastication; nonstimulated saliva is that collected after hours without chewing).

Numerous investigations indicate that the average mercury concentration in saliva of amalgam bearers is significantly higher than in subjects without this type of filling (e.g., [27, 149, 195, 261]). An additional increase was found after the chewing of chewing gum (e.g., [27, 195]). Halbach estimated the total absorbed quantity of mercury based on combined readings of the mercury content in intraoral air and saliva samples before and after chewing paraffin. He calculated a total absorbed amount of 4.8 μg Hg/day, of which 3.7 μg Hg/day was derived from intraoral air and the rest (approximately 1 μg Hg/day) from other sources such as saliva [87]. This amount represents 2% of the provisional tolerable weekly intake (PTWI) value for a person weighing 70 kg (see above information on release and uptake).

Dentlearn.ir

It is occasionally postulated that the mercury content of single saliva samples could be used to estimate the individual exposure to mercury from dental amalgam [124]. But due to the great variety of influencing factors, including varying salivary flow rate, different chemical forms of mercury, chewing habits, and intake of foods and beverages and their composition, it is meanwhile generally accepted that isolated saliva samples cannot be used as a reliable indicator for the absorption of mercury from amalgam restorations (e.g., [79, 89, 90, 197]). No clear difference was found between mercury levels in saliva samples of persons who ascribed their health problems or symptoms to amalgam fillings and subjects with amalgam fillings but without health complaints [149]. Considerable interindividual variations in data were found, as in previous studies.

4.3.1.6 Mercury in Scalp Hair

Blood methylmercury is incorporated in hair and is therefore a recognized screening indicator for dietary exposure to methylmercury [45, 46]. Once incorporated into the formed hair strand, the concentration of mercury remains unchanged. Thus, hair samples may be used to assess former methylmercury concentrations in blood [23]. However, hair analysis is impaired, first by difficulties in differentiating between exogenous metal contamination from water, air, or cosmetic treatment and the metal deposited endogenously, and second by the lack of information on the mechanisms and kinetics by which endogenous trace elements are incorporated into the hair. Analyses have shown that inorganic mercury accumulates in hair only to a small extent [23]; nevertheless, based on scalp hair analyses from German dental students, it was proposed to use this method to monitor occupational exposure to mercury vapor [259]. But some studies have indicated that the confounding effect of methylmercury and other sources of mercury is much too high to use the mercury concentration in hair as a reliable indicator for a person's exposure to mercury vapor from, for instance, amalgam fillings or occupational activities [23, 76, 153]. This is particularly true for subjects with regular dietary intake of methylmercury, such as from fish. Despite the generally accepted limitations of the method, two recent papers have reported correlations between the mercury content in neonatal scalp hair and amalgam exposure of the mother [143, 198]. Both reports claimed that fish consumption in the study populations was minimal and therefore not considered a confounder.

Key Note

According to the literature, analysis of neither saliva samples nor scalp hair is a reliable indicator of exposure to inorganic mercury from amalgam restorations.

4.3.1.7 Transplacental Distribution of Mercury from Dental Amalgam

One specific study on sheep has frequently been cited by the media [250]. This study investigated the maternal–fetal distribution of radioactively labeled mercury from amalgam fillings placed in ewes at 112 days of gestation. Samples of body fluids, feces, and tissue biopsies were collected during the subsequent observation period. Mercury levels in ewes rose to a maximum 40–80 days after amalgam placement. Mercury was found in fetal blood and amniotic fluid within 2 days after insertion of the restorations. The highest Hg concentrations in organs of the adult ewes were observed in kidneys (9 μg Hg/g tissue) and liver (1 μg Hg/g tissue), whereas the fetuses showed highest levels in the liver (0.1 μg Hg/g tissue) and pituitary gland (0.1 μg Hg/g tissue). Concentrations in fetuses were significantly lower than in ewes. The placenta appeared to concentrate mercury progressively as pregnancy advanced. Accumulations of substances in the placenta are generally considered to be a protective mechanism. More recent studies of the offspring of rats and mice that had amalgam restorations placed during pregnancy have also found that mercury vapor emitted from amalgam surfaces may cross the placenta and ultimately deposit in fetal organs in dose-dependent amounts correlating to the number of amalgam restorations in the mother [235, 236]. So far, no animal studies have documented any signs of brain damage in relation to the amounts of mercury that may be deposited in fetal organs as a result of placing amalgam fillings in the pregnant mothers. As mentioned below, the limitations of the animal models must be taken into consideration (eating habits and patterns, masticatory intensity and pattern, difficulties in refinement of occlusal adjustment of fillings) when attempting to extrapolate these results to the human situation. Human findings

Dentlearn.ir

have been significantly different from results obtained in animal studies. This may be due to operational differences during placement of fillings, such as difficulties with occlusal adjustment in animal models, and different masticatory function (sheep are ruminants). One human study included the collection of amniotic fluid by amniocentesis from 95 pregnant women and 20 additional women during delivery. Blood samples from mothers and their neonates as well as breast milk samples were also collected. No correlations were found between mercury levels and either the number of amalgam fillings or their surface area [123].

Biopsies of liver, renal cortex, and cerebral cortex of 108 children and 46 fetuses were analyzed in one autopsy study. The authors postulated that there was a correlation between the mercury levels in the organs of the children and fetuses and the number of maternal amalgam fillings [56]. However, the study did not compare the mercury concentrations in all of the organ biopsies but rather selected a different number of organ specimens in selected age groups. It was quite intensely discussed that this selection would be problematic regarding the applied statistical tests, and the significance of the presented correlations was therefore questioned (see below). In another autopsy study, mercury, cadmium, and lead concentrations in brain and renal tissues of 20 fetuses and 15 babies were analyzed [147]. Mercury levels in kidneys were significantly higher than in brain tissue. In addition, an increasing mercury concentration in fetal kidneys (but not in the brain) was observed with an increasing number of amalgam fillings in mothers [147].

A clinical study compared the blood level of mercury in 185 pregnant women and their newborn infants [230]. There was a correlation between mercury concentrations in the blood of mothers and their babies and the women's fish consumption, but blood mercury levels did not correlate with the number and dimension of amalgam fillings in mothers. Another study compared the mercury concentrations in the blood of mothers and their infants. The participants were subdivided into two groups: mothers with old amalgam fillings and mothers with recently placed restorations. There was no significant difference between the two groups [231]. Taken together, total mercury concentration in blood is highly dependent on fish consumption [9], and blood levels are not a sensitive indicator of inorganic mercury, as already mentioned in this chapter. A more recent study showed a significant correlation between amalgam fillings and the concentration of inorganic mercury in maternal plasma and the umbilical cord [245]. As mentioned above, similar correlations were found between the number of amalgam fillings in the mother and the concentration of mercury in scalp hair from newborn babies [143, 198].

Key Note

The scientific literature has documented that mercury is trapped in the placenta, which acts as protective barrier. But mercury passes the placental barrier to some extent and may be deposited in fetal organs. Organic mercury and mercury vapor pass the barrier more readily than inorganic mercury. A number of animal and human studies have shown correlations between the number and extent of maternal amalgam restorations placed during pregnancy and mercury levels in different specimens from fetuses. No deleterious effects have been documented as a result of in utero exposure to mercury from maternal amalgam restorations. However, based on the fact that mercury can, to some degree, pass the placental barrier, health agencies in a number of countries have recommended that women avoid extensive amalgam work during pregnancy. This is in line with the widespread recommendation that pregnant women should keep their intake of organic mercury low by following certain restrictions on the intake of seafood during pregnancy.

4.3.1.8 Mercury in Breast Milk

It is well established that both organic and inorganic mercury in the blood of lactating women may be excreted via breast milk. Results from animal studies (e.g., sheep [249]) raised public concerns about mercury in the breast milk of mothers with amalgam fillings. A number of recent human studies have confirmed a correlation between the number of maternal amalgam fillings and the mercury level in breast milk [49, 57, 58, 191, 242]. A correlation between maternal fish consumption and the mercury level in breast milk samples was also evident [57, 58, 191]. In milk samples collected during the first week after delivery, the mercury was found to depend both on fish consumption and the number of amalgam fillings [57, 58]. In samples collected 2 months later, mercury concentrations in milk were dependent only on fish consumption [58]. After 2 months of breastfeeding,

Dentlearn.ir

mercury concentration above the detection limit were found in only approximately 33% of the milk samples, and the levels were significantly lower compared with those determined during the first week after delivery [58]. It has been suggested that this reflects that a larger amount of milk is produced later in the lactation period, which dilutes the amount of mercury excreted. It was postulated that the use of chewing gum, bruxism, and so on would significantly influence mercury levels in breast milk [249]. The only study so far presenting data from women who chew gum daily or grind their teeth did not, however, find any recognizable influence of these habits on the mercury level in breast milk [58].

It is remarkable that the mercury concentration in breast milk is lower than or equal to mercury levels in formula milk [57] and cow's milk [58], two alternatives to breast milk. German studies concluded that the exposure of breastfed babies to mercury from maternal amalgam fillings is of lesser importance than maternal fish consumption [58]. The relatively low mercury burden in both breast milk and formula milk, plus the numerous benefits of breastfeeding, contradict any limitations on nursing, even for mothers with a high number of dental amalgam fillings [57, 242]. A Swedish study could not support inorganic absorption through breast milk as a significant source of exposure [207]. In summary, the majority of scientific reports support the view that the uptake of inorganic mercury via breast milk does not play a significant role regarding mercury exposure of infants.

Key Note

A correlation exists between the number of maternal amalgam surfaces and the amount of mercury found in breast milk. An even stronger correlation was found in relation to maternal fish consumption. The possible amalgam-related mercury level in breast milk is lower than or equal to mercury levels in formula milk and cow's milk. The majority of the literature supports the view that the benefits of breastfeeding far outweigh the possible low-level mercury exposure from breast milk. To avoid any unnecessary exposure of infants to potentially harmful substances, a number of public agencies recommend that women avoid extensive restorative treatments during pregnancy and lactation.

4.3.2 Immunotoxicity

Based on results from animal studies, mercury was for many years considered an immunosuppressive substance that increased the susceptibility of experimental animals to infectious agents by inhibiting both the humoral and the cellular immune system (for review, see [67]). More recent experiments on rodents have shown an immune complex glomerulonephritis following exposure to inorganic mercury, and hence an immune stimulatory effect. Further, a number of studies provide evidence of mercury-induced autoimmune reactions in genetically susceptible rodents [67, 109]. The clinical relevance of these experimental findings in genetically susceptible strains of animals – also regarding a low mercury exposure such as from amalgam fillings – remains unclear.

A number of clinical studies have investigated the potential influence of mercury from amalgam on various parameters of the human immune system. Mackert and colleagues measured the levels of the three major populations of lymphocytes in persons with and without amalgam fillings [151]. Comparing the groups, no statistically significant differences between mean lymphocyte counts or the count of any of the six investigated lymphocyte subgroups and the number or size of amalgam fillings were found. A further study also compared two groups of patients, one group receiving amalgam fillings for the first time, and the other group having all of their existing amalgam restorations removed [258]. The absolute and relative numbers of granulocytes, T-lymphocytes, T4- and T8-cells, B-lymphocytes, and natural killer cells were determined before and after these treatments. The authors found no differences between the groups; amalgam fillings did not influence the numbers or proportions of these cell types. Cascorbi and colleagues examined a large number of immunological parameters in patients who attributed various symptoms to their amalgam fillings. No differences between the group of patients and a group of healthy individuals without amalgam restorations were found. It may therefore be concluded from these data that the immunological functions of patients with symptoms supposedly caused by amalgam fillings were within a physiologic range [38].

One possible consequence of the influence of amalgam on the immune system could be an increased risk of immunological diseases. Acute glomerulonephritis and Henoch–Schőnlein purpura are two examples of diseases with a well-known immunomediated etiol-

Dentlearn.ir

ogy. Herrström and colleagues performed a case-controlled study on Swedish children who suffered from these diseases [100]. Their findings did not indicate an increased risk of illness associated with amalgam restorations.

Some authors have claimed in recent years that special in vitro tests, lymphocyte proliferation assays, performed on blood samples may be used as tools to diagnose immune-system-mediated adverse effects of amalgam restorations. But a number of studies have revealed that these in vitro lymphocyte proliferation assays are not appropriate for selecting those patients whose symptoms would disappear after amalgam replacement [40, 127, 145]. Most importantly, two lymphocyte proliferation assays (lymphocyte transformation assay, or LTT, and memory lymphocyte immunostimulation assay, MELISA) together with other relevant parameters such as a standard patch test for dental materials and the numbers of T- and B-lymphocytes, monocytes, granulocytes, and natural killer cells in peripheral blood, were investigated in different groups of subjects: patients with amalgam fillings and symptoms; subjects with amalgam restorations but without symptoms; patients suffering from oral lichenoid reactions adjacent to amalgam fillings; and healthy subjects without amalgam restorations. None of the investigated parameters was indicative of significant differences between amalgam patients and control subjects. With the in vitro lymphocyte proliferations assays, a high frequency of positive results was obtained among healthy subjects with and without dental amalgam. It was consequently concluded that in vitro lymphocyte proliferation cannot be used as an objective marker of mercury allergy or so-called mercury hypersensitivity in dental amalgam bearers [40].

A number of parameters have been investigated in patients suffering from lichenoid reactions next to amalgam restorations, including release of interferon gamma (INFγ), phenotypes of peripheral lymphocyte subsets, frequency of circulating cells expressing the interleukin(IL)-2 receptor, serum concentrations of IL-6, and lymphocyte reactivity. No specific or typical in vitro lymphocyte reactivity was found. Further, the lymphocyte transformation assay was not able to differentiate between so-called mercury-tolerant and mercury-intolerant patients [40, 41, 42, 127, 145], nor were immunohistologic examinations of specimens from oral lichen planus and oral lichenoid reactions able to disclose specific diagnostic features in specimens from lesions adjacent to amalgam restorations [144].

Key Note

Current scientific data do not indicate that immune functions in humans are impaired by mercury released from amalgam restorations.

4.3.3 Neurotoxicity

A WHO report concluded that an exposure to mercury vapor exceeding 80 μg/m^3, corresponding to a urinary mercury level of 100 μg/g creatinine, is associated with a high risk of developing classical neurological symptoms of mercury intoxication and proteinuria [255]. An exposure to a mercury vapor concentration of between 25 and 80 μg/m^3 corresponding to a level of 30–100 μg/g creatinine was associated with an increased frequency of certain less severe toxic effects, such as objectively detectable tremor and evidence of impaired nerve conduction velocity, without apparent clinical manifestation. Results from studies on persons occupationally exposed to mercury have been used to establish such LOAEL values (see also Chap. 1). Studies on dental personnel who are occupationally exposed to levels of mercury below the aforementioned values suggest that lower concentrations of mercury vapor than previously anticipated may cause faint behavioral side effects [62, 63, 169, 183, 202]. There are, however, some difficulties in using occupational exposure studies to predict possible consequences for patients with amalgam restorations. Occupationally exposed individuals may experience episodic exposure (e.g., from spills) that may result in peak urinary levels significantly above their mean concentrations of mercury in urine. Short periods of high exposure may be responsible for neurological alterations being revealed by neurobehavioral tests. It must also be considered that dentists may develop a tremor due to the frequent use of vibrating equipment, such as hand pieces or rotating instruments [267]. This may mimic a mercury-induced tremor and be mistaken as such.

Clinical Practice Advice

A mechanically induced hand tremor (i.e., caused by frequent use of vibrating and rotating instruments) should not be mistaken for a mercury-induced tremor.

Dentlearn.ir

The mercury body burden of dental personnel has often shown higher levels than that of the general population because dental personnel handle mercury in the clinic, remove or assist in removing amalgam fillings, and may also have amalgam fillings themselves. A concentration of 1–5 μg Hg U/l has been considered within the normal range for the population not subject to occupational exposure [61, 91, 95, 120, 131, 266]. Subtle and nonspecific symptoms of mercury intoxication have been discussed in the literature at concentrations above 25–50 μg Hg U/l [105, 130, 152, 154, 205]. From Table 4.3 it can be seen that some dental personnel still suffer concentrations above the normal range for nonoccupational groups. In the United States, the mean concentration decreased dramatically during the period 1968–1985, probably reflecting higher operator hygiene, and from 1985 to 1995, also due to a decrease in caries prevalence and an increase in the use of alternative materials. However, in 1995, 2% of the dentists still experienced levels >20 μg Hg U/l, and some reported outdated methods for processing amalgam, such as squeeze-cloth techniques [159]. In 2003 only 0.6% of the dentists experienced a level >20 μg Hg U/l [44]. Occupational studies from countries where old-fashioned techniques are still practiced are not representative for dental practices where modern techniques are applied.

As an example of a nonoccupational study of possible amalgam effects on neurobehavioral performance, a study of 129 nuns living under identical environmental conditions but with individual dental status found no evidence of decreased cognitive function as a result of mercury release from amalgam restorations [211]. When the health conditions of almost 300 twin pairs (pairwise genetically identical but with different individual dental status) were studied, no negative health effects associated with dental amalgam were found [26]. The authors concluded that the study did not indicate any adverse effects from dental amalgam on physical or mental health or memory functions in the general population. This conclusion was confirmed by a German study on elderly patients [185]. Also, a group of healthy adult employees demonstrated no detectable subtle neuropsychological deficits (i.e., cognitive or fine motor functioning defects) due to mercury exposure from amalgam fillings [72]. Recently a major study of American military veterans failed to find any association between amalgam exposure and neurological signs or clinically evident peripheral neuropathy [121].

In recent years a possible link between mercury exposure from preservatives (thimerosal) in vaccines and the development of autism has been a matter of controversy [154]. Critical reviews have concluded that reliable epidemiological studies do not support a link between thimerosal and autism; this is supported by data from Denmark, where the use of thimerosal-containing vaccines was discontinued in 1992 with no effect on the rise of autism (see [154]).

Most importantly, ongoing randomized clinical trials on neurobehavioral effects of dental amalgam in children have not found statistically significant differences in neurobehavioral assessments or nerve conduction velocity when comparing children with amalgam fillings with amalgam-free children who received resin composite materials [19, 53]. Numerous studies on groups of dental patients attributing general symptoms to the presence of amalgam restorations have also failed to document neurobehavioral changes that could be attributed to mercury release from dental amalgam fillings (see Sect. 4.7).

Key Note

The neurotoxic characteristics of mercury vapor are well documented. Available scientific data indicate that exposure to low concentrations of mercury released from dental amalgam fillings does not pose a risk of adverse neurobehavioral effects to the general population. Dentists and dental personnel, however, need to consider modern techniques for processing and handling amalgam in order to avoid unnecessary exposure risks.

4.3.4 Fertility Dysfunction and Teratogenicity

Animal experiments have provided evidence that high concentrations of all chemical forms of mercury may have significant reproductive effects (e.g., [219]). Some clinical studies also reported serious consequences to persons who were occupationally exposed to mercury, most probably to mercury levels significantly exceeding the TLV [219]. In recent years, concerns about possible adverse effects have been expressed among dental assistants previously exposed to now outdated handling procedures for dental amalgam, such as squeeze-cloth techniques and the heating of copper amalgam. Ongoing studies in Scandinavia aim at elucidating the possible long-term effects of such exposures (see Chap. 11). Studies in recent years have

Dentlearn.ir

Table 4.3 Mercury concentration in urine of dental personnel

		Mean	Range
USA	1968 [115]	40 µg/l	30% >50µg/l
USA	1985 [177]	14 µg/l	5% >50 µg/l
Sweden	1986 [184]	4 µg/l	
Control		3 µg/l	
USA	1987 [129]	12 µg/l	13% >20 µg/l
Norway	1990 [114]	8 µg/l	0–55 µg/l
USA	1995 [159]	5 µg/l	2% >20 µg/l
Sweden	1997 [132]	5 µg/l	2–27 µg/l
Control		4 µg/l	0–23 µg/l
Venezuela	2001 [204]	22 µg/l	
Mexico	2002 [170]	3 µg/l	0.2–12 µg/l
The Netherlands	2003 [95]	11 µg/l	5–22 µg/l
USA	2003 [44]	4 µg/l	0.6% >20 µg/l
Scotland	2004 [202]	5 µg/l	0.4–27 µg/l
Turkey	2005 [118]	6 µg/l	2–16 µg/l

emphasized that a continuous focus on applying contemporary regulations and recommendations for mercury hygiene in dental clinics is still needed in some regions (e.g., [118, 202]; see also Sect. 4.3.3).

One Polish study in particular, reporting five cases of the spina bifida malformation out of a total of 117 babies of female dental personnel, received great public attention [223]. But subsequent publications criticized the arguments put forward in that report and pointed to serious shortcomings of the study (for review, see [136]). According to other reports, neither female dental assistants nor the wives of dentists exhibited an increased risk of spontaneous miscarriage [36, 93, 142]. No increased rate of congenital malformation was observed in the children of dental personnel [36, 68]. A Norwegian investigation addressed the fertility of female dentists compared with teachers; the dentists revealed neither an increased risk of fertility dysfunctions nor a delayed conception period [50]. Most recently, the results of a large Finnish case-control study comprising more than 3,500 births, 1,002 miscarriages, and 801 additional abnormalities concluded that no strong association or consistent dose–response relationship was observed between exposure to chemical agents in dental work and the risk of miscarriage [142]. The authors stated that, in general, there is no need to restrict work in dental clinics during pregnancy; it is, however, important to conform to good occupational hygiene during pregnancy in dental workplaces. In a large cohort study of nondental professionals in New Zealand, no association between complications of pregnancy and childbirth and cumulative amalgam exposure was found during a 20-year outcome period [15].

The possible correlation between the number of amalgam fillings and mercury concentration in morning urine and ejaculate was analyzed in 80 German men whose wives had undergone fertility treatment [92]. No positive correlation could be documented between the parameters of mercury concentrations in urine and ejaculate and the quality of semen (fertility index). Thus, no correlation was found between a man's

Dentlearn.ir

fertility index and number of dental amalgam restorations. The authors concluded that no evidence exists for a hypothesized relationship between mercury burden from amalgam and male fertility disorders [92].

Key Note

According to the available scientific literature, provided that contemporary recommendations for safe handling and storage of mercury in dental clinics are maintained, the handling of dental amalgam does not imply risks of fertility disorders or teratogenicity in dental personnel. This also applies for people with dental amalgam restorations who do not experience occupational exposure.

4.4 Local Toxic Reactions

4.4.1 Cytotoxicity and Implantation Studies

When tested in various in vitro systems, metal ions similar to those that can be released from amalgam cause cytopathogenic effects ranging from reduced metabolic activity to cell necrosis [116, 214, 216, 252]. Specifically, copper and zinc were highly cytotoxic in human fibroblast cultures compared with silver, indium, and mercury. Gallium revealed the least toxicity [116]. In short-term in vitro studies on gingival fibroblasts, it has been shown that mercury from amalgam was more toxic than composite monomers and inhibited growth of oral bacteria [25, 200, 201].

Fresh amalgam specimens reduced the proliferation rate of oral cultured fibroblasts, whereas 7-day-old samples had no effect [213]. Similar data were reported for composite resins: Fresh samples were significantly more cytotoxic than "aged" specimens [213]. Consecutive extracts of 2-week-old amalgam specimens were less and less cytotoxic simultaneous to the decreasing release of zinc from one amalgam, or were more cytotoxic in the case of a gallium alloy simultaneous to an ongoing release of gallium. The consecutive eluates of another amalgam that released almost no substances were permanently low in cytotoxicity [252].

It can be concluded that in vitro cytotoxicity varies between brands, depending on the stability of the amalgam and the nature of the released substances. Apparently, amalgams that liberate zinc and copper are the most cytotoxic. These short-term studies indicate that amalgams may initially cause cytotoxic reactions that diminish over time. Further, gallium alloys are not necessarily less cytotoxic than silver amalgams.

The importance of aging regarding cytotoxity of amalgam has been documented in implantation studies. A rapid decrease in toxicity after implantation in rabbit muscle was equivalent to the findings of in vitro cytotoxicity studies [217]; amalgam with a high level of copper was more cytotoxic than γ2 products. Later studies have confirmed that amalgam is well tolerated by connective tissues after a short period of time [192, 232] (see also Sect. 4.4.3).

4.4.2 Pulp Reactions

The following pulp reactions may occur immediately after application/condensation of amalgam in deep cavities with a remaining dentin thickness (RDT) of less than 0.5 mm (Fig. 4.6) [174]:

- Reduced number of odontoblasts
- Odontoblast nuclei in dentin tubules
- Dilated capillaries
- Slight to severe inflammatory cell infiltration in the odontoblast layer

Whether these immediate reactions are caused by the condensation pressure or the penetration of copper, mercury, or other substances has not yet been fully clarified.

Long-term studies have shown mercury, silver, tin, and zinc to be present in the dentin of unlined cavities of amalgam restorations, and mercury has been detected in dentin tubules and pulp of both unlined and lined restorations (Fig. 4.7) [106, 107]. Lining refers to the application of a regular cavity base as well as the use of liquid liners or varnishes. Histological studies did not confirm a toxic effect of these substances on pulpal tissue. Usually only slight or no inflammatory alterations can be observed 1–2 months after application of amalgam restorations. A substantial apposition of irregular dentin may be the only histological indication of a pulpal effect (Fig. 4.8). It is generally agreed that the microbiological challenge from bacteria and their metabolic products poses a greater threat to pulpal health than pulp-toxic effects due to substances released from dental restorative materials. The deposit of corrosion products in microspaces between amalgam filling and dental hard tissue or in dentin tubules covered by amalgam may reduce penetration and multiplication of a substantial number of microorganisms.

Dentlearn.ir

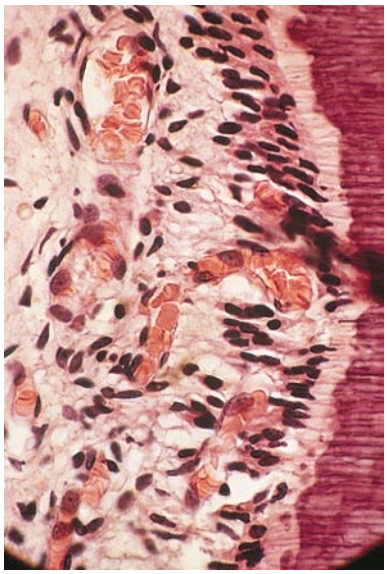

Fig. 4.6 Pulp reaction 1 month after application of an amalgam filling. Dilated blood vessels close to the predentin; otherwise, no noteworthy alterations. Distance between pulp and cavity is 0.52 mm (Courtesy of B. Möller, Malmö, Sweden)

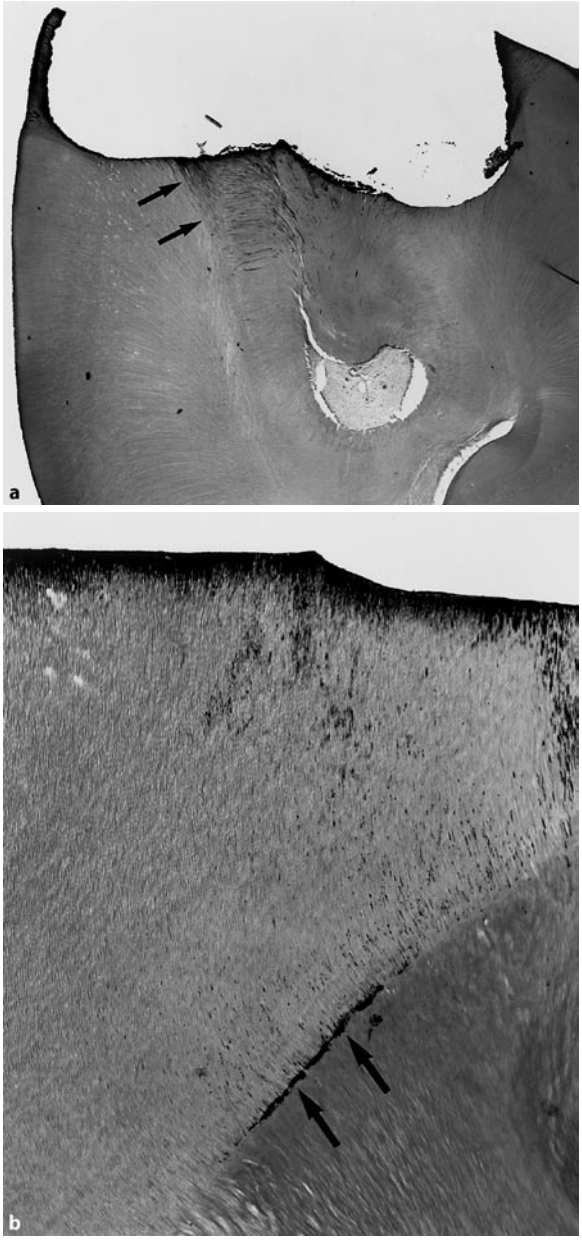

Fig. 4.7a,b Demineralized minipig tooth originally filled with amalgam. **a** The black lines in dentin show autometallographic visualized mercury (*arrows*). This method causes the precipitation of silver ions adjacent to mercury molecules. **b** The higher magnification of the dentin shows an accumulation of mercury in the tubules of the transition zone between regular and irregular dentin (*arrows*). The real volume of mercury is lower than demonstrated by the silver deposition [107] (Courtesy of European Journal of Oral Sciences)

Clinical Practice Advice

An appropriate cavity base or lining should be used in deep cavities for pulp protection to prevent the risk of an immediate pulp reaction after insertion of amalgam. Similar pulp protection (e.g., a liner) should be considered in medium-depth or shallow cavities, especially in young people with wide and open dentin tubules. This will protect the patient from unpleasant symptoms due to thermal conduction.

4.4.3 Reactions of the Oral Mucosa

4.4.3.1 Mercury

Oral manifestations of verified mercury intoxication in occupationally exposed persons are very rare. Severe gingivitis, bleeding gums, ulcerations of the oral mucosa, swollen salivary glands, and altered saliva-

Dentlearn.ir

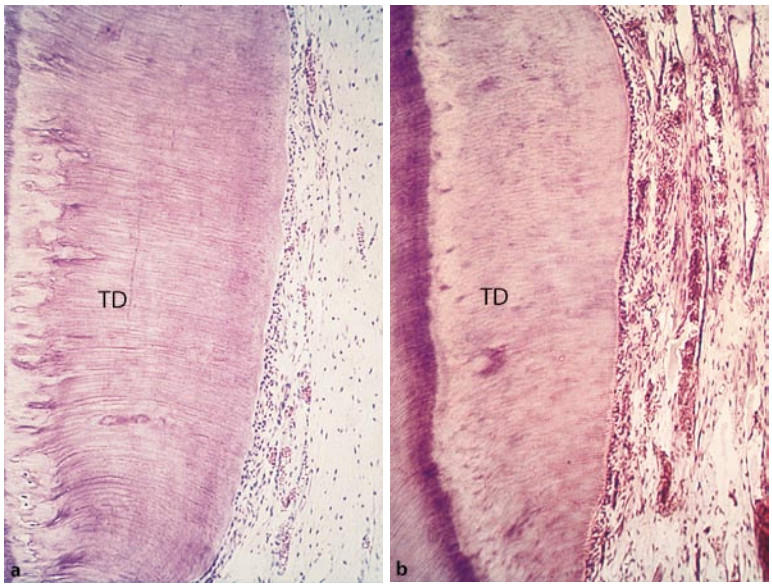

Fig. 4.8a,b Irregular tertiary dentin (*TD*) beneath the cavity of a primate tooth. **a** Originally filled with carious human dentin and amalgam for 7 days; after removal of the first filling, the cavity was refilled with amalgam for another 104 days; no inflammation of the pulp. **b** Same treatment as in **a**; hyperemia and mild cellular infiltration in the pulp (Courtesy of I. Mjör, Gainsville, Florida, USA)

tion (hyposalivation or hypersalivation) have been observed. These alterations may result in local necroses or loosening or spontaneous loss of teeth [71, 160, 203] (Fig. 4.5). A bluish mercury line along the gingiva – clinically similar to a lead or bismuth line (Burtonian line) – has been described in relation to chronic exposure to high concentrations of elemental mercury [71].

An acute intoxication with elemental mercury may cause a progressive periodontitis associated with necrosis of the gingiva [160, 203]. Other oral manifestations are local desquamation of the buccal or lingual mucosa and the gingiva, as well as swollen salivary glands. Periodontitis caused by mercury is characterized by a different clinical acute progression compared with infectious periodontitis. It is generally accepted that mercury intoxication does not trigger a periodontitis but rather accelerates the progression of a preexisting periodontitis. The mechanisms of tissue destruction associated with mercury have not yet been clarified in detail. Abundant mercury deposits have been found in inflamed and necrotic tissue of individuals who suffered severe intoxication. Therefore, it was suggested that these deposits may accelerate degradation of the tissue via a local cytotoxic reaction.

Key Note

Severe mercury intoxication, for instance in persons with extensive occupational exposure to mercury, may cause pronounced intraoral reactions, including necroses and loosening or loss of teeth. No correlation between the development and progression of gingivitis or periodontitis and the presence of amalgam fillings has been documented.

4.4.3.2 Amalgam

Oral amalgam pigmentations (tattoos) are relatively common clinical lesions produced by unintended deposition or displacement of amalgam into the oral soft tissue during dental operative or surgical procedures. The incidence of amalgam tattoos varied between 1% and 8% in different study populations (e.g., [104, 196]). Amalgam tattoos can often be diagnosed because of their opacity under radiographic examination. Over time, corrosion products leach into surrounding tissue, causing discoloration. Usually, amalgam tattoos present as flat blue-black pigmentations (Fig. 4.9a).

Dentlearn.ir

They may appear similar to other pigmented intraoral lesions, such as nevi, racial pigmentations, and melanotic macules. Histologically the tissue alterations seem to be related to the amount and size of metallic particles and to the depth of their location in the tissue. In superficial lesions, a tissue reaction is often absent. The particles may appear as dark granular fragments that can be found in collagen and elastic fibers of the connective tissue as well as intracellularly and in blood vessel walls (Fig. 4.9b). When only fine particles are implanted, tissue reactions are minimal or even lacking (e.g., [37, 265]).

Larger particles generally elicit chronic granulomatous inflammations characterized by localized infiltration with lymphocytes, plasma cells, and macrophages (e.g., [104, 265]).

Large and dense implanted aggregates are surrounded by macrophages and/or condensed fibrous tissue. This reaction may be due to dissolution of amalgam by tissue fluids. In a number of recent studies, no mercury but silver, sulphur, copper, and lead were found in the products of amalgam tattoo decay (e.g., [265]). The failure to detect mercury adjacent to the tattoos may be explained by the active role of histiocytes, fibroblasts, multinucleated foreign giant cells, lymphocytes, and granulocytes. Amalgam displaced into deeper tissue layers will most frequently trigger a chronic inflammation [104]. In immunohistologic examination of biopsies from amalgam tattoos, some tissue reactivity to the alloy deposits was visualized, for example, increased metallothionein activity, which is assumed to be associated with detoxification of substances such as heavy metals [138, 144]. Since amalgam tattoos are normally totally asymptomatic, the clinical relevance of these findings remains to be proven.

In one case, a fragment of an amalgam restoration was unintentionally left in the alveolar cavity during extraction of a molar [119]. The female patient suffered from pain in her mandible for some years. By panorama radiography, the amalgam fragment was seen surrounded by a translucent area, which was diagnosed as an inflammatory process in close contact with the mandibular nerve canal. The patient recovered completely after surgical removal of the amalgam deposit.

Clinical Practice Advice

Unintended amalgam contamination of soft and hard tissues should be avoided. According to the literature, implanted amalgam does not normally cause acute tissue reactions and is normally totally asymptomatic. Therefore, these fragments of amalgam generally do not need to be removed except for diagnostic reasons.

Oral lichen planus (OLP) is a rather common disease with a prevalence of about 2% in the adult population. It is well described in textbooks. Oral lichenoid reactions (OLRs) are lichen-like oral lesions that do not show the typical clinical and histological diagnostic findings of classic OLP. OLRs are relatively frequent, and it has been documented that some are associated with drug therapies (Table 4.4) [163] or dental materials, most frequently amalgam. The lesions may be white (leukoplakia-like or lichen-planus-like), so-

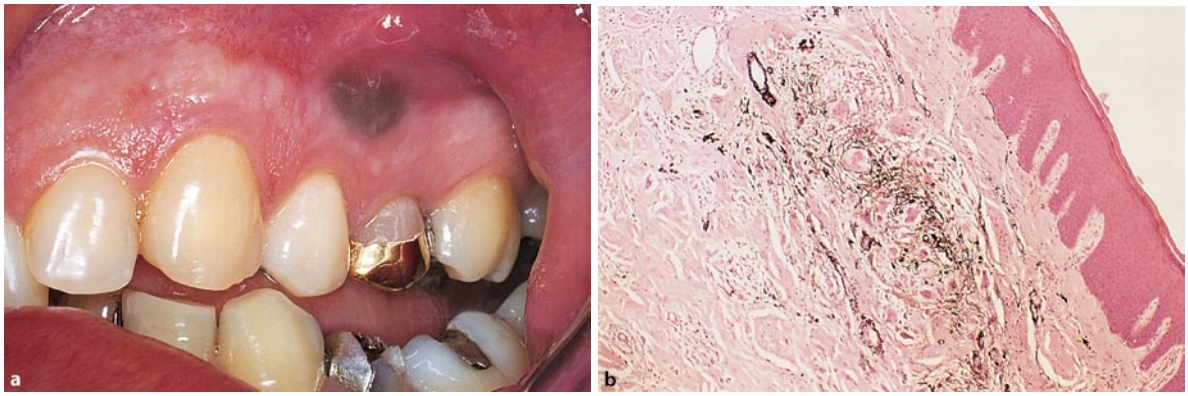

Fig. 4.9a,b Amalgam tattoo. **a** Discoloration of the gingiva/oral mucosa. **b** Amalgam particles in the connective tissue; almost no tissue reaction is visible

Dentlearn.ir

called lichenoid reactions, but some of them may be also erythema-like (Fig. 4.10) or even ulcerative (see review in [104]). Previous reports hypothesized a possible link between such lesions and electrogalvanic events due to metal restorations (see review in [104]), but neither clinical nor experimental studies provide evidence of this hypothesis. Therefore, terms like "galvanic lesion" are no longer used in the current scientific literature [104].

Histological examination of biopsies, including immunohistochemistry, failed to detect specific differences between OLP and OLRs (e.g., [31, 111, 135, 239]). Recently a single case report described the development of an OLR lesion adjacent to an amalgam tattoo [228]. Patch tests of patients with OLP and OLRs have generated no clear results (see Sect. 4.5).

4.5 Allergies

Studies addressing the prevalence of allergic reactions in professionals occupationally exposed to metallic mercury indicate that allergy to metallic mercury is rare. Only isolated cases of allergic type I reactions caused by mercury are available in the literature (e.g., [30, 60, 166]). Only two patients out of about 4,000 individuals who were referred to a department of occupational dermatology revealed a mercury-induced dermatosis due to occupational exposure. Both patients had handled unset amalgam or mercury with their bare, unprotected hands [117]. Miller and colleagues investigated the incidence of positive skin test reactions in dental students. No significant increase in the number of allergic individuals was found as stu-

Table 4.4 Drugs that may cause oral lichenoid reactions (according to McCartan and McCreary [163])

Drug group	Drug
Antihypertensives	Methyldopa Oxyprenolol Practolol Propanolol
Antimalarial drugs	Chloroquine Pyrimethamine Quinacrine
Antimicrobials	Ketaconazole Paraaminosalicylic acid Tetracycline
Metals	Bismuth/Arsenic Gold
Nonsteroidal anti-inflammatory drugs (NSAIDs)	Fenclofenac Phenylbutazone Unspecified NSAID Naproxen
Hypoglycemic drugs	Tolbutamide Chlorpropamide
Penicillamine	Penicillamine
Miscellaneous	Allopurinol Amiphenazole Carbamazapine Cyanamide Levamisole Lithium Lorazepam Metopromazine Pyritinol

Dentlearn.ir

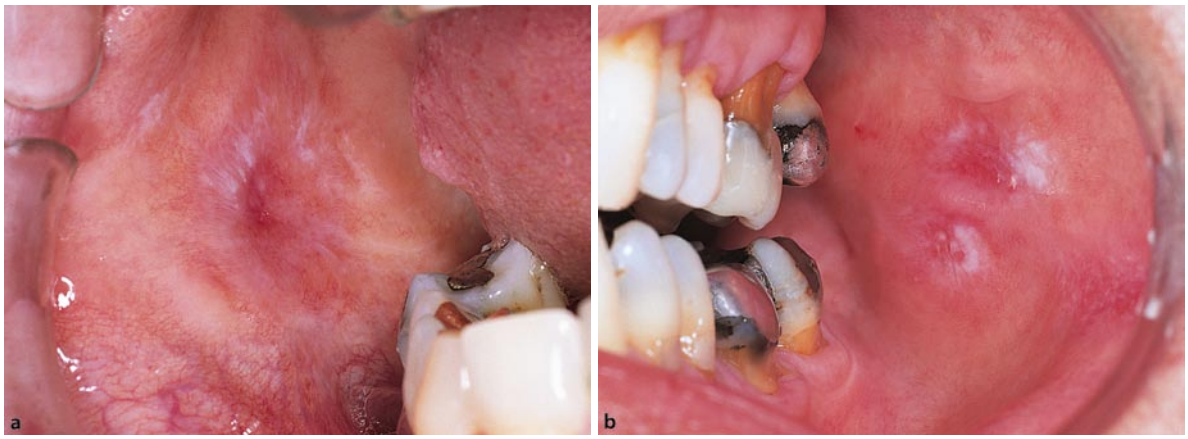

Fig. 4.10a,b Primary erythema-like mucosa reaction adjacent to amalgam restorations. **a** A 57-year-old woman with an erythematous OLR lesion in the contact area of an amalgam filling, buccally of 47. **b** A 46-year-old woman with a primary erythematous OLR lesion in the contact area of amalgam restorations buccally in 27 and 37

dents progressed through the dental curriculum [171]. The authors concluded that mercury is not a significant allergen for dental professionals provided that contemporary recommendations for mercury hygiene are adopted.

Delayed allergic type reactions to amalgam restorations most frequently present as contact lesions in the oral mucosa. Only rare cases of generalized stomatitis and systemic dermatitis have been described [28, 73, 176, 241, 248] (Fig. 4.11). Based on observations of some degree of healing of oral lichen lesions after removal of amalgam restorations, a number of previous reports suggested that OLP might be associated with allergy to mercury from dental amalgam. Since the 1990s, more detailed studies have, however, revealed that a close topographical relationship between lesions and amalgam restorations appears to be a rather good predictor of the nature of the lesion and thus of the outcome of removal of adjacent amalgam restorations [111]. A number of studies have thus demonstrated that in patients with lesions confined to the mucosa in close contact with dental amalgam, the complete resolution of OLR occurs more frequently than in patients with more diffuse lesions extending beyond the contact area (Figs 4.12–4.17 and Fig. 14.5a in Chap. 14) [31, 33, 94, 110, 126, 128, 194, 238]. Further, patients with defined contact lesions more frequently react with a positive patch test reaction to components of dental amalgam than patients with more widespread diffuse lesions. Type IV allergic reaction may thus be an influencing factor in cases of defined contact lesions, whereas lesions extending beyond the contact area may have other causes such as OLP. A study of the resolution of lichen planus following removal of amalgam restorations in patients with proven mercury allergy showed that, except in intractable cases, removal of all amalgam fillings is not necessary to achieve total improvement of the contact lesions [224].

Fig. 4.11 Rare case of dermatitis in the armpit of a 45-year-old woman due to an allergic reaction to amalgam components (Courtesy of N. Veien, Aalborg, Denmark)

Dentlearn.ir

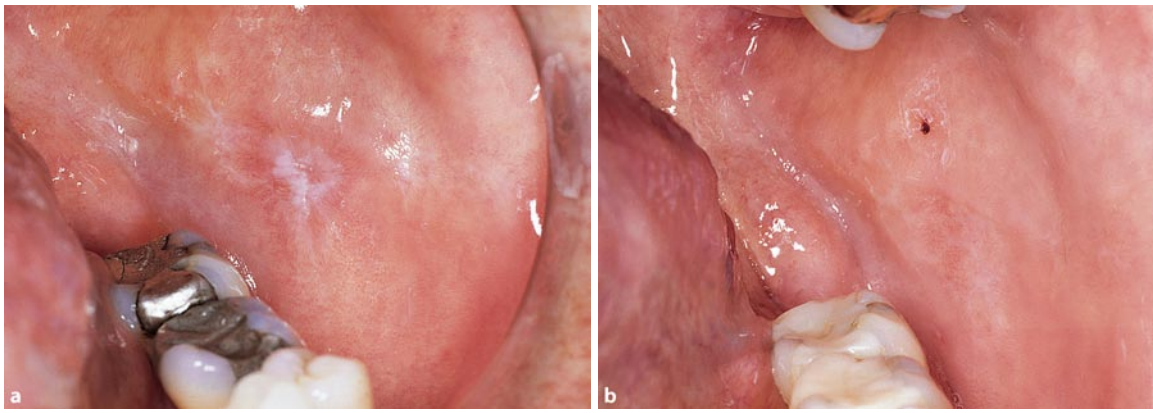

Fig. 4.12a,b Contact lesion before and after replacement of an amalgam restoration in a 44-year-old woman. **a** White contact lesion in the contact area of an amalgam filling in 37. **b** Remission 1 month after amalgam was replaced by composite resin

Fig. 4.13a–d Contact lesion before and after replacement of amalgam in a 52-year-old woman. **a**, **b** White contact lesion in the contact area of an amalgam restoration in 45. **c**, **d** Remission after the buccal part of the amalgam filling in 45 was replaced with composite resin

Dentlearn.ir

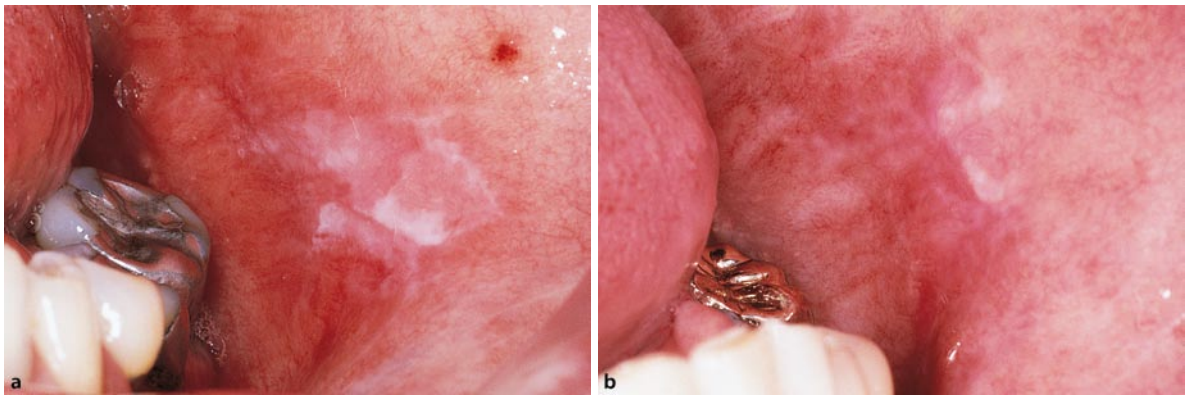

Fig. 4.14a,b Contact lesion before and after replacement of amalgam in a 59-year-old woman. **a** Primarily white contact lesion in the contact area of a large amalgam filling in 36. **b** Remission after replacement of amalgam by a partial gold crown

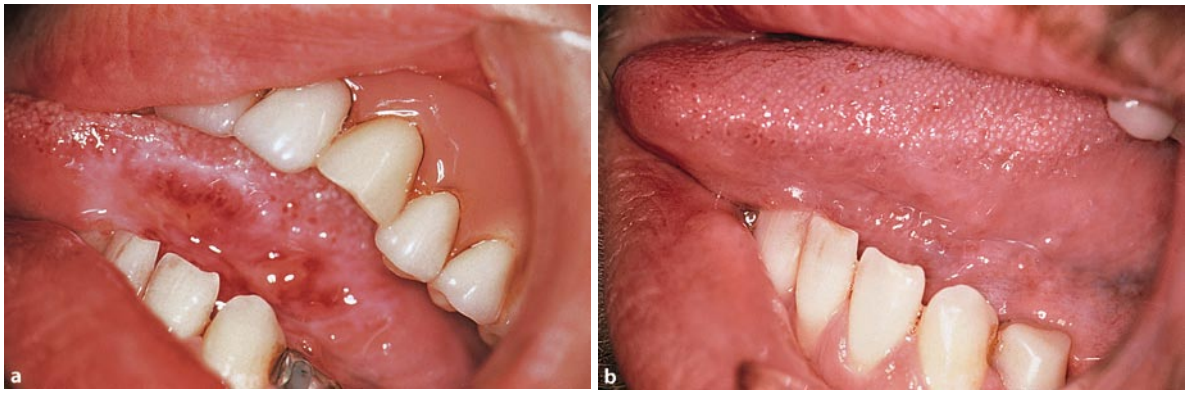

Fig. 4.15a,b Contact lesion before and after replacement of amalgam in a 41-year old man. **a** Primarily erythema-like mucosal lesion at the margin of the tongue in the contact area of a large amalgam restoration in 34. **b** Complete remission after replacement of the amalgam by a composite resin buildup

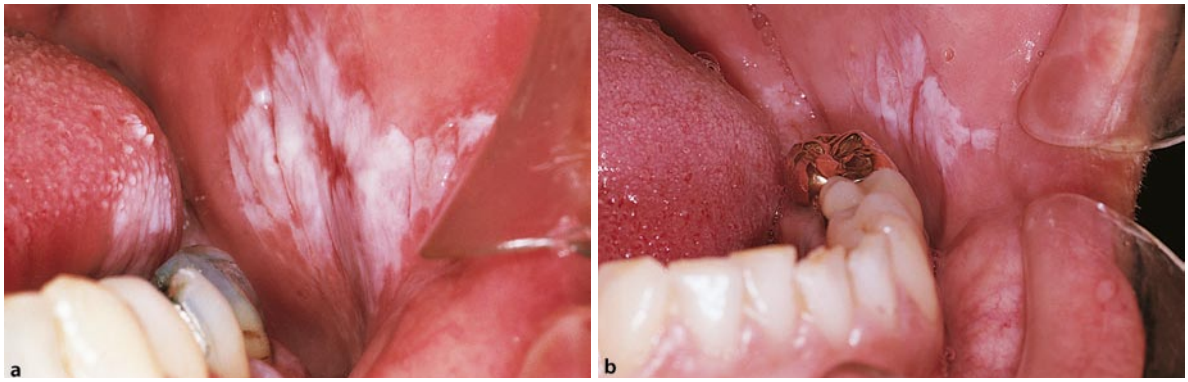

Fig. 4.16 Contact lesion before (**a**) and after (**b**) replacement of amalgam in a 43-year-old man; extended white lesion in the contact area of an amalgam restoration in 34

Dentlearn.ir

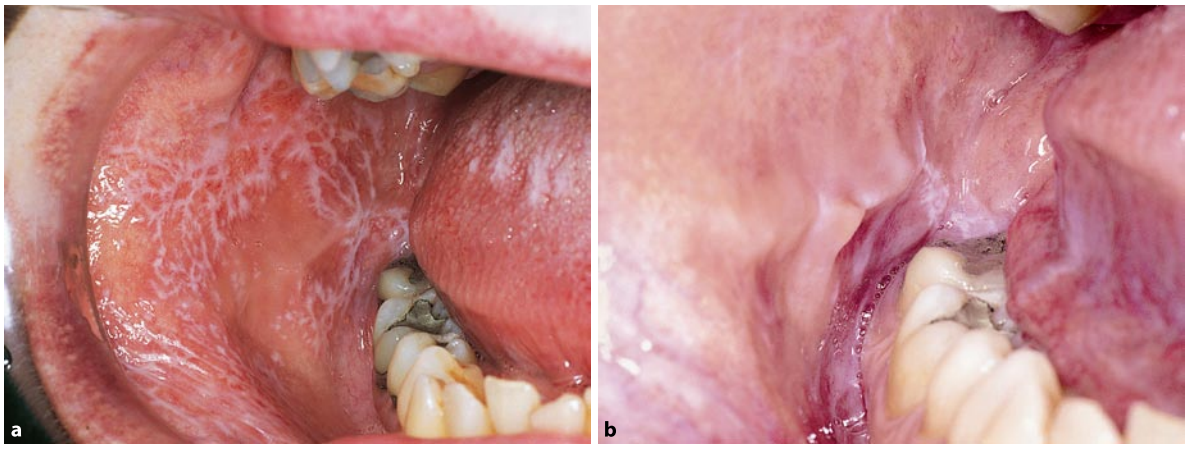

Fig. 4.17a,b Lichen-planus lesion on a 55-year-old woman. **a** Extended lichenoid lesion of the right buccal mucosa; several amalgam restorations in the lower and upper jaw. **b** Significant remission without replacement of amalgam

In a Swedish study of adolescent students, no evidence was found for an association between the number of amalgam restorations and the prevalence of eczema, allergic rhinoconjunctivitis, asthma, or hypersensitivity to specific allergens [97]. A parallel investigation of 15-year-olds analyzed a number of cellular and humoral immune factors and the relationship between these parameters and amalgam fillings and mercury levels in plasma [98]. No significant influence of the number of amalgam surfaces or mercury concentrations in plasma on the examined immune factors was found. A subsequent study on 19-year-old high school students revealed a weak correlation between mercury levels in plasma and immunoglobulin IgG_2 [101]. These data, however, were not confirmed by other investigations, and their clinical significance remains unclear.

Recently a few cases of symptoms to zinc released from dental amalgam have been presented [162, 262, 263]. One female patient revealed a coated, burning tongue, gingivitis, and a widespread erythema of the oral mucosa. A buccal dermatitis emerged 1 week after a filling with a zinc-containing amalgam was placed. A patch test revealed a positive reaction to zinc. The dermatitis healed spontaneously after replacement of the restoration [262]. Another woman had extensive eczema on her hands and feet 1 year after she had five amalgam restorations. She had a positive patch reaction to zinc. Symptoms cleared completely within less than a month after all her amalgam restorations had been replaced with zinc-free materials [263]. The third case suffered from facial eczema and had positive patch reactions to tin, indium, and zinc [162]. Many years previously, she had had a retrograde root canal filling with amalgam in an upper central incisor. A black discoloration of the gingiva could be seen together with a granular radiopaque material extending from the incisal alveolar area to the lower part of the anterior nasal aperture. The foreign bodies were surgically removed, and the patient's dermal symptoms cleared within some months after surgery [162].

Key Note

Immediate allergic reactions (type I) to components of dental amalgam are extremely rare. Delayed allergic reactions (type IV) may occur in the oral mucosa. They are usually limited to the area in contact with an amalgam filling.

Clinical Practice Advice

A close topographical relationship between oral mucosa lesions and amalgam restorations appears to be the best predictor for partial or total remission after amalgam removal. It is generally unnecessary to replace amalgam fillings that are not in direct contact with mucosal lesions. For diagnosis, histology does not appear to be helpful (e.g., [239]), and patch testing is of limited relevance [111].

Dentlearn.ir

4.6 Carcinogenicity

Studies of human risk groups occupationally exposed to mercury vapor and other inorganic forms of mercury at much higher concentrations than dental personnel or patients with amalgam fillings (e.g., miners or workers in the chlorine alkali industry) have generally failed to demonstrate a link between mercury exposure and the development of cancer. A recent investigation comprising almost 7,000 workers in mercury mines and factories in Spain, Slovenia, Italy, and Ukraine also provided no evidence for an increased rate of cancer [29]. Increased mortality due to lung cancer was observed in two mines (Slovenia and Ukraine). Because no correlation between the incidence of lung cancer and the duration of employment or the estimated mercury exposure was found, however, the reported elevated rate of lung cancer in both mines was related to the coexposure to silica and radon. It was concluded from these findings that exposure to inorganic mercury in mines and processing facilities does not seem strongly related to an increased risk of cancer [29].

Likewise, studies on groups of patients with amalgam fillings revealed no correlation between existing restorations and the development of general diseases, including cancer (e.g., [3, 4, 26, 211]). Ahlqwist and colleagues initiated a prospective study in 1968–1969 on approximately 1,500 Swedish women. They concluded in the latest status report of this study that the mercury levels found in the serum of amalgam bearers do not cause negative consequences regarding mortality or frequency of diseases (including cancer) in a population of middle-aged and older women [4]. More recently, a large cohort study in New Zealand followed 20,000 persons from 1977 to 1997 and linked data on regular dental treatment with cancer registrations and hospital admissions. No association between amalgam fillings and cancer was found [15].

4.7 Clinical Studies

4.7.1 Relationships Among Symptoms, General Diseases, and Amalgam Fillings

As a result of the intense debate on possible adverse effects of dental amalgam fillings, increased attention has been focused on patients who related their symptoms to the presence of amalgam restorations. A number of treatment facilities diagnosing and treating these patients were established, particularly in Scandinavian countries, and since the 1990s an increasing number of scientific papers have reported data and experiences gained through multidisciplinary examinations of patients attributing symptoms to their amalgam fillings [e.g., [10, 34, 35, 51, 78, 80, 81, 83, 96, 136, 148, 158, 168, 168a, 182, 229]. These reports characterize the patient group as very heterogeneous, revealing a broad variety of symptoms (Table 4.5) compared with the rather well-defined set of effects that have been documented for occupational and accidental mercury exposures. This was clearly exemplified by a large German study in which 34 dental practices participated in a multicenter study addressing the characterization of symptom patterns found in patients exposed to amalgam [168]. The majority of the participating practices claimed to practice "holistic dentistry" with a focus on the substitution of amalgam restorations. About 7,000 patients with known dental status completed a questionnaire listing 48 symptoms that might be associated with mercury toxicity. Although the aim of the study was to define criteria for symptoms that would justify replacing amalgam restorations, the authors failed to document a link between the presence of amalgam restorations and certain symptoms or their intensity. Thus, no differences between persons with and without amalgam restorations could be found. It was subsequently concluded that these data gave no support to establishing a set of standard criteria of specific symptoms for the replacement of amalgam fillings. None of the abovementioned patient studies report a correlation between mercury parameters (for instance, in body fluids) and the presented symptoms. Many cases of previously undiagnosed general diseases, including cancer, were reported (e.g., [10, 34, 35, 96, 133]). Relatively high frequencies of mental disorders and somatization were found [10, 11, 34, 35, 80, 81, 96, 133, 136, 148, 158, 182, 229].

The studies on amalgam patient groups did not support the hypothesis that release of mercury from amalgam fillings is the cause of "amalgam disease," but they suggest that there may be various explanations for the patients' complaints. The majority of papers underscore the overrepresentation of patients with somatization disorders (e.g., [10, 34, 35, 78, 80, 81, 134, 182]) and support the recommendation that individuals with complaints self-attributed to dental amalgam should be screened for underlying dental, physical, and psychiatric conditions (see also Chap. 14). A simi-

Dentlearn.ir

Table 4.5 Symptoms that have been attributed to the presence of amalgam fillings (according to Herrström and Högstedt [96] and Schuurs et al. [220])

Oral symptoms	Burning mouth
	Metallic taste
	Toothache
	Dry mouth
	Gingivitis
	Red throat
	Painful chewing muscles
Somatic symptoms	Muscle pain
	Headache
	Neurological symptoms (e.g., impaired memory and concentration, restless legs)
	Painful joints
	Dizziness
	Abdominal distress
	Cold fingers and/or cold feet
	Trembling hands
	Impaired vision
	Allergy (nose, eyes)
	Skin problems
	Coughing, shortness of breath
	Chest pains
	Heart palpitations
	Lower back pain
	Genital symptoms
	Hearing loss, tinnitus
	Diarrhea
	Sweating
	Constipation
	Loss of hair
Psychological symptoms	Lack of energy to cope with daily work or household duties
	Impaired quality of life
	Fatigue
	Anxiety
	Depression
	Restlessness
	Sleeping disorder
	Irritability

Dentlearn.ir

larity to multiple chemical sensitivity syndrome has been mentioned [158] (see also Sect. 4.8).

Only two large epidemiological cohort studies on the possible impact of the presence of dental amalgam on the development of general disease have been conducted [2, 3, 4, 15]. Ahlqwist's team followed almost 1,500 women from 1968 and onwards, and Bates's team followed 20,000 people in the New Zealand Defence Force for 20 years. At the 24-year follow-up, Ahlqwist investigated the general mortality rate and the diagnoses of myocardial infarction, stroke, diabetes, and cancer. No outcome was correlated with serum mercury concentration [4]. In the large New Zealand cohort, Bates's team was able to examine a wider range of health outcomes in relation to detailed dental data [15]. Specific attention was focused on disorders of the nervous system and kidneys. No evidence of any association between amalgam and the "chronic fatigue syndrome" that has frequently been associated with amalgam exposure was provided. Also, no positive association between kidney disorders and amalgam exposure could be established, which is a particularly important result because the kidney is a primary target of inorganic mercury toxicity. Interestingly, the results suggested an association between amalgam exposure and multiple sclerosis (see below). As for two neurological diseases, Alzheimer's and Parkinson's, which have been hypothesized to be caused by amalgam, the authors suggest follow-up studies on the New Zealand cohort permitting investigation of disease outcomes more prevalent in the elderly. In this cohort there were insufficient cases for investigating Alzheimer's or Parkinson's disease [15].

Mainly based on animal experiments and cell culture studies, theories have been put forward that link mercury exposure, for instance from amalgam, to the development of neurodegenerative disorders such as Alzheimer's disease and multiple sclerosis. Further, a few autopsy studies have reported elevated levels of metal ions in brain specimens from Alzheimer's disease patients (e.g., [254]), whereas others did not [212]. Human studies on people exposed to identical living conditions (nuns) or with identical genetic background (twins) failed to demonstrate an association between the presence of amalgam restorations and the outcome of neurobehavioral tests or the emergence of neurodegenerative diseases [26, 211]. Clinical studies on Alzheimer's patients did not indicate a link between exposure to mercury, such as from amalgam, and pathogenesis of the disease (e.g., [77, 102]). More recently, the theory of a correlation between edentulism and the risk of developing Alzheimer's disease was presented [146]. Because the development of this theory implies that tooth loss is automatically correlated to a previous high rate of treatment with dental amalgam, this theory is subject to current critical debate.

As seen with patients alleging general symptoms caused by amalgam fillings, a number of anecdotal case reports have presented the experience of improved health conditions in patients suffering from multiple sclerosis who had their amalgam fillings replaced (e.g., [222]). However, based on analyses of the heavy metal content in biopsies taken from different brain regions of deceased patients with multiple sclerosis, it was concluded that there is no indication of mercury participation in the etiology of this neurological disorder [48]. Furthermore, recent investigations specifically addressed a possible correlation between the presence of amalgam fillings and the pathogenesis of multiple sclerosis [12, 39, 167]. None of these studies documented an association between the number of amalgam fillings and the time period of exposure on the one hand and the etiology of multiple sclerosis on the other hand. Most recently, the New Zealand cohort study [15] suggested that the possibility that multiple sclerosis could be associated with dental amalgam deserves further investigation in larger population studies than those previously performed.

Key Note

No study on groups of patients with dental amalgam restorations has documented a link between the presence of amalgam restorations and the development of general or systemic diseases (e.g., [2, 3, 4, 16, 26]). A recent large epidemiological study indicated that the observed possible association between dental amalgam and multiple sclerosis deserves further investigation [15].

Since the 1990s, a number of papers have reported findings indicating an association between the uptake of organic mercury compounds (but not inorganic mercury) and neurological cardiovascular alterations (e.g., [84, 85, 226]). A correlation between the absorption of organic mercury compounds and the progression of arteriosclerosis of the carotid has been shown in Finnish fishermen [206].

Dentlearn.ir

Key Note

The majority of recent reports on patients who attributed their health complaints to amalgam have emphasized the importance of thorough medical diagnostics in order to elucidate general medical or psychological problems underlying the symptoms attributed to amalgam fillings. Further, one report has documented the important role of a balanced informative dialogue with the patient [133]. Such dialogue should preferably not exclusively focus on biocompatibility aspects of amalgam but should also address the possible risks and benefits associated with alternatives to amalgam. The current scientific literature does not support replacing well-functioning amalgam restorations with alternatives such as composites.

4.7.2 Removal of Amalgam Restorations

4.7.2.1 Effect on Health Improvement

Anecdotal reports on improved general health status following removal of amalgam fillings have often been presented in the public media. As described above, a clear correlation between specific symptoms or diseases and the presence of amalgam fillings has not been proven despite extensive research efforts. On a group level, removal of amalgam restorations did not result in any significant effects on general health. In one patient group, the same frequency of sick leave was found 2 years before and 2 years after the removal of amalgam fillings (for review, see [152]). A 7-year prospective follow-up study supported the previous findings in that the study results seriously question the hypothesis that dental amalgam is an important cause of distress and health complaints, and it concluded that the hypothesis that removing dental amalgam will reduce health complaints to normal levels could not be supported [182]. A randomized clinical study recently showed that a health promotion program was similarly effectice as amalgam removal for reducing participants's subjective complaints and mental stress [168a]. Furthermore, low mercury level body fluids was not a precondition for subjective improvement.

Some authors have claimed that a variety of methods are appropriate for diagnosing "amalgam disorders," such as readings of electric current and voltage in the oral cavity, serum tests, saliva tests, and the application of chelating agents. Several scientific studies, however, have failed to document the reliability of these methods, including the use of chelating agents [208, 220, 246] and lymphocyte assays [40, 41, 42, 145] (see also Sect. 4.3.2). Studies examining the effect of suggested "detoxification" drugs based on chelating agents, such as dimercaptosuccinic acid (DMSA) or 2,3-dimercapto-1-propanesulfonic acid (DMPS), revealed no significant improvements of subjective symptoms or effects except for clear placebo effects [83, 168a, 208]. Up to 42% of the patients suffered from adverse effects caused by the chelating agents.

4.7.2.2 Mercury Burden in Relation to Removal of Amalgam Fillings

Patients as well as dental personnel are potentially exposed to mercury vapor during removal of amalgam fillings. A review of the literature, however, showed that the concentrations generated are clearly below the internationally recommended threshold values for occupational exposure and far below the threshold levels of toxic effects (for review, see [215]; see also Sect. 4.3.3). Water cooling and vacuum suction during removal of amalgam significantly reduce the evaporization of mercury to levels far below those recommended for short-term and long-term (TLV) exposures. In patients having amalgam fillings removed, a minor transient increase in mercury concentration in plasma has been seen. After 1 month, mercury levels in plasma had declined to the preremoval level [27, 173, 209]. Removal of a relatively high number of amalgam fillings resulted in a half-life of mercury in plasma of 1–3 years before plasma levels were equivalent to those in subjects without amalgam restorations (e.g., [18, 173, 209]), whereas patients who had a mean of 4.3 amalgam surfaces removed showed a significantly shorter half-life of mercury in plasma of 5–13 days [88]. The mean half-life of mercury in urine after removal of amalgam was approximately 46 days [209]. Within 12 months after all amalgam fillings were removed, urinary mercury concentration was similar to values measured in patients who had never been treated with amalgam restorations [18].

Björkmann and colleagues monitored the fecal excretion of mercury in relation to amalgam removal. Two days after removal, the median mercury concentration was considerably elevated compared with the control group. Sixty days thereafter, mercury concentration was still slightly higher than in samples from the control group. The authors suggested that this might be the consequence of a higher mercury body

Dentlearn.ir

burden in subjects who had amalgam restorations removed. But they also emphasized that the effects from previous uptake of mercury related to diet and patient age may have had a significant impact on the fecal excretion of it [27]. As already mentioned in this chapter, fecal excretion is not a valid indicator of systemic exposure to mercury released from amalgam fillings (see also Sect. 4.3.1).

The application of a rubber dam can significantly reduce peak values of mercury in plasma after removal of amalgam restorations [21, 125]. But patients who had their amalgam removed with or without a rubber dam generally revealed mercury concentrations that were far below the relevant threshold values. It has therefore been forwarded that the application of rubber dams may be of very limited importance from a toxicological point of view [125].

Key Note

Except for very rare cases of an assumed acute allergy (anaphylactic reaction) [30, 166] and single cases of temporary dizziness and nausea ("metal-fume fever") [173], no associations between nonspecific symptoms and mercury exposure during removal of amalgam have been presented in the scientific literature.

4.8 Public Discussion

Billions of amalgam fillings have been placed since the precursors of contemporary amalgam formulations were introduced in the beginning of the 19th century. The known toxic potential of mercury – being one of the major constituents of amalgam – has over the years been the obvious reason for public concern. Reports on a broad variety of maladies supposedly caused by amalgam fillings have been published in the media. Anecdotal improvements following replacement of amalgam have also been described. Persistent pressure and discussions have forced public health agencies to intensify scientific studies on the potential risks to systemic health due to amalgam fillings. This chapter has attempted to summarize the current scientific literature.

In recent decades, several comprehensive reviews on possible health effects from amalgam were initiated by public health authorities [54, 69a, 70, 140, 172, 178, 179, 186, 234, 257]. Generally, all of these reviews concluded that the available data document that exposure to amalgam does not pose a health risk for the general population. Therefore, replacing intact amalgam fillings is not indicated except in cases of verified allergy. An additional conclusion was drawn in the European Union report on amalgam: "…less information is currently available on the toxicity of alternative dental filling materials than on amalgam" [70]. For health protection reasons, a number of countries have adopted recommendations for a restricted use of amalgam as a dental filling material, including Germany, Austria, Sweden, Finland, and Denmark. As of January 2008 Norway adopted a ban on amalgam primarily for environmental reasons. Two countries, Sweden and Denmark, issued a ban on the use of amalgam for environmental reasons, together with an open clause allowing the use of amalgam for certain purposes until sufficiently suitable replacement materials have been developed. The status of potential replacement materials is evaluated regularly. So far, amalgam can still be used in Denmark and Sweden with some restrictions. In both countries amalgam has been replaced, for example, by compomers and glass ionomers for restorations in deciduous teeth. Most western European countries and a number of states in the United States have at present issued regulations on the discharge of mercury-contaminated waste and waste water from dental clinics in order to significantly reduce the uncontrolled disposal of mercury-containing waste [6] (see also Chap. 13).

It is noteworthy that despite low-risk conclusions from most authorities and the majority of the scientific literature there is still some public concern about amalgam whereas the risk of side effects from the increasing use of alternatives in general seems not to cause any fear (see also Chap. 5). The combination of the fact that mercury is a well known toxic substance and anecdotal case reports in the media describing miraculous healings after removal of amalgam has kept the public attention alive. As mentioned before in this chapter, a broad variety of complaints, generally nonspecific, and a random combination of symptoms characterize the group of patients attributing subjective symptoms to the presence of dental amalgam restorations. So far, however, no scientifically approved diagnostic technique or method is available to identify this so-called amalgamism. This fact apparently leaves a basis for continued sensitive discussions about whether absence of proof can be taken as evidence of a nonexistent risk.

Grandjean and others have made parallels to the variety of so-called environmental illnesses that have emerged, particularly at the end of the 20th century [82]. The patients are predominantly women who tend

Dentlearn.ir

to be well informed and attend support groups. They are often dissatisfied with the health care system and have sought alternative ways of diagnosis and treatment. Somatization and mood and anxiety disorders have been found to occur more frequently in these patients than in controls [82]. Thus, Grandjean concluded in 1991:

The epidemic of amalgamism closely resembles other clusters of alleged environmental disease. A single type of exposure is identified by the patient as a cause of non-uniform combinations of symptoms, thus overlooking the growing evidence of multi-causality in chronic disease. With the multitude of toxic chemicals in the environment, public anxiety is growing, and public information about the risk involved may not necessarily dampen such anxieties. As a well-documented hazard, mercury is an obvious focus of concern. Whether or not mercury toxicity plays a role in some patients, the emergence of "amalgam disease" as an epidemic may be looked upon as manifestation of severe difficulties in modern society in dealing with risk communication and in controlling chemical hazards. [82]

Since the late 1990s, patient societies (in Germany, for example) have expressed increasing concerns about dental composite resins and have presented lists of symptoms allegedly caused by composites. The complaints on these lists are widely similar to the symptoms linked to amalgam [227] (see also Chap. 5). Thus, the conclusions of Grandjean are obviously still valid [82].

Conclusions for the Dental Practitioner

The following diagnostic recommendations are made based on the current scientific literature:

1. Lichenoid mucosal reactions restricted to areas in direct contact with amalgam fillings will often improve after amalgam has been removed.
2. Patients with concerns and anxieties about possible health risks caused by amalgam restorations or other filling materials should be given objective and well-balanced information about the current knowledge regarding biocompatibility of amalgam and alternative materials.
3. Patients with a variety of general and nonspecific symptoms at first require a comprehensive examination and diagnosis of their dental status. Therapy may include a broad spectrum of dental procedures, such as treatment of caries, pulpitis, occlusal dysfunctions, and periodontitis. The medical history should particularly address the intake of drugs because their adverse effects may mimic symptoms frequently attributed to dental restorations, such as altered taste sensations, dry mouth (xerostomia), burning mouth, and so on (see also Chaps. 8 and 14). In relevant cases, substitution of the drug under suspicion as the causative agent should be discussed with the patient's physician. If a patient's symptoms indicate possible mercury intoxication, excessive use of chewing gum or severe bruxism may be the cause. These patients may reveal increased mercury levels in plasma and urine. Therefore, mercury concentrations should be determined. If concentrations approximate the LOAEL value (HgU: 25–35 μg/g creatinine, HgB: 20–25 μg/l) patients should be advised to avoid excessive consumption of chewing gum. Excessive teeth grinding should be alleviated by inserting an occlusal splint. Removal of amalgam fillings may be considered under these circumstances.
4. Patients who attribute a complex spectrum of symptoms to the presence of amalgam fillings, without objective signs of mercury intoxication, pose a challenge for the treating dentist. If a comprehensive medical history, a careful dental diagnosis, and patient treatment and information fail to improve the situation, close collaboration between the dentist and various medical specialists is necessary. Most importantly, the patient's general physician should be included. Numerous reports on large groups of patients who held amalgam fillings responsible for their general symptoms have revealed that one or more medical or psychological conditions was responsible for the complaints in the majority of these patients. The dentist as a member of a medical team needs to be aware of his or her responsibility and should encourage the patient to undergo a comprehensive general medical examination. An unfortunate result of an uncritical focus on amalgam restorations may be that underlying but severe medical diagnoses are ignored.

Dentlearn.ir

References

1. Agency for Toxic Substances and Disease Registry (ATSDR): Toxicological profile for mercury. Agency for Toxic Substances and Disease Registry, Atlanta, 2001.
2. Ahlqwist, M., Bengtsson, D., Lapidus, L.: Number of amalgam fillings in relation to cardiovascular disease, diabetes, cancer and early death in Swedish women. Commun Dent Oral Epidemiol 21, 40–44 (1993).
3. Ahlqwist, M., Bengtsson, D., Lapidus, L., Lindstedt, G., Lissner, L.: Concentrations of blood, serum and urine components in relation to number of amalgam tooth fillings in Swedish women. Community Dent Oral Epidemiol 23, 217–222 (1995).
4. Ahlqwist, M., Bengtsson, C., Lapidus, L., Bergdahl, I.A., Schütz, A.: Serum mercury concentration in relation to survival, symptoms, and diseases: results from the prospective population study of women in Gothenburg, Sweden. Acta Odontol Scand 57, 168–174 (1999).
5. Al-Salehi, S.K., Hatton, P.V., Miller, C.A., McLeod, C., Joiner A.: The effect of carbamide peroxide treatment on metal ion from dental amalgam. Dent Mat 22, 948–953 (2006).
6. Arenholt-Bindslev, D.: Environmental aspects of dental materials. Eur J Oral Sci 106, 713–720 (1998).
7. Arenholt-Bindslev, D., Quist, I., Jensen, P.H., Fuglsbjerg, S., Danscher, G.L.: Visualization of mercury in the oral mucosa and in exfoliated oral epithelial cells from amalgam- and nonamalgam bearers. J Dent Res 80, 1273 (2001).
8. Arvidson, B., Arvidsson, J., Johansson, K.: Mercury deposits in neurons of the trigeminal ganglia after insertion of dental amalgam in rats. Bio Metals 7, 261–263 (1994).
9. Ask, K. Åkesson, A. Berglund, M. Vahter, M.: Inorganic mercury and methylmercury in placentas of Swedish Women. Environ Health Perspect 110, 523–526 (2002).
10. Bagedahl-Strindlund, M., Ilie, M., Furhoff, A.S.K., Tomson, Y., Larsson, K.S., Sandborgh-Englund, G., Torstenson, B., Wretlin, K.: A multidisciplinary clinical study of patients suffering from illness associated with mercury release from dental restorations: psychiatric aspects. Acta Psyciatr Scand 96, 475–482 (1997).
11. Bailer, J., Rist, F., Rudolf, A., Staehle, H.J., Eickholz, P., Triebig, G., Bader, M., Pfeifer, U.: Adverse health effects related to mercury exposure from dental amalgam fillings: toxicological or psychological causes? Psychol Med 31, 255–263 (2001).
12. Bangsi, D., Gharirian, P., Ducic, S., Morisset, R., Ciccocioppo, S., McMullen, E., Krewski, D.: Dental amalgam and multiple sclerosis: a case-control study in Montreal, Canada. Int J Epidemiol 27, 667–671 (1998).
13. Barregård, L., Horvat, M., Schütz, A.: No indication of in vivo methylation of inorganic mercury in chloralkali workers. Environment Res 67, 160–167 (1994).
14. Barregård, L.: Exposure to Hg in the general population of Europe and the Artic. In: Pirrone, N., Mahaffey, K. (eds): Dynamics of Mercury Pollution on Regional and Global Scales. Springer, New York 2006, pp 385–404.
15. Bates, M.N., Fawcett, J. Garrett, N. Cutress, T. Kjellström, T.: Health effects of dental amalgam exposure: a retrospective cohort study. Int J Epidemiol 33, 894–902 (2004).
16. Bates, M.N.: Mercury amalgam dental fillings: An epidemiologic assessment. Int J Hyg Environ Health 209, 309–316 (2006).
17. Becker, K., Schulz, C., Kaus, S., Seiwert, M., Seifert, B.: German environmental survey 1998 (GerES III): environmental pollutants in the urine of the German population. Int J Hyg Environ Health 206, 15–24 (2003).
18. Begerow, J., Zander, D., Freier, I., Dunemann, L.: Long-term mercury excretion in urine after removal of amalgam fillings. Int Arch Occup Environ Health 66, 209–212 (1994).
19. Bellinger, D.C., Trachtenberg, F., Barregard, L., Tavares, M., Cernichiari, E., Daniel, D., McKinlay, S.: Neuropsychological and renal effects of dental amalgam in children. A randomized clinical trial. JAMA 295, 1775–1783 (2006).
20. Berglund, A.: Estimation by a 24-hour study of the daily dose of intra-oral mercury vapor inhaled after release from dental amalgam. J Dent Res 69, 1646–1651 (1990).
21. Berglund, A., Molin, M.: Mercury levels in plasma and urine after removal of all amalgam restorations: the effect of using rubber dams. Dent Mater 13, 297–304 (1997).
22. Berglund, A., Bergdahl, J., Hansson, Mild K.: Influence of low frequency magnetic fields on the intraoral release of mercury vapor from amalgam restorations. Eur J Oral Sci 106, 671–674 (1998).
23. Berglund, M., Lind, B., Björnberg, K.A., Plam, B., Einarsson, O., Vahter, M.: Inter-individual variations of human exposure biomarkers: a cross-sectional assessment. Environ Health 4, 20–31 (2005).
24. Bernardo, M., Luis, H., Martin, M.D., Leroux, B.G., Rue, T., Leitao, J., DeRouen, TA.: Survival and reasons for failure of amalgam versus composite posterior restorations placed in a randomised clinical trial. J Am Dent Assoc 138, 775–783 (2007).
25. Beyth, N., Domb, A.J., Weiss, E.I.: An in vitro quantitative antibacterial analysis of amalgam and composite resins. J Dent 35, 201–206 (2007).
26. Björkman, L., Pedersen, N.L., Lichtenstein, P.: Physical and mental health related to dental amalgam fillings in Swedish twins. Community Dent Oral Epidemiol 24, 260–267 (1996).
27. Björkman, L., Sandborgh-Englund, G., Ekstrand, J.: Mercury in saliva and feces after removal of amalgam fillings. Toxicol Appl Pharmacol 144, 156–162 (1997).
28. Bleiker, T.O., English, J.S.C.: Acute contact allergy to dental amalgam. Contact Dermatitis 38, 112 (1998).
29. Boffetta, P., Garcia-Gomez, M., Pompe-Kirn, V., Zaridze, D., Bellander, T., Bulbulyan, M., Caballero, J.D., Ceccarelli, F., Colin, D., Dizdarevic, T., Espanol, S., Kobal, A., Petrova, N., Sallsten, G., Merler, E.: Cancer occurrence among European mercury miners. Cancer Causes Control 9, 591–599 (1998).
30. Bolewska, J.: Et sjældent tilfælde af en akut allergisk reaction overfor kviksølv i tilslutning til amalgamterapi. [Acute allergic reaction to mercury: a case report] Tandlægebladet 90, 627–628 (1986).
31. Bolewska, J., Holmstrup, P., Møller-Madsen, B., Kenrad, B., Danscher, G.: Amalgam associated mercury accumulations in normal oral mucosa, oral mucosa lesions of lichen planus and contact lesions associated with amalgam. J Oral Pathol Med 19, 39–42 (1990).
32. Boyd, N.D., Benediktsson, H., Vimy, M.J., Hooper, D.E., Lorscheider, F.L.: Mercury from dental "silver" tooth fillings impairs sheep kidney function. Am J Physiol 261, R1010–1014 (1991).
33. Bratel, J., Hakeberg, M., Jontell, M: Effect of replacement of dental amalgam on oral lichenoid reactions. J Dent 24, 41–45 (1996).

Dentlearn.ir

34. Bratel, J., Haraldson, T., Meding, B., Yontchev, E., Öhman, S.C., Ottosson, J.O.: Potential side effects of dental amalgam restorations (I). An oral and medical investigation. Eur J Oral Sci 105, 234–243 (1997).
35. Bratel, J., Haraldson, T., Ottosson, J.O.: Potential side effects of dental amalgam restorations (II). No relation between mercury levels in the body and mental disorder. Eur J Oral Sci 105, 244–250 (1997).
36. Brodsky, J.B., Cohen, E.N., Whitcher, C., Brown, B.W., Wu, M.: Occupational exposure to mercury in dentistry and pregnancy outcome. J Am Dent Assoc 111, 779–780 (1985).
37. Buchner, A, Hansen, L.: Amalgam pigmentation (amalgam tattoo) of the oral mucosa: a clinicopathological study of 268 cases. Oral Surg 48, 139–147 (1980).
38. Cascorbi, I., Manger, B., Knorr, U., Schiele, R., Katalinic, A., Petschelt, A.: Das Immunsystem bei Patienten mit Amalgamfüllungen. [The immune system in patients with amalgam restorations] Dtsch Zahnärztl Z 49, 764–766 (1994).
39. Casetta, I., Invernizzi, M., Granieri, E.: Multiple sclerosis and dental amalgam: Case-control study in Ferrara, Italy. Neuroepidemiology 20, 134–137 (2001).
40. Cederbrant, K., Gunnarsson, L.G., Hultman, P., Norda, R., Tibbling-Grahn, L.: In vitro lymphoproliferative assays with $HgCl_2$ cannot identify patients with systemic symptoms attributed to dental amalgam. J Dent Res 78, 1450–1458 (1999).
41. Cederbrant, K., Gunnarson, L.G., Marcusson, J.A.: Mercury intolerance and lymphocyte transformation test with nickel sulfate, palladium chloride, mercuric chloride and gold sodium thiosulfate. Environ Res 84, 140–144 (2000).
42. Cederbrant, K., Hultman, P.: Characterization of mercuric mercury (Hg2+)-induced lymphoblasts from patients with mercury allergy and from healthy subjects. Clin Exp Immunol 121, 23–30 (2000).
43. Chen Li, J.H., Lee, H.C., Ju, C.P.: Effect of addition of palladium on properties of Ag_2Hg_3 (γ-1) phase. Biomat 18, 939–946 (1997).
44. Chou, H.N., Korach, E.M., Gruninger, S.E., Siew, C.: Urinary mercury levels in dentists, 1984–2001. J Dent Res 82, 1457 (2003).
45. Clarkson, T. W.: The toxicology of mercury. Crit Rev Clin Lab Sci 34, 369–403 (1997).
46. Clarkson, T. W.: The three modern faces of mercury. Review. Environ Health Perspect 11 (Suppl 1), 11–23 (2002).
47. Clarkson, T.W., Magos, L.: The toxicology of mercury and its chemical compounds. Critical Reviews in Toxicology 36, 609–662 (2006).
48. Clausen, J.: Mercury and multiple sclerosis. Acta Neurol Scand 87, 461–464 (1993).
49. Costa, S.L., Malm, O., Dorea, J.G.: Breast-milk mercury concentrations and amalgam surface in mothers from Brasilia, Brazil. Bio Trace Elem Res 106, 145–151 (2005).
50. Dahl, J.E., Sundby, J., Hensten-Pettersen, A., Jacobsen, N.: Dental workplace exposure and effect on fertility. Scand J Work Environ Health 25, 285–290 (1999).
51. Dalen, K., Lygre, G.B., Kløve, H., Gjerdet, N.R., Askevold, E.: Memory functions in persons with dental amalgam. J Dent 31, 487–492 (2003).
52. Danscher, G., Hørsted-Bindslev, P., Rungby, J.: Traces of mercury in organs from primates with amalgam fillings. Exp Mol Pathol 52, 291–299 (1990).
53. DeRouen, T.A., Martin, M.D., Leroux, B.G., Townes, B.D., Woods, JS., Leitao, J., Castro-Caldas, A., Luis, H., Bernardo, M., Rosenbaum, G., Martins, I.P.: Neurobehavioral effects of dental amalgam in children. A randomised clinical trial. JAMA 295, 1784–1792 (2006).
54. Department of Health and Human Services (U.S.): Dental amalgam: a scientific review and recommended public health service strategy for research, education and regulation. Department of Health and Human Services, Public Health Services, Washington, DC 1993.
55. Drasch, G., Schupp, I., Riedl, G., Günther, G.: Einfluss von Amalgamfüllungen auf die Quecksilberkonzentration in menschlichen Organen. [The influence of amalgam fillings on the Hg-concentration in human organs]. Dtsch Zahnärztl Z 47, 490–496 (1992).
56. Drasch, G., Schupp, I., Höfl, H., Reinke, R., Roider, G.: Mercury burden of human fetal and infant tissues. Eur J Pediatr 153, 607–610 (1994).
57. Drasch, G., Aigner, S., Roider, G., Staiger, F., Lipowsky, G.: Mercury in human colostrum and early breast milk. Its dependence on dental amalgam and other factors. J Trace Elem Med Biol 12, 23–27 (1998).
58. Drexler, H., Schaller, K.H.: The mercury concentration in breast milk resulting from amalgam fillings and dietary habits. Environment Res 77, 124–129 (1998).
59. Dunne, S.M., Abraham, R., Pankhurst, C.L.: A 3-year longitudinal, controlled clinical study of a gallium-based restorative material. Brit Dent J 198, 355–359 (2005).
60. Duxbury, A.J., Ead, R.D., McMurrough, S., Watts, D.C.: Allergy to mercury in dental amalgam. Br Dent J 152, 47–48 (1982).
61. Dye, B.A., Schober, S.E., Dillon, C.F., Jones, R.L., Fryar, C., McDowell, M., Sinks, T.H.: Urinary mercury concentrations associated with dental restorations in adult women aged 16–49 years: United States, 1999–2000. Occup Environ Med 62, 368–375 (2005).
62. Echeverria, D., Heyer, N.J., Martin, M.D., Naleway, C.A., Woods, J.S., Bittner, A.C.: Behavioral effects of low-level exposure to Hg^0 among dentists. Neurotoxicol Teratol 17, 161–168 (1995).
63. Echeverria, D., Aposhian, H.V., Woods, J.S., Heyer, N.J., Aposhian, M.M., Bittner, A.C., Mahurin, R.K.: Neurobehavioral effects from exposure to dental amalgam Hg^0: new distinctions between recent exposure and Hg body burden. FASEB 12, 971–980 (1998).
64. Edlund, C., Björkman, L., Ekstrand, J., Sandborgh-Englund, G., Nord, E.E.: Resistance of the normal human microflora to mercury and antimicrobials exposure to mercury from dental amalgam fillings. Clin Infect Dis 22, 944–950 (1996).
65. Ekstrand, J., Björkman, L., Edlund, C., Sandborgh-Englund, G.: Toxicological aspects on the release and systemic uptake of mercury from dental amalgam. Eur J Oral Sci 106, 678–686 (1998).
66. Emmot, N., Slayne, M.: Legislation and policy concerning mercury in the European Union. In: Pirrone, N., Mahaffey, K. (eds): Dynamics of Mercury Pollution on regional and Global Scales. Springer, New York 2006, pp 65–80.
67. Eneström, S., Hultman, P.: Does amalgam affect the immune system? A controversial issue. Int Arch Immunol 106, 180–203 (1995).
68. Ericson, A., Källén, B.: Pregnancy outcome in women working as dentists, dental assistants or dental technicians. Int Arch Occup Environ Health 61, 329–333 (1989).

Dentlearn.ir

69. European Commission: Ambient air pollution by mercury. Position paper. Luxembourg, 2001
69a. European Commission: Scientific Committee on Emerging and Newly Identified Health Risks (SCENIHIR): The safety of dental amalgam and alternative dental restoration materials for patients and users. http://ec.europa.eu/health/ph_risk_en.htm (2007).
70. EU Working Group: Dental Amalgam. A report with reference to The Medical Devices Directive 93/42/EEC from an ad hoc working group mandated by DGIII of the European Commission, 1998.
71. Fahmy, M.S.: Oral and dental affections in mercury-exposed workers. Community Dent Oral Epidemiol 6, 161–165 (1978).
72. Faktor-Litvak, P., Hasselgren, G., Jacobs, D., Begg, M., Kline, J., Geier, J., Mervish, N., Schoenholtz, S., Grazianoo, J.: Mercury derived from dental amalgams and neuropsychologic function. Environ Health Perspect 111, 719–723 (2003).
73. Fardal, Ø., Johannessen, A.C., Morken, T.: Gingivo-mucosal and cutaneous reactions to amalgam fillings. Case report. J Clin Perio 32, 430–433 (2005).
74. Ferracane, J., Adey, J., Wiltbank, K., Nakajima, H., Okabe, T.: Vaporization of Hg-In amalgams during setting and after abrasion. Dent Mat 15, 191–195 (1999).
75. Fredin, B.: The distribution of mercury in various tissues of guinea-pigs after application of dental amalgam fillings (a pilot study). Sci Total Environ 66, 263–268 (1987).
76. Frisch, M., Schwartz, B.S.: The pitfalls of hair analysis for toxicants in clinical practice. Environ Health Perspect 110: 433–436 (2002).
77. Fung, Y.K., Meade, A.G., Rack, E.P., Blotcky, A.J.: Brain mercury in neurodegenerative disorders. J Toxicol Clin Toxicol 35, 49–54 (1997).
78. Furhoff, A.K., Tomson, Y., Ilie, M., Bågedahl-Strindlund, M., Larsson, K.S., Sandborgh-Englund, G., Torstenson, B., Wretlind, K.: A multidisciplinary clinical study of patients suffering from illness associated with release of mercury from dental restorations. Medical and odontological aspects. Scand J Prim Health Care 16, 247–252 (1998).
79. Ganss, C., Gottwald, B., Traenckner, I., Kupfer, J., Eis, D., Mönch, J., Gieler, U., Klimek, J.: Relation between mercury concentrations in saliva, blood, and urine in subjects with amalgam restorations. Clin Oral Invest 4, 206–211 (2000).
80. Gottwald, B., Traenckner, I., Kupfer, J., Ganss, C., Eis, D., Schill, W.B., Gieler, U.: "Amalgam disease" – poisoning, allergy, or psychic disorder? Int J Hyg Environ Health 204, 223–229 (2001).
81. Gottwald, B., Kupfer, J., Traenckner, I., Ganss, C., Gieler, U.: Psychological, allergic and toxicological aspects of patients with amalgam-related complaints. Psychother Psychosom 71, 223–232 (2002).
82. Grandjean, P.: The amalgamism controversy: exposing the dilemmas in environmental health. In: P. Hørsted-Bindslev, L. Magos, P. Holmstrup, D. Arenholt-Bindslev (eds): Dental Amalgam – A Health Hazard? Munksgaard, Copenhagen 1991, pp 118–122.
83. Grandjean, P., Guldager, B., Larsen, I.B.N., Jørgensen, P.H., Holmstrup, P.: Placebo response in environmental disease. J Occup Environ Med 39, 707–714 (1997).
84. Grandjean, P., Budtz-Jørgensen, E., White, R.F., Jørgensen, P.J., Weihe, P., Debes, F., Keiding, N.: Methylmercury exposure biomarkers as indicators of neurotoxicity in children aged 7 years. Am J Epidemiol 150, 301–305 (1999).
85. Grandjean, P., Cordier, S., Kjellström, T., Weihe, P. Budtz-Jørgensen, E.: Health effects and risk assessment. In: Pirrone N., Mahaffey, K. (eds): Dynamics of Mercury Pollution on Regional and Global Scales. Springer, New York 2006, pp 511–540.
86. Hahn, G.J., Kloiber, R., Vimy, M.J., Takahashi, Y., Lorscheider, F.L.: Dental "silver" tooth fillings: a source of mercury exposure revealed by whole body image scan and tissue analysis. FASEB J 3, 2641–2646 (1989).
87. Halbach, S.: Combined estimation of mercury species released form amalgam. J Dent Res 74, 1103–1109 (1995).
88. Halbach, S., Kremers, L., Willruth, H., Mehl, A., Welzl, G., Wack, F.X., Hickel, R., Greim, H.: Systemic transfer of mercury from amalgam fillings before and after cessation of emission. Environ Res 77, 115–123 (1998).
89. Halbach, S., Hickel, R., Meiners, H., Ott, K., Reichl, F.X., Schiele, R., Schmalz, G., Staehle, H.J.: Amalgam im Spiegel kritischer Auseinandersetzungen. [The critical dispute on amalgam] Deutscher Ärzte-Verlag, Cologne 1999.
90. Halbach, S., Hickel, R., Meiners, H., Ott, K., Reichl, F.X., Schiele, R., Schmalz, G., Staehle, H.J.: Entgegnung der Autoren des Materialienbandes „Amalgam im Spiegel kritischer Auseinandersetzungen" [Reply of the authors of the book "The Critical Dispute on Amalgam"]. Institut der Deutschen Zahnärzte, Cologne 2001.
91. Halbach, S.: Amalgam. Gesundheitsrisiko und interdisziplinäres problem? [Amalgam. Health risks and inter disciplinary problems] Internistische Praxis 43, 441–450 (2003)
92. Hanf, V., Forstmann, A., Costea, J.E., Schieferstein, G., Fischer, I., Schweinsberg, F.: Mercury in urine and ejaculate in husbands of barren couples. Toxicol Lett 88, 227–231 (1996).
93. Heidam, L.S.: Spontaneous abortions among dental assistants, factory workers, painters, and gardening workers: a follow up study. J Epidemiol Commun Health 38, 149–155 (1984).
94. Henriksson, E., Mattsson, U., Håkansson, J.: Healing of lichenoid reactions following removal of amalgam. J Clin Periodontol 22, 287–294 (1995).
95. Herber, R.F.M., deGee, A.J., Wibowo, A.A.E.: Exposure of dentists and assistants to mercury: mercury levels in urine and hair related to conditions of practice. Comm Dent Oral Epidemiol 16, 153–158 (2003).
96. Herrström, P., Högstedt, B.: Clinical study of oral galvanism: no evidence of toxic mercury exposure but anxiety disorder an important background factor. Scand J Dent Res 101, 232–237 (1993).
97. Herrström, P., Högstedt, B.: Dental restorative materials and the prevalence of eczema, allergic rhino-conjunctivitis and asthma in schoolchildren. Dental amalgam and allergy in schoolchildren. Scand J Primary Health Care 12, 3–8 (1994).
98. Herrström, P., Holmén, A., Karlsson, A., Raihle, G., Schütz, A., Högstedt, B.: Immune factors, dental amalgam, and low-dose exposure to mercury in Swedish adolescents. Arch Environment Health 49, 160–164 (1994).
99. Herrström, P., Schütz, A., Raihle, G., Holthuis, N., Högstedt, B., Råstam, R.: Dental amalgam, low-dose exposure to mercury, and urinary proteins in young Swedish men. Arch Environ Health 50, 103–107 (1995).
100. Herrström, P., Högstedt, B., Aronson, S., Holmén, A., Råstam, L.: Acute glomerulonephritis, Henoch–Schönlein purpura and dental amalgam in Swedish children: a case-control study. Sci Tot Environment 191, 277–282 (1996).

Dentlearn.ir

101. Herrström, P., Högstedt, B., Holthuis, N., Schütz, A., Råstam, R.: Allergic disease, immunoglobulins, exposure to mercury and dental amalgam in Swedish adolescents. Arc Occup Environ Health 69, 339–342 (1997).
102. Hock, C., Drasch, G., Golombowski, S., Müller-Spahn, F., Willershausen-Zönnchen, B., Schwarz, P., Hock, U., Growdon, J.H., Nitsch, R.M.: Increased blood mercury levels in patients with Alzheimer's disease. J Neural Transm 105, 59–68 (1998).
103. Holland, R.I.: Release of mercury vapor from corroding amalgam in vitro. Dent Mater 9, 99–103 (1993).
104. Holmstrup, P.: Reactions of the oral mucosa related to silver amalgam. A review. J Oral Pathol Med 20, 1–7 (1991).
105. Hørsted-Bindslev, P.: Mercury and the dental patient. In: Hørsted-Bindslev, P., Magos, L., Holmstrup, P., Arenholt-Bindslev, D. (eds): Dental Amalgam–A Health Hazard? Munksgaard, Copenhagen 1991, pp 41–61.
106. Hørsted-Bindslev, P., Bolewska, J., Arenholt-Bindslev, D., Danscher, G.: Dentinal transport of mercury from dental silver amalgam restorations. Progr Histo Cytochem 23, 321–326 (1991).
107. Hørsted-Bindslev, P., Danscher, G, Hansen, J.C.: Dentinal and pulpal uptake of mercury from lined and unlined amalgam restorations in minipigs. Eur J Oral Sci 105, 338–343 (1997).
108. Hørsted-Bindslev, P., Danscher, G., Jensen, P., Kjærgaard, P., Hansen, J.C.: Minipig amalgam restorations cause accumulation of mercury in kidney and liver. J Dent Res 77, 824 (1998).
109. Hultman, P., Lindh, U., Hørsted-Bindslev, P.: Activation of the immune system and systemic immune-complex deposits in Brown Norway rats with dental amalgam restorations. J Dent Res 77, 1415–1425 (1998).
110. Issa, Y., Duxbury, A.J., Macfarlane, T.V., Brunton, P.A.: Oral lichenoid lesions related to dental restorative materials. Br Dent J 198, 361–366 (2005).
111. Issa, Y., Brunton, P.A., Glenny, A.M., Duxbury, A.J.: Oral lichenoid lesions and amalgam fillings. Review. EBD 7, 74–75 (2006).
112. Jensen, S.J.: Maximum content of mercury in dental silver amalgams. Scand J Dent Res 93, 84–88 (1985).
113. Joint FAO/WHO Expert Committee on Food Additives: Toxicological recommendations and information on specifications. Food and Agriculture Organization of the United Nations, Rome; World Health Organization, Geneva 2003.
114. Jokstad, A.: Mercury excretion and occupational exposure of dental personnel. Commun Dent Oral Epidemiol 18, 143–148 (1990).
115. Joselow, M .M., Goldwater, I.J., Alvarez, A., Hemdon, J.: Absorption and excretion of mercury in man. XV. Occupational exposure among dentists. Arch Environ Health 17, 39–43 (1968).
116. Kaga, M., Sakai, T., Fujita, M., Oguchi, H.: Comparative cytotoxic evaluation of gallium alloy and amalgams in cell culture. Pediatric Dent J 2, 109–114 (1992).
117. Kanerva, L., Komulainen, M., Estlander, T., Jolanki, R.: Occupational allergic contact dermatitis from mercury. Contact Dermatitis 28, 26–28 (1993).
118. Karahalil, B., Rahravi, H., Ertas, N.: Examination of urinary mercury levels in dentists in Turkey. Hum Exp Toxicol 24, 383–388 (2005).
119. Kaufmann, T., Bloch, C., Schmidt, W., Jonas, L.: Chronic inflammation and pain inside the mandibular jaw in an alveolar cavity of an extracted molar tooth. Ultrastruct Pathol 29, 405–413 (2005).
120. Kingman, A., Albertini, T., Brown, L.J.: Mercury concentrations in urine and whole blood associated with amalgam exposure in a US military population. J Dent Res 77, 461–471 (1998).
121. Kingman, A., Albers, J.W., Arezzo, J.C., Garabrant, D.H., Michalek, J.E.: Amalgam exposure and neurological function. Neuro Toxicol 26, 241–255 (2005).
122. Kiremitci, A., Bolay, S.: A 3-year clinical evaluation of a gallium restorative alloy. J Oral Rehabil 30, 664–667 (2003).
123. Kleemann, D., Weinhold, J., Strubelt, O., Pentz, R., Jungblut, J.R., Klink, F.: Der Einfluss von Amalgamfüllungen auf die Quecksilberkonzentrationen in Fruchtwasser und Muttermilch. [The influence of amalgam fillings on the Hg-concentrations in amnion fluid and breast milk] Dtsch Zahnärztl Z 3, 142–145 (1990).
124. Krauss, P., Deyhle, M., Maier, K.H., Roller, E., Weiss, H.D., Clèdon, P.: Field study on the mercury content of saliva. Toxicol Environ Chem 63, 29–46 (1997).
125. Kremers, L., Halbach, S., Willruth, H., Mehl, A., Welzl, G., Wack, F.X., Hickel, R., Greim, H.: Effect of rubber dam on mercury exposure during amalgam removal. Eur J Oral Sci 107, 202–207 (1999).
126. Laeijendecker, R., Dekker, S.K., Burger, P.M., Mulder, P.G.H., VanJoost, T., Neumann, M.H.A.: Oral lichen planus and allergy to dental amalgam restorations. Arch Dermatol 140, 1434–1438 (2004).
127. Laine, J., Happonen, R.P., Vainio, O., Kalimo, K.: In vitro lymphocyte proliferation test in the diagnosis of oral mucosal hypersensitivity reactions to dental amalgam. J Oral Pathol Med 26, 362–366 (1997).
128. Laine, J., Kalimo, K., Happonen, R.P.: Contact allergy to dental restorative materials in patients with oral lichenoid lesions. Contact Dermatitis 36, 141–146 (1997).
129. Langan, D.C., Steffek, A.J., Naleway, C.A.: Mercury hygiene practices. CDA J 14, 24–29 (1987).
130. Langworth, S., Almkvist, O., Söderman, E., Wikström, B.O.: Effects of occupational exposure to mercury vapor on the central nervous system. Br J Ind Med 49, 545–555 (1992).
131. Langworth, S., Elinder, C.G., Sundquist, K.G., Vesterberg, O.: Renal and immunological effects of occupational exposure to inorganic mercury. Br J Ind Med 49, 394–401 (1992).
132. Langworth, S., Sällsten, G., Barregård, L., Cynkier, I., Lind, M.-L., Söderman, E.: Exposure to mercury vapor and impact on health in the dental profession in Sweden. J Dent Res 76, 1397–1340 (1997).
133. Langworth, S.: Experiences from the amalgam unit at Huddinge hospital–somatic and psychosomatic aspects. Scand J Work Environ Health 23, 65–67 (1997).
134. Langworth, S., Björkman, L., Elinder, C.G., Järup, L., Savlin, P.: Multidisciplinary examination of patients with illness attributed to dental fillings J Oral Rehabil 29, 705–713 (2002).
135. Larsson, Å., Warfvinge, G.: The histopathology of oral mucosal lesions associated with amalgam or porcelain-fused-to-metal restorations. Oral Dis 1, 152–158 (1995).
136. Larsson, K.S.: The dissemination of false data through inadequate citation. J Internal Med 238, 445–450 (1995).
137. Leistevuo, J., Järvinen, H., Österblad, M., Leistevuo, T., Huovinen, P., Tenovuo, J.: Resistance to mercury and antimicrobial agents in *Streptococcus mutans* isolates from human subjects in relation to exposure to dental amalgam fillings. Antimicrob Agents Chemother 44, 456–457 (2000).

Dentlearn.ir

138. Leite, C.M.A., Botelho, A.S., Oliveira, J.R., Cardoso, S.V., Loyola, A.M., Omez, R.S., Vaz, R.R.: Immunolocalization of HLA-DR and metallothionein on amalgam tattoos. Braz Dent J 15, 99–103 (2004).
139. Letzel, H., Van'T Hof, M.A., Marshall, G.W., Marshall, S.J.: The influence of the amalgam alloy on the survival of amalgam restorations: a secondary analysis of multiple controlled clinical trials. J Dent Res 76, 1787–1798 (1997).
140. Life Sciences Research Office: Review and analysis of the literature on the potential adverse health effects of dental amalgam. Prepared for the Trans-agency Working Group on the Health Effects of Dental Amalgam. U.S. Department of Health and Human Services. Rockville, Maryland, LSRO Office 2004.
141. Lin, J.H.C., Marshall, G.W., Marshall, S.J.: Microstructures of Curich amalgams after corrosion. J Dent Res 62, 112–115 (1983).
142. Lindbohm, M.L., Ylöstalo, P., Sallmén, M., Henriks-Eckerman, M.L., Nurminen, T., Forss, H., Taskinen, H.: Occupational exposure in dentistry and miscarriage. Occup Environ Med 64, 127–133 (2007).
143. Lindow, S.W., Knight, R., Batty, J., Haswell, S.J.: Maternal and neonatal hair mercury concentrations: the effect of dental amalgam. BJOG 110, 287–291 (2003).
144. Little, M.C., Griffiths, C.E.M., Watson, R.E.B., Pemberton, M.N., Thornhill, M.H.: Oral mucosal keratinocytes express RANTES and ICAM, but not interleukin-8, in oral lichen planus and oral lichenoid reactions induced by amalgam fillings. Clin Exp Dermatol 28, 64–69 (2003).
145. Loftenius, A., Skoglund, A., Ekstrand, J., Hovmark, A., Møller, E.: No evidence for specific in vitro lymphocyte reactivity to $HgCl_2$ in patients with dental amalgam-related contact lesions. J Oral Pathol Med 28, 364–370 (1999).
146. Lund, J.P., Mojon, P., Pho, M., Feine, J.S.: Alzheimer's disease and edentulism. Age Ageing 32, 228–229 (2003).
147. Lutz, E., Lind, B., Herin, P., Krakau, I., Bui, T.H., Vahter, M.: Concentrations of mercury, cadmium and lead in brain and kidney of second trimester fetuses and infants. J Trace Elements Med Biol 10, 61–67 (1996).
148. Lygre, G.B., Grønningsaeter, A.G., Gjerdet, N.R.: Mercury and dental amalgam fillings. Tidsskr Nor Laegeforen 118, 1698–1701 (1998).
149. Lygre, G.B., Høl, P.J., Eide, R., Isrenn, R., Gjerdet, N.R.: Mercury and silver in saliva from subjects with symptoms self-related to amalgam fillings. Clin Oral Invest 3, 216–218 (1999).
150. Maas, C., Brück, W., Haffner, H.T., Schweinsberg, F.: Untersuchung zur Bedeutung einer cerebralen Quecksilberbelastung aus Amalgamfüllungen durch direkten Mund- und Nase-Hirn-Transport. [Investigations on the possible cerebral mercury exposure from dental amalgam fillings through a direct nose-brain transport] Zbl Hyg 198, 275–291 (1996).
151. Mackert, J.R., Leffel, M. S., Wagner, D.A., Powell, B.J.: Lymphocyte levels in subjects with and without amalgam restorations. J Am Dent Assoc 122, 49–53 (1991).
152. Mackert, J.R., Berglund, A.: Mercury exposure from dental amalgam fillings: absorbed dose and the potential for adverse health effects. Crit Rev Oral Bio Med 8, 410–436 (1997).
153. Magos, L.: Mercury metabolism and toxicology. In: P. Hørsted-Bindslev, L. Magos, P. Holmstrup, D. Arenholt-Bindslev (eds): Dental Amalgam – A Health Hazard? Munksgaard, Copenhagen 1991, pp 11–32.
154. Magos, L., Clarkson, T.W.: Overview of the clinical toxicity of mercury. Ann Clin Biochem 43, 257–268 (2006).
155. Mahler, D.B.: The high-copper dental amalgam alloys. J Dent Res 76, 537–541 (1997).
156. Mahler, D.B., Adey, J.D., Fleming, M.A.: Hg emission from dental amalgam as related to the amount of Sn in the Ag-Hg (gamma-1) phase. J Dent Res 73, 1663–1668 (1994).
157. Mahler, D.B., Engle, J.H., Adey, J.D.: Effect of Pd on the clinical performance of amalgam. J Dent Res 69, 1759–1761 (1990).
158. Malt, U.F., Nerdrum, P., Oppedal, B., Gundersen, R., Holte, M., Löne, J.: Physical and mental problems attributed to dental amalgam fillings: a descriptive study of 99 self-referred patients compared with 272 controls. Psychosom Med 59, 32–41 (1997).
159. Martin, M.D., Naleway, C., Chou, H.-N.: Factors contributing to mercury exposure in dentists. J Am Dent Assoc 126, 1502–1511 (1995).
160. Martin, M.D., Williams, B.N., Charleston, J.D., Oda, D.: Spontaneous exfoliation of teeth following severe elemental mercury poisoning: case report and histological investigation for mechanism. Oral Surg Oral Med Oral Pathol Oral Radiol Endod 84, 495–501 (1997).
161. Manhart, J., Chen, H.Y., Hamm, G., Hickel, R.: Review of the clinical survival of direct and indirect restorations in posterior teeth of the permanent dentition. Oper Dent 29, 481–508 (2004).
162. Matsuzaka, K., Mabuchi, R., Nagasaka, H., Yoshinari, M., Inoue, T.: Improvement of eczematous symptoms after removal of amalgam-like metal in alveolar bone. Bull Tokyo Dent Coll 47, 13–17 (2006).
163. McCartan, B.E., McCreary, C.E.: Oral lichenoid drug eruptions. Oral Dis 3, 58–63 (1997).
164. McDaniel, S., Campbell, T., Seaburn, D.: Somatic fixation in patients and physicians: a biopsychosocial approach. Fam Syst Med 7, 5–16 (1989).
165. McDermott, A.J., Kothari, S., Short, R.D., Van Noort, R., Alexander, M.R.: Surface chemistry of a high-copper dental amalgam. J Dent Res 77, 1999–2004 (1998).
166. McGivern, B., Pemberton, M., Theaker, E.D., Buchanan, J.A.G., Thornhill, M.H.: Delayed and immediate hypersensitivity reactions associated with the use of amalgam. Br Dent J 188, 73–77 (2000).
167. McGrother, C.W., Dugmore, C., Phillips, M.J., Raymond, N.T., Garrick, P., Baird, W.O.: Multiple sclerosis, dental caries and fillings: a case-control study. Br Dent J 187, 261–264 (1999).
168. Melchart, D., Wühr, E., Weidenhammer, W., Kremers, L.: A multicenter survey of amalgam fillings and subjective complaints in nonselected patients in the dental practice. Eur J Oral Sci 106, 770–777 (1998).
168a. Melchart, D., Vogt, S., Köhler, W., Streng, A., Weidenhammer, W., Kremers, L., Hickel, R., Felgenhauer, N., Zilker, T., Wühr, E., Halbach, S.: Treatment of health complaints attributed to amalgam. J Dent Res 87, 349–353 (2008)
169. Meyer-Baron, M., Schaeper, M., Seeber, A.: A meta-analysis for neurobehavioural results due to occupational mercury exposure. Arch Toxicol 76, 127–136 (2002).
170. Millán, M.A.P., Correa, F.G.: Determination of mercury in urine of Mexican dentists by neutro activation analysis. J Radioanal Nucl Chem 254, 305–309 (2002).
171. Miller, E.G., Perry, W., Wagner, M.H.: Prevalence of mercury hypersensitivity in dental students. J Prosthet Dent 58, 235–237 (1987).

Dentlearn.ir

172. Ministère du travail et des affaires sociales: L'amalgame dentaire et ses alternative. Evaluation et gestion du risque. [Dental amalgam and its alternatives: a risk evaluation] Conseil supérieur d'hygiène publique de France. Lavoisier, Paris 1998.
173. Molin, M., Bergman, B., Marklund, S.L, Schütz, A., Skerfving, S.: Mercury, selenium, and glutathione peroxidase before and after amalgam removal in man. Acta Odontol Scand 48, 189–202 (1990).
174. Möller, B., Granath, L.-E.: Reaction of the human dental pulp to silver amalgam restorations. Acta Odontol Scand 31, 187–192 (1973).
175. Myers, GJ., Davidson, PW., Cox, C., Shamlaye, C., Palumbo, D., Cernichiari, E., Sloane-Reeves, J., Wilding, GE., Kost, J., Haung, LS., Clarkson, TW.: Prenatal methylmercury exposure from ocean fish consumption in the Seychelles Child Development Study. Lancet 361, 1868–1892 (2003)
176. Nakayama, H., Niki, F., Shono, M., Hada, S.: Mercury exanthem. Contact Dermatitis 9, 411–417 (1983).
177. Naleway, C., Sakakguchi, R., Mitchell, E., Muller, T., Ayer, W.A., Hefferren, J.J.: Urinary mercury levels in U.S. dentists, 1975–1983: review of Health Assessment Program. J Am Dent Assoc 111, 37–42 (1985).
178. National Board of Health and Welfare [Sweden]. Possible health effects and dental amalgam. National Board of Health and Welfare, Stockholm, 1994.
179. National Institute of Dental Research: Effects and side-effects of dental restorative materials. An NIH Technology Assessment Conference. Bethesda, Maryland, 26–28 August 1991. Adv Dent Res 6, 1–144 (1992).
180. National Research Council [U.S.]: Toxicological Effects of Methylmercury. National Academy Press, Washington DC 2000.
181. Neo, J., Chew, C.L, Osborne, J.W., Mahler, D.B.: Clinical evaluation and microstructural analysis of a direct placement gallium restorative alloy. J Dent 28, 123–129 (2000).
182. Nerdrum, P., Malt, U.F., Høglend, P., Oppedal, B., Gundersen, R., Holte, M., Löne, J.: A 7-year prospective quasi-experimental study of the effects of removing dental amalgam in 76 self-referred patients compared with 146 controls. J Psychosom Res 57, 103–111 (2004).
183. Ngim, C.H., Foo, S.C., Boey, K.W., Jeyaratnam, J.: Chronic neurobehavioral effects of elemental mercury in dentists. Br J Int Med 49, 782–790 (1992).
184. Nilsson, B., Nilsson, B.: Mercury in dental practice. II. Urinary mercury excretion in dental personnel. Swedish Dental Journal 10, 221–232 (1986).
185. Nitsche, I., Müller, F., Smith, J., Hopfenmüller, W.: Amalgam fillings and cognitive abilities in a representative sample of the elderly population. Gerodontology 17, 39–44 (2000).
186. Norwegian report: Bruk av tannrestaureringsmaterialer i Norge, IK-2652. [The use of dental restorative materials in Norway]. Statens Helsetilsyn, Oslo 1998.
187. Okabe, T., Yamashita, T., Nakajima, H., Berglund, A., Zhao, L., Guo, I., Ferracane, J.L.: Reduced mercury vapor release from dental amalgams prepared with binary Hg-In liquid alloys. J Dent Res 73, 1711–1716 (1994).
188. Olsson, S., Berglund, A., Bergman, M.: Release of elements due to electrochemical corrosion of dental amalgam. J Dent Res 73, 33–43 (1994).
189. Olsson, S., Bergman, M.: Daily dose calculations from measurements in intra-oral mercury vapor. J Dent Res 71, 414–423 (1992).
190. Osborne, J.W., Summit, J.B.: Direct-placement gallium restorative alloy: a 3-year clinical evaluation. Quintessence Int 30, 49–53 (1999).
191. Oskarsson, A., Schultz, A., Skerfving, S., Hallen, I.P., Ohlin, B., Lagerkvist, B.J.: Total and inorganic mercury in breast milk in relation to fish consumption in lactating women. Arch Environ Health 51, 234–241 (1996).
192. Ozbas, H., Yaltirik, M., Bilgic, B., Issever, H.: Reactions of connective tissue to compomers, composite and amalgam root-end filling materials. Int Endod J 36, 281–287 (2003).
193. Østerblad, M., Leistevuo, J., Leistevuo, T., Järvinen, H., Pyy, L.: Antimicrobial and mercury resistance in aerobic gram-negative bacilli in fecal flora among persons with and without dental amalgam fillings. Antimicrob Agents Chemother 39, 2499–2502 (1995).
194. Östman, P.O., Anneroth, G., Skoglund, A.: Amalgam-associated oral lichenoid reactions. Clinical and histologic changes after removal of amalgam fillings. Oral Surg Oral Med Oral Pathol Oral Radiol Endod 81, 459–465 (1996).
195. Ott, K.H.R.: Die Messung der Quecksilber-Belastung im Speichel. [Mercury levels in saliva] Dtsch Zahnärztl Z 48, 154–157 (1993).
196. Owens, B.M., Johnson, W.W., Schuman, N.J.: Oral amalgam pigmentations (tattoos): a retrospective study. Quintessence Int 23, 805–810 (1992).
197. Pesch, A., Wilhelm, M., Rostek, U., Schmita, N., Weishoff-Houben, M., Ranft, U., Idel, H.: Mercury concentrations in urine, scalp hair, and saliva in children from Germany. J Expo Anal Environ Epidemiol 12, 252–256 (2002)
198. Razagui, I.B., Haswell, S.J.: Mercury and selenium concentrations in maternal and neonatal scalp hair: relationship to amalgam-based dental treatment received during pregnancy. Biol Trace Elem Res 81, 1–19 (2001).
199. Ready, D., Qureshi, F., Bedi, R., Mullany, P., Wilson, M.: Oral bacteria resistant to mercury and to antibiotics are present in children with no previous exposure to amalgam restorative materials FEMS Microbiol Lett 223, 107–111 (2003).
200. Reichl, F.-X., Esters, M., Simon, S., Seiss, M., Kehe, K., Kleinsasser, N., Folwaczny, M., Glas, J., Hickel, R.: Cell death effects of resin-based dental material compounds and mercurials in human gingival fibroblasts. Arch Toxicol 80, 370–377 (2006).
201. Reichl, F.-X., Simon, S., Esters, M., Seiss, M., Kehe, K., Kleinsasser, N., Hickel, R.: Cytotoxity of dental composite (co)monomers and the amalgam component Hg^{2+} in human gingival fibroblasts. Arch Toxicol 80, 465–472 (2006).
202. Ritchie, K.A., Burke, F.J.T., Gilmour, W.H., Macdonald, E.B., Dale, I.M., Hamilton, R.M., McGowan, D.A., Binnie, V., Collington, D., Hammersley, R.: Mercury vapor levels in dental practices and body mercury levels of dentists and controls. Br Dent J 197, 625–632 (2004).
203. Ritzau, M.: Gingivostomatitis mercurialis. Tandlaegebladet 73, 470–481 (1969).
204. Rojas, M., Guevara, H., Rincón, R., Rodriques, M., Olivet, C.: Occupational exposure and health effects of metallic mercury among dentists and dental assistants: a preliminary study. Valencia, Venezuela; 1998. Acta Cientif Venezol 51, 32–38 (2001).
205. Sällsten, G., Thoren, J., Barregaard, L., Schutz, A., Skarping, G.: Long-term use of nicotine chewing gum and mercury exposure from dental amalgam fillings. J Dent Res 75, 594–598 (1996).

Dentlearn.ir

206. Salonen, J.T., Seppänen, K., Lakka, T.A., Salonen, R., Kaplan, G.A.: Mercury accumulation and accelerated progression of carotid atherosclerosis: a population-based prospective 4-year follow-up study in men in eastern Finland. Atherosclerosis 148, 265–273 (2000).
207. Sandborgh-Englund, G., Ask, K., Belfrage, E., Ekstrand, J.: Mercury exposure in utero and during infancy. J Toxicol Environ Health 6, 317–320 (2001).
208. Sandborgh-Englund, G., Dahlqvist, R., Lindelöf, B., Söderman, E.W., Jonzon, B., Vesterberg, O., Larsson, K.S.: DMSA administration to patients with alleged mercury poisoning from dental amalgam: a placebo-controlled study. J Dent Res 73, 620–628 (1994).
209. Sandborgh-Englund, G., Elinder, C.G., Langworth, S., Schutz, A., Ekstrand, J.: Mercury in biological fluids after amalgam removal. J Dent 77, 615–624 (1998).
210. Sandborgh-Englund, G., Nygren, A.T., Ekstrand, J., Elinder, C.G.: No evidence of renal toxicity from amalgam fillings. Am J Physiol 271, R941–R945 (1996).
211. Saxe, S.R., Snowdon, D.A., Wekstein, M.W., Riley, K.P., Greiner, P.A., Markesbery, W.R.: Dental amalgam and cognitive function in older women: findings from the nun study. J Am Dent Assoc 126, 1495–1501 (1995).
212. Saxe, S.R., Wekstein, M.W., Kryscio, R.J., Henry, R.G., Cornett, C.R., Snowdon, D.A., et al.: Alzheimer's disease, dental amalgam and mercury. J Am Dent Assoc 130, 191 (1999).
213. Schedle, A., Franz, A., Rausch-Fan, X.H., Samorapoompichit, P., Boltz-Nitulescu, G., Slavicek, R.: Zellkulturuntersuchungen von zahnärztlichen Werkstoffen: Komposit im Vergleich zu Amalgam. [Cell culture study of dental materials: Composite compared to amalgam] Z Stomatol 6, 39–42 (1994).
214. Schedle, A., Samorapoompichit, P., Rausch-Fan, X.H., Franz, A., Füreder, W., Sperr, W.R., Sperr, W., Ellinger, A., Slavicek, R., Boltz-Nitulescu, G., Valent, P.: Response of L-929 fibroblasts, human gingival fibroblasts, and human tissue mast cells to various metal cations. J Dent Res 74, 1513–1520 (1995).
215. Schmalz, G., Arenholt-Bindslev, D.: Quecksilber-Exposition beim Entfernen von Amalgam-Füllungen. Eine Literaturübersicht. [Mercury exposure during removal of amalgam restorations. A review] Dtsch Zahnärztl Z 50, 870–874 (1995).
216. Schmalz, G., Arenholt-Bindslev, D., Hiller, K.A., Schweikl, H.: Epithelium-fibroblast co-culture for assessing mucosal irritancy of metals used in dentistry. Eur J Oral Sci 105, 86–91 (1997).
217. Schmalz, G., Schmalz, C.: Toxicity tests on dental filling materials. Int Dent J 31, 185–192 (1981).
218. Schulte, A.H.B., Stoll, R., Wittich, M., Pieper, K., Stachniss, V.: Quecksilberkonzentration im Urin von Kindern mit und ohne Amalgamfüllungen. Schweiz Monatsschr Zahnmed 104, 1336–1340 (1994).
219. Schuurs, A.H.B.: Reproductive toxicity of occupational mercury. A review of the literature. J Dent 27, 249–256 (1999).
220. Schuurs, A., Exterkate, R., ten Cate, B.: Biological mercury measurements before and after administration of a chelator (DMPS) and subjective symptoms allegedly due to amalgam. Eur J Oral Sci 108, 511–522 (2000).
221. Shaini, F.J., Wahab, F.K., Ellakwa, A.E., Shortall, A.C.C., Fleming, G.J.P., Marquis, P.M.: Marginal adaptation and micro-porosity of class II restorations of a high copper amalgam and a palladium-free gallium-based alloy. J Oral Rehabil 33, 924–933 (2006).
222. Siblerud, R.L, Kienholz, E.: Evidence that mercury from silver dental fillings may be an etiological factor in multiple sclerosis. Sci Total Environ 142, 191–205 (1994).
223. Sikorski, R., Juszkiewicz, T., Paszkowski, T., Szprengier-Juszkiewicz, T.: Women in dental surgeries: reproductive hazards in occupational exposure to metallic mercury. Int Arch Occup Environ Health 59, 551–557 (1987).
224. Smart, E.R., MacLeod, R.I., Lawrence, C.M.: Resolution of lichen planus following removal of amalgam restorations in patients with proven allergy to mercury salts: a pilot study. Br Dent J 178, 108–112 (1995).
225. Soncini, J.A., Maserejian, N.N., Trachtenberg, F., Tavares, M., Hayes, C.: The longevity of amalgam versus compomer/composite restorations in posterior primary and permanent teeth. Findings from the New England Children's Amalgam Trial. J Am Dent Assoc 138, 763–772 (2007).
226. Sørensen, N., Murata, K., Budtz-Jørgensen, E., Weihe, P., Grandjean, P.: Prenatal methylmercury exposure as a cardiovascular risk factor at seven years of age. Epidemiol 10, 370–375 (1999).
227. Staehle, H.J.: Eine Risikoabschätzung bei Kunststoff-Materialien. [A risk assessment of composite materials] Zahnärztl Mitteil 87, 24–34 (1997).
228. Staines, K.S., Wray, D.: Amalgam associated amalgam-tattoo-related lichenoid lesion. Contact Dermatitis 56, 240–241, (2007).
229. Stenman, S., Grans, L.: Symptoms and differential diagnosis of patients fearing mercury toxicity from amalgam fillings. Scand J Work Environ Health 23, 59–63 (1997).
230. Stoz, F., Aicham, P., Janovic, J., Steuer, W., Mayer, R.: Ist ein generelles Amalgam-Verbot gerechtfertigt? [Is a ban on dental amalgam justified?] Z Geburtsh u Neonat 199, 35–41 (1995).
231. Stoz, F., Aicham, P., Jovanovic, S., Steuer, W., Mayer, R.: Auswirkungen von in der Schwangerschaft neu gelegten Amalgam-Zahnfüllungen auf die Hg-Konzentration bei Mutter und Kind. [The possible influence of amalgam placement during pregnancy on maternal and newborn mercury levels] Zentralbl Gynäkol 117, 45–50 (1995).
232. Sumer, M., Muglali, M., Bodrumlu, E., Guvenc, T.: Reactions of connective tissue to amalgam, intermediate restorative material, mineral trioxide aggregate, and mineral trioxide aggregate mixed with Chlorhexidine. JOE 32, 1094–1096 (2006).
233. Summers, A.O., Wireman, J., Vimy, M.J., Lorscheider, F.L., Marshall, B., Levy, S.B., Bennett, S., Billard, L.: Mercury released from dental "silver" fillings provokes an increase in mercury- and antibiotic-resistant bacteria in oral and intestinal floras of primates. Antimicrob Agents Chemother 37, 825–834 (1993).
234. Swedish Medical Research Council: Potential biological consequences of mercury released from dental amalgam. Swedish Medical Research Council, Stockholm 1992.
235. Takahashi, Y., Thuruta, S., Hasegawa, J., Kameyama, Y., Yshida, M.: Release of mercury from dental amalgam fillings in pregnant rats and distribution of mercury in maternal and fetal tissues. Toxicology 163, 115–126 (2001).
236. Takahashi, Y., Tsuruta, S., Arimoto, M., Tanaka, H., Yoshida, M.: Placental transfer of mercury in pregnant rats which received dental amalgam restorations. Toxicology 185, 23–33 (2003).
237. The European Food Safety Authority (EFSA): EFSA provides risk assessment on mercury in fish: precautionary advice given to vulnerable groups. Press release, 18 Mar 2004.

Dentlearn.ir

238. Thornhill, M.H., Pemberton, M.N., Simmons, R.K., Theaker, E.D.: Amalgam-contact hypersensitivity lesions and oral lichen planus. Oral Surg Oral Med Oral Pathol Oral Radiol Endod 95, 291–299 (2003).
239. Thornhill, M.H., Sankar, V., Xu, X.J., Barrett, A.W., High, A.S., Odell, E.W., Speight, P.M., Farthing, P.M.: The role of histopathological characteristics in distinguishing amalgam-associated oral lichenoid reactions and oral lichen planus. J Oral Pathol Med 35, 233–240 (2006).
240. Tyas, M.H., Ewers, G.J.: Clinical evaluation of three amalgam alloys. Austr Dent J 38, 225–228 (1993).
241. Ulukapi, I.: Mercury hypersensitivity from amalgam: Report of case. J Dent Child 62, 363–364 (1995).
242. Ursinyova, M., Masanova, V.: Cadmium, lead and mercury in human milk from Slovakia. Food Addit Contam 22, 579–589 (2005).
243. U.S. Environmental Protection Agency: Water quality criterion for the protection of human health: methylmercury. U.S. Environmental Protection Agency, Washington, DC 2001.
244. U.S. Food and Drug Administration: CDRH consumer information. Questions and answers on dental amalgam. U.S. Environmental Protection Agency, Washington, DC 2006.
245. Vahter, M., Åkesson, A., Lind, B., Björs, U., Schütz, A., Berglund, M.: Longitudinal study of methylmercury and inorganic mercury in blood and urine of pregnant and lactating women, as well as in umbilical cord blood. Environ Res 84, 186–189 (2000).
246. Vamnes, J.S., Eide, R., Isrenn, R., Hol, P.H., Gjerdet, N.R.: Diagnostic value of a chelating agent in patients with symptoms allegedly caused by amalgam fillings. J Dent Res 79, 868–874 (2000).
247. Van Nieuwenhuysen, J.P., D'Hoore, W., Carvalho, J., Qvist, V.: Long-term evaluation of extensive restorations in permanent teeth. J Dent 31, 395–405 (2003).
248. Veien, N.K.: Stomatitis and systemic dermatitis from mercury in amalgam dental restorations. Dermatol Clin 8, 157–160 (1990).
249. Vimy, M.J., Hooper, D.E., King, W.W., Lorscheider, F.L.: Mercury from maternal "silver" tooth fillings in sheep and human breast milk. A source of neonatal exposure. Biol Trace Elem Res 56, 143–152 (1997).
250. Vimy, M.J., Takahashi, Y., Lorscheider, F.L.: Maternal fetal distribution of mercury ($_{203}$Hg) released from dental amalgam fillings. Am J Physiol 27, R939–R945 (1990).
251. Von Fraunhofer, J.A., Kellney, J.I., DePaola, L.G., Meiller, T.F.: The effect of a mouthrinse containing essential oils of dental restorative materials. Gen Dent 54, 403–407 (2006).
252. Wataha, J.C., Nakajima, H., Hanks, C.T., Okabe, T.: Correlation of cytotoxicity with elemental release from mercury- and gallium-based dental alloys in vitro. Dent Mater 10, 298–303 (1994).
253. Wennberg, M., Lundh, T., Bergdahl, I.A., Hallmans, G., Jansson, J-H., Stegmayr, B., Custodio, H.M., Skerfving, S.: Time trends in burdens of cadmium, lead, and mercury in the population of northern Sweden. Environmental Research 100, 330–338 (2006).
254. Wenstrup, D., Ehmann, W.D., Markesbery, W.R.: Trace element imbalances in isolated subcellular fractions of Alzheimer's disease. Brain Res 533, 125–131 (1990).
255. WHO: Environmental health criteria 118. Inorganic mercury. World Health Organization, Geneva 1991.
256. WHO: Joint FAO/WHO Expert Committee on Food Additives: Summary report of the fifty-third meeting of the Joint FAO/WHO Expert Committee on Food Additives (JECFA), Rome, 1–10 June 1999.
257. WHO: Dental amalgam and alternative direct restorative materials. In: Mjör, I.A., Pakhomov, G.N. (eds): Oral Health Division of Noncommunicable Diseases. World Health Organization, Geneva (1997).
258. Wilhelm, M., Dunninger, P., Ruppel, R., Tony, H.P., Wilms, K., Klaiber, B.: Failure to detect any effect of amalgam restorations on peripheral blood lymphocyte populations. Clin Invest 70, 728–734 (1992).
259. Wilhelm, M., Müller, F., Idel, H.: Biological monitoring of mercury vapor exposure by scalp hair analysis in comparison to blood and urine. Toxicology Letters 88, 221–226 (1996).
260. Willershausen-Zönnchen, B., Zimmermann, M., Defregger, A., Schramel, P., Hamm, G.: Quecksilberkonzentration der Mundschleimhaut bei Patienten mit Amalgamfüllungen. [Mercury concentration in the oral mucosa in patients with amalgam restorations] Dtsch Med Wochenschr 117, 1743–1747 (1992).
261. Wirz, J., Dillena, P., Schmidli, F.: Quecksilbergehalt im Speichel. [Mercury levels in saliva] Quintess Zahnärztl Lit 42, 1161–1165 (1991).
262. Wöhrl, S., Hemmer, W., Focke, M., Götz, M., Jarisch, R.: Oral symptoms due to zinc as a minor component of dental amalgam. Contact Dermatitis 44, 246–263 (2001).
263. Yanagi, T., Shimizu, T., Abe, R., Shimizu, H.: Zinc dental fillings and palmoplantar pustulosis. Lancet 366, 1050 (2005).
264. Youdelis, W.V.: Amalgam as a restorative material: is there anything new? J Esthet Dent 4, 61–63 (1992).
265. Zhang, X., Gelderblom, H.R., Zierold, K., Reichart, P.A.: Morphological findings and energy dispersive X-ray microanalysis of oral amalgam tattoos. Micron 38, 543–548 (2007).
266. Zimmer, H., Ludwig, H., Bader, M., Bailer, J., Eickholz, P., Staehle, H.J., Triebig, G.: Determination of mercury in blood, urine and saliva for the biological monitoring of an exposure from amalgam fillings in a group with self-reported adverse health effects. Int J Hyg Environ Health 205, 205–211 (2002).
267. Åkesson, I., Lundborg, G., Horstmann, V., Skerfving, S.: Neuropathy in female dental personnel exposed to high frequency vibrations. Occup Environ Med 52, 116–123 (1995).

Dentlearn.ir

5 Resin-Based Composites

G. Schmalz

Contents

5.1 Introduction ... 99
5.2 Basic Material Properties ... 99
5.2.1 Composition ... 99
5.2.2 Setting Reaction ... 104
5.2.3 Release of Substances ... 105
5.2.4 Biodegradation of Monomers ... 107
5.3 Systemic Toxicity ... 108
5.3.1 Preclinical Studies ... 108
5.3.2 Estrogenicity ... 108
5.3.3 Clinical Symptoms and Complaints ... 109
5.4 Local Toxicity and Tissue Compatibility ... 110
5.4.1 Cytotoxicity ... 110
5.4.2 Influence on Cell Metabolism ... 112
5.4.3 Antimicrobial Properties ... 112
5.4.4 Implantation Tests ... 114
5.4.5 Pulp Reactions ... 114
5.4.6 Hazards for Eyes ... 120
5.4.7 Inhalation of Resin-Based Composite Particles ... 121
5.4.8 Reactions of Gingiva and Oral Mucosa ... 121
5.5 Allergies ... 121
5.5.1 Prevalence ... 122
5.5.2 Preclinical Studies ... 123
5.5.3 Allergic Reactions in Patients ... 124
5.5.4 Allergic Reactions in Dental Personnel ... 125
5.6 Mutagenicity and Carcinogenicity ... 127
5.7 Public Discussion ... 127
Conclusions for the Dental Practitioner ... 128
Appendix ... 129
References ... 130

5.1 Introduction

Resin-based composites are primarily used as anterior and posterior filling materials. Products with similar composition are also applied as pit and fissure sealants, luting composites (e.g., for luting ceramic and indirect composite restorations), and for crown build-ups and the bonding of brackets and orthodontic bands. Furthermore, resin-based composites are used for temporary crowns and bridges and most recently as root canal sealers. Today, resin-based composites represent one of the most important groups of materials in dental practice. A large number of products are available on the market. Unfortunately, the market life span of some of these products is often limited to a few years, which makes it very difficult to assess their clinical performance. Composite resin monomers are also applied in many nondental areas, including the printing and car industries and as adhesives such as for attaching artificial fingernails [141, 179]. An exposure originating from such nondental applications may cause sensitization; that is, subsequent exposure of the affected person to a dental resin may then cause an allergic reaction.

Resin-based composites are in many cases applied together with certain auxiliary materials, such as acids or adhesives. Because the biological effects of resin-based composites occur despite the various types of use, and because they are very similar and often cannot be differentiated from effects caused by the auxiliary materials, all of these types of substances will be addressed together in this chapter. Furthermore, "compomers" (polyacid-modified resin-based composites) will also be covered in this chapter, as they are chemically closely related to resin-based composites. However, light-curing glass ionomer cements (resin-modified glass ionomers) will be discussed in Chap. 6.

5.2 Basic Material Properties

5.2.1 Composition

Resin-based filling composites are very complex mixtures containing many substances. These are usually classified into the following groups:

- Filler particles
- Matrix resins and corresponding catalyst systems
- Coupling agents between fillers and matrix resins

Dentlearn.ir

The **filler** content of modern hybrid-type resin-based composites usually varies between 60 and 70 volume percent (vol.%), or 70 and 85 weight percent (wt.%). Filler particles mainly consist of finely ground quartz, boron silicate, lithium–aluminum silicate glasses, and highly dispersed amorphous silicon dioxide. Radiodensity is generated by adding special glasses that contain, for instance barium, strontium, or zinc [100, 169, 234, 275]. Particle sizes of modern resin-based composites vary between 0.04 µm (microfiller particles) and 0.6–3.0 µm (macrofiller particles). Recently, so-called nanofiller particles have been added to resin-based composites, with particle sizes from 100 nm down to 5 nm (0.005 µm). Nanoparticles and microfiller particles are used in clusters/complexes (older formulations) or dispersed forms (newer formulation). Classification of resin-based composites is usually based on the type and size of the fillers (Fig. 5.1). Modern fine-particle hybrid-type resin-based composites should contain particles with a size between 0.6 µm and 1 µm, which are combined with microfillers and partly nanofillers/nanofiller complexes. Some resin-based composites contain fluoridated filler particles (for instance, based on YbF_3), which release varying amounts of fluoride depending on the product. Composites with prepolymer fillers are also available. These consist of finely ground filler-containing resin-based composite (prepolymerized). The size and distribution of filler particles are decisive for the physical and mechanical characteristics of resin-based composites. So-called flowable composites reveal an improved flow capacity, which is generally caused by reduced filler content.

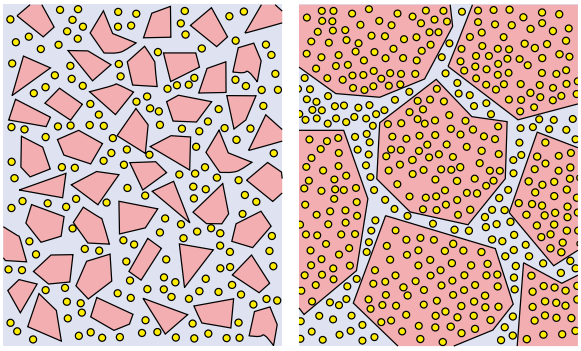

a **b**

Fig. 5.1a,b Schematic composition of a resin-based composite. **a** Fine particle hybrid. **b** Prepolymer filler resin

The **matrix resin** consists of a mixture of various monomers, for example, Bis-GMA and/or UDMA (full names and molecular weights are specified in Table 5.5), as well as various modifications of these molecules (Fig. 5.2). Other ingredients of the composite matrix are comonomers (EGDMA, DEGDMA, TEGDMA) and various additives such as photoinitiators (e.g., camphorquinone), co-initiators (e.g., DMABEE, DEAEMA), inhibitors (e.g., BHT), ultraviolet absorbers, photostabilizers, and pigments [52, 182, 239]. TEGDMA has an important function because it decreases the viscosity of the matrix, thus allowing increased filler content. The addition of antimicrobial and fluoride-containing monomers is intended to reduce or prevent plaque formation on the surface of fillings [107, 181, 221]. More recent resin-based composites (ormocers) are based on a Si–O scaffold with methacrylic side chains, which are necessary for polymerization. Bisphenol A dimethacrylate (Bis-DMA) and ethoxylated Bis-DMA are used as comonomers. So far, no detailed information about these base monomers is available in the literature. Autopolymerizing resin-based composites are applied for buildups.

So-called ring-opening monomers were developed to reduce or overcome the polymerization shrinkage of resin-based composites. Most recently, oxiranes [139] and siloranes [231] (a combination of siloxanes and oxiranes) are being discussed more and more (Fig. 5.2), with a siloran-based product being marketed at present.

Polymerization in products currently used today is mainly initiated by light; the light-sensitive initiator camphorquinone (absorption maximum at a wavelength of 468 nm) acts together with an aliphatic amine-type catalyst. Bleaching resin-based composites may contain the light initiator lucerin (absorption maximum at a wavelength of 380 nm) instead of the yellowish camphorquinone. Newer materials contain acid-stable catalysts instead of amine derivatives. The polymerization reaction in autopolymerizing resin-based composites is started by an aromatic amine/peroxide system, e.g., dimethylparatoluidine (DMP)/benzoyl peroxide.

The **coupling** between filler particles and matrix resin is obtained through trifunctional alcoxy silanes, which are mostly called "silanes" in the literature. Si–OH groups generate the link to the filler surfaces; the unsaturated vinyl or methacryl groups polymerize with base monomers and comonomers. The type of applied

Dentlearn.ir

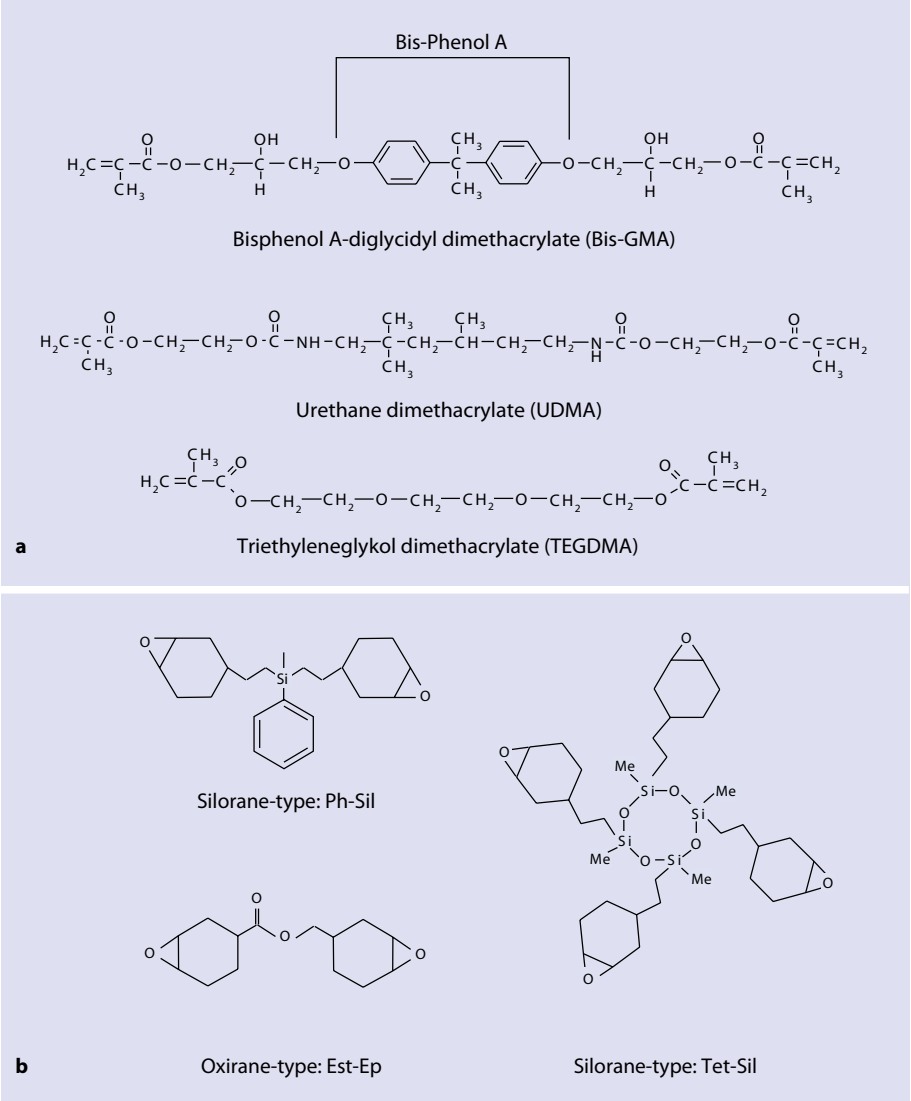

Fig. 5.2a,b Chemical structure of composite resin monomers. **a** Conventional monomers: Bis-GMA, UDMA, TEGDMA. **b** Ring opening monomers: oxiranes [108, 139, 153] and siloranes [231] (chemical names in [231])

silane depends, among other things, on the filler used. Methacrylate is replaced by an epoxy group in silanes that are used for silorane composites (see above).

Pit and fissure sealants have mainly the same composition as filler-containing resin-based composites. However, the filler content is much lower; some products even contain no fillers at all. Fluoride-releasing fillers are added to other products in an attempt to obtain an additional caries-protective effect [252]. Autopolymerizing (aromatic amine/peroxide-initiated) or light-curing (e.g., camphorquinone/aliphatic-amine-initiated) pit and fissure sealants are available. Some sealants are transparent, some are supplied in different colors, others are opaque, and others may appear in a different color under halogen light, which makes them visible.

Luting resin-based composites are used for adhesively fixing indirect composite and ceramic restora-

Dentlearn.ir

tions (partly for metallic restorations, too). The composition of these materials is basically the same as for filling composites; however, some of them contain an autopolymerizing as well as a light-curing initiator system (dual-curing luting resin-based composites). The autopolymerizing component of most products is based on an aromatic amine/peroxide catalyst system. The viscosity of luting resin-based composites is tailored via the filler content. Brackets and orthodontic bands are bonded to the tooth enamel with low-viscous resin-based composites, mainly of the fine-particle hybrid type (see above). Autopolymerizing luting composites are also available. Newer self-adhesive luting composites (so-called self-adhesive resin cements) contain acid monomers with several methacrylate and phosphate groups.

Compomers also consist of filler particles and an organic matrix. Information provided here will refer to the first and widely used product, Dyract, for which the most information is available. The filler (a radiopaque, fluoride-containing silicate glass) comprises approximately 72 wt.% and contains about 13 wt.% fluoride. UDMA is used as base monomer together with a special (acidic) monomer with polymerizable acrylate residues and carboxyl groups (trichlorobenzene). Polymerization is initiated by light irradiation. Additions of cetylamine hydrofluoride are intended to increase fluoride release. The material is applied in combination with an adhesive. Compomers are also used for luting inlays, crowns, and bridges. These materials are autopolymerizing.

Auxiliary substances that are used in combination with resin-based composites are various acids, silanes, and adhesives. Phosphoric acid (30–40%) is widely applied for the acid-etch technique, mainly incorporated in a gel that contains highly dispersed silicon dioxide and polymer particles as thickening agents. These acids are applied on enamel and on dentin, but the application time on dentin is generally shorter than on enamel (the "etch-and-rinse" technique). It has also been reported that 1.37% NaF was added to 37% phosphoric acid used for bonding brackets in an attempt to produce a caries-protective effect [151].

Silicon-dioxide-based dental ceramics used for inlays, partial crowns, and veneers need to be conditioned before adhesive luting. The inner surface of the restoration must be etched first (e.g., with 7.5% hydrofluoric acid or 10% ammonium bifluoride solution) [253]. Then a silan preparation is applied to the etched ceramic surface to generate a chemical bond between the resin matrix of the luting resin-based composite and the ceramic. Ceramics based on aluminium oxide and zirconium oxide are not etched but are only treated with a silan preparation (see also Chap. 6).

Adhesives consist of methacrylates (e.g., 2-hydroxymethyl-methacrylate, or HEMA, and 4-methacryl-oxyethyl-trimellitic-anhydride, or 4-META), dimethacrylates (e.g., TEGDMA), phosphonated penta-acryl esters, acryl amides, aldehydes (e.g., glutaraldehyde), and organic acids [266]. Bis-DMA may be also used as component. Solvents are ethanol, acetone, or water. Some adhesives contain fillers, e.g., nanofillers. Recently, an adhesive containing an antimicrobial monomer (MDPB) has been marketed. This molecule consists of an antimicrobial group (pyridinium bromide) linked through a spacer of 12 C-groups to a methacrylate group [107].

The first step in (dentin) adhesion is the chemical conditioning of the surface, whereby the smear layer will be completely (Fig. 5.3) or partially (Fig. 5.4) removed [267]. In general, inorganic acids (e.g., phosphoric acid) or organic acids (e.g., 10% maleic acid) are used in this process.

Exposed dentinal collagen bundles may be additionally stabilized by glutaraldehyde. Hydrophilic monomers, such as HEMA and/or TEGDMA, may diffuse into this zone and form a hybrid layer (see Figs. 5.3 and 5.4). Subsequently, the hydrophobic resin monomer will polymerize and bond to this hybrid layer. Tags are generated by a deeper diffusion of polymerizing components of an adhesive into dentin tubules. Fluoride may be part of primers (e.g., NaF) as well as bonding monomers (e.g., boron–fluoride fillers) [172].

Self-etching monomers have been introduced to combine the conditioning step with the hydrophilic monomer infiltration step (priming). The demineralization of dental hard tissues is limited to the area of monomer infiltration. Mild self-etching monomers with a pH of 2.0 (e.g., DMP) or strong self-etching preparation with a pH of 0.8 (Adper Prompt L-Pop) are available today. Some products combine all substances used for adhesion in one container (one-bottle system; see Fig. 5.5) [268]. The main problem with these products is the hydrolytic stability of the monomers under acidic conditions. Different amino acids have been incorporated into acrylates (acrylamide-based monomers) [162, 262], which are also interesting from a biological point of view [37].

Dentlearn.ir



Fig. 5.3 Morphology of the interface between an adhesive (All-Bond 2) and dentin after removal of the smear layer. *T* tags, *HS* hybrid layer, *K* matrix resin and resin-based composite

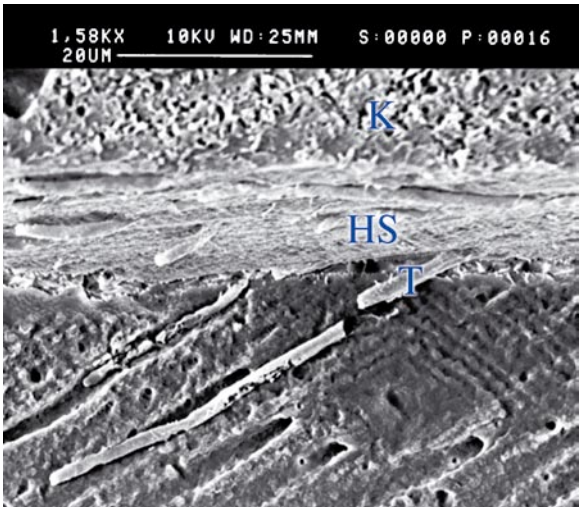

Fig. 5.4 Morphology of the interface between adhesive (Prime & Bond) and dentin after modification of the smear layer. *T* tags, *HS* hybrid layer, *K* composite



Fig. 5.5 Morphology of the interface between adhesive and dentin after application of a one-step/one-bottle system. The hybrid layer (*HS*) and the generated tags (*T*) are clearly visible, but there is no separate layer of matrix resin [119]

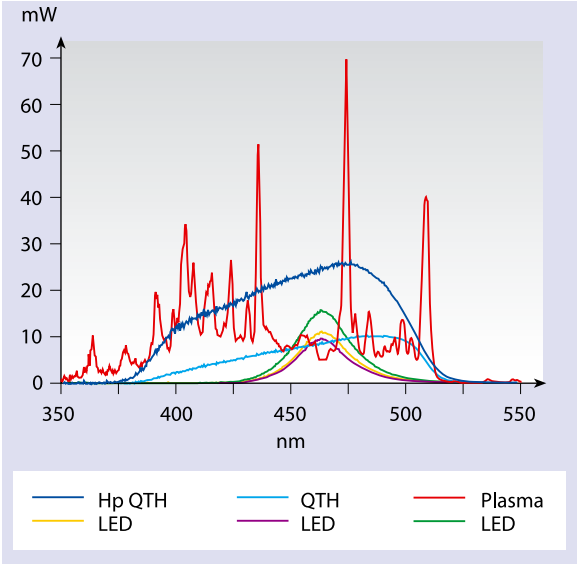

Fig. 5.6 Emission spectra of various light polymerization devices for resin-based composites (see Table 5.1). *Hp* high power, e.g., Astralis 10; QTH Quartz-tungsten halogen

Light-curing units are needed for polymerizing most resin-based composites. Most devices emit light with a wavelength between 400 and 500 nm according to the light initiators used (mostly camphorquinone). Quartz–tungsten halogen (QTH) light-curing units, which were the standard curing unit for many years, are now being replaced more and more by light-emitting diode (LED) devices. LED curing units emit light within a very narrow range of wavelength (Fig. 5.6). Between 10% and 15% of the energy is transformed into light energy by modern LED curing units, whereas for the QTH units, this is only 0.7%. Table 5.1 summarizes the various types of light-curing units that are presently available.

Dentlearn.ir

Table 5.1 Different polymerization lamps and their light intensity (manufacturers' information)

Type of light	Device/producer	Light intensity
LED	Bluephase/Ivoclar Vivadent Smartelite PS/Dentsply De Trey Translux Power Blue/Heraeus Kulzer Elipar Free Light II/3M Espe LE Demetron 1/Kerr Hawe	1,200 mW/cm² 950 mW/ cm² up to 1,000 mW/cm² 1,200 mW/cm² 1,000 mW/cm²
Quartz-tungsten halogen	Optilux 501/Kerr Hawe Translux CL/Heraeus Kulzer Elipar 2500/3M ESPE	1,000 mW/cm² 650 mW/cm² 800 mW/cm²
Plasma	ADT 1000 PAC/ADT Apollo 95 E/DMDS	1,200 mW/cm² 1,370 mW/cm²

5.2.2 Setting Reaction

Resin-based composites set through a polymerization of matrix monomers by opening the double bonds at both methacrylate residues of the monomers, thus generating an additive cross-linking (radical chain polymerization). Epoxides (oxiranes, siloranes) set via an opening of the epoxy ring and the formation of ether bonds (cationic polymerization).

The polymerization of resin-based composites will be either chemically initiated or, more frequently today, cured by light initiation (light-curing composites). The number of double bonds that are opened during this process and then participate in the polymerization process is called the **conversion rate**. For resin-based composites, this rate varies between 35% and 77% [5, 7, 27, 51–53]. The conversion rate of light-curing resin-based composites depends on a sufficient external light supply and on the color of the material [23]. The limited penetration depth of the light into the resin-based composite plays a decisive role. At a depth of 2 mm, the initial light intensity is reduced by 10–100 times [182]. Thus, far more than 20% of the initial double bonds are still present in the set resin. The clinical significance of such an incomplete polymerization has not yet been fully clarified. However, the studies of Pearson and Longman revealed that a shorter irradiation time (and thus a reduced conversion rate) will cause an increased solubility of the resin-based composite [178].

In connection with plasma arc curing units, some manufacturers have recommended very short irradiation periods, which may partly result in incomplete setting of the resin and increased release of residual monomers [98, 156, 248]. In addition, the surface of resin-based composites (based on acrylates) may reveal a pronounced inhibition of the polymerization if oxygen is in contact with the resin surface during the setting reaction. In these cases, conversion rates of only 25% have been documented (this is termed an "oxygen inhibition layer"). An increased solubility of this superficial layer will, of course, also influence the biological properties of the material.

The **eluable residual monomer** content must be differentiated from the conversion rate. Residual monomers are those components that are released from the resin into various extraction media: hydrophilic (e.g., physiological saline solution), hydrophobic (e.g., DMSO, ethanol), or mixed (e.g., 75% ethanol and 25% water). Ferracane reported a weak correlation between conversion rates and eluted residual monomers if water was used as extraction medium. A better correlation was found if an ethanol–water mixture was applied [51]. Tanaka et al. [254] found a good correlation between conversion rate and the release of TEGDMA and Bis-GMA into an aqueous medium. Approximately one-tenth of the nonreacted methacrylate groups exist as residual monomers [51].

Dentlearn.ir

Key Note

Resin-based composites release residual monomers (and other substances) because of a conversion rate of 35–77%. Released compounds can **directly** cause biological reactions. Polymerization shrinkage is a material property that may **indirectly** influence the tissue compatibility (Fig. 5.7). This volume change may cause marginal gaps that may allow penetration of bacteria with subsequent pulpitis. Shrinkage of modern filling resins generally ranges between 2 vol.% and 3 vol.% [181].

It has been speculated that resin-based composite fillings in large mesio-occlusodistal (MOD) cavities may generate an inwardly directed bending of cusps due to high polymerization shrinkage (see above), with subsequent postoperative pain [232]. Oxirane-based or silorane-based resin-based composites have a significantly lower shrinkage (approximately 0.8 vol.%) [273].

Setting of compomers is primarily caused by a polymerization, whereas the acid-base reaction of the carboxyl group, including components of the glass fillers, is of only secondary importance. Thus, the contribution of this acid-base reaction to the entire setting is considered minor (no setting of compomers in the dark!).

Fig. 5.7 Cervical filling after 6 years of clinical service. Due to an insufficient adhesion and pronounced polymerization shrinkage of the resin-based composite, a gap has been formed in contact with dentine, an initial caries is visible

Resin-based luting composites (dual-curing) reveal a setting reaction in the dark in addition to light polymerization. This means that these materials will set without light irradiation. But under these circumstances, only a "chemical" polymerization will take place in those areas where the mobility of molecules is not decisively or at least partially restricted by light polymerization. The conversion rate of resin-based luting composites varies significantly depending on the product. If only autopolymerization occurs (setting reaction in the dark), then the conversion rate will not be as high as with an additional light polymerization. The conversion rate of some products without light polymerization will be up to 45% lower [196]. Therefore, sufficient light irradiation is necessary even for dual-curing resins in order to guarantee adequate polymerization [20].

Self-adhesive resin-based luting composites ("universal cements"), which are recent to the market, may be used with and without light activation. These products set by a polymerization of acidic monomers, but at the same time, a setting reaction between the acid residues and the alkaline filler particles in the originally hydrophilic matrix will take place, which is subsequently converted into a hydrophobic matrix. Other luting resins that are solely chemically curing will set when oxygen access is blocked. Detailed information about the setting reaction of those luting composites is not available in the literature.

5.2.3 Release of Substances

The **amount of substances** that can be released from resin-based composites is naturally dependent on the extraction medium [63]. According to different reports, between 0.4 wt.% and 1.5 wt.% Bis-GMA or 4.6–11 wt.% of the original weight of all organic substances is extractable with organic solvents (e.g., tetrahydrofurane, ethanol) [63, 113]. Comonomers, such as TEGDMA, were identified in comparably higher amounts (0.04–2.3 wt.%) [239]. Significantly less Bis-GMA leaches into aqueous extraction media (0.03–0.07 wt.%) [113], but higher quantities of more "hydrophilic" monomers do, such as TEGDMA (up to

Dentlearn.ir

0.4 wt.%) [239]. Taken together, approximately 2 wt.% of the organic matrix is elutable by aqueous media [53]. It was observed that, in general, very many substances are released from the resin matrix, regardless of the composite or the extraction medium. The amount of these leachable substances declines asymptotically over time (Fig. 5.8).

The liberated quantity of substances from filler particles remained constant over a period of 6 months, in contrast to the resin matrix [63]. Altogether, quartz fillers release fewer substances than glass fillers do, which contain barium [234, 235]. No information is so far available on the release of nanoparticles from resin-based composites during filling placement, contouring, or polishing and during its in-use phase. Considerations of health effects of nanoparticles are gaining increasing interest in toxicology. Inhalation and resorption via dermal routes have been the primary focus of discussion [263].

The **composition of the eluates** depends on the composition of the resin-based composite and the extraction medium. One study found that 34 individual compounds were released from four different resin-based composites [239]. The same substances were segregated from the unpolymerized as well as from polymerized resin matrix (solvent: methanol), e.g., Bis-GMA, Bis-EMA, UDMA, TEGDMA, EGDMA, and methylmethacrylate (MMA) [239]. TEGDMA generally represented the major share of the segregated substances (see Appendix Table 5.5) [74]. From filler particles, silicon, boron, sodium, and barium can leach into water, depending on the filler type [169].

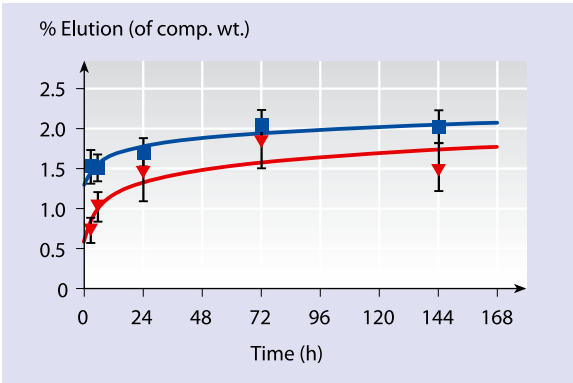

Fig. 5.8 Cumulative release of components from a resin-based composite in percentage of the weight of the composite specimen. ▼ In water, ■ In a mixture of 75% ethanol and 25% water [51, 52]

Formaldehyde is released from resin-based composites into water under certain circumstances. It was observed that a particularly high concentration was generated if the superficial oxygen-inhibited surface layer on the resin-based composite was not removed [170]. Even 115 days after polymerization, formaldehyde was identified in the extract of resin-based composites [170]. This also applies to light-curing glass ionomer cements [197]. Formaldehyde is very likely generated by an oxidation of unsaturated methacrylate groups, such as during polymerization or/and as a degradation product of the oxygen-inhibited surface layer (or oxygen-methacrylate polymer) [170].

Bisphenol A (BPA) was found in the extract of one pit and fissure sealant and in saliva in contact with resin-based composites [165]. A subsequent study by the same researchers basically confirmed these results [185]. However, these investigations have been criticized by other authors, primarily due to methodological problems of the applied analytical technique [65, 74, 104, 159]. Imai et al. found only trace amounts of BPA in unpolymerized resin-based composites [106]. Even if resin-based composites were deliberately contaminated with BPA, only extremely low quantities of this substance were released [106]. Wada et al. also found no BPA release after testing 24 different resin-based composite products [269]. Other authors found TEGDMA and minute amounts of Bis-GMA in Bis-GMA/TEGDMA-based pit and fissure sealants after extraction with distilled water [74] or ethanol [159], but no BPA was identified. Also for orthodontic adhesives, no BPA could be detected in the extraction medium (99% v/v alcohol) with a detection limit of 0.1 ppm [43]. Acetonitrile extraction of 28 resin-based composites and dental sealants showed no BPA, with the exeption of a Bis-DMA-containing sealant [145]. Minute amounts of BPA were detected after placement of UDMA-based and Bis-GMA-based composite fillings [202]. However, this technique may even overestimate the BPA amount because of the limited specificity of the antibody used [111].

Our own investigations with pit and fissure sealants revealed that only a material containing Bis-DMA released BPA into saliva immediately after application, but in much smaller amounts than in the report cited above [6, 165]. These data were confirmed by Fung et al., who analyzed the saliva and blood samples of a larger patient population [60]; even when small amount of BPA was present in saliva immediately after placement of the sealant, it could not be detected in the blood samples (detection limit 5 ppb). Similar

Dentlearn.ir

experiments were done by Joskow et al. [118] with a more sensitive analytical method. A Bis-GMA-based pit and fissure sealant that contained no primary BPA contamination released no BPA into saliva [6]. It was possible, in vitro, to cleave Bis-DMA hydrolytically or enzymatically, thus detecting BPA [216]. But no BPA could be separated from Bis-GMA-based pit and fissure sealants by means of a chemical or enzymatic hydrolysis [216]. This was confirmed by experiments exposing Bis-GMA to an enzyme mix from stimulated rat livers [138]. Obviously, Bis-DMA is initially eluted from Bis-DMA-based pit and fissure sealants [159] and is then degraded to BPA in saliva [216].

Fluoride is released from fluoride-containing resin-based composites and compomers depending on the product, but it is also partly incorporated into the adjacent tooth substance [131]. However, the released quantity dramatically decreases after a 24-h elution, and the total segregated amount is altogether smaller than from conventional or light-curable glass ionomer cements [131, 265]. A caries-prophylactic effect is also expected based on the liberation of calcium and hydroxyl ions due to the addition of adequate glasses. However, the clinical caries-prophylactic benefit due to the release of these ions from resin-based composites and compomers is controversial.

Adhesives can also hydrolytically degrade over time [74, 101], which will result in decreased adhesion. The hybrid layer consisting, among others, of collagen and resin may degrade due to collagen degradation via endogenous matrix metalloproteinases (MMP), a group of zinc- and calcium-dependent endopeptidases [89, 259]. Liquid can come into contact with the adhesive via dentin tubules. Additionally, diffusion of small ions or molecules is possible through nanoleakage areas, which occur within the hybrid layer and which can be shown by silver stain (Fig. 5.9) [259]. Single-bottle systems (all-in-one adhesives) contain water as solvent. These may act as semipermeable membranes, being penetrable for water, which may probably promote degradation. Contact of adhesives with dentin fluid beneath the tags may generate small resin particles in the dentin tubules (Fig. 5.10), which have even been identified in primary dentin and in the odontoblast layer of the pulp [32, 258]. Those resin particles were also identified in the pulp [72].

5.2.4 Biodegradation of Monomers

Little information is available regarding uptake, distribution, metabolism, and excretion of substances released from resin-based composites. Biodegradation of these substances has been studied in vitro in enzyme mixtures and whole-animal experiments. Enzymes such as choline esterases (a group of esterases that hydrolyze choline ester at a higher rate than other esterases [54]) have been used for in vitro studies. These esterases have been shown to hydrolyze Bis-GMA to bis-(2,3-dihydroxypropyl) ether (BADPE-4OH) by the



Fig. 5.9 Nanoleakage. The silver staining (here in *white*) indicates a gap (*arrow*) in the hybrid layer and towards the dentin (Courtesy of T. Pioch, Heidelberg, Germany)

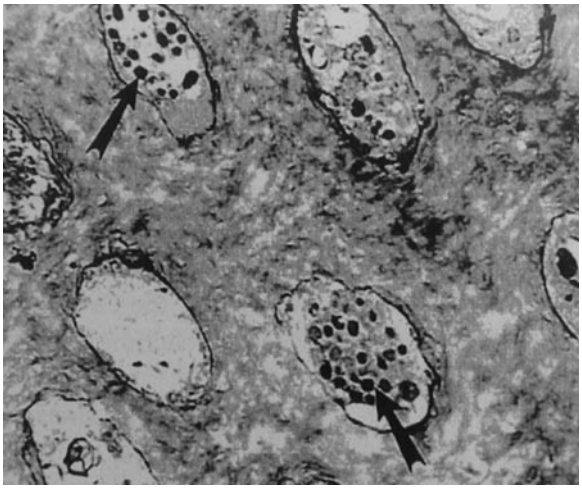

Fig. 5.10 Resin globules in dentine tubules (*arrows*) [32] (Courtesy of C. A. De Souza Costa, Araraquara, São Paulo, Brazil)

Dentlearn.ir

loss of two molecules of methacrylic acid [55, 201]. However, biodegradation also depends on the molecular chemistry. It was shown that chemically modified Bis-GMA (e.g., ethoxylated Bis-GMA) degrades under the abovementioned conditions to a lesser degree [54]. The same enzyme converted TEGDMA into triethylene glycole and methacrylic acid [277]. If TEGDMA is mixed with an enzyme mixture from stimulated rat livers (S-9 mixture), biological activity changes, and it is also assumed that TEGDMA is cleaved into triethylene glycole and methacrylic acid [231]. It was also shown that HEMA hydrolyzes under acidic conditions into thylene glycole and methacrylic acid [162]. EGDMA, which is also used as comonomer in resin-based composites, may be metabolized to HEMA, and one of these may be present as an impurity in the other [69].

Recently, data from animal studies have been presented concerning biodegradation of HEMA/TEGDMA [188–192]. Both "water-soluble" substances are used in a variety of resin-based composites (TEGDMA) and adhesives (HEMA/TEGDMA) and thus are released from materials. Swallowed HEMA/TEGDMA was almost completely absorbed by the organism. The substances were primarily excreted through the lungs via CO_2 [188, 189]. Further investigations are necessary to clarify these substances' metabolism as well as the clinical significance of these data.

Key Note

The degradation pathway of HEMA/TEGDMA to CO_2 has not yet been completely clarified. TEGDMA is either degraded to CO_2 analogous to valine or malate, or, via the formation of intracellular and biologically highly active epoxides, to pyruvate and subsequently to CO_2 [190–192].

5.3 Systemic Toxicity

5.3.1 Preclinical Studies

Acute systemic toxicity was determined by means of LD_{50} (the calculated dose of a chemical substance that kills 50% of the experimental population; see Chap. 2). Results show (see Table 5.2) that base monomers and comonomers with an LD_{50} of >2,000 mg/kg body weight cannot be classified as toxic (see Chap. 2). In addition, these data refer to the pure monomers, whereas the amounts of substances released from the polymerized materials are very low. Thus, an acute toxic reaction cannot be expected based on current knowledge.

No data are available in the dental literature regarding the systemic toxicity of adhesives, resin-based luting composites, or adhesive resins for bonding orthodontic brackets. It should be critically emphasized at this point that the manufacturers of these materials possess comprehensive test data, but these are not published as scientific studies for public access due to a variety of reasons [251].

5.3.2 Estrogenicity

It is well-known from environmental sciences that some chemical substances generate an estrogen-like biological reaction by binding to estrogen receptors of relevant cells at "subtoxic" concentrations (endocrine disruptors). Bisphenol A (BPA) is one of these compounds. BPA is used in the production of several types of resins used in a variety of products, including food and drink containers, CDs, DVDs, and as a protective lining in metal food and drink containers. This environmental exposure may be responsible for the low

Table 5.2 Systemic toxicity of base monomers and comonomers used in resin-based composites; substances were applied orally [16, 35, 222, 233, 240]

Substance	LD_{50} [a] [mg/kg (rats)]
Bis-GMA	> 5,000
UDMA	> 5,000
TEGDMA	10,837
Bisphenol A	3,250
Glycidylmethacrylate	597
Methylmethacrylate	8,000
HEMA	5,888
Maleic acid	708
Phosphoric acid	1,530
Glutaraldehyde	600

[a] Median lethal dose; the calculated dose of a chemical substance that causes death of 50% of the experimental population

Dentlearn.ir

but measurable BPA urine concentration in the general population [118]. BPA is also a component of a variety of molecules that are present in resin-based composites, including pit and fissure sealants. Because of its widespread use, its safety has attracted the attention of national (e.g., the U.S. National Institute of Environmental Health Sciences in 2007) and international (the European Commission in 2003) agencies [48, 112]. As already mentioned, BPA can be released from resin-based composites under certain circumstances. One study postulated that a specific brand of pit and fissure sealants releases BPA at concentrations that may trigger estrogenic reactions in cell cultures. Thus, caution should be exercised if pit and fissure sealants are applied. One filling material based on ormocer technology also caused an estrogenic effect in vitro [271].

Based on the aforementioned investigations, the estrogenic behavior of BPA, Bis-GMA, Bis-DMA, and other related molecules was intensely investigated in cell culture systems [60, 87, 145, 161, 256]. All of these studies showed consistently that BPA, Bis-DMA, and Bis-DMA-containing pit and fissure sealants caused estrogen-like effects. But these effects were generally much smaller than those reactions caused by the control substance, estradiol. This is in accordance with our own experiments, which revealed that Bis-DMA can be cleaved into BPA by enzymes. These enzymes may also be present in saliva [6, 216]. All of these in vitro investigations showed that Bis-GMA does not behave in an estrogen-like manner [60, 87, 161, 256], which is also true for the Bis-GMA degradation product BADPE-4OH [138].

However, another in vitro study showed that out of 24 different resin-based composite product eluates, six extracts were estrogenic, but no BPA was found in the eluate (cell culture medium). It was suggested that an initiator (2,2-dimethoxyphenylactetophenone, or DMPA) and a photostabilizer (2-hydroxy-4-methoxybenzophenone, or HMBP) might be responsible for this effect. However, the authors concluded that the relevant concentrations could only be present shortly after setting, and thus the clinical relevance of the results remained unclear [269].

In vivo studies with ovariectomized mice showed that Bis-GMA at a concentration of 25 μg/kg body weight caused no significant changes in uterine normalized weights. A slight increase in the connective tissue was observed at a concentration of 100 μg/kg body weight, but no increase in cell number was generated. The authors concluded from their investigations that, despite a very high dose, the measured effects were very low compared with estradiol. They also hypothesized that contaminations might play a certain role. Taken together, no risk could be linked to the use of pit and fissure sealants based on Bis-GMA. Data regarding long-term application are not available, however [149, 236].

Studies of patients who were treated with a Bis-DMA-based pit and fissure sealant indicated, only directly after application, a very minor estrogen-like effect of the sampled saliva in an extremely highly sensitive in vitro system. After 1 h after application, this effect was no longer detectable. A Bis-GMA-based pit and fissure sealant revealed no estrogen-like effect [4]. These investigations and calculations of released substances based on "worst-case conditions" as well as comparison with those amounts of estrogenic substances that are consumed daily in the diet show that BPA may leach from Bis-DMA-based pit and fissure sealants. However, the doses were so minute that no clinically relevant estrogen-like effect is expected in patients. Bis-GMA-based materials that contain no BPA or Bis-DMA contaminants will not cause estrogenic effects on patients under physiologic conditions.

Key Note

The cited studies show that, based on present knowledge, use of Bis-GMA-based (and Bis-DMA-free) pit and fissure sealants and resin-based composites will not cause a clinically relevant estrogen-like effect on patients. Thus, the postulated estrogen-like effect is no reason to restrict indications for these resin-based materials.

5.3.3 Clinical Symptoms and Complaints

A summary of diseases that supposedly have been successfully treated by the removal of composite fillings after "electroacupuncture according to Voll" (EAV) [201] is shown in Table 5.3. EAV testing, however, is not a scientifically approved method (see Chap. 2). However, the compilation should point out that patients have linked a number of very unspecific symptoms (psychosomatic symptoms or so-called disturbed existential orientation) to resin-based composites.

Interestingly, these allegations are similar to the complaints associated with claimed adverse effects due to amalgam (see Chap. 4) and dental alloys (see Chap. 8) [242]. A great variety of other chemicals in

Dentlearn.ir

daily life, such as dyes, varnishes, mothballs, glues, etc., are also blamed for similar unspecific symptoms (this may be termed "multiple chemical sensitivity syndrome"), but the toxicological background is also being questioned [140, 245].

The frequency of patients' claims that systemic adverse effects are caused by nonamalgam materials (primarily resin-based composites) has increased in the past few years in Norway, according to Gjerdet and Askevold [67] (Fig. 5.11). The number of patients who referred their complaints to amalgam decreased in the same period of time. Simultaneous to this tendency in Norway, the use of amalgam decreased, whereas resin-based composites were applied more frequently.

Key Note

Claims of patients who link their unspecific symptoms to dental materials are very difficult to verify. Psychological/psychiatric causes are also described in the literature. The frequency of complaints obviously correlates with the frequency of application of the specific materials in a population. The general strategy for treating these patients is equivalent to that of treating patients who associate other materials, such as amalgam or alloys, with their complaints.

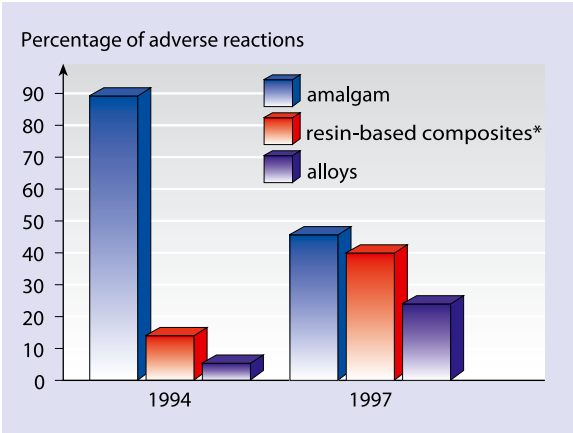

Fig. 5.11 Development of the frequency of adverse effects to various materials in Norway between 1994 and 1997 [67] (* all plastic filling materials except amalgam, but primarily resin-based composites)

5.4 Local Toxicity and Tissue Compatibility

5.4.1 Cytotoxicity

Comprehensive data based on cell culture experiments are available for base monomers of resin-based composites, comonomers, and catalyst systems [64, 79, 187]. The cytotoxicity of base monomers, expressed by the TC_{50} (the concentration that causes a 50% reduction of metabolism or cell death) is different for each individual substance. Very low concentrations may partly cause a biological reaction (see Table 5.4). Interestingly, bifunctional monomers (i.e., having two methacrylate groups) were generally more toxic than monofunctional monomers.

Resin-based composites are cytotoxic before polymerization and immediately thereafter (Fig. 5.12), whereas almost no reaction is caused by set specimens [120, 205, 208]. This applies also to compomers [206]. Composite samples whose superficial oxygen-inhibited and unpolymerized monomeric surface layer was not removed were more toxic than specimens without this layer after mechanical removal [210].

Table 5.3 Complaints associated with resin-based composite fillings after electroacupuncture according to Voll (EAV) testing [244]

Amenorrhea	Migraine
Basalioma	Fatigue
Bronchitis	Nephritis
Chronic sinusitis	Neurodermatitis
Depression	Polyarthritis
Joint diseases	Rheumatism
Cardiac arrhythmia	Insomnia
Hypertension	Tenesmus
Iridocyclitis	Tinnitus
Disturbances of concentration	Urethrocystitis
Headache	Vaginitis
Coxitis	Cystitis
Physical inefficiency	

Dentlearn.ir

In addition, cytotoxicity also depends on the degree of polymerization (conversion rate) [23]. Resin-based composite samples were significantly more toxic after a short polymerization time (15 s) compared with specimens that were exposed to longer irradiation times of 30 s and 60 s [23]. Cytotoxicity also depends on the basic chemistry of the resin matrix: Ormocer-based and silorane-based resin-based composites have proved less toxic in tests than methacrylate-based materials [215, 271]. Filler content influences cytotoxicity, too. For instance, flowable resin-based composites were significantly more cytotoxic over a longer period of time compared with similar materials with regular filler content [272].

Adhesives were also investigated in various cytotoxicity tests. It was found that these materials were differently toxic in contact with various cell types (e.g., mouse fibroblasts or pulp fibroblasts) depending on the product [86]. But in most cases, pronounced cell toxicity was observed [25, 36, 134, 135, 168]. When dentin was placed between the test substance and target cells, the effective concentration of some toxic substances leaching from adhesives decreased at the target cells [80]. Relatively hydrophilic substances, such as HEMA and TEGDMA, diffuse through dentin, specifically in the case of a thin dentin layer [17, 18]. The concentration of these compounds at the target cells was found to be so high that damage of pulp cells might be possible in vivo [17]. A glutaraldehyde-containing adhesive provoked a more pronounced reaction compared with products without glutaraldehyde and adhesives with a low pH (self-etching adhesives) [61]. An adhesive with a low pH caused only a cell reaction when placed on a dentin layer with a thickness of approximately 100 µm [61]. It remains to be questioned whether the cytotoxic effect of glutaraldehyde declines during the passage through dentin, as the antimicrobial effect is enhanced during diffusion through dentin [46]. Further studies are necessary.

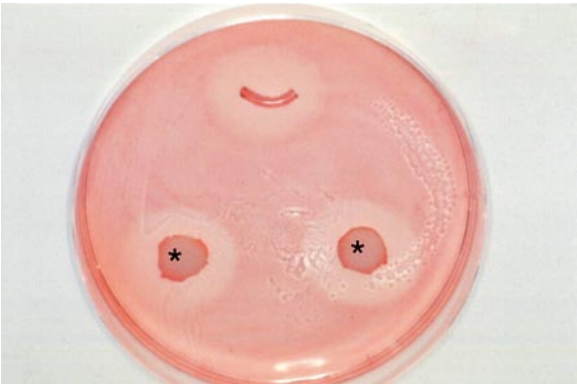

Fig. 5.12 Cell culture test with resin-based composite: The material is moderately toxic shortly after polymerization, which is indicated by the decolorized zone (= cell death) around the test material (*asterisk*)

Table 5.4 Cytotoxicity of base monomers, comonomers, and initiators used in resin-based composites in mouse fibroblasts [79, 187]

Substance	TC_{50}[a]
Bisglycidylmethacrylate (Bis-GMA)	9.35 µM
Urethandimethacrylate (UDMA)	17.4 µM
Triethyleneglycoldimethacrylate (TEGDMA)	124.5 µM
Camphorquinone	235 µM
N,N dihydroxyethyl-*p*-toluidine (DHEpT)	760 µM
Bisglycidylether of bisphenol A (BGE-BPA)	14 µM
Ethoxylated bisphenol A dimethacrylate (E-BPA)	3 µM
Bisphenol A (BPA)	28 µM
Glycidylmethacrylate (GMA)	48 µM
1,6 hexanedioldimethacrylate (HDDM)	28 µM
2-hydroxyethylmethacrylate (HEMA)	3600 µM

[a]Median toxic concentration; calculated concentration of a chemical substance, either dissolved or air, that causes an expected 50% reduction of a specific biological function in a defined experimental group exposed to the substance for specific period of time

Key Note

Taken together, cytotoxicity tests show that cytotoxic substances leach from resin-based composites and auxiliary materials, particularly when unset or shortly after polymerization [239]. Comparing studies between amalgam and resin-based composites using equivalent test systems revealed a similar cytotoxicity pattern for both groups of materials [205, 208]. Therefore, it is necessary to investigate possible damage of adequate target cells on patients and operator (pulp, oral mucosa, gingiva, skin) in consecutive studies.

Dentlearn.ir

5.4.2 Influence on Cell Metabolism

Composite resin eluates/monomers may cause cytotoxic reactions and, as will be shown later, allergic reactions, as well as alterations of the genome (mutagenicity). Therefore, it can be concluded that composite resin eluates/monomers may interfere with cell metabolism at nonlethal concentrations. Several ways for such an interference will be delineated in the next paragraph, and Fig. 5.13 provides an overview.

A key molecule in handling nonenzymatic detoxification of substances in the cells is the tripeptid glutathione (GSH). It is, among others, responsible for maintaining the redox balance in the cell. It was shown that 2–6 h after different cells (gingival fibroblasts and pulp fibroblasts) were exposed to HEMA or TEGDMA, the GSH level decreased, indicating GSH depletion, but the level of GSSH (i.e., oxidized GSH) did not increase [44, 45, 246]. Thus, the depletion of GSH was apparently not due to its "consumption" in maintaining the redox balance of the cells (in that case, the GSSH concentration would have increased), but rather to a direct interaction of GSH with the monomers. As a consequence, the intracellular level of reactive oxygen species (ROS; H_2O_2, superoxide anion, OH radical) increased after exposure to HEMA, TEGDMA, or composite resin eluates [26, 238, 246]. However, camphorquinone, after irradiation with blue light used for resin-based composite curing, directly increased intracellular and extracellular ROS concentration [142].

As a consequence of increased intracellular ROS (i.e., redox imbalance), **DNA damage** via oxidation of DNA bases resulting in single-strand or double-strand breaks has been observed [1], and DNA damage (TEGDMA) and chromosome alteration such as the formation of micronuclei (TEGDMA, HEMA) have also been described [225]. As was expected, (ROS-associated) DNA damage also led to a cell cycle delay in order to give the cell the necessary time to repair DNA damages. Relevant signal molecules for cell cycle delay and DNA repair (e.g., ATM) were activated [223–225]. If DNA damage cannot be repaired, cells will undergo **apoptosis** (programmed cell death) [148]. Apparently, a functioning p-53 (tumor suppressor protein) prevents mutation to occur [1].

An increased ROS level after HEMA, TEGDMA, or composite resin eluate exposure leads to apoptosis [11, 148, 186, 238]. This may, for instance, be a consequence of cell cycle arrest (see above) or of an activation of the mitochondria-associated caspase-9 pathway by activation of relevant procaspases [225]. Methacrylates may interfere with cellular cholesterol and phospholipids [24] and thus alter membrane-related functions. Mitochondrial damage was demonstrated after exposure to TEGDMA [143]. Apoptosis, however, also occurred independent of ROS [238].

Nuclear factor kappa B (NFκB), a key regulator for **immunologic reactions** including inflammation and regeneration, was upregulated by HEMA in primary skin fibroblasts [238]. This is in line with the observation that expression of proinflammatory mediators such as interleukin (IL)-6, IL-8, and prostaglandin E2 (PGE2) by epithelial and hematopoetic cells is influenced by TEGDMA exposure [163, 221]. Also, blocking (PI-3-kinase) and activating mitogen-activated protein (MAP)-kinase pathways by TEGDMA increased the NFkB level [238]. Increased NFkB levels seem to block apoptosis. MAP-kinases [198] are also influenced by TEGDMA and HEMA, and they are involved in tissue regeneration and cell differentiation, for example, by influencing RUNX-2, a key regulator for hard tissue formation. As a consequence, gene expression for biomineralization is down regulated in pulp cells after TEGDMA exposure.

Key Note

Composite resin eluates/monomers influence a number of key regulators of cell metabolism. Redox imbalance apparently plays a major role. Many aspects are yet unknown, and some data are even contradictory. But they show that cell function is influenced by these substances in concentrations occurring in vivo, for instance, after application of an adhesive on the dental pulp or in very deep cavities [225]. Therefore, traditional concepts that relate adverse effects of resin-based composites and dental adhesives mainly to inflammation of adjacent tissues (e.g., pulpitis) or to allergic reactions (e.g., allergic contact dermatitis) should be expanded: These substances also may interfere with immune reactions, wound healing, and cell differentiation and regeneration (for example, resulting in the lack of dentin neogenesis after pulp capping with dental resin materials).

5.4.3 Antimicrobial Properties

Bacteria may be the cause of material-associated tissue damages. Therefore, the influence of resin-based composites and their individual components on bacterial

Dentlearn.ir

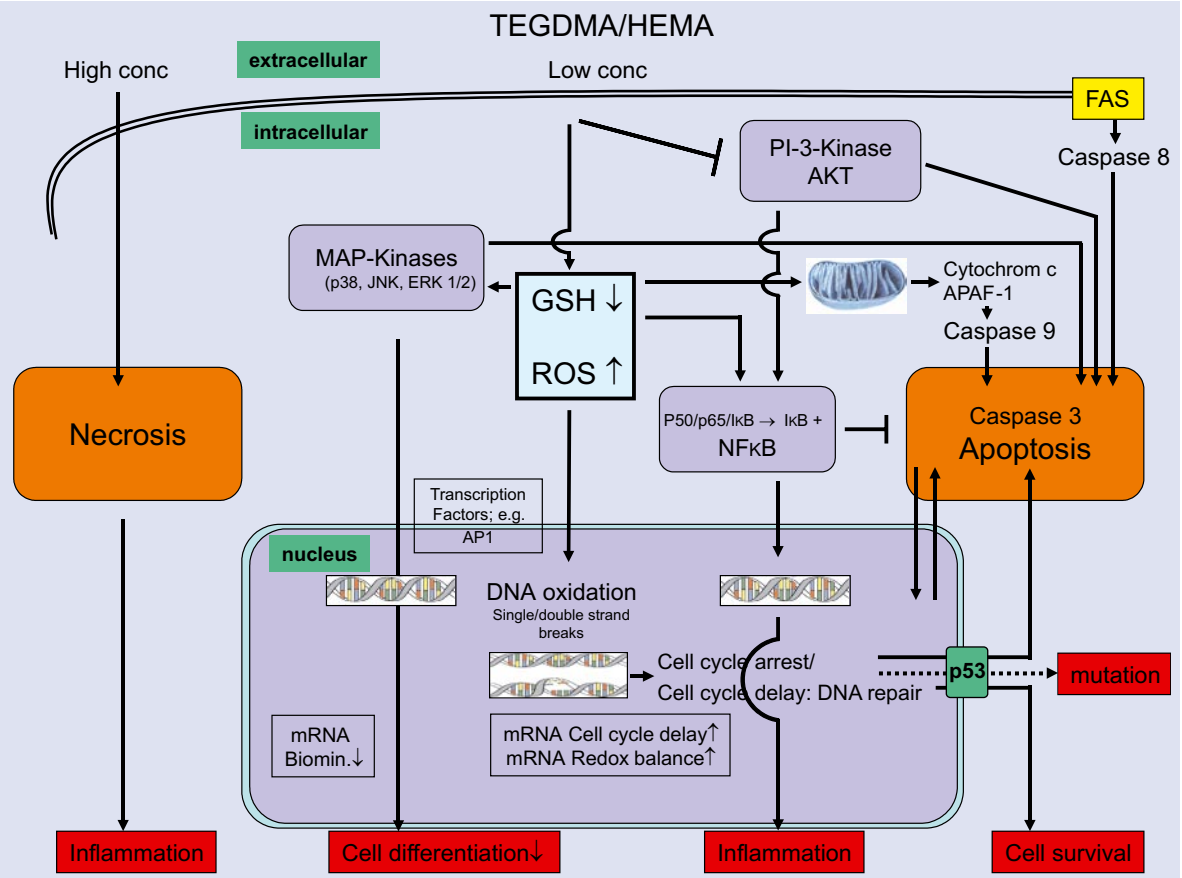

Fig. 5.13 Schematic and simplified overview of the influence of HEMA/TEGDMA on cell metabolism. For details, see Sect. 5.4.2

growth has been investigated. These studies revealed that resin-based composites and luting composites as well may increase the growth of *Streptococcus mutans*, a bacterial strain that is significant in contributing to caries generation [58, 207]. In addition, Hansel et al. [83] investigated the influence of base monomers (Bis-GMA, UDMA) and comonomers (TEGDMA, EGDMA) on the in vitro proliferation of caries-relevant bacteria (*Streptococcus sobrinus* and *Lactobacillus acidophilus*). It was found that the base monomers had no influence or only a slightly growth-inhibiting effect on these cultures, but both of the comonomers tested (TEGDMA, EGDMA) promoted bacterial proliferation. Because these substances usually leach from resin-based composites at higher concentrations than base monomers do, an overall increased bacterial growth may be the consequence in the presence of resin-based composites. Even the addition of fluoride could not prevent plaque formation on the surface of these materials [12].

Imazato et al. synthesized a monomer with a specific antimicrobial group, methacryloyloxy-dodecylpyridinium-bromide (MDPB), which was incorporated in resin-based composites and adhesives [107–109]. This monomer can penetrate dentin when unset, and its effect in dentin is more pronounced compared with 0.2% chlorhexidine. The molecule is immobilized by polymerization; subsequently, diffusion through dentin is no longer possible [109, 219]. The antimicrobial activity of a substance is often associated with cytotoxic effects on (pulp) cells. However, through the immobilization of MDPB by the polymerization process, no pulp cell damage has been observed [214].

The adhesion behavior of bacteria on the surface of resin-based composites is also of clinical relevance. Modern resin-based composites are characterized by relatively hydrophobic monomers to reduce water sorption and thus possible moisture expansion and discoloration by extrinsic stains. However, this promotes the adherence of bacteria. Negative electric potentials

Dentlearn.ir

at the surface are supposed to reduce microbial adhesion [203]. Besides unspecific adhesion phenomena, bacteria can also bind by means of specific adhesins (e.g., lectins) to special structures (e.g., sugar residues of glycoproteins), which are absorbed from saliva by the material. Bacteria adhere better and more tightly to resin-based composites than to ceramics (Fig. 5.14) [218].

Key Note

It may be concluded from the aforementioned studies that resin-based composites may promote bacterial growth; this aspect needs to be considered when planning a treatment with composite fillings. It also emphasizes the high-quality requirements regarding marginal adaptation of composite restorations. Antimicrobial monomers are effective in the unset state, and further diffusion through dentin is stopped by the polymerization process.

5.4.4 Implantation Tests

Resin-based composites were implanted in muscles, subcutaneously, and in alveolar bones of small experimental animals [21, 211, 217, 257]. Unset resin-based composite specimens and those tested immediately after polymerization caused tissue damage after short-term tissue contact (mainly 1–2 weeks). But completely set specimens were usually inert [21, 137, 211, 217, 247, 257]. However, some resin-based composites were more damaging to tissue after subcutaneous implantation than amalgam, when simultaneously tested [158]. Altogether, a good correlation was found between results from cytotoxicity studies and implantation tests with these materials.

Dental adhesives have been implanted subcutaneously in rats, and even after 60 days the adjacent connective tissue showed signs of chronic inflammation mediated by macrophages and giant cells engulfing displaced resin components [260].



Fig. 5.14 Accumulation of bacteria on the surface of a luting resin-based composite (*left*), but not on ceramic (*right*)

5.4.5 Pulp Reactions

5.4.5.1 Diffusion Through Dentin

The dental pulp may be damaged by the cavity preparation, specifically in the case of insufficient water cooling, as well as by filling materials (together with auxiliary materials). In the latter case, one must differentiate between a **direct toxic effect** of substances that leach from the material and the damaging effect due to bacterial toxin subsequent to a microbial colonization of the cavity floor (**indirect effect**). Biologically active molecules must penetrate from the cavity floor through the dentin to the pulp in order to cause an inflammatory pulpal reaction (see Chap. 2). However, dentin may act as an effective diffusion and absorption barrier [173, 175, 213], which is specifically due to the **smear layer** generated during cavity preparation. Permeability is lower in dentin distant from the pulp compared with dentin in the vicinity of the pulp [174, 213]. An obliteration of dentin tubules beneath a caries lesion (dentinal sclerosis) can reduce permeability (Fig. 5.15). Permeability of tertiary dentin varies and is dependent on its structure, which is associated with the intensity of the irritation that triggers the formation of tertiary dentin. Detailed information about this effect is lacking [264].

Acids (such as phosphoric acid or citric acid) or complexing agents (such as ethylene-diamine-tetraacetic acid, or EDTA) can increase the permeability of dentin by removing the smear layer and expanding the orifices of the dentin tubules [152, 175]. The well-known pain reaction after cementation of restorations with (acidic) phosphate cement is also considered an indication of

Dentlearn.ir

pulp damage. Thus, the application of acids on dentin has been declining for many years. Recent studies, however, have shown that dentin may act as a buffer [22]. A reaction of hydroxy apatite with free acid-derived protons will bind the protons, and subsequently, the pH value will increase. Further, it was shown that applying acids only increases the permeability of thin dentin discs (<500 μm) significantly [213]. Therefore, no clinically relevant damage due to an increased permeability or caused by an effect of acid protons themselves is to be expected in medium deep or shallow cavities (Fig. 5.16). Furthermore, experiments have tried to additionally decrease the permeability by reducing the duration of acid etching [77]. A reduction in the acid concentration from 37% to 10% had no effect on permeability in medium-deep and shallow cavities [77].

Permeability will, however, be increased drastically by acids in deep cavities, which increases the diffusion of toxic substances from dentin adhesives and resin-based composites, and specifically of bacteria and their toxins, to the pulp. Dentin in deep cavity areas reveals a significantly higher number of dentin tubules with larger diameter compared with shallow or medium-deep cavities (Fig. 5.17) [213]. Therefore, special procedures are necessary in deep cavities to protect the pulp. Interestingly, no significant influence on healing was detected after a direct application of phosphoric acid on the exposed pulp. But these trials were performed on pulps of young experimental animals with a high regenerative capacity. It has not yet been clarified how a predamaged pulp would react under these circumstances [13].

Components of composite resin eluates or adhesives, such as TEGDMA and HEMA, can diffuse through dentin within a few minutes [77]. The subsequent effective concentration in the pulp may cause tissue damage [3, 62, 187], and this also was observed on teeth that were predamaged by caries [75]. The reaction was specifically pronounced in the case of a low remaining dentin thickness [76]. Luting of crowns with resin-based composites also caused such reactions [3]. At this point it should be considered that the very low volume of the pulp will result in comparably high local concentrations, even if only small amounts of substances diffuse through dentin.

5.4.5.2 Usage Tests

A large number of animal experiments and studies with human teeth that had to be extracted for orthodontic reasons have been performed in order to determine the actual risk of pulp damage due to resin-based composites (usage tests). All of these studies consistently revealed that no pulp reaction is to be expected in medium-deep or shallow cavities with a comparably thick remaining dentin layer, if penetration of bacteria beneath the filling is avoided (Fig. 5.18) [59, 71, 85, 110, 184, 274]. This is also the case when an acid (e.g., phosphoric acid) is applied on vital dentin [66,



Fig. 5.15 **a** Increased formation of peritubular dentine (*arrows*) beneath a carious lesion (dentinal sclerosis). **b** For comparison: dentin located close to the pulp, same tooth

Dentlearn.ir

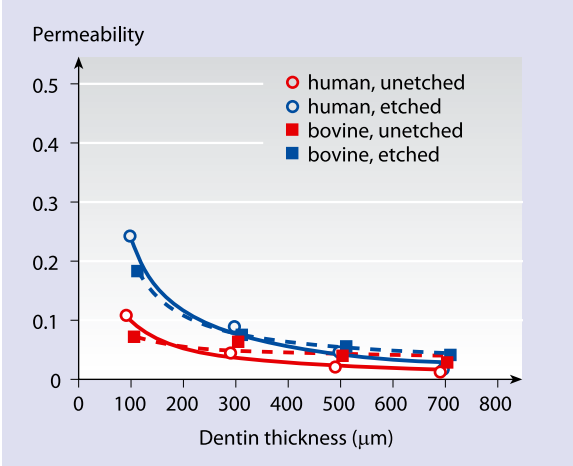

Fig. 5.16 A statistically significant increase of the permeability (here measured as hydraulic conductivity) was found only with very thin dentine discs [213]

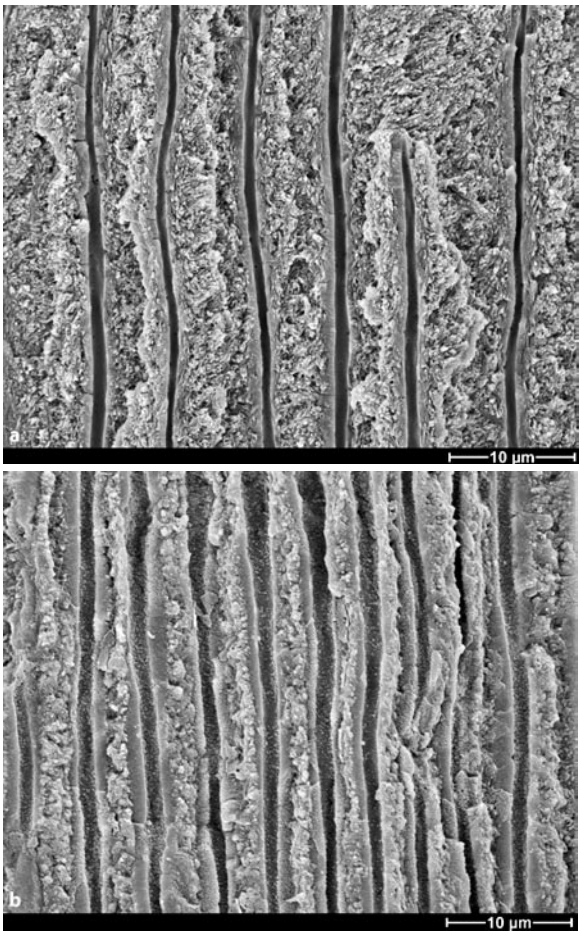

Fig. 5.17 Scanning electron microscopic images of dentin. **a** At the enamel-dentin junction. **b** Close to the pulp, same tooth

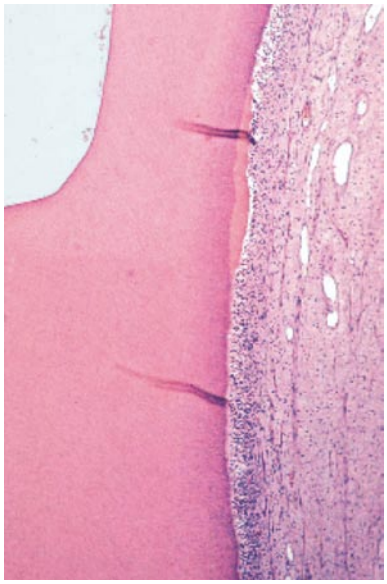

Fig. 5.18 After application of a resin-based composite in a medium depth cavity, no inflammatory reactions of the pulp are visible, except for a slight formation of tertiary dentin (30 days after application) (magnification ×80)

274]. These results are largely in accordance with the aforementioned data from in vitro experiments, which showed that penetration of potentially toxic substances from shallow or medium-deep cavities to the pulp is overall very low.

Comparatively few studies have addressed the effect of resin-based composites or adhesives on the pulp in deep cavities. Furthermore, reported data are rather contradictory. On teeth of experimental animals (mainly subhuman primates), these materials caused no pulp damage [261]. Human teeth, however, showed histologically pronounced inflammatory reactions after the application of resin-based composites and adhesives in deep cavities [42, 91]. Small resin particles derived from dentin adhesives were documented in dentin tubules and in pulp; these particles were surrounded by macrophages, a situation indicative of a foreign body or inflammatory reaction [32, 72].

Information on the influence of resin-based composites and adhesives on the immunologic status of the pulp and its regenerative capacity is scarce. A sup-

Dentlearn.ir

pression of immune competent cells by monomers was found [32, 117], which will increase the pulp's susceptibility to bacterial toxins [25]. Further research on this aspect is necessary.

Clinical Practice Advice

No pulp damage is to be expected if resin-based composites or adhesives are applied in shallow or medium cavities, even after prior acid-etching of the dentin (total etch/total bonding technique). In these situations, adhesives may serve as sealants and thus as protection against potentially penetrating bacteria (see below). In deep cavities, however, especially if microexposure of the pulp cannot be excluded, the use of a calcium hydroxide preparation applied on the deepest part of the cavity is still recommended. If a calcium hydroxide suspension is used for this purpose, then it should be covered by suitable glass ionomer cement.

5.4.5.3 Bacteria at the Cavity Floor

It is generally accepted today that bacteria at the cavity floor may be one cause for a pulp reaction after application of a resin-based composite or adhesive. Resin-based composites and adhesives are capable of promoting bacterial growth [58, 83, 209]. Analysis of bacterial species under resin-based composite fillings that had to be replaced showed a large spectrum of mainly anaerobic bacteria; quantitatively, there were reported to be up to eight times more microorganisms under resin-based composite fillings than under amalgam fillings under similar clinical conditions [243].

A prerequisite for bacterial colonization of the cavity floor is a gap between the filling and the cavity wall. This can be prevented almost completely by the enamel-etch technique in cavities whose margins are entirely located in enamel. However, problems will arise if the cavity margins (e.g., cervical/proximal) are located in dentin/cementum and if the cavity is overall clinically difficult to access. In such cases, it is indeed clinically very difficult to apply the adhesive technique correctly. Adhesives may help decrease the marginal gap in these cases, but gaps cannot be eliminated completely [28].

Bacteria that are present beneath a composite resin filling may cause a pulpal reaction even in shallow or medium cavities, where no direct chemical-toxic effect of substances leaching from composites or adhesives is expected. This difference may be explained by the fact that the release of leachables from materials decreases over time (due to the setting reaction), and furthermore, the dentin barrier may provide sufficient protection for the pulp. However, bacteria proliferate; therefore, the amount of segregated bacterial toxins will increase with time. As a result, the dentin barrier for protecting the pulp will no longer be sufficient. The application of a "sealing" adhesive may prevent further penetration of bacteria into the dentinal tubulus, even in the presence of a gap between the adhesive and the resin-based composite (Fig. 5.19). Adhesives with antimicrobial effects may be further advantageous if residual bacteria were left behind in the cavity or if they penetrate through a marginal gap. For the abovementioned antimicrobial monomer MDPB, it is postulated that, after setting, this material has an antimicrobial effect on bacteria that come into contact with it [41, 107, 219].

5.4.5.4 Direct Pulp Capping with Dentin Adhesives

Adhesives and resin-based composites have been recommended for pulp capping [30, 93, 114]. In particular, Cox and colleagues published data about experiments using teeth of subhuman primates [30, 157]. They reported that after an artificial pulp exposure, hemostasis, application of 2.5% NaOCl ("chemical lavage"), and application of different resin-based composites and adhesives, no or only slight inflammatory reaction occurred. Also, complete dentin bridge formation at the exposure site was observed if no bacteria had been present [30, 157]. Inoue et al. divided the contact area of adhesives and tissue into three zones: (1) a layer of set resin with inclusion of tissue ("soft tissue hybrid layer"), (2) a layer of single resin particles in the tissue, followed by (3) a layer of tissue containing nonpolymerized monomers [114].

Interestingly, a number of pulp capping studies using subhuman primates confirm these results. Similar studies on dogs, sheep, and rats, however, showed opposite results: slight to moderate inflammation with no or only little dentin regeneration [136, 147]. Also, if the cavities had been contaminated briefly with the saliva after the preparation and then disinfected with 2% chlorhexidine (to simulate the clinical situation more closely), 45% of the pulps were no longer vital after a direct pulp capping with resin-based composites and ad-

Dentlearn.ir

hesives [171]. Furthermore, tertiary dentin formation was found in only 25% of the cases. The control group, in which calcium hydroxide was applied, showed a usual reactive dentin formation in 82% of cases and only a share of 7% necrosis (Fig. 5.20). These data have been confirmed by other animal studies [147, 176].

Similar investigations on human teeth revealed retarded wound healing and no or less "bridging," persisting inflammatory cells, and a foreign body reaction in most cases [2, 32, 90, 97]. The foreign body reactions may have resulted from resin particles, which were documented in the tissue after the direct application of adhesives on the dental pulp [33, 72]. No clinical long-term studies (longer than 1 year) are available regarding the success rate of the application of dentin adhesives for pulp capping. Moreover, it should be taken into consideration that dentin adhesives may degrade over the years [88].

It should be considered, when assessing the partially good results after the application of dentin adhesives for direct pulp capping, that these studies were performed on young, mostly "juvenile" pulps with a high regenerative potency [13]. Furthermore, the size of these pulps in correlation with the pulp exposure is higher compared with pulps of adult patients. Overall, data regarding the use of calcium-hydroxide-based materials is much more substantial compared with that for adhesives. Therefore, most manufacturers of adhesives do not specify that these products should be used for direct pulp capping, and in some cases, they even declare it as a contraindication.

Clinical Practice Advice

Resin-based composites and adhesives should not be used for direct pulp capping in daily practice, due to the contradictory data in the literature and the availability of an effective alternative (calcium-hydroxide-based materials). Studies have documented consistently that success of direct capping is decisively dependent on avoiding bacterial infection. This corresponds to clinical experience and underlines the requirement to seal the cavity immediately after a direct capping to avoid bacterial penetration.

In contrast to the direct application of resin-based composites and adhesives on the exposed pulp, which has not yet been biologically substantiated, other biologically oriented treatment strategies are based on targeted stimulation of pulpal stem cells. It is the objective of these studies to induce the differentiation of pulpal stem cells into odontoblast-like cells, with a subsequent guided formation of dentin [34, 264]. In this context, the use of signaling proteins has been discussed, such as bone morphogenetic proteins (BMPs), transforming growth factor (TGFβ1), and bone sialo-



Fig. 5.19 Intact sealing of dentin tubules despite of gap formation in the resin-based composite (*arrow*) [119]; intact sealing may prevent bacteria/bacterial toxins from penetrating towards the pulp

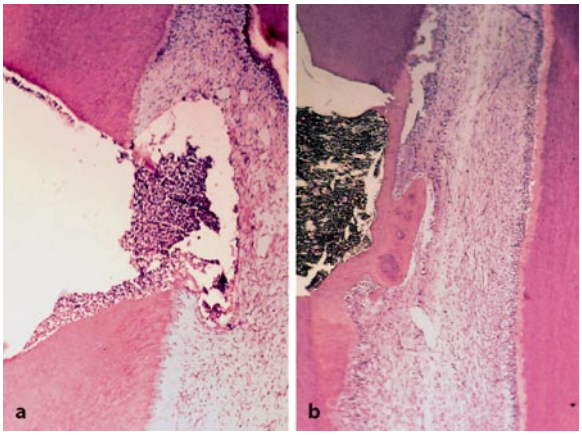

Fig. 5.20 **a** Pulp abscess after direct application of a dentin adhesive/resin-based composite on the pulp. (magnification ×80) **b** Control: noninflamed pulp after capping with calcium hydroxide and tertiary dentine formation 30 days after application (magnification ×120) (Courtesy of H. Stanley, Gainesville, Florida, USA)

Dentlearn.ir

protein (BSP). These strategies may eventually create new treatment concepts in the future.

5.4.5.5 Thermal Effects of Light-Curing Units

Studies on primate teeth have documented that an increase of 5.5°C of the temperature in the pulp will cause irreversible pulpal damage in 15% of all cases [278]. Therefore, it is of clinical interest to determine the temperature rise that may be associated with polymerization of a resin and the thermal radiation of a curing unit.

The exothermal setting reaction of resin-based composite causes, independently of the light source, a temperature increase in the material of up to 12°C within 10 s [99, 102]. The additional temperature increase due to the curing light unit occurs continuously during the entire irradiation period. Taken together, a temperature rise of 15.5–18.6°C was found in resin-based composite during the application of a QTH curing unit, and an increase of 8.2–12.1°C was found when an LED unit had been used and the irradiation time had been the same. Thus, the temperature effect was significantly lower with an LED unit compared with the QTH curing device tested [99, 177]. However, early LED curing units had a comparatively low power density. If temperature rise is measured for LED and QTH curing units at the same power density for both devices, previous findings that LED curing units induce less temperature rise are not true in general; temperature rise is mainly related to the power density [8].

Dentin is, however, an excellent thermal insulator, a fact that is well known from endodontic studies with heated and liquefied gutta-percha. Therefore, it is not the temperature rise in the resin-based composite but the temperature rise of the pulp that is of clinical interest. An intrapulpal temperature increase of 8 °C for a period of 10 s was documented during the application of a plasma arc lamp, with a remaining dentin thickness of 1 mm [81]. Other lamp types caused an increase of 2–6 °C. Thus, it cannot be excluded that the pulp will be thermally damaged during extended irradiation times and with a thin remaining dentin layer. Energy-rich halogen lamps under the same conditions caused a temperature increase of 4.7 °C (information provided by Ivoclar/Vivadent, Ellwangen, Germany). Overall, these data underscore that for light-curing units that are on the market, data on thermal effects should be available.

5.4.5.6 Postoperative Sensitivity and Clinical Studies

In recent years, the application of resin-based composites, especially in the posterior region, has been investigated in many studies. The main focus of these investigations usually has been wear, marginal gap formation, and color stability. Pulp reactions were either not or only superficially considered as pain and in sensibility tests. In general, no pulp damage was reported by these studies. However, the application of resin-based composites – especially when used without adhesives – caused postoperative sensitivity in up to 30% of all cases. Even up to 56% of patients reported pain during mastication after the application of posterior resin restorations; this applies to direct as well as to indirect restorations. The symptoms disappeared within several weeks in most cases. However, in some cases they persisted [167]. The frequency of these spontaneous complaints has decreased with the use of currently available adhesives [49, 57, 167]. Interestingly, these postoperative sensitivities also occur in cases of small occlusal cavities.

Investigations with a modern resin-based composite revealed that 4.8% of the fillings had to be replaced due to postoperative complaints [47]. Another resin-based composite was associated with a failure rate of 6% after 1 year, mainly caused by postoperative sensitivity. Twelve fillings had to be replaced. One tooth had to be treated endodontically, due to postoperative pain and enamel fracture [19]. Trauma caused by preparation, microleakage with bacterial penetration, polymerization shrinkage, and deformation of the restoration under stress have been discussed as possible causes for postoperative sensitivity [167]. Thermal conductivity and the effects of prolonged acidic application are obviously without clinical significance. Today it is believed that a pumping effect during loading, together with a gap between the restoration and the dentin at the bottom of the cavity with open dentine tubules, are the main reasons for postoperative sensitivity; this situation may cause dislocation of liquid within the dentine tubules, which is then associated with pain (Fig. 5.21).

A different mechanism is probably responsible for clinical symptoms occurring after the use of special resin-based composites occurring several months after application. Materials with an intended release of antimicrobial substances (so-called smart materials) also had a rather high water uptake, with subsequent expansion. This expansion leads to cusp fractures in extended cavities and to painful sensations [19].

Dentlearn.ir

Even small gaps in the hybrid layer ("nanoleakage"), which have been demonstrated in scanning electron microscopy by silver staining despite the application of an adhesive, have been held responsible for postoperative sensitivities. This nanoleakage has been attributed, among other things, to incomplete penetration of the demineralized dentin by the primer and the adhesive resin. Self-etching primers, which combine demineralization and diffusion of monomers in one molecule, may be clinically advantageous in this respect [39, 200].

Cervical dentin hypersensitivities can be treated in certain cases by applying adhesives in the cervical area. The aim of this approach is to seal the orifices of the dentin tubules and thus prevent movement of liquid in the tubules, which may trigger pain (Fig. 5.22). However, it is also possible that neurotoxic effects caused by some adhesives inhibit nerval conductivity and thus stop clinical hypersensitivities [166]. The strong toxicity of glutaraldehyde-containing adhesives, which are marketed for treating hypersensitivities, may also play a role [220]; glutaraldehyde causes a coagulation of proteins within the dentin tubules [40].

Clinical Practice Advice

A suitable adhesive should be applied to prevent or reduce postoperative sensitivities, even if it does not seem necessary for filling retention in small occlusal cavities. The important effect is the sealing of dentin tubules (see Fig. 5.19). If postoperative pain nevertheless occurs, it should be monitored. The patient should be informed that the pain will usually disappear with time. In addition, only those materials should be selected for daily practice whose pulp compatibility has been assessed in clinical studies for a sufficiently long period of time and that caused no postoperative pain.

5.4.6 Hazards for Eyes

Most current resin-based composites are polymerized with blue light ranging between 400 nm and 500 nm. Theoretically, this may cause thermal damage to the retina at high light intensities and long irradiation times. Mutagenic effects of polymerization lights in bacterial cultures were also shown after long irradiation times [212, 241]. However, in the dental practice, acute tissue damage seems to be rather unlikely because the exposure times are much shorter. Reversible damage to eyes (e.g., afterimages) may occur, especially after direct glare. Irreversible photochemical

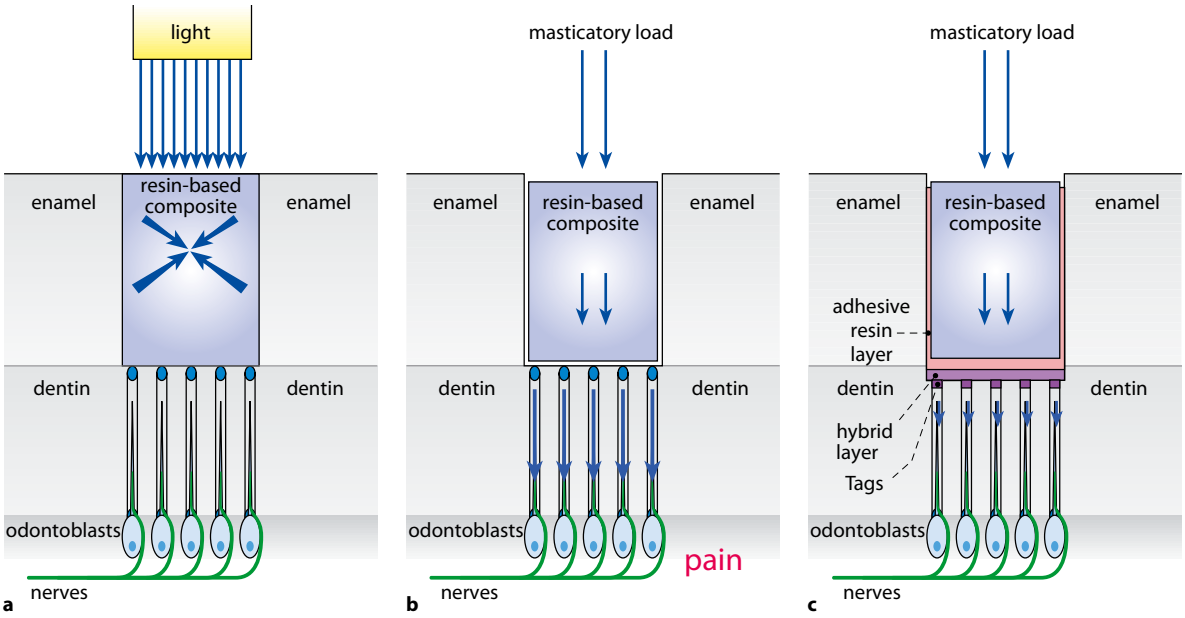

Fig. 5.21 Proposed mechanism for the generation of postoperative sensitivity upon masticatory load. **a** Polymerization shrinkage and gap formation. **b** A pumping effect and dislocation of liquid in the dentine tubules with subsequent irritation of the odontoblast-associated pain receptors may occur during masticatory load. **c** Sealing of the orifices of the dentine tubules will reduce or completely prevent the shifting of liquid

Dentlearn.ir

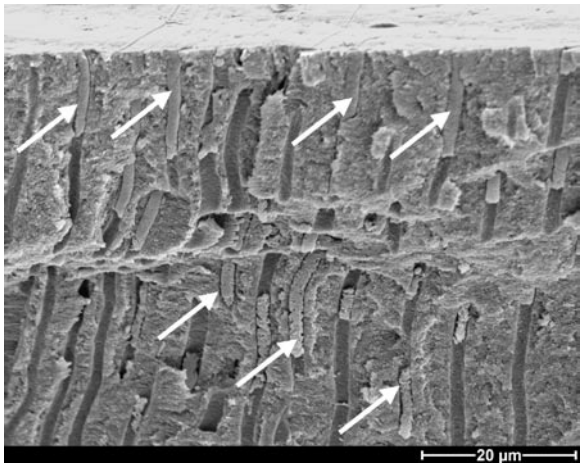

Fig. 5.22 Application of an adhesive for treatment of cervical hypersensitive teeth. The orifices of the dentine tubules are obliterated by the adhesive resin (*arrows*)

damage (loss of acuity) is theoretically possible. The limit value for exposure time in the case of direct irradiation is 3.4 min/24 h. To prevent any adverse effects on the eyes, protective glasses should be used, or protective shields should be attached to the end of the light guide of the polymerization lamp. This seems to be particularly important for plasma lamps. However, studies addressing the side effects of these devices regarding potential risks for eyes or vision are currently not available.

5.4.7 Inhalation of Resin-Based Composite Particles

During the grinding and polishing of composite resin fillings, particles in the 0.5–10-µm size range may be produced [68]. Animal experiments have shown that inhalation of such particles may lead to foci of chronic lung inflammation around these particles [68]. Although the clinical relevance of these results is still unclear, it is recommended to prevent inhalation during grinding and shaping of composite resin restorations, such as by the use of a rubber dam or suction and water spray [11].

5.4.8 Reactions of Gingiva and Oral Mucosa

Observations of patients showed that the gingiva next to sound enamel surfaces was less inflamed than that adjacent to composite-resin fillings, especially in cases in which the fillings ended subgingivally (Fig. 5.23) [78]. These effects increased in patients who did not brush their teeth for 7 days in order to induce an experimental gingivitis [38]. In a retrospective clinical study, it could also be shown that the degree of inflammation as well as the probing depth was higher adjacent to resin-based composite fillings compared with amalgams or gold alloys [276]. Plaque samples taken from intraoral resin-based composite surfaces revealed an increased number of *Mutans* streptococci compared with samples from the surfaces of glass ionomer cements [250]. These results are in line with aforementioned in vitro data that documented increased bacterial proliferation due to resin-based composites [50, 58, 207]. From these studies, it can be concluded that reactions of the gingiva and the periodontium in contact with resin-based composites are probably due to increased plaque accumulation on these materials.

In the course of shaping, finishing, or removing composite resin restorations, resin particles may be trapped in adjacent soft tissues, such as the gingiva. This may be the reason for a chronic inflammation [82]. Unintentional implantation of a resin-based composite material used for temporary crowns into the oral submucous connective tissue led to a circumscribed swelling, moderate local inflammation, and little pain together with swelling of regional lymph nodes after 5 days. After removal, healing occurred without further problems (Fig. 5.24).

Unintentional contact of phosphoric acid with the gingiva or the oral mucosa may cause local irritations or chemical burn (Fig. 5.25). However, no information is available in the literature regarding whether this contact may cause pronounced or long-term damage.

Clinical Practice Advice

Acids that are used to etch ceramics may cause severe chemical burn of soft tissues after unintentional contact. Therefore, if such acids are used (e.g., for repair of fractured ceramics) all soft tissues (intraoral and extraoral) must be properly protected.

5.5 Allergies

Allergies due to dental materials, especially resin-based composites and adhesives, may affect patients and dental personnel as well. Generally, resin-based

Dentlearn.ir

Fig. 5.23 Gingivitis adjacent to a cervical composite resin filling

composites and adhesives may cause immediate reactions (type I) or delayed reactions (type IV; see Chap. 2). However, the identification of a specific allergy type may be difficult in certain cases.

5.5.1 Prevalence

Resin-based composites and adhesives contain a variety of substances that are considered to be allergens [95, 96]. This applies to base monomers and comonomers as well as to additives such as initiators and inhibitors (see Chap. 14). For instance, based on an investigation of more than 16,000 referred patients, benzoyl peroxide ranks 4th in the list of most often found allergens, and MMA ranks 10th [193]. Within the group of (methyl)methacrylates, HEMA, TEGDMA, and EGDMA belong to those substances with the highest sensitization potency [69, 124]. Formaldehyde and glutaraldehyde, which are released during polymerization of resin-based composites or from some adhesives, are classified as "important contact allergens" (see Chap. 1).

Reports by Danish dentists indicate that 2% of them are suffering from allergic side effects caused by resin-based composites [155]. In a group of Swedish dentists interviewed on the subject, 2% also reported

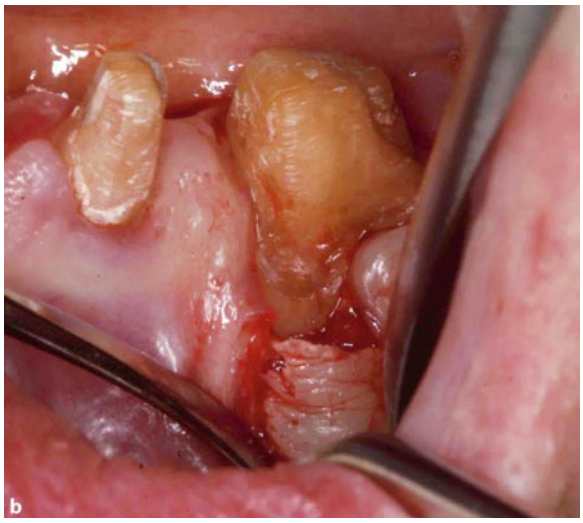

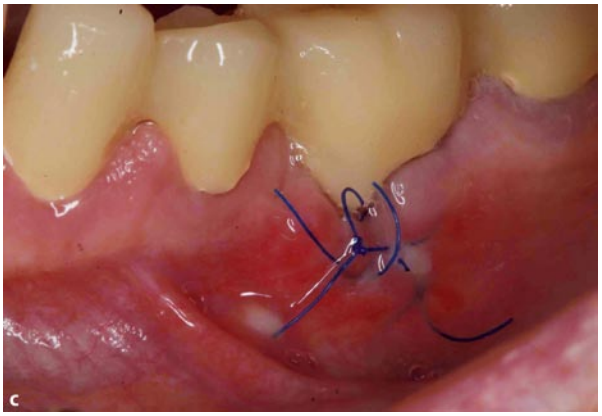

Fig. 5.24a–c Unintentionally implanted resin-based composites after crown preparation. **a** Localized swelling. **b** Retrieved material, **c** healing after removal

Dentlearn.ir

eczema on their hands after contact with resin-based composites or adhesives [164]. Interestingly, the frequency of allergy to resin-based composites and associated auxiliary materials has increased continuously in the past few years among dental personnel parallel to an increased use of these materials in dental practice (Fig. 5.26) [128]. A study in Sweden showed a 1-year prevalence of self-reported hand eczema of 14.9% among more than 3,000 Swedish dentists, 28% apparently being allergic in nature and 5% being due to acrylates [270]. In a recent study, it was reported that from 1,632 subjects in a special dental patient/dental personnel patch test series (1995–2004), 2.3% of the patients and 5.8% of dental personnel reacted positively to (meth-)acrylate compounds. The most common allergens in both groups were HEMA, followed by EGDMA, TEGDMA, and MMA [69].

The importance of (di-)methacrylates and other resin-based composite additives as allergens is underscored by the fact that commercial test series for patch tests of these substances are available on the market. A main problem for the diagnosis and prevention of allergic reactions is that these materials (like many others in dentistry) are complex mixtures, and their composition is generally not declared in detail by the manufacturers.

5.5.2 Preclinical Studies

Preclinical assessment of the allergenic potency of resin-based composites and their ingredients is very frequently performed with the maximization test on guinea pigs (see Chap. 2). It was found that up to 87% of the experimental animals (13 out of 15) showed an allergic reaction after sensitization with a commercially available Bis-GMA-based product. Bis-GMA and contaminants as well were identified as the cause [14]. Söhoel et al. tested two different Bis-GMA/TEGDMA-containing resins that were used for the bonding of brackets. Both substances generated a sensitization in 50% of the experimental animals, with subsequent allergic reaction [237]. Dentin adhesives that contained HEMA, among other substances, were also allergenic in animal experiments [130]. Painting a 50% HEMA solution on mouse ears (twice per week for 6 weeks) influenced the expression of IL-10 in spleen cells and of IL-6 in stimulated draining lymph node cells. This demonstrated the influence of HEMA on the immune system [199]. Overall, base monomers and additives of resin-based composites have shown a clear allergenic potency in animal experiments. The transferability of these preclinical results to human patients is generally considered to be good [237].

Fig. 5.25 Chemical burn after inadvertent contact of phosphoric acid with gingiva (Courtesy of D. Arenholt-Bindslev, Århus, Denmark)

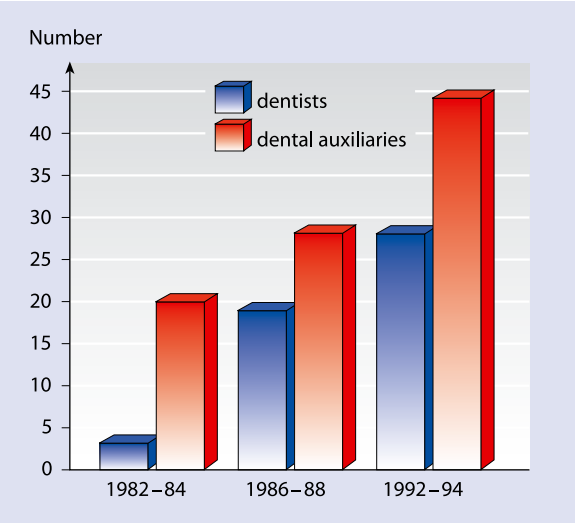

Fig. 5.26 Frequency of allergic reactions of dentists and dental assistants [128]

Dentlearn.ir

5.5.3 Allergic Reactions in Patients

Hallström [73] reported the case of a 6-year-old girl who suffered anaphylactic shock after application of a pit and fissure sealant. Asthmatic symptoms appeared in the night after the sealant had been applied. During the following 2 days and nights, severe urticaria with skin rashes and swellings on the entire body accrued, followed by formation of blisters on the child's face, ears, and lips (Fig. 5.27). There was also very intense itching. Intraorally, blisterlike lesions of the gingiva next to the treated teeth were visible. The fissure sealant was removed, and all symptoms disappeared within a period of 2 days. But during this 2-day period, the girl's condition briefly worsened – despite medication with a high dosage of a corticoid-containing drug – likely because of the removal of the pit and fissure sealants. The sealant contained Bis-GMA and TEGDMA, among other ingredients. Subsequent allergy tests with acrylates triggered no allergic reactions, which is not unusual in these types of allergies [73]. However, for ethical reasons, this girl was not reexposed to the suspected pit and fissure sealant [73]. Rix and Andersen reported a similar case [195]. A 6-year-old boy who was treated with a pit and fissure sealant felt queasy 15 min after application of the resin; he also seemed to be absent-minded and became pale. The estimated diagnosis was an anaphylactic reaction caused by a dental material based on acrylates.

Signs of allergy have been observed after application of a resin-based composite for the bonding of orthodontic bands. Three days after treatment, a 14-year-old boy revealed swollen lips, intraoral inflammatory symptoms, perioral erythema, and itching. The set bonding resin used as well as the initiator caused a positive reaction in a patch test. After the bands were

Fig. 5.27 Extraoral allergic reactions (type I) after application of a pit and fissure sealant (Courtesy of U. Hallström, Lund, Sweden)

Fig. 5.28a,b Localized swelling of the upper lip after placement of a resin-based composite filling containing TEGDMA. The patient was tested positive (patch test) to TEGDMA. **a** Intraoral view. **b** Extraoral view (Courtesy of D. Arenholt-Bindslev, Århus, Denmark)

Dentlearn.ir

cemented with carboxylate cement, the symptoms were no longer observed [103]. After fitting of fixed orthodontic appliances with a Bis-GMA resin, swelling of the upper lips along with gingival inflammation was observed in two patients who tested positive in the patch test to Bis-GMA (one of the patients also reacted positively to EGDMA and to HEMA) [29]. Similar reactions were observed in another patient who revealed an allergy to a resin-based composite used for temporary crowns and bridges [129].

In another case, an adhesive and a composite resin filling caused marked swellings in the left area of the upper lip and in the neck [180] (see also Fig. 5.28). The patient had difficulties in swallowing, but breathing was normal. She was referred to a hospital, from where she was discharged after 24 h. After the administration of adrenaline, the swelling disappeared. Nathanson and Lockart reported on a patient with a contact allergy to resin-based composite [160]. Two other patients with equivalent allergy (to Bis-GMA) were documented by Axell et al. [10]. Kanerva and Alanko described a patient with recurrent stomatitis as well as swelling of the lips and perioral eczema subsequent to a dental appointment [121]; a patch test was "highly" positive for Bis-GMA, among other substances. Koch [133] reported on a patient whose resin-based composite fillings had to be replaced by amalgam fillings because of an allergic reaction to Bis-GMA. In another patient, merely the visit to a dental practice – without contact with resin-based composites – caused a severe facial dermatitis. The patient was a worker in the printing industry and had a proven allergy to dimethacrylates. The authors supposed that airborne particles in the dental practice had triggered the allergic reaction [15].

Lichenoid reactions of the oral mucosa in direct contact with resin-based composites have also been documented [146]. The mucosal alterations were limited to the contact area with the resin material and healed once the composite was replaced by another material. An allergic component cannot be excluded in these situations (see below). Three out of five tested patients [146] showed a positive result for formaldehyde (patch test); one case revealed a positive reaction to EGDMA (a comonomer contained in some resin-based composites) [9].

Formaldehyde, which is a very reactive hapten, may cause an allergic reaction. This substance was found in set resin-based composites up to 115 days after polymerization. This is particularly the case if the material is in contact with air during the polymerization and thus an oxygen-inhibited surface layer is present. Allergies to formaldehyde may occur as asthma [204] (for further details, please see relevant textbooks). Local reactions to formaldehyde may manifest as pronounced gingivitis (Fig. 5.29).

Clinical Practice Advice

Compared to the extended worldwide use of resin-based composites and adhesives, the frequency of dentistry-related instances of allergic reactions to these substances, although some very severe, can be considered to be rather low. In any case, this should not be the reason to abandon these materials all together. But it should be emphasized that a comprehensive medical history of the patient and knowledge about adequate emergency measures are highly important. Knowledge of the composition of the materials applied is essential, and information provided by the manufacturers (e.g., through safety data sheets or instructions for use) may not be adequate [94].

5.5.4 Allergic Reactions in Dental Personnel

Piirilä et al. described allergic reactions in 12 persons (six dental assistants and six dentists) [183]. Nine of them suffered from asthma, two showed a rhinitis, and one person had laryngitis. A series of clinical tests showed that all 12 patients were allergic to acry-

Fig. 5.29 The patient (without clinical symptoms) requested the replacement of amalgam fillings with resin-based composite. The placed resin-based composite fillings caused a pronounced reaction of the gingiva and the adjacent oral mucosa caused by an allergy to formaldehyde (Courtesy of P.-O. Lind, Oslo, Norway)

Dentlearn.ir

lates – in 10 cases, to those substances that are usually contained in dentin adhesives. The authors also reported that the number of cases with occupationally caused asthma (due to acrylates) increased from three (1985–1991) to 14 (1992–1997) [183]. This increase happened a few years after the introduction of dentin adhesives and the increased use of resin-based composites in the posterior region.

In 1989, Kanerva et al. had reported seven cases (six dental assistants, one dentist) of allergic contact dermatitis to substances contained in resin-based composites (Fig. 5.30) [122]. Eczemas located on hands and in the face were present in most cases. In one case, an induration (thickening) of the fingertips was observed. Another patient suffered from respiratory problems. Four individuals (dental assistants) were allergic to Bis-GMA. Two dental assistants were allergic to TEGDMA and TEGDA. In four cases, an allergy to epoxy resin was additionally found. The dental assistants had to quit their jobs; the dentists could continue to use resin-based composites if they wore suitable gloves. In 1995, another case of an allergic contact dermatitis to resin-based composite and to BPA in a dental assistant was described [116].

The same authors reported a dentist with hand dermatitis that was spreading to the forearms, chest, neck, and face. HEMA was identified as the cause [126]. Symptoms of conjunctivitis were also found in two dental technicians who were sensitized to TEGDMA, among other substances [124]. A laboratory assistant with contact dermatitis and a positive patch test to HEMA showed persistent paresthesia of the fingertips (even after 6 weeks of absence from work) and also gastrointestinal symptoms such as nausea and diarrhea [150]. A 58-year-old dental assistant complained about a moderate to severe paresthesia of the fingertips of both hands [127]; a patch test revealed an allergy exclusively to HEMA (from a dentin adhesive). A 60-year-old dentist who complained of dermatitis, induration, and fissuring of the fingertips reacted positively to acrylates, including HEMA and TEGDMA, in the patch test [123]. An orthodontist suffered repeatedly from pharyngitis during work. Results of a prick test were negative, but the patch test showed sensitization to a number of acrylates, TEGDMA and HEMA among others [125]. Dental nurses seem to be at special risk, as larger numbers of such personnel are reported as being sensitized to acrylate (especially HEMA and EGDMA) compared with dentists [115].

Interestingly, other professional groups having contact with methacrylates are at risk of sensitization to these substances and of allergic contact dermatitis (ACD). One of these professional groups consists of beauticians who apply methacrylate artificial nails and who specialize in nail sculpturing [141, 179]. In two cases of patients who had ACD due to working with methacrylate artificial nails, mucosal erythema and edema developed after a crown was luted with a resin-based composite during dental treatment [141].

Key Note

Overall, the available investigations and case reports show that the number of allergies in dental personnel is increasing; comparatively fewer cases, however, have been observed among patients. Thus, dental personnel must be considered a risk group. In this context, it needs to be considered that monomers may penetrate commonly used gloves (e.g., from latex or nitrile) within a short period of time [154, 194]. Neoprene gloves have been recommended as the best (relative) protection [4]. (See also Chap. 12).

Fig. 5.30 Allergic contact dermatitis of a dentist after contact with resin-based composites

Dentlearn.ir

5.6 Mutagenicity and Carcinogenicity

Bis-GMA and UDMA were not mutagenic in eukaryotic cells or in bacterial cultures in vitro. However, in the presence of cholesterol esterase, Bis-GMA formed a degradation product (see above), BADPE-4OH, which then produced micronuclei in cultured human lymphocytes [249]. TEGDMA caused major DNA strand deletions [229] and induced micronuclei in mammalian cells (chromosomal damage) [230]. Triphenylstibane, a contaminant of some Bis-GMA products, was also shown to be genotoxic [92, 144]. Glutaraldehyde, which is contained in some adhesives, was mutagenic in vitro, as were the glutaraldehyde-containing adhesives [226–228]. Numeric chromosomal aberrations were induced by dimethyl-p-toluidine (DMPT), a frequently used accelerator in catalyst systems [255]. Some bonding resins for orthodontic brackets caused positive results in the Ames test [31, 56]; one of these products was subsequently taken off the market. TEGDMA caused no mutagenic effects in vitro if it was pretreated with enzymes derived from rat liver. It was concluded from these findings that TEGDMA is degraded in vivo [190]. But no information is available so far about kinetics and the resulting intermediary metabolic products. It would be important to investigate the metabolic fate of this substance in animal experiments [230].

Recently, adhesives containing acryl amides have been marketed. On the one hand, acryl amides are classified as "likely carcinogenic" by the International Agency for Research on Cancer; on the other hand, no increased frequency of carcinomas has been observed in humans exposed to these substances [70]. The acryl amide used in dental adhesives is nonmutagenic, according to the manufacturer's information. This information is based on nonpublished data. In our own studies, increased formation of micronuclei has been observed [37].

The assessment of data on in vitro mutagenicity regarding clinical significance (the disease impact of such effects) is difficult (see Chap. 2) [132]. The concentrations necessary to trigger these mutagenic reactions were far above those values expected in patients with resin-based composites. On the other hand, no threshold concentrations regarding the harmlessness of mutagenic substances have been defined so far. In addition, the concentration at the local contact area with tissue is not known, but in the case of adhesives is expected to be in the range of mutagenic reactions.

Key Note

Dental personnel have frequent and direct contact with these substances and must, therefore, be considered a risk group. Because these substances are partially able to penetrate commonly used gloves [4, 154, 194], it is recommended to avoid any skin/glove contact ("no-touch" technique). Neoprene gloves have been recommended as the best (relative) protection [4]. The mutagenic characteristics of light with a wavelength of 450 nm as well as the importance of protecting shields attached to polymerization lamps have already been addressed.

5.7 Public Discussion

Possible health risks caused by resin-based composites and corresponding auxiliary materials are intensively and sometimes very emotionally discussed in public, similar to discussions on amalgam and dental alloys. Careless and uncritical extrapolation of data from (in vitro) investigations to patients is frequently the trigger for this kind of discussion, for instance, the postulated estrogenic effect of pit and fissure sealants.

Patients who link their complaints to a specific material, including the use of resin-based composites, have founded organizations for patients' protection on various occasions. Recently, a "green consumer encyclopedia" was published in Denmark; it recommends the use of amalgam in the posterior region to prevent an estrogenic effect due to resin-based composites [84].

Interestingly, the general symptoms that patients associate with resin-based composites and adhesives are very similar to those linked to amalgam and dental alloys. The number of patients with such symptoms is very low as a proportion of the total population, despite the frequent use of these materials. However, there is a high level of suffering in individual cases, which require comprehensive and time-consuming consultations and interdisciplinary assessment and treatment by physicians and dentists. Patients who claim their symptoms to be due to amalgam and dental alloys could be successfully treated by this approach. Therefore, adequate diagnostic and treatment centers should not concentrate on a specific material (e.g., metals or alloys) but should include the entire spectrum of intraorally applied materials.

Furthermore, it is necessary to distinguish between the "general risk" for a biomaterial and the "individual

Dentlearn.ir

risk." The general risk for presently available resin-based composites and adhesives is such that their withdrawal from the market is generally not justified. However, the individual risk may be such that the use of a specific material should not be allowed in a special patient situation, such as in cases of allergy.

Conclusions for the Dental Practitioner

1. Beneath a composite resin restoration, a suitable base should be placed to protect the pulp from material components and bacterial toxins. This base may be an adhesive in shallow or medium-depth cavities. Demineralized dentin needs to be completely penetrated by primer resin. Thus, the application times of the single components of the respective adhesive system have to be carefully followed as indicated by the manufacturers. It is still recommended to apply a protective layer of calcium hydroxide in deep cavities, either as cement or as a suspension. This layer can be fixed by a glass ionomer cement. The strict following of every single step of the adhesive technique is required to prevent bacterial penetration and consequent pulp damage due to bacteria as far as possible. However, marginal gaps cannot be completely prevented, even today and under optimal conditions.
2. Dentin adhesives are not recommended for direct pulp capping because contradictory results regarding possible pulp damage have been published, and an efficient alternative (calcium hydroxide materials) is available.
3. Because resin-based composites and adhesives may promote bacterial proliferation, which may subsequently cause inflammation of the gingiva, patients must practice intensive oral hygiene to prevent this inflammation.
4. Inhalation of composite resin particles during grinding and shaping of a newly placed restoration should be prevented by suitable measures such as a rubber dam or the use of suction/water coolant.
5. Dental personnel should always avoid any contact of skin or even gloves with resin-based composites or dentin adhesives, including during instrument cleaning and waste disposal ("no-touch" technique). Some manufacturers have taken this problem into account by packaging composites and dentin adhesives in a way that allows a no-touch technique (e.g., one-way application systems, disposable packaging).
6. Protective shields should be attached to the end of the light guide of polymerization lamps to protect the eyes of dental personnel.
7. If oral lichenoid reactions occur that are limited to the contact area with the filling material, this restorative material should be replaced by a different material. If mucosal lesions are not limited to the contact area with the material, then the material is very likely not the cause for the tissue alteration.
8. Resin-based composites and adhesives must not be used in cases of allergy to these materials or to their components. A profound knowledge of the composition of these materials is essential in order to analyze and prevent these and other side effects.

Dentlearn.ir

Appendix

Table 5.5 Substances released from resin-based composites [6, 63, 216, 239]

Abbreviation	Molecular weight	Molecular formula	Substance
Bis-DMA	364	$C_{23}H_{24}O_4$	Bisphenol A-dimethacrylate
Bis-GMA	512	$C_{29}H_{36}O_8$	Bisphenol A-glycidyldimethacrylate
Bis-PMA	480	$C_{29}H_{36}O_6$	Propoxylated bisphenol A-dimethacrylate
Bis-EMA	452	$C_{27}H_{32}O_6$	Epoxylated bisphenol A-dimethacrylate
UDMA	470	$C_{23}H_{38}N_2O_8$	1,6-bis(methacrylyloxy-2-ethoxycarbonylamino)-2,4,4-trimethyl-hexane
UPGMA	968	$C_{51}H_{76}N_4O_{14}$	Urethan bisphenol A-dimethacrylate
TEGDMA	286	$C_{14}H_{22}O_6$	Triethyleneglycoldimethacrylate
TEGMMA	218	$C_{10}H_{18}O_5$	Triethyleneglycolmonomethacrylate
TetEGDMA	330	$C_{16}H_{26}O_7$	Tetraethyleneglycoldimethacrylate
DEGDMA	242	$C_{12}H_{18}O_5$	Diethyleneglycoldimethacrylate
EGDMA	198	$C_{10}H_{14}O_4$	Ethyleneglycoldimethacrylate
DDDMA	310	$C_{18}H_{30}O_4$	1,10-Decandioldimethacrylate
HDDMA	254	$C_{14}H_{22}O_4$	1,6-Hexandioldimethacrylate
HEMA	130	$C_6H_{10}O_3$	2-hydroxyethylmethacrylate
PDDMA	240	$C_{13}H_{20}O_4$	1,5-Pentandioldimethacrylate
BDDMA	226	$C_{12}H_{18}O_4$	1,4-Butandioldimethacrylate
MBDDMA ½	258	$C_{13}H_{22}O_5$	BDDMA-methanoadduct ½
DBDDMA ½	384	$C_{20}H_{32}O_7$	BDDMA-autoadduct ½
PRDMA	212	$C_{11}H_{16}O_4$	1,2-Propandioldimethacrlyate
DMTCDDA	304	$C_{18}H_{24}O_4$	Bis(acryloxymethyl)tricyclo [5.2.1.0^{2,6}]decane
BEMA	176	$C_{11}H_{12}O_2$	Benzylmethacrylate
SIMA	248	$C_{10}H_{20}O_5Si$	3-Trimethoxysilanpropylmethacrylate
TMPTMA	338	$C_{18}H_{26}O_6$	Trimethylolpropantrimethacrylate
MMA	100	$C_5H_8O_2$	Methylmethacrylate
MAA	86	$C_4H_6O_2$	Methacrylic acid

Dentlearn.ir

References

1. Achanta, G., Huang, P.: Role of p53 in sensing oxidative DNA damage in response to reactive oxygen species-generating agents. Cancer Res 64, 6233–6239 (2004).
2. Accorinte, M.L.R., Loguerico, A.D., Reis, A., Muech, A., Calvacanti de Araújo, V.: Adverse effects of human pulps after direct pulp capping with the different components from a total-etch, three step adhesive system. Dent Mater 21, 599–607 (2005).
3. Al-Fawaz, A., Gerzina, T.M., Hume, W.R.: Movement of resin cement components through acid-treated dentin during crown cementation in vitro. J Endod 19, 219–223 (1993).
4. Andreason, H., Boman, A., Johnson, S., Karlson, S., Barregard, L.: On permeability of methyl methacrylate, 2-hydroxyethyl methacrylate and triethyleneglycol dimethacrylate through protective gloves in dentistry. Eur J Oral Sci 111 (6), 529–535 (2003).
5. Antonucci, J.M., Toth, E.E.: Extent of polymerization of dental resins by differential scanning calorimetry. J Dent Res 62, 121–125 (1983).
6. Arenholt-Bindslev, D., Breinholt, V., Preiss, A., Schmalz, G.: Time-related bisphenol A content and estrogenic activity in saliva samples collected in relation to placement of fissure sealants. Clin Oral Investig 3, 120–125 (1999).
7. Asmussen, E.: Factors affecting the quantity of remaining double bonds in restorative resin polymers. Scand J Dent Res 90, 490–496 (1982).
8. Asmussen, E., Peutzfeld, A.: Temprature rise induced by some light emitting diode and quartz-tungsten-halogen curing units. Eur J Oral Sci 113, 96–98 (2005).
9. Auzerie, V., Mahé, E., Marck, Y., Auffret, N., Descamps, V., Crickx, B.: Oral lichenoid eruption due to methacrylate allergy. Contact Dermatitis 45, 241 (2001).
10. Axell, T., Björkner, B., Fregert, S., Niklasson, B.: Standard patch test series for screening of contact allergy to dental materials. Contact Dermatitis 9, 82–84 (1983).
11. Becher, R., Kopperud, H.M., Al, R.H., Samuelsen, J.T., Morisbak, E., Dahlman, H.J., Lilleaas, E. M., Dahl, J. E.: Pattern of cell death after in vitro exposure to GDMA, TEGDMA, HEMA and two compomer extracts. Dent Mater 22, 630–640 (2006).
12. Benderli, Y., Ulukapi, H., Balkanli, O., Külekci, G.: In vitro plaque formation on some dental filling materials. J Oral Rehabil 24, 80–83 (1997).
13. Bergenholtz, G.: Evidence of bacterial causation of adverse pulpal responses in resin-based dental restorations. Crit Rev Oral Biol Med 11, 467–480 (2000).
14. Björkner, B., Niklasson, B., Persson, K.: The sensitizing potential of di-(meth)acrylates based on bisphenol A or epoxy resin in the guinea pig. Contact Dermatitis 10, 286–304 (1984).
15. Bong, J.L., English, J.S.C.: Allergic contact dermatitis from airborne exposure to acrylates. Contact Dermatitis 43, 242 (2000).
16. Borzelleca, J.F., Larson, P.S., Hennigar, G.R. Jr, Huf, E.G., Crawford, E.M., Smith, R.B. Jr.: Studies on the chronic oral toxicity of monomeric ethyl acrylates and methyl methacrylate. Toxicol Appl Pharmacol 6, 29–36 (1964).
17. Bouillaguet, S., Virgillito, M., Wataha, J., Ciucchi, B., Holz, J.: The influence of dentine permeability on cytotoxicity of four dentine bonding systems, in vitro. J Oral Rehabil 25, 45–51 (1998).
18. Bouillaguet, S., Wataha, J.C., Hanks, C.T., Ciucchi, B., Holz, J.: In vitro cytotoxicity and dentin permeability of HEMA. J Endod 22, 244–248 (1996).
19. Braun, A.-R., Frankenberger, R., Krämer, N.: Clinical performance and margin analysis of Ariston pHc versus Solitaire I as posterior restoration after one year. Clin Oral Investig 5, 139–147 (2001).
20. Breeding, L.C., Dixon, D.L., Caughman, W.F.: The curing potential of light-activated resin-based composites luting agents. J Prosthet Dent 65, 512–518 (1991).
21. Brentegani, L.G., Bombonato, K.F., Carvalho, T.L.: Immediate implantation of glass ionomer cement granules increases osteogenesis during rat alveolar wound healing. J Nihon Univ Sch Dent 38, 141–145 (1996).
22. Camps, J., Pashley, D.H.: Buffering action of human dentin in vitro. J Adhes Dent 2, 39–50 (2000).
23. Caughman, W.F., Caughman, G.B., Shiflett, R.A., Rueggeberg, F., Schuster, G.S.: Correlation of cytotoxicity, filler loading and curing time of dental composites. Biomaterials 12, 737–740 (1991).
24. Caughman, G.B., Schuster, G.S., Rueggeberg, F.: Cell lipid alterations resulting from prolonged exposure to dimethylaminoethylmethacrylate. Clin Oral Investig 3, 181–187 (1999).
25. Cavalcanti, B.N., Rode, S.M., Marques, M.M.: Cytotoxicity of substances leached or dissolved from pulp capping materials. Int J Endod 38, 505–509 (2005).
26. Chang, H.H., Guo M.K., Kasten, F.H., Chang M.C., Huang, G.F., Wang, Y. L.: Stimulation of glutathione depletion, ROS production and cell cycle arrest of dental pulp cells and gingival epithelial cells by HEMA. Biomaterials 26, 745–753 (2005).
27. Chung, K., Greener, E.H.: Degree of conversion of seven light-cured posterior composites. J Oral Rehabil 15, 555–562 (1988).
28. Ciucchi, B., Bouillaguet, S., Delaloye, M., Holz, J.: Volume of the internal gap formed under composite restorations in vitro. J Dent 25, 305–312 (1997).
29. Connolly, M., Shaw, L., Hutchinson, I., Ireland, A.J., Dunnill, M.G., Sansom, J. E.: Allergic contact dermatitis from bisphenol A-glycidyldimethacrylat during application of orthodontic fixed appliance. Contact Dermatitis 55, 367–368 (2006).
30. Cox, C.F., Hafez, A.A., Akimoto, N., Otsuki, M., Suzuki, S., Tarim, B.: Biocompatibility of primer, adhesive and resin composite systems on nonexposed and exposed pulps of nonhuman primate teeth. Am J Dent 11, S55–S63 (1998).
31. Cross, N.G., Taylor, R.F., Nunez, L.J.: "Single-step" orthodontic bonding systems: possible mutagenic potential. Am J Orthod 84, 344–350 (1983).
32. De Souza Costa, C.A., Hebling, J., Hanks, C.T.: Current status of pulp capping with dentin adhesive systems: a review. Dent Mater 16, 188–197 (2000).
33. De Souza Costa, C.A., Lopes do Nascimento, A.B., Teixeira, H.M., Fontana, U. F.: Response of human pulps capped with a self-etching adhesive system. Dent Mater 17, 230–240 (2001).
34. Decup, F., Six, N., Palmier, B., Buch, D., Lasfargues, J.-J., Salih, E., Goldberg, M.: Bone sialoprotein-induced reparative dentinogenesis in the pulp of rat's molar. Clin Oral Investig 4, 110–119 (2000).
35. Deichmann, W.: Toxicity of methyl, ethyl, and N-butyl methacrylate. J Ind Hyg Toxicol 23, 343–351 (1941).
36. Demarco, F.F., Tarquinio, S.B., Jaeger, M.M., de Araujo, V.C., Matson, E.: Pulp response and cytotoxicity evaluation of 2 dentin bonding agents. Quintessence Int 32, 211–220 (2001).
37. Demirci, M., Hiller, K.-A., Bosl, C., Galler, K., Schmalz, G., Schweikl, H.: The induction of oxidative stress, cytotoxicity and genotoxicity by dental adhesives. Dent Mater 24, 362–371 (2008).

Dentlearn.ir

38. Dijken van, J.W.V., Sjöström, S., Wing, K.: Development of gingivitis around different types of composite resin. J Clin Periodont 14, 257 (1987).
39. Dörfer, C.E., Staehle, H.J., Wurst, M.W., Duschner, H., Pioch, T.: The nanoleakage phenomenon: influence of different dentin bonding agents, thermocycling and etching time. Eur J Oral Sci 108, 346–351 (2000).
40. Dondi dall'Orologio G., Lone A., Finger W.J.: Clinical evaluation of the role of glutardialdehyde in a one-bottle adhesive. Am J Dent 15, 330–334 (2002).
41. Ebi, N., Imazato, S., Noiri, Y., Ebisu, S.: Inhibitory effects of resin composites containing bactericide-immobilized filler on plaque accumulation. Dent Mater 17, 485–491 (2001).
42. Elbaum, R., Remusat, M., Brouillet, J.L.: Biocompatibility of an enamel-dentin adhesive. Quintessence Int 23, 773–782 (1992).
43. Eliades T., Hiskia A., Eliades G., Athanasiou A. E.: Assessment of bisphenol A release from orthodontic adhesives. Am J Orthod Dentofacial Orthop 131 (1), 72–75 (2007).
44. Engelmann, J., Janke, V., Volk, J., Leyhausen, G., von Neuhoff N., Schlegelberger, B. et al.: Effects of Bis-GMA on glutathione metabolism and apoptosis in human gingival fibroblasts in vitro. Biomaterials 25, 4573–4580 (2004).
45. Engelmann J., Leyhausen G., Leibfritz D., Geurtsen W.: Effect of TEGDMA on the intracellular glutathione concentration of human gingival fibroblasts. J Biomed Mater Res (Appl Biomater) 63, 746–751 (2002).
46. Ergücü Z., Hiller K.-A., Schmalz G.: Influence of dentin on the effectivity of antibacterial agents. J Endod 31, 124–129 (2005).
47. Ernst, C.-P., Martin, M., Stuff, S., Willershausen, B.: Clinical performance of a packable resin composite for posterior teeth after three years. Clin Oral Investig 5, 148–155 (2001).
48. European Union: Risk Assessment Report, vol. 37. 4,4'-Isopropylidenediphenol (bisphenol A). Institute for Health and Consumer Protection, Ispra, Italy, 2003.
49. Felden, A., Schmalz, G., Federlin, M., Hiller, K.-A.: Retrospective clinical investigation and survival analysis on ceramic inlays and partial ceramic crowns: results up to 7 years. Clin Oral Investig 2, 161–167 (1998).
50. Felton, D., Bergenholtz, G., Cox, C.F.: Inhibition of bacterial growth under composite restorations following GLUMA pretreatment. J Dent Res 68, 491–495 (1989).
51. Ferracane, J.L.: Elution of leachable components from composites. J Oral Rehabil 21, 441–452 (1994).
52. Ferracane, J.L.: Current trends in dental composites. Crit Rev Oral Biol Med 6, 302–318 (1995).
53. Ferracane, J.L., Condon, J.R.: Rate of elution of leachable components from composite. Dent Mater 6, 282–287 (1990).
54. Finer, Y., Santerre, J.P.: The influence of resin chemistry on a dental composite's biodegradation. J Biomed Mater Res 69 A, 233–246 (2004).
55. Finer, Y., Santerre, J.P.: Salivary esterase activity and its association with the biodegradation of dental composites. J Dent Res 83 (1), 22–26 (2004).
56. Fredericks, H.E.: Mutagenic potential of orthodontic bonding materials. Am J Orthod 80, 316–324 (1981).
57. Friedl, K.-H., Hiller, K.-A., Schmalz, G., Bey, B.: Clinical and quantitative marginal analysis of feldspathic ceramic inlays at 4 years. Clin Oral Investig 1, 163–168 (1997).
58. Friedl, K.-H., Schmalz, G., Hiller, K.-A.: Flüssigkeitskulturen zur Prüfung der Wirkung zahnärztlicher Werkstoffe auf das Bakterienwachstum. [Liquid cultures for testing the antibacterial effect of dental materials] Dtsch Zahnärztl Z 47, 826–831 (1992).
59. Fuks, A.B., Funnell, B., Cleaton-Jones, P.: Pulp response to a composite resin inserted in deep cavities with and without a surface seal. J Prosthet Dent 63, 129–134 (1990).
60. Fung, E.Y.K., Ewoldsen, N.O., St.Germain, H.A., Marx, D.B., Miaw, C.L., Siew, Ch., Chou, H.N., Gruninger, S.E., Meyer, D.M.: Pharmacokinetics of bisphenol A released from a dental sealant. J Am Dent Assoc 131, 51–58 (2000).
61. Galler, K., Hiller K.-A., Ettl T., Schmalz, G.: Selective influence of dentin thickness upon cytotoxicity of dentin contacting materials. J Endod 31, 396–399 (2005).
62. Gerzina, T.M., Hume, W.R.: Effect of dentine on release of TEGDMA from resin composite in vitro. J Oral Rehabil 21, 463–468 (1994).
63. Geurtsen, W.: Substances released from dental resin composites and glass ionomer cements. Eur J Oral Sci 106, 687–695 (1998).
64. Geurtsen, W., Lehmann, F., Spahl, W., Leyhausen, G.: Cytotoxicity of 35 dental resin composite monomers/additives in permanent 3T3 and three human primary fibroblast cultures. J Biomed Mater Res 41, 474–480 (1998).
65. Geurtsen, W., Spahl, W., Leyhausen, G.: Variability of cytotoxicity and leaching of substances from four light-curing pit and fissure sealants. J Biomed Mater Res 44, 73–77 (1999).
66. Gilpatrick, R.O., Johnson, W., Moore, D., Turner, J.: Pulpal response to dentin etched with 10% phosphoric acid. Am J Dent 9, 125–129 (1996).
67. Gjerdet, N.R., Askevold, E.: National reporting of adverse reactions to dental materials. The Norwegian Registry. J Dent Res 77, 823 (1998).
68. Goldberg, N.B., Goldberg, A.F., Gergans, G.A., Loga, S., Taschini, P., Molnar, Z.V.: A rabbit lung model for testing reaction to inhaled dental restorative particles. Chest 101, 829–832 (1992).
69. Goon, A.T., Isaksson, M., Zimerson, E., Goh, C.L. Bruze, M.: Contact allergy to (meth)acrylates in the dental series in southern Sweden: simultaneous positive patch test reaction patterns and possible screening allergens. Contact Dermatitis, 55, 219–226 (2006).
70. Granath, F., Tornqvist, M.: Who knows whether acylamide in food is hazardous to humans? J Natl Cancer Inst 95, 842–843 (2003).
71. Grieve, A.R., Alani, A., Saunders, W.P.: The effects on the dental pulp of a composite resin and two dentine bonding agents and associated bacterial microleakage. Int Endod J 24, 108–118 (1991).
72. Gwinnett, A.J., Tay, F.: Early and intermediate time response of the dental pulp to an acid etch technique in vivo. Am J Dent 11, 35–44 (1998).
73. Hallström, U.: Adverse reaction to a fissure sealant. Report of a case. J Dent Child 60, 143–146 (1993).
74. Hamid, A., Hume, W.R.: A study of component release from resin pit and fissure sealants in vitro. Dent Mater 13, 98–102 (1997).
75. Hamid, A., Hume, W.R.: Diffusion of resin monomers through human carious dentin in vitro. Endod Dent Traumatol 13, 1–5 (1997).
76. Hamid, A., Hume, W.R.: The effect of dentine thickness on diffusion of resin monomers in vitro. J Oral Rehabil 24, 20–25 (1997).
77. Hamid, A., Sutton, W., Hume, W.R.: Variation in phosphoric acid concentration and treatment time and HEMA diffusion through dentin. Am J Dent 9, 211–214 (1996).
78. Hammer, B., Hotz, P.: Inspection of 1 to 5-year-old amalgam, composite and cast gold fillings. Schweiz Monatsschr Zahnheilkd 89, 301–314 (1979).

Dentlearn.ir

79. Hanks, C.T., Strawn, S.E., Wataha, J.C., Craig, R.G.: Cytotoxic effects of resin components on cultured mammalian fibroblasts. J Dent Res 70, 1450–1455 (1991).
80. Hanks, C.T., Wataha, J.C., Parsell, R.R., Strawn, S.E.: Delineation of cytotoxic concentrations of two dentin bonding agents in vitro. J Endod 18, 589–596 (1992).
81. Hannig, M., Bott, B.: In vitro pulp chamber temperature rise during composite resin polymerization with various light-curing sources. Dent Mater 15, 275–281 (1999).
82. Hansasuta, C., Neiders, M.E., Aguirre, A., Cohen, R.E.: Cellular inflammatory response to direct restorative composite resins. J Prosthet Dent 69, 611–616 (1993).
83. Hansel, C., Leyhausen, G., Mai, U.E., Geurtsen, W.: Effects of various resin composite (co)monomers and extracts on two caries-associated micro-organisms in vitro. J Dent Res 77, 60–67 (1998).
84. Hansen, K.: Gyldendals Grønne Forbrugerleksikon. [The Green Consumer's Encyclopedia] Gyldendal, Copenhagen 1999, p 496.
85. Harnirattisai, C., Hosoda, H.: Pulpal responses to various dentin bonding systems in dentin cavities. Dent Mater J 10, 149–164 (1991).
86. Hashieh, I.A., Cosset, A., Franquin, J.C., Camps, J.: In vitro cytotoxicity of one-step dentin bonding system. J Endod 25, 89–92 (1999).
87. Hashimoto, Y., Nakamura, M.: Estrogenic activity of dental materials and bisphenol A related chemicals in vitro. Dent Mater J 19, 245–262 (2000).
88. Hashimoto, M., Ohno, H., Kaga, M., Endo, K., Sano, H., Oguchi, H.: In vivo degradation of resin-dentin bonds in humans over 1-3 years. J Dent Res 79, 1385–1391 (2000).
89. Hebling, J., Pashley, D.H., Tjaderhane, L., Tay, F.R.: Chlorhexidine arrests subclinical degradation of dentin hybrid layers in vivo. J Dent Res 84 (8), 741–746 (2005).
90. Hebling, J., Giro, E.M., Costa, C.A.: Biocompatibility of an adhesive system applied to exposed human dental pulp. J Endod 25, 676–682 (1999).
91. Hebling, J., Giro, E.M., Costa, C.A.: Human pulp response after an adhesive system appllication in deep cavities. J Dent 7, 557–564 (1999).
92. Heil, J., Reifferscheid, G., Waldmann, P., Leyhausen, G., Geurtsen, W.: Genotoxicity of dental materials. Mutat Res 368, 181–194 (1996).
93. Heitmann, T., Unterbrink, G.: Direct pulp capping with a dentinal adhesive resin system: a pilot study. Quintessence Int 26, 765–770 (1995).
94. Henriks-Eckermann, M.-L., Suuronen, K., Jolanke, R., Alanko, K.: Methacrylates in dental restorative materals. Contact Dermatitis 50, 233–237 (2004).
95. Hensten-Pettersen, A.: Allergiske reaksjoner pa dentale materialer. [Allergic reactions to dental materials] Nor Tannlegefor Tid 94, 573 (1984).
96. Hensten-Pettersen, A.: Skin and mucosal reactions associated with dental materials. Eur J Oral Sci 106, 707–712 (1998).
97. Hørsted-Bindslev, P., Vilkinis, V., Sidlaukas, A.: Direct capping of human pulps with dentin bonding system or with calcium hydroxide cement. Oral Surg Oral Med Oral Radiol Endod 96, 591–600 (2003).
98. Hofmann, N., Hugo, B., Schubert, K., Klaiber, B.: Comparison between a plasma arc light source and conventional halogen curing units regarding flexural strength, modulus, and hardness of photoactivated resin composites. Clin Oral Investig 4, 140–147 (2000).
99. Hofmann N., Hugo B., Klaiber B.: Effect of irradiation type (LED or QTH) on photo-activated composite shrinkage strain kinetics, temperature rise, and hardness. Eur J Oral Sci 110, 471–479 (2002).
100. Hosoda, H., Yamada, T., Inokoshi, S.: SEM and elemental analysis of resin composites. J Prosthet Dent 69, 669–676 (1990).
101. Hsu, C.Y.S., Donly, K.J., Drake, D.R., Wefel, J.S.: Effects of aged fluoride-containing restorative materials on recurrent root caries. J Dent Res 77, 418–425 (1998).
102. Hussey, D.L., Biagioni, P.A., Lamey, P.J.: Thermographic measurement of temperature change during resin composite polymerization in vivo. J Dent 23, 267–271 (1995).
103. Hutchinson, I.: Hypersensitivity to an orthodontic bonding agent. A case report. Br J Orthod 21, 331–333 (1994).
104. Imai, Y.: Comments on "Estrogenicity of resin-based composites and sealants used in dentistry". Environm Health Perspect 107, A290–A292 (1999).
105. Imai, Y., Komabayashi, T.: Elution of bisphenol A from composite resin: a model experiment. Dent Mater J 19, 133–138 (2000).
106. Imai, Y., Watanabe, M., Ohsaki, A.: Analysis of major components and bisphenol A in commercial Bis-GMA and Bis-GMA-based resins using high performance liquid chromotography. Dent Mater J 19, 263–269 (2000).
107. Imazato, S., Ehara, A., Torii, M., Ebisu, S.: Antibacterial activity of dentine primer containing MDPB after curing. J Dent 26, 267–271 (1998).
108. Imazato, S., Kinomoto, Y., Tarumi, H., Russell, R.R.B., McCabe, J.F.: Incorporation of antibacterial monomer MDPB in dentin primer. J Dent Res 76, 768–772 (1997).
109. Imazato, S., Walls, A.W.G., Kuramato, A., Ebisu, S.: Penetration of an antibacterial dentine-bonding system into demineralized human root dentine in vitro. Eur J Oral Sci 110, 168–174 (2002).
110. Inokoshi, S., Shimada, Y., Fujitani, M., Otsuki, M., Shono, T., Onoe, N., Morigami, M., Takatsu, T.: Monkey pulpal response to adhesively luted indirect resin composite inlays. Oper Dent 20, 111–118 (1995).
111. Inoue, K., Wada, M., Higuchi, T., Osgio, S., Umeda, T., Yoshimura, Y., Nakazawa, H.: Application of liquid chromatography-mass spectrometry to the quantification of bisphenol A in human semen. J Chromatogr B Analyt Technol Biomed Life Sci 773 (2), 97–102 (2002).
112. Interim NTP CERHR Report on the Reproductive and Developmental Toxicity of Bisphenol A. Center for the Evaluation of Risks, U.S. Department of Health and Human Services (2007).
113. Inoue, K., Hayashi, I.: Residual monomer (Bis-GMA) of resin composites. J Oral Rehabil 9, 493–497 (1982).
114. Inoue, T., Miyakoshi, S., Shimono, M.: The in vitro and in vivo influence of 4-META/MMA-TBB resin components on dental pulp tissues. Adv Dent Res 15, 101–104 (2001).
115. Isaksson, M., Lindberg, M., Sundberg, K., Hallander, A., Bruze, M.: The development and course of patch-test reactions to 2-hydroxyethyl methacrylate. Contact Dermatitis 53, 292–297 (2005).
116. Jolanki, R., Kanerva, L., Estlander, T.: Occupational allergic contact dermatitis caused by epoxy diacrylate in ultraviolet-light-cured paint, and bisphenol A in dental composite resin. Contact Dermatitis 33, 94–99 (1995).
117. Jontell, M., Hanks, C.T., Bratel, J., Bergenholtz, G.: Effects of unpolymerized resin components on the function of accessory cells derived from the rat incisor pulp. J Dent Res 74, 1162–1167 (1995).

Dentlearn.ir

118. Joskow R., Barr D. B., Barr J. R., Calafat A. M., Needham L. L., Rubin C.: Exposure to bisphenol A from bis-glycidyl dimethacrylate-based dental sealants. J Am Dent Assoc 137 (3), 353–362 (2006).
119. Kaaden C., Schmlaz G., Powers J. M.: Morphological characterization of the resin dentin interface in primary teeth. Clin Oral Investig 7, 235–240 (2003).
120. Kaga, M, Ito, Y., Okabe, T., Oguchi, H., Ota, M.: Quantitative evaluation by measuring affected area for cytotoxicity of dental materials. Shika Zairyo Kikai 9, 591–599 (1990).
121. Kanerva, L., Alanko, K.: Stomatitis and perioral dermatitis caused by epoxy diacrylates in dental composite resins. J Am Acad Derm 38, 116–120 (1998).
122. Kanerva, L., Estlander, T., Jolanki, R.: Allergic contact dermatitis from dental composite resins due to aromatic epoxy acrylates and aliphatic acrylates. Contact Dermatitis 20, 201–211 (1989).
123. Kanerva L., Estlander T., Jolanki R.: False negative patch test reaction caused by testing with dental composite acrylic resin. Int J Dermatol 35, 189–192 (1996).
124. Kanerva, L., Estlander, T., Jolanki, R.: Occupational allergic contact dermatitis caused by acrylic tri-cure glass ionomer. Contact Dermatitis 37, 49–50 (1997).
125. Kanerva, L., Estlander, T., Jolanki, R., Pekkarinen, E.: Occupational pharyngitis associated with allergic patch test reactions from acrylics. Allergy 47, 571–573 (1992).
126. Kanerva, L., Jolanki, R., Leino, T., Estlander, T.: Occupational allergic contact dermatitis from 2-hydroxyethyl methacrylate and ethylene glycol dimethacrylate in a modified acrylic structural adhesive. Contact Dermatitis 33, 84–89 (1995).
127. Kanerva, L., Mikola, H., Henriks-Eckerman, M.L., Jolanki, R., Estlander, T.: Fingertip paresthesia and occupational allergic contact dermatitis caused by acrylics in a dental nurse. Contact Dermatitis 38, 114–116 (1998).
128. Kanerva, L., Lahtinen, A., Toikkanen, J., Forss, H., Estlander, T., Susitaival, P. Jolanki, R.: Increase in occupational skin diseases of dental personnel. Contact Dermatitis 40, 104–108 (1999).
129. Kanerva, L., Zwanenburg, R.: Allergic contact reactions to poly(oxy-1,2-ethanediyl)α,α'-[(1-methylethylidene)di-4,1-phenylene]bis[ω-[(2-methyl-1-oxo-2-propenly)oxyl] (BIS-EMA). Contact Dermatitis 43, 115–117 (2000).
130. Katsuno, K., Manabe, A., Kurihara, A., Itoh, K., Hisamitsu, H., Wakumoto, S., Yoshida, T.: The adverse effect of commercial dentine-bonding systems on the skin of guinea pigs. J Oral Rehabil 25, 180–184 (1998).
131. Kawai, K., Heaven, T.J., Retief, D.H.: In vitro dentin fluoride uptake from three fluoride containing composites and their acid resistents. J Dent 25, 291–296 (1997).
132. Kirkland, D., Pfuhler, S., Twaets, D., Aardema, M., Corvi, R., Darroudi, F., et al.: How to reduce false positive results when undertaking in vitro genotoxicity testing and thus avoid unnecessary follow-up animal tests: report of an ECVAM Workshop. Mutat Res 628, 31–55 (2007)
133. Koch P.: Allergic contact stomatitis from BIS-GMA and epoxy resins in dental bonding agents. Contact Dermatitis 49, 104–105 (2003).
134. Koga, M., Noda, M., Ferracane, J.L., Nakamura, W., Oguchi, H., Sano, H.: The in vitro cytotoxicity of eluates from dentin bonding resin and their effect on tyrosine phosphorylation of L929 cells. Dent Mater 17, 333–339 (2001).
135. Koliniotou-Koubia, E., Dionysopoulos, P., Koulaouzidou, E.A., Kortsaris, A.H., Papadogiannis, Y.: In vitro cytotoxicity of six dentin bonding agents. J Oral Rehabil 28, 971–975 (2001).
136. Koliniotou-Koumpia, E., Tziafas, D.: Pulpal responses following direct pulp capping of healthy dog teeth with dentine adhesive systems. J Dent 33, 639–647 (2005).
137. Kolokuris, I., Bletes, P., Edonomides, N., Vlemmas, I.: Experimental study of the biocompatibility of a new glass ionomer root canal sealer (Ketac-Endo). J Endod 22, 395–398 (1996).
138. Kostoryz, E.L., Eick J.D., Glaros, A.G., Judy, B.M., Welshons, W.V., Burmaster, S., Yourtee, D.M.: Biocompatibility of hydroxylated metabolites of Bis-GMA and BFDGE. J Dent Res 82, 367–371 (2003).
139. Kostoryz, E.L., Tong, P.Y., Chappelow, C.C., Eick, J.D., Glaros, A.G., Yourte, D.M.: In vitro cytotoxicity of solid epoxy-based dental resins and their components. Dent Mater 15, 363–373 (1999).
140. Lacour, M., Zunder, T., Schmidtke, K., Vaith, P., Scheidt, C.: Multiple chemical sensitivity syndrome (MCS) – suggestions for an extension of the U.S. MCS-case definition. Int J Hyg Environ Health 208, 141–51 (2005).
141. Lazarov, A.: Sensitization to acrylates is a common adverse reaction to artificial fingernails. J Eur Acad Dermatol Venereol 21, 169–174 (2007).
142. Lee, S., Pagoria, D., Raigrodski, A., Geurtsen, W.: Effects of combinations of ROS scavengers on oxidative DNA damage caused by visible-light-activated camphorquinone/N,N-dimethyl-p-toluidine. J Biomed Mater Res B Appl Biomater 83(2), 391–399 (2007).
143. Lefeuvre, M., Amjaad, W., Goldberg, M., Stanislawski, L.: TEGDMA induces mitochondrial damage and oxidative stress in human gingival fibroblasts. Biomaterials 26, 5130–5137 (2005).
144. Leyhausen, G., Heil, J., Reifferscheid, G., Geurtsen, W.: Das gentoxische Potential von Kompositbestandteilen. [Genotoxic properties of composite resin ingredients]. Dtsch Zahnärztl Z 50, 134–136 (1995).
145. Lewis J. B., Rueggeberg, F.A., Lapp C.A., Ergle J.W.: Identification and characterization of estrogen-like components in commercial resin-based dental restorative materials. Clin Oral Investig 3, 107–113 (1999).
146. Lind, P.O.: Oral lichenoid reactions related to composite restorations. Preliminary report. Acta Odontol Scand 46, 63–65 (1988).
147. Lu, Y., Li, X., Li, H., Pi, G.: Histological evaluation of direct pulp capping with a self-etching adhesive and calcium hydroxide in beagles. Oral Surg Oral Med Oral Pathol Oral Radiol Endod 102, e78–e84 (2006).
148. Mantellini, M.G., Botero, T.M., Yaman, P., Dennison, J.B., Hanks, C.T., Nör, J.E.: Adhesive resin induces apoptosis and cell-cycle arrest of pulp cells. J Dent Res 82, 592–596 (2003).
149. Mariotti, A., Söderholm, K.J., Johnson, S.: The in vivo effects of Bis-GMA on murine uterine weight, nucleic acids and collagen. Eur J Oral Sci 106, 1022–1027 (1998).
150. Mathias, C.G., Caldwell, T.M., Maibach, H.I.: Contact dermatitis and gastrointestinal symptoms from hydroxyethylmethacrylate. Br J Dermatol 100 (4), 447–449 (1979).
151. Meng, C.L., Wang, W.N., Yeh, I.S.: Fluoridated etching on orthodontic bonding. Am J Orthod Dentofac Orthop 112, 259–262 (1997).
152. Michelich, V., Pashley, D.H., Withford, G.M.: Dentin permeability. A comparison of functional versus anatomical tubular radii. J Dent Res 57, 1019–1024 (1978).
153. Millich, F., Jeang, L., Eick, J.D., Chappelow, C.C., Pinzino, C.S.: Elements of light-cured epoxy-based dental polymer systems. J Dent Res 77, 603–608 (1998).

Dentlearn.ir

154. Munksgaard, E.C.: Permeability of protective gloves to (di)methacrylates in resinous dental materials. Scand J Dent Res 100, 189–192 (1992).
155. Munksgaard, E.C., Hansen, E.K., Engen, T., Holm, U.: Self-reported occupational dermatological reactions among Danish dentists. Eur J Oral Sci 104, 396–402 (1996).
156. Munksgaard, E.C., Peutzfeldt, A., Asmussen, E.: Elution of TEGDMA and Bis-GMA from a resin and a resin composite cured with halogen or plasma light. Eur J Oral Sci 108, 341–345 (2000).
157. Murray, P.E., Hafez, A.A., Smith, A.J., Cox, C.F.: Identification of hierarchial factors to guide clinical decision making for successful long-term pulp capping. Quintessence Int 34, 61–70 (2003).
158. Nadarajah, C., Cohen, R.E., Neiders, M.E., Aguirre, A.: Cellular inflammatory responses to implanted dental materials. J Prosthet Dent 75, 552–561 (1996).
159. Nathanson, D., Lertpitayakun, P., Lamkin, M.S., Edalatpour, M., Chou, L.L.: In vitro elution of leachable components from dental sealants. J Am Dent Assoc 128, 1517 (1997).
160. Nathanson, P., Lochart, P.: Delayed extraoral hypersensitivity to dental composite material. Oral Surg Oral Med Oral Pathol 47, 329–333 (1979).
161. Nathanson, D., Ghulman, M., Ashayeri, N., Chou, L.: In vitro estrogenic activity of leachable components from dental sealants and components. J Dent Res 78, 130 (1999).
162. Nishiyama, N., Suzuki, K., Yoshida, H., Teshima, H., Nemoto, K.: Hydrolytic stability of methacrylamide in acidic aqueous solutions. Biomaterials 25, 965–969 (2004).
163. Noda M., Wataha J.C., Lockwood P.E., Volkmann K.R., Kaga, M., Sano, H.: Sublethal, 2-week exposures of dental material components alter TNF-α secretion of THP-1 monocytes. Dent Mater 19, 101–105 (2003).
164. Örtengren, U., Andreasson, H., Karlsson, S., Meding B., Barregard, L.: Prevalence of self-reported hand eczema and skin symptoms associated with dental materials among Swedish dentists. Eur J Oral Sci 107, 496–505 (1999).
165. Olea, N., Pulgar, R., Perez, P., Olea-Serrano, F., Rivas, A., Novillo-Fertrell, A., Pedraza, V., Soto, A.M., Sonnenschein, C.: Estrogenicity of resin-based composites and sealants used in dentistry. Environ Health Perspect 104, 298–305 (1996).
166. Onur, M.A., Çehreli, Z.C., Tasman, F., Gümrükcüoglu, A.: Neurotoxic effects of fifth-generation dentin adhesives on rat sciatic nerve. J Endod 27, 676–678 (2001).
167. Opdam, N.J., Feilzer, A.J., Roeters, J.J., Smale, I.: Class I occlusal composite restorations: in vivo post-operative sensitivity, wall adaptation, and microleakage. Am J Dent 11, 229–234 (1998).
168. Osorio, R.M., Hefti, A., Vertucci, F.J., Shawley, A.L.: Cytotoxicity of endodontic materials. J Endod 24, 91–96 (1998).
169. Oysaed, H., Ruyter, I.E.: Water sorption and filler characteristics of composites for use in posterior teeth. J Dent Res 65, 1315–1318 (1986).
170. Oysaed, H., Ruyter, I.E., Sjövik Kleven, I.J.: Release of formaldehyde from dental composites. J Dent Res 67, 1289–1294 (1988).
171. Pameijer, C.H., Stanley, H.R.: The disastrous effects of the "total etch" technique in vital pulp capping in primates. Am J Dent 11, S45–S54 (1998).
172. Park, S.H., Kim, K.Y.: The anticariogenic effect of fluoride in primer, bonding agent, and composite resin in the cavosurface enamel area. Oper Dent 22, 115–120 (1997).
173. Pashley, D.H.: Smear layer: physiological considerations. Oper Dent 3, 13–29 (1984).
174. Pashley, D.H., Derkson, G.D., Tao, L., Derkson, M., Kalathoor, S.: The effects of a multi-step dentin bonding system on dentin permeability. Dent Mater 4, 60–63 (1988).
175. Pashley, D.H., Michelich, V., Kehl, T.: Dentin permeability: effects of smear layer removal. J Prosthet Dent 46, 531–537 (1981).
176. Pascon, E.A., Sousa, C.J.A., Ricucci, D., Langeland, H.: Dentin and pulp tissue response to direct acid etching. J Dent Res 80, 191(2001).
177. Palmer, T.M., Yost, M.P., Latey, M.L., Ashton, J.A., Syndergaard, B.D., Christensen, R.P.: Light emitting diode resin polymerization compared to three other methods. J Dent Res 81, A-486 (2002).
178. Pearson, G.J., Longman, C.M.: Water sorption and solubility of resin-based materials following inadequate polymerization by a visible-light curing system. J Oral Rehabil 16, 57–61 (1989).
179. Perale, L., De Marchi, S., Cecchin, E., Sechi, L. A.: Methacrylates allergy in a professional beautician. Contact Dermatitis 53 (3), 181–182 (2005).
180. Petersen, J.K.: Akut angioødem udløst af en dentinbinder og komposit plastmateriale. [Acute angioedema caused by a dentin bonding agent and composite] Tandlægebladet 100, 223–225 (1996).
181. Peutzfeldt, A.: Resin composites in dentistry: the monomer systems. Eur J Oral Sci 105, 97–116 (1997).
182. Phillips, R.W.: Science of Dental Materials. W.B. Saunders, Philadelphia, 1991.
183. Piirilä, P., Kanerva, L., Keskinen, H., Estlander, T., Hytönen, M., Tuppurainen, M., Nordman, H.: Occupational respiratory hypersensitivity caused by preparations containing acrylates in dental personnel. Clin Exp Allergy 28, 1404–1411 (1998).
184. Plant, C.G., Tobias, R.S., Browne, R.M.: Pulpal response to an experimental adhesion promoter. J Oral Pathol 15, 196–200 (1986).
185. Pulgar, R., Olea-Serrano, M.F., Novillo-Fertrell, A., Rivas, A., Pazos, P., Pedraza, V., Navajas, J.M., Olea N.: Determination of bisphenol A and related aromatic compounds released from Bis-GMA-based composites and sealants by high performance liquid chromatography. Environ Health Perspect 108, 21–27 (2000).
186. Quinlan, C.A., Zisterer, D.M., Tipton, K.F., O'Sullivan, M.I.: In vitro cytotoxicity of a composite resin and compomer. Int Endod J 35, 47–55 (2002).
187. Ratanasathien, S., Wataha, J.C., Hanks, C.T., Dennison, J.B.: Cytotoxic interactive effects of dentin bonding components on mouse fibroblasts. J Dent Res 74, 1602–1606 (1995).
188. Reichl, F.X., Durner, J., Hickel, R., Kunzelmann, K.H., Jewett, A., Wang, M.Y., et al.: Distribution and excretion of TEGDMA in guinea pigs and mice. J Dent Res 80, 1412–1415 (2001).
189. Reichl, F.X., Durner, J., Kunzelmann, K.H., Hickel, R., Spahl, W., Hume, W.R., et al.: Biological clearance of TEGDMA in guinea pigs. Arch Toxicol 75, 22–27 (2001).
190. Reichl, F.X., Durner, J., Hickel, R., Spahl, W., Kehe, K., Walther, U., et al.: Uptake, clearance and metabolism of TEGDMA in guinea pigs. Dent Mater 18, 581-589 (2002).
191. Reichl, F.X., Durner, J., Manhart, J., Spahl, W., Gempel, K., Kehe, K., et al.: Biological clearance of HEMA in guinea pigs. Biomaterials 23, 2135–2141 (2002).
192. Reichl, F.X., Durner, J., Manhart, J., Hickel, R., Spahl, W., Liebl, B., et al.: Toxicokinetic of HEMA in guinea pigs. J Dent 30, 353–358 (2002).
193. Richter, G., Geier, J.: Dentalwerkstoffe – Problemsubstanzen in der allergologischen Diagnostik? Teil I. [Dental material – are there problematic substances for allergy diagnostics? Part I.] Hautarzt 47, 839 (1996).

Dentlearn.ir

194. Rietschel, R.L., Huggins, R., Levy, N., Pruitt, P.M.: In vivo and in vitro testing of gloves for protection against UV-curable acrylate resin system. Contact Dermatitis 11, 279–282 (1984).
195. Rix, M., Andersen, U.M.: Anafylaktisk chock udlost af tandlak, inneholdende metacrylat. [Anaphylactic reaction elicited by a fissure sealant, containing methacrylate] Tandlaegernes Nye Tidsskrift 10, 358–359 (1995).
196. Rueggeberg, F.A., Caughman, W.F.: The influence of light exposure on polymerization of dual-cure resin cements. Oper Dent 18, 48–55 (1993).
197. Ruyter, I.E.: Physical and chemical aspects related to substances released from polymer materials in an aqueous environment. Adv Dent Res 9, 344–347 (1995).
198. Samuelsen, J.T., Dahl J.E., Karlsson, S., Morisbak, E., Becher, R.: Apoptosis induced by the monomers HEMA and TEGDMA involves formation of ROS and differential activation of the MAP-kinases p38, JNK and ERK. Dent Mater 23, 34–39 (2007).
199. Sandberg, E., Dahlgren, U.I.: Application of HEMA on intact mouse skin. Effects on the immune system. Contact Dermatitis 54, 186–191 (2006).
200. Sano, H., Takatsu, T., Ciucchi, B., Horner, J.A., Matthews, W.G., Pashley, D.H.: Nanoleakage: leakage within the hybrid layer. Oper Dent 20, 18–25 (1995).
201. Santerre, J.P., Shajii, L., Leung, B.W.: Relation of dental composite formulations to their degradation and the release of hydrolyzed polymeric-resin-derived products. Crit Rev Oral Biol Med 12, 136–151 (2001).
202. Sasaki N., Okuda K., Kato T., Kakishima H., Okuma H., Abe K., Tachino H., Tuchida K., Kubono K.: Salivary bisphenol A levels detected by ELISA after restoration with composite resin. J Mater Sci Mater Med 16 (4), 297–300 (2005).
203. Satou, N., Morikowa, A., Ohmoto, K., Urabe, H., Shintani, H., Wakasa, K., Yamaki, M.: Adhesion of streptococci to saliva-coated and uncoated composite-based resins. J Mat Sci: Materials in Medicine, 749–752 (1996).
204. Savonius, B., Keskinen, H., Tuppurinen, M., Kanerva, L.: Occupational respiratory disease caused by acrylates. Clin Exp Allergy 23, 416–424 (1993).
205. Schedle, A., Franz, A., Rausch-Fan, X., Samorapoompichit, P., Boltz-Nitulescu, G., Slavicek, R.: Zellkulturuntersuchungen von zahnärztlichen Werkstoffen: Komposit im Vergleich zu Amalgam. [Cell culture testing of dental materials: a comparison between composite resin and dental amalgam] Z Stomatol Suppl. 6, 39–42 (1994).
206. Schiemann, S., Hannig, M., Albers, H.-K.: Zur potentiellen Zytotoxizität von Zementen auf Glasionomerbasis. [The cytotoxicity of glass ionomer based cements] Zahnärztl Welt/Reform 107, 518–524 (1998).
207. Schmalz, G.: Der Einfluss verschiedener Frontzahnfüllungsmaterialien auf das In-vitro-Wachstum von *Streptococcus mutans*. [Influence of different anterior filling materials on the in vitro growth of *Streptoccus mutans*] Dtsch Zahnärztl Z 32, 575–579 (1977).
208. Schmalz, G.: Die Gewebeverträglichkeit zahnärztlicher Materialien – Möglichkeiten einer standardisierten Prüfung in der Zellkultur. [Biocompatibility of dental materials – possibilities of a standardized cell culture testing] Thieme, Stuttgart 1981.
209. Schmalz, G.: Die lokale Gewebeverträglichkeit von Komposit-Kunststoffen. In: Neue Füllungsmaterialien. [Local biocompatibility of composite resins. In: New Filling Materials] Hanser, Munich 1990.
210. Schmalz, G.: The biocompatibility of nonamalgam dental filling materials. Eur J Oral Sci 106, 696–706 (1998).
211. Schmalz, G., Bühler, H.-J.: Toxizitätsprüfungen von Füllungsmaterialien im Ratten-Implantationstest. [Toxicity testing of filling materials in the rat implantation test] Dtsch Zahnärztl Z 38, 254–260 (1983).
212. Schmalz, G., Nunez, L.J.: Apparent effect of visible light upon *Salmonella* bacteria. J Dent Res 65, 540 (1986).
213. Schmalz, G., Hiller, K.-A., Nunez, L.J., Stoll, J., Weis, K.: Permeability characteristics of bovine and human dentin under different pretreatment conditions. J Endod 27, 23–30 (2001).
214. Schmalz, G., Hiller K.-A.: Bioactive approaches in restorative dentistry. Adv Dent Res 2008 [in press].
215. Schmalz, G., Hiller, K.-A., Bosl, C., Schweikl, H.: Generation of reactive oxygen species by dental composites. AADR 35th Meeting & Exhibition in Orlando, FL. J Dent Res 85 (spec iss A, www.dentalresearch.org), 1653 (2006).
216. Schmalz, G., Preiss, A., Arenholt-Bindslev, D.: Bisphenol A content of resin monomers and related degradation products. Clin Oral Investig 3, 114–119 (1999).
217. Schmalz, G., Schmalz, C.: Toxicity tests on dental filling materials. Int Dent J 31, 185–192 (1981).
218. Schmalz, G., Erlenkötter, M., Hickel, R., Schweikl, H., Hiller, K.-A.: Bacteria adherence on materials under dynamic conditions. J Dent Res 82 (spec iss A, www.dentalresearch.org), 1451, 2003.
219. Schmalz, G., Ergücü, Z., Hiller, K.-A.: Effect of dentin on the antibacterial activity of dentin bonding agents. J Endod 30, 352–358 (2004).
220. Schmalz, G., Schuster, U., Koch, A., Schweikl, H.: Cytotoxicity of low pH dentin-bonding agents in a dentin barrier test in vitro. J Endod 28, 188–192 (2002).
221. Schmalz G., Schweikl H., Hiller K.-A.: Release of prostaglandin E2, IL-6 and IL-8 from human oral epithelial culture models after exposure to compounds of dental materials. Eur J Oral Sci 108, 242–248 (2000).
222. Schuchardt & Co.: Methyl methacrylate (no. 64200), 2-hydroxyethyl methacrylate (no. 800588), 2,3-epoxypropyl methacrylate (no. 800609), 2,2-bis(4-hydroxy phenyl)-propane (no. 803546). Datenblätter [data sheets]. Hohenbrunn, Germany.
223. Schweikl, H., Altmannsberger, I., Hanser, N., Hiller, K.-A., Bolay, C., Brockhoff, G. et al.: The effect of triethylene glycol dimethacrylate on the cell cycle of mammalian cells. Biomaterials 26, 4111–4118 (2005).
224. Schweikl, H., Hartmann, A., Hiller, K.-A., Spagnuolo, G., Bolay, C., Brockhoff, G., et al.: Inhibition of TEGDMA and HEMA-induced genotoxicity and cell cycle arrest by N-acetylcysteine. Dent Mater 23, 688–695 (2006).
225. Schweikl, H., Spagnuolo, G., Schmalz, G.: Genetic and cellular toxicology of dental resin monomers. J Dent Res 85, 870–877 (2006).
226. Schweikl, H., Schmalz, G.: The V79/hprt mammalian gene mutation assay for the evaluation of dental materials for mutagenicity. J Dent Res 73, 953 (1994).
227. Schweikl, H., Schmalz, G.: Glutaraldehyde-containing dentin bonding agents are mutagens in mammalian cells in vitro. J Biomed Mater Res 36, 284–288 (1997).
228. Schweikl, H., Schmalz, G., Göttke, C.: Mutagenic activity of various dentine bonding agents. Biomaterials 17, 1451–1456 (1996).
229. Schweikl, H., Schmalz, G., Rackebrandt, K.: The mutagenic activity of unpolymerized resin monomers in *Salmonella typhimurium* and V79 cells. Mutat Res 415, 119–130 (1998).

Dentlearn.ir

230. Schweikl, H., Schmalz, G., Spruss, T.: The induction of micronuclei in vitro by unpolymerized resin monomers. J Dent Res 80, 1615–1620 (2001).
231. Schweikl, H., Schmalz, G., Weinmann W.: Mutagenic activity of structurally related oxiranes and siloranes in *Salmonella typhimurium*. Mutat Res 521, 19–27 (2002).
232. Segura, A., Donly, K.J.: In vitro posterior composite polymerization recovery following hygroscopic expansion. J Oral Rehabil 20, 495–499 (1993).
233. Sigma Aldrich Vertriebs GmbH.: Methyl methacrylate (no. 64200), triethylen glycol dimethacrylate (no. T5537). Datenblätter [data sheets]. Deisenhofen, Germany.
234. Söderholm, K.J.M.: Filler leachability during water storage of six composite materials. Scand J Dent Res 98, 82–88 (1990).
235. Söderholm, K.J., Zigan, M., Ragan, M., Fischlschweiger, W., Bergman, M.: Hydrolytic degradation of dental composites. J Dent Res 63, 1248–1254 (1984).
236. Söderholm, K.J., Mariotti, A.: Bis-GMA-based resins in dentistry: are they safe? J Am Dent Assoc 130, 201–209 (1999).
237. Söhoel, H., Gjerdet, N.R., Hensten-Pettersen, A., Ruyter, I.E.: Allergenic potential of two orthodontic bonding materials. Scand J Dent Res 102, 126–129 (1994).
238. Spagnuolo, G., Mauro, C., Leonardi, A., Santillo, M., Paterno, R., Schweikl, H. et al.: NF-kappaB protection against apoptosis induced by HEMA. J Dent Res 83, 837–842 (2004).
239. Spahl, W., Budzikiewics, H., Geurtsen, W.: Determination of leachable components from four commercial dental composites by gas and liquid chromatography/mass spectrometry. J Dent 26, 137–145 (1998).
240. Spealman, C.R., Main, R.J., Haag, H.B., Larson, P.S.: Monomeric methyl methacrylate. Ind Med 14, 292–298 (1945).
241. Speck W.T., Rosenkranz H.S.: Base substitution mutations induced in *Salmonella* strains by visible light (450 nm). Photochem Photobiol 21, 369–371 (1975).
242. Sperl, K.: Risikominimierung dentaler Legierungen. Rundschreiben der Interessengemeinschaft der Zahnmetallgeschädigten e.V. vom 5.12.1995. [Risk management of dental alloys. Circular letter of the patient organization of dental alloy victims, 5 Dec 1995].
243. Splieth C., Bernhardt O., Heinrich A., Bernhardt H., Meyer G.: Anaerobic microflora under Class I and Class II composite and amalgam restorations. Quintessenz Int 34 (7), 497–503 (2003).
244. Staehle, H.J.: Eine Risikoabschätzung bei Kunststoff-Materialien. [Risk assessment for composite resins] Zahnärztl Mitt 87, 24–34 (1997).
245. Staudenmayer H., Binkley K. E., Leznoff A., Phillips S.: Idiopathic environmental intolerance. Part 2: a causation analysis applying Bradford Hill's criteria to the psychogenic theory. Toxicol Rev 22, 247–261 (2003).
246. Stanislawski, L., Lefeuvre, M., Bourd, K., Soheili-Majd, E., Goldberg, M., Perianin, A.: TEGDMA-induced toxicity in human fibroblasts is associated with early and drastic glutathione depletion with subsequent production of oxygen reactive species. J Biomed Mater Res A 66, 476–482 (2003).
247. Steinbrunner, R.L., Setcos, J.C., Kafrawy, A.H.: Connective tissue reactions to glass ionomer cements and resin composites. Am J Dent 4, 281–284 (1991).
248. Stoll, R., Kook, K., Kunzelmann, K.H., Zöfel, P., Stachniss, V.: Influence of a high-speed polymerization method on the marginal integrity of composite fillings in class-II cavities. Clin Oral Investig 4, 42–49 (2000).
249. Suarez, S., Sueiro, R.A., Garrino, J.: Genotoxicity of the coating lacquer on food cans, bisphenol A diglycidyl ether (BADGE), its hydrolysis products and a chlorhydrin of BADGE. Mutat Res 470, 221–228 (2000).
250. Svanberg M., Mjör I.A., Orstavik D.: *Mutans Streptococci* in plaque from margins of amalgam, composite, and glass-ionomer restorations. J Dent Res 69, 861–864 (1990).
251. Svendsen, O., Garthoff, B., Spielmann, H., Hensten-Pettersen, A., Jensen, J.C., Kuijpers, M.R. et al.: Alternatives to the animal testing of medical devices. The report and recommendations of ECVAM Workshop 17. ATLA 24, 659–669 (1996).
252. Swartz, M.L., Phillips, R.W., Norman, S.D., Elliason, S., Rhodes, B.F., Clark, H.E.: Addition of fluoride to pit and fissure sealants – a feasibility study. J Dent Res 55, 757–771 (1976).
253. Swift, B., Walls, A.W.G., McCabe, J.F.: Porcelain veneers: the effects of contaminants and cleaning regimens on the bond strength of porcelain to composite. Br Dent J 23, 203–208 (1995).
254. Tanaka, K., Taira, M., Shintani, H., Wasaka, K., Yamaki, M.: Residual monomers (TEG-DMA and Bis-GMA) of a set visible-light-cured dental resin composite when immersed in water. J Oral Rehabil 18, 353–362 (1991).
255. Taningher, M., Pasquini, R., Bonatti, S.: Genotoxicity analysis of N,N-dimethylaniline and N,N-dimethyl-p-toluidine. Environ Mol Mutagen 21, 349–356 (1993).
256. Tarumi, H., Imazato, S., Narimatsu, M., Matsuo, M., Ebisu, S.: Estrogenicity of fissure sealants and adhesive resins determined by reporter gene assay. J Dent Res 79, 1838–1843 (2000).
257. Tassery, H., Remusat, M., Koubi, G., Pertot, W.J.: Comparison of the intraosseous biocompatibility of Vitremer and super EBA by implantation into the mandible of rabbits. Oral Surg Oral Med Oral Pathol Oral Radiol Endod 83, 602–608 (1997).
258. Tay, F.R., Pang, W.R., Gwinnett, A.J., Wey, S.H.Y.: A scanning electron microscopic study of the extent of resin penetration into human coronal dentin following a total etch technique in vivo. Cells and Materials 4, 317–329 (1994).
259. Tay, F.R., Pashley, D.H., Loushine, R. J., Weller, R.N., Monticelli, F., Osorio, R.: Self-etching adhesives increase collagenolytic activity in radicular dentin. J Endod 32, 862–868 (2006).
260. Teixeira, H.M., Do Nascimento, A.B., Hebling, J., De Souza, Costa, C.A.: In vivo evaluation of biocompatibility of three current bonding agents. J Oral Rehabil 33 (7); 542–550 (2006).
261. Torstenson, B.: Pulpal reaction to a dental adhesive in deep human cavities. Endod Dent Traumatol 11, 172–176 (1995).
262. Torii, Y., Itou, K., Nishitani, Y., Yoshiyama, M., Ishikawa, K., Suzuki, K.: Effect of self-etching primer containing N-acryloyl aspartic acid on enamel adhesion. Dent Mater 19, 253–258 (2003).
263. Tsuji J.S., Maynard A.D., Howard P.C., James J.T., Lam C., Warheit D.B., Santamaria A.B.: Research strategies for safety evaluation of nanomaterials, part IV: risk assessment of nanoparticles. Toxicol Sci 89 (1), 42–50 (2006).
264. Tziafas, D., Smith, A.J., Lesot, H.: Designing new treatment strategies in vital pulp therapy. J Dent 28, 77–92 (2000).
265. Ulukapi, H., Benderli, Y., Soyman, M.: Determination of fluoride release from light-cured glass-ionomers and a fluoridated composite resin from the viewpoint of curing time. J Oral Rehabil 23, 197–201 (1996).
266. Van Meerbeek, B., Inokoshi, S., Braem, M., Lambrechts, P., Vanherle, G.: Morphological aspects of the resin-dentin interdiffusion zone with different dentin adhesive systems. J Dent Res 71, 1530–1540 (1992).

Dentlearn.ir

267. Van Meerbeek, B., Perdigao, J., Lambrechts, P., Vanherle, G.: The clinical performance of adhesives. J Dent 26, 1–20 (1998).
268. Van Meerbeek, B., De Munck, J., Yoshida, Y., Inoue, S., Vargas, M., Vijay, P., et al.: Buonocore memorial lecture. Adhesion to enamel and dentin: current status and future challenges. Oper Dent 28, 215–235 (2003).
269. Wada, H., Tarumi, H., Imazato, S., Narimatsu, M., Ebisu, S.: In vitro estrogenicity of resin composites. J Dent Res 83, 222–226 (2004).
270. Wallenhammar, L.M., Ortengren, U., Andreasson, H., Barregard, L., Bjorkner, B., Karlsson, S., Wrangsjo, K., Meding, B.: Contact allergy and hand eczema in Swedish dentists. Contact Dermatitis 43, 192–199 (2000).
271. Wataha, J.C., Rueggeberg, F.A., Lapp, C.A. Lewis, J.B., Lockwood, P.E., Ergle, J.W., Mettenburg, D.J.: In vitro cytotoxicity of resin-containing restorative materials after aging in artificial saliva. Clin Oral Investig 3, 144–149 (1999).
272. Wataha J.C., Lockwood P.E., Bouillaguet S., Noda M.: In vitro biological response to core and flowable dental restorative materials. Dent Mater 19, 25–31 (2003).
273. Weinmann, W., Luchterhandt, T., Guggenberger, R., Stippschild, A., Then, S.: Comparative testing of volumetric shrinkage and sealing of silorane and methacrylate filling materials. J Dent Res 81, A-417 (2002).
274. White, K.C., Cox, C.F., Kanka, J., Dixon, D.L., Farmer, J.B., Snuggs, H.M.: Pulpal response to adhesive resin systems applied to acid-etched vital dentin: damp versus dry primer application. Quintessence Int 25, 259–268 (1994).
275. Willems, G., Lambrechts, P., Braem, M., Vanherle, G.: Composite resins in the 21st century. Quintessence Int 24, 641–658 (1993).
276. Willershausen B., Köttgen C., Ernst C.-P.: The influence of restorative materials on marginal gingival. Eur J Med Res 6, 433–439 (2001).
277. Yourtee, D.M., Smith R.E., Russo K.A., Burmaster, S., Cannon, J. M., Eick, J.D., Kostoryz, E.L.: The stability of methacrylate biomaterials when enzyme challenged: kinetic and systematic evaluations. J Biomed Mater Res 57, 522–531 (2001).
278. Zach, L., Cohen, G.: Pulp response to externallly applied heat. Oral Surg Oral Health Oral Pathol 19, 515–530 (1965).

Dentlearn.ir

6 Cements and Ceramics

Contents

6.1 Introduction 139
References 140
6.2 Zinc Phosphate Cements 141
6.2.1 Basic Material Properties 141
6.2.2 Systemic Toxicity and Allergies 142
6.2.3 Local Toxicity and Tissue Compatibility . . 143
6.2.4 Mutagenicity and Carcinogenicity 147
References 147
Conclusions for the Dental Practitioner . . 147
6.3 Glass Ionomer Cements 149
6.3.1 Basic Material Properties 149
6.3.2 Systemic Toxicity and Allergies 151
6.3.3 Local Toxicity and Tissue Compatibility . . 151
6.3.4 Mutagenicity and Carcinogenicity 156
Conclusions for the Dental Practitioner . . 156
References 156
6.4 Zinc Oxide and Eugenol Cements 160
6.4.1 Basic Material Properties 160
6.4.2 Systemic Toxicity and Allergies 160
6.4.3 Local Toxicity and Tissue Compatibility . . 162
6.4.4 Mutagenicity and Carcinogenicity 163
Conclusions for the Dental Practitioner . . 163
References 164
6.5 Calcium Hydroxide Cements 166
6.5.1 Basic Material Properties 166
6.5.2 Systemic Toxicity and Allergies 168
6.5.3 Local Toxicity and Tissue Compatibility . . 169
6.5.4 Mutagenicity and Carcinogenicity 173
Conclusions for the Dental Practitioner . . 173
References 174
6.6 Dental Ceramics 177
6.6.1 Basic Material Properties 177
6.6.2 Systemic Toxicity and Allergies 180
6.6.3 Local Toxicity and Tissue Compatibility . . 180
6.6.4 Mutagenicity and Carcinogenicity 183
Conclusions for the Dental Practitioner . . 184
References 185

6.1 Introduction

G. Schmalz

Cements and ceramics have a very long tradition as dental materials, and they have been used for a great variety of different applications. Cements and ceramics are basically inorganic, nonmetallic, hydrophilic materials, although there are some exceptions. Cements are powder–liquid systems that set via salt or chelate formation. Ceramics are fired, cast, or pressed under heat; subsequently, they are shaped into the desired form, such as by an additional milling or by "sonoerosion."

The basic components of many types of cement are the following:

- Zinc oxide or silicon dioxide as powder
- Phosphoric acid, polyacrylic acid, or eugenol as liquid (Table 6.1)

Setting calcium hydroxide materials are also usually classified as cements [5]. Calcium phosphate cements are a recent development [4] and are considered to be bioactive (osteoconductive and osteoinductive). The main disadvantages of calcium phosphate cements are their poor mechanical properties and washing-out effects, which restrict their actual use to bone regeneration and root canal therapy [1]. These materials are discussed in detail in Chap. 7.

In addition to the cements that will be comprehensively described in this chapter, various other similar dental cements have been used in the past. These will not be discussed here in detail because they are of little or no clinical importance today, but they are as follows:

Silicate cements have been used for many years as anterior filling material. However, these materials have been replaced more and more by adhesively applied resin-based composites, not least due to the high risk

Dentlearn.ir

Table 6.1 Basic components of frequently used dental cements

Liquid / Powder	Phosphoric acid	Polyacrylic acid	Eugenol
Silicon oxides	Silicate cement	Glass ionomer cement	
Zinc oxide	Zinc phosphate cement	Polycarboxylate cement	Zinc oxide and eugenol cement

of pulp damage that was associated with silicate cements when used without a cavity base [e.g., 7]). However, bacteria proliferating beneath silicate cement fillings on the cavity floor were also deemed responsible for pulp damage [e.g., 3]).

Polycarboxylate cements have primarily been used as luting materials. They reveal good pulp compatibility [7, 10]. The initial pain occurring after luting fixed restorations with zinc phosphate cement was not observed if cast restorations were inserted with polycarboxylate cements. However, these materials shrink more extensively than zinc phosphate cements [9].

Silicophosphate cements (also called stone cement) are a combination of silicate and zinc phosphate cement in which zinc oxide is mixed with glass powder. They have been used as filling material and for cementing indirect restorations. These materials are occasionally recommended by opponents of amalgam as an alternative to amalgam. However, only a small amount of information about their biological characteristics is available in the literature. The solubility of silicophosphate cements is similar to that of silicate cements [11]. A cell culture study showed that silicophosphate cement was much more toxic after mixing and when set compared with a zinc phosphate cement [6, 8]. Silicophosphate cements have caused a chronic pulpitis after application to the vital dentin of experimental animals [6]. Furthermore, comparably inferior technical properties have been measured. Thus, silicophosphate cements are usually classified as inappropriate for definitive restorations, particularly because much better alternatives are now available [2].

References

1. Ambard, A. J., Mueninghoff, L.: Calcium phosphate cement: review of mechanical and biological properties. J Prosthodont 15, 321–328 (2006).
2. Bauer, C.M., Kunzelmann, K.-H., Hickel, R.: Silikophosphat- und Glasionomerzemente – eine Amalgamalternative? [Silicophosphate and glass ionomer cements – are they an alternative to amalgam?] Dtsch Zahnärztl Z 51, 339–341 (1996).
3. Brännström, M., Vojinovic, O., Nordenvall, K.J.: Bacteria and pulpal reactions under silicate cement restorations. J Prosthet Dent 41, 290–295 (1979).
4. Brown, W.E., Chow, L.C.: Dental restorative cement pastes. U.S. patent 4,518, 430 (1988).
5. Craig, R.G. (ed): Restorative Dental Materials, 10th edn. Mosby Year Book, St. Louis 1997.
6. Dahl, B.L., Tronstad, L., Spangberg, L.: Biological tests of a silicophosphate cement. J Oral Rehabil 2, 249–257 (1975).
7. Klötzer, W.T., Langeland, K.: Tierexperimentelle Prüfung von Materialien und Methoden der Kronen- und Brückenprothetik. [Animal testing on materials and methods for being used in crown and bridge restorations] Schweiz Monatsschr Zahnheilkd 83, 163–244 (1973).
8. Leirskar, J., Helgeland, K.: Toxicity of special dental cements in a cell culture system. Scand J Dent Res 85, 471–479 (1977).
9. Oilo, G.: Linear dimensional changes during setting of two polycarboxylate cements. J Oral Rehabil 3, 161–166 (1976).
10. Oilo, G.: Luting cements: a review and comparison. Int Dent J 41, 81–88 (1991).
11. Wilson, A.D., Crisp, S., Lewis, B.G.: The aqueous erosion of silicophosphate cements. J Dent 10, 187–197 (1982).

Dentlearn.ir

6.2 Zinc Phosphate Cements

H. Stanley †

A variety of cementing materials are currently used as bases and luting agents, but zinc phosphate cement has been used for many decades [14]. The phosphoric acid-based cements originated from Ostermann's formula of 1832, which was composed of calcium oxide and anhydrous phosphoric acid. Around the turn of the century (1902), Fleck established a formula very similar to that in use today [24].

Zinc phosphate cement is primarily used for the cementation of indirect restorations, such as crowns and bridges. However, it is also applied for temporary fillings, cavity bases, and buildups of teeth beneath crowns. Zinc phosphate cement primarily has contact with the pulp–dentin system and in certain cases (e.g., temporary fillings) with the gingiva.

6.2.1 Basic Material Properties

6.2.1.1 Composition and Setting Reaction

The powder is mainly a mixture of zinc oxide and up to 13% magnesium oxide. The liquid is an aqueous solution of phosphoric acid containing 38–59% H_3PO_4, 30–55% water, 2–3% aluminum, and 0–10% zinc (Table 6.2). The aluminum is essential to the cement-forming reactions, and the zinc moderates the reaction between powder and liquid, allowing adequate working time and permitting a sufficient quantity of powder to be added for optimum properties in the cement [25].

When the powder is mixed with liquid, the phosphoric acid attacks the surface of the particles, dissolving the zinc oxide, which releases zinc ions into the liquid. The aluminum in the liquid is essential to cement formation because it reacts with the phosphoric acid to form a zinc aluminophosphate gel on the remaining portion of the particles. Thus, the set cement reveals a cored structure consisting primarily of nonreacted zinc oxide particles (28 μm in diameter) embedded in a cohesive amorphous matrix of zinc aluminophosphate (glasslike phosphate) [14, 23].

Excess water that forms during the setting reaction diffuses out of the cement, leaving pores in the interior. When a high liquid-to-powder ratio is used, the number of pores in the set cement increases further. Pores with a diameter of about 0.5 μm are concentrated at the lower level of the cement. Hopeite crystals with a height of 5–10 μm grow only at or near the surface of the cement in a humid environment [22]. An early exposure of the cement to humidity after application will interfere with the setting reaction.

Cements for cavity bases: A layer of cement, thick enough to be called a base, may be placed under a permanent restoration to encourage recovery of the injured pulp and to protect it against the numerous types of insult to which it may be subjected. The insult may come from preparation trauma, from thermal shock when the tooth is restored with metal, or, depending on the particular restorative materials (metallic or nonmetallic), from chemical irritation. The base may serve as a replacement or substitute for the protective dentin that has been destroyed by caries, erosion, or cavity preparation, for instance [14]. Today, cement bases have become clinically less important since dentinal adhesives have been introduced.

Cements as luting agents: The word "luting" describes the use of a moldable substance to seal a space or cement two components together, such as a precision casting and the tooth surface. Subsequently, both parts are connected by a mechanical wedging [14, 23]. Today, adhesive luting materials are increasingly being used; these materials are discussed in Chap. 5. Conventional luting cements are materials that can be used for cementing precision castings. They are of finer grain compared with base cements and are capable of forming films of 25 μm or less. Zinc phosphate cement is the oldest of the luting cements; it has the longest track record and serves as the standard with which newer systems are to be compared [14].

Powder–liquid ratio: The compressive strength of zinc phosphate cements is dependent on the powder–liquid ratio. The recommended powder–liquid ratio for zinc phosphate cement is about two parts powder to one part liquid by weight, or 1.4 g/0.5 ml [14]. The powder–liquid ratio for commercial materials ranges from 2.5 to 3.5 g/ml [25]. The compressive strength of most set commercial luting zinc phosphate cements, when properly manipulated, lies between 80.0 and 110 MPa [23–25].

Dentlearn.ir

Table 6.2 Composition of zinc phosphate cement – powder and liquid [13]

	Weight percentage	
	Range	Typical
Powder		
ZnO	75–100	90.3
MgO	0–13	8.2
SiO_3	0–5	0.1
Bi_2O_3	0–5	0.1
BaO, Ba_2SO_4, CaO	0–3	0.1
Liquid		
H_3PO_4 (free acid)	38–59	38.2
H_3PO_4 (combined with Al and Zn)	10–19	16.2
Al	2–3	2.5
Zn	0–10	7.1
H_2O	28–38	36.0

Key Note

Working and setting time can be increased by reducing the powder–liquid ratio. However, this will reduce the physical and mechanical properties of the cement and result in a lower initial pH value [23], which may impair biocompatibility.

6.2.1.2 Release and Degradation

Two physical properties of the cement that are relevant to the retention of fixed restorations such as inlays, crowns, and bridges are the mechanical characteristics and solubility. High solubility can induce loss of the cement needed for retention and may create plaque retention sites, which, through enhanced plaque accumulation, is directly related to its biological properties [23].

A longer exposure time of zinc phosphate cement to humidity will result in release of substances even from well-set cement. This applies also to cement mixtures with a high powder–liquid ratio after a longer period of time in the oral cavity [13]. Hopeite crystals formed by moisture adhere weakly to the cement surface. Thus, their presence significantly reduces any adhesive properties of the cement and increases its solubility. The surface of the cement has a distinctly washed-out or powdery appearance to a depth of about 4 μm [22].

The discrepancies in outcome between clinical observations and results from in vitro studies regarding solubility of zinc phosphate cements are mainly due to the aggressive chemical attack by saliva, plaque, diet, and food decomposition in the oral cavity, as compared to the exposure to distilled water only, which has been used in most in vitro studies [13].

6.2.2 Systemic Toxicity and Allergies

A search of the literature using the keywords "systemic toxicity," "allergies," and "zinc phosphate cements" for the period from 1980 to 2006 in the largest worldwide

Dentlearn.ir

database of medical and scientific literature (Medline) was unsuccessful. Therefore, it may be concluded that there is no indication of systemic toxicity or allergy due to zinc phosphate cement (see also Stanley [29]).

6.2.3 Local Toxicity and Tissue Compatibility

6.2.3.1 Cytotoxicity

Various zinc phosphate cements have been shown to be clearly cytotoxic immediately after mixing [7]. Completely set specimens that were eluted in 0.9% saline solution or in cell culture medium for 7 days were not cytotoxic (cell culture medium) or only slightly cytotoxic (saline solution) in cultures of periodontal ligament fibroblasts (PDL). Toxic reactions were observed in a permanent growing cell line (3T3 mouse fibroblasts) [7]. Schmalz et al. [20] also documented that the toxicity of zinc phosphate cements in mouse fibroblast cultures and PDL cell cultures was dependent on the setting time. In addition, toxicity was dependent on the setting conditions. A clear toxic reaction was observed when the cement set at 0% relative air humidity, but the cement was almost nontoxic after setting at 100% relative air humidity and subsequent aging for 7 days [18].

Reducing the powder–liquid ratio increased cell damage in studies in which a dentin disc was placed between cells and test material [17]. Advanced experiments with three-dimensional cultures also revealed that a proper powder–liquid ratio and a dentin layer of at least 0.5 mm prevented cell damage [17, 19].

Key Note

Cytotoxicity studies show that zinc phosphate cements are cytotoxic immediately after mixing. But after complete setting (at 100% relative air humidity), almost no cell damage is caused, particularly in the presence of dentin between the material and cells.

6.2.3.2 Implantation Studies

Older studies on rats and guinea pigs showed that subcutaneous implanted zinc phosphate cements cause a pronounced inflammatory reaction immediately after mixing, which disappeared after a few weeks [2, 16]. Zinc phosphate cement was also largely nontoxic 90 days after intraosseous implantation [33].

6.2.3.3 Pulp Reactions – Histopathology

The acidity of the cement during application is very high due to the presence of phosphoric acid. The pH is about 2 at 2 min after mixing. Subsequently, it increases to 5.5 within 24 h. Thus, it may be concluded that potential pulp damage caused by acid attacks from the zinc phosphate cement (e.g., by released protons) is possible only during the first hours after application [14]. The thickness of the dentin layer influences the degree of the acid's penetration. But dentin can also act as a solid buffer substance for acids, thus reducing the penetration of protons [8, 21].

Zinc phosphate cement, when used as base (i.e., a thick mix or a puttylike mass), is not a highly toxic material (Fig. 6.1). Although there is some lifting of the odontoblast layer, the number of displaced cells and infiltrating inflammatory cells is countable, implying the presence of a moderate lesion. Figure 6.2 shows that 36 days after a thick mix had been placed, no signs of inflammation were present [28]. A significantly higher proportion of liquid (phosphoric acid) is necessary if zinc phosphate cement is used as the luting agent, in order to secure a thin film. In a study to evaluate the effect of crown cementation on primary dentin with patent tubules, previously unrestored teeth received full crown preparations with a nontraumatic, high-speed, water-cooled cutting technique. Aluminum shell crowns or self-curing resin crowns were ce-

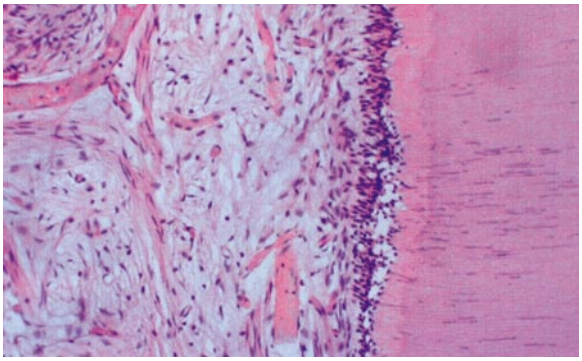

Fig. 6.1 Pulp reaction after application of a powder-rich mixture of zinc phosphate cement (1 day after application, remaining dentin thickness 0.72 mm, magnification ×350). The number of infiltrating inflammatory cells and displaced odontoblasts is low [5]

Dentlearn.ir

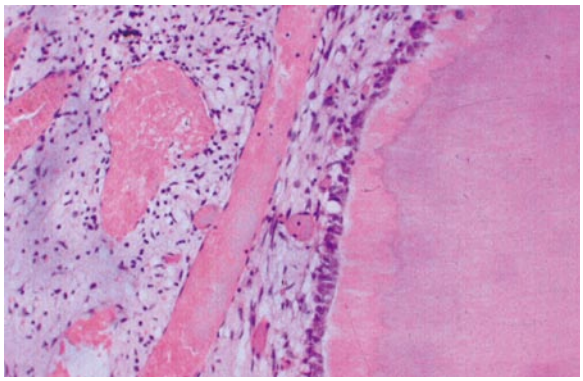

Fig. 6.2 Pulp reaction after application of a powder-rich mixture of zinc phosphate cement (36 days after application, remaining dentin thickness 1.41 mm, magnification ×320). Regenerated layer of odontoblasts, formation of tertiary dentin, and lack of inflammatory cells [5]

mented over the prepared teeth. The control specimen crowns were cemented with zinc oxide eugenol (ZOE) and the experimental specimens with zinc phosphate cement. Some preparations were first coated with either a thin wash of calcium hydroxide or two coats of a copal varnish. No signs of pulp inflammation resulted when a temporary crown was cemented with ZOE cement (Fig. 6.3).

However, if a thin mix of zinc phosphate cement was used to lute a crown over freshly cut dentin without the use of an appropriate liner, a different response was seen (the liner being a suspension of zinc oxide or calcium hydroxide in an organic or inorganic solvent). Evidently, when the patient bites down on a tongue blade, the phosphoric acid within the mix of zinc phosphate cement is pushed into the dentin tubules in such quantity that it may destroy the odontoblasts right in place. After 4 days, a widespread three-dimensional lesion appeared that involved all of the pulp tissue, exhibiting intrapulpal edema, a diffuse infiltration of neutrophils, and a deep, centrally located collection of neutrophils (Fig. 6.4). When either a calcium hydroxide liquid or copal varnish was used as a lining material, the pulp response was either greatly reduced or remained similar to the control [26].

Few studies have compared the pulp reactions caused by zinc phosphate cement with those due to glass ionomer cement (GIC; see also Sect. 6.3). Pameijer and Stanley found that when they permitted an anhydrous water-hardening GIC (Chembond) to harden under continuous pressure in class V preparations in primates to simulate the clinical conditions of inlay, onlay, and crown cementation, pulp abscesses and severe hemorrhage occurred when the remaining dentin thickness (RDT) was 0.5 mm or less [10]. When comparing the average responses of this product at 25 and 56 days with zinc phosphate cement without copal varnish, the zinc phosphate specimens with RDT values within a similar range revealed no abscess formations or hemorrhage. Because the worst lesions occurred only when the RDT was about 0.5 mm or less, it was recommended that a calcium hydroxide coating (a small dab) be applied when using GIC to just those areas where the clinician judged the RDT to be thin (less than 1 mm) and close to the pulp before seating indirect restorations. This provided the required pulp

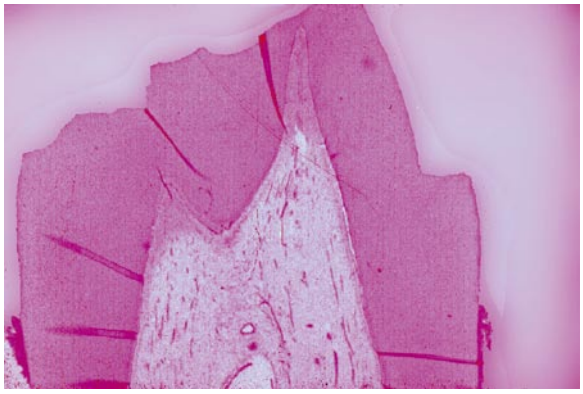

Fig. 6.3 Pulp reaction after cementation of a crown with zinc oxide eugenol cement (4 days after application, magnification ×10). Only an eosinophilic staining of pulp horns is visible due to a hyperemic reaction; the pulpal tissue, however, is intact (Courtesy of H. Berk, Boston, USA)

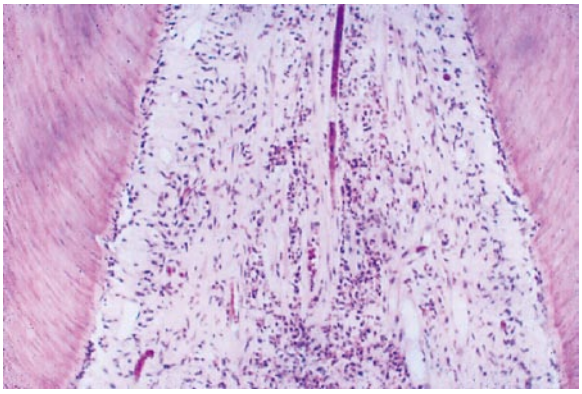

Fig. 6.4 Pulp reaction after application of a low powder mixture of zinc phosphate cement under pressure for luting a crown (4 days after application, magnification ×10). A diffuse infiltrate of leucocytes is seen in the whole pulpal tissues. Most odontoblasts are missing and are replaced by leucocytes (Courtesy of H. Berk, Boston, USA)

Dentlearn.ir

protection of the critical areas without decreasing the overall adhesion benefits of the GIC on dentin.

In 1991, Pameijer and Stanley repeated their 1984 study and held fabricated class V inlays under pressure until an encapsulated and machine-mixed form of a GIC luting cement (Ketac-Cem) hardened, again simulating the hydraulic pressure occurring during crown cementation [10, 11]. They found when the RDTs beneath the inlays were greater than 1.0 mm, very little pulp response occurred. But in teeth with less than 1.0 mm of RDT, the responses began to increase, particularly so if less than 0.5 mm, but without abscess formation or evidence of severe hemorrhage as in their previous study [10]. Although the GIC specimens with RDTs less than 1.0 mm showed less response at 5 days than the zinc phosphate cement did, at 60 days the zinc phosphate cement responses had faded while the GIC responses increased. Data on various luting cements from different animal and human studies with RDTs less than 0.5 mm showed that the acute cellular reaction caused by zinc phosphate cement was lower than that with GIC. Polycarboxylate cement generated the least chronic inflammatory cell reaction, followed by zinc phosphate cement and GIC, whereas the formation of tertiary dentin occurred in the converse order.

Clinical Practice Advice

Cast restorations should be cemented with thick mixes to minimize the initial toxic cell reaction and optimize the physical and mechanical properties of the luting agent. It is not recommended to reduce the powder-liquid ratio in order to increase the working time. Deep cavity areas (close to the pulp) should be lined with a calcium hydroxide preparation for pulp protection.

6.2.3.4 Pulp Reactions – Clinical Observations

When a luting procedure is performed with zinc phosphate cement, the patient may complain almost immediately of a stinging sensation that lasts a short time. This sensation is supposedly due to excess phosphoric acid reaching the pulp through patent dentin tubules [6, 26]. A young tooth with wide-open dentinal tubules is more susceptible to inflammatory responses than is an older tooth. Actually, very few teeth in middle-aged or elderly people are susceptible to this phenomenon because of the presence of sclerotic dentin, which reduces the patency of dentinal tubules, and reparative dentin, which lines the cut tubules on the pulp side and prevents acids from reaching the pulp even under the extreme pressure of luting procedures. Also, if the RDT of virgin dentin with open tubules is 1.5 mm or greater, the irritating agents appear not to reach the pulp.

Although the stinging sensation is short-lived, the subsequent response of the pulp is probably similar to that seen in Fig. 6.4. Because the presence of sclerotic dentin and reparative dentin and the quantity of the RDT cannot be predicted, the best protection against phosphoric acid penetration is provided by coating the dentin with two coats of an appropriate varnish, a dentin-bonding agent, or a thin wash of calcium hydroxide. Calcium hydroxide plugs the dentin tubules and neutralizes acids; hydrophilic resin primers infiltrate the collagen mesh produced by acid-etching of the dentin and seal the patent dentin tubules (see also Chap. 5). These procedures eliminate 90% of the severity of the adverse pulp responses, making them similar to those of polycarboxylate cement (Fig. 6.5) [28, 30, 31].

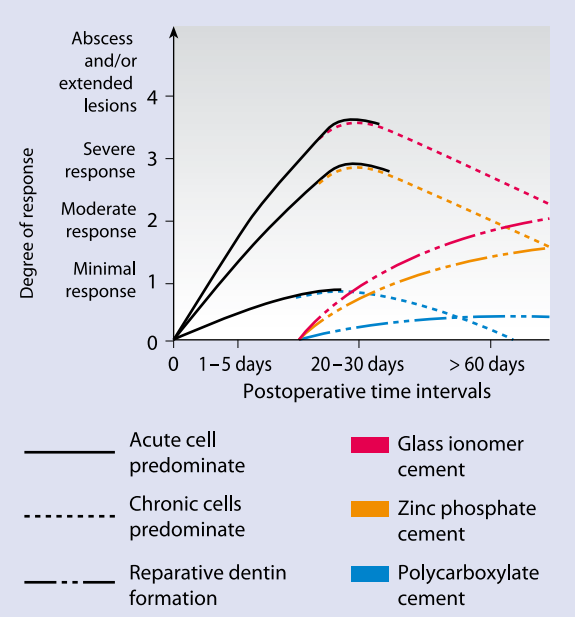

Fig. 6.5 Pulp reactions summarized from the relevant literature. The graphs showing experimental data are not representative per se, but they display a general interpretation of the information that is currently available. Effects of the cementation of inlays at a remaining dentin thickness of ≤0.5 mm: Glass ionomer cement without additional pulp protection causes a stronger reaction than zinc phosphate cement; polycarboxylate cement does not cause an equally severe reaction [31]

Dentlearn.ir

When doing a full crown restoration to treat a tooth largely destroyed by caries, it may be necessary to build up the tooth before taking an impression. This should simultaneously protect the pulp beneath. However, in preparing a full crown without any defect (such as for bridge restorations), the dentist may not appreciate how close he or she may be to the pulp, especially to the pulp horns. These open dentinal tubules with a very short RDT are most susceptible to the stinging sensation.

Clinical Practice Advice

Temporary cementation of a restoration (i.e., luting with a sedative temporary cement, such as one based on ZOE) may reduce pain during the following definitive cementation with zinc phosphate cement. If, after a luting procedure, the tooth remains hypersensitive for an extended period of time, the only recourse is to remove the restoration and lute temporarily with a sedative cement such as ZOE. The therapeutic action of eugenol helps reverse the symptoms and enhances resolution of the pulp lesion. After proper treatment of the patent dentinal tubules, the restoration may then be recemented.

6.2.3.5 Microgaps ("Microleakage")

Brännström and colleagues reported in 1971 that an infection due to penetration of bacteria through microscopic gaps around the restoration (particularly toward the cavity floor) represents the greatest risk to the pulp, even more than the toxicity of the restorative material [3, 4]. Stanley did not find a correlation between the presence, absence, or number of microorganisms and the occurrence or severity of pulp lesions. Lesions that could possibly be associated with microorganisms were found, as well as lesions without bacteria and normal pulps revealing microorganisms [27, 30]. Three pulp studies were performed between 1988 and 1995 [1, 12, 32]. A total of 211 teeth were stained using the Brown–Brenn technique in order to identify bacteria. Forty-three specimens (20.4%) revealed marginal gaps; 21 (48.8%) of these samples showed no pulpal lesions (normal pulps remained).

Another aspect that should be considered is the number of bacteria present. Intensive attempts have been made to quantify the amount of bacteria, even if only four or five individual microorganisms were found. In their studies, Stanley et al. found only a few bacteria on a 0–3 grading scale (0.5), and only a few samples revealed microbial invasion of the dentin beneath. The statistical analyses indicated that an RDT of less than 0.75–0.8 mm between pulp and microorganisms is necessary for pronounced pulp lesions to occur [15, 27].

The assumption that cement is washed out at the crown margin within a few days, in an amount sufficient to allow microorganisms and their inflammatory toxic metabolic products to fill the resulting gap and then somehow circumvent the remaining cement and finally reach the pulp horns, seems to be very unlikely, according to the author of this chapter.

6.2.3.6 Gingival Reactions

Microbial plaque is the most important etiological factor of an inflammation of the gingiva. This basically applies also to periodontitis. Rough material surfaces, like those of zinc phosphate cements, are themselves a base for increased plaque accumulation. Thus, if zinc phosphate cement has contact with gingival tissue (e.g., subgingival restoration margins) plaque-associated gingivitis may occur [9]. Periodontal destruction due to zinc phosphate cement that remains in the gingival sulcus may also be triggered by an increased plaque accumulation [34] (Fig. 6.6). In an older report, toxic

Fig. 6.6 Zinc phosphate cement that was left in the sulcus (*arrow*) with adjacent periodontal destruction, very likely caused by increased plaque accumulation at the rough surface of the cement (Courtesy of G. Schmalz, Regensburg, Germany)

Dentlearn.ir

properties of phosphate cements associated with slight to severe gingivitis have been described [9].

6.2.4 Mutagenicity and Carcinogenicity

No information regarding mutagenic or carcinogenic effects of zinc phosphate cements is available in the scientific literature. The composition of these cements does not provide any indication for such effects to occur.

Conclusions for the Dental Practitioner

1. No systemic or allergic reactions caused by zinc phosphate cements have been documented up to now. Only local reactions need to be considered.
2. No pulp reaction is to be expected if a thick, baselike mix is used. The application of calcium hydroxide is recommended in the deepest areas of the cavities that are close to pulp because microexposures of the pulp cannot be ruled out here, and thus the setting reaction of the zinc phosphate cement may be impaired and its solubility increased.
3. When using zinc phosphate cement as a luting agent for indirect restorations, such as inlays, crowns, or bridges, severe pulp reactions (clinical and histological) may occur in deep cavities with a low RDT. Lesions will heal if obliterated or sclerotic dentin (middle-aged or senior-aged patients) is present or if the pulp was originally sound. However, it is always recommended to coat areas that are very close to the pulp (<0.5 mm RDT) with an appropriate substance (e.g., calcium hydroxide preparation) before the restoration is cemented. Temporary luting of a restoration with ZOE reduces pain during cementation with zinc phosphate cement.
4. If, after a luting procedure with zinc phosphate cement, the tooth reveals persistent clinical symptoms (pain!), and other treatment options are unsuccessful, the only recourse is to remove the restoration and recement temporarily with a sedative cement (e.g., ZOE). If symptoms reverse, the restoration may be recemented after an appropriate pretreatment of the dentin, such as with a calcium hydroxide preparation.

References

1. Blosser, R.L., Rupp, N.W., Stanley, H.R., Bowen, R.L.: Pulpal and microorganism responses to two experimental dental bonding systems. Dent Mater 5, 140–144 (1989).
2. Boyd, J.B., Mitchel, D.F.: Reaction of subcutaneous connective tissue of rats to implanted dental cements. J Prosthet Dent 11, 174 (1961).
3. Brännström, M., Nyborg, H.: The presence of bacteria in cavities filled with silicate cement and composite resin materials. Swed Dent J 64, 149–155 (1971).
4. Brännström, M., Vojinovic, O.: Response of the dental pulp to invasion of bacteria around three filling materials. ASDC J Dent Child 43, 83–89 (1976).
5. Dubner, R., Stanley, H.R.: Reaction of the human dental pulp to temporary filling materials. Oral Surg 15, 1009–1017 (1962).
6. Gilmore, H.W.: Textbook of Operative Dentistry. Mosby Year Book, St. Louis 1967, p 149.
7. Hanks, C.T., Anderson, M., Craig, R.G.: Cytotoxic effects of dental cements on two cell culture systems. J Oral Pathol 10, 101–112 (1981).
8. Hanks, C.T., Wataha, J.C., Sun, Z.: In vitro models of biocompatibility: a review. Dent Mater 12, 186–193 (1996).
9. Klötzer, W.T.: Die Reaktion der Gingiva in Kontakt mit zahnärztlichen Materialien. [The reaction of the gingiva in contact with dental materials] Dtsch Zahnärztl Z 28, 1181–1191 (1973).
10. Pameijer, C.H., Stanley, H.R.: Primate pulp response to anhydrous Chembond. J Dent Res 63, 171 (1984).
11. Pameijer, C.H., Stanley, H.R.: Biocompatibility of a glass ionomer luting agent. Part II: Crown cementation. Am J Dent 4, 134–142 (1991).
12. Pameijer, C.H., Stanley, H.R.: Pulpal reaction to a dentin bonding agent. Am J Dent 8, 140–144 (1995).
13. Peyton, F.A., Anthony, D.H., Asgar, K., Charbeneau, G.T., Craig, R.G., Myers, G.E.: Restorative Dental Materials. Mosby Year Book, St. Louis 1960, pp 460–471.
14. Phillips, R.W.: Skinner's Science of Dental Materials, 9th edn. W.B. Saunders, Philadelphia 1991, pp 479–488.
15. Reeves, R., Stanley, H.R.: The relationship of bacterial penetration and pulpal pathosis in carious teeth. Oral Surg 22, 59–65 (1968).
16. Sayegh, F.S., Reed, A.J.: Tissue reactions to a new restorative material. J Prosthet Dent 22, 468–478 (1969).
17. Schmalz, G., Garhammer, P., Schweikl, H.: A commercially available cell culture device modified for dentin barrier tests. J Endod 22, 249–252 (1996).
18. Schmalz, G., Hiller, K.-A., Aslan-Dörter, F.: New developments in the filter test system for cytotoxicity testing. J Mater Sci Mater Medicine 5, 43–51 (1994).
19. Schmalz, G., Schuster, U., Nützel, K., Schweikl, H.: An in vitro pulp chamber with three-dimensional cell cultures. J Endod 25, 24–29 (1999).
20. Schmalz, G., Sharaf, M.: Die Verwendung unterschiedlicher Zellarten im Agar-Diffusions-Test. [The use of different cell lines in the agar diffusion test] Z Zahnärztl Implantol 4, 240–245 (1988).
21. Schmalz, G., Schuster, U., Koch, A., Schweikl, H.: Cytotoxicity of low pH dentin-bonding agents in a dentin barrier test in vitro. J Endod 28, 188–192 (2002).
22. Servais, G.F., Cartz, L.: Structure of zinc phosphate dental cement. J Dent Res 50, 613–620 (1971).

Dentlearn.ir

23. Shen, C.: Dental cements for bonding applications. In: Anusavice, K.J. (ed): Phillips' Science of Dental Materials, 10th edn. W.B. Saunders, Philadelphia 1996, pp 555–556.
24. Smith, D.C.: Past, present and future of dental cements. In: Craig, R.G. (ed): Dental Materials Review. University of Michigan School of Dentistry, Ann Arbor 1977, pp 53–55.
25. Smith, D.C., Norman, R.D., Swartz, M.L.: Dental cements: current status and future prospects. In: Reese, J.A., Valega T.M. (eds): Restorative Dental Materials – An Overview (FDI). Quintessence Publishing (on behalf of FDI), London 1985, pp 33–74.
26. Stanley, H.R.: Human pulp response to restorative dental procedures, revised edn. Storter Printing, Gainesville, Florida, 1981, pp 61–64.
27. Stanley, H.R.: The relationship of bacterial penetration and pulpal lesions. In: Anusavice, K.J. (ed): Quality Evaluation of Dental Restorations. Quintessence, Chicago 1989, pp 303–323.
28. Stanley, H.R.: Biologic responses of dentin and pulp to dental restorative procedures: scientific background and therapeutic recommendations. In: Hardin, J.F. (ed): Clark's Clinical Dentistry, vol IV, revised edn. Lippincott, Philadelphia 1990, pp 14–15.
29. Stanley, H.R.: Local and systemic responses to dental composites and glass ionomers. Adv Dent Res 6, 55–64 (1992).
30. Stanley, H.R.: Dental iatrogenesis. Int Dent J 44, 9–11 (1994).
31. Stanley, H.R.: Biocompatibility of dental materials. In: Anusavice, K.J. (ed): Phillips' Science of Dental Materials, 10th edn. W.B. Saunders, Philadelphia 1996, pp 75–109.
32. Stanley, H.R., Bowen, R.L., Cobb, E.W.: Pulp responses to a dentin and enamel adhesive bonding procedure. Oper Dent 13, 107–110 (1988).
33. Zmener, O., Dominguez, F.V.: Tissue response to a glass ionomer used as an endodontic cement. A preliminary study in dogs. Oral Surg Oral Med Oral Pathol 56, 198–205 (1983).
34. Zyskind, K.: Periodontal health as related to preformed crowns: report of case. J Dent Child 56, 385–387 (1989).

Dentlearn.ir

6.3 Glass Ionomer Cements

G. Schmalz

Glass ionomer cements (GICs; also known as polyalkenoate cements) were introduced in 1972 by Wilson and Kent [120]. Today, GICs are used as filling material for cavity bases and buildups as well as for root canal fillings (orthograde/retrograde; see also Chap. 7) and as luting agents for indirect restorations such as inlays, crowns, and bridges. In addition, GICs have been occasionally applied as pit and fissure sealants. Adhesion to both enamel and dentin makes GICs attractive for their application in dentistry.

The cermet cements used up to this time are glass ionomer cements with metal additives (e.g., silver). An increasing number of combinations between glass ionomer cements and resin-based composites have been developed in recent years ("hybrid ionomers"). A broad spectrum of new materials has entered the market, ranging in composition between materials with a pronounced resin-based composite characteristic (compomers, polyacid-modified resin-based composites) and materials that are very similar to conventional glass ionomer cements with an aqueous base (resin-modified glass ionomer cements). Compomers are discussed in Chap. 5, and resin-modified glass ionomer cements will be covered in this chapter.

6.3.1 Basic Material Properties

6.3.1.1 Composition

Conventional glass ionomer cements are powder and liquid systems. The powder contains finely ground glass (containing, for example, calcium and sodium fluorophosphoaluminosilicate). The liquid typically consists of a polyacrylic acid (47.5%) with a molecular weight of about 10,000 D (or higher) and additional polycarboxylic acids such as maleic acid, tartaric acid, and itaconic acid. Cermet cements contain elemental silver, which is incorporated in sintered glass–silver particles. The size and distribution of the glass particles are decisive for the mechanical and optical properties of the cement. Materials with particularly finely ground particles are used as luting agents, whereas cements with larger particles are applied as filling materials in visible areas, such as cervical fillings. Densely packed particles result in materials with improved mechanical characteristics. It is recommended to pretreat the cavity briefly (15–20 s) with polyacrylic acid in order to remove the smear layer, increase the wettability of dentin, and enhance the adhesion between dentin and the GIC. Gels containing 10–40% polyacrylic acid are mostly used for this procedure. Most products currently on the market contain 10–25% polyacrylic acid. Aluminum chloride is also added to some products [110, 119].

Resin-modified glass ionomer cements consist of a glass powder (e.g., SiO_3, AlF_3, SrO, Na_3AlF_6) and a liquid composed of polymerizable groups attached to the polyacrylic acid and/or hydrophilic monomers (e.g., 2-hydroxyethyl methacrylate, or HEMA). Various catalysts are applied, such as diphenyliodonium chloride (DPICl), which is biologically very active [38]. The manufacturers of resin-modified glass ionomer cements also recommend substances for the pretreatment of dentin, such as products used together with conventional glass ionomer cements or products used together with resin-based composites, such as self-etching primers (see also Chap. 5) [11, 18]. A comparatively new development is the use of amino acids in an attempt to make acid groups more available for salt bridging to dental hard structures in combination with new methacrylic-based or other monomers [17].

6.3.1.2 Setting Reaction

Conventional glass ionomer cements set through an acid-base reaction. The acid causes an initial release of calcium ions from the glass, followed by a segregation of aluminum ions. These ions replace the protons of the acidic groups, thus generating insoluble calcium and later aluminum carboxylates. Glass ionomers are initially very acidic (pH 1.6–3.7) [109]. The completely set cements reveal a pH between 5.4 and 7.3.

Key Note

The setting reaction depends on a correct water balance. Exsiccation as well as pronounced exposure to humidity during the setting reaction will negatively influence the material properties and, for instance, increase solubility, which will then elevate toxicity [4, 96].

Resin-modified glass ionomer cements are light-curable (e.g., quartz–tungsten–halogen or light-emitting diode light, which is also used for resin-based com-

Dentlearn.ir

posites). Setting of resin-modified GICs is a highly exothermic reaction, and some of these products generate more heat than resin-based composites, perhaps due to a high concentration of HEMA [9, 54]. An acid-base reaction will occur in time, too. Thus, resin-modified GICs will also set without light irradiation in the dark, in contrast to compomers. Some products additionally set through a chemically initiated polymerization. It has been proposed to replace HEMA by amino acid acrylates and methacrylate derivatives [121].

6.3.1.3 Release and Degradation

6.3.1.3.1 Fluorides

Various studies have documented that glass ionomer cements release fluoride. This release depends on various factors, primarily the setting reaction and elution time. Higher amounts of fluoride are initially released. Fluoride release drops significantly within a few hours (Fig. 6.7), but some fluoride release has been found for a period of up to 2 years [31]. GICs leach lower amounts of fluoride into artificial saliva than into deionized water [26]. Fluoride leaching is increased at low pH and due to esterases [37]. Fluoride was also found in the saliva of children whose deciduous teeth were filled with glass ionomer cement [32, 41, 108]. Cermet cements generally segregate significantly less fluoride than conventional GICs, since about 40% of the fluorine-containing glasses are replaced by silver. External fluoride application (e.g., fluoride-containing toothpastes or fluoride gels) may increase the fluoride concentration in GICs, similar to dental hard tissues. Subsequently, fluoride release increases again, particularly after application of fluoride gels [32, 55, 58, 99]. Fluoride is very likely released by means of three mechanisms: surface wash-off, diffusion through pores and cracks, or diffusion through the bulk [58].

Released fluoride diffuses into the adjacent dental hard tissue [112], which causes a reduced acid solubility in vitro compared with untreated tooth specimens [114]. It is, however, controversial whether the amounts of fluoride released are of clinical relevance for caries prevention (Fig. 6.8) [46, 106, 115].

Resin-modified glass ionomer cements also release fluoride, similar to conventional GICs. Some studies have reported a different fluoride release from various products [47, 48], whereas other authors did not find statistically significant differences [33, 67]. Overall, so-called compomers (see Chap. 5) release considerably less fluoride than resin-modified GICs do (Fig. 6.7).

6.3.1.3.2 Additional Ions

Other ions are released besides fluoride, including calcium, sodium, silicon, strontium, and aluminum. Leaching of these ions varies among products [3, 29, 36, 37]. The extended release of aluminum has been

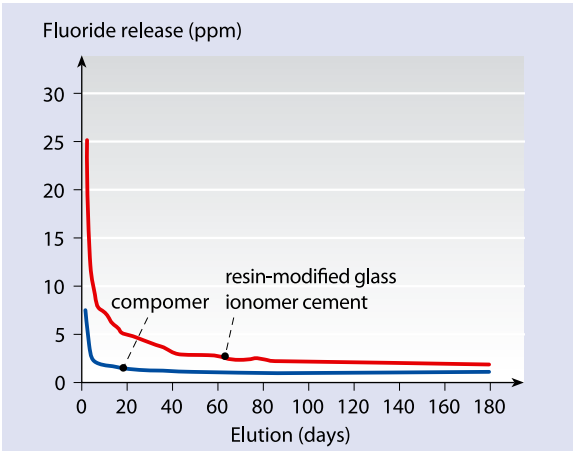

Fig. 6.7 Fluoride is released from glass ionomer cements at differing amounts. Overall, there is an initially high rate of release, which decreases in time asymptotically [33]

Fig. 6.8 Clinical aspect of a class V restoration with glass ionomer cement after 11 years without marginal caries

Dentlearn.ir

intensively discussed regarding biocompatibility [29, 40, 73, 85] (see also Sect. 6.3.2). Some GICs contain zinc compounds, and zinc ions leached into liquids [72]. Silver ions leach from cermet cements [87].

6.3.1.3.3 Organic Components

Organic components are mainly released from resin-modified GICs, but little data are available. Leaching of HEMA, ethylene-glycol compounds, camphorquinone, and a specific initiator (DPICl) have been documented [38, 52, 53]. DPICl is characterized by a very high cytotoxicity and has been identified as a cause of the comparatively high toxicity of the product that contains this initiator, Vitrebond [38]. HEMA, which is segregated by resin-modified GICs, can diffuse through dentin in vitro (see Chap. 5).

Key Note

Low amounts of formaldehyde leach from some resin-modified GICs [86], which is of particular concern with respect to a possible allergic reaction.

6.3.2 Systemic Toxicity and Allergies

No data have been published about the systemic toxicity of GICs. But because these products are medical devices and thus have to be certified according to various national and international regulations and standards, the systemic toxicity of GICs must be assessed prior to their market launch. Unfortunately, much of the data about the systemic toxicity of individual products is never published [107]. However, it may be concluded that these materials should not pose an acute systemic risk. The chronic toxic behavior of GICs has not yet been characterized.

Because of the positive preclinical biocompatibility results, GICs have been used for bone replacement in comparatively large quantities in patients, for instance, in treating bony cranial defects. Two of these patients died. Although their deaths could not be linked unequivocally to the use of this material, both patients had an extremely high aluminum concentration in their lumbar cerebrospinal fluid, plasma, and urine. It is, however, unknown whether the reason for this high aluminum concentration was the material itself or the possibility that it had been applied incorrectly (e.g., premature exposure to humidity). In any event, the use of GIC for bone replacement was not pursued further [40, 85]. Aluminum-free GICs are presently being developed for bone surgery, but clinical experience is still lacking [42]. Aluminum ions are also released when GICs are used for dental procedures. However, due to the low amounts, systemic toxic reactions are extremely unlikely to occur [71].

No cases of allergies to conventional GICs have been published. Only Mjör [63] reported one case, in which a generalized urticaria occurred after the application of GIC. But no details, such as patch test reaction, were given. Resin-modified GICs contain monomers, such as HEMA, that are known allergens. Because these substances are primarily released from resin-based composites, the biological reactions to them are reviewed in Chaps. 5 and 14. The information provided there also applies to resin-modified GICs. Furthermore, the generation of formaldehyde, which may elicit allergic reactions, has also been observed with these materials.

6.3.3 Local Toxicity and Tissue Compatibility

6.3.3.1 Cytotoxicity

The cytotoxicity of glass ionomer cements has been intensively investigated in a number of studies using different cell types (including cultured pulp cells and gingival cells) [12, 38, 68, 78, 92, 95, 97]. It was consistently documented that the cytotoxic behavior, similar to that of other cements and resin-based composites, depends on the setting condition. Nonset materials are very cytotoxic, whereas set specimens are not cytotoxic or are only slightly cytotoxic. Interestingly, one specific glass ionomer cement product, Ketac-Cem, caused no alterations of cell morphology, it but inhibited RNA and protein synthesis of the treated gingival fibroblasts. Epithelial cells were unaffected [12]. Thus, substances leaching from glass ionomer cements at concentrations that are "sublethal" for the cells can nevertheless influence cell metabolism. A series of studies additionally indicated that toxicity varies among products [100]. In general, the cytotoxic effect of freshly mixed GICs was referred to their acidity and their fluoride release as well [56], although other ions have also been taken into consideration, including aluminum [69]. The amount of leached aluminum ions, however, was apparently too low to cause cytotoxic reactions [1]. The cytotoxicity of GIC is appar-

Dentlearn.ir

ently greater than that of mineral trioxide aggregate (MTA) [116].

In contrast to resin-based composites, the toxicity of GICs is influenced by the relative air humidity in the environment. Very low air humidity increases the toxicity [94]. Low air humidity (<60%) causes an incomplete setting of the GIC, thus increasing solubility and cytotoxicity [4, 94].

6

Key Note

Dentin between filling material and cells significantly reduces the toxicity of glass ionomer cements [23]. Conventional glass ionomer cements were not cytotoxic in a dentin barrier test using three-dimensional cultures (Fig. 6.9) [98]. Obviously, dentin may act as an acid buffer and as an absorption medium for fluorides.

Resin-modified glass ionomer cements have caused various reactions, some rather toxic in the uncured state [2]. But after setting, some products were only slightly toxic [27]. However, cytotoxicity was mainly greater for these materials than for Portland cement, which strongly resembles MTA [61]. On the other hand, one product, Vitrebond, was consistently cytotoxic in different studies using different cell lines and different evaluation methods [21, 38, 53, 59, 94]. These materials were also assessed in dentin barrier tests. Most products were almost completely noncytotoxic, also assessed using three-dimensional cultures as target cells. Only Vitrebond was consistently cytotoxic, and increasingly so with decreasing dentin thickness between the test material and the target culture [35, 93, 98]. It has been suggested that the pronounced cytotoxic effect of this product is caused by the catalyst DPICl [38].

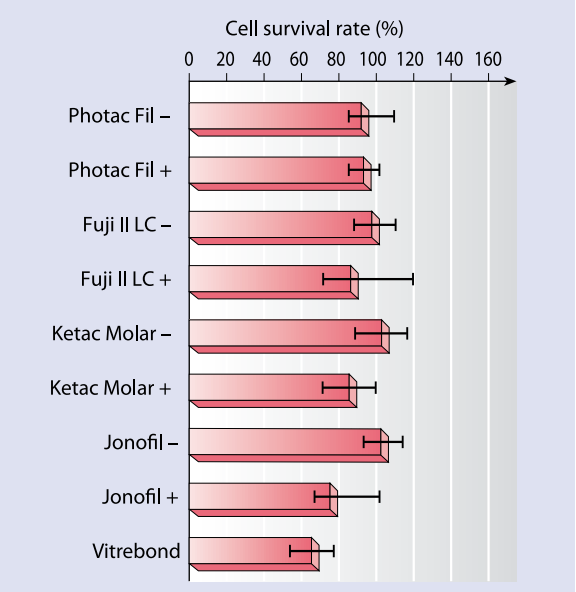

Fig. 6.9 Conventional glass ionomer cements were not cytotoxic in the dentin barrier test (100% cell vitality). The pretreatment of the dentin with polyacrylic acid (+) caused a slight toxicity. A resin-modified glass ionomer cement (Vitrebond) caused a cytotoxic reaction

6.3.3.2 Antimicrobial Properties

Antimicrobial properties of GICs have been investigated in vitro and in vivo. It was found that freshly mixed specimens inhibited bacterial growth in general, equivalent to their cytotoxic behavior, whereas set samples revealed no antimicrobial effect (Fig. 6.10) [20, 33, 91, 99]. Specifically the proliferation of *Streptococcus mutans* and *Streptococcus sanguinis* was inhibited, but growth of *Streptococcus milleri* and *Streptococcus casei* was not affected [74, 88, 91]. The application of fluoride-containing toothpastes increased the antimicrobial properties slightly, whereas fluoride gels caused a clear increase in the antimicrobial potency [99]. A specific antimicrobial effect of cermet cements, due to the addition of silver, was not observed. The antimicrobial properties tended to be lower compared with conventional GICs [33, 91].

In addition to their antimicrobial effect, GICs also reveal a decreased microbial adhesion, for instance, compared with resin-based composites [74]. Reduced bacterial adhesion and inhibited bacterial growth obviously depend on the fluoride release among other factors [74, 105]. Some authors suppose that acidity or leaching zinc ions are also responsible for these antimicrobial properties additional to fluoride release [19, 51, 82, 83, 88, 90]. Antimicrobial properties vary, depending on the product [100].

Resin-modified GICs also reveal antimicrobialcharacteristics [83]. Studies over a period of 180 days showed a significant correlation between fluoride release and antimicrobial properties [33]. However, no difference was found in vivo between the number of bacteria on the surface of various glass ionomer cements after 1 year of clinical service compared to resin-

Dentlearn.ir

based composites and enamel [117]. But other authors have documented an inhibition of bacteria on GIC restorative surfaces [30] and at the margin of fillings [105]. The number of *Streptococcus mutans* in in vivo plaque samples from glass ionomer cements was lower compared with those taken from resin-based composites. These differences could be explained by the different fluoride supply of individual patients.

It is very difficult to evaluate whether fluoride release from GICs is of clinical relevance for caries prevention. This assessment must be based on clinical studies [46]. A number of studies give some indication of a caries-protective effect. There was significantly less secondary caries around class V cavities filled with GIC compared with resin-based composite [115]. GICs revealed less marginal caries than amalgam after a period of 3 years [106]. GIC fillings in class II cavities showed more fractures than amalgam or resin-based composite restorations after 5 years of clinical service, but less secondary caries [65]. However, other studies, which addressed the causes for filling renewals in dental practices using questionnaires, revealed that secondary caries were the main reason for failed GIC restorations [10, 64]. But it has to be considered that "secondary caries" in these studies were diagnosed without prior standardization by the participating dentists, and thus the results should be interpreted with a certain reservation [10, 64].

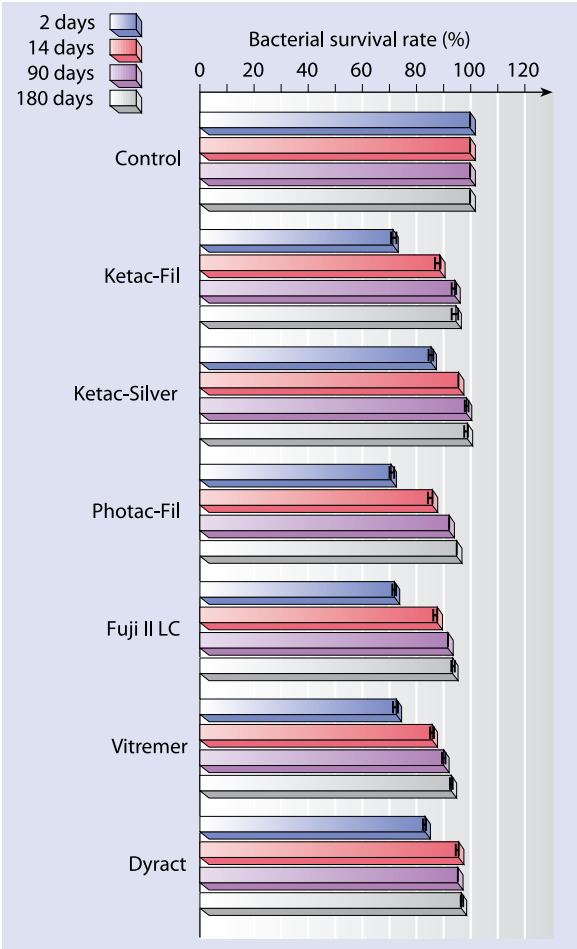

Fig. 6.10 Influence of glass ionomer cement and hybrid ionomers on the growth of bacteria: Some glass ionomer cements inhibit bacterial growth. The effect, however, decreases with increasing age of the materials [33]

Key Note

Overall, the available studies provide certain indication that fluoride release and its associated bacterial inhibition may cause a lower incidence of secondary caries to some extent. But very few studies (specifically, controlled and prospective investigations) have been performed to clarify this aspect. Thus, fluoride release cannot be correlated with certainty to a decreased rate of secondary caries.

6.3.3.3 Implantation Studies

In line with results from cytotoxicity studies, conventional GICs caused an inflammatory reaction in rats a few days after subcutaneous implantation, which almost completely healed after a longer period of time [6]. GICs were also implanted in bone of experimental animals. After an initial inflammatory reaction, the implants were completely surrounded by and incorporated in bone [5, 8, 122]. An integration of GIC by bone was documented [50]. GIC was even discussed and patented as bone replacement material in bone surgery because of its potential osteoinductive effect and thus was applied in various studies [44]. Based on two fatalities (see Sect. 6.3.2) after clinical application of this material for the reconstruction of skull defects, GIC is no longer used in bone surgery, although the applied GIC could not clearly be confirmed to be the cause of the complications [85]. An implantation study revealed that very thin mixes of GIC (e.g., used as a pit and fissure sealant) generate much more pronounced tissue reactions than a thick mix of the same product (used as filling material) [104].

Dentlearn.ir

A resin-modified GIC, Vitrebond, which has been characterized by high cytotoxicity, caused a severe tissue reaction after implantation in rats [89]. This material was also not compatible when implanted in bone, unlike conventional GICs [73]. However, another study characterized this product as bone-compatible [111].

6.3.3.4 Pulp Reactions

Pulp studies on different experimental animals consistently showed that the first products that were launched on the market elicited moderate pulp reactions. But these effects were lower than those observed with silicate cements [57, 75]. Later investigations documented a pronounced initial pulp reaction, which healed with time [113]. Newer conventional GICs do not damage pulp if the pulp is not exposed and is completely covered by dentin, and bacterial penetration can be prevented [66, 95, 97, 101]. This applies also to relatively deep cavities (Fig. 6.11). But interestingly, only minor tertiary dentin formation was observed in many cases. This may be indicative of a sublethal influence on the metabolism of odontoblasts. However, a very severe pulp reaction will be the consequence of bacterial colonization of the cavity floor beneath the GIC (Fig. 6.12) [7, 97].

When applied on the exposed pulp, GICs have caused very severe pulp reactions, including abscess formation, in various studies with different species of experimental animals (Fig. 6.13) [77, 95, 97]. The possible cause of these effects may be that the setting reaction is inhibited due to the contact with the humid pulp surface, and thus solubility of the cements increases [1]. Subsequently, high amounts of various ions, including fluoride, will leach. Other authors have discussed bacteria as a potential trigger for inflammatory reactions of the exposed dental pulp.

The results of the animal studies discussed above were confirmed in various human pulp studies with teeth that had to be extracted for orthodontic reasons. Older materials triggered moderate pulp reactions [13], whereas newer products caused no damage when the pulp was completely covered by dentin [8, 39].

GICs used as luting agents caused severe pain in certain cases, which made it necessary to remove the restorations [14]. The exact causes for these clinical reactions have not yet been fully clarified. Incorrect handling (e.g., pronounced drying of the prepared tooth prior to cementation) [102] was discussed as well as excessive pressure during cementation or an insufficient remaining dentin thickness [103]. GICs require a certain degree of humidity to secure hydration and thus a complete setting reaction. Very dry dentin may cause an incomplete setting and subsequently an increased solubility. It should also be considered that the cement might withdraw the necessary water needed for hydration of the cement from the pulp (hygroscopic effect), which then may cause pain. Animal

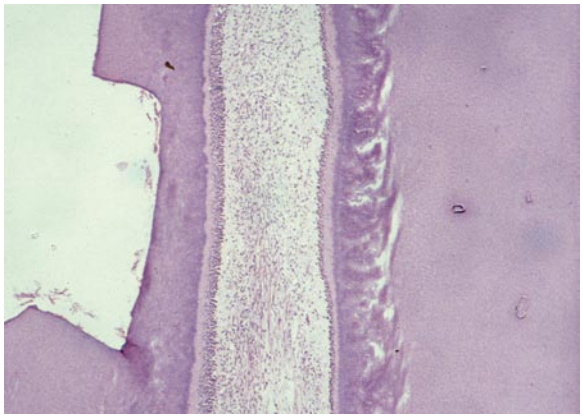

Fig. 6.11 No pulp reaction after application of a conventional glass ionomer cement in deep cavities (30 days after application, magnification ×80)

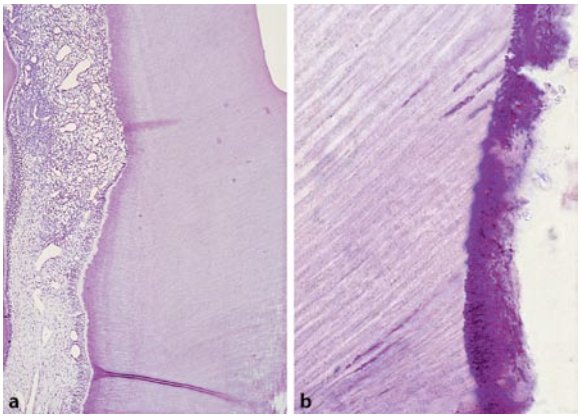

Fig. 6.12a,b **a** Pronounced inflammatory reaction of the pulp after application of a conventional glass ionomer cement (90 days after application, magnification ×80). **b** Bacteria in the associated dentin tubules (magnification ×400)

Dentlearn.ir

Fig. 6.13 Pronounced inflammatory reaction of the pulp after application of a conventional glass ionomer cement on the exposed pulp (30 days after application, magnification ×80)

experiments performed by Pameijer et al. [76] documented that an increased frequency of pulp reactions occurred when the cement was applied with excessive pressure. However, bacteria in microgaps have also been held responsible for these clinical reactions [79–81]. But this seems to be very unlikely because the clinical reactions generally appeared a few hours after cementation of the restorations with the GIC. Bacteria usually need a much longer period of time to proliferate under the given circumstances. However, fewer cases of postluting pain have been noticed in recent years after cementation with GICs.

Clinical Practice Advice

It should be considered that deep cavity areas close to the pulp should be built up (eventually in combination with a calcium hydroxide material) before a restoration is cemented with GIC. In addition, overdrying of the dentin should be avoided prior to cementation.

Pretreating enamel and dentin with polyacrylic acids in combination with conventional GICs, in order to increase their adhesion, is also recommended. However, this would increase dentin permeability, too. A slightly higher cell reaction was observed in a dentin barrier test [96], but no clinical data are available that might confirm negative consequences. Commonly used adhesives as alternatives to polyacrylic acid have been recommended for use in combination with resin-modified GICs, equivalently to resin-based composites. The results regarding adhesion varied: Some authors reported no increased adhesion [49], whereas other authors described a considerably improved bond between the resin-modified GIC and dentin [62, 70]. The biological effect of adhesives is discussed in Chap. 5.

Resin-modified GICs elicited no pulp damage in various animal experiments when no bacterial penetration occurred [24, 28, 34]. Cox et al. [16] applied two resin-modified GICs, one of them the highly cytotoxic Vitrebond, directly on the exposed pulp of experimental animals. The authors observed good pulp compatibility, but these authors also recommend dentin adhesives for direct pulp capping. Other studies showed that this approach is associated with a high risk of pulpal damage (see also Chap. 5). Other authors found pulp damage after the application of Vitrebond on the exposed pulp with displacement of its components to the coronary pulp tissue. Even after 300 days, no hard tissue barrier formation occurred, but chronic inflammation was observed [25]. Recent studies on human teeth described no pulp reaction after the use of Vitrebond in deep cavities [15, 22]. However, it should be taken into consideration that all of these experiments were performed on intact teeth with sound pulps that possessed a high regenerative capacity. It is not known how predamaged pulps would react.

Clinical Practice Advice

There is no sound scientific evidence for applying resin-modified glass ionomer cements for direct pulp capping. Therefore, the dentist should prefer well-proven materials based, for instance, on calcium hydroxide for direct pulp capping.

6.3.3.5 Reactions of Gingiva and Oral Mucosa

In contrast to zinc phosphate cement, no histologic inflammatory reaction was observed when GIC was brought into contact with the oral mucosa of hamsters for several days [45]. Clinical studies also showed that GIC is not damaging to the oral mucosa. Optimally shaped GIC fillings that were in contact with the gingiva caused no increased inflammation compared with control teeth with no restorations (Fig. 6.14) [117, 118].

Dentlearn.ir

6.3.4 Mutagenicity and Carcinogenicity

Conventional and resin-modified GICs were not mutagenic in the Ames test [27, 60]. One resin-modified GIC that was repeatedly characterized as cytotoxic elicited genotoxic and mutagenic reactions in several in vitro tests and in one in vivo test [43], with components in the liquid being responsible for this reaction [84]. Again, a no-touch technique is recommended for the dental personnel.

Fig. 6.14 Healthy gingiva next to a class V glass ionomer cement restoration

Conclusions for the Dental Practitioner

1. Glass ionomer cements are, in general, cytotoxic shortly after mixing but are inactive when set. They can be applied on vital dentin if one is certain that the pulp is not exposed.
2. Deep cavities are always associated with the risk of a (potentially unrecognized) pulp exposure. Therefore, it is recommended to cover areas close to the pulp (and pulp exposures) with a calcium-hydroxide-based material.
3. When GICs are used as luting agents for restorations, the tooth should not be excessively dried. Areas close to the pulp should not only be covered with a calcium hydroxide material, but defects should be built up prior to cementation.
4. Resin-modified GICs can be used virtually in the same way as conventional GICs, but the product Vitrebond should always be used in combination with a calcium-hydroxide-based material in medium-deep and deep cavities.
5. Resin-modified GICs should not come into direct contact with skin and gloves because these materials contain potentially allergenic substances, such as HEMA (see Chap. 5 on resin-based composites).
6. Light-curing units used together with resin-modified GICs should be operated with caution, as with resin-based composites (see Chap. 5).
7. Because varying reactions have been observed with various GICs, assessment of their biocompatibility should not just be based on the group or type of material, but adequate data should be requested for each individual product.

References

1. Andersson, O.H., Dahl, J.E.: Aluminium release from glass ionomer cements during early water exposure in vitro. Biomaterials 15, 882–888 (1994).
2. Aranha, A. M., Giro, E. M., Souza, P. P., Hebling, J., de Souza Costa, C. A.: Effect of curing regime on the cytotoxicity of resin-modified glass ionomer lining cements applied to an odontoblast-cell line. Dent Mater 22, 864–869 (2006).
3. Bapna, M.S., Mueller, H.J.: Leaching from glass ionomer cements. J Oral Rehabil 21, 577–583 (1994).
4. Barry, T.I., Clinton, D.J., Wilson, A.D.: The structure of a glass ionomer cement and its relationship to the setting process. J Dent Res 58, 1072–1079 (1979).
5. Bauer, J.G., Al-Rubayi, A.: Tissue response to direct filling materials. J Prosthet Dent 58, 584–589 (1987).
6. Beetke, E., Bening, B., Sobkowiak, E.A., Bienengräber, V.: Zur Frage der Gewebeverträglichkeit von Sanal und Calcinat. [Tissue compatibility of Sanal and Calcinat] Zahn-Mund-Kieferheilkd 62, 243 (1974).
7. Bergenholtz, G., Cox, C.F., Loesche, W.J., Syed, S.: Bacterial leakage around dental restorations: its effect on the dental pulp. J Oral Pathol 11, 439–450 (1982).
8. Blackman, R., Gross, M., Seltzer, S.: An evaluation of the biocompatibility of a glass ionomer-silver cement in rat connective tissue. J Endod 15, 76–79 (1989).

Dentlearn.ir

9. Bourke, A.M., Walls, A.W., McCabe, J.F.: Light-activated glass polyalkenoate (ionomer) cements: the setting reaction. J Dent 20, 115–120 (1992).
10. Burke, F.J.T., Cheung, S.W., Mjör, I.A., et al.: Restoration longevity and analysis of reasons for the placement and replacement of restorations provided by vocational dental practitioners and their trainers in the United Kingdom. Quintessence Int 30, 234–242 (1999).
11. Burrow, M.F., Nopnakeepong, U., Phukkanon, S.: A comparison of microtensile bond strength of several dentin bonding systems to primary and permanent dentin. Dent Mater 18, 239–245 (2002).
12. Caughman, W.F., Caughman, G.B., Dominy, W.T., Schuster, G.S.: Glass ionomer and composite resin cements: effects on oral cells. J Prosthet Dent 63, 513–521 (1990).
13. Cooper, I.R.: The response of the human dental pulp to glass ionomer cements. Int Endod J 13, 76–88 (1980).
14. Council on Dental Materials, Instruments and Equipment. Reported sensitivity to glass ionomer luting cements. J Am Dent Assoc 109, 476 (1984).
15. Costa, C.A., Giro, E.M., do Nascimento, A.B., Teixeira, H.M., Hebling, J.: Short-term evaluation of the pulp-dentin complex response to a resin-modified glass ionomer cement and a bonding agent applied in deep cavities. Dent Mater 19, 739–746 (2003).
16. Cox, C.F., Erickson, R.L., Glasspoole, E.: Histologic pulp response of a new tri-cure glass ionomer. J Dent Res 72, 348, abstract 1960 (1993).
17. Culbertson, B.M.: New polymeric materials for use in glass ionomer cements. J Dent 34, 556–565 (2006).
18. De Munck, J., van Meerbeek, B., Yoshida, Y., Inou, S., Suzuki, K., Lambrechts, P.: Four-year water degradation of resin-modified glass ionomer adhesive bonded to dentin. Eur J Oral Sci 112, 73–83 (2004).
19. De Schepper, E.J., Thrasher, M.R., Thurmond, B.A.: Antibacterial effects of light-cured liners. Am Dent J 2, 74–76 (1989).
20. De Schepper, E.J., White, R.R., von der Lehr, W.: Antibacterial effects of glass ionomers. Am Dent J 2, 51–56 (1989).
21. De Souza Costa, C.A., Hebling, J., Garcia-Godoy, F., Hanks, C.T.: In vitro cytotoxicity of five glass ionomer cements. Biomaterials 24, 3853–3858 (2003).
22. De Souza Costa, C.A., Teixeira, H.M., do Nascimento, A.B., Hebling, J.: Biocompatibility of resin-based dental materials applied as liners in deep cavities prepared in human teeth. J Biomed Mater Res, part B, 175–184 (2006).
23. Deux, D., Bonin, P., Boivin, R., Poulard, J.: Etude experimentale de l'influence d'un fond de cavité à base de verre ionomere photopolymerisable sur la pression et la temperature pulpaires. Rev Fr Endod 9, 25–30 (1990).
24. Dogon, I.L., van Leeuwen, M.J., Heeley, J.D.: Biological investigation of a new light cured glass ionomer restorative material. J Dent Res 71, 524 (1992).
25. Do Nascimento, A.B., Fontana, U.F., Teixeira, H.M., Costa, C.A.: Biocompatibility of a resin-modified glass ionomer cement applied as pulp capping in human teeth. Am J Dent 13, 28–34 (2000).
26. El Mallakh, B.F., Sarkar, N.K.: Fluoride release from glass ionomer cements in de-ionized water and artificial saliva. Dent Mater 6, 118–122 (1990).
27. Ersev, H., Schmalz, G., Bayirli, G., Schweikl, H.: Cytotoxic and mutagenic potencies of various root canal filling materials in eukaryotic and prokaryotic cells in vitro. J Endod 25, 359–363 (1999).
28. Felton, D., Cox, C.F., Odom, M., Kanoy, B.E.: Pulpal response to chemically cured and experimental light-cured glass ionomer cavity liners. J Prosthet Dent 65, 704–712 (1991).
29. Forss, H.: Release of fluoride and other elements from light-cured glass ionomers in neutral and acidic conditions. J Dent Res 72, 1257–1262 (1993).
30. Forss, H., Jokinen, J., Spets-Happonen, S., Seppä, L., Luoma, H.: Fluoride and *mutans streptococci* in plaque grown on glass ionomer and composite. Caries Res 25, 454–458 (1991).
31. Forsten, L.: Short- and long-term fluoride release from glass ionomers and other fluoride-containing filling materials in vitro. Scand J Dent Res 98, 179–185 (1990).
32. Forsten, L.: Fluoride release and uptake by glass ionomers. Scand J Dent Res 99, 241–245 (1991).
33. Friedl, K.-H., Schmalz, G., Hiller, K.-A., Shams, M.: Resin-modified glass ionomer cements: fluoride release and influence on *Streptococcus mutans* growth. Eur J Oral Sci 105, 81–85 (1997).
34. Gaintantzopoulou, M.D., Willis, G.P., Kafrawy, A.H.: Pulp reactions to light-cured glass ionomer cements. Am J Dent 7, 39–42 (1994).
35. Galler, K., Hiller, K.-A., Ettl, T., Schmalz, G.: Selective influence of dentin thickness upon cytotoxicity of dentin contacting materials. J Endod 31, 396–399 (2005).
36. Geurtsen, W.: Substances released from dental resin composites and glass ionomer cements. Eur J Oral Sci 106, 687–695 (1998).
37. Geurtsen, W., Bubeck, P., Leyhausen, G., Garcia Godoy, F.: Effects of extraction media upon fluoride release from a resin-modified glass ionomer cement. Clin Oral Investig 2, 143–146 (1998).
38. Geurtsen, W., Spahl, W., Leyhausen, G.: Residual monomer/additive release and variability in cytotoxicity of light-curing glass ionomer cements and compomers. J Dent Res 77, 2012–2019 (1998).
39. Hannig, M., Albers, H.K., Bössmann, K.: Die Pulpaverträglichkeit von Glasionomerzementen. [Pulp compatibility of glass ionomer cements] Zahnärztl Welt/Reform 101, 272–275 (1992).
40. Hantson, P.H., Mahieu, P., Gersdorff, M., Sindic, C.J.M., Lauwerys, R.: Encephalopathy with seizures after use of aluminium-containing bone cement. Lancet 344, 1647 (1994).
41. Hatibovic-Kofman, S., Koch, G.: Fluoride release from glass ionomer cement in vivo and in vitro. Swed Dent J 15, 253–258 (1991).
42. Hatton, P.V., Hurrell-Gillingham, K., Brook, I.M.: Biocompatibility of glass ionomer bone cements. J Dent 34, 598–601 (2006).
43. Heil, J., Reifferscheid, G., Waldmann, P., Leyhausen, G., Geurtsen, W.: Genotoxicity of dental materials. Mutat Res 368, 181–194 (1996).
44. Helms, J., Geyer, G., Zöllner, W., Gasser, O.: Bone replacement part made of glass ionomer cement. U.S. patent 5.314.474 (1994).
45. Homayoun, R., Ajagbe, O.: Biocompatibility of glass ionomer versus zinc phosphate. J Dent Res 72, 367 (1993).
46. Hørsted-Bindslev, P.: Fluoride release from alternative dental materials. J Dent 22 (suppl 1), 17–20 (1994).
47. Hørsted-Bindslev, P., Larsen, M.J.: Release of fluoride from conventional and metal-reinforced glass ionomer cements. Scand J Dent Res 98, 451–455 (1990).
48. Hørsted-Bindslev, P., Larsen, M.J.: Release of fluoride from light cured lining materials. Scand J Dent Res 99, 86–88 (1991).
49. Irie, M., Suzuki, K.: The effect of primers on bond strength of polyacid-modified resin composites (compomers). Dent Mater J 18, 108–115 (1999).

Dentlearn.ir

50. Jonck, L.M., Grobbelaar, C.J., Strating, H.G.: Biological evaluation of glass ionomer cement (Ketac-O) as an interface material in total joint replacement: a screening test. Clin Mater 4, 201–224 (1989).
51. Jonck, L.M., Grobbelaar, C.J.: Ionos bone cement (glass ionomer): an experimental and clinical evaluation in joint replacement. Clin Mater 6, 323–359 (1990).
52. Joshikawa, T., Hirasawa, M., Tosaki, S., Hirota, K.: Concentration of HEMA eluted from light-cured glass ionomer. J Dent Res 73, 133 (abstract) (1994).
53. Kan, K.C., Messer, L.B., Messer, H.H.: Variability in cytotoxicity and fluoride release of resin-modified glass-ionomer cements. J Dent Res 76, 1502–1507 (1997).
54. Kanchanavasita, W., Pearson, G.J., Anstice, H.M.: Temperature rise in ion-leachable cements during setting reaction. Biomaterials 16, 1261–1265 (1995).
55. Kawahara, H., Imanishi, Y., Oshima, H.: Biological evaluation on glass ionomer cement. J Dent Res 58, 1080–1086 (1979).
56. Kawase, T., Suzuki, A.: Studies on the transmembrane migration of fluoride and its effects on proliferation of L-929 fibroblasts (L-cells) in vitro. Arch Oral Biol 34, 103–107 (1989).
57. Klötzer, W.T.: Pulp reactions to a glass ionomer cement. J Dent Res 54, 678, abstract 75 (1975).
58. Kuhn, A.T., Wilson, A.D.: The dissolution mechanism of silicate and glass ionomer dental cements. Biomaterials 6, 378–382 (1985).
59. Koulaouzidou, E.A., Papazisis, K.T., Economides, N.A., Beltes, P., Kortsaris, A.H.: Antiproliferative effect of mineral trioxide aggregate, zinc oxide-eugenol cement, and glass ionomer cement against three fibroblastic cell lines. J Endod 31, 44–46 (2005).
60. Li, Y., Noblitt, T.W., Dunipace, A.J., Stookey, G.K.: Evaluation of mutagenicity of restorative dental materials using the Ames Salmonella/microsome test. J Dent Res 69, 1188–1192 (1990).
61. Min, K.-S., Kim, H.-I., Park, H.-J., Pi, S.-H., Hong, C.-U, Kim, E.-C.: Human pulp cells response to Portland cement in vitro. J Endod 33, 163–166 (2007).
62. Miyazaki, M., Rikuta, A., Iwasaki, K., Ando, S., Onose, H.: Influence of environmental conditions on bond strength of a resin-modified glass ionomer. Am J Dent 10, 287–290 (1997).
63. Mjör, I.A.: Problems and benefits associated with restorative materials: side-effects and long-term cost. Adv Dent Res 6, 7–16 (1992).
64. Mjör, I.A.: The reasons for replacement and the age of failed restorations in general dental practice. Acta Odontol Scand 55, 58–63 (1997).
65. Mjör, I.A., Jokstad, A.: Five-year study of Class II restorations in permanent teeth using amalgam, glass polyalkenoate (ionomer) cermet and resin-based composite materials. J Dent 21, 338–343 (1993).
66. Mjör, I.A., Nordahl, I., Tronstad, L.: Glass ionomer cements and dental pulp. Endod Dent Traumatol 7, 59 (1991).
67. Momoi, Y., McCabe, J.F.: Fluoride release from light-activated glass ionomer restorative cements. Dent Mater 9, 151–154 (1993).
68. Müller, J., Bruckner, G., Kraft, E., Hörz, W.: Reaction of cultured pulp cells to eight different cements based on glass ionomers. Dent Mater 6, 172 (1990).
69. Müller, J., Hörz, W., Bruckner, G., Kraft, E.: An experimental study on the biocompatibility of lining cements based on glass ionomer as compared with calcium hydroxide. Dent Mater 6, 35–40 (1990).
70. Nakanuma, K., Hayakawa, T., Tomita, T., Yamazaki, M.: Effect of the application of dentin primers and a dentin bonding agent on the adhesion between the resin-modified glass ionomer cement and dentin. Dent Mater 14, 281–286 (1998).
71. Nicholson, J.W., Braybook, J.H., Wasson, E.A.: The biocompatibility of glass-poly(alkenoate) (glass ionomer) cements: a review. J Biomater Sci Polymer End 2, 277–285 (1991).
72. Nourollahi, M., Meryon, S.D.: The antibacterial properties of four elements released from dental restorative materials. Int Endod J 22, 9–16 (1989).
73. Oliva, A., Della Ragione, F., Salerno, A., Riccio, V., Tartaro, G., Cozzolino, A., D'Amato, S., Pontoni, G., Zappia, V.: Biocompatibility studies on glass ionomer cements by primary cultures of human osteoblasts. Biomaterials 17, 1351–1356 (1996).
74. Palenik, C.J., Behnen, M.J., Setcos, J.C., Miller, C.H.: Inhibition of microbial adherence and growth by various glass ionomers in vitro. Dent Mater 8, 16–20 (1992).
75. Pameijer, C.H., Segal, E., Richardson, J.: Pulpal response to glass ionomer cements in primates. J Prosthet Dent 46, 36–40 (1981).
76. Pameijer, C.H., Stanley, H.R., Ecker, G.: Biocompatibility of a glass ionomer luting agent. Part II: crown cementation. Am J Dent 4, 134–142 (1991).
77. Paterson, R.C., Watts, A.: The response of the rat molar pulp to glass ionomer cement. Brit Dent J 151, 228–230 (1981).
78. Peltola, M., Salo, T., Oikarinen, K.: Toxic effects of various retrograde root filling materials on gingival fibroblast and rat sarcoma cells. Endod Dent Traumatol 8, 120–124 (1992).
79. Plant, C.G., Browne, R.M., Knibbs, P.J., Britton, A.S., Sorahan, T.: Pulpal effects of glass ionomer cements. Int Endod J 17, 51–59 (1984).
80. Plant, C.G., Tobias, R.S., Browne, R.M., Sorahan, T., Rippin, J.W.: Toxicity testing of inlay cements. Clin Mater 1, 291–301 (1986).
81. Plant, C.G., Knibbs, P.J., Tobias, R.S., Britton, A.S., Rippin, J.W.: Pulpal response to a glass ionomer luting cement. Brit Dent J 165, 54–58 (1988).
82. Prati, C., Fava, F., Di Gioia, D., Selighini, M., Pashley, D.H.: Antibacterial effectiveness of dentin bonding systems. Dent Mater 9, 338–343 (1993).
83. Prati, C., Fava, F., Selighini, M., Pashley, D.H.: Antibacterial activity of restorative materials. J Dent Res 72, 127 (abstract) (1993).
84. Ribeiro, D.A., Marques, M.E.A., Salvadori, D.M.F.: Genotoxicity and cytotoxicity of glass ionomer cements on Chinese hamster ovary (CHO) cells. J Mater Sci: Mater Med 17, 495–500 (2006).
85. Renard, J.L., Felten, D., Bequet, D.: Post-operative osteoneurosurgery aluminium encephalopathy. Lancet 344, 63–64 (1994).
86. Ruyter, I.E., Sjovik Kleven, I.: Formaldehyde release from light-cured glass ionomer restorative materials. J Dent Res 73, 293 (abstract) (1994).
87. Sarkar, N.K., El Mallakh, B., Graves, R.: Silver release from metal reinforced glass ionomers. Dent Mater 4, 103–104 (1988).
88. Saxton, C.A., Harrap, G.J., Lloyd, A.M.: The effect of dentifrices containing zinc citrate on plaque growth and oral zinc levels. J Clin Periodontol 13, 301–306 (1986).
89. Souza, P.P.C., Andreza, M.F.A., Hebling, J., Giro, E.M.A., De Souza, C.A.: In vitro cytotoxicity and in vivo biocompatibility of contemporary resin-modified glass ionomer cements. Dent Mater 22, 838–844 (2006).
90. Scherer, W., Lippman, N., Kaim, J.: Antimicrobial properties of glass ionomer cements and other restorative materials. Oper Dent 14, 77–81 (1989).

Dentlearn.ir

91. Schmalz, G.: Antimikrobielle Eigenschaften eines Zinkoxidphosphat-Zementes und eines Glasionomer-Zementes mit und ohne Silberzusatz. [Antimicrobial properties of a zinc phosphate and a glass ionomer cement with and without silver admixture] Dtsch Zahnärztl Z 42, 628–632 (1987).
92. Schmalz, G.: Agar overlay method. Int Endod J 21, 59–66 (1988).
93. Schmalz, G., Garhammer, P., Schweikl, H.: A commercially available cell culture device modified for dentin barrier tests. J Endod 22, 249–252 (1996).
94. Schmalz, G., Hiller, K.-A., Aslan-Dörter, F.: New developments in the filter test system for cytotoxicity testing. J Mat Sci Mat in Med 5, 43–51 (1994).
95. Schmalz, G., Schmalz, C., Rotgans, J.: Pulp tolerance of glass ionomer and zinc oxide-phosphate cements. Dtsch Zahnärztl Z 41, 806–812 (1986).
96. Schmalz, G., Schuster, U., Pfeifer, S.: Cytotoxicity testing of glass ionomer cements using transfected pulp derived cells. J Dent Res 79, 431 (2000).
97. Schmalz, G., Thonemann, B., Riedel, M., Elderton, R.J.: Biological and clinical investigations of a glass ionomer base material. Dent Mater 10, 4–13 (1994).
98. Schuster, U., Schmalz, G., Thonemann, B., Mendel, N., Metzl, C.: Cytotoxicity testing with three-dimensional cultures of transfected pulp-derived cells. J Endod 27, 259–265 (2001).
99. Seppä, L., Forss, H., Ogaard, B.: The effect of fluoride application on fluoride release and the antibacterial action of glass ionomers. J Dent Res 72, 1310–1314 (1993).
100. Sidhu, S.K., Schmalz, G.: The biocompatibility of glass ionomer cement materials. Am J Dent 14, 387–396 (2001).
101. Six, N., Lasfargues, J.J., Goldberg, M.: In vivo study of the pulp reaction to Fuji IX, a glass ionomer cement. J Dent 28, 413–422 (2000).
102. Smith, D.C., Ruse, N.D.: Activity of glass ionomer cements during setting and its relation to pulp sensitivity. J Am Dent Assoc 112, 654–657 (1986).
103. Stanley, H.R.: Local and systemic responses to dental composites and glass ionomers. Adv Dent Res 6, 55–64 (1992).
104. Steinbrunner, R.L., Setcos, J.C., Kafrawy, A.H.: Connective tissue reactions to glass ionomer cements and resin components. Am J Dent 4, 281–284 (1991).
105. Svanberg, M., Mjör, I.A., Örstavik, D.: *Mutans streptococci* in plaque from margins of amalgam, composite and glass ionomer restorations. J Dent Res 69, 861–864 (1990).
106. Svanberg, M.: Class II amalgam restorations, glass ionomer tunnel restorations, and caries development on adjacent tooth surfaces: a three-year clinical study. Caries Res 26, 315–318 (1992).
107. Svendsen, O., Garthoff, G., Spielmann, H., Hensten-Pettersen, A., Jensen, J.C., Kuijpers, M.R., Leimgruber, R., Liebsch, M., Müller-Lierheim, W.G.K., Rydhög, G., Sauer, U.S., Schmalz, G., Sim, B., Stea, S.: Alternatives to the animal testing of medical devices. ATLA 24, 59–69 (1996).
108. Takahashi, K., Emilson, C.G., Birkhed, D.: Fluoride release in vitro from various glass ionomer cements and resin composites after exposure to NaF solutions. Dent Mater 9, 350–354 (1993).
109. Tam, L.E., Pulver, E., McComb, D., Smith, D.C.: Physical properties of calcium hydroxide and glass ionomer base and lining materials. Dent Mater 5, 145 (1989).
110. Tay, F.R., Smales, R.J., Ngo, H., Wei, S., Pashley, D.H.: Effect of different conditioning protocols on adhesion of a GIC to dentin. J Adhes Dent 3, 153–167 (2001).
111. Tassery, H., Remusat, M., Koubi, G., Pertot, W.J.: Comparison of the intraosseous biocompatibility of Vitremer and Super EBA by implantation into the mandible of rabbits. Oral Surg Oral Med Oral Pathol Oral Radiol Endod 83, 602–608 (1997).
112. Thornton, J.B., Retief, D.H., Bradley, E.L.: Fluoride release from and tensile bond strength of Ketac-Fil and Ketac-Silver to enamel and dentin. Dent Mater 2, 241–245 (1986).
113. Tobias, R.S., Browne, R.M., Plant, C.G., Ingram, D.V.: Pulpal response to a glass ionomer cement. Brit Dent J 144, 345–350 (1978).
114. Tsanidis, V., Koulurides, T.: An in vitro model for assessment of fluoride uptake from glass ionomer cements by dentin and its effect on acid resistance. J Dent Res 71, 7–12 (1992).
115. Tyas, M.J.: Cariostatic effect of glass ionomer cement: a five year clinical study. Aust Dent J 36, 236–239 (1991).
116. Vajrabhaya, L., Korsuwannawong, S., Jantarat, J., Korre, S.: Biocompatibility of furcal perforation repair material technique: Ketac Molar versus ProRoot MTA. Oral Surg Oral Med Oral Pathol Oral Radiol Endod 120, e48–e50 (2006).
117. Van Dijken, J.W.V., Persson, S., Sjöström, S.: Presence of *Streptococcus mutans* and lactobacilli in saliva and on enamel, glass ionomer cement, and composite resin surfaces. Scand J Dent Res 99, 13–19 (1991).
118. Van Dijken, J.W.V., Sjöström, S.: The effect of glass ionomer cement and composite resin fillings on marginal gingiva. J Clin Periodontol 18, 200–203 (1991).
119. Van Dijken, J.W.: Four-year evaluation of the effect of 10% polyacrylic acid or water rinsing pre-treatment on retention of glass polyalkenoate cement. Eur J Oral Sci 104, 64–66 (1996).
120. Wilson, A.D., Kent, B.E.: A new translucent cement for dentistry. The glass ionomer cement. Br Dent J 132, 133–135 (1972).
121. Xie, D., Chung, I.-D., Wu, W., Mays, J.: Synthesis and evaluation of HEMA-free glass ionomer cements for dental applications. Dent Mater 20, 470–478 (2004).
122. Zmener, O., Dominguez, F.V.: Tissue response to a glass ionomer used as an endodontic cement. A preliminary study in dogs. Oral Surg Oral Med Oral Pathol 56, 198–205 (1983).

Dentlearn.ir

6.4 Zinc Oxide and Eugenol Cements

G. Schmalz and B. Thonemann

Zinc oxide and eugenol cements (ZOE) are primarily used as temporary filling material, for temporary luting of cast restorations, for indirect pulp capping, and as root canal sealers (the latter application is reviewed in Chap. 7). The biological properties of the ZOE materials include wanted effects (e.g., pain reduction or treatment) as well as unwanted reactions. Eugenol and isoeugenol are not only used in dentistry but are also frequent ingredients in cosmetics, fragrances, and foodstuffs [26].

6.4.1 Basic Material Properties

6.4.1.1 Composition and Setting Reaction

ZOE consists of two main components: zinc oxide powder and eugenol (2-methoxy-4-allylphenol). When zinc oxide is mixed with eugenol, a zinc oxide–eugenol chelate will form in the presence of humidity [40]. The mixture sets within a period of 12–24 h. The addition of resin, quartz, calcium phosphate, or zinc acetate accelerates the setting of the material (see Chap. 7). Because oil of cloves contains about 70% eugenol, some products use it instead of pure eugenol.

6.4.1.2 Release and Degradation

The setting reaction of ZOE to zinc-oxide-eugenolate is reversible. If ZOE is located in an aqueous environment, then the superficial eugenolate complex is hydrolyzed, eugenol leaches, and zinc hydroxide as well as zinc oxide remain in the material [5]. Eugenol release depends on the powder–liquid ratio. ZOE with a powder–liquid ratio of 2:1 releases high quantities of eugenol during hydrolysis because of its high share of eugenolate. Maximum eugenol release from ZOE was observed within the first 5 h after mixing and represented 4–5% of the entire quantity of eugenol [22].

6.4.2 Systemic Toxicity and Allergies

The LD_{50} of eugenol when applied intraperitoneally in mice is 1,109.6 mg/kg body weight [42]. Eugenol is a chemically defined flavoring agent and is classified as a dietary supplement [9]. So far, no systemic toxic effects after the application of ZOE in dentistry have been reported.

6.4.2.1 Preclinical Allergy Studies

Eugenol was weakly allergenic in the guinea pig maximization test, whereas isoeugenol was a strong allergen [3]. This may be due to a different metabolic pathway for the two substances [8]. Also, Hilton et al. [14] reported that eugenol caused a positive reaction in the maximization test on guinea pigs as well as in experiments on mice. In addition, eugenol generated a statistically significant increase of serum IgE concentration in mice [14]. On the other hand, it was found that eugenol at a concentration of 10 μg/g body weight completely prevented an experimentally induced systemic anaphylactic reaction in rats [18]; the experimental animals showed a significant decrease of the histamine level in serum compared with the control group [18]. Kallus et al. were unable to elicit an allergic reaction to ZOE in the guinea pig maximization test, although an allergic potential of eugenol was found in association with periodontal dressings and mouth-rinsing solutions [16]. The authors explained their findings by the inflammation–inhibitory potency of eugenol.

6.4.2.2 Allergic Reactions of Patients

Cross-reactions between eugenol and Peru balm have been reported [29]. Peru balm may be, along with others, a component of so-called eugenol-free zinc oxide materials, such as noneugenol periodontal dressing materials. A 50-year-old patient developed an allergic reaction after application of a noneugenol periodontal dressing. Two weeks previously, a eugenol-containing periodontal dressing material had been used on this patient. A slight redness of the palatal mucosa was visible after this eugenol-containing periodontal dressing material was removed. Therefore, a different, eugenol-free dressing material was applied during the subsequent treatment. Immediately after application, the patient reported a burning mouth and swelling of the tongue. Her arms and face became red, and she complained of nausea, abdominal pain, urticaria, and hot flushes [25].

In other cases, ZOE used for temporary luting has led to a gingival and mucosal inflammation after a res-

Dentlearn.ir

toration was luted with a ZOE preparation or after the use of a ZOE temporary cavity dressing. Hypersensitivity to eugenol was confirmed by patch testing [21, 30].

A survey of dentists addressing the frequency of adverse effects to dental materials in their patients revealed a total number of 147 patients suffering from side effects of dental materials. Of these, 26 patients revealed adverse effects to eugenol-containing temporary filling materials. Redness, swelling, or pain of the oral mucosa, gingiva, and lips occurred in 25 cases, but no systemic reactions were documented (Fig. 6.15) [13].

Isoeugenol and eugenol are often ingredients of fragrances marketed for personal and domestic use. Eugenol is often used in perfumes, and 2.5% of patients suspected of perfume allergy show a positive reaction to eugenol [41]. Isoeugenol is frequently used in deodorants [7] and may cause allergic contact dermatitis. Isoeugenol is one of the two most frequent allergens for patients who test positive for fragrances, and eugenol ranks in the middle [37]. It should be realized that a number of patients who react positively to isoeugenol are also allergic to eugenol, although in animal studies, isoeugenol and eugenol did not cross-react [37].

6.4.2.3 Allergic Reactions of Dental Personnel

The above mentioned survey [13] also showed that 48 out of 115 dentists suffered from occupational health problems, and two of them complained about side effects to eugenol-containing materials. Of dentists who suffered from dermatitis, six out of 25 revealed a non-occupational allergic contact dermatitis, and 12 revealed an occupational allergic contact dermatitis [28]. Five of these 12 persons reacted positively to eugenol, and two of them additionally to isoeugenol [28].

Patch tests on dental personnel addressing occupational allergens revealed that 36.9% of them had an occupational allergenic contact dermatitis, and 46.2% had an irritative contact dermatitis [6]. Four dentists of the 12 who suffered from an occupational allergic contact dermatitis reacted positively to eugenol [6]. One dental assistant revealed an occupational allergic contact dermatitis caused by eugenol, which was contained in a temporary filling material [17].

Key Note

Eugenol and its derivatives are often used as scent in cosmetics and fragrances; in addition to geraniol, eugenol is one of the most frequently applied scents in European antiperspirants [26]. An allergic contact dermatitis to fragrance products may be associated with a sensitization to eugenol [26].

Sensitization may also be caused by foods, since eugenol is used as a flavoring agent [23]. For instance, eugenol may be added to chewing gum up to a concentration of 221 ppm and to chocolate up to 750 ppm [9]. Eugenol occurs naturally in cloves, bay leaves, camphor, and cinnamon [9]. An allergy to these spices may also be caused by eugenol, and vice versa.

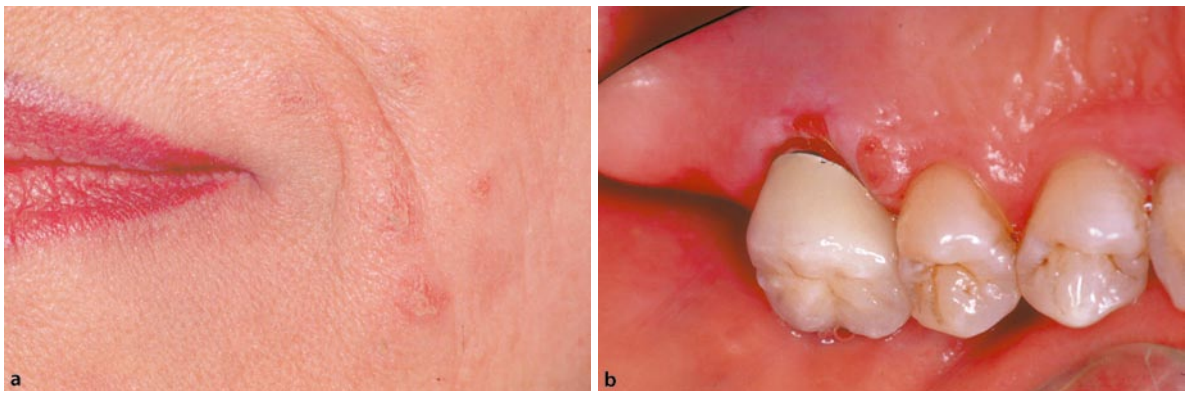

Fig. 6.15a,b Allergic reaction. **a** Perioral eczema (partially covered by cosmetics). **b** Reaction of the gingiva after temporary cementation of a crown with a zinc oxide and eugenol cement. The patient reacted positively to eugenol in the patch test

Dentlearn.ir

Clinical Practice Advice

Each dentist should be familiar with the allergenic potency of eugenol-containing products. But these materials can generally be used without restriction in dental practice, based on the available data and clinical experience, if the usual contraindications are considered in patients who are allergic to these substances.

6.4.3 Local Toxicity and Tissue Compatibility

6.4.3.1 Cytotoxicity

Eugenol, which is a phenol derivative, is highly cytotoxic in vitro [32]. Hensten-Pettersen and Helgeland [12] documented a pronounced cytotoxic reaction of eugenol in four different test systems even 24 h after mixing. However, if dentin is present as a barrier between ZOE and cells, no or only slight cytotoxic effects have been observed [36]. Thus, dentin possesses a protective effect that may be related to an adsorption of eugenol to calcium apatite and to certain proteins, such as albumin, in dentin [33].

6.4.3.2 Antimicrobial Properties

ZOE materials have antimicrobial properties against a great variety of oral bacteria. In contrast to other restorative materials such as glass-ionomer cements and resin-based composites, usually no bacteria are found at the cavity floor beneath ZOE fillings. Besides other factors, this is considered a cause for the healing of an existing pulp inflammation by ZOE application and for its pulp compatibility, even if ZOE is applied very close to a nonexposed pulp that has to be covered by a complete dentin layer [1].

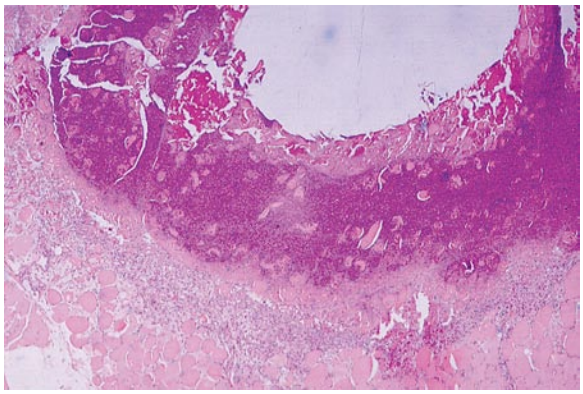

Fig. 6.16 Implantation study: pronounced necrosis and inflammatory reaction in the tissue after intramuscular implantation of a zinc oxide eugenol cement (7 days after application, magnification ×80)

6.4.3.3 Implantation Studies

ZOE cements have triggered an initial pronounced inflammation when implanted in muscle (Fig. 6.16), which decreased over time (up to 60 days after implantation) [4, 34, 35]. These results are in accordance with cytotoxicity data (see above). In both test methods, cells and the ZOE cement are in close contact (no protective dentin layer in between).

6.4.3.4 Pulp Reactions

A direct application of ZOE cements on the exposed vital pulp will cause a severe inflammatory reaction and pulp necrosis [38], which is equivalent to the aforementioned pronounced cytotoxicity. If there is a complete dentin layer between pulp and ZOE, no inflammatory reactions will occur (Fig. 6.17). This has been proven in various experimental animals and human teeth [10, 19, 24, 31]. ZOE is recommended as a nontoxic reference substance in respective (pulp-dentin test according to ISO 7405; see also Chap. 3). The protective effect of dentin was also shown in vitro (see above). This is corroborated by the finding that the concentration of eugenol at the cavity floor was 100 times higher than in the pulp when ZOE was applied on dentin with a thickness of 2 mm [15]. This effect may be explained by the adsorption of eugenol to inorganic and organic dentin components (see above) [15, 33]. Tertiary dentin was formed beneath cavities filled with ZOE but to a much lesser extent than with calcium hydroxide [10, 24].

ZOE has a pain-relieving effect. When applied in deep cavities, ZOE suppresses the excitability of nerves in the pulpal tissue [39]. This may be due to the capability of eugenol to block transmission of action potentials of nerves [39]. Eugenol blocked the conduction of stimuli in isolated sciatic nerves of frogs at a concentration of 0.01% [20]. In vitro studies have

Dentlearn.ir

shown an interaction of eugenol with vallinoid receptors on nerve cells playing an important role in nociception, which may lead to inhibition of pain transmission [11]. In addition, eugenol inhibits inflammation. It inhibits cyclooxygenase activity and thus reduces the formation of prostaglandins and leukotrienes from arachidonic acid [2] (see also Chap. 7).

Clinical Practice Advice

To prevent a pulp necrosis, microperforations of the remaining dentin have to be excluded with certainty when ZOE cements (e.g., as a cavity base) are applied. The powder–liquid ratio should be as high as possible to reduce the quantity of unbound and leachable eugenol. Under these circumstances, ZOE cements are not pulp-damaging and may be used for pain relief and treatment of a reversible pulpitis.

6.4.4 Mutagenicity and Carcinogenicity

Eugenol was mutagenic in the mouse micronucleus test [42]. This effect could not be reproduced in transgenic mice [27]. Based on these findings, the use of ZOE materials is not contraindicated.

Conclusions for the Dental Practitioner

1. Zinc oxide and eugenol cements are not pulp-damaging when used for indirect pulp capping. However, in deep cavities there is always the risk of microperforations of the remaining dentin. Therefore, the deepest areas should be covered by a calcium hydroxide preparation. To avoid a pulp necrosis, ZOE must not be applied on the exposed pulp.
2. ZOE should not be used on patients who are allergic to eugenol. Eugenol is often found in fragrances and cosmetics, which may also result in an allergy. Furthermore, cross-allergies with Peru balm have been reported. Peru balm may be an ingredient in noneugenol ZOE materials. A number of patients who are allergic to isoeugenol (used in personal deodorants) may also be allergic to eugenol.
3. Dental personnel should avoid any skin contact with eugenol and ZOE in order to prevent an occupational contact dermatitis.

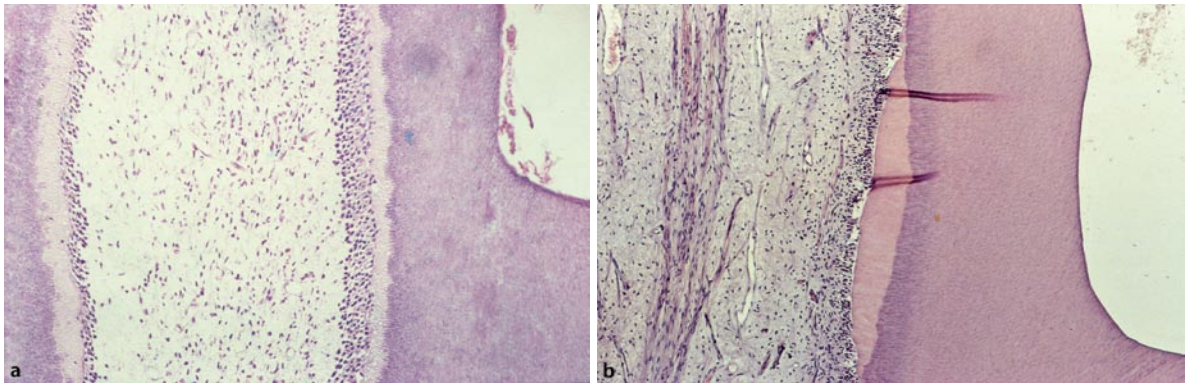

Fig. 6.17a,b Noninflamed pulp after application of zinc oxide eugenol. **a** 7 days after application. **b** 90 days after application (magnification ×80)

Dentlearn.ir

References

1. About, I., Murray, P.E., Franquin, J.C., Remusat, M., Smith, A.J.: Pulpal inflammatory responses following non-carious class V restorations. Oper Dent 26, 336–342 (2001).
2. Anamura, S., Dohi, T., Shirakawa, M., Okamoto, H., Tsujimoto, A.: Effects of phenolic dental medicaments on prostaglandin synthesis by microsomes of bovine tooth pulp and rabbit kidney medulla. Arch Oral Biol 33, 555–560 (1988).
3. Barratt, M.D., Basketter, D.A.: Possible origin of the skin sensitization potential of isoeugenol and related compounds. (I). Preliminary studies of potential reaction mechanisms. Contact Dermatitis 27, 98–104 (1992).
4. Bauer, J.G., Al-Rubayi, A.: Tissue response to direct filling materials. J Prosthet Dent 58, 584–589 (1987).
5. Becker, R.M., Hume, W.R., Wolinksy, L.E.: Release of eugenol from mixtures of ZOE in vitro. J Pedod 8, 71–77 (1983).
6. Berova, N., Stransky, L., Krasteva, M.: Studies on contact dermatitis in stomatological staff. Dermatol Monatsschr 176, 15–18 (1990).
7. Bruze, M., Johansen, J.D., Andersen, K.E., Frosch, P., Goossens, A., Lepoittevin, J.–P., Rastogi, S.C., White, I., Menne, T.: Deodorants: an experimental provocation study with isoeugenol. Contact Dermatitis 52, 260–267 (2005).
8. Buckley, D.A., Basketter, D.A., Smith Pease, C.K., Rycroft, R.J.G., White, I.R., McFadden, J.P.: Simultaneous sensitivity to fragrances. Br J Dermatol 154, 885–888 (2006).
9. Fenaroli, G., Burdock, G.A.: Fenaroli's Handbook of Flavor Ingredients, vol. 1, 3rd edn. CRC, Cleveland, USA 1994.
10. Goldberg, M., Lasfargues, J.J., Legrand, J.M.: Clinical testing of dental materials: histological considerations. J Dent 22, S25–S28 (1994).
11. Guénette, S.A., Ross, A., Marier, J.-F., Beaudry, F., Vachon, P.: Pharmacokinetics of eugenol and its effects on thermal hypersensitivity in rats. E J Pharmacol 562, 60–67 (2007).
12. Hensten-Pettersen, A., Helgeland, K.: Evaluation of biologic effects of dental materials using four different cell culture techniques. Scand J Dent Res 85, 291–295 (1977).
13. Hensten-Pettersen, A., Jacobsen, N.: Perceived side effects of biomaterials in prosthetic dentistry. J Prosthet Dent 65, 138–144 (1991).
14. Hilton, I., Dearman, R.J., Fielding, I., Basketter, D.A., Kimber, I.: Evaluation of the sensitizing potential of eugenol and isoeugenol in mice and guinea pigs. J Appl Toxicol 16, 459–464 (1996).
15. Hume, W.R.: Influence of dentine on the pulpward release of eugenol or acids from restorative materials. J Oral Rehabil 21, 469–473 (1994).
16. Kallus, T., Hensten-Pettersen, A., Mjör, I.A.: Tissue response to allergenic leachables from dental materials. J Biomed Mater Res 17, 741–755 (1983).
17. Kanerva, L., Estlander, T., Jolanki, R.: Dental nurse's occupational allergic contact dermatitis from eugenol used as a restorative dental material with polymethylmethacrylate. Contact Dermatitis 38, 339–340 (1998).
18. Kim, H.M., Lee, E.H., Kim, C.Y., Chung, J.G., Kim, S.H., Lim, J.P., Shin, T.Y.: Antianaphylactic properties of eugenol. Pharmacol Res 36, 475–480 (1997).
19. Klötzer, W.T., Langeland, K.: Testing of materials and methods for crown and bridge prosthesis on animals. Schweiz Monatsschr Zahnheilkd 83, 163–244 (1973).
20. Kozam, G.: The effect of eugenol on nerve transmission. Oral Surg Oral Med Oral Pathol 44, 799–805 (1977).
21. Landro, A.D., Valsecchi, R., Marchesi, L.: Allergic reaction with persistent hypopigmentation due to temporary tattooing with henna in a baby. Contact Dermatitis 52, 338–342 (2005).
22. Lindqvist, L., Otteskog, P.: Eugenol: liberation from dental materials and effect on human diploid fibroblast cells. Scand J Dent Res 88, 552–556 (1980).
23. Malten, K.E., van Ketel, W. G., Nater, J. P., Liem, D. H.: Reactions in selected patients to 22 fragrance materials. Contact Dermatitis 11, 1–10 (1984).
24. Murray, P.E., Hafez, A.A., Smith, A.J., Cox, C.F.: Hierarchy of pulp capping and repair activities responsible for dentin bridge formation. Am J Dent 15, 236–243 (2002).
25. Poulsom, R.C.: An anaphylactoid reaction to periodontal surgical dressing: report of case. J Am Dent Assoc 89, 895-896 (1974).
26. Rastogi, S.C., Johansen, J.D., Frosch, P., Menne, T., Bruze, M., Lepoittevin, J.-P., Dreier, B., Andersen, K.E., White, I.R.: Deodorants on the European market: quantitative chemical analysis of 21 fragrances. Contact Dermatitis 38, 29–35 (1998).
27. Rompelberg, C.J., Steenwinkel, M.J., van Asten, J.G., van Delft, J.H., Baan, R.A., Verhagen, H.: Effect of eugenol on the mutagenicity of benzo[a]pyrene and the formation of benzo[a]pyrene-DNA adducts in the lambda-lacZ-transgenic mouse. Mutat Res 369, 87–96 (1996).
28. Rudzki, E.: Occupational dermatitis among health service workers. Derm Beruf Umwelt 27, 112–115 (1979).
29. Rudzki, E., Grzywa, Z.: Dermatitis from propolis. Contact Dermatitis 9, 40–45 (1983).
30. Sarrami, N., Pemperton, M.N., Thornhill, M.H., Theaker, E.D.: Adverse reactions associated with the use of eugenol in dentistry. Br Dent J 193, 257–259 (2002).
31. Schmalz, G.: Die biologische Prüfung von Füllungsmaterialien am Göttinger Miniaturschwein – eine Pilot-Studie. [Biological testing of filling materials using the Göttingen miniature pig] Dtsch Zahnärztl Z 36, 357–360 (1981).
32. Schmalz, G., Rotgans, J.: Een in vitro onderzoek naar de toxciteit van een reuk-en smaakloos zinkoxyde-eugenolcement (isoprotect). [An in vitro study on the toxicity of an odour-free and flavourless zinc oxide and eugenol cement] Ned Tijdschr Tandheelkd 86, 85–88 (1979).
33. Schmalz, G., Hoffmann, M., Weis, K., Schweikl, H.: Influence of albumin and collagen on the cell mortality evoked by zinc oxide-eugenol in vitro. J Endod 26, 284–287 (2000).
34. Schmalz, G., Lamberts-Hepp, U.: Toxizitatsprüfungen von Füllungsmaterialien am Kaninchen.[Toxicity tests of filling materials in the rabbit] Zahnärztl Welt/Reform 92, 46–51 (1983).
35. Schmalz, G., Schmalz, C.: Toxicity tests on dental filling materials. Int Dent J 31, 185–192 (1981).
36. Schmalz, G., Schuster, U., Nützel, K., Schweikl, H.: An in vitro pulp chamber with three-dimensional cell cultures. J Endod, 25, 24–29 (1999).
37. Schnuch, A., Lessmann, H., Geier, J., Frosch, P.J., Uter, W.: Contact allergy to fragrances: frequencies of sensitization from 1996 to 2002. Results of the IVDK. Contact Dermatitis 50, 65–76 (2004).
38. Sela, J., Ulmansky, M.: Reaction of normal and inflamed dental pulp to Calxyl and zinc oxide and eugenol in rats. Oral Surg Oral Med Oral Pathol 30, 425–430 (1970).

Dentlearn.ir

39. Trowbridge, H., Edwall, L., Panopoulos, P.: Effect of zinc oxide-eugenol and calcium hydroxide on intradental nerve activity. J Endod 8, 403–406 (1982).
40. Wilson, A.D., Clinton, D.J., Miller, R.P.: Zinc oxide-eugenol cements: IV. Microstructure and hydrolysis. J Dent Res 52, 253–260 (1973).
41. Wöhrl, S., Hemmer, W., Focke, M., Götz, M., Jarisch, R.: The significance of fragrance mix, balsam of Peru, colophony and propolis as screening tools in the detection of fragrance allergy. Br J Dermatol 145, 268–273 (2001).
42. Woolverton, C.J., Fotos, P.G., Mokas, M.J., Mermigas, M.E.: Evaluation of eugenol for mutagenicity by the mouse micronucleus test. J Oral Pathol 15, 450–453 (1986).

Dentlearn.ir

6.5 Calcium Hydroxide Cements

H. Stanley (†) and B. Thonemann

Calcium hydroxide cements are used for direct and indirect pulp capping. The long-term goals of these procedures are a vital and pain-free pulp. The vital pulp tissue of a tooth contributes to the formation of secondary dentin, peritubular dentin (sclerotic or obliterated dentin), and reactionary/regenerative dentin (tertiary dentin), which is triggered by biological and pathological irritation or stimuli (see also Sect. 2.2.4). By the application of a material on the exposed pulp, tooth repair is intended, which in many aspects resembles tooth development. Therefore, relevant signaling molecules and genetically activated metabolic pathways will be similar in both instances.

The pulpal tissue extends into the tubular dentin and is responsible for the flexibility, wetness, and elasticity of dentin. These properties of the vital pulp protect the tooth from possible damage due to mastication [70, 73]. In addition, a nonvital tooth requires a load 2.5 times higher than does a vital tooth in order to generate a proprioceptive reaction, which is, for instance, necessary for a patient to localize a painful tooth.

Calcium hydroxide suspensions will also be described in this chapter for a better understanding of the mode of action. These suspensions also harden, but they do not set like cements. Similar to zinc oxide eugenol cements, the biological properties of calcium hydroxide materials include side effects (such as local necroses) but also wanted biological effects, such as initiation of new dentin formation. Because the latter effect may also be triggered by other materials and substances, these compounds will be reviewed below in the section on alternatives to calcium hydroxide. Calcium hydroxide materials are also used as root canal sealers or for apexification procedures (i.e., drug-induced formation of an apical calcified tissue barrier in teeth with incomplete root formation). This application will be described in detail in Chap. 7.

6.5.1 Basic Material Properties

6.5.1.1 Composition and Setting Reaction

6.5.1.1.1 Calcium Hydroxide

Various calcium hydroxide materials have been recommended for direct pulp capping. Besides calcium hydroxide, these compounds can contain water (suspensions), organic solvents (liner), calcium salicylate (cements), and resin monomers. All of these materials are characterized by a different pH. Aqueous calcium hydroxide suspensions reveal a pH of 12–13, and autosetting calcium-hydroxide-based salicylate cements (in the preset condition) have a pH of 10–11. Resin-based materials, however, show a pH of 11–12 before polymerization [67].

Calcium hydroxide suspensions (pH 12–13): The mixture of calcium hydroxide powder with water results in pastes with different viscosities depending on the powder-liquid ratio. Aqueous calcium hydroxide suspensions reveal the highest degree of alkalinity and thus the strongest bactericidal effects [67]. Calcium hydroxide suspensions contain trace amounts of calcium chloride, calcium oxide, potassium chloride, sodium chloride, and sodium bicarbonate besides water. Barium sulfate may be added to increase radiopacity. To improve the handling properties of the suspension, methyl cellulose may be added to some products [5]. Calcium hydroxide suspensions do not set in a classic sense; rather, they solidify because of the evaporation of water and formation of calcium carbonate.

Calcium hydroxide cements (pH 10–12): The tissue-destructive properties of calcium hydroxide suspensions prompted the development of products that are able to stimulate dentinogenesis, the formation of tertiary dentin ("bridging") without causing a necrosis of the remaining pulpal tissue, as is the case with most calcium hydroxide suspensions (Fig. 6.18) [72]. Therefore, calcium hydroxide materials with a lower pH were developed, including autosetting calcium-salicylate cements (e.g., Dycal, KerrLife) and calcium-

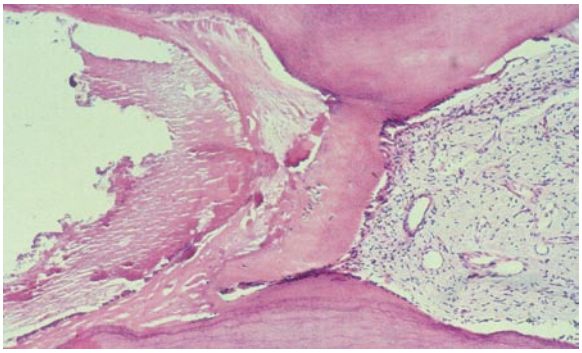

Fig. 6.18 "Bridging" after application of calcium hydroxide on the exposed pulp (30 days after application, magnification ×80) (Courtesy of G. Schmalz, Regensburg, Germany)

Dentlearn.ir

hydroxide-containing compounds based on resins (e.g., Prisma VLC Dycal).

6.5.1.1.2 Alternatives to Calcium Hydroxide

There have been frequent attempts in the past to replace calcium hydroxide with other substances. For instance, cyanoacrylates, glucocorticoids, dental adhesives, and, most recently, mineral trioxide aggregate (MTA), have been discussed, as well as biologically active signaling molecules.

Typical cyanoacrylate products (e.g., superglue) contain ethyl cyanoacrylate, isobutyl cyanoacrylate, or N-butyl-cyanoacrylate. In addition, methyl acrylates are added as thickening agents as well as stabilizers, such as hydroquinone and organic sulphonic acids. Cyanoacrylates have been used, for instance, as surgical tissue glues. Most available superglues are mixtures of different cyanoacrylates and are not approved for medical application. Dental materials consist of ethyl cyanoacrylate (Cyanoveneer, Epiglue) or isobutyl cyanoacrylate (Histoacryl) [7]. Pulp capping with cyanoacrylates, although recommended by some authors, has not become a standard procedure in dentistry.

Furthermore, glucocorticoid compounds containing hydrocortisone (cortisol) or dexamethasone have been recommended for direct pulp capping [23]. These substances are often combined with antibiotics (1 g Ledermix: 10 mg triamcinolone, 30.21 mg demeclocyclin calcium).

Recently, dental adhesives have been proposed for direct pulp capping [1, 17]. Information about the composition of dental adhesive systems can be found in Chap. 5.

Mineral trioxide aggregate (MTA), which has been introduced mainly as a retrograde root canal filling material or for apexification procedures, has also been recommended for direct pulp capping [3, 21, 24, 48, 54, 83]. MTA powder consists primarily of tricalcium silicate, tricalcium aluminate, tricalcium oxide, and silicate oxide [79]. Bismuth oxide is added to increase radiopacity. The powder is mixed with water.

Other materials have been described for their potential application as pulp capping products; type I collagen sponges, enriched homologous collagen solutions, dentin matrix extracts, and bovine cancellous bone enriched with calcitonin have been investigated [13, 64]. Recently, different recombinant growth factors, such as members of the TGF superfamily, have also been applied for direct pulp capping [53]. The use of these substances, however, is still experimental.

6.5.1.2 Release and Degradation

6.5.1.2.1 Calcium Hydroxide Preparations

Calcium hydroxide suspensions release permanently high amounts of hydroxyl ions. Contact with air triggers a reaction with CO_2 and the formation of calcium carbonate. When commercially available calcium hydroxide suspensions were stored in contact with air, the concentration of calcium carbonate increased to 5.5% during a 6-week period. But this reaction did not influence pH, and subsequent mixing of the dried paste with distilled water restored the original (antimicrobial) efficiency [9].

Release of hydroxyl ions from calcium hydroxide salicylate cements is influenced by the cements' composition. Most hydroxyl and calcium ions are released from suspensions. No hydroxyl ions are released when hydrophobic substances are added, such as paraffin oil as a plasticizer. Calcium-hydroxide-containing resins release almost no hydroxyl ions compared with aqueous calcium hydroxide suspensions, whereas the modern calcium hydroxide salicylate cements, which contain ethyltoluol sulphonamide, show a permanent release of hydroxyl ions but at a lower concentration than calcium hydroxide suspensions [67].

Autosetting calcium hydroxide salicylate cements may have little stability in an aqueous environment [37]. Disintegration of these compounds was observed after a long period of time when they had been applied as a cavity base [31]. The disintegration of these products was accelerated in the case of marginal microgaps of the restoration ("microleakage") [58]. However, calcium hydroxide compounds are also exposed to humidity from the pulp beneath a restoration, which may further accelerate the disintegration of these materials [66]. Calcium-hydroxide-containing resins are less susceptible to chemical disintegration [67].

Clinical Practice Advice

Because calcium hydroxide salicylate cements are susceptible to disintegration, only very thin layers should be applied in cavities. The disintegration of thicker layers of calcium hydroxide materials may cause misinterpretation of x-rays when the resulting voids are erroneously diagnosed as recurrent caries. In addition, larger voids in a cavity base may reduce the mechanical stability of the restoration.

Dentlearn.ir

6.5.1.2.2 Alternatives to Calcium Hydroxide

Cyanoacrylates polymerize at room temperature when in contact with humidity or water and thereby form esters. The resulting polymer is not disintegrated by phagocytosis in vivo, but hydrolysis of the polymer will generate formaldehyde and alkyl cyanoacrylate as well as CO_2 and water. The amounts of formaldehyde released are dependent on the product [22].

Nonpolymerizing constituents of dental adhesives that are used for direct pulp capping, such as residual monomers, can diffuse into the adjacent tissues. Details regarding release of substances are reviewed in Chap. 5.

Hydration of MTA powder generates a colloidal gel that solidifies, forming a hard structure. The average setting time of MTA is approximately 3 h [79]. With hydration, MTA forms a silicate hydrate gel and calcium hydroxide [11]. The biological response to MTA has been linked to that of calcium hydroxide, and it was postulated that the mechanisms of action were similar [34, 35]. MTA stimulates reparative dentin formation. Pulps capped with MTA showed complete bridge formation with no signs of inflammation [21, 83].

Substances like glucocorticoids, collagens, and signaling molecules (such as members of the TGF superfamily) are soluble and interact with the biological environment, including drugs. Further information regarding metabolism of these substances can be found in textbooks of pharmacology.

6.5.2 Systemic Toxicity and Allergies

6.5.2.1 Calcium Hydroxide

There are no indications in the current literature that calcium hydroxide materials may cause systemic effects or antigen-antibody reactions [75]. But local effects can be expected because of the high alkalinity of the adjacent tissue.

6.5.2.2 Alternatives to Calcium Hydroxide

6.5.2.2.1 Cyanoacrylates

No systemic toxic effects caused by cyanoacrylates have been reported in the literature, although some cases of allergic contact allergy have been documented [16, 38, 77]. Cases of onychodystrophy (malformation of nails) and eczema at the fingertips have been associated with contact with ethyl-2-cyanoacrylate, which is used as glue for artificial fingernails [32]. Asthma cases caused by cyanoacrylate vapors are very rare [15, 76].

6.5.2.2.2 Glucocorticoids and Synthetic Steroids

These substances reveal a strong anti-inflammatory effect. Resorption of topically applied steroids, which are frequently used in dermatology, may cause an adrenocortical suppression (suppression of the adrenocorticoids under stress). As a consequence, no endogenous glucocorticoid is secreted. The extent of the suppression depends on the intensity of the effect of the steroids, the treatment period, the applied amount, and the treated tissue.

The use of topically applied glucocorticoids in dentistry does not significantly decrease the secretion of adrenocorticoids. Serious systemic reactions may be caused by glucocorticoids (see review by Fritsch [25]). However, no systemic effects have been reported in the literature after topical application of glucocorticoids for direct pulp capping.

Cases of allergic contact dermatitis after the topical treatment of skin with steroids have been documented in the current literature [85] and have been partly linked to constituents of the soap base (e.g., lanolin). There is no indication that topically applied glucocorticoids in dentistry have an allergic potency.

6.5.2.2.3 Mineral Trioxide Aggregate

No reports have been published that indicate systemic reactions or allergies caused by MTA.

6.5.2.2.4 Medical Collagen Products

Theoretically, these materials could be of immunological relevance, since collagen in commercial materials is mostly derived from animal tissues (bovine, porcine, etc.). However, those parts of the molecules that are primarily responsible for an antigen-antibody reaction are removed by a pretreatment, such as cross-linking of collagen or enzymatic treatment. However, in view of the frequent application of medical collagen products, relatively few cases of IgE-mediated immediate hypersensitivity reactions to bovine collagen, including joint inflammation, edema, and fever, are reported in the current literature [8, 49, 74].

Dentlearn.ir

Transient adverse reactions (including bruising, redness, and swelling) to bovine collagen derived dermal fillers are reported to occur at a rate of 2.1% [56]. Therefore, for application of injectable bovine collagen in plastic surgery, patient screening and testing are recommended [4, 47]. Allergenicity to injectable bovine collagen is reliably determined by skin testing, and a positive skin test is reported in 3.0–3.5% of patients [42]. However, today there is no indication that topically applied medical collagens in dentistry have an allergic potency. There is presently no indication in the literature that the use of animal tissues might transfer bovine spongiform encephalopathy or Creutzfeld–Jacob syndrome.

6.5.2.2.5 Growth Factors

Autologous, homologous, or recombinant growth factors have been tested in animal experiments. So far, no reports have been published regarding systemic effects or allergies to these substances when applied for direct pulp capping.

6.5.3 Local Toxicity and Tissue Compatibility

6.5.3.1 Cell Cultures

Calcium hydroxide was extremely toxic in cells derived from human salivary glands at a concentration of 1 mmol [26]. Calcium hydroxide was also toxic to periodontal cells and in permanent cell lines [36]. However, calcium hydroxide preparations were not toxic in other studies [14, 28, 39, 41], or else the reactions varied depending on the product tested [28, 41]. Obviously, cytotoxicity is dependent on the material tested and thus on the released amounts of calcium hydroxide. Additionally, calcium hydroxide is transformed in cell culture media into calcium carbonate, which is nontoxic. Therefore, tests using media extracts showed nontoxic results for these materials [14]. Thus, the results strongly depend on the method used.

6.5.3.2 Antimicrobial Properties

The antimicrobial properties of calcium hydroxide have been extensively investigated in in vitro tests. Contradictory results were found. While Lado et al. [44] observed a more pronounced antimicrobial effect caused by calcium hydroxide salicylate cements in comparison to suspensions [44], Staehle et al. [67] reported that calcium hydroxide suspensions generate a stronger antimicrobial effect than calcium-hydroxide-containing cements based on salicylate or resins. (See also Chap. 7.) Some types of bacteria, including *Enterococcus faecalis* and *Candida albicans*, are resistant to calcium hydroxide.

6.5.3.3 Pulp Reactions

6.5.3.3.1 Calcium Hydroxide Preparation: Indirect Pulp Capping

To understand the histopathology involved in the indirect pulp capping procedure, some basic information seems necessary (see also textbooks on endodontology). If the bacterial penetration lies within 0.75 mm of the pulp or if the bacteria have invaded previously formed reparative dentin, the degree of pulpal diseases (inflammation) becomes extreme and most likely irreversible (Fig. 6.19) [57]. If carious dentin is removed, except for the last deep layer overlying some intact, mostly bacteria-free (uninfected) secondary or tertiary dentin, the bulk of the acid-producing bacteria is eliminated. The placing of a satisfactory gap-free restoration may deprive the potentially remaining bacteria of an abundant substrate supply and may prevent their

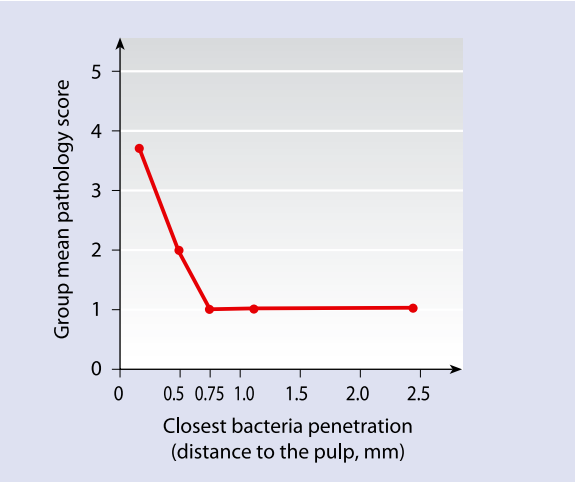

Fig. 6.19 Reaction of the pulp to bacterial contamination of the carious dentin. No pathologic reaction of the pulp is visible as long as the distance between pulp and the bacterial invasive front is greater than 0.75 mm. But at a distance of 0.3–0.5 mm, the formation of an abscess and chronic inflammatory process can be observed (Courtesy of R. Reeves, Bethesda, Maryland, USA [57])

Dentlearn.ir

multiplication and the production of toxins, which might have caused an inflammatory pulpal reaction.

In addition to its alkaline and antimicrobial effect, calcium hydroxide reduces dentin permeability, for example, via deposits on or in dentin. Some authors recommend calcium hydroxide preparations to stimulate the formation of reactionary/regenerative dentin. Calcium hydroxide preparations, however, trigger tertiary dentin formation in humans only if the preparations are in direct contact with the pulp. Calcium hydroxide, when in direct contact with the dental pulp, induces a superficial necrosis of the pulpal tissues. But in the case of a remaining dentin layer between the calcium hydroxide preparation and the pulp, an immediate reaction is visible only if the thickness of the dentin layer is 5–10 µm or less [27, 29].

6.5.3.3.2 Calcium Hydroxide Preparations: Direct Pulp Capping

As mentioned above, products with a very high pH as well as materials with a slightly lower pH are currently available. Accordingly, there are two different modes of tissue reactions. Because the bridge formation resulting from the original calcium hydroxide products of high pH (12–13) has been described for many years, and some present-day products still maintain a high pH, it is appropriate to describe healing leading to bridge formation with the basic calcium hydroxide formulas and then the variations induced with the newer, less alkaline products [71, 72].

Calcium hydroxide preparations with high pH (12–13): The effect of calcium hydroxide during direct pulp capping on the pulp has been well documented. Most of the results subsequently reviewed were obtained under optimum, primarily experimental, conditions. Alkalinity of the tissue is the basis for the desired effect (e.g., bridging). The following zones of tissue reaction can be observed histologically after application of calcium hydroxide for direct pulp capping:

- *Zone of obliteration* (early changes, caustic effect, area of superficial debris): The pulp tissue immediately in contact with calcium hydroxide is usually completely deranged and distorted because of the caustic effect of the drug (a chemical cautery). This zone consists of debris, dentinal fragments, hemorrhage, blood clot, blood pigment, and particles of calcium hydroxide [62, 64]. Schroeder and Granath [62] explained that the zone of obliteration results from a combination of the pressure of medicament application and the chemical injury due to the high concentration of hydroxyl ions. This zone can be visualized after 1 h of contact between the calcium hydroxide and the tissue [20].
- *Zone of coagulation necrosis:* Because the tissue together with its plasma proteins within the zone of obliteration take the brunt of the calcium hydroxide chemical thrust, a weaker chemical effect reaches the subjacent, more apical tissue and results in a zone of coagulation necrosis and thrombosis (the mummified zone; Fig. 6.20) [62, 68]. The zone of coagulation necrosis (0.3–0.7 mm thick) represents the devitalized tissue without complete obliteration of its structural architecture. Although the cellular detail is greatly diminished, outlines of capillaries (filled with hemolyzed erythrocytes), nerve bundles, and pyknotic nuclei can still be recognized [71].
- *The line of demarcation:* Between the deepest level of the zone of coagulation necrosis and the subjacent vital pulp tissue, a line of demarcation develops. Glass and Zander believed that this line resulted from the reaction of the calcium hydroxide with the tissue protein to form proteinate globules (Fig. 6.20) [29].
- *Early stages of dentin bridge formation:* Within several days, as the repair process progresses, immediately subjacent to the line of demarcation, proliferation of mesenchymal cells and cell differentiation occurs (perhaps to secondary odontoblasts).
- *Calcification of the bridge:* Calcification occurs soon after the predentin has developed. Initially, irregular dentin is formed (fibrodentin with included cells). Subsequently, tubular dentin is attached to this zone after approximately 2–3 months.

Key Note

The calcium-hydroxide-triggered coagulation necrosis seems to be a stimulus that is sufficient to initiate healing in the subjacent vital pulp tissue. This process will then initiate the differentiation of cells to odontoblast-like pulp cells (secondary odontoblasts), which will finally result in a bridging. (For details, see [69, 82]).

Calcium hydroxide preparations with comparatively lower pH (9–10): With some of the new hard-setting formulations with comparatively low pH, tissue will be less extensively damaged than with calcium hydroxide suspensions. But there is still sufficient tissue irritation to stimulate healing of the pulp wound. A sufficient

Dentlearn.ir

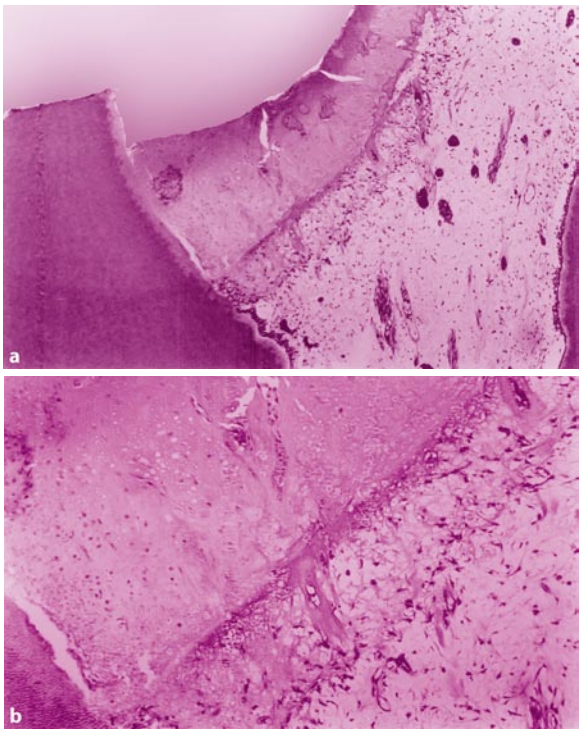

Fig. 6.20a,b Direct pulp capping. **a** Capping of a pulp exposure (*upper left*) with a calcium hydroxide suspension; histologic image after 7 days. A distinct mummified zone and a line of demarcation are visible (magnification ×80). **b** Higher magnification of the same histologic specimen. A clear line of demarcation can be observed with formation of a new odontoblast-like layer beneath the line of demarcation (magnification ×200) (Courtesy of C. Turner, Gainesville, Florida, USA [81])

hydroxyl ion concentration capable of stimulating the differentiation and regeneration of tissue still exists to produce a dentinal bridge. The capacity to make a more uniform dentinal bridge right up against the capping material is a great advantage (Figs. 6.21 and 6.22).

The desired alkalinity of the pulp tissue as well as the biological effect of calcium hydroxide products requires direct contact between calcium hydroxide and pulp tissue. It is of particular importance that the effect of the calcium hydroxide material is not inhibited by bleeding or coagulated blood.

The exact, detailed mechanism of the dentinogenesis resulting in bridging is not yet clear. It appears to depend on the extent of the stimulus. With less extensive stimuli (for example, less intense preparation trauma), local odontoblasts will be stimulated, resulting in tertiary dentin formation (reactionary dentinogenesis). Extensive stimuli, such as caused by pulp exposure, will cause loss of the original odontoblasts (reparative dentinogenesis). These processes are controlled by a great variety of growth factors, similar to the processes during tooth development [82], with TGF β-1 apparently playing a major role [30]. The expression of fibronectin and tenascin has been shown after direct pulp capping with a calcium hydroxide preparation; these are indicators of wound healing and odontogenesis [55].

So-called tunnel defects may cause a problem. These defects, which are located in newly formed dentin, create tunnels and thereby open communications between the calcium hydroxide and the pulp and may act as access for bacteria [18]. This problem underscores that a tight restoration and sealing of the cavity is decisive for the success of a direct pulp capping. Bacterial infection is the most important reason for failure of a direct pulp capping [50].

6.5.3.3.3 Alternatives to Calcium Hydroxide

Cyanoacrylates: Because of their cytotoxicity, cyanoacrylates may cause local reactions. Although bridging has been observed after capping an exposed pulp with isobutyl cyanoacrylate [7], the proliferation of histiocytes and the generation of foreign body giant cells were documented in the adjacent pulp tissue [33]. Therefore, cyanoacrylates are not routinely applied in dental practice [33].

Glucocorticoids and synthetic steroids: No bridging was observed after direct pulp capping with glucocorticoid-containing materials [84]. Hydrocortisone and dexamethasone inhibited collagen synthesis [84]. Glucocorticoid materials cause rapid relief of pain of the pulp.

Clinical Practice Advice

Because glucocorticoids will cause analgesia of the pulp when applied topically, these products may be used for the initial treatment of pulpal pain. But since they do not generate reparative dentin formation (bridging), glucocorticoids are not appropriate for permanent pulp capping.

Dental adhesives: Biological reactions triggered by modern dental adhesives are reviewed in Chap. 5. Because of contradictory data in the current literature, dentin adhesives cannot be recommended for routine pulp capping procedures in daily dental practice, at

Dentlearn.ir

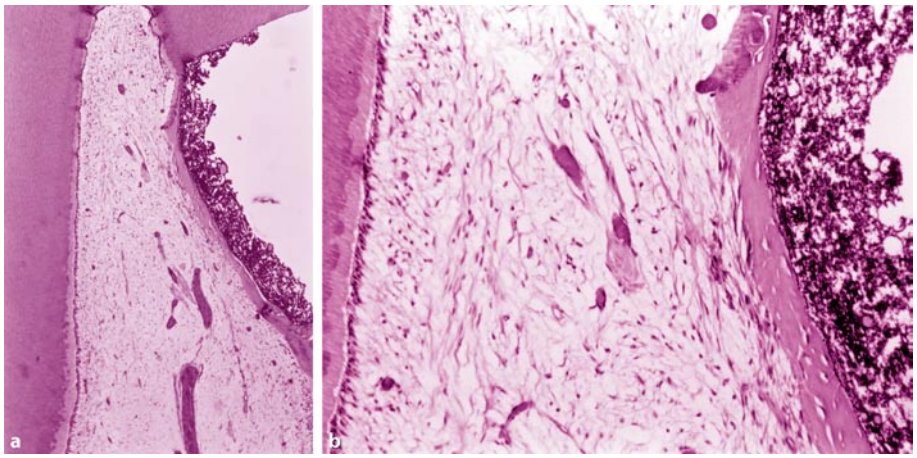

Fig. 6.21a,b Direct pulp capping. **a** Status 63 days after pulp capping with Nu-Cap. A thin layer of reparative dentin is visible at the interface between the capping material and the vital pulp tissue (magnification ×80). **b** Higher magnification (×200) of the same histologic specimen. A bridging and regular histologic appearance of the pulp without inflammatory cells can be observed (Courtesy of C. Turner, Gainesville, Florida, USA [81])

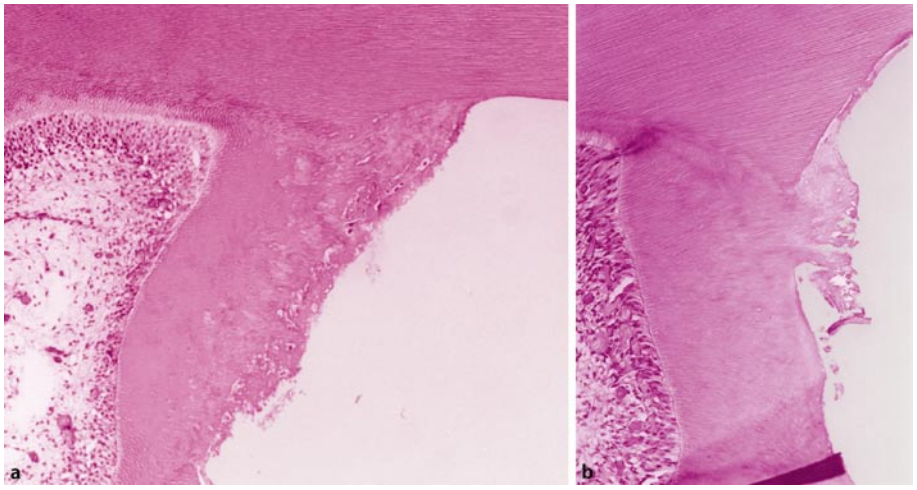

Fig. 6.22a,b Direct pulp capping. **a** Sixty-four days after direct capping with Prisma VLC Dycal, odontoblast-like cells have generated a distinct reparative dentin bridge with tubular dentin (magnification ×41). **b** Higher magnification (×82) of the same histologic specimen [72]

least not before further long-term clinical studies are available.

Mineral trioxide aggregate: The pH of MTA increases from an initial value of 10.2 to 12.5 during the setting reaction within 3 h after mixing [79]. For the material MTA-Angelus, after 24 h a pH of 10.4 was reported. After 10 days, the pH decreased to 7.6 [61]. Therefore, a local reaction due to increased pH seems possible. Nevertheless, MTA was less cytotoxic than a zinc oxide and eugenol cement [80] and less toxic than a resin-modified GIC [51]. MTA promotes the expression of cytokines and osteocalcin in cultures with human osteosarcoma cells [43] and osteonectin and sialophosphoprotein mRNA in cultured human pulp cells [51]. MTA showed a better tissue compatibility after intraosseous implantation in guinea pigs than a modified zinc oxide and eugenol cement did. Bone formation was documented directly adjacent to the MTA implant in six out of 21 cases [78]. When

Dentlearn.ir

MTA was used for direct pulp capping in primates, an inflammation of the pulp was observed in only one of six cases after a period of 5 months. Interestingly, bridging was documented in all cases [24]. MTA and a calcium hydroxide suspension were used for pulp capping in dogs. After 2 months, MTA application had led to better bridge formation and less inflammation than the calcium hydroxide suspension [10].

Key Note

Data regarding direct pulp capping with MTA are very promising [3, 10, 12, 21, 48, 54, 83], although little clinical experience with this material is available so far.

Medical collagen products: Collagen sponges (type I collagen) or enriched collagen (type I) solutions cause rapid wound healing due to their chemotactic activity. But collagen gels, when used for direct pulp capping, have generated only incomplete bridging [13]. Hydroxyl apatite, which is supposed to possess an osteoconductive and/or osteoinductive potency, is controversial regarding its applicability as a pulp capping agent [2, 40]. However, demineralized dentin [52] and bone matrix enriched with calcitonin [64] both reveal a bridging effect. In addition, demineralized dentin is hetero-inductive (induction of bone formation by a dentin matrix) in muscles, subcutaneous tissue, bone defects, and so on, as well as homo-inductive when applied for pulpotomy [52].

Growth factors: These molecules stimulate reparative dentin formation, but contradictory data have been reported for TGF β1 [53]. Although a number of studies indicate stimulation of dentin formation in exposed pulps and in nonexposed situations due to biologically active molecules, such as bone morphogenetic proteins (BMPs), EDTA-dissolved dentin extracts, or osteogenic proteins [6, 19, 53, 65], the molecular mechanisms of these effects have not yet been clarified [46]. More important, the interplay between inflammation and dentin regeneration deserves special attention because inflammation apparently interferes with dentin regeneration [60]. Furthermore, the structure of the newly formed dentin should be investigated because there is evidence that it is of the osteodentin type [63]. Therefore, more investigations on the use of biologically active molecules for direct pulp capping are warranted.

6.5.4 Mutagenicity and Carcinogenicity

One study indicated that calcium hydroxide had no genotoxic effect and did not cause any oxidative DNA damage [59]. No data indicating a mutagenic or carcinogenic effect of calcium hydroxide or calcium hydroxide cements have been published in the scientific literature. These effects are more than unlikely to occur regarding the composition of these products, which also applies to the alternative materials as well (mutagenicity of dental adhesives is reviewed in Chap. 5).

Conclusions for the Dental Practitioner

1. Calcium hydroxide products are still the standard for direct pulp capping in daily dental practice, although the therapeutic effect is at least partially correlated with tissue necrosis. Calcium hydroxide preparations, which are primarily not analgesic, are also recommended to be used for indirect pulp capping in cases when no direct analgesic effect is deemed necessary.
2. For direct pulp capping, calcium hydroxide must be applied directly onto the pulp with no blood clots between the pulp and the calcium hydroxide in order to induce dentin bridging. An immediate bacteria-tight sealing of the cavity is decisive for the success of the therapy.
3. Glucocorticoid-containing drugs should be used only for initial pain therapy because they do not induce regenerative dentin formation. In addition, these agents may cause chronic inflammation of the pulp.
4. Other materials or substances, including dental adhesives, medical collagens, and biological signaling molecules, have been recommended as direct pulp capping agents. However, these products are controversially discussed in the literature, are still experimental, or, in the case of dental adhesives, are definitely not recommended for this purpose.
5. MTA has great potential as pulp capping material and can be recommended for this indication if further clinical studies support the positive experimental data.

Dentlearn.ir

References

1. Akimoto, N., Momoi, Y., Kohno, A., Suzuki, S., Otsuki, M., Cox, C.F.: Biocompatibility of Clearfil Linder Bond 2 and Clearfil AP-X system on nonexposed and exposed primate teeth. Quintessence Int 29, 177–188 (1998).
2. Alliot-Licht, B., Jean, A., Gregoire, M.: Comparative effect of calcium hydroxide and hydroxyapatite on the cellular activity of human pulp fibroblasts in vitro. Arch Oral Biol 39, 481–489 (1994).
3. Andelin, W.E., Shabahang, S., Wright, K., Torabinejad, M.: Identification of hard tissue after experimental pulp capping using dentin sialoprotein (DSP) as a marker. J Endod 29, 646–650 (2003).
4. Baumann, L., Kaufman, J., Saghari, S.: Collagen fillers. Dermatol Ther 19, 134–140 (2006).
5. Berk, H.: The effect of calcium hydroxide-methylcellulose paste on the pulp. J Dent Child 17, 65 (1950).
6. Bègue-Kirn, C., Smith, A.J., Ruch, J.V., Wozney, J.M., Purchio, A., Hartmann, D., Lesot, H.: Effects of dentin proteins, transforming growth factor beta 1 (TGF beta 1) and bone morphogenetic protein 2 (BMP2) on the differentiation of odontoblast in vitro. Int J Dev Biol 36, 491–503 (1992).
7. Bhaskar, S.N., Cutright, D.E., Boyers, R.C., Margetis, P.M.: Pulp capping with isobutyl cyanoacrylate. J Am Dent Assoc 79, 640–644 (1969).
8. Bonnet, C., Charriere, G., Vaquier, J., Bertin, P., Vergne, P., Treves, R.: Bovine collagen induced systemic symptoms: antibody formation against bovine and human collagen. J Rheumatol 23, 545–547 (1996).
9. Bremer, K., Albers, H.K.: Antibakterielle Wirksamkeit von Calciumhydroxid in Abhängigkeit vom Alter des Präparates. [Antibacterial effect of calcium hydroxide depending upon the age og the preparation] Quintessenz 38, 1275–1279 (1987).
10. Briso, A.L.F., Rahal, V., Mestrener, S.R., Junior, E.D.: Biological response of pulps submitted to different capping materials. Braz Oral Res 20, 219–225 (2006).
11. Camilleri, J., Motesin, F.E., Di Silvo, L., Pitt Ford, T.R.: The chemical constitution and biocompatibility of accelerated Portland cement for endodontic use. Int Endod J 38, 834–842 (2005).
12. Camilleri, J., Pitt Ford, T.R.: Mineral trioxide aggregate: a review of the constituents and biological properties of the material. Int Endod J 39, 747–754 (2006).
13. Carmichael, D.J., Dick, H.M., Dodd, C.M.: Histologic effects of antigenically altered collagen as a heterograft for mammalian pulp exposures. Arch Oral Biol 19, 1121–1126 (1974).
14. Cavalcanti, B.N., Rode, S.M., Marques, M.M.: Cytotoxicity of substances leached or dissolved from pulp capping materials. Int Endod J 38, 505–509 (2005).
15. Chan, C.C., Cheong, T.H., Lee, H.S., Wang, Y.T., Poh, S.C.: Case of occupational asthma due to glue containing cyanoacrylate. Ann Acad Med Singapore 23, 731–733 (1994).
16. Conde-Salazar S.L., Rojo, S., Guimaraens, D.: Occupational allergic contact dermatitis from cyanoacrylate. Am J Contact Dermat 9, 188–189 (1998).
17. Cox, C.F., Hafez, A.A., Akimoto, N., Otsuki, M., Suzuki, S., Tarim, B.: Biocompatibility of primer, adhesive and resin composite systems on non-exposed pulps of non-human primate teeth. Am J Dent 11, S55–S63 (1998).
18. Cox C.F., Subay R.K., Ostro E., Suzuki S., Suzuki S.H.: Tunnel defects in dentin bridges: their formation following direct pulp capping. Oper Dent 21, 4–11 (1996).
19. Duque, C., Hebling, J., Smith, A.J., Giro, E.M.A., Oliveira, M.F., De Souza Costa, C. A.: Reactionary dentinogenesis after applying restorative materials and bioactive dentin matrix molecules as liners in deep cavities prepared in nonhuman primate teeth. J Oral Rehabil 33, 452–461 (2006).
20. DeFreitas, J.F.: Characterization and aqueous extraction of calcium hydroxide materials. Aust Dent J 27, 352–356 (1982).
21. Faraco Junior I.M., Holland, R.: Histomorphological response of dogs' dental pulp capped with white mineral trioxide aggregate. Braz Dent J 15, 104–108 (2004).
22. Feldman, D.S., Sierra, D.S.: Tissue adhesive in wound healing. Encyclopedic Handbook of Biomaterials and Bioengineering. D.L. Wise, D.J. Trantolo, D.E. Altobelli, M.J. Yaszemski, J.D. Gresser, E.R. Schwartz (eds). Marcel Dekker, New York (1995), pp 1347–1378.
23. Fiore-Donno, G., Baume, L.J.: Effects of pulp capping compounds containing corticosteroids on the human dental pulp. Acta Helv Odont 6, 23–28 (1962).
24. Ford, T.R., Torabinejad, M., Abedi, H.R., Bakland, L.K., Kariyawasam, S.P.: Using mineral trioxide aggregate as a pulp-capping material. J Am Dent Assoc 127, 1491–1494 (1996).
25. Fritsch, P.: Dermatologie und Venereologie: Lehrbuch und Atlas. [Dermatology and Venerology: textbook and atlas] Springer Verlag, Berlin (1998).
26. Fujisawa, S., Atsumi, T., Satoh, K., Sakagami, H.: Interaction between 2-ethoxybenzoic acid (EBA) and eugenol, and related changes in cytotoxicity. J Dent Res 82, 43–47 (2003).
27. Gängler, P.: Vergleichende vitalmikroskopische und histologische Untersuchungen zum Wirkungsmechanismus der Pulpaüberkappungsmittel Kalziumhydroxid und Zinkoxid-Eugenol. [Comparative vital microscopy and histological study on the mechanism of action of the pulp capping materials calcium hydroxide and zinc oxide and eugenol] Zahn Mund Kieferheilk 65, 376–381 (1977).
28. Geurtsen, W., Leinenbach, F., Krage, T., Leyhausen, G.: Cytotoxicity of four root canal sealers in permanent 3T3 cells and primary human periodontal ligament fibroblast cultures. Oral Surg Oral Med Oral Pathol Oral Radiol Endod 85, 592–597 (1998).
29. Glass, R.L., Zander, H.A.: Pulp healing. J Dent Res 28, 97–107 (1949).
30. Goldberg, M., Smith, A.J.: Cells and extracellular matrices of dentin and pulp: a biological basis for repair and tissue engineering. Crit Rev Oral Biol Med 15, 13–27 (2004).
31. Grajower, R., Bielak, S., Eidelman, E.: Observations on a calcium hydroxide lining in retrieved deciduous teeth, with proximal amalgam fillings. J Oral Rehabil 11, 561–569 (1984).
32. Guin, J.D., Baas, K., Nelson, A.P.: Contact sensitization to cyanoacrylate adhesive as a cause of severe onychodystrophy. Int J Dermatol 37, 31–36 (1998).
33. Herod, E.L.: Cyanoacrylates in dentistry: a review of the literature. J Can Dent Assoc 56, 331–334 (1990).
34. Holland, R., de Souza, V., Nery, M.J., Otoboni Filho, J.A., Bernabe, P.F., Dezan, E. Jr.: Reaction of rat connective tissue to implanted dentin tubes filled with mineral trioxide aggregate or calcium hydroxide. J Endod 25, 161–166 (1999).
35. Holland, R., de Souza, V., Nery, M.J., Faraco Junior I.M., Bernabe, P.F., Otoboni Filho, J.A., Dezan Junior, E.: Reaction of rat connective tissue to implanted dentin tube filled with mineral trioxide aggregate, Portland cement or calcium hydroxide. Braz Dent J 12, 3–8 (2001).

Dentlearn.ir

36. Huang, F.M., Tai, K.W., Chou, M.Y., Chang, Y.C.: Cytotoxicity of resin-, zinc oxide-eugenol-, and calcium hydroxide-based root canal sealers on human periodontal ligament cells and permanent V79 cells. Int Endod J 35, 153–158 (2002).
37. Hwas, M., Sandrik, J.L.: Acid and water solubility and strength of calcium hydroxide bases. J Am Dent Assoc 108, 46–48 (1984).
38. Jacobs, M.C., Rycroft, R.J.: Allergic contact dermatitis from cyanoacrylate? Contact Dermatitis 33, 71 (1995).
39. Jaunberzins, A., Gutmann, J.L., Witherspoon, D.E., Harper, R.P.: Effects of calcium hydroxide and transforming [correction of tumor] growth factor-beta on collagen synthesis in subcultures I and V of osteoblasts. J Endod 26, 494–499 (2000).
40. Jean, A., Kerebel, B., Kerebel, L.M., Legeros, R.Z., Hamel, H.: Effects of various calcium phosphate biomaterials on reparative dentin bridge formation. J Endod 14, 83–87 (1988).
41. Klaiber, B., Mittermayer, C.: Capping materials in the cell culture test. Dtsch Zahnärztl Z 36, 148–155 (1981).
42. Klein A.W.: Collagen substances. Facial Plast Surg Clin North Am 9, 205–218 (2001).
43. Koh, E.T., Torabinejad, M., Pitt, F.T., Brady, K., McDonald, F.: Mineral trioxide aggregate stimulates a biological response in human osteoblasts. J Biomed Mater Res 37, 432–439 (1997).
44. Lado, E.A., Pappas, J., Tyler, K., Stanley, H.R., Walker, C.: In vitro antimicrobial activity of six pulp-capping agents. Oral Surg Oral Med Oral Pathol 61, 197–200 (1986).
45. Lehner, T., Lyne, C.: Adrenal function during topical oral treatment with triamcinolone acetonide. Br Dent J 129, 164–167 (1970).
46. Lesot, H., Bègue-Kirn, C., Kubler, M.D., Meyer, J.M., Smith, A.J., Cassidy, N., Ruch, J.V.: Experimental induction of odontoblast differentiation and stimulation during reparative processes. Cell Mater 3, 201–217 (1993).
47. Lowe, N.J., Maxwell, C.A., Patnaik, R.: Adverse reactions to dermal fillers: review. Dermatol Surg 31, 1616–1625 (2005).
48. Menezes, R., Bramante, C.M., Letra, A., Carvalho, V.G., Garcia, R.B.: Histologic evaluation of pulpotomies in dog using two types of mineral trioxide aggregate and regular and white Portland cements as wound dressing. Oral Surg Oral Med Oral Pathol Oral Radiol Endod 98, 376–379 (2004).
49. Mullins, R.J., Richards, C., Walker, T.: Allergic reactions to oral, surgical and topical bovine collagen. Anaphylactic risk for surgeons. Austr NZ J Ophthalmol 24, 257–260 (1996).
50. Murray P.E., Winsor L.J., Smyth T.W., Hafez A.A., Cox C.F.: Analysis of pulpal reactions to restorative procedures, materials, pulp capping, and future therapies. Crit Rev Oral Biol Med 13, 509–520 (2002).
51. Min, K.-S., Kim, H.-I., Park, H.-J., Pi, S.-H., Hong, C.-U., Kim, E.-C.: Human pulp cells response to Portland cement in vitro. J Endod 33, 163–166 (2007).
52. Nakashima, M.: Dentin induction by implants of autolyzed antigen-extracted allogeneic dentin on amputated pulps of dogs. Endod Dent Traumatol 5, 279–286 (1989).
53. Nakashima, M., Nagasawa, H., Yamada, Y., Reddi, A.H.: Regulatory role of transforming growth factor-beta, bone morphogenetic protein-2, and protein-4 on gene expression of extracellular matrix proteins and differentiation of dental pulp cells. Dev Biol 162, 18–28 (1994).
54. Pitt Ford, T.R. Torabinejad, M., Abedi, H.R., Bakland L.K., Kariyawasam, S.P.: Using mineral trioxide aggregate as a pulp-capping material. J Am Dent Assoc 127, 1491–1494 (1996).
55. Piva, E., Tarquinio, S.B.C., Demarco, F.F., Silva, A.F., de Araújo, V.C.: Immunohistochemical expression of fibronectin and tenascin after direct pulp capping with calcium hydroxide. Oral Surg Oral Med Oral Pathol Oral Radiol Endod 102, e66–e71 (2006).
56. Pollack, S.: Some new injectable dermal filler materials: Hylaform, Restylane, and Artecoll. J Cutan Med Surg 3 (suppl 4), 27–35 (1999).
57. Reeves, R., Stanley, H.R.: The relationship of bacterial penetration and pulpal pathosis in carious teeth. Oral Surg Oral Med Oral Pathol 22, 59–65 (1966).
58. Rehfeld, R.L., Mazer, R.B., Leinfelder, K.F., Russell, C.M.: Evaluation of various forms of calcium hydroxide in the monitoring of microleakage. Dent Mater 7, 202–205 (1991).
59. Ribeiro, D.A., Marques, M.E., Salvadori, D.M.: Antimicrobial endodontic compounds do not modulate alkylation-induced genotoxicity and oxidative stress in vitro. Oral Surg Oral Med Oral Pathol Oral Radiol Endod 102, e32–e36 (2006).
60. Rutherford, R.B., Gu, K.: Treatment of inflamed ferret dental pulps with recombinant bone morphogenetic protein-7. Eur J Oral Sci 108, 202–206 (2000).
61. Santos, A.D., Moraes, J.C., Araujo, E.B., Yukimitu, K., Valerio Filho W.V.: Physico-chemical properties of MTA and a novel experimental cement. Int Endod J 38, 443–447 (2005).
62. Schroeder, U., Granath, L.E.: Early reaction of intact human teeth to calcium hydroxide following experimental pulpotomy and its significance to the development of hard tissue barrier. Odontol Rev 22, 379–395 (1971).
63. Six, N., Decup, F., Lasfargues, J.–J., Salih, E., Goldberg, M.: Osteogenic proteins (bone sialoprotein and bone morphogenic protein-7) and dental pulp mineralization. J Mater Sci 13, 225–232 (2002).
64. Sluka, H., Lehmann, R., Flores-de Jacoby, L.: Verwendung von organischer Knochenmatrix als Material für die direkte Überkappung der Pulpa. [The use of organic bone matrix for direct pulp capping] Dtsch Zahnärztl Z 34, 467–469 (1979).
65. Smith, A.J., Tobias, R.S., Cassidy, N., Plant, C.G., Brown, M., Beque-Kirn, C., Ruch, J.V., Lesot, H.: Odontoblast stimulation in ferrets by dentin matrix components. Arch Oral Biol 39, 13–22 (1994).
66. Staehle, H.J.: Experimentelle Untersuchungen über das Löslichkeitsverhalten verschiedener Unterfüllungsmaterialien. [Experimental studies on the solubility of different base materials] Dtsch Zahnärztl Z 42, 633–638 (1987).
67. Staehle, H.J., Pioch, T., Hoppe, W.: The alkalizing properties of calcium hydroxide compounds. Endod Dent Traumatol 5, 147–152 (1989).
68. Stanley, H.R.: Diseases of dental pulp. In: Tiecke, R.W. (ed): Oral Pathology. McGraw-Hill, New York 1965, pp 95–103.
69. Stanley, H.R.: Biologic responses of dentin & pulp to dental restorative procedures: scientific background and therapeutic recommendations. In: Hardin, J.F. (ed): Clark's Clinical Dentistry. Lippincott, Philadelphia 1990, p 27.
70. Stanley, H.R., Broom, C.A., Spiegel, E.H., Schultz, M.S.: Detecting dentinal sclerosis in decalcified sections with the Pollak trichrome connective tissue stain. J Oral Pathol 9, 359–371 (1980).
71. Stanley, H.R., Lundy, T.: Dycal therapy for pulp exposures. Oral Surg Oral Med Oral Pathol 34, 818–827 (1972).
72. Stanley, H.R., Pameijer, C.H.: Pulp capping with a new visible-light-curing calcium hydroxide composition (Prisma VLC Dycal). Oper Dent 10, 156–163 (1985).

Dentlearn.ir

73. Stanley, H.R., Pereira, J.C., Spiegel, E., Broom, C., Schultz, M.: The detection and prevalence of reactive and physiologic sclerotic dentin, reparative dentin and dead tracts beneath various types of dental lesions according to tooth surface and age. J Oral Pathol 12, 257–289 (1983).
74. Stolman, L.P.: Human collagen reactions. Dermatol Surg 31, 1634 (2005).
75. Stuart, W., Crowley, L.V., Turner, D.W., Pelleu, G.B., Jr., Osetek, E.: Humoral response to endodontic cements. J Endod 5, 214–219 (1979).
76. Thomsen, G. F.: Arbejdsbetinget astma udlost af cyanoakrylatlim. [Occupational asthma induced by cyanoacrylete glue] Ugeskr Laeger 156, 5131–5132 (1994).
77. Tomb, R.R., Lepoittevin, J.P., Durepaire, F., Grosshans, E.: Ectopic contact dermatitis from ethyl cyanoacrylate instant adhesives. Contact Dermatitis 28, 206–208 (1993).
78. Torabinejad, M., Ford, T.R., Abedi, H.R., Kariyawasam, S.P., Tang, H.M.: Tissue reaction to implanted root-end filling materials in the tibia and mandible of guinea pigs. J Endod 24, 468–471 (1998).
79. Torabinejad, M., Hong, C.U., McDonald, F., Pitt, F.T.: Physical and chemical properties of a new root-end filling material. J Endod 21, 349–353 (1995).
80. Torabinejad, M., Hong, C.U., Pitt, F.T., Kettering, J.D.: Cytotoxicity of four root end filling materials. J Endod 21, 489–492 (1995).
81. Turner, C., Courts, F.J., Stanley, H.R.: A histological comparison of direct pulp capping agents in primary canines. J Dent Child 54, 423–428 (1987).
82. Tziafas, D., Smith, A.J., Lesot, H.: Designing new treatment strategies in vital pulp therapy. J Dent 28, 77–92 (2000).
83. Tziafas, D., Pantelidou, O., Alvanou, A., Belobasakis, G., Papadimitriou, S.: The dentinogenic effect of mineral trioxide aggregate (MTA) in short term capping experiments. Int Endod J 35 (3), 245–254 (2002).
84. Uitto, V.J., Antila, R., Ranta, R.: Effects of topical glucocorticoid medication on collagen biosynthesis in the dental pulp. Acta Odontol Scand 33, 287–298 (1975).
85. Wilkinson, S.M.: Hypersensitivity to topical corticosteroids. Clin Exp Dermatol 19, 1–11 (1994).

Dentlearn.ir

6.6 Dental Ceramics

G. Schmalz

Dental ceramics comprise a comprehensive palette of different nonmetallic, inorganic materials. They are primarily used for inlays, veneers, partial crowns, full crowns, and for copings. They are also used for frame works and for veneering of metal/ceramic copings and frameworks (metal ceramics or porcelain-fused-to-ceramics), artificial teeth, and for root canal posts. Ceramics are further applied as implant materials, for example as coatings for titanium implants, as full ceramic implants, or as bone replacement materials. Ceramics are rigid materials that are shaped by sintering, casting, pressing, milling, or sonoerosion. Dental ceramics are also available as prefabricated inlays (inserts). Certain ceramics, such as those used for implants, are inert or tolerated by the tissue and, at the same time, can accelerate biological processes because of the release of certain ions to promote the apposition of new bone. These ceramics belong to the group of bioactive materials. Some ceramics, including aluminum oxide and zirconium oxide ceramics, are also used in orthopedics. Thus, experience from the field of orthopedics may be used for assessing a material's compatibility concerning dental application. High-performance ceramics yield excellent technical properties, which makes them suitable to be used as copings or frameworks for crowns and bridges. To improve their aesthetics, they have to be veneered with other, mainly silicium oxide ceramics.

Ceramics are rigid materials and therefore generally need to be luted to dental hard tissues. The necessary materials, such as luting composite resins and other luting cements, are reviewed in other chapters of this book. However, these luting agents and other auxiliary materials (etching agents) also need to be considered when assessing the compatibility of ceramics. For the biological evaluation of metal ceramics, the influence of the processing of the ceramic on the alloy used as a coping/framework material must also be included (see Chap. 8).

6.6.1 Basic Material Properties

6.6.1.1 Composition

Dental ceramics can be classified based on various criteria, for instance, on the raw materials, their chemical composition, the shaping methods, the firing temperature, or the type of clinical application. The classification according to composition is based on the chemistry of the principal components (see Table 6.3). Accordingly, oxides may be distinguished from nonoxides. Nonoxides, such as silicon carbide, silicon nitrite, and aluminum nitrite, are of minor importance in dentistry due to their black color.

Oxide ceramics used in dentistry are primarily based on silicon oxide (SiO_2), aluminum oxide (Al_2O_3), and zirconium oxide (ZrO_2). Originally, mainly feldspathic ceramics (SiO_2-based) were used in dentistry; these were obtained from frits of potassium and sodium feldspars and sintered to the desired shape (for example, metal ceramics). Later, glass ceramics and dental ceramics based on Al_2O_3 and ZrO_2 were introduced (for example, metal-free ceramic restorations). The term "titanium ceramic" is used in the literature for a feldspathic ceramic used for the veneering of titanium.

Some dental ceramics can be combined, such as an Al_2O_3-ceramic framework veneered with SiO_2 ceramic. Lanthanum glass is used as a coupling agent, which infiltrates the aluminum oxide framework. Lanthanum glass consists of 39% lithium oxide [7]. Additives (such as leucite) that are listed in Table 6.3 are intended to improve the mechanical properties of the ceramics, in particular to limit crack propagation. Lithium oxide is supposed to promote the formation and growth of leucite crystals [3]. Further additives in dental ceramics are fluxing agents and coloring pigments, such as metal oxides, as well as fluorescents such as oxides of cesium and samarium. Uranium salts were previously added at a concentration of 1,000 ppm to simulate the natural luminescence of teeth [3, 47]. Because of the radioactivity of uranium salts, alternatives are now applied, such as oxides of rare earths [47]. Lead is contained in traces in natural feldspar and for dental ceramics ISO 6872 [25] requires <300 ppm lead.

Auxiliary substances are necessary for processing dental ceramics. Silicon oxide ceramic is usually etched with hydrofluoric (HF) acid (for example, 5% HF eventually combined with <10% H_2SO_4, or 9.6% HF). These acids are generally applied in the dental laboratory for 1–2 min prior to adhesive luting. Some authors also recommend their direct application on the patient for the intraoral repair of silicon oxide ceramic (Fig. 6.23) [12]. Silane agents are then applied on the etched ceramic surface to improve the bond between the luting composite and the ceramic (see also Chap. 5).

Some calcium phosphate materials are regarded as ceramics, too. These substances represent a very

Dentlearn.ir

Table 6.3 Classification of dental ceramics according to composition (main compounds) [14, 27, 53]

Main compound	Frequently used additives (selection)
Silicon dioxide (SiO_2) (Feldspar-based)	Al_2O_3 (30 µm grain size), through potassium feldspar ($K_2OAl_2O_36SiO_2$) and sodium feldspar ($Na_2OAl_2O_36SiO_2$) Glimmer (in glass ceramic) Leucite ($K_2OAl_2O_34SiO_2$) (in glass ceramic) Lithium oxide (in glass ceramic) Lithium disilicate (in glass ceramic)
Aluminum oxide (Al_2O_3) Aluminum oxide (2-5 µm grain size) as corundum (α-Al_2O_3) Magnesium-Aluminum Spinel ($MgAl_2O_4$)	Lanthanum glass (low viscosity infiltration cast as matrix within the sinter scaffold; In-Ceram systems), ZrO_2 as additive to Al_2O_3 powder
Zirconium dioxide (ZrO_2)	Yttrium oxide (Y_2O_3) Yttrium-stabilized tetragonal zirconia polycrystals (YTZP)
Calcium phosphate Hydroxyl apatite (HA) Tricalcium phosphate (α-TCP, β-TCP) Tetracalcium phosphate (TTCP) Mixtures	

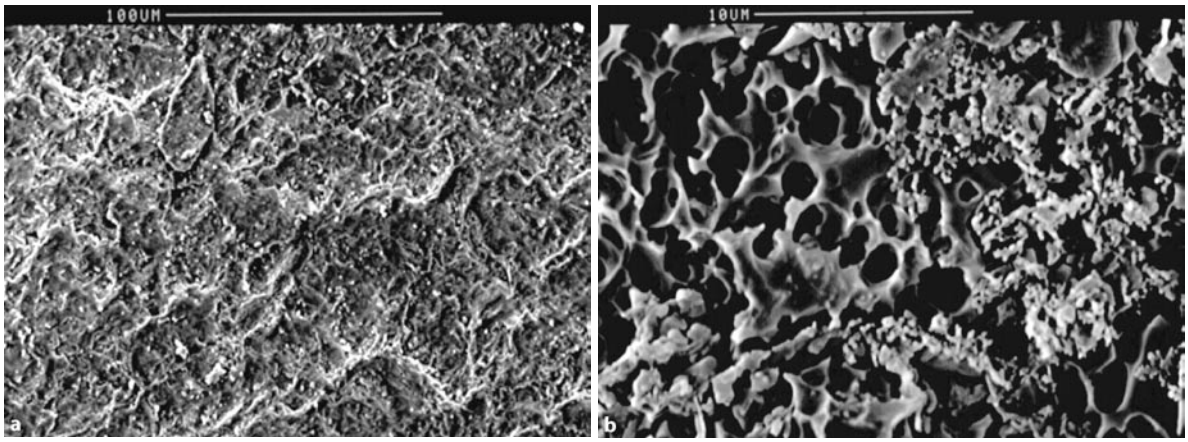

Fig. 6.23a,b Silicon oxide ceramic. **a** Not acid-etched. **b** Acid-etched with hydrofluoric acid; leucite crystals were dissolved

heterogeneous group of materials, including sintered hydroxyl apatite (HA) with a very low solubility and tricalcium phosphate (TCP) ceramics with varying resorption behaviors. Calcium phosphate ceramics usually consist of 100% of the respective mineral phase (TCP or HA). A few products contain small amounts of CaO, and other materials contain 1.2% to 2.4% organic residues derived from their natural origin [64].

Calcium phosphate ceramics are used in dentistry for coating metal implants in order to transform the metallic implant surface into a more bioactive state and thus to accelerate the bone apposition (biofunctionalizing of surfaces) [32]. Certain silicon oxide ceramics (bioglasses) also belong to the group of bioactive materials. Various calcium phosphate ceramics, including mixtures of hydroxyl apatite and TCP, are used for sur-

Dentlearn.ir



Fig. 6.24 Ceramic surface (Empress): The left side was treated with an acidic fluoride gel for 60 min. A morphologic alteration of the surface can be seen (**b**, higher magnification) compared with the untreated right side (**c**, higher magnification). This reveals the solubility of the ceramic caused by the fluoride gel after extended application time

gical procedures, such as filling of periodontal defects [41]. Calcium phosphate ceramics can also serve as carrier substances for growth factors [55]. Closely related to calcium phosphate ceramics are calcium phosphate cements. They are described in more detail in Chap. 7.

6.6.1.2 Release and Degradation

Dental ceramics are commonly regarded as insoluble or only very slightly soluble at best. However, their initial strength decreases significantly because of permanent load and the aqueous media [52, 59]. Thus, degradation occurs, which may be of a chemical nature (solubility in an acidic, neutral, or alkaline environment), a mechanical nature (wear), or a combination of the two [3]. Some calcium phosphate ceramics are intentionally engineered for a gradual resorption (e.g., β–TCP) [69]. The release of substances can generate unwanted effects (biological and mechanical) on the one hand, or it may promote biocompatibility on the other hand, such as in terms of improved bone apposition (bioactivity) [6].

From **silicon oxide ceramics** (metal ceramics), silicon, boron, sodium, potassium, and aluminum are released into various diluents at different pH values; silicon, sodium, and potassium are leached in higher amounts than are boron and aluminum [42]. Solubility is highest in an alkaline environment (formation of soluble silicates), followed by acidic and neutral diluents [42], but this may vary for different ceramics. Aluminum oxide and zirconium oxide additives decrease solubility [3]. The release of lead was below the detection limit (0.005 mg/l), if the ceramic specimens were exposed to the solubility test conditions of ISO 6672 (see below) [information provided by DIN, German Institute of Standardization, WG Dental Ceramics]. Solubility depends on surface finish, too, but to a different extent, depending on the material [52]. The solubility of ceramics with a high melting point is reduced by a final firing or glazing, whereas final surface finish and polish reduce the solubility of ceramics with a low melting point [52]. The solubility of various silicon oxide ceramics in 4% (v/v) acetic acid at 87°C (according to ISO 6872: 80°C) has been found to vary between 9 µg/cm²/16 h (ceramic with a high melting point) and 89 µg/cm²/16 h (ceramic with a low melting point) [52]. These data and other values reported in the literature are below the requirements according to ISO 6872 (100 µg/cm²/day, ceramic in contact with the oral environment) and are considered to be low [3, 25, 56].

Chelating agents, such as EDTA and citric acid, are able to increase the solubility of glasses. However, no data about potential effects on ceramics have been published [3]. Lithium may be released from lithium-containing ceramics, particularly under slightly alkaline conditions [4]. Based on these in vitro studies

Dentlearn.ir

(elution at a temperature of 80°C and pH of 11), it can be extrapolated that 28 crowns with a surface area of 74 cm^2 may leach 1.2 mg of lithium per day [4]. Less lithium (30 µg/day) will be released under physiological conditions and a slightly lower pH [4].

Acidic fluoride compounds dissolve silicon oxide ceramic: 8% SnF_2 severely etched ceramic surfaces [3, 5]. A 1.23% acidulated phosphate fluoride (APF) gel decreased surface reflectance, increased surface roughness, and dissolved the surface of silicon oxide ceramics, especially on autoglazed and overglazed specimens and when applied for more than 1 min [11, 12, 16, 20] (Fig. 6.24). A 1.23% APF foam did not appear to cause as much surface change as did the 1.23% APF gel, and a neutral 2% NaF gel had no influence at all [31]. Fluoride-containing toothpastes have no effect on ceramic surfaces [3]. Hydrofluoric acid deeply dissolves silicon oxide ceramic. Therefore, it is used to improve the bond between ceramic and luting resin [12].

Aluminum oxide ceramics leach only minimal amounts of ions under physiological conditions [32]. Aluminum oxide ceramics used for frameworks (core ceramics) are more soluble than those applied for dentin and enamel layers (dentin and enamel ceramics), which are designed for completely covering the framework [56]. The maximum solubility is defined by ISO 6872 with 2,000 µg/cm^2/16 h [25]. The following concentrations have been documented: aluminum, 64 ppm; silicon, 45 ppm; calcium, 20 ppm; lanthanum, 300 ppm [56]. But no aluminum was detected in tissues adjacent to aluminum oxide ceramic [73].

The solubility of **zirconium oxide ceramic** in 4% acetic acid at 80°C (according to ISO 6872 [25]) was found to vary between 0 and 4 µg/cm^2 (depending on the shade) and thus was far below the ISO threshold values [5].

Key Note

Substances are released from dental ceramics into the oral cavity. Acidic fluoride preparations with elevated fluoride concentrations may promote the degradation of silicon oxide ceramics and thereby may increase surface roughness. However, ceramics are not affected by normal toothpastes.

Calcium phosphate ceramics release calcium and phosphate into adjacent tissues [32]. The leaching rate is determined by the composition, structure, porosity, and other factors, and can, therefore, be controlled within certain limits [32]. Overall, HA and fluorine apatite ceramics are less soluble than TCP [32]. But even HA coatings of implants may be resorbed with time [50].

6.6.2 Systemic Toxicity and Allergies

In general, the systemic toxicity and the allergenic potency of ceramics are considered to be extremely low [1, 3]. Only dental laboratory technicians might be exposed to an inhalation of ceramic dust due to processing and finishing of dental ceramics that may cause silicosis (fibrotic pneumoconiosis). These lung diseases have been observed in workers in the ceramic industry who were exposed to ceramic dust for an extended period of time [37]. The risk to a dental laboratory technician of developing silicosis due to ceramic dust is currently unknown [37]. However, dental technicians are also exposed to other dust sources (for instance, investment materials, sand blasting, and polishing compounds) [37]. The patient's silicosis risk is considered "very minimal" [37] if commonly accepted safety measures, such as dust removal, are followed.

Released lithium is of toxicological interest based on its specific effect as a psychotropic drug. Worst-case calculations (28 crowns, surface area 74 cm^2, pH 11, 80°C) indicated a daily release of 30 µg (and up to 1,200 µg at pH 11) [4]. According to the literature, the acceptable daily intake of lithium is 2,000 µg/day [21]. The daily alimentary intake varies between 8.6 and 17 µg per day [43]. For treating manic-depressive patients (those suffering bipolar disorders), 600–2,100 µg/day may be administered [19].

Key Note

Ceramics are usually nontoxic in patients. Due to the relatively low amounts of released lithium, unwanted side effects caused by lithium leaching from dental ceramics are very unlikely to occur [4].

6.6.3 Local Toxicity and Tissue Compatibility

6.6.3.1 Cell Cultures

Silicon oxide ceramics of different compositions made by various manufacturers were tested and found to be nontoxic in different cell culture assays (agar overlay

Dentlearn.ir

test, Millipore filter test, MTT test) [60]. This was confirmed by testing extracts of different silicon oxide and zirconium oxide ceramics on gingival fibroblasts [66]. Erbium oxide, used for coloring dental ceramics, also proved to be nontoxic [66]. A glass ceramic with a low melting point was slightly more toxic than the control (Teflon) before and after treatment of the surface with 4% acetic acid for 16 h (according to ISO 6872), but was less toxic than a composite resin, for instance. The cells' enzymatic activity was reduced to 87–88% (ceramic before etching) and 75–80% (ceramic after etching) compared with 100% in the control [22]. A lithium-containing ceramic (Empress 2) was initially significantly more cytotoxic than other commonly used dental ceramics, which were used as controls. Cytotoxicity decreased after storage for 1–2 weeks in a sterile water/3% albumin solution but reappeared after repolish [38]. However, less cytotoxicity is reported, if a clinically relevant and less polishing procedure is used [10a]. Further studies are needed to elucidate the clinical relevance of these data. Silicon oxide particles caused a toxic reaction in macrophage cultures, very likely because of a positive surface charge of these particles [8]. Ceramic particles in the nanoscale range may, however, elicit a cell reaction even if the ceramic itself is not toxic [70]. This is important regarding the inhalation of dust or, in orthopedics, wear debris.

Aluminum oxide ceramic containing lanthanum glass was tested on osteoblasts. After an initial adhesion, cells in the scanning electron microscope revealed signs of an alteration (necrosis) after 2 or more days. These damages were even more pronounced in cells incubated with the control ceramic consisting of silicon oxide [6]. This is contradictory to the overall minute release of substances from aluminum oxide ceramic. But release of ingredients from silicon oxide ceramic was even lower, while cell damage was more severe [6]. Other causes than the release of ions might also play an important role, such as absorption of certain proteins on the surface of the material. Lanthanum-chlorine reveals a TC_{50} of 800 μM on L-929 fibroblasts, which is indicative of a low cytotoxicity [6].

Zirconium oxide ceramics were nontoxic in various cell cultures (human gingival fibroblasts, 3T3 cells, L-929 cells) [66]. The smallest particles (submicron range) triggered an apoptotic reaction in human stem cells derived from bone marrow, but extracts were nontoxic in this test, too [68]. However, small particles are not of major relevance in dentistry, in contrast to the application of such materials for hip replacement, where wearing of the material may cause displacement of such particles into the surrounding tissue. Thus, it may be concluded that zirconium oxide ceramic is almost noncytotoxic.

Calcium phosphate ceramics (hydroxyl-apatite) support growth and metabolism of human gingival fibroblasts and therefore may be considered biocompatible [54]. Various HA ceramics were nontoxic in osteoblast cultures. High extract concentrations of one product inhibited cell growth [33]. No toxicity was observed in chondrocyte cultures [34].

Key Note

Although ceramics are not totally biologically inert, the cytotoxicity is generally regarded as low. However, because exceptions are possible, cytotoxicity testing is also necessary for ceramics.

6.6.3.2 Implantation Studies

Silicon oxide ceramic did not cause inflammation after implantation in muscle (Fig. 6.25) [58]. Bioglasses based on silicon oxide were osteoconductive and osteoinductive when implanted in bone [13]. Aluminum oxide ceramic, before and after infiltration with lanthanum glass, was found to cause a significantly thicker connective tissue encapsulation and an increased number of inflammatory cells 12 weeks after subcutaneous implantation, compared with Teflon and titanium [36]. On the other hand, aluminum oxide ceramic resulted in osseointegration in other studies and

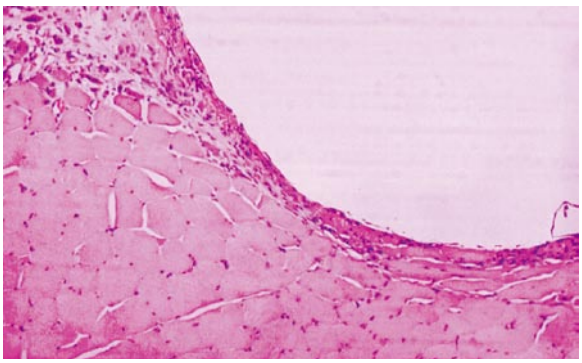

Fig. 6.25 No tissue reaction after intramuscular implantation of silicon oxide ceramic (7 days after application, magnification ×80)

Dentlearn.ir

thus revealed a good compatibility with surrounding bone [48, 72]. There are obviously differences between the compatibility of various ceramics, and these may be correlated to different indications and applications and different contact with tissue (for example, core ceramic versus implant ceramics). Zirconium oxide ceramic showed good osseointegration when implanted in guinea pigs [1, 49].

Calcium phosphate ceramics have been implanted in various animal models. Results were heterogeneous according to the materials tested and depended mainly on the following parameters:

- Ca/P ratio
- Chemical purity
- Removal of organic compounds from raw materials
- Sintering technique
- Crystal structure (monophase or polyphase)
- Size and type of pores, interconnectivity

Numerous macrophages and foreign body giant cells were observed histologically during the first weeks after implantation of absorbable TCP ceramics [55]. The integration of nonsoluble hydroxyl-apatite ceramic in bone without any cellular interface (osseointegration) indicates good biocompatibility [32, 55].

6.6.3.3 Pulp Reactions

Postoperative sensitivities have been observed in a few cases after the (adhesive) luting of ceramics (inlays, crowns) [46, 63, 67]. However, these complaints could primarily have been caused by the luting resin rather than the ceramic (see also Chap. 5 and Sect. 6.3). Because ceramic is a brittle material, a certain minimum layer of thickness and thus a sufficient cavity preparation is necessary to prevent fractures.

Clinical Practice Advice

The teeth of younger patients with an extended pulp are susceptible to preparation trauma in association with ceramic restorations. This aspect needs to be taken into consideration when deciding on a ceramic restoration and assessing the biocompatibility of these materials.



Fig. 6.26 Rough surface of an aluminum oxide coping (*bottom*); smooth surface of the veneering ceramic (*top*)

6.6.3.4 Gingival Reactions

Silicon oxide ceramics are innocuous for the gingiva. The application of acidic fluoride solutions, however, may roughen the surface, which increases the risk of bacterial adhesion [3]. The significance of rough ceramic surfaces has been demonstrated on patients. Exposed core ceramic with vacuoles and lacunas generated an enhanced plaque accumulation with increased inflammation in the adjacent gingiva compared with crowns in which the gingiva was in contact with glazed ceramic. Metal ceramic crowns, which were used as controls, revealed less plaque/gingivitis compared with crowns with exposed framework ceramic, but showed more plaque/inflammation compared to such crowns with smoothly glazed veneering ceramic [30]. Frameworks made of aluminum oxide ceramic also reveal a rough surface. These should be completely covered by glazed ceramic in order to prevent plaque accumulation as much as possible (Fig. 6.26). For many years, aluminum oxide and zirconium oxide ceramics have been used for hip joint implantation [65]. Based on experiences from this type of application, these ceramics can be regarded as tissue-compatible (except for the wear debris).

Silicate granulomas can be generated by implanting colloidal silicon dioxide in soft tissues, sometimes at a certain distance from the application site, since colloidal silicon dioxide can be transported within tissue. The clinical relevance of this phenomenon regarding dental ceramic restorations is still unknown [37].

Dentlearn.ir

Fig. 6.27 Hydroxyl apatite for the filling of a cyst cavity

Key Note

Hydrofluoric acid (which is used for conditioning silicon oxide ceramic) diffuses into cells and acts as a metabolic toxin. If hydrofluoric acid comes into contact with skin or mucosa, it may not cause an immediate chemical burn, but within 24–48 h, deep tissue necroses occur [12]. A concentration of 2% hydrofluoric acid can generate an erosion of the cornea [10]. Therefore, hydrofluoric acid should be handled with the greatest caution.

On various occasions, gingival inflammations adjacent to metal ceramic crowns have been reported. However, this situation should be attributed to the alloy rather than to the ceramic (see Chap. 8).

6.6.3.5 Periapical Area

Hydroxyl apatite (HA) used in animal experiments to fill periapical defects after apicectomy healed with direct bone apposition. The formation of new bone, however, was not superior compared with those defects where no material was implanted [9] (Fig. 6.27).

6.6.3.6 Implants

The comprehensive literature about dental ceramic implants or implants coated with ceramic cannot be reviewed here, particularly the question about the usefulness of coatings with calcium phosphate ceramics (absorbable or nonabsorbable, porous or dense, HA or TCP, thickness of the coat, and so on; refer to respective textbooks) [28, 35, 69]. The effect of HA and TCP as a coating regarding the stimulation of direct bone apposition has been frequently demonstrated [29, 69, and many more]. The advantages must be balanced against the risk of a loss of the coating [61]. In addition, ceramic coats may change the corrosion of implant alloys [69]. The incorporation of growth factors in ceramic coats is currently under investigation [69]. However, osseointegration also depends on other factors, such as (occlusal) loads [61] and the surface properties of a material to adsorb certain proteins in a defined way, which are important for the growth of relevant cells (osteoblasts, for instance) [7].

Aluminum oxide implants were completely integrated in bone (as was demonstrated on human histology) and exhibited a good biocompatibility [2]. TCP, mixed with HA if necessary, was biocompatible in many studies addressing the filling of periodontal defects [41, 62, and many more]. HA and TCP were also used as a substitute (in part) for autologous bone for sinus lift procedures [23, 57]. This area is currently the subject of intensive research.

6.6.4 Mutagenicity and Carcinogenicity

The addition of uranium oxide to various dental silicon oxide ceramics used for crowns or bridges caused radioactivity of up to 4.2 times the background radiation (measured by Geiger counter) [39], and artificial teeth revealed values of 2.3 times the background radiation (^{238}uranium mainly emitted as α-particles). It was calculated that uranium-containing dental ceramics would expose epithelial tissue to an annual dose of 2.7 rem [3, 41]. This value exceeds the current threshold dosage of 1.5 rem (exposure to radiation nowadays is measured in sieverts, or Sv, with 1 Sv =100 rem). However, a patient would have to swallow 60 pulverized crowns per week before the amount of absorbed radioactive substances reached the threshold value [3]. Therefore, it was assumed that patients were not at risk [3, 39, 40, 44]. But problems might occur for dental technicians because of their exposure to dust and ceramic powder [39]. But again, the calculated exposure to radiation was far below the threshold values [3]. Nevertheless, radioactive fluorescent additives were replaced by alternative substances in the 1970s and 1980s (see also Sect. 6.6.1 on composition).

Relevant standards (ISO 6872, ISO 4824) therefore initially required that additives that increase radioactivity may not be used in dental ceramics. The latest

Dentlearn.ir

version of these standards states that dental ceramics may not exceed an activity concentration of 1 Bq/g^{238} uranium (1 Bq =1 Becquerel =1 radioactive decay per second) [25, 26]. Today, radiation of dental ceramics is only due to natural radionuclides (mainly α and γ emitters) and much below the materials dated back to the times, when uranium salts had been added. Feldspathic ceramic specimens showed an activity concentration (Uranium/Thorium chains) of 0.015 Bq/g [67a], which is in the same order of magnitude as for the human body. Alpha-particles, although being more toxic to tissues than γ radiation, may only play a minor role for oral tissues, because α-particles have a maximum range of 30 μm in tissues and they may already be absorbed by saliva and plaque covering the restoration before reaching radiosensitive cells in the basal layer of the oral mucosa [67a]. Higher levels of γ radiation were measured for feldspathic ceramic than for background radiation and were related to naturally occurring Potassium 40 (^{40}K). However, the calculated activity concentration was again below the threshold limit for ^{40}K of 10 Bq/g [67a, 24] and no radiation related adverse effects of dental ceramics have been documented in the literature [67a].

Aluminum oxide ceramics have generated no teratogenic [17] or mutagenic effects in animals, nor were they found to affect fertility [71].

Raw materials used for zirconium oxide ceramics (e.g., Zirkon, $ZrSiO_4$) may contain contaminants such as thorium, uranium, and their decay products [18, 48,]. These contaminants generate α-, β-, and γ-radiation. Data from the literature indicate an activity concentration of up to 11,500 Bq/kg for zircon powder [49]. The amounts of these contaminants have meanwhile been significantly reduced by purification procedures. In 1994, a comparative study with artificial hip joints documented an activity concentration of 0.1–1 Bq/g for aluminum oxide ceramic. The activity concentration of zirconium oxide ceramic was much higher (1–5 Bq/g); other sources reported a dose as high as 40 Bq/kg [49]. Overall, however, the effective activity of zirconium oxide ceramic was below the administrative threshold of 1 mSv/year and far below the mean value of the annual exposure to natural radiation (1.5– 3.5 mSv/year) [49, 51].

Calcium phosphate ceramic was neither carcinogenic nor teratogenic in animal experiments [45].

Conclusions for the Dental Practitioner

1. Ceramics are generally considered as biocompatible materials, although relatively little data are available. Few ceramics have been shown to be cytotoxic in vitro. The clinical relevance of these findings remains unclear. Auxiliary materials such as luting agents also have to be considered in the course of assessing the biocompatibility of ceramic restorations.
2. Acids used for etching ceramics (e.g., hydrofluoric acids) should be used only in the laboratory. If these substances are directly used on patients in exceptional circumstances, then this should be done using a rubber dam and other protective procedures (eye protection and so on).
3. Ceramics require an adequate layer of thickness to prevent fractures. This makes it necessary to prepare more extended cavities compared with direct restorations or metal inlays. The teeth of young patients may suffer from pulpal trauma due to preparation, which may cause an artificial pulp exposure.
4. Acidic fluoride compounds (such as 1.23% AFP gels) may roughen the ceramic surfaces, subsequently increasing plaque accumulation. This must be taken into consideration if patients regularly use such substances, such as after radiotherapy. Neutral fluoride compounds might be recommended for patients with silicate ceramic restorations [15].
5. Commonly accepted (and in some countries, required by law) occupational protective measures in the dental laboratory, such as suction units and mouth guards, should be used as protection against dust during the processing of dental ceramics. It is essential to wear gloves and eye protection when handling hydrofluoric acid.
6. Zirconium oxide ceramic reveals a considerably higher level of radioactivity compared with aluminum oxide and silicon oxide ceramic. The radioactivity depends on the purity of the raw materials. However, the activity concentration of modern zirconium oxide ceramics is below the administrative threshold values.

Dentlearn.ir

References

1. Aldini, N.N., Fini, M., Giavaresi, G., Torricelli, P., Martini, L., Giardino, R., Ravagliolo, A., Krajewski, A.M., Mazzocchi, M., Dubini, B., Ponzi-Bossi, M.G., Rustichelli, F., Stanic, V.: Improvement in zirconia osseointegration by means of a biological glass coating: an in vitro and in vivo investigation. J Biomed Mater Res 61, 282–289 (2002).
2. Anneroth, G., Ericsson, A.R., Zetterqvist, L.: Tissue integration of Al_2O_3-ceramic dental implants (Frialit) – a case report. Swed Dent J 14, 63–70 (1990).
3. Anusavice, K.J.: Degradability of dental ceramics. Adv Dent Res 6, 82–89 (1992).
4. Anusavice, K.J., Zhang, N.Z.: Chemical durability of Dicor and lithia-based glass-ceramics. Dent Mater 13, 13–19 (1997).
5. Ardlin, B.I.: Transformation-toughened zirconia for dental inlays, crowns and bridges: chemical stability and effect of low-temperature aging on flexural strength and surface structure. Dent Mater 18, 590–595 (2002).
6. Bagambisa, F.B., Kappert, H.F., Schilli, W.: Cellular and molecular biological events at the implant interface. J Craniomaxillofac Surg 22, 12–17 (1994).
7. Bagambisa, F.B., Kappert, H.F., Schilli, W.: Interfacial reactions of osteoblasts to dental and implant materials. J Oral Maxillofac Surg 51, 52–56 (1994).
8. Bagchi, N.: What makes silica toxic? Br J Industr Med 49, 163–166 (1992).
9. Beck-Coon, R.J., Newton, C.W., Kafrawy, A.H.: An in vivo study of the use of a nonresorbable ceramic hydroxyapatite as an alloplastic graft material in periapical surgery. Oral Surg Oral Med Oral Pathol 71, 483–488 (1991).
10. Beiran, I., Miller, B., Bentur, Y.: The efficacy of calcium gluconate in ocular hydrofluoric acid burns. Hum Exp Toxicol 16, 223–228 (1997).

10a. Brackett M.G., Lockwood P.E., Messer R.L., Lewis J.B., Bouillaguet S., Wataha J.C.: In vitro cytotoxic response to lithium disilicate dental ceramics. Dent Mater 24, 450–456 (2008).

11. Butler, C. J., Masri, R., Driscoll, C. F., Thompson, G. A., Runyan, D. A., Anthony von Fraunhofer, J.: Effect of fluoride and 10% carbamide peroxide on the surface roughness of low-fusing and ultra low-fusing porcelain. J Prosthet Dent 92, 179–183 (2004).
12. Canay, S., Hersek, N., Ertan, A.: Effect of different acid treatments on a porcelain surface. J Oral Rehabil 28, 95–101 (2001).
13. Chan, C., Thompson, I., Robinson, P., Wilson, J., Hench, L.: Evaluation of Bioglass/dextran composite as a bone graft substitute. Int J Oral Maxillofac Surg 31, 73–77 (2002).
14. Claus, H.: Werkstoffkundliche Grundlagen der Dentalkeramik. [Fundamentals on dental ceramics] Dent Lab 28, 1743–1750 (1980).
15. Council of Dental Materials, Instruments, and Equipment, Council on Dental Therapeutics. Status report: effect of acidulated phosphate fluoride on porcelain and composite restorations. J Am Dent Assoc 116, 115 (1988)
16. Demirel, F., Yüksel, G., Muhtarogullari, M., Cekiç, C.: Effect of topical fluorides and citric acid on heat-pressed all-ceramic material. Int J Periodontics Restorative Dent 25, 277–281 (2005).
17. Domingo, J.L., Gomez, M., Bosque, M.A., Corbella, J.: Lack of teratogenicity of aluminium hydroxide in mice. Life Sci 45, 243–247 (1989).
18. Fischer-Brandies, E., Pratzel, H., Wendt, T.: Zur radioaktiven Belastung durch Implantate aus Zirkonoxid. [Radioactive burden resulting from zirconia implants] Dtsch Zahnärztl Z 46, 688–690 (1991).
19. Gelenberg, A.J., Kane, J.M., Keller, M.B. et al.: Comparison of standard and low serum levels of lithium for maintenance treatment of bipolar disorder. N Eng J Med 321, 1489–1493 (1989).
20. Gonzales, E., Naleway, C. A., Fan, P. L., Jaseiskis, T.: Decrease in reflectance of porcelains treated with APF gels. Dent Mater 4, 289–295 (1988).
21. Goyer, R.A.: Toxic effects of metals: Lithium. In: Toxicology. The Basic Science of Poisons. Amdur, M.O., Doull, J., Klaassen, C. D. (eds). Pergamon Press, Elmsford, New York (1984), pp 665–666.
22. Griggs, J.A., Wataha, J.C., Kishen, A.: Effect of hydrolyzed surface layer on the cytotoxicity and chemical resistance of low fusing porcelains. Dent Mater 19, 353–358 (2003).
23. Haas, R., Baron, M., Donath, K., Zechner, W., Watzek, G.: Porous hydroxyapatite for grafting the maxillary sinus: a comparative histomorphometric study in sheep. Int J Oral Maxillofac Implants 17, 337–346 (2002).
24. Council of the European Communities: Council Directive 96/29/EURATOM of 13 May 1996, http://ec.europa.eu/energy/nuclear/radioprotection/doc/legislation/9629_en.pdf. Cited May 2008.
25. International Organization for Standardization: ISO FDIS 6872: Dental ceramic. Geneva 2007.
26. International Organization for Standardization: ISO 4824: Dentistry – ceramic denture teeth. Geneva, 2000
27. Kappert, H.F., Krah, M.: Keramiken – eine Übersicht. [Ceramics – an overview] Quintessenz Zahntech 27, 668–704 (2001).
28. Kawahara, H.: Cellular responses to implant materials: biological, physical and chemical factors. Int Dent J 33, 350–375 (1983).
29. Köster, K., Karbe, E., Kramer A., Heide, H., König, R.: Experimenteller Knochenersatz durch resorbierbare Calcium-Phosphat-Keramik. [Experimental bone replacements by resorbable calcium phosphate ceramic] Langenbecks Arch Chir 341, 77–86 (1976).
30. Küpper, H., Bieniek, K.W.: Hi-Ceram und Parodont: eine klinische Studie. [Hi-Ceram and the periodontium. A clinical study] Dtsch Zahnärztl Z 44, 795–797 (1989).
31. Kula, K., Kula, T. J.: The effect of topical APF foam and other fluorides on veneer porcelain surfaces. Pediatr Dent 17, 356–361 (1995).
32. Lacefield, W.R.: Materials characteristics of uncoated/ceramic-coated implant materials. Adv Dent Res 13, 21–26 (1999).
33. Lang, H., Kruppenbacher, J.P., Mertens, Th.: Toxizität von Hydroxylapathitkeramiken auf menschliche und tierische Osteoblasten. [Toxicity of hydroxyapatite ceramics on human and animal osteoblasts] Dtsch Zahnärztl Z 44, 135–137 (1989).
34. Lawton, D.M., Lamaletie, M.D.J., Gardner, D.L.: Biocompatibility of hydroxyapatite ceramic: response of chondrocytes in a test system using low temperature scanning electron microscopy. J Dent 17, 21–27 (1989).
35. Letic-Gavrilovic, A., Scandurra, R., Abe, K.: Genetic potential of interfacial guided osteogenesis in implant devices. Dent Mater J 19, 99–132 (2000).
36. Limberger, F., Lenz, E.: Biologische Prüfung der In-Ceram-Keramik im Vergleich mit Kobaltbasis-Legierungen und den Metallen Titan, Tantal und Niob im Tierexperiment. [Biological tests on In-Ceram ceramics compared with cobalt alloys and the metals titanium, tantal, and niobium in animal experimentation] Dtsch Stomatol 41, 407–410 (1991).

Dentlearn.ir

37. Mackert, J.R.: Side-effects of dental ceramics. Adv Dent Res 6, 90–93 (1992).
38. Messer, R.L.W., Lockwood, P.E., Wataha, J.C., Lewis, J.B., Norris, S., Bouillaguet, S.: In vitro cytotoxicity of traditional versus contemporary dental ceramics. J Prosthet Dent 90, 452–458 (2003).
39. Moore, J.E., MacCulloch, W.T.: The inclusion of radioactive compounds in dental porcelains. Br Dent J 136, 101–106 (1974).
40. Nally, J.N., Meyer, J.M., Niederer, J.: Uranium content of special dental porcelains and β (beta) activity. Helv Odont Acta 13, 32–35 (1969).
41. Nery, E.B., LeGeros, R.Z., Lynch, K.L., Lee, K.: Tissue response to biphasic calcium phosphate ceramic with different ratios of HA/ßTCP in periodontal osseous defects. J Periodontol 63, 729–735 (1992).
42. Nishiyama, M., Takamisawa, M., Ohashi, M.: A study of dental porcelain solubility – dissolving of component elements and resultant surface roughness and abrasion. J Nihon Univ Sch Dent 25, 262–276 (1983).
43. Noel, L., Leblanc, J.-C., Guérin, T.: Determination of several elements in duplicate meals from catering establishments using closed vessel microwave digestion with inductively coupled plasma mass spectrometry detection: estimation of daily dietary intake. Food Addit Contam 20, 44–56 (2003).
44. O'Riordan, M.C., Hunt, G.J.: Radioactive fluorescers in dental porcelains. (British) National Radiological Protection Board (1974).
45. Ozaki, T.: An experimental study on the biological safety of calcium phosphate glass ceramic. Nippon Seikeigeka Gakkai 64, 1215–1225 (1990).
46. Pallesen, U., van Dijken, J.W.V.: An 8-year evaluation of sintered ceramic and glass ceramic inlays processed by the Cerec CAD/CAM system. Eur J Oral Sci 108, 239–246 (2000).
47. Peplinski, D.R., Wozniak, W.T., Moser, J.B.: Spectral studies of new luminophors for dental porcelain. J Dent Res 59, 1501–1506 (1980).
48. Piatelli, A., Podda, G., Scarano, A.: Histological evaluation of bone reactions to aluminium oxide dental implants in man: a case report. Biomaterials 17, 711–714 (1996).
49. Piconi, C., Macauro, G.: Zirconia as a ceramic biomaterial. Biomaterials 20, 1–25 (1999).
50. Pilliar, R.M., Deporter, D.A., Watson, P.A., Pharoah, M., Chipman, M., Valiquette, N., Carter, S., DeGroot, K.: The effect of partial coating with hydroxyapatite on bone remodeling in relation to porous-coated titanium-alloy dental implants in the dog. J Dent Res 70, 1338–1345 (1991).
51. Porstendörfer, J., Reineking, A., Willert H.-G.: Radiation risk estimation based on activity measurements of zirconium oxide implants. J Biomed Mater Res 32, 663–667 (1996).
52. Risito, C., Lüthy, H., Löffel, O., Schärer, P.: Chemische Löslichkeit und Festigkeit von niedrigschmelzenden Dentalporzellanen. [Chemical solubility and strength of low fusing dental ceramics] Schweiz Monatsschr Zahnmed 105, 611–616 (1995).
53. Roulet, J.F., Janda, R.: Future ceramic systems. Oper Dent 26, 211–228 (2001).
54. Ruano, R., Jäger, R.G., Jäger, M.M.M.: Effect of a ceramic and a nonceramic hydroxyapatite on cell growth and procollagen synthesis of cultured human gingival fibroblasts. J Periodontol 71, 540–545 (2000).
55. Rueger, J.M., Linhart, W., Sommerfeldt, D.: Biologische Reaktionen auf Calciumphosphatkeramik-Implantationen. [Biological reactions after the implantation of calcium phosphate ceramics] Orthopäde 27, 89–95 (1998).
56. Schäfer, R., Kappert, H.F.: Die chemische Löslichkeit von Dentalkeramiken. [The chemical solubility of dental ceramics] Dtsch Zahnärztl Z 48, 625–628 (1993).
57. Scher, E.L., Day, R.B., Speight, P.M.: New bone formation after a sinus lift procedure using demineralized freeze-dried bone and tricalcium phosphate. Implant Dent 8, 49–53 (1999).
58. Schmalz, G., Schmalz, C.: Toxicity tests on dental filling materials. Int Dent J 31, 185–192 (1981).
59. Schwickerath, H.: Dauerfestigkeit von Keramik. [Fatigue resistance of ceramics] Dtsch Zahnärztl Z 41, 264–266 (1986).
60. Sjögren, G., Sletten, G., Dahl, J.E.: Cytotoxicity of dental alloys, metals, and ceramics assessed by Millipore filter, agar overlay, and MTT tests. J Prosthet Dent 84, 229–236 (2000).
61. Steflik, D.E., Corpe, R.S., Young, T.R., Buttle, K.: In vivo evaluation of the biocompatibility of implanted biomaterials: morphology of the implant-tissue interactions. Implant Dent 7, 338–350 (1998).
62. Strub, J.R., Gaberthüel, T.W.: Trikalziumphosphat und dessen biologisch abbaubare Keramik in der parodontalen Knochenchirurgie. Eine Literaturübersicht. [Tricalcium phosphate and its biologically degradable ceramic in periodontal bone surgery. A literature review] Schweiz Monatsschr Zahnheilk 88, 798–803 (1978).
63. Studer, S., Lehner, C., Brodbeck, U., Schärer, P.: Short-term results of IPS-Empress inlays and onlays. J Prosthod 5, 277–287 (1996).
64. Tadic, D., Epple, M.: A thorough physicochemical characterisation of 14 calcium phosphate-based bone substitution materials in comparison to natural bone. Biomaterials 25, 987–994 (2004).
65. Tateishi, T., Yunoki, H.: Research and development of alumina and zirconia artificial hip joint. Clin Mat 12, 219–225 (1993).
66. Uo, M., Sjögren, G., Sundh, A., Watari, F., Bergman, M., Lerner, U.: Cytotoxicity and bonding property of dental ceramics. Dent Mater 19, 487–492 (2003).
67. Van Dijken, J.W.V., Höglund-Aberg, C., Olofsson, A.-L.: Fired ceramic inlays: a 6-year follow up. J Dent 26, 219–225 (1998).
67a Veronese, I., Guzzi, G., Giussani, A., Cantone, M.C., Ripamonti, D.: Determination of dose rates from natural radionuclides in dental materials. J Environ Radioact 91, 15–26 (2006).
68. Wang, M. L., Tuli, R., Manner, P. A., Sharkey, P. F., Hall, D. J., Tuan, R. S.: Direct and indirect induction of apoptosis in human mesenchymal stem cells in response to titanium particles. J Orthop Res 21, 697–707 (2003).
69. Wataha, J.C.: Materials for endosseous dental implants. J Oral Rehabil 23, 79–90 (1996).
70. Yamamoto, A., Honma, R., Sumita, M., Hanawa, T.: Cytotoxicity evaluation of ceramic particles of different sizes and shapes. J Biomed Mater Res 68A, 244–256 (2004).
71. Zelic, O., Dimitrijevic, B., Vasilijevska, M., Dujic, A., Lekic, P.C.: A dental implant: aluminium trioxide exhibited no effect on mouse reproductive and mutanogenic potential. J Clin Periodontol 25, 892–896 (1998).
72. Zetterqvist, L., Anneroth, G., Nordenram, A.: Tissue integration of Al_2O_3-ceramic implants: an experimental study in monkeys. Int J Oral Maxillofac Impl 6, 285–293 (1991).
73. Zetterqvist, L., Anneroth, G., Nordenram, A., Wroblewski, R.: X-ray microanalytical and morphological observations of the interface region between ceramic implant and bone. Clin Oral Impl Res 6, 104–113 (1995).

Dentlearn.ir

7 Root Canal Filling Materials

G. Schmalz

Contents

7.1 Introduction ... 187
7.1.1 Classification ... 187
7.1.2 Requirements ... 188
7.1.3 Clinical Data and Biocompatibility ... 189
7.1.4 Mandibular Nerve Injuries ... 189
7.1.5 Rubber Dam ... 190
7.2 Gutta-Percha ... 191
7.2.1 Composition ... 191
7.2.2 Release and Degradation ... 191
7.2.3 Systemic Toxicity and Allergies ... 191
7.2.4 Local Toxicity and Tissue Compatibility ... 192
7.2.5 Antimicrobial Properties ... 194
7.2.6 Clinical Data and Mandibular Nerve Injuries ... 194
7.3 Root Canal Sealers ... 195
7.3.1 Overview ... 195
7.3.2 Zinc Oxide Eugenol Sealers ... 195
7.3.3 Polyketone-Based Sealers ... 200
7.3.4 Epoxy-Based Sealers ... 201
7.3.5 Calcium-Hydroxide-Based Sealers ... 203
7.3.6 Mineral Trioxide Aggregate ... 205
7.3.7 Calcium Phosphate Cement ... 207
7.3.8 Silicones ... 208
7.3.9 Resin-Based Sealers ... 208
7.4 Materials for Retrograde Root Canal Fillings ... 210
7.4.1 Composition and Setting Reaction ... 211
7.4.2 Systemic Toxicity and Allergies ... 211
7.4.3 Local Toxicity and Tissue Compatibility ... 211
7.4.4 Clinical Data ... 212
Conclusions for the Dental Practitioner ... 213
References ... 213

7.1 Introduction

Bacteria are the most important cause of disease of the dental pulp and the periapical tissue. Therefore, root canal filling materials are used to seal a root canal after its final, definite preparation and thereby prevent its infection or reinfection. The ultimate goal of the treatment is healing of the inflamed apical periodontium or prevention of an inflammation. Sufficient biocompatibility of materials used in the course of the treatment is considered a prime prerequisite for undisturbed healing, as well as other factors such as tight sealing of the root canal to prevent microbial penetration (Fig. 7.1). Recently, new materials, known as bioactive materials, have become available; these are supposed to actively promote the healing processes, for instance, the regeneration of periapical bony tissue. "Osseoinductive" materials induce bone formation by initiating the differentiation of pluripotent connective tissue cells to bone-forming cells. "Osseoconductive" materials serve as a scaffold for the ingrowth of precursor osteoblasts.

7.1.1 Classification

Root canal filling materials can be classified into three groups:

- Points
- Sealers
- Thermoplastic materials

Points are prefabricated materials for root canal filling. Shape and size can be equivalent to those of instruments used for the root canal preparation. Gutta-percha points are most frequently used, whereas titanium posts are used less often. Silver points were occasionally used in the past; however, they are no longer recommended due to insufficient sealing capacity and increased corrosion and toxicity.

Sealers are "pastes" that are mixed and set via a chemical reaction lasting a certain period of time, which differs among products from minutes to days. Currently, sealers are generally applied in combination with points.

Dentlearn.ir

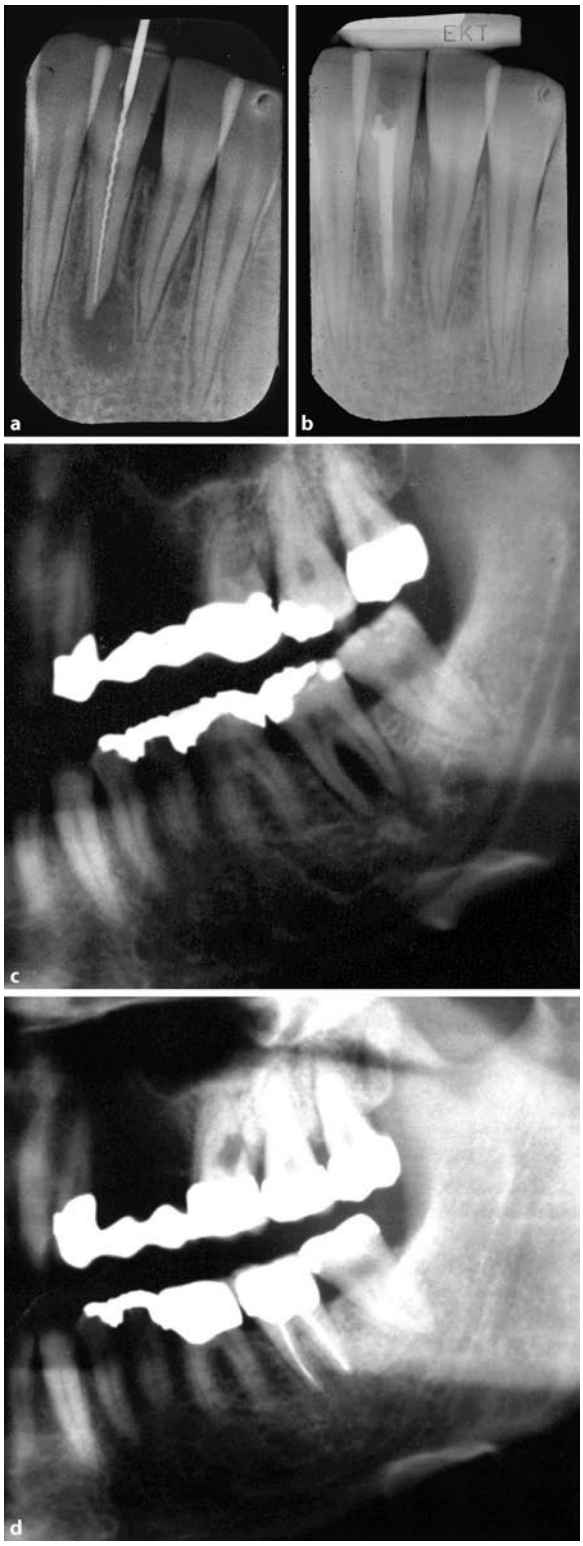

Fig. 7.1 Radiographs taken after a successful root canal treatment. Healing of a chronic apical inflammation in the anterior (**a**,**b**) and posterior region (**c**,**d**)

Gutta-percha is not only used for points but is also applied in a **thermoplastic** state. It is either completely or only superficially heated or liquefied in order to better adapt to the root canal walls. Thermoplastic gutta-percha is usually combined with a sealer.

A new approach for root canal treatment involves chemical cleansing of the root canal system without any further preparation and subsequent incorporation of a sealer (without gutta-percha) using negative pressure. This represents a totally new method of root canal treatment [153]. However, only very limited data about this technique are available so far.

7.1.2 Requirements

Root canal filling materials have to meet a number of physical, biological, and handling-related requirements (details can be found in textbooks on endodontology). The biological requirements include the following features:

- No systemic toxicity
- Nonallergenic
- Compatible with local (periapical) tissue
- Sterile or sterilizable
- Antimicrobial activity (specifically in the presence of anaerobic bacteria, such as *Actinomyces* strains and *Enterococcus faecalis*) [100, 217, 233]
- Promotion of periapical healing

Key Note

It is particularly important that root canal filling materials have an acceptable degree of tissue compatibility because these materials are in close contact with vital tissue at the tip of the root (i.e., not separated by an epithelial barrier, equivalent to an implant).

However, the requirement for local tissue compatibility is somewhat in contradiction to the requirement for an "antimicrobial effect." Such an effect is, in the context of standard endodontic treatment, mainly of an unspecific nature aimed at killing bacteria present in the root canal system. This is in contrast to antibiotics, which specifically influence metabolic processes of bacteria at defined concentrations. Endodontic materials with antimicrobial activity are very desirable for many reasons: A complete biomechanical preparation and the entire removal of the invaded microbiota are technically very difficult due to the complex anatomy

Dentlearn.ir

of the root canal system. Furthermore, bacteria can, in addition to the main root canal, penetrate into accessory canals, the apical "canal delta," and up to 1 mm into the dentin.

A number of studies have documented that the antimicrobial activity of commonly used endodontic materials is often closely related to their toxicity against adjacent cells. This was clearly shown for zinc oxide eugenol (ZOE) sealers with and without formaldehyde. Materials containing formaldehyde revealed very good antimicrobial activity but have also been shown to be extremely toxic (see Sect. 7.3.2 on ZOE sealers). This should be taken into account when selecting an appropriate material for root canal filling. Materials that are antimicrobially effective (and toxic) for just a short period of time after mixing might be an interesting alternative. After complete setting, such materials no longer exhibit any antimicrobial activity, but they are also not toxic or only slightly toxic and thus allow healing of the periapical tissue in the long run.

Furthermore, dentists must consider that the requirement for appropriate biological properties of root canal filling materials has to be consistent with requirements for adequate physical and handling features. For instance, the stimulation of periapical bone formation, e.g., by materials releasing calcium hydroxide, should not result in a partial disintegration of the root canal sealer with subsequent increased permeability and microleakage of the endodontic filling. Therefore, bioactive properties of such root canal sealers are acceptable only if the endodontic filling completely seals the root canal for a long period of time. At present, ideal materials that fulfill all requirements of an optimal root canal filling are not yet available. Therefore, compromises are always necessary. In this context, the biocompatibility of endodontic filling materials has to be considered an important factor but not the only parameter for selecting a material.

Key Note

Inappropriate physical properties of root canal filling materials may indirectly cause adverse biological effects. The most important property in this context is sufficient sealing capacity of the endodontic filling. A penetration of bacteria alongside a leaky root canal filling from the oral cavity into the periapical area has to be prevented, as well as the formation of retention niches for remaining bacteria. Leaky root canal sealers, therefore, may indirectly cause a periapical inflammation.

7.1.3 Clinical Data and Biocompatibility

Clinical success rates of 70–95% have been reported for root canal fillings [174, 205, 257]. Clinical success depends on a variety of factors [83]:

- Anatomical circumstances (e.g., the possibility of mechanical preparation of and access to the root canals and their curvature)
- The severity of pulpal disease (e.g., the presence and extent of periapical lesions)
- Technical problems occurring during the endodontic treatment (e.g., fracture of instruments)
- Sufficient restoration (providing a bacteria-tight coronal sealing and thus preventing bacterial penetration)
- Suitable materials

Interestingly, few clinical studies have compared the success rate of endodontic treatments depending on the application of different materials. Recently, Orstavik et al. [174] examined 675 roots (out of 810 treated ones) 0.5–4 years after treatment. Three different sealers had been used (AH26, Kloroperka, and ProcoSol). Within the given limits of such a study, the influence of the sealer was demonstrated only in cases without periapical lesion before treatment, with Kloroperka revealing the lowest rates of success [174]. However, a much stronger association of clinical success was found with other variables, e.g., the periapical status before treatment or overinstrumentation [174]. Therefore, endodontic materials represent only one aspect out of several parameters that are important for the clinical success of an endodontic treatment. No material is currently available that is able to compensate for deficiencies of the treatment technique (e.g., insufficient preparation of the root canal). In this context the most important properties of endodontic materials are the sealing capacity, in order to prevent infections or reinfections, and the biological properties, which should allow an undisturbed healing of the periapical tissue. Biocompatibility of endodontic materials plays a major role, with the potential for mandibular nerve injury if overfilling occurs.

7.1.4 Mandibular Nerve Injuries

Problems of insufficient biocompatibility, in particular neurotoxic properties [39, 40, 41], become clinically directly evident in the case of extended overfilling of the root canals in the lower molar, with a consequent mandibular nerve injury. Such incidents occur rela-

Dentlearn.ir

tively rarely in routine dental practice but may have dramatic consequences in each individual case. The causes of these incidents vary but can include over-instrumentation/overpreparation combined with mechanical trauma of the adjacent nerve or degeneration of the nerve following a mechanical compression caused by the endodontic material or toxicity (in particular, neurotoxicity) of the material [39]. An insufficient biocompatibility of the applied root canal filling material is of specific importance in such cases (Fig. 7.2).

Mandibular nerve damage is indicated by a disturbed sensibility, which may manifest as follows [57]:

- Hyperesthesia (increased sensitivity to touching stimuli)
- Hypoesthesia (reduced sensitivity to touching stimuli)
- Dysesthesia (stimuli are sensed as different and unpleasant, e.g., touching causes pain)
- Complete anesthesia
- Painful anesthesia (rare), e.g., triggered by cold stimuli

Consequences of a disturbed sensitivity may be the following:

- Saliva dropping out of the angle of the mouth
- Labial ulcer caused by unnoticed biting on the lip
- Labial burning due to unnoticed heat exposure

Fig. 7.2 Excessive overfilling of the root canal and extrusion of a paraformaldehyde-containing sealer into the mandibular canal. The patient complained of total anesthesia [57] (Courtesy of J.E. Hausamen, Hannover, Germany)

Clinical Practice Advice

If a mandibular nerve injury due to overextension of an endodontic sealer into the mandibular nerve canal is suspected, the patient should be referred for surgical treatment as soon as possible to remove the sealer and treat the nerve according to the degree of the damage [183, 212]. Immediate treatment includes, for instance, the prescription of steroids combined with the application of cold and wet packs to prevent edema and inhibit inflammation.

7.1.5 Rubber Dam

A rubber dam should generally be used for each root canal treatment (for details, see textbooks on endodontology). The original rubber dam consisted of powdered latex. Allergies to latex have been documented (see Chap. 14), and allergic reactions to the rubber dam have increasingly been reported in the dental literature in recent years [56, 76, 132, 139]. These are mostly type I (immediate) reactions [132], causing symptoms such as a localized contact urticaria (Fig. 7.3) or anaphylactic shock [76]. Latex-free rubber dams are also available, e.g., based on silicone, which reveal mechanical properties similar to those of latex rubber dams (according to manufacturers' information). It may be possible in the future to completely replace latex-containing rubber dams if these new or similar materials prove successful in daily practice. However, one recent case of a type IV reaction to a latex-free rubber dam has been reported [232].

Fig. 7.3 Perioral urticaria after application of a latex-based rubber dam. Positive radioallergosorbent test reaction indicated IgE antibodies to latex [76] (Courtesy of E.A. Field, Liverpool, UK)

Dentlearn.ir

7.2 Gutta-Percha

7.2.1 Composition

Gutta-percha is a natural product made of the bark of the gutta-percha tree (*Isonandra percha*). Gutta-percha is chemically a polymer based on isoprene. Two different types of gutta-percha are used in endodontics: **α-gutta-percha**, which is characterized by a better flow behavior and relative volume stability and so is preferred for injectable techniques, and **β-gutta-percha**, which is more flexible and is primarily used for points.

Gutta-percha points have different compositions; the ranges are shown in Table 7.1. These differences between individual products may be the cause of different technical and biological properties. Previously, cadmium-containing pigments were added to gutta-percha points; the yellow color was supposed to facilitate removal of gutta-percha points in case a revision was needed. However, modern gutta-percha points contain other dyes, so cadmium compounds are no longer added. Cadmium impurities in zinc oxide vary within accepted threshold concentrations [206]. Gutta-percha points whose surface is heated before application contain resin or metal (titanium) points in their interior [23, 254]. Calcium hydroxide is added to some gutta-percha points in substantial amounts (52%) in order to benefit from its biological effects [6, 112]. These products, however, are primarily used as endodontic dressings (see also Sect. 7.3.6 on calcium hydroxide sealers). Iodoform and chlorhexidine have been added to gutta-percha as well as tetracycline [161]. Gutta-percha is soluble in certain organic diluents, such as eucalyptus oil.

Gutta-percha can be used as a point, without warming, in combination with a sealer as filling material in a prepared root canal. Furthermore, techniques have been described that require the heating of the points (e.g., Thermafil, Densfil) [254] to achieve a better adaptation of the gutta-percha to the walls of the root canal. Other methods use liquefied gutta-percha (at 70°C or 160–200°C), which is injected into the root canal (Ultrafil, Obtura) [265] or liquefied by means of rotating instruments in the root canal (the McSpadden technique).

7.2.2 Release and Degradation

Gutta-percha seems to be rather stable against degradation under alkaline hydrolytic and enzymatic conditions [239]. However, the slightly toxic reactions observed with certain brands may lead to the conclusion that small amounts of substances are released, e.g., zinc ions from the zinc oxide filler [164]. Substances specifically added to influence the biological properties, such as calcium hydroxide or antimicrobial active substances, are also released. In the case of calcium hydroxide, contradictory data are reported; some authors found no change in the pH of the eluate [6, 44], whereas others found a moderate increase of the pH to 9.5–10.9 [12, 58, 62]. But the amount of released hydroxide ions was obviously so low that no alteration of the pH value was documented in buffer, saliva, or serum [148].

7.2.3 Systemic Toxicity and Allergies

No reports documenting a systemic toxic reaction to gutta-percha points are available in the accessible scientific literature. Older products (made before 1988, according to the manufacturers' information) contained cadmium-based dyes [206]. But even in

Table 7.1 Composition and phase structures of gutta-percha points

Composition	Phase structures
Zinc oxide: 33–61.5%	α phase: Natural product
Gutta-percha: 19–45%	β phase: Emerging after warming of the α phase and rapid cooling
Heavy metals: 1.5–31.2%	γ phase: Not used in dentistry
Additives (e.g., colophony): 1–4.1%	
Pigments: 1.5–3.4%	

Dentlearn.ir

these cases no systemic toxicity is to be expected due to the minute amounts and the extremely low solubility of cadmium [206].

Allergic reactions to gutta-percha seem to be very rare as well. So far, only one case of a suspected allergic reaction has been documented [33]. Gutta-percha was applied beyond the root apex in a female patient who was allergic to latex. The operator did not wear latex gloves. Nevertheless, pain, lip swelling, and a diffuse urticaria occurred after the endodontic treatment. The gutta-percha point was removed 4 weeks later. Thereafter, the patient's symptoms disappeared. It should be noted that gutta-percha and latex are natural products derived from trees that belong to the same botanical family [33]. So far, however, no increased frequency of sensitization to latex has been documented in patients with endodontic gutta-percha fillings. Thus, the general use of gutta-percha for endodontic fillings cannot be discouraged [208].

The question whether patients with a latex allergy should be treated with gutta-percha points is more difficult to answer. No cross-reactivity has been found between extracts of different gutta-percha points and natural latex [54, 99, 125]. Data regarding raw gutta-percha are contradictory [54, 99]. Gutta-balata, which may be added to some gutta-percha points, has caused cross-reactivity with natural latex [54]. The recommendation to avoid overfilling of root canals with gutta-percha in patients who are allergic to latex is, however, clinically often very difficult to accomplish.

Proteins that may be the cause of cross-reactivity between latex and gutta-percha are removed from raw gutta-percha by a purification process before the material is used for gutta-percha points (according to the manufacturers' information). This process minimizes the allergenic risk. Analyses of the protein content of gutta-percha points documented concentrations of 2–5 μg/ml, whereas raw gutta-percha contained >200 μg/ml [125]. Two case reports about patients with pronounced allergy to latex are documented in the literature; these patients were endodontically treated with gutta-percha successfully and without symptoms [132, 142].

Clinical Practice Advice

Only highly purified gutta-percha should be used in patients with a latex allergy. If necessary, synthetic gutta-percha points can be applied (e.g., Synthapoints).

7.2.4 Local Toxicity and Tissue Compatibility

Gutta-percha caused no or only slight toxic reactions in various cell cultures using different toxicity assays [126, 146, 221]. Similar data have been documented after implantation in the tibia [119] as well as the mandible of guinea pigs [223] and after subcutaneous implantation in rats [162, 263] and rabbits [204] (Fig. 7.4). Interestingly, some gutta-percha products were more toxic in vitro than others [203]. This was also observed in vivo in histological studies. An activation of the complement system was observed only with certain gutta-percha products [89]. Subcutaneous implantation of one product in rats caused no reactions after 1 year, whereas another product triggered a chronic inflammation [111, 263].

Sonat et al. [220] investigated the tissue reaction in dogs after application of Sealapex, pure calcium hydroxide, and gutta-percha. Gutta-percha caused the least amount of apical healing. Cells of the surrounding periodontal ligament encapsulated the material, but no periapical regeneration was observed. Other authors, however, reported periapical healing [48]. There are obviously differences among individual gutta-percha products regarding their biocompatibility.

The tissue reaction to gutta-percha also depends on the particle size. Macrophages and foreign body giant cells were observed after subcutaneous implantation of gutta-percha particles (50–100 μm) in guinea pigs, which may potentially interfere with the apical healing process. However, larger gutta-percha particles caused no adverse biological reaction [218]. Mouse macrophages released prostaglandins E_2 and I_1 when exposed to small gutta-percha particles (50–100 μm); the cell culture supernatant had the potential of bone resorption, which could not, however, be attributed to prostaglandins but to interleukin-1-alpha [219].

Increased temperatures, such as when applying heated or liquefied gutta-percha, and their effects on the surrounding tissue have been intensively discussed in the literature. The temperatures inside the root canals generally exceeded the temperatures at the root surfaces. This indicates that dentin acts as a good thermal insulator [260]. If the temperature at the root surface is increased by 10°C for longer than 1 min, then the periodontal tissue may be damaged [69].

Temperatures between 45°C and 80°C have been measured inside root canals during the vertical condensation of gutta-percha (heating of gutta-percha points within the root canal using a hot instrument) [156]. The temperature increase at the root surface

Dentlearn.ir

varied between 3°C and 4°C (at the enamel–cementum junction) [101] and 4–7°C at a distance of 2 mm to the apical foramen [8] (Fig. 7.5). Less increased temperatures were observed when heated gutta-percha was used together with a sealer [15].

The Endotec method represents a similar technique: Gutta-percha is heated inside the canal with a heated spreader [47]. Increased temperatures with an average of 11°C were recorded at the root surface in vitro during the application of this technique, the highest temperatures (range 4.5°–13°C) being measured at the enamel-cementum junction (Fig. 7.5) [93]. Animal experimentation excluded periodontal damage after use of this treatment method [47]. Similar methods have been marketed recently under different names.

The thermomechanical compaction (condensation) of gutta-percha (the McSpadden technique) has been shown to increase the temperature within root canals to 55–100°C [52, 59, 77, 78]. Recorded temperatures at the root surface varied between 15.4°C and 35°C [80, 102] depending on the rotational speed of the compactor (see Fig. 7.5) [102]. These in vitro data significantly exceeded the abovementioned threshold of 10°C. Subsequent animal experiments documented an average temperature increase at the root surface of 18.3°C at a rotational speed of 10,000 min^{-1} despite the application of a sealer (range 14°C–22.5°C; see Fig. 7.5). After condensation, the temperature increase dropped below 10°C within 15–30 s [199]. Histological studies of the periodontium [200] documented that 20% of the experimental teeth showed resorptions of the cementum in the central area of the root after 20 days, but without signs of pronounced inflammation. After 40 days, 28% of the analyzed teeth revealed resorptive alterations of the root; 22% of these roots were ankylotic. Control teeth (subjected to lateral condensation) showed neither resorption of the cementum nor ankyloses.

Clinical Practice Advice

It may be concluded from these data that thermomechanical compaction (condensation), specifically at a higher rotational speed (>10,000 min^{-1}), may damage the periodontal tissues.

The principle of the Obtura method is to heat gutta-percha up to a temperature of 160°C (method I) or 200°C (method II) [260] and inject it into the root canal (Figs. 7.5 and 7.6). The intracanal temperature that was generated by Obtura I was up to 75°C [60], and a maximum of 67°C was found with Obtura II [260]. The maximum temperature increase at the root surface

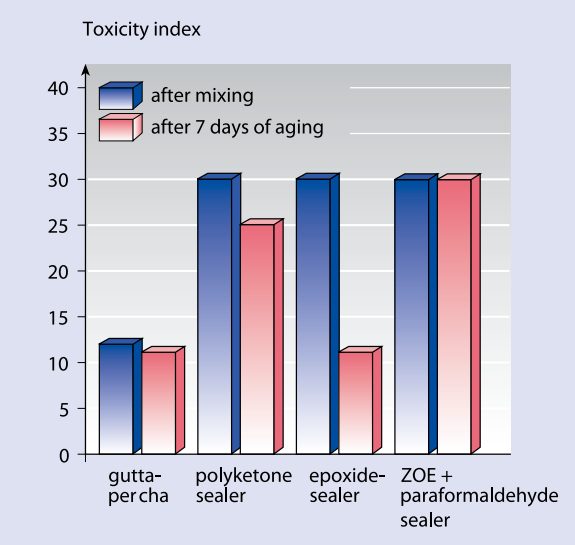

Fig. 7.4 Local toxicity of different root canal filling materials in implantation tests low toxicity (= low toxicity index) of gutta-percha, decreasing toxicity of an epoxy sealer with increasing aging time [204]

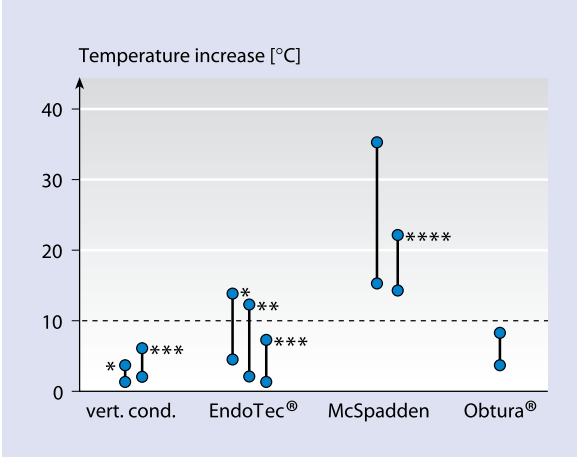

Fig. 7.5 Temperature increase (minimum and maximum values) at the root surface after application of heated injectable gutta-percha. A temperature increase of >10°C for more than 1 min may cause bone damage (*cervical area, **central root surface area, ***root end, ****with sealer) [69]

Dentlearn.ir

was 8.9°C [260]. Temperature increase was highest in the central area of the root, probably due to the higher volume of the root canal in this area. Damage to the periodontium was considered to be rather unlikely because the critical temperature increase of 10°C was not reached. Apparently the gutta-percha cools down significantly before it reaches the root canal [259]. A temperature increase at the bone surface next to a tooth that was treated using this method did not exceed 1.1°C with or without the application of a sealer [97]. Gutmann et al. [97] reported that the Obtura method (with and without a calcium-hydroxide-based sealer) caused no damage to the periodontal tissues of dogs after 72 h compared with the control technique (lateral condensation).

The Ultrafil method is based on injecting gutta-percha that was heated to 70°C into the root canal. Periodontal damage seems to be unlikely, similar to the aforementioned investigations. Langeland et al. [147], however, reported an acute apical inflammation briefly after overfilling of root canals with heated gutta-percha in primates; this changed into a chronic inflammation with foreign body reactions after several months. However, it should be considered that gutta-percha particles may trigger such an inflammatory reaction [228].

Clinical Practice Advice

Heat-related tissue damage due to the injection of heated gutta-percha is unlikely if the method is applied correctly. Overfilling of root canals with gutta-percha must be avoided to prevent a foreign-body-related inflammation.

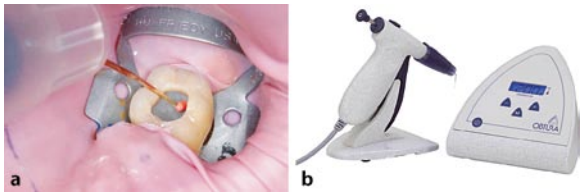

Fig. 7.6 **a** According to the Obtura method, gutta-percha is heated up to 200°C and subsequently applied in the root canal using an injection device. **b** The device (Courtesy of JADENT, Aalen, Germany)

7.2.5 Antimicrobial Properties

Gutta-percha has a limited antimicrobial activity, e.g., in anaerobic cultures of bacteria taken from root canals [164, 258]. The occurrence and size of the inhibition zones vary according to the applied bacteria and the tested products [258]. Zinc oxide is supposed to cause antimicrobial effects, releasing zinc ions due to hydrolysis [164]. The addition of iodoform increased the antimicrobial effect [157], and added tetracycline was also active against *Enterococcus faecalis* [161]. On the other hand, iodoform may cause toxic or allergic reactions. Substantial clinical data on iodoform-containing gutta-percha is not available.

7.2.6 Clinical Data and Mandibular Nerve Injuries

Gutta-percha, such as when used for the lateral condensation technique, is currently considered the gold standard for root canal treatment; a deficient marginal adaptation is compensated for by an appropriate sealer. Gutta-percha is presently the endodontic filling material that causes the least controversy.

However, liquefied gutta-percha (the McSpadden technique) used in combination with a calcium hydroxide sealer and which extruded from the root canal into the mandibular nerve canal has caused pronounced nerve injuries with persisting local anesthesia, numbness, and intermittent attacks of "pinpricking" in the lip and chin. When the gutta-percha was surgically removed, a total loss of sensory function was the initial consequence, followed by a subsequent paresthesia. Subjective dysesthesia symptoms included sensations of warmth, cold, burning, pain, tingling, pricking, numbness, itching, and formication [165]. The authors concluded that the elevated temperature of gutta-percha was the cause of the nerve damage [74].

Other authors reported six cases of paresthesia after overfilling of gutta-percha or chloropercha (gutta-percha dissolved in chloroform) [165]. However, symptoms completely disappeared within 3 months at the most. In one case, in which the patient refused to have the gutta-percha in the mandibular canal surgically removed, the symptoms improved after 1 year, but tingling sensations of the gingiva and the lips remained [25].

Dentlearn.ir

7.3 Root Canal Sealers

7.3.1 Overview

Root canal sealers are used to fill the remaining space between gutta-percha points and the root canal wall as tightly as possible. Sealers can be classified into various groups according to their composition:

- Zinc oxide eugenol (ZOE) materials
- Polyketone products
- Epoxy resins
- Calcium-hydroxide-based materials
- Mineral trioxide aggregate (MTA)
- Calcium phosphate cement
- Silicone-based sealers
- Resin-based sealers

In the past, chloropercha was frequently used. However, due to the possible health risk posed by chloroform (carcinogenicity), this type of sealer is no longer recommended.

For a number of years, a glass ionomer cement sealer was used for root canal and root end filling. This material was not found to be cytotoxic or mutagenic in a commonly used bacterial mutagenicity test (the Ames test) and was well tolerated after implantation [70, 137, 177]. However, this material is no longer available.

7.3.2 Zinc Oxide Eugenol Sealers

7.3.2.1 Composition

The group of ZOE sealers comprises a relatively large number of different products; the typical composition of one of these materials, Grossman sealer, is shown in Table 7.2. Some ZOE sealers contain additives such as thymol or thymoliodide in order to increase the antimicrobial effect (Rickert, Tubli-Seal). Other products contain hydroxyl apatite [86] or calcium hydroxide [175] to improve apical sealing and bone regeneration. Clove oil and Peru balm are used as alternatives for eugenol. Clove oil is the natural raw material that contains approximately 70–85% eugenol. Eucalyptus oil has also been used to replace eugenol, at least partially [175].

ZOE sealers may also contain colophony to increase the adhesiveness of the cement, to adjust the speed of the setting reaction, and to decrease solubility or disintegration. The exact chemical composition of colophony may change because of the natural raw material, which is the product of conifers [234]. Modified ZOE preparations (see Table 7.2) are characterized by better mechanical properties regarding strength, setting behavior (fast/regular), and so on [266].

Some ZOE sealers contain paraformaldehyde, including N2 (7% of the powder) or SPAD (87% in one

Table 7.2 Composition (in weight %) of zinc oxide eugenol (ZOE) sealers

	Powder	Liquid	Additives
Standard material (Grossman sealer)	Zinc oxide 42%	Eugenol	Thymol/thymoliodide (Rickert, Tubli-Seal)
	Stabilite 27%		Formaldehyde (N2, SPAD[a])
	Bismuth carbonate 15%		Hydroxyl apatite (Bioseal)
	Barium sulfate 15%		Calcium hydroxide (CRCS)
	Sodium borate anhydrate 1%		
Modified ZOE materials (Super EBA)	Zinc oxide 60%	Orthohydroxy-benzoic acid 62.5%	
	Aluminum oxide 34%	Eugenol 37.5%	
	Resins (e.g., colophony 6%)		

[a]The powder contains zinc oxide, among other compounds, but the liquid is eugenol-free

Dentlearn.ir

of the two liquids). The chemical synonym of formaldehyde is trioxymethylene. Formaldehyde is supposed to enhance the disinfecting effect of the materials. On the other hand, the use of root canal sealers containing paraformaldehyde has been strictly rejected by the European Society of Endodontology [73].

7.3.2.2 Setting Reaction and Release of Substances

ZOE sealers set in a humid environment, forming ZOE chelates. This setting reaction takes about 24 h. Additives, however, such as colophony, dicalcium phosphate, or zinc acetate can accelerate the speed of the setting reaction [262]. The setting reaction is reversible – hydrolytic conditions may cause the release of eugenol and zinc ions. A further degradation of the material releasing eugenol may be caused by HCO_3^- (derived from tissue fluid), since the affinity of zinc to HCO_3^- is greater than to eugenol [168]. Formaldehyde-containing root canal sealers based on ZOE release formaldehyde over a prolonged period of time [134].

7.3.2.3 Systemic Toxicity and Allergies

Many authors have investigated the biological effects of eugenol. These studies documented a low systemic toxicity [264]; furthermore, eugenol is an approved food additive [75]. The oral LD_{50} varies between 1,930 mg/kg (rat) and 3,000 mg/kg (mouse) [158]. On the other hand, eugenol, like colophony, is a known contact allergen [154] (for more information, see Sect. 6.4). Eugenol and its derivatives are used in fragrance mixtures. Allergies linked to these mixtures may be caused by the presence of eugenol [188]. Eugenol and ZOE were only moderately allergenic or nonallergenic in preclinical application tests, but this finding may be due to a suppression of clinical symptoms of an allergy by eugenol [106, 109, 123]. Some "eugenol-free" materials contain Peru balm, which is an important contact allergen as well [127]. Some authors have documented that Peru balm is the second most frequent allergen among the patients included in their studies [104]. Peru balm consists of approximately 250 substances, including small amounts of eugenol.

Practical Clinical Device

Patients with an allergy to eugenol (or to fragrances) should not be treated with materials containing eugenol, isoeugenol, or Peru balm.

Allergic reactions to filling materials containing ZOE have been observed [108], and dental personnel have shown allergic contact dermatitis due to eugenol-containing materials [22, 108, 124]. Formaldehyde, which is released from ZOE sealers containing paraformaldehyde, is a known allergen (hapten) as well. The occurrence of a contact urticaria in the mandible after exposure to a formaldehyde-containing root canal sealer has been documented; the complaints, however, subsided after application of a corticoid-based drug. The patient reacted positively to formaldehyde in a patch test [66].

It has also been reported in the literature that the application (and overfilling) of a paraformaldehyde-containing sealer caused anaphylactic shock [98]. Immediately after root canal filling, the patient suffered from hot flushes, general itching, and shortness of breath. After 30 min, the patient lost consciousness and showed typical shock symptoms, with a systolic blood pressure of 50 mmHg. With emergency treatment, the patient survived. The subsequent patch test was positive for formaldehyde; a high concentration of IgE was assessed [98].

Other authors have reported seven cases of allergic reaction – four cases of anaphylactic shock and three of generalized urticaria – to formaldehyde in endodontic sealers [35]. Respiratory and cutaneous reactions as well as anaphylactic reactions prevailed. The authors reviewed the literature and found 35 similar cases, with 15 cases of life-threatening anaphylactic reactions [35].

7.3.2.4 Local Toxicity and Tissue Compatibility

Eugenol has caused a cytotoxic reaction in various cell culture tests and assays [203]. Similar data were documented for ZOE-based materials [107]. Compared with other root canal sealers, the reported degree of cytotoxicity for a ZOE sealer ranked somewhere in the middle, and no difference was found if the materials were allowed to set for 24 h or for 7 days. These materials were, however, significantly less toxic than a formaldehyde-containing ZOE sealer [70] (Fig. 7.4).

Dentlearn.ir

A ZOE sealer without paraformaldehyde was tested and found to be nonmutagenic [209], but paraformaldehyde-containing endodontic sealers tested positive [53, 150, 173].

The effect of ZOE sealers on nerve conduction has been investigated as well. In vitro studies showed that eugenol may impair the conduction of various nerves [39, 140, 176]. Based on the effective concentration, it may be concluded that a *reversible* damage to nerves in vivo is possible [39]. Formaldehyde, however, *irreversibly* suppressed the nerve conduction in vitro at concentrations that may also occur in vivo [39]. Studies performed with mixed ZOE pastes documented a reversible inhibition of nerve conduction, whereas paraformaldehyde-containing materials caused irreversible damage [41].

Eugenol (similar to aspirin) inhibits prostaglandin H synthesis (cyclooxygenase, or COX; COX-1 and COX-2 are isoenzymes of the prostaglandin H synthase) and thus inhibits prostaglandin synthesis, consecutively suppressing inflammation and, therefore, pain (Fig. 7.7).

ZOE sealers have influenced immune system cells in vitro; low concentrations of material extracts stimulated the cells, and higher concentrations inhibited them [34]. A specific strong inhibition of immune cells was observed when formaldehyde-containing sealers were investigated [34]. The intramuscular injection of a mixture of pulp tissue and formaldehyde-containing ZOE sealers caused a very pronounced effect on the immune system, with proliferation of lymphocytes and an increased antibody titer [26, 27]. Alterations of the immune system may influence the host's defense toward bacteria in a negative way or may increase inflammatory reactions. Current knowledge in this field is still very limited.

ZOE sealers triggered moderate to severe inflammation in rats after subcutaneous implantation, which continuously decreased with increasing postoperative observation time (up to 120 days). However, even after a long observation period, slightly higher toxic reactions were observed compared with a calcium-hydroxide-based sealer (Apexit) [138]. Other authors confirmed these data using a similar experimental setting [137]. A ZOE sealer, which was subcutaneously injected in guinea pigs, was more irritating than a cal-

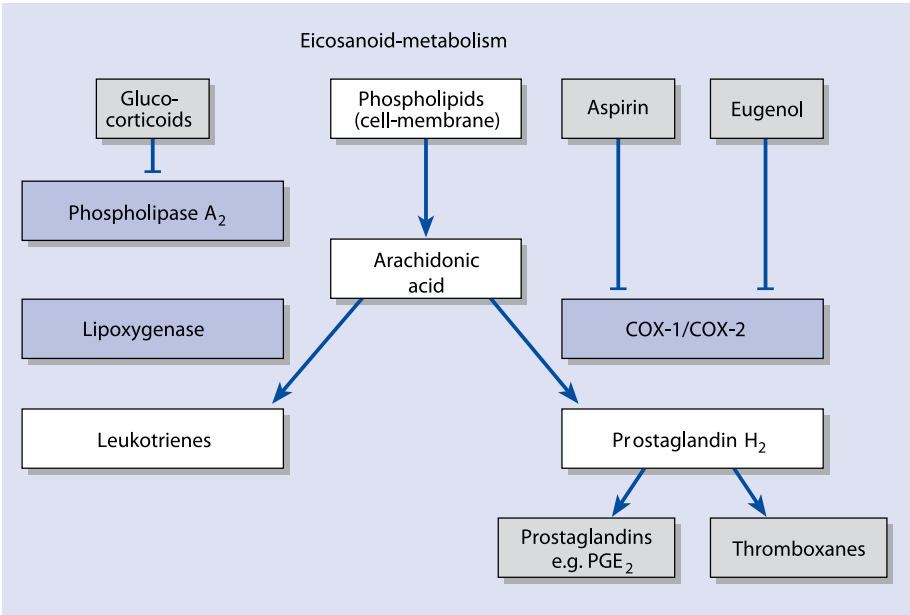

Fig. 7.7 Eicosanoid metabolism: eugenol inhibits the prostaglandin-H-synthase (COX-1, COX-2) and thus inhibits the synthesis of prostaglandins, which results in, among other things, pain reduction

Dentlearn.ir

cium-hydroxide-based or a silicone-based sealer even after an observation period of up to 80 days [269]. In particular, pronounced reactions were found after implantation of ZOE sealers containing paraformaldehyde (Fig. 7.8).

After application of a ZOE and a calcium hydroxide sealer into the root canals of ferrets [110], a periapical inflammation was generally found with the ZOE material, whereas this was the case in only three out of 10 teeth that were treated with calcium hydroxide. In another study, a paraformaldehyde-containing ZOE sealer caused pronounced periapical inflammation in dog teeth [67]. Tepel et al. [242] reported that ZOE sealers containing paraformaldehyde significantly impaired apical healing. An intentional overfilling of root canals (anterior teeth) with a paraformaldehyde-containing sealer in animal experiments resulted in severe periapical inflammation 6 months after treatment. These reactions were significantly less severe when a ZOE sealer without paraformaldehyde was used. A formaldehyde-containing ZOE sealer that was applied for pulpectomy of human teeth caused extensive necrosis [145].

Key Note

Data show that ZOE sealers are characterized by a moderate local toxicity, which is significantly increased if paraformaldehyde is added.

7.3.2.5 Aspergillosis

A number of case reports document that paraformaldehyde-containing ZOE sealers may cause an aspergillosis of the maxillary sinus when the root canals of upper posterior teeth are overfilled and the sealers are pressed into the maxillary sinus [18, 19, 20, 130, 133, 149]. Aspergillosis presents itself radiologically through a homogeneous cloudy maxillary antrum with one or more round or oval radiopaque objects (Fig. 7.9) [19]. These radiopaque concrements consist of calcium phosphate compounds and calcium sulfate compounds, which are deposited in the necrotic areas of the mycelia [130]. Computed tomographic densitometry can be used to differentiate between dental and aerogenic causes of aspergillosis [143]. It has been recommended to remove the mycotic tissue by surgery. Systemic antimycotic therapy is necessary only in cases of an invasive aspergillosis [130].

Clinical symptoms may vary. Most patients complain of intermittent pain, sensitivity of the cheeks, and occasional nasal complaints. Other patients do not reveal any clinical symptoms, and in these cases the aspergillosis is usually detected as an accessory finding of a radiographic examination [19]. Tests with fungal cultures have revealed that zinc oxide added to the culture medium may significantly increase the growth of various *Aspergillus* strains [20]. *Aspergillus* spores were detected in containers with zinc oxide [18]. It may be speculated that local damage of

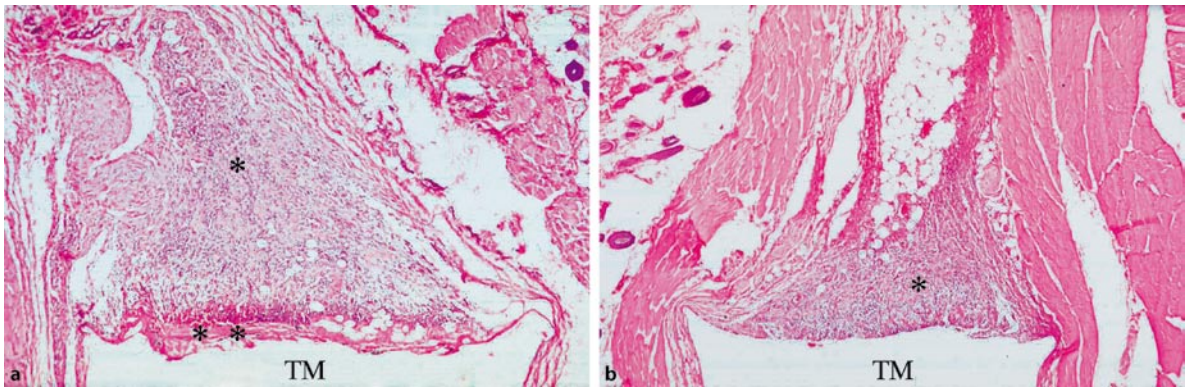

Fig. 7.8a,b Histologic reaction after implantation of a paraformaldehyde-containing root canal sealer (rat, subcutaneous). **a** Implantation immediately after mixing caused necrosis (**) at the contact area with the test material (*TM*) and excessive inflammation (*). (magnification ×80) **b** Implantation of "aged" specimens 7 days after mixing causes extensive inflammatory reactions as well (*) (magnification ×80)

Dentlearn.ir

the sinus mucosa caused by paraformaldehyde is the prerequisite for a zinc-induced growth of *Aspergillus* (mostly *Aspergillus fumigatus*) [19]. *Aspergillus* spores could also be transported into the sinus via contaminated ZOE sealers [170].

Clinical Practice Advice

All of the available information on adverse effects and the high toxicity of paraformaldehyde-containing ZOE sealers gives rise to the recommendation to not use these materials in clinical practice. Furthermore, other ZOE sealers should be applied with great caution to avoid any overfilling of root canals.

7.3.2.6 Antimicrobial Properties

ZOE sealers, even when completely set (e.g., 7 days after mixing), revealed pronounced antimicrobial properties when in direct contact with *Enterococcus faecalis* suspensions [85]. It has repeatedly been documented that ZOE sealers possess a significantly higher antimicrobial potency than calcium-hydroxide-based materials, regardless of the type of microorganisms used for the tests [1, 5, 185, 216]. Obviously, eugenol is the primarily causative substance for this effect. Eugenol is bactericidal at concentrations between 10^{-2} and 10^{-3} M [155]. Concerning bacteria-contaminated dentin, Orstavik [172] reported that ZOE sealers disinfect dentin tubules to a depth of 250 µm (Table 7.3). A further comparative study with anaerobic bacteria showed that a ZOE sealer was a stronger antimicrobial agent than calcium-hydroxide-based materials or a glass ionomer cement [1] but was less antimicrobial than an epoxy-based sealer (AH26) [105].

Various investigations have shown the good antimicrobial properties of ZOE sealer that contained paraformaldehyde (see Table 7.3) [42], such as in cultures of *Staphylococcus aureus* [185] and a great variety of other microorganisms, including those isolated from infected root canals [186, 241].

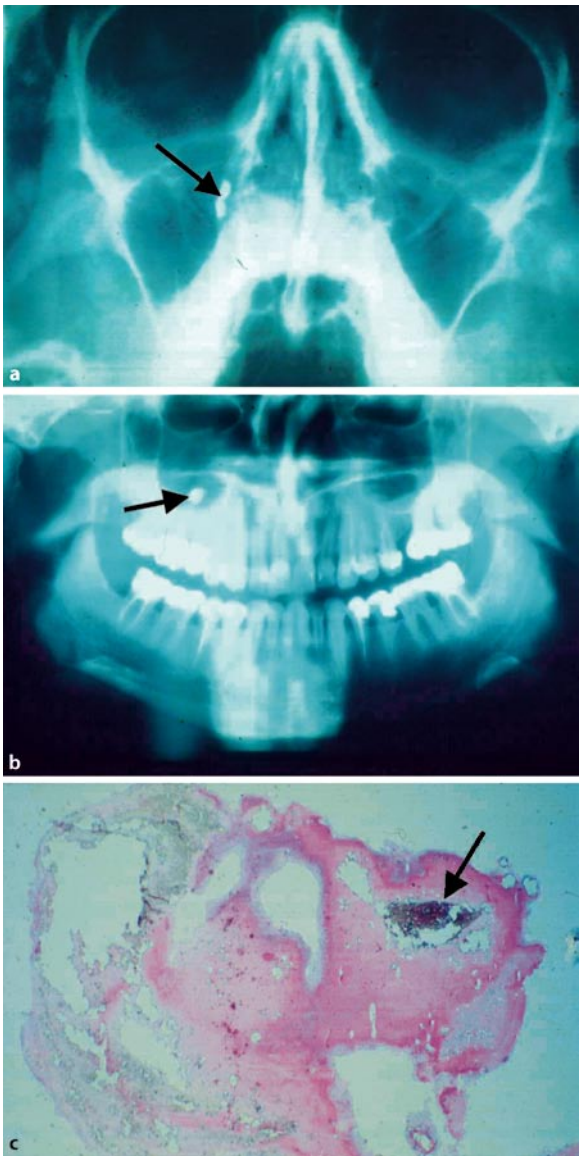

Fig. 7.9a-c Aspergillosis of the right maxillary sinus. **a** Overfilled root canal sealer in the sinus. **b** Severe radiologic shadow of the maxillary sinus (*arrow*). **c** The histologic section (not decalcified section) reveals an aspergillosis containing root canal filling material (*arrow*) [130] (Courtesy of P. Reichart, Berlin, Germany)

7.3.2.7 Clinical Data and Mandibular Nerve Injuries

ZOE sealers have been used for many decades as root canal filling materials. Clinically, their biocompatibility is generally considered good. Individual cases of mandibular nerve injury have been described when the sealer was pressed into the mandibular canal [201]. More severe problems, however, may occur with paraformaldehyde-containing pastes. According to a review of the literature in 1988, more than

Dentlearn.ir

Table 7.3 Disinfectant effect of various sealers in vitro on dentine infected with *Enterococcus faecalis* [172]

Sealer	Depth of disinfected zone (µm)
Epoxy sealer (AH 26)	1,000
ZOE sealer (CRCS)	250
ZOE sealer (Procosol)	250
ZOE sealer containing formaldehyde (Endomethasone[a])	700
CH sealer (Sealapex)	0

[a] Until 1993, the material Endomethasone contained formaldehyde; subsequently, the sealer was available as Endomethasone N without formaldehyde (according to the manufacturer's information)

40 cases of paresthesia of the inferior alveolar nerve subsequent to a root canal filling were observed in the 1960s and 1970s. These patients were mainly treated with paraformaldehyde-containing root canal sealers. Symptoms were irreversible without surgical treatment [39]. A more recent review presented 26 such cases, and it is again emphasized that paraformaldehyde is the main problem in such cases [184]. This is equivalent to data based on in vitro investigations showing that formaldehyde-containing root canal sealers irreversibly suppress nerve conduction [39, 140, 176]. Therefore, there is indication that the release of formaldehyde played an important role in these incidents [39].

Paresthesia also occurred in some cases in the upper jaw when ZOE-based sealers without formaldehyde were endodontically overfilled. In one case, the paresthesia lasted for 4 months [141]; in two other cases, it lasted 1 year and 2 years, respectively [144].

Table 7.4 Composition of a polyketone-based sealer (Diaket) [41]

Powder	Liquid
Zinc oxide 97%	Propionylacetophenone (76%)
Bismuth phosphate 3%	Vinylcopolymers (23.3%)
	Dichlorophene (0.5%)
	Triethanolamine (0.2%)

7.3.3 Polyketone-Based Sealers

7.3.3.1 Composition, Setting Reaction, and Release of Substances

One sealer based on polyketone (Diaket) has been on the market since 1952 (Table 7.4). This material sets via the formation of a chelate complex composed of a ketone and zinc. No data are available regarding the release of toxic substances.

7.3.3.2 Systemic Toxicity and Allergies

Although this product has been on the market for many years, no reports have been published indicating any systemic toxic properties or allergenic potential.

7.3.3.3 Local Toxicity

Assessment of local toxicity in cell culture experiments generally revealed toxic properties that were, however, low compared with ZOE-based sealers containing paraformaldehyde [126, 128, 271]. Our own studies with fibroblast cultures confirmed these results, but revealed as well that cytotoxicity decreases after the material has set [203]. This was confirmed in studies with primary pulp cells [159]. The emulsifying of the sealer with Tween 80 (a nonionic detergent) increased cytotoxicity. This indicates that the cytotoxic substances are not water-soluble [222]. The polyketone-based sealer was nonmutagenic in a commonly used bacterial mutagenicity test (the Ames test) [209] and caused an inhibition of nerve conduction in vitro, which was partially reversible [41].

Diaket caused an initial toxic tissue reaction directly after intramuscular implantation. This reaction decreased when the material was aged before implantation (see Fig. 7.4). Intraosseal implantation of this endodontic sealer caused a chronic inflammatory reaction when the material was mixed in a sealer-like consistency [223]. Similar results were reported after subcutaneous implantation [84, 171]. The reactions, however, partly or completely disappeared over time [187, 202, 228]. Sealer mixed to a thick consistency (a double amount of powder) revealed better compatibility with bone, in particular directly after application [167]. A mild inflammatory reaction due to this root canal filling material has been reported when it was overfilled into the periapical area of rat molars. The material was slowly absorbed and tended to fibrous

Dentlearn.ir

encapsulation [166]. Diaket was pronounced antimicrobial in cultures of *Staphylococcus aureus* [185].

7.3.4 Epoxy-Based Sealers

Several epoxy-based sealers are available on the market. The product AH26 is offered in two versions, with silver and silver-free. A further development of this product is named AHPlus (also marketed as Top Seal). The composition of these materials is described in Table 7.5.

7.3.4.1 Setting Reaction and Release of Substances

The setting reaction of AH26 includes a polymerization process that causes the release of formaldehyde via hydrolysis of the hexamethylene tetramine to ammonia and formaldehyde [134]. The concentration of formaldehyde released during this process is 300 times lower than with formaldehyde-containing ZOE sealers [224]. Other studies with a different analytical technique confirmed these findings, but the difference between both types of sealers was smaller. In contrast to formaldehyde-containing ZOE sealers, however, no formaldehyde was detected when AH26 was completely set (2 weeks after mixing) [134]. AHPlus sets much faster than AH26 does [272], and it is reported to not release any formaldehyde [134].

7.3.4.2 Systemic Toxicity and Allergies

Epoxy resins are mainly biologically active substances, and the epoxy monomer bisphenol A diglycidyl ether (BADGE) is an important contact allergen [127]. However, no reports have been published in the available literature that indicate systemic toxic reactions due to an epoxy-based sealer. Kallus et al. published positive test results after application of AH26 in the guinea pig maximization test. Accordingly, sensitized guinea pigs documented a more pronounced tissue reaction after subcutaneous implantation of AH26 compared with nonsensitized animals [123].

Table 7.5 Composition of epoxy-based sealers [210]

AH26®		AHPlus™
Silver-containing	**Silver-free**	
Powder	**Powder**	**Paste B**
Bismuth(III)-oxide (60%)	Bismuth(III)-oxide (60%)	Calcium tungstenate
Hexamethylene tetramine (25%)	Hexamethylene tetramine (25%)	Adamantane amine, N,N′-Dibenzoyl-5-oxanonane-diamine-1,9-TCD-diamine
Titanium dioxide (5%)	Titanium dioxide (5%)	Zirconium dioxide
Silver (10%)	Bismuth oxide (instead of silver) 10%	Silicon dioxide
		Poly(dimethyl) siloxane
Liquid	**Liquid**	**Paste A**
Bisphenol A-diglycidylether (BADGE)	Bisphenol A-diglycidylether (BADGE)	Bisphenol A-diglycidylether
		Calcium tungstenate
		Zirconium dioxide
		Silicon dioxide
		Pigment

Dentlearn.ir

Nevertheless, these sealers obviously cause allergies only in rare cases. One case of an allergy to AH26 has been documented. The clinical symptoms included erythema of the face and nape of the neck, and the patch test was positive [117]. Another case showed generalized skin reactions, which were successfully treated with cortisol [94]. The manufacturer of AH26 reported in 1999 only six cases of an allergy (since 1988), despite the widespread use of the product and the long period of time it had been on the market (see Fig. 14.13 and 14.14 in Chap. 14) [94].

7.3.4.3 Local Toxicity

Some authors [126] reported that AH26 was not cytotoxic, whereas others observed a very pronounced cytotoxic reaction in cell cultures [37, 88, 175]. However, these studies also documented a lesser cytotoxicity of AH26 compared with ZOE sealers containing paraformaldehyde [146, 221]. The discrepancy between various toxicity data for AH26 reported in the literature can be explained, at least partly, by the fact that different time intervals between mixing of the material and contact with a living tissue had been chosen in the various experiments. Our studies revealed that the test material AH26 was cytotoxic in cultures of mouse fibroblasts directly after mixing. This reaction was significantly lower when the material was tested 7 days after mixing (see Fig. 7.4) [203]. These data were confirmed on primary pulp fibroblasts of rats [159] and on human oral fibroblasts [9]. AH26 was also highly cytotoxic in immune-competent cells immediately after mixing, but the set material caused a significantly lesser cytotoxic reaction [34]. The initial high cytotoxicity was explained by the formation of formaldehyde during the setting reaction [224]. AH26 inhibited the nerve conduction in vitro as well [10], but this effect was partially reversible [41]. Only slightly toxic reactions have been observed with AHPlus [65].

It was repeatedly found after subcutaneous, intramuscular, or intraosseous implantation in small experimental animals that the epoxy-based sealers were initially toxic, but the tissue reactions subsided partially or completely after an extended observation period (Fig. 7.10; see also Fig. 7.4) [17, 203]. After implantation into the tibias of rabbits, no toxic reaction was observed after an observation period of 3 months. Obviously, the in vivo toxicity depends on the setting reaction. Implanted specimens caused a very pronounced reaction immediately after mixing, whereas 7-day-old specimens had no toxic effect at all [204]. Overfilling of rat molars triggered inflammatory reactions, but overfilled AH26 was phagocytized in the course of time [166].

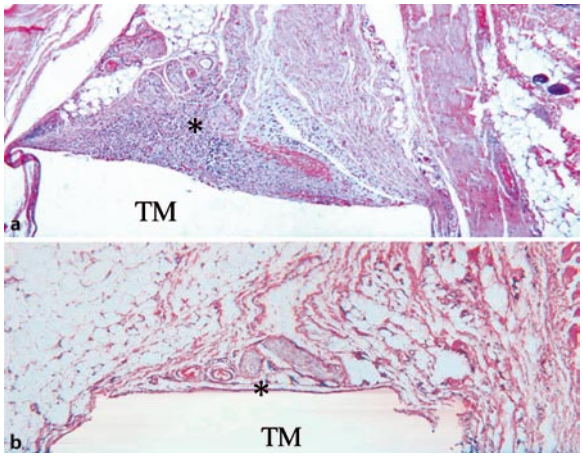

Fig. 7.10a,b Histologic reaction after implantation of an epoxy sealer (rat, subcutaneous). **a** Implantation immediately after mixing causes an inflammatory reaction (*) at the contact area with the test material (*TM*). (magnification ×80) **b** Implantation of "aged" specimens 7 days after mixing causes no or only minimal inflammatory reaction combined with an incipient encapsulation by connective tissue (*) (magnification ×80)

Key Note

Epoxy-based sealers are initially toxic, but toxicity considerably declines when the materials are set, and then no tissue reactions, or only slight ones, are observed.

7.3.4.4 Mutagenicity

Some epoxy compounds are mutagenic; therefore, the mutagenicity of analogous root canal sealers has been investigated using in vitro and in vivo methods. Test systems using bacterial as well as mammalian cell systems have indicated mutagenic properties linked to AH26 (with and without silver) [70, 173, 209, 211, 236]. This effect was dependent on the setting reaction. Freshly mixed material was mutagenic; however specimens that were investigated after a storage period of 7 days showed no mutagenicity [118, 209]. The cause

Dentlearn.ir

of these mutagenic properties is probably formaldehyde released during the initial setting reaction, or, alternatively, the epoxy monomer BADGE. The liquid of the root canal sealer BADGE was clearly mutagenic in a bacterial mutagenicity test [209, 211].

AHPlus was also mutagenic in in vitro test systems, but only directly after mixing. Compared with AH26, an approximately 10-fold higher concentration of the eluate was necessary to trigger a similar mutagenic effect. No mutagenicity was observed 24 h after mixing [118, 151, 210, 236]. Mutagenicity data that are available up to now are difficult to interpret. BADGE is hydrolyzed by enzymes to bisphenol A diglycerine ether, which is nonmutagenic [179]. However, it has not yet been clarified whether this cleavage also occurs at the interface with oral tissues.

Clinical Practice Advice

Epoxy-based sealers can be applied in patients because the set materials were nonmutagenic in most studies. Dental personnel, however, should avoid repeated and prolonged skin contact with the unset material.

7.3.4.5 Antimicrobial Properties

Various studies have revealed pronounced antimicrobial properties of AH26 [185]. Parallel to toxicity, the antimicrobial effect decreased with increasing setting reaction [111]. Heling and Chandler [105] as well as Orstavik [172] showed that AH26 has a similar good disinfecting effect on infected bovine dentin, which can be ascribed to the initial release of formaldehyde (see Table 7.3) [224]. Interestingly, AHPlus, which is reported to not release formaldehyde, was also very effective in the same test system with *Enterococcus faecalis* as the test strain [198].

7.3.4.6 Clinical Studies and Mandibular Nerve Injuries

As already mentioned, this root canal sealer has been commonly applied since the 1950s without causing any noteworthy biological problems [94]. However, a few case reports describe paresthesia after extensive overfilling of the root canals of mandibular teeth with AH26, related to the release of formaldehyde shortly after mixing of the material [16, 225].

7.3.5 Calcium-Hydroxide-Based Sealers

7.3.5.1 Composition

The composition of various calcium-hydroxide-based products (CH sealers) is different, but they share two ingredients: calcium hydroxide and salicylate (Table 7.6). One ZOE sealer also contains calcium hydroxide [175], but this product should be classified as a ZOE sealer because the main effects are based on ZOE [14, 38, 235]. Some authors recommend the application of calcium oxide ("quicklime"), which is transformed via an exothermic reaction after contact with humidity into calcium hydroxide ("slaked lime"). Calcium oxide is supposed to have the same properties as calcium hydroxide combined with better penetration into tubules and removal of nonmineralized extracellular matrix [95, 96].

7.3.5.2 Setting Reaction and Release of Substances

Setting CH sealers harden mainly through the formation of a chelate between calcium ions and salicylates. The release of OH^- and Ca^{++} ions differs between various products. CH suspensions release the highest number of ions. For instance, in distilled water Sealapex and CRCS® caused an increase of pH to 9.14 and 8.6, respectively, 24 h after mixing [55, 63]. CH suspensions elevated the pH value to approximately 12.5 [43]. The release of OH ions is also dependent on the addition of so-called plasticizers such as ethyltoluenesulfonamide. OH^- ions released from CH suspensions penetrated dentin tubules to the root surface after the smear layer in the root canal was removed [81]. However, this was not the case if setting CH sealers were used in combination with gutta-percha points [71, 72]. Therefore, no OH^- ions are available for diffusion through dentin tubules when the material is set.

7.3.5.3 Systemic Toxicity and Allergies

No reports regarding systemic toxic or allergic reactions are available in the literature.

Dentlearn.ir

Table 7.6 Composition of calcium hydroxide-based sealers [138] (abridged)

Sealapex	Apexit
Mixed material	**Basic material**
Calcium hydroxide (25%)	Calcium hydroxide (31.9%)
Zinc oxide (6.5%)	Colophony (31.5%)
Silicon dioxide (3%)	Silicon dioxide (8.1%)
Barium sulfate (20.4%)	Calcium oxide (6%)
Titanium oxide (2.2%)	Zinc oxide (5.5%)
Isobutyl salicylate and ethyltoluol sulfonamide (33%)	Miscellaneous (8.9%)
	Activator
	Trimethylhexane dioldisalicylate (25%)
	Alkaline bismuth carbonate (18.2%)
	Bismuth oxide (18.2%)
	Silicone dioxide (15,0%)
	1,3-Butanedioldisalicylate (11.4%)
	Colophony (5.4%)
	Tricalcium phosphate (5%)
	Miscellaneous (1.4%)

7.3.5.4 Local Toxicity and Tissue Compatibility

Taken together, CH sealers were only slightly toxic in various cell cultures (compared with other materials) [89, 253]. The high pH of these materials is buffered by the culture medium, and calcium ions are bound as insoluble calcium carbonate. Differences between individual products are related to various amounts of released ions. CH products did not influence immunocompetent cells in vitro [34]. A salicylate-based CH sealer was nonmutagenic in a standard bacterial mutagenicity test assay (the Ames test) [70]. Sealapex caused complete inhibition of nerve conduction in vitro, which was irreversible after an exposure period of 30 min [40].

Subcutaneous implantation of a CH sealer in rats caused pronounced inflammatory reactions after 5 and 15 days. The degree of inflammation, however, decreased considerably after 60 and 120 days [138]. A CH and silicone-based sealer caused the least inflammatory reactions up to 80 days after subdermal injection in guinea pigs (compared with a ZOE sealer) [269].

ZOE and CH sealers were assessed in a usage test in ferrets [110]. The periapical tissue of teeth treated with a CH sealer was inflamed in only three out of 10 cases, whereas the ZOE sealer generally caused tissue reactions. The most pronounced hard tissue formation at the root apex in dogs and monkeys was observed when a CH sealer was used; gutta-percha, AH26, and a ZOE sealer induced no or only slight hard tissue formation [220, 235]. However, in this context the increased risk of a comparatively high solubility of CH sealers was mentioned [235].

Dentlearn.ir

Key Note

CH sealers are characterized by a low toxicity, which occurs only in the initial period after application. There is clear indication that these materials may stimulate the formation of hard tissue. However, an inferior marginal adaptation together with microleakage due to increased solubility is a potential risk to be considered for this group of materials.

7.3.5.5 Antimicrobial Properties

Various studies showed consistently that CH sealers are antimicrobial agents but to a lesser degree than ZOE sealers, regardless of the microorganisms used for the experiments [1, 5, 185, 216, 230]. CH sealers had a certain antimicrobial activity in cultures of anaerobic bacteria (which are present in a root canal with necrotic pulp tissue and anaerobic conditions) in the agar diffusion test, but ZOE sealers were more effective [1]. A comparative set of experiments addressing the antimicrobial effect of different root canal sealers against 21 strains of bacteria documented that aqueous calcium hydroxide was the substance with the least efficacy [241]. This low antimicrobial activity was explained with the buffer capacity of the assay system. Also, on *Enterococcus faecalis*-infected dentin, a CH sealer was not an effective disinfectant (compared with AHPlus or a ZOE sealer) [198].

Cultures of *Enterococcus faecalis* were inhibited by a CH sealer [89]; in other studies, however, calcium hydroxide sealers (and suspensions) had little effect on this bacterial strain [244]. Moreover, Sealapex caused no disinfection of bacterially contaminated dentin (*Enterococcus faecalis*) 4 h after incubation, in contrast to a ZOE sealer (Table 7.3) [172, 198]. Enterococci isolated from root canals with persistent apical infection were also resistant to calcium hydroxide. *Candida* strains were resistant to calcium hydroxide suspensions as well [256].

Key Note

CH-based sealers are characterized by selective antimicrobial properties with little or no effect on *Enterococcus faecalis* and *Candida albicans*. Their antimicrobial effect (and their cytotoxicity as well) is lower than that of ZOE sealers.

7.3.5.6 Clinical Data and Mandibular Nerve Injury

Clinical success rates of CH sealer are in the same range as for the previously mentioned sealers [229]. A special point of interest is the induction of calcified tissue, both in healing apical granulomes and in closing a still open apical foramen (Fig. 7.11). The term "apexification" is generally used in this context but is not entirely correct, since an induced closure of an apical foramen does not result in a regular "apex." Therefore, the term "root-end closure" may be more appropriate. Animal experiments revealed osteocementum and cementoid substances, respectively, at and around an open apex when CH suspensions were applied for 3 and 6 months [8, 51, 226]. The newly formed hard tissue covered the root tip incompletely and was in some cases separated from the surface of calcium hydroxide by a fibroblast layer [8]. Clinical success rates (barrier formation) vary between 74% and 100% [7, 90, 131, 267].

The mechanism of the induction of hard tissue has not yet been clarified. There is obviously a correlation between the high alkaline pH value and calcium ions that are released from the material [249]. The alkalinization of the adjacent tissue arrests root resorption and supports healing [250], for instance by inhibiting osteoclast activity [249]. Furthermore, calcium ions are supposed to influence cell differentiation, activate macrophages, and form calcium phosphate complexes [68]. An increased formation of extracellular adenosine triphosphate (ATP), which accelerates the mineralization of bone and dentin, is also supposed to play a role [2], as are the distinct antimicrobial properties of these materials [68]. Calcium hydroxide promotes the release of growth factors that are bound in dentin, such as transforming growth factor beta 1 (TGF-β1), which may participate in hard tissue formation as well [252].

Mandibular nerve injuries, in the context of application of a CH sealer, seldom occur. Two cases could be found in the literature, both dealing with a calcium hydroxide suspension [3, 268].

7.3.6 Mineral Trioxide Aggregate

Mineral trioxide aggregate (MTA) is currently being intensively investigated for use as a root canal sealer and for pulp cappings, apexification, sealing of perforations, and root end filling [192, 214, 248]. MTA was also used for pulpotomies on deciduous teeth and led

Dentlearn.ir

Fig. 7.11a-c Healing of a chronic apical inflammation with osteolysis. **a** Root canal debridement. **b** Application of a calcium hydroxide material. **c** Formation of a hard tissue barrier at the root end (Courtesy of B. Thonemann, Regensburg, Germany)

to a higher success rate than both formocresol and ZOE pastes [64].

7.3.6.1 Composition and Setting Reaction

Mineral trioxide aggregate comprises a mixture of tricalcium silicate, tricalcium aluminate, tricalcium oxide, and silicate oxide [175]. It is marketed in both white (WMTA) and grey (GMTA) forms, with Al_2O_3, MgO, and FeO being present in higher concentrations in the grey material [11]. The powder is mixed with water. To facilitate placement of the material into the root canal, polypropylene glycol was proposed instead of water [115]. The mixing of the powder with water generates a colloidal gel that sets within 3–4 h [248]. These materials are supposed to be very similar to Portland cement regarding their chemical, physical, and biological behaviors [197]. The setting time of 3–4 h is followed by a maturation period [192].

7.3.6.2 Release of Substances

For the biological behavior of the material, it is important to note that calcium hydroxide is produced as a byproduct of the hydration reaction and is released [46].

7.3.6.3 Systemic Toxicity and Allergy

No data are available for systemic toxicity and allergy. However, based on the material's composition, neither of these adverse type reactions is to be expected.

7.3.6.4 Local Toxicity and Tissue Compatibility

Mineral trioxide aggregate was found to be less cytotoxic than amalgam, ZOE, and epoxy-based sealers [175, 246]. Camilleri et al. [46] observed no or only little toxicity of eluates of GMTA and WMTA, with no difference between the two formulations; cell growth, however, was poor when cells were seeded in direct contact with the test material. It was shown with different cell lines that cytotoxicity increased somewhat over time [45, 178]. This can be explained by the generation of calcium hydroxide over time.

Dentlearn.ir

MTA influences cell metabolism; it increases the expression of alkaline phosphatase, osteonectin, osteopontin, and osteocalcin (osteogenic phenotype) in different cell lines (a.o., periodontal ligament fibroblasts), as well as interleukins (-1 alpha, -1 beta, and -6) [30, 136]. However, no stimulation of prostaglandin E2 release by macrophages or gingival cells was observed after MTA exposure [160].

GMTA and WMTA proved to be tissue compatible when implanted into rat subcutaneous tissue [46, 113]. When used in canine teeth with open apices, the use of MTA led to the deposition of new cementum [213]. Overfilling, however, impaired the results [213]. The proposed mode of action is that calcium ions are released from the material, which together with tissue phosphates form hydroxyapatite [115]. There are similarities in the tissue reaction toward calcium hydroxide [115]. In a canine study, after pulpectomy and perforation of the apical cemental barrier, cementum deposition was observed after root canal filling, with no difference between materials using water or polypropylene glycol if the material stayed within the canal. Intentional overfilling impaired the results [115].

Used for repairing furcation perforations in the canine model, after 12 weeks no furcation was free of inflammatory cells, but GMTA showing slightly better results than the tested tricalcium phosphate cement [169]. In another study, GMTA showed mostly a lack of inflammation but cementum apposition and better results than amalgam [182]. When used to repair lateral perforation, MTA elicited cementum deposition and small areas of ankylosis with little inflammation [114].

7.3.6.5 Antimicrobial Properties

Grey and white MTA of different manufacturers, as well as Portland cement, were tested against a number of bacteria, including *Enterococcus faecalis* and *Candida albicans*. All MTA formulations and Portland cement revealed the same results, indicating an antimicrobial effect against all bacteria; however, this was lower than with ZOE and CH formulations [238]. The antimicrobial effect of MTA against *Enterococcus faecalis* has also been shown by other authors [215].

7.3.6.6 Mutagenicity

No mutagenicity was found in the Ames test [129] or comet assay [36], mouse lymphoma cells [190], or Chinese hamster ovary cells [191].

Key Note

Although multiple preclinical biological investigations about MTA have been published in recent years that indicate very promising biological characteristics, data on clinical testing, especially as an endodontic sealer, are sparse apart from a number of case studies [192].

7.3.7 Calcium Phosphate Cement

Calcium phosphate cements basically consist of tetracalcium phosphate and dicalcium phosphodihydrate or dehydrated dicalcium phosphate, which can be mixed with a 1-molar solution of dibasic sodium phospho-heptahydrate, for instance [91]. No inflammatory reactions, or only very slight ones, were observed 30 days after the material had been subcutaneously implanted into the connective tissue of rats [270] and mice [24]. More distinct reactions were caused in these studies by a ZOE-based sealer. This is in accordance with results published by Hong et al. [116] after intentional overfilling of the root canals of anterior teeth of experimental animals: The calcium phosphate cement caused only a minimal periapical alteration. No inflammatory reactions were observed when this material was used as root canal filling material in rat molars. Calcium phosphate cement even tended to cause cementum formation [270]. Comprehensive clinical data are not yet available.

A strongly basic calcium phosphate cement is obtained by preparing cements from mechanically activated tetracalcium phosphate (maTTCP), which led to the formation of $Ca(OH)_2$ during the setting reaction to nanocrystalline apatite [87]. Antimicrobial activity in comparison with a CH cement (Kerr-Life) on *Streptococcus salivarius*, *Staphylococcus epidermidis*, and a clinical isolate of plaque showed larger bacteria inhibition zones and thus stronger antimicrobial activity of the prepared calcium phosphate cement [87]. This was probably due to the higher pH. These materials are not yet on the market but seem to be very promising for

Dentlearn.ir

the future. No clinical data are available yet for this relatively new group of materials.

7.3.8 Silicones

7.3.8.1 Composition

The first of those materials were based on C-silicones (condensation cross-linking silicones); a newer material is based on A-silicones (addition cross-linking), such as RoekoSeal. (see also Chap. 11.) Gutta-percha powder has recently been introduced into a silicone matrix (polydimethylsiloxane), marketed as GuttaFlow, the manufacturer claiming an improved seal by slight (0.2%) expansion [31]. Silver particles have been added as a preservative [31].

7.3.8.2 Systemic Toxicity and Allergy

No data are available for systemic toxicity and allergy. However, based on the composition of the material, neither of these adverse types of reactions is to be expected.

7.3.8.3 Local Toxicity and Tissue Compatibility

A silicone-based sealer was less cytotoxic on different cell lines than other sealers were (such as a ZOE sealer and EndoRez) and evoked less apoptosis [4, 32]. GuttaFlow was shown to exhibit a comparatively low cytotoxicity and less cell damage than with resin-based systems or AH26 [31], and it was only slightly more cytotoxic than the pure silicone sealer [65].

An A-silicone-based root canal sealer was nontoxic 6 weeks after subcutaneous implantation in rats [92]. It caused less tissue damage compared with the CH- and ZOE-based materials that were investigated in the same study [269]. However, current clinical experience with regard to this material is limited.

7.3.8.4 Antimicrobial Properties

On dentin that was infected with *Enterococcus faecalis*, a silicone sealer was ineffective in killing the bacteria within the dentin, in contrast to AHPlus and a ZOE sealer [198].

7.3.9 Resin-Based Sealers

7.3.9.1 Composition and Setting Reactions

To improve the sealing and bonding to root canal dentin, resin-based sealers have been introduced. Because these sealers may not adhere to gutta-percha, special points have been developed. Resilon is such a point material. It is a thermoplastic copolymer of polycaprolactone and urethane methacrylate [31]. Resilon points are bonded to the root canal dentin via a dual-curing resin sealer (Epiphany system) [31]. The composition is depicted in Table 7.7. The material is used together with a dentin primer.

Other recently marketed products (RC-Sealer, EndoRez, Table 7.7) do not use a separate dentin primer. They are also dual curing. Complete setting for Epiphany sealer varies from 30 minutes to seven days [31]. For the RC sealer a setting time of 24 h is described and for and EndoRez 15–20 min. The RC-sealer is used together with Resilon points or gutta-percha points, EndoRez together with resin coated gutta-percha points.

7.3.9.2 Degradation and Release of Substances

Resilon is susceptible to alkaline and enzymatic degradation via ester bond cleavage [239, 240]. Information on the degradation of resin-based sealers is scarce.

7.3.9.3 Local Toxicity and Tissue Compatibility

Standard cell culture experiments showed that Epiphany primer, sealer, and the points were severely cytotoxic (more cytotoxic than AH26 and silicone-based sealers), possibly due to the presence of hydrophilic monomers (HEMA) [31, 32]. In another study, EndoRez and Epiphany were strongly cytotoxic (even 7 days after curing), but RC sealer (see Table 7.7) was only slightly to moderately cytotoxic [65].

EndoRez is reported to elicit a severe tissue reaction 10 and 30 days after implantation into the subcutaneous connective tissue of rats, which after 90–120 days decreased but with a few inflammatory cells still being present in some specimens [273]. Apparently, the material had somewhat disintegrated [273]. Ten days after implantation into bone, a more distinct inflammatory reaction was observed than with (silicone)

Dentlearn.ir

Table 7.7 Composition of resin-based root canal filling systems; information from the literature [31, 65, 275] and from material safety data sheets

Epiphany system®[1]			RC – Sealer®[2]		EndoRez®	
Primer	Sealer	Point (Resilon)	Sealer	Point	Sealer	Point
AMPS* and hydrophilic monomers solution	**Resin Matrix:**	Copolymer of polycaprolactone and urethane methacrylate	**Liquid:**	Resilon or Gutta-percha	2,2'-(p-Tolylimino)Diethanol	Resin-coated (Polybutadien-Diisocyanat-Methacrylate) Gutta-percha
Camphorquinone	UDMA	Bioactive glass	4-META		Triethylene Glycol Dimethacrylate (TEGDMA)	
*2-acrylamido-2-methylpropane sulfonic acid	PEGDMA	Radiopaque fillers	HEMA		Diurethane dimethacrylate (DUDMA)	
	EBPADMA	Coloring agent	Dimethacrylates		Benzoylperoxide	
	Bis-GMA		**Powder:**		Zinc oxide	
	Fillers:		Polymethylmethacrylate		Barium sulfate	
	Silane-treated barium-borosilicate glasses		Zirconium oxide		Pigments	
	Barium sulfate		Amorphous silica			
	Silica		TBB (tri-n-butylborane) partially oxidated			
	Calcium hydroxide		Polymerization initiator			
	Bismuth oxychloride					
	Amines					
	Peroxide					
	Photo-initiator					
	Stabilizers					
	Pigments					

Materials of similar or identical composition: [1]: Real Seal® (primer, sealer, points); [2]: Hybrid Root Seal® and MetaSEAL®

Dentlearn.ir

controls; however, after 60 days no difference could be observed [275]. The response of subcutaneous rat connective tissue to Resilon and gutta-percha was examined at 7, 15, 30, and 60 days. Initially, both materials elicited an inflammatory reaction, which significantly decreased with time. No difference was observed between the two materials [29]. There are data indicating that the material is well tolerated in the periapical tissues of subhuman primates [152].

7.3.9.4 Antimicrobial Properties

The root canal sealer Epiphany showed lower antimicrobial activity on *Enterococcus faecalis* than with Endomethasone, Sealapex, and Diaket, but slightly greater than AH26 [28]. No antimicrobial properties were found with Resilon against a spectrum of bacteria, including *Enterococcus faecalis* [161]. The same was true for EndoRez [215]. Apparently the antimicrobial properties of these materials are rather limited.

7.3.9.5 Clinical Data

Clinical data in a noncontrolled test with EndoRez used together with gutta-percha showed, after 14–24 months, clinically and radiographically a success rate of 91% [274], which is within the range of clinical success reported with other materials (see above). However, sufficient clinical data are not available.

7.4 Materials for Retrograde Root Canal Fillings

These materials are used for the retrograde sealing of a root canal in order to promote regeneration of the apical periodontal attachments (Fig. 7.12) [261]. They are used during a surgical procedure that is associated with early exposure of a comparatively large surface area to humidity and the presence of a bony defect, in contrast to materials used for a regular root canal filling. Furthermore, a regular endodontic access cavity is often not possible (e.g., due to the presence of root canal posts that cannot be removed). At the same time, part of the root canal is probably microbially contaminated. Therefore, materials that are used for retrograde root canal filling need to meet specifically high standards of sealing capacity, stimulation of hard tissue formation, and stability in a humid environment.

Various materials have been and are currently used for retrograde root canal fillings. A selection of these materials is shown in Table 7.8. The inserts that are mentioned in this table are applied after a standardized ultrasonic preparation in combination with an appropriate cement (e.g., one based on ZOE or polyketone) [231].

Amalgam was frequently used in the past [175], but because of the release of metallic components into the adjacent tissue, its use has significantly decreased in recent years. This also applies to silver points, which may cause unwanted tissue reaction in the periapical tissue due to increased corrosion.

Table 7.8 Materials for retrograde root canal fillings (selection)

Plastic materials	Rigid materials
(Amalgam)[a]	Titanium inserts
Glass ionomer cements, particularly light-curing products	Ceramic inserts
Zinc oxide eugenol cements; e.g., SuperEBA	(Silver points)[a]
Polyketone-based sealer	
Mineral trioxide aggregate[b]	
Composite resin /dentin adhesive[b]	

[a] Materials in parentheses are no longer recommended

[b] Only limited clinical data are available for these materials

Dentlearn.ir

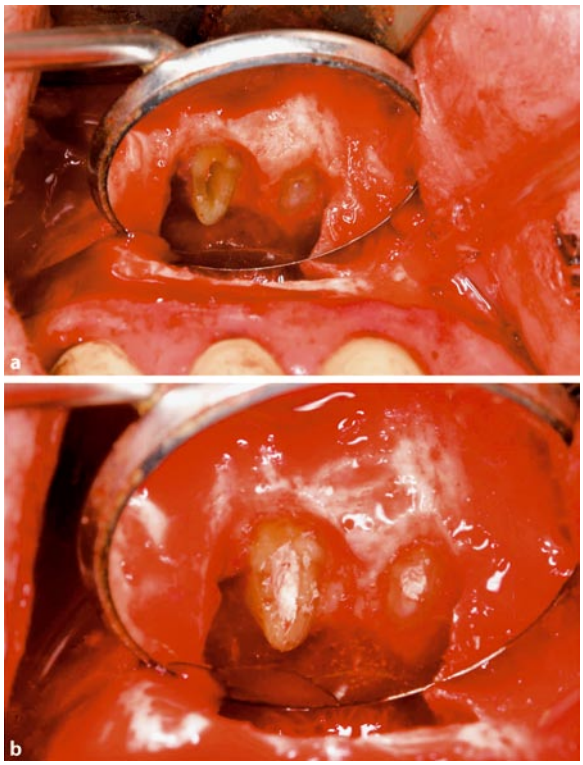

Fig. 7.12a,b Clinical aspect of a retrograde root canal filling. Because of the surgical procedure, the root canal filling material has to fulfill specific requirements regarding biocompatibility and sealing capacity despite early exposure to humidity. **a** Prepared apical cavity. **b** Retrograde filling of the root canal

7.4.1 Composition and Setting Reaction

All of the materials used for retrograde root canal fillings have already been reviewed in this and other chapters. Furthermore, the use of a resin-based composite for retrograde fillings has also been documented in the literature using a 1:1 mixture of bisphenol A diglycidylether methacrylate (Bis-GMA) and TEGDMA, with ytterbium trifluoride as radiopaque substance [194, 195].

7.4.2 Systemic Toxicity and Allergies

The group of materials used for retrograde root canal fillings is very heterogeneous. A very large number of reports have been published that specifically address the actual or claimed systemic toxic effects of composite resins and amalgam. This is also true for allergies. Details are reviewed in the particular chapters of this book. In general, no clear contraindications have been defined for the application of one of these materials based on systemic toxicity data. If a patient has a known allergic reaction to a material or its components, then it should not be used for endodontic procedures in that patient (see Chap. 14).

7.4.3 Local Toxicity and Tissue Compatibility

Cell culture experiments for assessing local toxicity have consistently shown that all setting materials used for retrograde root canal fillings are cytotoxic immediately after mixing. However, once set, their cytotoxicity is significantly lower and for some materials no longer existent. This is especially the case for MTA.

All materials for retrograde fillings were investigated in implantation studies. Parallel to the results of cell culture experiments, a clear correlation between the local toxic reaction and the setting process was found. Freshly mixed materials triggered an inflammation, but specimens were much less damaging, with some variations depending on the material.

Usage tests with a ZOE cement, amalgam, and gutta-percha as retrograde filling material in dogs documented no inhibition of bony wound healing. Dental hard tissue (cementum) had been formed in contact with all materials after an observation period of 45 days [103]. A similar study, but with intentionally infected root canals, showed that amalgam after a short and a long observation period (up to 8 weeks) caused clear inflammatory reactions in the apical region [49, 50]. This was very likely due to amalgam's lack of sealing ability. These results are equivalent to data from clinical studies that indicated an insufficient long-term prognosis of retrograde root canal fillings made with amalgam [82].

Modified ZOE cements caused the best results in animal experiments that investigated retrograde root canal fillings and infected root canals (compared with glass ionomer cement, amalgam, and composite resin) [251]. One material (SuperEBA) even seemed to initiate the new formation of cementum [82].

The poorest results were caused by the composite resin. The resin could not be applied in the cavity with sufficient marginal adaptation, so only a superficial sealing of the infected root canals was possible [82]. Another study documented the apposition of cementum to composite resin; however, this was in non-infected root canals [193]. It may be concluded that the toxicity of a composite resin for retrograde root ca-

Dentlearn.ir

nal fillings is low, but its sealing capacity is obviously insufficient. Studies in monkeys showed better results after reimplantation when a ZOE-based sealer combined with gutta-percha was used rather than amalgam [180].

A polyketone-based sealer (Diaket) promoted the apical deposition of cementum after root-end resections in dogs, which is indicative of good biocompatibility [189]. A similar study in dogs that analyzed Diaket with and without the addition of tricalcium phosphate granulate showed cementum formation of more than 50% in all 12 teeth after 60 days, and five of the 12 teeth revealed a complete formation of new cementum. A preosteoid or cementoid matrix was formed in direct contact with the root canal filling material. Obviously, the addition of tricalcium phosphate had an osteoinductive effect; the formation of cementum was significantly increased [261]. A light-curable glass ionomer cement (Vitrebond) and a ZOE sealer resulted in acceptable tissue reactions in infected root canals with no, or only minor, inflammation, which was attributed to the good sealing behavior and the distinct antimicrobial activity of these materials [50].

MTA caused no periradicular inflammation, and a complete and thick cementum layer had formed on top of the filling material in five out of six investigated teeth 5 months after surgery [13, 247]. This is in accordance with results from canine studies that showed a better cementoblast-inductive effect compared with amalgam [181, 245]. After experimental induction of apical inflammation prior to root canal treatment and periapical surgery in dogs, MTA was as effective as an epoxy sealer or a CH sealer mixed with zinc oxide [237]. It is also documented that MTA stimulates the release of cytokines from bone cells, which promotes the formation of hard tissue [135] (also see above).

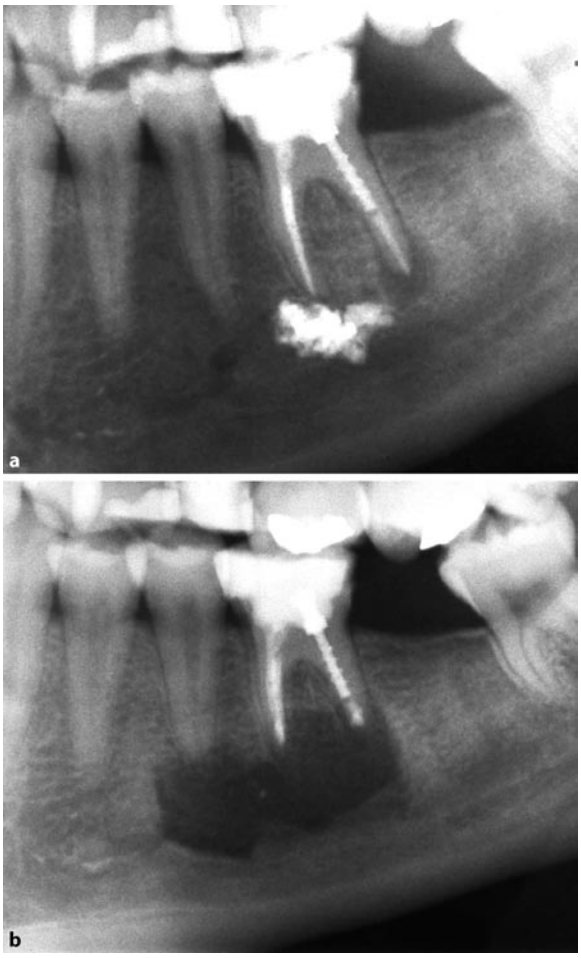

Fig. 7.13a,b Treatment after extrusion of a root canal sealer into the mandibular canal. **a** Situation after excessive overfilling of a lower left first molar. **b** Situation after surgical removal (Courtesy of J.T. Lambrecht, Basel, Switzerland)

7.4.4 Clinical Data

More recent clinical studies have documented a lower success rate after the application of amalgam for retrograde fillings compared with other materials [61, 82, 121]. Gingival discolorations, dispersion of amalgam particles in the surrounding tissue, and their corrosion are additional disadvantages when amalgam is used for retrograde fillings [79, 122]. Clinical studies with a reinforced ZOE-based root canal filling material (SuperEBA) showed a success rate of 88% regarding healing of apical lesions of molar teeth, an improvement in 8% of the cases and a failure in 4% [255]. The application of a resin- based composite resulted in clinical success rates of 90% or higher [194, 195, 196].

Clinical Practice Advice

Amalgam and silver points are no longer recommended for retrograde root canal fillings. Modified ZOE materials and light-curable glass ionomer cements as well as polyketone-based sealers (possibly in combination with preformed inserts) are better alternatives. MTA shows very promising results, but more clinical data are necessary. If these data are positive, MTA can be recommended for retrograde fillings.

Dentlearn.ir

Conclusions for the Dental Practitioner

1. Gutta-percha used as a cone (point) or heated is characterized by comparatively good biocompatibility. However, only products with a proven good biocompatibility should be used. Thermomechanical condensation, specifically at a rotational speed higher than 10,000 min^{-1}, can cause heat-induced resorptions of cementum and periodontal ankylosis. Overfilling of root canals with injectable gutta-percha should be avoided because this may initiate foreign body reactions.
2. Systemic toxicity is not caused by any of the reviewed root canal sealers, according to the available literature. Rare cases of allergies to epoxy-based sealers and ZOE products have been documented, specifically for the latter if they contain paraformaldehyde.
3. Because all root canal sealers are at least initially toxic, they should always be applied together with a (gutta-percha) point to keep the contact area with vital tissue to a minimum. This will increase the sealing capacity, and subsequent access for revision or post placement is possible.
4. An appropriate sealer should not be neurotoxic and should be tissue compatible over the long term, at least after setting. Sealers that release calcium hydroxide and stimulate bone formation can be recommended if they do not disintegrate over time and become permeable.
5. Materials with distinct antimicrobial properties frequently reveal a high local toxicity as well, and they are also partially allergenic or mutagenic (in vitro). This applies particularly for paraformaldehyde-containing root canal sealers that continuously release formaldehyde. Because alternative materials are available, the routine use of formaldehyde-releasing root canal sealers is no longer recommended by many authors and scientific associations.
6. Rare but severe adverse effects have been reported after overfilling of root canals of lower molar teeth, with subsequent injury of the mandibular nerve, especially due to formaldehyde-releasing materials. If a material is overfilled into the mandibular canal, then the patient should be immediately referred to a surgeon to remove the material from the mandibular canal as soon as possible, if necessary (Fig. 7.13).
7. Modified ZOE materials and polyketone-based sealer cements (eventually combined with a titanium or ceramic insert) have shown good results when applied for retrograde root canal fillings. Composite resins caused inconsistent results. MTA may be an excellent alternative in the future.
8. Root canal sealers are biologically very active shortly after mixing, like other setting dental materials. Dental personnel should protect themselves by avoiding direct contact with the unset materials.

References

1. Abdulkader, A., Duguid, R., Saunders, E. M.: The antimicrobial activity of endodontic sealers to anaerobic bacteria. Int Endod J 29, 280–283 (1996).
2. Abiko, Y.: Studies on calcium-stimulated adenosine triphosphatase in the albino rabbit dental pulp: its subcellular distribution and properties. J Dent Res 56, 1558–1568 (1977).
3. Ahlgren, F.K., Johannessen, A.C., Hellem, S.: Displaced calcium hydroxide paste causing inferior alveolar nerve paresthesia: report of a case. Oral Surg Oral Med Oral Pathol Oral Radiol Endod 96, 734–737 (2003).
4. Al-Awadhi, S., Spears, R., Gutmann, J.L., Opperman, L.A.: Cultured primary osteoblast viability and apoptosis in the presence of root canal sealers. J Endod 30, 527–533 (2004).
5. Al-Khatib, Z., Baum, R. H., Morse, D. R., Yesilsoy, C., Buambhani, S., Furst, M. L.: The antibacterial effect of various endodontic sealers. Oral Surg Oral Med Oral Pathol 70, 784–790 (1990).
6. Andrade Ferreira, F.B., Silva, E., Souza, P.A.D., Vale, M.S., Moraes, I.G., Granjeiro, J.M.: Evaluation of pH levels and calcium ion release in various calcium hydroxide endodontic dressings. Oral Surg Oral Med Oral Pathol Oral Radiol Endod 97, 388–392 (2004).
7. Andreasen, J. O., Andreasen, F.M., Andersson, L. (eds): Textbook and Color Atlas of Traumatic Injuries of the Teeth, 4th edn. Blackwell Munksgaard, UK 2007.
8. Andreasen, J. O., Kristerson, L.: The effect of extra-alveolar root filling with calcium hydroxide on periodontal healing after replantation of permanent incisors in monkeys. J Endod 7, 349–354 (1981).
9. Arenholt-Bindslev, D., Hørsted-Bindslev, P.: A simple model for evaluating relative toxicity of root filling materials in cultures of human oral fibroblasts. Endod Dent Traumatol 5, 219–226 (1989).

Dentlearn.ir

10. Asgari, S., Janahmadi, M., Khalikhani, H.: Comparison of neurotoxicity of root canal sealers on spontaneous bioelectrical activity in identified Helix neurons using an intracellular recording technique. Int Endod J 36, 891–897 (2003).
11. Asgari, S., Parirokh, M., Eghbal, M.J., Brink, F.: Chemical differences between white and gray mineral trioxide aggregate. J Endod 31, 101–103 (2005).
12. Azabal-Arroyo, M., Menasalvas-Ruiz, G., Martin-Alonso, J., Arroquia, J.J.H., Vega-del Barrio, J.M.: Loss of hydroxyl ions from gutta-percha points with calcium hydroxide in their composition: an in vivo study. J Endod 28, 697–698 (2002).
13. Baek, S.-H., Plenk Jr., H., Kim, S.: Periapical tissue responses and cementum regeneration with amalgam, SuperEBA, and MTA as root-end-filling material. J Endod 31, 444–449 (2005).
14. Barbosa, S. V., Araki, K., Spangberg, L. S.: Cytotoxicity of some modified root canal sealers and their leachable components. Oral Surg Oral Med Oral Pathol 75, 357–361 (1993).
15. Barkhordar, R. A., Goodis, H. E., Watanabe, L., Koumdjian, J.: Evaluation of temperature rise on the outer surface of teeth during root canal obturation techniques. Quintessence Int 21, 585–588 (1990).
16. Barkhorder, R.A., Njuyen, N.T.: Paresthesia of the mental nerve after overextension with AH-26 and gutta-percha: report of a case. J Am Dent Assoc 110, 202–203 (1985).
17. Batista, R.F.C., Hidalgo, M.M., Hernandes, L. Consolaro, A., Velloso, T.R.G., Cuman, R.K.N., Caparroz-Assef, S.M., Bersani-Amado, C.A.: Microscopic analysis of subcutaneous reactions to endodontic sealer implants in rats. J Biomed Mater Res 81A, 171–177 (2007).
18. Beck-Mannagetta, J.: Zinc and aspergillus. Oral Surg Oral Med Oral Pathol 81, 138–139 (1996).
19. Beck-Mannagetta, J., Necek, D.: Radiologic findings in aspergillosis of the maxillary sinus. Oral Surg Oral Med Oral Pathol 62, 345–349 (1986).
20. Beck-Mannagetta, J., Necek, D., Grasserbauer, M.: Zahnärztliche Aspekte der solitären Kieferhöhlen-Aspergillose. [Dental aspects of the solitary aspergillosis of the maxillary sinus] Z Stomatol 83, 283–315 (1986).
21. Behrend, G. D., Cutler, C. W., Gutmann, J. L.: An in vitro study of smear layer removal and microbial leakage along root-canal fillings. Int Endod J 29, 99–107 (1996).
22. Berova, N., Stransky, L., Krasteva, M.: Studies on contact dermatitis in stomatological staff. Dermatol Monatsschr 176, 15–18 (1990).
23. Bertrand, M. F., Pellegrino, J. C., Rocca, J. P., Klinghofer, A., Bolla, M.: Removal of Thermafil root canal filling material. J Endod 23, 54–57 (1997).
24. Bilginer, S., Esener, T., Soylemezoglu, F., Tiftik, A. M.: The investigation of biocompatibility and apical microleakage of tricalcium phosphate based root canal sealers. J Endod 23, 105–109 (1997).
25. Blanas, N., Kienle, F., Sándor, G.K.B.: Inferior alveolar nerve injury caused by thermoplastic gutta-percha overextension. J Can Dent Assoc 70, 384–387 (2004).
26. Block, R.M., Lewis, R.D., Sheats, J.B., Burke, S.H.: Antibody formation to dog pulp tissue altered by N2-type paste within root canal. J Endod 3, 309–315 (1977).
27. Block, R. M., Sheats, J. B., Lewis, R. D., Fawley, J.: Cell-mediated immune response to dog pulp tissue altered by N2 paste within the root canal. Oral Surg Oral Med Oral Pathol 45, 131–142 (1978).
28. Bodrumlu, E., Semiz, M.: Antibacterial activity of a new endodontic sealer against *Enterococcus faecalis*. J Can Dent Assoc 72, 637–637c (2006).
29. Bodrumlu, E., Muglali, M., Sumer, M., Guvene, T.: The response of subcutaneous connective tissue to a new endodontic filling material. J Biomed Mater Res B Appl Biomater 84, 463–467 (2008).
30. Bonson, S., Jeansonne, B.G., Lallier, T.E.: Root-end filling materials alter fibroblast differentiation. J Dent Res 83, 408–413 (2004).
31. Bouillaguet, S., Wataha, J.C., Tay, F.R., Brackett, M.G., Lockwood, P.E.: Initial in vitro biological response to contemporary endodontic sealers. J Endod 32, 989–992 (2006).
32. Bouillaguet, S., Wataha, J.C., Lockwood, P.E., Galgano, C., Golay, A., Krejci, I.: Cytotoxicity and sealing properties of four classes of endodontic sealers evaluated by succinic dehydrogenase activity and confocal laser scanning microscopy. Eur J Oral Sci 112, 182–187 (2004).
33. Boxer, M. B., Grammer, L. C., Orfan, N.: Gutta-percha allergy in a health care worker with latex allergy. J Allergy Clin Immunol 93, 943–944 (1994).
34. Bratel, J., Jontell, M., Dahlgren, U., Bergenholtz, A.: Effects of root canal sealers on immunocompetent cells in vitro and in vivo. Int Endod J 31, 178–188 (1998).
35. Braun, J.J., Zana, H., Purohit, A., Valfrey, J., Scherer, Ph., Haikel, Y., de Blay, F., Pauli, G.: Anaphylactic reactions to formaldehyde in root canal sealant after endodontic treatment: four cases of anaphylactic shock and three of generalized urticaria. Allergy 58, 1210–1215 (2003).
36. Braz, M.G., Camargo, E.A., Salvadori, D.M.F., Marques, M.E.A., Ribeiro, D.A.: Evaluation of genetic damage in human peripheral lymphocytes exposed to mineral trioxide aggregate and Portland cement. J Oral Rehab 33, 234–239 (2006).
37. Briseno, B.M., Willershausen-Zönnchen, B., Sonnabend, E.: The effect of root canal filling materials on gingival fibroblasts cultures. Schweiz Mschr Zahnheilk 10, 294–298 (1991).
38. Briseno, B. M., Willershausen, B.: Root canal sealer cytotoxicity on human gingival fibroblasts. 1. Zinc oxide-eugenol-based sealers. J Endod 16, 383–386 (1990).
39. Brodin, P.: Neurotoxic and analgesic effects of root canal cements and pulp-protecting dental materials. Endod Dent Traumatol 4, 1–11 (1988).
40. Brodin, P., Roed, A: Effects of eugenol on rat phrenic nerve and phrenic nerve-diaphragm preparations. Arch Oral Biol 29, 611–615 (1984).
41. Brodin, P., Roed, A., Aars, H., Orstavik, D.: Neurotoxic effects of root canal filling materials on rat phrenic nerve in vitro. J Dent Res 61, 1020–1023 (1982).
42. Broisman, H., Van Houte, J., Gron, P., Krakow, A. A.: Antimicrobial effects of N2 in vitro. Oral Surg Oral Med Oral Pathol 45, 116–122 (1978).
43. Byström, A., Clarsson, R., Sundqvist, G.: The antibacterial effect of camphorated paramonochlorophenol, camphorated phenol and calcium hydroxide in the treatment of infected root canals. Endod Dent Traumatol 1, 170–175 (1985).
44. Calt, S., Serper, A., Özcelik, B., Dalat, M.D.: pH changes and calcium ion diffusion from calcium hydroxide dressing materials through root dentin. J Endod 25, 329–331 (1999).
45. Camilleri, J., Montesin, F.E., Papaioannou, S., McConald, F, Pitt-Ford, T.R.: Biocompatibility of two commercial forms of mineral trioxide aggregate. Int Endod J 37, 699–704 (2004).

Dentlearn.ir

46. Camilleri, J., Montesin, F.E., Di Silvio, L., Pitt-Ford, T.R.: The chemical constitution and biocompatibility of accelerated Portland cement for endodontic use. Int Endod J 38, 834–842 (2005).
47. Castelli, W. A., Caffesse, R. G., Pameijer, C. H., Diaz-Perez, R., Farquhar, J.: Periodontium response to a root canal condensing device (Endotec). Oral Surg Oral Med Oral Pathol 71, 333–337 (1991).
48. Castellucci, A., Gambarini, G.: Obturation of iatrogenically damaged root canals with injectable thermoplasticized gutta-percha: a case report. Int Endod J 28, 108–110 (1995).
49. Chong, B. S., Pitt-Ford, T. R., Kariyawasam, S. P.: Tissue response to potential root-end filling materials in infected root canals. Int Endod J 30, 102–114 (1997).
50. Chong, B. S., Pitt-Ford T.R., Kariyawasam, S. P.: Short-term tissue response to potential root-end filling materials in infected root canals. Int Endod J 30, 240–249 (1997).
51. Chosack, A., Sela, J., Cleaton, Jones P.: A histological and quantitative histomorphometric study of apexification of nonvital permanent incisors of vervet monkeys after repeated root filling with a calcium hydroxide paste. Endod Dent Traumatol 13, 211–217 (1997).
52. Cohen, B. D., Combe, E. D., Lilley, J. D.: Effect of thermal placement techniques on some physical properties of gutta percha. Int Endod J 25, 292–296 (1992).
53. Connor, T. H., Barrie, M. D., Theiss, J. C., Matney, T. S., Ward Jr, J.B.: Mutagenicity of formalin in the Ames assay. Mutat Res 119, 145–149 (1983).
54. Costa, G.E., Johnson, J.D., Hamilton, R.G.: Cross-reactivity studies of gutta-percha, gutta-balata, and natural rubber latex (*Hevea brasiliensis*). J Endod 27, 584–587 (2001).
55. da Silva L. A., Leonardo, M. R., da Silva R. S., Assed, S., Guimaraes, L. F.: Calcium hydroxide root canal sealers: evaluation of pH, calcium ion concentration and conductivity. Int Endod J 30, 205–209 (1997).
56. de Andrade, E.D., Ranali, J., Volpato, M.C., Oliveira, M.M.: Allergic reaction after rubber dam placement. J Endod 26, 182–183 (2000).
57. Dempf, R., Hausamen, J. E.: Lesions of the inferior alveolar nerve arising from endodontic treatment. Aust Endod J 26, 67–71 (2000).
58. Distler, W., Petschelt, A.: Über die Freisetzung von $Ca(OH)_2$ aus Guttaperchaspitzen. [The release of calcium hydroxide from gutta-percha points] Dtsch Zahnärztl Z 52, 199–201 (1997).
59. Dollard, W. J., Sabala, C. L., Pelleu, G. B.: Root canal temperature during obturation with the McSpadden compactor technique. J Dent Res 62, 216 (1983).
60. Donley, D. L., Weller, R. N., Kulild, J. C., Jurcak, J. J.: In vitro intracanal temperatures produced by low- and high-temperature thermoplasticized injectable gutta-percha. J Endod 17, 307-309 (1991).
61. Dorn, S. O., Gartner, A. H.: Retrograde filling materials: a retrospective success-failure study of amalgam, EBA, and IRM. J Endod 16, 391–393 (1990).
62. Economides, N., Koulaouzidou, E.A., Beltes, P., Kortsaris, A.H.: In vitro release of hydroxyl ions from calcium hydroxide gutta-percha points. J Endod 25, 481–482 (1999).
63. Ehrman, D.: The alkalinizing properties of endodontic cements – an in vitro study of hydroxyl ions release. Tel Aviv University, The Maurice and Gabriela Goldschleger School of Dental Medicine (1995).
64. Eidelman, E., Holan, G., Fuks, A. B.: mineral trioxide aggregate vs. formocresol in pulpotomized primary molars: a preliminary report. Pediatr Dent 23, 15–18 (2001).
65. Eldeniz, A.U., Mustafa, K., Orstavik, D., Dahl, J.E.: Cytotoxicity of new resin-, calcium hydroxide- and silicone-based root canal sealers on fibroblasts derived from human gingiva and L929 cell line. Int Endod J 40, 329–337 (2007).
66. El-Sayed, F., Seite, B. D., Sans, B., Bayle, L. P., Marguery, M. C., Bazex, J.: Contact urticaria from formaldehyde in a root-canal dental paste. Contact Dermatitis 33, 353 (1995).
67. Engstrom, B., Spangberg, L.: Effect of root canal filling material N2 when used for filling after partial pulpectomy. Sven Tandläk Tidskr 62, 815–829 (1969).
68. Erdogan, G.: The treatment of nonvital immature teeth with calcium hydroxide-sterile water paste: two case reports. Quintessence Int 28, 681–686 (1997).
69. Eriksson, A. R., Albrektson, T.: Temperature threshold levels for heat-induced bone tissue injury: a vital microscopic study in the rabbit. J Prosthet Dent 50, 101–107 (1983).
70. Ersev, H., Schmalz, G., Bayirli, G., Schweikl, H.: Cytotoxic and mutagenic potencies of various root canal filling materials in eukaryotic and prokaryotic cells in vitro. J Endod 25, 359–363 (1999).
71. Esberard, R. M., Carnes Jr, D.L., del Rio, C.E.: Changes in pH at the dentin surface in roots obturated with calcium hydroxide pastes. J Endod 22, 402–405 (1996).
72. Esberard, R. M., Carnes Jr, D.L., del Rio C.E.: pH changes at the surface of root dentin when using root canal sealers containing calcium hydroxide. J Endod 22, 399–401 (1996).
73. European Society of Endodontology: Consensus report of the European Society of Endodontology on quality guidelines for endodontic treatment. Int Endod J 27, 115–124 (1994).
74. Fanibunda, K., Whitworth, J., Steele, J. G.: The management of thermomechanically compacted gutta percha extrusion in the inferior dental canal. Br Dent J 184, 330–332 (1998).
75. Fenaroli, G., Burdock, G. A.: Fenaroli's Handbook of Flavor Ingredients. CRC, Cleveland, Ohio 1994.
76. Field, E.A., Longman, L.P., al-Sharkawi, M., King, C.M.: An immediate (type I) hypersensitivity reaction during placement of a dental rubber dam. Eur J Prosthodont Restor Dent 5, 75–78 (1997).
77. Figdor, D., Beech, D. R., Waterson, J. G.: Factors affecting heat generation in the McSpadden compaction technique. J Dent Res 62, 664 (1983).
78. Figdor, D., Beech, D. R., Waterson, J. G.: Heat generation in the McSpadden compaction technique. J Dent Res 62, 405 (1983).
79. Fischer, E. J., Arens, D. E., Miller, C. H.: Bacterial leakage of mineral trioxide aggregate as compared with zinc-free amalgam, intermediate restorative material, and SuperEBA as a root-end filling material. J Endod 24, 176–179 (1998).
80. Fors, U., Jonasson, E., Bergquist, A., Berg, J. O.: Measurements of the root surface temperature during thermomechanical root canal filling in vitro. Int Endod J 18, 199–202 (1985).
81. Foster, K. H., Kulild, J. C., Weller, R. N.: Effect of smear layer removal on the diffusion of calcium hydroxide through radicular dentin. J Endod 19, 136–140 (1993).
82. Frank, A. L., Glick, D. H., Patterson, S. S., Weine, F. S.: Long-term evaluation of surgically placed amalgam fillings. J Endod 18, 391–398 (1992).

Dentlearn.ir

83. Friedman, S., Löst, C., Zarrabian, M., Trope, M.: Evaluation of success and failure after endodontic therapy using a glass ionomer cement sealer. J Endod 21, 384–390 (1995).
84. Friend, L. A., Browne, R. M.: Tissue reactions to some root filling materials. Br Dent J 125, 291–298 (1968).
85. Fuss, Z., Weiss, E. I., Shalhav, M.: Antibacterial activity of calcium hydroxide-containing endodontic sealers on *Enterococcus faecalis* in vitro. Int Endod J 30, 397–402 (1997).
86. Gambarini, G., Tagger, M.: Sealing ability of a new hydroxyapatite-containing endodontic sealer using lateral condensation and thermatic compaction of gutta-percha, in vitro. J Endod 22, 165–167 (1996).
87. Gbureck, U., Knappe, O., Hofmann, N., Barralet, J.E.: Antimicrobial properties of nanocrystalline tetracalcium phosphate cements. J Biomed Mater Res B Appl Biomater 83, 132–137 (2007).
88. Gerosa, R., Menegazzi, G., Borin, M., Cavalleri, G.: Cytotoxicity evaluation of six root canal sealers. J Endod 21, 446–448 (1995).
89. Geurtsen, W., Leyhausen, G.: Biological aspects of root canal filling materials – histocompatibility, cytotoxicity, and mutagenicity. Clin Oral Invest 1, 5–11 (1997).
90. Ghose, L. J., Baghdady, V. S., Hikmat, B. Y. M.: Apexification of immature apices of pulpless permanent anterior teeth with calcium hydroxide. J Endod 13, 285–290 (1987).
91. Goodell, G. G., Mork, T. O., Hutter, J. W., Nicoll, B. K.: Linear dye penetration of a calcium phosphate cement apical barrier. J Endod 23, 174–177 (1997).
92. Gorduysus, M. O., Etikan, I., Gokoz, A.: Histopathological evaluation of the tissue reactions to Endo-Fill root canal sealant and filling material in rats. J Endod 24, 194–196 (1998).
93. Götze, W., Herrmann, F., Krah, M.: Zur Wurzelkanalfüllung mit dem Endotec-Instrument. [Root canal filling with the Endotec instrument] Zahnärzt Welt Reform 98, 774–775 (1989).
94. Grützner, A. E.: Stellungnahme zur Sicherheit und Wirksamkeit von AH-26-Wurzelkanalfüllmaterial. [Statement on the safety and effectiveness of AH26 root canal filling material] Schweiz Monatsschr Zahnmed 109, 1135 (1999).
95. Guigand, M., Vulcain, J. M., Dautel-Morazin, A., Bonnaure-Mallet, M.: An ultrastructural study of root canal walls in contact with endodontic biomaterials. J Endod 23, 327–330 (1997).
96. Guigand, M., Vulcain, J. M., Dautel-Morazin, A., Bonnaure-Mallet, M.: In vitro study of intradentinal calcium diffusion induced by two endodontic biomaterials. J Endod 23, 387–390 (1997).
97. Gutmann, J. L., Creel, D. C., Bowles, W. H.: Evaluation of heat transfer during root canal obturation with thermoplasticized gutta-percha. Part I. In vitro heat levels during extrusion. J Endod 13, 378–383 (1987).
98. Haikel, Y., Braun, J. J., Zana, H., Boukari, A., de Blay, F., Pauli, G.: Anaphylactic shock during endodontic treatment due to formaldehyde in a root canal sealant. J Endod 26, 529–531 (2000).
99. Hamann, C., Rodgers, P.A., Alenius, H., Halsey, J.F., Sullivan, K.: Cross-reactivity between gutta-percha and natural rubber latex: assumptions vs. reality. J Am Dent Assoc 133, 1357–1367 (2002).
100. Hancock III, H. H., Sigurdsson, A., Trope, M., Moiseiwitsch, J.: Bacteria isolated after unsuccessful endodontic treatment in North American population. Oral Surg Oral Med Oral Pathol Oral Radiol Endod 91, 579–586 (2001).
101. Hand, R. E., Huget, E. F., Tsaknis, P. J.: Effects of a warm gutta-percha technique on the lateral periodontium. Oral Surg 42, 395–401 (1976).
102. Hardie, E. M.: Further studies on heat generation during obturation techniques involving thermally softened gutta-percha. Int Endod J 20, 122–127 (1987).
103. Harrison, J. W., Johnson, S. A.: Excisional wound healing following the use of IRM as a root-end filling material. J Endod 23, 19–27 (1997).
104. Hausen, B. M.: Rauchen, Süßigkeiten, Perubalsam – ein Circulus vitiosus? [Smoking, sweets, Peru balm a circulus vitriosus?] Akt Dermatol 27, 136–143 (2001).
105. Heling, I., Chandler, N. P.: The antimicrobial effect within dentinal tubules of four root canal sealers. J Endod 22, 257–259 (1996).
106. Hensten-Pettersen, A., Orstavik, D., Wennberg, A.: Allergenic potential of root canal sealers. Endod Dent Traumatol 1, 61–65 (1985).
107. Hensten-Pettersen, A., Helgeland, K.: Evaluation of biologic effects of dental materials using four different cell culture techniques. Scand J Dent Res 85, 291–296 (1977).
108. Hensten-Pettersen, A., Jacobsen, N.: Perceived side effects of biomaterials in prosthetic dentistry. J Prosthet Dent 65, 138–144 (1991).
109. Hilton, I., Dearman, R. J., Fielding, I., Basketter, D. A., Kimber, I.: Evaluation of the sensitizing potential of eugenol and isoeugenol in mice and guinea pigs. J Appl Toxicol 16, 459–464 (1996).
110. Holland, G. R.: A histological comparison of periapical inflammatory and neural responses to two endodontic sealers in the ferret. Arch Oral Biol 39, 539–544 (1994).
111. Holland, R., de Souza, V., Nery, M. J., de Mello, W., Bernabe, P. F. E., Otoboni Filho, J. A.: Reaction of rat connective tissue to gutta-percha and silver points. Aust Dent J 27, 224–226 (1982).
112. Holland, R., Murata, S. S., Dezan, E., Garlipp, O.: Apical leakage after root canal filling with an experimental calcium hydroxide gutta-percha point. J Endod 22, 71–73 (1996).
113. Holland, R., de Souza, V., Nery, M.J., Otoboni Filho, J.A., Bernabe, P.F., Dezan, E. Jr.: Reaction of rat connective tissue to implanted dentin tubes filled with mineral trioxide aggregate or calcium hydroxide. J Endod 25, 161–166 (1999).
114. Holland, R., Filho, J.A.O., de Souza, V., Nery, M. J., Bernabe, P.F.E.: Mineral trioxide aggregate repair of lateral root perforations. J Endod 27, 281–284 (2001).
115. Holland, R., Mazuqueli, L., de Souza, V., Murata, S.S., Dezan Jr., E., Suzuki, P.: Influence of the type of vehicle and limit of obturation on apical and periapical tissue response in dogs' teeth after root canal filling with mineral trioxide aggregate. J Endod 33, 693–697 (2007).
116. Hong, Y.C., Wang, J.T., Hong, C.Y., Brown, W.E., Chow, L.C.: The periapical tissue reactions to a calcium phosphate cement in the teeth of monkeys. J Biomed Mater Res 25, 485–498 (1991).
117. Hørsted-Bindslev, P., Söholm, B.: Overfølsomhed over for rodfyldningsmaterialet AH26. (Allergic reaction to the root canal sealer AH26). Tandlaegebladet 80, 194–197 (1976).
118. Huang, T.H., Lee, H., Kao, C.T.: Evaluation of the genotoxicity of zinc oxide eugenol-based, calcium hydroxide-based, and epoxy resin-based root canal sealers by comet assay. J Endod 27, 744–748 (2001).
119. Hunter, H.A.: The effect of gutta percha, silver points, and Rickert's root sealer on bone healing. J Can Dent Assoc 23, 385–388 (1957).
120. International Organization for Standardization: ISO 6876 – dentistry: dental root canal sealing materials. International Organization for Standardization, Geneva 1986.

Dentlearn.ir

121. Jesslen, P., Zetterqvist, L., Heimdahl, A.: Long-term results of amalgam versus glass ionomer cement as apical sealant after apicectomy. Oral Surg Oral Med Oral Pathol Oral Radiol Endod 79, 101–103 (1995).
122. Jou, Y.T., Pertl, C.: Is there a best retrograde filling material? Dent Clin North Am 41, 555–561 (1997).
123. Kallus, T., Hensten-Pettersen A., Mjor, I.A.: Tissue response to allergenic leachables from dental materials. J Biomed Mater Res 17, 741–755 (1983).
124. Kanerva, L., Estlander, T., Jolanki, R.: Dental nurse's occupational allergic contact dermatitis from eugenol used as a restorative dental material with polymethylmethacrylate. Contact Dermatitis 38, 339–340 (1998).
125. Kang, P., Vogt, K., Gruninger, S.E., Meyer, D., Hillmann, M., Guldalian, T.K., Siew, C.: Immuno cross-reactivity between Gutta Percha and natural rubber latex. J Dent Res 81, A–410 (2002).
126. Kawahara, H., Yamagami, A., Nakamura J.M.: Biological testing of dental materials by means of tissue culture. Int Dent J 18, 443–467 (1968).
127. Kayser D., Schlede E. (eds): Chemikalien und Kontaktallergie – Eine bewertende Zusammenstellung. [Chemicals and contact allergy – an overview] Bundesinstitut für gesundheitlichen Verbraucherschutz und Veterinärmedizin (BgVV). Urban & Vogel, Munich 2001.
128. Kettering, J. D., Torabinejad, M.: Cytotoxicity of root canal sealers: a study using HeLa cells and fibroblasts. Int Endod J 17, 60–66 (1984).
129. Kettering, J. D., Torabinejad, M.: Investigation of mutagenicity of mineral trioxide aggregate and other commonly used root-end filling materials. J Endod 21, 537–539 (1995).
130. Khongkhunthian, P., Reichart, P.A.: Aspergillosis of the maxillary sinus as a complication of overfilling root canal material into the sinus: report of two cases. J Endod 27, 476–478 (2001).
131. Kleier, D.J., Barr, E.S.: A study of endodontically apexified teeth. Endod Dent Traumatol 7, 112–117 (1991).
132. Kleier, D.J., Shibilski, K.: Management of the latex hypersensitive patient in the endodontic office. J Endod 25, 825–828 (1999).
133. Kobayashi, A.: Asymptomatic aspergillosis of the maxillary sinus associated with foreign body of endodontic origin. Report of a case. Int J Oral Maxillofac Surg 24, 243–244 (1995).
134. Koch, M.J.: Formaldehyde release from root-canal sealers: influence of method. Int Endod J 32, 10–16 (1999).
135. Koh, E.T., Pitt-Ford, T.R., Torabinejad, M., McDonald, F.: Mineral trioxide aggregate stimulates cytokine production in human osteoblasts. J Bone Miner Res 105, 406 (1995).
136. Koh, E.T., Torabinejad, M., Pitt-Ford, T.R., Brady, K., McDonald, F.: Mineral trioxide aggregate stimulates a biological response in human osteoblasts. J Biomed Mater Res 37, 432–439 (1997).
137. Kolokouris, I., Beltes, P., Economides, N., Vlemmas, I.: Experimental study of the biocompatibility of a new glass-ionomer root canal sealer (Ketac-Endo). J Endod 22, 395–398 (1996).
138. Kolokouris, I., Economides, N., Beltes, P., Vlemmas, I.: In vivo comparison of the biocompatibility of two root canal sealers implanted into the subcutaneous connective tissue of rats. J Endod 24, 82–85 (1998).
139. Kosti, E., Lambrianidis, T.: Endodontic treatment in cases of allergic reaction to rubber dam. J Endod 28, 787–789 (2002).
140. Kozam, G.: The effect of eugenol on nerve transmission. Oral Surg Oral Med Oral Pathol 44, 799–805 (1977).
141. Kozam, G.: Hemilabial paraesthesia of iatrogenic endodontic origin. Q Nat Dent Assoc 37, 23–25 (1978).
142. Knowles, K.I., Ibarrola, J.L., Ludlow, M.O., Anderson, J.R., Newcomb, B.E.: Rubber latex allergy and the endodontic patient. J Endod 24, 760–762 (1998).
143. Krennmair, G., Lenglinger, F.: Maxillary sinus aspergillosis: diagnosis and differentiation of the pathogenesis based on computed tomography densitometry of sinus concretions. J Oral Maxillofac Surg 53, 657–663 (1995).
144. LaGarde, P.: Paresthesies du territoire mentonnier, secondaires à un traitement endodontique. [Paraesthesis of the chin area, following an endodontic treatment] Information Dentaire 60, 17–23 (1978).
145. Lambjerg-Hansen, H.: Vital pulpectomy and root filling with N2 or Endomethasone. Int Endod J 20, 194–204 (1987).
146. Langeland, K.: Root canal sealants and pastes. Dent Clin North Am 18, 309–327 (1974).
147. Langeland, K., Liao, K., Costa, N., Pascon, E. A.: Efficacy of Obtura and Ultrafil root filling devices. J Endod 13, 135 (1987).
148. Larsen, M. J., Hørsted-Bindslev, P.: A laboratory study evaluating the release of hydroxyl ions from various calcium hydroxide products in narrow root canal-like tubes. Int Endod J 33, 238–242 (2000).
149. Legent, F., Billet, J., Beauvillain, C., Bonnet, J., Miegeville, M.: The role of dental canal fillings in the development of Aspergillus sinusitis. A report of 85 cases. Arch Otorhinolaryngol 246, 318–320 (1989).
150. Lewis, B.: Formaldehyde in dentistry: a review for the millennium. J Clin Pediatr Dent 22, 167–177 (1998).
151. Leyhausen, G., Heil, J., Reifferscheid, G., Waldmann, P., Geurtsen, W.: Genotoxicity and cytotoxicity of the epoxy resin-based root canal sealer AH plus. J Endod 25, 109–113 (1999).
152. Louw, N.P., Pameijer, C.H., Norval, G.: Histopathological evaluation of a root canal sealer in subhuman primates. J Dent Res 80, 654 (2001).
153. Lussi, A., Imwinkelried, S., Hotz, P., Grosrey, J.: Long-term obturation quality using noninstrumentation technology. J Endod 26, 491–493 (2000).
154. Malten, K.E., Van Ketel, W.G., Nater, J.P., Liem, D.H.: Reactions in selected patients to 22 fragrance materials. Contact Dermatitis 11, 1–10 (1984).
155. Markowitz, K., Moynihan, M., Liu, M., Kim, S.: Biologic properties of eugenol and zinc oxide-eugenol. A clinically oriented review. Oral Surg Oral Med Oral Pathol 73, 729–737 (1992).
156. Marlin, J., Schilder, H.: Physical properties of gutta-percha when subjected to heat and vertical condensation. Oral Surg Oral Med Oral Pathol 36, 872–879 (1973).
157. Martin, H., Martin, T.R.: Iodoform gutta percha: MGP, a new endodontic paradigm. Dent Today 18, 76–81 (1999).
158. Material data safety sheet – Eugenol. http://www.sciencelab.com/xMSDS-Eugenol-9924007. Cited Oct 2007.
159. Matsumoto, K., Inoue, K., Matsumoto, A.: The effect of newly developed root canal sealers on rat dental pulp cells in primary culture. J Endod 15, 60–67 (1989).
160. Melegari, K. K., Botero, T. M., Holland, G. R.: Prostaglandin E2 production and viability of cells cultured in contact with freshly mixed endodontic materials. Int Endod J 37, 357–362 (2006).
161. Melker, K. B., Vertucci, F. J., Rojas, M. F., Progulske-Fox, A., Bélanger, M.: Antimicrobial efficacy of medicated root canal filling materials. J Endod 32, 148–151 (2006).
162. Mitchell, D. F.: The irritational qualities of dental materials. J Am Dent Assoc 59, 954–966 (1959).

Dentlearn.ir

163. Molloy, D., Goldman, M., White, R.R., Kabani, S.: Comparative tissue tolerance of a new endodontic sealer. Oral Surg Oral Med Oral Pathol 73, 490–493 (1992).
164. Moorer, W.R., Genet, J.M.: Antibacterial activity of gutta-percha cones attributed to the zinc oxide component. Oral Surg Oral Med Oral Pathol 53, 508–517 (1982).
165. Morse, D.R.: Endodontic-related inferior alveolar nerve and mental foramen paraesthesia. Compend Contin Educ Dent 18, 963–976 (1997).
166. Muruzabal, M., Erausquin, J.: Response of periapical tissues in the rat molar to root canal fillings with Diaket and AH-26. Oral Surg Oral Med Oral Pathol 21, 786–804 (1966).
167. Nencka, D., Walia, H., Austin, B.P.: Histologic evaluation of the biocompatibility of Diaket. J Dent Res 74, 101 (1995).
168. Nielsen, T.H., Arenholt-Bindslev, D., Kilian, M., Philipsen, H. P.: Chelate root filling cements: biological properties. J Endod 19, 17–21 (1993).
169. Noetzel, J., Özer, K., Reisshauer, B.-H., Anil, A., Rössler, R., Neumann, K., Kielbassa, A.M.: Tissue responses to an experimental calcium phosphate cement and mineral trioxide aggregate as materials for furcation perforation repair: a histological study in dogs. Clin Oral Investig 10, 77–83 (2006).
170. Odell, E., Pertl, C.: Zinc as a growth factor for *Aspergillus* sp. and the antifungal effects of root canal sealants. Oral Surg Oral Med Oral Pathol Oral Radiol Endod 79, 82–87 (1995).
171. Olsson, B., Wennberg, A.: Early tissue reaction to endodontic filling materials. Endod Dent Traumatol 1, 138–141 (1985).
172. Orstavik, D.: Antibacterial properties of endodontic materials. Int Endod J 21, 161–169 (1988).
173. Orstavik, D., Hongslo, J.K.: Mutagenicity of endodontic sealers. Biomaterials 6, 129–132 (1985).
174. Orstavik, D., Qvist, V., Stoltze, K.: A multivariate analysis of the outcome of endodontic treatment. Eur J Oral Sci 112, 224–330 (2004).
175. Osorio, R.M., Hefti, A., Vertucci, F.J., Shawley, A.L.: Cytotoxicity of endodontic materials. J Endod 24, 91–96 (1998).
176. Ozeki, M: The effects of eugenol on the nerve and muscle in crayfish. Comp Biochem Physiol 50, 183–191 (1975).
177. Peltola, M., Salo, T., Oikarinen, K.: Toxic effects of various retrograde root filling materials on gingival fibroblasts and rat sarcoma cells. Endod Dent Traumatol 8, 120–124 (1992).
178. Pérez, A.L., Spears, R., Gutmann, J.L., Opperman, L.A.: Osteoblasts and MG-63 osteosarcoma cells behave differently when in contact with ProRoot MTA and White MTA. Int Endod J 36, 564–570 (2003).
179. Pfeiffer, E., Metzler, M.: Zur genetischen Toxizität von Bisphenol A-diglycidylether (BADGE) und seinem Hydrolyseprodukt in vitro. [Genotoxicity of bisphenol A diglycidylether (BADGE) and its hydrolytic products in vitro] Lebensmittelchemie 53/54, 54 (1999/2000).
180. Pitt-Ford, T.R., Andreasen, J.O., Dorn, S.O., Kariyawasam, S.P.: Effect of various sealers with gutta-percha as root-end fillings on healing after replantation. Endod Dent Traumatol 12, 33–37 (1996).
181. Pitt-Ford, T.R., Hong, C.E., Torabinejad, M.: Mineral trioxide aggregate as a root-end filling material. J Endod 20, 188 (1994).
182. Pitt-Ford, TR., Torabinejad, M., McKendry, D.J., Hong, C.U., Kariyawasam, S.P.: Use of mineral trioxide aggregate for repair of furcal perforations. Oral Surg Oral Med Oral Pathol Oral Radiol Endod 79, 756–763 (1995).
183. Pogrel, M.A.: Damage to the inferior alveolar nerve as the result of root canal therapy. J Am Dent Assoc 138, 65–69 (2007).
184. Poveda, R., Bagán J.V., Fernández, J.M.D., Sanchis, J.M.: Mental nerve paraesthesia associated with endodontic paste within the mandibular canal: report of a case. Oral Surg Oral Med Oral Pathol Oral Radiol Endod 102: e46–e49 (2006).
185. Pumarola, J., Berastegui, B., Brau Canalda, C., Jimenez de Anta, M.: Antimicrobial activity of seven root canal sealers. Oral Surg Oral Med Oral Pathol 74, 216–220 (1992).
186. Pupo, J., Biral, R.R., Benatti, O., Abe, A., Valdrighi, L.: Antimicrobial effects of endodontic filling cements on microorganisms from root canal. Oral Surg Oral Med Oral Pathol 55, 622–627 (1983).
187. Rappaport, H.M., Lilly, G.E., Kapsimalis, P.: Toxicity of endodontic filling materials. Oral Surg Oral Med Oral Pathol 18, 785–802 (1964).
188. Rastogi, S.C., Johansen, J.D., Frosch, P., Menné, T., Bruze, M., Lepoittevin, J.P., Dreier, B., Andersen, K.E., White, I.R.: Deodorants on the European market: Quantitative chemical analysis of 21 fragrances. Contact Dermatitis 38, 29–35 (1998).
189. Regan, J. D., Gutmann, J.L., Iacopino, A.M., Diekwisch, T.: Response of periradicular tissues to growth factors introduced into the surgical site in the root-end filling material. Int Endod J 32, 171–182 (1999).
190. Ribeiro, D.A., Duarte, M.A.H., Matsumoto, M.A., Marques, M.E.A., Salvidori, D.M.F.: Biocompatibility in vitro tests of mineral trioxide aggregate and regular and white Portland cements. J Endod 31, 605–607 (2005).
191. Ribeiro, D.A., Matsumoto, M.A., Duarte, M.A.H., Marques, M.E.A., Salvadori, D.M.F.: Ex vivo biocompatibility tests of regular and white forms of mineral trioxide aggregate. Int Endod J 39, 26–30 (2006).
192. Roberts, H.W., Toth, J.M., Berzins, D.W., Charlton, D.C.: Mineral trioxide aggregate material use in endodontic treatment: a review of the literature. Dent Mater 24(2),149–164 (2008).
193. Rud, J., Munksgaard, E. C., Andreasen, J. O., Rud, V.: Retrograde root filling with composite and a dentin-bonding agent. 2. Endod Dent Traumatol 7, 126–131 (1991).
194. Rud, J., Rud, V., Munksgaard, E.C.: Long-term evaluation of retrograde root filling with dentin-bonded resin composite. J Endod 22, 90–93 (1996).
195. Rud, J., Rud, V., Munksgaard, E.C.: Retrograde root filling with dentin-bonded modified resin composite. J Endod 22, 477–480 (1996).
196. Rud, J., Rud, V., Munksgaard, E.C.: Periapical healing of mandibular molars after root-end sealing with dentine-bonded composite. Int Endod J 34, 285–292 (2001).
197. Saidon J., He J., Zhu Q., Safavi K., Spanberg L.S.: Cell and tissue reactions to mineral trioxide aggregate and Portland cement. Oral Surg Oral Med Oral Pathol Oral Radiol Endod 95, 483–489 (2003).
198. Saleh, I.M., Ruyter, I.E., Haapasalo, M., Orstavik, D.: Survival of *Enterococcus faecalis* in infected dentinal tubules after root canal filling with different root canal sealers in vitro. Int Endod J 37, 193–198 (2004).
199. Saunders, E.M.: In vivo findings associated with heat generation during thermomechanical compaction of gutta-percha. Part I. Temperature levels at the external surface of the root. Int Endod J 23, 263–267 (1990).
200. Saunders, E.M.: In vivo findings associated with heat generation during thermomechanical compaction of gutta-percha. Part II. Histological response to temperature elevation on the external surface of the root. Int Endod J 23, 268–274 (1990).

Dentlearn.ir

201. Scarano, A., Di Carlo, G., Quaranta, A., Piattelli, A.: Injury of the inferior alveolar nerve after overfilling of the root canal with endodontic cement: a case report. Oral Surg Oral Med Oral Pathol Oral Radiol Endod 104, e56–e59 (2007).
202. Scheufele, J.: Untersuchungen und Erfahrungen mit dem neuartigen Wurzelfüllmittel Diaket. [Studies on a new root canal filling material, Diaket] Dtsch Zahnärztl Z 7, 913–919 (1952).
203. Schmalz, G.: Die Gewebeverträglichkeit zahnärztlicher Materialien – Möglichkeiten einer standardisierten Prüfung in der Zellkultur. [Biocompatiblity of dental materials – possibilities of a standardized testing in cell cultures] Thieme, Stuttgart 1981.
204. Schmalz, G.: Modifikation des Kaninchen-Implantations-Tests zur biologischen Prüfung von Wurzelkanalfüllmaterialien. [A modification of the rabbit implantation test for testing root canal filling materials] Zahnärztl Prax 38, 366–370 (1987).
205. Schmalz, G.: Die Wurzelkanalbehandlung – Klinische Erfolge. [Root canal treatment – clinical success] Dtsch Zahnärztl Z 45, 251–256 (1990).
206. Schmalz, G.: Cadmiumgehalt von Guttapercha-Stiften. [Cadmium content of gutta-percha points] Zahnärztl Mitt 88, 68–69 (1998).
207. Schmalz, G., Schmalz, C.: Toxicity tests on dental filling materials. Int Dent J 31, 185–192 (1981).
208. Schürer, N.: Latex-Allergie in der Zahnheilkunde. Stellungnahme der Deutschen Gesellschaft für Zahn-, Mund- und Kieferheilkunde. [Latex allergy in dentistry – a statement of the German Scientific Dental Society (DGZMK)] Dtsch Zahnärztl Z 54 (1999).
209. Schweikl, H., Schmalz, G.: Evaluation of the mutagenic potential of root canal sealers using the Salmonella/microsome assay. J Mater Sci Mater Medicine 2, 181–185 (1991).
210. Schweikl, H., Schmalz, G., Federlin, M.: Mutagenicity of the root canal sealer AHPlus in the Ames test. Clin Oral Invest 2, 125–129 (1998).
211. Schweikl, H., Schmalz, G., Stimmelmayr, H., Bey, B.: Mutagenicity of AH26 in an in vitro mammalian cell mutation assay. J Endod 21, 407–410 (1995).
212. Scolozzi, P., Lombardi, T., Jaques, B.: Successful inferior alveolar nerve decompression for dysaesthesia following endodontic treatment: Report of 4 cases treated by mandibular sagittal osteotomy. Oral Surg Oral Med Oral Pathol Oral Radiol Endod 97, 625–631 (2004).
213. Shabahang, S., Torabinejad, M., Boyne, P.P., Abedi, H., McMillan, P.: A comparative study of root-end induction using osteogenic protein-1, calcium hydroxide, and mineral trioxide aggregate in dogs. J Endod 25, 1–5 (1999).
214. Shabahang, S., Torabinejad, M.: Treatment of teeth with open apices using mineral trioxide aggregate. Pract Periodontics Aesthet Dent 12, 315–320 (2000).
215. Sipert, C.R., Hussne, R.P., Nishiyama, C.K., Torres, S.A.: In vitro antimicrobial activity of Fill Canal, Sealapex, mineral trioxide aggregate, Portland cement and EndoRez. Int Endod J 38, 539–543 (2005).
216. Siqueira, J.F., Goncalves, R.B.: Antibacterial activities of root canal sealers against selected anaerobic bacteria. J Endod 22, 78–80 (1996).
217. Sjögren, U., Figdor, D., Persson, S., Sundqvist, G.: Influence of infection at the time of root filling on the outcome of endodontic treatment of teeth with apical periodontitis. Int Endod J 30, 297–306 (1997).
218. Sjögren, U., Sundqvist, G., Nair, P.R.N.: Tissue reaction to gutta-percha particles of various sizes when implanted subcutaneously in guinea pigs. Eur J Oral Sci 103, 313–321 (1995).
219. Sjögren, U. Ohlin, A., Sundqvist, G., Lerner, U.H.: Gutta-percha-stimulated mouse macrophages release factors that activate the bone resorptive system of mouse calvarial bone. Eur J Oral Sci 106, 872–881 (1998).
220. Sonat, B., Dalat, D., Günhan, O.: Periapical tissue reaction to root fillings with Sealapex. Int Endod J 23, 46–52 (1990).
221. Spangberg, L.: Biological effects of root canal filling materials. 2. Effect in vitro of water-soluble components of root canal filling material on HeLa cells. Odontol Revy 20, 133–145 (1969).
222. Spangberg, L.: Biological effects of root canal filling materials. 5. Toxic effect in vitro of root canal filling materials on HeLa cells and human skin fibroblasts. Odontol Revy 20, 427–436 (1969).
223. Spangberg, L.: Biological effects of root canal filling materials. 7. Reaction of bony tissue to implanted root canal filling material in guineapigs. Odontol Tidskr 77, 133–159 (1969).
224. Spangberg, L.S., Barbosa, S.V., Lavigne, G.D.: AH26 releases formaldehyde. J Endod 19, 596–598 (1993).
225. Spielman, A., Gutman, D., Laufer, D.: Anesthesia following endodontic overfilling with AH-26. Oral Surg Oral Med Oral Pathol 52, 554–556 (1981).
226. Steiner, J.C., Van Hassel, H.J.: Experimental root apexification in primates. Oral Surg Oral Med Oral Path 31, 409–415 (1971).
227. Stevens, R.H., Grossman, L.I.: Evaluation of the antimicrobial potential of calcium hydroxide as an intracanal medicament. J Endod 9, 372–374 (1983).
228. Stewart, G.: A comparative study of three root canal sealing agents. Oral Surg Oral Med Oral Pathol 11, 1029–1041 (1958).
229. Stoll, R., Betke, K., Stachniss, V.: The influence of different factors on the survival of root canal fillings: a 10-year retrospective study. J Endod 31, 783–790 (2005).
230. Stuart, K.G., Miller, C.H., Brown Jr., C.E., Newton, C.W.: The comparative antimicrobial effect of calcium hydroxide. Oral Surg Oral Med Oral Pathol 72, 101–104 (1991).
231. Sumi, Y., Hattori, H., Hayashi, K., Ueda, M.: Titanium-inlay – a new root-end filling material. J Endod 23, 121–123 (1997).
232. Sunay, H., Tanalp, J., Güker, N., Bayirli, G.: Delayed type allergic reaction following the use of nonlatex rubber dam during endodontic treatment. Int Endod J 39, 576–580 (2006).
233. Sundqvist, G., Figdor, D., Persson, S., Sjögren, U.: Microbiologic analysis of teeth with failed endodontic treatment and the outcome of conservative re-treatment. Oral Surg Oral Med Oral Pathol Oral Radiol Endod 85, 86–93 (1998).
234. Sunzel, B., Soderberg, T. A., Johansson, A., Hallmans, G., Gref, R.: The protective effect of zinc on rosin and resin acid toxicity in human polymorphonuclear leukocytes and human gingival fibroblasts in vitro. J Biomed Mater Res 37, 20–28 (1997).
235. Tagger, M., Tagger, E.: Periapical reactions to calcium hydroxide-containing sealers and AH26 in monkeys. Endod Dent Traumatol 5, 139–146 (1989).
236. Tai, K.W., Huang, F.M., Huang, M.S., Chang, Y.C.: Assessment of the genotoxicity of resin and zinc-oxide eugenol-based root canal sealers using an in vitro mammalian test system. J Biomed Mater Res 59, 73–77 (2002).
237. Tanomaru-Filho, M., Luis, M.R., Leonardo, M.R., Tanomaru, J.M.G., Silva, L.A.B.: Evaluation of periapical repair following retrograde filling with different root-end filling materials in dog teeth with periapical lesions. Oral Surg Oral Med Oral Pathol Oral Radiol Endod 102, 127–132 (2006).

Dentlearn.ir

238. Tanomaru-Filho, M., Tanomaru, J.M.G., Barros, D.B., Watanabe, E., Ito, I.Y.: In vitro antimicrobial activity of endodontic sealers, MTA-based cements and Portland cement. J Oral Sci 49, 41–45 (2007).
239. Tay, F.R., Pashley, D.H., Williams, M.C., Raina, R., Loushine, R.J., Weller, R.N., Kimbrough, W.R., King, N.M.: Susceptibility of a polycaprolactone-based root canal filling material to degradation. I. Alkaline hydrolysis. J Endod 31, 593–598 (2005).
240. Tay, F.R., Pashley, D.H., Yiu, C.K., Yau, J.Y., Yiu-fai, M., Loushine, R.J., Weller, R.N., Kimbrough, W.F., King, N.M.: Susceptibility of a polycaprolactone-based root canal filling material to degradation. II. Gravimetric evaluation of enzymatic hydrolysis. J Endod 31, 737–741 (2005).
241. Tchaou, W.S., Turng, B.F., Minah, G.E., Coll, J.A.: Inhibition of pure cultures of oral bacteria by root canal filling materials. Pediatr Dent 18, 444–449 (1996).
242. Tepel, J., Darwisch el Sawaf, M., Hoppe, W.: Reaction of inflamed periapical tissue to intracanal medicaments and root canal sealers. Endod Dent Traumatol 10, 233–238 (1994).
243. Timpawat, S., Sripanaratanakul, S.: Apical sealing ability of glass ionomer sealer with and without smear layer. J Endod 24, 343–345 (1998).
244. Torabinejad, M., Chivian, N.: Clinical applications of mineral trioxide aggregate. J Endod 25, 197–205 (1999).
245. Torabinejad, M., Hong, C.U., Lee, S. J., Monsef, M., Pitt-Ford, T.R.: Investigation of mineral trioxide aggregate for root-end filling in dogs. J Endod 21, 603–608 (1995).
246. Torabinejad, M., Hong, C.U., Pitt-Ford, T.R., Kettering, J.D.: Cytotoxicity of four root end filling materials. J Endod 21, 489–492 (1995).
247. Torabinejad, M., Pitt-Ford, T.R., McKendry, D.J., Abedi, H.R., Miller, D.A., Kariyawasam, S.P.: Histologic assessment of mineral trioxide aggregate as a root-end filling in monkeys. J Endod 23, 225–228 (1997).
248. Torabinejad, M., Watson, T.F., Pitt-Ford, T.R.: Sealing ability of a mineral trioxide aggregate when used as a root end filling material. J Endod 19, 591–595 (1993).
249. Tronstad, L., Andreasen, J.O., Hasselgren, G., Kristerson, L.: pH changes in dental tissues after root canal filling with calcium hydroxide. J Endod 7, 17–21 (1981).
250. Tronstad, L., Andreasen, J.O., Hasselgren, G., Kristerson, L., Riis, I.: pH change in dental tissues after root fracture. Scand. J Dent Res 88, 370–376 (1980).
251. Trope, M., Löst, C., Schmitz, H. J., Friedman, S.: Healing of apical periodontitis in dogs after apicoectomy and retrofilling with various filling materials. Oral Surg Oral Med Oral Pathol Oral Radiol Endod 81, 221–228 (1996).
252. Tziafas, D., Smith, A. J., Lesot, H.: Designing new treatment strategies in vital pulp therapy. J Dent 28, 77–92 (2000).
253. Vajrabhaya, L., Sithisarn, P., Wilairat, P., Leelaphiwat, S.: Comparison between Sulphorhodamine-B dye staining and 51Cr-release method in cytotoxicity assay of endodontic sealers. J Endod 23, 355–357 (1997).
254. Valli, K.S., Rafeek, R.N., Walker, R.T.: Sealing capacity in vitro of thermoplasticized gutta-percha with a solid core endodontic filling technique. Endod Dent Traumatol 14, 68–71 (1998).
255. von Arx, T., Gerber, C., Hardt, N.: Periradicular surgery of molars: a prospective clinical study with a one-year follow-up. Int Endod J 34, 520–525 (2001).
256. Waltimo, T.M., Siren, E.K., Orstavik, D., Haapasalo, M.P.: Susceptibility of oral *Candida* species to calcium hydroxide in vitro. Int Endod J 32, 94–98 (1999).
257. Weiger, R., Axmann-Krcmar, D., Löst, C.: Prognosis of conventional root canal treatment reconsidered. Endod Dent Traumatol 14, 1–9 (1998).
258. Weiger, R., Manncke, B., Löst, C.: Antibakterielle Wirkung von Guttaperchastiften auf verschiedene, endodontopathogene Mikroorganismen. [Antibacterial effect of gutta-percha points on different endodontopathogenic microorganisms] Dtsch Zahnärztl Z 48, 658–660 (1993).
259. Weller, R.N., Jurcak, J.J., Donley, D.L., Kulild, J.C.: A new model system for measuring intracanal temperature. J Endod 17, 491–494 (1991).
260. Weller, R.N., Koch, K.A.: In vitro radicular temperatures produced by injectable thermoplasticized gutta-percha. Int Endod J 28, 86–90 (1995).
261. Williams, S.S., Gutmann, J.L.: Periradicular healing in response to Diaket root-end filling material with and without tricalcium phosphate. Int Endod J 29, 84–92 (1996).
262. Wilson, A.D., Clinton, D.J., Miller, R.P.: Zinc oxide-eugenol cements. IV. Microstructure and hydrolysis. J Dent Res 52, 253–260 (1973).
263. Wolfson, E.M., Seltzer, S.: Reaction of rat connective tissue to some gutta-percha formulations. J Endod 1, 395–402 (1975).
264. Woolverton, C.J., Fotos, P.G., Mokas, M.J., Mermigas, M. E.: Evaluation of eugenol for mutagenicity by the mouse micronucleus test. J Oral Pathol 15, 450–453 (1986).
265. Wu, M.K., de Gee A.J., Wesselink, P.R.: Leakage of AH26 and Ketac-Endo used with injected warm gutta-percha. J Endod 23, 331–336 (1997).
266. Yaccino, J.M., Walker III, W.A., Carnes Jr, D.L., Schindler, W.G.: Longitudinal microleakage evaluation of SuperEBA as a root end sealing material. J Endod 25, 552–554 (1999).
267. Yates, J.A.: Barrier formation time in nonvital teeth with open apices. Int Endod J 21, 313–319 (1988).
268. Yatsuhashi, T., Nakagawa, K., Matsumoto, M., Kasahara, M., Igarashi, T., Ichinohe, T., Kaneko, Y.: Inferior alveolar nerve paresthesia relieved by microscopic endodontic treatment. Bull Tokyo Dent Coll 44, 209–212 (2003).
269. Yesilsoy, C., Coren, L. Z., Morse, D. R., Kobayashi, C.: A comparative tissue toxicity evaluation of established and newer root canal sealers. Oral Surg 4, 459–467 (1988).
270. Yoshikawa, M., Hayami, S., Tsuji, I., Toda, T.: Histopathological study of a newly developed root canal sealer containing tetracalcium-dicalcium phosphates and 1.0% chondroitin sulfate. J Endod 23, 162–166 (1997).
271. Zmener, O., Cabrini, R.L.: Adhesion of human blood monocytes and lymphocytes to different endodontic cements. J Endod 12, 150–155 (1986).
272. Zmener, O., Spielberg, C., Lamberghini, F., Rucci, M.: Sealing properties of a new epoxy resin-based root-canal sealer. Int Endod J 30, 332–334 (1997).
273. Zmener, O.: Tissue response to a new methacrylate-based root canal sealer: preliminary observations in the subcutaneous connective tissue of rats. J Endod 30, 348–351 (2004).
274. Zmener, O., Pameijer, C.H.: Clinical and radiographic evaluation of a resin-based root canal sealer. Am J Dent 17, 19–22 (2004).
275. Zmener, O., Banegas, G., Pameijer, C.H.: Bone tissue response to a methacrylate-based endodontic sealer: a histological and histometric study. J Endod 31, 457–459 (2005).

Dentlearn.ir

8 Dental Alloys

J. C. Wataha and G. Schmalz

Contents

8.1 Introduction 221
8.2 Basic Material Properties 221
8.2.1 Composition 221
8.2.2 Corrosion and Release of Elements 224
8.3 Systemic Toxicity 228
8.3.1 Absorption, Distribution, and Excretion 229
8.3.2 Implanted Dental Alloys 230
8.3.3 Nonimplanted Dental Alloys 231
8.3.4 Clinical Symptoms and Complaints 232
8.4 Local Toxicity and Tissue Compatibility .. 232
8.4.1 Corrosion and Local Toxicity 232
8.4.2 Implanted Dental Alloys 233
8.4.3 Nonimplanted Dental Alloys 234
8.4.4 Local Clinical Symptoms and Complaints 237
8.5 Allergies 240
8.5.1 Mechanisms 240
8.5.2 Diagnosis and Frequency of Allergies to Metal Ions 241
8.5.3 Clinical Symptoms 242
8.6 Mutagenicity, Carcinogenicity, and Teratogenicity 242
8.7 Public Concerns and Controversies 244
8.7.1 Palladium in Dental Alloys 246
8.7.2 Nickel in Dental Alloys 246
Conclusions for the Dental Practitioner .. 248
Appendix 249
References 250

8.1 Introduction

Alloys are used in almost every aspect of dentistry. More than 3,000 alloys are available on the market for applications that put them into long-term direct or indirect contact with epithelium, connective tissue, or bone. Given this long-term intimate contact with vital tissue, it is paramount that alloy biocompatibility be investigated and understood (Fig. 8.1). In the past 20 years, many studies about the biocompatibility of dental alloys have been published. However, research in this area has generated as many questions as it has answered, and there is little doubt that much more will be learned about the biocompatibility of these materials. The biocompatibility of dental alloys will be reviewed in this chapter (except for amalgam; see Chap. 4). Reviews of the current literature on this subject have been recently published [47, 122, 152]. Reviews of general concepts of biocompatibility are available as well [117, 153].

Fig. 8.1 Example of a pronounced gingivitis after seating of ceramic alloy crowns, despite good oral hygiene

The tissue compatibility of various dental alloys is not always known in detail. Thus, it is impossible to list "good" or "bad" alloys for any given application. The aim of this chapter is to present fundamental principles that can serve as guidelines for assessing the tissue compatibility of presently available alloys as well as of new alloys.

8.2 Basic Material Properties

8.2.1 Composition

8.2.1.1 Elements

An alloy is any mixture of two or more metals or nonmetals (elements). In dentistry, alloys usually contain at least four metals, and often six or eight different

Dentlearn.ir

metals. Thus, dental alloys are metallurgically complex. Alloy compositions are diverse, and much of this diversity has developed in the past 20 years as the price of gold and (later) palladium has increased. This evolution of alloy composition has continued, and today there are many types of alloys in dentistry that were unknown just a few years ago. For many years, most dental alloys were based on gold, that is, they contained gold as their most common element. However, today's alloys may be based on silver, gold, palladium, nickel, cobalt, or titanium (Table 8.1). Minor elements in dental alloys may be even more diverse. Over 25 elements in the periodic table of elements are used in today's dental alloys.

The complexity and diversity of today's dental alloys make understanding their biocompatibility difficult because any element in an alloy may be released and influence vital tissue. Furthermore, because of their rapid evolution, the biological properties of many dental alloys are not fully understood.

8.2.1.2 Weight Percentage vs. Atomic Percentage

The composition of dental alloys can be expressed in two ways: either as the weight percentage (wt.%) of elements or the percentage of the number of atoms of each element in the alloy (atomic percentage, or at.%). By far, wt.% is the most common way of describing an alloy's composition and is used by alloy manufacturers and standards organizations.

Table 8.1 Components of dental alloys (except amalgam) [35, 151]

Alloy	Typical component elements
Crowns and bridges	
Gold-based	Au, Ag, Cu, In, Pd, Pt, Zn
Palladium-based	Pd, Ag, Cu, Ga
Silver-based	Ag, Pd
Cobalt-based	Co, Cr, Mo, Fe, C, Si, Mn
Nickel-based	Ni, Co, Mo, Fe, C, Be, Mn
Orthodontics/endodontics	
Titanium–vanadium alloys	Ti, V, Cr, Al, Sn
Stainless steel (iron-based)	Fe, Ni, Cr, C
Nickel–titanium (Nitinol®)	Ni, Ti
Cobalt–chromium-nickel (Elgalloy®)	Co, Cr, Ni, Mo, Mn, Be, C, Fe
Beta titanium	Ti, Mo, Zr, Sn
Implants	
"Pure" titanium (cp titanium)	Ti, O, N, C, Fe, H
Titanium alloy (Ti6Al4V)	Ti, Al, V, O, N, C, Fe, H
316 stainless steel	Fe, Ni, Cr, C, Si, Mn, P, Co, Mo
Cobalt–chromium (Vitallium®)	Co, Cr, Mo, Fe, C, Si, Mn

Dentlearn.ir

Key Note

An alloy's biological properties are best understood by knowing the atomic composition because the atomic percentage better predicts the number of atoms available to be released and thereby affect the vital tissues.

It is important to understand that the wt.% and at.% of an alloy may be substantially different from one another [35]. Table 8.2 gives the wt.% and at.% for several common dental alloys. The gold-based alloy contains 76 wt.% gold, but only 57% of its atoms are actually gold atoms. Thus, the amount of gold in the alloy is considerably less than one might think at first glance. Similarly, the wt.% of copper is only 11%, but 24% of the atoms are copper. The differences between wt.% and at.% are greatest when large differences exist among the atomic weights of the component elements. For the silver–palladium alloy in Table 8.2, the at.% and wt.% are very similar because the atomic weights of the component elements are also similar. For the titanium alloy (Ti6Al4V), 10% of the atoms are aluminum, 5% are hydrogen, and only 81% are titanium. The abundance of titanium is much less than it appears when expressed as wt.%.

8.2.1.3 Phases

Another way of describing an alloy is by its phase structure. Phases are areas within an alloy that have essentially the same composition. Single-phase alloys have (more or less) a similar composition throughout their structure. However, elements in some alloys combine in such a way that some areas differ in composition from other areas. Thus, the alloy is not homogeneous throughout its structure (multiple-phase alloy). Random cross-sections of a single-phase alloy (Fig. 8.2a) at the microscopic level show that all of the alloy has essentially the same composition. However, microscopic examination of a multiple-phase alloy (Fig. 8.2b) reveals (in this case) two different phases. These other phases may have characteristic morphologies, and two, three, or more phases may coexist in the alloy. The phase structure of an alloy is critical to its corrosion properties and to its biocompatibility [154]. The interaction between the biological environment and the phase structure is what determines which element will be released and, therefore, how the body will respond to the alloy.

8.2.1.4 Analysis of Dental Alloys

Dental alloys are classified as medical devices, so their use must be documented by the dentist and the laboratory technician. Information about the composition of an alloy is available in the literature or from manufacturers [26]. If there are doubts about the alloy's composition or type, metal shavings can be taken from intraoral restorations, placed on a carrier, and then characterized by scanning microscopy and energy-dispersive x-ray (EDX) analysis [43, 122] (see Fig. 2.21b

Table 8.2 Composition in weight percent (wt.%) and atomic percent (at.%) of three types of alloys

Gold-based alloy[a]			Silver-based alloy[a]			Titanium alloy[a]		
Element	wt.%	at.%	Element	wt.%	at.%	Element	wt.%	at.%
Ag	10	14	Ag	73	69	Ti	90	81
Au	76	57	Pd	25	25	Al	6	10
Cu	11	24	Zn	2	3	V	4	3
Pd	2	3				O	0.13	0.40
Pt	0.1	0.1				N	0.05	0.2
Zn	1	2				Fe	0.25	0.20
						C	0.08	0.30
						H	0.12	5

[a]Because of rounding errors, the alloy components do not always add up to 100%

Dentlearn.ir

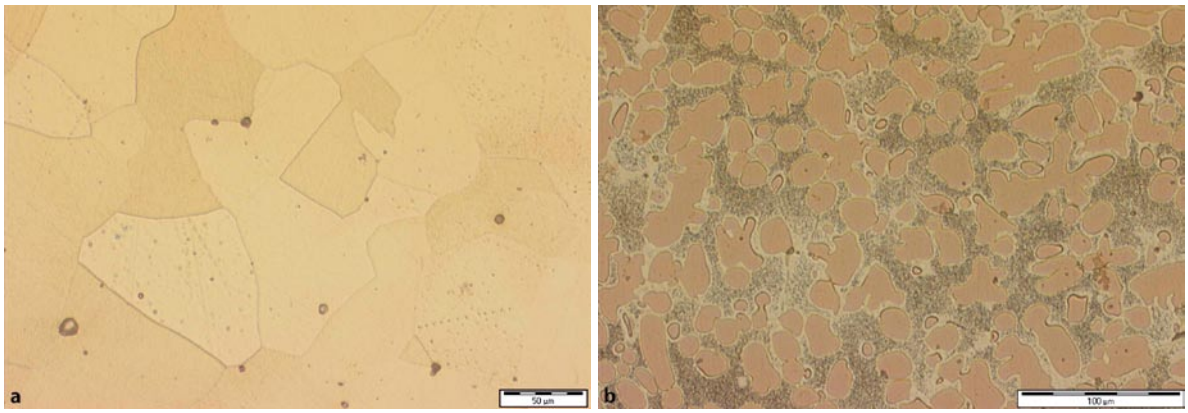

Fig. 8.2a,b Grinding-etch images of alloy surfaces (magnification ×200). **a** Single-phase alloy (Portatur, T: casting alloy 77% Au, 13% Ag, 8.5% Cu, 1% Pt, 0.2% In, 0.2% Zn), equal composition of the mixed crystal. **b** Multiple-phase alloy (ECO E2: casting alloy 39% Ag, 20% Au, 20% Pd, 16% In, 5% Zn). Corroded phase (*dark*) consists of Au–Ag, and the less corroded phase (*light*) consists of Pd–In; the composition represents an average of the compositions of the phases, according to the manufacturer (Courtesy of M. Stümke, Pforzheim, Germany)

in Chap. 2). The accuracy of this analysis is generally ±1% (see Chap. 2). Information about alloy composition is a prerequisite for a targeted diagnosis in a patient who has adverse clinical signs or symptoms that may be attributable to the alloy.

8.2.2 Corrosion and Release of Elements

8.2.2.1 Fundamentals

The primarily electrochemical corrosion of alloys involves the ionization of elements that are released into the environment, e.g., saliva [35]. Thus, elements that are initially uncharged lose electrons and become positively charged ions as they are released into solution. Corrosion is a chemical property of an alloy that influences other properties, including esthetics and strength. From a biocompatibility standpoint, corrosion of an alloy indicates that some of the alloy mass is available to affect the tissues around it. The released elements may or may not cause problems in the tissues around the alloy [17]. (Current definitions of fundamentals of corrosion of metals and alloys are reviewed, for example, in ISO 8044 [67].)

Corrosion is measured in a variety of ways:

- By observing the alloy for deterioration or discoloration of its surface (e.g., tarnish)
- By testing the alloy for altered current flow (electrochemical testing)
- By direct measurement of released elements (e.g., atomic absorption spectroscopy, atomic emission spectroscopy) [21]

Perhaps the most relevant measure of corrosion from the standpoint of biocompatibility is identifying and quantifying elements that are released. The corrosion of an alloy is of fundamental importance to its biocompatibility because the release of elements from the alloy is always necessary for an alloy to have adverse biological effects such as toxicity, allergy, or mutagenicity.

Key Note

The biological response to an alloy depends on the biological effects of released elements, the quantities released, the duration of tissue exposure to these elements, and other factors [167]. Thus, corrosion of an alloy and the release of elements are necessary but not sufficient for an alloy to adversely affect vital tissues.

A number of factors influence the corrosion of dental alloys [81]:

- Composition of the alloy (particularly at the surface)
- Phase structure of the alloy
- Surface structure (roughness, presence of oxides)

Dentlearn.ir

- Crevices, pits
- Thermal treatment/history
- Combinations of alloys (gold coating, soldering)
- Time in service

One fundamental idea about alloys that must be considered is that elemental release and corrosion occurs from all alloys, regardless of type or composition. However, the amount of corrosion and elemental release may vary dramatically among alloys. One of the most basic factors that influences element release from an alloy is its composition. Some elements, including copper, zinc, and nickel, have higher tendencies to be released than elements such as gold and palladium. These tendencies for release (labilities) are related to the electronic structure of the elements at the atomic level. The lability of an element may be substantially modified by other elements around it. For example, in dental alloys, it is known that palladium can reduce the lability of copper [156], and the formation of TiO_2 on the surface of titanium substantially reduces the lability of titanium [92]. Another factor influencing element lability is the phase structure of the alloy. In general, the presence of multiple phases increases the risk of element release from the alloys because of the potential for electrochemical corrosion among the phases [154]. Finally, surface characteristics of an alloy, such as surface roughness and the presence of oxides, can influence element release. Surface roughness tends to increase elemental release because rough surfaces have high surface areas that expose more atoms to the external environment and create local microenvironments that vary the exposure of the surface to elements such as oxygen. The oral environment near the alloy also influences corrosion. For example, reduced pH significantly increases the corrosion of some alloys, particularly those based on nickel. Corrosion is also particularly high in crevices, gaps, and pits, and in the local environment of the gingival sulcus (via "pitting corrosion" or "crevice corrosion") [109].

Interestingly, the composition of the surface of dental alloys can be significantly different from the composition of the bulk of the alloy. The surface composition may have a direct bearing on which elements are released. For some gold alloys, the surface was found to be significantly lower in gold than in the bulk of the alloy (Fig. 8.3) [166]. Copper was dramatically higher at the surface, and silver was moderately higher. When placed into a biological medium (cell culture medium), this alloy released far more copper than gold or silver. The elevated copper release may have been caused by its prevalence at the surface and copper's high lability. In these studies, the surface of a silver–palladium alloy was not so different from the bulk, and this was reflected in the release of these elements into a biological medium. Palladium, however, demonstrated a low tendency to be released. Although present at 12 at.% at the surface, only 3% of the atoms released were palladium.

Thermal treatment, such as firing of a ceramic alloy, may cause an alteration of the structure within the alloy. Consequently, 2–3.5-fold more copper and zinc may be released in specific cases [124]. Metal oxides, which are generated during the firing process, increase the attachment between ceramic and alloy. Oxides at the crown margin that are not covered by ceramic may promote elemental release and increase the toxicity of the alloy. Thus, these exposed oxides may cause gingivitis adjacent to ceramic alloy restorations (Figs. 8.1 and 8.4) [43, 124]. In this context it should be noted that recasting of base metal alloys (50% old and 50% new material) has been shown to significantly increase the release of elements and cytotoxicity [2].

The juxtaposition of different alloys may increase corrosion when they are in permanent contact. Some laboratories have adopted the practice of placing a gold surface coating on a nickel-based or cobalt-based alloy to improve the corrosion behavior of the base metal alloy. However, this strategy seems to be ill-advised based on reports of patients who experienced significant problems after insertion of cobalt-based partial denture frameworks that had been gold-coated (Fig. 8.5).

Clinical Practice Advice

Gold surface coating of nickel-based or cobalt-based alloys should be discouraged because the combination of the alloys and their permanent contact may enhance corrosion rather than retard it. Furthermore, there are significant problems with the integrity of the long-term bonds between coatings and the alloys [173].

Finally, the release of ions from alloys may decrease with the time it is exposed to a liquid environment [3] although elemental release may continue for extended periods [162]. Solders may increase the corrosion of dental alloys. Therefore, only those solders or alloy combinations should be used that have a low tendency for corrosion [169].

Dentlearn.ir

Clinical Practice Advice

Gluing and welding are associated with a lower increase of corrosion than soldering and, therefore, are preferred if possible.

If there is no direct intraoral contact between different alloys, corrosion may generate an electric potential at the surface of the various alloys (galvanic cell), but no electron current will flow. In this case, ionic currents in saliva may only cause deposits on the alloy with higher nobility. Proximal contact between two alloys does not necessarily result in an electrical contact, since some alloys build up nonadhering oxide layers [69]. A galvanic cell increases corrosion to a much lesser degree than a local cell, i.e., corrosion without a galvanic counterpart [173].

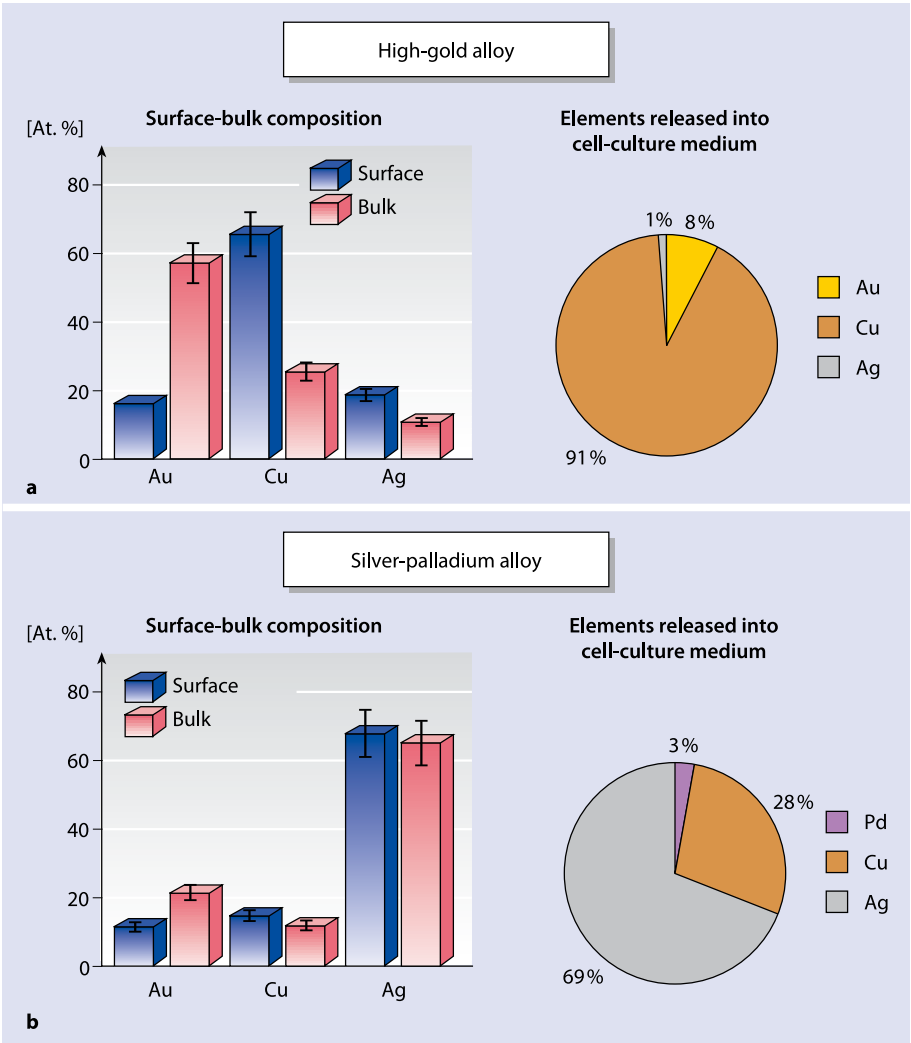

Fig. 8.3a,b Correlation between the surface composition, bulk composition of the alloy, and release of elements from the dental alloys. **a** Surface and bulk of the alloy reveal a significantly different composition. The surface layer contains relatively little gold, but a high percentage of copper and silver. This correlation is reflected by the elemental release (primarily copper) after 24 h. **b** Surface and bulk composition of the alloy are similar. The elemental release is proportional to the composition of the superficial layer, except for palladium. Palladium occupies 12% of the surface but only 3% of the mass released in the culture medium [166]

Dentlearn.ir

8.2.2.2 Implanted Dental Alloys

Studies with dental and orthopedic alloys have documented that all implanted materials release elements into the adjacent tissues [151]. Titanium and titanium alloys usually release relatively small amounts into the neighboring tissues. Release from cobalt-base alloys, nickel-base alloys, or stainless steel is an order of magnitude higher [92]. The amount of released elements varies among the different types of alloys as well as within the same groups of alloys [46]. High concentrations of nickel and chromium were found in the soft tissue adjacent to implanted nickel-chromium alloys, whereas different alloys with almost identical composition had different release characteristics [111]. The amounts of released elements that are systemically distributed from local tissues are not well understood or documented. Animal studies that have investigated the release of titanium from titanium alloys revealed that titanium ions tended to stay in the local tissue, contrary to aluminum ions and vanadium ions. Vanadium ions were most rapidly excreted. The distribution of aluminum was intermediate between titanium and vanadium [87]. The rate of release of elements at the implantation site plays a major role in the tendency of elements to accumulate locally around these alloys. More studies are necessary to resolve these questions.

The corrosion of titanium alloys may be enhanced by the use of acidic fluoride preparations [62, 78, 95]. The following limits have been proposed for the composition of such preparations:

- 0.05% NaF at a pH of 4.0
- 0.1% NaF at a pH of 4.3
- 2% NaF at a pH of 6.2 [143]

Fig. 8.4 Pronounced inflammation of the gingiva after seating of ceramic alloy crowns, with little plaque (papilla bleeding index at teeth without crowns <0%)

8.2.2.3 Nonimplanted Dental Alloys

Based on the literature, there is little doubt that elements are released from nonimplanted dental alloys, particularly over long periods of time [24, 44, 46, 120, 154], and can be identified in saliva [45, 104, 123, 170, 172] or in the adjacent gingiva or mucosa [44, 74, 108, 120, 171]. Furthermore, small changes in an alloy's composition can result in big differences in elemental

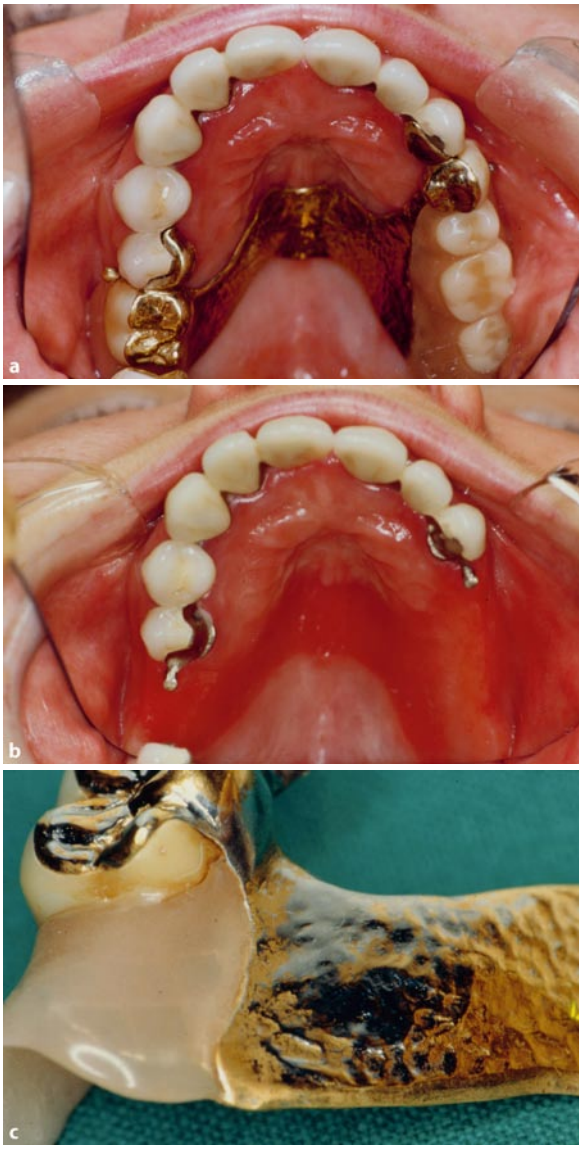

Fig. 8.5a–c Gold coating of nickel-based and cobalt-based-alloys. **a** Gold-coated partial denture. **b** Pronounced redness of the palate beneath the denture base. **c** Insufficient adhesion of the gold coating

Dentlearn.ir

release. For example, the differences in composition between alloys B and C in Fig. 8.6 are relatively small, but the total mass released from alloy C is over three times as great. The comparison of these two alloys also demonstrates the point that reduced nobility can result in higher amounts of elemental release. Alloy B has about 53 at.% of its elements as noble elements (gold + platinum + palladium), whereas alloy C has about 42 at.% of its elements as noble. Generalizations are normally not appropriate for predicting element release, however. Multiple-phase alloys release considerably more mass, even in alloys with a high gold content (alloy A) compared with single-phase alloys of similar composition. In Fig. 8.6, total elemental release from alloy D is significantly lower than that of alloy C despite alloy D's lower noble metal content (22.8 at.%).

Although generalizations are not always accurate, several statements can be made about release from non-implanted dental alloys based on analyses of elemental release from many different alloy compositions:

- Alloys containing titanium or alloys with a high gold content generally have the highest corrosion resistance [70], but the corrosion of titanium is increased by high concentrated fluoride solutions [62, 78]. (High gold alloys are characterized by a gold content of >65 wt.% gold. The share of Au- and Pt-group metals is >75 wt.% [ISO 1562] [65].
- Alloys with a reduced gold content are as resistant to corrosion in electrochemical tests as alloys with a high gold content [129], but are less corrosion resistant in immersion tests [64]. (Alloys with reduced gold content reveal a share of Au- and/or Pt-group metals between 25 wt.% and 75 wt.% [ISO 8891] [64] .
- Pd–Ag alloys are more resistant to corrosion than Pd–Cu alloys.
- Co–Cr alloys tend to be more corrosion resistant than Ni alloys [23, 72]. The corrosion stability of Ni alloys is further markedly reduced by beryllium [25]. Therefore, beryllium should no longer be used in dental alloys, if possible [32, 66].
- Multiple-phase alloys tend to have higher elemental release [91].
- Copper, cadmium, nickel, and zinc reveal a relatively high corrosion tendency (lability). But silver has a lower lability. Finally gold, palladium, and platinum have low lability and are unlikely to be released at high levels from nearly any alloy [91].
- Palladium may reduce the corrosion tendency of copper of a gold-based alloy [91].
- An acidic pH generally increases the elemental release from dental alloys. This is especially true for nickel-based alloys [46]. This point is of clinical interest because acid-producing dental plaque frequently adheres to dental alloys.
- Toothbrushing can increase the release of metal ions from some alloys, specifically nickel-based alloys [163].
- Salivary proteins form a metal–protein complex on the surface of an alloy [30], which can increase corrosion, particularly of nickel–titanium alloys [36].

Key Note

It is important to know that the relative number of individually released metal ions generally does not represent their relative content in the alloys. Thus, data regarding corrosion of the applied alloy or alloy combinations should be requested from the manufacturer. Oxides of ceramic alloys that are not covered by ceramic need to be removed, such as by using a recommended pickling solution. High corrosion resistance (in addition to other parameters) is very important when selecting an appropriate alloy.

8.3 Systemic Toxicity

The tissue compatibility of a dental alloy is determined by a number of factors in addition to elemental release, e.g., the tissue's exposure time to the alloy. For example, a copper band used for an impression may cause only minor adverse effects because it is present in the oral cavity for only a short period of time. The function of an alloy also influences its tissue compatibility. Alloys that are subject to abrasion due to opposing occlusion or restorations may release higher levels of elements. Intraoral location of the alloy influences its tissue compatibility. Alloys that are used in bone may have to meet higher requirements for corrosion resistance than those that are used for crowns, metal bases of partial dentures, or orthodontic wires. The exact requirements are not yet known. But many alloys that are used for crowns can result in failures when implanted. Finally, the surface adhesion properties of an alloy – that is, how bacteria, cells, or biologically active molecules (glycoproteins) are bound to different alloy surfaces – can considerably influence tissue compatibility. The toxicology of individual elements that are used for dental alloys cannot be reviewed in

Dentlearn.ir

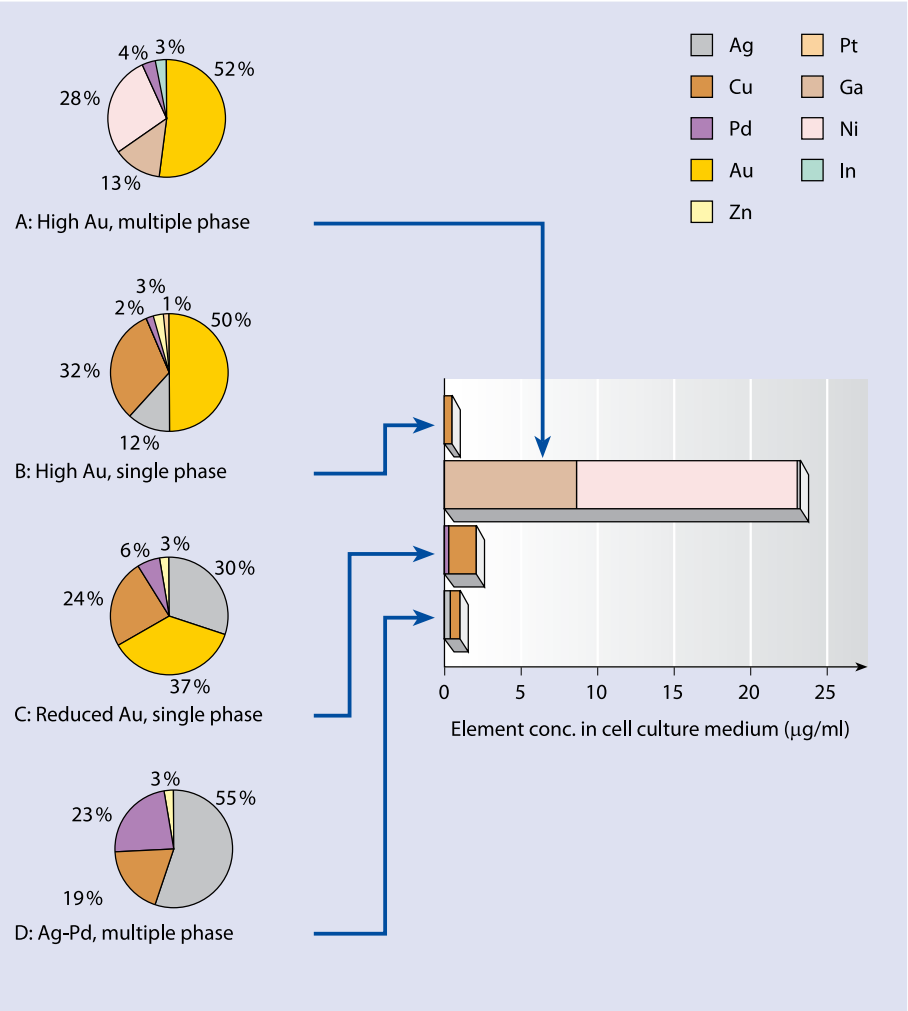

Fig. 8.6 The diagram emphasizes the problems related to predicting elemental release: The single-phase alloy with low gold content (*C*) releases three times as much mass into the cell culture medium after 72 h as the single-phase alloy with higher gold content (*B*). The multiple-phase alloy with higher gold content (*A*) releases 20-fold as much mass as the equivalent single-phase alloy (*B*). The silver–palladium alloy (*D*) releases a relatively small amount of mass despite its multiple-phase microstructure [156, 166]

this chapter; details can be found in text books on toxicology.

8.3.1 Absorption, Distribution, and Excretion

One concept related to systemic toxicity of dental alloys that is that elements released from a dental alloy into the oral cavity are not necessarily inside the body. Elements that are released from dental alloys into the oral cavity may only gain access to the body through the epithelium in the gut, the gingiva, or, for elements that form vapors (such as mercury), through the lungs (**absorption**). However, for dental implants, elements that are released into the bony tissues around the implant are, by definition, inside the body. It is for this reason that elemental release from dental implants

Dentlearn.ir

is thought to be more important biologically than elemental release from other dental alloys.

The route by which an element gains access inside the body is critical to its biological effects [49]. A good example of the importance of route is the systemic toxicity of palladium ions. If administered orally to mice, palladium ions will have an LD_{50} (median lethal dose; the calculated dose of a chemical substance that will kill 50% of the experimental population) of 1,000 mg/kg body weight (compare Chap. 2). If administered into the peritoneum of mice, the LD_{50} drops to 87 mg/kg body weight [157]. The toxic dose for intravenous administration is one order of magnitude lower yet. Few studies have documented the systemic toxicity of particulate forms of dental alloys [112]. However, results from these tests are difficult to interpret because the absorbed dose is largely unknown.

Once inside the body, the **distribution** of a metallic element mediates its ability to cause systemic toxicity. Metal ions may be distributed by diffusion through tissues, the lymphatics, or the bloodstream. Metallic particles (0.5–10.0 μm) may also be ingested by cells such as macrophages, which are themselves transported by the lymphatics or blood vessels [77].

Ultimately, metal ions can be deposited to many tissues or organs, each harboring its characteristic amount (**deposition**) [16]. This applies also for noble metals, such as platinum, which may be released from high gold alloys and will be harbored in the organism [8, 105]. The distribution of metals in tissues is unique for each metal and even for each chemical form of the metal. For instance, the oxidation state and chemical form of the metal will significantly influence its absorption, distribution, retention half-life, and **excretion**. Ultimately, the body generally eliminates these metals through the urine, feces, or lungs. The rate of elimination is also unique to each element. Thus, a "dose" of metal ions that is administered to the body by a dental alloy will be distributed systemically only to the extent that it gains access inside the body [61]. For example, if palladium ions are given intravenously to rats, 20% of the palladium will remain in the rats after 40 days. However, if the same palladium is administered orally, only 1% will remain in the rats after 3 days [157]. The low apparent retention of orally administered palladium is in large part a result of the low percentage of the palladium that actually gets into the body tissues. Most of the palladium is directly excreted.

8.3.2 Implanted Dental Alloys

Most of the information about systemic toxicity of implanted dental alloys has come from the orthopedic literature concerning alloys used for hip and other prostheses. Like dental implants, these alloys are placed into bone; therefore, their biological behavior is of interest to dentistry. However, the orthopedic implants represent a "worst case" when compared with dental implants because they generally have larger surface areas and are often subjected to friction and wear. Thus, information from the orthopedic literature is useful but not directly applicable to dentistry.

Dental implants (and their orthopedic counterparts) are primarily composed of titanium, titanium alloys, cobalt-chromium alloys, and stainless steel (see Table 8.1). In human studies that have retrieved tissues at autopsy from subjects with metallic orthopedic implants, elements from these alloys can be detected at elevated levels in distant tissues and organs [92, 151]. For example, titanium can be detected above normal levels in lung, kidney, spleen, liver, serum, and urine in humans and animals with orthopedic implants. For serum levels, the normal concentration of titanium is about 3 ng/g. In human patients who had titanium or titanium alloy orthopedic implants for 22–70 months, serum levels ranged from 8 ng/g to 37 ng/g. These numbers should be compared with a normal total body burden of 15 mg of titanium, a normal total daily intake of 0.3–1 mg of titanium, and a normal daily excretion of 0.3 mg [151]. In dental implants, little evidence exists concerning the systemic distribution of metals from implants in various tissues and organs. At least one study in rabbits could not detect titanium systemically for implants in bone that were not in frictional motion [82]. For other alloys such as cobalt-chromium and stainless steel, there is ample evidence that the released elements are distributed systemically [18]. Despite their presence in tissues, there is little or no evidence that metallic elements from titanium-based implants cause any systemic toxicity. The detection of toxicity over prolonged, low-dose exposures is problematic, however, and there is concern that the presence of these elements represents a biological risk [17].

Dentlearn.ir

Key Note

In the context of the risk–benefit ratio, the known benefits of titanium-based implanted dental alloys currently far outweigh any defined risks from the presence of elevated systemic concentrations of released elements in various tissues or organs.

8.3.3 Nonimplanted Dental Alloys

Unlike implanted alloys, elements that are released from nonimplanted dental alloys may or may not gain access into the body. There is some evidence, however, that elements from dental crowns and other alloys gain access to local gingival tissues or the oral mucosa. In dogs, elevated gingival copper levels have been demonstrated adjacent to crowns composed of brass (copper-zinc alloy) [27, 55]. It should be noted that brass is extremely corrosion-prone in the mouth and not representative of dental alloys used today. A study in patients with inflamed gingiva adjacent to various dental alloys (high gold or reduced gold alloys, palladium-based and cobalt-chromium alloys) demonstrated many alloy components in the adjacent gingiva and mucosa [44, 120]. In other studies, extremely sensitive techniques have been used to demonstrate the presence of components of crowns and amalgams in human gingival tissues adjacent to dental alloys. These levels are generally low, however [108].

There is little evidence to demonstrate that elements released from nonamalgam dental alloys contribute significantly to the systemic body burden of elements. This result is not surprising when the normal daily dietary intake of metals in dental alloys is considered [21] (Table 8.3). In most cases, the amounts of elements that are released from dental alloys are far below those taken in as part of the diet. For example, the amount of zinc released from a dental alloy (generally <0.1 μg/day) is far below that eaten (14,250 μg/day). However, in several cases, dental alloys may release levels that approach dietary intakes. For example, nickel released from nickel-based crowns may approach the daily intake level of 400 μg/day.

It must be stressed that release of mass from an alloy that approaches dietary levels does not predict systemic toxicity or other effects from the alloy. There are two problems with using daily dietary intake as a "ruler" for assessing the safety of dental alloys. First, there is no information that the dietary levels themselves have any meaning for long-term biological safety. The amount of titanium (750 μg/day) that we eat daily in our diet may or may not be safe. It is simply an empirical fact that we eat this much. Thus, if an alloy releases this much titanium (which it generally does not), we really do not know if the alloy is safe. We are led to a sense of security by this comparison because we observe that we do not suffer ostensibly from the dietary intake. Again, in terms of risks and benefits, it is likely that the benefits of the titanium in the products we use (sunscreen, drugs, cosmetics, foodstuffs) far outweigh the risks of any long-term exposure to the metal. This balance must be established for each metal.

The second reason that daily dietary intake may not be a useful ruler for biological safety is that it does not take into account local elevated concentrations of elements that may occur around the alloy. For example, the amount of copper released from a dental crown may approach 1 μg/day, which is far below the 3,100 μg/day that we eat. However, in the gingival crevice adjacent to the crown, the concentration of copper might be much higher. Furthermore, the concentration that is required to have a local adverse effect may be much lower than concentrations necessary to cause systemic effects through the oral route. An epithelial cell in the gingiva may begin to suffer from copper levels as low as 10 μg/g. Thus, we should not be biased

Table 8.3 Estimated daily dietary intake of some elements that are used for dental alloys [21]

Element	Daily dietary intake (μg)
Cadmium	50
Chromium	240
Cobalt	250
Copper	3,110
Gold	< 7
Iron	23,250
Molybdanium	400
Nickel	400
Silver	25
Titanium	750
Zinc	14,250

Dentlearn.ir

too much by the daily dietary intake of metals when assessing the biological risk of dental alloys.

Nonimplanted dental alloys are mostly processed by lab technicians, who inhale metal dusts (besides other dusts) generated by the finishing and polishing of alloy restorations. An elevated risk of lung fibrosis (particularly due to beryllium dust) has been discussed (see Chap. 12) [102]. Cobalt–chromium particles (in addition to asbestos and ceramic particles) also were detected in autopsy samples taken from a lab technician who suffered from a lung fibrosis [97]. But appropriate suction units decrease dust concentrations below threshold values [22], and the use of beryllium in dental alloys is no longer recommended [32, 66].

Key Note

In summary, systemic toxicity from dental alloys has not been demonstrated. There is evidence that released metals can and do gain access to the body, and these metals may be widely distributed. However, no studies have shown that the presence of these metals causes systemic toxicity. Further studies will undoubtedly continue to assess the possibility of systemic toxicity as long-term data (i.e., over years or decades) become available.

8.3.4 Clinical Symptoms and Complaints

Although scientific studies do not indicate systemic toxicity caused by dental alloys, some patients refer to dental alloys as the cause of many health complaints. Few high-quality epidemiological data regarding the frequency of these complaints in patients are available. Cross-sectional studies, however, have indicated a frequency of 0.01–0.02% [43], compared to complaints about cosmetics at a frequency of up to 12% [80] and, in another survey, to some sort of adverse reaction to a personal care product over the course of a year in 23% of women and 13.8% of men [103].

A summary of the general (i.e., nonoral) complaints shows that the indicated symptoms are often of unspecific nature and may be triggered by other factors, such as concurrent systemic diseases (Table 8.4). Furthermore, a similar spectrum of symptoms is reported by patients who attribute their complaints to amalgam or resin-based composites (see also Chaps. 4 and 5).

Clinical Practice Advice

Many adverse symptoms attributed by patients to their dental alloy restorations may also occur from concurrent systemic diseases or drugs the patient may be taking. This fact should be a prime consideration when assessing the impact of dental alloys; patients with these symptoms often have "multiple morbidity" [43].

Interestingly, the majority of patients citing adverse effects from dental alloys are females in the age group of 50–59 years [43]. This gender and age group also often complains about the same clinical symptoms purportedly caused by dentures or fillings (e.g., amalgam) [58, 135, 179]. No correlation between these symptoms and hormonal levels in menopausal women could be found [142]. Furthermore, neither the systemic nor the local application of estrogens had a significant therapeutic effect [142]. Possible psychological causes of these complaints are reviewed elsewhere in this book (see also Chaps. 1, 4, and 5).

Key Note

In patients who complain about problems purportedly caused by dental alloys or other materials, a comprehensive medical history and a careful oral examination are necessary to exclude other diseases or factors in the oral cavity (such as elevated plaque accumulation) as a cause. Determining the cause of nonspecific symptoms requires intense collaboration of the dental practitioner with general physicians and psychiatrists. This approach is similar for patients who complain about problems with other dental materials.

8.4 Local Toxicity and Tissue Compatibility

8.4.1 Corrosion and Local Toxicity

Dental alloys are in long-term intimate contact with local tissues, and "microenvironments" are often formed between the alloy and the tissues. For example, a dental crown often extends into the gingival sulcus. If elements from the alloy are released into this sulcus, they may reach high concentrations because they are

Dentlearn.ir

Table 8.4 Frequency (%) of the 20 most often claimed nonoral patient complaints related to alloys [133]

Symptoms	All alloys	Au-based	Pd-based
General fatigue	77	74	81
Tiredness	74	67	78
Lack of energy	73	66	76
Nervousness	72	72	74
Headache	71	62	77
Impaired memory	70	70	75
Joint pain	69	62	80
Muscle pain	67	55	77
Impaired vision	64	63	69
Dizziness	64	65	61
Irritability	61	59	63
Insomnia	58	55	57
Depression	58	49	62
Mood swings	58	57	57
Cardiac arrhythmia	48	43	54
Shivering	48	50	52
Low blood pressure	44	47	40
Undecidedness	43	41	45
Diarrhea	42	45	37

diluted less by saliva and may experience elevated corrosion, for example, crevice corrosion. A similar situation exists beneath the metal framework of a removable partial denture. Elements released on the tissue side of the framework may not be diluted by oral fluids to the same extent as elements released from the opposite side of the framework. Consequently, metal ion concentrations may be higher next to the tissue than in the saliva.

The risk of local effects from dental alloys exists for both implanted and nonimplanted alloys. However, in general the risk is greater for implanted alloys because the elements that are released have less inhibited access into the body. Elements released from nonimplanted alloys must first gain access into or across the epithelial barrier before they can alter tissue functions.

8.4.2 Implanted Dental Alloys

Tissue necrosis and inflammation have been well documented in animal studies in which alloys with high corrosion behavior were implanted into bone, connective tissue, or muscle. Examples of these metals include pure copper, nickel, zinc, and aluminum, and

Dentlearn.ir

alloys such as brasses [85]. The mechanisms by which these released elements cause these adverse biological responses are not understood but are being actively investigated.

If levels of released elements are low, the situation is especially difficult. Although not proven, the significant element release associated with nickel-based and cobalt-based alloys is thought to be at least partly responsible for the inability of these materials to osseointegrate with bone, even though no severe necrosis or inflammation occurs around the implants [151]. The lack of osseointegration may be related both to the relatively large amounts of elements released from these alloys and to the nature of elements being released. Although previously considered a normal biological response, fibrous encapsulation of alloys is currently considered to be an unwanted biological response, particularly around intraosseous implants.

If the levels of released elements are low, as with titanium and titanium alloys, then the biological response over months and years is generally favorable. These materials will osseointegrate with bone and maintain this tissue integration for many years [151]. Such success has been repeatedly documented in human studies. The reason why these alloys osseointegrate is not fully understood but is thought to be at least partly related to the low release of elements. Thus, titanium remains successfully integrated in bone for years despite a persistent presence of titanium around the implants. It may be that the presence of titanium has few biological liabilities or that the levels are insufficient to cause such liabilities.

However, it should be stressed that a low release of elements is a necessary but not a sufficient condition for osseointegration. For example, gold-based alloys or even pure gold will generally not osseointegrate despite very low levels of elemental release [140]. Factors such as surface oxide formation and oxide conformation are probably important. The oxide may have a favorable effect on the extracellular matrix architecture and cellular activity in the surrounding tissue. The attachment of osteoblasts to implants is an important condition for good tissue compatibility and, thus, for optimal osseointegration. It is likely that the protein layer that adheres to the surface of the material is of critical importance for these processes [141]. Current evidence suggests that adsorption of extracellular matrix proteins in a manner that preserves their native conformations is more conducive to cell adhesion and osseointegration compared to a change of this conformation after adsorption. Material properties such as charge affect the way proteins interact with an implant alloy [141]. Much research is being done in this area.

8.4.3 Nonimplanted Dental Alloys

Although the release of elements from nonimplanted dental alloys is well established, the local biological effects of these elements are still a topic of intense debate. The central question of this debate is whether the levels of released elements are sufficient to alter the normal biological functions of the tissues around the alloys. Unfortunately, insufficient evidence exists to definitively answer this question. Current evidence to address this controversy has been published in the form of in vitro and in vivo studies.

8.4.3.1 Cell Cultures

At sufficiently high concentrations, **metal ions** alter cellular metabolism or lead to cell death. The effect of silver ions on cellular mitochondrial activity is a case in point [158] (Fig. 8.7). The mitochondrial activity shown in this figure is often used because it is indicative of the cell's ability to provide energy for other cellular processes. At a low concentration (<2.0 μM), cellular mitochondrial activity is essentially unchanged from normal. However, as the concentration of silver ions increases, cellular activity falls dramatically. Above 10 μM, activity is essentially zero.

This example of silver is indicative of almost all metal ions, except that each metal ion has its own critical threshold above which cellular activity deteriorates. In general, the toxicity of these metal ions is reported as the concentration to depress cellular activity by 50%, or the toxic concentration 50% (TC_{50} value). TC_{50} values (after 24 h of exposure) for metal ions range from 6 μM to 3,000 μM, depending on the cell type and toxicity parameter being measured [118, 119, 158, 175, 176] (see Appendix, Table 8.7). The shape of the curve shown in Fig. 8.7 is different for each metal ion, but the dose-dependent trend is usually similar. In general, as the exposure time increases, the concentration of metal ions required to cause a 50% reduction in cell activity also decreases (Fig. 8.8); that is, the longer the metal ions are in contact with cells, the fewer the metal ions required to cause cellular problems [158, 165]. But various metal ions may interact to produce their toxic behavior, causing an increase or decrease

Dentlearn.ir

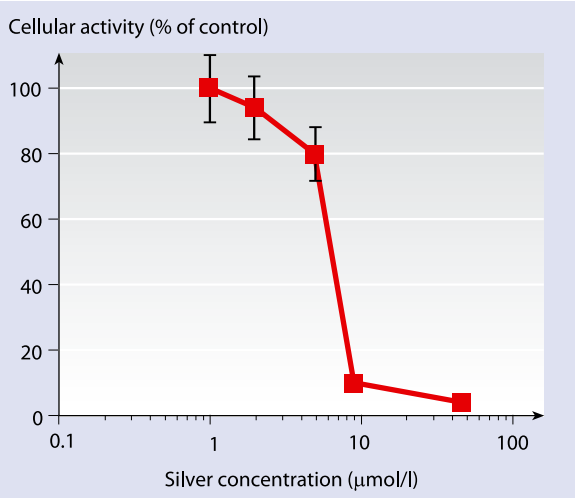

Fig. 8.7 Typical dose-response curve. The activity of mitochondria was measured after a 24-h treatment with different silver ion concentrations. The TC_{50} concentration according to this graphic is 6 µM; the control cultures were not incubated with silver [158]

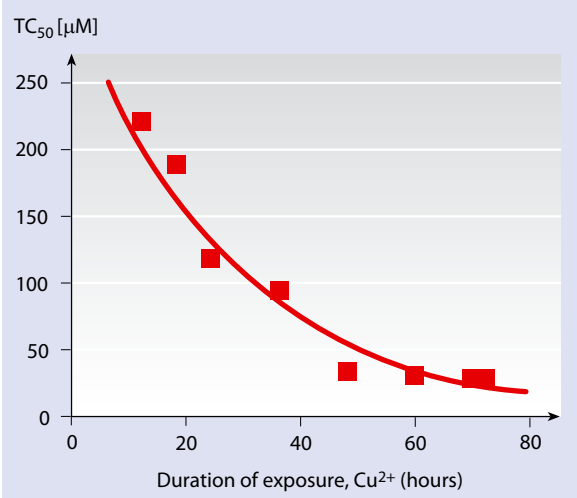

Fig. 8.8 Influence of exposure time on the TC_{50} concentration (with Cu ions). More copper is needed after short-term exposure to inhibit cell growth by 50% compared with longer exposure periods [158]

in cytotoxicity. The molecular reaction mechanisms to most metal ions are largely unknown, although a great deal is being discovered regarding metals of environmental importance that are also commonly used in dentistry, such as mercury and nickel [159]. Metals such as chromium, nickel, and cobalt may also cause apoptosis at concentrations below those that lead to cellular necrosis [50]. At a cellular level, studies have investigated how metals affect several cellular functions, such as osteoclast function [98], the function of cellular mitochondria [89], cytokine release [125], the activity of transcription factors [148], the synthesis of glutathione [161], and the structure of the cytoskeleton [31]. Recent reports also indicate that metal ions may amplify cellular responses to inflammatory activators such as lipopolysaccharide (LPS). For example, low levels of nickel ions may increase LPS-induced cytokine secretion by 3–4-fold or may enhance expression of intracellular antioxidant proteins such as heme oxygenase-1. The combined effects of metal ions and LPS have profound implications for the safety of alloys, which harbor plaque and release metal ions into adjacent periodontal tissues [149, 160, 168].

Dental alloys also may, depending on their composition, damage cells in culture [155]. It has been documented that some alloys are cytotoxic over a longer period of time in vitro [164] or change human gingival cells in vitro [88]. In basic terms, cellular damage could be correlated to elemental release from the alloys [90, 124, 156]. In these studies, multiple-phase alloys, which generally have higher corrosion rates, were more cytotoxic than similar single-phase alloys [99, 100].

However, the correlations between the release of metal ions and cytotoxicity are extremely complex. Dental alloys that do not cause cell damage release metal ions into the cell culture medium as well. Obviously, ion concentration and exposure time are not sufficient in these cases to cause cell damage. Thus, the release of metal ions is necessary to cause cell damage but is not sufficient in every case.

Ceramic alloys may be more cytotoxic after thermal treatment. This fact should be considered in correlation with gingivitis adjacent to crowns made of these alloys (Figs. 8.1, 8.4, 8.10). Titanium was generally not cytotoxic [13, 150]. The combination of different alloys [137] or of alloys and solders caused a different cytotoxicity compared with the ceramic alloy. Thus, the toxicity of an alloy–solder combination cannot be theoretically deduced from the toxicity of the individual alloys (Fig. 8.9).

Results from in vitro tests are, despite constant further development, of limited value for predicting

Dentlearn.ir

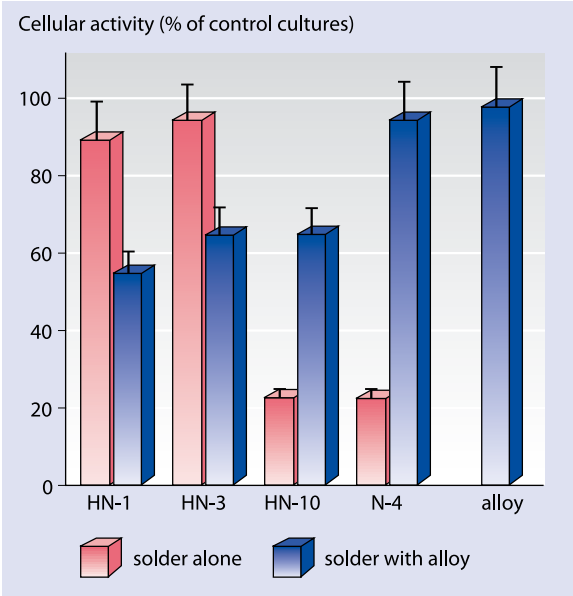

Fig. 8.9 Influence of the combination of an alloy with different solders (HN-1, HN-3, HN-10, N-4) on the toxicity. The single blue column (*right*) shows the toxicity of the individual alloy. The other blue columns represent the toxicity of combinations of solder and alloy [169]

alloy-caused reactions in patients. Only short-term exposures of alloys are used in most in vitro tests, in contrast to many years of exposure in vivo. For in vitro tests, single cell types are used that are often specifically altered to grow outside the body. Thus, there is always uncertainty whether these cells react the same way as cells inside the body. In general, in vitro tests will not cover interactions between various cell types, which is a frequent feature of biological reactions in vivo. However, these tests can evaluate the general biological characteristics of materials (see Chap. 2).

8.4.3.2 Adhesion of Bacteria

Plaque is the primary cause of gingivitis and (in addition to other factors) periodontitis. Plaque accumulation results from insufficient oral hygiene and restorations that impair the patient's ability to perform adequate oral hygiene. But alloys may influence plaque accumulation as well; furthermore, a decreased pH underneath plaque may increase corrosion of some alloys, particularly those based on nickel or cobalt.

Different factors affect microbial adhesion, accumulation of bacteria, and the formation of a dental plaque on dental alloys. Alloys containing copper and silver showed stronger antimicrobial effects in vitro than metals used for denture bases [5]. In addition, a number of in vitro investigations have documented that a high surface energy and a rough surface structure promote bacterial adhesion [106]. Greater plaque levels have been shown to accumulate on titanium implants than on natural teeth, perhaps due to the higher free surface energy of titanium. But this plaque can be removed with appropriate oral hygiene [107].

Materials in the oral cavity are covered by an acquired pellicle immediately – within microseconds – after coming into contact with saliva [86], which makes the differences in bacterial adhesion and free surface energy that are observed in vitro irrelevant. In general, the pellicle reduces bacterial adhesion independent of the material's free surface energy [106, 134] (see also Chap. 2). Siegrist et al. found in patients no specific trends under experimental pontics made of various alloys [131], but certain materials generated a specific colonization after 4 h and 24 h. Numbers of bacteria could only be correlated with surface roughness after 4 h. This is similar to the studies of Hannig [53, 54], who did not find pronounced differences of the plaque's ultrastructure that accumulated on various materials after 24 h (gold reduced alloys, titanium alloys, resin-based composites, cements, and ceramic). But Steinberg et al. [134] documented that certain periodontopathogenic bacteria adhered better to a titanium alloy (Ti6Al4V) than to commercially pure (cp) titanium. They also found that saliva generally reduces this microbial adhesion. Taken together, there is no clear indication that certain groups of alloys result in a plaque accumulation that cannot be removed by appropriate oral hygiene. But there is an agreement that surface roughness is a risk factor for increased bacterial accumulation.

Fig. 8.10 Severe inflammation adjacent to ceramic alloy crown not induced by plaque accumulation

Dentlearn.ir

Clinical Practice Advice

Intraoral alloy surfaces should be as smooth as possible (surface polish) to minimize or prevent plaque formation. This will prevent plaque-associated gingivitis and periodontitis in the vicinity of dental alloys and will minimize corrosion of these alloys as well.

8.4.3.3 Implantation Tests

Studies in experimental animals are also performed in addition to in vitro tests to assess the biologic effects of dental alloys. For example, alloys may be implanted subcutaneously or intramuscularly [14, 110]. It is often difficult to replicate a clinical alloy-tissue interface in an animal model. For this reason, animal implantation tests are difficult to interpret in the context of clinical dental use, and these tests may be less relevant than some in vitro tests they were designed to replace [93]. For instance, implantation tests do not simulate the extraepithelial application of dental alloys. Furthermore, shape, size, and surface characteristics of an alloy may influence the subsequent biological reaction. Finally, intraoral conditions (chewing, brushing, plaque, vicinity to other alloys) are not accounted for in most implantation tests in animals.

Only a few studies have reported the biological reaction of nonimplanted dental alloys in a clinically relevant environment. If highly corrosive alloys (such as brasses) are seated on canine teeth, the adjacent gingiva will react with a considerable inflammation caused by released elements [55]. The relevance of these canine studies is uncertain because most current dental alloys release 100–1,000 times less mass than the brasses used in these studies. It is uncertain whether these lower amounts are of clinical relevance. The combination of pure titanium implants and crowns made of a high gold alloy increased corrosion in primates but did not interfere with osseointegration [41].

8.4.4 Local Clinical Symptoms and Complaints

8.4.4.1 Subjective Complaints

Subjective complaints linked to dental alloys in the oral cavity have been reviewed in several publications [43, 74, 122, 133, 173]. These reviews indicate that burning mouth and metallic taste are by far the most frequent complaints (Table 8.5).

The causes for a burning mouth are not known. Allergies are often claimed to be the cause, yet few patients were shown to have a verifiable allergy in a study addressing burning mouth syndrome [43]. Furthermore, burning mouth was also indicated as a subjective adverse effect to various other dental materials, such as acrylates (see also Chap. 9). Therefore, it is very difficult to associate these subjective symptoms with a particular material. Burning mouth is likely caused by many factors [10]. Besides dental materials, neuron-pathogenic conditions [38, 40] and psychiatric stresses, and even diseases, probably play major roles in the pathogenesis of burning mouth syndrome.

Metallic taste is also a frequently indicated subjective symptom of patients [43]. It may be noticed when new amalgam restorations are placed in direct contact with gold-based alloys. In general, these symptoms disappear within few days after a passivating layer of oxide has formed on the surface of the amalgam filling.

Taken together, it is nearly impossible to relate a patient's subjective complaints to biological features of dental alloys [122]. Based on the reviews regard-

Table 8.5 Frequency of subjective oral complaints of patients [122]

Complaints	Frequency (%)
Burning mouth	72
Metallic taste	56
Electric sensations	44
Dry mouth	40
Taste irritation	37
Gingival bleeding	31
Gingivitis	28
Oral vesicles	24
Paresthesia	20
Toothache	20
Red tongue	16
Increased salivary flow	13
Palatinal erythema	9

Dentlearn.ir

ing corrosion and toxicity, it may be concluded that these symptoms are more frequent after application of corrosion-prone alloys, such as gold-reduced alloys. This hypothesis, however, has not been confirmed: The relative distribution of alloys in a group of patients with subjective complaints was equivalent to the distribution of alloys within the population, based on sales numbers of the most important vendor of alloys in the investigated region (Degussa) [121]. Thus, other causes need to be considered because equivalent patient symptoms have been reported for nearly all types of dental materials. Therefore, it may be speculated that various health factors such as illness and mental condition may also play a role [11, 58]. Nevertheless, the clinician cannot ignore systemic disease and drug side effects as contributors to these types of symptoms.

Clinical Practice Advice

A number of drugs, including those for treating rheumatic disease, cause adverse oral effects such as metallic taste [51]. Smith and Burtner [132] summarized the most frequent adverse effects of 200 frequently prescribed drugs. Alterations of taste and other intraoral complaints were most commonly reported.

Metal analyses of saliva are of little importance for diagnosing material-related subjective complaints in the dental office because major variations in the analytic results have been observed in the same patients. Furthermore, the oxidation state of the metals (ions or metallic particles), relevant threshold concentrations, and possible interactions of various metals are simply unknown [45, 115, 122]. Voltages between different alloys in the oral cavity without permanent contact (oral galvanism) have been cited as the cause of subjective complaints in some patients. In Chap. 2, the relevance of voltage readings is critically reviewed based on the scientific literature. A permanent contact between different alloys, however, can cause symptoms in rare cases, such as metallic taste due to increased corrosion.

8.4.4.2 Gingival Inflammation

Metals such as nickel and copper have been reported to cause gingivitis when they are released from alloys into adjacent oral tissues [7, 139, 171, 174]. Other reports considered metals that were released from high gold and gold-reduced alloys as causative for discoloration and hyperplasia of the adjacent gingiva, particularly in the vicinity of crowns made of ceramic alloys (Fig. 8.10) [73, 74, 133]. In these cases, gingival inflammation persisted even after stringent plaque control measures were implemented, suggesting that plaque was not only the cause of inflammation. It should be reemphasized that the cytotoxicity of ceramic alloys is considerably increased after thermal treatment [124]. Incomplete removal of the superficial oxide layer at the crown margin could contribute to gingival inflammation [90, 122]. A metal analysis of the adjacent gingiva is of little diagnostic importance in the dental practice because of the same confounding variables previously mentioned (see also Chap. 2) in applying salivary analyses [45, 118, 120].

Clinical Practice Advice

If oral plaque reduction strategies fail to resolve a persistent gingival inflammation adjacent to alloy or ceramic-alloy restorations, the practitioner should consider removing the crowns to resolve the problem.

Fig. 8.11 Geographic tongue or fissured tongue in a patient with subjective oral complaints (burning tongue)

Dentlearn.ir

8.4.4.3 Alterations of the Tongue

Interestingly, 16% of those patients who indicated complaints related to dental alloys revealed an alteration of the tongue, usually a fissured or geographic tongue [43, 122] (Fig. 8.11). No epidemiological data regarding alloy-induced fissured or geographic tongue are available, but the literature indicates a frequency in the general population of about 7% [6]. Whether these tongue alterations predispose for other problems, such as burning tongue, is under discussion [145, 180].

8.4.4.4 Palatal Erythema

Palatal erythema underneath a metal base has been observed on various occasions (Fig. 8.12; see also Chap. 9). The causes for these reactions may be toxic or allergic in nature, an insufficient fit of a denture, or bacterial or fungal infection [9, 12]. Latter causes can be excluded by oral hygiene education and cleaning of dentures, such as by using a 0.1–0.2% chlorhexidine solution. If these procedures do not improve the oral condition, then an elimination test (not wearing the restoration for a specific period of time) or insertion of a metal-free temporary restoration is recommended.

8.4.4.5 Lichenoid Reactions

Lichenoid reactions have been documented in correlation with amalgam fillings [19], resin-based composites [79], and dental alloys [56, 76]. A lichenoid reaction is generally considered a disease state independent of oral lichen planus and is often a material-related reaction or a combination of the two (Fig. 8.13). The influence of a material can be of a mechanical (e.g., acute edge), toxic-irritative, or allergenic nature.

Clinical Practice Advice

A lichenoid reaction that is limited to the contact area of the material with oral tissues may be material induced. (See also Chap. 8.5.) The use of alternative materials is strongly recommended in these cases.

Fig. 8.12a,b Redness of palate. **a** Partial denture with gold coating. **b** Pronounced redness of the palatal area that was covered by the metal base

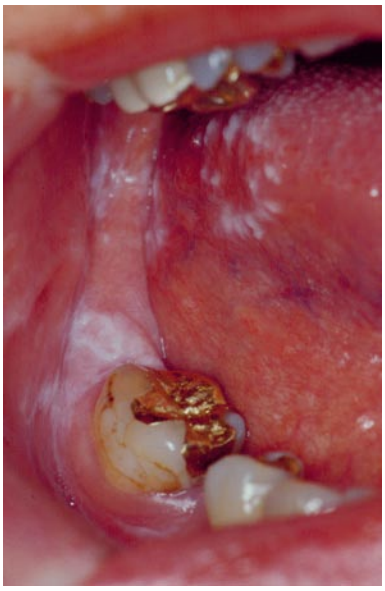

Fig. 8.13 Lichenoid reaction of the mucosa contacting an alloy

Dentlearn.ir

8.5 Allergies

8.5.1 Mechanisms

As far as is known, metal ions cannot act as allergens themselves [49, 114]. Rather, they act as haptens, binding to resident molecules and altering these molecules such that the body "sees" the complex as foreign. Because of their ability to bind many types of molecules in the body, such as proteins, nucleic acids, and carbohydrates, the potential for many types of complexes is great. Little is known about the specific metal complexes that cause the allergic response or whether these complexes are even similar among different allergic individuals. Knowledge to date indicates that metals in alloys cannot cause an allergic response without being released from the alloy. Thus, allergic reaction to an alloy is not possible unless an element is released from the alloy. Clinically, this statement has been substantiated by individuals who have documented allergic responses to metal ions such as palladium ions but who demonstrate no allergic response to palladium metal because so few ions are released [146].

The exposure of metal ions to the oral mucosa may elicit different reactions than if the ions are exposed to the skin. Oral exposure has been reported to cause tolerance (e.g., to nickel) [71, 147]. The frequency of nickel allergies in a group of 14–18-year-old adolescents was 30% among girls, 3% among boys, and 31% among ear-pierced individuals versus 2% among non-ear-pierced subjects. None of the girls who was treated with an orthodontic device before being pierced revealed a sensitivity against nickel, whereas 35% were "nickel-positive" if the piercing was done prior to orthodontic treatment. These results reveal a possible tolerance to nickel that was caused by (nickel-containing) orthodontic wires [71]. This phenomenon, however, has not been observed or reported for nickel-containing casting alloys.

It is often difficult to determine whether an inflammatory response to a metal is mediated by an allergic mechanism or a toxic mechanism or some combination of both. The boundaries between these two mechanisms are not always clear. Classically, allergic responses are characterized by dose independence; that is, the body's reaction is independent of the dose applied. Thus, low doses that would not cause inflammation via toxicity would cause inflammation by activating Langerhans cells [114]. In reality, the boundaries between toxicity and allergy are not as clear. Nickel allergy occurs in 15–20% of females [151]. This means that 80–85% of females will not react to nickel at allergic doses, i.e., at very low concentrations. In toxicity reactions (i.e., at higher concentrations), the response of a population is much more uniform. A true allergic response involves recognizing a metal–protein complex as foreign and can specifically activate the Langerhans cells. However, the absence of allergy does not preclude metals from affecting immune cells. Metal ions may alter or disrupt normal immune pathways in nonspecific ways that then cause an inflammatory response [48, 52, 125]. This type of interaction could be viewed as a toxic response because it does not involve recognition of a specific metal–protein complex. The relationships between allergy and toxicity are still active areas of research. It is possible for very low levels of metal ions to be released in an allergic individual with no measurable allergic response. Only if these levels are exceeded does the concept of dose independence apply. This would explain why some patients who were sensitive in the patch test to a metal did not show clinical signs of an allergic reaction, although the metal was a component of an alloy in their oral cavity [104].

It is possible for metal ions to cross react in their induction of allergic responses. A cross-allergy occurs when antigens are sufficiently similar that allergy to one antigen will guarantee that the individual will be allergic to the second antigen even with no previous exposure. Cross-reactivity is difficult to prove, but it is suspected for palladium and nickel (see also Chap. 1). A number of studies have reported that patients who are sensitive to palladium are nearly always also sensitive to nickel [1, 43, 60, 157]. This incidence is further decreased by the relatively low corrosion rate of palladium alloys. Nickel exposure occurs from a variety of sources, including foods (see Appendix, Table 8.8) and corrosion of utensils. Thus, in patients in whom nickel sensitivity is suspected, all sources of nickel exposure need to be examined as possible causes.

Clinical Practice Advice

A number of studies have documented that patients who are allergic to palladium are likely to be allergic to nickel as well [43, 60, 122]. Thus, the clinician should carefully consider whether palladium-containing alloys should be applied in patients with nickel allergy, although the incidence of documented allergies to palladium-containing dental alloys is less than to nickel-containing alloys. This incidence is further decreased by the relatively low corrosion rate of palladium alloys. Nevertheless, this possibility should be discussed with the patient.

Dentlearn.ir

8.5.2 Diagnosis and Frequency of Allergies to Metal Ions

Allergy to metals is generally assessed by either applying the metal (ion) to the skin in a patch or by injecting a small amount of a solution of the ion below the skin (see also Chap. 2). Even with careful administration and interpretation by experienced physicians, assessment of the response is difficult. With metal ions, the salt (anion) of the metal ion is also important to the response. Thus, the chloride salt may elicit a different response than the sulfate or nitrate does. The oxidation state of the metal also affects the outcome of the test. The metal salts are generally in some liquid vehicle, and the nature of the vehicle will affect the results, whether it be water, oil, or petrolatum. Even the type of patch may influence the results. Additionally, many salts irritate the skin, and it is often difficult to distinguish between inflammation caused by the irritant effect and irritation caused by the allergic effect [75]. Therefore, these examinations have to be done by an experienced allergist. In one study of patients with inflammatory oral reactions and a documented positive response to a patch test using metal salts, no skin response was observed when alloy discs containing the offending metals were placed on the skin [43].

The incidence of hypersensitivity to clinical dental products in general appears to be quite low [56]. In one study, only one in 400 prosthodontic patients had adverse effects of any kind to the material. Of these, 27% were related to base metal alloys and noble alloys. In general, redness, swelling, pain, and lichenoid reactions were common signs and symptoms of the responders. Some systemic reactions were also reported. One problem in assessing the incidence of problems related to dental metals is that the symptoms can be distant from the site of the material.

Current studies indicate that about 15% of the general population is sensitive to nickel, about 8% to cobalt, and 8% to chromium [59]. Documented allergies have also been reported for mercury, copper, gold, platinum, tin, zinc, and titanium [15, 96, 113, 130, 138, 177]. However, the frequencies of these allergies are not well defined. Recently, gold has attracted special interest because large parts of the population have dental gold alloy restorations [94], and in patient groups with dermatological/mucosal problems, 5–15% reacted positively to gold sodium thiosulfate 0.5–2% in petrolatum, which is commonly used for patch testing [42, 68]. There is even one study indicating that gold-containing dental restorations are increasingly associated with gold allergic reactions [115]. A Norwegian adverse reaction unit for dental biomaterials reported after 4 years of activity (1993–1997) that of the patients who were patch tested, 23% were positive to gold, 28% to nickel, 14% to cobalt, 9% to palladium, and 6% to mercury [144].

Oral lichenoid reactions have been reported to heal in a number of cases after removal of the gold alloy restorations, and in single cases, burning mouth was reported to disappear [94]. However, contact dermatitis reactions to high gold alloys may also be due to small amounts of substances like nickel or cobalt not declared in the composition of the alloy [29]. The same may be true for titanium-based implant materials, which may – as was shown for orthopedic titanium alloys – contain trace amounts (0.012–0.034 wt.%) of nickel [127] .

There have been reports of allergic responses to other metals, although they are less well documented. It is clear that the frequency of hypersensitivities to metal ions differs considerably among the metals. The reasons for these differences are probably related to the frequency of exposure of the population to the metals, the likelihood that the metals are released as ions from the metal, and the biological interactions of the metal ions with cells, macromolecules, and tissues. There is also probably a genetic component to the metal allergy. For example, the high incidence of nickel allergy is probably a result of the high frequency of exposure through metallic jewelry, the lability of nickel ions from alloys, and the biological interactions of nickel ions with the tissues [136]. The population is also commonly exposed to gold jewelry, but the incidence of allergy to gold is generally comparatively rare. This lower incidence probably results from the low levels of gold that tend to be released and may result from the inability or reduced ability of gold ions to interact with tissues in a manner that promotes the allergic response. The reasons why some metal ions cause allergy whereas others do not is unknown. One study revealed that not more than 10% of a group of patients who related their intraoral complaints to dental materials had a verifiable allergy [43].

Key Note

Allergies are a documented cause for clinical reactions to dental alloys, but at a much lower frequency than patients often expect.

Dentlearn.ir

8.5.3 Clinical Symptoms

A study of 139 patients suffering from adverse effects to base metal alloys documented that 99 subjects revealed local symptoms and 33 patients had symptoms at sites distant from the restoration. Ten patients had showed *only* extraoral symptoms [57]. Such symptoms also occur after exposure to gold alloys (Fig. 8.14). Nickel-containing alloys, which are frequently used in orthodontic wires, may give raise to allergic perioral reactions [68] (Fig. 8.15). Manifestations on the abdomen and on limbs have been observed [128]. A case of nail dystrophy caused by lichen planus in a patient with gold allergy, with healing after removal of the dental gold restorations has been reported [178]. Intraoral symptoms present mainly as inflammation of the gingiva or the oral mucosa that was in contact with the alloy (Figs. 8.16–8.18). Lichenoid alterations of the gingiva may also be caused by an allergy (see also Fig. 8.13).

Clinical Practice Advice

When evaluating a patient complaint about adverse effects from a dental alloy, the medical history or anamnesis should also include patient problems related to jewelry (e.g., earrings), watches, or metal attachments to clothing, glasses frames, etc. This information may indicate a metal-related allergy.

Fig. 8.14 Extraoral reaction in a 48-year-old woman after insertion of metal ceramic restoration; reaction subsided after exchange of the crowns with all-ceramic restorations

8.6 Mutagenicity, Carcinogenicity, and Teratogenicity

Information on the carcinogenic activity of elements in dental alloys is incomplete or unavailable. Most evidence about the mutagenic or carcinogenic activity of metallic elements has come from industrial settings where large numbers of people (workers) have been exposed to metallic compounds for years and show increased incidence of neoplasias. There is little or no evidence from the dental literature that indicates that dental alloys are carcinogenic [56]. In other databases, however, there is literature that documents the mutagenic potential of metal ions. Mutagenicity can be measured in bacterial systems (e.g., Ames test [84]) or in mammalian cells (e.g., micronucleus test; see also Chap. 2). The reliability of these in vitro systems in predicting in vivo mutagenesis or carcinogenesis is currently limited at best.

Fig. 8.15 Perioral allergic reaction in a 15-year-old girl after insertion of nickel-containing orthodontic wires (CuNiTi); patch test positive for nickel (Courtesy of D. Arenholt-Bindslev, Århus, Denmark)

Overall, there is no evidence that dental alloys cause or contribute to neoplasia in the body. As with toxic and allergic reactions, alloys must release elements for mutagenesis to occur. It is imperative to realize that the form of the metal is critical to its

Dentlearn.ir

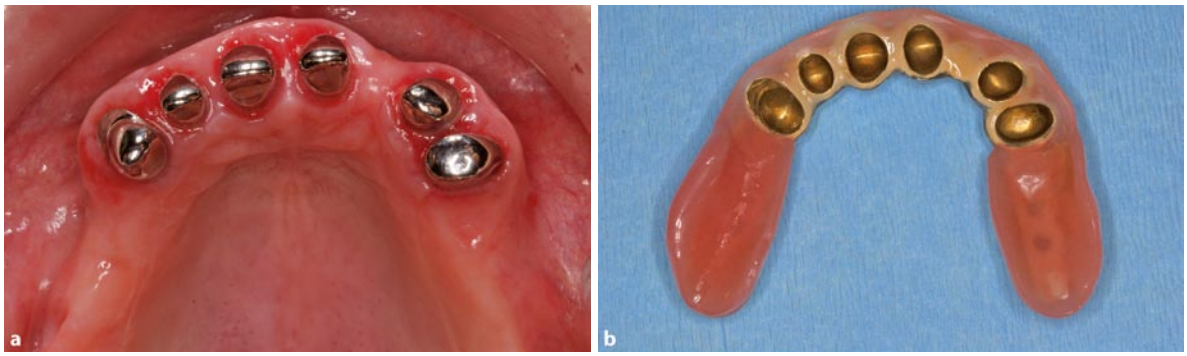

Fig. 8.16 **a** Pronounced (not plaque-related) gingivitis in a female patient around the telescopes with a positive patch test to gold and chromium. **b** Patient's prosthesis

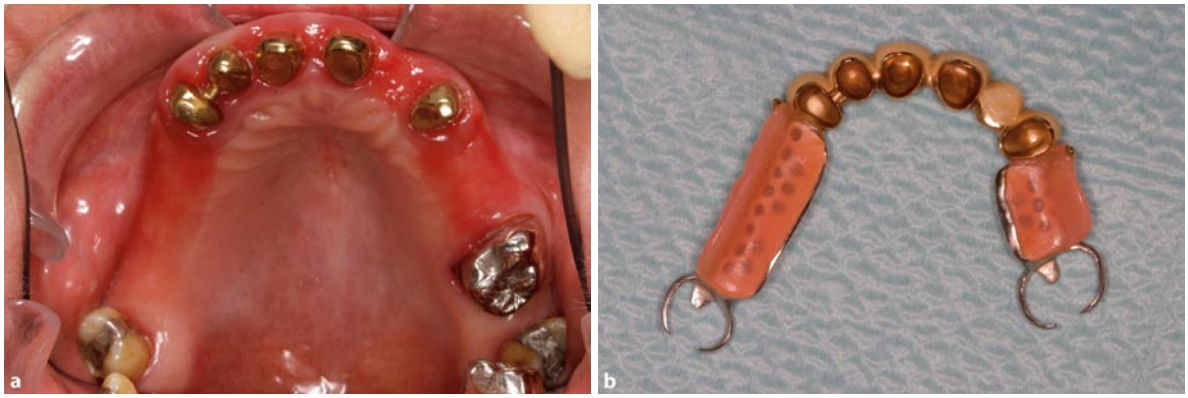

Fig. 8.17 **a** Pronounced (not plaque-related) inflammation of the gingiva and the adjacent oral mucosa in a female patient with a positive patch test to gold, benzoyl peroxide, and hydroquinone. **b** Patient's prosthesis

mutagenic activity. For example, knowing the oxidative state of chromium is crucial for understanding its mutagenic potential. Chromium(III) is not a mutagen, but chromium(VI) is. The molecular form of the metal is also important. Nickel ions are weak mutagens, but nickel subsulfide (Ni_2S_3) is highly mutagenic [4]. Therefore, it is improper to state that a metal is mutagenic or carcinogenic per se because the mutagenic activity will depend on the specific form and oxidative state of the metallic element in question.

Key Note

In dental laboratories, the vapor form of elements such as beryllium is a common mutagenic threat. These vapors are created during the casting of prosthodontic appliances. Beryllium-containing alloys should, therefore, no longer be used if possible. Laboratory personnel may also be exposed to a variety of metals via inappropriate inhalation of small particulates generated during polishing and grinding. Measures to protect laboratory personnel from particulate exposure should be routinely taken [32] (see Sect. 8.3.3).

Table 8.6 lists the known effects of metal ions as mutagens or carcinogens [84, 91]. The data in this table have been collected from many areas of research in the medical, environmental, and industrial literature. Clearly, the data are far from complete. Research is badly needed in this area. Metal ions may exist in several oxidative states or molecular forms, each having its own mutagenic potential. In some cases such as cadmium(II) ions, the two forms (Cd^0 and Cd^{2+}) have similar effects, each known to be able to induce carcinogene-

Dentlearn.ir

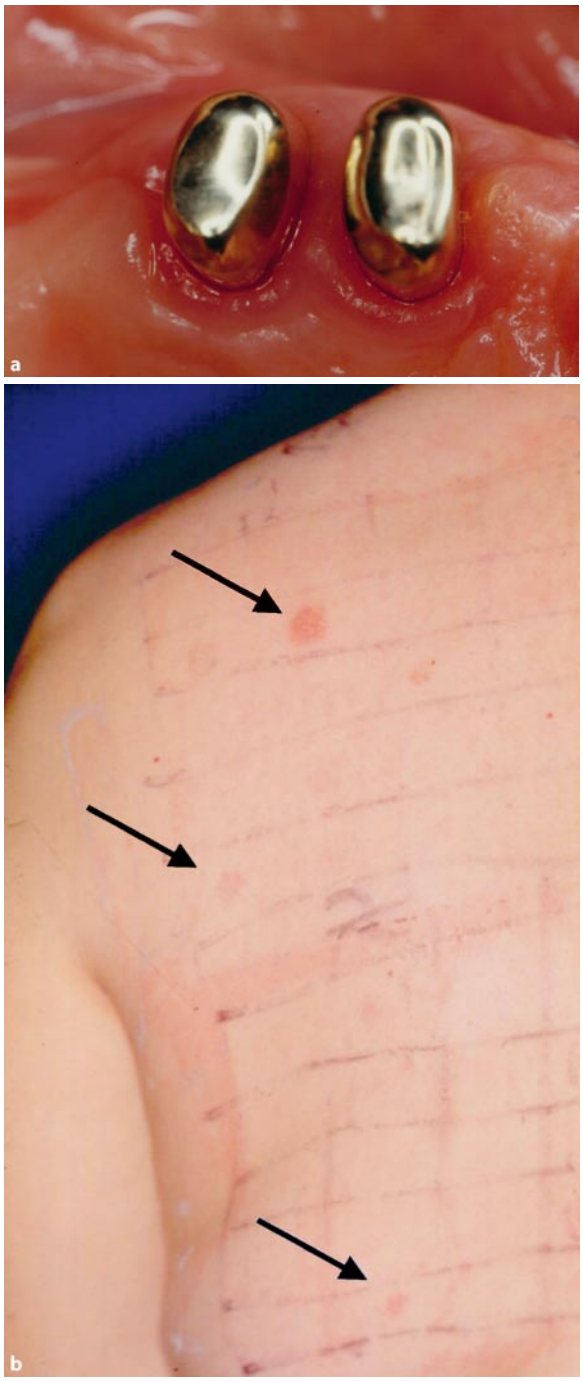

Fig. 8.18a,b Palladium allergy. **a** Pronounced (not plaque-related) gingivitis in a female patient with an allergy to palladium and palladium-containing alloy. **b** Positive patch test to nickel (*upper arrow*), cobalt (*central arrow*), and palladium (*lower arrow*)

sis. For other elements, the different forms may have different effects. For example, with nickel subsulfide (Ni_2S_3), there have been studies linking exposure with respiratory tract neoplasia. Thus, nickel subsulfide is a documented carcinogen. For nickel chloride ($NiCl_2$) and nickel sulfate ($NiSO_4$), the evidence is much less clear, and a weak mutagenic effect is suspected [34]. Some ions such as tin(II), copper(II), and iron(II) are known mutagens but have never been shown to induce neoplasia. It is likely that the mutations induced by these metals are relatively easy to repair by the body when compared with mutations induced by other metal ions. Thus, the mutations are less likely to lead to carcinogenesis. But the current data are too incomplete to answer these questions. More recent in vitro studies with palladium and gallium chloride indicated a weak mutagenic potency of these ions [91].

To summarize, it is clear that metallic ions may act as mutagens or carcinogens in certain forms or through certain specific routes of exposure. These data have been determined primarily through long-term epidemiological studies and are therefore subject to the limitations associated with these types of studies. For example, it is dangerous and misleading to assume that a correlation between metal ion exposure and carcinogenesis proves a cause-and-effect relationship. The evidence at this point in time is simply empirical. Mechanistic evidence is needed, and this is an active area of research, particularly regarding nickel, arsenic, cadmium, and other environmentally important metals.

Key Note

The use of metals in dentistry relies on accepting the biological risks associated with the use as well as the benefits these metals bring to dentistry. We can show that the risks of neoplasm are very low when using these dental alloys. Indeed, all evidence indicates that the risk is exceedingly small. However, it is not possible to prove that the risk is zero. At the same time, we must also strive to minimize this risk by using alloys that do not contain and release known carcinogenic elements.

8.7 Public Concerns and Controversies

As for other dental materials (e.g., amalgam and resin-based composites), certain patient groups oppose the use of specific alloys or particular components. In

Dentlearn.ir

Table 8.6 Metallic elements in dental alloys with known mutagenicity or carcinogenicity [4, 34, 63, 84, 91]

Element	Form	Mutagenic/carcinogenic	Remarks
Beryllium	Be^0	Carcinogenic	Be derivatives, too
	Be^{2+}	Carcinogenic	Be derivatives, too
Cadmium	Cd^0	Carcinogenic	Cd derivatives, too
	Cd^{2+}	Carcinogenic	Cd derivatives, too
Chromium	Cr^{3+}	Nonmutagenic	Very reactive; kills cells before reaching cell nucleus
	Cr^{6+}	Carcinogenic	
Cobalt	Co^0	Potentially carcinogenic	
	Co^{2+}	Potentially carcinogenic	
Copper	Cu^{1+}	Unknown	
	Cu^{2+}	Mutagenic, but noncarcinogenic	
Gallium	Ga^{3+}	Likely nonmutagenic	Data from in vitro studies
Gold		Unknown	Minor risk in dental alloys due to its very low tendency to corrode; organic and inorganic forms likely different
Indium		Unknown	
Iron	Fe^{2+}	Mutagenic but noncarcinogenic	High dietary intake
Nickel	Ni^0	Potentially carcinogenic	
	Ni_2S_3	Carcinogenic	Nickel subsulfide
	$NiCl_2$	Weakly mutagenic	
	$NiSO_4$	Weakly mutagenic	
Palladium	Pd^{2+}	Limited data, potentially mutagenic	Minor risk in dental alloys due to its low corrosion rate
Platinum		Unknown	Minor risk in dental alloys due to its very low tendency to corrode; organic and inorganic forms likely different
Silver	Ag^{1+}	Limited data, likely nonmutagenic	
Tin	Sn^{2+}	Mutagenic but noncarcinogenic	
	Sn^{4+}	Unknown	
Zinc	Zn^{2+}	Nonmutagenic	High daily intake

recent years, palladium and, to a lesser extent, nickel were frequently viewed as harmful when used in dental alloys. Interestingly, a number of subjects who object to these dental alloys have their tongues pierced (Fig. 8.19) without asking about the composition of the jewelry used in the piercing alloy. Damage due to tongue piercing has been described in the literature [28, 83, 101].

Dentlearn.ir

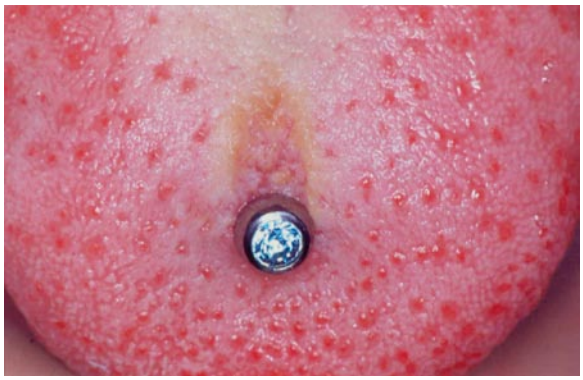

Fig. 8.19 Pierced tongue with inflammatory reaction of unknown genesis. The female patient was unaware of the composition of the alloy that was used

8.7.1 Palladium in Dental Alloys

Palladium is a very common component of dental casting alloys of all types, and its use increases periodically in response to the increased cost of gold. Although there is no evidence that palladium causes more biological harm than other elements, there has been protracted controversy about the safety of its use in dental alloys. It is clear that in an ionic form (Pd^{2+}), palladium ions can cause toxicity at sufficiently high concentrations. However, in studies that ranked the toxicity of palladium ions relative to other major metal ions in dental alloys, palladium is among the least toxic of the metal ions and is less toxic than gold ions with several cell lines [118]. Palladium ions are also capable (as haptens) of causing hypersensitivity reactions in the mouth [157]. In most cases, these hypersensitivity reactions occur in people with nickel hypersensitivity. According to most studies, it is rare for an individual to exhibit palladium hypersensitivity in the absence of nickel hypersensitivity; thus, a cross-allergy between nickel and palladium is suspected [1]. Almost all studies documenting the incidence of palladium hypersensitivity have been done by skin exposure. Little evidence is available about hypersensitivity through the oral route or about the mutagenic or carcinogenic effects of palladium ions. One study in mice that were fed palladium chloride at high levels throughout their lifespan indicated that palladium ions had a "slight" carcinogenic potential, but the differences were nearly not statistically significant from controls [126]. Although palladium ions have known adverse biological effects, the risk of using palladium in dental alloys is low because of the low rate of palladium release from these alloys [157].

Key Note

It appears unlikely that palladium used in dental alloys poses a biological risk any higher than for other noble metals such as gold or platinum. When the benefits of using palladium in dental alloys are considered (beneficial physical properties), the risk–benefit ratio of using palladium is exceedingly favorable.

8.7.2 Nickel in Dental Alloys

Potential "dangers" that might be caused by nickel-containing dental alloys have also generated public controversy, but, interestingly, to a smaller degree compared with palladium. The nickel content of some dental alloys is greater than 70 wt.%, and nickel-containing alloys are used in removable partial dentures, crowns, orthodontic appliances, and endodontic files. Like palladium ions, nickel ions have documented adverse biological effects if present in sufficient concentrations [136]. For example, nickel is toxic to cells. In some forms, such as nickel carbonyl, the toxicity is extreme [49]. For nickel ions, studies have demonstrated that the toxicity of nickel ions is no greater than that seen with many other components of dental alloys. However, nickel is a well-documented allergen. Nickel is also carcinogenic, especially in some forms such as nickel subsulfide (Ni_2S_3) [4]. Finally, nickel ions have recently been reported to cause a potent and persistent inflammatory response in connective tissues [48, 151]. This inflammatory response is not allergically mediated, although many of the same cells are involved.

Unlike palladium, nickel is released from nickel-containing dental alloys into the body in higher amounts. This release has been demonstrated in orthopedics and dentistry, both in vitro and in vivo [46]. In this sense, the risk of using nickel-containing alloys is greater than that for palladium because the ions that mediate adverse biological responses are released in potentially large amounts. However, the central question is whether the amounts released are sufficient in vivo to cause or contribute to these adverse biological effects. Active research continues in this area.

Dentlearn.ir

Worldwide, there are certainly significant benefits of using nickel-containing alloys in dentistry. For applications such as orthodontic wires or endodontic files, these alloys are arguably the best alloys currently available. However, the risks associated with nickel-containing alloys are higher than for other dental alloys. Thus, the risk–benefit ratio is somewhat less favorable for these alloys.

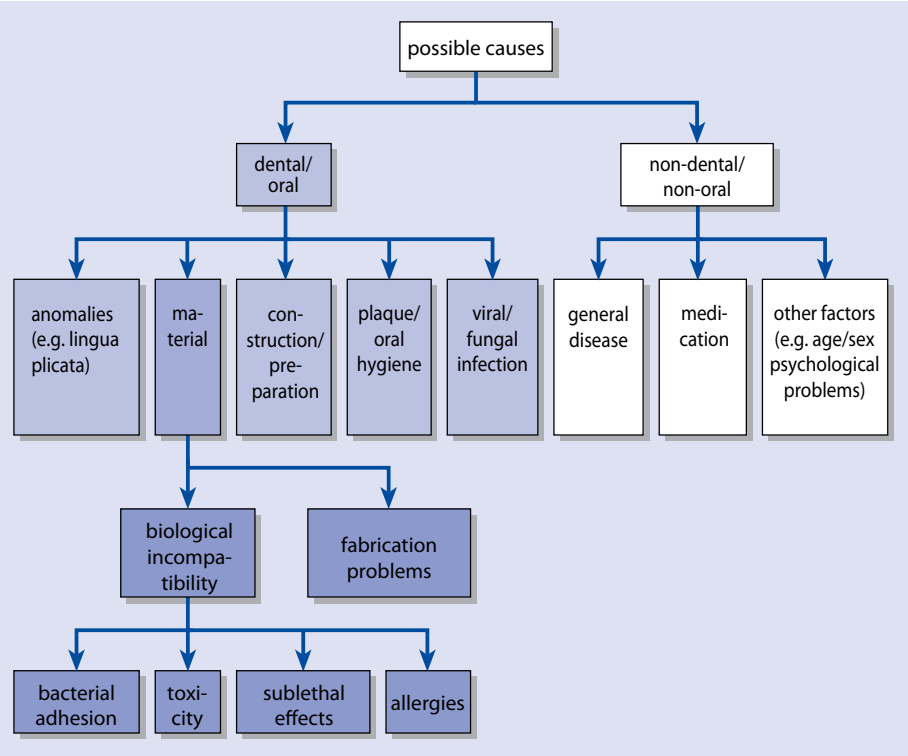

Fig. 8.20 Simplified diagrammatic illustration of possible causes or factors related to symptoms after application of dental alloys [122]. Sublethal effects are influences of metals on the cellular metabolism, for instance, an increased synthesis of proinflammatory interleukins [125]

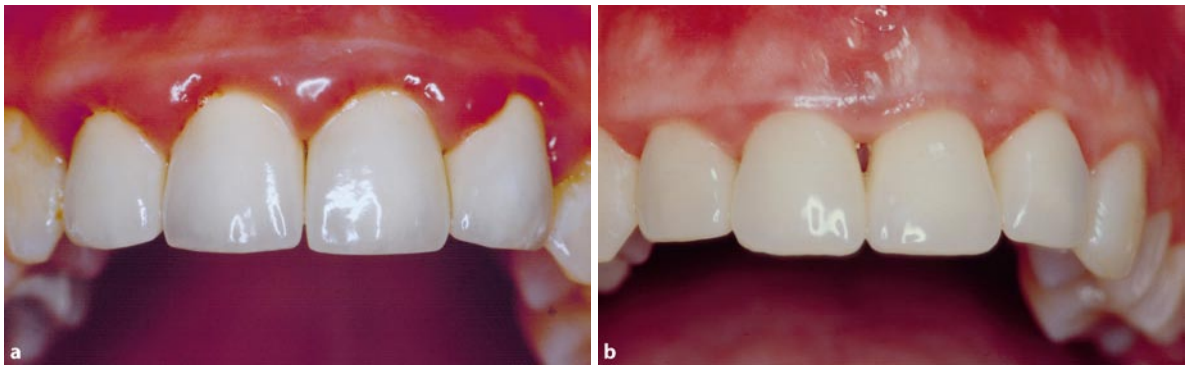

Fig. 8.21a,b Reaction after replacement of metal-containing crowns (ceramic alloy crowns) by metal-free restorations: **a** Patient with pronounced gingivitis due to the PFM crowns; **b** Situation after removal of the crowns and seating of temporary resin crowns

Dentlearn.ir

Conclusions for the Dental Practitioner

1. Corrosion of dental alloys is a necessary but not sufficient condition for adverse tissue reactions. Good corrosion resistance should be considered an important criterion for alloy selection.
2. The corrosion of dental alloys may be significantly increased by improper processing (e.g., formation of pits, crevices, or gold coating). This principle also applies for inappropriate processing of dental solders. Acids, including those found in some fluoride preparations, may significantly enhance the corrosion of dental alloys, including titanium alloys. Nickel alloys are especially susceptible to lower pH.
3. A local reaction (gingivitis) adjacent to alloys may be caused by exposed oxide layers in the marginal area of crowns made of ceramic alloys (Fig. 8.21). Thus, the lab technician should completely remove oxide layers that are not covered by ceramic.
4. Saliva tests or analyses of the metal concentrations of (inflamed) gingiva or mucosa adjacent to metal restorations are of little benefit for diagnosing adverse effects from alloys.
5. Multiple causes may be responsible for alloy-related symptoms in the oral cavity (as well as in extraoral sites; see Fig. 8.20). Therefore, diagnosis requires a comprehensive and meticulous dental examination, including a potential improvement of oral hygiene, in order to exclude plaque-associated reactions. These examinations are usually time consuming. Knowledge about the exact composition of the alloy used is a prerequisite for an appropriate, accurate diagnosis. For this, the splinter or chip test has been successfully applied [43, 122] (see Chap. 2).
6. Allergies to dental alloys have been documented, although their frequency is low. It is not recommended to patch-test an alloy before applying it ("prophetic examination") because the patch itself may sensitize the patient. Furthermore, a negative patch test is no guarantee of current or future absence of hypersensitivity. All evidence currently available indicates that dental alloys for prosthodontic restorations are not carcinogenic.

Dentlearn.ir

Appendix

Table 8.7 Cytotoxicity of cations of metals frequently used in dental alloys. For determining the TC_{50}, different cell lines were used: mouse fibroblasts (L-929 and Balb/c 3T3 cells), kidney epithelial cells, and gingival fibroblasts [116, 119, 158]. Cell activity was assessed measuring mitochondrial enzyme activity (MTT assay)

Test substance	L-929 Zellen MTT assay TC_{50} [μM] [119]	Kidneys epithelial cells MTT assay TC_{50} [μM] [119]	Gingival fibroblasts MTT assay TC_{50} [μM] [119]	L-929 cells ^{3}H-thymidin assay TC_{50} [μM] [116]	Balb/c 3T3 cells MTT assay TC_{50} [μM] [158]
$AgNO_3$	4.8	4.6		18 (Ag_2SO_4)	5.8 (Ag_2SO_4)
$ZnCl_2$	7	9.5	81	189	28
$HAuCl_4$ $3H_2O$	21	36	210	77	91
$CdCl_2$	10	26			1.1
$HgCl_2$	11	13	24		
H_2PtCl_6	33	302		17 ($PtCl_4$)	
$CuCl_2$ $2H_2O$	139	251	273	97	240
$CoCl_2$ $6H_2O$	100	108		49	
$NiCl_2$ $6H_2O$	188	379		166	190
$PdCl_2$	281	134		240	
$MnCl_2$ $4H_20$	556	216			360
$CrCl_3$ $6H_2O$	1,790	2,130	3,011	>1,000 ($CrCl_2$)	
$MoCl_5$	775	927	1,585	>1,000	
$NbCl_5$	676	921			
$GaCl_3$	1,530	2,140		53	200
$InCl_3$	2,310	2,110	4,200	30	>435
$SnCl_2$ $2H_2O$	3,110	2,280		>1,000	

Dentlearn.ir

Table 8.8 Nickel concentration in foodstuffs [37]

Food	Usual serving size	Nickel content (mg)
Milk		
Cow's milk, 3.5 % fat and 0.3% fat	250 ml	2.5
Sheep milk	250 ml	57.5
Dairy products		
Butter	20 g	2.0
Edamer cheese, all fat grades	40 g	35.6
Eggs		
Hen's egg	60 (1 egg)	14.4
Meat		
Mutton meat	150 g	9.0
Mutton, liver	150 g	39.0
Beef, pure flesh	150 g	1.5
Pork, pure flesh	150 g	1.5
Fish		
Herring	200 g	60.0
Pike	200 g	100.0
Salmon	200 g	4.0
Seafood		
Lobster	150 g	99.0
Scallop	150 g	0.5
Grain		
Corn, whole grain	40 g	0.1
Weat, whole grain	40 g	13.6
Rice, unpolished	60 g (side dish)	108.0
Vegetable		
Cauliflower	200 g	60.0
Broccoli	200 g	100.0
Fruit		
Apple	200 g	22.0
Cherries	200 g	120.0
Alcoholic beverages		
Pale ale	400 ml	4–800
White wine, medium quality	200 ml	12.6
Coffee or tea		
Coffee, roasted	20 g*	15.4
Black tea	2 g*	0.1

* amounts for one pot

References

1. Aberer, W., Houb, H., Strohal, R., Salvicek, R.: Palladium in dental alloys – the dermatologists' responsibility to warn? Contact Dermatitis 28, 163 (1993).
2. Al-Hiyasat, A. S., Darmani, H.: The effects of recasting on the cytotoxicity of base metal alloys. J Prosthet Dent 93, 158–163 (2005).
3. Al-Hiyasat, A. S., Darmani, H., Bashabsheh, O. M.: Cytotoxicity of dental casting alloys after conditioning in distilled water. Int J Prosthodont 16, 597–601 (2003).
4. Arrouijal, F.Z., Hildebrand, H.F., Vophi, H., Marzin, D.: Genotoxic activity of nickel subsulphide-α Ni_3S_2. Mutagenesis 5, 583–589 (1990).
5. Aughtun, M., Brauner, A.: Antibakterielle Wirkung unterschiedlicher Dentallegierungen auf Keime der oralen Mikroflora in vitro. [Antibacterial effects of different dental alloys on oral bacteria] Dtsch Zahnärztl Z 43, 869–873 (1988).
6. Axell, T.: A prevalence study of oral mucosal lesions in an adult Swedish population. Odontol Revy 27, 1–103 (1976).
7. Bader, J., Rozier, R.G., McFall, W.T.: The effect of crown receipt on measure of gingival status. J Dent Res 70, 1385–1389 (1991).
8. Begerow, J., Neuendorf, J., Turfeld, M., Raab W., Dunemann, L.: Long-term urinary platinum, palladium and gold excretion of patients after insertion of noble-metal dental alloys. Biomarkers 4, 27–37 (1999)
9. Bell, J.A., Brockmann, S.L., Feil, P., Sackuvich, D.A.: The effectiveness of two disinfectants on denture base acrylic resin with an organic load. J Prosthet Dent 61, 580–583 (1989).
10. Bergdahl, B.J., Anneroth, G., Anneroth, I.: Clinical study of patients with burning mouth. Scand J Dent Res 102, 299–305 (1994).
11. Bergdahl, M., Bergdahl, J.: Perceived taste disturbance in adults: prevalence and association with oral and psychological factors and medication. Clin Oral Investig 6, 145–149 (2002).
12. Bergendal, T., Holmberg, K.: Studies of candida serology in denture stomatitis patients. Scand J Dent Res 90, 315–322 (1982).
13. Berstein, A., Bernauer, I. Marx, R., Geurtsen, W.: Human cell culture studies with dental metallic materials. Biomaterials 13, 98–100 (1992).
14. Bessing, C., Kallus, T.: Evaluation of tissue response to dental alloys by subcutaneous implantation. Acta Odontol Scand 45, 247–255 (1987).
15. Björkner, B., Bruze, M., Moller, H.: High frequency of contact allergy to gold sodium thiosulfate. An indication of gold allergy? Contact Dermatitis 30, 144–151 (1994).
16. Black, J.: Systemic effects of biomaterials. Biomaterials 5, 11–18 (1984).
17. Black, J.: Does Corrosion Matter? J Bone Joint Surg (Br) 70, 517–520 (1988).
18. Black, J., Maitin, E.C., Gelman, H., Morris, D.M.: Serum concentrations of Cr, Co, and Ni after total hip replacement: a six month study. Biomaterials 4, 160–164 (1983).
19. Bolewska, J., Hansen, H.J., Holmstrup, P., Pindborg, J.J., Stangerup, M.: Oral mucosal lesions related to silver amalgam restorations. Oral Surg Oral Med Oral Pathol 70, 55–58 (1990).
20. Brauner, H., Haussner, T.: Zum Korrosionsverhalten von Palladiumbasislegierungen. [Corrosion properties of palladium alloys] Dtsch Zahnärztl Z 44, 119–121 (1989).

Dentlearn.ir

21. Brune, D.: Metal release from dental biomaterials. Biomaterials 7, 163–175 (1986).
22. Brune, D., Beltesbrekke, H.: Dust in dental laboratories. Part I: types and levels in specific operations. J Prosthet Dent 43, 687–692 (1980).
23. Bumgardner, J.D., Lucas, L.C.: Cell culture evaluation of nickel based dental casting alloys. J Dent Res 72, 368 (1993).
24. Bumgardner, J.D., Lucas, L.C.: Corrosion and cell culture evaluations of nickel-chromium dental casting alloys. J Appl Biomater 5, 203–213 (1994).
25. Bumgardner, J.D., Lucas, L.C.: Cellular response to metallic ions released from nickel-chromium dental cast alloys. J Dent Res 74, 1521–1527 (1995).
26. Bundeszahnärztekammer (eds): Das Dental Vademekum. [The Dental Vademecum] Deutscher Ärzte-Verlag, Cologne 2001.
27. Burns, J.K., Lucas, L.C.: Atomic absorption analyses in a canine copper dental alloy study. J Dent Res 68, 322 (1989).
28. Campbell, A., Moore, A., Williams, E., Stephens, J., Tatakis, D.N.: Tongue piercing: impact of time and barbell stem length on lingual gingival recession and tooth chipping. J Periodontol 73, 289–297 (2002).
29. Čelecič A., Baučič M., Stipetič J., Baučič I., Miko S., Momčilovič B: Ion release from gold/platinum dental alloy: could release of other elements be accountable in the contact allergy attributed to the gold? J Mater Sci Mater Med 17, 301–305 (2006).
30. Clark, G.C., Williams, D.F.: The effects of proteins on metallic corrosion. J Biomed Mater Res 16, 125–134 (1982).
31. Can G., Akpinar G., Can A.: Effects of base-metal casting alloys on cytoskeletal filaments in cultured human fibroblasts. Int J Prosthodont 17 (1), 45–51 (2004).
32. Comité Européan de Normalisation: Resolution 6, CEN/TC 055, 2002–02-26. Comité Européen de Normalisation, Brussels 2002.
33. Coombs, R., Gell, P.: Classification of allergic reactions responsible for clinical hypersensitivity and disease. In: Gell P., Coombs R., Kochmann P. (eds): Clinical Aspects of Immunology. Blackwell, Oxford 1982.
34. Costa, M.: Molecular mechanisms of nickel carcinogenesis. Ann Rev Pharmacol 31, 321–337 (1991).
35. Craig, R.G., Powers, J.M. (eds): Restorative Dental Materials, 11th edn. Harcourt Health Sciences, St. Louis 2002, pp 125–162.
36. Endo, K.: Chemical notification of metallic implant surfaces with biofunctional proteins (part 2). Corrosion resistance of a chemically modified NiTi alloy. Dent Mat J 14, 199–210 (1995).
37. Fachmann, W., Kraut, H., Scherz, W., Seuser, F., Souci, W.: Die Zusammensetzung der Lebensmittel [The Composition of Food], 6th edn. Med Pharm, Stuttgart, 2000.
38. Femiano, F., Scully, C., Gombos, F.: Idiopathic dysgeusia; an open trial of alpha lipoic acid (ALA) therapy. Int J Oral Maxillofac Surg 31, 625–628 (2002)
39. Fontana, M.G.: Corrosion Engineering, 3rd edn. McGraw-Hill, New York 1986, pp 153–218.
40. Forssell, H., Jaaskelainen, S., Tenovuo, O., Hinkka, S.: Sensory dysfunction in burning mouth syndrome. Pain 99, 41–47 (2002).
41. Foti, B., Tavitian, P., Tosello, A., Bonfil, J.-J., Franquin, J.-C.: Polymetallism and osseointegration in oral implantology: pilot study on primate. J Oral Rehabil 26, 495–502 (1999).
42. Fowler, J. A., Taylor, J., Storrs, F., Sherertz, E., Rietschel, R., Pratt, M., Toby Mathias, C. G., Marks, J., Maibach, H., Fransway, A., DeLeo, V., Belsito, D.: Gold allergy in North America. Am J Contact Dermat 12, 3–5 (2001).
43. Garhammer, P., Schmalz, G., Hiller, K.-A., Reitinger, T., Stolz, W.: Patients with local adverse effects from dental alloys: frequency, complaints, symptoms, allergy. Clin Oral Investig 5, 240–249 (2001).
44. Garhammer, P., Schmalz, G., Hiller, K.-A., Reitinger, T.: Metal content of biopsies adjacent to dental cast alloys. Clin Oral Investig 7, 92–97 (2003).
45. Garhammer, P., Hiller, K.-A., Reitinger T., Schmalz, G.: Metal content of saliva of patients with and without metal restorations. Clin Oral Investig 8, 238–242 (2004).
46. Geis-Gerstorfer, J.G., Sauer, K.H., Pässler, K.: Ion release for Ni-Cr-Mo and Co-Cr-Mo alloys. Int J Prosthodont 4, 152–158 (1991).
47. Geurtsen, W.: Biocompatibility of dental casting alloys. Crit Rev Oral Biol Med 13, 71–84 (2002).
48. Goebeler, M., Meinardus-Hager, G., Roth, J., Goerdt, S., Sorg, C.: Nickel chloride and cobalt chloride, two common contact sensitizers, directly induce expression of intercellular adhesion molecule-1 (ICAM-1), vascular cell adhesion molecules-1 (VCAM-10, and endothelial leukocyte adhesion molecules (ELAM-1) by endothelial cells. J Invest Dermatol 100, 759–765 (1993).
49. Goyer, R.A.: Toxic effects of metals. In: Klaassen C.D., Amdur M.O., Doull J. (eds): Casarett and Doull's Toxicology, 3rd edn. MacMillan, New York 1986, pp 582–635.
50. Granchi. D., Cenni, E., Ciapetti, G., Savarino, L., Stea, S., Gamberini, S., Gori, A., Pizzoferrato, A.: Cell death induced by metal ions: necrosis and apoptosis? J Mater Sci Mater Med 9, 31–37 (1998).
51. Gromnica-Ihle, E.: Der Rheumatiker in der Zahnarztpraxis. [The rheumatic patient in the dental practice] Zahnärztl Mitt 89, 44–48 (1999).
52. Hallab, N. J., Mikecz, K., Vermes, C., Skipor, A., Jakobs, J. J.: Orthopaedic implant related metal toxicity in terms of human lymphocyte reactivity to metal protein complexes produced from cobalt-base and titanium-base implant alloy degradation. Mol Cell Biochem 222, 127–136 (2001).
53. Hannig, M.: Transmission electron microscopy of early plaque formation on dental materials in vivo. Eur J Oral Sci 107, 55–64 (1999).
54. Hannig, M.: Ultrastructural investigation of pellicle morphogenesis at two different intraoral sites during a 24-h period. Clin Oral Investig 99, 88–95 (1999).
55. Hao, S.Q., Lemons,J.E.: Histology of dog dental tissues with Cu-based crowns. J Dent Res 68, 322 (1989).
56. Hensten-Pettersen A.: Casting alloys: side-effects. Adv Dent Res 6, 38–43 (1992).
57. Hensten-Pettersen, A., Jacobsen, N.: Perceived side effects of biomaterials in prosthetic dentistry. J Prosthet Dent 65, 138–144 (1991).
58. Herrström, P., Högstedt, B.: Clinical study of oral galvanism: no evidence of toxic mercury exposure but anxiety disorder an important background factor. Scand J Dent Res 101, 232–237 (1993).
59. Hildebrand, H.F., Veron, C., Martin, P.: Nickel, chromium, cobalt dental alloys and allergic reactions: an overview. Biomaterials 10, 545–548 (1989).
60. Hindsén M., Spiren A., Bruze M.: Cross reactivity between nickel and palladium demonstrated by systemic administration of nickel. Contact Dermatitis 53, 2–8 (2005).
61. Hodgson, E., Levi, P.E.: Modern Toxicology. Elsevier, Amsterdam 1987, pp 205–207.

Dentlearn.ir

62. Hösch, A., Strietzel, R.: Korrosion von Titan in thiocyanat-, chlorid- und fluoridhaltigen künstlichen Speicheln. [Corrosion of titanium in artificial saliva containing thiocyanate, chloride and fluoride] Dtsch Zahnärztl Z 49, 767–769 (1994).
63. International Agency for Research on Cancer: IARC monographs on the evaluation of carcinogenic risks to humans – list of IARC evaluation. IARC, Lyon 1996, pp 1–40.
64. International Organization for Standardization: ISO 8891 – Dental casting alloys with noble metal content of at least 25% but less than 75%. International Organization for Standardization, Geneva 1998.
65. International Organization for Standardization: ISO 1562 – Casting gold alloys. International Organization for Standardization, Geneva 2004.
66. International Organization for Standardization: ISO 16744: Dentistry – base dental materials for fixed dental restorations. International Organization for Standardization, Geneva 2003.
67. International Organization for Standardization: ISO 8044 – Corrosion of metals and alloys – basic terms and definitions. International Organization for Standardization, Geneva 1999.
68. Khamaysi Z., Bergman R., Weltfried S.: Positive patch test reactions to allergens of dental series and the relation to the clinical presentations. Contact Dermatitis 55, 216–218 (2006).
69. Kappert, H.F.: Oraler Galvanismus unter besonderer Berücksichtigung des Amalgams. [Oral galvanism especially considering amalgam] Phillip J 7, 233–240 (1990).
70. Kappert, H.F.: Metallegierungen in der Zahnheilkunde. [Alloys in dentistry] Zahnärztl Mitt 7, 46–54 (1992).
71. Kerosuo, H., Kullaa, A., Kerosuo, E., Kanerva, L., Hensten-Pettersen, A.: Nickel allergy in adolescents in relation to orthodontic treatment and piercing of ears. Am J Orthod Dentofacial Orthop 109, 148–154 (1996).
72. Khamis, E., Seddik, M.: Corrosion evaluation of recasting nonprecious dental cast alloys. Int Dent J 45, 209–217 (1995).
73. Kratzenstein, B., Sauer, K.H., Weber, H., Geis-Gerstorfer J.: In vivo-Korrosionsuntersuchungen goldhaltiger Legierungen. [In vivo study on the corrosion of gold alloys] Dtsch Zahnärztl Z 41, 1272–1276 (1986).
74. Kratzenstein, B., Sauer, K.H., Weber, H.: In vivo-Korrosionserscheinungen von gegossenen Restaurationen und deren Wechselwirkungen mit der Mundhöhle. [In vivo corrosion of cast restorations and their interaction with the oral environment] Dtsch Zahnärztl Z 43, 343–348 (1988).
75. Lang, B.R., Morris, H.F., Razzoog, M.E. (eds): International workshop: Biocompatibility, toxicity and hypersensitivity to alloy systems used in dentistry, The University of Michigan Press, Ann Arbor 1986.
76. Larsson, A., Warfvinge, G.: The histopathology of oral mucosal lesions associated with amalgam or porcelain-fused to metal restorations. Oral Diseases 1, 152–158 (1995).
77. Lee, J.M., Savati, E.A., Betts, F., DiCarlo, E.F., Doty, S.B., Bullough, P.G.: Size of metallic and polyethylene debris particles in failed cemented total hip replacements. J Bone Joint Surg 74-B, 380–384 (1992).
78. Lenz, E.: Der Einfluss von Fluoriden auf das Korrosionsverhalten von Titan. [Influence of fluorides on the corrosion of titanium] Dtsch Zahnärztl Z 52, 351–354 (1997).
79. Lind, P.O.: Oral lichenoid reactions related to composite restorations. Acta Odontol Scand 46, 63–65 (1988).
80. Lodén, M., Wessmann C.: Mascaras may cause irritant contact dermatitis. Int J Cosmet Sci 24, 281–285 (2002).
81. Lucas, L.C., Lemons, J.E.: Biodegradation of restorative metallic systems. Adv Dent Res 6, 32–37 (1992).
82. Lugowski, S.J., Smith, D.C., McHugh, A.D., Van Loon, J.C.: Release of metal ions from dental implant materials in vivo: determination of Al, Co, Cr, Mo, Ni, V, and Ti in organ tissue. J Biomed Mater Res 25, 1443–1458 (1991).
83. Martinello, R.A., Cooney, E.L.: Cerebellar brain abscess associated with tongue piercing. Clin Infect Dis 36, E 32–34 (2003).
84. Marzin, D., Phi, H.V.: Study of mutagenicity of metal derivative with Salmonella thyphimurium TA102. Mutat Res 155, 49–51 (1985).
85. McNamara, A., Williams, D.F.: Enzyme histochemistry of the tissue response to pure metal implants. J Biomed Mater Res 18, 185–206 (1984).
86. Meckel, A.H.: The formation and properties of organic films on teeth. Arch Oral Biol 10, 585–598 (1965).
87. Merritt, K., Margevicius, R.W., Brown, S.A.: Storage and elimination of titanium aluminum, and vanadium salts, in vivo. J Biomed Mater Res 26, 1503–1515 (1992).
88. Messer, R.L.W., Bishop, S., Lucas, L.C.: Effect of metallic ion toxicity on human gingival fibroblast morphology. Biomaterials 20, 1647–1657 (1999).
89. Messer, R.L.W., Doeller, J.E., Kraus, D.W., Lucas, L.C.: An investigation of fibroblast mitochondria enzyme activity and respiration in response to metallic ions released from dental alloys. J Biomed Mater Res 50, 598–604 (2000).
90. Messer, R.L.W., Lucas, L.C.: Cytotoxicity of nickel-chromium alloys: bulk alloys compared to multiple ion salt solutions. Dent Mater 16, 207–212 (2000).
91. Metalor: Biocompatibility, Allergies and Resistance to Corrosion: 8 Years of Research. Metalor, Neuchatel, Switzerland, 1996, pp 7–64.
92. Michel, R.: Trace metal analysis in biocompatibility testing. CRC Crit Rev Biocomp 3, 235–317 (1987).
93. Mjör, I.A., Hensten-Pettersen, A., Skogedal, O.: Biologic evaluation of filling materials. A comparison of results using cell culture techniques, implantation tests, and pulp studies. Int Dent J 27, 124–129 (1977).
94. Möller H.: Dental gold alloys and contact allergy. Contact Dermatitis 47, 63–66 (2002).
95. Nakagawa M., Matsuya S., Shiraishi T., Ohta M.: Effect of fluoride concentration and pH on corrosion behavior of titanium for dental use. J Dent Res 78, 1568–1572 (1999).
96. Namikoshi, T., Yoshimatsu, T., Suga, K., Fujii, H., Tasuda, K.: The prevalence of sensitivity to constituents of dental alloys. J Oral Rehabil 17, 377–381 (1990).
97. Nayebzadeh, A., Dufresne, A., Harvie, S., Begin, R.: Mineralogy of lung tissue in dental laboratory technicians' pneumoconiosis. Am Ind Hyg Assoc J 60, 349–353 (1999).
98. Nichols, K.G., Puleo, D.A.: Effect of metal ions on the formation and function of osteoclastic cells in vitro. J Biomed Mater Res 35, 265–271 (1997).
99. Niemi, L., Hensten-Pettersen, A.: In vitro cytotoxicity of Ag-Pd-Cu-based casting alloys. J Biomed Mater Res 19, 549–561 (1985).
100. Niemi, L., Syrjänen, S., Hensten-Pettersen, A.: The biocompatibility of a dental Ag-Pd-Cu-Au-based casting alloy and its structural components. J Biomed Mater Res 19, 535–548 (1985).
101. O'Dwyer, J.J., Holmes, A.: Gingival recession due to trauma caused by a lower lip stud. Br Dent J 192, 615–616 (2002).

Dentlearn.ir

102. Occupational Safety & Health Administration (OSHA): Preventing adverse health effects from exposure to beryllium in dental laboratories. Hazard Information Bulletin HIB 2002-04-19, U.S. Department of Labor, Washington, DC 2002. www.osha.gov.
103. Orton, D. I., Wilkinson, J. D.: Cosmetic allergy: incidence, diagnosis, and management. Am J Clin Dermatol 5 (5), 327–337 (2004).
104. Pfeiffer, P., Schwickerath, H.: Löslichkeit von Dentallegierungen im Speichel. [The solubility of dental alloys in saliva] Dtsch Zahnärztl Z 44, 751–753 (1989).
105. Philippeit, G., Angerer, J.: Innere Platinbelastung der Allgemeinbevölkerung. [Internal platinum load of the population] Umweltmed Forsch Prax 4, 3–6 (1999).
106. Quirynen, M., Bollen, C.M.: The influence of surface roughness and surface-free energy on supra- and subgingival plaque formation in man. A review of the literature. J Clin Periodontol 22, 1–14 (1995).
107. Quirynen, M., van Steenberghe, D.: Bacterial adhesion to oral implants and assessment of attachment and marginal bone level. Dtsch Zahnärztl Z 48, 158–160 (1993).
108. Rechmann, P.: LAMMS and ICP-MS detection of dental metallic compounds in not-discoloured human gingiva. J Dent Res 71, 599 (1992).
109. Reclaru, L., Meyer, J.-M.: Study of corrosion between a titanium implant and dental alloys. J Dent 22, 159–168 (1994).
110. Reuling, N., Keil, M., Pohl-Reuling, B.: Histokompatibilität von Implantatwerkstoffen. [Histocompatibility of implant materials] Dtsch Zahnärztl Z 46, 694–698 (1991).
111. Reuling, N., Wisser, W., Jung, A., Denschlag, H.O.: Release and detection of dental corrosion products in vivo: development of an experimental model in rabbits. J Biomed Mater Res 24, 979–991 (1990).
112. Reuling, N., Fuhrman, R., Keil, M.: Subakute systemische Toxizität dentaler Edelmetall-Legierungen. [Subacute systemic toxicity of dental noble alloys] Dtsch Zahnärztl Z 47, 747–752 (1992).
113. Richter, G., Geier, J.: Dentalwerkstoffe – Problemsubstanzen in der allergologischen Diagnostik? [Dental materials – problematic substances for allergy testing?] Hautarzt 47, 839–843 (1996).
114. Roitt, I., Brostoff, J., Male, D.: Immunology, 2nd edn. Mosby, New York 1989, pp 22.1–22.10.
115. Schaffran, R.M., Storrs, F.J., Schalock, P.: Prevalence of gold sensitivity in asymptomatic individuals with gold dental restorations. Am J Contact Dermat 10, 201–206 (1999).
116. Schedle, A., Samorapoompichit, P., Rausch-Fan, X.H., Franz, A., Füreder, W., Sperr, W.R., Sperr, W., Ellinger, A., Slavicek, R., Boltz-Nitulescu, G., Valent, P.: Response of L-929 fibroblasts, human gingival fibroblasts, and human tissue mast cells to various metal cations. J Dent Res 74, 1513–1520 (1995).
117. Schmalz, G.: Concepts in biocompatibility testing of dental restorative materials. Clin Oral Investig 1, 154–162 (1997).
118. Schmalz, G.: The biocompatibility of non-amalgam dental filling materials. Eur J Oral Sci 106, 696–706 (1998).
119. Schmalz, G., Arenholt-Bindslev, D., Pfüller, S., Schweikl, H.: Cytotoxicity of metal cations used in dental cast alloys. ATLA 25, 323–330 (1997).
120. Schmalz, G., Garhammer, P., Hiller, K.-A., Reitinger, T.: Metal content of biopsies from the neighborhood of casting alloys. J Dent Res 78, 236 (1999).
121. Schmalz, G., Hiller, K.-A., Garhammer, P., Reitinger, T.: Distribution of alloys in patients with local adverse effects to their alloys. J Dent Res 79, 618 (2000).
122. Schmalz, G., Garhammer, P.: Biological interactions of dental cast alloys with oral tissues. Dent Mater 18, 396–406 (2002).
123. Schmalz, G., Hiller, K.-A., Garhammer, P., Reitinger, T.: Metal content of saliva from patients with and without metal restorations. J Dent Res 80, 1254 (2001).
124. Schmalz, G., Langer, H., Schweikl, H.: Cytotoxicity of dental alloy extracts and corresponding metal salt solutions. J Dent Res 77, 1772–1778 (1998).
125. Schmalz, G., Schuster, U., Schweikl, H.: Influence of metals on IL-6 release in vitro. Biomaterials 19, 1689–1694 (1998).
126. Schroeder, H.A., Mitchener, M.: Scandium, chromium (VI), gallium, yttrium, rhodium, palladium, indium in mice: effects on growth and life span. J Nutrition 101, 1431–1438 (1971).
127. Schuh, A., Thomas, P., Kachler, W., Göske, J., Wagner, L., Holzwarth, U., Forst, R.: Das Allergiepotenzial von Implantatwerkstoffen auf Titanbasis. [Allergic potential on titanium based implant materials] Orthopäde 34, 327–333 (2005).
128. Schultz, J.C., Connelly, E., Glesne, L., Warshaw, E. M.: Cutaneous and oral eruption from oral exposure to nickel in dental braces. Dermatitis 15, 154–157 (2004).
129. Schultz, I., Melle, B., Lenz, E.: Der Zusammenhang von Biokorrosion und Edelmetallgehalt in Dentallegierungen. [The interrelation of biocorrosion and the noble metal contents of dental alloys] Dtsch Zahnärztl Z 52, 355–360 (1997).
130. Schweitzer, A.: Erstfeststellung einer Titan-Allergie. [First report on a titanium allergy] Dermatosen 45, 190 (1997).
131. Siegrist, B.E., Brecx, M.C., Gusberti, F.A., Joss, A., Lang, N.P.: In vivo early human dental plaque formation on different supporting substances. A scanning electron microscopic and bacteriological study. Clin Oral Implants Res 2, 38–46 (1991).
132. Smith, R.G., Burtner, A.P.: Oral side-effects of the most frequently prescribed drugs. Spec Care Dentist 14, 96–102 (1994).
133. Sperl, K.: Risikominimierung dentaler Legierungen. Rundschreiben der Interessengemeinschaft der Zahnmetallgeschädigten e.V. vom 5.12.1995. [Minimizing the risk of dental alloys. Circular letter of the patient group damaged from dental alloys, 5 Dec 1995]
134. Steinberg, D., Sela, M.N., Klinger, A., Kohavi, D.: Adhesion of periodontal bacteria to titanium, and titanium alloy powders. Clin Oral Implants Res 9, 67–72 (1998).
135. Steinmann, F., Ott, K.: Studie über die Beschwerdebilder von Patienten mit Verdacht auf eine Amalgam-Unverträglichkeit. [Study on the symptoms of patients with suspected amalgam incompatibility] Dtsch Zahnärztl Z 53, 152–155 (1998).
136. Sunderman, F.W. (ed): Nickel in the human environment. IARC No. 53, 3–485 (1984).
137. Takeda, S., Akiyama, M., Sakane, K. Sakai, T., Nakamura, M.: Effects of metal combinations on cytotoxicity evaluation using a dynamic extraction method. Dent Mater J 19, 373–380 (2000).
138. Tamai, K., Mitsumori, M., Fujishiro, S., Kokubo, M., Ooya, N., Nagata, Y., Sasai, K., Hiraoka, M., Inamoto, T.: A case of allergic reaction to surgical metal clips inserted for postoperative boost irradiation in a patient undergoing breast-conserving therapy. Breast Cancer 8, 90–92 (2001).
139. Taylor, T.D., Morton, Jr T.H.: Ulcerative lesions of the palate associated with removable partial denture castings. J Prosthet Dent 66, 213–221 (1991).
140. Thomson, P., Larsson, C., Ericson, L. E., Sennerby, L., Lausmaa, J., Kasemo, B.: Structure of the interface between rabbit cortical bone and implant of gold, zirconium and titanium. J Mater Sci Mater Med 8, 653–665 (1997).

Dentlearn.ir

141. Thull, R.: Physicochemical principles of tissue material interactions. Biomol Eng 19, 43–50 (2002).
142. Tourne, L.P.M., Fricton, J.R.: Burning mouth syndrome: clinical review and proposed clinical management. Oral Surg Oral Med Oral Pathol 74, 158–167 (1992).
143. Tschernitschek H., Borchers L., Geurtsen W.: Nonalloyed titanium as a bioinert metal – a review. Quintessenz Int 36 (7–8), 523–530 (2005).
144. Vamnes, J.S., Lygre, G.B., Grönningsaeter, A.G., Gjerdet, N.R.: Four years of clinical experience with an adverse reaction unit for dental biomaterials. Community Dent Oral Epidemiol. 32, 150–157, (2004)
145. Van der Waal, I., Schulten, E.A.J.M.: Burning-Mouth-Syndrome. Dtsch Zahnärztl Z 55, 230–233 (2000).
146. Van Loon, L.A.J., Elsas, P.W., Bos, J.D., Tenharkel-Hagenaar, H.D., Krieg, S.R., Davidson, C.L.: T-lymphocyte and Langerhans cell distribution in normal and allergenically induced oral mucosa in contact with nickel-containing dental alloys. J Oral Pathol 17, 129–137 (1988).
147. Vreeburg, K.J.J., de Groot, K., von Blomberg, M., Scheper, R.J.: Induction of immunological tolerance by oral administration of nickel and chromium. J Dent Res 63, 124–128 (1984).
148. Wagner, M., Klein, C.L., Van Kooten, T.G., Kirkpatrick, C.J.: Mechanisms of cell activation by heavy metal ions. J Biomed Mater Res 42, 443–452 (1998).
149. Wang, J. Y., Wicklund, B. H., Gustilo, R. B., Tsukayama, D. T.: Titanium, chromium and cobalt ions modulate the release of bone-associated cytokines by human minocytes/macrophages in vitro. Biomaterials 17 (23), 2233–2240 (1996).
150. Wang, R.R., Li, Y.: In vitro evaluation of biocompatibility of experimental titanium alloys for dental restorations. J Prosthet Dent 80, 495–500 (1998).
151. Wataha, J.C.: Materials for endosseous dental implants. J Oral Rehabil 23, 79–90 (1996).
152. Wataha, J.C.: Biocompatibility of dental casting alloys: a review. J Prosthet Dent 83, 223–234 (2000).
153. Wataha, J.C.: Principles of biocompatibility for dental practitioners. J Prosthet Dent 86, 203–209 (2001).
154. Wataha, J.C., Craig, R.G., Hanks, C.T.: Release of elements of dental casting alloys into cell-culture medium. J Dent Res 70, 1014–1081 (1991).
155. Wataha, J.C., Craig, R.G., Hanks, C.T.: Precision of and new methods for testing in vitro alloy cytotoxicity. Dent Mat 8, 65–71 (1992).
156. Wataha, J.C., Craig, R.G., Hanks, C.T.: Element release and cytotoxicity of Pd-Cu binary alloys. Int J Prosthodont 8, 228–232 (1995).
157. Wataha, J.C., Hanks, C.T.: Biological effects of palladium and risk of using palladium in dental casting alloys. J Oral Rehabil 23, 309–320 (1996).
158. Wataha, J.C., Hanks, C.T., Craig, R.G.: The in vitro effects of metal cations on eukaryotic cell metabolism. J Biomed Mater Res 25, 1133–1149 (1991).
159. Wataha, J.C., Hanks, C.T., Craig, R.G.: In vitro synergistic, antagonistic, and duration of exposure effects of metal cations on eukaryotic cells. J Biomed Mater Res 26, 1297–1309 (1992).
160. Wataha, J.C., Sun, Z.L., Hanks, C.T., Fang, D.N.: Effect of Ni ions on expression of intercellular adhesion molecule 1 by endothelial cells. J Biomed Mater Res. 36 (2), 145–151 (1997).
161. Wataha, J.C., Lewis, J.B., Lockwood, P.E., Rakich, D.R.: Effect of dental metal ions on glutathione levels in THP-1 human monocytes. J Oral Rehabil 27, 508–516 (2000).
162. Wataha, J.C., Lockwood, P.E.: Release of elements from dental casting alloys into cell-culture medium over 10 months. Dent Mater 14, 158–163 (1998).
163. Wataha, J.C., Lockwood, P.E., Frazier, K.B., Khajotia, S.S.: Effect of toothbrushing on elemental release from dental casting alloys. J Prosthodont 8, 245–251 (1999).
164. Wataha, J.C., Lockwood, P.E., Nelson, S.K., Bouillaguet, S.: Long-term cytotoxicity of dental casting alloys. Int J Prosthodont 12, 242–248 (1999).
165. Wataha, J.C., Lockwood, P.E., Schedle, A.: Effect of silver, copper, mercury and nickel ions on cellular proliferation during extended, low-dose exposures. J Biomed Mater Res 52, 360–364 (2000).
166. Wataha, J.C., Malcolm, C.T.: Effect of alloy surface composition on release of elements from dental casting alloys. J Oral Rehabil 23, 583–589 (1996).
167. Wataha, J.C., Malcolm, C.T., Hanks, C.T.: Correlation between cytotoxicity and the elements released by dental casting alloys. Int J Prosthodont 8, 9–14 (1995).
168. Wataha, J.C., Rathanasathien, S., Hanks, C.T., Sun, Z.L.: In vitro IL-1beta and THF-alpha release from THP-1 monocytes in response to metal ions. Dent Mater 12, 322–327 (1996).
169. Wataha, J.C., Schmalz, G.: Konzepte zur Biokompatibilität. [Concepts for biocompatibility] Zahnärztl Mitt 91, 1830–1834 (2001).
170. Weber H., Sauer K. H., Paulssen W.: In vivo-Korrosionsuntersuchungen an edelmetallfreien Legierungen. [In vivo corrosion testing on non-precious dental alloys] Dtsch Zahnärztl Z 40, 838–841 (1985).
171. Wirz, J.: Schädigung des Parodontes durch zahnärztliche Werkstoffe. [Damage of the periodontium due to dental materials] Zahnärztl Welt/Reform 102, 146–162 (1993).
172 Wirz, J., Dillena, P., Schmidli, F.: Metalle im Speichel. [Metals in saliva] Quintessenz 43, 869–874 (1992).
173. Wirz, J., Jäger, K., Schmidli, F.: Klinische Korrosion. [Clinical corrosion] Schweiz Monatsschr Zahnmed 97, 1151–1156 (1987).
174. Wirz, J., Rateitschak, E., Schmidli, F.: Werkstoffbedingte Gingivaentzündung. [Inflamed gingiva due to dental materials] Quintessenz 11, 1903–1906 (1987).
175. Yamamoto, A., Honma, R., Sumita, M.: Cytotoxicity evaluation of 43 metal salts using murine fibroblasts and osteoblasts. J Biomed Mater Res 39, 331–340 (1998).
176. Yamamoto, A., Honma, R., Tanaka, A., Sumita, M.: Generic tendency of metal salt cytotoxicity for six cell lines. J Biomed Mater Res 47, 396–403 (1999).
177. Yamauchi, R., Morita, A., Tsuji, T.: Pacemaker dermatitis from titanium. Contact Dermatitis 42, 52–53 (2000).
178. Yokozeki H., Niiyama S., Nishioka K.: Twenty-nail dystrophy (trachyonychia) caused by lichen planus in patient with gold allergy. Contact Dermatitis 152, 1087–1089 (2005).
179. Yontchev, E., Meding, B., Hedegard, B.: Contact allergy to dental materials in patients with orofacial complaints. J Oral Rehabil 13, 183–190 (1986).
180. Zegarelli, D.J.: Burning mouth: an analysis of 57 patients. Oral Surg Oral Med Oral Pathol 58, 34–38 (1984).

Dentlearn.ir

9 Polymethylmethacrylate Resins

W. Geurtsen

Contents

9.1	Introduction	255
9.2	Basic Material Properties	255
9.2.1	Composition and Setting Reaction	255
9.2.2	Release of Substances and Degradation	256
9.3	Systemic Toxicity	258
9.4	Local Toxicity and Tissue Compatibility	259
9.4.1	Cytotoxicity	259
9.4.2	Microbial Effects	261
9.4.3	Implantation Studies	262
9.4.4	Pulp Reactions	262
9.4.5	Reactions of the Gingiva and Oral Mucosa	262
9.4.6	Burning Mouth Syndrome	263
9.5	Allergies	264
9.6	Mutagenicity and Carcinogenicity	265
	Conclusions for the Dental Practitioner	266
	References	267

9.1 Introduction

Currently, dental polymethylmethacrylates (PMMAs) are used primarily for dentures and orthodontic devices. In addition, PMMAs are used for individual impression trays and temporary crowns. The application of PMMA as a veneering material no longer plays a major role. According to the setting reaction, PMMAs are classified as heat polymerizing, light curing, or chemically (auto)curing. Chemically curing systems require a special catalyst system that initiates the polymerization process without exogenous energy (see Sect. 9.2.1). PMMAs are also used in daily life for nondental purposes: as bone cements and acrylic glass, as a base for various stains, for artificial fingernails and nail varnish, and so on. This fact is important to the dental profession because allergies to PMMA may be caused by acrylic materials used for nondental application as well.

9.2 Basic Material Properties

9.2.1 Composition and Setting Reaction

Most dentures and removable orthodontic devices are made of heat-polymerizing or autopolymerizing PMMAs [20, 66]. Acrylics reinforced by glass, aramide fiber, or polyhedraloligosilsesquioxane, which are supposed to be more fracture resistant, have not yet succeeded on the market [54, 69, 70, 115].

Methyl esters of methacrylic acid are the basic modules of PMMA, but many other components are also contained in acrylics used for prosthetic dentistry and orthodontics. Heat-polymerizing denture acrylics are generally based on PMMA, whereas light-polymerizing and microwave-polymerizing products are derived partly from PMMA and also from urethane dimethacrylates [14]. Occasionally, ethylene glycol dimethacrylate (EGDMA) is added to increase cross-linking of the polymer chains [37].

Decomposition of the initiator (mainly dibenzoyl peroxide) into radicals under heat initiates the setting of heat-polymerizing products. Polymerization of chemically-curing (autopolymerizing) acrylics that set at room or oral temperature is triggered by a redox system. These materials require an accelerator, such as a tertiary amine, sulfinic acid, or substituted barbituric acid. The most important combination is an amine–peroxide redox system [30, 66, 118].

Light-curing, slightly filled – up to 15 weight percent (wt.%) – acrylics are used to repair and reline dentures, orthodontic devices, and individual impression trays. Monomer–polymer conversion of these products is decisively dependent on the duration of the light irradiation, equivalent to light-curable composite resins. The degree of polymerization varies between 77 wt.% and 97 wt.%.

Permanent soft liners are applied in certain situations, for instance, to compensate for denture bases with differing resiliency, to minimize the risk of pres-

Dentlearn.ir

sure marks in cases of unfavorable morphology of the alveolar ridge (defects, undercuts, etc.), or for patients with systemic disease. These materials are basically polysiloxanes that may be combined with derivatives of acrylic acid, polyacrylates, or plasticizers such as dibutyl phthalate [14].

9.2.2 Release of Substances and Degradation

Two aspects are of particular importance: monomer–polymer conversion and residual monomer content. The rate of monomer-polymer conversion indicates how many unsaturated double bonds react to saturated single bonds during polymerization. Residual monomer refers to those substances (monomers, additives, reaction products) that are not firmly incorporated in the polymer network and may therefore leach. Subsequently, these components may cause local and/or systemic side effects.

The concentration of residual monomers and elutable additives depends on a great variety of different parameters. The most important factors are the following:

- Polymerization type
- Polymerization time
- Polymerization temperature
- Surface finish and structure

In general, heat-polymerized PMMA contains significantly fewer residual monomers than chemically cured acrylic resin. Thicker areas show smaller concentrations of residual monomers compared with thin layers [27, 113, 114]. An increase in temperature during autopolymerization, for instance from 30°C to 60°C, causes a significant decrease in the amount of residual monomers. Heat-polymerized acrylic resin contains smaller quantities of releasable substances if the polymerization temperature is increased, e.g., from 70°C to 100°C, and the setting time is extended. Vallitu et al. documented that when polymerization was extended from 15 min to 12 h at a temperature of 100°C, the residual content of methylmethacrylate (MMA) of heat-polymerizable denture acrylic decreased considerably – in fact, from more than 1 wt% to less than 0.1 wt% [118]. Surface finish also influences the release of residual monomers. It has been documented that the final application of a light-curing resin may considerably reduce the elution of residual monomers from chemically cured PMMA acrylic.

Key Note

Depending on the aforementioned parameters, the amount of residual monomers may be approximately 3–5 wt.% in chemically curing PMMA resin and 0.1–1.5 wt.% in heat-polymerizable acrylics.

Numerous researchers have tried to identify the components that generally leach from polymerized resin (Table 9.1). Most authors used high-performance liquid chromatography, gas chromatography, gas chromatography/mass spectroscopy, and, occasionally, infrared spectroscopy [3, 7, 38, 63, 100, 114, 117]. Residual monomers or additives were extracted by means of aqueous media including distilled water, natural or artificial saliva, Ringer's solution, and organic diluents (methanol, ethanol, tetrahydrofurane, acetone, etc.) [38, 116].

Methylmethacrylate (MMA) in particular was identified in aqueous in vitro extracts. It was released over a period of several days [38, 116]. These laboratory findings were confirmed by in vivo data [7, 114]. Baker et al. investigated the MMA level of saliva of patients with dentures [7] and found that autopolymerizable resin releases MMA over a period of 1 week after insertion (up to 45 μg/ml saliva). However, resin that was polymerized for 3 h at a temperature of 70°C did not leach MMA. Further, MMA was not found in the urine or blood of the participants. The authors concluded that the intraorally released MMA concentrations were far below the threshold doses. But it must be emphasized that this statement regarding intraoral uptake is derived from the maximum values for absorption from air (410 mg/m^3 based on an exposure time of 8 h). In vitro studies, however, revealed that heat-polymerized acrylic also releases MMA over several days but in significantly smaller quantities than autopolymerized products [114, 116].

Another important ingredient in aqueous eluates is formaldehyde. Tsuchiya et al. documented that this substance is released from autopolymerized resin in relatively high amounts (40–50 nmol/ml on the 1st day) in vitro and in vivo (saliva), but heat- polymerized and microwave-polymerized specimens did not leach formaldehyde [113]. In contrast, other authors found formaldehyde in water extracts of heat-polymerized acrylics but in much smaller quantities compared with the simultaneously tested autopolymerized samples [99]. In principle, two mechanisms of formaldehyde formation were discussed. First, a primary oxidation of unsaturated methacrylate groups is possible.

Dentlearn.ir

Table 9.1 Ingredients and leaching substances from polymethylmethacrylate (PMMA) resins [8, 37, 62, 66, 97, 113]

Substance	Function
Methylmethacrylate (MMA)	Monomer
Methacrylic acid	Degradation product of methacrylate monomers
Ethylene glycol dimethacrylate	Monomer
Dibenzoyl peroxide (DBP)	Initiator
N,N-dimethyl-p-toluidine (tertiary amine)	Accelerator of autopolymerizing resins
Hydroquinone	Stabilizer
Resorcinol	Stabilizer
Pyrogallol	Stabilizer
Urethane dimethacrylate (UDMA)	Matrix monomer of light-polymerizing and microwave-polymerizing resins
Poly(ethyl-methacrylate)	Matrix monomer of light-curing resins
Ethoxylized bisphenol A-dimethacrylate	Matrix monomer of light-curing resins
Camphorquinone	Photoinitiator of light-curing resins
Inorganic fillers	Fillers of light-curing resins (up to 15 wt.%)
Pigments such as CdS and CdSe	Coloring
Organic stains (phenol derivatives)	Coloring
Copper	Eventually, component of the initiator system
Dibutyl-phthalate	Plasticizer
Phenyl salicylate	Eventually, UV absorber
Dicyclohexyl phthalate	Plasticizer
Biphenyl	Reaction product of DBP
Phenyl benzoate	Reaction product of DBP
Benzoic acid	Reaction product of DPB
Formaldehyde	Oxidation product of MMA

Secondly, oxygen can copolymerize with methacrylate groups during the initial phase of the polymerization. Decomposition of this copolymer will then result in the formation of formaldehyde [88, 99].

Dibutyl phthalate (a plasticizer) was also detected in aqueous extracts of heat-polymerized acrylic and in saliva as well [62, 63].

Biphenyl and phenyl benzoate could be found in ethanol extracts. It may be speculated that these com-

Dentlearn.ir

pounds are reaction or decomposition products of the initiator dibenzoyl peroxide that are generated during the polymerization.

Trace amounts of phenylsalicylate were documented by Lygre et al. [63]. This substance could be a contaminant of the production of PMMA, or it could also serve as an ultraviolet absorber.

Taken together, studies addressing the residual monomer content and the leachable substances from heat-polymerizing and autopolymerizing PMMA acrylics have shown that fairly high amounts of substances, specifically MMA, may leach into the oral cavity during the initial days after polymerization. Clinical-experimental investigations documented a correlation between residual monomer concentration and irritation of the oral mucosa [3, 4]. This clearly indicates that the eluable share of residual monomers and additives should be as low as possible. Therefore, it is recommended that dentures and orthodontic devices be stored in water before insertion for a long-enough period of time. A storage period of up to 24 h in warm water (37–50°C) is recommended depending on the type of resin and the type of polymerization [7, 114, 116].

Clinical Practice Advice

The concentration of residual monomers should be as low as possible because leaching of substances is primarily responsible for unwanted side effects. In this regard, MMA and formaldehyde are of particular importance. Heat-polymerizing acrylic resins generally reveal a higher rate of polymerization and thus a lower level of residual monomers compared with autopolymerizing products.

A polymerization of several hours at the highest possible temperature and subsequent storage of the denture or orthodontic device for 24 h in water will minimize the concentration of residual monomers.

9.3 Systemic Toxicity

The acute oral LD_{50} (median lethal dose; the calculated dose of a chemical substance that will kill 50% of the experimental population; see Chap. 2) of dibenzoyl peroxide in rats is 950 mg/kg body weight [30]. It has been reported that the acute oral LD_{50} of MMA in rats is 8.4 g/kg body weight or 9 g/kg body weight. This very high concentration indicates a very low acute systemic toxicity of MMA [12, 22, 59]. A study on rats receiving MMA "orally" through a stomach tube is in accordance with this assessment. Five minutes after oral application, methacrylic acid, a degradation product of MMA generated by a nonspecific carboxyl esterase, was identified in the blood with a peak after 10–15 min. Alterations of organs (liver, kidneys, heart, spleen, brain, lung, and guts) were not found. These data point to a low acute toxicity of orally applied MMA, which is rapidly hydrolyzed by enzymes in blood serum and subsequently metabolized to less toxic substances, such as pyruvate, via the citric acid cycle [9, 89]. The half-life of MMA in human blood varies between 20 min and 40 min [19].

Animal studies on dogs indicated that MMA released from the bone cement of hip implants is also excreted via the lungs [68]. Karlsson et al. documented a relaxing effect of MMA on the nonstriated muscles of blood vessels [51]. Various authors have reported cardiovascular effects [5,10, 72–74, 91], inhibited peristalsis of the ileum [72, 73], and inhibited gastric motor function due to inhaled MMA vapor in rat experiments [109]. The LC_{50} (median lethal concentration; the concentration of a chemical that kills 50% of the experimented population) of MMA vapor in rats is 7,093 ppm [110].

Rats were also used to study the embryo-fetal toxicity of MMA. It was found that MMA, when injected intraperitoneally at LD_{50} concentration, may cause malformations and other injury to embryos or fetuses [107]. Patients take up leaching substances from PMMA resins through the oral cavity, but dental personnel and lab technicians are also exposed to MMA-vapor. Measurements of the formaldehyde and MMA concentrations in the air of a dental laboratory subsequent to the processing of dentures provided no indication of critical values [13]. The maximum allowable concentration values for MMA in Germany are 50 ppm or 210 mg/m^3 compartment air [21]. Legal regulations for dental laboratories are based on a directive regarding hazardous substances and the technical rules for hazardous materials, TRGS 900, which is based on this regulation [111, 119]. It was reported that MMA vapor in dental practices caused vertigo [40]. There is no evidence, however, that serious problems may be caused by inhaling PMMA ingredients, although MMA may irritate the eyes, skin, and respiratory system.

Dentlearn.ir

Key Note

It has not been documented that MMA may cause acute systemic reactions or embryo-fetal alterations in patients or, after inhalation, in dental personnel or lab technicians if all relevant legal regulations are observed. But it should be kept in mind that MMA is an easily flammable substance that may irritate the eyes and respiratory system.

9.4 Local Toxicity and Tissue Compatibility

9.4.1 Cytotoxicity

The cellular compatibility of solid specimens, aqueous resin extracts, formaldehyde, and MMA was investigated in permanent cells and primary cultures as well [19, 30, 79, 113]. Nakamura and Kawahara [79] studied the toxicity of 2-week-old aqueous extracts of two heat-polymerized acrylics and three chemically curing products. Although none of the eluates generated noteworthy cellular alterations, it has to be considered in this connection that the two most important extractable substances, MMA and formaldehyde, are volatile. It is very likely that the test solutions did not contain the original concentrations of these two substances due to the extended extraction time. Another study revealed clear toxic reactions caused by solid specimens of two orthodontic acrylic resins (one autopolymerizing, one light-curable) in permanent cultures of fibroblasts and keratinocytes. The light-curing material was cytotoxic if the oxygen-inhibited surface layer was not removed. Both products were no longer toxic 30 days after setting [101] (see also Fig. 9.1). Polymer samples made of polyethylmethacrylate/tetrahydrofurfuryl methacrylate or polymethylmethacrylate were more toxic directly after polymerization compared with aged specimens, and preincubation of the specimens in serum-containing medium decreased cytotoxicity in osteoblast cultures [33].

Similar data were documented in an investigation of solid samples of PMMA-based bone cement using permanent bone cell cultures. Toxicity decreased over time as well. The authors concluded that the initial high toxicity immediately after polymerization was due to various released radicals [77]. Compatibility, however, depends on the general composition (e.g., type of base resin) and on material aspects or the particular formulation of the individual product as well. Contrary to the aforementioned study, no toxic effects in primary human gingival fibroblast cultures and osteoblast-like cells were caused by aqueous 24-h and 7-day extracts of another PMMA-type bone cement [60]. Hensten-Pettersen and Wictorin found only a slight or moder-

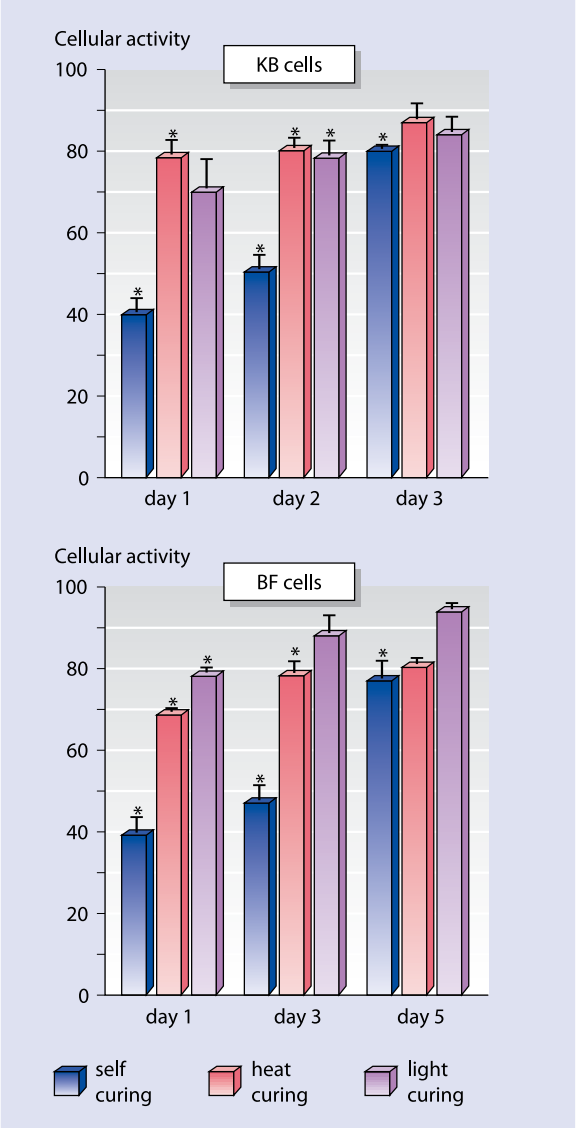

Fig. 9.1 Influence of aqueous eluates of heat curing, light curing, and self curing denture acrylic resins on cell activity (enzyme activity) *KB cells* human oral epithelial cells, *BF cells* human mucosal fibroblasts, *asterisks* indicate significant differences compared with nontoxic control [42]

Dentlearn.ir

ate cytotoxicity of solid specimens. Interestingly, the type of polymerization (heat-polymerizing or autopolymerizing) was of lesser significance than the nature of the product [39]. But it must be emphasized that the cytotoxicity of the specimens was not determined until 2 weeks after polymerization.

The cytotoxicity of heat-polymerizing, light-polymerizing, and autopolymerizing acrylic resins was investigated in a more recent study (Fig. 9.1). The autopolymerizing product showed the highest cytotoxicity, whereas the light-curable material was the least cytotoxic. Cytotoxicity of all products decreased after several extractions using aqueous cell culture medium [42]. Similar data were reported by Cimpan et al. and Kedjarune et al. [17, 53]. These researchers also found that autopolymerizing acrylics are significantly more toxic than heat-polymerizing products.

Formaldehyde caused pronounced toxic effects at those concentrations that were identified in aqueous extracts. But MMA generated no noticeable toxic alterations at concentrations that were found in equivalent eluates [30]. The TC_{50} (median toxic concentration) of MMA in permanent L-929 cells was 5 µM after an incubation period of 2 days [114]. Treatment of cells with formaldehyde at a concentration of 50 nmol/ml decreased cell numbers to 20% of that of untreated control cultures. Schmalz found a high cytotoxicity of MMA in permanent L-929 cells. DNA and protein metabolism were inhibited at a concentration of 2 mM [102].

Besides MMA and formaldehyde, other substances that leach from PMMA acrylics may also contribute to cytotoxic effects (see Table 9.2). The relatively hydrophilic cross-linking agent EGDMA and the initiator dibenzoyl peroxide were comparably toxic in primary human fibroblasts derived from gingiva and periodontal ligament. But the accelerating substance N,N-dimethyl-p-toluidine and the photoinitiator camphorquinone were only moderately cytotoxic. Urethane dimethacrylate (UDMA), an important base monomer in light-polymerizing resins, elicited severe cytotoxic effects [31]. Furthermore, Stea et al. reported that N,N-dimethyl-p-toluidine may cause reversible cell damage associated with a retarded replication cycle [108].

Table 9.2 TC_{50} (median toxic concentration) values of several resin compounds [31, 96]

Substance	TC_{50}	Reference
Methylmethacrylate	5.0 mM (L-929 cells)	[96]
Ethylene glycol dimethacrylate	2.31 mM (3T3 fibroblasts) 0.46–1.17 mM (primary human fibroblasts)	[31] [31]
Dibenzoyl peroxide	3.8 mM (3T3 fibroblasts) 0.43–0.83 mM (primary human fibroblasts)	[31] [31]
N,N-dimethyl-p-toluidine (tertiary amine)	3.43 mM (3T3 fibroblasts) 2.3–4.25 mM (primary human fibroblasts)	[31] [31]
Urethane dimethacrylate	0.1 mM (3T3 fibroblasts) 0.08–0.14 mM (primary human fibroblasts)	[31] [31]
Ethoxylized bisphenol A-dimethacrylate	0.33 mM (3T3 fibroblasts) 0.21–0.78 mM (primary human fibroblasts)	[31] [31]
Camphorquinone	2.22 mM (3T3 fibroblasts) 2.17–2.4 mM (primary human fibroblasts)	[31] [31]
Dicyclohexyl phthalate	0.73 mM (3T3 fibroblasts) 0.69–0.85 mM (primary human fibroblasts)	[31] [31]
Formaldehyde	5.0 mM (L-929 cells)	[96]

Dentlearn.ir

Clinical Practice Advice

Data from studies addressing cellular compatibility underscore the recommendation to store dentures for 1 day in water to significantly reduce the amount of residual monomers. Heat-polymerizing products should be preferred over autopolymerizing materials if possible. Furthermore, patients should be advised not to wear dentures at night at first because this might contribute to irritation of the mucosa due to an accumulation of residual monomers in the tissue.

9.4.2 Microbial Effects

Besides cytotoxicity, microbial effects, promotion, or inhibition of the proliferation of microorganisms may also be decisive for the biocompatibility of a compound or material. It has been well known since the beginning of the 1970s from in vitro and in vivo observation that PMMA acrylics and, particularly, permanent soft relining materials may promote the growth of various fungi and bacteria (Fig. 9.2) such as *Candida albicans* and other *Candida* species, *Escherichia coli,* and *Pseudomonas aeruginosa*. In addition, MMA, phthalate, and the cross-linking substance may stimulate microbial proliferation. But "microclefts" between permanent soft relining materials and the "hard" denture base may stimulate microbial growth, too [2, 24, 25]. This was corroborated by clinical studies on patients wearing dentures with a permanent soft relining. It was found that up to 85% of these patients suffered from oral fungi identifiable by culture techniques. An inflamed mucosa was clearly correlated with these microorganisms [65, 121]. Colonization of permanent soft reliners was significantly enhanced by the salivary denture pellicle or serum components [83, 84]. In this context it was observed that proliferation of fungi (*Candida* ssp.) was closely associated with poor denture hygiene [121, 122]. The tendency toward fungal colonization could be reduced if the permanently soft relining material were sealed with a particular varnish [86].

But it was also found that higher concentrations of MMA (>0.5%) are bactericidal, whereas larger quantities of the plasticizers benzyl benzoate and benzyl salicylate are fungicidal [83]. Schmalz confirmed these observations in an in vitro study with *Streptococcus mutans*. Both MMA and N,N-dimethyl-p-toluidine promoted bacterial growth at lower concentrations, but they inhibited proliferation at higher concentrations [104]. In addition, it was found in more recent experiments that the cross-linking agent EGDMA may increase the proliferation of the two important caries pathogens *Streptococcus sobrinus* and *Lactobacillus acidophilus* [36].

Fig. 9.2 **a** Inflammation of the oral mucosa beneath a denture base; polymethylmethacrylate resin. **b** Plaque at the denture base. **c** Decrease of the inflammation after thorough cleaning and storage in chlorhexidine (Courtesy of G. Schmalz, Regensburg, Germany)

Dentlearn.ir

Candida albicans plays an important role in the etiology of "denture stomatitis" [16]. It was found, for instance, that the pellicle of dentures of stomatitis patients contained an increased concentration of cell particles derived from *Candida albicans*. There was also an elevated concentration of salivary compounds that promoted adhesion of this microorganism. These substances were not identified in the denture pellicle of sound subjects [23]. Adherence or accumulation of *Candida albicans* was promoted by a rough surface structure of PMMA-based dentures. Permanent soft, porous relining materials promoted adhesion in some patients, but not in all [92, 93, 120, 122]. Besides *Candida albicans*, other microorganisms were found on dentures at higher concentrations. These findings indicate that not only mechanical retention but also chemical factors, such as leaching substances, may influence the accumulation of microorganisms on acrylic resins.

It is of particular interest that dentures may transfer certain pathogenic and highly virulent microbes from the oral cavity to the distal gastrointestinal tract or respiratory system. For instance, Matsuura et al. reported that *Staphylococcus aureus* colonized dentures and tongues of "resected" patients with extended oral tissue defects at much higher concentration than in edentulous "nonresected" patients [67].

Clinical Practice Advice

Staphylococcus aureus, a highly virulent microorganism found in the nose, can be transferred via dentures and the oral cavity to the gastrointestinal tract and respiratory system, where it may cause severe diseases including pneumonia and gastroenteritis. These findings underline the importance of regular careful denture hygiene. In addition, patients at risk should disinfect their dentures regularly with, for instance, chlorhexidine [64].

9.4.3 Implantation Studies

Local reactions are primarily dependent on the amount of substances leached and their toxicity. Thus, heat-polymerized products should cause fewer effects than autopolymerizing materials [44]. This was corroborated by an in vivo implantation study on rats and rabbits. Specimens of various acrylic resins were implanted and caused a mild to severe tissue irritation depending on the product. Tissue irritation decreased between the 1st and 16th days of the implantation period. This may be explained by a reduced release of residual monomers over time, which was also detected in an experimental in vivo study with two PMMA bone cements on rabbits after implantation into the femoral bone marrow [98]. Rapid release of MMA from bone cements was verified under simulated in vivo conditions; 50% of the unbound MMA was released within 15 min after immersion of the mixed specimens into an aqueous environment [106]. PMMA implants were also very well tolerated after insertion into the alveolar bone of dogs or the limb bones of baboons. No signs of inflammatory reactions in adjacent tissues were found [80, 90].

9.4.4 Pulp Reactions

Autopolymerizing PMMA resins caused pulp irritations when used for temporary restorations [56]. This might be due to the release of residual monomers, particularly during the first days after polymerization. On the other hand, the setting of the material may cause high temperatures (80–120°C) that could be responsible for irritation of the dental pulp. Temperatures higher than 42°C were measured in the pulp cavity; this is considered the critical temperature regarding irreversible pulpitis [30, 58, 103].

Clinical Practice Advice

Temporary restorations should be removed before polymerization reaches the maximum setting temperature. Polymerization of PMMA temporaries should be completed outside the oral cavity.

9.4.5 Reactions of the Gingiva and Oral Mucosa

Irritation of the oral mucosa beneath or adjacent to resin restorations is certainly the most severe local clinical adverse effect.

Denture stomatitis is characterized by three degrees of severity [94]:

- Punctual erythemas: small reddish areas that are not elevated above the level of the mucosa; these areas are covered by the denture and may also be associated with partial or complete dentures

Dentlearn.ir

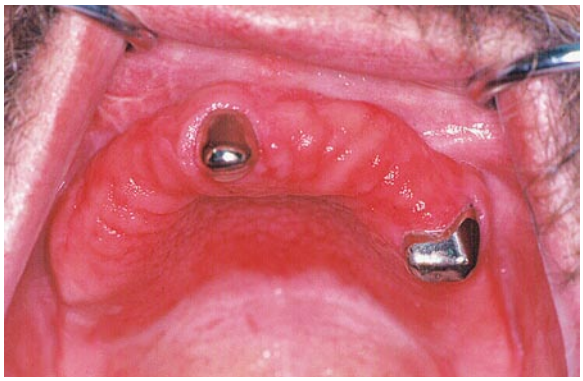

Fig. 9.3 Pronounced inflammation of the palatal mucosa beneath a polymethylmethacrylate denture with papillary hyperplasia (Courtesy of G. Handel, Regensburg, Germany)

Table 9.3 Possible causes of burning mouth syndrome

Systemic causes	Local causes
Vitamin deficiency (e.g., B6 or B12)	Microorganisms
Mental causes (such as depression)	Quantity and composition of saliva
Allergies	Residual monomers
Blood diseases (e.g., iron deficiency anemia, Addison's anemia)	Deficiency of restorations/ dentures
	Helicobacter colonization

- Sheet-like erythemas: extensive erythemas that are also located beneath dentures and have a high tendency to bleed
- Papillary hyperplasia: nodule-like hyperplasia with a diameter of 2–3 mm and a size of 3–4 mm that develop particularly on the palate (Fig. 9.3)

In an experimental clinical study, Austin and Basker documented a clear association between irritation of the mucosa beneath dentures and the release of residual monomers [3]. Three cases of denture stomatitis were examined. The residual monomer concentration of all analyzed dentures exceeded the normal levels by 6–11-fold. It was reported in 1962 that dentures with a residual monomer concentration of 0.6–3% a year after insertion did not cause mucosal irritations [6]. In addition to released substances, mainly MMA and formaldehyde, microorganisms (e.g., *Candida albicans*) may significantly contribute to the development and severity of a denture stomatitis [34]. This was especially observed on dentures with a permanently soft relining [65], but both effects should interact in most cases because various leaching substances may promote microbial proliferation.

9.4.6 Burning Mouth Syndrome

The etiology of burning mouth syndrome is much more complex. Local and systemic factors have been discussed by several authors. The most important factors are summarized in Table 9.3 [16, 32, 78, 82]. A clinical study of 22 patients who suffered from burning mouth syndrome revealed an allergy to MMA in five cases, as well as a high residual monomer concentration in their dentures. Three of these five patients were free of symptoms after they received new dentures with a low residual monomer content. This was corroborated by findings on four further patients in this investigation who suffered from an irritation (not an allergy) of the mucosa caused by residual monomers. Their symptoms disappeared after "postpolymerization" of the dentures. The complaints of the remaining 11 patients were generated by the following causes: a poor dental prosthesis, diseases such as iron deficiency anemia, Addison's anemia, and burning mouth without discernible or diagnosable cause (idiopathic burning mouth) [1]. Recently, a possible correlation between burning mouth syndrome or atrophic glossitis and colonization of the oral cavity with *Helicobacter pylori* was investigated. Sixteen percent of the patients who suffered from a burning mouth syndrome revealed *Helicobacter pylori* in the tongue mucosa. These findings indicate that an oral mucosa that has been already damaged by a burning mouth syndrome is more susceptible to colonization with *Helicobacter pylori*, although no final conclusions can be presently made. This could be an important source for the oral transmission of this microorganism, which is frequently associated with gastritis [28]. One possible consequence of these data is that the oral cavity and oral diseases are important factors for the health or disease of the entire gastrointestinal tract.

Dentlearn.ir

Key Note

Chemical parameters, like residual monomers, and also mechanical factors (porous or rough denture surface) and particularly poor denture hygiene are decisive for the colonization of bacteria and fungi. Permanent soft relining materials are especially susceptible to fungal contamination. Therefore, it is recommended that the surface of these materials be sealed. Adequate sealants are available on the market. Patients should be motivated to practice good denture hygiene in order to prevent, or at least minimize, microbial contamination.

The etiology of burning mouth syndrome has not yet been fully clarified. Local (MMA, formaldehyde, fungi) as well as systemic factors (e.g., vitamin deficiency) have been discussed by several authors. It is of special interest that oral mucosa that has been predamaged by burning mouth syndrome may serve as a reservoir for *Helicobacter pylori*. This microorganism, frequently found in gastritis, may then be transmitted to other persons.

9.5 Allergies

Skin contact with MMA and PMMA may result in allergic reactions [76]. For example, MMA has been classified as an important contact allergen [53]. The contact dermatitis of four persons (one orthodontist, one apprentice, two lab technicians) was traced back to MMA [48]. One dentist had to quit his profession due to a very severe allergy to MMA. Mild to moderate dermatosis on the hands or fingers is the most frequent consequence of allergic reactions in dental personnel and dental technicians (Fig. 9.4) [40]. A recent Swedish publication reported that 3% of the dental personnel in one rural district suffer from contact dermatitis caused by acrylates [85].

Fig. 9.4 Dentist suffering from an allergy to methylmethacrylate contact dermatitis (Courtesy of P.J. Frosch, Dortmund, Germany)

A survey among 251 dentists in Berlin in 1985 revealed that 14 dentists, nine assistants, and 78 patients suffered from an allergy to acrylates. Klaschka and Galandi supposed that specifically initiators, like dibenzoyl peroxide, were the cause of the allergies of the dentists and assistants [55]. Out of 13,325 persons, 137 dentists reported a very low frequency in patients of adverse effects caused by dental materials, and 46 individuals revealed a verified or supposed allergy [45]. Tschernitschek et al. documented that between 1982 and 1997, 13% of 311 supposedly allergic patients revealed an allergy, which was the cause of their complaints [112]. Methylmethacrylates, in particular autopolymerizing materials, triggered the allergy in eight cases (Fig. 9.5). An extensive urticaria without intraoral symptoms due to an allergy to MMA released from a denture was also observed (see Figs. 9.6 and 9.7) [61].

Besides MMA, almost all other components of PMMA acrylates can cause an allergy [41, 43, 46, 48–50]. The initiator dibenzoyl peroxide elicits allergic reactions relatively often, especially in dental assistants and dental technicians. Further important allergens in lab technicians are ethylene glycol dimethacrylates and hydroquinone [29, 95, 96, 105]. It was documented in animal experiments (guinea pigs) that after sensitization with MMA, cross-allergies to other acrylates may develop [15]. The in vitro leukocyte migration inhibition assay revealed that MMA, a specific antigen, causes cellular immunity, although the immune reaction is not dependent on the concentration [123].

It has been reported several times that nail varnish or acrylic substances used for artificial fingernails caused allergic reactions (type IV) [11, 26, 81]. Particularly regarding this connection, dentists should always consider a possible cross-allergy to various acrylates.

Taken together, the frequency of allergies to components of PMMA resins, particularly MMA and dibenzoyl peroxide, has increased in the past decades

Dentlearn.ir

in patients, dental personnel, and lab technicians [49, 95, 112]. Data from the literature indicate a disproportionately high increase in occupationally exposed dental personnel, since more and more resin-based materials are used in dentistry [49, 95, 96]. However, allergies of patients to dental resins and their components are still very rare [95]. Repeated and comprehensive patch tests to verify an allergy to acrylates should be avoided because an active sensitization may, in fact, be caused by the test [53].

Key Note

Allergies to MMA or other components of denture acrylates are relatively rare in the general population, but the number of persons allergic to acrylates and additives of resins due to occupational exposure is increasing. The dental team should be scrupulous in avoiding any skin contact with unset resin or individual components because in extreme cases a sensitization may cause occupational disability. Even gloves do not sufficiently protect skin against contact with monomers.

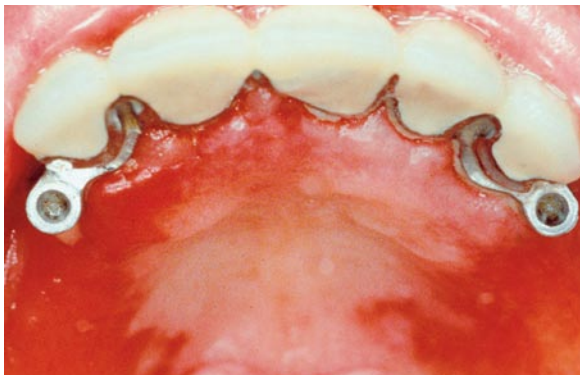

Fig. 9.5 Patient with combined fixed/removable denture in the upper jaw. The mucosa of the upper jaw is reddened due to inflammation. Allergies to various metals and resin compounds were diagnosed (Courtesy of H. Scheller, Mainz, Germany)

9.6 Mutagenicity and Carcinogenicity

Older studies reported generation of fibrous sarcomas and carcinomas after subcutaneous implantation of PMMA [57, 87]. These data were not confirmed by subsequent publications [35, 71, 75]. Long-term studies on industrial workers who had been exposed to MMA for a long period of time indicated no carcinogenic effect. In general, it may be concluded that the rapid degradation and excretion of MMA should prevent an accumulative toxic effect or severe systemic adverse reactions [5].

Fig. 9.6 Older female patient with an allergy-caused dermatitis at an index finger. The patient, who revealed a telescope denture in the upper jaw and a full denture in the lower jaw, was allergic to acrylates (Courtesy of H. Tschernitschek, Hannover, Germany)

Fig. 9.7 Allergic contact reaction in a 58-year-old woman with tingling sensations at the palate and at the tongue; patch test was positive for hydroquinone and the base resin, Palapress (Courtesy of G. Schmalz, Regensburg, Germany)

Dentlearn.ir

Conclusions for the Dental Practitioner

1. Depending on the type of polymerization, PMMA resins may contain between 0.1% and 5% releasable residual monomers and additives, mainly MMA and formaldehyde. These substances can contribute considerably to local adverse effects such as "denture stomatitis."
2. Although previous studies reported a possible carcinogenic and embryotoxic potency of MMA, these severe side effects have not been documented in the more recent literature. Furthermore, long-term studies on patients who are occupationally exposed to higher concentrations of compounds of PMMA resins indicated no increased frequency of tumors.
3. It is important, however, to recognize that basically all components of PMMA resins are allergenic. Cross-sensitizations within the group of methacrylate compounds are possible. MMA is the most significant allergen for patients.
4. To prevent an allergy, a best possible monomer-polymer conversion rate is crucial. Heat-polymerizing acrylics should be preferred over autopolymerizing products. Furthermore, dentures, acrylic orthodontic devices, and so on should be stored in water (37°C) several hours before insertion to remove the major share of leachable substances. Temporary crowns made with autopolymerizing acrylic resin should be removed from the oral cavity in time prior to complete setting to avoid thermal damage to the pulp.
5. MMA, the initiator dibenzoyl peroxide, and the cross-linking agent EGDMA are the most common allergens for occupationally exposed dental professionals. To prevent sensitization of these persons that could result in occupational incapacity, any direct skin contact with acrylic components should be avoided.
6. In this context, it needs to be considered that under all circumstances, latex or polyvinyl chloride (PVC) gloves are not sufficient protection. Many acrylates penetrate rubber and PVC very rapidly, thus getting into contact with skin despite protective gloves.
7. Rooms where dental resins are processed, dental laboratories, and clinics should be ventilated regularly and for a sufficiently long period of time to minimize the concentration of volatile acrylic compounds in compartmental air and thereby reduce the risk of inhalation.
8. If patients suffer from an incompatibility with PMMA resins, particularly an allergy, adequate similar materials are necessary for their treatment (e.g., for edentulous patients). Various alternative products are available (see Table 9.4). In such situations, a product based on polyvinyl is frequently used. This material also contains PMMA but in a very low concentration. Fewer data exist for the alternatives to PMMA-based resins.

Table 9.4 Examples of alternatives to Polymethylmethacrylate (PMMA)-based resins on the market (Information provided by the manufacturers)

Name of product	Material	Type of processing
Promysan STAR (pedrazzini-dental.de)	Thermoplastic resins based on polyester	Injection die casting
Eclipse (dentsply.com; degudent.com)	Urethane dimethacrylate and urethane dimethacrylate oligomers free of MMA, PMMA, and dibenzoyl peroxide	Single-component material, light curing
Valplast (valplast.com)	Polyamide (nylon)	Injection die casting
Luxene (luxene.com)	Polyvinyl-based resin with small amounts of PMMA	Molding technique or injection die casting
Sinomer, Puran (novodent.com)	PMMA polymer, without MMA monomer, without dibenzoyl peroxide	Molding technique, preferentially under high temperature (boiling water)
Polyan (polyapress-gmbh.com)	See: Sinomer, Puran	Injection die casting

Dentlearn.ir

References

1. Ali, A., Bates, F.J., Reynolds, A.J., Walker, D.M.: The burning mouth sensation related to the wearing of acrylic dentures: an investigation. Br Dent J 161, 444–447 (1986).
2. Anil, N., Hekimoglu, C., Büyükba, N., Ercan, M.T.: Microleakage study of various soft denture liners by autoradiography: effect of accelerated aging. J Prosthet Dent 81, 394–399 (2000).
3. Austin, A.T., Basker, R.M.: The level of residual monomer in acrylic denture base materials – with particular reference to a modified method of analysis. Br Dent J 149, 281–286 (1980).
4. Austin, A.T., Basker, R.M.: Residual monomer levels in denture bases – the effect of varying short curing cycles. Br Dent J 153, 424–426 (1982).
5. Autian, J.: Structure-toxicity relationships of acrylic monomers. Environm Health Perspect 11, 141–152 (1975).
6. Axelson, B., Nyquist, G.: The leaching and biological effect of the residual monomer of methyl methacrylate. Odontol Revy 13, 370–379 (1962).
7. Baker, S., Brooks, S.C., Walker, D.M.: The release of residual monomeric methyl methacrylate from acrylic appliances in human mouth: an assay for monomer in saliva. J Dent Res 67, 1295–1299 (1988).
8. Barron, D.J., Rueggeberg, F.A., Schuster, G.S.: A comparison of monomer conversion and inorganic filler content in visible light-cured denture resins. Dent Mater 8, 274–277 (1992).
9. Bereznowski, Z.: In vivo assessment of methyl methacrylate metabolism and toxicity. Int J Biochem Cell Biol 27, 1311–1316 (1995).
10. Blanchet, L.J., Bowman, D.C., McReynolds, H.D.: Effects of methyl methacrylate vapors on respiration and circulation in unanesthetized rats. J Prosthet Dent 48, 344–348 (1982).
11. Boehncke, W.H., Schmitt, M., Zollner, T.M., Hensel, O.: Nail polish allergy. An important differential diagnosis in contact dermatitis. Dtsch Med Wochenschr 122, 849–852 (1997).
12. Borzelleca, J.F., Larson, P.S., Hennigar, G.R., Huf, E.G., Crawford, E.M., Smith, R.B.: Studies on the chronic oral toxicity of monomeric ethyl acrylates and methyl methacrylates. Toxicol Appl Pharmacol 6, 29–36 (1964).
13. Brune, D., Beltesbrekke, H.: Levels of methylmethacrylate, formaldehyde, and asbestos in dental workroom air. Scand J Dent Res 89, 113–116 (1981).
14. Bundeszahnärztekammer und Kassenzahnärztliche Bundesvereinigung (ed.): Das Dental Vademeckum (DDV) [The Dental Vademecum], 7. Ausg., pp 598–603. Deutscher Ärzteverlag, Köln 2001.
15. Chung, C.W., Giles, A.L.: Sensitization potentials of methyl, ethyl, and n-butyl methacrylates and mutual cross-sensitivity in guinea pigs. J Invest Dermatol 68, 187–190 (1977).
16. Cibirka, R.M., Nelson, S.K., Lefebvre, C.A.: Burning mouth syndrome: a review of etiologies. J Prosthet Dent 78, 93–97 (1997).
17. Cimpan, M.R., Matre, R., Cressey, L.I., Tysnes, B., Lie, S.A., Gjertsen B.T., Skaug, N.: The effect of heat- and autopolymerized denture base polymers on clonogenicity, apoptosis, and necrosis in fibroblasts: denture base polymers induce apoptosis and necrosis. Acta Odontol Scand 58, 217–228 (2000).
18. Cimpan, M.R., Cressey, L.I., Skang, N., Halstensen, A., Lie, S.A., Gjertsen, B.T., Matre, R.: Patterns of cell death induced by eluates from denture base acrylic resins in U-937 human monoblastoid cells. Eur J Oral Sci 108, 59–69 (2000).
19. Corkill, J.A., Lloyd, E.J., Hoyle, P., Crout, D.H.G., Ling, R.S.M., James, M.L., Piper, R.J.: Toxicology of methyl methacrylates: the rate of disappearance of methyl methacrylate in human blood in vitro. Clin Chim Acta 68, 141–146 (1976).
20. Danilewicz-Stysiak, Z.: Experimental investigations on the cytotoxic nature of methyl methacrylate. J Prosthet Dent 44, 13–16 (1980).
21. Deutsche Forschungsgemeinschaft (DFG): MAK- und BAT-Werte-Liste 1996, Mitteilung 32 der Deutschen Forschungsgemeinschaft. [German National Science Foundation] Bonn 1996.
22. Deichmann, W.: Toxicity of methyl, ethyl and n-butyl methacrylate. J Ind Hyg Toxicol 23, 343–351 (1941).
23. Edgerton, M., Levine, M.J.: Characterization of acquired denture pellicle from healthy and stomatitis patients. J Prosthet Dent 68, 683–691 (1992).
24. Engelhardt, J.P., Grün, L.: Das Verhalten von Mikroorganismen gegenüber Methylmethacrylat, Vernetzer und Weichmacher. [Reaction of microorganisms to methylmethacrylates, wetting and softening agents] Dtsch Zahnärztl Z 27, 466–473 (1972).
25. Engelhardt, J.P.: Die Beständigkeit zahnärztlicher Kunststoffe gegenüber Mikroorganismen. [Resistance of dental plastic materials to microorganisms] Schweiz Mschr Zahnheilk 83, 656–669 (1973).
26. Erdmann, S.M., Sachs, B., Merk, H.F.: Adverse reactions to sculptured nails. Allergy 56, 581–582 (2001).
27. Fletcher, A.M., Purnaveja, S., Amin, W.M., Ritchie, G.M., Moradians, S., Dodd, A.W.: The level of residual monomer in self-curing denture-base materials. J Dent Res 62, 118–120 (1983).
28. Gall-Trošelj, K., Mravak-Stipetic, M., Jurak, I., Ragland, W.L., Pavellic, J.: Helicobacter pylori colonization of tongue mucosa – increased incidence in atrophic glossitis and burning mouth syndrome (BMS). J Oral Pathol Med 30, 560–563 (2001).
29. Gebhardt, M., Geier, J., Welker, D.: Kontaktallergie auf Prothesenkunststoffe und Differentialdiagnostik der Prothesenintoleranz. [Contact allergies to denture acrylics and differential diagnosis of denture intolerance] Dtsch Zahnärztl Z 51, 395–398 (1996).
30. Geurtsen, W.: Die zelluläre Verträglichkeit zahnärztlicher Komposite – Untersuchungen am Modell transformierter und nicht-transformierter Zellen. [Cellular compatibility of dental composites – studies with transformed and non-transformed cells] Hanser, München 1988.
31. Geurtsen, W., Lehmann, F., Spahl, W., Leyhausen, G.: Cytotoxicity of 35 dental resin composite monomers/additives in permanent 3T3 and three human primary fibroblast cultures. J Biomed Mater Res 41, 474–480 (1998).
32. Göcke, R., Simm, R., Szymanska, D., Seyfarth, M., von Schwanewede, H.: Multivariate Speichelanalysen bei Patienten mit Stomatitis prothetica. [Multivariate salivary analyses in patients with stomatitis prothetica] Dtsch Zahnärztl Z 52, 368–372 (1997).
33. Gough J. E., Downes S.: Osteoblast cell death on methacrylate polymers involves apoptosis. J Biomed Mater Res 57 (4), 497–505 (2001).
34. Grosse, G., Schröder, H.: Histologische Untersuchungen auf Pilze bei Stomatitis prothetica. [Histological study of fungi in denture stomatitis] Dtsch Zahnärztl Z 42, 98–101 (1987).
35. Habal, M.B., Powell, R.D.: Biophysical evaluation of the tumorigenic response to implanted polymers. J Biomed Mat Res 14, 447–454 (1980).
36. Hansel, C., Leyhausen, G., Mai, U.E.H., Geurtsen, W.: Effects of various resin composite (co)monomers and extracts on two caries-associated micro-organisms in vitro. J Dent Res 77, 60–67 (1998).

Dentlearn.ir

37. Harrison, A., Huggett, R., Jagger, R.C.: The effect of a cross-linking agent on the abrasion resistance and impact strength of an acrylic resin denture base material. J Dent 6, 299–304 (1978).
38. Harrison, A., Huggett, R.: Effect of the curing cycle on residual monomer levels of acrylic resin denture base polymers. J Dent 20, 370–374 (1992).
39. Hensten-Pettersen, A., Wictorin, L.: The cytotoxic effect of denture base polymers. Acta Odontol Scand 39, 101–106 (1981).
40. Hensten-Pettersen, A., Jacobsen, N.: Perceived side effects of biomaterials in prosthetic dentistry. J Prosthet Dent 65, 138–144 (1991).
41. Herrmann, D.: Allergien auf zahnärztliche Werkstoffe. [Allergies to dental materials] In: Voß, R., Meiners, H. (eds.): Fortschritte der Zahnärztlichen Prothetik und Werkstoffkunde [Proceedings of Prosthodontics and Dental Material Sciences], Band 4. Hanser, München 1989.
42. Huang, F-M., Tai, K-W., Hu, C-C., Chang, Y-C.: Cytotoxic effects of denture base materials on a permanent human oral epithelial cell line and on primary human oral fibroblasts in vitro. Int J Prosthodont 14, 439–443 (2001).
43. Kaaber, S.: Allergy to dental materials with special reference to the use of amalgam and polymethylmethacrylate. Int Dent J 40, 359–365 (1990).
44. Kallus, Th.: Evaluation of the toxicity of denture base polymers after subcutaneous implantation in guinea pigs. J Prosthet Dent 52, 126–134 (1984).
45. Kallus, Th., Mjör, I.A.: Incidence of adverse effects of dental materials. Scand J Dent Res 99, 236–240 (1991).
46. Kanerva, L., Estlander, T., Jolanki, R.: Allergic contact dermatitis from dental composite resins due to aromatic epoxy acrylates and aliphatic acrylates. Contact Dermatitis 20, 201–211 (1989).
47. Kanerva, L., Jolanki, R., Estlander, T.: Dentist's occupational allergic contact dermatitis caused by coconut diethanolamide, N-ethyl-4-toluene sulfonamide and 4-tolyldiethanolamine. Acta Derm Venereol 73, 126–129 (1993).
48. Kanerva, L., Estlander, T., Jolanki, R., Tarvainen, K.: Occupational allergic contact dermatitis caused by exposure to acrylates during work with dental protheses. Contact Dermatitis 28, 268–275 (1993).
49. Kanerva, L., Estlander, T., Jolanki, R.: Occupational skin allergy in the dental profession. Dermatol Clinics 12, 517–532 (1994).
50. Kanerva, L., Estlander, T., Jolanki, R.: Allergy caused by acrylics: past, present and prevention. In: Elsner, P., Lachapelle, J.M., Wahlberg, J.E., Maibach, H.I. (eds): Prevention of Contact Dermatitis – Current Problems in Dermatology, vol. 25. Karger, Basel 1996, pp 86–96.
51. Karlsson, J., Wendling, W., Chen, D., Zelinsky, J., Jeevanandam, V., Hellman, S., Carlsson, C.: Methylmethacrylate monomer produces direct relaxation of vascular smooth muscle in vitro. Acta Anaesthesiol Scand 39, 685–689 (1995).
52. Kayser, D., Schlede, E. (eds.): Chemikalien und Kontaktallergie – Eine bewertende Zusammenstellung. Bundesinstitut für gesundheitlichen Verbraucherschutz und Veterinärmedizin. [Allergies to chemicals and contact allergies – an evaluating review. National Institute for Consumers' Health Protection and Veterinary Medicine] Urban & Vogel, München 2001.
53. Kedjarune, U., Charoenworaluk, N., Koontongkaew, S.: Release of methyl methacrylate from heat-cured and autopolymerized resins: cytotoxicity testing related to residual monomer. Australian Dent J 44, 25–30 (1999).
54. Kim S. K., Heo S. J., Koak J. Y., Lee Y. M., Chung D. J., Lee J. I., Hong S. D.: A biocompatibility study of a reinforced acrylic-based hybrid denture composite resin with polyhedraloligosilsesquioxane. J Oral Rehabil 34, 389–395 (2007).
55. Klaschka, F., Galandi, M.E.: Allergie und Zahnheilkunde aus dermatologischer Sicht. [Allergy and dentistry from the dermatologist's viewpoint] Dtsch Zahnärztl Z 40, 364–371 (1985).
56. Klötzer, W., Langeland, K.: Tierexperimentelle Prüfung von Material und Methoden der Kronen- und Brückenprothetik. [Testing of materials and methods for crown and bridge prostheses on animals] Schweiz Monatsschr Zahnheilkd 83, 163–244 (1973).
57. Laskin, D.M., Robinson, I.B., Weinmann, J.P.: Experimental production of sarcomas by methyl methacrylate implants. Proc Soc Exp Biol Med 87, 329–332 (1954).
58. Lauer, Ch.: Experimentelle Untersuchungen zur Wärmeentwicklung im Pulpakavum durch Kunststoffprovisorien. [Experimental investigations on the heat development in the pulp cavity by resin temporary materials] Dtsch Zahnärztl Z 41, 468–472 (1986).
59. Lawrence, W.H., Malik, M., Autian, J.: Development of a toxicity evaluation program for dental materials and products. II. Screening for systemic toxicity. J Biomed Mat Res 8, 11–34 (1974).
60. Leyhausen, G., Kunert, M., Bubeck, P., Geurtsen, W.: Cytocompatibility of ionomer- and resin-based bone cements. J Dent Res 77, 119 (1998).
61. Lunder, T., Rogl-Butina, M.: Chronic urticaria from an acrylic dental prosthesis. Contact Dermatitis 43, 232–233 (2000).
62. Lygre, H., Solheim, E., Gjerdet, N.R., Berg, E.: Leaching of organic additives from dentures in vivo. Acta Odontol Scand 51, 45–51 (1993)
63. Lygre, H., Solheim, E., Gjerdet, N.R.: Leaching from denture base materials in vitro. Acta Odontol Scand 53, 75–80 (1995).
64. Mähönen, K., Virtanen, K., Larmas, M.: The effect of prosthesis disinfection on salivary microbial levels. J Oral Rehabil 25, 304–310 (1998).
65. Mäkilä, E., Hopsu-Havu, V.K.: Mycotic growth and soft denture lining materials. Acta Odont Scand 35, 197–205 (1976).
66. Marxkors, R., Meiners, H.: Taschenbuch der zahnärztlichen Werkstoffkunde [Dental Material Sciences], 4th ed. Hanser, München 1993.
67. Matsuura, T., Kohada, A., Yamamoto, T., Miyake, Y., Akagawa, Y., Suginaka, H., Tsuru, H.: High incidence of *Staphylococcus aureus* from dentures and tongues of maxillary resection patients. Oral Microbiol Immunol 12, 354–357 (1997).
68. McLaughlin, R.E., DiFazio, C.A., Hakala, M., Abbott, B., MacPhail, J.A., Mack, W.P., Sweet, D.E.: Blood clearance and acute pulmonary toxicity of methylmethacrylate in dogs after simulated arthroplasty and intravenous injection. J Bone Joint Surg 55-A, 1621–1628 (1973).
69. Miettinen, V.M., Vallittu, P.K.: Water sorption and solubility of glass fiber-reinforced denture polymethyl methacrylate resin. J Prosthet Dent 76, 531–534 (1996).
70. Miettinen, V.M., Vallittu, P.K.: Release of residual methyl methacrylate into water from glass fibre-poly(methyl methacrylate) composite used in dentures. J Dent 18, 181–185 (1997).
71. Miller, E.G., Washington, V.H., Bowles, W.H., Zimmermann, E.R.: Mutagenic potential of some chemical components of dental materials. Dent Mater 2, 163–165 (1986).
72. Mir, G.N., Lawrence, W.H., Autian, J.: Toxicological and pharmacological actions of methylmethacrylate monomers I: Effects on isolated, perfused rabbit heart. J Pharmaceut Sci 62, 778–782 (1973).

Dentlearn.ir

73. Mir, G.N., Lawrence, W.H., Autian, J.: Toxicological and pharmacological actions of methylmethacrylate monomers II: Effects on isolated guinea pig ileum. J Pharmaceut Sci 62, 1258–1261 (1973).
74. Mir, G.N., Lawrence, W.H., Autian, J.: Toxicological and pharmacological actions of methylmethacrylate monomers III: Effects on respiratory and cardiovascular functions of anesthetized dogs. J Pharmaceut Sci 63, 376–381 (1974).
75. Mitchell, D.F., Shankwalker, G.B., Shazer, S.: Determining the tumorigenicity of dental materials. J Dent Res 39, 1023–1028 (1960).
76. Mjör, I.A.: Potential hazards in the handling of dental materials. In: Mjör, I.A. (ed.): Dental Materials: Biological properties and clinical evaluations. CRC, Boca Raton, Florida, 1985, pp 193–202.
77. Moreau, M.F., Chappard, D., Lesourd, M., Montheard, J.P., Basle, M.F.: Free radicals and side products released during methylmethacrylate polymerization are cytotoxic for osteoblastic cells. J Biomed Mater Res 40, 124–131 (1998).
78. Morneburg, Th.: Zum „Behandlungserfolg" bei Prothesenunverträglichkeit. [Success rate in patients with denture intolerance] Dtsch Zahnärztl Z 50, 742–745 (1995).
79. Nakamura, M., Kawahara, H.: Long-term biocompatibility test of denture base resins in vitro. J Prosthet Dent 52, 694–699 (1984).
80. Nathanson, D., Gettleman, L., Schnitman, P., Shklar, G.: Histologic response to porous PMMA implant materials. J Biomed Mat Res 12, 13–33 (1978).
81. National Institute for Occupational Safety and Health: Controlling chemical hazards during the application of artificial fingernails. Appl Occup Environ Hyg 16, 509–511 (2001).
82. Niedermeier, W.: Psychogene Prothesenunverträglichkeit oder sialogene Schleimhautintoleranz? [Psychogenic denture intolerance or sialogenic mucosal incompatibility] Dtsch Zahnärztl Z 51, 73–80 (1996).
83. Nikawa, H., Yamamoto, T., Hamada, T.: Effect of components of resilient denture-lining materials on the growth, acid production and colonization of *Candida albicans*. J Oral Rehabil 22, 817–824 (1995).
84. Nikawa, H., Hamada, T., Yamamoto, T., Kumagai, H.: Effects of salivary or serum pellicles on the Candida albicans growth and biofilm formation on soft lining materials in vitro. J Oral Rehabil 24, 594–604 (1997).
85. Ohlson C.G., Svensson, L., Mossberg, B., Hök, M.: Prevalence of contact dermatitis among dental personnel in a Swedish rural county. Swed Dent J 25, 13–20 (2001).
86. Olan-Rodriguez, L., Minah, G.E., Driscoll, C.F.: *Candida albicans* colonization of surface-sealed interim soft liners. J Prosthodont 9, 184–188 (2000).
87. Oppenheimer, B.S., Oppenheimer, E.T., Danishefsky, A.P., Stout, A.P., Eirich, F.R.: Further studies of polymers as carcinogenic agents in animals. Cancer Res 15, 333–340 (1955).
88. Oysaed, H., Ruyter, I.E., Sjovik Kleven, I.J.: Release of formaldehyde from dental composites. J Dent Res 67, 1289–1294 (1988).
89. Pantucek, M.: On the metabolic pathway of methylmethacrylate. FEBS Lett 2, 206–208 (1969).
90. Peterson, L.J., Pennel, B.M., McKinney, R.V., Klawitter, J.J., Weinstein, A.M.: Clinical, radiographical, and histological evaluation of porous rooted polymethylmethacrylate dental implants. J Dent Res 58, 489–496 (1979).
91. Phillips, H., Cole, P.V., Lettin, A.W.: Cardiovascular effects of implanted acrylic bone cement. Br Med J 772, 460–461 (1971).
92. Radford, D.R., Challacombe, S.J., Walter, J.D.: Adherence of phenotypically switched *Candida albicans* to denture base materials. J Prosthet Dent 11, 75–81 (1998).
93. Radford, D.R., Challacombe, S.J., Walter, J.D.: Denture plaque and adherence of *Candida albicans* to denture-base materials in vivo and in vitro. Crit Rev Oral Biol Med 10, 99–116 (1999).
94. Reichart, P.: Mundschleimhautveränderungen. Manual zur klinischen Untersuchung. Deutsche Mundgesundheitsstudie III. [Alterations of the oral mucosa: manual for clinical assessment. German Study on Oral Health III. Institute of German Dentists] Institut der Deutschen Zahnärzte (1997).
95. Richter, G., Geier, J.: Dentalwerkstoffe – Problemsubstanzen in der allergologischen Diagnostik? Teil I. [Dental materials – problem substances in allergologic diagnosis? I: Analysis of test results in patients with mouth mucosa/dental material problems] Hautarzt 47, 839–843 (1996).
96. Richter, G.: Dentalwerkstoffe – Problemsubstanzen in der allergologischen Diagnostik? Teil II. [Dental materials – problem substances in allergologic diagnosis? II: Patch test diagnosis and relevance evaluation of selected dental material groups] Hautarzt 47, 844–849 (1996).
97. Röhrbein, W., Bork, K.: Allergien auf Zahnersatzmaterialien. [Allergies to prosthetic materials] Zahnärztl Mitt 78, 350–356 (1988).
98. Rudigier, J., Scheuermann, H., Kotterbach, B., Ritter, G.: Restmonomerabgabe und Freisetzung aus Knochenzementen. [Release and diffusion of methylmethacrylic monomers after the implantation of self curing bone cements] Unfallchirurgie 7, 132–137 (1981).
99. Ruyter, I.E.: Release of formaldehyde from denture base polymers. Acta Odontol Scand 38, 17–27 (1980).
100. Ruyter, I.E., Oysaed, H.: Analysis and characterization of dental polymers. In: CRC Critical Reviews in Biocompatibility, vol. 4, issue 3. CRC, Boca Raton, Florida, 1988, pp 247–279.
101. Schendel, K.U., Lenhardt, M., Fusenig, N.E., Komposch, G.: Testung der Toxizität von in der Kieferorthopädie verwendeten Kunststoffen. [Testing of the toxicity of plastics used in orthodontics] Fortschr Kieferorthop 53, 263–272 (1992).
102. Schmalz, G.: Der Einfluß von Methyl-Methacrylat-Monomer auf den Stoffwechsel von L-Zellen. [The effect of methyl-methacrylate monomer on L-cell metabolism] Dtsch Zahnärztl Z 34, 193–195 (1979).
103. Schmalz, G.: Die Gewebeverträglichkeit zahnärztlicher Materialien. [The tissue compatibility of dental materials] Thieme, Stuttgart 1981.
104. Schmalz, G.: Die lokale Gewebeverträglichkeit von Komposit-Kunststoffen. [The local tissue compatibility of composite resins] In: Neue Füllungsmaterialien. [New filling materials] Hanser, München 1990, 89–110.
105. Schnuch, A., Geier, J.: Kontaktallergene bei Dentalberufen. [Contact allergenes in dental health professionals] Dermatosen 42, 253–255 (1994).
106. Schoenfeld, C.M., Conrad, G.J.: Monomer release from methacrylate bone cements during simulated in vivo polymerization. J Biomed Mat Res 13, 135–147 (1979).
107. Singh, A.R., Lawrence, W.H., Autian, J.: Embryonic-fetal toxicity and teratogenic effects of a group of methacrylate esters in rats. J Dent Res 51, 1632–1638 (1972).

Dentlearn.ir

108. Stea, S., Granchi, D., Zolezzi, C., Ciapetti, G., Visentin, M., Cavedagna, D., Pizzoferrato, A.: High-performance liquid chromatography assay of N,N-dimethyl-p-toluidine released from bone cements: evidence for toxicity. Biomaterials 18, 243–246 (1997).
109. Tansy, M.F., Benhayem, S., Probst, S., Jordan, J.S.: The effects of methyl methacrylate vapor on gastric motor function. J Am Dent Assoc 89, 372–376 (1974).
110. Tansy, M.F., Landin, W.E., Kendall, F.M.: LC50 value for rats acutely exposed to methyl methacrylate monomer vapor. J Dent Res 59, 1074 (1980).
111. Technische Regel für Gefahrstoffe: TRGS 900 – Grenzwerte in der Luft am Arbeitsplatz – Luftgrenzwerte. [Technical regulations for hazardous substances: TRGS 900 – Threshold values in air at the work place – threshold values for air] BarbBl. 10/2000 p. 34–63; eingearbeitete Änderungen: 4/2001 p. 56; 9/2001 p. 86.
112. Tschernitschek, H., Wolter, S., Körner, M.: Allergien auf Zahnersatzmaterialien. [Allergies and prosthetic materials] Dermatosen/ Occup Environ 46, 244–248 (1998).
113. Tsuchiya, H., Hoshino, Y., Kato, H., Takagi, N.: Flow injection analysis of formaldehyde leached from denture-base acrylic resins. J Dent 21, 240–243 (1993).
114. Tsuchiya, H., Hoshino, Y., Tajima, K., Takagi, N.: Leaching and cytotoxicity of formaldehyde and methyl methacrylate from acrylic resin denture base materials. J Prosthet Dent 71, 618–624 (1994).
115. Vallittu, P.K., Lassila, V.P., Lappalainen, R.: Acrylic resin-fiber composite – part I: The effect of fiber concentration on fracture resistance. J Prosthet Dent 71, 607–612 (1994).
116. Vallittu, P.K., Miettinen, V., Alakuijala, P.: Residual monomer content and its release into water from denture base materials. Dent Mater 11, 338–342 (1995).
117. Vallittu, P.K.: The effect of surface treatment of denture acrylic resin on the residual monomer content and its release into water. Acta Odontol Scand 54, 188–192 (1996).
118. Vallitu, P.K., Ruyter, I.E., Buykuilmaz, S.: Effect of polymerization temperature and time on the residual monomer content of denture base polymers. Eur J Oral Science 106, 588–593 (1998).
119. Verordnung zum Schutz vor gefährlichen Stoffen: GefStoffV – Gefahrstoffverordnung. [Regulation for the protection against hazardous substances] BGBl. I pp. 2233; 2000 pp. 739, 747, 932, 1045 (1999).
120. Verran, J., Maryan, C.: Retention of *Candida albicans* on acrylic resin and silicone of different surface topography. J Prosthet Dent 77, 535–539 (1997).
121. Wright, P.S., Clark, P., Hardie, J.M.: The prevalence and significance of years in persons wearing complete dentures with soft-lining materials. J Dent Res 64, 122–125 (1985).
122. Wright, P.S., Young, K.A., Riggs, P.D., Parker, S., Kalachandra, S.: Evaluating the effect of soft lining materials on the growth of yeast. J Prosthet Dent 79, 404–409 (1998).
123. Zafiropoulos, C.G., Apostolopoulos, A.X., Patramani, I.: Study of the antigenic properties of methyl methacrylate using the leukocyte-migration inhibition test. Dent Mater 1, 200–204 (1985).

Dentlearn.ir

10 Oral Hygiene Products

A. Richards

Contents

10.1	Introduction	271
10.2	Toothpastes and Mouthwashes	271
10.2.1	Systemic Toxicity	272
10.2.2	Local Toxicity and Biocompatibility	276
10.2.3	Allergies	279
10.2.4	Mutagenicity, Carcinogenicity, and Teratogenicity	282
10.3	Tooth Bleaching Agents	284
10.3.1	Carbamide Peroxide	284
10.3.2	Systemic Toxicity	284
10.3.3	Local Toxicity and Tissue Compatibility	285
10.4	Fluoride Varnishes and Gels	286
10.4.1	Gels	286
10.4.2	Varnishes	287
10.4.3	Vehicle Substances	287
	Conclusions for the Dental Practitioner	288
	References	289

10.1 Introduction

Oral hygiene products are usually not classified as dental materials. Their use is at least in part regulated by other laws, such as regulations regarding cosmetics. But there is no clear borderline. Bleaching agents, for instance, may contribute to a change in the aesthetic appearance. But on the other hand, bleaching agents are considered medical devices in many countries equivalent to dental materials – for many good reasons. Furthermore, side effects due to oral hygiene products have been observed that are similar to those caused by dental materials. Thus, such adverse effects were often erroneously attributed to dental materials. In order to diagnose side effects and identify their possible causes, information about adverse effects of oral hygiene products can be very helpful.

10.2 Toothpastes and Mouthwashes

Toothpastes and mouthwashes are the two most important oral hygiene products available to patients. These products differ from dental materials used in the dental office in a number of specific ways. The biggest difference is that, generally, these products are purchased by the patient without reference to a dental health professional. Also, oral hygiene products are classified as cosmetic preparations, which means they may not be subjected to the same rigorous controls as would be applied to drugs or medical devices (see also Chap. 3).

Historical reviews describe how mouthrinses and toothpastes have been used for more than 3,000 years [50, 58, 74]. Throughout this time and up to the present day, they have been formulated to clean stains from the teeth, disguise malodor, and prevent or treat diseases in the teeth and supporting tissues.

Because it has been shown that bacteria play a prime role in the etiology of the major oral diseases, many of the so-called active ingredients are directed toward the oral microflora or sequelae of their metabolism. Cleaning stains from teeth requires an abrasive, and the overall sales success of a product may depend on flavoring agents, which give a sensation of well-being, cleanliness, and reduced fears of oral malodor. These substances influence the compatibility of a product. A product's biocompatibility may be altered by a change in any of these substances – their addition or removal or merely an alteration in their concentration. Other classes of substances contained in oral hygiene products include humectants, homogenizers, preservatives, foaming agents, and so on.

Nearly all ingredients are potentially harmful, and the risk of harmful effects depends on concentration. Many antimicrobial agents added to toothpastes and mouthwashes possess powerful antimicrobial properties in concentrations that are used in other cosmetic products, such as soap. But these concentrations may

Dentlearn.ir

Fig. 10.1 Many different toothpastes are available on the market, although their ingredients are often similar

10

Table 10.1 Ingredients commonly used in toothpastes and mouthwashes

Abrasives[a]	Silicon dioxide, calcium carbonate, aluminium trihydrate, trisodium phosphate
Foaming agents	Sodium lauryl sulfate, cocosamidepropylbetaine, Triton-X 100, calcium glycerophosphate, stearyl etoxylate
Binding agents	Carboxymethylcellulose, xantham gum, silica gel, cellulose gum, hydroxyethylcellulose, carbopol (carbomer)
Humectants	Glycerol, polyethylene glycol, propylene glycol
Flavorings	Saccharin, sorbitol, xylitol, peppermint oil, anise oil, menthol, eucalyptol
Antimicrobials	Chlorhexidine, triclosan
Colorants	Titanium dioxide, azulene
Preservatives	Methylparahydroxybenzoates, ethanol
Anticalculus agents	Tetrasodiumpyrophosphate, disodium azacycloheptane diphosphonate
Fluoride salts	Sodium fluoride, sodium monofluorophosphate, stannous fluoride, amine fluoride (bis-(hydroxyethyl-)-aminopropyl-N-hydroxyethyloctadecylamine dihydrofluoride)

[a] Abrasives are not used in mouthwashes, and ethanol is only rarely added to toothpastes.

not be compatible with the oral environment. At the same time, it is difficult to formulate products capable of maintaining suitable concentrations of the active agents for a suitable period of time because the fluids in the mouth are constantly replaced by new saliva and lost through swallowing. This situation means that the effect can be sustained only by frequent use of the product or by a high substantivity (adhesion to teeth and/or oral mucosa), which in turn increases the risk of harmful effects of chronic exposure.

Although these products are designed to be expectorated after use, total excretion by this route is impossible even in adults. The situation is worse in small children, who always inadvertently swallow at least half of a mouthrinse or toothpaste even though they may attempt to expectorate. Because lifelong use of the product may be desirable, it becomes mandatory to examine the potential systemic toxicity of all ingredients.

As will be appreciated from the introduction, this is a vast field, and the variety of different products available is innumerable. A selection of commonly available toothpastes is shown in Fig. 10.1, but it is important to realize that names and composition of these products are in a constant state of change. There are, however, specific substances that are commonly used for the same purpose in many different products; these substances are shown in Table 10.1.

It is the purpose of this chapter to review some of the limited knowledge available about compatibility or potential side effects of oral hygiene products. The first aim is to critically assess the products in order to provide adequate information to patients. The second aim is to facilitate diagnosis of side effects and assignment of symptoms to possible causes, particularly to differentiate them from symptoms caused by dental materials.

10.2.1 Systemic Toxicity

10.2.1.1 Acute Systemic Toxicity

Acute systemic toxic reactions from normal use of toothpastes and mouthrinses are unlikely, provided that patients closely adhere to the instructions for use provided by the manufacturers. Thus, although a portion of these products is always ingested, and many ingredients may also reach the bloodstream from direct absorption through the oral mucosa, the

Dentlearn.ir

amounts are usually too small to cause acute systemic effects.

Unfortunately, products are not always used according to manufacturers' instructions. Acute systemic ill effects due to wrongful ingestion of mouthwashes by children are not uncommon. The most serious cases that have been reported relate to intoxication and poisoning due to the alcohol content of mouthwashes

Alcohol: Alcohol may be regarded as an essential ingredient of most mouthwashes, as it acts as a solvent for the aromatic oils, scents, and flavoring agents that, albeit temporarily, mask oral malodor. Many laypersons and professionals as well are not aware that most mouthwashes contain alcohol. In product labeling, some manufacturers have used the term "emulgator" to include alcohol. In 1995 Gagari and Kabani reported that the six most commonly used brands of commercially available mouthrinses in North America contained from 6% to 26.9% ethanol [66]. Today, more than two decades later, one of the mouthrinses most commonly sold worldwide contains more than 25% ethanol.

Many mouthwashes have attractive colors and a pleasant taste. They may be unwittingly stored within easy reach of young children. Parents, being familiar with the symptoms of intoxication in adults, have not always regarded alcohol intoxication after ingestion of a mouthwash by children as a serious condition. But alcohol intoxication in preschool children is more serious than it may be in adults; alcohol-induced hypoglycemia is a serious complication in children [38, 139, 168]. It may result in irreparable damage to the liver and brain, and a fatal case has been reported of a 4-year-old child who ingested a mouthrinse containing 10% alcohol [149].

An analysis of reports of the American Association of Poison Control Centers for 1994 revealed that in that year there were 2,937 calls to poison control centers related to suspected overingestion of alcohol from mouthrinses. This figure represents an estimated incidence of 168 exposures per 100,000 children under 6 years of age [155].

Concerns about the dangers of alcohol poisoning of small children has prompted the American Dental Association to require manufacturers of mouthwashes containing more than 5% alcohol to furnish bottles with child safety tops and warning labels before the association will grant its "seal of acceptance." The American Academy of Pediatrics has gone a step further and recommended to the U.S. Food and Drug Administration that over-the-counter (OTC) products should be limited to a maximum alcohol content of 5% v/v and that these products should also have child-safe bottle tops.

Key Note

Physicians and dentists should be aware of the potential lethal consequences of mouthwash ingestion by small children and demand adequate labeling of products. Health professionals should also warn parents of these dangers.

Fluorides: Fluoride is another ingredient of oral hygiene products that is a potential cause of acute systemic toxicity, particularly in small children. However, although there are numerous reports of accidental fluoride poisoning in both children and adults, there are no reports that use or abuse of commercially produced toothpastes and mouthrinses containing fluoride have had lethal consequences. This is probably because, from the outset, controlling agencies in both North America and Europe have limited the quantity of fluoride that may be added to these products and have required that the size of packages should not be large enough for fatal accidents to occur, even if, for example, a child swallowed the entire contents of a tube of toothpaste.

The probable toxic dose (PTD) of fluoride, defined as the lowest dose that could cause serious or life-threatening symptoms requiring immediate emergency treatment, has been proposed by Whitford to be 5 mg F/kg of body weight (bw) [172, 173] and is often referred to by international administrations. This value is based, among others, on reports of three fatalities in children who ingested 15 mg F^- or more per kilogram of body weight (as tablets) [173]. This means that a 3- to 4-year-old child weighing 15 kg could ingest a whole 75-ml tube of "normal" (0.1% F^-) fluoridated toothpaste before reaching this limit, whereas a 5-year-old child weighing 20 kg who swallowed 0.5 l of a 0.05% mouthrinse could be at risk [172].

In Europe, the maximum permitted concentration of fluoride in toothpaste for OTC sales is 0.15%, but products containing as much as 1.3% (e.g., Fluodontyl 1350) are available in pharmacies in some European countries.

Dentlearn.ir

Key Note

Because the use of fluoride-containing toothpastes is ubiquitous, with these products accounting for more than 95% of all toothpastes sold, it is important that package size and, especially, fluoride contents continue to be controlled. Parents should be made aware that toothpaste use by preschool children should be supervised. Manufacturers should be encouraged to include this advice in labels.

10.2.1.2 Chronic Systemic Toxicity

Chronic systemic toxicity resulting from long-term use of oral hygiene products has not been reported except for investigations of relationships between the use of fluoridated toothpaste by young children and the prevalence of dental fluorosis (see information below on fluoride in toothpaste).

There has been interest in the past about concentrations of lead, cadmium, and titanium in toothpastes [21, 22, 151]. Today, such heavy metals with a documented potential for producing systemic toxicity must not be present in toothpastes and mouthrinses, or they are regulated so that amounts likely to add to the known daily burden from other sources will not exceed the calculated tolerable daily dose. Many other substances that are approved ingredients of toothpastes and mouthwashes are classified as "generally recognized as safe" (GRAS) by the U.S. Food and Drug Administration. These are substances that are known to occur naturally in normal food or have traditionally been used as additives to foods for many years with no untoward effects being noticed so far.

It is important to emphasize that producers bear the burden of responsibility for ensuring that substances that cause systemic toxic effects are not contained in toothpastes.

Fluorides in toothpaste: Chronic systemic toxicity from ingesting fluoride toothpastes and mouthrinses can be expected to result in dental fluorosis and/or osteofluorosis. The latter is not likely to occur from normal use of mouthwashes and toothpastes, as 4 ppm fluoride has been set as a maximum concentration in drinking water to avoid crippling skeletal changes [52]. This would be equivalent to ingesting more than 8 mg of fluoride daily over many years, which would mean swallowing more than 8 g of toothpaste containing 0.1% fluoride or 40 ml of mouthwash (0.01% fluoride) daily. Even at a concentration of 8 ppm fluoride in drinking water, only older subjects revealed increased density in their bone structure with no symptoms of illness [105].

But it has been shown in numerous studies that 2- to 3-year-old children swallow more than half of the toothpaste they apply to their toothbrush. Even 6- to 7-year-olds may ingest 25% of the toothpaste, whereas older children and adults swallow no more than 5–6% [9, 75, 121, 122, 156].

Clinical Practice Advice

Dentists should know that the amounts of toothpaste used by preschool children need to be properly controlled because ingestion of toothpaste containing fluoride increases the risk of dental fluorosis. Parents should be advised to apply only small amounts of fluoride-containing toothpaste to the toothbrushes of their preschool children, e.g., a pea-size amount, as shown in Fig. 10.2.

There is no doubt that use of fluoridated toothpastes contributes to daily fluoride intake; this has been demonstrated by elevated levels of fluoride concentrations in plasma and urine after toothpaste use [43, 45, 48, 136].

From the information available on amounts of fluoridated toothpaste (average concentration about 1,000 ppm) used and ingested by children of different ages, it has been possible to calculate fluoride doses



Fig. 10.2 Parents should be advised to use only a pea-size amount of toothpaste for preschool children, and toothpaste labels should contain this instruction

Dentlearn.ir

from toothpaste [56]. In Table 10.2, these amounts are compared with doses calculated for Swedish children who had been given fluoride tablets under supervised conditions. More than 28% of the Swedish children exhibited mild fluorosis [72]. As can be seen from the table, the calculated fluoride intake (per kilogram of body weight) from toothpaste is similar to intake in the tablet study until 4 years of age, after which it is less. It can be concluded from these data that dental fluorosis can, theoretically, be expected to occur as a result of fluoridated toothpaste ingestion alone.

For several years, an increasing number of toothpastes specifically designed for small children has been available with fluoride concentrations from 0.025% to 0.05%. Apart from the problem of burdening parents with different products for their children's various ages, it should be considered that use of these "low-fluoride" toothpastes still requires careful control of the amounts used. Thus, a 50% reduction of the fluoride concentration is of little benefit if the child applies twice as much paste.

Epidemiological evidence showing that use of fluoride toothpaste (mean fluoride concentration 1,000 ppm) in preschool children may be a risk factor for fluorosis has been reported in a few studies [130, 140]. These reports were based on subjects who had simultaneously been exposed to fluoride from sources other than drinking water and toothpaste. Most recently, the risk of fluorosis was studied in the population of Goa, where toothpaste was the only source of fluoride apart from drinking water containing less than 0.1 ppm fluoride [113]. These authors found that use of fluoridated toothpaste is a risk factor for dental fluorosis and that among children with fluorosis, the severity of lesions was significantly increased in those who began brushing before the age of 2 years. This study in particular has confirmed that fluoride in toothpaste, just like any other source of fluoride, can cause dental fluorosis.

The prevalence of fluorosis in the children who had used fluoride toothpaste in Goa was 12.9%, which is lower than that found by other authors in areas with multiple sources of fluoride. Thus, fluoride, from whatever source, is cumulative so that the risk of fluorosis increases with the number of fluoride sources or increase in total fluoride intake. Also, it is important to mention that among the children with fluorosis in the Goan study, 75% displayed only extremely mild levels of fluorosis, and in areas with 1.0 mg fluoride per liter of drinking water, a prevalence of dental fluorosis of 60% is to be expected if drinking water is the sole source of fluoride exposure [56, 72].

Fluoride in mouthrinses: An extensive study of mouth rinsing capabilities of 474 preschool children (ages 3–5 years) showed that all subjects swallowed a significant portion of a mouthwash containing 0.025% fluoride [171]. Some children swallowed all of the rinse. The authors calculated that if a 0.1% fluoride rinse had been used, these subjects would have ingested, on average, 1.2–2.02 mg of fluoride depending on their age and the volume and duration of rinse. These figures were calculated after excluding those subjects who inadvertently swallowed all of the mouthrinse despite rigorous instruction to the contrary. The results of this study clearly illustrate that mouthrinses in general and

Table 10.2 Calculated fluoride intake according to age in children using a 1,000-ppm fluoride toothpaste compared with calculated median fluoride dose for children with fluorosis prevalence of 28% who were given fluoride tablets [56]

Age (years)	Toothpaste use/day (g)	Toothpaste ingested (%)	Fluoride intake (mg fluoride/kg body weight)[a]	
			1,000-ppm toothpaste	Swedish tablet study
2	1.16	48	0.047	0.042
3	1.16	48	0.039	0.035
4	1.12	42	0.029	0.031
5	1.00	34	0.019	0.027
6	1.32	25	0.013	0.024

[a] Fluoride intake from toothpastes alone can cause dental fluorosis.

Dentlearn.ir

fluoridated mouthwashes in particular should not be prescribed for children under 7 years of age.

Clinical Practice Advice

The dentist should know the potential adverse effects of fluorides, and dental patients should be advised accordingly. In the general public, there has in recent years been a tendency to avoid using fluoride-containing toothpastes because of fear of adverse effects. It should therefore be kept in mind that when handled with care, fluorides have for decades proven their immense importance in preventing tooth decay.

Fig. 10.3 Mechanical abrasion of tooth substance (Courtesy of P. Hørsted-Bindslev, Århus, Denmark)

10.2.2 Local Toxicity and Biocompatibility

Local effects of the use or abuse of oral hygiene products may lead to damage to the hard tissues, particularly after prolonged use, as well as to soft tissue reactions, which may occur immediately or after prolonged exposure. Damage to the hard tissue can occur by mechanical abrasion, which is most pronounced in dentine, or chemical erosion, which is most severe in the enamel (Fig. 10.3).

10.2.2.1 Mechanical Abrasion

Abrasives are an essential component of toothpastes because they enable mechanical removal of stained tooth pellicle. Thus, brushing teeth with water alone is not sufficient for at least one-fifth of the population because they will develop staining of their teeth within 2 weeks. This staining can be removed with one or two brushing sessions with a toothpaste containing an abrasive [97].

There has been much discussion in the literature concerning measuring the abrasiveness of toothpastes, and manufacturers have from time to time advertised their products as superior because of postulated low abrasivity. As a result, standards for assessing the abrasivity of toothpastes have been established. The accepted test procedures employ dentine as the substrate and standardized procedures for brushing, using slurries of the toothpaste to be tested. The brushes used and the pressure with which they are applied are also standardized. The amount of dentine that has been abraded away after a standard time is then assessed using profilometry or by irradiating dentine samples before testing and measuring radioactivity in the toothpaste slurry after testing [71].

The application of laboratory methods for assessing toothpaste abrasivity has shown that it is necessary to use a relevant substrate (natural teeth, dentine). Furthermore, it has been shown that a product's abrasivity cannot be assumed from knowledge of the abrasive compound incorporated in the product alone because abrasivity may also by influenced by a host of other factors, including abrasive particle size and other constituents of the toothpaste.

Both in vitro [161, 177] and in vivo [108] studies have shown that a toothpaste's ability to remove stain is directly related to abrasivity. Presumably, such findings have formed the basis for advertising claims for special products purported to be particularly efficient for removing, for example, tobacco stains, although when measured, these products have sometimes not been found to be more abrasive than "ordinary" toothpastes available on the market.

A possible correlation between the ability of toothpastes to abrade dentine in test systems and the prevalence and severity of toothbrushing abrasion in the population at large has not been demonstrated. One study that aimed to identify factors related to the prevalence and severity of toothbrushing erosions was only able to identify the method of brushing (for example, horizontal brushing) as a significant factor [11]. Therefore, despite massive advertising campaigns for low-abrasive toothpastes, it seems likely that this factor is not very important in the clinical situation. Clinicians may consider it prudent to advise patients to use a less abrasive toothpaste (dental erosion) or a more abra-

Dentlearn.ir

sive one (staining). But there is no evidence that all patients should be warned of the dangers of using specific toothpastes because of high abrasivity. In general, the range of abrasivity of toothpastes on the market is very small. The unrestricted application of so-called antisensitivity toothpastes to patients with dentine hypersensitivity and pronounced dentine abrasion or erosion has been critically questioned because more than half of the 10 in vitro tested pastes exhibited relatively high levels of abrasion of exposed dentine.

In this connection it is interesting to note that, a few decades ago, tooth powders as opposed to toothpastes were popular, and the abrasivity of these products was at least 10 times higher than the abrasivity of toothpastes currently marketed – but this apparently did not give rise to excessive damage to teeth at that time [129].

Fig. 10.4 Erosion of the enamel in a 25-year-old man caused by excessive consumption of soft drinks (Courtesy of M. J. Larsen, Århus, Denmark)

Key Note

The abrasivity of all commercially available toothpastes is generally low. Therefore, it seems to be unlikely that minor differences between products are of clinical significance.

10.2.2.2 Hard Tissue Erosion

Chemical erosion of dental hard tissues is most dramatically apparent in the dental enamel, whereas physical abrasion is most apparent in dentine. Erosion of enamel is seen after frequent exposure to acidic solutions (pH 4.0 or less; see Fig. 10.4). The literature is mostly limited to investigations of soft drinks with low pH, excessive consumption of which has been associated with enamel erosion. All international standards require that the pH of toothpastes be within the range 4.5–10.0. Despite this, the U.S. Food and Drug Administration approved in 1985, for example, acidulated phosphate-fluoride mouthwashes (pH 3.0–4.5) for OTC sales.

Key Note

Although there are no reports linking the use of mouthwashes to dental erosion, it would seem prudent that the pH of mouthrinses should not be lower than 4.0. Regular use of such mouthwashes could be expected to result in erosion of dental enamel.

10.2.2.3 Soft Tissue Reaction

Acute reactions of the oral soft tissues to oral hygiene products may present as epithelial peeling, mucosal ulceration, and inflammation, gingivitis, and petechiae. Patients may complain of a burning or stinging sensation, soreness or pain, staining of the teeth and tongue, and taste disturbances.

Differential diagnosis of these conditions is difficult because the changes observed may be direct chemical injury or irritation of the soft tissues, or they may represent allergic reactions as described in the following section of this chapter. A complicating factor in distinguishing between allergy and reactions of the tissues to direct injury is that in both cases the reaction may be affected by the length of time the product is used, the frequency of application, and the concentrations of the components responsible for the reactions observed.

Generally, very few attempts have been made to systematically study adverse effects of toothpastes and mouthwashes. However, it would seem from the reports available that the prevalence of local toxic reactions to these products may be higher than most dental professionals imagine.

A study of possible adverse effects to four commercially available mouthrinses was carried out by Kowitz et al. in 1976. This study involved 104 dental or hygienist students who rinsed with 20 ml of mouthwash for 5 s twice daily for 2 weeks. Rinsing periods were separated by 1-week periods without rinsing and with the use of a toothpaste that had previously been shown to have no effect on these subjects. A total of 40 reactions were recorded among 100 subjects who used

Dentlearn.ir

each of the four mouthrinses. Epithelial peeling, mucosal alteration, inflammation, and petechiae were recorded in more than 25% of the subjects [101]. These changes disappeared when use of the mouthwash in question was discontinued and were confirmed by the reappearance of reactions when the same mouthwash was used for an additional period in these subjects. Unfortunately, these authors did not describe the contents of the mouthwashes tested, nor did they perform further tests to ascertain whether any of the reactions observed were allergy mediated.

Adverse effects similar to those described for mouthwashes have also been documented by the same authors in a study involving commercially available toothpastes [100]. One interesting aspect of this study was that there were clear differences between the products tested, and one product produced a very low reaction rate (a few percent) compared with a reaction rate greater than 15% for the product causing the highest incidence of adverse reactions. Again, no attempts were made to identify the ingredients possibly responsible for the reactions observed, although detergents and flavoring oils were named as possible candidates. Most of the reactions recorded were without symptoms. More studies in this field are clearly needed.

Key Note

Many ingredients of mouthwashes (e.g., high levels of ethanol) could be expected to produce acute local reactions in soft tissues, especially if they are used in high concentrations or if exposure times are increased.

10.2.2.4 Detergents

Sodium lauryl sulfate (SLS), also called sodium dodecyl sulfate, is a powerful detergent that is capable of denaturing proteins. It is the detergent most commonly used in toothpastes and mouthwashes and is also present in other products such as hair shampoo. Detergents are used because they cause toothpastes to foam when applied (which is a consumer preference), but they are also useful emulsifiers.

Possible toxic effects of SLS in toothpastes were first reported in 1937 by Kitchin and Graham, who stated that 1.5% SLS does not produce inflammation in oral soft tissues after 30 days of brushing [96]. These findings were later corroborated by several authors [63, 146]. The latter authors reported reduction in keratinization of human oral epithelium with a 9.9% anionic detergent, and local reactions with 7.5% SLS have been reported in rats and humans [3, 76].

Key Note

On the basis of these studies and many others, toothpastes containing 2% or less SLS have been considered not harmful for short exposure periods. Despite this knowledge, products containing 2% or more SLS can still be found, although the vast majority of toothpastes contain 2% or less SLS.

Recently, epitheliolysis of oral mucosa (in seven patients) was discussed as an adverse effect caused by a toothpaste (5–10% sodium tripolyphosphate, 1.2% SLS, pH 9.2) [134]. Some toothpastes contain other detergents such as stearylethoxylate, which has been shown to be less toxic than SLS in cell cultures of human oral mucosa [6]. Some toothpastes recommended for children contain lowered concentrations of SLS (0.5%) to reduce the experience of a "burning" sensation. Other manufacturers have omitted SLS in toothpaste for children and instead have incorporated a zwitterionic detergent, cocoamidopropyl betaine (CAPB).

Differences in the ability of different detergents to irritate the oral mucosa have been demonstrated in a double-blind crossover trial with toothpastes containing SLS (0.5%, 1.0%, and 1.5%) or CAPB (0.64%, 1.27%, and 19%). The pastes were applied for 2 min twice daily in cap splints for 4 days. This exaggerated exposure was sufficient to cause 42 desquamative reactions to SLS-containing toothpaste compared with three reactions for CAPB. No oral desquamations were observed with a toothpaste that contained no detergent [87].

The significance of these findings is illustrated by studies of patients with recurrent aphthous ulcers [85, 86]. These studies showed significantly fewer aphtous ulcerations with placebo (detergent-free) or CAPB toothpastes than with SLS toothpaste. These findings prompted these researchers to recommend SLS-free toothpastes for patients with recurrent aphthous ulceration. They also pointed out that in an uncontrolled study in which amelioration of aphthous ulcerations was observed with use of an enzyme-containing toothpaste [99], the findings might be due to the stearylethoxylate detergent in the toothpaste

Dentlearn.ir

rather than to the presence of enzymes. This postulate is also supported by two other controlled studies, which failed to demonstrate an effect of enzymes on the frequency of aphthous ulcers [42, 82].

Although it has been shown that ulcer size, frequency, and pain may be reduced in patients with recurrent aphthous stomatitis by the use of toothpastes without SLS or with a milder detergent [24, 35], the apparent reduction in the incidence of ulcers in self-reported studies could be due to increased pain caused by SLS, which would make the patients more aware of the numbers of aphthae. This may explain why one double-blind crossover study of 47 patients, throughout which the patients were regularly examined for ulcers (as opposed to patient reporting), failed to find differences between numbers of ulcer days, numbers of ulcer episodes, and numbers of ulcers with SLS-free and SLS toothpaste [80].

Key Note

It is questionable whether foaming agents in oral hygiene products are justifiable simply on the ground of consumer acceptability. However, because they may also be useful emulsifiers, it is important to choose detergents with the least toxic effects on oral tissues. Patients with recurrent oral aphthae will probably experience fewer and less severe symptoms if they change to toothpastes without sodium lauryl sulfate.

10.2.2.5 Alcohol

Other conditions likely to lead to primary irritation of the oral mucosa are low pH and high alcohol content [53]. The use or abuse of a mouthwash containing 26% alcohol may be associated with hyperkeratotic areas of the oral mucosa (oral mucosal white lesions) [12, 66].

Bolanowski et al. [20] tested pain response with various alcohol concentrations and seven alcohol-containing mouthwashes. It was clearly demonstrated that an increasing intensity of oral pain is directly correlated with alcohol concentrations from 7.5% to 35%. Using a 30-s rinsing time, these researchers also noted that the time required for postrinsing pain to cease increased with increasing alcohol concentrations. The amount of pain induced by any particular oral rinse was not necessarily the same as the pain produced by water controls matched for alcohol content, thereby indicating that other ingredients of mouthrinses can exacerbate the pain induced by alcohol.

Key Note

Alcohol concentrations of more than 7.5% can result in oral pain sensation, which may be exaggerated by other ingredients of a mouthwash.

10.2.2.6 Chlorhexidine

Chlorhexidine mouthwashes have been associated mainly with brown discoloration of the teeth and tongue and with altered taste sensation [84]. Superficial desquamation of the oral mucosa by chlorhexidine has also been reported [64, 181]. Staining and altered taste reactions to chlorhexidine are related to concentration and length of exposure. It seems likely that the presence and severity of staining are also affected by dietary factors [1], and an electron microscopic study has provided evidence suggesting that chlorhexidine augments the incorporation of sulfated proteins into plaque, which then interacts with iron to produce a stained material [169].

Local reactions to antimicrobial agents other than chlorhexidine have also been reported. Benzethonium chloride (0.2%) caused desquamative lesions of the oral mucosa in four out of five subjects in one study [69] and discoloration of the tongue and around some of the teeth in eight out of 12 subjects in another study [36]. Burning sensations have been reported by subjects rinsing with cetylpyridium chloride [30].

10.2.3 Allergies

10.2.3.1 Prevalence

Both IgE-mediated (type I) and delayed allergic reactions (type IV) may occur. IgE-mediated reactions have been seen as urticaria, edema, erythema, and, occasionally, vesicle formation in the oral mucosa. The delayed-type reactions, which may occur as late as 24–48 h after contact with the allergen, may be seen as erythema, ulceration, and epithelial peeling.

A study of 48 toothpastes available on the market in Finland revealed that almost half of these products contained compounds widely recognized as allergens [145]. Although the authors identified 30 allergens

Dentlearn.ir

in the toothpastes sold, the prevalence of allergic reactions to oral hygiene products is apparently low. Toothpastes, for example, have been estimated to cause health problems of any kind in less than 2% of users, which is a much lower prevalence than for other cosmetic products [124].

It has been reported that in a 26-year period among 46,000 eczema patients in Copenhagen, only five cases were shown to be caused by toothpastes. At the same time, these authors reported three positive reactions to toothpaste flavoring among 206 consecutive eczema patients [126]. These results indicate that one important explanation for the scarcity of reports on toothpaste reactions may be lack of recognition. Some patients with a diagnosis of burning mouth syndrome, viral or aphthous ulcers, or atypical gingivostomatitis could have a toothpaste or mouthwash allergy [111].

Other reasons have been suggested to explain the paradox of the apparent rarity of allergic reactions to toothpastes, which contain an abundance of known allergens. In particular, it has been proposed that there is rapid dispersal and absorption of allergens through the well-vascularized mucosa, a short period of contact between ingredients and the buccal mucous membrane, and dilution and removal of potential allergens by saliva [59].

Clinical Practice Advice

Allergic reactions to oral hygiene products are relatively rare and often affect atopic patients. Patients with allergic diseases such as asthma, hay fever, or allergic skin are particularly susceptible. These patients should be informed about potential allergens in mouthwashes and toothpastes.

10.2.3.2 Allergy Testing

Testing for allergic reactions to toothpastes and mouthwashes can give false negative reactions because of too-low concentrations of the sensitizer, or false positive reactions due to the contents of detergents, abrasives, and so on [5].

There is no need to test the oral mucosa directly because whenever the oral mucosa is sensitized, so is the skin [60] (see also Chaps. 2 and 14). However, there may be marked differences in the concentrations required to elicit a response. Thus, in a study of patch testing on the palatal mucosa in patients with a positive skin test to a common eczema allergen, microscopic reactions in the mucosa were seen only when the allergen concentration was 5–12 times the concentration used in the skin test [125].

Detergents in mouthwashes and toothpastes may produce primary irritant reactions under a closed patch test. It has therefore been recommended that these products be tested uncovered on the forearm and that positive reactions be checked by testing on at least three control subjects. Similarly, mouthwashes nearly always contain alcohol and other components that readily evaporate and thereby cause irritation under a closed patch test, so it has been recommended that such solvents be allowed to evaporate for 20 min before the patch test area is covered [61].

These procedures are, of course, only the first steps in establishing an accurate diagnosis. They should be followed by attempts to define which ingredient(s) of the product in question are responsible for the symptoms. Clearly, all of these procedures require the services of an experienced dermatologist and should not be attempted by dental professionals. However, when suspected allergic reactions are confirmed, the dentist responsible for the patient should ensure that these findings are reported.

Clinical Practice Advice

Although the number of reports is scarce, and allergic reactions are therefore probably rare, clinicians should consider the allergic potential of oral hygiene products, especially when advocating or prescribing mouthrinses or toothpastes for atopic patients. These individuals, about 10% of the population, are characterized by the following:

- Immediate vascular exudative reaction of the skin to specific exciting agents
- A tendency to acquire forms of familial idiosyncrasy such as hay fever
- The presence of increased levels of IgE

10.2.3.3 Allergens

Flavoring agents: Cinnamon (cinnamic aldehyde) flavor is the most commonly reported allergen in oral hygiene products. Contact urticaria has been reported from a mouthwash [115], and toothpastes containing

Dentlearn.ir

cinnamic aldehyde have been shown to cause a number of oral and skin reactions [95, 103, 111, 112, 142, 165].

Individuals have widespread exposure to peppermint and spearmint, which are common flavoring agents in food, chewing gum, and sweets. They are also the most commonly used flavors used in toothpastes, and although the risk of sensitization is extremely low, it does occur. Natural spearmint oil consists of carvone (more than 50%), limonene, pinene, phellandrene, dipentene, cineole, linalool, and esters of dihydrocuminyl alcohol and dihydrocarveol. Menthol is the most important sensitizer in peppermint, and L-carvone is the most important sensitizer in spearmint [176]. The latter may be added to toothpaste and merely listed as "flavoring."

Figure 10.5 shows a case of allergic contact cheilitis in a 71-year-old woman with a 3-year history of sore mouth, fissuring of the lips, and edema of the surrounding skin. Patch testing gave a positive reaction for spearmint oil [157]. The vermilion border of the lips has a modified epithelium, which is more likely to develop allergic reactions than is the oral mucosa [147].

Other authors have reported confirmed contact allergy to carvone [73, 77, 78], peppermint [5], and menthol [158, 174] in toothpastes. In 1998, Flemming and Forsyth [62] reported a lichenoid reaction in the oral mucosa of a 34-year-old woman who had a 9-year history of oral burning and discomfort related to mint-flavored mouthwashes and foods. Patch testing gave positive reactions for both peppermint oil and menthol, and subsequent avoidance of all forms of mint resulted in a marked improvement in her oral symptoms. There are two reports of mint-flavored toothpastes that have induced asthma [160, 163].

Anethole, a common though often unlisted flavoring agent in toothpastes, gave positive reactions to patch testing in a 64-year-old woman who, apart from cheilitis and perioral eczema as shown in Fig. 10.6, exhibited erythema and desquamation of the oral mucosa and experienced loss of taste. Avoidance of anethole-containing toothpaste resulted in normal perioral skin and oral mucosa and a return of taste sensation [65].

Chlorhexidine: Chlorhexidine has been one of the most routinely prescribed mouthrinses since its introduction by Loe in 1969 [109]. Before that time, chlorhexidine had already been widely used in medical practice for more than a decade, particularly for topical antisepsis such as presurgery skin preparation, burn prophylaxis, and lubricating creams used in obstetrical/gynecological and urological procedures. Despite this extensive use of chlorhexidine, "virtual absence of sensitization" was reported in 1977 in a review of its safety [143].

Since then, there have been reports of reactions to chlorhexidine mouthrinses [92, 118, 162, 180], including two with potential anaphylactic responses. There are also reports of chlorhexidine-induced contact dermatitis [25, 55, 93, 102, 128, 138, 154], also with an anaphylactic response. There have been serious episodes of acute anaphylactic shock during general anesthesia, particularly in Japanese patients [94, 98]. In eight cases reported by Ohtoshi et al. in 1986, a specific IgE antibody was shown to be the mediator

Fig. 10.5 Allergic contact cheilitis from spearmint oil in a toothpaste [157] (Courtesy of Munksgaard, Copenhagen, Denmark)

Fig. 10.6 A 64-year-old woman with cheilitis and perioral eczema from anethole, a common, though often unlisted, flavoring in toothpastes [65] (Courtesy of Munksgaard, Copenhagen, Denmark)

Dentlearn.ir

of the reaction [127]. Of particular dental interest are two cases of highly probable anaphylactic reactions following irrigation of postextraction tooth sockets with 0.2% chlorhexidine [131, 132]. Also, a case of cardiac arrest following preoperative application of 0.05% chlorhexidine to the nasal mucosa has been described. Subsequent allergy testing gave a strong positive result for chlorhexidine, and this patient related that he had previously experienced a red, blotchy skin rash after chlorhexidine 1% had been applied to his gums by a dental hygienist [27].

Clinical Practice Advice

Although chlorhexidine is used extensively and nearly always without allergic problems, the possibility of extreme acute reactions is not unknown. The clinician should be aware of these risks when using and prescribing chlorhexidine.

In addition to the substances described above, which have been reported on a number of occasions, there are many other ingredients of oral hygiene products for which hypersensitivity reactions have been described when they have been used in other products or where there is only one report of an allergic response from a toothpaste or mouthwash. These substances may therefore be regarded as potential allergens in oral hygiene products and include acetamide, azulene, benzoates, chloroacetamide, dichlorophene, formaldehyde, propolis, and thymol [145].

10.2.4 Mutagenicity, Carcinogenicity, and Teratogenicity

Toothpastes, as opposed to toothbrushing, may not be essential for maintaining oral health. However, the overwhelming evidence that use of fluoride-containing toothpaste reduces the incidence of dental caries has prompted dental health professionals to encourage daily use of these products. Patients have evidently accepted this recommendation, and not only do nearly all toothpastes sold contain fluoride, but the volume of sales of oral hygiene products has increased in many countries. At the same time, patients continue to use both toothpastes and mouthwashes as part of their personal hygiene repertoire to achieve social acceptance and a sense of well-being from clean teeth and fresh breath.

As a result, patients may experience long-term or even lifelong exposure to these products. Because it is well known that long-term exposure to some substances can result in neoplastic changes in tissues, this situation places a responsibility on manufacturers, regulatory bodies, and health professionals to ensure that such substances are not included in oral hygiene products. This includes substances that have been implicated as possible carcinogens (or have mutagenic or teratogenic properties) in animal experiments and have been classified as carcinogenic, probably carcinogenic, or possibly carcinogenic in humans (see also [31, 51]).

A number of substances (including tetrachloroethylene and benzene) that are rated as probable human carcinogens are among those that are prohibited ingredients for cosmetic products in Europe. This list is, and will continue to be, under constant revision. For example, the present list includes chloroform, which is now classified as a known human carcinogen. Earlier, chloroform was used in concentrations of up to 3.5% in some toothpastes and mouthrinses, and results of long-term safety studies had been presented that stated that a concentration of up to 3.5% chloroform should be innocuous [40].

In the United States and Europe, products that intend to treat or prevent disease or otherwise affect the structure or functions of the human body are classified as drugs or medical devices. These products are subjected to more rigorous control than may be the case for cosmetic preparations. However, mouthwashes and toothpastes (and other cosmetic products claiming a drug effect) that contain "active" ingredients with a proven effect on, for example, gingivitis, plaque, or calculus, may be reclassified in the United States as OTC drugs not requiring a doctor's prescription. Such a reclassification has the advantage of a more rigorous appraisal of the toxicity and possible carcinogenicity, teratogenicity, and mutagenicity of the ingredient in question.

An example of such a substance is the antimicrobial triclosan (2,4,4′-trichloro-2′-hydroxydiphenyl ether), which has been used for many years in cosmetics such as deodorants and soaps. Use of this compound as a drug for gingivitis/plaque control in toothpastes and mouthrinses required that safety information be submitted to an OTC review panel in the United States. This information included investigations about the mutagenicity, carcinogenicity, and teratogenicity of triclosan, which is approved and considered safe for use (at particular concentrations) in toothpastes and mouthrinses [41]. But there were also critical com-

Dentlearn.ir

ments [2, 164], and for more than a decade, the use of triclosan in not only oral hygiene products but also other common household products such as hair shampoo and hand soaps gave rise to serious concern. Triclosan was earlier considered to be a nonspecific biocide that attacked the cell membranes of bacteria and certain fungi and was therefore unlikely to give rise to development of cellular resistance. However, it is now known that, at least under laboratory conditions, sublethal concentrations of triclosan may be associated with the development of resistant organisms. Furthermore, it was discovered that triclosan targets lipid synthesis [117] and acts mainly by specifically inhibiting fatty acid biosynthesis. These findings are alarming because many antimicrobials used for treating infections also operate in a similar way. Therefore, daily exposure to triclosan may represent a public health risk if mutant strains develop in pathogens that would also be resistant to antibiotics. Studies of this problem continue and have led some researchers to call for banning daily exposure to this substance. Others have called for proof that the results of laboratory studies of specific organisms are relevant because, so far, studies have failed to demonstrate development of cross-resistance in the homes of users versus nonusers of antimicrobial products [34] or in the mouths of patients using triclosan toothpaste for 6 months [57]. In Europe in 2006, the European Commission's Scientific Committee on Consumer Products [148] published an opinion on the basis of the available data, stating that "there is presently no evidence of clinical resistance and cross-resistance occurring from the use of triclosan in cosmetic products." Such an opinion is, of course, subject to revision in response to new research results that may become available.

Lists of chemicals considered carcinogenic in humans are expected to continue to grow, so more substances will be classified as prohibited ingredients for oral hygiene products. This will also occur as substances that currently are generally recognized as safe (GRAS) are reappraised, so some of these substances (which may occur naturally in some foods) will be considered risk factors for cancer or reproductive disturbances. On the other hand, many constituents of oral hygiene products have been tested already or are extremely unlikely to be implicated in this way because they are substances already present in the human organism.

The only oral hygiene product that has been placed under suspicion for association with cancer on the basis of studies in humans is mouthwashes. These have been the subject of considerable debate and several investigations since the first suspicion was raised by Weaver et al. in 1979 [170].

They studied 200 patients with squamous cell cancers of the head and neck. Eleven of these patients did not use alcohol or tobacco, but 10 of these 11 had used a mouthwash several times daily for more than 20 years. Comparison of these patients with 50 patients without head and neck cancers showed a significantly higher frequency of mouthwash use among patients with cancer. The authors of this study cautioned that their sample of nonsmoking, nondrinking patients was small (10 persons) and that a relationship between mouthwash use and cancer was not evident when patients with cancer who used tobacco and alcohol were analyzed.

Other researchers have since studied the possible relationship between mouthwash use and oral cancer [18, 114, 178]. Although some of these studies found an elevated risk of oral cancer in mouthwash users, dose–response relationships were not found. The problem is complicated by the confounding factors of alcohol and tobacco use, both of which have long been associated with oral cancers. Thus, in a case-control study of oral and pharyngeal cancer using 1,114 patients and 1,268 population-based controls, it was shown that the risk of these cancers increases in nondrinkers with the amount smoked; similarly, risks among nonsmokers increase with the level of alcohol intake [17]. Among consumers of both alcohol and tobacco, the risk of oropharyngeal cancer was increased more than 35-fold among those who consumed two or more packs of cigarettes and more than four alcoholic drinks a day.

In a critical evaluation of the epidemiologic evidence for an association between mouthwash use and cancer of the oropharynx, seven case-control studies were identified. The authors of the evaluation found that few of the available studies adhered to the basic methodological principles of case-control design. It was concluded that the data for an overall association and the analyses of patients with other clinical risk factors do not support a link between mouthwash use and oral cancer [49].

The inference from these studies of mouthwash use has otherwise been that the alcohol content of the mouthwashes could promote the development of oral cancer, as is assumed to be the case with alcoholic beverages. Despite this, few studies have thoroughly investigated the alcohol content of the products. This is surprising because the content may vary from 0% to 26%. This factor alone warrants further investigation.

Dentlearn.ir

It has recently been pointed out that analyses of data are confusing because use of tobacco and alcoholic beverages is associated with mouthwash use. Also, both alcohol and tobacco use are notorious for being underreported, which would lead to spuriously elevated odds ratios for mouthwash use. This means that odds ratios of 1.4 and 1.6 (that is, reported increases in risk of as much as 60%) can readily be accounted for by under-ascertainment of confounding factors. This applies even though a confounder has been measured and adjusted for; therefore, causal interference for associations of low magnitude is not justified [152].

Heavy alcohol intake and tobacco use are, however, established causes of oropharyngeal cancer and have been shown to be important risk factors for oral dysplasia [119]. Tobacco smoking and drinking have been calculated to account for three-quarters of all oral and pharyngeal cancers in the United States [17].

Key Note

At the present time, there is insufficient evidence linking mouthwash use per se with oral cancer. The alcohol content of mouthwashes might be associated with oral cancer, but this has not been proven. Regular daily use of alcohol-containing mouthwashes could contribute to elevated risks of oral cancers among smokers. Although further studies are warranted, it should be remembered that proof of real health benefits of using mouthwashes with alcohol content as high as 26% is also lacking.

10.3 Tooth Bleaching Agents

Toothpastes may effectively remove stained pellicle from tooth surfaces by mechanical abrasion, but removal of intrinsic staining may require chemical agents. Throughout history, various acids such as oxalic acid [19] and hydrochloric acid [179] have been recommended. For the last 50 years, bleaching of teeth with hydrogen peroxide (30–35%) or compounds that release hydrogen peroxide, such as carbamide peroxide and sodium perborate, have been described as most suitable for bleaching vital and nonvital teeth [4, 8, 32].

10.3.1 Carbamide Peroxide

During the last decade, much attention has been focused on tooth whiteners, which are usually carbamide peroxide gels. Carbamide peroxide is a mild antiseptic that has also been used in skin care preparations, hair dyes, and an experimental chewing gum [54]. Carbamide peroxide (also called urea hydrogen peroxide, perhydrit, hyperol, or perhydrol urea) is an addition complex of hydrogen peroxide with urea, which has a mild effect on plaque and gingivitis, as documented in over 20 publications during the 1970s [110]. On contact with saliva, carbamide peroxide dissociates to hydrogen peroxide (34%) and urea, a process that is delayed in some tooth-whitening products by the addition of carbopol, which also increases viscosity [10].

Haywood and Heymann [79] were the first to report on bleaching of teeth with 10% carbamide peroxide gels placed in custom-built trays to be worn by patients at night for 2–6 weeks. Subsequently, a number of products became available with 10–15% carbamide peroxide gels, not only for professional use but also in kits with custom-fabricated trays for OTC sales direct to consumers, who adjust the prefabricated trays to the teeth alignment. Some of these kits for home use contain so-called conditioners to be used prior to bleaching, which may consist of citric acid or phosphoric acid to etch tooth surfaces and, in some cases, titanium oxide coloring for application after bleaching.

The appearance of bleaching kits for home use prompted a number of authors to review the available toxicity data on carbamide peroxide and its active constituent, hydrogen peroxide [7, 13, 70, 89, 106, 110].

10.3.2 Systemic Toxicity

The systemic toxicity of carbamide peroxide has been investigated in two rat studies [26, 39] and in an LD_{50} (the calculated dose of a chemical substance that kills 50% of the experimental population) study in mice [175]. This last study showed that whiteners with carbopol in addition to carbamide peroxide have a higher toxicity than carbamide peroxide alone (LD_{50} 87.2 mg/kg body weight versus 143.8 mg/kg body weight). In the rat studies, Cherry et al. showed that 5,000 mg/kg body weight produces serious lethal symptoms [26], and Dahl and Becher showed that 15 mg/kg gave rise to histological changes in the gastric mucosa that were not seen with 5 mg/kg body weight. These authors also found more pronounced reactions in the gastric mucosa with a carbamide peroxide product with carbopol [39].

On the basis of their results, Dahl and Becher calculated an exposure limit for humans of 10 mg carbamide peroxide per day (safety factor of 100). They

Dentlearn.ir

then calculated that by following a manufacturer's instructions for a 10% carbamide peroxide gel (90 mg of 10% carbamide peroxide gel per tooth, for 10 teeth for an overnight bleaching), an adult might be exposed to 9 mg of carbamide peroxide per day if he or she swallowed 10% of the gel applied [39].

The calculated exposure limit of 10 mg per day for an adult human has been described as misleading by other authors [7, 106]; they regard the changes in the gastric mucosa of rats to be an acute local effect caused by direct contact of the test agents rather than a true systemic effect, as no changes were found in the kidneys or liver of rats given 15 mg/kg body weight. They have also questioned the clinical relevance of the calculations used by Dahl and Becher [39] to estimate the amounts of gel likely to be swallowed because these may not be applicable to the product tested.

Although gastric mucosa effects are probably not suitable for measuring a true systemic toxicity, an exposure limit based on such changes may still be relevant because it has, for example, been reported that 10% of 7,617 American dentists have seen patients complaining of stomach and/or throat problems during bleaching procedures [29]. Also, another study with a 2-h application of such gels in prefabricated trays showed that only 4–20% of carbamide peroxide was retained [133]. So the estimated 10% swallowed may be regarded as conservative.

Reports of accidental ingestion of hydrogen peroxide with a lethal outcome in humans are rare but have occurred in children 1–3 years old and in individuals exposed to much stronger concentrations (35%) than are used in home bleaching products [28, 68, 182]. There are also reports of a 26-month-old child and a 33-year-old woman who, with treatment, survived ingestion of 35% hydrogen peroxide [67, 90].

The mechanisms involved in hydrogen peroxide poisoning are gastric catabolism of hydrogen peroxide to oxygen and water, followed by uptake by the bloodstream. Venous embolization occurs when the amount of oxygen evolved exceeds the maximum blood solubility of oxygen. Cerebral infarction after ingestion of 35% hydrogen peroxide has been described in one report [153], and successful treatment with hyperbaric oxygen of an apparent stroke following ingestion of concentrated hydrogen peroxide has recently been described [120].

Carbamide peroxide (10%) as used in bleaching agents delivers 3.5% hydrogen peroxide. Exposures to 3% hydrogen peroxide (common household strength) are usually benign, as illustrated by nearly 12,000 exposures reported in the United States in 1987 [107]. Gas embolism has, however, been described in a 2-year-old boy who survived ingestion of an unknown amount of 3% hydrogen peroxide [135].

10.3.3 Local Toxicity and Tissue Compatibility

Local toxicity of brief exposure to the soft tissues of 3% hydrogen peroxide or 10% carbamide peroxide is apparently limited, as evidenced from their use in mouthwashes. However, many carbamide peroxide bleaching systems sold for home use are anhydrous and extremely hypertonic and thus might be expected to produce gingival lesions with prolonged contact (Figs. 10.7 and 10.8). Erosive gingival lesions are not normally expected to occur with limited/occasional use of

Fig. 10.7 Lesion of the interdental papilla between teeth 12 and 13 due to insufficient protection of the gingiva by a rubber dam during tooth bleaching in a dental office (Courtesy of M. Gaardmand and T. Strickertsson, Århus, Denmark)

Fig. 10.8 Skin lesions on a dentist's fingertips, caused by unintentional contact with a bleaching agent in a dental office (Courtesy of M. Gaardmand and Strickertsson, Århus, Denmark)

Dentlearn.ir

3% hydrogen peroxide mouthwashes, although there is one report of a case of ulcerations on the tongue and alveolar and labial mucosa, which were erythematous and painful in a student who rinsed three to five times daily for periods of 1–2 min [137].

Dental hypersensitivity was reported to occur in about one-half of young patients taking part in an at-home tooth bleaching protocol with 10% carbamide peroxide [37]. Because most complaints of tooth sensitivity in this study were made by teenagers rather than by the 7–11-year-old children also treated, the author suggested that this sensitivity might have been caused by increased frequency of use (beyond that prescribed) by this group of patients.

Increased sensitivity of teeth to cold stimuli has been found to be the most common side effect described in investigations of home tooth bleaching [10]. Also, most investigators who used 30–35% hydrogen peroxide for professional tooth bleaching in the dental office reported some posttreatment sensitivity that dissipated with time.

Permanent pulpal damage as a result of vital tooth bleaching does not seem to occur. Furthermore, a controlled study of teeth treated with heat and 35% hydrogen peroxide three times for 30 min and extracted 1 h, 3 days, 15 days, and 30 days postprocedure failed to show histological changes different from those observed in the control teeth, despite reports of sensitivity by 78% of the patients [33]. It has been recommended that vital teeth in patients with large restorations, extensive erosions/abrasions of the cervical tooth surface, or pronounced enamel cracks should be bleached with caution because increased penetration of potential toxic substances to the pulp could occur and might subsequently cause complaints (e.g., pain, increased sensitivity) [123].

It seems likely that increased sensitivity may be explained by an effect of agents at the tooth surface (particular cervical dentine), as a number of electron microscope studies have demonstrated increased porosity of tooth surfaces exposed to carbamide peroxide. Such studies have also demonstrated clearly deleterious effects in the form of frank etching of enamel surfaces when prebleaching acidic solutions such as phosphoric acid, hydrochloric acid, or citric acid were used [14–16, 116, 166]. This may cause an exposure of the orifices of the dentine tubules and increased irritation of intratubular or intrapulpal pain receptors.

A number of reviewers have addressed the issue of possible genotoxicity of peroxide-containing bleaching agents. It has been concluded on the basis of numerous animal and cytotoxicity studies that hydrogen peroxide at concentrations of 12% in gels, dentifrices, and mouthrinses is not carcinogenic, mutagenic, or teratogenic [110].

Key Note

It can be concluded that there is a place for tooth bleaching agents in some situations. In light of potential side effects, there seem to be good arguments that tooth whiteners should be used only under professional supervision. At the same time, the advantages of overnight use of tooth whiteners require further documentation in view of the reported side effects of this mode of treatment. European Union regulations now require professional control.

10.4 Fluoride Varnishes and Gels

Topical fluoride applications with aqueous solutions with high fluoride content have been used by health professionals for more than half a century. During the last three decades, varnishes and gels containing fluoride have also been used for topical fluoride application. Gel products have dominated the market for many years in the United States, where gels for use at home in prefabricated or custom-built trays have been developed. Fluoride varnishes, which are for professional use only, have only recently begun to be used in the United States but have been popular among dentists and hygienists in Europe, and Scandinavian countries in particular, for decades.

The majority of studies on the effect of varnishes have been done with Duraphat varnish, and studies on the caries-reducing effect of this product have been subjected to a meta-analysis [81]. Results of a meta-analysis of fluoride gel studies have also recently been published [167]. These meta-analyses do not suggest that the effects of these two methods are superior or inferior to applications of aqueous solutions of 2% sodium fluoride, which is in keeping with conclusions of earlier reviews [141, 150].

10.4.1 Gels

Deleterious effects of these products have mainly been associated with the fluoride content of the gels. The fluoride in gels may be sodium fluoride, stannous fluoride, amine fluoride, or acidulated phosphate fluoride (APF). Stannous fluoride has a disagreeable taste and

Dentlearn.ir

may stain teeth. APF has an acidic taste (pH approximately 3.0) and will etch teeth and ceramic or composite restorations.

However, the most serious risk of side effects of use or abuse of fluoride gels concerns the fluoride dose, which may be ingested even when the gels are used in closely fitting trays. For this reason, products designed for home use usually contain 1.1% sodium fluoride or about one-half of the fluoride concentration used in gels for professional application.

Spak and colleagues used 3 g of a low-fluoride gel (0.42% fluoride) for a 5-min application in pairs of trays individually constructed for 10 adults. About 40% of the gel was swallowed and caused gastric injuries in seven of the 10 subjects, observed at gastroscopy 2 h after application (Fig. 10.9) [159]. These authors concluded that the injuries to the gastric mucosa are probably of minor clinical significance because recovery of the mucosa is rapid, and gels are normally applied only two to four times annually. On the other hand, they also pointed out that their results illustrate that if gels are to be used at home, patients must be well informed and instructed to use a minimum of gel and to expectorate all excess gel. Furthermore, they recommend low-fluoride gels instead of 1.23% fluoride gels for small children.

In another study, plasma fluoride and urinary excretion were studied in children and adults after application of gels containing 1.23% or 0.1% fluoride [47]. These authors warn against indiscriminate use of fluoride gels in home treatment programs, especially in children, because some subjects demonstrated plasma fluoride levels sufficient to cause a decrease in urinary concentration ability. One of the adults in this study experienced gastrointestinal symptoms. Assuming the potential toxic dose (PTD) of fluoride to be 5 mg/kg body weight [172, 173], Whitford stated that the average body weight of a 2-year-old child is 12.3 kg and that a child of this weight would need to swallow only 5 ml of a 1.23% APF gel to reach the PTD.

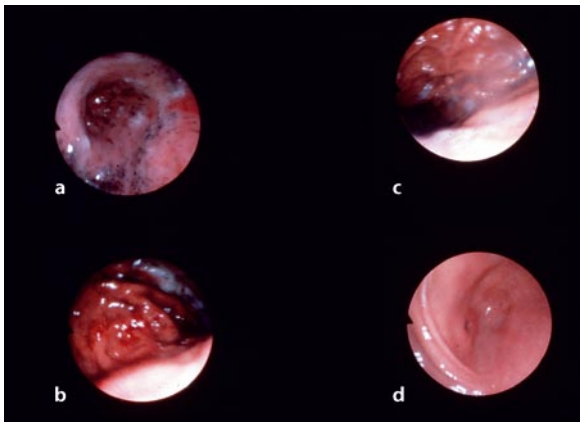

Fig. 10.9 **a** Petechiae and erosions of the gastric mucosa (gastroscopic image) from the antral to the corpus region. **b** Two hours after swallowing a 1.23% fluoride gel. **c**, **d** Normal gastric mucosa of the same patient before swallowing the gel (Courtesy of J. Ekstrand, Stockholm, Sweden)

Key Note

There is no doubt that there is a real risk of acute toxic doses of fluoride in small children, in particular with the use of fluoride gels. Chronic toxic effects of fluoride are not expected to occur as a result of the single, large ingested doses of fluoride associated with gel treatments. The prevalence of dental fluorosis has been shown not to be increased after fluoride gel treatments [104].

10.4.2 Varnishes

Fluoride concentrations in varnishes are much higher than in gels. However, varnishes are designed for use only by health professionals in the dental office, and the amounts used are much smaller than for gels. In addition, fluoride is released much more slowly from varnishes, in which fluoride is in suspension rather than dissolved and the varnish is designed to adhere to the teeth. However, the varnish will be completely swallowed in time. For all of these reasons, systemic fluoride exposure from varnishes is expected to be lower than for gels. This has been confirmed by measurements of plasma fluoride after use of a varnish containing 5% sodium fluoride. Thus, despite the high fluoride concentrations, the plasma fluoride levels recorded after varnish use were lower by a factor of 10 than those found with fluoride gels [46].

10.4.3 Vehicle Substances

The substances used to form the fluoride vehicle in gels and varnishes should also be considered possible candidates for causing adverse effects of these products. In the case of gels, this component consists of cellulose, which is not expected to be associated with any form of toxicity in the amounts involved in fluoride applications. For example, in an experiment in which

Dentlearn.ir

five human volunteers consumed 10 times the acceptable daily intake (25 mg/kg body weight) of methyl cellulose for 23 days, measurements of a wide variety of plasma biochemistry parameters provided no indication of any adverse effects [44].

The relevant varnishes marketed at the present time are Duraphat and BiFluorid. Duraphat contains 5% sodium fluoride in a neutral colophonium base, and BiFluorid contains 6% sodium fluoride and 6% calcium fluoride suspended in a mixture of ethyl acetate and isoamylpropionate. The latter mixture is not expected to give rise to toxic reactions. Ethyl acetate is a naturally occurring constituent of many fruits, including apples, and isoamylpropionate is generally recognized as being of low toxicity.

Colophony, also called rosin, is derived from certain species of pine trees. It is considered safe for ingestion, but its widespread use in industry has shown that sensitivity reactions can readily occur. Colophony is the third highest cause of occupational asthma [144], usually from inhalation in timber industries. In one study, 4% of tested patients demonstrated contact allergy to colophony [23]. In another study, the prevalence of contact allergy in the general population was estimated to be about 0.5% [126] (see also Chaps. 6, 7, and 14).

Therefore, because the use of Duraphat varnish is widespread, it might be expected to be responsible for sensitization on a large scale. A report published in 1993 stated that this product was sold in 140 countries, with 15,000 packages sold annually in Sweden alone [91]. These authors reported on a dental nurse with dermatitis of the hand and a patient with allergic contact stomatitis. These two cases are the only patch-test-confirmed occurrences of hypersensitivity to Duraphat that have been reported. These authors speculated on this paradox and suggested that reasons for the apparent lack of reported cases could be explained by the fact that Duraphat is mostly used in children, and colophony hypersensitivity among children is uncommon. In keeping with other observations of allergic reactions described in this chapter, it was also considered that the mucosa is less sensitive than the skin and is protected by salivary flow. Finally, there is the possibility that some cases go unrecognized. This last assumption is supported by a report of three hypersensitivity-like reactions to Duraphat reported by Norwegian hygienists [83]. This information was derived from data on side effects of dental treatment requested from 169 hygienists, 128 of whom regularly applied Duraphat.

Key Note

On the limited evidence available, it is concluded that although hypersensitivity reactions to the colophony component of Duraphat can occur, they are very likely to be extremely rare.

Conclusions for the Dental Practitioner

1. Oral hygiene products are subject to regulation in many countries. Contents may have to be declared; only approved concentrations of some substances are allowed; and other substances are not admissible as ingredients (U.S. Federal Food, Drug, and Cosmetic Act of 1938, and European Council Directive 76/768/EEC of July 1976, with their subsequent amendments).
2. Despite such regulation, information about the type and concentration of fluoride content of toothpastes, for example, is frequently insufficient. Only a few manufacturers indicate that the amount of fluoridated toothpaste used in children should be limited. The instruction "use only a pea-size amount," as shown in Fig. 10.2, should appear on toothpaste tubes and labels.
3. Adverse effects to oral hygiene products are rare. However, many products still contain substances that are superfluous for real health benefit. Therefore, regular investigation of side effects of new product formulations is desirable.
4. Dental health professionals should consider claims of health benefits of oral hygiene products with sound scepticism and should continue to demand documentation both of health benefits and adverse effects of these products. To avoid unnecessary risks, potentially deleterious substances (e.g., alcohol) should not be added at higher concentrations without a documented therapeutic effect.
5. Vital teeth in patients with large restorations, extended erosions/abrasions in the cervical tooth area, or pronounced enamel cracks should be bleached with caution because toxic substances could penetrate to the pulp.

Dentlearn.ir

References

1. Addy, M., Moran, J., Davies, R.M., Beak, A., Lewis, A.: The effect of single morning and evening rinses of chlorhexidine on the development of tooth staining and plaque accumulation. J Clin Periodontol 9, 134–140 (1982).
2. Aiello, A. E., Larsin, E.: Antibacterial cleaning and hygiene products as an emerging risk factor for antibiotic resistance in the community. Lancet Infect Dis 3, 501–506 (2003).
3. Albers, H.-K., Jung, G., Gotze, W.: Klinische und histologische Untersuchungen über den Einfluss einer netzmittelhaltigen Zahnpaste auf die Gingiva. [Clinical and histological study on the influence of a detergent-containing toothpaste upon the gingiva] Dtsch Zahnärztl Z 33, 559–565 (1978).
4. Ames, J.W.: Removing stains from mottled enamel. J Am Dent Assoc 24, 1674–1677 (1937).
5. Andersen, K.E.: Contact allergy to toothpaste flavours. Contact Dermatitis 4, 195–198 (1978).
6. Arenholt-Bindslev, D., Bleeg, H.S., Richards, A.: Toxicity of sodium dodecyl sulphate and other detergents in cultures of human oral mucosa epithelium. ATLA 20, 28–38 (1992).
7. Attin, T.: Sicherheit und Anwendung von carbamid-peroxidhaltigen Gelen bei Bleichtherapien. [The safety and use of carbamide-peroxide gels for bleaching] Dtsch Zahnärztl Z 53, 11–16 (1998).
8. Bailey, R.W., Christen, A.G.: Bleaching of vital teeth stained with endemic fluorosis. Oral Surg Oral Med Oral Pathol 26, 871–878 (1968).
9. Barnhart, W.E., Hiller, L.K., Leonard, G.J., Michaels, S.E.: Dentifrice usage and ingestion among four age groups. J Dent Res 53, 1312–1317 (1974).
10. Bartlett, D.W., Walmesley, A.D.: Home bleaching. Dent Update 19, 287–290 (1992).
11. Bergstrom, J., Lavstedt, S.: An epidemiological approach to toothbrushing and dental abrasion. Community Dent Oral Epidemiol 7, 57–64 (1979).
12. Bernstein, M.L.: Oral mucosal white lesions associated with excessive use of Listerine mouthwash: report of two cases. Oral Surg Oral Med Oral Pathol Oral Radiol Endod 46, 781–785 (1978).
13. Berry, J.H.: What about whiteners? Safety concerns explored. J Am Dent Assoc 121, 223–224 (1990).
14. Bitter, N.C., Sanders, J.L.: The effect of four bleaching agents on the enamel surface: a scanning electron microscopic study. Quintessence Int 24, 817–824 (1993).
15. Bitter, N.C.: A scanning electron microscopy study of the effect of bleaching agents on enamel: a preliminary report. J Prosthet Dent 67, 852–855 (1992).
16. Bitter, N.C.: A scanning electron microscope study of the long-term effect of bleaching agents on the enamel surface in vivo. Gen Dent 46, 84–88 (1998).
17. Blot, W.J., McLaughlin, J.K., Winn, D.M., Austin, D.F., Greenberg, R.S., Preston-Martin, S., Bernstein, L., Schoenberg, J.B., Stemhagen, A., Faumeni, J.F. Jr.: Smoking and drinking in relation to oral and pharyngeal cancer. Cancer Res 48, 3282–3287 (1988).
18. Blot, W.J., Winn, D.M., Faumeni, J.F.: Oral cancer and mouthwash. J Natl Cancer Inst 70, 251–253 (1983).
19. Bogue, G.: Bleaching teeth. Dent Cosmos 14, 1–3 (1871).
20. Bolanowski, S.J., Gescheider, G.A., Sutton, S.V.W.: Relationship between oral pain and ethanol concentration in mouthrinses. J Periodont Res 30, 192–197 (1995).
21. Brown, P.L., Cutress, T.W.: Lead and cadmium in New Zealand toothpastes and containers. N Z Dent J 73, 85–87 (1977).
22. Brune, D.: Minor and trace inorganic components of toothpastes. Scand J Dent Res 88, 517–520 (1980).
23. Bruze, M.: Systemically induced contact dermatitis from dental rosin. Scand J Dent Res 102, 376–378 (1994).
24. Chahine, L., Sempson, N., Wagoner, C.: The effect of sodium lauryl sulfate on recurrent aphthous ulcers: a clinical study. Compend Contin Educ Dent 18, 1238–1240 (1997).
25. Chang, S.H., Lee, A.Y., Lee, Y.S.: A case of immunologic contact urticaria to chlorhexidine. Ann Dermatol 2, 47–49 (1990).
26. Cherry, D.V., Bowers, D.V., Thomas, L., Redmond, A.F.: Acute toxicological effects of ingested tooth whiteners in female rats. J Dent Res 72, 1298–1303 (1993).
27. Chisholm, D.G., Calder, I., Peterson, D., Powell, M.: Intranasal chlorhexidine resulting in anaphylactic circulatory arrest. Brit. Med J 315, 785 (1997).
28. Christensen, D.W., Faught, W.E., Black, R.E., Woodward, G.A., Timmons, O.D.: Fatal oxygen embolization after hydrogen peroxide ingestion. Crit Care Med 20, 543–544 (1993).
29. Christensen, G.J.: Home-use bleaching survey. Clin Res Assoc Newsl 15, 2–3 (1991).
30. Ciancio, S.G., Mather, M.L., Bunnell, H.L.: Clinical evaluation of a quaternary ammonium containing mouthrinse. J Periodontol 46, 397–401 (1975).
31. Classification and labelling of dangerous substances (directive 83.467/EEC). Off J Econ Communities (EEC), no. L257/24, 16 September 1983.
32. Cohen, S.C., Parkins, F.M.: Bleaching tetracycline-stained vital teeth. Oral Surg Oral Med Oral Pathol 29, 465–471 (1970).
33. Cohen, S.C., Chase, C.: Human pulpal responses to bleaching procedures on vital teeth. J Endodont 5, 134–138 (1979).
34. Cole, E.C., Addison, R.M., Rubio, K.E., Leese, P.D., Dulaney, M.S., Wilkins, J., Gaber, D.J., Wineinger, T., Criger, D.A.: Investigation of antibiotic and antibacterial agent cross-resistance in target bacteria from homes of antibacterial product users and nonusers. J Appl Microbiol 95, 664–676 (2003).
35. Coli, P., Jontell, M., Hakeberg, M.: The effect of a dentifrice in the prevention of recurrent aphthous stomatitis. Oral Health Prev Dent 2, 133–141 (2004).
36. Compton, F.H., Beagrie, G.S.: Inhibiting effect of benzethonium and zinc chloride mouthrinses on human dental plaque and gingivitis. J Clin Periodontol 2, 33–43 (1975).
37. Croll, T.P.: Tooth bleaching for children and teens: a protocol and examples. Quintessence Int 25, 811–817 (1994).
38. Cummins, L.H.: Hypoglycemia and convulsions in children following alcohol ingestion. J Pediat 58, 23–31 (1961).
39. Dahl, J.E., Becker, R.: Acute toxicity of carbamide peroxide and a commercially available tooth-bleaching agent in rats. J Dent Res 74, 710–714 (1995).
40. De Salva, S.J., Volpe, A., Leigh, G., Regan, T.: Long-term safety studies of chloroform-containing dentifrice and mouth-rinse in man. Food Cosmet Toxicol 13, 529–532 (1975).
41. De Salva, S.J., Kong, B.M., Lin, Y.-J.: Triclosan: a safety profile. Am J Dent 2, 185–196 (1989).
42. Donatsky, O., Worsaae, N., Schiodt, M., Johnsen, T.: Effect of Zendium toothpaste on recurrent aphthous stomatitis. Scan J Dent Res 91, 376–380 (1983).
43. Dooland, M.B., Wylie, A.: Urinary fluoride levels in preschool children in relation to the use of fluoride toothpaste. Aust Dent J 33, 101–103 (1988).
44. Eastwood, M.A., Brydon, W.G., Anderson, D.M.: The effects of dietary methylcellulose in man. Food Addit Contam 7, 9–19 (1990).

Dentlearn.ir

45. Ekstrand, J., Erhnebo, M.: Absorption of fluoride from fluoride dentifrice. Caries Res 14, 96–102 (1980).
46. Ekstrand, J., Koch, G., Petersson, L. G.: Plasma fluoride from concentration and urinary flow excretion in children following application of the fluoride-containing varnish Duraphat. Caries Res 14, 185–189 (1980).
47. Ekstrand, J., Koch, G., Lindgren, L.E., Peterssen, L.G.: Pharmacokinetics of fluoride gels in children and adults. Caries Res 15, 213–220 (1981).
48. Ekstrand, J., Koch, G., Petersson, L.G.: Plasma fluoride concentration in preschool children after ingestion of fluoride tablets and toothpaste. Caries Res 17, 379–384 (1983).
49. Elmore, J.G., Horwitz, R.I.: Oral cancer and mouthwash use: evaluation of the epidemiologic evidence. Otolaryngol Head Neck Surg 113, 253–261 (1995).
50. Emslie, R.D.: A history of oral hygiene measures. Community Dent Oral Epidemiol 8, 225–229 (1980).
51. Environmental Protection Agency. Proposed guidelines for carcinogenetic, mutagenic and reproductive risk. Fed Register 61, 17960–18011 (1996).
52. Environmental Protection Agency: National primary and secondary drinking water regulations: fluoride: final rule. Fed Register 51, 11396–11342 (1986).
53. Esposito, E.J., Gray, W.A.: Effect of water and mouthwashes on the pH of oral mucosa. Pharmacol Ther 2, 33–41 (1975).
54. Etemadzadeh, H.: Plaque-growth inhibiting effect of chewing gum containing urea hydrogen peroxide. J Clin Periodontol 18, 337–340 (1991).
55. Evans, R.J.: Acute anaphylaxis due to topical chlorhexidine acetate. Br Med J 304, 686 (1992).
56. Fejerskov, O., Baelum, V., Richards, A.: Dose-response and dental fluorosis. In: Fejerskov O, Ekstrand J, Burt BA (eds). Fluoride in Dentistry. Munksgaard. Copenhagen 1996, pp 153–166.
57. Fine, D.H., Furgang, D., Bonta, Y., DeVizio, W., Volpe, A.R., Reynolds, H., Zambon, J.J., Dunford, R.G.: Efficacy of a triclosan/NaF dentifrice in the control of plaque and gingivitis and concurrent oral microflora monitoring. Am J Dent 11, 259–270 (1998).
58. Fischman, S.L.: Hare's teeth to fluorides, historical aspects of dentifrice use. In: Embery G., Rølla G. (eds): Clinical and Biological Aspects of Dentifrices. Oxford University Press, Oxford 1992, pp 1–9.
59. Fisher, A.A.: Allergic contact dermatitis. Cutis 15, 149–153 (1975).
60. Fisher, A.A.: Contact stomatitis, glossitis and cheilitis. Otolaryngol Clin North Am 7, 827–830 (1974).
61. Fisher, A.A.: Contact stomatitis. Dermatol Clin 5, 709–717 (1987).
62. Flemming, C.J., Forsyth A.: D5 patch test reactions to menthol and peppermint. Contact Dermatitis 38, 337 (1998).
63. Flores de Jacoby, L., Thor, G., Lange, D.E.: Vergleichende klinische und zytologische Untersuchungen nach Anwendung zweier Zahnpasten. [Comparative clinical and cytological studies after the use of two toothpastes] Dtsch Zahnärztl Z 30, 385–388 (1975).
64. Flotra, L., Gjermo, P., Waerhaug, J.: Side effects of chlorhexidine mouthwashes. Scan J Dent Res 79, 119–125 (1971).
65. Franks, A.: Contact allergy to anethole in toothpaste associated with loss of taste. Contact Dermatitis 38, 354–355 (1998).
66. Gagari, E., Kabani, S.: Adverse effects of mouthwash use. A review. Oral Surg Oral Med Oral Radiol Endod 80, 432–439 (1995).
67. Gilberson, T.P., Kern, J.D., Pettigrew, D.W., Eaves, C.C., Haynes, J.F.: Near fatal hydrogen peroxide ingestion. Ann Emerg Med 18, 778–779 (1989).
68. Giusti, G.V.: Fatal poisoning with hydrogen peroxide. Forensic Sci 2, 99–100 (1973).
69. Gjermo, P., Baasted, K., Rolla, G.: The plaque-inhibiting capacity of 11 anti-bacterial compounds. J Periodontol Res, 102–109 (1970).
70. Goldstein, G.R., Kiremidjian-Schumacher, L.: Bleaching: Is it safe and effective? J Prosthet Dent 69, 325–328 (1993).
71. Grabenstetter, R.J., Broge, R.W., Jackson, F.L., Radike, A.W.: The measurement of the abrasion of human teeth by dentifrice abrasives: a test utilizing radioactive teeth. J Dent Res 17, 1060–1068 (1958).
72. Granath, L., Widenheim, J., Birkhed, D.: Diagnosis of mild enamel fluorosis in permanent maxillary incisors using two scoring systems. Community Dent Oral Epidemiol 13, 273–276 (1985).
73. Grattan, C.E.H., Peachey, R.D.: Contact sensitization to toothpaste flavouring. J R Coll Gen Pract 35, 498 (1985).
74. Griffiths, B.M.: Dentifrices – an item of historical interest. N Z Dent J 62, 296–301 (1966).
75. Hargreaves, J.A., Ingram, J.S., Wagg, B.G.: A gravimetric study of the ingestion of toothpaste by children. Caries Res 6, 237–243 (1972).
76. Hatton, E.H., Fosdick, L.S., Calendra, J.: The toxicity and rubefacient action of sulphated higher alcohols. J Dent Res 19, 87–92 (1940).
77. Hausen, B.M.: Zahnpasta-Allergie durch L-carvon. [Dentifrice allergy due to L-carvone] Akt Dermatol 12, 23–24 (1986).
78. Hausen, B.M.: Zahnpasta-Allergie. [Dentifrice allergy] Dtsch Med Wochenschr 109, 300–302 (1984).
79. Haywood, V.B., Heymann, H.O.: Nightguard vital bleaching. Quintessence Int 20, 173–176 (1989).
80. Healy, C.M., Paterson, M., Joyston-Bechal, S., Williams, D.M., Thornhill, M..H.: The effect of sodium lauryl sulfate-free dentifrice on patients with recurrent oral ulceration. Oral Dis 5, 39–43 (1999).
81. Helfenstein, U., Steiner, M.: Fluoride varnishes (Duraphat): a meta-analysis. Community Dent Oral Epidemiol 22, 1–5 (1994).
82. Henricsson, V., Axell, T.: Treatment of recurrent aphthous ulcers with Aureomycin[R] mouthrinse or Zendium[R] dentifrice. Acta Odontol Scand 43, 47–52 (1985).
83. Hensten-Pettersen, A., Jakobsen, N.: Possible side effects related to dental hygienists' treatment. Acta Odontol Scand 52, 157–161 (1994).
84. Hepso, H.U., Bjornland, T., Skoglund, L.A.: Side-effects and patient acceptance of 0.2% versus 0.1% chlorhexidine used as a post-operative prophylactic mouthwash. Int J Oral Maxillofac Surg 17, 17–20 (1988).
85. Herlofson, B. B., Barkvoll, P.: Oral mucosal desquamation caused by two toothpaste detergents in an experimental model. Eur J Oral Science 104, 21–26 (1996).
86. Herlofson, B.B., Barkvoll, P.: Sodium lauryl sulphate and recurrent aphthous ulcers. A preliminary study. Acta Odontol Scand 52, 257–259 (1994).
87. Herlofson, B.B., Barkvoll, P.: The effect of two toothpaste detergents on the frequency of recurrent aphthous ulcers. Acta Odontol Scand 54, 150–153 (1996).
88. Hjorth, N., Jervoe, P.: Allergic contact dermatitis and dermatitis from a flavour of toothpaste. Tandlægebladet 71, 937–942 (1967).
89. Howard, W.R.: Patient-applied tooth whiteners – are they safe with supervision? J Am Dent Assoc 123, 57–60 (1992).
90. Humberston, C.L., Dean, B.S., Krenzelok, E.P.: Ingestion of 35% hydrogen peroxide. J Toxicol Clin Toxicol 28, 95–100 (1990).

Dentlearn.ir

91. Isaksson, M., Bruze, M., Bjorkner, B., Niklasson, B.: Contact allergy to Duraphat. Scand J Dent Res 101, 49–51 (1993).
92. Jaacob, H., Jalil, R.: An unusual hypersensitivity reaction to chlorhexidine. J Oral Med 41, 145–146 (1986).
93. Kabasawa, Y., Kanzaki, T.: Allergic dermatitis from the surfactant in Hibitane. Contact Dermatitis 12, 378–379 (1989).
94. Kinehara, M., Tanaka, Y., Chujo, T.: A case of anaphylactic shock and contact dermatitis caused by the external use of chlorhexidine gluconate. Hifubyoh-Shinryoh 8, 743–746 (1986).
95. Kirton, V., Wilkinson, D.S.: Sensitivity to cinnamic aldehyde in a toothpaste (2). Further studies. Contact Dermatitis 1, 77–80 (1975).
96. Kitchin, P.C., Graham, W.C.: Sodium alkyl sulfate as a detergent in toothpaste. J Am Dent Assoc 24, 736–755 (1937).
97. Kitchin, P.C., Robinson, H.B.: How abrasive need a dentifrice be? J Dent Res 27, 501–505 (1948).
98. Kobayashi, Y., Shiratori, R., Kaneko, Y., Kaneko, K., Yamomoto, T.: Anaphylaxis caused by a disinfectant. J Clin Anesth (Japan) 10, 814–816 (1986).
99. Koch, G.: Effekten af enzymtandpasta på recidiverende after. [The effect of enzyme containing dentifrice on recurrent aphtous ulcers] Tandlaekartidningen 73, 264–272 (1981).
100. Kowitz, G.M., Lucatorto, F.M., Bennett, W.: Effects of dentifrices on soft tissues of the oral cavity. J Oral Med 28, 105–109 (1973).
101. Kowitz, G.M., Lucatorto, F.M., Cherrick, H.M.: Effects of mouthwashes on the oral soft tissues. J Oral Med 31, 47–50 (1976).
102. Kume, A., Hazano, S., Higashi, N.: Two cases of contact dermatitis due to Hibitane (chlorhexidine gluconate). Skin Res (suppl 11), 276–280 (1991).
103. Lamey, P.J., Lewis, M.A., Rees, T.D., Fowler, C., Binnie, W.H., Forsyth, A.: Sensitivity to the cinnamoaldehyde component of toothpaste. Brit Dent J 168, 115–118 (1990).
104. Larsen, M.J., Kirkegaard, E., Fejerskov, O., Poulsen, S.: Prevalence of dental fluorosis after fluoride-gel treatments in a low-fluoride area. J Dent Res 64, 1076–1079 (1985).
105. Leone, N.C., Stevenson, C.A., Hilbish, T.F., Sosman, M.C.: A roentgenologic study of a human population exposed to high-fluoride domestic water. Am J Roentgenol 74, 874 (1955).
106. Li, Y.: Toxicological considerations of tooth bleaching using peroxide-containing agents. J Am Dent Assoc 128, 31–36 (1997).
107. Litovitz, T.L., Schmitz, B.F., Matyunas, N., Martin, T.G.: 1987 Annual Report of the American Association of Poison Control Centers National Data Collection System. Am J Emerg Med 6, 479–515 (1988).
108. Lobene, R.R.: Clinical studies of the cleaning functions of dentifrices. J Am Dent Assoc 105, 798–802 (1982).
109. Loe, H.: Present day status and direction of future research on the etiology and prevention of periodontal disease. J Periodontol 40, 678–682 (1969).
110. Lynch, E., Samarawickrama, D.Y.D., Claxson, A.W.D., Hawkes, J.E., Naughton, D.P., Grootveld, M.C.: Safety aspects concerning the therapeutic and cosmetic applications of hydrogen peroxide (H_2O_2) -containing gels, whiteners, oral rinses and dentifrices. J Ir Dent Assoc 40, 78–82 (1994).
111. Magnussen, B., Wilkinson, D.S.: Cinnamic aldehyde in toothpaste. Contact Dermatitis 1, 70–76 (1975).
112. Maibach, H.I.: Cheilitis: occult allergy to cinnamic aldehyde. Contact Dermatitis 15, 106–107 (1986).
113. Mascarenhas, A.K., Burt, B.A.: Fluorosis risk from early exposure to fluoride toothpaste. Community Dent Oral Epidemiol 26, 241–248 (1998).
114. Mashberg, A., Barsa, P., Grossman, M.L.: A study of the relationship between mouthwash use and oral and pharyngeal cancer. J Am Dent Assoc 110, 731–734 (1985).
115. Mathias, C.G., Chappler, R.R., Maibach, H.I.: Contact urticaria from cinnamic aldehyde. Arch Dermatolog 116, 74–76 (1980).
116. McGuckin, R.S., Babin, J.F., Meyer, B.J.: Alterations in human enamel surface morphology following vital bleaching. J Prosthet Dent 68, 754–760 (1992).
117. McMurry, L.M., Oethinger, M., Levy, S.B.: Triclosan targets lipid synthesis. Nature 394, 531–532 (1998).
118. Moghadam, B.K., Drisko, C.L., Gier, R.E.: Chlorhexidine mouthwash-induced fixed drug eruption. Case report and review of the literature. Oral Surg Oral Med Oral Pathol 71, 431–434 (1991).
119. Morse, D.E., Katz, R.V., Pendrys, D.G., Holford, T.R., Krutchkoff, D.J., Eisenberg, E., Kosis, D., Mayne, S.T.: Smoking and drinking in relation to oral epithelial dysplasia. Cancer Epidemiol Biomarkers Prev 5, 769–777 (1996).
120. Mullins, M.E., Beltran, J.T.: Acute cerebral gas embolism from hydrogen peroxide ingestion successfully treated with hyperbaric oxygen. J Toxicol Clin Toxicol 36, 253–256 (1998).
121. Naccache, H., Simard, P.L., Trahan, L., Demers, M., Lapointe, C., Brodeur, J.M.: Variability in the ingestion of fluoride by young children. Caries Res 24, 359–363 (1990).
122. Naccache, H., Simard, P.L., Trahan, L., Brodeur, J.M., Demers, M., Lachapelle, D., Bernhard, P.M.: Factors affecting the ingestion of fluoride dentifrice by young children. J Public Health Dent 52, 222–226 (1992).
123. Nathanson, D.: Vital tooth bleaching: sensitivity and pulpal considerations. J Am Dent Assoc 128 (suppl.), 41–44 (1997).
124. Nater, J.P., De Groot, A.C.: Unwanted effects of cosmetics and drugs used in dermatology, 3rd edn. Amsterdam, Elsevier Science Publishers 1993, pp 187–189.
125. Nielsen, C., Klaschka, F.: Teststudien an der Mundschleimhaut bei Ekzemallergikern. [Study on the oral mucosa in allergy patients] Deutsche Zahn-, Mund-, und Kieferheilkunde 57, 201–218 (1971).
126. Nielsen, N.H., Menne, T.: Allergic contact sensitization in an unselected Danish population. The Glostrup Allergy Study, Denmark. Acta Derm Venereol (Stockh) 72, 456–460 (1992).
127. Ohtoshi, T., Yamauchi, N., Tadokoro, K., Miyachi, S., Suzuki, S., Miyamoto, T., Muranaka, M.: IgE antibody-mediated shock reaction caused by topical application of chlorhexidine. Clin Allergy 16, 155–161 (1986).
128. Osmundsen, P.E.: Contact dermatitis to chlorhexidine. Contact Dermatitis 8, 81–83 (1982).
129. Pader, M.: Oral Hygiene Products and Practice. Marcel Dekker, New York 1988, pp 433–434.
130. Pendrys, D.G., Katz, R.V.: Risk of enamel fluorosis associated with fluoride supplementation, infant formula, and fluoride dentifrice use. Am J Epidemiol 130, 1199–1208 (1989).
131. Petersen, J.K.: Anaphylactic shock after local chlorhexidine treatment: a case report. Tandlægebladet 98, 335–338 (1994).
132. Petersen, J.K.: A case of anaphylactic shock following use of chlorhexidine in the oral cavity. Tandlægebladet 99, 733 (1995).
133. Ploeger, B.J., Robinson, R.A., Robinson, D.F., Christensen, R.P.: Quantitative in vivo comparison of five carbamide peroxide bleach gels. J Dent Res 70, 376 (1991).
134. Plonait, D.R., Reichart, P.A.: Epitheliolyse der Mundschleimhaut (Mucosal Peeling) als Nebenwirkung von Zahncreme. [Mucosal peeling as a side effect of dentifrice] Mund Kiefer Gesichts Chir 3, 78–81 (1999).

Dentlearn.ir

135. Rackoff, W.R., Merton, D.F.: Gas embolism after ingestion of hydrogen peroxide. Pediatrics 85, 593–594 (1990).
136. Rajan, B.P., Gnanasundaram, N., Santhini, R.: Serum and urine fluoride levels in toothpaste users. J Indian Dent Assoc 59, 137–142 (1987).
137. Rees, T.D., Orth, C.F.: Oral ulcerations with use of hydrogen peroxide. J Periodontol 57, 689–692 (1986).
138. Reynolds, N.J., Harman, R.R.M.: Allergic contact dermatitis from chlorhexidine diacetate in a skin swab. Contact Dermatitis 22, 103–104 (1990).
139. Ricci, L.R., Hoffmann, S.A.: Ethanol-induced hypoglycemic coma in a child. Ann Emergency Med 11, 202–204 (1982).
140. Riordan, P.J., Banks, J.A.: Dental fluorosis and fluoride exposure in Western Australia. J Dent Res 70, 1022–1028 (1991).
141. Ripa, L.W.: An evaluation of the use of professional (operator-applied) topical fluorides. J Dent Res (Spec Iss) 69, 786–796 (1990).
142. Romaguera, C., Grimalt, G.: Sensitization to cinnamic aldehyde. Contact Dermatitis 4, 195–196 (1978).
143. Rushton, A.: Safety of hibitane II. Human experience. J Clin Periodontol 4, 73–79 (1977).
144. Sadhra, S., Foulds, I.S., Gray, C.N., Koh, D., Gardiner, K.: Colophony – uses, health effects, airborne measurement and analysis. Annals Occup Hyg 38, 385–396 (1994).
145. Sainio, E., Kanerva, L.: Contact allergens in toothpaste and a review of their hypersensitivity. Contact Dermatitis 33, 100–105 (1995).
146. Schmeiser, R., Guelzow, H.J.: Vergleichende klinische Untersuchung einer tensidhaltigen mit einer tensidfreien Zahnpasta. [Comparative clinical study of two dentifrices with and without tensides] Dtsch Zahnärztl Z 47, 229–231 (1992).
147. Schoenfeld, R.J., Schoenfeld, F.I.: Angular cheilitis. Cutis 19, 213 (1977).
148. Scientific Committee on Consumer Products: SCCP opinion on triclosan. SCCP/1040/06 (2006).
149. Selbst, S.M., DeMaio, J.G., Boenning, D.: Mouthwash poisoning: report of a fatal case. Clin Pediatr (Phila) 42, 162–163 (1985).
150. Seppa, L.: Topical fluorides. Proc Finn Dent Soc 85, 445–456 (1989).
151. Shapiro, I.M., Cohen, G.H., Needleman, H.L., Tuncay, O.C.: The presence of lead in toothpaste. J Am Dent Assoc 86, 394–395 (1973).
152. Shapiro, S., Castellana, J.V., Sprafka, J.M.: Alcohol-containing mouthwashes and oropharyngeal cancer: a spurious association due to underascertainment of confounders? Am J Epidemiol 144, 1091–1095 (1996).
153. Sherman, S.J., Boyer, L.V., Sibley, W.A.: Cerebral infarction after ingestion of hydrogen peroxide solution. Stroke 25, 1065–1067 (1994).
154. Shimizu, M., Murata, M., Saburi, H., Ohtoshi, T.: A case of contact urticaria due to chlorhexidine gluconate. Skin Res 31 (Suppl 6), 235–239 (1989).
155. Shulman, J.D., Wells, L.M.: Acute ethanol toxicity from ingesting mouthwash in children younger than six years of age. Pediatr Dent 19, 405–408 (1997).
156. Simard, P.L., Lachapelle, D., Trahan, L., Naccache, H., Demers, M., Brodeur, J.M.: The ingestion of fluoride dentifrice by young children. J Dent Child 56, 177–181 (1989).
157. Skrebova, N, Brocks, K, Karlsmark, T.: Allergic contact cheilitis from spearmint oil. Contact Dermatitis 39, 35 (1998).
158. Smith, I.L.F.: Acute allergic reaction following the use of toothpaste. Brit Dent J 125, 304–305 (1969).
159. Spak, C.J., Sjostedt, S., Eleborg, L., Veress, B., Perbeck, L., Ekstrand, J.: Studies of human gastric mucosa after application of 0.42% fluoride gel. J Dent Res 69, 426–429 (1990).
160. Spurlock, B.W., Dailey, T.M.: Shortness of (fresh) breath-toothpaste-induced bronchospasm. N Engl J Med 323, 1845–1846 (1990).
161. Stookey, G.K., Burkhard, T.A., Schemehorn, B.R.: In vitro removal of stain with dentifrices. J Dent Res 61, 1236–1239 (1982).
162. Staab, W., Gängler, P.: Allergische Reaktion auf Chlorhexidindigluconat. Ein kasuistischer Bericht. [Allergic reactions to chlorhexidine digluconate] Stomatol DDR 32, 700–703 (1982).
163. Subiza, J., Subiza, J.L., Valdivieso, T., Escribano, P.M., Garcia, R., Jerez, M., Subiza, E.: Toothpaste flavour-induced asthma. J Allergy Clin Immunol 90, 1004–1006 (1992).
164. Tan, L., Nielsen, N.H., Young, D.C., Trizna, Z.: Use of antimicrobial agents in consumer products. Council on Scientific Affairs, American Medical Association. Arch Dermatol 138, 1082–1086 (2002).
165. Thyne, G., Young, D.W., Ferguson, M.M.: Contact stomatitis caused by a toothpaste. N Z Dent J, 85, 124–126 (1989).
166. Titley, K., Torneck, C.D., Smith, D.: The effect of concentrated hydrogen peroxide solutions on the surface morphology of human tooth enamel. J Endodont 14, 69–74 (1988).
167. van Rijkom, H.M., Truin, G.J., van't Hof, M.A.: A meta-analysis of clinical studies on the caries-inhibiting effect of fluoride gel treatment. Caries Res 32, 83–92 (1998).
168. Varma, B.K., Cincotta, J.: Mouthwash induced hypoglycemia. Am J Dis Child 132, 930–931 (1978).
169. Warner, R.R., Myers, M.C., Burns, J., Mitra, S.: Analytical electron microscopy of chlorhexidine induced tooth stain in humans: direct evidence for metal-induced stain. J Periodontol Res 28, 255–265 (1993).
170. Weaver, A., Fleming, S.M., Smith, D.B.: Mouthwash and oral cancer: carcinogen or coincidence? J Oral Surg 70, 255–260 (1979).
171. Wei, S.H., Kanellis, M.J.: Fluoride retention after sodium fluoride mouth-rinsing by preschool children. J Am Dent Assoc 106, 626–629 (1983).
172. Whitford, G.M.: Fluoride in dental products. In: The Metabolism and Toxicity of Fluoride. Karger, Basel 1989, pp 128–131.
173. Whitford, G.M.: Fluoride toxicology and health effects. In: Fejerskov, O., Ekstrand, J., Burt, B.A. (eds) Fluoride in Dentistry. Munksgaard, Copenhagen 1989, pp 167–181.
174. Wilkinson, S.M., Beck, M.H.: Allergic contact dermatitis from menthol in peppermint. Contact Dermatitis 30, 42–43 (1994).
175. Woolverton, C.J., Haywood, V.B., Heymann, H.O.: Toxicity of two carbamide peroxide products used in nightguard vital bleaching. Am J Dent 6, 310–314 (1993).
176. Worm, M., Jeep, S., Sterry, W., Zuberbier, T.: Perioral contact dermatitis caused by L-carvone in toothpaste. Contact Dermatitis 38, 338 (1998).
177. Wulknitz, P.: Cleaning power and abrasivity of European toothpastes. Adv Dent Res 11, 576–579 (1997).
178. Wynder, E.L., Kabat, G., Rosenberg, S., Levenstein, M.: Oral cancer and mouthwash use. J Natl Cancer Inst 70, 255–260 (1983).
179. Younger, H.B.: Bleaching fluorine stain from mottled enamel. Texas Dent J 57, 380–382 (1939).
180. Yusof, W.Z., Khoo, S.P.: Mucosal sensitivity to chlorhexidine mouthwash. Singapore Dent J 13, 39–40 (1988).
181. Yusof, Z.A.: Chlorhexidine mouthwash: a review of its pharmacological activity, clinical effects, uses and abuses. Dent J Malaysia 10, 9–16 (1988).
182. Zecevic, D., Gasparec, Z.: Death caused by hydrogen peroxide. Z Rechtsmed 84, 57–59 (1979).

Dentlearn.ir

11 Materials for Short-Term Application in the Oral Cavity

G. Schmalz

Contents

11.1	Introduction	293
11.2	Impression Materials	294
11.2.1	Basic Material Properties	294
11.2.2	Systemic Toxicity	295
11.2.3	Local Toxicity and Tissue Compatibility	295
11.2.4	Allergies	299
11.2.5	Mutagenicity	299
11.3	Periodontal Dressings	299
11.3.1	Basic Material Properties	300
11.3.2	Systemic Toxicity	300
11.3.3	Local Toxicity and Tissue Compatibility	301
11.3.4	Allergies	302
11.3.5	Mutagenicity	302
11.4	Suture Materials	303
11.4.1	Basic Material Properties	303
11.4.2	Systemic Toxicity	303
11.4.3	Local Toxicity and Tissue Compatibility	303
11.4.4	Allergies	305
11.4.5	Mutagenicity	306
	Conclusions for the Dental Practitioner	306
	Appendix	307
	References	307

11.1 Introduction

This chapter reviews the biocompatibility of materials that are present in the oral cavity for a relatively short period of time. Impression materials stay in the oral cavity only for a few minutes, but if they accidentally remain in the gingival sulcus, they come into contact with deeper soft tissue and eventually even bone for several days. Periodontal dressing and dental suture materials are applied only for a few days, but dental personnel may repeatedly come into contact with these materials.

Materials for temporary fillings, crowns, and bridges also have only limited contact time with the patient. Materials used for these purposes are mainly reviewed in other chapters of this book (see Chaps. 5, 6, and 9).

A material for temporary fillings of small cavities (Cavit), which has been on the market for several decades, consists of zinc oxide, calcium sulfate, zinc sulfate, glycol acetate, polyvinyl acetate, polyvinyl chloride acetate, triethanol amine, and pigments. The material sets through a reaction of water (e.g., from saliva) with calcium sulfate and zinc sulfate. This reaction is associated with a considerable expansion – approximately five times greater than for zinc oxide eugenol (ZOE) – which initially may cause a tight sealing [122]. Overall, however, the sealing capacity regarding penetration of bacteria is controversial. Both sufficient [7, 55] and insufficient sealing [5, 61] have been reported. Bacterial penetration at the cavity margin generally increased over time [55].

Cell culture experiments revealed a lower toxicity for Cavit than for ZOE [123]. Histologic pulp studies on experimental animals and humans documented a displacement of odontoblasts into dentine tubules and a hyperemic reaction of the pulp several days after application [20, 122]. Ten out of 15 patients reported pain after application of Cavit on vital dentin [122]. It has been assumed that a pronounced uptake of water by this material may be the cause for this clinical reaction. Widerman et al. [122] calculated that Cavit incorporates water up to 18% of its initial weight during the setting reaction. These distinct hygroscopic properties may cause a shift of water from the pulp toward the material, which may be responsible for the aforementioned symptoms. The pain reactions were much less severe when Cavit was mixed with water before application into the cavity [55].

Clinical Practice Advice

It is not recommended to apply Cavit on vital dentin. If Cavit is used on nonvital teeth, then a sufficiently thick layer is necessary due to its dubious sealing capacity. Furthermore, it should be applied for only a few days.

Dentlearn.ir

Temporary soft relining materials for denture bases may also be classified as materials with short-term contact in patients, although in some cases an application for several weeks may be necessary (see Chap. 9). Some of these materials may contain plasticizers, such as phthalates. The use of these substances (for example, diethylhexyl phthalate) is controversial at present. The application of soft relining materials based on silicone is not associated with these problems.

11.2 Impression Materials

11.2.1 Basic Material Properties

11.2.1.1 Composition

Silicones: Currently, two different types of silicones are differentiated according to their setting reaction: addition-linking silicones (A-silicones; vinyl polysiloxane, or VPS) and condensation-linking silicones (C-silicones). The base paste of C-silicones consists of low molecular polydimethylsiloxanes with terminal hydroxyl groups, fillers (e.g., diatomite, ZnO, or TiO_2), and other additives (e.g., coloring pigments). The catalyst paste contains, among other things, tetrafunctional alkoxysilanes and catalysts, such as zinc octoate or dibutyltin dilaurate [15, 124]. The composition of A-silicones is illustrated in Table 11.1. Vinyl polysiloxanes are intrinsically hydrophobic, which may result in an insufficient adaptation to the tooth and in bubbles on gypsum casts. To increase hydrophilicity (wettability), intrinsic surfactants (e.g., Silwet) have been added [23]. Information provided by the manufacturers is sparse.

Polysulfides: A mercaptane prepolymer with a molecular weight of approximately 2,000–4,000 and a minimum of three functional SH groups comprises about 80% of the base paste. ZnO, TiO_2, $CaCO_3$ and $CaSO_4$ are used as fillers. Lead peroxide, organic peroxides, and metal salts are used as co-reactor, among others. The use of lead oxide (up to 87%) in the catalyst paste (for instance, to increase radiopacity) causes a brown color. Furthermore, the catalyst paste contains sulfur (about 3.5%), castor oil, and plasticizers such as dimethyl phthalate or dibutyl phthalate.

Polyether: The composition of a typical polyether material is reviewed in Table 11.2. Because an increased number of allergy cases were documented after their launch (see 11.2.4), the catalyst of polyether materials was changed in the 1980s.

Hydrocolloids: These consist of agar (about 6–15%), borax (0.2%), potassium sulfate (1–2%), benzoate (0.1%), and water (80–85%). Agar is a polymer of galactose that was esterified with sulfuric acid.

Alginate: Alginate impression materials contain actual alginate (12–15% of the powder), calcium donators (hydrated or semihydrated calcium sulfate), a retarder (e.g., trisodium phosphate), fillers (70%), and other additives. In former times, up to 20% of lead compounds (lead silicate) were added to improve the physical properties and to increase radiopacity [30]. Lead is no longer added to alginates. Some products may contain antimicrobial agents such as quaternary ammonium compounds [4], which may influence the biological properties (see below).

Table 11.1 Composition of A-silicones

Base	Catalyst
Hydrogen siloxane	Vinyl siloxane
Silicone oil	Silicone oil
Fillers (e.g., quartz)	Fillers (e.g., silicates)
Pigments	Pigments
Hydrophilizers	Platinum complex
Vinyl siloxane	

Table 11.2 Composition of a typical polyether material

Base	Catalysts
Aziridine polyether (oxyalkylene copolymer)	Alkylsulfonium compound
Fillers (diatomite, highly dispersed silicic acid)	Fillers (diatomite, highly dispersed silicic acid)
Plasticizers	Plasticizers
Pigments	Pigments
Scents	Esters and copolymers

Dentlearn.ir

Zinc oxide eugenol: ZOE impression materials are usually two-paste systems. The zinc-oxide paste contains zinc oxide (80%), colophony (19%), oils, and additional resins. The accelerator pastes contain clove oil or eugenol (56%), colophony (16%), and various oils. Occasionally, Canada balm or Peru balm are added as well. Information about the exact compositions is rare and varies among manufacturers.

11.2.1.2 Setting Reaction, Release, and Degradation

C-silicones set through a poly-condensation reaction under the formation of ethanol, which evaporates over time and, therefore, may cause shrinking of the impression material. A-silicones set via a poly-addition reaction, during which the double bonds of the terminal vinyl groups react with the Si–H groups of the catalyst through a platinum-triggered catalysis. No reaction products are released [15, 124].

Polysulfides set via a poly-condensation. Water and lead sulfide (only in cases of lead-containing materials) may be generated besides the polymer.

Polyether materials set via a cationic-initiated polymerization, at which a terminal aziridine ring of the base polymers is opened, thus allowing a chain formation via nitric compounds.

Hydrocolloids are liquefied by heating, which causes a sol-gel transition. They solidify when cooled down [124].

Alginates set after the addition of water via a transition from a water-soluble sodium alginate into a water-insoluble calcium alginate under simultaneous formation of sodium sulfate.

Zinc oxide eugenol materials set via the formation of a complex (for details of the setting reaction and degradation, please see Chap. 6.4 and Chap. 7).

No data are available regarding the degradation of most impression materials.

11.2.2 Systemic Toxicity

Silicones are used in many medical disciplines, including as implant material. Data derived from these applications indicate that completely set silicone is not acutely toxic in general [87]. No data regarding systemic toxic effects caused by impression silicones are available. The acute oral LD_{50} (rats) of stannous octoate is 3,400 mg/kg body weight [92] and of dibutyltin laurate is 175 mg/kg body weight [93]. Systemic toxic effects of dibutyltin laurate, e.g., in thymus [113], brain [112], and liver [69] of experimental animals, have been reported. But the applied quantities were several orders of magnitude higher than those amounts that may be generated during the use of silicone-based impression materials, and they were mostly used over several weeks. When used correctly, silicone impression materials should not cause any systemic toxic effects in patients.

Polysulfides contain lead peroxide, among others, which can cause acute and severe systemic toxic effects when swallowed or inhaled [30]. A short-term application in the oral cavity should not cause any systemic toxic reactions [78]. Dimethyl, diethyl, and dibutyl phthalates may be systemically toxic when applied in high concentrations in animal experiments, according to the U.S. Occupational Safety and Health Administration. The amounts that are applied in impression materials in the oral cavity should not cause these effects [11, 94, 107].

No information is available in the literature regarding systemic toxic effects of **polyether** or **hydrocolloid** impression materials.

Alginates are present in our daily diet in a great variety of products (e.g., as emulsifiers, in some brands of beer, and in ice cream and salad dressings). They are considered systemically nontoxic because their oral LD_{50} is >5,000 mg/kg body weight. No results have been published in the literature referring to systemic toxic effects of alginates used as impression material. Lead-containing materials, which were previously available on the market, caused an increased lead concentration in the blood of dental personnel [67, 108]. Current impression alginates are lead-free.

The systemic toxicity of **Zinc oxide eugenol** is reviewed in Chap. 6.4 and Chap. 7.

11.2.3 Local Toxicity and Tissue Compatibility

11.2.3.1 Cytotoxicity

A-silicones (VPS) were generally nontoxic in different test systems with various cells [15, 114, 120].

Dentlearn.ir

These materials were even recommended as nontoxic reference material for one cell culture system [99]. C-silicones, however, were in part severely toxic in cell culture investigations [15, 97, 114, 120]. Some C-silicones caused a toxic reaction even after exposure periods of 10 and 30 min [13] or 1h [15]. It has been presumed that the catalyst would be responsible for the pronounced local toxicity of C-silicones [47, 97]. No information is available on the influence of surfactants on the cytotoxicity of so-called hydrophilic A-silicones.

A **polysulfide** material was slightly toxic in various cell cultures but more toxic than an A-silicone [97]. The catalyst paste was more cytotoxic than the base paste [97]. In another study, a polysulfide material proved to be even less toxic than an A-silicone [114].

A **polyether** material, shortly after mixing, was more toxic than polysulfides and A-silicones in various investigations, but the toxicity decreased over time [97]. This material was also less toxic in kidney cells than A-silicone or polysulfide-based materials [114].

Basic components of **hydrocolloids** are recommended in other contexts for direct contact with cell cultures (e.g., agar diffusion test; see Chap. 2), so they are basically considered nontoxic. The low cytotoxicity has been documented in some experiments related to additives [97]. This also applies to **alginates** [97]. The cytotoxicity of **ZOE** is reviewed in Chap. 6.4 and Chap. 7.

11.2.3.2 Implantation Tests

C-silicones caused the most pronounced reactions after subcutaneous implantation in rats (Fig. 11.1); the least effects were generated by A-silicones. Moderate reactions were triggered by polyether-based and polysulfide-based impression materials, whereas hydrocolloids caused mild to moderate effects. A pronounced inflammatory reaction was evoked by ZOE, but this was lower than for C-silicones. In general, toxicity decreased with increased aging of the test specimens (up to 7 days) before implantation [98]. A high toxicity of C-silicones was found after submucosal and subcutaneous implantation in dogs [9]. Investigations on the oral mucosa documented a lower toxicity of A-silicones than of the polysulfide-based and polyether-based materials that were also investigated [119].

After submoucosal implantation in monkeys polysulfide-based materials with and without lead oxide, a polyether, a hydrocolloid, and a lead-containing alginate all were more toxic 2 days after implantation compared with the nontoxic control. All impression materials caused an inflammatory swelling. Histological assessment revealed a very severe inflammatory reaction caused by all of the materials except for the hydrocolloid, the polyether, and the polysulfide without lead oxide [30]. Similar investigations by other authors documented only a weak correlation between lead content and a toxic reaction. Therefore, it is very likely that other ingredients were responsible for the toxicity [109].

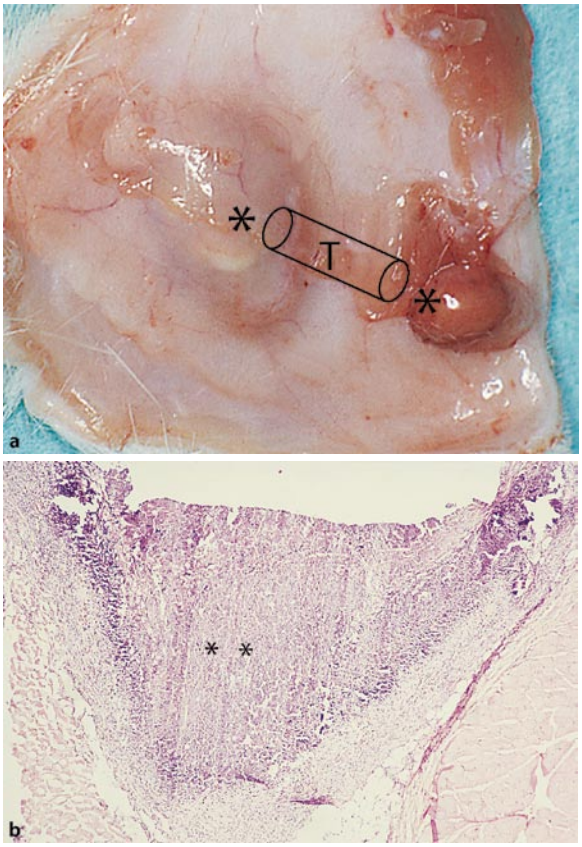

Fig. 11.1a,b Tissue reaction after subcutaneous implantation of a C-silicone (rat, 14 days after application in tissue). **a** Macroscopically, a clear swelling at the contact areas to tissue (*) is visible (*T* Teflon tube as material carrier). **b** Histology (magnification ×80) shows extensive acute inflammatory reaction (**)

Dentlearn.ir

Key Note

Overall, the results from implantation tests show good correlation with findings from cell culture experiments. A-silicones as well as hydrocolloids and alginates can be described as nontoxic. The least biocompatibility applies to C-silicones, whereas the local toxicity of other impression materials ranges between these two. Because of the short-term application, the increased cytotoxicity of C-silicones should not have negative effects on patients. Direct and repeated skin contact by dental personnel, however, should be avoided. Contact with the eyes, which may happen when mixing a liquid catalyst into a putty impression material by hand, should also be avoided, such as by wearing protective glasses or by using a paste catalyst.

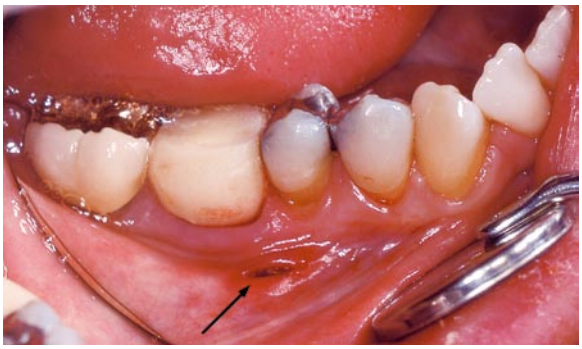

Fig. 11.2 Impression material in a surgical wound; local inflammation (swelling, redness, pain) after impression material was left unintentionally in a periodontal pocket [85] (Courtesy of M.H. Ree, Amsterdam, Netherlands)

11.2.3.3 Periodontal and Pulpal Damage

The use of impression materials is only one part of the dental treatment sequence in restorative dentistry. For example, a traumatic preparation technique (e.g., injuring the biologic width) or insertion of retraction cords too deep into the sulcus may not only traumatize the periodontium but might also cause side effects due to impression materials, which may be left unintentionally in the gingival sulcus under these circumstances (see Fig. 5.24). Electrosurgical methods for widening the gingival sulcus prior to impression are controversial. Burn marks at the root surface and significant recessions with apical dislocation of the epithelial attachment have been reported, but other authors did not observe these alterations [89]. It was reported from a situation involving human teeth, which had to be extracted for orthodontic reasons, that electrosurgery caused retarded healing compared with the application of adrenaline-containing cords (healing after 4 days), with healing completed clinically only after 16 days. Significantly more recessions were observed histologically after electrosurgery, but no damages of the alveolar bone were documented [89]. It has to be considered at this point that correct application of electrosurgery is important for a successful treatment; this, however, is not easy. Considerate placement of retraction material is apparently not associated with tissue damage [26].

No periodontal damage due to impression materials has been reported if they are applied correctly. But impression material has occasionally been unintentionally left in the gingival sulcus, with subsequent partial dislocation into the cancellous bone [85]. Over 20 such cases have been published in the literature (e.g., [16, 73, 74]), although the frequency of these incidences is probably higher in reality (Fig. 11.2). In eight out of 125 consecutive cases, remnants of impression material were found in the gingival sulcus after impression taking, in three cases only after very careful inspection [64]. In addition, a sinusitis induced by a chronic foreign body was found after displacement of impression material into the maxillary sinus via a periodontal pocket (Fig. 11.3) [54].

Most published reports addressing clinical symptoms as a consequence of impression material left in the periodontal sulcus were related to polysulfide materials [18, 22, 32, 46, 82, 85, 102]. However, other reports documented that these problems may also be caused by polyether materials [85], C-silicones [110], and A-silicones [105]. The clinical manifestations associated with various materials are rather uniform. In general, a pronounced local and painful inflammation emerges after 1–2 days, eventually in combination with the formation of an abscess. Histological analysis revealed a polymorphonuclear infiltrate with scattered lymphocytes and histiocytes. Necrotic debris and bacteria colonies were also noted [12]. Spontaneous healing occurs within 1 week after surgical removal of the foreign body, which is, however, partly associated with a loss of alveolar bone [25, 32, 85, 102, 105].

Compounds of impression materials, such as the lead-containing catalyst of polysulfide materials, were

Dentlearn.ir

held responsible for these reactions [28, 85]. However, because the clinical symptoms were uniform despite the different nature of the residual materials, a potential bacterial infection is more likely, i.e., the displacement of bacteria from the oral cavity into the submucosal connective tissue through infected material, eventually in combination with a communication to the oral cavity via a sinus tract.

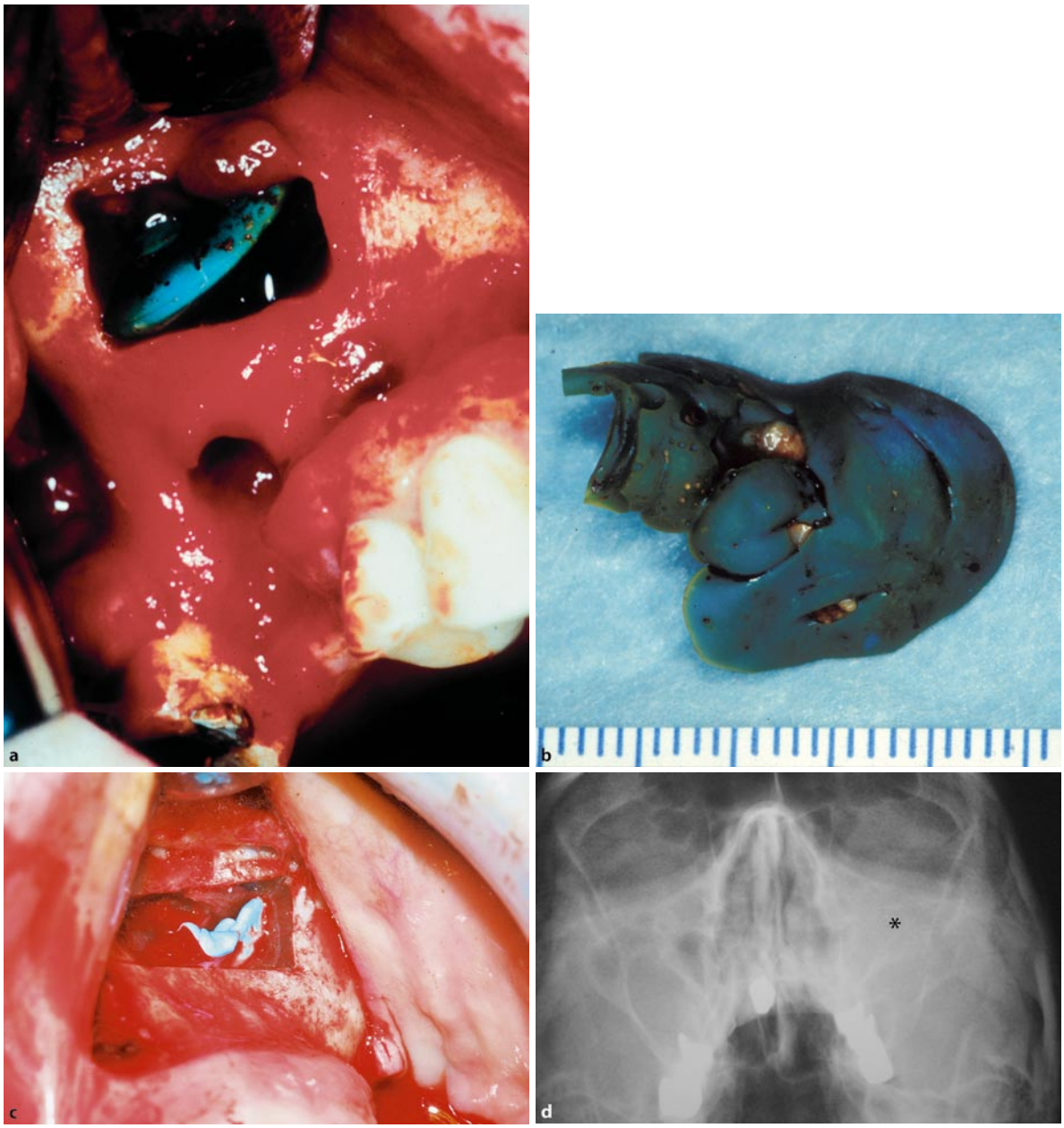

Fig. 11.3a–d Two cases of maxillary sinusitis after displacement of impression material through a periodontal pocket into the sinus. **a** Impression material in exposed maxillary sinus. **b** Removed impression material. **c** Impression material in open maxillary sinus. **d** X-ray image of the affected sinus reveals the cloudiness of the left maxillary sinus (*asterisk*) (Courtesy of M. Kunkel, Mainz, Germany)

Dentlearn.ir

Clinical Practice Advice

It is important for the subgingival area of the sulcus to be carefully controlled for remnants of impression material, particularly in patients with deep periodontal pockets. Impression materials that are intensely colored facilitate inspection of the sulcus and help keep impression material from being unintentionally left in the sulcus. Radiopaque impression material would also be beneficial [30].

An increased frequency of herpes simplex manifestation of the lips was observed after frequent impressions with specific impression materials (C-silicones). The symptoms were related to the number of impressions and to the cytotoxicity of these impression materials [48, 49]. The virus genome, already present in the patient, is very likely activated through locally irritating impression materials; the infection rate of the population with herpes simplex virus is approximately 90% [48, 49]. For A-silicones, animal experimentation showed no dermal irritancy, which – seen together with the lacking cytotoxicity – can also be assumed for the patient [65]. Interestingly, oral mucosa reactions lasting shortly less than 3 days were reported by 14 out of 38 dental students who had received multiple impressions with an alginate containing a quaternary ammonium compound as disinfectant [4]. The symptoms included inflammation, pain, itching, tissue sloughing, and color change of the gingiva; nine of the students also reported extraoral reactions [4].

Few studies have addressed the question of pulpal damage due to impression materials. Pulp damages were caused by thermoplastic impression materials that are no longer used today [56]. No pulpal alterations were found after crown preparation and subsequent impression using C-silicones [60]. The pulpal blood circulation, determined by radioactive markers on experimental animals, was not significantly influenced by a polyether material, contrary to the results with a thermoplastic impression material. Overall, it can be concluded that current impression materials do not cause pulpal damage. The displacement of impression material into the exposed pulp is possible, but this condition usually requires a pulpectomy for a number of (nonmaterial-related) reasons, such as pulp infection or mechanical trauma of the pulp.

11.2.4 Allergies

Allergic reactions have mainly been reported in the context of ZOE pastes and a polyether-based material. Allergies to ZOE-based impression materials were observed in animal experiments and in patients; the causes were very likely eugenol and/or colophony [50] (see Chap. 6.4 and Chap. 7). In some cases, the use of a polyether material caused mucosal burning directly after impression, and reddening, swelling, and blister formation were observed 24 h later in the area of the affected intraoral mucosa and the tongue [10, 19, 68, 71, 100, 117]. In addition, extraoral symptoms with swollen lips and extensive exanthemas of the face and the neck were observed. Patients always showed a strong reaction to the mixed material and the catalyst paste in the patch test. Consequently, the manufacturer changed the catalyst at the beginning of the 1980s. Since then, fewer reports about allergic reactions to polyether materials have been published [49].

There are some indications that quaternary ammonium compounds used in some alginate impression materials may lead to clinical symptoms closely resembling an allergic reaction [4]. The allergenic potential of quaternary ammonium compounds has been described; however, the number of cases seems to be low [83].

11.2.5 Mutagenicity

These effects normally have to be tested by commercial test laboratories for premarket certification of the materials, but such data are usually not published. In this context there is no indication in the available literature of mutagenic properties of impression materials.

11.3 Periodontal Dressings

In general, periodontal dressings are used to improve the patient's comfort in the following ways:

- Avoidance of an abundant formation of granulation tissue, extended bleeding, or plaque formation
- Pain reduction
- Fixation of the flap or transplant
- Protection of exposed bone and the transplant donor site
- Local application of drugs

Dentlearn.ir

The application of these materials is controversially discussed in the literature. Some authors found better clinical results after periodontal surgery using such dressings [14, 104], whereas others found that rinsing with 0.2% chlorhexidine solution was more effective [27] (see also periodontology textbooks).

11.3.1 Basic Material Properties

11.3.1.1 Composition

Periodontal dressings are frequently classified as eugenol-containing and eugenol-free materials. The powder or the white paste of eugenol-containing materials consists of zinc oxide, aluminum silicate, colophony, and tannic acid. The liquid or the initiating paste contains eugenol with antiseptic additives such as thymol or septol. The setting time is shortened by the addition of zinc acetate and zinc stearate. Eugenol-free materials contain, for instance, zinc oxide with additives of various oils and lorothidol, an antifungal substance related to hexachlorophene. The other paste contains unsaturated fatty acids with added chlorothymol as antimicrobial substance (Coe-Pak). Another commonly used dressing consists of calcium sulfate, zinc oxide, zinc sulfate, a resin, and a glycol solvent (Peripac). A light-curable periodontal pack is available as well. It consists of polyether-urethane-dimethacrylate, silanized SiO_2, light initiators, accelerators, and further additives [1]. A number of products previously contained asbestos fillers, e.g., PPP [29], Septo-pack [75], and Ward's Wondrpak [40].

Cyanoacrylates were used as periodontal dressings or as an alternative to suture materials for the fixation of flaps. These materials are reviewed in Chap. 6.5.

Antimicrobial additives are applied as well, but antibiotics are no longer used [35]. Chlorhexidine as dihydrochloride [79] or as acetate [76] was occasionally recommended. Detailed information about some commonly used products is provided in Table 11.3 in the Appendix [91].

11.3.1.2 Setting Reaction and Release of Substances

Eugenol-containing products set via a complex formation, and the kinetics of substance release are equivalent to those of other ZOE materials (see Chap. 7). Eugenol-free periodontal dressings based on calcium sulfate (Peripac) set through a glycol-water exchange with subsequent formation of gypsum [91]. Another eugenol-free product that contains unsaturated fatty acids (Coe-Pak) sets by soap formation [91]. Light-curable periodontal dressings set, like equivalent resin-based composites, via a polymerization after irradiation with visible light (Fig. 11.4).

Fig. 11.4 Application of a light-curable periodontal dressing

The release rate and solubility of a eugenol-free periodontal dressing (Peripac) was high during the initial 24 h and decreased over time. The solubility of another eugenol-free product (Coe-Pak) increased after 48 h. Furthermore, the solubility of a eugenol-containing material (Ward's Wondrpak) was consistently low and did not change over time [40]. It may be concluded from these data that solubility is time- and product-dependent. A classification based on eugenol-containing and eugenol-free products does not reflect the different solubility patterns.

11.3.2 Systemic Toxicity

A study investigating the systemic toxicity of a number of periodontal dressings (Coe-Pak, Peripac, Ward's Wondrpak) documented an LD_{50} >2,000 mg/kg body weight [41]. It may be concluded, based on these data and experiences with the application of respective material compounds in other medical disciplines, that the use of periodontal dressings does not pose a systemic health risk for patients.

The previous addition of asbestos fibers in some products was a risk for dental personnel [3, 29]. The exposure of experimental animals to dust of an asbestos-containing periodontal dressing caused lung alterations in the terminal bronchi that were related to the asbestos content [57]. Such asbestos-caused alterations can result in fibrosis and emphysema [29], although the

Dentlearn.ir

extensive literature about asbestos fibers cannot be addressed at this point (for details, see textbooks on toxicology). No cases of asbestos-caused disease (e.g., pneumoconiosis) in dental personnel due to the application of asbestos-containing periodontal dressings have been documented. Asbestos has not been used for commercial periodontal dressings since the 1980s [90].

11.3.3 Local Toxicity and Tissue Compatibility

11.3.3.1 Cytotoxicity

Eugenol-free periodontal dressings have been developed to prevent eugenol-associated toxicity [17, 52]. However, various in vitro studies have revealed that eugenol-containing periodontal dressings may cause less growth inhibition of permanent cells and primary human leukocytes than some eugenol-free products [53, 86]. On the other hand, a eugenol-free material based on calcium sulfate (Peripac) was the least cell-damaging product when compared with eugenol-containing materials and some other eugenol-free products [91].

Set specimens of a light-curable periodontal dressing were not cytotoxic in various cell cultures and different cell types. Other eugenol-free dressing materials showed moderate to severe cytotoxicity in these studies. Unpolymerized light-curable material, however, was cytotoxic [31]. Light curing is hampered due to different thicknesses of layers of the periodontal dressing.

Key Note

The fact that a material does not contain eugenol does not necessarily mean cytocompatibility. Therefore, classification into eugenol-containing and eugenol-free materials regarding cytocompatibility does not make sense. Each periodontal dressing has to be assessed individually.

11.3.3.2 Implantation Tests

Results of implantation tests were also not uniform. For instance, eugenol-containing materials caused no tissue reactions after implantation in the subcutaneous connective tissue of rats, whereas eugenol-free materials caused a mild reaction in some cases [34]. At direct bone contact in rabbits, no difference between eugenol-containing and eugenol-free periodontal dressings was observed [28]. After subcutaneous implantation in rats, a eugenol-containing product caused a more severe reaction than a eugenol-free material (PPC, Coe-Pak) after an observation period of 7–14 days [72]. Ward's Wondrpak (eugenol-containing) was more toxic than Peripac and Coe-Pak (both eugenol-free) immediately after application, whereas Peripac caused the most pronounced reaction after 3 days. Coe-Pak caused the least damage [121].

In summary, findings from implantation tests are not as uniform as those in cell culture tests. Again, it can be concluded that differentiating the irritative behavior based on the eugenol content of the dressing is not justified.

11.3.3.3 Local Reactions in the Oral Cavity

A eugenol-containing (Ward's Wondrpak) and two eugenol-free (Coe-Pak, Peripac) periodontal dressings caused no toxic reactions of the sound mucosa of rats [37]. However, the application of all products on fresh gingivectomy wounds caused a similar toxicity-based reduced mitotic activity after 1 day. No difference compared with the control (no dressing application) was documented after 3 days and 5 days [37].

A eugenol-containing (Ward's Wondrpak) and a eugenol-free light-curable periodontal dressing (Barricaid) were applied for 7 days in dogs after periodontal surgery. Signs of acute inflammation were observed after the two dressing materials had been removed, but no difference between products was found. After another week, all surgical sites had healed [106]. Peripac caused more pronounced and more frequent pain, as well as swellings, after gingivectomy than a eugenol-containing product and Coe-Pac in a clinical study. But no statistically significant differences in clinical assessment of the healing process, bleeding tendency, or algesia were found [39].

Key Note

For the dentist, it is important to know that the risk of local tissue damage of nonsurgical and surgical sites due to toxicity of periodontal dressings is low. In summary, none of the available products shows distinct advantages or disadvantages related to the local toxicity of their materials. Further clinical studies are necessary to determine whether the low toxicity of the light-curable material after setting is clinically relevant.

Dentlearn.ir

11.3.3.4 Antimicrobial Properties

Local inflammations caused by periodontal dressings have been linked to toxic reactions and plaque accumulation as well (Fig. 11.5). Therefore, various antimicrobial additives have been added by manufacturers, or else dentists are recommended to mix them into the dressing material shortly before its application.

A eugenol-free periodontal dressing (Coe-Pak) caused almost no effects on a great variety of bacteria in vitro, whereas Peripac was more effective. A ZOE dressing revealed the most distinctive antimicrobial properties, including action against *Candida albicans*, followed by Peripac [75]. Other studies documented an antimicrobial activity of Coe-Pac and Wondrpak, which, however, decreased over time. Peripac showed this effect only during the setting period. Plaque growth in vitro was lowest on Peripac [38]. Furthermore, additional investigations revealed that eugenol-containing and eugenol-free periodontal dressings were not antimicrobial in cultures of staphylococci and beta-hemolyzing streptococci of group A [91].

Key Note

Eugenol-containing periodontal dressings and Peripac have antimicrobial properties, which, however, are low and decrease over time.

The addition of antibiotics (tetracycline) to a commercial periodontal dressing changed the sensitivity of oral bacteria and caused the formation of resistance.

Fig. 11.5 Plaque beneath a removed periodontal dressing

Therefore, the addition of antibiotics is no longer recommended [35].

Chlorhexidine is one of the most common antiseptic agents used in dentistry (see Chap. 10). Therefore, it would seem reasonable to add this substance to periodontal dressings to improve their antimicrobial properties. However, periodontal dressings containing chlorhexidine digluconate revealed clinically no increased plaque inhibition [6]. A lower plaque accumulation was observed beneath a periodontal dressing that contained chlorhexidine dihydrochloride. Chlorhexidine dihydrochloride is slightly water soluble, which may explain the extent of efficiency [79]. The addition of chlorhexidine acetate to a periodontal dressing (Coe-Pak) also accelerated wound healing after gingivectomy, probably due to lower plaque accumulation. Chlorhexidine acetate is more water soluble than the dihydrochloride [76]. The literature indicates that the addition of antimicrobial substances may cause a candidiasis [75].

11.3.4 Allergies

Animal experiments (maximization test; see also Chap. 2) revealed clear reactions to a ZOE-containing periodontal dressing (see also Chap. 6.4 and Chap. 7). These effects are very likely caused by eugenol and/or colophony [40, 50]. Allergic reactions to these materials have also been observed in patients (contact stomatitis) [50, 51, 63, 81].

A eugenol-free periodontal dressing (Coe-Pak) containing Peru balm caused a clear positive allergic reaction in animal experiments [40]. However, a dressing based on calcium sulfate (Peripac) generated only a minor reaction [40]. A cross-reactivity was documented between eugenol and Peru balm [40]. Moreover, Peru balm is ranked third on the list of the most frequently found allergens [42].

11.3.5 Mutagenicity

No data on mutagenicity regarding periodontal dressings are available in the literature. It has already been emphasized that such data have to be determined by commercial test laboratories for premarket certification, but they need not be published. In this context, there is no indication of mutagenic properties of periodontal dressings.

Dentlearn.ir

11.4 Suture Materials

Suture materials are applied in many medical areas, and for each of these areas discipline-specific aspects play a role regarding aspects such as composition, solubility, and surface structure. This section will concentrate on possible side effects of those suture materials normally used in dentistry.

11.4.1 Basic Material Properties

11.4.1.1 Composition

Suture materials can be differentiated based on the following:

- Structure: as monofil or polyfil (plaited) threads
- Chemistry: as absorbable or nonabsorbable materials

Natural products such as silk (polyfil) belong to the group of nonabsorbable materials. Synthetic nonabsorbable suture products consist, for instance, of polyamides, polypropylene, and polyester [8, 36]. Polyamides are available as monofil, polyfil, and pseudopolyfil (many polyamide fibers have a polyamide coat) threads. Polyester threads are available as polyfil and pseudopolyfil, and polypropylene threads are monofil. For several years now, Teflon (expanded polytetrafluoroethylene, or ePTFE) with an almost monofil structure has been used in dentistry as suture material [45].

In former times, catgut was often used as absorbable suture material. It was made of the submucosa of the small intestine of sheep or of bovine subserosa. In order to extend the absorption period, some materials were tanned with a chromium salt solution. However, the use of catgut is no longer permitted in the European Union, as a precaution against bovine spongiform encephalopathy. Synthetic absorbable threads consist of, for instance, polydioxanone [111] or polyglactin with polyglycolic acid [111]. Poly-L-lactide and poly-ε-caprolactone are also used [70, 116]. The properties of these suture materials can be customized by different composition and different molecular weights [21]. These absorbable suture materials are similar to biodegradable polymers, which are used as (temporary) tissue replacement, for tissue augmentation (bone and periodontium), and as drug carriers with long-term effect.

Tissue glues (cyanoacrylates) are also recommended as alternatives to suture materials (see also Chap. 6.5).

11.4.1.2 Degradation

Some so-called nonabsorbable suture materials can degrade over time by depolymerization [43]. Polyamide decays in tissue after 1–2 years [43]. Tissue fluid can penetrate between single-thread filaments of pseudopolyfil polyamide-based suture materials after a breakage of the polyamide coat [80]. Polypropylene and Teflon threads are resistant to absorption.

Absorbable synthetic suture materials degrade within days or weeks by hydrolytic cleavage, releasing glycolic acid [43]. Copolymerisates of glycolic acid and lactic acid (e.g., Vicryl, poly-p-dioxanone) are degraded by a hydrolytic cleavage of the ester bonds as well as subsequent metabolism in the citric acid cycle and in the respiratory chain to water, glucose, and carbon dioxide. The absorption of polydioxanone is slower [84]. The acids that are generated through the degradation process acidify the wound area temporarily [2].

11.4.2 Systemic Toxicity

No data regarding the systemic toxicity of dental suture materials are available, and there are no indications for such a property. Based on this fact and on experiences from other medical disciplines, it may be concluded that the current suture materials pose no systemic toxic risk.

11.4.3 Local Toxicity and Tissue Compatibility

No information about the cytotoxic behavior of suture materials usually applied in dentistry has been published. Regarding nonabsorbable suture materials, it has been stated that polypropylene should be one of the least reactive materials [66]. Polypropylene and a polyamide material caused only a minimal tissue reaction after intramuscular implantation in rats and an observation period of up to 30 days. A longer period after implantation of a pseudofil polyamide suture material, however, was associated with a more severe inflammation [8]. This was confirmed by other studies,

Dentlearn.ir

which documented a granulomatous tissue reaction after a longer period after implantation of polyamide threads [80]. In another study, polypropylene sutures also revealed only minimal histological responses [95]. Monofil sutures from ePTFE produced minimal tissue responses when implanted in the dorsum of rabbits, in contrast to other materials such as silk [103].

Two absorbable suture materials (a copolymer of ε-caprolactone and poly-L-lactide) caused no, or a very minor, reaction and only mild foreign body reactions after implantation in rabbits [70]. Other absorbable materials were toxic after intramuscular implantation in rats, but were less toxic in bone [21]. More information regarding the local toxic behavior of absorbable materials based on polylactide, polyglycolide, or related materials can be found in the literature about materials for tissue replacement or techniques (tissue engineering).

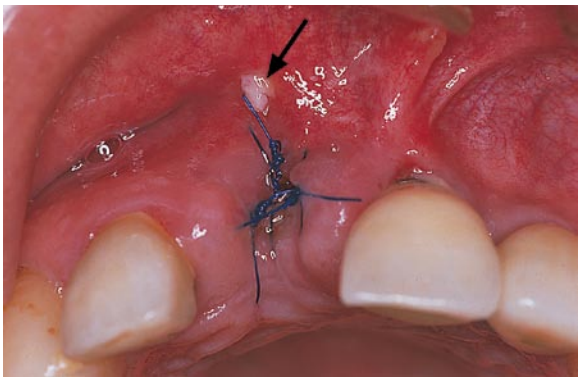

Fig. 11.6 Mechanical trauma of the oral mucosa (*arrow*) caused by a polypropylene thread that was cut too short

11.4.3.1 Reactions at the Suture Site

In animal experimentation, nonabsorbable suture materials caused mild reactions in dogs (buccal oral mucosa) in the case of monofil threads (polyamide) and pronounced reactions after application of polyfil silk threads. The latter results contradict findings from other areas of the body. This may be interpreted as an indication that the material itself is not the only cause for the tissue damage, but rather the structure, which facilitated penetration of bacteria and saliva to the depth of the tissue [62, 101]. Anti-infective therapy in a canine model reduced biofilm formation and inflammation along the suture track. Under these experimental conditions, silk sutures again elicited more severe tissue reactions than the monofil PTFE suture regardless of infection control [59].

In patients, various nonabsorbable suture materials (silk, Teflon, polyester, polypropylene) were compared in a clinical study after surgical procedures (mostly periodontal surgeries) [45]. It was found that polypropylene threads (diameter 3/0) traumatized the surrounding tissue because of their low flexibility, particularly if they were cut short (Fig. 11.6). The clinical parameters revealed no difference in healing results dependent on the suture material used. But the number of investigated patients (n=23) was very low, making identification of differences difficult. In another clinical study, the tissue reaction to silk and ePTFE was histologically evaluated in a split-mouth design; it was found that the connective tissue inflammatory infiltrate was significantly greater with silk than with ePTFE. This was related to an increased amount of plaque in the suture canals of the silk sutures [58].

In accordance with the implantation studies mentioned previously, a pseudopolyfil polyamide-based suture material was clinically associated with an increased tissue reaction and was thus more toxic than polypropylene. This may have been caused by a degradation of the polyamide material [125]. Plaited suture material can cause granulomas when applied in intercutaneous sutures; this effect may be caused by the thread structure [24].

11.4.3.2 Bacterial Colonization

As mentioned above, bacterial colonization of suture materials is of clinical importance. Applied in the oral cavity of rabbits or dogs, silk sutures were totally covered with a thick layer of bacterial plaque and debris after 3–14 days, in contrast to monofil synthetic materials [77, 101]. In a clinical study, after 7 days in the tissue, silk revealed the most distinct colonization and Teflon the least (Fig. 11.7) [45]. Coated polyester threads showed gaps in the coating layers, which may be the cause for an increased bacterial adhesion [45]. The reason for the pronounced bacterial colonization of silk is the distinct capillarity and the greater surface of a plaited (i.e., polyfil) thread. The lower adherence of bacteria to Teflon threads may be explained by the relatively smooth surface.

Dentlearn.ir

Clinical Practice Advice

It is important for dentists to know that the current dental suture materials are not tissue damaging per se when applied only for a few days. The risk of bacterial contamination of the tissue is greater for polyfil threads (e.g., silk) than for monofil materials (e.g., polypropylene, Teflon). But when polypropylene threads are applied, threads with the smallest possible diameter (fit to fulfill their purpose) should be used, and in order to avoid mechanical trauma of the tissue, the threads should not be cut short.

11.4.4 Allergies

Allergies to catgut that was tanned by chromium salts have been documented in physicians [33] and, in very rare cases, in patients suffering from a chromium allergy [88]. Allergies to stains in synthetic absorbable suture materials (antrachinone compounds), or more specifically to their degradation products (quinizarine), are also possible [115]. One case of allergic reaction was reported after the use of a polypropylene suture (Prolene), which was confirmed by patch testing [96]. Silk sutures have also been reported to cause



Fig. 11.7 Polyfil (**a**,**b**) and monofil (**c**,**d**) suture materials prior to application (**a**,**c**) and 7 days after use (**b**,**d**). The polyfil thread (silk) shows a much higher bacterial colonization compared with the monofil material (polypropylene)

Dentlearn.ir

an allergic reaction [83]. However, despite the widespread use of sutures in the medical field, few reports in the literature concern allergic reactions to current suture materials.

11.4.5 Mutagenicity

It has already been emphasized that these data have to be generated in commercial test laboratories for premarket certification. However, this information does not need to be published. In this context, there is no indication for mutagenic properties of suture materials commonly used in dentistry.

Conclusions for the Dental Practitioner

1. Due to their short-term contact, there is no evidence that impression materials cause adverse toxic effects in patients when applied correctly. This also applies to materials with a comparably pronounced local toxicity, such as C-silicones. Allergies may occur, but the current rate seems to be very low.
2. Because some impression materials are characterized by distinct local toxic effects, dental personnel should avoid repeated skin contact. This applies specifically to the mixing of putty materials. Some gloves, such as those based on latex, may impair the polymerization of certain impression materials (e.g., A-silicones). Eyes must be protected by appropriate glasses when liquid catalysts are used.
3. The periodontal sulcus has to be carefully monitored for remnants of impression materials after each impression in order to avoid the formation of an abscess caused by remaining material particles. A clear coloring of the impression material facilitates identifying these material particles. Radiopaque materials would be advantageous.
4. The application of periodontal dressings is controversial at present. Rinsing with 0.2% chlorhexidine has been recommended as an alternative.
5. A distinction between periodontal dressings of eugenol-containing and eugenol-free materials does not correspond to their biological behavior. No general recommendations for a certain material can be made because of varying results regarding biocompatibility. Eugenol-containing materials and those that contain Peru balm may elicit an allergic reaction in sensitized persons with a potential of cross-allergy.
6. The possible adhesion of bacteria should be considered when selecting a suture material. Polyfil threads and specifically silk threads have shown an increased microbial colonization. Monofil polypropylene threads are preferable based on their low bacterial adhesion (prevention of infection) and good biocompatibility. But these materials are lacking in flexibility and can cause mechanical tissue irritation when applied incorrectly.

Dentlearn.ir

Appendix

Table 11.3 Chemical composition of frequently used periodontal dressings [information provided by the manufacturers, e.g., by material safety data sheets]

Product	Manufacturer	Type of material	Components of the powder and the base paste, respectively	Components of the liquid and the catalyst paste, respectively
Coe-Pak	GC America	Paste–paste	Coco fatty acids 24% Hydrated resin[a] Chlorine thymol[a]	Zinc oxide 46% Magnesium oxide 9% Lorothidole[a]
Kirkland Periodontal Pak	Pulpdent Corp. of America	Powder–liquid	Zinc oxide 40% Turpentine resin 40% Tannin 20%	Eugenol 46.5% Peanut oil 46.5% Turpentine resin 7%
Nobetec	Nordiska Dental AB (Sweden)	Powder–liquid	Zinc oxide 30–70% Colophony 30–70% Corrig.	Eugenol 30–70% Canada balm 30–70% Peru balm 5–10%
Peripac	DeTrey (Germany)	Paste (one component)	Calcium sulfate 68.25% Zinc sulfate 0.99% Zinc oxide 6.37% Polymethylacrylate[a] Glycol derivative[a] Ascorbic acid[a] Scents and pigments	
Septo-pack	Septodont (France)	Paste (one component)	Zinc oxide 28.25% Dibutyl phthalate 9.9% Zinc sulfate 8.075% N-butyl-polymethacrylate amyl acetate 0.45% Excipients ad 100%	
Voco pac	Voco Chemie (Germany)	Paste–paste	Colophony ~50% Fats ~45% Corrig. 5% 6-Chlorine thymol 1.72%	Zinc oxide 44% Magnesium oxide ~30% Fats ~20% 6-Chlorine thymol 1% Scents Corrig. ad 100%

[a] No quantitative data are provided by the manufacturer.

References

1. Alpar, B., Günay, H., Geurtsen, W., Leyhausen, G.: Cytocompatibility of periodontal dressing materials in fibroblast and primary human osteoblast-like cultures. Clin Oral Investig 3, 41–48 (1999).
2. Agrawal, C.M., Athanasiou, K.A.: Technique to control pH in vicinity of biodegrading PLA-PGA implants. J Biomed Mater Res 38, 105–114 (1997).
3. American Dental Association: Hazards of asbestos in dentistry. Council on Dental Materials and Devices ADA. J Am Dent Assoc 92, 777–778 (1976).
4. Baker, P.S., Plummer, K.D., Parr, G.R., Parker, M.H.: Dermal and mucosal reactions to an antimicrobial irreversible hydrocolloid impression material: a clinical report. J Prosthet Dent 95, 190–193 (2006).
5. Barthel, C.R., Strohbach, A., Briedigkeit, H., Gobel, U. B., Roulet, J. F.: Leakage in roots coronally sealed with different temporary fillings. J Endod 25, 731–734 (1999).
6. Bay, L.M., Langebaek, J.: Effect of chlorhexidine-coated dressings on plaque formation after gingivectomy. Scand J Dent Res 86, 303–304 (1978).
7. Beach, C. W., Calhoun, J. C., Bramwell, J. D, Hutter, J. W., Miller, G. A.: Clinical evaluation of bacterial leakage of endodontic temporary filling materials. J Endod 22, 459–462 (1996).

Dentlearn.ir

8. Beardsley, S.L., Smeak, D.D., Weisbrode, S.E.: Histologic evaluation of tissue reactivity and absorption in response to a new synthetic fluorescent pigmented polypropylene suture material in rats. Am J Vet Res 56, 1248–1252 (1995).
9. Beetke, E., Bening, G., Sobkowiak, E.A., Bienengräber, V.: Zur Frage der Gewebsverträglichkeit von Sanal und Calcinat. [Biocompatibility of Sanal and Calcinat] Dtsch Zahn-, Mund- u Kieferheilkd 62, 243–251 (1974).
10. Blankenau, R.J., Kelsey, W.P., Cavel, W.T.: A possible allergic response to polyether impression material: a case report. J Am Dent Assoc 108, 609–610 (1984).
11. Calley, D., Autian, J., Guess, W.L.: Toxicology of a series of phthalate esters. J Pharm Sci 55, 158–162 (1966).
12. Cataldo, E., Santis, H.: Response of the oral tissue to exogenous foreign materials. J Periodont 45, 93–106 (1974).
13. Chen, S.-Y., Chen, C.-C., Kuo, H.-W.: Cytotoxicity of dental impression materials. Bull Environ Contam Toxicol 69, 350–355 (2002).
14. Cheshire, P.D., Griffiths, G.S., Griffiths, B.M., Newman, H.N.: Evaluation of the healing response following placement of Coe-Pak and experimental pack after periodontal flap surgery. J Clin Periodontol 23, 188–193 (1996).
15. Ciapetti, G., Granchi, D., Stea, S., Savarino, L., Verri, E., Gori, A., Savioli, F., Montanaro, L.: Cytotoxicity testing of materials with limited in vivo exposure is affected by the duration of cell-material contact. J Biomed Mater Res 42, 485–490 (1998).
16. Clark, S.M.: Rubber-base foreign body. J Prosth Dent 31, 439–440 (1974).
17. Colman, G.: A study of some antimicrobial agents used in oral surgery. Br Dent J 113, 22–28 (1962).
18. Cowan, A.: Rubber base impression: an unusual complication. J Irish Dent Ass 21, 157–158 (1975).
19. Dahl, B.L.: Tissue hypersensitivity to dental materials. J Oral Rehabil 5, 117–120 (1978).
20. Dietz, G.: Tierexperimentelle Pulpareaktion auf das provisorische Kavitätenverschußmittel Cavit. [Animal experimentation on the pulp reaction of the temporary filling material Cavit] Dtsch Zahnärztl Z 33, 223–224 (1978).
21. Ekholm, M., Hietanen, J., Lindqvist, Ch., Rautavuori, J., Santavirta, S., Suuronen, R.: Histological study of tissue reactions to ε-caprolactone-lactide copolymer in paste form. Biomaterials 20, 1257–1262 (1999).
22. Eliasson, S.T., Holte, N.O.: Rubber-base impression material as a foreign body. Report of a case. Oral Surg Oral Med Oral Pathol 48, 379–380 (1979).
23. Erkut, S., Can, G.: Effects of glow-discharge and surfactant treatments on the wettability of vinyl polysiloxane impression materials. J Prosthet Dent 93, 356–363 (2005).
24. Ethicon, Produktinformation – Stand 01/2002. [Product information, January 2002] Ethicon GmbH, Robert-Koch-Str. 1, 22851 Norderstedt, Germany.
25. Evans, G.H.: Rubber base impression material. Oral Surg Oral Med Oral Pathol 70, 523 (1990).
26. Ferrari, M., Cadidiaco, M.C., Ercoli, C.: Tissue management with a new gingival retraction material: A preliminary clinical report. J Prosthet Dent 75, 242–247 (1996).
27. Freidline, C.W., Porter, C.B.: Alternative to periodontal pack. Gen Dent 30, 159–160 (1982).
28. Frisch, J., Bhaskar, E.: Tissue response to eugenol containing periodontal dressings. J Periodontol 38, 402–408 (1967).
29. Fulton, R.S., Madden, R.M., Cheff, S.O.: Ultrastructural pulmonary changes in mice exposed to aerosolized periodontal pack powder. Dent Mater 5, 194–200 (1989).
30. Gettleman, L, Nathanson, D., Shklar, G., Brathwaite, W.J., Darmiento, L., Levine P., Judes, H.: Preliminary evaluation of the histotoxicity and radiopacity of lead-containing elastic impression materials. J Am Dent Assoc 69, 987–993 (1978).
31. Gilbert, A.D., Lloyd, C.H., Scrimgeour S.N.: The effect of a light-cured periodontal dressing material on HeLa cells and fibroblasts in vitro. J Periodontol 65, 324–329 (1994).
32. Glenwright, H.D.: Bone regeneration following damage by polysulphide impression material. A case report. J Clin Periodont 2, 250–252 (1975).
33. Gola, M., Francalanci, P., Campolmi, P., Sertoli, A.: Catgut dermatitis. Contact Dermatitis 15, 104–105 (1986).
34. Guglani, L.M., Allen, E.F.: Connective tissue reaction to implants of periodontal packs. J Periodontol 36, 279–282 (1965).
35. Handelman, S.L., Garnick, J., Slusar, R.J.: Effect of oxytetracycline in a periodontal pack on sensitivity and numbers of tongue flora. J Periodontol 40, 480–484 (1969).
36. Hansen, H.: Nahtmaterialien. [Suture materials] Chirurg 57, 53–57 (1986).
37. Haugen, E.: The effect of periodontal dressings on intact mucous membrane and on wound healing. A methodological study. Acta Odontol Scand 38, 363–370 (1980).
38. Haugen, E., Gjermo, P., Orstavik, D.: Some antibacterial properties of periodontal dressings. J Clin Periodontol 4, 62–68 (1977).
39. Haugen, E., Gjermo, P.: Clinical assessment of periodontal dressings. J Clin Periodontol 5, 50–58 (1978).
40. Haugen, E., Hensten-Pettersen, A.: The sensitizing potential of periodontal dressings. J Dent Res 57, 950–953 (1978).
41. Haugen, E., Hensten-Pettersen, A.: Evaluation of dressings by hemolysis and oral LD_{50} tests. J Dent Res 58, 1912–1913 (1979).
42. Hausen, B.M.: Contact allergy to balsam of Peru. II. Patch test results in 102 patients with selected balsam of Peru constituents. Am J Contact Dermat 12, 93–102 (2001).
43. Kamann, W.K.: Naht und Nahttechnik. [Suture and suture technique] In: Hetz, G. (Ed.) Aktueller Stand der Parodontologie. [State of the Art in Periodontology] Spitta Verlag, Balingen 2002, pp 1–8.
44. Kanarek, B.: Foreign body in the antrum. Brit Dent J 118, 214 (1965).
45. Karutz, J., Briedigkeit, H., Göbel, U.B., Radlanski, R.J., Kleber, B.–M.: Klinische und mikrobiologische Untersuchung zur Eignung verschiedener Nahtmaterialien in der Parodontalchirurgie. [Clinical and microbiological studies on the suitability of suture materials for periodontal surgery] Dtsch Zahnärztl Z 56, 653–658 (2001).
46. Kent, W.A., Shillingburg H.T., Tow, H.D.: Impression material foreign body: report of a case. Quintessence Int 19, 9–11 (1988).
47. Kim, S., Dörscher-Kim, J.E., Liu, M., Grayson, A.: Functional alterations in pulpal microcirculation in response to various dental procedures and materials. Proc Finn Dent Soc 88 (suppl I), 65–71 (1992).
48. Klötzer, W.T., Ben-Ur, Z., Bonn, B.: Zur Toxizität elastomerer Abformmaterialien. [Toxicity of elastomer impression materials] Dtsch Zahnärztl Z 38, 1020–1023 (1983).
49. Klötzer, W.T., Reuling, N.: Biokompatibilität zahnärztlicher Materialien: Teil II. Materialien mit Schleimhautkontakt. [Biocompatibility of dental materials. Part II. Materials contacting the oral mucosa] Dtsch Zahnärztl Z 45, 437–442 (1990).

Dentlearn.ir

50. Koch, G., Magnusson, B., Nyquist, G.: Contact allergy to medicaments and materials used in dentistry (II). Sensitivity to eugenol and colophony. Odontol Revy 22, 275–289 (1971).
51. Koch, G., Magnusson, B., Nobreus, N., Niqvist, G.: Contact allergy to medicaments and materials used in dentistry (IV). Odontol Revy 24, 109–114 (1973).
52. Kozan, G., Mantell, G.M.: Effect of eugenol on oral mucous membranes. J Dent Res 57, 954–957 (1978).
53. Kreth, K.H., Zimmermann, E.R., Collings, C.K.: Effect of periodontal dressings on tissue culture cells. J Periodontol 37, 48–53 (1966).
54. Kunkel M., Reichert, T.E.: Chronische Sinusitis maxillaris durch Abformmaterial. [Chronic sinusitis maxillaris evoked by impression material] Zahnärztl Mitt 94, 238–239 (2004).
55. Lamers, A. C., Simon, M., van Mullem, P. J.: Microleakage of Cavit temporary filling material in endodontic access cavities in monkey teeth. Oral Surg Oral Med Oral Pathol. 49, 541–543 (1980).
56. Langeland, K., Langeland L.K.: Pulp reactions to crown preparation, impression, temporary crown fixation, and permanent cementation. J Prosthet Dent 15, 129–143 (1965).
57. Legan, J., Madden, R., Thoma, G.: Biologic exposure to dental materials. Oral Surg 36, 908–914 (1973).
58. Leknes, K.N., Roynstrand, I.T., Selvig, K.A.: Human gingival tissue reactions to silk and expanded polytetrafluoroethylene sutures. J Periodontol 76, 34–42 (2005).
59. Leknes, K.N., Selvig, K.A., Boe, O.E., Wikesjö, U.M.E.: Tissue reactions to sutures in the presence and absence of anti-infective therapy. J Clin Periodontol 32, 130–138 (2005).
60. Lenz, E., Lang, V.: Vergleichende Untersuchungen biologischer Eigenschaften von Kunststoffen zur temporären Versorgung mit Kronen und Brücken. [Comparative studies on temporary resins for crowns and bridges] Stomatol DDR 40, 100–102 (1990).
61. Liberman, R., Ben-Amar, A., Frayberg, E. Abramovitz, I., Metzger, Z.: Effect of repeated vertical loads on microleakage of IRM and calcium sulphate-based temporary fillings. J Endod. 12, 724–729 (2001).
62. Lilly, G.E.: Reaction of oral tissues to suture materials. Oral Surg Oral Med Oral Pathol 26, 128–133 (1968).
63. Lysell, L.: Contact allergy to rosin in a periodontal dressing. J Oral Med 31, 24–25 (1976).
64. Marshak, B.L., Cardash, H.S., Eng, R.C.S., Ben-Ur, Z.: Incidence of impression material found in the gingival sulcus after impression procedure for fixed partial dentures. J Prosthet Dent 57, 306–308 (1987).
65. Mazzanti, G., Daniele, C., Tita, B., Vitali, F., Signore, A.: Biological evaluation of a polyvinyl siloxane impression material. Dent Mater 21, 371–374 (2005).
66. Miller, J.: Evaluation of a new surgical suture (Prolene). Am Surg 39, 31–39 (1973).
67. Mjör, I.A.: Blood Pb analyses and alginate impression materials. Scand J Dent Res 82, 401–402 (1974).
68. Mountcastle, E.A., James, W.D., Rodman, O.G.: Allergic contact stomatitis to a dental impression material. J Am Acad Dermatol 15, 1055–1056 (1986).
69. Mushtaq, M., Mukhtar, H., Datta, K.K., Tandon, S.G., Seth, P.K.: Toxicological studies of a leachable stabilizer di-n-butylin dilaurate (DBTL): effects on hepatic drug metabolizing enzyme activities. Drug Chem Toxicol 4, 75–88 (1981).
70. Nakamura, T., Shimizu, Y., Matsue, T., Okumura, N., Hyon, S.H., Nishiya, K.: A novel bioabsorbable monofilament surgical suture made from (ε-caprolactone, L-lactide) copolymer. In: Planck, H., Dauner, M., Renardy, M. (eds): Degradation Phenomena on Polymeric Biomaterials. Springer, Berlin 1992, pp 153–162.
71. Nally, F.F., Storrs, J.: Hypersensitivity to a dental impression material. A case report. Brit Dent J 134, 244–246 (1973).
72. Nezwek, R.A., Caffesse, R.G., Bergenholtz, A., Nasjleti, C.E.: Connective tissue response to periodontal dressing. J Periodontol 51, 521–529 (1980).
73. O'Leary, T.J., Standish, S.M., Bloomer, R.S.: Severe periodontal destruction following impression procedures. J Periodontol 44, 43–48 (1973).
74. Olson, R.E.: Foreign body removal: report of case. J Am Dent Ass 76, 1041–1043 (1968).
75. O'Neil, T.C.A.: Antibacterial properties of periodontal dressings. J Periodontol 46, 469–474 (1975).
76. Othman S., Haugen, E., Gjermo, P.: The effect of chlorhexidine supplementation in a periodontal dressing. Acta Odontol Scand 47, 361–366 (1989).
77. Parirokh, M., Asgary, S., Eghbal, M.J., Stowe, S., Kakoei, S.: A scanning electron microscope study of plaque accumulation on silk and PVDF suture materials in oral mucosa. Int Endod J 37, 776–781 (2004).
78. Pearson, S.L.: A new elastic impression material: a preliminary report. Brit Dent J 99, 72–75 (1955).
79. Plüss, E.M., Engelberger P.R., Rateitschak, K.H.: Effect of chlorhexidine on dental plaque formation under periodontal pack. J Clin Periodontol 2, 136–142 (1975).
80. Postlethwait, R.: Five year study of tissue reaction to synthetic sutures. Ann Surg 190, 54–57 (1980).
81. Poulsom, R.C.: An anaphylactoid reaction to periodontal surgical dressing: report of case. J Am Dent Assoc 89, 895–896 (1974).
82. Price, D., Whitehead, F.J.H.: Impression materials as foreign bodies. Brit Dent J 133, 9–14 (1972).
83. Purohit, A., Kopferschmitt-Kubler, M.-C., Moreau, C., Popin, E., Blaumeiser, M., Pauli, G.: Quaternary ammonium compounds and occupational asthma. Int Arch Occup Environ Health 73, 423–427 (2000).
84. Ray, J.A., Doddi, N., Regula, D., Williams, J.A.: Polydioxanone (PDS), a novel monofilament synthetic adsorbable suture. Surg Gynecol Obstet 153, 497–507 (1981).
85. Ree, M.H.: An unusual swelling following endodontic and prosthodontic treatment of a mandibular molar due to a foreign body reaction. Int Endod J 34, 562–567 (2001).
86. Rivera-Hidalgo, F., Wyna, V.J., Horton, J.E.: Effect of soluble extracts from periodontal dressings on human granulocytic leucocytes in vitro. J Periodontol 48, 267–272 (1977).
87. Rodgers, K., Klykken, P., Jacobs, J., Frondoza, C., Tomazic, V., Zelikoff, J.: Immunotoxicity of medical devices. Symposium overview. Fundam Appl Toxicol 36, 1–14 (1997).
88. Rudzki, E., Rebandel, P., Grzywa, Z.: Patch tests with occupational contactants in nurses, doctors and dentists. Contact Dermatitis 20, 247–250 (1989).
89. Ruel, J., Schuessler, P.J., Malament, K., Mori, D.: Effect of retraction procedures on the periodontium in humans. J Prosthet Dent 44, 508–515 (1980).
90. Sachs, H.A., Farnoush, A., Checchi, L., Joseph, C.E.: Current status of periodontal dressings. J Periodontol 55, 689–696 (1984).

Dentlearn.ir

91. Sachse, R.E., Müller, R.L., Bschorer, R., Frerich, B., Jorissen, A.: Untersuchungen zur Biokompatibilität von Parodontalverbänden. [Investigations on the biocompatibility of periodontal dressings] Dtsch Zahn-Mund-Kieferheilkd 79, 631–639 (1991).
92. Safety data sheet for Fascat 2003 catalyst (2002) http://www.atofinachemicals.com/plants/canada/pdf/ds/41.PDF. Cited 2007.
93. Safety data sheet for dibutyltin dilaurate (2003) http://physchem.ox.ac.uk/MSDS/DI/dibutyltin_dilaurate.html. Cited 2007.
94. Safety data sheet. http://www.osha-slc.gov/dts/sltc/methods/organic/org104/org104.html. Cited 2007.
95. Salthouse, T.N., Biologic response to sutures. Otolaryngol Head Neck Surg 88, 658–664 (1980).
96. Sánchez–Morillas, L., Reano Martos, M., Rodriguez Mosquera, M., Iglesias Cadarso, A., Pérez Pimiento, A., Dominguez Lázaro, A.R.: Delayed sensitivity to Prolene®. Contact Dermatitis 48, 338–339 (2003).
97. Schmalz, G.: Die Gewebeverträglichkeit zahnärztlicher Materialien – Möglichkeiten einer standardisierten Prüfung in der Zellkultur. [Biocompatibility of dental materials – possibilities of standardized testing in cell cultures] Thieme, Stuttgart 1981.
98. Schmalz, G., Merkle, G.: Die lokale toxische Wirkung von Abdruckmaterialien. [The local toxicity of impression materials] Zahnärztl Prax 36, 6–13 (1985).
99. Schuster, U., Schmalz, G., Thonemann, B., Mendel, N., Metzl, C.: Cytotoxicity testing with three-dimensional cultures of transfected pulp-derived cells. J Endod 27, 259–265 (2001).
100. Schwarze, G.: Akute kontaktallergische Reaktion der Mundschleimhaut bei konservierender Zahnbehandlung. [Acute contact allergic reaction of the oral mucosa during conservative treatment] Z Hautkr 52, 1200–1202 (1977).
101. Selvig, K.A., Biagiotti, G.R., Leknes, K.N., Wikesjö, U.M.: Oral tissue reactions to suture materials. Int J Periodontics Restorative Dent 18, 474–487 (1998).
102. Senderovitz, F., Kardel, K.M.: Gingival abscess caused by elastic impression material (thiokol). Tandlaegebladet 72, 1074–1077 (1968).
103. Setzen, G., Williams, E.F.: Tissue response to suture materials implanted subcutaneously in a rabbit model. Plast Reconstr Surg 100, 1788–1795 (1997).
104. Sigusch, B.W., Pfitzner, A., Nietzsch, T., Glockmann, E.: Periodontal dressing (Vocopac®) influences outcomes in a two-step treatment procedure. J Clin Periodontol 32, 401–405 (2005).
105. Sivers, J.E., Johnson, G.K.: Adverse soft tissue response to impression procedures: report of case. J Am Dent Assoc 116, 58–60 (1988).
106. Smeekens, J.P., Maltha, J.C., Renggli, H.H.: Histological evaluation of surgically treated oral tissues after application of a photocuring periodontal dressing material. An animal study. J Clin Periodontol 19, 641–645 (1992).
107. Smith, C.C.: Toxicity of butyl stearate, bibutyl-phthalate and methoxyethyl oleate. Arch Industr Hy Occup Med J 310–318 (1953).
108. Söremark, R.: Some biological effects caused by prosthetic materials. Swed Dent J 3, 1–7 (1979).
109. Spranley, T.J., Gettleman, L., Zimmerman, K.L.: Acute tissue irritation of polysulfide rubber impression materials. J Dent Res 62, 548–551 (1983).
110. Starke, G.: Bericht über eine Schwellung. [Report on a swelling] Quintessenz 1, 27–28 (1981).
111. Stewart, D.W., Buffington, P.J., Wacksman, J.: Suture material in bladder surgery – a comparison of polydioxanone, polyglactin, and chromic catgut. J Urol 143, 1261–1263 (1990).
112. Subramoniam, A., Husain, R., Seth, P.K.: Reduction of phosphoinositides and diacylglycerol levels in repeatedly dibutyltindilaurate-treated rat brain. Toxicol Lett 57, 245–250 (1991).
113. Subramoniam, A., Khandelwal, S., Dwivedi, P.D., Khanna, S., Shanker, R.: Dibutyltin dilaurate induced thymic atrophy and modulation of phosphoinositide pathway of cell signalling in thymocytes of rats. Immunopharmacol Immunotoxicol 16, 645–677 (1994).
114. Sydiskis, R.J., Gerhardt, D.E.: Cytotoxicity of impression materials. J Prosthet Dent 69, 431–435 (1993).
115. Tomihata, K., Suzuki, M., Sato, H., Kitagawa, M.: Sensitizer contained in heat-decomposed dye. J Biomed Mater Res 54, 531–539 (2001).
116. Tscheliessnigg, K.H., Stadler, H., Höfler, H., Hellbom, B., Kraft-Kinz, J.: Resorbierbares Nahtmaterial im Rahmen der Herz- und Gefäßchirurgie? [Absorbable suture material in heart and vessel surgery?] Chirurg 54, 738–741 (1983).
117 Van Groeningen, G., Nater, J.P.: Reactions to dental impression materials. Contact Dermatitis 1, 373–376 (1975).
118. Van Hassel H.J., Natkin, E.: Intraosseous injection of Mercaptan: a case report. J Prosth Dent 21, 529–531 (1969).
119. Van Vuuren, P.A., Ligthelm, A.J., Ferreira, M.R.: Evaluation of the biocompatibility of five elastomeric impression materials. J Dent Assoc S Afr 37, 863–866 (1982).
120. Welker, D., Neupert, G.: Verbesserte Biokompatibilität von neueren Alginat- und Silikonabformwerkstoffen. [Improved biocompatibility of the newer alginate and silicone impression materials] Zahn Mund Kieferheilkd Zentralb 74, 818–822 (1986).
121. Wennberg, A., Mjör, I.: Short term implantation studies of periodontal dressings. J Periodont Res 18, 306–310 (1983).
122. Widerman, F. H., Eames, W. B., Serene, T. P.: The physical and biologic properties of Cavit. J Am Dent Assoc 82, 378–382 (1971).
123. Wijbergen, M. J. G., van Weelderen, B., van Mullem, P. J., Wolters, J. M. L.: Capping of exposed pulps with Cavit-W or Nimeticap. Oral Surg Oral Med Oral Pathol 54, 318–322 (1982).
124. Wirz, J., Wöstmann, B.: Die Präzisionsabformung. Ein Leitfaden für Theorie und Praxis. [The precision impression – guide for theory and practice] ESPE Dental AG, Seefeld, Germany 1999.
125. Wood, D., Collins, J., Walshaw, R.: Tissue reaction to nonabsorbable suture materials in the canine linea alba: a histologic evaluation. J Am Anim Hosp Assoc 20, 39–44 (1984).

Dentlearn.ir

12 Occupational Exposures

A. Hensten and N. Jacobsen

Contents

12.1 General Aspects 311
12.1.1 Introduction 311
12.1.2 Exposure Modalities 312
12.1.3 Absorption Routes 312
12.1.4 Nature of Reactions 312
12.2 Clinical Symptoms and Related Materials 313
12.2.1 Historic Aspects 313
12.2.2 Nondermal Reactions 313
12.2.3 Dermal Reactions 315
12.2.4 Relevant Substances and Materials 316
12.3 Prophylactic Measures and Safety Precautions 318
12.3.1 General Considerations 318
12.3.2 Handling of Dental Materials 319
Conclusions for the Dental Practitioner .. 321
Appendix 321
References 322

12.1 General Aspects

12.1.1 Introduction

Every occupation involves some kind of health hazard associated with the assigned functions. The medical specialty dealing with the relationship between health and work is called *occupational medicine*. In principle, occupational medicine should be concerned with all aspects of this relationship, including the positive impact of having a job. For obvious reasons, however, occupational medicine focuses on health problems.

The gross occupational risk parameters in a specific occupation are the *standard mortality ratio* (SMR), which is the ratio of observed deaths among members of an occupation to the national average death rate within the same age range, and the *life expectancy*. Neither of these parameters identifies dentistry as an especially risky occupation [63]. The causes of death for dentists are similar to those of the population at large [64]. However, these facts do not imply the absence of occupation-related health problems or nuisances.

Occupational hazards are divided into physical, ergonomic, psychosocial, and chemical factors. In addition, some hazards are specific to the work performed. Occupational hazards in dentistry are summarized in Table 12.1. Hazards associated with *biomaterials* are classified among the chemical factors.

The level of exposure to chemical factors in dentistry is influenced by the quality of physical conditions, such as air volume, ventilation, air conditioning, humidity regulation, etc., and by the protective measures taken. Biomaterial-related reactions are

Table 12.1 Occupational hazards in dentistry

Physical factors	Ergonomic factors	Psychological/psychosocial factors	Chemical factors	Specific factors
Space	Unnatural postures	Unmet, stressful demands	Dental materials	Infected aerosols and other materials
Ventilation	Overload of work	Professional isolation	Barrier equipment	
Temperature	Instrument vibrations	Interpersonal conflicts	Anaesthetics	
Noise	Static muscular work		Drugs, remedies	
Light			Detergents, disinfectants	
X-ray, laser radiation			Radiographic solutions	

Dentlearn.ir

difficult to distinguish from reactions to other factors connected with the running of a dental clinic or dental laboratory, and some reactions are transient and soon forgotten. In addition, it is conceivable that poor ergonomics, poor psychosocial relations, and workload stress contribute to reducing resistance to chemical hazards.

12.1.2 Exposure Modalities

Clinical dental personnel are exposed to biomaterial-related components as solids, liquids, powderized materials, fumes, and grinding dusts, depending on the type of work performed. Amalgam processing releases mercury vapor, and the production of composite restorations includes contact with monomer and oligomer components, chemical-activated or light-activated catalysts, and inhibitors. Etchants, solvents, and adhesives are part of the restorative, endodontic, orthodontic, and fissure-sealing techniques, and impression materials contribute with chemically active components and particulate dusts. Exposure to some of these components is enhanced by the use of rotary instruments for grinding and polishing.

Dental laboratory technicians also handle a series of biomaterials associated with indirect restorative techniques, such as metal alloys, ceramics, and polymeric materials. In addition, laboratory personnel are exposed to accessories such as waxes, modeling and die materials, and a series of chemicals connected with the various steps in the processing procedures. The technicians' higher exposure to grinding and polishing dusts and to volatiles of monomers distinguish dental laboratory staff from clinical staff.

Key Note

The dentist must be aware that staff working in dental practices and dental technical laboratories handle materials and chemicals that represent a potential occupational health hazard.

12.1.3 Absorption Routes

Most biomaterial components are xenobiotics, i.e., "foreign" substances, which have to cross membrane barriers to do any harm. The routes of entrance in the occupational setting are through the skin, the respiratory pathways, and the eye mucosa. The uptake of xenobiotic molecules through lung alveoli takes place in a tissue anatomically adjusted for absorption, whereas skin is intended to protect vital tissues from the passage of potentially harmful substances. However, absorption through skin does take place and is facilitated if the skin has been compromised by frequent hand washing, the use of gloves or dressings, or injury from other causes. Absorption is guided by the principles of passive membranous transport: Lipophilic, nonpolar substances are transported by diffusion after dissolution in the phospholipid membranes, whereas small, hydrophilic, polar molecules diffuse through the membranous pores. This means that lipophilic substances have easier access than hydrophilic substances and that small molecules pass more readily than large ones.

12.1.4 Nature of Reactions

As outlined in the introduction to Chap. 1, the toxic effect of xenobiotics depends on the dose and the chemical nature of the absorbed substance. However, small molecular biomaterial components may act as haptens that bind to specific surface protein molecules of the dendritic Langerhans cells in skin and form antigens [5]. New exposure to the component may give allergic immune reactions, and even small doses may be sufficient to elicit allergic reactions.

Chemically-induced toxic reactions with relevance to biomaterials are outlined in Table 12.2. Acute reactions are often experienced by dental personnel but

Table 12.2 Adverse reactions to dental materials among dental personnel

	Local reactions	Systemic reactions
Acute reactions	Dermal injury Conjunctivitis Rhinitis Respiratory tract reactions	Nausea Headache Dizziness
Cumulative reactions	Dermatosis Peripheral nerve injury	Central nervous system, liver, kidney injury Pneumoconiosis

Dentlearn.ir

are of modest severity and transient nature and are difficult to include or exclude as being biomaterial-related. Local cumulative dermatoses are frequent and often bearable, but they are sometimes so severe that continued work is prohibited. Systemic cumulative chronic disorders are severe, but are limited to single cases reported after many years of exposure (see, e.g., Sect. 12.2).

12.2 Clinical Symptoms and Related Materials

12.2.1 Historic Aspects

Early reports in the German, French, and English literature indicate that the dental profession has been aware of the hazards associated with biomaterials and chemicals for a long time [27]. Among a series of soaps, disinfectants, surface anaesthetics, and other drugs, biomaterials containing iodine, tricresol, and eugenol were listed as the main dermatological hazards, supplemented with methylmethacrylate (MMA) monomer after the introduction of "plastics" in dentistry. Parallel with the shift in biomaterials use, the list of causative agents was supplemented with potentially allergenic substances such as nickel, chromium, and cobalt; catalysts of resin-based restorative materials and impression materials; and epoxy-based materials. Nondermatological complaints were only exceptionally reported, but the profession was well aware of the hazards associated with mercury in dental amalgam [14].

12.2.2 Nondermal Reactions

Severe systemic disorders among dental personnel have been associated with prolonged exposure to metallic mercury vapor by clinical staff and to MMA vapor by dental laboratory technicians.

12.2.2.1 Amalgam-Related and Mercury-Related Hazards

Because mercury is a nonessential metal, its optimum tissue concentration is zero, but mercury is introduced into the body by foods, water, and air and by mercury vapor arising from amalgam fillings (see also Chap. 4). Dental personnel are exposed to additional mercury vapor during the cutting, filling, and polishing of amalgam restorations and all the other handling of mercury associated with amalgam therapy.

It is a fact that autopsy samples from dental personnel who handled amalgam have shown an increased accumulation of mercury in target tissues such as the renal cortex and the pituitary gland [53], although no pituitary dysfunction has been revealed [41].

Mercury is recognized as an occupational hazard for personnel in certain industries and for dental personnel. The World Health Organization (WHO) recommends a threshold limit value (TLV) of 25 μg per cubic meter of mercury vapor in air relating to a 40-h work week. National TLVs are often 50 μg per cubic meter with a short-term exposure limit (STEL) of 500 μg [8]. The occupational exposure is monitored by the determination of mercury as microgram of mercury per gram of creatinine, corresponding approximately to a liter of "standard" urine. The European Union (EU) Scientific Committee on Occupational Exposure Limits has recommended that the limit be 30 μg of mercury per gram of creatinine [62]. The classic symptoms of prolonged exposure to mercury vapor are tremor, erethism, and proteinuria, indicating toxic effects on the central nervous system (CNS) and the kidneys.

Early investigations in Norwegian dental clinics indicated that the airborne mercury was well below the TLV, although occasional excesses were demonstrated [52]. Similar results were shown for the urine concentration in the sense that the mean urine concentration was about 8 μg/l and 95% was within 20 μg/l, but some "stray" cases were measured above 20 μg/l [37]. Other investigations showed both lower (Sweden, Germany) and higher figures (United States, UK), all well below the TLV [8]. However, the possibility of subclinical effects at lower exposure levels cannot be excluded. In a report from WHO in 1991, it was stated that mercury exposure in the range of 25–80 μg/m^3 might lead to subtle adverse effects on psychomotor performance and nerve conduction velocity, as well as tremor, sometimes associated with diffuse subjective symptoms in particularly sensitive individuals [71], as reported later [21].

The occupational exposure to mercury in dentistry has been reduced with increasing mercury hygiene and decreasing use of amalgam. Monitoring of dental personnel in Norway over 40 years from 1959 indicates a considerable decrease in urine mercury concentration over time. However, concentrations exceeding any limit value occasionally occurred, particularly among dental nurses in the 1960s [24]. It is conceivable that some of these effects were associated

Dentlearn.ir

with unsafe handling of copper amalgam at that time. Alleged mercury-associated health complaints among this group of dental nurses are now (2007) being studied by medical experts. A preliminary report indicates that some of these nurses may have occupation-dependent cognitive injuries affecting emotions, memory, and concentration capability [29], similar to those cited above. Such health effects may affect vulnerable groups of individuals, for instance, in association with polymorphism of brain-derived neurotropic factor [22]. Health effects of this kind may become more of a concern with increasing age [36].

Occupational medicine has also focused on mercury-associated teratogenic effects among female dental personnel [23, 65], effects on the probability of conception linked to each menstrual cycle (fecundity) [66], and analysis of miscarriage [43]. The results are diverse and inconclusive, perhaps because investigations of this kind are easily subject to scientific pitfalls. In agreement with a WHO review [18], a fair conclusion would be that no clear teratogenic effects or effects on fertility have been shown among dental personnel.

Key Note

Dental personnel should limit their mercury exposure by following strict hygienic routines and reducing the possibility of accidental spills. Mercury vapor from removal of old amalgam fillings has attracted specific attention as a source of increased mercury exposure [8]. This exposure is significantly reduced by water spray and vacuum suction [9].

12.2.2.2 Methylmethacrylate-Related Reactions

Resin-based prosthodontic restorations are processed in the dental laboratory by chemical, thermal, and light-curing techniques, all including the use of liquid and volatile MMA monomer. MMA is chemically similar to lipid-soluble organic solvents that have resulted in permanent injury to the central nervous systems of chemical laboratory personnel and painters. The administrative TLV is 307 mg of MMA per cubic meter. MMA is readily absorbed by inhalation and penetrates skin, causing dermal irritation and injury and contact allergy (see Sect. 12.2.3). As pointed out by Russian investigators [35], the uptake may result in acute symptoms such as headache, dizziness, nausea, and mucosal irritation, or worse: Chronic symptoms include reduced tolerance to solvents, impaired short-term memory, concentration difficulties, and psychological changes. Swedish investigators have pointed out that symptoms of this kind are difficult to distinguish from stress symptoms and effects of aging and burnout [6]. Danish investigations indicated a difference in the incidence of these symptoms between dental laboratory technicians with high (long-term) and low (short-term) exposure to MMA and patients who consulted medical expertise [13]. A follow-up investigation using subtle neuropsychological test methods to compare opticians and dental technicians indicated an association between exposure to MMA and adverse CNS dementia symptoms [67]. This association disappeared with high age.

Other serious consequences of inhaled MMA vapor are the development of asthma [59]. In addition, handling of MMA monomer may also lead to local effects such as injury of the peripheral nerve tissue, giving symptoms of finger numbing. The numbing may be combined with a cold feeling, blanching, and, sometimes, motor disturbances of fingers of the dominant hand [57]. Biopsies from dental laboratory technicians have shown direct pathological effects on nerve fibers [20]. The multiplicity of MMA toxicity is a continuing concern, particularly for dental technicians [42].

12.2.2.3 Reactions Related to Grinding Dusts and Fumes

Dusts are particles identical to the parent composition; **fumes** are particles formed by combustion accompanied by a chemical change. Inhaled particulate dusts and fumes after grinding, blasting, and polishing procedures of biomaterials may be lodged in the respiratory pathways depending on their aerodynamic diameters and may produce deleterious effects in the form of interstitial lung disease, *pneumoconiosis*. The best-known occupational form of this lung disease is silicosis and asbestosis among mining and construction workers [69].

Case reports and epidemiological and clinical investigations [6, 12, 19, 32, 48, 55] show that dental laboratory technicians may develop pneumoconiosis after long-term unprotected exposure to grinding dusts containing chromium, cobalt, molybdenum, nickel, or aluminum–iron–titanium particles derived from base metal alloys. In addition, silica and silicon carbide particles form abrasives and powderized materials such as

Dentlearn.ir

plaster of Paris and investments and aluminum oxide from sandblasting procedures increase the respiratory exposure to potentially harmful dusts.

Chromium–cobalt dust has attracted the most attention because it has been associated with the more serious nodular form of pneumoconiosis, as compared with the diffuse form associated with silica-containing materials. Pneumoconiotic lung disease is detrimental to lung function and as such is a registered occupational disease. Asbestosis and silicosis are associated with increased risk of lung cancers [69]. Tobacco smoking is an important confounding factor. More recent reports, particularly from the eastern part of Europe, underscore these findings.

Chronic beryllium lung disease, a chronic granulomatous lung disease brought about by immunologic mechanisms, has also been reported among dental laboratory technicians [40]. Exposure to beryllium dusts is specifically warned against by health authorities.

Key Note

The severe reactions discussed above are preventable and rare, but they demonstrate the importance of an adequate protective rationale in dentistry work.

12.2.2.4 Other Nondermal Reactions

Questionnaire surveys of Scandinavian dental personnel [27, 31–34] showed that acute nondermatological complaints of less severity occurred in the respiratory pathways (nose, throat, bronchi, lungs) and in conjunctiva and sinuses, together with reactions of a systemic nature (headache, nausea). The percentage of such reactions varied from 15% to 18% depending on the nature of work performed. Reactions of this kind occurred independently of dermal reactions. Causative factors included the following:

- Vapor from cold-curing acrylics (technicians, orthodontists)
- Dust from debonding procedures (orthodontists)
- Cyanoacrylates and resilient liners (prosthodontists)
- Cleansers and dust from trimming plaster models or mixing alginate (chairside assistants)
- Polishing and grinding of acrylic, metal, or ceramic products (technicians)
- Latex gloves and paper masks (periodontists)

A Swedish survey assessed the prevalence of conjunctivitis among dental personnel as 16–18%. Risk evaluation by dental personnel themselves gave the following ranked list of five biomaterials: fissure sealant, composite, glass ionomer bonding, primer, and cold-curing acrylate [45].

In addition, vasomotor finger symptoms such as coldness, blanching, numbness, prickling, and pain have been recorded for dental personnel in many surveys. The use of gloves is sometimes associated with reactions of this kind. However, the explanation may not always be the biomaterial impact; physical strain associated with the elasticity of gloves may be an important factor. Vasomotor finger reactions should not be confused with the chronic neuropathological finger reactions reported after prolonged MMA exposure.

12.2.3 Dermal Reactions

Dermatoses following contact with chemically active substances are referred to as either *irritative* or *allergic* contact dermatitis. The irritative type may be of *acute toxic* nature, causing direct and immediate cytotoxic effects on skin cells. However, a more common reaction among dental personnel is *cumulative insult* dermatitis, caused by repeated contact with the chemical agents at subtoxic concentrations. An irritative dermatitis is restricted to the areas of exposure and is self-limiting once the irritant is removed [28].

The *allergic* type of contact dermatitis (ACD) is described as contact allergy and is acquired through previous sensitization with a foreign substance. Once sensitization is induced, ACD is self-perpetuating in the sense that new exposure to extremely low doses of the allergen may elicit dermal reactions. ACD is classified as type IV, delayed hypersensitive reactions, and is expressed as eczematous lesions mostly localized to the exposure areas (fingers) and sometimes as more generalized urticarial reactions. Combinations of irritant and allergic dermatoses are common. Both irritative and allergic contact dermatitis may occur as a result of photoactivation at the appropriate wavelength of otherwise inert substances to become either more toxic/irritating or more potent haptens [38].

IgE-based immediate allergic reactions (type I) with dermal expression (contact urticaria) with potential asthmatic and anaphylactic features are usually associated with exposure to full antigens, such as pro-

Dentlearn.ir

teins associated with latex products. However, increasing evidence indicates that immediate reactions may also be caused by hapten/carrier conjugates [28].

According to a recent review, skin symptoms constitute the main occupational health problem in dentistry [61]. Questionnaire studies from the Scandinavian countries in the 1990s confirmed earlier observations and supported case reports on reactions to bonding materials and latex gloves [27, 31–34]. The percentage of dental personnel having experienced dermatoses of some kind varied from 20% to 40% and included irritative as well as allergic reactions to work-related causes such as hand washing, disinfection procedures, and so on (Fig. 12.1). With few exceptions, the dermal reactions were localized to fingers and hands and comprised all levels of severity, resulting in dermal thickening, blisters, fissures, desquamation, and bleeding sores often combined with problems localized to nails or nail beds. The relatively mild reactions were often described as seasonal and temperature-related or humidity-related, improving during nonworking periods. Dermatoses caused by specific or unspecified allergies in atopic individuals were the most severe. *Atopy* is a constitutional predisposition associated with increased IgE production or reduced surface barrier function and may be present in about 10% of a population.

For reasons indicated earlier, the "real" prevalence of biomaterial-related skin reactions among dental personnel is difficult to assess. Danish dentists reported a 38% prevalence of skin reactions in 1996 [49]. Later surveys among Swedish dental personnel indicated a prevalence of hand dermatitis of 15–20% and 26–27% for male and female dentists, respectively, compared with 7.6% and 19.6% for the controls. The corresponding prevalence among chairside assistants, about 20%, did not differ significantly from that of referents [44, 45]. The hand dermatitis was correlated with the prevalence of atopic dermatitis and with eczema in childhood. About 12% of the reactions were assumed to be caused by dental material and about 41% by latex gloves, indicating that more than 50% of the adverse effects were associated with biomaterials. In another survey, 14.9% of about 3,000 dentists reported having had hand eczema the previous year [70]. Statistics from Finland published in 1999 indicated that the incidence rate of ACD had increased over the last years, whereas the level of irritant dermatitis had been stable [39].

Fig. 12.1 A 22-year-old dental nurse presenting severe irritative hand dermatitis (nonallergic) caused by frequent hand washing and wearing of disposable gloves (Courtesy of D. Arenholt-Bindslev, Århus, Denmark)

12.2.4 Relevant Substances and Materials

The multiplicity of biomaterials in dental practice comprises a long list of potential allergens, which are primarily discussed in relation to safety for dental patients. However, the same allergens are of interest in an occupational context. An example is the commonly used activator *N.N-dimethyl-p-toluidine*, which has led to oral allergic reactions in patients and corresponding dermal reactions in dental personnel [60]. In fact, patient-relevant allergenic components are also relevant for dental personnel, and sometimes at a higher risk of adverse reactions, because the possibility of exposure to the chemically active starting ingredients is higher. The potential allergens in dental materials are thoroughly described in Chap. 14, whereas in this chapter the focus will be on occupational aspects.

12.2.4.1 Metals

Alloys used in dental materials comprise about 34 different metals. Some of these metal ions or metal salts are sensitizers and are therefore included in commercial allergy test kits. In the occupational setting, the predominant allergens in this group are nickel, chromium, and cobalt found in casting alloys for removable prosthodontic devices [50]. In addition, nickel–chromium alloys are used for ceramic fusion [30]. Surveys of dental personnel have occasionally revealed dermal reactions to these metals and to mercury. Dental laboratory technicians are first in line when metal allergies are discussed. A German survey on dental

Dentlearn.ir

technicians showed ACD reactions attributed to nickel and chromium [58]. Positive patch tests were also registered for cobalt and palladium.

12.2.4.2 Polymer-Associated Substances

Because polymer materials are increasingly used in dental treatment, this group of allergenic substances is becoming more important as occupational sensitizers. Plastic chemicals, followed by rubber chemicals, are the most common causes at present of ACD among dental personnel in Finland [39]. Of these, the MMA and other acrylate monomers are the most important (Fig. 12.2), sometimes showing cross-reactions by patch testing [58] (see also Chap. 14, Sect. 14.2.2.3). Case reports from dermatological testing confirm this pattern of occupational risk factors.

Fig. 12.2a,b Two cases of contact allergic skin reactions to methacrylate-based dental materials. **a** A 40-year-old male dentist who subsequently had to discontinue working as a dentist due to severe methacrylate allergy. **b** Eczema primary located at the fingertips of a 56-year-old male dentist (Courtesy of D. Arenholt-Bindslev, Århus, Denmark)

12.2.4.3 Miscellaneous

Formaldehyde is a strong allergen formed after oxidation of nonreacted double bonds during polymerization processes and is sometimes present as residuals after chemical treatment of wet-strength paper for face masks, etc. Colophony is a natural resin obtained as a secondary product of the pine tree in the paper industry. Outside dentistry, colophony may be present in sticky materials such as glues, varnishes, tapes, and waterproof paper. Colophony may show cross-reaction with another natural resin, balsam of Peru, which is used in cosmetics for obtaining consistency and making them "stick." Eugenol is an aromatic ether chelated with zinc oxide for temporary fillings, surgical packs, and so on. Similar to colophony, eugenol is still used in dentistry despite reports of allergenic characteristics.

12.2.4.4 Rubber Chemicals

Protective latex products such as gloves, dams, and polishing devices contribute to the range of allergens in dentistry. Natural rubber latex is an emulsion of 1,4-cis-polyisoprene particles, wax plant proteins, and peptides obtained from the rubber tree (*Hevea brasiliensis*) vulcanized to rubber by a process requiring a series of chemical additives such as accelerators, vulcanizers, and antioxidants. Depending on the quality of postvulcanizing washing, residual chemical additives and intracellular proteins are present in various degrees. In addition, latex products are often coated with powders, such as cornstarch derivatives [16]. Chemical additives and powders together with residual soaps on the inside of rubber gloves often lead to irritant skin reactions for dental personnel [68]. In addition, the chemical additives contain potential haptens that may cause delayed hypersensitive reactions (ACD). The allergenic potential is reflected in standardized general epidermal test kits, such as the *thiuram mix* and *carbamix* (accelerators), the *mercaptomix* (vulcanizers), and the *black rubber mix* (antioxidants) in the commercial test kits. The prevalence of latex-related ACD on hands and fingers among health personnel is high and increasing. The clinical expressions vary from red and itching eczematous reactions to chronic skin thickening and desquamation, with a clear borderline at the wrist (Fig. 12.3). A survey from Scotland indicated that about one-fifth of dental practitioners reported reactions to the use of latex gloves. Dental

Dentlearn.ir

students reported a comparable rate, which increased with increasing years of clinical practice [4].

However, latex reactions among dental personnel (and patients) are not limited to the delayed type. The presence of residual plant protein allergens facilitates the development of IgE-mediated, immediate-type allergy with different expression depending on the route of entrance. Glove contact with skin or oral mucosa may cause urticarial reactions, and airborne protein allergens may cause symptoms from the respiratory pathways and the conjunctiva [26] (see also Chap. 14). There is also a possibility for anaphylactic reactions. Atopic individuals are at greater risk compared with others. Members of the medical and dental professions are increasingly aware of the hypersensitivity problems associated with latex products.

Respiratory allergic reactions to natural rubber latex have been ascribed to airborne allergen particles spread by powdered latex products. A reduction of latex aeroallergens and latex-specific IgE antibodies in sensitized health care personnel after removal of powdered natural rubber latex gloves in a hospital was documented [3]. Preventive measures such as the use of nonpowdered latex gloves with a low level of latex proteins led to a significant reduction of aeroallergens in the occupational environment and thus to a reduction of natural latex allergy among German health care workers [2].

12.3 Prophylactic Measures and Safety Precautions

12.3.1 General Considerations

The occupational hazards in connection with dental practice are governed by national environmental and occupational laws regulating all aspects of working conditions, including the storage and handling of chemicals such as dental materials. Specific national

Fig. 12.3a–d Two cases of contact allergic skin reactions to disposable natural rubber latex surgical gloves. **a** A 20-year old dental nurse with eczema on the fingers, palm, and wrists. (Courtesy of D. Arenholt-Bindslev, Århus, Denmark). **b**,**c**,**d** A 47-year-old male dentist with eczema on the (**b**) hands, (**c**) wrists, and (**d**) fingers

Dentlearn.ir

bodies are responsible for enforcing laws and regulations in this field. As early as the planning stage of a dental workplace, compliance with such regulations, with regard to the physical conditions listed in Table 12.1, should be considered. Detailed recommendations are available for physical conditions such as general ventilation, process ventilation, inner climate, noise, radiation, etc. There are, of course, national differences in the statutory requirements.

Dental materials are classified as medical devices regulated by EU Directive 93/42 EEC [15], stating safety requirements for patients and personnel. Some countries also require labeling of products containing potentially hazardous chemicals according to an elaborate system regulated by the health authorities [17]. It is important to know and comply with safety guidelines, including those applying to the handling of dental materials, adapted to the profile of activity of that particular workplace. It is equally important to cooperate with all members of the dental team to obtain good compliance. As head of the dental team, the dentist bears the responsibility of ensuring that all members of the team are well informed about all occupational safety guidelines. Such guidelines are closely connected with the infection control regimen, including adequate hand washing; the use of gloves, surgical masks or face shields, and protective clothing; and the limiting of droplets and splatter through high-volume evacuation.

All general requirements for physical environmental factors also apply to laboratory work. In addition, high-quality process ventilation is vital for safe processing of prosthetic products such as acrylic removable prostheses and impression trays. Effective point suction is an indispensable condition when grinding and polishing work is performed (Fig. 12.4).



Fig. 12.4 Point suction for reducing inhalation of dusts, etc., generated by dental laboratory procedures (Courtesy of E. Östergaard, Århus, Denmark)

12.3.2 Handling of Dental Materials

12.3.2.1 "No-Touch" Technique for Resin-Based Materials

It is vital to read and comply with manufacturers' instructions for the use and safe handling of dental materials. The quality of such instructions varies. A precaution sheet for an adhesive system may serve as an example of good product handling information [38]: "The system contains an etchant gel containing phosphoric acid, a primer containing a methacrylate (HEMA), and an adhesive containing both HEMA and Bis-GMA." The two latter substances are known contact allergens as well as irritants.

The governing principle for occupational safety is to prevent contact with skin and eyes to avoid irritant injuries and reduce the possibility of sensitization. The use of gloves, rubber dams, and a *no-touch* technique are highly recommended. Unintended contamination of product containers with nonpolymerized material should be totally avoided (Fig. 12.5a). In recent years, manufacturers have aimed to design packages that substantially reduce the risk of such contamination during daily handling of the products (Fig. 12.5b, c).

If contact with skin occurs, immediate washing with soap is essential. Glove contact with resins necessitates discarding the glove, washing the hands, and regloving. Because dentin primer is a severe eye irritant, immediate flushing with large amounts of water should follow accidental contact with eyes, and a physician should be consulted. If accidental spills of etchants occur, flushing with large amounts of water is recommended. Precautions of this kind apply to the handling of all multicomponent resin-based materials intended to be processed in the dental clinic.

12.3.2.2 Amalgam and Mercury Precautions

Exposure to mercury is minimized by proper storage of mercury-containing materials in unbreakable, tightly sealed containers; proper control of globular mercury droplets; and avoidance of heating mercury or amalgam [25]. Safe amalgam processing also in-

Dentlearn.ir

Fig. 12.5 **a** Contamination of packages and material containers with unpolymerized material should be strongly avoided. **b**, **c** Examples of packages designed to eliminate the risk of unintended surface contamination with nonpolymerized material (Courtesy of D. Arenholt-Bindslev, Århus, Denmark)

cludes using a *no-touch* technique and modern capsule amalgamators in combination with water spray and high-speed suction during amalgam processing and removal [56]. In 1998 the Fédération Dentaire International issued a statement, "Recommendations on Dental Mercury Hygiene" (see Appendix). Similar advice was published by the American Dental Association in 2003 [1].

12.3.2.3 Barrier Equipment

Surgical face masks, gloves, and protective glasses are important parts of infection control and reduce the exposure to biomaterial-related components. However, liquid acrylate monomers and similar chemicals penetrate surgical latex or polyvinyl chloride (PVC) gloves [51]. Special attention should be paid to the fact that surgical gloves offer a very limited barrier to monomers of low molecular weight. Dental patients with a verified allergy to a range of methylmethacrylates found in dentin adhesives thus developed positive patch test reactions when specimens of glove material were placed as a barrier between the test materials and the skin [7]. It has been documented that methylmethacrylate monomers penetrate different glove materials – e.g., latex, nitril, PVC – within a few minutes [47, 51]. Further, electron microscopic investigations have documented that the insides of disposable surgical gloves disintegrate following exposure to methylmethacrylates [46]. Polyethylene-based glove material was shown to provide the most efficient barrier function against methylmethacrylates [7]. Due to the very limited physical properties (poor comfort and flexibility), this type of glove material is so far unsuitable for use in dental practice.

Face masks are of differing quality and not always reliable protectors from vapors and small particle dusts. Moreover, prescription glasses or safety glasses that are practical for the dentist cannot prevent conjunctival contact with vapors derived from biomaterials. The fact that face masks of wet-paper strength quality *have* elicited allergic dermal reactions by residual formaldehyde from the production process, and above all, the increasing frequency of reactions to surgical latex gloves illustrate the ironic situation that hygienic and preventive measures may actually increase the potential of adverse occupational effects even though some other biomaterial-related reactions are prevented. There are reasons to believe that decreasing the allergen content of latex products by extensive washing for the production of "hypoallergenic" products may actually increase the possibility of penetration. Market surveillance studies such as one performed in Finland [54] may be useful but may collide with the free-market principle within the EU.

Dentlearn.ir

Regarding the use of light-curing dental materials, dental personnel are exposed to radiation sources emitting ultraviolet radiation and visible light capable of causing eye damage [10]. The use of such sources is increasing with respect to both curing of nonpolymerized materials and tooth bleaching products [11]. Preventive measures include reading the manufacturer's operating instructions carefully and using radiation-filtering protection spectacles. It was recently shown that some products marketed for eye protection against emissions from light sources used in dental practice may be of inadequate quality. Dental personnel should therefore request documentation on the quality of the eye protection equipment delivered by the suppliers of light-emission sources for odontological applications.

There is no common solution to the occupational problems related to barrier equipment except to keep updated on information from the producers and the health authorities. Careful selection of biomaterials and barrier equipment on an individual basis is necessary.

Conclusions for the Dental Practitioner

1. Occupational risks related to the handling and use of dental materials should be considered seriously by the dental team. Legal regulations in this field are increasing.
2. The steady introduction of new materials and new technologies necessitates a constant alert for occupational health problems that may be associated with biomaterials.
3. The dental team should be aware that in relation to the frequent use of protective measures such as disposable gloves and face masks, there is an additional risk of developing adverse reactions.
4. Whenever possible when handling dental materials, a no-touch technique should be practiced to avoid direct contact with glove material or skin.

Appendix

Fédération Dentaire International: Recommendations on Dental Mercury Hygiene, 1998

1. All personnel involved in the handling of mercury should be trained with respect to the potential hazard of mercury vapor and the necessity for observing good mercury hygiene practices.

2. All personnel should know the potential sources of mercury vapor in the dental surgery, i.e. spills; open storage of amalgam scrap; and open storage of used capsules; trituration of amalgam; placement, polishing or removing amalgam, heating of amalgam-contaminated instruments; leaky capsules and leaky bulk mercury dispensers. They should also be aware of the proper handling of amalgam waste and environmental issues.

3. All dental personnel should work in well ventilated spaces, having fresh air exchanges and outside exhaust. If the spaces are air-conditioned, the air conditioning filters should be periodically replaced.

4. The dental surgery atmosphere should be periodically checked for mercury vapor. Monitoring should be considered in case of mercury spill or suspected spill, or when there is reasonable concern regarding the concentration of mercury vapor in the surgery. Monitors may be of the dosimeter type. Mercury vapor analyzers (handheld monitors often used by industrial hygienists) which give rapid readout may also be used. They are especially useful for rapid assessment after a spill or clean up.

5. Do not carpet dental surgeries. Non-absorbing, easy to clean surfaces such as continuous seamless sheet flooring carried up the walls are preferred.

6. Use the pre-capsulated alloy whenever possible, which eliminates the possibility of a bulk mercury spill. It also eliminates a mercury dispenser as a source of leaks.

7. If bulk mercury is used, minimise the amount of mercury stored. Mercury should be stored in unbreakable, tightly sealed containers, in a well-ventilated place away from any source of heat.

Dentlearn.ir

8. Mercury and amalgam equipment should be used only in areas that have impervious and suitably lipped surfaces, so that spilled mercury or excess amalgam is confined and recovery facilitated. Care should be taken in handling liquid mercury to minimise possibilities of spills (e.g. use a funnel when mercury is being dispensed into amalgamator; place a lipped tray under mercury dispenser).

9. If pre-capsulated alloys are not used, the removal of excess mercury prior to placement should be minimised by selecting an appropriate alloy to mercury ratio.

10. Only capsules that remain sealed during amalgamation should be used.

11. An amalgamator with a completely enclosed arm should be used. The amalgamator should comply with ISO specifications 7488.

12. Single-use capsules from pre-capsulated alloy should be recapped, if possible, after use. Used capsules should be placed in a container with a tight lid, or in plastic bags. If reusable capsules are used, they should be reassembled after use.

13. A mercury dispenser, if used, should be handled with care and periodically checked for mercury leakage.

14. The mercury dispenser orifice should be examined after use for residual mercury. Any mercury droplets remaining should be disposed of as described in recommendation #17.

15. A no-touch technique should be used with mercury and amalgam at all times.

16. Ultrasonic condensers should not be used.

17. High volume evacuation should be used during placement or removal of amalgam.

18. All amalgam scrap should be salvaged and stored in a tightly closed container. If the scrap is stored dry, then mercury vapor can escape into the room air when the container is opened. If the scrap is stored under photographic fixer solution, then special disposal of the fixer may be necessary.

19. Any spilled mercury should be cleaned up immediately by suitable means. Small amounts of mercury may be formed into amalgam by triturating with alloy powder and the resultant scrap added to the scrap container. Droplets may be picked up using an adhesive tape or a hypodermic syringe. Commercial mercury spill clean up kits may be used to manage spills. After a spill clean up the area should be well ventilated, preferably through open windows. Air conditioning or heating should be shut down during this period to minimise distribution of mercury vapor throughout the building. In countries which have regulations regarding major spills, these regulations should be followed accordingly.

20. Avoid heating of mercury or amalgam or any equipment used with amalgam. Instruments contaminated with amalgam should be cleaned to remove the amalgam contaminant before heat sterilisation or heat disinfection.

References

1. ADA Council on Scientific Affairs. Dental mercury hygiene recommendations. J Am Dent Assoc 134, 1489–1499 (2003).
2. Allmers, H., Schmengler, J., Skudlik, C.: Primary prevention of natural rubber latex allergy in the German health care system through education and intervention. J Allergy Clin Immunol 110, 318–323 (2002).
3. Allmers, H., Brehler, R., Chen, Z., Raulf-Heimsoth, M., Fels, H., Baur, X.: Reduction of latex aeroallergens and latex specific IgE antibodies in sensitized workers after removal of powdered natural rubber latex gloves in a hospital. J Allergy Clin Immunol 102, 841–846 (1998).
4. Amin, A., Palenik, C.J., Cheung, S.W., Burke, F.T.J.: Latex exposure and allergy: a survey of general dental practitioners and dental students. Int Dent J 48, 77–83 (1998).
5. Andersen, K.E., Benesra, C., Burrows, D. et al.: Contact dermatitis. A review. Contact Dermatitis 16, 55–78 (1987).
6. Andersson, I., Bornberger, S., Persson, B., Åkerstedt, K.: Tandteknikerprosjektet 1982/83. [The project on dental technicians 1982/83] Tannteknikeren 1984 53, 92–132 (1984).
7. Andersson, T., Bruze, M., Björkner, B.: In vivo testing of the protection of gloves against acrylates in dentin-bonding systems on patients with known contact allergy to acrylates. Contact Dermatitis 41, 254–259 (1999).
8. Arenholt-Bindslev, D., Schmalz, G.: Mercury exposure in connection with removal of amalgam fillings – a literature survey. Tandlægebladet 100, 2–8 (1996).
9. Babich, S., Burakoff, R.P.: Occupational hazards of dentistry. A review of literature from 1990. N Y State Dent J 63 (8), 26–31 (1997).

Dentlearn.ir

10. Bruzell, E.M., Jacobsen, N., Hensten-Pettersen, A.: Health hazards associated with curing light in the dental clinic. Clin Oral Invest 8: 113–117 (2004).
11. Bruzell, E.M., Johnsen, B., Aalerud, T.N., Christensen, T.: Evaluation of eye protection filters for use with dental curing and bleaching lamps. J Occup Environ Hyg 4, 432–439 (2007).
12. Chaudat, P.: Pathologie pulmonaire des prosthesites dentaires. [Lung diseases among dental technicians] Information Dentaire 64, 4157–4160 (1982).
13. Christiansen, M.L., Adelhardt, M., Kjærgaard Jørgensen, N., Gyntelberg, F.: Methylmetakrylat – en årsag til toksisk hjerneskade? [Methylmethacrylate – a cause of toxic brain damage?] Ugeskrift for læger 148, 1491–1494 (1986).
14. Cook, T.A., Yates, P.O.: Fatal mercury intoxication in a dental surgery. Br Dent J, 553–555 (1969).
15. Council Directive 93/42/EEC of 14 June 1993 concerning medical devices. OJ NoL 169/1 (1993).
16. Cronin, E.: Rubber. In: Contact Dermatitis. Churchill Livingstone, Edinburgh 1980, pp 714–770.
17. Dahl, J.E., Østergaard, E.: Labelling on dental products. Nor Tannlegeforen Tid 109, 80–83 (1999).
18. Dental Amalgam. A report with reference to the medical devices directive 93/42/EEC from an ad hoc working group mandated by DG III of the European Commission (1998).
19. De Vuyst, P., Van de Weyer, R., Decoster, A. et al. Dental technicians pneumoconiosis. A report of two cases. Am Rev Resp Dis 133, 316–320 (1986).
20. Donaghy, M., Rushworth, G., Jacobs, J.M.: Generalized peripheral neuropathy in a dental technician exposed to methyl methacrylate monomer. Neurology 41, 1112–1116 (1991).
21. Echeverria, D., Heyer, N.J., Martin, M.D., Naleway, C.A., Woods, J.S., Bittner, A.C. Jr.: Behavioral effects of low level exposure to Hg among dentists. Neurotoxicol Teratol 17, 161–168 (1995).
22. Echeverria, D., Woods, J.S., Heyer, N.J., Rohlman, D.S., Farin, F.M., Bittner, A.C., Li T, Garabedian C.: Chronic low-level mercury exposure, BDNF polymorphism, and associations with cognitive and motor function. Neurotoxicol Teratol 27, 781–796 (2005).
23. Ericson, A., Källen, K.L.: Pregnancy outcome in women working as dentists, dental assistants or dental technicians. Int Arch Occup Environ Health 61, 329–333 (1989).
24. Lenvik, K., Woldbæk, T. Halgar, K. Exposure to mercury among dental personnel – a presentation of historic measurement data. Nor Tannlegeforen Tid 116, 350–356 (2006).
25. Fung, Y.K., Molrar, M.P.: Toxicity of mercury from dental environment and from amalgam restorations. Clin Toxicol 30, 49–61 (1992).
26. Hamman, C.P., Kick, S.A.: Allergies associated with medical gloves. Occupational Dermatoses 12, 547–559 (1994).
27. Hensten-Pettersen, A., Jacobsen, N.: The role of biomaterials as occupational hazards in dentistry. Int Dent J 40, 159–166 (1990).
28. Hensten-Pettersen, A.: Skin and mucosal reactions associated with dental materials. Eur J Oral Sci 106, 707–712 (1998).
29. Hilt, B., Svendsen, K., Aas, O., et al.: Eksponering for kvikksølv hos tannhelepersonell og forekomst av mulige seneffekter. [Mercury exposure in dental personnel and the occurrence of late injuries] http://www.stolav.no/stolav/resources/kvikksolvrapportny
30. Herö, H., Bergman, B., Grimsdottir, M., Kerosuo, H.: Metals in the mouth – durable and safe? Nor Tannlegeforen Tid 109: 134–139 (1999).
31. Jacobsen, N., Hensten-Pettersen, A.: Perceived side effects of biomaterials in prosthetic dentistry. J Prosthetic Dent 65, 138–144 (1991).
32. Jacobsen, N., Derand, T., Hensten-Pettersen, A.: Profile of work related health complaints among Swedish dental laboratory technicians. Comm Dent Oral Epidemiol 24: 138–144 (1996).
33. Jacobsen, N., Åsenden, R., Hensten-Pettersen, A.: Occupational health complaints and adverse reaction as perceived by personnel in public dentistry. Comm Dent Oral Epidemiol 19, 155–159 (1991).
34. Jacobsen, N., Hensten-Pettersen, A.: Self reported occupation related health complaints among Norwegian dental laboratory technicians. Quintessence Int 24: 409–415 (1993).
35. Jedrychowsky, W.: Styrene and methacrylate in the industrial environment as a risk factor of chronic obstructive lung disease. Int Arch Occup Environ Health 51, 151–157 (1982).
36. Jones, L., Bunnell, J., Stillman, J.: A 30-year follow-up of residual effects on New Zealand School Dental nurses, from occupational mercury exposure. Hum Exp Toxicol 26, 367–374 (2007).
37. Jokstad, A.: Mercury excretion and occupational exposure of dental personnel. Comm Dent Oral Epidemiol 18, 143–148 (1990).
38. Kanerva, L., Estlander, T., Jolanki, R.: Dental problems. In: Guin, J.D. (ed): Practical Contact Dermatitis. McGraw-Hill, New York 1995, pp 397–432.
39. Kanerva, L., Lathinen, A., Toikkanen, J. et al.: Increase in occupational skin disease of dental personnel. Contact Dermatitis 40, 104–108 (1999).
40. Kotloff, R. M., Richman, P.S., Greenacre, J.K., Rossman, M.D.: Chronic beryllium disease in a dental laboratory technician. Am Rev Respir Dis 147, 205–207 (1993).
41. Longworth, S., Rojdmark, S., Akselsson, A.: Normal pituitary hormone response to thyrotropin releasing hormone in dental personnel exposed to mercury. Swed Dent J 14, 101–103 (1990).
42. Leggat, P.A., Kedjarune, U.: Toxicity of methyl methacrylate in dentistry. Int Dent J 53, 126–131 (2003).
43. Lindblom, M.L., Ylöstalo, P., Sallmen, M., Henriks-Eckerman, M.L., Nurminen, T., Forss, H., Taskinen, H.: Occupational exposure in dentistry and miscarriage. Occup Environ Med 64: 127–133 (2007).
44. Lönnroth, E.-C., Shahnavaz, H.: Atopic dermatitis, conjunctivitis, and hand dermatitis among Swedish dental personnel, including use of personal protective devices. Swed Dent J 22, 105–115 (1998).
45. Lönnroth, E.-C., Shahnavaz, H.: Adverse health reactions in skin, eyes, and respiratory tract among dental personnel in Sweden. Swed Dent J 22, 33–45 (1998).
46. Lönnroth, E.-C., Ruyter, I.E.: Resistance of medical gloves to permeation by methyl methacrylate (MMA), ethylene glycol dimethacrylate (EGDMA), and 1,4-butanediol dimethacrylate (1,4-BDMA). Int J Occup Safe Ergon 9, 289–299 (2003).
47. Lönnroth, E.-C., Wellendorf, H., Ruyter, I.E.: Permeability of different types of medical protective gloves to acrylic monomers. Eur J Oral Sci 111, 440–446 (2003).
48. Morgenroth, K., Kronenberger, H.: Lung changes from dental materials. Quintessence of Dental Technology 8, 45–48 (1984).
49. Munksgaard, E.C., Hansen, E.K., Engen, T., Holm, U.: Self reported occupational dermatological reactions among Danish dentists. Eur J Oral Sci 104: 396–402 (1996).
50. Munksgaard, E.C.: Toxicology versus allergy in restorative dentistry. Adv Dent Res 6, 17–21 (1992).

Dentlearn.ir

51. Munksgaard, E.C.: Permeability of protective gloves to (di)methacrylates in resinous dental materials. Scand J Dent Res 100, 182–192 (1992).
52. Norseth, T.: Kvikksølveksponering på offentlige tannklinikker i Oslo. [Mercury exposure in public dentistry in Oslo] Nor Tannlegeforen Tid 87, 371–376 (1977).
53. Nylander, M., Friberg, L., Eggleston, D., Björkmann, L.: Mercury accumulation in tissues from dental staff and controls in relation to exposure. Swed Dent J 13, 225–245 (1989).
54. Palusuo, T., Mäkinen-Kiljunen, S., Alenius, H., Reunala, T., Yip, E., Turjanmaa, K.: Measurement of natural rubber latex allergen levels in medical gloves by allergen-specific IgE-ELISA inhibition, RAST inhibition, and skin prick test. Allergy 53, 59–67 (1998).
55. Person, B., Selden, A., Bornberger, S., Andersson, I., Karlsson, M.: Dammlunga hos tandtekniker – en brancheundersöknming. [Pneumoconiosis in dental laboratory technicians – an occupational investigation] Svenska Läkaresällskapets handlingar. Hygiea 98, 114–121 (1989).
56. Pohl, L., Bergman, M.: The dentist's exposure to elemental mercury vapor during clinical work with amalgam. Acta Odont Scand 126, 1502–1511 (1995).
57. Rajaniemi, R.: Clinical evaluation of occupational toxicity of methylmethacrylate monomer to dental technicians. J Soc Occup Med 36, 56–59 (1986).
58. Rustmeyer, T., Frosch, P.J.: Occupational skin disease in dental laboratory technicians. (I). Clinical picture and causative factors. Contact Dermatitis 34, 125–133 (1996).
59. Savonius, B., Keskinen, H., Tuppurainen, M., Kanerva, L.: Occupational respiratory disease by acrylates. Clin Exp Allergy 23, 416-424 (1993).
60. Santosh, V., Ranjith, K., Shrutakirthi, D.S., Sachin, V., Balachandran, C.: Results of patch testing with dental materials. Contact Dermatitis 40, 50–51 (1999).
61. Schedle, A., Ortengren, U., Eidler, N., Gabauer, M., Hensten, A.: Do adverse effects of dental materials exist? What are the consequences, and how can they be diagnosed and treated? Clin Oral Impl Res 18 (suppl. 3), 232–256 (2007).
62. Scientific Committee on Occupational Exposure Limits: Recommendations from scientific committee on occupational exposure limits for elemental mercury and inorganic divalent mercury compounds. Office for Official Publications of the European Community, Luxembourg 2002.
63. Scully, C., Cawson, P.A., Griffiths, M.: Occupational Hazards to Dental Staff. British Dental Association, London 1990, pp 1–21.
64. Shimpo, H., Yokoyama, E., Tsurumaki, K.: Causes of death and life expectancies among dentists. Int Dent J 48, 563–570 (1998).
65. Sikorski, R., Juszkievicz, T., Pazkowski, T., Szprengler-Juszkiewicz, T.: Women in dental surgeries; reproductive hazards in occupational exposure to metallic mercury. Int Arch Occup Environ Health 59, 551–557 (1987).
66. Sundby, J., Dahl, J.E.: Are women in the workplace less fertile than women who are not employed? J Womens Health 3, 65–72 (1994).
67. Steendahl, U., Prescott, E., Damsgaard, M.T.: Metylmetakrylat og organisk demens. En dosis-respons analyse blandt tandteknikere og optikere. [Methylmethacrylate and organic demens; a dose–response analysis among dental technicians and optometrists] Ugeskrift for læger 154, 1421–1428 (1992).
68. Turjanmaa, K., Knudsen, B., Wrangsjö, K.: Gloves and dental dams – protection or risk? Nor Tannlegeforen Tid 109, 164–167 (1999).
69. Wagner, G.R.: Asbestosis and silicosis. Lancet 349, 1311–1315 (1997).
70. Wallenhammar, L.M., Örtengren, U., Andreasson, H., Barregaard, L., Björkner, B., Karlsson, S., Wrangsjö, K., Meding B.: Contact allergy and hand eczema in Swedish dentists. Contact Dermatitis 43, 192–199 (2000).
71. WHO: Environmental Health Criteria 118. Inorganic mercury. World Health Organization, Geneva 1991.

Dentlearn.ir

13 Environmental Aspects

D. Arenholt-Bindslev

Contents

13.1 Introduction 325
13.2 Environmental Aspects of Dental Amalgam 325
13.2.1 Mercury in the External Environment ... 325
13.2.2 Environmental Mercury Burden Related to the Use of Amalgam in Dentistry 327
13.2.3 Amalgam Separating Devices – Regulations and Recommendations 330
13.2.4 Interment and Cremation 331
13.3 Environmental Aspects of Composite Dental Filling Materials 332
Conclusions for the Dental Practitioner .. 332
References 332

13.1 Introduction

Waste generated in dental clinics can be classified into three major categories:

- Sharps
- Infectious waste
- Chemical waste

In general, the amount of waste generated in dental clinics is considered to be relatively small compared with that of industries and other health care facilities such as hospitals. In most countries, the characteristics of dental clinic waste have caused it to be addressed in laws and regulations covering waste disposal. All hazardous wastes from dental clinics must therefore be handled according to the applicable regulations, and the staff must be adequately trained to collect and handle the waste according to the current regulations.

Hazardous wastes generated by the handling of dental filling materials are generally classified as chemical wastes, which can be subclassified as liquids and solids (Table 13.1). Among the liquids, mercury-contaminated wastewater and disposal of photographic solutions are of major environmental concern. Except for wastewater, the majority of national regulations require liquid chemical wastes to be stored individually in polyethylene or polystyrene tanks appropriately labeled according to the classification type and disposed of with the assistance of a licensed waste disposal service. In many countries, documented delivery of such hazardous waste to a licensed transporter for further handling is required.

Examples of solid wastes are listed in Table 13.1. Mercury/amalgam-contaminated wastes (e.g., scrap amalgam), lead foils from radiographic films, and mercury-containing batteries are the solid waste categories of particular environmental concern. Because digital radiography is being introduced in an increasing number of dental clinics, this picture may change.

13.2 Environmental Aspects of Dental Amalgam

13.2.1 Mercury in the External Environment

The major natural deposits of mercury are found in areas of previously high volcanic activity: China, Spain, and South America (Fig. 13.1). From these deposits,

Table 13.1 Categories of liquid and solid waste generated in dental offices

Solid chemical wastes	Liquid chemical wastes
Mercury- and amalgam-contaminated wastes Batteries Metals Dental material residues Drug residues Disinfectant residues X-ray film lead foils	Mercury- and amalgam-contaminated wastewater and sludge Photographic solutions Plating solutions Monomers Solvents Disinfectants Oil Acids/alkalis Drug residues

Dentlearn.ir

Fig. 13.1 Natural deposits of mercury are primarily found in areas of previously high volcanic activity

mercury is circulated naturally in the biosphere. Recent estimates indicate that natural sources (volcanoes, surface waters, soil, and vegetation) release 2,700 tons of mercury annually to the global atmosphere, while the contribution from major industrial sources accounts for 2,250 tons per year [35]. The majority of anthropogenic emissions originate from combustion of fossil fuels, which, together with combustion of waste, accounts for approximately 70% of the total quantified atmospheric emission from anthropogenic sources [35]. Once released into the atmosphere, mercury can be transported widely and deposited to very remote locations as far away as the Arctic and Antarctica.

In recent decades, gold production has attracted increased attention as a major source of mercury release to the environment. Following very old, traditional techniques, mercury is used for the final recovery (amalgamation) of extracted gold and silver particles. The mercury is discharged into aquatic systems during gold prospecting and into the atmosphere when the amalgam is burned. Gold production in South America has been estimated to have released about 2,000–3,000 tons of mercury into the Brazilian Amazon environment during the latest gold rush, which was accelerated by a factor of 8–10 because of the increase in gold prices during the 1970s [27]. Recent research has called attention to the considerable impact of environmental mercury concentrations in the ecosystem of the complex tropical rainforest river basins and the frequent occurrence of human mercury exposure levels that may lead to adverse health effects [27].

Because of increasing awareness and regulations, the global demand for mercury has declined from around 9,000 tons per year in the 1960s to 6,000–7,000 tons in the 1980s, and to around 3,500 tons per year in 2003 [28]. Globally, the gold mining, chloralkali, and electrical equipment industries (batteries) are the largest consumers of mercury, accounting for about 75% of the total consumption [28].

Mercury has a wide variety of applications in industry, agriculture, the military, medicine, and dentistry. At the global level it has been estimated that around 7.5% of the mercury is used in dentistry [28]. In the European Union, where industrial mercury reduction programs have been initiated, 34.5% of the mercury consumption has been ascribed to dentistry [28].

Even though mercury may affect a number of basic biological mechanisms, the uptake and toxicokinetics of mercury in its different chemical forms vary considerably in different species [9]. Environmental mercury, predominantly in the organic methylmercury form, accumulates in food chains, particularly in the aquatic environment, where a high degree of biomagnification occurs in the food chain of predatory species [36]. The highest concentrations are achieved in the muscle tissues of the long-lived predatory fish such as pike in fresh water and shark in ocean waters. Carnivorous sea mammals also have some of the highest concentrations.

Biomagnification on the order of a millionfold has been reported as mercury ascends the aquatic food chain [12] (Fig. 13.2). Dietary mercury exposure in humans from aquatic food chains has been observed in North Atlantic, Mediterranean, Canadian, and Amazon Basin populations, among others [36]. Relatively high levels of mercury have thus been found in human organs, blood, urine, and hair due to intake of fish and marine mammals with high levels of organic mercury [e.g., 16, 17, 24, 29, 36]. In areas with polluted water, further increases of methylmercury levels in living organisms such as fish will be found, with a tendency to increasing levels with increasing size and age of fish [31, 36]. Mercury biomagnification in food chains in unpolluted as well as polluted areas has resulted in fish consumption advisory programs across North America and northern Europe [16, 26, 32]. Recognizing that fish consumption provides important nutrients, action programs aiming at controlling pollution and thus preserving fish and shellfish resources for both wildlife and humans have been initiated in the form of agreements, recommendations, and legal regulations at regional, national, and global levels [35].

Dentlearn.ir

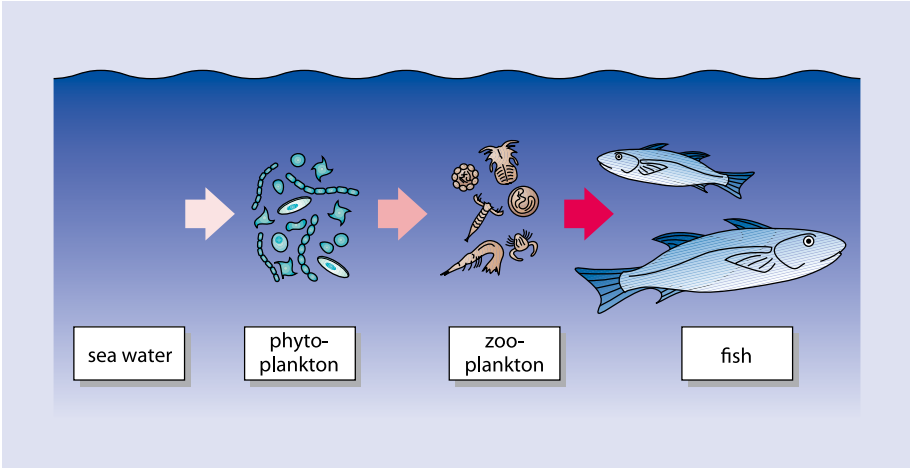

Fig. 13.2 From the natural background level of mercury in unpolluted ocean waters, a biomagnification of a millionfold may occur as mercury ascends the aquatic food chain

13.2.2 Environmental Mercury Burden Related to the Use of Amalgam in Dentistry

The relative mercury contribution from dental clinics to the environmental mercury pollution is not well documented. As mentioned above, mercury consumption for dental purposes was estimated at around 7% on a worldwide basis [28]. National surveys show that in a number of countries, mercury consumption in dentistry has declined markedly in recent years. In Sweden and Denmark, for example, a reduction of between 50% and 75% has occurred over the last 10 years [4, 11], which reflects the fact that a declining number of amalgam fillings are produced per year [4], even though for larger amalgam fillings there may be a stagnation (Fig. 13.3).

Figure 13.4 illustrates the mercury cycle in dentistry. Because of the value of dental scrap amalgam, there has been a tradition of collection and sale for refinement. Because the value of metals is subject to market-related changes, the economic interests in the recycling of amalgam scrap may subsequently change. There are no exact data on the extent to which primary amalgam surplus is collected and recycled. A recent Danish report summarized information from authorized collectors and estimated the total amount of mercury collected as primary amalgam surplus to be 120–680 kg of mercury per year, corresponding to 10–56% of the estimated yearly mercury consumption in dentistry in the same period [11]. To avoid emission of mercury vapor during storage, scrap should be stored in unbreakable containers sealed with tight lids. Until recently, recommendations for temporary storage of amalgam scrap included storage under liquid, most efficiently using radiographic fixer [1, 18]. Recently a dry storage system has been introduced as being more effective and reliable than liquid storage [43]. However, more research seems to be needed in this area.

As mercury evaporates from amalgam undergoing decomposition by heating, amalgam scrap and extracted teeth with amalgam fillings should not be disposed of in waste undergoing incineration. To ensure proper handling and recycling, the dentist should take care that amalgam scrap is disposed of by companies that adhere to government regulations.

Amalgam particles in wastewater discharged from dental clinics may accumulate in wastewater treatment plants. It has been reported that the majority of mercury entering a large modern municipal wastewater treatment plant is removed effectively from the wastewater stream and retained in the sewage sludge [7]. The subsequent handling of the residual sludge may thus result in mercury emissions to the environment. It has been shown that by incineration of wastewater sludge almost the entire mass of mercury removed from the wastewater can be discharged to the atmosphere [7].

Dentlearn.ir

Sunlight-mediated emission of elemental mercury from soil mixed with municipal sewage sludge has also been demonstrated [10]. Mercury accumulation in wastewater treatment plants has caused concern among regulators and resulted in point source reduction strategies, including the dental profession. The relative contribution from dental clinics is, however, scarcely elucidated. One of the first studies, a Danish investigation reporting analyses of mercury content in sewage from 20 dental clinics, concluded that from clinics without amalgam separators, up to 800 mg of mercury was discharged with the wastewater per dentist per day (mean 250 mg/dentist/day), corresponding with values in the range of 200 g of mercury per

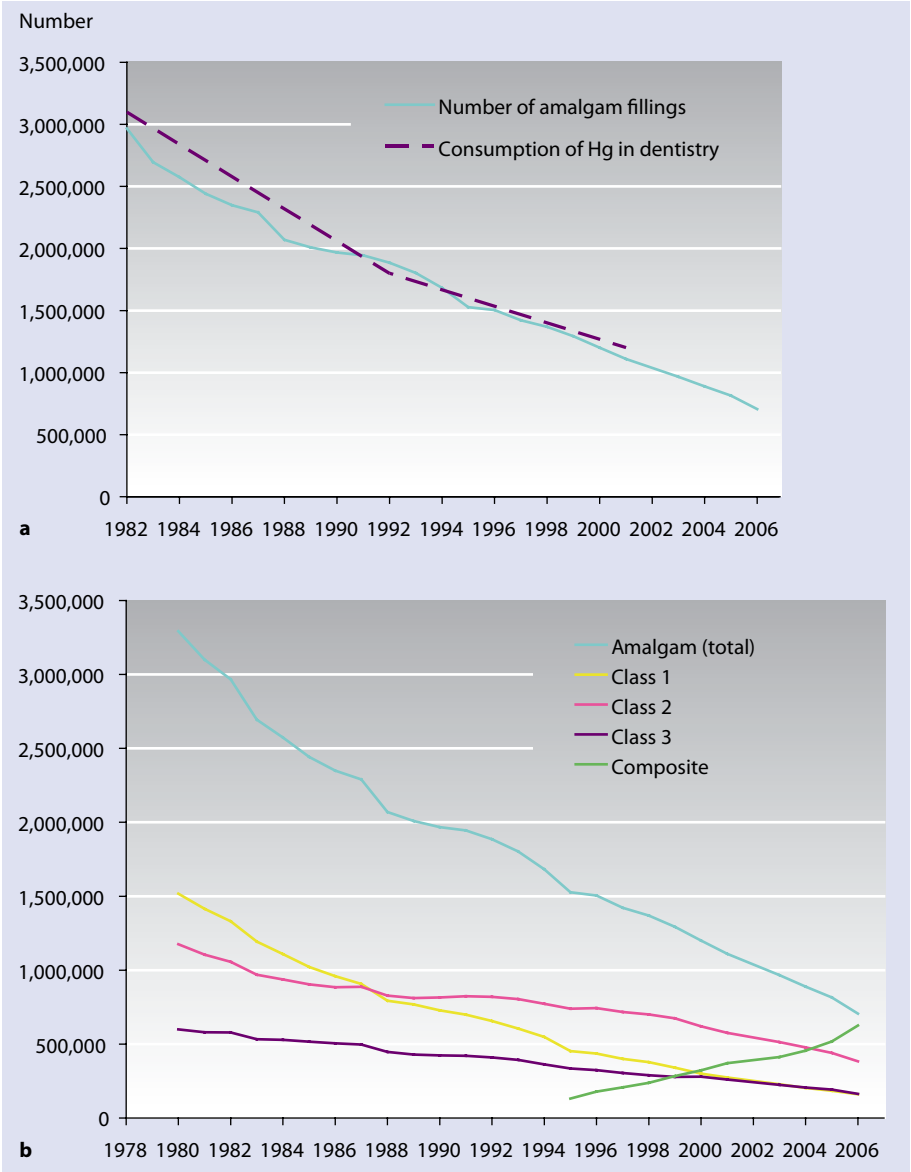

Fig. 13.3 **a** Decreasing numbers of amalgam restorations produced per year in Denmark in the period 1980–2006, adapted from the Danish Dental Association, Statistics on National Health Insurance. **b** The mercury consumption in dentistry in Denmark during the period 1982–2001 compared with the total number of amalgam restorations produced during the same period

Dentlearn.ir

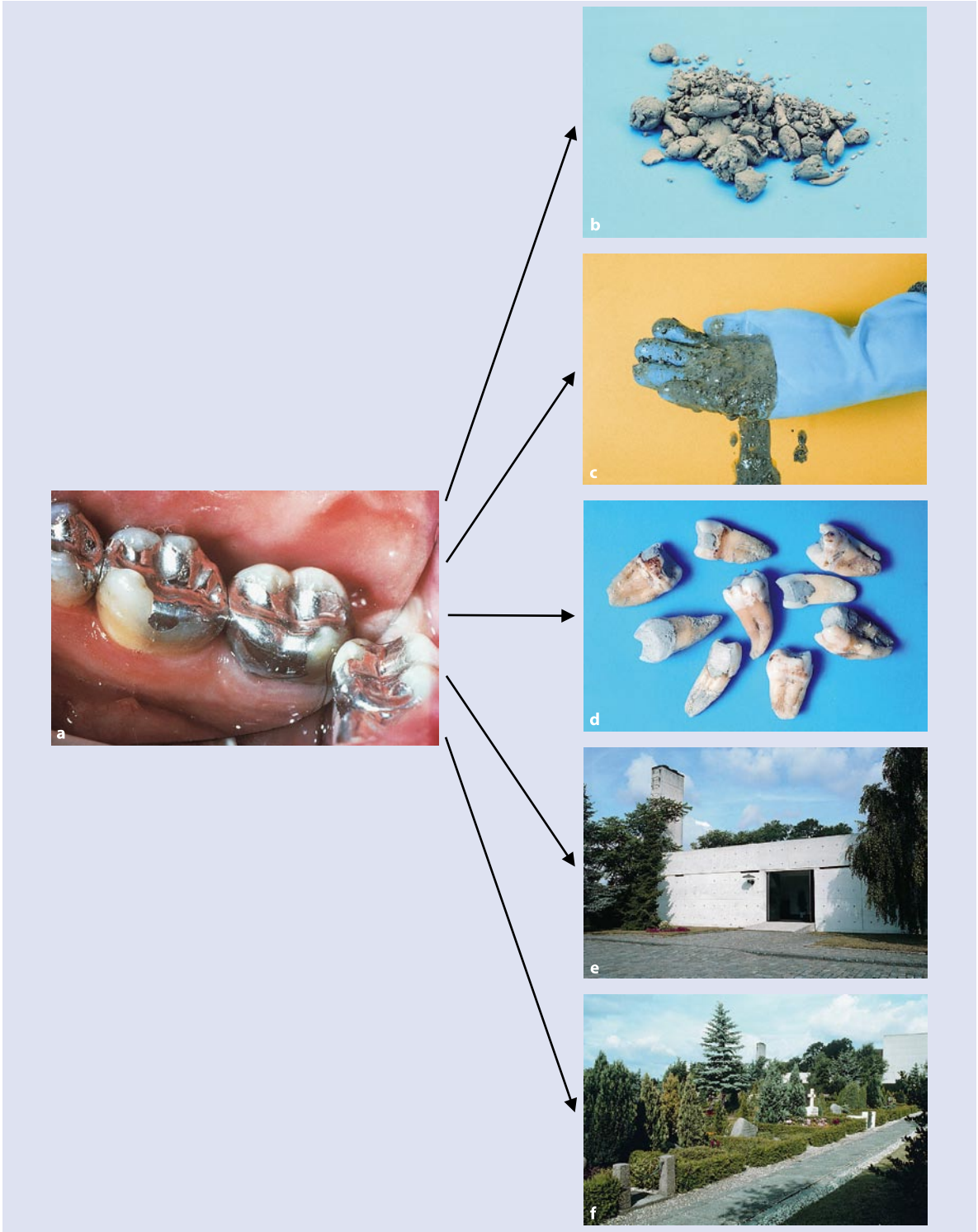

Fig. 13.4a–f Routes of amalgam from the dental practice to the environment. **a** Amalgam fillings. **b** Primary amalgam surplus (amalgam scrap). **c** Amalgam-contaminated sludge collected in amalgam separator. **d** Extracted teeth with amalgam fillings. **e** Crematorium. **f** Cemetery

Dentlearn.ir

dentist per year (mean 57 g/dentist/year) [3]. Clinics equipped with a modern amalgam-separating device showed results of approximately 10% of the results obtained in clinics without an amalgam separator (mean 35 mg/dentist/day) [3]. The data from this Danish study correspond rather well with previous studies, which, however, all included smaller numbers of clinics [14, 15, 19, 38]. Newer designs of amalgam separators, approved by more recent testing programs (Germany, Denmark), may result in further reductions compared with clinics without amalgam separators [13]. Most recently, the efficiency of the sedimentation type of amalgam separators has been questioned [20], and a supplementary device for further improving the recovery rate of sedimentation-type amalgam separators has been introduced [21].

Despite the ongoing debate on the efficacy of different types of amalgam-separating devices, a number of reports have in recent years shown significantly declining mercury levels in the sludge that is generated in wastewater treatment plants following installation of amalgam separators in dental clinics [2, 4, 5, 40, 41; T. Tuominen, 2002, Western Lake Superior Sanitary District Dental Mercury Reduction Program, personal communication]. This strongly suggests that separators can play an important role in decreasing the amount of mercury reaching wastewater treatment plants (Fig. 13.5). Reduction rates of up to 80% have been reported [5, 41].

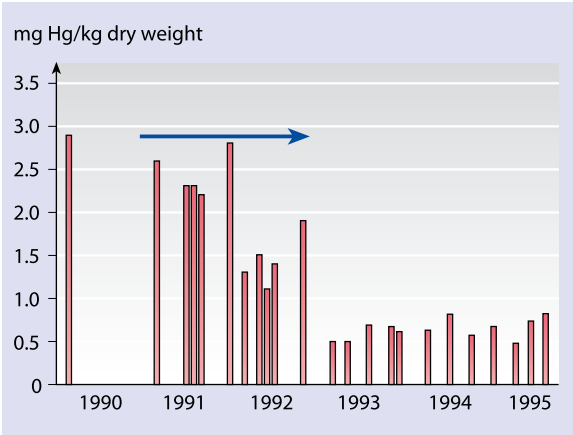

Fig. 13.5 Mercury levels in the sludge generated in the wastewater treatment plant in Skive, Denmark (population 28,000; 17 dental practices) during the years 1990–1995. The *arrow* indicates the transition period when amalgam separators were installed in the dental practices

A few studies have demonstrated that there is no obvious correlation between the amount of amalgam work performed in a clinic and the mercury level in the discharged wastewater [3, 20, 38]. In a German study, the mercury level in wastewater from one clinic was determined on five consecutive days [38]. No correlation was found between the number of amalgam surfaces removed or produced and the amount of mercury determined in the wastewater. It has been suggested that some amalgam particles may be released continuously from sediments in dental units and tubes to the water stream even when no amalgam work is performed [6, 20]. Further, the amount of mercury released was shown to be significantly correlated with daily water flow rate peaks, which may be the result of water flushing in relation to specific procedures, such as cleaning of the tubes [20]. It has subsequently been suggested that data dealing with mercury derived from dental amalgam waste may thus be related to deposits in the sewage sludge that occurred much earlier than the time of monitoring [23].

According to the literature, the solubility of amalgam particles in tap water as well as in sewage is low [25, 39]. In a German laboratory study simulating wastewater treatment processes, no soluble mercury was detected from amalgam particles in sludge [25]. It has therefore been stressed that the environmental impact consideration based on the "total recoverable mercury" test principle used by many environmental agencies may possibly overestimate the environmental impact and thus result in exaggerated concern over the environmental impact of mercury from this source [13].

13.2.3 Amalgam Separating Devices – Regulations and Recommendations

Regulations and/or recommendations requiring amalgam separators in dental clinics have been adopted in a number of European countries, including Sweden, Norway, Denmark, Germany, the Netherlands, Austria, Switzerland, and Belgium, and in several states in the United States. Further countries and regions are considering regulations. In the 1980s a few countries (Sweden, Germany, and Denmark) developed national test programs for the approval of amalgam separators. Later, an International Organization for Standardiza-

Dentlearn.ir

tion (ISO) standard for efficacy testing of amalgam-separating devices was adopted (ISO 11143) [22]. Amalgam separators are generally designed according to one or more of the following basic principles:

- Sedimentation
- Centrifugation
- Filtration

Additional technologies include ion exchange principles by which, for example, polymers are used to trap fine amalgam particles. In order to refine the recovery rate, these principles are often combined with sedimentation-based devices. Systems that include electrolysis and chemicals are also available. The efficacy of the amalgam separator and the risk of mercury release from amalgam deposits in chairside traps, dental unit waste line tubing, vacuum pump filters, tubes, and drains in the sewer system is very sensitive to the choice of disinfection procedures [8]. Products based on oxidation (e.g., chlorine-containing products) thus facilitate the release of mercury and thereby pose a risk of unintended increased mercury release from amalgam deposits in the dental clinic. According to the ISO standard, the manufacturer is responsible for delivering detailed instructions about the installation, use, and maintenance of the amalgam-separating device. In the majority of systems, the amalgam sludge is collected in a sealed container that can be handled by an approved maintenance service or collector or delivered directly to the environmental authorities, with no need for the dental clinic staff to come into direct contact with the collected material. Some systems require that the dental staff regularly empty the collection container. In this case, it is of utmost importance that all handling be performed strictly according to the manufacturer's instructions and to national environmental and safety regulations. The amalgam sludge may be contaminated with microorganisms, and release of mercury vapor during handling has been documented [e.g., 42].

To reduce the mercury waste circulation in general, Sweden and Denmark, as part of point source reduction strategies, have adopted environmental regulations banning the use of mercury, including discontinuing the use of amalgam in dentistry (intended to have been effectuated by 1997 and 1999, respectively). The Danish regulation will be effective only when appropriate alternatives to dental amalgam have been developed. Restrictions on the use of dental amalgam have been issued, and amalgam can no longer be used in children. However, in both Sweden and Denmark the final decisions have been postponed, and at present (May 2008), none of the bans on dental amalgam has been effectuated. As of January 2008 Norway adopted a ban on amalgam for environmental reasons.

13.2.4 Interment and Cremation

Particularly in Scandinavia, the possible environmental effects of burying and cremating the dead with amalgam fillings have been debated. The amount of data in this area is, however, very limited. Analyses of soil and drain water samples from a Danish cemetery showed that no detectable amounts of mercury were found in drain water samples collected consecutively over 1 year, which indicates that the minute amounts of mercury potentially released from buried persons with amalgam restorations are not mobilized from cemetery soil [6].

During cremation, mercury bound in amalgam fillings will be released as mercury vapor. The frequency of cremation is increasing in most Western countries, and it has been claimed that cremation will become a major source of mercury vapor emission. Also in this area, the amount of published data is sparse and primarily based on rough estimates. According to a Swedish review, the mercury emission from cremations may amount to about 7% of the total emission of mercury in Sweden [26]. The few available reports on this issue estimated that a mean amount in the order of 1–4 g of mercury is emitted per cremation [33, 37]. A Swiss study of 60 cremations with known amalgam status monitored the amount of mercury during cremation in relation to an accepted level of 200 μg Hg/m^3 and concluded that the amount of mercury contamination during cremation as a result of amalgam fillings is so low that no additional preventive measures are required at crematoria [30]. A New Zealand study found no elevated mercury levels in soil in the vicinity of crematoria [34]. In Sweden, extensive point reduction strategies have been adopted during the last few decades to reduce the evident accumulation of mercury in food chains, in particular the problem of high levels of mercury in fish from lakes where the mercury sources were unknown [26]. As part of these strategies, since 1992 new crematoria in Sweden and crematoria performing more than 1,000 cremations per year must be equipped with

Dentlearn.ir

emission filters. Similar regulations are expected in Denmark.

Key Note

For the dentist it is important to know that mercury-contaminated wastewater is released from dental clinics to the sewers, thus posing a possible risk of adding to the mercury burden in sludge. However, the efficacy of modern amalgam separators is presently being proven in practice, and it has been shown that the outfall of amalgam particles into sewers can be reduced to well below 10% of the original mercury level [3]. Mercury vapor emission generated by incinerating mercury-contaminated solid waste, primarily extracted teeth with amalgam fillings, is easily prevented by adopting simple routines for proper collection. Cremation or interment of deceased persons seems to be of minor environmental significance except in specific areas.

13.3 Environmental Aspects of Composite Dental Filling Materials

There are so far no indications that solid wastes containing residues of methacrylate-based materials pose a significant burden on the environment. Major residues of acrylates and contaminated containers should be disposed of as chemical waste, while minor residues can be disposed of with general clinic waste. It seems to be generally agreed that dental acrylates are decomposed by combustion to mainly carbon dioxide and water.

From a theoretical point of view, the question of a possible environmental impact of dental waste containing methacrylate-based potentially estrogenic compounds has been raised in the popular media. This issue has not been fully elucidated (see Chap. 5). In relative terms, the impact may, however, be considered negligible. According to estimates by the Danish Board of Health, the total amount of dental composites/resins containing bisphenol A diglycidylether methacrylate (Bis-GMA) and bisphenol A dimethacrylate (Bis-DMA) amounts to less than 0.01% of the estimated total amount of bisphenol A-containing products or chemicals used in Denmark per year [6].

Conclusions for the Dental Practitioner

It is important for the dentist to realize that in some respects, the theoretical environmental problems related to wastes generated in dental practice may seem to be negligible in comparison to, for instance, industrial pollution and combustion of fossil fuels. Modern societies, however, face general trends toward increased environmental awareness and responsibility, so dental staff must be well informed about dentistry-related environmental aspects, including the following [44]:

1. The dental team must be able to identify the different hazardous waste categories generated in dental practice.
2. The dental team must keep themselves informed about developments in the national laws and regulations covering waste disposal so that hazardous dental clinic waste is handled correctly according to national regulations. Regarding handling procedures and waste management in relation to dental materials, the safety data sheets, safety labeling, and manufacturer's instructions for use should be consulted thoroughly.
3. The dental team must have a basic understanding of environmental responsibility. As a consequence of the standing debate on environmental aspects of dental materials (particularly amalgam), the dentist should ideally be informed on how the estimated environmental burden from dental materials in question relates to similar pollution from nondental sources.

References

1. ADA Council on Scientific Affairs: Dental mercury hygiene recommendations. J Am Dent Assoc 130, 1125 (1999).
2. Anderson, C.T.: Community-wide dental mercury study. MCES and Minnesota Dental Association Report. MCES report no. 01-507 (2001).
3. Arenholt-Bindslev, D., Larsen, A.H.: Mercury levels and discharge in waste water from dental clinics. Water Air and Soil Poll 86, 93–99 (1986).

Dentlearn.ir

4. Arenholt-Bindslev, D., Sundberg, H.: Trygt i munden – farligt i miljøet? (Safe in the mouth – an environmental hazard?) Tandlægebladet 103, 83–90 (1999). [Also published in Tandläkartidningen (S) 91, 51–57 and Finnish Dent J 7, 160–171 (1999).]
5. Arenholt-Bindslev, D.: Environmental aspects of dental restorative materials: A review of the Danish situation. In: Mercury in the environment. Eds. D. Laudal et al. Sewickley, AWMA and EPA publishing, pp. 471–481 (2000).
6. Arenholt-Bindslev, D.: Environmental aspects of dental materials. Eur J Oral Sci 106, 713–720 (1998).
7. Balogh, S., Liang, L.: Mercury pathway in municipal wastewater treatment plants. Water Air Soil Poll 80, 1181–1190 (1995).
8. Batchu, H., Chou, H., Rakowski, D., Fan, P.L.: The effect of disinfectants and line cleaners on the release of mercury from amalgam. J Am Dent Assoc 137, 1419–1425 (2006).
9. Berlin, M.: Mercury. In: Friberg, L., Nordberg, G.F., Vouk, V.B. (eds): Handbook on the Toxicology of Metals. Amsterdam, Elsevier 1986, pp 387–446.
10. Carpi, A., Lindberg, S.E.: Sunlight-mediated emission of elemental mercury from soil amended with municipal sewage sludge. Environ Sci Technol 31, 2085–2091 (1997).
11. Christensen, C.L., Skårup, S., Maag, J., Jensen, S.H.: Mass flow analyses of Mercury 2001. Environmental Projekt no. 917 2004. Ministry of the Environment, Danish Environmental Protection Agency, Copenhagen 2004.
12. Clarkson, T., Magos L.: The toxicology of mercury and its chemical compounds. Crit Rev Toxicol 36, 600–662 (2006).
13. Fan, P.L., Arenholt-Bindslev, D., Schmalz, G., Halbach, S., Berendsen, H.: Environmental issues in dentistry – mercury. Int Dent J 47, 105–109 (1997).
14. Fischer, W., Bohrer, G..: Amalgamentsorgung im Bereich Abwasser. [Amalgam release to the waste water stream]. Schweiz Monatschr Zahnmed 99, 61–68 (1988).
15. Gräf, W., Sühs, L., Pfarrer, R.: Die Umweltbelastung durch Quecksilber, Silber, Entwickler und Fixierer aus Zahnärtzlicher Praxis. [Environmental burden from mercury, silver, radiographic developers and fixatives from dental clinics] Zahnärztl Mitteil 78, 214–218 (1988).
16. Grandjean, P., Cordier, S., Kjellström, T., Weihe, P., Budtz-Jørgensen, E.: Health effects and risk assessments. In: Pirrone, N., Mahaffey, K.R. (eds): Dynamics of Mercury Pollution on Regional and Global Scales. Springer Science, New York 2006, pp 511–538.
17. Hansen, J.C., Danscher, G.: Organic mercury: an environmental threat to the health of dietary-exposed societies? Rev Environ Health 12, 107–116 (1997).
18. Haller, B., Kropp R., Götze, W., Logemann, E.: Quecksilberdampfmessungen bei der Aufbewahrung von Amalgamproben in verschiedenen Flüssigkeiten. [Mercury vapour release from amalgam test specimens stored under different storage conditions]. Dtsch Zahnärztl Z 42, 758–762 (1987).
19. Hogland, W., Jensson, B., Petersson, P.: Kvicksilverutsläpp från Tandvårdsverksamheten i Lund. (Mercury outlet from dental clinics in Lund, Sweden) Internrapport 31, 32 University of Lund (1990).
20. Hylander, L.D., Lindvall, A., Uhrberg, R., Gahnberg, L., Lindh, U.: Mercury recovery in situ of four different dental amalgam separators. Sci Tot Environ 366, 320–336 (2006).
21. Hylander, L.D., Lindvall, A., Gahnberg, L.: High mercury emissions from dental clinics despite amalgam separators. Sci Tot Environ 362, 74–84 (2006).
22. International Organization for Standardization: ISO 11143: Dental equipment – amalgam separators. International Organization for Standardization, Geneva 1999.
23. Jones, D.W.: Putting dental mercury pollution into perspective. Br Dent J 197, 175–177 (2004).
24. Kehrig, H, Malm, O., Akagi, H., Guimaraes, J.R.D., Torres, J.P.M.: Methylmercury in fish and hair samples from the Balbina reservoir, Brazilian Amazon. Environ Res 77, 84–90 (1998).
25. Kunkel, P., Cook, K., Mueller P., York B.: Investigation of the fate of mercury in wastewater treatment processes. Water Environ Tech 8, 49–53 (1996).
26. Lindqvist, O., Johansson, K., Aastrup, M., Andersson, A., Bringmark, L., Hovsenius, G., Håkanson, L., Iverfeldt, Å., Meili, M., Timm, B.: Mercury in the Swedish environment. Recent research on causes, consequences and corrective methods. Water Air and Soil Poll 55, 1–251 (1991)
27. Malm, O.: Gold mining as a source of mercury exposure in the Brazilian Amazon. Environ Res 77, 73–78 (1998).
28. Maxon, P.A.: Global mercury production, use and trade. In: Pirrone, N., Mahaffey, K.R. (eds): Dynamics of Mercury Pollution on Regional and Global Scales. Springer Science, New York 2006, pp 25–50.
29. Mahaffey, K.R., Mergler, D.: Blood levels of total and organic mercury in residents of the Upper St. Lawrence River basin, Quebec. Association with age, gender, and fish consumption. Environ Res 77, 104–114 (1998).
30. Matter-Grütter, C., Baillod, R., Imfeld, T., Lutz, F.: Quecksilber-Emissionsmessungen in einem Krematorium. [Mercury emission measurements in a crematorium] Schweiz Monatsschr Zahnmed 105, 1023–1028 (1995).
31. WHO: Mercury – environmental aspects. Environmental health criteria 86. World Health Organization, Geneva 1989.
32. Mohapatra, S.P., Nikolova, I., Mitchell, A.: Managing mercury in the Great Lakes: an analytical review of abatement policies. J Environment Management; 83, 80–92 (2007).
33. Mörner, S., Nilsson, T.: Kvicksilverutsläpp från Göteborgs krematorier. (Mercury release from crematories in Gothenburg, Sweden) Göteborg: Göteborgs Kommun (1986).
34. Nieschmidt, A.K., Kim, N.D.: Effects of mercury release from amalgam dental restorations during cremation on soil mercury levels of three New Zealand crematoria. Bull Environ Contam Toxicol 58, 744–751 (1997).
35. Pirrone N., Mahaffey K.R.: Where we stand on mercury pollution and its health effects on regional and global scales. In: Pirrone, N., Mahaffey, K.R. (eds): Dynamics of Mercury Pollution on Regional and Global Scales. Springer Science, New York 2006, pp 1–21.
36. Renzoni, A., Zino, F., Franchi, E.: Mercury levels along the food chain and risk for exposed populations. Environ Res 77, 68–72 (1998).
37. Rivola, J., Krejci, J., Imfeld, T., Lutz, F.: Feuerbestattung und Quecksilberumweltlast. [Cremation and mercury release to the environment] Schweiz Monatschr Zahnmed 100, 1299–1303 (1990).
38. Senkpiel K., Pasch J., Ohgke H., Heckert, J.: Bestimmung der absoluten Quecksilber-Tages- und Stundenfracht im Abwasser einer Zahnärtzlichen Behandlungseinheit. [Measurements of the absolute daily and hourly release of mercury from a dental unit] Hyg Med 14, 283–288 (1989).

Dentlearn.ir

39. Senkpiel, K., Pasch, J., Ohgke, H., Beckert, J.: Zur ionogenen Freisetzung von Quecksilber aus Dentalamalgam im Abwasser und Klärschlamm. (Mercury ions released from dental amalgam to the waste water stream and to sewage) Zbl Hyg 188, 254–261 (1989).
40. Shaw, M.: Reduction in mercury loading to four Toronto area sewage treatment plants due to implementation of an amalgam separator bylaw. Report from the Toronto Sewer District. http://www.epa.gov/region5/air/mercury/meetings/June04/shaw.pdf. Cited July 2007.
41. Stone, M.E.: The effect of amalgam separators on mercury loading to wastewater treatment plants. Can Dent J 32, 593–600 (2004).
42. Stonehause, C.A., Newman, A.P.: Mercury vapour release from a dental aspirator. Br Dent J 190, 558–560 (2001).
43. Sutow, E.J,. Hall, G.C., Maclean, C.A.: Effectiveness of wet and dry mercury vapour suppressant systems in a faculty of dentistry clinic. J Oral Rehabil 31, 822–826 (2004).
44. Wilson, N.H., Bellinger, E.G., Mjör, I.A.: Dental practice and the environment. Int Dent J 48, 161–166 (1998).

Dentlearn.ir

14 Diagnosis of Side Effects of Dental Materials, with Special Emphasis on Delayed and Immediate Allergic Reactions

D. Arenholt-Bindslev, R. Jolanki and L. Kanerva

Contents

14.1 General Diagnostic Aspects and Irritant/Allergic Stomatitis 335
14.2 Delayed Allergic Reactions (Cell Mediated) 338
14.2.1 Clinical Picture 338
14.2.2 Verified Contact Allergic Reactions to Dental Materials and Substances Released by Dental Materials 340
14.2.3 Epicutaneous Test (Patch Test) 353
14.3 Immediate Allergic Reactions (IgE Mediated) 353
14.3.1 Clinical Picture 353
14.3.2 Verified Immediate Allergic Reactions to Dental Materials 354
14.3.3 Chemicals with Low Molecular Weight .. 356
14.3.4 Skin Test with Low Molecular Weight Compounds 357
14.3.5 Management of Acute Allergic Reactions 357
14.4 Diagnosis of Side Effects Caused by Dental Materials 357
14.4.1 Anamnesis 357
14.4.2 Local Irritative Reactions 358
14.4.3 General Symptoms 358
14.4.4 Allergy 359
14.4.5 Defining the Causative Agent(s) 361
14.4.6 The Importance of Communication 361
References 361

14.1 General Diagnostic Aspects and Irritant/Allergic Stomatitis

Dental patients may ascribe a wide variety of local and/or general symptoms to side effects caused by dental materials. Surveys have, however, indicated that true side effects to dental materials are rare and generally of relatively low severity [73, 82, 83, 92]. When diagnosing symptoms attributed to the intraoral presence of dental materials, careful consideration of possible alternative causes of the symptoms is thus important. Materials-related local and systemic toxic effects and some allergy aspects are described in the previous chapters. Symptoms of allergic reactions to dental materials are often nonspecific and therefore represent particular challenges to the diagnostic skills of the dentist. A major part of the present chapter is therefore focused on describing verified clinical allergic reactions to components of dental materials in order to compile a comprehensive information base for considering allergy as a possible cause of specific as well as nonspecific symptoms presented by patients as side effects of dental materials.

An irritant stomatitis and an allergic stomatitis may present with identical clinical symptoms and with clinical appearances resembling, for instance, classic oral vesiculobullous or ulcerative lesions. Relevant differential diagnoses to consider as alternatives to dental-material-related side effects are specific mucosal disease, oral irritative reactions (e.g., mechanical insults, fungi, bacteria), gnathofunctional disorders (e.g., muscular/denture dysfunction), general diseases, side effects of drugs, and nutritional deficiencies/disorders. A number of local symptoms alleged to be side effects of dental materials are listed in Table 14.1 together with possible alternative causes. Descriptions of more general, nonspecific symptoms attributed to dental amalgam, composites, and metals can be seen in Chaps. 4, 5, and 8, respectively. Examples of symptoms and conditions verified as side effects of materials used in dentistry have been compiled in Table 14.2.

Key Note

The oral mucosa is more resistant to primary irritants than the skin is. There is also a lower tendency of sensitization through mucous membranes than through skin (see, e.g., Chap. 2). Further to the importance of regional histomorphological differences, mucosal reactions to contactants are modified by saliva, which cleanses, buffers, and contains microorganisms such as yeasts and bacteria, which may influence the clinical picture of a stomatitis.

Dentlearn.ir

Table 14.1 Examples of local symptoms/reactions commonly alleged to be side effects of dental materials, and possible alternative causative factors to consider

	Symptoms/reactions	Possible causative factors
Nonspecific clinical findings	Burning mouth Dysgeusia Soreness Itching Erythema/ulceration Gingivitis Discoloration Xerostomia Hypersalivation	General disease Gnathofunctional disorders Side effects of medication Infections (bacterial, fungal, viral) Nutritional deficiencies/disorders
Clinically evident mucosal reactions Localized/diffuse	Erythema/ulceration Lichenoid lesions Erythema multiforme-like lesions Lupus Erythematosus-like lesions Aphtous stomatitis-like lesions	Mucosal disease/infection Side effects of medication
Extraoral reactions	Edema Exanthema Eczema Cheilitis	General disease Skin disease Local infection (bacterial, fungal, viral)

Table 14.2 Examples of verified side effects of materials used in dentistry

Local Allergic or irritant	Lichenoid/leucoplakic lesions Erythema/ulceration Dysgeusia Intraoral numbness Itching Gingivitis Stomatitis Cheilitis Contact dermatitis Glossodynia/orodynia
Systemic	Urticaria Recurrent angioedema Systemic dermatitis Anaphylactic reaction

The oral mucosa is subject to two major types of local reactions: (1) primary irritative reactions (toxic) and (2) allergic sensitization/allergic reactions. An *acute irritant reaction* may occur as a reaction to unintended prolonged mucosal contact with an irritant chemical or product (Fig. 14.1a), e.g., enamel etching products or bonding agents applied to dental tissues during placement of composite resin restorations. Such reactions are normally confined to the mucosal area in contact with the irritant material. The chemical composition of the contacting agent may significantly influence the severity of the tissue reaction (Fig. 14.1b, c) as well as the length of the healing period, which depends on a number of factors including the depth of the lesion [11].

A *chronic irritant reaction* may develop due to repeated or constant mechanical insult(s) or exposure to irritant (toxic) agents in low concentrations over long periods. Like acute irritant reactions, chronic reactions are most frequently located in the area in contact with the irritant agent/insult. Chronic irritant reactions may be seen, for example, in areas of the oral mucosa in direct contact with corroded amalgam or metal restorations. An irritant reaction may often be multifactorial, e.g., the result of combined chemical, mechanical, and biological (microorganisms) exposures. Mucosal lesions, such as oral lichen lesions, are often more susceptible to irritant exposure than normal mucosa (Fig. 14.2).

Dentlearn.ir

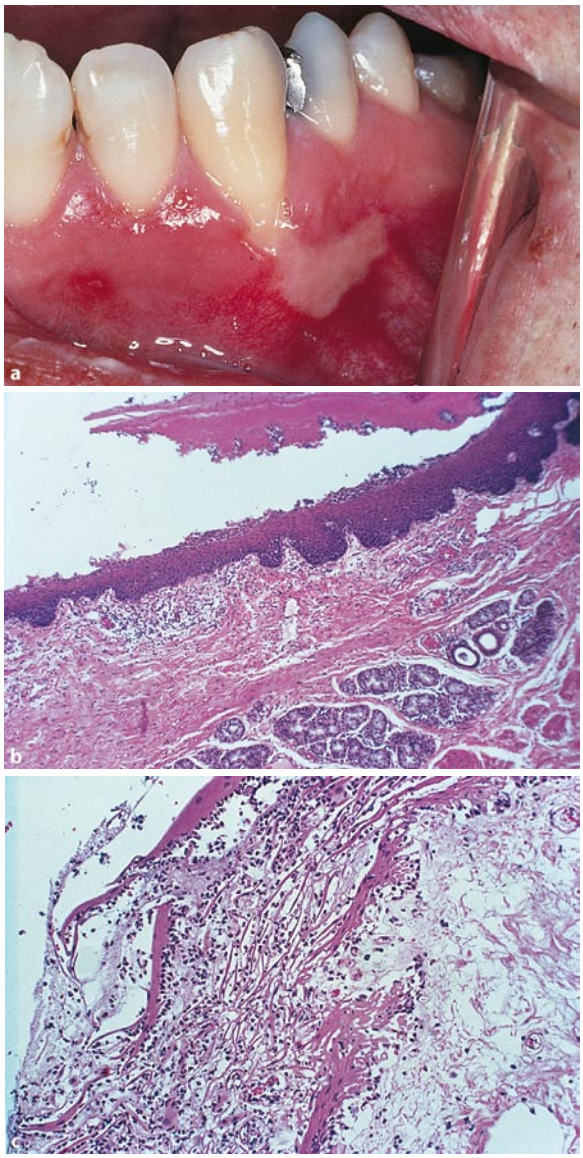

Fig. 14.1 **a** Irritative lesion caused by unintended prolonged exposure to an enamel etch product during insertion of a composite restoration. **b** Experimental exposure of oral mucosa to an enamel etch product (37% phosphoric acid; 24 h after 5-min exposure). Denaturated superficial cell layers separated from lower vital strata by a zone of koilocyte-like cells. Intact connective tissue with only focal accumulations of inflammatory cells [11]. **c** Experimental exposure of oral mucosa to a dentin bonding agent (35% HEMA, 5% glutaraldehyde; 24 h after 5-min exposure). Almost total necrosis of the oral epithelium and juxtaepithelial connective tissue. Marked edema and inflammatory reaction in the underlying tissue [11]

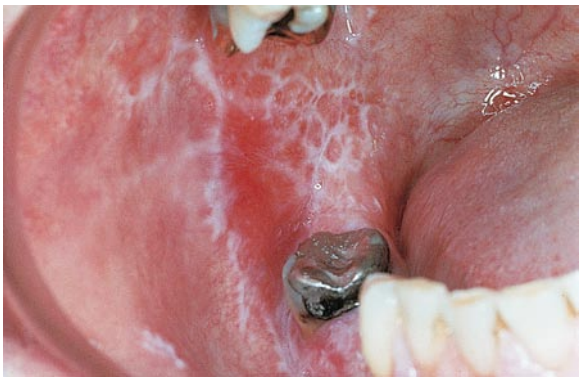

Fig. 14.2 Exacerbation (chronic irritative reaction) of a buccal mucosa lichen lesion in contact with a corroded amalgam restoration

Clinical Practice Advice

In most cases, the clinical features of irritant lesions will be different from lesions caused by contact allergy. The diagnosis is obtained by exclusion (eliminating the irritant) and ultimately by a negative patch test. A biopsy is of very limited diagnostic value (no discrimination between allergy and irritancy is to be expected) but in certain cases may be helpful for excluding or verifying oral mucosal disease.

Coombs et al. [34] classified allergic reactions into four main types, which have been further elaborated (see also Chap. 1). Of these, two types of allergic reactions are associated with the effects of dental materials: immediate (or IgE mediated, type I) and delayed (or cell mediated, type IV). These will be discussed in more detail below, beginning with delayed reactions, which are the most common.

Key Note

Immediate allergic reactions (IgE mediated) and the more frequent *delayed allergic reactions* (cell mediated) are the allergy types that have been seen as side effects to dental materials.

Dentlearn.ir

14.2 Delayed Allergic Reactions (Cell Mediated)

14.2.1 Clinical Picture

Delayed allergic reactions (cell mediated or type IV) normally develop within hours or days following the exposure. The reactions are closely related to specifically sensitized T lymphocytes, which react with the allergen and release lymphokines, eliciting an inflammatory reaction. The subjective symptoms of a *general allergic contact stomatitis* are often more prominent than the clinical signs. Patients may complain of burning sensations, numbness, soreness, and loss of taste. Itching is less usual. The clinical appearance varies from barely visible changes to mild erythema to a fiery red color. Edema may be present. In cases involving the tongue, lingual papillae may disappear, and the mucosa may have a smooth, waxy, glazed appearance. If vesicles develop, they rupture quickly to form erosions. Lips and commissures may also be affected. A wide variety of allergenic substances has been implicated as possible causes of general allergic contact stomatitis, including lipstick, soap, perfume, topical anesthetics, and nail varnish [85]. Such reactions have very rarely been reported in relation to dental restorative materials, whereas a general allergic stomatitis involving several oral sites has been described, for example, in relation to oral hygiene products (see also Chap. 10) [20, 42, 55, 64]. Allergic contact stomatitis may mimic the oral changes of a vitamin deficiency or systemic disease. Textbooks list great numbers of systemic diseases that may affect the oral mucosa, and these need to be taken into consideration (e.g., viral and bacterial infections, diseases of the blood and blood-forming organs, and endocrine, nutritional, and metabolic disorders).

Allergic stomatitis is often accompanied by *cheilitis*. The usual picture of allergic cheilitis is dryness, scaliness, fissuring, and angular cheilitis (Fig. 14.3). This clinical picture may accompany stomatitis or may be caused by contactants applied directly to the lips. Lips rarely show edema and vesiculation. Allergic cheilitis does not normally have a zone of normal skin immediately adjacent to the vermilion border, in contrast to *perioral dermatitis* (Fig. 14.4), which is considered a specific "skin disease." Perioral dermatitis is most frequently seen in younger women and can be successfully treated with tetracyclines, among other medications.

A local allergic contact stomatitis elicited by metals or acrylates used in dentures, prosthetic framework, fillings, inlays, crowns, or implants most often shows a sharp delineation adjacent to or contacting the eliciting material. The lesions are generally well defined and may be whitish or erythematous (Fig. 14.5a, b; see also Chap. 4). The white lesions are often lichenoid but may also appear as uncharacteristic leukoplakias. Erythematous contact lesions may appear identical to irritative reactions, such as gingivitis or the result of mechanical trauma.

Fig. 14.3 Allergic contact cheilitis caused by hydroquinone in denture base acrylate [176] (Courtesy of V. Torres, Lissabon, Portugal)

Fig. 14.4 Perioral dermatitis (Courtesy of K. Turnanmaa, Tampere, Finland)

Dentlearn.ir

In allergic reactions to denture base material, there is normally a sharp line between the red, inflamed mucosa covered by the denture and the adjacent uninvolved area (Fig. 14.6a, b) [91]. However, the clinical picture of a microbial infection or an ill-fitting plate (e.g., obstructive sialadenitis) may give a very similar clinical appearance (Fig. 14.7). In cases of no functional problems and no microbial infection, skin testing (e.g., patch testing) may be considered to establish or exclude the diagnosis of an allergic contact stomatitis.

Key Note

The dentist should know that a general allergic contact stomatitis is more frequently seen as a reaction to substances like cosmetics, oral hygiene products, soaps, fragrances, or nail varnish than in relation to exposure to dental restorative materials. A general allergic contact stomatitis is often accompanied by cheilitis. Allergic reactions to dental materials are most often well defined and located in mucosal areas in direct contact with the eliciting material.

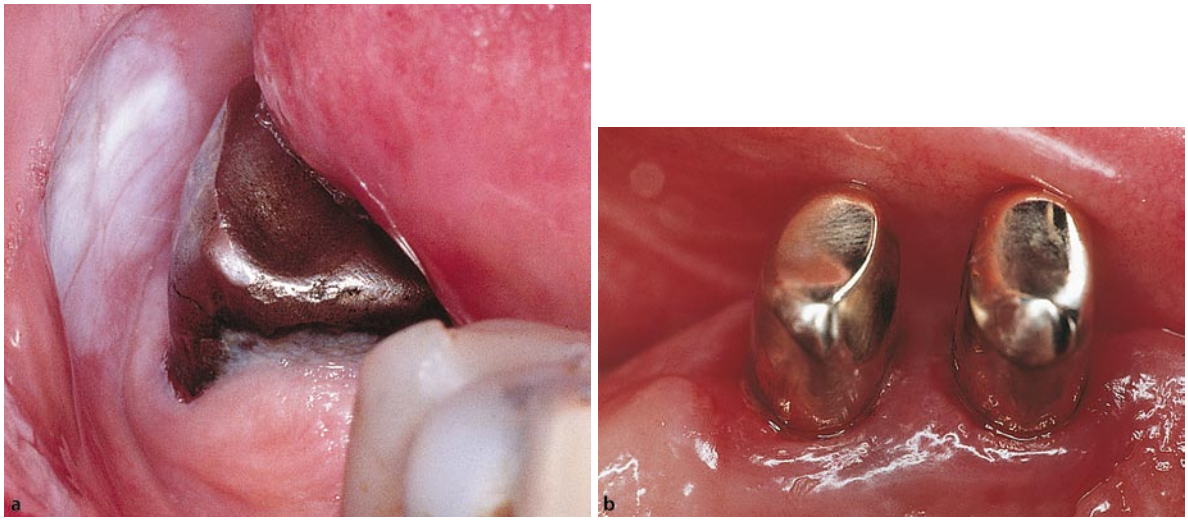

Fig. 14.5 **a** White contact lesion adjacent to corroded amalgam restoration. Allergy to mercury and mercury compounds was confirmed by patch testing. **b** Erythematous contact lesion adjacent to 23 and 24. Allergy to nickel, palladium, and cobalt was confirmed by patch testing (Courtesy of G. Schmalz, Regensburg, Germany)

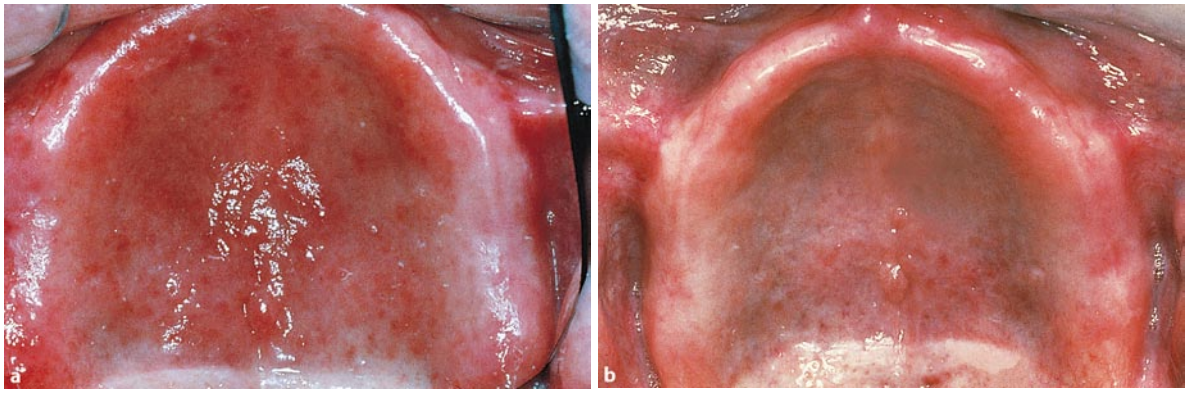

Fig. 14.6 **a** Allergic reaction to methylmethacrylate (MMA) in denture base material. **b** Same patient after substitution of MMA-containing denture base material with a polycarbonate material (Courtesy of S. Kaaber, Århus, Denmark)

Dentlearn.ir

Fig. 14.7 Denture stomatitis caused by infection with *Candida albicans*

14.2.2 Verified Contact Allergic Reactions to Dental Materials and Substances Released by Dental Materials

Recent multicenter surveys on the prevalence and relevance of contact dermatitis allergens in the general population have reported that some constituents found in dental materials belong among the allergens most frequently causing positive reactions in patients referred for patch testing: nickel, balsam of Peru (or Peru balm), cobalt, formaldehyde, and glutaraldehyde [e.g., 126, 174, 184, 200]. Other highly ranked allergens are fragrance mix, neomycin, and thimerosal (a mercury-based chemical widely used as a preservative in the past). A Scandinavian multicenter study of patch test reactions with dental screening series (more than 4,000 patients, primarily dental patients and personnel) showed that the most frequent allergic patch test reactions in this specific patient group were caused by nickel, mercury, gold, benzoic acid, palladium, cobalt, and methacrylates [114]. Reports from national centers of clinics performing patch test evaluations of dental patients and personnel have also ranked nickel, gold, resin-based materials, cobalt, palladium, and mercury as the allergens most frequently causing positive patch test reactions [e.g., 7, 57, 120, 185]. Minor national variations can be seen.

Within the dental field, from a questionnaire study on material-related side effects in prosthetics, the incidence was calculated to be about 1:400. Of these side effects, about 27% were related to base-metal alloys from removable partial dentures (cobalt, chromium, nickel) and to noble gold-based alloys for porcelain-fused-to-metal restorations [73]. The complaints consisted of intraoral reactions (including lichenoid reactions and redness, swelling, and pain of the oral mucosa and lips), and a few instances of systemic reactions. In orthodontics, the incidence was 1:300, and the majority of reactions were related to metal parts of the extraoral anchorage devices or intraoral fixed appliances [82] (see also Chap. 8). The incidence was estimated to be 1:300 in periodontics and 1:2,600 in pedodontics [83]. None of these reactions was related to dental metals.

In dental practice, the side effects most frequently seen are related to dental amalgam [92]. Because the aforementioned studies were based on observations attributing clinical reactions or anamnestic information to the side effects of dental materials, a true prevalence of allergic reactions cannot be deduced. Occupational skin disease from metals routinely handled by the dental profession has seldom been reported (see also Chap. 12).

14.2.2.1 Dental Metals

Nickel: As mentioned, according to international data, nickel is the most common cause of contact allergy. Allergy to nickel occurs 10 times more often in women than in men [118, 146]. In general, nickel-hypersensitive subjects have been found to tolerate orthodontic treatment with nickel-containing devices without symptoms [133], although there are case reports of allergic skin reactions from orthodontic or prosthetic appliances [41, 82, 118, 119, 137, 161, 171, 180, 189]. Relatively few reports of allergic contact dermatitis from stainless steel utensils have been published, among these a rare case of stomatitis after exposure to an impression tray containing 6.7% nickel [149]. On the other hand, intraoral stainless steel appliances may cause systemic contact dermatitis without stomatitis; that is, only extraoral (remote) clinical signs are present (Fig. 14.8a,b) [41, 118, 119, 171, 180, 189]. One such example was reported in a 14-year-old atopic boy after initiation of an orthodontic treatment [119]. The symptoms were crusted yellowish vesicles on and around the lips and reddish eczema with scaling and fissures spreading to the scalp, abdomen, and legs. Patch testing showed positive allergic reactions to nickel and cobalt.

Considering the widespread use of nickel-containing stainless steel in orthodontics, the development of severe dermatitis in this context may be regarded as very rare. In rare cases, a nickel allergic reaction in orthodontic patients may present only with local

Dentlearn.ir

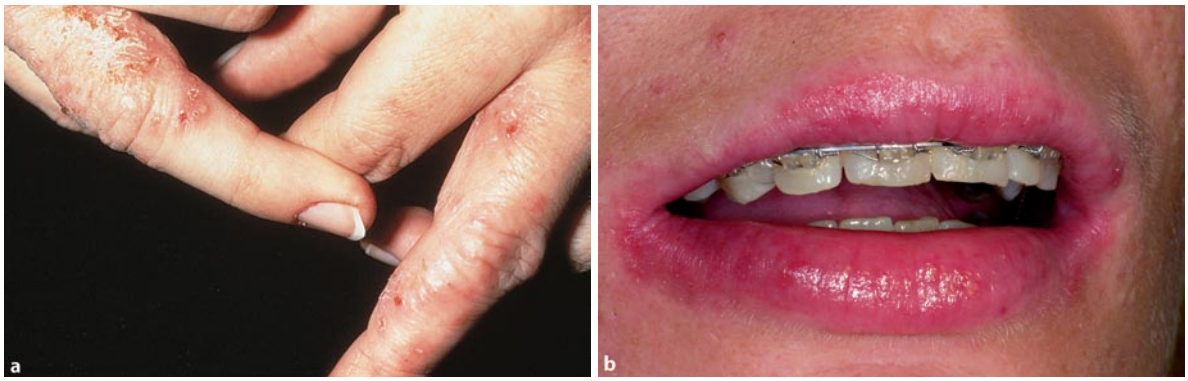

Fig. 14.8 **a** Vesicular dermatitis following insertion of orthodontic appliances in a 15-year-old girl. No stomatitis. Positive patch test result to chromate. Peroral provocation with chromium triggered a blister dermatitis. (Courtesy of N. Veien, Aalborg, Denmark) **b** Perioral eczema in a 24-year-old woman wearing a fixed orthodontic appliance. No intraoral symptoms or signs. Positive patch test to nickel

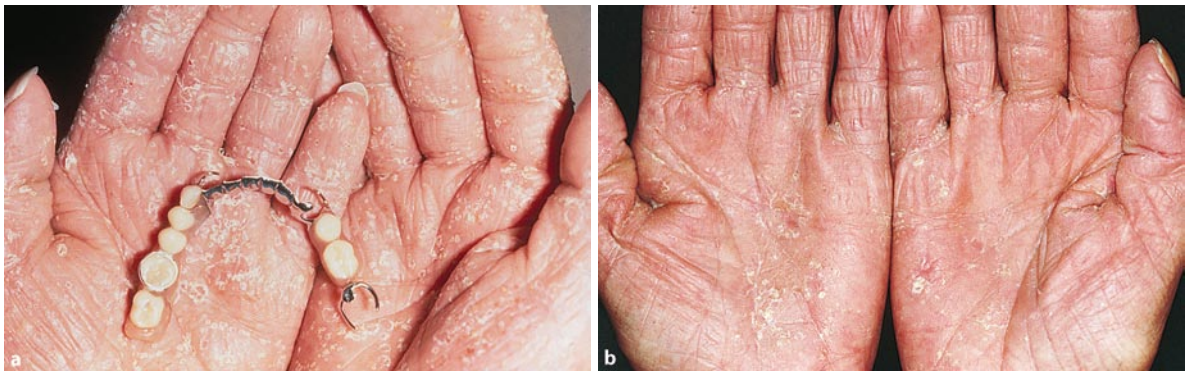

Fig. 14.9 **a** Severe dermatitis of the hand caused by cobalt in a stainless steel denture framework. **b** Marked improvement after covering of the denture framework surface with gold (Courtesy of N. Veien, Aalborg, Denmark)

symptoms in the adjacent oral mucosa or skin [e.g., 43]. In a case with oral symptoms from a nickel-containing dental alloy, the lesion healed after the offending denture was removed [135]. The patient was negative to nickel on normal skin patch testing, but intraoral rechallenge confirmed the mucositis diagnosis [135]. A gold alloy framework was inserted with a successful result. It is possible that metals other than nickel, such as chromates, caused the adverse reaction (e.g., [189]).

In two studies the frequency of nickel dermatitis in adolescents was investigated in relation to gender, onset, duration and type of orthodontic treatment, and the age at which ears were pierced [86, 118]. The results suggested that orthodontic treatment does not increase the risk of developing nickel hypersensitivity. Rather, treatment with fixed intraoral orthodontic appliances at a young age, before experiencing ear piercing, may induce tolerance and reduce the frequency of nickel sensitization [186] (see also Chap. 8).

Cobalt: Cobalt and chromates are common sensitizers; however, this sensitization seldom arises from dental products. Cobalt allergy is often associated with nickel or chromate allergy; for instance, cobalt allergy results from concomitant sensitization because cobalt is present in nickel and chromate products. Most cases of cobalt allergy occur in association with nickel sensitivity in women and chromate sensitivity in men [35]. There is one report of a patient in whom the chrome-cobalt pins used to fasten porcelain teeth to acrylic dentures produced extensive stomatitis and cheilitis [52]. Patients allergic to cobalt in cast denture framework have developed generalized dermatitis (Fig. 14.9) [76, 189].

Dentlearn.ir

Chromium: Allergic contact dermatitis caused by chromate salts was first reported in 1925 and is still common. Hexavalent chromium compounds are considered the strongest chromium sensitizers; according to maximization tests (see Chap. 2), they are categorized as strong to extreme sensitizers. On the other hand, it is generally accepted that chromium metal itself does not act as a hapten and is, accordingly nonsensitizing. It is important to emphasize this difference from certain other metals, such as nickel. Theoretically, fluids such as sweat and plasma can transform metallic chromium into allergenic chromate salts. Saliva may have a similar effect on intraoral devices containing chromium [102]. Chromate contact allergy has a high incidence among workers in the construction industry, probably due to the presence of soluble hexavalent chromium in some cements. Chrome is commonly used in the process of tanning leather, which leaves variable residual chrome on the leather surface. It may also occur in green tattoo pigments. A recent case report showed multiple manifestations of chromate contact allergy due to exposure to the allergen from multiple sources, including construction work (cement), a leather hair tie, leather shoes, and tattoos [58].

Chromate contact allergy has varied clinical presentations. It is often unclear whether chromates or other metals and metal salts caused the allergic reactions that were elicited by dental alloys. Case reports describe patients with generalized eczematoid dermatitis following insertion of dentures with metal framework [53]. Skin tests were strongly positive to nickel and chromium, and the dermatitis subsided after use of the denture was stopped. In most instances in which an allergic reaction is attributed to a metallic chrome object, nickel is the actual sensitizer. A single case of hand dermatitis in a patient who was allergic to chromate but negative on patch testing to nickel has, however, been described (Fig.14.8a) [189]. The dermatitis had appeared shortly after insertion of a stainless steel orthodontic appliance and cleared when the dental appliance was removed. Rare cases of systemic contact dermatitis from chromate in dental cast crowns have also been reported [63].

Mercury (dental amalgam): According to Vernon, Hildebrand, and Martin [190], only 39 cases of amalgam allergy had been reported by 1986, but several investigators have recently shown that it is more common. It seems evident that some patients with allergic contact stomatitis or oral lichen planus (OLP) improve after their amalgam restorations are replaced (Fig. 14.10). (For more details, see Chap.4.)

Irritant reactions from amalgam do occur (Fig. 14.2). Amalgam may thus be an influencing factor in lichen patients, without an allergic mechanism. The true nature of OLP-like lesions in contact with amalgam fillings is not fully clear. OLP may be one disease or a number of similar immunologic or other responses to various interacting stimuli such as plaque, calculus, and mercury from corroding amalgam fillings. Occupational amalgam allergy has very seldom been described in dentists or dental nurses (see Chap. 4).

Palladium: Dermatitis caused by palladium was earlier considered rare, but more recently a number of papers have reported that a significant number of patients who are allergic to nickel also have positive patch test reactions to palladium chloride. In a group of 1,356 unselected eczema patients, 8.3% had an allergic skin-patch reaction to palladium chloride [5]. However, more than 90% of these also reacted to nickel. This was confirmed by other studies [e.g., [199]. Therefore, reactions to palladium chloride may reflect cross-reactions to nickel sulfate due to their proximity in the periodic table. Other possibilities include the following:

- Real sensitivity to palladium chloride, provoked, for instance, by metallic jewelry or orthodontic appliances
- False positive reactions due to the presence of trace amounts of nickel sulfate in the test material
- Concomitant sensitization to both metals

In a study on guinea pigs, palladium chloride was found to be a more potent sensitizer than nickel sulfate [197]. In a patient study including patch testing of 1,307 consecutive dermatology clinic patients with palladium chloride, 2.4% were positive; the majority of these also showed a reaction to nickel sulfate [38]. When patch-tested with a metallic palladium disc, none of them developed a positive reaction. The authors concluded that patients positive to palladium chloride tolerate skin (and apparently mucosal) contact with metallic palladium. It is therefore uncertain whether metallic palladium in the mouth could be dissolved into its salt and accordingly induce contact stomatitis in patients with dental devices containing palladium (see also Chap. 8).

So far, relatively few cases of dentally relevant palladium-induced allergy have been reported. These were mostly related to dental alloys [51, 116, 123, 127, 188]. General, nonspecific symptoms and irritation of

Dentlearn.ir

Fig. 14.10 **a**,**b** Contact lesion in relation to a corroded amalgam restoration. **c**,**d** Total remission after replacement with composite restoration

the oral mucosa were reported to clear when the palladium-containing dental restoration was removed. Another case with combined sensitization to palladium and platinum from a dental alloy (two metal–ceramic bridges and two platinum alloy crowns) was reported [123]. The 36-year-old female patient described swelling and pain of the oral mucosa adjacent to the bridges. The affected areas sometimes became bullous and ulcerative and then superinfected. Symptoms cleared completely after replacement with ceramic and titanium casts. More recently, the first case of palladium-induced granulomatous contact dermatitis was reported in a 15-year-old girl following body piercing with jewelry containing palladium [87].

Gold: Gold salts can be strong sensitizers, but allergy to metallic gold is considered rare. Occupational gold allergy has been reported in the electronics and gold-plating industries. Patch tests for gold allergy include gold salts (goldsodiumthiosulfate, sodium thiosulfatoaurate, potassium dicyanoaurate) because gold leaf, metallic gold, or gold scrapings may yield false negative results. In the last decade, quite a number of gold-allergic reactions (approximately 10% of referred patient groups) were reported in different studies [6, 21, 54, 56, 120, 140, 154, 160, 185], and authors have emphasized that gold is not entirely safe for piercing the ears [144, 164].

Oral symptoms caused by metallic gold in dental applications have manifested as erythema with or without erosions and lichenoid reactions [e.g., 185]. There seems to be a correlation between a positive patch reaction to gold and the presence of dental gold [6, 28, 160, 185]. A number of patient studies have, however, shown that relatively few positive patch test reactions to gold are clinically relevant in relation to oral findings [e.g., 7, 120, 185]. Most important, no correlation was found between positive patch test results to metals and burning mouth syndrome (BMS) [120, 185]. Because allergic patch test reactions to gold salts are common, and mechanisms other than allergy are often involved in OLP and BMS, there is no guarantee that the OLP and burning mouth symptoms of patients who give a positive result in the gold patch test will

Dentlearn.ir

disappear when the dental gold is removed. Metals other than gold may be the cause of gold jewelry dermatitis or stomatitis because gold jewelry is not made of pure 24-carat gold but contains nickel, copper, zinc, silver, or palladium (the constituents of 14-carat or 18-carat gold). Wiesner and Pambor [201] described the case of a 34-year-old woman referred by her dentist because of suspected mercury allergy. One month previously, all of her amalgam restorations had been redone. One week later, redness of the tongue and erosions of the oral mucosa had occurred. Additionally, she reported itching in contact areas of gold jewelry. Patch testing revealed strong reactions to gold and a weak reaction to mercury. Symptoms resolved upon cessation of exposure to the allergens. Ceramics were recommended for future dental restorations.

Platinum: Platinum salts are recognized as potent sensitizers under certain circumstances; for example, there is a high incidence of occupational asthma and rhinitis caused by platinum salts in precious metal refineries. Platinum rarely causes allergic contact dermatitis. Soluble platinum salts have however caused dermatitis, but they more often cause occupational contact urticaria, allergic rhinoconjunctivitis, and asthma. A single case of contact stomatitis due to combined sensitization to palladium and platinum from a dental alloy (bridge) has been reported [123]. Symptoms were recurrent swelling and pain of the oral mucosa with occasional development of bullous ulcerative lesions, which resolved after removal of the bridges.

Silver: Metallic silver is very rarely the cause of allergic contact dermatitis. Silver nitrate (lapis) was previously used as an antiseptic agent. Laine and colleagues reported some dental patients who reacted to silver nitrate on patch testing, but the clinical significance of this finding is not known [129].

Tin: Tin is found in dental amalgam alloy, tin solder, and some dental cast alloys. In 1987 the first cases of tin allergy were reported [141], but they seem to be rare [39]. Nakayama et al. reported on a patient with pustulosis palmoplantaris (a pustular skin disease of the hands and feet) whose skin disease was cured by the total replacement of tin-containing dental alloys with gold alloys [145]. They also reported clearing of pustulosis palmoplantaris or lichen planus in patients with allergy to other metals, including chromate, mercury, platinum, tin, and zinc, after elimination of allergen-containing dental alloys [145].

Zinc: As mentioned in Chap. 4, a few cases of symptoms to zinc released from dental amalgam have recently been published [139, 202, 205]. One week after an amalgam restoration was placed, a female patient experienced a buccal dermatitis; coated, burning tongue; gingivitis; and a widespread erythema of the oral mucosa. She later showed a positive patch test reaction to zinc. Symptoms remitted after the amalgam was removed [202]. Another woman developed extensive eczema on her hands and feet a year after she had five amalgam restorations. She had a positive patch reaction to zinc. Symptoms cleared completely within less than a month after all her amalgam restorations had been replaced with zinc-free materials [205]. A third patient suffered from facial eczema and had positive patch reactions to tin, indium, and zinc [139]. Many years before, she had had a retrograde root canal filling with amalgam in an upper central incisor. A black discoloration of the gingiva could be seen together with a granular radiopaque material extending from the incisal alveolar area to the lower part of the anterior nasal aperture. The foreign bodies were surgically removed, and the dermal symptoms cleared within some months after surgery [139].

Titanium: A few reports indicate that even titanium can act as an allergen, for instance through implanted pacemakers, hip prostheses, and spectacle frames [4, 142, 162, 204]. There are so far extremely few reports on suspected allergic reactions to titanium in dental alloys, which have therefore been suggested as an alternative cast metal for dental patients sensitized to components of, e.g., chrome-cobalt alloys [128, 194]. Schweitzer reported a case of a dental patient sensitized to various metals including nickel, cobalt, chromium, palladium, and copper [162]. She reacted with pain, periorbital edema, and facial erythema after insertion of a metal-ceramic dental restoration (titanium grade 1). Titanium allergy was claimed following a positive reaction to a specimen of the titanium alloy in a patch test. Two similar cases were described by Mitchell et al. [142]. Allergy was not verified by patch testing; the diagnosis was based on the fact that symptoms remitted after the titanium restorations were replaced with gold inserts. It has recently been stressed that because most of the claimed allergic reactions to titanium could not be verified by patch testing with titanium, the described reactions are more likely to be allergic reactions to nickel, for example, since traces of nickel have been found in most titanium grades except iodidtitanium [159].

Dentlearn.ir

14.2.2.2 Rare Metals

Vilaplana and colleagues [193] reported allergic patch test reactions to rare metal allergens such as rhodium, beryllium, copper, and zinc, in addition to allergic reactions to common allergens such as nickel and mercury.

Beryllium: A few reports exist on patients developing gingivitis adjacent to beryllium-containing alloy in their dental restorations [65]. A positive patch test reaction to beryllium sulfate, a component of the alloy, confirmed the allergy.

Cadmium: A single study reported positive patch test reactions to cadmium chloride in dental patients tested with a denture material screening series [59]. The report gained some attention; the results have, however, been questioned because cadmium chloride is generally considered to be a very rare allergen. Moreover, the authors reported that cadmium salts are no longer used as pigments in denture materials [59].

Indium, iridium: Five cases of indium and iridium allergy in patients exposed to dental alloys have been reported [138]. The clinical symptoms were systemic, not oral, but were not described in detail.

14.2.2.3 Acrylate-Based Materials

Biocompatibility aspects of acrylate-based dental materials are reviewed in Chaps. 5 and 9. A major portion of the acrylates used in dentistry are known sensitizers (see Tables 14.3 and 14.4). So far, relatively few dental patients have been reported to be sensitized to dental acrylates. The allergenic potential of acrylates, particularly components of composite resins and dentin bonding agents, is, however, reflected by the increasing number of allergic reactions among dental personnel occupationally exposed to dental methacrylates (Fig. 14.11) [110, 143, 150] (see also Chap. 12). Evaluations of contact allergy epidemics have stressed that the first cases most often appear as a result of occupational exposure, whereas cases among consumers appear later [174]. More patient reactions may therefore appear in the future.

Acrylates are neurotoxic – seven out of 10 dermatology clinic patients with allergy to acrylates complained of paresthesia of the fingertips [105], which was reported to be caused by methylmethacrylate (MMA) and 2-hydroxymethylmethacrylate (HEMA). In recent years, identical symptoms have been reported in an increasing number of case reports on side effects of artificial acrylate-based fingernail cosmetics [e.g., 131, 165]. Acrylates may also cause more widespread dermatitis of the hand or face. Dermatitis of the face and eyelids may be airborne [108, 179] but is more probably "handborne" from contaminated hands [95]. Nondermal symptoms such as allergic conjunctivitis and respiratory hypersensitivity reactions (rhinitis, pharyngitis, asthma) elicited by acrylate exposure have also been described, thus far primarily in relation to occupational exposure [47, 134, 150, 177]. The mechanism is still unclear; it may be a delayed-type allergy, although immediate IgE-mediated allergic reaction is difficult to exclude. So far, the latter type of allergic reactions have not been confirmed by conventional allergy testing and therefore had to be confirmed by provocation test [150].

Fig. 14.11 A 40-year-old male dentist suffering from occupational allergic contact dermatitis. Positive patch test to several components found in methacrylate-based dental materials

Dentures: Kaaber et al. reported 12 cases of allergic reactions to the constituents of denture bases and suggested that sensitization reactions to various types of denture allergens are not unusual in patients with burning mouth syndrome (BMS) [91]. In addition to the burning mouth symptoms, 73% of the patients had stomatitis ranging from distinct erythema to a generalized fiery red surface accompanied by edema in the adjacent soft tissue (see Fig. 14.4a,b). The remaining 26% of the patch-positive patients had no obvious inflammatory changes. Since the report of Kaaber et al. [91], very few reports on verified allergy to denture base acrylates have been published [e.g., 33, 124]. In a

Dentlearn.ir

Table 14.3 Dental screening series of Chemotechnique Diagnostics (Malmö, Sweden) with patch test concentrations (*pet* petrolatum, *aq* aqua)

		Concentration (%) vehicle
Acrylates	Methylmethacrylate	2.0 pet
	Triethyleneglycoldimethacrylate	2.0 pet
	Urethane dimethacrylate	2.0 pet
	Ethyleneglycoldimethacrylate	2.0 pet
	Bis-GMA	2.0 pet
	1,4-Butandioldimethacrylate	2.0 pet
	Bis-MA	2.0 pet
	2-Hydroxyethylmethacrylate	2.0 pet
	N,N-dimethylaminoethylmethacrylate	0.2 pet
	1.6-Hexandioldiacrylate	0.1 pet
	Tetrahydrofurfurylmethacrylate	2.0 pet
Activators and inhibitors	N,N-Dimethyl-4-toluidine	5.0 pet
	4-Tolyldiethanolamine	2.0 pet
	Methylhydroquinone	1.0 pet
	Camphoroquinone	1.0 pet
Metals	Potassium dichromate	0.5 pet
	Mercury	0.5 pet
	Cobalt(II) chloride hexahydrate	1.0 pet
	Gold sodium thiosulfate	0.5 pet
	Nickel sulfate hexahydrate	5.0 pet
	Copper sulfate	2.0 pet
	Palladium chloride	2.0 pet
	Aluminium chloride hexahydrate	2.0 pet
	Tin	50.0 pet
Fragrances	Eugenol	2.0 pet
	Colophony	20.0 pet
Antimicrobial	Formaldehyde	1.0 aq
Ultraviolet absorbers	2(2-hydroxy-5-methylphenyl)benzotriazol (Tinnuvin P)	1.0 pet
	2-hydroxy-4-methoxy-benzophenon	2.0 pet
Resin carrier	N-Ethyl-4-toluensulfonamide	0.1 pet
Additional acrylates, dental	2-hydroxypropyl methacrylate	2.0 pet
	Tetraethyleneglycol dimethacrylate	2.0 pet
	Ethyl cyanoacrylate	10.0 pet
Additional dental materials, staff	Glutaraldehyde	0,2 pet
Additional dental materials, patients	Bis-EMA	2,0 pet
	R-(L)-Carvone	5.0 pet
	Balsam of Peru	25.0 pet
	Epoxy resin	1.0 pet

Dentlearn.ir

Table 14.4 Dental screening series of Trolab (Hermal, Reinbek, Germany) with patch test concentrations (*pet* petrolatum, *aq* aqua)

		Concentration (%) vehicle
Acrylates	2-hydroxyethylmethacrylate (HEMA)	1.0 pet
	Methylmethacrylate (MMA)	2.0 pet
	Ethyleneglycoldimethacrylate (EGDMA)	2.0 pet
	Triethyleneglycoldimethacrylate (TEGDMA)	2.0 pet
	Bis-GMA	2.0 pet
	Urethandimethacrylate (UEDMA)	2.0 pet
Epoxy resin compounds	Bisphenol A (BPA)	1.0 pet
Activators and inhibitors	N,N-Dimethyl-p-toluidine	2.0 pet
	Hydroquinone	1.0 pet
	Benzoyl peroxide	1.0 pet
Metals	Ammoniated mercury	1.0 pet
	Potassium dicyanoaurate	0.002 aq
	Sodium thiosulfatoaurate	0.25 pet
	Palladium chloride	1.0 pet
	Ammonium tetrachloroplatinate	0.25 pet
	Amalgam	5.0 pet
	Amalgam alloy metals	20.0 pet
Aromas	Menthol	1.0 pet
	Peppermint oil	2.0 pet
Fragrances	Eugenol	1.0 pet

group of patients complaining of BMS, 23% had skin patch reactions to MMA [8]. Symptoms resolved following replacement with nylon-based dentures. The authors recommended focusing on reducing the residual monomer to a minimum level. On the other hand, Helton and Storrs, found no positive patch test results when they used 25 known allergens found in dentures to test eight denture-wearing patients suffering BMS [71]. A more recent German study included 732 patients with denture-related stomatitis or oral complaints [59]. The patients underwent testing with a denture-material patch test series. Benzoyl peroxide (BPO) and cadmium chloride were the top allergens, with about 9% positive reactions. The authors assessed the clinical relevance of the positive reactions as doubtful and concluded that in most patients, denture-related complaints are not caused by contact allergies. A rare case of prolonged asthmatic reaction (over 13 years) due to MMA allergy was published by Basker and Hunter [15]. Further, a Japanese report described a case of severe cheilitis caused by acrylate allergy in a denture patient [121]. (See also Sect. 14.2.2.4 on activators and inhibitors.)

Key Note

Rare cases of allergic reactions to denture base acrylates have been presented. But according to the current literature, it can be concluded that in most patients, denture-related complaints are not caused by contact allergic reactions

Dental composite resins and dentin bonding agents: All composite resins and dentin bonding systems contain acrylate sensitizers. However, so far a relatively limited number of reports on dental patients with allergic reactions to composite-resin acrylates have been published. In recent years an increasing number of reports have emerged that describe hypersensitivity from

Dentlearn.ir

dental acrylates in patients previously sensitized via nondental exposure, e.g., from the printing industry, from the manufacturing of contact lenses and hearing aids, or from acrylic fingernail cosmetic products [e.g., 24, 90, 131, 169].

Symptoms experienced by dental patients sensitized to acrylates have included lichenoid reactions, stomatitis (partly papulous), burning mouth, perioral eczema, and urticaria-like complaints [23, 24, 67, 90, 111, 131, 132, 153] (Fig. 14.12). The mechanisms behind those reactions that were IgE-like is not yet clear (see also Sect. 14.3). Further, Lind reported on a patient with a severe generalized stomatitis following replacement of amalgam fillings with composite fillings [132] (Fig. 14.12d). The patient had a positive patch test reaction to formaldehyde, which may be released from dental composites as a degradation product [132]. A few reports on immediate allergic reactions have also appeared [67, 153]. (See also Chap. 5.) Confirmatory data on allergy testing were unfortunately not always presented.

In patients sensitized by nondental exposure, mucosal edema developed after insertion of dental crowns using an acrylate-based cement [131]. Similarly, Jung et al. [90] reported painful intraoral blisters, edema, and erythema of the upper lip and oral mucosa adjacent to an upper central incisor, which the day before had been restored with a temporary acrylate crown fixed with an acrylate-based cement. Patch testing showed a positive reaction to HEMA and ethylene glycol-dimethacrylate (EGDMA). The patient's history, which included eczematous reaction to light-cured sculptured nails 3 years previously, made it likely that HEMA in light-cured nail products was the putative allergen [90]. The potential severity of nondental acrylate sensitization was exemplified by Bong and English

Fig. 14.12 **a** A 54-year-old woman presented with lichenoid desquamative gingivitis regarding 11–16. On suspicion of allergic reaction to composite dental restorations in the region, composite fillings were substituted with light-curing glass ionomer cement (GIC). The dentist was not aware that the GIC contained methacrylates. **b** Seven months following the exchange, the lichenoid lesions were still present. **c** The patient requested porcelain veneers on 16, 13, 12, and 11; remission of the lichenoid reaction was subsequently seen and did not reappear. (Courtesy of P.-O. Lind, Oslo, Norway) **d** In a 61-year-old woman, extensive allergic stomatitis followed replacement of all amalgam restorations with composite restorations. Positive patch test to formaldehyde. The patient improved after removal of the composite fillings [132] (Courtesy of P.-O. Lind, Oslo, Norway)

Dentlearn.ir

[24], who presented a case of a dental patient previously occupationally sensitized to HEMA, triethylene glycol dimethacrylate (TEGDMA), and bisphenol A diglycidylether methacrylate (Bis-GMA) by his work in a printing company. He developed a severe facial dermal allergic reaction from visiting a dental clinic for a routine examination. No acrylate work had been performed.

Patch testing of sensitized patients with an extensive methacrylate test series revealed that interpatient cross-reactions to acrylates vary [32, 93, 94, 99]. Furthermore, concomitant sensitization to the various acrylates of the composites also occurs. (See also Chap. 1.) Because dental personnel, for example, are often exposed to various composites, and because differences in the composition between batches may even occur, it may be difficult to reveal the origin of the sensitization. The well-known sensitizer HEMA was shown in a number of surveys to be the most common sensitizer among patients referred for patch testing with acrylate test series [e.g., 60, 61, 62, 131, 168]. HEMA is currently used in a great number of bonding agents/adhesives, often combined with organic solvents (acetone, alcohol), which may facilitate penetration through the biological barriers of skin and mucosa.

14.2.2.4 Activators and Inhibitors

Widely used activators (primarily in denture acrylate formulations) are included in the commercial dental patch series (Table 14.3), namely the tertiary amine N,N-dimethyl-p-toluidine (DMpT) and another amine accelerator, 4-tolyldiethanolamine. Despite their widespread use, only a few reports on allergic reactions due to dental use are available.

DMpT: Few case reports have been presented. Kaaber, Thulin, and Nielsen reported one positive skin reaction to DMpT among 53 denture wearers [91]. A few other reports on patients with "denture sore mouth syndrome" from DMpT are available [44, 178, 191]. Interestingly, DMpT has also caused allergy from its use in bone cement, causing aseptic loosening of total hip replacements.

4-Tolyldiethanolamine: This amine is a less toxic accelerator than DMpT. A few papers have reported positive patch test reactions to 4-tolyldiethanolamine in dental personnel [50, 97, 157] as well as in dental patients [44, 157].

Benzoyl peroxide (BPO): In a few dental patients, BPO has caused stomatitis [37, 44, 59, 91], and a few cases of occupational allergic contact dermatitis have been described [40, 98, 152]. Two of these reactions were induced by airborne contact. Loosening of external limb prostheses (hip, arm) due to an allergic reaction to BPO in acrylic bone cement has been reported [84, 195].

In addition to prosthetic applications, BPO is used for treating acne and stasis ulcers. BPO in acne preparations and baking additives is a rare sensitizer but is more common when used on leg ulcers.

Camphoroquinone: Camphoroquinone is used as an initiator for visible-light-cured dental acrylic composite materials and primers. It has been included in the dental screening series because it is widely used in dentistry. One unfortunate case of active sensitization from patch testing has been reported [136].

Hydroquinone and methyl hydroquinone (inhibitors): Hydroquinone is used in acrylic systems to prevent unintended spontaneous polymerization. Hydroquinone has several other applications and is used, for instance, in bleaching creams and radiographic developers. It has caused occupational depigmentation (vitiligo) in relation to photographic development [100]. Monobenzyl ether of hydroquinone is both a stronger inducer of depigmentation and a sensitizer. Hydroquinone released from acrylic dentures has on rare occasions caused gingivostomatitis [176] (Fig. 14.6).

14.2.2.5 Epoxy Compounds

Diglycidyl ether of bisphenol A (BADGE): Epoxy resins based on diglycidylether of bisphenol A are strong contact sensitizers [88] (see also Chap. 14, Sect. 14.2.2.7). BADGE-based epoxy resins are used in adhesives, surface coatings, electrical insulation, plasticizers, and polymer stabilizers in the building industry, electron microscopy, sculpture, and so on. BADGE-based epoxy resin is a common occupational allergen, and it belongs to the standard patch testing tray. It is used in the production of some dental composite resins, which may thus contain BADGE as an impurity. There is some evidence that BADGE and epoxy acrylates may cross-react in some individuals. Some of the patients sensitized to dental composite resins have also shown a positive patch test reaction to BADGE, and vice versa [32, 93, 94, 99].

Dentlearn.ir

Bisphenol A/epichlorohydrin: Bisphenol A (BPA) is the raw material in the production of epoxy and acrylic resins. Only a few cases of allergic contact dermatitis have been reported [48]. Also, epichlorohydrin, another starting substance in the production of epoxy resin, may act as an allergen in persons occupationally exposed in epoxy resin production plants. One case of occupational allergic contact dermatitis in a dental assistant that was caused by BPA has been reported [89]. There is one published case of BMS in a patient with denture of unknown composition [187]. The patient had a positive patch test reaction to BPA and epoxy resin. It was hypothesized that epoxy resin used for denture repair could have caused the sensitization. BPA is also used as an additive in polyvinyl chloride (PVC) plastics. Two cases of the development of contact allergy to BPA in PVC gloves – a dentist and an oral hygienist who had used disposable PVC gloves – have been reported [3].

14.2.2.6 UV Absorbers

2-Hydroxy-4-methoxy-benzophenone (benzophenone-3): Benzophenones are incorporated as ultraviolet (UV) absorbers in some dental composite materials as well as other plastics, textiles, and sunscreens. Allergic and photoallergic contact dermatitis has been reported from sunscreens [100]. There are so far no reports of dentistry-related allergic reactions.

2-(2-Hydroxy-5-methylphenyl) benzotriazole (trade name Tinuvin P): Tinuvin P is a UV absorber for dental materials, acrylates, plastics, cosmetics, dyes, and so on. There is one report on allergic reaction to Tinuvin P in a dental composite [22]. Allergic contact dermatitis caused by Tinuvin P has been reported with cosmetics, plastic watchstraps, colostomy bags, and tape sewn onto underwear.

Formaldehyde leaching from dental acrylates: Cases of lichenoid reactions contacting resin-composite materials believed to be caused by formaldehyde leached from resin composites have been reported [23, 132] (Fig. 14.12d). Significant amounts of formaldehyde may be released from methacrylate-based dental restorative materials as well as from denture base acrylates [148, 181]. Active sensitization from this source of formaldehyde is probably negligible [49].

Glass ionomer cements: There are so far no reports of patients or dental staff with a verified allergic reaction to components of conventional glass ionomer cements.

Light-cured hybrid glass ionomers: A 30-year-old dental nurse developed occupational fingertip dermatitis typical of allergic contact dermatitis caused by acrylate compounds [104]. Her dermatitis healed on vacations but relapsed on reexposure. She had daily exposure to light-curing hybrid glass ionomers, bonding agents, dentin primers, and dental resins. Patch testing revealed that she had become sensitized to HEMA as well as to hybrid glass ionomer, which contain the same sensitizers as other dental acrylates.

Clinical Practice Advice

The dentist should be aware that because of the widespread and increasing application of acrylates in nondental professions and in the population in general, dental patients may have become sensitized (or cross-reactive) to acrylates identical or similar to those used in dental applications.

14.2.2.7 Root Canal Sealers and Cavity Liners

Allergenic components are constituents of the most widely used root canal sealers.

Although the sensitizing potential of sealers has been documented in animal studies, the number of verified hypersensitivity reactions in humans following root canal treatment is very small. The few case reports have described reactions to eugenol in zinc eugenol cement and BADGE in the resin AH_{26} (see also Chap. 7). The allergenic potential of epoxy-containing root canal sealers is well documented [72]. Reactions in dental patients are rare but have been described [78, 79] (Figs. 14.13 and 14.14). A severe allergic reaction caused by root canal filling with AH_{26} is shown in Fig. 14.14. Some hours following root filling of tooth 36, the patient developed swelling and erythema of the right side of the face and neck. Symptoms were erythema of the soft tissue adjacent to 36 and tenderness to percussion. The symptoms subsided after a few days. The patient recalled that similar symptoms, though less pronounced, had arisen previously in relation to root canal treatment. The patient was referred to a dermatologist, and a strongly positive patch test to bisphenolglycidyl dimethacrylate (Bis-MA), Bis-GMA, and epoxy acrylate was demonstrated. After removal of the root filling, the canals were obturated

Dentlearn.ir

Fig. 14.13 Allergic reaction (delayed) to components of the root canal sealer AH_{26} (Courtesy of P. Hørsted-Bindslev, Århus, Denmark)

Fig. 14.14 Severe angioedema. Allergic reaction to epoxy components of the root canal sealer AH_{26} (Courtesy of J. Kølsen Petersen, Århus, Denmark)

using gutta-percha points sealed with a zinc eugenol cement, without complications. Epoxy resin compounds can be found in glues and paints, and sensitization from nondental exposure prior to root canal treatment is more likely.

N-ethyl-4-toluene sulfonamide is used in at least one cavity liner (Alkaliner). Because of its widespread use in some countries, N-ethyl-4-toluene sulfonamide has been included in dental patch test screening series (Table 14.3). In a Swedish multicenter study, nine out of 1,657 patients with oral symptoms had an allergic patch test reaction to N-ethyl-4-toluene sulfonamide (Björkner, unpublished). There is one report on a dentist with allergic patch test reactions to N-ethyl-4-toluene sulfonamide [97].

14.2.2.8 Antimicrobials

Formaldehyde: Formaldehyde is one of the most common sensitizers, and details of allergic contact dermatitis from formaldehyde can be found in textbooks. It should be remembered that a high number of antimicrobials are formaldehyde releasers, and the user may become allergic to either formaldehyde or the formaldehyde releaser. Formaldehyde is included in both the standard patch test series and the dental screening series (Table 14.3). Some dermatology clinics have also included glutaraldehyde and glyoxal in their series.

Glutaraldehyde: Glutaraldehyde has been used as a germicidal agent for disinfecting dental and dialysis equipment. It has also been used in some dentin adhesives and bonding agents. Glutaraldehyde is moderately irritative and considered to be sensitizing [100]. Sensitization to glutaraldehyde has occurred mainly through its use as a cold-sterilizing solution in hospitals and dental clinics. Contact dermatitis has been reported in operating theater staff, in an assistant at a renal dialysis unit, and in dental assistants [36, 100]. Glutaraldehyde and formaldehyde usually do not cross-react. If a subject is allergic to both, it indicates concomitant sensitization. Irritant mucosal reactions (ulcerations) have been described following unintended prolonged mucosal exposure to glutaraldehyde containing dentin bonding agents and a dentine desensitizing agent [11].

Glyoxal: Glyoxal (ethanediol) is a dialdehyde that can be a component in many products used to disinfect dental equipment and rooms in dental practices, for example. One report described a dental nurse who had developed occupational allergic contact dermatitis from glyoxal, glutaraldehyde, and neomycin [113]. A Finnish study described 20 patients with contact allergy to glyoxal. Five of these patients had handled glyoxal-based disinfectants in dental care [2].

Benzalkonium chloride: Contact allergy to benzalkonium chloride and glutaraldehyde was described in a dental nurse handling a sterilizing solution [36].

Chlorhexidine: Since the introduction of chlorhexidine in the 1950s, allergic contact dermatitis, generalized dermatitis, photosensitive dermatitis, fixed drug

Dentlearn.ir

eruption, contact urticaria, occupational asthma, and immediate IgE-mediated hypersensitivity reactions, including anaphylaxis, have been reported (see information below on immediate allergic reactions). In view of its wide use, delayed allergic contact reactions can be considered very rare; however, when they occur, they may cause a severe dermatitis reaction [60]. Immediate reactions due to exposure to the chemical are more important than delayed reactions [49, 175]. (See also Sect. 14.3.3 and Chap. 10.)

14.2.2.9 Other Disinfectants

1,2-Benzisothiazolin-3-one (BIT): About 10 cases of occupational contact allergy from vinyl (PVC) gloves due to antimicrobial BIT were reported in 2006–2007 in Finland. Most of the patients had worked in dentistry or health care [1].

N-benzyl-N,N-dihydroxyethyl-N-cocoalkyl-ammonium chloride: Hand dermatitis from N-benzyl-N, N-dihydroxyethyl-N-cocoalkyl-ammonium chloride, present in some disinfectant wipes used in dentistry, was reported in a dental nurse [151]. The same compound is present in some mouth rinse products.

Sodium hypochlorite: Sodium hypochlorite (NaOCl) is widely used for disinfection and as an irrigation solution in root canal treatment. It has also been introduced in relation to abrasive caries excavation techniques (e.g., Carisolv). Allergy is uncommon, but rare cases have been described from dental use (local as well as systemic symptoms) [30, 117].

Monoethanolamine: Most recently, the first case of a dental nurse developing work-related vesicular dermatitis following sensitization to ethanolamine was published [183]. She had been exposed for several years to a commercial product containing ethanolamine used for cold sterilization of dental instruments.

14.2.2.10 Fragrances and Colophony

Eugenol: Eugenol is the essential chemical constituent of clove oil and is also present in cinnamon oil, perfumes, soaps, bay rum, oil of carnation (hyacinth), pimento oil (allspice), flower oils, food spices, chewing gum, and flavorings. When eugenol is used in dental preparations, such as impression pastes, surgical packing, and cements, it may produce contact stomatitis and allergic cheilitis [192] (see also Chaps. 6, 10, and 11). Allergic eczema and rhinitis have been described in dental personnel [107]. Eugenol is highly soluble and continuously released from zinc oxide eugenol materials. An allergic reaction to flavorings in chewing gum, presenting as intermittent perioral eczema, was reported in a 10-year-old girl [20]. Eugenol is one of the eight components in the fragrance mixture that belongs to the standard patch test tray. It seems to be a less common sensitizer than cinnamic aldehyde, cinnamic alcohol, or isoeugenol, which may be found in oral hygiene products (see also Chap. 10).

Colophony (rosin): Rosin is widely used as a fragrance as well as a flavoring agent. It may be present in dental materials such as periodontal dressings, impression materials, cements, and cavity varnishes. An allergic reaction to Duraphat was reported in a dental nurse with hand dermatitis [80, 112]. Patients have developed allergic contact stomatitis and widespread eczematous dermatitis after dental treatment [27]. Colophony may also be part of the gum base in chewing gum, and oral contact allergy (painful ulcerations, burning mouth) has been misdiagnosed as an oral mucosa disease [20, 64] . Patients with allergic patch test reactions to colophony often also react to Balsam of Peru and fragrance mix [115].

Balsam of Peru: Because of its antiseptic and aromatic properties, balsam of Peru (or Peru balm or *Myroxylon pereirae* resin) is widely used as a fragrance as well as a flavoring agent. It can be found worldwide, not only in many health care and cosmetic products but also as a common flavoring agent in food, drinks, and sweets. It is a ubiquitous contact sensitizer that, according to several national and international surveys, belongs to the "top five" group of allergens most frequently causing positive patch test reactions in patients referred to dermatology clinics [e.g., 126, 184, 200]. In dentistry, balsam of Peru may be found in oral hygiene products and in some dental materials, such as periodontal dressings and impression materials. Oral exposure to balsam of Peru in sensitized individuals may elicit allergic reactions in the orofacial region (e.g., lips and the oropharyngeal mucosa). As an example, painful tongue erosions were recently related to the intake of large quantities of diet cola drink [81]. Cross-reaction with orange juice may take place [81].

Dentlearn.ir

Clinical Practice Advice

The dentist should be aware that fragrances and flavorings frequently found in food, drinks, sweets, cosmetics, and oral hygiene products may, in sensitized individuals, elicit allergic reactions in the orofacial region after oral exposure. Such reactions may be misdiagnosed as oral mucosa disease or adverse reactions to dental materials.

14.2.3 Epicutaneous Test (Patch Test)

When contact allergy from dental products is suspected, epicutaneous patch testing needs to be considered. Patch testing should be performed only by dermatologists. In patch testing, the test materials are occluded for 48 h, whereupon the first reading is performed. It is very important to perform at least one more reading at 72 h (3-day reading) or 96 h (4-day reading). Sometimes a reading after 7 days is done to detect very late reactions, caused, for example, by corticosteroids or neomycin. The presence of erythema combined with edematous infiltration with or without papules or vesicles is used as the criterion for an allergic patch test reaction (see also Chap. 2). There is no need to perform an epimucosal patch test to detect contact allergy in the oral mucosa because the epicutaneous test gives the applicable information. A method for intraoral patch testing has been described but has never received large clinical use [13].

Patch testing includes a standard series (20–30 substances), a dental screening series, and, eventually, additional haptens (allergens) brought in by the patients. Quite a large number of test substances are commercially available (e.g., see Tables 14.3 and 14.4). Some specialized dermatology clinics have modified the standard series by including further relevant substances/haptens.

Key Note

When a patient is referred to a dermatologist for patch testing, the dentist should ensure that relevant allergens are included in the test series.

Regarding patch testing with acrylates, analyses have shown that undeclared but highly sensitizing acrylates may constitute up to 46% of several acrylate-based products [101]. Patients as well as dental personnel have normally been exposed to a number of acrylate-based products that may therefore contain numerous different acrylates, a major portion of them being undeclared. On patch testing, the sensitized patients may show allergic patch test reactions to many acrylates, but because their exposure history is unknown, it cannot be concluded whether the allergic patch test reactions represented cross-allergy or concomitant allergy. Patients may even develop allergic reactions to other types of impurities present in the acrylate resins – for instance, to epoxy resin, which may have been used in the manufacture of epoxy acrylates.

In theory, the commercial patch test substances may sensitize, but the current patch test concentrations seem to be safe. Since some of the acrylates are potent sensitizers, the possibility of active sensitization in relation to diagnostic procedures has been considered a problem, particularly in relation to this group of substances. In some cases, patch testing with patients' "own" acrylates is relevant [109, 196] and may be the only way to detect new allergens. Possible sensitization during testing with the patient's own acrylates, however, has to be considered. A dental patient has been reported to have been sensitized from patch testing with 100% dentin bonding acrylates [106]. It is recommended that the patch test concentration not exceed 1% pet for dentin bonding components and dental composite resins. Experienced laboratories may use higher test concentration (second patch test sessions).

Key Note

Provocation tests with undiluted acrylates should not be done on the skin because of the risk of active sensitization.

14.3 Immediate Allergic Reactions (IgE Mediated)

14.3.1 Clinical Picture

An immediate allergic reaction (IgE mediated; type I) occurs when an allergen enters the circulation by ingestion or parenteral routes, localizes in a target tissue (e.g., in the oral cavity), and binds with IgE mast cell complexes, which release histamine and may cause oral vesiculo-ulcerative lesions, urticaria, angioedema, or/and anaphylactic shock.

Dentlearn.ir

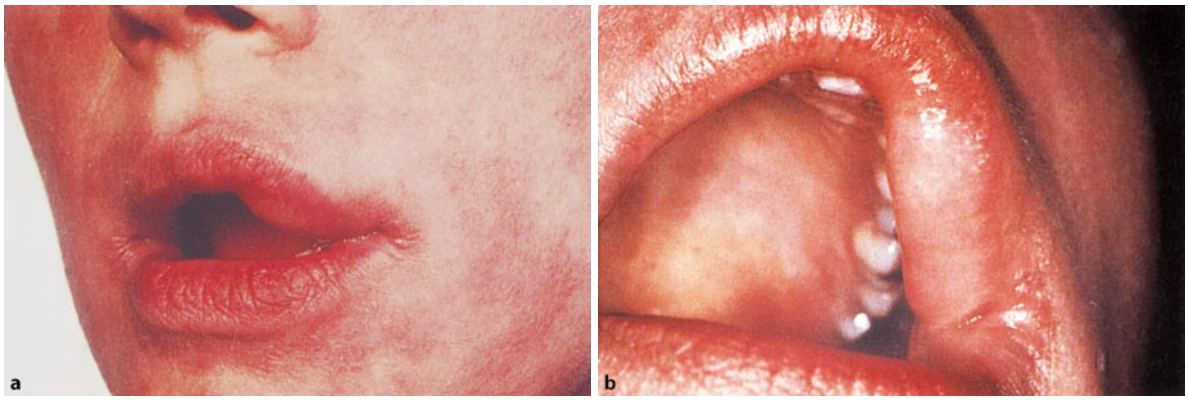

Fig. 14.15 **a**,**b** Swelling of the upper lip (immediate IgE-mediated allergic reaction to natural rubber latex) following contact with disposable latex gloves worn by the dentist [29] (Courtesy of F.J.T. Burke, Glasgow, Scotland, and Quintessence Publishing)

Angioedema produces a diffuse swelling of the facial tissues over a large area. The most frequent manifestation is a single swollen lip (Fig. 14.15); however, the upper as well as the lower lip, the eyelids, or the whole face may be affected. The tongue and floor of the mouth may also be swollen. The most common causes are foods and drugs.

Contact urticaria is a local immediate urticarial and/or erythemal or pruritic reaction at the site of epidermal or mucosal contact with the causative agent. Generalized cutaneous reactions, rhinitis, asthma, or anaphylaxis may be associated. The symptoms range from invisible subjective symptoms to mild erythema and/or itching, and even death has been reported. Contact urticaria may be allergic or nonallergic. The best-known allergic reactions are the IgE-mediated immediate reactions caused by proteins (for example, natural rubber latex proteins), but chemicals may cause similar reactions. Extensive lists of causative agents are found in textbooks.

14.3.2 Verified Immediate Allergic Reactions to Dental Materials

Natural rubber latex (NRL) is the most important cause of contact urticaria in general, especially for medical and dental personnel. Dental patients are also a special risk group because mucosal contact in sensitized individuals usually gives a stronger reaction than skin contact. Dental patients should always be asked about a possible latex allergy. In cases of known allergy, no rubber equipment such as rubber gloves, dental rubber dams, or rotating rubber tools can be used. The clinical symptoms are urticaria, rhinoconjunctivitis, asthma, Quincke's edema, and, in severe cases, anaphylaxis. An increasing number of cases of anaphylactic reactions to NRL have been reported, including in dentistry [29] (Figs. 14.15–14.17). Reviews have reported that up to 10% of oral health care workers have positive prick tests to NRL (e.g., [182]). Two studies among dental students in Germany and Canada showed increasing incidence of type I allergies to latex gloves during the course of study [70, 172]. Encouraging news, however, is that a reduction in the use of powdered latex gloves coincides with a marked decline in the number of latex skin allergic reactions and occupational asthma [9, 10]. The powder is not considered an allergen (see below); however, it acts as a carrier of the latex proteins, thereby spreading the allergens in the occupational environment.

Nitrile gloves: Nitrile gloves do not contain NRL proteins. A number of other chemicals are, however, identical in NRL and nitrile gloves. Contact urticaria caused by nitrile gloves has been described [26, 75]. The nitrile glove itself as well as the rubber chemical, morpholinyl mercaptobenzothiazole, have led to positive allergic tests. Nitrile gloves also contain benzothiazoles, which probably caused the contact urticaria reaction.

Cornstarch: Cornstarch used in powdered NRL gloves may also be the cause of glove allergy, although the allergen in the glove powder is usually NRL released from the glove into the powder.

Dentlearn.ir

Fig. 14.16 Female patient **a** before and **b** after provocation test with disposable powdered latex gloves. Immediate development of periorbital swellings and asthma. (Courtesy of H. Allmers, Osnabrück, Germany)

Fig. 14.17 Contact urticaria (immediate, IgE-mediated allergic reaction) following occupational exposure to latex proteins in disposable gloves (Courtesy of K. Turjanmaa, Tampere, Finland)

Gutta-percha: Gutta-percha is obtained from the viscous milky latex of the *Palaquium* tree from southeast Asia. Compared with the manufacture of rubber, no preservatives or vulcanizing agents are added to gutta-percha. Zinc oxide, which acts as filler; barium sulfate, which results in radiopacity; and pigment are added to the final gutta-percha product. Gutta-percha and natural rubber are derived from trees in the same botanical family and may have the potential of cross-reactivity. A case of NRL allergy in a dental hygienist who had a root canal treatment was reported [25]. Despite avoiding latex gloves during the surgery, the patient reported immediate discomfort, lip and gum swelling, a throbbing sensation around the tooth, and diffuse urticaria. She developed persistent oral discomfort, swelling, and urticaria. Four weeks later the gutta-percha point was removed, and the patient experienced immediate relief of her oral discomfort. The urticarial lesions resolved within a few hours. The authors were not able to demonstrate an allergic prick test or IgE antibodies to gutta-percha, but they did conclude that allergic reactions may occur in patients with NRL allergy as a result of exposure to gutta-percha during endodontic surgery. As discussed in Chap. 7, this conclusion remains controversial. Natural rubber and gutta-percha

Dentlearn.ir

represent examples of isomerism. Both are high-molecular-weight polymers and are structured from the same basic building units. According to older studies, gutta-percha and NRL do not cross-react.

Fibrin tissue (bovine protein): Two cases of patients who developed urticaria and shortness of breath 1 h after dental examination and tooth extraction have been published [147, 203]. In both cases, extraction sockets had been filled with fibrin tissue (Hemofibrine) to stop bleeding. The causative agent was believed to be the fibrin tissue (bovine protein).

14.3.3 Chemicals with Low Molecular Weight

Haptens may also cause IgE-mediated type I allergic reactions. The hapten binds to a protein or another macromolecule, and the resulting hapten-carrier conjugate acts as the allergen.

14.3.3.1 Metals

A number of metals may cause contact urticaria, including cobalt [167] and nickel [45, 46]. Platinum is a strong type I allergen [14], and iridium, one of the platinum group metals, was also reported to induce respiratory allergy and contact urticaria [19]. Other metals in the platinum group that have caused immediate allergy are ruthenium, rhodium, and palladium. Sodium fluoride has caused contact urticaria in a few cases [31]. A few controversial case reports on immediate-type allergic reactions to mercury from dental amalgam are discussed in Chap. 4.

14.3.3.2 Antimicrobials

Formaldehyde: Formaldehyde has caused anaphylaxis after application of a formaldehyde-containing root canal sealer [198]. The patient had a positive radioallergosorbent test (RAST; see also Chap. 2, Sect. 2.3.1) to formaldehyde, whereas skin prick testing and patch tests were negative.

Chlorhexidine: Chlorhexidine caused anaphylactic reactions in two dental patients in Denmark (for details, see Chap. 10). Both patients were healthy and unaware of their allergy. The first developed anaphylaxis when chlorhexidine liquid was sprayed into the cavity after extraction of a wisdom tooth. The other patient suffered from pericoronitis and developed anaphylaxis when Hibitane Dental Gel 1% (e.g., chlorhexidine) was applied to the gingival pocket. Furthermore, a number of severe cases of allergic reactions to chlorhexidine applied to compromised mucosa or skin surfaces have been reported [16], and two cases of anaphylactic shock following application of chlorhexidine on unbroken skin have been reported [12, 125].

Chloramine-T: In some countries, the use of chloramine-T for disinfection purposes has greatly increased. Asthma, allergic rhinitis, and contact urticaria in dental staff have been reported [103].

14.3.3.3 Fragrances and Flavorings

Eugenol: Eugenol in dental preparations may produce stomatitis, eczema, or contact urticaria, probably nonimmunological [156]. Contact urticaria may possibly be induced by many other fragrances, too, although reports are scarce. Contact urticaria was reported from cinnamic aldehyde and benzaldehyde [163].

14.3.3.4 Medicaments

- Local anesthetics, such as benzocaine, have induced contact urticaria, although reactions are rare (for a review, see [100]).
- Corticosteroids may elicit both delayed and immediate allergies. Propylene glycol is widely used in medical lotions and creams and may induce immediate skin reactions.
- Various antibiotics also used by dentists, such as rifamycin, may cause contact urticaria.
- Pain-relieving chemicals, such as aminophenazone, have caused contact urticaria.
- Dental personnel may develop contact urticaria from their patients' topical medicaments, or vice versa, e.g., from antiinflammatory ointments such as etofenamate or from monoethyl fumarate (for a review, see pharmacology textbooks).

Rubber chemicals: On rare occasions, chemicals, and not the NRL proteins, have been reported to cause contact urticaria from rubber products [17].

Acrylates: Immediate hypersensitivity, such as contact urticaria, pharyngitis, and/or bronchial asthma, has been reported from cyanoacrylates, methylmethacrylate, acrylic acid, and nonspecified acrylates [67, 96,

Dentlearn.ir

153, 155, 158], but the mechanism of action is not known. Recently, 30 cases of respiratory hypersensitivity (mainly asthma) from acrylates were reported [150]. Prick tests were negative, indicating that something other than IgE-mediated mechanisms may have been involved.

14.3.4 Skin Test with Low Molecular Weight Compounds

For skin testing with proteins, see the information on prick testing in Chap. 2, Sect. 2.3.1. Because the low-molecular-weight-compound allergen is believed to be a hapten–carrier conjugate, the skin testing should ideally be performed with a hapten-carrier conjugate and not the hapten. In some cases, positive skin-test reactions may be obtained with the hapten without conjugation, using, for example, patch test substances in petrolatum. However, haptens in petrolatum (e.g., the patch test substances) often do not give an allergic prick-test reaction. Preformed hapten-carrier systems have therefore been developed. Human serum albumin (HSA) has been used as the carrier. Commercial HSA–hapten prick-test substances are not available.

14.3.5 Management of Acute Allergic Reactions

Dental restorative materials can theoretically induce immediate allergic and pseudoallergic reactions similar to other allergic reactions caused by chemicals and drugs used in dental practice, so the dentist must be prepared to manage an immediate reaction. Grading of symptoms observed in relation to immediate allergic (IgE-mediated; anaphylactic) reaction is presented in Table 14.5, and textbooks should be consulted for further details. A thorough medical history is essential to avoid challenging a patient with an agent for which intolerance has been proven.

Table 14.5 Grading of symptoms observed in relation to immediate allergic (IgE-mediated; anaphylactic) reaction

	Symptoms
Grade I	Skin reaction (flush, urticaria, pruritus) Agitation Headache Mucosal reactions
Grade II	Generalized urticaria Hypotension Tachycardia Nausea, vomiting Arrhythmia Intestinal spasms
Grade III	Shock Bronchospasms (wheezing); increasing occlusion of the airways Laryngeal Quincke's edema Spasms
Grade IV	Block of circulation and respiration

14.4 Diagnosis of Side Effects Caused by Dental Materials

14.4.1 Anamnesis

A firm strategy for thorough examination of dental patients alleging symptoms as side effects of dental materials is recommended. First of all, a thorough medical history will elucidate the patient's general health status. Special attention must be focused on proven allergies and medication aspects. A comprehensive checklist for examination is given in Table 14.6. Patients often attribute common drug-induced symptoms such as dysgeusia (e.g., metallic taste), burning mouth, stomatitis, glossitis, sore gums, discoloration, and similar symptoms to the effects of dental materials rather than to medication. Oral side effects of the 200 most frequently prescribed drugs in the United States in the 1990s include the following [166]:

- Xerostomia
- Dysgeusia
- Stomatitis
- Glossitis
- Discoloration of the tongue
- Hypersalivation
- Gingivitis
- Orodynia
- Gingival hyperplasia
- Alveolitis sicca (dry socket)
- Discoloration of the teeth
- Candidiasis

Clinical Practice Advice

If drug effects are suspected, temporary substitution of the drug in question should be discussed with the patient's physician.

Dentlearn.ir

Table 14.6 Checklist for anamnesis and clinical examination of patients ascribing symptoms to side effects of dental materials

Anamnesis
- Subjective symptoms
- Previous and present diseases, illnesses
- Allergies (history, eliciting factors)
- Medication (past, present)
- Previous examinations, treatment regimes
- Tobacco
- Alcohol
- Oral hygiene routines
- Social relations

Clinical examination
A. General health status
B. Odontological status
- Dental status praesens diagram
- Restorations (materials)
- Abrasion
- Caries
- Periodontal status
- Salivation
- Temporomandibular function
  - Joints
  - Muscular function
  - Occlusion / articulation
- Removable prosthetic appliances
  - Function
- Oral mucosa
  - General features
  - Lesions in contact with dental materials
  - Lesions without contact to dental materials
  - Detailed description of lesions (color, surface characteristics, texture, morphology)
- X-rays
  - Preferably an OTP or full status
  - Description of caries
  - Periodontium, marginal/apical
  - Endodontic treatments
  - Retained teeth
  - Other findings
- Additional tests (when relevant)
  - Pulp vitality
  - Mucosal smear (examination for fungal infection)
  - Sialometry
  - Biopsy

Diagnoses
- Odontological
- Others

Conclusions

Odontological treatment

The dentist should be aware that both nutritional deficiencies and extensive intake of nutritional additives (e.g., so-called health products) may also cause oral symptoms. Adjusting nutritional intake or temporarily discontinuing intake of nutritional additives may be recommended. Furthermore, attention should be focused on the patient's use of oral hygiene products, chewing gum, and cosmetics, since these products may contain substances that can potentially elicit irritative or allergic reactions [e.g., 20, 42, 55, 64].

Key Note

When allergy is suspected, the patient should be specifically questioned whether oral or skin symptoms occurred in relation to dental treatment or whether rash or eczema developed after the wearing of watches, earrings, other jewelry, etc. In cases where such skin symptoms are present, referral to a dermatologist for further evaluation is most often relevant.

14.4.2 Local Irritative Reactions

In cases of *acute local irritative reactions* (see also Sect. 14.1.1), the causative exposure should be discontinued and measures taken to secure minimal chemical, mechanical, and biological (plaque) exposure during the healing period. *Chronic irritative reactions* may often be multifactorial. Diagnosis is obtained by exclusion, and exposure to the eliciting material or insult should be eliminated. In many cases it may be relevant to include histologic examination of a swab from the oral mucosa to diagnose or exclude a fungal or bacterial irritation.

14.4.3 General Symptoms

Patients linking *general (often unspecific) symptoms* to dental materials, as described in previous chapters in relation to dental amalgams, alloys, and composites, represent a major challenge to the practicing dentist. In these cases, the diagnostic strategy outlined in Table 14.6 should be followed. Studies have shown that in many cases, marked improvement can be achieved by thorough dental diagnostics and treatment in combination with an open and informative dialogue with the patient. Relief or satisfying improvement of symptoms in up to 90% of patients initially complaining of symp-

Dentlearn.ir

toms related to amalgam fillings were thus reported after thorough odontological and medical diagnosis and dialogue, extensive dental treatment, altered medication when indicated, and strengthening of the patient's social network [77, 130]. In a number of the patients, the dental treatment even included placement of new amalgam fillings. The studies have emphasized the importance of considering differential diagnoses. It was, for example, shown that about half of a patient group claiming symptoms of electric currents were found to suffer from symptoms due to mandibular dysfunction [68]. When more than 200 patients with self-diagnosed so-called oral galvanism were evaluated, it was in all cases possible to identify one or several probable medical diagnoses (among these, two cases of undiagnosed cancer) [74]. The authors found a total of 23 cases of previously undiagnosed conditions and called attention to the fact that further to adequate dental diagnostics and treatment, there may often be a need for thorough medical investigation of patients presenting nonspecific general symptoms [74].

Key Note

Because a nonodontological medical diagnosis, as mentioned above, may be highly relevant, consultation with other medical professionals (e.g., internists, dermatologists, psychiatrists) should be thoroughly considered in cases of persisting general symptoms that cannot be explained by odontological diagnoses.

14.4.4 Allergy

14.4.4.1 Delayed Allergic Reactions (Type IV)

A Finnish study focused on the role of *contact allergies* in oral mucosal diseases [7]. The study included almost 500 patients who had been referred to a dermatology clinic and had undergone patch testing with a dental screening series. Of these patients, 24 had oral mucosal symptoms in combination with at least one positive patch test reaction. A clinically relevant connection between the oral mucosal symptoms and the contact allergy detected was seen in 10 out of 24 cases. A probable connection was found in a further two out of 24 cases; however, a mechanical etiology for the local oral reaction could not be excluded in these latter two cases. The majority of the positive patch test reactions in this group of patients with oral symptoms were caused by mercury or gold. Clinical findings were lichenoid/leukoplakic mucosa lesions; this is in accordance with the prevailing view that contact allergy in the oral mucosa predominantly manifests as lichenoid lesions or localized contact stomatitis. In summary, 19% of almost 500 patients referred to a dermatology clinic showed positive patch test reactions to dental screening series; of these, only 5% (24 patients) had positive patch test reactions *and* oral mucosal symptoms. And of these, the positive patch test was considered relevant or probable for the oral symptoms in only half of the cases (2.5% of the referred patients). In the remaining patients, no clinical connection was found between allergy (primarily gold) and the oral symptoms (oral symptoms, positive patch test to gold, no dental gold restorations). It thus seems that even in a selected group of patients, relevant links between oral problems and a positive patch test are relatively rare. Later reports comprising a smaller number of patients have confirmed this trend [57, 120, 185].

A number of studies on delayed-type allergic reactions of the oral mucosa have shown that oral mucosal lesions restricted to the contact area opposing the dental restoration, especially if epicutaneous tests are positive, are usually cured when the restoration is replaced. If the lesion greatly exceeds the contact area, the contacting material may not be an etiologic factor, and replacing it may have no or only limited effect. This has particularly been demonstrated in the case of mucosal lesions in contact with amalgam fillings (see Chap. 4 for details).

The role of allergy in *burning mouth syndrome (BMS)* seems to be a matter of debate in the literature. The findings in different studies have been inconsistent. In fact, so far very few verified cases have been published of dental material contact allergy manifesting as burning mouth or glossodynia. Most of these were related to acrylic denture base materials (see Sect. 14.2.2.3). The majority of reports, however, suggest that in most patients, denture-related complaints are not caused by contact allergies [59]. A number of recent surveys have not found a correlation between BMS and positive patch test reactions to constituents of dental restorative materials [120, 185]. A BMS prevalence of 4–5% among middle-aged and elderly Scandinavian women was reported [66]. The results pointed toward multifactorial associations among different factors of local, systemic, and psychological origin. Individuals who had psychological problems, reported craniomandibular symptoms or dry mouth, or were treated with female sex hormones were found to be more prone to report burning mouth sensations

Dentlearn.ir

[66]. Causes of BMS to consider as alternatives to dental material allergy thus include gnathofunctional disorders, side effects of medication, mucosal infections, and psychogenic disorders [18].

Key Note

When consideration of allergic reaction seems relevant, the patient should be referred to relevant specialists, e.g., dermatologists, for further evaluation. The dentist should participate in the subsequent diagnostic process by supplying detailed information on relevant dental materials, previous exposures, and treatments. The referring dentist should ensure that the assumed allergen and additional relevant allergens are included in the testing.

Clinical Practice Advice

The role of allergy in relation to cases of orodynia (BMS) is debated. So far, very few verified cases linking BMS and allergy to dental restorative materials have been published.

14.4.4.2 Evaluation of Patch Test Results

In general, most dental materials contain potentially allergenic substances. For certain material groups, in particular for dental (meth)acrylates, this has been clearly emphasized by a relatively high prevalence of allergic reactions due to occupational exposure. Studies of dental patient groups subjected to patch testing with dental screening series have frequently shown positive reactions to metals, primarily gold and nickel. In recent years, the number of allergic reactions to (meth)acrylates has increased in the general population due to multiple exposures in nondental professions and also among the general population, for example in relation to acrylate sculpturing of artificial fingernails (see Sect. 14.2.2.3). In a recent Swedish report, the overall frequency of (meth)acrylate contact allergy was close to 3% in a consecutive group of 1,632 patients referred to a dermatology clinic for patch testing with a dental screening test series [61]. The group was comprised of 81% dental patients and 19% dental personnel. Due to the increasing exposure to acrylates in the general population, an increasing number of dental patients developing allergic reactions to dental methacrylates may be expected in the future.

A positive patch test result may not always be considered relevant for clinical dental aspects (e.g., oral symptoms/positive skin test to gold salts/no dental gold restorations), and a positive patch test may also not be indicative of symptoms (e.g., the presence of amalgam restorations/no oral or systemic symptoms/positive skin test to mercury compounds). In rare cases of strong suspicion of allergic reaction but a negative patch test with the routine dental screening series, patch testing with the material in question may be considered. As mentioned earlier in this chapter, dental materials, particularly composites, are composed of numerous chemicals that are not all declared to the dentist. Case reports have thus demonstrated negative patch test results to dental screening series but positive patch test results to diluted test samples of the material under suspicion. Because, however, there may be a risk of iatrogenic sensitization in this context, such testing should be planned and conducted only by specialists experienced in this field.

Routine use of skin patch testing should be avoided because the test procedure itself may, in some cases, provoke sensitization of the patient. The main indication for an epicutaneous test is the presence of local intraoral symptoms close to a dental restoration or a prosthetic or orthodontic appliance. Also, severe cases of generalized intraoral desquamations or erosions and/or perioral eczema should be referred for allergic evaluation when efforts to diagnose alternative causes have failed. Further, as described previously, rare cases of remote skin reactions related to intraoral materials, such as nickel, have been reported.

Once a positive skin test has been confirmed by a dermatologist, the clinical relevance of the positive skin reaction should be carefully considered as described above. Some patients with allergy to several components of dental materials, including four to six different metals, have been reported [69, 122].

In cases in which a relevant link between clinical symptoms, a patch test, and the oral presence of an allergen can been established, the offending material(s) should be replaced. Rapid remission of symptoms will confirm the positive allergy test, and the patient should be made aware of his or her allergic status and be advised to report it to future dental practitioners. Some authors have suggested prescribing topical steroids for symptomatic relief of acute symptoms during the diagnostic process. However, this should be avoided whenever possible because steroid therapy may interfere with the sometimes tedious process of identifying the allergen.

Dentlearn.ir

Key Note

Because the prevalence of relevant allergic reactions to dental materials is very low even in a selected group of referred dental patients, the clinical relevance of a positive patch result should be evaluated carefully.

14.4.4.3 Immediate Allergic Reactions

The diagnosis of an immediate allergic reaction (e.g., contact stomatitis, urticaria, anaphylaxis) includes precise history taking to identify the allergy source. For reactions not occurring in direct connection to dental treatment but which were brought to the dentist's attention, pharmaceuticals (e.g., penicillin, aspirin, sulfa), foods, cosmetics, and oral hygiene products (e.g., mouthwashes) are relevant candidates for initial consideration [85]. Elimination of the suspected allergen is the obvious ultimate treatment objective. Antihistamines may be prescribed to alleviate acute symptoms, but this may delay the identification of a specific allergen or mask the effects of withdrawal of a suspected causative agent.

In cases of *acute (immediate) allergic reactions* (anaphylaxis) occurring in the dental clinic, adequate emergency treatment should be initiated (see Table 14.5; see also [173]). As to defining the cause of the reaction, all dental treatments and exposures must be described in detail to reveal possible eliciting allergen(s). For this type of reaction, natural latex proteins and local anesthetics are examples of more obvious candidates for initial consideration than dental materials.

14.4.5 Defining the Causative Agent(s)

In any case of suspected side effects of dental materials, problems may arise in the context of defining the composition of the product under suspicion. Full declaration of dental materials is not required by regulations. This situation compromises both preventive and diagnostic measures. Reviews have revealed that up to 46% undeclared, highly sensitizing acrylates were present in a number of analyzed acrylate products [101, 170]. With the rapid introduction of complex dental materials, it can be concluded that health professionals currently need more accurate safety data sheets and product declarations in order to perform a competent biocompatibility assessment in each individual patient case [170].

14.4.6 The Importance of Communication

The number of products available for dental purposes is growing, and new materials and treatment regimes are rapidly and continuously introduced. In recent years, the communication attitude of patients seems to have undergone a gradual change toward a less authoritative, more information-requesting approach. The dentist must be prepared to meet the growing requests for information about, for instance, biocompatibility characteristics of our materials. For several decades, dental amalgam has been subject to intensive, often unbalanced, aggressive public discussions in the media. Since the beginning of the 1990s, a growing concern about possible side effects of acrylate-based dental materials has also emerged. The latter concern has been supported by an increasing number of reports on significant occupational allergic aspects in relation to this material group. As a result of the public debate, a great many – to some degree – unsubstantiated concerns have been raised, and a large number of claimed side effects to dental materials have been presented in dental practice. These claims must all be handled with competence in a serious and adequate way. Recent surveys have clearly emphasized the great importance of an informative dialogue during this process (see above). The dental profession must realize that, now more than previously, confidence between the patient and the dentist depends very much on an open dialogue with information exchange, and the dentist must be sufficiently qualified to meet the patient's request for information with scientifically based knowledge. This seems to be particularly important in relation to the relatively new and partially controversial issue of dental material biocompatibility.

References

1. Aalto-Korte, K., Alanko, K., Henriks-Eckerman, M.-L., Jolanki, R.: Antimicrobial allergy from polyvinyl chloride gloves. Arch Dermatol 142, 1326–1330 (2006).
2. Aalto-Korte, K., Mäkelä, E.A., Huttunen, M., Suuronen, K., Jolanki, R.: Occupational contact allergy to glyoxal. Contact Dermatitis 52, 276–281 (2005).
3. Aalto-Korte, K., Alanko, K., Henriks-Eckerman, M.-L., Estlander, T., Jolanki, R.: Allergic contact dermatitis from bisphenol A in PVC gloves. Contact Dermatitis 49, 202–205 (2003).
4. Abdallah, H.I., Balsara, R.K., O'Riordan, A.C.: Pacemaker contact sensitivity: clinical recognition and management. Ann Thorac Surg 57, 1017–1018 (1994).
5. Aberer, W., Holub, H., Strohal, R., Slavicek, R.: Palladium in dental alloys – the dermatologists' responsibility to warn? Contact Dermatitis 28, 163–165 (1993).

Dentlearn.ir

6. Ahlgren, C., Ahnlide, I., Björkner, B., Bruze, M., Liedholm, R., Møller, H., Nilner, K.: Contact allergy to gold is correlated to dental gold. Acta Derm Venereol 82, 41–44 (2002).
7. Alanko, K., Kanerva, L., Jolanki, R., Kannas, L., Estlander, T.: Oral mucosal diseases investigated by patch testing with a dental screening series. Contact Dermatitis 34, 263–267 (1996).
8. Ali, A., Bates, J.F., Reynolds, A.J., Walker, D.M.: The burning mouth sensation related to the wearing of acrylic dentures: an investigation. Br Dent J 161, 444–447 (1986).
9. Allmers, H., Schmengler, J., Skudlik, C.: Primary prevention of natural rubber latex allergy in the German health care system through education and intervention. J Allergy Clin Immunol 110, 318–323 (2002).
10. Allmers, H., Schmengler, J., John, S.M.: Decreasing incidence of occupational contact urticaria caused by natural rubber latex allergy in German health care workers. J Allergy Clin Immunol 114, 347–351 (2004).
11. Arenholt-Bindslev, D., Hørsted-Bindslev P., Philipsen, H.P.: Toxic effects of two dental materials on human buccal epithelium in vitro and monkey buccal mucosa in vivo. Scand J Dent Res 95, 467–474 (1987).
12. Autegarden, J.E., Pecquet, C., Huet, S., Bayrou, O., Leynadier, F.: Anaphylactic shock after application of chlorhexidine to unbroken skin. Contact Dermatitis 40, 215 (1999).
13. Axell, T., Spiechowicz, E., Glanz, P.O., Andersson, G., Larsson, A.: A new method for intra-oral patch testing. Contact Dermatitis 15, 58–62 (1986).
14. Baker, D.B., Gann, P.H., Brooks, S.M., Gallagher, J., Bernstein, I.L.: Cross-sectional study of platinum salts sensitization among precious metals refinery workers. Am J Ind Med 18, 653–664 (1990).
15. Basker, R.M., Hunter, A.M.: A severe asthmatic reaction to poly(methylmethacrylate) denture base resin. Brit Dent J 169, 250–251 (1990).
16. Beaudouin, E., Kanny, G., Morisset, M., Renaudin, J.M., Mertes, M., Lexenaire, M.C., Mouton, C., Nacson, F., Moneret–Vautrin, D.A.: Immediate hypersensitivity to chlorhexidine: literature review. Allerg Immunol (Paris) 36, 123–126 (2004).
17. Belsito, D. V.: Contact urticaria caused by rubber. Analysis of seven cases. Dermatol Clin 8, 61–66 (1990).
18. Bergdahl, M., Bergdahl, J.: Burning mouth syndrome: prevalence and associated factors. J Oral Pathol Med 28, 350–354 (1999).
19. Bergman, A., Svedberg, U., Nilsson, E.: Contact urticaria and anaphylactic reactions caused by occupational exposure to iridium salt. Contact Dermatitis 32, 14–17 (1995).
20. Beswick, S.J., Ramsay, H.M., Tan, B.B.: Contact dermatitis from flavourings in chewing gum. Contact Dermatitis 40, 49–50 (1999).
21. Björkner, B., Bruze, M., Möller, H.: High frequency of contact allergy to gold sodium thiosulfate. An indication of gold allergy? Contact Dermatitis 30, 144–151 (1994).
22. Björkner, B., Niklasson. B.: Contact allergy to the UV absorber Tinuvin P in a dental restorative material. Am J Contact Dermatitis 8, 6–7 (1997).
23. Blomgren, J., Axell, T., Sandahl, O., Jontell, M.: Adverse reactions in the oral mucosa associated with anterior composite restorations. J Oral Pathol Med 25, 311–313 (1996).
24. Bong, J.L., English, J.S.C.: Allergic contact dermatitis from airborne exposure to acrylates. Contact Dermatitis 43, 242 (2000).
25. Boxer, M.B., Grammer, L.C., Orfan, N.: Gutta-percha allergy in a health care worker with latex allergy. J Allergy Clin Immunol 93, 943–944 (1994).
26. Brehler, R.: Contact urticaria caused by latex-free nitrile gloves. Contact Dermatitis 34, 296 (1996).
27. Bruze, M.: Systemically induced contact dermatitis from dental rosin. Scand J Dent Res 102, 376–378 (1994).
28. Bruze, M., Andersen, K.E.: Gold – a controversial sensitizer. Contact Dermatitis 40, 295–299 (1999).
29. Burke, F.J.T., Wilson, M.A., McCord, J.F.: Allergy to latex gloves in clinical practice: case reports. Quintessence 26, 859–863 (1995).
30. Caliskan, M.K., Türkin, M., Alper, S.: Allergy to sodium hypochlorite during root canal therapy: a case report. Int Endod J 27, 163–167 (1994).
31. Camarasa, U.G., Serra-Baldrich, E., Lluch, M., Malet, A.: Contact urticaria from sodium fluoride. Contact Dermatitis 28, 294 (1993).
32. Carmichael, A.J., Gibson, J.J., Walls, A.W.G.: Allergic contact dermatitis to bisphenol A-glycidyldimethacrylate (BIS-GMA) dental resin associated with sensitivity to epoxy resin. Brit Dent J 183, 297–298 (1997).
33. Chen, A.Y., Zirwas, M.J.: Denture stomatitis. Skin Med 6, 92–94 (2007).
34. Coombs, R.R.A., Gell, P.G.H., Lachmann, P.H. (eds): Clinical Aspects of Immunology, 3rd edn. Blackwell, Oxford 1975.
35. Cronin E. (ed): Contact Dermatitis. Churchill Livingstone, Edinburgh 1980.
36. Cusano, F., Luciano, S.: Contact allergy to benzalkonium chloride and glutaraldehyde in a dental nurse. Contact Dermatitis 28, 127 (1993).
37. Danilewich-Stysiak, Z.: Allergy as a cause of denture sore mouth. J Prosthet Dent 25, 16–18 (1971).
38. de Fine Olivarius, F., Menné, T.: Contact dermatitis from metallic palladium in patients reacting to palladium chloride. Contact Dermatitis 27, 71–73 (1992).
39. de Fine Olivarius, F., Balslev, E., Menné, T.: Skin reactivity to tin chloride and metallic tin. Contact Dermatitis 29, 11–111 (1993).
40. Dejobert, Y., Martin, P., Piette, F., Thomas, P., Bergoend, H.: Contact dermatitis caused by benzoyl peroxide in podiatrists. Contact Dermatitis 40, 163 (1999).
41. De Silva, B.D., Hoherty, V.R.: Nickel allergy from orthodontic appliances. Contact Dermatitis 42, 102–103 (2000).
42. Downs, A.M.R., Lear, J.T., Sansom, J.E.: Contact sensitivity in patients with oral symptoms. Contact Dermatitis 39, 258–259 (1998).
43. Dunlapp, C.L., Vincent, S.K., Barker, B.F.: Allergic reaction to orthodontic wire. JAMA 118, 449–450 (1989).
44. Dutree-Meulenberg, R.O., Kozel, M.M., van Joost, T.: Burning mouth syndrome: a possible etiologic role for local contact hypersensitivity. J Am Acad Dermatol 26: 935–940 (1992).
45. Espana, A., Alonso, M.L., Soria, C., Guimaraens, D., Ledo, A.: Chronic urticaria after implantation of 2 nickel-containing dental prostheses in a nickel-allergic patient. Contact Dermatitis 21, 204–205 (1989).
46. Estlander, T., Kanerva, L., Tupasela, O., Keskinen, H., Jolanki, R.: Immediate and delayed allergy to nickel with contact urticaria, rhinitis, asthma and contact dermatitis. Clin Exp Allergy 23, 306–310 (1993).
47. Estlander, T., Kanerva, L., Kari, O., Jolanki, R., Mölsä, K.: Occupational conjunctivitis associated with type IV allergy to methacrylates. Allergy 51, 56–59 (1996).
48. Estlander, T., Jolanki, R., Henriks-Eckerman, M.-L., Kanerva, L.: Occupational contact allergy to bisphenol A. Contact Dermatitis 40, 52–53 (1999).

Dentlearn.ir

49. Estlander, T., Alanko, K., Jolanki, R.: Dental materials. In: Frosch, P.J., Menné, T., Lepoittevin, J.-P. (eds): Contact Dermatitis, 4th edn. Springer-Verlag, Berlin 2006, pp 653–678.
50. Farli, M., Gasperini, M., Francalanci, S., Gola, M., Sertoli, A.: Occupational contact dermatitis in 2 dental technicians. Contact Dermatitis 22, 282–287 (1990).
51. Fernández-Redondo, V., Gomez-Centeno, P., Toribio, J.: Chronic urticaria from a dental bridge. Contact Dermatitis 38, 178 (1998)
52. Fischer, A.A. (ed): Contact Dermatitis, 3rd edn. Lea & Fibiger, Philadelphia 1986.
53. Foussereau, J., Laugier, P.: Allergic eczemas from metallic foreign bodies. Trans St Johns Hosp Dermatol Soc 52, 220–225 (1966).
54. Fowler, J., Taylor, J., Storrs, F., Sherertz, E., Rietschel, R., Pratt, M., Mathias, C.G., Marks, J., Maibach, H., Fransway, A., DeLeo, V., Belsito, D.: Gold allergy in North America. Am J Contact Dermat 12, 3–5 (2001).
55. Ganter, G., Disch R., Borelli, S., Simon, D.: Contact dermatitis and stomatitis due to amine fluoride. Contact Dermatitis 37, 248 (1997).
56. Garner, L.A.: Contact dermatitis to metals. A review. Dermatol Ther 17, 321–327 (2004).
57. Garhammer, P., Schmalz, G., Hiller, K.A., Reitinger, T., Stolz, W.: Patients with local adverse effects from dental alloys; frequency, complaints, symptoms, allergy. Clin Oral Invest 5, 240–249 (2001).
58. Gass, J.K., Todd, P.M.: Multiple manifestations of chromate contact allergy. Contact Dermatitis 56, 290–291 (2007).
59. Gebhardt, M., Geier, J., Welker, D.: Kontaktallergie af Prothesenkunststoffe und Differentialdiagnostik der Protesenintoleranz. [Contact allergy to prosthetic acrylates and differential diagnostic considerations] Dtsch Zahnärztl Z 51, 395–398 (1996).
60. Goon, A.T., White, I.R., Rycroft, R.J., McFadden. J.P.: Allergic contact dermatitis from chlorhexidine. Dermatitis 15, 45–47 (2004).
61. Goon, A.T., Isaksson, M., Zimerson, E., Goh, C.L., Bruze, M.: Contact allergy to (meth)acrylates in the dental series in southern Sweden: simultaneous positive patch test reaction patterns and possible screening allergens. Contact Dermatitis 55, 219–226 (2006).
62. Goon, A.T., Bruze, M., Zimerson, E., Goh, C.L., Isaksson, M.: Contact allergy to acrylates/methacrylates in the acrylate and nail acrylics series in southern Sweden: simultaneous positive patch test reaction patterns and possible screening allergens. Contact Dermatitis 57, 21–27 (2007).
63. Guimaraens, D., Gonzalez, M.A., Condé-Salazar, L.: Systemic contact dermatitis from dental crowns. Contact Dermatitis 30, 124–125 (1994).
64. Gupta, G., Forsyth, A.: Allergic contact reactions to colophony presenting as oral disease. Contact Dermatitis 40, 332–333 (1999).
65. Haberman, A.L., Pratt, M., Storrs, F.J.: Contact dermatitis from beryllium in dental alloys. Contact Dermatitis 28, 157–162 (1993).
66. Hakeberg, M., Berggren, U., Hägglin, C., Ahlqwist, M.: Reported burning mouth symptoms among middle aged and elderly women. Eur J Oral Sci 105, 539–543 (1997).
67. Hallström, U.: Adverse reaction to a fissure sealant: Report of case. J Dent Children 3, 143–146 (1993).
68. Haraldson, T.: Oral galvanism and mandibular dysfunction. Swed Dent J 9, 129–133 (1985).
69. Hay, I.C., Ormerod, A.D.: Severe oral and facial reaction to 6 metals in restorative dentistry. Contact Dermatitis 38, 216 (1998).
70. Heese, A., Peters, K.P., Stahl, J., Koch H.U., Hornstein, O.P.: Incidence and increase in type I allergies to rubber gloves in dental medical students. Hautarzt 46, 15–21 (1995).
71. Helton, J., Storrs, F.: The burning mouth syndrome: lack of a role for contact urticaria and contact dermatitis. J Am Acad Dermatol 31, 201–205 (1994).
72. Hensten-Pettersen, A., Orstavik, D., Wennberg, A.: Allergenic potential of root canal sealers. Endod Dent Traumatol 1, 61–65 (1985).
73. Hensten-Pettersen, A., Jacobsen, N.: Perceived side effects of biomaterials in prosthetic dentistry. J Prosthet Dent 65, 138–144 (1991).
74. Herrström, P., Högstedt, B.: Clinical study of oral galvanism: no evidence of toxic mercury exposure but anxiety disorder an important background factor. Scand J Dent Res 101, 232–237 (1993).
75. Horn, H.M., Aldridge, R.D.: Contact urticaria due to nitrile gloves. Contact Dermatitis 49, 163–164 (2003).
76. Hubler, W.R.,Jr., Hubler, W.R., Sr.: Dermatitis from a chromium dental plate. Contact Dermatitis 9, 377–383 (1983).
77. Hugoson, E.: Results obtained from patients referred for the investigation of complaints related to oral galvanism. Swed Dent J 10, 15–28 (1986).
78. Hørsted-Bindslev, P., Søholm, B.: Overfølsomhed overfor rodfyldningsmaterialet AH26. [Allergic reaction to the root canal sealer AH26] [Danish with English summary] Tandlægebladet 80, 194–197 (1976).
79. Hørsted-Bindslev, P.: Clinical testing of dental materials – general clinical aspects. J Dent 22(Supp. 2), S29–S32 (1994).
80. Isaksson, I., Bruze, M., Björkner, B., Niklasson, B.: Contact allergy to Duraphat. Scan J Dent Res 101, 49–51 (1993).
81. Jacob, S.E., Steele, T.: Tongue erosions and diet cola. Ear Nose Throat J 86, 232–233 (2007).
82. Jacobsen, N., Hensten-Pettersen A.: Occupational health problems and adverse patient reactions in orthodontics from 1987–2000. Eur J Orthod 25, 591–598 (2003).
83. Jacobsen, N., Aasenden, R., Hensten-Pettersen, A.: Occupational health complaints and adverse patient reactions as perceived by personnel in public dentistry. Community Dent Oral Epidemiol 19, 155–159 (1990).
84. Jager, M., Balda, B.R.: Loosening of a total hip prosthesis at contact allergy due to benzoyl peroxide. Arch Orthop Traumat Surg 94, 175–178 (1979).
85. Jainkittivong, A., Langlais, R.P.: Allergic stomatitis. Semin Dermatol 13, 91–101 (1994).
86. Janson, G.R.P., Dainesi, E.A., Consolaro, A., Woodside, D.G., Freitas, M. R.: Nickel hypersensitivity reaction before, during, and after orthodontic therapy. Am J Orthod Dentofacial Orthop 113, 655–660 (1998).
87. Jappe, U., Bonnekoh, B., Gollnick, H.: Persistent granulomatous dermatitis due to palladium body-piercing ornaments. Contact Dermatitis 40, 111–112 (1999).
88. Jolanki, R.: Occupational skin diseases from epoxy compounds. Epoxy resin, epoxy acrylates and 2,3-epoxypropyl trimethyl ammonium chloride (thesis). Acta Derm Venereol (Stockh) suppl 169, 1–80 (1991).
89. Jolanki, R., Kanerva, L., Estlander, T.: Occupational allergic contact dermatitis caused by epoxy diacrylate in ultraviolet-light-cured paint, and bisphenol A in dental composite resin. Contact Dermatitis 33, 94–99 (1995).

Dentlearn.ir

90. Jung, P., Jarisch, R., Hemmer, W.: Hypersensitivity from dental acrylates in a patient previously sensitized to artificial nails. Contact Dermatitis 53, 119–120 (2005).
91. Kaaber, S., Thulin, H., Nielsen, E.: Skin sensitivity to denture base materials in the burning mouth syndrome. Contact Dermatitis 5, 90–96 (1979).
92. Kallus, T., Mjör, I.A.: Incidence of adverse effects of dental materials. Scand J Dent Res 99, 236–240 (1991).
93. Kanerva, L., Jolanki, R., Estlander, T.: Occupational dermatitis due to an epoxy acrylate. Contact Dermatitis 14, 80–84 (1986).
94. Kanerva, L., Estlander, T., Jolanki, R.: Allergic contact dermatitis from dental composite resins due to aromatic epoxy acrylates and aliphatic acrylates. Contact Dermatitis 20, 201–211 (1989).
95. Kanerva, L., Turjanmaa, K., Estlander, T., Jolanki, R.: Occupational allergic contact dermatitis caused by 2-hydroxyethyl methacrylate (2-HEMA) in a new dentin adhesive. Am J Contact Dermatitis 2, 24–30 (1991).
96. Kanerva, L., Estlander, T., Jolanki, R., Pekkarinen, E.: Occupational pharyngitis associated with allergic patch test reactions from acrylics. Allergy 47, 571–573 (1992).
97. Kanerva, L., Jolanki, R., Estlander, T.: Dentist's occupational allergic contact dermatitis caused by coconut diethanolamide, N-ethyl-4-toluenesulfonamide and 4-tolyldiethanolamine. Acta Dermatol Venereol (Stockh) 73, 126–129 (1993).
98. Kanerva, L., Tarvainen, K., Estlander, T., Jolanki, R.: Occupational allergic contact dermatitis caused by mercury and benzoyl peroxide. Eur J Dermatol 4, 359–361 (1994).
99. Kanerva, L., Estlander, T., Jolanki, R., Tarvainen, K.: Dermatitis from acrylates in dental personnel. In: Menne, T., Maibach, H.I. (eds): Hand Eczema. CRC, Boca Raton, Florida 1994, pp 231–254.
100. Kanerva, L., Estlander, T., Jolanki, R.: Dental problems. In: Guin, J.D. (ed): Practical Contact Dermatitis. MacGraw-Hill, New York 1995, pp 397–432.
101. Kanerva, L., Henriks-Eckerman, M.L, Jolanki, R., Estlander, T.: Plastics/acrylics: material safety data sheets need to be improved. Clin Dermatol 15, 533–546 (1997).
102. Kanerva, L., Aitio, A.: Dermatotoxicological aspects of metallic chromium. Eur J Dermatol 7, 79–84 (1997).
103. Kanerva, L., Alanko, K., Estlander, T., Sihvonen, T., Jolanki, R.: Occupational allergic contact urticaria from chloramine-T solution. Contact Dermatitis 37, 180–181 (1997).
104. Kanerva, L., Estlander, T., Jolanki, R.: Occupational allergic contact dermatitis of dental nurse caused by acrylic tricure glass ionomer. Contact Dermatitis 37, 49–50 (1997).
105. Kanerva, L., Mikola, H., Henriks-Eckerman, M.L., Jolanki, R., Estlander, T.: Fingertip paresthesia and occupational allergic contact dermatitis caused by acrylics in a dental nurse. Contact Dermatitis 38, 114–116 (1998).
106. Kanerva, L., Lauerma, A.I.: Iatrogenic acrylate allergy complicating amalgam allergy. Contact Dermatitis 38, 58–59 (1998).
107. Kanerva, L., Estlander, T., Jolanki, R.: Dental nurse's occupational allergic contact dermatitis from eugenol used as a restorative dental material with polymethylmethacrylate. Contact Dermatitis 38, 339–340 (1998).
108. Kanerva, L., Tarvainen, K., Jolanki, R., Henriks-Eckerman, M.-L., Estlander, T.: Air-borne occupational allergic contact dermatitis due to trimethylolpropane triacrylate (TMPTA) used in the manufacture of printed circuit boards. Contact Dermatitis 38, 292–294 (1998).
109. Kanerva, L., Estlander T.: Contact leukoderma caused by patch testing with dental acrylics. Am J Contact Dermatitis 9: 196–198 (1998).
110. Kanerva, L., Lahtinen, A., Toikkanen, J., Forss, H., Estlander, T., Susitaival, P., Jolanki, R.: Increase in occupational skin diseases of dental personnel. Contact Dermatitis 40, 104–108 (1999).
111. Kanerva, L., Alanko, K., Estlander, T.: Allergic contact gingivostomatitis from temporary crown made of methacrylates and epoxy diacrylates. Allergy 54, 1316–1321 (1999).
112. Kanerva, L., Estlander, T.: Occupational allergic contact dermatitis from colophony in 2 dental nurses. Contact Dermatitis 41, 342–343 (1999).
113. Kanerva, L., Miettinen, P., Alanko, K., Estlander, T., Jolanki, R.: Occupational allergic contact dermatitis from glyoxal, glutaraldehyde and neomycin sulfate in a dental nurse. Contact Dermatitis 42, 116–117 (2000).
114. Kanerva, L., Rantanen, T., Aalto-Korte, K., Estlander, T., Hannuksela, M., Haravima, R.J., Hasan, T., Horsmanheimo, M., Jolanki, R., Kalimo, K., Lahti, A., Lammintausta, K., Lauerma, A., Niinimäki, A., Turjanmaa, K., Vuorela, A.M.: A multicenter study of patch test reactions with dental screening series. Am J Contact Dermat 12, 83–87 (2001).
115. Karlberg, A.-T.: Colophony. In: Kanerva, L., Elsner, P., Wahlberg, J.E., Maibach, H.I. (eds): Condensed Handbook of Occupational Dermatology. Springer, Berlin 2004, pp 312–330.
116. Katoh, N., Hirano, S., Kishimoto, S., Yasuno, H.: Dermal contact dermatitis caused by allergy to palladium. Contact Dermatitis 40, 226–227 (1999).
117. Kaufman, A.Y., Keila, S.: Hypersensitivity to sodium hypochlorite. J Endod 15, 224–226 (1989).
118. Kerosuo, H., Kullaa, A., Kerosuo, E., Kanerva, L., Hensten-Pettersen, A.H.: Nickel allergy in adolescents in relation to orthodontic treatment and piercing of ears. Am J Orthod Dentofac Orthop 199, 148–154 (1996).
119. Kerosuo, H., Kanerva, L.: Systemic contact dermatitis caused by nickel in a stainless steel orthodontic appliance. Contact Dermatitis 36, 112–113 (1997).
120. Khamaysi, Z., Bergman, R., Weltfriend, S.: Positive patch test reactions to allergens of the dental series and the relation to the clinical presentations. Contact Dermatitis 55, 216–218 (2006).
121. Kobayashi, T., Sakuraoka, K., Hasegawa, Y., Konohana, A., Kurihara, S.: Contact dermatitis due to an acrylic dental prosthesis. Contact Dermatitis 35, 370–371 (1996).
122. Koch, P., Bahmer, F.A.: Oral lichenoid lesions, mercury hypersensitivity and combined hypersensitivity to mercury and other metals: histologically-proven reproduction of the reaction by patch testing with metal salts. Contact Dermatitis 33, 323–328 (1995).
123. Koch, P., Baum, H.P.: Contact stomatitis due to palladium and platinum in dental alloys. Contact Dermatitis 34, 253–257 (1996).
124. Koutis, D., Freeman, S.: Allergic contact stomatitis caused by acrylic monomer in a denture. Australas J Dermatol 42, 203–206 (2001).
125. Krautheim, A.B., Jermann, T.H., Bircher, A.J.: Chlorhexidine anaphylaxis: case report and review of the literature. Contact Dermatitis 50, 113–116 (2004).
126. Krob, H.A., Fleischer, A.B. Jr, D'Agostina, R. Jr, Haverstock, C.L., Feldman, S.: Prevalence and relevance of contact dermatitis allergens: a meta-analysis of 15 years published T.R.U.E. test data. J Am Acad Dermatol 51, 349–353 (2004).

Dentlearn.ir

127. Kütting, B., Brehler, R.: Klinisch relevante solitäre Palladiumallergie [Clinically relevant solitary Palladium allergic reaction]. Hautarzt 45, 176–178 (1994).
128. Könönen, M., Rintanen, J., Waltimo, A., Kempainen, P.: Titanium framework removable partial denture used for a patient allergic to other metals: a clinical report and literature review. J Prosthet Dent 73, 4–7 (1995).
129. Laine, J., Kalimo, K., Happonen, R.P.: Contact allergy to dental restorative materials in patients with oral lichenoid lesions. Contact Dermatitis 36, 141–146 (1997).
130. Langworth, S.: Experiences from the amalgam unit at Huddinge hospital – somatic and psychosomatic aspects. Scand J Work Environ Health 23, 65–67 (1997).
131. Lazarov, A.: Sensitization to acrylates is a common adverse reaction to artificial fingernails. J Eur Acad Dermatol Venereol 21, 169–174 (2007).
132. Lind, P.O.: Oral lichenoid reactions related to composite restorations. Preliminary report. Acta Odontol Scand 46, 63–65 (1988).
133. Lindsten, R., Kurol, J.: Orthodontic appliances in relation to nickel hypersensitivity. A review. J Orofac Orthop 58, 100–108 (1997).
134. Lindström, M., Alanko, K., Keskinen, H., Kanerva, L.: Dentist's occupational asthma, rhinoconjunctivitis, and allergic contact dermatitis from methacrylates. Allergy 57, 543–545 (2002).
135. Lyzak, W.A., Flaitz, C.M., McGuckin, R.S., Eichmiller, F., Brown, R.S.: Diagnosis and treatment of an oral base-metal contact lesion following negative dermatologic patch tests. Ann Allergy 73, 161–165 (1994).
136. Malanin, F.K.: Active sensitization to camphoroquinone and double active sensitization to acrylics with long-lasting patch test reactions. Contact Dermatitis 29, 284–285 (1993).
137. Mancuso, L., Anonide, A., Borghi, S., Isola, V.: Positive patch test reactions to nickel, cobalt, and potassium dichromate in a series of 576 patients. Cutis 47, 119–122 (1991).
138. Marcusson, J.A., Cederbrant, K., Heilborn, J.: Indium and iridium allergy in patients exposed to dental alloys. Contact Dermatitis 38, 297 (1998).
139. Matsuzaka, K., Mabuchi, R., Nagasaka, H., Yoshinari, M., Inoue, T.: Improvement of eczematous symptoms after removal of amalgam-like metal in alveolar bone. Bull Tokyo Dent Coll 47, 13–17 (2006).
140. McKenna, K.E., Dolan, O., Walsh, M.Y., Burrows, D.: Contact allergy to gold sodium thiosulphate. Contact Dermatitis 32, 143–146 (1995).
141. Menné, T., Andersen, K.E, Kaaber, K., Osmundsen, P.E., Andersen, J.R., Yding, F., Valeur, G.: Tin: An overlooked contact sensitizer? Contact Dermatitis 16, 9–10 (1987).
142. Mitchell, D.L., Synnott, S.A., VanDercreek, J.A.: Tissue reaction involving an intraoral skin graft and CP titanium abutments: a clinical report. Int J Oral Maxillofac Implants 5, 79–84 (1990).
143. Munksgaard, E.C., Hansen, E.K., Engen, T., Holm, U.: Self-reported occupational dermatological reactions among Danish dentists. Eur J Oral Sci 104, 396–402 (1996).
144. Nakada, T., Iijima, M., Nakayama, H., Maibach, H.I.: Role of ear piercing in metal allergic contact dermatitis. Contact Dermatitis 36, 233–236 (1997).
145. Nakayama, H., Nogi, N., Kasahara, N., Matsuo, S.: Allergen control. An indispensable treatment for allergic contact dermatitis. Derm Clinics 8, 197–204 (1990).
146. Nielsen, N.H., Menné, T.: Nickel sensitization and ear piercing in a unselected Danish population. Contact Dermatitis 29, 16–21 (1993).
147. Ockenfels, H.M., Seemann, U., Goos, M.: Allergy to fibrin tissue in dental medicine. Contact Dermatitis 32, 363–364 (1995).
148. Oysæd, H., Ruyter, I. E., Sjøvik-Kleven, I. J.: Release of formaldehyde from dental composites. J Dent Res 67, 1289–1294, (1988).
149. Pauluzzi, P., Kokelj, F., Daris, F.: Allergic contact dermatitis from nickel in an amalgam carrier. Contact Dermatitis 32, 123 (1995) (with erratum).
150. Piirilä, P., Kanerva, L., Keskinen, H., Estlander, T., Hytönen, M., Tuppurainen, M., Nordman, H.: Occupational respiratory hypersensitivity caused by preparations containing acrylates in dental personnel. Clin Exp Allergy 28, 1404–1411 (1998).
151. Placucci, F., Benini, A., Guerra, L., Tosti, A.: Occupational allergic contact dermatitis from disinfectant wipes used in dentistry. Contact Dermatitis 35, 306 (1996).
152. Quirce, S., Olaguibel, J.M., Farcia, B.E., Tabar, I.E.: Occupational airborne contact dermatitis due to benzoylperoxide. Contact Dermatitis 29, 165–166 (1993).
153. Rix, M., Andersen, U. M.: Anafylaktisk chok udløst af tandlak indeholdende metacrylat .[Anaphylactic reaction elicited by fissure sealant, containing methacrylate] Tandlaegernes Nye Tidsskrift 10, 358–359 (1995).
154. Räsänen, L., Kalimo, K., Laine, J., Vainio, O., Kotiranta, J., Pesola, I.: Contact allergy to gold in dental patients. Brit J Dermatol 134, 673–677 (1996).
155. Sala, E., Hytönen, M., Tupasela, O., Estlander, T.: Occupational laryngitis with immediate allergic or immediate type specific chemical hypersensitivity. Clin Otolaryngol Allied Sci 21, 1404–1411 (1996).
156. Safford, R.J., Basketter, D.A., Allenby, C.F., Goodwin, B.F.J.: Immediate contact reactions to chemicals in the fragrance mix and a study of the quenching effect of eugenol. Br J Dermatol 123, 596–606 (1990).
157. Santosh, V., Ranjith, K., Shrutakirthi, D. S., Sachin, V., Balachandran, D.: Results of patch testing with dental materials. Contact Dermatitis 40, 50–51 (1999).
158. Savonius, B., Keskinen, H., Tuppurainen, M., Kanerva, L.: Occupational respiratory disease caused by acrylics. Clin Exp Allergy 23, 416–424 (1993).
159. Schuh, A., Thomas, P., Kachler, W., Göske, J., Wagner, L., Holzwarth, U., Forst, R.: Das Allergiepotenzial von Implantatwerkstoffen auf Titanbasis. [Allergic potential of titanium implants] Orthopade 34, 327–333 (2005).
160. Schaffran, R.M. , Storrs, F.J., Schalock, P.: Prevalence of gold sensitivity in asymptomatic individuals with gold dental restorations. Am J Contact Dermat 10, 201–206 (1999).
161. Schultz, J.C., Connelly, E., Glesne, L., Warshaw, E.M.: Cutaneous and oral eruptions from oral exposure to nickel in dental braces. Dermatitis 15, 154–157 (2004).
162. Schweitzer, A.: Erstfeststellung einer Titan-Allergie. [The documentation of a titanium allergic reaction] Dermatosen 45, 190 (1997).
163. Seite-Bellezza, D., el-Sayed, F., Bazex, J.: Contact urticaria from cinnamic aldehyde and benzaldehyde in a confectioner. Contact Dermatitis 31, 272–273 (1994).
164. Silva, R., Pereira, F., Bordalo, O., Silva, E., Barros, A., Goncalo, M., Correia, T., Pessoa, G., Baptista, A., Pecegueiro, M.: Contact allergy to gold sodium thiosulfate. A comparative study. Contact Dermatitis 37, 78–81 (1997).

Dentlearn.ir

165. Slodownik, D., Williams, J.D., Tate, B.J.: Prolonged paresthesia due to sculptured acrylic nails. Contact Dermatitis 56, 298–299 (2007).
166. Smith, R.G., Burtner, P.: Oral side-effects of the most frequently prescribed drugs. Spec Care Dentist 14, 96–102 (1994).
167. Smith, J.D., Odom, R.B., Maibach, H.I.: Contact urticaria from cobalt chloride. Arch Dermatol 111, 1610–1611 (1975).
168. Sood, A., Taylor, J.S.: Acrylic reactions: a review of 56 cases. Contact Dermatitis 48, 346–347 (2003).
169. Sood, A., Taylor, J.S.: Allergic contact dermatitis from hearing aid materials. Dermatitis 15, 48–50 (2004).
170. Spahl, W., Budzikiewicz, S., Geurtsen, W.: Determination of leachable components from four commercial dental composites by gas and liquid chromatography/mass spectrometry. J Dent 26, 137–145 (1998).
171. Staerkjaer, L., Menné, T.: Nickel allergy and orthodontic treatment. Eur J Orthod 12, 284–289 (1990).
172. Tarlo, S., Sussman, G.L., Holness, L.: Latex sensitivity in dental students and staff: a cross-sectional study. J Allergy Clin Immunol 3, 396–401 (1997).
173. Terezhalmy, G.T., Batizy, L.G. (eds): Urgent Care in the Dental Office. Quintessence, Carol Stream, Illinois, 1998, pp 41–43.
174. Thyssen, J.P., Johansen, J.D., Menné, T.: Contact allergy epidemics and their controls. A review. Contact Dermatitis 56, 185–195 (2007).
175. Timmer, C.: Antimicrobials and disinfectants. In: Kanerva, L., Elsner, P., Wahlberg, J.E., Maibach, H.I. (eds): Handbook of Occupational Dermatology. Springer, Berlin 2000, pp 462–473.
176. Torres, V., Mano-Azul, A., Coreia, T., Soares, A.P.: Allergic contact cheilitis and stomatitis from hydroquinone in an acrylic dental prosthesis. Contact Dermatitis 29, 102–103 (1993).
177. Torres, M.C., Linares, T., Hernandez, D.: Acrylates induced rhinitis and contact dermatitis. Contact Dermatitis 53, 114 (2005).
178. Tosti, A., Bardazzi, F., Piancastelli, E., Brasile, G.P.: Contact stomatitis due to N,N-dimethyl-paratoluidine. Contact Dermatitis 22, 113 (1990).
179. Tosti, A., Rapacchiale, S., Piraccini, B.M., Peluso, A.M.: Occupational airborne contact dermatitis due to ethylene glycol dimethacrylate. Contact Dermatitis 24, 152–153 (1991).
180. Trombelli, I., Virigilli, A., Corazza, M., Lucci, R.: Systemic contact dermatitis from an orthodontic appliance. Contact Dermatitis 27, 259–260 (1992).
181. Tsuchiya, H., Hoshino, Y., Tajima, K., Takagi, N.: Leaching and cytotoxicity of formaldehyde and methylmethacrylate from acrylic resin denture base materials. J Prosthet Dent 71, 618–624 (1994).
182. Turjanmaa, K., Alenius, H., Mäkinen-Kiljunen, S., Reunala, T., Palosuo, T.: Natural rubber latex allergy (review). Allergy 51, 593–602 (1996).
183. Ulrich, S., Skudlik, C., John, S.M.: Occupational allergic contact dermatitis from monoethanolamine in a dental nurse. Contact Dermatitis 56, 292–293 (2007).
184. Uter, W., Hegewald, J., Aberer, W., Ayala, F., Bircher, A.J., Brasch, J., Coenraads, P.J., Schyttelaar, M.L., Elsner, P., Fartasch, M. et al.: The European standard series in 9 European countries 2002/2003 – first results of the European Surveillance System on Contact Allergies (ESSCA). Contact Dermatitis 53, 136–145 (2005).
185. Vamnes, J.S., Morken, T., Helland, S., Gjerdet, N.R.: Dental gold alloys and contact hypersensitivity. Contact Dermatitis 42, 128–133 (2000).
186. Van Hoogstraten, I.M., Andersen, K.E., Von Blomberg, B.M., Boden, D., Bruynzeel, D.P., Burrows, D., Camarasa, J.G., Doomms-Goossens, A., Kraal, G., Lahti, A., et al.: Reduced frequency of nickel allergy upon oral nickel contact at an early age. Clin Exp Immunol 85, 441–445 (1991).
187. Van Joost, T., van Ulsen J., van Loon, L.A.J.: Contact allergy to denture materials in the burning mouth syndrome. Contact Dermatitis 18, 97–99 (1988).
188. Van Loon, L.A.J, Van Elsas, P.W., Davidson, C.L.: Contact stomatitis and dermatitis to nickel and palladium. Contact Dermatitis 11, 294–297 (1984).
189. Veien, N.K., Borchorst, E., Hattel, T., Laurberg, G.: Stomatitis or systemically-induced contact dermatitis from metal wire in orthodontic materials. Contact Dermatitis 30, 210–213 (1994).
190. Vernon, C., Hildebrand, H.F., Martin, P.: Dental amalgams and allergy (review). J Biol Buccale 14, 83–100 (1986).
191. Verschueren, G.L.A., Bruynzeel, D.P.: Allergy to N,N-dimethyl-p-toluidine in dental materials. Contact Dermatitis 24, 149 (1991).
192. Vilaplana, J.: Contact dermatitis from eugenol in mouthwash. Contact Dermatitis 24, 223–224 (1991).
193. Vilaplana, J., Romaguera, C., Cornellana, F.: Contact dermatitis and adverse oral mucous membrane reactions related to the use of dental prostheses. Contact Dermatitis 30, 80–84 (1994).
194. Vilaplana, J., Romaguera, C.: New developments in jewelry and dental materials. Contact Dermatitis 39, 55–57 (1998).
195. Vincenzi, C., Cameli, N., Vassilopoulou, A., Tosti, A.: Allergic contact dermatitis due to benzoyl peroxide in an arm prosthesis. Contact Dermatitis 24, 66–67 (1991).
196. Vozmediano, J., Manrique, A.: Active sensitization to (meth) acrylates. Contact Dermatitis 39, 314 (1998).
197. Wahlberg J.E., Boman, A.: Palladium chloride – a potent sensitizer in the guinea pig. Am J Contact Dermatitis 1, 112–113 (1990).
198. Wantke, F., Hammer, W., Haglmuller, T., Gotz, M., Jarisch, R.: Anaphylaxis after dental treatment with a formaldehyde-containing tooth-filling material. Allergy 50, 274–276 (1995).
199. Wataha, J.C., Hanks, C.T.: Biological effects of palladium and risk of using palladium in dental casting alloys. J Oral Rehabil 23, 309–320 (1996).
200. Wetter, D.A., Davis, M.D., Yiannis, J.A., Chang, J.F., Connolly, S.M., el-Azhary, R.A., Farmer, S.A., Fett, D.D., Johnson, J.S., Linehan, D.L., Richardson, D.M., Schroeter, A.L: Patch test results from the Mayo Clinic contact dermatitis group 1998–2000. J Am Acad Dermatol 53, 416–421 (2005).
201. Wiesner, M., Pambor, M.: Allergic contact dermatitis from gold. Contact Dermatitis 38, 52–53 (1998).
202. Wöhrl S., Hemmer W., Focke M., Götz M., Jarisch R.: Oral symptoms due to zinc as a minor component of dental amalgam. Contact Dermatitis 44, 246–263 (2001).
203. Wütrich, B., Bianchi-Kusch, E., Johansson, S.G.: Allergic urticaria and angioedema caused by a hemostatic sponge of bovine fibrin used in tooth extraction. Allergy 51, 49–51 (1996).
204. Yamauchi, R., Morita, A., Tsuji, T.: Pacemaker dermatitis from titanium. Contact Dermatitis 42, 52–53 (2000).
205. Yanagi, T., Shimizu, T., Abe, R., Shimizu, H.: Zinc dental fillings and palmoplantar pustulosis. Lancet 366, 1050 (2005).

Dentlearn.ir

Subject Index

A
acetamide 282
acryl amide 102, 127
acrylate 126
– immediate hypersensitivity 356
– prevalence of contact allergy 360
acupuncture 36
acute allergic reaction
– management of 357
– symptoms 357
agar-overlay test 14, 56
AH26 189, 199, 200, 201, 202, 203, 208, 210
– allergy 201, 350
AHPlus 201, 202, 203, 208
alcohol 273
– in mouthwashes 279, 283
– in oral hygiene products 273
alginate *see* impression materials
– cytotoxicity 295
Alkaliner
– allergy 351
allergy 3, 24
– allergic reactions 347
– dental screening series 346, 347
– disinfectants 352
– extraoral symptoms 242
– immediate-type 30
– sodium hypochlorite 352
– test 24, 28, 39
alloys 34, 221
– allergy 241
– analysis 34, 223
– burning mouth syndrome 237
– clinical symptoms and complaints 232
– components 222
– composition 225, 226
– corrosion 224, 228, 248
– gingivitis 221, 248
– influence of nobility 228
– lichenoid reactions 239
– metallic taste 237
– microbial adhesion 236
– nonoral patient complaints 233
– phase structure 223
– predicting elemental release 229
– pronounced inflammation 227
– release of elements/ions 225, 227, 231
– subjective complaints 237
– surface adhesion properties 228
– surface coating 225
– systemic toxicity 228, 232
– thermal treatment 225
– tissue necrosis and inflammation 233
– uptake in gingival tissue 231
– welding 226
alternative medicine 36
aluminum 150, 151, 314
aluminum oxide 315
Alzheimer's disease 87
amalgam
– allergy 80, 81, 342
– breastfeeding 71
– composition 60
– contact lesions 81, 82, 339, 343
– corrosion 64
– corrosion products 60
– cytotoxicity 76
– dental personnel 74
– dermatitis 81
– "detoxification" 88
– electrochemical activity 61
– environmental aspects 325
– fertility dysfunction 74
– fetal exposure 70
– handling 319
– immunotoxicity 72
– magnetic fields 64
– mercury emission 60
– mercury-free 63
– mercury release 64
– mercury uptake 64
– neurobehavioral performance 74

Dentlearn.ir

– neurotoxicity 73
– occupational exposure 73, 74, 313
– oral lichenoid reactions (OLRs) 73, 79, 80, 84, 90, 343
– placement 322
– precautions 314
– pregnancy 71, 75
– pulp reactions 76
– removal 84, 88, 322
– replacement of 88
– rubber dam 89
– saliva 69
– setting reaction 60
– spina bifida 75
– systemic diseases 87
– systemic toxicity 64
– teratogenicity 74
– waste 321, 325
– wastewater 327
amalgamator 322
"amalgam disease" 85
– diagnostic recommendations 90
amalgam scrap 322, 327
– recycling 327
– storage 327
amalgam separators 328, 332
– regulations 330
amalgam tattoo 78
American National Standards Institute 50
Ames test 14, 25
ammonium bifluorid 102
anamnesis 357
– checklist 358
anemia 263
anesthesia 190
anethole 281
angioedema 354
apexification 205
aphthous ulceration 280
– detergents in toothpastes 278
apoptosis 18, 112
applied kinesiology 36
artificial fingernails 99, 126, 168, 264, 348, 360
asbestos fibers 301
atomic absorption spectrometry (AAS) 34, 224
atomic emission spectroscopy 224
atopy 316, 318
Australian Therapeutic Goods Act 50
autism 74
azulene 282

B

BADGE 201, 203, 349, 350
– allergy 201, 349, 350
balsam of Peru (*see* Peru balm)
barrier equipment 320
benzalkonium chloride
– allergy 351
benzethonium chloride
– in mouthwashes 279
benzoates 282
benzoic acid, allergy 340
benzoyl peroxide (BPO) 100, 122, 209 *see also* dibenzoyl peroxide
– allergy 243, 264, 347, 349
beryllium 228, 243, 315, 345
bioactive material 1, 187
biocompatibility 1
bioenergy 37
biomagnification 326
biomaterial 1
biopsy 34, 337
– metal analysis 35
biphenyl 257
Bis-DMA 100, 106, 107, 109, 332
Bis-EMA 106
bisglycidylmethacrylate *see* Bis-GMA
Bis-GMA 100, 104, 106, 108, 109, 111, 124, 125, 127, 209, 211, 332
– allergy 123 ff, 128, 349
bisphenol A (BPA) 350 *see* BPA
bisphenol A diglycidyl ether *see* BADGE
bisphenol A dimethacrylate *see* Bis-DMA
black rubber mix 317
bleaching agents 284
– dental hypersensitivity 286
bone morphogenetic proteins (BMPs) 118, 173
BPA 106, 108, 109, 111, 332
– allergy 350
bridging 166
Buehler test 24
burning mouth syndrome (BMS) 237, 263, 280, 343, 359

C

cadmium 243, 345
– allergy 347
calcium hydroxide 195
calcium-hydroxide-based sealers 203
– antimicrobial properties 205
– clinical data 205
– composition 203
– implantation studies 204

Dentlearn.ir

– mandibular nerve injury 205
– nerve conduction 204
– neurotoxicity 204
– release of substances 203
– setting reaction 203
calcium hydroxide cements 166
– allergy 168
– antimicrobial properties 169
– carcinogenicity 173
– composition 166
– cytotoxicity 169
– mutagenicity 173
– pulp reaction 169
– release and degradation 167
– setting reaction 166
– systemic toxicity 168
calcium hydroxide salicylate cements 167
calcium phosphate cements 139, 207
calcium phosphate ceramics 178
calcium-salicylate cements 166 *see also* calcium hydroxide cements
camphorquinone 100, 209
– allergy 349
CAPB 278
– systemic toxicity 284
carbamide peroxide 284
– hydrogen peroxide 284
– soft tissue lesions 285
carbamix 317
carcinogenicity 4, 25
carvone 281
catgut 303
Cavit 293
cell cultures 17
– three-dimensional 17
cell cycle delay 112
CEN 55
ceramic alloys 228
– cytotoxicity 235
– oxide 228
– treatment 238
cermet cement 149, 150
cetylpyridium chloride
– in mouthwashes 279
cheilitis 281, 338, 339, 341, 347, 352
chelating agent 88
chemical lavage 117
chip test 34, 39
chloramine
– allergy 356
chlorhexidine 279, 300, 302
– allergy 281, 351, 356
chloroacetamide 282
chloroform
– in toothpastes 282
chloropercha 195
choline esterases 107
chromium 314, 316
– allergy 243, 341, 342
– cheilitis 341
– dermatitis 341, 342
– stomatitis 341
chromium–cobalt 315
cinnamon (cinnamic aldehyde) 161
– allergy 280
clinical assessment 48, 56
clinical examination 358
– checklist 358
clinical studies 14, 26, 39, 48, 56
CO_2-snow 33
cobalt 314, 316, 317
– allergy 339, 340, 341
– cheilitis 341
– contact lesion 339
– dermatitis 341
– stomatitis 341
cobalt-based alloys 227
cocoamidopropyl betaine (CAPB) 278
Coe-Pak 307
collagen *see* medical collagen
colophony (rosin) 196, 299, 317
– allergy 352
– in flouride varnish 288
Comité Européen de Normalisation (CEN) 55
compatibility 28
– individual 13, 28
compomers 102, 105
composites *see* resin-based composites
concurrent sensitization 4
conformity assessment 46, 51
conjunctivitis 315
contact dermatitis 28, 315
– allergic 28
– MMA 264
contact urticaria 315, 354
conversion rate 104
copper amalgam 74, 314
– health effects 314
cornstarch 354
corrosion 224
– acidic fluoride preparation 227
– electric potential 226
corrosives 53
cosmetics 45, 161

Dentlearn.ir

cremation 331
crevice corrosion 233
cross-reaction 4, 240, 264, 349, 350, 352
crowns
– components 222
cyanoacrylates 167, 168, 171, 300, 356
cyclooxygenase 163

D

delayed allergic reaction
– clinical picture 338
delayed type hypersensitivity 28
dental ceramics 177
– allergy 180
– aluminum oxide (Al_2O_3) ceramics 177, 180
– calcium phosphate ceramics 178, 180
– carcinogenicity 183
– composition 177
– cytotoxicity 181
– feldspathic ceramics 177
– fluorides 180, 184
– gingival reaction 182
– glass ceramics 177
– implant 183
– implantation studies 181
– lanthanum glass 177
– lead 179
– mutagenicity 183
– natural radionuclide 184
– oxide ceramics 177
– pulp reactions 182
– radiation 183
– release and degradation 179
– silicon oxide (SiO_2) ceramics 177, 179
– solubility 179
– systemic toxicity 180
– titanium ceramic 177
– tricalcium phosphate ceramics 178
– zirconium oxide (ZrO_2) ceramics 177, 180
dental hypersensitivity
– bleaching agents 286
dental implant 24, 47, 229, 230
dental personnel 312, 313
– adverse reactions 312
– mercury 313
– resin-based composites 122ff, 127ff
dental technical laboratory 312
dentin 114
– diffusion 114
– hypersensitivity 120
– permeability 21, 114, 115
– reactionary 166, 171
– reactive 20
– regeneration 21, 117, 166
– sclerosis 20, 22
– tertiary 20
– thermal insulator 119
dentin-barrier test 14, 18, 19, 56, 152
dentin bonding agents *see also* resin-based composites
– allergies 121ff, 348
dentinogenesis 166
denture base acrylates 347
– allergies 264, 266, 347
denture base materials
– allergy 339
denture hygiene 262, 264
dentures 255, 345
– allergy 265
– gingivostomatitis 349
– gold coating 227
– hydroquinone 349
– stomatitis 227
denture stomatitis 262
– allergy 339
– burning mouth syndrome (BMS) 263
– fungal infection 261, 264, 340
deodorants 161
dermatitis
– dental personnel 316
dermatoses 315
– allergic 315
– irritative 315
Diaket 200, 212
dibenzoyl peroxide 258 *see also* benzoyl peroxide (BOP)
dibutyl phthalate 257
dichlorine–difluorine–methane 33
dichlorophene 282
dimethylparatoluidine *see* DMPT
dimethyl sulfoxide 15
diphenyliodonium chloride (*see* DPICL)
disinfectants
– allergy 352
DMP *see* DMPT
DMPT 100, 102, 127, 316, 349
– allergy 349
DMSO 15
DNA damage 18, 25
dose range 8
dose-response curve 8, 235
downstream user 48
DPICl 149, 151, 152
drugs
– oral side effects 7, 357

Dentlearn.ir

Duraphat 288
dust 314
dysesthesia 190, 194

E
ECHA 48
EDTA 114
EDX analysis 34, 223
EGDMA 125, 126
– allergy 122ff, 348
electrical phenomenon 32
electroacupuncture 36, 109
elimination test 30, 239
eluable residual monomer 104
eluate 15
enamel cracks 34
endodontic files 247
endodontic usage test 14, 23, 56
Endomethasone 200
Endotec 193
energy dispersive x-ray analysis (*see* EDX)
epichlorohydrin 350
epimucosal test 29
epoxy-based sealers 201 *see also* AH26 and AHPlus
– allergy 349, 350
– antimicrobial properties 203
– clinical studies 203
– cytotoxicity 202
– implantation studies 202
– mandibular nerve injury 203
– mutagenicity 202
– nerve conduction 202
ePTFE *see* suture materials
erethism 67, 68, 313
essential requirements 46, 48
estrogenicity 108
eucalyptus oil 195
eugenol 17, 139, 160, 162, 195, 196, 199, 295, 299, 300, 301, 306, 317
– allergy 160, 196, 350, 352, 356
European Chemicals Agency (ECHA) 48
extract 15
eye damage 120, 321
eye protection 121, 128, 321

F
face mask 317, 320
FACS 18
FDA 49
FDA review 50
fibrin tissue
– adverse reaction 356
fibroblasts 17
– gingival 17
– immortalized 17
– mouse 17
– pulp 17
fibrous encapsulation 19, 234
filter test 56
fine tremor 67
fingernails *see* artificial fingernails
fish consumption 71, 326
fissure sealants 101, 106, 109, 124
fixed dose 16
flammables 53
flavorings
– allergy 353
fluorides 15, 150
– in mouthwashes 275
– in toothpastes 273
– release 15
fluoride varnishes and gels
– adverse reactions 286
– colophony 288
fluorosis 275
Food and Drug Administration (FDA) 49
formaldehyde 106, 122, 125, 189, 195, 213, 256, 260, 317
– allergy 125, 340, 348, 350, 351, 356
– cytotoxicity 260
– in oral hygiene products 282
fracture of instrument 189
fragrances 161, 196 *see also* perfumes
– allergy 161, 352
fumes 314

G
gallium alloy 63, 64, 76
galvanic cell 226
genotoxicity 25
geographic tongue 238
geraniol 161
GHS 52
GHTF 45, 51, 57
gingivitis 122, 238, 247, 277, 336, 357
– allergy 243, 338, 344, 345, 348
gingivostomatitis 280
glass ionomer cement, light-cured (*see* resin-modified glass ionomer cements)
glass ionomer cements 212
– allergy 151
– aluminum 150, 151
– antimicrobial properties 152
– carcinogenicity 156

Dentlearn.ir

– composition 149
– cytotoxicity 151
– fluoride 150
– gingival reactions 155
– implantation studies 153
– mutagenicity 156
– postoperative pain 154
– pulp capping 155
– pulp reactions 154
– setting reaction 149
– systemic toxicity 151
Global Harmonization Task Force (GHTF) 45, 50
Global Medical Device Nomenclature 51
glomerulonephritis 72
glossodynia 336, 359
gloves 317, 320, 355
glucocorticoid 167, 168, 171
glutaraldehyde 25, 102, 108, 111, 120, 122, 127, 337
– allergy 122, 340, 351
glutathione 112
glycidylmethacrylate *(see* GMA)
glyoxal (ethanediol)
– allergy 351
GMA 106, 111
gold 222 ff, 360
– allergy 241, 243, 340, 343, 360
  – burning mouth syndrome 343
  – oral symptoms 343
Grossman sealer 195
gutta-percha 191, 209, 213, 355
– allergy 191, 355
– antimicrobial properties 194
– cadmium 191
– calcium hydroxide 191
– cell cultures 192
– chlorhexidine 191
– composition 191
– heated 192
– implantation studies 192
– iodoform 194
– liquefied 188, 191, 192, 194
– overfilling 194
– particle size 192
– release and degradation 191
– synthetic 192
– systemic toxicity 191

H

hand eczema
– dental personnel 316
hand washing 316
haptens 125, 196, 240, 246, 356
harmonized standards 46
hazardous waste 325, 332
Helsinki Declaration 26
HEMA (hydroxymethylmethylmethacrylate) 102, 108, 115, 122, 125, 126, 149, 151, 208, 209, 337
– allergy 122 ff, 151, 345, 348, 350
Henoch–Schőnlein purpura 72
herpes simplex 299
high-copper amalgam 60
holistic approach 37
HPRT test 14, 25
hybrid ionomer 149
hydraulic conductivity 116
hydrocolloid *see* impression materials
hydrofluoric acid 102, 177, 180, 183, 184
hydrogen peroxide 284
– systemic toxicity 284
hydroquinone 349
– allergy 243, 265, 338
hydroxyl apatite 115, 178, 183, 195
hyperesthesia 190
hypersensitivity 29
– type IV 29
hypoesthesia 190

I

immediate allergic reaction (IgE mediated) 353
– clinical picture 353
implantation tests 14, 19
– bone 19
– intramuscular 19
– subcutaneous 19
implant usage test 56
impression materials 294, 306
– allergy 299
– composition 294
– cytotoxicity 295
– implantation studies 296
– maxillary sinus 298
– mutagenicity 299
– periodontal damage 297
– pulp reactions 297
– setting reaction 295
– systemic toxicity 295
incineration 327
– mercury-contaminated solid waste 332
– wastewater sludge 327
indium 245, 345
interdisciplinary collaboration 10, 359
interment 331

Dentlearn.ir

International Organization for Standardization (ISO) 54
intraosseous implant test 24
iridium 345
iron deficiency 263
irritant 53
ISO 54
isoeugenol 161, 196
itaconic acid 149

L

labeling 52, 53
Langerhans cells 29
latex 32, 190, 192, 317, 318
– allergy 190, 192, 354, 355
– immediate allergic reaction (IgE mediated) 354
latex gloves 316
LC_{50} 39
LD_{50} 14, 17, 39
– acute 16
LED curing unit 103, 104, 119
legal regulations 45
– Australia 50
– European Economic Area 46
– European Union 45
– Japan 51
– United States 49
leucite 177, 178
leukoplakia 338
lichenoid reactions (*see* oral lichenoid reactions)
life expectancy 311
light-curing glass ionomer cement (*see* resin-modified glass ionomer cements)
light-curing unit 103
– hazards for eyes 120
– protective shield 128
– thermal effect 119
light-emitting diodes 103
light intensity 104
limit test 16
limonene 281
lithium 179, 180
lithium oxide 177
LOAEL 11
local lymph node assay 14, 24
local reaction 3
LOEL 10
lorothidol 300
low-copper amalgam 60
LTT (lymphocyte transformation assay) 32, 73
lucerin 100
lung disease
– occupational exposure 315
luting resin-based composite 101

M

maleic acid 102, 108, 149
mandibular nerve injury 189
material safety data sheet 49
matrix metalloproteinases 107
maximization test 14, 24
McSpadden technique 191, 193
MDPB 102, 113, 117
medical collagen 168, 173
Medical Device Amendment 49
Medical Device Directive 45
medicaments
– allergy 356
MedWatch 50
MELISA (memory lymphocyte immunostimulation assay) 32, 73
menthol 281
mercaptomix 317
mercury 316
– allergy 81, 340
– anthropogenic emission 326
– bacterial resistance 69
– biomagnification 326
– blood 67
– breast milk 71
– carcinogenicity 85
– chronic toxicity 67
– circulation in dentistry 327
– consumption in dentistry 327
– dental personnel 74
– deposition in organs 66
– estimated intake 65
– feces 67, 69
– fertility dysfunction 74
– fetal exposure 70
– global consumption 326
– hair 70
– handling of 319
– immunotoxicity 72
– intoxication 68
– natural deposits 325
– neurobehavioral performance 74
– neurotoxicity 73
– occupational exposure 73, 74, 313
– placenta barrier 70
– precautions 321
– saliva 69

Dentlearn.ir

– spillage 322
– spina bifida 75
– storage 321
– systemic toxicity 64, 67, 78
– teratogenicity 74
– threshold value 65
– urine 67, 68, 313
– vaccine 74
mercury line 67, 78
4-META 102, 209
metal analyses of saliva 238
metal ceramics 177
metal ions 230
– absorption 229
– allergy 241
– carcinogenicity 245
– cytotoxicity 234, 249
– deposition 230
– distribution 230
– estimated daily dietary intake 231
– excretion 230
– gingivitis 238
– mutagenicity 245
– uptake in gingival tissue 231
metallic taste 33, 237, 238, 357
metal–protein complex 240
methylmercury 65, 326
– bacterial conversion 69
– body burden 65
methylmethacrylate (MMA) 108, 256, 263, 339
– allergy 263, 264, 339, 340
– occupational exposure 314
microarray test 19
micronucleus test 14, 25
mineral trioxide aggregate *see* MTA
molybdenum 231, 314
mouse ear swelling test 24
mouse lymphoma test 14
mouthwashes 271
– alcohol 283
– alcohol content 279
– alcohol intoxication 273
– allergy 277, 280, 281
– chemical erosions 277
– ingredients 271
– irritation of the soft tissue 277
MTA 167, 168, 172, 205, 210, 211, 213
– antimicrobial properties 207
– composition 206
– cytotoxicity 206
– furcation repair 207
– implantation studies 207
– pulpectomy 207
– setting reaction 206
MTT test 14, 17
mucosal damage 23
mucosa usage test 23
multiple chemical sensitivity syndrome 110
multiple-phase alloys 228
multiple sclerosis 87
mutagenicity 4, 25, 39

N

nail dystrophy 242
nail products 348 *see also* artificial finger nails
nanoleakage 107, 120
natural rubber latex *(NRL; see* latex)
neoprene gloves 126
N-ethyl-4-toluene sulfonamide *(see* Alkaliner)
neutral red 17
nickel 245, 246, 314, 316, 360
– perioral eczema 341
– risk-benefit ratio 247
– tolerance 341
nickel, allergy 240, 339, 340
– contact dermatitis 340
– contact lesion 339
– stomatitis 340
nickel-based alloys 227
– nickel release 231
nickel-based crowns 231
nickel–chromium alloys 227
nickel concentration in foodstuffs 250
nickel–titanium alloys 228
nitrile gloves
– allergy 354
N. N-dimethyl-p-toluidine *see* DMPT
NOAEL 11
Nobetec 307
nocebo 9
NOEL 11
noninvasive products 47
non-γ2 amalgam 60
Notified Body 47
no-touch technique 26, 128, 319

O

Obtura 191, 193, 194
occupational exposure 14
occupational hazard 311

Dentlearn.ir

odontoblast reaction 20, 21
OECD
– guidelines 54
oral battery 33
oral galvanism 33
oral lichenoid reactions (OLR) 79, 80, 239, 241, 281, 336, 338, 340, 343, 348, 350, 359
– amalgam 73, 79, 80, 83, 90, 342, 343
– dental alloys 239, 241
– resin-based composites 125, 128
oral lichen planus (OLP)
– amalgam 84, 342
Organization for Economic Cooperation and Development (OECD) 54
ormocer 100, 109, 111
orthodontic alloys
– components 222
orthodontic wires 240, 242, 247
osseoconductive 187
osseoinductive 187
osseointegration 234
overfilling 203, 213
overinstrumentation 189
oxide layer 238
oxiranes 100, 104, 105
oxygen inhibition layer 104

P

palatal erythema 239
palladium 230, 245, 246, 317
– LD_{50} 230
– risk-benefit ratio of 246
palladium, allergy 240, 244, 339, 340, 342
– contact lesions 339
– dermatitis 343
– stomatitis 343
paraformaldehyde 196, 197, 199, 200, 213 *see also* formaldehyde
paresthesia 200, 203
paresthesia of the fingertips 345
Parkinson's disease 87
passivation layer 61
patch testing 28, 29, 39, 353
– dental screening series 353
– evaluation of results 360
– indication 360
– prevalence of contact allergy 360
peppermint 281
perfumes 161 (*see also* fragrances)
periapical lesions 189
periodontal dressings 160, 299, 306
– allergy 302
– antimicrobial properties 302
– composition 300
– cytotoxicity 301
– implantation studies 301
– mutagenicity 302
– setting reaction 300
– systemic toxicity 300
perioral dermatitis 338
Peripac 307
permanent cell line 17
Peru balm 160, 195, 196, 306, 340, 352
Pharmaceutical Affairs Law 51
γ2 phase 60
phenyl benzoate 257
phenylsalicylate 258
phosphoric acid 102, 108, 139
phthalates 294
placebo 9
plaster of Paris 315
platinum 228, 241, 245, 250
– allergy 344
PMMAs
– allergy 264, 265, 339
– alternatives 266
– burning mouth syndrome (BMS) 263
– carcinogenicity 265
– composition 255
– conversion 256
– cytotoxicity 259
– leaching substance 257
– microbial effect 261, 263
– mutagenicity 265
– occupational exposure 265
– precautions 266
– pulp reactions 262
– residual monomers 256, 258, 261
– setting reaction 255
– systemic toxicity 258
pneumoconiosis 180, 314
point suction 319
polyacrylic acid 139
polyalkenoate cement *see* glass ionomer cements
polyamide *see* suture materials
polycarboxylate cement 140, 145
polyether
– cytotoxicity 295
polyglycolic acid *see* suture materials
polymethyl methacrylate 17, 255

Dentlearn.ir

polysulfide
– cytotoxicity 295
polyvinyl chloride *see* PVC
Portland cement 206
prick test 28, 30, 357
primary cultures 17
proinflammatory mediators 112
prophetic test 30
propolis 282
protective glasses 320
proteinuria 67, 68, 313
provocation test 30, 345, 353, 355
pulp 20
– abscess 118
– bacterial colonization 117
– capping 20
– gangrene 23
– inflammation 20
– predamaged 22
– sensitivity 33
– stem cells 118
– vitality 33
pulp capping 166, 168, 169, 170
– indirect 169
pulp-capping test 56
pulp/dentin test 14, 20, 39, 56
pustulosis palmoplantaris 344
PVC 350, 352

Q

Quartz-tungsten halogen 103, 104, 119

R

radiation source 321
radioallergosorbent test 28, 32
RAST 32
REACH 45, 48
reactive oxygen species 18, 112
removable orthodontic devices 255
reporting system 56
reproductive toxicity 14
resin-based composites
– allergy 121, 348
  – anaphylactic shock 124
  – contact dermatitis 126, 345
  – dental personnel 125, 345
  – eczema 126
  – lichenoid reaction 125, 128, 348, 350
  – maximization test 123
  – perioral eczema 125, 348
  – prevalence 122
– antimicrobial properties 112
– bacterial colonization 117
– biodegradation 107
– carcinogenicity 127
– cell metabolism 112
– clinical symptoms and complaints 109, 345, 348
– composition 99
– cytotoxicity 110
– direct pulp capping 117, 128
– DNA damage 112
– environmental 332
– environmental aspects 332
– estrogenicity 108
– extraction media 104
– filler particles 100
– fluoride 107
– gingiva and oral mucosa 121
– gloves 126, 127
– implantation studies 114
– microexposure of the pulp 117
– mutagenicity 127
– nanoparticles 100
– plaque accumulation 121
– postoperative sensitivity 105, 119, 120
– public discussion 127
– pulp reactions 114
– release of substance 105
– setting reaction 104
– shrinkage 105
– systemic toxicity 108
resin-based sealers 208
– antimicrobial properties 210
– composition 208
– cytotoxicity 208
– setting reaction 208
resin globules 107
resin-modified glass ionomer cement 149
– allergy 151, 348, 350
– antimicrobial properties 152
– carcinogenicity 156
– cytotoxicity 151
– fluoride 150
– implantation studies 153
– mutagenicity 156
– pulp capping 155
– pulp reactions 154
– systemic toxicity 151
retraction cords 297
retrograde root canal filling 210
– allergy 211
– systemic toxicity 211

Dentlearn.ir

risk 5, 14, 39, 56
– acceptable 14
– analysis 6, 56
– assessment 14, 15, 56
– evaluation 6
– general 127
– group 16, 39, 127
– individual 127
– management 7, 56
– perception 6, 10
– phrases 53
– reassessement 15
root canal 23
root canal filling materials
– antimicrobial activity 189
– clinical success 189
– neurotoxic properties 189
– physical properties 189
– points 187
– requirements 188
– sealers 187
– sealing 189
root-end closure 205
rosin *see* colophony (rosin)
R-phrases 52
rubber chemicals
– allergy 356
rubber dam 190
– latex-free 190

S

safety 2
safety data sheet 49, 57
saline 15
saliva 34, 39, 106, 107
– amalgam 69
– Bis-DMA 106
– Bis-GMA 107
– BPA 107
– metal analysis 35, 69, 238, 248
salivary proteins 228
saliva test 248
self-adhesive resin-based luting composites 105
self-adhesive resin cements 102
self-etching monomers 102
septol 300
Septo-pack 307
side effect 2
silanes 100
silica and silicon carbide particles 314
silicate cement 17, 22, 139
silicate granuloma 182
silicone (impression material)
– cytotoxicity 295
– implantation studies 296
silicone (root canal sealers) 208
– antimicrobial properties 208
– cytotoxicity 208
– implantation studies 208
silicophosphate cement 140
silicosis 180
siloranes 100, 104, 105, 111
silver 60, 69, 76, 152, 187, 201, 222, 235, 344
skin equivalent 23
skin reactions 316
– dental personnel 316
skin resistance 36
SLS
– toxic effects 278
smear layer 21, 102, 114
sodium hypochlorite 117
– allergy 352
sodium lauryl sulfate (SLS) 278
soft drinks
– allergy 352
– erosions 277
soft liners 255
soft tissue hybrid layer 117
solders 225, 236
– cytotoxicity 236
spearmint 281
S-phrases 52
spina bifida 75
standard mortality ratio 311
standards 54, 162
– harmonized 54
– horizontal 55
– semihorizontal 55
– vertical 55
standard series 29, 353
stearylethoxylate 278
STEL 11
stomatitis 335
– allergic 335, 338
– denture related 262, 340
– gold coating 227
– irritant 335
stone cement 140
substantial equivalency 50
Super EBA 195, 210, 211
surface adhesion properties 228
surgically invasive products 47

Dentlearn.ir

surveillance system 56
suture materials 303
– allergy 305
– bacteria 304
– biofilm formation 304
– composition 303
– cytotoxicity 303
– degradation 303
– implantation studies 303
– mechanical trauma 305
– mutagenicity 306
– systemic toxicity 303
systemic toxicity 3

T

tartaric acid 149
TC_{50} 39
TCP 178
TDI 11
TEGDMA 100, 102, 104, 106, 108, 111, 115, 122, 124, 126, 127, 209, 211, 349
– allergy 124, 126, 349
telescope crown 13
teratogenic effect 26
teratogenicity 4, 14
tetracycline 302
thiuram mix 317
thorium 184
threshold values 7
thymol 195, 282, 300
TI 11
tin
– allergy 344
– pustulosis palmoplantaris 344
tissue compatibility 1, 16
tissue engineering 2
titanium 230, 231, 314
– allergy 344
  – traces of nickel 344
titanium alloys 227, 234
tolerance 240
4-tolyldiethanolamine
– allergy 349
tooth fracture 27
toothpastes 271
– abrasion 276
– accidental fluoride poisoning 273
– allergens 279
– allergic reactions 277, 281
– chemical erosions 277
– chronic fluoride toxicity 274, 276
– ingredients 271
– irritation of the soft tissue 277
tooth whiteners 284
toxicity 2
– acute 16
– chronic 16
– local 16
– relative 19
– systemic 16
– unspecific 17
transforming growth factor beta 1 (TGF-β1) 118, 167, 171, 173, 205
tremor 66, 68, 73, 313
tricalcium phosphate ceramics *see* TCP
triclosan (2,4,4′-trichloro-2′-hydroxydiphenyl ether)
– cross-resistance development 283
– in oral hygiene products 282, 283, 284
triethyleneglycoldimethacrylate *see* TEGDMA
tunnel defects 21, 171
TWI 11

U

UDMA 100, 102, 106, 108, 111, 127, 209
Ultrafil 194
^{238}uranium 183
uranium salts 177
urethandimethacrylate *see* UDMA
UV absorbers
– allergy 350

V

ventilation 319, 321
vitamin deficiency 338
Voco pac 307
voltage 32

W

wastewater treatment plants 328
– mercury accumulation 328, 330
Western blotting 18
workplace, dental 319

Z

zinc, allergy 84, 344
– dermatitis 344
zinc oxide and eugenol cement 14, 19, 20, 160, 172
– allergy 160
– antimicrobial properties 162
– carcinogenicity 163
– composition 160
– cytotoxicity 162

Dentlearn.ir

– implantation studies 162
– mutagenicity 163
– pulp reactions 162
– setting reaction 160
– systemic toxicity 160
zinc oxide eugenol sealers 195
– allergy 196
– antimicrobial properties 199
– aspergillosis 198
– clinical data 199
– composition 195
– cyclooxygenase 197
– cytotoxicity 196
– immune system 197
– mandibular nerve injury 199
– nerve conduction 197
– prostaglandin synthesis 197
– setting reaction 196
– systemic toxicity 196
zinc phosphate cement 17, 141
– allergy 142
– carcinogenicity 147
– composition 141
– cytotoxicity 143
– gingival reaction 146
– implantation studies 143
– microgap 146
– microleakage 146
– mutagenicity 147
– postoperative pain 145
– pulp reactions 143, 147
– setting reaction 141
– solubility 142
– systemic toxicity 142

Dentlearn.ir