Edited by
Thomas J. Hilton, DMD, MS
Jack L. Ferracane, PhD
James C. Broome, DDS, MS

Illustrations by
José dos Santos, Jr, DDS, PhD

SUMMITT'S FUNDAMENTALS OF OPERATIVE DENTISTRY

A Contemporary Approach, Fourth Edition

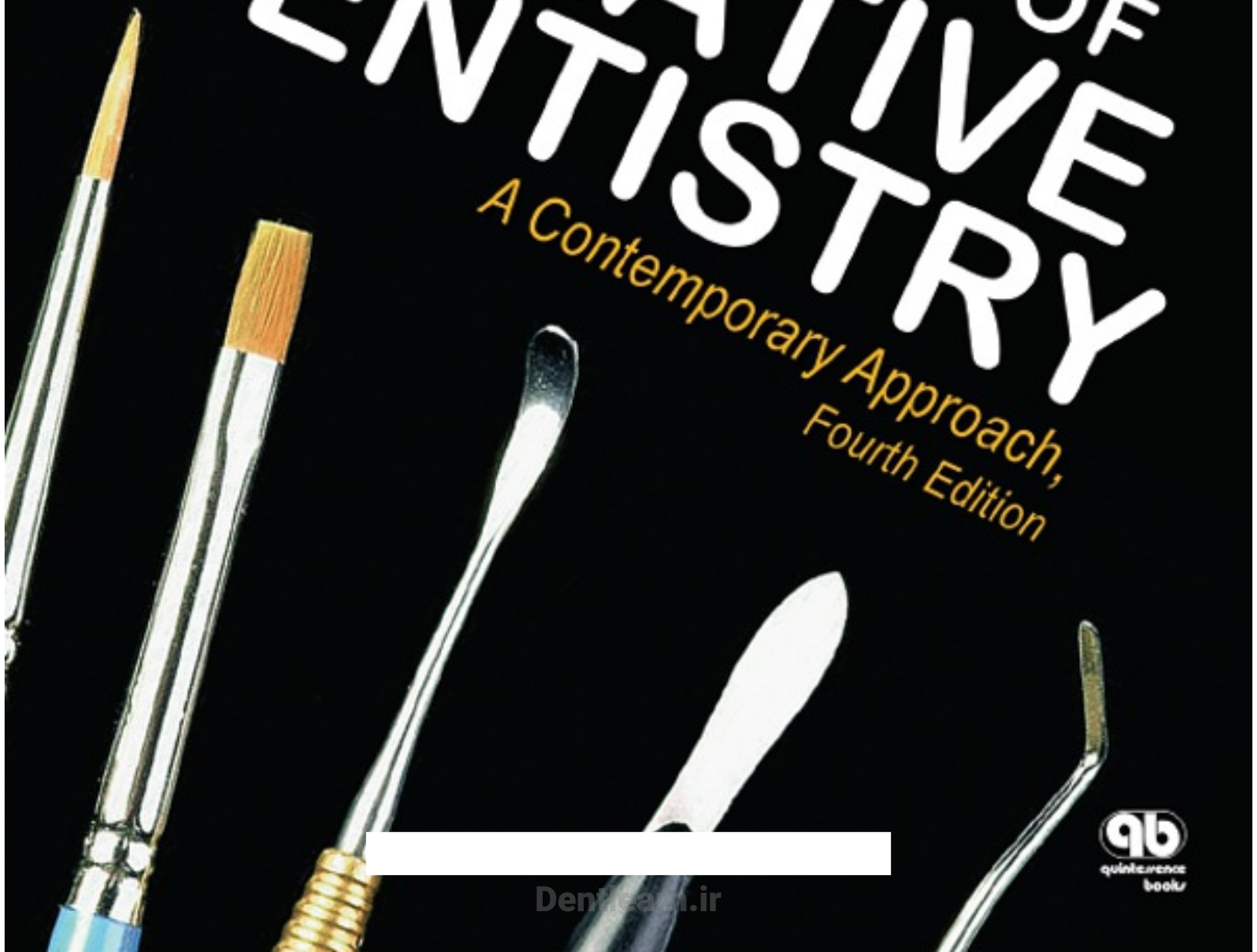

Dentcam.ir

Summitt's Fundamentals of Operative Dentistry: A Contemporary Approach

Fourth Edition

Dentlearn.ir

SUMMITT'S FUNDAMENTALS OF OPERATIVE DENTISTRY

A Contemporary Approach, Fourth Edition

Edited by

Thomas J. Hilton, DMD, MS
Alumni Centennial Professor in Operative Dentistry
Department of Restorative Dentistry
School of Dentistry
Oregon Health and Science University
Portland, Oregon

Jack L. Ferracane, PhD
Professor and Chair
Department of Restorative Dentistry
Division Director, Biomaterials and Biomechanics
School of Dentistry
Oregon Health and Science University
Portland, Oregon

James C. Broome, DDS, MS
Professor and Associate Dean for Clinical Affairs

Dentlearn.ir

Department of Restorative Sciences
School of Dentistry
University of Alabama at Birmingham
Birmingham, Alabama

Illustrations by

José dos Santos, Jr, DDS, PhD
São Paulo, Brazil



Quintessence Publishing Co, Inc
Chicago, Berlin, Tokyo, London, Paris, Milan, Barcelona, Beijing,
Istanbul, Moscow, New Delhi, Prague, São Paulo, Seoul, Singapore, and Warsaw

Dentlearn.ir

Library of Congress Cataloging-in-Publication Data

Fundamentals of operative dentistry.
Summitt's fundamentals of operative dentistry : a contemporary approach / edited by Thomas J. Hilton, Jack L. Ferracane, James C. Broome ; Illustrations by José dos Santos Jr. -- Fourth edition.
p. ; cm.
Fundamentals of operative dentistry
Operative dentistry
Preceded by Fundamentals of operative dentistry / edited by James B. Summitt ... [et al.]. 3rd ed. c2006.
Includes bibliographical references.
ISBN 978-0-86715-528-0 I. Hilton, Thomas J., editor of compilation. II. Ferracane, Jack L., editor of compilation. III. Broome, James C., editor of compilation. IV. Title. V. Title: Fundamentals of operative dentistry. VI. Title: Operative dentistry.
[DNLM: 1. Dentistry, Operative--instrumentation. 2. Dentistry, Operative--methods. 3. Dental Caries--therapy. 4. Dental Materials--therapeutic use. 5. Dental Prosthesis. 6. Esthetics, Dental. WU 300]
RK501
617.6'05--dc23

2013016328

5 4 3 2 1



© 2013 Quintessence Publishing Co Inc

Quintessence Publishing Co Inc
4350 Chandler Drive
Hanover Park, IL 60133

All rights reserved. This book or any part thereof may not be reproduced, stored in a retrieval system, or

permission of the publisher.

Editor: Bryn Grisham
Design: Will Jotzat
Production: Sue Robinson
Printed in China

Dentlearn.ir

To my wife and best friend, DeaDea, for her constant love, support, and encouragement; to my parents for instilling in me the qualities that have served me throughout my life; and to my role models and mentors, including the coeditors and book's new namesake, for inspiring me to strive for excellence.
—TJH

To Tricia, my wife and best friend, whose support in all things means more to me than she will ever know.
—JLF

To my beautiful granddaughter, Sophia McAlister Ward, and the women who made me a grandfather—my wife and true love, Mary, and my wonderful daughter, Kristy.
—JCB

Dentlearn.ir

In Memoriam



Dr J. D. (Dave) Overton, DDS (1953–2013)

Dr J. D. (Dave) Overton, dds, an author of two chapters in this book, passed away on April 20, 2013, at the age of 60 years following a 4-year battle with mesothelioma. Dave was a superb operative dentistry educator, and, for 10 years, he was the leader of the faculty who taught operative dentistry at the Dental School at the University of Texas Health Science Center in San Antonio. He was unwavering in his devotion to student learning and dedicated to ensuring that the operative dentistry curriculum at his institution was based on the best evidence. That dedication is reflected in his contributions to this textbook. He will be greatly missed. His legacy of excellence in operative dentistry will benefit present and future generations of dental professionals and their patients.

Dentlearn.ir

Contents

In Memoriam
Preface
Contributors

1 **Biologic Considerations**
Terry J. Fruits, Sharukh S. Khajotia, and Jerry W. Nicholson

2 **Patient Evaluation and Problem-Oriented Treatment Planning**
William F. Rose, Jr, Carl W. Haveman, and Richard D. Davis

3 **Esthetic Considerations in Diagnosis and Treatment Planning**
J. William Robbins

4 **Color and Shade Matching**
Rade D. Paravina

5 **Caries Management: Diagnosis and Treatment Strategies**
Bennett T. Amaechi, J. Peter van Amerongen, Cor van Loveren, and Edwina A. M. Kidd

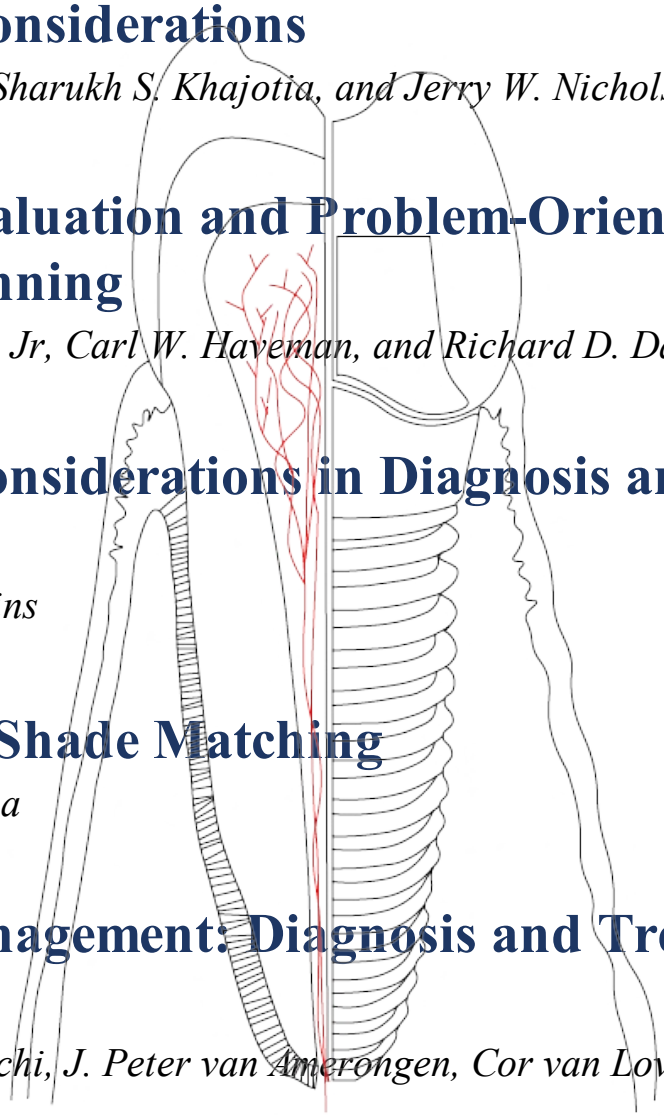

@dental books_Lib
Dentlearn.ir

6 Pulpal Considerations

Thomas J. Hilton and James B. Summitt

7 Nomenclature and Instrumentation

James B. Summitt

8 Field Isolation

James B. Summitt

9 Adhesion to Enamel and Dentin

Lorenzo Breschi, Jack L. Ferracane, Milena Cadenaro, Annalisa Mazzoni, and Thomas J. Hilton

10 Direct Anterior Restorations

Marcos A. Vargas, Cathia Bergeron, David F. Murchison, Joost Roeters, and Daniel C. N. Chan

11 Direct Posterior Esthetic Restorations

Thomas J. Hilton and James C. Broome

12 Amalgam Restorations

J. D. Overton, James B. Summitt, and John W. Osborne

13 Diagnosis and Treatment of Root Caries

Bruce A. Matis, Carlos González-Cabezas, and Michael A. Cochran

14 Fluoride-Releasing Materials

Deniz Cakir-Ustun, Nathaniel C. Lawson, and John O. Burgess

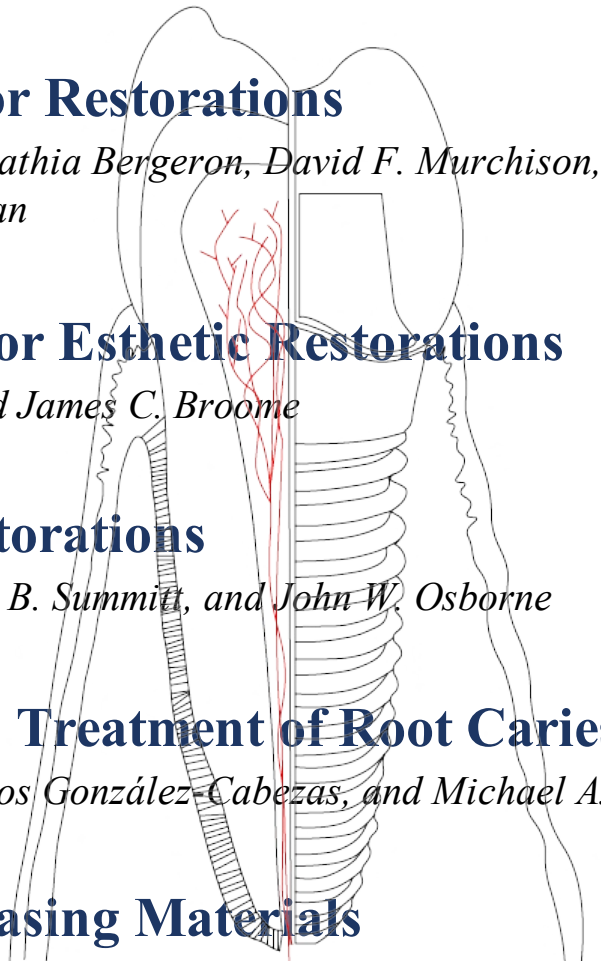

@dentallibooks_Lib

Dentlearn.ir

15 **Class 5 Restorations**
J. D. Overton, Thomas J. Hilton, Mark L. LittleStar, and Clifford B. Starr

16 **Natural Tooth Bleaching**
Van B. Haywood, Juliana da Costa, and Thomas G. Berry

17 **Porcelain Veneers**
Jeffrey S. Rouse and J. William Robbins

18 **Anterior Ceramic Crowns**
Jeffrey S. Rouse

19 **Esthetic Inlays and Onlays**
Dennis J. Fasbinder, Gisele Neiva, and J. William Robbins

20 **Cast Gold Restorations**
Patrice P. Fan, Richard Stevenson, and Thomas G. Berry

21 **Restoration of Endodontically Treated Teeth**
James C. Broome and J. William Robbins

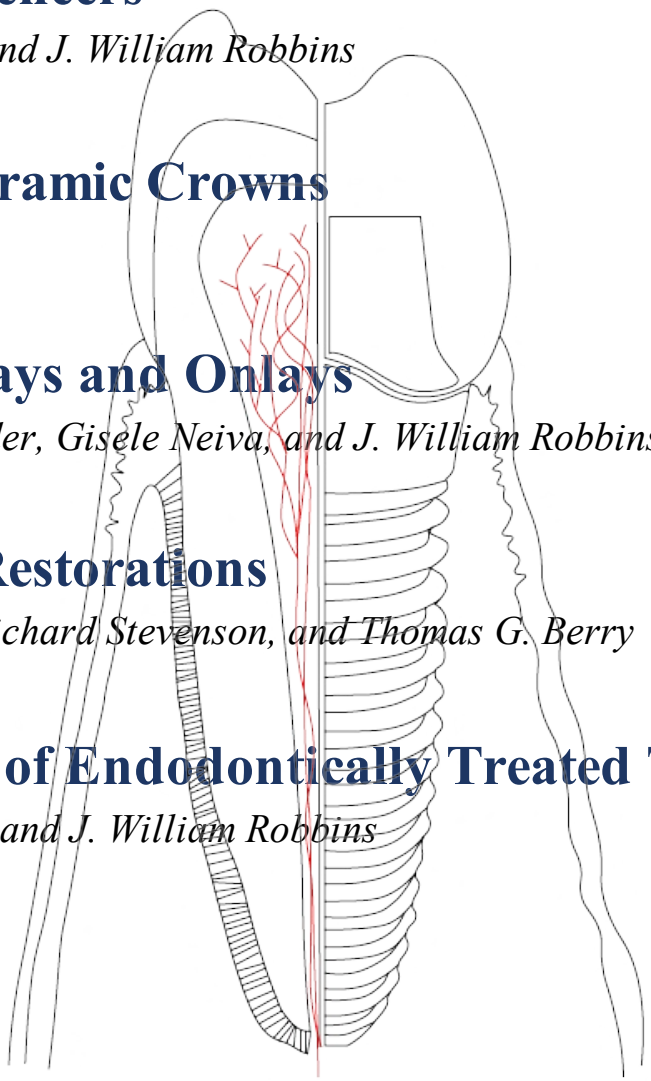

@dental_books_Lib

Dentlearn.ir

Preface

This textbook is about contemporary operative dentistry. The Academy of Operative Dentistry has defined *operative dentistry* as that branch of dentistry concerned with the management of teeth, by direct or indirect means, that are defective through disease, trauma, wear, and/or abnormal development, or are unesthetic, to a state of normal form, function, health, and appearance. This includes preventive/preservative, diagnostic, biologic, mechanical, and therapeutic procedures, applying all relevant aspects of dental technology and biomaterials and other oral and dental sciences.

The book is a blend of traditional, time-proven methods and recent scientific developments. Whereas preparations for cast gold restorations have changed relatively little over the years, preparations for amalgam and resin composite restorations are smaller and allow for less sound tooth structure to be removed because of the development of adhesive technologies. While we still use many luting agents in the traditional manner, adhesive cements provide greater retention for cast restorations and allow expanded use of ceramic and resin composite materials. Many concepts of caries management and pulpal protection have changed drastically as well. It is our hope that this textbook, which represents an ardent effort to present current concepts and the latest scientific evidence in restorative and preventive dentistry, will be helpful to students, educators, and practicing dentists during this time of rapidly developing technologies.

Several themes echo throughout this textbook. The first is the attempt to provide a scientific basis for the concepts described. The authors are clinically active, and many are engaged in clinical and laboratory research in the areas of cariology, restorative dentistry, and/or dental materials. Whenever possible, the diagnosis and treatment options described are based on current research findings. When convincing evidence is not available, we have attempted to present a consensus founded on a significant depth of experience and informed thought.

A second theme reflected in the book is our commitment to conservative dentistry. The treatment modalities described involve the preservation of as much sound tooth structure as possible within the framework of the existing destruction and the

Dentlearn.ir

patient's expectations for esthetic results. When disease necessitates a restoration, it should be kept as small as possible. However, it must be kept in mind that a conservative philosophy is also based on predictability. The treatment that is most predictable in terms of functional and esthetic longevity, based as much as possible on scientific evidence, must also be considered the most conservative. Therefore, when an extensive amount of tooth structure has been destroyed and remaining cusps are significantly weakened, occlusal coverage with a restoration may be the most predictable and therefore most conservative treatment. When portions of axial tooth surfaces are healthy, their preservation is desirable. In the conservative philosophy on which this book is based, a complete-coverage restoration (complete crown) is generally considered the least desirable treatment alternative, unless the tooth condition is such that a complete-coverage restoration will provide the most predictable clinical outcome.

The book describes techniques for the restoration of health, function, and esthetics of individual teeth and the dentition as a whole. Included are descriptions of direct conservative restorations fabricated from dental amalgam, resin composite, and resin-ionomer materials. Also detailed are techniques for partial- and complete-coverage indirect restorations of gold alloy, ceramics, metal-ceramic, and resin composite.

This fourth edition has been updated with new information based on evidence reported since the third edition. Because of new evidence, all chapters were revised, reference lists were expanded, and new authors were added to 11 chapters. A new chapter on color and shade matching has been added because of the increased emphasis on esthetic procedures in restorative dentistry. In addition, the chapter on adhesion to enamel and dentin has been completely rewritten.

This edition has also undergone a change in editorship with Tom Hilton taking the role of lead editor and the addition of Jack Ferracane and Jim Broome as co-editors, both of whom participated in the planning, editing, and revision of this textbook as a whole and were invaluable and tireless in seeing this project through.

As in the previous editions, the primary objective in producing this book is to provide students and practitioners with current and practical concepts of prevention and management of caries as a disease and of restoration of individual teeth. It is our hope that the changes made in this edition will make it of greater benefit to those who use it.

Dentlearn.ir



Title Change to this Edition

One of the significant changes to the fourth edition of the textbook is the title, with the addition of "Summitt's" before *Fundamentals of Operative Dentistry: A Contemporary Approach*. This addition is to honor Dr James B. Summitt, long-time clinician, educator, and researcher and the lead editor of the previous two editions of this book. He has been and continues to be a mentor to virtually all of the editors and authors of this textbook, as well as to many in the profession. Earlier versions of the preface have noted that Dr G. V. Black, the father of operative dentistry, was one of dentistry's greatest innovators and original thinkers. Dr Summitt is of the same breed as G. V. Black. While trained in traditional operative techniques and materials, Dr Summitt has always led the advance of new technology and innovation. Dr Summitt embodies the essence of what this textbook is about: looking to recent scientific innovations and incorporating them into our practices and dental school curricula. We are humbled and honored to know Dr Summitt as a personal friend, advocate for the profession, relentless devotee to evidence-based dentistry, and, most importantly, a role model of character and integrity.

Dentlearn.ir

Contributors

Bennett T. Amaechi, BDS, MS, PhD, FADI
Associate Professor and Director of Cariology
Department of Comprehensive Dentistry
Dental School
University of Texas Health Science Center at San Antonio
San Antonio, Texas

Cathia Bergeron, DMD, MS
Associate Professor
Department of Operative Dentistry
Faculty of Dentistry
Université Laval
Québec City, Canada

Thomas G. Berry, DDS, MA
Professor
Department of Restorative Dentistry
School of Dental Medicine
University of Colorado Denver
Denver, Colorado

Lorenzo Breschi, DDS, PhD
Associate Professor
Department of Medical Sciences
Division of Dental Sciences and Biomaterials
University of Trieste

Dentlearn.ir

Trieste, Italy

James C. Broome, DDS, MS
Professor and Associate Dean for Clinical Affairs
Department of Restorative Sciences
School of Dentistry
University of Alabama at Birmingham
Birmingham, Alabama

John O. Burgess, DDS, MS
Assistant Dean for Clinical Research
Director of the Biomaterials Graduate Program
Department of Clinical and Community Sciences
Division of Biomaterials
School of Dentistry
University of Alabama at Birmingham
Birmingham, Alabama

Milena Cadenaro, DDS, PhD, MS
Associate Professor
Department of Medical Sciences
Division of Dental Sciences and Biomaterials
University of Trieste
Trieste, Italy

Deniz Cakir-Ustun, DDS, MS
Associate Professor
Department of Clinical and Community Sciences
Division of Biomaterials
School of Dentistry
University of Alabama at Birmingham
Birmingham, Alabama

Dentlearn.ir

Daniel C. N. Chan, DMD, MS, DDS
Associate Dean for Clinical Services
Department of Restorative Dentistry
School of Dentistry
University of Washington
Seattle, Washington

Michael A. Cochran, DDS, MSD
Professor Emeritus
Department of Restorative Dentistry
Division of Operative Dentistry
School of Dentistry
Indiana University
Indianapolis, Indiana

Juliana da Costa, DDS, MS
Associate Professor and Preclinical Director
Department of Restorative Dentistry
School of Dentistry
Oregon Health and Science University
Portland, Oregon

Richard D. Davis, DDS
Private practice in endodontics
San Antonio, Texas

Patrice P. Fan, DDS, MSD, FRCD(C)
Affiliate Faculty
Department of Restorative Dentistry
School of Dentistry
Oregon Health and Science University
Portland, Oregon

Dentlearn.ir

Private practice in prosthodontics
Saint-Germain-en-Laye, France

Dennis J. Fasbinder, DDS
Clinical Professor
Department of Cariology, Restorative Sciences, and Endodontics
School of Dentistry
University of Michigan
Ann Arbor, Michigan

Jack L. Ferracane, PhD
Professor and Chair
Department of Restorative Dentistry
Division Director, Biomaterials and Biomechanics
School of Dentistry
Oregon Health and Science University
Portland, Oregon

Terry J. Fruits, DDS, MEd
Professor and Chair
Department of Operative Dentistry
Donald A. Welk Professorship of Restorative Dentistry
College of Dentistry
University of Oklahoma Health Sciences Center
Oklahoma City, Oklahoma

Carlos González-Cabezas, DDS, MSD, PhD
Associate Professor
Department of Cariology, Restorative Sciences, and Endodontics
School of Dentistry

Dentlearn.ir

University of Michigan
Ann Arbor, Michigan

Carl W. Haveman, DDS, MS
Clinical Associate Professor
Department of Comprehensive Dentistry
Dental School
University of Texas Health Science Center at San Antonio
San Antonio, Texas

Van B. Haywood, DMD
Professor
Department of Oral Rehabilitation
College of Dental Medicine
Georgia Regents University
Augusta, Georgia

Thomas J. Hilton, DMD, MS
Alumni Centennial Professor in Operative Dentistry
Department of Restorative Dentistry
School of Dentistry
Oregon Health and Science University
Portland, Oregon

Sharukh S. Khajotia, BDS, MS, PhD
Assistant Dean for Research and Graduate Programs
Professor and Chair
Department of Dental Materials
College of Dentistry
Affiliate Associate Professor of Chemical, Biological and
Materials Engineering
College of Engineering

Dentlearn.ir

University of Oklahoma
Oklahoma City, Oklahoma

Edwina A. M. Kidd, BDS, DDS, PhD, DSc(Med)
Emeritus Professor
Division of Conservative Dentistry
Dental Institute
King's College London
London, United Kingdom

Nathaniel C. Lawson, DMD
Resident
Department of Restorative Dentistry
College of Dentistry
University of Illinois at Chicago
Chicago, Illinois

Mark L. LittleStar, DDS
Assistant Professor
Department of Comprehensive Dentistry
Dental School
University of Texas Health Science Center at San Antonio
San Antonio, Texas

Bruce A. Matis, DDS, MSD
Professor Emeritus
Department of Restorative Dentistry
School of Dentistry
Indiana University
Indianapolis, Indiana

Annalisa Mazzoni, DDS, PhD
Associate Researcher

Dentlearn.ir

Department of Medical Sciences
Division of Dental Sciences and Biomaterials
University of Trieste
Trieste, Italy

David F. Murchison, DDS, MMS
Clinical Professor
Department of Diagnostic Sciences
Baylor College of Dentistry
Texas A&M Health Science Center
Dallas, Texas

Gisele Neiva, DDS, MS
Clinical Associate Professor
Department of Cariology, Restorative Sciences, and Endodontics
School of Dentistry
University of Michigan
Ann Arbor, Michigan

Jerry W. Nicholson, MA, DDS
Professor Emeritus
Department of Restorative Dentistry
Dental School
University of Texas Health Science Center at San Antonio
San Antonio, Texas

John W. Osborne, DDS, MSD
Professor Emeritus
Department of Restorative Dentistry
School of Dental Medicine
University of Colorado Denver

Dentlearn.ir

Denver, Colorado

J. D. Overton, DDS*
Clinical Associate Professor
Department of Restorative Dentistry
Dental School
University of Texas Health Science Center at San Antonio
San Antonio, Texas

Rade D. Paravina, DDS, MS, PhD
Director for Houston Center for Biomaterials and Biomimetics
Associate Professor
Department of Restorative Dentistry and Prosthodontics
School of Dentistry
University of Texas Health Science Center at Houston
Houston, Texas

J. William Robbins, DDS, MA
Private practice in general dentistry
Clinical Professor
Department of General Dentistry
Dental School
University of Texas Health Science Center at San Antonio
San Antonio, Texas

Joost Roeters, DDS, PhD
Professor
Department of Cariology, Endodontology, and Pedodontology
College of Dental Science
Radboud University Nijmegen Medical Center
Nijmegen, The Netherlands

William F. Rose, Jr, DDS

Dentlearn.ir

Assistant Professor
Department of Comprehensive Dentistry
Dental School
University of Texas Health Science Center at San Antonio
San Antonio, Texas

Jeffrey S. Rouse, DDS
Private practice in prosthodontics
Clinical Adjunct Associate Professor
Department of Prosthodontics
Dental School
University of Texas Health Science Center at San Antonio
San Antonio, Texas

Clifford B. Starr, DMD
Clinical Professor
Department of Operative Dentistry
College of Dentistry
University of Florida
Jacksonville, Florida

Richard Stevenson, DDS
Professor and Chair
Division of Restorative Dentistry
School of Dentistry
University of California, Los Angeles
Los Angeles, California

James B. Summitt, DDS, MS
Clinical Professor
Department of Comprehensive Dentistry
Dental School

Dentlearn.ir

University of Texas Health Science Center at San Antonio
San Antonio, Texas

J. Peter van Amerongen, DDS, PhD
Former Associate Professor
Department of Cariology, Endodontology, and Pedodontology
Academic Center for Dentistry Amsterdam (ACTA)
Amsterdam, The Netherlands

Cor van Loveren, DDS, PhD
Professor
Department of Preventive Dentistry
Academic Center for Dentistry Amsterdam (ACTA)
Amsterdam, The Netherlands

Marcos A. Vargas, DDS, MS
Professor
Department of Family Dentistry
College of Dentistry
University of Iowa
Iowa City, Iowa

Dentlearn.ir



Biologic Considerations

Terry J. Fruits
Sharukh S. Khajotia
Jerry W. Nicholson

Success in clinical dentistry requires a thorough understanding of the anatomical and biologic nature of the tooth, with its components of enamel, dentin, pulp, and cementum, as well as the supporting tissues of bone and gingiva (Fig 1-1; see also Fig 1-9a). Dentistry that violates the physical, chemical, and biologic parameters of tooth tissues can lead to premature restoration failure, compromised coronal integrity, recurrent caries, patient discomfort, or even pulpal necrosis.

Dentlearn.ir

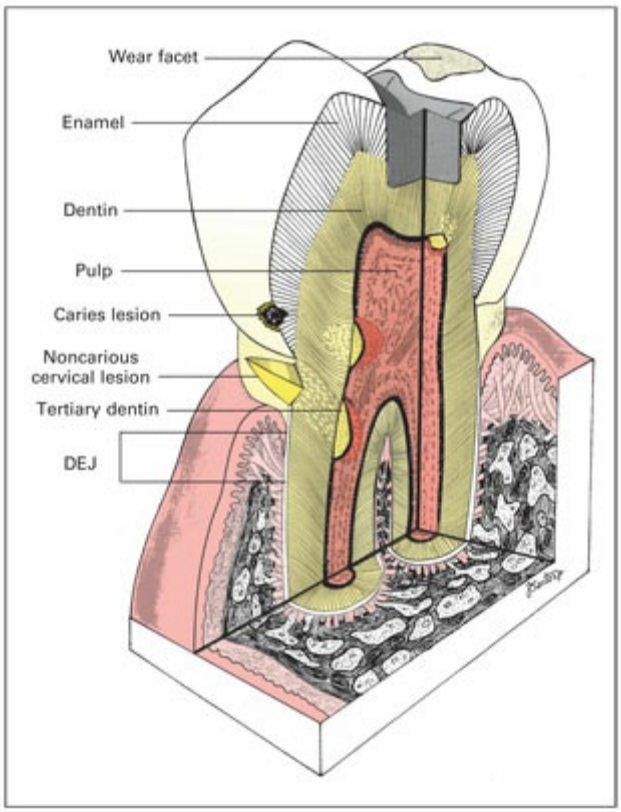

Fig 1-1 Component tissues and supporting structures of the tooth. DEJ—dentinoenamel junction.

The principles, materials, and techniques that constitute operative dentistry are effective only when utilized within a framework based on these biologic parameters. This chapter presents a morphologic and histologic review of tooth tissues with emphasis on their clinical significance for the practice of restorative dentistry.

Enamel

Enamel provides the shape and hard, durable outer surface of teeth, which protects the underlying dentin and pulp (see Fig 1-9a). Both color and form contribute to the esthetic appearance of enamel. Much of the art of restorative dentistry comes from efforts to simulate the color, texture, translucency, and contours of enamel with synthetic dental materials, such as resin composite or porcelain. Nevertheless, the lifelong preservation of the patient's own enamel is one of the defining goals of the discipline of operative dentistry. Although enamel is capable of lifelong service, its crystalline mineral makeup and rigidity, exposed to an oral environment of occlusal, chemical, and bacterial challenges, make it vulnerable to acid demineralization, attrition (wear), and fracture (Fig 1-2). Mature enamel is unique compared with other tissues because, besides alterations in its mineral content, repair or

Dentlearn.ir

replacement can only be accomplished through dental therapy.

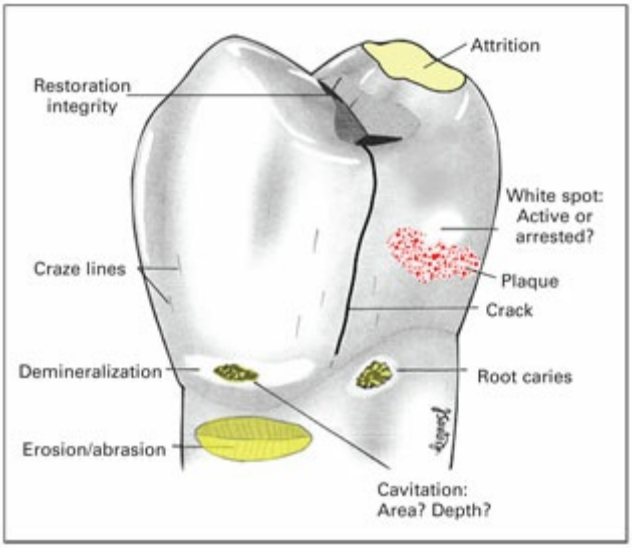

Fig 1-2 Observations of clinical importance on the tooth surface.

Permeability

At maturity, enamel is 96% inorganic hydroxyapatite mineral by weight and more than 86% hydroxyapatite mineral by volume. Enamel also contains a small volume of organic matrix, as well as 4% to 12% by volume water, which is contained in the intercrystalline spaces and in a network of micropores opening to the external

and the pulpal interstitial space and dentinal tubule fluids.[2] Various fluids, ions, and low–molecular weight substances, whether deleterious, physiologic, or therapeutic, can diffuse through the semipermeable enamel. Therefore, the dynamics of acid demineralization, reprecipitation or remineralization, fluoride uptake, and vital bleaching therapy are not limited to the surface but are active in three dimensions.[3–6] When teeth become dehydrated, as from nocturnal mouth breathing or rubber dam isolation for dental treatment, the empty micropores make the enamel appear chalky and lighter in color (Fig 1-3). The condition is reversible with return to the "wet" oral environment. There is some evidence that the permeability of the enamel decreases with age and may be affected by various dental procedures, such as tooth whitening, acid etching, or the physical removal of the outermost layer of enamel.[7–9]

Dentlearn.ir



Fig 1-3 Color change resulting from dehydration. The right central incisor was isolated by rubber dam for approximately 5 minutes. Shade matching of restorative materials should be determined with full-spectrum lighting before isolation.

Lifelong exposure of semipermeable enamel to the ingress of elements from the oral environment into the mineral structure of the tooth results in coloration intensity and resistance to demineralization. The yellowing of older teeth may be attributed to thinning or increased translucency of enamel, accumulation of trace elements in the enamel structure, and perhaps the sclerosis of mature dentin. This yellowing may be treated conservatively with at-home or in-office bleaching. The enamel remineralization process benefits from the incorporation of fluoride from water sources or toothpaste and from the fluoride concentrated in the biofilm (plaque) that adheres to enamel surfaces. Enamel damaged by acid-producing biofilm bacteria can be repaired by remineralization with fluoride, which increases the rate of conversion of hydroxyapatite into more stable and less acid-soluble crystals of fluorohydroxyapatite or fluoroapatite.[10] There has been a considerable amount of research recently directed at further enhancing the effectiveness of fluoride remineralization by creating new delivery systems that increase the available calcium and phosphate required to form fluoro-hydroxyapatite and fluoroapatite.[11] With aging, color (hue) is intensified, but acid solubility of enamel, pore volume, water content, and permeability are reduced, although a basic level of permeability is maintained.[12]

Clinical appearance and defects

The dentist must pay close attention to the surface characteristics of enamel for evidence of pathologic or traumatic conditions. Key diagnostic signs include color changes associated with demineralization, cavitation, excessive wear, morphologic faults or fissures, and cracks (see Fig 1-2).

Dentlearn.ir

Color

Enamel translucency is directly related to the degree of mineralization, and its color is primarily a function of its thickness and the color of the underlying dentin. From approximately 2.5 mm at cusp tips and 2.0 mm at incisal edges, enamel thickness decreases significantly below deep occlusal fissures and tapers to become very thin in the cervical area near the cementoenamel junction (CEJ). Therefore, the young anterior tooth has a translucent gray or slightly bluish hue near the incisal edge. A more chromatic yellow-orange shade predominates cervically, where dentin shows through thinner enamel. Coincidentally, in about 10% of teeth, a gap between enamel and cementum in the cervical area leaves vital, potentially sensitive dentin completely exposed.[13]

Anomalies of development and mineralization, extrinsic stains, antibiotic therapy, and excessive fluoride can alter the natural color of the teeth.[14] However, because caries is the primary disease threat to the dentition, enamel discoloration related to demineralization caused by acid from a few microorganisms, primarily mutans streptococci, within biofilm[15] is a critical diagnostic observation. Subsurface enamel porosity from demineralization is manifested clinically as a milky white opacity termed a *white spot lesion* (Figs 1-2 and 1-4). Early enamel fissure–caries lesions are difficult to detect on bitewing radiographs. However, diagnostic accuracy can be improved by a systematic visual ranking of the enamel discoloration adjacent to pits and fissures, which in turn is correlated with the histologic depth of demineralization.[16,17] In the later stages of enamel demineralization extending to near the dentinoenamel junction (DEJ), the white-spot opacity is evident not only when the tooth is air dried but also when it is wet with saliva.[18] It may take 4 to 5 years for demineralization to progress through the enamel,[19] but with improved plaque removal and remineralization, the lesion may arrest and, with time, appear normal again. In one study, 182 white spot lesions in 8-year-old children were reevaluated at age 15 years: 9% had cavitated, 26% appeared unchanged, and 51% appeared clinically sound.[20] In addition, sealing an initial caries lesion with resin has also been shown to be an effective method for arresting its further development.[21,22]

Dentlearn.ir

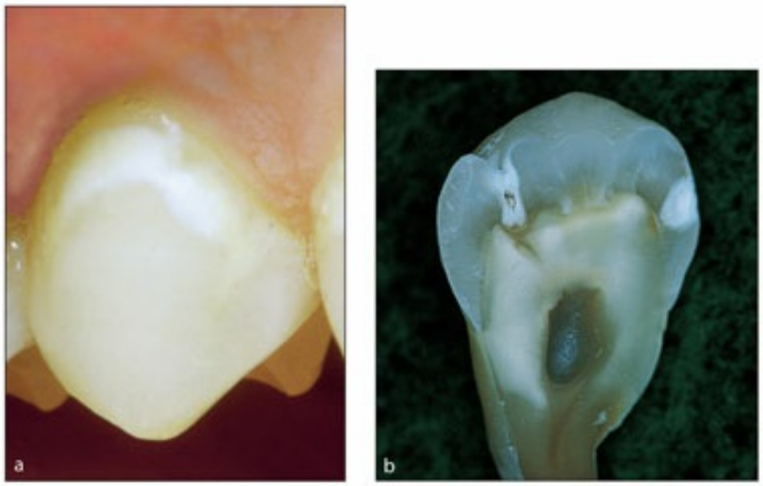

Fig 1-4 *(a)* White spot lesion on the facial surface of the maxillary premolar. *(b)* Premolar with both an occlusal fissure-caries lesion (Class 1), extending into the dentin, and a proximal smooth-surface caries lesion (Class 2).

A longstanding chalky and roughened white-spot appearance of the facial or lingual enamel surface (see Fig 1-4a) may be a result of factors such as inadequate oral hygiene, a cariogenic diet, and an insufficient amount of saliva resulting from medical conditions or medication. All of these factors place the patient at a higher risk for caries.[23] As the caries progresses, the overlying enamel takes on a blue or gray tint that provides a clinical sign indicating advanced dentin involvement. With the advent of effective remineralization, dentin bonding techniques, and fissure sealants, several authorities have suggested that invasive restorative procedures or replacement restorations should be considered only if caries lesion extension to dentin can be confirmed by visual signs of deep discoloration, enamel cavitation to dentin, or radiographic evidence.[24,25]

Cavitation

In the early stages of an enamel caries lesion, acid from the biofilm penetrates through the eroded crystal spaces to form a subsurface lesion of demineralized and porous mineral structure that appears clinically as a white spot. The acid protons follow the direction of the widened intercrystalline spaces of the affected enamel rods toward the DEJ. If the cariogenic biofilm, the etiology of the lesion, is not regularly removed through preventive measures, the lesion will progress in depth to the DEJ and into the dentin. When seen in two dimensions, as in a radiograph, smooth-surface enamel lesions are triangular, with the base of the triangle at the enamel surface; in a three-dimensional view, the proximal enamel lesion is a cone with its base equivalent in location and area to the demineralized enamel surface and

Dentlearn.ir

its apex closest to the DEJ. The deepest demineralized enamel rods, those at the apex of the cone, are first to be demineralized to the depth of the DEJ because of their longer time of exposure to the acid concentrations produced by the biofilm. The nature of enamel caries lesions in occlusal fissures is similar, but the shape is more complex because it occurs simultaneously at the confluence of two or more cuspal lobes, each with divergent rod directions (see Fig 1-4b). In two dimensions, a fissure-caries lesion presents with the apex of the triangular-shaped lesion located where the initial demineralization occurs simultaneously in both of the opposing

divergent rods of both opposing lobes toward the dentin, the lesion widens to form a broader base that parallels the DEJ.

Along with regular plaque removal, topical fluoride applications help to limit or even reverse enamel demineralization.[26] Some preventive materials attempt to replace minerals in the subsurface enamel lesion using home applications of amorphous and reactive calcium phosphate complexes.[27] Another product employing synthetic hydroxyapatite in an acid paste is said to repair defects and replace crystals within a matter of minutes.[28]

Unless prevention or remineralization can abort or reverse the carious demineralization, the dentin structure is compromised and can no longer support the enamel, which eventually breaks away to create a "cavity" (Fig 1-5). A restoration must then be placed. Untreated, the cavitation expands to compromise the structural strength of the crown, and microorganisms proliferate and infiltrate deep into dentin to jeopardize the vitality of the pulp. When the caries lesion extends past the CEJ, as in root caries (see Fig 1-2), factors such as isolation, access, and gingival tissue response complicate the restorative procedure.



Fig 1-5 Maxillary molar with extensive carious dentin. This is only the initial entry through unsupported enamel into the carious dentin; the final preparation of the tooth will likely remove at least the distolingual cusp and the marginal ridge to eliminate any unsupported enamel.

Wear

Dentlearn.ir

Enamel is as hard as steel,[29] with a Knoop Hardness Number of 343 (compared with 68 for dentin). However, enamel will wear because of attrition or frictional contact against opposing enamel or harder restorative materials, such as porcelain. The normal physiologic contact wear rate for enamel is 15 to 29 μm per year.[30] Restorative materials that replace or function against enamel should have compatible wear, smoothness, and strength characteristics. Heavy occlusal wear is demonstrated when rounded occlusal cuspal contours are ground to flat facets (see Figs 1-1 and 1-2). Depending on factors such as bruxism, other parafunctional habits, malocclusion, age, and diet, cusps may be lost completely and enamel abraded away so that dentin is exposed and occlusal function compromised (Fig 1-6). In preparing a tooth for restoration, a cavity outline form should be designed so that the margins of restorative materials avoid critical, high-stress areas of occlusal contact.[31] The potential effects of lost vertical dimension from tooth wear may be offset by active tooth eruption and apical cemento-genesis.[32,33]



Fig 1-6 Excessive occlusal enamel and dentin loss from a combination of bruxism, attrition, and erosion. (Courtesy of Van B. Haywood, Augusta, Georgia.)

Faults and fissures

Various defects of the enamel surface may contribute to the accumulation and retention of plaque. Perikymata (parallel ridges formed by cyclic deposition of enamel), pitting defects formed by termination of enamel rods, and other hypoplastic flaws are common, especially in the cervical area.[1] Limited linear defects or craze lines result from a combination of occlusal loading and age-related loss of resiliency but are generally not clinically significant. Organic films of surface pellicle and dental cuticles, extending 1 to 3 μm into the enamel, may play key roles in ion exchange and in adhesion and colonization of bacterial plaque on the enamel surface.[33,34]

Of greater concern are the fissure systems on the occlusal surfaces and, to a lesser extent, on buccal and lingual surfaces of posterior teeth. A deep fissure is formed by

Dentlearn.ir

incomplete fusion of lobes of cuspal enamel in the developing tooth. The resulting narrow clefts provide a protected niche for acidogenic bacteria and the nutrients they require (Fig 1-7; see also Fig 1-4b). It is estimated that caries lesions are five times more likely to occur in occlusal fissures and two and a half times more likely to occur in buccal and lingual fissures than in proximal smooth surfaces.[35] The 2000 US Surgeon General's report,[36] which was based on a national survey of dental health, confirms that overall caries experience, especially that of smooth-surface lesions, is declining. A report from the National Center for Health Statistics, based on the US National Health and Nutrition Examination Survey comparing various survey time periods from 1988–1994 through 2007–2008, indicated that the incidence of untreated caries in the overall US population has been steadily decreasing.[37] This survey found that the only segment of the population that had shown a significant increase in caries over this time period was the segment consisting of children who were 2 to 4 years of age.[38] The fissured surfaces of the teeth are relatively inaccessible for plaque-control measures and account for nearly 90% of total decayed, missing, and filled surfaces (DMFS) in US schoolchildren. Several studies offer evidence that the physical barrier provided by an enamel-bonded resin fissure sealant is an effective preventive treatment for high-caries-risk patients and for individual teeth with incipient enamel pit and fissure lesions.[39–41]

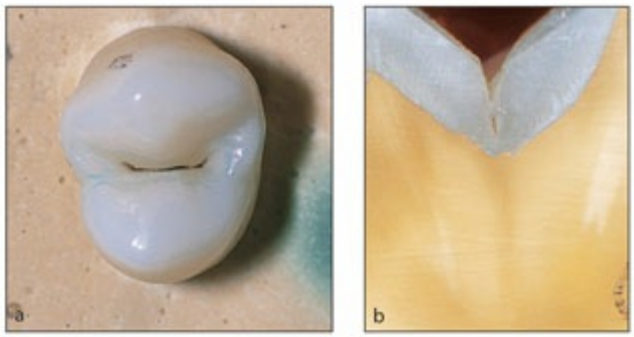

Fig 1-7 *(a)* Fissured occlusal surface of a maxillary premolar. *(b)* Cross section of the fissure shown in *a*.

Cracks

Although craze lines in the surface enamel are of little consequence, pronounced cracks that extend from developmental grooves across marginal ridges to axial surfaces, or from the margins of large restorations, may portend coronal or cuspal fracture. A crack defect is especially critical when the crack, viewed within a cavity preparation, extends through dentin or when the patient has pain while chewing (Fig 1-8). A cracked tooth that is symptomatic or involves dentin requires a restoration

Dentlearn.ir

that provides complete coronal coverage or at least adhesive splinting.[42,43] It should be noted, however, that even if a crack is identified early in patients with a diagnosis of reversible pulpitis and a crown is placed, subsequent root canal treatment may still be necessary in about 20% of the cases.[44]



Fig 1-8 *(a)* Molar with pronounced cracks extending across the mesial and distal marginal ridges. *(b)* Same molar with the occlusal restoration removed, exposing a mesiodistal incomplete fracture across the pulpal floor. (Courtesy of Van B. Haywood, Augusta, Georgia.)

Rod and interrod crystal structure

Enamel is a mineralized epidermal tissue. Ameloblast cells of the developing tooth secrete the organic matrix gel to define the enamel contours and initiate its mineralization. Calcium ions are transported both extra- and intracellularly to form "seeds" of hydroxyapatite throughout the developing matrix. These hydroxyapatite seeds form nidi for crystallization, and the crystals enlarge and supplant the organic matrix. The repeating molecular units of hydroxyapatite, $Ca_{10}(PO_4)_6(OH)_2$, make up the building blocks of the enamel crystal. However, the majority of apatite units exist in an impure form in which carbonate is substituted in the lattice, resulting in a destabilizing effect on the crystal. When exposed to plaque acids, the carbonated components of the crystal are the most susceptible to demineralization and the first to be solubilized. Both the therapeutic substitution of fluoride into the enamel apatite crystal and the facilitatory role of fluoride to enhance remineralization following cycles of acid dissolution are key to the dynamics of remineralization. In the presence of fluorides, enamel crystals in the incipient caries lesion are replaced or repaired with fluoroapatite or fluorohydroxyapatite, which are relatively insoluble. Therefore, the best outcome of repeated cycles of demineralization-remineralization, when accompanied by plaque control and fluoride availability, is a more caries-resistant enamel.[6]

The maturing ameloblast cell develops a cytoplasmic extension, the *Tomes' process*, which simultaneously secretes enamel protein matrix and initiates the

Dentlearn.ir

mineralization and orientation of enamel crystals. The divergent directions of the crystals generated from the central and peripheral surfaces of Tomes' processes, repeated in a symmetric pattern, form the two basic structural units of enamel: cylindric enamel rods and the surrounding interrod enamel. Figure 1-9 shows electron microscope photomicrographs of enamel, progressing from a macrostructural image to ultrastructural images showing individual enamel crystals.

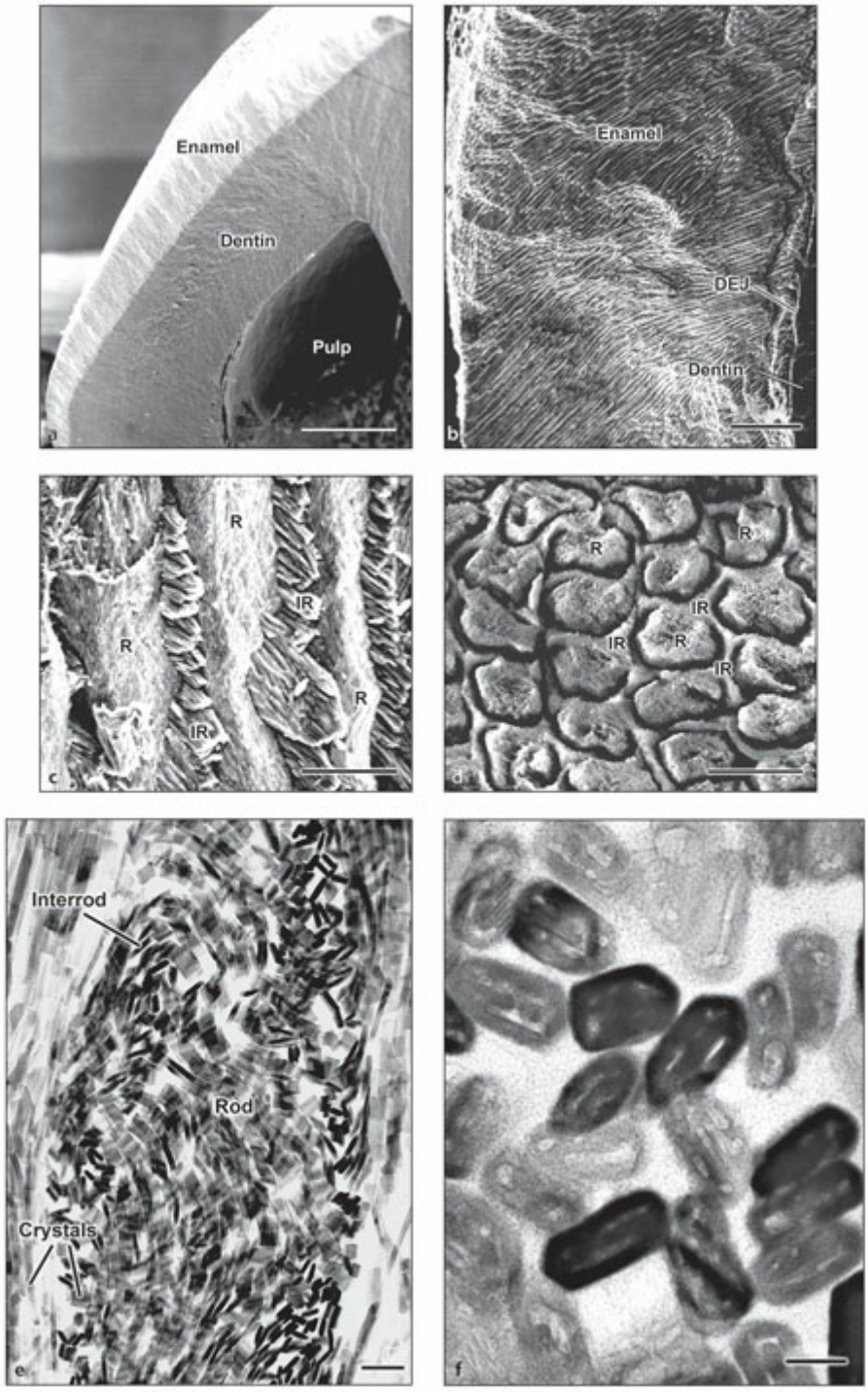

Fig 1-9 Enamel composition. *(a)* Scanning electron photomicrograph of a cross section of a tooth crown showing enamel as the outer protective covering for the tooth. (Bar = 1 mm.) *(b)* Scanning

Dentlearn.ir

electron photomicrograph showing the complex of enamel rods and the DEJ. (Bar = 100 µm.) *(c)* Scanning electron photomicrograph showing enamel rods (R) and interrod enamel (IR). (Bar = 6 µm.) *(d)* Scanning electron photomicrograph of a cross section of enamel rods (R) and interrod enamel (IR). Note the connecting isthmus between the two enamel components and the gap (sheath) around the rods. (Bar = 10 µm.) *(e)* Transmission electron photomicrograph showing divergent crystal orientation in rodent enamel rod and interrod enamel. (Bar = 0.1 µm.) *(f)* Transmission electron photomicrograph showing the elongated hexagonal shape of hydroxyapatite crystals in enamel. The dimensions of each crystal are in the range of 30 × 60 nm. (Bar = 20 nm.) (Reprinted from Nanci[12] with permission.)

The crystals in the enamel rods and interrod enamel differ only in the orientation of the crystals: Interrod crystals are almost perpendicular to rod crystals. In mature enamel, the closely packed, hexagonal crystals have cross-sectional dimensions of approximately 30 × 60 nm (see Fig 1-9f). The matrix proteins, enamelins, and water of hydration form a shell, or envelope, around each crystal. With the exception of the amorphous inner and outer enamel surface, the rod and interrod enamel are thought to be continuous throughout the thickness of the enamel. The multitude of crystals that form these two entities may also span the width of the enamel structure. The appearance of light and dark bands observed in sectioned specimens of enamel are known as *Hunter-Schreger bands* (Fig 1-10). This optical effect, seen under magnification in cut or fractured sections of tooth structure, is a result of the variation of light reflection from the bands of the enamel crystals that are oriented in different directions. The variation in both density and orientation of these crystals may have a direct effect on both the degree of mineral dissolution when exposed to acidic solutions as well as the susceptibility of different areas of the tooth to the development of crack lines in enamel.[45,46] The crystals within the cylinders of rod enamel run parallel to the long axis of the rods, which are approximately perpendicular to the enamel surface. A narrow space filled with organic material around three-fourths of each rod, called the *rod sheath*, separates the two enamel units. However, the two separate enamel components are connected at the portion of the rod circumference that is not bounded by the rod sheath to form an isthmus of confluent crystals (see Fig 1-9d). In cross section, the rod core and the connecting isthmus of interrod enamel together have traditionally been described as keyhole-shaped and as the basic repeating structural unit of enamel. However, recent studies show the interrod enamel to be continuous within the enamel mass and to be a step ahead of the rod in development. Therefore, the current interpretation of the structure of enamel is that of cylindric enamel rods embedded in the surrounding interrod enamel.[12]

Dentlearn.ir

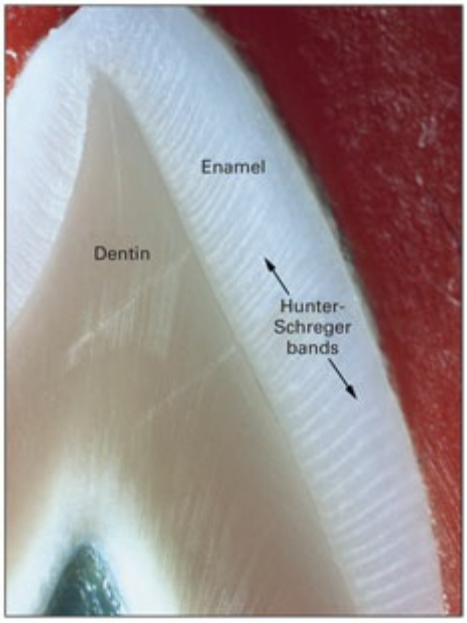

Fig 1-10 The appearance of Hunter-Schreger bands (alternate dark and light bands) viewed on the labial surface of a maxillary canine using reflected light. (Reprinted from Lynch et al[45] with permission.)

Enamel and acid etching

The spacing and divergent orientation of the crystals in the rod and in the interrod enamel make the enamel rod differentially soluble when exposed for a brief time to weak acids. Depending on the acid, contact time, and plane of cavity preparation, either the ends or the sides of the crystals may be preferentially exposed. Different etch patterns have been described depending on the type and contact time of the etchant and whether the primary dissolution affects the rod or the interrod structure.[47,48]

The initial effect of acid contact in etching enamel for bonding to restorative materials is to remove about 10 μm of surface enamel, which typically contains no rod structure. Then, with rod and interrod structure exposed, the differential dissolution of enamel rod and interrod structure forms a three-dimensional macroporosity (Fig 1-11). The acid-treated enamel surface has a high surface energy so that resin monomer flows into, intimately adapts to, and polymerizes within the pores to form retentive resin tags that are up to 20 μm deep. At the same time, the

multitude of microporosities. It is these countless numbers of minitags, formed within the individual crystal cores, that contribute most to the enamel-resin bond.[49] Because there are 30,000 to 40,000 enamel rods per square millimeter of a surface of cut enamel, and t surface area 10- to

Dentlearn.ir

20-fold, the attachment of resin adhesives to enamel through micromechanical interlocking is extremely strong.[50,51]



Fig 1-11 Scanning electron photomicrograph of an acid-etched enamel surface. Note the keyhole-shaped rods and uneven surface formed by the disparity in depth of rod heads and rod peripheries. (Bar = 10 μm.)

As stated, the crystals within the enamel rod cylinders run parallel to the length of the enamel rods, which are approximately perpendicular to the external enamel surface. A cavity wall preparation that is perpendicular to the surface will expose predominantly the sides of both the enamel rods and their crystals. This configuration is recommended for amalgam preparations because it preserves the dentinal support of the enamel, but it does not present the optimum bondable enamel substrate. When the transverse section or face of the crystal, rather than its side, is exposed to acid, the central core of the crystal is most susceptible to acid dissolution. Resin bond strengths are twice as high when adhering to the acid-etched ends of the crystals as compared with the sides of the crystals.[52] Thus, a tangential cut or bevel of approximately 45 degrees across a 90-degree cavosurface angle of a prepared cavity will expose the ends of the rods and their rod crystals. Beveling enamel cavosurface angles of cavity preparations for resin composite is generally recommended to expose the ends of the rods and to maximize the integrity of the restoration at its margins.[53,54] An exception is on occlusal surfaces, where beveling would extend tapering resin margins into areas of increased stress. Regardless of the variation in the etch pattern, the orientation of the enamel crystals, or the selected tooth surface, the acid-etch modification of enamel for micromechanical retention provides a conservative, reliable alternative to macromechanical undercuts traditionally used for retention of restorations.[55]

Dentlearn.ir

Strength and resilience

Enamel is hard and durable, but the rod sheaths, where the crystals of the interrod enamel abut three-fourths of each enamel rod cylinder, form natural cleavage lines through which longitudinal fracture may occur. The tensile bond strength of enamel rods is as low as 1¼ MPa.[56] The fracture resistance between enamel rods is weakened if the underlying dentinal support is pathologically destroyed or mechanically removed (Fig 1-12). Fracture dislodgment of the enamel rods that form the cavity wall or cavosurface margin of a dental restoration creates a gap defect. Leakage or ingress of bacteria and their by-products may lead to secondary caries lesions.[57] Some clinical dental treatments and procedures, such as whitening treatments or acid etching prior to restorative procedures, can directly affect the mechanical properties of enamel, including its hardness and modulus of elasticity.[58,59] When resin composite is adhesively bonded to approximately parallel opposing walls of a cavity preparation, stress development due to polymerization shrinkage has led to reports of enamel microcracks and crazing at margins.[60,61] Therefore, beveling acute or right-angle enamel cavosurface margins so that the bond near margins is primarily to cross-sectional rods and not to the sides of rods is believed to be beneficial in preventing these fractures.[62] Considering the variation in direction of enamel rods and interrod enamel and the structural damage caused by high-speed eccentric bur rotation, planing the cavosurface margin with hand instruments or low-speed rotary instruments to remove any friable or fragile enamel structure is recommended as a finishing step.

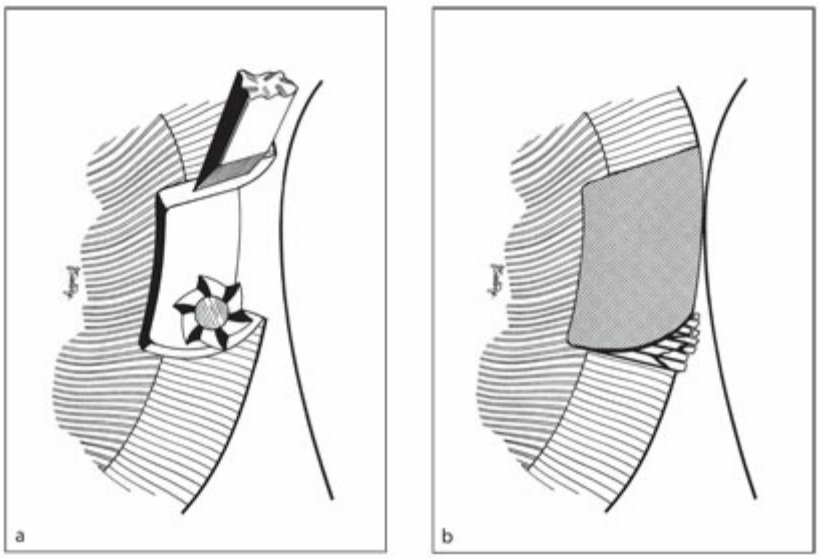

Fig 1-12 *(a)* Coronal section through an interproximal box in a cavity preparation. Use of a rotary instrument (bur), which may leave the proximal wall with an acute enamel angle and undermined enamel, requires careful planning. *(b)* Marginal defect, resulting from improper cavity wall

Dentlearn.ir

preparation, leads to eventual loss of enamel at the restoration interface.

Although enamel is incapable of self-repair, its protective and functional adaptation is noteworthy. Carious demineralization to the point of cavitation generally takes several years. In comparison with the underlying dentin, enamel demineralization is much slower because the apatite crystals in enamel are 10 times larger than those in dentin[63] and offer less surface-to-volume exposure to acids. The crystals are pressed so tightly together that their hexagonal shape is distorted,[12] but this tight adaptation makes for little or no space for acid penetration between the crystals. With preventive measures and exogenous or salivary renewal of calcium, phosphates, and especially fluorides, the dynamics of demineralization can be stopped or therapeutically reversed. Additionally, the crystals are separated by a thin organic matrix that provides some additional strain relief to help prevent fracture.[64] Studies on the mechanical properties of enamel indicate that the structural and compositional characteristics of the minor protein component found surrounding the enamel rods and individual hydroxyapatite crystals may significantly affect the mechanical properties of enamel.[65]

Enamel thickness and its degree of mineralization are greatest in occlusal and incisal areas of enamel where masticatory contact occurs.[66] The enamel rods are

a functional adaptation to occlusal stress, the spiraling weave of rod direction is so pronounced at the cusp tips of posterior teeth that it is referred to as “gnarled” enamel. If enamel were uniformly crystalline, it would shatter with occlusal function. An enamel structure with divergent crystal orientations organized into two interwoven substructures—enamel rods and interrod enamel—yet bound at a connecting area by continuous crystals provides a strong latticework. The enamel rods, which are parallel to each other and perpendicular to the surface structurally, limit the lateral propagation of occlusal stress and transfer it unidirectionally to the resilient dentinal foundation.[67]

Dentin

Dentin provides both color and an elastic foundation for the enamel. The radicular (root) dentin covered with cementum and the coronal (crown) dentin supporting the enamel form the bulk of the structure of the tooth. The strength and durability of the coronal structures are related to dentinal integrity. To the extent that open dentinal

Dentlearn.ir

tubules can become closed and impermeable, dentin is a protective barrier and chamber for the vital pulp tissues. As a tissue without substantive vascular supply or innervation, it is nevertheless able to respond to external thermal, chemical, or mechanical stimuli.

Dentinoenamel junction

The transition between the highly mineralized enamel and the collagen-containing dentin is a complex junction of two structurally different tissues. This interface, the DEJ, must resist fracture and separation under the extreme forces from occlusal loading. The DEJ has been described as a transitional area rather than a definite line demarcating the junction of the two tissues. Although various methods of measurement have resulted in a wide range of values for the mean width of the DEJ, a majority of studies seem to report values for the DEJ width that fall within a range of 2 to 15 µm.[68–71] It has been noted that the width of the DEJ may vary for different locations in the tooth.[68] The transitional band of the DEJ appears to be scalloped with wavelike crests pointing outward toward the enamel; there is conjecture that this interlocking scalloped form may increase the strength of the interface between the two types of tissue.[69,71] The scalloping has been observed to be larger in posterior teeth that are exposed to heavier occlusal wear.[72] Some collagen fibers from the dentinal material extend through this transitional area and are embedded in the more highly mineralized enamel. These embedded collagen fibers may also add to the overall strength and resilience of the junction between the two tissues.[73] A 200- to 300-µm layer of dentin that transitions from the bulk dentin into the DEJ complex, which includes the mantle layer of dentin, has been described as a *soft zone* of dentin because it contains tubules with little to none of the highly mineralized peritubular lining seen in other sections of dentinal tubules. This soft zone exhibits a reduced stiffness in comparison with bulk dentin, and it may play a significant role in providing a cushioning soft layer between the enamel and bulk dentin of the tooth.[74]

Support

Tooth strength, rigidity, and integrity rely on an intact dentinal substrate. To appreciate the magnitude of occlusal loading, a mean maximum bite force of 738 N (166 lb)[75] applied to an average contact area of 4 mm^2 distributed over 20 occlusal contacts[76] produces more than 26,000 psi (180 MPa) of stress. Investigators have

Dentlearn.ir

reported that resistance to tooth fracture is compromised with increasing depth and/or width of cavity preparation.[77,78] Dentin has a tensile strength of 40 MPa (6,000 psi) and a compressive strength of 266 MPa (40,000 psi).[79] A posterior tooth with an endodontic access preparation retains only a third of the fracture resistance of an intact tooth.[80] In vitro studies report that large mesio-occlusodistal (MOD) preparations increase the strain or deflection of facial cusps threefold compared with that of intact control teeth, and coronal stiffness decreases more than 60%.[80] Elastic deformation of the crown and cuspal flexure are factors that can contribute to noncarious cervical lesions,[81] cervical debonding of restorations,[82] marginal breakdown,[83] fatigue failure, crack propagation, and fracture.[84,85] Removal and replacement of dental restorations over a patient's lifetime generally result in successively larger or deeper preparations.[86] Therefore, to preserve coronal integrity, a conservative approach that combines localized removal of carious tooth structure with preservation of sound tooth structure, placement of sealants, and placement of bonded restorations is recommended.[87] If a large preparation is required, the dentist should consider complete coverage of the occlusal surface with an onlay or a crown. As with enamel, there is evidence that chemical treatments applied to the tooth during certain dental treatments, such as higher concentrations of tooth-whitening agents, may have adverse effects on the fracture toughness of dentin.[60,88]

Morphology

Dentin is primarily composed of small, thin apatite crystal flakes embedded in a protein matrix of cross-linked collagen fibrils. The thickness of the apatite crystals varies from 3.5 nm near the DEJ to about 2 nm close to the pulp. Although a random orientation is found for most of these thin apatite crystal platelets, it has been observed that there is a significant increase in the amount of parallel coalignment of these particles in areas where high strain might be expected, such as cusps.[89] The odontoblast, with its cell body at the pulp periphery and its extended process within the dentinal tubule, secretes the organic dentin matrix and regulates mineralization.

traversing the full 3.0- to 3.5-mm (3,000- to 3,500-µm) thickness of the dentin from the pulp to the DEJ. The mean tubule diameter near the pulpal wall is 2.5 µm. Within the first 0.5 mm from the pulp, the mean diameter decreases rapidly down to 1.9 µm, tapers more gradually over the next 2 mm of its length, and then tapers very little in the final 1.5 mm of the tubule to terminate in a diameter of 0.8 µm at the DEJ.[90] The

Dentlearn.ir

tubules comprise about 10% of dentin volume.[90] Near the axial coronal area of the DEJ, the tubule paths form a double curve or S shape, whereas tubules near the DEJ in occlusal areas and root surfaces form a relatively straight path to the pulpal interface. In mature dentin, the odontoblastic process extends within the dentinal tubule to about one-third the dentinal thickness.[91] Variations, such as the density of tubules and the degree and quality of cross-linking of collagen fibers, have been observed between the structure of coronal dentin and root dentin. These variations could affect the degree of demineralization achieved with phosphoric acid or other acids, the stability and durability of the hybrid layer, and bond strength in these areas of the tooth.[92] (See chapter 9 for more on bonding to dentin and enamel.)

Unlike enamel, which is acellular and predominantly mineralized, dentin is, by volume, 45% to 50% inorganic apatite crystals, about 30% organic matrix, and about 25% water. Dentin is typically pale yellow in color and is slightly harder than bone. Two main types of dentin are present: *(1) intertubular dentin*, the structural component of the hydroxyapatite-embedded collagen matrix forming the bulk of dentin structure, and *(2) peritubular dentin*, limited to the lining of the tubule walls (Fig 1-13). Peritubular dentin has little organic matrix but is densely packed with miniscule apatite crystals. Though primary intertubular dentin remains dimensionally stable, the hypermineralized peritubular lining gradually increases in width over time.[93] The relative and changing proportions of mineralized crystals, organic collagen matrix, and cellular and fluid-filled tubular volume determine the clinical and biologic responses of dentin. These component ratios vary according to location (depth) in the dentin, age, and the history of trauma to the tooth.

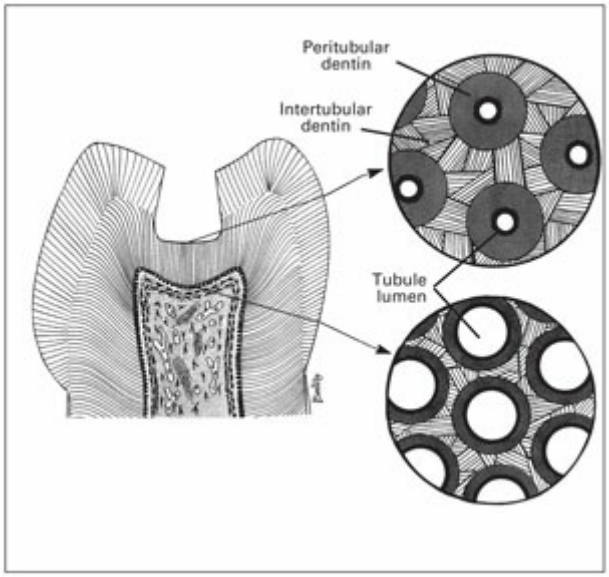

Fig 1-13 Dentin near the DEJ *(top)* and near the pulp *(bottom)* is compared to show relative differences in intertubular and peritubular dentin and in lumen spacing and volume.

Dentlearn.ir

dentin compromise its function as a protective barrier. When the external covering of enamel or cementum is removed from dentin through cavity preparation, root planing, caries, trauma, or abrasion and erosion, the exposed tubules, if patent, become conduits between the pulp and the external oral environment. The exposure of the tubules with cavity preparation is somewhat offset by a layer of tenacious grinding debris, the *smear layer*, which adheres to the surface and partially plugs the tubular orifices.[94] For optimum success, dentin bonding systems must remove, modify, or penetrate this organic-inorganic barrier to facilitate resin diffusion and micromechanical bonding with the demineralized dentinal substrate.[95] However, the removal of the smear layer with acids during dentin bonding procedures causes an increase in the local dentinal permeability along with an outward fluid movement from the tubules, which results in adverse conditions for adhesive bonding.[96] Currently available dentin adhesives are capable of establishing an effective immediate bond strength in the wet environment presented by the cut dentinal surface; however, there are still some questions concerning the long-term effectiveness of these bonds because of problems involving the degradation of the resin and/or hydrolysis of the collagen.[97–99]

When injury or active caries affects dentin, the immediate inflammatory response is pulpal vasodilation, increased blood flow, and increased interstitial fluid pressure, which results in an increased outward flow rate of tubular fluid.[100] In vitro studies have shown that the fluid outflow may partially counteract the inward diffusion of toxic solutes through the tubules by 50% to 60%.[101] In addition, vasodilation and temporary gaps between the junctional complexes of adjacent odontoblast cells accommodate the passage of plasma proteins, such as albumin and immunoglobulins, into the dentinal fluid. These components agglutinate within the tubules to limit the diffusion to the pulp of exogenous stimuli and possibly to provide a direct immune response to bacteria.[102,103] Thus, with exposure of the tubules, a vascular response and accelerated outward flow of the tubular fluid constitute an immediate protective response. Nonetheless, tubules that are blocked or constricted provide the pulp with better protection from the permeation of noxious substances.

The diffusion gradient is reduced by both smaller tubular diameters and greater tubular lengths, ie, greater remaining dentinal thickness (RDT). Indeed, the functional diameter of the tubule is only a fraction of the anatomical lumen, because intratubular cellular, collagenous, and mineral inclusions restrict flow through the

Dentlearn.ir

capacity of a full thickness of dentin create an effective biofilter of diffusion products.[105,106]

There are also regional differences in dentinal permeability. The coronal occlusal dentin (pulpal floor of a cavity preparation) is inherently less permeable than is the dentin around the pulp horns or axial surfaces.[107,108] As a result, although the fissured occlusal surfaces of posterior teeth often require cavity preparation, only about 30% of the subjacent dentinal tubules are patent over their entire length. However, gingival areas of preparations, such as prepared proximal boxes or crown margins, which are relatively more susceptible to microleakage and development of recurrent caries lesions, are located where the dentin is most permeable.[109,110]

The presence of bacteria or their by-products in deep dentin causes an acute histopathologic and inflammatory response within the pulp.[111,112] Even restored teeth are at risk of continued toxic diffusion through the phenomenon of *microleakage*, the flux of substances between the oral environment and the restoration-tooth interface due to the presence of interfacial gaps and possibly the differing coefficients of thermal expansion of tooth structure and restorative materials[111] (Fig 1-14). No restorative material or technique can ensure a complete hermetic seal of the restoration-tooth interface, and leakage at the gingival (cementum or dentin) margins of resin-bonded restorations is commonly reported.[113,114] Through marginal defects, differential thermal expansion, and capillary action, various cytotoxic components or bacterial endotoxins may diffuse through the dentinal substrate to reach the pulp. Clinically, an open margin or leaking restoration contributes to a wide range of problems, from marginal stains to sensitivity and chronic pulpitis, and is therefore frequently cited as the reason for replacement of an existing restoration[115] (Fig 1-15).

Dentlearn.ir

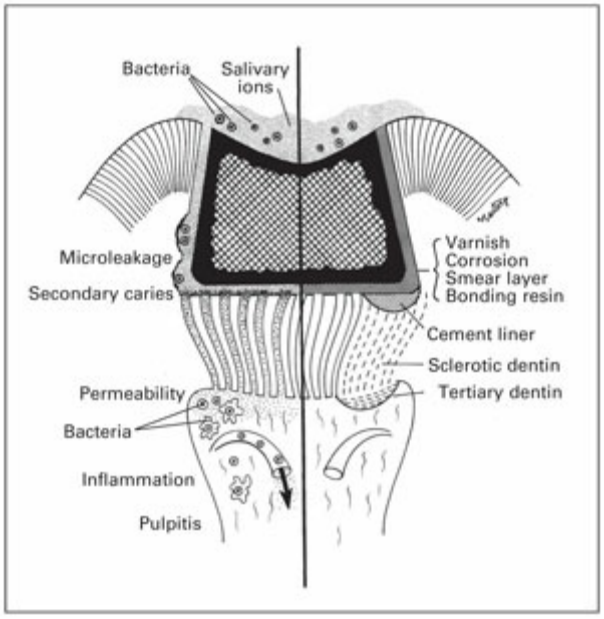

Fig 1-14 Leaking restoration interface *(left)*; sealed restoration interface *(right)*. Microleakage is exacerbated by polymerization shrinkage, condensation gaps around the restorative material, and/or differences in thermal expansion. When microleakage is present, the tubule openings in dentin form a potential pathway between the oral environment and the pulp. Various restorative materials, together with the tooth's defenses of tubule sclerosis and reparative dentin, restrict the noxious infiltration.

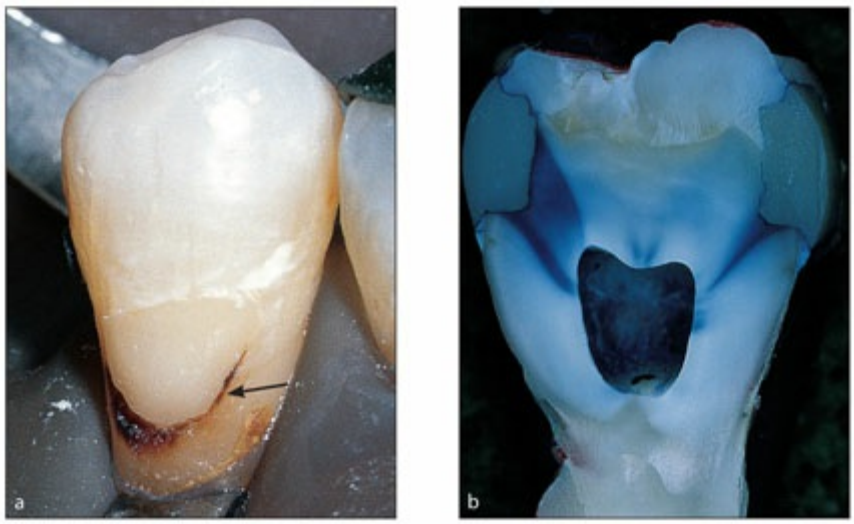

Fig 1-15 *(a)* Failed resin composite restoration. Polymerization shrinkage and cervical debonding created a restoration-wall gap defect (*arrow*, cervical margin), leading to microleakage and secondary caries. *(b)* In vitro dye penetration reveals microleakage and diffusion through dentinal tubules.

Tubular conduits connecting the pulp to the external oral environment create a virtual micropulpal exposure. Newly erupted teeth with relatively open tubules are particularly vulnerable to pulpal effects from active caries and rapid penetration of

Dentlearn.ir

bacteria.[116] Without treatment, loss of tooth structure due to carious demineralization or excessive wear results in a diminished thickness of dentin separating the pulp from the oral environment. If the threatening stimuli are moderate and slow in developing, the dentin-pulp complex may have time to hypermineralize or sclerose

Blockage of the tubules and dentinal repair are the most important defensive reactions of the dentin. However, with trauma, rapid advance of a caries lesion, or deep cavity preparation, a minimal RDT with numerous open tubules renders the pulp vulnerable to the influx of noxious substances. Without intervention, bacteria eventually reach the level of the PDJ, and pulpal necrosis is the probable outcome.[117]

Dentinal substrates

The form and constituency of dentinal tissue are not static, and changes in its basic components may occur throughout the life of the tooth. Some of the variations in the dentinal tissue occur during its natural sequence of development or aging, while other variations result from the effects of external factors on the tooth, such as caries, injury, or wear. An understanding of these variations in the dentinal tissue is important because they are related to the long-term success of dental procedures and therapies.

Primary and secondary physiologic dentin

Bioactive signaling molecules and growth factors in the inner dental epithelium differentiate ectomesenchymal cells of the dental papilla into mature odontoblast cells. They synthesize and secrete extracellular organic matrix, which, following mineralization, forms the primary and secondary physiologic dentin[93,118] (Fig 1-16). The first-formed, 150-µm-thick layer of primary dentin subjacent to the enamel is termed *mantle dentin*. It differs from other primary dentin in that it is 4% less mineralized, and the collagen fiber orientation is perpendicular rather than parallel to the DEJ. Following mantle deposition, odontoblasts begin to form odontoblastic processes and create tubules as the cell bodies converge pulpally. When mature, as long as the root apex remains undeveloped and open, the odontoblasts produce primary dentin, mainly intertubular dentin, at a rate of 4 to 8 µm/day. Approximately 2 to 3 years following tooth eruption, and coincident with root apexification, the bulk of dentin surrounding the pulp chamber and canal systems, termed *circumpulpal dentin*, is completely formed. The synthesis of dentin then slows to 1 to 2 µm/day,

Dentlearn.ir

decreasing in rate with age but continuing as long as the tooth is vital. The tubules remain regularly spaced and continuous with tubules within the primary dentin. As the tooth matures, this secondary dentin is distributed gradually and asymmetrically to create pulp-chamber volume reduction with a relatively constricted occlusogingival dimension. The pulp horns and root canals are also gradually reduced in volume. With this ongoing reduction in size of the pulp, the inherent risk of pulpal exposure during cavity preparation tends to decrease with the age of the patient. Before starting a cavity preparation or crown preparation, the dentist should radiographically assess the size and location of the pulpal tissues in relation to the size and location of the caries lesion in order to anticipate the need for an indirect pulp capping procedure and to attempt to avoid a pulpal exposure.



Fig 1-16 Primary and secondary dentin. *(left)* Primary dentin and large pulp chamber and root canals are shown in a mandibular molar after eruption but before completion of root formation, when accelerated primary dentin formation ceases and secondary dentinogenesis begins. *(right)* Mature molar that has had gradual and continued deposition of secondary dentin. Note the large mesiobuccal pulp horn that is susceptible to exposure with deep cavity preparation. There is asymmetric deposition of secondary dentin on the pulp chamber roof and floor to narrow the vertical dimension. (Courtesy of James A. Gillis, San Antonio, Texas.)

Outer dentin

In the first-formed dentin near the DEJ, the tubules of the outer dentin (Fig 1-17; see also Fig 1-13) are relatively far apart, and, with time, mineral supplementation of peritubular walls progressively narrows the lumen. With relatively fewer tubules at the periphery, around 20,000 tubules/mm^2, and small tubule diameters of approximately 0.8 µm, the tubule lumens only constitute about 4% of the surface area of cut outer dentin[119] (see Fig 1-17). However, there is extensive terminal branching of the tubules in the outer 250 µm of dentin and regularly spaced connecting branches between tubules. Smaller fine canaliculi and even microfine 0.1-µm pores extend from the tubule walls to permeate the intertubular dentin (Figs 1-18 and 1-

Dentlearn.ir

19). Similar to the vascular system, this highly interconnected and fluid-filled tubular system acts as a transporting medium for mineral exchange and for bioactive molecules released from the dentinal matrix.[90,120] This networking of tubules may account for the paradox that pressure as localized as an explorer tip moving across a surface of cut dentin may indirectly stimulate a plexus of neurons to cause a sensation of pain. Also, when the prepared dentinal surface is acid etched for resin bonding, the highly mineralized peritubular walls are the first to be solubilized to create wide funnel-shaped tubules and expose connecting branches. Resin penetration into tubules and branches, together with the micromechanical bond of the resin-dentin hybrid layer, form a mechanical interlocking of resin tags to create the best possible bond to the etched dentin substrate.[121]

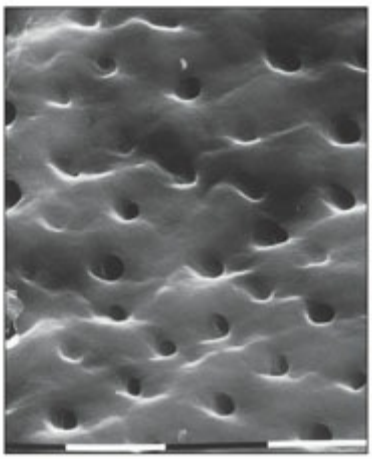

Fig 1-17 Scanning electron photomicrograph of tubules in outer dentin. All highly mineralized peritubular dentin has been removed in the specimen preparation. (Bar = 10 µm.)

Dentlearn.ir

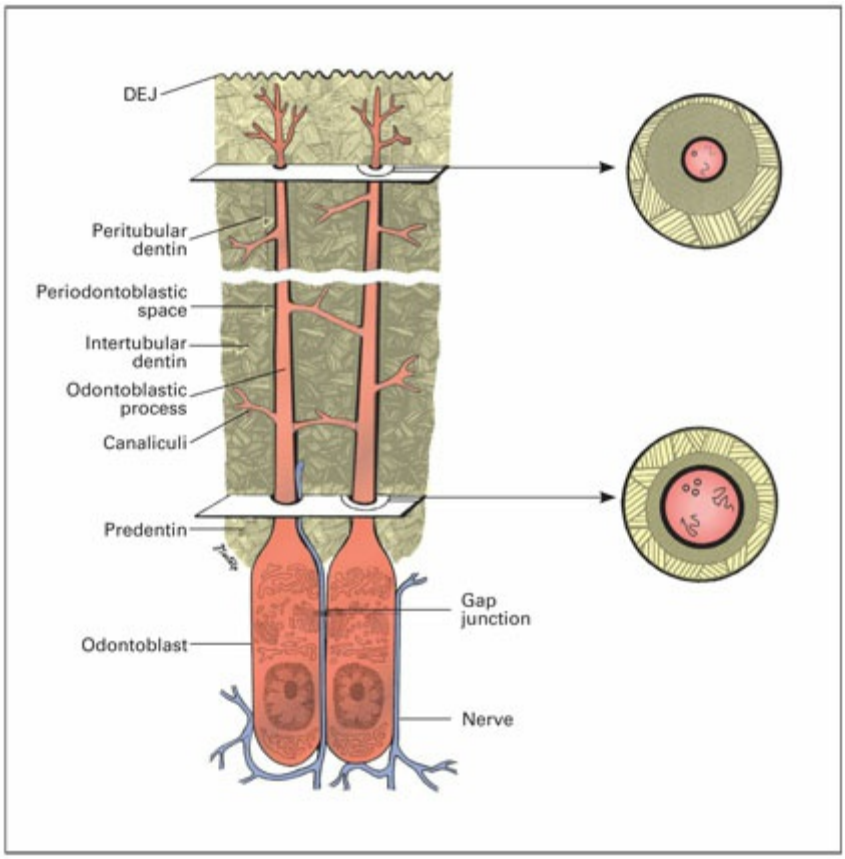

Fig 1-18 Odontoblastic cell process and tubule system through dentin. Continual deposition of peritu-bular dentin and minerals, accelerated by a chronic, noxious stimulus, gradually occludes the tubules peripherally. Note the terminal branching and interconnections between odontoblastic cell processes and between cellular walls. Direct neural penetration of dentin is limited to less than 20% of the tubules and rarely beyond the predentin.

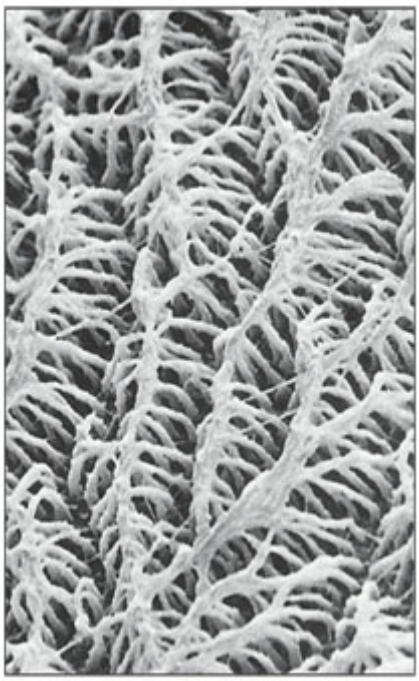

Dentlearn.ir

Fig 1-19 Scanning electron photomicrograph of resin penetration into a dentinal tubule system after etching with phosphoric acid. The dentin was then demineralized with hydrochloric acid and the organic component removed with sodium hypochlorite, leaving the resin to illustrate tubule configuration. Note the cross-branching of tubules; this illustrates the complexity of the dentinal tubule. (Courtesy of Jorge Per-digao, Minneapolis, Minnesota.)

It has been shown that the resin bond to dentin deteriorates over time.[97,98,122] The degradation of denuded collagen in the layer of resin-infiltrated dentin is currently considered to be one of the main problems related to the deterioration of this bond. Current research attempting to identify the cause of this degradation of the bond between resin and dentin suggests a link to water sorption–induced hydrolysis of the hydrophilic resin components[123] and the breakdown of the protein within the

MMPs are released from the dentinal matrix during the acid-conditioning step and degrade the strength of the bond by attacking the collagen fibers in the hybrid layer.[125] Evidence has been presented for various suggested approaches to resolve this bond degradation problem. One approach suggests that the use of an MMP inhibitor, such as chlorhexidine digluconate (often used during dental procedures as an antibacterial agent) or galardin (a synthetic protease inhibitor), incorporated into dentin bonding systems may be able to counterattack the effects of this endogenous enzyme on the dentin bond.[125,126] Another approach suggests the incorporation of some form of amorphous calcium phosphate nanoprecursor into the dentin bonding system to attempt to accomplish both interfibrillar and intrafibrillar remineralization of the degraded dentinal tissue.[127] Adhesion to tooth structure is discussed in more detail in chapter 9.

Because the processes of the odontoblastic cells extend no farther than the inner third of adult dentin (approximately 1.0 mm), cavity preparations or caries lesions confined to the outer dentin do not directly sever or degrade the vital cellular component of the dentin-pulp complex. Peripheral preparations or lesions with a substantial remaining dentin thickness of 2.0 mm or more provide a sufficient physiologic barrier to safeguard pulpal health from routine restorative techniques.[128] One important exception is an extensive crown preparation without water coolant and with constant, as opposed to intermittent, cutting, which may generate a level of heat or rate of temperature increase capable of creating histopathologic evidence of pulpal injury.[129]

Inner dentin

Dentlearn.ir

The dentinal substrate near the predentin and PDJ is quite different from that near the DEJ. The 20-μm-thick predentin layer consists of newly secreted organic matrix awaiting mineralization. The converging tubules at the predentin, the portion of the dentin closest to the pulp, number up to 58,000/mm^2 in cross section and contain the processes of the odontoblast cells[130] (Figs 1-20 and 1-21). Careful cavity preparation and proper restorative technique are required to limit surgical trauma to the odontoblast cell bodies and prevent their injurious displacement into the tubules,[131] but with good technique and a healthy pulp prior to tooth preparation, the likely outcome of a deep preparation is pulpal healing without clinical symptoms. The tubule diameters near the PDJ are larger (2.5 to 3.0 μm), the distance between tubule centers is half that between tubule centers at the DEJ, and the peritubular dentin is diminished in thickness or absent.[132] At the PDJ, the area of the intertubular dentin is as little as 12% of the surface, and the volume of the fluid-filled tubule lumens approaches 80%.[90,133] Therefore, at this level, the dentin is more permeable and about 22 times wetter than the dentin at the DEJ.[134] The fluid in the dentinal tubules is an extension of the interstitial fluid within the pulp, which has a positive pressure of 5 to 20 mm Hg. Therefore, the deeper the cavity preparation, the greater the outward flow of dentinal fluid from the exposed tubules to "wet" the cut surface. Some moisture has been shown to facilitate dentin bonding.[135] However, studies of various bonding systems incorporating simulated pulpal pressure in deep dentin have demonstrated "overwet" conditions and lower bond strengths for some adhesives, but not for others.[91,136–138] Also, deep cavity preparation extending near to the pulp may injure the cellular tissues, and a minimal RDT, whether from preparation, trauma, or a caries lesion, places the pulp in close proximity to toxic or immunologic stimuli.[139]



Fig 1-20 Scanning electron photomicrograph of tubules in inner dentin of tooth in Fig 1-17. The

Dentlearn.ir

section was approximately parallel to the walls of the pulp chamber. All highly mineralized peritubular dentin has been removed in the specimen preparation. (Bar = 10 µm.)

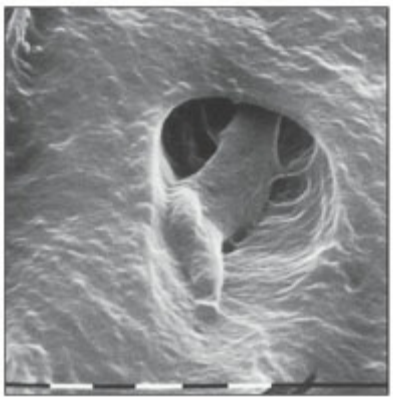

Fig 1-21 Magnified tubule orifice with collagen matrix and odontoblastic process. (Bar = 1.0 µm.)

Carious dentin

The caries process is driven by the presence of a biofilm containing acid-producing bacteria on the tooth surface. Without intervention, a progression of destructive changes occurs, prompting pulpal and dentinal responses. This begins with the subsurface enamel lesion and is followed by dentin demineralization, cavitation, infection of demineralized dentin, dentin-matrix dissolution, and, ultimately, pulpal necrosis.[140] The degree and type of response is related to the caries activity, which may vary from active and rapidly progressive to chronic and slowly progressive or arrested. Over time, with the changing interplay of the oral environment, lesion development, host response, and preventive practices, the same lesion may assume any of these forms.

The earliest dentinal response occurs adjacent to the center or apex of the enamel lesion, where the deepest demineralization of enamel rods approaches the DEJ. Even before the enamel lesion reaches the DEJ histologically, acid protons, solubilized matrix components, and released bioactive molecules diffuse through the tubules contiguous with the affected enamel rods to stimulate morphologic changes and metabolic activity in the affected primary odontoblasts. Mineralizing components are released into the tubular fluid of the periodontoblastic space to augment the existing peritubular walls and to form a localized zone of hypermineralized dentin subjacent to the enamel lesion of permeable enamel rods.[141,142]

When the enamel rod dissolution and enamel porosity reach the DEJ, the hypermineralized zone then becomes subject to accelerated acid dissolution. In

Dentlearn.ir

contrast to enamel, dentin demineralization is more rapid because of the tubular network and the high surface-to-volume ratio of the small hydroxyapatite crystallites embedded in the collagen.[143] Clinically, the affected dentin is often distinguished from normal dentin by decreased hardness and by a yellow-brown discoloration due to acid effect on the organic dentin matrix or possibly from exogenous staining.[144] Unchecked, demineralization of the soft and discolored dentin progresses toward the pulp (Fig 1-22). However, as long as the enamel surface remains intact, the dentin lesion is relatively sterile and devoid of viable bacteria.[16] Incipient, noncavitated lesions may be arrested with plaque control or with other noninvasive preventive therapies.[145]

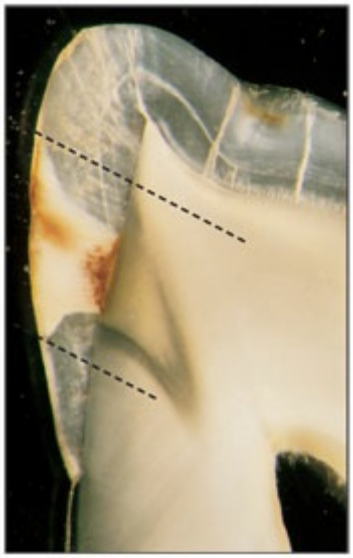

Fig 1-22 Precavitated smooth-surface caries lesion with demineralization of enamel rods in the center of an enamel lesion extending to the DEJ; dentin demineralization is guided by the direction of dentinal tubules. Note that the affected dentin area at the DEJ is adjacent to the enamel rods that have suffered demineralization at the outer surface *(dotted lines)* as well as those that have been demineralized to the DEJ. (Reprinted from Bjørndal and Mjör[140] with permission.)

A pivotal point of caries lesion progression occurs if the 20- to 50-µm surface

cavitated. Within the defect, which is generally inaccessible to brushing or flossing, the facultative cariogenic bacteria multiply to generate a destructive acidic environment. A pathologic cycle of tooth destruction, infection, and tubular invasion of the dentin structure ensues (Fig 1-23; see also Fig 1-5). Following the demineralization of the peritubular walls and the intertubular crystals, proteolytic enzymes from the bacteria disrupt the cross-linked collagen framework of intertubular dentin. Clinically, advanced or acutely infected dentin differs from normal dentin or dentin of an arrested caries lesion in that it is soft, readily

Dentlearn.ir

excavated, wet, and generally light yellow to orange in color.[146] This amorphous lesion is referred to as *infected dentin* and histologically as the *zone of destruction*. Beneath this zone, where the dentin matrix is still intact and limited bacterial penetration is confined to the tubules, the dentin is termed *affected dentin*.[147] Only select microorganisms invade the tubules. In the outer superficial or cavitated lesion, strains of gram-positive streptococcus prevail, whereas anaerobic rods are the bacteria primarily found in deep dentinal tubules and infected pulps and root canals.[148] If the caries lesion progress is gradual, the pH gradient in the deeper tubules below the affected dentin promotes recrystallization of the solubilized minerals. The precipitated crystals, called the *zone of sclerosis*, occlude the tubule lumens to restrict diffusion of toxins to the pulp. However, without operative intervention, the acidic and bacterial front eventually breaches the hard tissue defenses that protect the pulp. The infusion of endotoxins and bacterial antigens into the pulp evokes severe immunologic, inflammatory, and cellular responses, with the probable outcome of irreversible pulpitis. However, several clinical studies of sealants, sealed restorations, and indirect pulp capping procedures in vital teeth suggest that even advanced or infected dentin caries lesions may be arrested in situ if the bonded materials successfully seal the lesion and entomb the bacteria.[149,150]

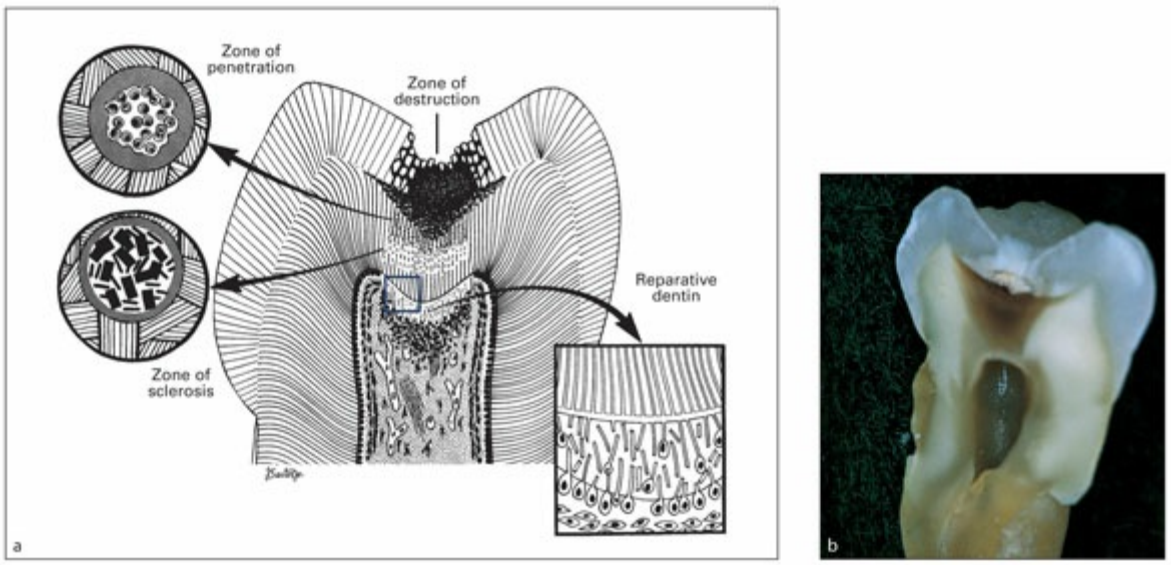

Fig 1-23 Tooth response to carious destruction of tooth surface. Acid demineralization and enzymatic destruction of the collagen matrix lead to cavitation, an irreversible change. *(a)* Bacteria fill and demineralize the lumens of the tubules peripherally, but dissolved minerals reprecipitate at a deeper level to augment sclerosis and hypermineralization of subcarious dentin. Reparative dentin with irregular and noncontinuous tubules forms a final barricade against bacterial metabolites. *(b)* Note the lateral spread of the caries lesion at the DEJ and a hypermineralized sclerotic zone around the pulp.

Dentlearn.ir

In the event of cavitation and dentinal infection, restorative treatment is necessary to remove the infected dentin and restore the integrity of the coronal surface. Discoloration is an unreliable guide to excavation of carious dentin, but the degree of dentin hardness, as determined by tactile feedback from excavating burs and hand instruments, is the most reliable guide to differentiation between infected, affected, and normal dentin.[151] As with dentin of different depths, some types of bonding systems are better suited to dentin altered by caries. Etch-and-rinse systems have bonded well to moist, caries-affected dentin,[152] and extended etching times have helped.[153] However, self-etching systems provide significantly reduced bond strengths when applied to affected and infected dentin.[154,155]

Altered dentin

Dentin experiences alterations in its morphology due to both the aging process and the localized defensive and repair responses to injury resulting from caries or wear. The mechanisms of biologic control and coordination of these pulpal and dentinal responses are beginning to be understood. The hard tissue responses to injury include tubular hypermineralization and sclerosis, which restrict the tubular diffusion of noxious agents. Also, tertiary dentinogenesis adds new barrier dentin at the pulpal interface. At the same time, a pulpal response is underway, including activation of odontoblastic and subodontoblastic cells, proliferation of vascular and neural tissues that support these cells, a heightened immune response, and inflammation.

Sclerotic dentin. A combination of abrasion, attrition, erosion from dietary sources or gastric acid, or occlusal stress may lead to the loss of enamel, cementum, and dentin. The progressive loss of tooth structure at the CEJ typically presents as a wedge-shaped defect. Although the etiology of the lesion is multifactorial, it is not primarily a result of demineralization from bacteria-produced acids, and it is termed a *noncarious cervical lesion* (NCCL). The exposed radicular dentin of an advanced NCCL differs in appearance from cut coronal dentin in that it is generally deep yellow in color and has a transparent, glossy surface[156] (Fig 1-24). These lesions may be episodically and acutely sensitive to touch or to changes in temperature, so the dentin is termed *hypersensitive*. The condition is directly related to the percentage of open or patent tubules between the exposed root surface and the pulp; nearly 75% are present in sensitive dentin versus about 24% in insensitive root dentin.[157] Sclerotic dentin is characterized by hypermineralization or blockage of the

Dentlearn.ir

tubules with whitlockite crystals and by a denatured collagen network. Studies have demonstrated acid-resistant, bacteria-embedded, hypermineralized, layered plaques on the surface of the sclerotic dentin of NCCLs.[158] The altered surface and substrate limit the formation of both the hybrid layer and the resin tags, so that the bond strengths observed during in vitro testing to sclerotic dentin in a NCCL is 20% to 40% less than the bond strengths to dentin in artificially created wedge-shaped lesions prepared with carbide cutting burs in the cervical area.[159] However, in a recent 8-year clinical study involving the preparation and restoration of 112 NCCLs, no increase was observed in the loss rate of restorations placed in sclerotic dentin when compared with restorations placed in normal dentin.[160] The optimum mechanical or chemical preparation of the hypermineralized surface, types of bonding systems, and techniques used to bond restorations to sclerotic dentin are still being investigated.[156,161]



Fig 1-24 Large NCCLs in the maxillary left central incisor, canine, and first premolar that illustrate the appearance of sclerotic dentin.

Hypermineralized dentin. Following root formation and for as long as the tooth is vital, the odontoblasts slowly produce extracellular dentin matrix and concentrate minerals for the production of physiologic secondary dentin. It is theorized that a portion of the mineralizing components released into the tubules gradually augments the thickness of the mineralized peritubular walls. As the tooth matures, beginning at the periphery of the dentin, the tubules become progressively hypermineralized and, with constriction of the lumen, less permeable. Just as secondary dentin deposition is primarily physiologic, tubular hypermineralization or sclerosis is an age-related process of the coronal dentin and, especially, of the root dentin.[162] However, with an external stimulus or irritation, such as a slowly progressing caries lesion, attrition, or restorative procedures, the rate of mineral augmentation to the tubular walls can be accelerated.

Mineral crystallization within the tubules, as in sclerotic dentin in the walls of

Dentlearn.ir

NCCLs, is also an important defensive response to attrition and to an active caries process in dentin. The apatite minerals of the inorganic dentin are dissolved in the acidic environment of the peripheral cavitated lesion. The supersaturated acidic solution is diluted and buffered by diffusion through and contact with the tubular walls, and the pH kinetics reverse to favor reprecipitation of calcium and phosphates. Platelike, cuboidal, or rhomboid mineral crystals form to barricade the open lumen[163] (Fig 1-25). Similar crystals are observed within tubules of coronal or root dentin exposed to the oral environment through attrition or abrasion.[164]

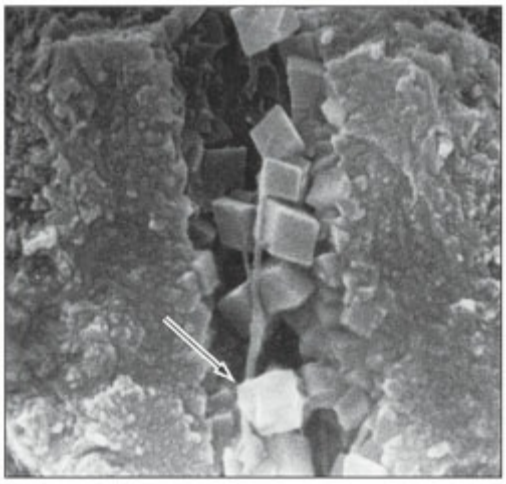

Fig 1-25 Intertubular precipitation crystallites *(arrow)* nearly occluding the dentin tubule. (Original magnification ×27,000. Reprinted from Yoshiyama et al[157] with permission.)

The combination of peritubular wall thickness and intratubular crystals creates a zone of hypermineralized dentin beneath exposed or carious dentin, the zone of sclerosis or *translucent zone* (see Fig 1-23a). Sclerotic dentin is frequently found beneath both active caries lesions and restorations and is an important defense reaction of the hard tissues because it limits the permeability of dentin.[165] Rate of caries lesion progression and patient age are important factors. Rapidly progressive caries lesions in newly erupted teeth can lead to dead tracts, empty tubules in which the odontoblast and its process are destroyed before any defensive restriction of the tubules can occur.[166] In one study, the sclerotic zones beneath caries lesions in young adults limited the dentin permeability to only 14% of the permeability of noncarious controls. With subjects aged 45 to 69 years, the dentin beneath caries lesions was completely impermeable.[167] However, as with the sclerotic dentin of NCCLs, the altered sclerosed dentinal substrate may limit bond strengths of restorative systems. It is not clear to what extent the genesis of the sclerotic dentin is purely physicochemical or biologically controlled. However, hard tissue responses to external noxious stimuli generally occur in conjunction with an active biologic

Dentlearn.ir

cellular response of tertiary dentinogenesis.

Tertiary dentin. Newly formed dentin at the dentin-pulp interface compensates for the loss of peripheral dentin from caries or injury and may provide a superior pulpal seal against noxious diffusion through the tubules (Fig 1-26). If the stimulus is relatively low-grade, such as from an incipient enamel caries lesion, the primary odontoblasts are metabolically reactivated to produce a localized tertiary dentin termed *reactionary dentin* (Fig 1-27a). At the same time, complex biochemical signaling systems promote proliferation of supportive vascular and neural tissues among the affected odontoblast cells. Paradoxically, despite being reactivated, the odontoblasts do not assume the increased size and complexity observed during secretion of the primary dentin matrix.[118] The affected odontoblasts are smaller and have a decreased cytoplasm-to-nucleus ratio.[170,171] The rate of reactionary dentin formation, the inclusion of tubular and cellular components, and the continuity of tubules in reactionary dentin with tubules in the overlying dentin all vary according to the severity of the stimulus. Reactionary dentin resulting from a mild, slowly progressing caries lesion may resemble secondary dentin with connecting tubules between the two tissues. An active noncavitated lesion may result in atubular reactionary dentin.[172] With a rapidly progressing caries lesion, neither tubular hypermineralization nor reactionary dentin has an opportunity to form.[173]

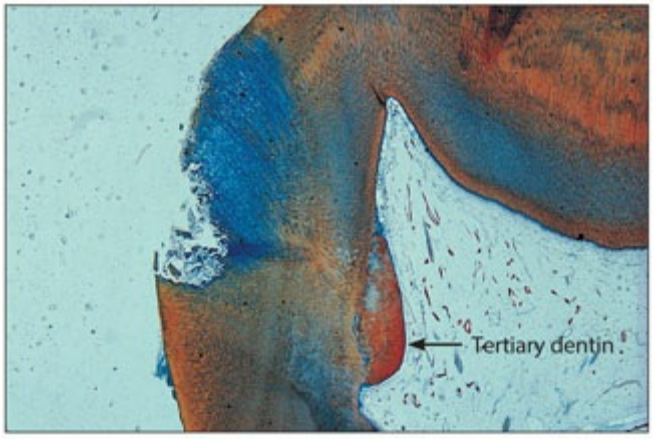

Fig 1-26 Reparative dentin forming a localized defense barrier and replacement for lost carious dentin at the periphery. The effectiveness of the diffusion barrier is shown by the absence of pulpal inflammation. (Reprinted from Trow-bridge[168] with permission.)

Dentlearn.ir

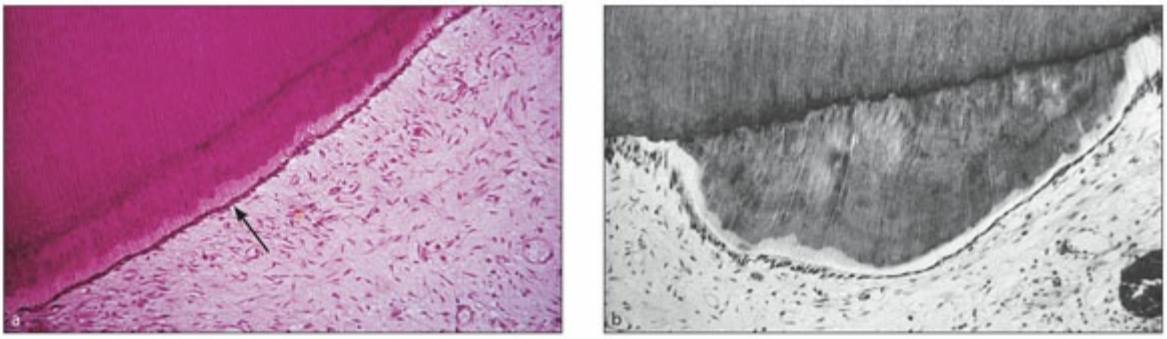

Fig 1-27*(a)* Reactionary dentin. Note the layer of intact primary odontoblast cells *(arrow)* and the regular pattern of tubules continuous with those of the physiologic secondary dentin. (Hematoxylin-eosin stain, original magnification ×56.) (Reprinted from Trowbridge[168] with permission.) *(b)* Reparative dentin. The dentin is produced by differentiation of subodontoblastic cells that replace the primary odontoblasts killed from the effects of caries. The tubules are less regular and not continuous with those of the overlying dentin. (Reprinted from Trowbridge[169] with permission.)

When cavity preparation reduces the RDT to less than 0.25 mm, the trauma to the odontoblastic cell bodies and their processes reduces their numbers by up to 41%.[174] Even before restorative tooth preparation, an advancing caries lesion generates hydrogen ions and endotoxins that have the potential to critically injure the primary odontoblasts. With a mechanical pulpal exposure, 100% of the primary odontoblasts are destroyed. Yet, with vital pulp tissue surrounding the area of destroyed cells, the dentin-pulp complex can recruit other pulpal cells, including stem cells, to become odontoblast-like cells.[175] The damaged odontoblasts appear to be replaced by differentiating dental pulp cells that show an increased production of collagen type I, which provides the basic framework for dentin, along with dentin sialoprotein and phosphophoryn, both of which are proteins that control the deposition of apatite crystals in dentin.[176] The cascade of biologic signals to other pulpal cells is complex because recruitment, migration to the odontoblastic layer, differentiation, and a change in form and function must precede the secretion of new dentin matrix. The process takes 20 to 40 days before dentinogenesis begins.[177] With a mechanical pulpal exposure, the formation of a tertiary dentin "bridge" is expedited by direct pulp capping procedures that limit bacterial contamination and seal the exposure site.[178] Tertiary dentin produced by odontoblast-like replacement cells is termed *reparative dentin* (Figs 1-26 and 1-27b). The layer of reparative matrix formed at the dentin-pulp interface, termed *interface dentin*, is atubular and is therefore a superior barrier because it seals and terminates the tubular pathways of the overlying dentin.[179,180] Depending on the nature and rate of progression of the caries lesion, subsequent layers of tertiary dentin, equivalent to wound healing or scar formation, may [172] onary and reparative

Dentlearn.ir

dentin can form beneath the same caries lesion because the periphery of a dentin lesion may be less advanced than the center.[171] To the extent that bacterial antigens and cytotoxins begin to breach the hard tissue barriers, the pulpal defenses must rely on increased vascular clearance, activated immune response, and inflammation.

Molecular signals link caries-inflicted or other injury to the tooth with the hard and soft tissue responses of the dentin-pulp complex. Until recently, mature dentin was considered inert and tertiary dentin a type of irritation response.[181] Recent research has identified molecules trapped within the mineralized dentin matrix that are equivalent to the signaling molecules responsible for the differentiation and activation of the embryonic preodontoblast cells. During primary dentinogenesis, they are synthesized and secreted by the odontoblasts into the extracellular dentin matrix. These bioactive molecules are embedded in both the soluble mineral and the insoluble collagen components of the dentin. Cells that have receptors for these growth factors, including odontoblasts and subodontoblastic cells,[182] are directed to various activities, including migration, metabolic functions, proliferation, and differentiation.[169]

Some of the active growth factors in dentin, such as bone morphogenetic protein-2 (BMP-2), are also present and instrumental in bone regeneration.[183] The foremost and most abundant of the numerous dentin growth factors is transforming growth

caries, TGF-β1 is a pivotal molecule that initiates tertiary repair and modulates the inflammatory reaction.[185] Experimental extracts of solubilized dentin matrix contain the released growth factors. When placed in deep, atraumatically prepared cavities with a minimum RDT, the growth factors diffuse across the dentin to stimulate both reactionary and reparative tertiary dentin.[186] With caries, growth factors are released by demineralization, caused by either bacterial or restorative etching acids, and then diffuse pulpally through the dentinal tubules to interact with the odontoblasts and pulpal cells.[187,188] Also relevant to pulpal therapy, dentin extracts or chips of dentin experimentally placed on vital pulp tissue expedite reparative dentinogenesis.[189] The therapeutic application of growth factors incorporated into restorative materials to induce dentin impermeability and repair has been investigated to some extent. In an animal study, the inclusion of TFG-β1 in a calcium phosphate/hydrosoluble polymer composite pulp capping material was found to trigger stem cells in the pulp to differentiate into odontoblast-like cells and to induce the formation of tertiary dentin.[190]

Dentlearn.ir

Sensitivity

Dentin can be painfully sensitive, but there is no direct anatomical explanation. Although sensitive to thermal, tactile, chemical, and osmotic agents, dentin is neither vascularized nor innervated, except in about 20% of tubules that have nerve fibers penetrating inner dentin by no more than a few microns. The possibility of the odontoblastic cell body and process having a role in direct transmission of sensation is doubtful.[93] The odontoblastic process does not extend beyond the inner third of mature dentin.[191] In addition, the cell membranes of odontoblasts are nonconductive, and there is no synaptic connection between the odontoblastic cell and the contiguous terminal branches of the pulpal nerve plexus. Finally, pain sensation remains even when concentrated anesthetic solutions are placed on the dentin surface or when the odontoblastic layer is disrupted.[192] However, recent studies demonstrating the ability of odontoblasts to generate action potentials[193] have led some researchers to believe that odontoblasts could possibly be directly involved in the sensory transduction process of the tooth through some form of mechanosensory system.[194]

Brännström et al[195] proposed a theory based on the capillary flow dynamics of the fluid-filled dentinal tubules (Fig 1-28a). Tubular fluid flow of 4 to 6 mm/sec is produced by the application of a stimulus that expands or contracts the tubular fluid volume and/or creates rapid shifts in the rate and/or direction of the fluid flow. An outward flow apparently causes more sensation than does flow in a pulpal direction.[197] Common clinical procedures associated with tooth preparation, such as air drying, cold water rinses, or pressure from probing and cutting dentin, generate outward fluid displacement. The "current," or hydrostatic pressure, displaces the odontoblastic cell bodies and stretches the intertwined terminal branches of the nerve plexus to allow the entry of sodium to initiate depolarization and the perception of pain.[198] Adenosine triphosphate (ATP), released from damaged cells or by stimulation of endothelial cells, may provide a chemical rather than mechanical explanation for depolarization, because ATP receptors have been identified on terminal branches of the pulpal sensory neurons.[199]

Ahlquist et al[200] correlated intensity of pain with rapid changes of hydrostatic pressure applied to smear-free dentin in axial walls of cavity preparations. Other evidence supporting the hydrodynamic theory is the in vivo correlation of tubule patency with hypersensitivity of root dentin. With hypersensitive root dentin, the degree of tubule closure from intratubular crystals was directly correlated with decreased sensitivi uli.[158,201] Chemical

Dentlearn.ir

compounds that promote intratubular crystallization, such as oxalates or strontium chloride, are active ingredients in some toothpastes and professional desensitizing compounds.[202] Other materials, such as potassium nitrate, resin-glutaraldehyde mixtures, fluoride varnish, and resin bonding agents, have also been successfully utilized clinically to reduce dentin sensitivity by occluding dentinal tubules through various mechanisms.[203,204]

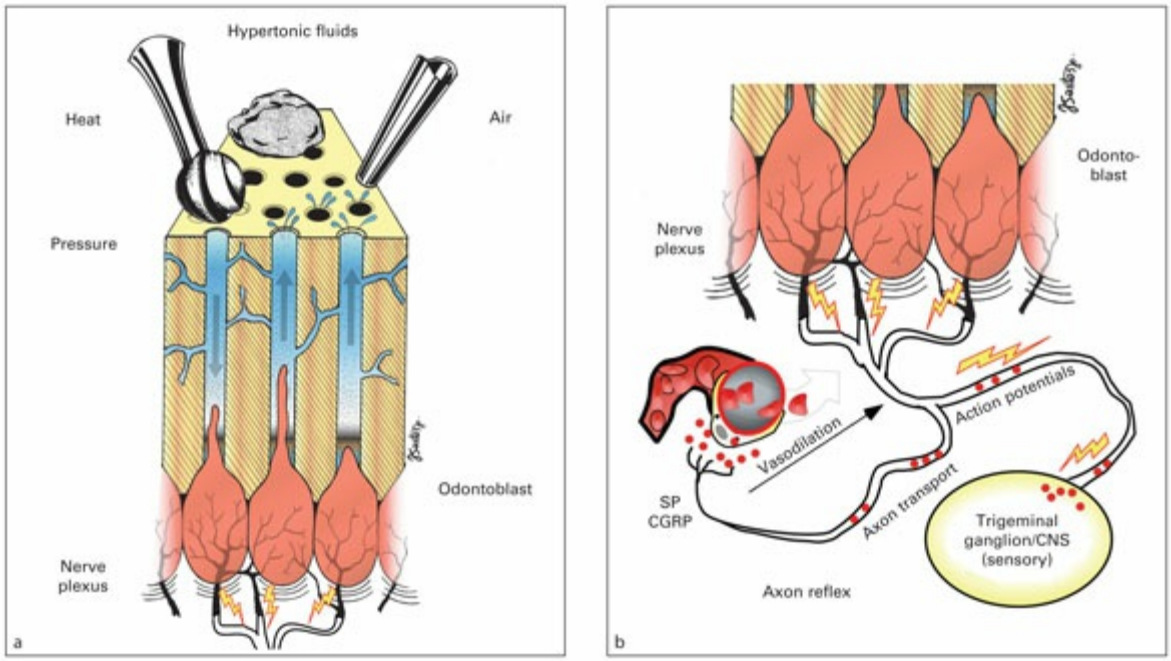

Fig 1-28*(a)* Hydrodynamic phenomenon explains the sensitivity of dentin, which is without significant innervation. Fluid dynamics of the tubules move the odontoblastic cell bodies and mechanically depolarize approximating sensory afferent nerve endings. *(b)* Axon loops from activated sensory nerves provide reflex efferent functions to pulpal, immunologic, and vascular cells by releasing neuropeptides, such as calcitonin gene-related peptide (CGRP) and substance P (SP), from terminal nerve endings. Whereas the sensory action potentials along nerve membranes are nearly instantaneous, the axonal transport of chemical factors and neuropeptide replacements may take hours or days.[196] CNS—central nervous system.

A painful stimulus-reflex response is protective as an alarm to avoid trauma or injury. However, the advantages of painful and sensitive dentin to foods and fluids are less clear, and pain is not a reliable indicator of histopathologic changes or of dentin demineralization caused by caries. It is possible that the major protective benefit of stimulating the sensory pulpal nerves is not the registering of pain in the central nervous system. Branches of these afferent nerves loop back via an axon reflex to stimulate the contractile components of the vascular complex (Fig 1-28b). When triggered, they release potent neuropeptides to activate vasodilation, increase blood flow, and elevate interstitial pressure.[196,205] Thus, rather than discomfort, homeostasis and pu ve outcomes of the

Dentlearn.ir

hydrodynamic response.

Conclusion

The elastic nature of dentin provides stress relief for brittle enamel. The integrity of dentin is related to coronal strength and durability and can be compromised by carious demineralization, traumatic injury, wear, or poor restorative techniques. Unlike the relatively homogenous nature of enamel, the dentinal substrate varies considerably with location, age, and response to external stimuli. Differences in dentinal permeability, wetness and dryness, hypermineralization, and pathologic events complicate comparative research studies on dentin and dentin bonding systems. The dentinal matrix can no longer be considered biologically inert. Signaling molecules and growth factors are released in dentin injury or demineralization to activate tertiary dentin repair and to initiate mobilization of pulpal defenses. The barrier protection of the pulpal tissue is directly related to the impermeability of the dentinal tubules. When carious metabolites, toxins, and bacterial by-products access the pulpal tissues through these portals, both hard (dentinal) tissue and soft (pulpal) tissue defensive reactions are activated to seal the tubules and repair the damage. Because of the numerous interactions between tissues of the dentin and pulp, the two are often discussed together as one complex.

Pulp

Dental pulp,[93,206] composed of 75% water and 25% organic material, is a viscous connective tissue of collagen fibers and organic ground substance supporting the vital cellular, vascular, and nerve structures of the tooth. It is a unique connective

apical foramen at the root apex, and it is completely encased within relatively rigid dentinal walls. Therefore, it is without the advantage of an unlimited collateral blood supply or an expansion space for the swelling that accompanies the typical inflammatory response of tissue to injury. However, the protected and isolated position of the pulp belies the fact that it is a sensitive and resilient tissue with great potential for healing.

The dental pulp fulfills several functions:

- *Formative:* Generates primary, secondary, and tertiary dentin (dentinogenesis)
- *Nutritive:* Provides the vascular supply and ground substance transfer medium for

Dentlearn.ir

metabolic functions and maintenance of cells and organic matrix

- *Sensory:* Transmits afferent pain sensation (nociception)
- *Protective:* Coordinates inflammatory, antigenic, neurogenic, and dentinogenic responses to injury and noxious stimuli

Additional protective functions include homeostasis and clearance of noxious and antigenic substances through the vascular and lymphatic systems and through defense cells, such as macrophages and leukocytes.

Morphology

The pulpal tissue is traditionally described in histologically distinct, concentric zones: the peripheral odontoblastic layer, the cell-free zone, the cell-rich zone, and the innermost pulp core (Fig 1-29).

The radicular and coronal pulp core is largely *ground substance*, an amorphous hydrated matrix gel that, with collagen fibrils, surrounds and supports the pulpal cells and the vascular and sensory elements. The matrix gel, like interstitial fluid, serves as a transfer medium for transporting nutrients and by-products between widely separated cells of the pulp core and the vasculature. Arterioles and venules, pass into and out of the pulp core through the apical foramen or foramina. Collagen is a component of all connective tissues, but in the pulp, the discrete bundles of fibers are dispersed, rather than organized into a supportive framework as in dentin. The proportion of collagen increases with age and is concentrated in the radicular pulp; this facilitates its removal with a barbed broach if a pulpectomy is required.

Dentlearn.ir

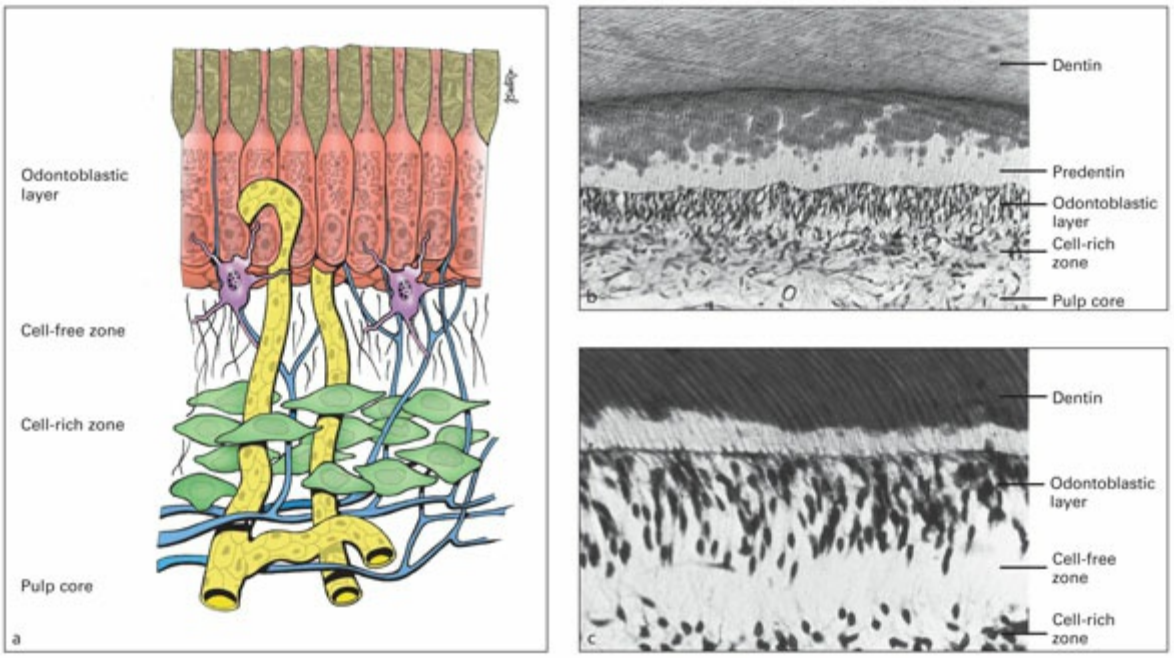

Fig 1-29*(a)* Pulpal histology: odontoblastic layer with immunocompetent dendritic cells, cell-free zone filled with both nerve and capillary plexuses, cell-rich zone of fibroblasts and undifferentiated cells, and pulp core. *(b and c)* Photomicrographs of dentin and underlying pulpal tissues. The multilayered appearance of odontoblast cells is an artifact. (Courtesy of Charles Cox, Birmingham, Alabama.)

The cell-rich zone consists of fibroblasts and undifferentiated cells. The cells of the stratified odontoblastic layer and of the cell-rich zone are separated and supported by a plexus of capillaries and axons that form the cell-free zone. Cells of the pulp function for matrix production, immune reactions, defense, vascular control, and inflammatory response.

Pulpal cells

Odontoblast cell bodies form the outer periphery of the pulp tissue. These specialized, postmitotic cells, each with a process extending into a dentinal tubule, form a single layer at the predentin-pulp interface. As long as the tooth remains vital, they produce and adapt the dentin matrix, including collagen, and they may provide an active transport of calcium ions.[207] The odontoblasts synthesize and secrete various noncollagenous proteins that affect the structure and mineralization of the dentin. Also synthesized are bioactive growth and signaling molecules that supplement neuropeptides within the pulp to coordinate pulpal-dentinal responses for healing and repair. The cellular morphology reflects the stage of activity: large, complex, and columnar when active; small and flattened when quiescent, injured, or aged. Each cell body forms a loose “plug” at the pulpal terminus of the dentinal

Dentlearn.ir

tubule and is therefore subject to the hydrostatic shear currents of the tubular fluid. The hydrodynamic effects range from "aspiration" of the cell bodies into the tubules and autolysis of the cells to minor displacement and depolarization of nerve terminals in close contact with the cells. The cell membranes are bound together through a variety of membrane junctions characterized as tight and permanent or gapped and adhesive.[208] Prominent fibers interconnect the cells to form a terminal web, which may orchestrate their secretory functions and stimulus responses as a unified zone. The membrane junctions may modulate either a physiologic barrier or a molecular sieve to regulate transfer of ions and plasma molecules between the interstitial fluid of the pulp and the tubular fluid.[209] Either injury or routine operative procedures can temporarily disrupt the odontoblastic barrier to permit infusion of plasma proteins and to increase outward tubular flow.[210,211]

Fibroblasts, the most numerous pulpal cells, form a dispersed but interconnecting network through their cytoplasmic extensions. They produce, maintain, and remodel pulpal matrix and collagen. They are concentrated in the cell-rich zone supporting the odontoblastic cells. Fibroblasts, undifferentiated mesenchymal cells, stem cells, pericytes, and smooth muscle cells supporting the capillary walls are all prime candidates to be progenitor cells capable of differentiation and phenotype conversion into matrix-secreting replacements for destroyed primary odontoblasts.[212]

Immunocompetent cells include macrophages, lymphocytes, and dendritic cells that function as a host defense system against foreign bodies and antigens.[118,206] *Macrophages* are large cells that are scavengers, able to phagocytize microorganisms, cellular debris, and damaged extracellular matrix. *Dendritic cells* are highly motile cells with branched extensions up to 50 μm long; they have great capacity for encoding antigens on their membrane surfaces. With early caries lesions or injury, they congregate among layers of injured or destroyed odontoblasts and even extend their branches into the affected tubules for surveillance of protein antigens.[213,214] Once antigens are captured, they migrate to nearby lymph nodes to present their encoded antigens to T-lymphocytes. This initial phase is the primary immune response in which memory T cells carrying the antigen "blueprint" are cloned and released back into the pulp tissue. After 3 to 5 days, following another antigen exposure, encoded dendritic cells or macrophages directly interface with the preprogrammed memory T cells in the pulp tissue to release proinflammatory cytokines.[215] With dental caries, this secondary phase of the cell-mediated immune response typically produces chronic inflammation because bacterial by-products diffuse into the pulp long before the organisms themselves directly reach and infect

Dentlearn.ir

the tissue.[168] Tubular sclerosis, tertiary dentin, and restorative treatment limit or eliminate the antigen stimulus, so an area in which there is chronic inflammation should revert to a healthy histologic state. However, if microorganisms penetrate the tertiary dentin that forms beneath the caries lesion, the host responds with a prompt and massive influx of neutrophilic and mononuclear leukocytes typical of an acute inflammatory response.[216]

Vascular system

The microvascular system of the pulp[217] contains vessels no larger than arterioles and venules. The primary function is maintenance of tissue homeostasis. The extent of the presence of true lymphatic vessels in normal pulp tissues is somewhat controversial[218,219]; lymphatic vessels exist in most tissues and serve to return tissue fluid and high–molecular weight plasma proteins back to the vascular system. It has been suggested by some investigators that true lymphatic vessels may not be present in all healthy pulpal tissue but may be formed only following inflammation. It has also been hypothesized that in some normal pulpal tissues, the interstitial fluids

through the apical foramina.[219,220] Capillaries supply oxygen and nutrients that dissolve in and diffuse through the viscous ground substance of the pulp to reach the cells. In turn, the circulation removes waste products, such as carbon dioxide, byproducts of inflammation,[166] and diffusion products that have permeated through the dentin so that they do not accumulate to toxic levels[221] (see Fig 1-14). The equilibrium between diffusion and clearance may be temporarily threatened by use of long-acting anesthetic agents that contain vasoconstrictors, such as epinephrine. An intraligamental injection of a canine tooth with 2% lidocaine with 1:100,000 epinephrine will cause pulpal blood flow to cease for 20 minutes or more.[222] Fortunately, the respiratory requirements of mature pulpal cells are so low that no permanent cellular damage ensues.

Inflammation, the normal tissue response to injury and the first stage of repair, is somewhat modified by the pulp's unique location within the noncompliant walls of the pulp chamber. A stimulus that produces cellular damage initiates neural and chemical signals that increase blood flow and capillary permeability. Plasma proteins, fluids, and leukocytes spill into the confined extracellular space and elevate interstitial fluid pressure.[223] The smooth muscle sphincters that regulate capillary blood flow are under the control of both neurons and local cellular conditions so that a localized vascular response to stimuli may occur independent of

Dentlearn.ir

the overall system. Theoretically, elevated extravascular tissue pressure could collapse the thin venule walls and start a destructive cycle of restricted circulation and expanding ischemia. However, the pulpal circulation is unique because it contains numerous arteriole "U-turns," or reverse flow loops, and arteriole-venule anastomoses, or shunts, to bypass the affected capillary bed.[224] Many of these capillaries are normally nonfunctional but facilitate instantaneous localized hyperemia in response to injury. Also, at the periphery of the affected area, where high tissue pressure is attenuated, capillary recapture and lymphatic adsorption of edematous fluids are expedited.[225] These processes confine the edema and elevated tissue pressure to the immediate inflamed area. Animal studies indicate that tissue pressure in an area of pulpal inflammation is two to three times higher than normal but is diminished to nearly normal levels approximately 1.0 mm from the affected area.[226]

Another protective effect of elevated but localized pulpal tissue pressure is a vigorous outward flow of tubular fluid to counteract the pulpal diffusion of noxious solutes through permeable dentin.[227,228] However, an inflammatory condition and higher tissue pressure may also induce *hyperalgesia*, a lowered threshold of sensitivity of pulpal nerves. Thus, an afflicted tooth exposed to the added stress of cavity preparation and restoration may become hypersensitive to cold or other stimuli.[200]

Innervation

Some patients seek dental services because their teeth, through caries lesion(s), injury, or exposed cervical dentin, are painful. Various noxious, thermal, electrical, and mechanical stimuli may be interpreted to some degree as pain. However, pain perception, termed *nociception*, is less important to preservation of pulp vitality than is the role of neuromediation of vascular, inflammatory, immune, and defense functions.[196]

Nociception

Innervation of the pulp[229] is primarily from sensory (afferent) axons, with their cell bodies located a great distance away in the trigeminal ganglion. There are also sympathetic (efferent) axons, with nuclei in the cervical sympathetic ganglia, which

purpose, myelin sheathing, diameter, and conduction velocity. Although a few large

Dentlearn.ir

and very high-conduction-velocity A-β nerves with a proprioceptive or touch pressure function have been identified, most sensory interdental nerves are either A-δ nerves or smaller, unmyelinated C fibers. About 13% of the nerves innervating premolars are myelinated A nerves,[230] but they gradually lose their myelin coating as they form the sensory plexus of the cell-free zone and branch into multiple free-end terminals.[231] Up to 40% of the tubules at the pulp horns contain neural filaments extending up to 200 μm into inner dentin,[232] but their role in nociception is unclear. The A-δ nerves have conduction velocities of 13.0 m/sec and low sensitization thresholds to react to hydrodynamic phenomena.[233,234] Activation of the A-δ system results in pain characterized as a sharp, intense jolt.[235]

About 87% of axons innervating premolars are smaller, unmyelinated C fibers, which are more uniformly distributed through the pulp.[236] The conduction velocities of C fibers are slower, 0.5 to 1.0 m/sec, and C fibers are only activated by a level of stimuli capable of creating tissue destruction, such as prolonged high temperatures or pulpitis. The C fibers are also resistant to tissue hypoxia and are not affected by reduction of blood flow or high tissue pressure. Therefore, pain may persist in anesthetized, infected, or even nonvital teeth.[237,238] The sensation resulting from activation of the C fibers is a diffuse burning or throbbing pain, and the patient may have difficulty locating the affected tooth.[235]

Neuromediation of pulpal functions

The close proximity of terminal sensory fibers to odontoblast cells responding to hydrodynamic fluid movement accounts for dentin sensitivity, but the central nervous system is not the sole terminus. As with the odontoblast cells, multiple branches from the axon form the same close apposition with fibroblast cells, perivascular cells, and immunocompetent cells. The terminal nerve ends contain receptors for released or generated bioactive factors caused by injury to the dentin, pulpal cells, or the interstitial environment (see Fig 1-28b). Examples include released dentin growth factors for tertiary dentinogenesis or nerve growth factor (NGF) from fibroblasts to activate sprouting and new growth of additional neurons.[239] Appropriate signals from nearby cells (paracrine), through the blood supply (endocrine), or even from the same cell (autocrine) trigger the release of potent neuropeptides stored within the terminal neurons. Two potent neuropeptides with receptor sites on vascular cells are calcitonin gene–related peptide (CGRP) and substance P; these induce vasodilation and increased blood flow to commence inflammation.[240,241] The importance of the neurogenic link was demonstrated when

Dentlearn.ir

teeth that were experimentally denervated and exposed to trauma showed significantly greater pulpal damage because they lacked sufficient inflammatory response.[242] The neuropeptides are so potent that the experimental stimulation of a single C fiber resulted in a detectable increase in blood flow.[243] The exchanges of factors and neuropeptides regulate the inflammatory, dentinogenic, and immunologic functions and other defenses of the dentin-pulp complex. The responses are dynamic, increasing or decreasing with the severity of the external stimulus and with the phase of response (acute, chronic, or healed). These effector functions of the sensory neurons are critical to the function and vitality of the dentin-pulp complex.

Restorative dentistry and pulpal health

Mechanically cutting tooth structure, especially dentin, during restorative treatments generates considerable physical, chemical, and thermal irritation of the pulp. However, if the dentist uses an acceptable and conservative technique and achieves bacterial control, even a mechanical pulp exposure or use of acidic restorative materials poses few problems for pulpal health.[244–247] With all restorative surgical procedures on tooth structure, maintenance of a thick RDT will decrease the chance of pulpal irritation or injury.[248] Although microleakage around restorations is ubiquitous, the fact that almost all pulps remain healthy is related to diminished virulence of the bacteria, relative impermeability of the dentin, and the healing potential of the pulp. An animal study reported 15% pulpal necrosis after a 5.5°C increase in intrapulpal temperature and up to 60% necrosis after an 11°C increase.[249] In vitro crown preparation studies without water coolant record increased intrapulpal temperatures of this degree.[250] Although a retrospective radiographic study of teeth prepared for crowns using only air coolant reported good success,[251] many authorities state that water coolant and intermittent rotary instrument contact with tooth structure during crown preparations is essential to avoid histopathologic damage.[252,253]

Materials utilized in the treatment and restoration of dental tissues can have a direct effect on the pulpal tissues. The main factor influencing the extent of the effect that these materials may exert on the dental pulp is the amount of the RDT. With a reduced RDT, the permeability of the dentin increases,[110] and thus it will more freely allow the penetration of various components of restorative materials into the pulp.[254] In vitro studies have introduced concern that some materials used in adhesive bonding techniques contain various components, such as monomers and acids, that may have deleterious effects on the health and function of pulpal

Dentlearn.ir

cells.[255–257] However, animal studies and clinical investigations have shown that many of these materials exhibit acceptable biocompatibility from a clinical aspect when not in direct contact with the pulp tissue.[258–260] Beyond the effects of chemical components of restorative materials, some materials are capable of creating damage to pulpal tissue due to high temperatures from exothermic reactions. Certain methacrylate-based provisional crown materials can generate temperatures during polymerization that are high enough to injure pulp tissue.[261] Tooth-whitening procedures that utilize various oxidizing agents to break down stains in tooth structures have also presented concerns in regard to their effects on the pulpal tissues. Studies have shown that higher concentrations of hydrogen peroxide can diffuse into the pulp and cause damage to the tissues.[262] There also are concerns about the use of certain high-energy light-curing units and the possibility of heat transfer to the pulp during photopolymerization of bonded restorative resins.[263,264]

The aged tooth is less able to respond to noxious stimuli and injury. Age-related changes include reduced blood supply, a smaller pulp chamber, 50% reduction of pulp cells with a lower ratio of pulp cells to collagen fibers, loss and degeneration of myelinated and unmyelinated nerves, decreased neuropeptides, loss of water from the ground substance, and increased intrapulpal mineralizations (denticles).[93,265] However, the aged tooth is generally less sensitive and is protected by sclerotic and tertiary dentin that make it impermeable to diffusion of injurious agents. The dentin-pulp complex is neither static nor noncompliant but is dynamic and adaptive to environmental stresses. Advances in clinical dentistry such as effective preventive measures, sensitive diagnostic tools, improved bonding systems and restorative materials, and conservative surgical preparations should extend the durability and biocompatibility of dental services to preserve the teeth for a lifetime. See chapter 6 for more on pulpal considerations in relation to restorative dentistry.

Potential for regenerative therapies

The regenerative powers of the dental stem cells and undifferentiated mesenchymal cells found in the pulp and other dental tissues have tremendous potential for future dental therapies. Research in the area of dental tissue regeneration involving these progenitor/stem cells is progressing rapidly. These progenitor cells can be found in several different dental tissues, such as the pulp of both exfoliated deciduous and permanent teeth, the periodontal ligament (PDL), the tips of developing roots, and from the tissue (dental follicle) that surrounds the unerupted tooth. All of these progenitor cells probably share a common lineage of being derived from neural crest

Dentlearn.ir

cells, and all have generic mesenchymal stem cell–like properties.[266] These mesenchymal stem cells have demonstrated the capability to regenerate dentinal, pulpal, and other tissues that are derived from mesenchymal-type cells. In addition to the mesenchymal progenitor cells that have been identified, a study has recently suggested that epithelial-type stem cells also might exist in the dental pulp of human primary teeth and could play a role in the development of a process for the repair or regeneration of tooth enamel.[267]

Techniques known as *cell homing* or *cell transplantation* are evolving as possible methods to regenerate pulpal tissue within the pulp chamber of a tooth. Some of these methods have shown the ability to regenerate a vascularized pulpal tissue within the confines of a mouse tooth, and the development of odontoblasts that produce a continuous layer of dentinlike tissue lining the dentinal wall of the pulp canal has been demonstrated.[268,269] The ability to regenerate an entire tooth from stem cells has also been investigated. The results of animal studies indicate that the process for regeneration of the various dental tissues required to regenerate a tooth is indeed possible.[270,271] However, there are significant technical difficulties that first must be overcome, such as the development of precise shapes, sizes, and interfaces for the different types of dental tissues.[272] As mentioned earlier in the discussion of the formation of tertiary dentin, research has also indicated the possibility of using a directed repair method that induces pulpal mesenchymal stem cells to repair dentin damaged by disease or trauma. Several experimental techniques have been investigated involving transplantation of various pulp cells, bone marrow cells, or extracellular matrix molecules that can differentiate into odontoblasts and which have the potential to direct a regenerative repair of damaged tissues.[183,273]

Progenitor/stem cells that reside in the PDL have been demonstrated to have the ability to induce alveolar bone formation, remodeling, and the regeneration of PDL tissue.[274,275] It has been shown that these PDL progenitor cells can assemble new PDL-like structures in vivo.[276] Clinical implications of this may include the ability to place implants with PDL progenitor cells applied to the surface that will regenerate both bone and a PDL in the interface between the implant and the bony socket. A clinical study performed on human subjects created what were termed as "ligaplants," which were implants coated with PDL-derived cells. These ligaplants were inserted into the subjects' jaws, and the cells were shown to produce a periodontal attachment in the implant site.[277]

Although research directed toward the clinical regeneration of dental tissues is

Dentlearn.ir

still in its early stages, the results of recent studies suggest that the possibility of tissue engineering of human dental tissues in situ is promising. The techniques for the practical applications of these technologies are still being investigated, but the results may have a significant impact on the future of restorative dentistry.

Gingiva

The gingival complex[278,279] forms the interface between the hard, mineralized structure of the tooth, the oral cavity, and the underlying periodontal tissues. As such, its structure and composition are designed to withstand functional forces, such as mastication and toothbrushing; to resist chemical effects of food, drink, and biofilms; and to protect against oral pathogens. Along with tooth-related characteristics, the position, color, contour, and symmetry of the gingiva define esthetic form. High or low gingival margins or red, swollen gingival tissues produce readily visible esthetic compromises. Periodontal disease affects up to 50% of the population in the United States.[280] Gingivitis, the most prevalent form, is characterized as a chronic but reversible inflammatory response of the gingiva to bacterial biofilm.[280] Gingivitis progresses to periodontitis, a more severe and destructive form of periodontal disease, characterized by a loss of PDL and alveolar bone supporting the teeth.[280,281] In general, gingivitis can be reversed and periodontitis can be controlled by the regular removal of supragingival and accessible subgingival biofilm.[282,283] When restorations are required, a healthy gingival response can be ensured by the clinician's insertion of restorations that precisely replicate the contours and surface smoothness of the tooth structure they are replacing, along with meticulous oral hygiene on the part of the patient.[284,285]

Morphology

A normal, healthy gingiva (Fig 1-30) presents a scalloped marginal outline, firm texture, coral pink or normally pigmented coloration (depending on ethnicity), and, in about 40% of the population, a stippled surface. Coronally, free gingiva includes

extends apically 1.0 to 2.0 mm to the free gingival groove, corresponding to the base of the sulcus and located at the level of the CEJ in a healthy situation. The main component of the gingiva, the *attached gingiva*, is firmly affixed to the periosteum of the alveolar bone and hard palate and to the supra-alveolar cementum of the root of

Dentlearn.ir

each tooth. The free and attached gingiva extends interproximally to form the *interdental papilla* that fills the gingival embrasure below the interproximal contacts. Figure 1-31 shows the various collagen fiber bundles that attach the tooth and gingival tissue to the bone and to each other. In a healthy periodontium in which the gingival tissue and bone have not receded apically, the interdental papilla completely fills the gingival embrasure. However, if the periodontal health is neglected, the interdental papilla may not completely fill the gingival embrasure. Unlike attached gingiva, the epithelial lining of the sulcus and of the papillary col between the facial and lingual sides of the papilla is not keratinized. Therefore, in a mouth that harbors periodontal pathogens, without effective oral hygiene procedures, both the sulcus and the papilla are susceptible to inflammatory reactions to the plaque biomass that accumulates there. The *vertical width* or *zone* of keratinized gingiva refers to the distance from the free gingival margin to the mucogingival junction. The *mucogingival junction* is the junction of the keratinized gingiva with the alveolar mucosa, which is mobile, darker red, and nonkeratinized. The usual width of keratinized gingiva varies by location on both the facial and lingual aspects of the teeth. Facially, it is normally widest in the incisor areas and narrowest in the canine and first premolar regions. Lingually, it varies from less than 2.0 mm in the area of the mandibular incisors to 9.0 mm on the lingual aspects of mandibular molars.[287]

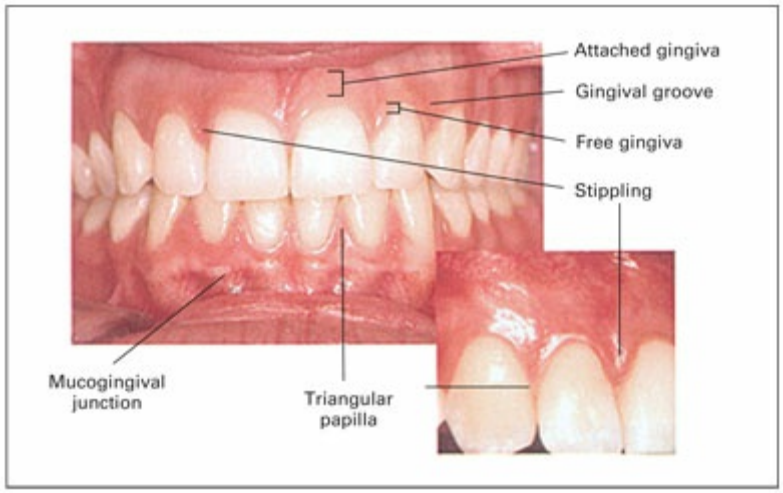

Fig 1-30 Clinically healthy, normal gingiva. (Reprinted from Chapple and Gilbert[286] with permission.)

Dentlearn.ir

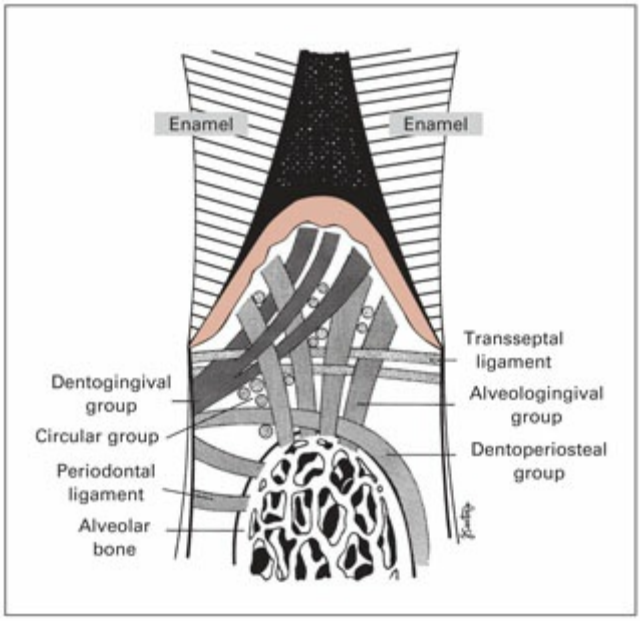

Fig 1-31 Interproximal papilla and attached gingiva. Various collagen fiber bundles continuous with the connective tissue attachment circle the teeth or attach the gingiva to the cementum and bone. The gingival embrasure or interdental space below the contact is prone to plaque accumulation, which is responsible for both caries lesion development and gingivitis.

The significance of the width (zone) of keratinized gingiva in restorative dentistry is somewhat controversial. Lang and Löe[287] evaluated sites without restorations in adults with effective oral hygiene and concluded that a minimum width of 2.0 mm of keratinized gingiva is required to prevent chronic gingival inflammation. Maynard and Wilson[288] recommended 5.0 mm of keratinized gingiva (2.0 mm of free and 3.0 mm of attached gingiva) to achieve predictability of gingival response to restorations with margins placed within the gingival crevice or sulcus. These same authors also advised that the thickness of the gingiva be evaluated. In clinical situations in which the tissue is thin enough to see the periodontal probe through the free gingival margin, the soft tissues may be unable to support intracrevicular restorative procedures.[288] In a human clinical study, Stetler and Bissada[289] compared areas of a narrow (less than 2 mm) zone of keratinized gingiva to wide (greater than 2 mm) zones. In sites with no restorations present, there was no clinical difference in gingival inflammation between narrow and wide areas. Teeth in narrow keratinized areas with subgingival restorations had greater inflammation.[289] In a similar study,[290] restored teeth with margins placed within the gingival sulcus adjacent to narrow areas of keratinized gingiva suffered increased recession and attachment loss. In summary, both the width (zone) and thickness of the gingival tissues should be evaluated prior to the placement of restorations that will extend subgingivally. In compromised areas, mucogingival therapy (soft tissue grafting)

Dentlearn.ir

prior to placing restorations should be considered.

Dentogingival complex and biologic width

The junctional epithelium and the subjacent connective tissue between the base of the gingival sulcus and the alveolar crest stabilize and seal the gingiva around the cervical enamel and supra-alveolar cementum surfaces. The combination of these two tissues (junctional epithelium and connective tissue attachment) is termed the *dentogingival junction*, and their combined vertical dimension is termed the *biologic width* (Fig 1-32). The junctional epithelium (or epithelial attachment) is nonkeratinized and provides intimate adhesion against the cervical enamel or, with gingival recession or attachment loss, against the cementum. With inflammation, a periodontal probe used to measure pocket depth may easily penetrate the junctional epithelium to the level of the connective tissue attachment. The *clinical attachment level* is the distance from the CEJ to the tip of the probe when the probe is in the sulcus. As a defensive mechanism against pathogenic bacterial penetration, the junctional epithelial cells have a high mitotic rate and are rapidly exfoliated and replaced. The cellular spacing and narrow, tapering width of the junctional epithelium layer facilitates the movement of *crevicular fluid*, a serum exudate containing defensive cells, complement, and antibodies, into the sulcus. These same characteristics of the epithelium also allow bacterial antigens and toxins to pass from the sulcus into the underlying tissues. The inflammatory response may become exaggerated and result in gingival edema, color changes, and bleeding, classic signs of gingivitis. The amount of crevicular fluid exudate and of bleeding with probing are two indices of gingival inflammation.[286,291]

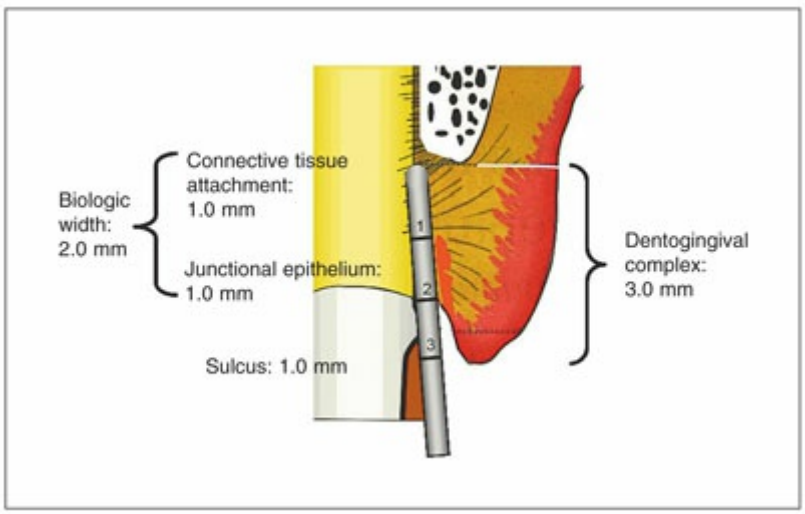

Fig 1-32 Biologic width and dentinogingival complex. Note that the gingival crown cavosurface margin is ideally no more than 0.5 mm into the sulcus (no closer than 2.5 mm from the osseous

Dentlearn.ir

crest). The tip of the periodontal probe has been pushed through the DEJ (junctional epithelium and connective tissue attachment) to the osseous crest (bone sounding).

The protective body defenses can be overcome by the chronic accumulation of pathogenic bacteria in the biofilm or at local plaque-retaining sites, such as calculus or imperfect restoration margins. With unfavorable genetic host factors, the inflammatory response can become destructive. Proliferation and apical migration of the junctional epithelial cells create greater pocket depths and a loss of attachment

and external epithelial layers are supported by a network of collagen fiber bands coursing around and between the teeth and anchoring the gingiva to the alveolar bone and cementum of the roots (see Fig 1-31). From periodontally healthy adult cadaver dissections, Vacek et al[292] reported that the mean vertical dimension of the junctional epithelium was 1.14 mm. The subjacent connective tissue attachment measured a relatively consistent 0.77 mm. Together, the mean biologic width dimension was 1.91 mm (1.75 mm for anterior teeth and 2.08 mm for posterior teeth). The results affirm an earlier dissection study by Gargiulo et al[293] in which the biologic width averaged 2.04 mm. Based on these dissections and on clinical experience, clinicians have generally accepted a 1.0-mm depth guideline for a healthy gingival sulcus. Thus, at a midfacial location, 3.0 mm (2.0 mm biologic width plus an additional 1.0-mm sulcus depth) is a simplified working concept of the average dimensions of the dentogingival complex (see Fig 1-32). Interproximally, with adjacent teeth present, the dentogingival complex dimension is reported to be in a range of 3.0 to 4.5 mm.[294,295]

Several clinical studies have demonstrated that the closer a crown margin is to the dentogingival attachment (ie, the deeper into the gingival sulcus the margin is placed), the greater the probability of an inflammatory response, as evidenced by increased gingival plaque, increased bleeding indices, and, with time, the loss of attachment.[296–298] A prospective clinical study[299] evaluating 480 metal-ceramic crowns found that the risk of gingival bleeding was related to the baseline oral hygiene index and was twice as high for intrasulcular margins as for supragingival margins. Thus, it is generally accepted that a supragingival crown margin is beneficial for periodontal health. However, a subgingival preparation margin is often necessary because of a short clinical crown, cervical or root caries lesions, a coronal fracture, or the need to hide the margin. Maintenance of the 2.0-mm dimension of the dentogingival junction is generally considered necessary for maintaining periodontal health. Although patient susceptibility varies, the assumption

Dentlearn.ir

is that a violation of the biologic width, especially into the connective tissue attachment, will lead to chronic inflammation and perhaps the loss of attachment, bone resorption, and gingival recession.[300]

It is difficult to clinically measure the separate tissue components that make up the biologic width. Kois[294,295] advocates the diagnostic use of a periodontal probe to confirm the level of the bone support to validate a biologically safe placement of the gingival margin. With anesthesia, the probe penetrates the midfacial sulcus to contact the osseous crest, a process called *bone sounding* (see Fig 1-32). The distance from the free gingival margin to the osseous crest defines the *dentogingival complex* (ie, the biologic width plus the sulcus depth). In 85% of subjects, a 3.0-mm reading confirms existence of an optimum biologic width, and the preparation margin may be safely placed 0.5 mm below the existing gingival margin. In addition, the preparation must follow the contours of the gingival margin, which parallels the CEJ, to avoid violation of the biologic width (or biologic zone), especially in the interproximal areas. With maxillary incisors, the proximal CEJ and junctional attachment may be scalloped as much as 3.5 mm incisal to the level of the facial CEJ (Fig 1-33). A midfacial reading greater than 3.0 mm confirms distant osseous support for the gingiva so that recession of the gingiva or interdental papillae may result following restorative procedures. An important anatomical study has demonstrated a quantitative relationship between the height of the gingival papilla and the distance from the alveolar crest to the base of the proximal contact. At a distance of 5.0 mm, 98% of the dental papillae completely filled the restored gingival embrasure; but at 6.0 mm, only 56% did so.[301] The dentist might be able to adjust the incisal/occlusal–gingival level of restored proximal contacts accordingly, in order to avoid an unesthetic space between the tip of the papilla and the proximal contact. If the dimension of the dentogingival complex is less than 3.0 mm, which suggests a compromised biologic width, a mucogingival flap and osseous resection (a crown lengthening procedure) is generally recommended to achieve the necessary dentogingival complex dimension in the area.[302]

Dentlearn.ir

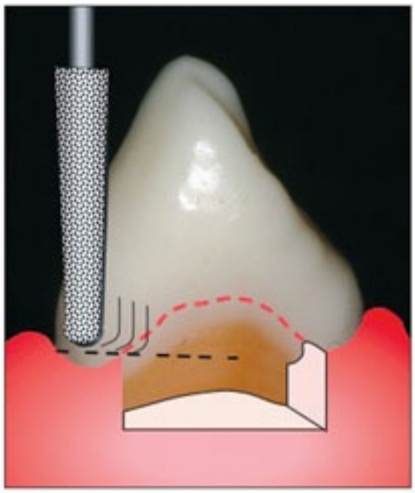

Fig 1-33 The dentist should carefully parallel and duplicate the pronounced curve of the interproximal gingiva (and CEJ) during crown preparation, as shown by the *pink dotted line*, to prevent violation of the biologic width.

The clinical imperative of a 2.0-mm biologic width is based on the averages of dimensions determined in the autopsy studies cited above; however, much variation was found in the dimensions of the individual tissues, particularly the depth of the sulcus and the length of the junctional epithelium.[292,293] Fifteen percent of teeth in the study by Vacek et al[292] had restoration margins less than 2.0 mm from the osseous crest with no related loss of attachment. In an animal study, Class 5 restorations were placed directly at the osseous crest. At 1 year, a functional biologic width re-formed apically with one-fifth the linear dimensions of the preoperative nonrestored controls.[303] A 2-year prospective clinical study evaluated the periodontal effects of

included patients with margins between 1.0 and 2.0 mm from the alveolar crest

mm or greater from the alveolar crest (within the sulcus). A marked increase in

periodontium was compromised. Even though gingival inflammation resulted from the violation of the connective tissue attachment, there were no signs of either gingival recession or bone resorption.[304] On the other hand, a review[305] of the literature on the placement of the gingival margin based on traditional concepts of biologic width concluded that the evidence is primarily based on opinion and anecdotal cases. Nevertheless, the authors suggest that "clinical experience and prudence" favor a 3.0-mm space between the alveolar crest and the restoration

Dentlearn.ir

margin.[305] For additional discussion of evaluation and management of tissue during crown preparation, see chapter 18.

Defective restorations and periodontal health

Dental restorations have a definite impact on the health of the periodontal tissues. In a longitudinal study involving 884 individuals, the probing depths and gingival recession were recorded for each individual at age 26 years and again at age 32 years. The results of the study showed that for a periodontal site in which a restoration was placed prior to the age of 26 years, the attachment loss in the corresponding periodontal site at age 32 years would be twice as likely to be ≥ 3.0 mm than if the adjacent tooth surface had remained sound until age 32 years.[306] In addition to the subgingival placement of the restoration margin described earlier, poor quality of the restoration margin, including marginal openings, roughness, and overhangs, may impair periodontal health. With an ideal preparation, it is technically possible to obtain a marginal discrepancy of less than 10 μm with a cast metal restoration and less than 50 μm with a ceramic restoration.[307] However, with additive effects of luting cement thickness, preparation design deficiencies, and technique errors, the interface discrepancy can be much greater. In a retrospective study of 42 crowns with intrasulcular margins and more than 4 years of service, the mean marginal discrepancy was 160 μm, and 15 crowns (36%) had discrepancies greater than 200 μm. The investigators reported a direct quantitative correlation between increased marginal discrepancy and an increased gingival index and crevicular fluid-flow volume.[308] Another study reported that, in addition to increased inflammation, radiographically determined bone loss was associated with crown margin discrepancies greater than 50 μm.[309] With a marginal discrepancy of 200 μm completely surrounding a restored tooth, the total computed area of exposed cement surface amounts to several square millimeters. This interface is rough, porous, and retentive to biofilm.[310]

A common problem with restoration margins, especially with Class 2 direct restorations, is the *overhang*, an extension of the restorative material beyond the cavity preparation. The morphologic variation in the cervical aspect of teeth, including furcations, fluting, convexities, and concavities, makes it difficult to consistently place a wedge and matrix band to fully adapt to the gingival cavosurface margin. Lervik et al[311] magnified bitewing radiographs and found that 25% of proximal-surface restorations presented overhangs. Of these, 29% were greater than

Dentlearn.ir

restorations with overhangs by the percentage of intrusion or invasion into the interproximal space and compared adjacent bone loss with the 100 contralateral nonrestored controls. They concluded that gingival displacement caused by large overhangs intruding 51% or more into the interproximal space is directly related to alveolar bone loss. In a literature review of overhanging dental restorations (ODRs) and their effects on the periodontium, Brunsvold and Lane[313] reported a prevalence range of interproximal overhangs from 25% to 76%. The authors attributed the wide range to differences in classification criteria and diagnostic methods. Their conclusions, which follow, are validated by recent studies and reviews[314,315]:

- Prevalence of ODRs is high, involving at least 25% of restored teeth.
- Radiographic and tactile exploration must be combined to improve ODR detection.
- Increased bone loss, attachment loss, pocket depth, and inflammation occur adjacent to teeth with ODRs; the periodontal destruction is related to the size of the ODR.

Restoration overhangs have been described as "permanent calculus." As with poor marginal fit of crowns, iatrogenic defects in restorations contribute to the retention and concentration of plaque biomass. Lang et al[316] found that an ODRs also alter the pathologic nature of the biofilm bacteria. Two sets of MOD onlays were made for each subject, one with normal contours and one with a 0.5- to 1.0-mm overhang. One of the restorations was temporarily cemented, and after 19 to 27 weeks, that restoration was removed and the other was placed in a crossover study design. With the overhanging restorations, a normally healthy sulcus microflora changed to a gram-negative, anaerobic culture typical of chronic periodontitis. It is important to note that when the onlays with overhangs were exchanged for the properly fitted restorations, equivalent to the clinical removal of an overhang, the gingival index and microflora returned to a healthy state. However, in a study in which amalgam overhangs were removed with an ultrasonic scaler and followed for 3 months, baseline gingival inflammation and early bone loss were not significantly

study, a combination of the removal of the overhangs, periodontal scaling, and antibiotics resulted in beneficial effects on the probing depths and clinical attachment levels, along with a reduction of the population of some pathologic bacteria.[318] Thus, in addition to encouraging patients' oral hygiene, the clinician should carefully plan the location of restoration margins and strive for excellent fit

Dentlearn.ir

and contour of the restoration. When overhangs are detected, their removal should be part of the treatment plan.[319]

Other parameters of restorations that have a less direct detrimental effect on the health of the periodontium are overcontoured axial surfaces, traumatic occlusion, and defective interproximal contacts. Undercontoured or "flat" facial and lingual profiles have been advocated to benefit periodontal health, while overcontoured restorations have been associated with biofilm retention.[320] Crowns are commonly overcontoured, from 0.7 to 1.28 mm wider than the buccolingual dimension of the teeth before restoration.[321] It appears that some latitude in facial and lingual contours is acceptable, but it is important to incorporate "fluting" in areas where the restoration abuts furcations to facilitate plaque removal.[322] A common clinical sign

periodontal support, is hypermobility. A clinical study of patients with periodontitis found a relationship between tooth mobility and increased loss of both attachment and bone.[323] In their review, the authors concluded that in patients with preexisting plaque-induced periodontitis, concomitant occlusal trauma may increase the rate of destruction, but "trauma from occlusion cannot induce periodontal tissue breakdown."[324]

Another aspect of restorations that relates to the health and comfort of the periodontium is deficient or open interproximal contacts. Acceptable interproximal contacts should contribute to tooth stability, deflect food to the vestibular or oral embrasures to protect the nonkeratinized gingival col, and prevent food impaction. However, when the level of oral hygiene is good and there is no food impaction, there is no clear relationship between deficient interproximal contacts and periodontal problems.[325] Indeed, the majority of healthy teeth, unless in heavy occlusion, have a slight interproximal gap that will often allow an 8-µm-thick strip of shimstock to pass through the contact.[326] Nevertheless, if the teeth are in contact preoperatively, authorities agree that the new restoration should restore the contact to prevent possible gingival irritation and patient discomfort from food impaction.

Conclusion

Just like the dentition, the periodontium is at risk from specific biofilm-induced destruction; therefore, long-term oral health requires routine effective plaque removal. Errors in diagnosis and treatment planning and iatrogenic problems associated with the restoration of teeth can exacerbate biofilm retention and contribute to inflammation, loss of connective tissue attachment, and loss of bone

Dentlearn.ir

support. A healthy periodontium is essential for the well-being, comfort, and esthetics of the oral structures.

Acknowledgment

The authors wish to thank John Dmytryk, associate dean for academic affairs and professor of periodontics at the University of Oklahoma College of Dentistry, for his review of and assistance with the section on the gingiva.

References

1. Fejerskov O, Thylstrup A. Dental enamel. In: Mjör IA, Fejerskov O (eds). Human Oral Embryology and Histology. Copenhagen: Munksgaard, 1986:5–89.
2. Wainwright WW, Lemoine FA. Rapid diffuse penetration of intact enamel and dentin by carbon 14 labeled urea. J Am Dent Assoc 1950;41:135–145.
3. Featherstone JDB, Ten Cate JM. Physicochemical aspects of fluoride enamel interactions. In: Ekstrand J, Fejerskov O, Silverstone LM (eds). Fluoride in Dentistry. Copenhagen: Munksgaard, 1988:125–149.

5. De Freitas PM, Turssi CP, Hara AT, Serra MC. Dentin microhardness during and after whitening treatments. Quintessence Int 2004;35:411–417.
6. Robinson C, Shore RC, Brookes SJ, Strafford S, Wood SR, Kirkam J. The chemistry of enamel caries. Crit Rev Oral Biol Med 2000;11:481–495.
7. Bertacci A, Chersoni S, Davidson CL, Prati C. In vivo enamel fluid movement. Eur J Oral Sci 2007;115:169–173.
8. Schiavoni RJ, Turssi CP, Rodrigues AL Jr, Serra MC, Pecora JD, Froner IC. Effect of bleaching agents on enamel permeability. Am J Dent 2006;19:313–316.
9. Kuhar M, Cevc P, Schara M, Funduk N. Enhanced permeability of acid-etched or ground dental enamel. J Prosthet Dent 1997;77:578–582.
10. Donly KJ, Stookey GK. Topical fluoride therapy. In: Harris NO, Garcia-Godoy F (eds). Primary Preventive Dentistry, ed 6. Upper Saddle River, NJ: Pearson Prentice Hall, 2004:241–284.
11. Cochrane NJ, Cai F, Huq NL, Burrow MF, Reynolds EC. New approaches to enhanced remineralization of tooth enamel [review]. J Dent Res 2010;89:1187–1197.
12. Nanci A. Enamel: Composition, formation, and structure. In: Nanci A (ed). Ten Cate's Oral Histology: Development, Structure, and Function, ed 6. St Louis: Mosby, 2003:145–191.
13. Muller CFJ, van Wyk CW. The amelo-cemental junction. J Dent Assoc S Afr 1984;39:799–803.
14. Hattab FN, Qudeimat MA, al-Rimawi HS. Dental discoloration: An overview. J Esthet Dent 1999;11:291–310.

recruits. Arch Oral Biol 1974;19:199–202.
16. Ricketts DN, Ekstrand KR, Kidd EA, Larsen T. Relating visual and radiographic ranked scoring systems for occlusal caries detection to histological and microbiological evidence. Oper Dent 2002;27:231–237.
17. Braga MM, Ekstrand KR, Martignon S, Imparato JC, Ricketts DN, Mendes FM. Clinical performance of two visual scoring systems in detecting and assessing activity status of occlusal caries in primary teeth. Caries Res 2010;44:300–308.

Dentlearn.ir

18. Ekstrand KR, Ricketts DN, Kidd EAM. Reproducibility and accuracy of three methods for assessment of demineralization depth on the occlusal surface: An in-vitro examination. Caries Res 1997;31:224–232.
19. Mejare I, Kallest IC, Stenlund H. Incidence and progression of approximal caries from 11 to 22 years of age in Sweden: A prospective radiographic study. Caries Res 1999;33:93–100.
20. Backer Dirks O. Posteruptive changes in dental enamel. J Dent Res 1966;45:503–511.
21. Garcia-Godoy F, Summitt JB, Donly KJ. Caries progression of white spot lesions sealed with unfilled resin. J Clin Pediatr Dent 1997;21:141–143.
22. Reynolds EC, Cai F, Cochrane NJ, et al. Fluoride and casein phosphopeptide-amorphous calcium phosphate. J Dent Res 2008;87:344–348.
23. Fontana M, Zero DT. Assessing patients' caries risk. J Am Dent Assoc 2006;137:1231–1239.
24. Van Amerongen JP, Davidson CL, Opdam NJM, Roeters FJM, Kidd EAM. Restoring the tooth: "The seal is the deal." In: Fejerskov O, Kidd EAM (eds). Dental Caries: The Disease and Its Clinical Management. Oxford: Blackwell Munksgaard, 2003:275–292.
25. Anusavice K. Clinical decision-making for coronal caries management in the permanent dentition. J Dent Educ 2001;65:1143–1146.
26. Hausen H. Benefits of topical fluorides firmly established. Evid Based Dent 2004;5:36–37.
27. Cai F, Shen P, Morgan MV, Reynolds EC. Remineralization of enamel subsurface lesions in situ by sugar-free lozenges containing casein phosphopeptide-amorphous calcium phosphate. Aust Dent J 2003; 48:240–243.
28. Yamagishi K, Onuma K, Suzuki T, et al. Materials chemistry: A synthetic enamel for rapid tooth repair. Nature 2005;433:819.
29. Caldwell RC, Muntz ML, Gilmore RW, Pigman W. Microhardness studies of intact surface enamel. J Dent Res 1957;36:732–738.
30. Lambrechts P, Braem M, Vuylsteke-Wauters M, Vanherle G. Quantitative in vivo wear of human enamel. J Dent Res 1989;68:1752–1754.
31. Christensen GT. Alternatives for Class 2 restorations. Clin Res Assoc Newsletter 1994;18(5):1–3.
32. Profitt WR, Fields Jr HW, Sarver DM. Contemporary Orthodontics, ed 4. St Louis: Mosby, 2007:63–64.
33. Fiorellini JP, Kim DM, Uzel NG. Anatomy of the periodontium. In: Newman MG, Takei HH, Klokkevold PR, Carranza FA (eds). Carranza's Clinical Periodontology, ed 11. St Louis: Elsevier Saunders, 2012:12–27.
34. Listgarten MA, Korostoff J. The development and structure of dental plaque (a bacterial biofilm), calculus, and other tooth-adherent organic materials. In: Harris NO, Garcia-Godoy F (eds). Primary Preventive Dentistry, ed 6. Upper Saddle River, NJ: Pearson Prentice Hall, 2004:23–44.
35. Kaste LM, Selwitz RH, Oldakowski RJ, Brunelle JA, Winn DM, Brown LJ. Coronal caries in the primary and permanent dentition of children and adolescents 1–17 years of age: United States, 1988–1991. J Dent Res 1996;75(special issue):631–641.
36. US Dept Health and Human Services. Oral Health in America: A Report of the Surgeon General. Rockville, MD: US Dept Health and Human Services, National Institute of Dental and Craniofacial Research, National Institutes of Health, 2000.
37. National Center for Health Statistics. Health, United States, 2010: With Special Feature on Death and Dying. Hyattsville, MD: National Center for Health Statistics, 2011:248.
38. Dye BA, Tan S, Smith V, et al. Trends in oral health status: United States, 1988–1994 and 1999–2004. National Center for Health Statistics. Vital Health Stat 11 2007(248):1–92.
39. Gooch BF, Griffin SO, Gray SK, et al. Preventing dental caries through school-based sealant programs: Updated recommendations and reviews of evidence. J Am Dent Assoc 2009;140:1356–1365.
40. Ahovuo-Saloranta A, Hiiri A, Nordblad A, Makela M, Worthington HV. Pit and fissure sealants for preventing dental decay in the permanent teeth of children and adolescents. Cochrane Database Syst Rev 2008; (4):CD001830.

of sealants in managing caries lesions. J Dent Res 2008;87:169–174.
42. Ailor JE Jr. Managing incomplete tooth fractures. J Am Dent Assoc 2000;131:1168–1174.
43. Geurtsen W, Schwarze T, Gunay H. Diagnosis, therapy, and prevention of the cracked tooth syndrome.

Dentlearn.ir

Quintessence Int 2003;34:409–417.
44. Krell KV, Rivera EM. A six year evaluation of cracked teeth diagnosed with reversible pulpitis: Treatment and prognosis. J Endod 2007;33: 1405–1407.
45. Lynch CD, O'Sullivan VR, Dockery P, McGillycuddy CT, Sloan AJ. Hunter-Schreger band patterns in tooth enamel. J Anat 2010;217:106–115.
46. Shimada Y, Tagami J. Effects of regional enamel and prism orientation on resin bonding. Oper Dent 2003;28:20–27.
47. Silverstone LM, Saxton CA, Dogon IL, Fejerskov O. Variation in the pattern of acid etching of human dental
48. Hewlett ER. Resin adhesion to enamel and dentin: A review. J Calif Dent Assoc 2003;31:469–476.
49. Van Meerbeek B, De Munck J, Yoshida Y, et al. Buonocore memorial lecture. Adhesion to enamel and dentin: Current status and future challenges. Oper Dent 2003;28:215–235.
50. Gwinnett AJ, Matsui A. A study of enamel adhesives. The physical relationship between enamel and adhesive. Arch Oral Biol 1967;12:1615–1620.
51. Buonocore MG. The Use of Adhesives in Dentistry. Springfield, IL: Thomas, 1975:75.
52. Munechika T, Suzuki K, Nishiyama M, Ohashi M, Horie K. A comparison of the tensile bond strengths of composite resins to longitudinal and transverse sections of enamel prisms in human teeth. J Dent Res 1984;63:1079–1082.
53. Opdam NJ, Roeters JJ, Kuijs R, Burgersdijk RC. Necessity of bevels for box only Class II composite restorations. Am J Dent 1993;6:85–87.
54. Hilton TJ, Ferracane JL. Cavity preparation factors and microleakage of Class II composite restorations filled at intraoral temperatures. Quintessence Int 2002;33:337–346.
55. Hobson RS, McCabe JF. Relationship between enamel etch characteristics and resin-enamel bond strength. Br Dent J 2002;192:463–468.
56. Giannini M, Soares CJ, de Carvalho RM. Ultimate tensile strength of tooth structures. Dent Mater 2004;20:322–329.
57. Kidd EAM, Toffenetti F, Mjör IA. Secondary caries. Int Dent J 1992;42: 127–138.
58. Zimmerman B, Datko L, Cupelli M, Alapati S, Dean D, Kennedy M. Alteration of dentin-enamel mechanical properties due to dental whitening treatments. J Mech Behav Biomed Mater 2010;3:339–346.
59. da Silva AP, de Oliveira R, Cavalli V, Arrais CA, Giannini M, de Carvalho RM. Effect of peroxide-base bleaching agents on enamel ultimate tensile strength. Oper Dent 2005;30:318–324.
60. Han L, Okamoto A, Fukushima M, Okiji T. Enamel micro-cracks produced around restorations with flowable composites. Dent Mater J 2005;24: 83–91.
61. Kahler B, Swain MV, Kotousov A. Comparison of an analytical expression of resin composite curing stress with in vitro observations of marginal cracking. Am J Dent 2010;23:357–364.
62. Marzouk MA, Simonton AL, Gross RD. Operative Dentistry—Modern Theory and Practice. St Louis: Ishiyaku EuroAmerica, 1985:33–37.
63. Simmelink JW. Histology of enamel. In: Avery JK (ed). Oral Development and Histology. Baltimore: Williams & Wilkins, 1987:140–150.
64. Boyde A. Enamel structure and cavity margins. Oper Dent 1976;1:13–28.
65. He LH, Swain MV. Influence of environment on the mechanical behaviour of mature human enamel. Biomaterials 2007;28:4512–4520.
66. Crabb HS, Darling AI. The gradient of mineralization in developing enamel. Arch Oral Biol 1960;52:118–122.
67. Spears IR, van Noort R, Crompton RH, Cardew GE, Howard IC. The effects of enamel anisotrophy on the distribution of stress in a tooth. J Dent Res 1993;72:1526–1531.
68. Xu C, Yao X, Walker MP, Wang Y. Chemical/molecular structure of the dentin-enamel junction is dependent on the intratooth location. Calcif Tissue Int 2009;84:221–228.
69. Habelitz S, Marshall SJ, Marshall GW, Balooch M. The functional width of the dentino-enamel junction determined by AFM-based nanoscratching. J Struct Biol 2001;135:294–301.

Dentlearn.ir

dentin-enamel junction in human third molars. J Biomed Mater Res 2003;64:372–377.
71. Shimizu D, Macho GA. Functional significance of the microstructural detail of the primate dentino-enamel junction: A possible example of exaptation. J Hum Evol 2007;52:103–111.
72. Brauer DS, Marshall GW, Marshall SJ. Variations in human DEJ scallop size with tooth type. J Dent 2010;38:597–601.

junction of human teeth. J Histochem Cytochem 1993;41:381–388.
74. Zaslansky P, Friesem AA, Weiner S. Structure and mechanical properties of the soft zone separating bulk dentin and enamel in crowns of human teeth: Insight into tooth function. J Struct Biol 2006;153:188–99.
75. Braun S, Bantleon HP, Hnat WP, Freudenthaler JW, Marcotte MR, Johnson BE. A study of bite force, part I: Relationship to various physical characteristics. Angle Orthod 1995;65:367–372.
76. Hoffmann F, Eismann D. The total surface and number of occlusal contacts in static and dynamic occlusion. Bilt Udruz Ortodonata Jugosl 1991;24:71–78.
77. Mondelli J, Steagall L, Ishikiriama A, de Lima Navarro MF, Soares FB. Fracture strength of human teeth with cavity preparations. J Prosthet Dent 1980;43:419–422.
78. Blaser PK, Lund MR, Cochran MA. Effects of designs of Class 2 preparations on resistance of teeth to fracture. Oper Dent 1983;8:6–10.
79. Jordan RE, Abrams L, Kraus BS. Kraus' Dental Anatomy and Occlusion, ed 2. St Louis: Mosby, 1992.
80. Reeh ES, Douglas WH, Messer HH. Stiffness of endodontically treated teeth related to restoration technique. J Dent Res 1989;68:1540–1544.
81. Rees JS, Jagger DC. Abfraction lesions: Myth or reality? J Esthet Restor Dent 2003;15:263–271.
82. Heymann HO, Sturdevant JR, Bayne S, Wilder AD, Sluder TB, Brunson WD. Examining tooth flexure effects on cervical restorations: A two-year clinical study. J Am Dent Assoc 1991;122:41–47.
83. Palamara D, Palamara JE, Tyas ML, Messer HH. Strain patterns in cervical enamel of teeth subjected to occlusal loading. Dent Mater 2000; 16:412–419.
84. el-Mowafy OM. Fracture strength and fracture patterns of maxillary premolars with approximal slot cavities. Oper Dent 1993;18:160–166.
85. Zidan O, Abdel-Keriem U. The effect of amalgam bonding on the stiffness of teeth weakened by cavity preparation. Dent Mater 2003; 19:680–685.
86. Brantley CF, Bader JD, Shugars DA, Nesbit SP. Does the cycle of rerestoration lead to larger restorations? J Am Dent Assoc 1995;126:1407–1413.
87. Burke FJ. From extension for prevention to prevention of extension: (minimal intervention dentistry). Dent Update 2003;30:492–498, 500,502.
88. Tam LE, Noroozi A. Effects of direct and indirect bleach on dentin fracture toughness. J Dent Res 2007;86:1193–1197.
89. Marten A, Fratzl P, Paris O, Zalansky P. On the mineral in collagen of human crown dentine. Biomaterials 2010;31:5479–5490.
90. Garberoglio R, Brännström M. Scanning electron microscopic investigation of human dentinal tubules. Arch Oral Biol 1976;21:355–362.
91. Mjör IA, Sveen OB, Heyeraas KJ. Normal structure and physiology. In: Mjör IA (ed). Pulp-Dentin Biology in Restorative Dentistry. Chicago: Quintessence, 2002:1–22.
92. Miguez PA, Pereira PNR, Atsawasuwan P, Yamauchi M. Collagen cross-linking and ultimate tensile strength in dentin. J Dent Res 2004;83:807.
93. Nanci A. Dentin-pulp complex. In: Nanci A (ed). Ten Cate's Oral Histology: Development, Structure, and Function, ed 6. St Louis: Mosby, 2003:192–239.
94. Pashley DH, Depew DD. Effects of the smear layer, Copalite, and oxalate on microleakage. Oper Dent 1986;11:95–102.
95. Ayad MF. Effects of rotary instrumentation and different etchants on removal of smear layer on human dentin. J Prosthet Dent 2001;85:67–72.
96. Tao L, Pashley DH. Dentin perfusion effects on the shear bond strengths of bonding agents to dentin. Dent

Dentlearn.ir

Mater 1989;5:181–184.
97. De Munck J, Van Landuyt K, Peumans M, et al. A critical review of the durability of adhesion to tooth tissue: Methods and results. J Dent Res 2005;84:118–132.
98. Hashimoto M. A review—Micromorphological evidence of degradation in resin-dentin bonds and potential preventional solutions. J Biomed Mater Res B Appl Biomater 2010;92:268–280.
99. Liu Y, Tjäderhane L, Breschi L, et al. Limitations in bonding to dentin and experimental strategies to prevent bond degradation. J Dent Res 2011;90:953–968.
100. Vongsavan N, Matthews RW, Matthews B. The permeability of human dentine in vitro and in vivo. Arch Oral Biol 2000;45:931–935.
101. Pashley DH, Matthews WG. The effects of outward forced convective flow on inward diffusion in human dentine, in vitro. Arch Oral Biol 1993;38:577–582.
102. Pashley DH, Kepler EE, Williams, EC, Okabe A. Progressive decrease in dentine permeability following cavity preparation. Arch Oral Biol 1983;28:853–858.
103. Love RM. The effect of tissue molecules on bacterial invasion of dentine. Oral Microbiol Immunol 2002;117:32–37.
104. Dai X-F, Ten Cate AR, Limeback H. The extent and distribution of intratubular collagen fibrils in human dentin. Arch Oral Biol 1991;36:775–778.
105. Michelich V, Pashley DH, Whitford GM. Dentin permeability: A comparison of functional versus anatomical tubular radii. J Dent Res 1978; 57:1019–1024.
106. Pashley DH. Dentine permeability and its role in the pathobiology of dentine sensitivity. Arch Oral Biol 1994;39(suppl):73S–80S.
107. Rauchenberger CR. Dentin permeability: The clinical ramifications. Dent Clin North Am 1992;36:527–542.
108. Richardson DW, Tao L, Pashley DH. Dentin permeability: Effects of crown preparation. Int J Prosthodont 1991;4:219–225.
109. Mjör IA. Frequency of secondary caries at various anatomical locations. Oper Dent 1985;10:88–92.
110. Pashley DH, Andringa HJ, Derkson GD, Derkson ME, Kalathoor SR. Regional variability in the permeability of human dentine. Arch Oral Biol 1987;32:519–523.
111. Bergenholtz G, Cox CF, Loesche WJ, Syed SA. Bacterial leakage around dental restorations: Its effect on the dental pulp. J Oral Pathol 1982; 11:439–450.
112. Bergenholtz G. Evidence for bacterial causation of adverse pulpal responses in resin-based dental restorations. Crit Rev Oral Biol Med 2000;11:467–480.
113. Hilton TJ. Can modern restorative procedures and materials reliably seal cavities? In vitro investigations: Part 1. Am J Dent 2002;15:198–210.
114. Fruits TJ, Knapp JA, Khajotia SS. Microleakage in the proximal walls of direct and indirect posterior resin slot restorations. Oper Dent 2006; 31:719–727.
115. Mjör IA, Moorhead JE, Dahl JF. Reasons for replacement of restorations in permanent teeth in general dental practice. Int Dent J 2000;50:361–366.
116. Piesco NP. Histology of dentin. In: Avery JK, Steele PF (eds). Oral Development and Histology, ed 3. New York: Thieme, 2002:172–189.
117. Langeland K. Tissue response to dental caries. Endod Dent Traumatol 1987;3:149–171.
118. Garant PR. Oral Cells and Tissues. Chicago: Quintessence, 2003.
119. Pashley DH. Dentin: A dynamic substrate—A review. Scanning Microsc 1989;3:161–176.
120. Smith AJ, Matthews JB, Hall RC. Transforming growth factor-β1 (TGF-β1) in dentine matrix. Ligand activation and receptor expression. Eur J Oral Sci 1998;106(suppl 1):179–184.
121. Chappell RP, Cobb CM, Spencer P, Eick JD. Dentine tubule anastomosis: A potential factor in adhesive bonding. J Prosthet Dent 1994;72: 183–188.
122. Hashimoto M, Ohno H, Kaga M, Endo K. Sano H, Oguchi H. In vivo degradation of resin-dentin bonds in humans over 1 to 3 years. J Dent Res 2000;79;1385–1391.
123. Ito S, Hashimoto M, Wadgaonkar B, et al. Effects of resin hydrophilicity on water sorption and changes in modulus of elasticity. Biomaterials 2005;26:6449–6459.

Dentlearn.ir

124. Pashley DH, Tay FR, Yiu C, et al. Collagen degradation by host-derived enzymes during aging. J Dent Res 2004;83:216–221.
125. Tay FR, Pashley DH, Loushine RJ, Weller RN, Monticelli F, Osorio R. Self-etching adhesives increase collagenolytic activity in radicular dentin. J Endod 2006;32:862–868.
126. Breschi L, Martin P, Mazzoni A, et al. Use of a specific MMP-inhibitor (galardin) for preservation of hybrid layer. Dent Mater 2010;26;571–578.
127. Tay FR, Pashley DH. Biomimetic remineralization of resin-bonded acid etched dentin. J Dent Res 2009;88:719–724.
128. Wisithphrom K, Murray PE, About I, Windsor LJ. Interactions between cavity preparation and restoration events and their effects on pulp vitality. Int J Periodontics Restorative Dent 2006;26:596–605.
129. Goodis HE, Pashley D, Staabholtz A. Pulpal effects of thermal and mechanical irritants. In: Hargreaves KM, Goodis HE (eds). Selzer and Bender's Dental Pulp. Chicago: Quintessence, 2002:371–388.
130. Mjör IA, Nordahl I. The density and branching of dentinal tubules in human teeth. Arch Oral Biol 1996;41:401–412.
131. Mjör IA. Initial reactions to tooth preparation. In: Mjör IA (ed). Pulp-Dentin Biology in Restorative Dentistry. Chicago: Quintessence, 2002: 23–37.
132. Fosse F, Saele PK, Eide R. Numerical density and distribution pattern of dentin tubules. Acta Odontol Scand 1992;50:201–210.
133. Pashley DH, Pashley EL, Carvalho RM, Tay FR. The effects of dentin permeability on restorative dentistry. Dent Clin North Am 2002;46:211–245.
134. Pashley DH. Dynamics of the pulpo-dentin complex. Crit Rev Oral Biol Med 1996;7:104–133.
135. Gwinnett AJ. Dentin bond strength after drying and rewetting. Am J Dent 1994;7:144–148.
136. Perdigão J. Dentin bonding—Variables related to the clinical situation and the substrate treatment. Dent Mater 2010;26(2):e24–e37.
137. Tay F, Gwinnett A, Wei S. The overwet phenomenon: A scanning electron microscopic study of surface moisture in the acid-conditioned, resindentin interface. Am J Dent 1996;9:109–114.
138. Moll K, Haller B. Effect of intrinsic and extrinsic moisture on bond strength to dentin. J Oral Rehabil 2000;27:150–165.
139. Mjör IA, Odont D. Pulp-dentin biology in restorative dentistry. Part 2: Initial reactions to preparation of teeth for restorative procedures. Quintessence Int 2001;32:537–551.
140. Bjørndal L, Mjör IA. Dental caries: Characteristics of lesions and pulpal reactions. In: Mjör IA (ed). Pulp-Dentin Biology in Restorative Dentistry. Chicago: Quintessence, 2002:55–75.
141. Bjørndal L, Thylstrup A. A structural analysis of approximal enamel caries lesions and subjacent dentin reactions. Eur J Oral Sci 1995;103:25–31.
142. Bjørndal L, Darvann T, Thylstrup A. A quantitative light microscopic study of the odontoblast and subodontoblastic reactions to active and arrested enamel caries without cavitation. Caries Res 1998;31:59–69.
143. Ten Cate JM, Larsen MJ, Pearch IEF, Fejerskov O. Chemical interactions between the tooth and oral fluids. In: Fejerskov O, Kidd EAM (eds). Dental Caries: The Disease and Its Clinical Management. Oxford: Blackwell Munksgaard, 2003:49–70.
144. Fejerskov O, Nyvad B, Kidd EAM. Clinical and histological manifestations of dental caries. In: Fejerskov O, Kidd EAM (eds). Dental Caries: The Disease and Its Clinical Management. Oxford: Blackwell Munksgaard, 2003:71–98.
145. Helfenstein U, Steiner J. Fluoride varnishes (Duraphat): A meta-analysis. Community Dent Oral Epidemiol 1994;22:1–5.
146. Maltz M, de Oliveira D, Fontanella V, Bianchi R. A clinical, microbiologic, and radiographic study of deep caries lesions after incomplete caries removal. Quintessence Int 2002;33:151–159.
147. Fusayama T. Two layers of carious dentin: Diagnosis and treatment. Oper Dent 1979;4:63–70.
148. Love RM, Jenkinson HF. Invasion of dentinal tubules by oral bacteria. Crit Rev Oral Biol Med 2002;3:171–183.
149. Mertz-Fairhurst EJ, Curtis JW Jr, Ergle JW, Rueggeberg FA, Adair SM. Ultraconservative and cariostatic

Dentlearn.ir

sealed restorations: Results at year 10. J Am Dent Assoc 1998;129:55–66.
150. Kidd EAM. How 'clean' must a cavity be before restoration? Caries Res 2004;38:306–313.
151. Bonecker M, Grossman G, Cleaton-Jones PE, Parak R. Clinical, histological and microbiological study of hand-excavated carious dentine in extracted permanent teeth. SADJ 2003;58:273–278.
152. Nakajima M, Sano H, Zhang L, Tagami J, Pashley DH. Effect of moist vs dry bonding to normal vs caries-affected dentin with Scotchbond Multi-Purpose Plus. J Dent Res 1999;78:1298–1303.
153. Arrais CA, Giannini M, Nakajima M, Tagami J. Effects of additional and extended acid etching on bonding to caries-affected dentine. Eur J Oral Sci 2004;112:458–464.
154. Yoshiyama Y, Tay FR, Toru Y, et al. Resin adhesion to carious dentin. Am J Dent 2003;16:47–52.
155. Wei S, Sadr A, Shimada Y, Tagami J. Effect of caries-affected dentin hardness on the shear bond strength of current adhesives. J Adhes Dent 2008;10:431–440.
156. El-din AK, Miller BH, Griggs JA. Resin bonding to sclerotic, noncarious, cervical lesions. Quintessence Int 2004;35:529–540.
157. Yoshiyama M, Masada J, Uchida A, Ishida H. Scanning electron microscopic characterization of sensitive vs. insensitive human radicular dentin. J Dent Res 1989;68:1498–1502.
158. Tay FR, Pashley DH. Resin bonding to cervical sclerotic dentin: A review. J Dent 2004;32:173–196.
159. Kwong SM, Cheung GS, Kei LH, et al. Micro-tensile bond strengths to sclerotic dentin using a self-etching and a total-etching technique. Dent Mater 2002;18:359–369.
160. van Dijken JWD. A prospective 8-year evaluation of a mild two-step self-etching adhesive and a heavily filled two-step etch-and-rinse system in non-carious cervical lesions. Dent Mater 2010;26:940–946.
161. Lopes GC, Baratieri CM, Baratieri LN, Monteiro S Jr, Carkoso Vieira LC. Bonding to cervical sclerotic dentin: Effect of acid etching time. J Adhes Dent 2004;6:19–23.
162. Torneck CD. Dentin-pulp complex. In: Ten Cate AR (ed). Oral Histology: Development, Structure, and Function, ed 4. St Louis: Mosby Year-Book, 1994:169–217.
163. Shimizu C, Yamashita Y, Ichigo T, Fusayama T. Carious change of dentin observed on longspan ultrathin sections. J Dent Res 1981;60:1826–1831.
164. Yagi T, Suga S. SEM investigations on the human sclerosed dentinal tubules [in Japanese]. Shigaku 1990;78:313–337.
165. Stanley HR, Pereira JC, Spiegel E, Broom C, Schultz M. The detection and prevalence of reactive and physiologic sclerotic dentin, reparative dentin and dead tracts beneath various types of dental lesions according to tooth surface and age. J Oral Pathol 1983;12:257–289.
166. Kim S, Trowbridge HO. Pulpal reaction to caries and dental procedures. In: Cohen S, Burns RC (eds). Pathways of the Pulp, ed 7. St Louis: Mosby, 1998:532–551.
167. Tagami J, Hosoda H, Burrow MF, Nakajima M. Effect of aging and caries on dentin permeability. Proc Finn Dent Soc 1992;88(suppl 1):149–154.
168. Trowbridge HO. Histology of pulpal inflammation. In: Hargreaves KM, Goodis H (eds). Seltzer and Bender's Dental Pulp. Chicago: Quintessence, 2002:227–246.
169. Trowbridge HO. Pulp biology: Progress during the past 25 years. Aust Endod J 2003;29:5–12.
170. Magloire H, Joffre A, Couble ML, Chavrier C, Dumont J. Ultrastructural alterations of human odontoblasts and collagen fibres in the pulpal border zone beneath early caries lesions. Cell Mol Biol Incl Cyto Enzymol 1981;27:437–443.
171. Bjørndal L, Darvann T. A light microscopic study of odontoblastic and non-odontoblastic cells involved in tertiary dentinogenesis in well-defined cavitated carious lesions. Caries Res 1999;33:500–560.
172. Bjørndal L. Presence or absence of tertiary dentinogenesis in relation to caries progression. Adv Dent Res 2001;15:80–83.
173. Bjørndal L, Mjör IA. Pulp-dentin biology in restorative dentistry. Part 4. Dental caries—Characteristics of lesions and pulpal reactions. Quintessence Int 2001;32:717–736.
174. Murray PE, About I, Lumley PJ, Franquin JC, Remusat M, Smith AJ. Cavity remaining dentin thickness and pulpal activity. Am J Dent 2002;15:41–48.
175. Tecles O, Laurent P, Zygouritsas S, et al. Activation of human dental pulp progenitor/stem cells in response

Dentlearn.ir

to odontoblast injury. Arch Oral Biol 2005;50:103–108.
176. Lee Y-L, Liu J, Clarkson BH, Lin C-P, Godovikova V, Ritchie HH. Dentinpulpal complex responses to carious lesions. Caries Res 2006;40:256–264.
177. Stanley HR, White CL, McCray L. The rate of tertiary (reparative) dentine formation in the human tooth. Oral Surg Oral Med Oral Pathol 1966;21:180–189.
178. Cox CF, Bogen G, Koper HM, Ruby JD. Repair of pulpal injury by dental materials. In: Hargreaves KM, Goodis HE (eds). Seltzer and Bender's Dental Pulp. Chicago: Quintessence, 2002:325–344.
179. Mjör IA, Ferrari M. Reactions to restorative materials, tooth-restoration interfaces, and adhesive techniques. In: Mjör IA (ed). Pulp-Dentin Biology in Restorative Dentistry. Chicago: Quintessence, 2002:101–103.
180. Izumi T, Inoue H, Matsuura H, et al. Changes in the pattern of horseradish peroxidase diffusion into predentin and dentin after cavity preparation in rat molars. Oral Surg Oral Med Oral Pathol Oral Radiol Endod 2001;92:675–681.
181. Tziafas D, Smith AJ, Lesot H. Designing new treatment strategies in vital pulp therapy. J Dent 2000;28:77–92.
182. Sloan AJ, Matthews JB, Smith AJ. TGF-β receptor expression in human odontoblasts and pulpal cells. Histochem J 1999;31:565–569.
183. Iohara K, Nakashima M, Ito M, Ishikawa M, Nakasima A, Akamine A. Dentin regeneration by dental pulp stem cell therapy with recombinant human bone morphogenetic protein 2. J Dent Res 2004;83:590–595.
184. Cassidy N, Fahey M, Prime SS, Smith AJ. Comparative analysis of transforming growth factor-β isoforms 1–3 in human and rabbit dentine matrices. Arch Oral Biol 1997;42:219–223.
185. D'Souza RN, Cavender A, Dickinson D, Roberts A, Letterio J. TGF-β1 is essential for the homeostasis of the dentin-pulp complex. Eur J Oral Sci 1998;106:185–191.
186. Smith AJ, Tobias RS, Cassidy N, et al. Odontoblast stimulation in ferrets by dentine matrix components. Arch Oral Biol 1994;39:13–22.
187. Smith AJ. Pulpal responses to caries and dental repair. Caries Res 2002;36:223–232.
188. Ferracane JL, Cooper PR, Smith AJ. Can interaction of materials with the dentin-pulp complex contribute to dentin regeneration? Odontology 2010;98:2–14.
189. Tziafas D, Alvanou A, Panagiotakopoulos N, et al. Induction of odontoblast-like cell differentiation in dog dental pulps after in vivo implantation of dentine matrix components. Arch Oral Biol 1995;40:883–893.
190. Zhang W, Walboomers XF, Jansen JA. The formation of tertiary dentin after pulp capping with a calcium phosphate cement, loaded with PLGA microparticles containing TGF-β1. J Biomed Mater Res A 2008; 85:439–444.
191. Goracci G, Mori G, Baldi M. Terminal end of the human odontoblast process: A study using SEM and

192. Brännström M, Aström A. The hydrodynamics of the dentine: The possible relationship to dental pain. Int Dent J 1972;22:219–227.

to human odontoblasts: Possible role in tooth pain transmission. J Biol Chem 2006;281:29002–29010.
194. Magloire H, Couble ML, Thivichon-Prince B, Maurin JC, Bleicher F. Odontoblast: A mechano-sensory cell. J Exp Zool B Dev Evol 2009; 312B:416–424.
195. Brännström M, Johnson G, Linden LA. Fluid flow and pain response in the dentin produced by hydrostatic pressure. Odontol Rev 1969;20: 15–16.
196. Byers MR, Närhi MV. Nerve supply of the pulpodentin complex and responses to injury. In: Hargreaves KM, Goodis H (eds). Seltzer and Bender's Dental Pulp. Chicago: Quintessence, 2002:151–179.
197. Andrew D, Matthews B. Displacement of the contents of dentinal tubules and sensory transduction in intradental nerves of the cat. J Physiol 2000;529(part 3):791–802.
198. Trowbridge HO. Intradental sensory units: Physiological and clinical aspects. J Endod 1985;11:489–498.
199. Alavi AM, Dubyak GR, Burnstock G. Immunohistochemical evidence for ATP receptors in human dental pulp. J Dent Res 2001;80:476–483.
200. Ahlquist M, Franzein O, Coffey J, Pashley D. Dental pain evoked by hydrostatic pressures applied to

Dentlearn.ir

exposed dentin in man: A test of the hydrodynamic theory of dental sensitivity. J Endod 1994;20:130–137.
201. Cuenin MF, Scheidt MJ, O'Neal RB, et al. An in vivo study of dentin sensitivity: The relation of dentin sensitivity and the patency of dentin tubules. J Periodontol 1991;62:668–673.
202. Kolker JL, Vargas MA, Armstrong SR, Dawson DV. Effect of desensitizing agents on dentin permeability and dentin tubule occlusion. J Adhes Dent 2002;4:211–221.
203. Ozen T, Orhan K, Avsever H, Tunca YM, Ulker AE, Akyol M. Dentin hypersensitivity: A randomized clinical comparison of three different agents in a short-term treatment period. Oper Dent 2009;34:392–398.
204. Yu X, Liang B, Jin X, Fu B, Hannig M. Comparative in vivo study on the desensitizing efficacy of dentin desensitizers and one-bottle self-etching adhesives. Oper Dent 2010;35:279–286.
205. Heyeraas KJ, Sveen OB, Mjör IA. Pulpal inflammation and its sequelae. In: Mjör IA (ed). Pulp-Dentin Biology in Restorative Dentistry. Chicago: Quintessence, 2002:39–54.
206. Okiji T. Pulp as a connective tissue. In: Hargreaves KM, Goodis H (eds). Seltzer and Bender's Dental Pulp. Chicago: Quintessence, 2002:95–122.
207. Linde A. Dentin mineralization and the role of odontoblasts in calcium transport. Connect Tissue Res 1995;33:169–179.
208. Sasaki T, Nakagawa K, Higashi S. Ultrastructure of odontoblasts in kitten tooth germs as revealed by freeze-fracture. Arch Oral Biol 1982; 27:897–904.
209. Bishop MA, Yoshida S. A permeability barrier to lanthanum and the presence of collagen between odontoblasts in pig molars. J Anat 1992;181:29–38.
210. Brännström M. Communication between the oral cavity and the dental pulp associated with restorative treatment. Oper Dent 1984;9:57–68.
211. Turner DF, Marfurt CF, Sattleberg C. Demonstration of physiological barrier between pulpal odontoblasts and its perturbation following routine restorative procedures: Horseradish peroxidase tracing study in the rat. J Dent Res 1989;68:1262–1268.
212. Smith AJ. Questions and controversies. In: Nanci A, Ten Cate AR (eds). Ten Cate's Oral Histology: Development, Structure, and Function, ed 6. St Louis: Mosby, 2003:192–239.
213. Sakurai K, Okiji T, Suda H. Co-increase of nerve fibers and HLA-DR and/ or factor-XIIIa-expressing dendritic cells in dentinal caries-affected regions of the human dental pulp: An immunohistochemical study. J Dent Res 1999;78:1596–1608.
214. Ohshima H, Nakakura-Ohshima K, Takeuchi K, Hoshino M, Takano Y, Maeda T. Pulpal regeneration after cavity preparation, with special reference to close spatio-relationships between odontoblasts and immunocompetent cells. Microsc Res Tech 2003;60:483–490.
215. Jontell M, Okiji T, Dahlgren U, Bergenholtz G. Immune defense mechanisms of the dental pulp. Crit Rev Oral Biol Med 1998;9:179–200.
216. Reeves R, Stanley HR. The relationship of bacterial penetration and pulpal pathosis in carious teeth. Oral Surg Oral Med Oral Pathol 1966; 22:59–65.
217. Suda H, Ikeda H. The circulation of the pulp. In: Hargreaves KM, Goodis HE (eds). Seltzer and Bender's Dental Pulp. Chicago: Quintessence, 2002:123–150.
218. Oehmke MJ, Knolle E, Oehmke HJ. Lymph drainage in the human dental pulp. Microsc Res Tech 2003;62:187–191.
219. Berggreen E, Haug SR, Mkony LE, Bletsa A. Characterization of the dental lymphatic system and identification of cells immunopositive to specific lymphatic markers. Eur J Oral Sci 2009;117:34–42.
220. Gerli R, Secciani I, Sozio F, Rossi A, Weber E, Lorenzini G. Absence of lymphatic vessels in human dental pulp: A morphological study. Eur J Oral Sci 2010;118:110–117.
221. Pashley DH. The influence of dentin permeability and pulpal blood flow on pulpal solute concentrations. J Endod 1979;5:355–361.
222. Kim S. Ligamental injection: A physiological explanation of its efficacy. J Endod 1986;12:486–491.
223. Stenvik A, Iverson J, Mjör IA. Tissue pressure and histology of normal and inflamed tooth pulps in Macaque monkeys. Arch Oral Biol 1972; 17:1501–1511.
224. Takahashi K, Kishi Y, Kim S. A scanning electron microscope study of the blood vessels of dog pulp using

Dentlearn.ir

corrosion resin casts. J Endod 1982;8:131–135.
225. Heyeraas KJ. Interstitial fluid pressure and transmicrovascular fluid flow. In: Inoki R, Judo T, Olgart L (eds). Dynamic Aspects of Dental Pulp. London: Chapman and Hall, 1990:189–198.
226. Tonder KJ, Kvinnsland I. Micropuncture measurement of interstitial tissue pressure in normal and inflamed dental pulp in cats. J Endod 1983;9:105–109.
227. Gerzina TMO, Hume WR. Effect of hydrostatic pressure on the diffusion of monomers through dentin in vitro. J Dent Res 1995;74:369–373.
228. Pashley DH, Matthews WG. The effect of outward forced convective flow on inward diffusion in human dentine in vitro. Arch Oral Biol 1993;38:577–582.
229. Nair PN. Neural elements in dental pulp and dentin. Oral Surg Oral Med Oral Pathol Oral Radiol Endod 1995;80:710–719.
230. Nair PNR, Luder HU, Schroeder HE. The number and size spectra of myelinated nerves in human premolars. Anat Embryol 1992;92:123–128.
231. Johnsen DC, Harshabarger J, Rymer HD. Quantitative assessment of neural development in human premolars. Anat Rec 1983;205:431–439.
232. Byers MR. Dental sensory receptors. Int Rev Neurobiol 1984;25:39–94.
233. Narhi M, Hirvonen TK, Hakamura M. Responses of intradental nerve fibers to stimulation of dentin and pulp. Acta Physiol Scand 1982; 115:173–178.
234. Närhi M, Virtanen A, Huopaniemi T, Hirvonen T. Conduction velocities of single pulp nerve fiber units in the cat. Acta Physiol Scand 1982; 116:209–213.
235. Figdor D. Aspects of dentinal and pulpal pain. Pain of dentinal and pulpal origin—A review for the clinician. Ann R Australas Coll Dent Surg 1994;12:131–142.
236. Nair PNR, Schroeder HE. Number and size-spectra of non-myelinated axons of human premolars. Anat Embryol 1995;192:35–41.
237. Edwall L, Scott D Jr. Influence of changes in microcirculation on the excitability of the sensory unit in the tooth of the cat. Acta Physiol Scand 1971;82:555–566.
238. Torebjörk HE, Hallin RG. Perceptual changes accompanying controlled preferential blocking of A and C fiber responses in intact human skin nerves. Exp Brain Res 1973;16:321–332.
239. Byers MR, Wheeler EF, Bothwell M. Altered expression of NGF and P75 NGF-receptor by fibroblasts of injured teeth precedes sensory nerve sprouting. Growth Factors 1992;6:41–52.
240. Gazelius B, Edwall B, Olgart L, Lundberg JM, Hokfelt T, Fischer JA. Vasodilatory effects and coexistence of calcitonin gene-related peptide (CGRP) and substance P in sensory nerves of cat dental pulp. Acta Physiol Scand 1987;130:33–40.
241. Olgart L. Neural control of pulpal blood flow. Crit Rev Oral Biol 1996; 7:159–171.
242. Byers MO, Taylor PE. Effect of sensory denervation on the response of rat molar pulp to exposure injury. J Dent Res 1993;72:613–618.
243. Andrew D, Matthews B. Some properties of vasodilatory nerves innervating tooth pulp in the cat. In: Shimono M, Maeda T, Suda H, Takahashi K (eds). Dentin/Pulp Complex. Tokyo: Quintessence, 1996:254–257.
244. Cox CF. Biocompatibility of dental materials in the absence of bacterial infection. Oper Dent 1987;12:146–152.
245. Mjör IA. Pulp-dentin biology in restorative dentistry. Part 7: The exposed pulp. Quintessence Int 2002;33:113–135.
246. Mjör IA, Ferrari M. Pulp-dentin biology in restorative dentistry. Part 6: Reactions to restorative materials, tooth restoration interfaces, and adhesive techniques. Quintessence Int 2002;33:35–63.
247. Murray PE, Lumley PJ, Smith AJ. Preserving the vital pulp in operative dentistry: 2. Guidelines for successful restoration of unexposed dentinal lesions. Dent Update 2002;29:127–134.
248. Murray PE, Smith AJ, Windsor LJ, Mjör IA. Remaining dentine thickness and human pulp responses. Int Endod J 2003;36:33–43.
249. Zach L, Cohen G. Pulp response to externally applied heat. Oral Surg Oral Med Oral Pathol 1965;19:515–530.

Dentlearn.ir

250. Ozturk B, Usumez A, Ozturk AN, Ozer F. In vitro assessment of temperature change in the pulp chamber during cavity preparation. J Prosthet Dent 2004;9:436–440.
251. Lockard MW. A retrospective study of pulpal response in vital adult teeth prepared for complete coverage restorations at ultrahigh speed using only air coolant. J Prosthet Dent 2002;88:473–478.
252. Seltzer S, Bender IB. Early human pulp reactions to full crown preparations. J Am Dent Assoc 1959;59:915–930.
253. Swerdlow H, Stanley H Jr. Reaction of human dental pulp to cavity preparation. 2. At 150,000 rpm with air-water spray. J Prosthet Dent 1959;9:121–131.
254. Hamid A, Hume WR. The effect of dentine thickness on diffusion of resin monomers in vitro. J Oral Rehabil 1997;24:20–25.
255. Lanza CRM, de Souza Costa CA, Furlan M, Alecio A, Hebling J. Transdentinal diffusion and cytotoxicity of self-etching adhesive systems. Cell Biol Toxicol 2009;25:533–543.
256. Spagnuolo G, D'Anto V, Valletta R, et al. Effect of 2-hydroxyethyl methacrylate on human pulp cell survival pathways ERK and AKT. J Endod 2008;34:684–688.
257. Mantellini MG, Botero TM, Yaman P, Dennison JB, Hanks CT, Nor JE. Adhesive resin induces apoptosis and cell-cycle arrest of pulp cells. J Dent Res 2003;82:592–596.
258. Koliniotou-Koumpia E, Papadimitriou S. Pulpal responses after application of current adhesive systems to deep cavities. Clin Oral Investig 2007;11:313–320.
259. Costa CAS, Oliveira MF, Giro EM, Hebling J. Biocompatibility of resin-based materials used as pulp capping agents. Int Endod J 2003;36:831–839.
260. Pameijer CH, Stanley HR. Pulp reaction to a dentin bonding agent. Am J Dent 1995;8:140–144.
261. Seelbach P, Finger WJ, Ferger P, Balkenhol M. Temperature rise on dentin caused by temporary crown and fixed partial denture materials: Influencing factors. J Dent 2010;38:964–973.
262. Costa CAS, Riehl H, Kin JF, Sacono NT, Hebling J. Human pulp responses to in-office tooth bleaching. Oral Surg Oral Med Oral Pathol Oral Radiol Endod 2010;109:e59–e64.
263. Park SH, Roulet JF, Heintze SD. Parameters influencing increase in pulp chamber temperature with light-curing devices: Curing lights and pulpal flow rates. Oper Dent 2010;35:353–361.
264. Jakubinek MB, O'Neill C, Felix C, Price RB, White MA. Temperature excursions at the pulp-dentin junction during the curing of light-activated dental restorations. Dent Mater 2008;24:1468–1476.
265. Freid K. Changes in pulpal nerves with aging. Proc Finn Dent Soc 1992;88(suppl 1):517–528.
266. Volponi AA, Pang Y, Sharpe PT. Stem cell-based biological tooth repair and regeneration. Trends Cell Biol 2010;20:715–722.
267. Nam H, Lee G. Identification of novel epithelial stem cell-like cells in human deciduous dental pulp. Biochem Biophys Res Commun 2009;386:135–139.
268. Kim JY, Xin X, Moioli EK, et al. Regeneration of dental-pulp-like tissue by chemotaxis-induced cell homing. Tissue Eng Part A 2010;16:3023–3031.
269. Huang GTJ, Yamaza T, Shea LD, et al. Stem/progenitor cell-mediated de novo regeneration of dental pulp with newly deposited continuous layer of dentin in an in vivo model. Tissue Eng Part A 2010;16:605–615.
270. Duailibi SE, Duailibi MT, Zhang W, Asrican R, Vacanti JP, Yelick PC. Bio-engineered dental tissues grown in the rat jaw. J Dent Res 2008;87:745–750.
271. Kim K, Lee CH, Kim BK, Mao JJ. Anatomically shaped tooth and periodontal regeneration by cell homing. J Dent Res 2010;89:842–847.
272. Yu J, Shi J, Jin Y. Current approaches and challenges in making a bio-tooth. Tissue Eng Part B Rev 2008;14:307–319.
273. Goldberg M, Lacerda-Pinheiro S, Jegat N, et al. The impact of bioactive molecules to stimulate tooth repair and regeneration as part of restorative dentistry. Dent Clin North Am 2006;50:277–298.
274. Mizuno H, Hata K-I, Kojima K, Bonassar LJ, Vacanti CA, Ueda M. A novel approach to regenerating periodontal tissue by grafting autologous cultured periosteum. Tissue Eng 2006;12:1227–1235.
275. Gay IC, Chen S, MacDougall M. Isolation and characterization of multipotent human periodontal ligament stem cells. Orthod Craniofac Res 2007;10:149–160.

Dentlearn.ir

276. Sonoyama W, Liu Y, Fang D, et al. Mesenchymal stem cell-mediated functional tooth regeneration in swine [epub 20 Dec 2006]. PLoS One 2006;1:e79.
277. Gault P, Black A, Romette J-L, et al. Tissue engineered ligament: Implant constructs for tooth replacement. J Clin Periodontol 2010; 37:750–758.
278. Lindhe H, Karring T, Araújo M. Anatomy of the periodontium. In: Lindhe J, Karring T, Lang N (eds). Clinical Periodontology and Implant Dentistry, ed 4. Oxford: Blackwell, 2003:327.
279. Holmstrup P. Anatomy of the periodontium. In: Wilson TG, Kornman KS (eds). Fundamentals of Periodontics, ed 2. Chicago: Quintessence, 2003:21–38.
280. Eke PI, Dye BA, Wei L, Thornton-Evans GO, Genco RJ. Prevalence of periodontitis in adults in the United States: 2009 and 2010. J Dent Res 2012;9:914–920.
281. Kornman KS. The pathogenesis of periodontitis. In: Wilson TG, Kornman KS (eds). Fundamentals of Periodontics, ed 2. Chicago: Quintessence, 2003:3–12.
282. Hillman JD, Brooks TA, Michalek SM, Harmon CC, Snoep JL, van der Weijden CC. Construction and characterization of an effector strain of *Streptococcus mutans* for replacement therapy of dental caries. Infect Immun 2000;68:543–549.
283. Tagg JR, Dierksen KP. Bacterial replacement therapy: Adapting "germ warfare" to infection prevention. Trends Biotechnol 2003;21:217–223.
284. Petersilka GJ, Ehmke B, Flemmig TF. Antimicrobial effects of mechanical debridement. Periodontol 2000 2002;28:56–71.
285. Ower P. The role of self-administered plaque control in the management of periodontal diseases: I. A review of the evidence. Dent Update 2003;30:60–68.
286. Chapple ILC, Gilbert AD. Understanding Periodontal Diseases: Assessment and Diagnostic Procedures in Practice. London: Quintessence, 2002:4–5.
287. Lang NP, Löe H. The relationship between the width of keratinized gingiva and gingival health. J Periodontol 1972;43:623–627.
288. Maynard JG Jr, Wilson RDK. Physiologic dimensions of the periodontium significant to the restorative dentist. Periodontol 1979;50:170–174.
289. Stetler KJ, Bissada NF. Significance of the width of keratinized gingiva on the periodontal status of teeth with submarginal restorations. J Periodontol 1987;58:696–700.
290. Koke U, Sander C, Heinecke A, Müller H. A possible influence of gingival dimensions on attachment loss and gingival recession following placement of artificial crowns. Int J Periodontics Restorative Dent 2003;23:439–445.
291. Wilson TG, Magnusson I. Examination of patients to detect periodontal diseases. In: Wilson TG, Kornman KS (eds). Fundamentals of Periodontics, ed 2. Chicago: Quintessence, 2003:255–257.
292. Vacek JS, Gher ME, Assad DA, Richardson AC, Giambarresi LI. The dimensions of the human dentogingival junction. Int J Periodontics Restorative Dent 1994;14:155–165.
293. Gargiulo AW, Wentz FM, Orban B. Dimensions and relations of the dentogingival junction in humans. J Periodontol 1961;32:261–267.
294. Kois JC. Altering gingival levels: The restorative connection. Part 1: Biologic variables. J Esthet Dent 1994;6:3–9.
295. Kois JC. New paradigms for anterior tooth preparation. Rationale and technique. Oral Health 1998;88:19–22,25–27,29–30.
296. Silness J. Periodontal conditions in patients treated with dental bridges. 2. The influence of full and partial crowns on plaque accumulation, development of gingivitis, and pocket formation. J Periodontal Res 1970;5:219–224.
297. Newcomb GM. The relationship between the location of subgingival crown margins and gingival inflammation. J Periodontol 1974;45:151–154.
298. Flores-de-Jacoby L, Zafiropoulos GG, Ciancis S. The effect of crown margin location on plaque and periodontal health. Int J Periodontics Restorative Dent 1989;9:197–205.
299. Reitemeier B, Hansel K, Walter MH, Kastner C, Toutenburg H. Effect of posterior crown margin

Dentlearn.ir

placement on gingival health. J Prosthet Dent 2002;87:167–172.
300. Kois JC. The restorative-periodontal interface: Biological parameters. Periodontol 2000 1996;11:29–38.
301. Tarnow DP, Magner AW, Fletcher P. The effect of the distance from the contact point to the crest of bone on the presence or absence of the interproximal dental papilla. J Periodontol 1992;63:995–996.
302. Loughlin DM, Glover ME, Loughlin RM. Clinical crown lengthening. In: Wilson GW, Kornman KS (eds). Fundamentals of Periodontics, ed 2. Chicago: Quintessence, 2003:406–427.
303. Tal H, Soldinger M, Dreiangel A, Pitaru S. Periodontal response to long-term abuse of the gingival attachment by supracrestal amalgam restorations. J Clin Periodontol 1989;16:654–659.
304. Günay H, Seeger A, Tschernitschek H, Geurtsen W. Placement of the preparation line and periodontal health—A prospective 2-year clinical study. Int J Periodontics Restorative Dent 2000;20:173–181.
305. Padbury A Jr, Eber R, Wang H-L. Interactions between the gingiva and the margin of restorations. J Clin Periodontol 2003;30:379–385.
306. Broadbent JM, Williams KB, Thomson WM, Williams SM. Dental restorations: A risk factor for periodontal attachment loss? J Clin Periodontol 2006;33:803–810.
307. Rosenstiel SF, Land MF, Jujimoto J. Contemporary Fixed Prosthodontics, ed 3. St Louis: Mosby, 2001:174.
308. Felton DA, Kanoy BE, Bayne MS, Wirthman GP. Effect of in vivo crown margin discrepancies on periodontal health. J Prosthet Dent 1991; 65:357–364.
309. Sorensen SE, Larsen IM, Jörgensen KD. Gingival and alveolar bone reaction to marginal fit of subgingival crown margins. Scand J Dent Res 1986;94:109–114.
310. Silness J, Hegdahl T. Area of the exposed zinc phosphate cement surfaces in fixed restorations. Scand J Dent Res 1970;78:163–177.
311. Lervik T, Riodan PJ, Haugejorden O. Periodontal disease and approximal overhangs on amalgam restorations in Norwegian 21-year-olds. Community Dent Oral Epidemiol 1984;12:264–268.
312. Jeffcoat MK, Howell TH. Alveolar bone destruction due to overhanging amalgam in periodontal disease. J Periodontol 1980;51:599–602.
313. Brunsvold MA, Lane JJ. The prevalence of overhanging dental restorations and their relationship to periodontal disease. J Clin Periodontol 1990;17:67–72.
314. Matthews DC, Tabesh M. Detection of localized tooth-related factors that predispose to periodontal infections. Periodontol 2000 2004;34: 136–150.
315. Parsell DE, Streckfus CF, Stewart BM, Buchanan WT. The effect of amalgam overhangs on alveolar bone height as a function of patient age and overhang width. Oper Dent 1998;23:94–99.
316. Lang NP, Kiel RA, Anderhalden K. Clinical and microbiological effects of subgingival restorations with overhanging or clinically perfect margins. J Clin Periodontol 1983;10:563–578.
317. Highfield JE, Powell RN. Effects of removal of posterior overhanging metallic margins of restorations upon the periodontal tissues. J Clin Periodontol 1987;5:169–181.
318. Roman-Torres CV, Cortelli SC, de Araujo MW, Aquino DR, Cortelli JR. A short-term clinical and microbial evaluation of periodontal therapy associated with amalgam overhang removal. J Periodontol 2006;77: 1591–1597.
319. Axelsson P. Diagnosis and Risk Prediction of Periodontal Diseases, vol 3. Chicago: Quintessence, 2002:181–186.
320. Youdelis RA, Weaver JD, Sapkos S. Facial and lingual contours of artificial complete crown restoration and their effects on the periodontium. J Prosthet Dent 1973;29:61–66.
321. Ehrlich J, Yaffe A, Weisgold AS. Faciolingual width before and after tooth restoration: A comparative study. J Prosthet Dent 1981;46:153–156.
322. Becker CM, Kaldahl WB. Current theories of crown contour, margin placement, and pontic design. J Prosthet Dent 1981;37:163–179.
323. Pihlstrom BE, Anderson KA, Aeppli D, Schaffer EM. Association between signs of trauma from occlusion and periodontitis. J Periodontol 1986;57:1–6.
324. Lindhe J, Nyman S, Ericsson I. Trauma from occlusion. In: Lindhe J, Karring T, Lang N (eds). Clinical Periodontology and Implant Dentistry, ed 4. Oxford: Blackwell Munksgaard, 2003:354–365.

Dentlearn.ir

325. Hancock EB, Mayo CV, Schwab RR, Wirthlin MR. Influence of interdental contacts on periodontal status. J Periodontol 1980;51:445–449.
326. DuBois LM, Niles SM, Boice PA. The magnitude of interproximal spaces between adjacent teeth. Am J Dent 1993;6:315–317.

Dentlearn.ir



Patient Evaluation and Problem-Oriented Treatment Planning

William F. Rose, Jr
Carl W. Haveman
Richard D. Davis

Excellence in dental care is achieved through the dentist's ability to assess the patient, determine his or her needs, design an appropriate plan of treatment, and execute the plan with proficiency. Inadequately planned and sequenced treatment, even when well executed, will result in less-than-ideal care. The process of identifying problems and designing the treatment for those problems is the essence of treatment planning and the focus of this chapter.

As an integral part of comprehensive dental care, treatment planning for the restoration of individual teeth must be done in concert with the diagnosis of problems and treatment planning for the entire masticatory system. The objective of this chapter is to present a problem-oriented approach to treatment planning for restorative dentistry. This approach begins with a comprehensive patient evaluation and gradually narrows its focus to the restoration of individual teeth. Emphasis is placed on the decision-making processes involved in identifying problems related to restorative dentistry and determining their causes, which will affect the treatment

Dentlearn.ir

outcome; assessing the demands of the oral environment; and selecting the materials, operative modalities, and sequence best suited to the treatment of these problems.

The Problem-Oriented Treatment Planning Model

Treatment planning is generally accomplished with either a treatment-oriented model or a problem-oriented model. In the *treatment-oriented model*, the dentist examining the patient finds certain intraoral conditions and mentally equates those problems to the need for certain forms of treatment. The examination findings are summarized in the form of a list of needed treatments, which then becomes the treatment plan. The *problem-oriented model* requires that the examination lead to the formulation of a list of problems. Each problem on the list is then considered in terms of treatment options, each of which has different advantages and disadvantages. The optimal solution for each problem is then chosen, and, after sequencing, this list of solutions becomes the treatment plan.

For patients with only a few, uncomplicated problems, the outcomes are similar whether the treatment plan is problem based or treatment based. In more complex cases, problems are often interrelated, and the solution to one problem may affect the treatment needed to resolve other problems. In these instances, the process of identifying and listing the individual problems enables the dentist to think through each one and to consider the various options for treating it without getting lost in the magnitude of the overall task.

The problem-oriented approach directs the dentist to perform a systematic evaluation of the patient so that no problems are overlooked, either in diagnosis or in treatment planning. It is designed to prevent tunnel vision of obvious pathoses at the expense of less obvious but equally important problems.

The problem-oriented treatment planning process includes the following steps: a thorough evaluation of the patient's general health and the stomatognathic system; identification of the problems requiring treatment; and development of an integrated treatment plan. Armed with knowledge of all the problems, the clinician envisions the state of the dentition after the seriously compromised and nonrestorable teeth have been removed. Based on this vision of the remaining sound dentition, the dentist visualizes the optimal state to which the patient's dentition can be restored and maintained. Treatment needed to achieve this optimal result can then be documented. This process of planning in reverse, starting with the desired end result, often enables the clinician to identify previously unrecognized or unforeseen problems and add them to the existing problem list to ensure that treatment of each

Dentlearn.ir

problem on the problem list is consistent with the desired optimal treatment goal. A list of integrated treatment steps can then be generated.

Problem list formulation

The dentist initially evaluates the patient from a subjective standpoint, ascertaining the chief complaint and the patient's goals of treatment. A medical and a dental history are then elicited. The objective portion of the assessment consists of a categorical evaluation of the patient, beginning with vital signs and an extraoral head and neck examination and progressing through a thorough intraoral evaluation. The examination procedures are standardized and routinely accomplished in the same order and fashion to simplify the procedure and to ensure that crucial steps are not omitted. Related nonclinical portions of the evaluation include examinations of radiographs, diagnostic casts (usually mounted on a semiadjustable articulator), and photographs.

The objectives of the examination are to distinguish normal from abnormal findings and to determine which of the abnormal findings constitute problems that require treatment or will influence treatment. From the findings of the initial examination, a problem list is established. If the problems are listed under categorical headings (eg, periodontal problems, endodontic problems), the dentist is unlikely to omit problems. This list is dynamic and can be modified as new problems arise.

Problem-oriented planning

In the next phase of treatment planning, the dentist considers the various problems with which the patient presents and uses clinical judgment based on evidence-based treatment concepts to estimate which teeth have a sufficiently favorable prognosis to justify being retained and which teeth, if any, should be removed. The dentist visualizes the state of the dentition after the removal of nonsalvageable teeth and then forms a mental image of the optimal condition to which the patient can be rehabilitated. This visualization requires the dentist to decide which teeth need to be replaced and which form of prosthodontic replacement and restorative treatment is most appropriate. Once this optimal condition has been visualized, a treatment solution is proposed for each problem on the problem list, with each individual solution planned to coincide with the final visualized optimal treatment objective.

If the treatment plan for any of the individual problems conflicts with the optimal treatment plan, eith lem or the optimal

Dentlearn.ir

treatment goal must be altered until they are coincident. When the clinician believes that, in consideration of all the problems and proposed treatments, the optimal treatment objective is feasible and maintainable, this list of individual treatments becomes the unsequenced treatment plan. For example, a patient presents with a chief complaint of a broken right maxillary central incisor that will require a crown to restore it, but the maxillary anterior facial gingival contours are asymmetric, which adversely affects the patient's smile. Esthetic crown lengthening of these teeth would greatly improve the smile. If the patient agrees to this procedure, then the broken incisor should initially be restored with a long-term provisional crown to satisfy the chief complaint. The esthetic crown lengthening would then be performed and a definitive crown placed following a satisfactory healing period.

Treatment sequencing

The final step in treatment planning, sequencing the treatment, is completed by arranging the solutions to the various problems in a set order (Box 2-1). The proposed treatment sequencing follows the logic of the medical model, so disease is treated in the priority of importance to the patient's overall health. This method of sequencing ignores the common technique of treating by specialty, where, for example, all the periodontal care is provided, followed by the endodontic care, which is followed by the restorative care.

Box 2-1 Sequence of treatment

- Chief complaint
- Medical/systemic care
- Emergency care
- Treatment plan presentation
- Disease control
- Reevaluation
- Definitive care
- Maintenance caren

Chief complaint

The patient's chief complaint should be addressed at the outset of treatment, even if only via discussion, and even if definitive treatment of this problem will be deferred.

Dentlearn.ir

Medical/systemic care

The medical/systemic care phase includes aspects of treatment that affect the patient's systemic health. These take precedence over the treatment of dental problems and must be considered before dental problems are addressed. This most commonly includes medically related diagnostic tests and consultations. An example is the investigation of the status and control of a patient's hypertension, anticoagulant therapy, or diabetes.

Emergency care

Problems addressed in the emergency care phase include those involving head and neck pain or infection. They are treated before routine dental problems but after acute problems involving the patient's systemic health. Evidence-based clinical judgment is exercised to determine the relative importance of systemic problems and dental emergency problems. A review of this topic is found in the text by Little et al.[1]

Treatment plan presentation

The treatment plan presentation (and patient acceptance of the treatment plan) should precede all nonemergency dental care. Presentation and discussion of the proposed treatment are the basis of informed consent and must not be overlooked. The use of intraoral and extraoral photographs of the patient often provides valuable information for educating the patient during this presentation. In addition to the primary or optimal treatment plan, the dentist should be prepared to present alternative plans that may be indicated based on extenuating circumstances, such as patient finances or the therapeutic response of teeth crucial to the success of the plan.

Disease control

The disease control phase consists of treatment designed to arrest active disease. Examples include endodontic treatment to control infection; periodontal treatment to control inflammation; and restorative care, linked with behavior modification, to control caries. Treatment in this phase is aimed at the control of active disease so that the disease processes would not progress even if no treatment beyond disease control were provided.

Reevaluation

Dentlearn.ir

The reevaluation phase consists of a formal reassessment, during which the dentist decides if all factors, including such criteria as the patient's treatment goals, oral hygiene, behavior modification, and response to periodontal therapy, warrant continuing with the original treatment plan. This is an important phase of treatment because it provides a predetermined point at which both patient and clinician may elect to alter or even discontinue treatment.

Definitive care

The definitive care phase is the final phase of treatment preceding maintenance care. Many of the procedures accomplished within the disease control phase, such as removal of carious tooth structure and placement of direct restorations, achieve both disease control and definitive restoration; however, a number of procedures that go beyond the treatment of active disease are possible. These include procedures designed to enhance function and esthetics, such as orthodontics, surgery, prosthodontics, and cosmetic restorative procedures. Treatment sequencing for most of these modalities is beyond the scope of this text; a detailed and comprehensive review is provided by Stefanac and Nesbit.[2]

Maintenance care

Maintenance care is an ongoing phase designed to maintain the results of the previous treatment and prevent recurrence of disease. The maintenance phase generally focuses on the maintenance of periodontal health; the prevention, detection, and treatment of caries; and the prevention of dental attrition, erosion, and abrasion.

Dental History and Chief Complaint

The key to successful treatment planning lies in identifying the problems that are present and formulating a treatment plan that addresses each problem so that each phase of treatment is designed to lead to the final, optimal treatment goal. The dentist who follows this approach begins by listening carefully to the patient and asking relevant questions. A thorough dental history serves as a guide for the clinical examination.

The dental history is divided into three components: *(1)* chief complaint, *(2)* dental treatment, and *(3)* symptoms related to the stomatognathic system. The chief complaint is addressed first and is recorded in the dental record in the patient's own words. By discussing the patient's chief concern at the outset, the dentist

Dentlearn.ir

accomplishes two important goals. First, the patient feels that his or her problems have been recognized, and the doctor-patient relationship begins positively; second, by writing out the chief complaint, the dentist ensures that it will not be omitted from the problem list. It is not uncommon to encounter a patient who has a multitude of significant dental problems but only a minor chief complaint. If the dentist focuses too quickly on the other problems and omits a discussion of the chief complaint, the patient may question the dentist's ability and desire to resolve the patient's chief concern.

A brief history of past dental treatment can provide useful information. The number and frequency of past dental visits reflect the patient's dental awareness and the priority he or she places on oral health. The dentist should elicit information about the past treatment of specific problems, as well as the patient's tolerance for dental treatment. All of this information can be of use in developing the treatment plan.

Questions about previous episodes of fractured or lost restorations, trauma, infection, sensitivity, and pain can elicit information that will alert the dentist to possible problems and guide him or her during the clinical and radiographic examination. Patients may not volunteer this information; hence, specific questions regarding thermal sensitivity, discomfort during chewing, gingival bleeding, and pain are warranted. When there is a history of symptoms indicative of pulpal damage or incomplete tooth fracture, specific diagnostic tests should be performed during the clinical examination.

Clinical Examination

Every patient examination should include an assessment of the extraoral and intraoral soft tissue conditions as well as the dentition. The reader is referred to standard texts on physical examination for details. The temporomandibular joint and associated musculature should be evaluated and a systematic assessment of any signs or symptoms of pathology conducted.[3] For the purpose of restorative treatment planning, the intraoral assessment involves an examination of the periodontium, dentition, and occlusion. Specific diagnostic tests may be performed as indicated, and a radiographic examination is completed at this time. The dentist should be sure to complete one portion of the evaluation before beginning another aspect of the examination (Box 2-2). The findings from each area are placed under the appropriate heading in the problem list. Some problems may be noted in the

Dentlearn.ir

evaluation of more than one system. For example, gingival bleeding and periodontal inflammation resulting from the impingement of a restoration on the periodontal attachment would be noted in both the periodontal examination and the evaluation of the existing restorations. At this stage, such duplication of effort is acceptable in the interest of completeness.

	Elements of the clinical examination
I. Evaluation of the dentition • Caries risk and plaque • Caries lesion detection and disease activity • Pulp • Existing restorations • Occlusion and occlusal contours • Axial tooth surfaces • Tooth integrity and fractures • Esthetics	II. Evaluation of the periodontium • Disease activity • Structure and contour of bony support • Mucogingival assessment • Tooth mobility III. Evaluation of radiographs VI. Evaluation of diagnostic casts (may include a diagnostic mounting in centric relation and use of a facebow)

The following sections describe the elements of the intraoral examination used to establish the restorative dentistry problem list.

Evaluation of the dentition

Caries risk and plaque

An assessment of caries risk (see chapter 5) should be accomplished, and the presence of plaque should be documented with a standardized plaque index. The O'Leary index, for example, is a simple, effective measure of plaque accumulation.[4] The use of a standardized index permits an objective assessment of plaque accumulation. Depending on initial findings, a dietary analysis and/or unstimulated salivary flow rate determination may be indicated. The determination of baseline caries risk and plaque levels at the time of initial examination provides a basis for communication with the patient and other clinicians and permits assessment of changes over time. This is important information in establishing a prognosis for restorative care and provides criteria for deciding whether treatment should progress beyond the disease control phase into the definitive rehabilitation stage.

The levels and location of plaque should be established at the outset of the examination. At the conclusion of the examination, the patient may be given a toothbrush and floss sible. Reassessment

Dentlearn.ir

immediately after the cleaning will establish the patient's hygiene ability and reveal the nature of hygiene instructions needed. A patient who sincerely tries to remove plaque but is unsuccessful in certain areas requires instruction in technique, whereas the patient who demonstrates effective hygiene while in the office but consistently presents with high plaque levels has a problem with motivation. This information is important in designing the treatment plan: A plan requiring a great deal of patient participation and compliance would not be appropriate for a patient with inadequate motivation, while a motivated patient who is teachable may well be suited to such a plan.

One of the most reliable indicators of future caries activity is the presence of an existing or recently treated caries lesion.[5] Three additional factors that heighten the risk of caries are *(1)* a large number of cariogenic bacteria, *(2)* frequent ingestion of cariogenic sugars, and *(3)* an inadequate flow of saliva.[6] Patients demonstrating active caries should receive an evaluation that entails more than simply a determination of levels and location of plaque.[7] Both a diet survey and a salivary flow assessment are useful in determining the patient's susceptibility to caries and the caries-related prognosis for restorative treatment.

Diet has been shown to be one of the most significant factors in caries risk. A review of more than 100 studies by van Palenstein Helderman et al[8] demonstrated that the frequency and duration of refined carbohydrate exposure is more predictive of caries occurrence than *Streptococcus mutans* counts. Using a diet survey, the patient itemizes all food and drink intake for a specified period (generally 1 week). From this diary, the dentist can identify the contribution of specific dietary habits to the patient's caries risk and can direct the patient's attention to these areas. The identification and management of episodic sugar and carbohydrate intake (snacking), as well as overall carbohydrate consumption, should be the focus of dietary intervention.[9,10]

Xerostomia, or dry mouth, is associated with increases in the number of cariogenic bacteria and increased caries activity.[11] Saliva provides lubrication; promotes oral clearance of fermentable carbohydrates, sugars, and acids; and possesses antimicrobial components and buffering agents.[11–13] Saliva is critical to tooth remineralization because it is a source of calcium, phosphates, and proline-rich proteins active in recrystallization of the tooth surface.[12,13] The patient's health status, medications, iatrogenic changes, and possibly aging can alter salivary flow and composition and, thereby, caries-risk status. Consideration should be given to assessing salivary flow rates in all caries-active patients. There is not complete

Dentlearn.ir

agreement as to the minimum salivary flow rate necessary to maintain oral health. Some authorities suggest that unstimulated salivary flow in a range less than 0.1 to 0.2 mL/min is the criterion for hypofunction.[14–16] However, others correlate clinical symptoms of hypofunction, such as dysphasia, dysphagia, xerostomia, and a higher incidence of caries lesions and/or candidiasis, with an unstimulated flow rate of less than 0.2 mL/min.[17,18]

Because the character of the microflora determines the cariogenicity of the plaque, periodic assessment of the number of cariogenic bacteria present in the plaque can indicate alterations in the caries susceptibility of patients at high risk of developing caries.[19,20] Although higher levels of *S mutans* (greater than 106 colony-forming units [CFUs]/mL of saliva) are not consistently indicative of caries activity, estimates of the number of bacteria are more useful for predicting the absence, rather than the presence, of an active infection.[20,21] By monitoring the levels at baseline and over time, the dentist can assess the effectiveness of caries-management measures.

Once plaque assessments have been completed, an examination of other areas can be accomplished. The visual examination of the dentition should be conducted in a dry field, with adequate lighting, using a mirror and explorer. Ideally, the dentist will employ some form of magnification to aid in the examination. A number of products providing 2× to 6× magnification are commercially available. Some magnifying lenses attach to eyeglasses and can be removed, while others are built directly into the lenses of specially constructed eyeglasses (see Fig 7-68). The use of magnification with adequate lighting significantly enhances the ability of the clinician to detect subtle signs of disease. If the presence of plaque and calculus partially obscures the dentition, debridement is required to accomplish a thorough examination.

Detection of caries lesions

The terms *carious lesion* and *caries lesion* are both acceptable to describe the effect of the caries process on a tooth, and both terms will be used interchangeably throughout this textbook.

fissure caries lesions and smooth-surface caries lesions (including those involving proximal surfaces, root surfaces, and lesions on other smooth surfaces). Detection of caries lesions requires both clinical (visual and tactile) and radiographic examinations.

Dentlearn.ir

Pit and fissure caries lesions. Pit and fissure caries lesions are generally found in areas of incomplete enamel coalescence. These areas are most commonly found on the occlusal surfaces of posterior teeth, the lingual surfaces of maxillary anterior teeth and maxillary molars, and the buccal pits of mandibular molars. Because pit and fissure lesions may begin in small enamel defects that lie in close approximation to the dentinoenamel junction, they may be difficult to detect. A pit and fissure lesion must be fairly extensive to be detected radiographically; these lesions generally appear as crescent-shaped radiolucencies immediately subjacent to the enamel[22] (Fig 2-1).



Fig 2-1*(a)* Occlusal caries. The shadowing around the stained pits in the second molar indicates the presence of carious dentin at the base of the fissure. *(b)* The caries lesion extends well into dentin. *(c)* The typical pattern of an occlusal caries lesion in cross section.

Historically, tactile examination with firm application of a sharp explorer into the fissure was the clinical technique most commonly used by dentists in the United States to locate pit and fissure lesions.[23] A sticky sensation on removal of the explorer has been the classic sign of pit and fissure caries. Clinical studies, however, have shown this method to be unreliable, producing many false-positive and false-negative diagnoses.[24] In addition, an explorer can cause cavitation in a demineralized pit or fissure, precluding the possibility of remineralization.[24–27]

Visual observation, with magnification, of a clean, dry tooth has been found to be a reliable, nondestructive method of detecting pit and fissure caries lesions,[24–28] which appear as gray or gray-yellow opaque areas that show through the enamel (see Fig 2-1a). However, stain within a fissure is not indicative of carious dentin at the base of the fissure.

Fiber-optic transillumination may be helpful in visualizing pit and fissure and other types of caries lesions. A variety of new technologies are being evaluated for detection of caries lesions. A discussion of these new technologies can be found in chapter 5.

When the presence of pit and fissure lesions is uncertain and the patient will be

Dentlearn.ir

available for recall evaluations, a sealant may be placed over the suspected area. Clinical investigation by Mertz-Fairhurst et al[29] indicates that sealed caries lesions do not progress. However, placement of sealants in fissures over known carious dentin cannot be recommended at present, because the risk of sealant loss makes this an injudicious practice. Mertz-Fairhurst et al[29] found the placement of a conservative amalgam or resin composite restoration, followed by the placement of a resin fissure sealant over the margins of the restoration and remaining fissures, to be a predictable and relatively conservative treatment for such lesions. A recent systematic review by Azarpazhooh and Main[30] recommended that sealants be placed on all permanent molars without cavitation as soon after eruption as isolation can be achieved.

Smooth-surface caries lesions. Of the three types of smooth-surface caries lesions, proximal lesions are the most difficult to detect clinically. Proximal caries lesions in posterior teeth are generally inaccessible to both visual and tactile examination and are usually detected radiographically. Proximal lesions in anterior teeth may be detected radiographically or with visual examination using transillumination[28] (Fig 2-2). Root caries lesions located on facial or lingual surfaces of the roots present few diagnostic problems. When root-surface lesions occur proximally, however, they are not readily visible on clinical examination and are generally detected through the radiographic examination (Fig 2-3). Smooth-surface caries lesions occurring on enamel in nonproximal areas are not difficult to detect clinically. These lesions, which are most commonly found in patients with high levels of plaque and a cariogenic diet or deficient salivary flow, occur on the facial and lingual enamel surfaces and are readily accessible during visual and tactile examination.

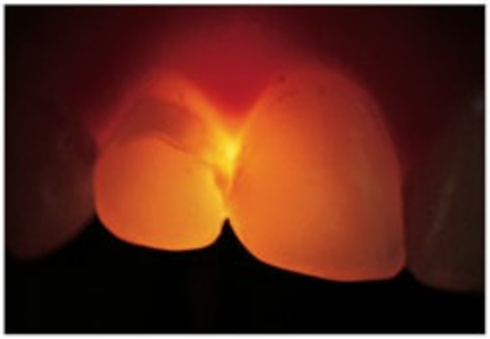

Fig 2-2 Proximal caries lesion detected in an anterior tooth with the use of transillumination.

Dentlearn.ir



Fig 2-3

Dental pulp

Evaluation of pulpal vitality in every tooth is not warranted; however, each tooth that will undergo extensive restoration, as well as all teeth that are critical to the plan of treatment and teeth with pulps of questionable vitality, should be tested.

The application of cold is a valuable method of vitality testing. Canned refrigerants present minimal risk to teeth and restorations. A cotton pellet saturated with an aerosol refrigerant spray, such as tetrafluoroethane, is placed on the tooth to determine its vitality. A similar test can be performed by placing a "pencil of ice" (made by freezing water inside a sterilized anesthetic cartridge) against a tooth.

An additional vitality test involves the use of an electric pulp tester. While it can provide information regarding pulp vitality, this test has limitations; it cannot be used in a wet field or on teeth with metallic proximal surface restorations unless measures are taken to insulate adjacent teeth. Furthermore, the numeric scale of the instrument does not reflect the health of the pulp or its prognosis. The electric pulp tester is merely a means of determining whether the tissue within the pulp senses electrical current. A high score may be due to the presence of a partially necrotic pulp or extensive reparative dentin, or it may be the result of poor contact between the tooth and the pulp tester.

When the results of pulp tests are not congruent with the clinical impression, additional tests are indicated. When neither thermal nor electric pulp tests provide a clear picture of pulp vitality and a restoration is indicated, the preparation can be initiated without the use of anesthetic. This is termed a *test cavity*. If pain or sensitivity is elicited when dentin is cut with a bur, pulpal vitality is confirmed. The restoration may then be completed after administration of local anesthetic.

Pulp vitality should be determined prior to restorative treatment. It is professionally embarrassing to discover that a recently restored tooth was nonvital prior to restoration and subsequently became symptomatic, requiring endodontic

Dentlearn.ir

treatment and a replacement restoration. It is advantageous to ascertain the pulpal prognosis of a tooth prior to restorative treatment. When pulpal prognosis is uncertain or guarded, it is often best to perform endodontic therapy before extensive restorative treatment. If the endodontic treatment is completed before restorative care, the repair or replacement of a recently completed large restoration may be avoided.

Planning for endodontic treatment and presenting it as part of the original treatment plan is generally more acceptable to the patient than presenting this treatment option after treatment has begun. An added benefit is that the endodontic prognosis can be established before the dentist commits to restorative care. When endodontic therapy is required, the feasibility of completing the endodontic procedures should be determined early in the course of treatment. The more critical the tooth is to the overall success of the treatment, the more important it becomes to complete the necessary endodontic treatment early in the treatment schedule. It is poor planning to rely on a tooth in the treatment plan when that tooth cannot be successfully treated with endodontics. Endodontic diagnosis can be challenging. A thorough discussion of this subject can be found in the text by Hargreaves and Cohen.[31]

When a posterior tooth has received endodontic treatment, placement of a complete-cuspal-coverage restoration is generally indicated to prevent fracture.[32,33] When an anterior tooth has received endodontic treatment, the least invasive form of restoration that satisfies the esthetic and functional needs of the patient is indicated.[34] If sufficient enamel and dentin remain for support, a bonded restoration, such as a resin composite restoration or a ceramic veneer, is preferred. If there is insufficient support for such a restoration after removal of carious tooth structure or defective restorations or following endodontic access preparation, a ceramic or metal-ceramic crown is the restoration of choice. A post is indicated primarily to retain a core in a tooth with extensive loss of coronal tooth structure.[32,35,36] When a post is needed, preparation of a small post space preserves dentin and provides optimal fracture resistance for the tooth[32,37] (see chapter 21).

Existing restorations

In the course of the intraoral examination, the serviceability of existing restorations must be evaluated. The following general criteria are used to evaluate existing restorations: *(1)* structural integrity, *(2)* marginal opening, *(3)* anatomical form, *(4)* restoration-related periodontal health, *(5)* occlusal and interproximal contacts, *(6)*

Dentlearn.ir

recurrent caries lesions, and *(7)* esthetics.

Structural integrity. The structural integrity of a restoration should be evaluated to determine whether it is intact or whether portions of the restoration are partially or completely fractured or missing. The presence of a fracture line dictates replacement of the restoration. If voids are present, the dentist must exercise clinical judgment in determining whether their size and location will weaken the restoration and predispose it to further deterioration or recurrent carious involvement (Fig 2-4).

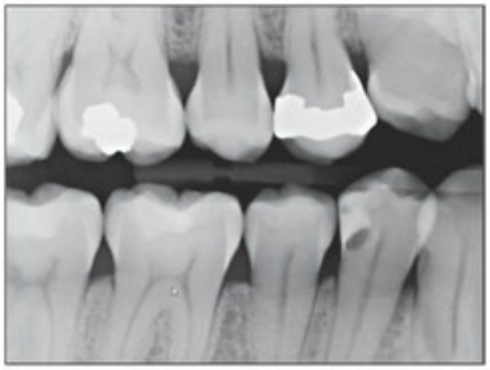

Fig 2-4 Bitewing radiograph illustrating a large void in the Class 2 resin composite restoration of the mandibular right first premolar.

Marginal opening. Few restorations have perfect margins, and the point at which marginal opening dictates replacement of the restoration is difficult to determine. For amalgam restorations, it has been demonstrated that marginal ditching neither implies the presence nor necessarily portends the development of caries lesions[38]; therefore, its existence does not dictate the replacement of amalgam restorations. Because the margins of amalgam restorations become relatively well sealed by the accumulation of corrosion products, a general guideline has been to continue to observe the restoration unless signs of recurrent caries lesions or marginal gaps are present.[39] An accumulation of plaque in the marginal gap is also an indication for repair or replacement of an amalgam restoration. Repair of noncarious marginal gaps in amalgam with a flowable resin composite or a sealant will enhance the longevity of the restoration.[40–42] A long-term, retrospective clinical study by Smales and Hawthorne[43] indicated that the repair of local defects in amalgam restorations is an effective alternative to restoration replacement.

For restorations that do not seal by corrosion, a marginal gap into which the end of a sharp explorer may penetrate should be considered for repair, or the restoration should be replaced. This is especially true for resin composite restorations, because bacterial growth has been shown to progress more readily adjacent to resin

Dentlearn.ir

composite than to amalgam or glass-ionomer materials.[44] Repair, sealing, or replacement of resin composite restorations with defective margins will result in significant improvement in the longevity of the restoration.[45] An increased susceptibility to caries has been reported in resin composite restorations whose marginal gaps exceeded 100 to 150 μm.[46] In anterior teeth, replacement is indicated when the tooth structure adjacent to the marginal gap becomes carious or when marginal staining is esthetically unacceptable. Often this stain may be associated with unbonded resin flash that can usually be polished away. The dentist must carefully evaluate the restoration margin to determine the need for replacement (Fig 2-5).



Fig 2-5

The presence of a marginal gap is less critical for restorations with anticariogenic properties (eg, glass-ionomer cement). Both in vitro[47–53] and in vivo[54–58] studies have shown that tooth structure adjacent to glass-ionomer restorations is less susceptible to caries attack than that adjacent to either resin composite or amalgam restorations. Consequently, restorations with anticariogenic properties generally should be replaced not because of marginal ditching but rather when a frank caries lesion has occurred or when some other defect indicates the need for treatment.

Anatomical form. *Anatomical form* refers to the degree to which the restoration duplicates the original contour of the intact tooth. Common problems include overcontouring, undercontouring, uneven or flat marginal ridges, inadequate facial and lingual embrasures, and lack of occlusal or gingival embrasures. Many restorations exhibit one or more of these problems yet adequately serve the needs of the patient and do not require replacement. The critical factor in determining the need for replacement is not whether the contour is ideal but whether pathosis has resulted, or is likely to result, from the poor contour.

Dentlearn.ir

Restoration-related periodontal health. Examination of restorations must include an assessment of the effect that existing restorations have on the health of the adjacent periodontium. Problems commonly encountered in this area are *(1)* surface roughness of the restoration, *(2)* interproximal overhangs, and *(3)* impingement of the restoration margin on the zone of attachment, called the *biologic width* or the *dentogingival junction* (the area, approximately 2 mm in the apicocoronal dimension, occupied by the junctional epithelium and the connective tissue attachment) (Fig 2-6; see also Fig 1-32).



Fig 2-6 Bitewing radiograph illustrating an amalgam overhang on the distal of the maxillary first molar.

All three of these phenomena can cause inflammation within the periodontium.[59–61] If restorative material extends vertically or horizontally beyond the cavosurface margin in the region of the periodontal attachment or impinges on the biologic width, the health of the periodontal tissue should be assessed (Fig 2-7). If other local etiologic factors have been removed and periodontal inflammation persists in the presence of these conditions, treatment should be initiated. In the case of overhanging restorations, pathosis may be eliminated and the restoration may be made serviceable simply by removing the overhang. If the periodontal inflammation fails to resolve, the restoration should be replaced. In the case of biologic width impingement, space for a healthy periodontal attachment must be gained through surgical crown lengthening or a combination of orthodontically forced eruption and surgical crown lengthening.

Dentlearn.ir



Fig 2-7 Periodontal inflammation caused by the encroachment of crown margins into the periodontal attachment area of the maxillary right central incisor.

Inflammatory changes suggestive of biologic width violations are common on the facial aspects of anterior teeth that have been restored with crowns. On occasion, however, evaluation of the marginal areas reveals inflammation even when an adequate space remains between the crown margin and the periodontal attachment apparatus, leaving the clinician puzzled as to the cause of the problem. If periodontal inflammation persists in the apparent absence of local etiologic factors, including biologic width impingement, the dentist should evaluate the entire cervical circumference of the restoration. Inflammatory changes on the facial aspect of a restoration are sometimes a manifestation of interproximal inflammation. Further evaluation may reveal an interproximal violation of biologic width from which the inflammatory reaction has extended to the more visible facial areas.

Even in the absence of impingement on biologic width, open or rough subgingival margins can harbor sufficient bacterial plaque to generate an inflammatory response. Gingival inflammation around a crown may also be due to an allergic reaction to a material in the crown. Several investigations have shown that low gold content or predominantly base metal alloys, especially those containing nickel and palladium, can cause such reactions, with an incidence of around 7%.[62–66]

During the assessment of existing restorations or the planning of future restorations, the location of margins is an important consideration. Supragingival margins result in significantly less gingival inflammation than do subgingival margins.[67] Supragingival margins should be the goal when overriding concerns (eg, esthetics or requirements for resistance and retention) do not contraindicate their use.

Occlusal and interproximal contacts. The dentist should assess all interproximal contacts with thin dental floss. In addition, the patient should be queried regarding

Dentlearn.ir

any problems encountered in the passing of floss through the contacts during home hygiene procedures. Contacts that do not allow the smooth passage of floss must be altered, or the restoration must be replaced, to permit the use of floss. The use of an interproximal contact–smoothing device is often effective in eliminating roughness that impedes the passage of floss (Fig 2-8).



Fig 2-8 An interproximal contact–smoothing device is useful for removing irregularities that impede the passage of floss.

Contacts that are open or excessively light should be evaluated to determine whether pathosis, food impaction, or annoyance to the patient has resulted. When any of these problems is present, steps should be taken to alleviate it. Generally, the placement or replacement of a restoration is required to establish an adequate proximal contact. When an open contact is identified, an attempt should be made to determine its cause. If occlusal contacts have moved a tooth and a restoration is to be placed to close the proximal contact, the occlusal contacts must be altered to prevent the open contact from recurring after the placement of the new restoration.

The occlusal contacts of all restorations should be evaluated to determine if they are serving their masticatory function without creating a symptomatic or pathogenic occlusion. In the absence of periodontally pathogenic bacteria, traumatic occlusion has not been found to initiate loss of periodontal attachment.[68–70] However, in a susceptible host and in the presence of periodontal pathogens, occlusal trauma can play a role in the progression of periodontal disease.[71–74] A more recent study indicates that these previous studies may have underestimated the impact that occlusal trauma has on the periodontium.[75] Existing restorations located in teeth exhibiting significant attachment deficits should be examined closely for the presence of hyperocclusion. Restorations in which occlusal contacts are creating primary occlusal trauma should be altered or replaced, as necessary, to resolve the problem.[76] Restorations that are in significant infraocclusion may permit the supraeruption of teeth and should be considered for replacement.

Dentlearn.ir

Recurrent caries lesions. The evaluation for carious tooth structure around existing restorations focuses on an examination of the margins. The dentist must use a combination of visual, tactile, and radiographic examinations to detect the presence of caries lesions. A radiolucent area surrounding a radiopaque restoration on a radiograph or the presence of soft tooth structure generally indicates a caries lesion and warrants either repair or replacement of the restoration.

Discoloration in the marginal areas is a more difficult sign to interpret. It often indicates leakage of some degree. In nonamalgam restorations without anticariogenic properties, discoloration that penetrates the margin often indicates the need for replacement of the restoration (Fig 2-9). This is not a definite indication, however, and clinical judgment is required. For example, in restorations with anticariogenic properties, leakage and staining may be observed with less concern for caries involvement, leaving esthetics as the primary consideration. This is not to imply that restorative materials with caries-resistant properties are immune to caries, however. Caries lesions have been documented adjacent to glass-ionomer restorations.[55,77] If the tooth structure adjacent to the margin of a restoration appears to be carious (either with undermined enamel or cavitation), rather than simply discolored, the restoration should be repaired or replaced, depending on location and extent of caries.

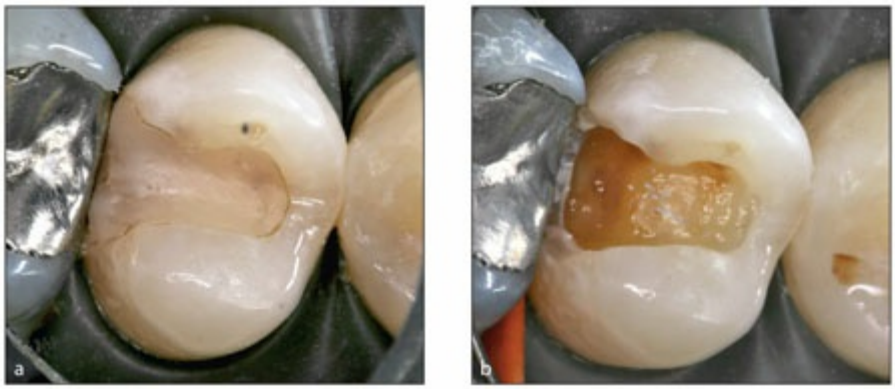

Fig 2-9*(a) (b)*

For amalgam restorations, the decision to replace a restoration when there is discoloration in the adjacent tooth structure is less clear because corrosion products may discolor tooth structure, even in the absence of caries lesions, especially when little dentin is present. When there is no apparent communication between the cavosurface margin and the stained area, and when the discoloration is primarily gray, then metal "show-through" should be suspected and observation is warranted (Fig 2-10). When the discolored area appears yellow or brown and appears to communicate with the cavosurface margin, replacement of the restoration is

Dentlearn.ir

indicated (Fig 2-11).



Fig 2-10 The shadow in the mesiofacial aspect of the maxillary right first molar is caused by amalgam that shows through the translucent enamel. No caries lesion is present.



Fig 2-11 The shadow located on the mesiolingual cusp adjacent to the larger occlusal amalgam restoration on the maxillary right first molar indicates the presence of carious dentin.

Esthetics. The esthetic evaluation of existing restorations is highly subjective. When the functional aspects of a restoration are adequate, it is often best to simply inquire whether or not the patient is satisfied with the esthetic appearance of the existing restorations. If the patient expresses dissatisfaction with the appearance of a restoration, the dentist must determine whether improvement is feasible. Care should be taken to ascertain the reason that the original restoration has less than optimal esthetics. An underlying problem may preclude improvement of the original esthetic problem, and an equally unsatisfactory result may occur in the replacement restoration. When replacing a restoration for esthetic reasons only, the dentist must carefully explain the risks (eg, endodontic complications) incurred in replacement.

Some of the more common esthetic problems found in existing restorations are *(1)* display of metal, *(2)* discoloration or poor shade match in tooth-colored restorations, *(3)* poor contour in tooth-colored restorations, and *(4)* poor periodontal tissue response in anterior restorations. (See chapter 3 for further discussion of esthetic problems.)

Dentlearn.ir

Occlusion, occlusal wear, and erosion

The occlusion can have significant effects on the restorative treatment plan. The following factors should be evaluated in the course of the occlusal examination: *(1)* occlusal interferences between the occlusion when the mandibular condyles are in centric relation (*centric occlusion* [CO]) and in maximal intercuspation (MI); *(2)* the number and position of occlusal contacts, as well as the stress placed on the occlusal contacts in MI; *(3)* occlusal interferences in working and nonworking excursive movements; *(4)* the amount and pattern of attrition of teeth and restorations resulting from occlusal function and parafunction; and *(5)* the interarch space available for placement of needed restorations.

Occlusal interferences. Most people have some difference between the positions of CO and MI and have no consequent pathosis. Working and nonworking contacts are also commonly noted during occlusal evaluations without consequential pathosis. These findings indicate that the existence of a discrepancy between these positions is not, in itself, an indication for occlusal equilibration. Findings from the occlusal examination that should be recorded in the restorative dentistry problem list and that do warrant treatment with occlusal adjustment are the following: *(1)* signs and symptoms of occlusal pathosis resulting from discrepancies between CO and MI (eg, mobility, excessive wear of teeth in the areas of interference between CO and MI, or periodontal ligament soreness); *(2)* occlusal discrepancies on teeth with periodontal disease; and *(3)* the need to restore the majority of the posterior occlusion.

This third factor does not imply the restoration of the majority of the posterior teeth but rather the restoration of the majority of the occlusal contacts. For example, insertion of a three-unit fixed partial denture in the mandibular right quadrant and several large restorations in the maxillary left quadrant results in the restoration of the majority of the occlusal contacts for the posterior teeth. There is no reason to fabricate the occlusion of the new restorations to duplicate the interferences that existed preoperatively. In such a case, occlusal equilibration should be completed prior to the restorative treatment. Through adjustment of only a very few occlusal contacts on teeth not involved in restorations and subsequent fabrication of the new restorations in CO, the occlusions of centric relation and MI become coincident.

Occlusal contacts. The number and position of occlusal contacts in the MI position, the force of the occlusal load, and the manner in which opposing teeth occlude in excursive function strongly influence the selection of restorative materials, as well as the design of the preparation and restoration. As the number of missing teeth

Dentlearn.ir

increases, so does the proportion of the occlusal load borne by each tooth. As occlusal stress increases, the dentist is forced to select the strongest of the available restorative materials and to design restorations that will provide the greatest strength in the areas of maximum stress. Likewise, the greater the potential for the patient to function on the restorations in lateral excursions, the greater the need for strength in the restorative material and the greater the imperative to select a material that will function without causing injury to the opposing dentition.

Wear. The clinician must be concerned with the abrasive potential of various restorative materials on the opposing dentition. Wear (mechanical and chemical) is a progressive phenomenon characterized by the loss of anatomical tooth form. Mechanical wear can be either *attrition* (tooth against tooth) or *abrasion* (other than tooth against tooth). Chemical wear is termed *erosion* and is the progressive loss of tooth structure through chemical processes that do not involve bacterial action. Wear may result from physiologic or pathologic causes. Physiologic wear is generally considered a slow, progressive surface degradation of tooth form manifesting as a flattening of cusp tips of posterior teeth and incisal mamelons of anterior teeth.[78,79] The mean annual physiologic occlusal wear has been estimated at 15 to 29 μm.[80,81] When wear becomes excessive, it presents restorative difficulties. Excessive occlusal wear is caused primarily by occlusal parafunction. In these instances, facets on opposing teeth match well, indicating the predominant pattern of parafunctional activity. Because altering occlusal parafunctional habits is extremely difficult, prevention of excessive occlusal wear is accomplished with the use of an occlusal appliance (Fig 2-12). The dentist should identify patients who demonstrate signs of excessive occlusal wear (especially patients who exhibit these signs at an early age) and include occlusal appliance therapy in the treatment plan.

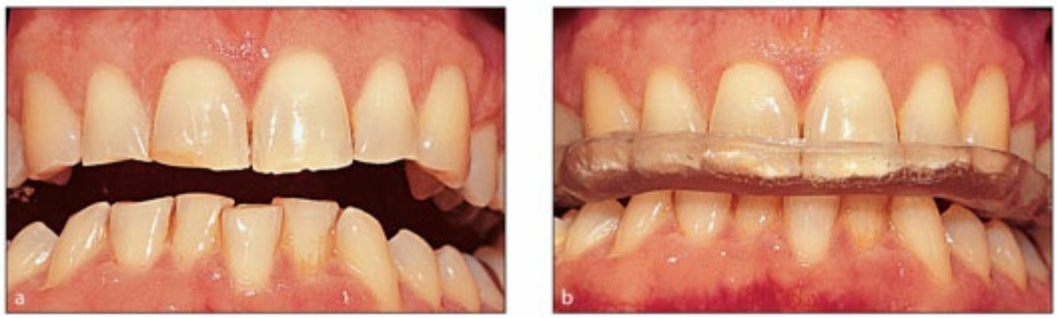

Fig 2-12*(a)* Significant occlusal attrition caused by a habit of parafunctional grinding in a patient less than 30 years old. *(b)* An occlusal acrylic resin appliance is used to minimize the abrasive trauma generated by the parafunctional grinding habit.

The restorative materials used in dentistry today have varying abrasive potential.

Dentlearn.ir

No single variable is predictive of abrasivity; it is a function of a number of mechanical properties.[39] Hardness is a useful indicator, but the best predictor of wear is the relative clinical performance of the various materials. In clinical determinations of wear behavior, occlusal contact of enamel to amalgam causes only slightly greater wear to the amalgam than enamel-to-enamel contact causes to enamel. The amalgam causes less wear to the opposing dentition than does enamel.[82] The wear rate of resin composite depends on the nature of the resin composite. Microfilled composites typically exhibit similar wear behavior as enamel to abrasive forces, while micro- and nanohybrid composites may demonstrate more or less wear depending on the size of their filler particles. Micro- and nanohybrids typically generate more wear on opposing enamel than does either amalgam or enamel. Nanofilled resin composites have demonstrated mechanical properties and wear that are equivalent to many microhybrids while exhibiting improved optical properties.[83–85] Polished cast gold is more wear resistant than enamel or amalgam and generates minimal wear of opposing tooth structure.

Ceramic restorations have demonstrated a consistent ability to severely abrade the enamel of the opposing dentition[78,86] (Fig 2-13). Manufacturers of dental ceramics called *low-fusing ceramic materials* claim that they are less abrasive to the opposing natural dentition than the conventional porcelains. Several authors have supported this hypothesis[87–90]; however, just as many have contradicted it.[91–93] Some have even reported that the low-fusing porcelains can result in significantly greater enamel wear than conventional porcelain.[92,94]



Fig 2-13 Extensive tooth structure has been lost in the mandibu-lar teeth because of wear caused by the opposing porcelain fixed partial denture.

Minimizing wear of enamel by dental ceramics can best be accomplished by following these guidelines95:

- Ensure anterior guidance, which disoccludes posterior teeth in excursive movements.

Dentlearn.ir

- Eliminate occlusal interferences.
- Use gold alloys in functional bruxing areas.
- If occlusion is on a ceramic surface, use small-particle veneering porcelains on the occluding surfaces.
- Polish ceramic surfaces periodically.
- Adjust occlusion periodically if needed.

Occasionally, the presence of abrasive substances in the mouth is the cause of excessive occlusal wear. When the vocation or lifestyle of a patient frequently places him or her in contact with airborne abrasives, prevention of wear is difficult. Education of the patient and use of an occlusal appliance will decrease the occlusal abrasion; however, decreasing the patient's exposure to the causative agent is the only reliable means of reducing the problem.

Erosion. As defined earlier, *erosion* is the progressive loss of tooth structure through chemical processes that do not involve bacterial action. Some authors have suggested the term *corrosion* be used instead of erosion and have referred to caries as biocorrosion.[96] Erosion can result from habits such as sucking lemons or swishing carbonated beverages or from the introduction of gastric acid into the oral cavity, which can occur with repeated regurgitation. Gastroesophageal reflux disease, frequently referred to as *GERD*, occurs in the presence of an incompetent esophageal sphincter and is a common cause of acid-related erosion of the dentition. While the dentist may be the first to detect the signs of this condition, referral to a physician to manage the disease is in order. Bulimia is another condition that may be detected by the dentist first. The frequent forced regurgitation associated with this disorder results in acidic dissolution of exposed tooth surfaces and can have devastating effects on the dentition.

Chemical erosion can be distinguished from mechanical wear by the location and character of the defects. Erosive lesions have a smooth, glassy appearance, and if the process is active, the teeth are frequently hypersensitive. When found on the occlusal surfaces of posterior teeth, these lesions are characterized by concave defects into which abrasive agents are unlikely to penetrate. Severely "cupped out" cusp tips and teeth that have restorations standing above the surrounding tooth structure, often termed "amalgam islands," are clinical findings commonly associated with chemical erosion (Fig 2-14).

Dentlearn.ir

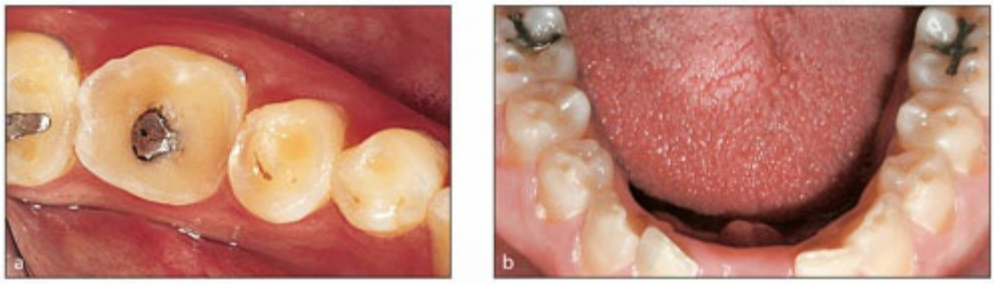

Fig 2-14*(a)* In the absence of facets that would indicate occlusal wear, significant loss of tooth structure is evidence of a chemical erosive process. Note both the amalgam restoration situated above the surrounding tooth structure and the smooth, glasslike character of the dentin. Also note the cratering pattern of the buccal cusp tips of the premolars. *(b)* In another patient, the loss of enamel on the buccal surfaces of the posterior teeth is suggestive of soft-drink swishing.

Erosion lesions appearing in both arches, primarily on the lingual surfaces of maxillary teeth and the occlusal surfaces of posterior teeth, are characteristic of erosion caused by gastric acid. Smooth lesions on the facial surfaces might be of chemical or mechanical origin. In instances of uncertainty, questions related to habits may elucidate the cause of mechanical abrasion, while a thorough history and medical evaluation may reveal the presence of acid-related erosion. When bulimia is the underlying problem, detection is often difficult. The dentist must be tactfully candid in discussing this possible etiology. The primary cause of the loss of tooth structure should always be determined and resolved before rehabilitative therapy is undertaken.

Often wear lesions are the result of a combination of attrition, abrasion, and erosion. Once enough enamel has been lost to expose the dentin, erosion and *three-body wear*, a form of abrasion, can severely exacerbate the loss of tooth structure. This happens commonly on the cusp tips and incisal edges, resulting in deep cratering or fissuring and a potential for enamel chipping and fracturing. Resin composite offers the opportunity to successfully restore these noncarious lesions with little or no preparation with a bur.[97] Early intervention in these lesions can prove a valuable service to patients (Fig 2-15). A thorough review of the loss of tooth structure from wear and erosion has been published by Verrett.[79]

Dentlearn.ir



Fig 2-15*(a)* Cratered noncarious occlusal lesions on the buccal cusps of both mandibular premolars. *(b)* Restoration of these lesions with a microhybrid resin composite.

Interarch space. When the dentist determines that significant loss of occlusal tooth structure has occurred and pulpal sensitivity has arisen, or that teeth have been so weakened by abrasion or erosion as to be at risk for fracture, restorative treatment is indicated. The dentist must evaluate the occlusion in MI and determine whether sufficient space exists for the placement of the restoration. If inadequate space is available, the dentist must either *(1)* gain space for adequate tooth reduction and restoration resistance form by surgical crown lengthening, orthodontic intrusion, or shortening the opposing tooth or *(2)* select a different restorative option that requires less bulk of material for resistance. Recognition of the space inadequacy prior to tooth preparation is essential.

In those cases in which generalized wear or erosion has resulted in the loss of an extensive amount of tooth structure, the dentist is faced with a significant restorative problem. In these instances, sufficient interarch space is often not available to restore the lost tooth structure without increasing the vertical dimension of occlusion. This represents a complex restorative process involving more than a consideration of the mechanics of individual tooth restoration.

Axial tooth surfaces

Unlike changes in occlusal contours, the alteration of the axial contours of teeth is not caused by tooth-to-tooth wear.

Although it is generally due to erosion or abrasion, occlusally generated stresses may contribute to this phenomenon in some instances.[98] The term *abfraction* is applied when noncarious cervical lesions (NCCLs) are thought to have a combined cause of abrasion and occlusally induced tooth flexure.[99–102] There is general

Dentlearn.ir

agreement that the etiology of NCCLs is multifactorial,[103] Preventive treatment for cervical abrasion is directed at altering the habit or other factor(s) causing the problem. Modification of tooth brushing habits to include the use of small, pea-sized amounts of minimally abrasive toothpastes with a neutral pH can reduce the rate of erosion and abrasion. If abfraction is suspected, treatment should include the nighttime wear of an occlusal appliance.

NCCLs should be included on the problem list to alert the patient to the problem and to ensure that the dentist addresses the possible causes and considers restorative treatment options. In the absence of symptoms, the extent of the lesion should be assessed and restorative intervention should be a matter of clinical judgment. A prudent approach would be to restore the area when tooth loss has progressed to the point that the normal tooth contour could be replaced with restorative material without leaving the restorative material too thin to withstand functional and abrasive stresses. The reader is referred to a 2003 paper on diagnosis and treatment of NCCLs[104] and to chapter 15 for a detailed discussion of etiology and treatment.

Tooth integrity and fractures

Tooth fractures are either complete or incomplete. A 2004 study[105] presented the risk indicators and incidence of complete cusp fractures in posterior teeth. The authors concluded that fewer than 10% of complete cusp fractures of posterior teeth occur in teeth without restorations and that the greatest risk indicator is the presence of a fracture line that is detectable through tactile examination. Lubisich et al[106] reported on the frequency and location of cracked teeth by averaging the results of 12 studies. Mandibular molars comprised 48% of the cracked teeth, while maxillary molars made up 28%. Maxillary premolars were 16% of the cracked teeth, and mandibular premolars were found to have cracks much less frequently at 6%. In the maxillary arch, the first molar and first premolar fractured slightly more frequently than the second molar and premolar. In the mandibular arch, the first molar cracked about twice as often as the second molar. In both arches, the nonholding cusps (maxillary facial cusps and mandibular lingual cusps) tended to fracture more often than the holding cusps. This trait was more pronounced in the mandibular arch.[107,108]

Incomplete tooth fractures are most commonly called *cracked teeth*, but several terms have been used over the years.[109,110] Cracked-tooth syndrome is a fairly common result of the incomplete fracture of a vital tooth. Patients suffering from cracked-tooth syndrome present with a series of symptoms that include discomfort during chewing, unexplained sensitivity to cold, and pain on application or release

Dentlearn.ir

of pressure.[111–117] Cracked-tooth syndrome may be found in restored or unrestored teeth.[118] In restored teeth, it is often associated with existing small to medium-sized restorations.[119,120] A practice-based study of 1,962 molars found that molars with resin composite restorations had 4 times the likelihood of having a crack compared with an unrestored molar, while a molar with an amalgam restoration had 7.7 times the likelihood of having a crack compared with an unrestored molar.[121] Another study of 51 patients concluded that teeth treated with Class 1 or 2 restorations have 29 times greater risk for cracks.[116] Often patients with multiple cracked teeth have parafunctional habits or malocclusions that have contributed to the problem. Cracked-tooth syndrome is an age-related phenomenon; the greatest occurrence is found among patients between 33 and 50 years of age.[118] A recent study of the etiology for increased incidence of incomplete and complete fractures includes intraoral jewelry, especially in the tongue.[122] Lip piercings have been associated with an increase in gingival recession and a slight increase in localized periodontitis.[123]

Cracked-tooth syndrome is often difficult to diagnose. The patient is frequently unable to identify the offending tooth, and evaluation tools, such as radiographs, visual examination, percussion, and pulp tests, are typically nondiagnostic. The two most useful tests are transillumination and the biting test.

Many teeth contain cracks and craze lines, most of which cause no symptoms; however, transillumination of a severely cracked tooth generally presents a distinctive appearance that permits the clinician to distinguish minor cracks from those deep enough to result in symptoms. When a tooth with a severe crack (one that extends into dentin) is transilluminated from either the facial or lingual direction, light transmission is interrupted at the point of the crack.[106] This results in the portion of the tooth on the side away from the light appearing quite dark.

The transition from bright illumination on one side of the tooth to darkness on the other is sudden rather than gradual, occurring abruptly at the point of the fracture (Fig 2-16). The biting test is the most definitive means of localizing the crack responsible for the patient's pain. By having the patient bite a wooden stick, rubber wheel, or one of the commercially available instruments designed for that purpose (eg, Tooth Slooth, Professional Results), the dentist is generally able to reproduce the patient's symptom and identify not only the cracked tooth but also the specific portion of the tooth that is cracked. Crunchy food placed sequentially on suspected teeth has also been suggested as a diagnostic aid.[124] Once the offending tooth has been identified, tooth preparation often allows visualization of the crack (Fig 2-17;

Dentlearn.ir

see also Fig 1-8).

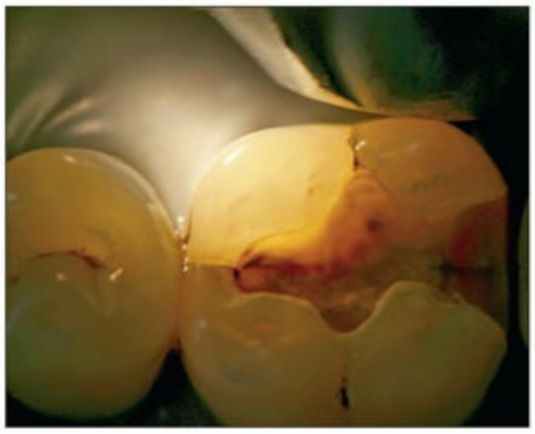

Fig 2-16 With the use of transillumination, cracks in the tooth are visible through the mesial and midlingual areas when the transmission of the light is disrupted.



Fig 2-17 The mesiodistal crack in the pulpal floor of the mandibular right second molar caused sharp pain upon chewing. The tooth is to be restored with an onlay to splint the tooth together during function, relieve the patient's symptoms, and prevent propagation of the crack.

Where direct diagnostic methods prove unsuccessful, indirect methods may be used. Orthodontic bands may be placed on suspected teeth to prevent separation of the crack during function. If the patient's symptoms subside, the diagnosis of cracked-tooth syndrome can be made.

In the treatment of incomplete tooth fracture, the tooth sections are splinted together with a complete-cuspal-coverage restoration.[114,115,119,125] Although a full-veneer crown is often the treatment of choice, cuspal coverage and protection may also be accomplished with the use of an amalgam restoration[126] or an indirectly fabricated onlay of metal, ceramic, or resin composite. Because of their potential to lose bond integrity over time, bonded intracoronal restorations presently have not been considered to be adequate for long-term resolution of the problem.[115,127,128]

Dentlearn.ir

However, several recent studies have demonstrated success with direct resin composite intracoronal or cuspal overlay restorations.[129–131] After their thorough review of the literature, Lubisich et al[106] concluded that cracked teeth with reversible pulpitis could be successfully treated with a full-coverage crown, complex amalgam, or a bonded ceramic or resin composite onlay.

While the diagnosis of incomplete tooth fracture has historically been symptom based, the dental operating microscope, with its high magnification capability, allows the dentist a new level of increased diagnostic sensitivity. An excellent review on the use of the surgical optical microscope in the diagnosis of early enamel and dentin cracks is available.[132]

Esthetic evaluation

In addition to an esthetic evaluation of existing restorations, an assessment of the esthetics of the entire dentition should be completed. Because dental esthetics is a subjective area, patients should be questioned about any dissatisfaction they may have regarding the esthetics of their dentition. In the absence of complaints by the patient, the dentist's impressions regarding esthetic problems should be tactfully conveyed to determine whether the patient would like the esthetic problems addressed. The dentist is often better able than the patient to determine how dental procedures might enhance the patient's appearance. If an agreement is reached between the patient and dentist as to the existence of specific esthetic problems, the problems should be included on the restorative dentistry problem list.

Commonly encountered esthetic problems that are related to or may be addressed by restorative dentistry include *(1)* stained or discolored anterior teeth; *(2)* unesthetic contours in anterior teeth (eg, unesthetic length, width, incisal edge shape, or axial contours); *(3)* unesthetic position or spacing of anterior teeth; *(4)* caries lesions and unesthetic restorations; *(5)* excessive areas of dark space in the buccal corridors due to a constricted arch form; and *(6)* unesthetic color and/or contour of tissue adjacent to anterior restorations. This last problem includes excessive gingival display, occasionally referred to as the "gummy smile." (See chapter 3 for a thorough discussion of esthetic considerations in diagnosis and treatment planning.)

The restorative treatment of esthetic problems may range from conservative therapy, such as bleaching, to more invasive measures, such as the placement of resin composite or ceramic veneers and posterior restorations or complete-coverage crowns. Additionally, adjunctive periodontal, endodontic, or orthodontic procedures may be helpful, depending on the nature of the original problem. Esthetic

Dentlearn.ir

restorations are discussed in subsequent chapters.

Evaluation of the periodontium

From a restorative dentistry perspective, the periodontium must be evaluated primarily for two reasons: *(1)* to determine the effect that the periodontal health of the teeth will have on the restorative dentistry treatment plan and *(2)* to determine the effect that planned and existing restorations will have on the health of the periodontium.

Evaluation of the periodontium consists of a clinical assessment of attachment levels, bony topography, and tooth mobility; a qualitative assessment of tissue health; and a radiographic evaluation of the supporting bone. The assessment of attachment levels involves periodontal probing of the entire dentition with both a straight probe for determination of vertical probing depths and a curved probe to explore root concavities and furcation areas. Any bleeding induced by gentle probing should be noted. A variety of tests are available to aid in determining the presence and identity of periodontal pathogens; however, the most consistent clinical indicator of inflammation is bleeding on probing.[133] Bleeding on probing does not always indicate the presence of active periodontal disease, but active disease has been consistently found to be absent when there is no bleeding on probing.[133]

The qualitative assessment of periodontal tissue health calls for a subjective assessment of the inflammatory status of the tissue; tissue color, texture, contours, edema, and sulcular exudates are noted. The presence of specific local factors, such as plaque and calculus, and their relationship to tissue inflammation should be noted. Abnormal mucogingival architecture, such as gingival dehiscences and areas of minimal attached gingiva, should be recorded. This is especially true when these anomalies are noted in the proximity of existing or planned restorations.

During examination of the periodontium, the dentist not only must be cognizant of periodontal inflammation adjacent to existing restorations but also must estimate the location of margins for future restorations and their potential for impinging on the biologic width. Review of radiographs, especially correctly angulated bitewing radiographs, during the periodontal examination enables the dentist to assess the relationship of existing and planned restorations to bone levels and to correlate radiographic signs with clinical findings.

When the clinical and radiographic portions of the periodontal examination have been completed, a periodontal prognosis should be established for all teeth; special attention should be given to teeth involved in the restorative dentistry treatment plan.

Dentlearn.ir

Teeth requiring restorative treatment that have a guarded periodontal prognosis should be noted in the restorative dentistry problem list. Until the periodontal prognosis becomes predictably positive, the restorative treatment of teeth with a guarded prognosis should be as minimal as possible, and treatment planning that relies on these teeth must remain flexible.

Evaluation of radiographs

The radiographic examination is an essential component of the comprehensive evaluation. Problems detected during the evaluation of radiographs should be listed under the appropriate headings on the problem list (eg, restorative, endodontic, periodontal).

Although radiographs can provide valuable information for use in diagnosis and treatment planning, exposure of patients to ionizing radiation must be minimized; therefore, discretion is required when the dentist orders radiographs. There are no inflexible rules for radiographic evaluation; rather, clinical judgment should be exercised. The goal is to minimize unnecessary exposure and cost but to avoid underutilization, which could result in inadequate diagnosis. The use of patient-specific criteria is the key. Different patients have different requirements both in terms of the radiographic views needed and the frequency with which radiographs should be repeated.

A reasonable guideline to follow is that all dentate patients should initially have a radiographic series completed that reveals the periapical areas of the entire dentition. This will permit detection of central lesions not visible on bitewing radiographs and will serve as a baseline, allowing the clinician to assess changes over time. Bhaskar[134] has reported that approximately 85% of central jaw lesions are apparent in views of the apical areas of the dentition but are not visible on bitewing radiographs. For patients with periodontal disease, periapical and/or vertical bitewing radiographs are indicated. For patients with no significant periodontal pathoses, a panoramic radiograph provides the necessary view. For all patients with approximating teeth, a series of films is indicated to show the proximal areas of posterior teeth. Bitewing radiographs serve this purpose.

The frequency with which radiographs should be updated is a matter of clinical judgment. The dentist should assess the etiologic factors present and determine whether new disease is likely to have occurred since the last radiographic examination. The dentist must weigh the risk of undetected disease against the cumulative risk of radiation exposure. A suggested guideline is to make new

Dentlearn.ir

bitewing radiographs of caries-active adults at 6- to 18-month intervals and of caries-inactive adults every 2 to 3 years.[135,136] Patients may be considered minimally susceptible to caries if they have had no caries lesions in recent years, demonstrate low plaque levels, have adequate salivary flow, have a noncariogenic diet, and exhibit no clinically discernible caries lesions. Periapical radiographs of the entire dentition should be repeated only as dictated by the specific needs of the treatment to be accomplished. For example, a patient under active treatment or maintenance for periodontal disease may require an updated radiographic series every 2 to 3 years to reevaluate bony contours, while another patient whose disease processes are controlled may require subsequent periapical radiographic updates only every 4 to 5 years.

In evaluating radiographic findings for restorative purposes, the dentist should note open interproximal contacts, marginal openings, overhanging restorations, periapical radiolucencies and radiopacities, and radiolucencies within the body of the tooth or the restoration (see Figs 2-4 and 2-6). The dentist must interpret "abnormal" radiographic findings with caution. Many phenomena that are detectable radiographically can also be detected clinically and should be verified clinically before treatment is planned. This is especially true when the clinician evaluates radiolucencies that appear to represent carious tooth structure but may in fact represent nonpathologic structures. An example of this is the radiographic phenomenon commonly known as "burnout" (Fig 2-18). *Burnout* is a radiolucency that is not caused by demineralization but instead occurs when the x-ray beam traverses a portion of the tooth with less thickness than the surrounding areas. It is most commonly found near the cervical area of a tooth and may be caused by concavities in the tooth or the angulation of the beam, but it is also related to the portion of the tooth not covered by enamel or alveolar bone.

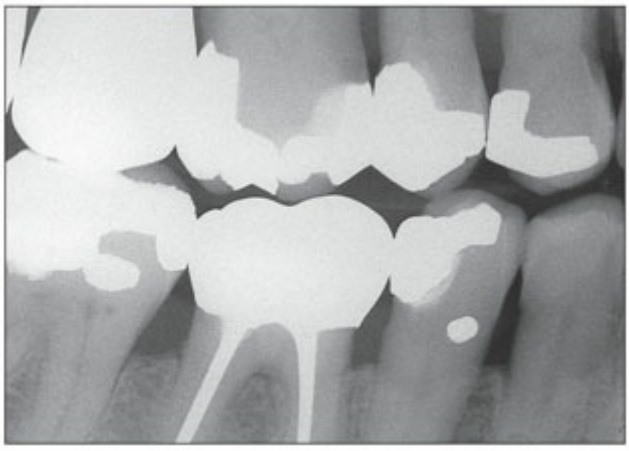

Fig 2-18 The radiolucent area beneath the restoration in the mesial surface of the maxillary first molar is radiographic burnout. No carious tooth structure is present.

Dentlearn.ir

The dentist must be careful not to mistakenly diagnose as demineralized tooth structure a decrease in radiopacity resulting from an abraded area. Likewise, the dentist must be cautious in diagnosing carious tooth structures beneath existing restorations, because certain radiolucent dental materials have a radiographic appearance similar to that of demineralized tooth structure. A comprehensive review of dental radiology has been provided by Goaz and White.[137]

Evaluation of diagnostic casts and photographs

The dentist can gain valuable information through an evaluation of diagnostic casts and patient photographs. The use of diagnostic casts and photographs allows the dentist to thoroughly analyze conditions while the patient is not in the chair. By examining diagnostic casts of the dentition, the dentist can see areas that are visually inaccessible during the clinical examination. Facets and marginal openings that may be difficult to discern intraorally are readily visible on the diagnostic casts. Facets on the casts of the dentition can be aligned to provide a guide to dynamic occlusal relationships. In addition, the dentist may use gypsum casts to complete diagnostic preparations and diagnostic wax-ups, simulating planned treatment. Where removable partial dentures are indicated, survey and design procedures may be completed on the diagnostic casts before restorative treatment is planned. The requirements of removable partial denture design may thus be considered during the planning of restorative care.

Although not every case requires the evaluation of casts mounted on a semiadjustable articulator, cases involving significant occlusal wear, multiple missing teeth, or the restoration of a significant portion of the occlusion should be evaluated with diagnostic casts mounted in centric relation. If multiple teeth are missing, the articulator maintains the correct interarch relationship, permitting buccal and lingual views of interarch spaces. Using a semiadjustable articulator that provides a reasonable approximation of the patient's intercondylar distance, condylar inclination, lateral guidance, and hinge axis of rotation, the dentist can simulate the patient's mandibular movements. This enables the clinician to assess the occlusal scheme and to plan restorative care accordingly.

Treatment Plan

Having completed a comprehensive examination, the dentist documents problems related to restorative dentistry on the restorative dentistry problem list (Fig 2-19).

Dentlearn.ir

Each problem on the list is then reevaluated. After consideration, some of the problems may be deleted. For example, a tooth with a defective restoration may also have a significant loss of periodontal attachment and, therefore, a poor periodontal prognosis. In such a case, the defective restoration is initially considered a problem, but, in view of the periodontal condition, the tooth would be planned for extraction rather than restoration. The defective restoration is then omitted from the restorative problem list. Sometimes the treatment planned to address a problem may lead to additional problems. For example, reducing an extruded tooth to the level of the occlusal plane may result in the need for elective endodontic treatment, surgical crown lengthening, and a full-coverage restoration.

Dentlearn.ir

PATIENT: Blank, Felina D.

PROBLEM LIST

Chief complaint: "My tooth hurts every time I chew, and lately iced tea has made it hurt, too."

Medical/systemic: Hypertension. Present blood pressure: 155/95

Restorative (also see charting):

- Incomplete tooth fracture of mesiolingual cusp, #19
- Caries lesions, #20, #21, #28 (high caries risk)
- Defective restorations, #2, #12
- Facial, noncarious cervical lesion, #12
- Worn incisal edges, #6 to #11
- Fluorosis stain, #8
- Biologic width impingement, #3, distal
- Patient wishes to whiten maxillary anterior teeth

Periodontal:

- AAP Case Type I (see periodontal charting form)
- Generalized marginal gingivitis
- Generalized minimal bone loss with 3- to 4-mm pockets
- Vertical defect, #3, distolingual (5 mm)
- Biologic width problem, #3, distal
- Plaque and calculus: Generalized interproximal plaque in all posterior sextants (modified O'Leary index: 50% plaque free), subgingival calculus revealed on bitewing radiographs of #19 and #30; supragingival calculus present on lingual surfaces of mandibular anterior teeth

Endodontic: None

Prosthodontic: Missing, #29

Orthodontic: None

Occlusion: Supraeruption, #4; excessive wear, #6 to #11

Temporomandibular dysfunction: None

Oral surgery: None

Fig 2-19 Example of a problem list.

Once the final problem list is formulated, the next step is to establish a plan for the treatment of each problem on the list. The treatment planned for each problem should be based on current research evidence to the extent possible.[138] Caries should be treated as a disease using a medical model,[139,140] and interventions to stop demineralization and bring about remineralization should be planned for early caries lesions.[140–142] (See chapter 5 for an in-depth review of current strategies for caries management.) A problem list worksheet (Fig 2-20) is a useful tool to help organize

Dentlearn.ir

the planning of treatment for each problem. It consists of an unsequenced list of problems and their associated solutions. Later, during the sequencing process, this list of treatments will be integrated into the comprehensive treatment plan.

PATIENT: Blank, Felina D.

PROBLEM LIST WORKSHEET

Problem	Treatment
Chief complaint: cracked #19	• Gold onlay
Hypertension	• Referral to physician for evaluation and treatment
Caries	• Educate patient: snacking, hygiene techniques, home fluoride use • Rx: neutral sodium fluoride (1.1%) gel or dentifrice • If caries continues, complete caries risk assessment (diet survey, *S mutans* culture) • #20, #21: Class 5 resin-modified glass-ionomer restorations
Defective restorations	• #2: Mesio-occlusodistal (MOD) amalgam • #4: Porcelain-fused-to-metal (PFM) crown (shorten to level occlusal plane) • #12: Mesio-occlusal resin composite
Abrasion: #12	• Class 5 resin composite restoration
Wear: #6 to #11	• Protective acrylic resin occlusal splint
Fluorosis: #8	• Microabrasion
Biologic width: #3	• Surgical crown lengthening
Patient desires to lighten maxillary anterior teeth	• Home bleaching, #5 to #12
Periodontal inflammation associated with local factors	• Patient education and hygiene instruction; goal: 90% plaque-free index • Prophylaxis; scaling/root planing in mandibular sextants and any areas not responding to initial care • Reevaluate; goal: eliminate bleeding on probing • Surgical crown lengthening, #3: osseous recontouring and soft tissue excision
Missing: #29	• Fixed partial denture (FPD), #28 to #30; PFM retainer, #28; three-quarter retainer, #30
Supraeruption: #4	• Shorten #4 when PFM crown is completed

Fig 2-20 Example of a problem list worksheet to accompany the problem list shown in Fig 2-19.

Planning the restoration of individual teeth is the "nuts and bolts" of restorative dentistry treatment planning. It requires the consideration of four primary factors as well as a number of modifying factors. The primary considerations are *(1)* the amount and form of the remaining tooth structure, *(2)* the functional needs of each

Dentlearn.ir

tooth, *(3)* the esthetic needs of each tooth, and *(4)* the final objective of the overall treatment plan.

Remaining tooth structure

The quantity and location of remaining tooth structure determine the resistance features available for the restoration and thus greatly influence the restorative design. These factors determine not only the resistance to displacement of the restoration but also the fracture resistance of the remaining tooth structure. The clinician should select the restoration that provides for the best retention and the optimal protection of the remaining tooth structure, using the least invasive design possible.

For the restoration of posterior teeth, an intracoronal restoration with amalgam or resin composite is generally the most conservative choice, and both materials have proven to be clinically successful. When the width of the intracoronal preparation of a posterior tooth exceeds one-third of the intercuspal width, the tooth becomes significantly more susceptible to cuspal fracture and the concern becomes not only restoration failure but also tooth fracture.[143]

Even more significant than restoration width to the susceptibility of a tooth to fracture is the depth of the preparation.[144] In instances of deep and/or wide preparations, the clinician must assess the need for occlusal coverage to protect the fracture-prone portions of the tooth. Often the assessment of remaining tooth structure and integrity can be accomplished only after removing the existing restoration and any defective tooth structure. For occlusal coverage, choices include cuspal-coverage amalgam, partial veneer restorations (eg, onlays, three-quarter crowns, or seven-eighths crowns), and complete crowns. The clinician should resist the temptation to progress immediately to a complete crown and instead should select the most conservative choice that satisfies the needs of the individual tooth and the overall treatment plan.

The quantity of remaining tooth structure has an equally important effect on the choice of restorations for anterior teeth. For conservative interproximal restorations in anterior teeth, resin composite is almost always indicated because sufficient tooth structure is generally available for effective resin-enamel and resin-dentin bonding. When extensive facial tooth structure has been esthetically compromised but the facial enamel and the majority of the lingual aspect of the tooth remain intact, a ceramic veneer affords a conservative alternative to a complete crown. The veneer satisfies the esthetic requirement but is considerably less invasive than complete

Dentlearn.ir

coronal coverage. When the facial enamel has been destroyed, significant lingual tooth structure has been lost, occlusal stress is exceptionally heavy, or there is very darkly pigmented dentin, veneers are not a viable option and complete crowns are required (Fig 2-21).



Fig 2-21 Facets and chipped incisal edges are evidence of the severe stresses placed on these anterior teeth by parafunction. Although they demonstrate tetracycline staining and possess a largely intact facial surface, these teeth would be poor candidates for veneer restorations. Complete-coverage restorations are indicated if the patient wishes to mask the tetracycline staining.

Functional needs

The choice of restorative materials and the design of restorations must accommodate the functional needs of the individual patient. This precludes the use of a cookbook approach to treatment planning and requires that the clinician assess the specific circumstances of each tooth before planning restorative procedures. The functional and parafunctional stresses of the occlusion are significant considerations in this decision process. For example, a patient with average-strength musculature, an anterior-guided disocclusion of posterior teeth in excursions, and minimal tendency toward parafunction may require only an intracoronal amalgam or resin composite restoration to restore mesial and distal surfaces of a posterior tooth. In a similar circumstance, a patient with heavy musculature, signs of parafunctional activity, and no anterior-guided disocclusion may require a cast metal restoration that covers the entire occlusal surface to minimize the chances of tooth fracture.

A useful guide in making decisions about material selection and restoration design is the evidence of functional demand provided by the existing dentition. Patients who present with a dentition exhibiting minimal destruction are good candidates for conservative, directly placed restorations. Patients whose teeth exhibit severe wear facets or considerable loss of tooth structure from occlusal attrition are best served by materials high in strength and wear resistance, such as cast metal or possibly

Dentlearn.ir

zirconia restorations.

Restorations planned for NCCLs pose little dilemma in terms of restorative choices. Any of the restorative materials suited to the restoration of Class 5 areas will serve satisfactorily. Glass-ionomer restorative materials have proven to be effective in the restoration of Class 5 areas, providing longevity in excess of 10 years.[145,146] Resin-modified glass-ionomer restorative materials provide an alternative to conventional glass-ionomer cements and have been shown to demonstrate exceptional retention. One study[147] found a retention rate of 98% after 3 years, and an independent study[148] found 100% retention after 5 years. Improvements in the performance of resin adhesives have made the retention of resin composites and polyacid-modified resin composite restorations predictable as well. A number of investigators have reported retention rates for resin composite restorations of over 95% after 3 years.[149,150] Another study reported a resin composite retention rate of 98% after 18 months, but over the following 2 to 3 years the loss rates increased considerably, resulting in a 75% retention rate after 8 years, with no significant difference in retention whether bonding to nonsclerotic or sclerotic dentin.[151] A comparative study of six resin bonding systems and a resin-modified glass ionomer with annual evaluation over a 13-year period concluded that all systems showed a continuous degradation of the bond, with variations dependent on the adhesion strategy. The best retention (about 65%) was achieved with the resin-modified glass ionomer, followed closely by a four-step etch-and-rinse system (about 64%).[146] The glass-ionomer materials offer the anticariogenic advantage of fluoride release, while the materials containing greater amounts of resin composite generally provide better esthetics and wear resistance.

Another strategy for the treatment of NCCLs involves a connective tissue graft or a coronally advanced flap alone or in combination with a resin-modified glass-ionomer restoration. Six-month to 2-year root-coverage results of better than 80%, and some as high as 90%, have been demonstrated. The amount of gingival coverage was unaffected by the presence of a resin-modified glass-ionomer restoration, demonstrating the compatibility of this material with the periodontium.[152,153]

The patient's level of caries activity will influence the selection of restorative materials. Patients whose caries risk assessment indicates a high potential for caries are good candidates for treatment with anticariogenic restorative materials as well as the use of a caries-management protocol.[154] Conventional glass-ionomer cements have been found through clinical study to provide an anticariogenic effect.[54–58] Resin-modified glass-ionomer materials have been found to inhibit simulated caries

Dentlearn.ir

in vitro[47–51] and have been shown to possess anticariogenic properties in the clinical environment.[52,55,56,155] None of the anticariogenic restorative materials presently available are able to withstand the stresses of occlusal function. In addition, in cases of severe caries challenge, such as occurs with patients having greatly diminished salivary flow due to medications or radiation therapy, exposure to additional sources of fluoride beyond that which can be provided by these dental materials is needed to maintain tooth health.[56,157]

Esthetic needs

Establishing the patient's esthetic priorities is essential in planning restorative care. In most instances, the dentist will have the choice of a tooth-colored or a non–tooth-colored restoration for a given situation. Because metals are generally superior in strength and durability, they are the materials of choice when strength and wear resistance are the overriding considerations. With the patient's input, the clinician must decide which requirement is more important, durability or esthetics.

For intracoronal, directly placed restorations in the anterior area of the mouth, resin composites are the obvious choice. They can be made to match most teeth in color and have been shown to be acceptable with a success rate of up to 95% after 5 years; the reasons for failure are surface discoloration, caries, and fracture of the restoration.[157–160] In stress-bearing areas in the posterior aspect of the mouth, amalgam has been the material of choice for direct intracoronal restorations.[161,162] When compared with large amalgam restorations, large resin composite restorations have not always fared as well in clinical studies as do the more conservative restorations.[163,164] Where full or partial occlusal coverage is required, amalgam has been found to yield favorable results, routinely providing service in excess of 10 years[165–167] (Fig 2-22). Recent studies, however, have demonstrated that large, multisurface resin composite restorations are performing as well as multisurface amalgam restorations in excess of 10 years of service.[168–170] In the high-caries-risk patient, amalgam remains the restoration of choice and can be a predictable alternative to crowns.[167,168]

Dentlearn.ir



Fig 2-22 Example of a large cuspal-coverage amalgam restoration. This restoration is 6 years old.

Cast metal restorations offer even greater longevity and should receive special consideration for patients with parafunctional habits (see chapter 20).[171–173] Although these indirect restorations may have accompanying complications, they offer an excellent service to the patient in maintaining tooth function.[174] When occlusal coverage is required in an area of esthetic concern, the clinician may choose between an all-ceramic and a metal-ceramic restoration. All-ceramic restorations generally provide a superior esthetic result, while the metal substructure of metal-ceramic restorations offers tremendous strength. However, recent improvements in the fabrication techniques of all-ceramic restorations have produced high-purity copings that have the potential to replace the metal copings for the metal-ceramic crowns. These copings are made through a slip-casting technique (In-Ceram Alumina, Vident) or a computer-aided milling process (Procera AllCeram, Nobel Biocare).[175] These crowns have demonstrated flexural strengths four to six times greater than conventional feldspathic and pressed porcelain systems.[176] The strongest of the ceramic cores is zirconia, which has a strength that approaches seven times that of conventional porcelains.[39]

Unfortunately, as the strength of the core ceramic increases, the esthetic value decreases, but this may be more important for teeth in the esthetic zone than for posterior teeth. A moderate-strength ceramic core, lithium disilicate (eMax [formerly IPS Empress 2], Ivoclar Vivadent), has good esthetics with or without veneering porcelains and is also four times as strong as traditional porcelains and about one-half as strong as zirconia.[39,176] Giordano[176] reports a success rate of about 97% for Procera from 2-year data in the United States and 5-year data from Europe and a 98% success rate for In-Ceram from 7-year data with anterior and posterior crowns. Other studies evaluating crown survival and clinical success provide favorable data for these stronger ceramic systems.[177–180]

Zirconia-based restorations are rapidly becoming the indirect restoration of

Dentlearn.ir

choice by many practitioners. They not only offer esthetics, biocompatibility, color stability, wear resistance, relatively low cost, and low thermal conductivity but also possess comparable strength to porcelain-fused-to-metal (PFM) restorations. Zirconia-based crowns and fixed partial dentures (FPDs) can be conventionally cemented in a manner similar to that for PFMs. Advances in computer-aided design/computer-assisted manufacture (CAD/CAM) technology have made the use of zirconia more readily available in dentistry. Zirconia has been recommended as suitable for posterior or anterior crowns, long-span FPDs, and implant abutments.[181] The primary concern with zirconia restorations has been the chipping and fracturing of the veneering porcelains. However, more refined processing procedures have started to yield much better results in preventing the loss of the surface porcelain.[182,183]

All-ceramic materials and fiber-reinforced resin materials have been marketed for use in the fabrication of FPDs. One clinical study reported a 93% success rate for 30 posterior lithium disilicate–based core ceramic FPDs after 2 years.[184] In a retrospective study of In-Ceram Alumina–core FPDs, Olsson et al[185] found successful results for anterior FPDs and promising survival rates (93%) for alumina-core posterior FPDs during a 5-year observaion period. Another study demonstrated a 90% success rate after 5 years with In-Ceram Alumina posterior FPDs.[186] Another promising technology is the computer-aided milling of single, large zirconia blanks for the cores of long-span posterior prostheses. A recent in vitro study reported on posterior zirconia-based FPDs spanning up to five units with a life expectancy comparable to metal-ceramic FPDs.[187] Although these results appear promising, more long-term clinical data is required to support the use of all-ceramic core materials as an alternative to metal or metal-ceramic materials for posterior FPDs. With regard to the single missing tooth, osseointegrated dental implants are replacing the traditional FPD as the treatment of choice in appropriate clinical situations.

Ultimately, predictably successful restorations depend on the choice of a system that fits the clinical situation, proper preparation of the tooth, careful laboratory fabrication of the restoration, and careful insertion technique.[188,189] Even though there has been marked improvement in the strength of all-ceramic restorations, they are still subject to fracture if proper preparation principles are not followed (Fig 2-23) . Chapters 17 to 20 are dedicated to the discussion of advantages and disadvantages of the different designs and materials of indirect restorations.

Dentlearn.ir



Fig 2-23 Example of a catastrophic failure of an all-ceramic crown. The crown is 5 years old. The failure is probably due to inadequate tooth preparation of the palatal cusp and excessive occlusal forces. The thin porcelain is visible at the mesial aspect of the fracture.

Final treatment objective

The anticipated ultimate outcome of restorative and prosthodontic rehabilitation is the final factor to consider when the design of a restoration is planned and the restorative material is selected. Teeth that may require one type of restoration to restore health and function may require a different treatment to meet the needs of the final treatment plan. For example, if implant treatment is planned or if no prosthodontic replacement is planned for teeth that are missing, the teeth adjacent to the edentulous area may require only conservative restorative care for the treatment of small caries lesions. In a different treatment plan that calls for replacement of the missing teeth with a removable partial denture, surveyed indirect restorations may be required for the teeth adjacent to the edentulous area. In a third variation of the same case, missing teeth may be replaced with an FPD and the teeth in question may be needed as FPD abutments.

When the final treatment objective has been visualized, it is often possible to identify certain teeth as key teeth, the retention and restoration of which are crucial to the success of the treatment plan. These teeth are often potential prosthodontic abutments and/or canine teeth, which are typically critical for developing an appropriate occlusal scheme in the final restorative rehabilitation. Because the success of the total treatment plan often hinges on these teeth, it is crucial to ascertain their periodontal and endodontic prognosis and to plan the restorative treatment that provides the best long-term prognosis. This may dictate an aggressive restorative design to achieve the most predictable success for these key teeth.

The following example serves to illustrate this principle. A hypothetical patient has a freestanding second molar that contains a defective mesio-occlusodistal (MOD) amalgam restoration. Although the facial wall location slightly undermines

Dentlearn.ir

the facial cusp, a replacement amalgam restoration appears likely to function adequately. In the comprehensive treatment plan, the tooth will serve as a distal abutment for a removable partial denture. With mere replacement of the defective amalgam restoration, the tooth is at some risk for cuspal fracture in the future. Fracture of the tooth would necessitate fabrication of a crown beneath the removable partial denture. By planning a crown prior to fabrication of the removable partial denture, a treatment plan somewhat more aggressive than would be dictated by the needs of the individual tooth, the prognosis for the ultimate treatment objective becomes more predictable and the risk of compromising the final result is reduced. This does not mean that every removable partial denture abutment should receive a crown, but it is intended to convey the importance of planning for predictable longevity in key teeth.

Treatment Sequence

Once the completed treatment has been envisioned and the design of the restorations required to address each problem on the restorative dentistry problem list has been established, the final step in establishing the restorative treatment plan is sequencing the treatment, which can present a significant challenge. Proper sequencing of all procedures involved is critical to successfully achieving the treatment goals. The dentist not only must be able to envision the ultimate outcome of treatment but must also understand the order in which the proce- dures must be performed to achieve that outcome. Considerable thought is required to understand and plan a treatment sequence that avoids unnecessary complications.

Most restorative treatment will fall into the categories of disease control or definitive rehabilitation treatment. Restorative treatment aimed at controlling active disease generally consists of direct restorative procedures using amalgam, resin composite, or glass-ionomer materials. Assuming that the patient's chief complaint has been satisfactorily addressed, the sequence of treatment within the disease control phase is dictated by three considerations: *(1)* severity of the disease process (ie, the most symptomatic tooth, the tooth with the deepest lesion, or the most debilitated tooth is restored first), *(2)* esthetic needs, and *(3)* effective use of time. At each appointment, treatment is rendered in the area in the most acute need of treatment. When possible, the restorations should be completed by sextant or quadrant to optimize the use of time.

Treatment provided in the definitive rehabilitation phase goes beyond that needed for the stabilization of active disease and includes restorative treatment designed

Dentlearn.ir

primarily to enhance esthetics (eg, ceramic veneers) and to provide optimum function (eg, replacement of missing teeth using FPDs) and resistance to oral stresses (eg, cast restorations).

One of the primary benefits of segregating the restorative treatment into these categories is that a formal reevaluation is completed at the end of the disease control phase before progressing into the definitive treatment phase. This is not to imply that the phased approach to restorative care is so structured as to preclude consideration of definitive care in the disease control phase. For example, a patient who has demonstrated good plaque control and has adequate finances may require an amalgam build-up on a maxillary first premolar as part of the disease control phase of treatment. Ultimately, it is anticipated that this tooth will receive an all-ceramic crown. However, this amalgam build-up would be esthetically unacceptable to the patient, and so the amalgam core may be immediately prepared for a crown and a provisional restoration placed during the disease control phase of care. The phased approach incorporates into the plan the opportunity to modify or curtail restorative treatment after the control of caries and the replacement of defective restorations. There can be many reasons for altering the original treatment plan, including the patient's desires, disease risk, failure to accomplish disease control, finances, or the doctor-patient relationship.

The patient's financial situation or third-party payment guidelines may dictate that treatment be divided into stages and completed over a period of time. Organization of treatment into phases serves the patient's most urgent needs first, directing resources into the management of active disease and allowing less acute problems to be addressed as finances permit.

As previously emphasized, treatment planning for restorative dentistry requires that the dentist recognize the sequence in which restorative care should be provided within the context of the overall plan. It is not enough to be able to envision the final goal of treatment; one must be able to visualize each step that must be accomplished to achieve this goal. The following example illustrates this point.

A patient presented stating that he wished to "close the spaces" between his front teeth (Fig 2-24a). Upon evaluation, this seemingly simple request revealed a complex set of problems. The dentist recognized the problem associated with the patient's chief complaint: diastemata resulting from a tooth-size versus jaw-size discrepancy. The dentist also recognized other esthetic problems associated with the anterior teeth (Fig 2-24b): fluorosis-related discolorations of the teeth and incomplete exposure of the crowns of the anterior teeth due to altered passive eruption of the maxillary lateral incisors.

Dentlearn.ir



Fig 2-24*(a)* The patient wished to close the diastemata adjacent to the maxillary lateral incisors. *(b)* A close-up view reveals, in addition to the diastemata and discolored anterior teeth, the unesthetically short clinical crowns of the maxillary lateral incisors. For better space distribution prior to ceramic veneer fabrication, the maxillary lateral incisors need to be repositioned distally

Dentlearn.ir

and their crowns lengthened. The mandibular canines are obstructing movement of the maxillary lateral incisors into the desired locations. *(c)* The maxillary lateral incisors have been repositioned orthodontically. Space was created by odontoplasty of the mandibular canines followed by resin composite restorations. The space redistribution permits diastema closure to be completed by adding restorative material to all six anterior teeth, which avoids the problem of making any single tooth excessively wide. *(d)* Mucogingival flap elevation reveals the osseous crest to be immediately adjacent to the cementoenamel junctions of the maxillary lateral incisors. This anatomical relationship is responsible for the gingiva covering a portion of the crowns of these teeth. *(e)* Ostectomy and osteoplasty have created approximately 3 mm of space for the combination of sulcus depth, connective tissue attachment, and epithelial attachment. This space will allow the gingival crest to reside at the level of the cervical margin of the veneers, displaying the entire crown of each tooth. *(f)* Three months after surgery, healing is complete and the teeth are ready for veneer preparation. *(g)* One month after veneer placement (maxillary first premolar to first premolar). The spaces have been closed, and the fluorosis-related discoloration has been eliminated. *(h)* The patient was extremely satisfied with the final results of his multidisciplinary treatment.

The dentist considered possible solutions to the diastema problem. The two most common solutions to this type of space-related problem are *(1)* closure of the spaces by the placement of restorations and *(2)* orthodontic retraction of the maxillary teeth, creating a smaller arch perimeter and reducing or eliminating the spaces between the teeth. An occlusal analysis revealed that the maxillomandibular dental relationships would not permit retraction of the maxillary anterior teeth (see Fig 2-24b). Thus, complete space closure would require filling all of the open spaces with tooth-colored restorative materials. A space analysis and a diagnostic wax-up revealed that closure of all of the spaces would result in excessive (unesthetic) widening of the maxillary lateral incisors and canines. Complete space closure would be esthetically acceptable only if it were accomplished by adding a small amount of restorative material to all of the maxillary anterior teeth. The two options available were *(1)* partial closure of the diastemata with tooth-colored restorative material, leaving small spaces between the maxillary lateral incisors and canines, or *(2)* orthodontic redistribution of the existing spaces followed by complete space closure using tooth-colored restorations placed on all six maxillary anterior teeth.

When presented with these possibilities, the patient stated that he would prefer complete space closure and would be willing to undergo orthodontic treatment to accomplish this. The dentist then visualized the optimal treatment goal and realized that the maxillary lateral incisors would need to be moved to a more distal position to equalize the anterior spacing. This was added to the problem list. Visualizing the distal movement of the maxillary lateral incisors, the dentist realized that the positions of the mandibular canines would interfere with this movement. This presented a new problem, which was added to the problem list. The dentist

Dentlearn.ir

considered two options: *(1)* orthodontic movement of the mandibular canines or *(2)* alteration of the contour of the mandibular canines to accommodate the repositioning of the maxillary lateral incisors. The orthodontic movement required to reposition the mandibular canines was deemed unfeasible, so the second option was selected.

Having determined the feasibility of orthodontic space redistribution for the maxillary anterior teeth, the dentist visualized the final result. Increasing the width of the anterior teeth using tooth-colored restorations (ceramic veneers) would increase the tooth-width to tooth-height ratio, making the maxillary lateral incisors appear unesthetically short and wide. Diagnostic periodontal probing and bone sounding procedures were completed to address this newfound problem. The relative locations of the cementoenamel junctions and the distances from the gingival crests to the osseous crests of the maxillary lateral incisors were determined. It was decided that the ideal solution for the "short tooth" problem of the maxillary lateral incisors was to expose the complete crown of these teeth through surgical crown lengthening before ceramic veneer placement. This plan was presented and was accepted by the patient.

In stepwise fashion, the entire problem complex was broken down into its individual components. Each component and its proposed solution were assessed. Any new problems that were created by proposed treatment were considered. The final chain of treatment was established and presented to the patient. By recognizing which form of treatment was required to address each component problem, the dentist was able to plan the entire sequence before initiating treatment. All of the proposed procedures were completed, and the treatment of the patient's anterior esthetic problem was realized (Figs 2-24c to 2-24h).

The Dental Record

Accurate and descriptive record keeping is essential to quality dental care. The dental chart should include findings from the history and examination, the problem list, the treatment plan, and a description of the treatment accomplished. This record serves several purposes:

- Organization and documentation of the examination findings, the problem list, the treatment plan, and the treatment rendered
- Documentation for third-party payment, if applicable
- Legal purposes

Dentlearn.ir

- Forensic purposes

Organizing and documenting the examination findings and the problem list enable the dentist to evaluate the patient's dental problems and plan the treatment when the patient is no longer present. Once treatment has begun, documentation of the sequenced treatment plan also permits the dentist to review the anticipated treatment without the need to reconsider the entire treatment planning process. Dental records should include the following information:

- Charting of examination findings, including existing restorations and dental relationships (eg, diastemata, dentoalveolar extrusion, tilted teeth), existing periodontal and endodontic conditions, occlusal relationships, and caries lesions and defective restorations
- Medical history and consultations
- Problem list
- Treatment plan
- Description of treatment provided
- Informed consent documentation
- Follow-up assessment

In addition to handwritten or, more recently, electronic entries in a dental record, pictorial charting is an efficient means of recording a great deal of information in a small area (Figs 2-25 and 2-26). Intraoral imaging devices, either conventional cameras or videographic recording devices, provide an extremely effective means of recording findings and documenting treatment and are an ideal complement to a pictorial charting system. These offer the added advantage of simplifying communication with the patient and third-party funding agencies.

Dentlearn.ir

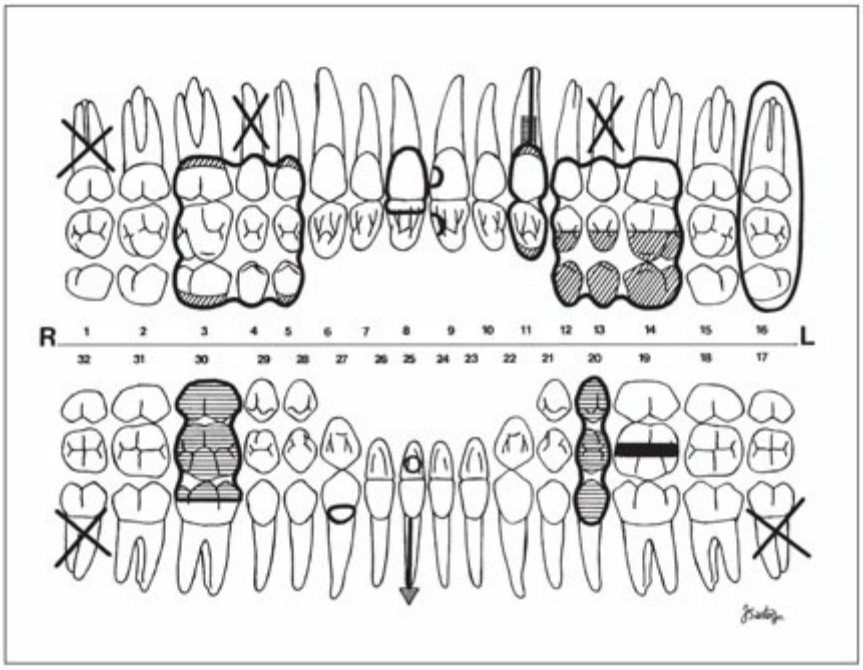

Fig 2-25 Example of a pictorial charting system used to record dental restorations. Any system that distinguishes among the various restorations is acceptable. In this example, tooth 1 is missing; tooth 4 has been replaced with a metal-ceramic FPD that extends from tooth 3 to tooth 5 with ceramic occlusal coverage; tooth 8 has a facial veneer; tooth 9 has a mesial resin composite restoration; tooth 11 has been endodontically treated and has a post and metal-ceramic crown; tooth 13 has been replaced by a metal-ceramic FPD that extends from tooth 12 to tooth 14 with metal occlusal coverage; tooth 16 is impacted; tooth 17 is missing; tooth 19 has an MOD amalgam restoration; tooth 20 has been restored with a metal crown; tooth 25 has been endodontically treated, received a retrograde restoration, and has a resin composite restoration in the lingual access opening; tooth 27 has a facial tooth-colored restoration; tooth 30 has a metal three-quarter crown; and tooth 32 is missing.

Dentlearn.ir

PATIENT: Blank, Felina D.

TREATMENT PLAN BY APPOINTMENT

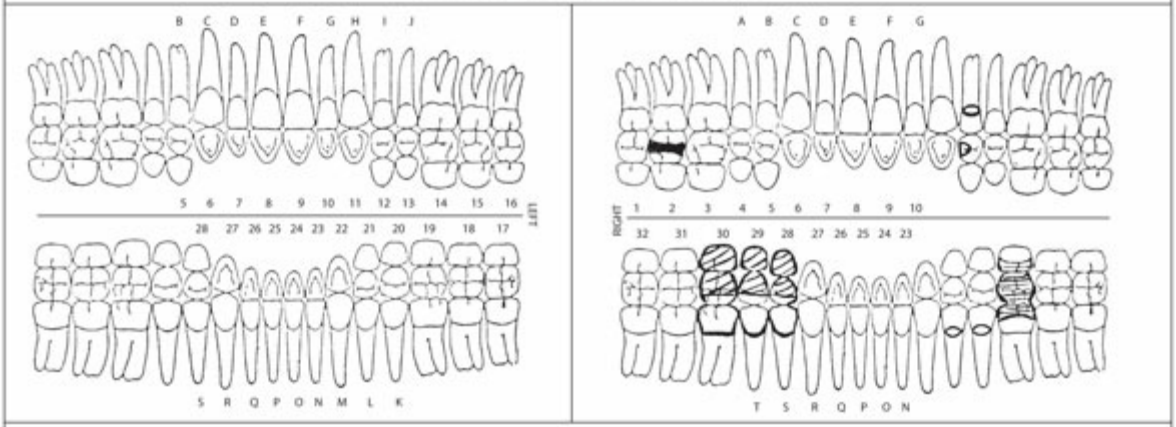

REMARKS

Appt	Problem	Treatment	Time	Total cost	Patient cost	Insur. code	Comp. date
1	CC: #19 Hypertension	Discuss & defer until after med Tx Refer to Dr Dogood	30 min				
2	Tx plan Caries Periodontics	Present Tx plan Counseling; diet and hygiene instruction Plaque index; prophylaxis; scale/root plane mandibular posterior sextants	Dr: 30 min Hygiene: 60 min				
3	Cracked: #19	Prep gold onlay	45 min				
4	Defective restorations: #2, #12	#2: MOD amalgam #12: MO resin composite #12: Class 5 resin composite	60 min				
5	Caries: #20, #21 #19	Resin-modified glass ionomer, Class 5 facial #20, #21 Deliver #19 gold onlay	60 min				
6	Biologic width: #3	Crown lengthening surgery	45 min				
7	Biologic width: #3	Postop evaluation (1 week)	10 min				
8	Reevaluation	Perio and hygiene reeval; confirm definite phase plan	20 min				
9	Missing: #29 Supraerupted: #4	Prep FPD, #28–#30 Shorten	2 h				
10	Missing: #29	Deliver FPD, #28–#30 Impression for occlusal splint	90 min				
11	Wear: #6–#11	Deliver occlusal splint	30 min				
12	Fluorosis: #8	Microabrasion; maxillary impression for bleaching stent	30 min				
13	Color: maxillary anterior teeth	Deliver bleaching stent & give use instructions	15 min				
14	Color: maxillary anterior teeth	Reevaluate bleaching results; reinforce hygiene	10 min				
15	Maintenance	Prophylaxis; fluoride; reexamination	Dr: 10 min Hygiene: 30 min				

Fig 2-26 Example of a combined written and pictorial treatment planning worksheet. The pictorial charts are for use in recording both completed treatment *(left)* and treatment yet to be accomplished *(right)*. Once completed, the treatment charted in pencil on the right may be erased. The remarks section is for making comments, generally in pencil (erased and updated as needed). The area below the remarks section is for the sequenced treatment plan. A treatment planning sheet such as this allows for quick review of the overall treatment plan and provides a profile of the current status of treatment.

The format used to document the care provided should reflect an orderly and

Dentlearn.ir

logical diagnostic and treatment sequence. A method commonly used in medicine that satisfies this requirement is the SOAP format. *SOAP* is an acronym for the steps involved whenever any treatment is rendered. *S* refers to subjective findings. This includes a summary of the patient's medical status, chief complaint, a description of his or her symptoms, and any other relevant information the patient provides. The patient's own words should be used as much as possible. The *O* refers to objective findings. These include both extraoral and intraoral examination findings (including vital signs) and the results of consultations and diagnostic tests. *A* refers to the assessment, which is the dentist's diagnosis, based on the subjective and objective findings present as well as overall patient assessment (for example, a patient with a high caries risk). The *P* refers to the plan of treatment (when the treatment is rendered immediately, it refers to the procedures or the treatment itself). An example of the use of the SOAP format is provided in Box 2-3.

Box 2-3 **Example of SOAP format**

S: Patient presents complaint of a "toothache that began yesterday and has hurt all night." (Patient points to tooth 30.) Patient states that ice water reduces the pain.
O: Teeth 27 and 30 are within normal limits (WNL) to percussion, palpation, and periodontal examination and are vital and normal to cold testing. Tooth 31 is painful to percussion, and pain is alleviated with the application of cold. Radiographs of teeth 27 to 31 are unremarkable, except for a deep mesio-occlusal amalgam restoration on tooth 31
A: Tooth 31 has irreversible pulpitis.
P: Patient advised of diagnosis. Patient consents to endodontic treatment on tooth 31. Appointment for pulpectomy on tooth 31 at 3:00 PM today.

The SOAP format is an excellent guide in the performance and documentation of care when a challenging diagnostic problem presents itself; however, it is less suited to the routine restorative care provided based on the treatment plan. When a straightforward diagnosis is made in the absence of symptoms and patient complaint, a more concise form of documentation is appropriate (Box 2-4).

Box 2-4 **Example of concise form**

DX: Caries in tooth 3, vital to cold and asymptomatic.

Dentlearn.ir

TX: Tooth 3: MOD amalgam (Tytin), Amalgambond, rubber dam. Local anesthesia: 36 mg lidocaine, with 0.018 mg epinephrine.
Plan: Schedule appointment for preparation of veneers for teeth 5 to 12.

There are times when the identification of a deceased individual must be accomplished through the use of dental records. A complete record of the dentition and restorations, a radiographic survey, and photographic records are useful for identification purposes.

The dental record is a legal document. The nature and clarity of the entries made should reflect the knowledge that it may be needed in a court of law to document examination findings, informed consent, and treatment completed. The records should be accurate and should contain the elements listed above. They should not contain erasures or text that has been obliterated by any means. If errors are made, a single line should be drawn through the mistake and the change should be initialed and dated. In the retrospective review of a legal investigation, the descriptiveness and clarity of the record is often held to be an indication of the quality of care provided.

Summary

Treatment planning for restorative dentistry can be a complex undertaking. Use of a logical and orderly problem-oriented approach can simplify the process. The following principles have been offered as guidelines:

- Be aware of pathoses that may be encountered and be able to distinguish the normal from the abnormal and stable from risk-prone situations.
- Organize abnormal findings into a problem list.
- Envision an overall restorative goal for the patient. This is the anticipated final state of rehabilitation. Not every patient can be restored to the ideal, but each patient has an optimum state of health that can be obtained given his or her circumstances.
- Determine a treatment plan for each problem so that each treatment contributes to the achievement of the anticipated ultimate treatment goal. This is the linchpin of restorative treatment planning. It requires that the dentist consider a number of

Dentlearn.ir

factors before selecting the optimum restorative option. Chief among these considerations are the overall goal of treatment, the functional and esthetic needs of each restorative situation (using the existing dentition and restorations as an indicator of the performance of future restorations), the strengths and weaknesses of the various restorative materials available, and the amount and location of remaining tooth structure.

- Recognize the sequence of steps needed to achieve a specific restorative objective. The dentist must know, for example, that a tooth fractured at the level of the osseous crest and in need of a crown will require endodontic treatment, a post and core, and crown lengthening surgery before fabrication of the definitive restoration.
- Sequence the treatment based on a logical model. Control active disease processes first, beginning treatment with teeth in the most acute need of care. Complete as much care as is feasible in each sextant at the same appointment. Establish a restorative prognosis for key teeth early in the treatment schedule. Consider nondental factors (especially third-party payment guidelines and time-related limits) when planning the treatment schedule.

References

1. Little JW, Falace DA, Miller CS, Rhodus NL. Dental Management of the Medically Compromised Patient, ed 7. St Louis: Mosby Elsevier, 2008.
2. Stefanac SJ, Nesbit SP. Treatment Planning in Dentistry, ed 2. St Louis: Mosby Elsevier, 2007.
3. Bickley LS. Bates' Guide to Physical Examination and History Taking, ed 10. Philadelphia: Lippincott, Williams, and Wilkins, 2008.
4. O'Leary TJ, Drake RB, Naylor JE. The plaque control record. J Periodontol 1972;43:38.
5. Disney JA, Graves RC, Stamm JW, Bohannan HM, Abernathy JR, Zack DD. The University of North Carolina Caries Risk Assessment study: Further developments in caries risk prediction. Community Dent Oral Epidemiol 1992;20:64–75.
6. Wyatt C, MacEntee M. Dental caries in chronically disabled elders. Spec Care Dentist 1997;17:196–202.
7. Caries diagnosis and risk assessment. A review of preventive strategies and management. J Am Dent Assoc 1995;126(suppl):1S–24S.
8. van Palenstein Helderman WH, Matee MIN, van der Hoeven JS, Mikx FHM. Cariogenicity depends more on diet than the prevailing mutans streptococcal species. J Dent Res 1996;75:535–545.
9. Mendoza M, Mobley CL, Hattaway K. Caries risk management and the role of dietary assessment [abstract 33]. J Dent Res 1995;74:16.
10. Mobley CC. Nutrition and dental caries. Dent Clin North Am 2003;47: 319–336.
11. Stack KM, Papas AS. Xerostomia: Etiology and clinical management. Nutr Clin Care 2001;4:15–21.
12. Kaufman E, Lamster IB. The diagnostic applications of saliva—A review. Crit Rev Oral Biol Med 2002;13:197–212.
13. Dodds MW, Johnson DA, Yeh CK. Health benefits of saliva: A review. J Dent 2005;33:223–233.
14. Ship JA, Fox PC, Baum BJ. How much saliva is enough? Normal function defined. J Am Dent Assoc

Dentlearn.ir

1991;122:63–69.
15. Valdez IH, Fox PC. Diagnosis and management of salivary dysfunction. Crit Rev Oral Biol Med 1994;4:271–277.
16. Guggenheimer JG, Moore PA. Xerostomia: Etiology, recognition and treatment. J Am Dent Assoc 2003;134:61–69.
17. Dodds M, Suddick R. Caries risk assessment for determination of focus and intensity of prevention in a dental school clinic. J Dent Educ 1995; 59:945–956.
18. Navazesh M, Christensen C, Brightman V. Clinical criteria for the diagnosis of salivary gland hypofunction. J Dent Res 1992;71:1363–1369.
19. van Houte JH. Bacterial specificity in the etiology of dental caries. Int Dent J 1980;30:305–326.
20. Hong X, Hu DY. Salivary *Streptococcus mutans* level: Value in caries prediction for 11–12-year-old children. Community Dent Health 2010; 27;4:248–252.
21. MacEntee MI, Clark DC, Glick N. Predictors of caries in old age. Gerontology 1993;10:90–97.
22. Wenzel A, Larsen MJ, Fejerskov O. Detection of occlusal caries without cavitation by visual inspection, film radiographs, xeroradiographs and digitized radiographs. Caries Res 1991;25:365–371.
23. Chan DCN. Current methods and criteria for caries diagnosis in North America. J Dent Educ 1993;57:422–427.
24. Bader JD, Brown JP. Dilemmas in caries diagnosis. J Am Dent Assoc 1993;124:48–50.
25. Bergman G, Linden LA. The action of the explorer on incipient caries. Sven Tandlak 1969;62:629–634.
26. Dodds MWJ. Dilemmas in caries diagnosis—Applications to current practice and need for research. J Dent Educ 1993;57:433–438.
27. Ekstrand K, Qvist V, Thylstrup A. Light microscope study of the effect of probing in occlusal surfaces. Caries Res 1987;21:368–374.
28. Braga MM, Mendes FM, Ekstrand KR. Detection activity assessment and diagnosis of dental caries lesions. Dent Clin North Am 2010;54:479–493.
29. Mertz-Fairhurst E, Curtis JW, Ergle JW, Rueggeberg FA, Adair SM. Ultraconservative and cariostatic and sealed restorations: Results at year 10. J Am Dent Assoc 1998;129:55–66.
30. Azarpazhooh A, Main PA. Pit and fissure sealants in the prevention of dental caries in children and adolescents: A systematic review. J Can Dent Assoc 2008;74:171–214.
31. Hargreaves KM, Cohen S. Cohen's Pathways of the Pulp, ed 10. St Louis: Mosby Elsevier, 2011.
32. Schwartz RS, Robbins JW. Post placement and restoration of endodontically treated teeth: A literature review. J Endod 2004;30:289–301.
33. Sorenson JA, Martinoff MD. Intracoronal reinforcement and coronal coverage: A study of endodontically treated teeth. J Prosthet Dent 1984;51:780–784.
34. Trope M, Maltz DO, Tronstad L. Resistance to fracture of restored endodontically treated teeth. Endod Dent Traumatol 1985;1:108–111.
35. Robbins JW. Guidelines for the restoration of endodontically treated teeth. J Am Dent Assoc 1990;120:558–566.
36. Goodacre CJ, Spolnik KJ. The prosthodontic management of endodontically treated teeth: A literature review. Part 1. Success and failure data, treatment concepts. J Prosthodont 1994;3:243–250.
37. Trabert KC, Caputo AA, Abou-Rass M. Tooth fracture: A comparison of endodontic and restorative treatments. J Endod 1978;4:341–345.
38. Kidd EAM, O'Hara JW. The caries status of occlusal amalgam restorations with marginal defects. J Dent Res 1990;69:1275–1277.
39. Anusavice KJ. Phillips' Science of Dental Materials, ed 11. St Louis: Saunders, 2003.
40. Summitt JB, Osborne JM. Initial preparations for amalgam restorations: Extending the longevity of the tooth-restoration unit. J Am Dent Assoc 1993;123:67–73.
41. Roberts HW, Charlton DG, Murchison DF. Repair of non-carious amalgam margin defects. Oper Dent 2001;26:273–276.
42. Gordan VV, Riley JL, Blaser PK, Garvan CW, Mjör IA. Alternative treatments to replacement of defective

Dentlearn.ir

amalgam restorations: Results of a seven-year clinical study. J Am Dent Assoc 2011;142:842–849.
43. Smales RJ, Hawthorne WS. Long-term survival of repaired amalgams, recemented crowns and gold castings. Oper Dent 2004;29:249–253.
44. Svanberg M, Mjör IA, Orstavik D. Mutans streptococci in plaque from margins of amalgam, composite and glass ionomer restorations. J Dent Res 1990;69:861–864.
45. Gordan VV, Shen C, Riley J, Mjör IA. Two-year clinical evaluation of repair versus replacement of composite restorations. J Esthet Restor Dent 2006;18:144–153.
46. O'Neal SJ, Miracle RL, Leinfelder KF. Evaluating interfacial gaps for esthetic inlays. J Am Dent Assoc 1993;124:48–54.
47. Gilmour ASM, Edmunds DH, Newcombe RG. Prevalence and depth of artificial caries-like lesions adjacent to cavities prepared in roots and restored with a glass ionomer or a dentin-bonded composite material. J Dent Res 1997;76:1854–1861.
48. Hara AT, Turssi CP, Serra MC, Nogueira MCS. Extent of the cariostatic effect on root dentin provided by fluoride-containing restorative materials. Oper Dent 2002;27:480–487.
49. Nagamine M, Itota T, Torii Y, Irie M, Staninec M, Inoue K. Effect of resin-modified glass ionomer cements on secondary caries. Am J Dent 1997; 10:173–178.
50. Souto M, Donley KJ. Caries inhibition of glass ionomers. Am J Dent 1994;7:122–124.
51. Tantbirojn D, Douglas WH, Versluis A. Inhibitive effect of a resin-modified glass ionomer cement on remote enamel artificial caries. Caries Res 1997;31:275–280.
52. Duque C, Negrini TC, Hebling J, Spolidoro DMP. Inhibitory activity of glass-ionomer cements on cariogenic bacteria. Oper Dent 2005;30: 636–640.
53. Mickenautsch S, Yengopal V. Absence of carious lesions at margins of glass-ionomer cement and amalgam restorations: An update of systematic review evidence. BMC Res Notes 2011;4:58.
54. Donly KJ, Segura A, Wefel JS, Hogan MM. Evaluating the effects of fluoride-releasing dental materials on adjacent interproximal caries. J Am Dent Assoc 1999;130:817–825.
55. Haveman CW, Summitt JB, Burgess JO, Carlson K. Three restorative materials and topical fluoride gel used in xerostomic patients. A clinical comparison. J Am Dent Assoc 2003;134:177–184.
56. McComb D, Erickson RL, Maxymiw WG, Wood RE. A clinical comparison of glass ionomer, resin-modified glass ionomer and resin composite restorations in the treatment of cervical caries in xerostomic head and neck radiation patients. Oper Dent 2002;27:430–437.
57. Qvist V, Laurberg L, Poulsen A, Teglers PT. Longevity and cariostatic effects of everyday conventional glass-ionomer and amalgam restorations in primary teeth: Three-year results. J Dent Res 1997;76:1387–1396.
58. Tyas M. Cariostatic effect of glass ionomer cement: A five-year clinical study. Aust Dent J 1991;36:236–239.
59. Maynard JG, Wilson RD. Physiologic dimensions of the periodontium fundamental to successful restorative dentistry. J Periodontol 1979;50: 170–174.
60. Than A, Duguid R, McKendrick AJW. Relationship between restorations and the level of periodontal attachment. J Clin Periodontol 1982;9:193–202.
61. Waerhaug J. Effect of rough surfaces upon the gingival tissues. J Dent Res 1956;35:323–327.
62. Faurschou A, Menne T, Johansen JD, Thyssen JP. Metal allergen of the 21 century—A review on exposure, epidemiology and clinical manifestations of palladium allergy. Contact Dermatitis 2011;64:185–195.
63. Raap U, Stiesch M, Reh H, Kapp A, Werfel T. Investigation of contact allergy to dental materials in 206 patients. Contact Dermatitis 2009; 60:339–343.
64. Song H, Yin W, Ma Q. Allergic palmoplantar pustulosis caused by cobalt in cast dental crown: A case report. Oral Surg Oral Med Oral Pathol Oral Radiol Endod 2011;111:e8–e10.
65. Schultz JC, Connelly E, Glesne L, Warshaw EM. Cutaneous and oral eruption from oral exposure to nickel in dental braces. Dermatitis 2004; 15:154–157.
66. Hansen PA, West LA. Allergic reaction following insertion of a Pd-Cu-Au fixed partial denture: A clinical report. J Prosthodont 1997;6:144–148.
67. Löe H. Reaction of marginal periodontal tissue to restorative procedures. Int Dent J 1968;18:759–778.
68. Glickman I. Inflammation and trauma from occlusion, co-destructive factors in chronic periodontal disease. J

Dentlearn.ir

Periodontol 1963;34:5–10.
69. Waerhaug J, Hansen ER. Periodontal changes incident to prolonged occlusal overload in monkeys. Acta Odontol Scand 1966;24:91–105.
70. Waerhaug J. The angular bone defect and its relationship to trauma from occlusion and downgrowth of subgingival plaque. J Clin Periodontol 1979;6:61–82.
71. Kantor M, Polson A, Zander H. Alveolar bone regeneration after removal of inflammatory and traumatic factors. J Periodontol 1976;47:687–695.
72. Lindhe JA, Svanberg G. Influence of trauma from occlusion on progression of experimental periodontitis in the beagle dog. J Clin Periodontol 1974;1:3–14.
73. Pihlstrom B, Anderson K, Aeppli D, Schaffer E. Association between signs of trauma from occlusion and periodontitis. J Periodontol 1986; 57:1–6.
74. Jin L, Cao C. Clinical diagnosis of trauma from occlusion and its relation with severity of periodontitis. J Clin Periodontol 1992;19:92–97.
75. Nunn ME, Harrel SK. The effect of occlusal discrepancies on perioodontitis. I. Relationship of initial occlusal discrepancies to initial clinical parameters. J Periodontol 2001;72:485–494.
76. Harrel SK, Nunn ME. The effect of occlusal discrepancies on periodontitis. II. Relationship of occlusal treatment to the progression of periodontal disease. J Periodontol 2001;72:495–505.
77. Mjör I. Glass-ionomer cement restorations and secondary caries: A preliminary report. Quintessence Int 1996;27:171–174.
78. Oh WS, DeLong R, Anusavice KJ. Factors affecting enamel and ceramic wear: A literature review. J Prosthet Dent 2002;87:451–459.
79. Verrett RG. Analyzing the etiology of an extremely worn dentition. J Prosthodont 2001;10:224–233.
80. Lambrechts P, Braem M, Vuylsteke-Wauters M, Vanherle G. Quantitative in vivo wear of human enamel. J Dent Res 1989;68:1752–1754.
81. Stober T, Dreyhaupt J, Lehnung U, Rammelsberg P. Occlusal wear of metal-free ceramic-filled polymer crowns after 2 years in service. Int J Prosthodont 2008;21:161–165.
82. Lambrechts P, Braem M, Vanherle G. Evaluation of clinical performance for posterior composites and dentin adhesives. Oper Dent 1987;2:53–78.
83. Lutz F, Kreci I, Barbakow F. Chewing pressure versus wear of composites and opposing enamel cusps. J Dent Res 1992;71:1525–1529.
84. Beun S, Glorieux T, Devaux J, Vreven J, Leloup G. Characterization of nanofilled compared to universal and microfilled composites. Dent Mater 2007;23:51–59.
85. Sadeghi M, Lynch CD, Shamat N. Eighteen-month clinical evaluation of microhybrid, packable, and nanofilled composites in class 1 restorations. J Oral Rehabil 2010;37:532–537.
86. Monasky DE, Taylor DF. Studies on the wear of porcelain, enamel and gold. J Prosthet Dent 1971;25:299–306.
87. Imai Y, Suzuki S, Fukishima S. Enamel wear of modified porcelains. Am J Dent 2000;13:315–323.
88. Metzler KT, Woody RD, Miller AW 3rd, Miller BH. In vitro investigation of the wear of human enamel by dental porcelain. J Prosthet Dent 1999;81:356–364.
89. Sorensen JA, Sultan E, Condon JR. Three-body in vitro wear of enamel against dental ceramics [abstract 909]. J Dent Res 1999;78(special issue):219.
90. Sorensen JA, Berge HX. In vivo measurement of antagonist tooth wear opposing ceramic bridges [abstract 2942]. J Dent Res 1999;78(special issue):473.
91. al-Hiyasat AS, Saunders WP, Smith GM. Three-body wear associated with three ceramics and enamel. J Prosthet Dent 1999;82:476–481.
92. Clelland NL, Agarwala V, Knobloch LA, Seghi RR. Relative wear of enamel opposing low-fusing dental porcelain. J Prosthodont 2003;12: 168–175.
93. Clelland NL, Agarwala V, Knobloch LA, Seghi RR. Wear of enamel opposing low-fusing and conventional ceramic restorative materials. J Prosthodont 2001;10:8–15.
94. Magne P, Oh WS, Pintado MR, DeLong R. Wear of enamel and veneering ceramics after laboratory and

Dentlearn.ir

chairside finishing procedures. J Prosthet Dent 1999;82:669–679.
95. Anusavice KJ, Esquivel-Upshaw JF. Less abrasive ceramic esthetic materials. In: Duke ES (ed). The Changing Practice of Restorative Dentistry [Proceedings of the 5th Annual Indiana Conference, 8–10 June 2000, Indianapolis]. Indianapolis: Indiana University School of Dentistry, 2002:216–236.
96. Grippo JO. Erosion vs corrosion. J Am Dent Assoc 2007;138:1535–1536.
97. Wilder Jr AD, Swift Jr EJ, Heymann HO, Ritter AV, Sturdevant JR, Bayne SC. A 12-year clinical evaluation of a three-step dentin adhesive in noncarious cervical lesions. J Am Dent Assoc 2009;140:526–535.
98. Pegoraro LF, Scolaro JM, Conti PC, Telles D, Pegoraro TA. Noncarious cervical lesions in adults: Prevalence and occlusal aspects. J Am Dent Assoc 2005;136:1694–1700.
99. Heymann HO, Sturdevant JR, Bayne S, et al. Examining tooth flexure effects. J Am Dent Assoc 1991;122:41–47.
100. Kuroe T, Hidemi I, Caputo AA, Konuma M. Biomechanics of cervical tooth structure lesions and their restoration. Quintessence Int 2000;31:267–274.
101. Lee WC, Eakle WS. Possible role of tensile stress in the etiology of cervical lesions of teeth. J Prosthet Dent 1984;52:374–380.
102. Whitehead SA, Wilson NHF, Watts DC. Development of noncarious cervical notch lesions in vitro. J Esthet Dent 1999;11:332–337.
103. Wood I, Jawad Z, Paisley C, Brunton P. Non-carious cervical tooth surface loss: A literature review. J Dent 2008;36:759–766.
104. LittleStar ML, Summitt JB. Non-carious cervical lesions: An evidence-based approach to their diagnosis. Tex Dent J 2003;120:972–980.
105. Bader JD, Shugars DA, Martin JA. Risk indicators for posterior tooth fracture. J Am Dent Assoc 2004;135:883–892.
106. Lubisich EB, Hilton TJ, Ferracane J. Cracked teeth: A review of the literature. J Esthet Restor Dent 2010;22:158–167.
107. Bader JD, Shugars DA, Sturdevant JR. Consequences of posterior cusp fracture. Gen Dent 2004;52:128–131.
108. Cavel WT, Kelsey WP, Blankenau RJ. An in vivo study of cuspal fracture. J Prosthet Dent 1985;53:38–42.
109. Ellis SG. Incomplete tooth fracture—Proposal for a new definition. Br Dent J 2001;190:424–428.
110. Rivera EM, Williamson A. Diagnosis and treatment planning: Cracked tooth. Tex Dent J 2003;120:278–283.
111. Cameron CE. Cracked tooth syndrome. J Am Dent Assoc 1964;68:405–411.
112. Cameron CE. The cracked tooth syndrome: Additional findings. J Am Dent Assoc 1976;93:971–975.
113. Cohen SN, Silvestri AR. Complete and incomplete fractures of posterior teeth. Compend Contin Educ Dent 1984;5:652–663.
114. Krell KV, Rivera EM. A six year evaluation of cracked teeth diagnosed with reversible pulpitis: Treatment and prognosis. J Endod 2007; 33:1405–1407.
115. Lynch CD, McConnell RJ. The cracked tooth syndrome. J Can Dent Assoc 2002;68:470–475.
116. Ratcliff S, Becker IM, Quinn L. Type and incidence of cracks in posterior teeth. J Prosthet Dent 2001;86:168–172.
117. Stanley HR. The cracked tooth syndrome. J Am Acad Gold Foil Oper 1968;11:36–47.
118. Hiatt WH. Incomplete crown-root fracture in pulpal-periodontal disease. J Periodontol 1973;49:369–379.
119. Guthrie RC, DiFiore PM. Treating the cracked tooth with a full crown. J Am Dent Assoc 1991;122:71–73.
120. Langouvardos P, Sourai P, Douvitsas G. Coronal fractures in posterior teeth. Oper Dent 1989;14:28–32.
121. Hilton TJ, Ferracane JL, Madden T, Barnes C. Cracked teeth: A practice-based prevalence survey [abstract 2044]. J Dent Res 2007;86(special issue A).
122. De Moor RJ, De Witt AM, De Bruyne MA. Tongue piercing and associated oral and dental complications. Endod Dent Traumatol 2000;16: 232–237.
123. Kapferer I, Benesch T, Gregoric N, Ulm C, Hienz SA. Lip piercing: Prevalence of associated gingival recession and contributing factors. A cross-sectional study. J Periodontal Res 2007;42:177–183.
124. Albers HF. Treating cracked teeth. ADEPT Report 1994;4:17–24.

Dentlearn.ir

125. Griffin JD. Efficient, conservative treatment of symptomatic cracked teeth. Compend Contin Educ Dent 2006;27:93–102.
126. Davis R, Overton JD. Efficacy of bonded and non-bonded amalgam in the treatment of teeth with incomplete fractures. J Am Dent Assoc 2000;131:469–478.
127. Eakle WS. Effect of thermocycling on fracture strength and microleakage in teeth restored with a bonded composite resin. Dent Mater 1986;2:114–117.
128. Hansen EK. In vivo cusp fracture of endodontically treated premolars restored with MOD amalgam or MOD resin fillings. Dent Mater 1988;4:169–173.
129. Opdam NJ, Roeters JJ, Loomans BA, Bronkhorst EM. Seven-year clinical evaluation of painful cracked teeth restored with a direct composite restoration. J Endod 2008;34:808–811.
130. Signore A, Benedicenti S, Covani U, Rivera G. A 4- to 6-year retrospective clinical study of cracked teeth restored with bonded indirect resin composite onlays. Int J Prosthodont 2007;20:609–616.
131. Wahl MJ, Schmitt MM, Overton DA, Gordon MK. Prevalence of cusp fractures in teeth restored with amalgam and with resin-based composite. J Am Dent Assoc 2004;135:1127–1132.
132. Clark DJ, Sheets CG, Paquette JM. Definitive diagnosis of early enamel and dentin cracks based on microscopic evaluation. J Esthet Restor Dent 2003;15:391–401.
133. Polson AM, Caton JG. Current status of bleeding in the diagnosis of periodontal disease. J Periodontol 1985;56(suppl):1.
134. Bhaskar SN. Radiographic Interpretation for the Dentist. St Louis: Mosby, 1986.
135. US Dept Health and Human Services. The Selection of Patients for X-ray Examination: Dental Radiographic Examination. US Dept Health and Human Services publication (FDA), 1987:87–88.
136. American Dental Association, US Dept of Health and Human Services. The Selection of Patients for Dental Radiographic Examination—2004.
137. Goaz PW, White SC (eds). Oral Radiology: Principles and Interpretation, ed 4. St Louis: Mosby, 2000.
138. Garcia LT, Summitt JB. The role of research evidence in clinical practice [guest editorial]. Tex Dent J 2003;120:942–943.
139. Anderson MH, Bales DJ, Omnell KA. Modern management of dental caries: The cutting edge is not the dental bur. J Am Dent Assoc 1993;124:37–44.
140. Holleron BW, Porteous NB, Amaechi BT. Treating caries as a disease and restoring carious teeth via remineralization. Tex Dent J 2003; 120:946–957.
141. Nicholson JW. Evidence-based approach to minimal restorative intervention for early carious lesions. Tex Dent J 2003;120:960–969.
142. Hudson P. Conservative treatment of the Class I lesion: A new paradigm for dentistry. J Am Dent Assoc 2004;135:760–764.
143. Larson TO, Douglas WH, Geistfeld RE. Effects of prepared cavities on the strength of prepared teeth. Oper Dent 1981;6:2–5.
144. Blaser PK, Lund MR, Cochran MA, Potter RH. Effect of designs of Class 2 preparations on the resistance of teeth to fracture. Oper Dent 1983;8:6–10.
145. Matis BA, Cochran M, Carlson T. Longevity of glass-ionomer restorative materials: Results of a 10-year evaluation. Quintessence Int 1996;27: 373–382.
146. van Dijken JWV, Pallesen U. Long-term dentin retention of etch-and-rinse and self-etch adhesives and a resin-modified glass ionomer cement in non-carious cervical lesions. Dent Mater 2008;24:915–922.
147. Duke ES, Robbins JW, Summitt JB, et al. Clinical evaluation of Vitremer in cervical abrasions and root caries [abstract 2578]. J Dent Res 1998;77:954.
148. Boghosian A, Ricker J, McCoy R. Clinical evaluation of a resin-modified glass ionomer restorative: 5-year results [abstract 1436]. J Dent Res 1999;78:285.
149. Robbins JW, Duke ES, Schwartz RS, Summitt JB. 3-year clinical evaluation of a dentin adhesive system in cervical abrasions [abstract 1436]. J Dent Res 1995;74:164.
150. Trevino DF, Duke ES, Robbins JW, Summit JB. Clinical evaluation of Scotchbond Multi-Purpose adhesive

Dentlearn.ir

system in cervical abrasions [abstract 3037]. J Dent Res 1996;75:397.
151. van Dijken JWV. A prospective 8-year evaluation of a mild two-step self-etching adhesive and a heavily filled two-step etch-and-rinse system in non-carious cervical lesions. Dent Mater 2010;26:940–946.
152. Santamaría MP, Ambrosano GMB, Casati MZ, Nociti Jr FH, Sallum AW, Sallum EA. Connective tissue graft plus resin-modified glass ionomer restoration for the treatment of gingival recession associated with non-carious cervical lesion: A randomized-controlled clinical trial. J Clin Periodontol 2009;36:791–798.
153. Santamaria MP, Feitosa DS, Nociti Jr FH, Casati MZ, Sallum AW, Sallum EA. Cervical restoration and the amount of soft tissue coverage achieved by coronally advanced flap: A 2-year follow-up randomized-controlled clinical trial. J Clin Periodontol 2009;36:434–441.
154. Haveman CW. Xerostomia management in the head and neck radiation patient. Tex Dent J 2004;121:482–497.
155. Donly KJ, Segura A, Kanellis M, Erickson RL. Clinical performance and caries inhibition of resin-modified glass ionomer cement and amalgam restorations. J Am Dent Assoc 1999;130:1459–1466.
156. Wood RE, Maxymiw WG, McComb D. A clinical comparison of glass ionomer (polyalkenoate) and silver amalgam restorations in the treatment of Class 5 caries in xerostomic head and neck cancer patients. Oper Dent 1993;18:94–102.
157. Macedo G, Raj V, Ritter AV. Longevity of anterior restorations. J Esthet Restor Dent 2006;18:310–311.
158. van Meerbeek B, Perdigao J, Lambrechts P, Vanherle G. The clinical performance of adhesives. J Dent 1998;26:1–20.
159. Millar BJ, Robinson PB, Inglis AT. Clinical evaluation of an anterior hybrid composite resin over 8 years. Br Dent J 1997;182:26–30.
160. van Dijken JWV, Olofsson AL, Holm C. Five year evaluation of class III composite resin restorations in cavities pre-treated with an oxalic- or a phosphoric acid conditioner. J Oral Rehabil 1999;26:364–371.
161. Pink FE, Minder NJ, Simmonds S. Decisions of practitioners regarding placement of amalgam and composite restorations in a general practice setting. Oper Dent 1994;19:127–132.
162. Bogacki RE, Hunt RJ, del Aguila M, Smith WR. Survival analysis of posterior restorations using an insurance claims database. Oper Dent 2002;27:488–492.
163. Barnes DM, Blank LW, Thompson VP, et al. A 5- and 8-year clinical evaluation of a posterior resin composite. Quintessence Int 1991;22: 143–154.
164. Statement on posterior resin-based composites. ADA Council on Scientific Affairs; ADA Council on Dental Benefit Programs. J Am Dent Assoc 1998;129:1627–1628.
165. Robbins JW, Summitt JB. Longevity of complex amalgam restorations. Oper Dent 1988;13:54–57.
166. Smales R. Longevity of cusp-covered amalgams: Survival after 15 years. Oper Dent 1991;16:17–20.
167. van Nieuwenhuysen JP, D'Hoore W, Carvalho J, Qvist V. Long-term evaluation of extensive restorations in permanent teeth. J Dent 2003; 31:395–405.
168. Opdam NJ, Bronkhorst EM, Loomans BA, Huysmans M. 12-year survival of composite vs. amalgam restorations. J Dent Res 2010;89: 1063–1067.
169. Hickel C, Manhart J. Longevity of restorations in posterior teeth and reasons for failure. J Adhes Dent 2001;3(1):45–64.
170. Opdam NJ, Bronkhorst EM, Roeters JM, Loomans BA. A retrospective clinical study on longevity of posterior composite and amalgam restorations. Dent Mater 2007;23:2–8.
171. Bentley C, Drake CW. Longevity of restorations in a dental school clinic. J Dent Educ 1986;50:594–600.
172. Leempoel PJB, Eschen S, DeHaan AFJ, Van't Hof MA. An evaluation of crowns and bridges in a general dental practice. J Oral Rehabil 1985;12:515–518.
173. Goodacre CJ. Designing tooth preparations for optimal success. Dent Clin North Am 2004;48:359–385.
174. Goodacre CJ, Benal G, Rungcharassaeng K, Kan JYK. Clinical complications in fixed prosthodontics. J Prosthet Dent 2003;90:31–41.
175. McLean JW. Evolution of dental ceramics in the twentieth century. J Prosthet Dent 2001;85:61–66.
176. Giordano R. A comparison of all-ceramic restorative systems: Part 2. Gen Dent 2000;48:38–45.
177. Boening KW, Wolf BH, Schmidt AE, Kastner K, Walter MH. Clinical fit of Procera AllCeram crowns. J

Dentlearn.ir

Prosthet Dent 2000;84:419–424.
178. Haselton DR, Diaz-Arnold AM, Hillis SL. Clinical assessment of high-strength all-ceramic crowns. J Prosthet Dent 2000;83:396–401.
179. McLaren EA, White SN. Survival of In-Ceram crowns in a private practice: A prospective clinical trial. J Prosthet Dent 2000;83:216–222.
180. Van Dijken JWV, Hasselroth L, Ormin A, Olofsson AL. Clinical evaluation of extensive dentin/enamel bonded all-ceramic onlays and onlay-crowns [abstract 2713]. J Dent Res 1999;78:444.
181. Al-Amleh B, Lyons K, Swain M. Clinical trials in zirconia: A systematic review. J Oral Rehabil 2010;37:641–652.
182. Heintze SD, Rousson V. Survival of zirconia- and metal-supported fixed dental prostheses: A systematic review. Int J Prosthodont 2010;23:493–502.
183. Thompson JY, Stoner BR, Piascik JR, Smith R. Adhesion/cementation to zirconia and other non-silicate ceramics: Where are we now? Dent Mater 2011;27:71–82.
184. Esquivel-Upshaw JF, Anusavice KJ, Young H, Jones J, Gibbs C. Clinical performance of a lithia disilicate–based core ceramic for three-unit posterior FPDs. Int J Prosthodont 2004;17:469–475.
185. Olsson KG, Furst B, Andersson B, Carlsson GE. A long-term retrospective and clinical follow-up study of In-Ceram Alumina FPDs. Int J Prosthodont 2003;16:150–156.
186. Vult von Steyern P, Johnsson O, Nilner K. Five-year evaluation of posterior all-ceramic three-unit (In-Ceram) FPDs. Int J Prosthodont 2001; 14:379–384.
187. Studart AR, Filser F, Kocher P, Gauckler LJ. In vitro lifetime of dental ceramics under cyclic loading in water. Biomaterials 2007;28:2695–2705.
188. Esquivel-Upshaw JF, Anusavice KJ. Ceramic design concepts based on stress distribution analysis. Compend Contin Educ Dent 2000;21:649–654.
189. Goodacre CJ, Campagni WV, Aquilino SA. Tooth preparations for complete crowns: An art form based on scientific principles. J Prosthet Dent 2001;85:363–376.

Dentlearn.ir



Esthetic Considerations in Diagnosis and Treatment Planning

J. William Robbins

Because beauty is primarily a matter of personal taste modified by social norms, visualizing beauty is a subjective experience. Creating a beautiful smile requires a foray into these subjective waters. This chapter provides comprehensive and, when possible, evidence-based guidelines that will enable dentists to provide esthetic as well as functional dentistry.

Esthetic Parameters

Facial height

The face can be divided vertically into thirds, and the length of the middle third of the face should approximately equal the lower third of the face when measured in repose[1] (Fig 3-1). The midface is measured from *glabella*, the most prominent point of the forehead between the eyebrows, to *subnasale*, the point below the base of the nose. The lower face is measured from subnasale to *soft tissue menton*, the lower border of the chin.

Dentlearn.ir

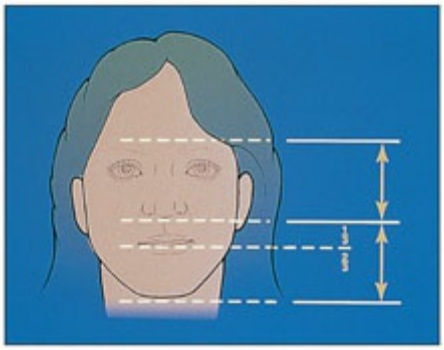

Fig 3-1 The length of the middle third of the face should equal the length of the lower third of the face.

Variations from the norm can reflect a continuum from underdevelopment to hypertrophic development of either one or both arches. However, regarding esthetic diagnoses that impact dental treatment, excessive length of the lower third of the face is most common. The long lower face is commonly the result of vertical maxillary excess and, in many cases, is accompanied by excess gingival display in the maxilla during full smile.

Lip length

The length of the upper lip is measured from subnasale to the inferior border of the upper lip in repose (Fig 3-2a). The average length of the upper lip is 20 to 22 mm in the young adult female and 22 to 24 mm in the young adult male.[2] The upper lip tends to lengthen with age. After age 40 years, the amount of incisal edge display decreases approximately 1 mm per decade.[3,4] When a patient presents with excess gingival display (more than 2 mm of gingiva exposed above the maxillary central incisors during full smile), lip length may be part of the etiology (Fig 3-2b).

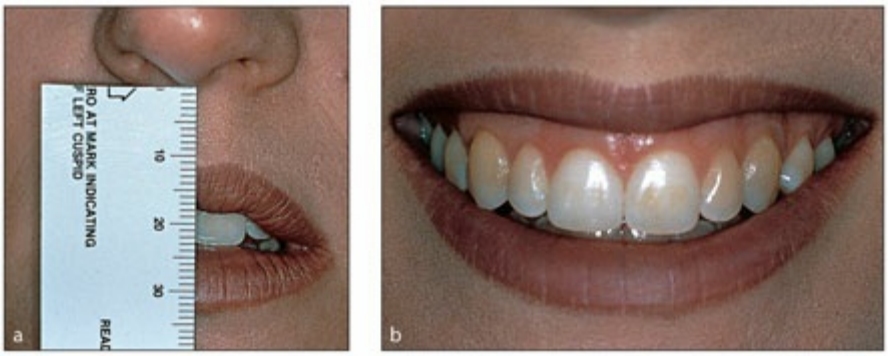

Fig 3-2*(a)* Lip length of 18 mm (average, 20 to 22 mm in women) causes gingival display in full smile. *(b)* Approximately 2 mm of gingival display in full smile.

Dentlearn.ir

Lip mobility

Mobility of the upper lip is measured from repose position to high smile position. The average lip mobility is 6 to 8 mm. In the patient with excess gingival display in full smile, hypermobility of the upper lip may be a contributing factor.

Symmetry

Outline symmetry is essential at the midline5; the maxillary central incisors should be mirror images of each other. Additionally, a line drawn between the maxillary central incisors should be perpendicular to the horizon[6] (Fig 3-3). Ideally, the maxillary dental midline should be coincident with the facial midline.[7] However, a 1- to 2-mm midline discrepancy has been shown to have a minimal effect on the overall beauty of the smile.[8] Asymmetry at the midline creates a visual tension in the observer, resulting in an unacceptable esthetic presentation. As the eye moves peripherally from the midline, deviations from perfect symmetry (eg, notched edges or slight differences in edge lengths) become acceptable, even desirable.[9]



Fig 3-3 Midline canted in relation to the horizon.

Incisal plane

The incisal plane should be parallel to the horizon; the interpupillary line is helpful in making this determination,[9] but only if the interpupillary line is parallel to the horizon. The incisal plane is evaluated from cusp tip of the maxillary right canine to cusp tip of the maxillary left canine. Although the incisal plane must be parallel to the horizon, it is generally not flat but instead has a curve that parallels the curve of the lower lip in full smile. In addition, it should not be canted up or down from right to left.

It is important not to perpetuate or create a canted incisal plane with restorations. If the interpupillary line is parallel to the horizon, the corners of the mouth should be pulled outward so that the upper lip parallels the interpupillary line (Fig 3-4). The relationship between the incisal plane and the interpupillary line, via the upper lip,

Dentlearn.ir

can then be visualized. To transfer this information to an articulator, a facebow may be used as long as the horizontal member of the facebow is made parallel to the horizon before attaching the bite fork. An incisal plane relationship bite may also be used. A bite registration paste is placed between the maxillary and mandibular incisors. A long cotton-tipped applicator is then embedded in the bite registration paste and set parallel to the horizon (Fig 3-5). This relationship bite can then be used to mount the maxillary cast with an accurate incisal plane orientation to the maxillary member of the articulator (Fig 3-6).

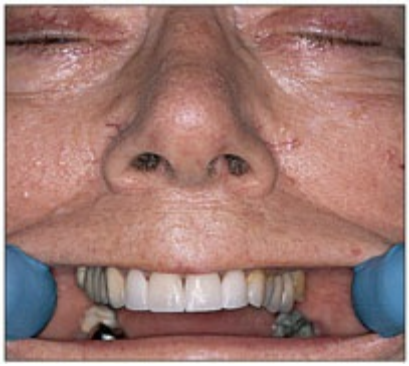

Fig 3-4 The upper lip is pulled to parallel the inter-pupillary line. The vermilion border of the upper lip is then used to evaluate the cant of the incisal plane and posterior occlusal plane in relation to the horizon.

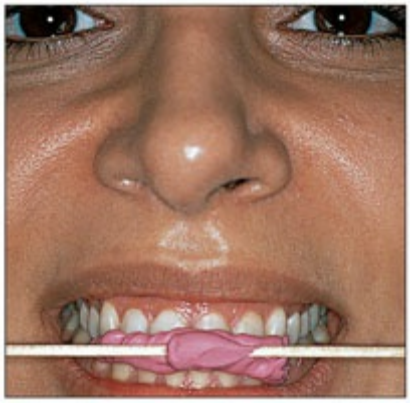

Fig 3-5 Bite registration paste is placed between the maxillary and mandibular anterior teeth, and a cotton-tipped applicator is embedded in the paste. The cotton-tipped applicator is then paralleled with the interpupillary line, and the paste is allowed to set.

Dentlearn.ir



Fig 3-6 The bite registration is placed on the maxillary cast, and the stick is set parallel to the maxillary member of the articulator to orient the cast for mounting.

Posterior occlusal plane

The buccal cusp tips of the maxillary posterior teeth should provide a visual progression from the canine cusp tips, with no step up or step down. In addition, the posterior occlusal plane should not be canted up or down from right to left.[6] It is important not to perpetuate or create a canted posterior occlusal plane. The same techniques used to ensure an accurate mounting of the incisal plane are used for the posterior occlusal plane.

Buccal corridor

The *buccal corridor* is the space between the buccal surfaces of the maxillary posterior teeth and the cheek. In full smile, the buccal corridor is almost filled with teeth. However, a minimal negative space frames the maxillary posterior teeth and is desirable.[6] Excess buccal corridor space (Fig 3-7) is usually due to a developmental problem, such as a constricted maxillary arch. Inadequate space in the buccal corridor is usually due to bulky posterior restorations.



Fig 3-7 A patient with excess space in the buccal corridors.

Dentlearn.ir

Lower lip

In full smile, the incisal edges of the maxillary anterior teeth ideally are cradled by the lower lip[10,11] (Fig 3-8). The smile may also be very pleasing when a space exists between the lower lip and the maxillary incisal edges, as long as the space is uniform from right to left (Fig 3-9). Conversely, none of the incisal edges of the maxillary anterior teeth should be concealed by the lower lip in full smile.

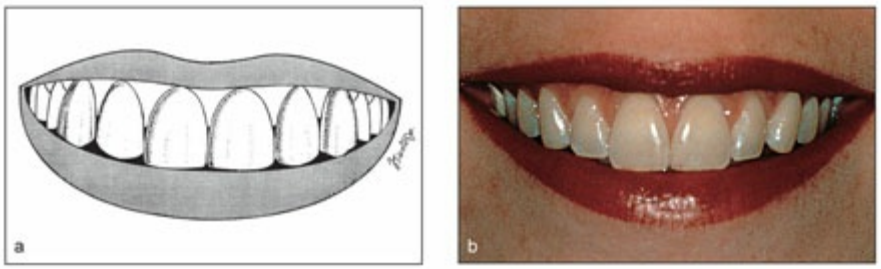

Fig 3-8*(a and b)* Ideal maxillary incisal edge position in relation to the lower lip and ideal relationship between the upper lip and the gingival line.

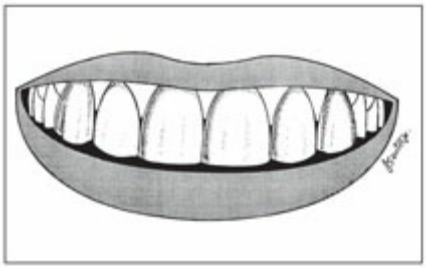

Fig 3-9 Uniform space between the maxillary incisal edges and the lower lip.

If there is a reverse incisal edge curve in relation to the lower lip or a significant space between the lower lip and the maxillary incisal edges during full smile, esthetics may be enhanced with increased incisal edge length. Conversely, if incisal edges of maxillary anterior teeth are hidden by the lower lip during full smile, there is likely a problem with the vertical position of the maxilla. The cause may be overeruption of maxillary anterior teeth, vertical maxillary excess, or both.

Upper lip

In full smile, the upper lip should ideally translate up to the gingival line[10] (see Fig 3-8b). This occurs in approximately 70% of the population. Approximately 10% have a high smile line, and approximately 20% have a low smile line.[11] To evaluate the gingival line, a straight line is drawn from the tooth-gingiva interface of the right maxillary canine to the tooth-gingiva interface of the left maxillary canine. The tooth-

Dentlearn.ir

gingiva interface of both central incisors should be on this line. The tooth-gingiva interface of the lateral incisors may either fall on the gingival line or be up to 1.5 mm below it[12] (Fig 3-10).

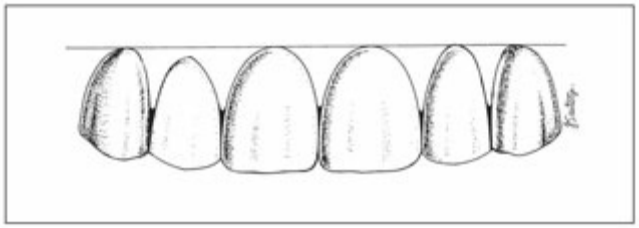

Fig 3-10 Gingival line from canine to canine. The maxillary lateral incisors can fall on this line or be up to 1.5 mm below it.

If the upper lip does not translate up to the gingival line during full smile, some of the clinical crowns of the maxillary anterior teeth remain covered. This results in a loss of dynamics in the smile. If, in full smile, the upper lip translates above the gingival line, the result is gingival display above the clinical crowns. Gingival display of 2 mm or more above the gingival line results in compromised esthetics.

Lip asymmetry

If a patient displays an upper lip asymmetry during full smile (Fig 3-11), it does not generally influence treatment. However, if a patient has an asymmetric upper lip translation, resulting in excess gingival display on one side, esthetic crown lengthening surgery may be accomplished to provide more symmetry in the posterior gingival display. Any time a patient has an upper lip asymmetry, he or she should be advised of the condition before restoration of the maxillary anterior teeth, because the brighter restored teeth will draw attention to the smile and accentuate the asymmetry.



Fig 3-11 Upper lip asymmetry.

If a patient has a lower lip asymmetry during full smile that results in a unilateral increase in negative space between the maxillary incisal edges and the lower lip, smile symmetry is l symmetric lower lip

Dentlearn.ir

is Botox (Allergan).

Lip asymmetries, which can play a significant role in the final restorative result, are commonly overlooked.

Incisal edge placement of maxillary central incisors

Determining the correct position of the incisal edges of the maxillary central incisors is essential and the first step in the provision of anterior restorative dentistry. The following five guidelines are used to determine the correct incisal edge position:

1. In full smile, the incisal edges of the maxillary anterior teeth should be cradled by the lower lip[10,11] (see Fig 3-8b).
2. In full smile, the buccal cusp tips of the posterior maxillary teeth should provide a visual progression from the canine cusp tip, with no step up or step down[6] (Figs 3-12 and 3-13).

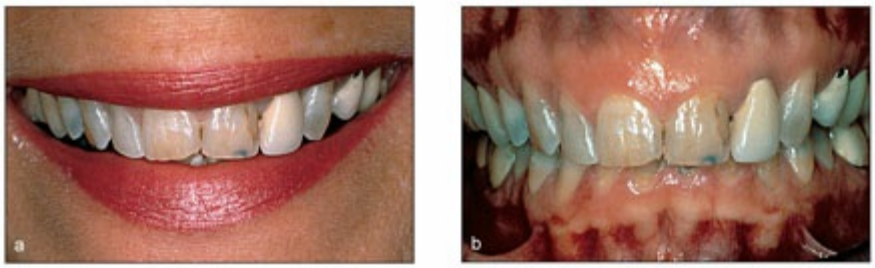

Fig 3-12*(a and b)* Note step up from maxillary left canine to maxillary left first premolar.



Fig 3-13 Note bilateral step down from maxillary canines to maxillary first premolars.

3. In gentle repose (have the patient say “M” or “Emma” and ask them to let their lips lightly fall apart), approximately 3 to 4 mm of the incisal edges of the maxillary central incisors should be displayed in the young adult female (Fig 3-14). In the young adult male, approximately 1 to 2 mm of the incisal edges should be displayed. After age 40 years, the amount of incisal edge display decreases approximately 1 mm per decade.[3]

Dentlearn.ir



Fig 3-14 Three millimeters of display of maxillary central incisors in repose.

4. The average length of the maxillary central incisor is 10 to 11 mm.[13]
5. When the patient says "F" or "V," the incisal edges of the maxillary central incisors should lightly touch the wet-dry border of the lower lip[14] (Fig 3-15).



Fig 3-15 Patient pronouncing an "F."

Steps 1 through 4 are used together to develop an approximation of the correct incisal edge position for the diagnostic wax-up. At this point, incisal edge position is dictated strictly by esthetics. After tooth preparation, provisional restorations that have been fabricated using the diagnostic wax-up are placed. The definitive incisal edge position is then developed dynamically, over time, in the provisional restorations to ensure suitable function and phonetics as well as esthetics. Step 5 is helpful in assessing phonetics with lengthened provisional restorations.

Facial contour of maxillary incisors

Divide the facial surface of the maxillary central incisor into two planes. The gingival half of the tooth should be parallel to and continuous in contour with the surface of the gingival tissue overlying the alveolus[15] (Fig 3-16). The incisal half is tapered back for ease in speaking and swallowing (Fig 3-17).

Dentlearn.ir

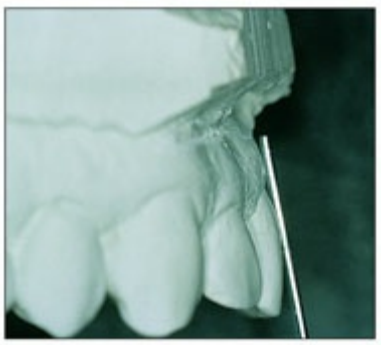

Fig 3-16 The gingival half of the maxillary central incisor is parallel to and continuous in contour with the surface of the gingival tissue overlying the alveolus.



Fig 3-17 The incisal half of the central incisor is contoured to feel comfortable to the patient during lip closure and speech.

Facial overcontouring of a partial- or full-coverage restoration in the gingival half can result in chronic gingival inflammation. Facial overcontouring in the incisal half may result in lip pressure, causing linguoversion of the overcontoured teeth or interference with the path of lip closure.

Lingual contour of maxillary incisors

Incorrect spacing between maxillary and mandibular anterior teeth may cause a lisp. A lisp can occur with too much or too little space, although it occurs most commonly with too little space.

If a patient develops a lisp after placement of provisional or definitive restorations, the position of the incisal edges of the mandibular incisors in relation to the maxillary central incisors when the patient makes an “S” sound must be determined. If the mandibular incisor approximates the cingulum or lingual concavity of the maxillary incisor, the lisp is corrected most commonly by increasing the lingual concavity of the maxillary incisors. If, however, the mandibular incisor approximates the incisal edge of the maxillary central incisor during the “S” sound,

Dentlearn.ir

the lisp can be corrected most commonly by changing the length of the maxillary central incisors.

Gingival zenith

The long axes of the maxillary anterior teeth are distally inclined. Therefore, the gingival contour adjacent to the maxillary incisors is not a symmetric, rounded arch form. Rather, the marginal gingiva has a parabolic shape with the highest point (*gingival zenith*) slightly distal to the midline of the tooth[12] (Fig 3-18).



Fig 3-18 The gingival zenith is slightly distal to the midline on the maxillary central and lateral incisors.

In gingival recontouring surgery, the gingival zenith should not be overemphasized. Although a distalized zenith is more common, many patients prefer a more symmetric gingival architecture.

Interproximal contact areas

Maxillary interproximal contact areas become progressively more gingival from central incisor to canine (Fig 3-19). The interproximal contact between the maxillary central incisors is in the incisal third of the teeth. However, the interproximal contact between the central and lateral incisors is at the junction of the incisal and middle thirds; it is slightly more gingival between the lateral incisors and the canines.[9]

Dentlearn.ir



Fig 3-19 Maxillary interproximal contact areas become progressively more gingival from central incisor to canine, and incisal embrasures increase in depth from midline to canine.

If the interproximal contact extends too far incisally, a closed and unnatural-appearing incisal embrasure results. If the interproximal contact does not extend far enough gingivally, an open gingival embrasure, or *black triangle*, results.

Incisal embrasures

The incisal embrasures increase from maxillary central incisor to canine (see Fig 3-19). While the incisal embrasure between the maxillary central incisors is minimal, the incisal embrasure between the maxillary central and lateral incisors is more pronounced and between the lateral incisors and canines is the most pronounced. Uniform incisal embrasures from maxillary canine to canine are esthetically unnatural.

Maxillary incisal edges and tooth morphology

In nature, it is impossible to determine sex based on tooth shape or incisal edge relationships.[11] However, tooth morphology and tooth-to-tooth relationships do convey information, albeit subjective, about the individual. In 1973, based on the writings of Frush and Fisher,[16,17] Lombardi[6] described relationships for fabricating complete dentures. His matrix is equally relevant for the dentulous patient today (Fig 3-20) and makes it possible to characterize the teeth in the diagnostic wax-up, the provisional restorations, and, ultimately, the definitive restorations.

Dentlearn.ir

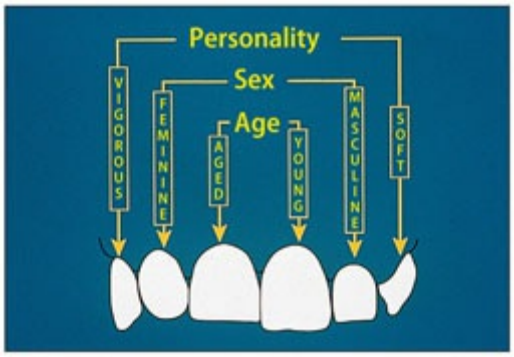

Fig 3-20 The Lombardi matrix describes characteristics associated with different incisal edge configurations.

Maxillary incisal edge shape (buccolingual)

Natural maxillary incisal edges, in a buccolingual direction, are not rounded but rather are sharp. Because of wear, the incisofacial line angle in adults is relatively sharp and blends into a 1-mm lingual facet before dropping off to the concave lingual surface (Fig 3-21). Rounded maxillary incisal edges give the restoration an unnatural appearance due to the light reflection off a curved surface.

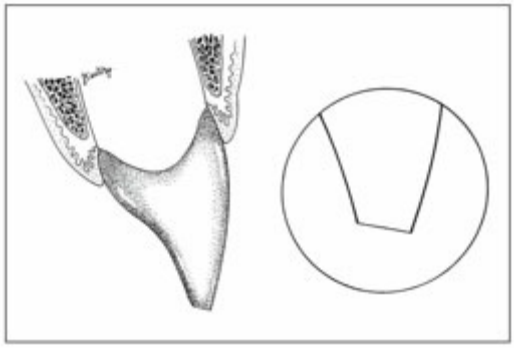

Fig 3-21 Maxillary incisal edge.

Halo effect

The natural incisal edge anatomy of the maxillary incisor commonly imparts a thin, white, opaque "halo effect" at the incisal edge that frames the incisal translucency (Fig 3-22). The halo effect is incorporated into porcelain restorations by building the sharp incisal edge anatomy into the crown or porcelain veneer (Fig 3-23).

Dentlearn.ir



Fig 3-22 "Halo effect" in natural maxillary incisors. Note the similarity in the outline form of the distal surfaces and distoincisal line angles of the maxillary lateral and central incisors.



Fig 3-23 Porcelain veneers on maxillary and mandibular teeth. Note the natural appearance of the maxillary incisal edges with the halo effect. (Porcelain veneers by Gilbert Young, CDT, Plano, Texas.)

Mandibular incisal edge shape

The incisal edge of the mandibular incisor should have a narrow, but defined, flat incisal table. This incisal table should be slightly canted facially. This is referred to as the *pitch* of the incisal table. The facial incisal line angle should be slightly beveled (Becker I, personal communication, 1997) (Fig 3-24; see also Fig 3-21). This incisal edge configuration not only enhances esthetics but also improves function. As the mandible moves forward, the disocclusion occurs efficiently on the leading incisofacial line angle of the mandibular incisor, rather than dragging on the broader facial surface.

Dentlearn.ir

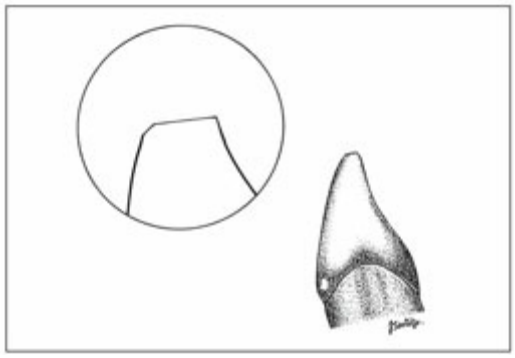

Fig 3-24 The incisal edge of a mandibular incisor. Note the pitch of the incisal table and the bevel of the incisofacial line angle.

Outline symmetry

The distal surfaces of the maxillary central and lateral incisors should be similar in outline form, as should the distoincisal line angles of these teeth[6] (see Fig 3-22). The outline symmetry of the maxillary central and lateral incisors should be similar. A large outline discrepancy (eg, a peg-shaped lateral incisor) negatively affects the beauty of the smile.

Facial contour of the maxillary incisors

The facial surfaces of the maxillary incisors should not be rounded mesiodistally but rather should be flat, with resulting bold mesial and distal line angles and deep facial embrasures (Fig 3-25). Restorations with rounded facial surfaces look unnatural; facial embrasures are not well defined, resulting in a lack of visual distinction of the maxillary anterior teeth.



Fig 3-25 Incisal view of natural maxillary incisors. Note the flat facial surfaces, bold mesial line angles, slightly less bold distal line angles, and deep facial embrasures.

Outline form of maxillary canines

The distal half of the maxillary canine should not be visible when viewed from the front[9] (Fig 3-26). As the eye moves laterally from the midline, each tooth should

Dentlearn.ir

appear proportionately narrower than its mesial neighbor. This is termed the *principle of gradation*.[6] After placement of porcelain restorations on the maxillary teeth, the most common offender of this principle is the canine. It appears too wide in relation to both the lateral incisor and the first premolar because the mesiodistal height of contour is too distal.



Fig 3-26 A smile that demonstrates the principle of gradation. The maxillary central incisor is visually the widest tooth, followed by the lateral incisor, the canine, and so on distally. The distal half of the canine must not be visible when viewed from the front to maintain the principle of gradation.

Correct placement of the mesiodistal height of contour on the facial surface of canine restorations involves the skills of both the dentist and the laboratory technician. First, the dentist must remove sufficient tooth structure on the distofacial half of the tooth to allow the technician to create the correct facial contours. Second, the technician must visualize the case from the front during final contouring of the restorations to ensure that the principle of gradation is heeded.

Color

Natural teeth are polychromatic. They generally have higher chroma in the gingival third, transitioning to a lower chroma and higher value in the middle third. The incisal third is characterized by the transition to incisal translucency, which is commonly framed by the halo effect (see Fig 3-22). Maverick colors can appear anywhere, and they individualize the tooth.

The chroma and value of the maxillary lateral incisor is commonly the same as that of the central incisor. In the maxillary canine, the chroma is generally higher, especially in the gingival third, and the value is lower. Incisal translucency is usually minimal in the maxillary canine, and seldom does the halo effect occur.

Polychromaticity in the individual tooth and between neighboring teeth is essential in porcelain restorations if natural beauty is the goal. Color in dentistry is described in greater detail in chapter 4.

Dentlearn.ir

Color modifiers

It has been stated that hair color, skin color, and lipstick color all significantly affect shade selection when restorations are being placed in the esthetic zone.[14] Of these modifiers, skin color is by far the most important. A given tooth shade will look lighter and higher in value in a patient with darker skin. Conversely, the same tooth shade will appear yellower and lower in value in a patient with very light skin.

When choosing a tooth shade for a patient with variable skin color, for instance, a white patient with a deep tan, the impact of the skin color must be discussed with the patient prior to treatment. If porcelain restorations are placed while the skin is tanned, the restorations will appear to become more yellow and lower in value as the skin color lightens.

Image

The overall presentation of the smile can be described as the image. Miller[10] discusses the differences between the "natural image" and the "media image." With the media image, the teeth are generally more symmetric, monochromatic, and very high in value. The natural image incorporates asymmetries, polychromaticity, and lower value with higher chroma. Dentists commonly make esthetic choices for patients based on their own notions of beauty rather than on the patient's desires.[18] When restoring maxillary anterior teeth, it is essential that the dentist understand the overall image that the patient desires. To maximize predictability when placing anterior restorations, the issue of overall smile presentation first must be developed to the patient's satisfaction in the provisional restorations.

Age characteristics of teeth

Both tooth color and surface texture relate information about the age of the patient (Figs 3-27 and 3-28).



Fig 3-27 Young teeth demonstrate higher value, lower chro-ma, higher surface texture, and lower luster.

Dentlearn.ir



Fig 3-28 Older teeth demonstrate lower value, higher chroma, lower surface texture, and higher luster.

Chroma and value

The value, or brightness, of a tooth is higher in young patients and decreases with age. Conversely, the chroma, or color saturation, is lower in young patients and increases with age.[5]

Surface texture

Surface texture is higher in the young patient and decreases as the patient ages.[5] The surface luster is a function of the amount of surface texture. Therefore, the young tooth with greater surface texture has a lower luster. As the surface texture is worn away with age, the surface luster increases.

It is important to communicate with the laboratory technician about texture and luster. For example, porcelain veneers with low value, low surface texture, and high luster are not appropriate for a 25-year-old patient.

Individual tooth length and proportion

The maxillary central incisors are the centerpiece of the smile.

The average length of the maxillary central incisor is 10 to 11 mm[13] (Fig 3-29). The ratio of height to width in the maxillary central incisor should be approximately 1.2 to 1.0. In other words, the width of the central incisor should be approximately 75% to 80% of its height.[13] When evaluating a smile, the dentist must start with the position and size of the maxillary central incisor. It is difficult, if not impossible, to develop optimum esthetics with short maxillary anterior teeth.

Dentlearn.ir



Fig 3-29*(a and b)* Short maxillary central incisors measuring 8 mm due to altered passive eruption. *(c)* After esthetic crown lengthening to treat altered passive eruption.

Tooth-to-tooth proportions

The principle of gradation[6] states that as the eye moves laterally from the midline, each tooth should appear proportionately narrower than its mesial neighbor. There has been much discussion about what this mesiodistal proportion should be. The golden proportion (1.618:1.0), which was formulated as one of Euclid's elements, has been proposed.[19] Viewed from the front, the maxillary central incisor would be 1.618 times wider than the lateral incisor, the lateral incisor would be 1.618 times wider than the visual width of the canine, and so on as the eye moves distally. However, developing esthetic proportions is not that simple. In a patient with a very tapered maxillary arch, the maxillary central incisors will appear wide, and the teeth may approximate the golden proportion. However, in a patient with a very square maxillary arch form, the golden proportion would result in unesthetically wide central incisors. To some degree, the width of the central incisor in relation to that of the lateral incisor is also a matter of personal taste. The golden proportion produces very bold central incisors,[6,20] which appeals to some individuals. However, in natural teeth situated in natural arch forms, the golden proportion seldom occurs. The natural proportion of the width of the maxillary central incisor to that of the lateral incisor, when measured with a caliper, is approximately 1.2 to 1.0.[18] The golden proportion is not based on actual tooth measurements but on the tooth proportions when viewed from the front. This proportion is approximately ¼ to 1.0 in nature (Fig 3-30).

Dentlearn.ir

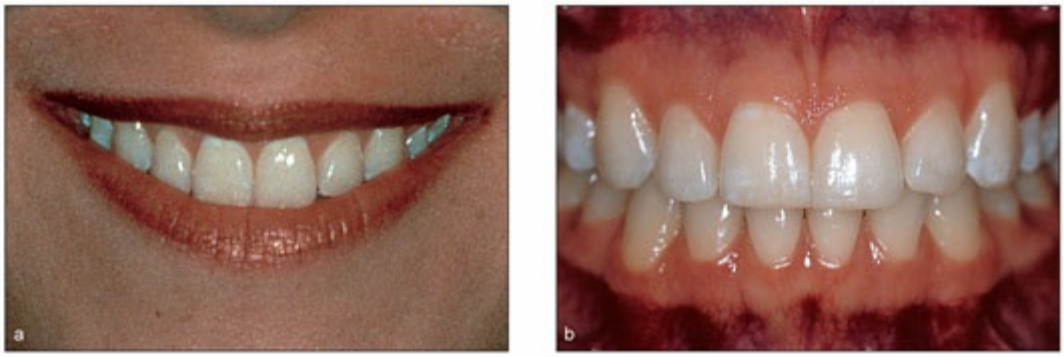

Fig 3-30*(a)* Note the beauty and proportionality of this natural smile. *(b)* The measurement of the visual widths of the maxillary central incisors and maxillary lateral incisosr reveals a natural proportion of central incisor to lateral incisor of ¼ to 1.0.

Because dental esthetics is a matter of taste, the ultimate decision on widths and proportions must be developed in provisional restorations with the patient.

Principle of illumination

Visually, light objects are perceived to approach the viewer and dark objects to recede from the viewer.[6] This principle must be considered when high-value porcelain or resin composite restorations are placed only on maxillary anterior teeth, because the result may be an unesthetic visual separation of the anterior and posterior teeth. A visual coupling of the front and back of the mouth may require placement of restorations on one or more maxillary premolars (Fig 3-31).

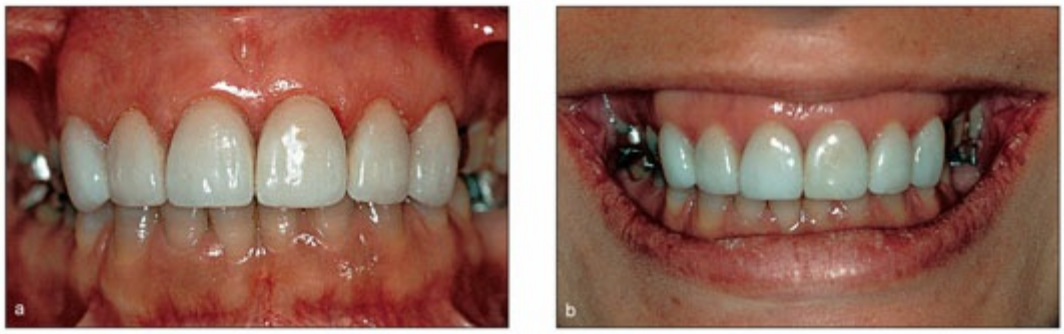

Fig 3-31*(a and b)* Porcelain veneers were placed only on the maxillary anterior teeth. Note that the maxillary first premolars are virtually invisible when viewed from the front. This results in a loss of visual coupling of the front and the back of the mouth. Note also the lower lip asymmetry.

Law of the face

The face of a tooth is that portion of the facial surface bound by transitional line angles when viewed from the front.[5] To make teeth of dissimilar widths appear similar, the apparent faces should be made equal.

Dentlearn.ir

To make an anterior tooth appear wider, the transitional facial line angles are moved into the interproximal facial embrasures. Conversely, to make an anterior tooth appear narrower, the transitional line angles are moved closer to the tooth midline (Fig 3-32).

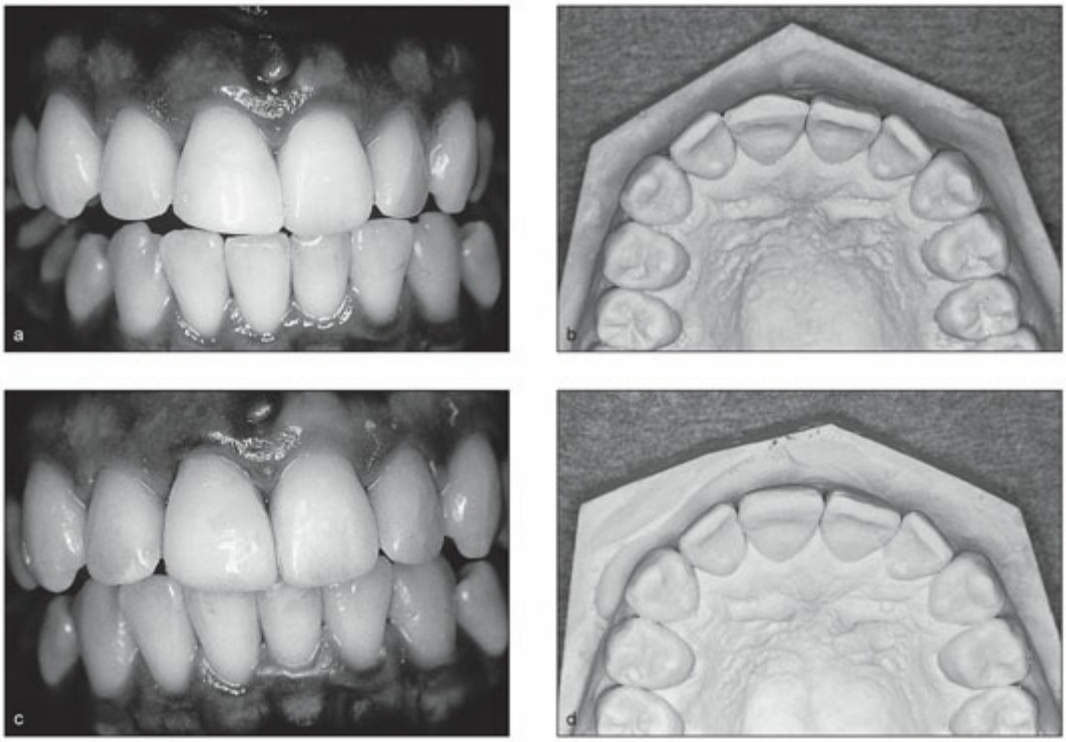

Fig 3-32*(a)* A direct bonded restoration on the maxillary right central incisor appears too wide. *(b)* The cast of the maxillary arch demonstrates that the mesiofacial and distofacial transitional line angles are too far into the facial embrasures, resulting in a visual widening of the tooth. *(c)* After replacement of the direct bonded restoration on the right central incisor, the tooth now appears narrower. *(d)* The cast of the patient after the direct bonded restoration was replaced. Note the narrower appearance of the tooth because the mesiofacial and distofacial transitional line angles are closer together.

Conclusion

The provision of esthetic and functional restorative dentistry must be based on a set of guidelines founded on the best clinical science available. These guidelines can then be used to determine a patient's overall orofacial presentation and to guide the diagnostic wax-up. Based on the diagnostic wax-up, the provisional restorations are fabricated and placed. It is at this point that the "eye of the artist" becomes helpful for developing the final shade, shape, contour, and incisal edge configuration of the provisional restorations, which will serve as the blueprint for the defintive restorations.

Dentlearn.ir

References

1. Proffitt WM. Contemporary Orthodontics, ed 2. St Louis: Mosby, 1992: 150.
2. Peck S, Peck L, Kataja M. The gingival smile line. Angle Orthod 1992; 62:91–100.
3. Vig RG, Brundo GC. The kinetics of anterior tooth display. J Prosthet Dent 1978;39:502–504.
4. Ibher N, Kloepper J, Penna V, Bartholomae J, Stark G. Changes in the aging upper lip—A photomorphometric and MRI-based study (on a quest to find the right rejuvenation approach). J Plast Reconstr Aesthet Surg 2008;61:1170–1176.
5. Heymann HO. The artistry of conservative esthetic dentistry. J Am Dent Assoc 1987;(special issue):14E–22E.
6. Lombardi RE. The principles of visual perception and their clinical application to denture esthetics. J Prosthet Dent 1973;29:358–382.
7. Brisman AS. Esthetics: A comparison of dentists' and patients' concepts. J Am Dent Assoc 1980;100:345–352.
8. Kokich V, Kiyak H, Shapiro P. Comparing the perception of dentists and lay people to altered dental esthetics. J Esthet Dent 1999;11:311–324.
9. Williams HA, Caughman WF. Principles of esthetic dentistry: Practical guidelines for the practitioner. In: Clark JW (ed). Clinical Dentistry. New York: Harper & Row, 1976:1–20.
10. Miller CJ. The smile line as a guide to anterior esthetics. Dent Clin North Am 1989;33:157–164.
11. Tjan AHJ, Miller GD, The JG. Some esthetic factors in a smile. J Prosthet Dent 1984;51:24–28.
12. Allen EP. Surgical crown lengthening for function and esthetics. Dent Clin North Am 1993;37:163–179.
13. Gillen RJ, Schwartz RS, Hilton TJ, Evans DB. An analysis of selected normative tooth proportions. Int J Prosthodont 1994;7:410–417.
14. Pound E. Applying harmony in selecting and arranging teeth. J Am Dent Assoc 1957;55:181–191.
15. Croll BM. Emergence profiles in natural tooth contour. Part 1: Photographic observations. J Prosthet Dent 1989;62:4–10.
16. Frush JP, Fisher RD. Introduction to dentogenic restorations. J Prosthet Dent 1955;5:586–595.
17. Frush JP, Fisher RD. How dentogenic restorations interpret the sex factor. J Prosthet Dent 1956;6:160–172.
18. Goldstein R. Study of need for esthetics in dentistry. J Prosthet Dent 1969;21:589–598.
19. Levin EI. Dental esthetics and the golden proportion. J Prosthet Dent 1978;40:244–252.
20. Preston JD. The golden proportion revisited. J Esthet Dent 1993;5: 247–251.

Dentlearn.ir



Color and Shade Matching

Rade D. Paravina

There is a significant professional interest in color and appearance in dentistry.[1,2] The number of publications listed on MEDLINE for the keywords *color* and *dentistry* has increased rapidly from only 109 in 1970 to 4,315 in 2010. The same is true for the public interest and demand related to esthetic and cosmetic dental procedures. According to a survey by the American Academy of Cosmetic Dentistry, virtually everyone believes that a smile is an important social asset, and three-quarters of adults feel that an unattractive smile can hurt a person's chances for career success.[3] Discolored, yellow, or stained teeth were identified as characteristics that make a smile unattractive. On the other hand, participants listed straightness, whiteness, and color of teeth as the first things they notice in a person's smile. The top two items related to desired changes in one's smile were whiter and brighter teeth. It is easy to notice that almost all of these remarks are associated with tooth color.

Therefore, color is a key component of the esthetic complex in dentistry, and to a significant extent color delineates *esthetic* from *nonesthetic* in our profession. A simple explanation on the importance of color in dentistry was offered by Dr Stephan Bergen, one of the pioneers of esthetic dentistry: "Color is unimportant to the physiologic success of a dental restoration, yet it could be the controlling factor

Dentlearn.ir

in the overall acceptance by the patient."[4]

Color

Color is a psychophysical sensation produced in the eye by visible light and interpreted by the brain. Color requires three components: light source, object, and observer.

A *light source* is any area or body that emits radiation in the visible spectral range. Some standard light sources are designated as A (incandescent), B, C, and D (daylight). Daylight is further categorized as D50, D55, D65, and D75, the designations corresponding to the correlated color temperature (CCT) in kelvin (the number after the letter *D* times 100 equals the CCT in kelvin). The *object* reflects, absorbs, or transmits the light from the source.[5] The reflected portion of light is used during shade matching in dentistry. The *observer* is the third part of the triplet. All visual sensations are brought to the brain through the eye. The retina has two types of nerve endings: rods and cones. While rods only record light (ie, they respond to black and white), cones enable color vision. The three types of cones are blue-, green-, and red-sensitive, or short, medium, and long wavelengths, respectively. Visual information from the eye is then relayed to the brain, where the messages from the rods and cones are interpreted.

Dimensions of color

Color is a three-dimensional phenomenon characterized by the dimensions of hue, value (lightness), and chroma (Fig 4-1).

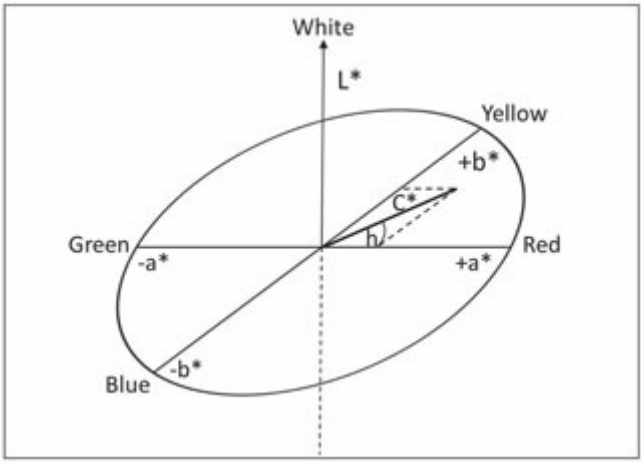

Fig 4-1 Color coordinates L*a*b*C*h. L*—lightness (vertical axis); a* (–a*, green; +a*, red); b* (–b*, blue; +b*, yellow); C* —chroma; h —hue.

Dentlearn.ir

Hue is a dimension that enables differentiation between "color families." For example, red, green, blue, and yellow represent hues (Fig 4-2). Graphically, hues are placed on the exterior of a closed hue circle that encompasses 360 degrees (see Fig 4-1). *Value,* or lightness, enables differentiation between light and dark colors (Fig 4-3). In the center of the hue circle exists a vertical value axis that progresses from pure black at the bottom to pure white at the top (see Fig 4-1). *Chroma* allows differentiation between pale versus strong, pale versus chromatic, and washed-out versus saturated colors (Fig 4-4). Chroma is represented as the distance from the achromatic value axis toward the particular hue on the circumference of the circle, and it increases with the increase of the distance from the vertical axis (see Fig 4-1). While hue is related to different colors, chroma is associated with the differences in strength of the same color (eg, pale red versus chromatic red).



Fig 4-2 Hue. Color families or color name.



Fig 4-3 Value. White to black, achromatic.



Fig 4-4 Chroma. Pale to strong, washed-out to chromatic.

Color notation systems

Various color notation systems have been used in dentistry. Historically, these include the Munsell hue-value-chroma (HVC) system and two formulas developed by the International Commission on Illumination (Commission Intérnationale de l'Eclairage [CIE]), CIE 1931 (xyY) and CIE 1964 (XYZ).

However, the most frequently used color notation system in dentistry is the CIELAB (CIE L*a*b* or CIE 1976) system[5] (see Fig 4-1). Any color can be designated by one of two classifications of coordinates related to the diagram in Fig 4-1. Rectangular coordinates of the CIELAB color space are L* (lightness), a* (–a*, green; +a*, red), and b* (–b*, blue; +b*, yellow), which mark a point on the vertical (L*) axis and on the circumference of the horizontal wheel. Polar coordinates are L*,

Dentlearn.ir

C^*_{ab} (chroma) and h_{ab} (hue), which mark a point on the vertical (L*) axis as well as the distance away from the vertical axis (C^*_{ab}) at a particular angle (h_{ab}) on the horizontal plane.

CIELAB color difference is designated as ΔE^*_{ab}, where the symbol Δ stands for difference and E stands for *Empfindung*, which means *sensation* in German. CIELAB color difference takes into account all aspects of color and is calculated using differences in either L*a*b* or light, chroma, and hue coordinates.

More recently, an advanced CIE color-difference formula, CIEDE2000, has been introduced.[6,7] Color difference in CIEDE2000 is designated as ΔE'. The CIEDE2000 formula is becoming more common in dental research as well.[8]

Additional Appearance Attributes

Tooth appearance attributes other than color include opacity, translucency, gloss, opalescence, fluorescence, and iridescence.

Opacity and translucency are exactly of opposite nature. *Opacity* is the ability of a material to block the passage of light through the material, whereas *translucency* is the ability of the material to allow light to pass through it.[2,9]

Gloss has physical, physiologic, and psychologic aspects. The following visual criteria define an object's gloss: specular gloss, contrast gloss (or luster), sheen, distinctness of image, haze, and surface phenomena. *Specular gloss* is the most frequently evaluated type in dentistry, and it corresponds in simple terms to the ratio of reflected to incident light energy, where the angle of the reflected light is equal and opposite to the angle of the incident light for a specified angle of incidence, source, and receptor angular apertures.[2,9]

Opalescence is an optical property that gives a material a bluish appearance under reflected light and an orange/brown appearance under transmitted light, while *fluorescence* is the absorption of light by a material and the spontaneous emission of light in a longer wavelength. Fluorescence is not usually detected with the color-corrected lights normally used in dental operatories; it is normally seen under ultraviolet lighting (eg, "black light" or sunlight). It is important for optimal esthetic matching that dental materials, such as porcelains, especially when used in veneers on the anterior teeth, have fluorescing agents in their composition; otherwise they may appear rather dull and not lifelike. *Iridescence* is the rainbowlike effect in which surfaces appear to be different colors depending on the illuminating and/or

Dentlearn.ir

viewing angle.[2,9]

Color and Appearance of Human Teeth

Tooth color varies from person to person, by dentition (primary versus permanent), by tooth within the same dentition, and within the same tooth. Permanent teeth are small, curved, whitish-yellowish, and slightly reddish. They exhibit color transitions from cervical to incisal, mesial to distal, and labial/buccal to lingual. Variations in thickness and translucency of the enamel and dentin are also present. In addition, tooth color changes throughout a person's lifetime due to various physiologic and pathologic conditions. Local color characteristics, such as enamel cracks and craze lines, enamel hypoplasia, fluorosis, tetracycline staining, or incisal halo, bring additional complexity to tooth color matching, communication, reproduction, and verification.[10,11] Interaction among color-related characteristics of human teeth and other attributes of appearance, such as translucency/opacity, gloss, fluorescence, and phosphorescence, makes working with color one of the most challenging tasks in esthetic and restorative dentistry (Fig 4-5).

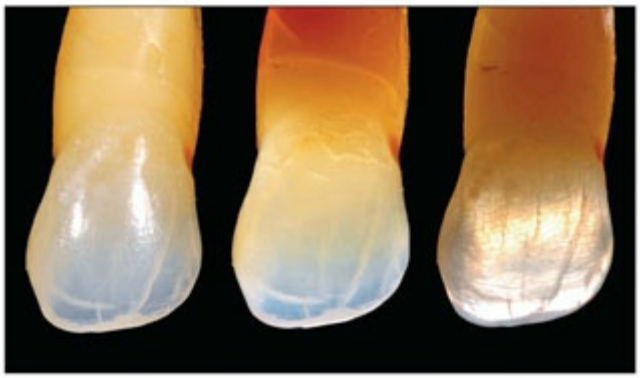

Fig 4-5 Interaction among color-related characteristics of human teeth and other attributes of appearance makes working with color one of the most challenging tasks in dentistry. (Courtesy of Adam J. Mieleszko, CDT, New York, New York.)

There are findings on the influence of sex, bleaching history, and smoking on the color of permanent teeth. A color difference (ΔE*) of 3.0 was recorded between teeth in males and females. Male teeth were significantly darker, more chromatic, and redder than female teeth. The color difference between bleached and nonbleached teeth was even greater (ΔE* = 4.6); nonbleached teeth were significantly darker, more chromatic, and of lower hue angle. As for the influence of smoking on tooth color, the color difference between nonsmokers and smokers was 2.7, with only the difference in lightness being statistically significant.[12] A

Dentlearn.ir

significant color difference (ΔE* = 8.2) has been shown between permanent and primary teeth, and primary teeth were found to be much lighter (ΔL* = 7.7), less chromatic (ΔC* = –2.5), and redder (Δh° = –4.2) than permanent teeth.[13]

Color-Matching Ability

Influence of sex and experience

The shade-matching abilities of color-normal men and women are equal. Therefore, sex should not be the criterion for choosing the person to perform shade matching. Shade-matching competency of dental students and professionals should be routinely tested.[14] Color deficiency is a weakness or absence in one or more cone systems. People with deficiencies in their cone systems are not "color blind"; rather, approximately 8% of males and 0.5% of females are color deficient. Different types of color deficiency compared with color-normal vision are illustrated in Fig 4-6. The literature is equivocal on whether years in practice or specialty affects shade-matching ability. Experience is relevant, but so is the status and age of the visual organ.[9]

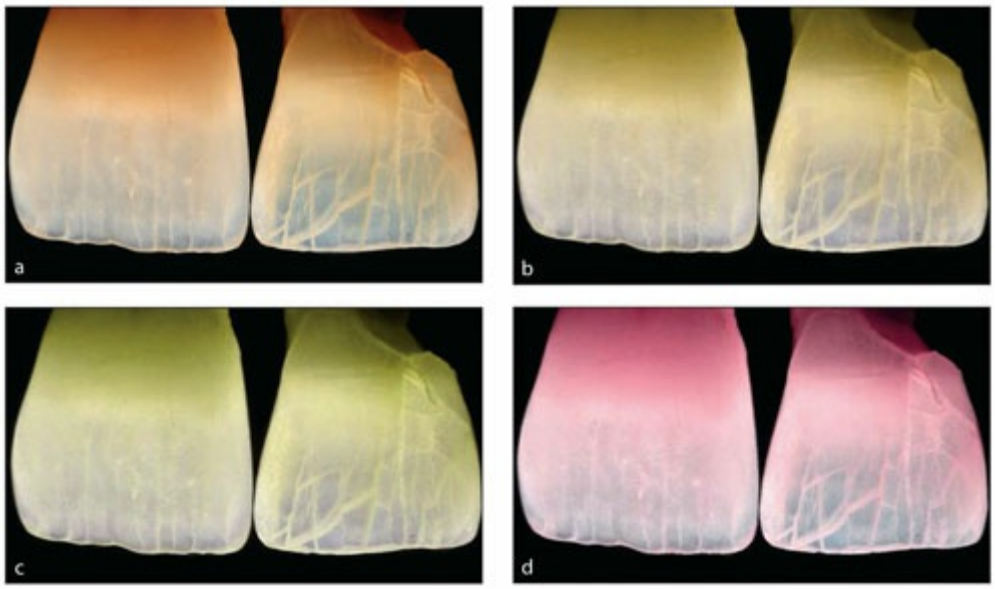

Fig 4-6*(a)* Image representing normal color vision. (Courtesy of Adam J. Mieleszko, CDT, New York, New York.) *(b to d)* Vischeck computer simulations representing different types of color deficiency: deuteranope (green photoreceptors of retina are absent) *(b)*, protanope (complete absence of red photoreceptors) *(c)*, and tritanope (blue receptors are absent) *(d)*.

Color education and training

Dentlearn.ir

Sproull stated in 1973 that "the technology of color is not a simple matter that can be learned without study; neither is it a complicated matter beyond the comprehension of dentists."[15] Color education and training can influence shade-matching results. Education and training should be the first step in the process, which would ideally result in predictable and enhanced esthetic outcomes.[1]

It is apparent that humans are not as good in color matching and reproduction as they might expect. When asked to match 16 pairs of tabs of two VITA Classical shade guides (Vident) using a visual method, the participants in a study correctly matched only 50%.[16] In another study, which more closely resembled clinical dentistry because no exact match was included in the choices, the observers' choice was the second or the third best match.[17]

Several color education and training programs are currently available.[1,10,11] Dental Color Matcher,[10] a free online color education and training program for esthetic dentistry, is in essence a computer game. Dental Color Matcher consists of interactive color-matching exercises using the VITA Linearguide 3D-Master shade guide (Vident) ("closest match," "exact match," and "match the pairs" exercises [Fig 4-7]), a didactic video, and a quiz. Upon program completion, all users can print a diploma and obtain two continuing education credit hours.

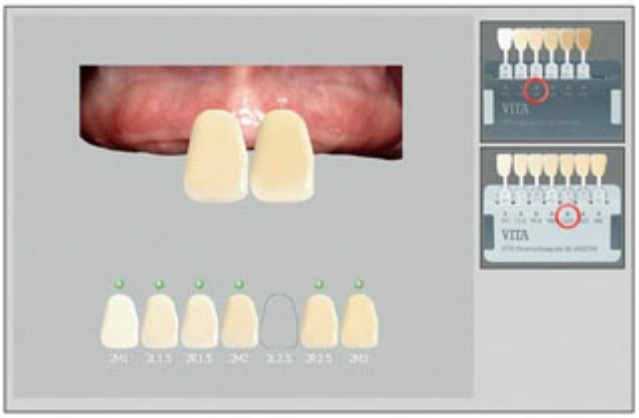

Fig 4-7 Dental Color Matcher: "closest match" exercise.

Color Matching and Measuring

Tooth color can be matched or measured visually and/or using color-measuring instruments. Dental shade guides are used for making visual comparisons, and this shade-matching method is predominant in dentistry today,[18] despite the fact that it is subjective and to a certain extent inconsistent. Dental color-measuring devices are objective, and while very beneficial, they are presently used by a relatively small

Dentlearn.ir

percentage of dental professionals. There is a need to carefully consider the meaning of the words *subjective* and *objective* when it comes to color in dentistry. While there is a difference in subjective color perception among color-normal individuals as well as for the same individual, these differences are typically not very pronounced. On the other hand, errors in instrument selection and use, differences from visual findings, and instrument inability to quantify optical illusions are some of the shortcomings associated with objective color matching. One should not forget that the design of all advanced color-measuring instruments incorporates the response of the so-called standard observer. Therefore, the objective might be good only as far as it corresponds to the subjective.

Dental shade guides

The primary requirements for dental shade guides are logical ordering and adequate color distribution within the tooth color space.[19–22] Three basic conceptions of dental shade guides are currently present:

1. VITA Classical and Classical-keyed products (empirical conception)
2. VITA 3D-Master shade guides (scientifically grounded)

combinations of these two, are shown in Fig 4-8.



these two: *(a)* Vintage Halo NCC (Shofu), *(b)* Ivoclar Chromascop (Ivoclar Vivadent), *(c)* Venus (Heraeus) *(top)* and Estelite (Tokuyama) *(bottom)*, and *(d)* Esthet-X (Dentsply/Caulk) *(top)* and

Dentlearn.ir

Trubyte Bioform (Dentsply/Caulk) *(bottom)*.

VITA Classical

The VITA Classical shade guide has been available since 1956. Since that time, it has been the gold standard for visual shade matching. The majority of resin composites are keyed to the VITA Classical shade guide system. Two tab arrangements are utilized for this system.

The VITA Classical *A-to-D arrangement* (Fig 4-9) distributes tabs into four

matching method with the tabs arranged from A to D encompasses initial selection of

in the second step.

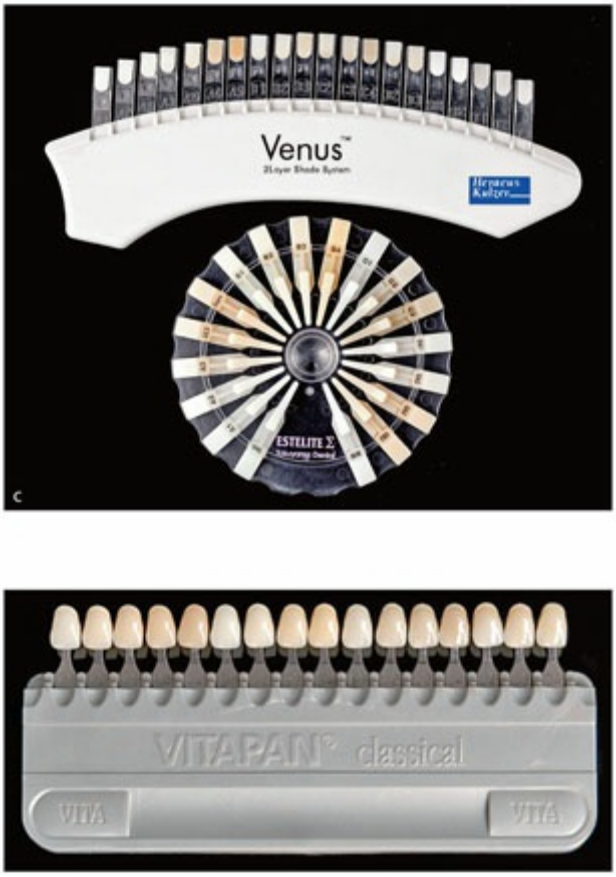

Fig 4-9 VITA Classical shade guide, A-to-D arrangement. From left to right: A1, A2, A3, A3.5, A4, B1, B2, B3, B4, C1, C2, C3, C4, D1, D2, D3, D4.

The VITA Classical *value scale arrangement* (Fig 4-10) represents a light-to-

Dentlearn.ir

dark arrangement, from 1 (B1) to 16 (C4). The only shade-matching instruction for this arrangement of tabs is to select the best overall match. The value scale is frequently used for visual monitoring of tooth-whitening efficacy, expressed in shade guide units (SGU). However, discrepancies in the visual light-to-dark arrangement and nonuniform color distribution in the VITA Classical value scale reduce to a certain extent its efficacy for this purpose.



Fig 4-10 VITA Classical shade guide, value scale arrangement. From left to right: B1, A1, B2, D2, A2, C1, C2, D4, A3, D3, B3, A3.5, B4, C3, A4, C4.

VITA 3D-Master

VITA 3D-Master shade guides are the Toothguide, Linearguide, and Bleachedguide. These shade-matching tools have been developed based on research findings.[16,23–26] They match the color range and distribution of human teeth better than other shade guides, so the probability of selecting a good match will be highest with these products.[27–29] Each 3D-Master tab is marked using a number-letter-

with 0 as the lightest and 5 the darkest. The letter represents hue, with the letter *L* corresponding to yellowish, *M* to medium, and *R* to reddish. The final number

Dentlearn.ir

represents chroma, with 1 being the least chromatic and 3 the most chromatic.

Toothguide was the first 3D-Master shade guide. Shade matching with the Toothguide requires three steps. In the first step (Fig 4-11), the lightness is determined using all tabs, and the number of possible shades is reduced from a total

determined in two separate subsequent steps. This shade-matching method can be challenging for those with little experience in tooth shade matching or with no or little knowledge of color physics.



Fig 4-12 VITA Toothguide 3D-Master: Vertical chroma variations (ranging from 1 to 3) are

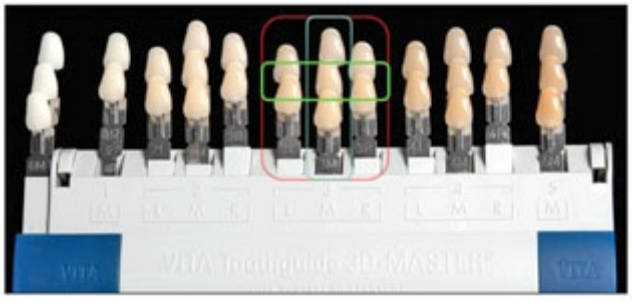

Fig 4-13 VITA Toothguide 3D-Master: Horizontal hue variations (L, M, and R) are present only

Dentlearn.ir

Linearguide 3D-Master has the same tabs as the Toothguide. However, its design and recommended shade-matching method are different. A single linear scale

pronounced color differences and the familiar linear tab arrangement simplify the

selected in step 1: 0-1, 2, 3, 4, or 5 (Fig 4-14b, light-gray holders). Users frequently describe the shade-matching method with Linearguide as self-explanatory and user-friendly.[17]



The 29-SGU Bleachedguide 3D-Master is the first shade guide developed for visual evaluation of tooth whitening (Fig 4-15). It exhibits a wider color range and a more consistent color distribution when compared with the VITA Classical shade guide and some other products. The inclusion of very light shades complements contemporary esthetic dentistry.[21,22] Bleachguide 3D-Master has recently replaced VITA Classical as an example of an appropriate shade guide for the evaluation of tooth whitening in the American Dental Association guidelines for bleaching products (dentist dispensed and over-the-counter) as well as for stain-removal products.[30]



Fig 4-15 Prototype of a 29-step VITA Bleachedguide 3D-Master.

Dentlearn.ir

Shade-matching conditions

Determining the optimal shade-matching conditions requires a consideration of light and environment. Either a ceiling light or a portable light (floor, table, or handheld light), can be used for shade matching. In either case, diffuse color-corrected light should be used for color matching and reproduction in the office and laboratory. Daylight (D65, D55, or similar) lamps and tubes with a color rendering index (CRI) of 90 or greater should be selected. The recommended light intensity is 1,000 to 1,500 lux. The immediate surroundings should ideally be neutral, such as light gray. Creation of a designated shade-matching and reproduction area in the office/laboratory is helpful.

Using handheld lamps (Fig 4-16) for shade matching can significantly reduce the influence of surrounding colors, especially if the ceiling light is off. These lamps usually come with instructions on the positioning, distance, and specific method to be used.



Fig 4-16 Handheld lamps for shade matching. From left to right: Optilume Trueshade (Optident), shade wand (Authentic Dental Lab), Rite-lite (AdDent), and Demetron Shade Light (Kerr).

Guidelines for shade matching

- Shade matching should be performed by individuals with normal color vision; color-deficient persons should be assisted. Tinted glasses or contact lenses should not be worn during shade matching or any other work with color in dentistry.
- The tooth whose color is to be matched should be cleaned with pumice or toothpaste and rinsed. The patient should remove any lipstick.
- To avoid a mistake in shade matching due to eye fatigue of the dentist, the procedure should be performed at the beginning of the appointment.
- The viewing angle should be approximately 45 degrees to the illumination angle. In the dental operatory, the tooth should be observed perpendicularly to its labial surface, with the eth. Shade-matching

Dentlearn.ir

distance should be 25 to 35 cm (or 10 to 14 inches). This corresponds to the viewing angle of 0 degrees, while the light (one-directional, two-directional, or circumferential) should be at a 45-degree angle to the tooth. In the dental laboratory, it is more typical that a table light is placed perpendicular to the dentition (a 0-degree lighting angle). In this case, the teeth should be viewed from approximately a 45-degree viewing angle.

- Whenever possible, the shade tabs should be placed on the same plane with the tooth to be matched and with the same relative edge position. When the adjacent tooth is present, tabs can be placed in front of it or horizontally or vertically in between the maxillary and mandibular teeth.
- A single shade-matching trial should last no more than 5 seconds at a time, because a vision pigment is used up quickly during color perception. A neutral, light-gray card should be observed between trials. In the past, light-blue cards were recommended, but they are now discouraged because of the after-effect phenomenon: When the blue cones are fatigued, a neutral field may appear slightly yellow.
- Wetting with water can reduce or neutralize surface texture differences between the tab and the tooth.
- The number of potential matches should be reduced as quickly as possible. These tabs should be separated from the other tabs before proceeding with final shade matching.
- Translucency, gloss, and local color characteristics should be visualized and documented.
- It is always good to verify the shade selection under different lights and at different angles to avoid or reduce metamerism. *Metamerism* occurs when two

under another.

The human eye cannot see lightness, chroma, and hue separately. Therefore, color matching is a comparison of the overall impression of color differences between observed objects. Humans can see differences in lightness, chroma, and hue, but these differences are dependent on one another. It is quite easy, for example, to confuse a decrease in chroma with an increase in lightness. The example with which many dental professionals are familiar is the A1 and B1 tabs of VITA Classical (B1 is considered to be the lightest shade in the system). Although the A1 tab actually has a higher lightness (value) than B1, it appears darker because it is more chromatic. Therefore, the best shade-matching advice and strategy is to simply select the best

Dentlearn.ir

match. When one must perform a dimension-by-dimension technique, identify value first, then chroma, and then hue.

Color-matching instruments and software

Color-matching instruments and software can be used independently or combined with a visual method. They can also be valuable for color communication, reproduction, and verification. Spectrophotometers and colorimeters are available, and some of them are capable of providing a detailed image of the tooth surface as well as a tooth color map.[31] An overview of available instruments and software is listed in Table 4-1.

Table 4-1 **Instruments and software for color matching in dentistry**[9,10,32]

	ClearMatch	Crystaleye	Easyshade Compact	SpectroShade Micro
Manufacturer	Clarity Dental	Olympus	Vident	MHT Optic Research
Device type	Software	Spectrophotometer	Spectrophotometer	Spectrophotometer
Measurement area	Complete tooth image	Complete tooth image	5-mm probe diameter	Complete tooth image
Relative cost	Low	High	Low	Moderate

Shade-matching results of instrumental measurements are typically given in the units of the CIELAB system and the best-matching shade tab(s). All listed compact and cordless color-matching instruments consist of a handpiece and a base unit (Figs 4-17 and 4-18). They have their own light sources and a means for electronic storage and transfer of information.[10] Tooth color–matching instruments can be categorized into complete tooth surface measurement devices and limited-area ("spot") measurement devices.

Dentlearn.ir



Fig 4-17 Shade-matching instrument: Spectro-shade Micro (MHT Optic Research).



Fig 4-18 Shade-matching instruments: Vita EasyShade Compact (Vident) *(left)* and Crystaleye (Olympus) *(right)*.

SpectroShade Micro (MHT Optic Research) uses a digital camera/light-emitting software, and a tooth-positioning guidance system[31] (see Fig 4-18). Crystaleye (Olympus) uses a combination of a traditional spectrophotometer and digital photography (see Fig 4-18). Virtual shade tabs in its database can be cross-referenced and superimposed with a natural tooth or dental restoration, thus enhancing color communication.[33] Vita Easyshade Compact (Vident) is a contact-type spectrophotometer with a 5-mm probe diameter and a variety of measurement modes (see Fig 4-18): tooth single mode, tooth area mode (cervical, middle, and incisal shades), restoration color verification (includes lightness, chroma, and hue comparison), and shade tab mode (practice/ training mode).[32,34] ClearMatch (Clarity Dental) is software that requires the use of a digital camera. It compares tooth color

Dentlearn.ir

with its own color database.

Instrumental shade matching has attracted a lot of attention from researchers,[10] starting from the performance assessment of shade-matching devices[35–37] and digital imaging systems[38–40] through comparisons between visual and instrumental findings,[41–43] evaluation of color of natural teeth[27,28,44,45] and various dental materials,[46–49] and tooth whitening.[50–53] While many of these systems have been shown to be reproducible and accurate and can be very helpful in providing quantitative differences, they will likely always be used as adjuncts to human shade matching because of the highly subjective and somewhat personal nature of the process.

Communicating color and appearance

Once the shade for indirect restorations is selected, analyzed, and agreed upon by the patient, the information should be transferred to the dental laboratory. In addition to the information obtained using visual and instrumental shade analysis, subsequent reference photography of the tooth, with the selected shade tab aligned next to it, is highly recommended as an effective communication tool (Fig 4-19). Uniformly calibrated monitors in the dental office and laboratory further contribute to enhanced communication on color and appearance. Digital imaging can be shared instantly via the Internet, email, CD-ROM, or other storage device. Inclusion of verbal and written instructions and custom-made or modified shade tabs is also recommended for complex cases.



Fig 4-19 Communication on color and appearance using various shade-matching techniques and digital photography. *(a)* Photographs should be taken so the shade tab designation is included in the photograph and can be viewed by the laboratory. *(b)* The black-and-white tab attached to the shade tab handle is used by the dental laboratory to calibrate the color of their computer monitor to the photograph.

Reproduction and Verification of Color and

Dentlearn.ir

Appearance

Color reproduction is a combination of dental art and science. Because different restorative techniques are described in other parts of this book, the three clinical cases presented here include only information about color-related properties of dental materials and offer examples of nonconventional yet very successful techniques for reproducing color and appearance.

Color-related properties of dental materials

Color-related properties of esthetic dental materials can be categorized as follows[1,9]:

- Color compatibility between materials and teeth, between different materials, and within the same material (batch color variations)
- Color stability during fabrication (condensation, firing, glazing, or at placement), polymerization and other types of setting, and after placement (aging and staining)
- Color interactions (blending and layering)

It is important to note that in spite of remarkable improvements associated with the optical properties of dental materials, one person can still experience different outcomes based solely on material selection.[9] Therefore, material selection can be critical for the esthetics and, consequently, for the overall success of a dental restoration. It is highly recommended to consult professional resources, such as MEDLINE, professional journals and newsletters,[53–59] and information from manufacturers regarding material selection. The following cases highlight different techniques for achieving excellent esthetic outcomes.

Case A: Five dimensions of color

The five dimensions of color technique (Fig 4-20) was developed by Lorenzo Vanini primarily for restoring natural color and appearance of teeth with direct resin composite restorations.[60,61] This approach encompasses the following elements:

Dentlearn.ir



Fig 4-20 Five dimensions of color technique. Facial *(a)* and palatal *(b)* views of the clinical situation show a nonvital, discolored, and severely compromised maxillary left central incisor with a

walking-bleach technique with 12% hydrogen peroxide, the tooth is prepared with a chamfer on the facial enamel *(c)* and 90-degree butt interproximal and lingual margins *(d)*. *(e)* A silicone index made from a mock-up or diagnostic wax-up is used for creation of the lingual wall and is adapted to all involved teeth. *(f)* A thin layer of universal enamel resin composite allows for easy reproduction of the natural anatomy of the lingual wall. Dentin body and enamel effects are then created: *(g)* dentin body is formed with lighter incisal mamelons (characterization type 1); *(h)* amber and white resin composite are used at the incisal and approximal margins (characterization type 3); *(i)* free spaces between margin and dentin mamelons are filled with opalescent blue (opalescent type 1) to increase the halo effect; *(j)* a thin layer of intense white is stratified to create a white-spot appearance (intensive type 2). The stratification is completed on the facial surface with a thin layer (0.8 mm) of universal enamel. In the facial *(k)* and palatal *(l)* views, the intensive, opalescent, and characterization elements give a natural, three-dimensional quality to the completed case. (Courtesy of Lorenzo Vanini, Chiasso, Switzerland.)

- Chromaticity is related to one hue (universal dentin) and different chroma levels (0, 0.5, 1, 2, 3, 4, 5, and 6).

Dentlearn.ir

value (older tooth biotype) and higher value (younger tooth biotype).

horizontal bands.

- Opalescents create the blue and amber hue of the incisal halo at the interproximal level and free enamel margin. The author describes different shapes: mamelon, split mamelon, comb-like, windowlike, and stainlike.
- Characterizations encompass five different types: two in dentin, mamelon, and band, and three in enamel, margin (younger teeth), stain, and cracks (adult and older teeth).

Case B: Natural layering concept

The natural layering concept (Fig 4-21) was developed by Didier Dietschi for the creation of highly esthetic direct restorations.[62,63] This method suggests single hue, single opacity, and broad chroma scales for mimicking dentin color and appearance. Enamel and corresponding materials are categorized as the following types: young enamel (white tint, high opalescence, less translucency), adult enamel (neutral tint, less opalescence, and intermediary translucency), and old enamel (yellow tint, more translucency). Only two basic layers, dentin and enamel, are used to enhance tooth and smile anatomy.



Fig 4-21 Natural layering concept. *(a)* A young patient presents with a healthy dentition but a highly irregular smile line. The patient wants improvement but demands a conservative solution. *(b)* Following placement of rubber dam, an index (made from a mock-up or wax-up) will serve to

Dentlearn.ir

guide proper placement of the two resin composite layers in three dimensions. *(c)* The restorations are placed using the natural layering concept. *(d)* The completed restorations demonstrate the satisfactory esthetic integration of the direct composite restorations using a modern hybrid material, which exhibits proper color, opacity, translucency, and opalescence. (Courtesy of Didier Dietschi, Geneva, Switzerland.)

Case C: Combined visual-instrumental technique

Shigemi Nagai and her team are among the leaders when it comes to combining visual and instrumental techniques[64–67] (Fig 4-22). Using sophisticated color-measurement instruments to their best advantage requires clinical/laboratory excellence and sound color science. This means not only knowing how, when, and why to use the instrument but also being able to understand and interpret the findings and to adjust the color and appearance of the dental restoration using principles of subtractive color mixing and complementary color theory, for both color control and final verification of the crowns and gingiva. This case provides an example of what is possible when this combination technique is utilized by experts in the field.

Dentlearn.ir



Fig 4-22 Combined visual-instrumental technique. A 32-year-old woman presents with missing maxillary lateral incisors. She wants to replace them with single implants and crowns. *(a to d)* Two narrow-diameter bone-level implants are placed, and zirconia all-ceramic crowns (Lava, 3M ESPE) are fabricated with Vita VM9 layered porcelain (Vident). *(e)* Although the color of the crowns is symmetric, a perceivable difference in the peri-implant soft tissue appearance is observed between the two implant-supported crowns. *(f and g)* Color mapping of the peri-implant tissue around the maxillary right lateral incisor shows that it has blanched, which can also be seen in the linked image. *(h)* At the 1-month follow-up appointment, an improvement in the optical properties of the peri-implant soft tissue of the maxillary right lateral incisor compared with *f* is observed. *(i)* The digital camera image shows an excellent color match of both maxillary lateral incisor crowns and an improved appearance of the peri-implant soft tissue. (Courtesy of Shigemi Nagai, Boston, Massachusetts.)

References

Dentlearn.ir

1. Chu SJ, Devigus A, Paravina RD, Mieleszko A. Fundamentals of Color: Shade Matching and Communication in Esthetic Dentistry, ed 2. Chicago: Quintessence, 2011.
2. Paravina RD, Powers JM. Esthetic Color Training in Dentistry. St Louis: Elsevier Mosby, 2004.
3. American Academy of Cosmetic Dentistry. Can a new smile make you appear more successful and

4. Bergen SF. Color in esthetics. N Y State Dent J 1985;51:470–471.
5. Berns RS (ed). Billmeyer and Saltzman's Principles of Color Technology, ed 3. New York: John Wiley & Sons, 2000.
6. Luo MR, Cui G, Rigg B. The development of the CIE 2000 color-difference formula: CIEDE2000. Color Res Appl 2001;26:340–350.
7. Colorimetry, ed 3 [Report CIE 015:2004]. Vienna: International Commission on Illumination, 2004:12–21.
8. Paravina RD, Kimura M, Powers JM. Evaluation of polymerization-dependent changes in color and translucency of resin composites using two formulae. Odontology 2005;93:46–51.
9. ASTM International Standards on Color and Appearance Measurement, ed 8. West Conshohocken, PA: ASTM International, 2008.
10. Paravina RD. Dental Color Matcher: An Online Educational and Training Program for Esthetic Dentistry.

11. Goodacre CJ, Paravina RD, Bergen SF, Preston JD. A Contemporary Guide to Color and Shade Selection for Prosthodontists [DVD]. Chicago: American College of Prosthodontists, 2009.
12. Paravina RD, O'Keefe KL, Kuljic BL. Colour of permanent teeth: A prospective clinical study. Balk J Stom 2006;10:93–97.
13. Paravina RD, Majkic G, Stalker JR, Kiat-Amnuay S, Chen JW. Development of a model shade guide for primary teeth. Eur Arch Paediatr Dent 2008;9:74–78.
14. Dentistry—Guidance on colour measurement [Publication ISO/TR 28642:2011]. Geneva: International Standardization Organization, 2011.
15. Sproull RC. Color matching in dentistry. Part I: The three-dimensional nature of color. J Prosthet Dent 1973;29:416–424.
16. Okubo SR, Kanawati A, Richards MW, Childress S. Evaluation of visual and instrument shade matching. J Prosthet Dent 1998;80:642–648.
17. Paravina RD. Performance assessment of dental shade guides. J Dent 2009;37(suppl 1):e15–e20.
18. Paravina RD, O'Neill PN, Swift EJ, Nathanson D, Goodacre CJ. Teaching of color in predoctoral and postdoctoral dental education in 2009. J Dent 2010;38(suppl 2):e34–e40.
19. Preston JD. Current status of shade selection and color matching. Quintessence Int 1985;16:47–58.
20. Miller LL. Shade matching. J Esthet Dent 1993;5:143–153.
21. Paravina RD, Powers JM, Fay RM. Color comparison of two shade guides. Int J Prosthodont 2002;15:73–78.
22. Paravina RD, Powers JM, Fay RM. Dental color standards: Shade tab arrangement. J Esthet Restor Dent 2001;13:254–263.
23. Hall NR. Tooth colour selection: The application of colour science to dental colour matching. Aust Prosthodont J 1991;5:41–46.
24. Hall NR, Kafalias MC. Composite colour matching: The development and evaluation of a restorative colour matching system. Aust Prosthodont J 1991;5:47–52.
25. Paravina RD, Johnston WM, Powers JM. New shade guide for evaluation of tooth whitening—Colorimetric study. J Esthet Restor Dent 2007;19: 276–283.
26. Paravina RD. New shade guide for tooth whitening monitoring: Visual assessment. J Prosthet Dent 2008;99:178–184.
27. Analoui M, Papkosta E, Cochran M, Matis B. Designing visually optimal shade guides. J Prosthet Dent 2004;92:371–376.
28. Paravina RD, Majkic G, Imai FH, Powers JM. Optimization of tooth color and shade guide design. J Prosthodont 2007;16:269–276.
29. Li Q, Yu H, Wang YN. In vivo spectroradiometric evaluation of colour matching errors among five shade

Dentlearn.ir

guides. J Oral Rehabil 2009;36:65–70.
30. Council of Scientific Affairs of the American Dental Association. Acceptance Program Guidelines—Home-Use Tooth Stain Removal Products. Chicago: American Dental Association, 2012.
31. Dozic A, Voit NF, Zwartser R, Khashayar G, Aartman I. Color coverage of a newly developed system for color determination and reproduction in dentistry. J Dent 2010;38(suppl 2):e50–e56.
32. VITA Easyshade Advance: Operating zahnfabrik.com/resourcesvita/shop/en/en_3055212.pdf. Accessed 20 May 2013.
33. Chu SJ, Trushkowsky RD, Paravina RD. Dental color matching instruments and systems. Review of clinical and research aspects. J Dent 2010;38(suppl 2):e2–e16.
34. Lehmann KM, Igiel C, Schmidtmann I, Scheller H. Four color-measuring devices compared with a spectrophotometric reference system. J Dent 2010;38(suppl 2):e65–e70.
35. Dozić A, Kleverlaan CJ, El-Zohairy A, Feilzer AJ, Khashayar G. Performance of five commercially available tooth color-measuring devices. J Prosthodont 2007;16:93–100.
36. Da Silva JD, Park SE, Weber HP, Ishikawa-Nagai S. Clinical performance of a newly developed spectrophotometric system on tooth color reproduction. J Prosthet Dent 2008;99:361–368.
37. Kim-Pusateri S, Brewer JD, Davis EL, Wee AG. Reliability and accuracy of four dental shade-matching devices. J Prosthet Dent 2009;101:193–199.
38. Denissen H, Kuijkens A, Dozić A. A photographic method to measure the colour characteristics of healthy gingiva. Int J Dent Hyg 2007;5:22–26.
39. Wee AG, Lindsey DT, Kuo S, Johnston WM. Color accuracy of commercial digital cameras for use in dentistry. Dent Mater 2006;22:553–559.
40. Carter K, Landini G, Walmsley AD. Automated quantification of dental plaque accumulation using digital imaging. J Dent 2004;32:623–628.
41. Paul S, Peter A, Pietrobon N, Hämmerle CH. Visual and spectrophotometric shade analysis of human teeth. J Dent Res 2002;81:578–582.
42. Li Q, Wang YN. Comparison of shade matching by visual observation and an intraoral dental colorimeter. J Oral Rehabil 2007;34:848–854.
43. Fani G, Vichi A, Davidson CL. Spectrophotometric and visual shade measurements of human teeth using three shade guides. Am J Dent 2007;20:142–146.
44. Haddad HJ, Salameh Z, Sadig W, Aboushelib M, Jakstat HA. Allocation of color space for different age

45. Yuan JC, Brewer JD, Monaco EA Jr, Davis EL. Defining a natural tooth color space based on a 3-dimensional shade system. J Prosthet Dent 2007;98:110–119.
46. Devigus A, Lombardi G. Shading Vita YZ substructures: Influence on value and chroma, part I. Int J Comput Dent 2004;7:293–301.
47. Sailer I, Holderegger C, Jung RE, et al. Clinical study of the color stability of veneering ceramics for zirconia frameworks. Int J Prosthodont 2007; 20:263–269.
48. Omar H, Atta O, El-Mowafy O. Difference between selected and obtained shade for metal-ceramic crown systems. Oper Dent 2008; 33:502–507.
49. Nakazawa M. Color stability of indirect composite materials polymerized with different polymerization systems. J Oral Sci 2009;51:267–273.
50. Lin CH, Chou TM, Chen JH, et al. Evaluation of the effect of laser tooth whitening. Int J Prosthodont 2008;21:415–418.
51. Chu SJ. Use of a reflectance spectrophotometer in evaluating shade change resulting from tooth-whitening products. J Esthet Restor Dent 2003;15(suppl 1):S42–S48.
52. Ontiveros JC, Paravina RD. Color change of vital teeth exposed to bleaching performed with and without supplementary light. J Dent 2009;37:840–847.

Accessed 20 May 2013.

Dentlearn.ir

55. US Air Force Dental Evaluation & Consultation Service website. functionalarea=DentalEvalConsultation&doctype=subpage&docname=CTB_106773. Accessed 20 May 2013.

60. Vanini L. Conservative composite restorations that mimic nature. A step-by-step anatomical stratification technique. J Cosmet Dent 2010; 26:80–98.
61. Vanini L, Mangani FM. Determination and communication of color using the five color dimensions of teeth. Pract Periodontics Aesthet Dent 2001;13:19–26.
62. Dietschi D. Clinical Application of the "Natural Layering Concept."

63. Dietschi D, Ardu S, Krejci I. A new shading concept based on natural tooth color applied to direct composite restorations. Quintessence Int 2006;37:91–102.
64. Ishikawa-Nagai S, Yoshida A, Da Silva JD, Miller L. Spectrophotometric analysis of tooth color reproduction on anterior all-ceramic crowns: Part 1: Analysis and interpretation of tooth color. J Esthet Restor Dent 2010;22:42–52.
65. Yoshida A, Miller L, Da Silva JD, Ishikawa-Nagai S. Spectrophotometric analysis of tooth color reproduction on anterior all-ceramic crowns: Part 2: Color reproduction and its transfer from in vitro to in vivo. J Esthet Restor Dent 2010;22:53–63.
66. Ishikawa-Nagai S, Da Silva JD, Weber HP, Park SE. Optical phenomenon of peri-implant soft tissue. Part II. Preferred implant neck color to improve soft tissue esthetics. Clin Oral Implants Res 2007;18:575–580.
67. Da Silva JD, Park SE, Weber HP, Ishikawa-Nagai S. Clinical performance of a newly developed spectrophotometric system on tooth color reproduction. J Prosthet Dent 2008;99:361–368.

Dentlearn.ir



Caries Management: Diagnosis and Treatment Strategies

Bennett T. Amaechi
J. Peter van Amerongen
Cor van Loveren
Edwina A. M. Kidd

Traditional caries management has consisted of the detection of caries lesions followed by immediate restoration. In other words, caries was managed primarily by restorative dentistry. However, when the dentist removes tooth structure with a handpiece, an irreversible process begins. Placing a restoration does not guarantee a sound future for the tooth; on the contrary, it may be the start of a restorative cycle in which the restoration will be replaced several times (Fig 5-1). This is reflected in the philosophy of Dr V. Kim Kutsch: "I get to the cause of the disease, instead of just treating the symptoms. When you're focused on just treating the symptoms surgically, which traditionally is what we've done in dentistry, you never catch up. You never get ahead."[1] Caries is like every other bacterial disease, and restoration without removal of the causative factors is like placing a new roof on a burning house.

Dentlearn.ir



Fig 5-1 Iatrogenic damage caused by repeated treatment procedures.

A new paradigm for caries management, patient-centered caries management (PCCM), is recommended.[2] PCCM is enabled by the International Caries Detection and Assessment System (ICDAS) clinical visual scoring system for caries detection and activity.[2] When integrated into the caries management by risk assessment (CAMBRA),[3,4] treatment of caries is a process that can be controlled so that lesions may never form or, if they do, lesion progression can be arrested. The PCCM strategy involves a comprehensive assessment and includes evaluation of the caries risk and protective factors, detection and diagnosis of caries, and determination of the activity of existing caries in order to establish the individual patient's caries risk. The information collected from the comprehensive assessment is synthesized into a personalized treatment plan, composed of preventive and noninvasive treatment options, operative and minimally invasive treatment options, and maintenance care involving recall appointments for reassessment and monitoring (Fig 5-2). The treatment options recommended for specific caries lesions and patients will depend on a variety of prognostic factors, including lesion activity, and the monitoring of lesion behavior over time. It is important to mention that preventive regimens will arrest the caries process by redressing the imbalance between demineralization and remineralization.[5]

Dentlearn.ir

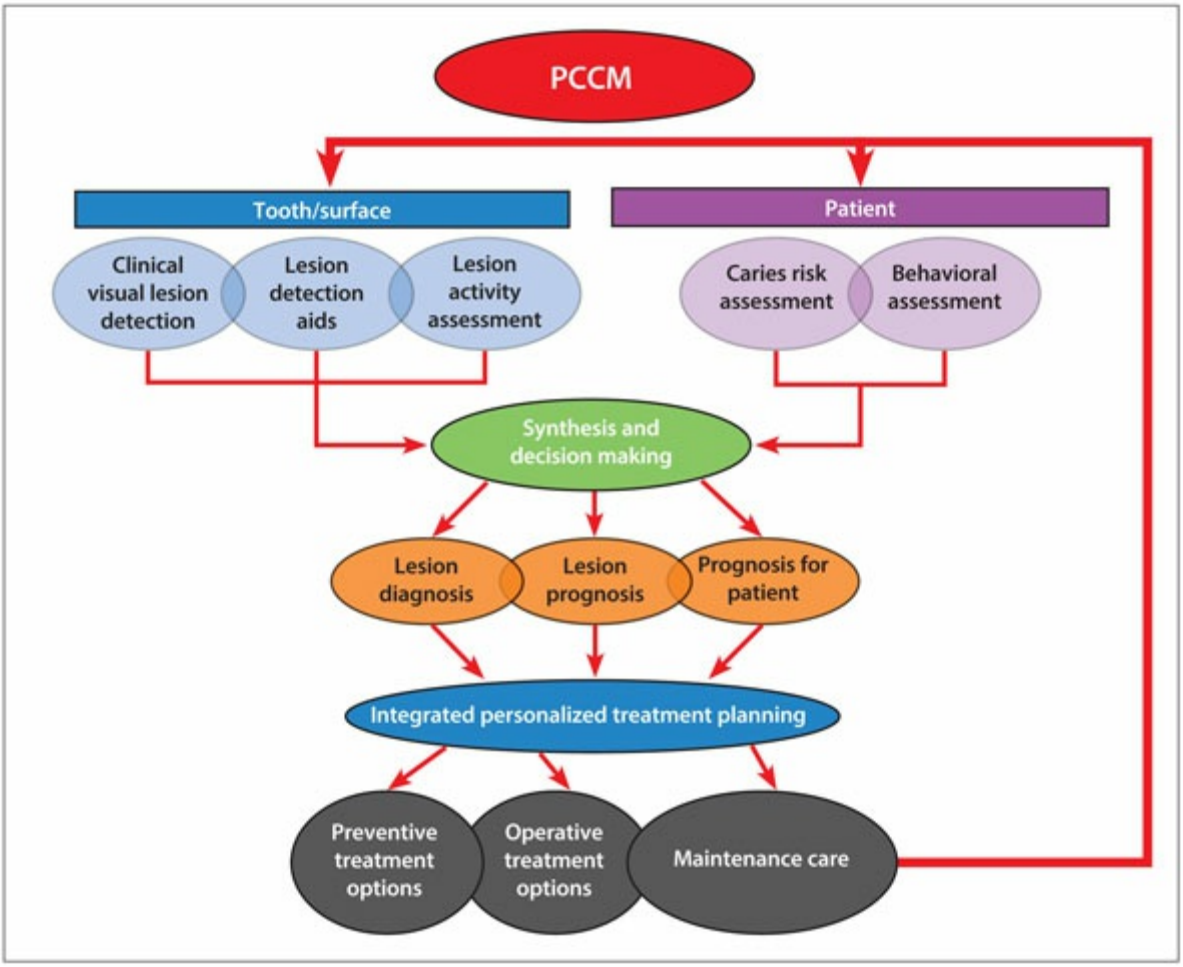

Fig 5-2 Algorithm for PCCM. (Modified from Pitts and Richards[2] with permission.)

The treatment goal in caries management should be to prevent new lesions from forming, to detect lesions sufficiently early in the process so that they can be treated and arrested by noninvasive means,[5] and to educate patients on the cause of the disease to gain their cooperation with recommended preventive strategies.

The Caries Process

Our understanding of the nature of any disease determines how we diagnose it and how we manage it. This general principle also applies to dental caries. Through scientific research, our understanding of the nature of caries and factors relating to its development has changed over time, as has the way we diagnose and manage the disease. The initiation of the development of dental caries by the concurrent action of three primary factors (the tooth, dental plaque, and diet) were presented in the 1960s in a model of overlapping circles.[6] Since then, the model has been

Dentlearn.ir

supplemented with factors that modulate the actions of the primary factors to determine the manifestation and clinical severity of caries[7] (Fig 5-3). At first sight, these circles constitute a simple model to explain caries risk, which is represented by the overlap of the three inner circles. When one of the risk factors increases, the respective circle becomes larger, as does the overlap of the circles, indicating increased caries risk.

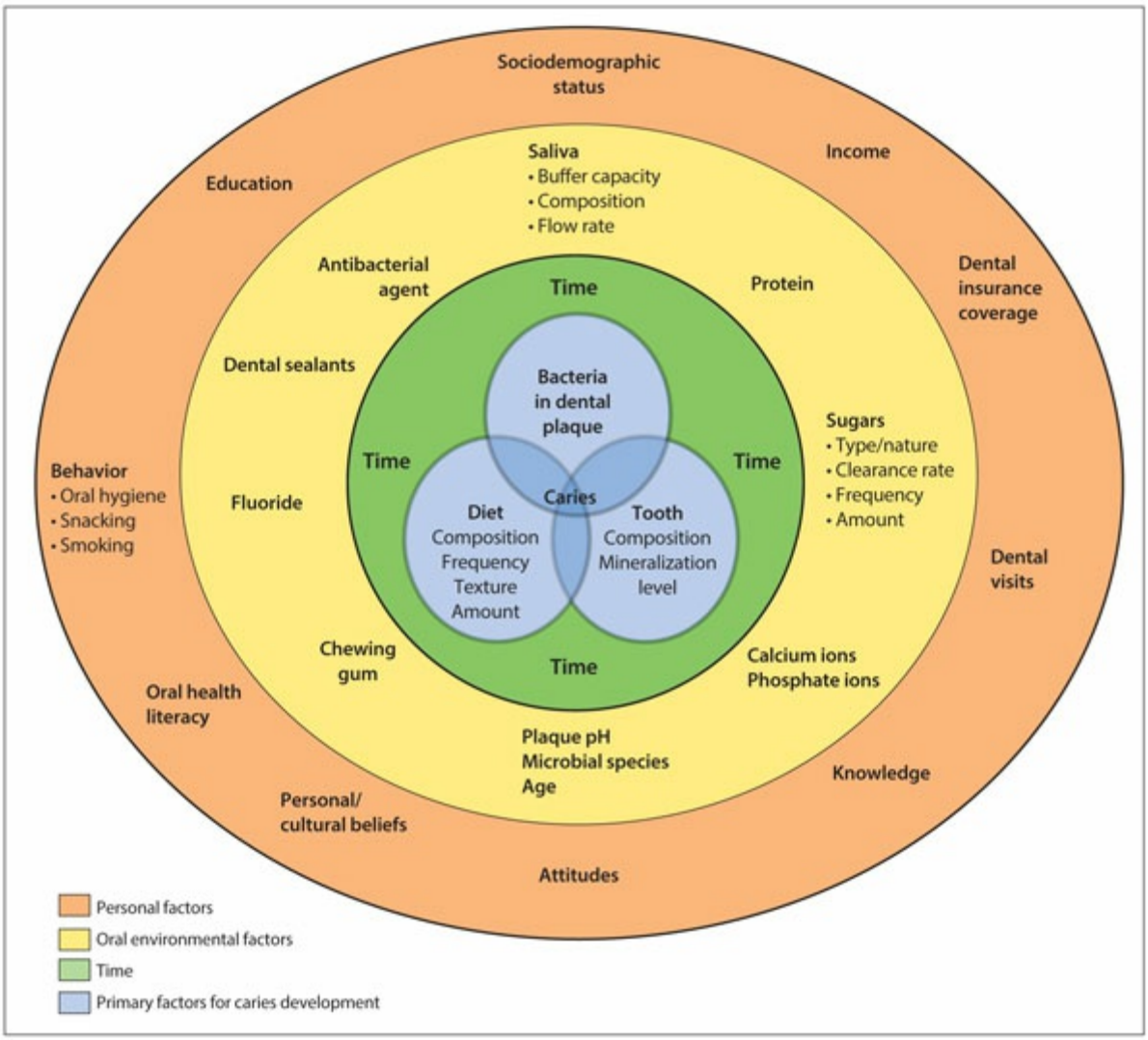

Fig 5-3 Factors influencing the equilibrium between the three prerequisites for the caries process as first described by Keyes and Jordan.[6] (Modified from Selwitz et al[7] with permission.)

Dental plaque

The prevalence of mutans streptococci and lactobacilli is associated with dental caries.[8–10] *Streptococcus mutans* is involved in caries lesion formation from its initiation, while lactobacilli flourish in a carious environment and contribute to caries progression. Dental plaque may be more cariogenic locally where mutans

Dentlearn.ir

streptococci and lactobacilli are concentrated, but in everyday practice it is difficult for the dentist to identify cariogenic plaque to make this knowledge useful in treating

levels quantified, but the procedure is quite complicated and requires the support of a microbiologic laboratory. It is easier to count mutans streptococci and lactobacilli in saliva, and kits are commercially available for this purpose. However, these counts do not give site-specific information and are poor predictors of high caries activity in general, although low counts or absence of mutans streptococci are good predictors of low caries activity.[11]

High numbers of mutans streptococci and lactobacilli are probably the consequence of a high sugar intake and the resulting periods of low pH levels in dental plaque.[12,13] Inversely, it has been shown that restriction of sugar intake reduces the numbers of mutans streptococci and lactobacilli.[12,14] In one study of Weight Watchers clients who complied with a non-cariogenic diet, the numbers of mutans streptococci and lactobacilli were reduced by half.[15] A comparable reduction was found in subjects who reduced their sugar intake frequency from 7.2 to ⅛ times per day.[16] However, the decrease in mutans streptococci was more pronounced on buccal than on proximal tooth surfaces, and, interestingly, the pH response to glucose was reduced in buccal but not in interdental plaque.[16,17] Six weeks after completing the sugar restriction period, the numbers of mutans streptococci increased again.[16]

The oral flora colonizes on teeth continuously, but it takes up to several days before the dental plaque contains enough acidogenic bacteria to lower plaque pH to the level that causes demineralization.[18] Theoretically, plaque removal every second day would be sufficient. If the dentition is professionally cleaned, an even lower frequency of home-care cleaning has been demonstrated to prevent caries.[19,20] But considering the caries prevalence in the prefluoride era, it is obvious that few people are capable of cleaning their teeth to a level adequate to prevent caries.

Teeth

Teeth consist of a calcium phosphate mineral that demineralizes when the environmental pH lowers. As the environmental pH recovers, dissolved calcium and phosphate can reprecipitate on remaining mineral crystals. This process is called *remineralization*. Remineralization is a slower process than demineralization. When remineralization is given enough time, it can eliminate the damage done during demineralization, but in the absence of this, the caries process will progress and a

Dentlearn.ir

lesion will develop. Dentin is more vulnerable than enamel because of structural differences and greater numbers of impurities in the crystal lattice, which facilitate its degradation in an acidic environment. For many years, much emphasis was given to the preeruptive effect of fluoride improving the quality of the dental hard tissues. However, it is now clear that posteruptive use of fluoride is far more protective against caries.[21–23] Enamel in primary teeth is less mineralized and more variable than permanent enamel. Optically it is more opaque, which may represent greater porosity. It gives the clinical impression of wearing more quickly and being less resistant to caries.[24]

Diet

Dietary carbohydrates are necessary for the bacteria to produce the acids that initiate demineralization. In general, dietary advice for caries prevention is based on three principles: *(1)* the drop in pH lasts for approximately 30 minutes; *(2)* the frequency of intake is more important than the quantity; and *(3)* the stickiness of foods is an important factor in their cariogenicity. It has become obvious, however, from many epidemiologic studies where fluoride is used daily, that sugar consumption and caries prevalence have become less tightly related for many individuals. Even when there was a significant correlation between sugar consumption and caries prevalence, the caries-preventive effect of sugar restriction was small. For instance, in Basel, Switzerland, wartime restriction reduced sugar supply from about 48 to 16 kg per person per year, but the number of caries-free children rose only from approximately 3% to 15%.[25,26] At that time, the improvement seemed impressive, but it was dwarfed by the effect of nationwide optimum fluoride administration, when the number of caries-free children rose from approximately 7% to more than 50%, with a reduction of sugar supplies from approximately 42 to 39 kg per person per year.[25] Obviously, fluoride administration was far more effective in reducing caries than lowering sugar supplies. With this evidence, the role of dietary counseling in caries prevention should be reexamined. This does not negate the value of diet analysis and advice for patients presenting with multiple caries lesions, but the importance of the proper use of fluoride should always be emphasized.

Information gathered with the reliable pH-telemetry method has revealed that a pH drop induced by eating may last for hours if there is no stimulation of the salivary flow.[18,27,28] Even the consumption of an apple can depress the pH for 2 hours or longer.[18] Long pH depressions will be most prevalent in areas where saliva has little or no access, and these areas are the most caries prone. It is unknown how

Dentlearn.ir

much additional harm is caused by a second sugar intake during such a period of low pH or how beneficial it is to omit a second sugar intake during that period. Foods believed to be "good" for teeth may not be better than foods that are supposedly "bad." A chocolate and caramel bar might be considered bad because it feels sticky. In reality, however, the caramel dissolves and leaves the mouth relatively quickly, whereas potato chips, generally considered less harmful, take a longer time to clear from the mouth.[29] During this retention, the carbohydrate fraction may be hydrolyzed to simple sugars, providing a substrate for the acidogenic bacteria.[30]

All the uncertainties about the determinants of the cariogenicity of foods make it impossible to provide strict dietary guidelines. To snack in moderation, limited to 3 or 4 snacks a day, is the only wise recommendation.

Time

Time affects the caries process in several ways. When caries was considered to be a chronic disease, time was introduced to indicate that the substrate (dietary sugars) must be present for a sufficient length of time to cause demineralization.[31] Now we know that caries is not a chronic disease and that its effects can be arrested or completely repaired if enough time is given for remineralization. Finally, it is clear that caries lesions do not develop overnight but take time; in fact, it may take years for a caries lesion to develop a distinct discontinuity or break in its surface integrity (otherwise called *cavitation*). This potentially gives the dentist and the patient ample time for preventive treatment strategies.

Fluoride

Experiments have shown that fluoride protects enamel more effectively when it is present in the ambient solution during acid challenges than when it is incorporated into the enamel crystal lattice.[21] One of the mechanisms by which fluoride inhibits demineralization is by reprecipitation of dissolved calcium and phosphate, which prevents these constituents from being leached out of the enamel into the plaque and saliva.[23] Part of the reprecipitation takes place at the surface of the tooth. This narrows the pores in the enamel surface that provide diffusion pathways for the acids produced in the dental plaque to penetrate into the enamel. Acid penetration is thus hampered. In addition, during periods in which the ambient pH is higher than 5.5, fluoride will facilitate remineralization, promoting lesion arrest and repair. A lack of fluoride constitutes a caries risk.

Dentlearn.ir

The retention of fluoride in the mouth is site specific. In plaque and saliva and in

of maxillary incisors and buccal surfaces in the mandibular molar region after rinsing with a fluoride solution.[32,33] In addition, it was observed that fluoride from passively dissolving fluoride tablets remained highly concentrated only at the site of tablet dissolution. There was very little or no transport of fluoride between the right and the left sides of the mouth and between the maxillary and mandibular arches.[33] Because of this, localized caries lesions in the mouth may be related to an insufficient spread of fluoride when subjects use fluoride toothpaste. When patients use fluoride toothpaste, they should be encouraged to spit out any excess rather than to rinse vigorously with water. Alternatively, the toothpaste slurry may first be used as a mouth rinse.

Saliva

The important role of saliva is clearly demonstrated by the rampant caries (Fig 5-4) that may occur in subjects with compromised salivary flow. These subjects lack the protective qualities of saliva (Table 5-1), of which the flow rate and buffering capacity may be the most important. Both help to neutralize and clear the acids and carbohydrates from dental plaque. Clearance, however, is not uniform throughout the mouth and may be slowest at the labial aspects of the maxillary incisors and buccal aspects of the mandibular molars. Other sites in the dentition may not be easily accessible to saliva as a result of an individual's anatomy, including interproximal spaces and fissures. Dental plaque in a cavitated area of a tooth may also be protected from salivary clearance.



Fig 5-4 Rampant caries. (Courtesy of Claudia Isabel Contreras, San Antonio, Texas.)

Table 5-1	Functions of components of saliva involved in the caries process

Dentlearn.ir

Components	Functions
Mucins, lysozyme, lactoferrin, lactoperoxidase	Antibacterial
Histamine, agglutinin, cystatines	Antibacterial
Secretory immunoglobulin A, alphaamylase, histatins, histidine-rich proteins	Antibacterial
Proline-rich glycoprotein, mucins	Lubrication/viscoelasticity
Mucins	Inhibition of demineralization
Proline-rich proteins, statherin, calcium phosphate	Remineralization
Bicarbonate, phosphate, urea, arginineric proteins	Buffering

The sites that are difficult for saliva to reach also may be difficult to reach with mechanical cleaning devices, such as a toothbrush or dental floss. Plaque and food may adhere for long periods of time in these areas, making these sites more prone to caries. Furthermore, this caries risk factor may be overlooked in children, whose teeth appear to be clean as judged from the sites that are easily cleaned. These children may brush twice daily, have only a moderate frequency of sugar intake per day, and still develop caries lesions at these sites. The most feasible way to prevent caries lesions at these sites is by thorough oral hygiene measures and use of a fluoride-containing toothpaste so that plaque is removed and fluoride is applied. In Fig 5-5a, a white spot lesion had developed on an erupting permanent second molar because of insufficient toothbrushing. However, the progression of the lesion was stopped by a better understanding of how, when, and why to brush; keeping the toothbrush at a right angle in the fissure; and using a toothpaste with fluoride. The arrested lesion is shown 1 year later (Fig 5-5b).

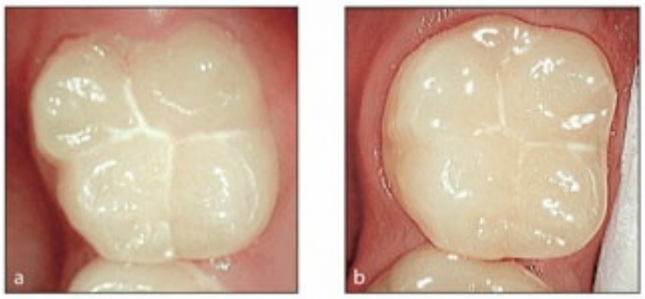

Dentlearn.ir

Fig 5-5*(a)* A permanent mandibular second molar with an active white spot lesion in the occlusal fissures. *(b)* The same lesion after 1 year of brushing with toothpaste containing fluoride. (Courtesy of Jette Christiansen, Copenhagen, Denmark.)

Social and demographic factors

Many studies have shown that, at least in the western world, dental caries is more prevalent in lower socioeconomic categories, in less affluent areas, and among some ethnic minorities[34] (Table 5-2). Differences related to socioeconomic status are very clear for the primary dentition and less clear for the permanent dentition, although this pattern may differ in other parts of the world. Studies have shown that for the prediction of caries lesion development, social and demographic factors may be successful in very young children without a long dental history, but for older children, clinical parameters such as the dmfs (decayed/missing/filled surfaces in primary teeth) and DMFS (decayed/missing/filled surfaces in permanent teeth) as shown in Table 5-3 are more predictive.[11,35–37] In the elderly population, however, root caries lesion development again seems to be more prevalent in people from lower socioeconomic backgrounds.

Table 5-2 **Percentages of 6- and 12-year-old caries-free children and mean dmfs and DMFS scores in children who were not caries free in 1989, 1993, and 1996, according to socioeconomic level[34]**

	6-year-old children						12-year-old children				
Socioeconomic status	**%**	**d**	**m**	**f**	**dmf ± SD**		**%**	**D**	**M**	**F**	**DMF ± SD**
Low											
1989	43	4.7	0.6	2.8	8.2 ± 8.5		46	0.2	0.0	3.4	3.6 ± 2.2
1993	39	4.8	0.3	2.7	7.8 ± 9.0		67	0.1	0.0	3.9	4.0 ± 3.1
1996	49	5.0	1.1	3.5	9.6 ± 9.8		50	0.1	0.0	3.1	3.2 ± 2.4
Medium											
1989	60	3.4	0.8	1.3	5.5 ± 6.9		49	0.2	0.1	3.5	3.9 ± 2.7
1993	69	4.0	0.3	1.4	5.8 ± 7.5		61	0.3	0.0	2.5	2.8 ± 1.9
1996	79	3.7	0.9	0.4	4.9 ± 5.3		89	0.0	0.0	3.6	3.6 ± 2.6
High											
					2.1 ±						2.9 ±

Dentlearn.ir

1989	77	1.5	0.0	0.6	1.3		59	0.9	0.2	1.8	2.0
1993	77	2.5	0.2	1.7	4.4 ± 3.5		63	0.3	0.0	1.7	2.1 ± 1.6
1996	84	1.6	0.9	2.2	4.7 ± 5.1		86	0.3	0.0	2.0	2.3 ± 2.1

dmfs–decayed/missing/filled surfaces in primary teeth; DMFS—decayed/missing/filled surfaces in permanent teeth, SD–standard deviation.

Table 5-3 **Timeline of strongest clinical predictors of caries incidence**[11]

	Age (y)						
	0 and 1	**2–5**	**6–9**	**10–13**	**14–21**	**22–45**	
Dentition	Primary	Primary	Mixed	Mixed	Early permanent	Mature permanent	M pe an re
Predictor*	Mutans streptococci	**dmfs, especially primary incisors;** mutans streptococci and lactobacilli	**dmfs, especially primary molars;** first molar occlusal morphology: DMFS	**DMFS, especially permanent first molars;** first molar occlusal morphology; incipient smoothsurface lesions	**Incipient smoothsurface lesions;** DMFS	Not studied	C an DI nu te pe dis

*The strongest predictors are in bold. dmfs–decayed/missing/filled surfaces in primary teeth; DMFS–decayed/missing/filled surfaces in permanent teeth.

Caries prediction

A good estimate of the caries risk is necessary to make the most appropriate treatment decisions. A recent study[38] described developmental trajectories of caries experience in the permanent dentition to age 32 years. Three caries-experience trajectories were identified and categorized as *high* (approximately 15% of the population), *medium* (approximately 43% of the population), and *low* (approximately 42% of the population) DMFS. All were relatively linear, although the higher trajectories were more S-shaped. The data suggest that, among individuals following a similar caries trajectory, caries rate is relatively constant across time. The trajectories already diverged at an early age of the individuals. This study

Dentlearn.ir

supports that indicators of past caries experience are the strongest predictors of future caries, and the status of the most recently erupted or exposed surfaces is a strong predictor for the newly emerging surfaces. One very elegant review plots the strongest clinical predictors against age and dentition[11] (see Table 5-3).The sensitivity and specificity of the predictors varied from 0.60 to 0.80, indicating that 20% to 40% of the children who developed caries lesions during the study were not identified as being at high risk for caries and that 20% to 40% of the children who were not caries active were, in contrast, predicted to develop caries lesions. In addition, it is important to recognize that none of the studies in the review were designed to predict the progression rate of carious demineralization at a specific site. So, even if it could be predicted that an individual would develop caries lesions, the lesion that is going to progress cannot be confidently identified.

Rate of caries lesion progression

The decline in caries prevalence has been accompanied by a change in lesion behavior. Caries lesions progress more slowly than they did several decades ago, probably due to increased use of fluoride, which delays lesion progression. It is clear that the progression rate is not the same for each site. Little is known about the progression rate of fissure caries lesions. Longitudinal epidemiologic data from the 1950s, when fluoride was not yet widely used, showed that it took approximately 1 year for an enamel fissure lesion to develop into a dentinal lesion.[39] More recent data from the same geographic area, after the introduction of fluoride toothpaste, showed that 50% of the enamel fissure lesions had progressed to involve dentin within 2 years while 75% had become dentinal lesions after 4 years.[39] Data from Switzerland showed that, for permanent first molars, approximately 10%, 20%, and 45%, respectively, of sound fissures, fissures with a yellowish discoloration, and fissures with a dark discoloration progressed to carious dentin or tooth restoration in 4 years.[40] These progression rates were slightly lower than those found by the same investigators 10 years earlier. It is the experience of many clinicians that not all initial fissure lesions will develop to involve the dentin but that a number of them may become arrested. In populations in which not all fissure lesions develop into open cavities, the dentist will be confronted with clinically undetected carious dentin at the base of occlusal fissures.[41] This is not a new phenomenon; it was discussed as early as 1931.[42] Today, reported progression rates of pit and fissure caries lesions vary greatly.[43,44]

Based on epidemiologic data from the 1950s, the progression rates in the

Dentlearn.ir

permanent dentition of proximal caries lesions from initial enamel lesions to involving dentin was estimated to be 2 years at age 7 years and approximately 4 years at age 12 years.[37] Data collected after fluoride supplementation became available showed a progression rate of 3 to 4 years for proximal caries lesions to reach the dentin in 12-year-olds.[44] Shwartz et al[45] concluded from data collected in Sweden and the United States that it takes an average of 4 years for caries lesions to progress through the proximal enamel of permanent teeth. The progression rate seemed to be independent of the DMFS of the individuals.

Not all caries lesions progress, however. In one study, more than 50% of initial proximal caries lesions in 13-year-old adolescents had not advanced during a 3-year period.[46] The majority of the lesions that progressed were found in the adolescents who had the highest number of lesions at the start of the study, which probably reflects the difference between caries-active and caries-inactive individuals. Recently, Mejàre et al[47] published data on the caries lesion prevalence on the proximal surfaces of the posterior teeth at various ages (Fig 5-6). The prevalence was low, with the distal surfaces of the first molars being the most prone to developing caries lesions.

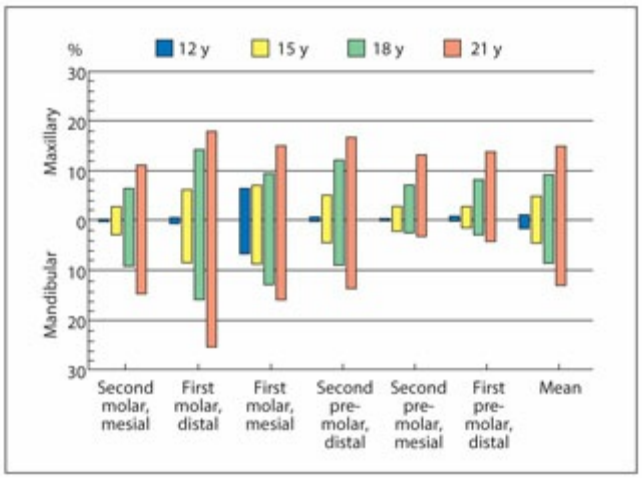

Fig 5-6 Prevalence (percentage of approximal surfaces affected) of dentinal lesions in the

Caries lesions on free smooth surfaces seem to progress more slowly than on proximal surfaces or in fissures. Many lesions do not progress into the dentin and even show regression to sound enamel.[37,48–50] In one study, dentists were asked at what point they would restore small noncavitated lesions on the buccal surfaces of teeth. Approximately 40% indicated that they would use a preventive rather than an operative strategy.[51] This indicates that many dentists believe that they are well able to judge the severity elopment.

Dentlearn.ir

Altogether, the evidence indicates that the decline in caries prevalence has been accompanied by a decline in caries lesion progression rates. Between the initiation of caries and the involvement of dentin in the caries process, there is ample time for a preventive management strategy. This implies that the early lesion should be detected so that preventive treatment can arrest its progress and bring about lesion arrest/remineralization. If this strategy is successful, operative intervention will not be required.

Detection and Diagnosis

Diagnosing a caries lesion as a deviation from the normal appearance of enamel or root surface involves integration of the information obtained by clinical examination of the oral cavity, use of caries diagnostic aids, conversation with the patient, and biologic knowledge of the caries process.[52] Unfortunately, this process is often referred to as *caries detection*, which is simply an objective method of determining whether or not clinical signs of caries are present at one point in time.[53] Caries, however, is a highly dynamic process characterized by alternating periods of demineralization and remineralization. Caries begins and progresses when demineralization outgains remineralization, which is seen in a frequent eating condition in which the pH of the oral environment is never allowed to come to neutrality, or in inadequate use of fluorides. While detection only describes the clinical signs of caries, diagnosis tries to estimate the dynamics and determinants of the process. White spot lesion is found by detection; after diagnosis, it may be called an *initial caries lesion*.

Detection

The primary objective of early detection of caries is to limit the progression and impact of the disease after onset at as early a stage as possible. This objective is based on the fact that caries is reversible as well as preventable. Restoration of a cavitated caries lesion is costly in terms of time, resources, and oral health; therefore, a major goal is the prevention of demineralization and promotion of remineralization of early caries. This goal can be achieved only if the early clinical signs of caries are detected and effective prophylactic intervention is employed to reverse or arrest the lesion before the need for restorative intervention. The conventional caries detection methods are visual and radiographic examinations.

Dentlearn.ir

Visual examination

The first clinical sign of caries is a chalky and matte (rough) whitish surface (hence *white spot lesion*) (Fig 5-7). Microscopically, this white spot is a porous surface that can easily be stained into brown or black discoloration by chromogens from foods; thus, a caries lesion can be seen either as a white or as a brown/black spot lesion (Fig 5-8). There are noncavitated and cavitated stages of dental caries that can be identified and described using clinical signs.



Fig 5-7 The first clinical sign of caries: a chalky and matte whitish surface.



Fig 5-8 White spot lesion discolored by staining has turned into a brown spot lesion.

Although it is the most common method used by clinicians, the detection of early caries by visual examination is considered subjective, less sensitive, and of poor specificity because of the various factors that might influence it. The presence of saliva, ambient light reflections, and bacterial plaque on tooth surfaces lowers the accuracy of visual examination, and the factors that affect color perception and interpretation render visual examination subjective. The sensitivity and specificity of this method of examination can be improved by certain prerequisites.

- *Clean tooth.* Most often the tooth is covered by a film of bacterial plaque that can camouflage a suspect lesion (Fig 5-9). It is necessary before caries detection that the plaque be removed gently with the explorer; detection may also be carried out immediately following prophylactic cleaning.

Dentlearn.ir



Fig 5-9 Reliable detection of caries lesions can be obstructed by plaque. *(a)* Plaque covers the labial surfaces and conceals a cavity in the maxillary right central incisor. *(b)* The same surface, cleaned, reveals the cavitated lesion. (Courtesy of K. R. Ekstrand, Copenhagen, Denmark.)

- *Dry tooth.* The teeth should be thoroughly dried with an air-water syringe (> 5 seconds) before all surfaces are carefully examined. The presence of saliva on tooth surfaces interferes with the detection of white spot lesions because of optical phenomena resulting from differences in the refractive indices of water (1.33), enamel (1.62) and air (1.0).[54] A white spot lesion is a porous surface, and the pores are filled with saliva when the lesion is wet. Because the refractive indices of water and enamel are so close, an early white spot lesion can hardly be distinguished from a sound enamel surface in the presence of saliva. When a white spot lesion is thoroughly dried, air replaces the saliva in the pores, making the lesion frostier and more clearly seen.

  Furthermore, drying the tooth surface during examination has diagnostic as well as prognostic functions. Removing water from the porous tissue enables the dentist to gauge how far through the enamel a lesion has progressed. A white spot lesion visible on a wet tooth surface indicates that demineralization is over halfway through the enamel, possibly extending into dentin. A white spot lesion that becomes visible only after thorough air drying will be less than halfway through enamel.[55–58] Prognostically, the latter condition has a better chance of complete reversal, while the former condition may only be arrested.[57]
- *Magnification and lighting.* It has been demonstrated that the accuracy of visual caries detection can be improved 50% with the use of a magnifying device, such as a prism loupe or a surgical microscope.[59] Good lighting aids vision. The mouth is a dark hole and the operating lamp illuminates it. The dental mirror can catch and reflect the light onto individual tooth surfaces.

General clinical criteria for visual caries detection. The identification of a caries lesion is a stepwise process. The diagnosis of a caries lesion should be preceded by

Dentlearn.ir

a series of questions so that the most appropriate type of intervention can be selected for the patient (ie, it provides a basis for a treatment decision)52: Is there a change from normal appearance of enamel or root surface (presence of a lesion)? Is the change consistent with the appearance of dental caries or developmental hypomineralization? If there is caries, is it cavitated (loss of surface integrity) or noncavitated? If it is noncavitated, is there a shadowing underneath the enamel or white (or brown/black) spot lesion? If there is a white (or brown/black) spot lesion, is it active or arrested?

The whitish appearance of a lesion is due to changes in the optical properties of enamel with demineralization or hypomineralization. Hence, carious white spots should be differentiated from developmental hypomineralizations such as fluorosis. The following factors may guide the dentist to a definitive diagnosis of a white spot as caries or developmental hypomineralization (Table 5-4).

Table 5-4 **Differences between white spots due to caries or developmental hypomineralization**

Characteristic	Caries	Hypomineralization
Appearance and texture	Opaque, chalky, and matte (rough) surface when air dried	Smooth, glossy, and less opaque surface when air dried
	May be discolored by extrinsic stain	No extrinsic discolorat
	Feels rough when the tip of a CPITN probe or blunt explorer is moved gently across the surface	Feels smooth when the tip of a CPITN probe or blunt explorer is moved gently across the surface
Location and distribution	Located in plaque stagnation areas	Located mainly in self-cleansing areas
		Bilateral or multiple corresponding teeth; eg, canines

CPITN–Community Periodontal Index of Treatment Needs.

Appearance and texture. After prolonged drying (> 5 seconds) with an air-water syringe, white spot lesions from developmental hypomineralization usually have smooth and glossy surfaces like a sound enamel surface, while active caries lesions have chalky, matte (rough) surfaces. This can be elicited by gently running the tip of a ball-ended Community Periodontal Index of Treatment Needs (CPITN) probe or blunt explorer on the surface of the lesion. Carious white spots can be discolored

Dentlearn.ir

after a long exposure in the oral environment, while the surface of developmental hypomineralization is not porous and cannot be easily discolored, except in mottling due to severe fluorosis.

Location and distribution. Caries occurs in plaque stagnation areas (areas that are difficult to reach by toothbrush), such as gingival margins, occlusal pits and fissures, buccal/lingual grooves and fossa, proximal areas below contact points, and stagnant areas created by overcrowding of teeth. Although developmental hypomineralization can occur at any point on the tooth surface, a white spot at the tip of the cusp or coronal third of a tooth is more likely to be a developmental anomaly because these areas are self-cleansing and harbor hardly any plaque. Moreover, white spots that occur on corresponding sites and have similar shape on all corresponding teeth (eg, all first premolars) in the four quadrants of the dentition are likely to be developmental hypomineralizations. These sites on those four teeth developed at the same time and would be equally affected by tooth mineralization factors.

Clinical visual caries scoring system. Efforts to improve examiner objectivity and caries status recording has led to the development of scoring systems to stage lesions along the continuum—from very small initial lesions, just visible to the human eye, through established white and brown spot lesions, to shadowing beneath the enamel, and to different extents of cavitation.[53] The International Caries Detection and Assessment System (ICDAS) is highly recognized among these systems.[60] It was developed for use with primary coronal caries, caries adjacent to restorations and sealants, and for root surface caries and includes noncavitated caries lesions. The ICDAS detection codes (Table 5-5) include a seven-point staging of caries, which enable a detailed recording of caries status during a patient's initial assessment comparison over time. It is also applied in caries risk evaluation and reevaluation. ICDAS is a two-stage, two-digit coding system comprised of a code for the restoration and sealant status of the tooth surface, followed by a code for the caries severity (see Table 5-5).

Table 5-5	ICDAS criteria for visual examination of caries lesions, including two-digit coding for restoration and caries severity[53] The International Caries Detection and Assessment System (ICDAS) is highly recognized among these systems.[53,53] The International Caries Detection and Assessment System (ICDAS) is highly recognized among these systems.[60]
First digit (restoration	

Dentlearn.ir

codes)	Second digit (caries severity codes)
0 = Not sealed or restored	0 = Sound tooth surface
1 = Partial sealant	1 = First visual change (opacity or discoloration) in enamel hardly visible on the wet surface but distinctly visible after air drying
2 = Full sealant	2 = Distinct visual change (opacity or discoloration) in enamel, visible without air drying
3 = Tooth-colored restoration	3 = Enamel breakdown, no dentin visible
4 = Amalgam restoration	4 = Dentin shadow (not cavitated into dentin)
5 = Stainless steel crown	5 = Distinct cavity with visible dentin
6 = Porcelain, gold, PFM crown or veneer	6 = Extensive distinct cavity with visible dentin
7 = Defective restoration	
8 = Temporary restoration	

PFM–porcelain fused to metal.

Although the ICDAS caries severity codes 1 and 2 of noncavitated caries (white or brown spot lesion) are based on clinical appearance of the lesion in relation to moisture on the surface, it has value for diagnosis, treatment, and prognosis. For occlusal surface caries, there is a high correlation between the ICDAS caries severity codes and the histologic depth of the lesions into enamel and dentin[55–58] (Table 5-6). Studies have demonstrated histologically that in ICDAS code-1 lesions the enamel demineralization is limited to the outer half of the enamel layer[55–58]; this lesion has higher chances of complete reversal with remineralization therapy. In an ICDAS code-2 lesion, the demineralization involves the entire enamel layer and outer third of the dentin layer,[55–58] and this lesion stands higher chances of being arrested rather than reversed.

Table 5-6	Correlation of the ICDAS caries severity codes with the histologic depth of the lesions into the tooth tissue on the occlusal surface,[55–58]
Score	Demineralization depth
0	No enamel demineralization

Dentlearn.ir

1	Enamel demineralization limited to the outer half of the enamel layer
2	Demineralization involving enamel and the outer third of the dentin
3-4	Demineralization involving the middle third of the dentin
5-6	Demineralization involving the pulpal third of the dentin

The ICDAS Committee also developed an International Caries Classification System (ICCS), a simplified format of ICDAS codes for general practice[2] (Table 5-

color coding facilitates communication between patients and the dental team.

Table 5-7	ICCS codes for general practice*			
	Stages of caries (0–3)			
Sites of caries (1–4)	0 No disease ICDAS 0	1 Initial lesion ICDAS 1 and 2	2 Moderate lesion ICDAS 3 and 4	3 Extensive lesion ICDAS 5 and 6
1. Pits and fissures	1.0	1.1	1.2	1.3
2. Approximal surfaces	2.0	2.1	2.2	2.3
3. Cervical and smooth surfaces	3.0	3.1	3.2	3.3
4. Root surfaces	4.0	4.1	4.2	4.3

*Reprinted from Pitts and Richards[2] with permission.
0 *(green)*–sound tooth surface; 1 *(yellow)*–distinct, visual noncavitated change in enamel; 2 *(orange)*–localized enamel breakdown; 3 (red)—distinct cavity with visible dentin.

Visual caries detection specific to different types of lesions. Pit and fissure lesions. Detection of carious structure in fissures and pits is most often performed by visual inspection, and good lighting and dry, clean teeth are prerequisites. Any sign of visible cavitation in the occlusal surface corresponds to progression of the lesion into the dentin.[55,56,61] When occlusal surface caries was recorded visually using a caries score ranking system (see Table 5-5), a high correlation with the histologic depth of the lesions i [55,56,61] Table 5-6).

Dentlearn.ir

Shadowing or grayish discoloration of the adjacent translucent enamel along the pits and fissures may indicate possible undermining of enamel by hidden caries. Opaque, matte texture of enamel adjacent to the stained pits and fissures may indicate the presence of active caries underneath them. When there is no caries underneath, discoloration will remain within the confines of the pit and/or fissure. However, lesions underneath (along the walls) will be discolored by stain that diffused through the porous lesion surface. Looking perpendicularly through the translucent adjacent healthy enamel along the pit and/or fissure, a clinician can observe these stained "wall" lesions as discoloration extending beyond the confines of the pit and/or fissure in the form of a "bottle-brush" appearance (Fig 5-10). These lesions are caused by plaque stagnation at the entrance to the fissure. When this plaque is cleaned off, the lesion is clearly visible. The patient can arrest this lesion by brushing with toothpaste containing fluoride.[62]

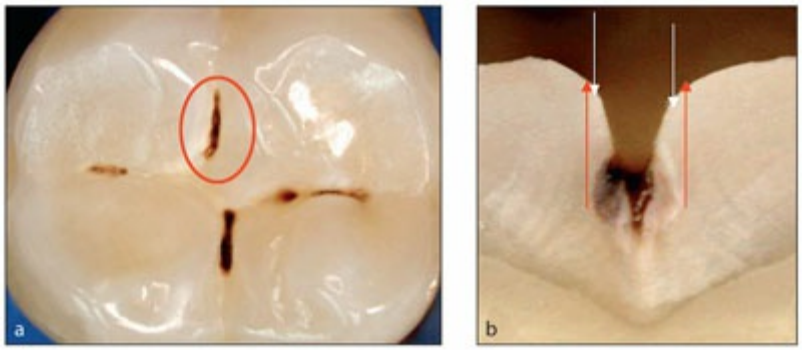

Fig 5-10 Illustration of the visual detection of lesions on the walls of stained pits/fissures. *(a)* A stained fissure *(red circle)* under visual examination. *(b)* Looking perpendicularly through the translucent adjacent healthy enamel along the fissure *(white arrows)*, lesions on the walls of the fissure are seen as discoloration extending (ie, underneath the translucent enamel) beyond the confines of the fissure with a "bottle-brush" appearance *(red arrows)*.

Careful examination of bitewing radiographs is also important, although occlusal enamel lesions will not be visible. Carious dentin, however, can usually be detected, and such lesions are often large (Fig 5-11). Bitewing radiographs provide a "safety net" for detecting occlusal lesions.[57,63]



Fig 5-11 The radiograph as "safety net": Occlusal carious dentin is well detected (man-dibular left first molar).

Dentlearn.ir

Tactile examination of fissures with a dental explorer has long been advocated as an important method to detect caries lesions, but research has shown this to be an unwise practice. The method is inaccurate,[64,65] and, worse, the explorer can damage a white spot lesion by breaking through the relatively intact surface zone[66] (Fig 5-12). Vigorous use of a sharp explorer can cause a cavity that will subsequently trap dental plaque and encourage lesion progression. Detection of fissure caries lesions should rely on sharp eyes, not sharp explorers. The clinician should use the explorer in the following appropriate ways:

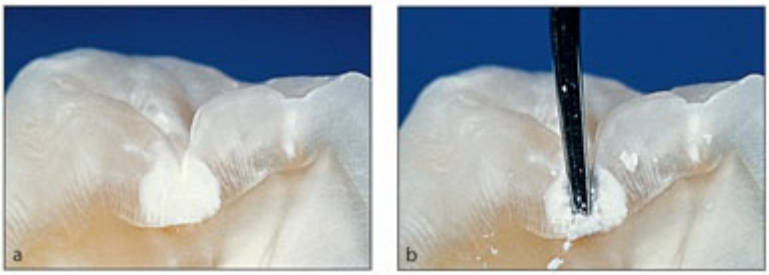

Fig 5-12*(a and b)* The explorer tip can easily damage white spot lesions.

- Detect and remove plaque in fissures, along gingival margins, and in proximal spaces.
- Gently "feel" margins and defects to confirm and assess cavitations. • Gently "feel" the hardness of root surface lesions.
- Gently "feel" the texture (roughness) of white spot lesions by gentle running of the tip of a ball-ended CPITN probe or blunt explorer on the surface of the lesion.

Lesions involving proximal surfaces. Extensive active proximal lesions can be revealed by shadowing or grayish discoloration of the undermined occlusal enamel ridge. Otherwise, when there is contact between proximal surfaces, the radiograph is the most accurate method for detecting demineralization. In the premolar and molar regions, lesion progression or arrest can be monitored, provided that subsequent bitewing radiographs are taken at approximately the same angulation.[66] The radiograph should be examined carefully to determine whether caries lesions are present in the outer enamel, at the dentinoenamel junction, in the outer half of dentin, or in the inner half of dentin (Fig 5-13).

Dentlearn.ir

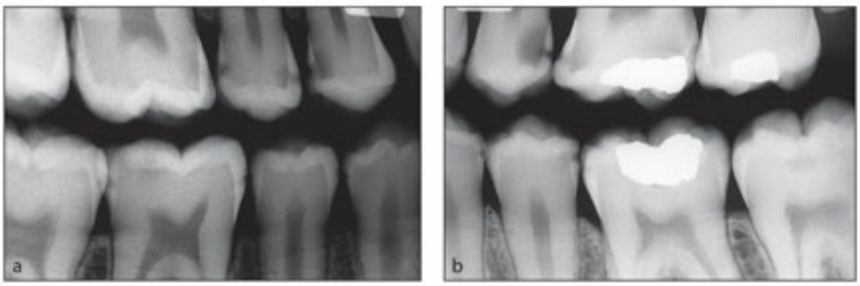

Fig 5-13*(a and b)* Radiographs showing proximal demineralizations in the outer enamel to the dentinoenamel junction and in the outer and inner half of dentin. (Occlusal lesions are visible on the mandibular left second molar and right first and second molars, and a recurrent caries lesion is underneath the restoration on the maxillary left first molar.)

For detection of proximal lesions in anterior teeth, the fiber-optic transillumination technique is particularly appropriate and convenient.[67] With this technique, a fine light, coned down to a 0.5-mm diameter, is transmitted through a contact area. A lesion appears as a dark shadow. It is difficult, however, to discriminate between demineralization extending just into enamel and that progressing further into dentin, especially in the posterior areas.

Finally, use of an orthodontic separator has been advocated in some cases to allow the dentist to see more clearly and to gently feel for a break in the enamel surface.[68]

Lesions on buccal, lingual, and root surfaces. Active caries lesions in smooth, free enamel surfaces are typically located close to the gingival margin and have chalky matte, whitish/ yellowish surfaces. A caries lesion on a root surface is seen as a clearly demarcated, light brown, dark brown, or black discolored area on the root surface or at the cementoenamel junction.[69] A root surface lesion is *cavitated* if there is loss of surface integrity or if the depth of the cavity is . 0.5 mm when measured with the ball of the CPITN probe. The diameter of the ball is 0.5 mm, so if the cavity accommodates the ball, then the depth is . 0.5 mm. If there is no loss of surface integrity or if the depth of the cavity is less than 0.5 mm (does not accommodate the ball), the lesion is *noncavitated*.[69]

Secondary or recurrent caries. *Secondary caries* o r *recurrent caries* are primary lesions at the margins of a restoration. The clinical criteria are thus identical to those for primary caries. The dentist can check that the restoration is secure in the cavity by pushing it with an explorer; a loose restoration ensures plaque stagnation, and active caries is likely to be present.

Dentlearn.ir

Radiographic examination

Bitewing radiography has a long history in the dentist's armamentarium for the detection of lesions that are clinically hidden from a careful clinical visual examination (eg, proximal caries). The importance of radiographs to diagnose initial caries lesions in proximal surfaces is well established.[70] It is possible to detect early proximal lesions amenable to preventive care. However, radiographic evaluation of occlusal surfaces has been found to be of minimal diagnostic value for detecting enamel caries and superficial dentinal caries because of the large amounts of surrounding sound enamel. In deeper occlusal lesions reaching the dentin, radiographs show a high *specificity* (the identification of true negatives). Although useful for proximal surfaces, the bitewing radiograph still cannot distinguish between cavitated and noncavitated proximal lesions; thus, it is necessary to establish what level of radiolucency should be accepted as cavitation.[71] This threshold will aid in determining the treatment strategy to be applied for a particular lesion (Fig 5-14). The threshold determines the *sensitivity* (the identification of true positives) and specificity of detection decisions. A low diagnostic threshold leads to detection of not only more small lesions but also more false-positive diagnoses, while a high threshold will increase the specificity but will lower the sensitivity because the small lesions will be missed. Although bitewing radiographs can be used to estimate the depth of the lesion, the radiographic extent of radiolucency is not precisely correlated to the histologic extent of the lesion. Radiographs have been shown to underestimate the depth of the lesion.[72] Bitewing radiography is associated with the problem of variation in the quality of radiographs and differences in the viewing conditions. Radiographs should be obtained using a film holder and beam-aiming device to take the guesswork out of tube alignment and allow comparable views to be taken on subsequent occasions.[66] Because lesions confined to enamel should be managed by preventive treatment, radiographic monitoring is important.

Dentlearn.ir

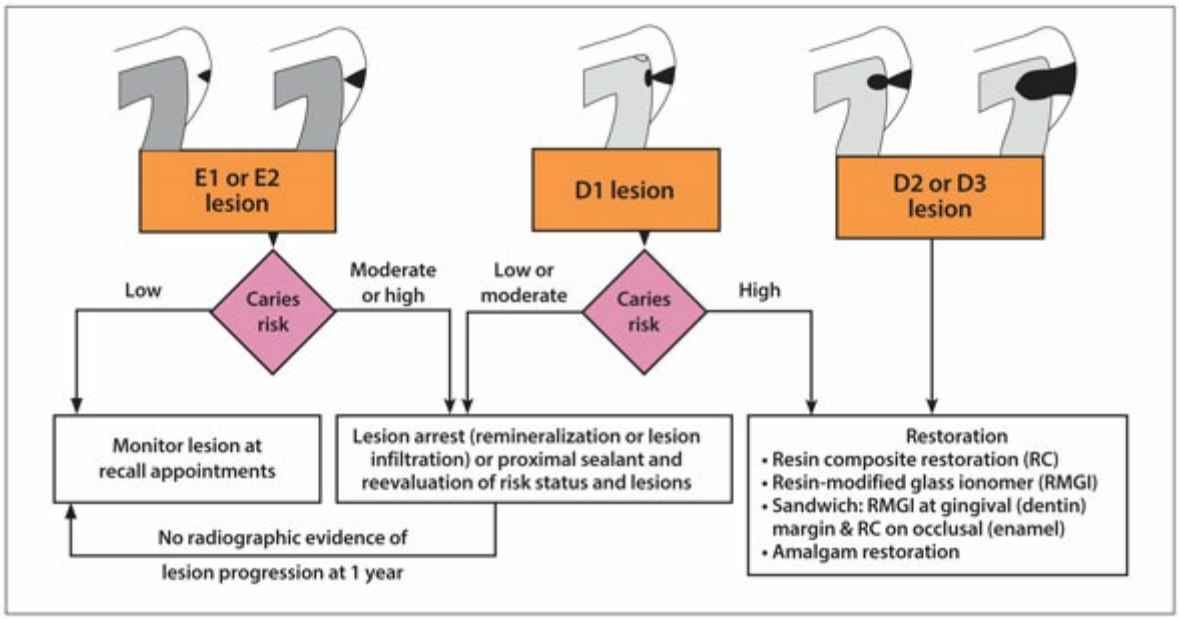

Fig 5-14 Algorithm for diagnosis and management of caries lesions in proximal coronal surfaces of permanent teeth based on radiographic classification of lesions. (Courtesy of the Department of Comprehensive Dentistry, University of Texas Health Science Center at San Antonio.) E1—less than halfway through proximal enamel; E2—more than halfway through proximal enamel, not penetrating past the dentinoenamel junction; D1—slightly past the DEJ; D2—less that halfway through dentin toward the pulp; D3—halfway or more through dentin.

Computer enhancement tools have been developed to allow images from video or digital radiographs to be enlarged to aid in early diagnosis. In addition, color enhancement increases visual contrast and has been proven to be an objective and reproducible methodology.[73–76] The Logicon Caries Detector software (Northrup Grumman)[73–75] and MiPACS Dental Enterprise Viewer (Medicor Imaging) are currently being used in conjunction with digital radiographs for clinical caries detection. The use of digital radiography permits image manipulation and reduces the amount of radiation required to obtain a diagnostic image. Although processing of digitized and directly captured images tended to perform more accurately than conventional radiography, studies have shown no significant difference between the two methods.[76] Thus, digital intraoral radiographs appear to be as accurate as film radiographs for the detection of dental caries. The sensitivity of digital systems is relatively high for detection of occlusal lesions into dentin but is of no value for detection of early enamel lesions.[76] Just like the conventional radiographic films, the main disadvantage of the digital radiography is the high number of false-positive results when used for occlusal caries detection.[77]

Caries detection aids

Dentlearn.ir

Caries is a dynamic process of alternating demineralization and remineralization that may result in progression, regression (reversal), or arrest (stabilization) of the lesion. Thus, the activities of a caries lesion continue to change over time as a result of continued change in mineral status of the lesion. Hence, there is a need for devices that aid in monitoring by quantitatively assessing the mineral changes over time within a caries lesion. The conventional caries detection methods, visual and radiographic examination, cannot quantitatively account for this dynamic of caries.

Diagnostic techniques capable of providing valid, reliable, and nonsubjective measurements are in demand. The readings in an acceptable instrument must be consistent between different models for the same operator on different occasions and for different operators. There are an increasing number of new technologies being developed to aid detection and monitoring of caries lesions. Most of these devices claim to detect and monitor caries activities based on the change in the reflectance, transmission, fluorescence, electrical conductance/ impedance, or ultrasound transmittal properties of enamel following demineralization. These claims have not been evaluated using controlled clinical trials. Although such instruments cannot make the clinical judgment of lesion activity when used once, a valid and reproducible method could be used longitudinally to measure lesion progression or arrest.

Diagnosis

Clinical observations have demonstrated that caries lesions can be arrested at any stage of lesion development provided that clinically plaque-free conditions are maintained. Thus, a caries lesion detected in a clinical examination can be active or inactive. An active lesion is considered to have a greater likelihood of transition (progress, arrest, or regress) than an inactive lesion. Hence, it must be determined whether the detected lesion is active or inactive. If the lesion is arrested, no treatment is required except for esthetic or functional reasons. If the lesion is active, treatment is needed to arrest lesion progression and must include preventive measures. It may also include restorative dentistry. Thus, caries diagnosis includes both caries detection and the assessment of lesion activity.[78]

Assessing caries activity

There are some features of individual lesions that indicate whether a lesion is active or arrested. These assessments are inevitably “best guesses,” but this is acceptable because most patients see their dentist at regular intervals. Thus, the initial diagnosis

Dentlearn.ir

should be refined at recall visits, and the effects of preventive treatment can be assessed. Table 5-8 lists parameters relevant in the assessment of caries activity.

Table 5-8	Characteristics of active and arrested lesions in enamel and roots		
Condition	**Tooth tissue**	**Active**	**Arrested**
Appearance	Enamel	Lesion is chalky (lacks luster) when air dried and is whitish or yellowish	Lesion has shiny surface when air dried and may be whitish, brownish, or blackish
	Root	Clearly demarcated and may be discolored yellowish/light brown *Note: Color change is not a reliable indicator*	Same as active lesion
Texture	Enamel	Feels rough when the tip of the probe (explorer) is moved gently across the surface	Feels hard and more smooth than rough when the tip of the probe is moved gently across the surface
	Root	Lesion has soft or leathery base on gentle probing using blunt or CPITN probe	Lesion has hard and shiny base using blunt or CPITN probe
Translucency	Enamel	Opaque	Semitransparent
	Root	NA	NA
Presence of plaque	Enamel	Lesion covered by plaque	Generally plaque free
	Root	Lesion covered by plaqu	Generally plaque free
Locations	Enamel	Mostly on plaque stagnation areas	Lesion area is usually plaque free
	Root	Anywhere	Same as active lesi
Cavitation	Enamel	From localized surface defect (microcavity) in enamel only to distinct cavity with soft or leathery base on gentle probing	From localized surface defect (microcavity) in enamel only to distinct cavity with hard base on probing with gentle pressure; surface of cavity may be shiny
		Cavitated if there is loss of surface integrity or if the depth is ≥ 0.5 mm measured	

Dentlearn.ir

	Root	using the ball of the CPITN probe; noncavitated if no loss of surface integrity or if the depth is < 0.5 mm	Same as active lesion

NA–not applicable.

The features of active and arrested lesions[79] at the individual sites are discussed in the following section.

Occlusal lesions. The visual features of occlusal caries lesions were presented in Table 5-5. The occlusal surface must be cleaned by the dentist with a brush before it is examined.

The following features indicate lesion activity:

- White spot lesions that have a matte or visibly frosted surface or are plaque covered (visible after drying or application of a disclosing solution)[62]
- Cavitated lesions, including small cavities and cavities exposing dentin (Fig 5-15)



Fig 5-15 Active occlusal caries.

- Lesions visible in dentin on bitewing radiographs[80]

The lesion may be arrested if white or brown spot lesions with a shiny surface[62] are present (Fig 5-16).



Dentlearn.ir

Fig 5-16 Arrested lesions.

Proximal lesions. Diagnosis of lesion activity is more difficult when the adjacent tooth precludes a direct visual assessment. (The radiographic features of proximal lesions are presented in chapter 2 and in preceding paragraphs.) The presence or absence of a cavity is relevant to lesion activity, but this cannot be determined from the radiograph unless the lesion is very deep. For an active caries lesion to be arrested, plaque must be removed regularly from the cavity. However, on a proximal surface, there is no access for the toothbrush, and even the most fastidious of flossers will only slide over the surface.

The following features tend to indicate lesion activity:

- A patient with proximal lesions on the radiograph who is at high risk for caries[71]
- A proximal lesion present radiographically plus persistent gingival inflammation despite the patient's attempts to remove plaque with dental floss[81]
- A lesion not present at previous examination

The following features indicate that the lesion may be arrested:

- Successive, reproducible bitewing radiographs showing no lesion progression
- A patient who is now judged to be at low risk for caries because, following preventive behavior, he or she presents with no new lesions

Smooth, free surface lesions. These are probably the most straightforward lesions for assessment because they are the most visible. Of all lesions, these are the ones most likely to be arrested by preventive treatment alone.

The following features indicate lesion activity:

- White spot lesions close to the gingival margin that have a matte or visibly frosted surface; these are often plaque covered (Fig 5-17)



Fig 5-17 Matte, white, active cervical lesions.

Dentlearn.ir

- Cavitated, plaque-covered lesions with or without exposed dentin; if dentin is exposed and soft, the dentin is heavily infected and the lesion is active (Fig 5-18)



Fig 5-18*(a and b)* Cavitated, active cervical lesions.

The following features indicate that the lesion is arrested:

- Shiny white or brown lesions, often well exposed due to gingival recession; the lesions are not plaque covered (Fig 5-19)



Fig 5-19 Shiny, white, arrested cervical lesion.

- Cavitated lesions, often dark brown, with hard dentin at their bases; the lesions are not plaque covered and are often remote from the gingival margin (Fig 5-20)



Fig 5-20 Brown, arrested lesion.

Root caries. Active lesions are:

- Close to the gingival margin and plaque covered
- Soft or leathery in consistency

Arrested lesions are:

- Often at some distance from the gingival margin and not covered with plaque (Fig

Dentlearn.ir

5-21)



Fig 5-21 Arrested root caries lesions.

• As hard as the surrounding healthy root surface[82]

Color is unreliable in differentiating active from inactive lesions. While arrested lesions may be dark, so may be the soft dentin in some active lesions. There currently is no clear explanation of why demineralized dentin is brown.

Recurrent caries. A caries lesion at the margin of a restoration is called *recurrent caries,* and its diagnosis on various tooth surfaces is the same as that described previously for primary lesions. The bitewing radiograph is very important in the diagnosis of recurrent caries lesions because they often form cervical to an existing proximal restoration, in the area of plaque stagnation. Lesions that are obviously in dentin as seen radiographically tend to be cavitated and active. However, research has shown that ditching and staining around an amalgam restoration[83] and staining around a tooth-colored restoration[84] are not reliable indicators of an active caries lesion beneath a restoration.

Assessing Caries Risk

Caries risk may be defined as the probability of an individual developing a certain number of caries lesions reaching a given stage of disease progression during a specified period.[85] It is a key and essential component of PCCM.[2] Because caries is a multifactorial disease, it is not surprising that the format of existing tools for caries risk assessment varies among developers and depends on the information the tool is tailored to collect. However, a tool for comprehensive caries risk assessment should consist of three major sections (Fig 5-22). The first part is the *subjective section* that collects the information given by the patient on his or her *(1)* oral hygiene attitude, including dental plaque control and use of fluoride/other anticaries agents; *(2)* dietary habits; *(3)* access to dental care; *(4)* use of tobacco; and *(5)* use of medications affecting caries risk. The second part is the *objective section* that

Dentlearn.ir

contains information gathered about the patient by the dentist through clinical examination, clinical tests (if applicable), and conversation and is composed of the *(1)* medical history, *(2)* social history, *(3)* existing caries and restorations, *(4)* saliva properties, and other oral conditions predisposing the patient to caries risk. The third part is the *synthesis section* that identifies the overall risk level (low, moderate, high) of the patient. Some tools may contain a fourth section that lists the preventive care options from which the clinician can develop a personalized preventive plan for an individual patient.

Dentlearn.ir

CARIES RISK ASSESSMENT FORM

Patient Name: _____ Age: _____ Patient #: _____ Initial Assessment Date: _____ Reevaluation date: _____

How often do you brush? _____ Floss? _____
Type of toothpaste used: _____
Do you brush your teeth before bedtime? Yes / No
Do your gums bleed when you brush? Yes / No
Do you use a mouthrinse? Yes / No Type: _____
Does your mouth feel dry? Yes / No
What relieves your dry mouth? _____

Do you use breath mints? Yes / No Type: _____
Do you chew gum? Yes / No Type: _____
Do you drink milk or eat cheese every day? Yes / No
How many snacks do you eat per day? _____
Type of snacks: _____
How many beverages do you drink per day? _____
Type of beverage: _____

When was your last dental visit? _____ Have you had a filling in the past 3 years? Yes / No
Do you use tobacco? Yes / No If No, have you ever used tobacco in the past? Yes / No

INTERVIEW PATIENT FOR INFORMATION ABOVE DASHED LINE
DENTIST COMPLETES INFORMATION BELOW DASHED LINE

Medications affecting oral disease risk: _____

CARIES RISK FACTORS	Initial Evaluation	
(Check where applicable)	YES	NO
1. Medical & Social History		
Autoimmune disease (eg, Sjögren, RA)		
Hyposalivary medications		
Radiation therapy		
Physical disability		
Eating disorder/GERD		
Diabetes		
Tobacco/alcohol		
Recreational drugs		
2. Predisposing Oral Conditions		
Plaque		
Malocclusion/crowding		
Appliances		
3. Caries		
Cavitated lesions		
Radiographic lesions		
White spots/initial caries lesions		
Recent restorations (past 3 yrs.)		
4. Dietary		
Sugary snacks		
Sugary drinks/soda		
5. Protective Factors		
Fluoridated water		
Fluoride toothpaste/mouthrinse		
Xylitol gum/mints		
6. Saliva		
Salivary flow		
Salivary pH		
Buffering capacity		

Interpret findings and determine overall risk (see guidelines Table 5-9)	OVERALL CARIES RISK STATUS		
	Low	Moderate	High

PREVENTIVE TREATMENT PLAN
(Check if recommended)
Oral Hygiene Instruction & Plaque Control
❑ Brush twice a day with a fluoride toothpaste
❑ Floss daily
❑ Prophylaxis
❑ Gross debridement
❑ Scaling & root planing
Diet
❑ Dietary assessment
❑ Dietary & oral health counseling
Saliva
❑ Unstimulated flow rate
❑ Stimulated flow rate
❑ Saliva retest
❑ Salivary flow stimulation counseling
❑ Salivary products
❑ Rx medications
Fluoride
❑ Professional application (APF, neutral NaF)
❑ OTC (ACT/Fluoriguard, Oral B 0.05% NaF)
❑ Rx (Prevident 1.1% NaF, Gel-Kam 0.4% SnF_2) ❑ 1 (at night) ❑ 2 (morning and night)
❑ Remineralization: Tooth #: ___ ___ ___ ___ ___ ___ ___ ___ Surfaces: ___ ___ ___ ___ ___ ___ ___ ___
❑ Topical fluoride varnish
❑ Rx fluoride supplement (NaF tablets)
Other
❑ Sealants: Tooth #: ___ ___ ___ ___ ___ ___ ___ ___
❑ Xylitol gum (After meals for 10 minutes)
Tobacco
❑ Cessation counseling
❑ Cessation program referral
Caries Risk Reevalution **Due Date** ❑ 3 mo. ❑ 6 mo. ❑ 12 mo.

Fig 5-22 Caries risk assessment form. (Modified from the Department of Comprehensive Dentistry, University of Texas Health Science Center at San Antonio with permission.)

Identifying the risk factors

Dentlearn.ir

Presence of caries

The presence of cavitated, noncavitated (initial lesions), and/ or radiographic (mainly proximal lesions) caries lesions is an indication that the patient is actively developing new caries that are progressing from initial caries to visible cavitations. Any of these findings is an indication that the patient is at risk of developing caries, and they should be carefully assessed, along with other caries risk factors, to determine the patient's overall caries risk.

Recent restorations (one or more within the past 3 years) is also an indication that the patient has been active in developing caries and should be seen to be at a risk of developing further caries, which places the patient in a high-caries-risk category. Combining this information with the date of the last dental visit gives an indication of the patient's caries activity over a period of time and also indicates the ability and interest of the patient in seeking dental care.

Dental plaque

Dental plaque is a risk factor for dental caries.[86] All patients with active lesions should be shown the relationship of disclosed plaque in the mouth to the lesions that are present. This makes advice on tooth cleaning relevant to the patient and specific to the lesion.

Note should be taken of the following experimental evidence[87]:

- Fluoride concentration of toothpaste. Confirm that the patient is using a toothpaste containing fluoride (1,000 ppm and above). Although the international recommendation is 1,000 ppm fluoride for younger children and up to 1,500 ppm for older children, the decision of what fluoride levels to use for children under 6 years should be balanced with the risk of fluorosis. The possible risk of fluorosis may necessitate recommending using toothpaste containing less than 1,000 ppm fluoride.[88]
- Frequency of brushing. Fluoride-containing toothpaste should be used twice a day, including immediately before bedtime.
- Toothbrushing in children. Check that a parent or caregiver is helping a child to brush and supervising the amount of toothpaste on the brush for children younger than 7 years of age. The adult should complete the brushing, paying particular attention to occlusal surfaces of erupting teeth.
- Rinsing behavior. Ask whether large volumes of water are used to wash away excess toothpaste. The message should be to "spit, don't rinse" or to use the

Dentlearn.ir

toothpaste slurry as rinse before spitting. This maintains the fluoride in contact with the teeth longer.

- Ability to remove plaque. When plaque is disclosed, can the patient remove it? On a subsequent visit, has he or she removed plaque? The answer to the second question defines the patient's motivation rather than his or her ability with a toothbrush.

It should also be remembered that placing a dental appliance such as an orthodontic appliance[89] or a partial denture[90] in the mouth can encourage plaque retention and explain the development of caries lesions.

Use of fluoride

Check the following:

- Does the patient's toothpaste contain fluoride?
- Does the patient live in an area in which the water is fluoridated?

The patient with multiple lesions is unlikely to live in an area with fluoridated water. It is also possible that he or she has selected (perhaps unwittingly) nonfluoride toothpaste.

Diet

The diet of a patient presenting with multiple lesions, whether white spots or cavities, should be analyzed for frequency of sugar intake. An inappropriate dietary habit, such as a sweet drink frequently consumed, will often be obvious.[91]

Saliva

A dry mouth predisposes to high caries risk,[92] and measuring salivary flow, particularly unstimulated, is useful because a low flow rate may help to explain multiple lesions. There are four common causes of dry mouth:

1. Medications, such as antidepressants, antipsychotics, tranquilizers, antihypertensives, and diuretics
2. Sjögren syndrome, which affects the salivary and lacrimal glands, leading to a dry mouth and dry eyes; rheumatoid arthritis may indicate the presence of this disorder

Dentlearn.ir

3. Eating disorders, which may induce hyposalivation; this, combined with a poor diet, can lead to extensive caries[93]
4. Radiation therapy in the region of the salivary glands for a head and neck malignancy, which often induces xerostomia

Patients with multiple caries lesions will have high salivary counts of mutans streptococci and lactobacilli. Many research studies have shown that these counts help predict caries risk.[94] This large volume of work appears to show that, in individual patients, low counts are often good predictors of low risk but that the opposite is not necessarily true. Therefore, the routine use of salivary counts for the prediction of risk status is not recommended for everyone.

Medical history

Medically compromised and handicapped people may be at high risk for developing caries, and the onset of such problems may explain a change in a patient's caries status.[95] For these patients, oral hygiene may be difficult, and long-term use of medicines can be a problem if the medicines are sugar based[96] or cause reduced salivary flow.

The most important caries risk factor in a medical history is the complaint of dry mouth, discussed previously. It is important to realize that the medical history is a factor that can change. A vigilant dentist will detect such changes and assist the patient with the potential dental consequences.

Social history

Many studies[97,98] have shown that social deprivation can predispose to caries. The dentist may notice high caries rates in siblings, and the patient or parent may possess little knowledge of dental disease. Concern about dental health may be low and dental visits irregular.

Guide to identifying the overall caries risk status of the patient

The dentist is now in a position to categorize the caries risk status (low, moderate, high) of a patient. Identifying the caries risk status can be facilitated by categorizing the information gathered in the subjective and objective sections of the assessment tool into "risk" (pathologic) factors that may increase caries risk and "protective"

Dentlearn.ir

factors that may decrease caries risk[99] (Fig 5-23). Certain factors and criteria as summarized in Table 5-9 and 5-10 may help a dentist in making the decision on the overall risk level of the patient.

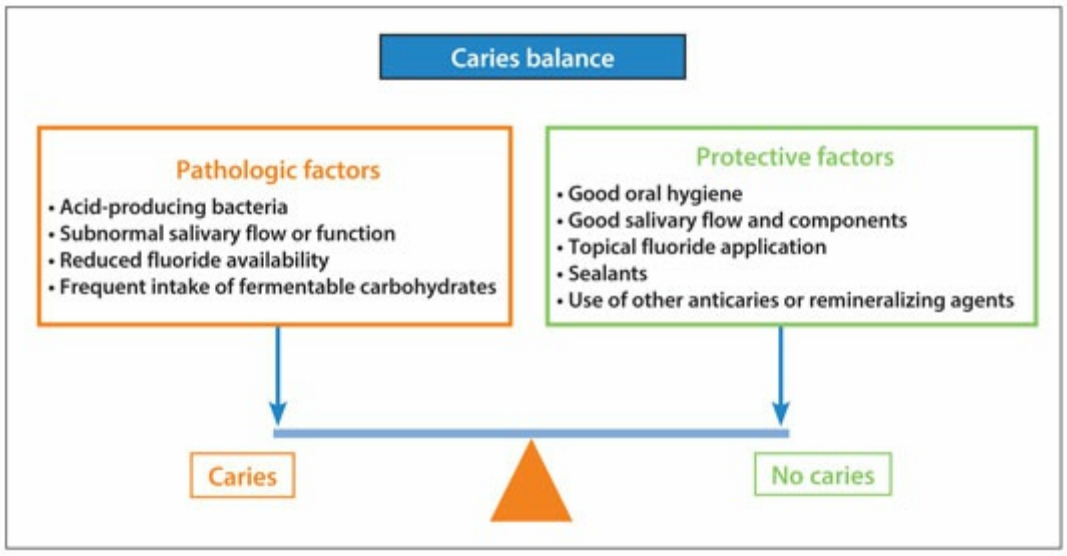

Fig 5-23 A schematic of the caries balance. (Modified from Featherstone[99] with permission.)

Table 5-9	**American Dental Association (ADA) recommended guide to identifying an overall caries risk status[100]**	
Caries risk category	**Younger than 6 years**	**6 years or older**
Low	No white spot or cavitated primary or secondary caries lesions during the last 3 years and no factors that may increase caries risk	No white spot or cavitated primary or secondary caries lesions during the last 3 years and no factors that may increase caries risk
Moderate	No white spot or cavitated primary or secondary caries lesions during the last 3 years but presence of at least one factor that may increase caries risk	One or two white spots or cavitated primary or secondary caries lesions in the last 3 years OR No white spot or cavitated primary or secondary caries lesions in the last 3 years but presence of at least one factor that may increase caries risk

Dentlearn.ir

High	• Any white spot or cavitated primary or secondary caries lesions during the last 3 years • Presence of multiple factors that may increase caries risk • Low socioeconomic status, especially in children too young for their risk to be based on caries history • Suboptimal fluoride exposure • Xerostomia	• Three or more white spots or cavitated primary or secondary caries lesions in the last 3 years • Presence of multiple factors that may increase caries risk • Suboptimal fluoride exposure • Xerostomia

Table 5-10	**Specific caries risk factors that may guide the overall caries risk status**	
Factor	**High risk**	**Low risk**
Plaque	Poor hygiene	Good hygiene
Type of diet	High sucrose	Low sucrose
Carbohydrate frequency	> 7 times per day	< 7 times per day
Resting SFR	< 0.2 mL/min	≥ 0.2 mL/min
Stimulated SFR	< 0.7 mL/min	≥ 0.7 mL/min
Buffer capacity	Low: ↓ pH	High: ↑ pH
Fluorides	Low: ↓ remineralization	Optimal: ↑ remineralization
Caries lesions	White spots	No white spots
Caries activity	Within last 3 years	None
Socioeconomic status	≤ Poverty level	> Twice the poverty level
Mother's caries history	High caries rate	Not caries active
Sibling caries history	High caries rate	Not caries active
Home dental care	None	Established

SFR–salivary flow rate.

Knowledge of the risk and protective factors serves both diagnostic and prognostic purposes and forms the basis for the preventive portion of the treatment plan, while the overall caries risk status forms the platform for the integrated, personalized treatment plan for the individual patient. This risk knowledge may be of great use to the dentist in explaining the lesions that are present and in identifying factors that need to be modified in order to reduce risk; poor plaque control and/or a frequently consumed er factors that cannot

Dentlearn.ir

be modified may affect the preventive management regimen and the prognosis. For instance, a patient with reduced salivary flow because of Sjögren syndrome is, and will remain, at high risk for caries. Furthermore, while the dentist might like to make the prediction, "This patient will develop new caries lesions within the next 12 months unless something is done to prevent it," it is difficult to predict accurately because caries is a multifactorial disease. Clinical and radiographic examination and dental history are the most important sources of information. Thus, a person with no active lesions, few or no restorations, and no history of needing restorations replaced may safely be designated as currently at low risk. On the other hand, a person with multiple active lesions, a heavily restored mouth, and a history of repeated replacement of restorations may be designated as being at high risk. Instead of concentrating on predicting the future, dentists should concentrate on controlling the caries lesions their patients have at present. The linchpin of the preventive approach is proper self care, and this also helps to prevent future lesions.

Risk-Based Caries Management

Traditionally, radiographic evidence of demineralization in enamel or to the dentinoenamel junction has led to the immediate decision to place a restoration. Such management is still an accepted part of some state board examinations. However, contemporary research has shown that this is not the correct approach. Radiographs may reveal demineralization, but this does not necessarily mean that there is an active lesion. If the lesion is arrested, it requires no treatment. Caries is caused by a multifactorial process, and its management should reflect this.[101] The general approach to active caries should be preventive treatment,[19] including plaque control, use of fluoride, and dietary modification. Restoration makes up only one part of a strategy to facilitate plaque control. Hence, the recommended caries management strategy is PCCM, which is enabled by the ICDAS clinical visual scoring systems for caries detection and activity[53,60] and integrated into the CAMBRA treatment approach.[3,4] With PCCM, treatment should be based on interpretation of the activity of the lesion and on future caries risk. Thus, a personalized treatment plan is developed from the information gathered through the risk assessment together with the overall caries risk status of the patient. The plan should involve the choice of appropriate treatment options (preventive and noninvasive treatment options; operative and minimally invasive treatment options), followed by maintenance care, including recall visits for reassessment and monitoring.

Dentlearn.ir

Establishing the right protocols can help protect patients. Figures 5-24 to 5-26 (see also Fig 5-14) demonstrate the algorithms for the management of lesions in occlusal pits/fissures, nonproximal smooth surfaces, proximal surfaces, and root surfaces, with different features leading to different treatment options depending on lesion activity and risk assessment. Boxes 5-1 to 5-3 depict the general guidelines for caries management in an individual patient; these contain all the elements of personalized treatment planning and are based on the acronym *PTPM* (plaque control, treatment of existing caries lesions, protection of surfaces at risk, and maintenance for prevention).

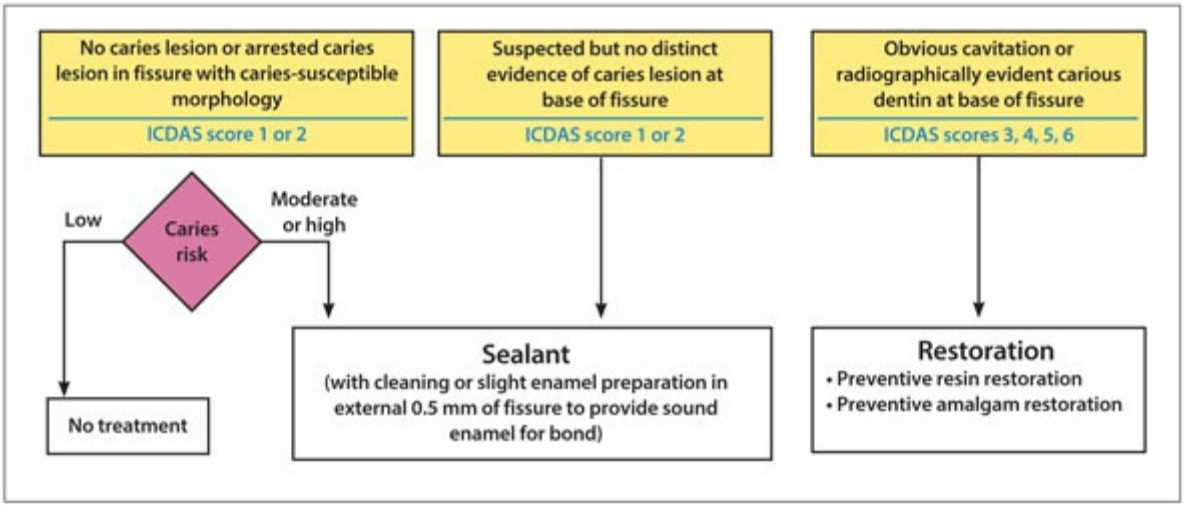

Fig 5-24 Algorithm for caries management in fissured surfaces of permanent teeth. (Courtesy of the Department of Comprehensive Dentistry, University of Texas Health Science Center at San Antonio.)

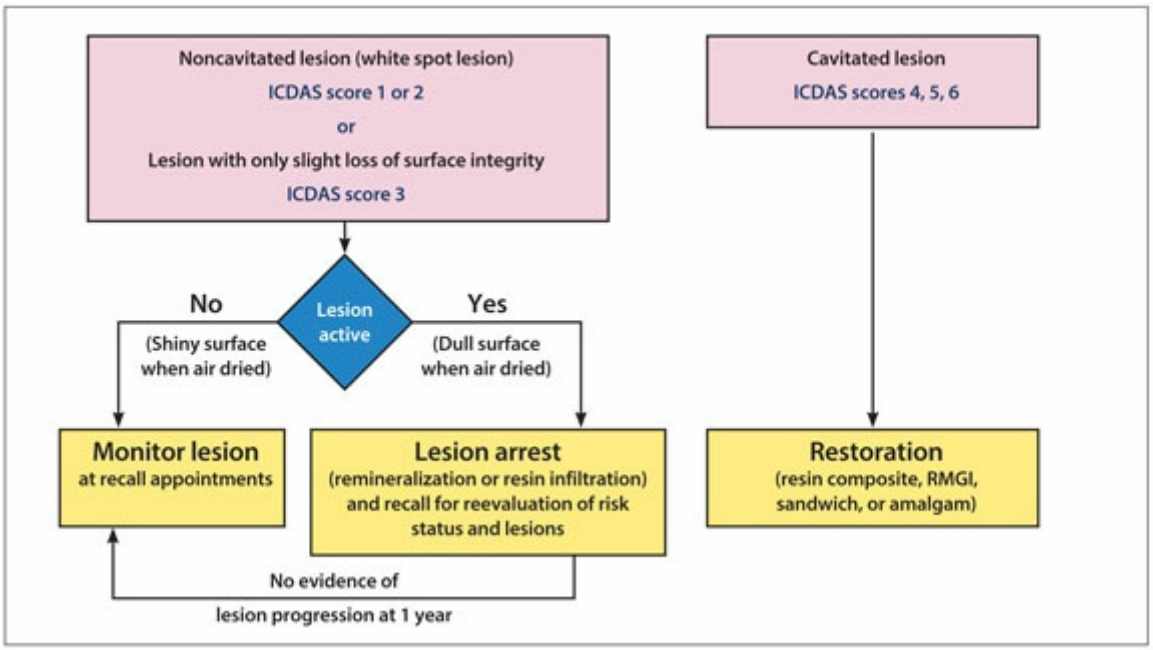

Dentlearn.ir

Fig 5-25 Algorithm for management of initial caries lesions in nonproximal coronal smooth surfaces of permanent teeth. RMGI—resin-modified glass ionomer. (Courtesy of the Department of Comprehensive Dentistry, University of Texas Health Science Center at San Antonio.)

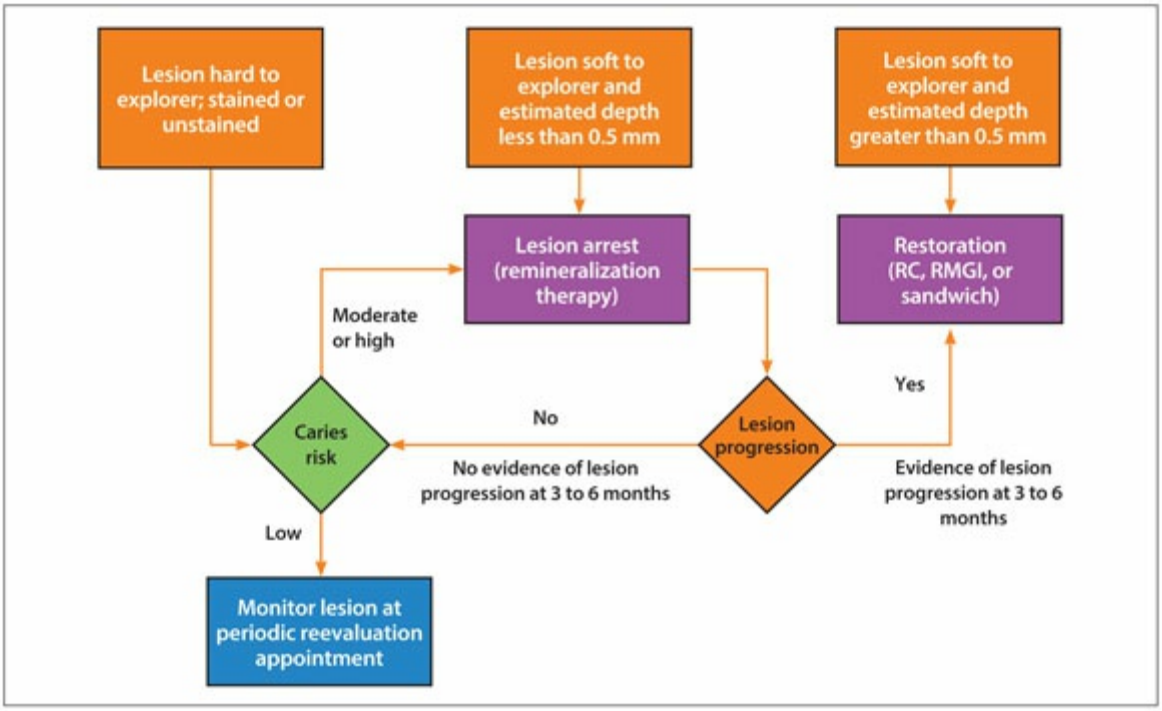

Fig 5-26 Algorithm for diagnosis and management of caries lesions in root surfaces of permanent teeth. RC—resin composite; RMGI—resin-modified glass ionomer. (Courtesy of the Department of Comprehensive Dentistry, University of Texas Health Science Center at San Antonio.)

Box 5-1	General guidelines for caries management for a high-caries-risk patient, based on PTPM

Step 1: Plaque control
- Provide prophylactic treatment followed by fluoride application
- See patient regularly to reinforce oral hygiene

Step 2: Treatment of existing caries lesions
- Treat noncavitated lesions as needed
- Restore cavitated lesions and seal surrounding pits and fissures as needed
- Salivary flow measurement to check for dry mouth and treat for xerostomia if needed

Step 3: Protection of surfaces at risk
- Seal all deep pits and fissures
- Apply fluoride varnish to exposed roots

Step 4: Maintenance care for prevention
- Review oral hygiene and dietary habits and advise patient to:
  - Reduce the number of between-meal sweet snacks

Dentlearn.ir

- Substitute snacks rich in protein
- Advise patient to brush at least twice daily with high fluoride delivery toothpaste
- Advise patient to floss once daily
- Provide home treatment and/or other adjunctive therapy:
  - Use over-the-counter fluoride rinse daily
  - Chew or suck xylitol-containing gum or candies three times daily
- Recall patient every 3 months to:
  - Reevaluate current caries risk
  - Receive fluoride varnish treatment of all teeth
- Obtain bitewing radiographs every 3 to 6 months to check for lesions

Box 5-2 **General guidelines for caries management for a moderate-caries-risk patient, based on PTPM**

Step 1: Plaque control
- Provide prophylactic treatment followed by fluoride application
- See patient regularly to reinforce oral hygiene

Step 2: Treatment of existing caries lesions
- Treat noncavitated lesions as needed
- Restore cavitated lesions and seal surrounding pits and fissures as needed

Step 3: Protection of surfaces at risk
- Seal all deep pits and fissures
- Apply fluoride varnish to exposed roots

Step 4: Maintenance care for prevention
- Review oral hygiene and dietary habits and advise patient to:
  - Reduce the number of between-meal sweet snacks
  - Substitute snacks rich in protein
- Advise patient to brush twice daily with over-thecounter fluoride toothpaste
- Advise patient to floss once daily
- Provide home treatment and/or other adjunctive therapy:
  - Use over-the-counter fluoride rinse daily
  - Chew or suck xylitol-containing gum or candies three times daily
- Recall patient every 3 to 6 months to:
  - Reevaluate current caries risk
  - Receive fluoride varnish treatment of all teeth
- Obtain bitewing radiographs every 12 to 18 months to check for cavities

Box 5-3 **General guidelines for caries management for a low-caries-risk patient, based on PTPM**

Dentlearn.ir

• Continue to reinforce oral hygiene

Step 2: Maintenance care for prevention
• Review oral hygiene habits
• Advise patient to brush twice daily with over-the-counter fluoride toothpaste
• Recall patient every 12 to 24 months to reevaluate current caries risk
• Obtain bitewing radiographs every 24 months to check for caries

Preventive and Noninvasive Treatment Options

The dentist is now in a position to develop the preventive treatment plan based on the identified risk factors associated with the individual patient. However, it may be pertinent to first discuss the concept of "caries balance"[99] (see Fig 5-23) as the ultimate objective of the practitioner, which should be to reduce the risk factors and increase the protective factors that relate to the individual patient. Our current knowledge of the caries process can be used to summarize that caries is:

- A process involving commensal bacteria in plaque
- Dependent on dietary fermentable carbohydrates
- Driven by frequency of eating
- Modified by the inherent nature of the tooth
- Modified by fluoride
- Modified by saliva
- Reversible in its early stages
- Controllable in terms of lesion formation and progression

Thus, it is clinically relevant to consider caries and its progression or regression as an ongoing and often changing balance between pathologic (risk) factors and protective factors[99] (see Fig 5-23). If the pathologic factors outweigh the protective factors, then caries lesions develop and progress. In the reverse situation, caries lesion development is inhibited, and an early lesion is arrested or reversed.

It is logical, from the above summary, to state that the development of caries lesions can be prevented and, if caries lesions form, their progression can be controlled. This can be achieved by changing the local biochemistry of the oral environment to one that reduces the proliferation of cariogenic bacteria, neutralizes plaque acid, and provides the required minerals for lesion remineralization through

Dentlearn.ir

alteration in oral hygiene and dietary behavior of the patient, fluoride application, and saliva stimulation.

The following approach may be applied in relation to the risk factors associated with the individual patient to develop a personalized preventive treatment plan for the patient:

- Caries-inactive/caries-controlled patients. These patients present with no new lesions and need only maintenance care, discussed in the following sections, to continue good oral hygiene with a fluoride-containing toothpaste.
- Caries-active patients with relevant risk factors that can potentially be changed. These patients present with lesions. Mechanical plaque control should be improved and consideration given to supplementing fluoride toothpaste with mouthrinses and/or chairside fluoride applications. Where diet investigation shows multiple sugar attacks, advice should be given as to how this might be improved.
- Caries-active patients with some risk factors that cannot be changed. These cases are difficult because the progress that can be made will depend very much on individual circumstances. For instance, if a disability is preventing adequate plaque control, is it possible for a caregiver to help? Social deprivation and level of education may mean that the preventive treatment required is not considered of sufficient importance by the patient, and it may, indeed, be unaffordable. In this case, motivational interviewing may help to increase inherent motivation. A dry mouth is often a permanent condition, and preventive treatments, plaque control including professional tooth cleaning, use of fluoride, dietary modification, and stimulation of salivary flow all may play a role. Saliva substitutes that contain fluoride and other inorganic ions will protect against caries, in addition to providing comfort and relief for dry mouth conditions, providing a protective coating for teeth and oral tissues, and helping to control bad breath.
- Caries-active patients with some risk factors that have not been identified. This is

detective work must continue, and the case must be managed as with the preceding

In caries management, choosing the right products can help protect patients. The following products and strategies can be selected in relation to the risk factors associated with the individual patient.

Dentlearn.ir

Self-applied preventive measures

Fluoride products

Fluoride dentifrices for plaque control. Regular dentifrices. The most plausible explanation for the decline of caries prevalence is the steady improvement in oral hygiene, which results in regular disturbance and partial removal of dental plaque, combined with a regular daily administration of fluoride, provided via

1,450 preschool children studied in the British National Diet and Nutrition Survey confirmed the significant caries-inhibiting effect of toothbrushing with a fluoride dentifrice twice daily. On a population basis, sugar-containing foods and drinks were not associated with caries experience, unless children brushed once a day or less.[103] Thus, the cornerstone of any preventive strategy for the management of caries is oral self care: twice daily careful cleaning of the teeth with a toothbrush and an effective fluoride toothpaste. Additionally, dental floss should be used, but patients should be instructed carefully, and the frequency of flossing should be recommended individually in relation to oral health needs and the characteristics of the patient: dental floss could be indicated for individuals with closed interdental spaces and interproximal brushes for periodontal patients or in those with open embrasures.[104] Flossing once daily may be recommended for caries prevention, but twice daily flossing may be required if gingivitis needs to be prevented as well.[105] In areas where the water is fluoridated to optimal levels, twice daily careful cleaning of the teeth with fluoride toothpaste is a safe and effective preventive treatment and caries management strategy.[106–108]

Dentifrices with antimicrobials. Some elements combined with fluoride in dentifrices can provide additional benefit and may be considered while advising a patient on the choice of toothpaste. The antimicrobial compound amine (Am) and stannous ions (Sn) have been combined with fluoride (F). Amine has intrinsic antiglycolytic properties, and therefore the antimicrobial effect of amine fluoride (AmF) is stronger as compared with sodium fluoride (NaF).[22,109–111] The stannous ion itself does not affect mineral dissolution, but studies have shown the antimicrobial activity of the SnF_2 complex in vivo.[112,113] Its effect on the inhibition of plaque formation is stronger as compared with other fluoride combinations. AmF/SnF_2 can be effective in low concentrations by slowing down bacterial growth through the inhibition of bacterial metabolism (eg, acid production) Triclosan in

Dentlearn.ir

toothpaste has long been demonstrated to provide antibacterial effects by disrupting bacterial cell walls.[114] These products may be more suitable for those patients at high caries risk because of their poor oral hygiene attitude.

High–fluoride content dentifrices. Prescription-strength topical fluorides are often recommended to patients at high caries risk after assessing fluoride exposure of the patient. Lower-level fluoride (eg, in the United States, 1,100 ppm fluoride) dentifrices generally lead to a caries reduction of around 25%88,115; this is insufficient protection for high-risk patients, and therefore alternative therapies are usually needed for these patients. A patient's daily use of a conventional 1,100-ppm fluoride-containing dentifrice may be substituted with a high-fluoride dentifrice (eg, 5,000 ppm). Clinical studies have shown that as much as a 75% reduction in caries incidence may be achieved through use of 5,000-ppm fluoride topical treatments.[115]

Options when plaque control is insufficient. If caries or caries lesion progression is not prevented, the reasons should be carefully examined. A first step in this procedure is to carefully assess the quality of the oral hygiene (Fig 5-27). If hygiene is adequate, it is appropriate to evaluate whether additional risk factors, such as multiple intake episodes of sugar-containing foods and drinks, are present. If so, these risks must be reduced as much as possible. In the meantime, the patient can be helped with professionally applied preventive measures, such as topical applications of concentrated fluoride solutions, gels, or varnishes[100,116] (Tables 5-11 and 5-12). The benefits of topical fluorides are firmly established based on a sizeable body of evidence from randomized controlled trials. The size of the reductions in caries increment in both the permanent and the primary dentitions emphasizes the importance of including topical fluoride delivered through toothpastes, rinses, gels, or varnishes in any caries prevention program.[117,118] Salivary flow can be stimulated by daily use of sugar-free chewing gum. When no additional risks can be identified, the fluoride supply must be intensified, perhaps by adding a third daily fluoride application in the form of additional brushing, a mouthwash, or a tablet (see Tables 5-11 and 5-12). Although fluoride toothpastes in comparison with mouthrinses or gels appear to have a similar degree of effectiveness for the prevention of dental caries in children,[119] topical fluorides (mouthrinses, gels, or varnishes) used in addition to fluoride toothpaste achieve a modest reduction in caries compared with toothpaste used alone.[120] If the daily oral hygiene procedures are inadequate, an attempt should be made to determine whether the problem is due to an inability to use a toothbrush or whether the patient simply is

Dentlearn.ir

noncompliant. The dentist or hygienist should apply disclosing solution to the teeth and watch as the patient demonstrates the oral hygiene procedures. If he or she is not able to remove the plaque, the patient should be taught alternative methods. Sometimes a patient can be helped by professionally applied preventive measures. If a patient is able to remove plaque but is not motivated to do so, the dentist/hygienist must try to determine the reasons. The patient may not be convinced of the necessity for thorough plaque removal. This puts the dentist/ hygienist in the realm of behavior modification, a subject not within the scope of this chapter but well discussed by Freeman and Ismail.[121]

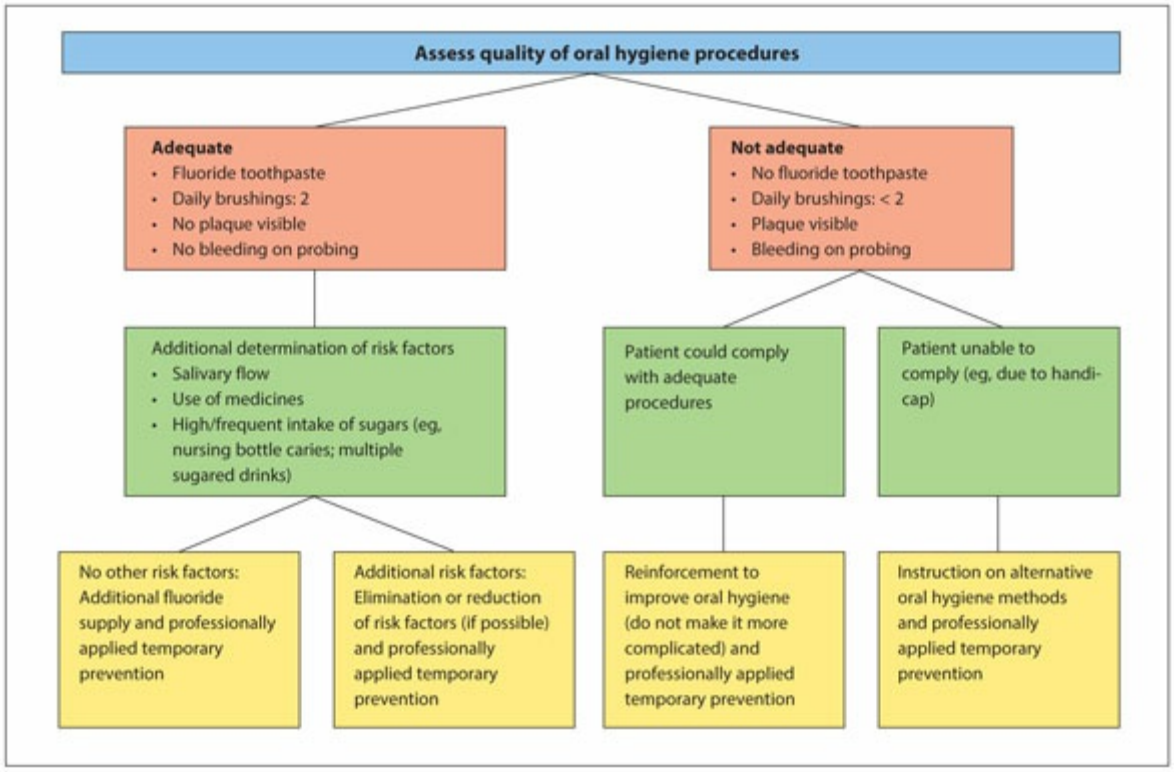

Fig 5-27 Assessment of oral hygiene procedures when caries or caries progression is not prevented.

Table 5-11	**Guidelines for basic preventive advice and the use of recommended preventive products***	
Basic preventive steps for moderate/high-risk patients		**Special needs**
Patient motivation	Emphasis on behavioral change	R, H
Diet counseling	Reduction of fermentable carbohydrate intake and frequency	R, H
	Reduction of soft drink consumption and frequency	

Dentlearn.ir

Toothbrushing	Twice daily with fluoride toothpaste (preferably three times a day)	R, H
Flossing	Daily, few times a week	R, H
Sugar-free gum	Two pieces for ≥ 5 minutes three times a day (after each meal preferred)	R, H
Sealants	All at-risk surfaces (sound or noncavitated)	H
Adjunct topical therapies for moderate/high-risk patients		**Special needs**
Home fluoride options:		
Prescription fluoride (5,000 ppm) toothpaste	• Brush at least twice a day (preferably three times a day), including immediately before going to bed • Follow motto "spit, don't rinse" • Apply via tray daily for patients with radiation-induced hyposalivation	R, H
Fluoride rinses	Twice daily/daily/weekly depending on need and produ	R, H
In-office fluoride options:		
Fluoride gel/foams	• 1.23% APF or neutral 2% NaF • 4 minutes, two to four times per year • For root caries, four times over 2 to 4 weeks	R, H
Fluoride varnishes	• Apply to lesions and other surfaces at risk two to four times per year depending on risk	R, H
Potentially helpful adjuncts to home fluoride:		**Special needs**
Xylitol chewing gum	• Xylitol must be listed as first ingredient • Two pieces for ≥ 5 minutes, three times per day (after each meal preferred) for 2 weeks	H
Calcium-based products	Includes paste, toothpaste, mints with/without fluoride; regimen depends on product	H

Dentlearn.ir

*Modified from Peters[116] with permission. H–hyposalivation; R–root caries.

Table 5-12	ADA evidence-based recommendations for professionally applied topical fluoride[100]		
	< 6 years	6–18 years	> 18 years
Low	May not receive additional benefit from topical fluoride	May not receive additional benefit from topical fluoride	May not receive additional benefit from topical fluoride
Medium	Varnish every 6 months	Varnish or fluoride gel application every 6 months	Varnish or fluoride gel application every 6 months
High	Varnish every 3 or 6 months	Varnish every 3 or 6 months	Varnish every 3 or 6 months
		or	or
		Fluoride gel application every 3 or 6 mon	Fluoride gel application every 3 or 6 months

Fluoride gels, mouthrinses, and supplements. The benefits of topical fluorides have been firmly established on a sizeable body of evidence from randomized controlled trials.[122] There is clear evidence of the caries-inhibiting effect of fluoride gel, with the best estimate of the magnitude of this effect, based on 14 placebo-controlled trials, being a 21% reduction in DMFS.[123,124] The most commonly available at-home-use fluoride gels for daily application come in prescription-strength 1.1% NaF. These are recommended for high-risk adults and children 6 years and older and are to be applied once daily over the tooth surfaces using a finger, toothbrush, or individually fitted trays, preferably immediately before bed. The gel should be left in contact with the teeth surfaces for 5 minutes, after which the individual should spit and not rinse. There is little information concerning effects on the primary dentition and on adverse effects, so the prescriber should take responsibility for possible side effects and misuse. Clinical trials have shown that, depending on the strengths and rinsing frequencies, supervised regular use of a fluoride mouthrinse is associated with a clear reduction in caries occurrence in children.[125] Over-the-counter (OTC) mouthrinses are available as 0.05% or 0.02% NaF (in the United States) for daily use. Prescription-strength 0.2% NaF rinses may

Dentlearn.ir

be used daily or weekly depending on the caries risk status of the patients. It is recommended that 10 mL of the fluoridated mouthrinse be swished around in the mouth for 1 minute. Clinical trials of both the daily and weekly regimen show an average caries reduction of 30%.[126]

Mouthrinses have also been formulated with acidulated phosphate fluoride (APF), stannous fluoride, ammonium fluoride, and amine fluoride. Acidulation of the solutions may increase the fluoride uptake into the tooth mineral.[22,127,128] Application of an acidulated product causes mild etching of the enamel, which creates micropores for increased fluoride diffusion and increases the surface-reactive area for fluoride. The result is increased uptake and accumulation of fluoride within a caries lesion or healthy tissue. Etching may also cause the transformation of apatite to brushite as an intermediate product. The brushite in turn is readily recrystallized into fluoroapatite when exposed to low concentrations of fluoride (< 1,000 ppm), especially in the presence of a low F/Ca ratio. In the presence of higher fluoride concentrations, however, brushite reacts instead to form calcium fluoride (CaF_2) globules, which are covered by salivary components preventing immediate dissolution. Under acidic challenge, the solubility of the CaF_2 globules increases to release calcium and fluoride in the environment. Therefore, the low pH of APF enhances more rapid fluoride uptake by enamel, while the presence of the orthophosphate prevents enamel dissolution by saturating the immediate environment of the tooth surface with phosphate ions (common ion effect).[22,127,128]

Caution: Although some of these mouthrinses tend to recharge glass-ionomer restorations, the pH of the topical fluoride used to recharge glass-ionomer restorations is important. Acidic topical fluoride solutions, such as APF solutions and other acidified fluoride preparations, degrade glass-ionomer materials, porcelain crowns, and veneers and should be avoided in these patients.[129–131] Resin-modified glass ionomers are more resistant to surface degradation than conventional glass ionomers but still degrade when exposed to acids and orange juice.[123] Resin composites are also degraded by frequent applications of acidic fluoride solutions, producing filler dislodgment and destruction of the filler-resin matrix interface.[132]

Nonfluoride products

Xylitol products. The noncariogenicity of xylitol, demonstrated in clinical studies through its use in chewing gum,[133,134] oral syrup,[135] and gummy bears,[136] is based on the inability of the cariogenic bacteria to metabolize this sugar and produce acid. Xylitol in gums and candies has been shown to have a caries-preventive effect,

Dentlearn.ir

which is probably based on stimulation of salivary flow, although an antimicrobial effect cannot be excluded. Xylitol chewing gums can be recommended for saliva stimulation, especially in moderate- and high-caries-risk individuals, and most essentially for patients with hyposali-vation. Two pieces of gum should be chewed for at least 5 minutes three times daily, preferably after each meal. The minimum effective dose for xylitol has not been established, but studies employing daily doses of between 0.9 and 7.0 g have been shown to be effective.[137] Although no minimum frequency of exposure has been established, there are some indications that there is an exposure frequency effect and that at least three exposures daily should be achieved.[137]

Calcium-based dentifrices and mouthrinses. Calcium-based agents, such as nanohydroxyapatite (nHAP), tricalcium phosphate (TCP), calcium sodium phosphosilicate (NovaMin, Nova-Min Technologies), and amorphous calcium phosphate (ACP), have been incorporated into toothpastes to prevent the development of caries and/or aid remineralization/arrest of caries lesions. nHAP-based toothpaste has been commercially available in Japan since the 1980s and was approved as an anticaries agent in 1993 in Japan, following an anticaries field trial in Japanese schoolchildren.[138] A combined fluoride plus functionalized β-TCP is currently being added into single-phase aqueous or nonaqueous topical fluoride formulations (eg, dentifrices, rinses, varnishes, etc).[139,140] In these formulations, functionalization of TCP with specific organic molecules (eg, fumaric acid or sodium lauryl sulfate) provides a barrier that prevents unwanted TCP-fluoride interactions and also provides targeted delivery of TCP when applied to the teeth. Placebo-controlled clinical studies have demonstrated products with functionalized TCP to improve remineralization of white spot lesions.[141,142]

The potential of NovaMin-based toothpaste to prevent demineralization and aid in remineralization of enamel has been demonstrated. When introduced into the oral environment, the material releases sodium, calcium, and phosphate that then can interact with the oral fluids, resulting in the formation of a crystalline hydroxycarbonate apatite layer.[143]

ACP technology is commercially available as toothpaste based on unstabilized ACP, in which a calcium salt and a phosphate salt are delivered separately intraorally via a dual-chamber device or delivered in a product with a low water activity.[144,145] As the salts mix with saliva, they dissolve, releasing calcium and phosphate ions. The mixing of calcium ions with phosphate ions results in the immediate precipitation of ACP or, in the presence of fluoride ions, amorphous

Dentlearn.ir

calcium fluoride phosphate (ACFP). In the intraoral environment, these phases (ACP and ACFP) are potentially very unstable and may rapidly transform into more thermodynamically stable, crystalline phases (eg, hydroxyapatite and fluorhydroxyapatite).[144] Clinical studies have demonstrated the ability of ACP-based dentifrices to lower the incidence of root caries[146] and ACP-based mouthrinses to promote remineralization of enamel subsurface lesions.[147] However, there is concern about promotion of dental calculus formation with long-term use.

Dietary management for caries prevention

Considerable evidence exists that between-meal snacks favor development of dental caries.[148] A frequent and prolonged eating pattern, such as snacking with sugary foods between meals, increases the caries risk of an individual[149] because in a frequent-eating condition the pH is seldom allowed to come to neutrality. Consequently, demineralization will outweigh remineralization, and caries will develop and progress. However, it is often not possible to gain the compliance of people when asking them to abstain from snacking. Alternatively, patients can be advised to snack smartly by choosing nonsugary and/ or low-fat snack foods, such as raw vegetables, fresh fruits, or whole-grain crackers or bread with margarine or peanut butter, low-fat (or filled milk) cheese, lean meats, or skim milk. The nature of the foods as well as food combinations influence their effect on the caries process. Thus, the following basic dietary principles may help to reduce the risk for dental caries:

- Eat a diet that is low in sucrose and retentive fermentable carbohydrates.
- Reduce the frequency of eating or drinking fermentable carbohydrates.
- Combine cooked and processed foods with nonacidogenic foods.
- Do not eat cariogenic snacks.
- Include foods of firm or hard texture.
- Choose fats in diet wisely to reduce risk of chronic disease while still benefiting from fat coating on tooth surfaces, which reduces the adherence of plaque.
- Chew sugarless gum (preferably with xylitol) for 15 to 20 minutes after eating to increase salivary benefits.
- Combine and sequence foods to encourage chewing and saliva production.
- Only eat sweets with noncariogenic sweeteners.

Dentlearn.ir

Professionally applied preventive measures

Varnishes, gels, and foams

Professionally applied topical fluorides in gels or varnishes have been shown to be effective in many clinical trials.[119,120,122,150] The benefits of topical fluorides are firmly established based on a sizeable body of evidence from randomized controlled trials. The size of the reductions in caries occurrence in both the permanent and the primary dentitions emphasizes the importance of including topical fluoride delivered through toothpastes, rinses, gels, or varnishes in any caries preventive program.[117] A substantial caries-inhibiting effect of fluoride varnish in both the permanent and the primary dentitions based largely on trials has been reported.[151–153] Fluoride varnish treatment twice a year at 6-month intervals prevented proximal caries in adolescents as much as 69% in high-, 66% in medium-, and 20% in low-risk individuals.[152] Table 5-12 summarizes the American Dental Association (ADA) Council on Scientific Affairs clinical recommendations for professionally applied topical fluoride.[100] Fluoride varnishes contain a high level of fluoride (5% NaF, 22,600 ppm F), and its application on tooth surfaces results in formation of a deposit of calcium fluoride globules that can act as a reservoir for the slow release of fluoride and calcium over time under acid challenge.

Several excellent studies confirm that fluoride varnish application is effective in reversing and arresting active enamel lesions and therefore reduces the need for restorative intervention.[154–160] Peyron et al[161] concluded that fluoride varnish application has a definite cariostatic effect on proximal caries. Following isolation of each quadrant of the dentition with cotton rolls, fluoride varnish is applied to the lesions and other surfaces at risk about two to four times per year, depending on the caries risk of the individual patient. The varnish can be dragged onto the proximal surfaces with dental floss using forward and backward strokes. Fluoride gels and foams, such as 1.23% acidulated phosphate fluoride or neutral 2% NaF, are applied with custom-made trays for 4 minutes, two to four times per year or, for root caries, four times over 2 to 4 weeks.

Pit and fissure sealants

Fissures are more susceptible to caries attack than smooth surfaces because fissure anatomy favors plaque maturation and retention.[162] However, lesions can be prevented, and active white spot lesions can be arrested by brushing alone.[62] Sealing

Dentlearn.ir

is a recommended procedure to prevent caries of the occlusal surfaces of permanent molars,[163] but it is only required if occlusal surfaces are not being cleaned. Pit and fissure sealants have been used successfully for many years to prevent caries by preventing the growth of bacteria that promote decay in pits and fissures in teeth. Sealants may be indicated for children and adults who, because of poor oral hygiene, may be at moderate or high risk of developing dental caries, have active white spot lesions (limited to enamel of pits and fissures), or have existing pits and fissures that are anatomically susceptible to caries.

Currently there are two main types of pit and fissure sealant materials available: resin-based sealants/composites and glass-ionomer cements. The effectiveness of resin-based sealants has been demonstrated in many studies.[164,165] Glass-ionomer cements contain fluoride, and it has been suggested that glass-ionomer sealants, through their fluoride release, can prevent the development of caries even after the visible loss of sealant material.[166] Pits and fissures in partially erupted molars where moisture control for placement of a conventional sealant is difficult can be temporarily protected with a recently developed moisture-tolerant material. This is a light-cured glass-ionomer material in varnish form that is recommended for site-specific, protective coating of enamel and dentin tooth surfaces, especially as a protective coating for at-risk surfaces.

Noninvasive Options for Treatment of Existing Lesions

Treatment of noncavitated lesions

Lesion arrest (remineralization therapy)

Active noncavitated caries lesions on occlusal, proximal, and nonproximal coronal smooth surfaces or root surfaces can be arrested. The choice of treatment for active noncavitated lesions on proximal coronal surfaces depends on the caries risk status of the patient as well as the depth of the lesion (see Fig 5-14). Arrest of active caries lesions can be achieved successfully with a combination of improved oral hygiene and application of topical fluoride agents, such as varnishes, gels, or foams. Application of the agent can be repeated every 3 months until caries activity is under control. This regimen should be employed with good oral hygiene and a daily use of high fluoride–containing toothpaste/or mouthrinse.

The average speed of progression of caries lesions on different surfaces has been

Dentlearn.ir

determined.[66,167] On proximal and free, smooth areas, caries proceeds slowly. It is thus reasonable to postpone restorative intervention. A procedure whereby the patient is examined regularly ("watchful waiting") creates the opportunity for arrest and remineralization. "Watchful waiting" implies that nothing is done, but in fact it is based on the intellectual decision not to restore because of knowledge of the caries process. The dentist is performing active preventive treatment by helping the patient to improve oral hygiene, by applying fluoride, and by encouraging the patient to modify his or her diet. These measures should always be carried out when active noncavitated lesions exist.

Occlusal sealants

The choice of management of an initial noncavitated caries lesion depends on the caries risk status of the individual patient and the location of the lesion in the dentition. When active fissure caries has been diagnosed or if a high risk has been established, and fissures have susceptible morphologic characteristics, sealants may be indicated (see Fig 5-24). After acid etching (for a lightly filled resin fissure sealant or a flowable resin composite) or conditioning (for a glass-ionomer cement), the sealant material is used to penetrate the fissures, rendering it self-cleansing to prevent plaque accumulation. This is especially important during the period of tooth eruption, although the application of sealants in suspect fissures is also advisable in older patients with high caries risk.[168] There are several advantages of fissure sealants: No irreversible interventions are necessary, active dentin lesions inadvertently covered by the resin do not progress further, and the possible development of new lesions in other sites of the fissure is prevented. Sealants have been used successfully for many years.[169] Concern has been expressed about placement of sealants over undetected dentin caries lesions. However, there is ample evidence that caries lesions do not progress as long as the fissure remains sealed.[170–175] Sealed, radiographically evident caries lesions have been shown in one study not to progress over a 10-year period.[174,175]

Proximal sealants

The concept of arresting caries by applying a resin barrier to the surface, as in occlusal fissure sealing, has also been transferred to proximal surfaces. Active caries lesions on proximal surfaces have been treated by application of either adhesives or fissure sealants after temporary tooth separation.[176–180] Clinical trials

Dentlearn.ir

suggest that novel techniques for sealing proximal lesions show promise.[176–180] However, proximal sealing techniques are as complex to apply and time-consuming as proximal restorations.

Lesion infiltration

Lesion infiltration technique is an emerging alternative method of treating active noncavitated lesions extending radiographically into inner enamel or the outer third of dentin that are located on the nonproximal and proximal coronal smooth surfaces.[181] In contrast to sealing of fissure caries, where the protective resin layer is established on the tooth surface, caries infiltration occludes lesion pores with low-viscosity light-curing resins in order to create a diffusion barrier and hence arrest caries progression. Following etching of the lesion with hydrochloric acid and achievement of a dried surface using ethanol and air drying, the low-viscosity infiltrant is applied on the lesion surface in two stages (Fig 5-28). In the first application, the infiltrant is allowed to infiltrate the lesion for 3 minutes and then is light cured. In the second application, the infiltrant is allowed to infiltrate for only 1 minute and then is light cured. The infiltration technique is based on the fact that if the lesion body is sufficiently well infiltrated with resin, lesion progression is significantly reduced in a cariogenic environment; moreover, infiltration might stabilize the fragile lesion structure.[181,182] However, the current infiltrant is radiolucent, making it difficult to determine the depth of infiltration or identify an already infiltrated lesion in a radiograph.

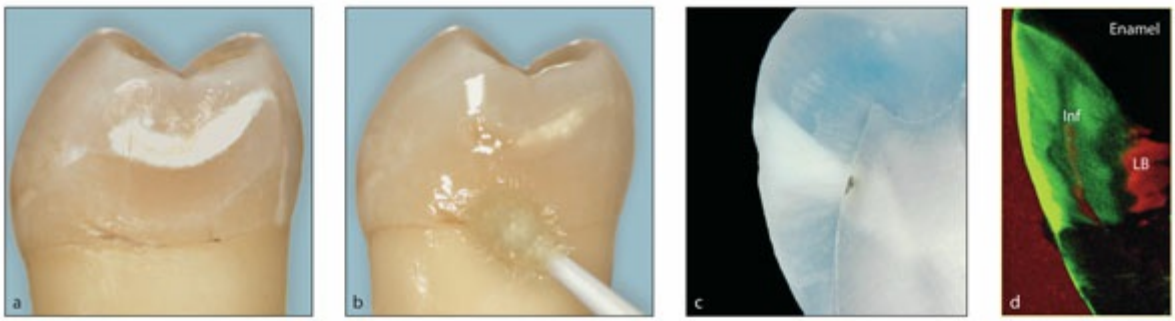

Fig 5-28 Caries infiltration. *(a)* Active noncavitated caries lesions (white spot lesion). *(b)* After application of an infiltrant, the lesion loses its whitish appearance. *(c)* The cross section of a noncavitated proximal caries lesion. *(d)* Confocal microscopic image of an infiltrated lesion. The infiltrant (Inf) is shown in green, whereas the remaining pores within the lesion are shown in red. The infiltrant almost completely penetrates the lesion body (LB) and thereby acts as a diffusion barrier inside the lesion. (Courtesy of Sebastian Paris and Hendrik Meyer-Lückel, Aachen, Germany.)

Dentlearn.ir

Treatment of cavitated lesions

Caries lesions may be detected at a relatively late point of development. This may be because of difficulties in detecting the early lesion, or it may be because the patient did not visit the dentist early in the lesion process. Although this may suggest the value of a rigorous, invasive approach, it is preferable to select a treatment option that is as conservative as possible because of the iatrogenic damage that may occur during preparation. Lussi and Gygax[183] showed that during the preparation of a proximal surface, the neighboring surface was damaged 100% of the time, despite very careful operating procedures. Iatrogenic preparation damage represents a dental health problem, because the damage increases the caries progression and the perceived need for restorative therapy of the adjacent teeth.[184]

Although lesions that are cavitated are treated traditionally by preparation and restoration, clinical observations suggest that caries lesions can be arrested at any stage of lesion development (ie, even at the cavitation stage if plaque-free conditions are maintained).[79] Thus, a preventive treatment approach is often successful, especially when the lesion is in a free, smooth surface. When a lesion is present in an occlusal or proximal surface, it will often be difficult to arrest lesion progression because of the difficulty of removing plaque. Before invasive procedures are initiated, noninvasive options must be explored and preventive measures taken.

Several authors have shown that when an occlusal lesion has cavitated, the dentin is always involved in the process.[55,56] Moreover, these lesions, mostly detectable on radiographs, contain many microorganisms and are therefore considered active.[57,58,64,65] Measures directed at a thorough removal of plaque are ineffective on the occlusal surface because the bristles of the toothbrush cannot get into the undermined cavity. Proximal cavitations are also difficult to reach. Dental floss will skim the surface but will not achieve access to the cavitated area. However, where there are cavitated areas on free, smooth surfaces, the situation is different. Those areas are easily reached by the toothbrush but may be difficult to clean due to undermining of the enamel. Removal of the overhanging enamel margins must be considered to aid in keeping the whole area free of plaque. Cavities in these surfaces, cleaned twice daily with a fluoride toothpaste, can be arrested and converted into leathery or hard lesions[79,185] (see Figs 5-20 and 5-21). When the activity of highly infected caries lesions is decreased and finally arrested, the carious layers contain few bacteria that can be cultivated.[186–189] Although occlusal or proximal caries lesions cannot be approached by preventive measures alone, in the primary dentition this method can be successful (Fig 5-29). Therefore,

Dentlearn.ir

undermined enamel margins should be eliminated so that when plaque is removed, fluoride can be applied easily to the carious dentin. Under ideal conditions, carious dentitions can be managed so that caries is arrested and demineralization and remineralization are in equilibrium (Fig 5-30; see also Fig 5-29).



Fig 5-29*(a and b)* Arrested caries lesions in the primary dentition.

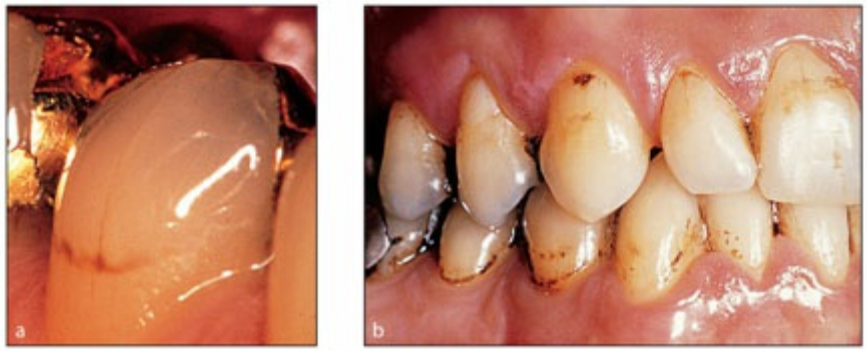

Fig 5-30*(a and b)* Arrested lesions seen as brownish "scar tissue."

Operative and Minimally Invasive Treatment Options

Restoration of noncavitated (initial) lesions

Bitewing radiographs are the most effective method of detecting proximal lesions, but correlation with surface integrity is poor. The algorithm shown in Fig 5-14 demonstrates that caries lesions on proximal surfaces are considered differently when it comes to restorative treatment. In addition to the caries risk status of the patient, the depth of the demineralization plays a role in the choice of treatment. Lesions that extend on the radiograph slightly past the dentinoenamel junction (D1

treatment. Such a decision is based on the fact that radiographs have been shown to considerably underestimate the histologic size of the lesion,[71] and the possible

Dentlearn.ir

prediction of the cavitation of proximal lesions is based on the radiographic depth and caries activity of the patient.[72] However, in contemporary populations, these deep proximal lesions are rarely cavitated. They should be treated preventively as described previously and reassessed clinically and radiographically at an appropriate recall interval, depending on the patient's caries risk status. Teeth separation using orthodontic elastic separators, allowing impression/inspection, may serve as an effective diagnostic tool for assessing surface integrity of proximal lesions.[72]

Restoration of cavitated lesions

Cavitated caries lesions are candidates for traditional restorative treatment, such as resin composite, resin-modified glass ionomer, or a sandwich technique combining resin-modified glass ionomer and resin composite or amalgam. It is necessary to have well-defined criteria for the decision to restore a tooth due to caries. The most important reason for placing a restoration is to aid plaque control. Elderton and Mjör[190] formulated the following indications for restorative treatment:

- The cavitated tooth is sensitive to hot, cold, sweetness, etc.
- Occlusal and proximal lesions extend deep into dentin (and cannot be reached by the toothbrush).
- The pulp is endangered.
- Previous attempts to arrest the lesion have failed, and there is evidence that the lesion is progressing (such evidence usually requires an observation period of months or years).
- The patient's ability to provide effective home care is impaired.
- Drifting is likely to occur through loss of proximal contact.
- The tooth has an unesthetic appearance.

Treatment will be directed in such a way that infected dental tissue is removed and the remaining cavity is adapted so that the restorative material can be optimally placed. The particular preparation methods and restorative procedures are discussed in subsequent chapters.

Preventive resin restorations and preventive amalgam restorations

Restoration of the carious surface should be accompanied with sealing of

Dentlearn.ir

surrounding pits and fissures. Sealed restorations placed directly over frankly cavitated lesions can arrest lesion progression. Sealing of restorations, therefore, conserves sound tooth structure, protects the margins of restorations, and prevents recurrent caries (secondary caries).[175]

Interim therapeutic restorations

Interim therapeutic restorations (ITRs) are utilized as part of comprehensive caries management when caries control is necessary prior to placement of definitive restorations. ITRs may be employed in patients with multiple caries lesions to temporarily restore the lesions prior to definitive restoration of the teeth.[191] It should be applied to children experiencing early childhood caries,[192] in cases of rampant caries, in very high caries risk cases, to uncooperative patients, to patients with special health care needs,[193] or when traditional cavity preparation and/or placement of traditional dental restorations is not feasible and needs to be postponed.[191–198] It is also used when there is need for stepwise excavation in children or adults with multiple open caries lesions prior to definitive restoration of the teeth.[199] ITRs may be used to reduce the levels of cariogenic bacteria in the oral cavity[200,201] and make the tooth surfaces more cleansable prior to placing definitive restorations.

The ITR procedure involves removal of caries using hand or low-speed rotary instruments, with caution not to expose the pulp, followed by restoration of the tooth with an adhesive restorative material, such as conventional or resin-modified glass-ionomer cement.[202] It is applicable mainly to single-surface or small two-surface restorations, where the greatest success has been achieved.[203] Maximum caries removal from the periphery of the lesion will help to minimize leakage of the restoration, while inadequate cavity preparation with subsequent lack of retention and insufficient bulk can lead to failure.[203] However, ITRs must be accompanied with maintenance care including oral hygiene instruction, topical fluoride application, and interviews to motivate and educate patients and modify their habits and risk factors during the time that they have transitional restorations.

Atraumatic restorative treatment

Atraumatic restorative treatment (ART) is a procedure based on excavation of carious tooth tissues using hand instruments alone. Thus, it eliminates the need for anesthesia and use of expensive equipment and restores the cavity with glass ionomer, an adhesi cture and releases

Dentlearn.ir

fluoride.[196,204] Some suggest that it may aid in remineralization of tooth structure. Removing carious tooth tissue with hand instruments alone and restoring the cavity with an adhesive material will conserve as much tooth structure as possible and prevent further decay. In addition to its use as a restorative material, glass ionomers can be applied in the very early stages of caries development. The glass ionomer adheres to the tooth and halts or slows the progression of lesions, probably because it slowly releases fluoride.[196] However, ART must be accompanied with maintenance care with oral hygiene instruction and topical fluorides to improve the treatment outcome, especially in high-caries-risk populations.

ART is minimally invasive, making it highly acceptable to patients. It is recommended as a definitive restoration for use in children as well as in fearful

community, such as the physically or mentally handicapped, people living in nursing homes, and the home-bound elderly.[198,204]

ART is considered as a preventive and definitive treatment modality for caries in communities with little or no access to traditional dental care. ART also has its place in the industrialized world as a minimal intervention, minimal invasion, and minimal cavity preparation for caries lesions. The World Health Organization actively promotes ART as a viable approach to meet the need for treatment of dental caries. ART is now considered as part of a total package of oral health care that is based on a philosophy of promoting health and preventing disease.[204]

Maintenance Care

A continuing care program is essential in PCCM because it creates the opportunity to engage the patients in the treatment of caries, and a high level of compliance is required for its success. Thus, as part of the initial management of caries in an individual patient, personalized oral health maintenance care should be included in the treatment planning. Maintenance care should be offered to all patients visiting the dental clinic. It is important to realize that the caries risk status of an individual can change over time. Von der Fehr et al[205] and Koch[206] have shown that normal individuals can turn into individuals with high caries risk. Within a short period of time, numerous initial caries lesions can develop when oral hygiene is withdrawn and a sugar-rich diet is offered.[205,206] However, when effective oral hygiene and application of topical fluoride are instituted and a normal, less sugar-rich diet is consumed, reversal of the situation seems possible. Caries risk assessment is

Dentlearn.ir

inevitably a "best guess" based on available evidence. Thus, recall and reassessment are important to review the original decision.

Recall and reassessment visits

The establishment of a recall visit should be a component of the maintenance plan to prevent future disease occurrence. A recall system is a means of establishing a continuing care regimen that provides opportunities to reassess and monitor the oral health of patients and to inform future treatment planning.[207] There is some evidence that recall visits, irrespective of the frequency, have a positive impact in terms of the preservation of the dentition.[208] However, the main objectives of the recall system are the following:

- Prevent new disease occurrence.
- Facilitate early detection of any newly developed disease.
- Assess the status of a previously diagnosed and treated disease.
- Enable the clinician or the patient to consider altering the treatment regimen to obtain a more favorable outcome.
- Provide evidence for future clinical governance and quality improvement services.
- Create opportunities to advise, reassess, and reinforce the appropriateness of previous advice.
- Monitor patient compliance with previous advice and treatment.
- Encourage patient behavior that will improve and maintain their oral and general health.
- Create the opportunity, where possible, of using motivational interviewing to increase the inherent motivation of the patient.

The United Kingdom National Institute for Clinical Excellence (NICE) issued a guidance document in 2004 recommending that the individual patient's caries risk status should inform his or her recall interval[209] (Box 5-5).The recommendations cover risk factors such as caries incidence and restorations; periodontal health and tooth loss; patients' well-being, general health and preventive habits; and pain and anxiety. The information collected during the caries risk assessment should be used to determine a personalized variable time interval to assess, reassess, and monitor the oral health and caries status of patients, based on the clinical judgment and

Dentlearn.ir

expertise of the dental team and discussions with the patient. The personalized interval should vary from 3 to 24 months, according to risk (see Boxes 5-1 to 5-3). The recommended recall interval should be discussed with the patient to seek his or her agreement to facilitate compliance with the visits. This interval should be reviewed at the next oral health visit for possible alteration, depending on the prevailing caries risk status and patient compliance; hence, it is important to inform patients that their recommended recall interval may vary over time. Furthermore, the patient's ability or desire to visit the dentist at the recommended interval and the financial costs to the patient of having the oral health review and any subsequent treatments should be discussed. The following key components are recommended at the recall visits:

Box 5-4	NICE[209] recommended method for determining a personalized recall interval

Step 1: Consider the patient's age, which sets the range of recall intervals.
• For children and teenagers under 18 years, the range is 3 to 12 months.
• For adults 18 years or older, the range is 3 to 24 months.

Step 2: Consider modifying factors in light of the patient's medical, social, and dental histories and findings of the clinical examination.

Step 3: Integrate all diagnostic and prognostic information, considering advice from other members of the dental team where appropriate. Use clinical judgment to determine the interval for the next oral health review.

Step 4: Discuss the recommended interval with the patient and record the agreed-upon interval or any reason for disagreement.

Step 5: At the next oral health review, consider whether the interval was appropriate. Adjust the interval depending on the patient's ability to maintain oral health between reviews.

- Discussion between the dental team and the patient (and/or his or her parent, guardian, or caregiver) concerning, where appropriate, the effects of oral hygiene, diet, fluoride use, tobacco, and alcohol on the oral health of the individual patient.
- Discussion on the risk factors that may influence the patient's oral health and their implications to future caries occurrence or failure of the treated lesions.
- General preventive advice on frequency of brushing and the use of fluoride

Dentlearn.ir

delivery agents; frequency of flossing[116] (see Table 5-11); and dietary advice, such as reduction of the number of between-meal sweet snacks and substitution with snacks rich in protein.

- Provision of the patient with self-applied (at-home use) caries-preventive agents, such as OTC fluoride rinses, and agents for salivary stimulation, such as xylitol-containing gum or candies[116] (see Table 5-11).
- Establishment of an interval for bitewing radiographs to check for lesions, especially proximal lesions. The current recommendation based on the evidence is that the interval should depend on the caries risk status of the individual patient and should be every 3 to 6 months for patients at high caries risk, every 12 to 18 months for moderate caries risk, and every 24 months for low caries risk.
- Recommendation of the next recall visit and the interval of the visit (see Box 5-4).

The advice is tailored to eliminate or at least minimize the risk factors and increase the protective factors (see Fig 5-23).

References

1. Kutsch VK, Kutsch CL. Manage caries: A minimally invasive approach. Dental Products Report 2006;40(4):18–24.
2. Pitts NB, Richards D; International Caries Detection and Assessment System Committee. Personalized treatment planning. Monogr Oral Sci 2009;21:128–143.
3. Young DA, Buchanan PM, Lubman RG, Badway NN. New directions in interorganizational collaboration in dentistry: The CAMBRA coalition model. J Dent Educ 2007;71:595–600.
4. Young DA, Featherstone JB, Roth JR. Caries management by risk assessment—A practitioner's guide. J Calif Dent Assoc 2007;35:679–680.
5. Lagerlof F, Oliveby A. Clinical implications: New strategies for caries treatment. In: Stookey GK (ed). Early Detection of Dental Caries. Indianapolis: Indiana University, 1996:297–321.
6. Keyes PH, Jordan HV. Factors influencing the initiation, transmission and inhibition of dental caries. In: Harris RJ (ed). Mechanisms of Hard Tissue Destruction. New York: Academic Press, 1963:261–283.
7. Selwitz RH, Ismail AI, Pitts NB. Dental caries. Lancet 2007;369:51–59.
8. Carlsson J, Grahnen H, Jonsson G. Lactobacilli and streptococci in the mouth of children. Caries Res 1975;9:333–339.
9. Keene H, Shklair I. Relationship of *Streptococcus mutans* carrier status to the development of caries lesions in initially cariesfree recruits. J Dent Res 1974;53:1295–1299.
10. Loesche W. Dental Caries: A Treatable Infection. Springfield, IL: Charles C. Thomas, 1982.
11. Powell LV. Caries prediction: A review of the literature. Community Dent Oral Epidemiol 1998;26:361–371.
12. De Stoppelaar JD, Van Houte J, Backer Dirks O. The effect of carbohydrate restriction on the presence of *Streptococcus mutans, Streptococcus sanguis* and iodophylic polysaccharide-producing bacteria in human dental plaque. Caries Res 1970;4:114–123.
13. McDermid AS, McKee AS, Ellwood DC, Marsh PD. The effect of lowering the pH on the composition and metabolism of a community of nine oral bacteria grown in a chemostat. J Gen Microbiol 1986;132:1205–1214.
14. Krasse B. The effect of the diet on the implantation of caries-inducing streptococci in hamsters. Arch Oral

Dentlearn.ir

Biol 1967;10:215–226.
15. Andreen I, Kohler B. Effects of Weight Watchers' diet on salivary secretion rate, buffer effect and number of mutans streptococci and lactobacilli. Scand J Dent Res 1992;100:93–97.
16. Wennerholm K, Birkhed D, Emilson CG. Effects of sugar restriction on *Streptococcus mutans* and *Streptococcus sobrinus* in saliva and dental plaque. Caries Res 1995;29:54–61.
17. Scheie AA, Arneberg P, Orstavik D, Afseth J. Microbial composition, pH-depressing capacity and acidogenicity of 3-week smooth surface plaque developed on sucrose-regulated diets in man. Caries Res 1984;18:74–86.
18. Imfeld T. Identification of Low Caries Risk Dietary Components. Basel: Karger, 1983.
19. Axelsson P, Lindhe J. Effect of controlled oral hygiene procedures in caries and periodontal diseases in adults. J Clin Periodontol 1978;5:133–151.
20. Axelsson P, Lindhe J, Nyström B. On the prevention of caries and periodontal disease. Results of a 15-year longitudinal study in adults. J Clin Periodontol 1991;18:182–189.
21. Ogaard B, RØlla G, Ruben J, Dijkman T, Arends J. Microradiographic study of demineralization of shark enamel in a human caries model. Scand J Dent Res 1988;96:209–211.
22. RØlla G, Ogaard B, de Almeida Cruz R. Clinical effect and mechanism of cariostatic action of fluoride-containing toothpastes: A review. Int Dent J 1991;41:171–174.
23. ten Cate JM, Duijsters PPE. The influence of fluoride in solution on tooth enamel demineralization. I. Chemical data. Caries Res 1983;17:193–196.
24. Wilson PR, Beynon AD. Differences between human deciduous and permanent enamel measured by quantitative microradiography. Arch Oral Biol 1989;34:85–88.
25. Gülzow HJ, Maeglin B, Mühlemann R, Ritzel G, Stäheli D. Caries morbidity and caries incidence in 7- to 15-year-old Basel school children in 1977 after 15 years of drinking-water fluoridation [in German]. SSO Schweiz Monatsschr Zahnheilkd 1982;92:255–266.
26. König KG. Changes in the prevalence of dental caries: How much can be attributed to changes in diet? Caries Res 1990:24(suppl 1):16–18.
27. Jensen ME, Schachtele CF. Plaque pH measurements by different methods on the buccal and proximal surfaces of human teeth after a sucrose rinse. J Dent Res 1983;62:1058–1061.
28. Jensen ME, Wefel JS. Human plaque pH responses to meals and the effects of chewing gum. Br Dent J 1989;167:204–208.
29. Kashket S, Van Houte J, Lopez LR, Stocks S. Lack of correlation between food retention on the human dentition and consumer perception of food stickiness. J Dent Res 1991;70:1314–1319.
30. Lingström P, Birkhed D. Plaque pH and oral retention after consumption of starchy snack products at normal and low salivary secretion rate. Acta Odontol Scand 1993;51:379–388.
31. Newbrun E. Cariology. Baltimore: Williams & Wilkins, 1978.
32. Vogel GL, Carey CM, Ekstrand J. Distribution of fluoride in saliva and plaque fluid after a 0.048 mol/L NaF rinse. J Dent Res 1992;71:1553–1557.
33. Dawes C, Weatherell JA. Kinetics of fluoride in the oral fluids. J Dent Res 1990;69(special issue):638–644.
34. Truin GJ, König KG, Bronkhorst EM, Frankenmolen F, Mulder J, van't Hof MA. Time trends in caries experience of 6- and 12-year old children of different socioeconomic status in The Hague. Caries Res 1998;32:1–4.
35. Demers M, Brodeur JM, Mouton C, Simard PL, Trahan L, Veilleux G. A multivariate model to predict caries increment in Montreal children aged 5 years. Community Dent Health 1992;9:273–281.
36. Grindefjord M, Dahlof G, Nilsson D, Modeer T. Prediction of dental caries development in 1-year-old children. Caries Res 1995;29:343–348.
37. Backer Dirks O. Posteruptive changes in dental enamel. J Dent Res 1966;45(suppl):503–511.
38. Broadbent JM, Thomson WM, Poulton R. Trajectory patterns of dental caries experience in the permanent dentition to the fourth decade of life. J Dent Res 2008;87:69–72.
39. Van Palenstein Helderman WH, Ter Pelkwijk L, Van Dijk JW. Caries in fissures of permanent first molars as a predictor for caries increment. Community Dent Oral Epidemiol 1989;17:282–284.

Dentlearn.ir

40. Marthaler TM, Steiner M, Bandi A. Will discolored molar fissures within 4 years become carious more frequently than nondiscolored ones? Observations from 1975 to 1988 [in German]. Schweiz Monatsschr Zahnmed 1990;100:841–846.
41. Creanor SL, Russell JI, Strang DM, Stephen KW, Burchell CK. Prevalence of clinically undetected occlusal dentin caries in Scottish adolescents. Br Dent J 1990;169:126–129.
42. Hyatt TP. Observable and unobservable pits and fissures. Dent Cosmos 1931;73:586–592.
43. Pessan JP, Toumba KJ, Buzalaf MA. Topical use of fluorides for caries control. Monogr Oral Sci 2011;22:115–132.
44. Maupomé G, Shulman JD, Clark DC, Levy SM, Berkowitz J. Toothsurface progression and reversal changes in fluoridated and no-longer-fluoridated communities over a 3-year period. Caries Res 2001;35:95–105.
45. Shwartz M, Gröndahl HG, Pliskin JS, Boffa J. A longitudinal analysis from bitewing radiographs of the rate of progression of proximal carious lesions through human dental enamel. Arch Oral Biol 1984;29:529–536.
46. Gröndahl HG, Hollender L, Malmcrona E, Sundquist B. Dental caries and restorations in teenagers. II. A longitudinal radiographic study of the caries increment of proximal surfaces among urban teenagers in Sweden. Swed Dent J 1977;1:51–57.
47. Mejàre I, Kallestal C, Stenlund H, Johansson H. Caries development from 11 to 22 years of age: A prospective radiographic study. Prevalence and distribution. Caries Res 1998;32:10–16.
48. Groeneveld A. Longitudinal study of prevalence of enamel lesions in a fluoridated and non-fluoridated area. Community Dent Oral Epidemiol 1985;13:159–163.
49. Kidd EAM, Joyston-Bechal S. Saliva and caries. In: Kidd EAM, Joyston Bechal (eds). Essentials of Dental Caries. Oxford: Oxford University Press, 1997:66–78.
50. Saxer UP, Marthaler TM. Caries increase over 10 years in young adults with and without a prevention program during the mandatory school year (II) [in German]. Quintessenz 1982;4:833–840.

J 1994;176:373–378.
52. Kidd EAM, Mejàre I, Nyvad B. Clinical and radiographic diagnosis. In: Fejerskov O, Kidd EAM (eds). Dental Caries: The Disease and Its Clinical Management. Copenhagen: Blackwell Munksgaard, 2003:111–128.
53. Topping GVA, Pitts NB; International Caries Detection and Assessment System Committee. Clinical visual caries detection. Monogr Oral Sci 2009;21:15–41.
54. Nyvad B, Fejerskov O, Baelum V. Visual-tactile caries diagnosis. In: Fejerskov O, Kidd EAM (eds). Dental Caries: The Disease and Its Clinical Management, ed 2. Copenhagen: Blackwell Munksgaard, 2008:49–68.
55. van Amerongen JP, Penning C, Kidd EAM, ten Cate JM. An in vitro assessment of the extent of caries under small occlusal cavities. Caries Res 1992;26:89–93.
56. Ekstrand KR, Ricketts DNJ, Kidd EAM. Reproducibility and accuracy of three methods for assessment of demineralization depth on the occlusal surface: An in vitro examination. Caries Res 1997;31:224–231.
57. Ekstrand KR, Ricketts DNJ, Kidd EAM, Qvist V, Schou S. Detection, diagnosing, monitoring and logical treatment of occlusal caries in relation to lesion activity and severity: An in vivo examination with histological validation. Caries Res 1998;32:247–254.
58. Espelid I, Tveit AB, Fjelltveit A. Variations among dentists in radiographic detection of occlusal caries. Caries Res 1994;28:169–175.
59. Forgie AH, Pine CM, Pitts NB. The use of magnification in a preventive approach to caries detection. Quintessence Int 2002;33:13–16.
60. Ismail AI, Sohn W, Tellez M, et al. The International Caries Detection and Assessment System (ICDAS): An integrated system for measuring dental caries. Community Dent Oral Epidemiol 2007;35:170–178.
61. Ekstrand KR, Kuzmina I, Bjørndal L, Thylstrup A. Relationship between external and histologic features of progressive stages of caries in the occlusal fossa. Caries Res 1995;29:243–250.
62. Carvalho JC, Thylstrup A, Ekstrand K. Results after 3 years non-operative occlusal caries treatment of erupting permanent first molars. Community Dent Oral Epidemiol 1992;20:187–192.
63. van Amerongen JP, van Amerongen-Pieko A, Penning C. Validity of caries diagnosis in molars with discolored fissures by radiography. J Dent Res 1993;72:344.

Dentlearn.ir

64. Penning C, van Amerongen JP, Seef RE, ten Cate JM. Validity of probing for fissure caries diagnosis. Caries Res 1992;26:445–449.
65. Ekstrand KR, Qvist V, Thylstrup A. Light microscope study of the effect of probing in occlusal surfaces. Caries Res 1987;21:368–374.
66. Pitts NB, Kidd EAM. Some of the factors to be considered in the prescription and timing of bitewing radiography in the diagnosis and management of dental caries. J Dent 1992;20:74–84.
67. Mitropoulos CM. The use of fibre-optic transillumination in the diagnosis of posterior-proximal caries in clinical trials. Caries Res 1985;19:379–384.
68. Rimmer PA, Pitts NB. Temporary elective tooth separation as a diagnostic aid in general dental practice. Br Dent J 1990;169:87–92.
69. Banting DW. The diagnosis of root caries. J Dent Educ 2001;65:991–996.
70. Kidd EA, Pitts NB. A reappraisal of the value of the bitewing radiograph in the diagnosis of posterior approximal caries. Br Dent J 1990;169:195–200.
71. Bakhshandeh A, Ekstrand KR, Qvist V. Measurement of histological and radiographic depth and width of occlusal caries lesions: A methodological study. Caries Res 2011;45:547–555.
72. Lunder N, von der Fehr FR. Approximal cavitation related to bitewing image and caries activity in adolescents. Caries Res 1996;30:143–147.
73. Gakenheimer DC. The efficacy of a computerized caries detector in intraoral digital radiography. J Am Dent Assoc 2002;133:883–890.
74. Tracy KD, Dykstra BA, Gakenheimer DC, et al. Utility and effectiveness of computer-aided diagnoses of dental caries. Gen Dent 2011;59:136–144.
75. Christensen GJ. Do dental radiographs show incipient carious lesions? Clinicians Rep 2011;4(3):2.
76. Heaven TJ, Weems RA, Firestone AR. The use of a computer-based image analysis program for the diagnosis of approximal caries from bitewing radiographs. Caries Res 1994;28:55–58.
77. Ricketts DN, Kidd EA, Smith BG, Wilson RF. Clinical and radiographic diagnosis of occlusal caries: A study in vitro. J Oral Rehabil 1995;22:15–20.
78. Featherstone JDB. Clinical implications: New strategies for caries prevention. In: Stookey GK (ed). Early Detection of Dental Caries. Indianapolis: Indiana University, 1996:287–295.
79. Nyvad B, Fejerskov O. Assessing the stage of caries lesion activity on the basis of clinical and microbiological examination. Community Dent Oral Epidemiol 1997;25:69–75.
80. Ricketts DNJ, Kidd EAM, Beighton D. Operative and microbiological validation of visual, radiographic and electronic diagnosis of occlusal caries in non-cavitated teeth judged to be in need of operative care. Br Dent J 1995;79:214–220.
81. Ekstrand KR, Brunn C, Brunn M. Plaque and gingival status as indicators for caries progression on proximal surfaces. Caries Res 1998;32:41–45.
82. Hellyer PH, Beighton D, Heath MR, Lynch E. Root caries in older people attending a general dental practice in East Sussex. Br Dent J 1990;169:201–206.
83. Kidd EAM, Joyston-Bechal S, Beighton D. Marginal ditching and staining as a predictor of secondary caries around amalgam restorations: A clinical and microbiological study. J Dent Res 1995;74:1206–1211.
84. Kidd EAM, Beighton D. Prediction of secondary caries around tooth-colored restorations: A clinical and microbiological study. J Dent Res 1996;75:1942–1946.
85. Hausen H. Caries prediction. In: Fejerskov O, Kidd EAM (eds). Dental Caries: The Disease and Its Clinical Management. Copenhagen: Blackwell Munksgaard, 2003:327–341.
86. Fejerskov 0, Manji F. Reactor paper: Risk assessment in dental caries. In: Bader JD (ed). Risk Assessment in Dentistry. Chapel Hill: University of North Carolina Dental Ecology, 1990:215–217.
87. Davies RM, Davies GM, Ellwood RB. Prevention. Part 4: Toothbrushing: What advice should be given to patients? Br Dent J 2003;195:135–141.
88. Walsh T, Worthington HV, Glenny AM, Appelbe P, Marinho VC, Shi X. Fluoride toothpastes of different concentrations for preventing dental caries in children and adolescents [review]. Cochrane Database Syst Rev 2010;(1):CD007868.

Dentlearn.ir

89. Zachrisson BK, Zachrisson S. Caries incidence and orthodontic treatment with fixed appliances. Scand J Dent Res 1971;79:183–192.
90. Drake CW, Beck JD. The oral status of elderly removable partial denture wearers. J Oral Rehabil 1993;20:53–60.
91. Kidd EAM, Nyvad B. Caries control for the individual patient. In: Fejerskov O, Kidd EAM (eds). Dental Caries: The Disease and Its Clinical Management. Copenhagen: Blackwell Munksgaard, 2003:303–312.
92. Tenovuo J. Salivary parameters of relevance for assessing caries activity in individuals or populations. Community Dent Oral Epidemiol 1997;25: 82–86.
93. Montgomery MT, Ritvo J, Ritvo J, Weiner K. Eating disorders: Phenomenology, identification and dental intervention. Gen Dent 1988;36:485–488.
94. Van Houte J. Microbiological predictors of caries risk. Adv Dent Res 1993;7:87–96.
95. Shou L. Social and behavioural aspects of caries prediction. In: Johnson NW (ed). Dental Caries: Markers of

96. Hobson P. Sugar-based medicines and dental disease. Community Dent Health 1985;2:57–62.
97. Beal JF. Social factors and preventive dentistry. In: Murray JJ (ed). Prevention of Oral Disease. Oxford: Oxford University Press, 1996:216–233.
98. Hunt RJ. Behavioural and sociodemographic risk factors for caries. In: Bader JD (ed). Risk Assessment in Dentistry. Chapel Hill: University of North Carolina Dental Ecology, 1990:29–34.
99. Featherstone JDB. Prevention and reversal of dental caries: Role of low-level fluoride. Community Dent Oral Epidemiol 1999;27:31–40.
100. American Dental Association Council on Scientific Affairs. Professionally applied topical fluoride: Evidence-based clinical recommendations. J Am Dent Assoc 2006;137:1151–1159.
101. Benn DK. Practical evidence-based management of the initial caries lesion. J Dent Educ 1997;61:853–854.
102. Brathall D, Hansel-Petersson G, Sundberg H. Reasons for the caries decline: What do the experts believe? Eur J Oral Sci 1996;104:416–422.
103. Gibson S, Williams S. Dental caries in pre-school children: Associations with social class, toothbrushing habit and the consumption of sugars and sugar-containing foods. Caries Res 1999;33:101–113.
104. Sicilia A, Arregui I, Gallego M, Cabezas B, Cuesta S. Home oral hygiene revisited. Options and evidence. Oral Health Prev Dent 2003;1(suppl 1):407–422.
105. Warren PR, Chater BV. An overview of established interdental cleaning methods. J Clin Dent 1996;7(special issue):65–69.
106. Marinho VC, Higgins JP, Sheiham A, Logan S. Fluoride toothpastes for preventing dental caries in children and adolescents [review]. Cochrane Database Syst Rev 2003;(1):CD002278.
107. Wong MC, Clarkson J, Glenny AM, et al. Cochrane reviews on the benefits/risks of fluoride toothpastes. J Dent Res 2011;90:573–579.
108. Pendrys DG, Katz RV, Morse DE. Risk factors for enamel fluorosis in a fluoridated population. Am J Epidemiol 1994;140:461–471.
109. Ten Cate JM. Fluorides in caries prevention and control: Empirism or science. Caries Res 2004;38:254–257.
110. Breitenmoser T. The antiglycolytic action on dental plaque of amine chlorides. Helv Odontol Acta 1975;19:13–17.
111. Van Loveren C. Antimicrobial activity of fluoride and its in vivo importance: Identification of research questions. Caries Res 2001;35(suppl 1): 65–70.
112. Liang N, White DJ, Cox E, Busemeyer BA. Antimicrobial effects of a stabilized stannous fluoride dentifrice in reducing plaque acid production—A single-brushing PGM study. J Clin Dent 1995;6(special issue):80–83.
113. White DJ, Cox ER, Gwynn AV. Effects of a stabilized stannous fluoride on plaque acid (toxin) production. J Clin Dent 1995;6(special issue):84–88.
114. van Loveren C, Buijs JF, ten Cate JM. The effect of triclosan toothpaste on enamel demineralization in a bacterial demineralization model. J Antimicrob Chemother 2000;45:153–158.
115. Tavss EA, Mellberg JR, Joziak M, Gambogi RJ, Fisher SW. Relationship between dentifrice fluoride concentration and clinical caries reduction. Am J Dent 2003;16:369–374.

Dentlearn.ir

116. Peters MC. Strategies for noninvasive demineralized tissue repair. Dent Clin North Am 2010;54:507–525.
117. Marinho VC. Cochrane reviews of randomized trials of fluoride therapies for preventing dental caries [review]. Eur Arch Paediatr Dent 2009;10:183–191.
118. Marinho VC. Evidence-based effectiveness of topical fluorides. Adv Dent Res 2008;20:3–7.
119. Marinho VC, Higgins JP, Sheiham A, Logan S. One topical fluoride (toothpastes, or mouthrinses, or gels, or varnishes) versus another for preventing dental caries in children and adolescents [review]. Cochrane Database Syst Rev 2004;(1):CD002780.
120. Marinho VC, Higgins JP, Sheiham A, Logan S. Combinations of topical fluoride (toothpastes, mouthrinses, gels, varnishes) versus single topical fluoride for preventing dental caries in children and adolescents [review]. Cochrane Database Syst Rev 2004;(1):CD002781.
121. Freeman R, Ismail A. Assessing patients' health behaviours. Essential steps for motivating patients to adopt and maintain behaviours conducive to oral health. Monogr Oral Sci 2009;21:113–127.
122. Marinho VC, Higgins JP, Logan S, Sheiham A. Topical fluoride (toothpastes, mouthrinses, gels, or varnishes) for preventing dental caries in children and adolescents [review]. Cochrane Database Syst Rev 2003;(4):CD002782.
123. Marinho VC, Higgins JP, Logan S, Sheiham A. Fluoride gels for preventing dental caries in children and adolescents [review]. Cochrane Database Syst Rev 2002;(2):CD002280.
124. Marinho VC, Higgins JP, Logan S, Sheiham A. Systematic review of controlled trials on the effectiveness of fluoride gels for the prevention of dental caries in children [review]. J Dent Educ 2003;67:448–458.
125. Marinho VC, Higgins JP, Logan S, Sheiham A. Fluoride mouthrinses for preventing dental caries in children and adolescents [review]. Cochrane Database Syst Rev 2003;(3):CD002284.
126. Ripa IW. Critique of topical fluoride methods (dentifrices, mouthrinses, operator-, and self-applied gels) in an era of decreased caries and increased experienced fluorosis prevalence. J Public Health Dent 1991;51:23–41.
127. Ogaard B. The cariostatic mechanism of fluoride. Compend Contin Educ Dent 1999;20:10–17.
128. Ogaard B, Seppä L, RØlla G. Professional topical fluoride applications—Clinical efficacy and mechanism of action. Adv Dent Res 1994;8:190–201.
129. Ortendahl T, Thilander B, Sverberg M. Mutans streptococci and incipient caries adjacent to glass ionomer cement or resin-based composite in orthodontics. Am J Orthod Dentofacial Orthop 1997;112:271–274.
130. Seeholzer HW, Dasch W. Bonding with a glass ionomer. J Clin Orthod 1986;22:165–169.
131. Wood RE, Maxymiw WG, McComb D. A clinical comparison of glass ionomer and silver amalgam in the treatment of class 5 caries in xerostomic head and neck cancer patients. Oper Dent 1993;18:94–102.
132. Haveman C, Burgess J, Summitt JB, Carlson K. Three restorative materials and topical fluoride gel used in xerostomic patients: A clinical comparison. J Am Dent Assoc 2003;134:177–184.
133. Ly KA, Milgrom P, Roberts MC, Yamaguchi DK, Rothen M, Mueller G. Linear response of mutans streptococci to increasing frequency of xylitol chewing gum use: A randomized controlled trial [ISRCTN43479664]. BMC Oral Health 2006;6:6.
134. Milgrom P, Ly KA, Roberts MC, Rothen M, Mueller G, Yamaguchi DK. Mutans streptococci dose response to xylitol chewing gum. J Dent Res 2006;85:177–181.
135. Milgrom P, Ly KA, Tut OK, et al. Xylitol pediatric topical oral syrup to prevent dental caries: A double-blind randomized clinical trial of efficacy. Arch Pediatr Adolesc Med 2009;163:601–607.
136. Ly KA, Riedy CA, Milgrom P, Rothen M, Roberts MC, Zhou L. Xylitol gummy bear snacks: A school-based randomized clinical trial. BMC Oral Health 2008;8:20.
137. van Loveren C. Sugar alcohols: What is the evidence for caries-preventive and caries-therapeutic effects? Caries Res 2004;38:286–293.
138. Kani K, Kani M, Isozaki A, Shintani H, Ohashi T, Tokumoto T. Effect of apatite-containing dentifrices on dental caries in school children. J Dent Health 1989;39:104–109.
139. Pfarrer AM, Karlinsey RL. Challenges of implementing new remineralization technologies. Adv Dent Res 2009;21:79–82.
140. Karlinsey RL, Mackey AC. Solid-state preparation and dental application of an organically-modified calcium phosphate. J Mater Sci 2009;44:346–349.

Dentlearn.ir

141. Amaechi BT, Karthikeyan R, Mensinkai PK, Najibfard K, Mackey AC, Karlinsey RL. Remineralization of eroded enamel by a NaF rinse containing a novel calcium phosphate agent in an in situ model: A pilot study. Clin Cosmet Investig Dent 2010;2:93–100.
142. Mensinkai PK, Ccahuana-Vasquez RA, Chedjieu I, et al. In situ remineralization of white-spot enamel lesions by 500 and 1,100 ppm F dentifrices. Clin Oral Investig 2012;16:1007–1014.
143. Burwell AK, Litkowski LJ, Greenspan DC. Calcium sodium phosphosilicate (NovaMin): Remineralization potential. Adv Dent Res 2009;21:35–39.
144. Cochrane NJ, Cai F, Huq NL, Burrow MF, Reynolds EC. New approaches to enhanced remineralization of tooth enamel. J Dent Res 2010;89: 1187–1197.
145. Tung MS, Eichmiller FC. Amorphous calcium phosphates for tooth mineralization. Compend Contin Educ Dent 2004;25(suppl 1):S9–S13.
146. Papas A, Russell D, Singh M, Kent R, Triol C, Winston A. Caries clinical trial of a remineralising toothpaste in radiation patients. Gerodontology 2008;25:76–88.
147. Chow LC, Takagi S, Carey CM, Sieck BA. Remineralization effects of a two-solution fluoride mouthrinse: An in situ study. J Dent Res 2000;79:991–995.
148. Burt BA, Eklund SA, Morgan KJ, et al. The effects of sugar intake and frequency of ingestion on dental caries increment in a three-year longitudinal study. J Dent Res 1988;67:1422–1429.
149. Duggal MS, Toumba KJ, Amaechi BT, Kowash MB, Higham SM. Enamel demineralization in situ with various frequencies of carbohydrate consumption with and without fluoride toothpaste. J Dent Res 2001; 80:1721–1724.
150. Ripa LW. Review of the anticaries effectiveness of professionally applied and self-applied topical fluoride gels. J Public Health Dent 1989;49(special issue):297–309.
151. Marinho VC, Higgins JP, Logan S, Sheiham A. Fluoride varnishes for preventing dental caries in children and adolescents [review]. Cochrane Database Syst Rev 2002;(3):CD002279.
152. Moberg Sköld U, Petersson LG, Lith A, Birkhed D. Effect of school-based fluoride varnish programmes on approximal caries in adolescents from different caries risk areas. Caries Res 2005;39:273–279.
153. Marinho V. Substantial caries-inhibiting effect of fluoride varnish suggested. Evid Based Dent 2006;7:9–10.
154. Seppä L, Hausen H, Tuutti H, Luoma H. Effect of a sodium fluoride varnish on the progress of initial caries lesions. Scand J Dent Res 1983;91:96–98.
155. Ogaard B, RØlla G, Helgeland K. Fluoride retention in sound and demineralized enamel in vivo after treatment with a fluoride varnish (Duraphat). Scand J Dent Res 1984;92:190–197.
156. Seppä L. Effects of a sodium fluoride solution and a varnish with different fluoride concentrations on enamel remineralization in vitro. Scand J Dent Res 1988;96:304–309.
157. Holmen L, Ogaard B, RØlla G, Thylstrup A. A polarized light and scanning electron microscope study of the effect of Duraphat treatment on in vivo caries. Scand J Dent 1986;94:521–529.

applied to enamel lesions formed in vivo with and without fluoride varnish treatment. Eur J Oral Sci 1996;104:378–383.
159. Attin T, Hartman 0, Hilgers RD, Hellwig E. Fluoride retention of incipient enamel lesions after treatment with a calcium fluoride varnish in vivo. Arch Oral Biol 1995;40:169–174.
160. Holm GB, Holst K, Mejàre I. The caries-preventive effect of a fluoride varnish in the fissures of the first permanent molar. Acta Odont Scand 1984;42:193–197.
161. Peyron M, Matsson L, Birkhed D. Progression of approximal caries in primary molars and the effect of Duraphat treatment. Scand J Dent Res 1992;100:314–318.
162. Ripa LW. Sealants revisited: An update of the effectiveness of pit and fissure sealants. Caries Res 1993;27:77–82.
163. Ahovuo-Saloranta A, Hiiri A, Nordblad A, Mäkelä M, Worthington HV. Pit and fissure sealants for preventing dental decay in the permanent teeth of children and adolescents [review]. Cochrane Database Syst Rev 2008;(4):CD001830.
164. Llodra JC, Bravo M, Delgado-Rodriquez M, Baca P, Galvez R. Factors influencing the effectiveness of

Dentlearn.ir

sealants—A meta-analysis. Community Dent Oral Epidemiol 1993;21:261–268.
165. Mejàre I, Lingström P, Petersson LG, et al. Caries-preventive effect of fissure sealants: A systematic review. Acta Odontol Scand 2003;61:321–330.
166. Seppä L, Forss H. Resistance of occlusal fissures to demineralization after loss of glass ionomer sealants in vitro. Pediatr Dent 1991;13:39–42.
167. Pitts NB, Kidd EAM. The prescription and timing of bitewing radiography in the diagnosis and management of dental caries: Contemporary recommendations. Br Dent J 1992;172:225–227.
168. Ripa LW, Leske GS, Varma OA. Longitudinal study of the caries susceptibility of occlusal and proximal surfaces of first permanent molars. J Public Health Dent 1988;48:8–13.
169. Simonsen R. Retention and effectiveness of dental sealant after 15 years. J Am Dent Assoc 1991;122:34–42.
170. Handelman S, Washburn F, Wopperer P. Two-year report of sealant effect on bacteria in dental caries. J Am Dent Assoc 1976;93:967–970.
171. Handelman S. Effect of sealant placement on occlusal caries progression. Clin Prev Dent 1982;4:11–16.
172. Mertz-Fairhurst E, Schuster G, Fairhurst C. Arresting caries by sealants: Results of a clinical study. J Am Dent Assoc 1986;112:194–197.
173. Mertz-Fairhurst EJ, Adair SM, Sams DR, et al. Cariostatic and ultraconservative sealed restorations: Nine-year results among children and adults. J Dent Child 1995;62:97–107.
174. Briley JB, Dove SB, Mertz-Fairhurst EJ. Radiographic analysis of previously sealed carious teeth [abstract 2514]. J Dent Res 1994;73:416.
175. Mertz-Fairhurst EJ, Curtis JW Jr, Ergle JW, Rueggeberg FA, Adair SM. Ultraconservative and cariostatic sealed restorations: Results at year 10. J Am Dent Assoc 1998;129:55–66.
176. Alkilzy M, Berndt C, Meller C, Schidlowski M, Splieth C. Sealing of proximal surfaces with polyurethane tape: A two-year clinical and radiographic feasibility study. J Adhes Dent 2009;11:91–94.
177. Alkilzy M, Berndt C, Splieth CH. Sealing proximal surfaces with polyurethane tape: Three-year evaluation. Clin Oral Investig 2010;15:879–884.
178. Abuchaim C, Rotta M, Grande RH, Loguercio AD, Reis A. Effectiveness of sealing active proximal caries lesions with an adhesive system: 1-year clinical evaluation. Braz Oral Res 2010;24:361–367.
179. Gomez SS, Basili CP, Emilson CG. A 2-year clinical evaluation of sealed noncavitated approximal posterior carious lesions in adolescents. Clin Oral Investig 2005;9:239–243.
180. Martignon S, Ekstrand KR, Ellwood R. Efficacy of sealing proximal early active lesions: An 18-month clinical study evaluated by conventional and subtraction radiography. Caries Res 2006;40:382–388.
181. Paris S, Hopfenmuller W, Meyer-Lueckel H. Resin infiltration of caries lesions: An efficacy randomized trial. J Dent Res 2010;89:823–826.
182. Ekstrand KR, Bakhshandeh A, Martignon S. Treatment of proximal superficial caries lesions on primary molar teeth with resin infiltration and fluoride varnish versus fluoride varnish only: Efficacy after 1 year. Caries Res 2010;44:41–46.
183. Lussi A, Gygax M. Iatrogenic damage to adjacent teeth during classical proximal box preparation. J Dent 1998;26:435–441.
184. Qvist V, Johannessen L, Bruun M. Progression of approximal caries in relation to iatrogenic preparation damage. J Dent Res 1992;71:1370–1373.
185 Nyvad B, Fejerskov O. Active root surface caries converted into inactive caries as a response to oral hygiene. Scand J Dent Res 1986;94:281–284.
186. Nyvad B, Fejerskov O. An ultrastructural study of bacterial invasion and tissue breakdown in human experimental root surface caries. J Dent Res 1990;69:2218–2225.
187. Parikh SR, Massier M, Bahn A. Microorganisms in active and arrested carious lesions of dentin. N Y State Dent J 1963;29:347–355.
188. Sarnat H, Massier M. Microstructure of active and arrested dentinal caries. J Dent Res 1965;44:1389–1401.
189. Schüpbach P, Lutz F, Guggenheim B. Human root caries: Histopathol-ogy of arrested lesions. Caries Res 1992;26:153–164.

Dentlearn.ir

190. Elderton RJ, Mjör IA. Treatment planning. In: Hörsted-Bindslev P, Mjör IA (eds). Modern Concepts in Operative Dentistry. Copenhagen: Munksgaard, 1988:59–88.
191. American Academy of Pediatric Dentistry. Guideline on pediatric restorative dentistry. Pediatr Dent 2008:30(7 suppl):163–169.
192. American Academy of Pediatric Dentistry. Policy on Early Childhood Caries (ECC): Unique challenges and treatment options. Oral Health Policies Reference Manual 2010/2011;32(6):45–47.
193. American Academy of Pediatric Dentistry. Policy on Interim Therapeutic Restorations (ITR). Oral Health Policies Reference Manual 2010/ 2011;32(6):39–40.
194. Nowak AJ, Casamassimo PS. The dental home. J Am Dent Assoc 2002; 133:93–98.
195. American Academy of Pediatric Dentistry. Policy on the dental home. Pediatr Dent 2007;29(suppl):22–23.
196. Yip HK, Smales RJ, Ngo He, Tay FR, Chu F. Selection of restorative materials for the atraumatic restorative treatment (ART) approach: A review. Spec Care Dent 2001;21:216–221.
197. Louw AJ, Sarvan I, Chikte UM, Honkala E. One-year evaluation of atraumatic restorative treatment and minimum intervention techniques on primary teeth. SADJ 2002;57:366–371.
198. Lo ECM, Holmgren CJ. Provision of Atraumatic Restorative Treatment (ART) restorations to Chinese pre-school children: A 30-month evaluation. Int J Paediatr Dent 2001;11:3–10.
199. Mandari GJ, Frencken JE, van't Hof MA. Six-year success rates of occlusal amalgam and glass-ionomer restorations placed using three minimal intervention approaches. Caries Res 2003;37:246–253.
200. Castro A, Feigal RF. Microleakage of a new improved glass ionomer restorative material in primary and permanent teeth. Pediatr Dent 2002;24:23–28.
201. Grossman ES, Mickenautsch S. Microscope observations of ART excavated cavities and restorations. SADJ 2002;57:359–363.
202. Berg JH. Glass ionomer cements. Pediatr Dent 2002;24:430–437.
203. Castro A, Feigal RF. Microleakage of a new improved glass ionomer material in primary and permanent teeth. Pediatr Dent 2002;24:23–27.
204. Lopez N, Simpser-Rafalin S, Berthold P. Atraumatic restorative treatment for prevention and treatment of caries in an underserved community. Am J Public Health 2005;95:1338–1339.
205. Von der Fehr FR, Löe H, Theilade E. Experimental caries in man. Caries Res 1970;4:131–136.
206. Koch G. Importance of early determination of caries risk. Int Dent J 1988;38:203–210.
207. Clarkson JE, Amaechi BT, Ngo H, Bonetti D. Recall, reassessment and monitoring. Monogr Oral Sci 2009;21:188–198.
208. Davenport C, Elley K, Salas C, et al. The clinical effectiveness and cost-effectiveness of routine dental checks: A systematic review and economic evaluation. Health Technol Assess 2003;7:iii–v, 1–127.
209. National Institute for Clinical Excellence (NICE). Dental Recall: Recall Interval Between Routine Dental

Dentlearn.ir



Pulpal Considerations

Thomas J. Hilton
James B. Summitt

Because caries is a bacterial infection, it has a deleterious effect on the pulp, ranging from mild inflammation to pulpal death. In addition, virtually all restorative procedures cause pulpal irritation. As discussed in chapter 1, the pulp has inherent defense mechanisms to limit damage caused by irritants. There are also a number of dental procedures performed with the goal of preserving pulpal health. Most of these procedures attempt to provide a barrier to external irritants by placing a protective sealer or liner on the cavity walls.

Before placing or cementing a restoration into a cavity preparation, the clinician must decide if a protective cavity base, sealer, or liner should be placed. While seemingly simple, this decision has been complicated by an ever-increasing number of products for sealing and lining. This chapter reviews pulpal considerations relevant to operative dentistry, including the effects of cavity preparation, caries, and restorative materials on the pulp. In addition, it defines the various protective materials, describes the ways they interact with and provide protection for the pulp, reviews the properties of current materials, and discusses the changes that have occurred in this area of operative dentistry in recent years.

Dentlearn.ir

Physiologic Considerations

The physiology of the pulp is influenced by several factors that form the basis for the decision to use a sealer, liner, and/or base.

Remaining dentinal thickness

No material that can be placed in a tooth provides better protection for the pulp than dentin. Dentin has excellent buffering capability to neutralize the effects of cariogenic acids,[1] and it insulates the pulp from temperature increases during cavity preparation.[2] The remaining dentinal thickness (RDT), from the depth of the cavity preparation to the pulp, is the single most important factor in protecting the pulp from insult.[1,3] In vitro studies have shown that a 0.5-mm thickness of dentin reduces the effect of toxic substances on the pulp by 75% and a 1.0-mm thickness reduces the effect of toxins by 90%.[4] Little pulpal reaction occurs when there is an RDT of 2 mm or more.[1] The greatest impact on the pulp occurs when the RDT is no more than 0.25 to 0.30 mm.[3,5,6] Conservation of remaining tooth structure is more important to pulpal health than is replacement of lost tooth structure with a cavity liner or base.

Causes of pulpal inflammation

Like other soft tissues, the pulp reacts to an irritant with an inflammatory response.[7,8] It was previously believed that pulpal inflammation was primarily the result of the toxic effects of dental materials.[9,10] More recent evidence, however, demonstrates that pulpal inflammatory reactions to dental materials are mild and transitory; significant adverse pulpal responses occur more as the result of pulpal invasion by bacteria or their toxins[3,11–18] (Fig 6-1a). Even early enamel caries lesions that extend less than one-fourth of the way to the dentinoenamel junction (DEJ) have been shown to induce a slight pulpal reaction, particularly when the caries lesion has advanced rapidly. This is probably due to an increase in the permeability of enamel, allowing the transmission of stimuli along enamel rods.[19,20]

Dentlearn.ir

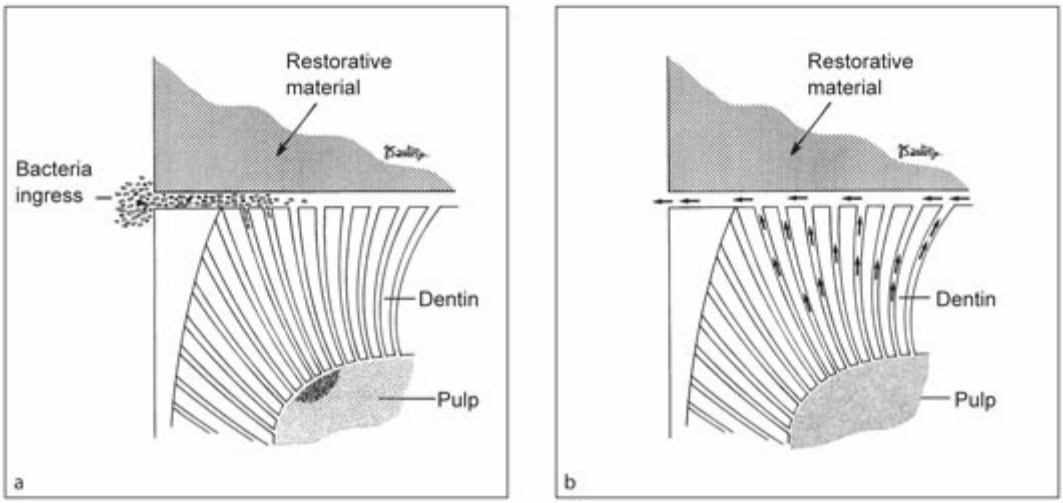

Fig 6-1 *(a)* Bacteria will penetrate the marginal gap and dentinal tubules from the saliva, which may cause pulpal irritation, pulpal necrosis, or recurrent caries. *(b)* If a restoration is not well sealed, fluid flows out of the dentinal tubules and into the space between the restorative material and the tooth surface *(arrows)*. A stimulus such as heat or cold causes a change in the flow rate, which is interpreted by mechanoreceptors as pain.

As a lesion progresses deeper into the tooth, pulpal reaction increases.[19] When actual pulpal encroachment by bacteria and/or their toxins has taken place, severe inflammation or pulpal necrosis frequently occurs.[14] The outward flow of fluid through dentinal tubules does not prevent bacteria or their toxins from reaching the pulp and initiating pulpal inflammation.[21] The caries process also induces the formation of reparative dentin and reactive dentin sclerosis, which increases the protective effects of the remaining dentin.[22]

When bacterial contamination is prevented, favorable responses have been found in pulpal tissue adjacent to many restorative materials. Those materials include amalgam, light-activated resin composite, self-curing resin composite,[23] zinc phosphate cement, silicate cement,[13] glass-ionomer cement, and acrylic resin.[24] Acid etching of dentin has long been considered detrimental to the pulp, but the pulp can readily tolerate the effects of low pH if bacterial invasion is prevented[12,23,25] and resin components are precluded from traversing the dentinal tubules and entering the pulp.[5,26]

A number of instrumentation techniques elicit pulpal responses as well. The most common are rotary instruments used in high- and low-speed handpieces for tooth preparation. Tooth preparation can be traumatic to the pulp, and a number of factors affect pulpal reaction. The degree of pulpal reaction is dependent on the amount of friction and desiccation.[27,28] One retrospective study indicated that high-speed preparation, with th rs, air coolant, and

Dentlearn.ir

intermittent water spray from the air-water syringe, rarely led to a need for postrestoration endodontic therapy.[29] However, the key to controlling both friction and desiccation is water spray at the site of contact between the bur and tooth structure. While some research has shown that this is more important than the amount of water that is used on a rotating bur,[28] another study has demonstrated that increased water spray volume can significantly reduce pulpal temperature rises caused by friction.[2] Frictional heat generated by tooth preparation can result in burn lesions in the pulp and abscess formation.[30] While it is often advantageous to refine aspects of a cavity preparation without water spray in order to aid visibility, this must be done conservatively. The pulp can tolerate dry preparation in a limited area, but the severity of the pulpal reaction increases as the area of dentin subjected to preparation without water spray increases.[28] Another consequence of desiccating dentin in a preparation is that dentinal fluid is lost from the tubules. The lost fluid may be replaced with chemicals that can elicit a harmful pulpal reaction.[28]

The temperature rise is considerably greater when enamel or a combination of enamel and dentin is prepared versus preparation of dentin alone.[31] Additionally, research has shown that pressure applied during rotary instrumentation has a greater effect on temperature rise than does rotational speed,[31] which is probably why preparation using low-speed rotary instrumentation has been shown to be more traumatic to the pulp than high-speed preparation.[30] Diamond burs tend to produce more temperature increase than do carbide burs,[30] and the reaction of the pulp tends to increase as the depth of the cavity preparation increases (and RDT decreases).[32,33] Considering the latter two findings, it should not be surprising that an occasional consequence of full-coverage restorations is pulpal necrosis.[34–36] Research has shown that 3% to 22% of teeth with full-coverage crowns require endodontic therapy.[35–37] It is clear that the combination of reducing water coolant and RDT and increasing bur speed and pressure can produce a significant increase in temperature during tooth preparation.[2,30,31,38] Therefore, the keys to minimizing adverse pulpal reaction from rotary instrumentation are the following:

- Adequate air-water coolant spray
- Light pressure
- Sharp rotary cutting instruments
- Preservation of tooth structure

Two relatively new methods for tooth preparation are available—lasers and

Dentlearn.ir

kinetic cavity preparation, also known as *air abrasion*. Animal studies have shown that air-abrasion cavity preparation is no more traumatic to the pulp than rotary instrumentation.[38,39] Likewise, the use of a variety of lasers, including carbon dioxide, erbium-doped yttrium aluminum garnet, neodymium-doped yttrium aluminum garnet, erbium-chromium–doped yttrium scandium gallium garnet and free-electron lasers, on tooth structure has demonstrated minimal pulpal response compared with that of high-speed rotary instrumentation.[40–44] The key to minimizing thermal pulpal insult during tooth preparation with a laser, as with preparation using rotary instrumentation, is the use of water coolant.[45]

One other modality commonly used in conjunction with operative dentistry—electrosurgery to remove gingival tissue for enhanced access during tooth preparation and impression making—may affect the dental pulp. Several animal studies have shown that as long as the contact of the electrosurgical probe is with intact enamel, little or no pulpal reaction ensues. However, if the probe contacts a metallic restoration, adverse and often severe pulpal reaction results.[46–49] This adverse reaction occurs regardless of whether a cavity base is present.[49] The pulpal response is more severe with increased contact time (longer than 0.4 seconds)[47] and decreased dentin thickness between the metallic restoration and the pulp.[46,49]

Causes of pulpal pain

The causes of pulpal pain and sensitivity, while not fully explained, are becoming better understood. Increased intrapulpal pressure on nerve endings, secondary to an inflammatory response, is one mechanism that may explain pain as a result of bacterial invasion.[1] However, this interpretation fails to explain sensitivity that occurs in the absence of inflammation. The explanation for pulpal pain in the absence of inflammation that is most accepted is the hydrodynamic theory, which is described in detail below.[50]

Causes of thermal sensitivity

Prevention of postoperative thermal sensitivity has long been a rationale for the placement of cavity bases beneath metallic restorations. Initial in vivo research documenting the alleged problem was sparse and poorly controlled. Although one study showed reduced postoperative sensitivity when thick cement bases were used,[51] another demonstrated that, by 6 months postoperatively, few patients had thermal sensitivity regardless of whether a cavity base had been placed.[52] In one

Dentlearn.ir

survey, 50% of patients questioned 24 hours after restoration placement reported some discomfort, but 78% of these patients described the discomfort as mild and fleeting.[53] Several more recent studies have demonstrated that a significant majority of patients receiving amalgam restorations do not experience postoperative thermal sensitivity, regardless of lesion depth or the absence or presence of a particular cavity sealer or liner. Of those patients with postoperative thermal discomfort, almost all describe it as minor, and it has almost always disappeared within 30 days.[54–60] Any discussion of the need for protection against postoperative thermal sensitivity must be tempered by the understanding that the prevalence and magnitude of this problem have likely been overestimated.

Theory of thermal shock

There are two theories about the cause of thermal sensitivity (usually to cold) following restoration placement and, consequently, two philosophies about how to best address the problem. The first theory states that sensitivity is the result of direct thermal shock to the pulp via temperature changes transferred from the oral cavity through the restorative material,[61,62] especially when remaining dentin is thin. Protection from this insult would then be provided by an adequate thickness of an insulating material with low thermal diffusivity.[62,63] It has been noted that resin composite exhibits such low thermal diffusivity that a thermal insulating base should be unnecessary in conjunction with resin composite restorations.[63,64] Use of an insulating base for thermal protection would therefore be limited to metallic restorative materials that exhibit higher rates of temperature transfer.

When a base is used to provide insulation to counter thermal sensitivity in amalgam restorations, the thickness of the material must be minimized in areas subject to occlusal loading. Research has shown that, as the thickness of the base increases, the fracture resistance of the overlying amalgam decreases.[65,66] Because temperature diffusion through amalgam to the floor of the cavity preparation is effectively reduced by 0.50 to 0.75 mm of basing material, if a base is used, its thickness should be restricted to no more than 0.75 mm.[63] Modulus of elasticity is the key property that determines how effectively a base or liner will support an amalgam restoration; a high modulus of elasticity indicates stiffness, while a low modulus of elasticity indicates flexibility. As the modulus of elasticity of a basing material decreases, the resistance to fracture of overlying amalgam decreases.[65–67]

Theory of pulpal hydrodynamics

Dentlearn.ir

The more widely accepted theory of thermal sensitivity holds that temperature sensitivity is based on pulpal hydrodynamics. Most restorations have a gap between the wall of the preparation and the restorative material that allows the slow outward movement of dentinal fluid (Fig 6-1b). Cold temperatures cause a sudden contraction of this fluid, resulting in a rapid increase in the flow, which is perceived by the patient as pain.[50] As dentin nears the pulp, tubule density and diameter increase,[1,68] as does permeability,[69] thus increasing both the volume and the flow of pulpal fluid susceptible to the hydrodynamic effects of cold temperatures. This may explain why deeper restorations are sometimes associated with more problems of sensitivity.[17]

According to this theory, if the tubules can be occluded, fluid flow is prevented and a cold temperature does not induce pain. The operative factor in reducing sensitivity to thermal change thus becomes effective sealing of dentinal tubules rather than placement of an insulating material of a certain thickness.[50] Scanning electron microscopic observations have revealed significantly higher numbers of open tubule orifices in hypersensitive dentin, lending credence to this theory.[70,71]

The theory of pulpal hydrodynamics has gained general acceptance in recent years and has changed the direction of restorative procedures away from thermal insulation and toward dentinal sealing. Thus, there is increasing emphasis on the integrity of the interface between restorative material and prepared tooth.

Cavity Sealers, Liners, and Bases

The terms *varnish*, *sealer*, *liner*, and *base*, used to describe a variety of materials, have been a source of confusion in dental literature. In 1995, McCoy[72] provided the following definitions for these terms.

- *Cavity sealers:* Materials in this category provide a protective coating to the walls of the prepared cavity and a barrier to leakage at the interface of the restorative material and the walls. The term *sealer* implies total prevention of leakage, but, in fact, the barrier provides various degrees of seal. Sealers usually coat all walls of a cavity preparation. Commonly used sealers fall into two categories:
  - *Varnish:* A natural rosin or gum (such as copal), or a synthetic resin, dissolved in an organic solvent such as acetone, chloroform, or ether.[73]
  - *Adhesive sealers:* Adhesive systems designed to provide sealing as well as bonding at the interface between restoration and cavity-preparation walls.

Dentlearn.ir

- *Cavity liners:* Cement or resin coating of minimal thickness (usually less than 0.5 mm) to achieve a physical barrier to bacteria and their products and/or to provide a therapeutic effect, such as an antibacterial or pulpal anodyne effect. Liners are usually applied only to dentin cavity walls that are near the pulp.
- *Cavity bases:* Materials to replace missing dentin, used for bulk buildup and/or for blocking out undercuts in preparations for indirect restorations.

Knowledge of the properties and indications for the materials in each category will aid in the selection process when the practitioner is faced with an array of choices.

Cavity sealers

Cavity sealers provide a protective coating for freshly cut tooth structure of the prepared cavity. The tooth-restoration interface has always been considered critical in dentistry, a fact apparent in the profession's emphasis on marginal adaptation of dental restorations. The concern is that any interfacial gap, even one not readily apparent under magnification, will allow microleakage. Kidd[74] defined *microleakage* as the passage of bacteria, fluids, molecules, or ions along the interface of a dental restoration and the wall of the cavity preparation. This process is theorized to cause marginal discoloration, secondary caries, and pulpal pathosis. A summary of some clinical studies on the percentage of clinical failures of existing restorations due to secondary caries is provided in Table 6-1.

Table 6-1 **Tooth-restoration interface: Materials and clinical failures***

Study	Composite	Amalgam	Glass ionomer
Opdam et al[75]	43%	23.5%	NA
Bernardo et al[76]	88%	66%	NA
Soncini et al[77]	51.8%	43.6%	NA
Opdam et al[78]	38%	29%	NA
Forss and Widström[79]	38.6%	50%	42.4%

*Numbers denote percentage of failures attributable to secondary caries. NA–not applicable.

Dentlearn.ir

Clearly, the junction between the restorative material and tooth structure is the source of a considerable number of restoration failures; providing a seamless transition from restoration to tooth structure has long been a goal in dentistry. Cavity sealers, used to fulfill this function, take two forms: varnishes and adhesive sealers.

Varnishes

As previously discussed, varnish is a natural gum (such as copal), a rosin, or a synthetic resin dissolved in an organic solvent, such as acetone, chloroform, or ether, that evaporates, leaving behind a protective film.[73] It is used as a barrier against the passage of bacteria and their by-products into dentinal tubules, and it reduces the penetration of oral fluid at the restoration-tooth interface. This film is very thin, usually 2 to 5 μm, and provides no thermal insulation.[80–82]

Copal varnishes were used for many years to fill the gap at the amalgam-tooth interface until corrosion products formed to reduce the gap.[80,83,84] Varnishes have also been used as barriers against the passage of irritants from cements and bacteria into dentinal tubules.[80] Two applications have been shown to be more effective than a single coat, but a third application does not significantly improve the coating of the cavity walls.[85] Copal varnish is capable of reducing dentin permeability by 69%[86] and significantly reducing microleakage for 4 to 6 months.[87–89] Although its use has diminished in recent years, varnish has commonly been used under amalgam restorations and before cementation of indirect restorations with zinc phosphate cement. Placement of copal varnish before crown cementation with zinc phosphate does not have a detrimental effect on retention.[90]

Adhesive sealers

The most recent materials to be used as cavity sealers have a demonstrated multisubstrate bonding ability that allows the restorative material to adhere to tooth structure. Examples include adhesive bonding systems, resin luting cements, and glass-ionomer luting cements. The benefits of using adhesive bonding systems (described in chapter 9) to attach resin composite materials to tooth structure are well documented and accepted. It is well established that acid etching will promote a reliable, durable bond to enamel.[12] Its mechanism of action (ie, the diffusion of dentin as a result of the demineralizing action of acid) is well accepted. Bonding systems also provide a chemical bond between the unfilled resin of the adhesive system and the resin composite. Enamel's more consistent and highly mineralized

Dentlearn.ir

structure provides a more reliable bond than that achieved to dentin.[91,92]

Researchers and clinicians have worked to develop cavity sealers that can improve the seal provided by cavity varnishes for amalgam restorations. Some studies have demonstrated that varnishes reduce, but do not eliminate, microleakage around amalgam restorations,[87,93,94] while other studies have shown no benefit or even increased microleakage when a varnish is used.[95–97] Because of postplacement amalgam marginal leakage, the duration of which is prolonged when the slower-corroding high-copper alloys are used, more effective and longer-lasting sealers have been sought. This has led to the frequent use of adhesive resins in conjunction with amalgam restorations.[98] At least one study has shown an adhesive to be inferior to varnish in the seal it provides99; others have shown adhesives and varnishes to exhibit similar degrees of microleakage, 100,101 while still others have shown adhesive resin to impart no greater seal than when no sealer at all is used.[95,102] However, numerous studies have shown resin adhesives to provide a significant reduction in leakage.[88,89,103–111]

While not unanimous, there is compelling evidence that adhesive resins used as sealers reduce interfacial microleakage compared with either unsealed or varnish-sealed amalgam restorations when evaluated in the short term (24 hours to 14 days). Superior sealing of dentinal tubules by bonding resins compared with varnish has also been demonstrated.[89,103,108,111] Animal research has demonstrated that dentin primers alone or in conjunction with dentin adhesives can significantly reduce dentin sensitivity[112] and that they have good pulpal compatibility when used in cavity preparations.[113,114] However, modern adhesives continue to exhibit leakage when cavity margins are on dentin or cementum.[92,115–118] Most in vitro research on the use of bonding systems with amalgam restorations is of short duration, and uncertainty exists concerning the durability of the bonded interface between amalgam and tooth structure.

Studies have found that both interfacial and dentinal tubule leakage increase significantly over periods of 1 month to 1 year after placement of the resin bonding/sealing resin and amalgam.[90,104,108,109]

Most important, numerous controlled clinical trials have failed to demonstrate a decrease in postoperative sensitivity with the use of adhesive agents under amalgam restorations compared with the use of either traditional sealers and liners or no cavity sealer at all.[54,56–59,119–122] These results are consistently found regardless of cavity depth and RDT.[57,58] Given these facts, there are some concerns about the use of adhesive resins under amalgam restorations. The insoluble adhesive layer may act

Dentlearn.ir

as a barrier to prevent amalgam corrosion products from ultimately sealing the tooth-restoration interface. As a result, the dentin bonding resins may potentially put the patient at greater risk for marginal leakage and recurrent caries in the long term. In addition, bonding resins are much more technique sensitive than varnishes,[118,123] and bonding systems are more expensive and time-consuming.[124] Researchers have also noted the tendency of self-curing adhesive sealers used in conjunction with amalgam restorations to spread to adjacent tooth surfaces, potentially giving rise to periodontal irritation.[59] Additional potential drawbacks to the use of adhesive sealers with amalgam include pooling of resin, resulting in radiographic artifacts,[125] and incorporation of sealer into the amalgam during condensation,[126] leading to significant loss of amalgam strength.[127,128] These considerations need to be weighed against clinical research evaluating the performance of bonded amalgam restorations. A number of studies have demonstrated clinical performance of bonded restorations that is comparable with that of nonbonded restorations.[54,59,120,122] One trial demonstrated equal performance of complex amalgam restorations (including at least one proximal surface and one cusp), using either pin retention or adhesive bonding over 6 years.[122] Those outcomes are encouraging because bonded amalgam restorations permit minimal tooth preparation rather than necessitating the removal of sound tooth structure to develop traditional resistance and retention form. However, the results of these clinical studies should be interpreted with some caution, because most have evaluated relatively low numbers of restorations and, with the exception of the 6-year study of large restorations cited above, have been of short duration (3 years or less) and have tested mostly small to moderate-sized restorations. With these precautions in mind, it should be noted that evidence is accumulating to support the use of adhesive sealers in conjunction with amalgam restorations.

Cavity liners

Cavity liners are placed with minimal thickness, usually less than 0.5 mm, and provide some type of therapeutic benefit, such as fluoride release, dentinal seal through adhesion to tooth structure, and/or antibacterial action that promotes pulpal health.[72]

Calcium hydroxide

Calcium hydroxide [$Ca(OH)_2$] has long been used as a liner because of its pulpal

Dentlearn.ir

compatibility and purported ability to stimulate reparative dentin formation with direct pulpal contact.[1] However, research has shown that not all formulations of calcium hydroxide have a stimulatory effect on human pulpoblasts.[129] There is a growing belief that reparative dentin formation is assisted, rather than stimulated, and that this is due to the antibacterial action of calcium hydroxide, which reduces or eliminates the inflammatory effects of bacteria and their byproducts on the pulp.[14,50,130,131] Research has also indicated that calcium hydroxide may release growth factors from dentin that can assist in pulpal healing.[131,132]

Conventional formulations of calcium hydroxide liners have demonstrated poor physical properties.[65,133] High solubility of some calcium hydroxide liners may lead to contamination of bonding resins and result in increased marginal leakage.[134] High solubility may also result in softening of the liner and in material loss under poorly sealed restorations.[50,135] Visible light–activated calcium hydroxide products have overcome most of these deficiencies. They exhibit improved physical properties[136] and significantly reduced solubility.[133] While the modulus of elasticity of the light-activated products has been shown to be higher than that of conventional calcium hydroxide in one study,[137] in another it was lower,[136] with a resulting reduced ability to support an overlying amalgam restoration.[138] These unfavorable physical properties restrict calcium hydroxide use to application over the smallest area that would suffice to aid in the formation of reparative dentin when a known or suspected pulp exposure exists.

Glass ionomer

Glass ionomer has been used as a cavity liner in an attempt to take advantage of two highly desirable properties: chemical bond to tooth structure and fluoride release.[133] Although fluoride release from glass ionomer decreases with time,[139] sustained release has been demonstrated[140] with corresponding uptake into adjacent tooth structure.[141] This is thought to aid in anticariogenic activity.[142] Like zinc phosphate, glass ionomer is quite acidic on initial mixing but tends to neutralize within 24 hours.[143] Pulpal response to both visible light–activated and conventional glass-ionomer formulations has been shown to be favorable when not in direct pulpal contact,[23,144–146] likely because glass ionomer decreases interfacial bacterial penetration.[6,17,18,145] The exact mechanism by which this is achieved is uncertain, but it may be due to one or more of the following: fluoride release, initial low pH,[147] chemical bond to tooth structure (physically excluding bacteria),[145] or release of a

Dentlearn.ir

metal cation.[148,149] Both visible light–activated and conventional glass-ionomer liners exhibit good physical properties, with the conventional version exhibiting reduced interfacial gap formation,[150] a higher modulus of elasticity,[151] and subsequently improved support for amalgam restorations.[138] Glass ionomer has been shown to reduce microleakage under amalgam restorations.[95,152] Conventional glass ionomers are relatively soluble in an acidic environment and are susceptible to rapid surface deterioration when subjected to acid etching.[153] Visible light–activated glass ionomers show improved resistance to acid solubility[136] while maintaining fluoride release and bond to tooth structure.[151] Therefore, the visible light–activated formulations are more desirable for use with resin composite restorations.

Glass-ionomer cements have been recommended as liners under resin composite restorations to reduce microleakage. The use of glass-ionomer cement as an intermediate layer between dentin and resin composite, particularly in Class 5 restorations, is often referred to as the *sandwich technique*. Glass ionomer use, most often in conjunction with Class 2 resin composite restorations, is sometimes called the *bonded-base technique*. Both techniques can be "open," in which the glass-ionomer cement at the gingival margin is exposed, or "closed," in which the glass-ionomer cement is completely covered by resin composite. Glass-ionomer cement liners, both visible light–cured and self-cured, have been studied extensively for their ability to seal the interface between resin composite and the cavity preparation. The preponderance of in vitro evidence indicates that glass-ionomer cement liners perform at least as well as, and in most cases significantly better than, bonding resins used alone to seal the restoration-tooth interface. This is probably due to the chemical bond to tooth structure, as well as a delayed set and increased strain capacity provided by the glass-ionomer cement. This may reduce the tendency for polymerization shrinkage stress to pull the resin composite away from the preparation walls.[154] In addition, the open sandwich or bonded-base restoration appears to be superior to the closed technique in achieving this seal.[155–164] The use of the open sandwich technique with posterior resin composite restorations is discussed in greater detail in chapter 11.

Cavity bases

As previously stated, cavity bases are used as dentin replacement materials, allowing for less bulk of restorative material or blocking out undercuts for indirect restorations[72] (Fig 6-2). Although cavity bases generally are not used for pulpal protection or health, they are briefly described here.

Dentlearn.ir

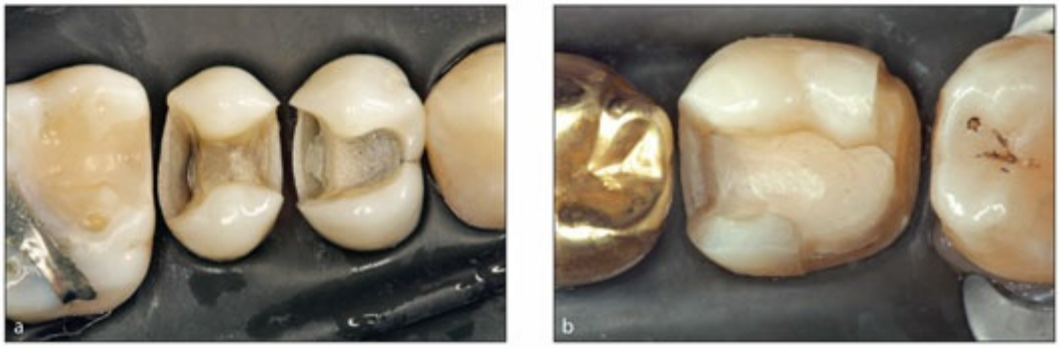

Fig 6-2 The primary use for bases is to block out undercuts in divergent preparations. Glass-ionomer bases are used here to block out undercuts in ceramic inlay preparations *(a)* and in a gold onlay preparation *(b)*.

Zinc oxide–eugenol and zinc phosphate cements

Zinc oxide–eugenol (ZOE) and zinc phosphate cements have been used for a number of years as bases under a variety of restorative materials. Although both provide excellent thermal insulation[13,63] and zinc phosphate cement exhibits excellent physical properties,[1] their use has diminished in recent years with the growing question of their benefit to pulpal health and with the advent of materials that release fluoride and adhere to dentin.[165]

Glass ionomer

As previously discussed, glass-ionomer materials have excellent mechanical properties, modulus of elasticity, and restoration support. As a result, glass ionomers can be used as cavity bases as well as cavity liners.

Guidelines for basing, lining, and sealing

Clinicians must always consider the limitations of currently available materials. The best possible base for any restoration is sound tooth structure. The following are guidelines for placement of bases, liners, and sealers:

- Do not remove sound tooth structure to provide space for a base. Maintaining sound dentin will enhance restoration support and provide maximum dentinal thickness for pulpal protection.
- Use bases as indicated for buildup materials and block-out materials for cemented indirect restorations. If used for direct amalgam restorations or bonded restorations, minimize the extent of the base. Basing a preparation to “ideal” depth

Dentlearn.ir

restorations and bonded resin or ceramic restorations lead to decreased bulk of restorative material and increased potential for restoration fracture.

- Use the minimum thickness of liner necessary to achieve the desired result. For liners under amalgam restorations, this should not exceed 0.5 mm.[167]
- While there is research support for the use of adhesive sealers (dentin bonding agents) under amalgam restorations, long-term clinical evidence is not strong.

Direct and Indirect Pulp Capping

Pulp capping is defined as "endodontic treatment designed to maintain the vitality of the endodontium."[168] Several favorable conditions must be present before considering direct or indirect pulp capping[168,169]:

- The tooth must have a vital pulp and no history of spontaneous pain.
- Pain elicited during pulp testing with a hot or cold stimulus should not linger after stimulus removal.
- A periapical radiograph should show no evidence of a periradicular lesion of endodontic origin.
- Bacteria must be excluded from the site by the restoration.

If these conditions can be met, an indirect pulp capping procedure is preferable to a direct pulp capping procedure. An indirect pulp capping procedure allows a protective thickness of dentin to remain adjacent to the pulp. Not only does this provide the advantages previously described for maintaining dentin (as RDT), but because RDT is directly related to odontoblast survival, reparative dentin formation is also enhanced.[3] In addition, avoiding pulp exposure means that there is less chance for infected debris to be introduced into the pulp to cause an inflammatory reaction.[3,170] Avoiding pulp exposure also means that there is no concern for hemorrhage from the pulp, a factor that has been associated with decreased success rates in direct pulp capping.[171–174]

Because of the uncertainty for success with either indirect or direct pulp capping procedures, pulpal health should be monitored for several months in teeth that are to receive indirect restorations or serve as abutments for fixed or removable partial dentures. If the pulpal status of a tooth is uncertain, the clinician should consider endodontic therapy before initiating restorative treatment.

Dentlearn.ir

Direct pulp capping

Considerable research has been done regarding direct pulp capping. However, a caveat is in order because much of this research has used animal models. While providing useful information, pulp capping outcomes in animals often do not reflect the outcomes of pulp capping in humans.[26,175,176] As such, pulp capping findings in animals must be interpreted with caution.

Pulps can be exposed as a result of trauma, caries, or mechanical reasons. The latter exposure is usually of iatrogenic origin. *Direct pulp capping* is an attempt to maintain pulpal vitality by placing a material directly over the exposed pulp. It is hoped that this will allow the pulp to heal normally, regenerate reparative dentin, and prevent the need for more extensive and expensive treatment, such as root canal therapy. Studies have indicated that pulp capping is more likely to be successful if the cause of the pulp exposure is mechanical rather than due to caries.[168,177] A carious exposure will cause bacterial contamination of the pulp resulting in inflammation[131] and a pulp that is less able to respond and heal, whereas mechanical exposure will likely cause less bacterial contamination and resulting inflammation.

After a pulp has been exposed, it is important to control pulpal bleeding before placing a pulp capping agent.[172] Increased bleeding that is difficult to stop can compromise the success of the procedure. This is likely due to one or both of two reasons. First, increased pulpal bleeding may be indicative of a higher level of pulpal inflammation and therefore a reduced capacity for pulpal healing. Second, the blood contamination of dentin adjacent to the exposure site may compromise the seal required to exclude bacterial contamination of the exposed pulp.

Pulpal bleeding is normally controlled with a cotton pellet saturated in a solution applied to the exposure site. A variety of solutions have been used in this situation. Water or saline are the most benign to the pulp.[178] Sodium hypochlorite, in concentrations ranging from 0.12% to 5.25%, is more caustic to the pulp but is extremely effective at controlling bleeding and is very effective at disinfecting the area. It has been used effectively in a number of studies and is likely the most commonly used agent for controlling pulpal bleeding. Chlorhexidine solution is an effectual antibacterial but is not as effective for controlling hemorrhage. Other solutions, such as those used to control gingival bleeding during impression taking, have less evidence to support their use in pulp capping, but short-term data seem to show few adverse effects on the pulp. One exception to this might be ferric sulfate, for which multiple clinical studies have indicated increased postoperative pain when it was used in conjunction with pulp capping.[173,179–184]

Dentlearn.ir

It has been suggested that age may have an impact on the success or failure of direct pulp capping, because older pulps have increased fibrosis and a decreased blood supply[185] and thus a decreased ability to mount an effective response to invading microorganisms.[174] However, there is no consensus in the literature regarding age as a factor in the success of direct pulp capping. Some studies have shown no relationship between success and patient age[172,177]; however, other research has found that age did have a bearing on success.[186,187]

The best chance for direct pulp capping to permit formation of a dentin bridge and to maintain pulpal vitality is in the presence of the most ideal conditions. If a large number of bacteria from a caries lesion or exposure to the oral flora have contaminated the pulp, the likelihood of regaining or maintaining a healthy pulp is slight. The adverse consequences of bacterial contamination of the pulp have been well documented.[12–14,23,24] Ideally, direct pulp capping would be attempted only when a small mechanical exposure of an otherwise healthy pulp occurs. A recent systematic review provided evidence that direct pulp capping of carious exposures can be carried out successfully.[188] However, the tooth should exhibit the favorable conditions noted previously. The tooth must be isolated with rubber dam, and adequate hemostasis must be achieved. The exposure should be covered with an appropriate pulp capping agent, and it must be possible to restore the tooth with a well-sealed restoration that will prevent subsequent bacterial contamination (Fig 6-3). The next section will consider the various materials that have been suggested for use as direct pulp capping agents.

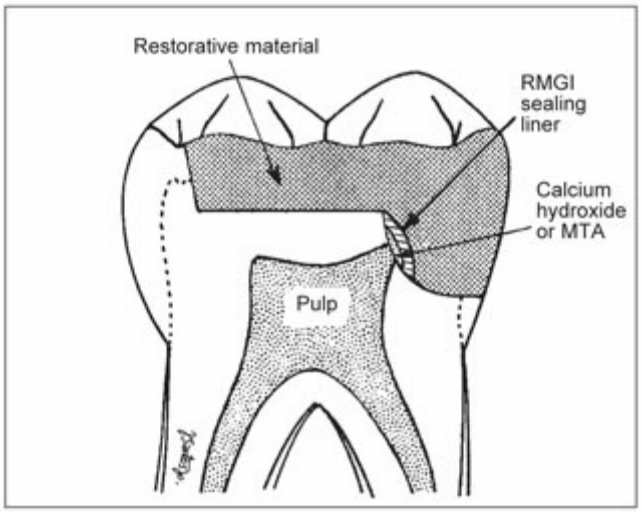

Fig 6-3 For a direct pulp capping procedure, a calcium hydroxide or mineral trioxide aggregate lining material is placed on the exposed pulpal tissue and a small amount of surrounding dentin. A sealing liner and/or a sealing restoration is then placed to seal out bacteria and their by-products. RMGI—resin-modified glass ionomer; MTA—mineral trioxide aggregate.

Dentlearn.ir

Direct pulp capping materials

Zinc oxide–eugenol. ZOE has been used in dentistry as a base, liner, cement, and provisional restoration for decades. What is most appealing about ZOE as a potential pulp capping agent is its antibacterial properties. ZOE releases eugenol in concentrations that are quite cytotoxic.[189–192] However, ZOE also exhibits high interfacial leakage.[193] Although it has been suggested that high leakage does not matter because ZOE provides a "bacterial seal" due to the eugenol release, it should be noted that eugenol release declines dramatically with time.[191] This would seem to imply that the effectiveness of ZOE at excluding bacterial penetration would decrease over time.

Clinical research on direct pulp capping with ZOE is sparse. One study found dramatic adverse outcomes for human teeth in which pulps were capped with ZOE. All teeth receiving ZOE pulp caps demonstrated chronic inflammation and a lack of dentin bridging and pulpal healing 12 weeks after pulp capping. However, all control teeth that had been pulp capped with calcium hydroxide showed healing within 4 weeks.[194]

Glass ionomer/resin-modified glass ionomer. Glass ionomer and resin-modified glass ionomer demonstrate cytotoxicity when in direct contact with cells, although not to the same degree as ZOE. Resin-modified glass-ionomer formulations tend to show greater cytotoxicity than does the conventional glass-ionomer form. However, both glass ionomer and resin-modified glass ionomer make excellent cavity liners/bases in deep preparations because of their ability to chemically adhere to tooth structure. The resultant seal prevents toxic elements from penetrating into the pulp. Glass ionomer and resin-modified glass ionomer also provide an excellent seal against bacterial penetration, with good biocompatibility when not in direct contact with the pulp.[6,17,192,195,196]

As with ZOE, there is little human clinical research to support direct pulp capping with glass ionomer and resin-modified glass ionomer. One study showed chronic inflammation and lack of dentin bridge formation up to 300 days after direct pulp capping with a resin-modified glass ionomer. The calcium hydroxide–treated control teeth demonstrated significantly better healing.[197]

Adhesive systems. In the early 1990s, it was suggested that dentin bonding agents could be used for direct and indirect pulp capping[198] based on the belief that they could provide an effective, permanent seal against bacterial invasion to promote pulpal healing. Ho esin-modified glass

Dentlearn.ir

ionomer, all components of adhesive systems are cytotoxic to pulpal cells.[199] The cytotoxic effects of the adhesive system components are synergistic with each other, increase with contact time, and are present in single- as well as multicomponent systems. Insufficiently cured adhesives exhibit greater cytotoxicity than adhesives that are well polymerized due to the presence of unpolymerized components.[199,200]

The interest in using adhesives for pulp capping was driven, at least in part, by the fact that some studies on nonprimates found that mechanical pulp exposures capped with adhesives generally resulted in pulpal healing.[201–203] These results were not unanimous, as some nonprimate studies did find inferior healing following pulp capping with adhesives compared with calcium hydroxide.[204,205] A number of studies on primates with noncontaminated mechanical pulp exposures capped with adhesive systems generally resulted in healing comparable with that of calcium hydroxide.[171,206–208] However, the outcome changes when the results are examined from studies of bacteria-contaminated mechanical pulp exposures in primates. This experimental regimen was chosen to more closely resemble the situation that might be encountered if a pulp exposure occurred due to caries or without a rubber dam in place. These contaminated exposures capped with adhesives resulted in poor pulpal healing compared with that of calcium hydroxide.[173,207]

When the results of human pulp capping studies are reviewed, the conclusions become very different than what would have been deduced from animal studies. Table 6-2 summarizes several human studies comparing pulp capping with calcium hydroxide versus adhesives. In each study cited, calcium hydroxide provided significantly improved pulpal repair compared with adhesive systems, regardless of whether it was an etch-and-rinse or self-etching system. There are several possible explanations for these poor outcomes in human studies. First are the direct cytotoxic effects produced by adhesives on pulpal cells.[199] Second is the difficulty in obtaining an adequate seal to protect against bacterial contamination. This poor seal may be due to one or more reasons. Etchant and primer components of adhesives are vasodilators, which can increase bleeding that contaminates adjacent dentin and degrades adhesion.[180,214,215] The increased moisture at the pulp capping site reduces polymerization of the adhesive. This has the dual detrimental effects of decreasing adhesion and increasing the availability of the unpolymerized and more toxic components of the adhesive.[216] Finally, resin components reduce the pulp's immune response, making it less likely that the pulp will be able to defend itself against bacterial contamination.[217] These findings were confirmed in a review of pulp capping with adhesives, in which De Souza Costa and others[175] concluded the

Dentlearn.ir

following: *(1)* adhesives result in inferior pulp healing; *(2)* adhesives result in chronic inflammation, even in the absence of bacteria; and *(3)* inflammation is a poor environment for pulpal healing.

Table 6-2	Human study outcomes comparing direct pulp capping with calcium hydroxide versus adhesive systems*			
Study†	**No. of teeth**	**Restoration**	**Time (mo)**	**Results‡**
Accorinte et al, 2006[209]	40	Etch-and-rinse/composite	2	Calcium hydroxide
De Souza Costa et al, 2001[26]	33	Self-etch/composite	10	Calcium hydroxide
Accorinte et al, 2008[210]	34	Self-etch/composite	3	Calcium hydroxide
Sübay and Demirci, 2005[211]	16	Etch-and-rinse/composite	1	Calcium hydroxide
Accorinte et al, 2005[212]	25	Etch-and-rinse/composite	2	Calcium hydroxide
Fernandes et al, 2008[213]	46	Etch-and-rinse/composite	1	Calcium hydroxide
Hörsted-Bindslev et al, 2003[214]	34	Etch-and-rinse/composite	2	Calcium hydroxide

*Reprinted from Hilton[169] with permission.
†All studies used mechanical exposures and performed histologic analysis.
‡Results column denotes which pulp cap material performed better.

Another issue in placing bonding resins directly on pulpal tissue is heat generation from a quartz-tungsten-halogen (QTH) or a light-emitting diode (LED) curing light. An intrapulpal temperature increase of more than 20°F (11.2°C) has been shown to cause irreversible damage in vivo.[218] One study investigated the temperature rise in a bonding resin during polymerization with a QTH curing light.[219] An increase of 18.2°C was found with a 10-second cure, and a 25.2°C increase was detected with a 20-second cure. Because most bonding resins require a 10-second cure, and some a 20-second cure, there is potential for the pulp to be exposed to dangerous heat levels. It was originally hoped that the LED curing lights would be shown to produce less heat than QTH lights. This was the case when first introduced, with LED lights demonstrating significantly less heat production than plasma arc curing

Dentlearn.ir

(PAC) lights and high-intensity QTH (HQTH) lights.[220] However, current LED lights demonstrate considerably higher light intensity output and are capable of generating much greater heat. This can be a biologic hazard to the pulp when little or no remaining dentin is present.[221]

Calcium hydroxide. Calcium hydroxide was introduced to the dental profession in 1921 and has been considered the gold standard of direct pulp capping materials for several decades for a number of reasons.[186] Calcium hydroxide has excellent antibacterial properties.[222] One study found a 100% reduction in microorganisms associated with pulpal infections after 1 hour of contact with calcium hydroxide.[223] Most important, calcium hydroxide has a long-term track record of clinical success as a direct pulp capping agent in periods of up to 10 years,[172,209,224] although reduced success rates have been found in studies in which dental students were the operators.[168,177,214,225]

Calcium hydroxide has some disadvantages as well. The self-curing formulations are highly soluble and are subject to dissolution over time,[226] although it has been noted that by the time the calcium hydroxide is lost due to dissolution, dentin bridging has occurred.[209] Calcium hydroxide has no inherent adhesive qualities and provides a poor seal.[227] Another criticism noted of calcium hydroxide is the appearance of so-called tunnel defects in reparative dentin formed beneath calcium hydroxide pulp caps.[228,229] A *tunnel defect* has been described as a patency from the site of the exposure through the reparative dentin to the pulp, sometimes with fibroblasts and capillaries present within the defect.[229] Other researchers have found that the quality of reparative dentin improves as the bridge gets thicker[230] and that the tunnel defects are not often patent with the pulp.[204] Of studies of direct pulp capping with calcium hydroxide, more did not report tunnel defects than did report them.[180,209,210,212,214]

Calcium hydroxide is believed to effect pulpal repair by one or more of several mechanisms of action. Calcium hydroxide possesses antibacterial properties, and this can minimize or eliminate bacterial in the capped pulp.[222] Traditionally, it has been believed that calcium hydroxide's high pH causes irritation of the pulpal tissue, which stimulates repair via some unknown mechanism.[132] In recent years, this "unknown mechanism" has been explained as the release of bioactive molecules. It is known that a variety of proteins are incorporated into the dentinal matrix during dentinogenesis. Of particular importance to the topic of pulp capping, at least two of these proteins, bone morphogenic protein (BMP) and transforming growth factor-β1

Dentlearn.ir

(TGF-β1), have demonstrated the ability to stimulate pulpal repair.[231–233] Furthermore, calcium hydroxide is known to solubilize these proteins from dentin, lending credence to the release of these bioactive molecules as a significant mediator in pulpal repair following pulp capping.[132,233]

Mineral trioxide aggregate. Mineral trioxide aggregate (MTA) has generated considerable interest as a direct pulp capping agent in recent years. Unset MTA is primarily calcium oxide in the form of tricalcium silicate, dicalcium silicate, and tricalcium aluminate. Bismuth oxide is added for radiopacity.[234,235] MTA is considered a silicate cement rather than an oxide mixture, and so its biocompatibility is due to its reaction products.[236] Interestingly, the primary reaction product of MTA with water is calcium hydroxide.[234,236–238]

As a result, many of the advantages and potential mechanisms of action for MTA are similar to those for calcium hydroxide, including its antibacterial and biocompatibility properties, high pH, radiopacity, and its ability to aid in the release of bioactive dentin matrix proteins.[237–243] There are some differences between MTA and calcium hydroxide. First, MTA is available in two colors, white and gray. The gray version is created by the addition of iron.[244] Another significant difference is the fact that MTA does provide some seal to tooth structure.[245]

There are several disadvantages to the use of MTA as well. It has shown high solubility, demonstrating 24% loss after 78 days' storage in water.[237,238] The presence of iron in the gray MTA formulation may darken the tooth.[242] A significant downside to MTA is the prolonged setting time of approximately 2 hours, 45 minutes.[240,241] This requires that pulp capping with MTA either be done in a two-step procedure, placing a provisional restoration to allow the MTA to set before placing the restoration, or using a quick-setting liner to protect the MTA during definitive restoration placement. The handling characteristics of the powder-liquid MTA are very different from the typical paste-paste formulations of calcium hydroxide that most practitioners find easy to handle. When compared with these paste-paste formulations of calcium hydroxide, MTA is very expensive. One gram of MTA powder costs approximately the same as 24 grams of calcium hydroxide base/catalyst paste, making MTA much less cost-effective per use.

A review of direct pulp capping studies in animals comparing MTA with calcium hydroxide generally reveals better pulpal healing with MTA.[246–250] As with pulp capping studies comparing adhesives with calcium hydroxide, the results are different when comparing MTA with calcium hydroxide in human studies. Most

Dentlearn.ir

human studies show similar outcomes of MTA and calcium hydroxide.[242,251–255] However, four studies do demonstrate superior performance of MTA.[251,256–258] These studies must be interpreted cautiously, because two of them are very short term (2 and 3 months),[251,256] and both share an interesting study characteristic: The pulp capped teeth were restored with a temporary ZOE material, while a definitive restoration was used in the other studies. As discussed in the section on ZOE, these materials leak significantly and lose their antibacterial eugenol-release rapidly. Thus, these results may highlight the ability of MTA to provide a seal over the pulp exposure that calcium hydroxide does not. The third study also suffers from some shortcomings, including the facts that the treatment was not randomly assigned and the study had too few subjects to adequately determine the outcome with appropriate power.[257] The fourth study was a practice-based trial of pulp caps for mostly carious pulp exposures with 358 participants followed for up to 2 years, which also showed significantly better outcomes with MTA compared with calcium hydroxide. A recent systematic review[188] showed significantly better outcomes for MTA with an indirect comparison between calcium hydroxide and MTA on the weighted pooled success rate. Additional human studies using MTA as the sole pulp capping

months to 4 years.[183,259,260]

On the basis of the literature to date, it would appear that MTA's success is likely due to the fact that it serves as a reservoir for calcium hydroxide and/or its capacity to provide a seal at the site of the pulp exposure. Even though MTA seals better than calcium hydroxide, it should be kept in mind that glass ionomer or resin-modified glass ionomer will be needed as a liner over either pulp capping material. In the case of calcium hydroxide, the glass-ionomer/resin-modified glass-ionomer liner is needed to provide a protective antibacterial seal that the calcium hydroxide alone cannot provide. In the case of MTA, the glass-ionomer/resin-modified glass-ionomer liner is needed to protect the MTA during restoration placement due to the prolonged setting time. Without this glass-ionomer/ resin-modified glass-ionomer protective sealer, it would be necessary to place a provisional restoration for a period of time until the MTA is set, requiring a second appointment for definitive restoration placement.

Success in direct pulp capping. With its long-term track record of clinical success, calcium hydroxide has long been considered the gold standard for direct pulp capping. However, the sum total of the latest research comparing calcium hydroxide and MTA shows that MTA demonstrates superior outcomes for direct pulp capping.

Dentlearn.ir

There are several keys to direct pulp capping success: restricting pulp capping to asymptomatic or mildly symptomatic teeth consistent with reversible pulpitis, controlling bleeding, providing a bacterial seal at the exposure site, and providing a well-sealed restoration following the pulp capping procedure.

Indirect pulp capping

Removal of carious tooth structure has been a basic step in dentistry. When the caries lesion is deep, every restorative dentist is faced with the decision as to the best way to proceed: Is it better to remove all carious dentin regardless of pulpal consequences or to stop short to avoid pulp exposure? When practitioners in a dental practice-based research network were given a hypothetical scenario that involved this question, only 17% responded that they would stop, leave the remaining carious dentin in place, and restore the tooth.[261] This procedure, in which carious dentin is allowed to remain adjacent to a vital pulp—rather than risk pulp exposure—and is covered with a cavity sealer or liner prior to restoration is termed an *indirect pulp capping procedure*, or *indirect pulp treatment*[262] (Fig 6-4). Pierre Fauchard first suggested indirect pulp capping 200 years ago.[263]

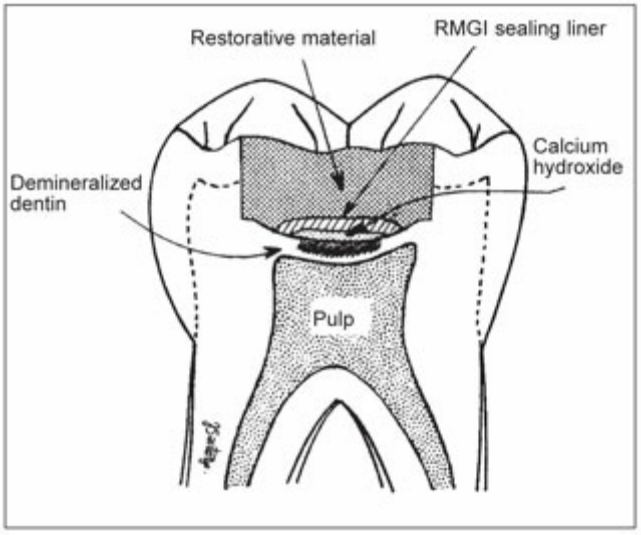

Fig 6-4 In an indirect pulp capping procedure, all carious, demineralized dentin is removed in the periphery of the preparation, but a small amount of demineralized dentin is left immediately over the area of the pulp. A calcium hydroxide lining material is placed to cover the remaining demineralized dentin. A sealing liner and/or a sealing restoration is then placed to seal out bacteria and their byproducts. RMGI—resin-modified glass ionomer.

The evidence regarding indirect pulp capping stands in contrast to the response of the practitioners, however. Several studies show that restored teeth with partial caries removal have equal success compared with restored teeth with complete

Dentlearn.ir

caries removal.[264–266] A number of studies have evaluated the fate of caries lesions in which partial caries removal was accomplished. Typically, an initial clinical and microbiologic assessment of the caries lesion is carried out, partial caries removal is accomplished, and a sealer or liner and restoration is placed for a period of 4 to 12 months before the tooth is reentered and reassessed. Invariably, these studies find that *(1)* the lesion color has changed from light brown to dark brown, *(2)* the tissue consistency has changed from soft and wet to hard and dry, *(3)* *Streptococcus mutans* and *Lactobacillus* have been significantly reduced to a limited number or even zero viable organisms, and *(4)* the radiographs show either no change or even a decrease in the radiolucent zone.

It is known that inflammation is present when active caries is adjacent to the pulp, but there is little to no inflammation if caries is arrested.[267] The type of liner is less important to success than the placement of a well-sealed restoration.[266,268–275] In addition, partial removal of carious dentin significantly reduces the chance of pulp exposure during caries excavation.[276,277] This is very important, because pulp exposures result in more pulp injury, inflammation, and poorer prognosis for pulp vitality than when pulp exposure is avoided.[278,279]

Two thorough systematic reviews confirmed the scientific validity of indirect pulp capping and concluded the following: *(1)* partial removal of carious dentin reduced the risk of pulp exposure by 98% compared with complete caries excavation in teeth with deep caries lesions; *(2)* there is no evidence that partial removal of carious dentin is detrimental in terms of signs, symptoms, pulpitis occurrence, or restoration longevity; and *(3)* there is substantial evidence that complete removal of carious dentin is not needed for success provided the restoration is well sealed.[280,281]

An indirect pulp capping procedure (Box 6-1) should be considered when there is a radiographically or clinically evident deep caries lesion encroaching on the pulp and the tooth has no history of spontaneous pain and responds normally to vitality tests. Pulp exposure must be avoided; if it occurs, it should be regarded as an iatrogenic event. A direct pulp capping procedure should be necessary only if the operator inadvertently exposes the pulp in attempting an indirect pulp capping procedure. With a deep caries lesion, the indirect pulp capping procedure is always preferred to a direct pulp capping procedure.

Box 6-1	**Protocol for indirect pulp capping procedures**
Diagnosis	

Dentlearn.ir

The preoperative status of the pulp and periradicular tissues should be evaluated carefully. The tooth is a candidate for indirect pulp capping only if the following conditions exist:

- There is no history of spontaneous pulpal pain.
- Pulpal vitality has been confirmed with thermal or electric pulp testing.
- Pain occurring during application of a hot or cold stimulus does not linger after the tooth returns to mouth temperature.
- A periapical radiograph shows no evidence of a periradicular lesion of endodontic origin

Treatment

1. Isolation: After administering anesthetic, isolate the tooth with a rubber dam.
2. Preparation: Prepare the tooth for the definitive restoration, leaving demineralized dentin only in the area immediately adjacent to the pulp. All peripheral carious tooth structure, particularly at the cavosurface margins, must be removed. Use a caries-disclosing dye if necessary to ensure complete carious dentin removal (other than that immediately adjacent to the pulp). After this is accomplished, use a spoon excavator or a large round bur in a low-speed handpiece at very low speed.
   Use very gentle, featherweight strokes over the area of the demineralized dentin to remove only the wet (soft, amorphous) carious dentin. Leave the dry,fibrous, place a layer of resin-modified glass ionomer that covers the calcium hydroxide and extends onto sound dentin on the periphery to provide a seal.
4. Restoration:
   a. Direct restorations: For direct restorations (bonded amalgam, resin composite, glass ionomer), place the definitive restoration. If time does not allow for placement of a definitive restoration at the first appointment, a glass-ionomer or reinforced ZOE provisional restoration should be placed and another appointment scheduled for the definitive restoration as soon as possible. The indirect pulp capping liner should not be disturbed during the subsequent restoration process.
   b. Indirect restorations: For indirect restorations (cast metal restorations, ceramic onlays, or crowns), place a definitive buildup (bonded amalgam, resin composite, glass ionomer) at the appointment in which the indirect pulp capping procedure was performed if time allows. Delay placement of the definitive restoration for 4 to 8 months. Before proceeding with the definitive restoration, ensure normal pulp vitality.

Precautions

- Use care in removing carious dentin near the pulp to prevent accidental pulp exposure.
- If a provisional restoration has previously been placed over an indirect pulp capping liner and the tooth is reentered for a restorative procedure, do not remove the indirect pulp capping material.
- Prior to excavation, use tactile exploration to confirm that dye-stained dentin lacks hardness.

Dentlearn.ir

demineralized dentin that gives some moderate resis tance to gentle scraping with a spoon excavator. 3. Lining: Place a calcium hydroxide liner over the remain ing demineralized dentin and allow it to set. Then	

For indirect pulp capping (Figs 6-5 and 6-6), after the initial entry into the carious dentin (see Fig 6-5c), a spoon excavator or large round bur, rotating very slowly in a low-speed handpiece, should be used to excavate the caries-softened dentin. Demineralized dentin not near the pulp should be completely removed, leaving hard, sound dentin. As the excavation of carious dentin nears the pulp, caution must be exercised to avoid pulp exposure. A spoon excavator may aid in tactile detection of softened dentin. The wet (soft, amorphous) carious dentin should be removed; as the pulp is approached, the dry, fibrous, demineralized dentin that offers some moderate resistance to gentle scraping with a spoon excavator should be allowed to remain.

Dentlearn.ir

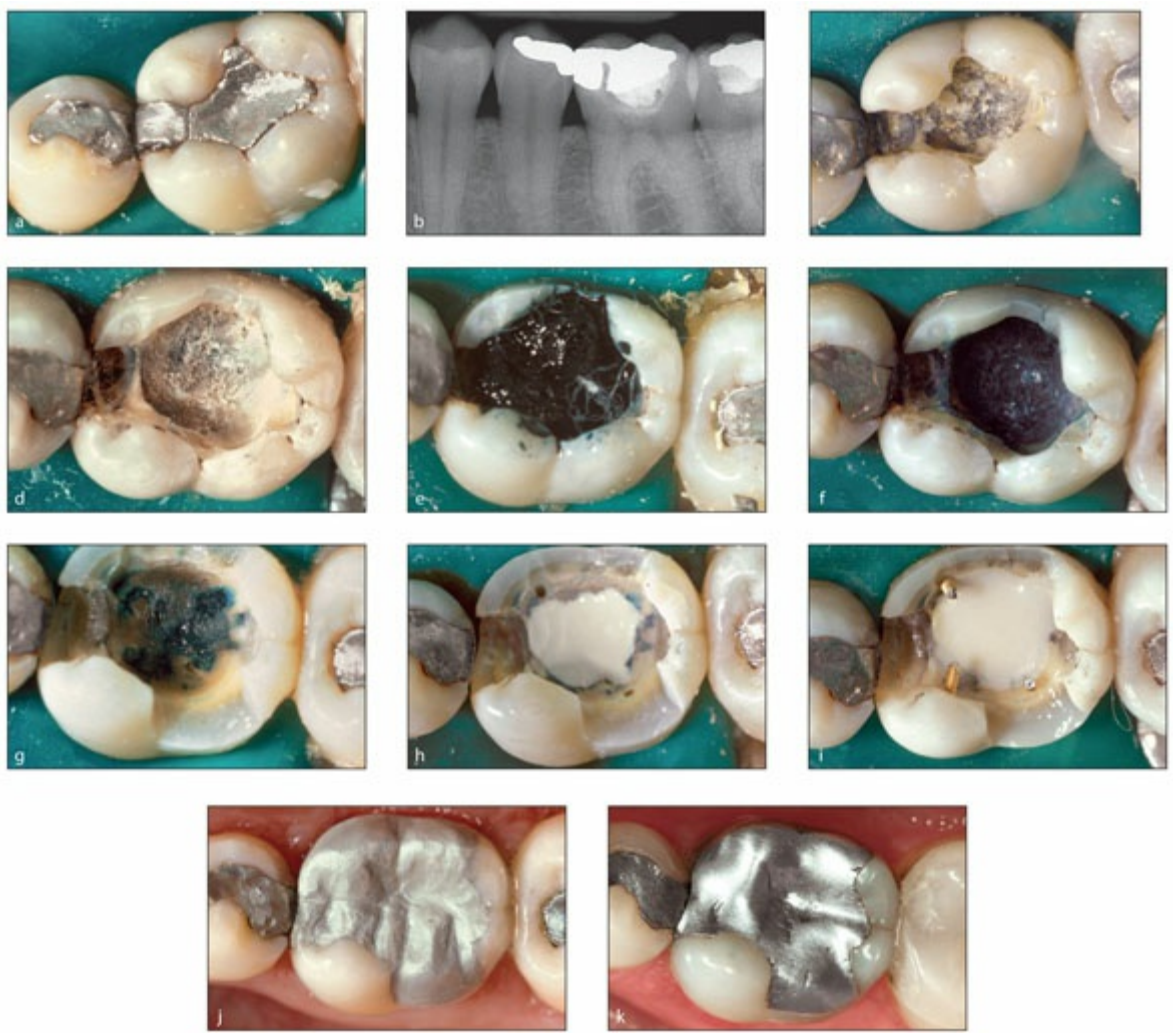

Fig 6-5 Indirect pulp capping procedure, mandibular left first molar. *(a)* Mandibular first molar with deep recurrent carious involvement. Preoperative evaluation indicated vital pulpal tissue and no history of pain. *(b)* Preoperative radiograph shows demineralized dentin around the base, under the amalgam, with carious demineralization advancing toward the pulp. *(c)* The old restoration and base are removed, revealing soft, carious dentin. *(d)* The preparation is widened to enable removal of a large amount of carious dentin and some undermined enamel. *(e)* A cotton pellet, saturated with a blue caries-disclosing dye solution (Cari-D-Tect, Gresco), is placed so that the dye coats all areas of the preparation. The cotton pellet is left in place for 10 seconds and removed. The area is then washed with air-water spray. *(f)* Note the remaining large amount of demineralized dentin, as revealed by the dye. The stained dentin is checked for softness, and softened dentin is removed with a large round bur rotating very slowly. The dye is reapplied and rinsed, and additional softened dentin is removed. *(g)* Most of the demineralized dentin has been removed. Only a small amount of dye-stained dentin is left; this dentin is believed to immediately overlie the pulp. *(h)* A calcium hydroxide liner (Dycal, Caulk/Dentsply) is placed over the remaining demineralized dentin. *(i)* A glass-ionomer liner (Vitrebond, 3M) is placed over the calcium hydroxide liner. The glass-ionomer liner provides some seal and improved strength for amalgam condensation. *(j)* The completed amalgam restoration immediately after placement. *(k)* The restoration after 7 years of service.

Dentlearn.ir

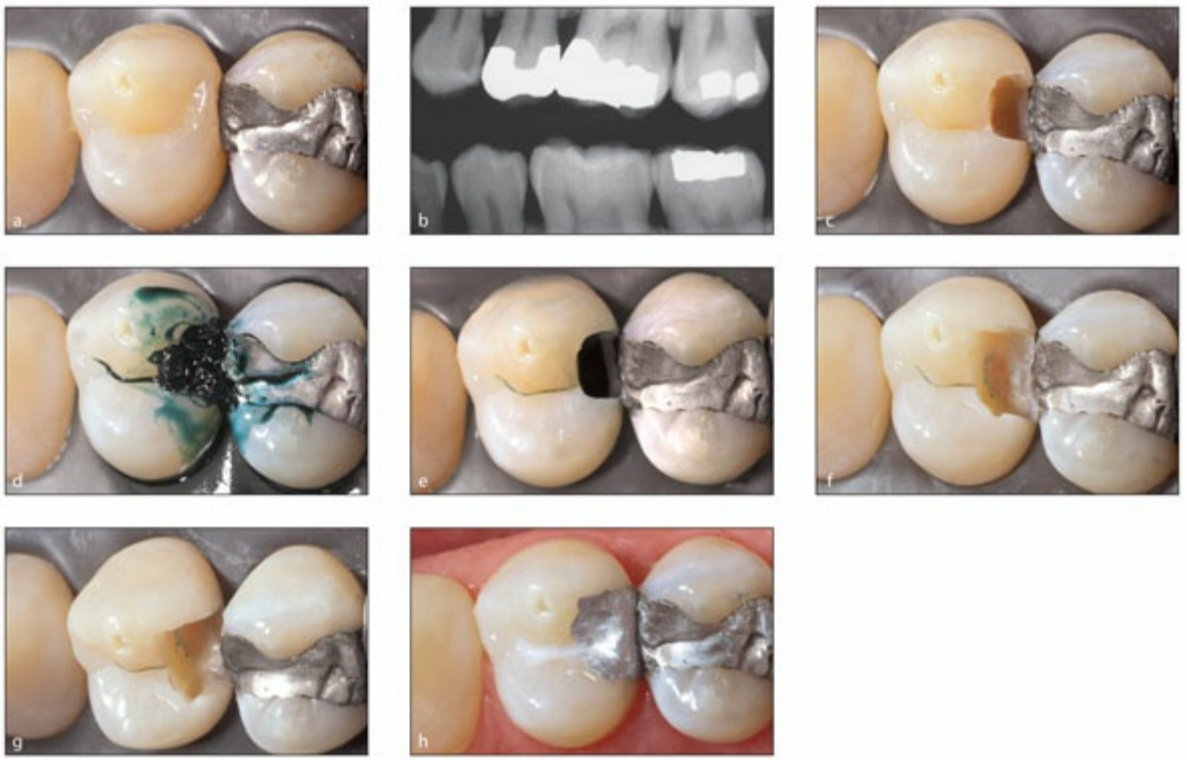

Fig 6-6 Indirect pulp capping procedure, maxillary left first premolar. *(a)* Maxillary left first premolar with extensive proximal caries on the distal surface. *(b)* Bitewing radiograph reveals the extent of the caries lesion. *(c)* Initial entry reveals soft, carious dentin. *(d)* Caries-disclosing dye is applied. *(e)* Dye-stained carious dentin. *(f)* After several applications of caries-disclosing dye and removal of caries-softened dentin, only a small amount of dye-stained dentin remains adjacent to the pulp chamber. *(g)* Calcium hydroxide and glass-ionomer liners are applied over the remaining demineralized dentin. *(h)* The completed amalgam restoration. The deep and stained fissure was addressed using a pit and fissure sealant.

Caries-disclosing dyes may be used to assist in excavation of carious dentin (see Figs 6-5e to 6-5g and 6-6d to 6-6g). Studies have demonstrated the benefit of these dyes to aid in identification and removal of demineralized dentin[282] and to greatly reduce remaining viable bacteria.[283] It must be recognized that the dyes stain not only demineralized dentin but also anything porous, such as debris that may have been left in the cavity preparation. In addition, noncarious deep dentin will absorb the dye[284–286] because of the increased number and size of the dentinal tubules in deep dentin; if this dye-stained sound dentin is removed, pulp exposure will result. There has been concern that, when using a dentin bonding system, the previous use of caries-disclosing dyes can reduce the strength of the bond to dentin and increase microleakage at the interface of the bonded restoration with the wall of the cavity.[287] However, the preponderance of evidence indicates that neither of these should be a concern.[288–290]

In the indirect procedure, all carious dentin is removed except for the last portion

Dentlearn.ir

of firm, leathery carious dentin immediately overlying the pulp. At this point, a calcium hydroxide liner is placed over the demineralized area of dentin (see Fig 6-5h). Placement of calcium hydroxide over this layer of leathery dentin has been shown to virtually eliminate all remaining bacteria and to render the residual carious dentin operationally sterile.[291,292] Then a layer of resin-modified glass ionomer is placed, covering the calcium hydroxide and extending onto sound dentin on the periphery to provide a seal (see Fig 6-5i). Resin-modified glass ionomer alone (without calcium hydroxide as an initial layer) is also effective at providing favorable clinical and microbiologic changes when used as a liner on remaining caries.[275] If any vital bacteria remain, a well-sealed restoration should isolate them from life-sustaining substrate and prevent further acid production, thereby arresting the caries process.[264,293] These facts argue against a two-step procedure in which the tooth is reentered for the purpose of excavating the remaining acid-affected dentin to confirm reparative dentin formation. Bacterial levels in caries lesions are reduced most significantly after the initial caries excavation and liner placement, with little additional benefit from the subsequent excavation.[71] In addition, a second caries removal procedure risks creating a pulp exposure and causing further traumatic insult to the pulp.[294] A glass-ionomer liner should be placed over the calcium hydroxide liner to improve strength during amalgam condensation and to enhance the seal (see Figs 6-5i and 6-6g). The definitive restoration should be placed to minimize microleakage at the interface of the restoration with the cavity-preparation walls (see Figs 6-5j and 6-6h).

The future of direct pulp capping materials

A number of materials are being investigated for future use as direct pulp capping agents. Hydroxyapatite elicited a better pulpal response than calcium hydroxide in one animal study because the hydroxyapatite acted as a scaffold for dentin formation.[295] It seems that the most promising research area in pulp capping likely relates to placing materials that either contain bioactive molecules or are capable of releasing them from the dentin matrix. Growth factors such as BMP and TGF-β1 offer intriguing potential as initiators and/or mediators in pulpal repair.[233] In an animal study, BMP and bone sialoprotein (BSP) were more effective for inducing reparative dentin than was calcium hydroxide.[296] Another animal study showed that TGF-β1 was able to stimulate pulpal stem cells to differentiate into odontoblast-like cells that produced reparative dentin.[232]

Dentlearn.ir

Antibacterial Efficacy of Restorative Materials

One of the keys to any successful restoration, but particularly for a tooth that has undergone a pulp capping procedure, is the ability to exclude bacteria and their by-products from entry into the pulp.[13,168] Of particular concern are the cariogenic bacteria, which tend to invade the interface between the restoration and the cavity preparation. Ultimately, these bacteria may lead to recurrent caries, and, if they reach the pulp in sufficient quantities, they will cause inflammatory and ultimately pathologic responses.[13] In particular, *S mutans* is often used in in vitro studies evaluating the efficacy of restorative materials against bacteria, because this organism is associated with recurrent caries[297] (see chapter 5).

The discussion so far has focused on the materials placed immediately adjacent to the site of near or actual pulp exposure. However, the seal provided by the restorative material will also affect the ultimate success of the procedure. Restorative materials can effectively prevent bacterial contamination by one of two means: *(1)* providing an impermeable seal with the cavity walls to physically exclude bacteria and the toxins they produce or *(2)* possessing antibacterial properties to destroy bacteria entering the restoration-tooth interface. No material yet provides an impermeable seal that can ensure the physical exclusion of bacteria.

Amalgam

Although typically not considered a material possessing antibacterial properties, dental amalgam has demonstrated varying levels of antibacterial activity.[297–301] This activity has been attributed to a variety of elements released from amalgam, including copper, mercury, zinc, silver, and chloride compounds. A number of studies have shown that amalgam is effective against cariogenic bacteria, including *S mutans, Actinomyces viscosus,* and *Lactobacillus* species.[297–301]

S mutans thrive and produce lactic acid in an acidic environment.[302] The tooth-amalgam interface has a decreased pH,303 which results in demineralization of tooth structure.[304] In vivo studies have shown that metallic solutions of copper, silver, and zinc are all capable of reducing acid production in plaque.[305] In one case, ions of these metals reduced acid production more than did fluoride in a comparable concentration.[306] All of these ions are released by amalgam and would therefore be present at the tooth-restoration interface.[298–301]

In addition to its antibacterial properties, amalgam is the only restorative material in which the marginal seal improves with time. This is due to the acidic environment

Dentlearn.ir

and low oxygen concentration that exists in the amalgam-to–cavity wall gap, which promotes corrosion. In conventional amalgam, the gamma-2 phase forms SnO_2, $SnCl_2$, and $Sn(OH)_2Cl$, which slowly fill the interfacial gap. In high-copper alloys, in which there is no gamma-2 phase (tin-mercury phase), the eta phase (copper-tin phase) corrodes to form CuO_2 and $CuCl_2$, but this occurs much more slowly. Corrosion in high-copper alloys may take twice as long as in conventional alloys to produce the same level of seal.[307]

Glass ionomer

Glass ionomer has the ability to decrease bacterial penetration,[145] possibly through its fluoride release, initial low pH,[147] physical exclusion of bacteria,[145] or release of a metal cation.[148,149] Whatever the mechanism, glass-ionomer restorative and liner/base materials inhibit cariogenic bacteria[151] and demineralization at tooth-restoration interfaces.[308,309] In vivo plaque studies assessing the level of cariogenic bacteria invariably show significantly lower levels of these organisms adjacent to glass ionomer compared to either resin composite or amalgam.[310–312]

Resin composite

In contrast to amalgam and glass ionomer, resin composite is most dependent on the formation of an impermeable seal to exclude bacterial penetration. This is because, as shown in in vitro bacterial-inhibition studies, there is little, if any, inhibitory effect demonstrated by resin composite against cariogenic bacteria,[149] and, therefore, there is little resistance to secondary caries activity.[309] This is true even if a resin composite contains fluoride.[309] In fact, research has indicated that certain monomers released from resin composite actually stimulate cariogenic bacterial growth.[313] In vivo plaque studies have demonstrated that levels of cariogenic bacteria in the plaque present on surfaces of resin composite restorations are significantly higher than on either amalgam or glass ionomer.[311–315] While certain adhesive systems are similar to resin composite in that they demonstrate no bacterial inhibition,[316] some glutaraldehyde-containing bonding systems have shown an inhibitory effect on cariogenic organisms.[316,317] As previously stated, the quality and durability of adhesive bonding to dentin is questionable, and an impermeable seal may not be achieved. Because resin composite does not have the ability to inhibit cariogenic bacteria, placement of a resin composite restoration with a margin in

Dentlearn.ir

dentin in a tooth that has been treated with pulp capping may decrease the chances of successful treatment.

Summary

- Most operative procedures are traumatic to the pulp, and the effects are at least somewhat cumulative. Excessive heat and dehydration should be avoided. Questionable teeth should receive pulp vitality testing before undergoing clinical procedures.
- Avoid exposing the pulp. The chances for tooth survival are excellent if the tooth is asymptomatic and well sealed, even if residual carious dentin remains.
- Control hemorrhage with water, saline, or sodium hypochlorite. Water and saline are the most benign to the pulp; sodium hypochlorite is more effective for controlling hemorrhage and disinfecting.
- Because no dentin remains between the capping material and the pulp for direct pulp capping, the problem of exposure of pulpal tissues and surrounding vital dentin to caustic or toxic materials is significant. The effects of thermal and chemical insults are magnified with an exposed vital pulp. While calcium hydroxide has been the gold standard for pulp capping because of its long track record of clinical success, MTA has demonstrated superior performance to calcium hydroxide in recent clinical studies. Either calcium hydroxide or MTA should be used with very meticulous clinical technique and excellent isolation. Indirect pulp capping is preferred to direct pulp capping; with proper diagnosis and good clinical procedure, direct pulp capping should rarely be required.
- Calcium hydroxide or glass ionomer are the materials of choice for indirect pulp capping. If the restoration-to–cavity wall interface is well sealed, calcium hydroxide eliminates or greatly reduces the number of viable bacteria in the remaining demineralized dentin. Dentin bonding resins adhere poorly to carious dentin, provide an inadequate seal, and impart little to no antimicrobial activity.
- Drawbacks attributed to the use of calcium hydroxide as a pulp capping agent include dissolution with acid etching, degradation under leaking restorations, and interfacial failure during amalgam condensation. While the most significant drawback of calcium hydroxide is its inability to provide a permanent seal against bacterial invasion, the integrity and durability of the bond achieved with dentin adhesives is questionable as well. ZOE, glass ionomer, resin-modified glass ionomer, and adhesives are poor direct pulp capping agents and should be

Dentlearn.ir

avoided for this application.

- When calcium hydroxide or MTA is used as a pulp capping material, it should be limited to as small an area as possible, and some method of protecting it should be considered during subsequent restorative procedures. Placement of a glass-ionomer lining material over the calcium hydroxide provides a combination of clinically proven materials associated with clinical success in pulp capping. Calcium hydroxide provides antibacterial properties; glass ionomer, especially resin-modified glass ionomer, provides resistance to acids, condensation pressures, and dissolution, as well as adhesion to the tooth structure and a source of fluoride in the event of leakage.
- Provide a well-sealed restoration immediately after pulp capping. This will provide protection against ongoing leakage and bacterial contamination that can compromise success.

Acknowledgment

The authors would like to acknowledge the Academy of Operative Dentistry for permitting the use of material in the section on direct pulp capping materials.[169]

References

1. Stanley HR. Human Pulp Response to Restorative Dental Procedures. Gainesville, FL: Storter, 1981.
2. Oztürk B, Usümez A, Oztürk AN, Ozer F. In vitro assessment of temperature change in the pulp chamber during cavity preparation. J Prosthet Dent 2004;91:436–440.
3. Murray PE, About I, Lumley PJ, Franquin JC, Remusat M, Smith AJ. Cavity remaining dentin thickness and pulpal activity. Am J Dent 2002; 15:41–46.
4. Meryon SD. The model cavity method incorporating dentine. Int Endod J 1988;21:79–84.
5. de Souza Costa CA, do Nascimento A, Texeira R. Response of human pulps following acid conditioning and application of a bonding agent in deep cavities. Dent Mater 2002;18:543–551.
6. Murray PE, Franquin JC, Remusat M, Smith AJ. Restorative pulpal and repair responses. J Am Dent Assoc 2001;132:482–491.
7. Weine FS. Endodontic Therapy, ed 3. St Louis: Mosby, 1982:118.
8. Heyeraas KJ, Sveen OB, Mjör IA. Pulp-dentin biology in restorative dentistry. Part 3: Pulpal inflammation and its sequelae. Quintessence Int 2001;32:611–625.
9. Stanley HR. Pulpal responses to ionomer cements—Biological characteristics. J Am Dent Assoc 1990;120:25–29.
10. Stanley HR, Going RE, Chauncey HH. Human pulp response to acid pretreatment of dentin and to composite restoration. J Am Dent Assoc 1975;91:817–825.
11. Bergenholtz G, Lindhe J. Effect of soluble plaque factors on inflammatory reactions in the dental pulp. Scand J Dent Res 1975;83:153–158.
12. Brännström M, Nordenvall KJ. Bacterial penetration, pulpal reaction and the inner surface of Concise enamel

Dentlearn.ir

bond. Composite fillings in etched and unetched cavities. J Dent Res 1978;57:3–10.
13. Cox CF, Keall CL, Keall HJ, Ostro E, Bergenholtz G. Biocompatibility of surface-sealed dental materials against exposed pulps. J Prosthet Dent 1987;57:1–8.
14. Watts A, Paterson RC. Bacterial contamination as a factor influencing the toxicity of materials to the exposed dental pulp. Oral Surg Oral Med Oral Pathol 1987;64:466–474.
15. Bergenholtz G, Spångberg L. Controversies in endodontics. Crit Rev Oral Biol Med 2004;15:99–114.
16. Ritter AV, Swift EJ. Current restorative concepts of pulp protection. Endod Top 2003;5:41–48.
17. Camps J, Déjou, Rémusat M, About I. Factors influencing pulpal response to cavity restorations. Dent Mater 2000;16:432–440.
18. Murray PE, Hafez AA, Smith AJ, Cox CF. Bacterial microleakage and pulp inflammation associated with various restorative materials. Dent Mater 2002;18:470–478.
19. Bjørndal L, Darvann T, Thylstrup A. A quantitative light microscopic study of the odontoblast and subodontoblastic reactions to active and arrested enamel caries without cavitation. Caries Res 1998;32:59–69.
20. Brännström M, Lind PO. Pulpal response to early dental caries. J Dent Res 1965;44:1045–1050.
21. Vojinović O, Nyborg H, Brännström M. Acid treatment of cavities under resin fillings: Bacterial growth in dentinal tubules and pulpal reactions. J Dent Res 1973;52:1189–1193.
22. Stanley HR, Pereira JC, Spiegel E, Broom C, Schultz M. The detection and prevalence of reactive and physiologic sclerotic dentin, reparative dentin and dead tracts beneath various types of dental lesions according to tooth surface and age. J Oral Pathol 1983;12:257–289.
23. Nordenvall KJ, Brännström M, Torstensson B. Pulp reactions and microorganisms under ASPA and Concise composite fillings. ASDC J Dent Child 1979;46:449–453.
24. Brännström M, Vojinović O. Response of the dental pulp to invasion of bacteria around three filling materials. ASDC J Dent Child 1976;43:83–89.
25. Kurosaki N, Kubota M, Yamamoto Y, Fusayama T. The effect of etching on the dentin of the clinical cavity floor. Quintessence Int 1990;21:87–92.
26. de Souza Costa CA, Lopes do Nascimento AB, Teixeira HM, Fontana UF. Response of human pulps capped with a self-etching adhesive system. Dent Mater 2001;17:230–240.
27. Hamilton AI, Kramer IR. Cavity preparation with and without waterspray. Effects on the human dental pulp and additional effects of further dehydration of the dentine. Br Dent J 1967;123:281–285.
28. Langeland K, Langeland LK. Cutting procedures with minimized trauma. J Am Dent Assoc 1968;76:991–1005.
29. Lockard MW. A retrospective study of pulpal response in vital adult teeth prepared for complete coverage restorations at ultrahigh speed using only air coolant. J Prosthet Dent 2002;88:473–478.
30. Stanley HR Jr, Swerdlow H. Reaction of the human pulp to cavity preparation: Results produced by eight different operative grinding techniques. J Am Dent Assoc 1959;58(5):49–59.
31. Peyton FA, Henry EE. The effect of high speed burs, diamond instruments and air abrasive in cutting tooth tissue. J Am Dent Assoc 1954;49:426–435.
32. Murray PE, About I, Lumley PJ, Franquin JC, Remusat M, Smith AJ. Human odontoblast cell numbers after dental injury. J Dent 2000;28: 277–285.
33. Mjör I. Pulp-dentin biology in restorative dentistry. Part 2: Initial reactions to preparations of teeth for restorative materials. Quintessence Int 2001;32:537–551.
34. Karlsson S. A clinical evaluation of fixed bridges, 10 years following insertion. J Oral Rehabil 1986;13:423–432.
35. Valderhaug J, Jokstad A, Ambjørnsen E, Norheim PW. Assessment of the periapical and clinical status of crowned teeth after 25 years. J Dent 1997;25:97–105.
36. Saunders WP, Saunders EM. Prevalence of periradicular periodontitis associated with crowned teeth in an adult Scottish subpopulation. Br Dent J 1998;185:137–140.
37. Felton D, Madison S, Kanoy E, Kantor M, Maryniuk G. Long-term effects of crown preparation on pulp vitality [abstract 1139]. J Dent Res 1989; 68(special issue):1009.
38. Laurell KA, Carpenter W, Daugherty D, Beck M. Histopathologic effects of kinetic cavity preparation for the

Dentlearn.ir

removal of enamel and dentin. An in vivo animal study. Oral Surg Oral Med Oral Pathol 1995;80:214–225.
39. James VE, Schour I. Early dentinal and pulpal changes following cavity preparations and filling materials in dogs. Oral Surg Oral Med Oral Pathol 1955;8:1305–1314.
40. Dostálová T, Jelínková H, Krejsa O, et al. Dentin and pulp response to Erbium:YAG laser ablation: A preliminary evaluation of human teeth. J Clin Laser Med Surg 1997;15:117–121.
41. Powell GL, Morton TH, Larsen AE. Pulpal response to irradiation of enamel with continuous wave CO_2 laser. J Endod 1989;15:581–583.
42. Sonntag KD, Klitzman B, Burkes EJ, Hoke J, Moshonov J. Pulpal response to cavity preparation with the Er:YAG and Mark III free electron lasers. Oral Surg Oral Med Oral Pathol 1996;81:695–702.
43. Srimaneepong V, Palamara JE, Wilson PR. Pulpal space pressure and temperature changes from Nd:YAG laser irradiation of dentin. J Dent 2002;30:291–296.
44. Rizoiu I, Kohanghadosh F, Kimmel AI, Eversole LR. Pulpal thermal responses to erbium, chromium:YSGG pulsed laser hydrokinetic system. Oral Surg Oral Med Oral Pathol Radiol Endod 1998;86:220–223.
45. Attrill DC, Davies RM, King TA, Dickinson MR, Blinkhorn AS. Thermal effects of the Er:YAG laser on a simulated dental pulp: A quantitative evaluation of the effects of a water spray. J Dent 2004;32:35–40.
46. D'Souza R. Pulpal and periapical immune response to electrosurgical contact of cervical metallic restorations in monkeys. Quintessence Int 1986;17:803–808.
47. Krejci RF, Reinhardt RA, Wentz FM, Hardt AB, Shaw DH. Effects of electro-surgery on dog pulps under cervical metallic restorations. Oral Surg Oral Med Oral Pathol 1982;54:575–582.
48. Robertson PB, Lüscher B, Spangberg LS, Levy BM. Pulpal and periodontal effects of electrosurgery involving cervical metallic restorations. Oral Surg Oral Med Oral Pathol 1978;46:702–710.
49. Spangberg LS, Hellden L, Robertson PB, Levy BM. Pulpal effects of electrosurgery involving based and unbased cervical amalgam restorations. Oral Surg Oral Med Oral Pathol 1982;54:678–685.
50. Brännström M. Communication between the oral cavity and the dental pulp associated with restorative treatment. Oper Dent 1984;9:57–68.
51. Miller BC, Charbeneau GT. Sensitivity of teeth with and without cement bases under amalgam restorations: A clinical study. Oper Dent 1984;9:130–135.
52. Piperno S, Barouch E, Hirsch SM, Kaim JM. Thermal discomfort of teeth related to presence or absence of cement bases under amalgam restorations. Oper Dent 1982;7:92–96.
53. Silvestri AR Jr, Cohen SH, Wetz JH. Character and frequency of discomfort immediately following restorative procedures. J Am Dent Assoc 1977;95:85–89.
54. Belcher MA, Stewart GP. Two-year clinical evaluation of an amalgam adhesive. J Am Dent Assoc 1997;128:309–314.
55. Browning WD, Johnson WW, Gregory PN. Postoperative pain following bonded amalgam restorations. Oper Dent 1997;22:66–71.
56. Gordan VV, Mjör IA, Hucke RD, Smith GE. Effect of different liner treatments on postoperative sensitivity of amalgam restorations. Quintessence Int 1999;30:55–59.
57. Gordan VV, Mjör IA, Moorhead JE. Amalgam restorations: Postoperative sensitivity as a function of liner treatment and cavity depth. Oper Dent 1999;24:377–383.
58. Kennington LB, Davis R, Murchison DF, Langenderfer WR. Short-term clinical evaluation of post-operative sensitivity with bonded amalgams. Am J Dent 1998;11:177–180.
59. Mahler DB, Engle JH, Simms LE, Terkla LG. One-year clinical evaluation of bonded amalgam restorations. J Am Dent Assoc 1996;127:345–349.
60. Baratieri LN, Machado A, Van Noort R, Ritter AV, Baratieri NMM. Effect of pulp protection technique on the clinical performance of amalgam restorations: Three-year results. Oper Dent 2002;27:319–324.
61. Going RE. Cavity liners and dentin treatment. J Am Dent Assoc 1964;69:415–422.
62. Peters DD, Augsburger RA. In vitro cold transference of bases and restorations. J Am Dent Assoc 1981;102:642–646.
63. Harper RH, Schnell RJ, Swartz ML, Phillips RW. In vivo measurements of thermal diffusion through restorations of various materials. J Prosthet Dent 1980;43:180–185.

Dentlearn.ir

64. Drummond JL, Robledo J, Garcia L, Toepke TR. Thermal conductivity of cement base materials. Dent Mater 1993;9:68–71.
65. Farah JW, Clark AE, Mohsein M, Thomas PA. Effect of cement base thicknesses on MOD amalgam restorations. J Dent Res 1983;62:109–111.
66. Hormati AA, Fuller JL. The fracture strength of amalgam overlying base materials. J Prosthet Dent 1980;43:52–57.
67. Pierpont W, Gray S, Hermesch C, Hilton T. Effect of various bases on the fracture resistance of amalgam [abstract 981]. J Dent Res 1993;72:226.
68. Mjör IA, Sveen OB, Heyeraas KJ. Pulp-dentin biology in restorative dentistry. Part 1: Normal structure and biology. Quintessence Int 2001;32: 427–446.
69. Pashley DH. Clinical considerations of microleakage. J Endod 1990;16: 70–77.
70. Duke ES, Lindemuth JS. Variability of clinical dentin substrates. Am J Dent 1991;4:241–246.
71. Yoshiyama M, Masada J, Uchida A, Ishida H. Scanning electron microscopic characterization of sensitive vs. insensitive human radicular dentin. J Dent Res 1989;68:1498–1502.
72. McCoy RB. Bases, liners and varnishes update. Oper Dent 1995;20:216.
73. Anusavice KJ. Phillips' Science of Dental Materials, ed 10. Philadelphia: Saunders, 1996:545.
74. Kidd EA. Microleakage: A review. J Dent 1976;4:199–206.
75. Opdam NJ, Bronkhorst EM, Loomans BA, Huysmans MC. 12-year survival of composite vs. amalgam restorations. J Dent Res 2010;89:1063–1067.
76. Bernardo M, Luis H, Martin MD, et al. Survival and reasons for failure of amalgam versus composite posterior restorations placed in a randomized clinical trial. J Am Dent Assoc 2007;138:775–783.
77. Soncini JA, Maserejian NN, Trachtenberg F, Tavares M, Hayes C. The longevity of amalgam versus compomer/composite restorations in posterior primary and permanent teeth: Findings from the New England Children's Amalgam Trial. J Am Dent Assoc 2007;138:763–772.
78. Opdam NJ, Bronkhorst EM, Roeters JM, Loomans BA. A retrospective study on longevity of posterior composite and amalgam restorations. Dent Mater 2007;23:2–8.
79. Forss H, Widström E. From amalgam to composite: Selection of restorative materials and restoration longevity in Finland. Acta Odontol Scand 2001;59:57–62.
80. Craig RG. Restorative Dental Materials, ed 9. St Louis: Mosby-Year Book, 1993:203–207.
81. Phillips RW. Skinner's Science of Dental Materials, ed 9. Philadelphia: Saunders, 1991.
82. Summitt JB. On bases, liners, and varnishes [letter]. Oper Dent 1994; 19:35.
83. Andrews JT, Hembree JH. Marginal leakage of amalgam alloys with high content of copper: A laboratory study. Oper Dent 1980;5:7.
84. Lin JHC, Marshall GW, Marshall SJ. Microstructures of Cu-rich amalgams after corrosion. J Dent Res 1983;62:112–115.
85. Pashley DH, O'Meara JA, Williams EC, Kepler EE. Dentin permeability: Effects of cavity varnishes and bases. J Prosthet Dent 1985;53:511–516.
86. Pashley DH, Livingston MJ, Outhwaite WC. Rate of permeation of isotopes through human dentin, in vitro. J Dent Res 1977;56:83–88.
87. Fitchie JG, Reeves GW, Scarbrough AR, Hembree JH. Microleakage of a new cavity varnish with a high-copper spherical amalgam alloy. Oper Dent 1990;15:136–140.
88. McComb D, Ben-Amar A, Brown J. Sealing efficacy of therapeutic varnishes used with silver amalgam restorations. Oper Dent 1990;15:122–128.
89. Moore DS, Johnson WW, Kaplan I. A comparison of amalgam microleakage with a 4-META liner and Copal varnish. Int J Prosthodont 1995;8:461–466.
90. Felton DA, Kanoy BE, White JT. Effect of cavity varnish on retention of cemented cast crowns. J Prosthet Dent 1987;57:411–416.
91. Erickson RL, Barkmeier WW, Kimmes NS. Fatigue of enamel bonds with self-etch adhesives. Dent Mater 2009;25:716–720.
92. Breschi L, Mazzoni A, Ruggeri A, Cadenaro M, Di Lenarda R, De Stefano Dorigo E. Dental adhesion

Dentlearn.ir

review: Aging and stability of the bonded interface. Dent Mater 2008;24:90–101.
93. Pashley DH, Depew DD. Effects of the smear layer, copalite, and oxalate on microleakage. Oper Dent 1986;11:95–102.
94. Sneed WD, Hembree JH Jr, Welsh EL. Effectiveness of three cavity varnishes in reducing leakage of a high-copper amalgam. Oper Dent 1984;9:32–34.
95. Marchiori S, Baratieri LN, de Andrada MA, Monteiro S Jr, Ritter AV. The use of liners under amalgam restorations: An in vitro study on marginal leakage. Quintessence Int 1998;29:637–642.
96. Mazer RB, Rehfeld R, Leinfelder KF. Effect of cavity varnishes on microleakage of amalgam restorations. Am J Dent 1988;1:205–208.
97. Wright W, Mazer RB, Teixeira LC, Leinfelder KR. Clinical microleakage evaluation of a cavity varnish. Am J Dent 1992;5:263–265.
98. Christensen G. Product use survey—1995. Clin Res Assoc Newsletter 1995;19(10):1–4.
99. Mahler DB, Engle JH, Adey JD. Bond strength and microleakage of amalgam adhesives [abstract 42]. J Dent Res 1992;71(special issue):111.
100. Dutton FB, Summitt JB, Garcia-Godoy F. Effect of a resin lining and rebonding on the marginal leakage of amalgam restorations. J Dent 1993;21:52–56.
101. Stefanoni JI, Abate PF, Polack MA, Macchi RL. In vitro marginal leakage in amalgam restorations [abstract 37]. J Dent Res 1996;75:1063.
102. Oliveira HP, Araújo MAJ, Figueiredo MOG. Adhesive amalgam: A microleakage study [abstract 69]. J Dent Res 1996;75(special issue):1086.
103. Ben-Amar A, Liberman R, Rothkoff Z, Cardash HS. Long term sealing properties of Amalgambond under amalgam restorations. Am J Dent 1994;7:141–143.
104. Cao DS, Hollis RA, Christensen RP, et al. Shear strength and microleakage of 23 adhesives for amalgam bonding [abstract 1760]. J Dent Res 1995;74(special issue):231.
105. Chang JC, Chan JT, Chheda HN, Iglesias A. Microleakage of a 4-methacryloxyethyl trimellitate anhydride bonding agent with amalgams. J Prosthet Dent 1996;75:495–498.
106. Hollis RA, Hein DK, Rasmussen TE, et al. Shear strength and microleakage of 14 amalgam bonding adhesives [abstract 2958]. J Dent Res 1996;75(special issue):387.
107. Meiers JC, Turner EW. Microleakage of dentin/amalgam alloy bonding agents: Results after 1 year. Oper Dent 1998;23:30–35.
108. Saiku JM, St Germain HA Jr, Meiers JC. Microleakage of a dental amalgam alloy bonding agent. Oper Dent 1993;18:172–178.
109. Tangsgoolwatana J, Cochran MA, Moore BK, Li Y. Microleakage evaluation of bonded amalgam
110. Tjan AHL, Tan DE, Sun JC, Tjan AH. Marginal leakage of amalgam restorations pretreated with various liners. Am J Dent 1997;10:284–286.
111. Turner EW, St Germain HA, Meiers JC. Microleakage of dentin-amalgam bonding agents. Am J Dent 1995;8:191–196.
112. Watanabe T, Sano M, Itoh K, Wakumoto S. The effects of primers on the sensitivity of dentin. Dent Mater 1991;7:148–150.
113. Suzuki S, Cox CF, White KC. Pulpal response after complete crown preparation, dentinal sealing, and provisional restoration. Quintessence Int 1994;25:477–485.
114. White KC, Cox CF, Kanca J 3rd, Dixon DL, Farmer JB, Snuggs HM. Pulpal response to adhesive resin systems applied to acid-etched vital dentin: Damp versus dry primer application. Quintessence Int 1994;25:259–268.
115. Hilton TJ, Schwartz RS, Ferracane JL. Microleakage of four Class II resin composite insertion techniques at intraoral temperature. Quintessence Int 1997;28:135–144.
116. Pameijer CH, Wendt SL Jr. Microleakage of "surface-sealing" materials. Am J Dent 1995;8:43–46.
117. Strydom C, Retief DH, Russell CM, Denys FR. Laboratory evaluation of the Gluma 3-step bonding system. Am J Dent 1995;8:93–98.

Dentlearn.ir

118. Tay FR, Gwinnett AJ, Pang KM, Wei SHY. Variability in microleakage observed in a total-etch wet-bonding technique under different handling conditions. J Dent Res 1995;74:1168–1178.
119. Browning WD, Johnson WW, Gregory PN. Clinical performance of bonded amalgam restorations at eighteen months [abstract 427]. J Dent Res 1997;76(special issue):67.
120. Mahler DB, Engle JH. Clinical evaluation of bonding amalgam in traditional Class I and Class II restorations. J Am Dent Assoc 2000;131:43–49.
121. Mazer RB, Leinfelder KF, Barnette JH. Post-operative sensitivity and margin adaptation of amalgam and composite restorations treated with ProBond adhesive [abstract 748]. J Dent Res 1995;74(special issue):105.
122. Summitt JB, Burgess JO, Berry TG, Robbins JW, Osborne JW, Haveman CW. Six-year clinical evaluation of bonded and pin-retained complex amalgam restorations. Oper Dent 2004;29:261–268.
123. Hilton TJ, Schwartz RS. The effect of air thinning on dentin adhesive bond strength. Oper Dent 1995;20:133–137.
124. Christensen GJ. Should you and can you afford to bond amalgams? J Am Dent Assoc 1994;125:1381–1382.
125. Tyler DW, Thurmeier J. Amalgam bonding: Visualization and clinical implications of adhesive displacement during amalgam condensation. Oper Dent 2001;26:81–86.
126. Boston DW. Adhesive liner incorporation in dental amalgam restorations. Quintessence Int 1997;28:49–55.
127. Charlton DG, Murchison DF, Moore BK. Incorporation of adhesive liners in amalgam: Effect on compressive strength and creep. Am J Dent 1991;4:184–188.
128. Millstein PL, Naguib GH. Effects of two resin adhesives on mechanical properties of set amalgam. J Prosthet Dent 1995;74:106–109.
129. Hanks CT, Bergenholtz G, Kim JS. Protein synthesis in vitro, in the presence of $Ca(OH)_2$-containing pulp-capping medicaments. J Oral Pathol 1983;12:356–365.
130. Cox CF. Biocompatibility of dental materials in the absence of bacterial infection. Oper Dent 1987;12:146–152.
131. Murray PE, Windsor LJ, Smyth TW, Hafez AA, Cox CF. Analysis of pulpal reactions to restorative procedures, materials, pulp capping, and future therapies. Crit Rev Oral Biol Med 2002;13:509–520.
132. Graham L, Cooper PR, Cassidy N, Nor JE, Sloan AJ, Smith AJ. The effect of calcium hydroxide on solubilisation of bioactive dentine matrix components. Biomaterials 2006;27:2865–2873.
133. Craig RG. Restorative Dental Materials, ed 8. St Louis: Mosby, 1989.
134. Krejci I, Lutz F. Mixed Class V restorations: The potential of a dentine bonding agent. J Dent 1990;18:263–270.
135. Pereira JC, Manfio AP, Franco EB, Lopes ES. Clinical evaluation of Dycal under amalgam restorations. Am J Dent 1990;3:67–70.
136. Tam LE, Pulver E, McComb D, Smith DC. Physical properties of calcium hydroxide and glass-ionomer base and lining materials. Dent Mater 1989;5:145–149.
137. Lewis BA, Burgess JO, Gray SE. Mechanical properties of dental base materials. Am J Dent 1992;5:69–72.
138. Pierpont WF, Gray SE, Hermesch CB, Hilton TJ. The effect of various bases on the fracture resistance of amalgam. Oper Dent 1994; 19:211–216.
139. Olsen BT, Garcia-Godoy F, Marshall TD, Barnwell GM. Fluoride release from glass ionomer–lined amalgam restorations. Am J Dent 1989; 2:89–91.
140. Mitra SB. In vitro fluoride release from a light-cured glass-ionomer liner/base. J Dent Res 1991;70:75–78.
141. Geiger SB, Weiner S. Fluoridated carbonatoapatite in the intermediate layer between glass ionomer and dentin. Dent Mater 1993;9:33–36.
142. Garcia-Godoy F, Jensen ME. Artificial recurrent caries in glass ionomer–lined amalgam restorations. Am J Dent 1990;3:89–93.
143. Charlton DG, Moore BK, Swartz ML. Direct surface pH determinations of setting cements. Oper Dent 1991;16:231–238.
144. Gaintantzopoulou MD, Willis GP, Kafrawy AH. Pulp reactions to light-cured glass ionomer cements. Am J Dent 1994;7:39–42.
145. Heys RJ, Fitzgerald M. Microleakage of three cement bases. J Dent Res 1991;70:55–58.

Dentlearn.ir

146. Hosoda H, Inokoshi S, Shimada Y, Harnirattisai C, Otsuki M. Pulpal response to a new light-cured composite placed in etched glass-ionomer lined cavities. Oper Dent 1991;16:122–129.
147. DeSchepper EJ, Thrasher MR, Thurmond BA. Antibacterial effects of light-cured liners. Am J Dent 1989;2:74–76.
148. Meryon SD, Jakeman KJ. Zinc release from dental restorative materials in vitro. J Biomed Mater Res 1986;20:285–291.
149. Scherer W, Lippman N, Kaim J. Antimicrobial properties of glass-ionomer cements and other restorative materials. Oper Dent 1989; 14:77–81.
150. Irie M, Suzuki K. Marginal gap formation of light-activated base/liner materials: Effect of setting shrinkage and bond strength. Dent Mater 1999;15:403–407.
151. Burgess JO, Barghi N, Chan DCN, Hummert T. A comparative study of three glass ionomer base materials. Am J Dent 1993;6:137–141.
152. Arcoria CJ, Fisher MA, Wagner MJ. Microleakage in alloy-glass ionomer lined amalgam restorations after thermocycling. J Oral Rehabil 1991;18:9–14.
153. Smith GE. Surface deterioration of glass-ionomer cement during acid etching: An SEM evaluation. Oper Dent 1988;13:3–7.
154. Nicholson JW, Croll TP. Glass-ionomer cements in restorative dentistry. Quintessence Int 1997;28:705–714.
155. Aboushala A, Kugel G, Hurley E. Class II composite resin restorations using glass-ionomer liners: Microleakage studies. J Clin Pediatr Dent 1996;21:67–71.

restorations in vitro. J Dent 1997;25:305–312.
157. Friedl KH, Schmalz G, Hiller KA, Mortazavi F. Marginal adaptation of composite restorations versus hybrid ionomer/composite sandwich restorations. Oper Dent 1997;22:21–29.
158. Kemp-Scholte CM, Davidson CL. Complete marginal seal of Class V resin composite restorations effected by increased flexibility. J Dent Res 1990;69:1240–1243.
159. Miller MB, Castellanos ER, Vargas MA, Denehy GE. Effect of restorative materials on microleakage of Class II composites. J Esthet Dent 1996; 8:107–113.
160. Prati C, Nucci C, Davidson CL, Montanari G. Early marginal leakage and shear bond strength of adhesive restorative systems. Dent Mater 1990;6:195–200.
161. Sidhu SK, Henderson LJ. In vitro marginal leakage of cervical composite restorations lined with a light-cured glass ionomer. Oper Dent 1992; 17:7–12.
162. Trushkowsky RD, Gwinnett AJ. Microleakage of Class V composite, resin sandwich, and resin-modified glass ionomers. Am J Dent 1996; 9:96–99.
163. Wells DL, Davis RD, Osborne PB. Effect of dentin treatment on the cervical marginal integrity of Class II composite restorations [abstract 199]. J Dent Res 1998;77(special issue):130.
164. Yap AUJ, Mok BYY, Pearson G. An in vitro microleakage study of the ‘bonded-base’ restorative technique. J Oral Rehabil 1997;24:230–236.
165. Manders CA, Garcia-Godoy F, Barnwell GM. Effect of a copal varnish, ZOE or glass ionomer cement base on microleakage of amalgam restorations. Am J Dent 1990;3:63–66.
166. Robbins JW. The placement of bases beneath amalgam restorations: Review of literature and recommendations for use. J Am Dent Assoc 1986;113:910–912.
167. Eames WB, Scrabeck JG. Bases, liners and varnishes: Interviews with contemporary authorities. Gen Dent 1980;33:201–207.
168. Baume LJ, Holz J. Long term clinical assessment of direct pulp capping. Int Dent J 1981;31:251–260.
169. Hilton TJ. Keys to clinical success with pulp capping: A review of the literature. Oper Dent 2009;34:615–625.
170. Hörsted-Bindslev P, Lovschall H. Treatment outcome of vital pulp treatment. Endod Top 2002;2:24–34.
171. Cox CF, Hafez AA, Akimoto N, Otsuki M, Suzuki S, Tarim B. Biocompatibility of primer, adhesive and resin composite systems on non-exposed and exposed pulps of non-human primate teeth. Am J Dent 1998;11(special issue):S55–S63.

Dentlearn.ir

172. Matsuo T, Nakanishi T, Shimizu H, Ebisu S. A clinical study of direct pulp capping applied to carious-exposed pulps. J Endod 1996;22:551–556.
173. Pameijer CH, Stanley HR. The disastrous effects of the "total etch" technique in vital pulp capping in primates. Am J Dent 1998;11(special issue):S45–S54.
174. Swift EJ, Trope M, Ritter A. Vital pulp therapy for the mature tooth—Can it work? Endod Top 2003;5:49–56.
175. de Souza Costa CA, Hebling J, Hanks CT. Current status of pulp capping with dentin adhesive systems: A review. Dent Mater 2000;16: 188–197.
176. de Souza Costa CA, Mesas AN, Hebling J. Pulp response to direct pulp capping with an adhesive system. Am J Dent 2000;13:81–87.
177. Al-Hiyasat A, Barrieshi-Nusair K, Al-Mari M. The radiographic outcomes of direct pulp capping procedures performed by dental students. J Am Dent Assoc 2006;137:1699–1705.
178. de Souza Costa CA, Edwards C, Hanks C. Cytotoxic effects of cleansing solutions recommended for chemical lavage of pulp exposures. Am J Dent 2001;14:25–30.
179. Accorinte M, Loguercio A, Reis A, Muench A, Araújo V. Response of human pulp capped with a bonding agent after bleeding control with hemostatic agents. Oper Dent 2005;30:147–155.
180. Silva G, Lanza L, Lopes-Júnior N, Moreira A, Alves J. Direct pulp capping with a dentin bonding system in human teeth: A clinical and histological evaluation. Oper Dent 2006;31:297–307.
181. Demir T, Cehreli Z. Clinical and radiographic evaluation of adhesive pulp capping in primary molars following hemostasis with 1.25% sodium hypochlorite: 2-year results. Am J Dent 2007;20:182–188.
182. Garcia-Godoy F, Murray P. Systemic evaluation of various haemostatic agents following local application prior to direct pulp capping. Braz J Oral Sci 2005;4:791–797.
183. Bogen G, Kim J, Bakland L. Direct pulp capping with mineral trioxide aggregate. J Am Dent Assoc 2008;139:305–315.
184. Nair P, Duncan H, Pitt Ford T, Luder H. Histological, ultrastructural and quantitative investigations on the response of healthy human pulps to experimental capping with mineral trioxide aggregate: A randomized controlled trial. Int Endod J 2008;41:128–150.
185. Bernick S, Nedelman C. Effect of aging on the human pulp. J Endod 1975;1:88–94.
186. Reuver J. 592 pulp cappings in a dental office—A clinical study (1966–1990) [in German]. Dtsch Zahnarztl Zeitschr 1992;47:29–32.
187. Horsted P, Sondergaard B, Thylstrup A, El Attar K, Fejerskov O. A retrospective study of direct pulp capping with calcium hydroxide compounds. Endod Dent Traumatol 1985;1:29–34.
188. Aguilar P, Linsuwanont P. Vital pulp therapy in vital permanent teeth with cariously exposed pulp: A systematic review. J Endod 2011;37: 581–587.
189. Torabinejad M, Hong CU, Pitt Ford TR, Kettering JD. Cytotoxicity of four root end filling materials. J Endod 1995;21:489–492.
190. Hume W. Effect of eugenol on respiration and division in human pulp, mouse fibroblasts, and liver cells in vitro. J Dent Res 1984; 63:1262–1265.
191. Hume W. An analysis of the release and the diffusion through dentin of eugenol from zinc oxide-eugenol mixtures. J Dent Res 1984;63: 881–884.
192. Koulaouzidou E, Papazisis K, Economides N, Beltes P, Kortsaris A. Antiproliferative effect of mineral trioxide aggregate, zinc oxide-eugenol cement, and glass ionomer cement against three fibroblastic cell lines. J Endod 2004;31:44–46.
193. Tewari S, Tewari S. Assessment of coronal microleakage in intermediately restored endodontic access cavities. Oral Surg Oral Med Oral Pathol Oral Radiol Endod 2002;93:716–719.
194. Glass R, Zander H. Pulp healing. J Dent Res 1949;28:97–107.
195. de Souza Costa C, Hebling J, Garcia-Godoy F, Hanks C. In vitro cytotoxicity of five glass-ionomer cements. Biomaterials 2003;24:3853–3858.
196. de Souza Costa C, Giro E, do Nascimento A, Teixeira HM, Hebling J. Short-term evaluation of the pulpo-dentin complex response to a resin-modified glass-ionomer cement and a bonding agent applied in deep cavities.

Dentlearn.ir

Dent Mater 2003;19:739–746.
197. do Nascimento AB, Fontana UF, Teixeira HM, de Souza Costa CA. Biocompatibility of a resin-modifed glass-ionomer cement applied as pulp capping in human teeth. Am J Dent 2000;13:28–34.
198. Kanca J 3rd. Replacement of a fractured incisor fragment over pulpal exposure: A case report. Quintessence Int 1993;24:81–84.
199. de Souza Costa CA, Vaerten MA, Edwards CA, Hanks CT. Cytotoxic effects of current dental adhesive systems on immortalized odontoblast cell line MDPC-23. Dent Mater 1999;15:434–441.
200. Ratanasathien S, Wataha JC, Hanks CT, Dennison JB. Cytotoxic interactive effects of dentin bonding components on mouse fibroblasts. J Dent Res 1995;74:1602–1606.
201. Tsuneda Y, Hayakawa T, Yamamoto H, Ikemi T, Nemoto K. A histopathological study of direct pulp capping with adhesive resins. Oper Dent 1995;20:223–229.
202. de Souza Costa CA, Mesas AN, Hebling J. Pulp response to direct capping with an adhesive system. Am J Dent 2000;13:81–87.
203. Olmez A, Oztas N, Basak F, Sabuncuoglu B. A histopathologic study of direct pulp-capping with adhesive resins. Oral Surg Oral Med Oral Pathol Oral Radiol Endod 1998;86:98–103.
204. Mestrener S, Holland M, Dezan R. Influence of age on the behavior of dental pulp of dog teeth after capping with an adhesive system or calcium hydroxide. Dent Traumatol 2003;19:255–261.
205. Trope M, McDougal R, Levin L, May KN, Swift EJ. Capping the inflamed pulp under different clinical conditions. J Esthet Restor Dent 2002;14:349–357.
206. Kitasako Y, Inokoshi S, Fujitani M, Otsuki M, Tagami J. Short-term reaction of exposed monkey pulp beneath adhesive resins. Oper Dent 1998;23:308–317.
207. Kitasako Y, Inokoshi S, Tagami J. Effects of direct resin pulp capping techniques on short-term response of mechanically exposed pulps. J Dent 1999;27:257–263.
208. Fujitani M, Shibata S, Van Meerbeek B, Yoshida Y, Shintani H. Direct adhesive pulp capping: Pulpal healing and ultra-morphology of the resin-pulp interface. Am J Dent 2002;15:395–402.
209. Accorinte M, Reis A, Loguercio A, de Araújo V, Muench A. Influence of rubber dam isolation on human pulp responses after capping with calcium hydroxide and an adhesive system. Quintessence Int 2006;37: 205–212.
210. Accorinte M, Loguercio A, Reis A, de Souza Costa C. Response of human pulps capped with different self-etch adhesive systems. Clin Oral Investig 2008;12:119–127.
211. Sübay R, Demirci M. Pulp tissue reactions to a dentin bonding agent as a direct capping agent. J Endod 2005;31:201–204.
212. Accorinte M, Lorguercio A, Reis A, Muench A, de Araújo V. Adverse effects of human pulps after direct pulp capping with the different components from a total-etch, three-step adhesive system. Dent Mater 2005;21:599–607.
213. Fernandes A, Silva G, Lopes N, Napimoga M, Benatti B, Alves J. Direct capping of human pulps with a dentin bonding system and calcium hydroxide: An immunohistochemical analysis. Oral Surg Oral Med Oral Path Oral Radiol Endod 2008;105:385–390.
214. Hörsted-Bindslev P, Vilkinis V, Sidlauskas A. Direct capping of human pulps with a dentin bonding system or with calcium hydroxide cement. Oral Surg Oral Med Oral Pathol Oral Radiol Endod 2003;95:591–600.
215. Abebe W, Pashley D, Rueggeberg F. Vasorelaxant effect of resin-based, single-bottle dentin bonding systems. J Endod 2005;31:194–197.
216. Jacobson T, Soderholm K. Some effects of water on dentin bonding. Dent Mater 1995;11:132–136.
217. Jontell M, Hanks CT, Bratel J, Bergenholtz G. Effects of unpolymerized resin components on the function of accessory cells derived from the rat incisor pulp. J Dent Res 1995;74:1162–1167.
218. Zach L, Cohen G. Pulp response to externally applied heat. Oral Surg Oral Med Oral Pathol 1965;19:515–530.
219. Puckett A, Thompson N, Phillips S, Reeves G. Heat generation during curing of a dentin adhesive and composite [abstract 1380]. J Dent Res 1995;74(special issue):184.
220. Ozturk B, Ozturk AN, Usumez A, Usumez S, Ozer F. Temperature rise during adhesive and resin composite

Dentlearn.ir

polymerization with various light curing sources. Oper Dent 2004;29:325–332.
221. Krämer N, Lohbauer U, Garcia-Godoy F, Frankenberger R. Light curing of resin-based composites in the LED era. Am J Dent 2008;21:135–142.
222. Barthel C, Levin L, Resiner H, Trope M. TNF-á release in monocytes after exposure to calcium hydroxide treated *Escherichia coli* LPS. Int Endod J 1997;30:155–159.
223. Stuart C, Miller C, Brown C, Newton C. The comparative antimicrobial effect of calcium hydroxide. Oral Surg Oral Med Oral Pathol Oral Radiol Endod 1991;72:101–104.
224. Robertson A, Andreasen M, Andreasen J, Norén J. Long-term prognosis of crown-fractured permanent incisors. The effect of stage root development and associated luxation injury. Int J Paediatr Dent 2000;10:191–199.
225. Barthel C, Rosenkranz B, Leuenberg A, Roulette J. Pulp capping of carious exposures: Treatment outcome after 5 and 10 years: A retrospective study. J Endod 2000;26:525–528.
226. Prosser H, Groffman D, Wilson D. The effect of composition on the erosion properties of calcium hydroxide cements. J Dent Res 1982;61: 1431–1435.
227. Ferracane J. Materials in Dentistry: Principles and Applications, ed 2. Philadelphia: Lippincott, Williams & Wilkins, 2001:63–64.
228. Kitasako Y, Ikeda M, Tagami J. Pulpal responses to bacterial contamination following dentin bridging beneath hard-setting calcium hydroxide and self-etching adhesive resin system. Dent Traumatol 2008;24: 201–206.
229. Cox CF, Subay RK, Ostro E, Suzuki S, Suzuki SH. Tunnel defects in dentin bridges: Their formation following direct pulp capping. Oper Dent 1996;21:4–11.

Pathol 1972;1:244–248.
231. Duque C, Hebling J, Smith A, Giro M, Freitas M, de Souza Costa C. Reactionary dentinogenesis after applying restorative materials and bioactive dentin matrix molecules as liners in deep cavities prepared in non-human primate teeth. J Oral Rehabil 2006;33:452–461.
232. Weibo Zhang X, Walboomers F, Jansen J. The formation of tertiary dentin after pulp capping with calcium phosphate cement, loaded with PLGA microparticles containing TGF-β1. J Biomed Mater Res A 2008;85:439–444.
233. Smith A. Vitality of the dentin-pulp complex in health and disease: Growth factors as key mediators. J Dent Educ 2003;67:678–689.
234. Camilleri J. Characterization of hydration products of mineral trioxide aggregate. Int Endod J 2008;41:408–417.
235. Torabinejad M, White D [inventors]. Loma Linda University, assignee. Tooth filling material and method of use. US patent 5,769,638. 23 Jun 1998.
236. Camilleri J, Pitt Ford T. Mineral trioxide aggregate: A review of the constituents and biological properties of the material. Int Endod J 2006;39:747–754.
237. Fridland M, Rosado R. Mineral trioxide aggregate (MTA) solubility and porosity with different water-to-powder ratios. J Endod 2003; 29:814–817.
238. Fridland M, Rosado R. MTA solubility: A long term study. J Endod 2005;31:376–379.
239. Camilleri J, Montesin FE, Di Silvio L, Pitt Ford TR. The chemical constitution and biocompatibility of accelerated Portland cement for endodontic use. Int Endod J 2005;38:834–842.
240. Torabinejad M, Hong CU, McDonald F, Pitt Ford TR. Physical and chemical properties of a new root-end filling material. J Endod 1995;21:349–353.
241. Islam I, Chng HK, Yap AU. Comparison of the physical and mechanical properties of MTA and Portland cement. J Endod 2006;32:193–197.
242. Aeinehchi M, Eslami B, Ghanbariha M, Saffar AS. Mineral trioxide aggregate (MTA) and calcium hydroxide as pulp-capping agents in human teeth: A preliminary report. Int Endod J 2002;36:225–231.
243. Tomson P, Grover L, Lumley P, Sloan A, Smith A, Cooper P. Dissolution of bioactive dentine matrix components by mineral trioxide aggregate. J Dent 2007;35:636–642.

Dentlearn.ir

244. Song J, Mante F, Romanow W, Kim S. Chemical analysis of powder and set forms of Portland cement, gray ProRoot MTA, white ProRoot MTA, and gray MTA-Angelus. Oral Surg Oral Med Oral Pathol Oral Radiol Endod 2006;102:809–815.
245. Luketić S, Malčić A, Jukić, S, Anić I, Šegović S, Kalenić S. Coronal microleakage of two root-end filling materials using a polymicrobial marker. J Endod 2008;34:201–203.
246. de Souza Costa C, Duarte P, de Souza P, Giro E, Hebling J. Cytotoxic effects and pulpal response caused by a mineral trioxide aggregate formulation and calcium hydroxide. Am J Dent 2008;21:255–261.
247. Briso A, Rahal V, Mestrener S, Dezan E Jr. Biological response of pulps submitted to different capping materials. Braz Oral Res 2006;20:219–225.

assessment of various vital pulptherapy materials. J Endod 2003;29:324–333.
249. Faraco I Jr, Holland R. Response of the pulp of dogs to capping with mineral trioxide aggregate or a calcium hydroxide cement. Dent Traumatol 2001;17:163–166.
250. Pitt Ford T, Torabinejad M, Abedi H, Bakland L, Kariyawasam S. Using mineral trioxide aggregate as a pulp-capping material. J Am Dent Assoc 1996;127:1491–1494.
251. Accorinte M, Holland R, Reis A, et al. Evaluation of mineral trioxide aggregate and calcium hydroxide cement as pulp-capping agents in human teeth. J Endod 2008;34:1–6.
252. Tuna D, Olmez A. Clinical long-term evaluation of MTA as a direct pulp capping material in primary teeth. Int Endod J 2008;41:273–278.
253. Iwamoto C, Adachi E, Pameijer C, Barnes D, Romberg E, Jefferies S. Clinical and histological evaluation of white ProRoot MTA in direct pulp capping. Am J Dent 2006;19:85–90.
254. Min K, Park H, Lee S, et al. Effect of mineral trioxide aggregate on dentin bridge formation and expression of dentin sialoprotein and heme oxygenase-1 in human dental pulp. J Endod 2008;34:666–670.
255. Qudeimat M, Barrieshi-Nusair K, Owais A. Calcium hydroxide vs mineral trioxide aggregates for partial pulpotomy of permanent molars with deep caries. Eur J Paediatr Dent 2007;8:99–104.
256. Chacko V, Kurikose S. Human pulpal response to mineral trioxide aggregate (MTA): A histological study. J Clin Pediatr Dent 2006;30:203–209.
257. Mente J, Geletneky B, Ohle M, et al. Mineral trioxide aggregate or calcium hydroxide direct pulp capping: An analysis of the clinical treatment outcome. J Endod 2010;36:806–813.
258. Hilton T, Mancl L, Ferracane J, et al. Direct pulp capping with MTA vs. CaOH in Northwest Precedent [abstract 2880]. J Dent Res 2012;92.
259. Caicedo R, Abbott P, Alongi D, Alarcon M. Clinical, radiographic and histological analysis of the effects of mineral trioxide aggregate used in direct pulp capping and pulpotomies of primary teeth. Aust Dent J 2006;51:297–305.
260. Farsi N, Alamoudi N, Balto K, Mushayt A. Clinical assessment of mineral trioxide aggregate (MTA) as direct pulp capping in young permanent teeth. J Clin Pediatr Dent 2006;31:72–76.
261. Oen K, Thompson V, Vena D, et al. Attitudes and expectations of treating deep caries: A PEARL Network survey. Gen Dent 2007;55:197–203.
262. American Academy of Pediatric Dentistry. Reference Manual 2005–2006. Guideline on pulp therapy for primary and young teeth. Pediatr Dent 2005;27(suppl 7):130–134.
263. Bogen G, Chandler N. Vital pulp therapy. In: Ingle J, Bakland L, Baumgartner C (eds). Ingle's Endodontics, ed 6. Ontario: Decker, 2008:1310–1329.
264. Mertz-Fairhurst EJ, Curtis JW Jr, Ergle JW, Rueggeberg FA, Adair SM. Ultraconservative and cariostatic sealed restorations: Results at year 10. J Am Dent Assoc 1998;129:55–66.
265. Foley J, Evans D, Blackwell A. Partial caries removal and cariostatic materials in carious primary molar teeth: A randomised controlled clinical trial. Br Dent J 2004;197:697–701.
266. Ribeiro C, Baratieri L, Pedigão J, Baratieri N, Ritter A. A clinical, radiographic, and scanning electron microscopic evaluation of adhesive restorations on carious dentin in primary teeth. Quintessence Int 1999;30:591–599.
267. Kuwabara R, Massler M. Pulpal reactions to active and arrested carious lesions. J Dent Child 1966;33:190–

Dentlearn.ir

204.
268. Besic F. The fate of bacteria sealed in dental cavities. J Dent Res 1943;22:349–354.
269. Fairbourn DR, Charbeneau GT, Loesche WJ. Effect of improved Dycal and IRM on bacteria in deep carious lesions. J Am Dent Assoc 1980;100:547–552.
270. Pinto AS, de Araújo FB, Franzon R, et al. Clinical and microbiological effect of calcium hydroxide protection in indirect pulp capping in primary teeth. Am J Dent 2006;19:382–386.
271. Bjørndal L, Thylstrup A. A practice-based study on stepwise excavation of deep carious lesions in permanent teeth: A 1-year follow-up study. Community Dent Oral Epidemiol 1998;26:122–128.
272. Maltz M, de Oliveira E, Fontanella V, Bianchi R. A clinical, microbiologic, and radiographic study of deep caries lesions after incomplete caries removal. Quintessence Int 2002;33:151–159.
273. Maltz M, Oliveira E, Fontanella V, Carminatti G. Deep caries lesions after incomplete dentine caries removal: 40-month follow-up study. Caries Res 2007;41:493–496.
274. Handelman S, Washburn F, Wopperer P. Two-year report of sealant effect on bacteria in dental caries. J Am Dent Assoc 1976;93:967–970.
275. Duque C, Negrini T, Sacono N, Spolidorio D, de Souza Costa C, Hebling J. Clinical and microbiological performance of resin-modifed glass-ionomer liners after incomplete dentine caries removal. Clin Oral Investig 2009;13:465–471.
276. Leksell E, Ridell K, Cvek M, Mejare I. Pulp exposure after stepwise versus direct complete excavation of deep carious lesions in young posterior permanent teeth. Endod Dent Traumatol 1996;12:192–196.
277. Magnusson B, Sundell S. Stepwise excavation of deep carious lesions in primary molars. J Int Assoc Dent Child 1977;8:36–40.
278. Bjørndal L, Larsen T, Thylstrup A. A clinical and microbiological study of deep carious lesions during stepwise excavation using long treatment intervals. Caries Res 1997;31:411–417.
279. Murray P, Hafez A, Windsor L, Smith A, Cox C. Comparison of pulp responses following restoration of exposed and non-exposed cavities. J Dent 2002;30:213–222.
280. Ricketts D, Kidd E, Innes N, Clarkson J. Complete or ultraconservative removal of decayed tissue in unfilled teeth [review]. Cochrane Database Syst Rev 2006;19(3):CD003808.
281. Thompson V, Craig R, Curro F, Green W, Ship J. Treatment of deep carious lesions by complete excavation or partial removal. J Am Dent Assoc 2008;139:705–712.
282. Starr CB, Langenderfer WR. Use of a caries-disclosing agent to improve dental residents' ability to detect caries. Oper Dent 1993;18:110–114.
283. Boston DW, Graver HT. Histological study of an acid red caries-disclosing dye. Oper Dent 1989;14:186–192.
284. Ansari G, Beeley JA, Reid JS, Foye RH. Caries detector dyes—An in vitro assessment of some new compounds. J Oral Rehabil 1999;26:453–458.
285. Kidd EAM, Joyston-Bechal S, Beighton D. The use of a caries detector dye during cavity preparation: A microbiological assessment. Br Dent J 1993;174:245–248.
286. Yip HK, Stevenson AG, Beeley JA. The specificity of caries detector dyes in cavity preparation. Br Dent J 1994;176:417–421.
287. Demarco FF, Matos AB, Matson E, Powers JM. Dyes for caries detection influence sound dentin bond strength. Oper Dent 1998;23:294–298.
288. Kazemi RB, Meiers JC, Peppers K. Effect of caries disclosing agents on bond strengths of total-etch and self-etching primer dentin bonding systems to resin composite. Oper Dent 2002;27:238–242.
289. Piva E, Meinhardt L, Demarco FF, Powers JM. Dyes for caries detection: Influence on composite and compomer microleakage. Clin Oral Investig 2002;6:244–248.
290. el-Housseiny AA, Jamjoum H. The effect of caries detector dyes and a cavity cleansing agent on composite resin bonding to enamel and dentin. J Clin Pediatr Dent 2000;25:57–63.
291. Dumsha T, Hovland EJ. Evaluation of long-term calcium hydroxide treatment in avulsed teeth—An in vivo study. Int Endod J 1995;28:7–11.
292. Leung RL, Loesche WJ, Charbeneau GT. Effect of Dycal on bacteria in deep carious lesions. J Am Dent

Dentlearn.ir

Assoc 1980;100:193–197.
293. Mertz-Fairhurst EJ, Schuster GS, Williams JE, Fairhurst CW. Clinical progress of sealed and unsealed caries. Part I: Depth changes and bacterial counts. J Prosthet Dent 1979;42:521–526.
294. Dumsha T, Hovland E. Considerations and treatment of direct and indirect pulp-capping. Dent Clin North Am 1985;29:251–259.
295. Hayashi Y, Imai M, Yanagiguchi K, Viloria IL, Ikeda T. Hydroxyapatite applied as direct pulp capping medicine substitutes for osteodentin. J Endod 1999;25:225–229.
296. Goldberg M, Six N, Decup F, et al. Application of bioactive molecules in pulp-capping situations. Adv Dent Res 2001;15:91–95.
297. Wallman-Björklund C, Svanberg M, Emilson CG. *Streptococcus mutans* in plaque from conventional and from non-gamma-2 amalgam restorations. Scand J Dent Res 1987;95:266–269.
298. Morrier JJ, Suchett-Kaye G, Nguyen D, Rocca JP, Blanc-Benon J, Barsotti O. Antimicrobial activity of amalgams, alloys and their elements and phases. Dent Mater 1998;14:150–157.
299. Nunez LJ, Schmalz G, Hembree J. Influence of amalgam, alloy, and mercury on the in vitro growth of *Streptococcus mutans*: I. Biological test system. J Dent Res 1976;55:257–261.
300. Orstavik D. Antibacterial properties of and element release from some dental amalgams. Acta Odontol Scand 1985;43:231–239.
301. Updegraff DM, Chang RW, Joos RW. Antibacterial activity of dental restorative materials. J Dent Res 1971;50:382–387.
302. Harper DS, Loesche WJ. Growth and acid tolerance of human dental plaque bacteria. Arch Oral Biol 1984;29:843–848.
303. Marek M, Hochman RF. Mechanism of crevice corrosion of dental amalgam [abstract 166]. J Dent Res 1975;54(special issue):242.
304. McTigue D, Brice C, Nanda CR, Sarkar NK. The in vivo corrosion of Dispersalloy. J Oral Rehabil 1984;11:351–359.
305. Afseth J, Oppermann RV, Rolla G. The in vivo effect of glucose solutions containing Cu++ and Zn++ on the acidogenicity of dental plaque. Acta Odontol Scand 1980;38:229–233.
306. Oppermann RV, Johansen JR. Effect of fluoride and non-fluoride salts of copper, silver and tin on the acidogenicity of dental plaque in vivo. Scand J Dent Res 1980;88:476–480.
307. Ben-Amar A, Cardash HS, Judes H. The sealing of the tooth/amalgam interface by corrosion products. J Oral Rehabil 1995;22:101–104.
308. Donly KJ, Gomez C. In vitro demineralization-remineralization of enamel caries at restoration margins utilizing fluoride-releasing composite resin. Quintessence Int 1994;25:355–358.
309. Gilmour AS, Edmunds DH, Newcombe RG. Prevalence and depth of artificial caries-like lesions adjacent to cavities prepared in roots and restored with a glass ionomer or a dentin-bonded composite material. J Dent Res 1997;76:1854–1861.
310. Svanberg M, Krasse B, Ornerfeldt HO. Mutans streptococci in interproximal plaque from amalgam and glass ionomer restorations. Caries Res 1990;24:133–136.
311. Svanberg M, Mjör IA, Orstavik D. Mutans streptococci in plaque from margins of amalgam, composite, and glass-ionomer restorations. J Dent Res 1990;69:861–864.
312. Zalkind M, Keisar O, Ever-Hadani P, Sela M. Accumulation of *Streptococcus mutans* on light-cured composites and amalgam: An in vitro study. J Esthet Dent 1998;10:187–190.
313. Hansel C, Leyhausen G, Mai UE, Geurtsen W. Effects of various resin composite (co)monomers and extracts on two caries-associated micro-organisms in vitro. J Dent Res 1998;77:60–67.
314. Skjörland KK. Plaque accumulation on different dental filling materials. Scand J Dent Res 1973;81:538–542.
315. Skjörland KK, Sonju T. Effect of sucrose rinses on bacterial colonization on amalgam and composite. Acta Odontol Scand 1982;40:193–196.
316. Carvalhaes Fraga R, Freitas Siqueira JJ, de Uzeda M. In vitro evaluation of antibacterial effects of photo-cured glass ionomer liners and dentin bonding agents during setting. J Prosthet Dent 1996;76:483–486.
317. Meiers JC, Miller GA. Antibacterial activity of dentin bonding systems, resin-modified glass ionomers, and

Dentlearn.ir

polyacid-modified composite resins. Oper Dent 1996;21:257–264.

Dentlearn.ir



Nomenclature and Instrumentation

James B. Summitt

Basic to any science is a language understood by the members of the community of the discipline. This chapter is devoted to a review of the language of operative dentistry and to the basic instrumentation of that discipline. *Operative dentistry* may be defined as that part of restorative dentistry involving assessment, prevention, and treatment of diseases and defects of the hard tissues of individual teeth to maintain or restore functional, physiologic, and esthetic integrity and health.

Nomenclature and Classification of Caries Lesions and Cavity Preparations

Systems for naming and numbering teeth

Each tooth may be identified by its location in the mouth and by its individual name. Examples include the maxillary right central incisor and the mandibular left second premolar. Areas of the mouth are referred to by *arch* (maxillary or upper and mandibular or lower) and by the side of the patient's midline (left and right) (Fig 7-1). Each arch is divided in half at the midline, forming four *quadrants* (maxillary

Dentlearn.ir

right and left quadrants and mandibular right and left quadrants). In addition, each tooth is identified as *primary* or *permanent*. Finally, the *individual name* of the tooth, eg, molar or central incisor, completes the identification. Examples of complete tooth names are mandibular left permanent first molar and maxillary right primary canine.

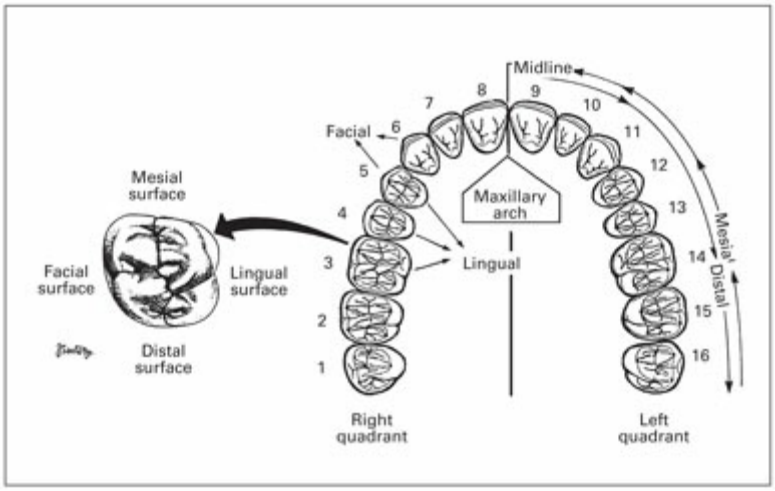

Fig 7-1 Nomenclature of directions and tooth surfaces.

Because their names are cumbersome, teeth are frequently referred to by number. The tooth-numbering systems primarily used today are the Universal system and the Fédération Dentaire Internationale (FDI) system (Fig 7-2). In the Universal system, the numbering begins with the maxillary (upper) right third molar (tooth 1), proceeds around the arch to the maxillary left third molar (tooth 16), then continues with the mandibular (lower) left third molar (tooth 17) and around the mandibular arch to the mandibular right third molar (tooth 32).

Dentlearn.ir

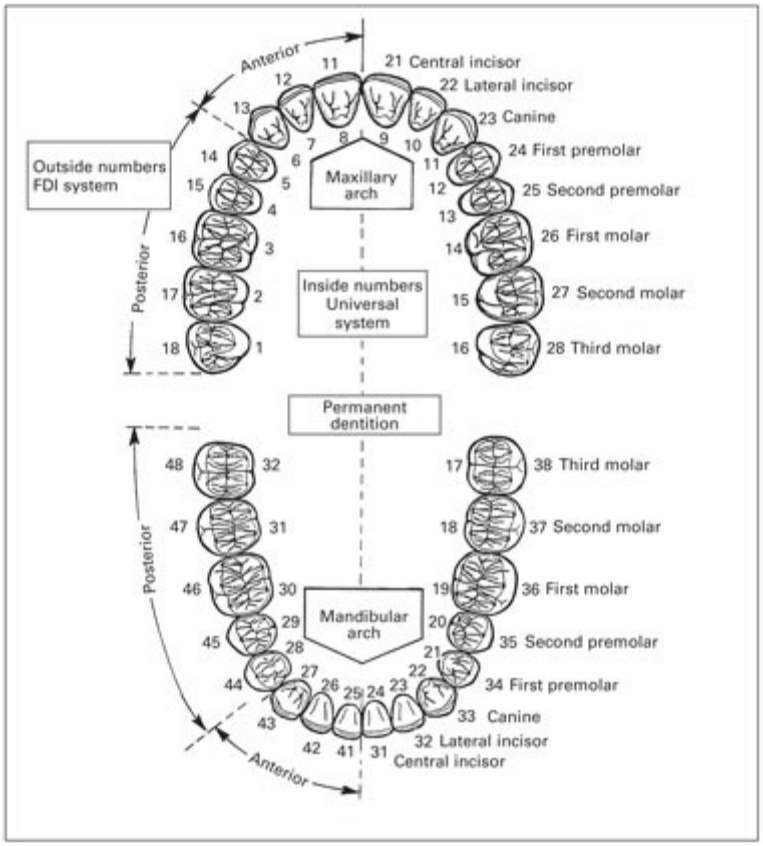

Fig 7-2 Tooth-numbering systems and nomenclature.

In the FDI system, the first digit of the tooth number represents a quadrant (1, maxillary right; 2, maxillary left; 3, mandibular left; and 4, mandibular right). The second digit represents the tooth (1, central incisor, regardless of the arch or quadrant; 2, lateral incisor; 3, canine; and so on to 8, third molar). The maxillary left first premolar would be identified as tooth 24; the mandibular right second molar would be identified as tooth 47.

Incisors and canines are referred to as *anterior teeth*, regardless of the arch; premolars and molars are referred to as *posterior teeth*.

In addition to quadrants, the mouth may also be divided into *sextants*, or sixths. There are three sextants in each arch, with divisions between the canines and first premolars—the maxillary right, anterior, and left sextants and the mandibular right, anterior, and left sextants.

Nomenclature of tooth surfaces and cavity preparations

The surfaces of the teeth are identified by their locations. Any surface or movement toward the midline of the arch is referred to as *mesial* (see Fig 7-1). A surface or

Dentlearn.ir

movement away from the midline is *distal*. Surfaces and movements toward the tongue are termed *lingual* (or *palatal* in the maxilla); those that are in the direction of the cheek or lips are termed *facial*. For the anterior teeth, facial may be referred to as *labial* (toward the lips); for posterior teeth, facial may be referred to as *buccal* (toward the cheek).[1]

On any tooth, *gingival* refers to an area or movement toward the gingiva (Figs 7-3 and 7-4). A distinction is made, however, between the chewing surfaces of posterior teeth, which are called *occlusal* (see Fig 7-4) and the biting edges of anterior teeth, which are called *incisal* (see Fig 7-3). A *proximal* surface is one that faces an adjacent tooth; it may be further identified as mesial or distal.[1] The contact between two adjacent teeth is referred to as the *interproximal contact*.

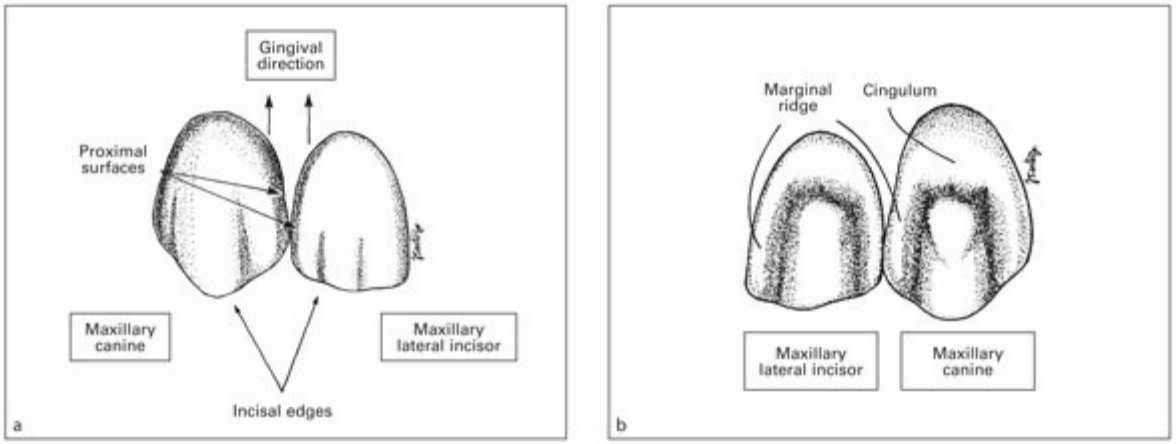

Fig 7-3 Directions, features, and tooth surfaces of anterior teeth. *(a)* Facial view. *(b)* Lingual view.

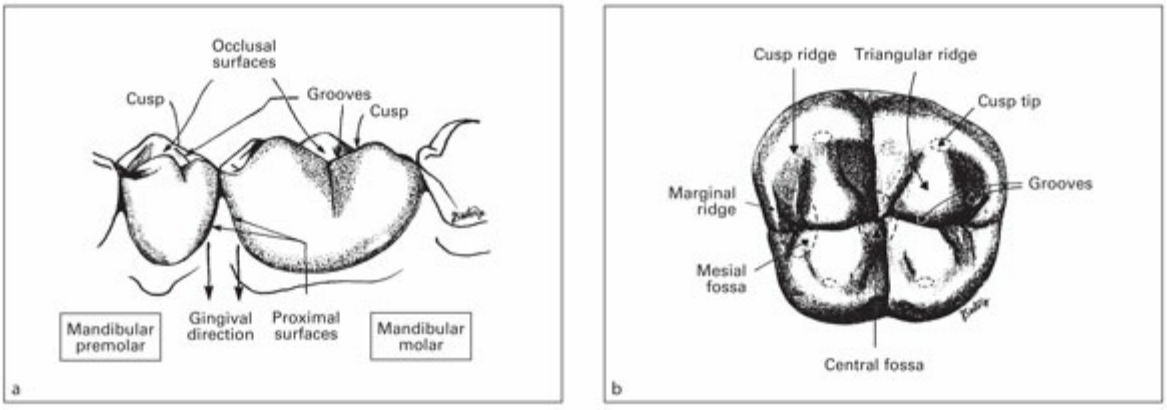

Fig 7-4 Directions, features, and tooth surfaces of posterior teeth. *(a)* Lingual view of mandibular right second premolar and first molar. *(b)* Occlusal view of mandibular right molar.

The anatomical contour of anterior teeth is less complicated than that of posterior teeth, in which the occlusal surfaces are characterized by grooves, cusp tips and

Dentlearn.ir

ridges, marginal ridges, and fossae. *Marginal ridges* (both mesial and distal) border the lingual surfaces of anterior teeth (see Fig 7-3b) and the occlusal surfaces of

elevations, such as cusps and/or ridges. A *fissure* is a developmental linear cleft usually found at the base of a groove; it is commonly the result of the lack of fusion of the enamel of adjoining dental cusps or lobes. A *pit* is a small depression in enamel, usually located in a groove and often at the junction of two or more fissures. A *fossa* is a hollow, rounded, or depressed area in the enamel surface of a tooth. For example, a mesial fossa lies just distal to a mesial marginal ridge[1] (see Fig 7-4b).

Because of the advent of bonding restorative materials to teeth, walls of cavity preparations are less distinct than they are in preparations for restorations that are retained by mechanical undercuts in the preparation walls or by nonadhesive cements. The walls of cavity preparations, however, are generally referred to by the same terms as the surface features of the teeth (eg, the gingival and distal walls) (Figs 7-5 to 7-9). Exceptions are the *pulpal wall* (or floor), which is only in the occlusal portion of a preparation and is the wall adjacent or nearest to the pulp chamber of the tooth (see Figs 7-6 and 7-7), and the *axial wall*, which, in all other areas of a preparation, is the wall adjacent or nearest to the pulp chamber or pulp canal(s) and is approximately parallel to the long axis of the tooth[1] (see Figs 7-5, 7-6, and 7-9).

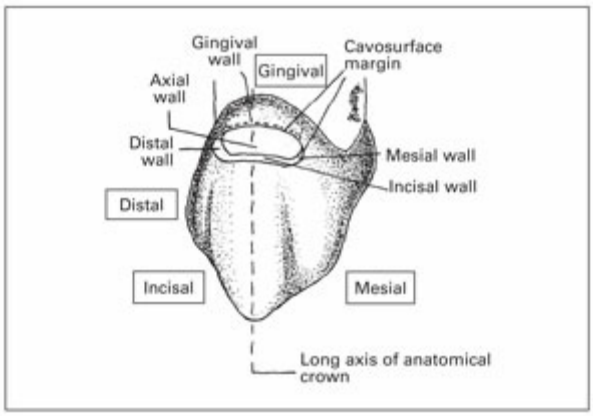

Fig 7-5 Class 5 cavity preparation in an anterior tooth (maxillary canine, facial view). In a posterior tooth, there would be an occlusal wall instead of an incisal wall.

Dentlearn.ir

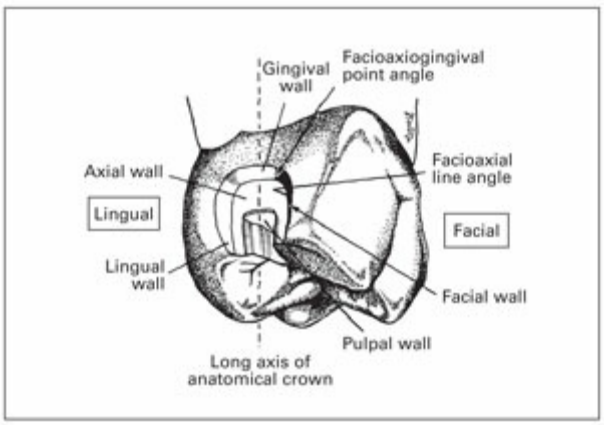

Fig 7-6 Class 2 cavity preparation (maxillary molar, proximal view).

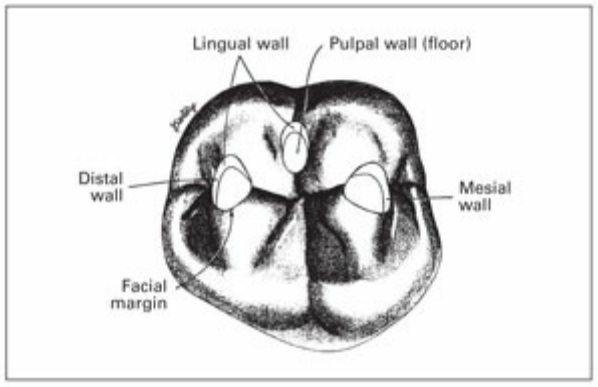

Fig 7-7 Class 1 cavity preparations in a posterior tooth. The occlusal surface of this mandibular right molar is viewed slightly from the facial aspect (occlusofacial), so the facial wall is hidden from view.

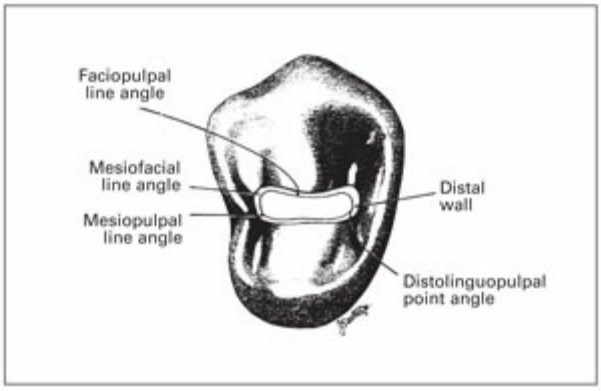

Fig 7-8 Class 1 cavity preparation in a posterior tooth (maxillary premolar, occlusal view). In a direct restoration (such as for amalgam), the facial and lingual walls would be parallel or convergent for retention of the amalgam. The walls of a preparation for bonded resin composite could diverge as shown here or by considerably more, because the restoration would be bonded to the enamel and dentin.

Dentlearn.ir

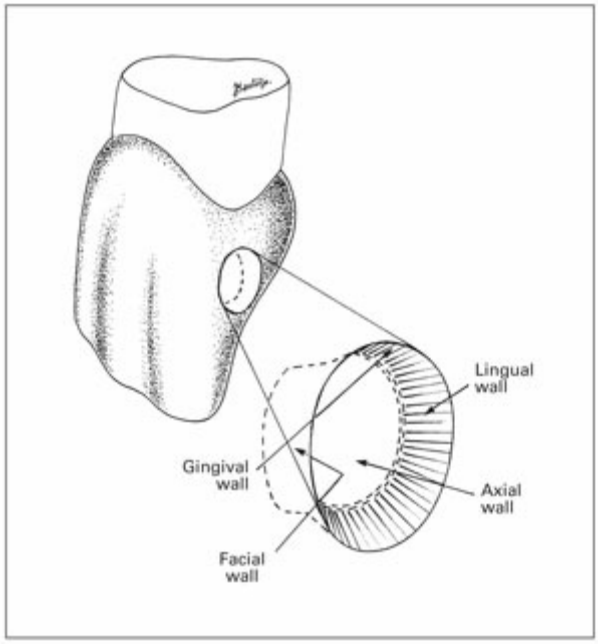

Fig 7-9 Class 3 cavity preparation (maxillary incisor, mesiofacial view). The preparation is for a bonded, tooth-colored restoration.

The junction of two walls in a cavity preparation is called a *line angle*.[1] Again, in preparations for bonded restorations, line angles may not be well defined, but the names for line angles may be used to refer to general areas of the preparation. For example, the meeting of the facial and axial walls forms the facioaxial (or axiofacial) line angle (see Fig 7-6). Similarly, the junction of three walls is referred to as a *point angle*. For example, the junction of the facial, axial, and gingival walls creates the facioaxiogingival (or axiofaciogingival or gingivofacioaxial) point angle. Again, the junction of two walls is often rounded, so it does not actually form a line, but it is still referred to as a line angle; likewise, a point angle is usually not a sharp point.

The *margins* (or *cavosurface angles*1) of a preparation, which are formed by the junction of a cavity wall and an external tooth surface, are identified by the names of the adjacent walls (eg, incisal margin, mesial margin, or gingival margin).

The *anatomical crown* of a tooth is the portion that extends from the cementoenamel junction, or cervical line, to the occlusal surface or incisal edge; it is covered by enamel (Figs 7-10 and 7-11). The *clinical crown* is the portion that is visible in the oral cavity.[1] Depending on the tooth, the clinical crown may include only part of the anatomical crown (see Fig 7-10), or it may include all of the anatomical crown and part of the root (see Fig 7-11).

Dentlearn.ir

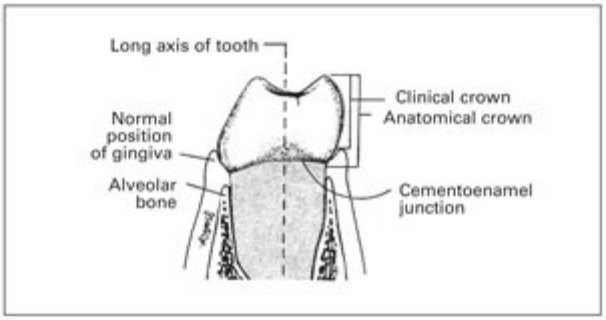

Fig 7-10 Anatomical and clinical crowns of a mandibular molar with the periodontal attachment at the normal, healthy level.

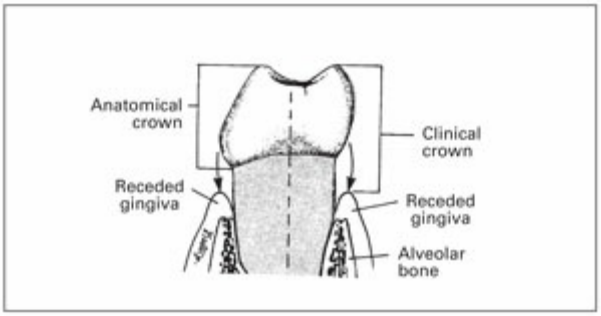

Fig 7-11 Anatomical and clinical crowns of a mandibular molar with the periodontal attachment at a more apical level (periodontal recession). With loss of gingival height comes an increase in the length of the clinical crown, but the anatomical crown, which is defined by the cementoenamel junction (or cervical line), stays constant. The occlusogingival dimension of the anatomical crown can be reduced by loss of occlusal tooth structure from wear or erosion.

Classification of caries lesions and tooth preparations

Near the beginning of the 20th century, G. V. Black, [2] who is known as the father of

in permanent teeth. The same classification is used to refer to cavity preparations, because the location of carious tooth structure is a major factor in the design of the cavity preparation and the selection of instruments (Fig 7-12).

Dentlearn.ir

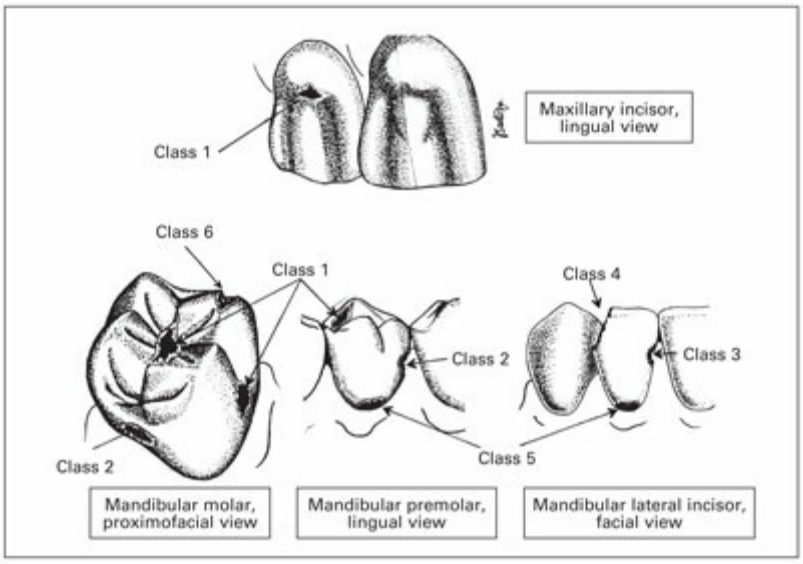

Fig 7-12 Classification of cavity preparations.

Class 1 (I) lesions occur in pits and fissures on the facial, lingual, and occlusal surfaces of molars and premolars and, less often, on the lingual surfaces of maxillary anterior teeth (most frequently lateral incisors, less frequently central incisors, rarely canines) (see Figs 7-7, 7-8, and 7-12).

Class 2 (II) lesions occur in the proximal surfaces of the posterior teeth (molars and premolars). If a proximal surface of a posterior tooth is involved in a restoration, it is a Class 2 restoration (see Figs 7-6 and 7-12).

Class 3 (III) lesions occur in the proximal surfaces of anterior teeth (central and lateral incisors and canines). Class 3 cavities do not involve an incisal angle (see Figs 7-9 and 7-12).

Class 4 (IV) lesions occur in the proximal surfaces of anterior teeth when the incisal angle requires restoration. The angle may have to be removed because of its fragility or for proper placement of the restoration, or it may have been fractured by trauma (Fig 7-13; see also Fig 7-12).

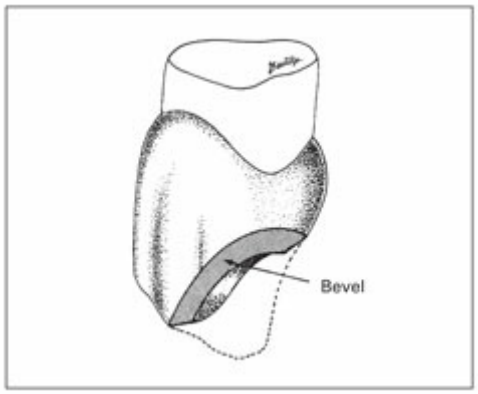

Dentlearn.ir

Fig 7-13 Class 4 preparation for a bonded, tooth-colored restoration (maxillary incisor, facial view).

Class 5 (V) lesions occur in smooth facial and lingual surfaces in the gingival third of teeth. Class 5 lesions begin close to the gingiva and may involve a cementum or dentin surface as well as enamel (see Figs 7-5 and 7-12).

Class 6 (VI) lesions are in pits or wear defects on the incisal edges of anterior teeth or the cusp tips of posterior teeth (Fig 7-14; see also Fig 7-12).

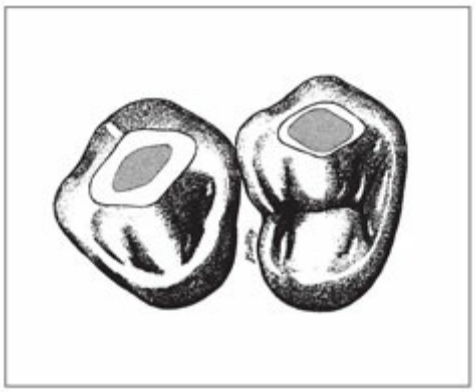

Fig 7-14 Class 6 preparations in the incisal edge of a maxillary canine and the cusp tip of a premolar (incisal/occlusal view). The dotted area of the preparation represents dentin; the clear area of the preparation represents enamel. The preparations have no mechanical, or undercut, retention; they are for bonded, tooth-colored restorations.

In addition to being named for their classifications, cavity preparations and restorations are named for the tooth surfaces involved. For example, a restoration involving the mesial and occlusal surfaces of a posterior tooth is called a *mesio-occlusal Class 2 restoration*; simply saying mesio-occlusal restoration identifies it as a Class 2 restoration because the proximal surface of a posterior tooth is involved. A preparation or restoration involving the mesial, occlusal, distal, and facial surfaces of a posterior tooth is called a *mesio-occlusodistofacial preparation* or *restoration*.

For brevity's sake, the names of the surfaces are often abbreviated (distal, *D*; lingual, *L*; facial, *F*; mesial, *M*; incisal, *I*; occlusal, *O*; buccal, *B*). A mesio-occlusal restoration in a posterior tooth is abbreviated *MO*, and a distolingual restoration in an anterior tooth is abbreviated *DL*.

Black's steps in cavity preparation

Treatment modalities for dental caries other than surgical removal of lesions are discussed in chapter 5. When it has been determined that nonsurgical means of

Dentlearn.ir

treating caries lesions will not suffice, however, restorative therapy is indicated. This involves the surgical removal of carious tooth structure and restoration of the tooth to its original anatomical form with a suitable restorative material. The design of the cavity preparation is determined first by the location of the caries lesion(s) in the tooth. The shape or outline of the cavity preparation, as it meets the external surface of the tooth, is referred to as *outline form*. Other factors influencing the design include the need to obtain access for the instruments as the operator is preparing the cavity or placing the restoration (*convenience form*) and the need to provide retention for the restorative material (*retention form*). Also required is resistance to stresses on the restoration and the tooth from forces of biting and chewing (*resistance form*). Because cavity preparation is a surgical procedure in which a mistake can mean injury to living tissue, it is essential that the operator be knowledgeable and highly skilled.

Sequential steps for cavity preparation were established by Black.[2] Black's steps represent a systematic, scientific procedure for efficiency in cavity preparation. Although the technology of bonding restorative materials to enamel and dentin was not available to Black, his steps of cavity preparation are generally as appropriate today as they were when he formulated them:

1. *Establish outline form.* Outline form is based primarily on the location and extent of the caries lesion, tooth fracture, or erosion. In carious teeth, the outline form is established after penetration into carious dentin and removal of the enamel overlying the carious dentin. The extent of carious dentin should be a primary determinant of the outline form of the preparation; the final outline is not established until the carious dentin and, usually, its overlying unsupported enamel have been removed.
2. *Obtain resistance form.* Resistance for the remaining tooth structure and for the restoration must be designed in the preparation so that the restoration will be resistant to displacement and both the tooth and the restoration will be resistant to fracture during function.
3. *Obtain retention form.* Retention may be obtained through mechanical shaping of the preparation to retain the restoration and/or via bonding procedures that attach the restorative material to tooth structure.
4. *Obtain convenience form.* Convenience form allows adequate observation, accessibility, and ease of operation during preparation and restoration of the tooth. Convenience form that involves the removal of sound, strong tooth structure should be limited to that which is necessary.

Dentlearn.ir

5. *Remove remaining carious dentin.* Removal of remaining carious dentin applies primarily to that in the deepest part (pulpally) of the preparation. Other carious tooth structure was removed when the outline form was established. Caries removal may necessitate a modification of the outline form.
6. *Finish enamel walls and cavosurface margins.* For indirect restorations (those requiring the making of an impression and fabrication of a stone duplicate of the preparation or the creation of a digital image), finishing involves making the walls relatively smooth. For direct and indirect restorations not utilizing bonding, finishing involves removing any unsupported, weak, or fragile enamel and making the cavosurface margin smooth and continuous to facilitate finishing of restoration margins. For bonded resin composite restorations, enamel that is not supported by dentin and is not going to be exposed to significant occlusal loading is frequently

   However, weak, fragile, or unsupported enamel should be removed to prevent fracture due to polymerization shrinkage.
7. *Clean the preparation.* Black referred to this step as "performing the toilet of the cavity." It includes washing or scrubbing away any debris in the preparation and drying the preparation. Afterward, the cavity is inspected for any remaining debris, fragile enamel, and demineralized tooth structure and altered if necessary; then the restoration is placed.

Instrumentation

Hand instruments

Black[2] organized not only the classification of cavity preparations and their parts but also the naming and numbering of hand instruments. *Cutting instruments*, which he also called *excavators*, were to be used in shaping the tooth preparation. All other

Metals

For many years, carbon steel was the primary material used in hand instruments for operative dentistry, because carbon steels were harder and maintained sharpness better than stainless steels. Stainless steels, which are more corrosion resistant than carbon steels, are now the preferred materials for hand instruments, because all instruments must be patients and because

Dentlearn.ir

the properties of stainless steels have improved. There are literally hundreds of formulas for stainless steels,[3] all based on iron and incorporating a significant amount of chromium, some carbon, and very often nickel. Chromium imparts corrosion resistance and brightness to the metal; carbon imparts hardness.

Cutting instruments

Before rotating instruments were available, dentists could cut well-shaped cavity preparations using sharp hand instruments alone. The process was slow. The advent of the dental handpiece in 1871,[4] first attached to a foot-operated engine, allowed increased speed of tooth preparation. Most tooth preparation today is accomplished with rotary instruments, but hand cutting instruments are still important for finishing many tooth preparations. Few preparations involving a proximal surface can be completed properly without the use of hand cutting instruments. It is crucial that hand instruments used for cutting tooth structure or carving restorative materials be sharp.

Design. Hand cutting instruments are composed of three parts: handle (or shaft), shank, and blade[2] (Fig 7-15). The *primary cutting edge* of a cutting instrument is at the end of the blade (called the *working end*), but the sides of the blade are usually beveled and also may be used for cutting tooth structure (Fig 7-16). The *shank* joins the blade to the handle of the instrument and is angled to keep the working end of the blade within 2 to 3 mm of the axis of the handle (Fig 7-17). This angulation is intended to provide balance, so that when force is exerted on the instrument it is not as likely to rotate, which would decrease the effectiveness of the blade and could possibly cause damage to the tooth or soft tissue. Figure 7-17a illustrates an instrument that has a single angle at the junction of the blade and the shank. Because the working end of the blade is not aligned with the handle, the instrument is said to be out of balance. Such an instrument may still be useful in tooth preparation. Its blade will usually be relatively short, and it will usually be used with minimal force. Figure 7-17b shows a shank that has two angles to bring the cutting edge into near alignment with the long axis of the handle to provide balance.

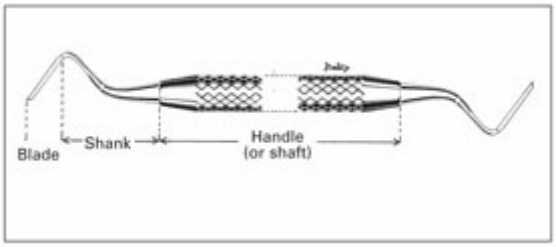

Fig 7-15 Components of a hand instrument. Although the handle is also called a *shaft*, that designation is little used.

Dentlearn.ir

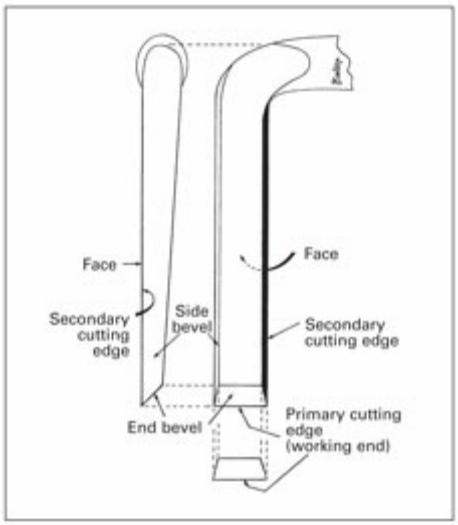

Fig 7-16 Blade bevels. Most hand cutting instruments not only have a bevel on the end of the blade but also have bevels on the sides. Although most of the work of a hand cutting instrument is accomplished with the end of the blade, the sides may also be used to plane or scrape walls and margins. (In the illustration on the right, the blade is lying face down.)

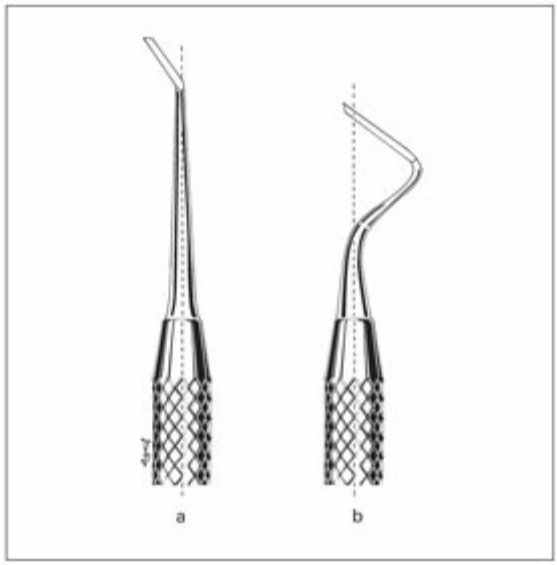

Fig 7-17 The shanks of instruments have multiple angles to keep the working end of the instrument within 2 to 3 mm of the long axis of the handle. *(a)* The working end of this instrument is not close to the long axis of the handle, and the instrument is therefore not balanced. *(b)* The shank of this instrument has two angles in it so that the working end is brought near (within 2 mm) to the long axis of the handle; this provides balance to facilitate control of the instrument during the application of force. The instrument is said to be contra-angled.

A variety of handle configurations are available (Fig 7-18). Padded handles (Fig 7-18b) are said to increase operator comfort and grip during use. Most metal handles today are round and have knurled areas for improved grip. The standard metal handle has a diameter of approximately ¼ inch (6.4 mm). Although little

Dentlearn.ir

research support can be found, handles with larger diameters, such as the 3/8-inch (9.5-mm) diameter handle illustrated in Fig 7-18c, are said to be more ergonomic and less likely to contribute to the development of carpal tunnel syndrome. A handle with an intermediate diameter (5/16 inch or 7.9 mm) is also available. The larger diameters are encouraged primarily for dental hygienists, who spend a large part of their day using hand instruments. A drawback to the use of larger handles in operative dentistry is the space they consume in an instrument tray.

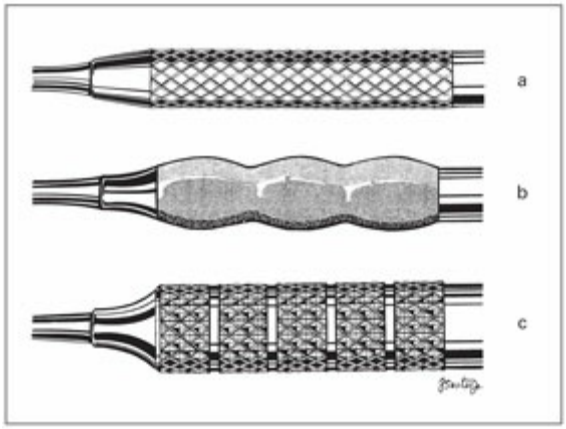

Fig 7-18 Instrument handle configurations. Instrument handles are available from most manufacturers in a variety of designs and diameters. *(a)* Standard stainless steel handle with a diameter of approximately 6.4 mm. *(b)* Padded handles are available; the diameter of the illustrated padded handle is approximately 8 mm. *(c)* Handles with larger diameters are said to be more ergonomic; the diameter of the one illustrated is approximately 9.5 mm.

Nomenclature. The terminology organized by Black[2] in the early part of the last century is still used today, with minor modifications. Most names Black assigned to cutting instruments were based on the appearance of the instrument, such as hatchet, hoe, spoon, and chisel. For an instrument that did not have the appearance of a commonly used item, Black based the name on the intended use (eg, gingival margin trimmer). Black called all cutting instruments used for tooth preparation *excavators*, and he referred to instruments as hatchet excavators, spoon excavators, etc. The term *excavator* is still applicable, but in the day-to-day language of operative dentistry, it is little used. In catalogs of instruments, however, cutting instruments are often indexed as excavators.

Black combined the name of each instrument with a designation of the number of angles in the shank of the instrument. Shanks may be *straight*, *monangle* (one angle), *binangle* (two angles), *triple-angle* (three angles), or *quadrangle* (four angles) (Fig 7-19). The term *contra-angled* refers to a shank in which two or more angles are necessary to bring the working end into near alignment (within 2 to 3 mm) with the axis of the handle (see Fig 7-17b).

Dentlearn.ir

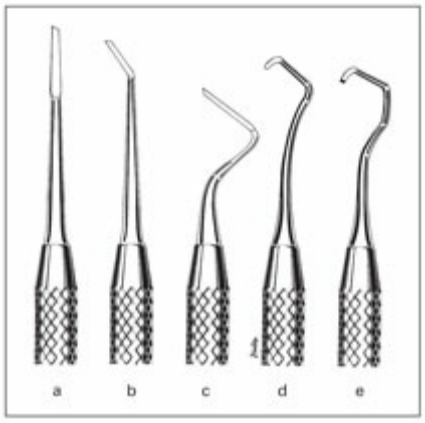

(c) binangle; *(d)* triple-angle; *(e)* quadrangle.

Hatchet. In a *hatchet* (also called an *enamel hatchet*), the blade and cutting edge are on a plane with the long axis of the handle; the shank has one or more angles (Figs 7-19e, 7-20a, 7-21, and 7-22). The face (see Fig 7-16) of the blade of the hatchet will be directed either to the left or the right in relation to the handle, and the instrument is usually supplied in a double-ended form. Therefore, there are left-cutting and right-cutting ends of the double-ended hatchet.



Fig 7-20*(a)* Binangle hatchet. *(b)* Binangle spoon. A double-ended hatchet or spoon would have a left-cutting end and a right-cutting end (see Fig 7-22).

Dentlearn.ir



Fig 7-21*(a and b)* Monangle hatchets (left-cutting).

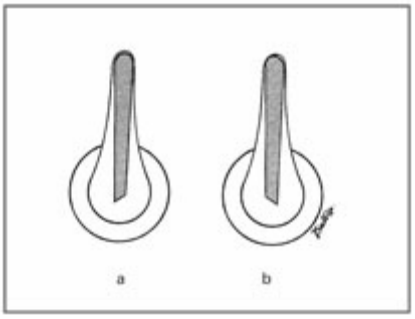

Fig 7-22 End view of binangle hatchets, paired: *(a)* right-cutting; *(b)* left-cutting. A double-ended binangle hatchet has left-cutting and right-cutting ends.

Chisel. A *chisel* has a blade that is either aligned with the handle (Figs 7-19a, 7-23, and 7-24d), slightly angled (Figs 7-19b, 7-24a, and 7-24b), or curved (Fig 7-24c) from the long axis of the handle, with the working end at a right angle to the handle.



Fig 7-23 Straight chisel with bevels on the sides of the blade, to give secondary cutting edges, as well as on the end (primary cutting edge).

Dentlearn.ir

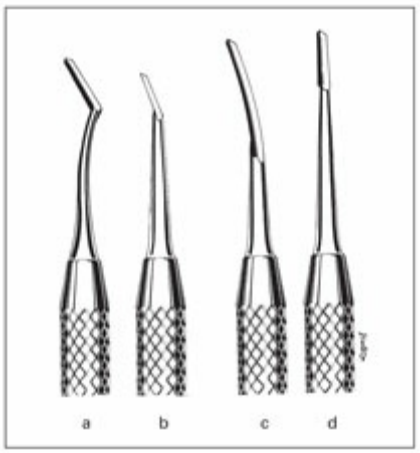

Fig 7-24 Chisels: *(a)* binangle; *(b)* monangle; *(c)* Wedelstaedt; *(d)* straight. The blades for *a*, *c*, and *d* are slightly rotated to visualize the face as well as the side bevel.

Hoe. A *hoe* has a cutting edge that is at a right angle to the handle, like that of a chisel. However, its blade has a greater angle from the long axis of the handle than does the chisel; its shank also has one or more angles (Figs 7-15, 7-19c, and 7-25). A general guideline for distinguishing between a hoe and a chisel will be given later in the chapter.

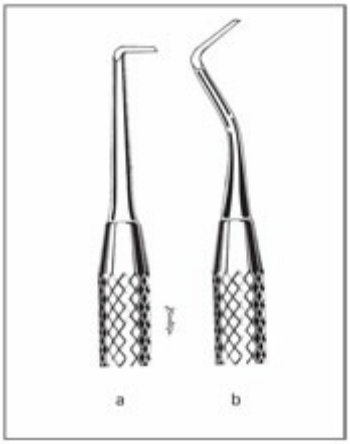

Fig 7-25 Hoes: *(a)* monangle; *(b)* binangle. The blade of a hoe has an angle from the long axis of the handle of greater than 12.5 centi-grades (45 degrees); in contrast, the blade of a chisel will have an angle from the long axis of the handle of 12.5 centigrades (45 degrees) or less (see Figs 7-33 and 7-34).

Spoon. The blade of a *spoon* is curved, and the cutting edge at the end of the blade is in the form of a semicircle (Figs 7-20b and 7-26b); this gives the instrument an outer convexity and an inner concavity that make it look somewhat like a spoon. Like the hatchet, the spoon has a cutting edge at the end of its blade that is parallel to the handle of the instrument; therefore, there are left-cutting and right-cutting spoons. The shank of some spoons holds a small circular, or disk-shaped, blade at its end,

Dentlearn.ir

and the cutting edge extends around the disk except for its junction with the shank; these are called *discoid spoons* (Figs 7-26a and 7-26c).

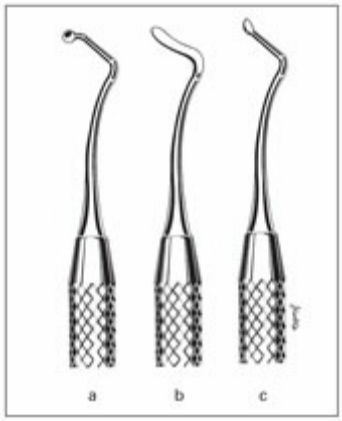

Fig 7-26 Spoons: *(a)* triple-angle discoid spoon; *(b)* binangle spoon (or *regular spoon* or *banana spoon*) ; *(c)* binangle discoid spoon. Spoons are used in tooth preparation for removing (or "spooning out") carious dentin.

Gingival margin trimmer. A *gingival margin trimmer* is similar to an enamel hatchet, except that the blade is curved and the bevel for the cutting edge at the end of the blade is always on the outside of the curve; the face of the instrument is on the inside of the curve (Figs 7-27 and 7-28). Gingival margin trimmers, like hatchets and spoons, come in pairs (left cutting and right cutting) (see Fig 7-27), but there are also mesial gingival margin trimmers and distal gingival margin trimmers (see Fig 7-28). Thus, a set of gingival margin trimmers is composed of four instruments: left-cutting and right-cutting mesial gingival margin trimmers and left-cutting and right-cutting distal gingival margin trimmers. Because these are usually double-ended instruments, one instrument is a mesial gingival margin trimmer (with left- and right-cutting ends), and the other is a distal gingival margin trimmer (with left- and right-cutting ends). Figure 7-28a illustrates a mesial left-cutting gingival margin trimmer. Figure 7-28b illustrates a distal left-cutting gingival margin trimmer. Contrasted with these is a right-cutting hatchet (see Fig 7-28c). Gingival margin trimmers have many uses in addition to trimming gingival margins (Fig 7-29).

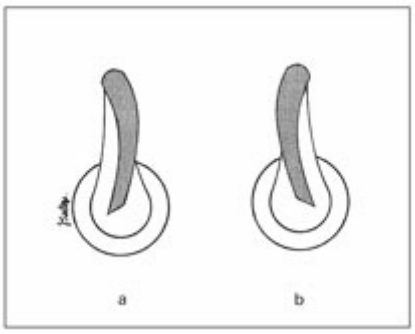

Fig 7-27 End view ft-cutting. A double-

Dentlearn.ir

ended gingival margin trimmer has both left-cutting and right-cutting ends, but there must be two double-ended gingival margin trimmers to complete a set, one double-ended mesial gingival margin trimmer and one double-ended distal gingival margin trimmer.



Fig 7-28*(a)* Left-cutting mesial gingival margin trimmer. *(b)* Left-cutting distal gingival margin trimmer. *(c)* Right-cutting binangle hatchet.

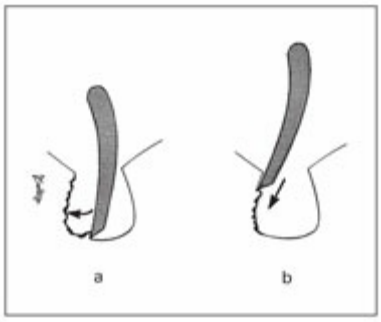

Fig 7-29*(a)* Gingival margin trimmer being used in a proximal box of a Class 2 preparation with a horizontal (left or right) stroke to scrape (plane) a gingival wall and margin. *(b)* Gingival margin trimmer being used with a vertical, or chopping, stroke to plane a facial or lingual wall and margin. A hatchet could be used in a similar way.

Off-angle hatchet. Black's instrument names apply to instruments that have cutting edges that are either parallel or at a right angle to the handle. Instruments have been developed that have blades rotated 45 degrees from the plane of the long axis of the handle; these are called *off-angle hatchets*.

Usage. Hand cutting instruments are, for the most part, made in pairs, and, as with the gingival margin trimmers, most instruments used today are double-ended and will have one of the pair on each end (see Figs 7-15, 7-22, and 7-27). A cutting instrument may be used with horizontal strokes, in which the long axis of the blade is directed at between 45 and 90 degrees to the surface being planed or scraped (see Fig 7-29a), or with vertical or chopping strokes, in which the blade is nearly

Dentlearn.ir

parallel to the wall or margin being planed (see Fig 7-29b). For horizontal (scraping) or vertical (chopping) strokes, the acute angle of the cutting edge is intended for use. The acute angle is the junction of the face of the blade with the bevel; in other words, the bevel is on the back of the blade, not the face of the blade. A double-ended hatchet, gingival margin trimmer, or spoon will have one end that is designated as right cutting and one that is designated as left cutting. In a double-ended hoe, in addition to allowing vertical or chopping strokes, one end is intended for pulling strokes (beveled end or end with distal bevel) and the other is intended for pushing strokes (contrabeveled end or end with mesial bevel).

The cutting edges of most hand cutting instruments used today are single beveled, as are all of those described here (see Fig 7-16). Double-beveled, or bi-beveled, cutting edges are also available but have limited application in contemporary operative dentistry (Fig 7-30). These instruments usually have narrow blades and are used for tasks such as adding mechanical retention points in areas of preparations that cannot be reached by a bur.

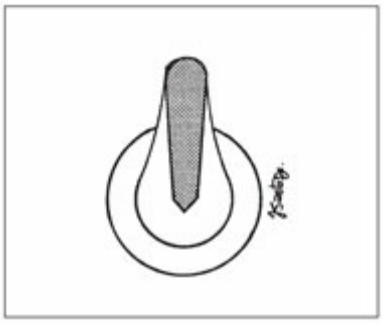

Fig 7-30 Bi-beveled cutting edge. These instruments are useful in placing retention points in some direct gold (gold foil) preparations but have little use in any of the preparations described in this book.

Numeric formulas. The configuration of the shanks combined with the appearance of the blade or the use of the instrument produces names such as straight chisel, monangle chisel, binangle hoe, and triple-angle hatchet. These are descriptive terms, but they are imprecise because they do not indicate sizes or angles. For more complete identification of hand cutting instruments, Black[2] developed a system of assigning numeric formulas to instruments (Figs 7-31 and 7-32). The formulas make use of the metric system. For designating the degree of angulation, *centigrades* are used. Centigrades are based on a circle divided into 100 units (Fig 7-33), as opposed to the 360-degree circle ordinarily used to designate angles. In a centigrade circle, a right angle has 25.0 centigrades.

Dentlearn.ir

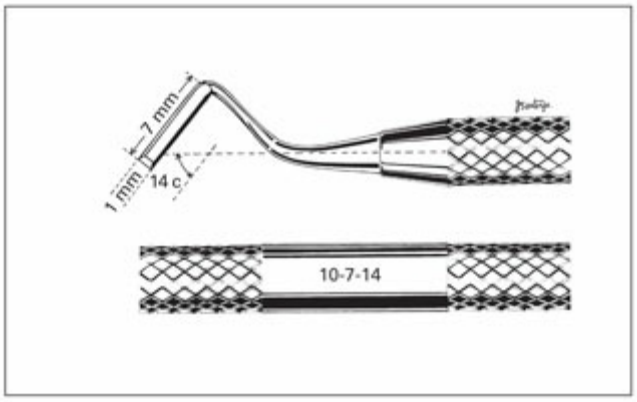

Fig 7-31 Black's three-number formula for instruments that have a primary cutting edge (working end) that is at a right angle (90 degrees) to the long axis of the blade: The first number is the width of the blade in tenths of a millimeter; the second number is the length of the blade in millimeters; and the third number is the blade angle, the angle the blade makes with the long axis of the handle, in centigrades (c). The complete name of the instrument illustrated would be binangle hatchet, 10-7-14. The formula would be the same if the blade were rotated 90 degrees on the shank to form a hoe, but the name would be different. Assuming the instrument illustrated is double-ended, the right-cutting end is shown.

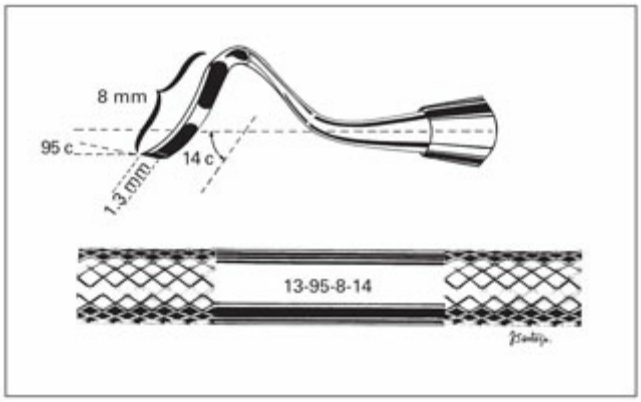

Fig 7-32 Black's four-number formula for instruments that have a primary cutting edge (working end) that is not at a right angle to the long axis of the blade: The first number is the width of the blade in tenths of a millimeter; the second number is the cutting edge angle, the angle the primary cutting edge makes with the long axis of the handle, in centigrades (c); the third number is the length of the blade in millimeters; and the fourth number is the blade angle, the angle the blade makes with the long axis of the handle, in centigrades. Illustrated is the right-cutting end of a distal gingival margin trimmer, 13-95-8-14.

Dentlearn.ir

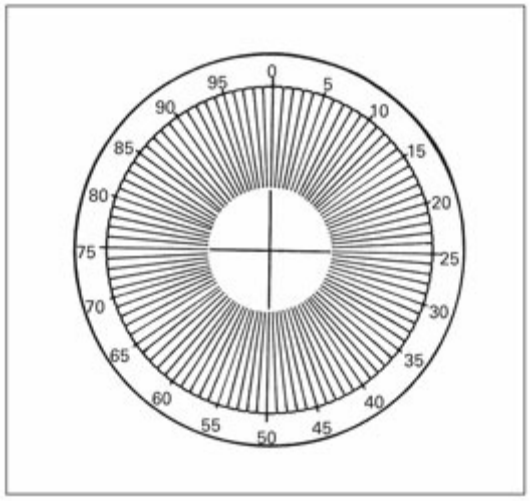

Fig 7-33 Centigrade scale. The circle is divided into 100 units.

Three-number formula. For instruments in which the primary cutting edge (at the end of the blade) is at a right angle to the long axis of the blade, Black developed a formula that has three numbers (see Fig 7-31). The first number is the width of the blade in tenths of a millimeter; the second is the length of the blade in millimeters, and the third is the angle (in centigrades) made by the long axis of the blade and the long axis of the handle (Fig 7-34).



Fig 7-34 Centigrade scale inset to show angulation indicator of 16.0 centigrades for the blade angle of this hoe (three-number formula). The vertical axis (0.0 centigrades) is the axis of the instrument's handle. If the blade of the instrument were ¼ mm wide and 10.0 mm long, the

Dentlearn.ir

formula for the instrument would be 14-10-16.

Four-number formula. For instruments in which the cutting edge at the end of the blade is not at a right angle to the long axis of the blade, such as gingival margin trimmers, Black designed a four-number formula (see Fig 7-32). The first number is the width of the blade in tenths of a millimeter; the second number is the angle (in centigrades) that the primary cutting edge (working end) makes with the axis of the handle (Fig 7-35); the third number is the length of the blade in millimeters; and the fourth number is the angle (in centigrades) that the long axis of the blade makes with the handle. In margin trimmers, a cutting edge angle of greater than 90 centigrades is intended for distal gingival margins (see Fig 7-32); an angle of 85 centigrades or less is intended for mesial gingival margins.

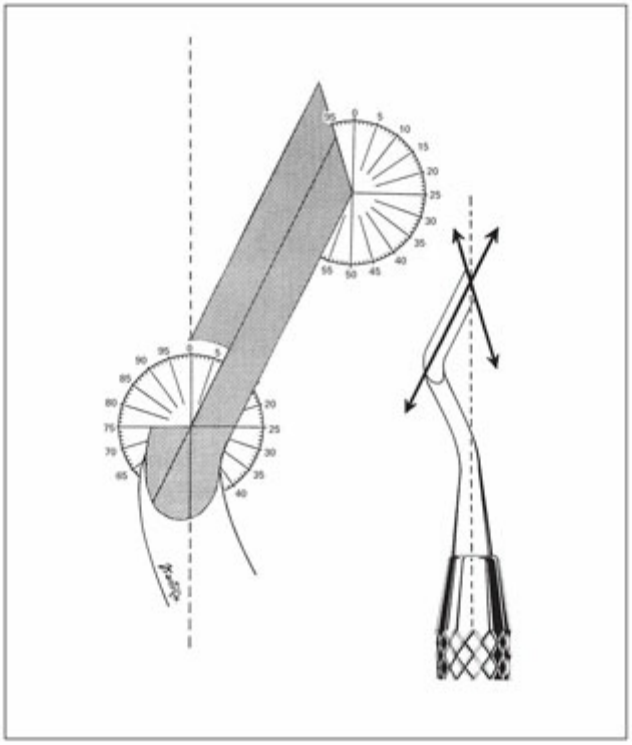

Fig 7-35 Centigrade scales inset to show angulation indicators of 7.0 centi-grades for the blade angle and 95.0 centigrades for the cutting edge angle of this gingival margin trimmer (four-number formula). The vertical axis (0.0 centi-grades) is the axis of the instrument's handle. If the blade were 1.5 mm wide and 10.0 mm long, the formula for the instrument would be 15-95-10-7.

Chisel versus hoe. Although Black defined a chisel as having a blade that is aligned with the handle or slightly curved from it, terminology has evolved so that a chisel may also have a blade that is angled from the handle up to 12.5 centigrades.[5] A chisel with a blade angled more than 3.0 or 4.0 centigrades from the axis of the handle must be binangle for the instrument to be balanced.

Dentlearn.ir

If the blade is angled more than 12.5 centigrades, the instrument is defined as a hoe. In a curved or angled chisel or a hoe, a blade with its primary cutting edge (and its face) on the side of the blade toward the handle is said to be *beveled*, or to have a *distal bevel* (see Figs 7-24a to 7-24c); a blade with its primary cutting edge (and its face) on the side of the blade away from the handle is said to be *contrabeveled*, or to have a *mesial bevel* (see Fig 7-19c).

Recommended instrument kit. Black recommended a long set of 96 cutting instruments, a university set of 44 cutting instruments, or a short set of 25 cutting instruments. Because bonding technology and high-speed handpieces were not available, the dental materials of the time were more limited, and a primary restorative material was direct gold; the longevity of restorations depended on the retention and resistance form developed with hand cutting instruments.

With access to advanced materials and technology, current use of hand cutting instruments is greatly diminished. The kit recommended in this chapter (Box 7-1) has only 12 hand cutting instruments (six double-ended instruments). Because it is now recognized that there is no need to plane walls and floors of cavity preparations to smoothness with hand instruments for a restoration to perform well, hand cutting instruments play only a small, albeit important, part in cavity preparation. If burs alone were used for shaping proximal preparations, excessive sound tooth structure would have to be removed from the tooth being restored or the bur would damage the adjacent tooth. Hand cutting instruments enable the dentist to shape and refine small proximal boxes without damaging adjacent teeth.

Box 7-1	Suggested operative dentistry instrument kit
A compact assembly of hand instruments that will satisfy most operators' needs during any amalgam, resin composite, glass-ionomer, ceramic, or cast gold restorative procedure is presented here. This kit is especially useful for students, residents, and practitioners have used the kit, and, although another instrument may have to be added for a specific situation from time to time, the kit will more than suffice for most procedures. The kit was designed with the sequence of most operative procedures in mind.	Therefore, instrument sequence in the kit proceeds from the mirror and explorer for examination, to the plastic instrument used to facilitate dam placement as well as for placement of materials, to tooth preparation instruments, to restoration placement instruments. The kit uses a 26-slot tray with a small well (open, boxlike section) from American Eagle. American Eagle has this tray and others available with customizable color-coded tabs to facilitate replacement of similarly color-coded instruments into the correct positions in the tray.
In slots (in this order, from left to right, with the open well	

Dentlearn.ir

to the rear):

- Mirror, no. 5 with handle
- Explorer-periodontal probe, XP23/QOW
- Cotton forceps (college, with serrations)
- Plastic instrument, no. 1-2
- Spoon, discoid, 11½-7-14
- Hatchet, 10-7-14
- Hoe, 12-10-16
- Gingival margin trimmer, 10-80-7-14
- Gingival margin trimmer, 10-95-7-14
- Wedelstaedt chisel, 10-15-3
- Applicator/spatula (American Eagle or Miltex)
- Condenser, SA1 (American Eagle or Miltex)
- Condenser, SA2 (American Eagle or Miltex)
- Condenser, SA3 (American Eagle or Miltex)
- Burnisher, beavertail-ovoid, 2/30
- Burnisher, PKT3
- Barghi no. 1 (paddle-shaped for composite) (American Eagle)
- Carver, cleoid-discoid, UWD5
- Carver, Walls no. 3
- Carver, Hollenback no. ½
- Carver, interproximal (IPC)
- Carver, no. 14L
- Articulating paper forceps
- Carrier, amalgam, medium/large

In well of tray:

- Scalpel handle, no. 3, flat
- Sharpening stone, flat, Arkansas or ceramic
- Tofflemire retainer, straight
- Tofflemire retainer, contra-angle
- Amalgam well, stainless steel, small (American Eagle or Miltex)

Clipped to lid of tray:

- Hemostat, mosquito, 5-inch curved
- Scissors, Quimby

Sterilized separately and available for each operative procedure:

- Anesthetic syringe
- Rubber dam kit (forceps; punch; frame; 1 each of clamps W2A, 27, and 212SA; and 2 W8ASA clamps [Hu-Friedy])
- Brasseler bur block (no. A600) with burs arranged in the following order:
  - Friction-grip burs, no. ⅛, ¼, 1, 2, 33 ½, 56, 169L,170, 329, 330, 7404, OS1F, 7803, 7901, ET9F
  - Latch burs, no. 2, 4, 6, 8
  - Mandrel for pop-on disks

Sterilized separately and available for occasional use:

- Condenser, SA4
- Hemostat, mosquito, 5-inch straight
- Mirror, no. 2 (on handle)
- Proximal contact disks (Thierman Products or Centrex) (see chapter 8)
- Rubber dam clamps, 00, W1A, W8A
- Scaler, McCalls, SM13s-14s
- Spatula, no. 24 (or 324)

Hatchets, hoes, chisels, and gingival margin trimmers have straight cutting edges and are designed to plane enamel and dentinal walls and margins in shaping cavity preparations, especially in areas of the preparation that cannot be reached with a bur. Spoons, on the other hand, have rounded cutting edges; their intended use is the removal of carious dentin. Although slowly rotating round burs are most useful in removing carious dentin, a spoon gives more tactile sensation and is preferred by many operators for evaluating the hardness and penetrability of dentin in tooth

Dentlearn.ir

preparation.

Noncutting instruments Non–tooth-cutting hand instruments are similar in appearance to cutting instruments, except that the blade used for tooth preparation is replaced with a part that has a totally different use. In noncutting instruments such as burnishers and condensers, the blade is replaced by a *nib* or *point*.[2] The flat end of the nib of a condenser is called the *face*. Amalgam carvers have carving blades instead of tooth-cutting blades.

Condensers, carvers, and burnishers are used to place dental amalgam and, to a certain extent, resin composite restorative materials. Plastic filling instruments are used to place resin composite and glass-ionomer materials, provisional restorative materials, and sometimes cavity-basing materials into tooth preparations. Spatulas may be necessary for mixing cavity-lining and cavity-basing materials, provisional restorative materials, and cements for luting inlays, onlays, and crowns.

Amalgam carriers. For dental amalgam restorations, amalgam is placed into the preparation with an *amalgam carrier*, an instrument with a hollow cylinder that is filled with amalgam (Fig 7-36). A plunger operated with a finger lever pushes the amalgam out of the carrier into the preparation.

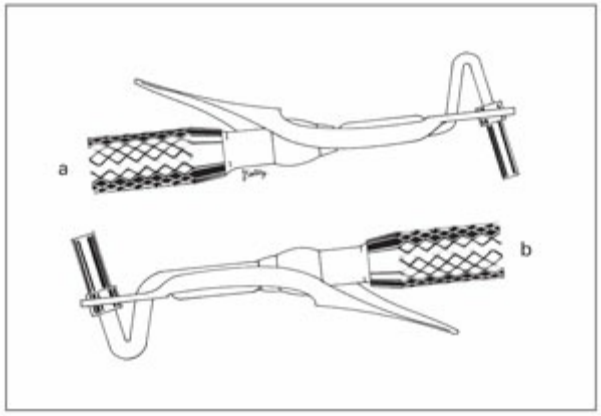

Fig 7-36 Amalgam carriers: *(a)* regular; *(b)* large. Amalgam carriers are usually supplied as double-ended instruments. They are available in several different diameters; for example, mini is 1.5 mm; regular (medium) is 2.0 mm; large is 2.5 mm; and jumbo is 3.0 to 3.5 mm. These are the approximate inside diameters of the cylinders of amalgam carriers and may vary slightly from manufacturer to manufacturer.

Condensers. *Condensers* are used to compress amalgam or to push resin composite or glass-ionomer materials into all areas of the preparation. The working ends, or nibs, of condensers may be any shape, but usually they are round with flat ends (faces). Figure 7-37 shows four round condensers of different sizes and

Dentlearn.ir

configurations. Other commonly used condenser nibs are triangular, rectangular, or diamond shaped. Amalgam is condensed by pushing the condenser directly into the preparation and confining the amalgam between the condenser face and the preparation floor through vertical pressure (vertical condensation). The amalgam is condensed against the vertical walls of the preparation (lateral condensation) by angling the nib and using the end for condensation or by lateral, or side-to-side, movements of the condenser, using the sides of the nib to condense the amalgam.



Fig 7-37 Condensers with round faces: *(a)* SA1, with 0.5- and 0.7-mm-diameter faces; *(b)* SA2, with 0.7- and 1.0-mm faces; *(c)* SA3, with 1.5- and 2.0-mm faces; *(d)* SA4, with a 2.5-mm face on the binangle end and a 1.5-mm face on the triple-angle or back-action end.

The condensation pressure applied to the amalgam with a condenser depends on the size of the face and the amount of force used by the operator. For small condensers, such as the SA1 condenser (see Fig 7-37a), little force is needed. The nibs of the SA1 condenser are 0.5 and 0.6 mm in diameter. For larger condensers, such as the SA3 (see Fig 7-37c), with nib diameters of 1.5 and 2.0 mm, a significant amount of force (6 to 8 lbs) gives optimum condensation.

When condensers are used in placing resin composite or glass-ionomer materials, the resin material is not actually condensed but is pushed or patted into all areas of the preparation with the largest condenser face that will fit into the area. Firm pressure will push the condenser into the increment of composite and risks forming a void in the restoration.

Carvers. *Carvers* are used to shape amalgam and resin composite and other tooth-colored materials after they have been placed in tooth preparations. Figure 7-38 shows the shapes of the blades of a cleoid-discoid carver. Figure 7-39 illustrates six commonly used carvers. In general, when a convex amalgam contour is being carved, a concave-shaped carver facilitates the shaping or carving. Likewise, a convex carver facilitates carving of a concave shape. A convex carver may be used

Dentlearn.ir

to carve a convex surface; the surface is carved tangentially, with multiple strokes. Whether a carver is used to carve amalgam or resin composite, it is important that the blade be sharp.

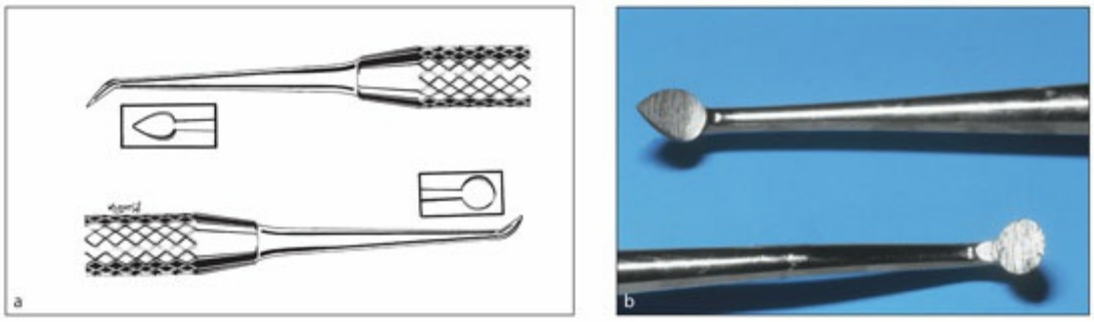

Fig 7-38*(a)* Cleoid-discoid carver: *(top)* cleoid end; *(bottom)* discoid end. This type of carver is a double-ended instrument. *Cleoid* means claw shaped. Both shapes are useful in carving occlusal surfaces of amalgam restorations. The point of the cleoid carver is used to carve the bases of grooves in the occlusal amalgam, and the tip is usually very slightly rounded so that the grooves it carves will not be sharp. *(b)* Cleoid *(top)* and discoid *(bottom)* ends of the cleoid-discoid carver.

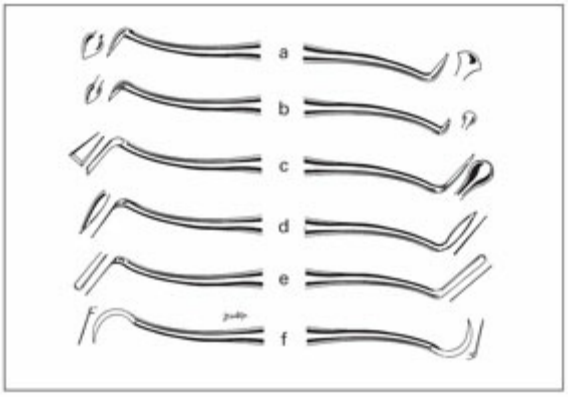

Fig 7-39 Amalgam carvers: *(a)* large cleoid-discoid (Tanner no. 5 [5T]) carver; *(b)* small cleoid-discoid (UWD5) carver; *(c)* Walls no. 3 carver; *(d)* Hollenback no. ½ carver; *(e)* interproximal carver (IPC); *(f)* no. 14L sickle-shaped carver.

The cleoid-discoid (or discoid-cleoid) carvers shown in Figs 7-39a and 7-39b are used primarily for occlusal carving in amalgam restorations. The Walls no. 3 carver (see Fig 7-39c) is useful for carving occlusal surfaces; the end that is shaped like a hoe is also useful for shaping cusps and for carving facial and lingual surfaces of large amalgam restorations. The Hollenback no. ½ carver (see Fig 7-39d) is useful for occlusal, proximal, and axial (facial and lingual) surfaces; several larger Hollenback carvers, with the same general shape, are also available. The interproximal carver (IPC) (see Fig 7-39e) has very thin blades and is extremely valuable for carving proximal amalgam surfaces near the interproximal contact area, as well as those surfaces mentioned for the Hollenback carver (occlusal, proximal,

Dentlearn.ir

axial). Other uses for this instrument include placing and shaping resin composite and glass ionomer and pushing retraction cord into a gingival sulcus. The no. 14L carver (see Fig 7-39f) can be used to carve proximal surfaces, or it may be used for carving convex facial and lingual surfaces of very large amalgam restorations. The no. 14L carver has a very strong, hollow-ground triangular blade, so it can be used to remove amalgam overhangs from completely set amalgam.

Although most of the shaping of resin composite restorations should be completed before the material is polymerized and most operators prefer to use rotary instruments for post-polymerization shaping, several amalgam carvers are also useful for carving resin composite. The discoid carvers are especially useful for lingual concavities of anterior teeth; cleoid and discoid carvers and the hoe-shaped end of the Walls no. 3 carver are useful for occlusal surfaces of posterior resin composite restorations. Another carver very useful for resin composite restorations is a disposable scalpel blade (no. 12 or no. 12B blade) mounted in a scalpel handle.

Burnishers. *Burnishers* are used for several functions. The word *burnish* is defined as "to make shiny or lustrous, especially by rubbing; to polish" and "to rub (a material) with a tool for compacting or smoothing or for turning an edge."[6] Burnishing is probably used in all of these ways in dentistry. Two frequently used double-ended burnishers are illustrated in Fig 7-40.

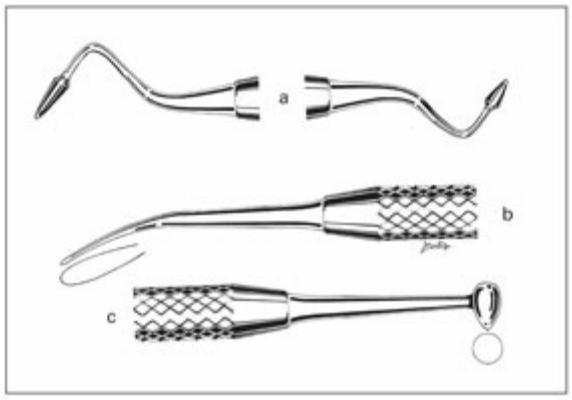

Fig 7-40 Burnishers: *(a)* PKT3 (rounded cone-shaped) burnisher, designed by Peter K. Thomas as a waxing instrument but useful in placing direct restorations as well; its rounded end and cone shape allow it to serve most functions that a small ball-shaped burnisher would serve, plus others; *(b)* beavertail (no. 2) burnisher; *(c)* football or ovoid (no. 30) burnisher. The ovoid burnisher, available in various sizes (eg, 28, 29, and 31), can be used for final condensation of amalgam and the initial shaping of the occlusal anatomy in amalgam. The beavertail and ovoid burnishers are useful for burnishing margins of cast gold restorations.

One use of burnishers is to shape metal matrix bands so that they impart more desirable contours to restorations. Large burnishers are used with considerable

Dentlearn.ir

force to pinch off freshly condensed amalgam at the margins, or, in other words, to impart some condensation and to begin shaping the occlusal surfaces of amalgam restorations. After the amalgam has been carved, a burnisher may be used with a gentle rubbing motion to smooth the surface. The PKT3 (P. K. Thomas no. 3) burnisher (see Fig 7-40a) and some other burnishers are also useful for sculpting occlusal anatomy in posterior resin composite restorations prior to polymerization of the resin.

Burnishers are used to "bend" cast gold near the margin to narrow the gap between the gold and the tooth. This closing of a marginal gap is best accomplished with a narrow burnisher, such as the side of a beavertail burnisher, used with heavy force in strokes parallel to the margin but about 1.0 to 1.5 mm away from it. If burnishing is accomplished directly on a thin gold margin, the gold can be bent severely and may break.

Plastic instruments. *Plastic instruments* (or plastic filling instruments) are so named because they were originally designed to use with plastic restorative materials, such as acrylic resins, or other nonmetal restoratives, such as the silicates, used in the middle of the 20th century. The name does not refer to the material from which the instrument itself is constructed. They are currently used to carry and shape tooth-colored restorative materials, such as resin composites and glass-ionomer restorative materials. Many specially designed instruments are available, in a myriad of shapes and sizes, for contouring resin composite and resin-modified glass ionomer prior to curing. A plastic instrument with a large, slightly curved, paddle-shaped blade (eg, Almore Gold Microfil Instrument, Almore; Fig 7-41a) is very useful for placing and contouring large, anterior resin composite restorations or veneers.

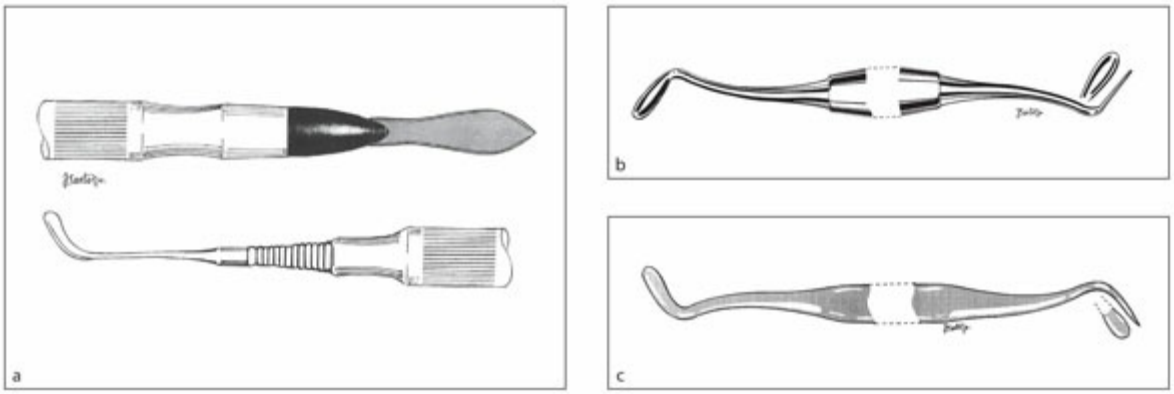

Fig 7-41 *(a)* The Almore Gold Microfil instrument is very useful for placing and contouring large, anterior resin composite restorations or veneers. *(b)* The no. 1-2 plastic instrument, made of stainless steel, is useful for placing a rubber dam, placing and shaping resin composite and other tooth-colored restorative materials, and packing gingival retraction cord into the sulcus around a

Dentlearn.ir

crown or abutment preparation before an impression is made. Some cord-packing instruments are similar to the no. 1-2 plastic instrument but may have serrated ends to provide better control of the cord. *(c)* A plastic instrument made of hard plastic, rather than metal, is preferred by some operators for placing resin composites.

A commonly used plastic instrument is the no. 1-2 (Fig 7-41b). The double-ended instrument has a nib or blade on each end, one at a 90-degree angle to the other. Other double-ended plastic instruments have a blade-type nib on one end and a condenser nib on the other. The bladed plastic instruments have many uses in operative dentistry in addition to carrying and contouring restorative materials. The IPC (see Fig 7-39e), for instance, is preferred by some operators for packing knitted cord and placing and shaping resin composite.

These instruments are now available in both hard plastic and metal, and metal instruments are available with several different coatings on blades or nibs to prevent resin materials from sticking to them. The original rationale for using an instrument made of plastic (Fig 7-41c) was to eliminate abrasion of metal by the quartz in resin composites, which caused grayness in the tooth-colored material. Because of changes in the inorganic fillers used in many of today's resin composites, the problem of metal abrasion and graying is unusual and material-specific, so even a stainless steel instrument functions well to carry and shape resin composite.

Cement spatulas. A variety of materials in operative dentistry require mixing, some on a glass slab, others on a paper pad. Several spatulas are available, and they vary in size and thickness (Fig 7-42). The larger cement spatulas were originally designed for mixing luting cements and the smaller spatulas for cavity liners, but since the advent of resin luting cements, the smaller spatulas are frequently used for mixing small amounts of those materials. The thinner spatulas are flexible; the thicker ones are rigid. Selection of a rigid or flexible cement spatula is dependent on the desired viscosity of the cement and personal preference.



Fig 7-42 Spatulas: *(a)* no. 24, a flexible spatula, is used for luting cements such as zinc phosphate and glass ionomer; *(b)* no. 24A is thicker, for more rigidity; *(c)* no. 313 is used for cavity liners, such as calcium hydroxide liners.

Dentlearn.ir

Sharpening of hand instruments

To assess sharpness, the user of the instrument should look at the cutting edge in bright light; the presence of a glint indicates that the edge is dull or rounded (Fig 7-43). Alternatively, the dentist can pull the instrument across hard plastic, such as the handle of a plastic mouth mirror or an evacuator tip. A dull blade will slide across the plastic; a sharp blade will cut into the surface, stopping movement. A specially made, sterilizable, sharpness-testing stick is also available (Fig 7-44) (Dalron Test Stick, American Eagle or Miltex).



Fig 7-43*(a)* The glint from the cutting edge of this hoe indicates that the blade is quite dull. *(b)* After sharpening, no glint is noticeable.

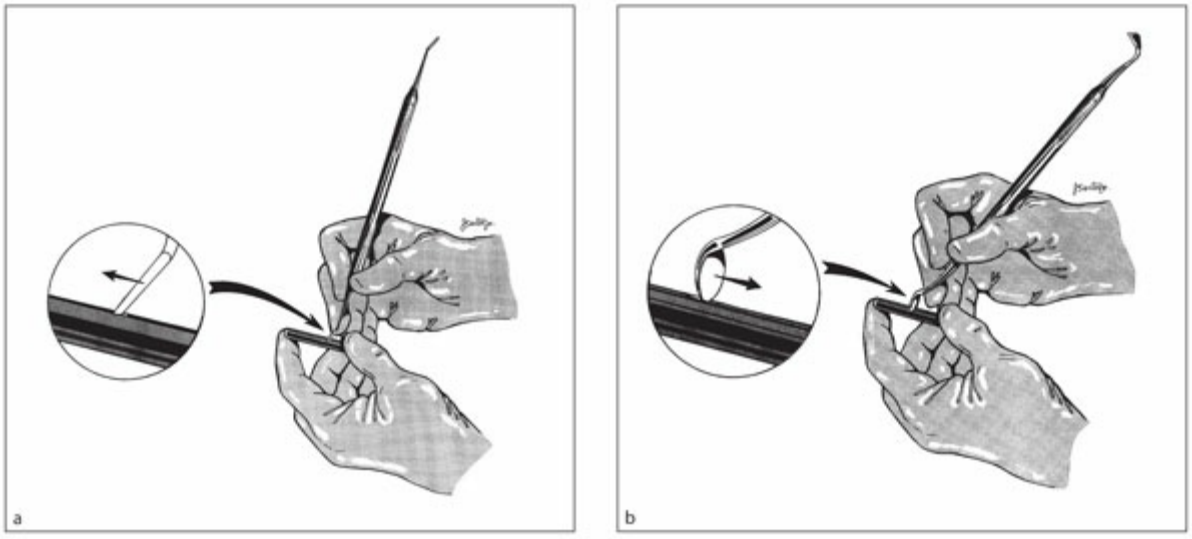

Fig 7-44 The sharpness-testing stick is a hard plastic stick used for testing the sharpness of instruments. To test sharpness, the blade should be applied to the stick at an angle that is similar to that applied during use and pulled or pushed in a direction that is similar to the direction of its intended use. *(a)* Testing the sharpness of a monangle chisel. *(b)* Testing the sharpness of the discoid end of a Walls no. 3 carver.

Sharpening is performed in different ways for different hand instruments. When chisels, hatchets, hoes, and margin trimmers are sharpened, the cutting-edge bevel is placed flat against a flat stone on a stable surface, and the instrument is pushed or pulled so that the acute cutting angle is moved forward, with fairly heavy force on

Dentlearn.ir

the forward stroke and with little or no force on the back stroke (Figs 7-45 and 7-46). Usually, unless the instrument has been badly neglected, only two or three forward strokes are required. Because the bevels of these instruments should usually make a 45-degree angle with the face of the blade, the blade should make a 45-degree angle with the surface of the sharpening stone (Figs 7-46 and 7-47).

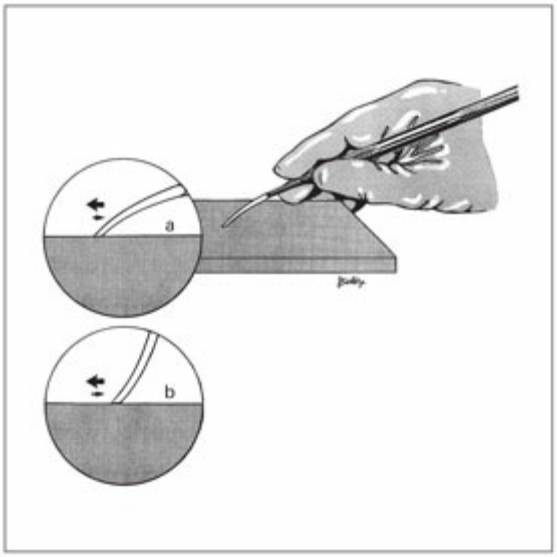

Fig 7-45 Sharpening the two ends of a double-ended Wedelstaedt chisel: *(a)* sharpening the contrabevel end (inside or mesial bevel); *(b)* sharpening the bevel end (outside or distal bevel). The end bevel (for the primary cutting edge or working end) of each blade is placed flat on the stone; the blade will make a 45-degree angle with the stone. In the primary sharpening stroke, the cutting edge is moved forward. Unless the instrument is very dull, only two or three fairly heavy forward strokes will be necessary to sharpen the cutting edge.

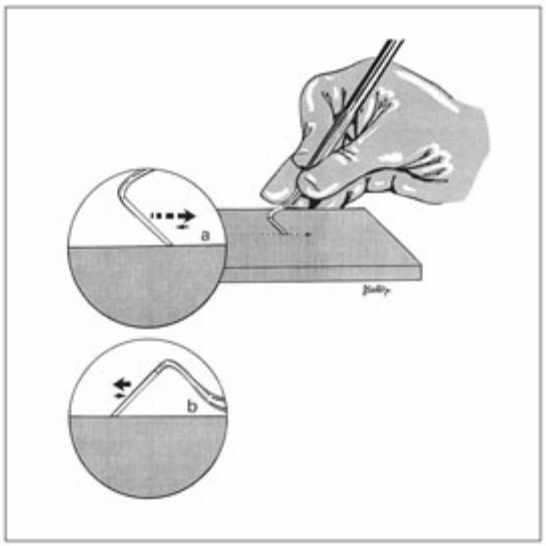

Fig 7-46 Sharpening the two ends of a double-ended binangle hoe: *(a)* sharpening the bevel end (outside or distal bevel); *(b)* sharpening the contrabevel end (inside or mesial bevel). The primary bevel is always flat against the stone; the face of the blade is up.

Dentlearn.ir

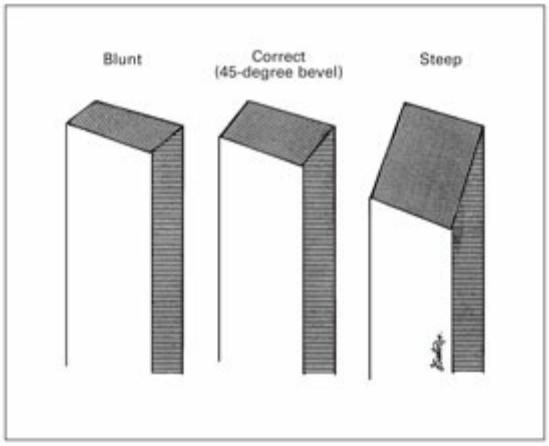

Fig 7-47 Bevels of sharpened cutting instruments. Working-end bevels of chisels, hatchets, and hoes, as well as the bevels of amalgam carvers, should be at approximately 45 degrees to the face of the blade. The cutting edge at the left is too blunt, the center blade has a correctly angled cutting edge, and the cutting edge at the right is too acute and will dull rapidly.

When spoons, discoid carvers, and cleoid carvers are sharpened, the instrument is rotated as the blade is advanced on the flat stone (Fig 7-48). The bevel is at 45 degrees, or slightly more or less, to the face, and the instrument is advanced on the stone with the bevel against the surface of the stone and the cutting edge of the instrument perpendicular to the path of advancement. When a blade with a rounded edge is being sharpened, the handle cannot simply be twirled to achieve the desired rotation but must actually be swung in an arc to keep the cutting edge of the blade perpendicular to the direction of the stroke and the bevel parallel with and against the surface of the stone.

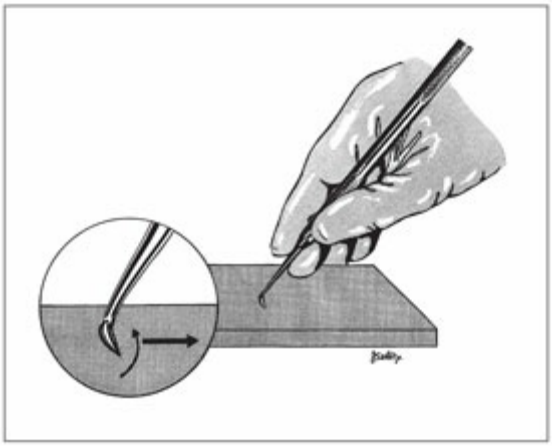

Fig 7-48 Sharpening a cleoid carver. The handle is swung in an arc to rotate the blade as the bevel is pulled forward on the stone. This movement is used to keep the cutting edge perpendicular to the direction of the stroke.

The discoid carver and spoon may be sharpened with a continuous rotation of the

Dentlearn.ir

blade; the shank moves clockwise from the 9 o'clock position to the 3 o'clock position in one motion. For the cleoid carver, however, the rotation begins with the shank in the 9 o'clock position and continues clockwise only until the bevel just next to the point is ground (see Fig 7-48); to sharpen the other side of the cleoid, the rotation begins with the shank at the 3 o'clock position and continues counterclockwise to the point. If sharpening both sides of a cleoid carver creates a sharp point at its tip, the junction of the bevels at the point should be slightly rounded.

The blade of a discoid spoon may be sharpened by grinding the face of the blade with a rotating stone (Fig 7-49). This method of sharpening also thins the blade, and care must be taken to avoid rendering the blade so thin that it could easily break.



Fig 7-49 Sharpening a discoid spoon with a rotating sharpening stone. A discoid spoon may also be sharpened on a flat stone; the blade is rotated as it is pulled with the cutting edge forward. If the face is ground with a rotating stone, the blade will be thinned and could be more likely to break during use.

Sharpening machines are available. A slowly rotating sharpening wheel is employed by one type of machine; an oscillating flat stone, or *hone*, is used by another. These machines are useful for sharpening instruments between patients and before sterilization.

When instruments are sharpened during an operative procedure, they should be sharpened with a sterile stone. When a stone is sterilized, it should not have oil in or on it, because the oil may thicken during the sterilization process and form a shellac-like coating that will prevent the abrasion needed for sharpening. A good substitute for oil is water. Stones lubricated with water should be washed well or cleaned in an ultrasonic cleaner after use to remove the metal filings prior to sterilization. A flat, white Arkansas stone or fine synthetic sharpening stone should be made a part of the operative dentistry instrument kit so that it is available during each procedure.

Mirrors, explorers, periodontal probes, and forceps

Mirrors, explorers, periodontal probes, and forceps are basic instruments that will

Dentlearn.ir

be needed during each appointment for diagnosis or treatment.

Mirrors. For every procedure performed in the mouth, the dentist must have clear and distinct vision of the field. Wherever possible, the field should be viewed with direct vision. When needed, the mouth mirror allows the operator to visualize areas of the mouth that he or she would not otherwise be able to see. It also allows the operator to maintain a body position that will reduce health problems associated with poor posture.

Almost as important as its allowing indirect visualization of obscure areas of the mouth is the mirror's function as a reflector of light into the area being examined or treated. A mirror that is positioned properly allows the operator to visualize the field of operation in the mirror and, at the same time, reflects the operating light into that area. To accomplish this, the light should be positioned behind and directed just to the side of the operator's head and into the mirror.

The mouth mirror can also serve as a retractor of soft tissue (tongue, cheeks, or lips) to aid access and visualization.

For clarity of vision, the reflective surface of the mirror should be on the external surface of the glass. This type of mirror is called a *front-surface mirror* (Fig 7-50a). Mouth mirrors are usually round and come in a variety of sizes (Fig 7-50b). The most widely used sizes for adults are the no. 4 and no. 5. For constricted areas in posterior regions of the mouth, when a rubber dam is in place, a smaller mirror, such as a no. 2, is helpful.

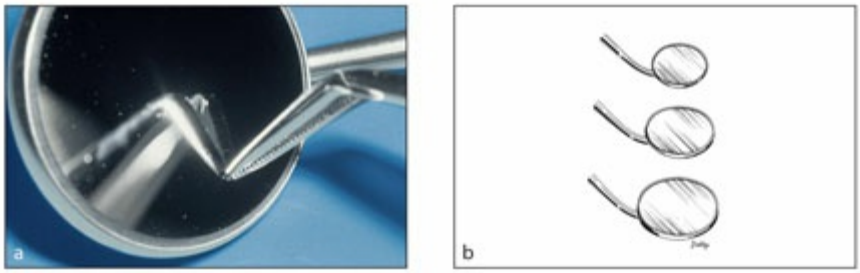

Fig 7-50*(a)* Front-surface mirror. Any object touching the mirror, such as the tips of the cotton forceps, will appear to be touching itself. *(b)* Mouth mirrors: *(top)* no. 2 (5/8-inch diameter); *(middle)* no. 4 (7/8-inch diameter); *(bottom)* no. 5 (15/16-inch diameter).

Explorers. *Explorers* are pointed instruments used to feel tooth surfaces for irregularities and to determine the hardness of exposed dentin. The explorer that is used most often is the shepherd's hook, or no. 23, explorer (Fig 7-51a). Another useful shape is a cowhorn explorer, which provides improved access for exploring proximal surfaces (Fig 7-51b). The no. 17 explorer is also useful in proximal areas

Dentlearn.ir

(Fig 7-51c).

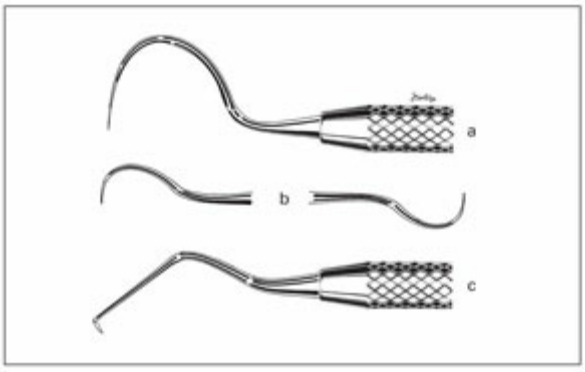

Fig 7-51 Dental explorers: *(a)* no. 23 explorer (shepherd's hook); *(b)* 3CH explorer (cowhorn or pigtail); *(c)* no. 17 explorer.

Periodontal probes. *Periodontal probes* are designed to detect and measure the depth of periodontal pockets. In operative dentistry, they are also used to determine dimensions of instruments and of various features of preparations or restorations. There are many periodontal probe designs; the differences are in the diameters, the position of the millimeter markings, the configuration of the markings (eg, whether they are notched or painted), and the design of the tip. Three commonly used probes are illustrated in Fig 7-52.

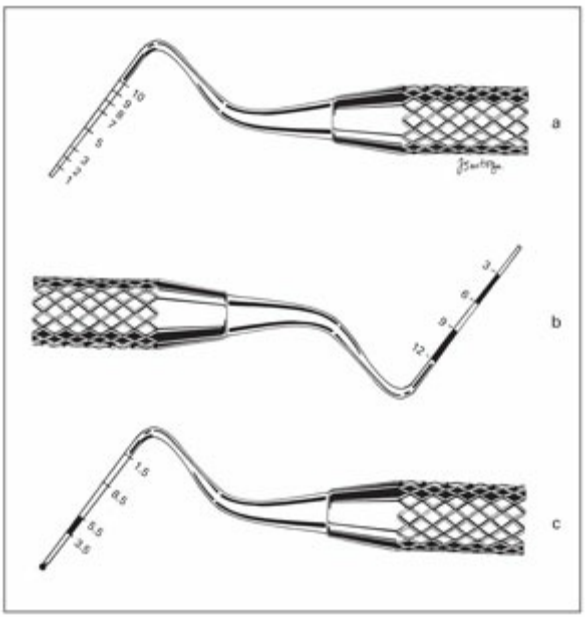

Fig 7-52 Periodontal probes: *(a)* QOW probe (Michigan O probe with Williams markings); *(b)* PCP12 probe (Marquis markings); *(c)* PSR (periodontal screening and recording) probe.

Forceps. Forceps of various kinds are useful in operative dentistry. *Cotton forceps* are used for picking up small items, such as cotton pellets (small cotton balls), and

Dentlearn.ir

carrying them to the mouth (Fig 7-53). Other forceps useful in operative dentistry include articulating paper forceps (Fig 7-54) and hemostatic forceps (hemostats) (Fig 7-55). A *hemostat* locks tightly, so it is often helpful in placing or removing items used to confine amalgam for condensation. *Articulating paper forceps* are designed to carry an inked tape to the mouth to mark the contacts of teeth in opposing arches during closure.



Fig 7-53 Cotton forceps: *(a)* College (no. 17); *(b)* Meriam (no. 18).

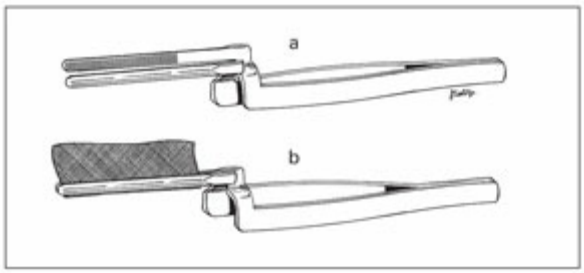

Fig 7-54 Articulating paper forceps: *(a)* Forceps handles provide a spring that keeps the jaws closed together; they are opened (as shown) by squeezing the handle. *(b)* The entire length of the piece of articulating paper or tape is supported by the jaws of the forceps.

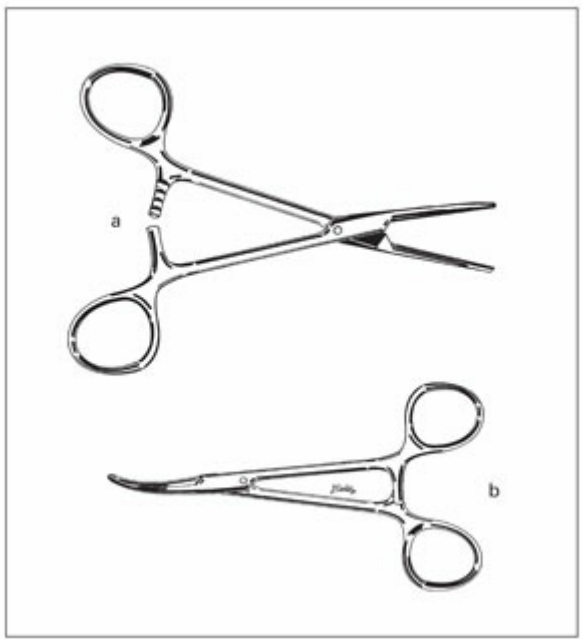

Dentlearn.ir

Fig 7-55 Hemostats: *(a)* Halstead mosquito straight, 7-inch; *(b)* Halstead mosquito curved, 5-inch.

Instrument grasps

The operator should master two basic instrument grasps, the *pen grasp*, which provides more flexibility of movement, and the *palm* or *palm-thumb grasp*, which provides limited movement but controlled power. Usually only one-handed grasps are used, but occasionally two-handed instrumentation is needed to make refinement of a preparation more precise (Fig 7-56).

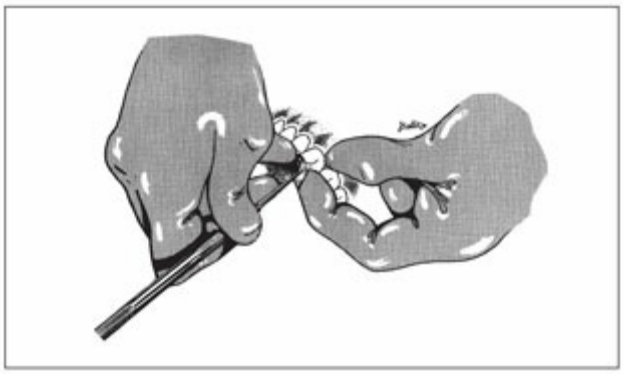

Fig 7-56 Two-handed instrumentation. The use of both hands can make refinement of a preparation more precise. The right hand is thrusting and rotating the instrument while the index finger of the left hand guides and assists the motion of the working end to refine a proximal margin of a Class 2 preparation. A similar dual-handed action is useful for condensing amalgam; it allows increased condensation force to be controlled.

Pen grasp. This is the most frequently used instrument grasp in operative dentistry. The pen grasp is actually different from the way one would grasp a pen (Fig 7-57); the handle of the instrument is engaged by the end, not the side, of the middle finger; this provides more finger power. The pen grasp is initiated by placement of the instrument handle between the thumb and index finger; the middle finger engages the handle near the shank or on the shank itself (Figs 7-57 and 7-58). The ring finger is braced against the teeth to stabilize instrument movement (see Fig 7-58).

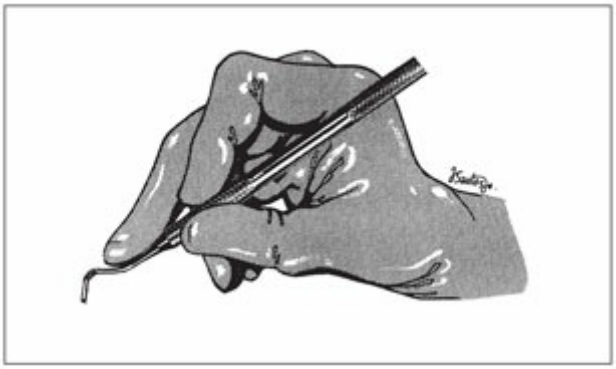

Dentlearn.ir

Fig 7-57 Pen grasp. The pen grasp is not actually the way a pen is held for writing. The instrument is held between the index finger and thumb, and the middle finger is placed atop the handle or shank, nearer the working end of the instrument, to provide more force, or thrust, directed toward the working end of the instrument.

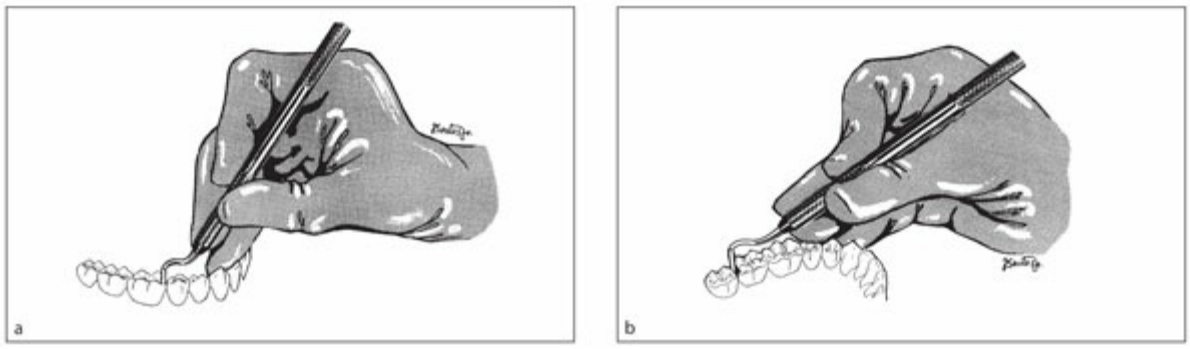

Fig 7-58*(a)* Pen grasp used in a chopping (downward) motion. The ring finger is resting on the incisal edges of the anterior teeth. During the use of any instrument in the mouth (with the exception of the mirror), a firm rest must be achieved on teeth or attached gingival tissue. *(b)* Pen grasp as the instrument is used more posteriorly and with a side-to-side or scraping motion. The small finger and ring finger are resting on the facial and occlusal surfaces, respectively.

Palm or palm-thumb grasp. In this grasp, the thumb serves as a brace (Fig 7-59). Side-to-side, rotating, or thrusting movements of the instrument by the wrist and fingers are controlled by the thumb, which is firmly in contact with the teeth (Fig 7-60).

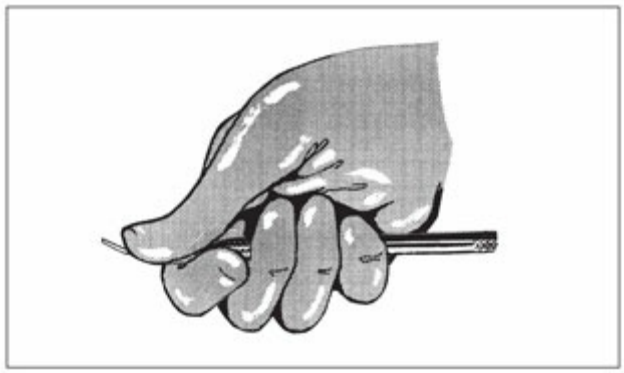

Fig 7-59 Palm-thumb grasp. The instrument is grasped much nearer to its end than in the pen grasp so that the thumb can be braced against the teeth to provide control during movement of the instrument.

Dentlearn.ir

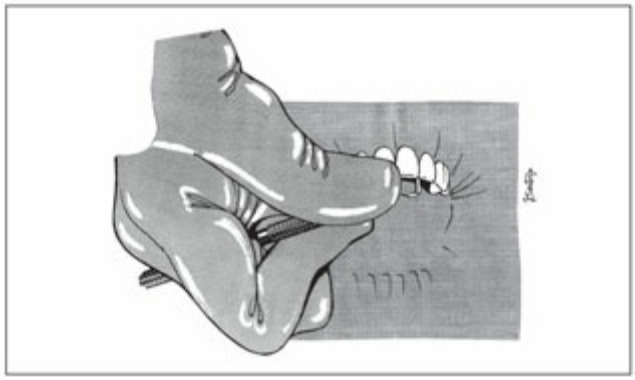

Fig 7-60 The palm-thumb grasp is used frequently when a hand cutting instrument, such as a gingival margin trimmer, is used in Class 3 preparations that have lingual access. The thumb is resting on the incisal edges of the teeth. The palm-thumb grasp is also used frequently with the Wedelstaedt chisel, usually for facial access in posterior and anterior operations, and occasionally for lingual access.

Instrument motions

The following are some of the many motions used with hand instruments:

- Chopping (in the direction of the working end of the instrument or parallel to the long axis of the blade)
- Pulling (toward the operator's hand)
- Pushing (away from the hand)
- Rotating
- Scraping (with the blade directed at an angle between 45 and 90 degrees to the surface being scraped and moved side to side or back and forth on the surface)
- Thrusting (forcibly pushing against a surface)

Rotating instruments

Handpieces

In dentistry, two basic types of handpieces are used: the straight handpiece (Fig 7-61) and the contra-angle handpiece (Fig 7-62). In the straight handpiece, the long axis of the bur is the same as the long axis of the handpiece. The straight handpiece is used more frequently for laboratory work but is occasionally useful clinically.

Dentlearn.ir



Fig 7-61 Straight handpiece. This handpiece is used occasionally in the mouth, but it is more frequently used extraorally, for tasks such as making adjustments to removable prostheses or adjusting and repolishing a cast gold or ceramic restoration prior to insertion. The bur installed in this handpiece is a tree-shaped denture bur.

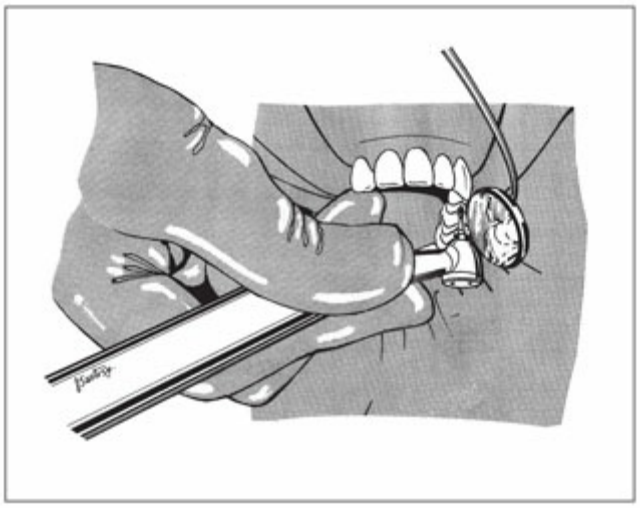

Fig 7-62 Contra-angle handpiece. This is a high-speed contra-angle handpiece, which is used with small-diameter burs for rapid cutting of tooth structure or restorations. A low-speed contra-angle is also useful for removal of carious dentin, with a slowly rotating round bur, and for shaping and polishing with abrasive disks and impregnated rubber polishers. Some operators also prefer the low-speed contra-angle for refining tooth preparations.

The primary handpiece used in the mouth is the contra-angle handpiece. As with hand instruments, *contra-angle* indicates that the head of the handpiece is angled first away from, and then back toward, the long axis of the handle. Also as with hand instruments, this contra-angle design is intended to bring the working point (the head of the bur) to within a few millimeters of the long axis of the handle of the handpiece to provide balance.

Dentlearn.ir

speed potential. Low-speed contra-angle handpieces have a typical free-running speed range of 500 to 15,000 rpm; some are able to slow to 200 rpm, and others are able to achieve speeds of 35,000 rpm. High-speed handpieces can achieve a free-running speed greater than 160,000 rpm, and some handpieces attain free-running speeds up to 500,000 rpm.[7] In the United States, most dentists are accustomed to air-turbine high-speed handpieces. The speed of these handpieces during tooth preparation is 180,000 rpm and lower, depending on the application pressure and the power of the handpiece. For air-turbine handpieces, speeds during tooth preparation are significantly less than their free-running speeds.

Electric handpieces (powered by an electric motor instead of an air-turbine) have been used for some time in Europe, and their use is rapidly growing in the United States. Most electric handpieces achieve free-running speeds of 200,000 rpm, an ideal speed for cutting enamel. Electric handpieces are very efficient in preparing teeth.

High-speed techniques are generally preferred for cutting enamel and dentin. Penetration through enamel and extension of the cavity outline are more efficient at high speed. Small-diameter burs should be used in the high-speed handpiece. High speed generates considerable heat, even with small-diameter burs, and should be used with air and water coolant sprays[8] and high-efficiency evacuation. For refining preparations, a high-speed handpiece may be slowed considerably and used with only air coolant and a gentle brushing or painting motion in which each application of the bur to the tooth is brief. This technique allows visualization and prevents overheating.[9]

Low-speed contra-angle handpieces, with round burs rotating very slowly, are used for removal of carious dentin. Low-speed contra-angle handpieces are also used for various finishing and polishing procedures that use abrasive disks, points, or cups.

There are two types of contra-angles based on their bur-locking, or *chucking*, mechanisms for the low-speed handpiece: a friction-grip chuck and a latch-type chuck. The shanks of the burs that fit into each of these types of contra-angle chuck are shown in Fig 7-63. The high-speed handpiece will receive only the friction-grip bur.

Dentlearn.ir

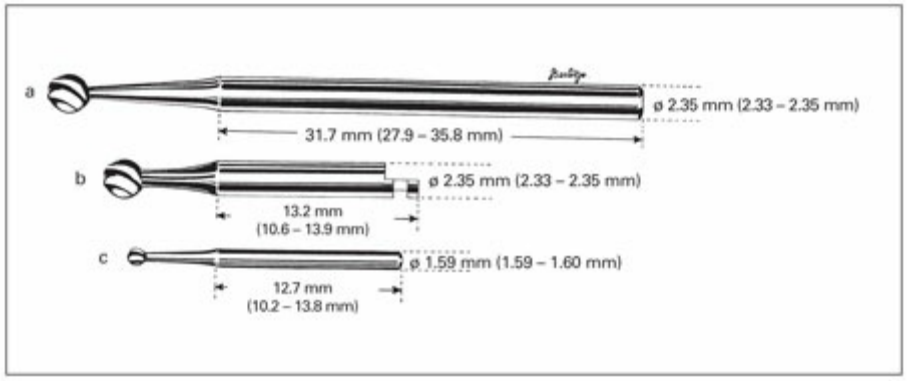

Fig 7-63 Typical dimensions (and ANSI/ADA standard dimension tolerances), in millimeters, of the three common bur designs: *(a)* straight handpiece bur; *(b)* latch-type bur for latch-type contra-angle handpiece; *(c)* friction-grip bur for friction-grip contra-angle handpiece.[10,11]

Burs

Hand-rotated dental instruments are known to have been used since the early 1700s. The foot engine came into use in dentistry in 1871 and the electric engine in 1872.4 The most significant advancement, which has made present-day high-speed cutting possible, is the tungsten carbide bur, which became available in 1947.[10]

Burs have three major parts: the head, the neck, and the shank (Fig 7-64). For the different types of handpieces or handpiece heads, there are burs with different designs and dimensions (see Fig 7-63).

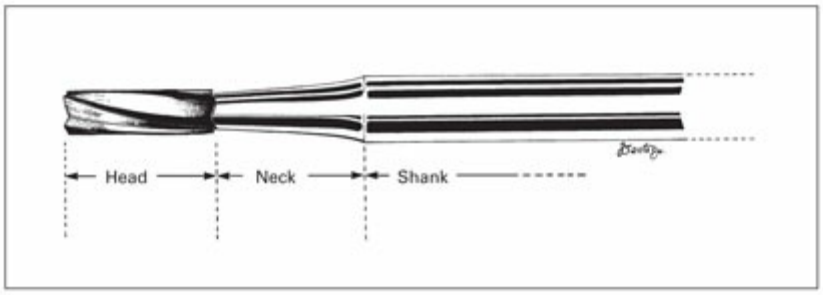

Fig 7-64 Parts of a rotary cutting instrument (bur).

The head of a bur is the portion that cuts. The cutting action is produced by blades on the head, and the blades are produced by cuts made into the head. The angle of the cutting edge of a blade (edge angle) is usually not acute; the angle is in the range of 90 degrees to provide strength to the blade and longevity of cutting efficiency of the bur. A cross section of a typical six-bladed bur is shown in Fig 7-65; the names of the faces and angles of the blades are also shown. The bur in Fig 7-65 has a negative rake angle, as do most burs used in dentistry.[10] The negative rake angle increases the life expectancy of the bur and provides for the most effective performance in low-

Dentlearn.ir

and high-speed ranges.

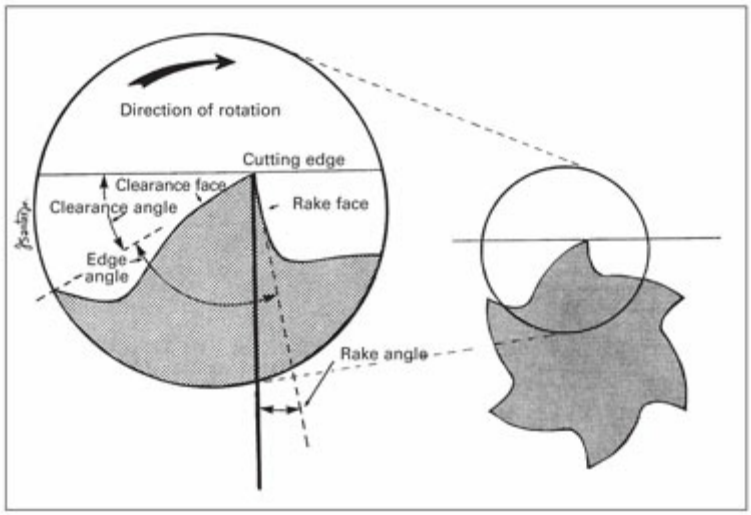

Fig 7-65 Typical bur head, viewed from the end of the bur nearest the handpiece.[5,10]

A positive rake angle would produce a more acute edge angle. Positive rake angles may be used to cut softer, weaker substances, such as soft carious dentin. If a blade with a positive rake angle were used to cut a hard material, such as sound enamel or dentin, it would dig in, leaving an irregularly cut surface, and the cutting edges of the blades would chip and dull rapidly.

The basic shapes of tooth-preparation burs used in operative dentistry are shown in Fig 7-66. Many other shapes are available; most are modifications of these five. Numbering systems have been introduced to describe the shapes of dental burs. The original system, introduced by SS White Dental Manufacturing, had nine shapes based on the burs available at that time.[10] That system has been modified and expanded as new burs have been developed. The American National Standards Institute/American Dental Association (ANSI/ADA) specification[11] provides standard characteristics for dental burs; this specification lists both the US numbers and the International Standards Organization (ISO) numbers for dental burs.

Dentlearn.ir

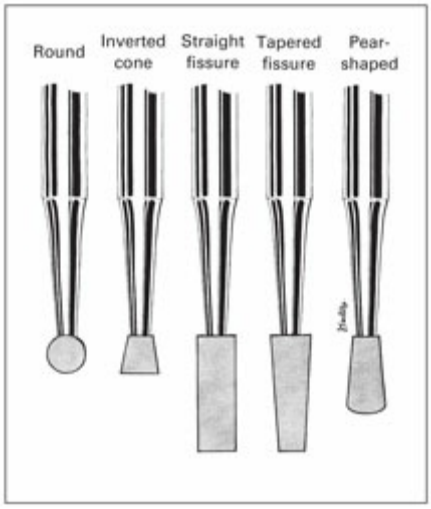

Fig 7-66 Basic bur head shapes for tooth preparation. Most burs used for tooth preparation are modifications of these burs. The primary modifications are lengthening of the bur heads and rounding of ends or corners to allow preparations to be cut without sharp line angles.

Prior to the advent of high-speed handpieces, it was found that additional cuts across the blades of a dental bur increased cutting efficiency; these cuts were called *crosscuts*. Today, with high-speed handpieces, crosscut burs are not normally of any benefit.

Table 7-1 shows diagrams, US bur sizes, and the head diameters of many available regular carbide tooth-preparation burs. ISO sizes for each type of bur can be calculated from the diameter: A bur with a diameter of 0.8 mm will have an ISO size of 008; a diameter of 1.0 mm will have an ISO size of 010. The ISO sizes are combined with the shape of the bur, so an ISO inverted cone 006 is an inverted cone bur with a 0.6-mm major diameter; from Table 7-1, it can be determined that an ISO inverted cone 006 corresponds with a US no. 33½ bur.

Dentlearn.ir

Table 7-1 Shapes and diameters of regular carbide burs used for tooth preparation (US designations*)



Round

Bur size	⅛₈	⅛	¼	½	1	2	3	4	5
Diameter (mm)	0.3	0.4	0.5	0.6	0.8	1.0	1.2	1.4	1.6
Bur size	6	7	8	9	11				
Diameter (mm)	1.8	2.1	2.3	2.5	3.1				



Inverted cone

Bur size	33½	34	35	36	37	39	40
Diameter (mm)	0.6	0.8	1.0	1.2	1.4	1.8	2.1



Straight fissure†

Bur size	55½	56	57	58	59	60
Diameter (mm)	0.6	0.8	1.0	1.2	1.4	1.6



Straight fissure, rounded end (straight dome)†

Bur size	1156	1157	1158
Diameter (mm)	0.8	1.0	1.2



Straight fissure, crosscut†

Bur size	556	557	558	559	560
Diameter (mm)	0.8	1.0	1.2	1.4	1.6



Straight fissure, rounded end, crosscut (straight dome crosscut)

Bur size	1556	1557	1558
Diameter (mm)	0.8	1.0	1.2



Tapered fissure†

Bur size	168	169	170	171
Diameter (mm)	0.8	0.9	1.0	1.2



Tapered fissure, rounded end (tapered dome)†

Bur size	1169	1170	1171
Diameter (mm)	0.9	1.0	1.2



Tapered fissure, crosscut†

Bur size	699	700	701	702	703
Diameter (mm)	0.9	1.0	1.2	1.6	2.1



Pear†

Bur size	329	330	331	332
Diameter (mm)	0.6	0.8	1.0	1.2



Long inverted cone, rounded corners (amalgam preparation)

Bur size	245	246
Diameter (mm)	0.8	1.2



End-cutting

Bur size	956	957
Diameter (mm)	0.8	1.0

* Adapted from American National Standards Institute/American Dental Association Specification 23 and catalogs of Midwest Dental Products and Brasseler.

† Some sizes available with a long head (L).

Dentlearn.ir

Table 7-2 Shapes and diameters of some of the available 12-bladed carbide finishing burs used for smooth cuts in tooth preparation and for finishing restorations (US designations*)

	**Egg**							
	Bur size	7404	7406	7408				
	Diameter (mm)	1.4	1.8	2.3				
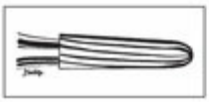	**Bullet**							
	Bur size	7801	7802	7803				
	Diameter (mm)	0.9	1.0	1.2				
	**Needle**							
	Bur size	7901	7902	7903				
	Diameter (mm)	0.9	1.0	1.2				
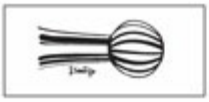	**Round**							
	Bur size	7002	7003	7004	7006	7008	7009	7010
	Diameter (mm)	1.0	1.2	1.4	1.8	2.3	2.7	3.1
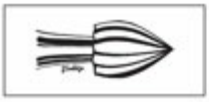	**Flame**							
	Bur size	7102	7104	7106	7108			
	Diameter (mm)	1.2	1.4	1.8	2.3			
	**Cone**							
	Bur size	7202	7204	7205	7206			
	Diameter (mm)	1.0	1.4	1.6	1.8			
	**Long pear (inverted taper)**							
	Bur size	7302	7303	7304				
	Diameter (mm)	1.0	1.2	1.4				
	**Straight fissure**							
	Bur size	7572	7583					
	Diameter (mm)	1.0	1.2					
	**Taper**							
	Bur size	7702	7713					
	Diameter (mm)	1.0	1.2					

*Adapted from catalogs of Midwest Dental Products and Brasseler.

It is useful to know the diameters and lengths of the burs used in tooth preparation so that they can be used as gauges of depth and distance. Bur head lengths may vary from manufacturer to manufacturer, so it is best to measure the individual burs being used and to use their dimensions as references for measuring preparation dimensions.

Another type of bur that is very useful in operative dentistry is the trimming and finishing bur. These burs come in a variety of shapes and sizes; the heads of some trimming and finishing burs are shown in Table 7-2. Trimming and finishing burs are excellent for making very smooth cuts in tooth preparations, for adjusting occlusion in enamel or of a restoration, and for contouring and finishing restorations. Trimming and finishing burs have more blades than tooth-preparation burs, and the greater the number of blades, the smoother the cut surface that can be attained. The number of blades necessary for a desired surface smoothness varies with the diameter of the

Dentlearn.ir

bur; typical trimming and finishing burs have 8 to 12, 16 to 20, or 30 blades.

Many designs of trimming and finishing burs are available for shaping and contouring esthetic restorations. One extremely useful type of trimming and finishing bur that is available with 8, 16, or 30 blades is a straight-sided taper with a safe (noncutting) end (called *esthetic trimming*, or *ET*, *burs* from Brasseler). This bur is designed so that the end will rest on the tooth surface without cutting tooth structure and allow contouring of the adjacent restoration; it is available in several different lengths and diameters, as well as with the different numbers of blades.

Diamonds. Used increasingly in operative dentistry, diamond burs are especially useful for preparations for bonded restorations. Several manufacturers produce diamonds that mimic the shapes of many of the carbide burs. Diamond burs cut tooth structure well and are acceptable substitutes for carbide burs, but many of the smaller sizes are not available as diamond burs. Diamond burs with fine-grit diamond surfaces are also useful for contouring and polishing esthetic restorations.

Air-abrasion technology

In the 1940s, an instrument called the Airdent (SS White) was introduced as a means of cavity preparation.[12] Because all restorations placed at that time depended on cavity-preparation shape for retention, and because the Airdent did not prepare undercuts in preparations, the technology soon lost favor. When it was reintroduced in the 1980s, it received a greater degree of acceptance because bonded restorations had become routine.[13] Etched enamel and dentin, rather than the shape of the cavity preparation, give retention to many restorations. A large number of air-abrasion units are being marketed for opening fissures, for some cavity preparations, and to facilitate repair of existing restorations with bonding technology. An example of a compact and relatively inexpensive air abrasion unit is pictured in Fig 7-67a. More recently, technology has been introduced that includes a curtain of water around the spray of alumina particles (Fig 7-67b). This water curtain reduces the amount of dust generated in the procedure.

Dentlearn.ir

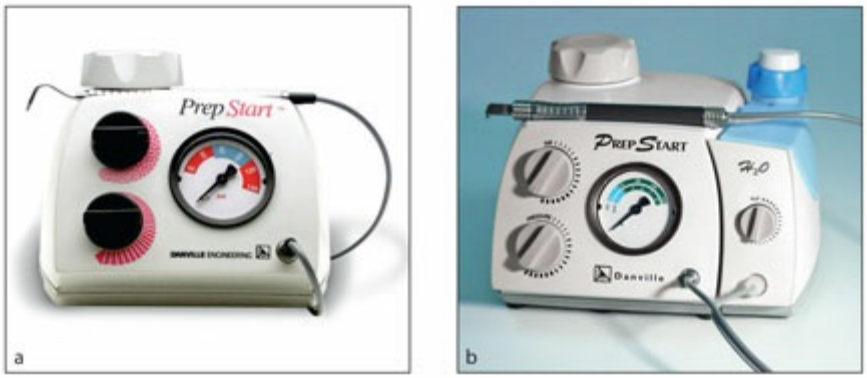

Fig 7-67 *(a)* PrepStart air-abrasion cavity-preparation unit (Danville Materials). *(b)* PrepStart H2O air-abrasion cavity-preparation unit (Danville Materials). This unit is an example of the use of new technology that provides a water curtain around the stream of alumina particles. This greatly reduces the amount of dust that is produced.

Sonic and ultrasonic technology

The use of sonic and ultrasonic technology for tooth preparation has been referenced in the literature for over two decades, especially in conjunction with endodontic biomechanical preparation,[14] and these tools remain popular for endodontic indications.[15] In addition, ultrasonic and sonic tooth preparation is a viable means for conservative cavity preparation.[16] Additional information on ultrasonic cavity preparation is provided in chapter 11.

Visualization and magnification

The quality, and therefore the serviceability and longevity, of dental restorations is dependent on the ability of the operator to see what he or she is doing. One of the primary advantages of the rubber dam in operative dentistry is improvement of the visualization of the operating field. Most current contra-angle handpieces have fiber-optic systems by which lights are placed in the contra-angle heads to improve visualization of the operating field.

Magnification devices are extremely helpful in restorative procedures, and some form of magnification is recommended for every dentist providing restorative dentistry services.[17] Available magnification devices run the gamut of effectiveness and expense. Among the finest magnifiers are the telescopes (Fig 7-68), which are the most expensive. Less expensive loupes are available from several manufacturers (Fig 7-69).

Dentlearn.ir



Fig 7-68*(a and b)* Binocular telescopes (in-the-lens type) manufactured by Designs for Vision. *(c)* Binocular telescopes (in-the-lens type) manufactured by Orascoptic. *(d)* Binocular telescopes (frame-mounted flip-down type) manufactured by Orascoptic. *(e)* Binocular telescopes (headband-mounted flip-down type) manufactured by Orascop-tic.



Fig 7-69*(a)* Binocular loupes manufactured by Almore International. *(b)* Binocular loupes manufactured by Edroy Products.

In choosing a magnification device, the operator is wise to select one that gives a focal distance in the range of 10 to 14 inches. The 2.0- to 4.0-diopter range is recommended. In addition, magnifiers are available that are mounted into the lenses of eyeglasses (see Figs 7-68a to 7-68c) or that flip down either from the glasses frame (see Fig 7-68d) or a headband (see Figs 7-68e and 7-69).

References

1. Glossary of Operative Dentistry Terms, ed 1. Washington, DC: Academy of Operative Dentistry, 1983.
2. Black GV. A Work on Operative Dentistry. Chicago: Medico-Dental, 1908.
3. Metals Handbook, ed 10, vol 1. Materials Park, OH: American Society of Metals, 1990:841–842,908–909.

Dentlearn.ir

4. Ring ME. Dentistry: An Illustrated History. New York: Abrams, 1985:251.
5. Charbeneau GT. Principles and Practice of Operative Dentistry, ed 3. Philadelphia: Lea & Febiger, 1988.
6. Webster's Ninth New Collegiate Dictionary. Springfield, MA: Merriam-Webster, 1988.
7. Young JM. Dental air-powered handpieces: Selection, use, and sterilization. Compend Contin Educ Dent 1993;14:358–366.
8. Lauer H, Kraft E, Rothlauf W, Zwingers T. Effects of the temperature of cooling water during high-speed and ultrahigh-speed tooth preparation. J Prosthet Dent 1990;63:407–414.
9. Bouschor CR, Matthews JL. A four-year clinical study of teeth restored after preparation with an air turbine handpiece with an air coolant. J Prosthet Dent 1966;16:306–309.
10. Roberson TM, Heymann HO, Swift EJ. Sturdevant's Art and Science of Operative Dentistry, ed 5. St Louis: Mosby-Elsevier, 2006.
11. American National Standards Institute/American Dental Association Specification No. 23 (Revised) for Dental Excavating Burs. Chicago: American Dental Association, 1982.
12. Black RB. Technique for nonmechanical preparation of cavities and prophylaxis. J Am Dent Assoc 1945;32:955–965.
13. Goldstein RE, Parkins FM. Air-abrasive technology: Its new role in restorative dentistry. J Am Dent Assoc 1994;125:551–557.
14. Dummer PM, Alodeh MH, Doller R. Shaping of simulated root canals in resin blocks using files activated by a sonic handpiece. Int Endod J 1989;22:211–215.
15. Kanter V, Weldon E, Nair U, et al. A quantitative and qualitative analysis of ultrasonic versus sonic endodontic systems on canal cleanliness and obturation. Oral Surg Oral Med Oral Pathol Oral Radiol Endod 2011;112:809–813.
16. Koubi S, Tassery H. Minimally invasive dentistry using sonic and ultrasonic devices in ultraconservative Class 2 restorations. J Contemp Dent Pract 2008;9:155–165.
17. Christensen GJ. Magnification. Clin Res Assoc Newsletter 1990;14(10):1.

Dentlearn.ir



Field Isolation

James B. Summitt

There are many ways to isolate an area of the mouth or a tooth so that restorative services can be performed without interference from soft tissues, the tongue, saliva, or other fluids. Various tongue- and cheek-retracting devices and suction methods may be used; some of these are discussed later in this chapter. By far the most complete method of obtaining field isolation is the rubber dam, the primary subject of this chapter.

Rubber Dam

Sanford C. Barnum is credited with introducing the rubber dam to the dental profession in 1864.[1] For many years, the rubber dam has been recognized as an effective method of obtaining field isolation, improving visualization, protecting the patient, and improving the quality of operative dentistry services. It has been demonstrated that most patients prefer the use of the rubber dam for restorative procedures.[2–4] The dam has been acknowledged as an important barrier for prevention of microbial transmission from patients to members of the dental care team. In addition, it is medicolegally prudent to use a dam for procedures in which small objects, such as dental burs or endodontic files, could be aspirated by the

Dentlearn.ir

patient.

Experts in restorative dentistry[5,6] have emphatically stated that the use of the rubber dam not only boosts the quality of restorations but also increases quantity of restorative services because patients are unable to talk or expectorate when the dam is in place. They have further stated that the operating field can only be maintained free of saliva and other contaminants with the dam in place, and the field is more accessible, airborne debris is reduced, and the patient feels more comfortable.

Complete isolation is important for the operative field, but not specifically the use of the rubber dam. One study[7] evaluated longevity and performance of facial cervical resin composite restorations: two-thirds were performed with rubber dam isolation and one-third with thorough isolation using a saliva ejector, cotton rolls, and gingival retraction cord. In 3 years, there was no significant difference in restorations were completely retained; of those placed using non–rubber dam isolation methods, all were retained at 3 years.

There is some evidence that indicates that rubber dam use during resin bonding procedures involving enamel leads to improved bond strengths[8] and reduced microleakage,[9] while other studies have shown no difference in outcomes for restorations placed with rubber dam or good cotton roll isolation (in cavities with enamel margins).[10–14] There is also evidence that salivary contamination can adversely affect the bond strength provided by some dentin bonding systems[15–17] and that restorations placed with a rubber dam in place prior to cavity preparation provided higher bond strength than if the rubber dam was placed after preparation.[18] It should again be emphasized that avoidance of contamination of the operating field is what is important in bonding procedures and other operative procedures and that adequate isolation can often be obtained by measures other than the use of the dam.

Most dentists are taught the use of the rubber dam in dental school, and many suffer tremendous frustrations during rubber dam applications. For the dam to be used and to actually save chair time, the practitioner must be able to apply it quickly and easily. This chapter is designed to describe methods that facilitate use of the rubber dam.

Instruments and materials

Rubber dam material

Dentlearn.ir

Rubber dam materials are currently available in an array of colors, ranging from green to lavender to gray to ivory. It is important in operative dentistry to use a dam color that contrasts with the color of teeth; the ivory-colored dam is therefore not recommended for operative dentistry procedures. The original gray dam is still available, but the bright colors have gained popularity. Some operators use the gray dam because they believe that it is better for matching shades in tooth-colored restorations. Because shades of restorative materials are selected prior to rubber dam placement and tooth color changes with the enamel desiccation that accompanies rubber dam use, the restorative shade is probably not affected by the use of a brightly colored rubber dam.

Because of the increased incidence of latex allergies, a number of nonlatex dams are now available. Some dental practices have gone to nonlatex dams exclusively as part of their efforts to be latex free. More information on latex allergies appears later in this chapter.

Rubber dam material is available in rolls, either 5 or 6 inches wide, from which squares may be cut. It is also available in sheets that are 5 inches square, usually used for children, and 6 inches square.

Rubber dam material is available in several thicknesses, or gauges (Table 8-1). The heavy and extra-heavy gauges are recommended for isolation in operative dentistry. If the rubber of the heavier gauges is passed through the interproximal tooth contacts in a single thickness and not bunched in the contacts, the heavy dams are no more difficult to apply than are the thinner materials, and heavier dams are less likely to tear. The heavier materials provide a better seal to teeth and retract tissues more effectively than the thinner materials.

Table 8-1 **Available rubber dam thicknesses (gauges)***

Gauge	Thickness (range)*
Thin	0.006 (0.005—0.007) inch
Medium	0.008 (0.007—0.009) inch
Heavy	0.010 (0.009—0.015) inch
Extra heavy	0.012 (0.0115—0.0135) inch
Special heavy	0.014 (0.0135—0.0155) inch

*Thickness ranges listed by Hygenic.

Dentlearn.ir

Latex rubber dam material has a shelf life of more than a year, but aging is accelerated by heat. Extra boxes of dam material can be stored in a refrigerator to extend the shelf life. Latex dam material that has exceeded its shelf life becomes brittle and tears easily; unfortunately, this is usually noticed during dam application. A simple test for the resistance of rubber dam material to tearing is to attempt to tear a sheet grasped with thumbs and index fingers; a strong dam will be very difficult to tear. Brittle dam material should be discarded. If the material was recently purchased, it should be returned to the supplier for replacement.

Napkin

The rubber dam napkin is a piece of strong, absorbent cloth or paper placed between the rubber dam and the patient's face. The napkin provides greater comfort for the patient, especially during unusually long procedures. Napkins are available in two shapes (Fig 8-1). The smaller napkin is usually used with rubber dam frames; the larger provides padding for the side of the face when retracting straps are used.



Fig 8-1 Rubber dam napkins (Hygenic) for longer procedures. Napkins provide padding between the rubber dam and the face and lips, making the dam more comfortable for the patient. The small napkin is for use with rubber dam frames. The larger napkin is for use with strap- or harness-type rubber dam holders.

Punch

At least two types of rubber dam punches are available (Fig 8-2). The Ainsworth-type punch, which is made by several manufacturers, is excellent if it is well made. The Ivory punch (Heraeus Kulzer) is also excellent and has a self-centering coned piston, or punch point, which helps to prevent partially punched holes (Fig 8-3). Punches should have hardened steel cutting tables (or anvils) with a range of hole sizes so that the dam will seal against teeth of various cervical dimensions (Fig 8-4).

Dentlearn.ir

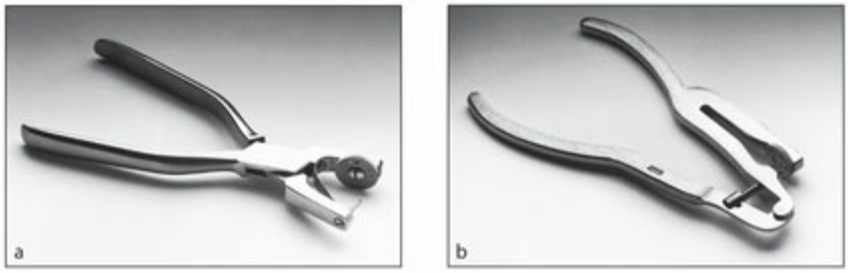

Fig 8-2*(a)* Ainsworth-design (Hygenic) rubber dam punch. *(b)* Ivory-design rubber dam punch.

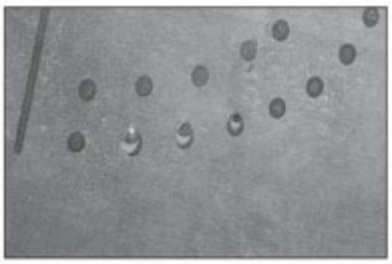

Fig 8-3 Partially punched holes. Stretched rubber dam shows the flaps of dam material left when holes are incompletely punched. The flaps will prevent proper seal. If the flaps are torn off, ragged edges can lead to tearing of the dam during application.



Fig 8-4 The cutting table, or anvil, of a rubber dam punch should have a range of hole sizes. Pictured is the cutting table from an Ivory punch.

Occasionally, the rim of a hole may be damaged because the rotating cutting table was not snapped completely into position before an attempt was made to punch a dam. Holes must be cleanly cut; incompletely punched holes (see Fig 8-3) will promote tearing of the dam during application or will affect the ability of the dam to seal.

A damaged hole rim in the cutting table will cause incomplete cutting. A damaged wheel should usually be replaced; the manufacturer of the punch can replace a damaged wheel.

Hole-positioning guides

Although many operators punch the holes without a positioning aid, most find it

Dentlearn.ir

helpful to have some form of guide to determine where the holes should be punched. There are several ways to mark a rubber dam so that holes can be located optimally.

Teeth as a guide. The teeth themselves, or a stone cast of the teeth, can be used in marking the dam. To use this method, the dam is held in the desired position in the mouth, or on the stone cast, over the teeth to be included in the isolation. The cusp tips of posterior teeth and incisal edges of anterior teeth can be visualized through the dam, and the centers of the teeth are marked on the dam with a pen. An advantage of this method is precise positioning of the marks even when teeth are malaligned. Its disadvantages include the time-consuming nature of the procedure and the inability to punch a dam before the patient is seated.

Template. Templates are available to guide the marking of the dam (Fig 8-5). These templates are approximately the same size and shape as the unstretched rubber dam itself. Holes in each template correspond to tooth positions. The template is laid over the dam, and a pen is used to mark through selected holes onto the dam. With the template, the dam can be marked and punched before the patient is seated.

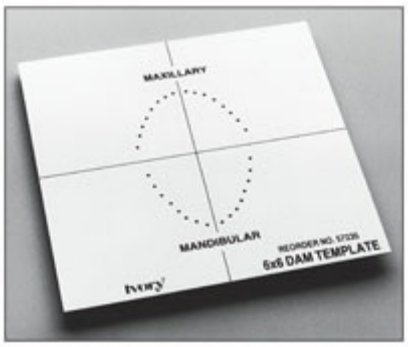

Ivory template for marking the dam. Marks corresponding to the teeth to be isolated are made on a 6-inch rubber dam through the holes with a felt-tipped or ballpoint pen.

Rubber dam stamp. Rubber stamps provide a very convenient and efficient way of marking the dam for punching (Fig 8-6). There are commercially available stamps, or stamps can be made by any rubber stamp manufacturer from a pattern, such as the one shown in Fig 8-7, or any custom design. Dams should be prestamped by an assistant so that the marks for the maxillary central incisors are positioned approximately an inch from the top of the dam. Exceptions to normal tooth position are easily accommodated.

Dentlearn.ir



Fig 8-6 Rubber dam stamp for the adult dentition.

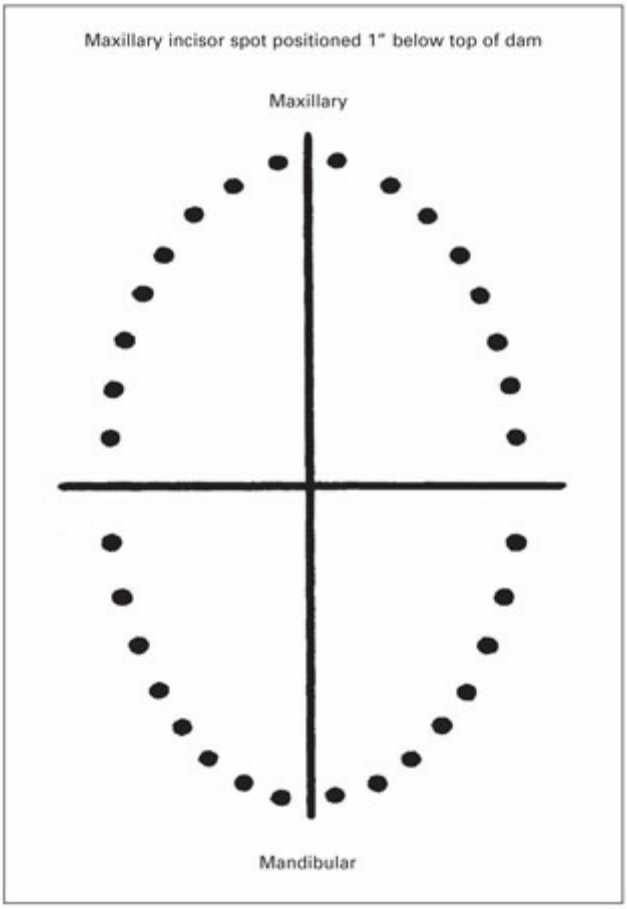

Fig 8-7 Pattern for a rubber dam stamp. This may be duplicated and taken to a rubber stamp manufacturer.

Rubber dam holders

Strap holders. Strap holders (Fig 8-8) provide the most cheek and lip retraction, access, and stability but may cause the most discomfort to the patient. A rubber dam napkin is a necessity for patient comfort when a strap holder is used. The Woodbury retractor grasps the dam material with spring-loaded clips. When posterior teeth are

Dentlearn.ir

isolated with a Woodbury-type holder, a tuck or fold in the dam may be needed (Fig 8-9).



Fig 8-8 Strap- or harness-type rubber dam holders provide excellent lip and cheek retraction. Pictured is a Woodbury retractor (Sulter Dental).



Fig 8-9 A fold or tuck is made in the rubber dam to provide an uncluttered operating field.

Frame holders. Frame holders are exemplified by the Young frame (Young Dental) and the Nygaard-Ostby frame (Coltène/ Whaledent) (Fig 8-10). A U-shaped Young-type frame is made by several manufacturers in both metal and plastic. The Young-type frames are available in both adult and child sizes. A plastic frame is advantageous when radiographs will be a part of the procedure because it is radiolucent. The plastic frames do not, however, stand up to heat sterilization as well as do metal frames, and they have a shorter life span. Metal frames are less bulky and last for years.[19] They are available with balls on the ends to protect the patient in the event that the frame is inadvertently pushed toward the eyes.

Dentlearn.ir

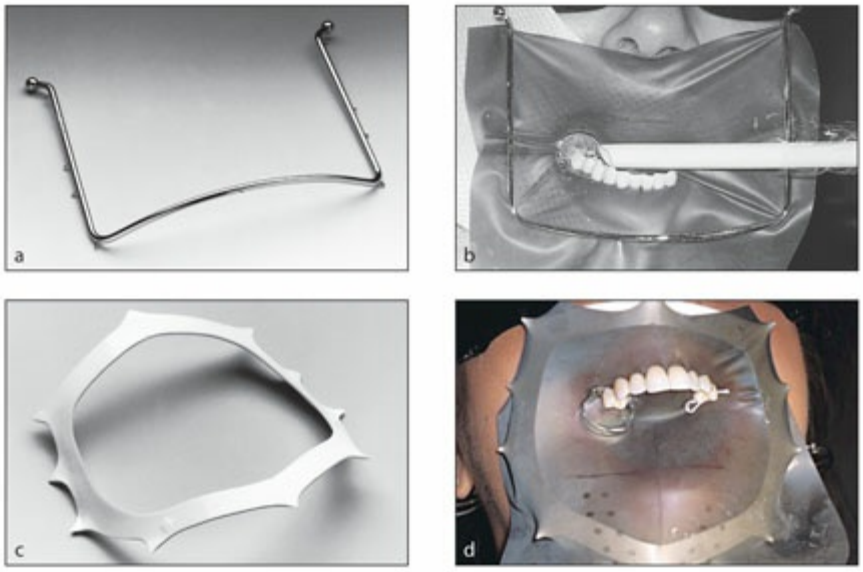

Fig 8-10*(a)* Metal Young frame with eye protectors. *(b)* Young frame inserted into the external surface of the dam. *(c)* Plastic Nygaard-Ostby frame. *(d)* Nygaard-Ostby frame inserted into the

The Young frame is usually positioned on the outside surface of the dam so that it is not in contact with the patient's face. The Nygaard-Ostby frame is normally positioned on the tissue surface or inside surface of the dam and touches the patient's face (or the rubber dam napkin). All frames have points or pegs over which the dam material is stretched to provide a clear operating field and to hold the frame in position. Some Young-type frames come with a hook on each side for attachment of a strap. The strap is run around the back of the head and can be tightened to pull the frame posteriorly to better retract lips and cheeks. If the operator doesn't find the strap useful, the hooks may be cut off, leaving an additional point on each side of the frame for attachment of the dam.

Preattached frames. One commercially available rubber dam (HandiDam, Aseptico) comes with a built-in frame and a rod for insertion to keep the dam open (Fig 8-11). OptraDam Plus (Ivoclar Vivadent) incorporates an integral frame that fits intraorally to assist in cheek retraction. This device may often be used without clamping. A similar device, OptraGate (Ivoclar Vivadent) is useful for retracting lips and cheeks in the anterior region. While not strictly a field isolation device, it helps to improve access and visualization of the field.

Dentlearn.ir



Fig 8-11 In the HandiDam, the frame is an integral part of the dam.

Clamp forceps

Ivory-type clamp forceps (Fig 8-12a) are available from several manufacturers and with differently angled beaks. Ivory forceps (Heraeus Kulzer) have stabilizers that prevent the clamp from rotating on the beaks (Fig 8-12b). This is usually advantageous, but it limits the use of these forceps to teeth that are within a range of normal angulation.

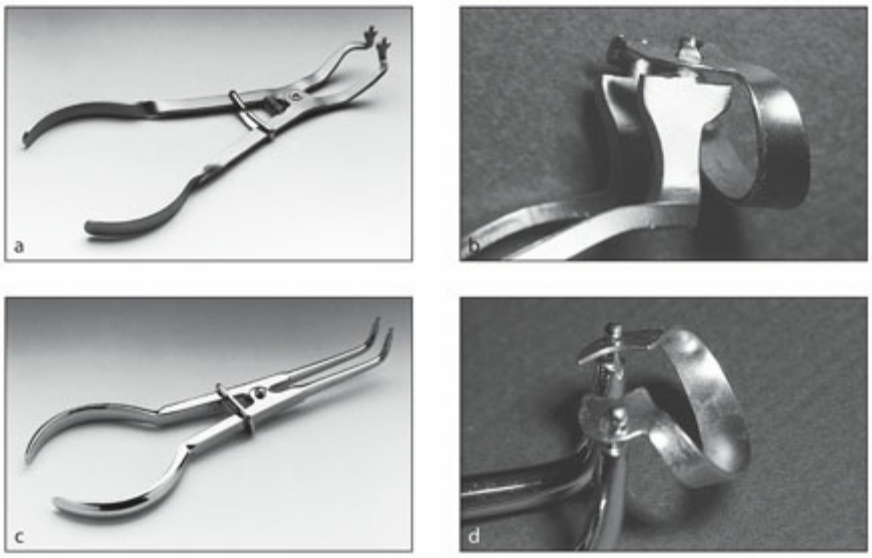

Fig 8-12*(a)* Ivory forceps. *(b)* Stabilizers near the tips of the Ivory-type forceps limit rotation of the clamp when it is held by the forceps. *(c)* Stokes-type forceps. *(d)* The tip design of the Stokes forceps provides more freedom for rotation of the clamp while it is held by the forceps.

Stokes-type clamp forceps (Fig 8-12c), which have notches near the tips of their beaks to locate the holes of a rubber dam clamp (Fig 8-12d), allow a range of rotation for the clamp so that it may be positioned on teeth that are mesially or distally angled.

Either of these types of clamp forceps will serve the practitioner well, and selection should be based on personal preference. The Ivory-type forceps are probably the most popular because of cost.

Dentlearn.ir

Clamps

Rubber dam clamps are the usual means of retaining the rubber dam. The three basic types of clamps and their parts are shown in Fig 8-13. When a posterior segment is isolated, the clamp is usually placed on the distalmost exposed tooth (Fig 8-14). The clamp may also be placed on an unexposed tooth (one for which a hole has not been punched) (Fig 8-15).

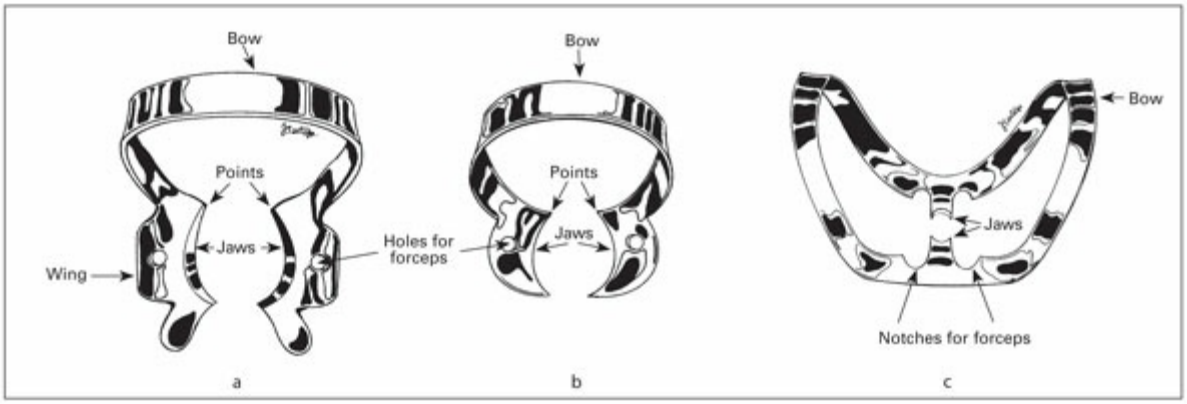

Fig 8-13*(a)* Winged rubber dam clamp; *(b)* wingless rubber dam clamp; *(c)* butterfly rubber dam clamp.



Fig 8-14 Isolated mandibular right quadrant. The clamp is positioned on the distalmost exposed tooth.



Fig 8-15 Isolated mandibular left quadrant with a second clamp placed on an unexposed molar on the right side of the mouth to give additional access to the lingual surfaces of the teeth in the left quadrant. The dam has been loosely stretched over the unexposed tooth to prevent the clamp from initiating a tear. The mirror and other instruments will now be unimpeded when the defective lingual margin of the crown on the first molar is treated.

Dentlearn.ir

There are clamps with jaw sizes to fit every tooth. Some clamps simply have a number designation; others have a W in front of the number. The W indicates that the clamp is wingless (see Fig 8-13b); those clamps that do not bear a W have wings (see Fig 8-13a) so that the dam may be attached to the wings before the clamp is placed on the tooth (Fig 8-16).



Fig 8-16 Winged clamp attached to the rubber dam. The edges of the hole are stretched over the wings of the clamp.

Manufacturers have reduced the number of clamps they produce, but a variety of clamp designs remain available. For the practice of operative dentistry, the number of clamps should be limited to a few that will satisfy most needs; these may be kept in the instrument kit and sterilized along with the other operative dentistry instruments. Clamps that will serve in most situations and are recommended for inclusion in operative dentistry instrument kits are listed in Table 8-2 and shown in Fig 8-17.

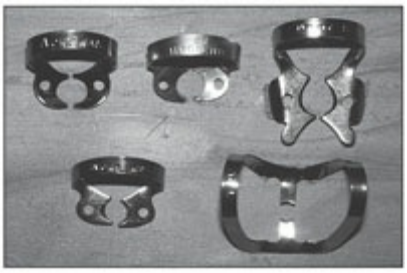

Fig 8-17*(left)* Clamps recommended for routine use: *(top row, left to right)* no. W8A, B1, 27; *(bottom row)* no. W2A clamp and no. 212SA retractor.

Table 8-2	**Clamps recommended for inclusion in operative dentistry instrument kits***		
Wingless clamps	**Winged clamps**	**Tooth fit**	**Note**
W8A, W8ASA,† or B1	8A or 27†	Molar	Bow extended distally in 27
W2A†	2A	Premolar	

Dentlearn.ir

212SA†		Premolar, canine, and incisor	For Class 5 isolation

*All clamps except B1 (Hygenic) and W8ASA (Hu-Friedy) are from Ivory catalog(Heraeus Kulzer).
†Recommended to be available for routine use.

Supplemental clamps, to be available on the rare occasions when the usual clamps will not suffice, should be packaged and sterilized separately. Recommended supplemental clamps are listed in Table 8-3 and shown in Fig 8-18.



Fig 8-18*(right)* Recommended supplemental clamps: *(left to right)* no. 00 (for mandibular incisors and other small teeth), no. W14A (for partially erupted molars), and no. W1A (for premolars with subgingival margins).

Table 8-3	**Recommended supplemental clamps***		
Wingless clamps	**Winged clamps**	**Tooth fit**	**Note**
W0	00†	Small incisor	
W1A†	1A	Premolar	Gingivally angled jaws
W14A†	14A†	Molar	For partially erupted molar

*All clamps are from Ivory catalog (Heraeus Kulzer).
† Clamps recommended to be available to supplement clamps listed in Table 8-2

No. W8A clamp. Although Ivory modified the design of the no. W8A clamp many years ago so that the jaw points do not extend so severely in a gingival direction, some still extend further gingivally than is desirable. The jaws of a no. W8A clamp, for most applications, should be approximately horizontal (Fig 8-19a, bottom) prior to expansion of the clamp for placement on a tooth. As the jaws are spread, the angle of the jaws will change to a gingival orientation; this is usually desirable, but before

Dentlearn.ir

the clamp is expanded, the jaws should have little or no gingival angulation.



Fig 8-19 Modification recommended for no. W8A clamps, to thin the jaws and reduce the extension of the jaw points toward gingival tissue. *(a) (top)* Clamp as received from the manufacturer; *(bottom)* clamp that has been modified. *(b)* The points are trimmed from the tissue side so that gingival extension is reduced and jaws are thinned. The bur being used in the high-speed handpiece is a no. 7803 bullet-shaped finishing bur. *(c)* Points that have been sharpened during modification must be dulled. If the points are left sharp, they can damage the surface of the tooth.

For no. W8A clamps in which the jaws have a significant gingival angulation, a modification procedure is recommended (Fig 8-19) unless deep subgingival placement of the points is needed. This modification may be made with a stone used in a low-speed handpiece or a finishing bur used in a high-speed handpiece. After the modification is made, the points, which have been sharpened by the modification procedure, must be blunted to prevent damage to tooth surfaces.

The no. W8ASA clamp (Hu-Friedy) incorporates most of the advantages of the modification of the no. W8A (Fig 8-20).



Fig 8-20 No. W8ASA clamp featuring most of the benefits of the modified no. W8A clamp shown in Fig 8-19.

Butterfly clamps. Most of the clamps listed in Tables 8-2 and 8-3 may act as *rubber dam retainers* (placed on the distal tooth or teeth to hold the dam on the quadrant or arch) or as *rubber dam and gingival tissue retractors* (to retract the dam and tissues away from a preparation margin in the cervical area of a tooth). One clamp, however, the butterfly clamp, no. 212SA (Fig 8-21a), is designed to serve as

Dentlearn.ir

a retractor only. Because of its double bow and the closeness of the points of each jaw, this clamp must often be stabilized on the tooth (Fig 8-21b), or it may rock mesiodistally during the procedure and damage the root. For retraction for a facial Class 5 restoration, dental impression compound (such as red or green compound, Kerr/ Sybron) should be used under the bows of the clamp on the occlusal (or incisal) and lingual aspects of the teeth to provide stabilization. The hole for the tooth that is to receive the no. 212SA retracting clamp should be offset facially from the line of teeth by approximately 1 mm (Fig 8-21c). This provides for a greater width of interdental rubber dam septum so that, when the dam is displaced apically for access to the gingival margin of a Class 5 restoration, a water-tight seal will be maintained.

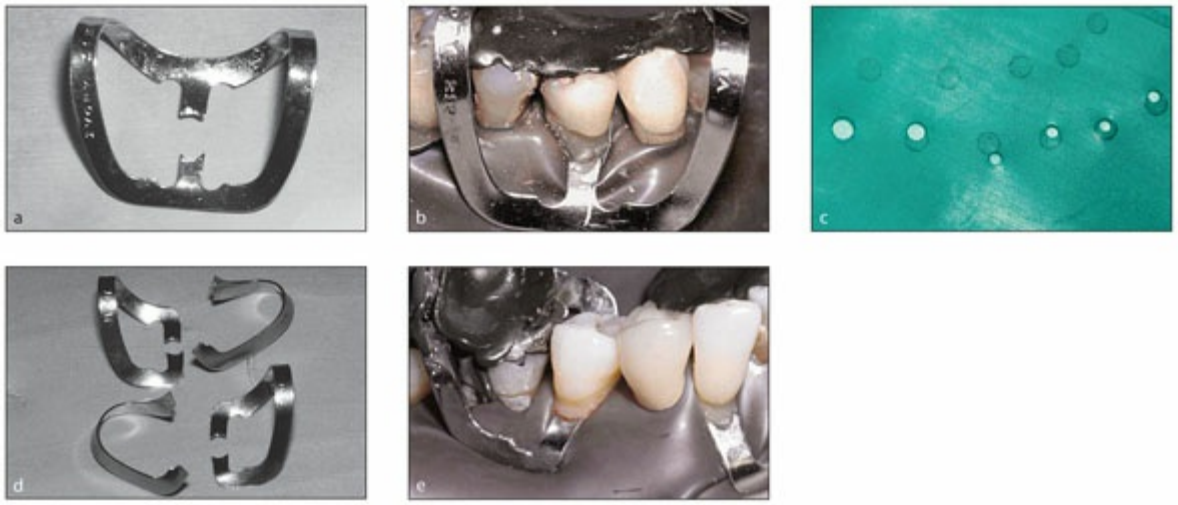

Fig 8-21*(a and b)* No. 212SA clamp (or retractor) for retracting the gingival tissue and rubber dam. *(c)* When a no. 212SA retracting clamp is to be used to retract the dam for a facial Class 5 restoration, the hole for the tooth to be restored should be punched approximately 1 mm facial to the normal hole location. *(d and e)* Two no. 212SA retractors may be modified to give two clamps for tissue and dam retraction for side-by-side restorations. The no. 212SA and the modified no. 212SA retractors must be stabilized with modeling compound or the jaws will damage tooth surfaces.

The double bow of the no. 212SA clamp precludes placement of two clamps on adjacent teeth. When two Class 5 restorations are to be placed on adjacent teeth, two no. 212SA clamps may be modified (Fig 8-21d); one of the bows of each clamp is cut off so that the remaining bow of one clamp extends to the right and the bow of the other extends to the left. If these clamps are stabilized with modeling compound, adjacent Class 5 restorations may be accomplished simultaneously (Fig 8-21e). A no. 212SA clamp or a modified no. 212SA clamp may be used on one root of a molar that has a long clinical crown as well as on single-rooted teeth.

Dentlearn.ir

Tooth contact. An important consideration when a clamp is selected is that only its jaw points contact the tooth; this gives four-point contact (Fig 8-22). No clamp jaw can ever be contoured to fit a tooth precisely, nor is there any reason for a clamp to fit precisely, because the dam, not the clamp, creates the seal. Molar clamps should have accentuated arches between the jaw points to ensure that the points are in contact with the tooth, even in teeth with very convex cervical areas. The distance between the points of a jaw, along with the stiffness of the bow of the clamp, determines the stability of the clamp. If there is contact between the tooth and any other part of the clamp's jaw, the contact points are brought closer together, thus reducing the stability of the clamp and allowing it to rotate on the tooth and, occasionally, to be dislodged from the tooth. Four-point contact is therefore very desirable.

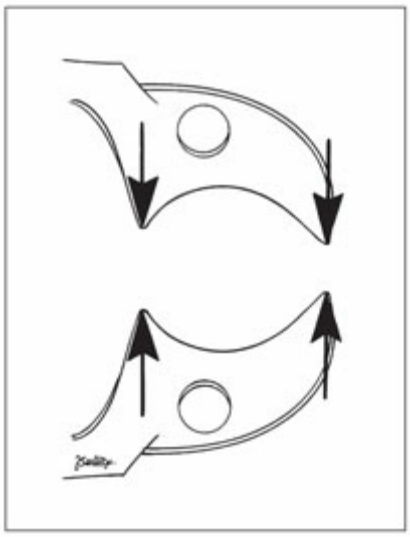

Fig 8-22 Rubber dam clamps should contact the tooth at the mesial and distal extent of the jaws. This four-point contact provides stability, or resistance to rotation or dislodgment, for the clamp.

The stiffness of the bow of the clamp should also be maintained. Clamps should be expanded with the clamp forceps no more than is necessary for the clamp to be passed over the facial and lingual heights of contour of the tooth. If a clamp has been overexpanded, it will grasp the tooth with less strength and is more likely to be dislodged. Occasionally, the jaws of clamps that have been overexpanded may be squeezed together so that enough of the strength returns, but it is usually best to discard a clamp that has been overexpanded.

Floss ligatures. Many clinicians and dental schools recommend that dental floss be attached to every clamp used in the mouth to allow retrieval if the clamp is dislodged or breaks. Certainly, it is wise to attach floss to the clamp that is

Dentlearn.ir

positioned in the mouth prior to application of the dam. After dam placement is completed, however, the floss causes leakage if it extends under the dam or is in the way if left to dangle in the operating field. A solution is to attach the floss to the clamp during application of the dam (see Fig 8-35a) and to cut and detach the floss from the clamp after the dam is in place. If the clamp dislodges or breaks after the dam is in place, it will either be catapulted from the mouth by the tension of the dam or be trapped by the dam so that it cannot be swallowed or aspirated.

When a winged clamp is attached to the dam during placement of the clamp onto a tooth, the attachment of a floss ligature to the clamp is redundant. Floss also need not be attached to a second clamp placed for retraction after the dam is in place.

Other retainers

Other methods are sometimes used for rubber dam retention:

- Dental floss or tape is placed doubly through a contact and then cut to a short length so that it does not impede access (Fig 8-23a).



Fig 8-23 Alternative methods for dam retention. *(a)* Dental tape placed doubly through the contact distal to the distalmost exposed tooth. *(b)* Short strip of rubber dam used to retain the dam. *(c)* Anesthetic cartridge plunger tied around the distal tooth with floss. *(d)* Elastic cord used as a rubber dam retainer (see Fig 8-34).

- A short strip of rubber dam material is cut from the edge of the rubber dam, stretched and carried through the contact, and then allowed to relax to retain the dam (Fig 8-23b).
- Floss is tied to a sterilized rubber plunger from an anesthetic cartridge or similar item and then tied around the most distal isolated tooth (Fig 8-23c).

Dentlearn.ir

- Elastic cord, eg, Wedjets (Hygenic), is placed interproximally to retain the dam (Figs 8-23d; see also Fig 8-34).

Modeling compound

Modeling compound may be used as an adjunct to the application of any clamp as a retainer or retractor. It is especially useful and necessary for anchoring and stabilizing the no. 212SA retainer (see Figs 8-21b and 8-21e).

For stabilizing a clamp, use of modeling compound, either red or green, is recommended. The clamp is positioned appropriately on the tooth and held in position with a finger until stabilization is completed. There are several effective methods for applying compound to stabilize a clamp. One of these techniques allows the practitioner to have prewarmed modeling compound immediately available and avoids the use of a flame. With this technique, modeling compound is placed into a plastic syringe, such as a large Monoject or impression syringe, which is then placed in a water bath at the appropriate temperature for the type of modeling compound used. The diameter of the aperture of the tip should be made larger to allow the softened compound to be ejected easily from the syringe. When the clamp is positioned, the practitioner removes the syringe with the prewarmed modeling compound from the water bath and flows it into the desired area to stabilize the clamp.

Another technique involves the use of the compound in stick form. A stick is held over a low alcohol flame and rotated and moved back and forth so that the length to be softened is heated evenly (Fig 8-24a). After the surface is softened, the stick is withdrawn from the flame to allow the heat to diffuse to the center of the stick. When the length is warmed to the center, there will no longer be a core of unsoftened compound to support the shape, and the softened length will sag or droop (Fig 8-24b). If the stick has been overheated, so that it elongates in addition to drooping, it should be cooled slightly in a container of water. Before the compound is taken to the mouth, the surface should be briefly reheated to enhance adhesion of the compound to the retracting clamp and teeth.

Dentlearn.ir

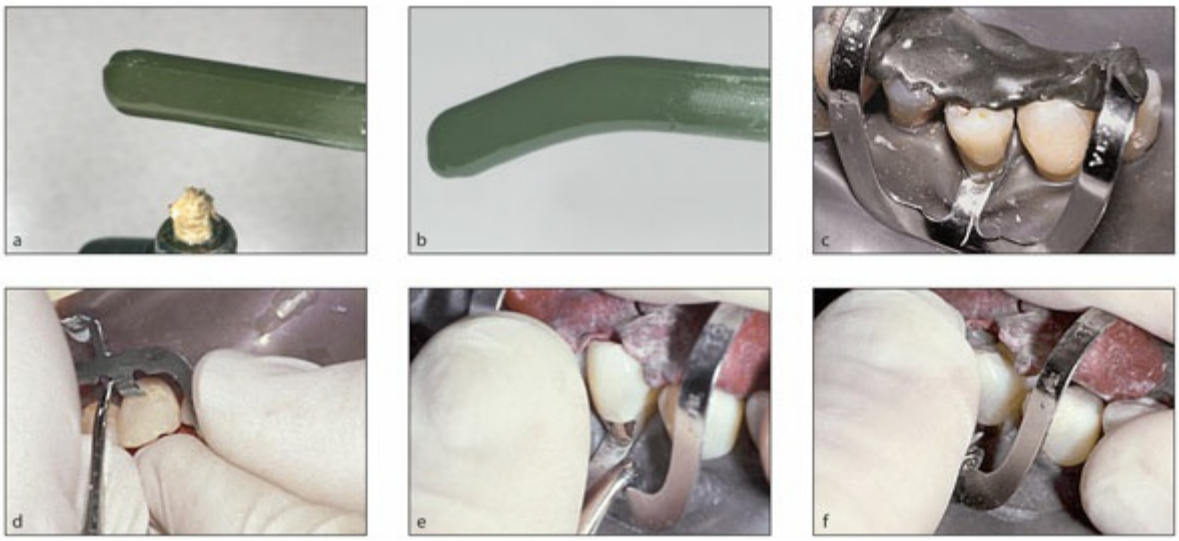

Fig 8-24 Use of modeling compound to stabilize a no. 212SA retractor. *(a)* The compound stick is warmed in an alcohol flame. *(b)* After warming, the stick is removed from the flame and held until the heat has diffused to the center of the stick so that the warmed end of the stick begins to droop. *(c)* Use of compound to stabilize a no. 212SA retractor is completed. *(d)* Removal of the clamp with forceps may be hampered by the compound on the lingual aspect. If so, a facial notch of the clamp may be engaged with an instrument such as a plastic instrument. *(e and f)* A no. 0 crochet hook (with handle made of laboratory acrylic) or a no. 34 surgical elevator modified to mimic a no. 0 crochet hook may be used to engage a notch of the clamp. Such a modified surgical elevator is manufactured by Hu-Friedy. The facial jaw of the clamp is then pulled facially away from the tooth surface and rotated occlusally or incisally to quickly remove the clamp and the stabilizing compound.

The compound should be applied to the retainer and teeth in a location as far away from the area to be restored as possible. The stick is then twisted and pulled away, leaving softened compound in place. The compound should be shaped and molded with damp, gloved fingers into embrasures and made to contact a large area of the clamp and the lingual surfaces of the teeth. It should then be cooled with the air syringe for 20 seconds or more. Stabilization of the retracting clamp is then completed (Fig 8-24c); the finger holding the clamp may now be released, and the clamp is tested for stability.

Compound should be kept away from the planned area of operation so that it will not inhibit access; in that regard, for a facial restoration, compound should be confined to the occlusal (or incisal) and lingual surfaces. Full advantage should be taken of the lingual surfaces for maximum dependability of attachment of the compound to the teeth. When the lingual surfaces are covered by the compound, the lingual notches for the clamp forceps will be covered. To remove the clamp with forceps, the operator would have to chip away the compound to expose a lingual notch. In a simpler method, an instrument is used to pull the facial jaw of the clamp

Dentlearn.ir

away from the facial surface and then occlusally (incisally) (Figs 8-24d to 8-24f).

Inverting instrument

Almost any instrument may be used for inverting the dam. Commonly used instruments include explorers such as the no. 23 (Fig 8-25a), plastic filling instruments such as the no. 1-2 (Fig 8-25b), or a beavertail burnisher (Fig 8-25c). Dental tape or floss used interproximally is also useful for dam inversion. Inversion of the dam is described later in this chapter and illustrated in Fig 8-38.



Fig 8-25 Inverting instruments. Note the tip of the air syringe in each instance; a high-volume stream of air is used to dry the tooth and dam surfaces to facilitate inversion. *(a)* No. 23 explorer. *(b)* No. 1-2 plastic instrument. *(c)* Beavertail burnisher.

Wedge

The wooden wedge, which is used to stabilize a matrix and hold it against the gingival margin of a cavity preparation involving a proximal tooth surface, is also useful for protecting the dam (Fig 8-26) when rotary cutting instruments are used in proximal areas. Placement of water-soluble rubber dam lubricant on the wedge enhances the ease of wedge placement.



Fig 8-26 Wooden wedges are used to protect the dam from being cut during a procedure that involves the use of burs or cutting instruments near the dam.

Scissors

Scissors are often useful in preparing the dam for insertion and are a necessity for cutting the dam for removal. Blunt-ended scissors are preferred by many operators,

Dentlearn.ir

but other scissors, such as sharp crown and collar scissors and Quimby scissors (see Fig 8-41b), will also serve well. Scissors used for cutting rubber dams must be sharp, or they will frustrate the operator.

Dental tape and floss

Waxed tape or floss, not unwaxed floss, is recommended for flossing the dam through interproximal contacts. Waxed tape, or ribbon floss (see Fig 8-35f), will carry more of a septum through a contact in a single pass than will the narrower floss, but the tape must be maintained flat and not bunched up, or it will be difficult to pass through the contact.

Interproximal contact disk

An interproximal contact disk (Thierman Products or Centrix) is used to plane rough enamel, amalgam, or resin composite contacts so that the floss will pass through without shredding and so that the dam can be flossed through without tearing (Fig 8-27). The plain metal disk, without abrasive, is recommended. This instrument should not be used in a contact that involves a gold casting because it can cut into the gold and produce additional obstruction to passage of the floss through the contact.

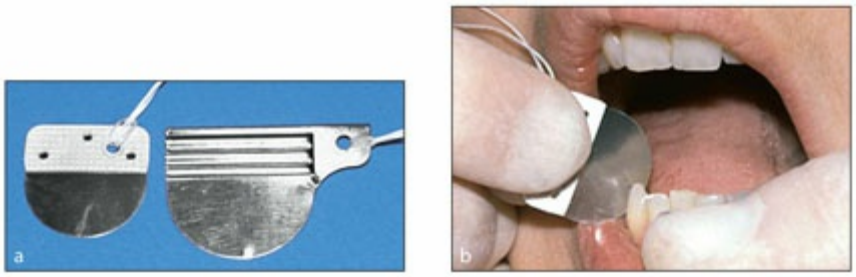

Fig 8-27*(a)* Interproximal contact disks or planes. The disk with the white plastic handle is from Thierman Products, and the disk with the metal holding area is from Centrix. *(b)* An interproximal contact disk is used to plane a rough contact.

The disk is placed into the occlusal embrasure and rocked facially and lingually as it is pushed firmly, but with control, gingivally. If it cannot be worked through the contact, the teeth should be separated slightly with a plastic instrument placed snugly into the gingival embrasure and rotated slightly while the disk is being pushed into the contact from the occlusal embrasure. Several passes of the disk through the contact will usually plane it smooth.

Lubricant

Dentlearn.ir

Rubber dam lubricant makes a significant difference in the ease with which the dam is applied. A water-soluble lubricant is preferred. A product that has proven especially suitable for lubricating the rubber dam is Velvachol water-miscible vehicle (Healthpoint) (Fig 8-28). Velvachol is a pharmaceutical product manufactured as a water-soluble ointment base, but it is an excellent dam lubricant. Petroleum-based lubricants, such as Vaseline (Chesebrough-Pond's), should be avoided as rubber dam lubricants because they are difficult to remove from the dam after application and therefore can impede bonding procedures and make inversion of the dam more difficult.



Fig 8-28 A water-soluble rubber dam lubricant, such as Velvachol, can be loaded into a syringe, such as a 3-mL disposable syringe. The lubricant can be dispensed from the syringe onto the tissue surface (underside) of the rubber dam or onto a glove for coating of the dam adjacent to the holes.

Water-soluble lubricant is applied in a thin coat in the area of the holes on the tissue surface of the dam before it is taken to the mouth (Fig 8-29). The lubricant makes passage of the dam through the interproximal contacts much easier, and the dam will often pass through the contacts in a single layer without the use of floss. If additional lubrication is desired, lubricant may be applied to the teeth prior to placement of the dam.



Fig 8-29*(a)* Water-soluble lubricant can be carried to the dam with a finger. *(b)* The dam lubricant is layered on the tissue surface of the dam in the area of the holes.

A lubricant for the lips will make the patient more comfortable during the procedure. Petroleum-based lubricants, such as Vaseline, cocoa butter, silicate lubricant, or lip balm, function well as lip lubricants.

Dentlearn.ir

Application and removal

Preparation of the mouth

Teeth should be cleaned, if necessary, and contacts should be checked with floss. The rapid passage of dental floss through each contact that will be involved in the isolation is very important and, if accomplished as a part of the routine, will save chair time. Any rough contact should be smoothed with the interproximal contact disk (see Fig 8-27b), not only to facilitate dam placement but also to enable the patient to clean each interproximal area during routine flossing.

If a restorative procedure that involves an occlusal surface is planned, maximum intercuspation contacts may be marked with articulating paper or tape prior to application of the dam. Centric occlusion markings may be coated with a clear light-cured resin or varnish to protect them from being rubbed off. An applicator or brush containing the liquid resin should be touched to the enamel adjacent to the markings and the material allowed to flow across the markings prior to curing (Fig 8-30).



Fig 8-30 The centric occlusion markings were protected by a varnish or light-cured resin during dam placement; had the markings not been protected, the placement procedure would likely have erased them.

If the lips are to be lubricated, this should be accomplished prior to application of the dam (Fig 8-31).



Fig 8-31 Lips are lubricated with petroleum-based lubricant prior to placement of the rubber dam.

Preparation of the dam

Use of a prestamped, dark (gray, green, or blue), heavy (or extra heavy) gauge dam

Dentlearn.ir

material is recommended. Various hole sizes should be used to ensure a seal around the variety of tooth sizes (Fig 8-32). For example, an Ivory punch has six hole sizes, numbered 1 (smallest) through 6 (largest) (see Fig 8-4). For standard latex heavy-gauge dams, recommended hole sizes are 5 for clamped molars; 4 for other molars; 3 for premolars, canines, and maxillary central incisors; and 2 for maxillary lateral incisors and mandibular incisors.



Fig 8-32 Varying hole sizes are used to seal the dam around various sizes of teeth.

Some variation from the recommended hole sizes may be needed, depending on the size of individual teeth, operator preference, dam material, and gauge of the dam, but a range of hole sizes should be used to prevent leakage between the dam and the teeth.

For operative procedures involving posterior teeth, the tooth or teeth to be restored should be exposed, as well as at least one tooth posterior to the most distal tooth to be restored, if possible. In addition, all teeth around to the central or lateral incisor on the opposite side of the same arch should be exposed. This extension of the area of isolation to the opposite side will hold the dam flat in the arch to give room for fingers and instruments in the area of the teeth to be restored. It will also expose teeth in the anterior area for finger rests during the operation (Fig 8-33).



Fig 8-33 The incisal edges of the anterior teeth are used as a finger rest.

For anterior restorations, exposure of the first premolar to the first premolar on the opposite side of the arch is recommended (Fig 8-34). This will provide room for the mirror and for hand instruments on the lingual aspect of the anterior teeth.

Dentlearn.ir



Fig 8-34 For an anterior restoration, the first premolars are exposed to provide anchorage for the dam and to leave adequate working room on the lingual aspect of the anterior teeth.

When a prestamped dam or a template is used, holes should be punched away from the spots to accommodate atypical alignment of teeth. In addition, when the dam is being prepared to provide isolation for Class 5 restorations, the hole for the tooth to receive a facial Class 5 restoration should be punched approximately 1 mm facial to the spot (see Fig 8-21c) to allow retraction with the no. 212SA clamp. No holes should be punched for missing teeth.

After the dam is punched, the tissue side of the dam should be lubricated with a water-soluble lubricant. A small dollop of lubricant is applied to the tissue surface and smeared over the surface of the dam in the area of the holes (see Fig 8-29b). The rubber dam frame can then be attached to the top and bottom of the dam, leaving a relaxed area or "pouch" of dam material between the top and bottom (see Fig 8-35b). Attaching the dam to the frame in this way holds the edges of the dam away from the holes for better visualization during application.

Placement of the dam

If a local anesthetic agent has been administered to provide pulpal anesthesia for the tooth or teeth being restored, at least a portion of the gingival tissue will have also been anesthetized. If an inferior alveolar block has been given, the lingual nerve will almost always have been anesthetized as well, so the gingival tissue lingual to the mandibular posterior teeth will also have been anesthetized. If infiltration anesthesia has been administered to maxillary teeth, the facial gingival tissue will have been anesthetized. For application of a rubber dam clamp, the portions of the gingival tissue that have not been anesthetized along with the delivery of pulpal anesthesia will not normally need to be anesthetized. When the clamp is applied, as long as the points of the clamp's jaws are firmly on the tooth and have not penetrated gingival tissue, the patient may feel some discomfort for a few seconds where the jaws are pressing against tissue. This pressure discomfort will usually disappear within 1 minute due to "pressure anesthesia," and injection anesthesia for the gingival tissue

Dentlearn.ir

is usually unnecessary. If additional gingival anesthesia is necessary, topical anesthetic solutions or gels may suffice.

When the clamp is applied to the tooth with the clamp forceps, the clamp should be expanded only enough to allow it to pass over the crown of the tooth. Overexpansion of the clamp will permanently distort it so that it will be weak, unstable, and more likely to dislodge from the tooth.

Dam over clamp. A wingless clamp is placed on the tooth. It is recommended that a finger be maintained over the inserted clamp to prevent its dislodgment until its stability on the tooth has been confirmed. The operator checks stability by engaging the bow of the clamp with an instrument and firmly attempting to pull it occlusally (Fig 8-35a). If the clamp rotates on the tooth, it is not stable and should be repositioned or replaced.

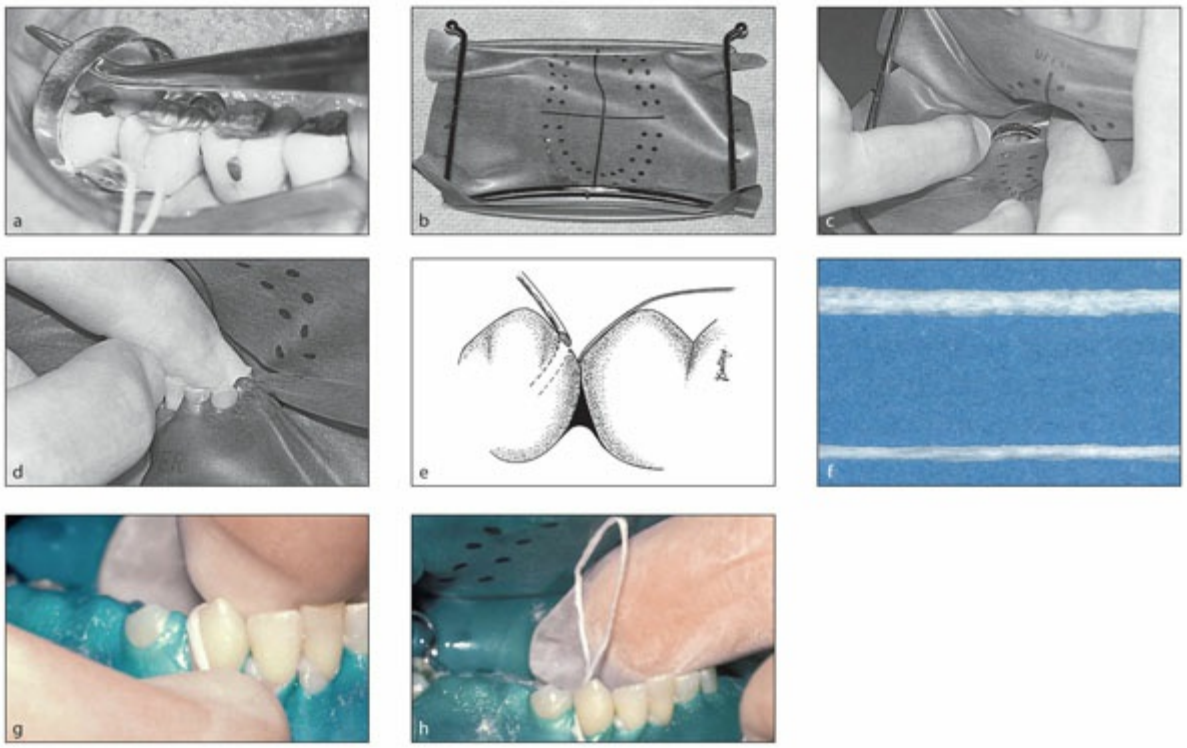

Fig 8-35 Dam over clamp method of dam application. *(a)* The clamp (modified no. W8A) is tested for stability. To do so, the operator attempts to pull the bow occlus-ally. *(b)* The dam is fitted loosely on the frame. *(c)* The distal hole of the dam is carried over the bow of the clamp. *(d)* The septa are worked through anterior contacts as a gloved fingernail is used to slightly separate teeth. *(e)* The leading edge of the dam is touching the occlusal aspect of the interproximal contact; floss is on the adjacent tooth. *(f)* Waxed dental tape, or ribbon floss *(top)*, if it is not folded or bunched, will carry more of the dam septum through the contact in a single pass than will waxed floss *(bottom)*, but either type will serve the purpose. *(g)* The dam septum is lying on the mesial aspect of the mandibular first premolar, with its leading edge at the mesial contact; the floss is lying on the distal aspect of the canine, ready to move to the contact, meeting the dam there. The floss will then carry at least a portion of the septum through the contact. *(h)* The floss has been doubled

Dentlearn.ir

back to the facial aspect and passed through the contact again, carrying another portion of the septum through the contact. The floss is then removed from the contact; one or both of the tails of the floss are pulled facially away from the teeth.

The top and bottom attachment points of the Young frame are engaged at the top and bottom of the dam to give a slackness or pouching of the dam (Fig 8-35b). The tissue side of the dam is lubricated in the area of the holes. Then, with a finger on each side of the distal hole in the dam, the dentist (or assistant) stretches the dam so that the hole is enlarged and appears to be an open slit; the hole is then carried over the bow and jaws of the clamp (Fig 8-35c). The hole at the opposite end of the row (usually for the lateral or central incisor on the opposite side) is then passed over the appropriate tooth, and the septa are worked through the interproximal contacts.

A gloved fingernail used to slightly separate the anterior teeth is very helpful, and floss is not usually needed to carry the dam through anterior interproximal contacts (Fig 8-35d). To use the "fingernail technique," the edge of the septum is positioned at the incisal extent of the contact and pulled gingivally with fingers on the facial and lingual aspects. This method also can frequently facilitate septum passage through interproximal contacts of posterior teeth.

Good lubrication of the dam is necessary for easy and quick application. The dam should be passed through each contact in a single layer. This may be accomplished by stretching a septum over one of the teeth adjacent to the contact and sliding the edge of the rubber to the contact so that a leading edge of dam is touching the contact (Fig 8-35e).

In posterior areas, the leading edge should be touching the occlusal portion of the contact in the occlusal embrasure. Waxed tape (ribbon floss) or waxed floss may then be used to move the dam progressively through the contact (Figs 8-35e to 8-35g). Tape will carry more of the rubber through the contact in a single pass than will floss. If tape is used, like the rubber, it should be taken through the contact in a single layer, not twisted or bunched up.

If the dam goes through with one pass of the floss, the floss should be removed from the contact without pulling the rubber back out. To accomplish this, the tail of the floss that is on the lingual side of the teeth is doubled back across the occlusal embrasure of the contact so that both ends are on the facial aspect; then the tape is pulled facially through the contact. If only a portion of the septum goes through the contact with the first pass of the floss or tape, the floss should be doubled back and passed through the contact again; it is then pulled facially out of the gingival embrasure (Fig 8-35h). The tape should be passed through repeatedly until the entire

Dentlearn.ir

septum has been carried through the contact.

Winged clamp in dam. Prior to lubrication of the dam, the clamp is placed into the distal hole so that the hole is stretched over the wings of the clamp from its tissue side (Fig 8-36a; see also Fig 8-16). The dam is then lubricated, and the frame is attached. The forceps are inserted into the holes of the clamp, and the clamp, dam, and frame are carried as a unit into place (Figs 8-36b and 8-36c). After the stability of the clamp is confirmed, the dam material on the wings of the clamp is pulled off the wings with finger tension or with a bladed instrument such as a plastic instrument. The remainder of the dam is placed as previously described (Fig 8-36d).



Fig 8-36 Winged clamp in dam method of dam application. *(a)* A winged clamp (no. 27) is inserted into the distal hole of the dam. *(b)* The clamp–dam frame assembly is carried to the mouth as a unit. *(c)* The clamp is placed on the mandibular second molar. *(d)* The dam has been applied to the quadrant, and a no. 1-2 plastic instrument is used to pull the edges of rubber off the wings of the clamp.

Wingless clamp in dam. The distal hole of the lubricated dam is passed over the bow of a wingless clamp, such as the modified no. W8A, so that the hole comes to rest at the junction of the bow and the jaw arms (Fig 8-37a). The frame is not attached to the dam at this point. The dam is gathered up and elevated to expose the jaw arms of the clamp, and the forceps are then inserted into the forceps holes (Fig 8-37). The gathered dam is carried to the mouth with one hand and the forceps with the other. After the clamp is applied to the distal tooth and the dam has been pulled over the jaws of the clamp, the frame is attached and the other teeth are isolated as previously described.

Dentlearn.ir

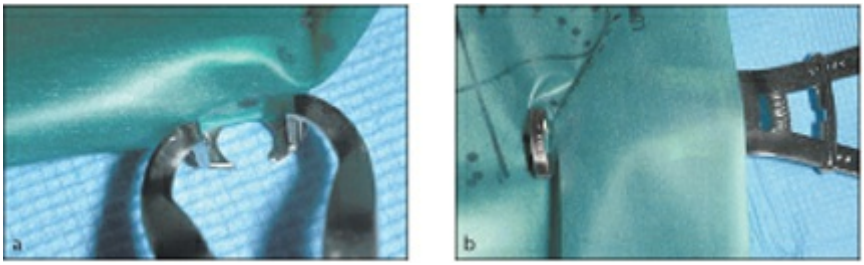

Fig 8-37 Wingless clamp in dam method of dam application. *(a)* The clamp in the dam. *(b)* Dam and clamp with forceps in place.

Clamp after dam. The dam is applied to the teeth and then the clamp is placed. This technique, occasionally necessary, is the most difficult.

Completion of application

Application of the napkin. For longer procedures, the use of a rubber dam napkin is recommended. The napkin may be positioned before or after the dam is in place on the teeth. For placement of the napkin after the dam has been applied, the frame is removed, the napkin is placed so that its edges remain on the skin and not in the mouth, and the frame is replaced.

Adjustment of the dam in the frame. The frame and dam are adjusted so that there is a minimum of folds and wrinkles and so that the dam does not obstruct the nostrils.

Washing of the dam. The dam and isolated teeth are washed with an air-water spray to remove the lubricant. After they are washed, the dam and teeth should be dried with air from the air syringe.

Inversion of the dam. The dam should be inverted around the necks of the teeth, at least in the area of the tooth or teeth to be restored. The edge of the dam that is against the tooth acts as a valve. If the edge is directed occlusally (Fig 8-38a), when a positive pressure is created by the tongue and cheeks under the dam, the valve opens, and saliva and other liquids under the dam are pushed between the tooth and dam to flood the operating field; then, when a negative pressure is created under the dam, the valve closes and the saliva is trapped in the field. When the dam is inverted, a positive pressure under the dam simply serves to push the valve more tightly against the tooth (Fig 8-38b) so that no flooding of the field occurs.

Dentlearn.ir

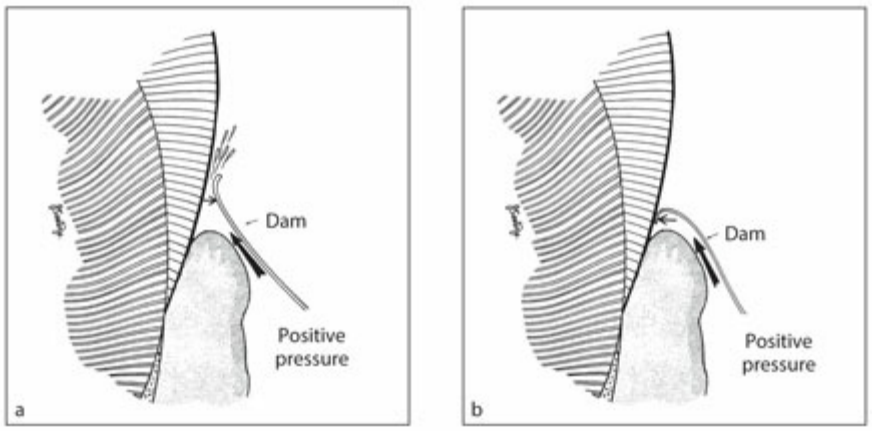

Fig 8-38*(a)* Without inversion of the dam, positive pressure under the dam, created by tongue movement, swallowing, etc, will cause leakage of saliva into the operating field. *(b)* With inversion of the dam, positive pressure under the dam only causes the dam to seal more tightly against the tooth, preventing leakage.

Almost any instrument may be used to tuck the edge of the dam gingivally (see Fig 8-25). A steady, high-volume stream of air should be directed at the tip of the instrument used to invert the dam, and the instrument should be moved along the margin of the dam so that the inversion is progressive.

Floss may be used to invert the dam in interproximal areas (Fig 8-39a). When it is used to carry the edge of the dam gingivally, the floss should not then be pulled occlusally for removal because it will frequently pull the edge of the dam with it, eliminating the inversion. Instead, the floss can be doubled over on itself on the lingual aspect and passed again through the contact. Then one end is pulled in a facial direction so that the floss rolls from the sulcus, leaving the dam inverted (Fig 8-39b). In this floss-facilitated inversion, a steady stream of air is as helpful as it is when inversion is accomplished with an instrument. The dam inverts more easily when the surfaces of the tooth and adjacent dam are dry.

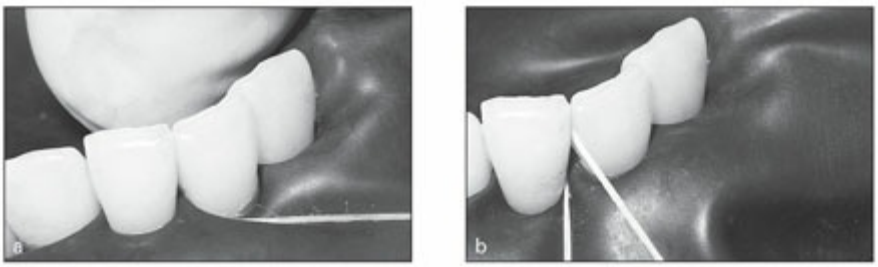

Fig 8-39*(a)* Floss is used to invert the dam in an interproximal area. *(b)* Floss is "rolled out" to the facial aspect to prevent reversal of the inversion it accomplished.

Ligation for retraction

Occasionally, becau eparation, a ligature

Dentlearn.ir

may be helpful for retracting the dam to a position cervical to the margin. Dental floss or tape is passed through one interproximal area, around the lingual aspect of the tooth, then back through the other interproximal area or contact. Then the floss or tape is tied, preferably with a surgeon's knot, on the facial aspect of the tooth. This ligation will usually carry the edge of the dam cervically to expose the area of the planned margin (Fig 8-40). After the ligature is tied securely, the tails of the floss or tape may be pulled to some portion of the rubber dam frame and attached to it, or they may be shortened to prevent their getting in the way of the operation. Prior to removal of the dam, the ligature should be cut with scissors or a sharp carver or scalpel blade and removed.

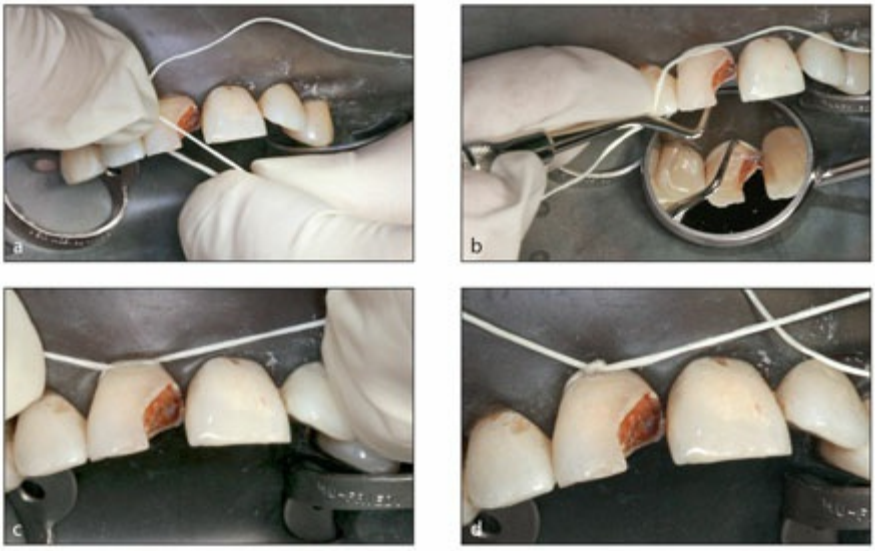

Fig 8-40 Dental floss is used to ligate the rubber dam for retraction of the dam cervical to a planned preparation. *(a)* The floss is first passed around the tooth. *(b)* It is then pushed cervically past the cingulum on the lingual aspect. *(c and d)* It is tied to secure it in a cervical position. (Courtesy of Joseph Connor, San Antonio, Texas.)

Protection of the dam

Torn dams provide poor isolation, so expenditure of a little effort to prevent tearing is worthwhile. An example of protection would be the use of a wedge interproximally when rotary instruments are used in the proximity of the dam (see Fig 8-26). Another example is the use of a second clamp to retract the dam below a margin that is near, or below, the level of the gingival crest (see Fig 8-47).

Removal of the dam

The interproximal septa are stretched and clipped with scissors (Fig 8-41). The scissors are held so that the tips are not in contact with any tissue (see Fig 8-41b).

Dentlearn.ir

When all septa are cut, the clamp is removed with the forceps and the dam is snapped from the teeth.



Fig 8-41*(a)* To remove the dam, the interproximal septa are stretched for cutting. *(b)* One blade of the scissors is used to pull the dam well away from any tissue before the septum is cut.

After the dam is free from the mouth, the teeth should be examined to ensure that no rubber remains around them or in the contacts. The frame should be removed from the dam, and the dam should be laid flat on a surface and examined to ensure that no pieces are missing (Figs 8-42a and 8-42b). If a piece is missing and unaccounted for, the mouth should be reexamined in the area of the missing piece of dam; any remnant should be removed (Fig 8-42c). A small piece of dam left subgingivally can cause inflammation, gingival abscess, or even significant loss of periodontal support.



Fig 8-42*(a)* While the dam is on the frame, it is difficult to determine if any portion is missing. *(b)* The dam is removed from the frame and laid on a flat surface. Note that a portion of dam is missing. *(c)* The missing piece is located in the mouth and removed.

Special considerations

Bite block

Patients often have difficulty keeping their mouths open or are uncomfortable with wide opening. A rubber bite block can relieve their discomfort, allow them to relax the musculature, and permit them to keep the mouth open without effort. Bite blocks are available in a variety of sizes (Figs 8-43a and 8-43b). A piece of floss or tape may be attached to the bite block to allow retrieval if necessary (Fig 8-43c). Figure 8-44 shows placement of the bite block after the dam is in place.

Dentlearn.ir



Fig 8-43*(a and b)* Rubber bite blocks are available in various sizes. *(c)* Floss is attached to the bite block for emergency retrieval if necessary.

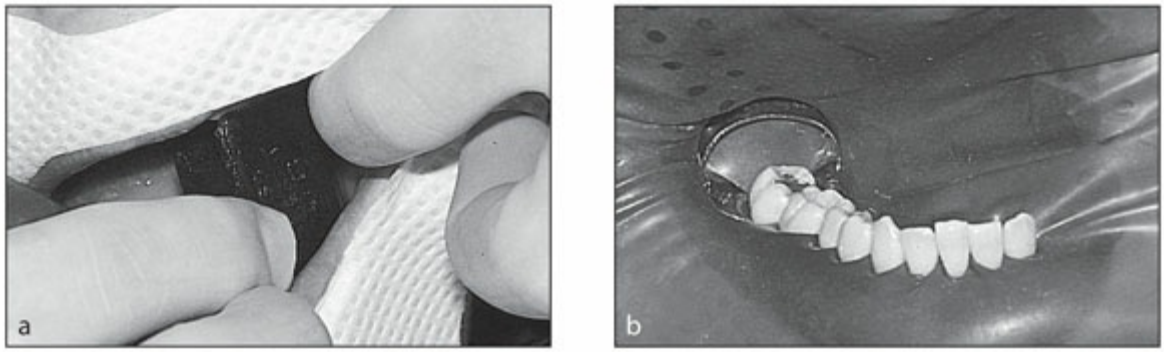

Fig 8-44*(a)* A bite block is inserted on the patient's left side after a rubber dam is applied to isolate the right quadrant. *(b)* The dam with a bite block in place aids access to the field and increases patient comfort.

Isolation for a fixed partial denture

Whenever possible, it is best to achieve isolation without incorporating a fixed partial denture into the isolated operating field. When a fixed partial denture must be included, there are several techniques that can be used; they are all somewhat time-consuming but often valuable. Two methods are described.

Cyanoacrylate method. Figure 8-45 illustrates this method. Holes for the teeth are punched in the dam. The holes for the abutment teeth are connected with a cut that is in an arc to give a "tongue" of dam material between the holes. The tongue of material is folded back, and a piece of dam material is attached with cyanoacrylate glue over the opening left when the tongue was folded back. This piece is glued into place so that there is a slit connecting the abutment holes and a tongue of material that is free to swing down over the attached piece of dam material.

Dentlearn.ir

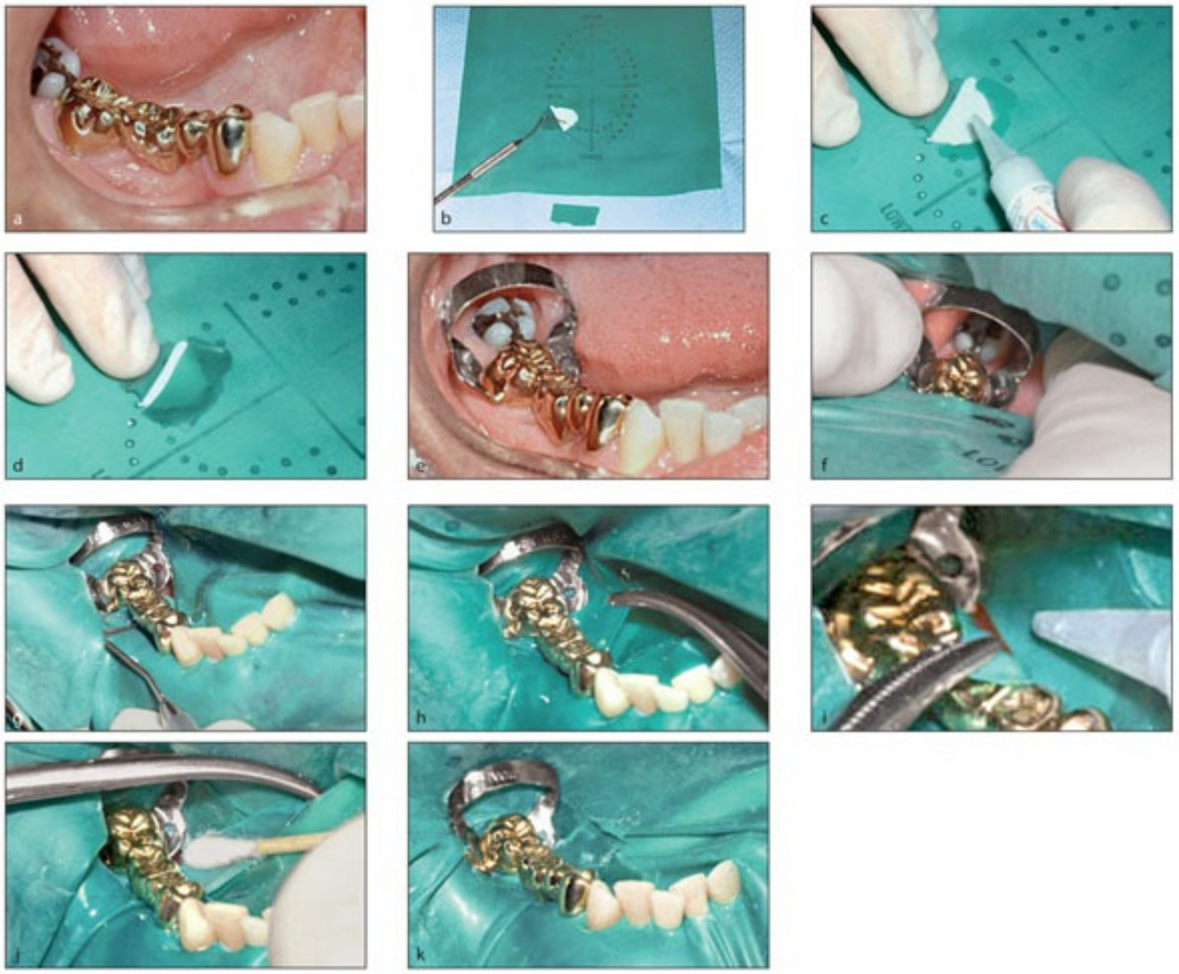

Fig 8-45 Rubber dam isolation around a fixed partial denture (cyanoacrylate method). *(a)* A four-unit fixed partial denture extends from the mandibular first premolar to the second molar. *(b)* The holes for the abutment teeth are connected with an arced cut. Note the small piece of dam material at bottom that will be used as shown in Figs 8-45c and 8-45d. *(c and d)* A small piece of dam is glued in place. *(e)* A no. W8A clamp is positioned on the second molar. *(f)* The dam is carried to place. *(g)* The tongue of dam material is tucked under the pontics with a periodontal probe. *(h)* The tongue of material is grasped and pulled lingually with a hemostat. *(i)* Glue is applied for attachment of the rubber dam tongue. *(j)* The tongue of dam material is held in place with a hemostat and a cotton-tipped applicator while the glue sets. *(k)* Isolation is complete.

The dam is inserted over all teeth for which holes have been punched, and the tongue of material is pulled under the pontic(s) and glued into place on the added piece of dam. Tension on the tongue while the glue is setting (10 to 15 seconds) will ensure that the dam is tight around the abutments after tension is released.

Ligation of septa around the retainer-pontic connectors. This method is illustrated in Fig 8-46. This procedure is for three-unit fixed partial dentures or splinted teeth. Holes are punched for each abutment, and, for three-unit fixed partial dentures, another hole is punched for the pontic. A piece of floss or suture material

Dentlearn.ir

is used to tie through the holes so that the septum between adjacent holes is stretched around the retainer-pontic connector. If floss is used, a "floss-feeder," made for carrying floss under partial denture pontics for oral hygiene measures, may be used to guide the floss under the pontic and pull it through. If suture material is used, the suture needle may be blunted and used for that purpose.

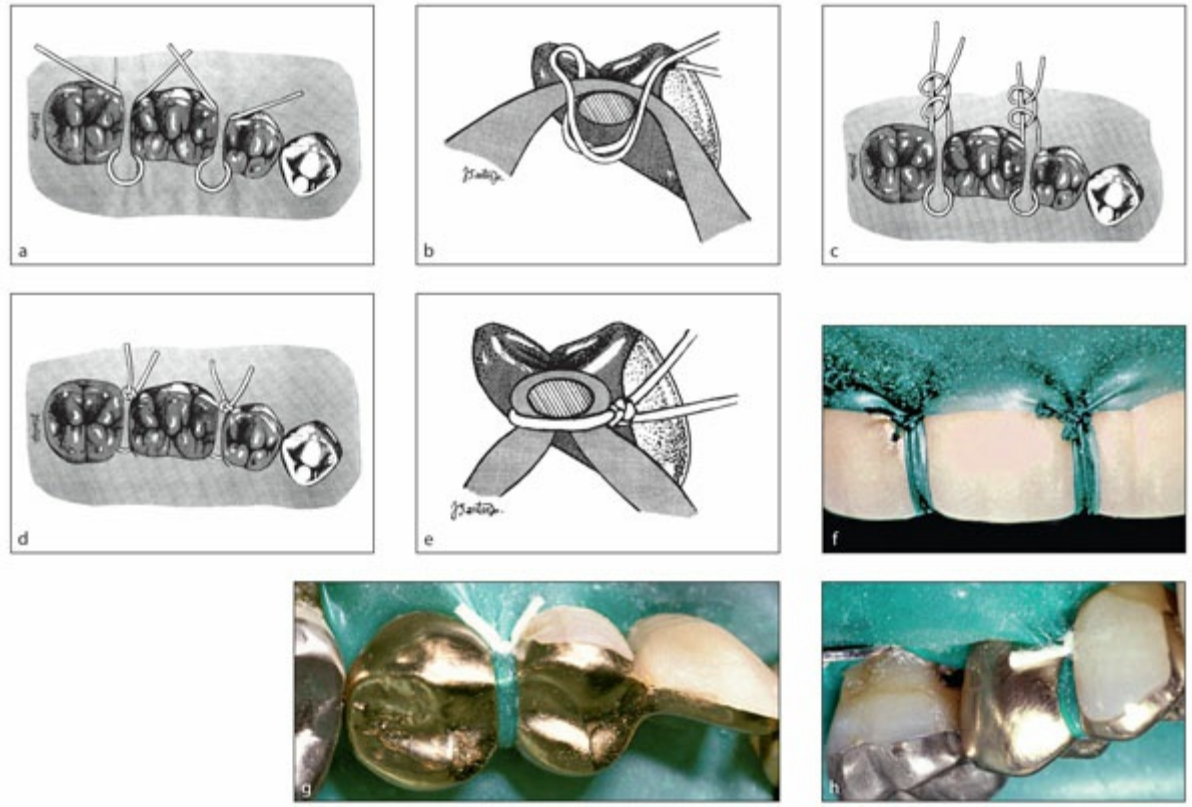

Fig 8-46 Isolation around a three-unit fixed partial denture or splinted teeth (ligation method). *(a)* Holes are punched for the abutment teeth and pontic, and the dam is positioned. The septa on the mesial aspect of the mesial abutment and the distal aspect of the distal abutment are flossed to place, and then the holes are stretched over the abutments and the pontic. *(b)* A ligature is threaded through an abutment hole on the facial aspect, under the retainer-pontic connector, through the same hole again on the lingual aspect, around the septum, through the pontic hole on the lingual aspect, back under the connector to the facial aspect, and back through the pontic hole. *(c to e)* The ends of the ligatures are tied together to pull the rubber septum tightly around the connector. *(f)* Sutures have been used for field isolation involving an anterior three-unit fixed partial denture. *(g and h)* Floss has been used for isolation involving a cantilevered canine pontic attached to splinted premolars.

Use of multiple clamps

In addition to the clamp on the distal tooth, which retains the posterior portion of the dam, a second (or third) clamp is often needed. When the no. 212SA or other butterfly clamp (retractor) is used to retract tissue and dam for a Class 5 or other restoration, it is almost invariably used in addition to the posterior clamp. If a cavity

Dentlearn.ir

that is at least partly subgingival is to be prepared, a clamp on that tooth will prevent the dam from riding up over the margin (Fig 8-47).



Fig 8-47 A clamp is used to retract the dam and give access to the gingival extent of a root restoration on this maxillary central incisor. A no. W1A clamp was used because of the apical inclination of its jaws.

Placement of clamp over dam

When it is desirable to clamp a tooth that was not considered when the dam was punched, the clamp may be applied over the dam (see Fig 8-15). The clamp jaws should be dull, so as not to cut through the dam, and the dam should be stretched loosely over the tooth being clamped, as stretching it tightly will cause the clamp jaw to perforate the rubber, initiating a tear in the dam.

Gingival relaxation incisions

When using a no. 212SA retractor for isolation for a Class 5 restoration, the jaw of the retractor should be positioned at least 0.5 mm (preferably 1.0 mm) gingival to the gingival margin of the planned restoration. This can usually be accomplished without laceration of tissue, because the free gingiva is elastic enough to be retracted. If, however, the free gingival margin is fibrous and difficult to displace gingivally, forced retraction could lacerate the tissue. In such a case, it is preferable to make one or two small incisions[20,21] to allow the tissue to be displaced without tearing.

For this technique (sometimes referred to as a *miniflap procedure*) to be successful, the periodontium must be healthy. The incisions should be confined to the keratinized gingival tissue and kept as short as possible (just long enough to allow adequate exposure for isolation). Incisions can often be limited to the free gingiva, and, although reattachment to previously unexposed cementum can be expected, unnecessary severing of attachment should be avoided. Full-thickness vertical incisions should be initiated at the mesial and/or distal aspects of the facial surface

Dentlearn.ir

and should be directed perpendicular to the root and surface of bone, first perpendicular to the gingival margin and slightly toward the interproximal papilla, then apically (Fig 8-48).

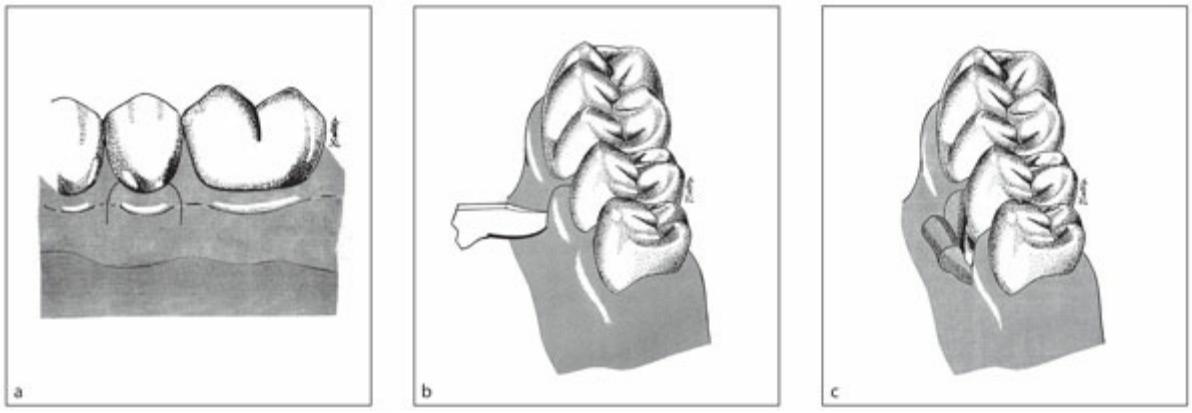

Fig 8-48*(a)* Gingival relaxation incisions are made within the keratinized gingival tissue. Either one or both can be made, depending on the amount of release needed for relaxation of the tissue. *(b)* The no. 15 scalpel blade is used to make the incision. *(c)* The tissue flap is reflected away from the root prior to application of the dam and no. 212SA retractor. The incisions are directed slightly into the papilla and then vertically.

The blade of a plastic instrument or a beavertail burnisher may be used to push the tissue and rubber dam back while the facial jaw of the no. 212SA clamp is being situated on the root of the tooth. Again, the jaw should be dull, not sharp, so that it will not damage the root surface. A finger should be used to hold the clamp in place while it is stabilized with compound (see Figs 8-24a to 8-24c). After the restorative procedure is completed, the no. 212SA clamp is removed (see Figs 8-24d to 8-24f), then the dam is removed. Any blood in the area is washed away. The reflected gingival tissue is returned to its original location and held there with a dampened gauze sponge and finger pressure for about 2 minutes to allow initiation of a fibrin clot. As long as the incisions were confined to keratinized tissue, no sutures or periodontal dressing are needed, and healing should proceed uneventfully. See chapter 15 for more information on soft tissue management in conjunction with Class 5 restorations.

Evacuation of fluid from the dam

If the dentist must work without an assistant, a very effective method for evacuation of fluid from the rubber dam involves the use of a suction tube anchored within the operating field. One evacuation method that uses a readily available item and is quick and easy involves the modification of a saliva ejector, as described by Lambert.[22] The molded plastic tip is cut off with a pair of crown scissors; then an

Dentlearn.ir

additional 0.4 inch of the plastic tube is cut off without cutting the wire within the plastic. The 0.4-inch length of plastic tubing is then pulled off the wire, leaving the wire extending from the end of the tube (Fig 8-49a); using forceps such as hemostats, the wire is bent in its center at a 90-degree angle in the direction of the tube to form an "L" shape. The wire is then carried under the jaw of the clamp and placed into the hole in the jaw of the clamp, usually on the lingual side of the clamped tooth. The taut rubber under the clamp jaw will hold the wire in place in the hole and push the tube against the dam (Figs 8-49b and 8-49c). This method will supply continuous fluid evacuation during the operative procedure.



Fig 8-49*(a)* For unassisted fluid evacuation from the dam,[22] a saliva ejector is modified. First, the tip is cut off; then another 0.4 inch, except for the wire, is cut off, and the protruding wire is bent at a right angle (in direction of tube) to form an L-shaped hook. *(b and c)* For fluid evacuation, the wire hook is carried under the jaw of the clamp and allowed to go into the forceps hole of the rubber dam clamp.

Sealing a root concavity

The rubber dam seals well on convex tooth surfaces. If the dam is retracted so that its edge goes across a root concavity, however, saliva will leak into the operating field. A solution is to seal the gap between the edge of the dam and the concave root surface. This may be accomplished with a provisional restorative material, such as Cavit (3M ESPE), which hardens with moisture (Fig 8-50).

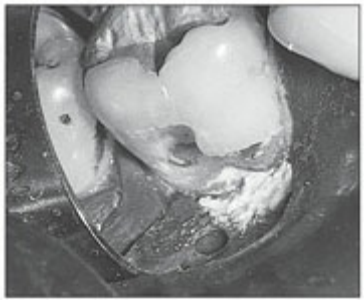

Fig 8-50 Sealing of the root concavity. The dam is retracted by the clamp to allow isolation for a large Class 5 restoration; the retraction is apical to the beginning of the root concavity of the furcation. The gap between the dam and the concave root surface is sealed with Cavit, a provisional restorative material that hardens when it comes into contact with moisture.

Repair of a torn rubber dam

Dentlearn.ir

A small tear in a dam may often be patched. A piece of dam material is cut to cover the tear, extending 1 cm or so beyond the tear on all sides. The piece is attached over the tear with cyanoacrylate glue.

Placement of a second dam over the first

If a dam is torn beyond repair during a procedure, the dentist might choose to remove the dam and replace it. Alternatively, another dam may be placed over the top of the first. Brownbill[23] recommended that this technique be used when there is leakage around teeth through incorrectly sized holes and when strong chemicals are to be used.

Latex allergies

There is an increasing awareness of latex sensitivity.[24–27] One survey[24] reported 3.7% of patients to have a latex allergy; the investigators recommended careful questioning of patients regarding a history of sensitivity to latex-based products so that the use of latex products, such as gloves and rubber dam, may be avoided with these patients.

For latex-sensitive patients, use of a latex dam should be avoided, as should other latex products. Nonlatex dam material is available from several manufacturers and should be on hand for latex-allergic patients. Current nonlatex dams have elastic properties very similar to latex. Some dentists have elected to use nonlatex dams exclusively for all their patients.

Summary of recommendations

Following are some of the protocols that facilitate rubber dam use:

- Use a heavy-gauge, prestamped dam.
- Floss through contacts prior to dam placement, planing any contact that shreds or tears the floss.
- Use a good water-soluble lubricant, such as Velvachol.
- Use a clamp designed for four-point contact on the tooth, and avoid overexpansion of the clamp so that the clamp will maintain its strength and will be stable as a retainer.
- Isolate enough teeth to hold the dam on the lingual aspect of the teeth away from the operating field and to provide exposed teeth for finger rests.

Dentlearn.ir

- With waxed floss, floss the dam through each interproximal contact in a single layer and avoid doubling or bunching the dam in the contact.
- Master the use of modeling compound to stabilize rubber dam retainers when necessary.

Other Methods of Isolation

Isolite

The Isolite (Isolite Systems) is a newer isolation device that provides illumination in addition to suction, retraction of tongue and cheek, and an integrated bite block (Fig 8-51). It is relatively simple to use and comfortable for the patient. Single-use mouthpieces come in six sizes (small, medium, and large regular; small, medium, and large DV [deep vestibule]). Mouthpieces conduct light so that it surrounds the teeth being isolated, and illumination is excellent. Many practitioners have incorporated the device in their practices. Like other devices that provide tongue retraction and suction, isolation is not as complete as that provided by the rubber dam. However, isolation with this device is excellent for many procedures.

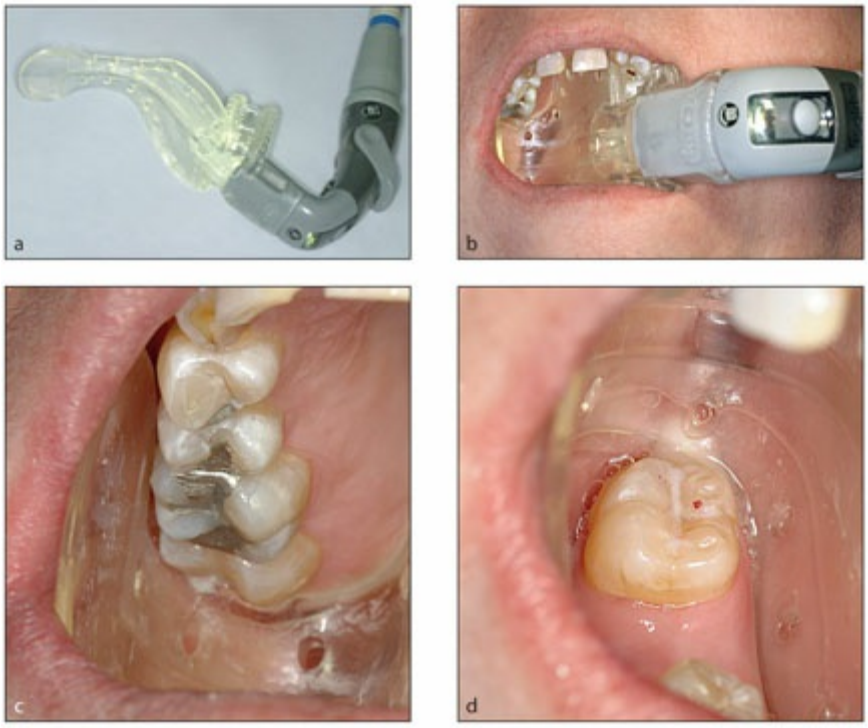

Fig 8-51 The Isolite provides tongue and cheek retraction, suction, an integrated bite block, and excellent illumination of the operating field. *(a)* Isolite device, with clear, flexible plastic, illuminated mouthpiece; *(b)* Isolite in place to isolate the right side of the mouth; *(c)* the isolated maxillary right posterior area; *(d)* t

Dentlearn.ir

Svedopter

The Svedopter (Miltex) is a metal tongue-retraction device for isolation in mandibular posterior areas (Fig 8-52). It is designed so that the vacuum evacuator tube passes anterior to the chin and mandibular anterior teeth, over the incisal edges of the mandibular anterior teeth, and down to the floor of the mouth, to either the left or the right of the tongue. A mirrorlike vertical blade is attached to the evacuator tube so that it holds the tongue away from the field of operation. Several sizes of vertical blades are supplied by the manufacturer. An adjustable horizontal chin blade is attached to the evacuation tube so that it will clamp under the chin to hold the apparatus in place.

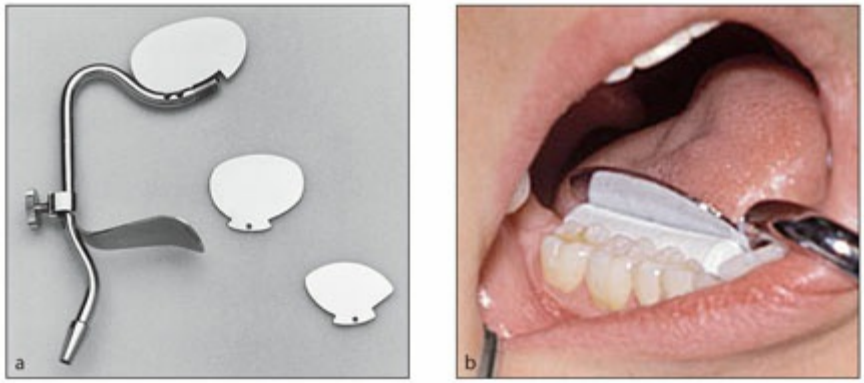

Fig 8-52 *(a)* The Svedopter tongue-retracting evacuation device is supplied with three sizes of vertical blades. *(b)* The Svedopter is used to hold the tongue away from the operating field.

Absorbent cotton rolls are placed adjacent to the Svedopter in the floor of the mouth and in the maxillary buccal vestibule adjacent to the opening of the parotid gland (Stensen) duct. The Svedopter is especially useful for preparation and cementation of fixed prostheses. It is less effective than the rubber dam for procedures in which total isolation from the fluids and vapors of the oral cavity is desired.

Hygoformic saliva ejector

The Hygoformic (Pulpdent) saliva ejector is used in the same way as the Svedopter for isolation in mandibular posterior areas, but it does not have a reflective blade (Fig 8-53). However, it is usually more comfortable and less traumatic to lingual tissues than is the Svedopter. For use, the saliva ejector must be re-formed (rebent) so that the evacuator tube passes under the chin, up over the incisal edges of the mandibular incisors, and then down to the floor of the mouth. The tongue-retracting coil should be loose s posteriorly enough

Dentlearn.ir

to hold the tongue away from the operating field. The Hygoformic saliva ejector is also used with absorbent cotton for maximum effectiveness.



Fig 8-53 The Hygoformic saliva ejector should be routinely rebent to pass under the chin, over the incisal edges of the mandibular incisors, and then down to the floor of the mouth. The apparatus should usually be uncoiled slightly to extend further posteriorly. *(a, left)* Hygoformic saliva ejector as received; *(a, right)* Hygoformic saliva ejector that has been reshaped. *(b and c)* Isolation achieved with the Hygoformic saliva ejector.

Vac-Ejector

The Vac-Ejector Moisture Control System (Coltène/Whaledent) is made to facilitate isolation when restoring posterior teeth (Fig 8-54a). The Vac-Ejector incorporates a bite block, tongue retractor for mandibular areas, and high-speed suction attachment. It comes with three flexible deflectors, one universal deflector for operating on either side in the maxillary arch (Figs 8-54b and 8-54c) and one for each side when operating in mandibular areas (Fig 8-54d). The bite block is adjustable, by rotation, for large or small arches; in Fig 8-54, it is adjusted for large arches. Although this product appears complex to assemble correctly, operators soon become skilled at rapid assembly.

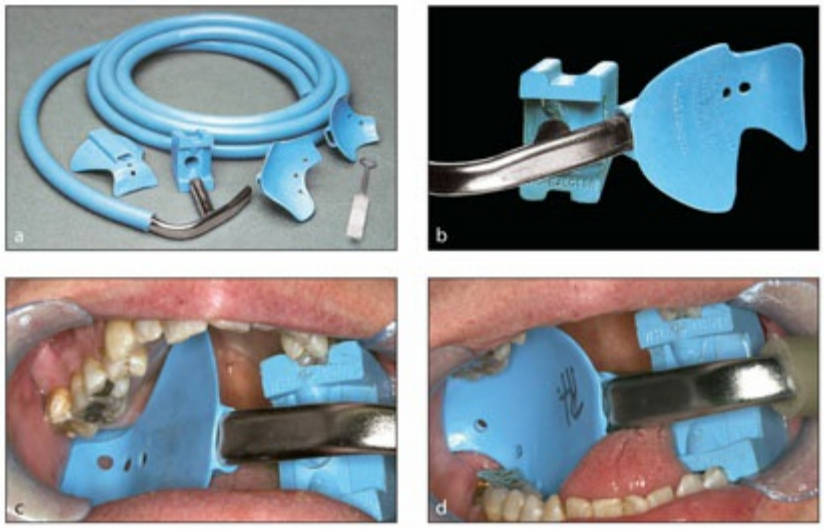

Fig 8-54 The Vac-Ejector provides a bite block, tongue retraction, and suction. *(a)* Parts of the Vac-Ejector; *(b)* assembled and ready for use for isolation of a maxillary posterior area; *(c)* in use for isolating the maxillary right posterior area; *(d)* in use for isolating the mandibular right posterior area.

Dentlearn.ir

Absorbent paper and cotton products

Absorbent materials are important in dentistry. Vacuum apparatuses remove fluids from the operating field by suctioning them; cotton and paper products help control fluids by absorbing them. Several types of absorbent cotton rolls are available in various diameters and lengths. These are placed into areas of the mouth where salivary gland ducts exit to absorb saliva and prevent salivary contamination of the operating field.

Isolation using absorbent materials with suctioning devices is less effective than using the rubber dam with suction, but in many procedures, the more complete isolation provided by the dam is unnecessary. In these situations, absorbent products are useful.

Small gauze sponges may be folded or rolled to substitute for cotton rolls. In addition, absorbent paper triangles, or parotid shields, such as Dri-Aid (Lorvic), are useful on the facial aspect of posterior teeth to absorb saliva secreted by the parotid gland (Fig 8-55).

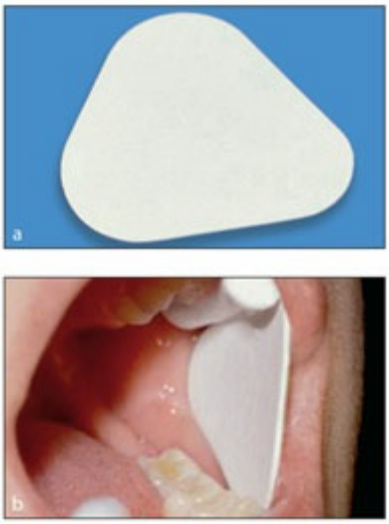

Fig 8-55*(a)* A parotid shield is triangular and made of absorbent paper. *(b)* A parotid shield may supplement a cotton roll in the buccal vestibule or may be used alone.

References

1. Christen AG. Sanford C. Barnum, discoverer of the rubber dam. Bull Hist Dent 1977;25:3–9.
2. Gergely EJ. Rubber dam acceptance. Br Dent J 1989;167:249–252.
3. Reuter JE. The isolation of teeth and the protection of the patient during endodontic treatment. Int Endod J 1983;16:173–181.
4. Stewardson DA, McHugh ES. Patients' attitudes to rubber dam. Int Endod J 2002;35:812–819.
5. Christensen GJ. Using rubber dams to boost quality, quantity of restorative services. J Am Dent Assoc 1994;125:81–82.

Dentlearn.ir

6. Small BW. Rubber dam—The easy way. Gen Dent 1999;47:30–33.
7. Trevino D, Duke E, Robbins J, Summitt J. Clinical evaluation of Scotchbond Multipurpose adhesive system in cervical abrasions [abstract 3037]. J Dent Res 1996;75:397.
8. Barghi N, Knight GT, Berry TG. Comparing two methods of moisture control in bonding to enamel: A clinical study. Oper Dent 1991;16:130–135.
9. Knight GT, Barghi N, Berry T. Microleakage of enamel bonding as affected by moisture control methods [abstract]. J Dent Res 1991;70:561.
10. Raskin A, Michotte-Theall B, Vreven J, Wilson NH. Clinical evaluation of a posterior composite 10-year report. J Dent 1999;27:13–19.
11. Smales RJ. Effect of rubber dam isolation on restoration deterioration. Am J Dent 1992;5:277–279.
12. Van Dijken JW, Hörstedt P. Effect of the use of rubber dam versus cotton rolls on marginal adaptation of composite resin fillings to acidetched enamel. Acta Odontol Scand 1987;45:303–308.
13. Eidelman E, Fuks AB, Chosack A. The retention of fissure sealants: Rubber dam or cotton rolls in a private practice. ASDC J Dent Child 1983; 50:259–261.
14. Straffon LH, Dennison JB, More FG. Three-year evaluation of sealant: Effect of isolation on efficacy. J Am Dent Assoc 1985;110:714–718.
15. Knight GT, Barghi N. Effect of saliva contamination on dentin bonding agents in vivo [abstract 434]. J Dent Res 1992;71:160.
16. Hegde MN, Hegde P, Shetty SK. The influence of salivary contamination on the shear bond strength of two newer generation dentin bonding agents—An in vitro study. J Conserv Dent 2008;11:127–130.
17. Park JW, Lee KC. The influence of salivary contamination on shear bond strength of dentin adhesive systems. Oper Dent 2004;29:437–442.
18. Aboushelib MN. Clinical performance of self-etching adhesives with saliva contamination. J Adhes Dent 2011;13:489–493.
19. Reid JS, Callis PD, Patterson CJW. Rubber Dam in Clinical Practice. Chicago: Quintessence, 1990.
20. Drucker H, Wolcott RB. Gingival tissue management with Class V restorations. J Am Acad Gold Foil Oper 1970;13:34–38.
21. Xhonga FA. Gingival retraction techniques and their healing effect on the gingiva. J Prosthet Dent 1971;26:640–648.
22. Lambert RL. Moisture evacuation with the rubber dam in place. J Prosthet Dent 1985;53:749–750.
23. Brownbill JW. Double rubber dam. Quintessence Int 1987;18:699–700.
24. Fay MF, Beck WC, Checchi L, Winkler D. Gloves: New selection criteria. Quintessence Int 1995;26:27–29.
25. Kosti E, Lambrianidis T. Endodontic treatment in cases of allergic reaction to rubber dam. J Endod 2002;28:787–789.
26. March PJ. An allergic reaction to latex rubber gloves. J Am Dent Assoc 1988;117:590–591.
27. Rankin KV, Jones DL, Rees TD. Latex reactions in an adult dental population. Am J Dent 1993;6:274–276.

Dentlearn.ir



Adhesion to Enamel and Dentin

Lorenzo Breschi
Jack L. Ferracane
Milena Cadenaro
Annalisa Mazzoni
Thomas J. Hilton

Adhesion

The process of *adhesion* may be defined simply as the joining together of two independent surfaces or materials for which contact is maintained without the aid of external forces. This definition does not say anything about the type, relative strength, or long-term stability of the adhesive joint but only declares that it exists. In the strictest sense, *adhesion* is a measure of the force of attraction between two different materials and is differentiated from *cohesion* in that the latter relates to the forces of attraction within a single material, ie, the forces holding it together. Adhesion can result from the formation of primary chemical bonds, such as covalent, ionic, or metallic, and strong, durable joints can be produced from each of these types of bonds. Adhesion also can result from strong secondary forces, such as hydrogen bonds and Van der Waals forces, which typically are of lower overall

Dentlearn.ir

durability than primary chemical bonds because of their lower bonding energies. Whether based on primary or secondary bonds, adhesion depends on strong molecular interactions between two surfaces in intimate contact, and both types of interactions are evident in dental adhesive materials. It is also common to "lock" one surface or material into another through a purely mechanical interaction, mediated by frictional forces between surfaces in close contact. This mechanical bonding does not truly represent an adhesive joint, as it depends on undercuts and obstructions to motion for its stability.

The extent to which one surface or material interacts with another depends on many factors, the most important relating to energy.[1] In nature, there is a desire for all objects to seek a reduced energy state, simply because this is the most stable object because molecules present at the surface have unsatisfied bonds. In other words, these molecules would prefer to be "covered" by other molecules to satisfy their bond complexes and reduce their overall energy state. This covering can occur by oxygen, water, or other molecules. The higher the energy of the surface, the more receptive it is to being bonded to by another material, such as an adhesive. Thus, practical approaches to raising the energy of a surface are typically sought to enhance adhesion. In dentistry, such approaches include surface cleaning by pumice or prophylactic pastes, etching with mild or strong acids, or cleaning with solvents to remove contaminants. When an adhesive material, typically in a liquid or paste form to facilitate application, is applied to a surface for bonding, the adhesive will to some extent spread out on the surface. This relative spreading is referred to as *wetting*, and it is very important to be able to enhance this physical effect in order to ensure good bonding. The reason is fairly obvious if one considers that bond strength is affected to a great extent by how much of the two independent materials are brought into intimate contact with one another. Thus, a liquid that beads up on a surface, like water on a freshly waxed automobile, does not spread and provides a minimum of surfaces in contact for bonding (Fig 9-1).

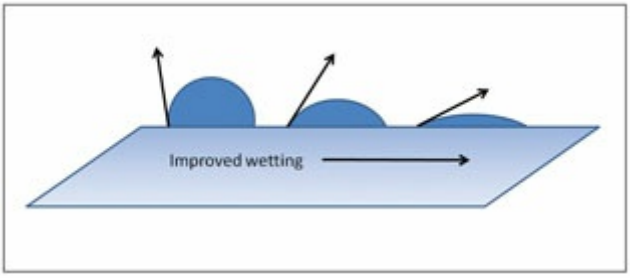

Fig 9-1 The *contact angle*, the angle between the surface and a tangent line drawn to the edge of the adhesive droplet through the droplet itself, depicts how well the adhesive wets the surface. The lower the contact angle, the better an adhesive will wet the surface and enhance adhesion.

Dentlearn.ir

On the other hand, solder flowing out onto a metal surface to create a union between two clean metal parts provides an example of good wetting. One critical property of the adhesive that affects the amount of spreading is the surface tension of the adhesive itself. The molecules of the adhesive have an affinity for one another that causes them to stay together rather than interact with the surface they contact. If this surface energy of the adhesive, or *surface tension*, is very high, the adhesive tends to bead up and not spread. Thus, an ideal condition for bonding is to have a substrate with high surface energy (ie, one that is clean) and an adhesive with low surface tension (ie, one that does not bead up).

The chemistry of the adhesive determines how well it will wet the substrate and ultimately how strongly it will attach. Like molecules attract like molecules, and therefore two materials with similar surface chemistry are more likely to interact and adhere. These interactions may come in the form of chemical interactions, such as primary chemical bonds, or via polar or secondary chemical interactions, such as hydrogen bonds. As noted previously, the latter are typically of lower bond energy and considered less stable. However, there are numerous examples of strong and durable bonds formed primarily from these secondary forces, such as wood glues and bonding to acid-etched enamel. In both cases, strong bonds are formed by an adhesive with relatively low surface tension flowing into all of the microscopic irregularities of a surface and spreading across it, providing intimate contact and the possibility for molecular interactions. These same requirements are present for establishing primary chemical bonds as well. Therefore, it is easy to understand why anything that inhibits the close contact between an adhesive and a surface, measured on the order of atomic sizes, will inhibit wetting and the molecular interactions required for adhesion.

Critical variables influencing adhesion are the surface roughness of the substrate, its cleanliness (ie, its lack of contamination), the viscosity of the adhesive, the dimensional change occurring in the adhesive during setting, and the durability of the adhesive and the new interface.[2] A rough surface, especially one with microscopic roughness, may produce a very high surface area and enhanced potential for surface interactions, as long as the adhesive can spread onto the surface and flow into the irregularities. This is the case with acid etching of enamel for bonding dental resin materials. This is also why the viscosity of the adhesive is so important; if the adhesive is too viscous, it will not flow adequately and cannot displace the air and/or molecules already present on the surface in order to create the required intimate contact. If the adhesive is too fluid, it will not stay in place on the substrate. The need for low viscosity to enhance flow explains why most adhesives or primers for

Dentlearn.ir

creating bonding to dentin have solvents to reduce their viscosity. However, if the surface has already been contaminated by molecules that have an equal or greater affinity for the surface, they will not be displaced by the adhesive, and the intimate contact will be hindered and the bonding reduced. While it is possible that the adhesive has a high affinity for interacting with the contaminant surface, an unstable situation may be created as the adhesive bonds to the contaminant because the stability of the overall joint then depends on how strongly the contaminant is attached to the substrate. This explains the need for cleaning the surface to produce a known, clean substrate for bonding. Frequent contaminants of tooth surfaces, such as water, saliva, and blood, must be routinely managed by the practitioner, typically with good isolation techniques such as rubber dam, cotton rolls, or other devices.

Once the adhesive is applied to the surface, it must transform from a liquid to a solid to effect bonding. Most dental adhesives, based on polymeric materials, undergo significant shrinkage during this hardening process. This shrinkage may have a deleterious effect on the bond by creating forces that physically pull the adhesive away from the substrate. This is especially a concern when the adhesive material is simultaneously being bonded to two opposing and rigid substrates, like the opposite walls of a cavity preparation. One can imagine this "tug of war" as the adhesion is being created between the two sides at nearly the same time that the material is pulling away by virtue of setting shrinkage. This issue is addressed to a great extent in later chapters (see chapter 11). Finally, the interface that forms between the substrate and the adhesive is expected to be durable and to resist external physical forces as well as chemical or biologic degradation, or else the joint fails. This complex interplay as it relates to bonding to dentin is addressed later in this chapter.

Substrates

The composition of the enamel and dentin substrates has been thoroughly reviewed in chapter 1. In terms of their influence on achieving adhesion, the important aspects of these substrates include their abundance of mineral as a potential site for chemical interactions in both and how the adhesion is affected by the high concentration of organic material in dentin, specifically collagen, as well as the significant water content of the latter. In addition, both substrates are highly *hydrophilic*, ie, water loving. It may seem that developing an adhesive for bonding to both of these substrates at the same time would be impossible, but the development of adhesive primers with enhanced hydrophilicity as agents for preparing the surfaces for bonding to the more ving) resin adhesive

Dentlearn.ir

has largely solved this concern, albeit after many years of study and development.

In the oral cavity, certain conditions may affect the normality of the enamel and dentin substrates and potentially influence bonding. Enamel and dentin may become hypomineralized, either through caries attack or as a direct result of a developmental anomaly, such as amelogenesis imperfecta, or through erosion, such as may occur with a patient suffering from bulimia or gastroesophageal reflux disease (GERD). These surfaces may be more difficult to bond to because of the weakened nature of the substrate.[3–6] In contrast, exposure to mineralizing solutions, such as fluoride, via intraoral application or via the water supply in certain regions, may produce hypermineralized enamel. This latter material may be more resistant to demineralization and potentially requires a longer etching time to produce an adequate surface for bonding. Teeth that have been highly stained from systemic absorption of chemicals in drug therapies, such as tetracycline, also may provide a modified enamel surface for bonding.

Over time, dentin may become more *sclerotic* (ie, calcified), thus affecting how well it may be demineralized during normal adhesive placement. Laboratory studies have shown that bonding to sclerotic dentin may be reduced as compared with normal dentin[7] but that extending etching time may enhance the bond for certain adhesives using strong acids.[8] The bond to sclerotic dentin is also lower than that for normal dentin when using adhesives containing milder organic acids (such as those used in the self-etching adhesives described later in this chapter),[9,10] but additional tooth preparation with burs or air abrasion may be beneficial for enhancing the bond.[11] Despite this reduced bond to sclerotic dentin, at least one clinical study showed equivalent results at 8 years for Class 5 restorations bonded to sclerotic and nonsclerotic dentin.[12] Others have reported clinical outcomes that show enhanced performance of the adhesives containing stronger acids when dealing with sclerotic dentin.[13]

Materials

Dental adhesives consist of three main components: *(1)* etchant, *(2)* primer, and *(3)* bonding resin. The latter is often referred to as the *adhesive resin*, but the entire system also is typically called an *adhesive*. The etchant is composed of acidic molecules that alter or remove the smear layer (defined in the Adhesive System Classification section) and demineralize the enamel and dentin and prepare it for bonding. The primer serves as a type of molecule that helps make the dentin surface, which is very hydrophilic, become more hydrophobic in order to accept the very

Dentlearn.ir

hydrophobic bonding resin. Thus, the primer typically contains a molecule or molecules with both hydrophilic and hydrophobic characteristics, ie, *amphiphilic*. It functions by penetrating the demineralized dentin and preparing it for the bonding resin. The bonding resin then becomes incorporated into the primed dentin and, once cured, forms the structural support of the bonded interface between the tooth and the subsequently placed restorative material. The entire process forms a zone of material that consists of components of both the dentin and the resin and is called the *hybrid layer* or *interdiffusion zone*.

All dental adhesive systems are based on polymeric materials. These materials have a variety of chemical characteristics, ranging from very hydrophilic (glass ionomer) to very hydrophobic (the adhesive resin component of many adhesive systems). Considering the hydrophilic nature of the tooth, especially dentin, it is logical that an adhesive also should have a hydrophilic nature when placed in order to wet the surface and penetrate the available microstructure. Attempts to bond unfilled monomers, the same as those used in dental composites and sealants, to an etched dentin surface is unsuccessful in large part because of the lack of hydrophilicity of the materials.[14] While a detriment during placement, this hydrophobic nature is considered to be beneficial once the material has established a bond with the tooth substrate. A hydrophobic polymeric layer is more insoluble and resistant to erosion and degradation by acids and other components of oral fluids than a more hydrophilic one.[15,16] Thus, the ideal adhesive would have a hydrophilic nature during placement and would become much more hydrophobic after curing. Such materials are not readily available to dentistry—instead a combination of hydrophilic and hydrophobic molecules are used in modern adhesives to effect durable bonding, with varied results explained in greater detail later in this chapter. Because enamel contains little water, hydrophobic monomers are capable of wetting and penetrating its etched structure with ease, as long as it has been dried adequately.

The major difference between hydrophilic and hydrophobic adhesives is the chemistry of their monomers and solvents. Monomers with alcohol, acid, hydroxyl,

collagen and hydroxyapatite of tooth structure than are molecules consisting predominantly of hydrocarbons. As hydroxyl, carboxylic, phosphate, and amide

so forth, on the polymer chain, and as ether and ester linkages are incorporated, the polymer becomes slightly more hydrophilic (Table 9-1). However, *hydrophilicity* is a relative term. A monomer like hydroxylethyl methacrylate (HEMA) is totally

Dentlearn.ir

miscible in water and serves as an excellent polymerizable wetting agent for dental adhesives (see Table 9-1). Bisphenol glycidyl methacrylate (bis-GMA), the main monomer used in most dental composites and many adhesives (the final component of the bonding system application process), is much more hydrophobic and will only absorb about 3% water by weight into its structure when polymerized[17] (see Table 9-1). A mixture of the two has intermediate characteristics and serves as a useful adhesive for the tooth. To enhance the wetting, spreading, and penetration of the polymerizable monomers into the dentin substrate, solvents are always added to the mixture as "thinning" agents. These solvents are typically water, ethyl alcohol, butyl alcohol, or acetone. The first three are very hydrophilic and thus enhance the interaction of the monomers with surface water, while acetone is good at displacing ("drying") water from within the dentin. However, any solvent not displaced during the placement procedure, such as by drying appropriately,[18] will be incorporated into the bonding layer and may serve as a weakening contaminant. Because it is not a polymerizable molecule and cannot bond with the newly formed polymer, such an agent is called a *plasticizer*, so named because it softens the polymer structure in the bonding layer by expanding the polymer network and reducing the beneficial physical entanglements of individual polymer chains that contribute to its strength.

Dentlearn.ir

Table 9-1	Abbreviations and molecular formulas of monomers, initiators and inhibitors, and additives and coupling agents used in adhesives
Abbreviation	**Molecular formula**
Monomers	
Bis-GMA bisphenol A glycerolate dimethacrylate *or* 2,2-bis (p-2'-hydroxy-3'-methacryloxypropoxyphenyl)-propane	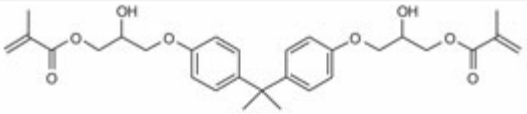
BPDM biphenyl dimethacrylate *or* 4,4-dimethacryloyloxyethyloxy-carbonylbiphenyl-3,3-dicarboxylic acid	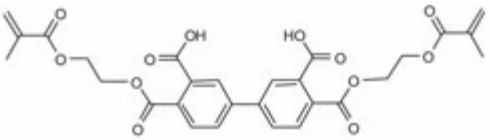
GDMA glycerol dimethacrylate *or* glycerol-1,3-dimethacrylate	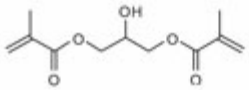
GPDM glycerol phosphate dimethacrylate *or* glycerol-2-dihydrogenphosphate-1,3-dimethacrylate	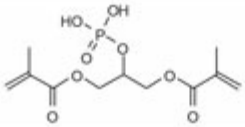
HDDMA 1,6-hexanediol dimethacrylate	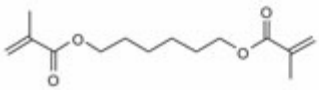
HEMA 2-hydroxyethyl methacrylate	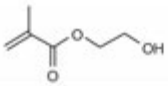
HEMA-phosphate 2-hydroxyethyl methacryl dihydrogenphosphate *or* 2-dihydrogenphosphate-1-methacrylate-etane	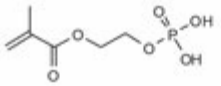
MAC-10 11-methacryloyloxy-1,1'-undecanedicarboxylic acid *or* 2-carboxyl-12-methacryl-dodecanoic acid	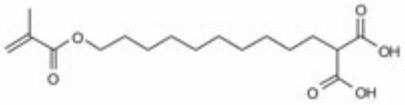
10-MDP 10-methacryloyloxydecyl dihydrogenphosphate *or* 10-methacrylate-1-dihydrogenphosphate-decane	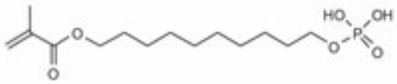
MDPB methacryloyloxydodecylpyridinium bromide *or* 12-methacryl-1-pyridyl-dodecane bromide	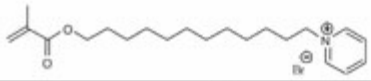
4-META 4-methacryloxyethyl trimellitate anhydride *or* 4-methacryloxy-ethyl trimellitic anhydride	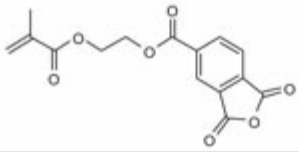
4-MET 4-methacryloyloxyethyl trimellitic acid	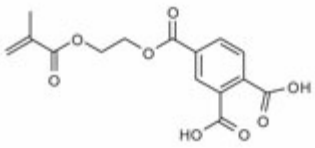

Dentlearn.ir

Table 9-1 *(cont)*	Abbreviations and molecular formulas of monomers, initiators and inhibitors, and additives and coupling agents used in adhesives
Abbreviation	**Molecular formula**
Monomers	
MMA methyl methacrylate	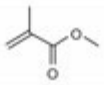
MMEP mono-2-methacryloyloxyethyl phthalate *or* PAMA: phthalic acid monomethacrylate	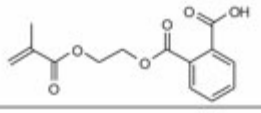
NGT-GMA N-tolylglycine glycidyl methacrylate *or* N-(2-hydroxy-3-[(2-methyl-1-oxo-2-propenyl)oxy]propyl)-N-tolyl glycine	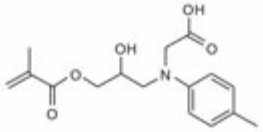
PAMM mono-(2-methacryloxyethyl)-phthalate *or* methacryloxyethyl phthalate *or* phthalic acid monoethyl methacrylate	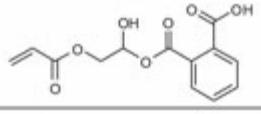
PEGDMA polyethylene glycol dimethacrylate	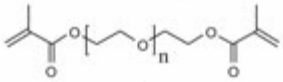
PENTA dipentaerythritol pentaacrylate monophosphate	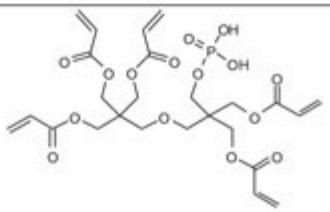
TCB butan-1,2,3,4-tetracarboxylic acid di-2'-hydroxyethyl-1'-methacrylate ester	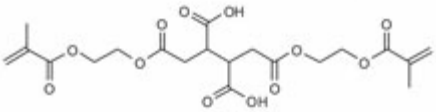
TEGDMA triethylenglycol dimethacrylate	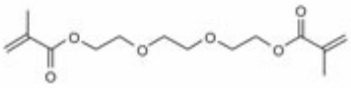
UDMA urethane dimethacrylate *or* 1,6-di(methacryloyloxyethylcarbamoyl)-3,3,5-trimethylhexaan	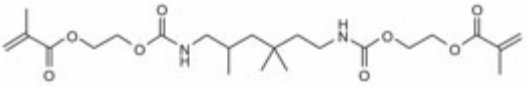
Initiators and inhibitors	
BHT butylhydroxytoluene *or* butylated hydroxytoluene *or* ,2,6-di-(tert-butyl)-4-methylphenol	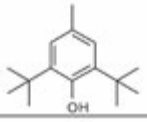
BPO benzoylperoxide (redox initiator)	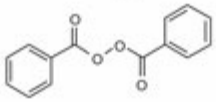

Dentlearn.ir

Table 9-1 *(cont)*	Abbreviations and molecular formulas of monomers, initiators and inhibitors, and additives and coupling agents used in adhesives
Abbreviation	**Molecular formula**
Initiators and inhibitors	
CQ camphorquinone *or* 1.7.7-trimethylbicyclo-[2,2,1]-hepta-2,3-dione (photoinitiator)	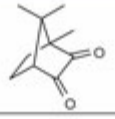
EDMAB 2-(ethylhexyl)-4-(dimethylamino)benzoate (co-initiator)	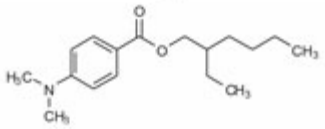
Additives and silane coupling agents	
Coupling agent A174 methacryloxypropyltrimethoxysilane	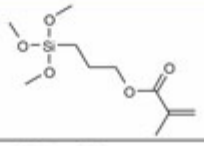
NaF sodium fluoride	

The monomers present in dental adhesives are similar to those used in dental composite restoratives, thus ensuring that there will be strong interaction between the adhesive and the overlying composite (see Table 9-1). But critical to achieving bonding to the tooth is the conversion of the monomers that penetrated the tooth structure into a rigid, strong polymer. This process, called *polymerization*, involves the chemical splitting of carbon-carbon double bonds of the monomers, followed by the formation of carbon-carbon single bonds linking one monomer to another, thus building a long chain of molecules much like adding links to a chain (Fig 9-2).

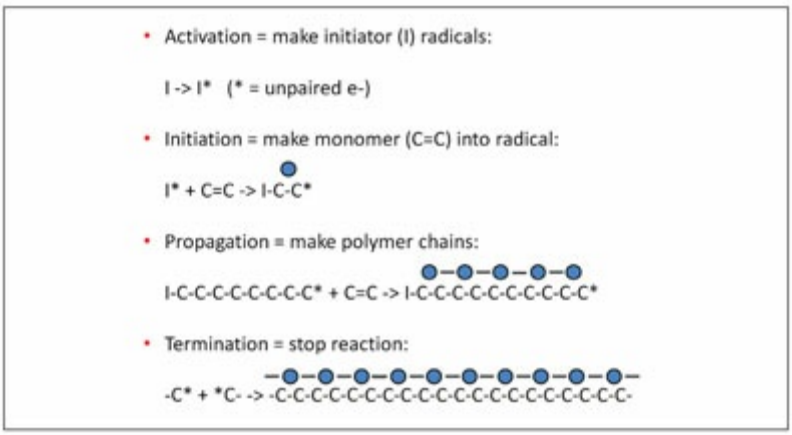

Fig 9-2 The steps in the process of the free radical polymerization reaction of an adhesive, showing the activation step that produces a free radical on the initiator (I); the initiation step where the active initiator (I*) collides with a monomer (C=C) and makes it become active (C*); the propagation step where the monomer containing the active radical (C-C*) collides sequentially with additional monomers, transferring the radical and extending the polymer chain; and the termination step where the radicals are extinguished and the polymer chain is terminated.

Dentlearn.ir

In fact, the reaction is termed an *addition reaction* for this reason. The covalent bonds linking molecules together are strong and produce a relatively stiff bonding layer that is capable of resisting many types of mechanical and chemical forces. The polymerization process typically is begun by exposing the adhesive to radiation from a high-intensity light source tuned to the same wavelength range (400 to 500 nm, blue light) that is absorbed by the purposely added photoinitiator.[19] Thus, photons of blue light are directed into the uncured adhesive, and the photoinitiator molecule within (typically camphorquinone) absorbs these photons, raising these molecules to an excited state from which they are capable of interacting chemically with the monomer molecules to split carbon-carbon double bonds and initiate the polymerization reaction. It is also possible to use chemicals in the absence of light energy to produce the reaction in what are called *self-curing materials*, as opposed to the *light-curing materials* just described. The extent to which the monomer molecules react to produce polymer determines the length of the polymer chains, which is directly related to the strength of the final polymer.[20] Thus, exposing the adhesive to adequate light energy and effecting adequate polymerization is critical for forming a strong and durable bonded interface with the tooth.

Accompanying the polymerization reaction is a volumetric change of the adhesive material. This is not surprising, because the molecules that formerly interacted at the level of secondary forces within a liquid state have now become permanently linked by stronger, primary chemical bonds characterized by shorter distances between molecules. The overall volume contraction depends on the size of the molecules reacting and the extent to which they reacted (polymerized) and can be as high as 10% for an unfilled resin. The same effect occurs when the dental composite, composed of much the same chemicals, polymerizes to fill the cavity preparation, forming the restoration. However, as the composite is typically filled heavily with reinforcing glass particles, its shrinkage is much lower because much of its volume is taken up by the nonshrinking filler. This difference in shrinkage between dental composites (particulate-filled polymers) and unfilled resins, as well as the reinforcing effect of the filler particles, explains in part why manufacturers often incorporate fillers in their adhesives. The goal is to decrease polymerization shrinkage and increase strength, while taking care not to add so much filler as to detrimentally increase the viscosity of the mixture, inhibiting its ability to flow and penetrate the surface. The shrinkage of the material during curing produces a dimensional change that causes stresses to build up between the tooth surface and the adhesive and ultimately between the tooth and the composite restorative through the adhesive.[21] These stresses can be very detrimental in that they may lead to the

Dentlearn.ir

composite and adhesive being pulled away from the tooth surface to which it is trying to establish a bond (Fig 9-3).

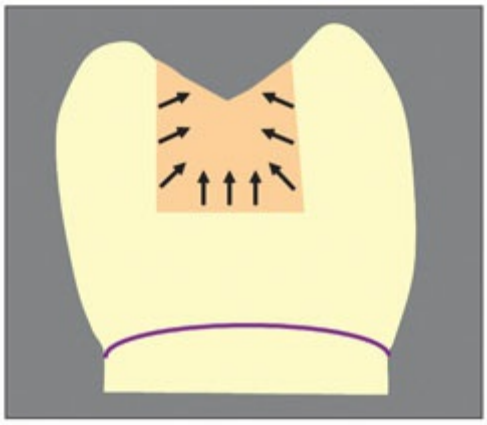

Fig 9-3 Curing of the dental composite causes it to shrink, pulling the material away from the cavity walls of the tooth and toward its center.

As noted earlier, the ideal adhesive would not change dimension during curing to avoid this potential problem. This explains why there is so much development of low-shrinking monomers for use in dental adhesives, composites, and cements.

Once the bond to the tooth is established, it is important that it be durable and able to withstand chemical and mechanical forces during function. Water, enzymes, acids, and other chemicals present in saliva, pulpal fluid, and the demineralized dentin all may contribute to the degradation of this bonding layer.[16,22] This subject is discussed further later in this chapter. But it is essential that the adhesive layer be able to remain intact during the cyclic imposition of stresses that occur during chewing, clenching, and grinding. Studies of the durability of this bonded layer have been reviewed[23,24] and are ongoing. Most adhesives have been found to be at least somewhat susceptible to degradation over time, both in vitro[25] and in vivo,[26] the magnitude varying based on the formulation of the materials and the environmental conditions.

History of adhesion systems

Buonocore[27] first demonstrated the use of phosphoric acid to increase the receptivity of enamel surfaces to adhesives, producing a 100-fold increase in resin-enamel bond strength. Gwinnett and Matsui[28] subsequently found that fluid resin penetrated etched enamel prisms to form resin microtags that interlocked with superficial enamel irregularities (Fig 9-4). However, concerns at that time about the potential adverse effects on the pulp after contact with dentin limited the application of phosphoric

Dentlearn.ir

acid etching to enamel.

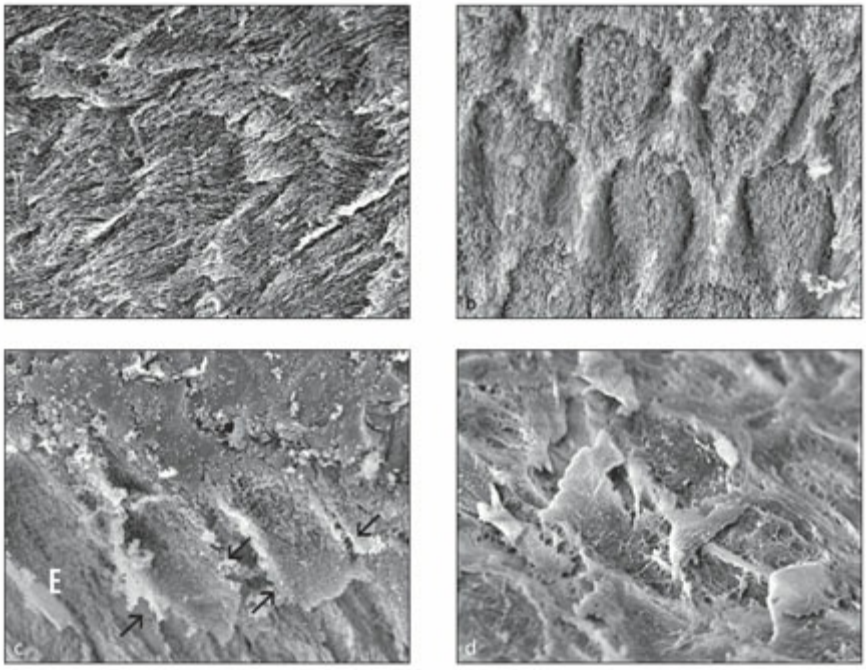

Fig 9-4 Adhesion to enamel occurs via penetration of liquid monomers that penetrate etched enamel prisms to form resin microtags that interlock with superficial enamel irregularities. *(a)* irregularities produced by the underlying enamel prisms. *(b)* FE-SEM image showing the effect of 35% phosphoric acid on the enamel surface. Enamel prisms and hydroxyapatite crystals are clearly visible after acid etching. *(c)* FE-SEM image showing the interaction between an etch-and-rinse adhesive system and etched enamel (E). Resin tags *(between arrows)* penetrate the prisms' boundaries and in between the crystals, interlocking with the enamel surface. *(d)* FE-SEM image showing residual cured adhesive applied on phosphoric acid–etched enamel after complete removal of the enamel substrate. The irregularities in the adhesive surface are due to the interlocking between the liquid resin into the etched enamel surface before curing.

The *total-etching technique*, in which enamel and dentin are etched simultaneously, was introduced by Fusayama.[29] In this technique, the smear layer (Figs 9-5a and 9-5c) created on the surface by cutting with the bur is removed, and 3 to 5 μm of superficial dentin is demineralized to expose the collagen network (Figs 9-5b and 9-5d) and produce funnel-shaped dentinal tubules.[32]

Dentlearn.ir

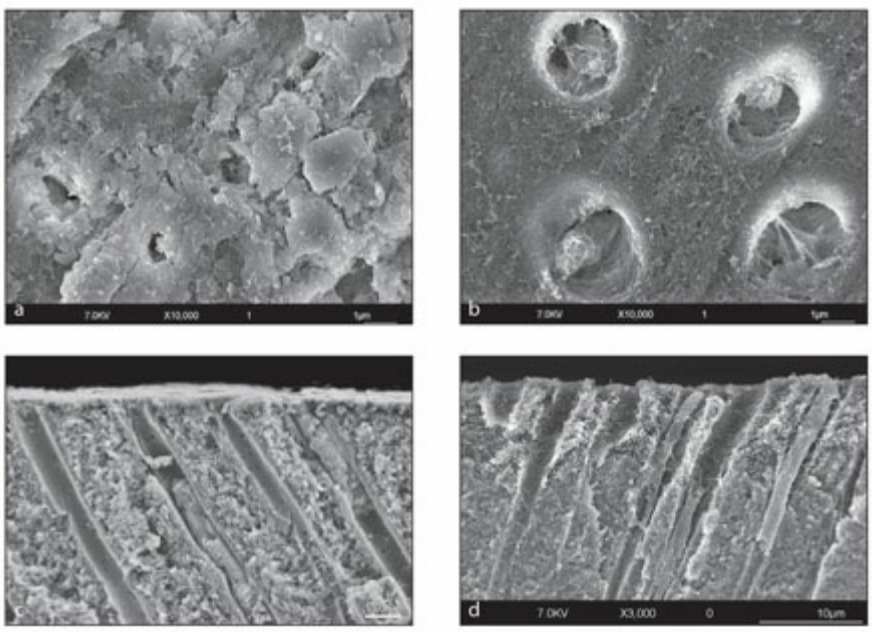

Fig 9-5*(a)* FE-SEM image of the smear layer obtained using a diamond bur with water irrigation on the dentin surface. An amorphous layer (approximately 1- to 5-µm thick) comprised of residual organic and inorganic debris as a result of mechanical instrumentation can be seen. This created smear layer obstructs the entrances of dentinal tubules, decreasing dentin permeability. *(b)* FE-SEM image showing the effect of 35% phosphoric acid on the dentin surface. The widened orifice of the tubule reveals the presence of intratubular structures suspended by a complex net of radial fibers connected to the surrounding inner lateral walls. The intratubular dentin appears as a porous structure characterized by a complex network of interconnecting collagen fibrills. (Reprinted from Breschi et al[30] with permission.) *(c)* Dentin cross section showing the smear layer on top of the mineralized dentin and smear plugs obliterating the tubules. *(d)* Etched dentin fractured longitudinally. Dentin tubule orifices appear funneled due to the demineralization of the peritubular dentin mineral. The intertubular dentin appears porous and demineralized up to 4 to 5 µm below the surface. (Reprinted from Breschi et al[31] with permission.)

Nakabayashi et al[33] first described the infiltration of resin monomers into acid-etched dentin (Figs 9-6a and 9-6b) to form a collagen fibril–reinforced resin matrix. This new structure was named the *hybrid layer* and is composed of collagen, resin monomers, and residual smear layer components (Figs 9-6c and 9-6d).

Dentlearn.ir

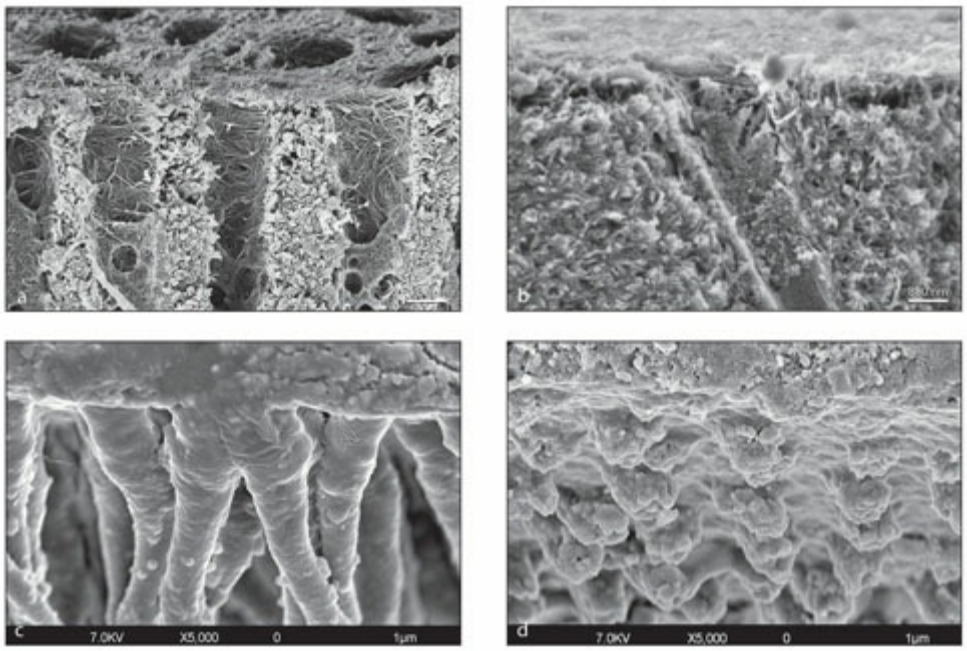

Fig 9-6 The hybrid layer formation occurs with penetration of the bonding systems into the acid-etched dentin (etch-and-rinse systems) or through a simultaneous demineralization and infiltration process (typical of self-etching systems). *(a)* FE-SEM image showing longitudinal view of dentin decalcification after etching with 35% phosphoric acid for 15 seconds (original magnification ×7,000). *(b)* FE-SEM image showing longitudinal view of decalcification of dentin after application of the etchant and primer agent of a strong self-etching adhesive (original magnification ×25,000). (Figs 9-6a and 9-6b courtesy of Sillas Duarte, Los Angeles, California.) *(c)* In-lens FE-SEM (FEI-SEM) image showing hybrid layer formation (continuous upper layer seen in the image) after the application of an etch-and-rinse adhesive. The image also shows the deep penetration of resin tags into the dentinal tubules exposed by the acid-etching process (image produced by demineralization of the dentin mineral to visualize the resin penetration). *(d)* FEI-SEM image showing hybrid layer formation (continuous upper layer seen in the image) after the application of a strong self-etching adhesive. The image also shows the minimal penetration of resin tags into the mildly etched dentin surface (image produced by demineralization of the dentin mineral to visualize the resin penetration). (Figs 9-6c and 9-6d reprinted from Breschi et al[22] with permission.)

The ability of dental adhesive systems to bond to tooth structures is currently recognized to depend on two main factors: *(1)* substrate demineralization, which partially removes the mineral phase and increases tooth receptivity, and *(2)* subsequent passive infiltration of monomers into the demineralized layer.[34,35] Cured adhesive forms a micromechanical bond with surface microporosities created during the demineralization process. Good bonding under clinical conditions depends on such interlocking and may also be influenced by other chemical interactions between functional monomers and the tooth substrate.[36,37]

Adhesive System Classification

Dentlearn.ir

mechanism of smear layer removal, and number of clinical steps.

Generation

with each generation (first through eighth) reflecting significant changes in product characteristics.

Solvent

adhesives have solvent concentrations of 8% to 49% and may be acetone, ethanol, or water based. The solvent contained in a given adhesive system has important clinical implications, particularly during air drying.[38] Many etch-and-rinse systems contain volatile solvents (eg, ethanol or acetone) that decrease viscosity and increase wetting and molecular mobility. Self-etching adhesives often contain water, which achieves the same effects and allows the dissociation of weak acids for enamel/dentin demineralization.[39] Organic solvents characterized by high vapor pressure (ie, evaporate easily) may contribute to the displacement of water from the collagen network and dentinal surface, allowing monomers to penetrate the collagen fiber network.[40,41]

Mechanism of smear layer removal

Adhesives are categorized by their approach to the removal of the *smear layer* (see Figs 9-5a and 9-5c). This 1- to 5-µm-thick amorphous layer is comprised of residual organic and inorganic debris and forms as a result of mechanical instrumentation of enamel and dentin.[42] The smear layer obstructs the entrances of dentinal tubules, decreasing dentin permeability by up to 86%.[43] This layer must be removed or made permeable to allow interaction between the monomers and the dentinal surface.

into two major types[22,44]: *(1)* etch-and-rinse adhesives and *(2)* self-etching or etch-and-dry adhesives.

Etch-and-rinse adhesives

These adhesives use a strong acid (usually 35% to 37% phosphoric acid at a pH of

Dentlearn.ir

approximately 0.9) to completely etch enamel and dentin, followed by a water rinse to remove the acid from the tooth surface.[34] They formerly were known as *total-etch* adhesives. The acid removes the smear layer from the enamel surface and demineralizes the superficial hydroxyapatite to reveal the enamel prisms (see Fig 9-4). On dentin, the acid demineralizes the superficial hydroxyapatite and removes the smear layer and *smear plugs* (debris occluding the dentinal tubules) to expose the collagen fibrils of the dentinal matrix and open the dentinal tubules, funneling their orifices[34] (see Figs 9-5 and 9-6). The adhesive then fills enamel and dentin porosities created by the etching procedure (see Figs 9-4c, 9-4d, and 9-6c).

Self-etching or etch-and-dry adhesives

These systems use a nonrinsing solution of acidic monomers to dissolve the smear layer on enamel and dentin surfaces[35] (Fig 9-7).Because the self-etching or primer agent is simply air dried, they are also called *etch-and-dry adhesives*.[22] These adhesives render the smear layer permeable to monomers rather than removing it completely[35,44] (see Figs 9-7b and 9-7c). Some self-etching adhesives simultaneously dissolve the smear layer and infiltrate enamel and dentin,[45] using the mineral content of the substrate to buffer the acidic monomers and inhibit their dentin-etching ability with increasing depth.[46]

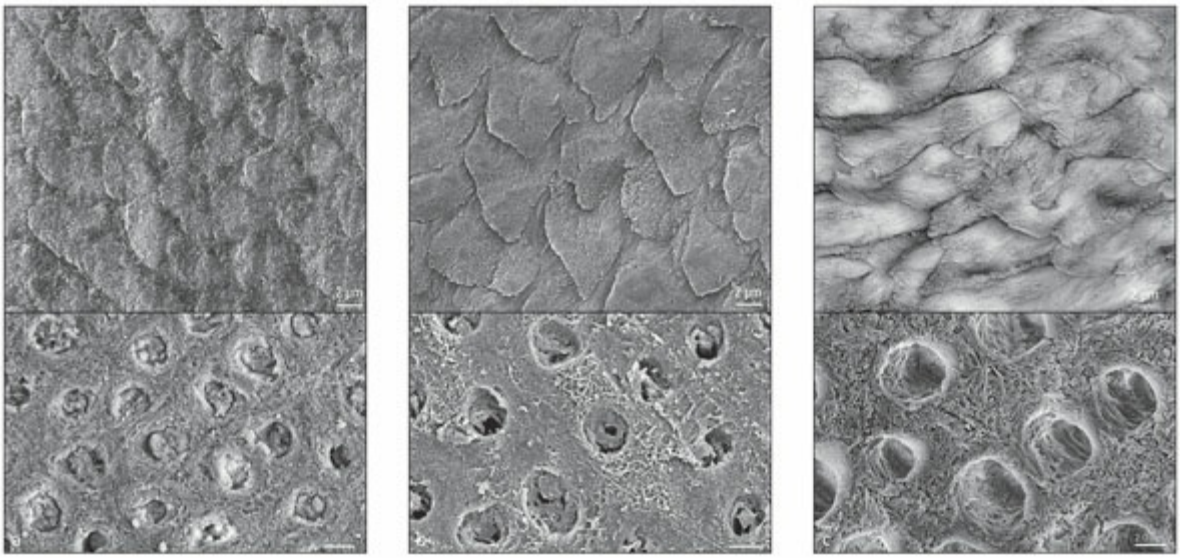

Fig 9-7*(a) (top)* SEM image showing mild decalcification on cut enamel due to the application of an ultramild self-etching adhesive (original magnification ×5,000). *(bottom)* FE-SEM image showing decalcification of dentin after application of ultramild self-etching adhesive (original magnification ×5,000). Note that some intertubular collagen is exposed, but smear layer remains within the tubules. *(b) (top)* SEM image showing decalcification patterns on cut enamel due to the application of a mild self-etching adhesive (original magnification ×5,000). *(bottom)* FE-SEM image showing decalcification of dentin after application of mild self-etching adhesive (original

Dentlearn.ir

magnification ×5,000). *(c) (top)* SEM image showing enamel etching patterns due to the application of a strong self-etching adhesive (original magnification ×5,000). *(bottom)* FE-SEM image showing decalcification of dentin after application of strong self-etching adhesive (original magnification ×5,000). Intertubular collagen is highly exposed, with no clear evidence of smear layer within the tubules. (Courtesy of Sillas Duarte, Los Angeles, California.)

to chemical composition and acidity, which determine their morphologic features.[35,44] Ultramild self-etching adhesives (pH > 2.5) are able to demineralize a few hundred nm; mild adhesives (pH . 2) have about a 1-µm interaction depth; intermediate-strength adhesives (pH = 1 to 2) have an interaction depth of 1 to 2 µm, and strong self-etching adhesives (pH < 1) have an interaction depth of several µm.[35] The formation of resin tags in dentin tubules can be assured only with the use of strong self-etching adhesives; mild and ultramild adhesives may fail to form such tags, only slightly demineralizing smear plugs and allowing limited resin infiltration[35] (see Figs 9-6d, 9-7b, and 9-7c).

Number of clinical steps

to the number of clinical steps involved in the adhesion procedure.[44]

Etch-and-rinse adhesives may be three- or two-step systems: in *three-step systems*, separate etchant, primer, and bonding resin are applied consecutively; in *two-step (self-priming) systems*, etching is followed by the application of a combined primer and bonding resin.

Self-etching adhesives may be two- or one-step systems: in *two-step self-etching adhesive systems*, a combined etching and primer agent is applied on enamel and dentin and air dried, followed by the application and polymerization of a bonding resin, while *one-step self-etching adhesives* combine etching, primer, and bonding resin in a single application. Many one-step systems are not all-in-one solutions and require mixing materials from two or more bottles before application. Nevertheless, they are applied as one-step agents on the enamel or dentin substrate.

The two-step etch-and-rinse and one-step self-etching adhesives are considered simplified adhesives compared with their multi-step counterparts (three-step etch-and-rinse and two-step self-etching adhesives, respectively).[47]

Dentlearn.ir

Three-Step Etch-and-Rinse Adhesives

Three-step etch-and-rinse adhesives are fourth-generation products that require the sequential application of the three agents (Table 9-2 and Box 9-1). These agents are generally considered the gold standard against which other systems are compared. The procedure is described in detail and serves as a foundation for relating the function of each component in the adhesive systems. (See Fig 9-8 for step-by-step application of etch-and-rinse adhesives.)

Table 9-2 **Components, compositions, and application procedures of the common adhesives**

Adhesive	Manufacturer	Composition	Application procedure
Three-step etch-and-rinse adhesives			
Adper Scotchbond Multi-Purpose	3M ESPE	Etching: 35% H_3PO_4	Etch for 15 s on enamel and dentin. Rinse for 15 s. Remove excess water with an air syringe or by blotting. Leave moist.
		Primer: HEMA, polyalkenoic acid polymer, water	Apply to enamel and dentin. Dry gently for 5 s.
		Bonding: bis-GMA, HEMA, tertiary amines, photoinitiator	Apply to enamel and dentin. Light cure for 10 s.
All-Bond 3	Bisco	Etching: 32% H_3PO_4	Etch for 15 s on enamel and dentin. Rinse for 15 s. Dry gently.
		Primer: Part A—ethanol, NGT-GMA; Part	Mix parts A and B (1:1) for 5 s. Apply 1 to 2 coats. Dry gently until

Dentlearn.ir

		B—bis-GMA, HEMA, BPDM	there is no visible movement of the material.
		Bonding: bis-GMA, UDMA, TEGDMA, glass filler	Apply one thin coat. Air dry/air thin. Light cure for 10 s.
Gluma Solid Bond	Heraeus Kulzer	Etching: 20% to 35% H_3PO_4	Etch 30 s on enamel. Etch 15 s on dentin. Rinse for 15 s. Dry gently.
		Primer: TEGDMA, HEMA, modified poly acrylic acid, maleic acid, ethanol, water, photoinitiators, stabilizers	Apply for 30 s. Dry for 1 to 2 s.
		Bonding: bis-GMA, TEGDMA, glass filler, SiO_2, photoinitiators, stabilizers	Apply and dry gently. Light cure for 40 s.
Optibond FL	Kerr	Etching: 37.5% H_3PO_4	Etch 15 s on enamel and dentin. Rinse for 15 s. Dry 3 s; do not desiccate.
		Primer: HEMA, GPDM, MMEP, PAMM, water, ethanol, CQ, BHT	Apply with light brushing motion for 15 s. Dry for 5 s.
		Bonding: bis-GMA, HEMA, GDMA, CQ, EDMAB, filler (fumed SiO2, barium, aluminoborosilicate, NaSiF6), coupling factor A174	Apply with light brushing motion for 15 s. Dry for 3 s. Light cure for 20 s.

Dentlearn.ir

Syntac	Ivoclar Vivadent	Etching: 37% H_3PO_4	Etch for 10 to 15 s on enamel and dentin. Rinse with water. Dry. Leave the dentin surface with a slightly glossy, wet appearance.
		Primer: TEGDMA, PEGDMA, maleic acid, dimethylketon, water	Apply; leave for 15 s. Dry thoroughly.
		Bonding: PEGDMA, glutaraldehyde, water	Apply for 10 s. Dry thoroughly. Light cure for 10 s.
Two-step etch-and-rinse adhesives			
Adper Scotchbond 1 XT Adhesive(also Adper Single Bond)	3M ESPE	Etching: 35% H_3PO_4	Etch for 15 s on enamel and dentin. Rinse for 15 s. Leave tooth moist.
		Bonding: dimethacrylates, HEMA, poly alkenoid acid copolymer, 5-nm silane treated colloidal silica, ethanol, water, photoinitiator	Apply two consecutive coats. Dry gently for 5 s. Light cure for 10 s.
Excite F	Ivoclar Vivadent	Etching: 37% H_3PO_4	Etch for 20 to 30 s on enamel. Etch for 10 to 15 s on dentin. Rinse for at least 5 s. Leave tooth moist.
		Bonding: HEMA, phosphonic acid	Apply for at least 10 s.

Dentlearn.ir

		acrylate, dimethacrylates, silicone dioxide, initia tors, potassium fluoride in alcohol solution, stabilizers	Disperse the adhesive with a weak stream of air. Light cure for 10 s.
Gluma Comfort Bond	Heraeus Kulzer	Etching: 20% to 35% H_3PO_4	Etch for 15 s on enamel and dentin. Rinse for 15 s. Dry for 1 to 2 s.
		Bonding: UDMA, HEMA, 4-META, modified polyacrylic acid, ethanol, glutar dehyde, water, photoinitiators, stabilizers	Apply three consecutive coats for 15 s. Dry gently. Light cure for 20 s.
One-Step Plus	Bisco	Etching: 32% H_3PO_4, 37% H_3PO_4 (Etch-37)	Etch for 15 s on enamel and dentin. Rinse thoroughly for 1 to 2 s.
		Bonding: BPDM, bis-GMA, HEMA, ace tone, photoinitiators, 8.5% by weight fluor aminosilicate glass fillers (1 μm)	Apply two coats to dentin. Agitate slightly for 10 to 15 s. Dry gently. Light cure for 10 s.
Optibond Solo Plus	Kerr	Etching: 37.5% H_3PO_4	Etch for 15 s on enamel and dentin. Rinse for 15 s. Dry gently; do not desiccate.
		Bonding: bis-GMA, HEMA, GDMA, etha nol, CQ, EDMAB, BHT, filler (fumed SiO_2, barium aluminoborosilicate,	Apply with light brushing motion for 15 s. Dry for 3 s. Light cure for 5 to 10 s.

Dentlearn.ir

		Na_2SiF_6) coupling factor A174	
		Etching: 35% H_3PO_4	Etch for 15 s on enamel and dentin. Rinse for 5 s. Dry briefly; do not desiccate.
PQ1	Ultradent	Bonding: ethyl alcohol, methacrylic acid, 2-hydroxy methacrylate, 40% filler	Apply for 10 s. Dry from 10 mm for 10 s. Light cure for 20 s.
Prime & Bond NT	Dentsply/ Caulk	Etching: 36% H_3PO_4	Etch for 30 s on enamel. Etch for 15 s on dentin. Rinse for 15 s. Dry gently.
		Bonding: PENTA, di- and trimethacrylate resins, cetylamine, hydrofluoride, acetone, nanofiller (amorphous silicon dioxide, 8 nm), resin R5-62-1, T-resin, D-resin, CQ	Apply for 20 s (may necessitate additional coats). Dry for 5 s. Light cure for 10 s.
XP BOND	Dentsply/ Caulk	Etching: 36% H_3PO_4	Etch for 30 s on enamel. Etch for 15 s on dentin. Rinse for 15 s. Dry gently.
		Bonding: PENTA, TCB, HEMA, TEGDMA, UDMA, tert-butanol, functionalized amor phous silica, ethyl-4-dimethylaminobenzo ate, CQ, stabilizer, t-butanolate	Apply. Leave the surface undisturbed for 20 s. Air dry for at least 5 s. Light cure for a minimum of 10 s.

Dentlearn.ir

Two-step self-etching/etch-and-dry adhesives			
AdheSE	Ivoclar Vivadent	Self-etching primer: acrylic ether phos phonic acid, bisacrylamide, water, CQ, stabilizers	Apply for 15 s. Disperse the excess with a strong stream of air.
		Bonding: bis-GMA, GDMA, HEMA, fumed silica, CQ, tertiary amine, stabilizers	Apply. Dry with a very weak stream of air. Light cure for 10 s.
Clearfil Protect Bond	Kuraray	Self-etching primer: MDPB, 10-MDP, HEMA, hydrophilic dimethacrylate, photoinitiator, water	Apply. Leave for 10 s. Dry gently.
		Bonding: 10-MDP, HEMA, bis-GMA, hydrophobic dimethacrylate, photoinitia tors, silanated colloidal silica	Apply bond. Dry gently. Light cure for 10 s.
Clearfil SE Bond (Clearfil Mega Bond in Japan)	Kuraray	Self-etching primer: 10-MDP, HEMA, photoinitiator, water	Apply for 20 s. Gently air blow.
		Bonding: 10-MDP, bis-GMA, HEMA, hydrophilic dimethacrylate, microfiller	Apply two consecutive coats. Dry from 2 cm. Light cure for 10 s.
Optibond XTR	Kerr	Self-etching primer: GPDM, hydrophilic co-monomers, water, ethanol, acetone	Apply for 20 s. Dry thin for 5 s.
		Bonding: Resin monomers, HEMA, inorganic fillers, ethanolr	Apply with light brushing motion for 15 s. Light cure for 10 s.

Dentlearn.ir

Peak SE	Ultradent	Self-etching primer: bis-GMA, HEMA, ethanol, methacrylic acid, water	Apply for 20 s. Dry for 3 s.
		Bonding: bis-GMA, HEMA, ethanol, methacrylic acid, silica filler	Apply for 10 s. Dry for 10 s. Light cure for 20 s.
One-stepself-etching/etch-and-dryadhesives			
All-Bond SE	Bisco	Part I: ethanol, sodium benzene, sulfinate Part II: HEMA, BPDM, GPDM, bis-GMA	Mix parts A and B (1:1) until uniformly pink. Apply 1 to 2 coats, 5 to 10 s for each coat. Dry gently from 5 cm for 5 s. Light cure for 10 s.
Clearfil S^3 Bond	Kuraray	10-MDP, bis-GMA, HEMA, phosphate methacrylates, BHT, ethanol, fluorides, CQ, siliciumdioxide nanoparticles	Apply; leave for 20 s. Dry for more than 5 s. Light cure for 10 s.
Easy Bond	3M ESPE	HEMA, bis-GMA, methacrylated phosphor ic esters, HDDMA, methacrylate functional ized polyalkenoic acid (Vitrebond copoly mer), finely dispersed bonded silica filler with 7-nm primary particle size, ethanol, water, initiators based on CQ, stabilizers	Scrub adhesive for 20 s on dentin. Air thin for 5 s. Light cure for 10 s.
	GC	4-MET, phosphoric ester-monomer, UDMA, TEGDMA,	Apply. Leave undisturbed for 5 to 10 s. Dry

Dentlearn.ir

G-Bond	America	acetone, water, stabi lizer, silica, filler, water, photoinitiator	under maximum air pressure for 5 s. Light cure 10 s.
I Bond	Heraeus Kulzer	UDMA, 4-META, glutaraldehyde, acetone, water, photoinitiators, stabilizers	Scrub adhesive for 20 s. Gently air thin. Light cure for 20 s.
One-Up Bond F	Tokuyama	Part A: MAC-10, photoinitiator, methacry loylalkylacid phosphate, multifunctional methacrylic monomers Part B: MMA, HEMA, water F-deliverable, microfiller (fluoroaluminosilicate glass), photointiators	Mix thoroughly until evenly pink. Use bonding within 90 s after mixing. Apply for at least 10 s. Light cure for 10 s.
Xeno V	Dentsply/ Caulk	Bifunctional acrylic amides, acrylamide alkylsulfonic acid, functionalized phosphor ic acid ester, acrylic acid, CQ, butylated benzenediol, water, tert-butanol	Apply uniformly. Dry gently for 20 s. Light cure for at least 20 s.

Box 9-1	**Clinical application steps, advantages, disadvantages, and common errors for three-step etch-and-rinse adhesives**
Etching	
1. Apply 35% to 37% phosphoric acid to enamel for 15 to 30 s and to dentin for 15 s. 2. Rinse the etched surface for 15 s with an air-water spray. 3. Gently air dry to remove excess moisture. 4. Apply 0.2% to 2% aqueous chlorhexidine solution. 5. Remove excess chlorhexidine solution with a moist cotton pellet.	
Priming	
1. Perform active applicat	to the dentin surface with

Dentlearn.ir

a small brush). 2. Apply water-free, acetone-based primers generously in multiple layers. 3. The primed surface should appear glossy after air drying; if it appears chalky, the primer must be reapplied. 4. Primers must be adequately air dried to evaporate all of the solvent; usually 30 to 40 s are needed for proper solvent evaporation.		
Bonding		
1. Generously apply the adhesive resin with a microbrush. 2. Use a bristle brush to thin and create a homogenous layer. 3. Cure for manufacturer recommended time, which is typically about 10 to 20 s.		
Advantages	**Disadvantages**	**Common clinical errors**
• Phosphoric acid etch provides the best bond to enamel. • Several research reports support their use on different substrates, including metals and porcelain. • The highest dentin bond strengths among all dentin adhesives. • Generally contain a dual-curing option for indirect restorations and bonded amalgams. • Can be used with chlorhexidine rewetting for bond preservation.	• Multiple bottles make their use more cumbersome. • Possibility of running out of one component before another. • Because primer and adhesive resin are dispensed into separate wells in the same plastic container, their sequential application may be reversed. • Thick adhesives may pool easily around preparation line angles and margins.	• Overetching dentin. • Suboptimal rinsing of the etching gel. • Overwet/overdry dentin surface. • Insufficient primer application/penetration. • Insufficient primer solvent evaporation. • Overthinning bonding component. • Suboptimal polymerization of the bonding component.

Step 1: Etching

Given the differences in the histologic characteristics of enamel and dentin, the etching considerations for these substrates differ.

Etching of enamel

In enamel, etching substantially enlarges the surface area available for bonding and almost doubles the original surface energy[48,49] (see Fig 9-4). Three morphologic patterns of enamel etching have been described.[30,48,49] Type I etching removes the core prism material while leaving the periphery intact; type II etching removes the peripheral material while leaving the prism core relatively unaffected; and type III etching takes a more random approach characterized by a combination of types I and

determined by the mineral content and morphologic characteristics of the enamel,

Dentlearn.ir

and the dentist has no control over the pattern resulting from acid etching.

Etching creates enamel microporosities within which the resin tag extensions of monomers interlock micromechani-cally. *Macrotags* form between enamel-prism peripheries, and *microtags* form in prism cores.[28,44] These tags are formed within a 550-µm-thick microporous layer by phosphoric acid etching[50,51] (see Fig 9-4).

Enamel etching is affected by the content and concentration of the acid-etching solution and by the application technique and timing. These factors have been investigated extensively.[52–55] Many etching solutions have been tested, including those containing phosphoric (10% to 50%), fluoridated phosphoric, pyruvic, citric, maleic, oxalic, tannic, ethylenediamine-tetraacetic, trichloracetic, and polyacrylic acids[56–59]; however, most of the adhesive systems use phosphoric acid. The physical state of the solution also affects etching; gels can be applied to the enamel surface in a more controlled manner than liquids and achieve wider and deeper enamel penetration.[60] Etching agent application methods have also been investigated to improve clinical success; gels may be applied using a continuous brushing technique to obtain more etched enamel substrate and thereby improve the marginal adaptation of resin composite restorations.[61,62] Extending etching times to 60 seconds has been shown to produce rougher enamel surfaces but no enhancement of bond strength.[63]

Enamel etching is also affected by the chemical composition of the enamel (eg, high fluoride concentration makes enamel more resistant to etching). Moreover, aprismatic enamel is also more resistant to etching.[64]

Etching of dentin

Fusayama's revolutionary total-etching technique[29] to treat dentin was initially resisted by dentists, who feared that adverse pulpal reactions would result from the use of 40% phosphoric acid to etch dentin. Subsequent studies found that such reactions occurred because of bacterial leakage rather than acid use and that acid etching could thus be safely used on dentin more than 0.5 mm thick, provided the dentin was sealed after the etching.[32]

The use of phosphoric acid to etch dentin removes the smear layer, demineralizes the first 3 to 5 µm of dentinal tissue, and creates funnel-shaped dentinal tubules. The latter effect is because of the presence of higher mineral content in peritubular dentin than in intratubular dentin.[30] Acid etching thus renders the dentinal structure porous, allowing the impregnation of adhesive components[22,44] (see Figs 9-5 and 9-6).

Several studies have investigated the effects of different etching times on bond

Dentlearn.ir

strength.[34] Although extended etching times have been found to increase substrate porosity, they do not necessarily increase bond strength. The determination of an appropriate etching time should consider *(1)* the ability of monomers to impregnate the substrate in relation to dentin demineralization and *(2)* the ability of collagen fibrils to maintain integrity when exposed to phosphoric acid for a given length of time.

Clinicians should seek to demineralize dentin only to the desired extent of infiltration; excessive demineralization may produce a weak zone comprised of suboptimally impregnated dentin at the base of the hybrid layer consisting of exposed collagen fibrils.[65–68] Etching should be limited to superficial dentin because the viscosity of primers and bonding agents allows only a few micrometers of impregnation (see Figs 9-5 and 9-6). Several studies have found that prolonged acid-conditioning times resulted in fracture within the demineralized dentin zone when specimens were stressed to failure.[69,70] These findings indicated that excessive acid conditioning caused deeper demineralization of intertubular and peritubular dentin, rendering them more susceptible to incomplete infiltration by resin monomers. The reduced infiltration decreased bond strength by creating a weak zone where failure was likely initiated. The results of these studies thus indicate that sound dentin should be etched for no longer than 15 seconds. For this reason, etchant is initially applied to the enamel (Figs 9-8a and 9-8b), followed by application to the dentin (Fig 9-8c), to ensure adequate etching of enamel without overetching dentin.

Dentlearn.ir

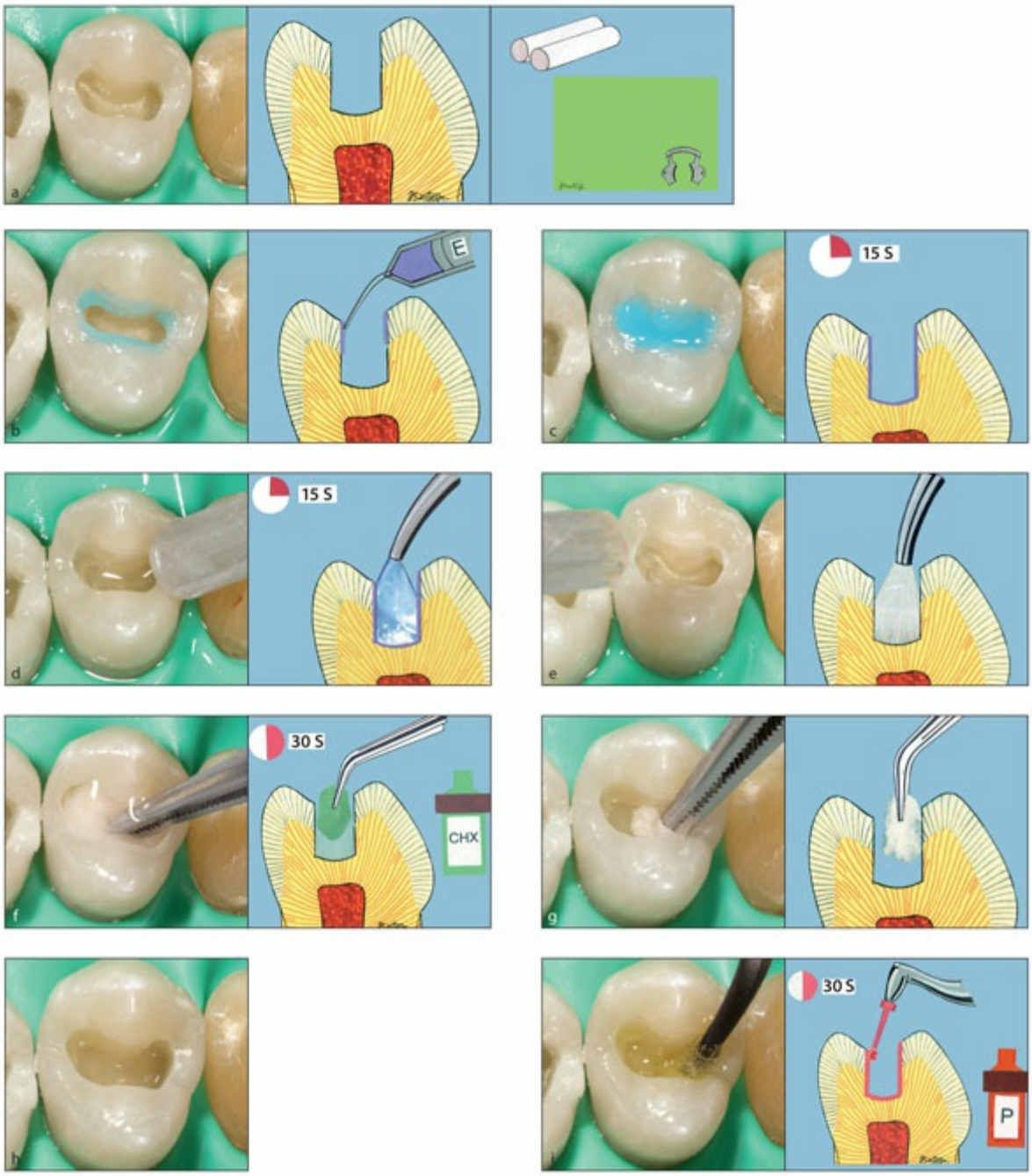

Fig 9-8 Step-by-step application of the three-step etch-and-rinse adhesives. *(a)* Preparation complete; ready for adhesive application. Appropriate isolation must be provided. *(b)* Phosphoric acid etchant gel is initially applied to the enamel margins only. *(c)* Phosphoric acid etchant gel is applied to the remaining prepared dentin surfaces and allowed to remain for 15 seconds. *(d)* Etchant gel is thoroughly rinsed with air-water spray for 15 seconds. *(e)* Preparation is dried. Frosty appearance of enamel confirms adequacy of etch. *(f)* The preparation is rewetted with an aqueous chlorhexidine solution for 30 seconds. *(g)* A damp cotton pellet is used to absorb excess chlorhexidine solution. *(h)* The glistening appearance of the dentin indicates the appropriate dentin moistness prior to applying the primer. *(i)* The primer component is actively applied for at least 30 seconds.

Dentlearn.ir

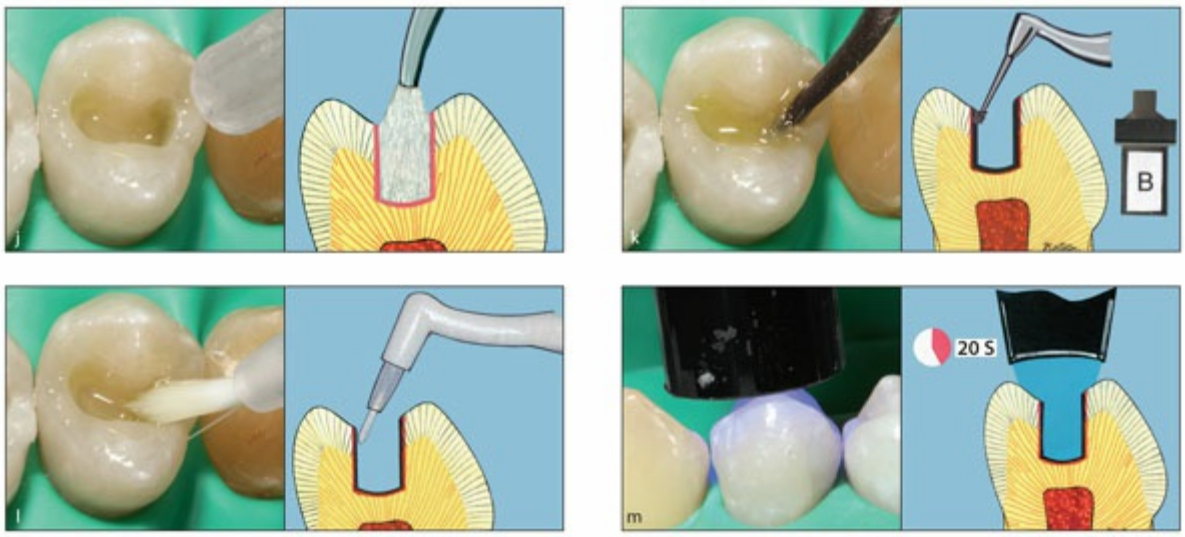

Fig 9-8*(cont)* *(j)* The primer component is air dried for 30 to 40 seconds to ensure thorough evaporation of solvents. *(k)* The adhesive component is actively applied to the entire preparation. *(l)* A bristle brush is used to absorb excess adhesive, avoid pooling, and distribute the adhesive evenly on all cavity walls. *(m)* The adhesive is light cured for 10 to 20 seconds prior to inserting the resin composite.

An immunohistochemical study of the collagen component of human dentin found that the aggressiveness of the etchant (pH and pKa) and the etching time affected the morphology of collagen fibrils and associated proteoglycans.[71] The exposure of dentinal collagen fibrils to an etching agent for more than 15 seconds may produce structural changes that weaken the hybrid layer.[72] However, in some cases, such as in the presence of aged or sclerotic dentin with a high mineral content, etching times of up to 30 seconds may be appropriate.[7,73]

After etching, the tooth should be rinsed with an intense air or water spray to remove the acid completely and stop the etching process (Fig 9-8d). The rinsing time should be similar to the etching time. When etching gels containing silica particles are used, particular care should be taken to rinse as long as instructed to ensure that all silica is removed from the dentinal tissue.[74]

After rinsing, the wetness of the dentin is an important clinical consideration. The first commercially available etch-and-rinse adhesive system was Clearfil Bond System-F (Kuraray), introduced in 1978. Clinicians who used this adhesive to etch dentin with 40% phosphoric acid followed by a dry-bonding technique reported adverse pulpal reactions.[34] In *dry bonding*, the cavity walls were dried after etching until the enamel margins were "frosty" to confirm the success of enamel etching. However, this technique has been found to cause the interfibrillar spaces between exposed dentinal collagen fibrils to collapse, preventing proper monomer

Dentlearn.ir

infiltration[75] (Fig 9-9). Although this technique achieved high resin-enamel bond strengths, resin-dentin bond strengths were insufficient to resist polymerization shrinkage forces. Thus, one or more walls would debond during resin composite polymerization, creating bacterial leakage through an increasingly permeable dentin that risked pulpal irritation.[32]

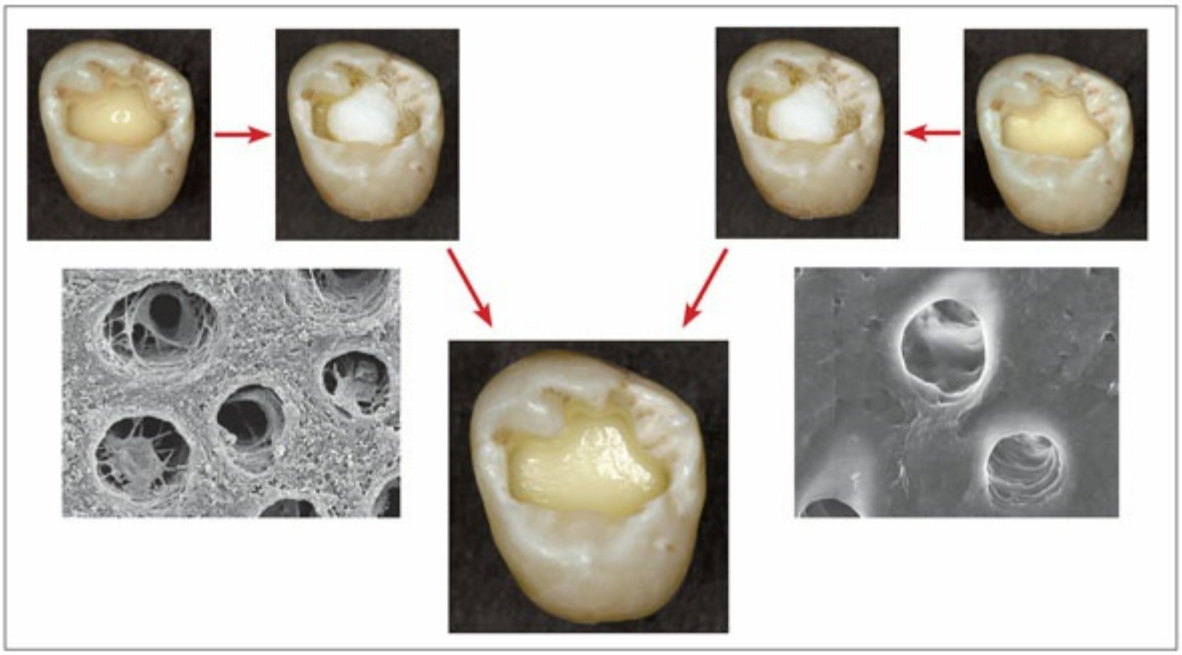

Fig 9-9 Wet bonding for the etch-and-rinse adhesive technique. The ultimate goal is to have a moist, glistening surface, as seen in the center photograph. If, after etching and rinsing, the surface is too wet, a moistened cotton pellet can be used to remove excess moisture (upper left). The SEM image on the left side shows large interfibrillar spaces in the intertubular dentin available for adhesive infiltration if the dentin surface remains moist. (Courtesy of Sillas Duarte, Los Angeles, California.) Conversely, if the dentin is overdried, a moist cotton pellet can be applied to the dried dentin for 30 seconds to remoisten the dentin surface (upper right). The SEM on the right side shows a compact intertubular surface due to collagen collapse. Under this condition, adhesive penetration is difficult to achieve due to the reduced intrinsic porosity of the collapsed collagen layer. (Reprinted from Breschi et al[30] with permission.)

The low resin-dentin bond strengths associated with dry bonding resulted in dentin sensitivity, microleakage, secondary caries, and loss of bonded restorations. To address these issues, Kanca[76,77] introduced the *wet bonding technique*, which used residual water on the dentin surface as a rewetting agent (see Fig 9-9). This technique increased resin-dentin bond strength, which provided a good dentin seal and reduced postoperative pain. By creating resin-dentin bonds that were equal or superior in strength to resin-enamel bonds, the wet bonding technique allowed clinicians to achieve safe, reproducible resin-dentin bonding.

Although the wet bonding technique[77] was proposed as a standard procedure with

Dentlearn.ir

the use of etch-and-rinse systems, it has not been standardized or made reproducible to date. Wet bonding can be performed using several different methods, and the proper degree of dentin wetness has not been determined.[78,79] The optimal surface wetness for wet bonding varies among acetone-, ethanol-, and water-based etch-and-rinse adhesive systems.[80] Additional factors, such as differences in the hydraulic conductance of superficial and deep dentin[81] and the presence of carious or sclerotic dentin in which whitlockite crystals completely or partially obliterate dentinal tubules,[82] prevent the achievement of uniform wetness on the axial, pulpal, and gingival walls. The same preparation may thus contain overly wet and overly dry regions, resulting in nonuniform resin bonding.

After the removal of pooled moisture by blotting or wiping with a slightly damp cotton pellet (see Fig 9-9), properly moist dentin should exhibit a shiny, hydrated surface.[83] Although drying techniques using air, absorbent paper, and cotton pellets have been proposed, absorbent moist cotton sponges[78,84] appear to be most effective. The rewetting of excessively dried dentin with water or a rewetting agent can raise collapsed collagen to a level comparable with that achieved with wet bonding.[80] Recently, the use of chlorhexidine has been proposed as a rewetting agent because of its capability to disinfect and stabilize the bond over time.[16,22,85–89] Bond stabilization occurs because chlorhexidine inhibits dentin endogenous enzymes that are claimed to participate in the bond degradation phenomena occurring at the adhesive interface[16,22] (see the sections on resin and collagen fibril degradation). Rewetting and bond stabilization can be accomplished simultaneously. After etching and rinsing, the cavity preparation is air dried (Fig 9-8e). In this way, the enamel can be assessed for adequate etching by checking for the frosty appearance of the enamel. The dentin can be rewetted with an aqueous chlorhexidine solution for 30 seconds (Fig 9-8f), and then a moist cotton pellet is used to absorb excess chlorhexidine solution and achieve the appropriate moisture level in the preparation (Figs 9-8g and 9-8h).

Step 2: Priming

Enamel priming

The application of a hydrophobic enamel bonding agent to air-dried enamel avoids the need for a separate primer application while still achieving effective bonding (see Fig 9-8e). Sealants can also be applied to acid-etched enamel without

Dentlearn.ir

additional treatment.[90] However, the enamel bonding process is not compromised by the application of primers to acid-etched enamel, and it may even be enhanced in situations where isolation is difficult. In wet bonding, primers should always be applied to acid-etched enamel to displace any residual surface moisture through solvent evaporation.

Dentin priming

Primers are mixtures of monomers, such as hydroxyethyl methacrylate (HEMA), triethyleneglycol dimethacrylate (TEGDMA), bis-GMA, and urethane dimethacrylate (UDMA), which have varying degrees of hydrophilic and hydrophobic properties (see Tables 9-1 and 9-2). Hydrophilic functionality facilitates monomer permeation into the collagen matrix to form a hybridized collagen-resin layer, and hydrophobic functionality facilitates restoration bonding to the resin matrix. Solvents are added to reduce the inherent viscosity of co-monomer blends, allowing them to infiltrate wet demineralized dentinal matrices[75,91] (see Table 9-2). The type of solvent in primer solutions has been found to significantly affect dentin bond strengths by influencing the ability to reexpand previously dried demineralized matrix.[92]

During rinsing of the etching agents, the presence of water maintains the full expansion of the demineralized dentinal matrix.[93,94] Subsequent air drying of dentinal surfaces removes most of the water from the matrix,[95] causing it to collapse in a manner similar to the collapse of collagen fibrils (see Fig 9-9). Collagen peptides come into contact with one another, forming new interpeptide hydrogen bonds that stabilize and stiffen the shrunken matrix.[96] Resin-dentin bonding is compromised by the lack of sufficient interfibrillar spaces available for resin penetration in such shrunken dentin.[75,97] To resolve these undesirable situations, the dentin must be rewetted and/or primers must be able to reexpand the collapsed matrix.[92]

Hybridization is believed to result from primer infiltration into the open network of the collagen matrix exposed by dentin demineralization and from subsequent in situ polymerization of the monomers present in the bonding agent. In wet bonding, some hydrogen-bound water remains in the intrafibrillar spaces of collagen as a water-bridged hydration network, even in completely demineralized dentin. Although solvents facilitate the replacement of water with adhesive monomers, primer monomer systems often fail to displace all intrafibrillar water.[98] This limitation suggests that monomer penetration into intrafibrillar spaces is somewhat restricted and that encapsulation and entanglement occur primarily in extrafibrillar

Dentlearn.ir

spaces.[98] After permeation, nonbonded, electrostatic, and hydrogen-bonding forces may thus develop between the monomer phase and collagen molecules.[99] Primers should be actively applied and agitated for at least 30 seconds on the dentin surface to improve penetration and enhance adhesion[100] (Fig 9-8i).

Primers should be gently air dried after application to volatilize any remaining solvent before the adhesive resin is applied (Fig 9-8j; see also Box 9-1). The extent of solvent evaporation depends on the clinician's technique and the co-monomer mixture.[101,102] Failure to adequately evaporate primer solvent will significantly adversely affect the bond to dentin and can have a more adverse affect on adhesion than just about any other application mistake.[103,104] Drying times of at least 10 seconds or longer are recommended.[17]

The effect of solvent type on the effectiveness of bonding and sealing of dentin has been the subject of numerous investigations. The results of one study suggested that primers with ethanol/water solvents show reduced technique sensitivity compared with those with acetone solvents, while verifying the importance of near-complete solvent removal for optimum results.[103]

Additional layers of primer should be added if the surface does not appear uniformly glossy.

Step 3: Bonding

Three-step adhesive systems use hydrophobic solvent-free monomer blends (usually bis-GMA and TEGDMA) as bonding agents (see Table 9-2). These agents should be applied to the primed surface with a brush and thinned to an optimal thickness of about 60 to 120 μm, depending on the viscosity of the adhesive (Figs 9-8k and 9-8l).

Because no solvent is present, using an air syringe to thin the adhesive resin layer should be used with care to avoid formation of a less homogenous surface, with some areas so thin that they do not cure[105,106] (ie, nothing but an oxygen-inhibited layer; see Fig 9-8l). Significant reductions in bond strength were observed when air thinning was compared with aggressive air thinning or brush thinning, suggesting that brush thinning may provide a better way to obtain a homogenous layer without over air thinning.[106] This is done by active application of the adhesive using a microbrush, then using a bristle brush to ensure an even coating of the resin (see Fig 9-8k; see also Box 9-1). Excess resin will be absorbed into the bristle brush. If the bristles become saturated, the brush can be squeezed in a gauze pad to remove the excess resin.

Dentlearn.ir

The adhesive resin should be properly cured before the restorative material is applied to ensure that successful adhesion is produced to the tooth surface (Fig 9-8m). The upper layer of the adhesive resin does not polymerize well because it is exposed to oxygen, which inhibits its cure, and for this reason is called the *oxygen-*

that may be involved in copolymerization with the restorative resin.[107,108]

Adequate light intensity is an important factor in curing the resin layer; prolonged curing times that slightly exceed the manufacturer recommendations have been shown to improve polymerization and adhesive properties.[109,110] However, because of the potential adverse effect on the pulp because of temperature increase, especially with curing devices with high power,[111] manufacturer recommendations for curing time should be strictly followed.

Two-Step Etch-and-Rinse Adhesives

Two-step (simplified) etch-and-rinse adhesive systems were developed in an effort to simplify clinical application.[22,44,112] (See Fig 9-10 for step-by-step application of the two-step etch-and-rinse adhesives.) Considered as fifth generation, these systems employ an etching procedure similar to that for three-step systems, followed by the application of a combined primer and bonding resin (Box 9-2; see also Table 9-2). These simplified adhesives have been commercially successful because of their ease of use and reduced application steps.

Box 9-2	**Clinical application steps, advantages, disadvantages, and common errors for two-step etch-and-rinse adhesives**	
Etching		
1. Apply 35% to 37% phosphoric acid to enamel for 15 to 30 s and to dentin for 15 s. 2. Rinse the etched surface for 15 s with an air-water spray. 3. Gently air dry to remove excess moisture. 4. Apply 0.2% to 2% aqueous chlorhexidine solution. 5. Remove excess chlorhexidine solution with a moist cotton pellet.		
Priming and bonding		
1. Apply primer/bonding solution generously, producing a shiny appearance, then vigorously rub at least 30 s. 2. Air dry to evaporate solvent for 30 to 40 s. 3. Actively reapply the primer/bonding solution and air dry. 4. Cure for manufacturer recommended time, which is typically about 10 to 20 s.		
Advantages	**Disadvantages**	**Common clinical errors**
	• Most two-step adhesives	

Dentlearn.ir

• Phosphoric acid etch provides the best bond to enamel. • Laboratory research supports their use on enamel and dentin. • High immediate bond strength. • The combined primer/bond bottle concept makes them extremely user friendly. • Can be used with chlorhexidine for bond preservation.	showed lower bond strengths than their three-step counterparts(produced by the same manufacturer). • Acetone-based adhesives may lose their efficacy with constant utilization due to rapid evaporation of volatile components. • More coats than those recommended by the manufacturer often needed to maximize bond strength. • Thick adhesives may pool easily around preparation line angles and margins. • Some adhesives are not compatible with self-curing or dual-curing composites(core buildup composites and resin luting cements). • Inclusion of hydrophilic components in bonding resin can cause increased hydrolytic degradation.	• Overetching dentin. • Suboptimal rinsing of the etching gel. • Overwet/overdry dentin surface. • Reduced impregnation of the primer adhesive agent. • Inadequate solvent evaporation. • Overthinning adhesive when air drying to remove solvent; failure to use multiple coats. • Suboptimal primer/bonding polymerization.

Although two- and three-step etch-and-rinse adhesive systems produce resin-dentin bonds with similar strengths immediately following application,[44] long-term bond strengths differ between the two systems.[22,24,113] Two-step etch-and-rinse adhesives combine primer solvents and hydrophilic components with the more hydrophobic monomers of bonding agents (see Table 9-2), causing them to behave as semipermeable membranes.[114] The polymerization achieved with these adhesives is frequently suboptimal,[109,115] resulting in increased potential for water absorption from the underlying dentin.[116] These characteristics negatively impact long-term bond stability.

The combined primer and bonding resins also contain high concentrations (up to 50%) of solvents[91] (see Table 9-2) that may interfere with adhesive polymerization.[101] Although solvents decrease adhesive viscosity, facilitate co-monomer infiltration into acid-etched dentin, and increase the mobility of radicals and growing polymer chains,[98,101,117] solvent concentrations greater than 20% by weight usually lower the degree of conversion by increasing the physical space between reactive species during polymerization.[118]

Dentlearn.ir

The presence of residual water during dentin bonding may also adversely affect the curing reaction by preventing the formation of properly cured polymers within the hybrid layer.[119,120] This effect is likely because of the phase separation of hydrophobic and hydrophilic domains.[121]

Step 1: Etching

The considerations discussed above for etching with three-step systems also apply to the use of two-step etch-and-rinse adhesives (Figs 9-10a to 9-10d). The dentinal tissue moisture level is even more critical than with three-step etch-and-rinse adhesives because two-step etch-and-rinse adhesives do not have the rewetting ability of primers used in three-step adhesives. If the dentin is overdried, it should be rewetted prior to the next step (Figs 9-10e to 9-10h).

Dentlearn.ir

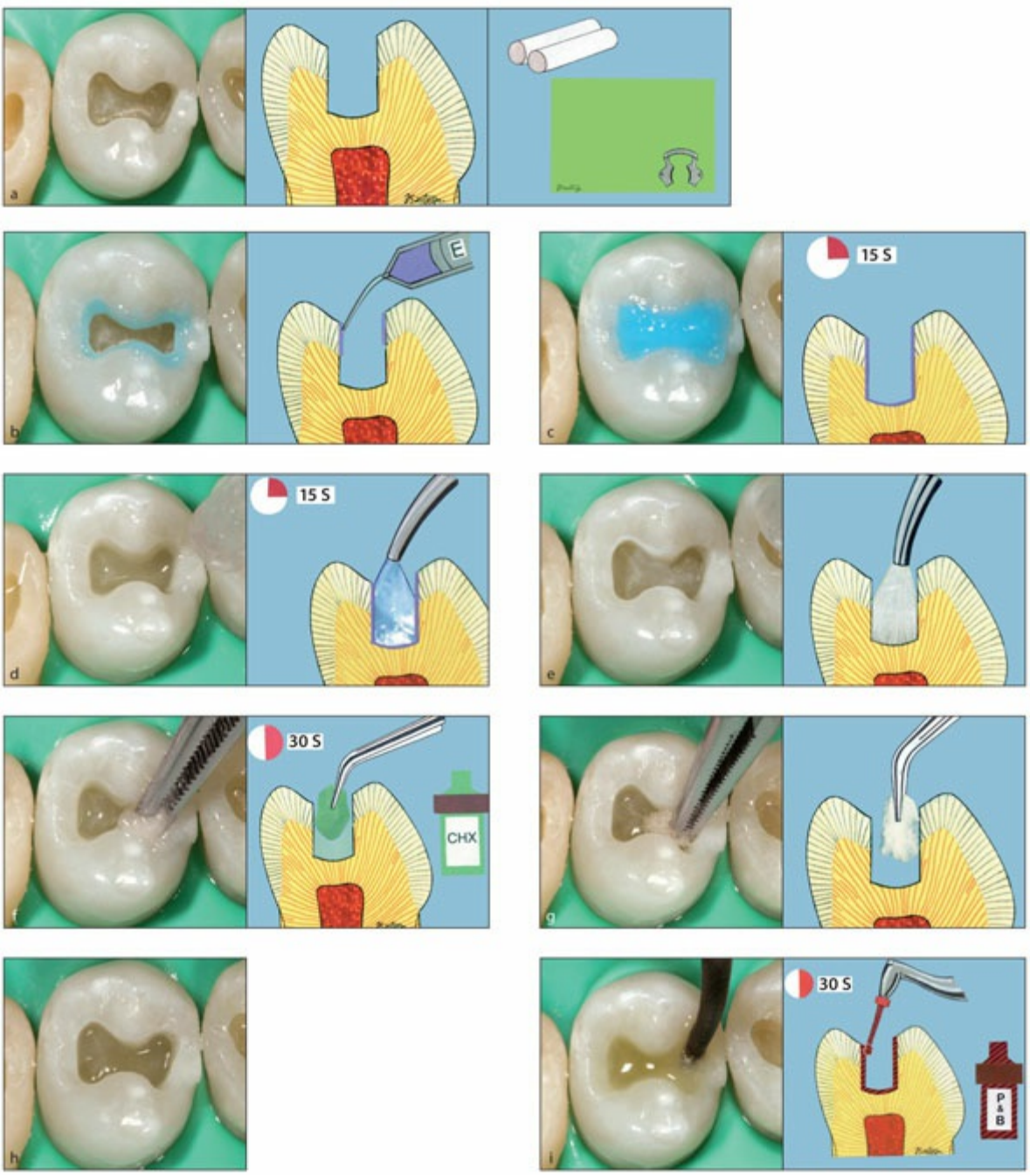

Fig 9-10 Step-by-step application of the two-step etch-and-rinse adhesives. *(a)* Preparation complete; ready for adhesive application. Appropriate isolation must be provided. *(b)* Phosphoric etchant gel is initially applied to the enamel margins only. *(c)* Phosphoric etchant gel is applied to the remaining prepared dentin surfaces and allowed to remain for 15 seconds. *(d)* Etchant gel is thoroughly rinsed with air-water spray for 15 seconds. *(e)* Preparation is dried. Frosty appearance of enamel confirms adequacy of etch. *(f)* The preparation is rewetted with an aqueous chlorhexidine solution for 30 seconds. *(g)* A damp cotton pellet is used to absorb excess chlorhexidine solution. *(h)* The glistening appearance of the dentin indicates the appropriate dentin moistness prior to applying the primer. *(i)* The combined primer-adhesive component is actively applied for 30 seconds.

Dentlearn.ir

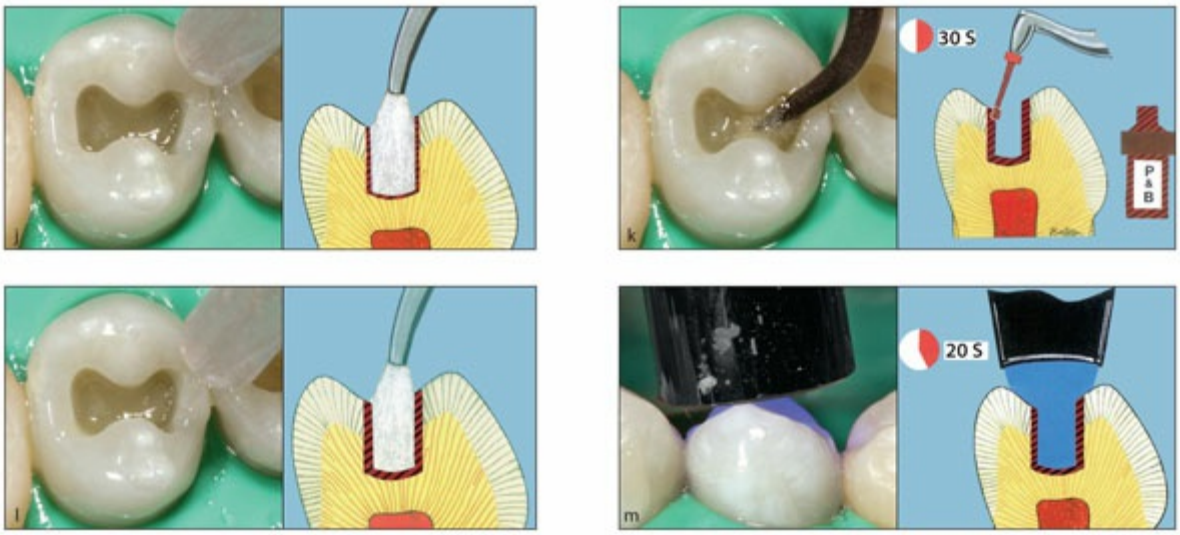

Fig 9-10*(cont) (j)* The primer-adhesive component is air dried for 30 to 40 seconds to ensure thorough evaporation of solvents. *(k)* The combined primer-adhesive component is actively reapplied for 30 seconds. *(l)* The primer-adhesive component is air dried for 30 to 40 seconds to ensure thorough evaporation of solvents. *(m)* The adhesive is light cured for 10 to 20 seconds prior to inserting the resin composite.

Step 2: Priming and bonding

Two-step etch-and-rinse adhesives contain a complex blend of monomers and solvents because of the combination of the amphiphilic properties of the primer and the more hydrophobic monomers of the bonding agent. Commercial adhesive co-monomer products commonly contain ethanol or acetone (see Table 9-2).

Several studies have found that the use of these adhesives results in the limited impregnation of demineralized dentin. Resin monomers have a limited capacity to diffuse into wet demineralized dentin,[122–124] producing a gradient of resin penetration with the highest concentration at the adhesive surface, lower concentrations within the hybrid layer, and little resin presence in the deepest portion of the demineralized zone.[125] Exposed and suboptimally impregnated collagen fibrils have been detected in the deepest areas of the hybrid layer with the use of these adhesives.[68]

Because of this difficulty impregnating the collagen fibril layer exposed by etching, the primer-adhesive agent should be applied with great care. Numerous clinical parameters have been found to affect the proper impregnation of the dentinal matrix (see Box 9-2):

Application time

Dentlearn.ir

Prolonged primer/bonding-agent application times increase monomer penetration into decalcified dentin and solvent/ water evaporation before light curing.[126,127] Recent studies have found that extended application times, even as little as 20 seconds, significantly increase the immediate and long-term bonding performance of the adhesives.[127–129]

Mode of application

The use of a rubbing action is essential to achieve a high immediate bond strength to dentin using acetone-, water-, and ethanol-based two-step etch-and-rinse adhesives[130] (Fig 9-10i). This action likely increases molecular kinetics and inward monomer diffusion in reaction to outward solvent diffusion, while also reducing dentinal wetness. Vigorous rubbing of demineralized dentin during the application of adhesive also improves the long-term stability of the dentin bond[131] by increasing the biomechanical characteristics of the hybrid layer.[132] Such vigorous application techniques can also improve the retention of restorations placed in noncarious cervical lesions, which typically pose a clinical challenge.[133]

Solvent evaporation

Before polymerization is performed, solvents should be completely evaporated to bring the reactant molecules into close proximity and to prevent residual solvent from plasticizing the polymer (Fig 9-10j). Adhesive solutions with higher solvent contents before light curing have lower degrees of conversion[101]; the higher solvent content also reduces the mechanical properties of adhesive polymers.[134,135]

When mixed with nonvolatile monomers, the evaporation capacity of solvents with relatively low vapor pressure (eg, water) is reduced as monomer concentration increases. It is thus impossible to achieve complete water evaporation from water-monomer mixtures.[136] The same principle applies to ethanol- and acetone-containing co-monomer mixtures; the nonvolatile monomer concentration increases as the solvent evaporates, thus reducing the vapor pressure of the remaining solvent and preventing complete solvent evaporation under clinical conditions. Thus, co-monomer composition as well as solvent type and content must be considered in determining optimal solvent concentration.

The adhesive layer must be carefully thinned, and application should be repeated to ensure adequate solvent evaporation with two-step etch-and-rinse adhesives[137] (Figs 9-10k and 9-10l). The use of a warm, dry airstream to evaporate the solvent

Dentlearn.ir

after the application of the primer/bonding agent may improve bond strength and hybrid layer quality by reducing the number of pores within the adhesive layer.[138]

Because adhesive solvents are volatile, the continuous transudation of dentinal fluid through open dentinal tubules before adhesive polymerization may create microscopic water-filled blisters along the adhesive interface.[116] After restoration placement, mastication may produce a pumping effect in these blisters that rapidly pushes fluid through the tubules, thereby potentially triggering the A-δ nerve fibers in the pulpal-dentin complex and causing sensitivity.[139]

Another issue is loss of solvent because of storage and handling. If the bottle is left uncapped, a significant amount of the volatile material can be lost rapidly. This results in alteration of the ratios from the manufacturer's intended formulation, which can then affect bonding. To avoid this, the bottle should be shaken and the material dispensed immediately prior to application.[140,141]

Curing time

Adhesive curing should be performed carefully to avoid compromised polymerization because of insufficient solvent removal, which results in the presence of high concentrations of hydrophilic monomers and water.[109,118] Manufacturer recommendations should be followed because resin permeability and monomer elution are related to the suboptimal polymerization of bonding resins[109,115,129] (Fig 9-10m).

Two-Step Self-Etching or Etch-and-Dry Adhesives

Because self-etching (etch-and-dry) adhesives contain acidic monomers that simultaneously condition and prime the dental substrate, they do not require a separate etching procedure (Boxes 9-3 and 9-4; see also Table 9-2). The salts removed from the enamel and dentin contribute to buffering of the acidity of the solution. Such systems have thus been described as more user friendly (shorter application time, fewer steps) and less technique sensitive (no wet bonding, simple drying) than etch-and-rinse systems.[35,44] Self-etching adhesives require only air drying, avoiding the need for rinsing after application.[22] Consequently, these adhesives do not remove the smear layer[35] (see Figs 9-5 to 9-7). While their use has been associated with lower postoperative sensitivity than that of etch-and-rinse adhesives, mainly when evaluated in deeper cavities[142,143] and likely because the

Dentlearn.ir

dentinal tubules remain partially obliterated by smear plugs,[144] other research has shown no difference between self-etching and etch-and-rinse adhesive systems in terms of postoperative sensitivity.[142,145–148]

Box 9-3	**Clinical application steps, advantages, disadvantages, and common errors for two-step self-etching or etch-and-dry adhesives**
Etching and priming	1. Selectively etch enamel with 35% to 37% phosphoric acid for 15 s. 2. Air-water rinse for 15 s, trying to minimize rinsing over the dentin. Dry gently. 3. Actively apply the self-etching primer agent on etched enamel and unetched smear layer–covered dentin for the time recommended by the manufacturer (typically 20 s). 4. Air dry to remove any excess solution and solvent and terminate the etching reaction.
Bonding	
1. Generously apply the adhesive resin with a microbrush. 2. Use a bristle brush to thin and create a homogenous layer.	

Dentlearn.ir

3. Cure for manufacturer recommended time, which is typically about 10 to 20 s.		
Advantages	**Disadvantages**	**Common clinical errors**
• No rinsing; quick application. No risk of overwet or overdry dentin. • Results of several studies support theiruse on dentin. • Additional chemical bonding is claimedto stabilize the hybrid layer for some adhesives. • Bonds well to enamel etched with phosphoric acid.	• If phosphoric acid etch not done first, enamel microleakage may result due to deficient enamel etch. • Prior etching of dentin surface with phosphoric acid may compromise bond to dentin. • Unknown effect of incorporating smear layer into adhesive zone. • Thick adhesives may pool easily around preparation line angles and margins.	• Insufficient etching on the enamel if selective preliminary enamel etch is not performed. • Inadvertent application of separate enamel etching agent to dentin.

Box 9-4	**Clinical application steps, advantage, disadvantages, and common errors for one-step self-etching or etch-and-dry adhesives**
	1. Selectively etch enamel with 35% to 37% phosphoric acid for 15 s. 2. Air-water rinse for 15 s, trying to minimize rinsing over the dentin. Dry gently. 3. Actively apply the one-step adhesive on etched enamel and unetched smear layer–covered dentin for the time recommended

Dentlearn.ir

Etching, priming, and bonding			by the manufacturer. 4. Air dry to remove any excess solution and solvent and terminate the etching reaction. 5. Reapply the adhesive in multiple layers using an active rubbing motion. 6. Air dry to remove any excess solution and solvent and terminate the etching reaction. 7. Cure for manufacturer recommended time, which is typically about 10 to 20 s.
Advantages	**Disadvantages**	**Common clinical errors**	
• Extremely simplified application procedure.	• Requires multiple layers. • Need for preliminary etching on enamel . • Lower bond strength than unsimplified counterparts (two-step systems). • Most of the adhesives are not compatible with self-curing or dual-curing composites (core buildup composites and resin luting cements). • Inclusion of hydrophilic components in bonding resin can cause increased	• Suboptimal polymerization. • Inadequate solvent evaporation. • Overthinning adhesive when air drying to remove solvent.	

Dentlearn.ir

	hydrolytic degradation.	

Two-step self-etching adhesives employ a self-etching primer followed by a hydrophobic and relatively solvent-free adhesive resin similar to that used in three-step etch-and-rinse adhesives (see Table 9-2 and Fig 9-5). These systems have demonstrated excellent performance under in vitro and in vivo conditions.[35,113,149] (See Fig 9-11 for step-by-step application of the two-step etch-and-rinse adhesives.)

Step 1: Self-etching and priming

Self-etching and priming of enamel

Clinically, the application of weak acids to enamel cannot produce the same extent of demineralization and typical frosty appearance obtained with the use of phosphoric acid[150,151] (see Fig 9-4). Self-etching primers produce a shallower and less retentive enamel-etching pattern because of insufficient penetration into the enamel surface.[35] In contrast to the macro- and microtags created by etch-and-rinse adhesives, self-etching primers intermingle primarily with the enamel surface to form *nanotags*. These tags are characterized by nanoretentive interlocking between enamel crystallites formed through inter- and intracrystallite resin penetration.[152]

Although some strong self-etching adhesives (pH < 1) create demineralized enamel that is morphologically similar to that created by phosphoric acid,[153] mild self-etching adhesives have shown unsatisfactory bonding to enamel, especially unground, aprismatic enamel.[35,154,155] The insufficient creation of enamel irregularities for penetration by self-etching adhesives results in low bond strength and poor marginal adaptation; thus, phosphoric acid should be preferred for enamel etching.[35,44,151]

The clinical use of self-etching adhesives on sound enamel is particularly problematic, especially in unbeveled preparations. Most studies[35,155–160] have confirmed that a preliminary separate etching procedure of enamel with phosphoric acid (> 15 seconds) should be included in the bonding procedure to achieve optimal enamel bonding results (Figs 9-11a to 9-11d; see Box 9-3).

Dentlearn.ir

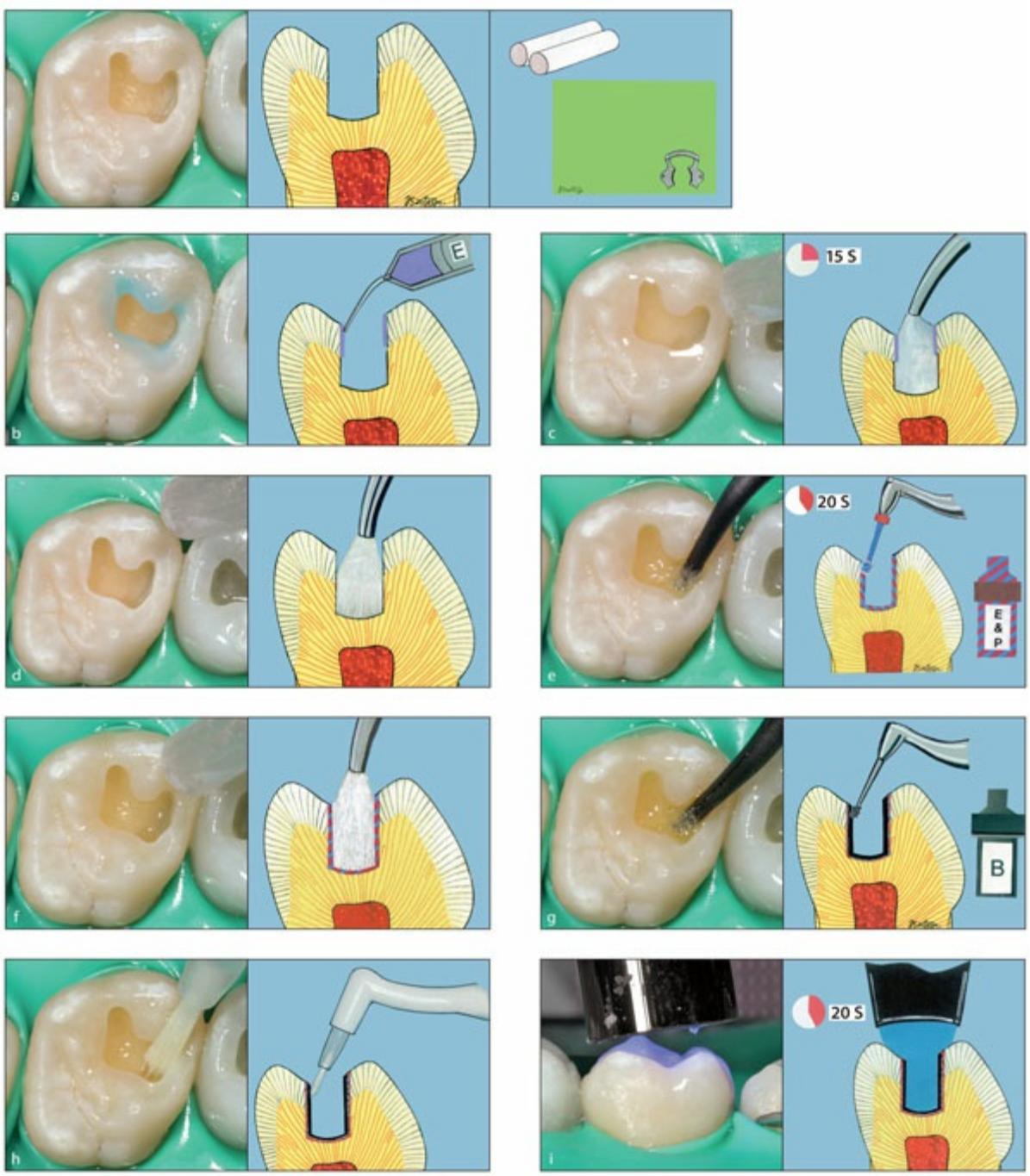

Fig 9-11 Step-by-step application of the two-step self-etching adhesives. *(a)* Preparation complete; ready for adhesive application. Appropriate isolation must be provided. *(b)* Phosphoric etchant gel is used to selectively etch the enamel margins of the preparation. *(c)* Etchant gel is thoroughly rinsed with air-water spray for 15 seconds. *(d)* Preparation is dried. Frosty appearance of enamel confirms adequacy of etch. *(e)* The combined etchant-primer component is actively applied for 20 seconds. *(f)* The etchant-primer-adhesive component is air dried for 30 to 40 seconds to terminate the etching reaction and ensure thorough evaporation of solvents. *(g)* The adhesive component is actively applied to the entire preparation. *(h)* A bristle brush is used to absorb excess adhesive, avoid pooling, and distribute the adhesive evenly on all cavity walls. *(i)* The adhesive is light cured for 10 to 20 seconds prior to inserting the resin composite.

Dentlearn.ir

Self-etching and priming of dentin

Although strong self-etching adhesives with improved enamel-etching performance are currently available, their ability to bond to dentin remains severely compromised. Their high intrinsic acidity does not allow complete buffering from the dissolved hydroxyapatite, leading to continuous etching[161] and incomplete polymerization.[115,161] Mild self-etching adhesives are thus preferred for dentin bonding.[35] Such adhesives partially demineralize dentin, leaving residual hydroxyapatite crystals that protect the collagen fibrils.[37]

Mild two-step self-etching adhesives have been found to exhibit excellent adhesion to smear layer–covered dentin, resulting in immediate bond effectiveness and longevity comparable with those achieved with ethanol-based, three-step etch-and-rinse systems that are sometimes considered the gold standard.[24,35,44,113,160] Two-step self-etching adhesives ensure simplified clinical application and reduced operator sensitivity by eliminating the need to etch dentin with phosphoric acid (see Box 9-3). The application of a self-etching adhesive to smear layer–covered dentin avoids most problems that are encountered when using etch-and-rinse adhesives, including excessive etching, suboptimal rinsing of the etching agent, and inappropriate adhesive application because of overwetting or overdrying of acid-etched dentin.[35,135,162] As mentioned previously for the etch-and-rinse systems, the primer-containing component should be actively applied to the preparation to enhance infiltration into the dentin surface and improve adhesion[127] (Figs 9-11e and 9-11f).

The reactive monomers contained in some mild two-step self-etching adhesives establish a chemical bond with the mineral component of dentin.[36,163,164] Specific functional monomers, such as 10-methacryloyloxydecyl dihydrogenphosphate (10-MDP), are responsible for this chemical interaction (see Table 9-2). Ionic bonds are

monomers and the calcium of hydroxyapatite.[165] The resulting hybrid layer exhibits micromechanical interlocking (a prerequisite for good bonding) and allows additional chemical interaction between functional monomers and the tooth substrate through the adhesion-decalcification mechanism.[35]

The ionic interaction of functional monomers with the tooth may produce stable ionic bonds.[35,163,165] For this reason, the removal of the smear layer created by the demineralization of dentin during phosphoric acid etching depletes most of the hydroxyapatite in dentin that could be available for such chemical interaction, which in turn reduces the bond strength created by mild two-step self-etching adhesives.[166]

Dentlearn.ir

Thus, manufacturers of mild self-etching adhesive systems recommend that phosphoric acid etching be used only on enamel (see Fig 9-11b).

A major advantage of two-step self-etching systems is that they are relatively technique insensitive; thus, time or technique of application is not as critical for these systems as for other adhesives.[128,167]

A concern with the bonding process for self-etching adhesives is how to best maximize the bond to enamel without compromising the bond to dentin. As noted previously, a separate application of phosphoric acid to enamel prior to self-etching adhesive application will significantly improve the bond to enamel. However, there is considerable evidence that etching dentin with phosphoric acid prior to application of a self-etching adhesive significantly reduces bond strength to dentin, likely because of poor infiltration into demineralized dentin.[168–170] Because it is often difficult to apply phosphoric acid etchant to enamel without involving dentin, this procedure must be approached with caution. Clinical studies in which this approach was used did not demonstrate adverse clinical performance in Class 5 restorations over 2 years[171] and 5 years,[172] demonstrating that careful clinical application using a selective phosphoric acid etching technique with self-etching systems can be successfully employed with some restorations.

Step 2: Bonding

The bonding agents of two-step adhesives contain hydrophobic and relatively unsolvated monomer blends (usually bis-GMA and TEGDMA; see Table 9-2). Thus, the clinical recommendations described above for three-step etch-and-rinse adhesives are also applicable to two-step self-etching systems (Figs 9-11g and 9-11h; see Box 9-3). These include brush thinning to optimize adhesive thickness, the use of a layered application to achieve a fully saturated surface, and the use of optimal curing times (Fig 9-11i).

One-Step Self-Etching or Etch-and-Dry Adhesives

One-step self-etching adhesives are the simplest and most recently developed adhesive systems. (See Fig 9-12 for step-by-step application of the one-step

because they may be multibottle (mixed just prior to use) or single-bottle (all-in-one) systems, respectively. One-step self-etching adhesives combine the three steps of the adhesion process into the application of a single solution containing complex

Dentlearn.ir

mixtures of hydrophilic and hydrophobic resin blends, acid, and water to activate etching (see Table 9-2). This chemical complexity has caused shelf-life problems.[173]

This class of adhesives has the highest hydrophilic monomer content of currently available adhesive systems; some of the earliest one-step adhesives are more acidic and hydrophilic than two-step self-etching primers[44,112] (see Table 9-2). Although these adhesives simplify clinical application, they result in lower immediate bond strengths than that produced with more complex adhesive systems.[35,44]

Adhesive interface stability may also be compromised by the use of one-step self-etching adhesives because of expedited aging phenomena affecting the hybrid layer.[22,24] The high hydrophilic monomer content of these formulations produces an adhesive interface after polymerization that acts as a semipermeable membrane on the dentin surface, allowing fluids to cross the interface because of osmotic pressure gradients.[154,174,175] Simplified adhesives thus demonstrate increased water sorption, which promotes polymer swelling and other water-mediated degradation phenomena.[15,22,24]

Although hydrophobic dimethacrylates have been added to one-step adhesives to produce stronger cross-linked polymer networks (see Table 9-2), the hydrophilic monomers tend to cluster before polymerization begins to create hydrophilic

and adhesive layers to reach the adhesive-composite interface.[175,178]

One-step self-etching adhesives have also shown lower degrees of conversion than have multistep systems.[109,115] The high concentration of hydrophilic domains and the presence of water result in suboptimal polymerization and reduced bond longevity because of the elution of unreacted monomers. This process creates a porous structure with reduced sealing ability along the adhesive interface.

Application to enamel

Like two-step self-etching adhesives, one-step systems have demonstrated a reduced ability to bond to unabraded enamel.[35,154,158,159,179] This clinically relevant problem is particularly pronounced for unbeveled preparations. For this reason, preliminary phosphoric acid etching of enamel (especially non-instrumented enamel) is recommended before the application of one-step adhesives[159,166] (Figs 9-12a to 9-12c; see Box 9-4).

Dentlearn.ir

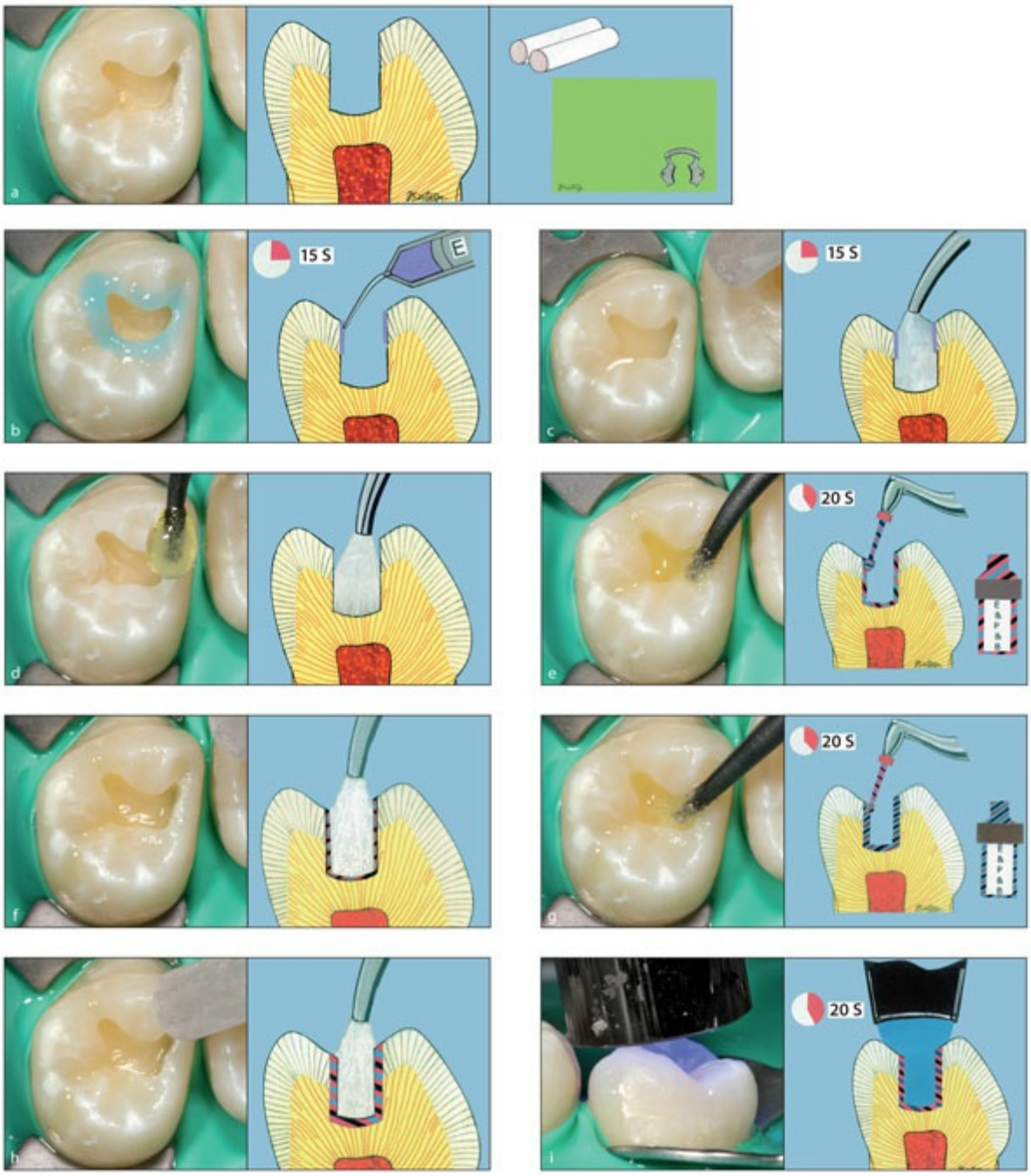

Fig 9-12 Step-by-step application of the one-step self-etching adhesives. *(a)* Preparation complete; ready for adhesive application. Appropriate isolation must be provided. *(b)* Phosphoric etchant gel is used to selectively etch the enamel margins of the preparation. *(c)* Etchant gel is thoroughly rinsed with air-water spray for 15 seconds and then air dried. *(d)* Preparation is dried. Frosty appearance of enamel confirms adequacy of etch. Applicator brush with combined etchant-primer-adhesive component is ready for application. *(e)* The combined etchant-primer-adhesive component is actively applied for the recommended time. *(f)* The etchant-primer-adhesive component is air dried for 30 to 40 seconds to terminate the etching reaction and ensure thorough evaporation of solvents. *(g)* The combined etchant-primer-adhesive component is actively reapplied. *(h)* The etchant-primer-adhesive component is air dried for 30 to 40 seconds to terminate the etching reaction and ensure thorough evaporation of solvents. *(i)* The adhesive is light cured for 10 to 20 seconds prior to inserting the resin composite.

Dentlearn.ir

Application to dentin

Efforts to improve the stability of the dentin-adhesive interface created by one-step adhesives have focused on several parameters: preliminary etching, hydrophobic coating, application mode, application times and multilayering, and appropriate polymerization.

Preliminary etching

As mentioned for the two-step self-etching systems, it can be clinically difficult to prevent the extension of phosphoric acid from enamel to dentin during etching, especially in small Class 2 preparations. Thus, preliminary phosphoric acid etching of dentin before the application of a self-etching adhesive has not been recommended (see Fig 9-12b and Box 9-4). Although preliminary dentin etching should be avoided with the use of adhesive formulations containing reactive monomers,[35,166] a recent study found that the application of some one-step adhesives to acid-etched dentin improved adhesion capability in comparison with application to smear layer–covered dentin.[159]

Self-etching adhesive products are intended to eliminate the need for phosphoric acid etching of dentin, thus simplifying clinical application and substantially reducing operator technique sensitivity. The effectiveness of an adhesive system applied to acid-etched dentin can be reduced dramatically by the potential operator-related problems mentioned above, including excessive etching, suboptimal rinsing of the etching agent, and inappropriate adhesive application because of overly wet or dry acid-etched dentin. Postoperative sensitivity may also result from increased dentin permeability after etching. To reduce operator sensitivity, the pre-etching of dentin before the application of one-step adhesives should be avoided.

Hydrophobic coating

One-step self-etching adhesives may be treated as primers that are subsequently covered with a hydrophobic coating, such as those employed in conventional three-step etch-and-rinse systems. This approach may improve adhesive performance; the application of an additional hydrophobic resin layer has been shown to improve immediate resin-dentin bond strength and reduce long-term adhesive interface degradation.[170,180–182]

Application mode

Dentlearn.ir

Active application produces consistent etching and enhances the interaction of acid monomers with the tooth structure, dispersing etching by-products into the surface (Figs 9-12d and 9-12e; see Box 9-4). The agitation of one-step adhesives brings fresh acidic solution into contact with the substrate, disperses air trapped in the solution, and mixes etching by-products to increase the efficiency of removal.[183] The use of an active brushing technique increases the immediate bond strength produced by one-step adhesives[184,185] and improves long-term stability.[183,184]

Application times and multilayering

The use of multilayering techniques or prolonged application times during dentin bonding[167,182,186,187] has been suggested to enhance the uniformity of adhesive infiltration and increase water and solvent evaporation[167] (Figs 9-12e to 9-12h; see Box 9-4).

Appropriate polymerization

The use of extended curing times that exceed the manufacturer recommendations has been found to improve polymerization and reduce permeability, potentially improving the performance of one-step adhesives[109,115] (Fig 9-12i; see Box 9-4).

Multimode or Universal Adhesive Systems

Dental manufacturers have recently made slight modifications of dentin adhesive formulations to produce a new class of universal adhesives. These materials are called *multimode* or *universal* because they can be used as self-etch, etch-and-rinse, or selective-etch systems. These adhesives have the ability to bond methacrylate-based restoratives, cement, and sealant materials to dentin, enamel, glass ionomer, and several indirect restorative substrates, including metals, alumina, zirconia, and other ceramics. All are modeled after self-etch systems and contain acidic monomers (see Table 9-1). Some earlier self-etch systems were noted to be negatively affected by pre-etching of dentin with phosphoric acid. Although these universal adhesives are new and just now being studied, early research appears to show that they are not adversely affected by this etch-and-rinse step either in vivo[188] or in vitro.[189,190]

The reported strong bond strengths of these new materials to metal and zirconia is likely a result of a functional acidic monomer MDP contained within the formulation

Dentlearn.ir

of most universal adhesives. This reactive monomer has been reported to have a strong affinity to dentin and enamel[191] and metal.[192] In addition, these materials form a chemical bond with zirconia (Zr-O-P).[193] It has also been shown that MDP-containing adhesives render the adhesive interface more resistant to biodegradation[194] because of the chemical bond with the residual hydroxyapatite crystals that remain available on the substrate after use of a self-etch approach on dentin. Some of these new formulations also contain silane coupling agents to aid adhesion to certain ceramic surfaces.[191]

The primary use of these adhesives is with light-activated resin composites in direct restorations. Nevertheless, because of the limited thickness of the adhesive layer, they can also be used to lute indirect restorations with self- or dual-cured composites and cements in combination with a self-curing activator. If the initial research on these materials is confirmed by longer-term studies, these adhesives should provide greater flexibility to the practitioner.

Role of the Smear Layer on Dental Adhesives

Cavity preparation is accomplished through the use of manual or mechanical instrumentation (ie, different burs or hand instruments) producing a smear layer both on enamel and dentin. Depending on the type of burs and their coarseness and the speed of the handpieces or the type of manual instruments, the thickness and composition of the smear layer produced may greatly vary.[195–198]

Medium-grit (100-µm) diamond bur preparation on enamel results in a rough and irregular surface with enamel fragments fractured or loosely attached to the enamel surface.[155] Moreover, numerous subsurface cracks are present. Dentin surfaces prepared with medium-grit diamond burs show more irregularities associated with a thicker (approximately 5-µm) and denser smear layer resulting in a compact smear plug that occludes dentinal tubules when compared with dentin prepared with tungsten carbide burs (smear layer thickness of approximately 2 µm).[199]

The smear layer is not strongly attached to the tooth substrate, and the adhesive systems should remove or modify it to permit an adequate impregnation of the underlying tooth surface and thus proper hybrid layer formation.[35] While etch-and-rinse adhesives completely dissolve the smear layer, self-etching (etch-and-dry) adhesives only modify it, and so their bond strength can be affected by the smear layer thickness.[35] Smear layer modification is correlated to the pH of the self-etching adhesives.[44] Strong self-etching adhesives are able to dissolve the smear layer,

Dentlearn.ir

while mild and ultramild self-etching adhesives cannot perform as well.[200] A thick smear layer can potentially impair the infiltration process of ultramild adhesives because the acidic monomers are neutralized by its components at an early stage, reducing the etching effect on the dentin.[196] It has been demonstrated that when ultramild self-etching adhesives are used, the thicker the smear layer, the lower the bond strength.[35,199,201] Thus, if a mild or ultramild adhesive will be used, an attempt should be made to reduce the smear layer thickness, such as by lightly abrading all cavity walls using fine-grit diamond burs.[202] Prolonged application time and active brushing of the adhesive during its application may also help to dissolve the smear layer, thereby promoting substrate infiltration and improving the bond strength of self-etching adhesives to dentin.[199]

Similarly, the smear layer is thought to interfere with the development of an adequate adhesive layer at the enamel interface when mild and ultramild self-etching adhesives are used. Because the smear layer is more easily dissolved than intact enamel, its neutralizing effect on acidic monomers of self-etching adhesives is faster. As a result, a thick smear layer might act as a barrier to adequate demineralization of the enamel substrate.[155] For this reason, the selective etching of enamel with phosphoric acid when using self-etching adhesives should always be performed.[35,155]

Glass-Ionomer Cements

Glass-ionomer cements, also called *polyalkenoates*, are the only dental materials in which the primary adhesion to tooth surfaces is via a true chemical bond.[203] Manufacturers provide these cements as two separate components: a powder that contains calcium aluminosilicate glass and a liquid that contains polyacrylic acid (and, in some cases, maleic acid) in water[203] (Fig 9-13). Setting occurs when the

Dentlearn.ir

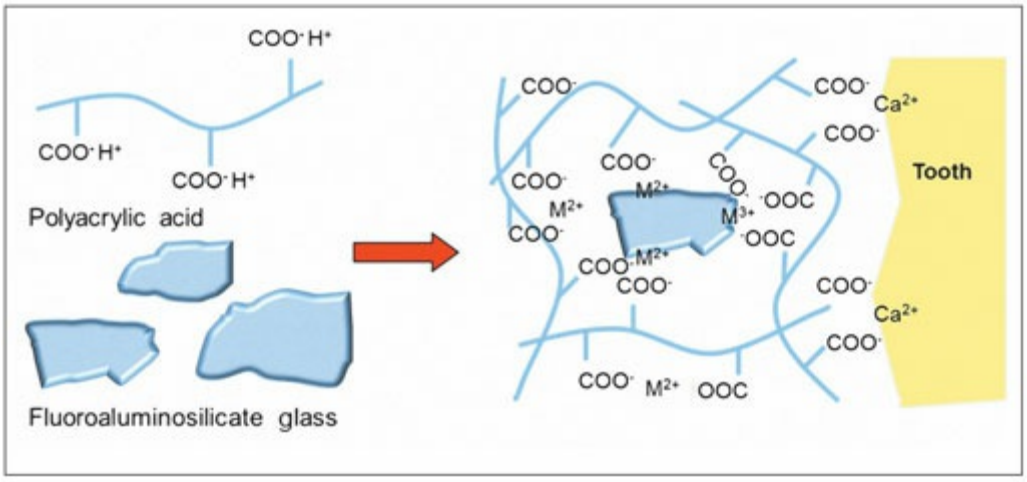

glass-ionomer material interact with the calcium content of tooth hydroxyapatite to form ionic bonds.

with the calcium content of tooth hydroxyapatite to form ionic bonds[204] (see Fig 9-13). When glass-ionomer cements are used to bond to dentin, smear layer removal and partial hydroxyapatite demineralization are frequently achieved through the application of a weak polyalkenoic acid conditioner. This procedure coats the collagen fibrils with hydroxyapatite and produces a pore-interspersed network.[205,206] The glass-ionomer material then acts as a self-etchant by hybridizing the partially demineralized dentin.[44] Some glass ionomers and polyalkenoic acid conditioners form a gel phase composed of calcium polycarboxylate salt at the bonded interface.[207]

The use of glass-ionomer cements produces bond-strength values similar to those of two-step self-etching adhesives on enamel and equal to those of one-step self-etching adhesives on dentin.[44] However, it is difficult to determine the true bond strength of glass ionomer to tooth structure, because examination of the failure surfaces typically shows residual glass-ionomer on the bonding surfaces, suggesting cohesive failure within the material.[208]

Adhesion to Intraradicular Dentin

Posts are routinely used to restore endodontically treated teeth because of the favorable properties of fiber posts in combination with several luting agents and adhesive systems.[209,210] However, the selection of a luting strategy that provides

Dentlearn.ir

reliable and long-lasting bonding to root dentin is difficult because of the large variety of products and the intrinsic difficulties of bonding within the endodontic space.

Posts can be cemented using conventional dual-curing resin-based cements in combination with etch-and-rinse or self-etching adhesives or using the recently formulated self-adhesive cements, which are all-in-one resin-based materials that allow simultaneous bonding between the intraradicular dentin and the post[211,212] (Figs 9-14 and 9-15). The procedure of bonding to intraradicular dentin differs from that to coronal dentin mainly because of the limited access to the endodontic or post space, which may lead to clinical errors that compromise adhesion.[213,214]

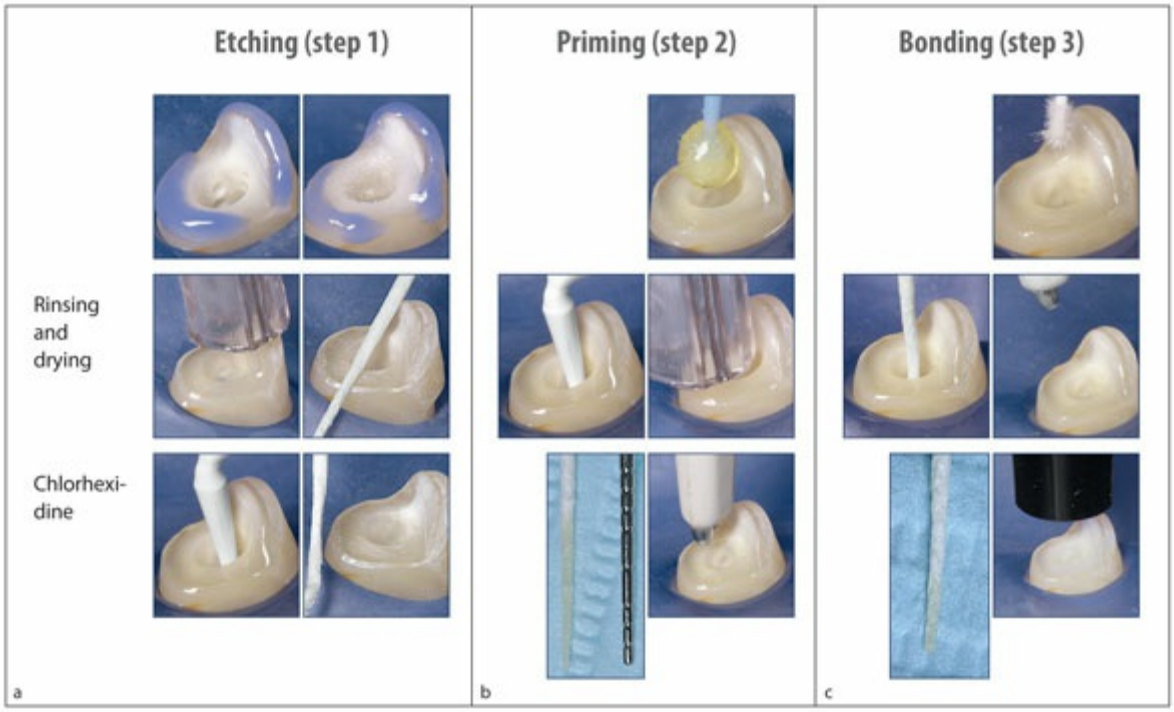

Fig 9-14 Step-by-step procedure of intraradicular bonding using a three-step etch-and-rinse adhesive. (Courtesy of Adamo Monari, Verona, Italy.) *(a)* In the etching step (1), enamel is etched with phosphoric acid gel, followed by placement of liquid phosophoric acid on the dentin and into the canal. This is to enhance diffusion of the acid down the canal and to improve rinsing for acid removal. Note that a paper point is used to ensure adequate removal of water after rinsing. *(b)* In the priming step (2), a thin microbrush is used to apply the primer, a paper point is used to remove excess primer, and it is gently air dried to evaporate the solvent. A periodontal probe is used to measure the extent of the prepared canal and is compared to the saturated length of the paper point to ensure that the primer has permeated to the complete depth of the canal preparation. *(c)* In the bonding step (3), a thin microbrush is used to apply the bonding agent, a paper point is used to remove excess bonding resin, and it is finally light cured.

Dentlearn.ir

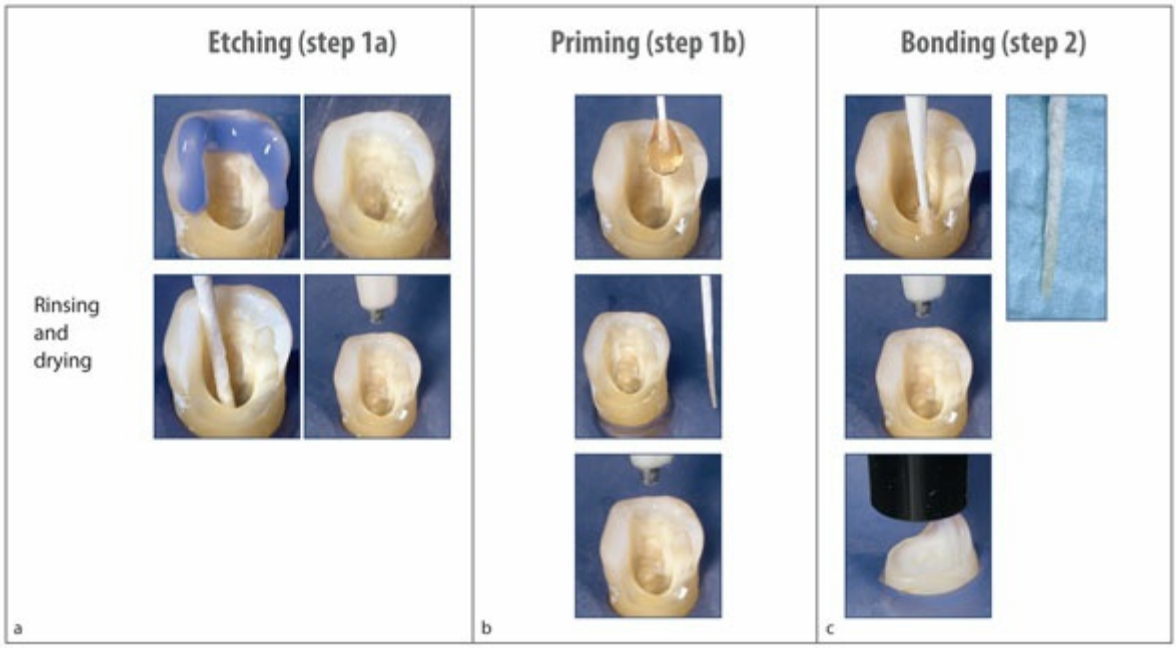

Fig 9-15 Step-by-step procedure of intraradicular bonding using a two-step self-etching adhesive. (Courtesy of Adamo Monari, Verona, Italy.) *(a)* In the etching step (1a), phosphoric acid gel is selectively applied to the enamel only. After rinsing, a paper point is used to remove water prior to priming. *(b)* In the priming step (1b), a thin microbrush is used to carry the primer to the full extent of the prepared canal, and a paper point is used to ensure adequate removal of excess primer/etchant prior to gentle air drying. *(c)* In the bonding step (2), a thin microbrush is used to apply the bonding agent, a paper point is used to remove excess bonding resin, and it is finally light cured.

The pulp tissue, predentin, mineralized dentin, and surrounding cement layer can be identified through analysis of the radicular substrate. *Predentin* is defined as the unmineralized organic matrix lining the innermost pulpal portion that is removed by pulpal tissue instrumentation and, in the case of post-space preparation, the use of calibrated burs. These root canal procedures create a dental substrate consisting of mineralized intraradicular dentin.[215,216] Although intraradicular and coronal dentin exhibit only minor morphologic and biochemical differences in substrate composition, significant differences have been found in the bond strengths to these different materials. Many studies also have shown that bond strength decreases from the coronal to the apical third of the root canal because of the significant reduction in the number of tubules toward the apical region and changes in the ratio of peritubular to intertubular dentin from the apical to the coronal third.[215,216] Although the greater proportion of intertubular dentin near the apex should result in higher bond strength in the apical third (versus coronal third) of the root, mineral deposits resistant to acid demineralization are frequently present near root apices and significantly affect the formation of the hybrid layer.[213]

Dentlearn.ir

These intrinsic substrate modifications result in reduced peritubular dentin infiltration and resin tag formation, compromising the achievement of high bond strength in the apical third of the root. The lower bond-strength values resulting from reduced adhesive impregnation reported by some authors[216] are likely because of a combination of these factors. Because hybrid layer thickness and resin tag morphology have recently been found to contribute only minimally to bond strength, the reduced bond strength to intraradicular dentin is likely because of factors other than substrate morphology, such as the clinical challenges posed by the limited endodontic space and the high cavity-configuration factor (C-factor).[217]

Clinicians would thus benefit from the development of a standardized, predictable, and reliable adhesive procedure for bonding within the endodontic space. To improve immediate bond strength and the long-term stability of the adhesive interface, operators also must be familiar with the primary factors that may negatively impact adhesion in this region and be able to critically evaluate clinical situations. Clinical factors (procedures and materials) and the geometric characteristics of the endodontic space can affect the use of adhesives and luting procedures in root canals.[213,218,219]

Because endodontic therapy seeks to disinfect the root canal space and fill it with an inert material, the creation of a tight seal with the tooth structure is mandatory. Adhesion to intraradicular dentin requires the creation of a perfectly clean post space because of the modification of intraradicular dentin caused by the use of sodium hypochlorite (NaOCl) rinses, ethylenediaminetetraacetic acid (EDTA), endodontic cements, gutta-percha, or other endodontic filling materials.[218]

Endodontic smear layers

The morphologic features, composition, and thickness of the endodontic smear layer are determined by endodontic instrument type, irrigation method, and tooth substrate type.[42] Whereas coronal smear layers contain materials derived from the dentinal matrix, endodontic smear layers contain a wider variety of inorganic and organic materials, including odontoblast fragments, microorganisms, and necrotic material.[220] The thickness of the smear layer ranges from 0.5 to 2.0 μm, with smear plugs obstructing dentinal tubule orifices and extending up to 40 μm into the tubules. Debris and pulp tissue remnants on dentinal surfaces within the root canal may prevent effective bonding; this endodontic smear layer forms a barrier that significantly affects adhesive bonds between instrumented canal walls and restorative materials and impacts the resin cementation of fiber posts. Although the

Dentlearn.ir

retention of the smear layer may be desirable in some adhesive dentistry applications, it should be removed in endodontic procedures.[221] Because the endodontic smear layer may harbor microorganisms and protect bacteria within dentinal tubules, removing it from infected root canals allows the penetration of intraradicular medications into the tubules.[222] Several studies have also reported that the removal of the smear layer promotes better adhesion of obturation materials and increases the penetration depth of sealers within the dentinal tubules by 10 to 80 μm.[220]

In addition to the smear layer produced by manual or rotary instrumentation of root canal walls, the subsequent preparation of the post space creates a thicker smear layer composed of debris and sealer/gutta-percha remnants that significantly influences fiber post adhesion.[223] In post-space preparation, the use of drills to remove the root-filling material produces this second smear layer. Drilling friction plasticizes the sealer and gutta-percha remnants contained within this layer, reducing the penetration and chemical action of fiber post bonding agents. Furthermore, the endodontic canal space allows only minimal irrigation. The achievement of optimal post retention thus requires the creation of clean dentinal surfaces after mechanical post-space preparation, particularly with the use of resin cements.[224]

Some authors have suggested that pretreatment with NaOCl and phosphoric acid[225] or a chelating agent can efficiently remove large areas of smear layer that would otherwise be unavailable for bonding and resin cementation of fiber posts, thereby improving post retention. The use of ultrasonic instrumentation and EDTA before bonding has also been suggested to reduce the presence of debris and open tubules.[226] Although these proposed pretreatments enhance the removal of the smear layer, the effectiveness of interfacial bonding is related primarily to the choice of bonding procedure.[227]

Clinical factors

Several clinical factors may affect adhesion to intraradicular dentin. The use of some disinfectants or medications during root canal preparation may adversely affect dentin-post bond strength,[228,229] as can bleaching and retreatment procedures.[218]

Irrigation of the endodontic space exposes radicular and coronal dentin to various disinfecting solutions that alter the dentinal surface and affect interactions with resin-based materials used for root canal obturation or coronal restoration.[213,230]

Dentlearn.ir

The effects of solutions such as EDTA and NaOCl on dentin have been investigated extensively.[229,231,232] Although NaOCl is usually recommended for endodontic irrigation, it has strong oxidizing properties and should not be used with resin-based materials. The use of NaOCl produces an oxygen-rich layer on the dentinal surface that can significantly reduce bond strength and increase microleakage.[231] Thus, the operator must employ clinical procedures that optimize adhesive-dentin and post-resin bond strength when using resin cements to lute endodontic posts. The use of a solution containing 10% ascorbic acid or 10% sodium ascorbate after NaOCl irrigation can improve adhesion to intraradicular dentin by completely reversing the compromised bond obtained with 5% NaOCl–treated dentin.[231]

Hydrogen peroxide (H_2O_2) may also be used during canal instrumentation to effectively remove pulp tissue remnants and dentin debris. However, the use of 3% H_2O_2 has been found to negatively affect the strength of bonds between resin cement and root canal dentin.[233] When it reacts with NaOCl, H_2O_2 breaks down and liberates water and oxygen, both of which may strongly inhibit the interfacial polymerization of resin-based bonding materials. The use of RC-Prep (Premier Dental Products) as a lubricant and demineralizing agent has also been found to reduce the strength of bonds between resins and root canal dentin. The polyethylene glycol vehicle (Carbowax, Dow Chemical) included as a lubricant in RC-Prep is difficult to eliminate completely during rinsing and inhibits resin polymerization. However, treatment with 10% ascorbic acid following the application of RC-Prep can restore bond strength to control values.[231]

Intraradicular irrigating solutions (NaOCl, H_2O_2, EDTA) directly affect the structural components of root canal dentin, significantly reducing microhardness.[232] Although these irrigants soften the dentinal walls, which may be clinically desirable because it permits rapid preparation and facilitates access to small, tight root canal spaces, adhesion and sealer performance are negatively impacted in chemically treated dentinal surfaces. The use of 0.2% chlorhexidine gluconate as an irrigating solution has been suggested to provide optimal obturation because it does not affect the microhardness and roughness of root canal dentin.[228]

Calcium hydroxide paste may be placed in the root canal between endodontic treatments for its antimicrobial properties and other beneficial effects. However, calcium hydroxide cannot be removed completely before obturation, and residual particles may form a physical barrier to bonding in some areas.[234] The high pH of calcium hydroxide may also neutralize the self-etching/primer solutions of self-etching adhesives, reducing etching effectiveness and bond strength.

Dentlearn.ir

Eugenol, which is included in some sealants and in zinc oxide–eugenol temporary cements, negatively affects resin polymerization and compromises bonding effectiveness because it can permeate dentin.[235] Like other phenolic compounds, eugenol is a radical scavenger that inhibits resin polymerization.[236] To avoid suboptimal polymerization and reduced bond strength, the application of a eugenol-based sealer or temporary material should be followed by the mechanical cleaning of root canal walls with detergent or alcohol to remove all residual material.[237] Such thorough cleaning may facilitate the removal of oily debris layers before bonding.[218,219]

During endodontic retreatment procedures, radicular and coronal dentin may be exposed to gutta-percha solvents (eg, chloroform, halothane) applied within the root canal.[238] These strong lipid solvents may alter the chemical composition of the dentinal surface and organic matrix, affecting the interaction with resin-based restorative materials. The solvents may be redeposited as a waxy film on the root canal surface, interfering with resin-dentin bonds and significantly reducing bond strength.[238] See chapter 21 for more on the restoration of endodontically treated teeth, including post preparation and cementation.

Bleaching

Tooth discoloration resulting from endodontic treatment is a serious problem that has received increasing attention in esthetic dentistry.[237] Although a variety of techniques can be used to improve esthetic outcomes, tooth whitening (bleaching) is the most conservative and cost-effective method of enhancing nonvital tooth appearance. However, bleaching has been associated with several side effects,[239] including reduced bond strength in resin-based restorative materials.[237] This reduction in bond strength is because of the oxygen-rich surface produced by H_2O_2-based products, which significantly inhibits adhesive polymerization.[240] Bond strength may be improved by placing the final restoration 1 week after a bleaching procedure to allow the release of residual oxygen. Extended polymerization times may partially mitigate polymerization inhibition when immediate bonding is necessary.[240]

Incompatibility between simplified adhesives and chemically/dual-cured composites and resin cements

Dentlearn.ir

The two-step etch-and-rinse and one-step self-etching adhesives have been found to be incompatible with chemically or dual-cured composite materials.[241,242] This results in reduced bond strength in inverse proportion to adhesive acidity. In addition, adverse chemical interactions occur between sub-optimally polymerized acidic adhesive resin monomers and catalysts in the composites.[242] These adhesives exhibit incompatibility with such composites because of the increased concentrations of lower-pKa acidic resin monomers that are included in these products to increase permeability.[243] These monomers can react with the basic components (aromatic tertiary amines) of the composite, inhibiting polymerization and/ or creating a hypertonic environment in which fluid is drawn osmotically from bonded hydrated dentin through the permeable adhesive layer.[243]

The use of an intermediate resin layer in three-step etch-and-rinse and most two-step self-etching adhesive systems (ones that do not contain an acidic monomer in their adhesive resin components) renders them compatible with chemically or dual-cured resin composites.[241] The resin layer is less acidic and less hydrophilic, which prevents the negative acid-base reaction. The layer also prevents direct contact with the acidic monomer components in the primer layer and reduces the permeability of resin-tooth interfaces.

Dual-curing adhesives are commonly used for bonding to root canal dentin because they can self-polymerize without light in the deep regions of the post cavity. However, the incompatibility between one-step self-etching adhesives and chemically/dual-cured composites precludes their use for indirect bonding in areas that are inaccessible to light activation. The use of one-step self-etching adhesives should thus be avoided in these situations, although the acid-base reaction may be overcome with the use of a ternary catalyst.[243,244]

Geometric factors

The endodontic use of methacrylate-based resin materials is affected by polymerization-associated shrinkage stresses that are great enough to cause debonding from dentin.[245] This debonding may result in reduced retention and increased leakage with the enhanced potential for bacterial invasion at the tooth-resin interface.

Feilzer et al[246] in 1987 found that shrinkage stress was related to the *C-factor*, defined as the ratio of bonded to unbonded surface area in the restoration. High C-factor values are indications of situations where the material is polymerizing under

Dentlearn.ir

exceed the bond strength to the tooth. The viscoelastic properties of the resin material also affect shrinkage stress; rigid resins produce high shrinkage stresses that have a greater potential to increase gap formation at the tooth-resin interface.[247] Bonds may be preserved if the elasticity of the surrounding materials is sufficient to relieve shrinkage stress caused by the wall-to-wall contraction of the resin material.[21] However, such relief is unlikely in deep root canals because of the geometry of the cavity and the thickness of resin films.[248] Root canal cavities have small unbonded surface areas that provide insufficient stress relief, increasing the probability of debonding in one or more bonded areas. Braga et al[249] found that shrinkage stress in composite restorations was affected more strongly by cavity depth than by diameter, which has negative implications in endodontic cavities. Negative geometric factors affect the cementation of endodontic posts to prepared post spaces, significantly compromising the ability to create leak-free interfaces. The C-factor in post spaces may exceed 200, whereas coronal restorations are characterized by C-factors of 1 to 5.[245,250]

Rheologic properties of the luting materials are also important during the luting procedure. In particular, a high percentage of filler in the resin cement has been found to significantly decrease bond strength because of increased polymerization stress at the interface.[217]

Evaluation of Bond Strength

The in vitro performance of adhesive systems is most frequently evaluated using macro- or microbond strength tests, the distinction being dependent on the size of the bonded area (Fig 9-16). Because dental research literature is replete with bonding studies, a brief review of the types of studies that will be encountered, as well as their primary strengths and weaknesses, will be provided.

Dentlearn.ir

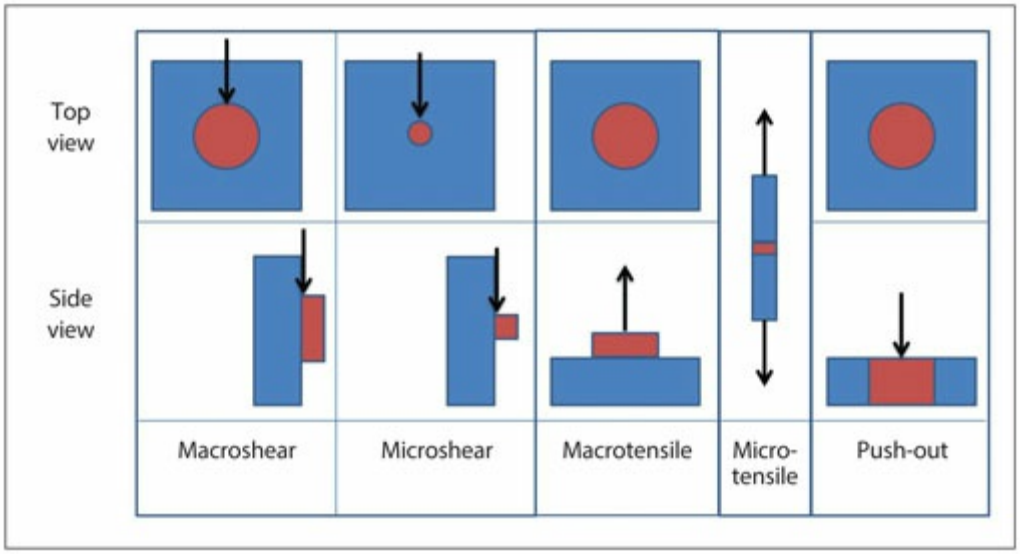

Fig 9-16 Schematic setups of the main bond-strength tests (*left to right*: macroshear, microshear, macrotensile, microtensile, push-out).

Macrobond strength tests

Bonded areas exceeding 3 mm^2 are assessed by macrobond strength tests[113] employing a shear, tensile, or push-/pull-out technique. Bond-strength values obtained using macrobond tests are usually lower than those obtained using microbond tests (area ~ 1 mm^2) because the increased surface area has a higher probability of containing large flaws that lead to bond failure[113,251,252] (see Fig 9-16).

Macroshear tests

In macroshear tests, a composite cylinder of restorative material is fixed to a flat enamel or dentinal surface after the application of adhesive (see Fig 9-16). Force is then applied parallel to the tooth surface until the bond fails.[251] Although loops, chisels, or knife edges have been used for load application, the use of a guillotine jig is recommended in the International Organization for Standardization (ISO) standard no. 11405.[253] Differences among studies in force-application devices as well as crosshead speed often prevent the direct comparison of test results.[252]

Although macroshear tests are the most commonly used method of assessing bond strength because of the simplicity of specimen preparation,[254] the stress generated at the bonding interface in such tests may lack uniformity. Such uneven stress may significantly affect the mode of bond failure.[255–258]

Dentlearn.ir

Macrotensile tests

In macrotensile tests, tensile force is applied to a cylinder of restorative material (typically composite) that has been polymerized onto a flat enamel or dentinal surface after the application of adhesive.[259] Although such tests are used less commonly than macroshear tests, they allow the evaluation of bond strength in luting agents used with hard materials such as metal alloys and ceramics.[260,261]

Push-/pull-out tests

In push-out tests, a specimen is embedded into a thin slice of material with its long axis oriented in the plane of the slice (see Fig 9-16). A compressive axial load is then applied to the upper surface of the specimen, extruding it through the base of the slice until debonding occurs.[262] The retention of posts luted in root canals[263,264] is typically assessed with push-out tests. This method also allows the concurrent microscopic analysis of marginal adaptation in the same specimen.[251]

The pull-out test is usually applied to fiber-reinforced composites, by which a single fiber, partially embedded within a resin matrix, is extracted under a tensile load.[265]

Microbond strength tests

Bonded surfaces with areas of 1 mm^2 or less are assessed using microbond strength tests, which may be divided into microshear and microtensile tests (see Fig 9-16).

Microshear tests

Microshear tests evaluate bond strength using restorative material buildups with small ($\leq$ 1 mm^2) cross sections of bonded areas. Specimen preparation for these tests is relatively simple, and multiple specimens can be prepared from a single tooth. However, it is impossible to confine the adhesive to the test area, as specified by ISO standard no. 11405 (2003). Furthermore, the distribution of stress in microshear tests is concentrated nonuniformly in the substrate, leading to the significant underestimation of stress. These shortcomings limit the recommended use of microshear tests to brittle substrates that are susceptible to fracture during specimen preparation, such as enamel or glass ionomers.

Microtensile tests

Dentlearn.ir

Bond strengths to dentin are most frequently evaluated using microtensile tests (μTBS). In these tests, large restorative material buildups are placed on a flat dentin surface after the application of adhesive. Multiple specimens may then be obtained from each tooth by removing 1 × 1–mm or smaller sections (ie, sticks) from the tooth-composite preparation. The specimens are then loaded to failure, and the tensile load at failure is divided by the cross-sectional area of the bonded interface to determine microtensile bond strength. Specimens may be prepared using trimming or nontrimming procedures[266,267]; the *nontrimming* technique is simpler and requires less preparation time. *Trimming* procedures create dumbbell- or hourglass-shaped specimens by trimming them at the interface. Although this technique improves the concentration of stress at the interface, specimen preparation is complex and highly operator dependent. The use of gripping devices or glue with specimenjig attachments, the speed of loading, and the alignment of specimens may also affect the results of microtensile tests.

Pretest failure occurs frequently during the preparation of specimens for microtensile tests. Several approaches to the consideration of such failures have been proposed, although each is associated with an analytic shortcoming. The exclusion of all pretest failures from statistical analyses may lead to the overestimation of bond strength, whereas the designation of a 0-MPa bond strength value to each failure may result in the underestimation of bond-strength. A predetermined bond-strength value, such as the lowest measured value within the

Hybrid Layer Aging and Interface Stability

Because the dentin substrate is impregnated by resin monomer blends during bonding, the stability of a bonded interface depends on the creation of a compact and homogenous hybrid layer.[22] Bonding with etch-and-rinse systems includes preliminary etching to demineralize the substrate and create a porous surface, followed by the application of bonding monomers.[33,34,37] The complete infiltration of the adhesive into the substrate is necessary to achieve a stable bond with these systems.[16,34,66,68,268,269] In self-etching adhesive systems, acidic co-monomers simultaneously demineralize and infiltrate the dentin; interface stability thus depends on effective co-monomer–substrate bonding.[35] Mild (pH ~ 2) two-step self-etching

contained within functional monomers and residual hydroxyapatite crystals on the

Dentlearn.ir

dentinal collagen scaffold; these bonds synergistically enhance long-term stability.[24,35] However, there is also some evidence of continued etching after curing for some aggressive one-step self-etching systems,[45,161] which would lead to exposed collagen and accelerated bond degradation.

Physical and chemical factors contribute to the clinical longevity of the hybrid layer. Physical factors affecting interface stability include occlusal chewing forces and repetitive expansion and contraction stresses produced by temperature changes within the oral cavity.[179,270] The interface is also affected by bacterial and acidic agents in dentinal fluid, saliva, food, and beverages, which produce various patterns of collagen fibril and resin degradation[16,23] and resin-monomer elution (likely because of suboptimal polymerization).[109,115]

The hybrid layer is created by the combination of the dentinal organic matrix with residual hydroxyapatite crystallites, resin monomers, and solvents; individual components may be affected by aging, and degradation may result from the synergistic combination of several components within the hybrid layer.[22]

Resin degradation

After storage, the hybrid layer may exhibit two patterns of degradation that compromise the strength of the resin-dentin bond: collagen fibril disorganization and the hydrolysis of resin from interfibrillar spaces within the hybrid layer.[268]

Hydrolysis is a primary means of resin degradation within the hybrid layer.[22,112] This chemical process involves the disruption of covalent bonds between polymers when water is added to ester bonds, resulting in the loss of resin mass[112,271] and contributing to the reduction in long-term bond strength created by dentinal adhesives.[16,22] In efforts to reduce such degradation, several studies have investigated the degree of water sorption within the hybrid layer produced by recently introduced simplified adhesive products.[15,16,22,23] Two-step etch-and-rinse and one-step self-etching adhesives employing hydrophilic acidic resins have shown high water sorption.[15] Water sorption significantly decreased the elastic modulus of resins, as plasticization of the polymer contributes to reduced bond strength in a manner similar to but independent of resin hydrolysis.[23,272]

Because hydrolytic degradation occurs only in the presence of water, it is closely associated with the hydrophilic properties of adhesives and the degree of water sorption.[112,273] The combination of hydrophilic and ionic resin monomers in two-step etch-and-rinse and one-step self-etching adhesive systems thus produces a

Dentlearn.ir

bonded interface that lacks a solvent-free hydrophobic resin coating.[112] Hybrid layers created using such systems behave as semipermeable membranes that permit the movement of water throughout the bonded interface, even after adhesive polymerization[114] (Fig 9-17).

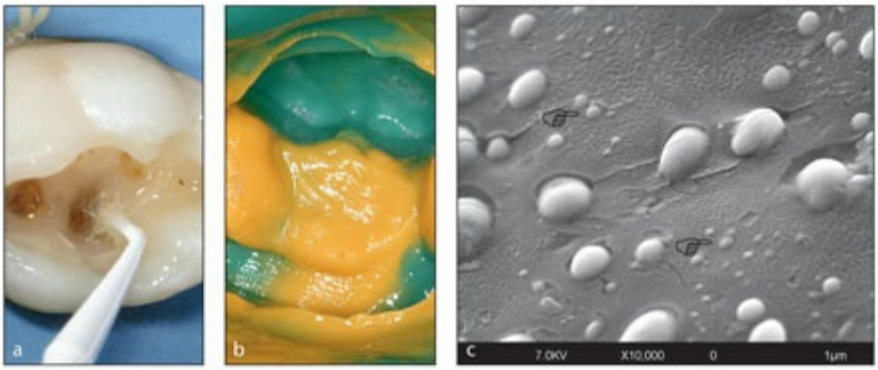

Fig 9-17 Illustrative steps of the in vivo analysis of the permeability of adhesives. A cavity was prepared and bonded *(a),* and an impression of the cavity floor was obtained *(b)*. After a cast with epoxy resin was poured, specimens analyzed under FE-SEM revealed water droplets emanating from the adhesive surface *(c)*. These droplets are the morphologic evidence of water that seeped from the adhesive layer during the setting time of the hydrophobic impression material, forming major droplets as well as minor droplets *(pointers)* over the adhesive. These droplets may compromise coupling between the adhesive and the resin-based restorative material. (Reprinted from Breschi et al[22] with permission.)

Etch-and-rinse adhesive systems are prone to nanoleak-age because of insufficient adhesive impregnation along the resin-dentin interface after demineralization.[65,67,177] The higher hydrophilic monomer content of two-step etch-and-rinse adhesives (versus three-step systems)[112] results in greater permeability after polymerization, which facilitates moisture uptake and increases nanoleakage expression.[114] Although all types of adhesive systems have shown variable degrees of incomplete polymerization associated with permeability to fluid movement,[109,115,274] these issues are more pronounced in simplified adhesives (eg, two-step etch-and rinse, one-step self-etching systems), likely because of a higher content of hydrophilic monomers[109,115,274] (Fig 9-18). Partially cured adhesives exhibit greater permeability, which may increase water sorption and compromise the long-term integrity of adhesive-composite bonds.[124] In contrast, more complete polymerization (and thus reduced permeability) can be achieved with the use of dentin bonding systems that include solvent-free hydrophobic monomers.[115]

Dentlearn.ir



Fig 9-18 Correlative transmission electron microscope (TEM) and FE-SEM examination of nanoleakage produced by a one-step self-etching adhesive. The adhesive was applied to the dentin passively (without agitation). *(a)* The TEM micrograph of the resin-dentin interface shows the presence of a 2 µm–thick hybrid layer *(white arrows)*. The entire hybrid layer is filled with fine, isolated silver grains that were probably affiliated with the partially demineralized, unstained collagen fibrils *(pointer)*. Very fine silver grains could be seen within the adhesive layer. A—adhesive; D—dentin; P—peritubular dentin; T—tubule impregnated by the adhesive. *(b)* FE-SEM images taken from a region within the fractured hybrid layer show that the latter was completely covered with fine silver grains, and *(c)* at higher magnification these fine silver grains were in the range of 5 to 20 nm in diameter. These silver grains were affiliated with the dehydrated and shrunken collagen fibrils. (Reprinted from Suppa et al[275] with permission.)

Collagen fibril degradation

Bond longevity may also be negatively impacted by increased water content at the bonded interface resulting from resin and collagen degradation. In addition, the degradation of collagen is caused primarily by the presence of water. Resin or collagen hydrolysis may degrade the hybrid layer, causing the loss of resin from interfibrillar spaces and the disorganization of collagen fibrils[268] and physically weakening the resin-dentin bond.[23] After long-term storage, bonded materials have exhibited resin elution and/or hydrolytic degradation of collagen matrices.[22,23] In vitro and in vivo studies have detected deterioration within the hybrid layer that indicates the presence of numerous exposed collagen fibrils.

The dentinal surface is often incompletely hybridized in resin-dentin bonding, regardless of the adhesive system used. Such incomplete hybridization may leave exposed collagen fibrils and residual adhesive solvent and/or surface water that increases vulnerability to hydrolytic degradation.[101,119,276]

Dentin bonding may also be affected by the breakdown of collagen matrices by host-derived proteinases released during the development of dentinal caries and periodontal disease.[277,278] The presence of matrix metalloproteinases (MMPs) in human dentin can be inferred based on evidence for colla-genolytic/ gelatinolytic activities in partially demineralized collagen matrices.[279–282] *MMPs* are zinc- and calcium-dependent endopeptidases that are incorporated within the mineralized

Dentlearn.ir

dentinal matrix during tooth development.[283] When released and activated during dentin bonding procedures, these endogenous enzymes can degrade extracellular matrix components[283] (Fig 9-19).

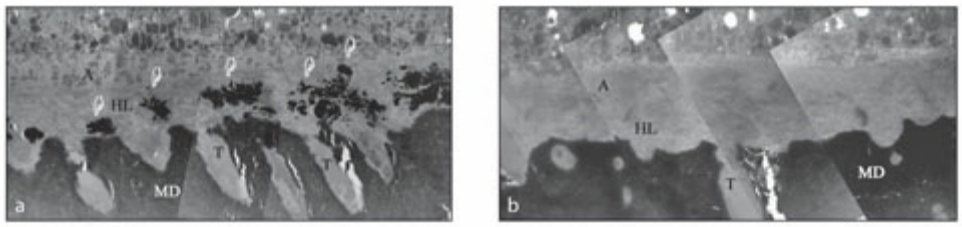

Fig 9-19 TEM images obtained combining numerous micrographs of a representative specimen treated without *(a)* or with *(b)* 0.2% chlorhexidine for 30 seconds, then bonded with a two-step etch-and rinse adhesive (Adper Scotchbond 1 XT) and stored for 2 years in artificial saliva at 37°C. *(a)* The control adhesive interface reveals extensive interfacial silver nanoleakage *(pointers)* due to individual silver grains and large clusters of silver deposits within the collagen fibrils of the hybrid layer. *(b)* If chlorhexidine was used, the adhesive interface revealed only very few scattered particles of silver nanoleakage within the hybrid layers. Bar = 2 μm. HL—hybrid layer; MD—mineralized dentin; T—dentinal tubules; A—filled adhesive. (Reprinted from Breschi et al[85] with permission.)

In vitro studies have found that MMPs thin or remove collagen fibrils from incompletely infiltrated hybrid layers in aged, bonded dentin,[85,87,89,284] and in vivo studies have observed MMP-induced collagen degradation in basal hybrid layers.[88,89] The use of chlorhexidine, an antibacterial agent with MMP-inhibiting properties, on acid-etched dentin during etch-and-rinse bonding procedures can maintain hybrid layer collagen integrity.[85–88] This effect confirms the indirect involvement of MMPs in collagen degradation (see Fig 9-19).

Cysteine cathepsins, which can be activated in mildly acidic environments, may also contribute to collagen degradation.[285] The activation of dentin-bound cathepsins may also activate matrix-bound MMPs, increasing long-term hybrid layer instability.[16,22]

Dentlearn.ir

References

1. Baier RE. Principles of adhesion. Oper Dent 1992;(suppl 5):1–9.
2. Marshall SJ, Bayne SC, Baier R, Tomsia AP, Marshall GW. A review of adhesion science. Dent Mater 2010;26:e11–e16.
3. Nakajima M, Sano H, Burrow MF, et al. Tensile bond strength and SEM evaluation of caries-affected dentin using dentin adhesives. J Dent Res 1995;74:1679–1688.
4. Yoshiyama M, Tay FR, Doi J, et al. Bonding of self-etch and total-etch adhesives to carious dentin. J Dent Res 2002;81:556–560.
5. William V, Burrow MF, Palamara JEA, Messer LB. Microshear bond strength of resin composite to teeth affected by molar hypomineral-ization using 2 adhesive systems. Pediatr Dent 2006;28:233–241.
6. Faria e Silva AL, De Moraes RR, De Sousa Menezes M, Capanema RR, De Moura AS, Martelli-Júnior H. Hardness and microshear bond strength to enamel and dentin of permanent teeth with hypocalcified amelogenesis imperfecta. Int J Paediatr Dent 2011;21:314–320.
7. Tay FR, Pashley DH. Resin bonding to cervical sclerotic dentin: A review. J Dent 2004;32:173–196.
8. Lopes GC, Baratieri CM, Baratieri LN, Monteiro S, Cardoso Vieira LC. Bonding to cervical sclerotic dentin: Effect of acid etching time. J Adhes Dent 2004;6:19–23.
9. Xie C, Han Y, Zhao XY, Wang ZY, He HM. Microtensile bond strength of one- and two-step self-etching adhesives on sclerotic dentin: The effects of thermocycling. Oper Dent 2010;35:547–555.
10. Kwong SM, Cheung GS, Kei LH, et al. Micro-tensile bond strengths to sclerotic dentin using a self-etching and a total-etching technique. Dent Mater 2002;18:359–369.
11. Camargo MA, Roda MI, Marques MM, de Cara AA. Micro-tensile bond strength to bovine sclerotic dentine: Influence of surface treatment. J Dent 2008;36:922–927.
12. Van Dijken JW. A prospective 8-year evaluation of a mild two-step self-etching adhesive and a heavily filled two-step etch-and-rinse system in non-carious cervical lesions. Dent Mater 2010;26:940–946.
13. Ritter AV, Heymann HO, Swift EJ, Sturdevant JR, Wilder AD. Clinical evaluation of an all-in-one adhesive in non-carious cervical lesions with different degrees of dentin sclerosis. Oper Dent 2008;33:370–378.
14. McLean JW. Dentinal bonding agents versus glass-ionomer cements. Quintessence Int 1996;27:659–667.
15. Malacarne J, Carvalho RM, de Goes MF, et al. Water sorption/solubility of dental adhesive resins. Dent Mater 2006;22:973–980.
16. Liu Y, Tjäderhane L, Breschi L, et al. Limitations in bonding to dentin and experimental strategies to prevent bond degradation. J Dent Res 2011;90:953–968.
17. Sideridou I, Tserki V, Papanastasiou G. Study of water sorption, solubility and modulus of elasticity of light-cured dimethacrylate-based dental resins. Biomaterials 2003;24:655–665.
18. Jacobsen T, Finger WJ, Kanehira M. Air-drying time of self-etching adhesives vs bonding efficacy. J Adhes Dent 2006;8:387–392.
19. Stansbury JW. Curing dental resins and composites by photopolymerization. J Esthet Dent 2000;12:300–308.
20. Sperling LH. Introduction to Physical Polymer Science, ed 4. Hoboken, NJ: Wiley & Sons, 2006.
21. Ferracane JL. Buonocore Lecture. Placing dental composites—A stressful experience. Oper Dent 2008;33:247–257.
22. Breschi L, Mazzoni A, Ruggeri A, Cadenaro M, Di Lenarda R, De Stefano Dorigo E. Dental adhesion review: Aging and stability of the bonded interface. Dent Mater 2008;24:90–101.
23. Hashimoto M. A review—Micromorphological evidence of degradation in resin-dentin bonds and potential preventional solutions. J Biomed Mater Res B Appl Biomater 2010;92:268–280.
24. De Munck J, Van Landuyt K, Peumans M, et al. A critical review of the durability of adhesion to tooth tissue: Methods and results. J Dent Res 2005;84:118–132.
25. Hashimoto M, Ohno H, Sano H, Kaga M, Oguchi H. Degradation patterns of different adhesives and bonding procedures. J Biomed Mater Res 2003;66:324–330.
26. Koshiro K, Inoue S, Tanaka T, et al. In vivo degradation of resin-dentin bonds produced by a self-etch vs. a total-etch adhesive system. Eur J Oral Sci 2004;112:368–375.

Dentlearn.ir

27. Buonocore MG. A simple method of increasing the adhesion of acrylic filling materials to enamel surfaces. J Dent Res 1955;34:849–853.
28. Gwinnett AJ, Matsui A. A study of enamel adhesives. The physical relationship between enamel and adhesive. Arch Oral Biol 1967;12:1615–1620.
29. Fusayama T. New Concepts in Operative Dentistry. Chicago: Quintessence, 1980.
30. Breschi L, Gobbi P, Mazzotti G, Ellis TH, Sacher E, Stangel I. Field emission in-lens SEM study of enamel and dentin. J Biomed Mater Res 1999; 46:315–323.
31. Breschi L, Gobbi P, Mazzotti G, Malconi M, Wllis TH, Stangel I. High resolution SEM evaluation of dentin etched with maleic and citric acid. Dent Mater 2002;18:26–35.
32. Pashley DH. The effects of acid etching on the pulpodentin complex. Oper Dent 1992;17:229–242.
33. Nakabayashi N, Kojima K, Masuhara E. The promotion of adhesion by the infiltration of monomers into tooth substrates. J Biomed Mater Res 1982;16:265–273.
34. Pashley DH, Tay FR, Breschi L, et al. State of the art etch-and-rinse adhesives. Dent Mater 2011;27:1–16.
35. Van Meerbeek B, Yoshihara K, Yoshida Y, Mine A, De Munck J, Van Lan-duyt KL. State of the art of self-etch adhesives. Dent Mater 2011;27:17–28.
36. Yoshida Y, Van Meerbeek B, Nakayama Y, et al. Evidence of chemical bonding at biomaterial-hard tissue interfaces. J Dent Res 2000;79:709–714.
37. Van Meerbeek B, Mohrbacher H, Celis JP, et al. Chemical characterization of the resin-dentin interface by

38. Perdigão J, Frankenberger R, Rosa BT, Breschi L. New trends in dentin/ enamel adhesion. Am J Dent 2000;13(special issue):25D–30D.
39. Van Meerbeek B, Perdigão J, Lambrechts P, Vanherle G. The clinical performance of adhesives. J Dent 1998;26:1–20.
40. Jacobsen T, Söderholm KJ. Some effects of water on dentin bonding. Dent Mater 1995;11:132–136.
41. Eick JD, Gwinnett AJ, Pashley DH, Robinson SJ. Current concepts on adhesion to dentin. Crit Rev Oral Biol Med 1997;8:306–335.
42. Pashley DH. Smear layer: Physiological considerations. Oper Dent 1984; 3(suppl):13–29.
43. Pashley DH, Livingston MJ, Reeder OW, Horner J. Effects of the degree of tubule occlusion on the permeability of human dentine in vitro. Arch Oral Biol 1978;23:1127–1133.
44. Van Meerbeek B, De Munck J, Yoshida Y, et al. Buonocore memorial lecture. Adhesion to enamel and dentin: Current status and future challenges. Oper Dent 2003;28:215–235.
45. Carvalho RM, Chersoni S, Frankenberger R, Pashley DH, Prati C, Tay FR. A challenge to the conventional wisdom that simultaneous etching and resin infiltration always occurs in self-etch adhesives. Biomaterials 2005;26:1035–1042.
46. Salz U, Mücke A, Zimmermann J, Tay FR, Pashley DH. pKa value and buffering capacity of acidic monomers commonly used in self-etching primers. J Adhes Dent 2006;8:143–150.
47. Tay FR, Pashley DH. Dental adhesives of the future. J Adhes Dent 2002; 4:91–103.
48. Gwinnett AJ. Histologic changes in human enamel following treatment with acidic adhesive conditioning agents. Arch Oral Biol 1971;16:731–738.
49. Silverstone LM, Saxton CA, Dogon IL, Fejerskov O. Variation in the pattern of acid etching of human dental

50. Gwinnett AJ. Structure and composition of enamel. Oper Dent 1992; (suppl 5):10–17.
51. Tagami J, Hosoda H, Fusayama T. Optimal technique of etching enamel. Oper Dent 1988;13:181–184.
52. Legler LR, Retief DH, Bradley EL. Effects of phosphoric acid concentration and etch duration on enamel depth of etch: An in vitro study. Am J Orthod Dentofacial Orthop 1990;98:154–160.
53. Carstensen W. The effects of different phosphoric acid concentrations on surface enamel. Angle Orthod 1992;62:51–58.
54. Shinchi MJ, Soma K, Nakabayashi N. The effect of phosphoric acid concentration on resin tag length and bond strength of a photo-cured resin to acid-etched enamel. Dent Mater 2000;16:324–329.
55. Gwinnett AJ, García-Godoy F. Effect of etching time and acid concentration on resin shear bond strength to

Dentlearn.ir

primary tooth enamel. Am J Dent 1992;5:237–239.
56. Lewinstein I, Rotstein I. Effect of trichloracetic acid on the microhardness and surface morphology of human dentin and enamel. Endod Dent Traumatol 1992;8:16–20.
57. Erickson RL, Barkmeier WW, Latta MA. The role of etching in bonding to enamel: A comparison of self-etching and etch-and-rinse adhesive systems. Dent Mater 2009;25:1459–1467.
58. Ermis RB, De Munck J, Cardoso MV, et al. Bonding to ground versus unground enamel in fluorosed teeth. Dent Mater 2007;23:1250–1255.
59. García-Godoy F, Dodge WW, Donohue M, O'Quinn JA. Effect of a fluoridated etchant on the shear bond strength of a composite resin to enamel. Int J Paediatr Dent 1992;2:25–30.
60. Baharav H, Cardash HS, Pilo R, Helft M. The efficacy of liquid and gel acid etchants. J Prosthet Dent 1988;60:545–547.
61. Baharav H, Cardash HS, Helft M, Langsam J. The continuous brushing acid-etch technique. J Prosthet Dent 1987;57:147–149.
62. Ben-Amar A, Baharav H, Liberman R, Nordenberg D. Continuous brushing acid-etch technique and microleakage of class V composite restorations. J Prosthet Dent 1988;59:573–576.
63. Barkmeier WW, Erickson RL, Kimmes NS, Latta MA, Wilwerding TM. Effect of enamel etching time on roughness and bond strength. Oper Dent 2009;34:217–222.
64. Shimada Y, Kikushima D, Tagami J. Micro-shear bond strength of resin-bonding systems to cervical enamel. Am J Dent 2002;15:373–377.
65. Sano H, Shono T, Takatsu T, Hosoda H. Microporous dentin zone beneath resin-impregnated layer. Oper Dent 1994;19:59–64.
66. Sano H, Yoshiyama M, Ebisu S, et al. Comparative SEM and TEM observations of nanoleakage within the hybrid layer. Oper Dent 1995;20:160–167.
67. Sano H, Takatsu T, Ciucchi B, Horner JA, Matthews WG, Pashley DH. Nanoleakage: Leakage within the hybrid layer. Oper Dent 1995;20:18–25.
68. Breschi L, Prati C, Gobbi P, et al. Immunohistochemical analysis of collagen fibrils within the hybrid layer: A FEISEM study. Oper Dent 2004;29:538–546.
69. Hashimoto M, Ohno H, Endo K, Kaga M, Sano H, Oguchi H. The effect of hybrid layer thickness on bond strength: Demineralized dentin zone of the hybrid layer. Dent Mater 2000;16:406–411.
70. Hashimoto M, Ohno H, Kaga M, et al. Over-etching effects on microtensile bond strength and failure patterns for two dentin bonding systems. J Dent 2002;30:99–105.
71. Breschi L, Gobbi P, Lopes M, et al. Immunocytochemical analysis of dentin: A double-labeling technique. J Biomed Mater Res A 2003;67:11–17.
72. Breschi L, Lopes M, Gobbi P, Mazzotti G, Falconi M, Perdigão J. Dentin proteoglycans: An immunocytochemical FEISEM study. J Biomed Mater Res 2002;61:40–46.
73. Lopes GC, Vieira LC, Araújo E, Bruggmann T, Zucco J, Oliveira G. Effect of dentin age and acid etching time on dentin bonding. J Adhes Dent 2011;13:139–145.
74. Perdigão J, Denehy GE, Swift EJ. Silica contamination of etched dentin and enamel surfaces: A scanning electron microscopic and bond strength study. Quintessence Int 1994;25:327–333.
75. Pashley DH, Ciucchi B, Sano H, Horner JA. Permeability of dentin to adhesive agents. Quintessence Int 1993;24:618–631.
76. Kanca J 3rd. Improving bond strength through acid etching of dentin and bonding to wet dentin surfaces. J Am Dent Assoc 1992;123:35–43.
77. Kanca J 3rd. Resin bonding to wet substrate. 1. Bonding to dentin. Quintessence Int 1992;23:39–41.
78. Pereira GD, Paulillo LA, de Goes MF, Dias CT. How wet should dentin be? Comparison of methods to remove excess water during moist bonding. J Adhes Dent 2001;3:257–264.
79. Tay FR, Gwinnett JA, Wei SH. Micromorphological spectrum from over-drying to overwetting acid-conditioned dentin in water-free acetone-based, single-bottle primer/adhesives. Dent Mater 1996;12:236–244.
80. Perdigão J, Frankenberger R. Effect of solvent and rewetting time on dentin adhesion. Quintessence Int 2001;32:385–390.

Dentlearn.ir

81. Fogel HM, Marshall FJ, Pashley DH. Effects of distance from the pulp and thickness on the hydraulic conductance of human radicular dentin. J Dent Res 1988;67:1381–1385.
82. Schüpbach P, Guggenheim B, Lutz F. Human root caries: Histopathology of advanced lesions. Caries Res 1990;24:145–158.
83. Kanca J 3rd. Wet bonding: Effect of drying time and distance. Am J Dent 1996;9:273–276.
84. Mohan B, Kandaswamy D. A confocal microscopic evaluation of resin-dentin interface using adhesive systems with three different solvents bonded to dry and moist dentin. An in vitro study. Quintessence Int 2005;36:511–521.
85. Breschi L, Mazzoni A, Nato F, et al. Chlorhexidine stabilizes the adhesive interface: A 2-year in vitro study. Dent Mater 2010;26:320–325.
86. Breschi L, Cammelli F, Visintini E, et al. Influence of chlorhexidine concentration on the durability of etch-and-rinse dentin bonds: A 12-month in vitro study. J Adhes Dent 2009;11:191–198.
87. Carrilho MR, Carvalho RM, de Goes MF, et al. Chlorhexidine preserves dentin bond in vitro. J Dent Res 2007;86:90–94.
88. Carrilho MR, Geraldeli S, Tay F, et al. In vivo preservation of the hybrid layer by chlorhexidine. J Dent Res 2007;86:529–533.
89. Hebling J, Pashley DH, Tjäderhane L, Tay FR. Chlorhexidine arrests sub-clinical degradation of dentin hybrid layers in vivo. J Dent Res 2005; 84:741–746.
90. Simonsen RJ, Neal RC. A review of the clinical application and performance of pit and fissure sealants. Aust Dent J 2011;56(suppl 1):45–58.
91. Van Landuyt KL, Snauwaert J, De Munck J, et al. Systematic review of the chemical composition of contemporary dental adhesives. Biomaterials 2007;28:3757–3785.
92. Carvalho RM, Mendonça JS, Santiago SL, et al. Effects of HEMA/solvent combinations on bond strength to dentin. J Dent Res 2003;82:597–601.
93. Pashley DH, Agee KA, Nakajima M, et al. Solvent-induced dimensional changes in EDTA-demineralized dentin matrix. J Biomed Mater Res 2001;56:273–281.
94. Carvalho RM, Yoshiyama M, Pashley EL, Pashley DH. In vitro study on the dimensional changes of human dentine after demineralization. Arch Oral Biol 1996;41:369–377.
95. Nakaoki Y, Nikaido T, Pereira PN, Inokoshi S, Tagami J. Dimensional changes of demineralized dentin treated with HEMA primers. Dent Mater 2000;16:441–446.
96. Maciel KT, Carvalho RM, Ringle RD, Preston CD, Russell CM, Pashley DH. The effects of acetone, ethanol, HEMA, and air on the stiffness of human decalcified dentin matrix. J Dent Res 1996;75:1851–1858.
97. Gwinnett AJ. Dentin bond strength after air drying and rewetting. Am J Dent 1994;7:144–148.
98. Pashley DH, Tay FR, Carvalho RM, et al. From dry bonding to water-wet bonding to ethanol-wet bonding. A review of the interactions between dentin matrix and solvated resins using a macromodel of the hybrid layer. Am J Dent 2007;20:7–20.
99. Vaidyanathan TK, Vaidyanathan J. Recent advances in the theory and mechanism of adhesive resin bonding to dentin: A critical review. J Biomed Mater Res 2009;88:558–578.
100. Haws SM, Vargas MA, Guzman S, Cobb DS. Effect of primer application on microleakage of composite resins [abstract 403]. J Dent Res 1997; 76(special issue):64.
101. Cadenaro M, Breschi L, Rueggeberg FA, et al. Effects of residual ethanol on the rate and degree of conversion of five experimental resins. Dent Mater 2009;25:621–628.
102. Dickens SH, Cho BH. Interpretation of bond failure through conversion and residual solvent measurements and Weibull analyses of flexural and microtensile bond strengths of bonding agents. Dent Mater 2005;21:354–364.
103. Balkenhol M, Huang J, Wöstmann B, Hannig M. Influence of solvent type in experimental dentin primer on the marginal adaptation of Class V restorations. J Dent 2007;35:836–844.
104. Hashimoto M, Tay FR, Svizero NR, et al. The effects of common errors on sealing ability of total-etch adhesives. Dent Mater 2006;22:560–568.
105. Schvaneveldt SL, Rozmajzl WF, Barkmeier WW, Latta MA. Bond strength of an adhesive polymerized

Dentlearn.ir

under nitrogen. Am J Dent 1996; 9:157–160.
106. Hilton TJ, Schwartz RS. The effect of air thinning on dentin adhesive bond strength. Oper Dent 1995;20:133–137.
107. Truffier-Boutry D, Place E, Devaux J, Leloup G. Interfacial layer characterization in dental composite. J Oral Rehabil 2003;30:74–77.
108. Endo T, Osada T, Finger WJ, Hoffmann M, Kanehira M, Komatsu M. Effect of oxygen inhibition of self-etching adhesives on enamel-dentin polymer bond. J Adhes Dent 2007;9:33–38.
109. Breschi L, Cadenaro M, Antoniolli F, et al. Polymerization kinetics of dental adhesives cured with LED: Correlation between extent of conversion and permeability. Dent Mater 2007;23:1066–1072.
110. Cadenaro M, Breschi L, Rueggeberg FA, et al. Effect of adhesive hydro-philicity and curing time on the permeability of resins bonded to water vs. ethanol-saturated acid-etched dentin. Dent Mater 2009;25:39–47.
111. Park SH, Roulet JF, Heintze SD. Parameters influencing increase in pulp chamber temperature with light-curing devices: Curing lights and pulpal flow rates. Oper Dent 2010;35:353–361.
112. Tay FR, Pashley DH. Have dentin adhesives become too hydrophilic? J Can Dent Assoc 2003;69:726–731.
113. Van Meerbeek B, Peumans M, Poitevin A, et al. Relationship between bond-strength tests and clinical outcomes. Dent Mater 2010;26:e100–e121.
114. Tay FR, Frankenberger R, Krejci I, et al. Single-bottle adhesives behave as permeable membranes after polymerization. I. In vivo evidence. J Dent 2004;32:611–621.
115. Cadenaro M, Antoniolli F, Sauro S, et al. Degree of conversion and permeability of dental adhesives. Eur J Oral Sci 2005;113:525–530.
116. Chersoni S, Suppa P, Breschi L, et al. Water movement in the hybrid layer after different dentin treatments. Dent Mater 2004;20:796–803.
117. Holmes RG, Rueggeberg FA, Callan RS, et al. Effect of solvent type and content on monomer conversion of a model resin system as a thin film. Dent Mater 2007;23:1506–1512.
118. Ye Q, Wang Y, Williams K, Spencer P. Characterization of photopolymerization of dentin adhesives as a function of light source and irradiance. J Biomed Mater Res 2007;80:440–446.
119. Wang Y, Spencer P, Yao X, Ye Q. Effect of coinitiator and water on the photoreactivity and photopolymerization of HEMA/camphoquinone-based reactant mixtures. J Biomed Mater Res A 2006;78:721–728.
120. Paul SJ, Leach M, Rueggeberg FA, Pashley DH. Effect of water content on the physical properties of model dentine primer and bonding resins. J Dent 1999;27:209–214.
121. Spencer P, Wang Y. Adhesive phase separation at the dentin interface under wet bonding conditions. J Biomed Mater Res 2002;62:447–456.
122. Wang Y, Spencer P. Hybridization efficiency of the adhesive/dentin interface with wet bonding. J Dent Res 2003;82:141–145.
123. Spencer P, Wang Y, Walker MP, Wieliczka DM, Swafford JR. Interfacial chemistry of the dentin/adhesive bond. J Dent Res 2000;79:1458–1463.
124. Spencer P, Ye Q, Park J, et al. Adhesive/dentin interface: The weak link in the composite restoration. Ann Biomed Eng 2010;38:1989–2003.
125. Hashimoto M, Tay FR, Sano H, Kaga M, Pashley DH. Diffusion-induced water movement within resin-dentin bonds during bonding. J Biomed Mater Res 2006;79:453–458.
126. de Carvalho Cardoso P, Loguercio AD, Vieira LC, Baratieri LN, Reis A. Effect of prolonged application times on resin-dentin bond strengths. J Adhes Dent 2005;7:143–149.
127. Reis A, de Carvalho Cardoso P, Vieira LC, Baratieri LN, Grande RH, Loguercio AD. Effect of prolonged application times on the durability of resin-dentin bonds. Dent Mater 2008;24:639–644.
128. Velasquez LM, Sergent RS, Burgess JO, Mercante DE. Effect of placement agitation and placement time on the shear bond strength of 3 self-etching adhesives. Oper Dent 2006;31:426–430.
129. Reis A, Ferreira SQ, Costa TR, Klein-Júnior CA, Meier MM, Loguercio AD. Effects of increased exposure times of simplified etch-and-rinse adhesives on the degradation of resin-dentin bonds and quality of the polymer network. Eur J Oral Sci 2010;118:502–509.

Dentlearn.ir

130. Dal-Bianco K, Pellizzaro A, Patzlaft R, de Oliveira Bauer JR, Loguercio AD, Reis A. Effects of moisture degree and rubbing action on the immediate resin-dentin bond strength. Dent Mater 2006;22:1150–1156.
131. Reis A, Pellizzaro A, Dal-Bianco K, Gones OM, Patzlaff R, Loguercio AD. Impact of adhesive application to wet and dry dentin on long-term resin-dentin bond strengths. Oper Dent 2007;32:380–387.
132. Higashi C, Michel MD, Reis A, Loguercio AD, Gomes OM, Gomes JC. Impact of adhesive application and moisture on the mechanical properties of the adhesive interface determined by the nano-indentation technique. Oper Dent 2009;34:51–57.
133. Loguercio AD, Raffo J, Bassani F, et al. 24-month clinical evaluation in non-carious cervical lesions of a two-step etch-and-rinse adhesive applied using a rubbing motion. Clin Oral Investig 2010;15:589–596.
134. Ikeda T, De Munck J, Shirai K, et al. Effect of evaporation of primer components on ultimate tensile strengths of primer-adhesive mixture. Dent Mater 2005;21:1051–1058.
135. Ikeda T, De Munck J, Shirai K, et al. Effect of air-drying and solvent evaporation on the strength of HEMA-rich versus HEMA-free one-step adhesives. Dent Mater 2008;24:1316–1323.
136. Pashley EL, Zhang Y, Lockwood PE, Rueggeberg FA, Pashley DH. Effects of HEMA on water evaporation from water-HEMA mixtures. Dent Mater 1998;14:6–10.
137. Hilton T, Schwartz R, Ferracane J. Fifth-generation bonding agent application technique effects on bond strength [abstract 214]. J Dent Res 1998;77(suppl 1):132.
138. Reis A, Klein-Júnior CA, de Souza FHC, Stanislawczuk R, Loguercio AD. The use of warm air stream for solvent evaporation: Effects on the durability of resin-dentin bonds. Oper Dent 2010;35:29–36.
139. Brännström M, Aström A. The hydrodynamics of the dentine; its possible relationship to dentinal pain. Int Dent J 1972;22:219–227.
140. Abate PF, Rodriguez VI, Macchi RI. Evaporation of solvent in one-bottle adhesives. J Dent 2000;28:437–440.
141. Perdigão J, Swift EJ, Lopes GC. Effects of repeated use on bond strengths of one-bottle adhesives. Quintessence Int 1999;30:819–823.
142. Unemori M, Matsuya Y, Akashi A, Goto Y, Akamine A. Self-etching adhesives and postoperative sensitivity. Am J Dent 2004;17:191–195.
143. Perdigão J, Geraldeli S, Hodges JS. Total-etch versus self-etch adhesive: Effect on postoperative sensitivity. J Am Dent Assoc 2003;134:1621–1629.
144. Van Meerbeek B, Dhem A, Goret-Nicaise M, Braem M, Lambrechts P, Vanherle G. Comparative SEM and TEM examination of the ultrastruc-ture of the resin-dentin interdiffusion zone. J Dent Res 1993;72:495–501.
145. Swift EJ, Ritter AV, Heymann HO, Sturdevant JR, Wilder AD. 36-month clinical evaluation of two adhesives and microhybrid resin composites in Class I restorations. Am J Dent 2008;21:148–152.
146. Van Landuyt KL, Peumans M, Fieuws S, et al. A randomized controlled clinical trial of a HEMA-free all-in-one adhesive in non-carious cervical lesions at 1 year. J Dent 2008;36:847–855.
147. Browning WD, Blalock JS, Callan RS, et al. Postoperative sensitivity: A comparison of two bonding agents. Oper Dent 2007;32:112–117.
148. Perdigão J, Anauate-Netto C, Carmo AR, et al. The effect of adhesive and flowable composite on postoperative sensitivity: 2-week results. Quintessence Int 2004;35:777–784.
149. Peumans M, Kanumilli P, De Munck J, Van Landuyt K, Lambrechts P, Van Meerbeek B. Clinical effectiveness of contemporary adhesives: A systematic review of current clinical trials. Dent Mater 2005;21:864–881.
150. Hannig M, Reinhardt KJ, Bott B. Self-etching primer vs phosphoric acid: An alternative concept for composite-to-enamel bonding. Oper Dent 1999;24:172–180.
151. Perdigão J, Lopes L, Lambrechts P, Leitão J, Van Meerbeek B, Vanherle G. Effects of a self-etching primer on enamel shear bond strengths and SEM morphology. Am J Dent 1997;10:141–146.
152. Hannig M, Bock H, Bott B, Hoth-Hannig W. Inter-crystallite nanoretention of self-etching adhesives at

153. Breschi L, Gobbi P, Falconi M, Mazzotti G, Prati C, Perdigão J. Ultra-morphology of self-etching adhesives

Dentlearn.ir

on ground enamel: A high resolution SEM study. Am J Dent 2003;16(special issue):57A–62A.
154. Pashley DH, Tay FR. Aggressiveness of contemporary self-etching adhesives. Part II: Etching effects on unground enamel. Dent Mater 2001;17:430–444.
155. Mine A, De Munck J, Vivan Cardoso M, et al. Enamel-smear compromises bonding by mild self-etch adhesives. J Dent Res 2010;89:1505–1509.
156. Peumans M, De Munck J, Van Landuyt KL, Poitevin A, Lambrechts P, Van Meerbeek B. Eight-year clinical evaluation of a 2-step self-etch adhesive with and without selective enamel etching. Dent Mater 2010;26:1176–1184.
157. Erickson RL, Barkmeier WW, Kimmes NS. Bond strength of self-etch adhesives to pre-etched enamel. Dent Mater 2009;25:1187–1194.
158. Frankenberger R, Lohbauer U, Roggendorf MJ, Naumann M, Taschner M. Selective enamel etching reconsidered: Better than etch-and-rinse and self-etch? J Adhes Dent 2008;10:339–344.
159. Taschner M, Nato F, Mazzoni A, et al. Role of preliminary etching for one-step self-etch adhesives. Eur J Oral Sci 2010;118:517–524.
160. De Munck J, Van Meerbeek B, Satoshi I, et al. Microtensile bond strengths of one- and two-step self-etch adhesives to bur-cut enamel and dentin. Am J Dent 2003;16:414–420.
161. Wang Y, Spencer P. Continuing etching of an all-in-one adhesive in wet dentin tubules. J Dent Res 2005;84:350–354.
162. Mine A, De Munck J, Cardoso MV, et al. Bonding effectiveness of two contemporary self-etch adhesives to enamel and dentin. J Dent 2009;37:872–883.
163. Yoshida Y, Van Meerbeek B, Nakayama Y, et al. Adhesion to and decalcification of hydroxyapatite by carboxylic acids. J Dent Res 2001;80: 1565–1569.
164. Fukegawa D, Hayakawa S, Yoshida Y, Suzuki K, Osaka A, Van Meerbeek B. Chemical interaction of phosphoric acid ester with hydroxyapatite. J Dent Res 2006;85:941–944.
165. Yoshida Y, Nagakane K, Fukuda R, et al. Comparative study on adhesive performance of functional monomers. J Dent Res 2004;83:454–458.
166. Van Landuyt KL, Kanumilli P, De Munck J, Peumans M, Lambrechts P, Van Meerbeek B. Bond strength of a mild self-etch adhesive with and without prior acid-etching. J Dent 2006;34:77–85.
167. Erhardt MC, Osorio R, Pisani-Proença J, et al. Effect of double layering and prolonged application time on MTBS of water/ethanol-based self-etch adhesives to dentin. Oper Dent 2009;34:571–577.
168. Torii Y, Itou K, Nishitani Y, Ishikawa K, Suzuki K. Effect of phosphoric acid etching prior to self-etching primer application on adhesion of resin composite to enamel and dentin. Am J Dent 2002;15:305–308.
169. Erhardt MC, Cavalcante LM, Pimenta LA. Influence of phosphoric acid pretreatment on self-etching bond strengths. J Esthet Restor Dent 2004;16:33–40.
170. Van Landuyt KL, Peumans M, De Munck J, Lambrechts P, Van Meerbeek B. Extension of a one-step self-etch adhesive into a multi-step adhesive. Dent Mater 2006;22:533–544.
171. Van Meerbeek B, Kanumilli P, De Munck J, Van Landuyt K, Lambrechts P, Peumans M. A randomized controlled study evaluating the effectiveness of a two-step self-etch adhesive with and without selective phosphoric-acid etching of enamel. Dent Mater 2005;21:375–383.
172. Kubo S, Kawasaki K, Yokota H, Hayashi Y. Five-year clinical evaluation of two adhesive systems in non-carious cervical lesions. J Dent 2006; 34:97–105.
173. Moszner N, Salz U, Zimmermann J. Chemical aspects of self-etching enamel-dentin adhesives: A systematic review. Dent Mater 2005;21: 895–910.
174. Tay FR, Pashley DH, Suh BI, Carvalho RM, Itthagarun A. Single-step adhesives are permeable membranes. J Dent 2002;30:371–382.
175. Chersoni S, Suppa P, Grandini S, et al. In vivo and in vitro permeability of one-step self-etch adhesives. J Dent Res 2004;83:459–464.
176. Wang Y, Spencer P, Hager C, Bohaty B. Comparison of interfacial characteristics of adhesive bonding to superficial versus deep dentine using SEM and staining techniques. J Dent 2006;34:26–34.
177. Tay FR, Pashley DH, Yoshiyama M. Two modes of nanoleakage expression in single-step adhesives. J

Dentlearn.ir

Dent Res 2002;81:472–476.
178. Tay FR, Pashley DH. Water treeing—A potential mechanism for degradation of dentin adhesives. Am J Dent 2003;16:6–12.
179. De Munck J, Van Landuyt K, Coutinho E, et al. Micro-tensile bond strength of adhesives bonded to Class-I cavity-bottom dentin after thermo-cycling. Dent Mater 2005;21:999–1007.
180. King NM, Tay FR, Pashley DH, et al. Conversion of one-step to two-step self-etch adhesives for improved efficacy and extended application. Am J Dent 2005;18:126–134.
181. Reis A, Albuquerque M, Pegoraro M, et al. Can the durability of one-step self-etch adhesives be improved by double application or by an extra layer of hydrophobic resin? J Dent 2008;36:309–315.
182. Pashley EL, Agee KA, Pashley DH, Tay FR. Effects of one versus two applications of an unfilled, all-in-one adhesive on dentine bonding. J Dent 2002;30:83–90.
183. Do Amaral RC, Stanislawczuk R, Zander-Grande C, Michel MD, Reis A, Loguercio AD. Active application improves the bonding performance of self-etch adhesives to dentin. J Dent 2009;37:82–90.
184. Loguercio AD, Stanislawczuk R, Mena-Serrano A, Reis A. Effect of 3-year water storage on the performance of one-step self-etch adhesives applied actively on dentine. J Dent 2011;39:578–587.
185. Do Amaral RC, Stanislawczuk R, Zander-Grande C, Gagler D, Reis A, Loguercio AD. Bond strength and quality of the hybrid layer of one-step self-etch adhesives applied with agitation on dentin. Oper Dent 2010;35:211–219.
186. Albuquerque M, Pegoraro M, Mattei G, Reis A, Loguercio AD. Effect of double-application or the application of a hydrophobic layer for improved efficacy of one-step self-etch systems in enamel and dentin. Oper Dent 2008;33:564–570.
187. Belli R, Sartori N, Peruchi LD, et al. Effect of multiple coats of ultra-mild all-in-one adhesives on bond strength to dentin covered with two different smear layer thicknesses. J Adhes Dent 2011;13:507–516.
188. Mena-Serrano A, Kose C, De Paula EA, et al. A new universal simplified adhesive: 6-month clinical evaluation. J Esthet Restor Dent 2013;25: 55–69.
189. Perdigão J, Sezinando A, Monteiro PC. Laboratory bonding ability of a multi-purpose dentin adhesive. Am J Dent 2012;25:153–158.
190. Muñoz MA, Luque I, Hass V, Reis A, Loguercio AD, Bombarda NH. Immediate bonding properties of universal adhesives to dentine. J Dent 2013;41:404–411.
191. Burgess J, Shah S, Cakir D, Bekc P, Ramp L. Shear bond strength to restorative materials and tooth structure. Presented at the 41st Annual Meeting of the American Association for Dental Research, Tampa, 23 March 2012.
192. Kadoma Y. Surface treatment agent for dental metals using a thirane monomer and a phosphoric acid monomer. Dent Mater J 2002;21: 156–169.
193. Chen L, Suh BI, Brown D, Chen X. Bonding of primed zirconia ceramics: Evidence of chemical bonding and improved bond strengths. Am J Dent 2012;25:103–108.
194. Yoshida Y, Yoshihara K, Nagaoka N, et al. Self-assembled nano-layering at the adhesive interface. J Dent Res 2012;91:376–381.
195. Barros JA, Myaki SI, Nör JE, Peters MC. Effect of bur type and conditioning on the surface and interface of dentine. J Oral Rehabil 2005;32:849–856.
196. Oliveira SS, Pugach MK, Hilton JF, Watanabe LG, Marshall SJ, Marshall GW Jr. The influence of the dentin smear layer on adhesion: A self-etching primer vs. a total-etch system. Dent Mater 2003;19:758–767.
197. Dias WR, Pereira PN, Swift EJ. Effect of bur type on microtensile bond strengths of self-etching systems to human dentin. J Adhes Dent 2004;6:195–203.
198. Tao L, Pashley DH, Boyd L. Effect of different types of smear layers on dentin and enamel shear bond strengths. Dent Mater 1988;4:208–216.
199. Senawongse P, Srihanon A, Muangmingsuk A, Harnirattisai C. Effect of dentine smear layer on the performance of self-etching adhesive systems: A micro-tensile bond strength study. J Biomed Mater Res 2010; 94:212–221.
200. Koibuchi H, Yasuda N, Nakabayashi N. Bonding to dentin with a self-etching primer: The effect of smear

Dentlearn.ir

layers. Dent Mater 2001;17:122–126.
201. Shinoda Y, Nakajima M, Hosaka K, Otsuki M, Foxton RM, Tagami J. Effect of smear layer characteristics on dentin bonding durability of HEMA-free and HEMA-containing one-step self-etch adhesives. Dent Mater J 2011;30:501–510.
202. Ermis RB, De Munck J, Cardoso MV, et al. Bond strength of self-etch adhesives to dentin prepared with three different diamond burs. Dent Mater 2008;24:978–985.
203. McCabe JF, Walls A (eds). Applied Dental Materials, ed 9. Hoboken, NJ: Wiley-Blackwell, 2008.
204. Walls AW. Glass polyalkenoate (glass-ionomer) cements: A review. J Dent 1986;14:231–246.
205. Yip HK, Tay FR, Ngo HC, Smales RJ, Pashley DH. Bonding of contemporary glass ionomer cements to dentin. Dent Mater 2001;17:456–470.
206. Inoue S, Van Meerbeek B, Abe Y, et al. Effect of remaining dentin thickness and the use of conditioner on micro-tensile bond strength of a glass-ionomer adhesive. Dent Mater 2001;17:445–455.
207. Coutinho E, Yoshida Y, Inoue S, et al. Gel phase formation at resin-modified glass-ionomer/tooth interfaces. J Dent Res 2007;86:656–661.
208. Mount GJ. An Atlas of Glass-Ionomer Cements: A Clinician's Guide. London: Martin Dunitz, 2002.
209. Ferrari M, Cagidiaco MC, Grandini S, De Sanctis M, Goracci C. Post placement affects survival of endodontically treated premolars. J Dent Res 2007;86:729–734.
210. Cagidiaco MC, Goracci C, García-Godoy F, Ferrari M. Clinical studies of fiber posts: A literature review. Int J Prosthodont 2008;21:328–336.
211. Radovic I, Mazzitelli C, Chieffi N, Ferrari M. Evaluation of the adhesion of fiber posts cemented using different adhesive approaches. Eur J Oral Sci 2008;116:557–563.
212. Mazzoni A, Marchesi G, Cadenaro M, et al. Push-out stress for fibre posts luted using different adhesive strategies. Eur J Oral Sci 2009; 117:447–453.
213. Breschi L, Mazzoni A, De Stefano Dorigo E, Ferrari M. Adhesion to intraradicular dentin: A review. J Adhes Sci Technol 2009;23:1053–1083.
214. Simonetti M, Radovic I, Vano M, et al. The influence of operator variability on adhesive cementation of fiber posts. J Adhes Dent 2006; 8:421–425.
215. Mjör IA, Smith MR, Ferrari M, Mannocci F. The structure of dentine in the apical region of human teeth. Int Endod J 2001;34:346–353.
216. Ferrari M, Mannocci F, Vichi A, Cagidiaco MC, Mjör IA. Bonding to root canal: Structural characteristics of the substrate. Am J Dent 2000;13: 255–260.
217. Ferrari M, Carvalho CA, Goracci C, et al. Influence of luting material filler content on post cementation. J Dent Res 2009;88:951–956.
218. Schwartz RS, Fransman R. Adhesive dentistry and endodontics: Materials, clinical strategies and procedures for restoration of access cavities: A review. J Endod 2005;31:151–165.
219. Schwartz RS. Adhesive dentistry and endodontics. Part 2: Bonding in the root canal system—The promise and the problems: A review. J Endod 2006;32:1125–1134.
220. Violich DR, Chandler NP. The smear layer in endodontics—A review. Int Endod J 2010;43:2–15.
221. Haapasalo M, Shen Y, Qian W, Gao Y. Irrigation in endodontics. Dent Clin North Am 2010;54:291–312.
222. Torabinejad M, Handysides R, Khademi AA, Bakland LK. Clinical implications of the smear layer in endodontics: A review. Oral Surg Oral Med Oral Pathol Oral Radiol Endod 2002;94:658–666.
223. Goracci C, Sadek FT, Fabianelli A, Tay FR, Ferrari M. Evaluation of the adhesion of fiber posts to intraradicular dentin. Oper Dent 2005;30:627–635.
224. Boone KJ, Murchison DF, Schindler WG, Walker WA. Post retention: The effect of sequence of post-space preparation, cementation time, and different sealers. J Endod 2001;27:768–771.
225. Serafino C, Gallina G, Cumbo E, Ferrari M. Surface debris of canal walls after post space preparation in endodontically treated teeth: A scanning electron microscopic study. Oral Surg Oral Med Oral Pathol Oral Radiol Endod 2004;97:381–387.
226. Serafino C, Gallina G, Cumbo E, Monticelli F, Goracci C, Ferrari M. Ultrasound effects after post space preparation: An SEM study. J Endod 2006;32:549–552.

Dentlearn.ir

227. Coniglio I, Magni E, Goracci C, et al. Post space cleaning using a new nickel titanium endodontic drill combined with different cleaning regimens. J Endod 2008;34:83–86.
228. Ari H, Erdemir A, Belli S. Evaluation of the effect of endodontic irrigation solutions on the microhardness and the roughness of root canal dentin. J Endod 2004;30:792–795.
229. Ari H, Yaşar E, Belli S. Effects of NaOCl on bond strengths of resin cements to root canal dentin. J Endod 2003;29:248–251.
230. Erdemir A, Ari H, Güngüneş H, Belli S. Effect of medications for root canal treatment on bonding to root canal dentin. J Endod 2004;30:113–116.
231. Morris MD, Lee KW, Agee KA, Bouillaguet S, Pashley DH. Effects of sodium hypochlorite and RC-prep on bond strengths of resin cement to endodontic surfaces. J Endod 2001;27:753–757.
232. Saleh AA, Ettman WM. Effect of endodontic irrigation solutions on microhardness of root canal dentine. J Dent 1999;27:43–46.
233. Nikaido T, Takano Y, Sasafuchi Y, Burrow MF, Tagami J. Bond strengths to endodontically-treated teeth. Am J Dent 1999;12:177–180.
234. Kim SK, Kim YO. Influence of calcium hydroxide intracanal medication on apical seal. Int Endod J 2002;35:623–628.
235. Kielbassa AM, Attin T, Hellwig E. Diffusion behavior of eugenol from zinc oxide-eugenol mixtures through human and bovine dentin in vitro. Oper Dent 1997;22:15–20.
236. Carvalho CN, de Oliveira Bauer JR, Loguercio AD, Reis A. Effect of ZOE temporary restoration on resin-dentin bond strength using different adhesive strategies. J Esthet Restor Dent 2007;19:144–152.
237. Arcari GM, Araújo E, Baratieri LN, Lopes GC. Microtensile bond strength of a nanofilled composite resin to human dentin after nonvital tooth bleaching. J Adhes Dent 2007;9:333–340.
238. Erdemir A, Eldeniz AU, Belli S, Pashley DH. Effect of solvents on bonding to root canal dentin. J Endod 2004;30:589–592.
239. Elkhatib H, Nakajima M, Hiraishi N, Kitasako Y, Tagami J, Nomura S. Surface pH and bond strength of a self-etching primer/adhesive system to intracoronal dentin after application of hydrogen peroxide bleach with sodium perborate. Oper Dent 2003;28:591–597.
240. Cadenaro M, Breschi L, Antoniolli F, Mazzoni A, Di Lenarda R. Influence of whitening on the degree of conversion of dental adhesives on dentin. Eur J Oral Sci 2006;114:257–262.
241. Tay FR, Pashley DH, Yiu CKY, Sanares AME, Wei SHY. Factors contributing to the incompatibility between simplified-step adhesives and chemically-cured or dual-cured composites. Part I. Single-step self-etching adhesive. J Adhes Dent 2003;5:27–40.
242. Cheong C, King NM, Pashley DH, Ferrari M, Toledano M, Tay FR. Incompatibility of self-etch adhesives with chemical/dual-cured composites: Two-step vs one-step systems. Oper Dent 2003;28:747–755.
243. Tay FR, Suh BI, Pashley DH, Prati C, Chuang SF, Li F. Factors contributing to the incompatibility between simplified-step adhesives and self-cured or dual-cured composites. Part II. Single-bottle, total-etch adhesive. J Adhes Dent 2003;5:91–105.
244. Suh BI, Feng L, Pashley DH, Tay FR. Factors contributing to the incompatibility between simplified-step adhesives and chemically-cured or dual-cured composites. Part III. Effect of acidic resin monomers. J Adhes Dent 2003;5:267–282.
245. Tay FR, Loushine RJ, Lambrechts P, Weller RN, Pashley DH. Geometric factors affecting dentin bonding in root canals: A theoretical modeling approach. J Endod 2005;31:584–589.
246. Feilzer AJ, De Gee AJ, Davidson CL. Setting stress in composite resin in relation to configuration of the restoration. J Dent Res 1987;66:1636–1639.
247. Davidson CL, Feilzer AJ. Polymerization shrinkage and polymerization shrinkage stress in polymer-based restoratives. J Dent 1997;25:435–440.
248. Dauvillier BS, Feilzer AJ, De Gee AJ, Davidson CL. Visco-elastic parameters of dental restorative materials during setting. J Dent Res 2000; 79:818–823.
249. Braga RR, Boaro LC, Kuroe T, Azevedo CL, Singer JM. Influence of cavity dimensions and their derivatives (volume and "C" factor) on shrinkage stress development and microleakage of composite

Dentlearn.ir

restorations. Dent Mater 2006;22:818–823.
250. Bouillaguet S, Troesch S, Wataha JC, Krejci I, Meyer JM, Pashley DH. Microtensile bond strength between adhesive cements and root canal dentin. Dent Mater 2003;19:199–205.
251. Salz U, Bock T. Testing adhesion of direct restoratives to dental hard tissue—A review. J Adhes Dent 2010;12:343–371.
252. Scherrer SS, Cesar PF, Swain MV. Direct comparison of the bond strength results of the different test methods: A critical literature review. Dent Mater 2010;26:e78–e93.
253. Dickens SH, Milos MF. Relationship of dentin shear bond strengths to different laboratory test designs. Am J Dent 2002;15:185–192.
254. Burke FJ, Hussain A, Nolan L, Fleming GJ. Methods used in dentine bonding tests: An analysis of 102 investigations on bond strength. Eur J Prosthodont Restor Dent 2008;16:158–165.
255. Versluis A, Tantbirojn D, Douglas WH. Why do shear bond tests pull out dentin? J Dent Res 1997;76:1298–1307.
256. Pashley DH, Sano H, Ciucchi B, Yoshiyama M, Carvalho RM. Adhesion testing of dentin bonding agents: A review. Dent Mater 1995;11:117–125.
257. van Noort R, Noroozi S, Howard IC, Cardew G. A critique of bond strength measurements. J Dent 1989;17:61–67.
258. DeHoff PH, Anusavice KJ, Wang Z. Three-dimensional finite element analysis of the shear bond test. Dent Mater 1995;11:126–131.
259. Mota CS, Demarco FF, Camacho GB, Powers JM. Tensile bond strength of four resin luting agents bonded to bovine enamel and dentin. J Prosthet Dent 2003;89:558–564.
260. Kern M, Barloi A, Yang B. Surface conditioning influences zirconia ceramic bonding. J Dent Res 2009;88:817–822.
261. Abreu A, Loza MA, Elias A, Mukhopadhyay S, Looney S, Rueggeberg FA. Tensile bond strength of an adhesive resin cement to different alloys having various surface treatments. J Prosthet Dent 2009;101:107–118.
262. Hull D, Clyne TW. An Introduction to Composite Materials, ed 2, Cambridge Solid State Science Series. Cambridge: Cambridge University Press, 1996.
263. Carvalho CA, Monticelli F, Cantoro A, Breschi L, Ferrari M. Push-out bond strength of fiber posts luted with unfilled resin cement. J Adhes Dent 2009;11:65–70.
264. Goracci C, Tavares AU, Fabianelli A, et al. The adhesion between fiber posts and root canal walls: Comparison between microtensile and push-out bond strength measurements. Eur J Oral Sci 2004;112:353–361.
265. Matthews F, Rawlings R. Composite Materials: Engineering and Science. Cambridge: Woodhead, 1999.
266. Neves A de A, Coutinho E, Poitevin A, Van der Sloten J, Van Meerbeek B, Van Oosterwyck H. Influence of joint component mechanical properties and adhesive layer thickness on stress distribution in micro-tensile bond strength specimens. Dent Mater 2009;25:4–12.
267. Neves A de A, Coutinho E, Cardoso MV, et al. Influence of notch geometry and interface on stress concentration and distribution in micro-tensile bond strength specimens. J Dent 2008;36:808–815.
268. Hashimoto M, Ohno H, Sano H, Kaga M, Oguchi H. In vitro degradation of resin-dentin bonds analyzed by
269. Eliades G, Vougiouklakis G, Palaghias G. Heterogeneous distribution of single-bottle adhesive monomers in the resin-dentin interdiffusion zone. Dent Mater 2001;17:277–283.
270. Gale MS, Darvell BW. Thermal cycling procedures for laboratory testing of dental restorations. J Dent 1999;27:89–99.
271. Tay FR, Pashley DH, Suh BI, Hiraishi N, Yiu CK. Water treeing in simplified dentin adhesives—Déjà vu? Oper Dent 2005;30:561–579.
272. Ito S, Hashimoto M, Wadgaonkar B, et al. Effects of resin hydrophilicity on water sorption and changes in modulus of elasticity. Biomaterials 2005;26:6449–6459.
273. Tay FR, Hashimoto M, Pashley DH, et al. Aging affects two modes of nanoleakage expression in bonded dentin. J Dent Res 2003;82:537–541.
274. Cadenaro M, Breschi L, Antoniolli F, et al. Degree of conversion of resin blends in relation to ethanol

Dentlearn.ir

content and hydrophilicity. Dent Mater 2008;24:1194–1200.
275. Suppa P, Breschi L, Ruggeri A, et al. Nanoleakage within the hybrid layer: A correlative FEISEM/TEM investigation. J Biomed Mater Res B 2005;73:7–14.
276. Yiu CK, Pashley EL, Hiraishi N, et al. Solvent and water retention in dental adhesive blends after evaporation. Biomaterials 2005;26:6863–6872.
277. Lee W, Aitken S, Sodek J, McCulloch CA. Evidence of a direct relationship between neutrophil collagenase activity and periodontal tissue destruction in vivo: Role of active enzyme in human periodontitis. J Periodontal Res 1995;30:23–33.
278. Tjäderhane L, Larjava H, Sorsa T, Uitto VJ, Larmas M, Salo T. The activation and function of host matrix metalloproteinases in dentin matrix breakdown in caries lesions. J Dent Res 1998;77:1622–1629.
279. Pashley DH, Tay FR, Yiu C, et al. Collagen degradation by host-derived enzymes during aging. J Dent Res 2004;83:216–221.
280. Mazzoni A, Mannello F, Tay FR, et al. Zymographic analysis and characterization of MMP-2 and -9 forms in human sound dentin. J Dent Res 2007;86:436–440.
281. Mazzoni A, Pashley DH, Tay FR, et al. Immunohistochemical identification of MMP-2 and MMP-9 in human dentin: Correlative FEI-SEM/TEM analysis. J Biomed Mater Res A 2009;88:697–703.
282. Mazzoni A, Carrilho M, Papa V, et al. MMP-2 assay within the hybrid layer created by a two-step etch-and-rinse adhesive: Biochemical and immunohistochemical analysis. J Dent 2011;39:470–477.
283. Visse R, Nagase H. Matrix metalloproteinases and tissue inhibitors of metalloproteinases: Structure, function, and biochemistry. Circ Res 2003;92:827–839.
284. Breschi L, Martin P, Mazzoni A, et al. Use of a specific MMP-inhibitor (galardin) for preservation of hybrid layer. Dent Mater 2010;26:571–578.
285. Tersariol IL, Geraldeli S, Minciotti CL, et al. Cysteine cathepsins in human dentin-pulp complex. J Endod 2010;36:475–481.

Dentlearn.ir



Direct Anterior Restorations

Marcos A. Vargas
Cathia Bergeron
David F. Murchison
Joost Roeters
Daniel C. N. Chan

As esthetic awareness grows and becomes more important throughout our society, patients demand highly esthetic restorations. Esthetic restorative materials must blend into the natural dentition by simulating the natural tooth in color, translucence, form, and texture yet also have adequate strength and wear characteristics, good marginal adaptation and sealing, insolubility, and biocompatibility. These materials must also remain color stable and maintain external tooth morphology to provide a functional, lasting esthetic restoration.[1] This chapter addresses the materials and clinical procedures used to place direct functional esthetic restorations in anterior teeth.

Resin composites, also called *resin-based composites*, *composite resins*, or simply *composites*, are by far the most commonly used restorative materials in the anterior region of the mouth.[2] Resin composites are currently the direct restorative materials that best fulfill the requirements of tooth preservation, excellent esthetics,

Dentlearn.ir

and durability. Resin composites may be used for the treatment of caries and tooth defects as well as for solving esthetic problems like diastemata, peg-shaped lateral incisors, misaligned teeth, and discolorations. Nonetheless, resin composites present some disadvantages: *(1)* they shrink during polymerization, *(2)* they require good isolation for proper bonding, *(3)* they are less resistant to wear than ceramics, *(4)* they are prone to chipping, *(5)* they do not bond as well to dentin and root surfaces as they do to enamel, and *(6)* they do not have antibacterial properties.[3]

Studies assessing the clinical longevity of resin composite as an anterior restorative material have found that 60% to 80% of all Class 3 and Class 5 restorations remain acceptable after 5 years. The most common reasons for repair or replacement of anterior composite restorations are marginal staining, surface discoloration, secondary caries, edge chipping in high-stress areas, and/or fracture of the restoration.[4–9] Class 4 composite restorations placed on fractured teeth present shorter longevity than Class 3 or Class 5 restorations because they are submitted to more stress from occlusal function.[10,11] The most common variables influencing the survival of anterior composite restorations are reported to be the individual practitioner, the location and size of the restoration, the patient age and caries risk, and the bonding substrate.[12–14]

Material Considerations

Resin composites

Resin composites contain four structural components: polymer matrix, filler particles, a coupling agent, and an initiator system. The *matrix* is the continuous phase to which the other ingredients are added. Most resin composite matrices are based on the bisphenol glycidyl methacrylate (bis-GMA) resin developed by R. L. Bowen of the National Institute of Standards and Technology and patented in 1962. Some resin composites use urethane dimethacrylate (UDMA) instead of bis-GMA, while many now use a combination of the two materials. Because of the high viscosity of bis-GMA, manufacturers typically add a low-viscosity monomer, such as triethylene glycol dimethacrylate (TEGDMA), as a polymerizable diluent. Recent progress in resin composite formulation includes the development of new monomers with reduced polymerization shrinkage or shrinkage stress and the incorporation of adhesive monomers to make self-adhesive composites.[3]

Filler particles are usually a type of radiopaque glass, zirconium oxide,

Dentlearn.ir

aluminum oxide, or silicon dioxide added to the matrix to improve the physical properties of the final composite. The filler improves translucency; reduces the coefficient of thermal expansion; reduces polymerization shrinkage of the composite; and makes the material stronger, harder, denser, and more resistant to wear. Generally, the greater the percentage of filler added (by volume or weight), the better the physical properties of the resin composite. However, filler loading has an upper limit, after which the material becomes too viscous for clinical use.

The filler particles are coated with an *organosilane*, a coupling agent capable of producing chemical bonding to the filler particles and the resin matrix. Without a coupling agent, the strength of the cohesive mass is reduced, and the filler particles tend to be lost, or "plucked," from the surface as preferential wear occurs in the softer surrounding resin matrix.[15]

Activation of the curing reaction may be accomplished by mixing two composite components (ie, autocuring or self-curing composites) or by exposing a single component to light of the proper wavelength (ie, light-cured composite). For self-curing materials, the first type of composites developed, one composite paste contains an initiator, typically benzoyl peroxide, which when attached by an amine molecule from the second paste splits into two active free radical molecules capable of initiating the polymerization reaction of methacrylate monomers. The more popular light-cured composites require a photoinitiator to activate the polymerization reaction, with camphorquinone being the most commonly used molecule. Current resin composite restorative materials require exposure to visible light, with most of the energy delivered in the range of 460 to 480 nm (blue light), which is the portion of the visible spectrum in which camphorquinone is most sensitive. The photoinitiation is most efficient when an amine molecule is also included in the formulation to act as a type of accelerator in the presence of the camphorquinone.

Light-cured resin composites are packaged in syringes or in unit doses. The main advantage of purchasing material in syringes is their lower cost. Unit doses allow insertion of the material directly into the preparation, minimizing trapped air bubbles.[16] The unit doses also make infection control procedures easier because they are discarded after use and require no disinfection. The use of syringes requires special attention during dispensing and handling. When dispensing, the material must be extruded in adequate amount and cut with a bladed instrument to avoid contamination from abrading or cutting the tip of the plastic syringe. Because the syringe is typically black to keep the material protected from external light, which would cause it to prematurely cure, small particles from the plastic syringe would

Dentlearn.ir

lead to a discoloring of the composite.

Physical characteristics

Resin composites have steadily improved through the years; they are now durable, esthetic, and predictable. Used in combination with an adhesive system, resin composites are reliably and durably bonded to dentin and enamel. Although adhesion to dentin is not yet as reliable as adhesion to enamel, advances in the understanding of dentin microstructure, permeability, and the bonded interface have steadily improved the quality and success of adhesive systems in recent years (see chapter 9).

Resin composites have several undesirable characteristics that must be overcome to achieve long-term clinical success. Volumetric shrinkage during polymerization is typically between 1.5% and 5.0%, which, when the material is placed into a bonded

stresses at the bonded tooth-composite interface, potentially leading to marginal defects.[17,18] Shrinkage stresses that occur in the early phase of polymerization when the composite is still relatively fluid are effectively relieved by deformation and flow of the material.[19] However, stresses occurring later in the process, after the material has acquired significant rigidity (called *gelation*), are not relieved by material flow. These residual stresses may leave the composite weakened and may reduce the adhesion to the tooth.[20,21] These stresses also may cause gap formation at the cavosurface margins, especially at those with the weakest bonds (usually dentin or cementum).[22] Marginal gaps may result in microleakage, sensitivity, staining at the margins of the restoration, and recurrent caries.[23–25] Investigations have determined that nanoleakage at the resin-dentin interface, as well as hydrolytic and enzymatic degradation of collagen bonds, contribute to a weakened adhesive interface over time.[26–28]

The use of incremental placement techniques, long enamel bevels, low-shrinkage materials, flexible resin liners, slow-setting resin-modified glass-ionomer liners, and modified light-curing protocols have all been recommended to help offset the effects of polymerization shrinkage and its stresses.[29–39] The *configuration factor* (*C-factor*) of a restoration, which is defined as the ratio of the bonded surface area to the nonbonded surface area of the restoration, influences the intensity of the stresses produced during polymerization. High C-factor preparations are conducive to high shrinkage stress compared with low C-factor preparations, because more of the composite is constrained and not free to flow or deform to relax stresses.[20,40]

Dentlearn.ir

Fortunately, for most anterior restorations the C-factor is favorable and stress at the adhesive interface is minimal. Additionally, the viscoelastic properties of the material influence shrinkage stress. High-stiffness materials will typically generate higher shrinkage stress, increasing the possibility of gap formation at the margins.

Resin composites have a coefficient of thermal expansion two to six times higher than that of tooth structure.[41] This means that resin composite expands and contracts more and at a greater rate than does tooth structure in response to changes in temperature. This mismatch may contribute to loss of adhesion and greater microleakage.[25] Over the years, significant improvements in adhesive systems have helped offset some of the inherent problems associated with resin composites.

Handling characteristics

An important factor for the clinician in the selection of a resin composite is the handling of the material. Ideally, resin composite materials should be soft and easily manipulated, should not stick to placement instruments and brushes, should adapt well to the cavity walls, and should not slump during placement. Handling is greatly influenced by the viscosity of the resin composite. According to their viscosity, resin materials adapt well to cavity walls, but they tend to be sticky and are prone to slump. When the viscosity is extremely low, as is the case with flowable resin composites, the risk of porosities inside the restoration increases if the material is not handled appropriately.[42] On the contrary, high-viscosity materials do not adapt to the tooth as easily and require careful attention during placement. Their use is advantageous because they are not sticky and maintain their shape during placement. Variation in the viscosity of resin composites does not always correlate directly with the filler content[43,44]; however, low-viscosity materials generally have lower filler loading. Differences in handling characteristics are also observed with variations in resin matrix chemistry, temperature, and humidity.[45–47]

Many instruments, offered in various shapes and surface coatings, are available for placing and shaping resin composite materials. The composition of a typical instrument kit contains a thin, flexible, bladed instrument; a small ovoid-shaped burnisher; a thin spatula; a concave-convex spatula; and different shapes of brushes (Fig 10-1). A gauze pad lightly moistened with alcohol may be used to clean the active part of the instrument during resin composite placement to prevent the material from sticking to the instrument. However, the alcohol should be allowed to evaporate from the instruments before contact with the resin material to avoid incorporating

Dentlearn.ir

alcohol into the composite. When using very sticky materials, it is recommended to use very small amounts of a purposely manufactured wetting resin to lubricate instruments (Fig 10-2). The use of these low-viscosity resins as lubricants must be tightly controlled because these materials could potentially dilute the resin composite and bring about a reduction in physical and mechanical properties.[48]



Fig 10-1 Commonly employed resin composite placement and contouring instruments and brushes.



Fig 10-2 Examples of wetting resins available on the market. They can be used in small amounts to lubricate instruments for easier manipulation of resin materials.

Optical characteristics

Modern resin composite kits sold by dental manufacturers contain multiple shades and various opacities for the purpose of matching shade and translucency of both enamel and dentin. This has facilitated the achievement of natural esthetics with resin composites. Unfortunately, there is great variability among materials and no consensus among manufacturers regarding nomenclature, shading, or degree of translucency/opacity.

The combination of optical properties from enamel and dentin provides the final appearance of normal tooth structure. These properties are modified by factors such as age, thickness of tooth tissue, and degree and quality of calcification. In a

Dentlearn.ir

"normal" unworn dentition, dentin provides chroma, opacity, and fluorescence. Enamel modifies the appearance of dentin by providing translucency and opalescence[49] (Fig 10-3).



Fig 10-3 Illustration emphasizing the differences in translucency for dentin *(left)* and enamel (overlay) *(right)* resin composite compositions. Applying layers with differing chroma and translucency and providing appropriate surface character can greatly enhance the lifelike appearance of anterior restorations.

Based on their optical properties, resin composite kits usually contain three types of materials: *(1)* a dentinlike material, designed to imitate the dentin's optical properties; *(2)* an enamel-like material, designed to simulate the enamel's optical properties; and *(3)* a translucent-like material, designed to mimic translucent areas of teeth. Manufacturers have various names for each type of material. Dentinlike materials may be called *opaque*, *dentin*, *body*, etc; enamel-like materials may be called *enamel*, *body*, etc; and translucent materials may be called *incisal*, *translucent*, etc. These different designations and names create confusion among practitioners. For a clear understanding of how to use a specific material, it is important for dentists to know what each name represents and the intended purpose of each system component.

When a single shade is used for a restoration, an intermediate opacity should be selected. Usually the manufacturer has designated the enamel-like material as intermediate opacity for this purpose. When multiple shades of resin composite are layered, the principle of replacing dentin with dentinlike materials and enamel with enamel-like materials should be observed (Fig 10-4).

Dentlearn.ir



Fig 10-4 Resin composite increments of the same thickness presenting four opacities: Dentin, Body, Enamel, and Translucent (Filtek Supreme Ultra, 3M ESPE).

Microfilled resin composites

Microfilled resin composites contain silica fillers of submicron size only. Because these small particles, with an average size of 0.04 μm, have a very high surface area–to-volume ratio, they require a large amount of monomer to wet their large surface area and therefore can only be incorporated into resin up to a relatively low volume fraction. Because the properties of the cured resin composite are dependent on the quantity of the stronger filler particle, these microfilled composites are relatively weak. To enhance the properties of these materials, manufacturers incorporate what are called *prepolymerized resin fillers* (PPRF) in addition to the submicron-sized fillers. The PPRF are produced by adding a high concentration of submicron fillers into a very dilute resin, then heat curing this viscous mixture to maximize polymerization, and finally grinding the filled polymer into 5- to 50-μm particles. These particles are then incorporated with additional microfiller particles to form the final restorative material for clinical use (Fig 10-5a). In this way, filler content is maximized, polymerization shrinkage is minimized, and the resin composite remains highly polishable because every individual silica particle is only about 0.04 μm in size.[50]

Dentlearn.ir



Fig 10-5 Most commonly used categories of resin composite: *(a)* the microfilled resins, such as Durafill VS (Heraeus Kulzer), contain only submicron particles *(right side)* along with PPRF *(left side)*; *(b)* the hybrid materials, such as Premise (Kerr), contain a combination of submicron particles and particles up to 4 μm in diameter; and *(c)* the nanofilled materials, such as Filtek Supreme Ultra, contain loose nano-sized filler particles (20 to 70 nm) and clustered nanosized particles.

Microfilled resin composites can be polished to the highest luster and smoothest surface of all the resin composites, and their primary indication is for esthetic areas where this luster is required, such as for direct resin composite veneers. Microfilled resin composites, in general, are not as strong as other types of composites and are not recommended for stress-bearing restorations.[41,51–54] Microfilled materials tend to absorb more water because of their increased resin content, with a resultant decrease in long-term color stability.[55] When a highly polished Class 4 restoration is needed, a hybrid material may be used as a substructure to maximize strength and wear resistance, then veneered with a microfilled resin composite for a smooth surface (see Fig 10-6).

Hybrid resin composites

Dentlearn.ir

As the name implies, *hybrid resin composites* contain a blend of submicron (0.04-μm) and small-particle (0.4- to 4.0-μm) fillers (Fig 10-5b). This combination of filler particles allows the highest levels of filler loading among current resin composites and a corresponding improvement in physical properties as compared with microfilled composites.[56,57] They can be polished to a fairly high luster, but not to the extent of a microfilled material. Hybrid resin composites are a combination of conventional and microfilled technology and can be used for anterior and posterior restorations. The high filler content also improves the hybrid material's resistance to

In the last decade, dental manufacturers have fabricated hybrid resin composites with an average particle size of less than 1 μm. Because of the submicron size, these materials are called *microhybrids* (eg, Point 4, Kerr). Submicron particles can be measured in μm or nm (1 μm = 1,000 nm), which explains why some materials in this category have been called *nano-hybrids*. While not always the case, many nanohybrids also contain PPRF to reduce overall curing shrinkage. These microhybrids and nanohybrids are easier to manipulate and polish than the regular hybrid composites and also maintain their luster better over time.[58]

Nanofilled resin composites

A new category of material, termed *nanofilled resin composites*, has appeared on the market in recent years. The research and development of these materials were designed with the objective of successfully integrating a high concentration of nanoparticles into resin composites to enhance mechanical properties, handling, and ease of polishing.[59,60] Unfortunately, the term *nano-* has been mistaken as only referring to particle size. Actually, *nano-* refers to the technology and manipulation of nanosized particles with the purpose of improving the final performance of the product. Few materials with a true nano-fill technology exist in the market at the moment (eg, Filtek Supreme Ultra, 3M ESPE) (Fig 10-5c). In general, these nanofilled composites are nonsticky and nonslumping.

The first generation of nanofilled materials was easy to polish but did not hold its luster over time and appeared dull to patients and dentists. They also tended to be too translucent and had somewhat of a gray appearance. Changes in their composition have led to improved materials that are more esthetic, very easy to polish, and better maintain their luster over time.[61]

Dentlearn.ir

Glass-ionomer restorative materials

Glass-ionomer restorative materials are not commonly used when esthetics is a major consideration in anterior restorations. They are often recommended for patients with high caries risk.[62,63] A review of clinical trials that studied the cariostatic effect of fluoride-releasing restorative materials concluded that there is no definite evidence for or against a treatment effect of inhibition of secondary caries by these materials.[64] However, studies involving patients at high risk for caries due to xerosto-mia showed a significant reduction in caries incidence adjacent to resin-modified glass-ionomer restorations, as compared with other restorative materials.[65,66] The traditional, chemically cured glass-ionomer materials are not highly esthetic, but esthetics has been greatly improved in the resin-modified glass-ionomer materials. From a physical property perspective, the resistance against erosive wear of both chemically cured and resin-modified glass-ionomer cements is lower than that for resin composites. Clinical trials of 5 years' duration have reported high retention rates in Class 5 restorations.[67–69] Though not as color stable nor as durable as resin composites, these materials are suitable for use in visible anterior areas when dentin margins are prevalent or when the patient has been identified as being at high risk for developing new caries lesions.[70] Glass-ionomer restorative materials are discussed in more depth in chapter 14.

Interproximal Lesions: Class 3

Interproximal caries lesions are smooth-surface lesions found slightly gingival to the proximal contact, without involving the incisal angle of the tooth. These lesions can usually be detected with an explorer, radiographically, or with transillumination. Clinical changes in translucency may be evident and may be enhanced if light is directed through the proximal area using a focused, intense light source (ie, *transillumination*). Caries lesions cause a more opaque appearance of tooth structure. Incipient lesions tend to be V-shaped and confined to enamel; deeper lesions tend to spread within dentin.

Incipient enamel caries lesions

A proximal noncavitated enamel lesion may not require restorative treatment. Although there is no doubt that the lesion is pathologic, research and clinical experience have shown that this lesion can be arrested or remineralized by

Dentlearn.ir

preventive therapies and regular topical fluoride application. Developing a caries-management plan based on individual risk factors will decrease the possibility that future invasive procedures will be necessary. Evidence supports the viability of remineralization of caries lesions in enamel.[71–75] Chapter 5 contains a more complete discussion on caries and remineralization processes.

Cavitated enamel caries lesions

When the enamel surface is cavitated, it is past the point of remineralization. If the cavitation is very shallow and deeper enamel has been remineralized, a restoration may not be necessary unless the lesion is esthetically displeasing. If the lesion is confined to enamel, enameloplasty or recontouring may be sufficient. If necessary, a conservative cavity preparation may be accomplished and then restored.

Dentinal caries lesions

With peripheral enamel margins

When the caries lesion has reached dentin, it then becomes necessary to remove caries with cavity preparation and restoration. When all margins are located in enamel, a combination of an adhesive and a resin composite are the restorative materials of choice.

With margins extending onto the root surface

In areas where there is little or no enamel for bonding, the marginal adaptation and seal of the restoration may be optimized in two distinct ways. For high-caries-risk patients, an open sandwich technique using a resin-modified glass-ionomer restorative material may be employed to seal the cervical portion of the restoration. The remaining cavity is then filled with resin composite for improved esthetics.[76] There is a debate regarding the effectiveness of the open sandwich technique, with studies showing both advantages and disadvantages of its use. However, studies demonstrate that the open sandwich technique reduces postoperative sensitivity and provides protection of dentin margins from demineralization.[77–79]

For low-caries-risk patients, the approach to treating lesions with dentinal margins is simply to employ a well-proven dentin bonding system and to restore with a resin composite. Because current dentin bonding systems have been demonstrated to be very effective in providing retention, mechanical undercuts at the

Dentlearn.ir

expense of healthy tooth structure have become unnecessary.[80]

Interproximal Lesions Involving the Incisal Angle: Class 4

Interproximal lesions involving the incisal angle are usually the result of undermining and compromising the integrity of the incisal enamel. This undermining can occur as a result of untreated large interproximal caries or when replacing a large Class 3 restoration. Additionally, these lesions can occur due to an injury that results in a fracture of the incisal angle. The need for Class 4 restorations due to traumatic fracture occurs most often among children or young adults. The frequency of fractures of permanent incisors in children is reported to range from 2.4%[81] to 20%.[82] Traumatic fractures are likely to be more horizontal than vertical.

Shade or Color Selection

Selection of the shade or color of resin composite restorative material is an important and sometimes demanding step in restoring an anterior tooth. Factors that influence shade selection, such as proper lighting, environmental factors, and color acuity and eye fatigue are also discussed in chapter 4.

Proper lighting

One of the first requirements for a good color match is proper lighting. Commonly used fluorescent tubes emit light with a green tint that can distort color perception. Color-corrected fluorescent tubes that approximate natural daylight are available and are recommended for dental treatment rooms. The objective is to obtain shadow-free, color-balanced illumination without distracting glare or false colors[83] (Box 10-1). Additionally, the operatory light should be turned off because the orange-yellow wavelengths of these lights will interfere with adequate shade selection. If proper lighting is not available, color selection can be made near a window. However, even daylight varies considerably from day to day and throughout the day. When shade selection is critical, it is wise to use multiple light sources to choose the best shade and to avoid problems with *metamerism*, a complication observed when the perceived color of objects (in this case, teeth and resin composite restorations) is different under different light sources.

Dentlearn.ir

Box 10-1	Color-corrected lighting[83]
Overhead lights (fluorescent tubes)	
• Color Rendering Index (CRI): 90 or higher • Spectral energy distribution (SED): Natural daylight • Color temperature: 5,500 K • Illumination intensity: Approximately 150 to 200 foot candles at 30 inches above floor	
Dental operating light	
• Illumination intensity: 1,000 to 2,000 foot-candles • Color temperature: Optimum 5,000 K, should be adjust able from 4,500 K to 5,500 K to assist in color matching	

Environmental factors

The environment influences the shade selection. To improve the accuracy of shade selection, the color of the room walls and of the patient and staff clothing should be neutral to avoid imparting a negative color cast. Additionally, the patient should be asked to remove lipstick prior to shade selection.

Color acuity and eye fatigue

When selecting color or shade, the operator should avoid staring at the tooth and shade guide for long periods of time. Staring at these objects during shade selection will cause the colors to blend, resulting in a loss of color acuity. The shade guide should be placed adjacent to the tooth to be restored and then viewed briefly to determine which shade or shades match the color of the tooth; then the eyes should be moved away. Arranging the shade guide based on the value or brightness (see Fig 4-10) of the shades can also facilitate shade selection. Ideally, the eyes should be "rested" by viewing the horizon through a window or by looking at an object that is a muted blue, violet, or gray color. Full details of shade matching are addressed in chapter 4.

The dental assistant and patient can also assist in shade selection. By viewing the shade guide and the tooth from several positions and by accepting input from the assistant and patient, the dentist can achieve an acceptable color match.

Achieving optimal color selection

With proper attention to detail, resin composites allow for a very predictable shade

Dentlearn.ir

blending. The color or shade selection should be accomplished before the restorative procedure is initiated, prior to rubber dam placement or cavity preparation. If patients have whitened their teeth, it is necessary to wait 2 weeks after bleaching for shade selection and optimal bonding results.[84] The tooth should be made clean and free of contaminants by using a prophylaxis cup with a slurry of pumice to remove plaque or debris from the tooth surface and to eliminate any stains. Teeth should be kept wet and hydrated during shade selection because dehydration causes *(1)* significant lightening of the color and *(2)* an increase in the opacity of enamel and dentin.

The patient should be positioned in such a way that the teeth receive enough light from the illuminant or light fixtures. Most manufacturers provide or recommend a shade guide for their products to offer an approximation of the colors available. The shade guides are only helpful for a general determination of the shade. Most of these shade guides are made of acrylic resins that have different optical properties than resin composites. Many composites are fabricated to match VITA shades, but some others use their own shade designations. Matching between the VITA shade guide and the corresponding shades of resin composites and glass ionomers has been shown to be relatively poor.[85–87] A major drawback of all the shade guides is the fact that the shade of the underlying tooth is not taken into account. There will always be an effect on the shade of the restoration caused by the underlying tooth structure unless the restoration is more than 2.5 mm thick.[88–90] To overcome problems associated with shade guide discrepancies, custom shade tabs should be fabricated for each shade of the resin composite material used in the practice. The shades should then be arranged by value or brightness, from light to dark (see Fig 4-10). These tabs are then held incisally adjacent to the tooth to be matched, and the selection can be narrowed down to three to four shades. For selection of the final shade, the middle portion of the tooth should be observed and matched to the closest of these shade tabs. The selected shade then becomes the overall or "basic shade" of the restoration (see Fig 4-19).

When a layering and multishaded technique is used to replicate missing tooth structure, it is important to realize that the thickness of each layer will affect the final shade. In esthetically challenging situations, the ultimate shade selection is best achieved by producing a mock-up using each of the different layers to accurately match not just a single shade but also the adjacent tooth structure.[91] The shade can be confirmed with a small amount of resin composite applied as a test shade, placed adjacent to the tooth and cured. This procedure should only be performed on unetched surfaces to facilitate removal after shade verification. For Class 4

Dentlearn.ir

restorations in which no tooth structure will remain lingual or facial to the planned restoration, the test shade should be placed in the approximate thickness of the tooth structure to be replaced to ensure adequate opacity or color density.

Tinting and opaquing

Many manufacturers of resin composites provide accessory shades that contain a number of intense colors and opaque resins, premixed in syringes or bottles. These materials are normally not necessary in conservative Class 3 restorations but can play an important role in large Class 4 restorations, diastema closures, and direct veneers. Opaque shades, or composites designated as dentin replacements, are used to block the show-through of darkness from the mouth that may cause a Class 4 restoration to appear too dark or low in value or too translucent (Fig 10-6). Opaque resins may also be needed to mask discolored tooth structure.[89,90]

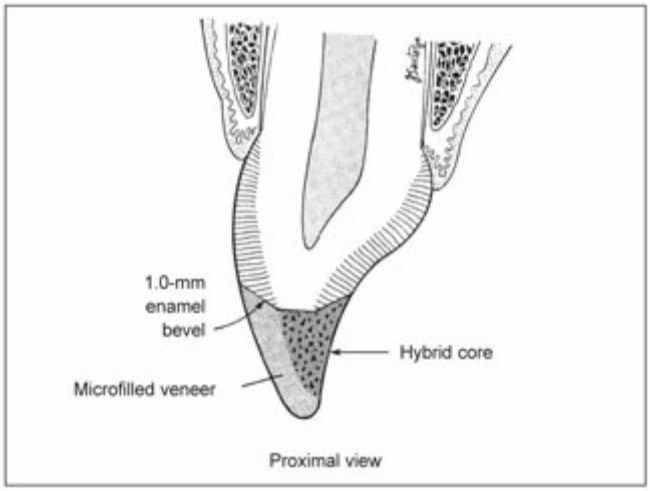

Fig 10-6 Opaque dentinlike resin composite should be used to block the show-through effect.

Masking agents should be applied in thin layers to allow sufficient space for the overlying composite to restore translucency. Use of the proper accessory shades can create the appearance of dentin overlaid with enamel. Accessory shades can also be used to recreate the yellow color seen in cervical areas or the translucency that appears in incisal areas. An ochre-shaded resin composite can be used to enhance chroma in the cervical areas, gray or blue may increase the "translucentincisal" effect, and white can be employed to reproduce a halo. Tints may be used to imitate white or brown spots that appear on adjacent teeth, although with the current ability to bleach teeth, the spots can usually be removed or their appearance neutralized with bleaching (see chapter 16).

Dentlearn.ir

Tooth Preparation

Class 3 interproximal lesions

Outline form for resin composite restorations is defect specific and determined solely by the extent of the caries lesion(s) and access for removal of carious tooth structure (Figs 10-7 to 10-9). There is no need for further extension of the preparation, and the removal of sound tooth structure to gain mechanical undercut retention is contraindicated.[92] Because the location of the caries in interproximal lesions is usually gingival to the contact point, the cavity preparation extends gingivally below the contact point. In contrast, the incisal portion of the contact point is not necessarily removed. When a lesion is limited to enamel, a round carbide or diamond bur is used in a high-speed handpiece for cavity preparation. The finished preparation resembles a saucer and has no retentive undercuts (see Fig 10-7). Adhesion to acid-etched enamel and dentin provides the necessary retention. Both laboratory and 3-year clinical data have demonstrated the durability of these saucer-shaped restorations.[93,94]

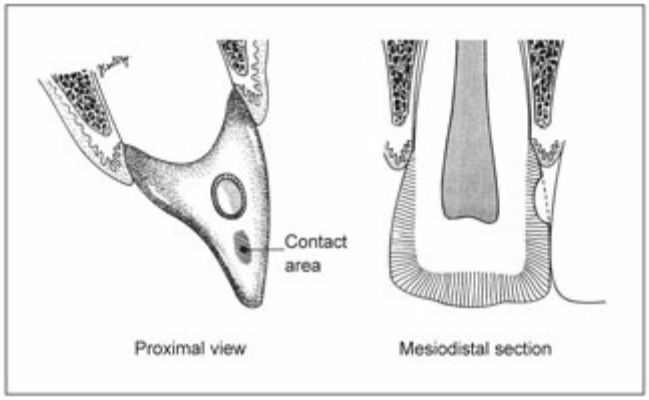

Fig 10-7 Saucer-shaped preparation in enamel. The caries lesion is usually located slightly gingival to the contact area. Every attempt should be made to maintain natural tooth contact between the adjacent teeth during restoration. If no cavitation is present, remineralization is preferable to restoration.

Dentlearn.ir

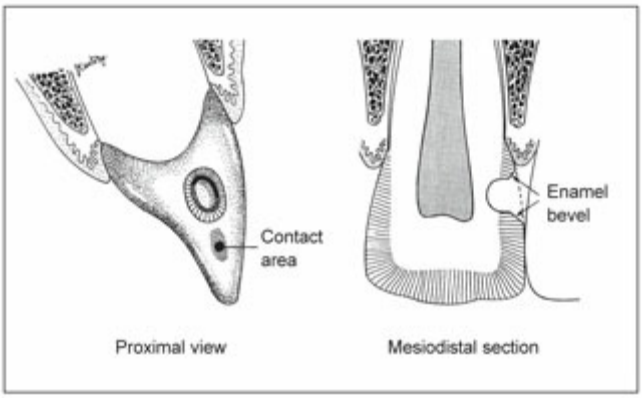

Fig 10-8 This preparation is similar to that in Fig 10-7, except the axial wall is extended into dentin and the external enamel margins are beveled.

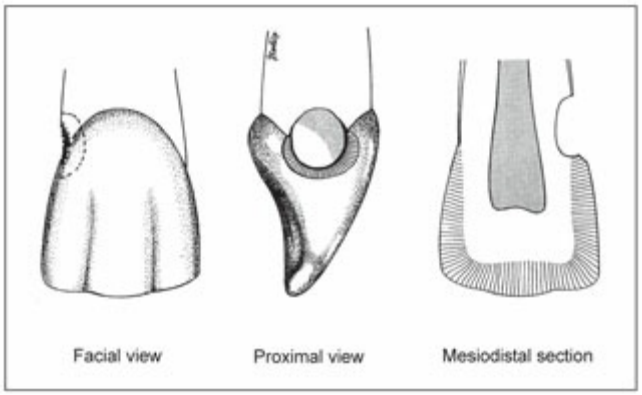

Fig 10-9 Caries lesion extending to the dentin-cementum surface. A bevel is placed only on enamel margins.

The lingual approach is preferred for larger Class 3 restorations, but it is not always possible depending on the location of the caries lesion. The number of burs used for cavity preparation should be kept to a minimum. A no. 2 round bur or a pear-shaped carbide bur or diamond in a high-speed handpiece can be used for initial access to the lesion. Initial penetration should be made through the marginal ridge, near the adjacent tooth but avoiding damage to it (Fig 10-10). The outline form of the preparation is then extended to provide access to the carious dentin. A spoon excavator and a large round bur may be used in the low-speed handpiece to excavate demineralized dentin.

Dentlearn.ir

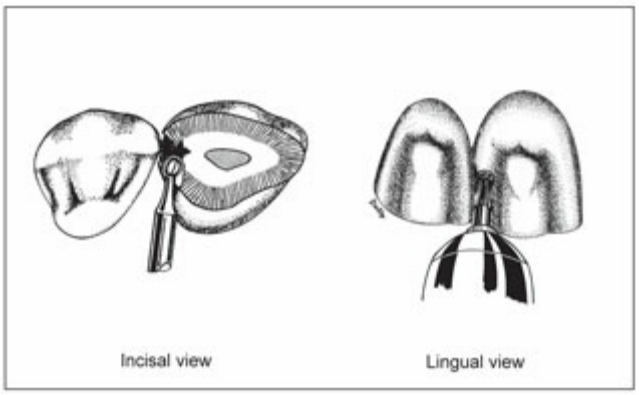

Fig 10-10 Initial penetration should be made through the marginal ridge, near the adjacent tooth but avoiding damage to it. Note the angulation of the long axis of the bur in relation to the location of the lesion.

The appearance of true enamel is more natural and esthetic than the most esthetic restorative material. To preserve facial esthetics, the Class 3 preparation should not be extended onto the facial surface unless necessitated by carious or missing enamel on that surface (Fig 10-11).

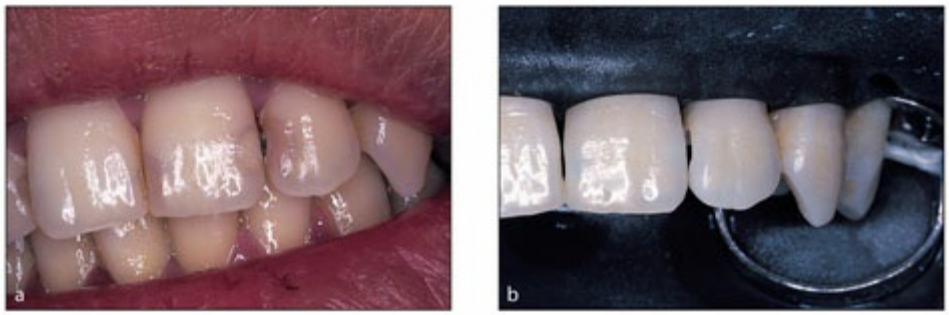

Fig 10-11 *(a)* Moderate-sized Class 3 caries lesions on the mesial and distal surfaces of the maxillary left central incisor and mesial surface of the lateral incisor. A preferable approach would be to leave facial enamel, if possible. *(b)* After cavity preparation, the labial margins are only slightly visible, and the labial enamel is supported by dentin.

composite.[95] The facial approach for access to carious dentin is indicated only when the caries lesion already involves the facial surface or when the adjacent tooth overlaps the tooth being restored, preventing a lingual approach. The outline should be as conservative as possible, preserving the facial enamel (Fig 10-12).

Dentlearn.ir

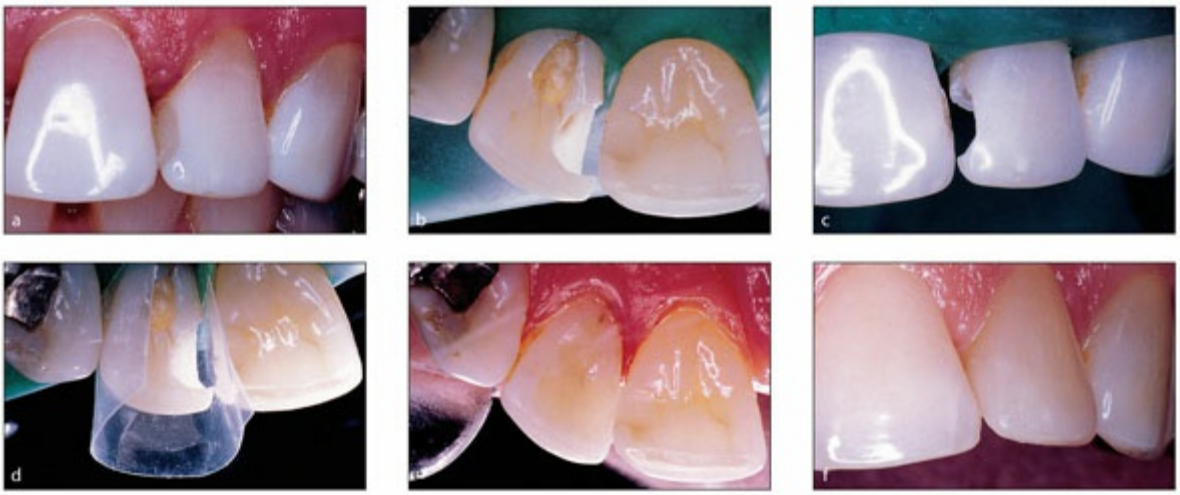

Fig 10-12 *(a)* A discolored anterior resin composite restoration to be replaced to improve esthetics. *(b)* Lingual view after the existing resin composite was removed, revealing unsupported facial enamel. *(c)* Completed preparation; observe that labial unsupported enamel has been preserved. *(d)* Clear matrix and interproximal wedge in place. *(e)* Lingual view of the finished and polished resin composite restoration. *(f)* Facial view of the Class 3 restoration illustrates the improved esthetic outcome.

Bevels have been advocated by some authors to reduce enamel fracture and provide a gradual shade transition for esthetics.[96,97] However, enamel bonds have been demonstrated clinically to be adequate without bevels.[13,98] An in vitro study using a silver-nitrate tracer revealed no significant differences in marginal microleakage in Class 3 restorations whether or not margins were beveled.[99] A flame-shaped finishing carbide or fine diamond bur, a gingival margin trimmer, or another hand instrument may be used to place bevels. Although a very wide bevel usually should be avoided, in situations where maximum esthetics is required, the bevel can be extended to 2 mm or more on the facial surface. Adequate depth of this bevel allows proper overlapping of the different opacities of the restorative layers, and the increased length allows a blending transition of the resin material onto the tooth surface. If the cervical enamel will be eliminated or compromised by a bevel with a resultant margin in or near dentin, the beveling procedure should be avoided in the cervical area (see Fig 10-9).

Resin-modified glass-ionomer restorations

Because of their cariostatic effect, resin-modified glass-ionomer restorative materials may be used in Class 3 restorations in patients at high risk for caries.[62,100] Preparations for these materials should resemble those for resin composite, but bevels are not prepared. The only reason why noncarious tooth structure should be

Dentlearn.ir

removed is to allow access for excavation of the carious dentin. Because these materials bond to enamel and dentin, the placement of retention grooves or points is not necessary[101] (Fig 10-13).

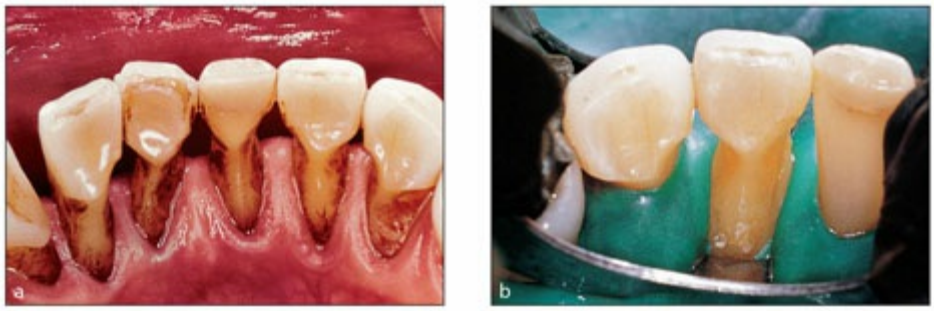

Fig 10-13*(a)* Lingual view of extensive root surface exposure and root caries lesions; the teeth are to be restored with resin-modified glass-ionomer material. *(b)* Completed excavation of carious tooth structure; the adhesive nature of the restorative material does not demand preparation of mechanical resistance and retention features. (Courtesy of Robert H. Poindexter, Kerrville, Texas.)

Class 4 interproximal lesions involving the incisal angle

Cavity preparation for interproximal lesions involving the incisal angle follows the conventional form of the Class 3 preparation and includes a portion of the incisal edge. Carious tooth structure and weak enamel are removed, and all enamel margins are beveled (Fig 10-14). A modified Class 4 preparation with extensive loss of incisal enamel is shown in Fig 10-15.

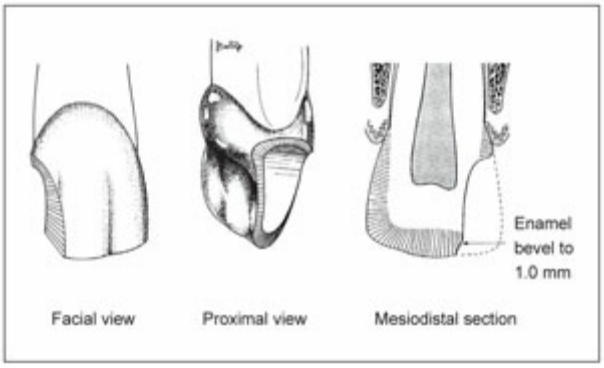

Fig 10-14 Typical Class 4 preparation. Incisal fracture caused by undermining and weakening of incisal enamel associated with a Class 3 lesion may necessitate a Class 4 cavity preparation, which is similar to a Class 3 preparation but includes a portion of the incisal edge.

Dentlearn.ir

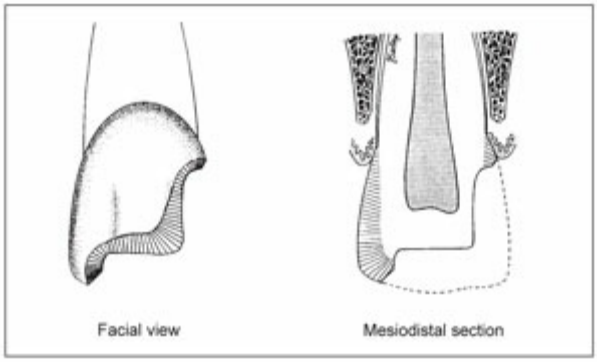

Fig 10-15 Class 4 preparation when loss of incisal enamel is extensive.

When a fracture has caused a need for restoration, if there is no carious or pulpal involvement, tooth preparation consists of rounding any sharp angles and placing a bevel on all enamel margins[102] (Fig 10-16). An enamel bevel of at least 1 mm should be placed around the periphery of the cavity. Increasing the width of the bevel beyond 1 mm has been shown to provide no additional strength,[103] but a wider bevel may provide a more harmonious esthetic blend between the resin composite and enamel. When replacing resin composite restorations, a preparation similar to that of a fractured tooth should be performed.

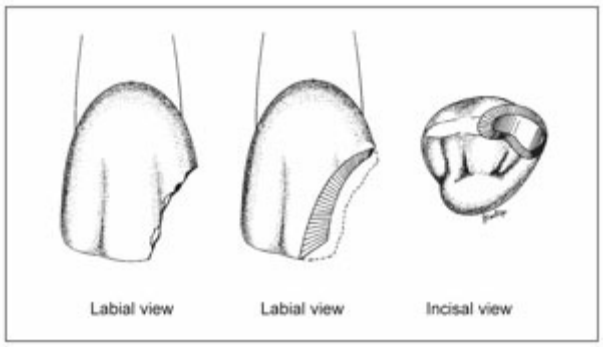

Fig 10-16 Fractures often require no preparation other than an enamel bevel.

On the facial surface, a longer bevel is needed for better esthetics. This bevel has a 60-degree angulation and is 2 to 3 mm in length. The bevel presents a scalloped or irregular out-line, has a variable thickness, starts inside the dentinoenamel junction (DEJ), and feathers and disappears onto the enamel surface (Fig 10-17). The purpose of this long bevel is to make the composite restoration blend onto the natural tooth structure and to make the transition between the two structures imperceptible. This functional-esthetic facial bevel is created first with a fine flame-shaped diamond bur and then blended on the surface with a medium-grit polishing disk. The polishing disk is also used to round sharp angles as needed. The facial bevel is often described as infinite because its margins are difficult to detect after they have been

Dentlearn.ir

blended with the disk and they appear to be disappearing onto the surface (Fig 10-18).

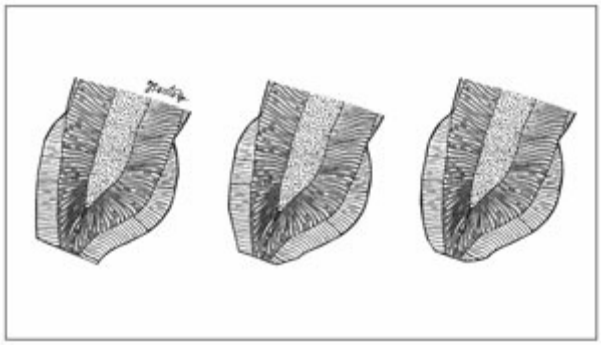

Fig 10-17 Facial and lingual bevels. The facial bevel is a disappearing bevel to allow feathering and blending of resin composite over tooth structure. Initial bevel placement is shown in the middle diagram. The facial-incisal line angle is rounded, and the facial bevel is blended to provide the disappearing bevel in the right diagram.



Fig 10-18*(a)* Existing discolored resin composite restoration in need of replacement. *(b)* Scalloped infinite bevel preparation for a Class 4 resin composite restoration.

On the lingual surface, where functional requirements are more important, the bevel should remain shorter than on the facial surface, limited to about 1 mm in length. The outline of the bevel can be straight and well defined. The bevel starts at the DEJ and has a 45-degree angulation (see Fig 10-17). In areas of strong occlusal stresses, cavity preparation must be designed to allow for sufficient thickness of resin composite so it is fracture resistant. A deeper bevel or a chamfer is prepared in areas exposed to occlusal loads in order to provide adequate marginal strength to the restoration.

If the original tooth fragment is available after traumatic fracture, in some instances the fragment may be reattached to the tooth by etching and bonding the fractured surfaces.[104–107] Clinical trials have shown these reattachments to be successful in terms of retention, in some cases for more than 7 years.[108,109] Fragment reattachment can often provide a more esthetic result than can a resin composite restoration, as long as the transition between the bonded fragment and the tooth is masked by preparing an enamel bevel and placing composite and blending it over

Dentlearn.ir

the enamel surfaces. The bevels should not extend into the dentin to allow the fragment to be repositioned correctly.

Use of pins

Retentive pins are not needed in resin composite restorations and should not be used. The adhesive technique provides sufficient retention, and the use of metallic pins in resin composite restorations can greatly reduce the esthetic appearance.[110] A study concluded that there was only a small (10%) increase in fracture resistance of large Class 4 resin composite restorations if pins supplemented bonding.[111] Pins in anterior teeth may encroach on the pulp and may discolor the restoration due to corrosion with marginal leakage. Some clinicians argue that if the adhesive bond is broken, it is better to lose the restoration than to have it held in place by the pins (Fig 10-19).

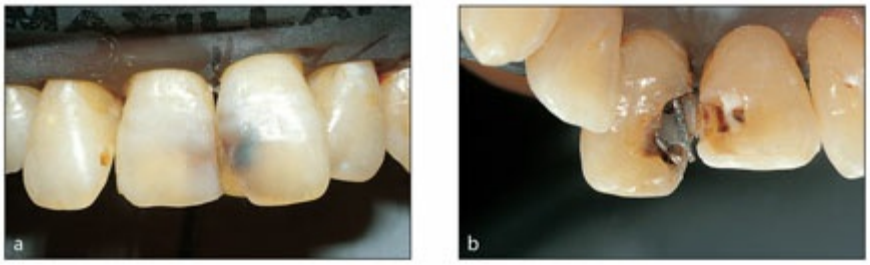

Fig 10-19*(a)* Labial view of a Class 4 resin composite restoration retained with two pins. Note the wear and color change of the composite material and evidence of corrosion discoloration or recurrent caries. *(b)* Lingual view after removal of the composite material.

Matrices

Class 3 restorations

The clear plastic strip is the most commonly used matrix with Class 3 restorations (Fig 10-20). The clear plastic matrix, when properly wedged, will reduce flash (excess material) at the gingival margin. It is placed between the teeth and adjacent to the cavity preparation. The resin composite may be shaped with an instrument, or the matrix strip may be pulled snugly around the tooth and held in place manually to provide shape to the restoration and intimately adapt the resin composite.

Dentlearn.ir

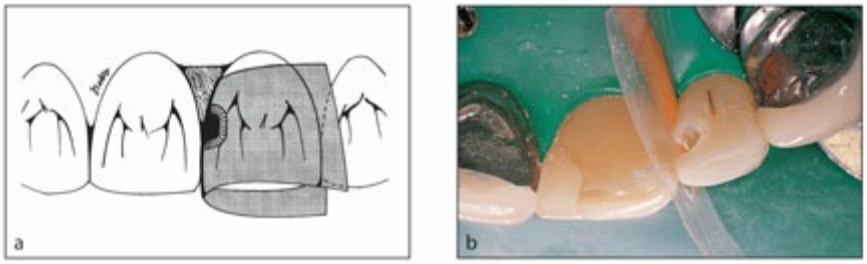

Fig 10-20*(a and b)* Lingual view of matrix and wedge placement for a typical Class 3 resin composite restoration.

Class 4 restorations

Different forms of matrices can be used to form the lingual and proximal aspects of a Class 4 restoration. One option is to use a portion of a thin, clear plastic crown form positioned to provide support until the lingual and proximal resin has been polymerized (Fig 10-21). The crown form should be trimmed to fit approximately 1 mm past the prepared margins. If the crown form is thicker than a clear plastic matrix strip, the contact areas should be thinned with an abrasive disk to allow contact of the restoration with the adjacent tooth. For Class 4 restorations with existing or mock-up resins in place, the clinician may prefer to use polyvinyl siloxane (PVS) impression material or putty to fabricate a lingual matrix that assists in shaping lingual and proximal contours (see Figs 10-25b to 10-25d). For creation of extensive restorations in which lingual contours and/or incisal length need to be changed, these may be developed in wax on a diagnostic cast of the teeth; then the lingual matrix is fabricated on the diagnostic wax-up. The matrix should extend to the facioincisal line angle to guide the shaping of the incisal edge and facilitate the creation of an incisal halo.

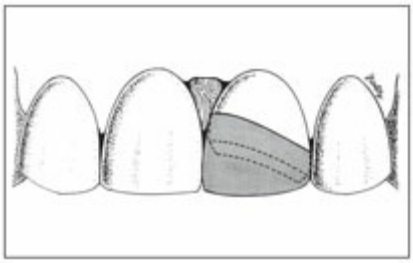

Fig 10-21 Clear plastic crown form and wedge in place for a Class 4 restoration.

Wedging

Wooden wedges are inserted between the teeth and against the matrix to seal the gingival margin, separate the teeth, protect interproximal gingiva, ensure adequate proximal contact, and push the rubber dam and proximal tissue gingivally to open the

Dentlearn.ir

gingival embrasure (see Fig 8-26). With proper rubber dam isolation, it is usually possible to have direct access to the gingival margin to be able to place and seal composite without the need for a wedge. Floss ligatures can greatly help in gaining access to the gingival margins by pushing the rubber dam and gingival tissues apically. When rubber dam cannot be used, care should be taken when inserting wedges because of the susceptibility of the gingiva to bleed upon removal. If the wedge will cause deformation of the matrix or poor cervical contours, it should not be used, or its use may be delayed until after a freehand increment of resin composite has been placed and sculpted in the cervical portion of the preparation and polymerized.

Placement and Curing of Resin Composite Restorations

Incremental placement and curing

Incremental placement and curing of the resin composite may be necessary for large light-cured restorations. Most resin composite should be placed in thicknesses not greater than 2 mm. In restorations exceeding 2 mm in thickness, incremental placement will ensure that each portion of composite is exposed sufficiently to the curing light and is adequately polymerized. Incremental placement is generally considered the standard of care in large preparations and is believed to offset some of the effects of polymerization stresses.[3] Although there is no definitive clinical data to support one composite placement method over another,[112] bulk curing of composite raises strong concerns over increased stress generation and tooth deformation.[29,39]

Polymerization of resin composite is initiated by the formation of free radicals that cause covalent bonding between resin monomers to produce a hardened resin composite structure. These free radicals are highly reactive to oxygen, and when they come into contact with air at the surface of the resin composite, an unpolymerized *air-inhibited layer* is formed.[113] A thin air-inhibited layer contains free radicals and is therefore reactive to new resin composite material applied to it. Even in the absence of an air-inhibited layer, if the restoration is freshly placed, free radicals remain that can induce a high degree of chemical attachment for the added increment.[114,115] Each increment should be exposed to the curing light for the appropriate material- and curing light–specific time. Inappropriately short curing times or the use of a poorly functioning curing light will result in resin composite

Dentlearn.ir

restorations with inferior physical properties and an increased chance that unreacted monomer, which may be cytotoxic and/or irritating to tissues, will leach out of the restoration with time.[116]

Visible light–curing units

Optimal polymerization depends on several factors: wavelength of the emitted light, *irradiance* of the light source (calculated as the power of the light divided by the area over which it is emitted; measured in mW/cm^2), light exposure time, *radiant exposure* (defined as the product of the irradiance and time; measured in mJ/cm^2), distance from light tip to composite surface, and type and shade of resin composite. Any light-curing unit with the prescribed wavelength may be used with any resin composite. However, it can be difficult to determine the optimal exposure time for any given combination of curing light and composite because recommendations on exposure time from curing light manufacturers and composite manufacturers often do not match. As a result, many clinicians will overexpose the restorations to ensure a cure as complete as possible.[117] The risk of increased exposure times, especially with high-intensity lights, is the generation of excessive heat within the tooth and in the surrounding tissues.[118,119]

Several types of light sources can be used for visible-light curing. Light-emitting diode (LED) devices have become increasingly popular in recent years because they are more energy efficient, lightweight, and portable (battery powered). The latest iteration of LEDs now generate multiple wavelengths at high irradiance and are therefore able to polymerize any type of restorative material.[120] Most dental composites contain the same photoinitiator, camphorquinone, as described earlier in this chapter. However, because camphorquinone is yellow and residual molecules that do not react may lend a yellowish color to the cured composite, manufacturers have identified less yellow–colored photoinitiators that absorb light energy at lower wavelengths (ie, closer to the UV spectrum at about 400 nm). The standard LED has minimal light output in this wavelength range, and therefore curing of resins containing these products necessitates the use of these newer multiple wavelength lights. Quartz-tungsten-halogen (QTH) lights are still widely found in dental offices and can cure effectively, as long as the incandescent bulb is well maintained and replaced periodically. Unfortunately, studies have reported very poor curing light maintenance in private practice.[121,122] Clinicians should use radiometers to assess the performance of their light units. Radiometers can be used to compare relative values of light output over time, but they may provide inaccurate values and cannot

Dentlearn.ir

be used to predict clinical performance.[123,124] Argon ion lasers and plasma arc curing units (PAC) are known for their very high intensity and short exposure times. However, these lights are much more costly than QTH or LED units. Furthermore, serious concerns have been raised about the stress generated in the composite when curing occurs at such a fast rate.[125]

For a more in-depth discussion of curing lights, see chapter 11.

Placement technique

Class 3 restorations

Bonding procedures should be carried out before placing the resin composite restoration. The entire preparation and a 2- to 3-mm area beyond the margins should be bonded for retention and to ensure proper marginal seal (see chapter 9 for a complete discussion of dentin adhesives) (Fig 10-22). The dentin adhesive system may be applied and polymerized either before or after the matrix and wedge have been placed (Fig 10-23). The dentist must take into consideration that inserting a well-adapted matrix can make access for etching, placing, and properly thinning the adhesive system more challenging.

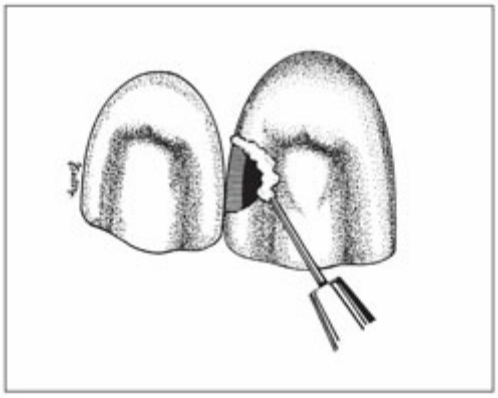

Fig 10-22 Application of gel etchant using a syringe tip. A matrix strip should be placed first to protect the adjacent tooth from the acid.

Dentlearn.ir

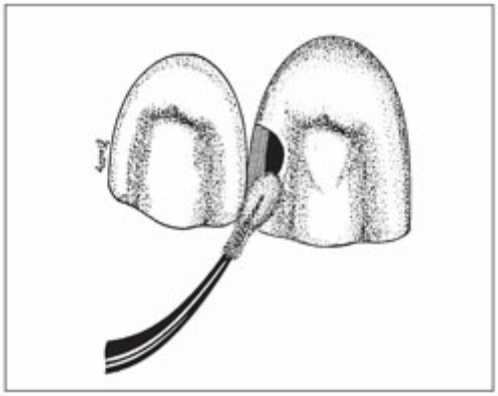

Fig 10-23 The primer and adhesive are placed with disposable brushes or applicators, and the adhesive is light cured in accordance with the manufacturer's protocol.

The resin composite dispensing tip should be inserted into the preparation and slowly injected. The composite can also be dispensed on a paper pad, rolled in a ball, and taken to the preparation with an instrument. Small Class 3 preparations of less than 2 mm can be filled in a single increment. Larger Class 3 restorations should be incrementally filled. Placement of multiple increments is recommended to optimize the degree of conversion of the resin composite in deep areas, to minimize the effects of polymerization shrinkage stress (Fig 10-24), and to create polychromatic restorations.

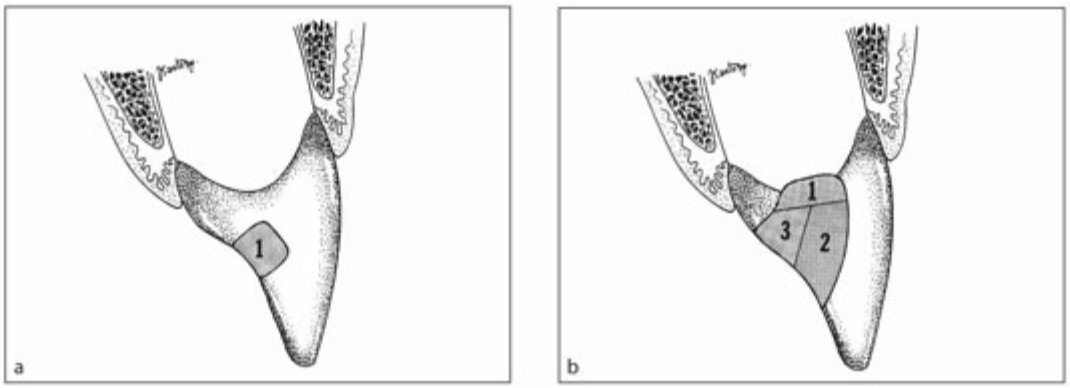

Fig 10-24*(a)* Small preparations may be filled in a single increment. *(b)* Large preparations require multiple increments to minimize the effects of polymerization shrinkage and ensure adequate polymerization.

After injection, the resin composite is adapted to the cavity walls and margins. A thin, bladed instrument is used for adaptation and contouring, or the matrix strip may be pulled tightly around the tooth to achieve close adaptation. When the material has been light cured, the wedge and matrix strip are removed and the restoration is inspected for voids. If external voids are present, they may be filled with additional resin composite material, which is then light cured.

Dentlearn.ir

Large “through and through” (ie, no facial or lingual tooth structure is left) Class 3 restorations often do not blend with the color and translucency of the surrounding tooth structure, and sometimes a show-through of the darkness of the mouth can be seen. In order to predictably achieve an imperceptible restoration, the *layering* or *stratified technique* should be employed. The cavity preparation is filled from the

dentinlike material, which is one or two shades darker than the basic shade. A 2-mm layer is placed against the axial wall and carefully adapted. One to two increments of dentinlike material may be necessary to replace the anatomical dentin. The final dentin increment should overlap part of the bevel (if present) to facilitate blending and masking. An enamel-like material, of the same shade as the basic shade, is then placed facially over the dentin increment to replace the anatomical enamel. This increment extends beyond the bevel and feathers over the natural tooth surface. This facial enamel increment should be placed in one application and built to establish the final facial contour of the restoration. Additionally, this increment should be in contact with the adjacent tooth to create the facial aspect of the proximal contact. After polymerization of the facial increment, a clear matrix can be placed interproximally to facilitate application and adaptation of the final enamel-like increment. The final increment is then placed over the lingual portion to complete the layering effect. If the clear matrix is used, it is pulled slightly toward the facial wall to carry the material and improve adaptation. Each increment of material should be light cured for approximately 20 seconds. The basic clinical steps for a Class 3 resin composite restoration are outlined in Box 10-2.

Box 10-2	**Clinical steps for a Class 3 or Class 4 resin composite restoration**

1. Select a shade before dehydration of the tooth.
2. Place a rubber dam.
3. Prewedging will aid in achieving an adequate proximal contact. Prewedge to protect the rubber dam and proximal gingival tissues during tooth preparation.
4. Initiate the cavity preparation by accessing the caries lesion through the marginal ridge with a no. 329 or 330 bur in a high-speed handpiece. Remove the proximal plate of enamel. Be careful to avoid damaging the adja cent tooth.
5. Remove the carious dentin with a round bur in a low speed handpiece running at very low speed.
6. Remove unsupported enamel, if appropriate, but pre serve as much facial enamel as possible and place bev els with a finishing bur and/or gingival margin trimmer.

Dentlearn.ir

7. Etch the enamel. Be careful not to etch the adjacent tooth; protect it with a matrix strip.
8. Place the primer and adhesive, following the manufac turer instructions.
9. Light cure as indicated.
10. If the preparation is large, place resin composite into the deep areas.
11. Light cure in increments no more than 2 mm thick for the appropriate time (material- and curing light–specific).
12. Place a clear plastic strip or other matrix and wedge.
13. Add composite and contour the matrix strip to contain the material in the proper shape.
14. Light cure.
15. Remove the wedge and matrix strip and inspect the restoration for voids; add resin composite if necessary.
16. Remove gingival flash with a no. 12 or 12B scalpel blade.
17. Remove flash from the other margins and contour the restoration with a finishing bur, finishing diamond, or abrasive disk.
18. Remove the rubber dam.
19. Check the occlusion and adjust as necessary.
20. Finish and polish with disks, rubber points, etc.
21. Apply etchant to the surface and margins; rinse, then apply and cure rebonding resin.

Class 4 restorations

Class 4 restorations are often complicated because of the difficulty in duplicating the natural tooth anatomical contours, surface texture, shade gradation, and opacities. To facilitate achievement of proper contours, custom matrices are employed. When treating a fracture of an incisal edge, a missing Class 4 restoration, or an existing Class 4 restoration that needs replacement, a custom matrix can be fabricated. In one technique, impression material or a rapid-set PVS material may be formed to provide a lingual matrix.[126] It should cover the lingual and incisal aspects of the tooth to be restored plus the lingual surfaces of one or two adjacent teeth. The matrix should extend facially only far enough to reach the facioincisal line angle. If tooth structure or a portion of a restoration is missing, then a quick mock-up of the restoration can be made. Expired resin composite or a seldom-used resin composite shade may be employed for this purpose. The tooth is dried, and composite is applied to form the desired tooth contours and light cured. Care should be taken in shaping the lingual aspect. After polymerization, the occlusion in maximum intercuspation and in excursive mandibular movements should be checked. The lingual contour can be finalized with a round or football-shaped carbide finishing

Dentlearn.ir

bur. A lingual matrix of impression material that reproduces the correct lingual contours, anterior guidance, and incisal length in the final restoration is then made.

In most cases, resin composite is layered in 2-mm increments to achieve desired coloring and complete polymerization. The incremental placement technique allows the clinician to shape the restoration to the desired form and contour. The preparation may be very slightly overfilled to allow subtractive contouring and finishing.

An *overlay technique* also may be used for Class 4 restorations to obtain a combination of strength and a very smooth surface.[127,128] The bulk of the restoration is built with a hybrid resin composite to provide strength. The final layer is a veneer of microfilled resin composite to provide a smooth, glossy surface. However, several modern hybrid and nanofilled resin composites present adequate strength and final gloss; thus, they can be used alone for the entire restoration.

To achieve imperceptible polychromatic restorations, a layering technique employing both enamel- and dentinlike materials is recommended[49,129] (Fig 10-25). Selection of dentin and enamel shades is based on the principle of the *basic shade*, in which the dentinlike material is one to two shades darker or more chromatic than the basic shade and the enamel-like material is the same shade as the basic shade. Dentin lobes, areas of high translucency, and halos may be incorporated into the restoration during layering.

Dentlearn.ir



Fig 10-25*(a)* Discolored, unesthetic Class 4 restoration that the patient desired to have replaced. *(b)* Lingual matrix fabricated from impression material to serve as a guide for contours and incisal length. *(c)* The defective restoration is removed, and long, scalloped bevels are placed for retention and esthetic blending of the tooth-restoration interface. *(d)* Application of the first layer of resin composite to restore lingual incisal contours. *(e)* A second layer of dentin-shade material is applied to mimic the underlying opacity and to attempt to mimic the shape of the dental mamelons. *(f)* Translucent material is applied at the incisal third to imitate incisal translucency. *(g)* An external layer of enamel-shade resin composite is feathered onto the facial surface and blended into the existing contours for a polychromatic, natural appearance. *(h)* A 12-fluted finishing bur establishes final contours and surface characteristics before employing disks and points to provide a final polish. *(i)* Flexible polishing disks conform to the facial contours of the tooth. *(j)* Abrasive-impregnated rubber points and/or cups may also be employed for polishing lingual contours and interproximal surfaces that are inaccessible to disks. *(k)* The completed restoration with a pleasing color match, surface characterization, and incisal edge morphology yields a highly esthetic outcome.

After proper etching and adhesive procedures are completed, the first layer is built up. A thin (0.2- to 0.3-mm) layer of enamel-shade composite resin is placed over the custom matrix and is limited to the size of the missing anatomical enamel

Dentlearn.ir

(see Fig 10-25d). The material should extend to the facioincisal line angle over the matrix. The custom matrix with the resin composite is carried to place in the mouth and positioned on the palatal aspect of the teeth. The resin composite is further adapted to the lingual bevel, if necessary, with an ovoid-shaped burnisher or a brush. The increment is light cured for the recommended time and the custom matrix removed. The second increment, the proper dentinlike material, should be placed to fill the angle produced by the surface of the first increment and the wall of tooth structure. The third increment, also a dentinlike material, reproduces the dentinal lobes (see Fig 10-25e). An interproximal carver or an ovoid-shaped bur-nisher is useful for forming these lobes, and a brush can be used to smooth the surface. When it is necessary to accentuate or make the lobes visible from the labial aspect or to create a high translucent incisal edge, a small increment of a translucent material is placed between the lobes, feathered over the incisal edge and over the bevel, smoothed, and light cured (see Fig 10-25f). A view from the incisal edge with an intraoral mirror should be used to evaluate the facial contour of each increment and to ensure that there is enough space for the following layer. A final enamel-like material increment is then placed to complete the facial contour of the restoration (see Fig 10-25g). This final layer should be placed in one increment to avoid voids and seams and contoured and shaped before polymerization until it closely resembles the desired shape. A matrix strip or an interproximal carver instrument is used to remove any excess and provide final proximal contours. Brushes are used to smooth and contour this final increment. After polymerization, the restoration is contoured, finished, and polished (see Figs 10-25h to 10-25k).

Figure 10-25 shows a step-by-step Class 4 resin composite restoration from beginning to end. The basic clinical steps for a Class 4 resin composite restoration are also outlined in Box 10-2.

Direct Resin Composite Veneers

Indirectly fabricated ceramic veneers are the gold standard for esthetics and longevity; however, direct resin composite veneers offer several advantages. Direct veneers generally provide a more conservative approach and can be placed in one visit without laboratory involvement or laboratory fees. Although the chair time required for placement of direct veneers can be considerable and experience is necessary to consistently achieve optimal results, the cost to the patient is generally lower than that for ceramic veneers. The lower cost may help to provide an alternate solution for many esthetic problems. Commonly, little or no enamel removal is

Dentlearn.ir

required. Resin composite will not cause premature wear of the opposing dentition and can be easily repaired and modified, unlike ceramic materials. However, resin composite veneers do not maintain their appearance as well as ceramic restorations over time. The percentage of practitioners providing direct ("freehand") resin composite veneers has declined in recent years, with a corresponding increase in the use of porcelain veneer restorations.[130] The clinical steps for a direct resin composite veneer are outlined in Box 10-3.

Box 10-3	**Clinical steps for a direct resin composite veneer**

1. Select resin shades prior to dehydration of the tooth.
2. Place a rubber dam and no. 212 (retractor) clamp, if desired. If rubber dam is not used, place gingival retraction cord to control sulcular fluid and retract the gingival tissue.
3. In most cases, the composite material is bonded directly to the tooth surface. If it is necessary to remove tooth structure to establish proper tooth alignment or to create space to mask dark tooth structure, a blunt ended diamond is recommended. Remove the smallest amount of tooth structure necessary to achieve the desired objective.
4. Etch the tooth surface with an appropriate etchant, such as 37% phosphoric acid. Protect adjacent teeth from the etchant with clear plastic strips.
5. Rinse the tooth thoroughly and dry the etched tooth surface with a stream of air.
6. Place a clear plastic strip or other matrix and wedge interproximally; apply adhesive resin and light cure for the appropriate time (material-specific instructions).
7. Apply opaque resin, if indicated, and light cure.
8. Add the selected resin composite, adapt and contour the material, and light cure for the appropriate length of time.
9. Add additional resin composite as necessary to achieve the proper shape, color, and translucency. Light cure each increment for the appropriate length of time.
10. Contour the gingival margins and remove flash with no. 12 or 12B scalpel blade.
11. Contour and finish the composite material with a carbide or diamond finishing bur.
12. Repeat the above process on adjacent teeth, if indicated.
13. Remove the rubber dam, if used.
14. Check the occlusion and adjust as necessary with finishing burs.
15. Finish and polish with disks, polishing points, etc.

Dentlearn.ir

16. Apply low-viscosity rebonding resin (surface sealer) to the restoration surface and margins.

Tooth preparation for direct resin veneers varies greatly, mainly according to tooth position and coloration. According to the position of the tooth, preparation may or may not be required. Teeth positioned lingually or those that are short cervicoincisally rarely require any preparation and can be brought into correct alignment and length by simply adding resin composite. Facially positioned teeth with or without rotation require some degree of preparation to allow space for the thickness of the material and to bring the tooth in alignment with the arch. Discolored teeth require preparation only if there is not enough space, about 1 mm, over the facial aspect to place a masking agent and resin composite.

Direct resin composite veneers can be produced by using single opacity shades or by layering various shades and opacities to obtain polychromatic esthetic restorations according to adjacent teeth, desired results, and patient expectations (Fig 10-26). If a tooth shows a dark discoloration, an opaque layer or masking agent is placed over the adhesive and polymerized[131] (Figs 10-27 and 10-28a to 10-28d). When necessary, white, orange, or brown tints may be used to add a natural look to

(Figs 10-28e and 10-28f). These color modifications will influence the surface shade unless the thickness of the resin composite exceeds 2.5 mm.[88–90] Translucency, the appearance of lobes or mamelons, and/or white or bluish characterization of the incisal edge may be added in the incisal third of the composite veneer. An attempt should be made to sculpt the resin composite to desired contours. If the restoration is slightly overcontoured, it may be finished and polished to proper contours. If it is slightly undercontoured in any area, additional resin composite material may be added.

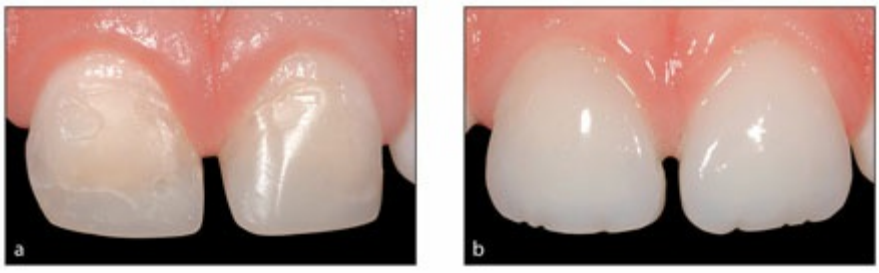

Fig 10-26 *(a)* Maxillary central incisors exhibit external stain, hypocalcification, and discolored restorations that require replacement. *(b)* Completed direct veneers mask stains and meet esthetic demands in this young patient.

Dentlearn.ir

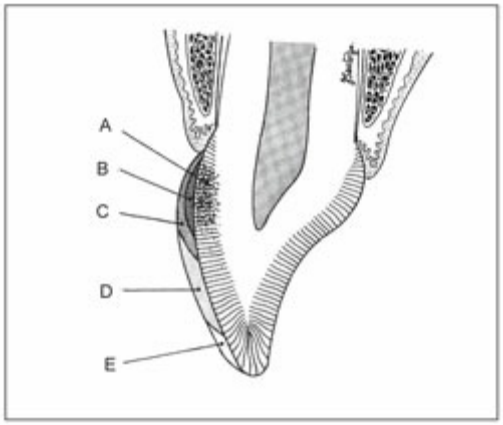

Fig 10-27 Facial veneering and masking of heavy stain/fluorosis using a combination of opaque, cervical, body, and translucent shades: stain/fluorosis (A); opaque shade (B); cervical shade (C); body shade (D); translucent shade (E).



Fig 10-28*(a)* Dark composite restorations on maxillary central incisors need replacement. *(b)* Isolation is achieved with a rubber dam. For veneer preparation and restoration, it is necessary to obtain maximum cervical retraction with floss ligatures. *(c)* The right central incisor has been prepared for a Class 4 restoration. The left central incisor has been prepared for a complete facial veneer. An intrinsic discoloration is present on the left central incisor, which will require masking with a layer of opaque composite. *(d)* Completed facial veneer on the left central incisor and Class 4 restoration on the right central incisor match the color of the adjacent teeth. A pleasing esthetic result with effective masking of stains can be achieved when the correct composite opacity is

characterization with white and caramel stains are applied to the resin composite. *(f)* Final result

Creating a diagnostic wax-up is recommended to reduce clinic time and increase the predictability of the final veneers. The wax-up will provide information on the final contours and the amount of material necessary to complete the veneers. The

Dentlearn.ir

diagnostic wax-up can be shown to the patients for their acceptance, or an impression can be made by PVS and an intraoral mock-up performed[132] (Fig 10-29). A custom matrix made from the wax-up, similar to the one described for a Class 4 restoration, can be fabricated from the wax-up to aid with placement of the veneers.

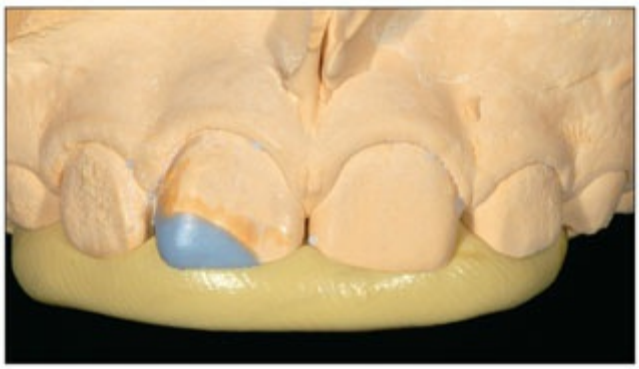

Fig 10-29 Wax-up of a Class 4 restoration for diagnostic purposes and patient presentation. Additionally, a PVS matrix can be made from the wax-up to aid in the restorative phase.

Diastema closure

The technique for diastema closure is similar to that for placement of direct veneers and Class 4 restorations. In most cases, no tooth structure has to be removed, and the resin composite is retained solely by adhesive bonding. For a small diastema (1 mm or less), an enamel-like resin composite is added to the proximal surfaces of the two adjacent teeth (Fig 10-30). For a moderate-sized to large diastema, an opaque or dentinlike material should be placed to block the show-through effect caused by the darkness of the mouth (Fig 10-31). A slight blending of the material onto the facial surface will help achieve a natural transition of shades and improve the esthetic outcome. The facial and incisal contours can then be established with an enamel-like resin composite. When closing a diastema, care should be taken to provide the proper tooth contours when placing and finishing the material. This is especially crucial in the gingival embrasure areas. If the diastema exceeds 2.5 mm, it may be necessary to use a combination of direct veneering and orthodontic movement to position the teeth into a more easily managed and esthetically pleasing location. Corrective enameloplasty of the distal-surface contours of the teeth to be restored, followed by building up of adjacent teeth, may improve the esthetic outcome.



Dentlearn.ir

Fig 10-30*(a)* A maxillary lateral incisor and canine with an existing diastema to be closed with resin composite. *(b)* Phosphoric acid etchant is applied; no preparation of natural tooth structure is required for adhesion. *(c)* Completed diastema closure showing improved esthetics and imperceptible blend of resin composite and natural enamel. Note the translucency of the incisal edge.



Fig 10-31*(a)* Labial view of finished diastema closure showing the use of body and translucent shades to simulate natural tooth color and translucency. *(b)* Moderate midline diastema. The patient's desire for esthetic improvement may be satisfied with resin composite. *(c)* Completed diastema closure. Note the physiologic contouring of the cervical aspect of the restorations and the homogenous luster of the composite material and natural tooth surface. (Figs 10-31b and 10-31c courtesy of Robert H. Poindexter, Kerrville, Texas.)

When diastema closure is performed, occlusal relationships and esthetic proportions as well as the overall facial esthetics must be considered. When anterior teeth are widened, it may also be necessary to lengthen them to preserve natural anatomical proportions. If occlusal relationships and facial appearance will allow, the proper tooth length can be established by adding to the incisal edge. It is also possible to improve the length-to-width ratio by surgical crown lengthening in some patients. The desired lengths and widths of teeth should be determined using a diagnostic wax-up before treatment is begun (Fig 10-32). A trial application or mock-up, assessing the esthetic alteration of the shape and color of the proposed restoration, may be accomplished with resin composite applied to unetched teeth.[134]



Fig 10-32 Diagnostic wax-up of proposed recontouring and closure of dia-stemata. This treatment planning procedure may assist in identifying tooth-size discrepancies, areas requiring esthetic recontouring, and gingival height and contour considerations. The cast may also be used for patient education and communication of treatment goals, as well as for fabrication of a lingual matrix and as a chairside guide for direct restorations.

Dentlearn.ir

Maintenance of the proper length and width relationships in anterior teeth is very important to achieving an esthetic result for resin composite veneers, porcelain veneers, and diastema closures (see chapter 3). A study evaluating the length and width of anterior teeth revealed that, on average, central incisors and canines are approximately equal in length and are 20% longer than lateral incisors.[133] The proper dimensions, length-to-width ratios, and width-to-width ratios are shown in Tables 10-1 and 10-2.

Table 10-1 **Dimensional averages (in mm) for maxillary incisors and canines***

	Males		Females	
Tooth	**Length**	**Width**	**Length**	**Width**
Central incisor	10.7	9.4	9.6	9.1
Lateral incisor	9.1	7.5	8.2	7.1
Canine	10.7	8.5	9.2	8.0

*Data from Gillen et al.[133]

Table 10-2 **Length/width and width/width* ratios for maxillary incisors and canines†**

	Males		
	Length/ width	**Width/width lateral**	**Width/width canine**
Central incisor	1.15:1	1.25:1	1.1:1
Lateral incisor	1.2:1	–	
Canine	1.25:1	1.15:1	–
	Females		
	Length/ width	**Width/width lateral**	**Width/width canine**
Central incisor	1.05:1	1.3:1	1.15:1
Lateral incisor	1.15:1	–	

Dentlearn.ir

Canine	1.15:1	1.15:1	–

*Width/width ratios are only listed for larger teeth to smaller teeth (eg, central incisor to lateral incisor).

†Data from Gillen et al.[133]

A periodontal probe or caliper may be used as a measuring device to evenly divide the space to be closed. Diastema closures frequently require augmenting two to six teeth with resin composite to achieve optimal esthetic relationships (Figs 10-33 and 10-34).



Fig 10-33*(a and b)* Diastema closures frequently require bonding of resin composite to two to six teeth to achieve proper esthetic relationships. Multiple composite veneers were needed for this patient.

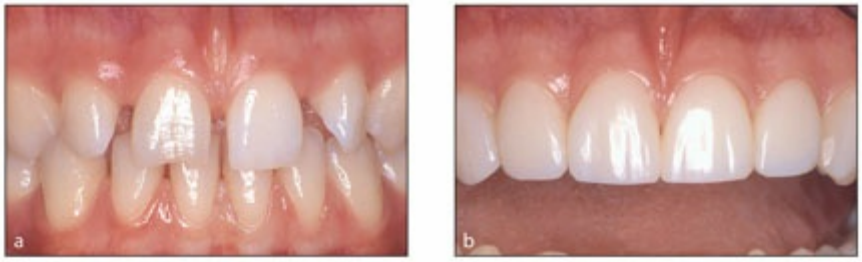

Fig 10-34*(a and b)* This diastema closure also required multiple composite veneers.

Most diastema closures can be accomplished without the use of a matrix or a wedge, thus providing better control of proximal contours in the gingival embrasure areas. When restoring adjacent teeth, the proximal contours are best built up one at a time. Sculptable microfilled or nanofilled resin composites are the preferred materials. A small amount of resin composite, just enough to provide half of the diastema closure, is placed on the mesiofacial line angle of the first tooth. A thin, bladed instrument is used to push and adapt the material on the facial surface. The remaining composite is carried toward the lingual, and the gingival embrasure is

Dentlearn.ir

contoured to the shape desired. Care should be taken to achieve the desired proximal contour and tooth width. It is very helpful to measure the width of the restored tooth with calipers and compare it to the adjacent tooth and the remaining space to ensure that proper symmetry is achieved. Following polymerization, the proximal surface of the first restoration should be finished and polished to the exact contour desired. The contours of the facial surface and incisal edge should be very close to the final desired shape but may be polished at the same time as the adjacent restoration. Fig 10-35 shows a step-by-step diastema closure without the use of a matrix.



Fig 10-35 Diastema closure using resin composite. *(a)* The diastema between maxillary central incisors measures slightly more than 1 mm. *(b)* Resin composite is placed into the diastema and polymerized to verify shade selection prior to the dehydration of the teeth that accompanies the

Dentlearn.ir

procedure. *(c)* Tooth surfaces are cleaned with a slurry of fine pumice. *(d)* Retraction cord has been placed to move the tissue of the interproximal gingival papilla. *(e)* Etchant is applied to only one central incisor; the etched area is larger than that needed for attachment of resin composite. A strip of clear, plastic matrix protects the other central incisor from being etched. After 30 seconds of etching, the surface is rinsed and thoroughly dried. *(f)* Adhesive resin is placed over the etched enamel and light polymerized. *(g)* Resin composite is placed so that it has slightly greater contour than the desired final restoration. *(h)* The resin composite has been light polymerized. *(i)* The resin composite is contoured with a coarse-grit disk. *(j)* The interproximal area is finished so that the resin composite will close one-half of the diastema. *(k)* Final polishing of the restoration is performed. *(l)* The restoration of the left central incisor is complete. *(m)* The mesial portion of the right central incisor is etched; a plastic matrix strip protects the adjacent tooth from the etchant. *(n)* After the etchant is rinsed away, the surface dried, and the resin adhesive applied and polymerized, resin composite is placed in contact with the adjacent restoration and polymerized. *(o)* The restorations are lightly separated by pushing a thin instrument against the contact from the gingival embrasure.



Fig 10-35*(cont)* *(p)* The gingival margins of the restoration are shaped with a no. 12 scalpel blade. *(q)* The proximal surface, gingival to the interproximal contact, is finished and polished using progressively finer-grit finishing strips. *(r)* Surfaces of the restorations are polished with an aluminum oxide polishing paste. *(s)* The diastema closure procedure is complete. (Courtesy of J. William Robbins, San Antonio, Texas.)

A tight, properly contoured contact can be achieved using a “pull-through” matrix technique. When placing the adjacent restoration, care should be taken to confine both the etchant and the bonding resin to prevent inadvertent splinting. After the adhesive resin is polymerized, a clear celluloid strip is placed in the contact area and the resin composite applied to the facial surface of the second tooth. After the material is blended to contour and shaped against the strip, the strip is slowly pulled to the lingual, drawing the material with it. When the material is midway through the contact, the strip sh terial in the contact

Dentlearn.ir

area. Wiping the strip with alcohol-dampened gauze prior to placement may help to release the material from the strip. A brush or placement instrument can be used to gently push the facial resin increment into contact with the already completed restoration on the adjacent tooth, and then the embrasures are shaped and refined and the composite polymerized. Although the polymerized resin will stick to the adjacent tooth, it can easily be separated by lightly rotating (torquing) an instrument between the teeth. Following separation, a clear celluloid strip is reinserted and contoured against the lingual contour of the tooth. A small amount of resin composite is placed against the strip to fill any deficiencies on the lingual surface, and the lingual portion of the strip is drawn tightly against the cingulum with a thumb or a finger. The strip is then pulled out to the facial, drawing the material into the lingual deficiencies. After polymerization, the teeth are again separated and finishing procedures are initiated.

Finishing and Polishing

Finishing includes the shaping, contouring, and smoothing of the restoration, while *polishing* imparts the shine or luster to the surface (see Fig 10-25k). Finishing a restoration is as important as adequate shade matching. Even when a good shade match has been obtained, if the finishing process does not simulate the adjacent tooth contours, the restoration will not appropriately blend with its surroundings. There are many products available for finishing and polishing, including diamond and carbide burs, scalpel blades and carving instruments, various types of flexible disks, abrasive-impregnated rubber points and cups, metal and plastic finishing strips, and polishing pastes.[134] The smoothest possible surface is obtained when the resin composite polymerizes against a clear plastic strip without subsequent finishing or polishing. However, such a surface typically has a higher resin content, because the monomers tend to work their way through the fillers like a sieve when the composite is pushed against a surface. This may yield a very smooth superficial layer but one that is less resistant to wear due to its reduced amount of reinforcing fillers.

The finishing and polishing process can affect many aspects of the final restoration, including surface shine, surface staining, and plaque accumulation. The composition of the composite material and the polishing system and protocol used all influence the finish and polish that can be obtained.[135–138] Polish retention over time is an important concern for clinicians and depends greatly on filler particle size. Composites with larger particles tend to be more difficult for the clinician to obtain smooth surfaces, and they show more surface roughness with time, as the

Dentlearn.ir

surface is exposed to abrasion and erosion from food and drinks.[139,141]

Instruments

Diamond and carbide burs

Ideally, a minimum of finishing should be imparted to a resin composite. This goal is easily achieved when contouring and smoothing of the restoration is obtained before polymerization. The 12-fluted carbide burs have traditionally been used to perform gross finishing of resin composites. Fine finishing diamonds are also available for finishing resin composite restorations and have been found to impart less surface damage to microfilled resin composites than carbide finishing burs[141] (Fig 10-36). These finishing burs and diamonds may be used to develop the proper macro- and microanatomy for the restoration. The transition from resin to enamel should be slowly smoothed until it is undetectable. These burs can be used dry to better visualize the margins and anatomy being developed, and they should always be used with light pressure to avoid overheating and possibly damaging the resin composite surface.

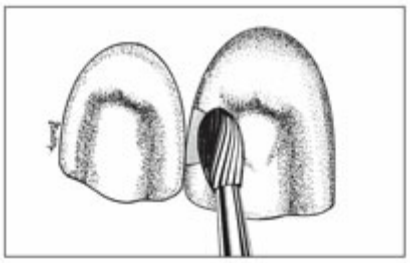

Fig 10-36 A finishing bur or fine diamond is used for gross finishing.

Scalpel blades and resin carving instruments

Blades and carving instruments are effective at refining gingival margins and interproximal areas. Burs and disks can cause damage to the soft tissue and cementum in the gingival area. A no. 12 or 12B scalpel blade is often used to safely remove excess material at the gingival margin. Blades and resin carving instruments are also used to refine embrasures (Fig 10-37).

Dentlearn.ir

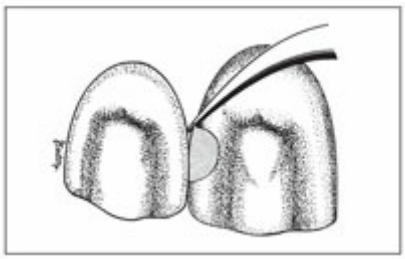

Fig 10-37 Gingival flash is removed with a no. 12 or 12B scalpel blade.

Disks

One brand of flexible disks (Sof-Lex, 3M ESPE) has practically become the standard in finishing and polishing. The disks in one Sof-Lex series have a soft, flexible backing and a series of grits that can provide a smooth, even finish. Another Sof-Lex series, and similar disks made by other manufacturers, have thin plastic or polymeric backings that allow access of the abrasive side into embrasures and interproximal areas. When all four grits are used in sequence, these flexible finishing disks are reported to provide either the smoothest or nearly the smoothest surfaces of any finishing systems.[136,142,143] Sequential use of disks with progressively finer grits produces a smooth, durable finish (Fig 10-38). Unfortunately, disks have the tendency to leave flat surfaces, unlike the normal rounded shapes found in natural teeth.

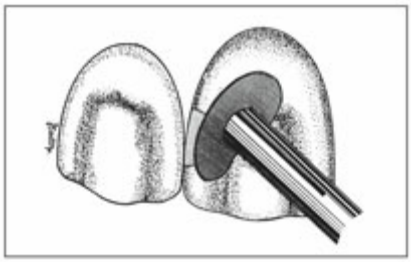

Fig 10-38 Polishing of the final restoration may be accomplished with flexible abrasive disks or abrasive-impregnated rubber points, cups, and/ or disks.

Dry finishing with disks used in sequence is reported to be superior or equal to wet finishing for smoothness, hardness, and color stability.[144] However, dry finishing tends to clog disks with abrasive particles and makes the disks work less efficiently.

Impregnated rubber points and cups

A wide variety of rubber finishing and polishing points and cups impregnated with abrasive materials are available. Like disks, rubber cups and points are used

Dentlearn.ir

sequentially from coarse to fine grit. The coarse grits may be effective for gross reduction and finishing, while the fine grits create a smooth, shiny surface. The primary advantage of rubber points and cups over disks is that they provide access to grooves, desirable surface irregularities, and the concave lingual surfaces of anterior teeth. The surfaces obtained with these cups tends to better resemble the natural anatomy of teeth.

Finishing strips

Finishing strips are used to contour and polish the proximal surfaces and margins gingival to the interproximal contact (Fig 10-39). They are available with metal or plastic backings. Most metal-backed strips are used for gross reduction, but care must be taken not to overreduce the restoration; these metal-backed strips will also remove enamel, cementum, and dentin. Plastic strips come in various widths and grits and can be used for both finishing and polishing. Like the flexible disks, finishing strips come in a series of grits, which should be used in series from coarsest to finest.

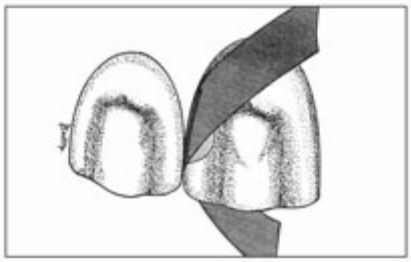

Fig 10-39 Polishing strips are used to contour and polish the proximal surface and margin.

Procedures

Contouring

Contouring has the purpose of shaping the restoration to simulate the natural contours and anatomy of a tooth. It is extremely important for the clinician to be familiar with the anatomy found in the natural dentition to readily and predictably obtain good restoration contours.

Contouring should be carried out in a sequence. The first step in contouring is the evaluation of the length of the restoration in relation with the adjacent teeth and the establishment of the facioincisal line angle. A medium-grit disk is used to reduce and contour the incisal edge. Young patients will have round incisal line angles in a mesiodistal direction because of the lack of wear; however, with age the teeth

Dentlearn.ir

become flatter as a result of wear. A palatal inclination of the incisal edge is observed with age in the maxillary anterior teeth. In contrast, a labial inclination is observed for the mandibular anterior teeth. The second step is to check the occlusion in maximum intercuspation and in excursive movements and adjust accordingly. The third step is to locate and contour the mesiofacial and distofacial transitional line angles. This is accomplished by using fine carbide or diamond burs or impregnated rubber cups. The transitional line angles are easily identified from an incisal view with an intraoral mirror. The fourth step is to contour tooth embrasures. The incisal embrasures can be easily contoured with medium-grit disks and the gingival embrasures with a no. 12 or 12B scalpel blade. Additionally, a perforated diamond strip (eg, Visionflex, Brasseler) is very effective in smoothing and contouring the gingival embrasures.

Finishing and characterization

Finishing should be done carefully to avoid damaging the surface or margins of the resin composite restoration. Medium-and fine-grit impregnated cups are sequentially used to progressively smooth the facial and lingual surfaces of the restoration. Similarly, a sequence of finishing strips is used on the proximal surfaces and margins. The dental floss should pass over the proximal resin surface smoothly and snap through the contact without shredding.

adjacent dentition onto the restoration. A fine diamond at low speed is useful to reproduce imbrication lines found in young teeth.

Polishing

A final surface polish can be obtained by using a diamond or silicon carbide–impregnated disk or cup. Aluminum oxide or diamond polishing pastes are also used to obtain a high polish.

Many operators have observed the development of a “white line” at the margins of resin composite restorations during finishing. The exact cause of this phenomenon is not known, but several investigators and clinicians have put forward possible explanations. One explanation[145–147] implicates traumatic finishing leading to microfractures in the resin composite or tooth structure at the interface. Other proposed causes include improperly rotating abrasive disks (the disks should rotate from resin composite to tooth),[148,149] inadequate polymerization of the resin composite material,[147] and polymerization shrinkage causing microfracture of

Dentlearn.ir

unsupported or fragile enamel at the margins.[150] When the white line presents an esthetic problem and more conservative procedures such as rebonding do not resolve it, the white area must be removed with a bur and additional composite must be bonded and finished.

A typical kit for finishing resin composites contains a fine diamond and a mandrel for disks to contour the restoration (Fig 10-40). It also contains rubber points to sequentially smooth the restoration and to provide final luster. Figure 10-41 illustrates a contouring and polishing sequence.



Fig 10-40 Kit for finishing and polishing resin composites.

Dentlearn.ir



Fig 10-41*(a)* Preoperative view of chipped resin composite restoration in need of replacement. *(b)* Cavity preparation for a Class 4 resin composite and facial veneering. *(c)* The first step in contouring is to establish the length of the restoration and position of the facioincisal line angle. *(d)* The position of the mesio- and distofacial line angles are marked with a pencil for visualization. *(e)* A fine flame-shaped diamond is used to contour the restoration and reproduce the fine anatomical details. *(f)* Surface characterization of an extracted human incisor. Some natural dentition is characterized by abundant secondary anatomy. *(g)* A coarse-grit silicon-impregnated rubber cup, the green Jiffy Polisher (Ultradent), is used to smooth the roughness left by the diamond bur. *(h)* A medium-grit rubber cup, Gloss Plus Polishers (Kerr), is used to further smooth the restoration. *(i)* A fine-grit diamond-impregnated cup, HiLuster Plus (Kerr), is used to obtain high gloss. *(j)* Final gloss is obtained before rubber dam removal. *(k)* The definitive restoration matches the surface characterization, gloss, and contours of the adjacent teeth.

Rebonding

Rebonding (also called *surface sealing* or *glazing*) is performed after the restoration is finished and polished. The margins are re-etched, and a coat of

Dentlearn.ir

unfilled or lightly filled low-viscosity resin is placed over the restoration surface and polymerized. Rebonding has been reported to improve marginal integrity, aid color stability, improve early wear resistance, and help reduce staining of the restoration.[151–156] The long-term effect of rebonding is questionable because this surface layer of low-viscosity resin is likely to wear quickly. A number of low-viscosity resins, called *surface sealers*, are now available for use in the rebonding procedure. Rebonding is rarely needed for anterior restorations when a proper placement and finishing protocol has been followed.

Techniques for Repair or Correction of Intraoral Restorations

Resin composites are effective for the repair or correction of intraoral restorations for many kinds of materials. By combining chemical bonding techniques as well as macro- and micromechanical retention, attachment of the resin composite to the old restoration can be obtained. In many cases, repair or correction requires less preparation and will reduce the risk of damage to the tooth when compared with complete replacement of defective or unesthetic restorations.[157,158] Macromechanical retention can be created by the preparation of undercuts in the old restoration, which can also improve the resistance form.

Micromechanical retention can be obtained by preparation with a coarse diamond bur or air abrasion. Air abrasion is effective on all resin composites, porcelain, acrylic resins, and metals. It may be performed with aluminum oxide particles or with a special aluminum oxide powder coated with a layer of silica (CoJet Sand, 3M ESPE).[159–161] The latter is designed to deposit a layer of silica on the surface of the air-abraded restoration. This may enhance chemical retention and allow silanization. On porcelain and resin composites containing glass, silanization is an effective method to maximize the chemical bond. Some silanes are directly applied to the surface, while others are activated when mixed with specific adhesive primers or resins. On metals, specific metal primers, applied after air abrasion, are effective in improving the bond strength.[162]

References

1. Hickel R, Roulet JF, Bayne S, et al. Recommendations for conducting controlled clinical studies of dental restorative materials. Clin Oral In-vestig 2007;11:5–33 [erratum 2008;12:97].
2. Stewardson D, Thornley eneral dental practice: Part

Dentlearn.ir

1, baseline data. Br Dent J 2010; 208(9):E17.
3. Ferracane JL. Resin composite—State of the art. Dent Mater 2011; 27:29–38.
4. van Noort R, Davis LG. A prospective study of the survival of chemically activated anterior resin composite restorations in general practice: 5-year results. J Dent 1993;21:209–215.
5. Millar BJ, Robinson PB, Inglis AT. Clinical evaluation of an anterior hybrid composite resin over 8 years. Br Dent J 1997;182:26–30.
6. Reusens B, D'hoore W, Vreven J. In vivo comparison of a microfilled and a hybrid minifilled composite resin in Class III restorations: 2-year follow-up. Clin Oral Investig 1999;3:62–69.
7. van Dijken JW, Olofsson AL, Holm C. 5-year evaluation of Class III composite resin restorations in cavities pre-treated with an oxalic- or a phosphoric acid conditioner. J Oral Rehabil 1999;26:364–371.
8. Närhi TO, Tanner J, Ostela I, et al. Anterior Z250 resin composite restorations: One-year evaluation of clinical performance. Clin Oral Investig 2003;7:241–243.
9. Wolff D, Kraus T, Schach C, et al. Recontouring teeth and closing diastemas with direct composite buildups: A clinical evaluation of survival and quality parameters. J Dent 2010;38:1001–1009.
10. Spinas E. Longevity of composite restorations of traumatically injured teeth. Am J Dent 2004;17:407–411.
11. Lucarotti PS, Holder RL, Burke FJ. Outcome of direct restorations placed within the general dental services in England and Wales (Part 1): Variation by type of restoration and re-intervention. J Dent 2005;33:805–815.
12. Smales RJ. Effects of enamel bonding, type of restoration, patient age and operator on the longevity of an anterior composite resin. Am J Dent 1991;4:130–133.
13. Qvist V, Strøm C. 11-year assessment of Class-III resin restorations completed with two restorative procedures. Acta Odontol Scand 1993;51: 253–262.
14. Stewardson D, Creanor S, Thornley P, et al. The survival of Class V restorations in general dental practice: Part 3, five-year survival. Br Dent J 2012;212(9):E14.
15. Leinfelder KF, Suzuki S. In vitro wear device for determining posterior composite wear. J Am Dent Assoc 1999;130:1347–1353.
16. Medlock JW, Zinck JH, Norling BK, Sisca RF. Composite resin porosity with hand and syringe insertion. J Prosthet Dent 1985;54:47–51.
17. Ferracane JL. Developing a more complete understanding of stresses produced in dental composites during polymerization. Dent Mater 2005;21:36–42.
18. Peutzfeld A. Resin composites in dentistry: The monomer systems. Eur J Oral Sci 1997;105:97–116.
19. Davidson CL, De Gee AJ. Relaxation of polymerization contraction stresses by flow in dental composites. J Dent Res 1984;63:16–48.
20. Choi KK, Ryu GJ, Choi SM, Lee MJ, Park SJ, Ferracane JL. Effects of cavity configuration on composite restoration. Oper Dent 2004;29:462–469.
21. Van Ende A, De Munck J, Mine A, Lambrechts P, Van Meerbeek B. Does a low-shrinking composite induce less stress at the adhesive interface? Dent Mater 2010;26:215–222.
22. Gordon M, Plasschaert A, Saiku J, Pelzner RB. Microleakage of posterior composite resin materials and an experimental urethane restorative material, tested in vitro above and below the cementoenamel junction. Quintessence Int 1986;17:11–15.
23. Eick JD, Welch F. Polymerization shrinkage of posterior composite resins and its possible influence on postoperative sensitivity. Quintessence Int 1986;17:103–111.
24. Ferracane JL, Mitchem JC. Relationship between composite contraction stress and leakage in class V cavities. Am J Dent 2003;16:239–243.
25. Lutz F, Krejci I, Barbakow F. Quality and durability of marginal adaptation in bonded composite restorations. Dent Mater 1991;7:107–113.
26. Hashimoto M, Tay FR, Ohno H, et al. SEM and TEM analysis of water degradation of human dentinal collagen. J Biomed Mater Res B Appl Biomater 2003;66:287–298.
27. Pashley DH, Tay FR, Yiu C, et al. Collagen degradation by host-derived enzymes during aging. J Dent Res 2004;83:216–221.
28. Tay FR, Hashimoto M, Pashley DH, et al. Aging affects two modes of nanoleakage expression in bonded

Dentlearn.ir

dentin. J Dent Res 2003;82:537–541.
29. Park J, Chang J, Ferracane J, Lee IB. How should composite be layered to reduce shrinkage stress: Incremental or bulk filling? Dent Mater 2008; 24:1501–1505.
30. Opdam NJ, Roeters JJ, Kuijs R, Burgersdijk RC. Necessity of bevels for box only Class II composite restorations. J Prosthet Dent 1998;80:274–279.
31. Davidson CL, Feilzer AJ. Polymerization shrinkage and polymerization shrinkage stress in polymer-based restoratives. J Dent 1997;25:435–440.
32. Weinmann W, Thalacker C, Guggenberger R. Siloranes in dental composites. Dent Mater 2005;21:68–74.
33. Marchesi G, Breschi L, Antoniolli F, DiLenarda R, Ferracane J, Cadenaro M. Contraction stress of low-shrinkage composite materials assessed with different testing systems. Dent Mater 2010;26:947–953.
34. Alster D, Feilzer AJ, De Gee AJ, Mol A, Davidson CL. The dependence of shrinkage stress reduction on porosity concentration in thin resin layers. J Dent Res 1992;71:1619–1622.
35. Choi KK, Condon JR, Ferracane JL. The effects of adhesive thickness on polymerization contraction stress of composite. J Dent Res 2000;79:812–817.
36. Braga RR, Ferracane JL, Hilton TJ. Contraction stress of flowable composites and their efficacy as stress-relieving layers. J Am Dent Assoc 2003; 134:721–728.
37. Uno S, Asmussen E. Marginal adaptation of a restorative resin polymerized at reduced rate. Scand J Dent Res 1991;99:440–444.
38. Lim BS, Ferracane JL, Sakaguchi RL, Condon JR. Reduction of polymerization contraction stress for dental composites by two-step light-activation. Dent Mater 2002;18:436–444.
39. Kwon Y, Ferracane J, Lee IB. Effect of layering methods, composite type, and flowable liner on the polymerization shrinkage stress of light cured composites. Dent Mater 2012;28:801–809.
40. Yoshikawa T, Sano H, Burrow MF, Tagami J, Pashley DH. Effects of dentin depth and cavity configuration on bond strength. J Dent Res 1999;78: 898–905.
41. Sakaguchi RL, Powers JM (eds). Craig's Restorative Dental Materials, ed 13. Philadelphia: Elsevier Mosby, 2012.
42. Leevailoj C, Cochran MA, Matis BA, Moore BK, Platt JA. Microleakage of posterior packable resin composites with and without flowable liners. Oper Dent 2001;26:302–307.
43. Opdam NJ, Roeters JJ, Peters TC, Burgersdijk RC, Kuijs RH. Consistency of resin composites for posterior use. Dent Mater 1996;12:350–354.
44. Tyas MJ, Jones DW, Rizkalla AS. The evaluation of resin composite consistency. Dent Mater 1998;14:424–428.
45. Lee IB, Chang J, Ferracane J. Slumping resistance and viscoelasticity prior to setting of dental composites. Dent Mater 2008;24:1586–1593.
46. Chiang YC, Knezevic A, Kunzelmann KH. Slumping during sculpturing of composite materials. Dent Mater 2008;24:1594–1601.
47. Kaleem M, Satterthwaite JD, Watts DC. Effect of filler particle size and morphology on force/work parameters for stickiness of unset resin-composites. Dent Mater 2009;25:1585–1592.
48. Tjan AH, Glancy JF. Effects of four lubricants used during incremental insertion of two types of visible light–activated composites. J Prosthet Dent 1988;60:189–194.
49. Villarroel M, Fahl N, De Sousa AM, De Oliveira OB Jr. Direct esthetic restorations based on translucency and opacity of composite resins. J Esthet Restor Dent 2011;23:73–87.
50. Chen RC, Chan DC, Chan KC. A quantitative study of finishing and polishing techniques for a composite. J Prosthet Dent 1988;59:292–298.
51. Goldman M. Fracture properties of composite and glass ionomer dental restorative materials. J Biomed Mater Res 1985;19:771–783.
52. Lambrechts PP, Ameye C, Vanherle G. Conventional and microfilled composite resins. Part II: Chip fractures. J Prosthet Dent 1982;48:527–538.
53. Tyas MJ. Correlation between fracture properties and clinical performance of composite resins in Class IV cavities. Aust Dent J 1990; 35:46–49.

Dentlearn.ir

54. Ferracane JL. Current trends in dental composites. Crit Rev Oral Biol Med 1995;6:302–318.
55. Tyas MJ. Color stability of composite resins: A clinical comparison. Aust Dent J 1992;37:88–90.
56. Shortall AC, Uctasli S, Marquis PM. Fracture resistance of anterior, posterior and universal light activated composite restoratives. Oper Dent 2001;26:87–96.
57. Ilie N, Hickel R. Investigations on mechanical behavior of dental composites. Clin Oral Investig 2009;13:427–438.
58. ADA Council on Scientific Affairs. Restorative materials. ADA Professional Product Review 2010;5(2):1–16.
59. Klapdohr S, Moszner N. New inorganic components for dental filling composites. Monatsh Chem 2005;136:21–45.
60. Chen MH. Update on dental nanocomposites. J Dent Res 2010;89:549–560.
61. Lefever D, Perakis N, Roig M, Krejci I, Ardu S. The effect of toothbrushing on surface gloss of resin composites. Am J Dent 2012;25:54–58.
62. Haveman CW, Summitt JB, Burgess JO, Carlson K. Three restorative materials and topical fluoride gel used in xerostomic patients: A clinical comparison. J Am Dent Assoc 2003;134:177–184.
63. Burgess JO, Gallo JR. Treating root surface caries. Dent Clin North Am 2002;46:385–404.
64. Wiegand A, Buchalla W, Attin T. Review on fluoride-releasing restorative materials—Fluoride release and uptake characteristics, antibacterial activity and influence on caries formation. Dent Mater 2007;23:343–362.
65. De Moor RJ, Stassen IG, van 't Veldt Y, Torbeyns D, Hommez GM. Two-year clinical performance of glass ionomer and resin composite restorations in xerostomic head- and neck-irradiated cancer patients. Clin Oral Investig 2011;15:31–38.
66. Haveman CW, Burgess JO, Summitt JB. Clinical comparison of restorative materials for caries in xerostomic patients [abstract 1441]. J Dent Res 1999;78:286.
67. Boghosian AA, Ricker J, McCoy R. Clinical evaluation of a resin-modified glass-ionomer restorative: 5-year results [abstract 1436]. J Dent Res 1999;78(special issue):285.
68. Brackett WW, Gilpatrick RO, Browning WD, Gregory PN. Two-year clinical performance of a resin-modified glass-ionomer restorative material. Oper Dent 1999;24:9–13.
69. Robbins JW, Duke ES, Schwartz RS, Trevino D. Clinical evaluation of a glass ionomer restorative in cervical abrasions [abstract 171]. J Dent Res 1996;75(special issue):39.
70. Perdigão J, Dutra-Corrêa M, Saraceni S, Ciaramicoli M, Kiyan V. Randomized clinical trial of two resin-modified glass ionomer materials: 1-year results. Oper Dent 2012;37:591–601.
71. Featherstone JD. The continuum of dental caries—Evidence for a dynamic disease process. J Dent Res 2004;83:39–42.
72. Ricketts DN, Pitts NB. Traditional operative treatment options. Monogr Oral Sci 2009;21:164–173.
73. Featherstone JD. Remineralization, the natural caries repair process—The need for new approaches. Adv Dent Res 2009;21:4–7.
74. Peters MC. Strategies for noninvasive demineralized tissue repair. Dent Clin North Am 2010;54:507–525.
75. Ferreira JM, Aragão AK, Rosa AD, Sampaio FC, Menezes VA. Therapeutic effect of two fluoride varnishes on white spot lesions: A randomized clinical trial. Braz Oral Res 2009;23:446–451.
76. Trushkowsky RD, Gwinnett AJ. Microleakage of Class V composite, resin sandwich, and resin-modified glass ionomers. Am J Dent 1996;9:96–99.
77. van Dijken JW, Kieri C, Carlen M. Longevity of extensive Class II open-sandwich restorations with a resin-modified glass-ionomer cement. J Dent Res 1999;78:1319–1325.
78. Vilkinis V, Hörsted-Bindslev P, Baelum V. Two-year evaluation of Class II resin-modified glass ionomer cement/composite open sandwich and composite restorations. Clin Oral Investig 2000;4:133–139.
79. Tantbirojn D, Rusin RP, Bui HT, Mitra SB. Inhibition of dentin demineralization adjacent to a glass-ionomer/composite sandwich restoration. Quintessence Int 2009;40:287–294.
80. van Meerbeek B, Peumans M, Gladys S, Braem M, Lambrechts P, Vanherle G. Three-year clinical effectiveness of four total-etch dentinal adhesive systems in cervical lesions. Quintessence Int 1996;27:775–784.

Dentlearn.ir

81. Alonge OK, Narendon S, Williamson DD. Prevalence of fractured incisal teeth among children in Harris County, Texas. Dent Traumatol 2001; 17:218–221.
82. Gutz DP. Fractured permanent incisors in a clinical population. J Dent Child 1971;38:94–95.
83. Young JM, Satrom KD, Berrong JM. Intraoral dental lights: Test and evaluation. J Prosthet Dent 1987;57:99–107.
84. Barghi N, Godwin JM. Reducing the adverse effect of bleaching on composite-enamel bond. J Esthet Dent 1994;6:157–161.
85. Browning WD, Contreras-Bulnes R, Brackett MG, Brackett WW. Color differences: Polymerized composite and corresponding Vitapan Classical shade tab. J Dent 2009;37(suppl 1):e34–e39.
86. Barutcigil C, Harorli OT, Yildiz M, Ozcan E, Arslan H, Bayindir F. The color differences of direct esthetic restorative materials after setting and compared with a shade guide. J Am Dent Assoc 2011;142:658–665.
87. da Costa J, Fox P, Ferracane J. Comparison of various resin composite shades and layering technique with a shade guide. J Esthet Restor Dent 2010;22:114–124.
88. Lee YK, Powers JM. Influence of background color on the color changes of resin composites after accelerated aging. Am J Dent 2007;20:27–30.
89. An JS, Son HH, Qadeer S, Ju SW, Ahn JS. The influence of a continuous increase in thickness of opaque-shade composite resin on masking ability and translucency. Acta Odontol Scand 2013;71:120–129.
90. Kim SJ, Son HH, Cho BH, Lee IB, Um CM. Translucency and masking ability of various opaque-shade composite resins. J Dent 2009;37:102–107.
91. Felippe LA, Monteiro S Jr, De Andrada CA, Di Cerqueira AD, Ritter AV. Clinical strategies for success in proximoincisal composite restorations. Part I: Understanding color and composite selection. J Esthet Restor Dent 2004;16:336–347.
92. Summitt JB, Chan DC, Dutton FB. Retention of Class 3 composite restorations: Retention grooves versus enamel bonding. Oper Dent 1993;18:88–93.
93. Kidd EA, Roberts GT. The saucer preparation. Part 2: Laboratory evaluation. Br Dent J 1982;153:138–140.
94. Roberts GT. The saucer preparation. Part 1: Clinical evaluation over 3 years. Br Dent J 1982;153:96–98.

96. Fusayama T. Ideal cavity preparation for adhesive composites. Asian J Aesthet Dent 1993;1:55–62.
97. Porte A, Lutz F, Lund MR, Swartz ML, Cochran MA. Cavity designs for composite resins. Oper Dent 1984;9:50–55.
98. Wilson NH, Wilson MA, Wastell DG, Smith GA. Performance of Occlusin in butt-joint and bevel-edged preparations: Five-year results. 4. Dent Mater 1991;7:92–98.
99. Ireland E, Xu X, Burgess JO. Microleakage of beveled and nonbeveled Class 3 resin restorations [abstract 207]. J Dent Res 1998;77(special issue):131.
100. Erickson RL, McComb D, Wood RE, et al. Caries inhibition by fluoride-releasing liners. Am J Dent 1992;5:293–295.
101. van Dijken JW. 3-year clinical evaluation of a compomer, a resin-modified glass-ionomer and a composite in Class III cavities. Am J Dent 1996;9:195–198.
102. Black JB, Retief DH, Lemons JE. Effect of cavity design on the retention of Class 4 composite resin restorations. J Am Dent Assoc 1981;103:42–46.
103. Bagheri J, Denehy GE. Effect of enamel bevel and restoration length on Class 4 acid-etch retained composite resin restorations. J Am Dent Assoc 1983;107:951–953.
104. Burke FJ. Reattachment of a fractured central incisor tooth fragment. Br Dent J 1991;170:223–225.
105. Croll TP. Emergency repair followed by complete-coronal restoration of a fractured mandibular incisor. Quintessence Int 1992;23:817–822.
106. Simonsen RJ. Restoration of a fractured central incisor using the original tooth fragment. J Am Dent Assoc 1982;105:646–648.
107. Worthington RB, Murchison DF, Vandewalle KS. Incisal edge reattachment: The effect of preparation utilization and design. Quintessence Int 1999;30:637–643.
108. Andreasen FM, Norén JG, Andreasen JO, Engelhardtsen S, Lindh-Strömberg U. Long-term survival of

Dentlearn.ir

fragment bonding in the treatment of fractured crowns: A multicenter clinical study. Quintessence Int 1995;26:669–681.
109. Cavalleri G, Zerman N. Traumatic crown fractures in permanent incisors with immature roots: A follow-up study. Endod Dent Traumatol 1995;11:294–296.
110. Darveniza M. Cavity design for Class 4 composite resin restorations—A systematic approach. Aust Dent J 1987;32:270–275.
111. Neumeyer S, Gernet W, Kappert HF, Hellekes E, Botsch H. PCR pinanchored anterior fracture restorations. Gen Dent 1992;40:200–202.
112. Ferracane JL. Buonocore lecture. Placing dental composites—A stressful experience. Oper Dent 2008;33:247–257.
113. Ruyter IE. Unpolymerized surface layers on sealants. Acta Odontol Scand 1981;39:27–32.
114. Suh BI. Oxygen-inhibited layer in adhesion dentistry. J Esthet Restor Dent 2004;16:316–323.
115. Papacchini F, Dall'Oca S, Chieffi N, et al. Composite-to-composite microtensile bond strength in the repair of a microfilled hybrid resin: Effect of surface treatment and oxygen inhibition. J Adhes Dent 2007;9:25–31.
116. Van Landuyt KL, Nawrot T, Geebelen B, et al. How much do resin-based dental materials release? A meta-analytical approach. Dent Mater 2011;27:723–747.
117. Rueggeberg FA. State-of-the-art: Dental photocuring—A review. Dent Mater 2011;27:39–52.
118. Hannig M, Bott B. In-vitro pulp chamber temperature rise during composite resin polymerization with various light-curing sources. Dent Mater 1999;15:275–281.
119. Nomoto R, McCabe JF, Hirano S. Comparison of halogen, plasma and LED curing units. Oper Dent 2004;29:287–294.
120. Price RB, Fahey J, Felix C. Knoop hardess of five composites cured with single-peak and polywave LED curing lights. Quintessence Int 2010; 41:e181–e191.
121. Pilo R, Oelgiesser D, Cardash HS. A survey of output intensity and potential for depth of cure among light-curing units in clinical use. J Dent 1999;27:235–241.
122. Barghi N, Fischer DE, Pham T. Revisiting the intensity output of curing lights in private dental offices. Compend Contin Educ Dent 2007;28: 380–384.
123. Rueggeberg FA. Precision of hand-held dental radiometers. Quintessence Int 1993;24:391–396.
124. Hansen EK, Asmussen E. Reliability of three dental radiometers. Scand J Dent Res 1993;101:115–119.
125. Sakaguchi RL, Wiltbank BD, Murchison CF. Contraction force rate of polymer composites is linearly correlated with irradiance. Dent Mater 2007;20:402–407.
126. Felippe LA, Monteiro S Jr, de Andrada CA, Ritter AV. Clinical strategies for success in proximoincisal composite restorations. Part II: Composite application technique. J Esthet Restor Dent 2005;17:11–21.
127. Zalkind M, Heling I. Composite resin layering: An esthetic technique for restoring fractured anterior teeth. J Prosthet Dent 1992;68:204–205.
128. Fahl N Jr, Denehy GE, Jackson RD. Protocol for predictable restoration of anterior teeth with composite resins. Pract Periodontics Aesthet Dent 1995;7(8):13–21.
129. Dietschi D. Optimising aesthetics and facilitating clinical application of free-hand bonding using the 'natural layering concept.' Br Dent J 2008;204:181–185.
130. Peumans M, van Meerbeek B, Lambrechts P, Vanherle G. Porcelain veneers: A review of the literature. J Dent 2000;28:163–177.
131. Felippe LA, Monteiro S Jr, Baratieri LN, Caldeira de Andrada MA, Ritter AV. Using opaquers under direct composite resin veneers: An illustrated review of the technique. J Esthet Restor Dent 2003;15:327–336.
132. Simon H, Magne P. Clinically based diagnostic wax-up for optimal esthetics: The diagnostic mock-up. J Calif Dent Assoc 2008;36:355–362.
133. Gillen RJ, Schwartz RS, Hilton TJ, Evans DB. Analysis of selected normative tooth proportions. Int J Prosthodont 1994;7:410–417.
134. ADA Council on Scientific Affairs. Polishing systems. ADA Professional Product Review 2010;5(1):1–16.
135. Pereira CA, Eskelson E, Cavalli V, Liporoni PC, Jorge AO, do Rego MA. *Streptococcus mutans* biofilm adhesion on composite resin surfaces after different finishing and polishing techniques. Oper Dent 2011;

Dentlearn.ir

36:311–317.
136. da Costa J, Ferracane J, Paravina RD, Mazur RF, Roeder L. The effect of different polishing systems on surface roughness and gloss of various resin composites. J Esthet Restor Dent 2007;19:214–224.
137. Endo T, Finger WJ, Kanehira M, Utterodt A, Komatsu M. Surface texture and roughness of polished nanofill and nanohybrid resin composites. Dent Mater 2010;29:213–223.
138. Marghalani HY. Effect of finishing/polishing systems on the surface roughness of novel posterior composites. J Esthet Restor Dent 2010; 22:127–138.
139. Cavalcante LM, Masouras K, Watts DC, Pimenta LA, Silikas N. Effect of nanofillers' size on surface properties after toothbrush abrasion. Am J Dent 2009;22:60–64.
140. Heintze SD, Forjanic M, Ohmiti K, Rousson V. Surface deterioration of dental materials after simulated toothbrushing in relation to brushing time and load. Dent Mater 2010;26:306–319.
141. Boghosian AA, Randolph RG, Jekkals VJ. Rotary instrument finishing of microfilled and small-particle hybrid composite resins. J Am Dent Assoc 1987;115:299–301.
142. Celik C, Ozgünaltay G. Effect of finishing and polishing procedures on surface roughness of tooth-colored materials. Quintessence Int 2009;40:783–789.
143. da Costa JB, Goncalves F, Ferracane JL. Comparison of two-step versus four-step composite finishing/polishing disc systems: Evaluation of a new two-step composite polishing disc system. Oper Dent 2011;36: 205–212.
144. Dodge WW, Dale RA, Cooley RL, Duke ES. Comparison of wet and dry finishing of resin composites with aluminum oxide discs. Dent Mater 1991;7:18–20.
145. Christensen GJ. Overcoming challenges with resin in Class II situations. J Am Dent Assoc 1997;128:1579–1580.
146. Jordan RE. Esthetic Composite Bonding, ed 2. St. Louis: Mosby, 1993:48.
147. Albers HF. Tooth-Colored Restoratives, ed 8. Santa Rosa, CA: Alto, 1996.
148. Farah J, Powers J. Composite finishing and polishing. Dent Advisor 1998;15:3.
149. Goldstein RE. Finishing of composites and laminates. Dent Clin North Am 1989;33:305–318.
150. Heath JR, Jordan JH, Watts DC. The effect of time of trimming on the surface finish of anterior composite resins. J Oral Rehabil 1993;20:45–52.
151. Dickinson GL, Leinfelder KF. Assessing the long-term effect of a surface penetrating sealant. J Am Dent Assoc 1993;124:68–72.
152. Lima AF, Soares GP, Vasconcellos PH, et al. Effect of surface sealants on microleakage of Class II restorations after thermocycling and long-term water storage. J Adhes Dent 2011;13:249–254.
153. Cilli R, de Mattos MC, Honorio HM, Rios D, de Araujo PA, Prakki A. The role of surface sealants in the roughness of composites after a simulated toothbrushing test. J Dent 2009;37:970–977.
154. Perez Cdos R, Hirata RJ, da Silva AH, Sampaio EM, de Miranda MS. Effect of a glaze/composite sealant on the 3-D surface roughness of esthetic restorative materials. Oper Dent 2009;34:674–680.
155. Gibson GB, Richardson AS, Patton RE, Waldman R. A clinical evaluation of occlusal composite and amalgam restorations: One-year and two-year results. J Am Dent Assoc 1992;104:335–337.
156. Kawai K, Leinfelder KF. Effect of surface-penetrating sealant on composite wear. Dent Mater 1993;9:108–113.
157. Sharif MO, Catleugh M, Merry A, et al. Replacement versus repair of defective restorations in adults: Resin composite. Cochrane Database Syst Rev 2010;(17):CD005971.
158. Gordan VV, Garvan CW, Blaser PK, Mondragon E, Mjör IA. A long-term evaluation of alternative treatments to replacement of resin-based composite restorations: Results of a seven-year study. J Am Dent Assoc 2009;140:1476–1484.
159. Cobb DS, Vargas MA, Fridich TA, Bouschlicher MR. Metal surface treatment: Characterization and effect on composite-to-metal bond strength. Oper Dent 2000;25:427–433.
160. Rodrigues SA Jr, Ferracane JL, Della Bona A. Influence of surface treatments on the bond strength of repaired resin composite restorative materials. Dent Mater 2009;25:442–445.
161. Rinastiti M, Ozcan M, Siswomihardjo W, Busscher HJ. Immediate repair bond strengths of microhybrid,

Dentlearn.ir

nanohybrid and nanofilled composites after different surface treatments. J Dent 2010;38:29–38.
162. Ikemura K, Endo T, Kadoma Y. A review of the developments of multipurpose primers and adhesives comprising novel dithiooctanoate monomers and phosphonic acid monomers. Dent Mater 2012;31: 1–25.

Dentlearn.ir



Direct Posterior Esthetic Restorations

Thomas J. Hilton
James C. Broome

The use of resin composite as a material for restoring posterior teeth has continued to increase. Patients are attracted to a restoration that matches the color of natural teeth.[1] Resin composite meets this demand and has become the most frequently used esthetic restorative material in dentistry.[2,3] In addition, resin composites avoid the concerns over the use of mercury-containing materials, are thermally nonconductive, and bond to tooth structure with the use of adhesives.[4,5] There are problems associated with using resin composite in posterior restorations, however, including shrinkage that occurs on setting[6]; occasional postoperative sensitivity[7,8]; less-than-ideal resistance to wear, particularly if functional cusps are replaced with resin composite; and restoration fracture.[9–11] Minimizing these negative aspects requires meticulous operative technique. Along with appropriate case selection, it is one of the most important variables governing the success of posterior resin composite restorations.[12–14]

Although some questions about longevity remain, there is increasing evidence that properly accomplished posterior resin composite restorations can be quite durable.[10,15,16] Earlier studies comparing the clinical performance of amalgam restorations to resin last longer. Because

Dentlearn.ir

studies are often of different duration, it is common to compute an annual failure rate (AFR) to allow a means of comparison. A review from the late 1990s found that high-copper amalgam restorations had an average 1.1% AFR as compared to 2.4% AFR for resin composite.[17] An analysis of more than 300,000 amalgam and resin composite restorations placed in posterior teeth and monitored during a 7-year period in private practices revealed that patients with resin composite restorations had a 16.4% greater chance of restoration failure than those with amalgam restorations at any time period in the analysis.[18] While this appears ominous for resin composite as a posterior restorative material, it should be noted that the probability of a posterior resin composite restoration surviving more than 5 years (93%) differed little from that of an amalgam restoration (94%). More recently, a review of 2,780 Navy and Marine recruits who had satisfactory posterior amalgam or composite restorations upon entry into the military showed that there was a 64% greater risk of composite failure compared with amalgam failure over a period of 3 years.[19] A controlled clinical trial of 1,748 amalgam and composite restorations showed that amalgam had a significantly lower AFR (0.8%) than composite (2.2%) after 7 years.[20] This study also established that larger restorations had a higher failure rate compared with smaller restorations, regardless of restorative material. The risk for secondary caries was 3.5 times greater for composite restorations versus amalgam.

However, a shift in the outcomes of clinical studies comparing amalgam with composite has taken place. Another controlled clinical trial of 1,262 restorations followed for 5 years found no significant difference in the clinical performance of amalgam (3.2% AFR) compared with composite (4.4% AFR). Similar to the previously mentioned clinical trial, larger restorations had a higher failure rate than smaller restorations.[21] Recently, long-term results in practice-based trials have been presented. A 10-year study of Class 1 and Class 2 restorations found no difference in the performance of amalgam (2.1% AFR) versus composite (⅛% AFR) restorations.[16] More recently, a 12-year trial of 1,949 large Class 2 restorations showed that composite performed significantly better (1.7% AFR) than a high-copper amalgam (2.4% AFR). In this study, patients who were considered to have a high caries risk had a significantly greater risk of restoration failure compared with low-caries-risk individuals. Furthermore, in the high-caries-risk patients, three-surface restoration longevity was significantly greater for the amalgam restorations, although there was no difference for four- and five-surface restorations.[22]

When it is used properly, resin composite has demonstrated the ability to perform

Dentlearn.ir

as well as amalgam in posterior restorations for up to 10 years.[16,23] Long-term success of resin composite posterior restorations depends on cavity size, restoration type, functional/occlusal stresses on the restoration, patient caries risk status, and tooth type.[20,22,23,24]

There are a number of valuable lessons to be learned regarding the durability of posterior restorations. First, there are a variety of explanations for the different study results based on restorative material and type of study, including patient selection, technique sensitivity, and differences in approach related to practice setting. At the current stage of material development, it is not possible to say that resin composite is a true amalgam replacement capable of providing clinical service to the same level of performance in all of the same clinical situations as amalgam. However, with appropriate case selection and clinical technique, posterior resin composite restorations can serve very acceptably. This chapter presents the factors that will lead to clinical success by examining the advantages, disadvantages, indications, and placement procedures for resin composite as a posterior restorative material.

Advantages of Resin Composite as a Posterior Restorative Material

Esthetics

Manufacturers have developed sophisticated resin composite systems with multiple shades, tints, and opaque resins that allow the practitioner to place highly esthetic restorations (Fig 11-1). Clinical studies often report excellent color matching of resin composite with tooth structure. One study found that 93% of posterior resin composite restorations provided an acceptable color match to adjacent tooth structure after 10 years,[10] while another study found that 94% of resin composite restorations still provided an excellent color match at 17 years.[15] Visible light–cured (VLC) resin composites have less amine content than the autocured systems, resulting in less yellowing of the restoration and greater color stability over time.[25] Microfilled resin composites have the smoothest surface finish of all the systems, and they better maintain their esthetics than other types through enhanced resistance to surface staining.[25]

Dentlearn.ir



Fig 11-1 Modern resin composite materials can provide an esthetic restoration, such as the mesio-occlusal restoration in the mandibular first molar. (Courtesy of Bill Dunn, United States Air Force Dental Corps.)

Conservation of tooth structure

In the past, it was recommended that preparation design for posterior resin composite restorations be patterned after the traditional amalgam preparation[14] as described by Dr G. V. Black. Researchers today recommend a more conservative approach.[26,27] The adhesive preparation has evolved to take advantage of resin composite's positive properties and to minimize its negative ones. The current design limits the removal of tooth structure to that needed to eliminate carious tooth structure and fragile enamel.[28]

The adhesive preparation for posterior Class 2 resin composite restorations differs from Black's traditional amalgam design in several ways[29]:

- The preparation tends to be shallower. Because retention is provided through bonding to tooth structure rather than mechanical undercuts, there is no need to penetrate to dentin if the caries lesion does not. This conserves tooth structure and expands the area of enamel available for bonding (Fig 11-2a).

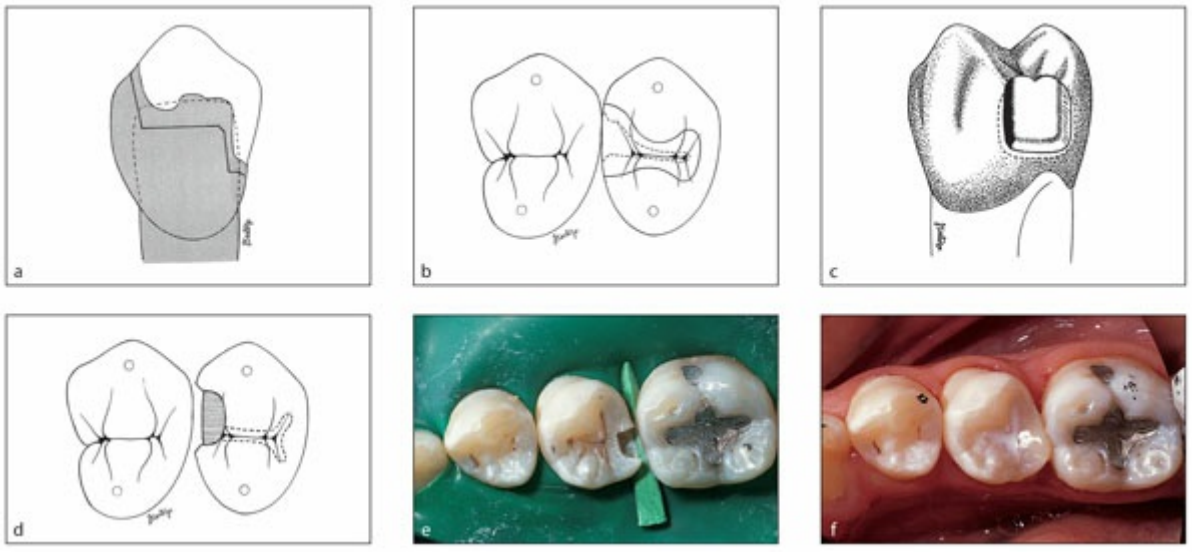

Fig 11-2 *(a)* The adhesive preparation *(upper solid line)* is extended only enough to provide

Dentlearn.ir

access and to remove carious tooth structure. It may not penetrate the dentinoenamel junction *(dotted line)*, unlike the traditional preparation *(lower solid line)*. *(b)* The more conservative outline form of the adhesive resin composite restoration *(dotted line)* compared with that of the

If there is no occlusal caries lesion, a Class 2 preparation for a resin composite restoration can be very conservative, similar to a Class 3 preparation. The occlusal fissures can be sealed *(dotted line)* after restoration placement. *(e)* A conservative Class 2 preparation has been made. The occlusal fissures are stained but not carious. *(f)* After the restoration is completed, a sealant is placed in the fissures.

- The preparation tends to have a narrower outline form, which allows less occlusal contact on the restoration and reduces wear.[30,31] A less bulky restoration helps to decrease the adverse effects of resin composite polymerization shrinkage, resulting in improved marginal integrity[28] and less cuspal deflection[32] (Fig 11-2b).

  decreases stress concentration associated with sharp line angles,[25] and enhances resin adaptation during placement[33,34] (Fig 11-2c).
- There is no "extension for prevention" (Fig 11-2d). The occlusal fissures are included in the preparation only if the presence of carious tooth structure dictates this need. Extending the Class 2 preparation through occlusal fissures does not make the restoration more resistant to fracture than the more conservative proximal slot restoration.[26,35] In clinical studies, use of a proximal slot preparation for posterior resin composite restorations showed no failures after more than 2 years of service[36] and 70% success after up to 10 years.[37] In this long-term study,[37] no restorations were lost due to wear or to loss of retention. This may be attributed to the study's requirement that there be an occlusal stop on enamel. Adjacent pits and fissures can be treated with sealants to enhance caries prevention[25] (Figs 11-2e and 11-2f). Figure 11-3 shows some examples of outline form of posterior resin composite restorations; each is designed to treat the pathosis presented, and none has a "standard" shape.

Dentlearn.ir

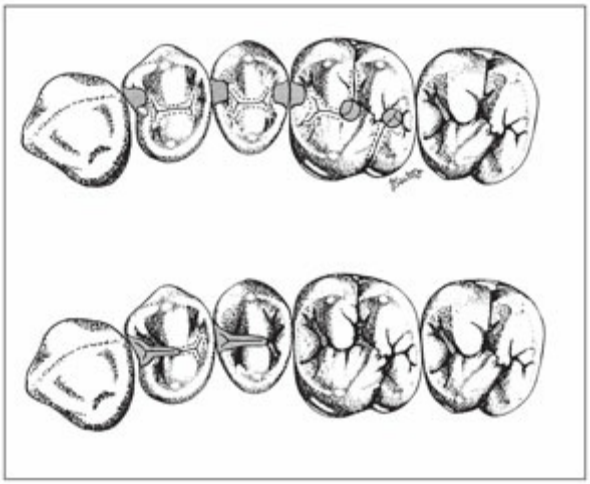

Fig 11-3 Outline of various Class 2 resin composite restorations. Access is limited to that required for removal of carious tooth structure and/or previous restoration(s), so outline form will vary based on the extent of caries lesions. Occlusal pits and fissures that are not carious may be treated with sealants. Deeply stained or demineralized fissures may be opened with a small bur (0.3- or 0.4-mm diameter) or air abrasion prior to sealing. (*Dashed outlines* indicate sealant; *dotted areas* indicate composite.)

Adhesion to tooth structure

The clinical success of bonded resin composite restorations is well documented.[10,15,38,39] The bond between resin composite and tooth structure achieved with bonding systems offers the potential to seal the margins of the restoration[40] and reinforce remaining tooth structure against fracture.[41,42] It has also been suggested that less cuspal flexure occurs with bonded resin composite restorations under subcatastrophic occlusal loads, providing protection against the propagation of cracks that can ultimately lead to fatigue failure.[43] However, not all studies have found that teeth with bonded restorations have an increased resistance to fracture.[43,44] The longevity of the bond is shortened by increased occlusal forces.[45] A study of nearly 11,000 posterior teeth found the prevalence of cusp fracture in posterior resin composite restorations to be no lower than that in amalgam restorations.[46] This supports the fact that bonded posterior restorations cannot be relied upon to provide long-term reinforcement of tooth structure.

Low thermal conductivity

Because resin composites do not readily transmit temperature changes, there is an insulating effect that may help to reduce postoperative temperature sensitivity.[41]

Dentlearn.ir

Elimination of galvanic currents

Resin composite does not contain metal and so will not initiate or conduct electrical currents.[25]

Radiopacity

Radiopaque restorative materials are necessary to allow the practitioner to evaluate the contours and marginal adaptation of the restoration as well as to distinguish among the restoration, caries lesions, and sound tooth structure.[47] Studies have shown that the detection of voids and recurrent caries lesions adjacent to restorations is enhanced when the radiopacity of the restorative material is equal to or slightly greater than the radiopacity of enamel.[48–50]

Most, although not all, modern resin composites have a radiopacity in excess of that of enamel.[51,52] For manufacturers to claim that a material is radiopaque, the American Dental Association requires them to demonstrate that a composite has a radiopacity greater than that of an equal thickness of aluminum, which has a radiopacity approximately equal to that of dentin.[53]

Alternative to amalgam

Amalgam, despite having a long track record of clinical success,[54–56] has declined in use as a restorative material primarily because of its unesthetic appearance but also because of its mercury content. Concerns about mercury in amalgam are more psychologic than scientific, as evidenced by a comprehensive literature review of 950 scientific and medical studies that found no correlation between dental amalgam and health problems.[57] Likewise, two extensive controlled clinical trials found no evidence of adverse health effects in children who received amalgam restorations compared with those who received composite restorations over 5 years[21] and 7 years.[20] Despite this, there is an increasing desire to find mercury-free alternatives to dental amalgam.[58] Patients are aware of indictments against amalgam, and some express concern about potential health hazards.[59] Amalgam is also less attractive to dental professionals as government agencies consider classifying it as hazardous waste[60] and requiring that dental offices install expensive separator systems to remove mercury from wastewater.[58,61] As a result, resin composite use in posterior restorations continues to gain popularity in the profession.[58]

Dentlearn.ir

Disadvantages of Resin Composite as a Posterior Restorative Material

Polymerization shrinkage

Despite improvements in resin composite formulations over the years, modern systems are still based on variations of the bisphenol glycidyl methacrylate (bis-GMA) molecule, which has been used for more than 40 years.[62] One of the major drawbacks of this material is the polymerization shrinkage that occurs during the setting reaction. Modern resin composites undergo volumetric polymerization shrinkage of 1.5% to 5%.[63–65]

Most of the problems associated with posterior resin composite restorations can be related directly or indirectly to polymerization shrinkage and the stress that develops during polymerization. During polymerization, resin composite may pull away from the least retentive cavity margins (usually those with little or no enamel on them), resulting in gap formation.[66–68] Tensile forces developed in enamel margins can result in marginal degradation from mastication.[69] Contraction forces on cusps can result in cuspal deformation,[70] enamel cracks and craze lines[71] (Fig 11-4), and, ultimately, decreased fracture resistance of the cusps.[72]

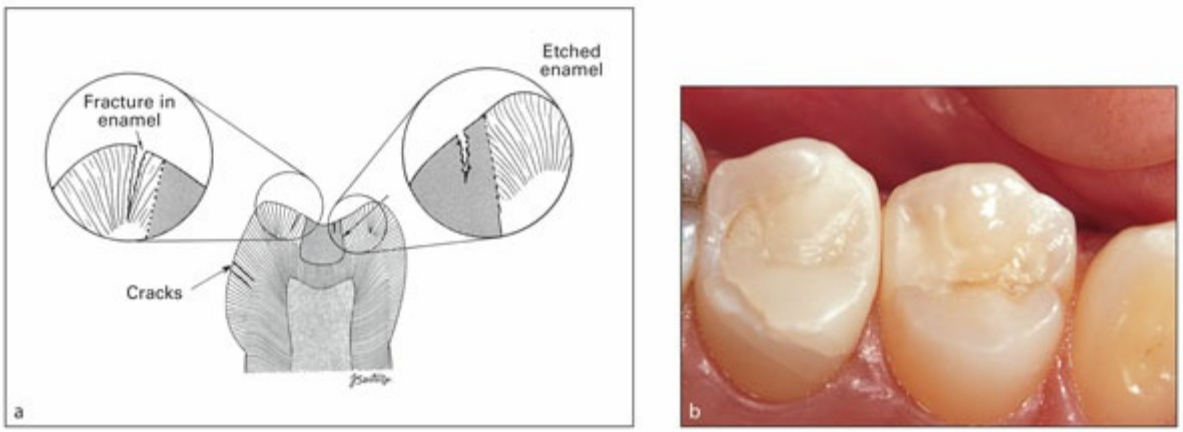

Fig 11-4*(a)* Polymerization shrinkage can cause crazing in the enamel or fractures within the resin composite. *(b)* Craze lines are evident in the lingual cusp of the maxillary right second premolar bonded to a very large Class 2 resin composite restoration.

Polymerization shrinkage occurs regardless of the system used to initiate the setting reaction. For many years, it was believed that autocured resin composite polymerizes toward the center of the mass of the resin composite, while VLC resin composite polymerizes toward the light source.[6,68] Research has provided evidence

Dentlearn.ir

that polymerization shrinkage occurs toward the walls of cavity preparations to which it is bonded most strongly, regardless of the initiator mode.[73,74]

A number of techniques have been suggested to decrease the adverse effects of polymerization shrinkage. The most commonly used technique is incremental placement of VLC resin composite, which decreases the effect of setting contraction by reducing the bulk of resin composite cured at a time.[68] In addition, incremental insertion reduces the ratio of bonded to unbonded surface area, which helps to relieve the stress developed at the bond between tooth and resin composite.[75] The incremental placement technique is discussed later in this chapter.

Autocured resin composites are sometimes recommended for posterior restorations, because an autocured composite tends to induce less polymerization stress than does a comparable bulk of VLC composite. This is due in part to greater porosity being incorporated into the autocured resin composite as a result of mixing. The incorporated oxygen inhibits the set of resin immediately adjacent to the voids and decreases the ratio of bonded to unbonded surface area.[76] The voids increase the free surface area for stress compensation by flow of the resin during the setting reaction.[77] In addition, because of a slower polymerization rate, autocured resin composites develop shrinkage stresses more slowly than do VLC materials. This allows for increased restorative material flow during polymerization.[78,79] However, a number of problems associated with the use of autocured resin composite in posterior restorations argue against its use. These problems are discussed in subsequent sections.

Decreasing the rate of polymerization of VLC resin composite can be accomplished by varying the intensity of the curing light. This has resulted in a form of curing for VLC resin composites variously referred to as *two-step* or *soft-start polymerization*. Some studies have shown that by reducing the initial irradiance to approximately 150 mW/cm^2, followed by high-level irradiance (650 mW/cm^2 or greater), the curing reaction is slowed, marginal integrity is enhanced, and mechanical properties are not adversely affected.[80–84] However, results with these reduced-irradiance curing regimens have been equivocal,[85] and it is difficult to assess whether or not the laboratory results will have any relation to clinical outcomes. Research has demonstrated that a truly significant decrease in polymerization shrinkage stress may require what many consider to be clinically impractical curing regimens.[85]

The best hope for overcoming the problems of polymerization shrinkage lies in the future development of tooth-colored materials that contract minimally during setting,

Dentlearn.ir

an area of vigorous research.[86–88] While it is intuitive to think that producing a material with zero shrinkage is ideal, this may not be true, because dental composites are based on polymers that absorb small amounts of water, the result of which is a slight volumetric expansion that may apply pressure to the cavity walls.

Secondary caries lesions

Several clinical studies and reviews of clinical studies have demonstrated that secondary caries is a significant cause of failure of posterior resin composite restorations.[20,89,90] It is believed that the marginal gap formed at the gingival margin as a result of polymerization shrinkage allows the ingress of cariogenic bacteria (Fig 11-5). Because marginal degradation has been demonstrated to increase with time,[91,92] the risk of secondary caries also increases with time.



Fig 11-5 *(a)* In these posterior resin composite restorations, the dark shadowing adjacent to the occlusal margins was caused by recurrent caries lesions. *(b)* After placement of a rubber dam, the resin composite restorations are removed and caries-detecting solution is placed. *(c)* Stained areas confirm the presence of demineralized tooth structure.

Studies have shown that levels of *Streptococcus mutans*, the organism linked most closely to the production of dental caries lesions,[93] are significantly higher in the plaque adjacent to proximal surfaces of posterior resin composite restorations than in plaque adjacent to either amalgam or glass-ionomer restorations. In addition, the organic acids of plaque have been found to soften bis-GMA polymers, and this in turn could have an adverse effect on wear and surface staining.[94] These facts emphasize the need for regular recall and close follow-up of patients with posterior resin composite restorations.

Postoperative sensitivity

Postoperative sensitivity has been associated with the placement of posterior resin composite restorations. Earlier clinical research noted postoperative sensitivity rates as high as 29% following placement of the restorations.[7] Some studies have continued to report postoperative sensitivity following the placement of

Dentlearn.ir

even small posterior resin composite restorations,[36,95] but reports of postoperative sensitivity have diminished with improvements in dentin adhesives and as dentists have become more proficient in the case selection and clinical techniques associated with successful posterior composite restorations.[16,89,95–97]

A number of reasons have been postulated for the occurrence of postoperative sensitivity, but the most commonly accepted theories relate to polymerization shrinkage. As previously discussed, polymerization shrinkage results in formation of a gap, which allows bacterial penetration and fluid flow within it. The bacteria or their noxious by-products may enter the dentinal tubules and cause pulpal inflammation and tooth sensitivity.[98] Gap formation also allows a slow, continuous outflow of dentinal fluid from the pulp through the tubules to the gap. Cold or other stimuli may cause a contraction of fluid in the gap, leading to a sudden, rapid outflow of tubular fluid that stimulates the nerve surrounding the odontoblastic processes and results in the perception of pain.[99]

Contraction forces of polymerization shrinkage may also result in cuspal deformation, with resultant cracking and crazing of remaining tooth structure (see Fig 11-4b), which can cause tooth sensitivity.[66] Flexure of resin composite under an occlusal load may cause hydraulic pressure in the tubular fluid to be transmitted to the odontoblastic processes, another possible cause of tooth sensitivity.[66,99]

Postoperative sensitivity can be a disturbing sequela for both patient and dentist. Obviously the discomfort associated with restoration placement is unpleasant for the patient. Likewise, it is often frustrating for the dentist to try to determine the cause and eliminate postoperative sensitivity. This frustration is increased with the awareness that patients who experience postoperative sensitivity within 1 month of posterior resin composite restoration placement are about twice as likely to have that restoration fail within 5 years as those who do not experience postoperative sensitivity. This risk increases as the size of the restoration increases.[8] Awareness of the potential for postoperative sensitivity allows the practitioner to forewarn the patient of this possibility. Careful adherence to the guidelines for case selection and restoration placement, including the rebonding procedure described later in this chapter, will help to reduce this problem.

Decreased wear resistance

The wear resistance of posterior resin composite restorations has been the subject of considerable attention. This characteristic has long been a concern for restoration

Dentlearn.ir

longevity,[100] although it has improved as refinements in materials have occurred.[16,96] In reports of clinical studies, it has been noted that no posterior resin composite restorations were replaced as a result of excessive wear after 7 years[101] and only one was replaced as a result of excessive wear in a 10-year study.[23] A practice-based retrospective study showed no failures in 1,955 posterior composite restorations due to wear after 10 years.[16]

Resin composite wear results from the combination of chemical damage to the surface of the material and mechanical breakdown.[102–105] Resin composites undergo wear by two different mechanisms: abrasion and attrition. *Abrasion* is generalized wear that occurs across the entire occlusal surface of the resin composite as a result of the abrasive action of particles during mastication (Fig 11-6). This type of wear occurs in all areas of the restoration. *Attrition* is the loss of material that occurs as a result of direct contact with opposing tooth surfaces in the occlusal contact areas of the restoration[106] (Fig 11-7). Generally, wear can be related to either material or clinical factors.

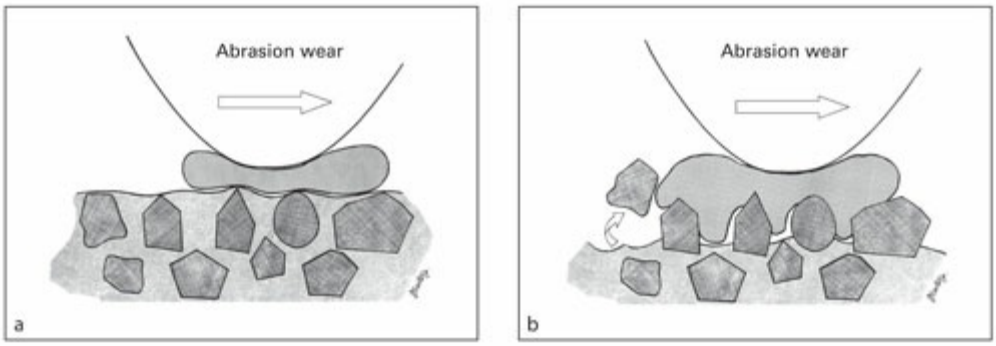

Fig 11-6 Abrasion wear occurs across the entire occlusal surface of the resin composite. *(a)* The softer resin is preferentially worn away, exposing the harder filler particles. *(b)* Eventually, enough of the filler particle is exposed so that it is "plucked" from the surface of the resin composite.

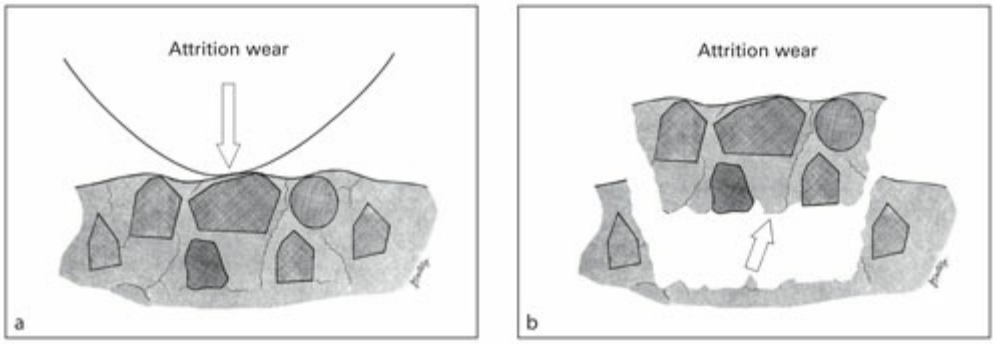

Fig 11-7 Attrition wear occurs in occlusal contact areas. *(a)* Cracks occur in the resin matrix as a result of occlusal stress. *(b)* Eventually, the cracks coalesce and result in loss of resin composite material from the surface.

Dentlearn.ir

Material factors relate primarily to the content, size, and distribution of the resin composite's filler particles.[107] Clinical studies, in general, have shown less heavily filled composites (less than 60% filled by volume) to exhibit unacceptable wear.[100] Because of their generally lower filler content (30% to 50%), microfilled composites are more subject to attrition[69] and marginal breakdown,[91,92,108] especially adjacent to occlusal contact areas.[69] However, they are more resistant to abrasion because of their smoother surfaces, decreased interparticle spacing, and lowered coefficient of friction.[109,110] The more heavily filled hybrid resin composites are more resistant to attrition than are the microfilled materials.[108] However, resin composites that have a larger mean particle size (greater than 3 μm) tend to have significantly higher abrasion wear.[31,88,100] This is due to the preferential wear of the resin between the fillers, which causes the filler to become loosened and ultimately lost from the resin matrix, leading to three-body wear and generalized loss of material[100] (Fig 11-8). A newer nanofilled composite formulation is providing in vitro and in vivo wear characteristics similar to microhybrid composites.[110,111]



Fig 11-8 A Class 2 lesion previously restored with a larger-particle resin composite. Pitting and generalized wear of the occlusal surface can be seen as a result of abrasion wear. In addition, interproximal abrasion wear has resulted in the loss of interproximal contact on the mesial.

The rate of wear varies with particle size as well. As mean filler particle size decreases (below 1 μm), the wear rate tends to be linear with time. Conversely, composites with larger filler particles tend to have more rapid wear initially but slower wear over time.[88,91,92,112,113]

Clinically relevant wear factors include the size of the restoration, its location in the arch, the occlusal load it must withstand, and how well the resin composite is cured. As the surface area and length of cavosurface margins increase, so does the exposure to occlusal forces, with a resultant increase in wear.[16,20,21,30,31,97,111] The more posterior a tooth, the greater the masticatory forces and the more rapid the wear of the restoration.[30,96,97,111,114] Fracture resistance decreases as a result of

Dentlearn.ir

fatigue from chewing,[115] and increased chewing pressure will result in increased wear.[116] Finally, if the clinician does not properly cure the composite material, the degree of conversion of the composite will suffer, and wear will increase.[108]

Proximal surfaces are subjected to the forces of abrasion during function as well, due to individual tooth movement during mastication that causes wear in the interproximal contact areas. Early research showed that proximal surface wear of posterior resin composite restorations was significantly greater than that of enamel proximal surfaces.[117,118] One study even found proximal wear rates to be higher than occlusal wear rates in resin composite restorations,[119] possibly due to increased contact time between contacting surfaces, differences in cure, or different environments. However, later studies do not indicate that proximal surface wear due to interproximal contact is a problem with current resin composites.[101,120,121]

Clinical studies show that resin composite formulations have acceptable wear characteristics for up to 17 years.[15,23,96,97] While some research reports that resin composites have significantly higher wear rates than amalgam,[106,122] other studies have indicated that posterior resin composite restorations resist wear as well as amalgam restorations,[23,104] including recent large practice-based trials.[16,22]

Other mechanical properties

Generally, the more closely the mechanical properties of a restorative material simulate those of enamel and dentin, the better the restoration's longevity.[88,123,124] A number of the mechanical properties of resin composite are inferior to those of tooth structure and of other restorative materials. These inferior properties can have an adverse effect on the durability of the restoration.

Resin composite materials have low fracture toughness in comparison with metallic restorative materials.[67] Indeed, bulk fracture of posterior resin composite restorations has been noted as a significant cause of failure in many clinical studies.[20,21,90,96,97] Increased filler loading of resin composite leads to improved fracture toughness.[103,115] Resin composite has a relatively high degree of elastic deformation (ie, a low modulus of elasticity) that is six to eight times that of amalgam.[99] Failures of resin composite restorations associated with the high elastic deformation of the material have included bulk fracture,[67] microcrack formation,[103] and relatively low resistance to occlusal loading.[7] As with fracture resistance, more highly filled composites exhibit less elastic deformation than their less-filled counterparts.[88]

Dentlearn.ir

The coefficient of thermal expansion of resin composite is another property that differs significantly from that of tooth structure.[125,126] Because the coefficient of thermal expansion of resin composite is higher than that of tooth structure, composite tends to expand and contract more than enamel and dentin when subjected to variations in temperature. This can increase marginal gap formation and exacerbate the effects of polymerization shrinkage on cuspal deformation, and it may result in the fracture of composite or enamel at the margins.[67,124] It has been demonstrated that as the mismatch in thermal-expansion properties between restorative material and the tooth structure increases, so does marginal leakage.[127] As the filler content of resin composite increases, however, the mismatch decreases.[125]

Water sorption

Water sorption is another factor influencing the clinical performance of resin composites. Water is absorbed preferentially into the resin component of resin composite materials, and water content is therefore increased when resin content is increased.[62,67] Because of the swelling of the resin matrix from water sorption, the filler particle bond to resin is weakened. If the stress is greater than the bond strength, the resulting debond is referred to as *hydrolytic breakdown*.[67,128] Incompletely cured resin composite will exhibit more water sorption and greater hydrolytic degradation.[129]

It has been suggested that the swelling of resin composite caused by water sorption can be beneficial due to closing of the marginal gap caused by polymerization shrinkage. However, studies have shown that the swelling from moisture absorption usually is not enough to overcome the polymerization shrinkage gap.[69] Even if water sorption did result in a closed marginal gap, it would only provide a close adaptation, without adhesion between the resin composite and tooth structure.[130]

Variable degree of conversion

Analysis of the amount of polymerization and cross-linking, or *degree of conversion*, of resin composites reveals that certain characteristics of this material are at odds with one another. As the degree of conversion of a resin composite material increases, the mechanical properties improve.[62,76,109] Clinical research has clearly demonstrated that a reduced degree of conversion causes significantly increased wear.[108] However, polymerization shrinkage also increases with more

Dentlearn.ir

conversion.[131] Resins with decreased filler content exhibit lower viscosity and thereby, improved cure.[132] However, a decreased filler content also results in inferior mechanical properties[88,103,115,125] and poorer clinical performance.[7,69,91,92] Achieving the best balance among these factors is a challenge for both manufacturers and clinicians.

VLC composites have been shown to achieve a somewhat higher degree of conversion than autocured materials.[132,133] Several factors influence the extent of polymerization of VLC composites. Lighter shades cure more easily and with less illumination time than darker shades.[6,134] Resin composites with larger (greater than 1.0 μm) or very small (less than 0.1 μm) filler particles tend to transmit light throughout the material more effectively than those with filler particles that are close in size to the wavelength of the curing light (~0.5 μm).[134,135] The longer the composite is subjected to the curing light, the more effective the cure,[136] but the thickness of each increment should be limited to 2.0 mm.[6,134] The degree of conversion is inversely related to the distance of the light tip from the resin composite,[136] and tip distances greater than 6.0 mm from the surface of the increment can significantly decrease resin composite cure.[137] Of course, the condition of the curing unit can, also impact the effectiveness of the cure.

Inconsistent dentin adhesion (marginal leakage)

Polymerization shrinkage causes the resin composite to pull away from cavity margins, resulting in gap formation.[66–68] Despite advances in dentin adhesive systems, they still do not consistently and reliably achieve bond strengths to dentin and cementum that are high enough to prevent this occurrence[138–141] (Fig 11-9; see also Fig 13-13). This sometimes results in open margins, sensitivity, interfacial staining, and bacterial invasion.[142] In addition, the bond between adhesive and tooth structure has been shown to degrade with aging, both in vitro and in vivo.[141,143–146]



Dentlearn.ir

Fig 11-9 Marginal staining/discoloration indicating degradation of adhesion between the resin composite and the cavity preparation that occurs with aging. Facial Class 5 resin composite restorations in the maxillary right first and second premolars after 3 years. Discoloration is evident, particularly at the gingival (dentin) margins of the restorations.

Technique sensitivity

Because of the negative aspects of using resin composite as a posterior restorative material described previously, one of the most important variables in clinical success is the placement technique.[13] Application technique has been shown to significantly affect adhesive bond strength.[147] Technique may also account for the great variability reported in clinical success rates for posterior resin composite restorations. The meticulous operative procedures demanded for placing these restorations require increased chair time. Clinical research has shown that posterior resin composite restorations require significantly more time to place than do comparable amalgam restorations.[23]

Indications for Resin Composite as a Posterior Restorative Material

Resin composite is now the state-of-the-art restorative material for direct-placement posterior restorations. It is popular with patients because of its esthetic and metal-free (especially mercury-free) characteristics. The esthetic and mechanical properties of modern resin composites have considerably improved since their introduction. Dentists use more resin composite than amalgam for direct-placement restorations,[148] and this discrepancy between the use of amalgam and resin composite will likely only increase in the future. Results of clinical studies demonstrate that resin composite can fare comparably with amalgam when used in posterior restorations.[16,21,22] Based on these facts and the previous discussion, resin composite is the first choice for direct-placement posterior restorations. The only absolute contraindication is if the patient is allergic or sensitive to resin-based materials. Otherwise, the clinician should consider other options only as clinical conditions dictate, including the following relative contraindications for resin composite use in posterior teeth:

- The restoration will replace supporting cusps. Extensive resin composite restorations including the supporting cusps of posterior teeth do not perform as

Dentlearn.ir

well as other restorative materials[11] (Fig 11-10).



Fig 11-10 Defective mesio-occlusodistal (MOD) amalgam restoration in the mandibular second premolar. Excessive width and need for cusp replacement precludes this amalgam restoration from being replaced with resin composite. A discolored fracture line and recurrent caries running from the MOD amalgam to the amalgam in the facial cusp tip would necessitate functional cusp coverage with the replacement restoration.

- Large restorations are required in the teeth of a patient with significant parafunction, bruxism, or heavy occlusal stress, where most or all function will be on the restoration and not on tooth structure.[9,12,15,24,37]
- The patient has a high caries risk and is noncompliant with oral hygiene instructions. Secondary caries is a significant cause of posterior composite failure.[20,22,39,149]
- The clinician is unable to obtain adequate field isolation.[150,151]

Also, in regard to resin composite restorations with margins in thin enamel near the cementoenamel junction or on cementum or dentin, the use of the *open sandwich technique* (also referred to as the *bonded-base technique* in Class 2 restorations) has been shown to provide acceptable clinical performance,[152–155] providing significant protection of the tooth structure near the gingival margin against demineralization.[152] In the open sandwich technique, a restorative resin-modified glass ionomer (RMGI) is used in the portion of the restoration near the gingival margin. In a Class 2 restoration, that would be the gingival increment of material placed in the proximal box. If this technique is to be used, however, it is important that the patient be at low risk of developing caries lesions. The main benefit of the open sandwich technique is an improved marginal seal and protection of the gingival margin against demineralization, but this benefit can be overwhelmed by increased plaque formation. A clinical trial evaluating the use of this technique found that 67% of recurrent caries lesions adjacent to the RMGI portion of an open sandwich

Dentlearn.ir

restoration occurred in subjects with poor oral hygiene.[154] For a description of the bonded-base technique, see the section on Class 2 resin composite restorations in this chapter.

Informed Consent

It is incumbent upon the dentist to provide the patient with appropriate information regarding the restorative procedures being recommended. This should include a description of the proposed procedures in lay language, any risks associated with the procedures, and other options the patient may wish to consider. In addition, the patient should be provided the opportunity to have his or her questions answered. This is sometimes referred to as the PARQ process (Procedures, Alternatives, Risks, Questions). Dlugokinski and Browning[156] surveyed dentists and patients regarding their respective attitudes and preferences toward informed consent. The survey focused on offering patients the alternatives of resin composite versus amalgam for direct-placement posterior restorations. The survey revealed that as a dentist performed more resin composite restorations compared with the number of amalgam restorations performed, the dentist was less likely to discuss the adverse aspects of resin composite.[156]

Conversely, the survey revealed some intriguing insights from the patient's perspective[156]:

- 100% of patients wanted the dentist to tell them about all aspects of alternative restorative materials.
- 75% of patients preferred a written explanation rather than simply an oral explanation.
- 82% of patients would not choose a posterior resin composite restoration to replace an adequate amalgam restoration.
- Patients were equivocal over cost as a factor for selecting amalgam versus resin composite: 43% would still choose a resin composite restoration even if it cost 50% more than an amalgam restoration and would not last as long (versus 36% preferring amalgam).

The results clearly show that patients do not want the dentist alone to decide which restoration will be placed. While most patients desire the dentist's recommendation, the ultimate decision is theirs, and they want to be fully informed

Dentlearn.ir

to make the best choice for their particular situation. Most patients want information in writing. Several commercial companies and the American Dental Association (ADA) offer pamphlets that explain the indications, advantages, and disadvantages of various restorative materials. The ADA also provides a document with information on various restorative materials that can be downloaded at no charge.[157]

Autocured versus Light-Cured Resin Composites

Autocured resin composite restorative materials largely disappeared from clinical practice in the 1980s because of the popularity of the light-cured materials. Some clinicians have recommended the use of autocured resin composites, either alone or in combination with VLC resin composites, for posterior applications.[158–160] The primary advantage of an autocured material is that it can be placed in bulk, saving time compared with the incremental insertion technique used with VLC materials.

Although more time-consuming, use of VLC resin composites has a number of advantages over the use of autocured resin composites. VLC composites achieve more complete polymerization,[133] resulting in superior mechanical properties,[62,71,137] and they exhibit better color stability.[161] Autocured composites tend to incorporate voids as a result of mixing two-paste systems,[77] and the increased porosity decreases tensile strength and surface smoothness,[162] accelerating wear.[163] Extended mixing and manipulation may interrupt the polymerization process and may compromise the integrity of the polymer network, resulting in reduced strength and wear resistance.[164]

VLC composites should be used with an incremental placement technique to reduce polymerization shrinkage stress and achieve optimal polymerization in the definitive restoration.[165] This technique allows the practitioner to build up and sculpt the restoration. Research has shown VLC composite increments to have adequate interfacial strength.[166] Perhaps most important, VLC resin composites performed better in clinical trials than autocured materials over 1 year[167] and 3 years.[117]

Direct Posterior Resin Composite Restorations

Preoperative evaluation

Dentlearn.ir

The factors noted as contraindications in the previous list should be considered in the preoperative evaluation. The occlusion should be marked with articulating paper as a guide to preparation design. The best type of resin composite for the restoration should be chosen. At present, the heavily filled small particle–hybrid composites (sometimes known as *micro-hybrids*) are considered best suited for posterior use.[12,16,22,88,90]

For many posterior resin composite restorations, shade selection is not critical. In fact, some clinicians prefer a deliberate shade mismatch to aid in subsequent finishing and future evaluation procedures. But when shade is important, shade selection should be performed before isolation of the tooth, because isolated teeth become dehydrated, and dehydration changes the shade of the enamel. A shade is chosen from the shade guide that accompanies the composite, and then a small portion of the composite is placed on the unprepared and unetched tooth and polymerized (Fig 11-11). The resin "test shade" can easily be removed because the tooth surface has not been etched or primed prior to its placement. See chapter 4 for more information on shade selection.



Fig 11-11 A small amount of resin composite is placed on the unprepared tooth to verify the shade prior to isolation with a rubber dam.

If the dentist is going to use a warm composite placement technique, an appropriate amount of resin composite may be transferred to a syringe tip (Centrix) that is amber-colored or opaque to prevent premature polymerization. The Centrix syringe tip is then placed in a composite warming tray (Calset, AdDent) at 60°C to 68°C (140°F to 155°F) (Fig 11-12). This will reduce the resin composite's viscosity and aid in subsequent placement. The rationale for this technique is discussed in the section on Class 2 resin composite restorations later in this chapter.



Dentlearn.ir

Fig 11-12 An appropriate resin is selected and placed into a light-protected syringe tip, and the protected syringe tip is put into a warmer (60°C to 68°C; 140°F to 155°F) to reduce viscosity.

Isolation

Securing and maintaining control of the operative field is essential to the success of the restoration. One clinical study has demonstrated no difference in the performance of posterior resin composite restorations whether or not a rubber dam was used during restoration placement.[168] A large retrospective practice-based study showed a high success of posterior composites even though a rubber dam was rarely used.[16] However, in another clinical study, the margins of all Class 2 resin composite restorations placed without a rubber dam demonstrated marginal leakage 4 to 6 weeks after placement.[169] With the advent of adhesive systems that use more hydrophilic components, research has shown that contamination with moisture or saliva affects some adhesives but not others.[170–172] Blood contamination will adversely affect adhesion in all bonding systems.[171–173] In the authors' opinion, the most reliable method to accomplish field isolation is the placement of a rubber dam. The rubber dam prevents moisture contamination and protects gingival tissues from laceration[169] (Fig 11-13).



Fig 11-13 The occlusion is marked and rubber dam isolation achieved. The rubber dam has been inverted around the teeth to ensure moisture control.

Sealants and Preventive Resin Restorations

Resin sealants

While not normally considered to be posterior resin composite restorations, resin fissure sealants have been in use as a preventive restorative procedure for several decades. Sealants provide an effective means of reducing the incidence of caries lesions in fissures.[174] Compared to teeth with unsealed fissures, teeth with resin-sealed fissures have demonstrated a 35% reduction in fissure caries lesions during a

Dentlearn.ir

5-year period,[175] a 43% reduction over 4 years,[176] and a 55% reduction over 7 years[177]. However, there are a number of factors that must be considered regarding fissure sealant effectiveness. Numerous clinical studies have demonstrated that sealants tend to fail at a rate of 5% to 10% per year.[178–181] This is significant because the caries rate for teeth in which sealants are partially or totally lost increases significantly, in many cases equaling the caries rate of unsealed teeth.[175–177,179,180] The key to resin sealant success in preventing caries lesions is total retention of the sealant.[174,175,177,180] Enhancing complete resin sealant retention will therefore enhance the caries-reduction benefit. Some factors that affect sealant retention and effectiveness include the following:

- Mandibular teeth show higher retention rates than maxillary teeth; premolars show higher retention rates than molars.[179,182]
- Annual recall of patients and repair of partially or totally lost sealants improves effectiveness.[179,181]
- Use of bonding agents following phosphoric acid etching and prior to sealant placement helps to wet fissures,[183] improve sealant penetration into fissures,[184] increase bond strength,[185,186] improve sealant adhesion to saliva-contaminated enamel,[185–187] and improve clinical retention of sealants.[174,188–190]
- Individual studies have demonstrated that light mechanical preparation of fissures with a very small bur (0.3- to 0.4-mm diameter, rounded tip) or air abrasion can provide clinical advantages, including exposing sound, unstained enamel prior to etchant placement; enhanced sealant penetration and attachment; decreased bubble formation; improved marginal adaptation[191,192]; decreased marginal leakage[193]; improved microbial elimination[194]; and increased clinical retention compared with unprepared fissures.[192] However, two systematic reviews concluded that the evidence for the benefit of mechanical preparation was conflicting and limited.[174,195]
- Clinical studies of RMGI sealants show good caries prevention but very poor mechanical retention compared with resin sealants. However, the caries-prevention benefits of RMGI sealants are comparable with those of resin sealants and should be considered when moisture control may compromise resin sealant retention.[174]
- Flowable resin composite materials have been shown to perform as well as fissure sealants. One short-term clinical study demonstrated comparable

Dentlearn.ir

performance for a flowable resin composite and a sealant,[196] while another showed improved performance of a flowable resin composite material when compared with a traditional resin sealant.[197]

- The level of caries activity is critical to the cost-effectiveness of sealants; if a patient exhibits a low caries index, then the value of this procedure is low.[198] Clinical parameters including occlusal fissure morphology; number of decayed, missing, or filled surfaces (DMFS); and the clinician's subjective judgment are all significant predictors of future occlusal caries activity.[199,200] Therefore, sealant use should be based on a determination of the patient's disease level and his or her potential for future fissure caries lesions; sealants should not be placed universally.[174]

Preventive resin restorations

A restoration that maximizes the benefits of conservative adhesive dentistry is the *preventive resin restoration* (PRR). Suggested by Ulvestad[201] in 1975 and popularized by Simonsen[202,203] and Simonsen and Stallard,[204] the PRR was developed to overcome problems associated with traditional "extension for prevention" in restorations necessitated by minimal occlusal caries lesions.

The PRR limits preparation to pits and fissures that are carious. Once the lesion is eliminated, no further preparation is performed. If the resultant preparation is restricted to a narrow and shallow opening of the fissure, a resin sealant (or flowable resin composite material) is placed. If additional tooth structure is removed, a posterior resin composite is placed in that area, and the remaining fissures and the surface of the resin composite restoration(s) are sealed with resin sealant material or flowable composite. A number of advantages have been ascribed to this technique, including the following:

- Conservation of tooth structure: One 5-year clinical study determined that the average occlusal amalgam occupied 25% of the occlusal surface compared to just 5% for an average PRR.[205]
- Enhanced esthetics: This is provided by the tooth-colored restorative material.[206]
- Improved seal of restorative material to tooth structure: This is achieved through the bond of resin composite to etched enamel with an adhesive resin.[207]
- Minimal wear: This is due to restricted cavity-preparation size, so that occlusal contacts on the restoration are limited.[208]

Dentlearn.ir

- No progression of sealed caries lesions: If a caries lesion is inadvertently allowed to remain in or at the base of a sealed fissure, it will not progress, because the sealant prevents nutrients from supplying cariogenic bacteria.[209]
- Good longevity: Clinical studies have demonstrated that PRRs are successful for periods of up to 10 years[206–210] and can equal[205] or exceed the performance of amalgam restorations.[209]

The same provisos concerning sealants must be applied to PRRs; that is, the sealants placed in association with PRRs will tend to be lost at a rate of 5% to 10% per year.[206,208,210] Therefore, these restorations must be monitored over time, and the sealants and/or restorations must be repaired or replaced as needed.[206,211]

Indications and contraindications

A PRR is indicated when some areas of the fissure system of a tooth are associated with carious dentin and others are not. The extent of the anticipated restoration should be such that occlusal forces will be limited primarily to tooth structure.

Technique

The preoperative evaluation, marking of occlusion, shade selection, and rubber dam isolation should be accomplished first (Fig 11-14a). After the resin composite is selected, it may be used directly from a unit-dose ampule; if it is in a syringe, it should be placed into a light-protected syringe tip (see Fig 11-12). If desired, the viscosity of the resin composite may be further reduced by heating it in a composite warming tray to enhance adaptation to the cavity preparation as described in the section on Class 2 restorations.

Dentlearn.ir

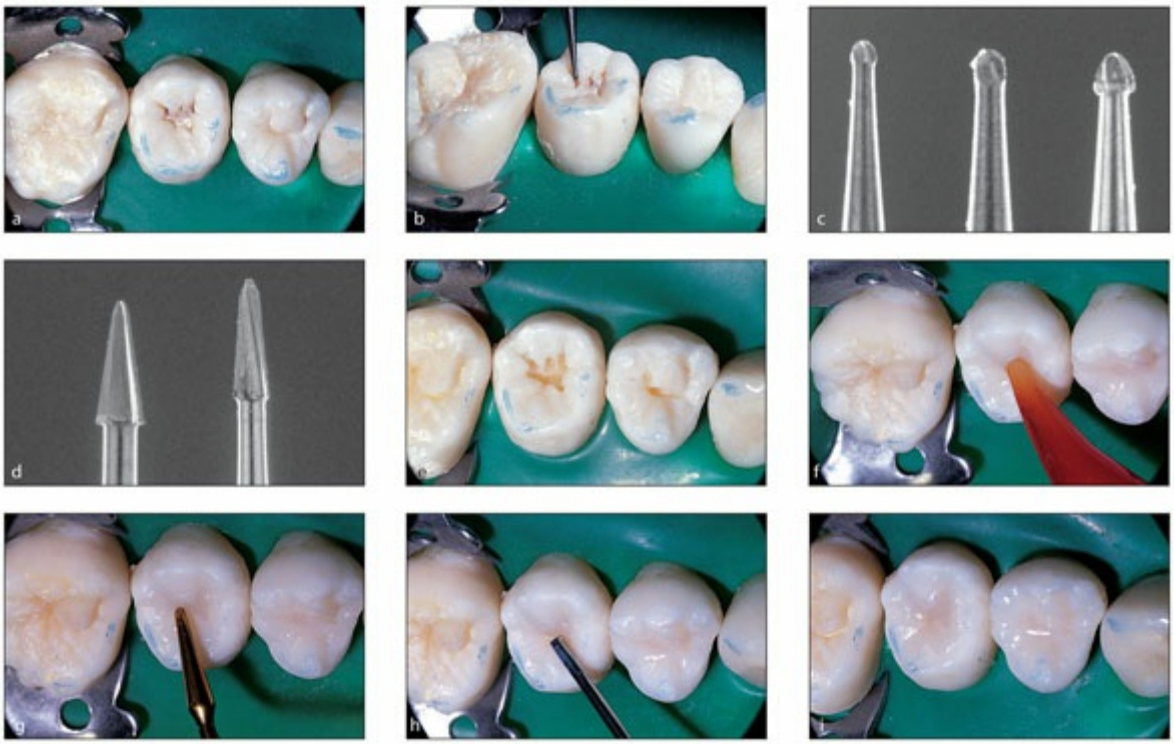

Fig 11-14 Technique for placing preventive resin restorations. *(a)* The occlusal surfaces of the maxillary first and second premolars exhibit demineralization of deep occlusal fissures. A rubber dam has been placed and inverted. The occlusion was marked prior to rubber dam placement. *(b)* Preparation is initiated with a small (no. 1/8) round bur in a high-speed handpiece. *(c)* 1/16, 1/8, and ¼ round burs (0.3, 0.4, and 0.5 mm in diameter, respectively) work well to open occlusal fissures. *(d)* Alternatively, fissurotomy burs (SS White) can be used to open occlusal fissures. *(e)* Completed preparations, which were limited to access for removal of carious tooth structure. The preparation of the first premolar was limited and mostly confined to fissure enameloplasty. Penetration to dentin was minimal in the second premolar, occurring in only limited locations. *(f)* After adhesive system placement, restorative resin composite is syringed into the deeper (greater than 0.5 mm) areas of the preparation. *(g)* A hand instrument, such as the PKT3 shown, is used to develop occlusal anatomy in the final resin composite increment prior to curing. *(h)* The occlusal surface is re-etched, and occlusal sealant is placed over the resin composite and any remaining pits and fissures. *(i)* Completed occlusal preventive resin restorations.

The conservative adhesive preparation eliminates demineralized dentin, overlying unsupported enamel, and associated demineralized enamel. The preparation should be initiated with the smallest instrument that will accomplish this limited preparation, such as a no. 1/16, ⅛, or ¼ round bur (Figs 11-14b and 11-14c), fissurotomy bur (Fig 11-14d), or air abrasion. Larger instrumentation is used only as the size of the caries lesion dictates. Any fragile or unsupported enamel remaining on the occlusal surface after removal of the demineralized dentin should be removed. No bevels should be placed on the occlusal margins of the preparation.

Typically, these restorations are limited in size and depth, so no pulpal protection is needed (Fig 11-14e), but a PRR is indicated even with a deep caries lesion when

Dentlearn.ir

areas of the fissure system are not carious. Etching and application of an adhesive agent are the same as with other adhesive restorative procedures. Those areas of the preparation that have extended into dentin are filled with a highly filled restorative resin composite, which should be cured in increments no greater than 2 mm in thickness (Fig 11-14f). If the preparation is narrow and shallow, sealant material, flowable resin composite, or warmed resin composite may be used. Prior to curing of the final increment, occlusal anatomy is sculpted with a hand instrument (Fig 11-14g). Occlusal sealant is then placed over the resin composite, through remaining prepared or unprepared etched fissures, and cured (Fig 11-14h). If, after the final increment is cured, excess restorative material is present, the surface should be adjusted to provide desired contours and anatomy. The entire fissure system, including the resin composite and sealant, should be re-etched and a surface-sealing resin applied.[31,212]

After completion of the restoration (Fig 11-14i), the rubber dam is removed and correct occlusion verified or obtained.

Other Class 1 Resin Composite Restorations

When a Class 1 restoration is being placed because of initial caries lesion(s), the PRR is usually the technique of choice. If there was a previous restoration, the outline form and depth of the preparation will be determined by the previous restoration and any new pathosis. Margins of occlusal preparations for resin composite should not be beveled.[213] Lining and bonding techniques should be used as described for Class 2 restorations.

Class 2 Resin Composite Restorations

As with PRRs, Class 2 restorations should be limited to obtaining access to the carious dentin and removing it and any overlying fragile or demineralized enamel.

Prewedging

Obtaining adequate interproximal contact in the definitive restoration starts at this stage of the restorative procedure, not at matrix placement or material insertion, as is the norm for amalgam restorations. Uncured resin composites, even the so-called packable composites, do not have the ability to hold the matrix band in close

Dentlearn.ir

adaptation to an adjacent tooth.[214,215] This makes obtaining an adequate interproximal contact one of the more difficult aspects of placing a Class 2 resin composite restoration. Placement of an interproximal wedge at the start of the procedure is recommended to open the contact with the adjacent tooth and to compensate for the thickness of the matrix band. It has been demonstrated that multiple wedging (ie, inserting a wedge initially and then reapplying seating pressure several times during the course of the procedure) is more effective in opening the contact than is a single placement of a wedge.[118] In addition, the wedge can protect the rubber dam from damage and the gingival tissues from laceration, thereby reducing leakage into the operative site.[27] Alternatively, a sectional matrix band ring can be used to effectively provide tooth separation.[216] Tooth separation obtained from prewedging promotes more conservative preparation and helps protect adjacent teeth from damage during preparation (Fig 11-15). Failure to take measures to protect adjacent teeth during proximal surface preparation with rotary instruments will usually result in damage to the adjacent teeth[217] (Fig 11-16). Furthermore, this damage makes it significantly more likely that the damaged surface will require subsequent restoration.[218] Strategies for protecting adjacent proximal surfaces of adjacent teeth during preparation of a proximal area are presented in Fig 11-17.



Fig 11-15 A wedge is placed before preparing the mesial surface of the maxillary second premolar; it provides tooth separation to help ensure adequate interproximal contact in the definitive restoration, and it helps prevent damage to the adjacent tooth, rubber dam, and gingival tissues.

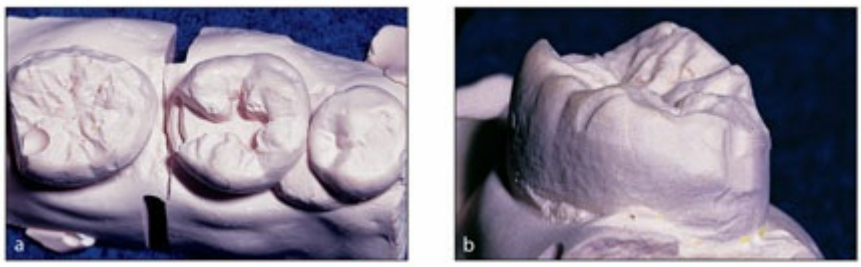

Fig 11-16 *(a)* Stone cast made following Class 2 preparation involving the distal surface of a mandibular first molar. *(b)* View of the mesial surface of the mandibular second molar shows the damage that resulted from inadequate protection during preparation of the distal surface of the first

Dentlearn.ir

molar.



Fig 11-17*(a)* A small piece of matrix band is placed prior to a Class 2 preparation to protect the proximal surface of the adjacent tooth. A wooden wedge has been placed to help maintain the matrix in position and to gain separation to aid in obtaining an appropriate contact in the definitive restoration. *(b)* Alternate strategies for protecting the proximal surfaces of adjacent teeth during tooth preparation of the second premolar: Interguard (Ultradent) is placed between the first and second premolars, and a circumferential metal matrix band is placed on the first molar. *(c)* The FenderWedge (Garrison Dental Solutions) is designed to provide simultaneous prewedging and protection of the adjacent tooth's proximal surface during cavity preparation. *(d)* FenderWedge in place prior to initiating preparation.

An alternative strategy for preparing the proximal surfaces of Class 2 preparations that provides protection of the adjacent proximal surface is the use of a special diamond preparation tip, half of which is "safe-sided" (ie, the diamond abrasive is only present on one side of the tip) (Figs 11-18a and 11-18b). These tips, which come in a variety of shapes and sizes (Fig 11-18c), can be used in sonic handpieces that fit a normal dental unit coupler or in a piezoelectric ultrasonic unit as might be used for scaling and root planing. It will usually be necessary to initiate the preparation with a rotary high-speed handpiece, because preparation with ultrasonic and especially sonic handpieces can be slower than with normal rotary handpieces.[219] Research has shown that pulpal temperature increase with ultrasonic preparation is not greater than that with water-cooled rotary preparation.[219] In addition, sonic preparation does not adversely affect adhesion as compared to rotary handpiece preparation with a carbide bur.[220] An example of the use of sonic preparation is shown in Fig 11-19.

Dentlearn.ir



Fig 11-18 *(a)* Example of a sonic preparation tip (KaVo), demonstrating the use of the diamond abrasive side to shape a proximal cavity preparation. *(b)* Example of the same sonic preparation tip, demonstrating the use of the safe, nonabrasive side to prevent damage to the adjacent tooth. *(c)* Examples of some of the many different sizes and shapes available for use in sonic or ultrasonic handpieces. Note that there are matching shapes/sizes for use on both the mesial and distal surfaces.

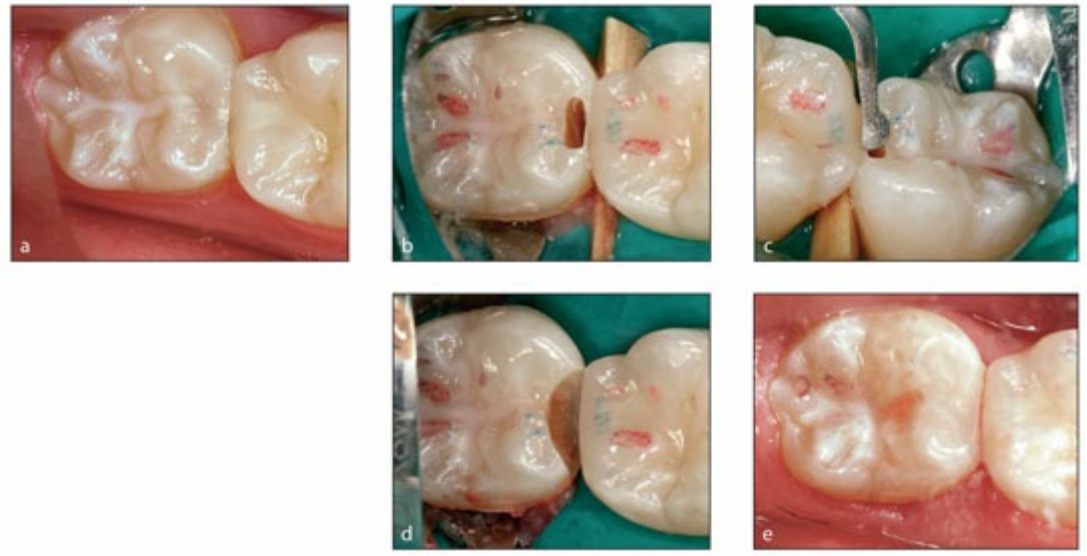

Fig 11-19 *(a)* Preoperative photograph of the mandibular left second molar. Bitewing radiographs revealed a caries lesion on the mesial proximal surface. Note that the occlusal surface had been treated with a pit and fissure sealant and was protected from caries, allowing tooth preparation to be limited to the proximal surface affected by caries. *(b)* Proximal preparation was initiated with a ¼ round bur and a rotary high-speed handpiece. Note that the proximal wall has been left intact. *(c)* A safe-sided diamond tip is used to remove the proximal wall. *(d)* Final preparation, after caries removal and refinement of the preparation with the safe-sided diamond preparation tip in a sonic handpiece. *(e)* Finished restoration.

Preparation

As a general principle, preparation should be limited to eliminating carious tooth structure and providing access for restoration placement and finishing (Figs 11-20a to 11-20c). If there are one or more areas of fissure caries lesions in the tooth, in addition to the proximal surface lesion(s), they should be treated separately, if possible, as described in the section on preventive resin restorations.

Dentlearn.ir

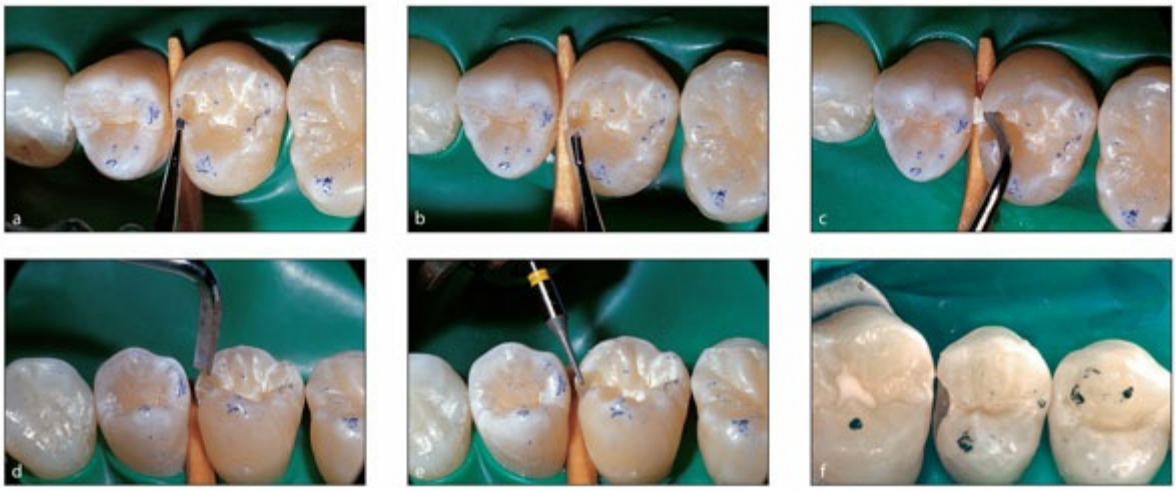

Fig 11-20*(a)* Preparation is initiated just inside the marginal ridge with a small round bur (no. ¼). *(b)* The preparation is extended with a no. 329 bur. Note that the proximal surface is left intact. *(c)* After the proximal surface is thinned, a spoon excavator is used to fracture and remove the thinned enamel. *(d)* Bevels at the cavo-surface margins of the proximal walls are placed with hand instruments. *(e)* Alternatively, fine-grit diamonds or carbide finishing burs can be used to place bevels. *(f)* When a preparation exits the external tooth surface at an obtuse angle (greater than 90 degrees), no beveling of proximal walls is necessary.

Bevel placement is a point of controversy with this preparation. When used in conjunction with adhesive agents and resin composites, bevels in enamel provide more area for acid etching and bonding. In addition, the bevel is designed to expose enamel rods transversely (cross-cut or "end-on") to achieve a more effective etching pattern. Research has indicated that etching of transversely exposed enamel rods (ends of rods) results in a bond that is significantly stronger than that attained with etching of longitudinally cut enamel rods (sides of rods).[221] Clinical research has demonstrated favorable results with the use of acid-etched, beveled preparations in Class 3 resin composite restorations.[222] The clinician must be judicious in bevel location for posterior resin composite restorations.

Following are recommendations regarding bevel placement in Class 2 preparations for resin composite restorations.

Facial and lingual proximal margins

Because enamel rods exit the tooth at approximately right angles to the external tooth surface, it is necessary for the cavity preparation to form an obtuse angle (greater than 90 degrees) with the external tooth surface to expose the ends of the enamel rods. If the external cavosurface margin forms a right angle with the tooth surface, conservative bevels (0.5 mm) should be placed at an approximately 45-degree angle to the surface, on the facial and lingual cavosurface margins of the proximal box

Dentlearn.ir

preparation (Figs 11-20d and 11-20e). This will achieve the benefits of beveling as well as aid in placing the margins in a more accessible location for finishing and polishing. Research has demonstrated that bevels on these margins significantly reduce marginal leakage.[223,224] If the preparation exits the tooth at an obtuse angle, no further beveling of the proximal walls is necessary (Fig 11-20f).

Gingival margins

The decision to place a gingival margin bevel requires clinical judgment. The gingival margin should be beveled only if the margin is in enamel well away from the cementoenamel junction and an adequate band of enamel remains (Fig 11-21; see also Fig 11-2c). When sufficient dentin-supported enamel remains for adequate bevel placement, resin composite adaptation is enhanced.[225] As the preparation nears the cementoenamel junction, the enamel layer is thinner than in other regions of the crown, and beveling the preparation increases the potential for removing the little enamel that remains. Because of the presence of prismless enamel in this region, acid etching is often less effective.[226] When a cavity preparation approaches within approximately 1 mm of the cementoenamel junction, adhesion is essentially no better than bonding to dentin[227,228] (Fig 11-22).

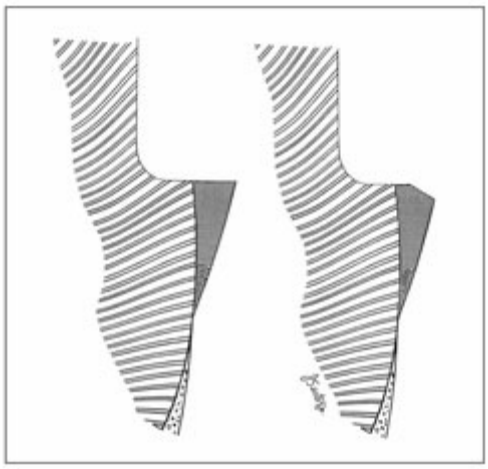

Fig 11-21 When enamel is adequate at the gingival margin, a bevel is placed to enhance resin composite adaptation and seal.



Fig 11-22 When a ace margin bevel is

Dentlearn.ir

placed to expose the ends of the enamel rods for etching. *(a)* Appropriate proximal cavosurface margin bevels when the enamel is well above the cementoenamel junction. Gingival as well as facial and lingual vertical cavosurface margins are beveled. *(b and c)* As the gingival margin approaches 1.0 to 1.5 mm from the cementoenamel junction *(b)*, or when it is apical to the cementoenamel junction *(c)*, no gingival bevel is placed. Note that the facial and lingual vertical cavosurface margins are still beveled.

at the gingival cavosurface margin (Fig 11-23), has been shown to significantly reduce microleakage as compared to a butt margin[229] (see Fig 11-23b) and would be preferable to placing the gingival margin on or near the cementoenamel junction. This type of marginal configuration should not be created intentionally with a bur, but if a lip of unsupported enamel remains after removal of demineralized dentin, it should be configured to an inverse bevel rather than planing the unsupported enamel off to form a butt margin in cementum or dentin.

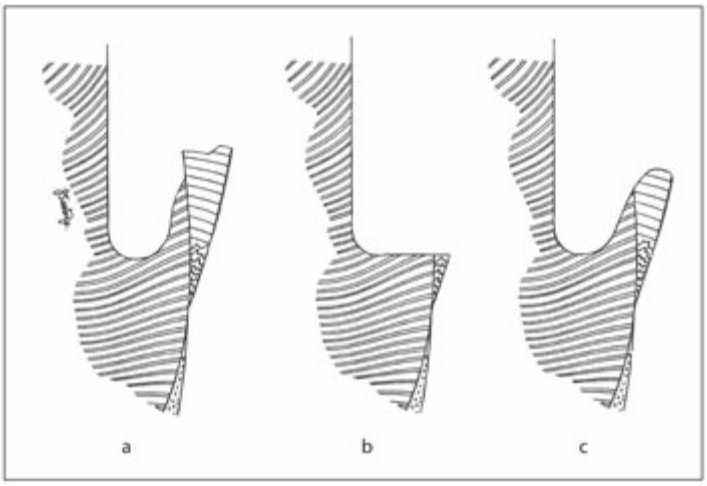

Fig 11-23*(a)* Excavation of a proximal caries lesion will sometimes result in a more gingival extent of the preparation in dentin than in enamel. *(b)* If the preparation is extended straight out to the cavosurface margin, remaining enamel for bonding is compromised. *(c)* Refining the preparation with a low-speed round bur or a sharp hand instrument to eliminate very thin enamel and prepare adhesion to the gingival margin. Assuming that removal of carious dentin created the situation shown in *a*, the marginal configuration shown in *c* is preferable to that in *b*.

Occlusal margins

The use of occlusal cavosurface margin bevels is not indicated. Some clinicians have advocated the use of bevels on occlusal cavosurface margins to maximize the exposure of end-cut enamel rods.[226] However, it has been noted that a normal preparation in the occlusal surface will result in end-cut enamel rods because of the orientation of the enamel rods in cuspal inclines[163] (Fig 11-24). Avoidance of

Dentlearn.ir

bevels on the occlusal surface prevents the loss of sound tooth structure, decreases the surface area of the definitive restoration, lessens the chance of occlusal contact on the restoration, eliminates a thin area of resin composite that would be more susceptible to fracture and wear, and presents a well-demarcated marginal periphery to which resin composite can be finished more precisely.[14,230,231]

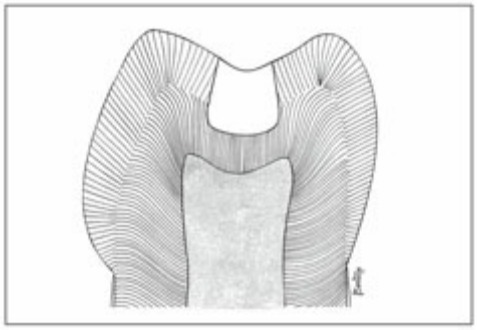

Fig 11-24 The enamel rods on the occlusal surface are oriented in such a way that the ends are exposed without beveling.

Placement of occlusal bevels has demonstrated no benefit to the longevity of Class 2 resin composite restorations.[30] A clinical study demonstrated that posterior resin composite restorations placed in cavities with beveled occlusal margins had significantly greater wear than those placed with occlusal butt margins.[213] A significant factor predicting the survivability of posterior resin composite restorations is the proportion of the occlusal surface restored[16,20,21,30]; this factor is increased by occlusal beveling. Therefore, occlusal cavosurface margin bevels should be avoided (Fig 11-25).



Fig 11-25 Finished preparation. The tooth has been prepared only in those areas where carious dentin was present. The preparation has not penetrated to dentin in other areas of the occlusal surface. Proximal facial, lingual, and gingival cavosur-face margins have been beveled; occlusal cavosurface margins have not been beveled.

It should be noted that occlusal enamel should not be left unsupported by dentin, particularly in an area of occlusal stress. Research has shown that unsupported

Dentlearn.ir

occlusal enamel, even if the lost dentin has been replaced with glass ionomer, RMGI, or bonded composite, is significantly weaker than enamel supported by dentin.[232]

Use of cavity liners

If used, calcium hydroxide liners should be limited to those areas of the preparation that are believed to be very close to the pulp, where there is the possibility of a minute pulpal exposure.[96] Placement of a calcium hydroxide liner over an extensive area of dentin provides no benefit to the pulp and decreases the surface area of dentin available for adhesion. Dissolution of the liner during acid etching can interfere with a sound bond to enamel and dentin.[233] If the preparation is conservative in size, no liner is required in addition to the adhesive agent. In deeper preparations and those in which the gingival margin approaches or extends beyond the cementoenamel junction, a glass-ionomer liner may be beneficial. Pulpal considerations are discussed in depth in chapter 6.

Glass-ionomer liners are reported to offer a number of potential advantages when used under posterior resin composite restorations. Glass-ionomer materials bond to both tooth structure and overlying resin composite,[234] and they introduce less polymerization stress into tooth structure than does resin composite.[79] Glass ionomer releases fluoride into adjacent tooth structure,[235] which may be advantageous because of the tendency for secondary caries lesions to occur adjacent to posterior resin composite restorations.[14] Use of a glass-ionomer liner has been demonstrated to improve marginal integrity[236] and decrease marginal leakage.[169,237,238] Less bulk of resin composite material is required to fill the preparation, reducing the amount of polymerization shrinkage[239] and improving marginal adaptation.[68] Glass-ionomer liners can reinforce the preparation walls by adhering to dentin and minimizing cuspal deformation under load.[239] Glass-ionomer liners also reduce the rise in pulpal temperature associated with application of the curing light during incremental insertion procedures.[240] With improvements in dentin adhesives, the use of glass ionomer under posterior resin composite restorations has been greatly reduced in recent years. However, use of a glass-ionomer liner on dentin cavity surfaces has been shown to significantly reduce postoperative sensitivity compared to use of a dentin adhesive alone.[241] Therefore, clinicians should consider use of a glass-ionomer liner even if an adequate band of enamel surrounds the entire preparation.

Dentlearn.ir

Bonded-base technique

If the gingival margin of a Class 2 preparation is in enamel but within 1 mm of the cementoenamel junction, or if it is in dentin, and an alternative restorative material is not appropriate (eg, amalgam), an RMGI restorative material should be placed as the initial increment in the proximal box. This technique, known as the *bonded-base* o r *open sandwich technique*, has demonstrated a number of advantages when compared with use of an adhesive agent alone. There is considerable in vitro evidence that the bonded-base technique results in improved marginal adaptation and a reduction in marginal leakage.[242–249] Additionally, glass ionomers have demonstrated good antibacterial activity against microorganisms associated with dental caries,[250] as well as reduced demineralization adjacent to dentin margins.[251] Most important, the bonded-base technique has demonstrated good clinical performance. The first evaluation of the bonded-base technique used a conventional restorative glass ionomer as the initial increment in the proximal box. Unfortunately, this technique showed poor clinical longevity.[252] However, use of an RMGI restorative material for the initial increment in the proximal box has proven to be a viable technique. One clinical study showed that RMGI provided significantly better cervical margin adaptation in Class 2 cavity preparations than did resin composite.[253] Several studies have shown that the bonded-base Class 2 restoration performs comparably with resin composite restorations using adhesive systems alone in most clinical parameters.[152–155] In addition, the bonded-base technique has demonstrated some important clinical advantages versus bonded Class 2 composite, including reduced postoperative sensitivity[155] and reduced in vivo demineralization adjacent to the gingival margin.[152] For these reasons, the bonded-base restoration should be considered whenever a posterior resin composite restoration will include a gingival margin in close proximity or apical to the cementoenamel junction.

The technique for accomplishing a bonded-base restoration is demonstrated in Fig 11-26. After completion of the preparation, the matrix is applied, and a wedge is placed. The gingival portion of the proximal box is treated with the RMGI conditioner. The RMGI is mixed, transferred to a light-protected Centrix syringe tip, and injected into the gingival aspect of the proximal box. Because glass ionomer does not have the same level of wear resistance as composite,[254,255] this increment of RMGI should remain apical to the proximal contact (Fig 11-26c). The surface of the RMGI increment is smoothed and light cured. The entire cavity preparation, including the RMGI in the gingival portion of the proximal box, is etched, and the adhesive system is applied according to the manufacturer's instructions. The

Dentlearn.ir

preparation is filled and finished as described in the subsequent sections of this chapter.



Fig 11-26*(a)* Following caries excavation, the gingival margin of the proximal box extends below the cementoenamel junction onto dentin. Note that the gingival margin extends to the fluted area of the root. *(b)* To perform the bonded-base technique, an RMGI restorative (versus a lining glass ionomer) is used. In this case, Vitremer (3M ESPE) was used. *(c)* Following treatment of the gingival portion of the proximal box with the RMGI conditioner, the RMGI restorative is mixed, placed into a Centrix syringe tip, injected into the gingival portion of the proximal box, smoothed, and cured. The RMGI should remain apical to the proximal contact. Note that two wedges have been used to contour the gingival margin of the matrix into the fluted area of the root. *(d)* Following etching and application of the adhesive system to the RMGI and remaining aspects of the cavity preparation, the preparation is filled using an incremental placement technique. *(e)* The completed restoration.

Adhesive system application

The adhesive system of the dentist's choice should be applied. Chapter 9 provides detailed information on adhesive system selection and application.

If the preparation is etched and the bonding resin is placed before application of the matrix, visualization and access to all areas of the preparation are better, and it is easier to brush-thin the adhesive and avoid pooling. A small piece of matrix band material, used to protect the adjacent proximal surface, may be kept in place. However, the wedge either should not be replaced at this time or should be placed between the matrix material and the preparation. This gives the resin adhesive

Dentlearn.ir

access to all areas of the preparation and provides an escape for the resin adhesive at the margin to prevent it from pooling. Placement of a matrix after adhesive application sometimes results in contamination of the preparation with blood or saliva, so the operator may prefer to place the matrix and wedge prior to etching and application of the adhesive. If so, special care must be taken to ensure the absence of pooling of the resin adjacent to the matrix. Enamel and dentin adhesives are discussed at length in chapter 9.

Matrix application

Several useful matrices are available, including the clear plastic matrix, the ultrathin (0.001-inch) Tofflemire metal matrix (Fig 11-27a), the thin (0.0015-inch) sectional matrix, and the Tofflemire metal matrix with photoetch-thinned (0.0005-inch) contact areas.



Fig 11-27 Two common matrices for Class 2 resin composite restorations. *(a)* Clear and metal matrix bands are shown with Tofflemire retainers. *(b)* The clear matrix is usually used with a light-reflecting wedge.

The clear matrix can be used in conjunction with a light-reflecting wedge (Fig 11-27b) and offers the advantage of allowing penetration of the curing light from multiple directions. This allows the clinician to cure the increments of resin composite from the proximal and gingival directions, rather than from the occlusal aspect only, to ensure adequate polymerization of each increment. In addition, it has been reported that this technique allows more favorable direction of the polymerization shrinkage. One study showed enhanced gingival margin adaptation using this technique when the proximal box was prepared in enamel,[256] although another study failed to show a similar benefit when the gingival margin was in dentin.[228] However, the clear matrix is thicker than the thinnest metal matrices, and its lack of rigidity makes placement through tight interproximal contacts difficult.[231] In addition, the rigidity and smoothness of the plastic, light-reflecting wedge makes it less effective than a wooden wedge in gaining the slight tooth separation needed to ensure adequate interproximal contact. Methods to compensate for this lack of

Dentlearn.ir

separation are described later in this chapter. However, because of these drawbacks, most clinicians prefer metal matrices and wooden wedges.

Tight interproximal contacts are more easily developed with the ultrathin metal matrices than with the clear matrices because they are easier to place, maintain their shape better, and can be burnished against the adjacent tooth. One disadvantage of a metal matrix that wraps around the facial and lingual surfaces of the tooth is that increments must be initially cured only from the occlusal aspect. After removal of the matrix, the proximal resin composite may be further polymerized from the facial and lingual aspects. To avoid flat proximal-surface contours, precontoured matrices should be used or the metal matrices should be shaped or contoured by burnishing before or after they are placed. The marginal ridge strength obtained with a contoured sectional matrix is significantly greater than that obtained with a straight, circumferential band.[257,258]

Other devices that are helpful in developing adequate interproximal contacts are the sectional matrix systems, used with metal rings with springlike properties (Fig 11-28; see also Figs 11-30g and 11-30i). After the sectional matrix and wooden wedge are placed, the ring is placed using a rubber dam clamp or similar forceps so that the vertical points of the ring are positioned in the facial and lingual embrasures adjacent to the box preparation. The ring holds the ends of the sectional matrix tightly against the tooth and exerts a continuous separating force between the teeth. The matrix should be burnished gently against the adjacent proximal contact (Fig 11-29). The sectional matrices in these systems are typically made of "dead soft" metal. Heavy burnishing will cause grooves to be formed in the matrix that will be replicated in the restoration. This makes for a rough, irregular contact that can tear and shred floss when the patient performs oral hygiene measures, so only light burnishing should be used.



Fig 11-28 *(a)* Palodent sectional matrix system (Dentsply/Caulk). *(b)* Composi-Tight sectional matrix system (Garrison Dental Solutions).

Dentlearn.ir



Fig 11-29 Sectional matrix and Composi-Tight ring in place. The matrix is burnished in the contact area to enhance proximal contour and contact.

These "ring" sectional matrix systems have a number of advantages: They provide tooth separation to ensure good interproximal contact; they provide better proximal contours for posterior resin composite restorations than traditional matrices; and they simplify matrix placement for single proximal-surface restorations as compared to a circumferential band.[259,260] In addition, these systems provide a tighter, longer-lasting contact in resin composite than does a standard matrix in a Tofflemire retainer.[257,261,262] It should be recognized that the ring provides progressive tooth separation, so if it is left in place for a long period of time, excess separation can occur, resulting in a very tight contact.

The placement of the ring relative to the prepared tooth and the wedge should vary based on the location of the proximal margins and the type of ring. Proper placement of the ring depends on facial and lingual extensions of the proximal box and the size and shape of the tines of the particular ring being used. Rings with wider tines (eg, the Palodent system, Dentsply/ Caulk) tend to limit the ability to place the ring in different locations relative to the wedge, whereas rings with narrower tines (eg, the Composi-Tight system, Garrison Dental Solutions) provide more flexibility in this regard. If the facial and lingual proximal extensions of the proximal box do not extend significantly onto the facial or lingual surfaces of the tooth, it is possible to place the ring with the tines occlusal to the wedge (Figs 11-30a and 11-30b) or between the wedge and enamel adjacent to the proximal surface being restored. However, if one or both of the proximal walls reach the facial or lingual surfaces of the tooth, placement of the tines of the ring in these locations may cause the matrix to be deformed (Fig 11-30c). In this case, the tines may be placed between the wooden wedge and the proximal surface of the adjacent tooth. The ring will have enough tension to separate the teeth adequately and to cause the wedge to wrap slightly around the tooth, providing a tight gingival seal and wrapping of the sectional matrix around the tooth to form the proper proximal contour (Fig 11-30d). Plastic wedges have been developed that allow additional wrapping of the wedge and matrix when the ring is placed between the wedge and the adjacent tooth surface (Figs 11-30e

Dentlearn.ir

and 11-30f). Newer rings have been designed to help overcome some of the concerns regarding the placement of the ring relative to the position of the wedge or the preparation walls. Some rings incorporate an inverted "V" shape, which allows the ring to straddle the wedge, provide tooth separation, and contour the matrix around the facial and lingual contours of the tooth (Figs 11-30g to 11-30k).



Fig 11-30 *(a)* Conservative proximal preparation allows the ring for a sectional matrix system to be placed above (coronal to) the wedge. This placement provides a separating action and contours the matrix to provide correct proximal contours. *(b)* Facial view showing placement of the ring. *(c)* In this preparation, the lingual proximal wall extends onto the lingual surface. The ring has been placed above (coronal to) the wedge. However, the lingual tine has caused the matrix to partially collapse into the preparation, resulting in the matrix band covering a portion of the gingival floor of the preparation. *(d)* The ring has been respositioned between the wooden wedge and the adjacent tooth. This prevents the tines from collapsing the matrix into the preparation. It also causes the wedge to bend, enhancing the gingival seal of the matrix and wrapping the matrix around the tooth to develop the appropriate proximal contour. *(e)* Plastic wedges are more flexible than wooden wedges and may be more useful when the ring must be placed between the wedge and the adjacent tooth (Wedge Wands, Garrison Dental Solutions). *(f)* The ring placed between the plastic wedge and the adjacent tooth. Note the pronounced wrapping of the wedge at the gingival aspect of the preparation. *(g)* Underside of an original sectional matrix ring *(left)* next to a sectional matrix ring (Garrison Dental Solutions) that incorporates a "V" shape to allow the tines to straddle

Dentlearn.ir

the wedge *(right)*. *(h)* The matrix ring in position. Note the "bumpers" on the tines that aid in adapting the matrix to the facial and lingual contours of the tooth. *(i)* Original "V-wedge" designed with tines to sit on top of an inserted interproximal wedge (Triodent). *(j)* V-wedge in place. Note that the placement of the tines is not affected by the wedge and that the matrix is contoured around the facial and lingual contours. *(k)* Current iteration of the V-wedge (Triodent).

Yet another type of sectional matrix involves a short piece of thin, stainless steel matrix material that is contoured only occlusogingivally and does not surround the tooth at all (Fig 11-31). This allows some light curing from facial and lingual aspects. The contoured matrix is secured with a wooden wedge and lies passively against the adjacent tooth surface or is held there with an instrument during curing of the first increment. That increment then holds the matrix against the adjacent tooth during placement of succeeding increments. When this technique is used, resin composite in facial and lingual embrasures must be contoured or sculpted with a thin-bladed instrument, such as an interproximal carver (IPC), prior to curing.



Fig 11-31 A passive sectional matrix is placed and wedged. Resin composite will be sculpted in the facial and lingual embrasures with a thin instrument such as an IPC.

Resin composite placement: Incremental technique

VLC resin composite should be placed in successive, laminated increments to ensure proper curing and prevent excessive polymerization shrinkage stress.[13] Incremental curing decreases the effects of polymerization shrinkage, enhances marginal adaptation, decreases gap formation, reduces marginal leakage, decreases cuspal deformation, makes the cusps more resistant to subsequent fracture, improves bond strength to cavity walls, and decreases postoperative sensitivity.[66,68,256,263–266] One of the greatest benefits to the incremental fill technique may be its effect on cavity configuration, or *C-factor*.

The C-factor is the ratio of bonded to unbonded restoration surface areas and has been shown to have a profound impact on polymerization shrinkage stress (see chapter 9). As the C-factor increases, that is, as the surface area of resin composite bonded to cavity walls increases relative to the surface area of unbonded resin composite, shrinkage stresses increase dramatically.[75,267,268] With incremental

Dentlearn.ir

placement and curing of resin composite, the C-factor of each increment is reduced compared with bulk placement and curing.[269] As the C-factor decreases, bond strength increases.[270] The end result is that the incrementally placed and cured restoration is bonded better to the cavity walls than if the preparation had been filled and the resin composite material cured in bulk.

First increment

Some general guidelines should be followed for the placement of the resin composite. Proper handling of the bonding system and resin composite at the gingival margin is critical because of the tendency for microleakage to occur in that area.[238] A clinical study that assessed gingival margin quality in Class 2 resin composite restorations showed that only 27% were satisfactory.[271] Therefore, techniques must be used to enhance the bond and reduce the adverse effects of polymerization shrinkage. First, an increment no thicker than 1 mm is placed against the gingival wall.[272] A thin first layer will ensure proper light irradiation throughout the increment.

If a clear matrix and light-reflecting wedge are being used, the initial curing should be directed through the flat end of the wedge. The scientific literature reveals that the amount of light that a reflecting wedge will transmit varies. One study indicated that 90% to 95% of the incident light is transmitted,[256] while another showed that it could be as low as 66%.[273] Because of the possible attenuation of light through the wedge, exposure time should be increased by 50% to ensure adequate polymerization. It has been suggested that the light-reflecting wedge will direct the curing light to the gingival margin of the restoration and draw the polymerization shrinkage toward that margin. When the gingival margin is on enamel, this method has been shown to result in better marginal adaptation than curing from an occlusal direction.[68,256,274,275] However, when the gingival margin is on dentin, this technique has failed to reduce gingival margin microleakage compared with other techniques.[228]

Because most plastic wedges are rigid and smooth, they may slip out of proper position easily and may not maintain the pressure necessary to ensure proper adaptation of the gingival aspect of the matrix band and separation from the adjacent tooth. Two suggestions may help to overcome this problem. After the plastic wedge is positioned, a wooden wedge may be inserted beside it on the side away from the tooth being restored. Alternatively, the plastic wedge can be maintained in its proper position by applying pressure to its flat end with the light-curing tip during curing of

Dentlearn.ir

the initial increment (Fig 11-32). After this is completed, the plastic wedge has accomplished its purpose and may be replaced with a wooden wedge for succeeding increments.

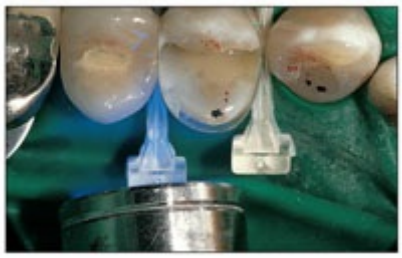

Fig 11-32 When a clear matrix and reflecting wedge are used, the initial cure for the gingival resin composite increment is through the wedge. The end of the light guide can be used to maintain pressure on the smooth plastic wedge during initial polymerization to help ensure complete insertion of the wedge. Because of loss of irradiance when curing through a wedge, cure times should be increased by one-half.

If a metal matrix that surrounds the tooth has been chosen, all increments must be cured from the occlusal aspect. The tip of the light should be positioned as close as possible to the resin being cured.[6] The output of curing lights diminishes considerably with distance, with 50% of light lost just 3 to 6 mm from the light tip.[276] After the metal matrix is removed, all proximal areas of the restoration should receive additional curing with the light to maximize restoration cure.[277]

Resin composites that are marketed for posterior use vary widely in their viscosity.[278] This can have an impact on adaptation of resin composite to the walls of a cavity preparation.[279] Adaptation of resin composite to cavity walls can have a dramatic effect on the bond strength; as adaptation worsens and voids increase, the bond decreases significantly.[280] Thicker-consistency resin composites have significantly increased cavity-wall voids compared with medium- or thinner-viscosity materials.[278] Resin composites that are supplied in preloaded resin composite tips or ampules tend to have a higher viscosity than do composites that are supplied in syringes.[278] Placement technique can also determine how well the resin composite adapts to the cavity-preparation walls. Use of Centrix placement tips (Fig 11-33) for resin composite decreases the viscosity of the material[278] and significantly decreases voids adjacent to the preparation walls compared with either smearing the material into place with a plastic instrument or “condensing” it.[279]

Dentlearn.ir

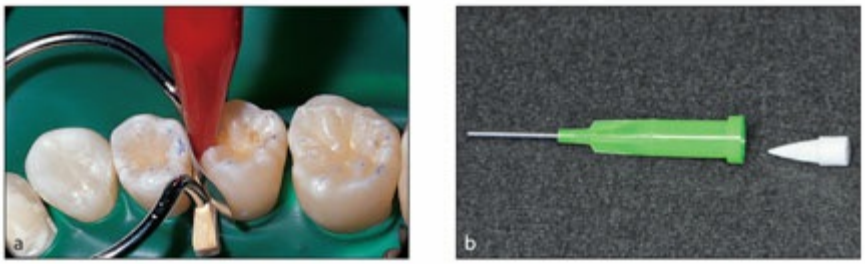

Fig 11-33 *(a)* Previously warmed resin composite is syringed into the preparation via a Centrix placement tip to maximize adaptation to the cavity walls. *(b)* Another Centrix syringe tip that can be used in conjunction with some warm resin composites has a metal tip that can be easily formed to various angles.

Injecting a heavily filled composite through a narrow placement tip can be difficult, if not impossible. A technique that will further enhance the flow of the resin composite into a cavity preparation is to use resin composite that has been warmed prior to injection.[281] The required amount of resin composite from either a syringe or a premanufactured compule tip is transferred into a Centrix syringe tip. The tip and composite can be warmed in a water bath; however, the tip should be sealed in a small plastic bag prior to immersion to protect the resin composite material from moisture. A more convenient means for warming composite is to use a commercial composite warmer (Calset, AdDent) to reduce the viscosity and improve flow.[282] The temperature to which the composite is warmed is based somewhat on individual preference but typically will be in a range of 140°F to 155°F (60°C to 68°C). This material can then be syringed into place more easily, and the lowered viscosity enhances resin composite adaptation to the cavity walls (see Fig 11-33a).

In addition to the above advantages for injecting warmed resin composite (ie, reduced viscosity and improved resin composite flow) other advantages have been demonstrated. Use of warmed resin composite leads to reduced marginal leakage in Class 2 resin composite restorations compared with using either room-temperature resin composite or flowable composite.[283,284] Warmed resin composite exhibits improved cure, as compared to room-temperature resin composite.[285,286] However, the rapid rate at which the warmed composite loses heat once it is placed into contact with the tooth likely minimizes the enhanced cure, and it does not therefore cause a significant increase in shrinkage.[287] Because most temperature increase is due to reaction kinetics and heat from the curing unit, the warmed resin composite adds very little temperature increase to that which already occurs.[285] Resin composite does not polymerize in the warming unit, even if kept at 130°F (55°C) for 4 hours or 158°F (70°C) for 15 minutes.[285] Finally, prewarming of the resin composite does not [288]

Dentlearn.ir

Flowable resin composites

Another method that has been suggested is the use of low-viscosity, or *flowable*, resin composites for the first increment of a proximal box or pulpal floor.[289] The rationale is that these materials flow more readily than standard hybrid formulations and will therefore easily and thoroughly adapt to all areas of the cavity preparation. Also, because of their lower filler content and reduced elastic modulus, it is theorized that these materials could act as "stress relievers" to absorb forces of polymerization shrinkage or cyclic loading.[290] However, the efficacy of this method has not been demonstrated.[290]

There are a number of problems associated with these materials. Because of their higher resin content,[291] flowable resin composites demonstrate up to three times greater polymerization shrinkage than do standard hybrid resin composite formulations.[291,292] This generates significantly greater polymerization shrinkage forces that surpass any benefit that might be derived from the lower elastic modulus.[293] This adversely impacts the adhesion of the resin composite to the cavity preparation, as higher polymerization shrinkage[294] and polymerization shrinkage stress[270] have been shown to significantly decrease bond strength. To address this issue, newer flowable dental composites with relatively high filler content have been developed that have lower shrinkage stress–generating characteristics due to specific modifications of their chemical formulations.

The use of a cured increment of a flowable resin composite in conjunction with Class 2 resin composite restorations has shown mixed results in studies of marginal leakage. Some studies have shown improved marginal seal,[295,296] and others have indicated worsened gingival seal.[297,298] However, the majority of studies show no benefit from using a cured portion of flowable composite as the initial increment in placement of a Class 2 resin composite restoration.[248,299–303] In addition, because of their lower filler load, many flowable resin composites have inferior mechanical properties compared with traditional resin composites.[290] This leads to concern that occlusal forces may introduce increased deflection of the overlying hybrid resin composite, which has a higher modulus of elasticity, due to the inability of the flowable resin composite to provide adequate support.[290] In fact, the use of a flowable resin liner in conjunction with a high-viscosity (packable) resin composite has been shown to reduce the strength of the polymerized packable material.[304]

The reduced viscosity of flowable resin composites improves adaptation to the

Dentlearn.ir

preparation but may also result in undesirable effects. One study found that use of a flowable composite always led to increased incidence of gingival margin overhangs in beveled Class 2 cavity preparations.[305]

An additional concern with flowable resin composites pertains to their radiopacity. Detection of voids and recurrent caries lesions is maximized when a restorative material has the same radiopacity as, or slightly greater radiopacity than, enamel.[48–50] Many flowable resin composites have not met the standard of being at least as radiopaque as enamel.[51,52,306–308]

Clinical trials using flowable resin composite for the initial increments in posterior resin composite restorations have not demonstrated any difference in either postoperative sensitivity[309,310] or overall clinical performance[310,311] compared with the use of heavily filled resin composite alone.

One suggestion that may hold promise for the use of flowable composites in conjunction with posterior resin composite restorations has been called the *snowplow technique*.[312] In this technique, an initial thin increment of flowable composite is placed over the gingival and/or pulpal floors of the cavity preparation. This layer is not cured at this stage, but rather an initial increment of heavily filled restorative resin composite is syringed or pushed into the unset flowable resin composite. Most of the flowable resin composite is displaced by the restorative composite and is subsequently removed from the cavity preparation with a hand instrument, microbrush, or bristle brush. As a result, most of the flowable composite, and therefore its potentially disadvantageous characteristics, is not present in the cavity preparation. Instead, there is only a small amount of flowable resin composite remaining in those areas of the cavity in which the higher-viscosity resin composite did not completely adapt to the preparation and that otherwise may have been void of restorative material. The combined increment of flowable resin composite and restorative resin composite is then cured. This technique has demonstrated significantly reduced void formation compared with placement of restorative composite alone.[312] It has also shown significantly decreased gingival margin leakage in Class 2 resin composite restorations when compared with use of a restorative resin composite alone or with placement of a cured increment of flowable resin composite prior to restorative resin composite placement.[248] It should be noted, however, that no clinical studies with this technique have been reported.

The physical and mechanical properties of flowable composite resins have improved considerably since their introduction. Some flowable composite resins

Dentlearn.ir

demonstrate properties comparable with those of hybrid restorative formulations.[313] Recently, a new composite resin and delivery system (Sonic-Fill, Kerr) has been introduced that uses a special handpiece to deliver sonic energy to a relatively stiff composite resin to dispense it into a cavity preparation quickly and easily. This method, like the warmed composite method, allows one to make a highly filled composite resin flow much more readily to fill and adapt to a cavity preparation, without compromising its mechanical properties. New "self-adhesive" flowable composites have also been developed; these are intended to be used alone, minus the additional step of bonding with a separate adhesive (Vertise Flow, Kerr; Fusio Liquid, Pentron). It is too soon to know if these materials will demonstrate adequate clinical performance. However, it is obvious that as flowable composite resins continue to improve, their use in posterior restorations will undoubtedly increase.

Additional increments

Subsequent increments should be placed in thicknesses no greater than 2 mm. An oblique layering technique should be used whenever access allows (Fig 11-34). An oblique layering technique is preferred because it leads to higher bond strength compared with either the use of horizontal increments or bulk placement.[265,314] In addition, incremental techniques in which the facial and lingual walls are linked by the composite increment during curing tend to show greater cuspal deformation, particularly when the final, occlusal composite increment engages both the facial and lingual cavity walls.[315,316] The restoration should be cured from the facial and lingual aspects after removal of the matrix (Fig 11-35). If a clear matrix is employed, the oblique technique (see Fig 11-34a) should be used, and additional curing from the facial and lingual aspects can be accomplished through the matrix to ensure a thorough cure.

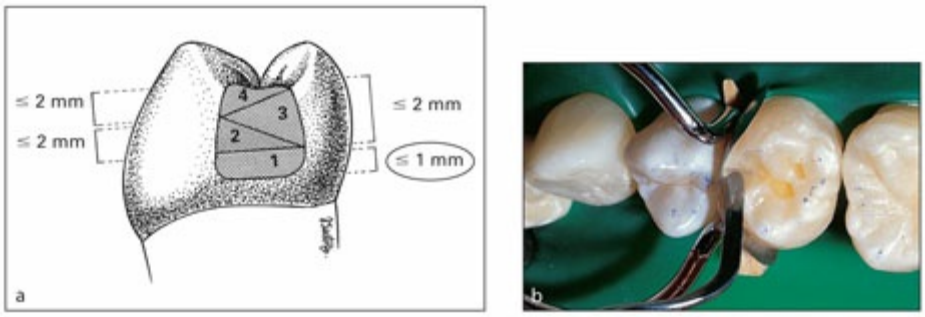

Fig 11-34 *(a)* If a metal matrix is used with a light-curing resin composite, a minimal (1 mm) gingival increment is placed and cured. The material is then layered in alternating oblique increments. No increment exceeds 2 mm in thickness. To minimize cuspal deformation and polymerization stress, an oblique increment should not contact both facial and lingual cavity walls. This placement technique can also be used with a clear matrix and reflecting wedge. *(b)* After the

Dentlearn.ir

initial increment is cured, the next increment is syringed into place and "ramped" obliquely with a plastic instrument or IPC. Here, the Composi-Tight matrix and ring are used, and an oblique increment is shaped with an IPC.



Fig 11-35 If a surrounding metal matrix was used, the restoration should be cured from the facial and lingual aspects after matrix removal.

When the proximal boxes have been filled and the resin composite polymerized,

the proximal box has been filled to the level of the pulpal floor, the proximal box and occlusal preparations can be incrementally filled and cured simultaneously. With the exception of the initial increment in the gingival aspect of the proximal box, subsequent resin composite increments should not contact both the facial and lingual preparation walls simultaneously; this is to minimize polymerization shrinkage stress[317] and cuspal deformation.[315] Figure 11-36 presents the placement of posterior resin composite restorations using a clear matrix and light-reflecting wedges.

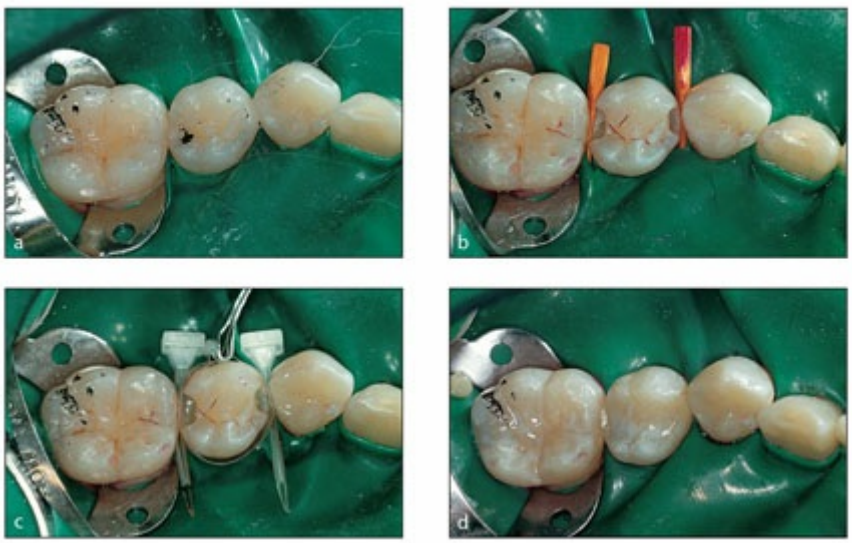

Fig 11-36 *(a)* Preoperatively, the occlusal contacts are marked and a rubber dam is placed. *(b)* Conservative mesio-occlusal and disto-occlusal preparations have been made in the mandibular left

Dentlearn.ir

second premolar. Wooden wedges are in place for prewedging. *(c)* A clear matrix and reflecting wedges in place. *(d)* When the resin composite restorations are completed, a surface sealer is placed.

An alternative to the layering techniques is the use of a conical light-curing tip (Fig 11-37). The proximal box is filled with composite to just gingival to the contact area, and the conical tip is wedged into the resin composite. The cone is used to apply pressure to the matrix band and push it against the adjacent tooth during curing. Subsequent increments restore the cone-shaped gap formed by the tip. This technique is designed to ensure adequate interproximal contact and to minimize the thickness of resin composite that the light must penetrate. While the technique has not become particularly popular and is relatively untested, study results have shown some benefits, including formation of fewer marginal gaps than in the more traditional incremental techniques,[318] reduced cusp deflection,[319] improved hardness, and decreased porosity.[320]

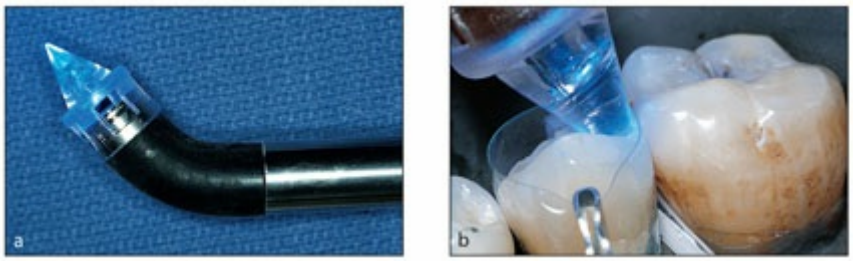

Fig 11-37 A conical light tip *(a)* can be placed into uncured resin composite increment *(b)* to provide curing while also pushing the matrix against the adjacent tooth to enhance proximal contact.

A similar technique to help establish interproximal contact is to place the first increment into the proximal box, but instead of pushing the matrix with the conical tip, it is held against the adjacent tooth during the polymerization with a plastic instrument, condenser, or similar instrument. That increment, after it is hardened, will then hold the matrix against the tooth as successive increments are placed.

Some manufacturers have devised instruments that are precontoured to provide a wedging effect of a matrix band against the adjacent tooth. These instruments are designed to ensure good contact while maintaining proper occlusogingival contours (Fig 11-38).

Dentlearn.ir



Fig 11-38 Examples of composite contact-forming instruments. *(a)* ContactPro (CEJ Dental). *(b)* TriMax (AdDent). *(c)* Perform Proximal Contact Instrument (Garrison Dental Solutions). *(d)* Preoperative photograph of a disto-occlusal amalgam restoration in a mandibular right second premolar to be removed due to a recurrent caries lesion. *(e)* Completed preparation with a matrix and a wedge in place. *(f)* An initial increment of composite has been placed into the proximal portion of the cavity preparation. The ContactPro has been inserted into the unpolymerized composite and rotated and wedged against the mandibular right first molar. The composite will be cured while the ContactPro is held in this position. *(g)* After removal of the ContactPro. Note that the cured composite between the tines of the contact-forming instrument is maintaining a definite interproximal contact. *(h)* Definitve restoration with appropriate proximal contact.

The use of balls of prepolymerized resin composite has also been suggested to aid in establishing interproximal contact. The normal incremental technique is used until the proximal box is filled to just gingival to the proximal contact. A small, slightly flattened ball of resin composite is precured on the tip of an instrument (eg, a Hollenback no. ½ carver). An additional increment of uncured resin composite is placed into the proximal box. The precured ball is pushed into this increment to wedge the matrix tightly against the adjacent tooth; then the resin composite is cured[321] (Fig 11-39).

Dentlearn.ir



Fig 11-39 Use of a precured resin composite ball to establish proximal contact. A small amount of composite is placed on the tip of an instrument (such as the Hollenback no. ½ carver) and cured. It is then pushed into uncured resin composite material in the proximal box. While the precured ball is wedged tightly against the contact, the composite in the proximal box is cured.

It has been suggested that it is not appropriate to restore both the mesial and distal surfaces at the same time, due to the difficulty in obtaining adequate proximal contacts. There is concern that it is not possible to achieve adequate interproximal separation for both proximal surfaces simultaneously. However, research has shown that better contacts are obtained when sectional matrix systems with rings are used simultaneously on the mesial and distal aspects (Fig 11-40) rather than sequentially.[261]



Fig 11-40 Simultaneous mesial and distal placement of sectional matrices and rings for an MOD restoration.

Final increment

Careful control of the final increment will minimize the amount of finishing. A number of techniques are helpful in accomplishing this goal. A rounded, cone-shaped instrument (eg, PKT3), slightly moistened with resin adhesive or a low-viscosity resin specifically designed to prevent sticking of resin composite to the instrument, may be used to shape and form the occlusal surface before curing (Fig 11-41a; see also Fig 11-14g). It is important that only a thin layer of low-viscosity resin be applied to the instrument to act as a lubricant. The best way to ensure this is

Dentlearn.ir

to place a drop of resin in a gauze sponge and then wipe the end of the instrument with the gauze. A fine-bristled brush (eg, sable) can be very helpful in smoothing the composite surface and achieving intimate adaptation of the resin composite to the cavosurface margins (Fig 11-41b) . Figure 11-42 shows a case of a relatively conservative tooth preparation being filled with warm composite.

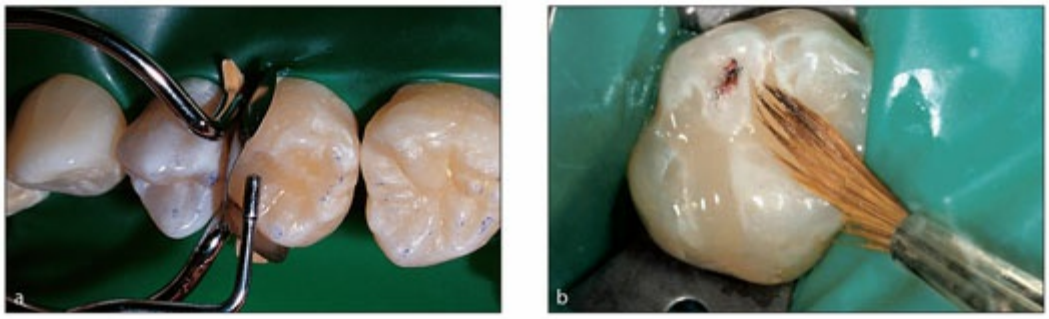

Fig 11-41*(a)* A small condenser or burnisher, lightly moistened with adhesive, is used to establish preliminary occlusal contours in the final resin composite increment before light curing. *(b)* A sable brush is used to smooth the composite surface and ensure intimate adaptation of the restorative composite to the cavosurface margins.

Dentlearn.ir



Fig 11-42 *(a)* Extensively demineralized and carious occlusal fissures and cavitated lesion in the mesial of the maxillary second premolar. *(b)* Proximal preparation is initiated with a no. ¼ round bur. *(c)* Initial proximal preparation, leaving a thin wall of enamel. *(d)* The thin wall of proximal enamel is removed with a spoon excavator. *(e)* Occlusal surface preparation initiated. *(f)* A no. 2 low-speed round bur is used for caries excavation. *(g)* Caries excavation completed. *(h)* A no. 7404 finishing bur is used to remove unsupported enamel and to smooth and blend external cavosurface margins. No bevels are placed on occlusal margins. *(i)* A gingival margin trimmer is used to place a gingival margin bevel. Note that the wedge has been removed to allow access for instrumentation. *(j)* Completed preparation. *(k)* An RMGI liner is placed on the dentin with a Dycal placement instrument. *(l)* Phosphoric acid etchant is placed as part of the three-step etch-and-rinse adhesive system placement. Note that a Mylar strip has been placed to protect the adjacent tooth from the etchant. *(m)* Following placement of the adhesive system, a sectional matrix band, wedge, and ring have been placed (Triodent). *(n)* The initial increment of warm composite is injected into the gingival floor of the preparation. This increment is limited to 1 mm or less in thickness. *(o)* The surface of the increment is gently smoothed with a round-end condenser

Dentlearn.ir

lightly lubricated with uncured resin from the adhesive system.

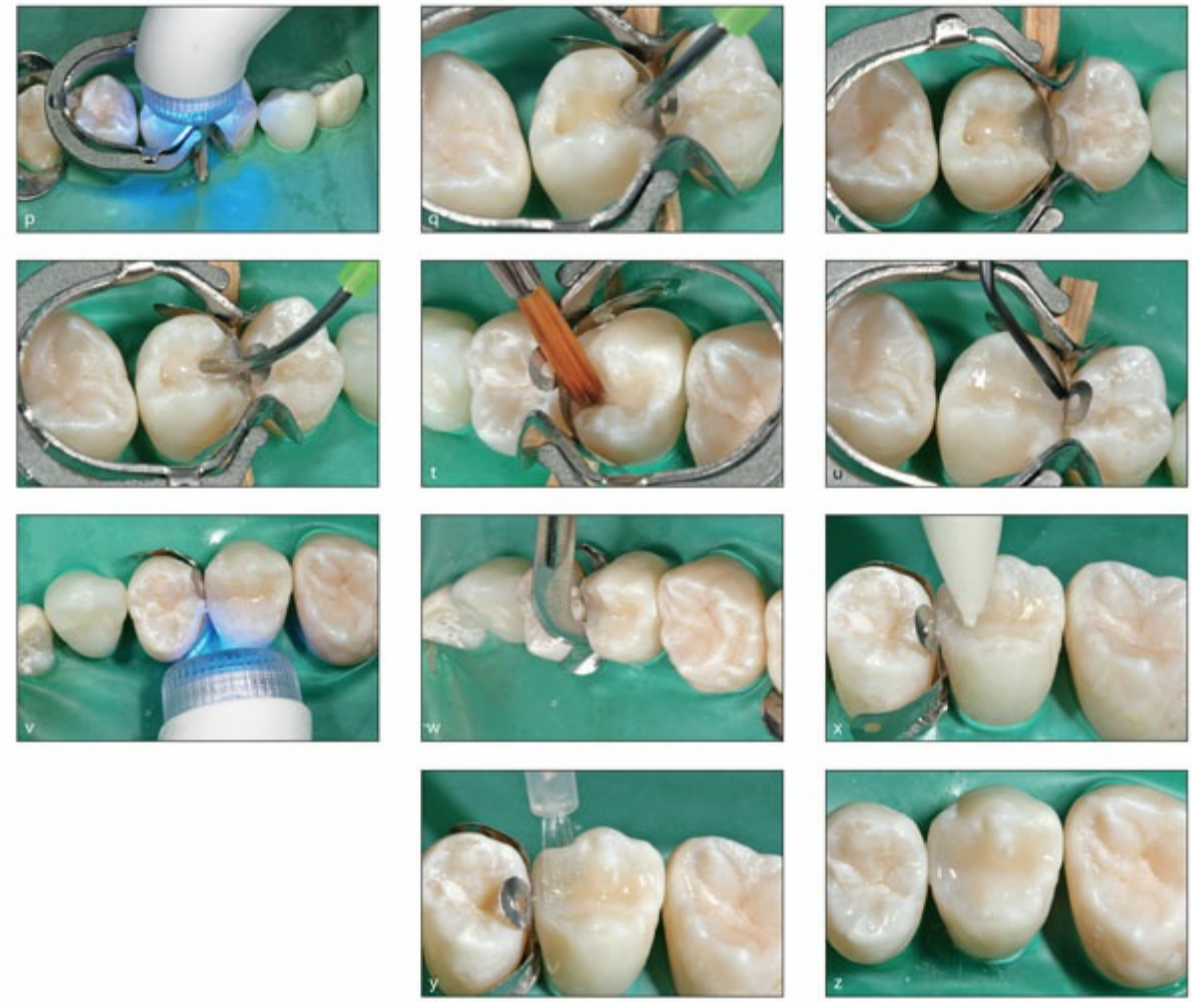

Fig 11-42 *(cont) (p)* The composite increment is cured with a light-emitting diode (LED) curing unit for 20 seconds. *(q)* The remaining increments will be placed using an oblique geometry, such that both the buccal and lingual cavity walls are not connected by the composite. Here composite is being injected into the lingual-proximal corner of the proximal box. *(r)* The proximal box has been filled to approximately the level of the axial-pulpal line angle with oblique increments of composite. At this point, remaining oblique increments can extend across the entire mesiodistal dimension of the preparation. *(s)* An oblique increment that extends across the entire mesiodistal dimension of the preparation is injected into the lingual-pulpal angle. *(t)* When the final occlusal oblique increments are placed, they should be smoothed with a fine-bristle brush, drawing the composite across the occlusal cavosurface margin to ensure intimate adaptation. *(u)* Prior to curing of the final occlusal increments, a thin, bladed instrument (eg, an IPC) is used to develop the occlusal embrasure anatomy. *(v)* Following placement of all composite increments, the wedge and ring are removed. The sectional matrix is wrapped around the proximal surface of the adjacent tooth but left in place. The restoration is then cured from the facial and lingual aspects to ensure the complete composite cure. *(w)* Finishing is initiated with a no.12B surgical blade to remove flash and initiate contour modification. *(x)* Further finishing, contouring, and polishing is accomplished with rotary instruments. *(y)* Following etching of the occlusal surface and all accessible margins, a low-viscosity rebonding agent is applied and cured. *(z)* The completed restoration.

Dentlearn.ir

A method for replacing occlusal anatomy and reducing finishing is called the *successive cusp build-up technique*.[322] With this procedure, incremental resin composite placement is accomplished as described in the preceding sections. However, the clinician stops the oblique layer placement and curing at a point judged to be the base of the pit and fissure anatomy for the definitive restoration. The final increments of resin composite are positioned and adapted to replace the missing portions of the inner inclines of the cusps, one cusp at a time. Because of their stiffer viscosity, packable resin composites work well in this situation. The packable resin composite can be adapted and shaped without slumping prior to curing. As each cusp is replaced with resin composite, it is briefly cured (5 seconds) to set the material in place. It is not necessary to fully cure each increment at this point, because the entire occlusal surface, and therefore all preceding increments, will be irradiated after the final cuspal incline is replaced with resin composite and is irradiated for the full curing time. This technique has been shown to provide enhanced occlusal anatomy, thereby reducing subsequent finishing. Figure 11-43 demonstrates this technique.

Dentlearn.ir

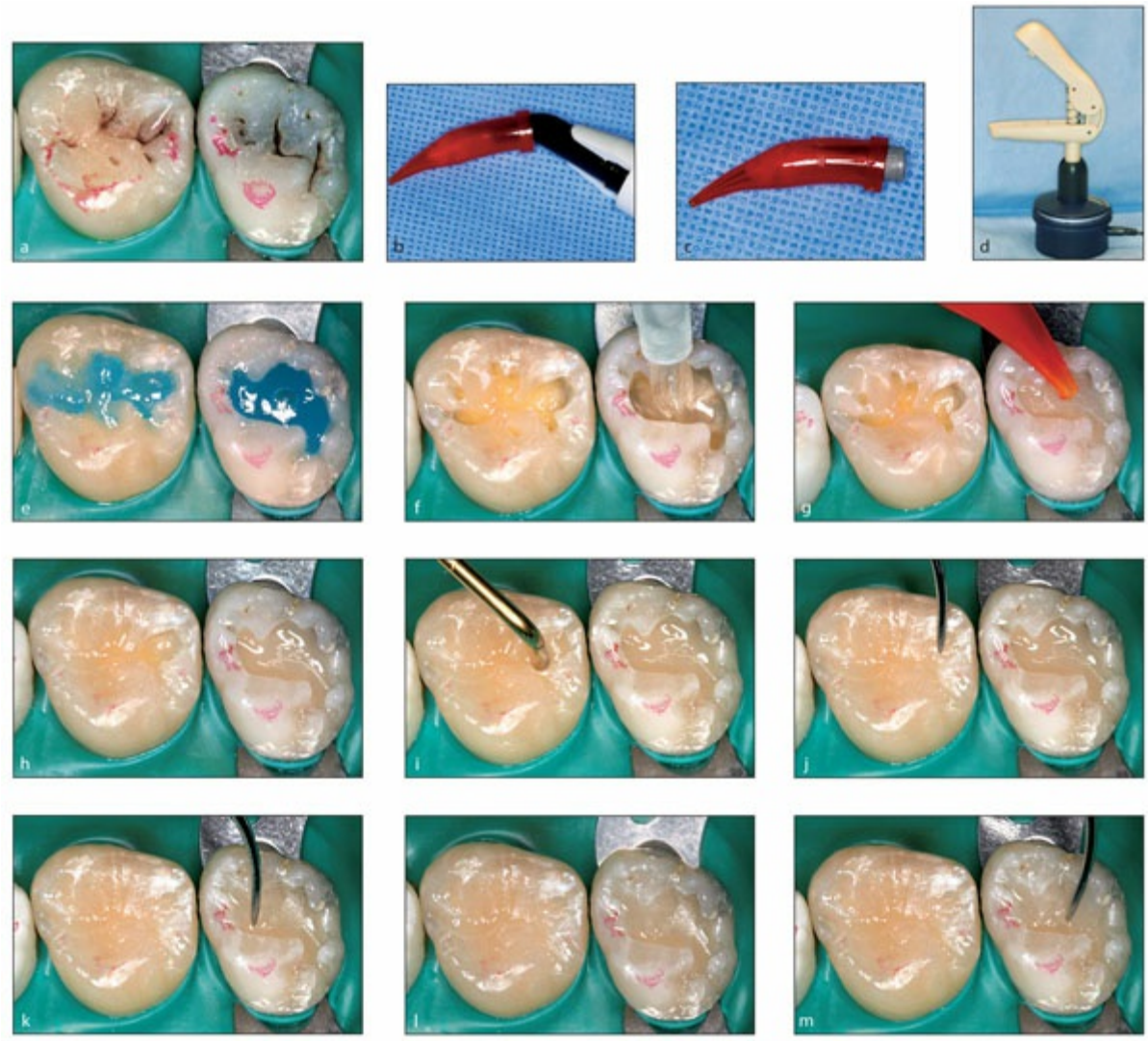

Fig 11-43 The successive cusp build-up technique. *(a)* Preoperative view of maxillary left molars with occlusal caries. Note that the occlusal contacts have been marked prior to rubber dam placement. *(b)* The appropriate resin composite shade is selected and transferred to a light-protected Centrix syringe tip. *(c)* The rubber plug is placed into the Centrix syringe tip. *(d)* The Centrix syringe tip is placed into the placement syringe and transferred to the composite warmer. *(e)* The completed preparations are etched. *(f)* The adhesive system is applied according to the manufacturer's instructions. *(g)* The warmed resin composite is injected into the preparations and cured in increments no thicker than 2 mm. *(h)* The initial warmed composite placement and curing is stopped at the anticipated level of the pits and fissures in the definitive restoration. Those aspects of the restoration that require little contouring for the final anatomy have been entirely filled with the warm composite (mesial/ central portions of the maxillary left first molar). *(i)* An increment of restorative composite (in this case, packable resin composite) is adapted to the lingual incline of the distofacial cusp of the maxillary left first molar. *(j)* A small instrument (PKT1) is used to form the missing cuspal anatomy in resin composite. The remaining tooth structure is used as a guide to replace the cusp inclines to the level of the fissure. The facial cuspal incline of the distolingual cusp has already been completed. *(k)* The lingual incline of the mesiofacial cusp of the maxillary left second molar is formed in resin composite to the level of the fissure. This increment is briefly cured (5 seconds). *(l)* The lingual incline of the mesiofacial cusp has been replaced in resin composite. *(m)* Each remaining cusp will be restored successively. Here the lingual incline of the distofacial cusp is being shaped with the PKT1. This increment will be cured for 5 seconds.

Dentlearn.ir

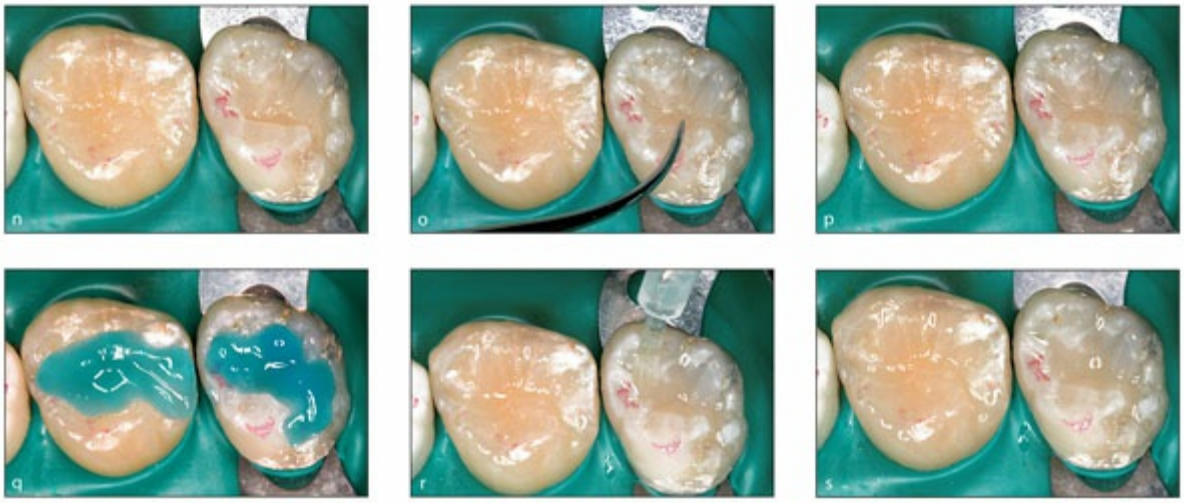

Fig 11-43 *(cont) (n)* The completed lingual inclines of the facial cusps of the second molar. *(o)* The facial incline of the lingual cusp is replaced in resin composite. Because this is the final resin composite increment, the entire occlusal surface will be light cured for the full irradition period. *(p)* The completed occlusal anatomy using the successive cusp build-up technique. While this technique takes slightly longer during placement, it reduces finishing time. *(q)* The restorations and adjacent enamel are re-etched. *(r)* The restorations are sealed with a surface sealing resin (Fortify, Bisco). *(s)* The completed restorations using the successive cusp build-up technique.

As a final step in resin composite placement and curing for Class 2 restorations, the wedge is removed and the matrix is wrapped against the adjacent tooth (Fig 11-44a). This allows access for the resin composite to be cured from the facial and lingual aspects to help ensure adequate polymerization throughout the entire restoration (see Fig 11-35). The matrix is allowed to remain in place to provide protection of the adjacent tooth during proximal-surface finishing (Fig 11-44b) and re-etching prior to sealing (Fig 11-44c).



Fig 11-44 *(a)* After the final resin composite increment has been placed and cured from the occlusal aspect, the wedge is removed and the matrix is wrapped against the adjacent tooth. This provides access for the proximal portion of the Class 2 restoration to be cured from the facial and lingual aspects to ensure the maximal cure. *(b)* The matrix is allowed to remain in place during finishing to protect the adjacent tooth from inadvertent damage when finishing the proximal portion of the restoration. *(c)* The matrix should also remain in place during re-etching and sealing to protect the adjacent tooth from being etched and bonded to the completed restoration.

Resin composite placement: Other techniques

Dentlearn.ir

Materials other than VLC resin composites have been suggested for placement in the proximal box preparation. Autocured (or self-curing) resin composites are available for this purpose in both low- and high-viscosity formulations. It has been suggested that the portion of the autocured resin composite adjacent to the cavity-preparation walls cures first, especially if used in conjunction with an autocured (or dual-cured) adhesive. The shrinkage of the autocured composite is said to be directed toward the cavity walls because of initiation of the curing reaction by the ongoing polymerization of the adhesive resin, and the reaction is said to be accelerated in that area by the higher temperature of the preparation walls due to body heat. This supposedly results in less polymerization shrinkage stress at the cavity margins,[158,159] thus improving marginal adaptation. However, research has failed to demonstrate either enhanced marginal adaptation[323] or reduced marginal leakage when this technique has been compared with VLC incremental placement techniques.[228]

Resin composite placement: Alternative polymerization techniques

A number of alternative techniques and devices have been introduced for curing VLC resin composites in recent years, including halogen units with variable curing intensities, lasers, plasma arc high-intensity units, and light-emitting diode (LED) curing units (Fig 11-45).



Fig 11-45*(a)* Argon laser light-curing unit (Laser-Med). *(b)* Variable-intensity halogen light-curing unit (Bisco). *(c)* Plasma arc curing high-intensity light-curing unit (DMD). *(d)* LED light-curing unit (Ultradent).

Dentlearn.ir

Argon laser units have demonstrated the ability to produce an increased degree of conversion of resin composite compared with standard halogen or tungsten-quartz-halogen (QTH) light-curing units.[324] In addition, the depth of cure with the laser is improved,[324] and bond strength is less affected as the light guide is moved further from the surface of the resin composite.[325] However, when the light guide is kept approximated to the composite increment, and increment depth is limited to 1.5 to 2.0 mm, no difference in bond strength is seen between that achieved with laser and standard halogen lights.[325,326] Laser light is monochromatic,[325] with the bandwidth of the laser being much narrower than that of the halogen light and centered at approximately 470 nm, which is the maximal absorption wavelength for camphorquinone, the photoinitiator most commonly used in resin adhesives and resin photoinitiators with absorption spectra differing from that of camphorquinone, making it possible that the argon laser–curing unit would be less likely to initiate the polymerization reaction than would a halogen unit. The high price of these units, compared with other resin composite polymerization options, has limited their use in the profession.

Plasma arc curing (PAC) units generate notably higher irradiance levels than do standard halogen units. PAC units also cure resin composite at a faster rate than do the halogen curing lights.[327] Considerable evidence has been accumulated to show that this increased rate of cure does not enhance adhesion of resin composite to cavity walls. Class 5 restorations cured with argon lasers or PAC units showed significantly increased microleakage[328] and poorer marginal adaptation[329] when compared with similar restorations cured with a standard halogen curing light. This is likely due to the fact that the rate at which the modulus of elasticity, or stiffness, of the setting composite develops has a significant impact on marginal integrity. Decreasing the polymerization reaction rate allows additional time for molecular conformational changes and material flow that can relieve polymerization shrinkage stress.[78,79] This has led to research in which the polymerization reaction rate is slowed even further by reducing the irradiance of halogen curing units. Lowering irradiance to 250 mW/cm^2 has been shown to significantly improve marginal adaptation in cavity preparations versus irradiating the resin composite in those same preparations at either 450 mW/cm^2 or 650 mW/cm^2.[80,330] There has been some concern, however, that simply reducing the irradiance to these levels, while enhancing marginal adaptation, might adversely affect mechanical properties.[330] This has led to the "two-step," "soft-start," or "ramped" curing technique. Regardless of

Dentlearn.ir

the name, the underlying principle is the same: initial curing at a diminished irradiance to initiate the polymerization reaction at a slower rate to minimize polymerization stress, followed by a period of higher irradiance to maximize the degree of conversion and mechanical properties. In laboratory studies, this technique has proven to significantly enhance marginal adaptation without impairing mechanical properties.[82,83,329] However, research has demonstrated that resin composite factors such as shade, translucency, photoini-tiator concentration, and elastic modulus are more important in determining cure than a particular curing mode[85,331] and that curing regimens that reduce polymerization shrinkage stress to a point that it is clinically significant are not feasible.[85]

Most recently developed are the LED curing units. These units have a number of advantages compared with other curing units, including a wavelength spectrum emission that is closely matched to camphorquinone. In addition, these units are more energy efficient, allowing them to be battery operated. The diodes have a life span that is approximately 1,000 times longer than the typical halogen bulb. While the earlier versions of LED curing units provided inadequate irradiance, the newer generation has overcome this deficiency. A disadvantage to standard units is their narrow wavelength spectrum, limiting their usefulness in curing any materials that do not use camphorquinone as the photoinitiator.[332,333] However, a number of newer LED products contain chips that emit light that initiates curing of multiple photoinitiators.[334]

A 1999 evaluation of dental practices reported that 46% of the halogen visible light–curing units used in private practices provided inadequate output to cure resin composite.[335] A later study showed an improvement in that percentage, but a large percentage of halogen units still had inadequate output.[336] More recently, an evaluation of light-curing units revealed that 67.5% of halogen and 15.6% of LED light units were considered unsatisfactory.[337] It is important for the practitioner to ensure that the light-curing unit is in proper working condition and provides adequate and accurate irradiance. Testing of units can be conveniently accomplished with a radiometer (Fig 11-46).

Dentlearn.ir



Fig 11-46 Commercial radiometers available to monitor adequacy of irradiance of visible light–curing units. (Courtesy of USAF Dental Evaluation and Consultation Service.)

Packable resin composites

Condensable or packable resin composites were specifically designed for posterior use. In these materials, the filler type, size, and/or particle distribution differ from those of conventional restorative hybrid and microfilled resin composite materials[338,339] in order to increase viscosity and impart a consistency that more closely mimics that of dental amalgam. Claims of enhanced clinical performance, reduced polymerization shrinkage, and enhanced wear characteristics have been made. The term *condensable* is not appropriate for these materials, because condensation, by definition, denotes an increase in density, as occurs when dental amalgam is condensed into a cavity preparation. Such a volume reduction does not occur with resin composites when they are packed into a preparation.[338]

Considerable in vitro research has been accomplished to test these materials. In general, properties such as wear,[338,340–343] flexural modulus,[344,345] flexural strength,[344–346] fracture toughness,[344,347] and polymerization shrinkage$_{338}$ of the packable resin composites are comparable, but not superior, to those of other hybrid or reinforced microfilled resin composites currently available. One clinical study of a packable composite showed extreme and unacceptable wear.[348] Of particular concern with the packable resin composites was the claim by some manufacturers that these materials could be bulk-cured in thicknesses of 5 mm or greater. Independent research has clearly demonstrated that this is not the case, and adequate polymerization for most resin composites can be accomplished only in thicknesses of 2 mm or less.[214,347]

In general, practitioners can anticipate that the handling characteristics of the packable resin composite formulations may vary somewhat from other hybrid or microfilled materials. In particular, they may have a heavier consistency with a "drier" feel. Clinical trials of packable composites, mostly short-term, have

Dentlearn.ir

demonstrated that, with proper technique, the clinical performance of these materials can be comparable with that of other resin composites.[349–352]

The decision to use these materials should be based on individual operator preference concerning handling characteristics and not on expectations of improved clinical performance.

Finishing

Placement procedures that minimize the need for finishing and polishing should be used. The smoothest surface that can be obtained is that of unfinished resin composite that has been cured against a smooth matrix.[353–356] Finishing and polishing procedures are inherently destructive to the restoration surface and may result in the formation of microcracks at and below the surface.[357,358] Because cracks may also be produced or exacerbated during mastication, the fracture toughness of the resin composite may be significantly reduced by destructive finishing techniques.[115]

A variation of the previously described soft-start technique for posterior resin composite restorations is the *pulse delay technique*. With this technique, the final composite increment is cured for a brief period (3 to 5 seconds) at very low irradiance (150 mW/cm^2) to initiate the curing reaction at a reduced rate. After 3 to 5 minutes, the composite is again cured with a high level of irradiance. During the interim between the two curing periods, the occlusal surface is shaped and finished.[359] It should be noted, however, that the effects of manipulating this incompletely cured resin composite on physical and mechanical properties and clinical performance have not been determined by independent research.

The finishing and polishing process for posterior resin composite restorations is similar to that used with other composite restorations. A no. 12 or 12B scalpel blade, sharp no. 14L carver, Wedelstaedt chisel, or other thin, sharp-edged hand instrument is useful for removing flash from the proximal and gingival margins and for shaping proximal surfaces of resin composite (Fig 11-47). The composite material can then be finished and blended to the tooth with successively finer grits of polishing points, cups, or disks. While the use of these rotary instruments will impact the surface contours and smoothness, the long-term surface finish is more dependent on the resin composite particle size than the particular polishing system used.[360] Ideally, the finishing process used should result in a surface that has an average roughness value of less than 0.2 μm, referred to as the *critical surface finish*. The critical surface finish is the smoothness of a resin composite at which

Dentlearn.ir

bacterial adhesion is significantly reduced compared with a rougher surface.[361] A number of polishing systems currently on the market are able to achieve this level of polish, including Sof-Lex disc series (3M ESPE) and Astropol (Ivoclar Vivadent) and Pogo (Dentsply/Caulk) disks, cups, and points.[361,362]

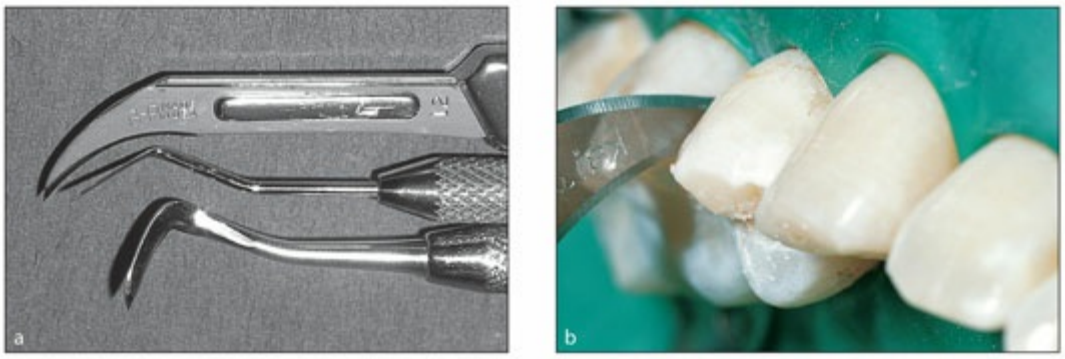

Fig 11-47 *(a)* Instruments useful in initial contouring and removal of flash: *(top)* no. 12B scalpel blade; *(middle)* IPC; *(bottom)* no. 14L carver. *(b)* No. 12B scalpel blade used to remove flash from a resin composite restoration in the distal aspect of a maxillary first premolar.

Aluminum oxide disks, used in series from coarse to very fine, tend to render some of the smoothest finishes to resin composite.[354,355,363] These work well for restoration contours that are relatively flat or convex, such as those in the facial and lingual proximal embrasure areas (Fig 11-48).



Fig 11-48 Aluminum oxide disk used to contour and polish the proximal surface of a resin composite restoration.

Abrasive disks are not practical for finishing occlusal surfaces. Shaping of these surfaces may be accomplished with multifluted carbide finishing burs or fine diamonds (Figs 11-49 and 11-50a). There is some controversy as to which of these instruments provides the smoothest surface and/or minimizes trauma-induced microleakage. Studies indicate that carbide finishing burs perform better,[363] finishing diamonds perform better,[364,365] or both perform equally well.[355,366] It is clear that the use of burs with 18 or fewer flutes leaves a significantly roughened surface, so these

Dentlearn.ir

burs should not be the final rotary instruments used in the finishing process.[355] Rubber or silicone disks, points, cups, and brushes impregnated with aluminum oxide, silicon dioxide, or diamond particles have been found to provide very acceptable results[353–355,360,362] and can be used to smooth the resin composite surface after initial finishing (Fig 11-50b). Finishing strips coated with aluminum oxide particles can be used to finish proximal surfaces (Fig 11-50c). As with the disks, these strips should be used in series, from coarse to very fine grit. A final high polish may be accomplished using a rubber prophylaxis cup with aluminum oxide or diamond polishing pastes.



Fig 11-49 Fine diamonds and multifluted carbide burs for finishing resin composite restorations come in a variety of sizes, shapes, and grits.



Fig 11-50*(a)* Finishing diamond used to refine occlusal anatomy in a resin composite restoration. *(b)* A flexible point impregnated with aluminum oxide is used for smoothing the occlusal surface of the restoration. (*c*) Aluminum oxide finishing strip for contouring/finishing/polishing the proximal surface gingival to the interproximal contact.

Rebonding and final cure

As previously mentioned, finishing procedures are destructive to the resin composite restoration and have been shown to adversely affect wear.[207] Finishing procedures can also exacerbate the marginal gaps formed during polymerization.[66–68]

For these reasons, the practitioner should consider rebonding the occlusal surface and all accessible restoration margins with an unfilled or lightly filled VLC resin. The lower the viscosity of the rebonding resin, the more effective it will be in

Dentlearn.ir

penetrating interfacial gaps and microcracks.[367,368] Several low-viscosity resins, called *surface sealers*, are available for use in rebonding. While not a widely used procedure, *rebonding*, the application of a low-viscosity resin to the finished surface and margins of a restoration, has been shown to improve the marginal integrity of resin composite restorations in vitro[369] and in vivo,[210] significantly reduce microleakage in vitro,[368,370–372] and reduce marginal staining in vivo.[31] Rebonding has been demonstrated in clinical studies to significantly reduce wear and prolong marginal integrity.[31,210,369]

Although the need for etching before rebonding is somewhat controversial, phosphoric acid is usually applied to the marginal areas for 10 seconds (Fig 11-51a) and then rinsed off and the area thoroughly dried. The rebonding resin is placed, thinned with a blotted brush (Fig 11-51b) or applicator, and light cured for 20 to 40 seconds. This not only will polymerize the rebonding resin, but it may also provide additional polymerization of the resin composite.[109,135,137] To prevent the rebonding resin from joining the restored tooth to the adjacent tooth, a piece of matrix or other thin material may be placed interproximally prior to performing the rebonding procedure. Alternatively, floss is passed through the interproximal contact after the rebonding resin has been applied and before it is cured. After curing, any ledges of excess rebonding resin should be removed with a sharp-bladed instrument.

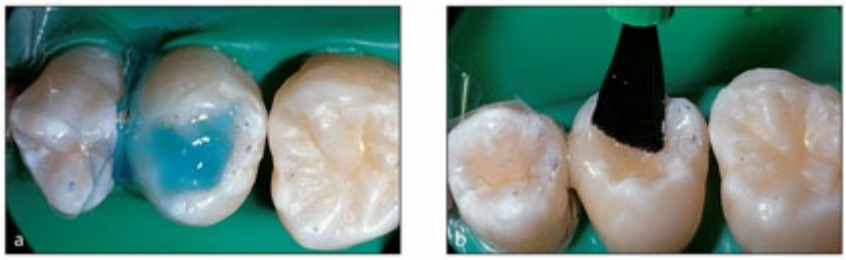

Fig 11-51*(a)* Etching the restoration margins prior to rebonding. Note the thin plastic shim placed interproximally to protect the adjacent tooth. *(b)* Rebonding resin is brushed onto the restoration surface and margins.

The proximal contact and contours are verified with dental floss (Fig 11-52). The rubber dam is removed, and the occlusion is checked. If further occlusal adjustment is required, rebonding resin should be reapplied in the areas that were adjusted.



Dentlearn.ir

Fig 11-52 Proximal contact and contours are verified with dental floss. Floss is wrapped around the proximal contact to confirm the appropriate contact area.

The Tunnel Restoration

An alternative to the traditional approach for gaining access to proximal carious dentin has been termed the *tunnel preparation* (Fig 11-53). It was first suggested by Jinks[373] in 1963 as a method for placing a silver alloy mixed with sodium silicofluoride in the distal aspect of primary second molars to "inoculate" permanent first molars with fluoride as they erupted. Hunt[374] and Knight[375] later modified this procedure for use as a conservative technique for restoring teeth with small proximal caries lesions.

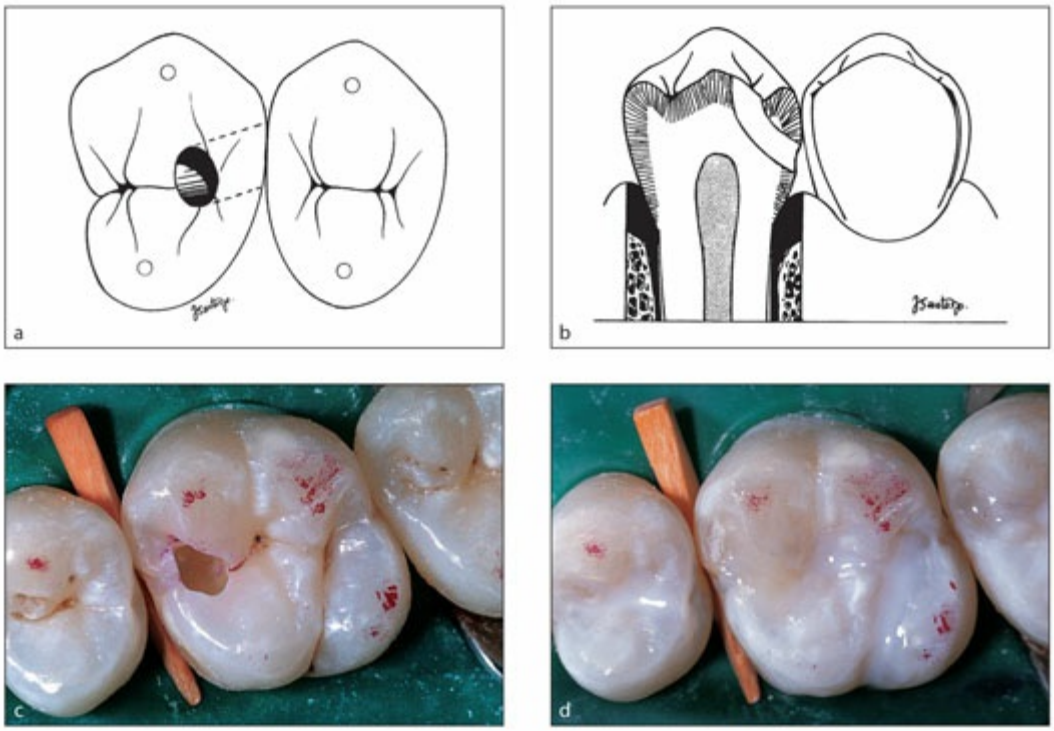

Fig 11-53 *(a)* In the tunnel preparation, access is made in the occlusal fossa adjacent to the marginal ridge. *(b)* A "tunnel" is made under the marginal ridge to the carious dentin, usually just below the interproximal contact. *(c)* Tunnel preparation access opening in the maxillary first molar. *(d)* Tunnel restoration. Occlusal fissures have been sealed.

Advantages

Several advantages are claimed for this technique. The outer surface of the proximal enamel is removed only if cavitated by caries, so there is less potential for a restorative overhang. Overhangs have been shown to occur 25% to 76% of the time with traditional Class 2 restorations; this can lead to inflammation within

Dentlearn.ir

periodontal tissues and bone loss.[376] With an occlusal approach, the marginal ridge is preserved, and destruction of tooth structure is minimized. A two-surface, Class 2 cavity preparation has been shown to reduce tooth stiffness by 46%; only a 20% reduction occurs with an occlusal preparation.[377] The perimeter of the restoration is reduced, decreasing the potential for microleakage.[378] Because minimal preparation is required interproximally, the potential for disturbance of the adjacent tooth is reduced. If the carious tooth structure is more extensive than originally thought and greater access is required, the preparation can easily be extended and converted into a more traditional Class 2 design.[379]

Disadvantages

Despite seemingly attractive benefits of the tunnel procedure, it remains largely unused in practice. It is a difficult procedure, demanding careful control of the preparation by the operator. The angulation of the bur for the preparation causes it to pass near the pulp. Studies have shown that the tunnel preparation often invades to within 1 mm of the pulp. A more traditional Class 2 preparation, in which penetration toward the pulp is determined by the depth of the caries lesion, tends to leave greater remaining dentinal thickness between the preparation and the pulp.[380,381] Because of the small entrance to the tunnel preparation, visibility is decreased, and removal of carious dentin is more uncertain.[374,379,382] In vitro studies on the effectiveness of caries lesion removal in the tunnel preparation have shown that there is a high rate of residual carious tooth structure after completion of the preparation.[381,383,384] For this reason, a caries-detecting solution should be used to disclose remaining carious tooth structure.

There is also concern that the marginal ridge is undermined and its strength reduced. As the diameter of the preparation increases, the marginal ridge strength decreases.[53,385,386] Although use of an adhesive restorative material has been shown to restore much of the strength of the marginal ridge,[53,385,386] this is not always the case,[380] and the degree to which marginal ridge strength is restored can depend on the size of the preparation.[385]

A number of clinical studies of tunnel restorations have been published (Table 11-1). Tunnel restorations tend to fail at a considerably higher rate than do other types of posterior restorations. Other problems noted in these studies include the fact that 34% to 41% of the restorations show either residual carious dentin or progression of enamel caries.[387,388] The most common causes of restoration failure

Dentlearn.ir

are marginal ridge fracture and secondary caries. In an evaluation of tunnel restorations compared with slot amalgam restorations, 21% of tunnel restorations failed during a 7-year period compared with zero failures for the slot restorations.[389] Another clinical study compared tunnel restorations in which the dentin was replaced with resin-modified glass ionomer and the remainder with resin composite to saucer-shaped Class 2 resin composite restorations over periods up to 79 months. The survival proportion for the tunnel restorations was 46% compared with 76% for the Class 2 resin composite restorations. The main cause of failure of the tunnel restorations was marginal ridge fracture, and secondary caries was significantly higher in the tunnel restorations (41% after 24 months) versus the Class 2 composite restorations (19% after 24 months).[391]

Table 11-1	**Longevity of tunnel restorations**		
Investigator(s)	**Study time (yrs)**	**No. of restorations**	**Annual failure rate**
Pilebro et al[387]	3	262	6.7
Strand et al[388]	3	161	10.0
Lumley and Fisher[389]	7	33	3.0
Hasselrot[390]	7	282	7.1
Hörsted-Bindslev et al[391]	4	54	13.4

Indications and contraindications

It is obvious from the previous discussion that tunnel restorations are not indicated and should be avoided. Other techniques discussed in this chapter (eg, the use of slot preparations) are more conservative and more predictable.

Dentlearn.ir

References

1. Liebenberg W. Assuring restorative integrity in extensive posterior resin composite restorations: Pushing the envelope. Quintessence Int 2000;31:153–164.
2. American Dental Association. Survey of Dental Services Rendered. Chicago: American Dental Association, 1999.
3. American Dental Association. Distribution of Dentists in the U.S. by Region and State. Chicago: American Dental Association, 1999.
4. Eakle WS. Fracture resistance of teeth restored with Class II bonded composite resin. J Dent Res 1986;65:149–153.
5. Morin DL, Delong R, Douglas WH. Cusp reinforcement by the acid-etch technique. J Dent Res 1984;63:1075–1078.
6. Ferracane JL. Materials in Dentistry: Principles and Applications. Philadelphia: Lippincott, 1995:88–102.
7. Stangel I, Barolet RY. Clinical evaluation of two posterior composite resins: Two-year results. J Oral Rehabil 1990;17:257–268.
8. Hayashi M, Wilson NH. Failure risk of posterior composites with postoperative sensitivity. Oper Dent 2003;28:681–688.
9. Van Dijken JW. Direct resin composite inlays/onlays: An 11 year follow-up. J Dent 2000;28:299–306.
10. Gaengler P, Hoyer I, Montag R. Clinical evaluation of posterior composite restorations: The 10-year report. J Adhes Dent 2001;3:185–194.
11. Van Nieuwenhuysen J, D'Hoore W, Carvalho J, Qvist V. Long-term evaluation of extensive restorations in permanent teeth. J Dent 2003;31:395–405.
12. Hickel R, Manhart R. Longevity of restorations in posterior teeth and reasons for failure. J Adhes Dent 2001;3:45–64.
13. Ferracane JL. Using posterior composites appropriately. J Am Dent Assoc 1992;123:53–58.
14. Leinfelder KF. Using a composite resin as a posterior restorative material. J Am Dent Assoc 1991;122(4):65–70.
15. Wilder AD Jr, May KN Jr, Bayne SC, Taylor DF, Leinfelder KF. Seventeen-year clinical study of ultraviolet-cured posterior composite Class I and II restorations. J Esthet Dent 1999;11:135–142.
16. Opdam N, Bronkhorst E, Roeters J, Loomans B. A retrospective clinical study on longevity of posterior composite and amalgam restorations. Dent Mater 2007;23:2–8.
17. Roulet J. Benefits and disadvantages of tooth-coloured alternatives to amalgam. J Dent 1997;25:459–473.
18. Bogacki R, Hunt R, del Aguila M, Smith W. Survival analysis of posterior restorations using an insurance claims database. Oper Dent 2002; 27:488–492.
19. Simecek J, Diefenderfer K, Cohen M. An evaluation of replacement rates for posterior resin-based composite and amalgam restorations in U.S. Navy and Marine Corps recruits. J Am Dent Assoc 2009;140:200–209.
20. Bernardo M, Luis H, Martin M, et al. Survival and reasons for failure of amalgam versus composite posterior restorations placed in a randomized clinical trial. J Am Dent Assoc 2007;138:775–783.
21. Soncini J, Maserejian N, Trachtenberg F, Tavares M, Hayes C. The longevity of amalgam versus compomer/composite restorations in posterior and primary teeth: Findings from the New England children's amalgam trial. J Am Dent Assoc 2007;138:763–772.
22. Opdam NJ, Bronkhorst EM, Loomans BA, Huysmans MC. 12-year survival of composite vs. amalgam restorations. J Dent Res 2010;89:1063–1067.
23. Mair LH. Ten-year clinical assessment of three posterior resin composites and two amalgams. Quintessence Int 1998;29:483–490.
24. Manhart J, Garcia-Godoy F, Hickel R. Direct posterior restorations: Clinical results and new developments. Dent Clin North Am 2002;46:303–339.
25. Wilson EG, Mandradjieff M, Brindock T. Controversies in posterior composite resin restorations. Dent Clin North Am 1990;34:27–44.

Dentlearn.ir

26. Summitt JB, Della Bona A, Burgess JO. The strength of Class II composite resin restorations as affected by preparation design. Quintessence Int 1994;25:251–257.
27. Warren JA, Clark NP. Posterior composite resin: Current trends in restorative techniques, part I. Pre-preparation considerations, preparation, dentin treatment, etching/bonding. Gen Dent 1987;35:368–372.
28. Hinoura K, Setcos JC, Phillips RW. Cavity design and placement techniques for Class 2 composites. Oper Dent 1988;13:12–19.
29. Black GV. A Work on Operative Dentistry. Chicago: Medico Dental, 1908.
30. Wilson NH, Wilson MA, Wastell DG, Smith GA. Performance of Occlusin in butt-joint and bevel-edged preparations: Five-year results. Dent Mater 1991;7:92–98.
31. Gibson GB, Richardson AS, Patton RE, Waldman R. A clinical evaluation of occlusal composite and amalgam restorations: One- and two-year results. J Am Dent Assoc 1982;104:335–337.
32. Suliman AA, Boyer DB, Lakes RS. Cusp movement in premolars resulting from composite polymerization shrinkage. Dent Mater 1993;9:6–10.
33. Douvitsas G. Effect of cavity design on gap formation in Class II composite resin restorations. J Prosthet Dent 1991;65:475–479.
34. Jacobsen PH. The restoration of Class II cavities by polymeric materials. J Dent 1984;12:47–52.
35. Castillo MD. Class II composite marginal ridge failure: Conventional vs. proximal box only preparation. J Clin Pediatr Dent 1999;23:131–136.
36. Kreulen CM, van Amerongen WE, Akerboom HB, Borgmeijer PJ. Two-year results with box-only resin composite restorations. ASDC J Dent Child 1995;62:395–400.
37. Nordbo H, Leirskar J, von der Fehr FR. Saucer-shaped cavity preparations for posterior approximal resin composite restorations: Observations up to 10 years. Quintessence Int 1998;29:5–11.
38. Busato AL, Loguercio AD, Reis A, de Oliveira Carrilho MR. Clinical evaluation of posterior composite restorations: 6-year results. Am J Dent 2001;14:304–308.
39. Pallesen U, Qvist V. Composite resin fillings and inlays. An 11-year evaluation. Clin Oral Investig 2003;7:71–79.
40. Manhart J, Chen HY, Mehl A, Weber K, Hickel R. Marginal quality and microleakage of adhesive Class V restorations. J Dent 2001;29:123–130.
41. Watts DC, McAndrew R, Lloyd CH. Thermal diffusivity of composite restorative materials. J Dent Res 1987;66:1576–1578.
42. Macpherson LC, Smith BG. Reinforcement of weakened cusps by adhesive restorative materials: An in-vitro study. Br Dent 1995;178:341–344.
43. Stamplia LL, Nicholls JI, Brudvik JS, Jones DW. Fracture resistance of teeth with resin-bonded restorations. J Prosthet Dent 1986;55:694–698.
44. Joynt RB, Wieczkowski G, Klockowski R, Davis EL. Effects of composite restorations on resistance to cuspal fracture in posterior teeth. J Prosthet Dent 1987;57:431–435.
45. Fissore B, Nicholls JI, Youdelis RA. Load fatigue of teeth restored by a dentin bonding agent and a posterior composite resin. J Prosthet Dent 1991;65:80–85.
46. Wahl M, Schmitt M, Overton D, Gordon M. Prevalence of cusp fractures in teeth restored with amalgam and with resin-based composite. J Am Dent Assoc 2004;135:1127–1132.
47. Espelid I, Tveit AB, Erickson RL, Keck SC, Glasspoole EA. Radiopacity of restorations and detection of secondary caries. Dent Mater 1991;7:114–117.
48. Goshima T, Goshima Y. The optimum level of radiopacity in posterior composite resins. Dentomaxillofac Radiol 1989;18:19–21.
49. Goshima T, Goshima Y. Radiographic detection of recurrent carious lesions associated with composite restorations. Oral Surg Oral Med Oral Pathol 1990;70:236–239.
50. Curtis P, von Fraunhofer J, Farman A. The radiographic density of composite restorative resins. Oral Surg Oral Med Oral Pathol 1990;70:226–230.
51. Turgut M, Attar N, Önen A. Radiopacity of direct esthetic restorative materials. Oper Dent 2003;28:508–514.
52. Sabbagh J, Vreven J, Leloup G. Radiopacity of resin-based materials measured in film radiographs and

Dentlearn.ir

storage phosphor plate (Digora). Oper Dent 2004;29:677–684.
53. Akerboom HB, Dreulen CM, van Amerongen WE, Mol A. Radiopacity of posterior composite resins, composite resin luting cements, and glass ionomer lining cements. J Prosthet Dent 1993;70:351–355.
54. Dawson AS, Smales RJ. Restoration longevity in an Australian defence force population. Aust Dent J 1992;37:196–200.
55. Klausner LH, Green TG, Charbeneau GT. Placement and replacement of amalgam restorations. Oper Dent 1987;12:105–111.
56. Robbins JW, Summitt JB. Longevity of complex amalgam restorations. Oper Dent 1988;13:54–57.
57. Life Science Research Office. Review and Analysis of the Literature on the Potential Adverse Health

2005.
58. Bonner P. Advances in dental materials: An exclusive interview with Dr. Karl Leinfelder. Dent Today 1994;March:32–34.
59. Bryant RW. Direct posterior composite resin restorations: A review. 1. Factors influencing case selection. Aust Dent J 1992;37:81–87.
60. Douglas DD. Environmental cops hot on the trail of mercury discharge: Dentists avert mercury pollution rules. AGD Impact 1995;23:8–12.
61. Amalgam. Your questions answered. Dent World 1992;(5):14–16.
62. Bowen RL, Marjenhoff WA. Dental composites/glass ionomers: The materials. Adv Dent Res 1992;6:44–49.
63. Naoum SJ, Ellakwa A, Morgan L, White K, Martin FE, Lee IB. Polymerization profile analysis of resin composite dental restorative materials in real time. J Dent 2012;40:64–70.
64. Pick B, Pelka M, Belli R, Braga RR, Lohbauer U. Tailoring of physical properties in highly filled experimental nanohybrid resin composites. Dent Mater 2011;27:664–669.
65. Tiba A, Charlton DG, Vanderwalle KS, Cohen ME. Volumetric polymerization shrinkage of resin composites under simulated intraoral temperature and humidity conditions. Oper Dent 2005;30:696–701.
66. Eick JD, Welch FH. Polymerization shrinkage of posterior composite resins and its possible influence on postoperative sensitivity. Quintessence Int 1986;17:103–111.
67. Lambrechts P, Braem M, Vanherle G. Evaluation of clinical performance for posterior composite resins and dentin adhesives. Oper Dent 1987;12:53–87.
68. Lutz F, Krejci I, Barbakow F. Quality and durability of marginal adaptation in bonded composite restorations. Dent Mater 1991;7:107–113.
69. Mazer RB, Leinfelder KF, Russell CM. Degradation of microfilled posterior composite. Dent Mater 1992;8:185–189.
70. Pearson GJ, Hegarty SM. Cusp movement of molar teeth with composite filling materials in conventional and modified MOD cavities. Br Dent J 1989;166:162–165.
71. Marzouk MA, Ross JA. Cervical enamel crazings associated with occlusoproximal composite restorations in posterior teeth. Am J Dent 1989;2:333–337.
72. Wieczkowski F, Joynt RB, Klockowski R, Davis EL. Effects of incremental versus bulk fill technique on resistance to cuspal fracture of teeth restored with posterior composites. J Prosthet Dent 1988;60:283–287.
73. Versluis A, Tantbirojn D, Douglas WH. Do dental composites always shrink toward the light? J Dent Res 1998;77:1435–1445.
74. Suh B, Wang Y. Determining the direction of shrinkage in dental composites by changes in surface contour for different bonding configurations. Am J Dent 2001;14:109–113.
75. Feilzer AJ, de Gee AJ, Davidson CL. Setting stress in composite resin in relation to configuration of the restoration. J Dent Res 1987;66:1636–1639.
76. Alster D, Feilzer AJ, De Gee AJ, Mol A, Davidson CL. The dependence of shrinkage stress reduction on porosity concentration in thin resin layers. J Dent Res 1992;71:1619–1622 [erratum 1993;72:87].
77. Feilzer AJ, de Gee AJ, Davidson CL. Setting stresses in composites for two different curing modes. Dent Mater 1993;9:2–5.
78. Kemp-Scholte CM, Davidson CL. Marginal integrity related to bond strength and strain capacity of composite

Dentlearn.ir

resin restorative systems. J Prosthet Dent 1990;64:658–664.
79. Feilzer AJ, de Gee AJ, Davidson CL. Curing contraction of composites and glass-ionomer cements. J Prosthet Dent 1988;59:297–300.
80. Feilzer AJ, Dooren LH, de Gee AJ, Davidson CL. Influence of light intensity on polymerization shrinkage and integrity of restoration-cavity interface. Eur J Oral Sci 1995;103:322–326.
81. Goracci G, Mori G, Casa de'Martinis L. Curing light intensity and marginal leakage of resin composite restorations. Quintessence Int 1996;27:355–362.
82. Koran P, Kurschner R. Effect of sequential versus continuous irradiation of a light-cured resin composite on shrinkage, viscosity, adhesion, and degree of polymerization. Am J Dent 1998;11:17–22.
83. Mehl A, Hickel R, Kunzelmann KH. Physical properties and gap formation of light-cured composites with and without 'softstart-polymerization.' J Dent 1997;25:321–330.
84. Uno S, Asmussen E. Marginal adaptation of a restorative resin polymerized at reduced rate. Scand J Dent Res 1991;99:440–444.
85. Lim BS, Ferracane JL, Sakaguchi RL, Condon JR. Reduction of polymerization contraction stress for dental composites by two-step light-activation. Dent Mater 2002;18:436–444.
86. Eick J, Robinson S, Byerley TJ, Chappelow CC. Adhesives and non-shrinking dental resins of the future. Quintessence Int 1993;24:632–640.
87. Glantz PO, Nilner K, Jendresen MD, Sundberg H. Quality of fixed prosthodontics after 15 years. Acta Odontol Scand 1993;51:247–252.
88. Willems G, Lambrechts P, Braem M, Vanherle G. Composite resins of the 21st century. Quintessence Int 1993;24:641–658.
89. Opdam N, Loomans B, Roeters F, Bronkhorst E. Five-year clinical performance of posterior resin composite restorations placed by dental students. J Dent 2004;32:379–383.
90. Brunthaler A, König F, Lucas T, Sperr W, Schedle A. Longevity of direct resin composite restorations in posterior teeth. Clin Oral Investig 2003;7:63–70.
91. Dickinson GL, Gerbo LR, Leinfelder KF. Clinical evaluation of a highly wear resistant composite. Am J Dent 1993;6:85–87.
92. Wendt SL Jr, Leinfelder KR. Clinical evaluation of a posterior resin composite: 3-year results. Am J Dent 1994;7:207–211.
93. Zickert I, Emilson CG, Krasse B. Correlation of level and duration of *Streptococcus mutans* infection with incidence of dental caries. Infect Immun 1983;39:982–985.
94. Asmussen E. Softening of BiSGMA-based polymers by ethanol and by organic acids of plaque. Scand J Dent Res 1984;92:257–261.
95. Perdigão J, Geraldeli S, Hodges JS. Total-etch versus self-etch adhesive: Effect on postoperative sensitivity. J Am Dent Assoc 2003;134:1621–1629.
96. Bayne SC, Heymann HO, Swift EJ Jr. Update on dental composite restorations. J Am Dent Assoc 1994;125:687–701.
97. da Rosa Rodolpho P, Cenci M, Donassollo T, Loguercio A, Demarco F. A clinical evaluation of posterior composite restorations: 17-year findings. J Dent 2006;34:427–435.
98. Brännström M. Infection beneath composite resin restorations: Can it be avoided? Oper Dent 1987;12:158–163.
99. Bryant RW, Mahler DB. Modulus of elasticity in bending of composites and amalgams. J Prosthet Dent 1986;56:243–248.
100. Willems G, Lambrechts P, Lesaffre E, Braem M, Vanherle G. Three-year follow-up of five posterior composites: SEM study of differential wear. J Dent 1993;21:79–86.
101. Türkün L, Aktener B, Ates M. Clinical evaluation of different posterior resin composite materials: A 7-year report. Quintessence Int 2003;34:418–426.
102. Bailey SJ, Swift EJ Jr. Effects of home bleaching products on composite resins. Quintessence Int 1992;23:489–494.
103. Ferracane JL, Marker VA. Solvent degradation and reduced fracture toughness in aged composites. J Dent

Dentlearn.ir

Res 1992;71:13–19.
104. Hengchang X, Tong W, Vingerling PA, Shiqing S. A study of surfaces developed on composite resins in vivo during 45 years: Observations by SEM. J Oral Rehabil 1989;16:407–416.
105. Wu W, Toth EE, Ellison JA. Subsurface damage layer of in vivo worn dental composite restorations. J Dent Res 1984;63:675–680.
106. Mair LH, Vowles RW, Cunningham J, Williams DF. The clinical wear of three posterior composites. Br Dent J 1990;169:355–360.
107. Johnson WW, Dhuru VB, Brantley WA. Composite microfiller content and its effect on fracture toughness and diametral tensile strength. Dent Mater 1993;9:95–98.
108. Ferracane JL, Mitchem JC, Condon JR, Todd R. Wear and marginal breakdown of composites with various degrees of cure. J Dent Res 1997;76:1508–1516.
109. Bayne SC, Taylor DF, Heymann HO. Protection hypothesis for composite wear. Dent Mater 1992;8:305–309.
110. Yesil ZD, Alapati S, Johnston W, Seghi RR. Evaluation of the wear resistance of new nanocomposite resin restorative materials. J Prosthet Dent 2008;99:435–443.
111. Palaniappan S, Bharadwaj D, Mattar DL, Peumans M, Van Meerbeek B, Lambrechts F. Nanofilled and microhybrid composite restorations: Five-year clinical wear performances. Dent Mater 2011;27:692–700.
112. Gerbo L, Leinfelder KF, Mueninghoff L, Russell C. Use of optical standards for determining wear of posterior composite resins. J Esthet Dent 1990;2:148–152.
113. Mitchem JC, Gronas DG. In vivo evaluation of the wear of restorative resin. J Am Dent Assoc 1982;104:333–335.
114. Lambrechts P, Braem M, Vuylsteke-Wauters M, Vanherle G. Quantitative in vivo wear of human enamel. J Dent Res 1989;68:1752–1754.
115. Ferracane JL, Antonio R, Matsumoto H. Variables affecting the fracture toughness of dental composites. J Dent Res 1987;66:1140–1145.
116. Lutz F, Krejci I, Barbakow F. Chewing pressure vs. wear of composites and opposing enamel cusps. J Dent Res 1992;71:1525–1529.
117. Cunningham J, Mair LH, Foster MA, Ireland RS. Clinical evaluation of three posterior composite and two amalgam restorative materials: 3-year results. Br Dent J 1990;169:319–323.
118. Wang JC, Charbeneau GT, Gregory WA, Dennison JB. Quantitative evaluation of approximal contacts in Class 2 composite resin restorations: A clinical study. Oper Dent 1989;14:193–202.
119. Wendt S, Ziemiecki T, Leinfelder K. Proximal wear rates by tooth position of resin composite restorations. J Dent 1996;24:33–39.
120. Baratieri L, Ritter A. Four-year clinical evaluation of posterior resin-based composite restorations placed using the total-etch technique. J Esthet Restor Dent 2001;13:50–57.
121. Wilson M, Cowan A, Randall R, Crisp R, Wilson N. A practice-based, randomized, controlled clinical trial of a new resin composite restorative: One-year results. Oper Dent 2002;27:423–429.
122. Hendriks FH, Letzel H, Vrijhoef MM. Composite versus amalgam restorations: A three-year clinical evaluation. J Oral Rehabil 1986;13:401–411.
123. Leinfelder KF. Composite resin systems for posterior restorations. Pract Periodontics Aesthet Dent 1993;5(3suppl 1):23–27.
124. Wilson HJ. Resin-based restoratives. Br Dent J 1988;164:326–330.
125. Craig RG (ed). Dental Restorative Materials. St Louis: Mosby, 1989.
126. Versluis A, Douglas WH, Sakaguchi RL. Thermal expansion coefficient of dental composites measured with strain gauges. Dent Mater 1996;12:290–294.
127. Bullard RH, Leinfelder KF, Russell CM. Effect of coefficient of thermal expansion on microleakage. J Am Dent Assoc 1988;116:871–874.
128. Söderholm KJ, Zigan M, Ragan M, Fischlschweiger W, Bergman M. Hydrolytic degradation of dental composites. J Dent Res 1984;63:1248–1254.
129. Mitchem JC. The use and abuse of aesthetic materials in posterior teeth. Int Dent J 1988;38:119–125.

Dentlearn.ir

130. Koike T, Hasegawa T, Manabe A, Itoh K, Wakumoto S. Effect of water sorption and thermal stress on cavity adaptation of dental composites. Dent Mater 1990;6:178–180.
131. Venhoven BA, de Gee AJ, Davidson C. Polymerization contraction and conversion of light-curing BisGMA-based methacrylate resins. Biomaterials 1993;14:871–874.
132. Ferracane J, Greener E. Fourier transform infrared analysis of degree of polymerization in unfilled resins—Methods comparison. J Dent Res 1984;63:1093–1095.
133. Asmussen E. Factors affecting the quantity of remaining double bonds in restorative resin polymers. Scand J Dent Res 1982;90:490–496.
134. Vandewalle K, Swift E. Estimated light exposure time for composite resin restorative materials. J Esthet Restor Dent 2011;4:201–204.
135. Rueggeberg FA, Caughman WF, Curtis JW Jr, Davis HC. Factors affecting cure at depths within light-activated resin composites. Am J Dent 1993;6:91–95.
136. Pires JA, Cvitko E, Denehy GE, Swift EJ. Effects of curing tip distance on light intensity and composite resin microhardness. Quintessence Int 1993;24:517–521.
137. Rueggeberg FA, Jordan DM. Effect of light-tip distance on polymerization of resin composite. Int J Prosthodont 1993;6:364–370.
138. Retief DH, Mandras RS, Russell CM. Shear bond strength required to prevent microleakage at the dentin/restoration interface. Am J Dent 1994;7:43–46.
139. Sorensen JA, Dixit NV, White SN, Avera SP. In vitro microleakage of dentin adhesives. J Am Dent Assoc 1991;4:213–218.
140. Tyas MJ. Clinical evaluation of five adhesive systems. Am J Dent 1994;7:77–80.
141. Breschi L, Mazzoni A, Ruggeri A, Cadenaro M, Di Lenarda R, Dorigo E. Dental adhesion review: Aging and stability of the bonded interface. Dent Mater 2008;24:90–101.
142. Coli P, Brännström M. The marginal adaptation of four different bonding agents in Class II composite resin restorations applied in bulk or in two increments. Quintessence Int 1993;24:583–591.
143. Watanabe I, Nakabayashi N. Bonding durability of photocured phenyl-P in TEGDMA to smear layer-retained bovine dentin. Quintessence Int 1993;24:335–342.
144. Hansen EK. In vivo cusp fracture of endodontically treated premolars restored with MOD amalgam or MOD resin fillings. Dent Mater 1988;4:169–173.
145. Schwartz R, Murchison D, Hermesch C, et al. Three-year clinical evaluation of three dentin treatments [abstract 1188]. J Dent Res 1997;76 (special issue):162.
146. Hashimoto M, Ohno H, Kaga M, Endo K, Sano H, Oguchi H. In vivo degradation of resin-dentin bonds in humans over 1 to 3 years. J Dent Res 2000;79:1385–1391.
147. Frankenberger R, Kramer N, Petschelt A. Technique sensitivity of dentin bonding: Effect of application mistakes on bond strength and marginal adaptation. Oper Dent 2000;25:324–330.
148. Beazoglou T, Eklund S, Heffley D, Meiers J, Brown L, Bailit H. Economic impact of regulating the use of amalgam restorations. Public Health Rep 2007;122:657–663.
149. Mjör IA, Jokstad A. Five-year study of Class II restorations in permanent teeth using amalgam, glass polyalkenoate (ionomer) cement and resin-based composite materials. J Dent 1993;21:338–343.
150. Besnault C, Attal J. Influence of a simulated oral environment on dentin bond strength of two adhesive systems. Am J Dent 2001;14:367–372.
151. Park J, Lee K. The influence of salivary contamination on shear bond strength of dentin adhesive systems. Oper Dent 2004;29:437–442.
152. Burgess JO, Summit JB, Robbins JW, et al. Clinical evaluation of base, sandwich and bonded Class 2 composite restorations [abstract 3405]. J Dent Res 1999;78(special issue):531.
153. Hubel S, Mejàre I. Conventional versus resin-modified glass-ionomer cement for Class II restorations in primary molars. A 3-year clinical study. Int J Paediatr Dent 2003;13:2–8.
154. van Dijken J, Kieri C, Carlen M. Longevity of extensive Class II open-sandwich restorations with a resin-modified glass-ionomer cement. J Dent Res 1999;78:1319–1325.
155. Vilkinis V, Hörsted-Bindslev P, Baelum V. Two-year evaluation of Class II resin-modifed glass ionomer

Dentlearn.ir

cement/composite open sandwich and composite restorations. Clin Oral Investig 2000;4:133–139.
156. Dlugokinski M, Browning WD. Informed consent: Direct posterior composite versus amalgam. J Am Coll Dent 2001;68:31–40.

Accessed 11 April 2013.
158. Bertolotti RL. Posterior composite technique utilizing directed polymerization shrinkage and a novel matrix. Pract Periodontics Aesthet Dent 1991;3(4):53–58.
159. Fusayama T. Indications for self-cured and light-cured adhesive composite resins. J Prosthet Dent 1992;67:46–51.
160. Fusayama T. Biologic problems of the light-cured composite resin. Quintessence Int 1993;24:225–226.
161. Tyas MJ. Colour stability of composite resins: A clinical comparison. Aust Dent J 1992;37:88–90.
162. de Gee AJ. Some aspects of vacuum mixing of composite resins and its effects on porosity. Quintessence Int 1979;10:69–75.
163. Leinfelder KF. Composite resins. Dent Clin North Am 1985;29:359–371.
164. Wilder AD, May KN, Leinfelder KF. Three-year clinical study of UV-cured composite resins in posterior teeth. J Prosthet Dent 1983;50:26–30.
165. Tjan AH, Bergh BH, Lidner C. Effect of various incremental techniques on the marginal adaptation of Class II composite resin restorations. J Prosthet Dent 1992;67:62–66.
166. Podshadley AG, Gullett CE, Binkley TK. Interface strength of incremental placement of visible light-cured composites. J Am Dent Assoc 1985;110:932–934.
167. Lutz F, Phillips RW, Roulet JF, Setcos JC. In vivo and in vitro wear of potential posterior composites. J Dent Res 1984;63:914–920.
168. Raskin A, Setcos J, Vreven J, Wilson N. Influence of the isolation method on the 10-year clinical behaviour of posterior resin composite restorations. Clin Oral Investig 2000;4:148–152.
169. Abdalla AI, Davidson CL. Comparison of the marginal integrity of in vivo and in vitro Class II composite restorations. J Dent 1993;21:158–162.
170. Fritz U, Finger W, Stean H. Salivary contamination during bonding procedures with a one-bottle adhesive system. Quintessence Int 1998;29:567–572.
171. Abdalla A, Davidson C. Bonding efficiency and interfacial morphology of one-bottle adhesives to contaminated dentin surfaces. Am J Dent 1998;11:281–285.
172. van Schalkwyk J, Botha F, van der Vyver P, de Wet F, Botha S. Effect of biological contamination on dentine bond strength of adhesive resins. SADJ 2003;58:143–147.
173. Raffaini M, Gomes-Silva J, Torres-Mantovani C, Palma-Dibb R, Borsatto M. Effect of blood contamination on the shear bond strength at resin/ dentin interface in primary teeth. Am J Dent 2008;21:159–162.
174. Beauchamp J, Caufield P, Crall J, et al; American Dental Association Council on Scientific Affairs. Evidence-based clinical recommendations for the use of pit-and-fissure sealants: A report of the American Dental Association Council on Scientific Affairs. J Am Dent Assoc 2008;139:257–268.
175. Horowitz HS, Heifetz SB, Poulsen S. Retention and effectiveness of a single application of an adhesive sealant in preventing occlusal caries: Final report after five years of a study in Kalispell, Montana. J Am Dent Assoc 1977;95:1133–1139.
176. Going RE, Haugh LD, Grainger DA, Conti AJ. Four-year clinical evaluation of a pit and fissure sealant. J Am Dent Assoc 1977;95:972–981.
177. Mertz-Fairhurst EJ, Fairhurst CW, Williams JE, Della-Giustina VE, Brooks JD. A comparative clinical study of two pit and fissure sealants: 7-year results in Augusta, GA. J Am Dent Assoc 1984;109:252–255.
178. Barrie AM, Stephen KW, Kay EJ. Fissure sealant retention: A comparison of three sealant types under field conditions. Community Dent Health 1990;7:273–277.
179. Chestnutt IG, Schafer F, Jacobson AP, Stephen KW. The prevalence and effectiveness of fissure sealants in Scottish adolescents. Br Dent J 1994;177:125–129.
180. Shapira J, Fuks A, Chosack A, Houpt M, Eidelman E. A comparative clinical study of autopolymerized and light-polymerized fissure sealants: Five-year results. Pediatr Dent 1990;12:168–169.

Dentlearn.ir

181. Wendt LK, Koch G. Fissure sealant in permanent first molars after 10 years. Swed Dent J 1988;12:181–185.
182. Eklund SA, Ismail AI. Time of development of occlusal and proximal lesions: Implications for fissure sealants. J Public Health Dent 1986; 46:114–121.
183. Davenport S, Feigal R. Contact angle and penetrativity of bonding agents effective in wet-bonding [abstract 425]. J Dent Res 1997;76 (special issue):67.
184. Symons AL, Chu CY, Meyers IA. The effect of fissure morphology and pretreatment of the enamel surface on penetration and adhesion of fissure sealants. J Oral Rehabil 1996;23:791–798.
185. Hitt JC, Feigal RJ. Use of a bonding agent to reduce sealant sensitivity to moisture contamination: An in vitro study. Pediatr Dent 1992;14:41–46.
186. Tulunoglu O, Bodur H, Uctasli M, Alacam A. The effect of bonding agents on the microleakage and bond strength of sealant in primary teeth. J Oral Rehabil 1999;26:436–441.
187. Choi JW, Drummond JL, Dooley R, Punwani I, Soh JM. The efficacy of primer on sealant shear bond strength. Pediatr Dent 1997;19:286–288.
188. Feigal RJ, Hitt J, Splieth C. Retaining sealant on salivary contaminated enamel. J Am Dent Assoc 1993;124:88–96.
189. Levy MP, Feigal RJ. Intermediate bonding agents increase clinical success of occlusal sealants on newly-erupted molars [abstract 1296]. J Dent Res 1996;75(special issue):179.
190. Feigal R, Musherure P, Gillespie B, Levy-Polack M, Quelhas I, Hebling J. Improved sealant retention with bonding agents: A clinical study of two-bottle and single-bottle systems. J Dent Res 2000;79:1850–1856.
191. Brocklehurst PR, Joshi RI, Northeast SE. The effect of air-polishing occlusal surfaces on the penetration of fissures by a sealant. Int J Paediatr Dent 1992;2:157–162.
192. Shapira J, Eidelman E. Six-year clinical evaluation of fissure sealants placed after mechanical preparation: A matched pair study. Pediatr Dent 1986;8:204–205.
193. Hatibovic-Kofman S, Wright GZ, Braverman I. Microleakage of sealants after conventional, bur, and air-abrasion preparation of pits and fissures. Pediatr Dent 1998;20:173–176.
194. Kramer PF, Zelante F, Simionato MR. The immediate and long-term effects of invasive and noninvasive pit and fissure sealing techniques on the microflora in occlusal fissures of human teeth. Pediatr Dent 1993;15:108–112.
195. Mickenautsch, S., Yengopal, V. Caries-preventive effect of glass ionomer and resin-based fissure sealants on permanent teeth: An update of systematic review evidence. BMC Res Notes 2011;4:22.
196. Autio-Gold JT. Clinical evaluation of a medium-filled flowable restorative material as a pit and fissure sealant. Oper Dent 2002;27:325–329.
197. Boksman L, Carson B. Two-year retention and caries rates of UltraSeal XT and FluoroShield light-cured pit and fissure sealants. Gen Dent 1998;46:184–187.
198. Eklund SA. Factors affecting the cost of fissure sealants: A dental insurer's perspective. J Public Health Dent 1986;46:133–140.
199. Bader JD, Graves RC, Disney JA, et al. Identifying children who will experience high caries increments. Community Dent Oral Epidemiol 1986;14:198–201.
200. Disney JA, Graves RC, Stamm JW, Bohannan HM, Abernathy JR, Zack DD. The University of North Carolina Caries Risk Assessment Study: Further developments in caries risk prediction. Community Dent Oral Epidemiol 1992;20:64–75.
201. Ulvestad H. Clinical trials with fissure sealant materials in Scandinavia. In: Silverstone LM, Dogon IL (eds). Proceedings of an International Symposium on the Acid Etch Technique. St Paul, MN: North Central University, 1975:165–174.
202. Simonsen RJ. Preventive resin restorations (I). Quintessence Int Dent Dig 1978;9:69–76.
203. Simonsen RJ. Preventive resin restorations (II). Quintessence Int Dent Dig 1978;9:95–102.
204. Simonsen RJ, Stallard RE. Sealant-restorations utilizing a diluted filled composite resin: One year results. Quintessence Int Dent Dig 1977; 8(6):77–84.
205. Welbury RR, Walls AW, Murray JJ, McCabe JF. The management of occlusal caries in permanent molars.

Dentlearn.ir

A 5-year clinical trial comparing a minimal composite with an amalgam restoration. Br Dent J 1990;169:361–366.
206. Städtler P. A 3-year clinical study of a hybrid composite resin as fissure sealant and as restorative material for Class I restorations. Quintessence Int 1992;23:759–762.
207. King NM, Yung LK, Holmgren CJ. Clinical performance of preventive resin restorations placed in a hospital environment. Quintessence Int 1996;27:627–632.
208. Houpt M, Fukus A, Eidelman E. The preventive resin (composite resin/ sealant) restoration: Nine-year results. Quintessence Int 1994;25:155–159.
209. Mertz-Fairhurst EJ, Curtis JW Jr, Ergle JW, Rueggeberg FA, Adair SM. Ultraconservative and cariostatic sealed restorations: Results at year 10. J Am Dent Assoc 1998;129:55–66.
210. Granath L, Schröder U, Sundin B. Clinical evaluation of preventive and Class-I composite resin restorations. Acta Odontol Scand 1992;50:359–364.
211. Qin M, Liu H. Clinical evaluation of a flowable resin composite and flowable compomer for preventive resin restorations. Oper Dent 2005;30:580–587.
212. Kawai K, Leinfelder KF. Effect of surface-penetrating sealant on composite wear. Dent Mater 1993;9:108–113.
213. Lang LA, Burgess JO, Lang BR, Wang RF. Wear of composite resin restorations in beveled and nonbeveled preparations [abstract 1226]. J Dent Res 1995;74(special issue):165.
214. Charlton D. SureFil high density posterior restorative. USAF Dental Items of Significance 1999;58:11.
215. Hilton T. Solitaire. USAF Dental Items of Significance 1999;56:16.
216. Loomans B, Opdam N, Bronkhorst E, Roeters F, Dörfer C. A clinical study on interdental separation techniques. Oper Dent 2007;32:207–211.
217. Lussi A, Gygax M. Iatrogenic damage to adjacent teeth during classical approximal box preparation. J Dent 1998;26:435–441.
218. Qvist V, Johannessen L, Brunn M. Progression of approximal caries in relation to iatrogenic preparation damage. J Dent Res 1992;71:1370–1373.
219. Vanderlei A, Borges A, Cavalcanti B, Rode S. Ultrasonic versus high-speed cavity preparation: Analysis of increases in pulpal temperature and time to complete preparation. J Prosthet Dent 2008;100:107–109.
220. Cehreli Z, Yazici A, Akca T, Ozgünaltay G. A morphological and micro-tensile bond strength evaluation of a single bottle adhesive to caries-affected human dentine after four different caries removal techniques. J Dent 2003;31:429–435.
221. Munechika T, Suzuki K, Nishiyama M, Ohashi M, Horie K. A comparison of the tensile bond strengths of composite resins to longitudinal and transverse sections of enamel prisms in human teeth. J Dent Res 1984;63:1079–1082.
222. Qvist V, Strøm C. 11-year assessment of Class-III resin restorations completed with two restorative procedures. Acta Odontol Scand 1993; 51:253–262.
223. Opdam NJ, Roeters JJ, Kuijs R, Burgersdijk RC. Necessity of bevels for box only Class II composite restorations. J Prosthet Dent 1998;80:274–279.
224. Opdam NJ, Roeters JJ, Burgersdijk RC. Microleakage of Class II box-type composite restorations. Am J Dent 1998;11:160–164.
225. Dietschi D, Scampa U, Campanile G, Holz J. Marginal adaptation and seal of direct and indirect Class II composite resin restorations: An in vitro evaluation. Quintessence Int 1995;26:127–138.
226. Martin FE, Bryant RW. Acid-etching of enamel cavity walls. Aust Dent J 1984;29:308–314.
227. Ferrari M, Mannocci F, Kugel G, Garcia-Godoy F. Standardized microscopic evaluation of the bonding mechanism of NRC/Prime & Bond NT. Am J Dent 1999;12:77–83.
228. Hilton TJ, Schwartz RS, Ferracane JL. Microleakage of four Class II resin composite insertion techniques at intraoral temperature. Quintessence Int 1997;28:135–144.

of Class 2 composite restorations. Oper Dent 1997;22:217–221.
230. Jordan RE, Suzuki M. Posterior composite restorations. Where and how they work best. J Am Dent Assoc

Dentlearn.ir

1991;122:30–37.
231. Barnes DM, Holston AM, Strassler HE, Shires PJ. Evaluation of clinical performance of twelve posterior composite resins with a standardized placement technique. J Esthet Dent 1990;2:36–43.
232. Grisanti LP 2nd, Troendle KB, Summitt JB. Support of occlusal enamel provided by bonded restorations. Oper Dent 2004;29:49–53.
233. Letzel H. Survival rates and reasons for failure of posterior composite restorations in multicentre clinical trial. J Dent 1989;17:S10–S17.
234. Hinoura K, Moore BK, Phillips RW. Tensile bond strength between glass ionomer cement and composite resin. J Am Dent Assoc 1987;114:167–172.
235. Yamamoto H, Iwami Y, Unezake T, Tomii Y, Tuchitani Y. Fluoride uptake around cavity walls: Two-dimensional mapping by electron probe microanalysis (EPMA-WDX) method. Oper Dent 2000;25:104–112.
236. Kemp-Scholte CM, Davidson CL. Complete marginal seal of Class V resin composite restorations effected by increased flexibility. J Dent Res 1990;69:1240–1243.
237. Hembree JH Jr. Microleakage at the gingival margin of Class II composite restorations with glass-ionomer liner. J Prosthet Dent 1989;61:28–30.
238. Prati C. Early marginal microleakage in Class II resin composite restorations. Dent Mater 1989;5:392–398.
239. Krejci I, Lutz F, Krejci D. The influence of different base materials on marginal adaptation and wear of conventional Class II composite resin restorations. Quintessence Int 1988;19:191–198.
240. Goodis HE, White JM, Marshall SJ, Koshrovi P, Watanabe LG, Marshall GW Jr. The effect of glass ionomer liners in lowering pulp temperatures during composite placement, in vitro. Dent Mater 1993;9:146–150.
241. Akpata ES, Sadiq W. Post-operative sensitivity in glass-ionomer versus adhesive resin-lined posterior composites. Am J Dent 2001;14:34–38.
242. Aboushala A, Kugel G, Hurley E. Class II composite resin restorations using glass-ionomer liners: Microleakage studies. J Clin Pediatr Dent 1996;21:67–71.
243. Miller MB, Castellanos ER, Vargas MA, Denehy GE. Effect of restorative materials on microleakage of Class II composites. J Esthet Dent 1996; 8:107–113.
244. Loguercio AD, Alessandra R, Mazzocco KC, et al. Microleakage in Class II composite resin restorations: Total bonding and open sandwich technique. J Adhes Dent 2002;4:137–144.
245. Wibowo G, Stockton L. Microleakage of Class II composite restorations. Am J Dent 2001;14:177–185.
246. Hagge M, Lindemuth J, Mason J, Simon J. Effect of four intermediate layer treatments on microleakage of Class II composite restorations. Gen Dent 2001;49:489–495.
247. Retief D, McCaghren R, Russell C. Microleakage of Vitrebond/P-50 Class II restorations. Am J Dent 1992;5:130–132.
248. Hilton T, Quinn R. Marginal leakage of Class 2 composite/flowable restorations with varied cure technique [abstract 502]. J Dent Res 2001;80(special issue):589.
249. Dietrich T, Lösche A, Lösche G, Roulet JF. Marginal adaptation of direct composite and sandwich restorations in class II cavities with cervical margins in dentine. J Dent 1999;27:119–128.
250. Herrera M, Castillo A, Bravo M, Liebana J, Carrion P. Antibacterial activity of resin adhesives, glass

Oper Dent 2000;25:265–269.
251. Tantbirojn D, Rusin R, Bui H, Mitra S. Inhibition of dentin demineralization adjacent to a glass ionomer/composite sandwich restoration. Quintessence Int 2009;40:287–294.
252. van Dijken J. A 6-year evaluation of a direct composite resin inlay/ onlay system and glass ionomer cement-composite resin sandwich restorations. Acta Odontol Scand 1994;5:368–376.
253. Andersson-Wenckert I, van Dijken J, Hörstedt P. Modified Class II open-sandwich restorations: Evaluation of interfacial adaptation and influence of different restorative techniques. Eur J Oral Sci 2002;110:270–275.
254. Braga RR, Condon JR, Ferracane JL. In vitro wear simulation measurements of composite versus resin-modified glass ionomer luting cements for all-ceramic restorations. J Esthet Restor Dent 2002;14:368–376.
255. Shabanian M, Richards LC. In vitro wear rates of materials under different loads and varying pH. J Prosthet Dent 2002;87:650–656.

Dentlearn.ir

256. Lutz F, Krejci I, Luescher B, Oldenburg TR. Improved proximal margin adaptation of Class II composite resin restorations by use of light-reflecting wedges. Quintessence Int 1986;17:659–664.
257. Loomans B, Opdam N, Roeters F, Bronkhorst E, Burgersdijk W, Dörfer C. A randomized clinical trial on proximal contacts of posterior composites. J Dent 2006;34:292–297.
258. Loomans B, Roeters F Opdam N, Kuijs R. The effect of proximal contour on marginal ridge fracture of class II composite resin restorations. J Dent 2008;36:828–832.
259. Hilton T. Composi-Tight sectional matrix system. USAF Dental Items of Significance 1999;56:15.
260. Hilton T. Palodent sectional matrix system. USAF Dental Items of Significance 1999;56:14.
261. Saber M, El-Badrawy W, Loomans B, Ahmed D, Dörfer C, El Zohairy A. Creating tight interproximal contacts for MOD resin composite restorations. Oper Dent 2011;36:304–310.
262. Loomans B, Opdam N, Roeters F, Bronkhorst E, Plasschaert A. The long-term effect of a composite resin restoraion on proximal contact tightness. J Dent 2007; 35:104–108.
263. Crim GA. Microleakage of three resin placement techniques. Am J Dent 1991;4:69–72.
264. Opdam NJ, Feilzer AJ, Roeters JJ, Smale I. Class I occlusal composite resin restorations: In vivo post-operative sensitivity, wall adaptation, and microleakage. Am J Dent 1998;11:229–234.
265. Félix S, González-López S, Mauricio P, Aguilar-Mendoza J, Bolaños-Carmona M. Effects of filling techniques on the regional bond strength to lateral walls in class I cavities. Oper Dent 2007;32:602–609.
266. Kim M, Park S. Comparison of premolar cuspal deflection in bulk or in incremental composite restoration methods. Oper Dent 2011;36:326–334.
267. Feilzer AJ, De Gee AJ, Davidson CL. Quantitative determination of stress reduction by flow in composite restorations. Dent Mater 1990;6:167–171.
268. Davidson CL, de Gee AJ, Feilzer A. The competition between the composite-dentin bond strength and the polymerization contraction stress. J Dent Res 1984;63:1396–1399.
269. Dauvillier B, Aarnts M, Feilzer A. Developments in shrinkage control of adhesive restoratives. J Esthet Dent 2000;12:291–299.
270. Yoshikawa T, Sano H, Burrow MF, Tagami J, Pashley DH. Effects of dentin depth and cavity configuration on bond strength. J Dent Res 1999;78:898–905.
271. Opdam NJ, Roeters FJ, Feilzer AJ, Smale I. A radiographic and scanning electron microscopic study of approximal margins of Class II resin composite restorations placed in vivo. J Dent 1998;26:319–327.
272. Bryant RW. Direct posterior composite resin restorations: A review. 2. Clinical technique. Aust Dent J 1992;37:161–171.
273. Ciamponi AL, Del Portillo Lujan VA, Santos JF. Effectiveness of reflective wedges on the polymerization of composite resins. Quintessence Int 1994;25:599–602.

Quintessence Int 1992;23:763–767.
275. Lutz E, Krejci I, Oldenburg TR. Elimination of polymerization stresses at the margins of posterior composite resin restorations: A new restorative technique. Quintessence Int 1986;17:777–784.
276. Price R, Dérand T, Sedarous M, Andreou P, Loney R. Effect of distance on the power density from two light guides. J Esthet Restor Dent 2000;12:320–327.
277. de Jong L, Opdam N, Bronkhorst E, Roeters J, Wolke J, Geitenbeek B. The effectiveness of different polymerization protocols for class II composite resin restorations. J Dent 2007;35:513–520.
278. Opdam NJ, Roeters JJ, Peters TC, Burgersdijk RC, Kuijs RH. Consistency of resin composites for posterior use. Dent Mater 1996;12:350–354.
279. Opdam NJ, Roeters JJ, Peters TC, Burgersdijk RC, Teunis M. Cavity wall adaptation and voids in adhesive Class I resin composite restorations. Dent Mater 1996;12:230–235.
280. Purk J, Dusevich V, Glaros A, Eick D. Adhesive analysis of voids in Class II composite resin restorations at the axial and gingival cavity walls restored under in vivo versus in vitro conditions. Dent Mater 2007; 23:871–877.
281. DaCosta J, McPharlin R, Hilton T, Ferracane J. Effect of heat flow on the flow of commercial composites. Am J Dent 2009;22:92–96.

Dentlearn.ir

282. Holmes R, Blalock J, Rueggeberg F. Composite film thickness at various temperatures [abstract 3265]. J Dent Res 2004;83(special issue A).
283. Aksu M, Neme A, Walker S, Pink F, Linger J, Wagner W. Effect of preheating composite on microleakage in Class II restorations [abstract 498]. J Dent Res 2004;83(special issue A).
284. Wagner W, Asku M, Neme A, Linger J, Pink F, Walker S. Effect of preheating composite on restoration microleakage. Oper Dent 2008;33: 72–78.
285. Trujillo M, Newman S, Stansbury J. Use of near-IR to monitor the influence of external heating on dental composite photopolymerization. Dent Mater 2004;20:766–777.
286. Daronch M, Rueggeberg F, De Goes M, Giudici R. Polymerization kinetics of pre-heated composite. J Dent Res 2006;85:38–43.
287. Rueggeberg FA, Daronch M, Browning WD, De Goes MF. In vivo temperature measurement: Tooth preparation and restoration with preheated resin composite. J Esthet Restor Dent 2010;22:314–322.
288. Li J, Nicander I, von Beetzen M, Sundström F. Influence of paste temperature at curing on conversion rate and bending strength of light-cured dental composites. J Oral Rehabil 1996;23:298–301.
289. Behle C. Flowable composites: Properties and applications. Pract Periodontics Aesthet Dent 1998;10:347,350–351.
290. Bayne SC, Thompson JY, Swift EJ Jr, Stamatiades P, Wilkerson M. A characterization of first-generation flowable composites. J Am Dent Assoc 1998;129:567–577.
291. Labella R, Lambrechts P, Van Meerbeek B, Vanherle G. Polymerization shrinkage and elasticity of flowable composites and filled adhesives. Dent Mater 1999;15:128–137.
292. Tolidis K, Setcos JC. Initial degree of polymerization shrinkage exhibited by flowable composite resins [abstract 3015]. J Dent Res 1999; 78(special issue):482.
293. Braga R, Hilton T, Ferracane J. Contraction stress of flowable composite materials and their efficacy as stress-relieving layers. J Am Dent Assoc 2003;134:721–728.
294. Oberholzer TG, Pameijer CH, Grobler SR, Rossouw RJ. The effect of different power densities and method of exposure on the marginal adaptation of four light-cured dental restorative materials. Biomaterials 2003;24:3593–3598.

Class II composite restorations. Oper Dent 2004;29:713–719.
296. Attar N, Turgut M, Gungor HC. The effect of flowable resin composites as gingival increments on the microleakage of posterior resin composites. Oper Dent 2004;29:162–167.
297. Chuang SF, Jin YT, Lin TS, Chang CH, Garcia-Godoy F. Effects of lining materials on microleakage and

298. Amin Parsa M, Kunzelmann KH. Effect of the “lining technique” on marginal adaptation [abstract 1684]. J Dent Res 2000;79(special issue):354.
299. Russell RR, Mazer RB. Microleakage of Class II restorations using a flowable composite as a liner [abstract 203]. J Dent Res 1998;77(special issue):131.
300. Walshaw PR, McComb D. Microleakage in Class 2 resin composites with low-modulus, intermediate materials [abstract 204]. J Dent Res 1998; 77(special issue):131.
301. Neme A, Maxson B, Pink F, Aksu M. Microleakage of Class II packable resin composites lined with flowables: An in vitro study. Oper Dent 2002;27:600–605.
302. Sensi LG, Marson FC, Monteiro S Jr, Baratieri LN, Caldeira de Andrada MA. Flowable composites as “filled adhesives:” A microleakage study. J Contemp Dent Pract 2004;5:32–41.
303. Cara R, Fleming G, Palin W, Walmsley A, Burke F. Cuspal deflection and microleakage in premolar teeth restored with resin-based composites with and without an intermediate flowable layer. J Dent 2007;35:482–489.
304. Rashid R, Ricks J, Monaghan P. Strengths of condensable composite resins with flowable liners [abstract 403]. J Dent Res 1999;78(special issue):156.

Class II resin composite restorations. Clin Oral Investig 1999;3:208–215.
306. Murchison DF, Charlton DG, Moore WS. Comparative radiopacity of flowable resin composites.

Dentlearn.ir

Quintessence Int 1999;30:179–184.
307. Bouschlicher M, Cobb D, Boyer D. Radiopacity of compomers, flowable and conventional resin composites for posterior restorations. Oper Dent 1999;24:20–25.
308. Imperiano M, Khoury H, Pontual M, Montes M, da Silveira M. Comparative radiopacity of four low-viscosity composites. Braz J Oral Sci 2007;6:1278–1282.
309. Perdigão J, Anauate-Netto C, Carmo A, et al. The effect of adhesive and flowable composite on postoperative sensitivity: 2-week results. Quintessence Int 2004;35:777–784.
310. van Dijken J, Pallesen U. Clinical performance of a hybrid resin composite with and without an intermediate layer of flowable resin composite: A 7-year evaluation. Dent Mater 2011;27:150–156.
311. Ernst C, Canbek K, Aksogan K, Willeshausen B. Two-year clinical performance of a packable posterior composite with and without a flowable composite liner. Clin Oral Investig 2003;7:129–134.
312. Opdam N, Roeters J, Deborri T, Peschier D, Bronkhorst E. Voids inside restored micropreparations using various resin composites and application techniques [abstract 3132]. J Dent Res 2002;81(special issue):389.
313. ADA Professional Product Review 2010;5(2):1–16.
314. Niu Y, Ma X, Fan M, Zhu S. Effects of layering techniques on the micro-tensile bond strength to dentin in resin composite restorations. Dent Mater 2009;25:129–134.
315. Donly KJ, Wild TW, Bowen RL, Jensen ME. An in vitro investigation of the effects of glass inserts on the effective composite resin polymerization shrinkage. J Dent Res 1989;68:1234–1237.
316. González-Lopéz S, Lucena-Martin C, de Haro-Gasquet F, Vilchez-Diaz M, de Haro-Muñoz C. Influence of different composite restoration techniques on cuspal deflection: An in vitro study. Oper Dent 2004;29:656–660.
317. Jedrychowski JR, Bleier RG, Caputo AA. Shrinkage stresses associated with incremental composite filling techniques in conservative Class II restorations. ASDC J Dent Child 2001;68:161–167.
318. Ericson D, Derand T. Reduction of cervical gaps in Class II composite resin restorations. J Prosthet Dent 1991;65:33–37.
319. Ericson D, Paulsson L, Sowiak H, Derand T. Reduction of cusp deflection resulting from composite polymerization shrinkage, using a light-transmitting cone. Scand J Dent Res 1994;102:244–248.
320. von Beetzen M, Li J, Nicander I, Sundström F. Microhardness and porosity of Class 2 light-cured composite restorations cured with a transparent cone attached to the light-curing wand. Oper Dent 1993;18:103–109.
321. Warren JA, Clark NP. Posterior composite resin: Current trends in restorative techniques. Part 2: Insertion, finishing, and polishing. Gen Dent 1987;35:497–499.
322. Liebenberg W. Successive cusp build-up: An improved placement technique for posterior direct resin restorations. J Can Dent Assoc 1996;62:501–507.
323. van Dijken JW, Hörstedt P, Waern R. Directed polymerization shrinkage versus a horizontal incremental filling technique: Interfacial adaptation in vivo in Class II cavities. Am J Dent 1998;11:165–172.
324. Tarle Z, Meniga A, Ristic M, Sutalo J, Pichler G, Davidson CL. The effect of the photopolymerization
325. Hinoura K, Miyazaki M, Onose H. Influence of argon laser curing on resin bond strength. Am J Dent 1993;6:69–71.
326. Shanthala BM, Munshi AK. Laser vs visible-light cured composite resin: An in vitro shear bond study. J Clin Pediatr Dent 1995;19:121–125.
327. Bouschlicher MR, Vargas MA, Boyer DB. Effect of composite type, light intensity, configuration factor and laser polymerization on polymerization contraction forces. Am J Dent 1997;10:88–96.
328. Puppala R, Hegde A, Munshi AK. Laser and light cured composite resin restorations: In-vitro comparison of isotope and dye penetrations. J Clin Pediatr Dent 1996;20:213–218.
329. Burgess JO, De Goes M, Walker R, Ripps AH. An evaluation of four light-curing units comparing soft and hard curing. Pract Periodontics Aesthet Dent 1999;11:125–132.
330. Unterbrink GL, Muessner R. Influence of light intensity on two restorative systems. J Dent 1995;23:183–189.
331. Sakaguchi R, Ferracane J. Effect of light power density on development of elastic modulus of a model light-activated composite during polymerization. J Esthet Restor Dent 2001;13:121–130.

Dentlearn.ir

332. Hammesfahr PD, O'Connor MT, Wang X. Light-curing technology: Past, present, and future. Compend Contin Educ Dent 2002;23(9 suppl 1):18–24.
333. Caughman W, Rueggeberg F. Shedding new light on composite polymerization. Oper Dent 2002;27:636–638.
334. Price R, Labrie D, Rueggeberg F, Felix C. Irradiance differences in the violet (405nm) and blue (469nm) spectral ranges among dental light-curing units. J Esthet Restor Dent 2010;22:363–378.
335. Pilo R, Oelgiesser D, Cardash HS. A survey of output intensity and potential for depth of cure among light-curing units in clinical use. J Dent 1999;27:235–241.
336. Barghi N, Fischer D, Pham TA. Revisiting the intensity output of curing lights in private dental offices. Compend Contin Educ Dent 2007; 28:380–384.
337. Al Shaafi M, Maawadh A, Al Qahtani M. Evaluation of light intensity output of QTH and LED curing devices in various government health institutions. Oper Dent 2011;36:356–361.
338. Choi KK, Ferracane JL, Hilton TJ, Charlton D. Properties of packable dental composites. J Esthet Dent 2000;12:224–234.
339. Tabassian M, Moon PC. Filler particle characterization in flowable and condensible composite resins [abstract 3022]. J Dent Res 1999;78 (special issue):483.
340. Barkmeier WW, Wilwerding TM, Latta MA, Blake SM. In vitro wear assessment of high density composite resins [abstract 2737]. J Dent Res 1999;78(special issue):448.
341. Dang HM, Sarrett DC. Wear behavior of flowable and condensable composite resins [abstract 2736]. J Dent Res 1999;78(special issue):447.
342. Knoblach L, Kerby R, Seghi R. Wear resistance of posterior condensable composite resins [abstract 2735]. J Dent Res 1999;78(special issue):447.
343. Suzuki S. In vitro wear of condensable resin composite restoratives [abstract 2734]. J Dent Res 1999;78(special issue):447.
344. Kelsey WP, Latta MA, Barkmeier WW. Physical properties of high density composite restorative materials [abstract 810]. J Dent Res 1999;78(special issue):207.
345. Ruddell DE, Thompson JY, Stamatiades PJ, et al. Mechanical properties and wear behavior of condensable composites [abstract 407]. J Dent Res 1999;78(special issue):156.
346. MacGregor KM, Cobb DS, Vargas MA. Physical properties of condensable versus conventional composites [abstract 411]. J Dent Res 1999;78(special issue):157.
347. Kerby R, Lee J, Knobloch L, Seghi R. Hardness and degree of conversion of posterior condensable composite resins [abstract 414]. J Dent Res 1999;78(special issue):157.
348. Flessa HP, Simoncic B, Kunzelmann KH, et al. Quantitative 3D wear analysis of composite fillings in vivo [abstract 1051]. J Dent Res 1998; 78(special issue):237.
349. Yip K, Poon B, Chu F, Poon E, Kong F, Smales R. Clinical evaluation of packable and conventional hybrid resin-based composites for posterior restorations in permanent teeth: Results at 12 months. J Am Dent Assoc 2003;134:1581–1589.
350. Lopes L, Cefaly D, Franco E, Mondelli R, Lauris J, Navarro M. Clinical evaluation of two "packable" posterior composite resins: Two-year results. Clin Oral Investig 2003;7:123–128.
351. Turkun LS, Turkun M, Ozata F. Two-year clinical evaluation of a packable resin-based composite. J Am Dent Assoc 2003;134:1205–1212.
352. Shi L, Wang X, Zhao Q, et al. Evaluation of packable and conventional hybrid resin composites in class I restorations: Three-year results of a randomized, double-blind and controlled clinical trial. Oper Dent 2010;35:11–19.
353. Chung KH. Effects of finishing and polishing procedures on the surface texture of resin composites. Dent Mater 1994;10:325–330.
354. Hoelscher DC, Neme AML, Pink FE, Hughes PJ. The effect of three finishing systems on four esthetic restorative materials. Oper Dent 1998;23:36–42.
355. Hondrum SO, Fernandez RJ. Contouring, finishing and polishing Class 5 restorative materials. Oper Dent 1997;22:30–36.
356. Pratten DH, Johnson GH. An evaluation of finishing instruments for an anterior and a posterior composite. J

Dentlearn.ir

Prosthet Dent 1988;60:154–158.
357. Leinfelder KF, Wilder AD, Teixeira ER. Wear rates of posterior composite resins. J Am Dent Assoc 1986;112:829–833.
358. Wu W, Cobb EN. A silver staining technique for investigating wear of restorative dental composites. J Biomed Mater Res 1981;15:343–348.
359. Kanca IJ, Suh B, Vinson W. Pulse activation of resin composite: Reducing stresses at cavosurface interfaces [abstract 678]. J Dent Res 1998; 77(special issue):190.
360. Yap A, Yap S, Teo C, Ng J. Finishing/polishing of composite and compomer restoratives: Effectiveness of one-step systems. Oper Dent 2004;29:275–279.
361. Bollen C, Lambrechts P, Quirynen M. Comparison of surface roughness of oral hard materials to the threshold surface roughness for bacterial plaque retention: A review of the literature. Dent Mater 1997;13:258–269.
362. Reis A, Giannini M, Lovadino J, Ambrosano G. Effects of various finishing systems on the surface roughness and staining susceptibility of packable composite resins. Dent Mater 2003;19:12–18.
363. Berastegui E, Canalda C, Brau E, Miquel C. Surface roughness of finished composite resins. J Prosthet Dent 1992;68:742–749.
364. Ashe MJ, Tripp GA, Eichmiller FC, George LA, Meiers JC. Surface roughness of glass-ceramic insert-composite restorations: Assessing several polishing techniques. J Am Dent Assoc 1996;127:1495–1500.
365. Kaplan BA, Goldstein GR, Vijayaraghavan TV, Nelson IK. The effect of three polishing systems on the

Prosthet Dent 1996;76:34–38.
366. Brackett WW, Gilpatrick RO, Gunnin TD. Effect of finishing method on the microleakage of Class V resin composite restorations. Am J Dent 1997;10:189–191.
367. Tay FR, Gwinnett AJ, Pang KM, Wei SH. Variability in microleakage observed in a total-etch wet-bonding technique under different handling conditions. J Dent Res 1995;74:1168–1178.
368. Reid JS, Saunders WP, Chen YY. The effect of bonding agent and fissure sealant on microleakage of composite resin restorations. Quintessence Int 1991;22:295–298.
369. Dickinson GL, Leinfelder KF. Assessing the long-term effect of a surface penetrating sealant. J Am Dent Assoc 1993;124:68–72.
370. Garcia-Godoy F. Microleakage of posterior composite restorations after rebonding. Compend Contin Educ Dent 1987;8:606–609.
371. Tjan AH, Tan DE. Microleakage at gingival margins of Class V composite resin restorations rebonded with various low-viscosity resin systems. Quintessence Int 1991;22:565–573.
372. Torstenson B, Brännström M. A new method for sealing composite resin contraction gaps in lined cavities. J Am Dent Assoc 1985;64:450–453.
373. Jinks GM. Fluoride-impregnated cements and their effect on the activity of interproximal caries. J Dent Child 1963;30:87–92.
374. Hunt PR. A modified Class II cavity preparation for glass ionomer restorative materials. Quintessence Int 1984;15:1011–1018.
375. Knight GM. The use of adhesive materials in the conservative restoration of selected posterior teeth. Aust Dent J 1984;29:324–331.
376. Brunsvold MA, Lane JJ. The prevalence of overhanging dental restorations and their relationship to periodontal disease. J Clin Periodontol 1990;17:67–72.
377. Reeh ES, Messer HH, Douglas WH. Reduction in tooth stiffness as a result of endodontic and restorative procedures. J Endod 1989;15:512–516.
378. Papa J, Wilson PR, Tyas MJ. Tunnel restorations: A review. Quintessence Int 1992;4:4–9.
379. Hunt PR. Microconservative restorations for approximal carious lesions. J Am Dent Assoc 1990;120:37–40.
380. Papa J, Cain C, Messer HH, Wilson PR. Tunnel restorations versus Class II restorations for small proximal lesions: A comparison of tooth strengths. Quintessence Int 1993;24:93–98.
381. Strand GV, Tveit AB. Effectiveness of caries removal by the partial tunnel preparation. Scand J Dent Res

Dentlearn.ir

1993;101:270–273.
382. Zenkner J, Baratieri LN, Monteiro SJ, et al. Clinical and radiographic evaluation of cement tunnel restorations on primary molars. Quintessence Int 1993;24:783–791.
383. Papa J, Cain C, Messer HH. Efficacy of tunnel restorations in the removal of caries. Quintessence Int 1993;24:715–719.
384. Strand GV, Tveit AB, Espelid I. Variations among operators in the performance of tunnel preparations in vitro. Scand J Dent Res 1994; 102:151–155.
385. Fasbinder DJ, Davis RD, Burgess JO. Marginal ridge strength in Class II tunnel restorations. Am J Dent 1991;4:77–82.
386. Hill FJ, Halaseh FJ. A laboratory investigation of tunnel restorations in premolar teeth. Br Dent J 1988;165:364–367.
387. Pilebro CE, van Dijken JWV, Stenberg R. Durability of tunnel restorations in general practice: A three-year multicenter study. Acta Odontol Scand 1999;57:35–39.
388. Strand GV, Nordbo H, Tveit AB, Espelid I, Wikstrand K, Eide GE. A 3-year clinical study of tunnel restorations. Eur J Oral Sci 1996;104:384–389.
389. Lumley PJ, Fisher FJ. Tunnel restorations: A long-term pilot study over a minimum of five years. J Dent 1995;23:213–215.
390. Hasselrot L. Tunnel restorations in permanent teeth. A 7 year follow up study. Swed Dent J 1998;22:1–7.
391. Hörsted-Bindslev P, Heyde-Petersen B, Simonsen P, Baelum V. Tunnel or saucer-shaped restorations: A survival analysis. Clin Oral Investig 2005;9:233–238.

Dentlearn.ir



Amalgam Restorations

J. D. Overton
James B. Summitt
John W. Osborne

The word *amalgam* means an alloy of mercury with another metal or metals.[1] This type of alloying is called *amalgamation*.[2] In dentistry, before these metals are combined with mercury to make dental amalgam, they are known as *dental amalgam alloys*. Prior to the development of high-copper amalgam alloys, dental amalgam alloys contained at least 65% by weight silver, 29% by weight tin, and less than 6% by weight copper. The high-copper amalgam alloys[3,4] contain between 12% and 30% by weight copper and at least 40% by weight silver.[5] This higher level of copper has resulted in the elimination of the highly corrodible and weak gamma 2 (tin-mercury) phase that existed in the low-copper dental amalgams.[6–8]

Zinc is added to amalgam to enhance its mechanical properties,[9] reduce marginal fracture,[10,11] and prolong the service of the restoration.[11,12] When moisture is incorporated during condensation of a zinc-containing low-copper amalgam, delayed expansion will occur.[13] Zinc-containing high-copper amalgams do not exhibit the phenomenon of delayed expansion,[14–16] but isolation to prevent any moisture contamination is important for both zinc-containing and zinc-free amalgam

Dentlearn.ir

restorations.[14] Contamination of dental amalgam with moisture will create porosity in the restoration, which will decrease strength and increase both corrosion and creep.[14,16]

This process by which amalgam alloy powder is mixed with liquid mercury is called *trituration*.[17] The powder may be of the lathe-cut variety (Fig 12-1a), which is made by milling an ingot of the alloy, or of the spherical type (Fig 12-1b), which is made by atomizing liquid alloy.[18] The spherical particles usually are not true spheres but take on various rounded shapes. Some dental amalgam alloys contain only lathe-cut particles, called *filings*; others contain only spheres, and some contain both spheres and filings. Those containing only filings are called *lathe-cut amalgam alloys*, those containing only spheres are called *spherical alloys*, and those containing both filings and spheres are called *admixtures*[5] (Fig 12-1c).

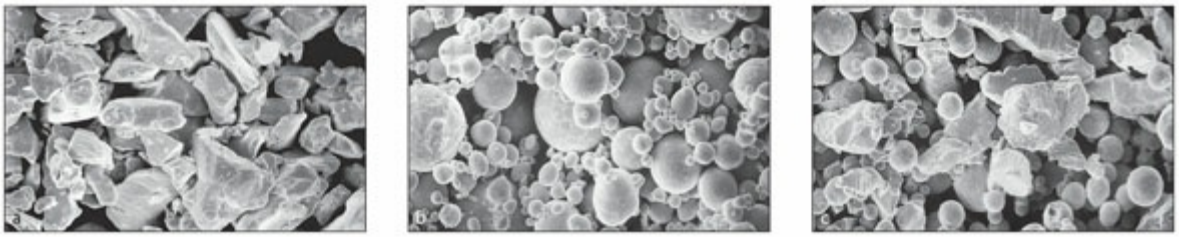

Fig 12-1 *(a)* Lathe-cut amalgam alloy particles. *(b)* Spherical amalgam alloy particles. *(c)* Admixed amalgam alloy particles.

Dental amalgam restorations contain approximately 50% mercury, and some people have concerns that mercury, which is known to be toxic when present in certain forms and in high doses, is present in the mouth. Mercury in amalgam is bound in the matrix phase. The metallic bonds in amalgam are very difficult to break, and only very heavy pressure or high heat can potentially cause the bonds in the restoration to degrade. During mastication, pressures of 200 MPa or higher are common, and this force, with friction, can generate heat in small areas. It has been theorized[19] that this heat could cause amalgam to release small amounts of mercury during function.[20] It has been estimated that for a patient having 12 amalgam restorations in his or her mouth, the amount of metallic mercury released per day would only be in the range of 1.7 µg.[21]

There is considerable evidence of the safety of dental amalgam.[19,22–27] To date, there is no confirmed evidence to indicate that the mercury in dental amalgam is related to any disease.[28–34] Research reveals that no toxic effect has been linked to the level of mercury released from amalgam, even when amalgam restorations are removed.[35,36] Several agencies, including the World Health Organization,[37] the US

Dentlearn.ir

Public Health Service,[38] the National Institutes of Health,[39] and the Swedish Medical Research Council,[40] have reaffirmed their positions that there are no data to compel a change in the current use of dental amalgam.[41,42] While no evidence refutes these claims, a general consensus exists to reduce mercury use in all industries because of concerns over environmental effects.[43]

Any component of amalgam or any other restorative material can elicit an allergic reaction, but hypersensitivity to mercury is extremely rare. Of those who have an established allergy to mercury, fewer than 1% demonstrate clinically observable reactions to mercury in dental amalgam restorations.[44] Raap et al[45] examined 206 patients thought to have a contact allergy to dental metals. Only 28 of the 206 patients examined had positive patch test reactions to metals used in dentistry, and some of these had reactions to more than one of the tested metals. Ten were positive to gold sodium thiosulfate, ten to palladium chloride, ten to nickel sulfate, and four to amalgam. In case reports on amalgam hypersensitivity, the presentation has been oral lichenoid lesions, erythematous lesions, burning, and/or itching.[46]

Dental amalgam has served as a dental restorative for more than 175 years; it was used as early as 1820 in Europe, and by the mid-1830s, it was in use in the United States.[42,44] In a survey conducted in 2005,[47] more than two-thirds of North American dentists who responded stated that they used dental amalgam. While the percentage is undoubtedly lower today, dental amalgam continues to be used extensively.

Advantages and Disadvantages

Dental amalgam has many advantages as a restorative material. It is strong, durable, and relatively easy to use. It wears at a rate similar to that of tooth structure. Over time, amalgam has the ability to bring about, through formation of corrosion products, reduced microleakage at its interface with tooth structure.[6,48] Resin composite placed at and below the gingival crest has been found to alter the subgingival microflora in favor of a more pathogenic mix.[49] Subgingival amalgam margins did not significantly alter the bacterial biofilm under the same conditions.[49] A review of insurance claim data indicated that molars restored with amalgam restorations required endodontic therapy much less frequently than those restored with resin composite50; however, this review was done prior to the development and implementation of current bonding systems, so future reviews may present different findings. When replacing restorations, it is much easier to avoid enlarging the cavity preparation during removal of amalgam than it is when removing resin

Dentlearn.ir

composite because of the contrast between the color of tooth structure and amalgam and because amalgam is not typically bonded to the walls of the preparation.[51–53] In contrast, removal of resin composite materials consistently results in a larger preparation than the original.[54] Of the long-term restorative materials, dental amalgam is the least time-consuming to place and has the lowest cost.

Clinical research does not support the often-made claim that dental amalgam causes cuspal fracture. Wahl et al[55] have presented data showing that teeth restored with amalgam do not fracture any more frequently than teeth restored with resin composite. Weakening of tooth structure by large restorative tooth preparations is a likelier cause of fracture in tooth structure adjacent to restorations.

Dental amalgam also has disadvantages. Its primary disadvantage is that it is not tooth-colored. In addition, it does not, on its own, bond to tooth structure, although amalgam bonding systems have been proven to provide a fairly reliable mechanical attachment of amalgam to enamel and dentin.[56] Amalgam must be handled properly to avoid excessive exposure of the dental staff to mercury vapor.[57,58] Despite its disadvantages, however, dental amalgam is an economic and reliable direct restorative material that is still used in a majority of dental practices. When placed properly in well-designed tooth preparations, it will serve well for long periods of time.[12,59,60] Many studies have demonstrated the excellent longevity of dental amalgam.[11,59,61–63]

This chapter addresses Class 1 and Class 2 preparations and placement techniques for dental amalgam. Complex restorations involving the replacement of cusps with dental amalgam are also described. Class 5 amalgam preparations and restorations are covered in chapter 15.

Resistance Form

There are two considerations for resistance form when a tooth is being prepared to receive an amalgam restoration. First, resistance form should be developed for the restoration; the restoration must be of adequate thickness and have a marginal design that will allow it to bear the forces of mastication without fracture or deformation. In that regard, the restoration must have adequate occlusogingival depth to resist fracture in function or parafunction (bruxing or clenching). Second, the remaining tooth structure must be left in such a state that it, too, will resist the forces of mastication. As much sound tooth structure as possible must be maintained. If adequate resistance form cannot be maintained in the tooth to resist masticatory

Dentlearn.ir

forces, the weak portion of the occlusal surface should be cut away and replaced with amalgam or another strong restorative material.[64]

To maximize resistance form for tooth structure, minimum sound tooth structure should be removed when teeth are prepared for Class 1 or Class 2 amalgam restorations. Several studies[65–69] have demonstrated that, as an amalgam restoration becomes wider faciolingually, the tooth is more subject to fracture and the integrity of the restoration is less likely to be maintained. In Class 2 restorations, an increase in the depth of the occlusal portion of an amalgam restoration has also been linked to a decrease in resistance to fracture of the tooth.[66] Class 2 restorations that are confined to the marginal ridge areas (proximal slot restorations) may minimize the severity of tooth fracture compared with Class 2 restorations that extend through occlusal grooves.[70,71] Based on this knowledge, the following goals should guide the preparation and restoration of teeth: *(1)* removal of carious tooth structure, *(2)* preservation of the integrity of the tooth and periodontium, and *(3)* maximization of the life of the restored tooth.[60,72]

Class 1 Preparation

Indications

Occlusal caries

The indication for an initial Class 1 amalgam restoration is carious tooth structure in the occlusal fissures (or in facial or lingual pits in posterior teeth) detected clinically and confirmed with bitewing radiographs. The objectives of treatment are to eliminate caries lesions, to remove any enamel that has been undermined by the caries process, to preserve as much sound tooth structure as possible, and to create a strong restoration that mimics the original sound tooth structure and allows little or no marginal leakage.

For the purpose of this chapter, it is necessary to review the definitions of the terms *groove*, *fissure*, and *pit*.[73] A *groove*, or a *developmental groove*, is a linear

ridges). A *fissure* is a developmental linear cleft, the result of incomplete fusion of the enamel of adjoining dental lobes. A *pit* is a pinpoint fissure or the junction of several fissures.

Dentlearn.ir

The presence of deep or stained fissures alone does not justify placement of a restoration. When there is concern that dentin at the base of a deep fissure may become carious, the fissure should be sealed with a resin fissure sealant or flowable resin composite material. In a tooth that has been determined to have a localized fissure caries lesion or lesions, the carious tooth structure should be removed and one or more occlusal restorations placed, with the number of restorations determined by the number of areas in which carious tooth structure was removed. Remaining fissures that are considered to be susceptible to caries should then be sealed with a resin sealant (Fig 12-2).

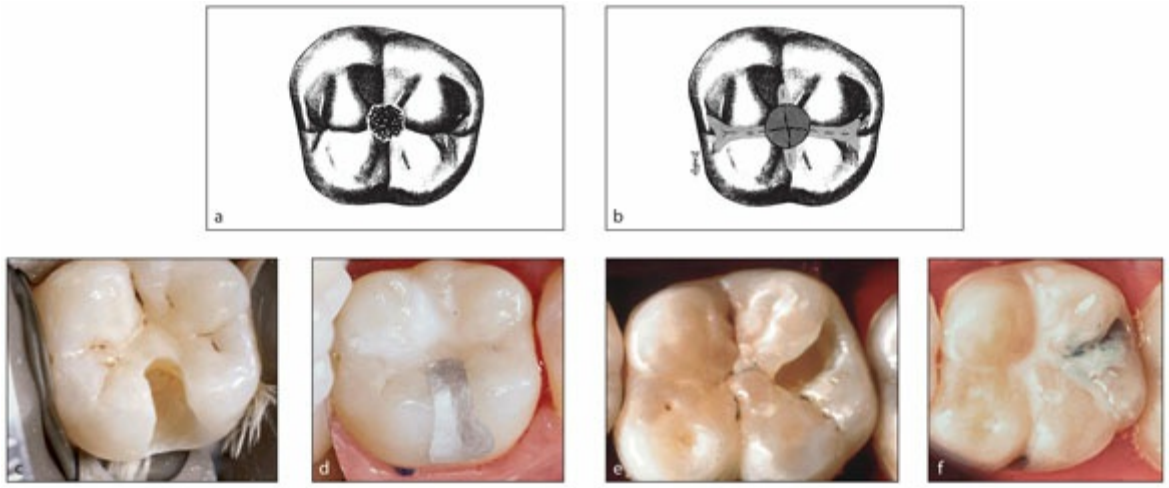

Fig 12-2 Amalgam should be used as a restorative material only in areas where actual carious tooth structure has been removed; remaining noncarious fissures and amalgam restoration margins are etched and sealed with resin fissure sealant. *(a)* This drawing shows the extent of carious dentin as if it could be seen through the occlusal enamel. *(b)* An amalgam restoration has been placed in the area where carious dentin and unsupported enamel were removed; the remaining fissures were sealed. *(c and d)* Occlusofacial preparation in mandibular molar; restoration with remaining occlusal fissures sealed. *(e and f)* Mandibular first molar preparation, sealed restoration, and sealed fissures.

If deep fissures that are to be sealed exhibit enamel demineralization or heavy stains, they may benefit from being prepared with a small bur (no. 1/16 or 1/8) to a width and depth of approximately 0.4 mm before being acid etched and sealed with a resin fissure sealant[74–76] (Fig 12-3). Alternatively, these fissures may be opened or cleaned with an air-abrasive instrument or an air-polishing prophylaxis unit[77–81] (Fig 12-4).

Dentlearn.ir

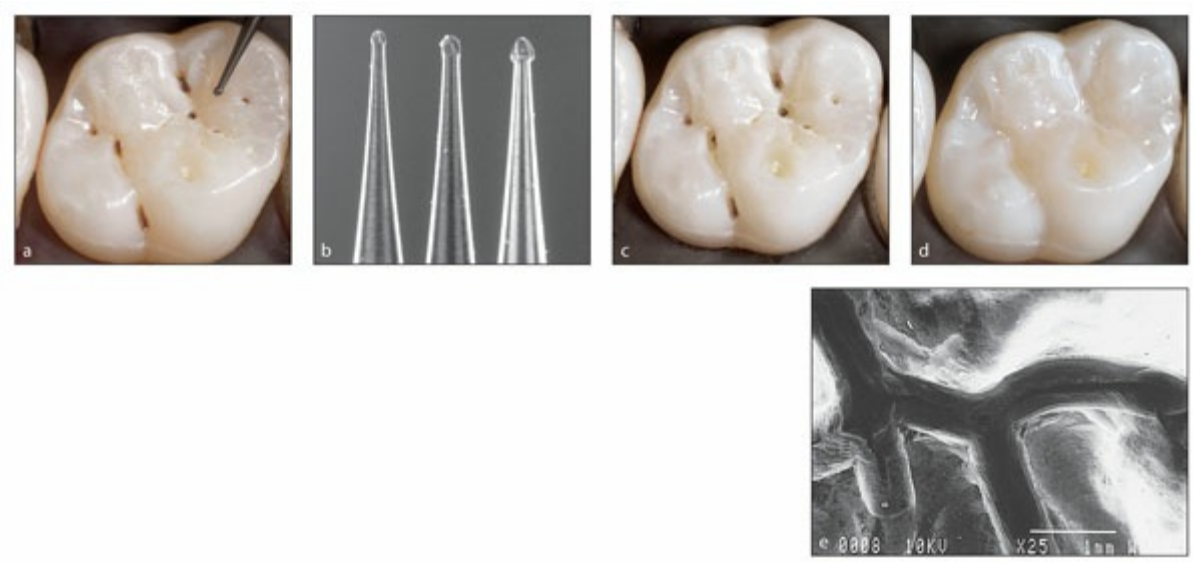

Fig 12-3 Fissures can be opened for sealing with a small round bur. *(a)* The fissure system of a maxillary first molar is shown before treatment with a no. 1/16 bur. *(b)* Any of three small round burs—nos. 1/16 bur (0.3- mm diameter), ⅛ bur (0.4-mm diameter), and ¼ bur (0.5-mm diameter)—may be used to open the fissures. *(c)* The fissures are prepared to the depth of the bur head. *(d)* The posttreatment occlusal surface shows the sealed fissures. *(e)* Scanning electron photomicrograph of fissures prepared with a small round bur.



Fig 12-4 Fissures can be opened with an air-abrasion unit (KCP FlexiJet, American Medical Technologies). *(a)* The fissure system of a mandibular molar is shown prior to air abrasion. *(b)* 50-µm alumina powder is projected into the fissure. *(c)* The fissures are shown after air abrasion. *(d)* Scanning electron photomicrograph of fissures opened with air abrasion.

Traditionally, in a Class 1 amalgam preparation, occlusal fissures, or at least those in the developmental grooves, have been included in the preparation even when areas of the fissure system have not been carious. The justification for this has been that carious dentin, although not evident visually or radiographically, may be lurking at the base of one of those fissures. There is strong evidence that carious dentin inadvertently left at the base of a sealed fissure does not progress[82–86] and that the sealing of fissures associated with occlusal amalgam restorations is an extremely effective treatment.[87–90] Therefore, the routine extension of cavity preparations through fissures not known to be carious cannot be justified. Additionally, extension of cavity preparations through grooves in which there are no

Dentlearn.ir

fissures is contraindicated.

Defective restorations and recurrent caries

Another indication for a Class 1 restoration is the replacement of a restoration that is defective beyond repair or associated with a recurrent caries lesion. A *recurrent caries lesion* is one that occurs adjacent to an existing restoration. Most restorations exhibit some leakage at their margins, although it is minimal in most cases. When the leakage becomes greater, usually because of a defective restoration or flexure of tooth structure or the restoration, plaque can form in the space between the tooth and the restoration, which can produce demineralization to form a caries lesion. There is some evidence that cleaning, etching, and sealing leaking amalgam margins with a resin sealant can prolong the life of a restoration.[91,92]

Outline form

When an occlusal restoration must be placed because of initial caries lesions, two guidelines should be applied in establishing the outline form: *(1)* carious tooth structure should be eliminated, and *(2)* margins should be placed on sound tooth structure. The enamel at the margin of the preparation should be supported by sound dentin. Any enamel that has been undermined by the removal of carious dentin should be removed. If a noncarious fissure is evident in the wall of a preparation, the preparation should not be extended solely to include the fissure; the fissure should instead be sealed after the amalgam has been placed.

If there is no cavitation in the area of the lesion, a bur such as a no. 329 or 330 is used to cut through the enamel to gain access to the carious dentin. The preparation is widened to give access to all carious dentin and to remove any unsupported enamel. The preparation should be widened only enough to obtain enamel walls supported by sound dentin.

Although the outline form should not contain sharp angles, sound tooth structure should not be removed simply to obtain wide, smooth curves in the outline form. The outline form should be smooth to facilitate the uncovering of the margins during carving of amalgam. If, after the amalgam is carved, the margins of the preparation are jagged or rough, it is difficult for the dentist to know if this is because the enamel margin is rough or because amalgam is extending past the margins onto the surface of the tooth (overextended amalgam or amalgam flash).

When a defective restoration or a restoration associated with a recurrent caries lesion is to be replaced, the outline form will be determined by several factors.

Dentlearn.ir

First, the outline form of the old restoration will have a major influence. Also, the outline form may have to be extended because of additional pathosis. Finally, the resistance form for the tooth structure or restoration may have to be improved, and that will affect the outline form.

Resistance and retention form

To provide retention form for the amalgam, opposing walls of Class 1 occlusal restorations should be parallel to each other or should converge slightly occlusally. Enamel rods in most areas of the occlusal surface are directed roughly parallel to the long axis of the tooth and are approximately perpendicular to the tooth surface,[93] a factor that should be considered when the angulation of the margin of the amalgam preparation is designed. To enhance their ability to resist fracture, enamel margins should be prepared at a right angle or slightly obtuse angle (90 degrees or greater), as enamel margins of less than 90 degrees are more subject to fracture, especially in function (Fig 12-5). Clinical research has shown that clinical survival of amalgam restorations is inversely related to the degree of unsupported enamel.[94]

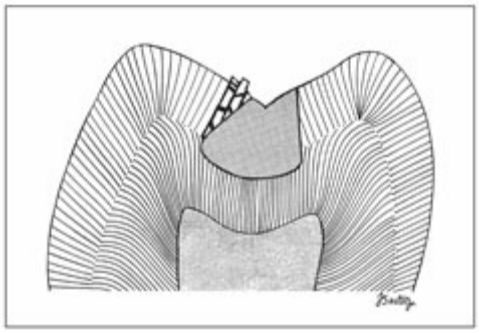

Fig 12-5 An acute cavosurface margin of enamel has the potential for fracture; a 90-degree enamel margin on the occlusal surface will withstand occlusion.

For resistance form in the amalgam restoration, amalgam margins should be approximately 90 degrees. Although many amalgam restorations will have amalgam margins that are significantly less than 90 degrees on the occlusal surface, very acute amalgam margins are much more subject to fracture (Fig 12-6). Marginal fracture will usually cause marginal gaps, or ditches, between the amalgam and the enamel.

Dentlearn.ir

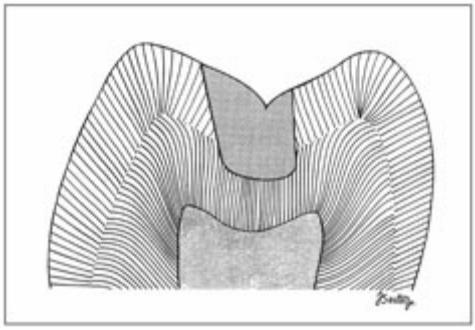

Fig 12-6 The left margin exhibits an acute "fin" of amalgam, which has a greater propensity for fracture, depending on the load applied to it during mastication. The right marginal configuration allows nearly a 90-degree angle for amalgam, imparting greater strength.

If the faciolingual width of the preparation exceeds one-third of the distance between the tips of the facial and lingual cusps (intercuspal distance), the remaining cusps themselves should be carefully evaluated. Even in narrower preparations, cusps should be evaluated for cracks that could lead to fracture, and the functional loading to which they will be exposed should be assessed. If a cusp is too weak to withstand function (Fig 12-7), it should be reduced for coverage with amalgam or attached in some way to the amalgam to provide cuspal reinforcement (described in the section on complex amalgam restorations).



Fig 12-7*(a)* The mesio-occlusodistal preparation in the premolar, after removal of a defective restoration, is greater than one-third the intercuspal distance; therefore, the cusps ideally should be protected by reduction and coverage with a restoration, or they should be cross-splinted (see Fig 12-39). *(b)* The mesio-occlusofacial preparation in the molar leaves facial cusps too thin to resist occlusal loading; they should be reduced and protected with a cuspal-coverage restoration. *(c)* The lingual cusp of the maxillary premolar, which was not protected or reinforced during restoration, has fractured.

It is generally accepted that occlusal amalgam restorations should have an occlusogingival thickness of at least 1.5 mm, and preferably 2.0 mm, to resist fracture during function (resistance form for the restoration). When carious dentin and the overlying enamel are removed, the preparation will be at least that depth and usually deeper.

Figure 12-8a shows a diagram of a cross section of the crown of a posterior tooth

Dentlearn.ir

with carious dentin at the base of the fissure. Figure 12-8b shows a cross section of the amalgam restoration that is indicated because of that caries lesion.

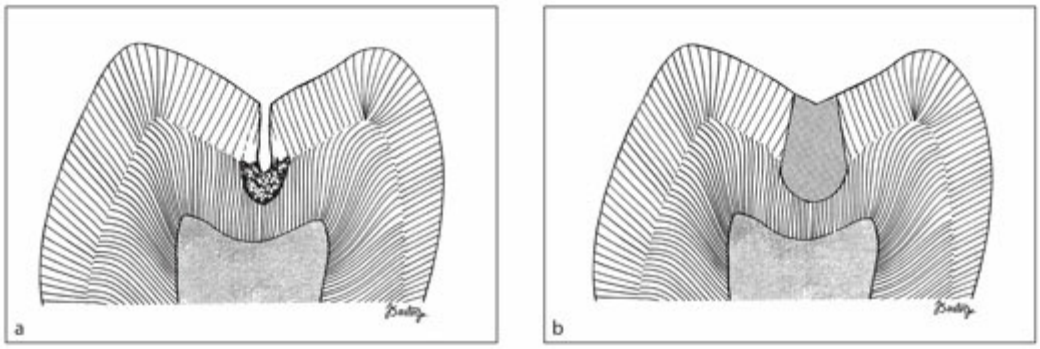

Fig 12-8*(a)* A fissure caries lesion in this tooth involves demineralization of the enamel at the depth of the fissure and advance of the lesion into dentin. *(b)* Tooth preparation involves removal of the carious dentin and of the enamel not supported by sound dentin. Only the diseased dentin is removed; additional dentin is not removed simply to create a flat pulpal floor for the preparation.

Figure 12-9 shows the outline form of several occlusal amalgam restorations; the outline form was determined by the extent of the demineralized dentin at the base of the fissures. Again, fissures not known to be carious, in a surface receiving an amalgam restoration due to fissure caries, should be sealed with a resin fissure sealant.

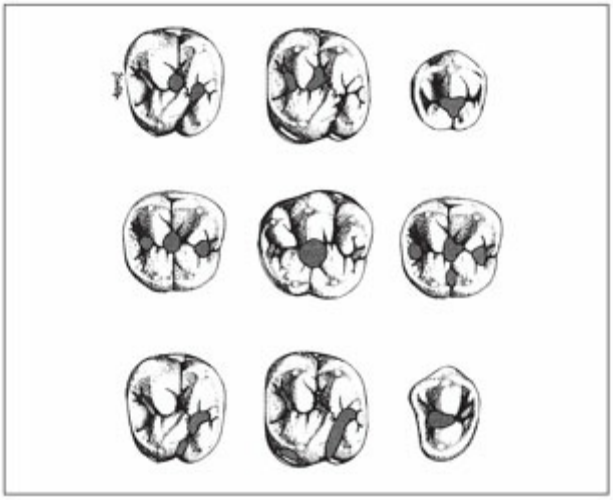

Fig 12-9 Outline form of various Class 1 preparations. The extent of carious demineralization is the determinant of outline form, so outline form will vary in every situation involving caries. Fissures not known to be carious should be sealed with a resin fissure sealant; fissures may be opened with a small bur to a depth of approximately 0.4 mm prior to sealing to ensure sound enamel for bonding.

If an occlusal caries lesion encroaches on the enamel of the proximal surface so that, when the carious dentin is removed, the proximal enamel has no dentinal support, consideration should be given to converting the Class 1 preparation to a

Dentlearn.ir

Class 2 preparation. An important part of this consideration should be the determination of the forces to which the marginal ridge will be exposed. If there is direct occlusal contact between the opposing tooth and the weakened marginal ridge, the marginal ridge should be removed and replaced with amalgam.

Class 2 Preparation

Indications

An initial Class 2 restoration is usually placed because a caries lesion is present in a proximal surface of a molar or premolar. Proximal caries lesions can sometimes be detected visually during a clinical examination, but they are usually detected with bitewing radiographs. The depth of the penetration of demineralization in enamel and dentin is actually greater than it appears to be in a bitewing radiograph. A caries lesion that appears radiographically to have penetrated about two-thirds of the way through the proximal enamel has actually penetrated the dentinoenamel junction (DEJ). However, even if the lesion has slightly penetrated the DEJ, the tooth still has the potential for remineralization if the etiologic conditions are changed[95–97] (see chapter 5). Each patient must be individually evaluated for improved oral hygiene, alteration of diet, and reduction in cariogenic bacteria before the decision is made to surgically remove a minimally deep caries lesion. In most cases, a restorative procedure should not be undertaken to treat a proximal caries lesion unless there is radiographic evidence of at least slight penetration of the lesion into dentin toward the pulp.[96]

Outline form

As with Class 1 restorations, Class 2 restorations that leave as much sound tooth structure as possible will contribute to resistance to fracture of the tooth. Tooth preparation necessitated by a caries lesion on a proximal surface should, when possible, avoid extension of the occlusal outline more than is necessary to allow access to the proximal lesion, to remove demineralized enamel and dentin, and to remove enamel not supported by sound dentin. If an occlusal caries lesion is present, it should be treated with a separate occlusal restoration. If the preparation necessitated by the occlusal caries lesion is in close proximity to the occlusal outline of the proximal preparation so that there is minimal or no sound tooth structure separating d. As when Class 1

Dentlearn.ir

occlusal restorations are placed, fissures not known to be carious but believed to be susceptible to caries should be sealed with a resin fissure sealant.[90] Fissures that contact the outline of a Class 1 or Class 2 preparation should be sealed. Retention form for the proximal restoration should be attained within the proximal preparation; the preparation should not be extended further into a sound occlusal surface to provide retention of the proximal restoration, because this will weaken the tooth's resistance to fracture.

Access to the proximal caries lesion is usually made by preparation through the marginal ridge (Fig 12-10). The proximal preparation begins with the creation of a slot, cut with a small bur in the center (mesiodistally) of the crest of the marginal ridge (Fig 12-10a) and occlusal to the proximal surface caries lesion (usually located faciolingually in the center of the interproximal contact area). The slot is deepened gingivally until the bur "falls" into the soft carious dentin, which has little resistance to the advance of the bur. The preparation is widened facially and lingually to eliminate all demineralized tooth structure at the DEJ and to remove enamel that is not supported by sound dentin. Demineralized enamel should usually be removed as well. However, if demineralization is superficial (less than half-way through the enamel) and there is evidence that the patient will reduce his or her caries risk status, consideration should be given to stopping the extension of the preparation short of removing some superficial demineralized enamel. After the amalgam restoration has been placed, the demineralized enamel can be treated with fluoride to enhance remineralization, or it can be acid etched and coated with light-cured resin for at least short-term protection from further demineralization.[98] Alternatively, a low-viscosity resin infiltrant (eg, Icon, DMG) can be applied to the demineralized enamel following acid etching to inhibit further demineralization.[99]

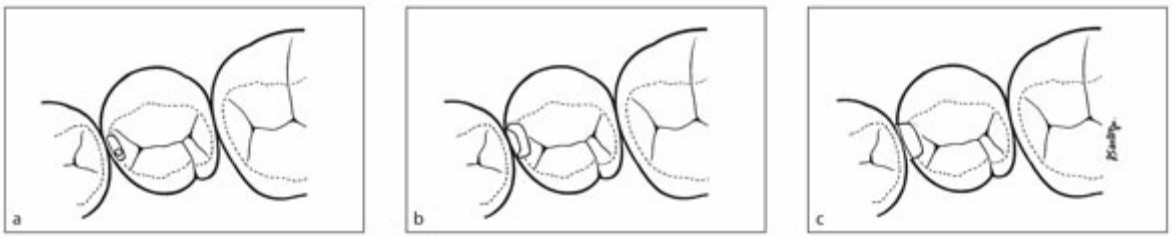

Fig 12-10*(a)* For a Class 2 preparation to treat an initial proximal surface caries lesion, an initial cut is made through the marginal ridge with a narrow bur to penetrate to carious dentin; then the slot is widened faciolingually. *(b)* The mesial and distal aspects of the proximal enamel plate are thinned to facilitate its fracture and removal. *(c)* The final preparation will be determined after removal of all carious tooth structure and removal of fragile enamel (retention would be by amalgam bonding or the addition of retention grooves).

The Class 2 restoration necessitated only because of a proximal caries lesion and

Dentlearn.ir

having an occlusal outline limited to the marginal ridge area will be referred to in this chapter and others as a *slot restoration*. If it involves the distal surface with access from the occlusal surface, it will be called a *disto-occlusal slot restoration* (Fig 12-11).



Fig 12-11 Preparations for proximal slot restorations. Note significant retention grooves. Such mechanical retention should be used when the restoration will not be bonded.

When preparing the tooth for the proximal slot restoration, a shell of enamel should be left between the preparation and the adjacent tooth (Figs 12-10b and 12-12). This will prevent accidental nicking, scarring, or other damage to the adjacent tooth. One study[100] found that proximal surfaces of adjacent teeth were damaged during Class 2 preparation 69% of the time and that these damaged surfaces were almost three times as likely to become carious as were undamaged surfaces. Special care to avoid damage to the adjacent tooth is warranted. Any nicking or scarring of an adjacent tooth should be polished away before the restoration is placed.

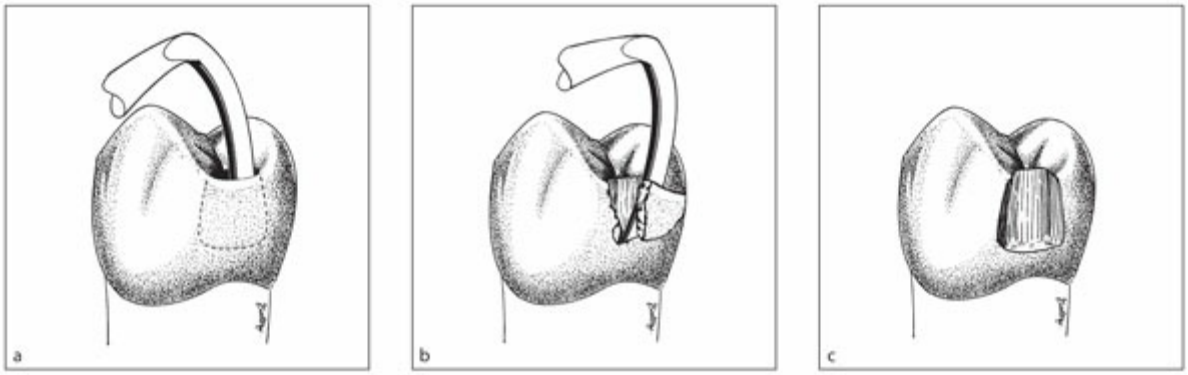

Fig 12-12*(a)* The plate of proximal enamel should be fractured with a hand instrument to prevent damage to the adjacent tooth by a bur. The instrument is placed in the slot. *(b)* The instrument is rotated to fracture the plate. *(c)* The fractured margins have been planed with a gingival margin trimmer or hatchet.

After the removal of carious tooth structure and fragile enamel, the proximal surface margins of a Class 2 amalgam preparation will not usually be in contact with the adjacent tooth (ed and undermined

Dentlearn.ir

enamel has been removed and a margin remains in contact with the adjacent tooth, consideration should be given to allowing contact to remain (Fig 12-13).



Fig 12-13 Class 2 proximal slot restoration showing the lingual cavosurface margin remaining in contact with the adjacent tooth after removal of all carious tooth structure and unsupported enamel.

During the removal of carious dentin, the demineralized dentin in the periphery of the preparation (at or near the DEJ) should be removed and the outline form extended to ensure that the enamel at the margins of the preparation is supported by sound dentin. Carious dentin should be removed with the largest round bur that will fit into the area. After the periphery of the preparation is clear of demineralized tooth structure, the carious dentin near the pulp should be removed. The bur should be rotated very slowly in a low-speed handpiece; the rotation should be so slow that the individual blades of the bur can be seen as it rotates. The blades of the slowly rotating bur are like multiple spoon excavator blades, but the depth that a blade can penetrate into the carious dentin is limited by the edge angle of the bur and by the depth of each bur blade toward the center of the bur, so the bur will remove only a limited depth of carious dentin during each rotation. During removal of deep carious dentin, this procedure is less likely to result in a pulpal exposure than the use of a spoon excavator.

Resistance and retention form

After the shape of the preparation is roughed out with a bur, hand instruments (eg, a gingival margin trimmer) may be used to fracture away the shell of enamel; to shape the facial, lingual, and gingival walls and margins; and to scrape away any fragile enamel from the margins (Fig 12-14). The facial and lingual walls of a Class 2 slot preparation should converge slightly toward the occlusal surface to provide retention form for the restoration (Fig 12-15).

Dentlearn.ir

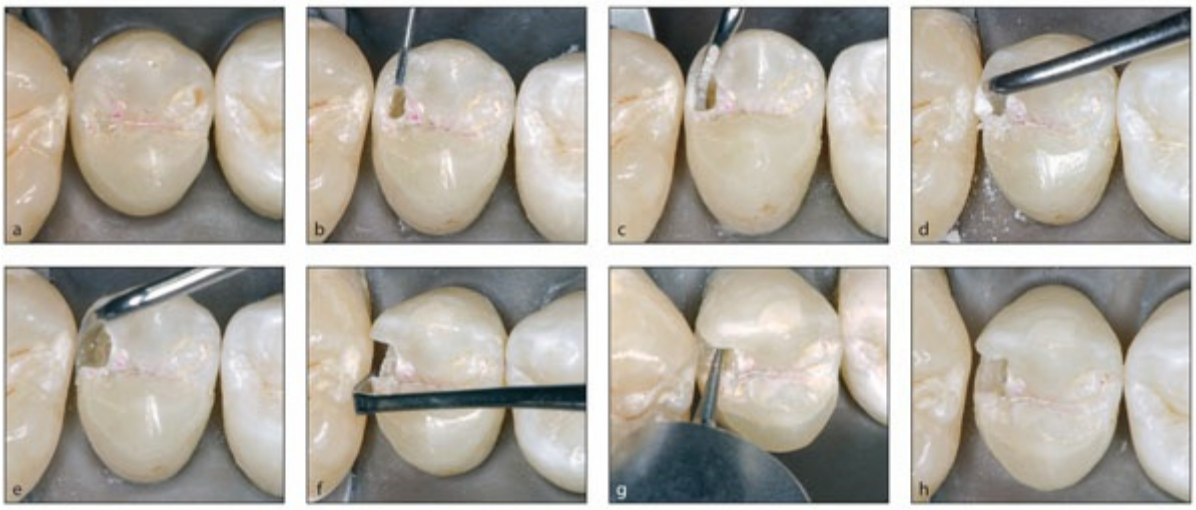

Fig 12-14*(a)* A disto-occlusal slot amalgam preparation will be made because an initial caries lesion is present. *(b)* A small bur is used to cut a slot, beginning at the crest of the marginal ridge and extending gingivally to "fall" into carious tooth structure. A thin plate of enamel separates the bur from the adjacent tooth to prevent damage to the adjacent tooth. *(c)* A gingival margin trimmer is placed into the slot created by the bur and rotated to apply pressure to the thin plate of proximal enamel. *(d)* The thin plate is fractured. *(e)* The walls and margins are planed with the margin trimmer to smooth them and to eliminate any remaining fragile enamel. *(f)* When there is some separation of the proximal margin from the adjacent tooth, a thin carver, such as this interproximal carver, may be used to carve and burnish the amalgam. If a portion of a proximal margin is in contact with the adjacent tooth, the carver may be used to carve and burnish the amalgam occlusal and gingival to the area of contact. *(g)* Retention grooves are placed with a no. ⅛ or ¼ bur. *(h)* The preparation is completed.

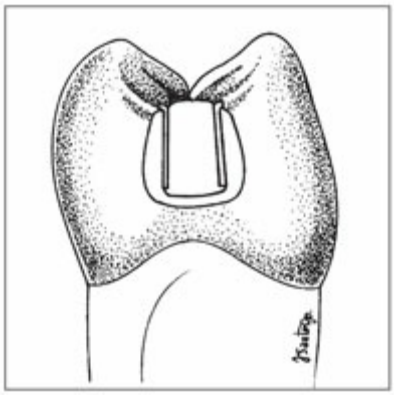

Fig 12-15 The proximal slot preparation, or the proximal box of a Class 2 preparation, should have walls that meet the proximal surface of the tooth at 90 degrees and converge occlusally to provide resistance and retention form.

To provide resistance form for the Class 2 amalgam restoration, the proximal preparation should have a mesiodistal dimension of about 1.5 mm or more. If there is sound dentin supporting occlusal enamel in the fossa adjacent to the marginal ridge, that dentin and enamel should be left intact. If the caries lesion extends from the proximal DEJ d should be removed

Dentlearn.ir

completely, especially in the areas near the DEJ, and sound dentin should be left in place.

The gingival floor of the proximal preparation may be flat and approximately perpendicular to the long axis of the tooth, or it may be curved and/or slanted faciolingually, as determined by the extent and configuration of the caries lesion that necessitated the restoration. The location of the gingival floor, therefore, should be determined by the gingival extent of the carious lesion. The gingival wall, like the facial and lingual walls of the proximal preparation, should form an angle of approximately 90 degrees with the surface of the tooth. This provides strength to both the amalgam and the enamel and prevents enamel not supported by sound dentin from being left at the margins of the restoration.

Convergence toward the occlusal surface of the facial and lingual walls of the proximal slot preparation gives retention form to the restoration to keep it from dislodging occlusally. Although with initial proximal surface caries lesions it is not often necessary to extend the Class 2 preparation into occlusal grooves, the operator will frequently need to replace an existing restoration that was prepared with an occlusal extension. If the restoration is extended into occlusal grooves, this extension will provide resistance to displacement of the restoration proximally (ie, toward the adjacent tooth). To provide enough resistance, however, the extension into the occlusal surface must have a faciolingual dimension of at least one-fourth the distance between the facial and lingual cusp tips[101] (*intercuspal distance*), and the facial and lingual margins of the occlusal extension must be approximately parallel to each other in a mesiodistal direction (Fig 12-16a).

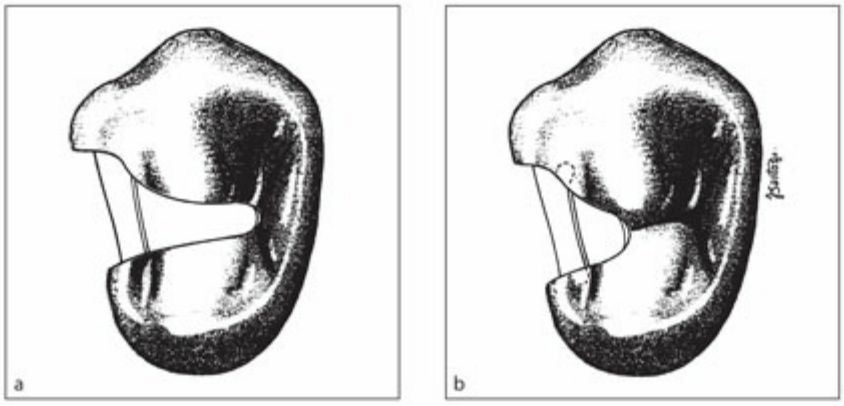

Fig 12-16*(a)* Although extension of a Class 2 preparation into occlusal grooves is not usually necessitated by carious tooth structure, if such an extension is already present from a previous restoration of the tooth, it will provide some resistance form for the proximal portion. Note the slight bevel of the axiopulpal line angle as part of the resistance form. *(b)* An extension without parallel cavosurface margins, however, will not provide the resistance form needed to prevent displacement of the proximal amalgam during mastication, so retention grooves *(dotted lines)* should be added.

Dentlearn.ir

Undercuts

If the extension into the occlusal surface is narrower, if there is no extension into the occlusal surface, as with the proximal slot restoration, or if no amalgam bonding system is to be used, *retentive undercuts* (retention grooves or points) must be cut into the dentin of the facial and lingual walls of the proximal box (Fig 12-16b). Use of a no. ¼ (ISO 005) round bur, with a head diameter of 0.5 mm,[101–103] or a no. ⅛ (ISO 004) round bur, with a head diameter of 0.4 mm, is recommended for preparation of retention grooves and points for Class 2 amalgam restorations (see Fig 12-14g). For a proximal slot restoration, retentive undercuts should be very distinct (at least 0.5 mm deep) and should oppose each other to form a dovetail effect in the dentin. Long grooves, extending from the gingival floor to the occlusal surface, are recommended for a proximal slot restoration[103,104] (Fig 12-17a). When no amalgam bonding system is used, if the occlusal extension is narrow, short retention grooves or retentive points should be prepared in the dentin of the facial and lingual walls to supplement the resistance form provided by the occlusal extension[102] (Fig 12-17b). If there is a bulky extension of amalgam into the occlusal surface of the tooth, retentive undercuts should not be necessary[101] (Fig 12-17c). For the preparation of any retentive undercuts with a bur, it is advisable to use a handpiece at low speed, without water spray, and to use magnification to enable visualization, because the location and direction of the undercuts are critical to the success of the restoration.



Fig 12-17*(a)* In a proximal slot or proximal box–only preparation, retention grooves should be long and very distinct. *(b)* In preparations with narrow occlusal extensions, short (0.5- to 1.0-mm) retention grooves or points are placed in facial and lingual walls just gingival to the occlusal DEJ. *(c)* When the occlusal extension is wide (1.5 mm or more faciolingually) and has parallel walls, retention points or grooves are not necessary.

Retentive undercuts in the dentin of the facial and lingual walls should be completely in dentin and not at the proximal DEJ; this obviates the removal of the dentinal support for the proximal enamel adjacent to the restoration. The undercuts

Dentlearn.ir

should not, however, be placed so far away from the DEJ that the pulp chamber could be penetrated. A good rule is to place a retentive undercut so that there is approximately 0.25 to 0.5 mm of dentin between the groove and the DEJ and so that the groove is approximately 0.5 mm deep and 0.5 mm wide. Again, the 0.5-mm diameter of the no. ¼ round bur, or the 0.4-mm diameter of the no. ⅛ bur, is ideal as a gauge of dimension. So that retentive undercuts do not penetrate through the dentin to the DEJ when they are placed in the facial and lingual walls, they should be cut parallel faciolingually to the DEJ and to the external surface of the tooth (Fig 12-18).

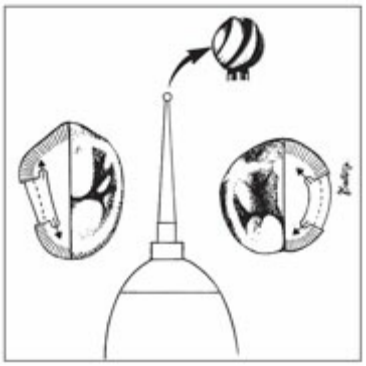

Fig 12-18 Location and direction of retentive undercuts (retention grooves) for the proximal portion of a Class 2 restoration. The illustrated grooves are approximately 0.5 mm wide and 0.5 mm deep (no. ¼ bur head is shown) and are directed approxi-mately parallel to the DEJ (and the external surface of the tooth). *(left)* For a fairly flat surface, such as the proximal surface of a maxillary premolar, the grooves are directed almost in the facial and lingual directions. *(right)* For a convex proximal surface, such as in a mandibular premolar, their direction is considerably vectored.

When retentive undercuts are necessary, they must be actual undercuts in the facial and lingual dentin that oppose each other (see Fig 12-18). This is especially important in proximal slot restorations if amalgam bonding is not used, because the undercuts are the only feature that will prevent dislodgment of the restoration proximally. In the preparation with a deep proximal box, the retention grooves should be in the proximal walls just inside the DEJ and not in the corners of the box (Fig 12-19); this is to reduce the risk of pulp exposure. Without correctly located, distinct retention grooves, a proximal slot restoration is more likely to become dislodged.

Dentlearn.ir

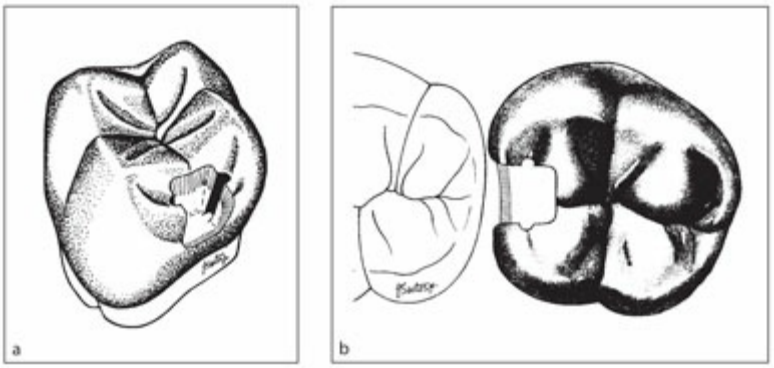

Fig 12-19 When, because of the axial depth of the carious dentin at the occlusal DEJ, the axial wall in a Class 2 preparation must be deeper pulpally than approximately 1 mm inside the DEJ, retention grooves (or points) should be placed so that they are just inside the proximal DEJ, not at the line angles of the deep preparation. *(a)* Proximal view of an axially deep Class 2 preparation showing retention grooves in dentin near the proximal DEJ and extending occlusally through the occlusal enamel; *(b)* occlusal view.

When well designed, the proximal slot restoration can last indefinitely. Figure 12-20 shows a Class 2 slot amalgam restoration that had been in function for more than 58 years.



Fig 12-20 The mesio-occlusal slot restoration in the maxil-lary first molar, placed by the late Dr Miles Markley of Denver, Colorado, had been in service for more than 58 years when this photograph was taken.

Mechanical retention

If a proximal box or slot is so wide that retentive undercuts will not oppose each other (Fig 12-21a), another type of retention and resistance method, such as amalgam bonding or a self-threading pin, placed horizontally or vertically, should be used (Fig 12-21b). Amalgam bonding and the use of pins are discussed later in this chapter.

Dentlearn.ir

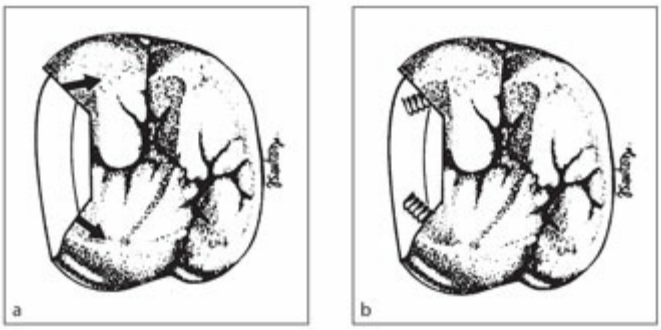

Fig 12-21 *(a)* Undercuts (retention grooves) should not be placed for a proximal box so wide that those undercuts, if placed parallel to the adjacent DEJ, would not oppose each other to provide needed undercut retention. *(b)* Instead, other types of resistance and retention features, such as these horizontal self-threading pins, should be employed.

Because the outline form of Class 2 amalgam restorations is always determined by the pathologic problem being treated, there are an infinite number of variations in occlusal outline form. Figure 12-22 illustrates the outline form of some typical Class 2 restorations that would be placed to treat initial caries lesions.

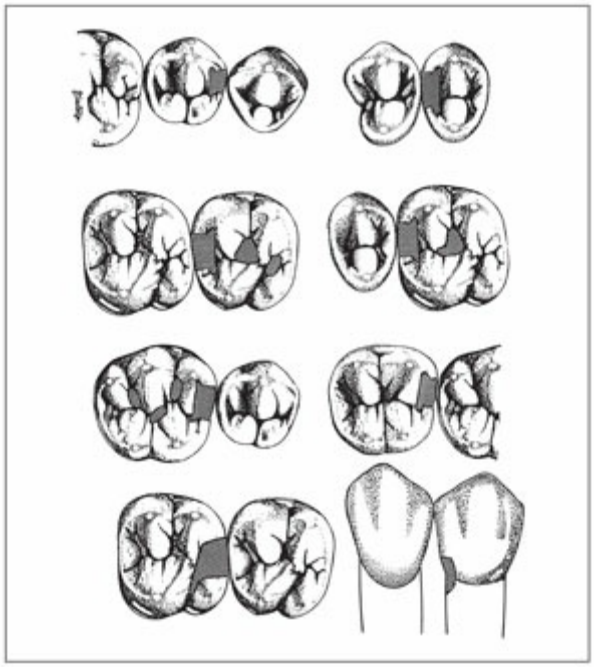

Fig 12-22 Typical outline forms of Class 2 restorations placed to treat initial caries lesions. Because outline form is determined by the pathosis present and the morphology and position of the tooth, there are an infinite number of variations. The bottom right-hand restoration represents a facial slot or keyhole restoration to treat root caries or caries at the CEJ.

Facial and lingual access

Most Class 2 amalgam restorations have occlusal access, as already discussed. If a proximal caries lesion is at or apical to the cementoenamel junction (CEJ), however,

Dentlearn.ir

it is often more conservative to use facial, and occasionally lingual, access.[105] The preparation for a Class 2 amalgam restoration with facial or lingual access, sometimes referred to as a *keyhole preparation* or a *facial* or *lingual slot preparation*, is similar to a slot preparation with occlusal access. The entire preparation is apical to the proximal contact. The location and configuration of the carious tooth structure and the access preparation determine the outline form of the keyhole preparation (see Fig 12-22, bottom right). Its margins, which are at least partly on cementum or dentin, should provide for cavosurface angles of approximately 90 degrees. Either amalgam bonding or groove retention, similar to that recommended for a proximal slot preparation with occlusal access, is indicated. Groove retention can usually be placed with a no. ¼ or ⅛ bur in the dentin of the occlusal and gingival walls; occasionally, grooves must be placed with a hand instrument, such as a gingival margin trimmer.

Replacement of restorations with occlusal extensions

Patients commonly will have existing Class 2 amalgam restorations that have extensions of the preparation through occlusal fissures and even through nonfissured grooves. Although this preparation outline form should not be advocated, existing restorations of this type will need to be replaced from time to time. Therefore, some design concepts to promote their longevity must be discussed. First, the narrower (faciolingually) the extension through the occlusal surface, the less marginal breakdown will occur[65,68] (Fig 12-23). Second, the junction of the proximal portion and the occlusal extension of the Class 2 amalgam preparation must have adequate depth (1.5 to 2.0 mm). The occlusal outline form at the junction of the proximal and occlusal components should not be sharp or jagged, but no more than a very small amount of sound cuspal enamel should be sacrificed to make the junction slightly rounded instead of sharp. It is generally accepted that, if there is an axiopulpal line angle at minimal occlusal depth, it should not be sharp; if there is such a sharp line angle, it should be rounded in order to reduce the concentration of stresses in that portion of the restoration.

Dentlearn.ir

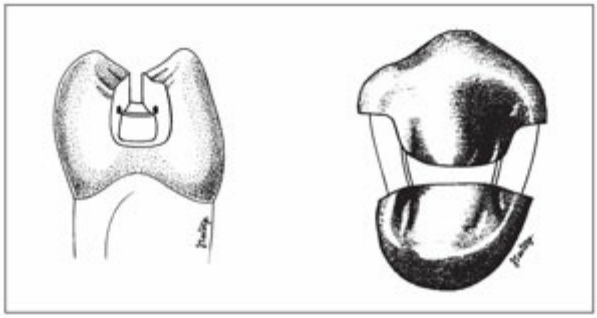

Fig 12-23 When extension through occlusal fissures or grooves cannot be avoided, such as when an old, defective amalgam restoration is being replaced, the faciolingual width of the occlusal portion of the preparation should be kept as narrow as possible to maintain tooth strength. *(left)* Proximal view; *(right)* occlusal view of mesio-occlusodistal preparation.

Complex Preparations

Historically, the term *complex amalgam restoration* referred to one that involved three or more surfaces of a tooth. The term has been redefined in recent years[61] to refer to an amalgam restoration that replaces one or more cusps.

When a cuspal-coverage restoration is indicated, a gold alloy casting is considered by many to be the restoration of choice. Gold has wear characteristics similar to those of enamel and has the ability to maintain a stable occlusion. Newer ceramic materials with high strength and wear resistance also represent viable options for these restorations. However, for various reasons, an indirect material cannot always be chosen as the definitive restoration. In these situations, amalgam is an excellent alternative restorative material.

The efficacy of the amalgam cuspal-coverage restoration has been shown in both laboratory and clinical studies.[61,62,106,107] The key to the successful placement of cuspal-coverage restorations is a thorough understanding of the underlying engineering principles. Preparations for amalgam restorations have traditionally been designed to provide adequate retention form. *Retention* has been defined as prevention of dislodgment of the restoration along the path of insertion (with tensile forces). *Resistance* is defined as prevention of dislodgment or fracture by oblique or compressive forces. Although retention form is important in the complex amalgam restoration, more emphasis should be placed on the resistance of both the restoration and the remaining tooth structure. Retention and resistance form can be obtained through the use of metal threaded pins, nonpin mechanical features, and amalgam bonding, all of which will be described.

Dentlearn.ir

Cuspal-coverage preparations

Often, individuals seek treatment because of a fractured cusp or cusps in posterior teeth. If the treatment option agreed upon for the tooth is a complex amalgam restoration, the tooth preparation will usually include removal of any existing restoration, removal of any carious tooth structure and fragile enamel and/or dentin, and preparation of margins to provide a cavosurface angle of approximately 90 degrees in all areas. In addition, weak cusps that have not fractured should be reduced for coverage and protection with amalgam.

The thickness of amalgam needed for cuspal protection will vary depending on the functional load to which the cusp will be exposed. A good guideline for amalgam thickness in centric holding cusps (stamp or functional cusps) of molars and premolars is 2.5 mm. In a facial cusp of a maxillary premolar, on those occasions when there is little or no function on the facial cusp, a reduced thickness of amalgam is acceptable to allow a maximum amount of facial enamel to remain for esthetics (Fig 12-24).



Fig 12-24*(a)* Because of a diagnosis of incomplete tooth fracture, the maxillary premolar has been prepared for a complex amalgam restoration. *(b)* The tooth has been restored with a complex amalgam restoration that protects the entire occlusal surface. *(c)* The occlusal height of the mesial aspect of the nonfunctioning facial cusp was only reduced 1.5 mm to preserve facial enamel for esthetics.

When cusps are reduced for coverage, the occlusal tooth structure should be reduced anatomically to provide for an adequate and consistent occlusal amalgam thickness. To facilitate consistent reduction, depth cuts are recommended. Figure 12-25 illustrates the use of depth cuts to ensure consistent reduction of occlusal tooth structure for coverage. Figure 12-26 shows a clinical case in which depth cuts provided consistent reduction.

Dentlearn.ir

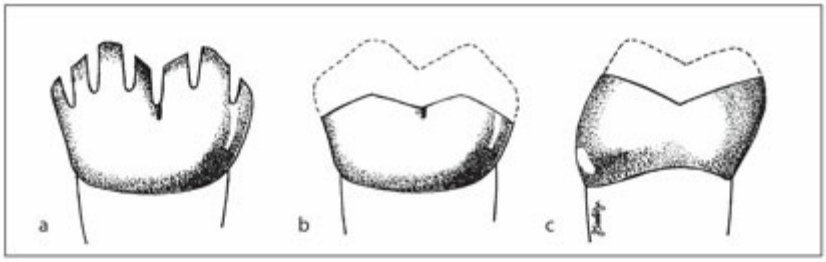

Fig 12-25 Depth cuts are used to provide for even reduction of occlusal tooth structure of a mandibular molar and consistent thickness of amalgam. *(a)* Depth cuts 2.5 mm deep; *(b)* cuspal reduction viewed from the facial aspect; *(c)* cuspal reduction viewed from the mesial aspect.



Fig 12-26 Reduction of weak cusps of a mandibular molar for coverage. *(a)* An instrument is placed so that it touches cusp tips of the adjacent teeth. A note can be made of the position of the cusps to be reduced so that they can be rebuilt in amalgam and carved to approximately the correct height before the rubber dam is removed. *(b)* Half the 5.5-mm length of a no. 169L bur head is used to make depth cuts approximately 2.5 mm deep in the cusps. *(c)* The depth cuts are completed. *(d)* The head of the handpiece is rotated so that the no. 169L bur can be used to reduce the cuspal structure between the depth cuts. *(e)* Facial cusps are reduced. *(f)* All cusps are reduced, and resistance features are placed. *(g)* Amalgam is placed, carved, and smoothed. The instrument is placed as it was prior to cusp reduction to ensure that cuspal height is similar to preoperative cuspal height. *(h)* Completed restoration. *(i)* Polished restoration.

The length of the head of the bur that is used for depth cuts must be known. Because head lengths vary from manufacturer to manufacturer, and even among burs of a single manufacturer, it is good practice to measure the length of a bur head prior

Dentlearn.ir

to preparation of depth cuts (Fig 12-27). A periodontal probe should be available for measuring the length of bur heads.



Fig 12-27*(a)* A Boley gauge is used to measure a no. 56 bur head (4 mm in this case). *(b)* A Boley gauge is used to measure a no. 330 bur head (2 mm in this case). The periodontal probe is another handy instrument for measuring bur head length.

Consistent reduction of cusps provides anatomical reduction rather than flat reduction. Anatomical reduction imparts adequate strength to the amalgam while preserving and protecting as much natural tooth structure as possible. Some operators reduce cusps to a flat surface perpendicular to the long axis of the tooth; no scientific justification for this practice can be found in the literature.

A timesaver in practice is to take note of cuspal height and cusp tip location or even to make a drawing or photograph prior to cuspal reduction so that cusps may be built and carved back to their original height prior to removal of the rubber dam (Fig 12-28; see also Figs 12-26a and 12-26g).

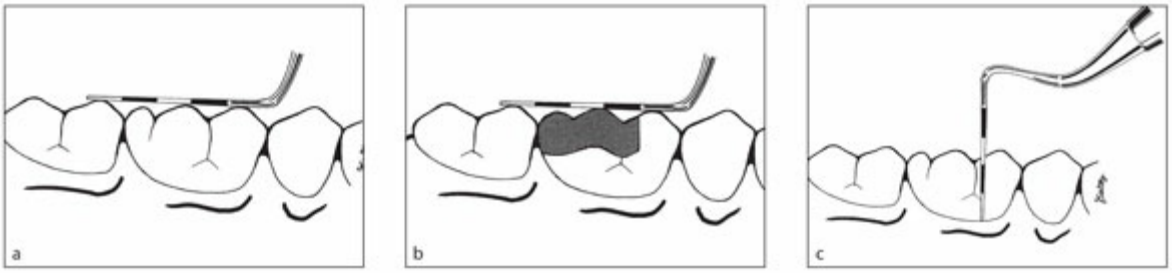

Fig 12-28 Preoperative registration of the height of cusps to be reduced and restored with amalgam. *(a)* The midfacial and distofacial cusps are to be reduced for coverage. A periodontal probe is placed along the facial cusp tips of the tooth to be restored and the adjacent teeth, and the relationships of the cusp tips to the probe are remembered or drawn. *(b)* The amalgam cusp tips of the carved restoration are seen to have a similar relationship to the probe. *(c)* If there are no adjacent teeth or cusp tips to guide the height of amalgam cusp tips, the distance from a landmark (such as the cervical line) may be measured with a periodontal probe.

Resistance and retention methods

For amalgam restorations that do not replace cusps, or at least large portions of cusps, the walls of the preparation provide retention and resistance form. Retention form is provided by convergent walls and undercuts placed in dentin. When a large

Dentlearn.ir

amount of cuspal tooth structure is lost or removed, the walls, or portions of them, which provide resistance and retention for the amalgam, are lost. For this reason, it is necessary to add features or adhesives to the preparation that will provide adequate resistance and retention for the restoration. Several methods of obtaining resistance and retention for complex amalgam restorations are discussed.

Pins

Although pins were first described in the 19th century,[108,109] Markley[110–112] popularized the concept of cemented stainless steel pins. Later, stainless steel pins,

dentin,[114] were developed. Laboratory studies have since investigated the properties of these three types of pins (cemented, friction-locked, and self-threading), and because of these studies, the self-threading pins are the primary pins in current use (Fig 12-29). In a study by Dilts et al,[115] self-threading pins were found to be more retentive in dentin than cemented or friction-locked pins. The authors also recommended a depth in dentin of 2 to 3 mm as optimum for self-threading pins. Moffa et al[116] found that a pin length of approximately 2 mm into amalgam provides optimum retention. The relationship between retention and the diameter of the pin has also been investigated. As would be expected, larger-diameter pins are more retentive.[115–117]

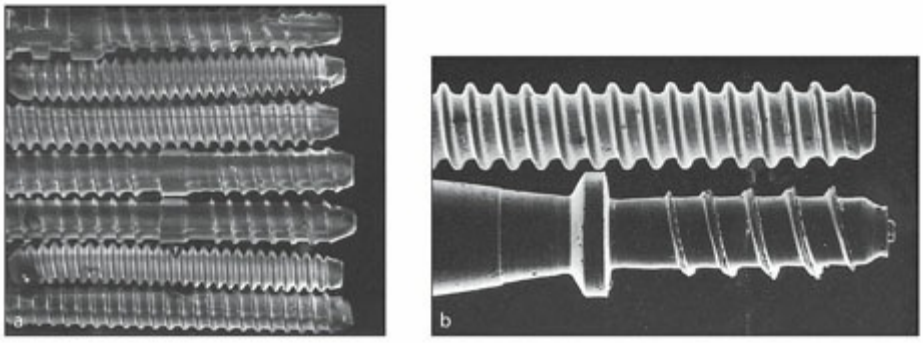

Fig 12-29 Scanning electron micrographs of self-threading pins. (Courtesy of John O. Burgess, University of Alabama at Birmingham School of Dentistry.) *(a) (top to bottom)* PPS (Brasseler; titanium alloy), Denlok (Denovo; stainless steel), Filpin (Ivoclar Vivadent; titanium), TMS (Thread Mate System) Link Plus (Coltène/Whaledent; titanium alloy), TMS Link Plus (Coltène/Whaledent; stainless steel), TMS Minim (Coltène/Whaledent; stainless steel), Stabilok (Fairfax Dental; stainless steel). *(b) (top)* TMS Minim pin; *(bottom)* Max pin (with threads more widely separated to allow for greater thickness of dentinal threads).

Self-threading pins have been manufactured in a variety of configurations. Some

Dentlearn.ir

are self-shearing and some have heads. Figure 12-29a shows several pins from various manufacturers. In one study of self-threading pins,[118] pins manufactured by Coltène/Whaledent demonstrated superior resistance and retention. Although several manufacturers have discontinued the production of retentive pins, those pins produced by Coltène/Whaledent are still available.

Currently marketed pins have the metal threads separated to provide thicker,

threads that shear and not the metal threads. The pin design with wider dentinal threads is retained well in dentin (Fig 12-29b). Another feature of many of the currently available pins is a shoulder stop. The purpose of this feature is to prevent

Max pin (Coltène/Whaledent) has an effective shoulder stop incorporated into its design. A shoulder is a part of the design of the Link Plus pin (Coltène/Whaledent), but its diameter is similar to that of the threads, so it does not provide an effective stop.[119] Although a definite shoulder stop is theoretically beneficial, there is no evidence of problems associated with pins that lack effective shoulder stops.

Minikin sizes are shown in Fig 12-30; a smaller size (Minuta, 0.0135-mm diameter

practical use for it. The gold-plated stainless steel TMS Regular and Minim pins (see Figs 12-35b and 12-35c) are also available as self-shearing pins and in double-shear (two pins in one) form as well as single-shear form. All TMS Link and Link Plus (with shoulder) pins are self-shearing; Link Plus Regular and Minim pins are also available in the two-in-one (double-shear) form. The Link and Link Plus pins are available in either gold-plated stainless steel or titanium alloy; these may be inserted manually or with any low-speed, latch-type handpiece. The bulk TMS pins are available only in gold-plated stainless steel and are usually inserted manually. Selection among these pins should be based on operator preference; they all have performed well in laboratory studies.[118,120]

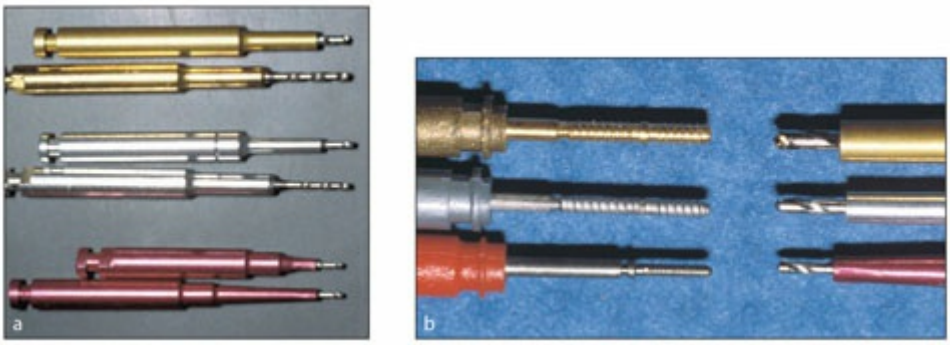

Dentlearn.ir

inch [0.675-mm] diameter, 2.0- and 5.0-mm lengths); Minim (silver, 0.021-inch [0.525-mm] diameter, 2.0- and 5.0-mm lengths); Minikin (red, 0.017- inch [0.425-mm] diameter, 1.5-mm

drill (2.0-mm depth-limiting); Minim (0.024-inch diameter) titanium alloy Link Plus pin with Minim

limiting).

Number of pins to use. It is difficult to develop a guideline that would determine the appropriate number of pins for all situations. It has been demonstrated that as the size and number of pins increase, the amount of resistance form imparted by the pins increases[121]; however, the number of pins used will vary with the size of pin, the amount of remaining tooth structure, other mechanical resistance features used, the use of amalgam bonding systems, and the expected functional requirements of the definitive restoration.

prepared and when pins are placed to protect the patient from aspiration and to prevent contamination by saliva in case there is pulpal perforation during pin

dentin surface, it is usually helpful to place an indentation or starting point in the

may be placed with a small bur, such as a no. ¼ or ⅛ bur.

To avoid perforation of either the pulp or the external surface of the tooth, location

of the tooth. If that much of the side of the tooth is exposed above the rubber dam, alignment is facilitated. Frequently, however, adjacent soft tissue under the rubber dam obscures visualization of the tooth surface in the area adjacent to the desired pin location. For alignment, the drill is placed against the external tooth surface, and the angulation of the drill is changed until the drill separates from the margin of the preparation; it is then rotated back until it just contacts the margin (Fig 12-31).

Dentlearn.ir

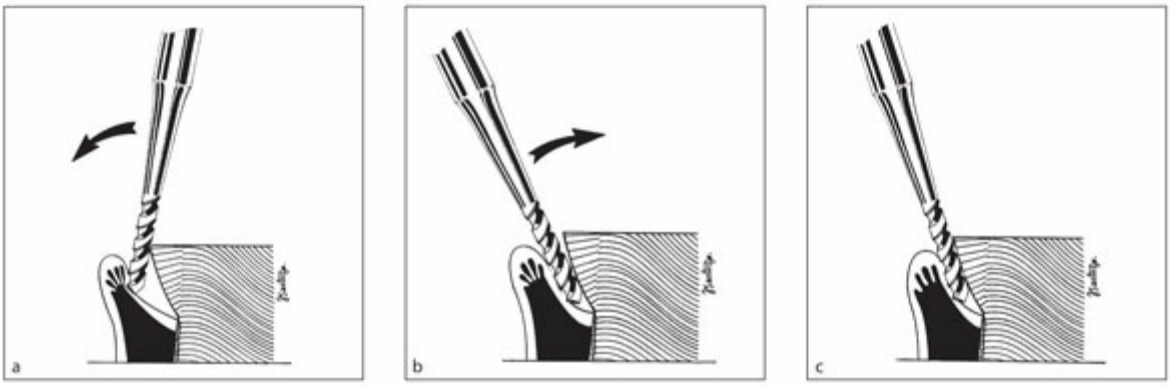

surface is obscured, the drill is placed in the sulcus so that the drill is touching the preparation margin; the drill is then rotated *(arrow)*. *(b)* With that movement, the tip contacts the external surface and the portion of the drill that was in contact with the margin is rotated slightly away from it; then the length of the drill is rotated *(arrow)*. *(c)* With that rotation, the drill returns just to touch the margin. It is now aligned parallel to the external surface.

preparation margin is coronal to the CEJ; a 1.0-mm distance from the DEJ is preferable.[115] If the nearby margin is apical to the CEJ, there should be at least 1.0

The most common location for pins is at the line angles of the tooth because of the greater thickness of dentin between the external surface and the pulp and the decreased risk of perforation. The risk of perforation is especially increased in furcation areas. Figure 12-32 illustrates the preferred locations for pins.[122] Areas to be avoided in posterior teeth include proximal areas and tooth structure that lies over furcations or concavities in the root. Wherever the pin is to be located, the external

(Fig 12-33).

Dentlearn.ir

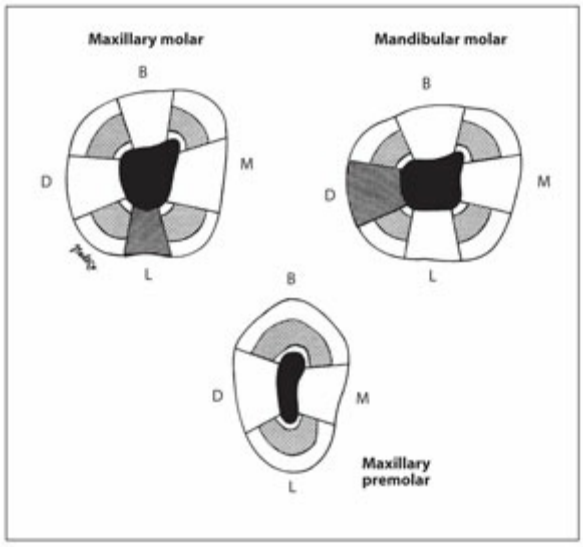

Fig 12-32 Preferred locations for pin placement. *(dotted areas)* The most preferred locations—at the line angles; *(white areas)* areas to avoid because of concavities, furcations, or thin dentin; *(lined areas on the molars)* areas where pins may be placed with added caution because the angulation of the root in relation to the crown is frequently severe.[122] B—buccal; M—mesial; L—ligual; D—distal.

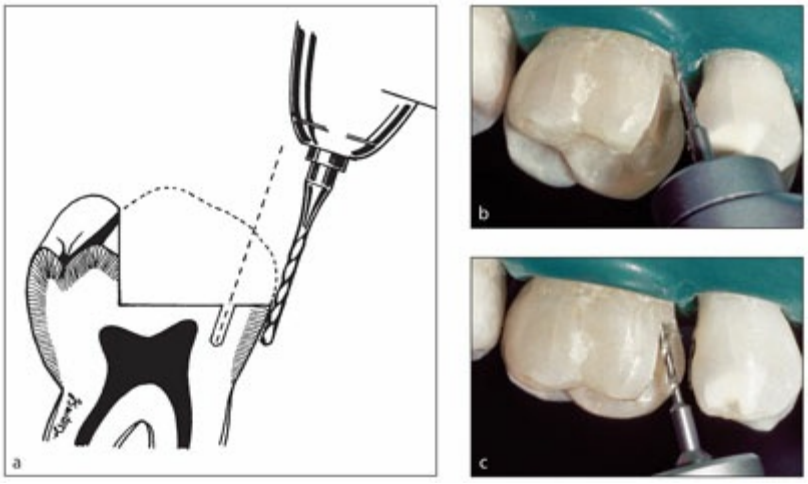

a pin should not be located immediately adjacent to a wall of the preparation; there should be access to condense amalgam around the full circumference of the pin. If a pin is located an optimal distance from the DEJ and a dentinal wall is adjacent to the

Dentlearn.ir

pin, a small “cove” may be cut in the dentin to provide adequate space for amalgam (Fig 12-34).

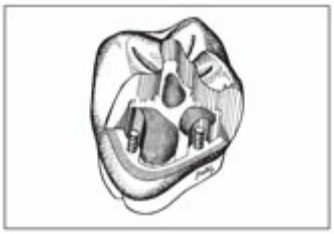

Fig 12-34 There should be adequate space around the full circumference of a pin for amal-gam. If a pin is located adjacent to a dentinal wall, a small cove may be cut in the wall to provide adequate space for condensation of amalgam.

it will be efficient at low speeds. A drill loses cutting efficiency with extended use

chemical vapor, or immersion in glutaraldehyde rather than in the steam autoclave. Drills should be discarded when a diminished cutting efficiency is sensed by the

the drill are obstructed by debris, the drill is dull, the handpiece is running in reverse, or the tip of the drill is in contact with enamel rather than dentin.

must be small to ensure that excessive stresses are not exerted on the dentin during insertion of the pin and that the pin will be retained by the dentin.

and less heat generation. Care must be taken, however, to avoid overenlargement of

If an amalgam bonding material is used in addition to pins, it is applied after the pins have been inserted so that amalgam can be condensed immediately after placement of the bonding material.

Insertion. The insertion of self-threading pins may be accomplished in more than one way. They may be inserted by hand, using a small pin wrench (Figs 12-35a and 12-35b), or with a low-speed or finger-driven handpiece[127] (Figs 12-35c, 12-36a, and 12-36b). Placement by hand is preferred by some dentists because *(1)* it allows the operator to feel the insertion and to reverse the pin one-quarter turn once the tip

Dentlearn.ir

and *(2)* stripping of the dentinal threads created by the self-threading pin is less likely. Insertion of pins with a low-speed handpiece is preferred by many because it is much more time efficient and the handpiece often allows easier access than inserting pins by hand. The thread design of some pins (such as the Link Plus series) provides for wider dentinal threads; dentinal stripping is less frequent when such designs are used.



Fig 12-35 Pins and pin drivers (or wrenches) (TMS system). *(a) (left to right)* Link Plus Regular pin, Link Plus Minim pin, and Link Series Minikin pin. A plastic Universal Hand Driver (for Link Plus and Link Series pins) is shown on the Link Plus Minim pin. *(b)* Metal hand wrenches or drivers with individual TMS gold-plated stainless steel pins: *(left to right)* Regular, Minim, and Minikin. The hand driver with the band around the handle is for Minim pins; the nonbanded hand driver is for Regular and Minikin pins. *(c)* A motorized or hand-operated handpiece may be used to place Link Plus and Link Series pins. *(left to right)* Link Plus Regular gold-plated stainless steel pin in handpiece, Link Plus Minim titanium alloy pin, and Link Series Minikin titanium alloy pin.

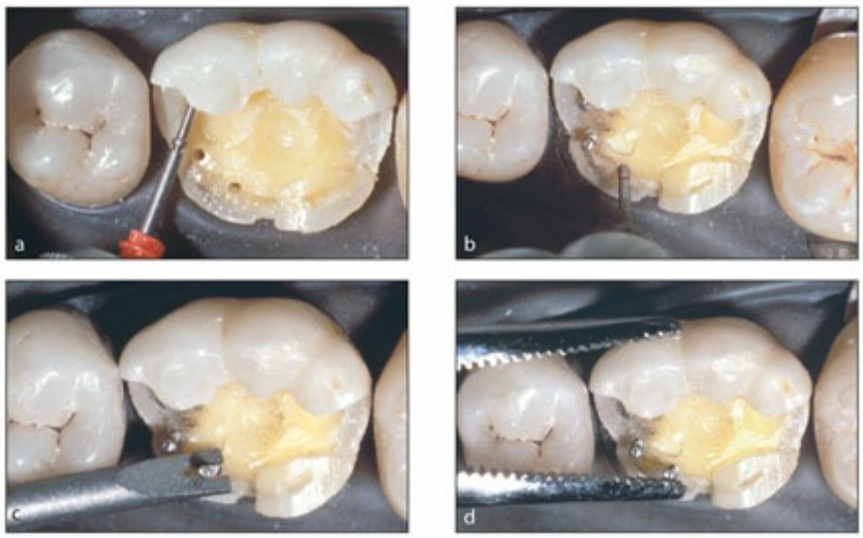

Fig 12-36*(a)* Insertion of a horizontal Link Series Minikin pin in a facial cusp of a mandibular molar. *(b)* A low-speed handpiece is used to insert a vertical Link Plus Minim pin. *(c)* To bend the pins, a Coltène/Whaledent pin bender can be used. *(d)* If a hemostat is used to bend the pin, the jaw of the hemostat should contact the pin at its tip, and very controlled pressure should be used in bending the pin.

Dentlearn.ir

Because the portion of a pin that will extend into the amalgam usually is only 2 mm long or less, the pin is aligned parallel to the external surface of the tooth, and

only reason for bending a pin is to keep it well within the bulk of the planned amalgam restoration. If bending should be needed, it may be accomplished with a small, fork-shaped pin bender (Fig 12-36c) or a small hemostat (Fig 12-36d) before the pin is shortened.

desired, so it will need to be shortened after insertion. The pin may be efficiently and safely cut by gently brushing the pin with either a thin fissure bur or a diamond bur in a high-speed handpiece. The small segment of pin that is sectioned is a potential projectile that should be controlled with an instrument when possible. Both the bur and the diamond should be used with air or water coolant to prevent the pin, and therefore the surrounding tooth structure, from being overheated during the operation. If a bur is used, it must be sharp. If the bur approaches from an oblique angle, the clockwise rotation of the bur can cause counterclockwise rotation of the pin so that it is unscrewed. Therefore, if the pin cannot be approached perpendicularly by the bur (Fig 12-37a), it should be grasped with the pin wrench, cotton forceps, or a hemostat to stabilize it during the cutting process (Fig 12-37b), or, minimally, an instrument should be pressed against the pin during the process to dampen vibration from the bur, which tends to initiate the unscrewing. A long, narrow diamond is preferred by many operators for cutting pins, because it causes less vibration and is less likely to "catch" in the metal of the pin to initiate reverse rotation (Fig 12-37c).

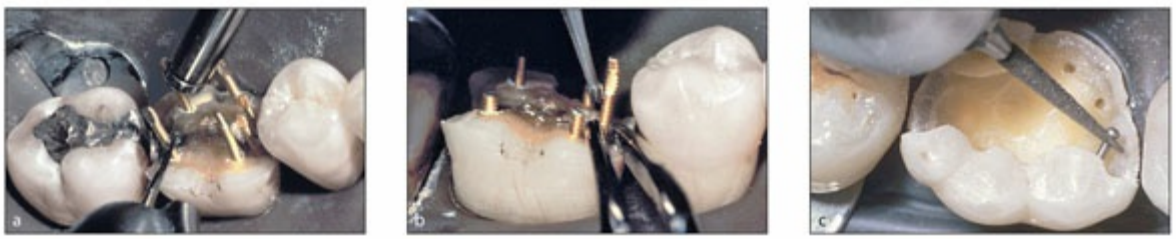

Fig 12-37 Shortening a pin. A light, brushing stroke and air or water coolant should be used while a pin is cut. *(a)* When a no. 169L tapered fissure bur is used to approach the pin at approximately 90 degrees, no stabilization is necessary. *(b)* When a no. 35 inverted cone bur is approaching the

needle-shaped diamond is approaching the pin at approximately 90 degrees.

Horizontal pins

Studies[128,129] have demonstrated the efficacy of using pins oriented horizontally, that

Dentlearn.ir

is, inserted into the dentin of a vertical wall of a preparation (Fig 12-38). Burgess[128] found two horizontal self-threading pins (TMS Minim and Minikin) placed into a free-standing facial cusp of a maxillary premolar to be effective in reinforcing the cusp (see Fig 12-38a). Other investigators[129] have found that horizontal pins, used to cross-splint cusps of maxillary premolars, reinforce and strengthen the cusps (Fig 12-39).

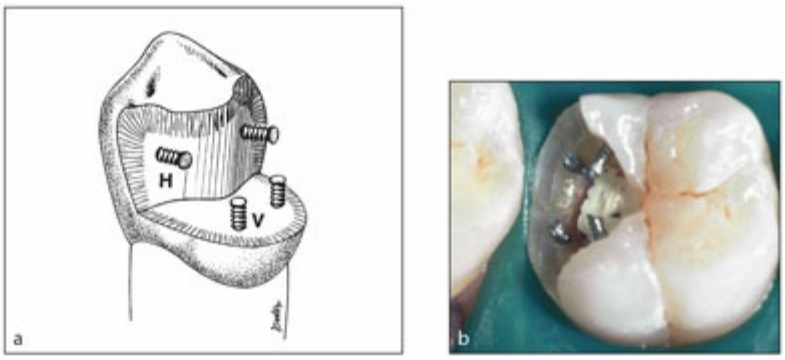

Fig 12-38*(a)* Horizontal pins (H) are used to attach the wall of a cusp to the amalgam restoration. Vertical pins (V) attach the restoration to the radicular portion of the tooth. *(b)* Horizontal pins can be used in conjunction with vertical pins. In this clinical situation, a proximal box had to be extended significantly facially and lingually to eliminate caries and unsupported enamel.



Fig 12-39 Horizontal pins are used to cross-splint the cusps of a maxillary premolar.

Adequate dentin must be present for horizontal pins to be employed. When the

1.0 mm from the DEJ. They should be directed approximately parallel to the adjacent DEJ (and external surface of the tooth). Because of their horizontal

penetration short of reaching its depth-limiting shoulder, it is probably because it has

enamel fracture.

Dentlearn.ir

Horizontal pins should be positioned fairly near to the occlusal surface in the dentin of a vertical wall, 0.5 to 1.0 mm gingival to the occlusal DEJ, so that their mechanical advantage is enhanced for reinforcement of the cusp. A horizontal pin should be oriented so that it will not be near the anticipated surface of the amalgam and so that amalgam may be condensed around the entire circumference of the pin.

important to determine what has been perforated, the external surface of the tooth or the pulp chamber. When the pulp chamber with a vital pulp has been perforated, the

Alternatively, a different type of resistance feature should be used. A perforation of the external surface of the tooth may be more problematic. If the perforation is

If the pin is inserted and the tip protruding on the external surface is cut even with the surface and polished, the pin will not totally obturate the perforation, and leakage

may be obturated with MTA or with amalgam.

Nonpin mechanical resistance and retention features

Birtcil and Venton[131] suggested that more attention be directed toward using the available tooth structure to provide retention and resistance form in complex amalgam restorations. They recommended parallelism in all walls of the preparation, proximal box form, retention grooves in the proximal line angles, box form in buccal and lingual groove areas of molars, dovetails, rectangular boxes in areas other than proximal surfaces, and reduction of undermined cusps for coverage with amalgam. In recent years, several additional nonpin resistance and retention methods have been described and investigated. These include the circumferential slot and the amalgapin, as well as adhesive bonding (described in the Amalgam Bonding section and in chapter 6).

Circumferential slots. Outhwaite et al,[132] who introduced the circumferential slot prepared with a no. 33½ inverted cone bur (Fig 12-40), compared it with four pins (TMS Minim) in an in vitro study and found no significant differences between the

Dentlearn.ir

resistance provided by the two techniques. They also reported that the pin restorations had a greater tendency to slip on their bases before failure, whereas slippage did not occur with circumferential slots. However, slot-retained restorations are more sensitive to displacement during matrix removal than are pin-retained restorations. In the design of preparation resistance form, *segmental slots* (short segments of circumferential slots) are used effectively. Some operators have called these segmental slots "cleats."

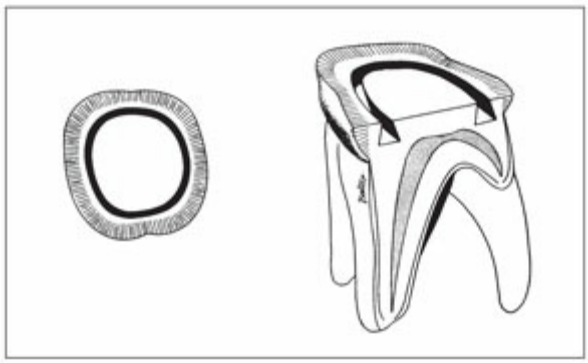

Fig 12-40 A circumferential slot is prepared with a small, inverted cone bur, such as a no. 33½.

Amalgapins. Seng et al[133] tested circular chambers that they cut vertically into dentin to provide resistance and retention form for the restoration; they called these features *amalgam inserts*. Preparations for the inserts were made with a no. 35 inverted cone bur and were approximately ¼ mm in diameter and depth. In their study, amalgam inserts provided resistance to displacement similar to that provided by self-threading pins. Shavell[134] described a variation of the amalgam insert, which

was prepared with a no. 1157 or 1156 bur and had a depth of 3.0 mm. Laboratory studies of the amalgapin[135,136] have demonstrated that the resistance to displacement provided by amalgapins is similar to that provided by pins. It has been demonstrated[136] that a depth of 1.5 to 2.0 mm is adequate for amalgapins and that an amalgapin with a diameter of 0.8 mm provides resistance similar to that of an amalgapin with a diameter of 1.0 mm. In addition to the burs advocated by Shavell (nos. 1156 and 1157), others with similar diameters (such as the nos. 330 and 56)

Dentlearn.ir

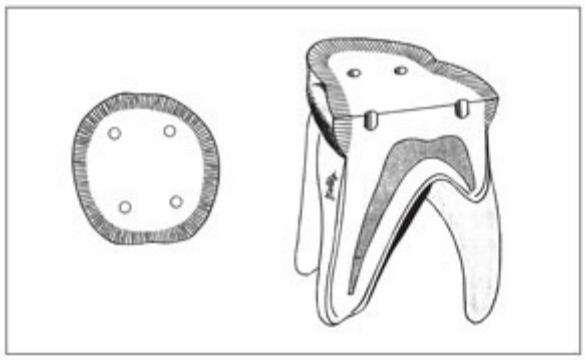

no. 330 bur, to a depth of approximately 1.5 mm.

Efficacy of resistance and retention methods

For the most part, the resistance form provided by various resistance and retention methods has been tested in flattened molars, as described by Buikema et al,[121] with 4.0-mm-high restorations retained by given macromechanical resistance features or amalgam bonding. These teeth were mounted at a 45-degree angle and were loaded in compression; the mean loads at the time of failure were calculated. Although this method of testing is not as enlightening as long-term clinical tests, it probably provides a good indicator of how well a resistance feature will perform in a clinical situation. It has been shown, however, that if these standard resistance-test restorations are loaded at a 90-degree angle instead of a 45-degree angle, the stainless steel pins provide significantly more resistance than amalgam inserts.[137,138] Few forces in the mouth are directed at a 90-degree angle to the long axis of the tooth, however, and few restorations are placed on preparations that are totally flat, without any walls or irregularities in the dentin.

One of the most telling studies pertaining to resistance form for complex amalgam

complex amalgam restorations that combined the use of boxes, shelves, and amalgapins as resistance and retention features. They then loaded specimens at 45 degrees, as in most previous studies of resistance form, but they loaded half of the restorations from one side and half from the other. Their finding was, generally, that more load was required to cause failure of a restoration when the resistance and

of the load were increased.

It is important to distribute mechanical resistance features into all areas of the preparation and not to cluster them in any one area.[138–140] Figures 12-42a to 12-42d show a restoration that originally replaced two missing cusps of a mandibular molar.

Dentlearn.ir

The probable cause of failure was that the resistance features (pins) were clustered in the lingual aspect of the cavity preparation. In function, there was nothing to attach the facial aspect of the restoration to the tooth. If two of the four vertical pins had been placed in the facial portion of the preparation (Fig 12-42e), or if two horizontal pins had been placed in the facial cusps (Figs 12-42f and 12-42g), the restoration would, in all likelihood, have had adequate resistance to withstand its load in function.

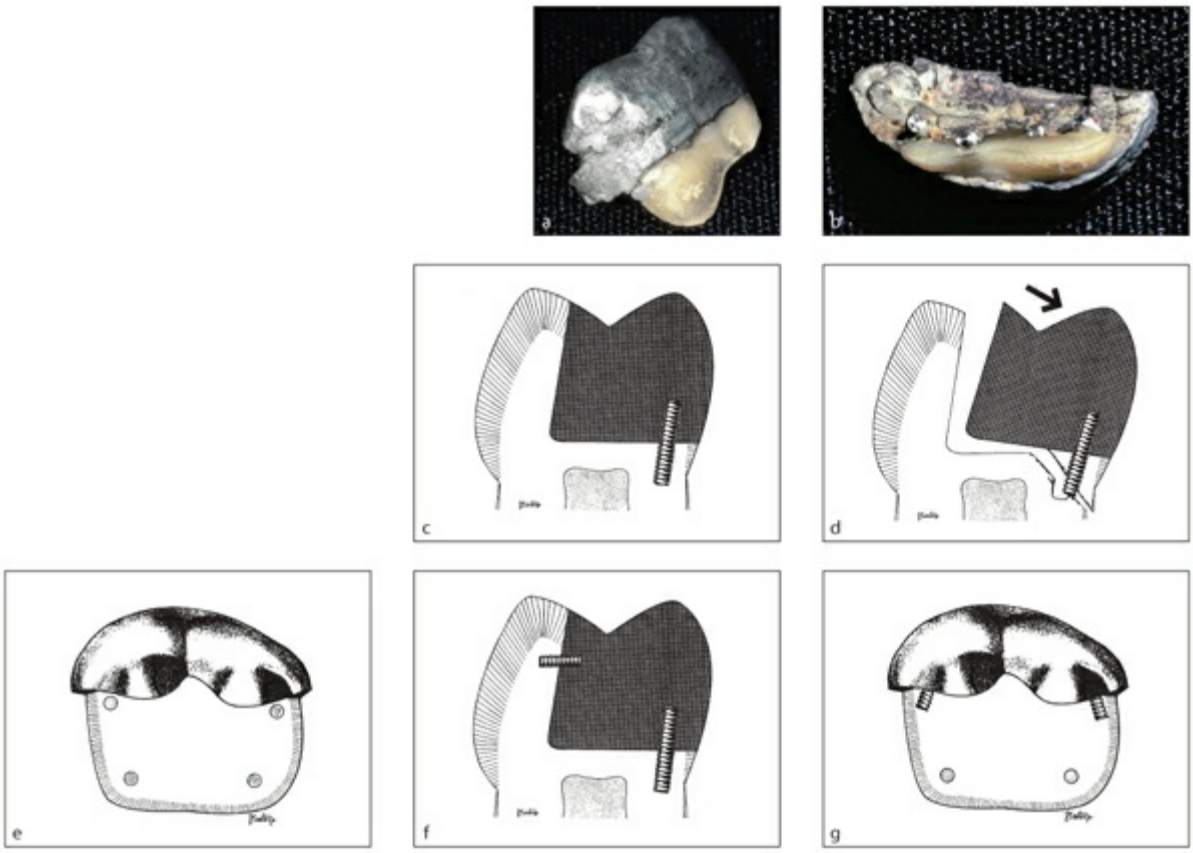

Fig 12-42*(a and b)* Failed complex amalgam restoration that replaced the lingual cusps of a mandibular molar. Note the fin of cervical tooth structure that fractured. *(c)* The dentin lingual to the pin was the only tooth structure that was opposing a lingually directed load on the restoration. *(d)* A load pushing the restoration lingually caused failure. Failure can be attributed to a lack of distribution of resistance and retention features. *(e)* Alternatively, had two of the four pins been placed vertically in the facial aspect of the preparation, this could have reduced the likelihood of failure. *(f and g)* Had two of the four pins been located horizontally, failure would likely have been averted.

When the technical requirements for placement of vertical pins can be met, vertical pins provide excellent retention and resistance form. However, risks are involved with pin placement: crazing of tooth structure, perforation into the pulp or periodontium, and weakening of the amalgam restoration over pins.[141] Additionally, the use of both vertical and horizontal pins may be limited by inadequate access; in

Dentlearn.ir

these cases, alternative resistance and retention methods should be employed. When a cusp has been reduced and increased resistance form is needed, adhesive bonding, an amalgapin, or a segment of a circumferential slot may be indicated.

Amalgam Bonding

The use of adhesive resins to increase the retention, resistance, and marginal seal of amalgam restorations has gained a strong foothold in restorative dentistry. There is now more than adequate evidence that properly bonded amalgam restorations will be as successful as pin-retained amalgam restorations. Several clinical studies have demonstrated success after several years of service.[107,142–145] In one clinical study of complex amalgam restorations,[142] all bonded and pin-retained restorations were

clinical study[107] in which 32 bonded (Amalgambond Plus with HPA powder, Parkell) and 28 pin-retained (TMS pins) amalgam restorations were compared; each restoration replaced at least one cusp, and, in some of the restorations, the only sources of retention were the pins or the adhesive bonding (see example in Fig 12-74). After 5 years, seven of the pin-retained and two of the bonded restorations had failed (N = 46). Failures of bonded restorations involved loss of another cusp. None of the bonded amalgam restorations had debonded. At 6 years, the results continued to demonstrate that bonded amalgam restorations performed as well as pin-retained amalgam restorations, with failure of one from each category in the 6th year (N = 27). The number and length of clinical studies[146] is now sufficient to indicate that bonded amalgam restorations can perform as well as restorations using mechanical resistance and retention features when the bonding technique is accomplished properly.

Pins and bonding can have an additive effect in which the resistance to displacement is superior to either technique alone.[147–150] In one in vitro study,[147] the mean resistance to dislodgment provided by a filled amalgam bonding material combined with self-threading pins was approximately equal to the sum of the mean resistance produced by pins alone and the mean resistance produced by bonding alone.

For use of bonding resins in amalgam restorations, research suggests the improved efficacy of filled resins compared with unfilled or minimally filled resins.[150–153] The method of incorporation of the filler varies from manufacturer to manufacturer. One system (Amalgambond Plus) uses very fine methyl methacrylate powder, added to

Dentlearn.ir

the liquid resin, as the filler.[154] Another system (All-Bond 2 and Liner F, Bisco) uses a filled flowable resin composite liner to provide the filled resin. With both systems, the amalgam is condensed into the filled resin while the resin is in a viscous liquid form. Microscopic "fingers" of resin are incorporated into the amalgam at the interface. When hardened, these provide the attachment of amalgam to resin. Because light cannot penetrate to the resin underlying amalgam restorations, it is important to use a self-curing or chemically activated bonding resin. The bonding resin of an amalgam bonding system is supplied in two parts that are to be mixed. The attachment of resin to tooth structure when amalgam bonding systems are used is accomplished as with other dental bonding systems, as described in chapter 9.

There is ample short-term evidence of decreased leakage of fluids when an amalgam bonding system is used compared with noncoated or varnish-coated amalgam cavity walls.[155–160] Many dentists have reported that amalgam bonding systems have reduced the incidence of postoperative tooth sensitivity, but most research has not supported these observations. Clinical studies[161,162] comparing postoperative sensitivity in bonded and nonbonded restorations have reported no significant difference. One study[163] involving 40 teeth with symptoms of cracked tooth syndrome prior to restoration found no difference in thermal sensitivity between pin-retained and bonded restorations at 2 weeks but found less thermal sensitivity in teeth with bonded restorations at 3 and 12 months.

For reinforcing cusps in posterior teeth weakened by significant pathosis or large restorations, there is in vitro evidence that amalgam bonding can result in some strengthening of teeth.[164–167] However, much of this effect may be lost with time.[168–170] At present, it is still advisable to reduce severely weakened cusps for replacement and protection with a strong restorative material.[141] The use of amalgam for this purpose is described in this chapter. Other types of occlusal-coverage restorations are described in chapters 19 and 20.

Evidence from clinical and laboratory studies supports the contributions to resistance to displacement that come from the various resistance features and methods (cavity form, threaded pins, slots, grooves, amalgapins, and filled adhesives). The resistance mechanisms used in any restoration should be selected based on the functional load to which the restoration is expected to be exposed. Amalgam bonding probably may be used as the sole means of retaining an amalgam restoration, but it will be more effective for supplementing mechanical resistance features in large, complex amalgam restorations, especially those replacing cusps.

Dentlearn.ir

Most preparations have some box form and surface irregularities that, when combined with resin bonding, can provide long-term retention of the restoration. A filled amalgam bonding system should be used. Amalgam bonding should be used when an improved initial seal is needed, such as after a direct or indirect pulp capping procedure in the tooth being restored. Adequate moisture control and meticulous attention to product instructions are necessary to duplicate the success that has been demonstrated in clinical trials.

Matrices

To confine the amalgam and allow adequate pressure for optimum condensation, the preparation must be boxlike, that is, with confining walls and floors. A Class 1 occlusal preparation provides these by virtue of its location and definition. Whenever an amalgam preparation extends from one surface of the tooth to another, some form of matrix is needed to confine the amalgam for condensation. If a matrix is not used, condensation forces will tend to push the amalgam out of the preparation rather than condensing the amalgam.

The simplest and fastest method of adequately providing a matrix should be used. Occasionally, as with the occlusolingual restoration of the maxillary molar, the blade of a hand instrument, placed on the lingual surface of the molar and held in place during condensation, may be adequate. In most cases, a matrix system, such as a Tofflemire matrix, is indicated. Rarely, a customized matrix will be necessary for a particular situation. A matrix system is needed in almost every case for multisurface Class 2 amalgam restorations.

There are myriad types of matrix systems; most involve thin pieces of stainless steel that are contoured and placed adjacent to the proximal portions of Class 2 preparations. The purpose of the matrix is to:

- Confine the amalgam so that adequate condensation forces can be applied.
- Allow re-establishment of contact with the adjacent tooth.
- Restrict extrusion of the amalgam and the formation of an overhang at a hidden margin, such as the proximal gingival margin.
- Provide for adequate physiologic contour for the proximal surface of the restoration.
- Impart an acceptable surface texture to the proximal surface, especially in the area of the contact that cannot be carved and burnished.

Dentlearn.ir

Tofflemire matrix

Probably the most commonly used type of matrix system in the United States is the Tofflemire system. The system consists of a matrix band and retainer (Fig 12-43). The Tofflemire retainer consists of four parts (see Fig 12-43b).



Fig 12-43 Tofflemire matrix system. *(a)* Matrix retainer. *(b)* Parts of the assembly: set screw (1), rotating spindle (2), slide (3), head (4), band (5). *(c)* Three common shapes of Tofflemire matrix flat bands (no. 1 is also called a *Universal band*; no. 2 and no. 3 are also called *MOD bands*). *(d)* Precontoured Dixieland Bands. *(e)* The matrix band is folded for insertion into the retainer. *(f)* One of the projections of a no. 2 or 3 band may be cut off if there is only one deep proximal area of the preparation. *(g)* Two types of Tofflemire retainer: *(top)* straight; *(bottom)* contra-angled.

Dentlearn.ir

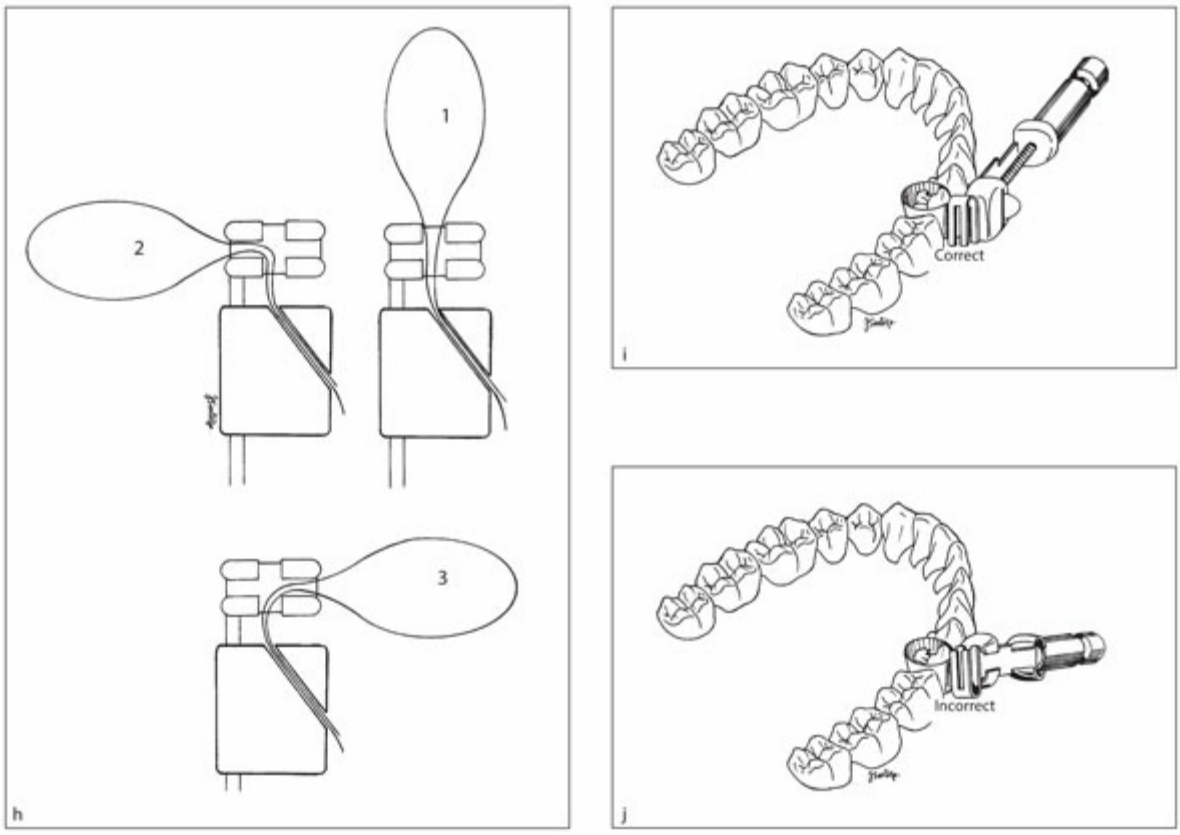

Fig 12-43*(cont) (h)* The loop of the band may extend from the head of the retainer in one of three directions: straight (1), left (2), right (3). *(i)* The matrix must be assembled with the slots in the head directed gingivally. *(j)* The slots in the head of the matrix should not be directed occlusally.

Parts

Head. This is the part that has the open side. In the U-shaped head, there are two slots in the open side. These slots are used to position the matrix band. The open side of the head should be held facing upward while the band is installed. The open side of the head faces gingivally when the band is placed around the tooth. There are two types of Tofflemire retainers based on the angulation of the head (see Fig 12-43g).

Slide. This element has a diagonal slot. The round ends of the band, when installed, extend at least 1 to 2 mm beyond the slot in the side of the slide. The amount of the band extending beyond the slot in the side of the slide will depend on the size of the tooth being treated. More of the band should extend from the slide for premolars than for molars. The slide is positioned near the head for installation of the band in the retainer and for placement of the band around the tooth.

Rotating spindle. This is used to adjust the distance between the slide and the head.

Dentlearn.ir

The retainer is held with the thumb and forefinger of one hand (contacting both the head and slide) while the rotating spindle is turned with the other hand, clockwise and counterclockwise, to advance and retract the slide. This movement adjusts the size of the loop of the matrix band.

Set screw. The threaded shaft of the set screw locks and unlocks the matrix band in the slide.

Types

The types of Tofflemire bands include flat bands of multiple shapes, precontoured bands, and bands with and without memory (dead-soft metal).

Flat bands. Bands for the Tofflemire system come in several shapes (see Fig 12-43c) and in three thicknesses: 0.0010, 0.0015, and 0.0020 inches. The thicker band is stiffer to resist deformation during condensation; the thinner bands are often used to help ensure a tight contact in Class 2 restorations. Any of the three thicknesses can be used to achieve excellent results, and selection is primarily a matter of operator preference.

By far the most frequently used shape is the no. 1, or Universal, band. The no. 2 (so-called MOD) band has two extensions projecting at its gingival edge to allow matrix application in teeth with very deep gingival margins in the proximal aspects of the tooth. In most cases, there will be only one deep area, so one of the extensions is usually cut off with scissors (see Fig 12-43f). The no. 3 band also has projections for deeper gingival margins, but the band is narrower than the no. 2 band. The no. 3 band is ordinarily considered suitable for premolars and the no. 2 band for molars, but the size that best suits the situation should be used.

Because these bands are flat, they should be contoured so that they will impart physiologic contours to the restorations. A flat band may be contoured before it is placed in the retainer. The band is laid on a paper pad or other compressible surface, and the area to be contoured is heavily rubbed with an ovoid burnisher, a beavertail burnisher, the convex back of the blade of a spoon excavator, or a convex side of the cotton forceps. A band may also be contoured after it has been applied to the tooth. The area to be contoured is rubbed with the back of the blade of the spoon excavator or with some other thin, convex instrument (Fig 12-44a). Contact with the adjacent tooth should be more than a pinpoint touch (Fig 12-44b).

Dentlearn.ir

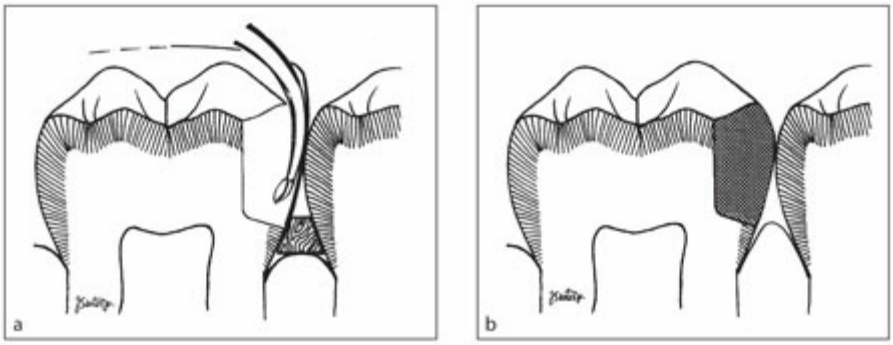

Fig 12-44*(a)* The convex side of a spoon excavator is used to impart a convex contour to the matrix band. *(b)* This will help to achieve a contact area, as opposed to a pinpoint contact, with the adjacent tooth.

Precontoured bands. Precontoured Tofflemire matrix bands are also available. One such band is the Getz Contour Matrix Band or Dixieland Band (Waterpik Technologies) developed by Dr Wilmer Eames (see Fig 12-43d). When these bands are removed from interproximal contacts, the contour must be considered, and the band must be rotated in such a way that the trailing edge does not break or alter the shape of the marginal ridge as the band is being removed.

Placement

Assembly. When the matrix retainer and band are assembled, the two ends of the matrix band must be even as they protrude from the diagonal slot of the slide. The loop can extend from the retainer in three different ways: straight, to the left, or to the right (see Fig 12-43h). The straight assembly is for restorations near the front of the mouth where the rubber dam–covered cheek will not get in the way if the retainer protrudes perpendicularly from the line of teeth. The right and left assemblies allow the retainer to be aligned parallel or tangent to the line of teeth in more posterior areas. The band should be placed in the retainer so that the loop extends from the appropriate side of the retainer and the set screw knob is directed toward the front of the mouth. Because of the shape of the Tofflemire matrix band, when it is placed in the retainer, one opening of the loop has a greater diameter than the other (see Fig 12-43e). In other words, the loop will be shaped somewhat like a funnel. The wider opening is oriented toward the occlusal aspect. The short knob of the set screw is tightened so that the matrix band is held securely.

Application. The matrix is applied to the tooth to be restored. The matrix band will slide easily through the interproximal contact area when the preparation has opened, at least partially, the contact. It will often slide through an intact contact as well (eg,

Dentlearn.ir

the mesial contact when there is a disto-occlusal preparation). If it will not slide through the intact contact, a bladed plastic filling instrument (such as the no. 1-2, shown in Fig 12-45) may be used to open the contact slightly to allow the band through. For this slight tooth separation, the blade of the instrument is placed in the gingival embrasure (gingival to the contact), moved occlusally until it is stopped by the contact, and rotated (torqued) very slightly. At the same time, the matrix band is slipped through the contact. When the matrix is around the tooth, it should be tightened snugly, but not too tightly, because a very tight matrix will deform the tooth.[171–173]



Fig 12-45 The blade of a plastic filling instrument has been placed into the gingival embrasure and is being slightly rotated (torqued) to provide enough separation to allow the matrix band to slip through the contact.

Wedging. Wooden wedges may be placed from either the facial or the lingual aspect. A wedge should usually be inserted from the side with the widest embrasure. For example, between the first and second premolars, the largest embrasure is usually the lingual embrasure. The wedge should be inserted tightly to enable development of an adequate contact despite the thickness of the matrix material.

Wedges are available in a variety of shapes and sizes. Figure 12-46a shows Wizard wedges (Waterpik Technologies), which are triangular and available in four sizes. Figures 12-46b and 12-46c show Sycamore wedges (Premier), which are shaped to aid the establishment of physiologic proximal contours. The Premier wedges, with seven color-coded sizes, are recommended for amalgam restorations.



Fig 12-46 Wooden interproximal wedges. *(a)* Wizard wedges have a triangular shape. *(b)* Premier Sycamore wedges are shaped to impart a more physiologic contour to the matrix. There is a larger selection of sizes, and they are color coded for easy selection. *(c)* Note the anatomical

Dentlearn.ir

shape of the Premier Sycamore wedges. The snow-sled point helps to prevent catching of the rubber dam during insertion.

The matrix band must extend gingival to the gingival margin of the proximal box of a Class 2 restoration, and the wedge must be positioned so that its base is also gingival to the gingival margin. If the wedge cannot be placed so that its base is gingival to the preparation margin, a concavity will be created in the matrix just occlusal to the gingival margin, and this concavity will be transferred to the amalgam. Occasionally, the gingival papilla will need to be surgically reflected from the interproximal area to allow the wedge to be positioned apical to the gingival margin. Another option is to use a rigid bladed instrument to hold the matrix against the gingival margin during condensation. Custom wedges may be made for special situations.

Contouring. The band should be burnished and contoured to impart the desired proximal contours to the restoration. This can be accomplished with the back (convex side) of a spoon excavator (see Fig 12-44a). The wedged matrix should be in solid contact with the adjacent tooth in the desired contact area. It should be possible to feel the convexity of the proximal surface of the adjacent tooth with an instrument through the matrix as the matrix is burnished.

Removal

In a multiple surface restoration, amalgam is condensed in the preparation after matrix placement. Amalgam condensation is discussed in the next section.

When amalgam placement using a Tofflemire matrix has been completed and preliminary carving of the occlusal aspect accomplished, first the slide and then the set screw of the matrix retainer is loosened. A finger or thumb is placed on the loop of the matrix band to keep it in place on the tooth, and the retainer is pulled occlusally to remove it. The distal end of the matrix band is grasped and pulled occlusally and lingually (if the free ends are on the facial aspect) and out of the distal contact of the tooth. The mesial end is then grasped and pulled facially and occlusally until the band is out of the contact. The matrix band can be grasped with fingers, cotton forceps, or a hemostat. There are a few techniques that may help the dentist remove the Tofflemire matrix without breaking the marginal ridge:

- As the matrix edge is coming out of the contact, the matrix can be tipped so that the edge will not “flip” the newly carved marginal ridge and break it.

Dentlearn.ir

- A condenser can be held against the marginal ridge to support it and prevent it from breaking as the matrix is removed.
- The movement of the band should be primarily to the facial or lingual aspect as the band slips occlusally out of the contact.

The matrix band should be used only once and then discarded.

Other matrix systems

Many matrix systems other than Tofflemire matrices are available (Figs 12-47 to 12-51). Each has its own advantages and disadvantages. In addition, stainless steel matrix material may be spot-welded to provide a custom matrix for any situation. One commercial system (Denovo) has prewelded bands in various sizes (see Fig 12-47). To remove a spot-welded matrix from a tooth after the restoration is placed, a small bur in a high-speed handpiece is used to cut through the welds and allow the two ends of the matrix to separate. The absence of a matrix retainer in the Denovo system is a distinct advantage.



Fig 12-47*(a and b)* Denovo matrix system.



Fig 12-48 T-band matrix.

Dentlearn.ir



Fig 12-49*(a and b)* AutoMatrix system (Dentsply). Note the cable-drive wrench for adjusting the size of the loop.



Fig 12-50*(a and b)* Palodent matrix system (Dentsply/Caulk). Note the metal ring for holding the ends of the matrix snugly against the facial and lingual enamel. It will also provide some tooth separation.

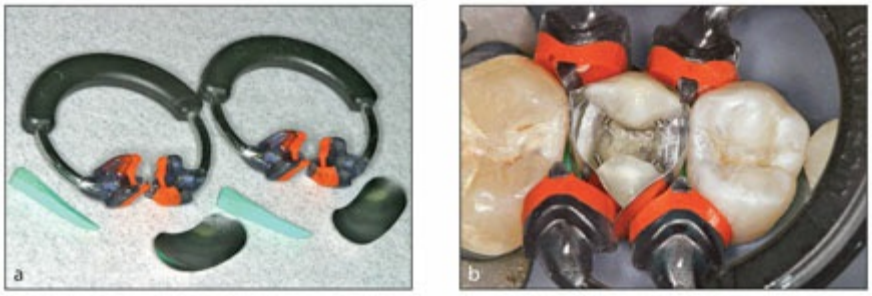

Fig 12-51*(a and b)* Ring systems made for use in placing resin composite restorations (such as these Composi-Tight Soft-Face 3D rings, Garrison) provide excellent matrices for amalgam as well.

T-bands have long been used in dentistry and provide a very simple and inexpensive matrix system (see Fig 12-48). The AutoMatrix system has a built-in matrix retainer that is much smaller than the Tofflemire matrix retainer, which is an advantage (see Fig 12-49). The Palodent matrix and some other matrix systems provide small, precontoured matrices that are placed, wedged, and held in place by a flexible ring. A major advantage of this system is that, for a restoration involving only one proximal surface, there is no need for the matrix to be placed in the other

Dentlearn.ir

contact (see Fig 12-50). If two proximal surfaces are to be restored, two small matrices, two wedges, and two rings may be used (Fig 12-51).

Reinforcing matrices with modeling compound

Among the desirable qualities of a matrix are adequate rigidity and the ability to maintain the shape established by the operator to impart the desired contour to the restoration. When a Class 2 preparation has only proximal boxes that are adjacent to other teeth, and when the preparation does not to any significant degree extend to facial and lingual surfaces, the stainless steel matrix is usually well supported by the adjacent tooth or teeth. In these cases, no reinforcement is necessary. In larger restorations that involve surfaces not supported by adjacent teeth, it is often desirable to reinforce or support the matrix in some way in these areas to maintain the rigidity and shape of the matrix.

Occasionally, a single unsupported area of a matrix may be reinforced during condensation by the operator, who places a finger or holds an instrument against the matrix in a facial or lingual area. For large unsupported areas, however, modeling compound may be used (Fig 12-52).



Fig 12-52 Modeling compound can be used to support a matrix. *(a and b)* The compound stick is heated over an alcohol flame, then removed from the flame to allow warmth to diffuse to the core of the stick. *(c)* When the warmed tip of the compound stick begins to droop, softness is uniform throughout, and the compound is ready for use. *(d)* A finger is dampened in water to prevent the

Dentlearn.ir

glove from sticking to the softened compound. *(e)* The compound has been pressed into place. It will be cooled with air to reharden it. *(f)* Compound has been broken into smaller pieces and inserted into a plastic syringe, which in turn is placed into a warm water bath. *(g)* Once the compound has softened, it can be easily ejected. Note that the tip has been shortened to provide a wider lumen so that the compound extrudes easily. *(h)* The matrix may be recontoured after application of the compound. A warmed instrument is used to soften the compound and reshape the matrix. *(i)* Any compound extending past the edge of the matrix should be trimmed to prevent chipping during amalgam condensation.

There are various ways of applying compound to support a metal matrix. Probably the simplest is to employ a stick of compound (see Fig 12-52a). Approximately 1 inch of one end of the compound stick is heated over an alcohol burner. The stick is moved back and forth, while being rotated, over the tip of the flame. After 5 to 10 seconds, the stick is removed from the flame (see Fig 12-52b) and held for a few seconds until the heat has diffused through the radius of the stick to its center, as indicated by its starting to droop or sag (see Fig 12-52c). At that point, the 1-inch end is soft enough to carry to the matrix and press into place with a dampened, gloved finger (see Figs 12-52d and 12-52e). If adhesion of the compound to the matrix and adjacent teeth is desired, the softened end of the stick should be passed through the flame again just before it is carried to the mouth; this will provide a tacky surface that will impart some adhesion. An alternative way to warm and deliver compound is to break up a stick of compound into smaller pieces and insert them into a plastic syringe. This syringe can then be placed into warm water so that the compound softens (see Fig 12-52f). Once softened, it is then possible to extrude the warmed composite from the syringe (see Fig 12-52g); it may be necessary to cut off a portion of the syringe tip to ensure an adequate lumen size to allow the composite to flow easily. This makes it straightforward to inject compound into the areas needed to stabilize the matrix or rubber dam clamp. The compound can be adapted with a dampened, gloved finger as described earlier.

After the compound is pressed into place (see Fig 12-52e), it is cooled and hardened with air from a three-way syringe. The matrix may be recontoured after compound application. A warmed instrument may be used inside the matrix to soften the compound and exert pressure on the matrix to give it the shape that will allow the restoration contours and shape to be similar to the original shape of the tooth (see Fig 12-52h). Again, the compound should be cooled with air after reshaping with a warmed instrument. If modeling compound extends occlusal to the occlusal edge of the matrix band, it should be trimmed back with a sharp instrument (see Fig 12-52i); otherwise pieces of compound could chip off during amalgam condensation and contaminate the amalgam.

Dentlearn.ir

If condensation forces dislodge the compound, matrix reinforcement will be lost; steps should be taken, therefore, to ensure that the compound does not dislodge. While it is soft, a portion of it may be pushed onto the cusps of an adjacent tooth to provide retention. The compound can usually be pried away from the adjacent teeth and matrix with an instrument such as a Hollenback carver or enamel hatchet. After the compound is removed, the matrix may be removed as previously described.

Matrices for bonded amalgam restorations

If a resin bonding system is used to coat the walls of the preparation, care should be taken to prevent or minimize resin application to the matrix. If resin is applied to the matrix, it may cause the matrix to stick to the amalgam. This sticking can lead to fracture of the amalgam during removal of the matrix. Attachment of the matrix to the amalgam is most significant when amalgam bonding materials are used. Because amalgam must be inserted immediately after placement of the adhesive, the bonding material cannot be placed before matrix application. A very small applicator should be used to apply the resin to the preparation walls so that it may be kept away from the matrix. It is advisable to try to stop the resin application approximately 1 mm short of the cavosurface margins that are adjacent to the matrix. Unless the set of the material is too advanced by the time the amalgam is placed, it will be pushed to the margin in a thin coat as the amalgam is condensed.

Matrices that resist adhesion to the bonding materials are available, but if a band that is specifically designed to prevent adhesion to the matrix is not used, the application of a very thin coat of wax with a wax pencil or crayon or with a piece of inlay wax or boxing wax may be helpful. The wax is rubbed onto the inner surface of the matrix band, and excess is rubbed off with a gloved finger.

Placement of Amalgam

The technique for amalgam placement is basically the same regardless of the type or classification of the preparation. Amalgam is mixed (triturated), carried to the cavity preparation, and condensed into the preparation so that voids are eliminated and all areas of the preparation are filled. The amalgam is then carved to reproduce the portion of the tooth that is missing.

Spherical alloys produce an amalgam that requires a lower mercury-alloy ratio and less condensation force. However, the direction of the condensing force is extremely important for spherical amalgams. They do not adapt to the cavity walls as

Dentlearn.ir

well as lathe-cut or admixture amalgams.[174] Spherical amalgams are said to be less condensable, and lateral condensation is even more important when spherical amalgams are used than when admixture amalgams are used. It is also somewhat more difficult to obtain good interproximal contacts in Class 2 amalgam restorations with spherical amalgams than with lathe-cut amalgams or admixtures. It has been demonstrated, however, that spherical amalgams are less sensitive to variations in condensation pressure than the amalgams containing nonspherical particles.[175] In addition, the spherical materials generally have a shorter working time and demonstrate a faster set than the admixtures.

Trituration

The trituration process includes the combining or mixing of liquid mercury with dry amalgam alloy powder. Electric amalgam mixers (also called *amalgamators* and *amalgam triturators*) are used for the trituration process (Fig 12-53). The objective is to remove the oxide coating and wet each particle of alloy with mercury.[8] This begins the reaction that will produce a solid mass. Although amalgam alloy pellets and bottled mercury are still available separately, the use of precapsulated amalgam alloy (that is, a weighed, standardized amount of amalgam powder and mercury sealed into a capsule) is strongly recommended. The precapsulated products are not only ready for trituration, but they also provide more consistent mixes of amalgam and virtually eliminate the possibility of mercury spills in the dental office.



Fig 12-53*(a)* Pro-Mix amalgamator (Dentsply/ Caulk). *(b)* Optimix amalgamator (Kerr/Sybron).

The duration and speed of trituration should be just enough to coat all alloy particles with mercury, produce the amalgam matrix, and provide a plastic mix. Excessive trituration should be avoided, because it generates heat that will cause the amalgam to set prematurely after trituration, and this will prevent adequate condensation and adaptation to the walls of the preparation, resulting in a weakened product. A mix of amalgam that is too plastic due to excess mercury or, as is more

Dentlearn.ir

frequently the case, is not plastic enough must be discarded. A good mix of amalgam is plastic enough to condense well. If the mix is too hard, brittle, or hot, reduction of the mixing time and/ or speed is indicated.

Condensation

Condensation is the process of compressing and directing the dental amalgam into the tooth preparation with amalgam-condensing instruments (called *condensers* or *pluggers*) until the preparation is completely filled, and then overfilled, with a dense mass of amalgam. Proper condensation promotes adaptation of the amalgam to the walls of the preparation, and it compacts the material, eliminating voids and reducing the amount of residual mercury in the restoration. Both voids and increased residual mercury have been associated with a weakened amalgam product, so effective condensation continues trituration[176] and increases the strength[175,176] and serviceability[12] of the restoration.

Adequate condensation technique requires that a significant amount of force be applied to the condenser.[177] The force should be 2 to 5 kg (5 to 10 lbs) for a condensable amalgam (admixture or conventional); the condensation force required for spherical amalgams will be considerably less,[175,176] because heavy forces with the condenser tend to push the spherical particles to the side and cause the condenser to "punch through" the amalgam mass. The size of the condenser nib (end) determines the amount of pressure actually transferred from the operator's hand to the amalgam mass; the larger the nib, the less force per unit area (pressure) is applied to the mass for a given force from the operator's hand. In other words, when a larger-faced condenser is used, the operator must exert more force on the condenser to deliver adequate condensation pressure. Larger condensers should be used for spherical amalgam, rather than for admixtures, to allow adequate force to be applied without displacement of the spherical amalgam to the side.

When amalgam bonding systems are used, amalgam must be condensed into the bonding resin on all walls of the preparation before filling of the preparation is begun. Adequate condensation force will cause a slight movement of the patient's mandible or head, and often this movement will need to be stabilized by the dentist or assistant. A secure finger rest will enable the operator to perform more controlled, forceful strokes, using arm as well as finger pressure. The condensers are held with the pen grasp or a modification. Many operators use a finger or thumb of the hand that is not holding the condenser to apply additional condensation force. It has been demonstrated that dentists tend to use less condensation pressure during

Dentlearn.ir

the later stages of amalgam placement; investigators[177] have emphasized the need for maintaining condensation pressures for both admixed and spherical amalgams throughout the condensation process.

After the preparation has been made ready to receive the amalgam, the amalgam alloy and mercury should be mixed (triturated) to give a plastic and moldable mass of amalgam. For most restorations, an amalgam carrier (see Fig 7-36) is valuable for delivering the amalgam to the preparation. For small restorations and for placing amalgam in proximal box preparations, care must be exercised to ensure that the increments of amalgam are small enough. If the increments are too large, the condensing force cannot be adequate to adapt the amalgam material at the deepest area of the increment. For very large complex amalgam preparations, the entire mix may be carried to the preparation, or the mix may be divided in half and carried to the preparation one half at a time with cotton forceps. No matter how the amalgam is carried, it should be spread in the preparation so that the increment is thin for optimum condensation. Each portion of amalgam carried to the preparation should result in an increment thickness of 1 mm or less to ensure maximum condensation effectiveness.

Condensers that fit into all areas of the preparation should be used. Flat-faced, round condensers are generally considered to allow maximum condensation pressure. Convex-ended condensers are also available, as are flat-ended condensers with diamond, rectangular, and triangular shapes. When spherical amalgams are used, the largest condenser that will fit into the area of the preparation where the amalgam is being condensed should be used. For all amalgams, a large condenser should be used for the overfilling of the preparation.

Amalgam must be condensed into the preparation as soon as trituration is completed. One increment of amalgam should not be allowed to set significantly before the next increment is added. Amalgam should be condensed both vertically and horizontally or laterally (toward the walls of the preparation). This will promote a close adaptation of the amalgam to the walls as well as to the floor of the preparation. Lateral condensation, whether or not an amalgam bonding system is being used, can be achieved in more than one way. One is to alter the direction of the face (end) of the condenser so that it is pushed toward the walls. Another method is to place the condenser into the preparation vertically, then to move it laterally toward the walls so that the side of the condenser condenses the amalgam against the walls (Fig 12-54a). Lateral condensation is especially important for spherical amalgams because, paradoxically, it is more difficult to adapt these materials to cavity walls.

Dentlearn.ir

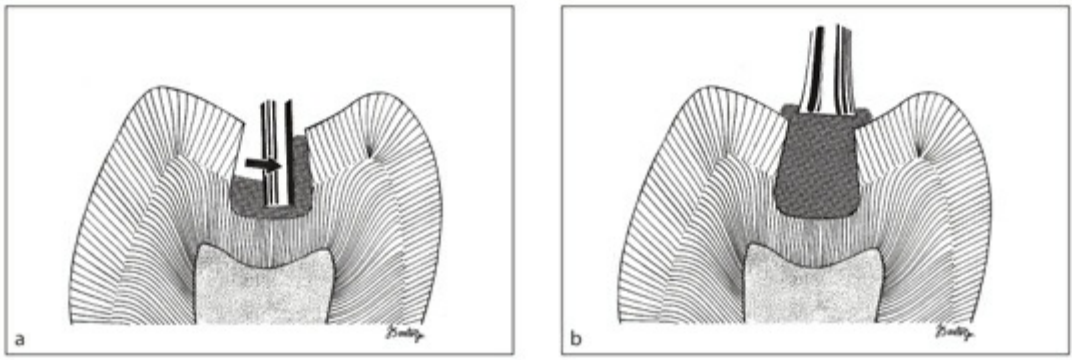

Fig 12-54*(a)* Lateral condensation toward all walls and toward the adjacent tooth in a Class 2 restoration will improve adaptation to the walls and ensure a contact area with the adjacent tooth. *(b)* Overfill should be condensed with a large condenser.

When amalgam is condensed, mercury tends to be brought to the surface, creating a mercury-rich amalgam on the surface. To reduce the amount of mercury left in the restoration (residual mercury), the preparation is overfilled (Fig 12-54b), and the mercury-rich excess is carved off. The lower the residual mercury in the carved restoration, the greater its strength[2] and the better the expected longevity of the restoration.

Condensation when amalgam bonding resins are used

As with the use of the matrix, there are some additional considerations and slightly altered techniques when amalgam bonding systems are used. Because the polymerization of amalgam bonding resins is chemically initiated, the amalgam must be ready to place when the two parts of the bonding resin are mixed to initiate polymerization. Although all walls of the cavity preparation should be coated, caution should be exercised to minimize the amount of bonding resin placed on the walls. One study demonstrated that a thin coat of amalgam bonding resin provided attachment of the restoration to tooth structure that was as strong as that provided by a thick coat, but without the problems caused by a thick coat.[178] One problem resulting from excess bonding resin is the reduction of the amalgam strength by incorporation of large amounts of resin into the bulk of the amalgam.[179] Another is the increased probability of transferring the bonding resin to the metal matrix during condensation, as described earlier. Another potential problem is the creation of voids in the proximal amalgam due to excess resin being pulled from the restoration during matrix removal.

After the bonding resin has been applied to the walls of the preparation, the amalgam is placed in the preparation and condensed against all walls within 1

Dentlearn.ir

minute. After amalgam has been condensed into the resin on all walls, it should be added in increments as described for nonbonded amalgam restorations.

Precarve burnishing

After it is condensed with amalgam condensers, the amalgam may be further condensed and shaping of occlusal anatomy begun with a large burnisher, such as an ovoid (football) bur-nisher (see Fig 12-62h). This is called *precarve burnishing*, and it should take place immediately after the completion of condensation. The burnisher should be used with heavy strokes, made in the mesiodistal and faciolingual directions, that pinch much of the amalgam off as the burnisher contacts the cusp inclines and, in some places, the margins of the preparation. It has been shown that precarve burnishing produces denser amalgam at the margins of restorations.[180] In addition to aiding condensation, precarve burnishing is the first step in shaping the occlusal surface of the restoration.

Carving

Amalgam can be carved with any bladed dental instrument that has a sharp edge. Numerous carvers are available, and each has its own merit. Recommended amalgam carvers that satisfy most amalgam carving needs include a small cleoid-discoid carver, a Walls no. 3 (or Tanner no. 5) carver, a Hollenback no. ½ carver, an interproximal carver, and a no. 14L sickle-shaped carver (see Fig 7-39). In addition, some cutting instruments, such as a small spoon excavator and hoe, make excellent amalgam carvers, especially for carving occlusal anatomy in large restorations. The carving instruments selected should allow the operator to create contours and occlusion that reproduce, or occasionally make improvements to, the missing tooth structure.

Carving can begin immediately after condensation and precarve burnishing. Before the setting of the amalgam is very advanced, amalgam carves very easily, but it is also easy to miscarve or overcarve, so care must be taken. As the setting of the amalgam advances, it does not carve as easily, but it remains carvable with sharp carvers for a long time. In fact, amalgam that has been in the mouth for many years can still be carved with sharp carvers. The need for sharp carvers cannot be overemphasized, and it is advisable to have a sterilized sharpening stone available during placement of a large amalgam restoration. Amalgam seems to cause rapid dulling of carvers, possibly because of the effect of the mercury in penetrating and imparting brittleness [181]

Dentlearn.ir

Most occlusal carving is performed with pulling strokes, but the pushing stroke can also be advantageous in developing occlusal anatomy. Smaller occlusal and Class 2 restorations should be carved with the enamel tooth surface as a guide (Fig 12-55). The carver should rest on the enamel adjacent to the preparation and be pulled in a direction parallel to the margin of the preparation. When a stroke that is perpendicular to the margin of the preparation is needed, the carver should be pulled from enamel to amalgam. If it is pulled from amalgam to enamel, it will be more likely to carve the surface of the amalgam to a level that is below the surface of the enamel. It is desirable that the two surfaces be even (at the same level) so that there is no "step down" from the enamel to the amalgam.

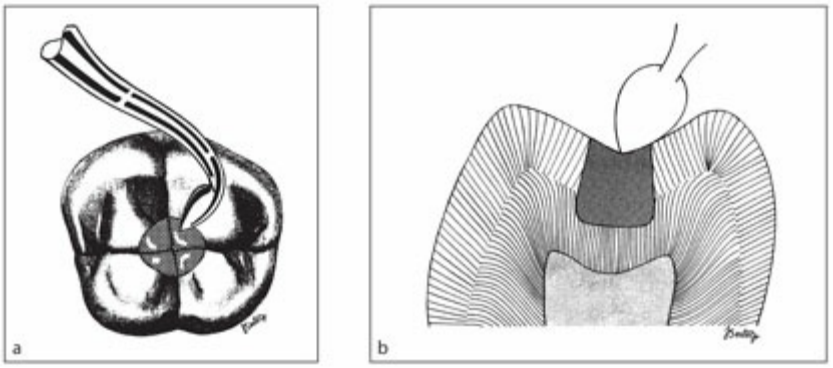

Fig 12-55 The enamel margin is used as a guide for carving smaller restorations. *(a)* Cleoid carver viewed from the occlusal aspect. *(b)* Cleoid carver viewed in cross section.

It is good to register a mental picture of the outline of the preparation before the amalgam is placed so that the outline can be visualized after carving. Amalgam preparations should have enamel margins that are not jagged or rough; if the margins of a carved restoration appear ragged, it will be because of thin amalgam flash that extends outside of the preparation onto the adjacent enamel surface. This flash is more difficult to remove when amalgam bonding resins are used. A sharp carver is even more necessary for effective removal of this flash.

Amalgam should not be overcarved such that groove anatomy is deep, leaving thin fins of amalgam adjacent to the preparation margins. The operator should try to develop margins that will leave a 75- to 90-degree angle at the margin of occlusal amalgam. Acute angles (fins) of amalgam at the margins on an occlusal surface are subject to fracture during function.

For Class 2 restorations, while the matrix is in place, the marginal ridge should be carved very nearly to the height of the adjacent marginal ridge (see Fig 12-62i). Development of the occlusal embrasure of the marginal ridge is begun with the tip of an explorer angled at approximately a 45-degree angle to the long axis of the tooth

Dentlearn.ir

and touching the matrix band (Fig 12-56; see also Fig 12-62j). The explorer tip should be moved from the facial enamel, past the margin of the box, to the center of the marginal ridge and then from the lingual enamel, past the margin of the box, to the center. The explorer should not be moved from the amalgam toward the margin, because this movement could easily result in overcarving, leaving the marginal ridge with a deficient contour.

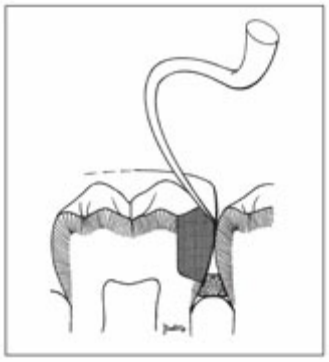

Fig 12-56 The tip of the no. 23 explorer is used at a 45-degree angle to the matrix to begin shaping the occlusal embrasure.

Most carving will be accomplished while the rubber dam is in place. For Class 2 restorations, after the matrix is removed, amalgam flash on proximal surfaces should be removed and the proximal contours should be refined. A thin carver, such as the interproximal carver, is useful for both removing flash and refining proximal contours (Fig 12-57; see also Figs 12-62w to 12-62y). Because the proximal contour is so crucial for periodontal health,[182] removal of the matrix is strongly advocated early in the carving process. While the amalgam is still soft, proper contours, as well as removal of excess amalgam from proximal margins, can readily be achieved. As previously stated, if a bonding system has been used, it is important to minimize the amount of bonding resin at proximal margins to prevent marginal voids that can be produced if the resin at margins is pulled out during carving. A very sharp carver will slice this incompletely set resin instead of catching and dislodging it.

Dentlearn.ir

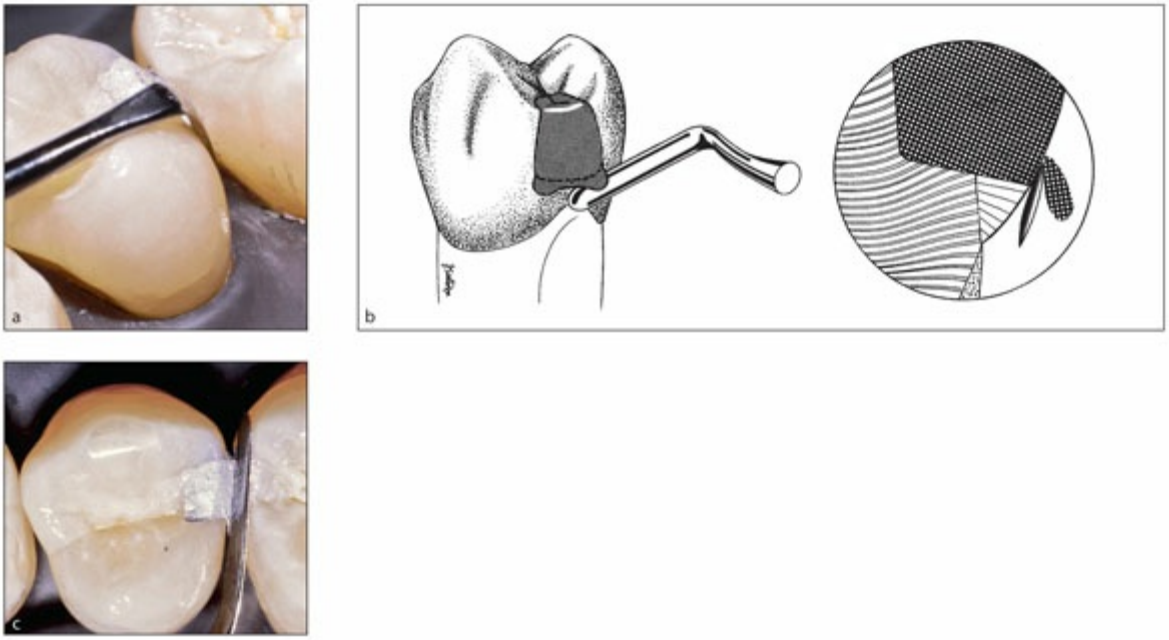

Fig 12-57*(a to c)* An interproximal carver is used to remove flash and to contour and burnish the amalgam in interproximal areas.

Adjusting the occlusion

When the carving appears to be correct, the dam is removed, and the occlusion is checked. This is accomplished with articulating ribbon (Fig 12-58), which marks the points of contact when the mandibular and maxillary teeth are brought together. It is wise not to ask the patient to close, because, if the amalgam has not been carved adequately, it will be "high" in the occlusion so that it contacts first, prior to any other tooth contact. The masseter muscles are very strong, and when the proprioceptive innervation relates to the patient's brain that there is something between the maxillary and mandibular teeth, it is reflex action for the patient to attempt to masticate it. In the case of a high amalgam restoration, disaster can result; the amalgam will usually be fractured, and the operator will have to remove amalgam and begin again.



Fig 12-58*(a)* For initial gross adjustment, a piece of articulating paper with a thickness of 20 µm (0.0008 inch) or more is useful. When articulating paper forceps are used, the total length of the piece of articulating tape or paper should be supported by the forceps. *(b)* For refining occlusion,

Dentlearn.ir

especially in complex amalgam restorations, an articulating tape with a thickness of 15 μm (0.0006 inch) or less is advantageous.

It is therefore best for the operator to perform the tapping of the teeth by grasping the patient's chin, having the patient close to very near contact, and then, by hand, manipulating the mandible so that mandibular and maxillary teeth are tapped together in maximum intercuspation position (MIP). The dentist's arm, no matter how strong, will be unable to impart nearly as much force in mandibular closure as the masseter muscles are capable of achieving. An alternative to this tapping by the dentist is to instruct the patient to "very, very gently, tap the back teeth together."

The amalgam must be carved until contacts on the restoration occur simultaneously with other occlusal MIP contacts on that tooth and adjacent teeth. These can be seen as marks made by articulating ribbon, but they should also be felt by the dentist with 0.0005-inch (12-μm) thick shimstock (Artus) (Fig 12-59). To do this, the patient should be instructed to close in MIP ("bite the back teeth together") while shimstock is in place on the tooth being restored. With the teeth in maximum intercuspation (MI), the shimstock should be held securely in place. The same test should be performed with the shimstock on adjacent teeth, and it should again be held securely (assuming that those teeth held shimstock prior to the restorative procedure). If the adjacent teeth do not hold the shimstock, the newly placed restoration is probably in hyperocclusion and needs additional carving.

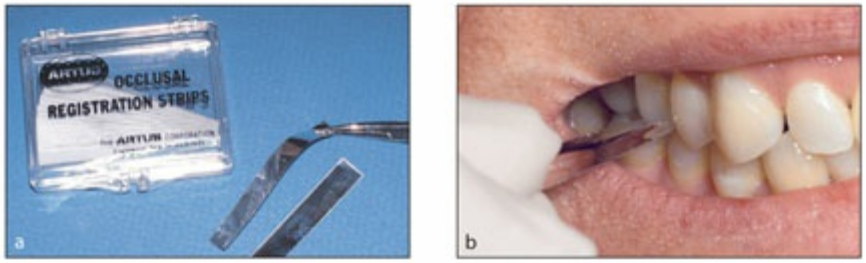

Fig 12-59 *(a)* Silver-colored shimstock (0.0005-inch-thick Mylar) is supplied in books with paper separators between the pieces. It may be held in the fingers or with a hemostat (as shown at right). *(b)* Shimstock is used to "feel" contacts between maxillary and mandibular teeth.

When the restoration occlusion is correct in MI, it must be checked to ensure that no interferences are caused by the restoration in excursive movements (laterotrusive, mediotru-sive [right or left], or protrusive movements) of the mandible. This may also be evaluated with the use of the shimstock. Two colors of articulating ribbon (preferably ribbons that do not easily cause smudge marks) are used, one color for latero-/ mediotrusive and protrusive excursions and the other to mark MI occlusal contacts. To eliminate excursive contacts in the amalgam, the amalgam marked with

Dentlearn.ir

the color used to register the excursions should be carved, and the amalgam marked with the MI marks should be preserved. For complex amalgam restorations, it should be ensured that the restoration does not cause interference in the slide between centric occlusion and MI.

Postcarve burnishing

Postcarve burnishing is the light rubbing of the surface of a carved amalgam restoration with a burnisher, such as the PKT3 (P. K. Thomas). Heavy forces should not be used, and postcarve burnishing should be avoided near the margins of restorations of fast-setting amalgam.[183] The purpose of postcarve burnishing is to smooth the surface of the restoration.

After completion of carving and postcarve burnishing, if the carving time was short and the amalgam is still fairly soft, the surface may be wiped over with a dry or water-damp cotton ball or cotton roll to provide additional smoothing. If the set of the amalgam is advanced so that the cotton will not smooth the surface, a rubber prophylaxis cup with damp flour of pumice or prophylaxis paste will smooth the amalgam (see the section on finishing and polishing). If the cup is used, it should be rotating at a very low speed and should be kept moving at all times; if the cup is allowed to rotate in one place, it will groove the recently carved amalgam.

Placement of amalgam in complex preparations

Several special considerations for placing complex amalgam restorations, such as the possible need for reinforcement of matrices with compound, have already been discussed. Following are some other considerations that may help the operator to successfully place complex amalgam restorations:

- Visualize the finished product, and shape the matrix to allow for that product.
- In addition to visualizing the height of the cusp tips before making the tooth preparation and building cusps back to that height, make a mental picture of facial and lingual contours before cutting away natural tooth structure so that you can reproduce the natural contours in amalgam as closely as possible. Note the contours by viewing down the line of teeth (in profile) from the facial and/or lingual aspect. Make sure that the final contours harmonize with the contours of other teeth in the quadrant (Fig 12-60; see also Fig 12-62ee).

Dentlearn.ir

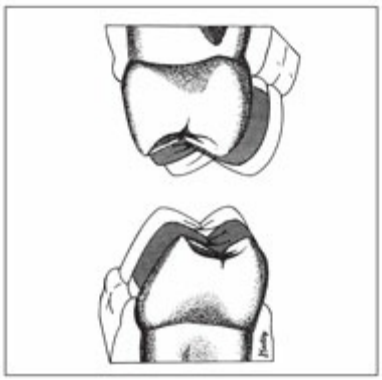

Fig 12-60 Facial and lingual contours are noted by looking down the line of teeth in a quadrant. The contour of the restoration must harmonize with natural tooth contours in the quadrant.

- Place larger increments of amalgam (eg, the entire two-spill [600-mg] mix), when replacing the entire occlusal surface of a molar or a half mix for less extensive restorations.
- Consider the use of carvers that contribute to proper contours, such as the no. 14L carver, which simplifies the carving of convex axial contours (Fig 12-61; see also Fig 12-62q).

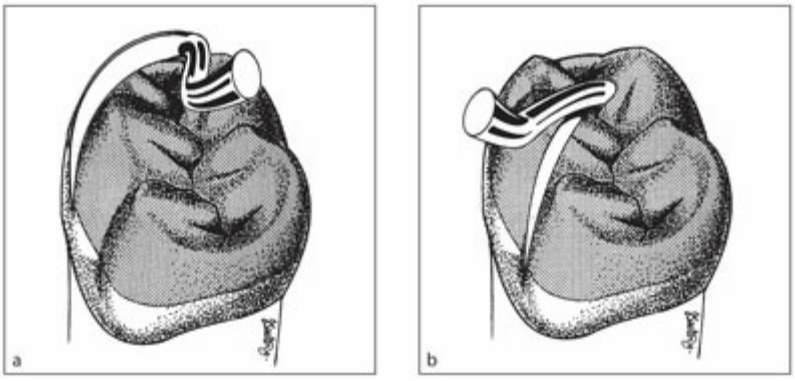

Fig 12-61*(a)* A no. 14L sickle-shaped carver will carve a very convex surface if it approaches the surface to be carved at just less than a 90-degree angle. *(b)* The same instrument will carve a surface with less convexity if it is rotated so that it approaches the surface at an angle of much less than 90 degrees.

- Because carving of large amalgam restorations involves the carving of more surface area, consider sharpening the carvers during the procedure to allow for more efficient carving.
- Smooth the carved amalgam with a water slurry of flour of pumice or with a prophylaxis paste.

A series showing the insertion of a complex amalgam restoration, beginning with matrix application and ending just before rubber dam removal, is shown in Fig 12-

Dentlearn.ir

62. Several amalgam preparations and restorations are shown in Figs 12-63 to 12-74.

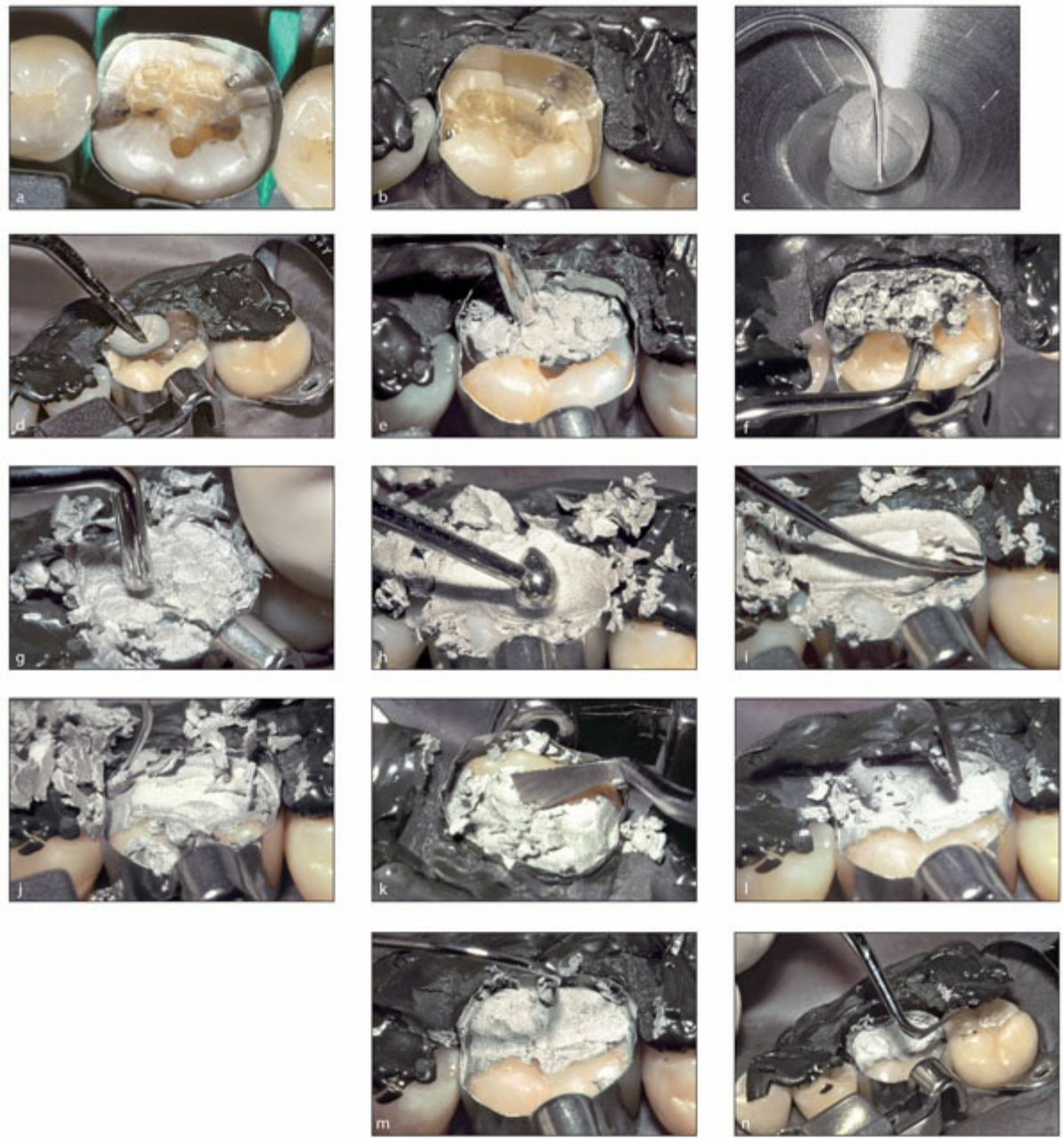

Fig 12-62 Condensation and carving of a complex amalgam restoration. *(a)* A Tofflemire matrix is placed and shaped to provide the desired contours. *(b)* The matrix is stabilized with modeling compound. *(c)* A two-spill mix of amalgam is halved. *(d)* Half of the mix of amalgam is carried to the preparation. *(e)* Amalgam is spread over the entire preparation floor and condensed. *(f)* A cavosurface margins. *(g)* Amalgam increments are added in 1-mm thicknesses until the preparation is overfilled. *(h)* Amalgam shaping is begun with a large ovoid burnisher used to pinch excess amalgam off against the enamel (precarve burnishing). *(i)* Marginal ridge shaping is begun by reducing amalgam in the area to the approximate desired height of the marginal ridge. *(j)* The occlusal embrasure is formed with an explorer tip. *(k and l)* A chisel-shaped carver (Walls no. 3)

Dentlearn.ir

is used to begin shaping cusps and grooves while the matrix is still in place. *(m)* An explorer tip is used to begin shaping the lingual contour inside the matrix. *(n)* The compound and matrix are removed.



Fig 12-62*(cont) (o to q)* A sickle-shaped carver (no. 14L) is used to remove gingival flash, shape proximal surfaces, and shape lingual contour. *(r and s)* The marginal ridge is adjusted to height by resting the carver (Walls no. 3) on the adjacent marginal ridges during carving. *(t to v)* The occlusal anatomy is refined with a hoe. *(w and x)* The proximal contours and contact position are refined with a very thin interproximal carver. *(y)* The occlusal embrasure is refined with an interproximal carver, which is rested on the adjacent enamel to guide the marginal ridge contour. *(z)* The surface is smoothed with a medium-grit prophylaxis paste in a rubber cup.

Dentlearn.ir

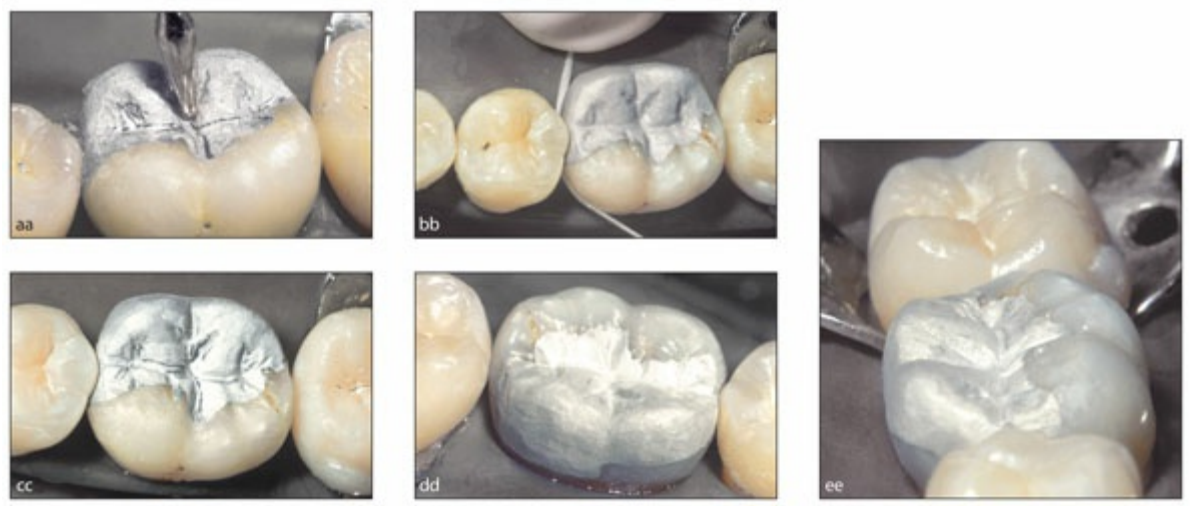

Fig 12-62*(cont) (aa)* The bases of the grooves are smoothed with a burnisher (PKT3). *(bb)* The proximal contours are "felt" with floss to ensure smoothness and to clear any amalgam carvings from the contact. *(cc to ee)* Carving is completed. Note that the lingual contour harmonizes with the contours of the adjacent teeth. The rubber dam is then removed, the occlusion is refined, and the surface is resmoothed with pumice or a prophylaxis paste.

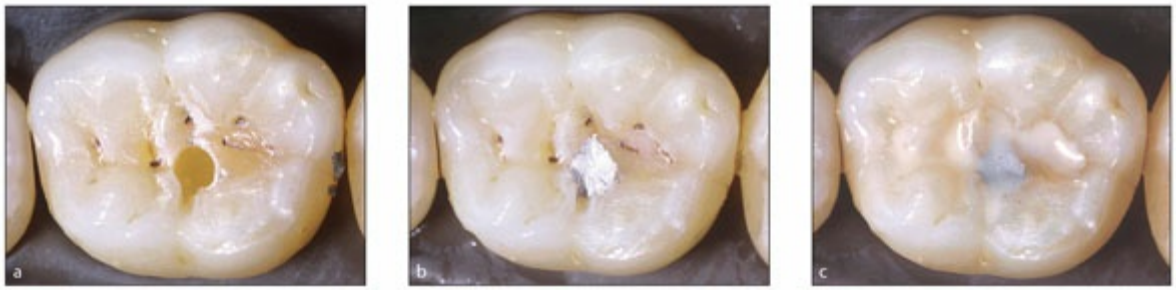

Fig 12-63*(a)* A small area of carious dentin and overlying unsupported enamel has been removed to complete the occlusal amalgam preparation. *(b)* The preparation is filled with amalgam. *(c)* The remaining occlusal fissures were opened with a no. ¼ bur to a depth of 0.5 mm, etched, and sealed with resin fissure sealant.

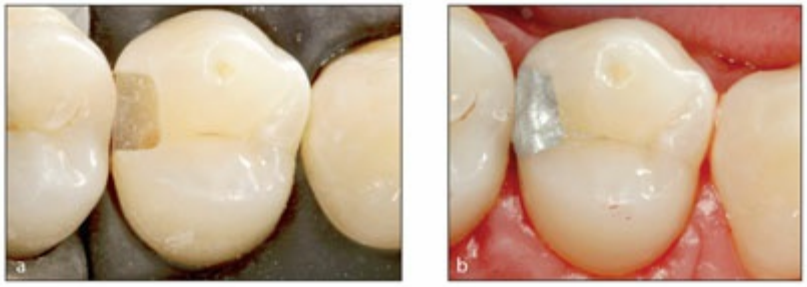

Fig 12-64*(a)* Disto-occlusal slot preparation with retention by bonding. *(b)* Slot restoration. There was no treatment of occlusal fissures.

Dentlearn.ir



Fig 12-65*(a)* Disto-occlusal slot preparation with retention grooves. *(b)* Slot restoration. The occlusal fissure was sealed.

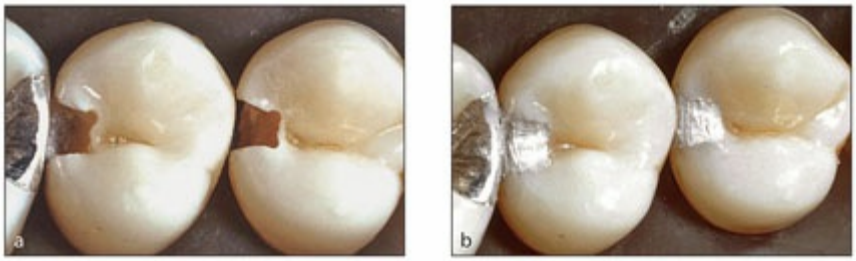

Fig 12-66*(a)* Disto-occlusal slot preparations. *(b)* Slot restorations.

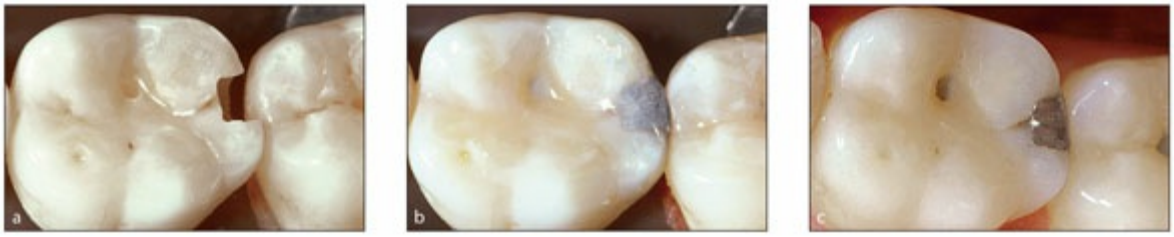

Fig 12-67*(a)* Small occlusal and disto-occlusal slot amalgam preparations. *(b)* Restorations with sealed occlusal fissures. *(c)* Restorations at 2 years.

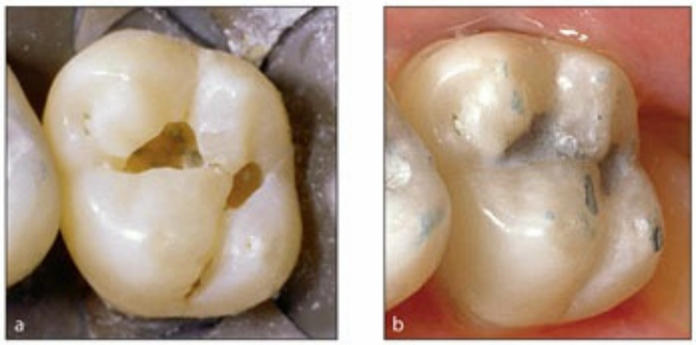

Fig 12-68*(a)* Occlusal preparations. *(b)* Restorations with remaining occlusal and lingual fissures sealed.

Dentlearn.ir

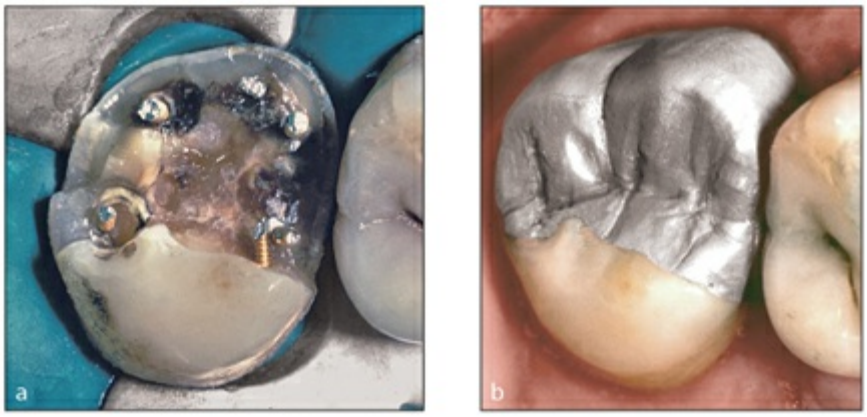

Fig 12-69*(a)* Complex amalgam preparation with vertical and horizontal pins in the molar and a disto-occlusal slot preparation in the premolar. *(b)* Restorations with sealed occlusal fissures.



Fig 12-70*(a)* Old resin composite restoration with recurrent caries. *(b)* Complex amalgam preparation with six vertical pins. *(c)* Complex amalgam restoration.

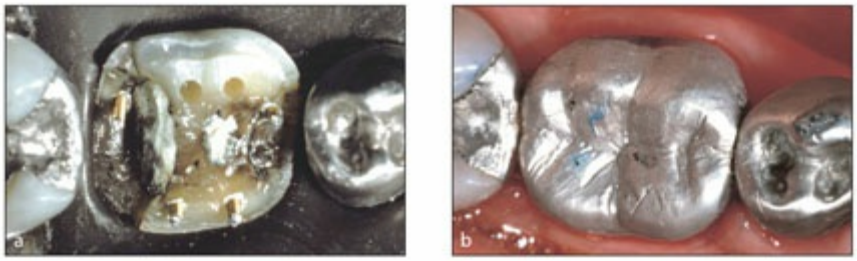

Fig 12-71*(a)* Complex amalgam preparation with pins, boxes, and amalgapins. *(b)* Complex amalgam restoration.



Fig 12-72*(a)* Complex amalgam preparation with boxes, amalgapins, and a shelf. *(b)* Complex amalgam restoration. *(c)* Restoration at 3 years.

Dentlearn.ir

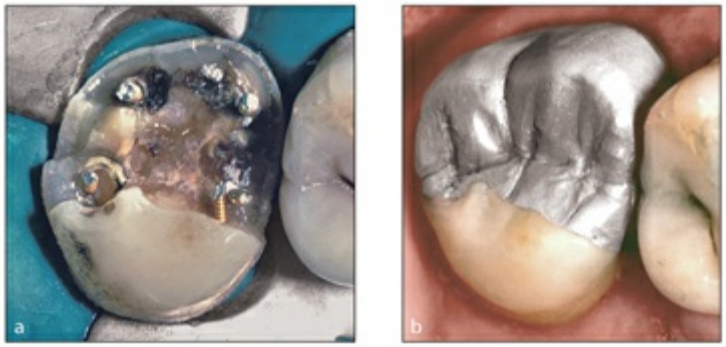

Fig 12-73 *(a)* Complex amalgam preparation with horizontal and vertical pins. *(b)* Complex amalgam restoration.



Fig 12-74 Complex amalgam restoration covering all cusps, with no mechanical retention form prepared; this restoration was bonded with a resin bonding system (Amalgambond Plus with HPA powder): *(a)* preparation; *(b)* completed restoration immediately after placement; *(c)* restoration at 6-year recall.

Finishing and Polishing Amalgam Restorations

Finishing of an amalgam restoration includes evaluating the restoration for problems and correcting them, ensuring that the margins of the amalgam restoration and the cavity-preparation walls are even and that the contours and occlusion are correct, and smoothing the restoration. *Polishing* is defined as smoothing the surface to a point of high gloss or luster. It has been demonstrated that polishing a high-copper amalgam restoration does not enhance its clinical performance,[184] but finishing is an important part of restoration placement. Finishing is usually accomplished at the placement appointment, but it may be refined at succeeding appointments.

Despite the lack of evidence that longevity is increased or performance improved when an amalgam restoration is polished, a high luster is often more comfortable to the patient's tongue than an unpolished surface, so polishing is sometimes desirable. There are no contraindications to polishing a restoration, but care must be taken not to create excessive heat during the polishing procedure. Excessive heat generation may be injurious to the pulp of a vital tooth.

After placement o with a burnisher or

Dentlearn.ir

with cotton until it is smooth. For amalgam with a more advanced set, a rubber cup with wet pumice or a prophylaxis paste may be used to smooth the restoration. Polishing of an amalgam restoration should be accomplished at a succeeding appointment, or at least some time after placement of the restoration. If an amalgam is adequately smoothed immediately after placement, imparting a high luster is usually a very simple and quick procedure.[185] If the restoration is not made smooth at placement, more time is required for polishing.

If, at the time of polishing, the restoration surface is not smooth, it should be smoothed. Gross smoothing of set amalgam can be accomplished with sharp amalgam carvers and finishing burs (Fig 12-75). For polishing convex surfaces (facial, lingual, and proximal), a series of progressively finer disks may be used (Fig 12-76). Alternatives for smoothing and polishing convex surfaces are the abrasive-impregnated rubber cups, using first the coarser cups and then the finer cups (Fig 12-77). Abrasive-impregnated rubber points are useful for smoothing and polishing concave surfaces, such as the occlusal surface. It is especially important that rubber polishers and abrasive disks are used with an abundance of air coolant and intermittent contact with the amalgam to prevent excessive generation of heat, which will bring liquid mercury to the surface of the amalgam, resulting in excessive volatilization of mercury and a weakened amalgam surface.



Fig 12-75 Finishing burs for a friction-grip handpiece: *(top to bottom)* no. 7404 (bud or egg shaped), no. 7803 (bullet shaped), no. 7901 (needle shaped).



Fig 12-76 Abrasive disks, manufactured for polishing resin composite restorations, are also useful for polishing amalgam. The brown-yellow series of Sof-Lex disks and the pop-on mandrel (3M

Dentlearn.ir

ESPE) are shown. Also available is the thicker but more flexible black-blue series of Sof-Lex disks.



Fig 12-77 Brasseler abrasive-impregnated cups and points for polishing amalgam restorations: (*left to right*) coarsest (black), prepolish (brown), high shine (green), and super high shine (green with yellow band).

Although the disks and rubber polishers are more convenient, a less expensive, time-tested alternative method is the use of a prophylaxis cup, first with pumice in a water carrier as the "prepolishing" step, and then with tin oxide in a water or alcohol carrier for a high shine. One study[185] showed the pumice and tin oxide polishing procedure to be faster, but the investigator concluded that the impregnated points and cups are more desirable because they do not produce splatter.

A highly polished amalgam restoration is often more pleasing to the dentist than to the patient. A high polish can make a posterior amalgam restoration more noticeable, and this can be esthetically unpleasant to the patient. If this should occur, air abrasion with 50-µm aluminum oxide (Microetcher, Danville Engineering) or abrasion with pumice and a prophylaxis cup may be used to eliminate the high shine without making the restoration noticeably rough to the patient's tongue.

Repair of Amalgam Restorations

When an amalgam restoration has a defective area but the remainder of the restoration is adequate, a repair procedure may be the most appropriate treatment. For instance, if a cusp that was left in place adjacent to an amalgam restoration has fractured but the remaining amalgam restoration is serviceable, it might be appropriate to simply build a new cusp with amalgam. Or, if an amalgam fracture has occurred in the mesial box portion of a mesio-occlusodistal restoration but the remaining disto-occlusal portion involves a very gingivally deep distal margin, the

Dentlearn.ir

most conservative and simplest treatment might be to replace only the mesio-occlusal portion of the restoration.

Attachment of new amalgam to old can be achieved, but the attachment strength is only 30% to 60% of unrepaired amalgam.[82,186,187] Additional mechanical retention should be considered.

References

1. Webster's Unabridged Dictionary of the English Language. New York: Portland House, 1989.
2. Anusavice KJ. Phillips' Science of Dental Materials, ed 10. Philadelphia: Saunders, 1996.
3. Innes DB, Youdelis WV. Dispersion strengthened amalgam. J Can Dent Assoc 1963;29:587–593.
4. Mahler DB. Discovery! The high-copper dental amalgam alloys. J Dent Res 1997;76:537–541.
5. Craig RG. Restorative Dental Materials, ed 9. St Louis: Mosby-Year Book, 1993.
6. Guthrom CE, Johnson LD, Lawless KR. Corrosion of dental amalgam and its phases. J Dent Res 1983;62:1372–1381.
7. Marek M, Okabe T, Butts MB, Fairhurst CW. Corrosion of the eta'(Cu-Sn) phase in dental amalgam. J Biomed Mater Res 1983;17:921–929.
8. Mitchell RJ, Okabe T. Setting reactions in dental amalgam. Part 1. Phases and microstructures between one hour and one week. Crit Rev Oral Biol Med 1996;7:12–22.
9. Sarkar NK, Park JR. Mechanism of improved corrosion resistance of Zn-containing dental amalgams. J Dent Res 1988;67:1312–1316.
10. Osborne JW, Berry TG. Zinc containing high copper amalgam: A three-year clinical evaluation. Am J Dent 1992;5:43–45.
11. Osborne JW, Norman RD. 13-year clinical assessment of 10 amalgam alloys. Dent Mater 1990;6:189–194.
12. Letzel H, van't Hof MA, Marshall GW, Marshall SJ. The influence of amalgam alloy on the survival of amalgam restorations: A secondary analysis of multiple controlled trials. J Dent Res 1997;76:1787–1798.
13. Schoonover IC, Souder W, Beall JR. Excessive expansion of dental amalgam. J Am Dent Assoc 1942;29:1825–1832.
14. Osborne JW, Howell ML. Effects of water contamination on certain properties of high copper amalgams. Am J Dent 1994;7:337–341.
15. Osborne JW. Expansion of contaminated dental amalgams assessed by photoelastic resin [abstract 2556]. J Dent Res 1998;77(special issue B):951.
16. Yamada T, Fusayama T. Effect of moisture contamination on high copper amalgam. J Dent Res 1981;60:716–723.
17. Pashley EL, Galloway SE, Pashley DH. Protective effects of cavity liners on dentin. Oper Dent 1990;15:11–17.
18. Demaree NC, Taylor DF. Properties of dental amalgams made from spherical alloy particles. J Dent Res 1962;41:890–896.
19. Osborne JW. Safety of dental amalgam. J Esthet Restor Dent 2004;16:377–388.
20. Dodes JE. The amalgam controversy. An evidence-based analysis. J Am Dent Assoc 2001;132:348–356.
21. Berglund A. Estimation by a 24-hour study of the daily dose of intraoral mercury vapor inhaled after release from dental amalgam. J Dent Res 1990;69:1646–1651.
22. Ahlquist M, Bergtsson C, Furnes B. Number of amalgam fillings in relation to cardiovascular disease, diabetes, cancer, and early death in Swedish women. Community Dent Oral Epidemiol 1988;16:227–231.
23. Björkman L, Pedersen NA, Lichtenstein P. Physical and mental health related to dental amalgam fillings in Swedish twins. Community Dent Oral Epidemiol 1996;24:260–267.
24. Henningsson M, Sundbom E. Defensive characteristics in individuals with amalgam illness as measured by

Dentlearn.ir

the percept-genetic method Defense Mechanism Test. Acta Odontol Scand 1996;54:176–181.
25. Kingman A, Albertini T, Brown LJ. Mercury concentration in urine and whole blood associated with amalgam exposure in a US military population. J Dent Res 1998;77:461–471.
26. US Department of Health and Human Services, Food and Drug Administration. Dental Devices: Classification of Dental Amalgam, Reclassification of Dental Mercury, Designation of Special Controls for Dental Amalgam, Mercury, and Amalgam Alloy. Federal Register 2009; 74(148):38685–38713.
27. Bains VK, Loomba K, Loomba A, Bains, R. Mercury sensitization: Review, relevance and a clinical report. Br Dent J 2008;205:373–378.

alleged adverse effects from dental amalgams. Acta Odontol Scand 1992;50:101–111.
29. Bagedahl-Strindlund M, Ilie M, Furhoff AK, et al. A multidisciplinary clinical study of patents suffering from illness associated with mercury released from dental restorations: Psychiatric aspects. Acta Psychiatr Scand 1997;96:475–482.
30. Bratel J, Haraldson T, Ottosson JO. Potential side effects of dental amalgam restorations: No relation between mercury levels in the body and mental disorders. Eur J Oral Sci 1997;105:244–250.
31. Mackert JR, Berglund A. Mercury exposure from dental amalgam fillings: Absorbed dose and the potential for adverse health effects. Crit Rev Oral Biol Med 1997;8:411–436.
32. Sundström A, Bergdahl J, Hyberg L, Bergdahl M, Nilsson LG. Cognitive status in persons with amalgam-related complaints. J Dent Res 2010;89:1236–1240.
33. Lauterbach M, Martins IP, Castro-Caldas A, et al. Neurological outcomes in children with and without amalgam-related mercury exposure: Seven years of longitudinal observations in a randomized trial. J Am Dent Assoc 2008;139:138–145.
34. Eyeson J, House I, Yang YH, Warnakulasuriya KA. Relationship between mercury levels in blood and urine and complaints of chronic mercury toxicity from amalgam restorations. Br Dent J 2010;208(4):E7.
35. Molin M, Bergman B, Marklund SL, Schutz A, Skerfving S. Mercury, selenium, and glutathione peroxidase before and after amalgam removal in man. Acta Odontol Scand 1990;48:189–202.
36. Sandborgh-Englund G, Elinder CG, Langworth S, Schutz A, Ekstrand J. Mercury in biological fluids after amalgam removal. J Dent Res 1998;77:615–626.
37. WHO consensus statement on dental amalgam. FDI World Dental Federation. FDI World 1997;6:9.
38. US Department of Health and Human Services, Public Health Service. Dental Amalgam: A Scientific Review and Recommended Public Health Service Strategy for Research, Education, and Regulation. Washington, DC: US Department of Health and Human Services, Public Health Service, Jan 1993.
39. National Institutes of Health. Technology Assessment Conference. Effects and Side-Effects of Dental Restorative Materials. Bethesda, MD: US Department of Health and Human Services, 1991.
40. Bergman B, Bostrom H. Larsson KS, Loe H (eds). Potential Biological Consequences of Mercury Released from Dental Amalgam. A State of the Art Conference in Stockholm, April 1992. Stockholm: Swedish Medical Research Council, 1992.
41. Berry TG, Nicholson J, Troendle K. Almost two centuries with amalgam: Where are we today? J Am Dent Assoc 1994;125:392–399.
42. Corbin SB, Kohn WG. The benefits and risks of dental amalgam: Current findings reviewed. J Am Dent Assoc 1994;125:381–388.

14 June 2013.
44. Miller A, Okabe T, DePaola DP, Cole JS. Amalgam and mercury toxicity: An update. Tex Dent J 1991;108:25–29.
45. Rapp U, Stiesch M, Reh H, Kapp A, Werfel T. Investigation of contact allergy to dental metals in 206 patients. Contact Dermatitis 2009:60; 339–343.
46. Kal BI, Evcin O, Dundar N, Tezel H, Unal I. An unusual case of immediate hypersensitivity reaction associated with an amalgam restoration. Br Dent J 2008;205:547–550.
47. Clinical Research Associates. Clinicians' preferences 2005: Survey data from 1652 random CRA Newsletter

Dentlearn.ir

48. Swartz ML, Phillips RW. In vitro studies on the marginal leakage of restorative materials. J Am Dent Assoc 1961;62:141–151.
49. Paolantonio M, D'ercole S, Perinetti G, et al. Clinical and microbiological effects of different restorative materials on the periodontal tissues adjacent to subgingival Class V restorations. J Clin Periodontol 2004;31:200–207.
50. Bogacki RE, Hunt RJ, del Aguila M, Smith WR. Survival analysis of posterior restorations using an insurance claims database. Oper Dent 2002;27:488–492.
51. Szep S, Barm C, Alamouti C, Schmidt D, Gerhard T, Heidemann D. Removal of amalgam, glass-ionomer cement and compomer restorations: Changes in cavity dimensions and duration of the procedure. Oper Dent 2002;17:613–620.
52. Gordan VV, Mondragon E, Shen C. Replacement of resin-based composite: Evaluation of cavity design, cavity depth, and shade matching. Quintessence Int 2002;33:273–278.
53. Mjör IA, Reep RL, Kubilis PS, Mondragon BE. Change in size of replaced amalgam restorations: A methodological study. Oper Dent 1998;23:272–277.
54. Krejci I, Lieber CM, Lutz F. Time required to remove totally bonded tooth-colored posterior restorations and related tooth substance loss. Dent Mater 1995;11:34–40.
55. Wahl MJ, Schmitt MM, Overton DA, Gordon MK. Prevalence of cusp fractures in teeth restored with amalgam and with resin-based composite. J Am Dent Assoc 2004;135:1127–1132.
56. Nakabayashi N, Watanabe A, Gendusa NJ. Dentin adhesion of "modified" 4-META/MMA-TBB resin: Function of HEMA. Dent Mater 1992; 8:259–264.
57. Ferracane JL, Engle JH, Okabe T, Mitchem JC. Reduction in operatory mercury levels after contamination or amalgam removal. Am J Dent 1994;7:103–107.
58. Engle JH, Ferracane JL, Wichmann J, Okabe T. Quantitation of total mercury vapor released during dental procedures. Dent Mater 1992;8:176–180.
59. Mjör IA, Jokstad A, Qvist V. Longevity of posterior restorations. Int Dent J 1990;40:11–17.
60. Osborne JW, Norman RD, Gale EN. A 14-year clinical assessment of 12 amalgam alloys. Quintessence Int 1991;22:857–864.
61. Robbins JW, Summitt JB. Longevity of complex amalgam restorations. Oper Dent 1988;13:54–57.
62. Smales RJ. Longevity of cusp-covered amalgams: Survivals after 15 years. Oper Dent 1991;16:17–20.
63. Smales RJ, Hawthorne WS. Long-term survival of extensive amalgams and posterior crowns. J Dent 1997;25(3–4):225–227.
64. Osborne JW, Summitt JB. Extension for prevention: Is it relevant today? Am J Dent 1998;11:189–196.
65. Berry TG, Laswell HR, Osborne JW, Gale EN. Width of isthmus and marginal failure of restorations of amalgam. Oper Dent 1981;6:55–58.
66. Blaser PK, Lund MR, Cochran MA, Potter RH. Effects of designs of Class 2 preparations on resistance of teeth to fracture. Oper Dent 1983;8:6–10.
67. Larson TD, Douglas WH, Geisfeld RE. Effect of prepared cavities on the strength of teeth. Oper Dent 1981;6:2–5.
68. Osborne JW, Gale EN. Relationship of restoration width, tooth position, and alloy to fracture at the margins of 13- to 14-year-old amalgams. J Dent Res 1990;69:1599–1601.
69. Vale WA. Cavity preparation. Irish Dent Rev 1956;2:33–41.
70. Caron GA, Murchison DF, Broom JC, Cohen RB. Resistance to fracture of teeth with various preparations for amalgam [abstract 208]. J Dent Res 1994;73:127.
71. El-Mowafy OM. Fracture strength and fracture patterns of maxillary premolars with approximal slot cavities. Oper Dent 1993;18:160–166.
72. Summitt JB, Osborne JW. Initial preparations for amalgam restorations. J Am Dent Assoc 1992;123:67–72.
73. Glossary of Operative Dentistry Terms. Washington DC: Academy of Operative Dentistry, 1983.
74. Dachi SF, Stigers RW. Reduction of pulpal inflammation and thermal sensitivity in amalgam-restored teeth treated with copal varnish. J Am Dent Assoc 1967;74:1281–1285.

Dentlearn.ir

75. Kramer PF, Zelante F, Simionato MRL. The immediate and long-term effects of invasive and noninvasive pit and fissure sealing techniques on the microflora in occlusal fissures of human dentin. Pediatr Dent 1993;16:108–112.
76. Shapira J, Eidelman E. The influence of mechanical preparation of enamel prior to etching on the retention of sealants: Three-year follow-up. J Pedod 1984;8:272–277.
77. Brocklehurst PR, Joshi RI, Northeast SE. The effect of air-polishing occlusal surfaces on the penetration of fissures by a sealant. Int J Paediatr Dent 1992;2:157–162.
78. DeCraene LG, Martens LC, Dermaut LR, Surmont PA. A clinical evaluation of a light-cured fissure sealant (Helioseal). J Dent Child 1989;56:97–102.
79. Garcia-Godoy F, Medlock JW. An SEM study of the effects of air-polishing on fissure surfaces. Quintessence Int 1988;19:465–467.
80. Goldstein RE, Parkins FM. Using air-abrasive technology to diagnose and restore pit and fissure caries. J Am Dent Assoc 1995;126:761–766.
81. Vesterhus Strand G, Raadal M. The efficiency of cleaning fissures with an air-polishing instrument. Acta Odontol Scand 1988;46:113–117.
82. Jeronimus DJ Jr, Till MJ, Sveen OB. Reduced viability of microorganisms under dental sealants. ASDC J Dent Child 1975;42:275–280.
83. Handelman SL, Washburn F, Wopperer P. Two-year report of sealant effect on bacteria in dental caries. J Am Dent Assoc 1976;93:967–970.
84. Handelman SL, Leverett DH, Iker HP. Longitudinal radiographic evaluation of the progress of caries under sealants. J Pedod 1985;9:119–126.
85. Mertz-Fairhurst EJ, Schuster GS, Williams JE, Fairhurst CW. Clinical progress of sealed and unsealed caries. Part I: Depth changes and bacterial counts. J Prosthet Dent 1979;42:521–526.
86. Swift EJ. The effect of sealants on dental caries: A review. J Am Dent Assoc 1988;116:700–704.
87. Going RE, Loesche WJ, Grainger DA, Syed SA. The viability of microorganisms in carious lesions five years after covering with a fissure sealant. J Am Dent Assoc 1978;97:455–462.
88. Jensen ME, Handelman SL. Effect of an autopolymerizing sealant on viability of microflora in occlusal dental caries. Scand J Dent Res 1980;88:382–388.
89. Mertz-Fairhurst E, Smith CD, Williams JE, et al. Cariostatic and ultraconservative sealed restorations: Six-year results. Quintessence Int 1992;23:827–838.
90. Mertz-Fairhurst E, Curtis JW, Ergle JW, Rueggeberg FA, Adair SM. Ultraconservative and cariostatic sealed restorations: Results at year 10. J Am Dent Assoc 1998;129:55–66.
91. Cassin AM, Pearson GJ, Picton DC. Fissure sealants as a means of prolonging longevity of amalgam restorations—An in-vitro feasibility study. Clin Mater 1991;7:203–207.
92. Gordan VV, Riley JL 3rd, Blaser PK, Mondragon E, Garvan CW, Mjör IA. Alternative treatments to replacement of defective amalgam restorations: Results of a seven-year clinical study. J Am Dent Assoc 2011;142:842–849.
93. Fernandes DP, Chevitarese O. The orientation and direction of rods in dental enamel. J Prosthet Dent 1991;65:793–800.
94. De C Luz MA, Ciaramicoli-Rodrigues MT, Garone Netto N, De Lima AC. Long-term clinical evaluation of fracture and pulp injury following glass-ionomer cement or composite resin applied as a base filling in teeth restored with amalgam. J Oral Rehabil 2001;28:634–639.
95. Anderson MH, Bales DJ, Omnell KA. Modern management of dental caries: The cutting edge is not the dental bur. J Am Dent Assoc 1993;124:37–44.
96. Anusavice KJ. Treatment regimens in preventive and restorative dentistry. J Am Dent Assoc 1995;126:727–743.
97. González-Cabezas C. The chemistry of caries: Remineralization and demineralization events with direct clinical relevance. Dent Clin North Am 2010;54:469–478.
98. Garcia-Godoy F, Summitt J, Donly K, Buikema D. Resistance to further demineralization of white spot lesions by sealing [abstract 1643]. J Dent Res 1993;72:309.

Dentlearn.ir

99. Paris S, Hopfenmuller W, Meyer-Lueckel H. Resin infiltration of caries lesions: An efficacy randomized trial. J Dent Res 2010;89:823–826.
100. Qvist V, Johannessen L, Bruun M. Progression of approximal caries in relation of iatrogenic preparation damage. J Dent Res 1992;71:1370–1373.
101. Summitt JB, Osborne JW, Burgess JO, Howell ML. Effect of grooves on resistance form of Class 2 amalgams with wide occlusal preparations. Oper Dent 1993;18:42–47.
102. Summitt JB, Howell ML, Burgess JO, Dutton FB, Osborne JW. Effect of grooves on resistance form of conservative Class 2 amalgams. Oper Dent 1992;17:50–56.
103. Summitt JB, Osborne JW, Burgess JO. Effect of grooves on resistance/ retention form of Class 2 approximal slot amalgam restorations. Oper Dent 1993;18:209–213.
104. Sturdevant JR, Taylor DF, Leonard RH, Straka WF, Roberson TM, Wilder AD. Conservative preparation designs for Class II amalgam restorations. Dent Mater 1987;3:144–148.
105. Battock RD, Rhoades J, Lund MR. Management of proximal caries on the roots of posterior teeth. Oper Dent 1979;4:108–112.
106. Liberman R, Judes H, Cohen E, Eli I. Restoration of posterior pulpless teeth: Amalgam overlay versus cast gold onlay restorations. J Prosthet Dent 1987;57:540–543.
107. Summitt JB, Burgess JO, Berry TG, Robbins JW, Osborne JW, Haveman CW. Six-year clinical evaluation of bonded and pin-retained complex amalgam restorations. Oper Dent 2004;29:269–276.
108. Dwinelle WH. Crystalline gold, its varieties, properties, and use. Am J Dent Sci 1855;5:249–297.
109. How WS. Bright metal screw posts and copper amalgam. Dent Cosmos 1839;31:237–238.
110. Markley MR. Pin reinforcement and retention of amalgam foundations. J Am Dent Assoc 1958;56:675–679.
111. Markley MR. Pin-retained and pin-reinforced amalgam. J Am Dent Assoc 1966;73:1295–1300.
112. Markley MR. Pin retained and reinforced restorations and foundations. Dent Clin North Am 1967;3:229–244.
113. Goldstein PM. Retention pins are friction-locked without use of cement. J Am Dent Assoc 1966;73:1103–1106.
114. Going RE. Pin-retained amalgam. J Am Dent Assoc 1966;73:619–624.
115. Dilts WE, Welk DA, Stovall J. Retentive properties of pin materials in pin-retained silver amalgam restorations. J Am Dent Assoc 1968; 77:1085–1089.
116. Moffa JP, Razzano MR, Doyle MG. Pins—A comparison of their retentive properties. J Am Dent Assoc 1969;78:529–535.
117. Dilts WE, Duncanson MG, Collard EW, Parmley LE. Retention of self-threading pins. J Can Dent Assoc 1981;47:119–120.
118. Burgess JO, Summitt JB. Retention and resistance provided by nine self-threading pins. Oper Dent 1991;16:55–60.
119. Marshall TD, Porter KH, Re GJ. In vitro evaluation of the shoulder stop in a self-threading pin. J Prosthet Dent 1986;56:428–430.
120. Eames WB, Solly MJ. Five threaded pins compared for insertion and retention. Oper Dent 1980;5:66–71.
121. Buikema DJ, Mayhew RB, Voss JE, Bales DJ. Pins and their relation to cavity resistance form for amalgam. Quintessence Int 1985;16:187–190.
122. Gourley JV. Favorable locations for pins in molars. Oper Dent 1980; 5:2–6.
123. Cooley RL, Marshall TD, Young JM, Huddleston AM. Effect of sterilization on the strength and cutting efficiency of twist drills. Quintessence Int 1990;21:919–923.
124. Ulusoy N, Denli N, Atakul F, Nayyar A. Thermal response to multiple use of a twist drill. J Prosthet Dent 1992;67:450–453.
125. Marshall TD, Cooley RL. Evaluation of the Max titanium alloy retentive pins. Am J Dent 1989;2:349–353.

1989;2:81–85.
127. Podshadley AG, Chambers MS. A new instrument for placement of self-threading retention pins. J Prosthet Dent 1994;71:429.

Dentlearn.ir

128. Burgess JO. Horizontal pins: A study of tooth reinforcement. J Prosthet Dent 1985;53:317–322.
129. Lambert RL, Robinson FB, Lindemuth JS. Coronal reinforcement with cross-splinted pin-amalgam restorations. J Prosthet Dent 1985;54:346–349.
130. Collins JF, Antonson DE. Treatment of external pin perforations. J Acad Gen Dent 1987;35:200–202.
131 Birtcil RF, Venton EA. Extracoronal amalgam restorations utilizing available tooth structure for retention. J Prosthet Dent 1976;35:171–178.
132. Outhwaite WC, Garman TA, Pashley DH. Pin vs. slot retention in extensive amalgam restorations. J Prosthet Dent 1979;41:396–400.
133. Seng GF, Rupell OL, Nance GL, Pompura JP. Placement of retentive amalgam inserts in tooth structure for supplemental retention. J Acad Gen Dent 1980;28:62–66.
134. Shavell HM. The amalgapin technique for complex amalgam restorations. J Calif Dent Assoc 1980;8:48–55.
135. Davis SP, Summitt JB, Mayhew RB, Hawley RJ. Self-threading pins and amalgapins compared in resistance form for complex amalgam restorations. Oper Dent 1983;8:88–93.

amalgapin-retained restorations. Oper Dent 1987;12:2–9.
137. Leach CD, Martinoff JT, Lee CV. A second look at the amalgapin technique. J Calif Dent Assoc 1983;11:43–49.
138. Summitt JB, Rindler EA, Robbins JW, Burgess JO. Effect of distribution of resistance features in complex amalgam restorations. Oper Dent 1994;19:53–58.
139. Plasmans PJ, Kusters ST, Thissen AM, Van't Hof MA, Vrijhoef MM. Effects of preparation design on the resistance for extensive amalgam restorations. Oper Dent 1987;12:42–47.
140. Certosimo AJ, House RC, Anderson MH. The effect of cross-sectional area on transverse strength of amalgapin-retained restorations. Oper Dent 1991;18:70–76.
141. Burgess JO, Hartsfield C, Jordan T. Strength of amalgam with varying amalgam thickness covering the pins [abstract 549]. J Dent Res 1990;69:177.
142. Belcher MA, Stewart GP. Two-year clinical evaluation of an amalgam adhesive. J Am Dent Assoc 1997;128:309–314.
143. Mach Z, Ruzickova T, Staninec M, Setcos JC. Bonded amalgam restorations: Three-year clinical results [abstract 3106]. J Dent Res 1998;77 (special issue B):1020.
144. Setcos JC, Staninec M, Wilson NH. Clinical evaluation of bonded amalgam restorations over two years [abstract 2589]. J Dent Res 1998; 77(special issue B):955.
145. Staninec M, Marshall GW, Lowe A, Ruzickova T. Clinical research on bonded amalgam restorations. Part 1: SEM study of in vivo bonded amalgam restorations. Gen Dent 1997;45:356–360,362.
146. Smales RJ, Wetherell JD. Review of bonded amalgam restorations and assessment in a general practice over five years. Oper Dent 2000;25:374–381.
147. Burgess JO, Alvarez AN, Summitt JB. Fracture resistance of complex amalgams. Oper Dent 1997;22:128–132.
148. Imbery TA, Burgess JO, Batzer RC. Comparing the resistance of dentin bonding agents and pins in amalgam restorations. J Am Dent Assoc 1995;126:753–758.
149. Imbery TA, Hilton TJ, Reagan SE. Retention of complex amalgam restorations using self-threading pins, amalgapins, and Amalgambond. Am J Dent 1995;8:117–121.
150. Lo CS, Millstein PL, Nathanson D. In vitro shear strength of bonded amalgam cores with and without pins. J Prosthet Dent 1995;74:385–391.
151. Diefenderfer KE, Reinhardt JW. Shear bond strengths of ten adhesive resin/amalgam combinations. Oper Dent 1997;22:50–56.
152. Ruzickova T, Staninec M, Marshall GW. SEM analysis of resin-amalgam adhesion after debonding [abstract 2289]. J Dent Res 1994;73(special issue):388.
153. Summitt JB, Miller B, Buikema DJ, Chan DC. Shear bond strength of Amalgambond Plus cold and at room temperature [abstract 1345]. J Dent Res 1998;77(special issue A):274.
154. Miller B, Chan DC, Cardenas HL, Summitt JB. Powder additive effect on shear bond strengths of bonded

Dentlearn.ir

amalgam [abstract 1346]. J Dent Res 1998;77(special issue A):274.
155. Ben-Amar A, Liberman R, Judes H, Nordenberg D. Long-term use of dentine adhesive as an interfacial sealer under Class II amalgam restorations. J Oral Rehabil 1990;17:37–42.
156. Berry FA, Tjan AH. Microleakage of amalgam restorations lined with dentin adhesives. Am J Dent 1994;7:333–336.
157. Charlton DG, Moore BK, Swartz ML. In vitro evaluation of the use of resin liners to reduce microleakage and improve retention of amalgam restorations. Oper Dent 1992;17:112–119.
158. Dutton FB, Summitt JB, Chan DC, Garcia-Godoy F. Effect of a resin lining and rebonding on the marginal leakage of amalgam restorations. J Dent 1993;21:52–56.
159. Korale ME, Meiers JC. Microleakage of dentin bonding systems used with spherical and admixed amalgams. Am J Dent 1996;9:249–252.
160. Tangsgoolwatana J, Cochran MA, Moore BK, Li Y. Microleakage evaluation of bonded amalgam
161. Browning WD, Johnson WW, Gregory PN. Postoperative pain following bonded amalgam restorations. Oper Dent 1997;22:66–71.
162. Kennington B, Davis RD, Murchison DF. Short-term clinical evaluation of post-operative sensitivity with bonded amalgams. Am J Dent 1998;11:177–180.
163. Davis R, Overton JD. Efficacy of bonded and nonbonded amalgam in the treatment of teeth with incomplete fractures. J Am Dent Assoc 2000;131:469–478.
164. Boyer DB, Roth L. Fracture resistance of teeth with bonded amalgams. Am J Dent 1994;7:91–94.
165. Eakle WS, Staninec M, Lacy AM. Effect of bonded amalgam on the fracture resistance of teeth. J Prosthet Dent 1992;68:257–260.
166. Oliveira JP, Cochran MA, Moore BK. Influence of bonded amalgam restorations on the fracture strength of teeth. Oper Dent 1996;21:111–115.
167. Pilo R, Brosh T, Chweidan H. Cusp reinforcement by bonding of amalgam restorations. J Dent 1998;26:467–472.
168. Bonilla E, White SN. Fatigue of resin-bonded amalgam restorations. Oper Dent 1996;21:122–126.
169. Gwinnett AJ, Yu S. Effect of long-term water storage on dentin bonding. Am J Dent 1995;8:109–111.
170. Santos AC, Meiers JC. Fracture resistance of premolars with MOD amalgam restorations lined with Amalgambond. Oper Dent 1994;19:2–6.
171. Bell JG. An elementary study of deformation of molar teeth during amalgam restorative procedures. Aust Dent J 1977;22:177–181.
172. Powell GL, Nicholls JI, Shurtz DE. Deformation of human teeth under the action of an amalgam matrix band. Oper Dent 1977;2:64–69.
173. Powell GL, Nicholls JI, Molvar MP. Influence of matrix bands, dehydration, and amalgam condensation on deformation of teeth. Oper Dent 1980;5:95–101.
174. Mahler DB. The amalgam-tooth interface. Oper Dent 1996;21:230–236.
175. Brown IH, Miller DR. Alloy particle shape and sensitivity of high-copper amalgams to manipulative variables. Am J Dent 1993;6:248–254.
176. Osborne JW, Phillips RW, Norman RD, Swartz ML. Influence of certain manipulative variables upon the static creep of amalgam. J Dent Res 1977;56:616–621.
177. Brown IH, Maiolo C, Miller DR. Variation in condensation pressure during clinical packing of amalgam restorations. Am J Dent 1993;6:255–259.
178. Overton JD, Vance RI. Effect of adhesive volume on the bond strength of bonded complex amalgam restorations. Am J Dent 2005;18:320–326.
179. Charlton DG, Murchison DF, Moor BK. Incorporation of adhesive liners in amalgam: Effect on compressive strength and creep. Am J Dent 1991;4:184–188.
180. Kanai S. Structure studies of amalgam. II. Effect of burnishing on the margins of occlusal amalgam fillings. Acta Odontol Scand 1966;24:47–53.
181. Kolman DG. Liquid metal induced embrittlement. ASM Handbook Vol 13A: Corrosion: Fundamentals,

Dentlearn.ir

Testing, and Protection. Materials Park, OH: ASM International, 2003:381–392.
182. Hazen SP, Osborne JW. Relationship of operative dentistry to periodontal health. Dent Clin North Am 1967;Mar:245–254.
183. Woods PW, Marker VA, McKinney TW, Miller BH, Okabe T. Determining amalgam marginal quality: Effect of occlusal surface condition. J Am Dent Assoc 1993;124:60–65.
184. Mayhew RB, Schmeltzer LD, Pierson WP. Effect of polishing on the marginal integrity of high-copper amalgams. Oper Dent 1986;11:8–13.
185. Eames WB. A clinical view of dental amalgam. Dent Clin North Am 1976;20:385–395.
186. Diefenderfer KE, Reinhardt JW, Brown SB. Surface treatment effects on amalgam repair strength. Am J Dent 1997;10:9–14.
187. Jessip JP, Vandervalle KS, Hermesch CB, Buikema DS. Effects of surface treatments on amalgam repair. Oper Dent 1998;23:15–20.

Dentlearn.ir



Diagnosis and Treatment of Root Caries

Bruce A. Matis
Carlos González-Cabezas
Michael A. Cochran

Evidence indicates that root caries was the major dental problem in ancient civilizations.[1,2] Today, demographic predictors suggest that root caries could become one of the more significant patient management issues of the future.[3–9] Greater life expectancies coupled with improved dental care have resulted in an increasing number of patients who retain most of their dentition into old age. About 75% of the US population aged 60 years or older are dentate (mean, 18.9 teeth).[10] With age, the occurrence of root surfaces exposed to the oral environment increases, predisposing the affected teeth to loss of cervical structure, cervical hypersensitivity, and root caries.[11] In a study assessing the periodontal status in the United States,[12] gingival recession of 1 mm or more was reported in 11.5% of 18- to 24-year-olds, 46.3% of 35- to 44-year-olds, 78.3% of 55- to 64-year-olds, and 86.5% of people aged 65 years or older. Consequently, the risk for root caries increases in the elderly, dentate patient.[8,13–18]

Dentlearn.ir

Definition, Clinical Appearance, and Location of Root Caries Lesions

The prevalent definition in the dental literature for a *root caries lesion* is "a soft, irregularly shaped lesion either *(1)* totally confined to the root surface or *(2)* involving the undermining of enamel at the cementoenamel junction, but clinically indicating that the lesion initiated on the root surface."[19] A root caries lesion can be initiated only if the root surface is first exposed to the oral environment.[7,12,20,21] A root caries lesion appears as a softening and/or cavitation in the root surface with no initial involvement of the adjacent enamel (Fig 13-1). These lesions generally begin at or slightly occlusal to the free gingival margin where dental plaque more frequently accumulates undisturbed but can extend into the gingival sulcus and/or undermine the coronal enamel as the lesion progresses (Fig 13-2). Lesions also begin at the margins of restorations that have their cervical interfaces on root structure. Two reports by Mjör[22,23] indicate that secondary caries lesions occur more frequently at cervical margins because many restorations terminate on root surfaces in areas where access and isolation are most difficult. Because dental plaque frequently accumulates at the gingival margin around the tooth, an active root caries lesion, if left untreated, can spread laterally, encircling the tooth[24] (Fig 13-3).



Fig 13-1 Root caries lesion on a tooth with gingival recession.



Fig 13-2 Root caries lesion undermining coronal enamel.

Dentlearn.ir



Fig 13-3 Active root caries lesion extending laterally.

Early-stage lesions can be difficult to diagnose by appearance, because color changes are frequently not obvious until some progression of the caries lesion has occurred. New lesions may appear as small, well-defined areas of a yellowish to light brown color. On probing, the dentin in an active lesion is softer than adjacent, unaffected cementum or dentin and can be removed with a sharp excavator. Advanced lesions appear darker brown to black and, if arrested, may be as hard or harder than the normal root surface. There has been an attempt by researchers to categorize lesions based on color (lighter lesions more active, darker lesions inactive) and/or texture (the harder the lesion, the less active).[25–28] While there has been some relationship shown between color, texture, and dominant microorganism, the data have been conflicting and the link remains tenuous.[29] Currently, color is not considered a reliable indicator of caries activity.[17,30–32]

Caries lesions may occur on any exposed root surface, but initial lesions on the facial and proximal surfaces are most common.[33] Some studies have suggested that 50% to 75% of root caries lesions begin proximally[34,35] (Fig 13-4). This increased incidence of root caries is likely due to limited access to the cleansing forces of the oral cavity (eg, tongue) and the loss of the protective interproximal tissue, allowing increased food and bacterial retention. Lingual/palatal locations are seen much less frequently as isolated lesions (Fig 13-5). In the mandible, molars appear to be the most susceptible to root caries, followed by premolars, canines, and incisors; in the maxilla, the order is reversed.[33,36,37] It is common for many of these lesions to be obscured by plaque and food debris, so accurate detection is best accomplished after thorough debridement and prophylaxis.

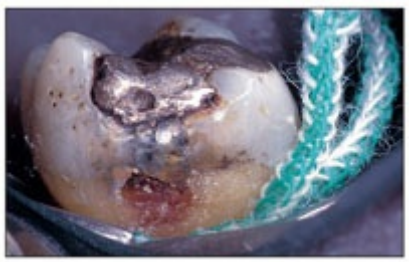

Dentlearn.ir

Fig 13-4 Proximal root caries lesion on a second molar.



Fig 13-5 Caries lesion on the lingual aspect of a second premolar.

Histochemistry, Histopathology, and Microbiology

The caries process on root surfaces is very similar to that in coronal caries. Plaque bacteria capable of metabolizing dietary carbohydrates into acids produce a drop in pH that lowers the plaque fluid saturation, initiating demineralization of the tooth structure. Saturation in plaque fluid, particularly near the tooth crystals, is what determines if tooth crystals demineralize, remineralize, or remain stable. It is the physicochemical basis for the caries process. For example, low pH (eg, 4.8) at higher levels of saturation will not demineralize enamel. Root surfaces are more vulnerable to chemical dissolution than enamel surfaces.[38] The drop in pH to undersaturate the biofilm in respect to cementum and dentin is much less than that required for enamel.[39–41] This means that, given the proper environment, both the initiation and progression of root surface caries lesions will occur more rapidly in dentin than in enamel.[42] Denaturation of collagen by collagenase-producing microorganisms, as well as degradation by nonspecific proteases, may accelerate the problem.[43] In addition, acid challenges can occur more readily and may continue for an extended period of time.[44] Frequent alterations in the delicate balance between the rates of demineralization and remineralization can result in the initiation of the caries process.[45–47]

While we tend to think of root surfaces as being covered with cementum, it has been shown that the cementum and enamel are not confluent in as many as 30% of teeth.[48] For patients receiving periodontal therapy, the cementum on accessible root surfaces is often partially removed during scaling and root planing procedures. Therefore, root caries lesions commonly begin on a dentin interface. Regardless of the surface, the creation of an acidic environment by cariogenic bacteria initiates the caries process. Cemental clefts can form due to physical and chemical changes, allowing infiltration of bacteria into the dentinal tubules. Surface dissolution

Dentlearn.ir

continues, followed by further demineralization and destruction of the collagen matrix.[49,50] Early microcavitation enlarges and produces the characteristic circumferential spreading seen with these lesions[50,51] (Fig 13-6).



Fig 13-6*(a)* Small lesion in a 45-year-old patient. At this stage, if the lesion is active (soft), with cavitation, a restoration should be placed to prevent circumferential spread, and a preventive regimen should be initiated. *(b)* Larger lesion in the same patient.

As demineralization progresses, there is a reactive sclerosing of the tubules and crystal formation, resulting in hyperminer-alization of the dentinal tubules.[52] This sclerosis is believed to be a result of the pulp's reaction to the stimulus of the caries process. The sclerotic appearance of many advanced lesions is probably related to the differences in mineral content found between the peritubular and intertubular dentin.[52,53] However, lesions can become arrested when conditions at the surface of the lesion change, leading to remineralization. Preventive regimens can lead to the arrest of root surface lesions. Arrested lesions frequently appear very dark and are hard on tactile examination.[54]

Many studies attempting to identify the etiology of root caries have used selective culture techniques that focus on the identification of a limited number of bacterial species.[55,56] Unfortunately, this type of culturing often excludes many species that may be directly or indirectly related. Studies of the predominant cultivable microflora as identified by microarrays, while more time and labor intensive,

root caries process.[46,57–59]

Currently, no specific single microorganism has been conclusively proven to cause root surface caries. Early studies[28,60,61] pointed to *Actinomyces viscosus* as a prime suspect. More recent studies, however, have questioned the dominant role of *Actinomyces* while emphasizing the importance of mutans streptococci and lactobacilli.[25,29,59,62–68] Lynch[29] and Zambon and Kasprzak[46] point out that, based on extensive research, *Streptococcus mutans* and *Lactobacillus* both fulfill the criteria for implicating bacteria in the etiology of a mixed infection. They also suggest that virulence factors of specific species probably play an important role in both the

Dentlearn.ir

formation and progression of root surface lesions. It is likely that root caries is a continuous, destructive process involving a succession of bacterial populations that vary depending on the condition of the substrate and the depth of the lesion.[57,67] Modern molecular biology techniques, involving ribosomal RNA sequencing and DNA and RNA probes, may offer solutions to defining both species and virulence factors associated with root caries.[59,69]

Prevalence and Incidence

Because root caries lesions can be initiated only when root surfaces are exposed to the oral environment, the population presumed to be most at risk are older adults. However, younger patients with periodontal problems are susceptible as well. The prevalence of 1 mm or more recession in people aged 30 years and older in the United States has been estimated at 58%, increasing with age. About 24 million persons in the United States are expected to have one or more tooth surfaces with recession of 3 mm or greater.[70] It also should be noted that root surface exposure does not mean that caries activity is inevitable. The actual prevalence of root caries is difficult to assess.[17,31,71]

Interpretation of data from prevalence and incidence studies is complicated by differences in diagnostic criteria, treatment decisions, and lack of homogeneity of the observed populations.[72] Numerous studies have reported the prevalence of root caries and its relationship to increasing age,[10,14,33,73–75] while international surveys have estimated that the disease affects a significant percentage of adults.[11,27,76–78] In addition, it has been suggested that approximately one in nine root surfaces is at risk of becoming carious.[33] The extent of root caries appears to have a negative correlation with the number of teeth present. Thus, the ongoing loss of teeth with age is likely to produce an underestimation of the prevalence of root caries.[14] Because more mandibular teeth are retained in older individuals, these teeth have a higher incidence of root caries lesions than do maxillary teeth.[33,79–81] Other studies[33,76,82–85] suggest that approximately 15% to 20% of all teeth with gingival recession are affected by root caries, and the mean number of teeth affected per person is about 2.8.[38,77,86–88] It has also been stated that if root caries prevalence is based on the presence of active, restored, and arrested lesions, virtually every dentate person older than 65 years of age is at risk.[88]

Incidence data have been derived primarily from studies conducted on selected populations, such as the chronically ill or nursing home residents. These

Dentlearn.ir

studies[37,74,89–92] vary in duration from 1 to 8 years and report root caries/root restoration experience ranging from 19% to 69% depending on the population observed. Two studies on noninstitutionalized adults older than 65 years of age have reported similar incidences of root caries, 44%[93] and 37%.[36] The attack rates (mean carious surfaces per mouth) calculated for exposed root surfaces in the latter two studies ranged from 3.9 to 5.5 over a 3-year period.

Despite the variability of available data, there was a general agreement that the prevalence of root caries will increase in the dentate older population as a result of the population retaining their teeth longer. However, the latest large-scale surveys in the United States suggest that root caries prevalence is declining despite an increase in tooth retention and no change in coronal caries. The overall prevalence of root caries for all adults decreased from 19% to 14%, with the greatest decline in adults aged 50 to 64 years (9%) and older adults living at the lowest level of income (16%).[10]

Risk Factors and Assessment

The risk factors associated with root caries are provided in Box 13-1. It is of critical importance that clinicians identify at-risk patients early in the root caries process, ideally before the disease is clinically apparent. Early detection permits preventive and chemotherapeutic intervention to potentially enhance treatment outcome.

Box 13-1	**Risk factors for root caries**
Exposure of root surfaces Attachment loss Gingival recession Periodontal pocketing Inadequate oral hygiene Low priority to patient Physical impairment Cognitive impairment Cariogenic diet Diminished salivary flow and/or buffering capacity Chronic medical conditions Medications Surgical/radiation therapy Physiologic aging Previous caries lesions/restorations Lack of access to and/or interest in dental services	

Dentlearn.ir

Low educational level
Removable prosthesis
Advanced age
Eight or more missing teeth
Male sex
Smoking, alcoholism, drug use
Possibly certain ethnicities

Because exposure of the root surface to the oral environment is a prerequisite for root surface caries, any patient with attachment loss, gingival recession, and/or periodontal pockets is at risk for initiation of the disease process.[94] Patients in this category who are frequently overlooked are patients with cervical and proximal restorations that terminate on cemental surfaces. Even though the root surface may not be readily visible, the need for and placement of these restorations has met the primary risk criteria.

All normal risk factors for caries lesion development are applicable to root caries, including inadequate oral hygiene, cariogenic diet, and poor utilization of routine dental services.[95,96] Past caries/restorative experience also has been shown to have a strong correlation and generally indicates the presence of conditions/behaviors that support caries activity[36,87,97–104] (Fig 13-7). Unfortunately, the effect of these conditions may be magnified in the root caries process as well as impacted by the myriad changes associated with aging and related health problems and treatments.[31,105]



Fig 13-7 Root caries lesion adjacent to an amalgam margin.

In relation to root caries activity, salivary flow rate is considered the most important of the nonmicrobial salivary parameters,[106–108] because the cariostatic activity or efficacy of other salivary parameters is dependent on the flow rate.[109] Unstimulated flow rate has been shown to have a greater effect on salivary clearance time than stimulated flow[110,111] and is more affected by conditions producing hypofunction of the salivary glands.[112] Loss or significant reduction of unstimulated salivary flow can result in xerostomia, or "dry mouth," and is positively correlated

Dentlearn.ir

with a number of adverse oral conditions, including rapidly progressive caries lesions and periodontal disease[113–115] (Fig 13-8). While there is debate as to the amount of saliva necessary to maintain oral health, an unstimulated flow rate of less than 0.1 mL/min is considered to be below normal.[112–117]



Fig 13-8 Caries lesion adjacent to a resin restoration in a xerostomic patient. Glass-ionomer restorations in the same patient did not exhibit recurrent caries lesions for the duration of the 5-year study.[77]

Hyposalivation can be caused by a variety of factors,[13,39,113] including radiation therapy of the head and neck, immuno-suppressive therapy, radioactive iodine therapy, autoimmune diseases, HIV infection, and a myriad of commonly prescribed medications (Box 13-2). Basic management of patients with hyposalivation involves finding ways to reduce their oral dryness. If functioning salivary gland tissue is present, stimulation of natural flow is preferable to saliva substitutes. Pilocarpine (Salagen, MGI Pharma) and cevimeline (Evoxac, Daiichi Pharmaceutical) can be extremely effective salivary gland stimulants.[118] However, they have numerous side effects, contraindications, and drug interactions that make consultation with the patient's primary care physician preferable before prescribing them. Oral moisturizers are sometimes the only option for relieving the symptoms of xerostomia. These saliva substitutes can be used on a regular basis, but some commercial products have been found to have the potential to demineralize dentin and should be avoided.[119]

Box 13-2	**Medications that induce xerostomic changes**
Antiasthmatics	Cold medications
Anticholinergics	Decongestants
Anticonvulsants	Dibenzoxazepine derivatives
Antidepressants	Diuretics
Antiemetics	Expectorants
Antihistamines	Monoamine oxidase inhibitors
Antihypertensives	Muscle relaxants
Anti-inflammatories	Neuroleptics

Dentlearn.ir

Antinauseants	Phenothiazine derivatives
Antiparkinsonians	Psychotropic drugs
Antipruritics	Sedatives
Antispasmodics	Sympathomimetics
Appetite suppressants	Tranquilizers
Central nervous system depressants	

The use of removable partial dentures has also been noted as a risk factor in this disease.[120,121] The position of retentive clasps and lingual/palatal connectors can contribute to retention of food debris and gingival recession. While the initial design may have been appropriate, prolonged wear and alterations of the clasps can produce physical stripping of the gingiva and abrasion of the tooth surface.

Other factors that contribute to the potential for root caries include previous caries and restorative experience. Studies have indicated that individuals who have active coronal caries lesions are 2 to 3.5 times more likely to develop root caries lesions.[122,123] Root caries is generally more prevalent and severe among men than woman.[10] Smoking has also been implicated as a risk factor in both periodontal disease[124] and root caries.[10] In the United States, 20- to 64-year-old non-Hispanic black adults present higher prevalence of root caries experience and untreated lesions than Mexican-American and non-Hispanic white adults. Income level and education are also associated with root caries prevalence, with people with higher income and education having lower prevalence of root caries experience and untreated root caries lesions. Interestingly, some of these trends are different for adults older than 64 years of age, where the differences in prevalence among the

Diagnosis

Although clinicians detect root caries lesions by judging changes in color (yellow, brown, black), texture (soft, hard), and surface contour (regular, irregular), examination strategies should focus on patients at risk for root caries. Therefore, the first step in the diagnosis of root caries is early identification of contributory factors and oral hygiene practices. Because plaque and debris often severely limit the

Dentlearn.ir

visibility of root surfaces, a thorough dental prophylaxis should precede any clinical examination of patients at risk for root caries. Gentle tissue displacement with an air syringe and retraction with hand instruments can offer a better view of subgingival and interproximal areas, while the use of transillumination and/or lighted mirrors as well as intraoral cameras can also enhance visibility and improve diagnostic capability.

Lynch[29] found texture to be the best predictor of microbiologic activity in root caries lesions. Tactile exploration should be done carefully with only moderate pressure, because the root surface is inherently softer than enamel. The gradient in tactile sensation between sound and carious cementum/ dentin is much less than that between sound and carious enamel.[19] Active lesions may or may not display obvious cavitation and are generally described as "tacky" or "leathery" to tactile exploration while offering some resistance to removal of the explorer tip. One study demonstrated that an alteration in the explorer tip (producing a 30-degree angle at the tip of the explorer) increased the ability of the operator to detect root caries lesions.[125] However, for those lesions that might be treated preventively, rather than restoratively, it is important to conduct the tactile exploration gently to avoid or to at least limit damaging the lesion surface, which increases the chances for remineralization. Radiographs can be useful in identifying early proximal root lesions but occasionally can be prone to misinterpretation because of cervical "burnout" artifacts. Vertical bitewing radiographs permit better evaluation of the proximal root surfaces in persons with significant loss of attachment[126] (Fig 13-9).

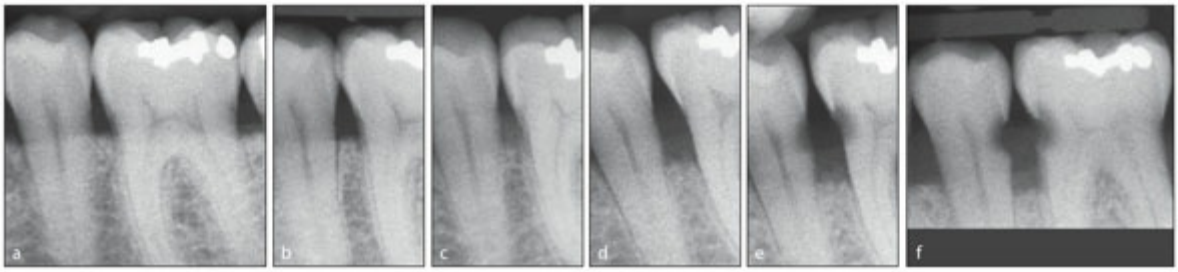

Fig 13-9*(a)* A 55-year-old man presented without gingival recession or caries lesions on the mandibular left first molar and second premolar. Follow-up at 2 years *(b)*, 5 years *(c)*, and 7 years *(d)*; no caries lesions were present. At the 8-year interval, bone loss was observed radiographically and clinically concomitant with significant accumulation of dental plaque and food residues, which increase the risk for root caries. *(e)* At the end of 8 years, root caries developed on the interproximal surfaces along with active periodontal disease and gingival recession. *(f)* Two years later, the patient returned with improved oral hygiene but continued caries lesion expansion and active periodontal disease. The saturation drop generated by the local biofilm in this case is enough to demineralize cementum/dentin but not enamel.

Recently, an integrated system for measuring dental caries was created by an

Dentlearn.ir

international collaboration of experts in caries diagnosis. The system is called the International Caries Detection and Assessment System (ICDAS) and includes codes for root caries.[127] Additionally, newer diagnostic tools such as those measuring the change in lesion fluorescence have shown promise.[54,128,129] The ultimate goal for this type of diagnostic aid is to eventually help clinicians differentiate between active and inactive lesions by finding a correlation between lesion severity and degree of mineral loss.

Preventive and Chemotherapeutic Strategies

Clinical observations and studies strongly suggest that root caries lesions can be arrested, obviating restorative therapy. Numerous studies have demonstrated success in preventing and/or arresting root caries through plaque removal, diet modification, topical fluoride application, and use of antimicrobials.[130,131]

Mechanical plaque removal using a fluoride dentifrice alone has been shown to play an important role in arresting active root caries.[132,133] Therefore, topical fluoride is accepted as an appropriate chemotherapeutic agent in the management of root caries. Prevention/arrest of root surface lesions has been demonstrated in both in situ and clinical studies using fluoridated water,[134–136] fluoride solutions,[137] fluoride gels,[26] fluoride mouthrinses,[138,139] fluoride dentifrices,[89,132,133] fluoride varnishes,[140] fluoride chewing gums,[141] and intraoral fluoride-releasing devices.[141,142] A synergistic, beneficial effect of argon laser irradiation and acidulated phosphate fluoride (APF) gels on root lesions in vitro has also been demonstrated.[143] However, although the optimum delivery system of fluoride for protection against root caries has yet to be determined, additional treatments with varnishes[41,144] and rinses[139] and an increase in concentration of fluoride in a dentifrice (ie, prescription level or 5,000 ppm) have been shown to be very effective.[145,146]

Chlorhexidine rinses (eg, Peridex, Zila; Periogard, Colgate) have been suggested for the management of root caries because of their ability to reduce levels of oral bacteria. However, a large clinical trial in low-income elderly patients found that regular rinsing with 0.12% chlorhexidine did not have a substantial effect on reducing root caries in this population.[147] On the other hand, several studies have found that using chlorhexidine varnish (eg, Cervitec, Ivoclar Vivadent) regularly is effective in reducing root caries incidence.[131,140,148]

A large number o uting dietary polyols

Dentlearn.ir

for sucrose in chewable dietary items. Xylitol, a 5-carbon sugar alcohol, has been under investigation since the early 1970s and has been found to be a safe and effective dietary supplement in humans (it received FDA clearance in 1963 for special dietary purposes). Xylitol is not metabolized by *S mutans* and has been shown to have an anticariogenic effect,[149,150] decrease plaque formation,[151] increase plaque pH,[152] and possibly enhance remineralization.[153] Extensive research over the past 25 years has demonstrated that consuming 5 to 10 g of xylitol daily in the form of chewing gum can result in a 30% to 85% reduction in dental caries.[154,155] Its specific effect on root caries is not well known, but it is expected to be effective on those surfaces; this effectiveness is supported by some early clinical data.[156]

In recent years, a variety of products containing calcium and phosphate have been developed.[157] Most of the testing has been done in enamel caries, but early studies suggest some of these products might be good adjunctives in the management of root caries.[158] The goal of the dental practitioner should be to initiate preventive and remineralization therapies that will inhibit or eliminate the disease process before tissue destruction occurs. The excavation of actively carious tooth structure and placement of restorative materials is, at best, a repair of the damages inflicted by the disease process and does not address the control of the disease itself.

Restorative Treatment

Clearly, many teeth with root caries lesions do not need restorative treatment. Accessible, shallow lesions can be made caries-free and easy to clean through debridement with hand instruments, finishing burs, and/or polishing disks.[26,159] Arrested lesions with a hard to leathery surface are often amenable to treatment with topical fluorides in combination with a chlorhexidine rinse.[25]

When a root caries lesion has progressed such that restoration of lost structure is necessary, the dentist faces difficulties that differ considerably from those posed by many coronal lesions. The challenges to the restorative dentist include impaired visibility, difficult access, moisture control, pulpal proximity, and the nature of the dentinal substrate itself. These factors tend to compromise the ideal restoration, which should conserve remaining tooth structure and provide long-term integrity of marginal seal. There is general agreement today that, when possible, adhesive fluoride-releasing restorative materials are preferred.[160]

Isolation is the key to long-term success in root surface restorations. The inability to obtain a dry operating field, unobstructed access, and good visibility frequently

Dentlearn.ir

result in a compromised restoration. The use of a rubber dam and retractors, retraction cord, and/or surgical exposure will usually satisfy the necessary criteria. At times, to obtain a satisfactory result, the isolation procedure may take more time than the actual preparation and restoration (Fig 13-10). See chapter 8 for specific recommendations.

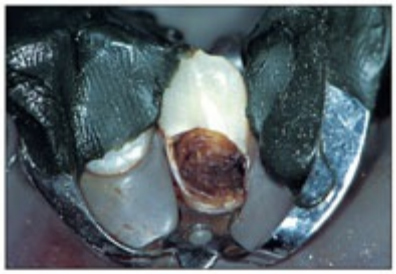

Fig 13-10 Because of the importance of a dry operating field, unobstructed access, and good visibility for treatment of root caries lesions, isolation is key to long-term success.

Preparation design for cervical restorations and the properties of dental materials are described in chapters 12, 14, and 15. A brief review of the available options follows. Preparation should involve removal of demineralized tooth structure with only minimal removal of sound tooth tissue for access and retention.

Silver amalgam

Amalgam has the longest clinical history of the direct restorative materials with the exception of the direct-filling golds. It has excellent wear characteristics (Fig 13-11), increasing marginal seal over time, and some bacteriostatic properties. Amalgam is relatively easy to place and is less sensitive to variations in handling than many other materials. Like direct gold, amalgam must be mechanically retained and does not offer significant chemotherapeutic benefit. With the introduction of adhesive fluoride-releasing materials and the current demand for tooth-colored restorations, the use of amalgam in cervical lesions has declined. While not recommended for use in xerostomic patients, it may still be the material of choice when isolation is a problem.

Dentlearn.ir



Fig 13-11 Eighteen-year-old amalgam restorations in mandibular incisors.

Resin composite

With the advent of relatively reliable dentin bonding systems, resin composite materials, including compomers (polyacid-modified resin composites) and flowable composites, have become extremely popular with dental practitioners (Fig 13-12). Unfortunately, all of these materials exhibit a degree of polymerization shrinkage that can severely stress the adhesive interface provided by dentin bonding systems. When this is combined with the difference in coefficient of thermal expansion between these materials and tooth structure, the result can be a loss of marginal seal and microleakage[161] (Fig 13-13). Fluoride release is less than that of glass ionomer, and these materials do not currently offer any fluoride recharge capability. They are primarily indicated in root caries situations in which esthetics is of major importance. Microfilled or hybrid resin composites appear to offer advantages over compomers and flowable composites. See chapters 10, 11, 14, and 15 for more detailed information about the use of resin composite and compomer.



Fig 13-12 Resin composites placed with three-step etch-and-rinse adhesive.

Dentlearn.ir



Fig 13-13*(a)* A resin composite restoration immediately after placement. *(b)* At 18 months, there is leakage at the restoration-cementum interface.

Glass-ionomer cement/resin-modified glass-ionomer cement

Glass-ionomer cement is the material of choice for most root caries lesions (see chapter 14). The material offers adhesive bonding, long-term fluoride release, and the ability to "recharge" or take up fluoride when exposed to an external source (eg, topical application, mouthrinse). Clinical studies have demonstrated successful 10-year longevity[162] (Fig 13-14) as well as reasonable success in xerostomic patients.[163–165]



Fig 13-14 A Ketac Fil (3M ESPE) conventional glass-ionomer restoration placed 10 years earlier.

Conclusion

The maintenance of periodontal health from early childhood will greatly reduce the incidence of root caries. When the lesion is detected early, preventive principles should be used to reverse the carious process, instead of repairing the lesion. Dental caries itself is a bacterial infectious disease associated with diet[1,166] and should be treated as such. Extensive research has moved our concept of caries from the early "worm theory" to a better understanding of the multifactorial, chronic nature of the disease. For this reason, modern dentistry has experienced a paradigm shift, with a move from complete reliance on the traditional surgical (restorative) approach to an acceptance of the fact that treatment of dental caries is not complete until the infection and contributing factors are controlled. This concept should guide the

Dentlearn.ir

management of both coronal and root surface caries. See chapter 5 for more detailed information about the caries process and caries prevention.

References

1. Katz RV. Development of an index for the prevalence of root caries. J Dent Res 1984;63:814–818.
2. Hardwick JL. The incidence and distribution of caries throughout the ages in relation to the Englishman's diet. Br Dent J 1960;108:9–17.
3. Douglass CW, Furino A. Balancing dental service requirements and supplies: Epidemiologic and demographic evidence. J Am Dent Assoc 1990;121:587–592.
4. Saunders RH Jr, Meyerowitz C. Dental caries in older adults. Dent Clin North Am 2005;49:293–308.
5. National Institutes of Health. Technology Assessment Conference. Effects and side effects of dental restorative materials. Bethesda, MD: US Department of Health and Human Services, 1991.
6. Brown L, Winn D, White B. Dental caries, restorations and tooth conditions in US adults, 1988–1991. J Am Dent Assoc 1996;127:1315–1325.
7. Winn DM, Brunelle JA, Selwitz RH, et al. Coronal and root caries in the dentition of adults in the United States, 1988–1991. J Dent Res 1996;75(special issue):642–651.
8. Warren JJ, Cowen HJ, Watkins CM, Hand JS. Dental caries prevalence and dental care utilization among the very old. J Am Dent Assoc 2000;131:1571–1579.
9. Anusavice KJ. Dental caries: Risk assessment and treatment solutions for an elderly population. Compend Contin Educ Dent 2002;23(10 suppl):12–20.
10. Dye BA, Tan S, Smith V, et al; National Center for Health Statistics. Trends in oral health status: United States, 1988–1994 and 1999–2004. Vital Health Stat 11 2007;(248):1–92.
11. Miller AJ, Brunell JA, Carlos JD, et al. Oral Health of United States Adults. National Institutes of Health, publication 87-2868. Bethesda, MD: US Department of Health and Human Services, 1987.
12. Brown LJ, Brunelle JA, Kingman A. Periodontal status in the United States, 1988–1991: Prevalence, extent, and demographic variation. J Dent Res 1996;75(special issue):672–683.
13. Astroth JD. Caring for the elderly adult: How to prevent, manage root surface caries. Dent Teamwork 1996;9:15–19.
14. Beck JD. The epidemiology of root caries: North American studies. Adv Dent Res 1993;7:42–51.
15. Christensen GJ. A new challenge—Root caries in mature people. J Am Dent Assoc 1996;127:379–380.
16. Shay K. Root caries in the elderly: An update for the next century. J Indiana Dent Assoc 1997–1998;76:37,39–43.
17. Leake JL. Clinical decision-making for caries management in root surfaces. J Dent Educ 2001;65:1147–1153.
18. Ettinger RL, Hand JS. Factors influencing the future need for treatment of root surfaces. Am J Dent 1994;7:256–260.
19. Katz RV. The clinical diagnosis of root caries: Issues for the clinician and researcher. Am J Dent 1995;8:335–341.
20. Katz R. The RCI revisited after 15 years: Used, reinvented, modified, debated, and natural logged. J Public Health Dent 1999;56:28–34.
21. Drury TF, Brown LJ, Zion GR. Tooth retention and tooth loss in the permanent dentition of adults: 1988–1991. J Dent Res 1996;75(special issue):684–695.
22. Mjör IA. Placement and replacement of restorations. Oper Dent 1981;6:49–54.
23. Mjör IA. Frequency of secondary caries at various anatomical locations. Oper Dent 1985;10:88–92.
24. Banting DW. The diagnosis of root caries. J Dent Educ 2001;65:991–996.
25. Beighton D, Lynch E, Heath MR. A microbiological study of primary root-caries lesions with different treatment needs. J Dent Res 1993;72:623–629.
26. Billings RJ, Brown LR, Kaster AG. Contemporary treatment strategies for root surface dental caries.

Dentlearn.ir

Gerodontology 1985;1:20–27.
27. Fejerskov O, Luan WM, Nyvad B, Budtz-Jørgensen E, Holm-Pedersen P. Active and inactive root surface

28. Syed SA, Loesche WJ, Pape HL Jr, Grenier E. Predominant cultivable flora isolated from human root surface caries plaque. Infect Immun 1975;11:727–731.
29. Lynch E. Relationship between clinical criteria and microflora of primary root caries. In: Stookey GK (ed). Early Detection of Dental Caries. Cincinnati, OH: Sidney Printing Works, 1996:195–242.
30. Hellyer P, Lynch E. The diagnosis of root caries—A review. Gerodontol-ogy 1990;9:95–102.
31. Galan D, Lynch E. Epidemiology of root caries. Gerodontology 1993;10:59–71.

1994;28:233–238.
33. Katz RV, Hazen SP, Chilton NW, Mumma RD Jr. Prevalence and intraoral distribution of root caries in an adult population. Caries Res 1982;16:265–271.
34. Hals E, Selvig KA. Correlated electron probe microanalysis and microra-diography of carious and normal dental cementum. Caries Res 1977;11:62–75.
35. Wag BJ. Root surface caries: A review. Community Dent Health 1984;1:11–20.
36. Lawrence HP, Hunt RJ, Beck JD. Three-year root caries incidence and risk modeling in older adults in North Carolina. J Public Health Dent 1995;55:69–78.
37. Leske GS, Ripa LW. Three-year root caries increments: An analysis of teeth and surfaces at risk. Gerodontology 1989;8:17–21.
38. Nyvad B, Fejerskov O. Root surface caries: Clinical, histopathological and microbiological features and clinical implications. Int Dent J 1982; 32:312–326.
39. Atkinson JC, Wu AJ. Salivary gland dysfunction: Causes, symptoms, treatment. J Am Dent Assoc 1994;125:409–416.
40. Hoppenbrouwers PM, Driessens FC, Borggreven JM. The mineral solubility of human tooth roots. Arch Oral Biol 1987;32:319–322.
41. Dawes C. What is the critical pH and why does a tooth dissolve in acid? J Can Dent Assoc 2003;69:722–724.
42. Dung TS, Liu AH. Molecular pathogenesis of root dentin caries. Oral Dis 1999;5:92–99.
43. Schüpbach P, Lutz F, Guggenheim B. Human root caries: Histopathology of arrested lesions. Caries Res 1992;26:153–164.
44. Erickson RL. Root surface treatment with glass ionomers and resin composites. Am J Dent 1994;7:279–285.
45. Park KK, Zitterbart PA, Christen AG. Preventive management of root caries: State of the art. Indiana Dent Assoc J 1987;66:11–19.
46. Zambon J, Kasprzak SA. Microbiology and histopathology of human root caries. Am J Dent 1995;6:323–328.
47. Wefel JS. Root caries histopathology and chemistry. Am J Dent 1994; 5:261–265.
48. Ramsey DJ, Ripa LW. Enamel prism orientation and enamel cementum relationship in the cervical region of premolars. Br Dent J 1969;126:165–167.
49. Johansen E. Electron microscopic and chemical studies of carious lesions with reference to the organic phase of affected tissues. Ann N Y Acad Sci 1965;131:776–785.
50. McIntyre JM, Featherstone JD, Fu J. Studies of dental root surface caries. 2: The role of cementum in root surface caries [comment]. Aust Dent J 2000;3:215.
51. Dietz W, Kraft U, Hoyer I, Klingberg G. Influence of cementum on the demineralization and remineralization process of root surface caries in vitro. Acta Odontol Scand 2002;60:241–247.
52. Love RM, Jenkinson HF. Invasion of dentinal tubules by oral bacteria. Crit Rev Oral Biol Med 2002;13:171–183.
53. Weber DF. Human dentin sclerosis: A microradiographic survey. Arch Oral Biol 1974;19:163–169.
54. Baysan A, Lynch E. Clinical reversal of root caries using ozone: 6-month results. Am J Dent 2007;20:203–208.
55. Beighton D, Lynch E. Comparison of selected microflora of plaque and underlying carious dentine associated with primary root caries lesions. Caries Res 1995;29:154–158.

Dentlearn.ir

56. Van Houte J, Lopman J, Kent R. The predominant cultivable flora of sound and carious human root surfaces. J Dent Res 1994;73:727–734.
57. Schüpbach P, Osterwalder V, Guggenheim B. Human root caries: Micro-biota of a limited number of root caries lesions. Caries Res 1996;30:52–64.
58. Brailsford SR, Shah B, Simons D, et al. The predominant aciduric micro-flora of root-caries lesions. J Dent Res 2001;80:1828–1833.
59. Preza D, Olsen I, Willunmsen T, et al. Microarray analysis of the micro-flora of root caries in elderly. Eur J Clin Microbiol Infect Dis 2009;28:509–517.
60. Jordan HV, Hammond BF. Filamentous bacteria isolated from human root caries. Arch Oral Biol 1972;17:1333–1342.
61. Socransky SS, Hubersak C, Propas D. Introduction of periodontal destruction in gnotobiotic rats by a human oral strain of Actimomyces naeslundii. Arch Oral Biol 1970;15:993–995.
62. Beighton D, Hellyer PH, Lynch EJ, Heath MR. Salivary levels of mutans streptococci, lactobacilli, yeasts, and root caries prevalence in non-institutionalized elderly dental patients. Community Dent Oral Epidemiol 1991;219:302–307.
63. Brown LR, Billings RJ, Kaster AG. Quantitative comparisons of potentially cariogenic microorganisms cultured from noncarious and carious root and coronal tooth surfaces. Infect Immun 1986;51:765–770.
64. Fure S, Romaniec M, Emilson CG, Krasse B. Proportions of Streptococcus mutans, lactobacilli and Actinomyces spp in root surface plaque. Scand J Dent Res 1987;95:119–123.
65. Keltjens HM, Schaeken MJ, van der Hoeven JS, Hendriks JC. Microflora of plaque from sound and carious root surfaces. Caries Res 1987;21:193–199.
66. Ravald N, Birkhed D. Factors associated with active and inactive root caries in patients with periodontal disease. Caries Res 1991;25:377–384.
67. Van Strijp AJ, van Steenbergen TJ, ten Cate JM. Bacterial colonization of mineralized and completely demineralized dentine in situ. Caries Res 1997;31:349–355.
68. Satome Y, Tada A, Hanada N, Yoshihara A, Miyazaki H, Senpuku H. Relationship of cariogenic bacteria levels with periodontal status and root surface caries in elderly Japanese. Gerodontology 2006;23:219–225.
69. Moore MA, Gregory RL, Switalski LM, Hakki ZW, Gfell LE, Kowolik MJ. Differential activation of human neutrophils by Streptococcus mutans isolates from root surface lesions and caries-free and caries-active subjects. Oral Microbiol Immunol 1998;13:41–46.
70. Albandar JM, Kingman A. Gingival recession, gingival bleeding, and dental calculus in adults 30 years of age and older in the United States, 1988–1994. J Periodontol 1999;70;30–43.
71. Burt BA, Ismail AI, Edlund SA. Root caries in an optimally fluoridated and high-fluoride community. J Dent Res 1986;65:1154–1158.
72. Clarkson JE. Epidemiology of root caries. Am J Dent 1995;8:329–334.
73. Banting DW, Ellen RP, Fillery ED. Prevalence of root surface caries among institutional older persons. Community Dent Oral Epidemiol 1980;8:84–88.
74. Banting DW, Ellen RP, Fillery ED. A longitudinal study of root caries: Baseline and incidence data. J Dent Res 1985;64:1141–1144.
75. Du M, Jiang H, Tai B, Zhou Y, Wu B, Bian Z. Root caries patterns and risk factors of middle-aged and elderly people in China. Community Dent Oral Epidemiol 2009;37:260–266.
76. Hellyer PH, Beighton D, Heath MR, Lynch EJ. Root caries in older people attending a general dental practice in East Sussex. Br Dent J 1990; 169:201–206.
77. Katz RV. Root caries—Is it the problem of the future? J Can Dent Assoc 1985;51:511–514.
78. Locker D, Slade GD, Leake JL. Prevalence of and factors associated with root decay in older adults in Canada. J Dent Res 1989;68:768–772.
79. Lohse W, Carter H, Brunelle J. The prevalence of root surface caries in a military population. Mil Med 1977;142:700–703.
80. Hix JO, O'Leary TJ. The relationship between cemental caries, oral hygiene status and fermentable carbohydrate levels. J Periodontol 1976;47:398–404.

Dentlearn.ir

81. Sumney DL, Jordan HV, Englander HR. The prevalence of root surface caries in selected populations. J Periodontol 1973;44:500–504.
82. Fure S, Zickert I. Prevalence of root surface caries in 55, 65, and 75-year-old Swedish individuals. Community Dent Oral Epidemiol 1990;18:100–105.
83. Gustavsen F, Clive JM, Tveit AF. Root caries prevalence in a Norwegian adult dental population. Gerodontics 1988;18:100–105.
84. Kalsbeek H, Truin GJ, Burgersdijk R, van't Hof M. Tooth loss and dental caries in Dutch adults. Community Dent Oral Epidemiol 1991;19:201–204.
85. Whelton HP, Holland TJ, O'Mullane DM. The prevalence of root surface caries amongst Irish adults. Gerodontology 1993;10:72–75.
86. Al-Khateeb S, Angma-Mansson B, DeJosselin E. In vivo quantification of changes in caries lesions in orthodontic patients [abstract]. J Dent Res 1996;75:127.
87. Beck JD, Kohout F, Hunt RJ. Identification of high caries risk adults: Attitudes, social factors and diseases. Int Dent J 1988;38:231–238.
88. Fejerskov O. Recent advancements in the treatment of root surface caries. Int Dent J 1994;44:139.
89. Jensen ME, Kohout F. The effect of a fluoride dentifrice on root and coronal caries in an older adult population. J Am Dent Assoc 1988; 117:829–832.
90. Ravald N, Hamp SE, Birkhed D. Long-term evaluation of root surface caries in periodontally treated patients. J Clin Periodontol 1986;13:758–767.
91. Ripa LW, Leske GS, Forte F. Effect of a 0.05% neutral NaF mouthrinse on coronal and root caries of adults. Gerodontology 1987;6:131–136.
92. Wallace MC, Retief DH, Bradley EL. Incidence of root caries in older adults [abstract 272]. J Dent Res 1988;67:147.
93. Hand JS, Hunt RJ, Beck JD. Coronal and root caries in older Iowans: 36-month incidence. Gerodontics 1988;4:136–139.
94. El-Hadary ME, Ramadan AE, Kamar AA, Nour ZM. A study of the incidence of and distribution of root surface caries and its relation to periodontal disease. Egypt Dent J 1975;21:43–52.
95. Vehkalahti MM, Vrbic VL, Peric LM, Matvoz ES. Oral hygiene and root caries occurrence in Slovenian adults. Int Dent J 1997;47:26–31.
96. Nyvad B, ten Cate JM, Fejerskov O. Arrest of root caries in situ. J Dent Res 1997;76:1845–1853.
97. Joshi A, Papas AS, Giunta J. Root caries incidence and associated risk factors in middle-aged and older adults. Gerodontology 1993;10:83–89.
98. Locker D. Incidence of root caries in an older Canadian population. Community Dent Oral Epidemiol 1996;24:403–407.
99. MacEntee MI, Clark DC, Glick N. Predictors of caries in old age. Gerodontology 1993;10:90–97.
100. Powell LV, Mancl LA, Senft GD. Exploration of prediction models for caries risk assessment of the geriatric population. Community Dent Oral Epidemiol 1991;19:291–295.
101. Scheinin A, Pienihakkinen K, Tiekso J, Holmberg S. Multifactorial modeling for root caries prediction. Community Dent Oral Epidemiol 1992;20:35–37.
102. Kitamura M, Kiyak HA, Mulligan K. Predictors of root caries in the elderly. Community Dent Oral Epidemiol 1986;14:34–38.
103. DePaola PF, Soparkar PM, Tavares M, Kent RL. The clinical profiles of individuals with and without root surface caries. Gerodontology 1989;8:9–15.
104. Fure S. Five-year incidence of caries, salivary and microbial conditions in 60-, 70-, and 80-year-old Swedish individuals. Caries Res 1998;32: 166–174.
105. Beck JD, Kohout FJ, Hunt RJ, Heckert DA. Root caries: Physical, medical and psychosocial correlates in an elderly population. Gerodontics 1986;3:242–247.
106. Dawes C. A mathematical model of salivary clearance of sugar from the oral cavity. Caries Res 1983;17:321–324.
107. Younger H, Harrison T, Streckfus C. Relationship among stimulated whole glandular salivary flow rates and

Dentlearn.ir

root caries prevalence in an elderly population: A preliminary study. Spec Care Dentist 1998;18: 156–163.
108. Diaz-Arnold AM, Marek CA. The impact of saliva on patient care: A literature review. J Prosthet Dent 2002;88:337–343.
109. Tenovuo J. Salivary parameters of relevance in assessing caries activity in individuals and populations. Community Dent Oral Epidemiol 1997; 25:82–86.
110. Bardow A, Hofer E, Nyvad B, et al. Effect of saliva composition on experimental root caries. Caries Res 2005;39:71–77.
111. Lagerlöf F, Dawes C. The effect of swallowing frequency on oral sugar clearance and pH changes by Streptococcus mitior in vivo after sucrose ingestion. J Dent Res 1985;64:1229–1232.
112. Dodds M, Suddick R. Caries risk assessment for determination of focus and intensity of prevention in a dental school clinic. J Dent Educ 1995;59:945–956.
113. Haveman CW, Redding SW. Dental management and treatment of xerostomic patients. Texas Dent J 1998;115:43–56.
114. Ravald N, Hamp SE. Prediction of root surface caries in patients treated for advanced periodontal disease. J Clin Periodontol 1981;8:400–414.
115. Sugihara N, Maki Y, Okawa Y, Hosaka M, Matsukubo T, Takaesu Y. Factors associated with root surface caries in elderly. Bull Tokyo Dent Coll 2010;51:23–30.
116. Bardow A, Nyvad B, Nauntofte B. Relationships between medication intake, complaints of dry mouth, salivary flow rate and composition, and the rate of tooth demineralization in situ. Arch Oral Biol 2001; 46:413–423.
117. Flink H, Tegelberg A, Lagerlöf F. Influence of the time of measurement of unstimulated human whole saliva on the diagnosis of hyposaliva-tion. Arch Oral Biol 2005;50:553–559.
118. Ferguson MM. Pilocarpine and other cholinergic drugs in the management of salivary gland dysfunction. Oral Surg Oral Med Oral Pathol 1993;75:186–191.
119. Meyer-Lueckel H, Schulte-Monting J, Kielbassa AM. The effect of commercially available saliva substitutes on predemineralized bovine dentin in vitro. Oral Dis 2002;8;192–198.
120. Nevalainen MJ, Narhi TO, Ainamo A. A 5-year follow-up study on the prosthetic rehabilitation of the elderly in Helsinki, Finland. J Oral Reha-bil 2004;31;647–652.
121. Steele JG, Sheiham A, Marcenes W, Fay N, Walls AW. Clinical and behavioural risk indicators for root caries in older people. Gerodontol-ogy 2001;18:95–101.
122. Hand JS, Hunt RJ, Beck JD. Incidence of coronal and root caries in an older adult. J Public Health Dent 1988;48:14–19.
123. Pappas A, Koski A, Guinta J. Prevalence and intraoral distribution of coronal and root caries in middle-aged and older adults. Caries Res 1992;26:459–465.
124. Tonetti MS. Cigarette smoking and periodontal diseases: Etiology and management of disease. Ann Periodontol 1998;3:88–101.
125. Newitter DA, Katz RV, Clive JM. Detection of root caries: Sensitivity and specificity of a modified explorer. Gerodontics 1985;1:65–67.
126. Jones JA. Root caries: Prevention and chemotherapy. Am J Dent 1995;8:352–357.
127. Topping GV, Pitts NB. Clinical visual caries detection. Monogr Oral Sci 2009;21:15–41.
128. Zhang W, McGrath C, Lo EC. Comparison of root caries diagnosis based on visual-tactile criteria and DIAGNOdent in vivo. J Dent 2009;37:509–513.
129. Karlsson L, Johansson E, Tranaeus S. Validity and reliability of laser-induced fluorescence measurements on carious root surfaces in vitro. Caries Res 2009;43:397–404.
130. Kynch E. Antimicrobial management of primary root caries lesions: A review. Gerodontology 1996;13:118–129.
131. Brailsford SR, Fiske J, Gilbert S, Clark D, Beighton D. The effects of the combination of chlorhexidine/thymol- and fluoride-containing varnishes on the severity of root caries lesions in frail institutionalised elderly people. J Dent 2002;30:319–324.
132. Emilson CG, Ravald N, Birkhed D. Effects of a 12-month prophylactic programme on selected oral bacterial

Dentlearn.ir

populations on root surfaces with active and inactive carious lesions. Caries Res 1993;27:195–200.
133. Nyvad B, Fejerskov O. Active root-surface caries converted into inactive caries as a response to oral hygiene. Scand J Dent Res 1986;94:281–284.
134. Brustman B. Impact of exposure to fluoride-adequate water on root surface caries in the elderly. Gerodontics 1986;2:203–207.
135. Hunt RJ, Eldredge JB, Beck JD. Effect of residence in a fluoridated community on the incidence of coronal and root caries in an older adult population. J Public Health Dent 1989;49:138–141.
136. Stamm JW, Banting DW, Imrey PB. Adult root caries survey of two similar communities with contrasting natural water fluoride levels. J Am Dent Assoc 1990;120:143–149.
137. Mukai Y, Lagerweij MD, ten Cate JM. Effect of a solution with high fluoride concentration on remineralization of shallow and deep root surface caries in vitro. Caries Res 2001;35:317–324.
138. Teranaka T, Koulourides T. Effect of 100 ppm fluoride mouthrinse on experimental root caries in human. Caries Res 1987;21:326–332.
139. Petersson LG, Hakestam U, Baigi A, Lynch E. Remineralization of primary root caries lesions using an amine fluoride rinse and dentifrice twice a day. Am J Dent 2007;20:93–96.
140. Tan HP, Lo EC, Dyson JE, Luo Y, Corbet EF. A randomized trial on root caries prevention in elders. J Dent Res 2010;89:1086–1090.
141. De Los Santos R, Lin YT, Corpron RE, Beltran ED, Strachan DS, Landry PA. In situ remineralization of root surface lesions using a fluoride chewing gum or a fluoride releasing device. Caries Res 1994;28:441–446.
142. Mirth DB, Shern RJ, Emilson CG, et al. Clinical evaluation of an intraoral device for controlled release of fluoride. J Am Dent Assoc 1982;105:791–797.
143. Hicks MJ, Westerman GH, Flaitz CM, Blankenau RJ, Powell GL, Berg JH. Effects of argon laser irradiation and acidulated phosphate fluoride on root caries. Am J Dent 1995;8:10–14.
144. Fure S, Lingstrom P. Evaluation of different fluoride treatments of initial root carious lesions in vivo. Oral Health Prev Dent 2009;7:147–154.
145. Baysan A, Lynch E, Ellwood R, Davies R, Petersson L, Borsboom P. Reversal of primary root caries using dentifrices containing 5,000 and 1,100 ppm fluoride. Caries Res 2001;35:41–46.
146. Ekstrand K, Martignon S, Holm-Pedersen P. Development and evaluation of two root caries controlling programmes for home-based frail people older than 75 years. Gerodontology 2008;25:67–75.
147. Wyatt CC, Maupome G, Hujoel PP, et al. Chlorhexidine and preservation of sound tooth structure in older adults. A placebo-controlled trial. Caries Res 2007;41:93–101.
148. Baca P, Clavero J, Baca AP, Gonzalez-Rodriguez MP, Bravo M, Valder-rama MJ. Effect of chlorhexidine-thymol varnish on root caries in a geriatric population: A randomized double-blind clinical trial. J Dent 2009;37:679–685.
149. Nuuja T, Meurman JH, Torkko H. Xylitol and the bactericidal effect of chlorhexidine and fluoride on *Streptococcus mutans* and *Streptococcus sanguis*. Acta Odontol Scand 1993;51:109–114.
150. Trahan L. Xylitol: A review of its action on mutans streptococci and dental plaque—Its clinical significance. Int Dent J 1995;45(suppl 1): 77–92.
151. Isotupa KP, Gunn S, Chen CY, Lopatin D, Makinen KK. Effect of polyol gums on dental plaque in orthodontic patients. Am J Orthod Dentofac Orthop 1995;107:497–504.
152. Aguirre-Zero O, Zero DT, Proskin HM. Effect of chewing xylitol chewing gum on salivary flow rate and the acidogenic potential of dental plaque. Caries Res 1993;27:55–59.
153. Wennerholm K, Arends J, Birkhed D, Ruben J, Emilson CG, Dijkman AG. Effect of xylitol and sorbitol in chewing-gums on mutans streptococci, plaque pH and mineral loss of enamel. Caries Res 1994;28:48–54.
154. Mäkinen KK, Bennett CA, Hujoel PP, et al. Xylitol chewing gums and caries rates: A 40-month cohort study. J Dent Res 1995;74:1904–1913.
155. Mäkinen KK, Mäkinen PL, Pape HR Jr. Stabilisation of rampant caries: Polyol gums and arrest of dentine caries in two long-term cohort studies in young subjects. Int Dent J 1995;45(suppl 1):93–107.
156. Mäkinen KK, Pemberton D, Mäkinen PL, et al. Polyol-combinant saliva stimulants and oral health in Veterans Affairs patients—An exploratory study. Spec Care Dentist 1996;16:104–115.

Dentlearn.ir

157. Reynolds EC. Calcium phosphate-based remineralization systems: Scientific evidence? Aust Dent J 2008;20:87–92.
158. Singh ML, Papas AS. Long-term clinical observation of dental caries in salivary hypofunction patients using a supersaturated calcium-phosphate remineralizing rinse. J Clin Dent 2009;20(3):87–92.
159. Wallace MC, Retief DH, Bradley EL. The 48-month increment of root caries in an urban population of older adults participating in a preventive dental program. J Public Health Dent 1993;43:133–137.
160. Burgess JO. Dental materials for the restoration of root surface caries. Am J Dent 1995;8:342–351.
161. Sidhu SK, Carrick TE, McCabe JF. Temperature mediated coefficient of dimensional change of dental tooth-colored restorative materials. Dent Mater 2004;20:435–440.
162. Matis BA, Cochran MA, Carlson TJ. Longevity of glass-ionomer restorative materials: Results of a 10-year evaluation. Quintessence Int 1996; 27:373–382.
163. Haveman CW, Burgess JO, Summitt JB. A clinical comparison of restorative materials for caries in xerostomic patients [abstract 1441]. J Dent Res 1999;78:286.
164. Hara AT, Turssi CP, Serra MC, Nogueira MCS. Extent of the cariostatic effect on root dentin provided by fluoride-containing restorative materials. Oper Dent 2002;27:480–487.
165. Haveman CW, Summitt JB, Burgess JO, Carlson K. Three restorative materials and topical fluoride gel used in xerostomic patients: A clinical comparison. J Am Dent Assoc 2003;134:177–184.
166. Van Houte J, Jordan HV, Laraway R, Kent R, Soparkar PM, DePaola PF. Association of the microbial flora of dental plaque and saliva with human root surface caries. J Dent Res 1990;69:1463–1468.

Dentlearn.ir



Fluoride-Releasing Materials

Deniz Cakir-Ustun
Nathaniel C. Lawson
John O. Burgess

Patient assessment for oral problems should always begin with a caries risk assessment, which differentiates patients into categories of high, moderate, and low risk (see chapter 5) (Fig 14-1). Treatment is based on this assessment and is specialized by category. High-risk patients need specialized treatment prior, during, and after definitive restorative care. Fluoride is an important adjunct in caries prevention. In addition to professionally applied fluorides and fluoride-containing dentifrices, fluorides may be introduced into the oral environment with fluoride-releasing restorative materials. Fluoride plays several significant roles in any caries-prevention program. These include the formation of fluorapatite, which is more acid resistant than hydroxyapatite, the enhancement of remineralization, interference with ionic bonding during pellicle and plaque formation, and the inhibition of microbial growth and metabolism.[1] High concentrations of fluoride (such as those used in tray applications of fluoride at 12,300 ppm)[2] are bactericidal, while lower concentrations enhance remineralization; all levels produce fluorapatite crystals. Even when fluoride is present at concentrations as low as 1 µmol/L (approximately 0.02 ppm F), the oral fluids (saliva, plaque fluid) are supersaturated

Dentlearn.ir

with fluorapatite, inducing the precipitation of the mineral phase fluorapatite in the tooth structure.[3] Therefore, fluoride-releasing materials are essential in treating the high-caries-risk patient.



Fig 14-1 A patient with high caries risk.

Caries is a multifactorial disease with a bacterial etiology.[4] Because the bacteria producing this disease are introduced into the oral cavity by transfer from an infected host, a possible method for preventing the disease may be by blocking that transfer.[5] However, once established in the oral biofilm, caries-causing bacteria are not easily removed. Dental caries results from bacteria that metabolize sucrose or other cariogenic sugars (fructose and glucose) and secrete organic acids (lactic, propionic, and formic) that cause the loss of mineral ions (calcium and phosphates) from the tooth (*demineralization*).[6] Minerals lost by this method can be replaced during periods of neutral pH (*remineralization*) from calcium and phosphates in the saliva.

Remineralization is a repair process that relies on calcium and phosphate ions to rebuild a new surface on the remnants of crystals present after demineralization. Remineralization is facilitated by fluoride and can arrest carious demineralization in enamel by the formation of a hard and less permeable outer surface. Fluorides are most effective in inducing remineralization on smooth surfaces of teeth.[7] Calcium levels may be the dominant factor in the remineralization process, as the ratio of components required for remineralization is 10 calcium ions to 6 phosphate ions to 2 fluoride or hydroxyl ions. Periods of demineralization and remineralization make up a continuous cycle by which minerals in tooth structure are removed and replaced. If the balance is tipped toward demineralization, caries lesions develop.

The caries process in dentin is similar to that in enamel, except that dentin demineralization begins at a higher pH (6.4, compared with 5.5 for enamel) and

Dentlearn.ir

proceeds about twice as rapidly because dentin has only half the mineral content of enamel. Low fluoride levels are insufficient to initiate dentin remineralization but are adequate to facilitate enamel remineralization.[8] Fluoride ion concentration in saliva is low, averaging about 0.03 ppm (1.6 μmol/L) in the normal subject.[9] The balance of mineral uptake and loss in enamel is shifted from net demineralization to net remineralization if adequate calcium is present.[10] Restorative materials that release fluoride are often recommended for caries on root surfaces, because root structure is primarily composed of dentin and these lesions require significantly greater amounts of fluoride than enamel caries lesions to promote remineralization.

Individuals with high-caries-risk profiles are those with frequent carbohydrate intake, reduced salivary flow, increased plaque retention, low fluoride exposure during tooth formation, and high bacteria counts. Fluoride from fluoridated drinking water is filtered through the body and appears in the saliva. A normal unstimulated salivary flow rate is approximately 0.3 mL/min, while stimulated salivary flow ranges from 1.5 to 2.5 mL/min.[9] Low salivary flow is often associated with *(1)* medications such as antihypertensives, antidepressants, and anticholinergics, *(2)* a history of head and neck irradiation, or *(3)* Sjögren syndrome.[11,12] Low salivary flow reduces the bicarbonate, calcium, and phosphate ions that are typically provided by the saliva, thus reducing its buffering ability and its ability to induce remineralization of demineralized tooth structure.

Exposure to high levels of fluoride during tooth formation produces fluorapatite crystals in tooth structure. Fluorapatite crystals have a critical pH of 4.5, allowing fluorapatite to resist acid demineralization significantly better than hydroxyapatite, which has a critical pH of 5.5.[13]

It is clear that fluoride plays a significant role in caries prevention. Unfortunately, patient compliance in caries-control programs requiring home fluoride applications is often poor. As an alternative, fluoride-releasing materials can supply levels of fluoride that may provide a measure of caries prevention, without relying on patient compliance. Therefore, fluoride-releasing materials can be an essential element in treating the high-caries-risk patient. This chapter discusses fluoride-releasing materials, their effectiveness in inhibiting recurrent caries, and their clinical longevity.

The Fluoride-Releasing Materials Continuum

The first popular fluoride-releasing tooth-colored restorative material was silicate

Dentlearn.ir

cement. This material had poor adhesion to the tooth, high intraoral solubility, poor mechanical properties, and did not survive well in the oral environment. However, recurrent caries lesions associated with these restorations were rare. This anticaries effect was associated with the fluoride released from the silicate cement.[14]

similarities in physical, mechanical, and setting properties. These include *(1)* resin composite, *(2)* compomer, *(3)* giomer, *(4)* resin-modified glass ionomer (RMGI), and *(5)* conventional glass ionomer (Fig 14-2). Fluoride-releasing resin composites are on one end of the continuum and release the least fluoride, while conventional glass ionomers are on the other end and demonstrate the highest levels of fluoride release. Compomers are more similar to resin composites, and RMGIs are more similar to conventional glass ionomers. Giomers are a new class of material and are positioned between resin-modified glass ionomers and compomers.

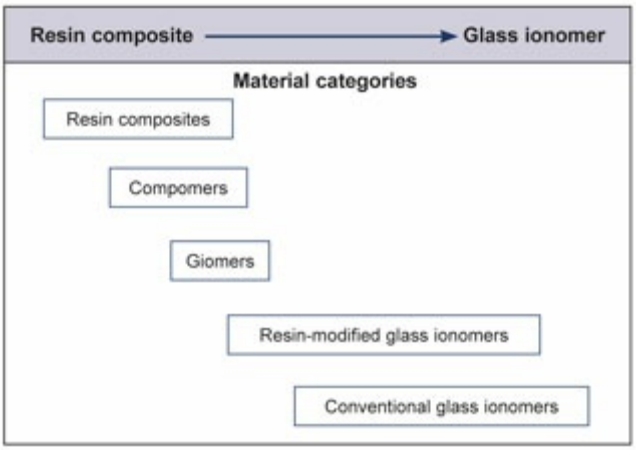

Fig 14-2 The fluoride-releasing material continuum. Fluoride release and recharge increase from left to right among the materials. Locations on the continuum are characterized by compositional variants, curing mechanisms, and mechanical and physical properties.

Table 14-1 compares the mechanical and physical properties of the different categories of fluoride-releasing materials. Table 14-2 describes the water content, supplied form, and setting mechanism (acid-base reaction or free radical polymerization) for these materials. Materials that are powder-liquid must have the powder mixed with the liquid to initiate set; paste-paste materials must have the two pastes mixed to initiate set; visible light–cured (VLC) materials must be illuminated by an appropriate curing light. Box 14-1 lists representative products in each category of the continuum.

Table 14-1	**Mechanical properties of materials on the fluoride-releasing materials continuum[16–24]**

Dentlearn.ir

	Material class				
	Glass ionomer	RMGI	Giomer	Compomer	Resin composite
Flexural strength (MPa)	30–67	60–93	115	94–115	76–135
Compressive strength (MPa)	99–198	143–184	325	217–295	217–315
Diametral tensile strength (MPa)	12	17–21	52	33–52	23–58
Shear bond strength (MPa)	4–8	7–13	12	11–13	17–30
Fluoride release	High	High	Moderate	Moderate	Low
Fluoride recharge	High	High	High	Moderate	Low

Table 14-2 Composition, form supplied, and setting reaction of the materials in the fluoride-releasing materials continuum

	Material class				
	Glass ionomer	RMGI	Giomer	Compomer	Resin composite
Composition	Contains water	Contains water	No water	No water	No water
Form	Powder-liquid	Powder-liquid or paste-paste	VLC paste	VLC paste	VLC paste or paste-paste
Setting reaction	Acid-base only	Acid-base and free radical	Free radical only	Free radical only	Free radical only

Box 14-1 Representative products in each category of the fluoride-releasing material continuum

Glass ionomer	RMGI	Giomer	Compomer	Resin composite
Ketac Fil*	Photac Fil*	Beautifil II[II]	Dyract AP†	Heliomolar‡ (contains fluoride)
				Tetric‡(contains

Dentlearn.ir

Fuji II[§]	Fuji II LC[§]		Compoglass[‡]	fluoride)
Ketac Molar*	Vitremer*		F2000*	SureFil[†] (contains fluoride)
Fuji IX[§]	Ketac Nano*			Z100* (No fluoride)

*3M ESPE

[†]Dentsply/Caulk

[‡]Ivoclar Vivadent

[§]GC America

[II]Shofu

The longevity and success of dental restorations depend on their ability to bond as well as seal the marginal interface (*adhesion*). This seal is affected by several of the properties of the restorative material, namely dimensional change during curing and the mismatch in thermal expansion between the material and the tooth. Both work to compromise the bond and seal. Glass ionomers chemically bond to dentin by an ionic bond with hydroxyapatite. The bond of conventional composites, compomers, and giomers to dentin is through micromechanical interlocking with collagen fibrils (*hybrid layer formation*) mediated by a dentin adhesive (see chapter 9). RMGIs contain components of glass ionomers (fluoro-aluminosilicate glasses and polyacrylic acid) as well as resin composites (photo- or chemical initiators and methacrylate monomers).[25] Because of their hybrid nature, RMGIs bond to dentin through both an ionic bond between polyacrylic acid and hydroxyapatite and mechanical interlocking with collagen and the resin monomer.[26] At the same time that this bond is being formed to the tooth, the material is being pulled away from the tooth surface as a result of contraction that occurs during the setting stage (*polymerization/setting shrinkage*). This contraction produces stress on the newly forming interfacial bond, leading to a loss of adhesion to the cavity walls when the tensile shrinkage stresses exceed the bond strength. This loss of adhesion compromises marginal seal, thereby increasing staining and postoperative cold sensitivity and potentially resulting in marginal caries.[27]

Gerdolle et al[28] measured polymerization shrinkage of four materials (RMGI, compomer, resin composite, and Ormocer) in vitro. Shrinkage values of materials ranked as follows: RMGI > compomer > Ormocer > resin composite. Another study by Attin et al[29] evaluated initial curing shrinkage of six RMGIs, a hybrid resin composite, and an autocured glass ionomer. Their study also showed that most of the RMGIs tested exhibited greater shrinkage than the hybrid composite or the autocured

Dentlearn.ir

glass ionomer. However, glass ionomers generate less polymerization shrinkage stress than do resin composites.[30] This factor, combined with water sorption by glass ionomers, can help to lessen the effects of polymerization shrinkage and reduce the probability of marginal gap formation.[31] Even when the bond resists the contraction forces, stresses may still be imposed on the interfacial bond during temperature changes in the mouth.

The coefficient of thermal expansion (CTE) measures the dimensional change of a material per degree change in temperature. The difference in CTE between the tooth structure (8.3×10^{-6}/°C to 1¼ $\times 10^{-6}$/°C, dentin and enamel respectively) 32 and the restorative materials causes additional stress at the restoration margin, which may further contribute to marginal failure. The CTE of glass ionomers is similar to that of human enamel and dentin, whereas composites have CTEs approximately twice that of human enamel and dentin.[33]

Another important property of glass ionomers is fluoride release, which can potentially help to mitigate the effects of less-than-perfect marginal adaptation. However, fluoride release diminishes with time. Fortunately, glass ionomers have the ability to replenish leached fluoride when exposed to topically applied high fluoride–containing solutions. This property, known as *recharge*, has the potential to provide a continuous low concentration of fluoride in the saliva[34] because the replenished fluoride can be released back to the oral environment. An essential factor in quantifying the recharge ability of the glass ionomer is the amount of fluoride at the surface of the material, where it reaches its maximum concentration.[35]

Resin composites

Fluoride can be incorporated into resin composites through three mechanisms: *(1)* adding fluoride compounds such as sodium fluoride (NaF) or stannous fluoride (SnF_2) *(2)* incorporating fluoride-releasing fillers; or *(3)* integrating fluoride into the resin matrix.[36] Fluoride-releasing resin composites have superior mechanical properties, no inherent adhesive properties (they need a bonding agent to adhere to tooth structure), greater CTEs, and better wear resistance compared with other materials in the continuum. However, they also have the lowest fluoride release and are least capable of being recharged.

Glass ionomers

Glass ionomers are comprised of a polyalkenoic acid polymer matrix and ion-

Dentlearn.ir

leachable fluoroaluminosilicate glass filler particles. Carboxylic acid chains on the polyalkenoic acid form ionic bonds with calcium and aluminum ions leached from the glass filler (Fig 14-3) to cross-link the polymer and form a rigid structure. The carboxylic ions also chelate with calcium (Ca^{2+}) ions in hydroxyapatite, allowing the material to chemically bond to tooth structure.[37] Thus, these materials are adhesive, release comparatively high levels of fluoride, and have CTEs similar to that of tooth structure (Fig 14-4). Early brand-name glass ionomers are still widely used today despite their relatively poor mechanical properties and wear resistance. A newer generation of high-viscosity glass ionomers (Ketac Molar [3M ESPE] and Fuji IX [GC America]) has improved mechanical properties and provides higher levels of fluoride release compared with traditional glass ionomers.[15,39] Although wear resistance is improved, these materials are still inferior to resin composites and should not be used to restore load-bearing areas in the permanent dentition (Fig 14-5). Walls and Mather[39] reported a 1-year wear rate of 73 μm, which is significantly greater than the < 10 μm of wear per year reported for various resin composites.[41,42] Frankenberger et al_{43} reported 8% and 40% failure rates for Class 1 and Class 2 glass-ionomer restorations, respectively, after 24 months.

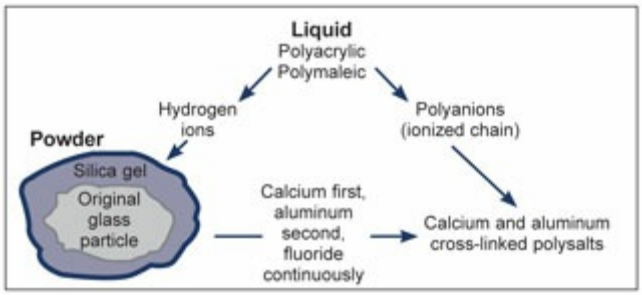

Fig 14-3 Schematic of the setting reaction of chemically cured glass ionomers.

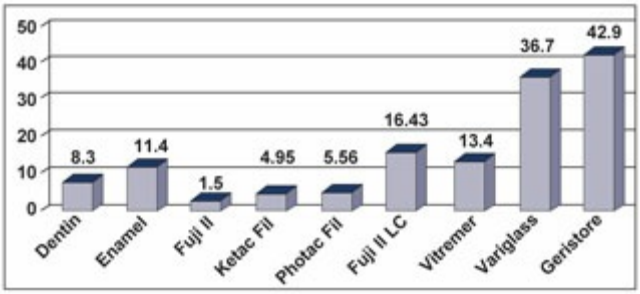

Fig 14-4 Thermal expansion (ppm/°C) of glass ionomers (Fuji II, Ketac Fil), RMGIs (Photac Fil, Fuji II LC, Vitremer), and compomers (Variglass [Dentsply/ Caulk], Geristore [DenMat]).[32,38]

Dentlearn.ir

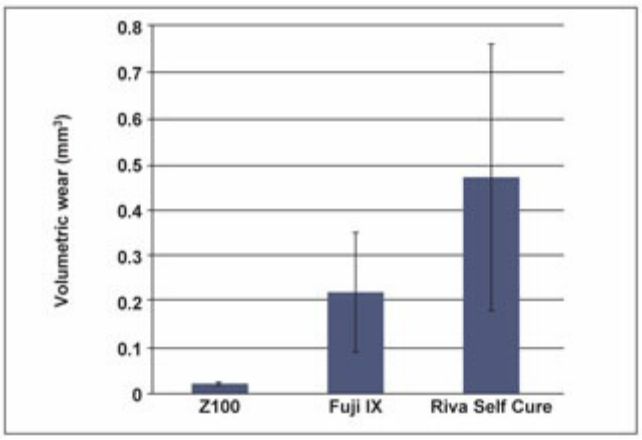

Fig 14-5 Volumetric wear of a composite (Z100) and two conventional glass ionomers (Fuji IX, Riva Self Cure [SDI]).[40]

Resin-modified glass ionomers

RMGIs contain elements of conventional glass ionomers and light-cured resins but have properties most similar to conventional glass ionomers. The matrix consists of polyalkenoic acids modified with unsaturated carbon bonds and/or mixed with (di)methacrylate monomer(s), allowing these materials to cure through acid-base–initiated ionic bonding and polymerization through free radical–initiated covalent bonding.[37] The amount of resin material in the different brands varies widely, because in recent years an effort has been made to increase the resin content to improve handling and strength of the RMGIs. RMGIs develop bond strength primarily through a chemical interaction with the hydroxyapatite in the tooth, but evidence for hybrid layer formation exists as well, especially for formulations with greater resin content.[44] RMGIs have been modified in several ways since the fluoride-releasing materials continuum was proposed. Improved manufacturing has led to smaller filler particles, resulting in a smoother restoration surface and increased fluoride release.[45] Recently, paste-paste RMGIs (those supplied as two pastes that are mixed together) have been marketed as luting cements and more recently as restorative materials. Paste-paste materials are easier to mix and place than those supplied in powder-liquid form. However, in one study, the paste-paste systems showed lower crown retention strength than powder-liquid systems.[46] RMGIs, like conventional glass ionomers, should not be used for restorations in occlusal load–bearing areas in the permanent dentition where heavy occlusal forces are present. However, the results of a 1-year clinical study suggest that RMGIs may be an acceptable short-term alternative to amalgam in pediatric restorations with respect to failure rate.[47]

Dentlearn.ir

Compomers

Compomers (polyacid-modified resin composites) are also blends of resin composites and conventional glass ionomers, created in an attempt to combine particular characteristics of both materials. However, they are primarily composite in composition, and their physical and mechanical properties are more similar to

are added to dimethacylate monomers in the matrix, and the fluoroaluminosilicate glass filler particles are partially silanized for bonding with the resin matrix.[37] Compomers require a dentin bonding system and acid etching of tooth structure to achieve a clinically acceptable bond.[48,49] These materials release more fluoride than resin composites but less than conventional glass ionomers or RMGIs. Their abrasion resistance is intermediate between RMGIs and resin composites. Compomer restorative materials and cements have undergone considerable improvements since their introduction. These improvements have produced materials with increased fluoride release and improved mechanical properties. Expansion due to water sorption was an early problem with compomers, but this problem is less severe in currently available products.[50] The monomer components of at least one of the available brands contains a small proportion of carboxylic acid

polymer but potentially capable of promoting an acid-base neutralization reaction following sorption of water after polymerization, with the subsequent release of fluoride ions.[51]

Giomers

A new class of material has been introduced to the market that is termed *giomer* (glass-ionomer and polymer). Giomers use prereacted glass-ionomer (PRG) technology to form a stable phase of glass-ionomer fillers in a resin matrix. The PRG filler is made by reacting fluoride-containing glass with polyalkenoic acid in water. The PRG filler is then freeze-dried, milled to a desired size, silanized, and added to the resin matrix.[52] The advantage of giomers is the enhanced availability and accessibility of the fluoride within the PRG fillers compared with that in resin-based materials (such as compomers and certain resin composites). In a polymerized dimethacrylate resin matrix, which is mostly hydrophobic, fluoride transfer is dependent on water sorption and segmental mobility of highly cross-linked polymer chains. In giomer materials, the PRG fillers are more accessible to release fluoride and recharge with fl y are available: *(1)*

Dentlearn.ir

surface-reacted PRG filler (S-PRG filler) and *(2)* fully reacted PRG filler (F-PRG filler). The difference between filler types is that only the ions on the surface of S-PRG filler particles leach from the glass and react with polyalkenoic acid. As a result, S-PRG fillers have only a thin outer layer of glass-ionomer phase surrounding an unreacted glass core, while the F-PRG fillers have been reacted more completely throughout.[52]

Giomer materials have fluoride recharge, biocompatibility, a smooth surface finish, excellent esthetics, and clinical durability, which have made them popular for restoration of root caries, noncarious cervical lesions, Class 5 cavities, and lesions in primary teeth.[51] A clinical trial of Class 1 and Class 2 giomer restorations in permanent teeth reported no failures of 41 restorations at the 8-year recall.[53] A recent in vitro study compared the fluoride release and recharge of two fluoride-containing resin composites, Gradia Direct X (GC America) and Tetric EvoCeram (Ivoclar Vivadent); a new giomer material, Beautifil II (Shofu); and a glass-ionomer cement, Fuji IX Extra (GC America), when aged in deionized water (pH 6.5) and lactic acid (pH 4.0) for 43 days. Fluoride release was measured during aging for 6 weeks. Each specimen was recharged in 5,000-ppm NaF solution for 5 minutes at 7 weeks of aging. Recharge was repeated weekly for 3 weeks and fluoride release measured 1, 3, and 7 days after each recharge. The cumulative fluoride released from the giomer into both media was substantially greater than the fluoride released from the other two composites, as was its recharge ability in both media. However, the glass-ionomer cement had the greatest fluoride release and recharge of all the materials.[54]

Fluoride Release

Several researchers have reported that fluoride released from restorative materials affects tooth structure. Decreased recurrent caries rates historically found around silicate restorations have been associated with their high level of fluoride release. Early in vivo work by Hals and Norderval[55] examined recurrent caries around Class 5 restorations and reported a lower occurrence of caries lesions around the silicate restorations. In 1957, Phillips and Swartz[56] measured the enamel solubility around fluoride-releasing restorative materials. Because the influence of water fluoridation in reducing enamel solubility was already well established, it was postulated that fluoride released from dental restorative materials could be incorporated into the tooth structure around the restorations, contributing to reduced enamel solubility.

Dentlearn.ir

This study demonstrated that fluoride present in silicate cements reduced the solubility of the adjacent enamel and suggested that fluoride in low concentrations could be added to dental materials to reduce enamel solubility.

In 1960, Norman et al[57] reported the fluoride content of powdered enamel exposed to fluoride released from porcelain, resin with added NaF, zinc phosphate cement, zinc phosphate cement with 10% calcium fluoride, 2% NaF, and silicate cements. Silicates released large amounts of fluoride for the first 24 hours, but the levels decreased with time. The enamel specimens exposed to the silicates had the greatest fluoride uptake (increase of 495%). The results of this study suggested that enamel exposed to materials releasing high levels of fluoride showed significant fluoride uptake. Furthermore, whenever large amounts of fluoride ions were present in solution, only a small percentage of the available fluoride ions (eg, 18% in the case of enamel exposed to silicate cement) was actually absorbed by the enamel. With smaller amounts of fluoride ions in the solution, a larger percentage was absorbed by the enamel. Even low levels of fluoride release for extended periods may be important for caries prevention, as it has been shown to be dependent on sustained low-level fluoride exposure rather than high-level, short-term bursts.[58]

Subsequently Norman et al[14] examined fluoride uptake by enamel slabs exposed to the same dental materials. The data from powdered enamel and intact enamel were generally in agreement. Most of the materials tested produced some measurable increase in enamel fluoride content, and fluoride increases correlated with reduced acid solubility of the intact enamel. Although the research confirmed that silicate cement released relatively high levels of fluoride, these materials ultimately tended to fail because of their high degree of solubility and poor mechanical properties.

The common denominator in this early research on the effects of various restorative materials on plaque and caries activity appeared to be the presence of fluoride.[59] Because fluoride was present in, and leached from, silicate cements, subsequent research was devoted to finding other materials with improved physical and mechanical properties that might release fluoride in a more predictable and clinically more successful manner. This preliminary work ultimately led to the development of glass-ionomer cement.

There are significant numbers of in vitro and in vivo studies that demonstrate the fluoride-releasing capability of glass ionomers.[50,60] Researchers have measured the fluoride release from four glass-ionomer cements in vitro and reported that the greatest release occurred on the first day; subsequently, it decreased sharply the

Dentlearn.ir

second day and gradually diminished over 3 weeks to a low-level, long-term release. After 1 year, all specimens were still releasing fluoride at daily levels of at least 0.5 ppm. Other studies have reported a "burst" of fluoride release, with high early release for 1 to 2 days followed by a rapid decline.[61–72] The early fluoride burst is most likely due to the availability at the material surface of fluoride ions from the matrix that were released during the reaction between the glass particles and polyalkenoate acid, as well as from soluble fluoride added to the glass-ionomer powder.[73] Prolonged fluoride release occurs as fluoride dissolves from the glass particles surrounded by an acidified hydrogel matrix[74] and then diffuses through the polymer matrix to be released from the surface in a time-dependent diffusion process.

In vivo research by Hatibovic-Kofman and Koch[75] and by Hattab et al[76] found significant increases of fluoride in saliva following the placement of glass-ionomer restorations. In the former study, salivary fluoride concentrations remained elevated 1 year after placement of glass-ionomer restorations (0.04 ppm before placement of restorations, 0.8 ppm 3 weeks after placement, and up to 0.3 ppm 1 year later).[75] In an in situ study, subjects wore maxillary appliances with four glass-ionomer (Ketac Fil, 3M ESPE) restorations every night.[76] The unstimulated salivary fluoride content was measured before insertion of the device and after overnight wear. In all subjects, salivary fluoride increased after wearing the appliance. Xu and Burgess[45] measured the compressive strength, fluoride-release, and fluoride-recharge profiles of 15 fluoride-releasing materials. The fluoride-release profiles of the glass-ionomer materials in this study are shown in Fig 14-6. The study demonstrated a negative (inverse) correlation between fluoride release and compressive strength (ie, materials that have a high level of fluoride release generally have lower strengths than materials with a low level of fluoride release).

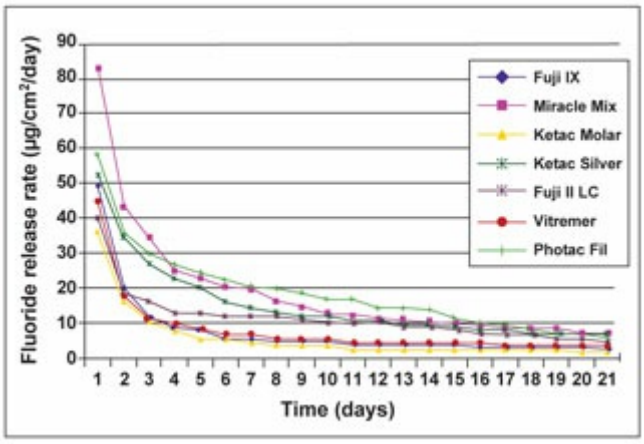

Fig 14-6 Fluoride-release profiles of some glass-ionomer restorative materials over 21 days45: conventional glass i ss ionomer, Miracle

Dentlearn.ir

Mix (GC America); silver-containing glass ionomer, Ketac Silver (3M ESPE); RMGIs, Fuji II LC, Vitremer (3M ESPE), and Photac Fil (3M ESPE).

Hsu et al[71] measured the fluoride released from an RMGI (Vitremer, 3M ESPE) and a high-viscosity conventional glass ionomer (Fuji IX) using a continuous flow rate apparatus adjusted to 20 mL/h. They reported that Vitremer released more fluoride than Fuji IX over an 8-hour period. In addition, the fluoride-release rate decreased rapidly after recharging, and most of the fluoride was released within 6 hours. This is a clinically significant finding because it indicates that the fluoride-releasing materials should be recharged with external neutral NaF daily to increase their fluoride release and reminer-alizing potential (Fig 14-7).

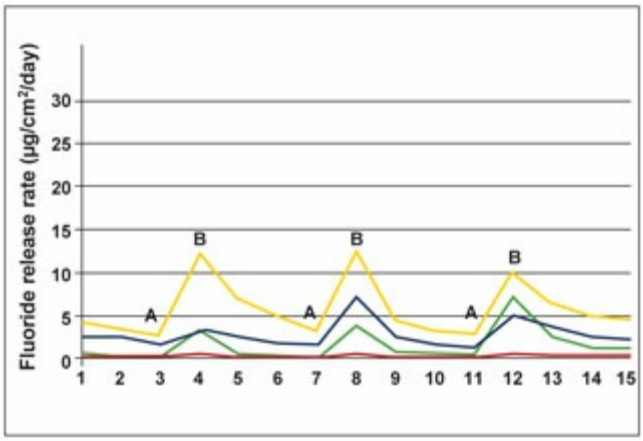

Fig 14-7 Fluoride-recharge profiles of fluoride-releasing restorative materials.[71] (A) Baseline amount of fluoride release prior to application of topical fluoride; (B) amount of fluoride release 1 day after recharge. Green—glass ionomer; yellow—RMGI; blue—compomer; red—composite.

Mousavinasab and Meyers[17] measured the amounts of fluoride released from four classes of fluoride-containing materials including three glass-ionomer cements (Fuji IX, Fuji VII, and Fuji IX Extra), one RMGI (Fuji II LC [GC America]), a compomer (Dyract Extra, Dentsply/Caulk) and a giomer (Beautifil). Cumulative fluoride release for up to 21 days was greatest from Fuji VII, followed by Fuji IX Extra, Fuji II LC, Fuji IX, Dyract Extra, and Beautifil, with the dimethacrylate resin–matrix materials—the compomer (Dyract) and giomer (Beautifil)—being significantly lower than the glass-ionomer materials. This work emphasizes the importance of the glass-ionomer matrix in determining the fluoride-releasing ability of glass-ionomer materials.

In a comprehensive study of fluoride-releasing materials, Cranfield et al[63] reported that pH influenced fluoride release in storage media, with a lower pH producing higher fluoride release, probably due to erosion of the glass-ionomer

Dentlearn.ir

surface. Moreau and Xu[77] also examined fluoride released from glass ionomers, a composite, and a compomer in vitro in varying pH solutions. They determined that these materials had increased fluoride release at a cariogenic pH—a useful property for anticaries effects.

Fluoride release from a restoration that can be incorporated into tooth structure and into the walls of the cavity preparation is perhaps the most important benefit of glass ionomer.[56,78,79] However, the fluoride release and incorporation into the tooth can be decreased and inhibited by a layer of adhesive if used beneath the RMGI to enhance bonding.[80,81] If applied to the surface of the restoration (ie, to reduce the potential for moisture loss during setting) the adhesive initially may reduce fluoride release from the surface and to whatever depth the adhesive penetrates into the surface porosity. However, the resin coating on restoration surfaces will in time be removed due to toothbrushing and mastication and therefore not have a significant impact on long-term fluoride release from the external surface of the restoration.[82,83]

Fluoride Recharging

Perhaps the most important variable in fluoride release is not the amount of fluoride released from the material initially after placement, because this declines rapidly with time (see Fig 14-6), but the ability of the material to be recharged with fluoride from external sources (see Fig 14-7). Forsten evaluated fluoride release[67] and uptake[84] by traditional glass ionomers to determine whether glass-ionomer materials could not only release fluoride but also take up fluoride from a fluoride-rich solution. He reported that after an initial high rate of fluoride release, a constant level occurred at about 3 weeks and that topical fluoride applications could recharge glass-ionomer restorations. Forsten[68,84] also reported a constant release rate of approximately 0.5 to 1.0 μg/mL during the second year for all glass ionomers except cermets (glass ionomers containing silver particles). Other investigators[79,85–87] have confirmed the recharge phenomenon when high fluoride–content solutions are applied to glass ionomers.

Compomers and RMGIs can be recharged as well.[88] RMGIs, such as Photac Fil (3M ESPE), Vitremer, and Fuji II LC, and conventional glass ionomers, such as Fuji IX and Ketac Molar demonstrate the greatest fluoride-recharge capacity. Fluoride-releasing resin composites, such as Heliomolar (Ivoclar Viva-dent) and Tetric Ceram (Ivoclar Vivadent), release little additional fluoride after being exposed to a fluoride-rich solution. Compomers, such as Dyract AP (Dentsyply/Caulk) and

Dentlearn.ir

Compoglass (Ivoclar Vivadent), have a recharge capacity between those of RMGIs and resin composites but are most similar to RMGIs. For materials with recharge capability, the fluoride release remains at increased levels for less than a day after

greatest recharge, followed by compomers. Traditional glass ionomers were intermediate, and fluoride-releasing resin composites had the least recharge (see Fig 14-7). This recharge capability may be due to the microporosities present in glass ionomers (Fig 14-8) and RMGIs. A recent in vitro study[18] compared fluoride release from a giomer and a compomer after fluoride-recharge regimes and concluded that giomers have significantly greater fluoride release and uptake following recharging than compomers.



Fig 14-8 Photomicrograph of porosity in Fuji IX that allows fluoride-rich materials to be absorbed and released.

The ability of a material to act as a fluoride reservoir is dependent on the type and concentration of fluoridating agent, the frequency of recharge, and the solubility and type of restorative material.[18] Once the fluoride is depleted, it may be replenished from other fluoride sources, such as toothpastes, mouthrinses, or topical fluoride solutions. High-concentration fluoride solutions such as gels, when applied to fluoride-releasing materials, produce greater fluoride recharge than low fluoride–containing toothpastes. The increased fluoride release after recharge is short-lived, and recharge must be accomplished daily to maintain an elevated level. After recharging, fluoride ions are released from these materials by washout of fluoride from their surface or their pores.[89]

The pH of the topical fluoride used to recharge glass-ionomer restorations is important. Acidic topical fluoride solutions, such as acidulated phosphate fluoride solutions and other acidified fluoride preparations, degrade glass-ionomer materials and should be avoided.[90–92] RMGIs are more resistant to surface degradation than

Dentlearn.ir

conventional glass ionomers but still degrade when exposed to acids.[92] Resin composites are also degraded by frequent applications of acidic fluoride solutions, producing filler dislodgment and destruction of the filler–resin matrix interface.[93]

Antibacterial Effects of Fluoride

The high fluoride levels released from glass-ionomer restorative materials in the first few days after placement may be beneficial because of antibacterial effects. Initial microleakage often occurs after restoration placement.[94] Fluoride has three effects on bacteria: *(1)* inhibition of metabolism, *(2)* inhibition of growth, *(3)* and bacterial death. Fluoride is bactericidal in concentrations significantly greater than the amount released by fluoride-releasing materials. Thus, a direct bactericidal effect probably does not occur from fluoride released by restorative materials. However, fluoride levels produced by fluoride-releasing materials probably affect bacterial metabolism. By reducing bacterial acid production and altering the environment, fluoride release effectively changes the succession of bacteria necessary for acid production. This subtle mechanism is difficult to measure but may profoundly reduce acid production and tooth demineralization by cariogenic bacteria.

Fluoride released from dental materials is incorporated into bacteria[9] and inhibits bacterial acid production.[10] However, the fluoride in plaque on teeth adjacent to or several teeth distant from a glass-ionomer restoration has not been shown to be increased, emphasizing that the effect is very local. Protection provided by fluoride-releasing materials is probably confined to tooth structure immediately adjacent to the restoration, and one study demonstrated the effective zone to be about 1 mm from the restoration's margins.[85] Several studies have postulated that caries formed around a restoration may in fact be new lesions formed adjacent to previous restorations and not secondary caries formed from carious material left under the previous restoration.[95–98] Fluoride-releasing materials may play an important role in controlling the development of new lesions.[99]

Norman et al[59] examined the effects of fluoride-containing and other restorative materials on bacterial plaque. They compared plaque composition associated with amalgam, gold foil, cast gold (inlay), methyl methacrylate resin, and silicate cement restorations. They reported that comparable plaque developed on all tested materials with the exception of the silicate cement. Based on this research, it appeared that the fluoride component of the silicate cement somehow altered the

Dentlearn.ir

composition of the plaque, both at the margin of the restoration and on the tooth surface. Loyola-Rodriguez et al[100] observed similar inhibition of *Streptococcus mutans* by resin-modified and conventional glass-ionomer restorative materials. Forss et al[101,102] demonstrated a higher level of fluoride in plaque growing on glass ionomer than in plaque growing on resin composite restorations, with a significant reduction of *S mutans* near the glass-ionomer restorations.

In an in vitro study, Palenik et al[103] measured the inhibition by six glass-ionomer materials of microbial adherence and growth of five different bacteria typical in human plaque (*Actinomyces viscosus, Streptococcus mitis, Streptococcus mutans, Lactobacillus casei,* and *Streptococcus sanguis*). All glass ionomers inhibited growth and/or plaque adherence to some degree. The extent of inhibition varied according to the material used and the specific bacterial species. Growth inhibition was directly related to the amount of fluoride ion released; materials with a higher rate of release had a greater effect. McComb and Erickson[104] demonstrated that a pH of 2.6 was produced with freshly mixed glass ionomer, rising ultimately to 7.4 during the setting reaction. These investigators proposed that both the low pH and the fluoride release were responsible for the antibacterial effects. DeSchepper et al[105] used an agar diffusion assay method to determine the inhibitory effects on *S mutans* of 11 glass-ionomer cements and their powder and liquid components. They measured the zone of inhibition of bacterial growth and the fluoride levels in the surrounding agar. Because glass-ionomer liquids (polyacids) are acidic, they inhibited bacterial growth. The mixed materials released significant amounts of fluoride, and the inhibition zones correlated well with fluoride levels; high fluoride-releasing materials had greater zones of inhibition than low fluoride-releasing materials. However, in a subsequent study[106] measuring the antibacterial effects of light-cured glass ionomers, a neutral NaF control was included. Although Vitrebond (3M ESPE) and XR Ionomer (Kerr) produced significant inhibition zones, the neutral NaF produced no inhibition zone. When the pH of the highly acidic tested materials was adjusted upward to 5 by adding sodium hydroxide, none had antibacterial effects. The authors concluded that the mechanism of action for bacterial inhibition was probably a combination of fluoride release and low pH. A recent study measured bacterial growth in vitro on a glass ionomer, an RMGI, a compomer, a giomer, and a resin composite and showed that the glass ionomer, despite releasing the most fluoride, had the lowest antibacterial properties. The study suggests that either fluoride release is not the dominant mechanism for reducing bacterial growth and biofilm formation on a restorative material or that the fluoride concentration produced from fluoride-releasing materials is too low to be

Dentlearn.ir

effective.[107]

Bacteria in plaque located on glass-ionomer restorations are affected less as the age of the restoration increases. Bacterial composition of plaque on glass-ionomer restorations, up to a month after placement,[101] generally show a strong positive correlation between fluoride release and reduced *S mutans* counts. However, the data on older restorations, which release less fluoride and have a higher pH, are equivocal regarding bacterial counts. Svanberg et al[108] showed lower bacterial counts and reduced fluoride levels in the bacteria, while Van Dijken et al[109] reported decreased antibacterial effect of the restorative materials. The difference between findings in these studies may be due to differences in the materials and/or the plaque sampling. Svanberg used a silver-containing glass ionomer, and the silver release may have provided additional antibacterial action compared with that of the

from the surface of the restorations,[109] whereas plaque was obtained from the restoration margins in the Svanberg study.[108] The concentration of fluoride may be higher in the more protected environment of restoration margins. Also, Van Dijken discontinued oral hygiene procedures for 1 week to allow plaque to accumulate prior to sampling.[109] Eliminating the potential for fluoride recharge of the surface from fluoride-containing toothpaste during the week preceding sampling may also have contributed to the reduced antibacterial effects in the Van Dijken study.

Do Fluoride-Releasing Materials Inhibit Caries?

As previously stated, several mechanisms have been suggested for the anticaries effect of fluorides. These include the formation of fluorapatite, which is more acid resistant than hydroxyapatite; the enhancement of remineralization; the interference of ionic bonding during pellicle and plaque formation; and the inhibition of microbial growth and metabolism.[1] Fluoride released from restorative materials can inhibit development of caries lesions through all of these mechanisms, although it seems likely that enhancement of remineralization is the most important mechanism of action for fluoride released from restorative materials. Evidence for the caries-inhibiting effect of fluoride-releasing materials comes from studies of the incidence of caries lesions adjacent to orthodontic bands and brackets, direct filling materials in patients at high risk for caries, and areas around atraumatic restorative technique (ART) restorations.[110]

Although not directly applicable, the effects of orthodontic luting materials on

Dentlearn.ir

adjacent tooth structure may supply valuable information regarding fluoride-releasing restorative materials, because enamel demineralization frequently occurs adjacent to fixed orthodontic appliances. White spot lesions appear within a few weeks after appliance placement, particularly with ill-fitting bands.[111–113] An increased cariogenic challenge is introduced around orthodontic bands and brackets due to markedly higher plaque retention levels caused by food retention and hindered patient oral hygiene efforts. A rise in cariogenic bacteria (*S mutans* and *Lactobacillus*) has been documented following placement of orthodontic appliances.[114] The overall occurrence of white spot formation during orthodontic therapy is 11% to 12%, with little difference between bonded brackets and zinc phosphate–cemented bands.[115] A daily rinse of 0.2% NaF retards but does not completely inhibit lesion formation.[115] Unfortunately, patients most in need of significant preventive intervention are often the least compliant. Fluoride-releasing resin composites and RMGI cements inhibit demineralization adjacent to orthodontic bands and brackets. Bands cemented with glass-ionomer cements have increased retention with less demineralization compared to those cemented with zinc phosphate.[116–118] Decreased enamel demineralization under orthodontic bands retained with conventional glass-ionomer cements in vivo has been reported.[119–123]

Three prospective in vivo studies describe fluoride-releasing restorative materials used in high-caries-risk patients. Wood et al[123] placed 54 pairs of Class 5 conventional glass-ionomer (Ketac Fil) and amalgam (Sybralloy, Kerr) restorations in xerostomic patients who had been treated with radiation for head and neck cancer. When topical fluoride was not used, glass-ionomer restorations had longer survival times than amalgam restorations. When a topical NaF solution (pH 5.8) was used, amalgam restorations had a longer survival time than the glass-ionomer restorations,

fluoride-releasing material, when used without a topical fluoride gel, was effective in inhibiting recurrent caries and that acidic fluoride solutions degrade glass-ionomer restorations. It also clearly demonstrates the effectiveness of fluoride-releasing materials in noncompliant patients.

Haveman et al[124] used a similar population to measure the effectiveness of fluoride-releasing materials in high-caries-risk patients. In this study, Class 5 restorations were placed using a conventional glass ionomer (Ketac Fil), an RMGI (Vitremer), and an amalgam (Tytin, Kerr). At the 2-year recall, recurrent caries lesions had occurred at the margins of 15% of the glass-ionomer restorations, 12% of the RMGI restorations, and 44% of the amalgam restorations. Restorations with fluoride-releasing m ries lesions near the

Dentlearn.ir

restoration than did amalgam restorations.

McComb et al[125] reported that fluoride-releasing materials reduced the incidence of recurrent caries lesions in 45 patients who had received head and neck radiation therapy. After removal of carious tooth structure, the investigators placed Class 5 glass-ionomer (Ketac Fil), RMGI (Vitremer), and resin composite restorations. At

they used topical fluoride in trays more than 50% of the time. Topical fluoride users had no recurrent caries lesions associated with these restorations. Nonusers had an 80% reduction in recurrent caries lesions adjacent to fluoride-releasing restorations compared with the non–fluoride-releasing materials. This evidence demonstrates that if a patient uses tray-delivered supplemental fluoride, a significant reduction in caries lesions can be expected because the concentration of fluoride in the tray materials is greater than that released from the restorative material. However, if the patient does not use supplemental fluoride, then the fluoride release from the restorations still provides some level of protection for the high-caries-risk patient.

These three studies suggest that fluoride-releasing materials are somewhat effective in preventing recurrent caries lesions. However, caries lesions developed around fluoride-releasing materials in each study, demonstrating that the remineralizing effects of fluoride released from restorations can be overwhelmed if the acid challenge is great enough and that fluoride is but one factor in preventing the development of new caries lesions in high-caries-risk patients.

The American Dental Association Center for Evidence-Based Dentistry recently featured a systematic review of caries incidence at margins of glass-ionomer and amalgam restorations. The review included 10 clinical studies that compared recurrent caries at the margins of amalgam and glass-ionomer restorations of the same cavity class in the same dentition. Restorations from permanent and primary dentitions were included in the analysis. Data were pooled and compared by meta-analysis. The study revealed that there was a 65% lower chance of developing recurrent caries around single-surface glass-ionomer restorations than corresponding amalgam restorations in permanent teeth. The study found no difference in recurrent caries rates around primary teeth.[126]

However, not all studies on recurrent caries inhibition demonstrate a clear benefit from fluoride release. Tyas[127] reported no significant difference in recurrent caries in teeth restored with resin composite (Silux, 3M ESPE) or glass ionomer (Fuji II) in a population at low risk for caries. In two other clinical reports[128,129] involving almost 7,000 restorations, recurrent caries lesions developed within 10 years for

Dentlearn.ir

amalgam restorations, 8 years for resin composite restorations, and 5 years for glass-ionomer restorations. Recurrent caries lesions led to the replacement of almost half of the glass-ionomer restorations. In these populations, fluoride released from glass-ionomer restorations did not provide protection against primary or recurrent caries. Mjör et al[130] reported that in 9,805 replacement restorations placed by 243 Norwegian dentists in general practice, glass ionomers provided little protection against recurrent caries. Unfortunately, these retrospective studies may show that clinicians used glass ionomers in patients at high risk for caries and other materials in patients at lower risk for caries. The results in both clinical studies may be due in

standardization in defining recurrent caries. Fluoride-releasing materials do not eliminate recurrent caries but should be viewed as one part of a complete program to reduce caries incidence.

How Much Fluoride Is Enough?

A common question is how much fluoride release from restorative materials is enough to inhibit recurrent or secondary caries. A minimum inhibitory concentration of 100 to 200 μg/mL of NaF is required to inhibit the growth of oral streptococci,[88] while 30 times that concentration is required to be bactericidal. Naturally occurring fluoride at concentrations as high as 21 μg/ mL does not produce any obvious effect on the composition of supragingival plaque. Although the fluoride levels in bacteria associated with glass-ionomer restorations are elevated, the effect of fluoride on reducing bacterial acid production, metabolism, and division has yet to be clarified.

However, another important aspect to be considered is that high levels of fluoride release produce remineralization of enamel and dentin. One study[131] demonstrated that enamel demineralization decreased as fluoride release from a resin composite restorative material increased. By extrapolating data, the authors concluded that a resin composite releasing 200 to 300 $\mu g/cm^2$ of fluoride over a 1-month period would completely inhibit secondary caries. Unfortunately, this is approximately 40 to 50 times more fluoride than is released by current fluoride-releasing resin composites. Eichmiller and Marjenhoff[64] authored an excellent review of fluoride-releasing materials and noted that caries inhibition and tooth remineralization potential have been shown in vitro by all fluoride-releasing materials when release rates were approximately 1 μg/mL. It has also been reported that fluoride concentrations of 0.03 to 0.08 ppm can shift the equilibrium from net

Dentlearn.ir

demineralization to net remineralization.[73]

The remineralization of dentin is more complex than that of enamel. Active dentinal caries destroys collagen matrix as well as demineralizing apatite crystals. Remineralization of dentin may be affected by the remaining mineral, the remaining collagen, or the ultrastructure of the dentin. Collagen matrix devoid of mineral does not support remineralization.[132] The difficulty in protecting root surfaces with fluoride-releasing materials may be due to the higher concentrations of fluoride needed to remineralize root surfaces compared with enamel surfaces. Wefel[132] reported that demineralized dentin, with its exposed organic matrix, did not act as a suitable matrix for remineralization and that remineralization did occur on any remaining apatite crystals. It seems clear that increased fluoride combined with calcium and phosphate is required to remineralize dentin and that the degree of remineralization that can occur in dentin may be controlled by the amount of remaining mineral content.

Based on the previous studies, it is recommended that materials with a long-term fluoride release rate of at least 2 to 3 μg/mL/day be used. With present materials, this rate of release can only be maintained when supplemental fluorides are used to recharge fluoride-releasing restorations. As has been previously stated, fluoride is only one factor needed to lower caries development, and saliva quantity and quality may be the single greatest factor in caries risk. Important proteins in saliva that stabilize calcium and phosphate are statherin, acid proline-rich proteins, and histatins. Saliva has protective properties, and when proper levels of phosphoproteins are present, calcium saturation is increased.[133]

Clinical Considerations

Although the inhibition of recurrent caries is evident for fluoride-releasing materials, their clinical effectiveness has been questioned based on the durability of the materials. Even in primary teeth, these materials should be used selectively, and the time that the material will be expected to survive based on how long the tooth will remain in the oral cavity should be evaluated against its strength and wear resistance. One report[134] describes the wear resistance of a compomer (Dyract) and shows that this material has poorer wear resistance than resin composite. At 1 year in a clinical evaluation of 91 Dyract restorations in conservative Class 1 and Class 2 restorations in primary teeth, the mean wear of Dyract was 190 μm, compared with approximately 10 μm for a wear-resistant resin composite. Another study[135]

Dentlearn.ir

measuring marginal adaptation of Class 2 restorations in the permanent dentition reported that compomers showed poor adaptation after 6 months of clinical wear, prompting the authors to recommend that compomers not be used as definitive restorations in load-bearing areas. Although the absolute numbers may vary, the typical compomer undergoes greater wear than the typical resin composite. A 4-year clinical evaluation of posterior compomer restorations revealed a 16% failure rate.[136] Therefore, compomers should not be used in Class 1 or Class 2 load-bearing areas in the permanent dentition. However, as the wear resistance and fluoride recharge of compomer restorative materials continue to improve, it is now apparent that they can be used with success in both Class 5 and Class 2 open sandwich restorations. Three in vivo studies[137–139] have reported the clinical success of Dyract as a Class 5 restorative material in noncarious cervical lesions. In these studies, the compomer was clinically acceptable at the end of 3 years[137] and was superior to RMGIs.[138,139] Though compomers have improved, much clinical testing is necessary to document their clinical performance before they can be endorsed for more expanded applications.

Treating the high-caries-risk patient requires special selection of restorative materials. RMGIs and compomers are recommended as the esthetic restorative materials of choice in Class 5 restorations in xerostomic patients and other patients at high risk for caries. This is because of the fluoride-release and fluoride-recharge capabilities of these materials. Because RMGIs and compomers have poorer wear resistance than resin composites, a resin composite should be used for restorations in load-bearing areas.

Another strategy for Class 2 and Class 5 restorations that extend gingivally below the cementoenamel junction is the open sandwich technique (Fig 14-9). In this technique, the fluoride-releasing material is placed along the gingival margin of a preparation (the proximal box of a Class 2 preparation) when the gingival margin extends to cementum or dentin. The RMGI is cured, and resin composite is placed in increments to restore the occlusal surface for adequate wear resistance (Fig 14-10). The open sandwich technique was clinically successful at the 5-year recall[140] of Class 2 composite restorations placed in patients with moderate to high caries risk. An RMGI (Vitremer) was placed in the gingival portion of the proximal box and covered with a resin composite (Z100, 3M ESPE). Another 6-year study found acceptable durability of RMGIs in open sandwich restorations.[141] The open sandwich technique in Class 2 restorations combines the wear resistance of a resin composite with the fluoride release and recharge potential of RMGIs. Conventional glass ionomers are less successful in the open sandwich technique.[142] Because of

Dentlearn.ir

increased fluoride release compared with that of resin composite, better handling, and a likely enhanced solubility resistance in an acidic environment, compomers have been suggested for this application. However, a 9-year clinical trial found no difference in the incidence of secondary caries using a compomer in an open sandwich technique versus a resin composite alone.[143]

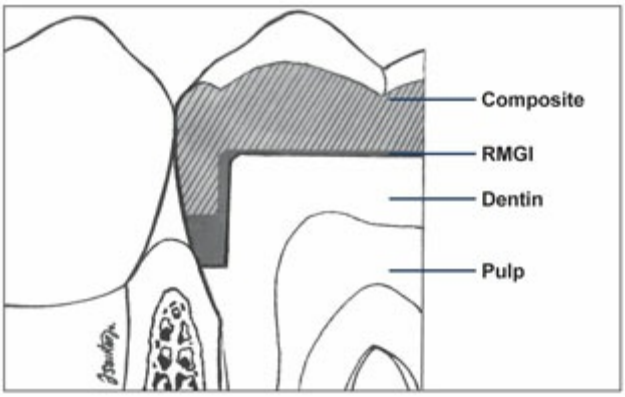

Fig 14-9 Illustration of the open sandwich technique.

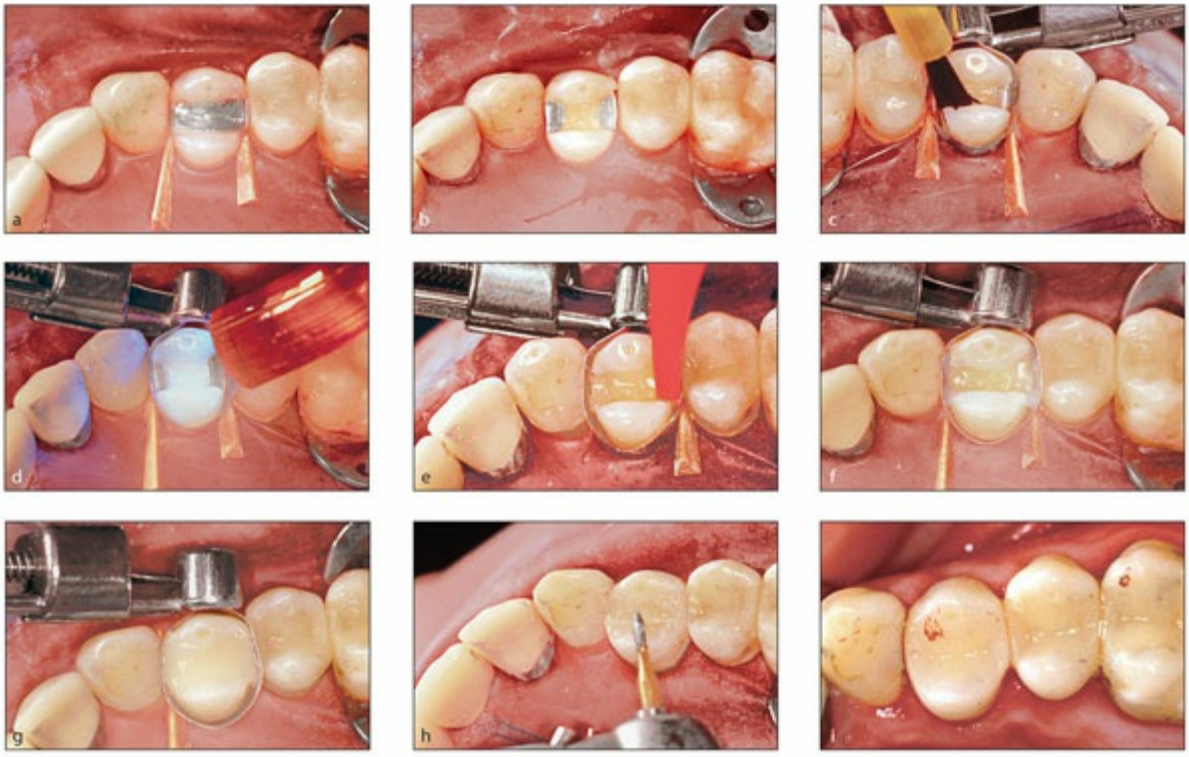

Fig 14-10 Open sandwich technique. The fluoride-releasing RMGI material is placed in the proximal box. A wear-resistant composite is placed on the occlusal surface. *(a)* Defective amalgam. *(b)* Cavity preparation. *(c and d)* Primer application and light curing of the primer. *(e)* RMGI placement. *(f)* Etching in preparation for adhesive and composite placement. Note that the RMGI is placed as a thin layer, apical to proximal contacts only. *(g)* Resin composite placement. *(h)* Finishing. *(i)* Definitive restoration.

Dentlearn.ir

As dental restorative materials continue to proliferate, it becomes increasingly difficult to choose an appropriate material for a particular clinical situation. Fluoride-releasing materials are no exception, and clinicians need guidelines to select and use these materials effectively (Table 14-3). Today, there is modest but growing evidence from clinical trials that fluoride-releasing materials, especially RMGIs and conventional glass ionomers, reduce recurrent caries. There is also evidence of a dose-response relationship between fluoride release and decreased caries. While materials with higher fluoride-releasing capability have a greater caries-inhibiting effect, these materials are not panaceas. The physical and mechanical limitations of glass ionomers and compomers, especially poor wear resistance[144–146]; staining and discoloration with products such as coffee, tea, wine, or exposure to daylight[147]; and maintenance of surface gloss,[147] contribute markedly to restoration failure (Figs 14-11 to 14-13).

Table 14-3	**Guidelines for recommended use of fluoride-releasing materials**
Glass ionomer	Provisional restorations or caries control for patients with high caries risk; Class 3 and Class 5 restorations; cores or buildups when half or more of the tooth remains; ART; sealants for erupting teeth
RMGI	Provisional restorations or caries control for patients with high caries risk; patients with moderate salivary flow; Class 3 and Class 5 restorations; buildups when half or more of the tooth remains; ART; open sandwich technique; sealants for erupting teeth
Giomer/compomer	High-caries-risk patients with diminished salivary flow; primary teeth; permanent Class 3 and Class 5 restorations.
Fluoride-releasing composite	Long-term provisional restorations; conservative Class 1, 2, 3, 4, 5 restorations; core buildups

ART—atraumatic restorative technique.



Fig 14-11 Marked color differences are seen with RMGI products (Fuji II LC A2) *(a)* compared with resin composites (Clearfil Majesty A2, Kuraray Dental) following immersion in a solution of

Dentlearn.ir

cranberry juice, coffee, and tea *(b)*.

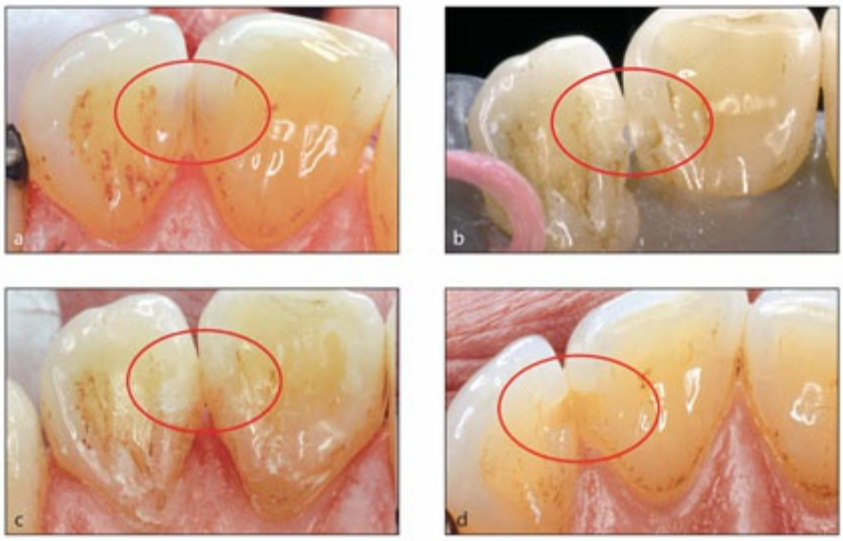

Fig 14-12 Clinical representation of a stained glass-ionomer restoration. *(a)* Caries. *(b)* Class 3 cavity preparation. *(c)* Restoration at baseline. *(d)* Restoration at 1-year recall. Note the shade difference compared with *(c)*.



Fig 14-13 Class 5 glass-ionomer restorations. The left central and right lateral incisors contain 2-year-old restorations, whereas the right central incisor contains a newly placed restoration of the same shade. Note the evident staining of the older restorations.

Fluoride-releasing materials should be used in high-caries-risk patients as one component of their overall treatment. High-caries-risk patients also require oral hygiene counseling, diet modification, saliva-replacement materials, and daily application of neutral NaF-containing toothpastes with added calcium and phosphate and xylitol to inhibit caries activity. An absolute requirement for these patients is frequent recall and site-specific quarterly applications of fluoride varnishes.

Dentlearn.ir

Generally a 5% NaF-containing varnish should be used in hard-to-clean areas that are prone to white spot lesion development. For patients with low salivary output and white spot lesion development, a regimen of calcium phosphate–containing material, such as MI Paste Plus (GC America) (a casein phospho-peptide with amorphous calcium phosphate–containing paste with 900 ppm fluoride), is also recommended to increase levels of calcium and phosphate in the saliva and promote remineralization. These recommendations, combined with frequent oral hygiene checks and reinforcement, should provide maximum benefit for the individual who is at high risk for caries.[148–149] See chapter 5 for more on managing high-caries-risk patients.

References

1. Niessen LC, Gibson G. Oral health for a lifetime: Preventive strategies for the older adult. Quintessence Int 1997;28:626–630.
2. Newbrun E. Topical fluorides in caries prevention and management: A North American perspective. J Dent Educ 2001;65:1078–1083.
3. Tenuta LM, Cury JA. Fluoride: Its role in dentistry. Braz Oral Res 2010;24(suppl 1):9–17.
4. Loesche WJ, Hockett, RN, Syed SA. The predominant cultivable flora of tooth surface plaque removed from institutionalized subjects. Arch Oral Biol 1972;17:1311–1325.
5. Douglass JM, Li Y, Tinanoff N. Association of mutans streptococci between caregivers and their children. Pediatr Dent 2008;30:375–387.
6. Featherstone JD. The caries balance: Contributing factors and early detection. J Calif Dent Assoc 2003;31:129–133.
7. Van Dorp CS, Ten Cate JM. Preventive measures and caries progression: An in vitro study on fissures and smooth surfaces of human molars. ASDC J Dent Child 1992;59:257–262.
8. ten Cate JM, Buijs MJ, Damen JJ. pH-cycling of enamel and dentin lesions in the presence of low concentrations of fluoride. Eur J Oral Sci 1995;103:362–367.
9. McIntyre J. The nature and progression of dental caries. In: Mount EJ, Hume WR (eds). Preservation and Restoration of Tooth Structure. London: Mosby, 1998:20–23.
10. Seppä L, Korhonen A, Nuutinen A. Inhibitory effect on S. mutans by fluoride-treated conventional and resin-reinforced glass ionomer cements. Eur J Oral Sci 1995;103:182–185.
11. Bardow A, Nyvad B, Nauntofte B. Relationships between medication intake, complaints of dry mouth, salivary flow rate and composition, and the rate of tooth demineralization in situ. Arch Oral Biol 2001;46: 413–423.
12. Billings RJ, Proskin HM, Moss ME. Xerostomia and associated factors in a community-dwelling adult population. Community Dent Oral Epidemiol 1996;24:312–316.
13. Meurman JH, ten Cate JM. Pathogenesis and modifying factors of dental erosion. Eur J Oral Sci 1996;104:199–206.
14. Norman RD, Platt JR, Phillips RW, Swartz ML. Additional studies on fluoride uptake by enamel from certain dental materials. J Dent Res 1961;40:529–537.
15. Yip HK, Smales RJ, Ngo HC, Tay FR, Chu FC. Selection of restorative materials for the atraumatic restorative treatment (ART) approach: A review. Spec Care Dentist 2001;21:216–221.
16. Lawson NC, Cakir D, Ramp LC, Beck P, Burgess J. Effect of light activation on resin-modified glass ionomer shear bond strength. Oper Dent 2012; 37:380–385.

Dentlearn.ir

17. Mousavinasab SM, Meyers J. Fluoride release by glass ionomer cements, compomer and giomer. Dent Res J (Isfahan) 2009;6:75–81.
18. Dhull KS, Nandlal B. Comparative evaluation of fluoride release from PRG-composites and compomer on application of topical fluoride: An in-vitro study. J Indian Soc Pedod Prev Dent 2009;27:27–32.
19. Manuja N, Pandit IK, Srivastava N, Gugnani N, Nagpal R. Comparative evaluation of shear bond strength of various esthetic restorative materials to dentin: An in vitro study. J Indian Soc Pedod Prev Dent 2011;29: 7–13.
20. McKenzie MA, Linden RW, Nicholson JW. The physical properties of conventional and resin-modified glass-

24:4063–4069.
21. Ilie N, Hickel R. Mechanical behavior of glass ionomer cements as a function of loading condition and mixing procedure. Dent Mater 2007;26: 526–533.
22. Lien W, Vandewalle KS. Physical properties of a new silorane-based restorative system. Dent Mater 2010;26:337–344.
23. Almuammar MF, Schulman A, Salama FS. Shear bond strength of six restorative materials. J Clin Pediatr Dent 2001;25:221–225.
24. Lawson NC, Burgess JO. Evaluation of the bond strength with the immediate dentinal sealing technique [abstract 3126]. J Dent Res 2008;87 (special issue B).
25. Berzins DW, Abey S, Costache MC, Wilkie CA, Roberts HW. Resin-modified glass-ionomer setting reaction competition. J Dent Res 2010;89:82–86.
26. Coutinho E, Cardoso MV, De Munck J, et al. Bonding effectiveness and interfacial characterization of a nanofilled resin-modified glass-ionomer. Dent Mater 2009;25:1347–1357.
27. Burgess J, Cakir D. Comparative properties of low-shrinkage composite resins. Compend Contin Educ Dent 2010;31(special issue):10–15.
28. Gerdolle DA, Mortier E, Droz D. Microleakage and polymerization shrinkage of various polymer restorative materials. J Dent Child 2008; 75:125–133.
29. Attin T, Buchalla W, Kielbassa AM, Helwig E. Curing shrinkage and volumetric changes of resin-modified glass ionomer restorative materials. Dent Mater 1995;11:359–362.
30. Dauvillier BS, Feilzer AJ, De Gee AJ, Davidson CL. Visco-elastic parameters of dental restorative materials during setting. J Dent Res 2000;79: 818–823.
31. Feilzer AJ, Kakaboura AI, De Gee AJ, Davidson CL. The influence of water sorption on the development of setting shrinkage stress in traditional and resin-modified glass ionomer cements. Dent Mater 1995;11: 186–190.
32. Park JB, Lakes RS. Biomaterials, ed 2. New York: Plenum, 1992.
33. Cardenas HL, Burgess JO. Thermal expansion of glass ionomers [abstract 946]. J Dent Res 1994;73(special issue):220.
34. Koch G, Hatibovic-Kofman S. Glass ionomer cements as a fluoride release system in vivo. Swed Dent J 1990;14:267–273.
35. Hadley PC, Milella E, Gerardi C, Hill RG, Billington RW. Distribution of fluoride in glass ionomer cement determined using SIMS. Biomater 2001;22:1563–1569.
36. Arends J, Dijkman GE, Dijkman AG. Review of fluoride release and secondary caries reduction by fluoridating composites. Adv Dent Res 1995;9:367–76.
37. Ruse ND. What is a “compomer”? J Can Dent Assoc 1999;65:500–504.
38. Norling B, Summitt J. Resin ionomer restorative materials: The new generation. J Esthet Dent 1994;6:207–215.
39. Walls AW, Mather E. Fuji IX restorations in occlusal cavities of molar teeth, 12-month data [abstract 1443]. J Dent Res 1999;78:286.
40. Robles R, Kalavacharla VK, Beek P, et al. Wear of glass ionomer restorative materials [abstract 865]. Presented at the 42nd Annual Meeting of the American Association of Dental Research, Tampa, 23 March 2012.
41. Mazer RB, Leinfelder KF. Evaluating a microfill posterior composite resin. A five-year study. J Am Dent Assoc 1992;123:33–38.

Dentlearn.ir

42. Barkmeier WW, Latta MA, Erickson RL, Wilwerding TM. Wear simulation of resin composites and the relationship to clinical wear. Oper Dent 2008;33:177–182.
43. Frankenberger R, Garcia-Godoy F, Krämer N. Clinical performance of viscous glass ionomer cement in posterior cavities over two years. Int J Dent 2009:781462.
44. Coutinho E, Yoshida Y, Inoue S, et al. Gel phase formation at resin-modified glass-ionomer/tooth interfaces. J Dent Res 2007;86:656–661.
45. Xu X, Burgess JO. Compressive strength, fluoride release and recharge of fluoride-releasing materials. Biomater 2003;24:2451–2461.
46. Johnson GH, Lepe X, Zhang H, Wataha JC. Retention of metal-ceramic crowns with contemporary dental cements. J Am Dent Assoc 2009; 140:1125–1136.
47. Daou MH, Tavernier B, Meyer JM. Clinical evaluation of four different dental restorative materials: One-year results. Schweiz Monatsschr Zahnmed 2008;118:290–295.
48. Elderton RJ, Aboush Y, Vowles RW, Bell CJ, Marshall KJ. Retention of cervical Dyract compomer restorations after two years [abstract 49]. J Dent Res 1996;75:24.
49. Gallo JR, Burgess JO, Ripps AH, et al. Three-year clinical evaluation of a compomer and a resin composite as class V filling materials. Oper Dent 2005;30:275–281.
50. Hermesch CB, Wall BS, McEntire JF. Dimensional stability of dental restorative materials and cements over four years. Gen Dent 2003;51: 518–523.
51. Milward PJ, Adusei GO, Lynch CD. Improving some selected properties of dental polyacid-modified composite resins. Dent Mater 2011;27: 997–1002.
52. Ikemura K, Tay FR, Endo T, Pashley DH. A review of chemical-approach and ultramorphological studies on the development of fluoride-releasing dental adhesives comprising new pre-reacted glass ionomer (PRG) fillers. Dent Mater 2008;27:315–339.
53. Gordan VV, Mondragon E, Watson RE, Garvan C, Mjör IA. A clinical evaluation of a self-etching primer and a giomer restorative material: Results at eight years. J Am Dent Assoc 2007;138:621–627.
54. Naoum S, Ellakwa A, Martin F, Swain M. Fluoride release, recharge and mechanical property stability of various fluoride-containing resin composites. Oper Dent 2011;36:422–432.
55. Hals E, Norderval IT. Histopathology of experimental in vivo caries around silicate fillings. Acta Odontol Scand 1973;31:357–367.
56. Phillips RW, Swartz ML. Effect of certain restorative materials on solubility of enamel. J Am Dent Assoc 1957;54:623–636.
57. Norman RD, Phillips RW, Swartz ML. Fluoride uptake by enamel from certain dental materials. J Dent Res 1960;39:11–16.
58. Robertson MA, Kau CH, English JD, Lee RP, Powers J, Nguyen JT. MI Paste Plus to prevent demineralization in orthodontic patients: A prospective randomized controlled trial. Am J Orthod Dentofacial Orthop 2011;140:660–668.
59. Norman RD, Mehra RV, Swartz ML, Phillips RW. Effects of restorative materials on plaque composition. J Dent Res 1972;51:1596–1601.
60. Perrin C, Persin M, Sarrazin J. A comparison of fluoride release from four glass-ionomer cements. Quintessence Int 1994;25:603–608.
61. Alvarez AN, Burgess JO, Chan DCN. Short-term fluoride release of six ionomers—Recharged, coated and abraded [abstract 260]. J Dent Res 1994;73:134.
62. Burkett L, Burgess JO, Chan DCN, Norling BK. Fluoride release of glass ionomers coated and not coated with adhesive [abstract 1242]. J Dent Res 1993;72:258.
63. Cranfield M, Kuhn AT, Winter GB. Factors relating to the rate of fluorideion release from glass-ionomer cement. J Dent 1982;10:333–341.
64. Eichmiller FC, Marjenhoff WA. Fluoride-releasing dental restorative materials. Oper Dent 1998;23:218–228.
65. Forsten L, Paunio IK. Fluoride release by silicate cements and composite resins. Scand J Dent Res 1972;80:515–519.
66. Forsten L. Fluoride release of glass ionomers. J Esthet Dent 1994;6: 216–222.

Dentlearn.ir

67. Forsten L. Short- and long-term fluoride release from glass ionomers and other fluoride-containing filling materials in vitro. Scand J Dent Res 1990;98:179–185.
68. Forsten L. Fluoride release from a glass ionomer cement. Scand J Dent Res 1977;85:503–504.
69. McKnight-Hanes C, Whitford GM. Fluoride release from three glass ionomer materials and the effects of varnishing with or without finishing. Caries Res 1992;26:345–350.
70. Mitra SB. In vitro fluoride release from a light-cured glass-ionomer liner/ base. J Dent Res 1991;70:75–78.
71. Hsu HM, Huang GF, Chang HH, Wang YL, Guo MK. A continuous flow system for assessing fluoride release/uptake of fluoride-containing restorative materials. Dent Mater 2004;20:740–749.
72. Woolford MJ, Grieve AR. Release of fluoride from glass polyalkenoate (ionomer) cement subjected to radiant heat. J Dent 1995;23:233–237.
73. Wiegand A, Buchalla W, Attin T. Review on fluoride-releasing restorative materials—Fluoride release and uptake characteristics, antibacterial activity and influence on caries formation. Dent Mater 2007;23:343–362.
74. De Moor RJ, Verbeeck RM, De Maeyer EA. Fluoride release profiles of restorative glass ionomer formulations. Dent Mater 1996;12:88–95.
75. Hatibovic-Kofman S, Koch G. Fluoride release from glass ionomer cement in vivo and in vitro. Swed Dent J 1991;15:253–258.
76. Hattab FN, el-Mowafy OM, Salem NS, el-Badrawy WA. An in vivo study on the release of fluoride from glass-ionomer cement. Quintessence Int 1991;22:221–224.
77. Moreau JL, Xu HH. Fluoride releasing restorative materials: Effects of pH on mechanical properties and ion release. Dent Mater 2010;26: e227–e235.
78. Hallgren A, Oliveby A, Twetman S. Fluoride concentration in plaque adjacent to orthodontic appliances retained with glass ionomer cement. Caries Res 1993;27:51–54.
79. Forsten L, Rytömaa I, Anttilla A, Keinonen J. Fluoride uptake from restorative dental materials by human enamel. Scand J Dent Res 1976;84: 391–395.
80. Vercruysse CW, De Maeyer EA, Verbeeck RM. Fluoride release of polyacid-modified composite resins with and without bonding agents. Dent Mater 2001;17:354–358.
81. Tam LE, Chan GP, Yim D. In vitro caries inhibition effects by conventional and resin-modified glass-ionomer restorations. Oper Dent 1997; 22:4–14.
82. Hotta M, Hirukawa H. Abrasion resistance of restorative glass-ionomer cements with a light-cured surface coating. Oper Dent 1994;19:42–46.
83. Kupietzky A, Houpt M, Mellberg J, Shey Z. Fluoride exchange from glass ionomer preventive resin restorations. Pediatr Dent 1994;16:340–345.
84. Forsten L. Fluoride release and uptake by glass ionomers. Scand J Dent Res 1991;99:241–245.
85. Tantbirojn D, Douglas WH, Versluis A. Inhibitive effect of a resin-modified glass ionomer cement on remote enamel artificial caries. Caries Res 1997;31:275–280.
86. Damen JJ, Buijs MJ, ten Cate JM. Uptake and release of fluoride by saliva-coated glass ionomer cement. Caries Res 1996;30:454–457.
87. Diaz-Arnold AM, Holmes DC, Wistrom DW, Swift EJ. Short-term fluoride release/uptake of glass ionomer restoratives. Dent Mater 1995;11:96–101.
88. Ekstrand J, Fejerskov O, Silverstone LM (eds). Fluoride in Dentistry. Copenhagen: Munksgaard, 1988:76.
89. Preston AJ, Higham SM, Agalamanyi EA, Mair LH. Fluoride recharge of aesthetic dental materials. J Oral Rehabil 1999;26:936–940.
90. Burgess JO, Cardenas HL. Surface roughness of topical fluoride treated glass ionomers [abstract 775]. J Dent Res 1995;74:108.
91. Diaz-Arnold AM, Wistrom DW, Swift EJ. Topical fluoride and glass ionomer microhardness. Am J Dent 1995;8:134–136.
92. El-Badrawy WA, McComb D. Effect of home-use fluoride gels on resin-modified glass-ionomer cements. Oper Dent 1998;23:2–9.
93. Papagiannoulis L, Tzoutzas J, Eliades G. Effect of topical fluoride agents on the morphologic characteristics and composition of resin composite restorative materials. J Prosthet Dent 1997;77:405–413.

Dentlearn.ir

94. Prati C, Tao L, Simpson M, Pashley DH. Permeability and microleakage of class II resin composite restorations. J Dent 1994;22:49–56.
95. Mjör IA, Toffenetti F. Secondary caries: A literature review with case reports. Quintessence Int 2000;31:165–179.
96. Özer L. The Relationship Between Gap Size, Microbial Accumulation and the Structural Features of Natural Caries in Extracted Teeth With Class II Amalgam Restorations [thesis]. Copenhagen: University of Copenhagen, 1997.
97. Kidd EA, Beighton D. Prediction of secondary caries around tooth-colored restorations: A clinical and microbiological study. J Dent Res 1996;75:1942–1946.
98. Kidd EA, Fejerskov O. What constitutes dental caries? Histopathology of carious enamel and dentin related to the action of cariogenic bio-film. J Dent Res 2004;83(suppl 1):C35–C38.
99. Benelli EM, Serra MC, Rodrigues AL Jr, Cury JA. In situ anticariogenic potential of glass ionomer cement. Caries Res 1993;27:280–284.
100. Loyola-Rodriguez JP, Garcia-Godoy F, Lindquist R. Growth inhibition of glass ionomer cements on mutans streptococci. Pediatr Dent 1994; 16:346–349.
101. Forss H, Jokinen J, Spets-Happonen S, Seppä L, Luoma H. Fluoride and mutans streptococci in plaque grown on glass ionomer and composite. Caries Res 1991;25:454–458.
102. Forss H, Nase L, Seppä L. Fluoride and caries associated microflora in plaque on old GIC fillings [abstract 2468]. J Dent Res 1994;73:410.
103. Palenik CJ, Behnen MJ, Setcos JC, Miller CH. Inhibition of microbial adherence and growth by various glass ionomers in vitro. Dent Mater 1992;8:16–20.

1028.
105. DeSchepper EJ, White RR, von der Lehr W. Antibacterial effects of glass ionomers. Am J Dent 1989;2:51–56.
106. DeSchepper EJ, Thrasher MR, Thurmond BA. Antibacterial effects of light-cured liners. Am J Dent 1989;2:74–76.
107. Al-Naimi OT, Itota T, Hobson RS, McCabe JF. Fluoride release for restorative materials and its effect on biofilm formation in natural saliva. J Mater Sci Mater Med 2008;19:1243–1248.
108. Svanberg M, Mjör IA, Orstavik D. Mutans streptococci in plaque from margins of amalgam, composite, and glass-ionomer restorations. J Dent Res 1990;69:861–864.
109. Van Dijken JW, Kalfas S, Litra V, Oliveby A. Fluoride and mutans streptococci levels in plaque on aged restorations of resin-modified glass ionomer cement, compomer and resin composite. Caries Res 1997; 31:379–383.
110. Frencken JE, Makoni F, Sithole WD. ART restorations and glass ionomer sealants in Zimbabwe: Survival after 3 years. Community Dent Oral Epidemiol 1998;26:372–381.
111. O'Reilly MM, Featherstone JD. Demineralization and remineralization around orthodontic appliances: An in vivo study. Am J Orthod Dento-facial Orthop 1987;92:33–40.
112. Øgaard B, Rølla G, Arends J, ten Cate JM. Orthodontic appliances and enamel demineralization. Part 2. Prevention and treatment of lesions. Am J Orthod Dentofacial Orthop 1988;94:123–128.
113. Rezk-Lega F, Øgaard B, Rølla G. Availability of fluoride from glass-ionomer luting cements in human saliva. Scand J Dent Res 1991;99: 60–63.
114. Lundström F, Krasse B. Streptococcus mutans and lactobacilli frequency in orthodontic patients: The effect of chlorhexidine treatments. Eur J Orthod 1987;9:109–116.
115. Gorelick L, Geiger A, Gwinnett A. Incidence of white spot formation after bonding and banding. Am J Orthod 1982;81:93–98.
116. Fricker JP, McLachlan MD. Clinical studies of glass ionomer cements. Part 2—A two-year clinical study comparing glass ionomer cement with zinc phosphate cement. Aust Orthod J 1987;10:12–14.
117. Norris DS, Mclnnes-Ledoux P, Schwaninger B, Weinberg R. Retention of orthodontic bands with new fluoride-releasing cements. Am J Orthod 1986;89:206–211.

Dentlearn.ir

118. Stirrups DR. A comparative clinical trial of a glass ionomer and a zinc phosphate cement for securing orthodontic bands. Br J Orthod 1991; 18:15–20.
119. Kvam E, Broch J, Nissen-Meyer JH. Comparison between a zinc phosphate cement and a glass ionomer cement for cementation of orthodontic bands. Eur J Orthod 1983;5:307–313.
120. Marcusson A, Norevall LI, Persson M. White spot reduction when using glass ionomer cement for bonding in orthodontics: A longitudinal and comparative study. Eur J Orthod 1997;19:233–242.
121. Ortendahl T, Thilander B, Svanberg M. Mutans streptococci and incipient caries adjacent to glass ionomer cement or resin-based composite in orthodontics. Am J Orthod Dentofacial Orthop 1997;112:271–274.
122. Seeholzer HW, Dasch W. Banding with a glass ionomer cement. J Clin Orthod 1988;22:165–169.
123. Wood RE, Maxymiw WG, McComb D. A clinical comparison of glass ionomer (polyalkenoate) and silver amalgam restorations in the treatment of class 5 caries in xerostomic head and neck cancer patients. Oper Dent 1993;18:94–102.
124. Haveman C, Burgess J, Summitt JB. A clinical comparison of restorative materials for caries in xerostomic patients [abstract 1441]. J Dent Res 1999;78:286.
125. McComb D, Erickson RL, Maxymiw WG, Wood RE. A clinical comparison of glass-ionomer, resin-modified glass ionomer and resin-composite restorations in the treatment of cervical caries in xerostomic head and neck radiation patients. Oper Dent 2002;27:430–437.
126. Mickenautsch S, Yengopal V. Absence of carious lesions at margins of glass-ionomer cement and amalgam restorations: An update of systematic review evidence. BMC Res Notes 2011;4:58.
127. Tyas MJ. Cariostatic effect of glass ionomer cement: A five-year clinical study. Aust Dent J 1991;36:236–239.
128. Mjör IA, Jokstad A. Five-year study of class II restorations in permanent teeth using amalgam, glass polyalkenoate (ionomer) cermet and resin-based composite materials. J Dent 1993;21:338–343.
129. Mjör IA. Glass-ionomer cement restorations and secondary caries: A preliminary report. Quintessence Int 1996;27:171–174.
130. Mjör IA, Moorhead JE, Dahl JE. Reasons for replacement of restorations in permanent teeth in general dental practice. Int Dent J 2000;50: 361–366.
131. Dijkman GE, de Vries J, Lodding A, Arends J. Long-term fluoride release of visible light-activated composites in vitro: A correlation with in situ demineralisation data. Caries Res 1993;27:117–123.
132. Wefel JS. Root caries histopathology and chemistry. Am J Dent 1994; 7:261–265.
133. Walsh LJ. Evidence that demands a verdict: Latest developments in remineralization therapies. Australasian Dent Pract 2009;20:48–59.
134. Peters TC, Roeters JJ, Frankenmolen FW. Clinical evaluation of Dyract in primary molars: 1-year results. Am J Dent 1996;9:83–88.
135. Kersten S, Besek MJ, Lutz F. Marginal adaptation of class-II-compomer restorations in vivo [abstract 2286]. J Dent Res 1999;78:391.
136. Krämer N, Garcia-Godoy F, Reinelt C, Frankenberger R. Clinical performance of posterior compomer restorations over 4 years. Am J Dent 2006;19:61–66.
137. Martin N, Jedynakiewicz NM, Fletcher JM. A clinical evaluation of a new compomer restorative at 3 years in the restoration of non-retentive cervical cavities [abstract]. J Dent Res 2002;82:A52.
138. Abdalla Al, Alhadainy HA, Garcia-Godoy F. Clinical evaluation of glass ionomers and compomers in class V carious lesions. Am J Dent 1997; 10:18–20.
139. Loher C, Kunzelmann RH, Hickel R. Clinical evaluation of glass ionomer cements (LC), compomer and composite restorations in class V cavities—Two year results [abstract 1190]. J Dent Res 1997;76:162.
140. Burgess JO, Summitt JB, Robbins JW, et al. Clinical evaluation of base, sandwich and bonded Class 2 resin composite restorations [abstract 304]. J Dent Res 1999;78:531.
141. Andersson-Wenckert IE, van Dijken JW, Kieri C. Durability of extensive Class II open-sandwich restorations with a resin-modified glass ionomer cement after 6 years. Am J Dent 2004;17:43–50.
142. Welbury RR, Murray JJ. A clinical trial of the glass-ionomer cement-composite resin “sandwich” technique in Class II cavities in permanent premolar and molar teeth. Quintessence Int 1990;21:507–512.

Dentlearn.ir

143. Lindberg A, van Dijken JW, Lindberg M. Nine-year evaluation of a polyacid-modified resin composite/resin composite open sandwich technique in Class II cavities. J Dent 2007;35:124–129.
144. Da Cunha MR, Puppin-Rontani RM, Ferracane JL, Correr-Sobrinho L. In vitro wear evaluation of dental materials in primary teeth. Am J Dent 2006;19:364–369.
145. Correr GM, Bruschi Alonso RC, Correr Sobrinho L, Puppin-Rontani RM, Ferracane JL. In vitro wear of resin-based materials—Simultaneous corrosive and abrasive wear. J Biomed Mater Res B Appl Biomater 2006;78:105–114.
146. Shabanian M, Richards LC. In vitro wear rates of materials under different loads and varying pH. J Prosthet Dent 2002;87:650–656.
147. Vance M, Cakir D, Beck P, Litaker MS, Burgess J. Color and gloss of direct esthetic restorative materials [abstract 1505]. J Dent Res 2009; 88(special issue A).
148. Reynolds EC. Anticariogenic complexes of amorphous calcium phosphate stabilized by casein phosphopeptides: A review. Spec Care Dentist 1998;18:8–16.
149. Shen P, Cai F, Walker G, Reynolds C, Reynolds EC. Enamel remineralization by a mouthrinse containing casein phosphopeptide-amorphous calcium phosphate and fluoride in an in situ model. Aust Dent J 2004;49(ADRF special research suppl):4.

Dentlearn.ir



Class 5 Restorations

J. D. Overton
Thomas J. Hilton
Mark L. LittleStar
Clifford B. Starr

Class 5 lesions are carious and noncarious defects found in the gingival third of facial and lingual tooth surfaces. As described in chapter 5, Class 5 caries lesions are produced by bacterial plaque attaching to the surface of teeth and producing acids that cause demineralization. A Class 5 lesion resulting from factors other than dental caries is known as a *noncarious cervical lesion* (NCCL). Chapter 13 contains an excellent discussion of the etiology of caries-damaged root surfaces that is applicable to the management and treatment of caries lesions in cervical areas. This chapter focuses mainly on the unique etiology, diagnosis, and restorative treatment of NCCLs (Fig 15-1). For restorative treatment in cervical areas, procedures are similar for caries lesions and noncarious lesions, except that carious dentin is removed in restorative treatment of caries lesions.

Dentlearn.ir



Fig 15-1*(a)* The canine has occlusal wear facets but no NCCL. NCCLs in the first premolar are occlusal and gingival to an existing resin composite restoration, suggesting an acid component to the tooth loss. The second premolar has an NCCL. *(b)* V-shaped lesions with a good volume of keratinized attached gingiva apical to the lesions. *(c)* A deep, V-shaped cervical notch in a maxillary canine. *(d)* NCCLs with gingival margins in enamel. *(e)* An isolated NCCL that exposed the pulp in a 70-year-old man. *(f)* Smooth NCCLs involving both enamel and root surfaces. The mandibular molar and second premolar have no keratinized attached gingiva remaining. A gingival cleft has developed on the maxillary second premolar.

Caries Lesions

Tooth color is not a good predictor of root caries damage. A root surface may be discolored and still have a hard, sclerotic surface that would not warrant preparation and placement of a restoration unless the discoloration presented an esthetic problem for the patient. In contrast, some root caries lesions will have the color of healthy tooth structure but will be soft when tested with a dental instrument. Caries-disclosing dyes may be inconsistent in identifying demineralized cementum/dentin on root surfaces. The best correlation to date for clinical detection of caries lesions on root surfaces is the softness of the surface as evaluated with a dental instrument.

Noncarious Cervical Lesions

Incidence

It appears that NCCLs are unique to modern man. In an anthropologic study of the skulls of humans living in the Copper Age and Middle Ages (2050–2080 BC and 1100–1400 AD), no NCCLs were found in 3,927 teeth from 259 individuals.[1]

Dentlearn.ir

Today, NCCLs can be found in the teeth of children as well as in adult teeth.

studies show incidence increasing with age.[2,3] One study[3] involved examination of 1,753 children at 12 years of age and then again at 14 years of age. Cervical or occlusal erosion was present in 56.3% of the children at 12 years of age and 64.1% of the same children at 14 years of age.[3] Another study[4] looked at 1,002 adult inhabitants of Rijeka, Croatia, chosen at random from four dental practices. After the exclusion of restored facial surfaces, 18% of the teeth had evidence of facial tooth wear. In this study, only 5% of subjects younger than 26 years of age were identified with cervical wear. With every 10-year increase in patient age, the lesions became more common. Cervical wear was identified in 48% of subjects older than 65 years of age.[4]

Etiology

The entire etiology of NCCLs has not been determined. While the various possible causes and their degree of involvement may be controversial, there is overwhelming evidence that the cause is multifactorial.[5–10] A review of the literature shows disparate opinions as to the primary cause, with nearly equal evidence to support toothpaste/toothbrush abrasion,[11–16] occlusal forces,[9,13,16–18] and low pH.[19–22] Thus, it is likely that varying combinations of stress factors contribute to the initial lesion and further loss of tooth structure. *Erosion*, the loss of tooth structure from chemical dissolution; *abrasion*, the loss of tooth structure by mechanical or frictional forces; and *abfraction* or *stress corrosion*, the loss of cervical tooth structure due to occlusal forces (Fig 15-2), have all been implicated in the formation of some NCCLs. Patients should be informed of the possible etiologies, implications of the presence of lesions, prevention methods, treatment alternatives, and expected outcomes. Failure to appropriately prevent and treat NCCLs can result in *(1)* progressive loss of tooth structure, *(2)* tooth sensitivity, *(3)* the need for endodontic therapy, *(4)* tooth loss, and *(5)* the occurrence of additional lesions.[23]

Dentlearn.ir

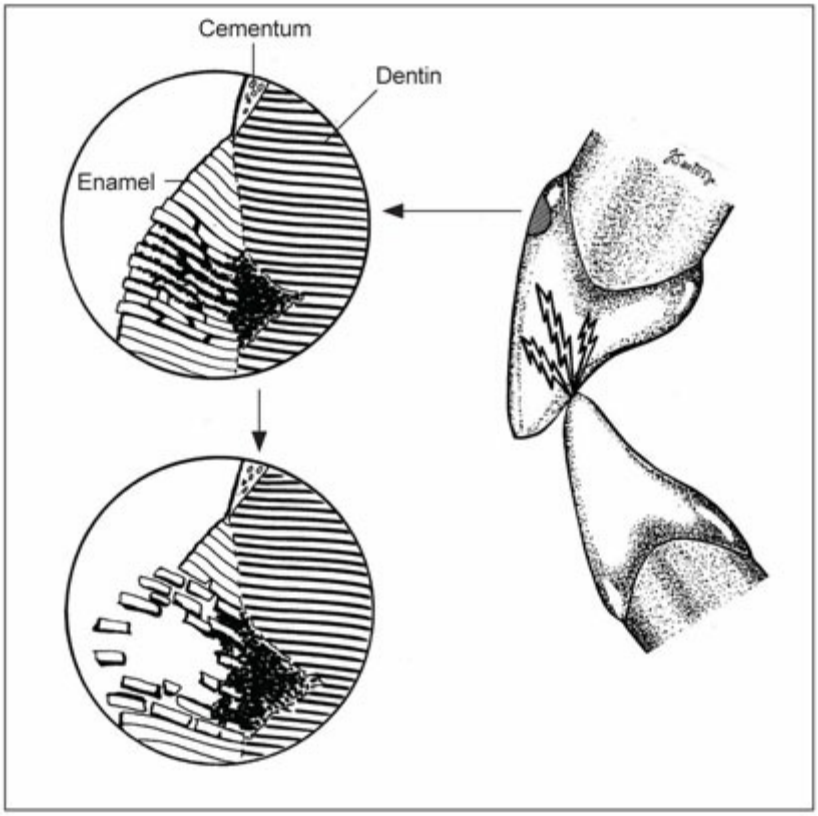

Fig 15-2 The abfraction theory holds that tooth flexure causes loosening of enamel rods, which initiates the cervical lesions.

The ability of ions in saliva to induce remineralization of demineralized tooth structure should be considered an important factor in the inhibition of NCCLs as well as in the inhibition of caries. Caries lesions and noncarious lesions are more common on facial surfaces of teeth than on lingual surfaces. While toothbrush/toothpaste force is a significant etiologic factor, an additional consideration could be differences in the chemistry and character of saliva in lingual and facial areas, which bring about differences in remineralization of tooth structure and the dilution and buffering of acids.[24,25] The effects of xerostomia on oral health are well documented[26–28] and are discussed in chapter 13. However, even in the healthy patient, dehydration from perspiration with physical activity can create impaired salivary flow and inhibit buffering of acids in the oral cavity.[29,30]

In addition to in vivo studies, laboratory studies have contributed to the knowledge base about NCCLs. Finite element analysis has predicted that occlusal loads could cause stress fractures or stress corrosion in the cervical areas of teeth.[31,32] Litonjua et al[33] found that without any acids present, occlusal loading had no effect in creating NCCLs in recently extracted teeth subjected to a toothpaste slurry and tooth brushing at the cervical margins. Brushing with the toothpaste slurry

Dentlearn.ir

caused similar cervical wear patterns regardless of whether the tooth was loaded. In contrast, Palamara et al[34] found that enamel dissolution increased significantly when teeth were subjected to cyclic tensile loads while immersed in 1% lactic acid (pH 4.5). The acidic environment and loading made the teeth more susceptible to cervical tissue loss. Volumetric loss was greater in the cervical third than in the middle third and much greater in the mesiobuccal segment (under tension) than in the distobuccal segment (under compression). These findings could offer some explanation for the differences in size, shape, and location of NCCLs.

The morphologic presentation of NCCLs, such as a "wedge" or a "saucer" shape, can perhaps aid the practitioner in discovering their etiology, but the ability to differentiate etiologies based on lesion shape has yet to be adequately supported with evidence.[35] Whitehead et al,[19] studying stress corrosion of enamel at low pH, found that axial loading of extracted premolar teeth in an acid solution resulted in macroscopic and microscopic features similar to those observed in NCCLs in vivo.Changes occurring only in the presence of acids would be consistent with the occlusal wear.[1] It appears that liquid acid, frequently found in modern diets, may be necessary to make occlusal loading a factor in the formation of cervical lesions.

Diet

Dietary (extrinsic) acids from foods such as soft drinks, wines, and fruits and fruit juices and gastric (intrinsic) acids that result from gastric reflux, bulimia, and other disorders are both capable of causing tooth dissolution. It is well established in the literature that acids cause dissolution of tooth structure.[23] Soft drinks, which contain citric and/or phosphoric acids, are probably the most frequent source for liquid dietary acids in the US population. Orange juice has also been shown in several studies to cause erosive loss of dentin and enamel.[36,37] When the pH of citric acid and phosphoric acid solutions was adjusted to be similar, citric acid caused more

Toothbrush abrasion

When a tooth is softened by acid dissolution, the effects of any mechanical wear are greatly accelerated. The effect of the acid on enamel and dentin makes the tooth more susceptible to abrasion and attrition (occlusal wear).[20] A study by Attin et al[21] confirmed previous studies[20,22] that showed that eroded enamel is extraordinarily sensitive to mechanical impacts, such as tooth brushing, immediately after

Dentlearn.ir

demineralization. The fact that a demineralized tooth surface can be remineralized if not exposed to brushing or other mechanical insult after it has been softened by demineralization is critical to understanding the etiology, prevention, and treatment of NCCLs. Tooth structure can be remineralized after a period of exposure to saliva.[39] These findings are contrary to past, and some current, recommendations by dentists that brushing immediately after a meal or other acid challenge should be routine. On the contrary, tooth structure loss as a result of abrasion can be minimized by delaying brushing by at least 1 hour.[21] In addition, patients with NCCLs should be encouraged to use a minimal amount of dentifrice and light forces when brushing. Anecdotal claims that the majority of toothbrush abrasion lesions appear on the opposite arch from the dominant hand have not been verified with clinical studies.[40]

Occlusion

Of all possible etiologies for NCCLs, occlusal stress forces have received the most attention in recent years.[41] Dentin and enamel have different tensile strengths. With occlusal loading, stress concentration occurs in the cervical area.[18,42] The *abfraction theory*, also known as the *occlusal stress* or *stress corrosion theory*, maintains that tooth flexure in the cervical area results in microfractures of the crystalline structure of the enamel and dentin in that area (see Fig 15-2). The lesion, in theory, would continue to enlarge as the bending and flexing is repeated. Associating wear facets (attrition) with NCCLs is an important component in this theory, and occlusal wear facets may indeed appear in combination with many NCCLs. Studies have found both occlusal wear and NCCLs to occur in the same teeth, but the degree to which this association has been found has varied from 15%[41] to 38%[40] to 95%.[17,43] The lack of consistent findings among studies could be due to variations in the definition of wear facets, differences in the populations studied, or differences in the exclusion criteria applied. While the studies differ on the significance that occlusal forces play in the etiology of NCCLs, no authors claim occlusion to be the solitary etiology for NCCLs.

Treatment approaches

Before any treatment is performed for a patient with one or more NCCLs, a careful examination and determination of possible causes for the lesions should be made. Considering that there is a general consensus in the literature that the etiology is multifactorial, the practitioner's initial approach should not be based on a single assumed cause. The mere presence of occlusal wear facets accompanying NCCLs

Dentlearn.ir

does not indicate that the cause is unifactoral (ie, that the lesion is the result of occlusal forces only). Likewise, for a patient with a known history of gastric esophageal reflux disease (GERD), it should not be assumed that the patient's NCCLs are solely the result of a constant intrinsic acid challenge that is causing cervical erosion. While there may be a primary etiology, other contributing factors must also be considered. In all cases of NCCLs, the dentist should obtain a careful health history and provide a thorough dental examination that includes, but is certainly not limited to, an occlusal analysis. The patient's oral hygiene habits should be discussed and evaluated, and a dietary analysis should be considered. Only after determining the probable causes should any treatment commence.[44]

The first goal of any treatment is to remove the causes of the NCCL(s). Once the etiologic factors for a patient are determined, the dentist can help the patient to understand them and to change those that are under his or her control. If a patient is experiencing acute sensitivity associated with one or more lesions, treatment to alleviate the sensitivity should be accomplished. This treatment could involve desensitizing the tooth, restoring the tooth, or possibly performing a periodontal procedure, such as a connective tissue graft, to cover and protect the affected area.[45–52]

Because of the location of Class 5 lesions, access for restorative treatment is often troublesome, moisture control can be exceedingly difficult to obtain and maintain, and soft tissue surgical approaches may be required. Because of the sclerotic nature of the tooth structure in a cervical lesion and the physical properties of restorative materials, long-term retention of the restoration presents a unique challenge. If a decision is made to place a restoration, some lesions can be treated without cavity preparation, and others require preparation to obtain adequate retention of the restoration.

Shallow lesions that lead to thermal sensitivity or sensitivity to touch should first be treated with bonding resins or desensitizing agents. These treatments are low-risk and have reasonable potential for success. Long-term cervical sensitivity studies are very difficult to standardize. Over the course of time, some teeth will become symptom-free without treatment.[53] Some of the self-etching dentin bonding systems show good promise for controlling cervical sensitivity without requiring any habit changes, such as tooth brushing changes and diet modification.[54] Desensitizing toothpaste and fluoride gel formulations are effective for treating cervical sensitivity; these require continuation of use for weeks or months, or longer, to maintain the therapeutic effect.[55] Dental pastes containing 8% arginine and calcium carbonate claim high immediate success for sensitive teeth but appear to require

Dentlearn.ir

continuous use to maintain the positive effect.[56] The use of fluoride varnish or fluoride desensitization solutions have proven effective in many situations.[57,58] A recent survey of over 200 private dental practitioners revealed widespread use of all of the treatments mentioned above.[59] But their belief was that fluorides were most successful for treating dentin hypersensitivity and that advice about dieting and tooth brushing were unsuccessful, though they often used this latter approach.

The decision to place a restoration because of a Class 5 lesion is not always easily made. Certainly, if active caries is present, treatment should be initiated to control the active disease and to prevent disease progression. Treatment decisions relating to NCCLs or arrested caries lesions, however, are more difficult. It is generally believed that NCCLs should be treated to protect remaining tooth structure if the amount of tooth structure lost is extensive or progressing, if esthetics is compromised, or to control sensitivity not relieved by less invasive procedures.[60–65] In contrast, a few clinicians believe that all noncarious Class 5 lesions require restorative treatment and describe many reasons for doing so.[62] The Academy of Operative Dentistry has published recommendations for the treatment of NCCLs in an attempt to aid clinicians in the sometimes-difficult treatment decisions and to provide objective guidelines.[23] Their recommendations state that the decision to restore a tooth affected with a NCCL should depend upon the following factors:

- Inability to eliminate or greatly reduce the rate of lesion progression through elimination of etiologic factors
- Esthetic unacceptability of the lesion to the patient
- Significant sensitivity of exposed dentin to cold liquids, food, and air
- Threat to the strength of the tooth and integrity of the coronal-radicular unit because of the lesion's depth

Of course the preferred treatment for a minimal lesion is to eliminate the causes and stop lesion progression. This prevents initiation of the "rerestoration cycle," that is, the repetitious replacement of lost or defective restorations with increasingly larger ones.[66,67]

Periodontal treatment

Periodontal surgery can be used to cover NCCL lesions associated with gingival recession by means of augmenting the gingival tissues in the affected area. While more expensive and more invasive than direct restorations, it is a valid treatment

Dentlearn.ir

modality because NCCLs involve exclusively or predominantly the anatomical root of the tooth. Zucchelli et al[68–70] have offered a triage method to determine if a case is favorable for surgical resolution. The authors have shown that the most coronal level of soft tissue advancement achievable with surgical procedures (eg, connective tissue graft, coronally advanced flap) can be determined through a simple procedure. The ideal papilla height is determined as the distance from the apical aspect of the interproximal contact point vertically in an apical direction to a point projected horizontally from the point where the gingival tissues cross the cementoenamel junction (CEJ) at the line angle (Fig 15-3a). This distance is then measured apically from the actual papilla tip and transferred to the facial root surface by the use of an imaginary horizontal line. This process is accomplished independently for both the mesial and distal aspects of the tooth so that two points, one per side, are determined. A smooth, curved line then connects the two points determined from the above procedure and provides the clinician with the maximum coronal root coverage (MRC) (Fig 15-3b). If the MRC is coincident or nearly so with the CEJ, then only root coverage surgery is performed and restorative treatment of the NCCL may not be indicated. If the MRC is apical to the CEJ, then a Class 5 restoration should be accomplished first, with the apical margin of the restoration at or just apical to the MRC. Placing the restoration prior to surgery allows better access for rubber dam and restoration placement, as well as providing a smooth, hard, and convex surface for coronal flap placement. The reader is referred to these papers[68–70] for more detailed information if surgery is under consideration.

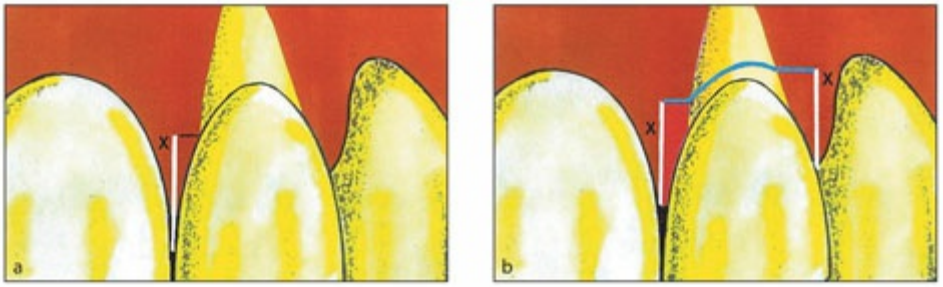

Fig 15-3 When a tooth has gingival recession, the maximum coronal root coverage (MRC) that can be achieved with soft tissue grafting can be determined. *(a)* The ideal papilla height is determined as the distance from the interproximal contact point vertically in an apical direction to a point projected horizontally from the point where the gingival tissues cross the CEJ at the line angle *x*. *(b)* This distance *x* is then measured apically from the actual papilla tip and transferred to the facial root surface by the use of an imaginary horizontal line. This process is accomplished independently for both the mesial and distal aspects of the tooth so that two points, one per side, are determined. A smooth, curved line then connects the two points determined from the above procedure and provides the clinician with the MRC.[68]

Dentlearn.ir

Access and Isolation of NCCLs

When cervical lesions occur supragingivally, access to the area for preparation and restoration is often easily obtained. But if the lesion has progressed to or below the free gingival margin, isolation for complete caries removal, tooth preparation, restoration placement, and finishing can be difficult. If a restoration is placed without obtaining complete access to sound tooth structure on all margins, carious tooth structure may remain and the restoration may fail.

One could justify a different restorative goal when the lesion is a noncarious lesion with a margin apical to the gingival crest. Here the restorative goal is to protect the remaining root surface from further damage from toothpaste/toothbrush abrasion without damage to the gingival attachment. A restoration that is smooth but finishes short of the subgingival portion of the lesion might be a good conservative answer. Finishing short is almost certainly superior to placing an overhanging restoration into what the day before was a healthy gingival sulcus. It is well established that a restoration overhang can adversely affect periodontal health.[71] Figure 15-4 shows such an overhang and the associated gingival inflammation.

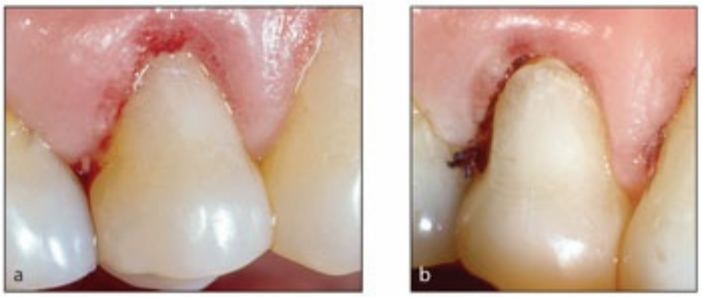

Fig 15-4*(a)* Gingival inflammation associated with a facial resin composite restoration on the second premolar. *(b)* A retraction cord moves gingiva to reveal the composite resin overhang on a Class 5 restoration.

Nonsurgical retraction

While a rubber dam is the ideal method of field isolation and moisture control for all direct-placement restorations, many Class 5 lesions can be adequately treated using retraction cord (see Fig 15-4b), cotton rolls, and other materials to isolate the lesion and absorb or evacuate moisture. If the lesion extends to or below the gingival margin, a rubber dam is useful to retract the tissue. Often an additional rubber dam–retracting clamp placed directly on the tooth to be restored will provide additional gingival retraction (Fig 15-5). A no. 212SA clamp is effective for this purpose (Fig 15-6a), but modifications to the clamp may be necessary to provide adequate retraction (Figs 15-6b to 15-6d; see also chapter 8).

Dentlearn.ir



Fig 15-5 An additional rubber dam clamp is sometimes helpful for retracting both rubber dam and soft tissue.

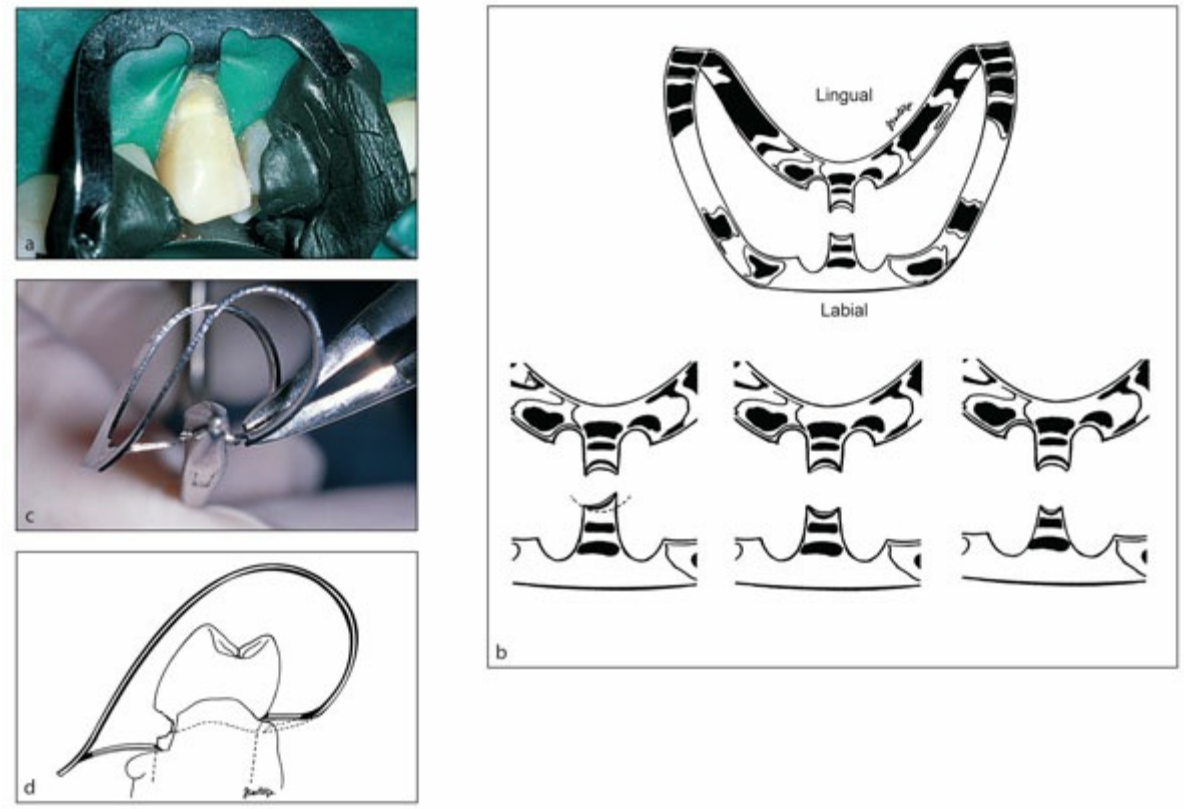

Fig 15-6*(a)* A no. 212SA clamp stabilized with modeling compound. *(b)* Modifications to the no. 212SA clamp are sometimes necessary for proper adaptation to the tooth. *(c)* With two sets of pliers, the lingual jaw of the no. 212SA clamp is bent incisally/occlusally so that it rests on lingual tooth structure, avoiding damage to gingival tissues. *(d)* A modified *(solid line)* and unmodified *(dotted line)* no. 212SA clamp lingual beak.

The clamp must be stabilized to keep it from moving and possibly damaging the restoration or the tooth surface during the operative procedure. Modeling compound is the traditional stabilizing material used (see Figs 15-6a and 8-21b). If lesions in two adjacent teeth are to be treated, modified no. 212SA clamps can be used to provide field isolation (see Figs 15-9d to 15-9h, 8-21d, and 8-21e).

Dentlearn.ir

Surgical retraction

Miniflap

As described in chapter 8, the use of miniflaps can often provide sufficient access to subgingival lesions.[72,73] One or two small incisions are made in gingival tissue, beginning at the gingival margin at the mesial and/or distal aspect of the lesion (Fig 15-7; see also Fig 8-48). Each incision is first directed at a right angle to the gingival margin and extended approximately a 1 mm (see Fig 15-7b); the scalpel is then turned so that the remainder of the incision is vertical, approximately parallel with the long axis of the tooth (see Fig 15-7e). It is essential that the entire lesion is exposed, including all demineralized tooth structure. The incision(s) should not be extended past the mucogingival junction. This will allow the small flap of keratinized tissue to be reflected for access, then replaced to the same position after completion of the restoration. Sutures are usually not necessary. If the flap extends past the mucogingival junction, sutures may be required after the restorative procedure has been completed.

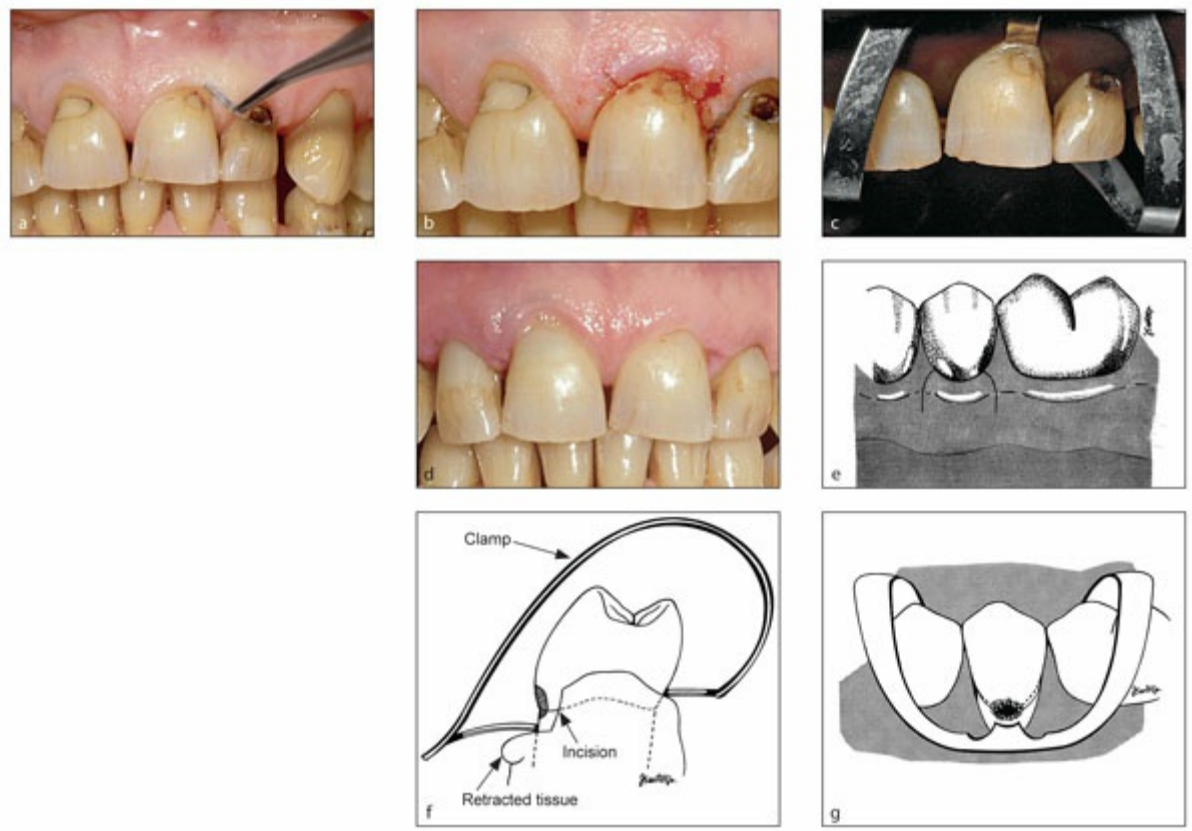

Fig 15-7*(a)* A plastic instrument is used to displace tissue to evaluate the lesion extent and the need for a miniflap. *(b)* Mesial and distal miniflap incisions are made at right angles to the gingival margin. These two incisions are connected with a sulcular incision. *(c)* The lesion is isolated with a rubber dam and a no. 212SA retracting clamp. *(d)* Postoperative appearance of the restoration and

Dentlearn.ir

the gingival tissues after 1 week. No sutures were used at the completion of the operative procedure. *(e)* Short vertical incisions are made within the keratinized tissue at right angles to the gingival margin and at the line angles of the tooth. If needed, vertical incisions are made parallel to the long access of the tooth. This allows additional tissue retraction with minimal trauma to the tissue or attachment apparatus. *(f and g)* The no. 212SA retracting clamp and rubber dam are shown in place. This clamp will often need to be stabilized with modeling compound or a similar material.

Gingivoplasty

Gingivoplasty has limited applications because most teeth do not have a sufficiently wide band of keratinized attached gingiva. The width of attached gingiva is determined by subtracting the probing depth from the width of keratinized tissue. If an adequate amount of attached, keratinized gingiva will remain after surgery, a gingivoplasty may be useful in providing access as long as the lesion to be treated will be fully exposed and the biologic width will not be violated[72,73] (Fig 15-8). If gingivoplasty would result in less than 3 mm of attached gingiva adjacent to the restoration, an apically positioned flap or graft procedure may be necessary to preserve or increase the zone of attached gingiva.[74] An inadequate zone of attached gingiva is an absolute contraindication for gingivoplasty.



Fig 15-8*(a)* Carious Class 5 lesions on the maxillary central incisors, requiring surgical access. *(b)* A gingivectomy exposes the full extent of the clinical crowns and provides access to the lesions. *(c)* Maxillary central incisors after placement of restorations. *(d)* Restorations and soft tissue after 2 weeks of healing.

Conventional flap surgery

On occasion, a miniflap would provide insufficient access, so a larger mucoperiosteal flap is required for a cervical restoration.[75–78] If restorations on two adjacent teeth are to be placed simultaneously and both require a surgical procedure for adequate access, a miniflap cannot be used; instead, a mucoperiosteal flap is necessary (Fig 15-9). Surgical crown lengthening with ostectomy may be necessary to provide sufficient access to the lesion and to reestablish dimension for a healthy connective tissue and junctional epithelial attachment[79] (Fig 15-10). A mucoperiosteal flap should be reflected and ostectomy performed as needed. In

Dentlearn.ir

some cases, repositioning the envelope flap to its original location will provide the optimal result for esthetics and function. In other cases, the flap will need to be apically positioned. While it is important to remember that the flap will not predictably reattach to the newly placed restoration, there is some evidence to indicate that both soft and hard tissue attachment to glass ionomer or resin-modified glass ionomer (RMGI) does occur. While amalgam has traditionally been used in these applications in posterior teeth, when a restoration is being placed in conjunction with a flap, placement of an all-RMGI restoration or an open sandwich restoration with the apical aspect of the restoration restored with RMGI provides an environment most likely to be conducive to tissue reattachment.[80–85]



Fig 15-9*(a)* Defective Class 5 restorations in the mandibular left canine and first premolar with subgingival margins. *(b)* An envelope flap is reflected, revealing larger defects than were originally evident. *(c)* A rubber dam provides good control of bleeding and moisture but insufficient isolation of the mandibular left canine. *(d)* A modified no. 212SA clamp or a Schultz clamp, stabilized with modeling compound, provides additional retraction and isolation. *(e)* The final preparations. *(f)* Pins were placed in the mandibular left canine for additional retention. *(g)* A custom matrix, stabilized with wedges and compound, provides lateral walls and support for amalgam placement. *(h)* The completed restorations. *(i)* The envelope flap is returned to place and sutured. *(j)* The definitive, polished restorations after 2 weeks of soft tissue healing.

Dentlearn.ir

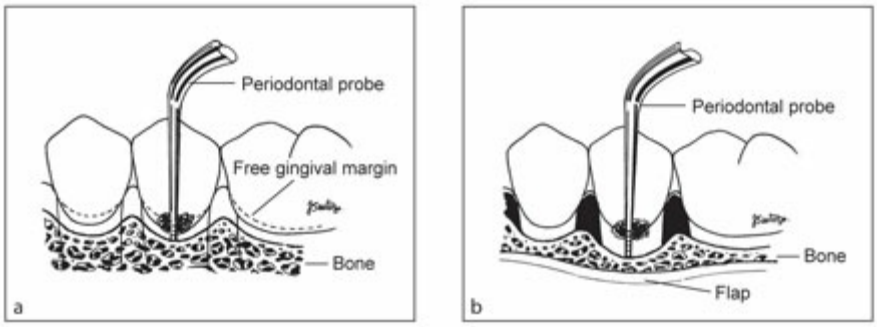

Fig 15-10*(a)* Occasionally, a caries lesion extends to the base of the sulcus, making restoration difficult. Sounding with the periodontal probe shows that the restoration is likely to encroach on the biologic width. Therefore, crown lengthening is indicated. *(b)* A full-thickness mucogingival flap is reflected and bone is removed so that 3 mm of root surface separate the bone and the caries lesion. The restoration can be placed prior to suturing, or restorative procedures can be delayed while the tissue heals.

For posterior teeth, soft tissue rebound is significant following crown lengthening surgery, which frequently results in deep pocket depths. If crown lengthening surgery in a posterior quadrant has been planned, the restorations should be placed 4 to 8 weeks after surgery. Too long of a delay could result in inadequate access to the lesions.[86] However, for anterior teeth, an increased delay between crown lengthening surgery and restoration placement may be indicated, particularly if esthetic reasons dictate that the gingival margins of restorations are located subgingivally. Deas et al[87] showed that the gingival crest height was not fully stable at 6 months.

Timing of surgery

A combined surgical-restorative procedure provides better access to the restorative site than a two-step procedure, in which crown lengthening surgery is accomplished several weeks prior to the restorative procedure. This is because, with the combined procedure, the soft tissue flap is reflected away from the area while the restoration is being placed (Fig 15-11). Moisture and hemorrhage control can best be provided with a well-placed rubber dam. Two interdependent goals are accomplished with a combined surgical procedure: The source of the gingival inflammation is eliminated, and the lost tooth structure is restored. In a broad sense, the tooth and the environment are restored simultaneously.

Dentlearn.ir



Fig 15-11*(a)* A 24-year-old man with numerous Class 5 caries lesions extending subgingivally. *(b)* An envelope flap provides access to the caries lesions. *(c)* After the flap is reflected, a rubber dam is placed. Bleeding is well controlled. *(d)* All carious tooth structure is removed, and provisional restorations are placed for caries control. The flap is apically repositioned. *(e)* One week postoperatively, the tissues are healing and the provisional restorations are coronal to the tissue.

If surgical crown lengthening is to be done prior to restoration of carious root lesions, at least 4 to 8 weeks must elapse after surgery to obtain maturation of the altered periodontium.[74] In esthetic areas, a longer healing period is often required to allow the gingival margin to stabilize before restoration placement.

Cervical Restorations: Materials, Design, and Retention

Once the decision to place a restoration has been made, the dentist must select a restorative material (Box 15-1) and design the cavity preparation. For any Class 5 restoration, the expected extent of the restoration should be determined by the extent of the lesion.

Box 15-1	**Class 5 restorative materials**
Nonesthetic materials	
Amalgam Gold foil (direct, not widely used) Gold inlay (indirect, not widely used)	
Esthetic materials	
Resin composite (with dentin bonding system) Resin composite (with glass-ionomer liner—sandwich technique) Flowable resin composite	

Dentlearn.ir

Glass ionomer
RMGI
Compomer
Porcelain inlay (not widely used)

Amalgam

Amalgam preparations will be the same whether the lesion requiring restoration is carious or noncarious. For NCCLs, preparation requires the removal of sound tooth structure to create a box form for amalgam bulk and retention, so the use of adhesive materials is usually preferred.

For the treatment of caries lesions, the preparation should be extended only to remove carious tooth structure and fragile enamel (Fig 15-12). There is no need to

than 1 mm. The cavosurface margins should be as close to 90 degrees as possible. Cavosurface bevels are contraindicated in preparations for amalgam or glass ionomer because of the low edge strength of these materials. With this design, the walls of the Class 5 preparation often diverge because of the curvature of the tooth surface. For nonbonded amalgam restorations, grooves should be placed in the dentin of both the occlusal and gingival walls to help retain the amalgam. In large preparations, pins or other retentive devices may also be beneficial. Amalgam bonding studies of Class 5 restorations have not been accomplished, but clinical studies have reported on restorations subjected to considerably more direct load than Class 5 restorations.[88–93] These studies indicate that bonding is an excellent method to retain amalgam. If the mesial and distal walls are flared so that the amalgam has no lateral walls to confine it for condensation, a custom matrix may be used to facilitate restoration placement and condensation. The simplest method for a facial Class 5 amalgam restoration is to use a hand instrument (Fig 15-13). If the preparation wraps well into the proximal areas, this method may not suffice. Another simple method uses a metal matrix band cut to a length that wraps around the lingual aspect of the tooth and extends slightly facial to the interproximal contacts (see Fig 15-9g). Interproximal wedges are placed to support and stabilize the matrix, and modeling compound may be softened and pressed interproximally if further support is needed.

Dentlearn.ir

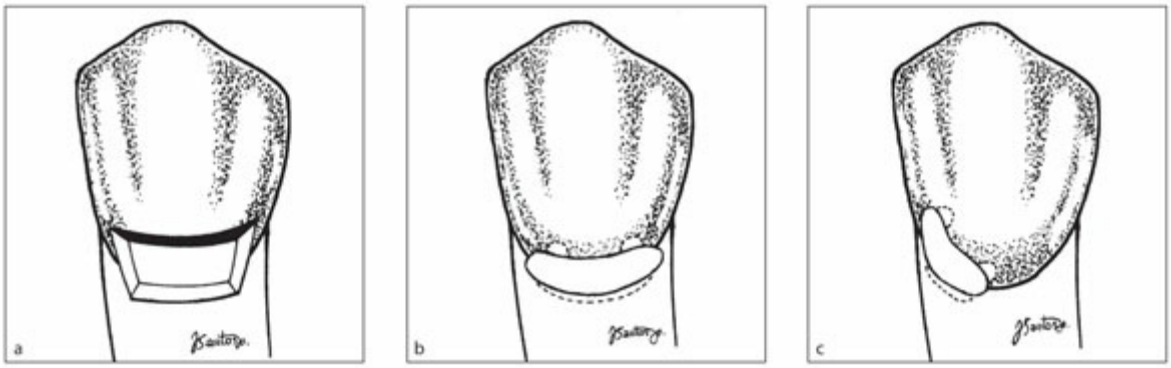

Fig 15-12*(a)* The traditional preparation for a Class 5 direct gold restoration had a trapezoidal outline form that required removal of sound, as well as carious, tooth structure. *(b and c)* The outline form currently recommended for all restorative materials includes removal of carious tooth structure and unsupported enamel. The *dotted lines* indicate retentive undercuts for amalgam restorations. Undercuts are not required when adhesive restorations are placed.



Fig 15-13 A hand instrument may be used as a matrix for Class 5 amalgam restorations.

After the amalgam has been carved to proper contours, a smoother surface may be attained with burnishing and then smoothing with a rubber cup and a fine abrasive paste. Although polishing has been shown to have no effect on marginal ditching,[94] a smooth surface tends to be less plaque retentive.

Bonded tooth-colored restorations

Many techniques and materials have been developed to encourage long-term retention of esthetic materials placed in cervical locations. Stresses due to polymerization shrinkage can cause resin composite to pull away from the tooth-restoration interface, leaving an open margin and pathway for leakage to occur, as has been shown in numerous in vitro studies.[95–98] For moderate-sized to large restorations, incremental resin composite placement is recommended to decrease the effects of polymerization shrinkage[78,99–102] (Fig 15-14).

Dentlearn.ir

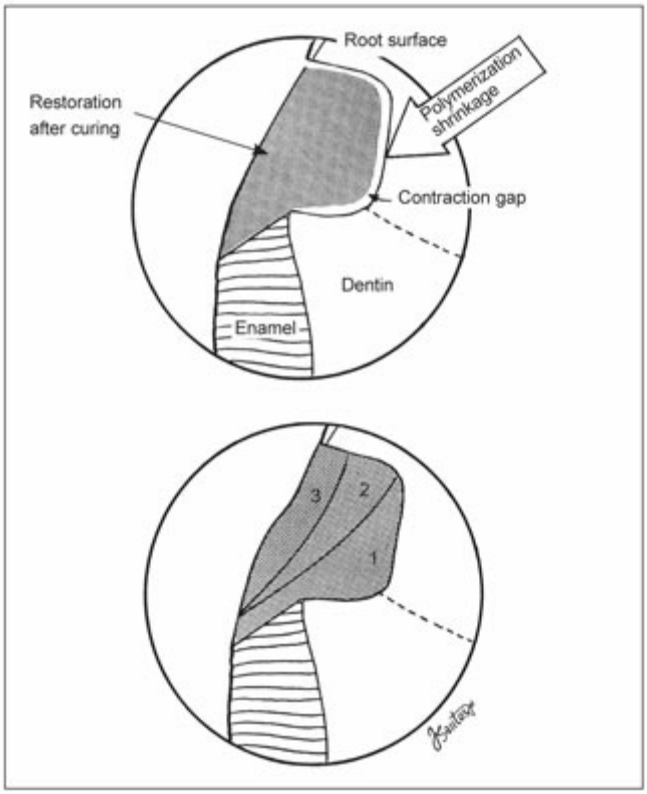

Fig 15-14 If the restoration is large, the resin composite should be placed in at least two increments (1, 2, 3) to compensate for polymerization shrinkage.

If the margins of the restoration will be completely on enamel, the retention of bonded restorations should be predictably successful. Beveling of enamel margins is recommended when it would expose the ends of the enamel rods to provide better etch and bond and/or to improve esthetic blending of the resin composite with the tooth structure.[99,103] Beveling the gingival margin that ends on cementum is not recommended.[104]

An often-overlooked treatment that may improve restoration longevity is occlusal adjustment to reduce eccentric loading of the tooth with the Class 5 restoration.[100] In theory, occlusal adjustment could decrease the dislodging forces placed on the cervical restoration during tooth flexure. To date, there are no controlled clinical trials to verify improved longevity of Class 5 restorations after altering occlusal contacts on the teeth.

Resin composite

The extent and depth of the lesion should determine the outline and depth of the preparation for resin composite, whether the lesion is carious or noncarious. For NCCLs, little or no preparation is required. Retention of a resin composite

Dentlearn.ir

restoration is primarily due to the bond, so the bonding system must be used meticulously. Although roughening the surface of a noncarious lesion has been thought to enhance the bond by removing some sclerotic dentin, one clinical trial found no increase in retention when sclerotic lesions were roughened with a bur.[105] Laboratory data have suggested that perhaps an increase in etch time for some etch-and-rinse adhesive systems improves the bond to sclerotic dentin, but depending on the degree of sclerosis, this risks overetching dentin.[106–108] The current self-etching adhesive systems appear to have inferior bonds to sclerotic dentin when matched against dentin bonding systems that require washing away of the etching gel,[109,110] and one clinical study demonstrated the significance of this difference.[111]

Failure to meticulously apply the components of the bonding system could lead to early failure of the restoration. This includes the use of multiple coats of primer if necessary, the application of primer or adhesive with an active scrubbing motion when indicated, the use or non-use of the air syringe for drying, and all other product-specific instructions. For small restorations, the resin composite may be inserted and cured in one increment unless esthetic considerations call for layering to achieve appropriate shading. For restorations that are moderate to large in size, the first increment of resin composite should be placed from about the midpoint of the gingival floor to the incisal or occlusal cavosurface margin and light polymerized. The second increment can then fill the remainder of the preparation.[112] Larger preparations may require more than two increments. Resin composite should be placed in increments no thicker than 2 mm to ensure adequate penetration of light for polymerization.[113] To preserve the cementum or dentin at the gingival margin, careful finishing with a no. 12 or 12B scalpel blade is recommended (Fig 15-15a). Diamond burs, carbide finishing burs, or aluminum oxide disks may be used for contouring (Fig 15-15b). Polishing may be performed with progressively finer-grit disks or abrasive-impregnated rubber points or cups. The highest luster may be achieved with microfilled and nanofilled composites, but most of the current generations of microhybrid and nanohybrid composites also polish well. One study's recommendation[114] to use microfilled composites instead of hybrids in Class 5 restorations because of their lower modulus of elasticity appears to have been refuted. In more recent studies by Browning et al[75] and Van Meerbeek et al,[115] it was concluded that there are no differences in retention rates between microfilled and hybrid resin composites. As with the placement of any resin composite restoration, careful technique is critical to long-term success. Rebonding, as discussed in chapter 11, is recommended for Class 5 restorations.

Dentlearn.ir



Fig 15-15*(a)* A no. 12 or 12B scalpel blade works well for removing flash. *(b)* Finishing disks may be used to contour and polish Class 5 restorations.

Flowable resin composite

Flowable resin composites have reduced filler particle loading, a lower elastic modulus, significantly higher polymerization shrinkage, a higher coefficient of thermal expansion, and lower fracture toughness relative to traditional resin composites.[116] Flowable resin composites have been recommended for Class 5 restorations with the suggestion that, as the tooth flexes, the less rigid restoration might be able to accommodate the change in cavity shape and therefore be more difficult to dislodge. Clinical trials have proven the theoretical to be incorrect.[75] Stiff restorations have performed as well or better than the flexible resin composites in long-term clinical trials. The use of a flowable resin composite as a liner has not been shown to improve clinical performance.[75,117,118]

Glass ionomer and RMGI

Glass ionomer has been used successfully in Class 5 restorations for many years. One clinical study reported an 80% retention rate of restorations placed without mechanical retention at 10 years.[119] Traditional glass-ionomer materials suffer surface degradation rather rapidly, especially in the presence of acidic foods. Both traditional glass ionomers and RMGIs appear to offer high levels of fluoride release

Dentlearn.ir

and excellent recharge capacity. Patients at high risk for caries would probably be well served with either glass-ionomer or RMGI restorations on root surfaces (see chapters 5, 13, and 14).

The preparation for glass-ionomer restorations is similar to that for dental amalgam but without the mechanical retention. Cavosurface bevels are not recommended for the preparation because glass ionomer is a brittle material that requires bulk for strength. A 90-degree butt joint approximately 1 mm deep is a reasonable minimum thickness. After cavity conditioning and placement of RMGI material into the preparation, it is light activated in a manner similar to light curing of resin composite. The use of a clear cervical matrix is optional. Most instructions for use recommend a delay of 2 to 5 minutes before polishing. Franco et al[120] reported that 96.4% of RMGI restorations were retained at 5 years, while only 51.5% of bonded resin composite restorations were retained in the same study. In a more recent study, 94% of Class 5 RMGIs were retained, which exceeded the success of composites (81% to 85%) and far exceeded that of conventional glass ionomers at 67%.[121] A review of Class 5 restorations concluded that glass-ionomer materials (both conventional and resin-modified) showed the highest retention rates.[122]

Glass-ionomer sandwich technique

Because autocured glass-ionomer materials often provide less-than-optimal esthetics[41] (Fig 15-16), some clinicians use the sandwich technique. Glass ionomer is used to replace the missing dentin, reduce leakage,[123–125] improve the potential for tissue attachment for subgingival restorations, and potentially increase retention. A veneer of resin composite is placed to enhance esthetics, increase color stability, improve marginal performance, provide a smoother surface, and increase abrasion resistance[76,126] (Fig 15-17). In one clinical study using the sandwich technique, a 100% retention rate was reported after 3 years.[79] Another clinical trial resulted in a 96% survival rate of sandwich restorations at 5 years, demonstrating the success rates attainable with this type of restoration.[127]

Dentlearn.ir



Fig 15-16*(a)* Multiple adjacent Class 5 lesions in the maxillary left canine through the second molar. *(b)* The teeth were restored with conventional glass ionomer, which is opaque and relatively unesthetic.

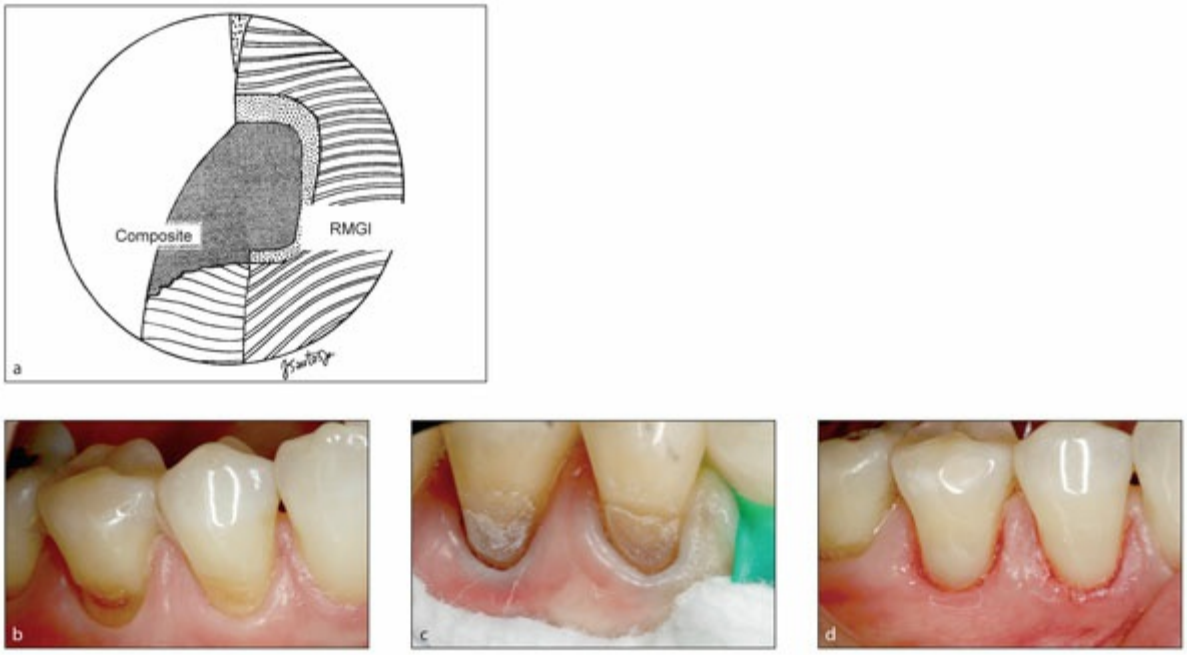

Fig 15-17*(a)* The sandwich technique combines a glass-ionomer base with a veneer of resin composite. *(b)* Class 5 NCCLs on the mandibular right first and second premolars. *(c)* Restorative RMGI (Fuji II LC, GC America) has been placed over all dentin surfaces. The RMGI extends to the gingival dentin margins but is left short of the occlusal enamel margin. The occlusal enamel margin is etched, and a three-step etch-and-rinse adhesive (Optibond FL, Kerr) is placed and cured over the entire lesion, including the RMGI and the etched enamel margin. *(d)* Completed restorations. The RMGI along the axial wall and enamel margin has been veneered with resin composite (Filtek Supreme, 3M ESPE). The apical dentin margin is restored with the RMGI restorative material.

Compomer

Compomer materials are polyacid-modified resin composites (see chapter 14). They are recommended to restore teeth that have carious cervical lesions and NCCLs.[62,63] On the continuum of fluoride-releasing materials, compomer materials fall between resin composites and RMGI materials but are much more like resin

Dentlearn.ir

composites. They require the use of a dentin bonding system. Most physical properties of compomers are inferior to those of conventional resin composites; however, compomers have very favorable handling characteristics. Specifically, their lack of "stickiness" has brought them ready acceptance in the marketplace. However, the marginal integrity of compomers has been worse than that of resin composites in long-term clinical trials.[128–141]

Dentinal Sensitivity

Dentinal sensitivity, a problem reported to affect anywhere from 8% to 74% of the population,[142–144] is often associated with gingival recession and NCCLs.[79] A survey of new patients found that, of 780 patients, 32% reported sensitivity, but only 5% had sought professional help.[145] Tooth sensitivity was the chief complaint in 60% of the referrals to a periodontal specialty clinic.[146] Sensitivity is caused by exposure of dentinal tubules that communicate between the pulp and the oral cavity; the degree of sensitivity is influenced by the number and size of the open tubules.[3,147] The *hydrodynamic theory*[148] is the most widely accepted explanation of dentinal sensitivity. Changes in the direction of fluid movement within open dentinal tubules are perceived as pain by mechanoreceptors near the pulp. Tactile, thermal, or osmotic stimuli can induce changes in fluid flow and elicit a pain response.

In a clinical study, caries-free teeth that were planned for extraction were stimulated to determine if exposed dentin was hypersensitive. Microscopic analysis of the teeth found that the teeth that were hypersensitive had eight times more open or patent tubules per unit area, and the tubule diameters in the sensitive teeth were twice as wide.[149]

Treatment or prevention of hypersensitivity is usually accomplished by the use of some method to occlude the open dentinal tubules.[59,150–152] Dentin adhesives provide at least short-term relief.[153–155] Stannous fluorides have also been used with positive results.[57,156] A study found that 10% strontium chloride solution, 2% sodium fluoride solution, and 40% for-malin solution significantly reduced dentin hypersensitivity, whereas a 5% solution of potassium nitrate did not.[157] A potassium chloride–containing chewing gum was found to be effective in the treatment of hypersensitive teeth.[158]

A recent systematic review concluded that there was insufficient clinical evidence to recommend oxalates for treating dentin hypersensitivity.[159] No treatment to date has been effective f treatments available

Dentlearn.ir

would suggest that, by using proper diagnostic and clinical skills, the dentist should be able to help most patients who have sensitive teeth.

Summary

The preponderance of evidence supports the conclusion that the loss of cervical enamel, cementum, and dentin is due to a combination of many factors. Contributing factors include the mechanical action of the toothpaste and toothbrush, intake of acidic foods, reflux of gastric acids into the oral cavity, bacteria-produced acids, inadequate buffering ability of saliva, inadequate salivary flow rate, and mechanical abrasion. While not completely understood, occlusal forces inducing stresses in the cervical areas of teeth may play a role in the development of cervical lesions. When the etiologic factors have been reduced or eliminated and all other conservative management of cervical lesions has been attempted, there may still be a need to restore areas where there has been significant cervical tooth loss. The decision to restore should be tempered by the certainty that restorations are not permanent.

References

2. Aubry M, Mafart B, Donat B, Brau JJ. Brief communication: Study of noncarious cervical tooth lesions in

2003;121:10–14.

2. Li P, Li J, Zhang Q. Investigations on the incidence of dental wedge-shaped defects and abrasion in 501 elderly population and their correlation [in Chinese]. Zhonghua Kou Qiang Yi Xue Za Zhi 1998;33:227–229.
3. Dugmore CR, Rock WP. The progression of tooth erosion in a cohort of adolescents of mixed ethnicity. Int J Paediatr Dent 2003;13:295–303.
4. Borcic J, Anic I, Urek MM, Ferreri S. The prevalence of non-carious cervical lesions in permanent dentition. J Oral Rehabil 2004;31:117–123.
5. Bader JD, McClure F, Scurria MS, Shugars DA, Heymann HO. Case-control study of non-carious cervical lesions. Community Dent Oral Epidemiol 1996;24:286–291.
6. Grippo J, Simring M, Coleman T. Abfraction, abrasion, biocorrosion, and the enigma of noncarious cervical lesions: A 20-year perspective. J Esthet Restor Dent 2012;24:10–25.
7. Wood I, Jawad Z, Paisley C, Brunton P. Non-carious cervical tooth surface loss: A literature review. J Dent 2008;36:759–766.
8. Osborne-Smith KL, Burke FJ, Wilson NH. The aetiology of the non-carious cervical lesion. Int Dent J 1999;49:139–143.
9. Ceruti P, Menicucci G, Mariani GD, Pittoni D, Gassino G. Non carious cervical lesions. A review. Minerva Stomatol 2006;55:43–57.
10. Pecie R, Krejci I, Garcia-Godoy F, Bortolotto T. Noncarious cervical lesions—A clinical concept based on the literature review. Part 1: Prevention. Am J Dent 2011;24:49–56.
11. Litonjua LA, Andreana S, Bush PJ, Tobias TS, Cohen RE. Wedged cervical lesions produced by toothbrushing. Am J Dent 2004;17:237–240.
12. Bartlett DW, Shah P. A critical review of non-carious cervical (wear) lesions and the role of abfraction,

Dentlearn.ir

erosion, and abrasion. J Dent Res 2006;85:306–312.

patients attending a university hospital in Trinidad. J Oral Rehabil 2008;35:128–134.
14. Michael JA, Townsend GC, Greenwood LF, Kaidonis JA. Abfraction: Separating fact from fiction. Aust Dent J 2009;54:2–8.
15. Pikdöken L, Akca E, Gürbüzer B, Aydil B, Taşdelen B. Cervical wear and occlusal wear from a periodontal perspective. J Oral Rehabil 2011;38:95–100.
16. Jiang H, Du MQ, Huang W, Peng B, Bian Z, Tai BJ. The prevalence of and risk factors for non-carious cervical lesions in adults in Hubei Province, China. Community Dent Health 2011;28:22–28.
17. Miller N, Penaud J, Ambrosini P, Bisson-Boutelliez C, Briançon S. Analysis of etiologic factors and periodontal conditions involved with 309 abfractions. J Clin Periodontol 2003;30:828–832.
18. Palamara D, Palamara JE, Tyas MJ, Messer HH. Strain patterns in cervical enamel of teeth subjected to occlusal loading. Dent Mater 2000;16:412–419.
19. Whitehead SA, Wilson NH, Watts DC. Development of noncarious cervical notch lesion in vitro. J Esthet Dent 1999;11:332–337.
20. Attin T, Koidl U, Buchalla W, Schaller HG, Kielbassa AM, Hellwig E. Correlation of microhardness and wear in differently eroded bovine dental enamel. Arch Oral Biol 1997;42:243–250.
21. Attin T, Buchalla W, Gollner M, Hellwig E. Use of variable remineralization periods to improve the abrasion resistance of previously eroded enamel. Caries Res 2000;34:48–52.
22. Davis WB, Winter PJ. The effect of abrasion on enamel and dentine and exposure to dietary acid. Br Dent J 1980;148:253–256.
23. American Academy of Operative Dentistry. Non-carious cervical lesions. Recommendations for clinical practice. Oper Dent 2003;28:109–113.
24. Dawes C. Physiological factors affecting salivary flow rate, oral sugar clearance, and the sensation of dry mouth in man. J Dent Res 1987;66:648–653.
25. Young WG. Anthropology, tooth wear, and occlusion ab origine. J Dent Res 1998;77:1860–1863.
26. Astroth JD. Caring for the elderly adult. How to prevent, manage root surface caries. Dent Teamwork 1996;9:15–19.
27. Atkinson JC, Wu AJ. Salivary gland dysfunction: Causes, symptoms, treatment. J Am Dent Assoc 1994;125:409–416.
28. Haveman CW, Redding SW. Dental management and treatment of xerostomic patients. Tex Dent J 1998;115(6):43–56.
29. Young WG, Khan F. Sites of dental erosion are saliva-dependent. J Oral Rehabil 2002;29:35–43.
30. Khan F, Young WG, Daley TJ. Dental erosion and bruxism. A tooth wear analysis from south east Queensland. Aust Dent J 1998;43:117–127.
31. Rees JS. The effect of variation in occlusal loading on the development of abfraction lesions: A finite element study. J Oral Rehabil 2002;29:188–193.
32. Geramy A, Sharafoddin F. Abfraction: 3D analysis by means of the finite element method. Quintessence Int 2003;34:526–533.
33. Litonjua LA, Bush PJ, Andreana S, Tobias TS, Cohen RE. Effects of occlusal load on cervical lesions. J Oral Rehabil 2004;31:225–232.
34. Palamara D, Palamara JE, Tyas MJ, Pintado M, Messer HH. Effect of stress on acid dissolution of enamel. Dent Mater 2001;17:109–115.
35. Maseki T, Tanaka H. Symmetry of non-carious cervical lesions in canines and premolars. Gerodontology 2006;23:183–186.
36. Hughes JA, Jandt KD, Baker N, et al. Further modification to soft drinks to minimise erosion. A study in situ. Caries Res 2002;36:70–74.
37. Absi EG, Addy M, Adams D. Dentine hypersensitivity—The effect of toothbrushing and dietary compounds on dentine in vitro: An SEM study. J Oral Rehabil 1992;19:101–110.
38. West NX, Hughes JA, Addy M. The effect of pH on the erosion of dentine and enamel by dietary acids in

Dentlearn.ir

vitro. J Oral Rehabil 2001;28:860–864.
39. Jaeggi T, Lussi A. Toothbrush abrasion of erosively altered enamel after intraoral exposure to saliva: An in situ study. Caries Res 1999;33:455–461.
40. Oginni AO, Olusile AO, Udoye CI. Non-carious cervical lesions in a Nigerian population: Abrasion or abfraction? Int Dent J 2003;53:275–279.
41. Piotrowski BT, Gillette WB, Hancock EB. Examining the prevalence and characteristics of abfractionlike cervical lesions in a population of U.S. veterans. J Am Dent Assoc 2001;132:1694–1701.
42. Kuroe T, Itoh H, Caputo AA, Konuma M. Biomechanics of cervical tooth structure lesions and their restoration. Quintessence Int 2000;31:267–274.
43. Mayhew RB, Jessee SA, Martin RE. Association of occlusal, periodontal, and dietary factors with the presence of non-carious cervical dental lesions. Am J Dent 1998;11:29–32.
44. LittleStar ML, Summitt JB. Non-carious cervical lesions: An evidenced-based approach to their diagnosis. Tex Dent J 2003;120:972–980.
45. Majzoub Z, Landi L, Grusovin MG, Cordioli G. Histology of connective tissue graft. A case report. J Periodontol 2001;72:1607–1615.
46. Saletta D, Pini Prato G, Pagliaro U, Baldi C, Mauri M, Nieri M. Coronally advanced flap procedure: Is the interdental papilla a prognostic factor for root coverage? J Periodontol 2001;72:760–766.
47. Ito K, Murai S. Adjacent gingival recession treated with expanded polytetrafluoroethylene membranes: A report of 2 cases. J Periodontol 1996;67:443–450.
48. Cordioli G, Mortarino C, Chierico A, Grusovin MG, Majzoub Z. Comparison of 2 techniques of subepithelial connective tissue graft in the treatment of gingival recessions. J Periodontol 2001;72:1470–1476.
49. Novaes AB Jr, Grisi DC, Molina GO, Souza SL, Taba M Jr, Grisi MF. Comparative 6-month clinical study of a subepithelial connective tissue graft and acellular dermal matrix graft for the treatment of gingival recession. J Periodontol 2001;72:1477–1484.
50. Rosetti EP, Marcantonio RA, Rossa C Jr, Chaves ES, Goissis G, Marcantonio E Jr. Treatment of gingival recession: Comparative study between subepithelial connective tissue graft and guided tissue regeneration. J Periodontol 2000;71:1441–1447.
51. Tözüm TF, Dini FM. Treatment of adjacent gingival recessions with sub-epithelial connective tissue grafts and the modified tunnel technique. Quintessence Int 2003;34:7–13.
52. Harris RJ. Connective tissue grafts combined with either double pedicle grafts or coronally positioned pedicle grafts: Results of 266 consecutively treated defects in 200 patients. Int J Periodontics Restorative Dent 2002;22:463–471.
53. Morris MF, Davis RD, Richardson BW. Clinical efficacy of two dentin desensitizing agents. Am J Dent 1999;12:72–76.
54. Baysan A, Lynch E. Treatment of cervical sensitivity with a root sealant. Am J Dent 2003;16:135–138.
55. Schiff T, Zhang YP, DeVizio W, et al. A randomized clinical trial of the desensitizing efficacy of three dentifrices. Compend Contin Educ Dent Suppl 2000;27:4–10.
56. Hamlin D, Mateo LR, Dibart S, Delgado E, Zhang YP. Comparative efficacy of two treatment regimens combining in-office and at-home programs for dentin hypersensitivity relief: A 24-week clinical study. Am J Dent 2012;25:146–152.
57. Thrash WJ, Dodds MW, Jones DL. The effect of stannous fluoride on dentinal hypersensitivity. Int Dent J 1994;44(suppl 1):107–118.
58. Thrash WJ, Jones DL, Dodds WJ. Effect of a fluoride solution on dentinal hypersensitivity. Am J Dent 1992;5:299–302.
59. Cunha-Cruz J, Wataha JC, Zhou L, et al. Treating dentin hypersensitivity: Therapeutic choices made by dentists of the northwest PRECEDENT network. J Am Dent Assoc 2010;141:1097–1105.
60. Baum LG, Phillips RW, Lund MR. Textbook of Operative Dentistry, ed 3. Philadelphia: Saunders, 1995:210–212,262.
61. Crispin BJ. Contemporary Esthetic Dentistry: Practice Fundamentals. Chicago: Quintessence, 1994:112.
62. Grippo JO. Noncarious cervical lesions: The decision to ignore or restore. J Esthet Dent 1992;4(suppl):55–64.

Dentlearn.ir

63. Levitch LC, Bader JD, Shugars DA, Heymann HO. Non-carious cervical lesions. J Dent 1994;22:195–207.
64. Powell LV, Gordon GE, Johnson GH. Sensitivity restored of Class V abrasion/erosion lesions. J Am Dent Assoc 1990;121:694–696.
65. Sturdevant CM, Roberson TM, Heymann HO, Sturdevant JR. The Art and Science of Operative Dentistry, ed 3. St Louis: Mosby, 1995:486–499.
66. Brantley CF, Bader JD, Shugars DA, Nesbit SP. Does the cycle of reresto-ration lead to larger restorations? J Am Dent Assoc 1995;126:1407–1413.
67. Fontana M, González-Cabezas C. Secondary caries and restoration replacement: An unresolved problem. Compend Contin Educ Dent 2000;21:15–18,21–24,26.
68. Zucchelli G. Testori T, De Sanctis M. Clinical and anatomical factors limiting treatment outcomes of gingival recession: A new method to predetermine the line of root coverage. J Periodontol 2006;77:714–721.
69. Zucchelli G, Gori G, Mele M, et al. Non-carious cervical lesions associated with gingival recessions: A decision-making process. J Periodontol 2011;82:1713–1724.
70. Zucchelli G, Mele M, Stefanini M, et al. Predetermination of root coverage. J Periodontol 2010;81:1019–1026.
71. Parsell DE, Streckfus CF, Stewart BM, Buchanan WT. The effect of amalgam overhangs on alveolar bone height as a function of patient age and overhang width. Oper Dent 1998;23:94–99.
72. Reagan SE. Periodontal access techniques for restorative dentistry. Gen Dent 1989;37:117–121.
73. Starr CB. Management of periodontal tissues for restorative dentistry. J Esthet Dent 1991;3:195–208.
74. Maynard JG Jr, Wilson RD. Physiologic dimensions of the periodontium significant to the restorative dentist. J Periodontol 1979;50:170–174.
75. Browning WD, Brackett WW, Gilpatrick RO. Two-year clinical comparison of a microfilled and a hybrid resin-based composite in non-carious Class V lesions. Oper Dent 2000;25:46–50.
76. Suzuki M, Jordan RE. Glass ionomer-composite sandwich technique. J Am Dent Assoc 1990;120:55–57.
77. Vandewalle KS, Vigil G. Guidelines for the restoration of Class V lesions. Gen Dent 1997;45:254–260.
78. McCoy RB, Anderson MH, Lepe X, Johnson GH. Clinical success of Class V composite resin restorations without mechanical retention. J Am Dent Assoc 1998;129:593–599.
79. Powell LV, Johnson GH, Gordon GE. Factors associated with clinical success of cervical abrasion/erosion restorations. Oper Dent 1995;20:7–13.
80. Kolhatkar S, Haque SA, Winkler JR, Bhola M. Root coverage in an HIV-positive individual: Combined use of a lateral sliding flap and resin-modified glass ionomer for the management of an isolated severe recession defect. J Periodontol 2010;81:632–640.
81. Santamaria MP, Suaid FF, Casati MZ, Nociti FH, Sallum AW, Sallum EA. Coronally positioned flap plus resin-modified glass ionomer restoration for the treatment of gingival recession associated with non-carious cervical lesions: A randomized controlled clinical trial. J Periodontol 2008;79:621–628.
82. Alkan A, Keskiner I, Yuzbasioglu E. Connective tissue grafting on resin ionomer in localized gingival recession. J Periodontol 2006;77:1446–1451.
83. Heithersay GS. Invasive cervical resorption following trauma. Aust Endod J 1999;25:79–85.
84. White C Jr, Certosimo AJ. Combining reconstructive and regenerative therapies. J Am Dent Assoc 1997;128:625–629.
85. Dragoo MR. Resin-ionomer and hybrid-ionomer cements: Part II, human clinical and histologic wound healing responses in specific periodontal lesions. Int J Periodontics Restorative Dent 1997;17:75–87.
86. Pontoriero R, Carnevale G. Surgical crown lengthening: A 12-month clinical wound healing study. J Periodontol 2001;72:841–848.
87. Deas DE, Moritz AJ, McDonnell HT, Powell CA, Mealey BL. Osseous surgery for crown lengthening: A 6-month clinical study. J Periodontol 2004;75:1288–1294.
88. Belcher MA, Stewart GP. Two-year clinical evaluation of an amalgam adhesive. J Am Dent Assoc 1997;128:309–314.
89. Summitt JB, Burgess JO, Berry TG, Robbins JW, Osborne JW, Haveman CW. Six-year clinical evaluation of bonded and pin-retained complex amalgam restorations. Oper Dent 2004;29:261–268.
90. Evans DB, Neme AM. Shear bond strength of composite resin and amalgam adhesive systems to dentin. Am

Dentlearn.ir

J Dent 1999;12:19–25.
91. Görücü J, Tiritoglu M, Ozgünaltay G. Effects of preparation designs and adhesive systems on retention of Class II amalgam restorations. J Prosthet Dent 1997;78:250–254.
92. Oliveira JP, Cochran MA, Moore BK. Influence of bonded amalgam restorations on the fracture strength of teeth. Oper Dent 1996;21:110–115.
93. Staninec M, Marshall GW, Lowe A, Ruzickova T. Clinical research on bonded amalgam restorations. Gen Dent 1997;45:356–362.
94. Mayhew RB, Schmeltzer LD, Pierson WP. Effect of polishing on the marginal integrity of high-copper amalgam. Oper Dent 1986;11:8–13.
95. Carvalho RM, Pereira JC, Yoshiyama M, Pashley DH. A review of polymerization contraction: The influence of stress development versus stress relief. Oper Dent 1996;21:17–24.
96. Choi KK, Condon JR, Ferracane JL. The effects of adhesive thickness on polymerization contraction stress of composite. J Dent Res 2000;79:812–817.
97. Ferracane JL, Mitchem JC. Relationship between composite contraction stress and leakage in Class V cavities. Am J Dent 2003;16:239–243.
98. Calheiros FC, Sadek FT, Braga RR, Cardoso PE. Polymerization contraction stress of low-shrinkage composites and its correlation with microleakage in Class V restorations. J Dent 2004;32:407–412.
99. Albers H. Tooth-Colored Restoratives, ed 8. Santa Rosa, CA: Alto Books, 1996:8c1–8c6.
100. Leinfelder KF. Restoration of abfracted lesions. Compendium 1994; 15:1396–1400.
101. Lutz E, Krejci I, Oldenburg TR. Elimination of polymerization stresses at the margins of posterior composite resin restorations: A new restorative technique. Quintessence Int 1986;17:777–784.
102. Tjan AH, Bergh BH, Lidner C. Effect of various incremental techniques on the marginal adaptation of Class II composite resin restorations. J Prosthet Dent 1992;67:62–66.
103. Hilton TJ, Ferracane JL. Cavity preparation factors and microleakage of Class III composite restorations filled at intraoral temperatures. Am J Dent 1998;11:123–130.
104. Owens BM, Halter TK, Brown DM. Microleakage of tooth colored restorations with a beveled gingival margin. Quintessence Int 1998;29:356–361.
105. Van Dijken JW. Clinical evaluation of three adhesive systems in Class V non-carious lesions. Dent Mater 2000;16:285–291.
106. Lopes GC, Baratieri CM, Baratieri LN, Monteiro S Jr, Cardoso Vieira LC. Bonding to cervical sclerotic dentin: Effect of acid etching time. J Adhes Dent 2004;6:19–23.
107. Lopes GC, Vieira LC, Monteiro S Jr, Caldeira de Andrada MA, Baratieri CM. Dentin bonding: Effect of degree of mineralization and acid etching time. Oper Dent 2003;28:429–439.
108. Lopes GC, Vieira LC, Arújo E, Bruggmann T, Zucco J, Oliveira G. Effect of dentin age and acid etching time on dentin bonding. J Adhes Dent 2011;13:139–145.
109. Kwong SM, Cheung GS, Kei LH, et al. Micro-tensile bond strengths to sclerotic dentin using a self-etching and a total-etching technique. Dent Mater 2002;18:359–369.
110. Tay FR, Kwong SM, Itthagarun A, et al. Bonding of a self-etching primer to non-carious cervical sclerotic dentin: Interfacial ultrastructure and microtensile bond strength evaluation. J Adhes Dent 2000;2:9–28.
111. Ritter AV, Heymann HO, Swift EJ Jr, Sturdevant JR, Wilder AD Jr. Clinical evaluation of an all-in-one adhesive in non-carious cervical lesions with different degrees of dentin sclerosis. Oper Dent 2008;33:370–378.
112. Crim GA. Microleakage of three resin placement techniques. Am J Dent 1991;4:69–72.
113. Jensen ME, Chan DC. Polymerization shrinkage and microleakage. In: Vanherle G, Smith DC (eds). Posterior Resin Composite Dental Restorative Materials. Utrecht, The Netherlands: Szulc, 1985:243–262.
114. Heymann HO, Sturdevant JR, Bayne S, Wilder AD, Sluder TB, Brunson WD. Examining tooth flexure effects on cervical restorations: A two-year clinical study. J Am Dent Assoc 1991;122:41–47.
115. Van Meerbeek B, Kanumilli PV, De Munck J, Van Landuyt K, Lambrechts P, Peumans M. A randomized, controlled trial evaluating the three-year clinical effectiveness of two etch & rinse adhesives in cervical lesions. Oper Dent 2004;29:376–385.
116. ADA Council on Scientific Affairs. Restorative materials. ADA Professional Product Review 2010;5(2):1–

Dentlearn.ir

16.
117. Ernst CP, Buhtz C, Rissing C, Willershausen B. Clinical performance of resin composite restorations after 2 years. Compend Contin Educ Dent 2002;23:711–714,716–717,720.
118. Tyas MJ, Burrow MF. Three-year clinical evaluation of One-Step in non-carious cervical lesions. Am J Dent 2002;15:309–311.
119. Matis BA, Cochran M, Carlson T. Longevity of glass-ionomer restorative materials: Results of a 10-year evaluation. Quintessence Int 1996;27: 373–382.
120. Franco EB, Benetti AR, Ishikiriama SK, et al. 5-year clinical performance of resin composite versus resin modified glass ionomer restorative system in non-carious cervical lesions. Oper Dent 2006;31:403–408.
121. Stewardson DA, Thornley P, Bigg T, et al. The survival of Class V restorations in general dental practice. Part 2, early failure. Br Dent J 2011;210:E19.
122. Heintze SD, Roulet JF. Glass ionomer derivates have better retention rates in cervical restorations compared to self-etching adhesive systems. J Evid Based Dent Pract 2010;10:18–20.
123. Brackett WW, Gilpatrick RO, Browning WD, Gregory PN. Two-year clinical performance of a resin-modified glass-ionomer restorative material. Oper Dent 1999;24:9–13.
124. Abdalla AI, Alhadainy HA. Clinical evaluation of hybrid ionomer restoratives in Class V abrasion lesions: Two-year results. Quintessence Int 1997;28:255–258.
125. Folwaczny M, Loher C, Mehl A, Kunzelmann KH, Hickel R. Class V lesions restored with four different tooth-colored materials—3-year results. Clin Oral Investig 2001;5:31–39.
126. Frazier KB, Rueggeberg FA, Mettenburg DJ. Comparison of wear-resistance of Class V restorative materials. J Esthet Dent 1998;10:309–314.
127. Tyas MJ, Burrow MF. Clinical evaluation of a resin-modified glass ionomer adhesive system: Results at five years. Oper Dent 2002;27:438–441.
128. Van Dijken JW. 3-year clinical evaluation of a compomer, a resin-modified glass ionomer and a resin composite in Class III restorations. Am J Dent 1996;9:195–198.
129. Huth KC, Manhart J, Selbertinger A, et al. 4-year clinical performance and survival analysis of Class I and II compomer restorations in permanent teeth. Am J Dent 2004;17:51–55.
130. Hse KM, Wei SH. Clinical evaluation of compomer in primary teeth: 1-year results. J Am Dent Assoc 1997;128:1088–1096.
131. Andersson-Wenckert IE, Folkesson UH, Van Dijken JW. Durability of a polyacid-modified composite resin (compomer) in primary molars. A multicenter study. Acta Odontol Scand 1997;55:255–260.
132. Roeters JJ, Frankenmolen F, Burgersdijk RC, Peters TC. Clinical evaluation of Dyract in primary molars: 3-year results. Am J Dent 1998;11:143–148.
133. Prati C, Chersoni S, Cretti L, Montanari G. Retention and marginal adaptation of a compomer placed in non-stress-bearing areas used with the total-etch technique: A 3-year retrospective study. Clin Oral Investig 1998;2:168–173.
134. Papagiannoulis L, Kakaboura A, Pantaleon F, Kavvadia K. Clinical evaluation of a polyacid-modified resin composite (compomer) in Class II restorations of primary teeth: A two-year follow-up study. Pediatr Dent 1999;21:231–234.
135. Di Lenarda R, Cadenaro M, De Stefano Dorigo E. Cervical compomer restorations: The role of cavity etching in a 48-month clinical evaluation. Oper Dent 2000;25:382–387.
136. Van Dijken JW. Durability of new restorative materials in Class III cavities. J Adhes Dent 2001;3:65–70.
137. Abdalla AI, Mahallawy SE, Davidson CL. Clinical and SEM evaluations of three compomer systems in Class V carious lesions. J Oral Rehabil 2002;29:714–719.
138. Folwaczny M, Mehl A, Kunzelmann KH, Hickel R. Clinical performance of a resin-modified glass-ionomer and a compomer in restoring non-carious cervical lesions. 5-year results. Am J Dent 2001;14:153–156.
139. Wucher M, Grobler SR, Senekal PJ. A 3-year clinical evaluation of a compomer, a composite and a compomer/composite (sandwich) in Class II restorations. Am J Dent 2002;15:274–278.
140. Huth KC, Manhard J, Hickel R, Kunzelmann KH. Three-year clinical performance of a compomer in stress-bearing restorations in permanent posterior teeth. Am J Dent 2003;16:255–259.

Dentlearn.ir

141. Qvist V, Laurberg L, Poulsen A, Teglers PT. Class II restorations in primary teeth: 7-year study on three resin-modified glass ionomer cements and a compomer. Eur J Oral Sci 2004;112:188–196.
142. Krauser JT. Hypersensitive teeth. Part 1: Etiology. J Prosthet Dent 1986; 56:153–156.
143. Gillam DG, Tang JY, Mordan NJ, Newman HN. The effects of a novel Bioglass dentifrice on dentine

144. Bartold PM. Dentinal hypersensitivity: A review. Aust Dent J 2006; 51:212–218.
145. Liu HC, Lan WH, Hsieh CC. Prevalence and distribution of cervical dentin hypersensitivity in a population in Taipei, Taiwan. J Endod 1998; 24:45–47.
146. Taani SD, Awartani F. Clinical evaluation of cervical dentin sensitivity (CDS) in patients attending general dental clinics (GDC) and periodontal specialty clinics (PSC). J Clin Periodontol 2002;29:118–122.
147. Cuenin MF, Schiedt MS, O'Neal RB, et al. An in vivo study of dentin sensitivity: The relation of dentin sensitivity and the patency of dentin tubules. J Periodontol 1991;62:668–678.
148. Brännström M, Lindén LA, Aström A. The hydrodynamics of the dental tubule and of pulp fluid. A discussion of its significance in relation to dentinal sensitivity. Caries Res 1967;1:310–317.
149. Absi EG, Addy M, Adams D. Dentine hypersensitivity. A study of the patency of dentinal tubules in sensitive and non-sensitive cervical dentine. J Clin Periodontol 1987;14:280–284.
150. Hodosh M, Hodosh SH, Hodosh AJ. About dentinal hypersensitivity. Compendium 1994;15:658,660,662.
151. Pashley DH, Muzzin K. Clinical management of dentin sensitivity. In: Clark JW (ed). Clinical Dentistry. Philadelphia: Lippincott, 1990:1–7.
152. Trowbridge HO, Silver DR. A review of current approaches to in-office management of tooth hypersensitivity. Dent Clin North Am 1990;34: 561–581.
153. Dondi dall'Orologio G, Malferrari S. Desensitizing effects of Gluma and Gluma 2000 on hypersensitive dentin. Am J Dent 1993;6:283–286.
154. Watanabe T, Sano M, Itoh K, Wakumoto S. The effects of primers on the sensitivity of dentin. Dent Mater 1991;7:148–150.
155. Swift EJ Jr, May KN Jr, Mitchell S. Clinical evaluation of Prime & Bond 2.1 for treating cervical dentin hypersensitivity. Am J Dent 2001;14:13–16.
156. Tarbet WJ, Silverman G, Fratarcangelo PA, Kanapka JA. Home treatment for dentinal hypersensitivity: A comparative study. J Am Dent Assoc 1982;105:227–230.
157. Kishore A, Mehrotra KK, Saimbi CS. Effectiveness of desensitizing agents. J Endod 2002;28:34–35.
158. Krahwinkel T, Theiss P, Willershausen B. Clinical effectiveness of a potassium chloride containing chewing gum in the treatment of hypersensitive teeth. Eur J Med Res 2001;6:483–487.
159. Cunha-Cruz J, Stout JR, Heaton LJ, Wataha JC; Northwest PRECEDENT. Dentin hypersensitivity and oxalates: A systematic review. J Dent Res 2011;90:304–310.

Dentlearn.ir



Natural Tooth Bleaching

Van B. Haywood
Juliana da Costa
Thomas G. Berry

History of Bleaching

For well over a century, bleaching in some form has been used to achieve a lighter and more desirable tooth color. Dental journals in the latter half of the 19th century frequently contained articles on the efficacy of bleaching teeth with different techniques.[1–3] The safety of the procedure was well investigated, and most of the bleaching agents were considered to be safe by the standards of the time. Although the process was thought to be time-consuming and relapse was considered a consistent problem, bleaching was well accepted by many dentists.[4–6] The following is a brief history of dental bleaching approaches.

By the mid-1800s, the in-office bleaching agent of choice for nonvital teeth was chloride of lime.[7–9] Around that time, Truman introduced chlorine from a calcium hydroxide and acetic acid solution for bleaching nonvital teeth; this was supplied commercially as a liquid chloride of soda.[5] Other agents used in the 1800s for nonvital tooth bleaching included aluminum chloride,[10] oxalic acid,[3,11] Pyrozone

Dentlearn.ir

(ether peroxide),[2] hydrogen dioxide (hydrogen peroxide or perhydrol),[12] sodium peroxide,[12] sodium hypophosphate,[8] and cyanide of potassium. The active ingredient common to all of these was an oxidizing agent that acted either directly or indirectly on the organic portion of the tooth. Sulfurous acid, in contrast, achieved results as a reducing agent.[13,14] Generally, the most effective yet safe bleaching agents were direct oxidizers or an indirect oxidizer such as a chlorine derivative.[6,15] However, the choice of bleaching agent depended primarily on the stain being removed. Iron stains were removed with oxalic acid, silver and copper stains with chlorine, and iodine stains with ammonia.[14–17] Metallic stains (such as those from amalgam) were considered the most resistant to bleaching. Concern about the effect of some of these bleaching agents on the teeth, tissues, and health of the patient was raised because certain agents, such as cyanide of potassium, were very poisonous[12] while others were highly caustic.

In the 1890s, the early emphasis was on bleaching nonvital teeth. However, by this time, a 3% solution of Pyrozone was being used safely as a mouthwash by both children and adults to reduce caries and to whiten the teeth.[18] A 5% solution proved to be safe and effective, but a 25% solution was caustic, causing tissue burns.[18] By 1910, an "in-office bleaching technique" similar to that used today, where high concentrations of hydrogen peroxide are used on well-isolated teeth, occasionally assisted by heat or light, was well established.[19]

Over the next few decades, the bleaching agents varied. By the 1940s, hydrogen peroxide and ether were used for vital teeth,[20] while, by the late 1950s, Pyrozone

the current "home bleaching technique," employing a custom-fit tray containing 10% carbamide peroxide solution, was first used by Klusmier.[23] However, the profession did not embrace the concept until it was described in an article published in 1989.[24]

In 1989, Haywood and Heymann wrote the first article on an at-home bleaching technique employing a custom-fit tray containing 10% carbamide peroxide solution,[24] and its publication coincided with the market introduction of carbamide peroxide as a bleaching agent.[25,26] This ushered in the current technique for at-home bleaching. Various chemical combinations have been tried. The effective ones all release oxidizing agents, whether supplied as hydrogen peroxide, carbamide peroxide, sodium percarbonate, or some other compound.[27] Following the popularity of the at-home bleaching by trays, there was a resurgence of in-office bleaching, with various light and chemical enhancements, as well as a proliferation of over-the-counter products. The terms *bleaching* and *whitening* are often used

Dentlearn.ir

interchangeably, and *lightening* is also used occasionally. There is not a clear distinction among the terms, although cosmetic products typically use the word *whitening* for the removal of surface stains, and true bleaching products, which change the inherent color of the tooth, are referred to as *bleaching* products.

Types and Nature of Stains/ Discolorations

Many types of color problems affect the appearance of the teeth. The cause of these problems varies, so the speed or efficacy with which they may be removed also varies. Discolorations may be extrinsic or intrinsic. *Extrinsic stains* are located on the surface of the tooth and are most easily removed by external cleaning. *Intrinsic stains* are located within the tooth and are accessible only by bleaching. Some extrinsic stains that remain on the tooth for a long time become intrinsic. Extrinsic color changes may be the result of poor oral hygiene. Intrinsic color changes may be caused by aging, microcracks in the enamel, tetracycline medication, excessive fluoride ingestion, severe jaundice in infancy, porphyria, dental caries, restorations, and thinning of the enamel layer, as well as ingestion of chromogenic foods and drinks and tobacco use. Other, less common medical situations and conditions may also cause the loss of desirable tooth color.

The causes of staining need to be assessed carefully to better predict the rate and degree to which bleaching will improve tooth color, because some stains are more responsive to the process than others.[24,28] For instance, the yellow discoloration of aging responds quickly to bleaching in most cases,[29] whereas a blue-gray tetracycline stain is tenacious and is seldom totally removed, only lightened.[26] In general, tetracycline-stained teeth are the slowest to respond to bleaching[30] (Fig 16-1). Brown (Fig 16-2a) or brown-fluoresced (Fig 16-2b) teeth are moderately responsive, and teeth discolored by age, genetics, smoking, or coffee are the fastest to respond.[31,32] White spots are not removed by bleaching but may be less noticeable when the remainder of the tooth is lighter.[33] By recognizing the likely cause of the stain, the dentist can better tell the patient the rate at which the teeth may lighten in color and the limits on the amount of improvement that can be expected.



Dentlearn.ir

Fig 16-1 Teeth demonstrating moderate, grayish tetracycline stain are excellent candidates for external bleaching but may take longer to respond.



Fig 16-2*(a)* Stain of unknown origin creates disfigurement in a 10-year-old boy with brownish areas surrounded by whiter areas. Brown stains are very amenable to bleaching treatments. *(b)* High fluoride content in drinking water can cause brown and white stains. The brown stain can be removed, but the white remains unchanged.

Discoloration from drug ingestion may occur either before or after the tooth is fully formed. Tetracycline is incorporated into the dentin sometime during tooth calcification (see Fig 16-1), probably through chelation with calcium, forming tetracycline orthophosphate.[34–36] There are several variations of tetracycline, and each derivative produces a different color in the tooth. Some teeth may be "banded" from the ingestion of different derivatives of tetracycline. When the teeth are exposed to sunlight, they become darker, with a distinct gray/blue-gray tinge. The teeth not exposed to the sunlight (ie, molars) do not darken to the same degree but remain more yellow in color. Tetracycline also has been reported to discolor fully formed, erupted permanent teeth. This discoloration is most often associated with minocycline, a drug commonly used in the treatment of acne.[37–39] The primary route of deposition is thought to be in the secondary dentin, although some reports suggest a staining similar to that of iron deposition.[40] Other antibiotics may also interact with calcium, iron, or other elements to form insoluble complexes that stain teeth.[41]

Excessive fluoride in drinking water, greater than 1 to 2 ppm, can cause metabolic alteration in the ameloblasts, resulting in a defective matrix and improper calcification of teeth.[42] An affected tooth shows a hypomineralized, porous subsurface enamel and a well-mineralized surface layer. These teeth have a glazed surface and may be very white except for areas of yellow, brown (see Fig 16-2b), or even black shading.

Some systemic conditions can cause tooth discoloration. Severe jaundice leads to staining by bilirubin. Erythroblastosis fetalis may also stain the teeth because of the destruction of red blood cells. Porphyria, a rare condition, manifests with purplish-brown teeth.

Dentlearn.ir

Aging is a common cause of discoloration. Over time, the underlying dentin tends to darken from the formation of secondary dentin, which is darker and more opaque than the original dentin. This occurs while the overlying enamel becomes thinner, a combination that often produces distinctly darker teeth. Additionally, chromogenic foods gradually build up stains in the enamel.

Dental caries produces varying stains depending on its stage of progression. Examples of caries-induced discolorations include an opaque white "halo," a grayish tinge, or a brown to black stain. These stains arise from the bacterial degradation of food debris. Metallic restorations, most notably dental amalgam, may cause a distinct staining of the tooth in addition to the shadow they may cast through adjacent enamel walls.

Another cause of discoloration to the tooth is trauma. The tooth may remain vital but can discolor, either from iron-containing hemoglobin in blood seeping into the dentinal tubules or from calcific metamorphosis (Fig 16-3). *Calcific metamorphosis* is the process by which the tooth deposits darker yellow secondary dentin in the pulp chamber, which may partially or completely obliterate the pulp chamber. Other more serious issues that may cause discoloration are a necrotic pulp that has resulted

resorption. Often in these cases, there is no pain, no swelling, no mobility, or any other symptom other than the onset of tooth darkening. Occasionally, caries and the resultant deep restoration may eventually result in pulpal death. A radiograph should always be taken of a single dark tooth, and pulp testing may also be indicated.

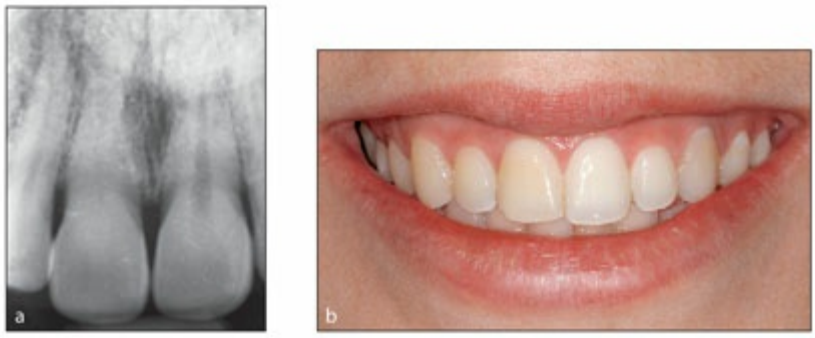

Fig 16-3*(a and b)* Calcific metamorphosis, seen in the maxillary right central incisor, is the condition in which the pulp chamber has been obliterated by secondary dentin. The tooth may

bleaching of the single dark tooth is best performed with tray application of the bleaching agent.

Indications for Bleaching

The primary indication for bleaching is patient dissatisfaction with tooth color,

Dentlearn.ir

either of all the teeth or teeth adjacent to restorations. While the source of the discoloration affects the degree of success and the rapidity with which it can be eliminated or minimized, it has been shown that even the most persistent discolorations can be lightened if the treatment is sufficiently extended.[43] Bleaching may be done in lieu of bonded resin composite restorations, porcelain veneers, or crowns to improve the tooth color. Patients may be satisfied with the results of bleaching such that more invasive treatment is not needed.[44] Even if porcelain or composite veneers are to be placed, the lighter color of the bleached teeth allows lighter and more translucent veneers, enhancing the natural appearance. Other indications include extending the esthetic life of existing crowns that are lighter than the adjacent natural teeth by returning the color of the natural teeth to the shade of the crown, or whitening a single dark tooth to the desired shade to match the adjacent teeth.

There is also a psychologic benefit of bleaching, especially in the 10- to 14-year individual's self-image. Bleaching removes a source of embarrassment, which may affect personality development during a child's middle school years.[45] Hence, the age of a bleaching patient can range from 10 years to 80 years or older. Patients tend to look most natural when the color of the teeth matches the white of the sclera in their eyes.[46] Therefore, a desired endpoint for bleaching is not the number of shade guide changes but a natural, beautiful appearance where the white of the teeth matches the white of the eyes.

Contraindications for Bleaching

Although bleaching is a safe and effective aid in improving the appearance of the teeth after a proper examination, not every discolored tooth requires bleaching. Superficial or extrinsic stains may be completely removed by a rubber cup with prophylaxis paste or by light abrasion with a rotary polishing device. The removal of discolored carious tooth structure and/ or a dark restoration and placement of a tooth-colored material may well make a marked improvement in the appearance of a tooth.

There are few contraindications for bleaching (Box 16-1), whether in-office or at-home dentist-prescribed techniques are being considered. In-office bleaching is not recommended for children with large pulps or teeth with cracks because of the higher concentrations of bleaching solutions used and subsequent sensitivity issues.

Dentlearn.ir

Likewise, exposed root surfaces and severe loss of enamel may be contraindications. At-home bleaching is generally not indicated for pregnant women or patients allergic to the ingredients in the carbamide peroxide preparations. Although there is no evidence that bleaching is harmful to the fetus or to infants, it has been recommended that pregnant and lactating women avoid bleaching because of the increased potential for gingival irritation.[47,48] Also, the mother's peace of mind should be taken into account so that she does not improperly relate bleaching problems to any issues that might occur with the birth or the baby. Because there is some evidence that peroxides may enhance the effect of known carcinogens, it may be prudent to have the patient forego tobacco use during the period of the bleaching process.[31,49,50] In one study of at-home bleaching, Nathanson and Parra[51] determined that there was no noticeable difference in the sensitivity reported by young patients compared with sensitivity reported by older patients, so larger pulp size may not be a factor for at-home bleaching. In a study of at-home bleaching with carbamide peroxide, Leonard et al[33] determined that there were no predictors of which individuals would experience sensitivity other than a history of sensitive teeth and more than one bleach application per day.[52] All other characteristics, such as pulp size, exposed dentin, cracks, gingival recession, caries, sex or age of the patient, or other physical characteristics, were not predictive of tooth sensitivity.

Box 16-1	**Contraindications for bleaching**
• Unrealistic expectations • Unwillingness to comply with treatment • Extensive existing tooth-colored restorations that do not need replacement or patient is unwilling to replace • Inability to tolerate taste (at-home bleaching) or technique (in-office) •Pregnancy or lactation	

There are some potential bleaching situations with guarded prognoses (Box 16-2). Patients with hypersensitive teeth are generally not good candidates for bleaching, although management of the sensitivity may allow successful bleaching of their teeth. Because bleaching tends to produce some sensitivity under ordinary circumstances, patients with preexisting tooth sensitivity must be cautioned that increased sensitivity, albeit transitory, will occur.[53] However, there are reasonable techniques, discussed later, to manage sensitivity.

Box 16-2	**Guarded prognoses for bleaching**

Dentlearn.ir

- History of sensitive teeth
- Translucent teeth
- Extremely dark gingival third of tooth that is visible when smiling
- Exposed root surfaces
- Extensive white spots that are very visible
- Temporomandibular disorder (TMD) or bruxism

Most teeth become more opaque upon bleaching, but some that are already translucent at the incisal edge may become more translucent and may not appear to whiten in that area (Fig 16-4). Patients should be informed of this potential challenge. One treatment for this situation, if the occlusal examination indicates it is possible, is the placement of bonded composite restorations on the lingual tooth surface to reduce the translucency. Teeth heavily stained in the gingival third have the poorest prognosis for complete lightening, as the root dentin and the deep dentin of the tooth are very different from dentin near the dentinoenamel junction in the shape, size, and number of dentin tubules per unit area.[53] Roots of teeth do not bleach as well as anatomical crowns, so patients with gingival recession that exposes roots will display yellow tooth structure in those areas.[54] White spots do not bleach but may be less noticeable if the background color of the tooth is lightened to avoid the contrast. Patients with a history of temporomandibular disorders (TMDs) may not be good candidates for at-home bleaching or may need to wear the tray during waking hours only. A special tray design that covers only the facial surfaces of the teeth may be helpful.[55] Bruxers also may have to alter wear times for at-home treatment or have several trays fabricated during treatment because they will often grind holes in the tray.



Dentlearn.ir

Fig 16-4 *(a)* A translucent incisal edge can often appear discolored and should be tested for discoloration. Prior to bleaching, the incisal edge appears bluish because of the darkness of the mouth seen through the translucent enamel. *(b)* To test for discoloration, block the light transmission by placing a white-gloved finger on the lingual of the tooth. If the discoloration disappears, the incisal edge is translucent; if it remains, the incisal edge is discolored. Discoloration responds well to bleaching, but translucency may create an esthetic problem. *(c)* A translucent incisal edge often becomes more translucent after bleaching. Patients should be informed of this possibility prior to bleaching. *(d)* After bleaching, if the translucency is unacceptable to the patient, some mechanism is needed to block the light transmission. The potential for improvement is evident by using the finger test again. Often a lingually placed bonded composite restoration can minimize translucence, as long as the restoration does not interfere with the patient's occlusion.

There is some evidence to suggest that the use of carbamide peroxide may retard the progression of caries.[56–61] Therefore, in carefully selected cases it is not essential to restore all active caries lesions prior to bleaching. Because it cannot be predicted to what shade a tooth will bleach, there is no way to know the proper shade to select for the restoration. It is best to perform bleaching and then select the shade after the proper stabilization time has passed. Only those caries lesions that are sensitive or near the pulp would need to be restored prior to bleaching and then possibly later resurfaced or replaced after bleaching to match the final shade.[62,63] Bleaching does interfere with the bonding process because it results in a very high oxygen concentration in the enamel and dentin, which hinders polymerization of the resin composite.[64–66] A 25% to 50% reduction in bond strength of composite to etched enamel, due to oxygen inhibition of polymerization of the adhesive resin tags within the etched enamel, has been reported. Some research has found that a delay of 7 to 10 days after bleaching allows dissipation of the excess oxygen from the tooth structure so that there is no interference with the polymerization reaction.[67] Another study showed that there is a need to wait at least 2 weeks for maximum bond strength of silorane-based or methacrylate-based restorations; otherwise, the enamel bond-strength reduction is 25% to 50%.[68] Waiting 1 to 2 weeks is also important in resin bonding to allow the shade of the bleached teeth to stabilize.[69] Patients with existing esthetic restorations must be warned that when bleaching lightens the natural tooth color, restorations may appear relatively dark and unattractive. The need for new restorations that are lighter in shade should be discussed with the patient prior to bleaching. Occasionally, the cost and number of restorations that would require replacement after bleaching or the danger of replacing a restoration such as a crown on a cracked tooth may be a contraindication to bleaching.

Dentlearn.ir

Mode of Action

The bleaching process is designed to enable the oxidizing agent to reach sites within the enamel and dentin to allow a chemical reaction to occur. No matter the bleaching technique or specific bleaching action, the intention is to deliver the active ingredient to the discolored segments of the tooth to dislodge or decolor the chromatic particles.

Hydrogen peroxide diffuses through the organic matrix of the enamel and dentin because of its low molecular weight.[70–74] It is not currently understood what gives the tooth its genetic color, and therefore it is not possible to state scientifically what exactly the bleaching process is changing within the tooth. Bleaching both removes extrinsic and intrinsic stains in or on the tooth that originated from external sources (nicotine, tetracycline, coffee, etc) as well as changes the genetic color of the tooth. People are born with different colors of teeth in the same manner as they have different colored eyes and hair. The teeth will change color at different rates for different patients, so the dentist cannot predict how long bleaching will take or what the final shade will be. Moreover, there is a limit to how white a tooth will become, and this limit differs from patient to patient. Further research is needed to determine what gives the tooth its baseline color and, in turn, the extent of the effect of the oxidation reaction that changes the tooth color during bleaching.

The chemistry of carbamide peroxide used in at-home bleaching is thought to be a bit different from that of hydrogen peroxide, although the final stages do involve the reaction of hydrogen peroxide with the compounds within the tooth. When introduced into the mouth, a solution of 10% carbamide peroxide agent breaks down

portions of the tooth in minutes (Fig 16-5). This 3:1 reduction of carbamide peroxide to the active hydrogen peroxide ion explains why bleaching formulations with carbamide peroxide typically are dosed at three times the concentration of those containing hydrogen peroxide. Bleaching not only removes discoloration from within the tooth, but it also alters/brightens the inherent color of the dentin itself.[75]

Dentlearn.ir

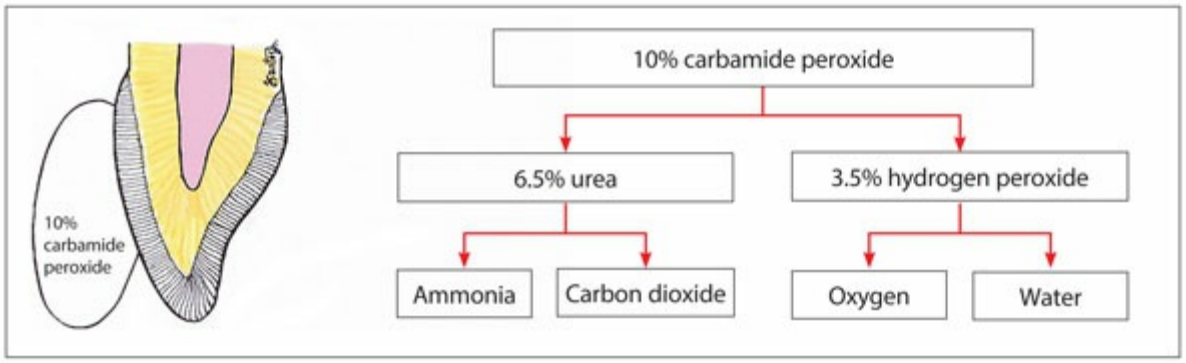

Fig 16-5 Carbamide peroxide penetrates through the enamel and the dentin to the pulp in 5 to 15 minutes. Carbamide peroxide dissociates in the tooth into urea and hydrogen peroxide. These two components further break down into ingredients that are common in the body and are easily metabolized by the body. Urea serves to elevate the pH of the local environment.

Treatment Planning and Patient Education

A basic understanding of the cause(s) of discoloration is necessary to better predict the course and duration of the treatment as well as the final outcome. The decision to use at-home or in-office bleaching is based on the patient's preference, financial situation, and ability and willingness to comply with the treatment protocol. Patients who are unwilling or unable to comply with the protocol for the at-home technique, or who are eager to finish bleaching in a very short period of time regardless of cost, are good candidates for in-office bleaching. Subsequent treatment procedures should be planned so that limits of the bleaching treatment are discussed in the context of solving the patient's other dental problems. The patient should be informed that the shade of any restoration placed previously will not be altered by bleaching, so bleaching should be performed before any esthetic restorative procedures. Information concerning the decision to bleach or not, as well as the rationale for and costs of choosing a particular method, must be recorded to verify that the dentist and patient agree on the procedures and their predicted outcomes.

A proper examination is essential to diagnosing the cause of discoloration as well as to determine if there are other contributing factors or concerns to address[76] (Box 16-3). Discoloration or staining may be an indication of dental conditions such as a necrotic pulp (Fig 16-6), decay, resorption (Fig 16-7), or faulty restorations. Without a proper examination and diagnosis of the cause of discoloration or staining, the disease process occurring in the tooth may be masked by removal of the only clinical symptom of the problem. For example, dark teeth could be a result of trauma to the tooth at an early age, and the tooth pulp may eventually become necrotic or abscess. It may take 1 to 20 years before this condition occurs.[77] Occasionally,

Dentlearn.ir

external resorption may be found clinically when carefully exploring at or beneath the gingival tissue, as this process generally occurs on the root of the tooth.

through radiographic examination. Bleaching discolored teeth for which the color change is the only indication of hidden pathology will change the color of the tooth while not resolving the pathology that is causing the discoloration. With the possible exception of caries, bleaching does not stop the pathology from continuing, and allowing the pathology to continue can result in the loss of teeth. Additionally, caries alone or around restorations may cause teeth to appear dark. A dental examination, complete with a screening radiograph of the anterior teeth and any single dark teeth, is recommended prior to initiating any type of bleaching. The examination should include an explanation of all treatment options available to the patient, taking into consideration the fact that existing restorations will not bleach, as well as other esthetic needs. After a proper examination, the cause of discoloration is diagnosed and the treatment plan developed (Box 16-4). Correctly diagnosed indications for bleaching may require varying treatment times or techniques, based on the type and depth of the stain/discoloration and the number of teeth involved. Single dark teeth may require a special single-tooth tray or multiple tray designs.[78]



Fig 16-6 A screening radiograph should always be taken of any anterior teeth being considered for bleaching, including a single dark tooth. *(a)* A left mandibular lateral incisor that is darker than adjacent teeth. This tooth was asymptomatic. *(b)* Periapical radiograph reveals apical radiolucency associated with the darkened tooth.

Dentlearn.ir

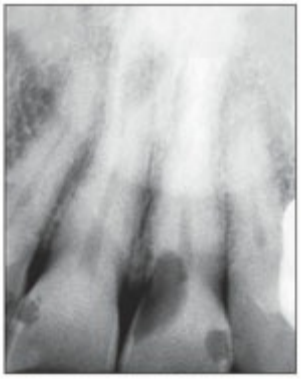

Fig 16-7 Root resorption without bleaching. The only indication of a problem with this tooth was a slight discoloration. The lesion was discovered on clinical and radiographic examination. (Courtesy of Tom McDonald, Athens, Georgia.)

Box 16-3	**Bleaching examination considerations**
• Intraoral soft and hard tissue examination (to rule out cancer, periodontal problems, recession, etc) • Radiographs (to assess periapical pathology, resorption, and single dark teeth) • Diagnosis of cause and location of tooth discoloration • Identification of esthetic restorations • Assessment of exposed roots, visible white spots, cracks, tooth or gingival architecture defects; overall esthetic/facial analysis; other appliances; and lifestyle issues • Complete sensitivity history and examination • Occlusal and TMD screening examinations	

Box 16-4	**Diagnosis of tooth discoloration**
Generalized tooth discoloration	**Single-tooth discoloration**
• Genetic color of the teeth	• Endodontic therapy
•Tetracycline staining	• Necrotic pulp with periapical radiolucency
• Coffee, tea, nicotine use	
• Multiple caries	• Calcific metamorphosis
• Multiple discolored restorations	• Silver point endodontic obturation or restorative material discoloration
• Multiple leaking restorations	• Caries
	• Discolored restoration
	• Leaking restorations

In addition to diagnosis of the cause of the discoloration, the dentist also should consider the overall (Box 16-5) and esthetic conditions (Box 16-6) of the patient. Certain changes in the treatment protocol may be required based on these

Dentlearn.ir

considerations.

Box 16-5	**Overall considerations for bleaching**

• *Sensitivity:* History of sensitivity and plans for sensitivity treatment before or during bleaching
• *Tray design:* Tray design for full-arch or single-tooth tray; decision to extend the tray onto tissue or to have no tissue con
tact; decision to incorporate spacers on teeth or to include other design features, such as no occlusal coverage for TMD
patients
• *Treatment time:* Daytime or nighttime usage plans for tray bleaching
• *Appliances:* Other appliances being worn with tray bleaching, such as orthodontic appliances or removable partial dentures
• *Combination treatment:* In-office bleaching requiring multiple visits versus a combination of in-office treatment followed by
tray treatment versus tray only treatment
• *Joint health:* TMD that may be aggravated by tray wear or by extended opening during in-office bleaching
• *Pregnancy:* Decision to not perform bleaching procedures on pregnant or nursing mothers for the psychologic concerns
related to birth issues, as well as pregnancy gingivitis and morning sickness

Box 16-6	**Esthetic considerations for bleaching**

• Compare the color of the teeth with the color of the sclera of the eyes to ascertain the whitening outcome potential.
• Determine if the patient has a ″gummy smile“ and short teeth, because whiter teeth accentuate excessive gingival display.
Periodontal therapy may be indicated.
• Identify other restorations that are displayed in a full smile, because they will not change color.
• Note alterations in individual tooth gingival architecture that may be more noticeable after bleaching.
• Point out exposed root surfaces that will not bleach, *and* demonstrate white spots that will not change color.
• Evaluate transparent areas of the incisal edge that may become more noticeable *and* discolored gingival areas that are
most difficult to bleach, especially tetracycline-stained areas.
effectiveness of the color change.

Shade selection and record collection

A shade guide identifies the existing tooth color to establish the baseline (Fig 16-8). If the shade guide does not have a match for the tooth color, it should be estimated. It is important that the patient agrees that the shade tab is the closest match to the

Dentlearn.ir

current shade of the teeth. This shade should be recorded in the chart with the patient observing the entry. It is also recommended to make preoperative photographs with the shade tab in the photograph. The advent of cost-effective digital dental cameras has made this mode an excellent method of recording the initial, interim, and final treatment conditions of the patient.



Fig 16-8 The shade guide tab establishes a record of the existing color. Digital photographs should be taken with the tab visible and the teeth edges in close approximation.

If using at-home bleaching techniques, the best way to ensure patient awareness of the effect of bleaching is to bleach one arch at a time. In addition to minimizing the potential for temporomandibular joint (TMJ) problems, it preserves one arch for an ongoing comparison of progress. Another reason for treating one arch at a time is to enable determination of the effectiveness of the bleaching procedure before the patient commits to bleaching of the second arch. If the first arch is deemed a success by the patient, the opposing arch can be bleached for an additional fee (Fig 16-9). Finally, bleaching one arch at a time reduces the number of teeth for which sensitivity may be a problem. The American Dental Association (ADA) reimbursement code for tray bleaching is also per arch, not per patient.



Fig 16-9 Note the strong contrast between the bleached maxillary teeth and the unbleached mandibular teeth (which match the shade tab). Bleaching one arch at a time is preferred to allow the patient to see that the process is working and to minimize sensitivity and occlusion issues. Some patients may choose not to bleach the opposing arch.

Dentlearn.ir

Impressions for diagnostic casts are necessary if bleaching trays are to be used for the at-home technique. The impressions can be made with alginate impression material if immediate pouring is planned. For delayed pouring, a polyvinyl siloxane impression from a putty-wash technique is more appropriate. Patients who gag easily may prefer an impression with a double-sided full-arch tray using a closed-mouth technique or use of a mandibular tray on the maxillary arch, or they may be candidates for a thermoplastic tray fabricated directly in the mouth without impressions.[79]

For added documentation, close-up photographs of the patient's teeth and a full-face photograph of the patient with a full smile should be kept as part of the patient's record. The photographs may be helpful in treatment planning, in reminding the patient of the original appearance of the teeth, and as a record for a ceramist fabricating any restorations. Photographs should be taken at a consistent magnification and pose. Placing the incisal edges of the teeth in the bleached arch in close proximity to the teeth in the unbleached arch is important so that both arches are the same distance from the camera; this helps to ensure the best comparison of the before and after shades, emphasizing the effect of bleaching.

Patient education

The patient should be well informed about the bleaching procedure. Information explaining the process, precautions, possible side effects, number of applications or appointments, anticipated total time for bleaching, and likely results should be provided. As with any patient instructions, providing written information concerning the procedure as well as treatment instructions is recommended. The dentist should also explain why the particular technique has been chosen. The steps of the procedure and consequences for not following them should be outlined. For the at-home technique, loading and insertion of the bleaching tray should be demonstrated and the length for each wear session outlined. Any questions the patient might have should be answered at this appointment. The patient should sign a consent form indicating that he or she has been informed about the procedure, its expected outcome, and any potential side effects. The consent form should also list other treatment options for this condition and state that those remain if the bleaching is not successful.

Current Bleaching Modalities

Dentlearn.ir

The three types of bleaching therapy are in-office bleaching, at-home bleaching, and over-the-counter products. In-office bleaching is the oldest method and may involve heat and light enhancement. At-home bleaching involves the application of a lower concentration of peroxide applied at home in a tray fabricated at the dental office. The third type of bleaching involves over-the-counter (OTC) products, which are totally consumer-managed without any examination, guidance, or instructions from the dentist. Generally, bleaching can first be categorized into treatment for either endodontically treated teeth or vital teeth. Furthermore, endodontically treated teeth can be bleached in the office, outside the office, or a combination of both inside and outside the office. Outside-the-office (at-home) treatment consists of applying

the patient is away from the office. The in-office technique accomplishes the application of the bleaching material in the office. Vital tooth bleaching also offers a choice between an in-office technique and an at-home technique. In-office techniques include the application of a bleaching material to teeth isolated by rubber dam and may include enhancement of the process by heat or light. At-home bleaching can be dentist-supervised or patient-managed. Dentist-supervised at-home bleaching uses a lower concentration of peroxide than in-office bleaching and may use carbamide or hydrogen peroxide, which is applied in a custom-fitted tray that the patient wears at home, usually while sleeping. The consumer-managed at-home bleaching systems are available in the form of tray systems, trayless systems, and paint-on products.

Nonvital tooth bleaching

Endodontically treated teeth are especially susceptible to discoloration from blood products caused by trauma or endodontic therapy or by necrotic tissue inadvertently

externally, or both (Fig 16-10).

Dentlearn.ir

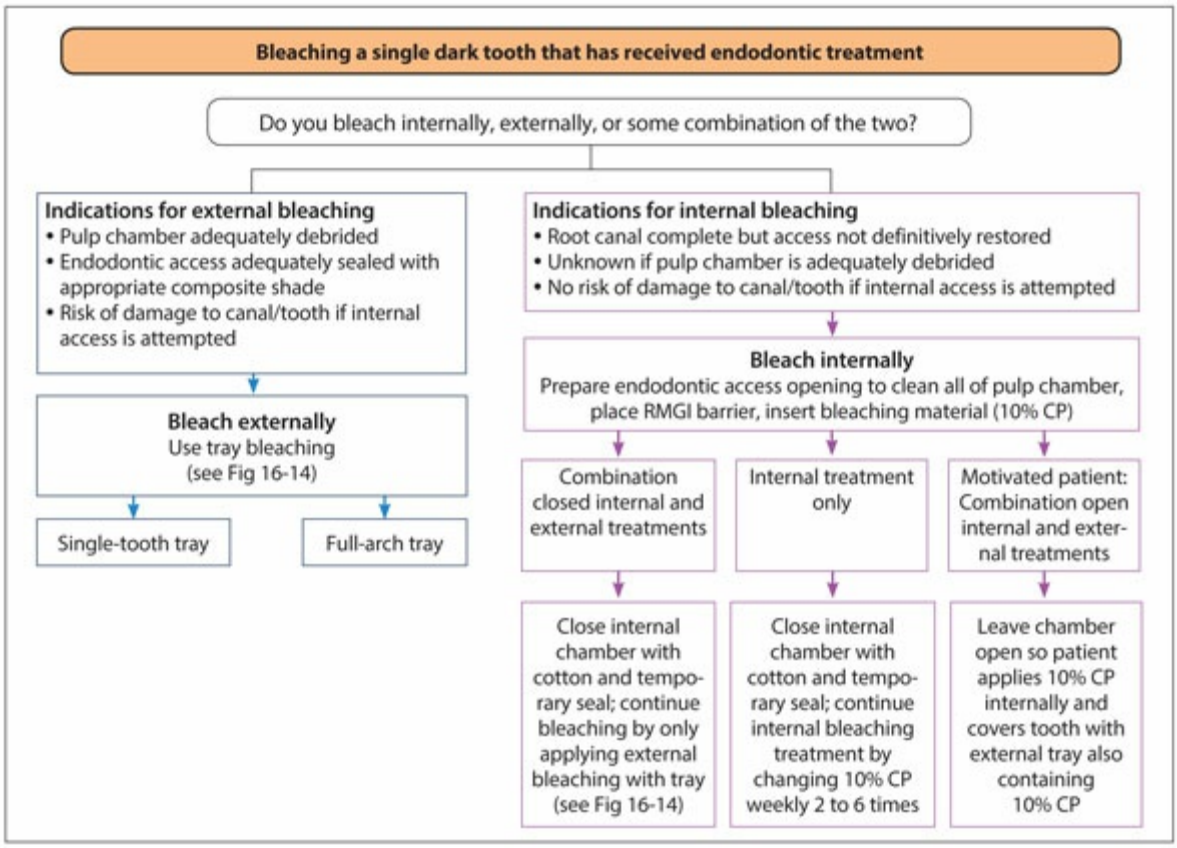

Fig 16-10 Algorithm for bleaching options on a single dark tooth that has received or needs of the two techniques. RMGI—resin-modified glass ionomer; CP—carbamide peroxide.

good option if the root canal treatment is complete but the endodontic access is not restored. The restorative dentist should open the access opening sufficiently to reach the incisal and lateral extents of the pulp chamber and clean it out (Fig 16-11). After the pulp chamber is cleaned, the gutta-percha is removed 2 mm below the cementoenamel junction, resin-modified glass ionomer is placed over the gutta-percha, and the bleaching agent is applied.

Dentlearn.ir

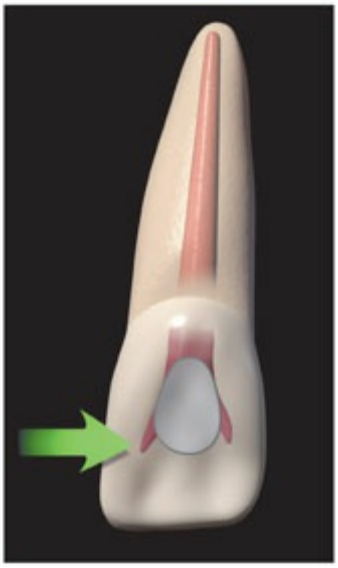

Fig 16-11 An endodontic access opening may not provide access to pulp tissue in the pulp horns *(arrow)*, which can cause darkening of the tooth. This is especially common in young teeth with large pulps. Access should be made to remove the remaining tissue. (Courtesy of Gary Chike, Augusta, Georgia.)

A historical bleaching method dating to the 1800s used 30% hydrogen peroxide applied to the pulp chamber in one of two techniques (Fig 16-12). One was a total in-office technique known as the *thermocatalytic technique*, and it involved the use of heat applied several times during a 30-minute period to enhance the action of the solution in the pulp chamber, after which the solution was rinsed out. The alternative to a total in-office procedure, called a *walking bleach*, used a paste of watery 30% hydrogen peroxide and sodium perborate powder that was sealed into the chamber to permit activation of the solution over several days. The patient returned weekly, and the solution was changed one to four times until the maximum lightening of the

by either method has been shown to return teeth to their desired color in 83% to 91% of cases.[81,82] However, because of the caustic nature of the high concentration of hydrogen peroxide and the possible detrimental effect of resorption, techniques using high concentrations of hydrogen peroxide are no longer recommended. Other safer options for walking bleach include the use of sodium perborate mixed with distilled water or anesthetic, or 10% carbamide peroxide sealed in the pulp chamber. The results of an in vitro study[83] demonstrated that after three applications there was no difference in the efficacy of sodium perborate mixed with water and sodium perborate mixed with either 5% or 30% hydrogen peroxide. Another study[84] showed no root resorption after 3 years using sodium perborate, with a 90% esthetic success rate initially and a 49% esthetic success rate after 3 years. A newer technique

Dentlearn.ir

involves the placement of 10% carbamide peroxide sealed into the chamber. This lower concentration of peroxide also provides a large safety margin. Additionally, one of the benefits of carbamide peroxide is the elevation of the pH, which may combat resorption. For the best combination of safety and effectiveness, the

water, or 10% carbamide peroxide alone, used after the placement of a protective barrier material in the cervical area.

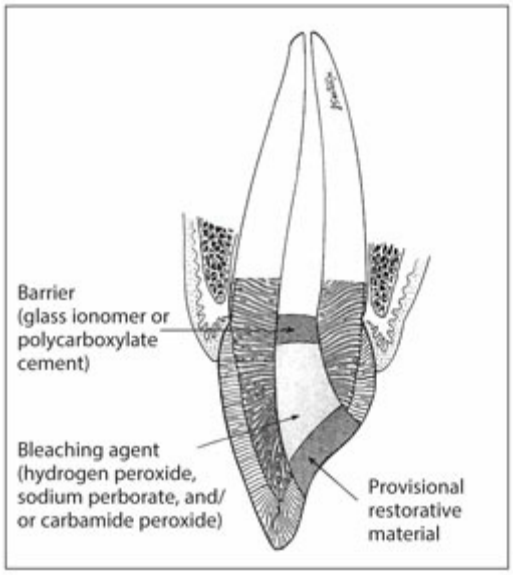

Fig 16-12 The restorative material blocking the canal at the cementoenamel junction seals the endodontic root filling material from the chamber and decreases dispersion of the bleaching agent through the root dentin.

A more serious problem than the danger of tissue burns from 30% hydrogen peroxide is the occurrence of external root resorption (Fig 16-13). This problem

and often causes tooth loss.[85,88–90] While the causes of root resorption are not fully known, a review of the literature indicates a number of possibilities. The patients in which root resorption occurred tended to be younger than 25 years old, and most had a history of traumatic injury. Some underwent bleaching with the application of heat and some did not, but heat does appear to be a causative factor. Animal studies have

hydrogen peroxide and resorption, with a resorption incidence of 18% to 25% when heat was applied[91,92] and 0% to 6% without heat application.[91,93] Any one of several factors may also need to be present for resorption to occur, including: *(1)* deficiency in the cementum, exposing the cervical dentin to the oral cavity (normally affecting approximately 10% of the population); *(2)* injury to the periodontal ligament,

Dentlearn.ir

triggering an inflammatory response (trauma); *(3)* infection, sustaining the inflammation; *(4)* lack of a seal over the gutta-percha; *(5)* high heat; and *(6)* high concentration of hydrogen peroxide.

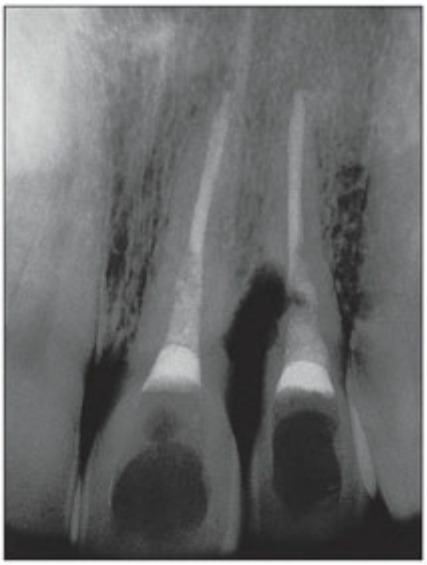

Fig 16-13 Severe external root resorption in the lateral incisor. This situation may result with or without bleaching and is found by clinical and radiographic examination. (Courtesy of Sandra Madison, Asheville, North Carolina.)

Cementum deficiencies expose permeable dentin that can allow toxic substances and bacteria from within the chamber and root canals to emerge at the root surface. This may cause an inflammatory process in the periodontal ligament.[94] A 30% solution of hydrogen peroxide is caustic enough to alter the chemical structure of cementum and dentin,[95] decrease their microhardness,[96] increase resorption,[97] and enhance transtubular movement of bacteria.[98] The solution diffuses through the radicular dentinal tubules at an increased rate if cementum deficiencies are present[90]

hydrogen peroxide is not as safe as originally believed. However, in addition to cementum defects, a history of trauma and marked overheating are major factors in resorption.

Research has been conducted to determine if a protective restorative material can be placed in the cervical portion of the tooth to prevent this resorption problem. Unfortunately, this barrier layer reduces the diffusion of hydrogen but does not prevent it[92,100] and does not necessarily protect the tooth against root resorption.[101] However, most of the teeth reported with cervical resorption did not have a barrier placed over the gutta-percha. It is not prudent to use heat or high concentrations of peroxide, and a barrier layer should be placed over the gutta-percha (Box 16-7).

Dentlearn.ir

Box 16-7	**avoid resorption**
•Use a low concentration of peroxide (10% carbamide peroxide or sodium perborate); 10% carbamide peroxide has the potential to increase the pH to basic, which may also prevent resorption. • Place a base over the root-filled portion of the tooth (glass ionomer or resin-modified glass ionomer). • Do not use high concentrations of peroxide, high heat, or light activation. prepared or later for touch-up if there is a color relapse after restoration.	

to 5 years, only 35% to 50% of the teeth maintain their esthetically pleasing appearance.[81,82,85] Therefore, the process must be repeated periodically. Unfortunately, rebleaching presents a problem for a tooth in which the access

would require removal of the previously bonded resin composite restoration. This removal generally results in additional loss of tooth structure, which weakens the

lingual access restored with resin composite is to bleach the tooth externally using the same techniques used for vital teeth. This can involve the use of either a single-tooth bleaching tray or a conventional tray covering all the teeth.

External bleaching

Tray bleaching works well on vital (Fig 16-14) and nonvital single dark teeth. The choice for bleaching can involve a tray covering all the teeth, as described later, or a single-tooth bleaching tray. A single-tooth tray is fabricated by first making the traditional tray, then removing the part of the tray covering the teeth on either side of the dark tooth (Fig 16-15). The patient applies the carbamide peroxide externally in the single dark-tooth mold and wipes the excess from the adjacent teeth. Use of the single-tooth tray allows the dentist to determine the maximum whitening of the darkest tooth prior to changing the color of the adjacent teeth. If the darker tooth does not lighten as much as the other teeth, then no treatment is applied to the adjacent teeth. If the single tooth gets lighter than the adjacent teeth, then a full tray can be used sparingly to match the adjacent teeth to the lighter single tooth. To avoid overlightening the adjacent teeth beyond the maximum lightening achieved by the original single dark tooth, hourly daytime wear rather than overnight treatment is

Dentlearn.ir

advocated.

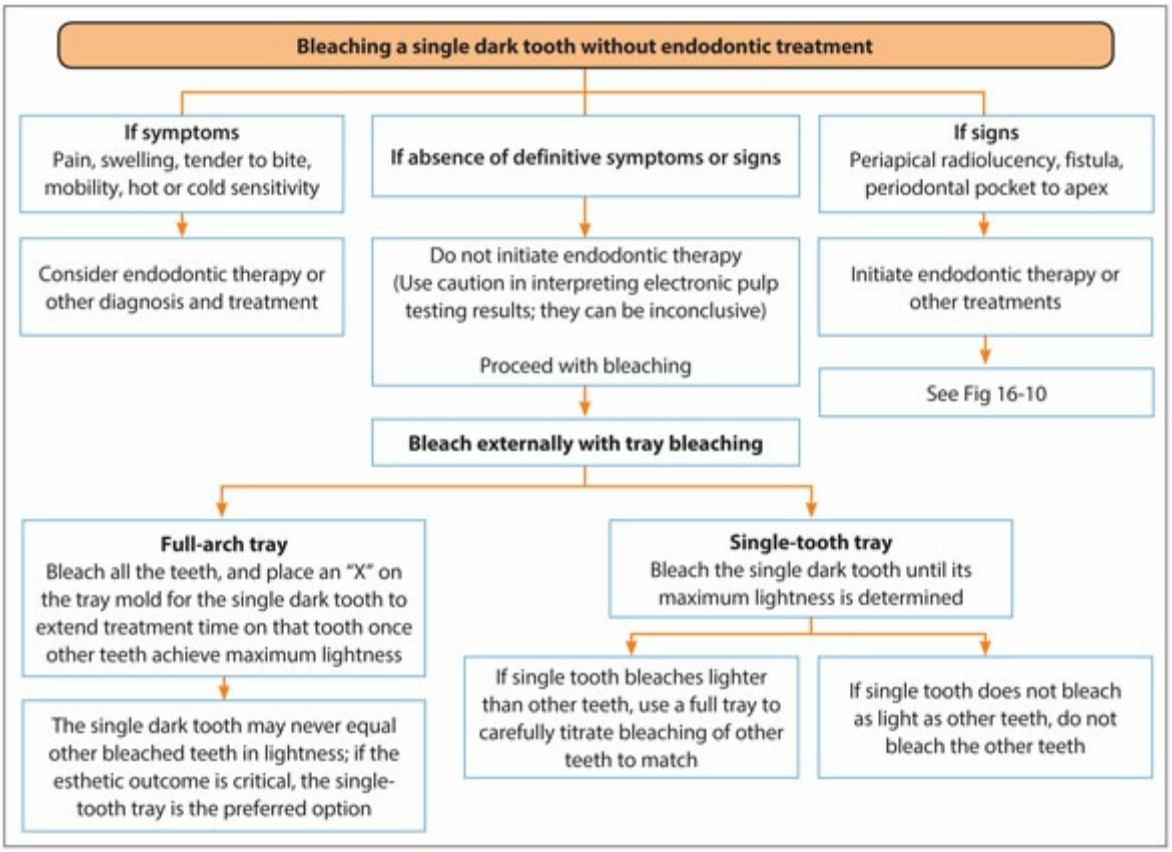

Fig 16-14 Algorithm for bleaching a single dark tooth that has not received or does not require endodontic therapy.

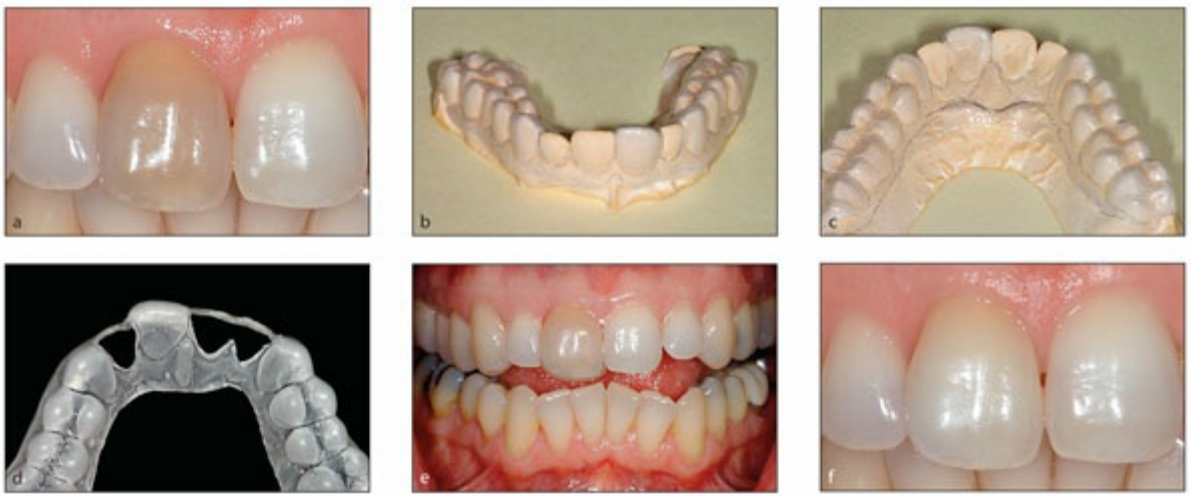

Fig 16-15*(a)* The best treatment for a single dark tooth is to fabricate a single-tooth bleaching tray. This tray allows the dentist to determine the maximum lightening of the single dark tooth prior to initiating any bleaching on the other teeth. *(b and c)* The single-tooth bleaching tray has to extend further onto the palate for retention, because the tray covering the teeth on either side of the single dark tooth will be removed to avoid bleaching them. *(d)* The tray is trimmed to fit around only the discolored tooth. *(e)* The patient places bleaching material only in the single dark tooth mold and inserts the tray. Excess gel extruding onto the adjacent teeth is wiped away by the

Dentlearn.ir

patient. *(f)* The discolored tooth is whitened while other teeth are not affected.

bleaching technique. It is accomplished by preparing the tooth in the same way as you would for the walking bleach technique combined with the at-home tray technique. That is, the pulp chamber is left open to allow the patient to place 10% carbamide peroxide inside the chamber and, at the same time, apply it externally

and may reduce the treatment time by as much as 50%.[102,103] However, it is best suited for patients who are very responsible and capable of applying the solution intraorally. With this technique, a barrier layer should be placed over the gutta-percha to prevent contamination of the root canal, but concern exists that the patient may not return to have the endodontic access opening restored, resulting in caries and loss of the tooth from neglect.

closed bleaching technique, where the dentist prepares the tooth for the traditional walking bleach technique and seals the chamber containing the 10% carbamide peroxide. However, rather than return for multiple changes of the peroxide paste, the fabrication of a single-tooth bleaching tray[77] allows the patient to continue the process of bleaching at home until the tooth reaches its maximum lightness. This approach allows for better patient and office management, as some single dark teeth may require 6 to 8 weeks of bleaching to resolve the discoloration. This same tray can be used for touch-up of the single tooth should it darken after several years. If the single tooth gets lighter than the adjacent teeth, then the original cast can be used to make a full tray. The full tray can then be used very sparingly during the day to lighten the adjacent teeth to match the new final shade of the single dark tooth. Conversely, if the dark tooth does not become as light as the adjacent teeth, then the adjacent teeth will remain untouched for the best esthetic outcome.

Once the tooth has reached its maximum lightness, the closure of the access opening is delayed for 2 weeks to allow the shade to stabilize and the bond strengths to return to normal values. At that time, the final shade is compared with the adjacent teeth to determine if any restorative adjustments are needed to match the single dark tooth to the adjacent teeth. Decisions must be made as to whether to place a stark white resin composite in the chamber to give a lighter appearance or to match the resin composite shade to the tooth shade exactly and whether to use a translucent or opaque composite restoration for closure (Fig 16-16).

Dentlearn.ir

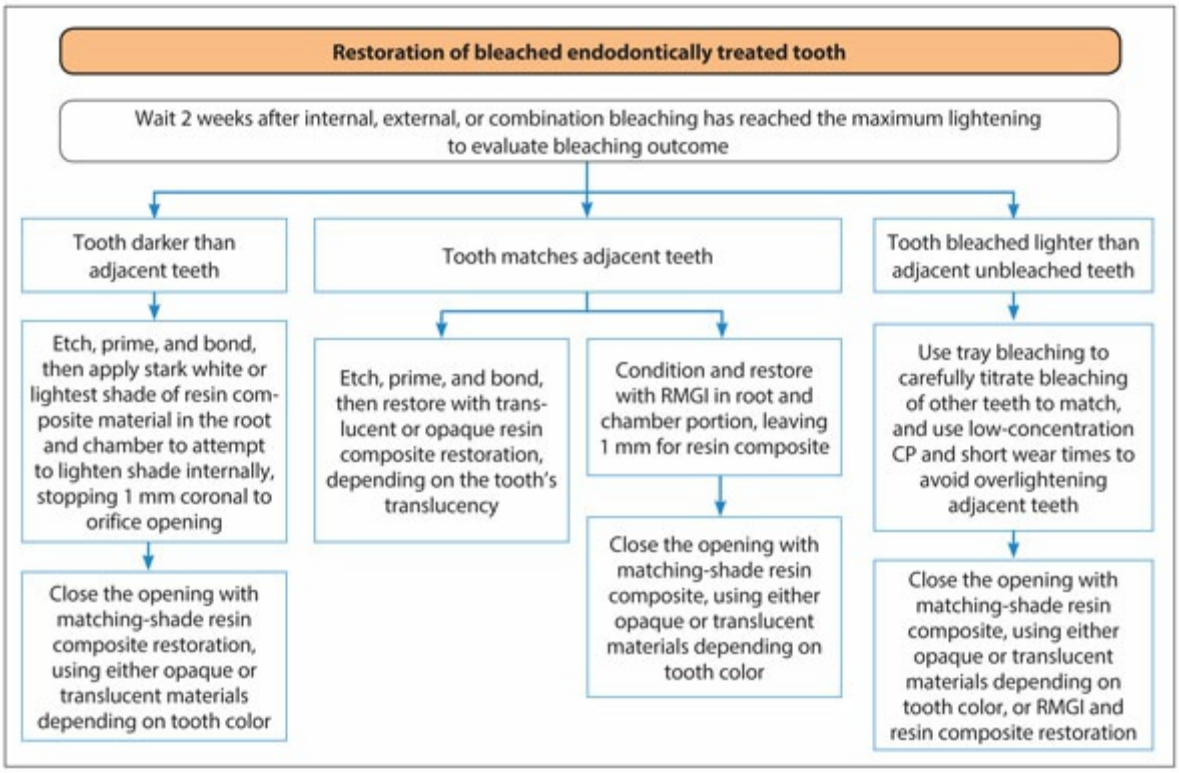

Fig 16-16 Algorithm for restoration of a bleached endodontically treated tooth. RMGI—resin-modified glass ionomer; CP—carbamide perioxide.

Vital tooth bleaching

Vital bleaching may be accomplished by either the in-office technique or take-home trays, and each has some variations. The in-office technique currently is not as popular as the at-home tray technique, but it has historically met with success, and there are some specific indications for its use.

In-office technique

In-office bleaching of vital teeth generally uses a 35% hydrogen peroxide solution placed directly on the teeth and may involve application of light and/or heat to enhance the peroxide release.[15,104] Because the hydrogen peroxide concentration is so high and the material is so caustic, soft tissues must be very well protected to prevent injury[74] (Fig 16-17).This technique is intended to produce the bleaching effect with limited need for patient compliance. It is indicated for achieving more rapid results (Fig 16-18) or for patients who may have difficulty following the regimen for the at-home technique (Box 16-8). Several questions must be asked (Table 16-1), and the potential disadvantages need to be taken into consideration: The fee is usually higher because more chair time is required; there is a possibility

Dentlearn.ir

of tissue injury from the more potent agent used (Fig 16-19); and the results of one in-office treatment may be inferior to the slower at-home method. In-office bleaching may require more than one visit to achieve the desired results.[105] In fact, manufacturers of in-office bleaching systems usually recommend at-home bleaching after in-office treatment is completed.[106] One study found that in-office bleaching combined with at-home bleaching does not improve tooth whitening compared with at-home bleaching alone.[107]

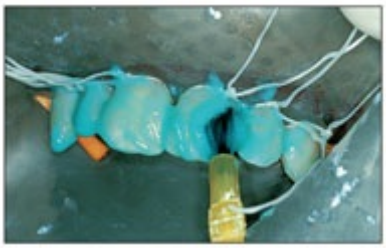

Fig 16-17 Rubber dam protects the soft tissues during an in-office bleaching procedure.



Fig 16-18 In-office bleaching can produce good results quickly but takes an average of three appointments. *(a)* Prior to bleaching. *(b)* After one bleaching session. (Courtesy of Sandra Madison, Asheville, North Carolina.)



Fig 16-19 A high concentration of hydrogen peroxide can produce a chemical burn, as shown on this patient's lip.

Box 16-8	**Indications for in-office bleaching**

- Patient is fully informed of all bleaching options before making the treatment choice.
- Patient has financial resources to continue treatment beyond one appointment and for additional tray treatment should
  that be indicated to complete the initial bleaching.

Dentlearn.ir

• Patient is unwilling or unable to use at-home tray application.
• Patient desires the process to be completed as quickly as possible due to an upcoming event.
• Patient does not have sensitive teeth or will premedicate with analgesics for sensitivity as needed.
• Patient does not want posterior teeth as light as anterior teeth, or posterior teeth do not show in smile analysis.
• Patient is willing to pay again for touch-up, office, or tray treatment in later years.
• Patient needs encouragement for compliance with tray bleaching.
• Patient understands that the outcome is the same with all bleaching techniques if treatment continues long enough;
cost-benefit and risk-benefit ratios are considered.

Table 16-1	**Questions regarding in-office bleaching**
Question	**Answers**
Does one in-office bleaching treatment yield the same outcome as tray bleaching?	Typically, no: The average is three in-office sessions to reach maximum tooth white ness, while the range is one to six treatm
Do the lights make a difference in the outcome of in-office bleaching?	No: Dehydration may give initial lighter appearance; tooth color changes at a certain rate regardless of "enhancement" of peroxide by the light.
When is the best time to evaluate the color change from in-office bleaching?	Two weeks or longer after treatment due to dehydration from isolation and heat (if used).
Is a combination of in-office and tray bleaching the best option?	Only if the patient wants to pay extra for the initial boost: The final outcome is the same whether one or the other or a combination is used.
What are the sensitivity issues for in-office bleaching?	Sensitivity with in-office treatment is greater than with tray bleaching, so sensitivity must be minimized by using shorter appointments on multiple visits rather than a single long appointment; patients may need to premedicate with nonsteroidal anti inflammatory drugs.

With in-office bleaching, a portion of the whitening effect is temporary, resulting from dehydration of teeth from the isolation technique. Dehydration alone has been shown to cause a transient 3- to 12-shade change (on a VITA Classic shade guide), or a ΔE (using a colorimeter) of 6.7 (which is approximately the difference between B1 and D3 or between A2 and B4 on the VITA Classic shade guide) [108] after 1 hour.[109] The effects of bleaching using rubber dam isolation must be evaluated after

Dentlearn.ir

1 to 2 weeks to allow rehydration of the teeth to a stable shade. Authors suggest from one to six in-office treatments, with the average being about three visits.[105] The lighter the teeth at the start of bleaching, the fewer visits required.

Because in-office bleaching utilizes a much more potent agent, the oral/perioral structures must be protected during the procedure. Generally, this is best accomplished with a well-placed rubber dam tightly adapted around the cervical areas of the teeth.[110,111] For the single isolated tooth or a minimal number of teeth, it may be possible to protect the gingiva with cotton rolls and a so-called liquid rubber dam (light-polymerized resin) (Fig 16-20). The light-polymerized resin is injected onto the gingival tissues surrounding the target teeth and then light cured to form a flexible protective shield that can be removed easily. Any material covering the teeth should be trimmed to the proper extension to allow the bleach to reach that area. Cotton rolls and cheek retractors may be needed to protect the lips and tongue.



Fig 16-20 A resin "paint-on" dam is applied and light cured around the target teeth. A 35% hydrogen peroxide bleaching material has been applied.

The teeth should not be anesthetized for in-office bleaching. This allows the patient to note any developing discomfort so the dentist can avoid overtreating the teeth during the several applications of the bleaching solution occurring in the appointment. The patient becomes the "control" for the number of applications that should be placed; he or she should be questioned after each application about any tooth discomfort or tingling in the gingiva, which likely indicates a gap forming between the teeth and the rubber dam. If any tooth discomfort is experienced, the treatment should be interrupted and continued at a future appointment to allow the teeth to recover. If the patient reports a tingling of the gingival tissues, the procedure should be immediately aborted, the dam removed, and the tissues rinsed with water (with or without baking soda) to neutralize the peroxide and avoid severe tissue burns (Fig 16-21). Although there are no clinical studies on treating tissue burns from bleaching solutions, empirical reports have suggested that in addition to water with baking soda, calcium hydroxide powder mixed with distilled water (Alejandro Iglesias, personal communication, 2010), as well as a zinc oxide–eugenol provisional cement (TempBond, Kerr) (T. Bob Davis, personal communication,

Dentlearn.ir

2011) are effective (Fig 16-22).



Fig 16-21 The gingival tissue around the canine has been chemically burned by contact with 35% hydrogen peroxide.



Fig 16-22*(a)* A soft tissue burn from a mild peroxide solution, resulting in a painful experience for the patient and white discoloration of the tissue. *(b)* Application of a zinc oxide–eugenol provisional material (TempBond) for 2 to 3 minutes until pain subsides. (Technique courtesy of T. Bob Davis, Dallas, Texas.) *(c)* Once the zinc oxide–eugenol provisional material is removed, both the whitish area and the pain are gone.

Manufacturers provide their bleaching agents in various forms. Some are very watery, while others are in a gel form. Some are packaged as a powder-liquid combination that is mixed to activate and then placed on the teeth, while others are provided as a ready-to-place solution in a syringe. The solution is directly applied to the facial and proximal areas of the teeth for the prescribed time interval. If access is limited because of the presence of restorations, the solution can be placed on the lingual surface. In such cases, the improvement of color, as observed from the facial surface, will take longer to occur. Etching of the enamel is not indicated. Heat releases the oxygen more rapidly and is optional.[112] If heat is to be used to speed the chemical reaction, the source should be a dental curing light or equipment specially fabricated for bleaching procedures.

The patient must be asked if any tooth sensitivity is occurring. Development of discomfort is the single most important limitation to the number of applications per appointment. Appointments for subsequent treatment are scheduled 1 week apart to allow sensitivity to abate.[113] Because the number of appointments necessary to achieve the desired whiteness is variable,[114] the patient should be so informed and the fee per appointment set in advance. Generally, it is recommended that in-office

Dentlearn.ir

bleaching be followed by at-home bleaching to enhance the effect and to minimize rebound.[106,115,116]

Laser- or light-assisted in-office bleaching. Dental lasers and other intense light sources have been advocated by manufacturers for use in bleaching. It is claimed that they provide a powerful energy source to enhance the action of the hydrogen peroxide by promoting a more rapid release of the bleaching agent. Some concern has been raised over the safety of the use of lasers. Effects on hard tissues depend on the type of laser used as well as the exposure time. The temperatures created by high-energy light sources can be great and are influenced by the absorptive properties of enamel and dentin. The temperature level attained is also a product of the type of laser used.[117] The argon laser, used appropriately, generates very little temperature rise in the pulp,[118,119] whereas the diode laser can generate high temperatures that are detrimental to the pulpal tissue.[120]

One manufacturer recommends use of an argon laser with a wavelength of 488 nm for 30 seconds to accelerate the activity of the bleaching gel, although it does not seem to be effective.[121] The gel is left on the tooth for 3 minutes and then removed. This is repeated four to six times. Another technique uses a carbon dioxide (CO_2) laser after the procedure with the argon laser to encourage deeper penetration of peroxide into the tooth structure. Anecdotal reports have indicated that moderate to severe post-procedure pain and sensitivity may occur. Pulpal irritation or even necrosis has been demonstrated following CO_2 laser use.[122] The ADA does not recommend CO_2 laser use for bleaching.[123] Studies of laser bleaching to date have not indicated any better results than with other in-office techniques, and the results are possibly not as good as those obtained with at-home bleaching.[121]

It is important to remember that the hydrogen peroxide performs the bleaching, not the laser. The laser merely serves as a heat source to enhance the bleaching agent in the same way that a conventional curing light does. Its only potential advantage is its faster rate of supplying heat. Its disadvantages are the cost of the laser itself, which translates to higher patient fees, and the potential for damage to pulpal tissues and the surrounding periodontal tissues. A study evaluating the use of a light-emitting diode laser in combination with 35% hydrogen peroxide showed that the laser did not add any benefit in the final outcome; moreover, it increased tooth sensitivity.[113,124]

Other manufacturers have made claims about the use of high-intensity lights and their role in tooth whitening. The preponderance of evidence at this time does not

Dentlearn.ir

support their efficacy in producing a superior result.[125–132] One article indicated that the amount of ultraviolet radiation in a popular bleaching light exceeded the international standards for radiation safety.[132] Another study indicated that the use of a high-intensity light might lead to increased proinflammatory cytokine (IL-1β) levels.[133]

Dentist-supervised at-home technique

At-home bleaching requires a proper dental and medical history, clinical examination, radiographs of the teeth to be treated, and impressions for tray construction. After tray fabrication, an insertion appointment is required unless the tray can be fabricated during the first visit. Some dentists like to see the patient at weekly recall visits to assess progress and compliance, while others see the patient at the completion of treatment. As previously stated, initial treatment of only one arch has advantages of increasing compliance, decreasing sensitivity, and allowing a lower entry fee for the patient. Plans for treatment of sensitivity and determination of total treatment time should be communicated to the patient during the first visit.

At-home bleaching is the more commonly used bleaching process compared with in-office bleaching because it is easy to perform, it is usually less expensive for the patient, and there is strong evidence for its effectiveness.[134–141] It uses a custom-fit tray (Fig 16-23) with a 10% solution of carbamide peroxide (approximately equal to a 3.5% solution of hydrogen peroxide). Although the process requires longer contact time compared with the in-office bleaching technique,[142] it is safe, and the results are generally excellent. Products carrying the "ADA accepted" label have passed a rigorous set of safety and efficacy standards.[48,110–112,115,143–146] Manufacturers have offered carbamide peroxide in a variety of concentrations, ranging from 10% to 20% or higher, but the best combination of safety, limited side effects, and speed of action is obtained with a 10% solution. An initial survey indicated that 90% of the dentists surveyed used a 10% carbamide peroxide formulation for at-home bleaching of vital teeth.[147] However, the 15% formulation is also very popular.



Dentlearn.ir

Fig 16-23 The original tray design involved a nonscalloped, nonreservoir tray made from a cast of a good alginate impression.

More recently, hydrogen peroxide products have been introduced for day wear in trays. These products can be applied in a tray and range in concentration from 7.5% to 9.5% hydrogen peroxide. They are only active for 30 to 60 minutes (Table 16-2), so the wear time is shortened per day, but the number of days to achieve results compared with nighttime bleaching with carbamide peroxide is extended. Hence, instructions for hydrogen peroxide products typically recommend use for 1 hour or less per application.[148] Carbamide peroxide is active for up to 10 hours, with about 50% of the active agent being used up in the first 2 hours.[2,149] Carbamide peroxide is designed for nighttime application to achieve the maximum benefit,[20,150,151] but it can be used for 2 to 4 hours during the day. There have also been high concentrations of carbamide peroxide (35% to 38%) introduced for which the manufacturers' recommended tray application is only 3 to 15 minutes per day. A 35% carbamide peroxide product is approximately equivalent to a 9.5% hydrogen peroxide product.

high-concentration carbamide peroxide products with traditional 10% carbamide peroxide tray bleaching.

Table 16-2 **Differences between carbamide peroxide (CP) and hydrogen peroxide (HP)**

	Carbamide peroxide	Hydrogen peroxide
Active time	2 to 10 hours due to carbopol amount	30 to 60 minutes
pH level	Neutral; elevates pH due to urea production	Low; pH stays constant during treatment
Lowest concentration	10% CP = 3.5% HP	6% HP = 17% CP
Effect of pH level	Caries process may not advance during bleaching due to elevation of pH to a basic level	pH does not change during treatment

Tray fabrication. Accurate impressions are critical to produce casts on which accurate vacuum-formed trays can be made. Because casts should be altered for tray fabrication, this often renders them unsuitable for other purposes. However, the

Dentlearn.ir

initial alginate impression, properly handled (impression kept wrapped in a wet paper towel, and the second pour accomplished within 45 minutes of the first pour), may be double-poured to provide an additional cast for other treatment needs.[152] Alternatively, polyvinyl siloxane impression materials provide multiple-pour accuracy over more extended time periods compared with alginate.[153] The cast for the bleaching tray should be trimmed to the thinnest and narrowest dimensions possible without damaging surfaces representing the teeth or periodontal structures (Fig 16-24). A model trimmer is used to trim the cast from the base rather than from the sides, until the vestibule is eliminated (see Fig 16-24a). The base of the cast should be as thin as 0.5 inch, or trimmed to a horseshoe shape, leaving only the maxillary or mandibular teeth and periodontal tissues remaining, with no palatal or tongue section included. The base should be flat, with the central incisors perpendicular to it (see Figs 16-24b and 16-24c). This makes it easier to adapt the vacuum-formed tray material around the teeth and avoids the development of folds and wrinkles during fabrication. If the palate or tongue section remains, it is helpful to drill a hole through that section so that the vacuum better adapts tray material in all areas of the cast.

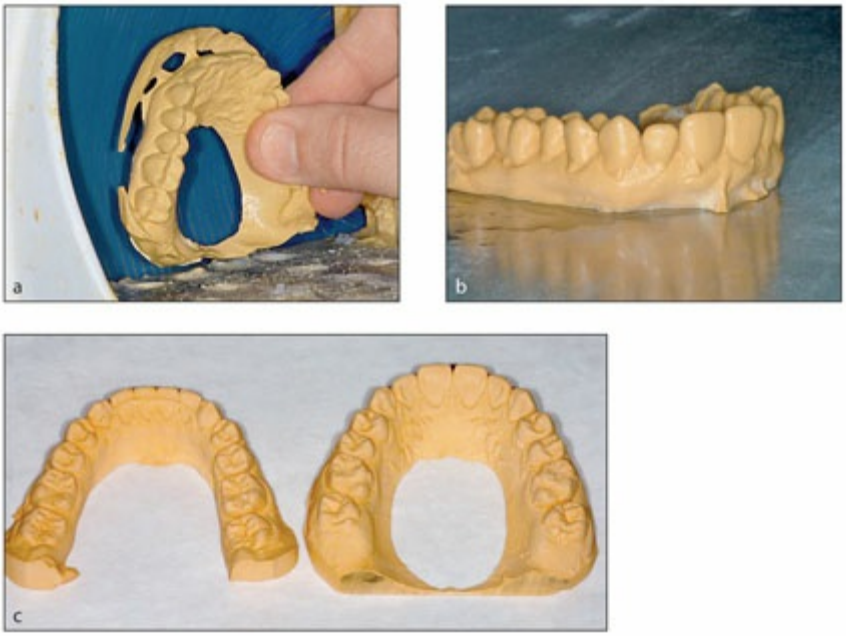

Fig 16-24 Trimming the stone cast for the bleaching tray is best accomplished using a nontraditional method. *(a)* The cast is trimmed from the base, keeping the central incisors parallel to the horizon. Gentle pressure is applied until the vestibule is removed. *(b)* In an ideally trimmed cast, there should be no vestibule, and the central incisors should be perpendicular to the tabletop to avoid wrinkles or folds in the tray material. *(c)* Casts work best in the vacuum former if there is no palate and no vestibule. In addition, a dry cast will allow the best adaptation of the tray material.

A number of materials have been used in tray fabrication, including materials used

Dentlearn.ir

in fabricating orthodontic position-ers, athletic mouthguards, provisional splints, and antisnoring devices. The original nightguard vital bleaching article[25,26] proposed use of a thick, semirigid material. The newer materials are thinner, softer, easier to shape and trim, and have reduced gingival and occlusal side effects. Additionally, one thermoplastic (boil and form) system uses a tray supplied by the manufacturer that is custom-fitted to the patient using heat. An alginate impression is not needed. This thermoplastic technique results in a tray formed in the patient's mouth at the first appointment.[79]

Decisions to be made about tray design include whether to scallop the tray borders and whether to add reservoirs. Some advocates of at-home bleaching were concerned that the agent would harm gingival tissues over time. They recommended a scalloped tray border, positioned 1 mm incisal/ occlusal to the soft tissue, to avoid contact of the tray or bleaching agent with the tissue[154,155] (Fig 16-25). This practice is not necessary for successful bleaching but may help when gingival tissues are very delicate.[156–158] Scalloping may be indicated for sticky, non–water-soluble materials, because they tend to adhere to the gingiva and may produce localized irritation. However, scalloping may be counterproductive if a water-soluble material is being applied, because the material is more rapidly washed out of this type of tray by saliva. Scalloping is not necessary when low concentrations of carbamide peroxide (10%) are used, but the higher the concentration of bleaching material, the more likely it is that there will be tissue irritation and the greater the need to scallop the tray so that it does not extend onto tissue. Hence, the tray design takes into consideration the concentration and type of material and the patient and his or her oral conditions and concerns. Additionally, scalloping can be annoying to the tongue or lips, depending on the patient and the teeth-to-tissue relationships. If tissue contact is preferred, the tray should not extend into undercuts or be tight enough to blanch tissue. The tray borders should be smooth. When tissue irritation during an at-home bleaching regimen has been reported, it often resulted from poor adaptation of a rigid tray and because the tongue, lips, and/or cheek have rubbed against an edge of the tray.[159]

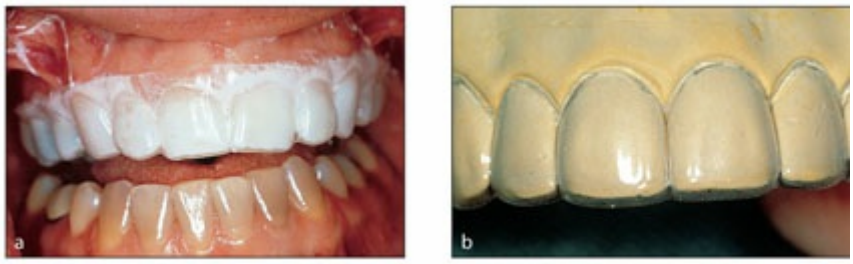

Fig 16-25 Depending on the patient, the bleaching agent, and the teeth, the tray can be designed

Dentlearn.ir

a s *(a) nonscalloped*, extending onto the tissue for low concentrations of peroxide, or *(b) scalloped* to avoid bleaching agent contact with the tissue. (White material was added to the tray for visibility in *a*.)

The patient should be able to close into the same occlusion with the thin tray in the mouth (Fig 16-26a) as without a tray (Fig 16-26b). If the anterior teeth are in contact in maximum intercuspation without the tray, then the anterior teeth should be in contact with the tray in place. The trays are too thin to adjust on the occlusal surfaces as in traditional appliances, so to achieve the proper anterior contact, the most posterior tooth molds of the tray should be removed (Fig 16-26c) and the occlusion reevaluated. The clinician should continue to remove the posterior tooth molds until anterior contact is achieved. Failure to maintain anterior contact will cause an increase in muscle activity[160] and may create headaches or muscle pain.



Fig 16-26*(a)* With the bleaching tray in place, the posterior teeth contact prematurely because of the arc of closure of the mandible, which keeps the anterior teeth from coming into contact. *(b)* Slight contact on the maxillary right central incisor in maximum intercuspation. *(c)* The mold of the terminal tooth is removed to allow further closure of the mandible. *(d)* Enough teeth are removed to allow the tray to contact the anterior teeth in the same manner as the natural teeth.

Foam liners for the tray have been advocated to hold the bleaching agent evenly against the teeth by preventing flow of the bleaching agent to the incisal portion of the maxillary tray or the gingival portion of the mandibular tray. Despite manufacturers' claims that the inclusion of foam liners gives a more rapid bleaching effect, research has failed to demonstrate an advantage.[161] Some techniques incorporate a reservoir on the facial intaglio surface of the tray to hold a greater volume of the agent in the target areas of the teeth to enhance the process[112,162] or to allow bleaching gel to flow from areas of high concentration to areas of reduced

Dentlearn.ir

concentration.[163] The theory is reasonable, but there is little evidence that the creation of reservoirs actually improves bleaching efficacy.[137] It is assumed that the solution degrades at the same rate whether it is present in greater volume in a reservoir or not. Some clinicians do not advocate placement of reservoirs in the tray, because this seems to waste bleaching material, increase the difficulty of tray fabrication, and reduce the comfort of the tray.[27,52,164–166]

Reservoir spaces are formed by using a manufacturer-supplied, light-polymerized resin, placed 0.5 to 1.0 mm thick on the facial surfaces of the teeth of the cast. The resin spacer should terminate 1.0 mm short of the gingival area and should not extend into the embrasures. Nail polish, die spacers, or tinfoil may also be used to form reservoir spaces. The reservoir design should allow tray borders to contact the tooth. Spacers should not be placed in areas of occlusion (such as incisal aspects of mandibular anterior teeth or lingual aspects of maxillary anterior teeth), because the contact of the opposing teeth will displace the material from the tray.

There may be some benefit to having the extra space provided by the reservoirs, such as to help in seating the tray and to avoid pressure on the teeth, which may result in less sensitivity, especially if a very viscous solution is used.[167] One study, however, has indicated no difference in patient comfort with or without tray reservoirs,[166] and several studies have shown no clinical difference in efficacy between reservoir and nonres-ervoir trays.[137,165,168]

When one tooth is darker and the other teeth are reasonably acceptable (see Figs 16-15a to 16-15c), a single-tooth bleaching tray can be fabricated in the same manner as described for the nonvital tooth (see previous section). This tray design works well with vital teeth also.

Patient instructions for at-home bleaching. Patient instructions should address expectations and the course of treatment, the technique for applying the bleaching agent, the frequency and length of time for wearing the tray, tooth sensitivity/tissue irritation problems, interim appointments, and variations in the total fee related to the course of treatment. It is critical that the patient understands the process and can make appropriate adjustments in the protocol (eg, discontinuing tray wear for 1 or 2 days if sensitivity begins to develop). The patient must recognize and inform the dentist of any developing problems early in the process. While this is a supervised procedure, most of the process occurs away from the dentist, so the patient becomes the progress monitor. The patient should be instructed to place enough bleaching agent into the tray to cover the facial surfaces of the target teeth. This includes the most posterior tooth visible when the patient smiles, laughs, or talks. Seating and

Dentlearn.ir

removing the tray should be demonstrated to ensure that the patient is able to do so without undue difficulty or harm to the tray or the oral structures. To avoid tissue injury, the tray should be "peeled" from the second molar area rather than being "dug out with fingernails" in the canine region (Fig 16-27).



Fig 16-27 The tray is removed by grasping the most terminal tooth rather than digging fingernails around the edges of the tray and into soft tissue.

Instructions for tray wear. The correct time for wearing of the tray depends both on the product being used and the patient's lifestyle. Ideally, carbamide peroxide is best worn overnight for maximum benefit of the product and compliance by the patient. Hydrogen peroxide is indicated for daytime wear because of the short active period of 30 to 60 minutes. While carbamide peroxide is ideally used overnight, the patient also can use it during the day, but the patient should understand that he or she is to wear the tray daily for 2 to 4 or more hours. Because the material maintains its potency for several hours, it is wasteful to wear it for fewer than 2 to 4 hours. One study demonstrated that 50% of the active agent remained after 2 hours.[2,149,168] The best option is probably for the patient to wear the tray during sleeping hours. Although the agent has lost most of its potency after 5 hours, compliance is much better when the bleaching treatment becomes part of a regular nightly routine. After the loaded tray is seated, the patient may use a damp cloth or finger to wipe the areas adjacent to the tray borders to remove any excess bleaching material. However, swallowing low concentrations of carbamide peroxide is not harmful as its original use was as an oral antiseptic to aid in wound healing. The patient should be reminded to rinse and gently brush the tray after each session before storing it in a cool or room-temperature environment until the next bleaching session.

The amount of time required for the bleaching process varies (Table 16-3). While some readily discernible improvement may occur within 2 to 14 days, it may take as long as 6 to 12 months.[159] The time required depends on the type of discoloration, patient compliance, and whether or not any tooth sensitivity occurs. It may be helpful for improving compliance to recall the patient after 5 to 7 days to check progress. The patient can be shown the shade tab representing the original color to contrast it with the new whiten the treated maxillary

Dentlearn.ir

arch with the untreated mandibular arch. At an interim appointment, tray adjustments may be necessary, and digital photographs can be taken to compare with the prebleaching photographs. The protocol can be reviewed to ensure that the patient is following it correctly. Alterations in protocol can be made to eliminate or minimize any problems or to speed the process. Some teeth may respond to bleaching more rapidly than others. More severely discolored and less responsive teeth may need more sessions of bleaching than others.[48,169] Some teeth with white spots exhibit a splotchy look as different portions of the tooth respond at different rates. The patient should be encouraged to continue treatment until the remainder of the tooth achieves the same color. The splotchy areas tend to abate on completion of treatment. Considerable whitening of the teeth is routinely predictable (Figs 16-28 to 16-33).

Table 16-3	**Treatment times for tray bleaching**
Normal teeth	3 days to 6 weeks (average of 2 weeks)
Nicotine-stained teeth	1 to 3 months
Tetracycline-stained teeth	1 to 12 months (average of 3 to 4 months)



Fig 16-28 Yellow-brown stains usually respond quickly to at-home bleaching. *(a)* Prior to bleaching. *(b)* After 1 month of bleaching the maxillary teeth using 10% carbamide peroxide in a tray.

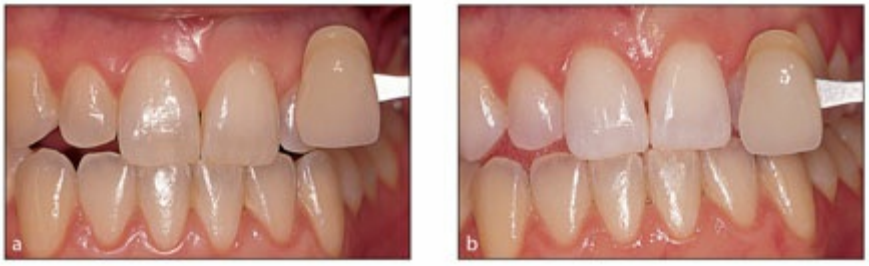

Fig 16-29 Many gray stains respond well to at-home bleaching. *(a)* Prior to bleaching. *(b)* Results after more than 4 weeks of bleaching the maxillary teeth with 10% carbamide peroxide.

Dentlearn.ir



Fig 16-30 White spots become less noticeable when the teeth are whitened. *(a)* Prior to bleaching. *(b)* After bleaching the maxillary teeth for about 6 weeks with 10% carbamide peroxide. Note that the white spot is unchanged but less noticeable.



Fig 16-31 Yellow-brown stains can be removed easily with at-home bleaching with 10% carbamide peroxide. *(a)* Prior to bleaching. *(b)* After bleaching for 6 weeks.



Fig 16-32 Yellow stains can be removed more readily from the coronal portion than from the root of the tooth. *(a)* Prior to bleaching. *(b)* After tray bleaching the maxillary teeth with 10% carbamide peroxide for 6 weeks. The roots retain their yellowish coloration, likely because of differences in composition and dentin tubule size and density between root dentin and coronal dentin.[54]

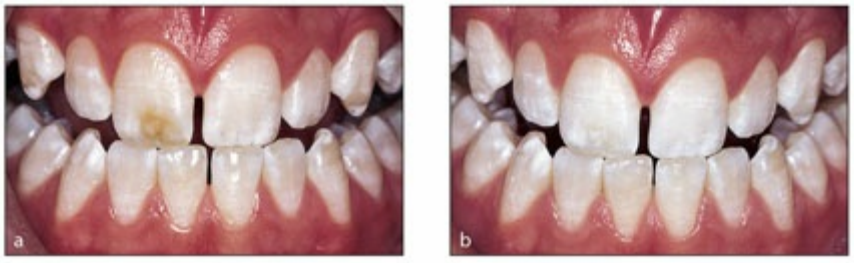

Fig 16-33*(a)* Unknown brown discoloration, possibly from trauma to a primary tooth, prior to bleaching. *(b)* After tray bleaching for about 6 weeks with 10% carbamide peroxide.

Dentlearn.ir

Consumer-managed at-home technique

Over-the-counter (OTC) products are available in the form of tray systems, trayless systems, and paint-on products. The fundamental problem with OTC products is that there is no examination and diagnosis of the cause of discoloration. Hence, any effective bleaching treatment may mask symptoms of another problem. Discoloration could indicate that the teeth are non-vital or could be caused by dental caries,

patients considering bleaching to have a proper clinical and radiographic examination performed by a dentist, even if they are considering using OTC products (Box 16-9).

Box 16-9	**Safety concerns for OTC bleaching**
• Lack of diagnosis for proper treatment (pathology masked; bleaching not indicated) • Potential for less esthetic outcome (restorations not identified; endodontic status not known) • Unknown safety of higher concentrations (no research above 15% CP or 6% HP; issues with unsupervised use) • Unknown quality of some products (pH, allergenic ingredients, etchants, other ingredients) • Patients may not receive any or maximum benefit avail able for whitening (due to shortened treatment time for difficult stains and discolorations, ineffective products)	

CP–carbamide peroxide; HP–hydrogen peroxide.

In the past, OTC bleaching agents did not prove very effective. Although the initial cost of the agent or system was distinctly lower than dentist-prescribed methods, its ineffectiveness led to repeated purchases of the product, so the final cost was significant and the results often unsatisfactory. Additionally, early reports cited detrimental effects of tooth structure erosion from overuse of poorly manufactured or formulated solutions.[170]

Recently introduced products have proven to be much more effective in whitening teeth. While the specific mode of application varies among the products, the manufacturers have made the products relatively easy for the patient to apply. One whitening system utilizes adhesive strips containing a relatively high concentration (approximately 6% to 14%) of hydrogen peroxide. The adhesive strips are designed to hold the peroxide against the teeth to allow it to effectively bleach. Patients are instructed to wear the strips for 30 minutes twice a day for maximum benefit. Studies

Dentlearn.ir

have shown the whitening strips to be effective[171,172] without significant tooth sensitivity or tissue irritation. They are relatively convenient and less expensive than dentist-supervised at-home techniques. The strips may be difficult for some patients to adapt to the target teeth, especially if the teeth are malaligned. In addition, the strips do not extend past the canines in many people's mouths, so posterior teeth are not whitened and the final result may not be pleasing in patients with a broad smile. Few studies have compared strips with daytime tray bleaching and nighttime tray bleaching using the same color measurement criteria as in previous tray-bleaching research. However, one study did show that daytime wear of hydrogen peroxide in the tray was equivalent to that of strips, but nighttime wear of carbamide peroxide was more efficacious.[138] There are many other OTC products on the market that change frequently, from paint-on products to different versions of strips. The original concentrations of many researched OTC products have been altered, so it is very difficult to find clinically useful research.

There are a few studies that have compared OTC strips using hydrogen peroxide with tray bleaching using carbamide peroxide and in-office bleaching using hydrogen peroxide. To obtain a six-shade color change on a VITA shade guide required 7 nights of tray bleaching with 10% carbamide peroxide, 16 days of a 6% hydrogen peroxide strip (OTC) worn twice a day, or 3 in-office treatments of 38% hydrogen peroxide.[138] If the three bleaching techniques are used for 2 weeks, then tray bleaching is most efficacious, similar to in-office but significantly better than OTC strips.[173]

Myriad other OTC products, from toothpastes to chewing gums, claim tooth whitening with little or no research to support their claims.[174] A great many of these products produce whitening by removing extrinsic or surface stains (with abrasives or peroxides), preventing staining (with chemicals), or merely physically removing food debris from already-white teeth (chewing gums).

Manufacturers continue to develop new OTC products. Although new chemistry may be introduced, their focus has been primarily on delivery systems that are easier and faster for the patient to apply. However, the most critical challenge with the use of OTC products is the lack of a proper prebleaching examination to determine if bleaching is appropriate for the patient. The lack of a proper examination may cause pathology to be masked by bleaching and appropriate treatment delayed.

A general summary of the three types of bleaching is that overnight tray bleaching produces the best results,[69] followed by daytime-wear tray bleaching. OTC bleaching strips are equal to in-office and similar to daytime-wear tray bleaching.

Dentlearn.ir

In-office bleaching should be used with tray bleaching to complete the process.

Techniques for tetracycline-stained teeth

Patients whose teeth have been stained by tetracycline ingestion present a very difficult esthetic challenge. Tetracycline can be deposited in fetal tooth buds if ingested by an expectant mother in the third trimester of pregnancy or by a child during the tooth-formation years, between the ages of 3 to 4 months and 7 to 8 years.[175] Tetracycline may also be deposited in the teeth in early adults if it is taken on a long-term basis for skin conditions, such as acne, especially during the formation of secondary dentin, during growth periods, and after trauma.[37,38]

Tetracycline has several different analogs (eg, tetracycline, doxycycline, oxytetracycline, minocycline, chlortetracycline, demeclocycline) that may produce various intensities of gray, blue, brown, and yellow in the teeth. If seemingly normal yellow teeth are not responsive to the conventional 2 weeks of bleaching treatment, they may actually be tetracycline stained.

Recent research has shown that tetracycline-stained teeth may respond to bleaching treatments but at a rate different from that of teeth stained by other agents[176,177] (Figs 16-34 and 16-35). Whereas the normal bleaching time is 2 to 6 weeks, some tetracycline-stained teeth may require 2 to 12 months of daily treatment to achieve a significant improvement.[30,178] Tetracycline-stained teeth do not generally lose all discoloration. Although the tooth color is often much improved, teeth may retain some grayish-blue tint.



Fig 16-34 Tetracycline stains are tenacious; results come more slowly than with other types of stains. *(a)* Prior to bleaching. *(b)* Treatment midpoint. *(c)* After approximately 7 months of at-home bleaching.



Dentlearn.ir

Fig 16-35 A generalized tetracycline stain. *(a)* Prior to bleaching. *(b)* After several weeks. *(c)* After more than 8 months of at-home bleaching with 10% carbamide peroxide.

Research on the longevity of color change achieved after bleaching tetracycline-stained teeth indicates that most patients will have some degree of lightening and that 8 in 10 patients can expect to retain that lightening for at least 1 year. Even those patients who experience some regression indicate that they were glad they bleached their teeth and would do it again. A follow-up study showed a very high patient satisfaction rate at 7.5 years after completion of bleaching.[30]

There are several factors to consider when bleaching tetracycline-stained teeth for extended periods.[110] First, the location of the stained area has a great influence on the prognosis for success. A tooth generally lightens from the incisal to the gingival area because the tooth gets progressively thicker from incisal to gingival. Teeth heavily stained in the gingival third have the poorest prognosis for complete lightening. The further toward the incisal edge the stain resides, the better the prognosis. In any situation, absolute predictions of success are unrealistic. Patients must understand that each discoloration responds differently and that they may not see significant results in the first few months.

A practical consideration is the amount of bleaching material necessary for extended treatment and the appropriate fee for service. Practitioners may choose either to increase the total fee or use the initial fee for normal bleaching treatment with a monthly fee for each additional month of treatment. The monthly fee is dependent on the amount of material the patient uses monthly (as determined by recording dosage in a log form) and the frequency of office visits (usually 1 to 2 months apart). Patients can then pay as they go for extended treatment if there is continued, albeit slow, improvement. Another more affordable option that has been shown to be effective is to bleach tetracycline-stained teeth using 6.5% hydrogen peroxide strips.[179]

Generally, teeth severely stained in gingival areas are candidates for porcelain veneers or crowns if maximum ideal esthetics is desired, but it is generally best to attempt bleaching first. Bleaching may achieve adequate results and avoid the need for veneers, even if the result is not quite as esthetic. The bleaching may have only a limited lightening effect, but it can reduce the amount of opacity necessary in the veneer for masking the stained tooth structure. This is especially important if the teeth are misaligned, because the veneer preparation may be extended closer to or into the darker dentin, making it difficult to obtain an even translucency in the veneers when areas of color contrast exist in the tooth. Even if the bleaching

Dentlearn.ir

treatment is ineffective, the patient is aware that the most conservative avenues have been attempted first and is assured that porcelain veneers or porcelain-fused-to-metal or all-ceramic crowns are the best remaining options. If the teeth under the veneers discolor, or if the veneers have been placed on non-bleached teeth, the natural teeth can be bleached under the veneers from the lingual.[180] This technique can easily lighten previously bleached teeth back to their original shade and hence return the veneers to their original appearance. Depending on the translucency of the veneers placed on nonbleached teeth, there can be some moderate lightening appearance in the veneers if they are relatively translucent.

Dentists and physicians are well aware of the effect of tetracycline ingestion on dental esthetics,[25,34,35] although the results of tetracycline absorption in teenagers treated for acne has only recently been reported.[181–189] Tetracycline is still the drug of choice for outpatient treatment of Rocky Mountain spotted fever and is the most widely prescribed drug for acne. Dentists should consider bleaching a reasonable treatment option for the discoloration resulting from this treatment if the patient is willing to comply with extended treatment and does not expect total elimination of the stain.

Factors affecting both the in-office and at-home bleaching processes

Several factors must be considered carefully before bleaching is initiated and then controlled during the process to ensure maximum benefit.

Surface cleanliness

All surface debris must be removed to distinguish intrinsic from extrinsic staining and to ensure that the agent has maximum contact with the tooth surface. However, bleaching should be delayed for several days after dental prophylaxis to allow any gingival or tooth sensitivity related to the prophylaxis to abate. Some stains begin

portion while the prophylaxis can remove the external stain.

Dentlearn.ir



Fig 16-36 Nicotine stains. *(a)* Prior to bleaching. *(b)* After bleaching.

Concentration of peroxide

The higher the concentration of peroxide, the more rapid the lightening effect up to a certain point, although the effect is not linear (ie, 20% is not twice as fast as 10%).[43,190] The limiting factor is how fast the tooth can change color. Once the maximum change rate of the tooth has been achieved, the additional concentration contributes only to sensitivity.[191] Hence, conversely, the higher the concentration, the greater the chance for sensitivity. In-office bleaching materials are usually supplied in concentrations of 35% hydrogen peroxide, although concentrations range from 15% to 50%.

Temperature (in-office bleaching)

The higher the temperature of the bleaching solution, the faster the rate of oxygen release and, therefore, the faster the rate of the chemical reaction. An increase of 10°C doubles the rate of chemical reaction.[192,193] However, this does not necessarily alter the rate of the tooth color change.[194] The rate of tooth color change is more dependent on the tooth than the material used for bleaching. Teeth change color at different rates and progress to a different whiteness. Additionally, temperatures elevated to an uncomfortable level may result in tooth sensitivity or even irreversible pulpal inflammation.[195] Bleaching materials are always applied without anesthesia to avoid overheating the tooth. Nonvital teeth should not be heated to a temperature higher than that acceptable for a vital tooth.

pH

The pH of the bleaching material can influence both the effects on the teeth from bleaching as well as the concern for existing decay. Enamel caries starts when the pH is below 5.5; dentin caries is initiated when the pH is below 6.8. Material Safety Data Sheets (MSDS) list hydrogen peroxide products with a pH around 5. Most carbamide peroxide materials approved by the ADA have a pH of approximately

Dentlearn.ir

7.[196] Materials with a significantly lower pH can cause tooth surface alterations by their acidic nature. However, carbamide peroxide breaks down quickly into hydrogen peroxide and urea when applied. Urea is primarily responsible for raising the pH in the oral cavity above 8 for a number of hours. Therefore, there is a potential for retarding caries activity during bleaching with carbamide peroxide.

Time

In addition to the concentration, the degree of bleaching is directly related to the amount of time the bleaching agent is in contact with the tooth. The longer the contact, the more lightening will occur (until the plateau of the tooth color change is reached); however, the longer the bleaching agent is in initial contact with the teeth, the greater the likelihood of tooth sensitivity.[197] Interestingly, the greatest sensitivity seems to occur in the first 2 weeks of treatment. After this initial time period, sensitivity does not continue to increase on all patients but tends to be more episodic.

Additives

Many of the peroxides have additives to alter their handling characteristics or patient acceptability of the product. Materials may be added to liquid hydrogen peroxide to form a gel for easier handling and safety, but this may also alter the efficacy of the material. Carbamide peroxide may also have various ingredients added to promote thickness, stickiness, or viscosity. Carbamide peroxide can have many different base vehicles, including variations of glycerin, glycol, and toothpaste base materials. Additionally, it is manufactured in many flavors, and some of the flavoring additives can cause mild adverse responses in certain patients.[198] Some products may contain gluten, making them inappropriate for celiac disease patients. Some flavors like banana may have cross-linkage to latex allergies.[199] Some mint flavors may promote aphthous ulcers or cause gingival burning.[200,201] The most significant additive to carbamide peroxide is carbopol. This ingredient thickens the material and prolongs the release of peroxide over time.

Safety factors

Safety concerns include the potential for tooth/pulpal problems, irritation of periodontal or other oral tissues, and systemic effects. The primary safety issue is the concern for masking existing pathology because of the potential of bleaching the only symptom, whic ant for the patient to

Dentlearn.ir

have a proper examination including radiographs prior to the initiation of any type of bleaching.

Tooth Sensitivity and Pulpal Concerns

Short-term pulpal response varies from patient to patient and even from tooth to tooth. Peroxide penetrates through the tooth to the pulp in a matter of 5 to 15 minutes.[72,202] The peroxide molecule is of such small size that it easily passes through the interstitial spaces of the tooth, rather than traveling down the dentinal tubules. Therefore, bleaching can produce sensitivity.[31] However, the pulp remains healthy and the sensitivity is completely reversible.[192,202,203] Patients undergoing at-home bleaching must also be informed that minor sensitivity may occur in as many as two-thirds of patients. Double-blind studies have reported sensitivity in 25% to 70% of patients. However, these studies also show that 20% to 30% of patients report sensitivity when a placebo is used, and 18% report sensitivity just from wearing the bleaching tray without any gel.[33] Manufacturers have included potassium nitrate and fluoride or amorphous calcium phosphate (ACP) in the bleaching gel. These new bleaching formulas have been shown to have varying degrees of effectiveness in decreasing tooth sensitivity.[139,204,205]

If sensitivity occurs, there are a number of approaches available involving either passive treatment or active treatment to resolve the sensitivity (Box 16-10). Passive treatment involves shortening the duration or frequency of treatment or interrupting the process for a day or more to allow the teeth to recover. The procedure can then be resumed.[206] Active treatment involves the application of medicaments using the same bleaching tray. Historically, fluoride has been applied for sensitivity. Fluoride acts as a tubule blocker to limit the fluid flow to the pulp.[207] It has been suggested that fluoride treatment prior to initiating bleaching may reduce sensitivity; however, there is little research showing this to be the case. Bleaching sensitivity is not directly related to tubule blockage, which is the mechanism of action of fluoride.

Box 16-10	**Treatment of patients with maximum sensitivity**
• Do not initiate bleaching immediately after the prophylaxis. • Brush with a potassium nitrate–containing toothpaste for 2 weeks prior to initiating bleaching . • Wear the empty tray 1 or 2 nights to become familiar with the feel and pressure of the tray.	

Dentlearn.ir

- Wear tray with potassium nitrate toothpaste (without sodium lauryl sulfate) 1 or 2 nights.
- Begin bleaching initially with shorter daytime periods using 10% carbamide peroxide with potassium nitrate and fluoride in the product.
- Continue brushing with desensitizing toothpaste during bleaching.
- Use tray delivery of potassium nitrate desensitizing materials 10 to 30 minutes in the tray as needed during treatment. Use a professional product or OTC desensitiz ing toothpaste with 5% potassium nitrate.
- Alternate or skip bleaching days, if sensitive.
- Avoid acidic drinks, cola, and fruit juices, which remove the smear layer.

A more direct treatment is the application of 3% to 5% potassium nitrate gel in the tray. Potassium nitrate preparations are available from several bleaching agent manufacturers.[208] Potassium nitrate penetrates the tooth to the pulp much like the peroxide molecule and has an anesthetizing or sedative effect on nerve transmission.[209,210] Potassium nitrate is found in many desensitizing toothpastes but generally takes 2 weeks to be effective via tooth brushing. However, application of a potassium nitrate toothpaste in the tray for 10 to 30 minutes before or after bleaching can reduce or eliminate sensitivity in many patients.[211] The best toothpaste to use is one that contains 5% potassium nitrate but does not contain sodium lauryl sulfate (SLS), which is a detergent foaming ingredient. SLS has been associated with removal of the smear layer and increased occurrence of aphthous ulcers.[201]

Often, treatment for sensitivity is a combination approach involving alteration of duration or frequency of treatment and use of medications, including anti-inflammatory medications, desensitizing toothpastes, and desensitizing medicaments applied in the tray. A combination of potassium nitrate and fluoride may be used in the tray to optimize the desensitizing results.[208,212,213] Questions have been raised about the effect of bleaching on the structure of the tooth itself.[214] Recent studies have shown that low-pH solutions can produce a detectable loss of calcium from the surface enamel, along with a slight loss in surface hardness to a depth of approximately 25 μm.[27,215–217] However, this loss has not been shown to be significant because the surface quickly remineralizes after the procedure is completed.[218–223] Moreover, a study concluded that "no obvious morphological or chemical composition alterations of enamel surface were detected in the neutral or alkaline bleaching solutions."[224] In fact, there is less change in the calcium content of

Dentlearn.ir

the tooth and surface hardness from 6 hours of bleaching with 10% carbamide peroxide than when a carbonated drink is consumed in a 2- to 3-minute period. No noticeable change in the surface luster and topography is seen clinically.[225]

Soft Tissue Response

The more powerful in-office bleaching agents (30% to 35% hydrogen peroxide) can easily produce tissue burns, turning the tissue white.[226–228] If the exposure is limited in duration and quantity, it is quickly reversible with no long-term consequences. Rehydration and application of an antiseptic ointment (eg, Orabase B, Colgate Oral Pharmaceutical), baking soda, calcium hydroxide powder mixed with distilled water, or zinc oxide–eugenol provisional cement (eg, TempBond) quickly returns the color to the tissue and removes the burning sensation (see Fig 16-22), reassuring the patient that the problem is not permanent.[66] Nevertheless, it can cause significant temporary discomfort and some alarm when first seen. It is important to protect soft tissues with rubber dam or other means to avoid tissue burns.

Although soft tissue irritation during at-home bleaching has been reported,[163] the irritation is most likely the result of an ill-fitting tray rather than the agent itself.[229] Reports of harmful effects to soft tissues from hydrogen peroxide indicate that the effects resulted from dosages and exposure times that greatly exceeded those prescribed in any at-home bleaching technique. At-home agents containing 10% carbamide peroxide are not potent enough to produce significant or long-lasting effects on the soft tissues.[230] However, the higher the concentration of carbamide or hydrogen peroxide used in the tray, the greater the need to avoid soft tissue contact by scalloping the tray.

Studies have indicated that approximately one-third of patients experience no detectable side effects after bleaching, and the other two-thirds experience only minor transitory tooth sensitivity and/or tissue irritation of short duration.[32] When examined at the cellular level, these effects on the soft tissue are less than or equal to those produced by commonly accepted dental medicaments, such as eugenol and end-odontic sealers.[230] The toxicity and mutagenicity of hydrogen peroxide are dose related. Concentrations used in the at-home bleaching technique are not sufficient to be of concern. A low dose of hydrogen or carbamide peroxide over a long period actually allows the cells of the oral tissues to adjust to the dosage even if it is increased beyond the original tolerable dosage. In the long history of these materials

Dentlearn.ir

involving tissue contact in patients ranging in age from infancy[231,232] to old age, there has been no demonstrated health problems of any type.[233,234]

Systemic Effects and Responses

There is more concern about possible adverse effects of at-home bleaching agents compared with the in-office agents, although the at-home concentrations are far lower than those of the in-office bleaching agents. In-office bleaching agents are carefully controlled and placed on the teeth only, avoiding contact with soft tissues. The patient swallows no solution. Very little, if any, of the agent is absorbed systemically. At-home bleaching agents, applied in the tray, unavoidably contact soft tissues in many areas over several hours each day. Additionally, it is likely that the patient will swallow small amounts of very dilute hydrogen peroxide during the bleaching procedure.[146] This has not proven to be a health concern or systemic factor, however. Some patients may have a throat irritation or may have tissue sensitivity to different flavors. Although very high concentrations of some forms of peroxide are mutagenic,[235,236] physiologic mechanisms quickly repair any limited damage that might occur.[237] Low levels of hydrogen peroxide do not cause significant problems.[238] Carbamide peroxide is used for the treatment of candidiasis in newborn infants.[231] In fact, hydrogen peroxide has been approved as safe for use as a human food additive. The Food and Drug Administration recognizes 3% hydrogen peroxide and 10% to 15% carbamide peroxide as GRAS (generally recognized as safe) for oral use, but there is very little research on systemic effects related to the use of carbamide peroxide concentrations higher than 10%. Another paper notes that the human body creates peroxide in amounts far greater than that typically used in tray bleaching, and because we naturally create peroxide, our bodies have salivary peroxidases that remove the peroxide.[239]

The conclusion, after decades of use and extensive research, is that the use of low concentrations of hydrogen peroxide for bleaching teeth is safe.[222,240–243] A recent examination of all the research on bleaching by the European Scientific Commission on consumer products suggested the following:

- Bleaching with low concentrations of peroxide is safe.
- OTC products are not recommended, but if the patient opts to use these products, he or she should have a proper oral examination by a dentist, then obtain a prescription to purchase OTC-type products.

Dentlearn.ir

- The maximum recommended concentration for products is 6% hydrogen peroxide (which is approximately equivalent to 17% carbamide peroxide).[244,245]

Other Considerations

Effect on restorations

Bleaching has little or no effect on most of the common restorative materials.[142,215,216] There are no reports in the literature indicating that bleaching exerts any negative impact on existing restorations that would require their replacement.[246] Perhaps its most significant effect is that it lightens teeth enough that previously placed restorations may appear comparatively dark, leading to the consideration of replacing restorations for esthetic rather than functional reasons. Bleaching has no effect on porcelain. It does encourage the release of mercury from some types of amalgam restorations.[247,248] The clinical significance of this is not known.[249] The surface of some types of resin composite is roughened slightly, and the hardness may be slightly decreased, but neither effect is clinically significant.[250–254] Moreover, the higher the concentration, the more evident the effects.[255] Bleaching does affect methyl methacrylate provisional restorative materials, causing them to yellow slightly.[256] Although bleaching releases much oxygen into the tooth, the bond of existing restorations is not weakened. There are no contraindications for bleaching in the presence of existing bonded restorations. However, as previously stated, the oxygen-rich tooth structure does not provide a good surface for bonding, because the released oxygen hinders the polymerization of the resin.[257] There may also be changes in the surface morphology that affect the bonding.[218,258–260] A delay of 1 to 2 weeks or more following the bleaching process allows this effect to dissipate so that bonding can effectively be performed.[63] This also allows the tooth shade to stabilize before selection of the restorative material shade.[69] A drying agent, such as acetone, can be used to diminish the oxygen in the outer layers of the tooth if there is concern that oxygen has been retained in the surface.[66]

Alternatives to bleaching

The alternatives to bleaching are more aggressive in relation to the tooth structure and/or to the gingival tissues. These procedures include microabrasion,

Dentlearn.ir

macroabrasion, bonded resin composite veneering, porcelain veneers, and porcelain or metal-ceramic crowns. Although all of these are legitimate treatment techniques with proven efficacy, they rely on the removal of tooth structure and/or the addition of materials that have finite replacement life cycles.

Microabrasion and macroabrasion

One decision in the esthetic treatment planning for a patient is whether to remove discoloration by bleaching or by removal of tooth structure. For example, fluorosis is often amenable to treatment with microabrasion. *Microabrasion* is a process in which the tooth surface is subjected to a combination of an acid and an abrasive[261–263] (Fig 16-37). The acid removes mineral content, leaving the outer 22 to 27 μm weakened enough so that the abrasive, with which the acid is mixed, quickly removes the stained outer surface of the tooth. Although the amount of enamel removed is very limited, this abrasive technique alters the outer surface of the enamel as the undesirable coloration is removed or at least modified. The abrasive, usually suspended in a water-soluble gel containing a low concentration of hydrochloric acid, is applied to the enamel with a rubber cup or stiff bristle brush for 20 to 30 seconds.[262] Superficial discolorations usually can be removed from the enamel surface, but it is not possible to know in advance whether the discoloration is superficial. Should the discoloration extend to the dentin or become more visible, a resin composite restoration will need to be placed to seal the defect and restore contour. The choice of resin composite poses a shade-selection dilemma as to whether the material should match the original tooth color or the color the tooth will be. It is best to bleach first unless the tooth enamel is of a chalky texture. Then when abrasive techniques are initiated, the tooth shade is already established should a resin composite restoration be required. Bleaching has been estimated to remove 80% of brown discolorations.[25] White discolorations are not removed but may be much less noticeable when the surrounding area of the tooth is lightened. If bleaching is unsuccessful, then the more aggressive techniques can be initiated. The patient should be informed of the treatment options (bleaching, abrasion, bonding composite or porcelain) before treatment and should understand the different fees for these procedures. A combination of microabrasion or macroabrasion and bleaching may be sufficient to bring about the desired result.

Dentlearn.ir



Fig 16-37 Differences between microabrasion and macroabrasion. *(a)* The patient presents with superficial white and brown stains. The discoloration will be bleached. *(b) Microabrasion* involves the application of hydrocholoric acid in a prophylaxis paste to first soften the enamel and then use of a geared-down slow-speed handpiece with heavy pressure and a special applicator to abrade the softened enamel. *(c) Macroabrasion* involves the use of fine diamond and carbide burs in a high-speed handpiece with water spray and light pressure. This removal system is similar to polishing a composite restoration. *(d)* The outcome is very similar. Microabrasion was completed on the maxillary right cental incisor and macroabrasion was completed on the maxillary left central incisor. There are some subtle surface differences. Caution should be used to avoid moving the line angles of the tooth proximally, which would give the tooth a wider appearance. (Courtesy of Rod Mackert, Augusta, Georgia)

Another form of abrasion is *macroabrasion*. In this technique, the abrasion can be achieved by applying a fine diamond or carbide finishing bur to the enamel at relatively low speeds and very light pressure (see Fig 16-37c). Some of the same instruments that are used to contour and polish composite restorations may also be used on enamel.[264] The effect is much the same as with the acid/abrasive technique. When using a high-speed handpiece, water should be applied to maintain the coloration of the teeth. As some teeth dehydrate, more subsurface defects may become visible; for these, treatment is not indicated. Air-abrasive techniques can also be used quite effectively for microabrasion or macroabrasion. Only fine abrasive particles should be used to avoid overreduction of the tooth. Overreduction can be corrected by adding resin composite to the undercontoured areas. With any technique used, it is important to maintain the correct position of the line angles of the teeth. If the mesial and distal line angles are moved further apart, then the tooth will appear wider. Facial embrasure spaces should be maintained to keep the individuality of the teeth.

Dentlearn.ir

All three techniques (diamond-bur surface alteration, chemical/physical microabrasion, and kinetic-energy preparation [air abrasion]) rely on the selective reduction of the outer surface of the tooth. While they may be very effective in removing a relatively shallow discolored area, they are not intended to eliminate overall discoloration, especially if it involves the underlying dentin. However, they are valuable techniques for treating limited areas and for supplementing tooth bleaching.[264] For patients with a limited demand for esthetic improvement in the color of the teeth, abrasion alone may satisfy the patient's needs. If abrasion techniques do not produce completely satisfactory results, more extensive and invasive procedures may be performed.

Bleaching before and after placement of veneers

Discolored teeth may be treated with bonded restorations to cover or disguise the underlying stain, and it may be possible to place the material with little or no tooth reduction. The esthetic restorative material, such as resin composite or porcelain (see chapter 17), is bonded to the tooth to provide good color and form. However, the natural appearance of the veneered surface depends strongly on some light reflecting from the underlying tooth structure. If the tooth structure is too darkly stained, the discoloration will show through the translucent resin composite or ceramic veneer. The only solution is to make the veneering material thicker and less translucent. To avoid overcontouring the tooth/restoration, it is necessary to remove more of the facial and proximal tooth structure to achieve the esthetic and functional objectives. Successful bleaching therapy can minimize the need for a thicker veneer and more tooth reduction.

Bleaching is possible even for teeth that have already received veneers.[180,226] Application of a bleaching agent to the lingual surface can alter the apparent color of the translucent restoration on the facial surface (Fig 16-38), thereby improving esthetics.

Dentlearn.ir



Fig 16-38 Bleaching six tetracycline-stained maxillary anterior teeth that have porcelain veneers. *(a)* Prior to bleaching. The patient was unhappy with the gray tones transmitting through the veneers from the underlying tetracycline-stained teeth. *(b)* Palatal view prior to bleaching. The gray tetracycline stain is obvious. *(c)* After 4 months of bleaching with 10% carbamide peroxide in a nonscalloped non-reservoir tray delivered from the lingual, the veneers appear lighter because the underlying teeth are no longer transmitting the gray stain of the tetracycline staining. *(d)* Palatal view after bleaching. The bleaching process has lightened the teeth noticeably.

Restoration of bleached teeth

If micro- or macroabrasion is not successful in removing discolorations after bleaching, or if there are defects or caries present, then a resin composite restoration may be indicated. Placement of the restoration should be delayed at least 1 to 2 weeks for the enamel-composite bond strength to return to normal and for the shade of the tooth to stabilize. These variances are related to the oxygen that enters the tooth from bleaching, and time must be allowed for the oxygen to leave the tooth. After that 1- to 2-week time frame, selecting which teeth need to be restored and the most appropriate treatment is the next step in completing the esthetic outcome.

Because the tooth color may bleach lighter than the traditional lightest shade (B1 on the VITA Classic shade guide) and because all teeth do not bleach to the same endpoint, it is helpful to have multiple shades of composite in small color shifts that are lighter than B1. If there are areas that need to be concealed, such as a white spot that could not be removed, then an opaque material is best, such as an A2 shade (VITA Classic shade guide), with a translucent enamel shade overlying the block-out material of the A2 opaque shade. Stark white tints may be used inside endodontically treated teeth to further lighten them, while pink composite may be helpful to neutralize remaining gray on the tooth from amalgam stains or severe

Dentlearn.ir

tetracycline staining or banding.

Because the shade of the resin composite material selected to restore highly bleached teeth will be a lighter shade, additional caution compared with using darker shades must be taken to avoid the operatory light or the room light from prematurely polymerizing the composite prior to the final form being achieved. Premature polymerization can be avoided by using the orange shield typically used to protect eyes from the curing light as a shield from the operatory light. While this bathes the area in orange, it supplies almost unlimited working time with adequate light to see the lingual and occlusal surfaces of the teeth.[265]

The combination of appropriate shade and other esthetic considerations, along with form and function, afford an excellent restoration of a bleached tooth or teeth. See chapter 10 for more information on anterior composite restorations.

Summary

- Whitening is best performed in a professionally supervised manner, with a proper examination and diagnosis, using appropriate materials for the patient and situation, with a fair fee for service.
- Low concentrations of peroxide, especially 10% carbamide peroxide in a custom-fitted tray, are generally the safest, most cost-effective, best-researched whitening treatments available.
- Other bleaching treatments, such as in-office bleaching procedures, may be indicated based on patient preference, lifestyle, finances, or other limitations, but these require informed consent after presenting cost-benefit and risk-benefit ratios.
- OTC nondentist bleaching does not have a good risk-benefit ratio because of the lack of a comprehensive examination to determine teeth staining/darkness etiology. Some products have minimal to no efficacy, while others that do in fact work are not as effective as claimed.

References

1. How WS. Esthetic dentistry. Dent Cosmos 1886;28:741–745.
2. Atkinson CB. Fancies and some facts. Dent Cosmos 1861;3:57–60.
3. M'Quillen JH. Elongation and discoloration of a superior central incisor. Dent Cosmos 1868;10:225–227.
4. Burchard HH. A Textbook of Dental Pathology and Therapeutics. Philadelphia: Lea & Febiger, 1898.
5. Kirk EC. Chemical principles involved in tooth discoloration. Dent Cosmos 1906;48:947–954.

Dentlearn.ir

6. Marshall JS. Principles and Practice of Operative Dentistry. Philadelphia: Lippincott, 1901:464–476.
7. Dwinelle WW. Ninth annual meeting of American Society of Dental Surgeons, Article X. Am J Dent Sci 1850;1:57–61.
8. Harlan AW. The dental pulp, its destruction, and methods of treatment of teeth discolored by its retention in the pulp chamber or canals. Dent Cosmos 1891;31:137–141.
9. Barker GT. The causes and treatment of discolored teeth. Dent Cosmos 1861;3:305–311.
10. Harlan AW. Proceedings of the American Dental Association—Twenty-third annual session. Dent Cosmos 1884;26:97–98.
11. Bogue EA. Bleaching teeth. Dent Cosmos 1872;14:1–3.
12. Kirk EC. Hints, queries, and comments: Sodium peroxide. Dent Cosmos 1893;35:1265–1267.
13. Kirk EC. The chemical bleaching of teeth. Dent Cosmos 1889;31:273–283.
14. Stellwagen TC. Bleaching teeth. Dent Cosmos 1870;12:625–627.
15. Fein RA, Goldstein RE, Garber DA. Bleaching Teeth. Chicago: Quintessence, 1987.
16. Atkinson WH. Bleaching teeth, when discolored from loss of vitality: Means for preventing their discoloration and ulceration. Dent Cosmos 1862;3:74–77.
17. Kirk EC. An American Textbook of Operative Dentistry, ed 2. Philadelphia: Lea Brothers, 1890:540–560.
18. Atkinson CB. Hints, queries, and comments: Pyrozone. Dent Cosmos 1893;35:330–332.
19. Fisher G. The bleaching of discolored teeth with H_2O_2. Dent Cosmos 1911;52:246–247.
20. Smith MS, McInnes JW. Further studies on methods of removing brown stains from mottled teeth. J Am Dent Assoc 1942;29:571.
21. Pearson HH. Bleaching of the discolored pulpless tooth. J Am Dent Assoc 1958;56:64–65.
22. Spasser JF. A simple bleaching technique using sodium perborate. N Y Dent J 1961;27:332–334.
23. Haywood VB. The "bottom line" on bleaching 2008. Inside Dent 2008; 4:82–89.
24. Haywood VB, Heymann HO. Nightguard vital bleaching. Quintessence Int 1989;20:173–176.
25. Goldstein FW. New "at-home" bleaching technique introduced. Cosmetic Dent GP 1989;June:6–7.
26. Haywood VB. Overview and status of mouthguard bleaching. J Esthet Dent 1991;3:157–161.
27. Leonard RH, Teixeira EC, Garland GE, Ritter AV. Effect on enamel micro-hardness of two consumer-available bleaching solutions when compared with a dentist-prescribed, home-applied bleaching solution and a control. J Esthet Restor Dent 2005;17:343–350.
28. Jordan RE, Boksman L. Conservative vital bleaching treatment of discolored dentition. Compend Contin Educ Dent 1984;5:803–805, 807.
29. Haywood VB. Current status of nightguard vital bleaching. Compend Contin Educ Dent 2000;21(suppl 28):S10–S17.
30. Leonard RH, Haywood VB, Caplan DJ, Tart ND. Nightguard vital bleaching of tetracycline-stained teeth 90 months post-treatment. J Esthet Restor Dent 2003;15:142–153.
31. Haywood VB. Nightguard vital bleaching: Information and consent form. Esthet Dent Update 1995;6:130–132.
32. Haywood VB, Leonard RH, Nelson CF, Brunson WD. Effectiveness, side effects and long-term status of nightguard vital bleaching. J Am Dent Assoc 1994;125:1219–1226.
33. Leonard RH Jr, Bentley C, Eagle JC, Garland GE, Knight MC, Phillips C. Nightguard vital bleaching: A long-term study on efficacy, shade retention, side effects, and patients' perceptions. J Esthet Restor Dent 2001; 13:357–369.
34. Mello HS. The mechanism of tetracycline staining in primary and permanent teeth. J Dent Child 1967;34:478–487.
35. Milch RA, Rall DP, Tobie JE. Bone localization of the tetracyclines. J Natl Cancer Inst 1957;19:87–93.
36. Fein RA. Reviewing vital bleaching and chemical alterations. J Am Dent Assoc 1991;2:55–56.
37. Parkins FM, Furnish G, Bernstein M. Minocycline use discolors teeth. J Am Dent Assoc 1992;123:87–89.
38. Poliak SC, DiGiovanna JJ, Gross EG, Gantt G, Peck GL. Minocycline-associated tooth discoloration in young adults. J Am Dent Assoc 1985; 254:2930–2932.
39. Dodson DL, Bowles WH. Production of minocyclines pigment by tissue extracts [abstract A1267]. J Dent

Dentlearn.ir

Res 1991;70(special issue):424.
40. Cheek CC, Heymann HO. Dental and oral discoloration associated with minocycline and other tetracycline analogs. J Esthet Dent 1999;11:43–48.
41. Chung HY, Bowles WH. Oxidative changes in minocycline leading to intrinsic dental staining [abstract A1855]. J Dent Res 1989;68(special issue):413.
42. Black GV, McKay FS. Mottled teeth: An endemic developmental imperfection of the enamel of the teeth heretofore unknown in the literature of dentistry. Dent Cosmos 1916;58:129.
43. Haywood VB. Tooth Whitening: Indications and Outcomes of Night-guard Vital Bleaching. Chicago: Quintessence, 2007.
44. Leonard RH Jr. Efficacy, longevity, side effects, and patient perceptions of nightguard vital bleaching. Compend Contin Educ Dent 1998;19:766–774.
45. Shulman JD, Maupome G, Clark DC, Levy SM. Perception of desirable tooth color among parents, dentists and children. J Am Dent Assoc 2004;135:595–604.
46. Mrazek B. “Don’t bleach until you see the white of their eyes.” Compend Contin Educ Dent 2004;25:472–476.
47. Goldstein RE, Garber DA. Complete Dental Bleaching. Chicago: Quintessence, 1995.
48. Haywood VB. Commonly asked questions about nightguard vital bleaching. J Indiana Dent Assoc 1993;72(5):28–33.
49. Berry JH. What about whiteners? Safety concerns explored. J Am Dent Assoc 1990;121:222–225.
50. Pieroli DA, Navarro MF, Coradazzi JL, Consolaro A. Evaluation of carcinogenic potential of bleaching agents in DMBA-induction model [abstract A2149]. J Dent Res 1996;75(special issue):332.
51. Nathanson D, Parra C. Bleaching vital teeth: A review and clinical study. Compend Contin Educ Dent 1987;8:490–497.
52. Leonard RH Jr, Haywood VB, Phillips C. Risk factors for developing tooth sensitivity and gingival irritation associated with nightguard vital bleaching. Quintessence Int 1997;28:527–534.
53. Pashley DH, Tay FR, Haywood VB, Collins MA, Drisko CL. Consensus-based recommendations for the diagnosis and management of dentin hypersensitivity. Compend Contin Educ Dent 2008;29(special issue):1–35.
54. Pashley DH. Dentin: A dynamic substrate—A review. Scanning Microsc 1989;3:161–174.
55. Robinson FG, Haywood VB. Bleaching and temporomandibular disorder using a half tray design: A clinical report. J Prosthet Dent 2000; 83:501–503.
56. Firestone AR, Schmid R, Muhlemann HR. Effect of topical application of urea peroxide on caries incidence and plaque accumulation in rats. Caries Res 1982;16:112–117.
57. Haywood VB. Bleaching and caries control in elderly patients. Aesthet Dent Today 2007;1(4):42–44.
58. Haywood VB. Orthodontic caries control and bleaching. Inside Dent 2010;6(4):2–6.
59. Lazarchik DV, Haywood VB. Use of tray-applied 10 percent carbamide peroxide gels for improving oral health in patients with special-care needs. J Am Dent Assoc 2010;141:639–646.
60. Bentley CD, Leonard R, Crawford JJ. Effect of whitening agents containing carbamide peroxide on cariogenic bacteria. J Esthet Dent 2000; 12:33–37.
61. Napimoga MH, de Oliveria R, Reis AF, et al. In vitro antimicrobial activity of peroxide based bleaching agents. Quintessence Int 2007;38:E329–E333.
62. Leonard RH, Austin SM, Haywood VB, Bentley CD. Change in pH of plaque and 10% carbamide peroxide during nightguard vital bleaching. Quintessence Int 1994;25:819–823.
63. Leonard RH, Bentley CD, Haywood VB. Salivary pH changes during 10% carbamide peroxide bleaching. Quintessence Int 1994;25:547–550.
64. Machado JD, Candido MS, Sundfeld RH, et al. The influence of time interval between bleaching and enamel bonding. J Esthet Restor Dent 2007;19:111–118.
65. Titley KC, Torneck CD, Smith DC, Adibfar A. Adhesion of composite resin to bleached and unbleached bovine enamel. J Dent Res 1988;67:1523–1528 [erratum 1989;68:inside back cov].
66. Barghi N. Making a clinical decision for vital tooth bleaching: At-home or in-office. Compend Contin Educ Dent 1998;19:831–838.

Dentlearn.ir

67. Barghi N, Godwin JM. Reducing the adverse effect of bleaching on composite-enamel bond. J Esthet Dent 1994;6:157–161.
68. Can-Karabulut D, Karabulut B. Influence of activated bleaching on various adhesive restorative systems. J Esthet Restor Dent 2011;23:399–408.
69. Matis BA, Cochran MA, Eckert G. Review of the effectiveness of various tooth whitening systems. Oper Dent 2009;34:230–235.
70. Bowles WH, Thompson LR. Vital bleaching: The effect of heat and hydrogen peroxide on pulpal enzymes. J Endod 1986;12:108–112.
71. Bowles WH, Ugwuneri Z. Pulp chamber penetration by hydrogen peroxide following vital bleaching procedures. J Endod 1987;13:375–377.
72. Cooper JS, Bokmeyer TJ, Bowles WH. Penetration of the pulp chamber by carbamide peroxide bleaching agents. J Endod 1992;18:315–317.
73. Haywood VB. Current concepts: Bleaching of vital teeth. Quintessence Int 1997;28:424–425.
74. Haywood VB. Comparison of at-home and in-office bleaching. Dent Today 2000;19(4):44–53.
75. McCaslin AJ, Haywood VB, Potter BJ, Dickinson GL, Russell CM. Assessing dentin color changes from nightguard vital bleaching. J Am Dent Assoc 1999;130:1485–1490.
76. Haywood VB. Pre-bleaching examination vital for optimum whitening. Compend Contin Educ Dent 2012;33:76–77.
77. Andreasen FM, Andreasen JO. Examination and diagnosis of dental injuries. In: Andreasen JO, Andreasen FM (eds). Textbook and Color Atlas of Traumatic Injuries to the Teeth, ed 3. St Louis: Mosby, 1994:195–217.
78. Haywood VB, DiAngelis AJ. Bleaching the single dark tooth. Inside Dent 2010;6(8):42–52.
79. Haywood VB, Caughman WF, Frazier KB, Myers ML. Fabrication of immediate direct thermoplastic whitening trays. Contemp Esthet Restor Pract 2001;9:2–3.
80. Freccia WF, Peters DD, Lorton L, Bernier WE. An in vitro comparison of nonvital bleaching techniques in the discolored tooth. J Endod 1982;8:70–77.
81. Brown G. Factors influencing successful bleaching of the discolored root-filled tooth. Oral Surg Oral Med Oral Pathol 1965;20:238–244.
82. Howell RA. The prognosis of bleached root-filled teeth. Int Endod J 1981;14:22–26.
83. Rotstein I, Zalkind M, Mor C, Tarabeah A, Friedman S. In vitro efficacy of sodium perborate preparations used for intracoronal bleaching of discolored non-vital teeth. Endod Dent Traumatol 1991;7:177–180.
84. Holmstrup G, Palm AM, Lambjerg-Hansen H. Bleaching of discoloured root-filled teeth. Endod Dent Traumatol 1988;4:197–201.
85. Friedman S, Rotstein I, Libfeld H, et al. Incidence of external root resorption and esthetic results in 58 bleached pulpless teeth. Endod Dent Traumatol 1988;4:23–26.
86. al-Nazhan S. External root resorption after bleaching: A case report. Oral Surg Oral Med Oral Pathol 1991;72:607–609.
87. Rotstein I, Torek Y, Misgav R. Effect of cementum defects on radicular penetration of 30% H_2O_2 during intracoronal bleaching. J Endod 1991;17:230–233.
88. Gimlin DR, Schindler WG.The management of postbleaching cervical resorption. J Endod 1990;16:292–297.
89. Harrington GW, Natkin E. External resorption associated with bleaching of pulpless teeth. J Endod 1979;5:344–348.
90. Lado EA, Stanley HR, Weisman MI. Cervical resorption in bleached teeth. Oral Surg Oral Med Oral Pathol 1983;55:78–80.
91. Madison S, Walton R. Cervical root resorption following bleaching of endodontically treated teeth. J Endod 1990;16:570–574.
92. Rotstein I, Friedman S, Mor C, et al. Histological characterization of bleaching-induced external root resorption in dogs. J Endod 1991;17:436–441.
93. Heller D, Skribner J, Lin LM. Effect of intracoronal bleaching on external cervical root resorption. J Endod 1992;18:145–148.

Dentlearn.ir

1997;128(suppl):51S–55S.
95. Rotstein I, Dankner E, Goldman A, et al. Histochemical analysis of dental hard tissues following bleaching. J Endod 1996;22:23–26.
96. Lewinstein I, Hirschfeld Z, Stabholz A, Rotstein I. Effect of hydrogen peroxide and sodium perborate on the microhardness of human enamel and dentin. J Endod 1994;20:61–63.
97. Rotstein I, Lehr Z, Gedalia I. Effect of bleaching agents on inorganic components of human dentin and cementum. J Endod 1992;18:290–293.
98. Heling I, Parson A, Rotstein I. Effect of bleaching agents on dentin permeability to *Streptococcus faecalis*. J Endod 1995;21:540–542.
99. Rotstein I, Torek Y, Lewinstein I. Effect of bleaching time and temperature on the radicular penetration of hydrogen peroxide. Endod Dent Traumatol 1991;7:196–198.
100. Brighton DM, Harrington GW, Nicholls JI. Intracanal isolating barriers as they relate to bleaching. J Endod 1994;20:228–232.
101. Costas FL, Wong M. Intracoronal isolating barriers: Effect of location on root leakage and effectiveness of bleaching agents. J Endod 1991;17: 365–368.
102. Carrillo A, Arredondo Trevino MV, Haywood VB. Simultaneous bleaching of vital teeth and an open-chamber non-vital tooth with 10% carbamide peroxide. Quintessence Int 1998;29:643–648.
103. Settembrini L, Gultz J, Kaim J, Scherer W. A technique for bleaching nonvital teeth: Inside/outside bleaching. J Am Dent Assoc 1997;128: 1283–1284.
104. Goldstein RE. Bleaching teeth: New materials—New role. J Am Dent Assoc 1987;115(special issue):44E–52E [erratum 1988;116:156].
105. Goldstein C. In practice. Contemp Esthet Restor Pract 2002;7:12–17.
106. Miller MB. Power bleaching—Does it work or is it marketing hype? Pract Proced Aesthet Dent 2002;14:636.
107. Dawson PF, Sharif MO, Brunton PA. A clinical study comparing the efficacy and sensitivity of home vs combined whitening. Oper Dent 2011;36:460–466.
108. Paravina RD, Powers JM, Fay RM. Dental color standards: Shade tab arrangement. J Esthet Dent 2001;13:254–263.
109. Russell MD, Gulfraz M, Moss B. In vivo measurement of colour changes in natural teeth. J Oral Rehabil 2000;27:786–792.
110. Goldstein RE. In-office bleaching: Where we came from, where we are today. J Am Dent Assoc 1997;128(suppl):11S–15S.
111. Haywood VB. Bleaching of vital and nonvital teeth. Curr Opin Dent 1992;2:142–149.
112. Frazier KB. Nightguard bleaching to lighten a restored, nonvital discolored tooth. Compend Contin Educ Dent 1998;19:810–813 [erratum 1998;19:864].
113. Kossatz S, Dalanhol AP, Cunha T, Loguercio A, Reis A. Effect of light activation on tooth sensitivity after in-office bleaching. Oper Dent 2011;36:251–257.
114. Reis A, Tay LY, Herrera DR, Kossatz S, Loguercio AD. Clinical effects of prolonged application time of an in-office bleaching gel. Oper Dent 2011;36:590–596.
115. Papathanasiou A, Kastali S, Perry R, Kugel G. Clinical evaluation of a 35% hydrogen peroxide in-office whitening system. Compend Contin Educ Dent 2002;23:335–338,340,343–344.
116. Matis BA, Cochran MA, Wang G, Eckert GJ. A clinical evaluation of two in-office bleaching regimens with and without tray bleaching. Oper Dent 2009;34:142–149.
117. Yu D, Powell GL, Higuchi WI, Fox JL. Comparison of three lasers on dental pulp chamber temperature. J Clin Laser Med Surg 1993;11:119–122.
118. Anic I, Pavelic B, Matsumoto K. In vitro pulp chamber temperature rises associated with the argon laser polymerization of composite resin. Lasers Surg Med 1996;19:438–444.
119. Powell GL, Morton TH, Whisenant BK. Argon laser oral safety parameters for teeth. Lasers Surg Med 1993;13:548–552.
120. Buchalla W, Attin T. External bleaching therapy with activation by heat, light or laser–a systematic review.

Dentlearn.ir

Dent Mater 2007;23:586–596.
121. Lima DA, Aguiar FH, Liporoni PC, Munin E, Ambrosano GM, Lovadino JR. In vitro evaluation of the effectiveness of bleaching agents activated by different light sources. J Prosthodont 2009;18:249–254.
122. Melcer J, Chaumette MT, Zeboulon S, et al. Preliminary report on the effect of the CO_2 laser beam on the dental pulp of the *Macaca mulatta* primate and the beagle dog. J Endod 1985;11:1–5.
123. ADA Council on Scientific Affairs. Laser-assisted bleaching: An update. J Am Dent Assoc 1998;129:1484–1487.
124. Christensen GJ. Bleaching teeth—Which way is best? J Esthet Restor Dent 2003;15:137–139.
125. Kugel G, Papathanasiou A, Williams AJ 3rd, Anderson C, Ferreira S. Clinical evaluation of chemical and light-activated tooth whitening systems. Compend Contin Educ Dent 2006;27:54–62.
126. Matis BA, Cochran MA, Franco M, et al. Eight in-office tooth whitening systems evaluated in vivo: A pilot study. Oper Dent 2007;32:322–327.
127. Marson FC, Sensi LG, Vieira LC, Araújo E. Clinical evaluation of in-office dental bleaching treatments with and without the use of light activation sources. Oper Dent 2008;33:15–22.
128. Haywood VB. In-office bleaching: Lights, applications, and outcomes. Curr Pract 2009;16(4):3–6.
129. Hein DK, Ploeger BJ, Hartup JK, Wagstaff RS, Palmer TM, Hansen LD. In-office vital tooth bleaching—What do lights add? Compend Contin Educ Dent 2003;24:340–352.
130. Jones AH, Diaz-Arnold AM, Vargas MA, Cobb DS. Colorimetric assessment of laser and home bleaching techniques. J Esthet Dent 1999; 11:87–94.
131. Browning WD, Swift EJ Jr. Critical appraisal. Power bleaching. J Esthet Restor Dent 2011;23:61–67.
132. Bruzell EM, Johnsen B, Aalerud TN, Dahl JE, Christensen T. In vitro efficacy and risk for adverse effects of light-assisted tooth bleaching. Photochem Photobiol Sci 2009;8:377–385.
133. Firat E, Ercan E, Gurgan S, Yucel OO, Cakir Y, Berker E. The effect of bleaching systems on the gingiva and the levels of IL-1β and IL-10 in gingival crevicular fluid. Oper Dent 2011;36:572–580 [erratum 2012;37:108].
134. Niederman R, Tantraphol MC, Slinin P, Hayes C, Conway S. Effectiveness of dentist-prescribed, home-applied tooth whitening. A meta analysis. J Contemp Dent Pract 2000;1(4):20–36.
135. Matis BA, Cochran MA, Echert G , Carlson TJ. The efficacy and safety of a 10% carbamide peroxide bleaching gel. Quintessence Int 1998;29: 555–563.
136. Matis BA, Mousa HN, Cochran MA, Eckert GJ. Clinical evaluation of bleaching agents of different concentrations. Quintessence Int 2000; 31:303–310.
137. Matis BA, Yousef M, Cochran MA, Eckert GJ. A clinical evaluation of a bleaching agent used with and without reservoirs. Oper Dent 2002;27:5–11.
138. Auschill TM, Hellwig E, Schmidale S, Sculean A, Arweiler NB. Efficacy, side effects and patients' acceptance of different bleaching techniques (OTC, in-office, at-home) . Oper Dent 2005;30:156–163.
139. Matis BA, Cochran MA, Echert G, Matis JI. In vivo study of two carbamide peroxide gels with different desensitizing agents. Oper Dent 2007;32:549–555.
140. Meireles SS, Hechmann SS, Santos IS, Della Bona A, Demarco FF. A double blind randomized clinical trial of at-home tooth bleaching using two carbamide peroxide concentrations: 6-month follow-up. J Dent 2008;36:878–884.
141. Da Costa JB, McPharlin R, Paravina R, Ferracane JL. Comparison of at-home and in-office tooth whitening using a novel shade guide. Oper Dent 2010;35:381–388.
142. Haywood VB. Nightguard vital bleaching: Current information and research. Esthet Dent Update 1990;1(2):20–25.
143. Li Y. Peroxide-containing tooth whiteners: An update on safety. Compend Contin Educ Dent 2000;21(suppl):S4–S9.
144. Haywood VB, Heymann HO. Nightguard vital bleaching: How safe is it? Quintessence Int 1991;22:515–523.
145. Howard WR. Patient-applied tooth whiteners: Are they safe, effective with supervision? J Am Dent Assoc 1992;123:57–60.

Dentlearn.ir

146. Haywood VB. History, safety, and effectiveness of current bleaching techniques and applications of the nightguard vital bleaching technique. Quintessence Int 1992;23:471–488.
147. Christensen GJ. Home-use bleaching survey—1991. Clin Res Assoc Newsletter 1991;15(10):2.
148. Mokhlis GR, Matis BA, Cochran MA, Eckert GJ. A clinical evaluation of carbamide peroxide and hydrogen peroxide whitening agents during daytime use. J Am Dent Assoc 2000;131:1269–1277.
149. Matis BA. Tray whitening: What the evidence shows. Compend Contin Educ Dent 2003;24:354–362.
150. Gaiao U, Matis BA, Cochran MA, Blackman D, Schultz F. Clinical study of 10% carbamide peroxide degradation in bleaching trays [abstract 235]. J Dent Res 1998(special issue);77:135.
151. Blackman D, Eckert GJ, Gaiao U, Matis BA, Schults FA. In vivo degradation of bleaching gel used in whitening teeth. J Am Dent Assoc 1999;130:227–235.
152. Haywood VB, Powe A. Using double-poured alginate impressions to fabricate bleaching trays. Oper Dent 1998;23:128–131.
153. Chen SY, Liang WM, Chen FN. Factors affecting the accuracy of elasto-metric impression materials. J Dent 2004;32:603–609.
154. Reinhardt JW, Eivins SE, Swift EJ Jr, Denehy GE. A clinical study of night-guard vital bleaching. Quintessence Int 1993;24:379–384.
155. Russell CM, Dickinson GL, Johnson MH, et al. Dentist-supervised home bleaching with ten percent carbamide peroxide gel: A six-month study. J Esthet Dent 1996;8:177–182.
156. Curtis JW, Dickinson GL, Downey MC, et al. Assessing the effects of 10 percent carbamide peroxide on oral soft tissues. J Am Dent Assoc 1996;127:1218–1223.
157. Scherer W, Palat M, Hittelman E, Putter H, Cooper H. At-home bleaching system: Effect on gingival tissue. J Esthet Dent 1992;4:86–89.
158. Schulte JR, Morrissette DB, Gasior EJ, Czajewski MV. Clinical changes in the gingiva as a result of at-home bleaching. Compend Contin Educ Dent 1993;14:1362–1372.
159. Haywood VB, Leonard RH, Dickinson GL. Efficacy of six months of nightguard vital bleaching of tetracycline-stained teeth. J Esthet Dent 1997;9:13–19.
160. Williamson EH, Lundquist DO. Anterior guidance: Its effect on electromyographic activity of the temporal and masseter muscles. J Prosthet Dent 1983;49:816–823.
161. Haywood VB, Leonard RH Jr, Nelson CF. Efficacy of foam liner in 10% carbamide peroxide bleaching technique. Quintessence Int 1993;24: 663–666.
162. Dunn JR. Dentist-prescribed home bleaching: Current status. Compend Contin Educ Dent 1998;19:760–764.
163. Matis BA, Gaiao U, Blackman D, Schultz FA, Eckert GJ. In vivo degradation of bleaching gel used in whitening teeth. J Am Dent Assoc 1999;130:227–235.
164. Small BW. Bleaching with 10 percent carbamide peroxide: An 18-month study. Gen Dent 1994;42:142–146.
165. Javaheri DS, Janis JN. The efficacy of reservoirs in bleaching trays. Oper Dent 2000;25:149–151.
166. Miller MB, Castellanos IR, Rieger MS. Efficacy of home bleaching systems with and without tray reservoirs. Pract Periodontics Aesthet Dent 2000;12:611–614.
167. Fischer DE [inventor]. Ultradent Products, assignee. Methods for treating a person's teeth using sticky dental compositions in combination with passive-type dental trays. US patent 6,036,943. 14 March 2000.
168. Matis BA, Yousef M, Cochran MA, Eckert GJ. Degradation of bleaching gels in vivo as a function of tray design and carbamide peroxide concentration. Oper Dent 2002;27:12–18.
169. Haywood VB. Nightguard vital bleaching and in-office bleaching. Con-temp Esthet Restor Pract 1998;2(4):78–81.
170. Cubbon T, Ore D. Hard tissue and home tooth whiteners. CDS Rev 1991;84(5):32–35.
171. Gerlach RW. Shifting paradigms in whitening: Introduction of a novel system for vital tooth bleaching. Compend Contin Educ Dent 2000;21(suppl):S4–S9.
172. Gerlach RW, Bibb RD, Sagel P. Initial color change and color retention with a hydrogen peroxide bleaching strip. Am J Dent 2002;15:3–7.
173. Bizhang M, Chun YH, Damerau K, Singh P, Raab WH, Zimmer S. Comparative clinical study of the effectiveness of three different bleaching methods. Oper Dent 2009;34:635–641.

Dentlearn.ir

174. Barbieri GM, Mota EG, Rodrigues-Junior SA, Burnett LH. Effect of whitening dentifrices on the surface roughness of commercial composites. J Esthet Restor Dent 2011;23:338–345.
175. Moffitt JM, Cooley RO, Olsen NH, Hefferren JJ. Prediction of tetracycline-induced tooth discoloration. J Am Dent Assoc 1974;88:547–552.
176. Haywood VB, Leonard RH. Six- and 12-month color stability after 6 months bleaching tetracycline teeth [abstract 2891]. J Dent Res 1996; 75(special issue):379.
177. Haywood VB. Extended bleaching of tetracycline-stained teeth: A case report. Contemp Esthet Restor Pract 1997;1:14–21.
178. Leonard RH, Haywood VB, Eagle JC, et al. Nightguard vital bleaching of tetracycline stained teeth: 54 months post-treatment. J Esthet Dent 1999;11:265–277.
179. Kugel G, Gerlach RW, Aboushala A, Ferreira S, Magnuson B. Long term use of 6.5% hydrogen peroxide bleaching strips on tetracycline stain: A clinical study. Compend Contin Educ Dent 2011;32(8):50–56.
180. Haywood VB, Parker MH. Nightguard vital bleaching beneath existing porcelain veneers: A case report. Quintessence Int 1999;30:743–747.
181. Caro I. Discoloration of the teeth related to minocycline therapy for acne. J Am Acad Dermatol 1980;3:317–318.
182. Wolfe ID, Reichmister J. Minocycline hyperpigmentation: Skin, tooth, nail, and bone involvement. Cutis 1984;33:457–458.
183. Salman RA, Salman DG, Glickman RS, Super S, Salman L. Minocycline induced pigmentation of the oral cavity. J Oral Med 1985;40:154–157.
184. Di Benedetto DC. Tetracycline staining in an adult. J Mass Dent Soc 1985;34:183,217.
185. Poliak SC, DiGiovanna JJ, Gross EG, Gantt G, Peck GL. Minocycline-associated tooth discoloration in young adults. JAMA 1985;254:2930–2932.
186. Berger RS, Mandel EF, Hayes TJ, Grimwood RR. Minocycline staining of the oral cavity. J Am Acad Dermatol 1989;21:1300–1301.
187. Rosen T, Hoffmann TJ. Minocycline-induced discoloration of the permanent teeth. J Am Acad Dermatol 1989;21:569.
188. Parkins FM, Furnish G, Bernstein M. Minocycline use discolors teeth. J Am Dent Assoc 1992;123(10):87–89.
189. Primosche RE. Tetracycline discoloration, enamel defects, and dental caries in patients with cystic fibrosis. Oral Surg Oral Med Oral Pathol 1980;50:301–308.
190. Matis BA, Wang Y, Jiang T, Eckert GJ. Extended at-home bleaching of tetracycline-stained teeth with concentrations of carbamide peroxide. Quintessence Int 2002;33:645–655.
191. Bernardon JK, Sartori N, Ballarin A, Perdigao J, Lopes G, Baratieri LN. Clinical performance of vital bleaching techniques. Oper Dent 2010;35:3–10.
192. Cohen SC. Human pulpal response to bleaching procedures on vital teeth. J Endod 1979;5:134–138.
193. Robertson WD, Melfi RC. Pulpal response to vital bleaching procedures. J Endod 1980;6:645–649.
194. Albers H. Lightening natural teeth. ADEPT Rep 1991;2:1–24.
195. Baik JW, Rueggeberg FA, Liewehr FR. Effect of light-enhanced bleaching on in vitro surface and intrapulpal temperature rise. J Esthet Restor Dent 2001;13:370–378.
196. Price RB, Sedarous M, Hiltz GS. The pH of tooth-whitening products. J Can Dent Assoc 2000;66:421–426.
197. Swift EJ Jr. Critical appraisal: At-home bleaching: Pulpal effects and tooth sensitivity issues, part 1. J Esthet Restor Dent 2006;18:225–228.
198. Endo H, Rees TD. Clinical features of cinnamon-induced contact stomatitis. Compend Contin Educ Dent 2006;27:403–409.
199. Mäkinen-Kiljunen S. Banana allergy in patients with immediate-type hypersensitivity to natural rubber latex: Characterization of cross-reacting antibodies and allergens. J Allergy Clin Immunol 1994;93: 990–996.
200. Chahine L, Sempson N, Wagoner C. The effect of sodium lauryl sulfate on recurrent aphthous ulcers: A clinical study. Compend Contin Educ Dent 1997;18:1238–1240.
201. Herlofson BB, Barkvoll P. Sodium lauryl sulfate and recurrent aphthous ulcers. A preliminary study. Acta

Dentlearn.ir

Odontol Scand 1994;52:257–259.
202. Thitinanthapan W, Satmanont P, Vongsa VN. In vitro penetration of the pulp chamber by three brands of carbamide peroxide. J Esthet Dent 1999;11:259–264.
203. Seale NS, McIntosh JE, Taylor AN. Pulpal reaction to bleaching of teeth in dogs. J Dent Res 1981;60:948–953.
204. Giniger M, MacDonald J, Spaid M, Felix H. A 180-day clinical investigation of the tooth whitening efficacy of a bleaching gel with added amorphous calcium phosphate. J Clin Dent 2005;16:11–16.
205. Borges BC, Borges JS, de Melo CD, et al. Efficacy of a novel at-home bleaching technique with carbide peroxides modified by CPP-ACP and its effect on the micro hardness of bleaching enamel. Oper Dent 2011;36:521–528.
206. Haywood VB. Treating sensitivity during tooth whitening. Compend Contin Educ Dent 2006;26(9 suppl):11–20.
207. Gaffar A. Treating hypersensitivity with fluoride varnishes. Compend Contin Educ Dent 1998;19:1088–1097.
208. Haywood VB, Caughman WF, Frazier KB, Myers ML. Tray delivery of potassium nitrate–fluoride to reduce bleaching sensitivity. Quintessence Int 2001;32:105–109.
209. Hodosh M. A superior desensitizer—Potassium nitrate. J Am Dent Assoc 1974;88:831–832.
210. Markowitz K. Tooth sensitivity: Mechanisms and management. Compend Contin Educ Dent 1993;14:1032–1046.
211. Browning WD. Haywood VB. Hughes N, Cordero R. Prebrushing with a potassium nitrate dentifrice to reduce tooth sensitivity during bleaching evaluated in a practice-based setting. Compend Contin Educ Dent 2010;31:220–225.
212. Tam L. Effect of potassium nitrate and fluoride on carbamide peroxide bleaching. Quintessence Int 2001;32:766–770.
213. Jerome CE. Acute care for unusual cases of dentinal hypersensitivity. Quintessence Int 1995;26:715–716.

exposed to 35% hydrogen peroxide alone, with saliva, and with 10% carbamide peroxide. J Esthet Restor Dent 2003;15:154–165.
215. Hunsaker KJ, Christensen GJ, Christensen RP. Tooth bleaching and chemicals—Influence on teeth and restorations [abstract A1558]. J Dent Res 1990;69(special issue):303.
216. Swift EJ Jr, Perdigaoa J. Effects of bleaching on teeth and restorations. Compend Contin Educ Dent 1998;19:815–820.
217. Tong LS, Pang MK, Mok NY, King NM, Wei SH. The effects of etching, microabrasion, and bleaching on surface enamel. J Dent Res 1993; 72:67–71.
218. Ben-Amar L, Liberman R, Gorfil C, Bernstein Y. Effect of mouthguard bleaching on enamel surface. Am J Dent 1995;8:29–32.
219. Leonard RH, Eagle JC, Garland GE, Matthews KP, Rudd AL, Phillips C. Nightguard vital bleaching and its effect on enamel surface morphology. J Esthet Restor Dent 2001;13:132–139.
220. Ernst CP, Marroquin BB, Willershausen-Zonnchen B. Effect of hydrogen peroxide–containing bleaching agents on the morphology of human enamel. Quintessence Int 1996;27:53–56.
221. Shannon H, Spence P, Gross K, Tira D. Characterization of enamel exposed to 10% carbamide peroxide bleaching agents. Quintessence Int 1993;24:39–44.
222. Stindt DJ, Quenette L. An overview of Gly-Oxide liquid in control and preventionof dental disease. Compend Contin Educ Dent 1989;10:514–519.
223. Attin T, Schmidlin PR, Wegehaupt F, Wiegand A. Influence of study design on the impact of bleaching agents on dental enamel micro-hardenss: A review. Dent Mater 2009;25:143–157.
224. Xu B, Li Q, Wang Y. Effects of pH values of hydrogen peroxide bleaching agents on enamel surface properties. Oper Dent 2011;36:554–562.
225. McCracken MS, Haywood VB. Demineralization effects of 10 percent carbamide peroxide. J Dent 1996;24:395–398.
226. Barghi N, Morgan J. Bleaching following porcelain veneers: Clinical cases. Am J Dent 1997;10:254–256.

Dentlearn.ir

227. Dorman HL, Bishop JG. Production of experimental edema in dog tongue with dilute hydrogen peroxide. Oral Surg Oral Med Oral Pathol 1970;29:38–43.
228. Martin JH, Bishop JG, Guentherman RH, Dorman HL. Cellular response of gingiva to prolonged application of dilute hydrogen peroxide. J Periodontol 1968;39:208–210.
229. Li Y. Toxicological considerations of tooth bleaching using peroxide-containing agents. J Am Dent Assoc 1997;128(suppl):31S–36S.
230. Woolverton CJ, Haywood VB, Heymann HO. Toxicity of two carbamide peroxide products used in nightguard vital bleaching. Am J Dent 1993;6:310–314.
231. Dickstein B. Neonatal oral candidiasis: Evaluation of a new chemotherapeutic agent. Clin Pediatr (Phila) 1964;3:485–488.
232. Franchi GJ. A practical technique for bleaching discolored crowns of young permanent incisors. J Dent Child 1953;20:68–69.
233. Munro IC, Williams GM, Heymann HO, et al. Tooth-whitening products and the risk of oral cancer. Food Chem Toxicol 2006;44:301–315.
234. Mahony C, Felter SP, McMillan DA. An exposure-based risk assessment approach to confirm the safety of hydrogen peroxide for use in home tooth bleaching. Regul Toxicol Pharmacol 2006;44(2):75–82.
235. Abu-Shakra A, Zeiger E. Effects of Salmonella genotypes and testing protocols on H_2O_2-induced mutation. Mutagenesis 1990;5:469–473.
236. Zeigler-Skylakakis K, Andrae U. Mutagenicity of hydrogen peroxide in V79 Chinese hamster cells. Mutat Res 1987;192(1):65–67.
237. Cantoni O, Murray D, Meyn RE. Effect of 3-aminobenzamide on DNA strand-break rejoining and cytotoxicity in CHO cells treated with hydrogen peroxide. Biochim Biophys Acta 1986;867:135–143.
238. White WE Jr, Pruitt KM, Mansson-Rahemtulla B. Peroxidase-thiocyanate-peroxide antibacterial system does not damage DNA. Antimicrob Agents Chemother 1983;23:267–272.
239. Li Y. The safety of peroxide-containing at-home tooth whiteners. Compend Contin Educ Dent 2003;24:384–389.
240. Freedman GA. Safety of tooth whitening. Dent Today 1990;9(3):32–33.
241. Reddy J, Salkin LM. The effect of a urea peroxide rinse on dental plaque and gingivitis. J Periodontol 1976;47:607–610.
242. Shipman B, Cohen E, Kaslick RS. The effect of a urea peroxide gel on plaque deposits and gingival status. J Periodontol 1971;42:283–285.
243. Tartakow DJ, Smith RS, Spinelli JA. Urea peroxide solution in the treatment of gingivitis in orthodontics. Am J Orthod 1978;73:560–567.
244. Scientific Committee on Consumer Products (SCCP), European Commission. Opinion on Hydrogen Peroxide in Tooth Whitening Products, publication SCCP/0844/04.
245. Scientific Committee on Consumer Products (SCCP), European Commission. Guidance Document on Epidemiological and clinical studies on Tooth Whitening Products, publication SCCP/0974/06.
246. Attin T, Hannig C, Wiegand A, Attin R. Effect of bleaching on restorative materials and restorations—A systematic review. Dent Mater 2004;20: 852–861.
247. Robertello FJ, Dishman MV, Sarrett DC, Elpperly AC. Effect of home bleaching products on mercury release from an admixed amalgam. Am J Dent 1999;12:227–230.
248. Rotstein I, Mor C, Arwaz JR. Changes in surface levels of mercury, silver, tin, and copper of dental amalgam treated with carbamide peroxide and hydrogen in vitro. Oral Surg Oral Med Oral Pathol Oral Radiol Endod 1997;83:506–509.
249. Hummert TW, Osborne JW, Norling BK, Cardenas HL. Mercury in solution following exposure of various amalgams to carbamide peroxides. Am J Dent 1993;6:305–309.
250. Elkhatib H, Nakajima M, Hiraishi N, Kitasako Y, Tagami J, Nomura S. Surface pH and bond strength of a self-etching primer/adhesive system to intracoronal dentin after application of hydrogen peroxide bleach with

Dentlearn.ir

sodium perborate. Oper Dent 2003;28:591–597.
251. Bailey SJ, Swift EJ Jr. Effects of home bleaching products on composite resins. Quintessence Int 1992;23:489–494.
252. Souyias J, Hoelscher DC, Neme AL. Effect of bleaching on posterior composite materials [abstract 1072]. J Dent Res 2000;79(special issue):278.
253. Cooley RL, Burger KM. Effect of carbamide peroxide on composite resins. Quintessence Int 1991;22:817–821.
254. Friend GW, Jones JE, Wamble SH, Covington JS. Carbamide peroxide tooth bleaching: Changes to composite resins after prolonged exposure [abstract A2432]. J Dent Res 1991;70(special issue):570.
255. Mallkondu O, Yurdaguven H, Say EC, Kazazoglu E, Soyman M. Effect of bleaching on microhardness of esthetic restorative materials. Oper Dent 2011;36:177–186.
256. Robinson FG, Haywood VB, Myers M. Effect of 10 percent carbamide peroxide on color of provisional restoration materials. J Am Dent Assoc 1997;128:727–731.
257. Nour El-din AK, Miller BH, Griggs JA, Wakefield C. Immediate bonding to bleached enamel. Oper Dent 2006;31:106–114.
258. Fasanaro TS. Bleaching teeth: History, chemicals, and methods used for common tooth discolorations. J Esthet Dent 1992;4:71–78.
259. Da Costa JB, Mazur RF. Effects of new formulas of bleaching gel and fluoride application on enamel microhardness: An in vitro study. Oper Dent 2007;32:589–594.
260. Zalkind M, Arwaz J, Goldman A, Rotstein I. Surface morphology changes in human enamel, dentin, and

261. Croll TP, Bullock GA. Enamel microabrasion for removal of smooth surface decalcification lesions. J Clin Orthod 1994;28:365–370.
262. Croll TP, Segura A, Donly KJ. Enamel microabrasion: New considerations in 1993. Pract Periodontics Aesthet Dent 1993;5:19–29.
263. Croll TP. Enamel microabrasion: Observations after 10 years. J Am Dent Assoc 1997;128(suppl):45S–50S.
264. Bodden KM, Haywood VB. Treatment of endemic fluorosis and tetracycline staining with microabrasion and nightguard vital bleaching: A case report. Quintessence Int 2003;34:87–91.
265. Dlugokinski MD, Rueggeberg FA, Caughman WF. Extraneous light effect on cure of photo-activated resin composite. J Am Dent Assoc 1998;129:1103–1109.

Dentlearn.ir



Porcelain Veneers

Jeffrey S. Rouse
J. William Robbins

The porcelain veneer has gained wide acceptance in recent years as a primary restoration in esthetic dentistry. Since its introduction in the early 1980s, it has undergone an evolution in both techniques and materials. A significant number of long-term clinical studies confirm the excellent durability of the porcelain veneer restoration.[1–7]

Indications and Limitations

Because of their conservative preparation and beautiful esthetics, porcelain veneers have become the treatment of choice for restoration of the anterior dentition.[8] Porcelain veneers may be used to modify a tooth's color, shape, length, and/or alignment; to close space; and to restore fractured and endodontically treated teeth. The patient should be informed, however, of the possible morbidity associated with a specific indication as well as the generally accepted limitations. Informed consent should include, but not be limited to, the following possible complications: *(1)* postoperative sensitivity, *(2)* marginal discoloration, *(3)* fracture, *(4)* debonding, and *(5)* wear of opposing teeth.

Dentlearn.ir

Treatment Planning

The patient's self-image must be considered during the initial patient interview.[9] A key element in the diagnostic phase is a clarification of the patient's expectations. If it can be determined initially that the patient's expectations are unrealistic, future disappointment may be avoided. Esthetic failures are as large a percentage of failure of veneers as technical failures.[5] A systematic approach to assessing the face and smile is every bit as important as preparation design and adhesive choice.

Assessment of the face

When a treatment plan is being developed that includes restoration of teeth in the esthetic zone, attention must be directed not only to the shape and color of the teeth but also to the shape of the face, the lips, the maxillary and mandibular lip lines, and the skin color. The teeth can be used to accentuate a positive feature or de-emphasize a negative feature. For example, a patient with a narrow face may desire longer and narrower teeth to emphasize the facial shape or shorter, rounded teeth to soften the narrowness of the face.

It is also important to evaluate skin color, especially if there is a possibility that it will change over time. For example, if porcelain veneers are being planned for a Caucasian patient with a dark tan, a determination must be made regarding the longevity of the tan prior to shade selection. If the dark tan is transient and skin color will revert to a lighter tone, this will significantly affect the decision on the color of the porcelain veneers. Veneers that appear to be bright and high in value against the tanned skin will look more yellow and lower in value as the skin tone becomes lighter. All of these parameters must be consciously considered during the diagnostic phase if consistently excellent results are to be obtained.

Assessment of the smile

After the facial features have been considered, attention must be directed to the smile and its components. During the initial interview, the dentist should pay close attention to the overall appearance of the patient's mouth as he or she speaks and is in repose. The dentist should note the maxillary incisal edge position in relation to the lower lip, the relationship of the maxillary incisal plane to the horizon, the amount of gingival display during smiling and speaking, the relationship of the anterior and posterior segments, and the overall quality of the smile. If the interpupillary line is parallel to the horizon, it may be used in evaluation of the

Dentlearn.ir

incisal plane. The dentist pulls the upper lip parallel to the interpupillary line and then uses the lip to evaluate the incisal plane for a cant (Fig 17-1). The acceptability of the incisal plane must be determined during the diagnostic phase, or discrepancies may be incorporated into the definitive restorations. (See chapter 3 for a more complete discussion of esthetic diagnosis.)



Fig 17-1 Pulling the upper lip parallel with the interpupillary line to examine the incisal plane. Note the sigmoid curve of the incisal plane.

Diagnostic aids

Mock-ups

With an understanding of esthetic diagnostic parameters, the dentist can use several diagnostic methods to develop a treatment plan that will predictably result in success. Preparation and waxing on a diagnostic cast are sometimes helpful to the dentist, especially when the veneers are intended to lengthen teeth, close spaces, or correct malaligned teeth. However, a diagnostic wax-up is not especially helpful in giving the patient a preview of the expected esthetic outcome. This can be accomplished more effectively by one of the intraoral techniques.

A mock-up of the desired result can be accomplished with direct placement of composite in the patient's mouth to simulate the desired outcome (Fig 17-2). Because the teeth are not acid etched before the intraoral mock-up, the composite can easily be removed from the tooth. This technique is especially helpful for simple procedures, such as diastema closure.



Fig 17-2*(a)* Diastema. *(b)* Diagnostic intraoral mock-up of diastema closure.

Dentlearn.ir

However, when major changes are being considered, such as lengthening several teeth, direct mock-up is too time-consuming (Fig 17-3a). In this situation, a diagnostic wax-up is done on a preoperative cast, and a matrix is made. Bis-acrylic provisional material is placed in the matrix, which is placed over the teeth intraorally and allowed to cure (Fig 17-3b). Once the excess flash is cleaned from the teeth, the patient may preview the projected outcome (Fig 17-3c). At this point, changes can be made (eg, shortening or lengthening of the teeth) until the patient is comfortable and satisfied. An impression can then be made of the corrected mock-up in the mouth, and the subsequent cast will serve as a reference cast for the laboratory technician. This same technique will be recommended as a preparation guide to insure the proper depth of reduction during treatment (Fig 17-3d). Another method is to construct a resin composite shell or overlay on a diagnostic cast. The shell is placed intraorally to allow the patient to visualize the projected result. This is an especially helpful diagnostic tool for the patient with excessive gingival display. The composite shell can extend over the gingiva to demonstrate the esthetic effect of surgically lengthening the clinical crowns (Fig 17-4).



Fig 17-3*(a)* A patient presents with pathologic wear and excessive anterior spacing requiring modification beyond a direct mock-up. *(b)* Bis-acryl provisional material is placed in a matrix made from a diagnostic wax-up and allowed to cure on unprepared teeth. *(c)* The patient can evaluate the esthetic alterations. *(d)* The matrix can also serve as a reduction guide for veneers.

Dentlearn.ir

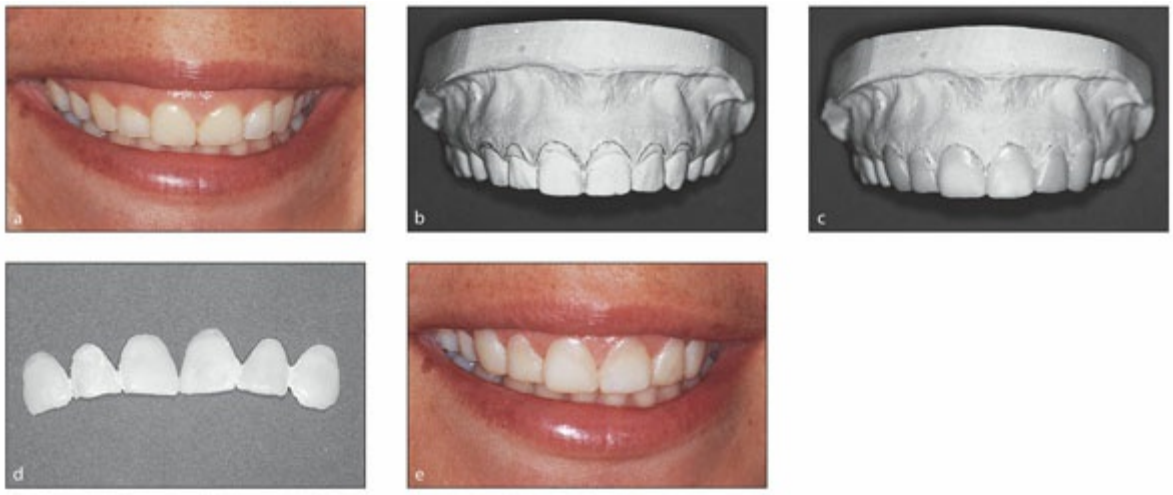

Fig 17-4*(a)* Short clinical crowns resulting from excess gingival coverage. *(b)* Preoperative study cast with lines drawn to aid in the fabrication of a diagnostic resin composite overlay. *(c and d)* Diagnostic resin composite overlay. *(e)* Diagnostic resin composite overlay demonstrating the benefit of crown lengthening of the anterior teeth.

Commonly, a preview of the projected outcome is achieved with the provisional restorations (Fig 17-5). A diagnostic wax-up is accomplished, and a stent is fabricated. After the preparations are completed and the final impression is made, the provisional restorations are constructed using the stent. Once the patient is satisfied with the provisional restorations, a cast of the arch, with the provisional restorations in place, is made and sent to the laboratory to serve as a blueprint for the definitive restorations.



Fig 17-5*(a)* Patient's preoperative presentation demonstrating multiple diastemas and reverse smile line. *(b)* Diagnostic wax-up. *(c)* Silicone matrix of wax-up. *(d)* Enamel-depth bonded veneer preparations with composite restorations removed. *(e)* Bis-acryl provisional restorations. *(f)* IPS e.max (Ivoclar Vivadent) definitive veneer restorations (Porcelain veneers by Lebeau Dental Laboratory, Renton, Washington.)

Dentlearn.ir

Computer imaging

Another diagnostic method involves computer imaging of the patient's smile, making the desired esthetic changes on the screen. This provides both the patient and the dentist with a preview of the expected result (Fig 17-6). However, imaging is limited because it does not allow for a dynamic evaluation in the same way that an intraoral mock-up allows the patient to experience the projected changes. Because many dentists do not have the in-office capability for computer imaging, the patient or a photograph of the patient may be sent to a location that offers the service.

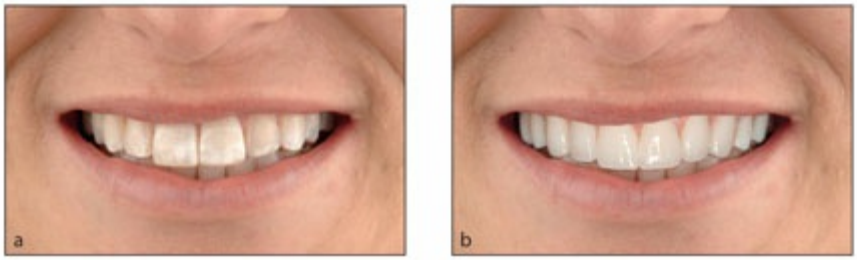

Fig 17-6*(a)* Preoperative presentation of a patient considering veneers to improve color and contour of her smile. *(b)* Computer simulations of smile changes (Envision A Smile) can help the patient visualize the final results.

Photographs

Preoperative photographs offer another important diagnostic aid; they document the preoperative condition and aid the technician in the fabrication of the veneers. The series should include a full-face smile; a retracted frontal image of maxillary and mandibular teeth in occlusion; a retracted frontal view with a shade tab held directly beneath the incisal edges of the maxillary incisors; a retracted close-up view of the teeth to be veneered, with and without a shade tab; and a postpreparation view of the teeth to be veneered, with a shade tab. Specialized dentin shade tabs are available to mimic dentin coloration (Fig 17-7). In addition, other photographs, such as a profile or a view of the intraoral diagnostic mock-up, should be included if they can benefit the laboratory technician.



Fig 17-7 Shade tab held under the incisal edges of the prepared teeth. This shade guide is specially designed to demonstrate the dentin color of the preparation.

Dentlearn.ir

Single Veneer

Perfectly matching a full-coverage restoration to an adjacent natural central incisor is an extremely difficult restorative procedure. Commonly, the porcelain veneer is the restoration of choice in this situation. If the tooth to be restored is not significantly discolored, the porcelain veneer is an excellent restorative option. The major advantage of the single porcelain veneer restoration is the dentist's ability to increase or decrease the value of the restoration with the bonding resin cement (Fig 17-8).



Fig 17-8*(a)* Right central incisor fractured and repaired with composite that has become stained. *(b)* Multiple shade photographs are made before tooth preparation to capture the texture, chroma, and maverick colors of the teeth. *(c)* Preparation color captured with dentin shade guide. *(d)* Definitive porcelain veneer restoration of the right central incisor.

Multiple Veneers

When the clinician has the option of veneering multiple anterior teeth, the problem of shade matching is minimized. It is easier to deal in even numbers when veneers are placed on anterior teeth. It is much simpler to veneer two central incisors than to attempt to match a veneer to a natural tooth. Therefore, the chances of obtaining an optimally esthetic result are enhanced when two, four, six, or eight veneers are placed.

An option that is commonly chosen is the placement of six veneers from canine to canine. In Fig 17-9, the anterior teeth are brighter and bolder, while the buccal corridor appears to become darker. This accentuates the anterior teeth and commonly creates the unpleasant illusion that the anterior teeth are larger and longer

Dentlearn.ir

as well as brighter. This does not usually occur when only the four incisors are veneered (Fig 17-10). Therefore, when veneers are planned for the incisors but there is no esthetic or functional requirement for canine veneers, the esthetic result is enhanced when the canines are left unrestored. However, when all six anterior teeth require veneers, consideration should be given to veneering one or more posterior teeth on each side, depending on the posterior extent of the smile and the maxillary arch form.



Fig 17-9 Porcelain veneers bonded on all maxillary anterior teeth. Note the apparent separation of anterior and posterior segments of the mouth because of the boldness of the porcelain veneers.

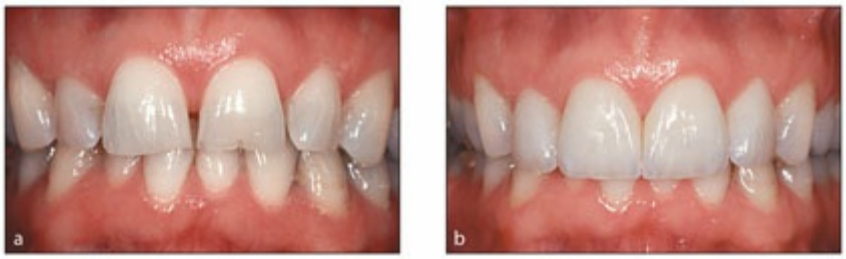

Fig 17-10*(a)* Preoperative view of maxillary central and lateral incisors. *(b)* Porcelain veneers bonded on the maxillary central and lateral incisors to blend esthetically with the maxillary canines. (Porcelain veneers created by Steve McGowan, CDT, Kenmore, Washington.)

Failure

The most common cause of failure of porcelain veneers is fracture.[5,10–12] Clinical studies report a modest 0% to 5% failure rate due to fracture. Higher fracture rates (7% to 14%)[12] were noted in cases with unfavorable occlusion, significant parafunction, large dentin bonding surfaces, and bonding to existing restorations. In a

(2) cohesive, and *(3)* adhesive. When a segment of a veneer fractures but remains intact, it is defined as a *static fracture* (Fig 17-11). These failures are caused by

the ceramic restoration and the amount of unsupported porcelain. The crack

Dentlearn.ir

fracture.[13,14] *Cohesive fractures* occur within the body of porcelain due to tensile loads from excessive functional or parafunctional loading (Fig 17-12). A cohesive failure results in the loss of a fragment of ceramic, requiring repair or replacement of the veneer. Enamel imparts stiffness to the tooth much like a metal coping does for a metal-ceramic crown. Removal of the enamel negatively affects the stress-strain distribution of the subsequent veneer. This leads to an increase in flexure under load and, ultimately, cohesive fracture.[14] The most important areas in which to maintain enamel are the incisal and cervical areas. Lack of adhesion in those areas produces higher stress on loading and increased risk of cohesive fracture.[15] Finally, an *adhesive fracture* is due to a failure of the bonding interface between the porcelain/luting composite and the tooth structure (Fig 17-13). It is a result of a weak bond or severe occlusal loading. Friedman[11] reports that 86% of the adhesive fractures occurred at a resin-dentin interface.

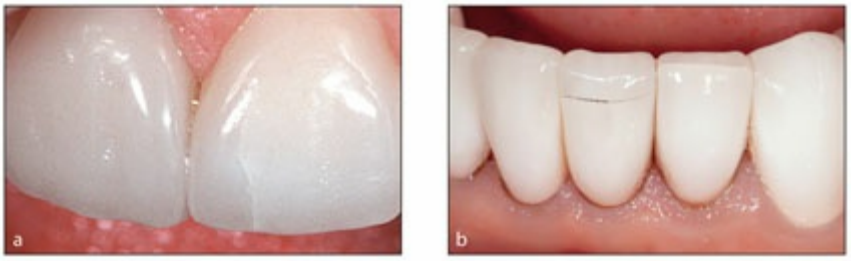

Fig 17-11 *(a)* Static fracture of a porcelain veneer. *(b)* Horizontal static fractures of mandibular incisors. These fractures are obvious to the patient because of the stain and refraction of light. A vertical static fracture of the canine is not as evident.



Fig 17-12 Cohesive fracture of maxillary left central incisor veneer due to excessive force.



Fig 17-13 *(a)* Exposed dentin surfaces provide a poor bonding substrate for veneers, increasing

Dentlearn.ir

the risk of fracture. *(b)* Adhesive failure of dentin-bonded veneer.

On rare occasions, a porcelain veneer will debond. When this happens, it is important to determine at which bonded interface the failure occurred. If the luting composite remains on the tooth, the failure is likely due to either inadequate etching of the veneer or the use of silane past its expiration date (Figs 17-14a and 17-14b). The stated shelf life of silane is approximately 1 year when it is refrigerated, but it is known that silane efficacy decreases with time. If the luting composite remains on the inside of the veneer, then there was a problem with either the bonding materials, the placement technique, or the bonding substrate (Figs 17-14c and 17-14d). Veneers that are bonded to a predominantly dentinal substrate have a significantly greater likelihood of debonding than veneers that are predominantly bonded to enamel.[10]

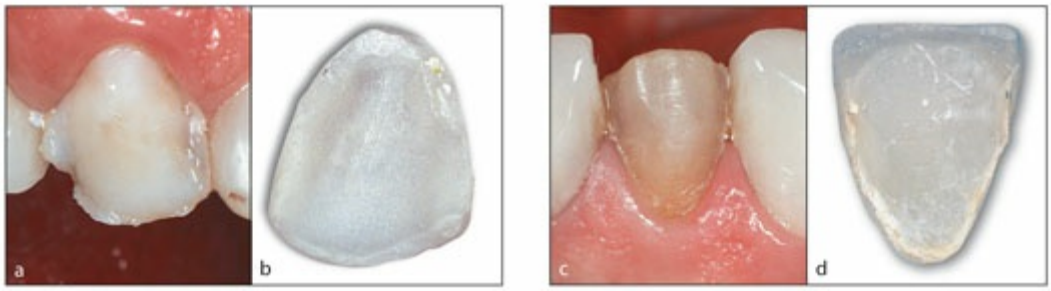

Fig 17-14*(a and b)* Debonding of the veneer leaving resin composite bonded to the tooth is a result of inadequate porcelain etching or contaminated silane. *(c and d)* Resin composite attached to the debonded veneer indicates a predominantly dentinal substrate.

Finally, marginal staining and leakage are common causes of failure of porcelain veneers.[1–5] The staining is caused by an influx of oral fluids containing chromogenic bacteria or organic stains. The composite-tooth interface is the primary site for the leakage. It has been noted that these areas of microleakage are always devoid of enamel.[11]

Tooth Preparation

The preparation of teeth for porcelain veneers is usually uncomplicated when the basic principles are understood and followed. Historically, veneers were placed on unprepared teeth, making the technique conservative and reversible. This led to overcontoured restorations, gingival irritation, and high failure rates[16,17] (Fig 17-15). The stress concentration is less severe on veneers fitted to prepared teeth.[18] In addition, the preparation removes the aprismatic and hypermineralized enamel

Dentlearn.ir

layers, which can be more resistant to acid etching.[19] Today, practitioners should focus on maintaining the preparation completely in enamel to maximize the resin bond strength and decrease the tensile stresses in the porcelain.[15,20] Even with the newest-generation bonding agents, the bond strength of porcelain with resin cement to enamel is far superior to the bond strength of porcelain with resin cement to dentin. Fractures, microleakage, and debonding are all failures that can be linked to preparations situated in dentin.[11]



Fig 17-15*(a)* Lack of preparation may create overcontoured restorations. *(b)* Ultraconservative full-veneer preparations resolve contour issues yet still maintain an enamel bond.

Anterior teeth

Gingival finish lines

When preparing teeth for porcelain veneers, it is essential to remember that the strongest and most predictable bond is to enamel. The more dentin that is exposed during the preparation, the poorer the bond of the veneer and the poorer the ultimate stress distribution during function.[19] For maxillary porcelain veneers, the gingival margin of the veneer should routinely be placed at the gingival crest or slightly subgingivally. A primary goal of the preparation is to have all margins on sound enamel, because the stress distribution in the veneer is much improved when all margins are bonded to enamel. The amount of exposed dentin in the central portion of the veneer preparation becomes much less important when all of the margins are bonded to enamel.[19] Because the enamel is only approximately 0.3 mm thick at 0.5 mm coronal or incisal to the cementoenamel junction,[21,22] it is difficult to obtain adequate preparation depth while preserving the enamel. There is also a significant decrease in the average enamel thickness as the patient ages. This decrease in enamel for patients aged 50 years and older increases the risk of dentin exposure and a less reliable bond.[23]

In a routine preparation, the facial enamel reduction must be exquisitely controlled. This cannot be accomplished freehand. It may only be accomplished with

Dentlearn.ir

the use of a depth guide.[24–27] The authors use single-head depth-cutting burs, although a dimpling technique with a 1-mm round bur has proven effective at preserving enamel[25,26] (Fig 17-16). After a 0.3-mm gingival depth cut and a 0.5-mm midfacial depth cut, the enamel is uniformly removed with a round-ended, cylinder diamond. Unless the teeth to be veneered are dark (low value), the gingival preparation should not routinely extend more than minimally into the gingival sulcus. In the midfacial area, the enamel thickness ranges from 0.8 to 0.9 mm on average. The preparation should deepen from the midfacial and taper into the incisal, increasing to 0.7 mm (Fig 17-17). This allows the technician to effectively disguise the transition from supported to unsupported porcelain.



Fig 17-16 Depth-cutting burs of different designs and depths.

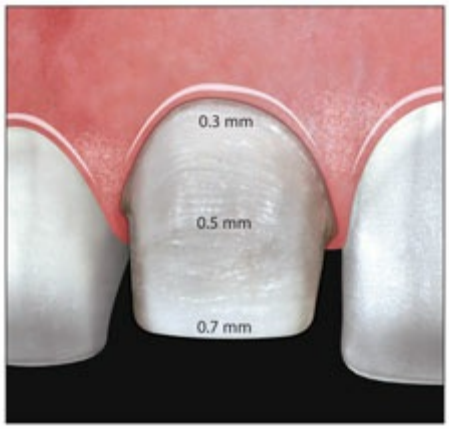

Fig 17-17 Average facial reduction for enamel-bonded veneer.

When mandibular anterior teeth are prepared for porcelain veneers, the considerations are different from those for maxillary teeth. In most patients, the gingival half of the mandibular incisors remains covered by the lower lip at all times, resulting in no esthetic display. In addition, the marginal gingiva of the mandibular anterior teeth is commonly thin, and the gingival sulcus is narrow and shallow, making the placement of gingival retraction cord very difficult. For these reasons, the gingival margins of the preparations for mandibular anterior teeth are ideally placed at lea

Dentlearn.ir

The long-term predictability of a porcelain veneer is directly proportional to the amount of enamel substrate in the preparation.[28] Preparation guides have been proposed as a technique to ensure that the tooth is properly prepared. Malpositioned and/or worn teeth, frequently the teeth requiring veneers, make use of a guide for preparation depth difficult (Fig 17-18a). The depth of reduction is formulated from the final contour and length of the tooth as it will be restored and not the preoperative position (Figs 17-18b and 17-18c). Traditional preparation guides only ensure that enough tooth structure has been removed for the laboratory. They do not limit the reduction, which is the key in veneer preparation. Aesthetic preevaluative temporaries (APTs)[29] assure enough reduction for the laboratory but also allow the dentist to limit the damage caused by overreduction. A silicone matrix is fabricated from a diagnostic wax-up or an approved intraoral mock-up (Fig 17-19a). After the patient is anesthetized and the teeth dried, bis-acrylic resin is injected into the matrix. It is seated and allowed to fully cure (Fig 17-19b). An important step in creating ideal positioning and thickness of the mock-up is allowing the acrylic to escape from the matrix when it is seated. Because the teeth are not prepared, the simulation will in most cases be very thin. If the acrylic is not allowed to flow easily from the matrix, it will be trapped, creating additional facial or incisal bulk. Reduction cuts into this oversized matrix will not provide accurate reduction. Slits in the matrix or vent holes from the facial will assist in encouraging the acrylic to flow from the form. The mock-up is not removed from the teeth but instead allowed to lock into the embrasures. This allows the dentist to perform ideal reduction of the mock-up before removing it from the teeth (Figs 17-19c and 17-19d). Once removed, the proper depth cuts will be found on the teeth, thus assuring ideal reduction without the inherent risk of overreduction created with traditional reduction guides (Figs 17-19e to 17-19h).



Fig 17-18*(a)* Malaligned teeth make preparation guides essential. *(b)* Reduction guide fabricated from the completed wax-up. *(c)* Reduction guide from the final waxed contours provides little assistance in determining proper reduction. The guide becomes valuable after tooth reduction, which may be too late to preserve enamel.

Dentlearn.ir



Fig 17-19*(a)* Clear polyvinyl siloxane matrix produced from a modified wax-up. (The camera flash imparts a blue tinge to the matrix.) A clear matrix serves as a reduction guide as well as the matrix for composite provisional veneer fabrication. *(b)* Bis-acryl resin is allowed to cure, demonstrating ideal final contours and locations of tooth structure in buccoversion. *(c)* Preparation depth cuts into the matrix provide an ideal guide for ultraconservative veneer preparation and lessen the likelihood of overpreparation. *(d)* The guide is removed and depth cuts visualized. *(e)* Completed preparations. *(f)* Traditional reduction guide demonstrates uniform preparation depths. *(g)* Definitive porcelain veneer restorations. *(h)* Smile at 4-year follow-up.

Interproximal contact area

For the purposes of veneer fabrication and placement, it is important that the preparation not be finished in the interproximal contact area. When the margin is stopped in the interproximal contact area, it is difficult to accurately capture the margin in the final impression. Additionally, veneer fabrication is more difficult for the laboratory technician, and bonding and finishing procedures are more difficult for the dentist. For these reasons, the preparation must either stop facial to the interproximal contact area (Fig 17-20a) or extend completely through the contact area to the lingual surface[22,30] (Fig 17-20b).

Dentlearn.ir

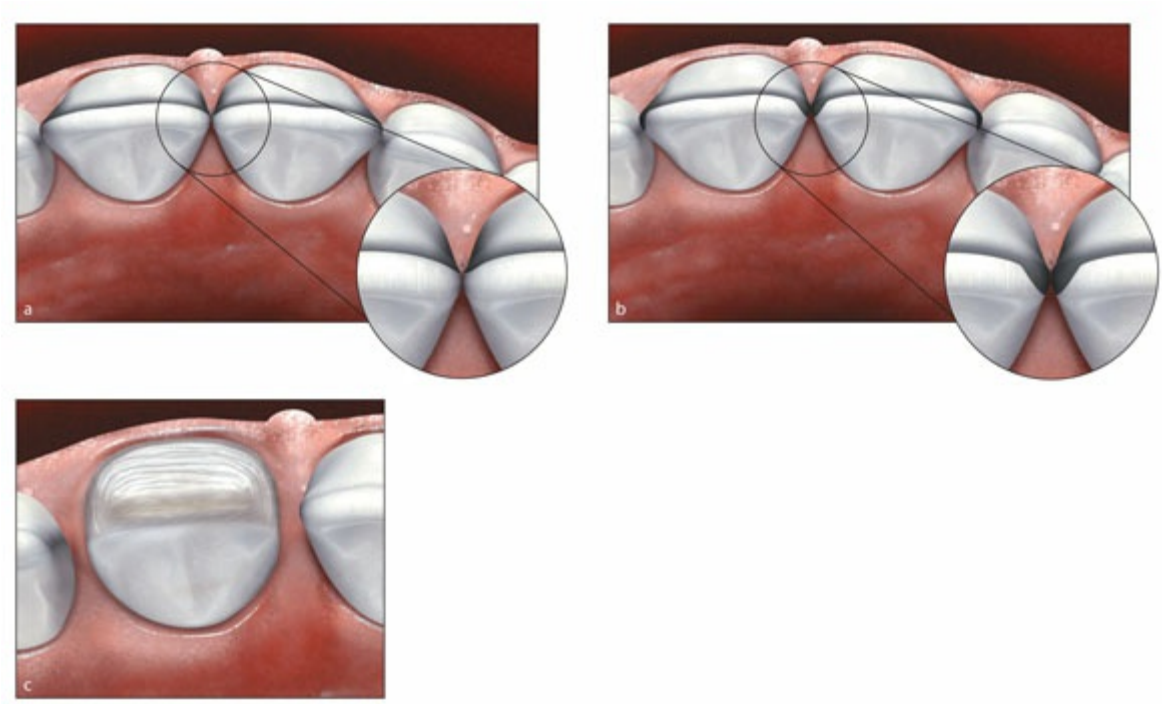

Fig 17-20 *(a)* Preparation extending slightly facial to the interproximal contact area. *(b)* Preparation extending completely through the interproximal contact area to the palatal surface. *(c)* Completed veneer preparation through the interproximal contacts. This preparation is commonly referred to as a *full veneer*.

A major long-term problem with porcelain veneers is marginal staining.[5,11] This staining is most apparent at the proximal margins. Therefore, the current trend is to extend the preparation through the interproximal contacts (Fig 17-20c) from the mesial aspect of the canine to the mesial aspect of the contralateral canine. There is no esthetic need to extend the preparation through the contact areas on the distal surfaces of the canines. By extending the preparation through interproximal contacts in areas other than the distal contacts of canines, any proximal marginal staining is concealed. With dark teeth (eg, tetracycline-stained teeth), it is imperative that the preparation extends completely through the interproximal contact area to the lingual surface (Fig 17-21). This decreases the risk of dark shadows appearing around the periphery of the veneer.[30]

Dentlearn.ir



Fig 17-21 *(a)* Traditional interproximal extension during veneer preparation will exhibit the tooth discoloration. *(b)* Placing the finish line to the lingual eliminates the chance of interproximal discoloration. *(c)* Preparation-shade photographs allow the technician to modify the ceramic to mask the severe tetracycline stains. *(d)* Completed veneers hide the significant discoloration while remaining lifelike.

Incisal edge

There is ongoing debate regarding the need to cover the incisal edge of a maxillary tooth with the porcelain veneer. If there is no esthetic requirement to change the incisal shape or length, and there is adequate remaining incisal tooth structure after facial reduction, the incisal margin may be terminated at the facioincisal line angle (Fig 17-22a). This preparation is most commonly indicated for linguoverted teeth. An alternative is the "window preparation" (Fig 17-22b). This preparation provides the most protection for the veneer during function; however, it results in a visible composite-veneer interface at the facioincisal margin. This preparation is most commonly indicated for the maxillary canine that has the correct length and incisal edge configuration and has a large lingual wear facet extending to the incisal edge. Because it is preferable not to place a veneer margin in a wear facet, the window preparation is appropriate. Neither of these preparations can be used, however, when the tooth is being lengthened incisally with the porcelain veneer. When the maxillary incisal edge is not reduced during the preparation, the veneer is inevitably thicker, and the incisal edge is too round buccolingually, lacking a more natural, sharp facioincisal line angle. Additionally, veneers that do not cover the incisal edge are significantly more difficult to orient correctly during bonding.

Dentlearn.ir

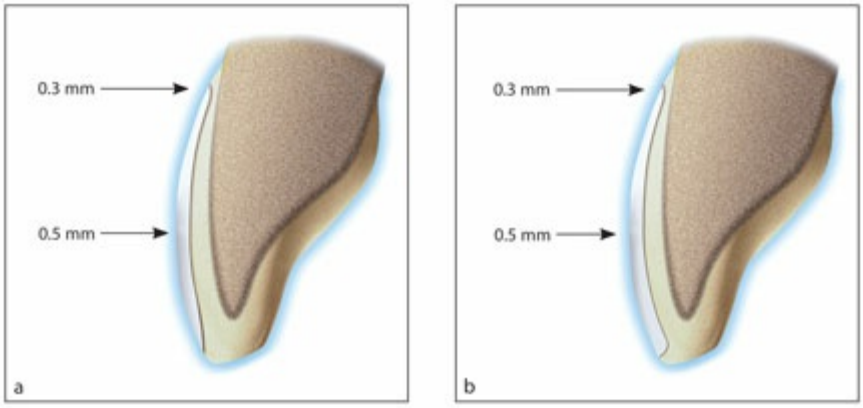

Fig 17-22*(a)* Veneer preparation that does not cover the incisal edge of the maxillary anterior tooth. *(b)* Window preparation on a maxillary anterior tooth.

The most universally applicable preparation, which allows the technician to incorporate the natural incisal translucency into the veneer, requires incisal edge reduction. If the incisal edge of the maxillary tooth is to be covered with the veneer, there must be room for at least 1 mm of porcelain over the incisal edge. However, a 1.5- to 2.0-mm incisal edge reduction from the final incisal edge position (Fig 17-23) allows the laboratory technician to provide maximum esthetics in the incisal third of the veneer. Therefore, a preoperative determination of the ideal incisal edge position must be made before the tooth is prepared. A diagnostic wax-up and preparation guide[29] can be helpful in this evaluation. In the case of a worn or fractured tooth, more incisal porcelain length is acceptable if the veneer remains bonded to enamel and the fit will provide a cement thickness of 100 µm or less.[13,31]

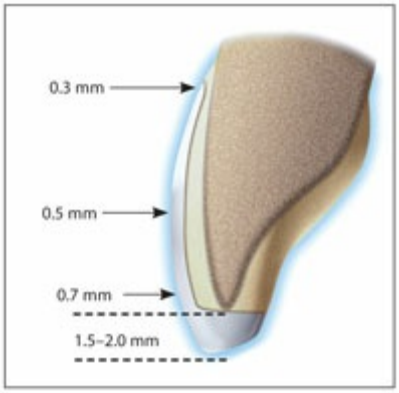

Fig 17-23 Standard veneer preparation for maxillary anterior teeth. Incisal reduction is 1.5 to 2.0 mm.

Traditionally, the lingual finish line configuration was a chamfer. This placed the thin veneer in the high–tensile stress lingual cingulum area of the tooth, significantly weakening the restoration and creating a higher risk of crack formation on the

Dentlearn.ir

lingual.[32] Today, the incisal edge should be flattened, leaving a butt finish line configuration on the lingual surface.[33] It is important to round the sharp facioincisal line angle of the preparation to prevent stress concentration in the bonded veneer and to allow for an undetectable transition from unsupported to supported porcelain (Fig 17-24). One notable exception to this rule is made for severely worn teeth. If the amount of enamel incorporated into the final preparation is predictive of the long-term success of the veneer, severely worn teeth would have a poorer survival rate. Creating a long chamfer on the lingual of worn teeth may access additional enamel. An in vitro report concluded that, on severely worn teeth, a palatal chamfer margin significantly increased the final veneer load-to-failure values compared with a shoulder finish line[34,35] (Fig 17-25).



Fig 17-24 Inadequate depth of preparation in the incisal third leads to an unsightly show-through of the preparation, which is seen to a greater degree on the left central incisor.

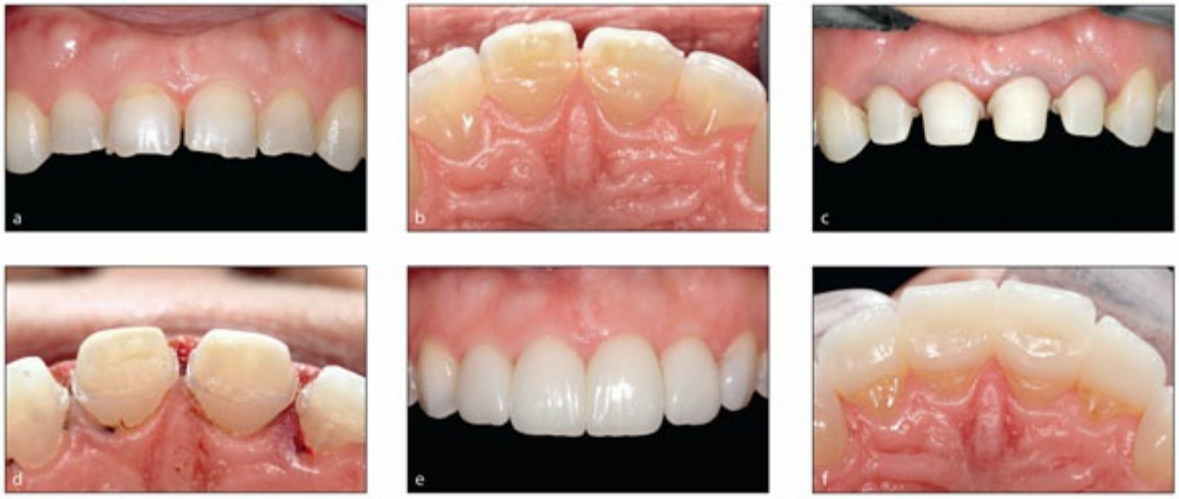

Fig 17-25*(a)* Significant wear on maxillary anterior teeth. Orthodontic intrusion aligns gingival architecture and creates restorative space. (Orthodontics by Jay Gibson, San Antonio, Texas.) *(b)* Parafunctional wear is evident on the lingual surfaces. *(c)* Full-veneer preparations. *(d)* Lingual finish lines carried below wear facets to access more bondable enamel. *(e)* Completed veneers. *(f)* Additional bonding to enamel is gained with a lingual chamfer extension, improving the strength of the restoration.

Dentlearn.ir

If the practitioner chooses to maintain the interproximal contact, the proximal portion of the preparation should follow the papilla and extend slightly under the interproximal contact to ensure coverage of the tooth in this area (Fig 17-26). This extension is called an *elbow preparation*. If the tooth is not prepared in this manner or extended through the contact, the darker, unprepared triangle of natural tooth structure results in less-than-optimal esthetics.

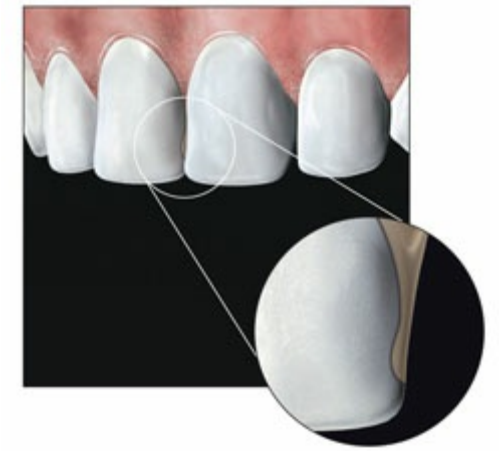

Fig 17-26 Extension of the veneer preparation into the subcontact area for improved esthetics.

The incisal edges of mandibular anterior teeth should be routinely covered with porcelain at least 1.5 to 2.0 mm thick (Fig 17-27). Incisal edge flattening with a resultant lingual butt margin is also recommended for mandibular anterior teeth. Again, the facioincisal line angle of the preparation must be rounded.

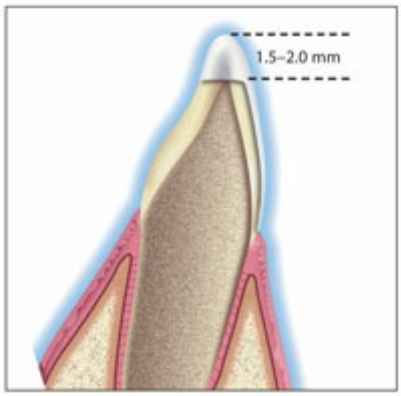

Fig 17-27 Veneer preparation on a mandibular incisor. There should be at least 1.5 to 2.0 mm of incisal porcelain in the definitive restoration, and the gingival margin is at least 1.0 mm incisal to the gingival crest.

When multiple teeth are being prepared, incisal reduction should be symmetric (eg, both prepared lateral incisors should be the same length) for more uniform

Dentlearn.ir

esthetics in the definitive restorations. After completion of all veneer preparations, the dentist should stand in front of the patient, retract the patient's lips, and confirm that the preparations are symmetric and the incisal edges parallel to the horizon.

Overlapping teeth

When overlapping teeth are being prepared, the paths of insertion of the veneers must be considered. Where there is significant misalignment of the teeth, it is usually impossible to develop paths of insertion for the veneers without extending the preparations completely through the interproximal contact areas. In addition, significant alteration of the interproximal contact position and straightening of the facial surfaces is usually facilitated when the teeth are prepared through the contact (Fig 17-28).



Fig 17-28*(a)* Correction of mild to moderate overlapping requires preparation through the contacts to allow contour alteration. *(b)* Porcelain veneer restorations demonstrating ideal alignment. Gingival contours are irregular because orthodontic alignment was not completed.

Space closure

Preparation of teeth for space closure presents a unique situation. To obtain smooth lingual contours, the proximal finish lines adjacent to the space must be made more lingual. The wider the space to be closed, the more lingually the tooth must be prepared (Fig 17-29). Also, the proximal margins adjacent to the space must be positioned subgingivally so that the gingival contours of the veneers minimize the black triangle between the bottom of the interproximal contact area and the tip of the papilla. However, the gingival margin of the veneer should be no closer than 2.5 mm to the crest of the alveolar bone.[36] As teeth separate, the scallop of the interproximal bone lessens, resulting in a wide, flat papilla. Extending the preparation subgingivally and lingually enables the technician to alter the interproximal contour of the veneers and reshape the papilla (Fig 17-30).

Dentlearn.ir

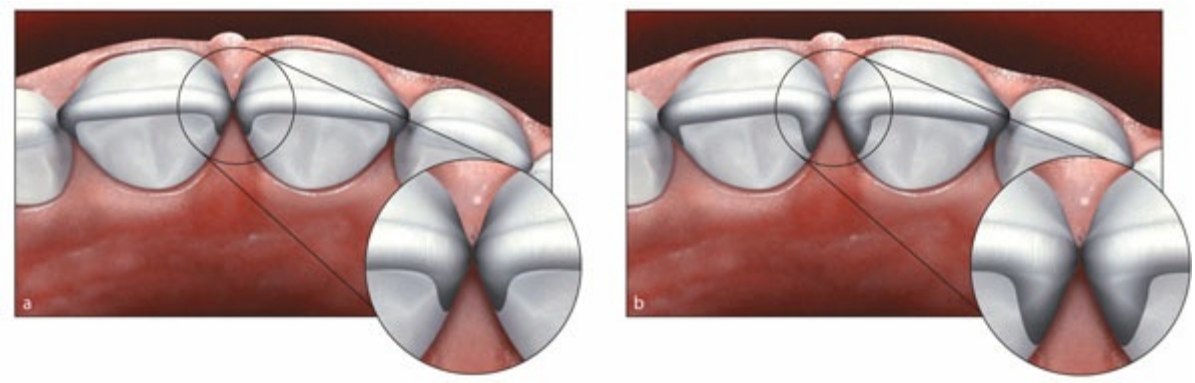

Fig 17-29*(a)* Porcelain veneer preparations for closing a small to moderate diastema. *(b)* Porcelain veneer preparations for closing a large diastema. The preparations involve more of the lingual surfaces of the central incisors to develop adequate lingual contours.

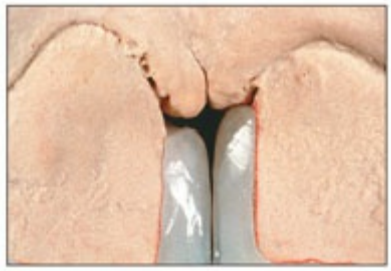

Fig 17-30 Overcontouring the veneers allows alteration of the interproximal papilla contour.

Premolars

The considerations for preparing maxillary premolars are similar to those for anterior teeth. The veneer preparation of the maxillary premolar may end on the facial surface of the tooth if the functional and esthetic requirements are met (Fig 17-31a). Ideally, the occlusal margin should be placed so that it is not in an occlusal contact area and so that the opposing cusp does not function across it. If the anterior guidance immediately disoccludes the posterior teeth in mandibular excursive movements, the occlusal margin can be placed anywhere on the lingual incline of the buccal cusp, as long as there is no occlusal stop directly on the margin (Fig 17-31b).

the occlusal margin to the central groove. In this circumstance, occlusal reduction must be adequate to allow for an onlay of at least 2-mm-thick porcelain over the buccal cusp, blending to the 0.3- to 0.5-mm reduction of the facial surface (Fig 17-31c). In mandibular premolars, because the esthetic cusp is also the functional cusp, the tooth must generally be prepared for a porcelain onlay rather than simply for a buccal porcelain veneer. The interproximal contact is rarely broken in second premolars. Esthetics may dictate extending through the mesial contact of first

Dentlearn.ir

premolars (Fig 17-32).

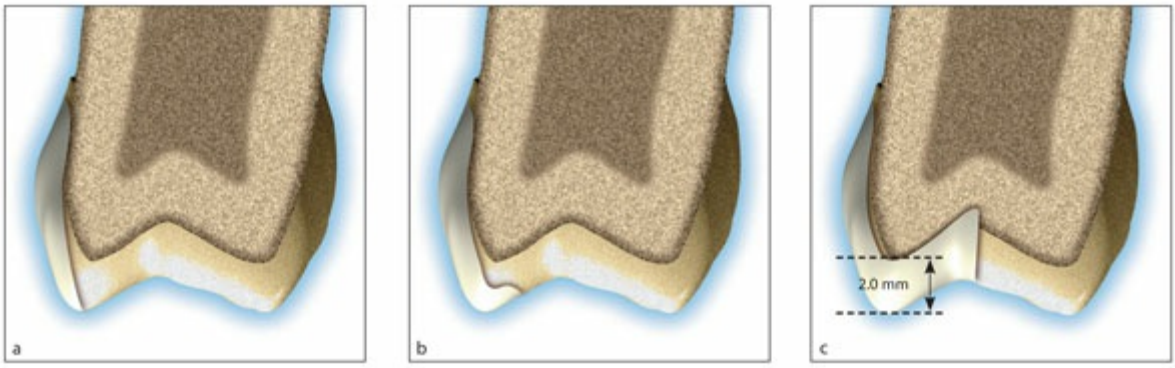

Fig 17-31*(a)* Porcelain veneer preparation that does not cover the buccal cusp of the maxillary premolar. *(b)* Veneer preparation overlapping the buccal cusp. There should be no occlusal stop directly on the veneer margin. *(c)* Porcelain veneer preparation that covers the buccal cusp of the maxillary premolar. Note the 2.0 mm of occlusal reduction on the buccal cusp.

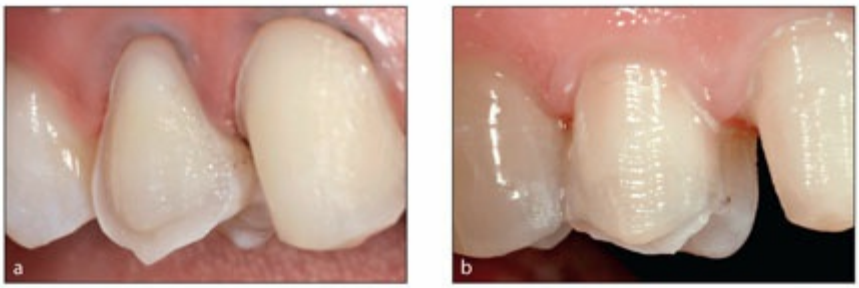

Fig 17-32*(a)* Typically, the interproximal contact remains facial to the contact for maxillary premolars. *(b)* When esthetics or function dictates, the mesial preparation of a maxillary first premolar will be extended to the lingual.

Existing restorations

Existing resin composite restorations can complicate the veneer preparation. Ideally, no margins should be finished on an existing resin composite restoration. One clinical study reported a significantly higher failure rate for porcelain veneers placed over existing resin composite restorations.[17] Bonding effectively to an existing restoration is questionable, particularly if it has been in place for any period of time. Water sorption, unsilanated surfaces of filler particles, and limited unpolymerized resin in the set composite lead to a significant decrease in bond strength.[10,24] The resin composite restoration should be removed during tooth preparation for the veneer, and the missing tooth structure should be replaced as part of the porcelain veneer[37] (Fig 17-33). While proper surface conditioning may eventually provide higher fracture strengths that eliminate the necessity of removing the aged composite restorations, the difficulty of maintaining the existing composite

Dentlearn.ir

restorations associated with the veneers makes it undesirable.[38] Furthermore, attempting to remove a failing Class 3 composite restoration at the margin of a veneer is a risky procedure that restorative dentists should avoid. However, small areas of resin composite can remain centrally in the preparation to serve as an undercut block-out material.



Fig 17-33*(a)* Teeth with Class 3 composite restorations are initially prepared as if the restoration is nonexistent. *(b)* Class 3 restoration demonstrated after initial tooth reduction. *(c)* The restoration is removed. *(d)* Preparation is modified to allow the veneer to incorporate the missing tooth structure. *(e)* Veneer preparations on the central and lateral incisors replacing composite restorations.

Fractured incisal edge

A unique indication for the porcelain veneer is the restoration of the fractured incisal edge of an incisor (Fig 17-34). Although there is little clinical data to support the use of veneers for this purpose, laboratory data are favorable.[31,37] The limits for the amount of missing tooth structure that can be replaced with a porcelain veneer are not known. However, anecdotal evidence seems to indicate that approximately 50% of the clinical crown can be replaced with a porcelain veneer when the preparation on the remaining tooth structure is in enamel. Because the veneered tooth does not require endodontic treatment for restorative reasons or the placement of a post and core, it is a highly desirable alternative to previous methods of restoring the fractured tooth. The preparation for this type of veneer extends to near the gingival crest on both the facial and lingual surfaces.

Dentlearn.ir



Fig 17-34 *(a)* Fractured mandibular right central incisor. *(b)* Preparation of the fractured mandibular right central incisor for a porcelain veneer. *(c)* Porcelain veneer bonded on the mandibular right central incisor. (Porcelain veneer created by Gilbert Young, CDT, Plano, Texas.)

Noncarious cervical lesions

Noncarious cervical lesions (NCCLs), caused by erosion, abrasion, and/or abfraction, provide a different, more sclerotic dentin substrate for bonding than surfaces not affected by these processes. Advancements in adhesive systems have improved adhesion to sclerotic dentin, with some studies showing no difference in adhesion to sclerotic dentin compared with unaffected dentin, while other studies demonstrate reduced bonding efficacy to sclerotic dentin compared with unaffected dentin. A number of factors can influence the quality of bonding to the sclerotic dentin, including the specific adhesive system, treatment of the dentin surface, and the placement technique.[39–46] Adhesion to NCCLs provides an additional challenge to providing bonded restorations. Therefore, the best treatment solution is to surgically cover these areas with connective tissue grafting.[47] (See chapter 15 for more on tissue grafting of NCCLs.) This results in more natural gingival architecture and allows the gingival margin of the veneer preparation to end on enamel. However, if the surgical option is not chosen and the esthetic demands require that the root be covered with a veneer, the preparation must extend onto the root surface. The patient should be advised that the risks of staining, microleakage, and/or veneer fracture in the gingival third are much greater because of the less-than-ideal bonding.[15] Full-coverage restorations must also be considered.

Impressions

When an impression is made of the maxillary teeth, retraction cord is placed to expose all gingival margins. This step is generally not necessary with mandibular teeth because the preparations are at least 1.0 mm incisal to the marginal gingiva. An accurate impression material, such as polyvinyl siloxane, polyether, or reversible hydrocolloid, is then used to make the final impression. See chapter 18 for more

Dentlearn.ir

information on taking impressions for esthetic indirect anterior restorations.

Provisional Restorations

The placement of provisional restorations over veneer preparations is an integral step in the predictable placement of porcelain veneers. Provisional restorations not only improve interim esthetics and decrease sensitivity, but they also provide essential diagnostic information, including veneer color, shape, length, and incisal edge configuration, that cannot be obtained in any other way.[48] When provisional restorations are being placed on one or two teeth, the procedure is best accomplished with freehand placement of composite. A small area in the incisal third of each tooth is etched with phosphoric acid for 15 seconds, washed, and dried. Adhesive resin (not self-etching adhesive) is placed over the entire preparation and light cured. A large increment of resin composite is then patted into place with correct contours, the gingival margins are smoothed with an explorer tip or other fine-tipped instrument, and the provisional restoration is light cured. There should be no overhanging resin composite at the margins, and the provisional restoration should require virtually no adjustment.

When provisional restorations are being placed on multiple teeth, it is preferable to use a clear matrix made on a preoperative diagnostic cast. A diagnostic wax-up is commonly required to change tooth length, alignment, and/or incisal edge configuration (Figs 17-35a and 17-35b). If the clear matrix is made of a plastic stent material, the diagnostic wax-up cast must be first duplicated (Fig 17-35c). If the matrix is made of a clear polyvinyl siloxane bite registration material, it can be made directly on the diagnostic wax-up cast. The teeth are spot etched with 30% to 40% phosphoric acid in the incisal third (Fig 17-35d), washed, and air dried. The entire preparation is covered with adhesive resin, which is then light cured (Fig 17-35e). A self-etching primer system should not be used because the provisionals will be bonded to the entire preparation and are difficult to remove without altering the preparations. The facial and incisal areas in the clear matrix are filled with resin composite (Fig 17-35f), and the matrix is placed over the prepared teeth (Fig 17-35g). The gingival two-thirds of the matrix is shielded from the polymerization light, and the incisal one-third is polymerized with the light for 10 seconds per tooth (Fig 17-35h). The gingival two-thirds is then lightly cured for 0.5 to 1 second per tooth (Fig 17-35i). The matrix is gently teased away from the tooth at the gingival margin to ensure that the resin composite does not stick to the matrix (Fig 17-35j). If the resin composite sticks to the matrix, the matrix is returned to place and the gingival

Dentlearn.ir

two-thirds is polymerized again for 0.5 second per tooth. The matrix is removed, and the excess partially cured resin composite is first removed proximally and lingually with a no. 12 or 12B scalpel blade (Fig 17-35k). Floss and a floss threader are then used in each gingival embrasure to ensure patency and that there are no overhangs (Fig 17-35l). The gingival margins are then carved with the no. 12 or 12B scalpel blade. If small areas of resin composite are chipped during the finishing process, adding additional resin composite easily repairs these areas. The incisal and facial embrasures are opened with a thin separating disk (Fig 17-35m), the occlusion is adjusted, and the provisional restorations are smoothed and polished (Figs 17-35n to 17-35p). Finally, the provisional restorations are coated with an adhesive to add a shine. This can improve the patient's initial esthetic impression of provisionals (Fig 17-35q). The entire restoration is light cured for 30 seconds per tooth (Figs 17-35r and 17-35s).

Dentlearn.ir



Fig 17-35 Fabrication of provisional restorations. *(a)* Preoperative casts. *(b)* Diagnostic wax-up. *(c)* Clear stent made from a duplicate cast of the diagnostic wax-up. *(d)* Prepared teeth are spot etched with 30% phosphoric acid on the incisal third. *(e)* The entire surface of each prepared tooth is coated with resin adhesive and light cured. *(f)* The facial and incisal areas of the clear matrix are filled with resin composite. *(g)* The filled matrix is placed over the prepared teeth. *(h)* The gingival two-thirds of the matrix is covered with a finger, while the incisal third is light cured for 10 seconds per tooth. *(i)* The gingival two-thirds is lightly cured for 0.5 to 1 second per tooth. *(j)* The matrix is gently teased away from the preparations to ensure that the resin composite does not stick to the matrix. *(k)* A no. 12 or 12B scalpel blade is used to remove the partially cured resin composite from proximal and lingual surfaces. *(l)* Floss and a floss threader are used in each gingival embrasure to ensure patency and overhang-free margins. *(m)* Facial and incisal embrasures are refined with a thin diamond disk. *(n and o)* A series of composite finishing disks are used to finish the facial surfaces.

Dentlearn.ir

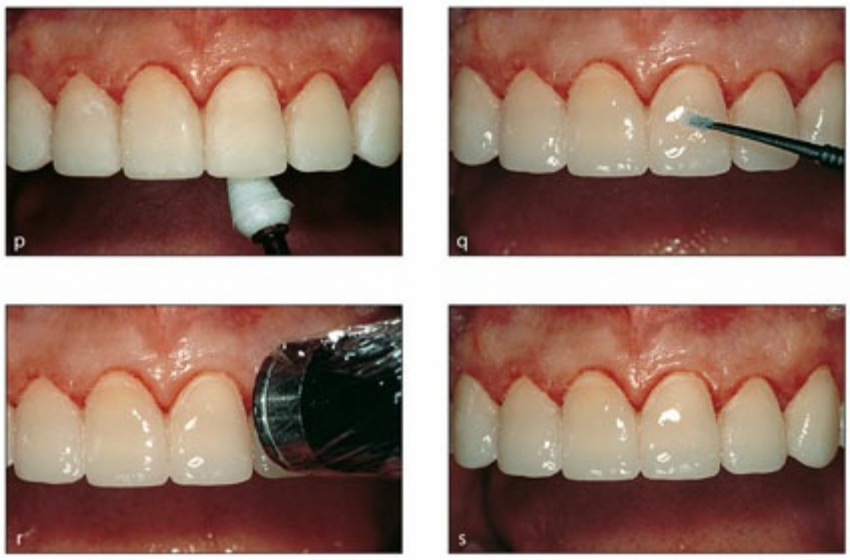

Fig 17-35*(cont) (p)* A composite polishing point is used to smooth and polish the lingual surfaces. *(q and r)* The facial surfaces of the provisional restorations are coated with an adhesive resin and light cured. *(s)* Completed provisional restorations.

Alternatively, the provisional restoration may be made in the laboratory. After the veneer preparations are completed, an impression is made and poured in fast-setting die stone (Snap-Stone, Whip Mix). The cast is separated from the impression in 5 minutes and covered with a separating medium; the provisional restoration is constructed with the same matrix technique as previously described. The provisional restoration, which is constructed from either bis-acryl or resin composite, can then be cemented with polycarboxylate cement or temporarily bonded with a resin composite as previously described (see Fig 17-5).

At the appointment for placement of the definitive veneers, the provisional restorations are removed. The resin composite over the small area of etched enamel in the incisal third of the facial surface is lightly removed with a diamond bur, cutting dry. If water is used, it is very difficult to determine the interface between the provisional composite and the tooth structure. The remaining resin composite is flicked off with a spoon excavator. If a veneer does not seat during the try-in, there is probably resin composite from the provisional restoration remaining in the etched area. The preparation should be closely inspected to ensure that all of the resin composite has been removed.

Placement

The anatomy of a porcelain veneer is illustrated in Fig 17-36. The laminate veneer

Dentlearn.ir

can be made from feldspathic porcelain, pressed/milled monolithic ceramic with stain, or pressed/milled core porcelain with a veneering ceramic addition. Advantages and disadvantages of each ceramic are discussed in chapter 18. The inner surface of the veneer must be etched with hydrofluoric acid or another ceramic etchant. This step is usually accomplished in the laboratory. The etching time provided by the manufacturer must be followed closely. In addition to the microporosities that assist in micromechanical retention, microcracks are increased as etching time increases. These microcracks decrease the flexural strength of the porcelain and weaken the veneer.[10] (For a detailed description of the steps in veneer placement, see Box 17-1.) The veneers are first tried in individually for marginal fit. They are then tried in together to ensure that interproximal contacts are correct. Finally, one veneer (or more) is filled with water or try-in paste and taken to the mouth for the color try-in. If the color is acceptable to the patient with water or water-soluble try-in paste, the dentist proceeds with the bonding procedure as outlined in Box 17-1.

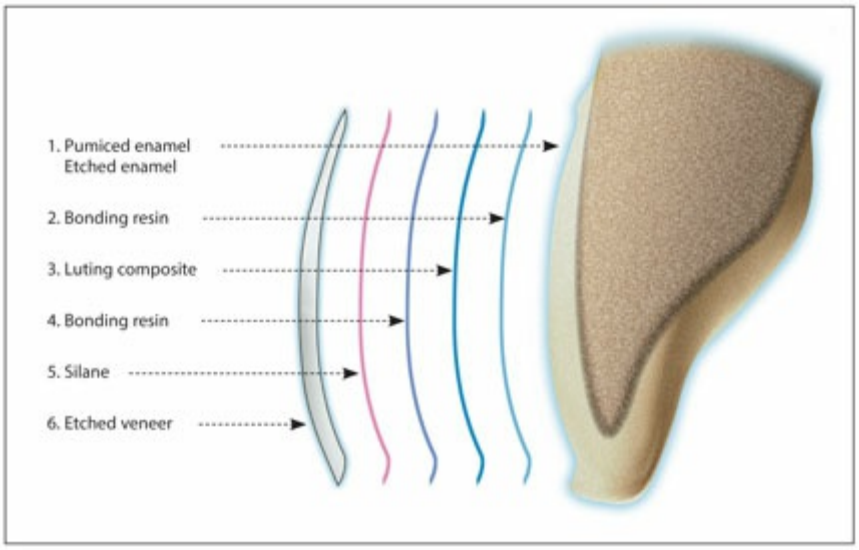

Fig 17-36 Anatomy of a porcelain veneer.

Box 17-1	**Procedures for insertion of porcelain veneers**
Veneer try-in 1. Check the veneers for fit on dies, and transilluminate to check for fracture lines. 2. Try in the veneers individually for fit and then all togeth er. Interproximal contact areas may need to be adjusted with a microfine diamond or disk. Do	

Dentlearn.ir

not make any other adjustments until the veneers are bonded.

3. Choose a shade of resin composite or water-soluble try in paste, place on the inside of the veneer, and try in.
4. If water-soluble try-in paste has been used, wash the veneer with water and air dry before loading with the unfilled resin and luting composite. If the shade is cor rect, skip steps 5 through 12, and proceed with step 13.
5. If the shade is incorrect, remove the try-in composite and select another shade, or customize the shade by adding tint to the luting composite.
6. If characterization (eg, blue in incisal areas, yellow at gingival areas) is required, tints and opaques should be placed only on the tooth and not on the inside of the veneer. The tints and opaques are brushed on the tooth in a thin layer and light cured for 30 seconds. All try-in composite must be removed from the tooth (facial, proximal, and lingual aspects) before the tints and opaques are cured. Because the tooth was not etched, the cured tints and opaques can be scraped off easily with an explorer at the end of the try-in.
7. Once a combination of composite, tint, and/or opaque has been determined, make note of it so that it can be reproduced exactly for final luting.
8. Clean the try-in resin composite from the inside of the veneer with acetone using two different beakers. Clean the bulk of the resin composite with a

14. Place clear plastic matrix or dead-soft metal matrix material on the distal aspects of both central incisors.
15. Etch both central incisors with 30% to 40% phosphoric acid for 20 seconds, wash for 3 seconds, and air dry to ensure adequate etch of the enamel.
16. Remoisten tooth surface with water or chlorhexidine.
17. If using a three-step etch-and-rinse bonding agent, actively apply several coats of primer and gently air dry until the tooth surface is completely dry. Check for a uniform shiny surface. If using a two-step etch-and-rinse or self-etching adhesive system, follow manufacturer instructions for drying and curing.
18. If using a three-step etch-and-rinse bonding agent, place the dentin adhesive on the tooth surface and the inner surface of the veneer. If using a two-step etch-and-rinse or self-etching adhesive system, place the component that contains the bonding resin on the inner surface of the veneer.
19. If tints or opaques are necessary, place them on the pre determined areas of the preparation and light cure for 90 seconds.

Placement

20. Place bonding resin and light-cured resin composite into the veneer being bonded. The operatory light should be turned off at this time.
21. With shimstock (0.0005-inch thickness) between the central incisors and clear plastic matrix strips or dead soft metal matrix material on the distal aspects of each

Dentlearn.ir

brush dipped in
the first beaker, then transfer the veneer to the second,
clean beaker of acetone to remove the remaining resin
composite.

Veneer preparation

9. Place the veneers, etched side down, on a 2 × 2–inch
gauze pad in a glass beaker of clean acetone, and place
the beaker in an ultrasonic cleaner for 5 minutes.
10. Remove the veneers from the acetone and dry.
11. If the veneers have already been etched, place silane on
the inner surface of the veneers and allow it to air dry.
If not already etched at a dental laboratory, etch with
hydrofluoric acid and then add silane as per instructions.

Tooth preparation

12. Place retraction cord in the sulcus of each prepared
tooth (but not the mandibular incisors if the margins
are more than 1.0 mm from the gingival crest).
13. Clean both central incisors with oil-free pumice paste.
(This should be done for each tooth just before etching.)
Ensure that all excess resin composite is removed on
the facial and proximal surfaces. Finishing of the mar
gins with a rotary instrument should be avoided,
because it will damage the root and remove the glaze
from the veneer. This will cause an increase in plaque
retention and elicit a gingival reaction.
30. Remove excess resin composite from the lingual sur
faces with an egg-shaped, 12-fluted
central incisor, gently place veneers onto both central incisors and tease into place. Ensure that excess resin composite appears at all margins.
22. Remove excess resin composite from veneers with a small brush or explorer, depending on viscosity.
23. While standing in front of the patient, visually inspect to ensure that veneers are placed correctly. Ensure that mesial surfaces are in contact.
24. Lightly press the facial surfaces of the veneers and light cure from the lingual aspect for 30 seconds, then light cure from the facial aspect for 30 seconds.
25. Remove the excess resin composite only on the distal surfaces of the central incisors with a no. 12 or 12B scalpel blade to ensure that the veneers on the lateral incisors will fit.
26. Visually inspect for voids and repair if possible.
27. Try in the left lateral incisor veneer to ensure correct fit.
28. Repeat steps 14 to 28 for each veneer being placed.

Finishing

29. Remove minimal gingival flash of resin composite with a no. 12 or 12B scalpel blade. Move blade from the veneer gingivally to avoid chipping the veneer's margin.
with a finishing diamond or bur. Be careful not to scar the cementum.
36. Polish all roughened porcelain using an abrasive impregnated rubber porcelain polishing system (Bras seler or Shofu). 37. Finish the proximal areas with finishing and polishing
strips. 38. Any visible porcelain that has been finished and smoothed with a rubber point should be polished with diamond polishing paste on a wet felt wheel and pro phylaxis cup at the gingival margin. Be careful not to polish the cementum. 39. With the retraction cord still in place, re-etch and rebond
(with rebonding or surface sealing resin) all margins.
40. Remove the retraction cord.
41. Have the patient return in 1 week to inspect for excess composite and rough areas. At this time, final esthetic reshaping may be accomplished.

Dentlearn.ir

carbide bur. 31. Smooth lingual surfaces with composite polishing points or disks. 32. Check and adjust the occlusion in maximum intercus pation position and in excursion (with special attention to the distal incisal edges of the maxillary lateral inci sors). 33. Reshape incisal edges and contours while standing in front of the patient. 34. Reshape and contour incisal embrasures with a finish ing diamond or thin separating disk. 35. Gingival margins should be smooth and require no finishing. If gingival margins are rough, smooth them	

There are many resin luting cement kits available with differing degrees of translucency and viscosity (Fig 17-37). Translucent cements are indicated as the standard material for veneer bonding. The more opaque cements tend to block the natural tooth color, resulting in a veneer with a less-natural appearance. The opaque cements are more commonly used to help block the darkness of discolored teeth. However, the use of these cements can result in a monochromatic appearance and an opaque line at the thin gingival margin of the veneer (Fig 17-38). It is preferable to block the darkness of discolored teeth with a layer of masking dentin porcelain, and/or with porcelain modifiers, in the body of the veneer rather than with an opaque cement (Fig 17-39).

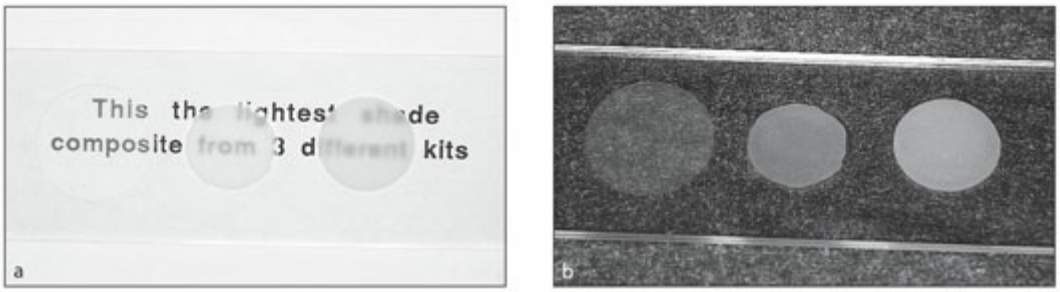

Fig 17-37*(a and b)* The lightest shade of luting composite from three different kits has been placed between two glass slides. The same materials are shown against two different backgrounds. Note the differences in translucency. (Fig 17-37a reprinted from Robbins[49] with permission.)

Dentlearn.ir

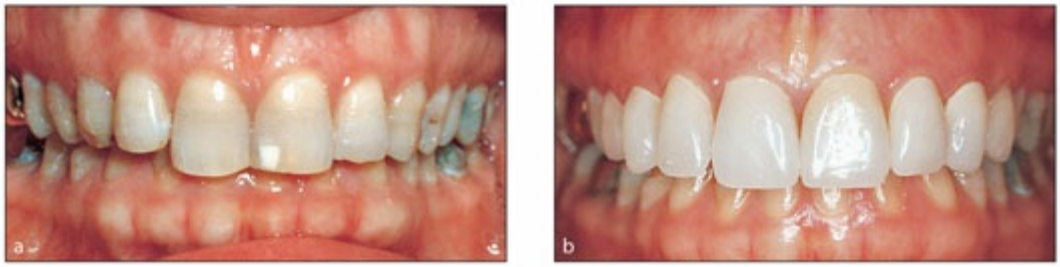

Fig 17-38*(a)* Moderately dark, tetracycline-stained teeth prior to veneer preparation. *(b)* Veneers bonded on dark teeth with opaque resin cement. Note the opaque gingival margins.



Fig 17-39 Veneers displaying different amounts of translucency. The left veneer is made from a very translucent porcelain, which allows most of the underlying tooth color to show through. The center veneer has a base layer of masking dentin porcelain, which is used to block dark underlying tooth color yet maintain some degree of polychromicity. The right veneer has a layer of opaque resin cement bonded to the inner surface of the veneer. The opaque resin is very reflective and results in a displeasing, monochromatic appearance.

The second major difference in veneer luting cements is their viscosity. Initially, most resin cements had a low viscosity so that the veneers could be placed with minimal pressure, thereby decreasing the risk of fracture.[50] However, the low-viscosity resins have some disadvantages: *(1)* Because of their honeylike consistency, it is more difficult to ensure correct veneer placement, especially when the veneers have no positive stop (ie, no incisal overlap); *(2)* cleanup of excess resin is more difficult; and *(3)* at least theoretically, the physical and mechanical properties are compromised because of the increased proportion of resin matrix. The major indication for the low-viscosity luting resin is the all-ceramic crown or a veneer that covers most of the tooth surfaces. Because of friction, high-viscosity luting resins will not allow complete seating of these restorations. Recently, interest in the higher-viscosity luting resins has increased because they overcome most of the disadvantages of the low-viscosity luting resins.

Friedman[51] has described a technique for using the highly filled resin composite from a standard restorative resin composite kit. The material is brought to room temperature and placed into the veneer in a thin layer through a ribbon tip. The thixotropic properties of the resin composite allow the highly filled material to flow

Dentlearn.ir

under moderate seating pressure. However, placing the ampule of composite in a hot water bath (160°F) or composite warmer (eg, Calset, AdDent) before ejecting the composite is a more effective method of improving the flow characteristics of the resin composite. With this technique, the seating of the veneers can be more accurately controlled, and cleanup is simplified (see Box 17-1).

The third difference between luting agents is in the chemical mechanism by which curing is initiated. The preferred method for bonding porcelain veneers is a light-curing luting composite. Light curing allows a longer working time, shorter finishing time, and superior color stability compared with dual-curing or chemically cured material. It used to be that if the porcelain thickness was greater than 0.7 mm, the light-curing composites did not reach their maximum hardness.[52] However, with current light-curing units, it is possible to cure through 2 mm or even greater thicknesses of ceramics.[53–55] It is advisable to avoid using a dual-curing resin luting cement because light-curing resin composites tend to be more color stable than dual-curing systems.[56] However, the ability of the curing light to penetrate through ceramic to the underlying adhesive and resin cement is dependent on the ceramic thickness, shade and translucency.[57]

In those situations in which the dentist is concerned about the adequacy of cure of a light-curing resin cement through a veneer, a dual-curing composite system is recommended. Dual-curing materials contain the initiation systems for both chemical-curing and light-curing composites. Even so, dual-curing resin materials should always be light cured, because any light will enhance the degree of conversion of a dual-curing material[58] and will provide for better color stability.[59] Additionally, if the veneer is to be bonded to a tooth preparation that includes a significant amount of dentin, light curing of the adhesive separately may produce significantly higher bond strengths to dentin than the traditional co-curing method (ie, not light curing until after the resin cement application).[60] However, curing the adhesive prior to luting the veneer runs the risk that cured, pooled adhesive will prevent adequate adaptation of the veneer to the preparation.

Color Management and Characterization

A common problem with porcelain veneers is the lack of color differentiation between the gingival and incisal portions of the restoration. Several methods of color characterization can be used to correct the monochromatism.[49,61,62] The best and most basic method makes the color changes in the porcelain itself. A color

Dentlearn.ir

diagram that outlines the desired shade and color changes and any other special characterization, such as hypocalcified or hyperchromatic areas, can be given to the laboratory technician. However, the most effective method of communicating color to the laboratory technician is with photographs (see Figs 17-8b and 17-8c). When characterization is incorporated into the veneer, it is permanent. If the esthetic result is not satisfactory during the try-in, it is difficult, if not impossible, to successfully modify the veneer.

A second commonly used method involves the modification of the color with the underlying luting composite. All porcelain veneer kits have several different shades of luting composite. If an appropriate shade of luting cement is not available, resin tints can be added to the luting composite to effect virtually any desired color.

A third and less commonly used method of characterization involves the direct placement of the resin tints on the tooth before placement of the veneer (Fig 17-40). During the try-in, the desired resin tints are placed on the tooth and light cured. The chosen base shade of luting composite is placed in the veneer, and the veneer is placed on the tooth. A determination is then made regarding the esthetic result. The veneer can be removed, and the cured resin tint on the tooth can easily be scraped off with an explorer because the enamel was not etched. If the esthetic result is acceptable, the dentist can proceed with the bonding, using the tints that were used during the try-in.



Fig 17-40 *(a)* Veneer preparations on the maxillary central and lateral incisors. *(b)* Placement of yellow resin tint in the gingival third and blue resin tint in the incisal third. *(c)* Kit of resin tints and opaques. *(d)* Monochromatic appearance of veneers tried in with try-in paste but without the use of resin tints. *(e)* Polychromatic appearance of bonded veneers after the placement of resin tints. (Reprinted from Robbins[62] with permission.)

The definitive restoration will not always exhibit the same color displayed at the

Dentlearn.ir

try-in. This occurs because the luting composite becomes more translucent when it is cured, allowing more of the underlying tooth color to show through.[63] Although not usually a problem, this color-change phenomenon will occasionally result in a disappointing esthetic result, especially when the dentist is attempting to match a single veneer to an adjacent natural tooth.

Discolored teeth

Darkly discolored teeth present the greatest challenge for porcelain veneers because the underlying tooth color, cement color, and ceramic thickness all influence the resulting color of the veneer.[64] There are many causes of tooth discoloration, including extrinsic staining, fluorosis, pulpal injury, drugs (eg, tetracycline), and previous restorations. The ideal method of dealing with stain is to remove it, when possible. Extrinsic stains are easily removed during tooth preparation. Because fluoride predominantly affects the enamel, the discoloration of fluorosis is also commonly diminished by tooth preparation.

However, the by-products of pulpal injury, tetracycline, and previous restorations are found predominantly in the dentin, making their removal more difficult. The restoration of the high-chroma, low-value tetracycline-stained tooth with a porcelain veneer is perhaps the most difficult treatment situation. Instinctively, practitioners prepare the discolored teeth more deeply to allow more room for porcelain. However, as more enamel is removed, the underlying color becomes darker (Fig 17-41). Herein lies the major difficulty in placing porcelain veneers on tetracycline-stained teeth. Additional tooth structure should only be removed in the areas of discoloration, not over the entire preparation. Tetracycline-stained teeth are often severely discolored in the middle third of the tooth, with other areas having an acceptable or easily modified color. Ideally the preparation should stay within the enamel in the gingival and incisal thirds and only deepen in the middle third. The amount of reduction required depends on the color of the preparation and the desired chroma/value of the definitive restoration.



Fig 17-41 Preparation of a severely tetracycline-stained maxillary central incisor, which demonstrates increased darkness with increased depth of preparation.

Dentlearn.ir

Ceramic buildup

The evolution of contemporary porcelain materials and sophisticated fabrication techniques has allowed laboratory technicians to block out significant discolorations with ultrathin veneers (Fig 17-42). Veneers with pressed or milled ceramic cores provide the technician the ability to block out many of the discolorations without overly opaquing the veneer and destroying the natural beauty of the restoration.[64] The color of the prepared tooth is used for the development of natural color. It is important that clinicians provide the laboratory with a photograph of the final preparation at a 1:1 magnification. With this photograph, the tooth can be measured by the technician and the maverick colors or discolorations located. Once blemishes have been identified, masking agents can be added selectively to the restoration. Color characteristic stains are routinely used to create optical effects and conceal discolorations in conservative veneer restorations. These stains are opaque metal oxides that are painted into wet porcelains. The stains are used to mask discoloration or further characterize the appearance of the veneer and are subsequently covered with a thin layer of opalescent or fluorescent porcelain prior to firing. It is possible to modify the color of the tooth by one to two shades for every 0.2 mm of tooth reduction.



Fig 17-42 *(a)* Removal of bonded resin composite veneers demonstrates significant discoloration of the maxillary right canine and left central incisor. *(b)* Final conservative full-veneer preparations. *(c)* Porcelain veneers bonded with translucent resin demonstrating significant color correction with contemporary porcelains.

Masking

It is difficult to mask dark underlying tooth color with a natural-appearing porcelain veneer (Fig 17-43). If the luting cement is sufficiently opaque to mask the dark color, the definitive restoration commonly appears lifeless and monochromatic.[65] Conversely, if the veneer and/or cement contains no opaque element, the darkness of the underlying tooth structure will be visible through the porcelain. As previously stated, it is preferable to incorporate the opaque elements into the porcelain rather than to attempt to mask the darkness with opaque resin composite. This requires excellent communication between the laboratory technician and the dentist.

Dentlearn.ir

Postpreparation photographs with a shade tab for color comparison are very helpful to the technician when porcelain veneers are being fabricated for discolored teeth (see Fig 17-21c). The photographs illustrate both the intensity of the darkness and the position of the bands of darkness.

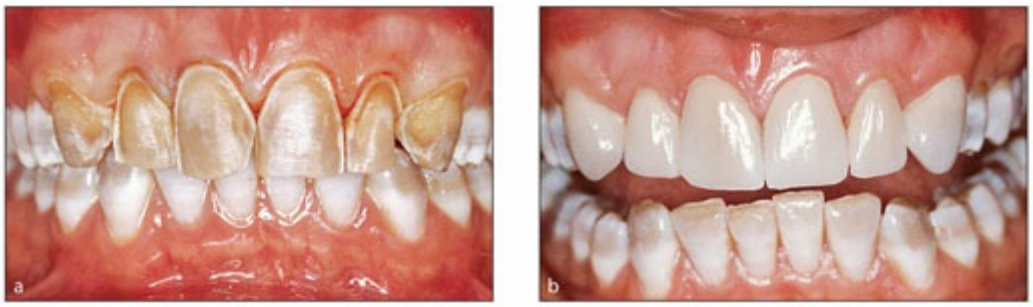

Fig 17-43 *(a)* Discolored maxillary anterior teeth prepared for porcelain veneers. *(b)* Discolored maxillary anterior teeth with bonded porcelain veneers. (Reprinted from Robbins[62] with permission.)

Several methods of masking dark underlying tooth color with resin composite have been proposed. Friedman[51] reported successful use of a standard highly filled restorative resin composite as the luting cement. Reid[61] discussed the use of complementary colors to mask underlying dark tooth color. For example, if the tooth is predominantly yellow, a violet tint is placed and light cured. This neutralizes the high-chroma yellow to a low-value gray. Opaque resin tint is then placed over the violet tint and light cured to increase the value, and the veneer is bonded in the routine manner. Although theoretically appealing, this technique has not proven to be of practical benefit.

When discoloration is localized rather than generalized, it can be removed mechanically with a bur and replaced with the appropriate shade of glass ionomer or resin composite. This is usually done after the veneer preparation is completed but before the final impression is made; however, it can be done immediately before cementation of the veneer.

Composite luting agent can be used to block underlying darkness to a limited degree. However, most of the masking must be accomplished with body modifiers that are incorporated into the porcelain veneer. Depending on the degree of darkness being masked, the technician must place 50 to 100 μm of die spacer on the refractory die prior to veneer fabrication. This allows space for an additional thickness of the luting composite, which aids in the masking of the underlying darkness. Although the appearance of discolored teeth can usually be improved with porcelain veneers, the patient must understand the limitations of the restoration.

Dentlearn.ir

Bleaching

When a discolored tooth can be lightened before veneer placement, the final result is routinely improved. This can be accomplished in endodontically treated teeth with a "walking bleach" technique[66] (Fig 17-44) (see also chapter 16). A 2.0-mm-thick base of glass-ionomer cement is placed in the base of the pulp chamber to protect the cervix from bleach. A paste mixture of sodium perborate and water is placed in the pulp chamber, which is sealed with a temporary cement for 3 to 5 days. This can be repeated for several treatments until the desired result is attained. The mixture is ultimately removed, and the access area is restored with a resin composite restoration. At this point, the tooth is prepared for the porcelain veneer restoration. If the darkness returns in future years, the walking bleach can be accomplished again through the lingual access without disturbing the porcelain veneer restoration.



Fig 17-44 *(a)* Discolored endodontically treated maxillary right central incisor. *(b)* Maxillary right central incisor after completion of walking bleach procedure. *(c)* Maxillary right central incisor with a porcelain veneer bonded in place. (Reprinted from Robbins[49] with permission.) (Porcelain veneer created by Danny Diebel, CDT, Austin, Texas.)

The success of bleaching vital teeth before veneer placement is not as clear-cut. It is known that vital teeth that have been bleached have the potential to revert toward their original color with time.[67] However, the effect that the placement of porcelain veneers has on this relapse is not known. If color relapse does occur, the veneer restorations will also get darker. There has been reported success in bleaching teeth that have veneers bonded to them (see chapter 16).

Bleaching teeth with 35% hydrogen peroxide[68] or carbamide peroxide[69] immediately before the bonding procedure has a catastrophic effect on the resultant bond strength. Any bonding procedure should be delayed at least 1 to 2 weeks after the completion of bleaching to maximize bond strength and allow for shade stabilization. It is hoped that future research will clarify the effects of bleaching on the success of porcelain veneers.

Crown and V

Dentlearn.ir

When a combination of veneers and crowns is placed, all restorations must be tried in individually and then simultaneously for fit. They must also be tried in for color evaluation with a try-in medium. If the veneer and crown shades do not match, it is preferable to make minor color modifications with the veneer luting resin to see if the veneers can be made to match the shade of the crowns, because these modifications can be made chairside. If that is not successful in matching the shade of the veneers and crowns, it is possible to attempt surface staining of the crowns. However, unless the office has a glazing oven, the crowns will have to be returned to the dental laboratory to complete the staining process. If it is necessary to return the case to the laboratory, then the dentist has the option of luting in whichever restorations the patient prefers, obtaining new shade photographs, and having the laboratory adjust the shade of the remaining restorations to the newly luted restorations. Alternatively, the entire case can be returned for refabrication and better shade matching.

Failure Repair

As mentioned earlier in the chapter, there are a number of causes for veneers to fail. However, it is possible to repair many such failures. When the luting composite remains on the inner surface of the veneer after a debonding event, it must be removed before the veneer can be rebonded. The bonding resin is removed either with air abrasion or a fine finishing diamond bur. The veneer is then cleaned with acetone and re-etched with 9.5% hydrofluoric acid for 20 to 90 seconds, depending on the type of porcelain. If 9.5% hydrofluoric acid is not available, 1.23% acidulated phosphate fluoride can be used to etch the porcelain; however, this requires a 10-minute etching time. The veneer is then washed, dried, silanated,[70] and rebonded. The patient must know that there is a significant risk of veneer fracture during removal of the luting composite.

A small percentage of veneers will fracture.[3–5] It is possible to repair fractured porcelain. First, the porcelain fracture site is etched with 9.5% hydrofluoric acid for 20 to 90 seconds. After the veneer is washed and dried, silane is placed and allowed to air dry. The repair is then accomplished with conventional bonded resin composite techniques. Because the hydrofluoric acid should not be allowed to contact natural tooth structure or soft tissue, this etching procedure should be performed with rubber dam isolation.

As noted, marginal staining around the veneer can occur. If the marginal stain is

Dentlearn.ir

superficial, it can be removed by tray bleaching with 10% carbamide peroxide for several days. After the stain has been removed, the margin can be etched with 30% to 40% phosphoric acid and sealed with a dentin bonding agent. If the stain is slightly penetrating at the margin (Fig 17-45), it can be mechanically removed with a small bur and the area restored with conventional bonded resin composite. When there is significant penetration of stain under the veneer, the entire veneer must be removed (Fig 17-46).



Fig 17-45 Minimally penetrating stain at the mesi-al margin of the maxillary right canine.



Fig 17-46 Deeply penetrating stain under the porcelain veneer on the maxillary right central incisor.

Veneer Removal

Removal of porcelain veneers is not only time-consuming but also difficult and technique sensitive, especially if the underlying tooth color is light. The veneer cannot be grooved with a bur and rotated (torqued) in the same manner that a cemented gold crown is removed. The veneer must be removed with a diamond bur in the same way that enamel is removed during initial tooth preparation.

The dentist starts removing the porcelain in the midfacial area with a back-and-forth sweeping motion with a barrel diamond (Fig 17-47a). This must be done without water spray so that the operator can visualize the subtle color difference between the veneer and tooth structure as the interface is reached. Therefore, the dental assistant must cool the tooth with a constant stream of air. Once this interface is apparent (Fig 17-47b), the diamond bur is moved laterally away from the area of exposed enamel toward the periphery of the preparation. Care must be taken to

Dentlearn.ir

remove as little enamel as possible during this step.



Fig 17-47 Veneer removal. *(a)* Initial removal of porcelain before tooth structure is reached. *(b)* Porcelain is removed until the first area of enamel is visualized. *(c)* Exploring margins with a no. 12 or 12B scalpel blade to remove remaining resin composite and porcelain.

The procedure continues until only a small amount of porcelain remains at the margins. If there has been microleakage at the margins, the remaining marginal porcelain can be removed with a no. 12 or 12B scalpel blade. However, if the marginal seal is intact, the remainder of the porcelain must be cautiously removed with the diamond bur.

It is very important that the operator not lose orientation in relation to the porcelain-tooth interface. If this occurs, it is very easy to inadvertently remove all of the enamel. For this reason, one veneer should be completely removed before starting veneer removal on the next tooth.

After all porcelain veneers have been removed, gingival retraction cord is packed to clearly expose all margins. As the final step of veneer removal, all margins are explored with a sharp no. 12 or 12B scalpel blade (Fig 17-47c), which commonly results in the removal of additional small areas of residual resin composite and porcelain.

Maintenance

The maintenance of the porcelain veneer restoration is similar to that of the porcelain crown. Devices such as an ultrasonic cleaner, air-abrasive polisher, and prophylaxis cup with pumice must be avoided. Surface stains may be removed from porcelain veneers with aluminum oxide polishing paste or diamond polishing paste on a felt wheel or rubber cup. Proximal stains may be removed with composite polishing strips. When scaling is performed around porcelain veneers, care must be taken not to chip the margins. If a fluoride preparation is needed by the patient, it should have a neutral pH; because of their ability to etch porcelain, neither acidulated phosphate fluoride nor stannous fluoride should be used.

The patient should be advised that foods and liquids with a high potential for

Dentlearn.ir

staining, such as coffee and tea, increase the potential for marginal staining. The patient also must be made aware of the potential for the porcelain to fracture. Activities such as ice chewing and fingernail biting must absolutely be avoided. It is a good idea to make an occlusal guard appliance for all patients who have porcelain veneer restorations. When porcelain veneer restorations will oppose natural teeth or when the patient has a history of a parafunctional habit, a protective appliance should be fabricated to protect both the porcelain veneers and the opposing teeth.

Acknowledgment

The illustrations for chapter 17 were completed by John Bonfardeci of Studio Giovanni.

References

1. Fradeani M, Redemagni M, Corrado M. Porcelain laminate veneers: 6- to 12-year clinical evaluation—A retrospective study. Int J Periodontics Restorative Dent 2005;25:9–17.
2. Beier US, Kapferer I, Burtscher D, Dumfahrt H. Clinical performance of porcelain laminate veneers for up to 20 years. Int J Prosthodont 2012; 25:79–85.
3. D'Arcangelo C, De Angelis F, Vadini M, D'Amario M. Clinical evaluation on porcelain laminate veneers bonded with light-cured composite: Results up to 7 years. Clin Oral Investig 2011;16:1071–1079.
4. Aykor A, Ozel E. Five-year clinical evaluation of 300 teeth restored with porcelain laminate veneers using total-etch and a modified self-etch adhesive system. Oper Dent 2009;34:516–523.
5. Layton D, Walton T. An up to 16-year prospective study of 304 porcelain veneers. Int J Prosthodont 2007;20:389–396.
6. Smales RJ, Etemadi S. Long-term survival of porcelain laminate veneers using two preparation designs: A retrospective study. Int J Prosthodont 2004;17:323–326.
7. Peumans M, De Munck J, Fieuws S, Lambrechts P, Vanherle G, Van Meerbeek B. A prospective ten-year clinical trial of porcelain veneers. J Adhes Dent 2004;6:65–76.
8. Edelhoff D, Sorensen JA. Tooth structure removal associated with various preparation designs for anterior teeth. J Prosthet Dent 2002;87: 503–509.
9. Levinson N. Psychological facets of esthetic dental health care: A developmental perspective. J Prosthet Dent 1990;64:486–491.
10. Peumans M, Van Meerbeek B, Lambrechts P, Vanherle G. Porcelain veneers: A review of the literature. J Dent 2000;28:163–177.
11. Friedman MJ. A 15-year review of porcelain veneer failure—A clinician's observations. Compend Contin Educ Dent 1998;19:625–628,630,632.
12. Dumfahrt H, Schäffer H, Porcelain laminate veneers. A retrospective evaluation after 1 to 10 years of service: Part II—Clinical results. Int J Prosthodont 2000;13:9–18.
13. Magne P, Douglas WH. Design optimization and evolution of bonded ceramics for the anterior dentition: A finite-element analysis. Quintessence Int 1999;30:661–672.
14. Magne P, Douglas W. Porcelain veneers: Dentin bonding optimization and biomimetic recovery of the crown. Int J Prosthodont 1999;12:111–121.
15. Troedson M, Dérand T. Shear stresses in the adhesive layer under porcelain veneers. A finite element

Dentlearn.ir

method study. Acta Odontol Scand 1998; 56:257–262.
16. Hahn P, Gustav M, Hellwig E. An in vitro assessment of the strength of porcelain veneers dependent on tooth preparation. J Oral Rehabil 2000;27:1024–1029.
17. Shaini FJ, Shortall AC, Marquis PM. Clinical performance of porcelain laminate veneers. A retrospective evaluation over a period of 6.5 years. J Oral Rehabil 1997;24:553–559.
18. Highton R, Caputo AA, Matyas J. A photoelastic study of stresses on porcelain laminate preparations. J Prosthet Dent 1987;58:157–161.
19. Schneider PM, Messer LB, Douglas WH. The effect of enamel surface reduction in vitro on the bonding of composite resin to permanent human enamel. J Dent Res 1981;60:895–900.
20. Seymour KG, Cherukara GP, Samarawickrama DY. Stresses within porcelain veneers and the composite lute using different preparation designs. J Prosthodont 2001;10:16–21.
21. Crispin B. Esthetic moieties. J Esthet Dent 1993;5:37.
22. Rouse J, McGowan S. Restoration of the anterior maxilla with ultraconservative veneers: Clinical and laboratory considerations. Pract Periodontics Aesthet Dent 1999;11:333–339.
23. Atsu SS, Aka S, Kucukesmen C, Kilicarslan MA, Atakan C. Age-related changes in tooth enamel as

341.
24. Walls AW, Steele JG, Wassell RW. Crowns and other extracoronal restorations: Porcelain laminate veneers. Br Dent J 2002;193:73–82.
25. Cherukara GP, Seymour KG, Zou L, Samarawickrama DY. Geographic distribution of porcelain veneer preparation depth with various clinical techniques. J Prosthet Dent 2003;89:544–550.
26. Cherukara GP, Davis GR, Seymour KG, Zou L, Samarawickrama DY. Dentin exposure in tooth preparations for porcelain veneers: A pilot study. J Prosthet Dent 2005;94:414–420.
27. Cherukara GP, Seymour KG, Samarawickrama DY, Zou L. A study into the variations in the labial reduction of teeth prepared to receive porcelain veneers—A comparison of three clinical techniques. Br Dent J 2002;192:401–404.
28. Chun, YP, Raffelt C, Pfeiffer H, et al. Restoring strength of incisors with veneers and full ceramic crowns. J Adhes Dent 2010;1:45–54.
29. Gürel G. Porcelain laminate veneers: Minimal tooth preparation by design. Dent Clin North Am 2007;51:419–431.
30. Rouse JS. Full veneer versus traditional veneer preparation: A discussion of interproximal extension. J Prosthet Dent 1997;6:545–549.
31. Wylie SG, Tan HK, Brooke K. Restoring the vertical dimension of man-dibular incisors with bonded ceramic restorations. Aust Dent J 2000;45:91–96.
32. Stappert CF, Ozden U, Gerds T, Strub JR. Longevity and failure load of ceramic veneers with different preparation designs after exposure to masticatory simulation. J Prosthet Dent 2005;94:132–139.
33. Castelnuovo J, Tjan AH, Phillips K, et al. Fracture strength and failure mode for different ceramic veneer designs [abstract 1373]. J Dent Res 1998;77:803.
34. Schmidt KK, Chaiyabutr Y, Phillips KM, Kois JC. Influence of preparation design and existing condition of tooth structure on load to failure of ceramic laminate veneers. J Prosthet Dent 2011;105:374–382.
35. Chaiyabutr Y, Phillips KM, Ma PS, Chitswe K. Comparison of load-fatigue testing of ceramic veneers with two different preparation designs. Int J Prosthodont 2009;22:573–575.
36. Kois JC. The restorative-periodontal interface: Biological parameters. Periodontol 2000 1996;11:29–38.
37. Andreason FM, Flugge E, Daugaard-Jensen J, Munksgaard EC. Treatment of crown fractured incisors with laminate veneer restorations. An experimental study. Endod Dent Traumatol 1992;8:30–35.
38. Gresnigt MM, Ozcan M, Kalk W, Galhano G. Effect of static and cyclic loading on ceramic laminate veneers adhered to teeth with and without aged composite restorations. J Adhes Dent 2011;13:569–577.
39. Bayne SC, Heymann HO, Wilder AD, et al. One-year clinical study of sclerotic vs. non-sclerotic dentin bonding [abstract 1221]. J Dent Res 1995;74:164.
40. Heymann HO, Bayne SC. Current concepts in dentin bonding: Focusing on dentinal adhesion factors. J Am

Dentlearn.ir

Dent Assoc 1993;124:27–36.
41. Tsai YL, Nakajima M, Wang CY, Foxton RM, Lin CP, Tagami J. Influence of etching ability of one-step self-etch adhesives on bonding to sound and non-carious cervical sclerotic dentin [epub ahead of print 25 November 2011]. Dent Mater J.
42. Lopes GC, Vieira LC, Araújo E, Bruggmann T, Zucco J, Oliveira G. Effect of dentin age and acid etching time on dentin bonding. J Adhes Dent 2011;13:139–145.
43. Xie C, Han Y, Zhao XY, Wang ZY, He HM. Microtensile bond strength of one- and two-step self-etching adhesives on sclerotic dentin: The effects of thermocycling. Oper Dent 2010;35:547–555.
44. Van Dijken JW. A prospective 8-year evaluation of a mild two-step self-etching adhesive and a heavily filled two-step etch-and-rinse system in non-carious cervical lesions. Dent Mater 2010;26:940–946.
45. Karakaya S, Unlu N, Say EC, Ozer F, Soyman M, Tagami J. Bond strengths of three different dentin adhesive systems to sclerotic dentin. Dent Mater J 2008;27:471–479.
46. Van Dijken JW. Durability of three simplified adhesive systems in Class V non-carious cervical dentin lesions. Am J Dent 2004;17:27–32.
47. Allen EP. Noncarious cervical lesions: Graft or restore? J Esthet Restor Dent 2005;17:332–334.
48. Rouse JS. Facial shell temporary veneers: Reducing chances for misunderstanding. J Prosthet Dent 1996;76:641–643.
49. Robbins J. Color management of the porcelain veneer. Esthet Dent Update 1992;3:132–135.
50. Barceleiro Mde O, De Miranda MS, Dias KR, Sekito T Jr. Shear bond strength of porcelain laminate veneer bonded with flowable composite. Oper Dent 2003;28:423–428.
51. Friedman M. Multiple potential of etched porcelain laminate veneers. J Am Dent Assoc 1987;122(special issue):83E–87E.
52. Linden JJ, Swift EJ, Boyer DB, Davis BK. Photo-activation of resin cements through porcelain veneers. J Dent Res 1991;70:154–157.
53. Lee IB, An W, Chang J, Um CM. Influence of ceramic thickness and curing mode on the polymerization shrinkage kinetics of dual-cured resin cements. Dent Mater 2008;24:1141–1147.
54. Foxton RM, Pereira PN, Nakajima M, Tagami J, Miura H. Effect of light source direction and restoration

134.
55. Koch A, Kroeger M, Hartung M, et al. Influence of ceramic translucency on curing efficacy of different light-curing units. J Adhes Dent 2007;9:449–462.
56. Kilinc E, Antonson SA, Hardigan PC, Kesercioglu A. Resin cement color stability and its influence on the final shade of all-ceramics. J Dent 2011;39(suppl 1):e30–e36.
57. Peixoto RT, Paulinelli VM, Sander HH, Lanza MD, Cury LA, Poletto LT. Light transmission through porcelain. Dent Mater 2007;23:1363–1368.
58. Cadenaro M, Navarra CO, Antoniolli F, et al. The effect of curing mode on extent of polymerization and microhardness of dual-cured, self-adhesive resin cements. Am J Dent 2010;23:14–18.
59. Koishi Y, Tanoue N, Atsuta M, Matsumura H. Influence of visible-light exposure on colour stability of current dual-curable luting composites. J Oral Rehabil 2002;29:387–393.
60. Chapman JL, Burgess JO, Holst S, Sadan A, Blatz MB. Precuring of self-etching bonding agents and its effect on bond strength of resin composite to dentin and enamel. Quintessence Int 2007;3:637–641.
61. Reid JS. Tooth color modification and porcelain veneers. Quintessence Int 1988;19:477–481.
62. Robbins J. Color characterization of porcelain veneers. Quintessence Int 1991;22:853–856.
63. Seghi R, Gritz MD, Kim J. Colorimetric changes in composite resins due to visible light polymerization [abstract 892]. J Dent Res 1988;67:224.
64. Chaiyabutr Y, Kois JC, Lebeau D, Nunokawa G. Effect of abutment tooth color, cement color, and ceramic thickness on the resulting optical color of a CAD/CAM glass-ceramic lithium disilicate-reinforced crown. J Prosthet Dent 2011;105:83–90.
65. Azer SS, Rosenstiel SF, Seghi RR, Johnston WM. Effect of substrate shades on the color of ceramic laminate veneers. J Prosthet Dent 2011; 106:179–183.

Dentlearn.ir

66. Rotstein I, Mor C, Friedman S. Prognosis of intracoronal bleaching with sodium perborate preparation in vitro: 1-year study. J Endod 1993;19: 10–12.
67. Haywood VB. Nightguard vital bleaching: Current concepts and research. J Am Dent Assoc 1997;128(suppl):19S–25S.
68. Torneck C, Titley K, Smith D, Adibfar A. The influence of time of hydrogen peroxide exposure on the adhesion of composite resin to bleached bovine enamel. J Endod 1990;16:123–128.
69. Godwin JM, Barghi N, Berry TG, et al. Time duration for dissipation of bleaching effects before enamel bonding [abstract 590]. J Dent Res 1992;71:179.
70. Hsu CS, Stangel I, Nathanson D. Shear bond strength of resin to etched porcelain [abstract 1095]. J Dent Res 1985;64:296.

Dentlearn.ir



Anterior Ceramic Crowns

Jeffrey S. Rouse

The provision of anterior ceramic crowns can be the most valuable and difficult service in dentistry. Protecting the natural dentition and providing an illusion of reality requires the practitioner to choose the correct ceramic system and prepare the site for success. This chapter discusses a systematic approach for selection of the proper ceramic system[1] and development of a foundation for the restoration that enables predictable results.

Decision-Making Factors

There are two common myths pertaining to anterior ceramics: *(1)* Strength is the most important decision-making factor, and *(2)* all-ceramic crowns are always more esthetic.

Strength should not be the overriding factor in choosing an anterior ceramic crown system. While it is true that metal-ceramic crowns are stronger than layered all-ceramic systems, the real question is how much strength is required. The answer is that the crown must be able to resist fracture under load. Normal incisal bite force averages between 100 and 300 N.[2,3] The weakest ceramic choice, a nonadhesively cemented porcelain jacket crown, has an adequate resistance to direct loading (545

Dentlearn.ir

N) for the anterior region. IPS Empress (Ivoclar Vivadent; 892 N) and IPS e.max (Ivoclar Vivadent; 1,200 N) have higher resistance to forces, which may be as much as an order of magnitude greater than those generated during normal function.[4,5] In addition, the ultimate strengths for axial and oblique loads on anterior ceramic systems exceed the maximum normal bite-force peaks.[4,5] Normal functional loads, therefore, should not damage all-ceramic crowns (Table 18-1). A systematic review showed survival rates of all-ceramic systems over 5 years to be equivalent to those of metal-ceramic systems. Lower survival rates for all-ceramic crowns are found when the crowns are placed on molars, where loads are significantly higher.[8]

Table 18-1	**Comparison of all-ceramic restorative systems[6,7]**			
Product	**Flexural strength (MPa)**	**Abrasiveness vs natural tooth**	**Special equipment**	**Other characteristics**
Traditional feldspathic porcelain	110–150	Varies; higher leucite content yields higher wear	Special refractory die	No core material; uniform translucency and shade throughout; etchable for bonding to tooth
Pressable ceramics				
IPS Empress	160–182	Comparable with natural tooth except when lay ered with conventional feldspathic porcelain	Special oven, die material, and molding process	Etchable for bonding to tooth; core material shaded and translucent
Optimal Pressable Ceramic (Pentron)	165	Same as for IPS Empress	Same as for IPS Empress	Same as for IPS Empress
IPS e.max Press (Ivoclar Vivadent)	400	Less wear than natural tooth	Same as for IPS Empress	Crown can be cemented or etched to bond; possible to do three-unit fixed partial denture for anterior teeth
Milled ceramics				
			Special die scan ner; computer	se translucent core; not

Dentlearn.ir

Procera (Nobel Biocare)	600	natural tooth	with modem; CAD/CAM machine	etchable, must be cemented
Zirconium oxide core ceramics	1,000	Less wear than natural tooth	Special CAD/CAM machine or dry pressed	Dense opaque core with limited dentin shades; not etchable, must be cement ed; may be used for limited fixed partial dentures
IPS e.max CAD (Ivoclar Vivadent)	360	Less wear than natural tooth	Special CAD/CAM machine and special oven for crystallizing the milled material	Milled material requires crystallization by heating at high temperature

All-ceramic systems are not always more esthetic. In the hands of an average laboratory technician, all-ceramic systems will be repeatedly more esthetic simply because of the lack of a metal core[6,9] (Fig 18-1). However, given proper preparation depths, skilled technicians can mimic natural teeth using a metal-ceramic system (Fig 18-2). The anterior restoration being fabricated will also play an important role in the patient perception. In a survey, more patients felt that single all-ceramic crowns were more natural and preferred them over metal-ceramic crowns. However, the opposite was true of anterior fixed partial dentures, where metal-ceramic was deemed to be more esthetic and preferred.[10]



Fig 18-1 All-ceramic crowns have a porcelain core, which facilitates an esthetic match. These crowns provide adequate strength to resist functional loads.

Dentlearn.ir



Fig 18-2*(a)* Porcelain layered over the metal substructure. Similar layering is accomplished for zirconia cores to mask the white opaque core. *(b)* Existing metal-ceramic crowns appear monochromatic and opaque. *(c)* With proper tooth reduction, a master ceramist can give metal-ceramic crowns a very lifelike quality. (Crowns fabricated by Lebeau Dental Laboratory, Renton, Washington.)

Metal-ceramic crowns are more appropriate for some patients and restorations than others. Teeth that are opaque or have high chroma and high value may be easier to match with metal-ceramic systems than with all-ceramic systems. A patient with a low lip line is a good candidate for metal-ceramics, because the esthetic weakness of metal-ceramics is most pronounced in the gingival third, where the opacity influences the brightness. The highly reflective opaque ceramic coating used to mask the metal is difficult to disguise when matching teeth with low color saturation or brightness (Fig 18-3). In the anterior region, many patients demand a perfect match of crown, tooth, and gingiva. This can be challenging for metal-core crowns. In an attempt to eliminate the gingival opacity, some ceramists stop the extension of the metal substructure up to 2 mm away from the shoulder.[11] This removes the highly reflective opacity in the gingival third, decreasing reflection and allowing light penetration into the cervical tooth structure, without decreasing the strength of the crown.[12,13] Light transmission illuminates the gingiva and eliminates the dark gingival shadow sometimes found around metal-ceramic crowns.[14]



Fig 18-3 Inadequate space for metal and porcelain may create unnatural opacity, as seen in this maxillary lateral incisor.

If practitioners should not make decisions based solely on the strength of metal-ceramic restorations or the esthetics of all-ceramic systems, then what criteria are

Dentlearn.ir

appropriate? When esthetic demands are high, an enamel-bonded veneer is the first choice. Adequate enamel must be present, and the patient should have no more than moderate parafunctional habits. It is commonly agreed that enamel-bonded veneers are the most predictable, most esthetic, and strongest restorations for anterior teeth (see chapter 17). However, veneers are contraindicated when a minority of the prepared tooth is in enamel; a sound bonding surface is critical to the strength and success of porcelain laminate restorations.

When veneers are contraindicated, choosing the correct anterior ceramic crown system is critical. The choice involves a hierarchy based on the esthetic goals of the patient, the preoperative condition of the tooth, and the load that the tooth will receive. The questions to be asked when deciding on the correct ceramic crown system are: *(1)* What are the esthetic demands, especially in the gingival third? *(2)* What is the quality of the bonding surface? *(3)* Does the patient have parafunctional habits? If so, what is the severity?

Esthetic demands

An evaluation of esthetics and a diagnosis should be conducted following the guidelines established in chapter 3. Patient expectations should be addressed before treatment begins. If there are limitations in the treatment, they should be discussed in advance. Diagnostic wax-ups or computer imaging may help determine what can be achieved with the restorations and aid in patient communication. Elements that affect the esthetic choice of materials include the color of the underlying structures (eg, post and core, discolored dentin, implant abutment) and the importance of the esthetic match in the gingival third.[14]

Veneers bonded to enamel provide some of the most beautiful and dependable restorations for anterior teeth. The thin laminate of porcelain provides an optical refractive index similar to that of translucent enamel, allowing the natural tooth to act as the color substrate. Therefore, when the tooth substrate is an ideal color, a veneer restoration can be placed that is almost imperceptible (Fig 18-4).

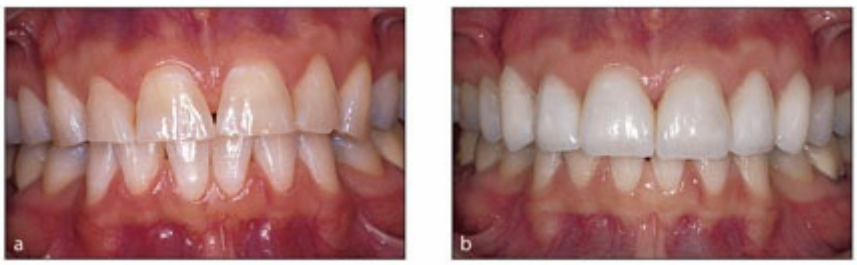

Fig 18-4*(a)* An increase in length and alteration of shape is required esthetically. The tooth color is acceptable, there are no restorations, and there is adequate enamel for bonding. Enamel-bonded

Dentlearn.ir

veneers are the restorations of choice. *(b)* When properly planned and constructed, enamel-bonded veneers are almost imperceptible.

A ceramic crown can be thought of as a veneer of "enamel" porcelain over a "dentin" ceramic core (Fig 18-5). This "dentin" core material can be feldspathic porcelain, castable glass, heat-pressed or milled leucite-reinforced ceramic, infiltrated alumina, heat-pressed or milled lithium disilicate, or zirconium oxide.[15] All cores can be laminated with veneering porcelain or stained. The type of core material used in a particular patient depends on the underlying tooth structure[16] (Table 18-2).



Fig 18-5 Unlike metal-ceramic crowns, cemented all-ceramic restorations are significantly influenced by the underlying color. In this case, an amalgam buildup shows through an all-ceramic crown on the maxillary left central incisor, making it too gray.

Table 18-2 **Selection criteria for anterior ceramic crown materials[16]**

Shade and appearance of natural teeth	Conventional feldspathic	Veneered OPC	Colored OPC	Veneered Empress	Colored Empress	IPS e.max	Procera	Zirconiu oxide
Vita A-1 to A-2; low color content, opaque, high brightness	×						×	×
Vita A-3; moderate color content, translucent body, opaque body	×	×	×	×	×	×	×	×

Dentlearn.ir

Vita A-3.5 to A-4; high color content, translucent or opaque	×	×	×	×	×	×	×	×
Altering shade from high color to low color			×		×	×	×	×
Translucent, low brightness, high color		×	×	×	×	×		
Translucent, grayish teeth		×		×				
Translucent, moderately bright teeth	×		×	×	×	×		

Because the core material has a perceptible effect on crown color,[14,16] an ideal core material should match the natural optical properties of dentin and mask any discoloration present. Today, the feldspathic porcelains most closely mimic the opalescent and fluorescent properties of natural teeth. They are translucent, color stable, brilliant, and natural. Therefore, if the underlying tooth color is acceptable, full feldspathic crowns produce the most natural result, because they allow the underlying tooth color to show through.[17]

If the "dentin" core color must be altered, the ceramic core selection changes (Fig 18-6). IPS Empress, IPS e.max Ceram (Ivoclar Vivadent), Optimal Pressable Ceramic (OPC) (Jeneric/ Pentron), and Finesse All-Ceramic (Dentsply Ceramco) allow broader choices of substrate color with intermediate translucency. In-Ceram Alumina (Vident), Procera (Nobel Biocare), Lava Ceram (3M ESPE) and In-Ceram Zirconia (Vident) provide a high-strength core that is relatively opaque. The influence of the core material is most noticeable in the gingival third. The more translucent the core, the more gray it appears as the darkness of the oral cavity shows through. This is most evident with translucent OPC and IPS Empress. A higher value or brightness is produced by the more opaque, reflective cores found in

Dentlearn.ir

alumina, zirconia, and metal-ceramic crowns.[18]



Fig 18-6 Dark prepared teeth are an esthetic challenge for all-ceramic restorations. The correct ceramic core must be chosen to minimize the effect of the discoloration.

Quality of the bonding surface

Anterior crowns can be fixed to the tooth by traditional cementation or by bonding. Traditional cementation utilizes a cement such as glass ionomer or resin-modified glass ionomer. Bonding uses a luting resin or a resin composite and resin adhesive. (In this chapter, the terms *cement* and *cementation* will be used to discuss insertion with traditional cements. The terms *resin cement*, *self-adhesive resin*, *bonding resin*, and *bonding* will be used in reference to resin bonding of restorations.) A traditional cement occupies the space between the restoration and the tooth surfaces, and none but the glass-ionomer cements provide adhesion to tooth structure. In most cases, bonding provides adhesion to both surfaces. Because of this, a bonded crown may not have the same requirements for tooth preparation as a cemented crown. In addition, bonding acts to transfer force from the ceramic material to the underlying tooth structure and strengthens an all-ceramic restoration that could be relatively weak if cemented with conventional cements that are brittle and do not reinforce the intaglio surface as well as resins.

When most all-ceramic crowns are bonded, the ceramic is etched to create micromechanical retention for the resin cement. Bonding procedures, such as those described in chapter 9, are performed on the tooth. When the resin cement is polymerized, it forms a rigid union between the restoration and the tooth. Under function, the porcelain-resin-dentin bond allows the resin to transfer load to underlying tooth structure.[19] Properly bonded crowns have fracture strengths far greater than human bite force,[20,21] but functional and parafunctional forces and the hydrodynamic nature of dentin may decrease bond strength with time. If the dentin bond is compromised, the porcelain becomes more susceptible to fracture. A study by Neiva et al[22] comparing the fracture strength of three ceramic materials reported

Dentlearn.ir

that bonded IPS Empress had a higher mean fracture strength than In-Ceram Alumina or Procera. However, with a compromised bond, IPS Empress was significantly weaker than the other systems.

The nature of the dentin surface significantly impacts the strength of the tooth-adhesive interface (Fig 18-7). The risk of debonding and fracture is magnified when the underlying dentin is less than optimal. Clinicians must recognize differences in dentin composition before planning restorations that depend on long-term dentin bonding.[23] Clinical evidence suggests that loss of cervical bonded restorations is more prevalent with deep or sclerotic dentin. Changes in the microstructure of dentin due to acid degradation (resulting from bulimia and gastrointestinal reflux) yields an accelerated sclerosing of the dentin and poor bond strengths.[24] Deep dentin can also significantly affect strength at the dentin-resin interface.[25] The density of the dentinal tubules is greatest near the pulp. Tubules represent 28% by volume of the dentin along the pulpal wall, compared with 4% by volume at the dentinoenamel junction.[23] Adhesive bond strengths in deep dentin are generally lower because there is less intertubular dentin space for bonding and greater moisture flow that may interfere with bonding.[26]



Fig 18-7 This patient displays signs of attrition from parafunc-tion, erosion from chewing aspirin and swishing acidic juices, and cervical notching from abrasion and abfraction.

In addition to a compromised dentin surface, bending forces beyond the ceramic limits are a contraindication to bonded ceramics. *Flexural fatigue*, or *abfraction*, is the pathologic loss of hard tooth substance by biomechanical loading forces (see Fig 18-7). This loss is thought to be the result of a combination of toothbrush abrasion and flexure and ultimate fatigue of enamel and/or dentin at some location distant from the actual point of loading and is more common in maxillary anterior teeth because of the higher buccal/lingual stress profile in the cervical region.[27] Eccentric forces can generate cervical flexure, resulting in stress concentrations in a bonded crown.[28] Cervical restoration failure occurs more commonly in mandibular incisors

Dentlearn.ir

than in maxillary incisors.[29] Tooth flexure can cause porcelain fracture or less obvious failure because of marginal leakage.

Carious or noncarious lesions or previous restorations may require a crown margin to be placed far apical to the gingival crest. Adhesion is affected by dentin moisture or other contaminants (blood, sulcular fluid, or saliva).[30–32] The inability to isolate subgingival margins prevents predictable dentin bonding and is therefore a contraindication to bonded ceramic crowns.[29] Strength is not a key criterion for a ceramic crown when the dentin bonding is maximized. When achieving the ultimate bond is compromised, however, a bonded ceramic crown may not be the restoration of choice.

Parafunction

Parafunction is a physiologically normal activation of voluntary skeletal muscles to produce behaviors that lack functional purpose and are potentially injurious. It occurs cyclically, and because it is mediated by the limbic system, it is harder to control and change.[33] Human bite force on anterior teeth rarely exceeds 200 N, well within the tolerances of most ceramic systems. Forces generated during diurnal parafunctional activity may be of significant force and duration to be damaging to all-ceramic systems. This can result in sudden, catastrophic failure.

A more gradual failure of an all-ceramic system comes from fatigue failure. Testing confirms that cyclic loading is much more damaging than static loading, given the same total time and maximum load.[34] Cyclic loading in a moist environment significantly decreases the mean failure load of an all-ceramic system.[35] Three modes of cyclic fracture can occur in an all-ceramic crown near the area of contact with an opposing tooth: *(1)* brittle-mode tensile cracks beginning on the occluding surface, *(2)* quasi-plastic mode microfractures within the ceramic material in a "yield" zone, and *(3)* radial cracking (undersurface tension flexes the core/ceramic veneer interface).[36] It has been postulated that these inner-surface cracks are the most likely cause of failure of cemented all-ceramic systems.[37] All of the fatigue modes of failure can occur with repeated functional loads. All-ceramic crowns have been shown in laboratory studies to be more susceptible to fatigue than metal-ceramic crowns.[38] However, severe loading during parafunctional episodes magnifies the damage by coalescence of microcracks into a macroflaw, accelerating the loss of strength and reducing the life span of the ceramic restoration. A thorough evaluation of the patient's parafunctional history is required in choosing an anterior ceramic system.

Dentlearn.ir

Hierarchical Approach

Once practitioners have answered questions regarding esthetics, bonding substrate, and parafunction, a hierarchical approach can be used to select the best anterior ceramic restoration for each patient. The choices begin with veneer crowns and conclude with metal-ceramic crowns. The type of ceramic crown is chosen when a tooth meets all the indications for that level. Refinement within the hierarchy is then made by meeting additional criteria.

Veneer crowns

Indications

1. Esthetics of primary importance
2. Mixed enamel and dentinal substrate
3. Minimal or no parafunction

Enamel-bonded porcelain laminate veneers are the most dependable and esthetic anterior ceramic restorations. A veneer allows the passage of light into the tooth, and the underlying tooth color provides a natural effect. A *veneer crown* is simply a veneer that covers the entire tooth. It is to be used only in selected cases, because transitions from thin to thicker porcelain make fabrication difficult. The preparation preserves remaining enamel and uses a conservative preparation design. The most common indication is for a peg-shaped lateral incisor. Another indication is a tooth with good enamel support, large proximal restorations, and endodontic access (Fig 18-8). The enamel is reduced by 0.5 mm, the proximal restorations are removed, and the margins are finished with a light chamfer.



Fig 18-8*(a)* This lateral incisor had a large area of enamel available for bonding after preparation, but the interproximal restoration and lingual endodontic access made it an ideal candidate for a veneer crown. *(b)* The preparation displays a subtle transition from 0.5 mm of facial reduction to 1.0 mm of lingual reduction. Because of caries gingival to the lingual composite, the lingual preparation extends into dentin in this one area. However, all other areas of the preparation are in enamel, including the cavosurface margins. *(c)* The veneer crown is in esthetic harmony with the natural central incisor and veneered canine.

Dentlearn.ir

Bonded all-ceramic crowns

Indications

1. High esthetic demands, especially in the gingival third
2. Dentin bonding substrate acceptable
3. Moderate to no parafunction

Key to bonded all-ceramic restorations is the ability to provide predictable dentin adhesion. Without a sound dentin-crown unit after bonding, all-ceramic bonded crowns are extremely weak and prone to fracture.[18–21] This class of ceramics includes feldspathic porcelain (on a refractory die or platinum foil), castable glass, injection-molded ceramics, and computer-aided design/computer-assisted manufacture (CAD/ CAM) milled crowns. These systems provide the finest esthetics of the anterior ceramic crown categories because they most closely match the translucency, brilliance, and qualities of natural tooth substrates. The difference between the systems is the varying degree of translucency in the core materials. Choices within this category should be based on which substrate most closely mimics that of the natural teeth. If the prepared tooth color is normal (Fig 18-9a), full feldspathic crowns produce the most natural core and have a biologic outcome and survival probability comparable with cored ceramic systems[39] (Fig 18-9b). However, when the crown substrate requires alteration of translucency or opacity, the core choice should be made accordingly.



Fig 18-9*(a)* When the tooth substrate is acceptable for bonding and color, a bonded, feldspathic all-ceramic crown is indicated. *(b)* The bonded feldspathic crown provides functional predictability and natural esthetics.

IPS Empress and OPC are both heat-processed or computer-milled, high-leucite pressed ceramics. They provide laboratories with multiple dentin shades and translucencies, which can be used to mask defects or match adjacent dentition. Once the proper dentin shade, or *stump*, is chosen, the core is fabricated using a lost-wax technique. The ceramist decides whether the crown will be cast in its entirety and then colored with s ig 18-10) or a cast

Dentlearn.ir

coping will be layered with feldspathic porcelain (the *veneered technique*) (Fig 18-11). Surface staining involves placing heavily pigmented characterization colors on the crown, which is then covered with a glazing powder and fired. The veneered technique is the recommended method for esthetic anterior ceramics, and the monolithic technique is the recommended method for strength (Fig 18-12). When the veneered technique is used, the preparation depth must allow adequate space to produce a substructure that resembles a veneer preparation. Enamel and incisal feldspathic porcelains are then veneered on the core. Both techniques provide very promising clinical results.[40] IPS Empress and OPC have comparable flexural strength.[41] The in vitro marginal fit of IPS Empress has been reported to provide a mean marginal opening of 28 to 99 µm, with the type of finish line explaining the difference in marginal fit.[42] A survival rate for anterior crowns of greater than 95% has been reported through 11 years of observation.[40] Heat-pressed ceramics offer mixed reports on wear values comparable with those of enamel.[43,44] Routine monitoring of opposing tooth wear is therefore important.

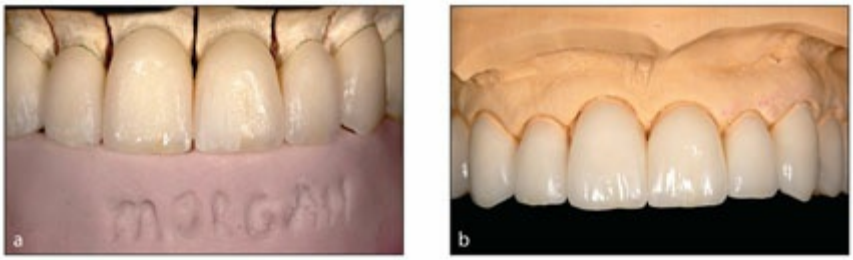

Fig 18-10*(a)* Monolithic ceramic restorations with the addition of characterizing staining effects. *(b)* Completed monolithic ceramic restorations with stain.



Fig 18-11*(a)* Wax-up with cutback allowing room for veneering ceramic. Note the design of the cutback to maintain the strength of the incisal edge in core ceramic. *(b)* Lithium disilicate pressed to allow space for veneering ceramic. *(c)* IPS e.max veneered definitive restorations.

Dentlearn.ir



Fig 18-12 The maxillary central and lateral incisors are restored with veneered IPS Empress crowns. When the tooth color is poor but a reliable bond is available, IPS Empress is a good choice because several core colors are available.

Cemented all-ceramic crowns

Indications

1. Moderate to high esthetic demands, especially in the gingival third
2. Poor-quality dentin bonding substrate
3. Moderate to no parafunction

Cemented all-ceramic crowns are used when esthetics is an overriding concern but the dentinal substrate does not provide for proper bonding. Because the core material is very strong, bonding to the underlying tooth structure is not necessary. Cementation requires fewer steps, is less technique sensitive, and has less opportunity for mishaps than do bonding procedures. Because the crown is cemented, the preparation must meet the retention and resistance requirements of any cemented crown. Esthetics is compromised slightly because the ceramic core is less translucent than bonded ceramic restorations and is more opaque than many natural tooth substrates. Because of the high strength of these ceramic materials, cemented ceramic crowns can be placed in patients with moderate or controlled parafunction.

The difference between the ceramic materials that must be bonded versus those that can be used in cemented crowns is found in the composition and processing techniques for the core. For example, In-Ceram Alumina is an 85% alumina, glass-infiltrated core. In-Ceram Spinell (Vident) is a mixture of alumina and magnesia made on a resin die. Procera crowns have a 99% alumina core fabricated on a die designed from digitized specifications made from the master die. IPS e.max is a lithium disilicate–based glass ceramic. In-Ceram Zirconia is a slip-cast or dry-pressed zirconia core.

The In-Ceram Alumina core may be fabricated through CAD/CAM milling or slip casting. Slip castings are created on a special gypsum die to which an alumina and water mixture or “slip” is applied and shaped. The core is sintered (baked at high

Dentlearn.ir

temperature) in a furnace, creating an interconnected porous network. The core material is then returned to the porcelain oven, and a lanthanum aluminosilicate glass is infiltrated into the pores of the core to add strength. The In-Ceram Alumina slip casting technique has been used for well over a decade. Today, milling technology has allowed crowns to be produced from a ceramic block with greater flexural strength than slip casting. Flexural strengths from 300 to 600 MPa have been reported for In-Ceram Alumina.[45] A clinical study of 163 anterior units demonstrated a 15-year survival rate of 87.5%, which is comparable with reports on metal-ceramic crowns.[46] Data from a different study showed that core fractures and porcelain fractures occurred at a rate of approximately 0.6% and 0.3% per year, respectively.[47] Additional in vivo studies confirm the high success rate of In-Ceram Alumina.[48,49] Marginal integrity has been shown to be within clinically acceptable standards.[50]

Procera is another system that uses an alumina core (Fig 18-13). The master die is scanned into a computer, and the surface contour of the die is mapped with the use of more than 50,000 measured values. An alumina coping is designed on the computer, and the relief space for the cementing agent is established. The data are then transmitted via modem to a production station, where the coping is manufactured with advanced powder technology and a CAD/CAM technique. The coping contains high-purity (99.9%) aluminum oxide powder, which is milled and sintered. A veneering porcelain that is compatible with the coping is layered to develop crown contours and esthetics. The flexural strength of the core is reported to be greater than 600 MPa, with a fracture toughness of 4.48 MPa-m^0.5.[51] The mean load to failure of the core/veneer porcelain system is clinically acceptable when the veneer porcelain is more than 0.4 mm thick. The veneering porcelain doubles in strength at 0.9 mm.[52] With a 0.6-mm-thick Procera core, a tooth reduction of 1.0 to 1.5 mm is

adaptation, and precision of fit for Procera crowns were less than 70 µm.[53] Data on the clinical fit of Procera crowns indicated a mean marginal gap width of 50 to 135 µm for crowns depending on the finish line configuration.[54] The survival rates of Pro-cera crowns were reported to be 97% to 100% in the anterior region after 5 and 7 years regardless of the cement used.[55,56]

Dentlearn.ir



Fig 18-13*(a)* The post and core does not allow bonding. A cemented crown is an appropriate choice for the central incisor. *(b)* A Procera crown was chosen to mask the color of the post and core and to esthetically match the other all-ceramic restorations.

Lithium discilicate provides clinicians with an extremely strong, etchable core material, making it bondable or cementable. This allows IPS e.max to be used for almost any fixed prosthetic need: veneers, crowns, and fixed partial dentures (Fig 18-14). Because of its ability to be cemented, IPS e.max is placed in the cemented crown category for this evaluation. The material is currently available in two varieties: IPS e.max Press or IPS e.max CAD. The pressed option requires the core pattern to be waxed to full contour and invested. The IPS e.max glass-ceramic ingots are heat pressed in a 920°C furnace under pressure and vacuum. The glass ceramic becomes viscous and flows into the lost-wax mold of the core. The IPS e.max core is coated with a glass ceramic containing fluoroapatite. These apatite crystals are similar in structure to those found in natural teeth. Reportedly, they allow the porcelain to mimic the optical properties of translucency, brightness, and opalescence of a natural



Fig 18-14*(a)* Multiple dentin shades and poor bonding substrates are indications for IPS e.max crowns. *(b)* The system allows ceramists to mask the tooth discoloration and provides an opportunity for the dentist to bond or lute the crowns. *(c)* The IPS e.max crown on the left central incisor provides natural esthetics even over an implant abutment.

tooth.[57] The IPS e.max CAD "blue block" is a lithium metasilicate crystal milling block. A milling unit creates a crown from a pattern generated in a computer. At this stage the crown is very weak. A second heat-treating process is performed in a porcelain furnace at approximately 850°C; the metasilicate is dissolved, and the lithium disilicate crystallizes. This results in a fine-grained glass ceramic with 70%

Dentlearn.ir

crystal volume incorporated into a glass matrix.[58] The IPS e.max core has a flexural strength of 350 ± 50 MPa, a fracture toughness of 3.2 MPa, and a failure load of 771 to 1,115 N.[59,60] In 2- to 5-year evaluations of IPS e.max restorations placed in general practice and in controlled clinical settings, the restoration survival rate was 94% to 100%.[61–64] Results from a study on the mean gap dimensions and marginal opening for incisor crowns showed that IPS e.max restorations had the smallest and most homogenous gap dimensions (46 ± 1 μm) compared with milled and infiltrated zirconia crowns.[65] In addition, two studies reported no evidence of abrasion of the ceramic or the opposing teeth in vitro or in vivo.[44,66]

All-ceramic cementable crown cores may also be fabricated in zirconium oxide. Numerous manufacturers provide zirconia cores with unique fabrication techniques and chemistries. Zir-conia has outstanding mechanical properties and high biocompatibility. Zirconium oxide produces an extremely strong core (998 to 1,183 N).[60,67,68] It is stronger than all other ceramic core materials.[69] Zirconia frameworks may be slip-cast like In-Ceram, dry-pressed, or milled from a solid block. Copings produced by a CAM system exhibited a mean marginal gap (66.4 ± 42.2 μm) well below the clinically acceptable 100-μm limit.[70] The relative translucency of a zirconium oxide ceramic core is roughly equivalent to that of a metal core.[18] Individual systems and framework thicknesses impact the levels of light transmission, making some systems more appropriate for anterior application and others for masking discoloration.[71] A recent comprehensive review of the literature on zirconia single crowns found limited long-term survival data.[72] A 3-year study of single units produced in a private practice showed a cumulative survival rate of 93%, with the majority of failures due to ceramic veneer chipping.[73] The drawback to the restoration continues to be the weaker veneering porcelains (Fig 18-15). Microtensile bond strengths vary significantly between zirconia substrates and veneering ceramics. Failures are mainly interfacial.[74] The rate of veneering ceramic fracture is significantly higher than with metal-ceramic restorations.[75] New approaches to zirconia coping design and veneering ceramic cooling rates have begun to improve the survival rates.[76] In an attempt to limit failures, researchers have focused on utilizing monolithic zirconia restorations. This is especially popular for posterior crowns and fixed partial dentures. The use of preshaded zirconia blocks, the use of a dye to shade a partially sintered zirconia block, and external shading and glazing have provided durable crowns but only acceptable esthetics for anterior restorations.[77]

Dentlearn.ir



Fig 18-15 Chipping of veneering ceramic on zirconia crowns is a significant disadvantage.

Metal-ceramic crowns

Indications

1. Moderate esthetic demands
2. Poor-quality dentinal substrate
3. Severe to no parafunction

Porcelain-fused-to-metal crowns have a long history of success.[78] Introduced in the late 1940s, metal-ceramic crowns continue to be the most common complete-coverage anterior restoration. Porcelain margins were developed in the 1960s, and the technique later evolved with the introduction of shoulder porcelains.[13] Recent development of opalescent and fluorescent porcelains has dramatically improved the esthetics of these restorations.[79]

The quality of the dentinal substrate does not play a role in the choice of metal-ceramic restorations because they are cemented, but resistance and retention requirements are of major importance. Patients with moderate to severe parafunction are best treated with porcelain-fused-to-metal crowns, which are inherently stronger than all-ceramic crowns.[80] Tooth contacts may be developed in metal rather than porcelain to decrease wear of the opposing dentition. Other indications for metal-ceramic crowns are a deep, tight incisor relationship and minimal dentin wall thickness after endodontic treatment. Neither situation allows sufficient reduction for all-ceramic crowns. Preparations can be modified because metal surfaces as thin as 0.5 mm are usually adequate (Fig 18-16). Metal ceramics are still preferred for fixed partial dentures even when patient perception of esthetics is key.[10]

Dentlearn.ir

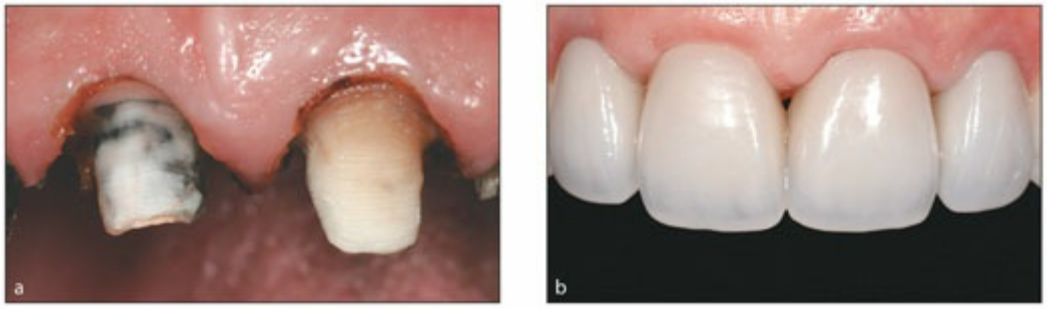

Fig 18-16*(a)* Endodontically treated and structurally compromised teeth are indications for metal-ceramic crowns. *(b)* Metal-ceramic crowns restore the central and lateral incisors. A porcelain butt-joint margin and 2 mm of metal reduction from the facial shoulder allow light to enter the tooth and illuminate the gingival third of the crown.

Today, clinicians have a plethora of anterior ceramic systems from which to choose. The decision should be based on esthetic goals, bonding requirements, and parafunctional habits rather than a favorite ceramic system. Dentists using a hierarchical approach to selecting anterior ceramic crowns will discover that several ceramic materials may be used within the same smile (Fig 18-17).

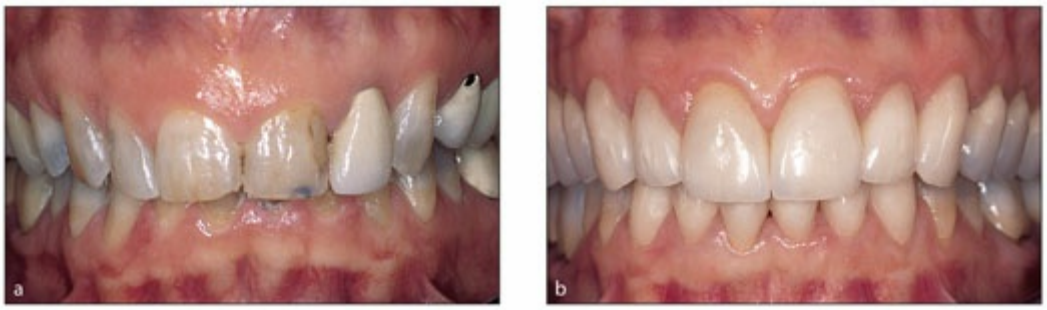

Fig 18-17*(a)* A careful consideration of the esthetic demands, bonding substrate, and any parafunctional habits may lead to the use of multiple systems within the same patient. *(b)* Veneers and bonded and cemented crowns were used to restore function and esthetics.

Anterior Tooth Preparation

To provide a tooth preparation that meets the restorative and technical guidelines and provides predictable results, practitioners must understand and blend the biologic, mechanical, and esthetic components of tooth preparation.[81] All three categories are equally important. Biologic principles dictate finish line position and pulpal preservation. Mechanical preparation principles include retention and resistance features, margin configuration, accuracy of fit, and integrity. Principles of esthetics require that the tooth-restoration interface is not a visual focal point.

Dentlearn.ir

Biologic principles

Finish line position

Margin location is the most important biologic parameter in predictably maintaining gingival health.[82–85] Even among patients receiving regular preventive dental care, subgingival margins are associated with increased probing depths and gingival inflammation.[82–84] The critical factor in maintaining healthy gingival tissue is the relationship between margin location and supracrestal fiber attachment.[86,87] If the restorative margins impinge on the supracrestal fiber attachment, chronic inflammation can result.[88–90] Practitioners must therefore balance the principles of periodontal health and the desire for concealed porcelain margins.[91] They must also be aware of the cervical limitations of crown preparations; a complete understanding of the dentogingival complex is paramount.

In 1921, Gottlieb[92] first described "an epithelial attachment of the gingiva to the hard tissues." Sicher[93] discussed the "dento-gingival junction" as the fibrous, connective tissue attachment of the gingiva and the epithelial attachment. The dimensions of this functional dentogingival unit were first reported by Gargiulo et al[94] (Fig 18-18a), who described the dentogingival junction as consisting of a sulcus, junctional epithelium, and gingival fiber attachment to cementum, coronal to the alveolar crest. The dimensions of the dentogingival junction were further refined by Vacek et al.[96] The term *biologic width* was given to this zone of connective tissue and epithelium by D. Walter Cohen (1962) in an unpublished presentation at Walter Reed Army Medical Center. This biologic zone was reintroduced to periodontics and restorative dentistry by Ing-ber et al[97] in 1977.

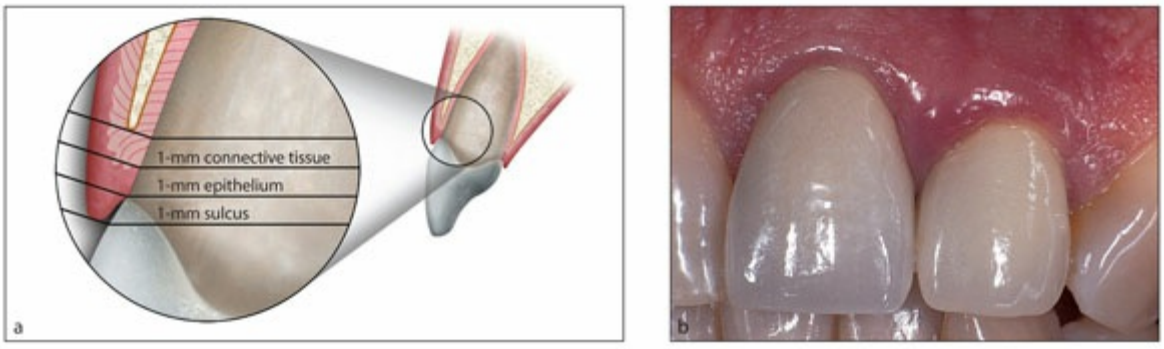

Fig 18-18*(a)* The biologic width comprises epithelial and connective tissue attachments. Crown preparations that impinge on the biologic width result in chronic inflammation. (Reprinted from Robbins[95] with permission.) *(b)* This crown preparation impinged on the biologic width interproximally. Inflammation had been present for 17 years.

Dentlearn.ir

Vacek et al[96] provided an arithmetic outline for evaluating the tissue-tooth interface. The average for the connective tissue attachment, the least variable of the biologic components, is 0.71 mm (0.35 to 1.74 mm). Connective tissue includes 10 different gingival fiber bundles, the periodontal ligament, cementum, and collagen fiber bundles embedded into the root surface; these embedded fiber bundles are called *Sharpey's fibers*. The connective tissue zone also contains the nerve and blood supply for the gingival tissues. The connective tissue attachment is the strongest part of the attachment and provides resistance that, under normal circumstances, prevents a periodontal probe or gingival retraction cord from penetrating to the bone. It includes the circumferential fibers that often produce facially evident inflammatory reactions to interproximal biologic width violations.[89,90]

Coronal to the connective tissue attachment is the epithelial attachment. The epithelial attachment has an average dimension of 1.03 mm (0.38 to 2.48 mm). The hemidesmosomal attachment of the epithelium provides a tight approximation of tissue to the tooth but is easily penetrated, especially in the presence of inflammation. The cells in this layer undergo a continual coronal migration with a complete turnover every 4 to 6 days.[98] They attach to enamel, cementum, dentin, and even porcelain.

The term *biologic width* describes a vertical measurement of 1.74 mm, the combined width of the connective and epithelial attachments. If the margin of a restoration violates the 2-mm biologic width, substantial gingival inflammation often results[88–90] (Fig 18-18b).

The difficulty for practitioners is that Gargiulo et al and Vacek et al's work presents a "contrived illusion of mathematical precision." The research suggests a vertical measurement of 1.19 mm for the sulcus. This would make the total dentogingival complex, biologic width plus sulcus, approximately 3 mm. Yet, clinically, the dimensions vary greatly from 0.43 to 6.03 mm. Not every tooth has the average biologic width of 2 mm and a 1-mm sulcular depth.[97] Each tooth presents unique gingival measurements that must be assessed and used in treatment. Individual measurements of the total dentogingival complex must, therefore, be used in making restorative decisions.[99]

If the goal is to place a restorative margin in the sulcus without violating the biologic width, the base of the sulcus must be identified. However, this is extremely difficult. The periodontal literature indicates that the tip of the periodontal probe often penetrates the base of the sulcus and may extend into the connective tissue.[100]

Dentlearn.ir

The depth of penetration depends on the level of inflammation, the diameter of the probe, and the pressure used on the probe. Because the sulcus depth can be identified only histologically, the distance from the free gingival margin to the crest of the alveolar bone is the only predictable measurement available to determine intracrevicular margin location. At the crown preparation appointment, the entire dentogingival complex is measured. After the administration of local anesthesia, a periodontal probe is pushed through the sul-cus until resistance is felt (Fig 18-19a). The probe is then angled away from the clinical crown while the tip is still touching the root surface (Fig 18-19b) and is pushed completely to the osseous crest (Fig 18-19c). This process is called *bone sounding*, and measurements are taken on the midfacial aspect of the tooth and at both facioproximal line angles. If the probe is not angled correctly, there is a greater risk of the tip of the probe skipping past the thin facial plate of bone, resulting in an inaccurate measurement.

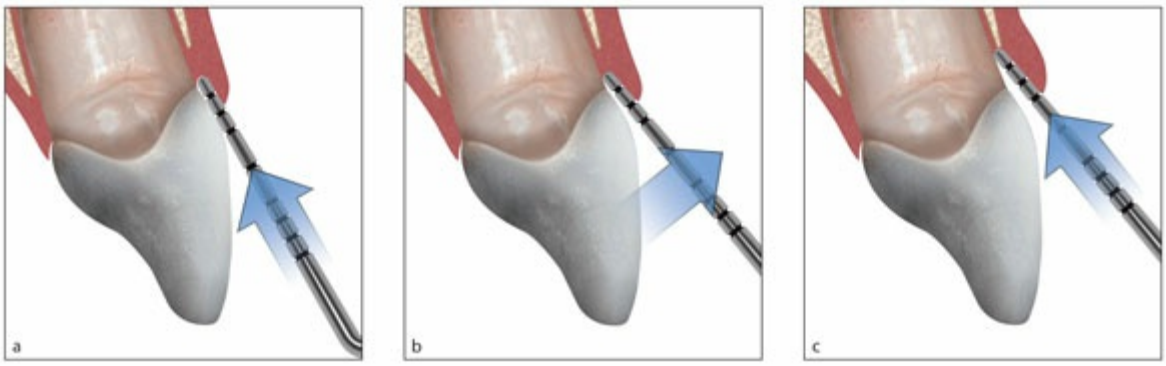

Fig 18-19*(a)* Crest classifications are based on the probing depths on the facial and interproximal surfaces from bone to free gingival margin. After the administration of local anesthesia, the probe is placed in the sulcus and pushed until it meets resistance. *(b)* The probe is angled to keep its tip on the root surface. *(c)* The probe is forced through the attachment apparatus until it engages

Measurements on anterior teeth can be categorized into three types of relationships between the free gingival margin and the alveolar crest: normal, low, and high.[99] This relationship will influence margin placement, determine the stability of the attachment levels of the gingiva against the tooth, and influence the need for crown lengthening surgery prior to restorative procedures. The critical factor in proper management of the soft tissues is accurate location of the alveolar crest, which allows the clinician to avoid impingement on the biologic width.

Normal crest relationship. In a normal crest relationship, the measurement from the free gingival margin to the osseous crest is 3.0 mm facially and 3.0 to 4.5 mm interproximally (Fig 18-20), which usually results in a gingival scallop of 3.0 to 4.0 mm and tissue levels that are stable in relation to the tooth. The normal crest is found

Dentlearn.ir

on 85% of anterior teeth.[99] In the normal crest relationship, restorative margins can be placed 0.5 to 1.0 mm into the sulcus facially and 0.5 to 2.5 mm interproximally. The apical limit of the restorative margin is 2.5 mm coronal to the osseous crest. The retraction technique is not critical in this crest relationship because the gingival level is stable. Typically, a normal crest relationship should yield no recession and no loss of papilla height following routine intervention. Research indicates that a normal crest relationship will reestablish itself even if the tissue is completely denuded, although it may take up to 3 years to return to its normal form.[101,102]

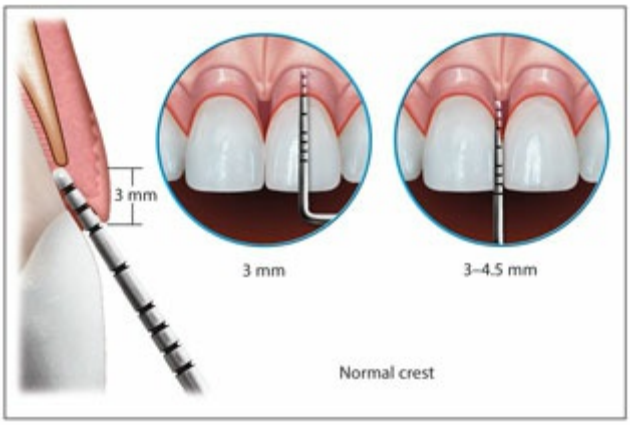

Fig 18-20 Bone sounding depths of 3.0 mm facially and 3.0 to 4.5 mm interproximally represent a normal crest relationship. The tissue should rebound completely after manipulation.

Low crest relationship. A low crest relationship is the most difficult of all crest positions to manage and is found in 13% of anterior teeth.[99] The relationship of the free gingival margin to the osseous crest is greater than 3.0 mm facially and greater than 4.5 mm interproximally (Fig 18-21). The gingival scallop does not mimic the osseous crest. Patients with low crests are at high risk for facial recession and loss of papilla height because of the increased distance from the alveolar crest to the gingival margin. The position of the soft tissues on the tooth is not stable in teeth with a low crest relationship and can easily be altered unintentionally during treatment.

Dentlearn.ir

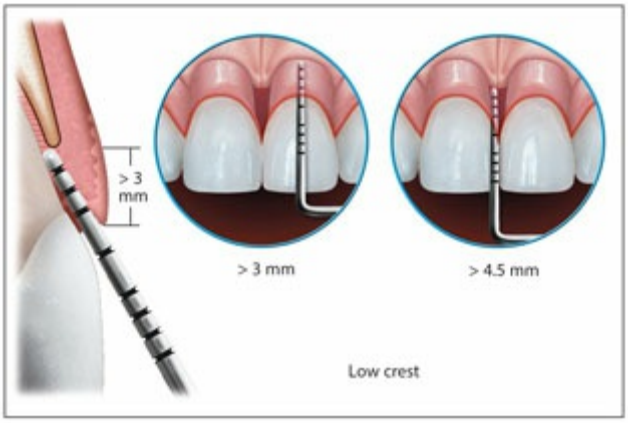

Fig 18-21 Bone sounding depths of greater than 3.0 mm facially and 4.5 mm interproximally represent a low crest relationship. Tissue response is not predictable after manipulation. Recession and "black triangles" are probable.

If maintenance of the tissue levels is critical during restorative procedures, practitioners have two options.[95] One option is to correct the low crest surgically before tooth preparation, creating a normal crest relationship and thus achieving predictability. This can be accomplished by reducing the tissue height with an osseous crest. However, if the position of the cementoenamel junction, root anatomy, gingival architecture, osseous support, or esthetic demands prevent proactive treatment, the second option is to take great care to avoid damage to the attachment during preparation and impression making. The finish line of the preparation should be located at or coronal to the free gingival margin, and there should be minimal, if any, tissue retraction during impression making. The patient should be warned of the possible tissue changes before the preparation begins and have an understanding of the treatment options if tissue loss does occur. While not predictable, thicker tissue seems more resistant to recession following intervention.[103]

High crest relationship. Patients with high crests are the least common (2%) and pose the greatest risk for violation of biologic width.[99] Probing measurements are less than 3 mm facially or interproximally (Fig 18-22). The tissue levels are very stable, and the gingival scallop is flat, less than 3 mm. The high crest relationship sometimes occurs when excessive tissue covers the anatomical crown, such as in altered passive eruption[104] or in patients with noncarious cervical lesions. However, it is most common adjacent to edentulous spaces where the gingival scallop has flattened. Margin location is determined by the demands of biologic width. High-crest teeth, by definition, will only allow an equigingival or supragingival restor o the alveolar crest.

Dentlearn.ir

These teeth are at high risk for biologic width impingement with intracre-vicular margin placement. Gingival retraction for impressions should be minimal.

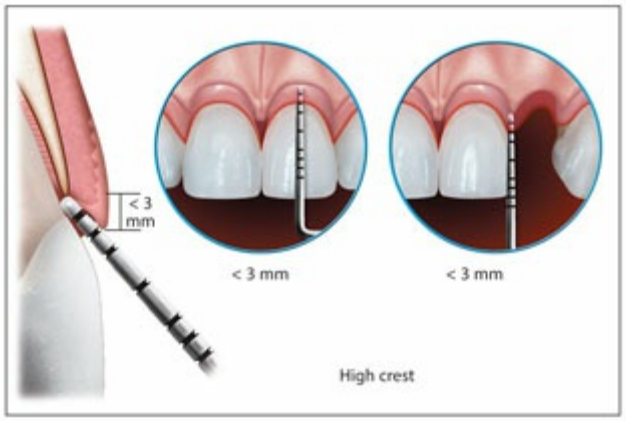

Fig 18-22 Bone sounding depths of less than 3.0 mm facially and interproximally represent a high crest relationship. Intracrevicular preparation is difficult without biologic width violation.

Pulpal preservation

Preoperative radiographs and pulp testing are important steps in determining pulp vitality prior to tooth preparation. Unfortunately, pulp testing cannot identify degrees of health. Separately or cumulatively, the effects of large restorations, leaking restorations, caries lesions, deep cracks, pins, etc, increase the chances of pulpal necrosis after tooth preparation. In one study, irreversible pulpitis occurred in 5.7% of cases in which crowns were placed on vital teeth.[105] Patients should be made aware of this risk preoperatively.

If the tooth preparation involves an increase of heat to the tooth, pulpal necrosis can occur. In one in vivo study in primates, pulpal injury occurred in 15% of teeth with a 5.5°C rise in temperature. An 11.1°C rise led to necrosis of the pulp in 60% of the teeth, and a 16.6°C rise caused necrosis of all the teeth tested.[106] Temperature changes have been monitored during complete crown preparation. When an air-water spray coolant was used, a temperature decrease in the pulp chamber from 37°C to 25°C after 4 minutes of exposure occurred. However, when only air coolant was used, the pulpal temperature rose from 37°C to 48°C after 1 minute of continuous exposure.[107] Therefore, continuous air-water coolant is a critical factor in maintaining pulpal health.

Mechanical principles

During tooth preparation, several mechanical principles must be followed. The preparations must incorporate retention and resistance form, structural durability,

Dentlearn.ir

and marginal integrity.

Resistance and retention

Retention is the feature of a crown preparation that resists dislodgment in a vertical direction or along the path of placement. In 1926, Ward[108] became the first practitioner to establish a standard for preparation taper. He prescribed 5% to 20% per inch or 3 to 12 degrees. Since then, recommendations have ranged from 3 to 5 degrees, to 6 degrees, to 10 to 14 degrees.[109] Jørgensen[110] indicated that there is a 50% reduction in retention when going from 5 to 10 degrees of taper. These tenets are heavily based on clinical empiricism and on two experiments in which crown and abutment analogs were pulled apart along their paths of insertion. The theoretical benefits of preparations with minimal convergence angles do not withstand scrutiny,[111–113] and such preparations are difficult to produce in clinical practice. Divergence from parallel might have to be as much as 12 degrees to be observed and produced clinically.[61,114] Routine preparations in practice have been measured at between 15 and 36 degrees without apparent detrimental effect to the longevity of the restorations.[115,116] For nonadhesively cemented restorations, the minimum convergence value required clinically is unknown, although total convergence up to 20 degrees has been shown to be acceptable.[113,117] Today, crowns with greater taper may be cemented with adhesive resin cements, minimizing the need to prepare the crowns to minimal convergence angles.[118]

Resistance is the feature of a tooth preparation that enhances the restoration's stability and resists dislodgment along an axis other than the path of placement.[119] Most retention studies utilize conventional pull-type tests to evaluate preparations and/or cements.[120,121] However, data on functional force vectors in the oral environment strongly suggest that these lift-off type forces are virtually nonexistent in the mouth.[122–124] During chewing, teeth are subjected to alternating combinations of buccolingual and occlusogingival forces.[125] These studies indicate that stresses that cause failure of an anterior restoration are repeated perpendicular or oblique forces.[112,124] Therefore, as Caputo and Standlee[126] concluded, "Resistance form is the most important factor that must be designed into any restoration if it is to succeed in function."

Resistance clinically is multifactoral. It is based on preparation taper, height, diameter, and cement type. Crowns generally loosen and fail by cleavage of the cement attachment without damaging the abutment or restoration.[113] The cement attachment fails when a portion of the abutment subjected to compressive and shear

Dentlearn.ir

forces is unable to withstand load application. Attachment failure is a progressive phenomenon linked to increasing abutment taper. Increasing the preparation taper from 10 to 20 degrees creates a broader stress distribution and greater stress within the cement.[113] The stress fields are consistently higher with greater taper and less surface area. The more parallel the walls of a preparation, the less stress on the cement lute irrespective of the preparation height. Taper becomes particularly important in teeth with a lower preparation surface area, such as an anterior tooth.[127] Clinically, a minimal preparation taper decreases the damaging effects of occlusal stress on the cement attachment, improving a crown's resistance even more than auxiliary preparation features like grooves or boxes.[128]

The height and diameter of the final preparation are also related to resistance.[129] Resistance is increased by lengthening the axial walls of the preparation.[130] The minimum height for resistance is one-half the diameter of the tooth.[131] This means that, on average, an anterior preparation must be 3.5 mm and a posterior preparation 4.0 mm in height. Of the total preparation height, the gingival 2.0 mm of the preparation must be on sound tooth structure to provide a proper ferrule,[132–135] and the other 1.5 mm or more can be in either tooth structure or buildup material (Fig 18-23). A *ferrule* is the marginal band of a crown that contacts tooth structure, providing protection from masticatory forces. In addition, the ferrule requires a dentin thickness of 1 mm from the external surface of the crown preparation to the wall of any endodontic preparation. In a comparison of in vivo restorations with and without 2 mm of remaining coronal tooth structure, the failure rate of the < 2 mm

18-24).



Fig 18-23 The minimum core height for an anterior ceramic crown is 3.5 mm. The cervical 2.0 mm of the facial and lingual aspects must be solid tooth structure for a proper ferrule.

Dentlearn.ir



Fig 18-24 Inadequate coronal preparation height significantly increases risk of failure.

Resistance is also affected by the mechanical properties of the cement.[113] The limiting threshold of each crown is the cement's resistance to fatigue under cyclic stress.[113] The more stress that will be placed on the cement, because of a severe taper and/or lack of preparation height, the more resistant the cement must be. Resin-modified glass-ionomer cements are more resistant than conventional glass-ionomer cements, which are in turn more resistant than zinc phosphate cements. Most research on resistance and retention data is conducted on nonadhesively cemented crowns. Today, however, adhesive cements allow the placement of crowns that do not meet standard taper and length requirements. Yet, because the hydrodynamic nature of dentin bonding makes it unpredictable, it is suggested that all crown preparations meet minimum requirements.[29]

Structural durability

Structural durability is the relationship between occlusal stress and material strength. It ensures that a restoration does not deform or fracture under load. In a metal-ceramic crown, the minimum metal thickness under porcelain is 0.4 to 0.5 mm for gold alloys and 0.2 mm for base-metal alloys. If the metal is too thin, it will flex under load, resulting in possible porcelain fracture. The minimum porcelain thickness over metal is 0.9 mm (0.2 mm for the opaque material and 0.7 mm for body porcelain). Ceramists prefer a 1.3- to 1.5-mm reduction for the axial surfaces of metal-ceramic crowns and a 2.0-mm reduction incisally/occlusally. The greater the reduction, the easier it is to mask the opaque material in the gingival third of the crown with body porcelain. Most bonded all-ceramic crowns require a minimum thickness of 1.0 mm to provide esthetics and adequate strength. Cemented all-ceramic crowns require an average circumferential tooth reduction of 1.5 mm for strength.

Dentlearn.ir

Marginal integrity

A completely closed margin is unattainable clinically. Even the finest margins are not sufficiently closed to prevent bacterial ingress. To place it in perspective, the width of a human hair is 50 μm; bacteria responsible for caries are 4 to 5 μm in diameter. Because bacteria are constantly passing under restoration margins, patient resistance to disease is more important than the marginal opening of crowns. What, then, is an acceptable marginal opening? One study reported that when the margin of an inlay or onlay could not be visualized, a marginal discrepancy of 119 μm was found to be acceptable.[137] Björn et al[138,139] reported that 83% of gold and 74% of porcelain crowns exhibited marginal defects; more than half were greater than 200 μm. However, defective margins are to blame in only 10% of failed restorations. While all practitioners should strive for the finest margins possible, it is impossible to achieve a closed margin. The best possible margin enables the patient to floss and care for the restoration, minimizing cement dissolution and maximizing the patient's natural resistance factors. Because 100 μm is the smallest detectable ledge,[140] this can be used as a practical criterion for evaluating fit.

What finish line design provides the best marginal integrity? Traditionally, the margin design selected does not have a significant effect on marginal seal of metal-ceramic restorations.[141,142] Shoulder (Fig 18-25a), shoulder-bevel (Fig 18-25b), and chamfer (Fig 18-25c) finish line preparations all allow acceptable marginal fit when complete seating is achieved. The shoulder-bevel margin is the least esthetic choice. The bevel should be used only with metal-ceramic crowns and is suited for structurally compromised teeth where ferrule extension is important. If porcelain is placed on a bevel, the cementation process may cause porcelain breakage. In two studies, the geometry exhibiting the least marginal discrepancy after cementation was a shoulder preparation, which was significantly better than that of a shoulder bevel or chamfer.[143,144] The shoulder finish line is thought to be better than the beveled shoulder because it allows the excess cement to escape more readily. The shoulder design exhibits less marginal distortion than a chamfer because of the crown's thickness adjacent to the margin. Stress analysis of various margin finish lines

stress concentration when loaded vertically, reducing the risk of catastrophic ceramic failure under load.[145,146] When utilizing metal-ceramic crowns, porcelain margins must provide an esthetic transition from tooth to crown, preventing the margin from becoming the visual focal point. Such margins are easier to fabricate and more predictable when they are fabricated on a 90-degree shoulder preparation.

Dentlearn.ir

This is true for metal-ceramic and most all-ceramic systems.[147–150] A chamfer requires minimal axial reduction and is appropriate for conservative all-ceramic restorations. It does not, however, provide an adequate reduction for metal-ceramic crowns. The opaque material used to mask the metal at the margin will show through the more translucent porcelain and will compromise the esthetics in the gingival third. A 90-degree shoulder between 1.0 and 1.5 mm in depth allows for a precise margin, maximum seating, and good esthetics.

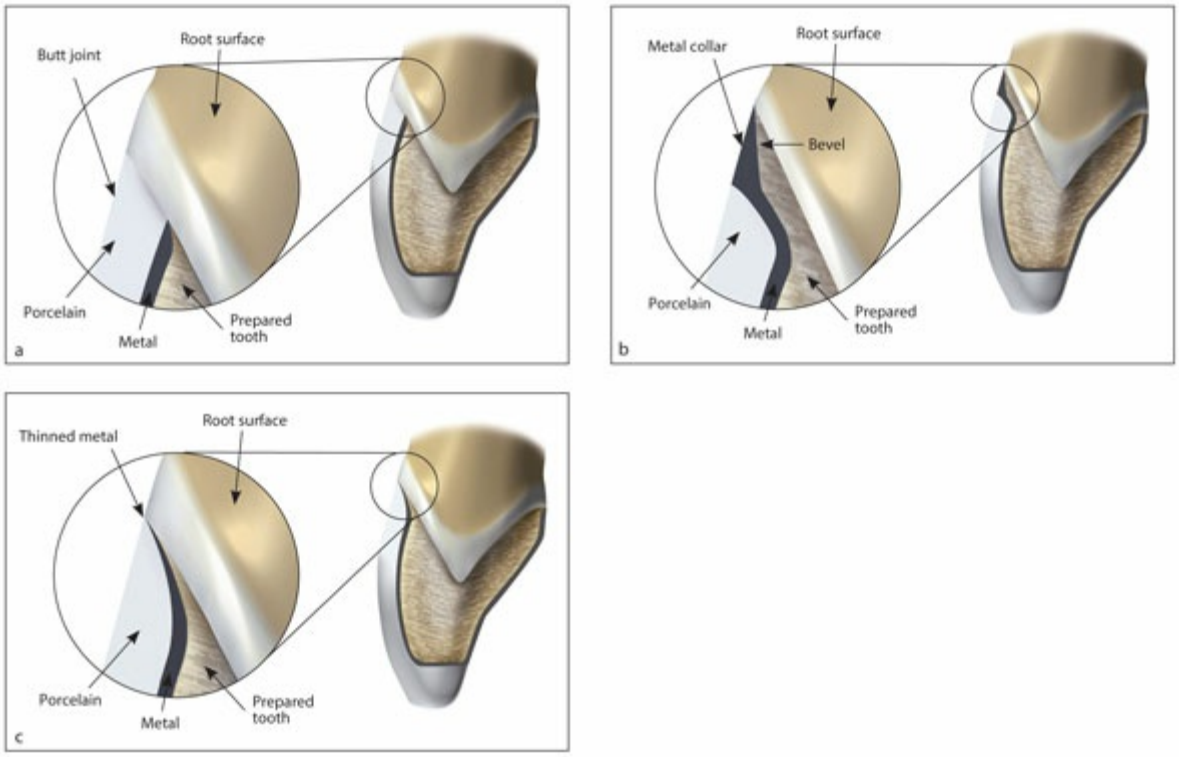

Fig 18-25*(a)* In the preferred substructure design for a porcelain facial margin, a uniform thickness of porcelain is carried to the finish line. *(b)* The preferred substructure design if a metal facial margin is desired. Metal covers the bevel and forms a butt joint with the porcelain. *(c)* A 1.0-mm chamfer can be used for anterior all-ceramic restorations and metal-ceramic restorations. The gingival esthetics may be compromised with metal-ceramic restorations because of the extension of the metal to the margin.

The ideal finish line form and depth for all-ceramic systems vary between type of ceramic and fabrication technique. They all have two common elements: adequate axial depth and uniform smoothness.[151] A study on the effect of preparation design on the marginal integrity of Procera crowns highlighted this fact. It demonstrated that a feather-edge finish line produced crowns with over twice the marginal opening of a chamfer or rounded shoulder finish line. Furthermore, the deeper axially the rounded shoulder, the tighter the marginal fit.[54] Crowns created from IPS Empress CAD material exhibited similar results.[42] The best finish line is a rounded axial-

Dentlearn.ir

gingival line angle with a butt-joint external cavosurface margin. Ideal cervical preparation taper is imperative with all-ceramic crowns. Ceramic systems cannot accurately reproduce the contours of auxiliary grooves or deep occlusal morphology, eliminating their use as resistance features.[54] In addition, adequate occlusal/incisal reduction is more critical with all-ceramic than with metal-ceramic restorations. Inadequate space prevents the use of monoblock all-ceramic crowns and can compromise esthetics and strength.[152]

Functional Crown Preparation Technique

With a complete understanding of the key components of intracrevicular tooth preparation, practitioners can achieve predictability with a standardized, controlled, and functional crown preparation.[153] This preparation design works for any type of anterior ceramic crown with modifications only in depth of preparation based on ceramic choice. This technique also minimizes the number of burs, bur changes, and cost. Only four burs are used in the technique sequence described below.

Bone sounding

Before beginning any anterior crown preparation, a comprehensive evaluation of the underlying osseous structure is critical. Bone sounding to the osseous crest with a periodontal probe, as described previously in this chapter, should be performed to determine the dimension of the total dentinogingival complex. If the probing depth is 3.0 mm facially and 3.0 to 4.5 mm interproximally, the crest relationship is normal and tissue levels should remain stable. If, however, the probings are not normal, the patient must be made aware of the possible complications involved in the treatment, and the preparation and impression must be altered accordingly (Fig 18-26).



Fig 18-26*(a)* Biologic dimensions around each anterior tooth must be evaluated. Visually, the tissue surrounding the preparations appears to be normal, but probing of the teeth demonstrates normal, high, and low osseous crest positions. *(b)* A 2-mm probing depth to bone facial to the left central incisor. Teeth with high crests are prone to biologic width violations. *(c)* Bone sounding on the left canine demonstrates a low crest. The tissue will be susceptible to recession.

Dentlearn.ir

Reduction guides

When the teeth are severely worn or malpositioned or the vertical dimension is to be altered in the definitive restorations, the dentist will require a guide to allow proper reduction (Figs 18-27a and 18-27b). Multiple reduction-matrix designs have been proposed in the literature. Most require the tooth to be prepared, after which the matrix is placed to confirm that the tooth was reduced adequately. The problem is that there is no recovery when the practitioner removes too much tooth structure. A more accurate guide would encourage the proper depth of reduction in all dimensions without the risk of blindly overreducing the tooth. Aesthetic preevaluative temporaries (APTs)[154] were developed as a preoperative opportunity for the patient to evaluate the esthetics of veneer restorations. This same technique can be used as a guide for proper tooth reduction for an anterior crown. The APT is fabricated from a properly contoured diagnostic wax-up (Fig 18-27c). Condensation silicone is adapted directly on the cast. It is placed in a pressure pot at 20 psi for 15 minutes. This will compress the silicone into the contours of the wax-up, producing a highly accurate matrix. A notch is made between the central incisors to be used as a seating guide intraorally. Deep cuts on the buccal aspect extending to the teeth or vent holes through to the teeth are made in the silicone, creating a spillway for the excess acrylic resin (Fig 18-27d). Without this escape route, the acrylic resin will not flow, preventing the matrix from fully seating. If the matrix does not seat properly, it creates an error in the reduction. After the patient is anesthetized, the matrix is loaded with a provisional material (made from a bis-acrylic resin) and seated. After the material is allowed to set, the matrix is removed. The acrylic resin will remain on the teeth, engaging the embrasures (Fig 18-27e). There will be a variety of thicknesses of the acrylic resin depending on the amount of ideal tooth morphology missing. This is the proposed position and contour of the definitive restorations. Proper reduction cuts are made into the matrix (Fig 18-27f), and then the remaining resin is removed. Any bur cuts on the teeth indicate the location and depth of reduction that is necessary. If there is no mark on the tooth, it is already reduced enough for the definitive restoration (Fig 18-27g), although some preparation may be necessary to provide gingival margins and an appropriate path of draw.

Dentlearn.ir



Fig 18-27*(a)* Significantly worn dentition requiring restoration at an increased vertical dimension of occlusion. *(b)* New vertical dimension is demonstrated on the articulated casts. *(c)* Missing tooth morphology is added in wax on the cast. *(d)* Silicone matrix for reduction guide and provisionals. The midline is marked, and vent holes are created on facial surfaces. *(e)* Bis-acryl resin is added to the matrix and seated completely. Once polymerized, the acrylic will remain on the teeth. This demonstrates the desired final contours and vertical alteration. *(f)* Incisal, facial, and lingual reduction cuts. *(g)* After removal of the remaining bis-acryl resin, tooth reduction can be visualized. Note that many teeth require little to no tooth removal for definitive restorations other than that required to establish gingival margins and a path of draw.

Incisal reduction

The amount of incisal edge reduction is dictated by the planned final incisal edge position. There should be a 2.0-mm reduction from that point. This requires that a diagnostic wax-up be completed before tooth preparation if the original incisal edge position is not acceptable. A laboratory-based retrospective analysis of dies prepared in general dental practices for all-ceramic crowns concluded that 86% had been underreduced incisally.[155] A 2.0-mm reduction allows the technician space to develop incisal translucency and natural tooth characteristics without a loss of fracture strength of the porcelain.[156] Initial depth cuts are made with a no. 330 carbide bur that has a 2.0- mm cutting-head length (Fig 18-28); note that no. 330 burs from some manufacturers have a head length of less than 2.0 mm, so the head length should be measured. This same carbide bur can be used to open proximal contacts and is also excellent for use in occlusal reduction of posterior teeth. A 1.2-mm-

Dentlearn.ir

diameter round-ended cylinder diamond is used to remove the remaining incisal edge tooth structure to the level of the incisal depth cuts (Fig 18-29). This diamond is also used for facial and cervical reduction.



Fig 18-28 Incisal reduction grooves are made and interproximal contact is broken with a no. 330 carbide bur with a 2.0-mm cutting-head length.



Fig 18-29 A 1.2-mm round-ended cylinder diamond completes the incisal reduction.

Facial reduction

Viewed from the proximal aspect, anterior teeth have three facial planes: cervical, midfacial, and incisal. Practitioners prepare teeth with little regard to this fact, and dies routinely demonstrate only one plane of reduction.[155] The incisal plane has been removed in the first step with a 1.2-mm-diameter round-ended cylinder diamond. The facial reduction focuses only on the midfacial plane, not the cervical. Depth cuts are prepared to the full depth of the diamond (Fig 18-30), which is aligned with the midfacial plane (Fig 18-31). The use of the 1.2-mm diamond as a depth gauge allows a more uniformly accurate preparation. Without the use of a device to help gauge reduction depth, teeth are routinely underprepared on the facial aspect.[157] At this time, the cervical plane should receive almost no reduction. If the bur is angled to the cervical aspect, the facial plane would be severely underreduced. After two or three depth cuts, the same diamond is used for the remaining gross facial reduction.

Dentlearn.ir



Fig 18-30 Multiple facial reduction grooves are made to the entire depth of the 1.2-mm-diameter diamond bur.



Fig 18-31 The facial reduction grooves must be oriented properly to ensure adequate midfacial reduction. The gingival plane is not prepared at this point.

Cervical reduction

The cervical finish line is initially produced at the free gingival margin circumferentially (Fig 18-32). The tissue is not retracted prior to initial preparation. The primary cord can push the free gingival margin apically and flatten out the normal architecture up to 1.5 mm, which potentially increases the chances of biologic width violations at the line angles or interproximal areas (see Fig 18-18b). The 1.2-mm round-ended diamond is then used to create a finish line with a rounded

thickness is 1.0 to 1.5 mm depending on the type of crown chosen. Underreduction adjacent to the finish line will affect the emergence profile and facial contour of the restoration.

Dentlearn.ir



Fig 18-32 The gingival third is reduced axially by 1.2 mm at the free gingival margin. At this point, finish line.

This can predispose the restoration to technical and/or esthetic failure. Utilizing a 1.2-mm-diameter diamond allows the practitioner a guide for preparation depth adjacent to the finish line. This is critically important because studies indicate a large (0.75 to 0.90 mm) variation between recommended tooth reduction and that actually achieved.[109]

Lingual reduction

The finish line on the lingual is established at the free gingival margin with the same 1.2-mm-diameter diamond. Depending on the crown chosen, this finish line can be a light chamfer for metal, using up to half of the diameter of the diamond, or a 1.2-mm shoulder for cemented all-ceramic systems if the bur is used to its full depth. The proper reduction on the lingual concavity is required to ensure functional anterior guidance, prevent interference with the envelope of function, and avoid development of contours that produce unacceptable phonetics. Without proper reduction, technicians are forced to over-contour the lingual aspect of the definitive restorations. This can move the condyle distally and produce joint discomfort. In addition, a lisp after definitive restoration placement indicates an overcontoured lingual surface. Air flow becomes constricted, producing a whistle. A football-shaped diamond is designed to mimic the lingual concavity and provides the necessary reduction of 0.5 to 1.5 mm, depending on the choice of material used (Fig 18-33). With the initial cervical reduction completed, a primary thin retraction cord is placed in the sulcus.

Dentlearn.ir

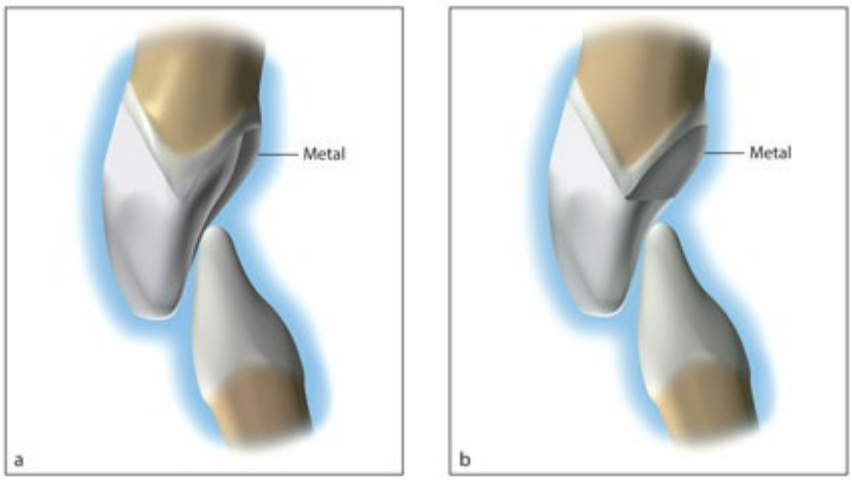

Fig 18-33*(a)* In the preferred occlusal relationship between a maxillary metal-ceramic crown and a natural mandibular incisor, the contact is on metal. *(b)* In a less desirable occlusal relationship, the opposing natural incisor contacts the restoration on porcelain. This is the recommended occlusal relationship when both maxillary and mandibular incisors are restored.

Preparation completion

The completion of the preparation begins by inserting a dry primary cord. The retraction of the tissue will allow unobstructed vision during margin refinement. A 1.6-mm-diameter round-ended diamond bur with 3 degrees of taper is used to finish the preparation. The taper on the diamond is designed to create a minimum convergence angle. The large tip will remove the J-lip on the external surface produced by the 1.2-mm diamond and create a crisp shoulder or chamfer circumferentially. A round-ended diamond is chosen because of its versatility and ease of use. The rounded tip can simply cleave the J-lip and produce a shoulder. If the side of the bur is used, it will remove the lip at an angle, producing a deep chamfer. The round end is suggested over a flat-ended diamond for fabricating a shoulder finish line. With a round-ended diamond, the practitioner can lock his or her wrist and allow the bur to simply traverse along the J-lip, thus producing the shoulder finish line. A flat-ended diamond requires a much more deft touch because the angle of the end must be altered constantly to match the contours of the preparation. Most practitioners find that the flat-ended bur produces an irregular, inadequate finish line. The margin should be developed to the coronal aspect of the primary cord facially and level with the free gingival margin interproximally (Fig 18-34). This will ensure an intracrevicular margin location after normal gingival tissue rebound, which takes up to 3 months in patients with normal crests. In patients with low or high crests, margins should not extend apical to the gingival crest.

Dentlearn.ir



Fig 18-34 The marginal lip is removed with a 1.6-mm round-ended diamond bur, leaving a 90-degree shoulder.

Impression Technique

An important factor in delivering high-quality restorations is providing the laboratory with an accurate impression. Practitioners must develop a technique that is reliable and repeatable.

Impression materials minimally displace gingival tissue, fluids, or debris, so successful retraction and isolation are mandatory. Various methods and techniques have been described in the literature for exposure of dry crown margins. They include mechanical, mechanical-chemical, rotary curettage, electrosurgery, and laser surgery (troughing). Regardless of the technique, four requirements must be satisfied for effective gingival retraction: *(1)* The tissue at the crown margins must be displaced horizontally to provide for an adequate bulk of impression material; *(2)* the tissue at the margin must be displaced vertically to expose the undercut apical to the finish line; *(3)* all gingival bleeding must be arrested; and *(4)* all hard and soft tissues must be dry.[158,159]

The mechanical-chemical technique, the most popular retraction technique today,[160,161] combines the mechanical displacement of the tissue with cord and the drying action of chemical agents. The retraction begins during crown margin preparation. The primary piece of dry cord (compression cord) is placed in the sulcus and cut so that the ends abut within the sulcus. After the final finish line preparation, aluminum sulfate gel is ejected around the sulcus. Aluminum sulfate is one of the least irritating of the retraction chemicals. It does not ionize readily, it retains its astringent qualities, and it is not toxic.[162] A larger, dry secondary cord (deflection cord) is packed through the aluminum sulfate, dragging the chemical into the sulcus. In studies by Laufer et al,[163,164] 50% to 90% of impressions of preparations with sulcular widths between 0.08 and 0.13 mm had defects. No

Dentlearn.ir

detectable difference in distortion of impressions of preparations was found with sulcular widths of 0.2 mm or greater. This was confirmed by Aimjirakul et al[165] in a gingival sulcus simulation model that demonstrated that the viscoelastic behavior of elastomers depends on the width of the sulcus. The polyether materials showed greater sulcular penetration than other impression materials, regardless of sulcular width, because of their greater hydrophilicity. To achieve a crevicular width of 0.2 mm, the secondary cord optimally must remain in the gingival crevice for 4 minutes prior to making the impression.[166]

Another difficult area for practitioners is managing the field. If the patient is involved in retracting the cheeks and lips and eliminating the parotid fluid flow, it frees the doctor and assistant to manage the tongue, saliva, sulcus, and impression. Absorbent parotid shields and cheek retractors are used to retract the lips and cheeks. The patient holds the retractors, leaving the operator's hands free (Fig 18-35). The double-packing technique, in a patient with a normal crest, should produce no apical migration of the gingival crest.[167–169] The technique must be modified for low- and high-crest patients. Finish lines should be kept supragingival or equigingival to avoid recession and biologic width impingements. The impression technique in a low-crest situation must use light packing pressure and smaller diameter cords to avoid trauma-induced recession. Rotary curettage, electrosurgery, and laser troughing are definitely contraindicated in low-crest patients. A high-crest patient simply lacks the depth for the normal retraction cords, and smaller cords are recommended. The secondary cord should be removed wet to prevent renewed hemorrhage. The preparation is washed and dried to evaluate tissue displacement and hemorrhage control.



Fig 18-35 The patient helps in the impression process by holding the cheek retractors, keeping the dentist's and assistant's hands free to work.

If the field is not dry, a 12.7% iron solution can be used to cauterize the tissue.

Dentlearn.ir

Ferric solutions provide minimal tissue injury, and healing is more rapid than with aluminum chloride.[162] It must be placed directly against the cut tissues because it coagulates blood so quickly; if not, it is washed away by the extraneous blood, leaving a bleeding site. There have been reports of the tooth absorbing the ferric ion. In vitro tests, however, have failed to show corrosive effects or staining.[162] A disadvantage to the use of ferric compounds is that they inhibit the setting of polyether impression materials. If a dry field cannot be achieved rapidly, the sulcus width will decrease, increasing the risk of defects in the impression. Chemical agents and secondary cord should be replaced and the retraction attempted again. Only after the field is acceptable is the impression material mixed or digital impression begun.

All impression materials are accurate enough to lead to production of well-fitting restorations.[170–172] Polyether and polyvinyl siloxane impression materials work well for multipurpose use and provide good soft and hard tissue detail.[173,174] Polyvinyl siloxane materials provide good elastic recovery; are dimensionally stable for indefinite periods; and are clean, odorless, and tasteless.[175] A disadvantage of polyvinyl siloxane is that because it is hydrophobic, it requires an absolutely dry field. Although many polyvinyl siloxane impression materials are advertised to be hydrophilic, research indicates that they are only reliable under dry conditions. In all situations, moisture leads to less detail reproduction compared with dry conditions.[176]

Latex gloves may inhibit the set of polyvinyl siloxane. Even casual contact of the teeth or soft tissues with latex gloves can cause an inhibition of polymerization intraorally.[177–179] (Fig 18-36). Latex gloves do not affect polyether impressions. Polyether materials are inherently hydrophilic, so small amounts of blood or saliva do not affect accuracy.[176] Polyether is affected by ferric solutions and some disinfecting solutions. Because of its rigid set, it can be difficult to remove from the mouth, and it has a bad taste and smell.[170,171] Polyvinyl siloxane and polyether materials can be used in a custom or stock tray, and studies have shown no difference in accuracy.[180,181] The working and setting times of the impression materials must be identified and followed precisely.

Dentlearn.ir



Fig 18-36 The staining of a latex glove indicates inhibition of polymerization of polyvinyl siloxane impression material.

For years, casts made from traditional impressions have been digitally scanned and copings fabricated from a virtual file. Today, these digital impressions can also be made intraorally, reducing the additional error associated with cast fabrication.[182] Digital impressions address many of the material-handling difficulties of traditional impressions (Fig 18-37). They do not, however, relieve the practitioner of the necessity of proper isolation and management of the field.[182] In fact, it makes these tasks even more critical. Many dental manufacturers have introduced digital impression systems (see chapter 19). Some scanning systems are part of a ceramic milling system designed to produce a crown or veneer virtually. A variety of ceramic and resin choices can be produced in the office or "shipped" virtually to a laboratory for fabrication.[183] Other technologies simply create a resin cast from which any laboratory procedure can be accomplished. While the research is currently rather limited on the accuracy of the images, it appears that digital replicas are well within the tolerances required of impression materials. An in vitro analysis was conducted on the cross-arch accuracy of digital impressions using conventional impressions as the control. Two different intraoral digital scanners demonstrated trueness and precision equivalent to that of the conventional techniques.[184] Currently, no one system appears to satisfy the needs of every practitioner or produce an accurate implant platform transfer. It does appear that the digital impression will begin to minimize the use of traditional impression materials in the near future.

Dentlearn.ir

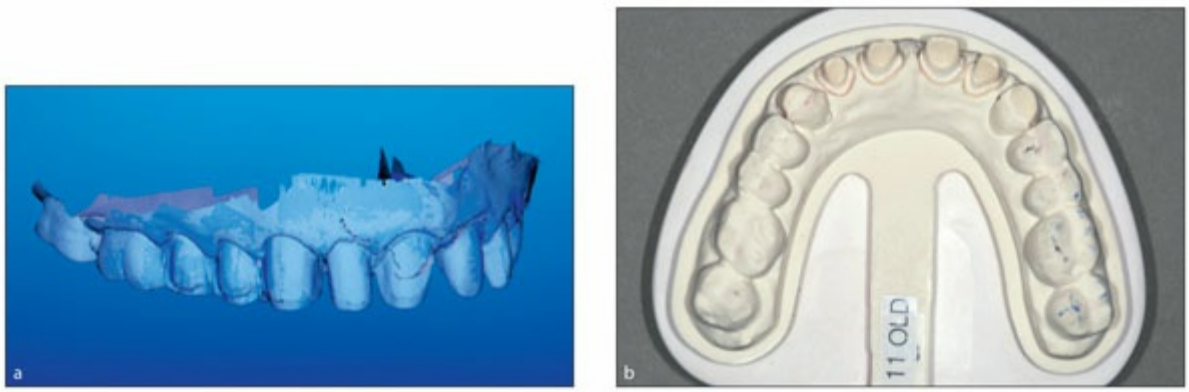

Fig 18-37*(a)* The intraoral digital image of prepared teeth. *(b)* The cast produced from digitized data.

Shade

Success of an anterior ceramic crown depends on how well critical information is communicated between the dentist and the laboratory. At least 75% of all remakes are caused by poor communication.[152] It is the dentist's challenge to predictably and accurately convey what is visualized in clear terms, allowing the technician to develop the "illusion of reality" in the ceramic material. The dentist must be able to perceive the color, understand and quantify the characteristics, and convey the information.

The experience of seeing color in teeth depends on several factors,[185] as defined in chapter 4.

The shade guide is less important than the understanding that the underlying color of the preparation may have a dramatic impact on the final esthetic results. Ceramists can adjust the ceramic choice, core color, translucency, and veneering ceramic to modify the crown to "block out" discoloration. This cannot be accomplished without communicating the preparation color information to the laboratory. Unfortunately, 93% of clinicians in a recent review of general practices failed to provide any information regarding the shade of the prepared tooth[155] (Fig 18-38).

Dentlearn.ir



Fig 18-38 Use of a stump shade guide is demonstrated in a photograph for the ceramist.

Communication between the dentist and the laboratory can occur in four ways:

1. *Diagrams:* A representation of the tooth may be drawn. While this can be helpful for communicating difficult contours and characteristics, it is difficult for the technician to interpret and very time-consuming.
2. *Custom stain tabs:* Painting colors on a shade tab can display chroma but cannot represent value. In addition, customizing is extremely time-consuming.
3. *Photographs:* Taking photographs of the teeth being restored along with matching shade guides is the most efficient and cost-effective method of shade selection (Fig 18-39).



Fig 18-39 Photographs for shade matching should be made at an angle to avoid excess glare on the tooth surface. The shade tab should be held in line with the long axis of the tooth.

4. *Colorimeter and spectrophotometer:* A digital analysis of color may be helpful but is still not reliable enough to create predictable results in clinical practice.

Photographs must provide an accurate representation of nature. A 35-mm digital

Dentlearn.ir

camera with neutral slide film (EPN 100, Kodak) maximizes the ceramist's ability to mimic reality. Digital photography has begun to replace film cameras. The ability to instantly view results and the elimination of film processing are tremendous advantages. Electronic transfer to the laboratory allows improved communication. The disadvantage is the multiple errors that can occur in color reproduction. The camera and monitors upon which the images are viewed must all be color-corrected to maximize results. Many operatory and laboratory shade-matching systems have been introduced with varying success.

The more photographs that are taken, the more information the technician can obtain. If the anterior ceramic crown does not match at try-in, more photographs should be taken of the crown to allow the ceramist to modify it correctly. Personal contact between the ceramist and the patient would be ideal, but this often is not possible.

Despite repeated experiments detailing the inaccuracy of the traditional visual shade-matching technique, digital analysis of color has not made significant inroads into the profession. Colorimeters and spectrophotometers have the potential to improve shade matching by eliminating the significant subjective factors and examiner variability. Research has emphasized two problems with color selection devices: device accuracy and tooth morphology. Most shade-matching devices have a high degree of reliability, but there is significant variability in the accuracy of the commercially available machines. Shade-matching systems have been reliable but variable between devices at matching shade guides. This means that the system can produce the same information on repeated measurements; however, it does not address the accuracy of the information.[186] Measuring the shade of homogenous porcelain shade tabs is certainly simpler than measuring the shade of a complex human tooth. The polychromatic color, surface texture, and varying translucency make intraoral applications more circumspect. Differences in tooth contour will also make positioning difficult. Researchers studied the intradevice repeatability and interdevice reliability between two shade-selecting devices in measuring the shade of natural dentition. The results showed a significant intradevice difference for all color parameters. The interdevice agreement rate for the systems on matching shade tabs was also moderate. The complexities of the human dentition apparently still pose a problem that digital recordings have yet to overcome.[187]

Restoration Placement

The classification of anterior ceramic crowns is based on whether the prosthesis is

Dentlearn.ir

adhesively retained or cemented. Veneers and bonded crowns rely on the formation of a resin bond between the tooth structure and porcelain. Cemented all-ceramic and metal-ceramic crowns are typically nonadhesively cemented with traditional cements rather than bonded to the preparation. Therefore, the placement protocol will vary significantly between the types of crowns.

Adhesive bonding of all-ceramic crowns

The goal of adhesive bonding is to provide a marginal seal of the crown and adhesively retain it to the tooth. Adhesive bonding is technique sensitive and demands proper preparation of ceramic and tooth surfaces. It has been demonstrated that a strong, dependable bond between resin and porcelain can be achieved. The porcelain intaglio surface is etched with hydrofluoric acid to create micromechanical retention sites.[188] Silane is added to the etched surface shortly before bonding and allowed to air dry. Silane coupling agents create a chemical bond of the adhesive resin to porcelain.[189]

The dentin-resin bond is less dependable than the resin-ceramic bond. Because hemorrhage and crevicular fluid flow may interfere with dentin bonding, teeth should be isolated with retraction cord before cementation. Preparations should be cleaned with pumice and/or antimicrobial solutions, such as chlorhexidine. Because light polymerization decreases with increasing porcelain thickness[190] and because polymerization of the adhesive before cementation may result in resin pooling and incomplete seating, resin cements must reach final polymerization with reduced or even no benefit of light activation, depending on the opacity and thickness of the ceramic restoration. This necessitates the use of dual-curing resin luting agents to ensure that the cement will polymerize with limited light exposure. However, dual-curing resin materials should always be light cured, because any light exposure will enhance the degree of conversion of a dual-curing material.[191]

Manufacturers have provided three alternatives for dentists for developing adhesion between resin cements and tooth structure: etch-and-rinse and self-etching adhesives and self-adhesive cements.[192] The *etch-and-rinse system* includes an etchant, primer, and dual-curing adhesive. A dual-curing resin cement is recommended for bonding of the crown for the same reason. Dual-curing adhesives have a slow, chemically activated autocuring component and a light-activated component. The inside of the crown is painted with adhesive before addition of the luting resin. The crown is gently placed and excess cement removed with a brush. Then the crown is seated with additional pressure or lightly tapped to extrude excess

Dentlearn.ir

luting resin at the margins. The luting resin is light cured through the facial and lingual aspects for 1 minute each. Excess resin is removed with a no. 12 or 12B scalpel blade. The occlusion is adjusted under water spray with diamond burs that have 15-and 8-μm diamond abrasive. Finally, the porcelain is polished with a porcelain polishing kit. This technique provides the highest cement-to-tooth bond but requires the most steps and has the greatest risk of field contamination.[192] *Self-etching systems* provide a self-etching primer to prepare the tooth. The cement is mixed, added to the crown, and seated over the preparation. After the components are chemically cured, the excess cement is removed with a scaler. The etch-and-rinse systems provide a more reliable bond and possibly a more stable bond than the self-etching technique.[193] The *self-adhesive systems* have a weak acid etchant, primer, and adhesive incorporated into the cement, appreciably reducing the risk of contamination. The bond strengths vary notably between systems.[192] Because of the nature of the chemistry, the etchant is not appropriate for enamel preparations. Some self-adhesive resin cements demonstrate high strength at baseline but lose strength dramatically over the first few months when compared with self-etching resin cements.[194]

Cementation of nonbonded crowns

The goals of nonadhesive cementation are complete seating of the crown and maximization of the physical properties of the cement. Classically, zinc phosphate was the cement of choice. Today, alternatives provide increased compressive strength and limited marginal dissolution. They include glass-ionomer and resin-modified glass-ionomer cements. The preparation should be thoroughly cleaned with pumice and/or an antimicrobial solution. If the soft tissue interferes with complete seating, retraction cord should be placed. The cement should be mixed according to the manufacturer's instructions and loaded into the crown, and the crown should be seated. If the crown has metal margins, the patient should bite on an orangewood stick or cotton roll; the stick can be moved up and down and back and forth for a few seconds. This technique, called *dynamic seating*, results in more complete seating of the crown.[195] Because of the risk of fracture, a cotton roll is recommended in place of the stick for all-ceramic crowns. Every effort should be made to keep the crown dry during the initial setting phase, that is, the first 5 minutes after cementation.[196] The physical and mechanical properties of most cements deteriorate if they become wet during setting. The final step is careful removal of the excess set cement with an explorer or scaler. This class of cement will not adhesively bond to most ceramic

Dentlearn.ir

systems.[197] Because of this lack of bond, the ceramic may fatigue quicker and be more prone to fracture.[198] However, conventional cements are recommended for high-strength ceramics, such as alumina or zirconia.

Acknowledgment

The illustrations for chapter 18 were completed by John Bonfardeci of Studio Giovanni.

References

1. Spear FM, Winter RR. Esthetic alternatives for anterior teeth. Presented at the Annual Meeting of American Academy of Restorative Dentistry, Chicago, 22 February 1997.
2. Pereira-Cenci T, Pereira LJ, Cenci MS, Bonachela WC, Del Bel Cury AA. Maximal bite force and its association with temporomandibular disorders. Braz Dent J 2007;18:65–68.
3. Hagberg C. Assessment of bite force: A review. J Craniomandib Disord 1987;1:162–169.
4. Asai T, Kazama R, Fukushima M, Okiji T. Effect of overglazed and polished surface finishes on the compressive fracture strength of machinable ceramic materials. Dent Mater J 2010;29:661–667.
5. Ludwig K. Studies on the ultimate strength of all-ceramic crowns. Dent Lab 1991;5:647–651.
6. Rosenblum MA, Schulman A. A review of all-ceramic restorations. J Am Dent Assoc 1997;128:297–307.
7. Kelly JR, Benetti P. Ceramic materials in dentistry: Historical evolution and current practice. Aust Dent J 2011;56(suppl 1):84–96.
8. Pjetursson BE, Sailer I, Zwahlen M, Hämmerle CH. A systematic review of the survival and complication rates of all-ceramic and metal-ceramic reconstructions after an observation period of at least 3 years. Part I: Single crowns. Clin Oral Implants Res 2007;18:73–85.
9. Pilathadka S, Vahalová D. Contemporary all-ceramic systems, part 2. Acta Medica 2007;50:105–107.
10. Rimmer SE, Mellor AC. Patients' perceptions of esthetics and technical quality in crowns and fixed partial dentures. Quintessence Int 1996;27: 228–235.
11. Paniz G, Kim Y, Abualsaud H, Hirayama H. Influence of framework design on the cervical color of metal ceramic crowns. J Prosthet Dent 2011;106:310–318.
12. Swain VL, Pesun IJ, Hodges JS. The effect of metal ceramic restoration framework design on tooth color. J Prosthet Dent 2008;99:468–476.
13. Schaffner VB, Jones DW. Light transmission in shoulder porcelain of metal-ceramic restorations. Presented at the Annual Meeting of the Academy of Prosthodontics, Orlando, Florida, 17 May 1994.
14. Trushkowsky RD. Esthetic and functional consideration in restoring endodontically treated teeth. Dent Clin North Am 2011;55:403–410.
15. Della Bona A, Kelly JR. The clinical success of all-ceramic restorations. J Am Dent Assoc 2008;139:8S–13S.
16. Campbell SD, Tu SJ, Lund PS. Translucency of a new ceramic crown material [abstract 395]. J Dent Res 1997;76:63.
17. Spear F, Holloway J. Which all-ceramic system is optimal for anterior esthetics? J Am Dent Assoc 2008;139:19S–24S.
18. Heffernan MJ, Aquilino SA, Diaz-Arnold AM, Haselton DR, Stanford CM, Vargas MA. Relative translucency of six all-ceramic systems. Part I: Core materials. J Prosthet Dent 2002;88:4–9.
19. Grossman DG. Photoelastic examination of bonded crown interfaces [abstract 719]. J Dent Res 1989;68:271.

Dentlearn.ir

20. Burke FJ, Fleming GJ, Abbas G, Richter B. Effectiveness of a self-adhesive resin luting system on fracture resistance of teeth restored with dentin-bonded crowns. Eur J Prosthodont Restor Dent 2006;14:185–188.
21. Mörmann W, Wolf D, Ender A, Bindl A, Göhring T, Attin T. Effect of two self-adhesive cements on marginal adaptation and strength of esthetic ceramic CAD/CAM molar crowns. J Prosthodont 2009;18:403–410.
22. Neiva G, Yaman P, Dennison JB, Razzoog ME, Lang BR. Resistance to fracture of three all-ceramic systems. J Esthet Dent 1998;10:60–66.
23. Marshall GW, Marshall SJ, Kinney JH, Balooch M. The dentin substrate: Structure and properties related to bonding. J Dent 1997;25:441–458.
24. Karakaya S, Unlu N, Say EC, Ozer F, Soyman M, Tagami J. Bond strengths of three different dentin adhesive systems to sclerotic dentin. Dent Mater J 2008;27:471–479.
25. Yousry MM, El Naga AA, Hafez RM, El-Badrawy W. Microshear bond strength and interfacial morphology of etch-and-rinse and self-etch adhesive systems to superficial and deep dentin. Quintessence Int 2011;42:e96–e106.
26. Pegado RE, do Amaral FL, Flório FM, Basting RT. Effect of different bonding strategies on adhesion to deep and superficial permanent dentin. Eur J Dent 2010;4:110–117.
27. Rees JS, Hammadeh M, Jagger DC. Abfraction lesion formation in maxillary incisors, canines and premolars: A finite element study. Eur J Oral Sci 2003;111:149–154.
28. Lee WC, Eakle WS. Stress-induced cervical lesions: Review of advances in the past 10 years. J Prosthet Dent 1996;75:487–494.
29. Heymann HO, Bayne SC. Current concepts in dentin bonding: Focusing on dentinal adhesion factors. J Am Dent Assoc 1993;124:27–36.
30. Jiang Q, Pan H, Liang B, Fu B, Hannig M. Effect of saliva contamination and decontamination on bovine enamel bond strength of four self-etching adhesives. Oper Dent 2010;35:194–202.
31. Suryakumari NB, Reddy PS, Surender LR, Kiran R. In vitro evaluation of influence of salivary contamination on the dentin bond strength of one-bottle adhesive systems. Contemp Clin Dent 2011;2:160–164.
32. Chung CW, Yiu CK, King NM, Hiraishi N, Tay FR. Effect of saliva contamination on bond strength of resin luting cements to dentin. J Dent 2009;37:923–931.
33. Gear RW. Neural control of oral behavior and its impact on occlusion. In: McNeill C (ed). Science and Practice of Occlusion. Chicago: Quintessence, 1997:59–60.
34. Jung YG, Peterson IM, Kim DK, Lawn BR. Lifetime-limiting strength degradation from contact fatigue in dental ceramics. J Dent Res 2000;79: 722–730.
35. Kelly JR, Rungruanganunt P, Hunter B, Vailati F. Development of a clinically validated bulk failure test for ceramic crowns. J Prosthet Dent 2010;104:228–238.
36. Lawn BR, Deng Y, Lloyd IK, Janal MN, Rekow ED, Thompson VP. Materials design of ceramic-based layer structures for crowns. J Dent Res 2002;81:433–438.
37. Wakabayashi N, Anusavice KJ. Crack initiation modes in bilayered alumina/porcelain disks as a function of core/veneer thickness ratio and supporting substrate stiffness. J Dent Res 2000;79:1398–1404.
38. Silva NR, Bonfante EA, Zavanelli RA, Thompson VP, Ferencz JL, Coelho PG. Reliability of metalloceramic and zirconia-based ceramic crowns. J Dent Res 2010;89:1051–1056.
39. Cehreli MC, Kokat AM, Ozpay C, Karasoy D, Akca K. A randomized controlled clinical trial of feldspathic versus glass-infiltrated alumina all-ceramic crowns: A 3-year follow-up. Int J Prosthodont 2011;24:77–84.
40. Fradeani M, Redemagni M. An 11-year clinical evaluation of leucite-reinforced glass-ceramic crowns: A retrospective study. Quintessence Int 2002;33:503–510.
41. Yilmaz H, Aydin C, Gul BE. Flexural strength and fracture toughness of dental core ceramics. J Prosthet Dent 2007;98:120–128.

ceramic crowns fabricated by a CAD/CAM system. J Prosthodont 2012;21:94–100.
43. Olivera AB, Marques MM. Esthetic restorative materials and opposing enamel wear. Oper Dent 2008;33:332–337.
44. Sorensen JA, Sultan E, Condon JR. Three-body in vitro wear of enamel against dental ceramics [abstract

Dentlearn.ir

909]. J Dent Res 1999;78:219.
45. Bottino MA, Salazar-Marocho SM, Leite FP, Vásquez VC, Valandro LF. Flexural strength of glass-infiltrated zirconia/alumina-based ceramics and feldspathic veneering porcelains. J Prosthodont 2009;18:417–420.
46. Rinke S, Tsigaras A, Huels A, Roediger M. An 18-year retrospective evaluation of glass-infiltrated alumina crowns. Quintessence Int 2011;42:625–633.
47. McLaren EA, White SN. Survival of In-Ceram crowns in a private practice: A prospective clinical trial. J Prosthet Dent 2000;83:216–222.
48. Kappert HF, Altvater A. Field study on the accuracy of fit and the marginal seal of In-Ceram crowns and bridges [in German]. Dtsch Zahnarztl Z 1991;46:151–153.
49. Haselton DR, Diaz-Arnold AM, Hillis SL. Clinical assessment of high-strength all-ceramic crowns. J Prosthet Dent 2000;83:396–401.
50. Zhang Y, Li J, Xue XQ, Chen ZY, Li XJ. A comparison of three-dimensional marginal adaptation among three all-ceramic crown systems. Shanghai Kou Qiang Yi Xue 2011;20:494–499.
51. Andersson M, Razzoog ME, Oden A, Hegenbarth EA, Lang BR. Procera: A new way to achieve an all-ceramic crown. Quintessence Int 1998;29:285–296.
52. Harrington Z, McDonald A, Knowles J. An in vitro study to investigate the load at fracture of Procera AllCeram crowns with various thickness of occlusal veneer porcelain. Int J Prosthodont 2003;16:54–58.
53. May KB, Russell MM, Razzoog ME, Lang BR. Precision of fit: The Procera AllCeram crown. J Prosthet Dent 1998;80:394–404.
54. Lin MT, Sy-Muñoz J, Muñoz CA, Goodacre CJ, Naylor WP. The effect of tooth preparation form on the fit of Procera copings. Int J Prosthodont 1998;11:580–590.
55. Zitzmann NU, Galindo ML, Hagmann E, Marinello CP. Clinical evaluation of Procera AllCeram crowns in the anterior and posterior regions. Int J Prosthodont 2007;20:239–241.
56. Odman P, Andersson B. Procera AllCeram crowns followed for 5 to 10.5 years: A prospective clinical study. Int J Prosthodont 2001;14:504–509.
57. Schweiger M, Holand W, Frank M, Rheinberger V. IPS Empress 2: A new pressable high-strength glass-ceramic for esthetic all-ceramic restorations. Quintessence Dent Technol 1999;22:143–151.
58. Culp L, McLaren EA. Lithium Disilicate: The restorative material of multiple options. Compend Contin Educ Dent 2010;31:716–725.
59. Seghi RR, Sorensen JA, Engelman MJ, et al. Flexural strength of new ceramic materials [abstract 1521]. J Dent Res 1990;89:299.
60. Pallis K, Griggs JA, Woody RD, Guillen GE, Miller AW. Fracture resistance of three all-ceramic restorative systems for posterior applications. J Prosthet Dent 2004;91:561–569.
61. Zimmer D, Gerds T, Strub JR. Survival rate of IPS-Empress 2 all-ceramic crowns and bridges Three year's results [in German]. Schweiz Monatsschr Zahnmed 2004;114:115–119.
62. Mansour YF, Al-Omiri MK, Khader YS, Al-Wahadni A. Clinical performance of IPS-Empress 2 ceramic crowns inserted by general dental practitioners. J Contemp Dent Pract 2008;9:9–16.
63. Toksavul S, Toman M. A short-term clinical evaluation of IPS Empress 2 crowns. Int J Prosthodont 2007;20:168–172.
64. Marquardt P, Strub JR. Survival rates of IPS Empress 2 all-ceramic crowns and fixed partial dentures: Results of a 5-year prospective clinical study. Quintessence Int 2006;37:253–259.
65. Yeo IS, Yang JH, Lee JB. In vitro marginal fit of three all-ceramic crown systems. J Prosthet Dent 2003;90:459–464.
66. Sorensen JA, Berge HX. In vivo measurement of antagonist tooth wear opposing ceramic bridges [abstract 2942]. J Dent Res 1999;78:473.
67. Guazzato M, Albakry M, Ringer SP, Swain MV. Strength, fracture toughness and microstructure of a selection of all-ceramic materials. Part II. Zirconia-based dental ceramics. Dent Mater 2004;20:449–456.
68. Guazzato M, Proos K, Sara G, Swain MV. Strength, reliability and mode of fracture of bilayered porcelain/core ceramics. Int J Prosthodont 2004;17:142–149.
69. Chong KH, Cai J, Takahashi Y, Wozniak W. Flexural strength of In-Ceram alumina and In-Ceram zirconia.

Dentlearn.ir

Int J Prosthodont 2002;5:183–188.
70. Baig MR, Tan KB, Nicholls JI. Evaluation of the marginal fit of a zirconia ceramic computer-aided machined (CAM) crown system. J Prosthet Dent 2010;104:216–227.
71. Baldissara P, Llukacej A, Ciocca L, Valandro FL, Scotti R. Translucency of zirconia copings made with different CAD/CAM systems. J Prosthet Dent 2010;104:6–12.
72. Al-Amleh B, Lyons K, Swain M. Clinical trials in zirconia: A systemic review. J Oral Rehabil 2010;37:641–652.
73. Ortorp A, Kihl M, Carlsson G. A 3-year retrospective and clinical follow-up study of zirconia single crowns performed in a private practice. J Dent 2009;37:731–736
74. Fazi G, Vichi A, Ferrari M. Microtensile bond strength of three different veneering porcelain systems to a zirconia core for all ceramic restorations. Am J Dent 2010;2:347–350.
75. Heintze SD, Rousson V. Survival of zirconia- and metal-supported fixed dental prostheses: A systemic review. Int J Prosthodont 2010;23:493–502.
76. Guazzato M, Walton TR, Franklin W, Davis G, Bohl C, Klineberg I. Influence of thickness and cooling rate on development of spontaneous cracks in porcelain/zirconia structures. Aust Dent J 2010;55:306–310.
77. Marchack BW, Sato S, Marchack CB, White SN. Complete and partial contour zirconia designs for crowns and fixed dental prostheses: A clinical report. J Prosthet Dent 2011;106:145–152.
78. Jones DW. Development of dental ceramics—A historical perspective. Dent Clin North Am 1985;29:621–644.
79. Rouse J, McGowan S. Restoration of the anterior maxilla with ultraconservative veneers: Clinical and laboratory considerations. Pract Periodontics Aesthet Dent 1999;11:333–339.
80. Campbell SD. A comparative strength study of metal-ceramic and all-ceramic materials: Modulus of rupture. J Prosthet Dent 1989;62:476–479.
81. Selby A. Fixed prosthodontic failure. A review and discussion of important aspects. Aust Dent J 1994;39:150–156.
82. Block PL. Restorative margins and periodontal health. J Prosthet Dent 1987;57:683–689.
83. Felton DA, Kanoy B, Bayne S, Wirthman G. Effect of in vivo crown margin discrepancies on periodontal health. J Prosthet Dent 1991;65:357–364.
84. Flores-de-Jacoby L, Zafiropoulus GG, Ciancio S. The effect of crown margin location on plaque and periodontal health. Int J Periodontics Restorative Dent 1989;9:197–205.
85. Sorensen JA, Torres TJ, Kang SK, Avera SP. Marginal fidelity of ceramic crowns with different margin designs [abstract 1365]. J Dent Res 1990;69(special issue):279.
86. Nevins M, Skurow HM. The intracrevicular restorative margin, the biologic width, and the maintenance of the gingival margin. Int J Periodontics Restorative Dent 1984;4(3):31–49.
87. Tarnow DP, Stahl SS, Magner A. Human gingival attachment response to subgingival crown placement. J Clin Periodontol 1986;13:563–569.
88. Kaiser DA, Newell DH. Technique to disguise the metal margin of the metal/ceramic crown. Am J Dent 1988;1:217–221.
89. Kois JC. The gingiva is red around my crowns: A differential diagnosis. Dent Econ 1993;4:101–105.
90. Kois JC. The restorative-periodontal interface: Biological parameters. Periodontol 2000 1996;11:1–10.
91. Hochman N, Yaffe A, Ehrlich J. Crown contour variations in gingival health. Compend Contin Educ Dent 1983;4:360–365.
92. Gottlieb B. Der Epithelansatz am Zähne. Dtsch Monatsschr Zahnheilkd 1921;39:142–148.
93. Sicher H. Changing concepts of the supporting dental structures. Oral Surg 1959;12:31–35.
94. Gargiulo AW, Wentz FM, Orban B. Dimensions and relations of the den-togingival junction in humans. J Periodontol 1961;32:261–267.
95. Robbins JW. Tissue management in restorative dentistry. Functional Esthetic Restorative Dent 2007;1:40–43.
96. Vacek JS, Gher ME, Assad DA, Richardson AC, Giambarresi LI. The dimensions of the human dentogingival junction. Int J Periodontics Restorative Dent 1994;14:154–165.
97. Ingber JS, Rose LF, Coslet JG. The “biologic width”: A concept in periodontics and restorative dentistry.

Dentlearn.ir

Alpha Omegan 1977;70:62–65.
98. Stern IB. Current concepts of the dentogingival junction: The epithelial and connective tissue attachments to the tooth. J Periodontol 1981; 52:465–476.
99. Kois JC. Altering gingival levels: The restorative connection. Part I: Biologic variables. J Esthet Dent 1994;6:3–9.
100. Spray JR, Garnick JJ, Doles LR, Klawitter JJ. Microscopic demonstration of the position of periodontal probes. J Periodontol 1978;49:148–152.
101. Van der Velden UJ. Regeneration of the interdental soft tissues following denudation procedures. Clin Periodontol 1982;9:455–459.
102. Pontoriero R, Carnevale G. Surgical crown lengthening: A 12-month clinical wound healing study. J Periodontol 2001;72:841–848.
103. Sanavi F, Wiesgold AS, Rose LF. Biologic width and its relation to periodontal biotypes. J Esthet Dent 1998;10:157–163.
104. Coslet JG, Vanarsdall R, Wiesgold A. Diagnosis and classification of delayed passive eruption of the dentogingival junction in the adult. Alpha Omegan 1977;10:24–28.
105. Jackson CR, Skidmore AE, Rice RT. Pulpal evaluation of teeth restored with fixed prostheses. J Prosthet Dent 1992;67:323–325.
106. Zach L, Cohen G. Pulpal response to externally applied heat. Oral Surg 1965;19:515–530.
107. Laforgia PD, Milano V, Morea C, Desiate A. Temperature change in the pulp chamber during complete crown preparation. J Prosthet Dent 1991;65:56–61.
108. Ward ML. The American Textbook of Operative Dentistry, ed 6. Philadelphia: Lea & Febiger, 1926:413.
109. Al-Omari WM, Al-Wahadni AM. Convergence angle, occlusal reduction, and finish line depth of full-crown preparations made by dental students. Quintessence Int 2004;35:287–293.
110. Jørgensen KD. The relationship between retention and convergence angles in cemented veneer crowns. Acta Odontol Scand 1955;13:35–40.
111. Wiskott A, Nicholls JI, Belser UC. The effect of abutment length and diameter on resistance to fatigue loading. Int J Prosthodont 1997;10: 207–215.
112. Wiskott A, Nicholls JI, Belser UC. The relationship between convergence angle and resistance of cemented crowns to dynamic loading. Int J Prosthodont 1996;9:117–130.
113. Wiskott HWA, Krebs C, Scherrer SS, Botsis J, Belser UC. Compressive and tensile zones in the cement interface of full crowns: A technical note on the concept of resistance. J Prosthet Dent 1999;8:80–91.
114. Ohm E, Silness J. The convergence angle in teeth prepared for artificial crowns. J Oral Rehabil 1978;5:371–375.
115. Mack PJ. A theoretical and clinical investigation into the taper achieved on crown and inlay preparations. J Oral Rehabil 1980;7:255–265.
116. Nordlander J, Weir D, Stoffer W, Ochi S. The taper of clinical preparations for fixed prosthodontics. J Prosthet Dent 1988;60:148–151.
117. Smith CT, Gary JJ, Conkin JE, Franks HL. Effective taper criterion for the full veneer crown preparation in preclinical prosthodontics. J Prosthodont 1999;8:196–200.
118. el-Mowafy OM, Fenton AH, Forrester N, Milenkovic M. Retention of metal ceramic crowns cemented with resin cements: Effect of preparation taper and height. J Prosthet Dent 1996;76:524–529.
119. Gilboe DB, Teteruck WR. Fundamentals of extracoronal tooth preparation. Part I. Retention and resistance form. J Prosthet Dent 1974;32:651–656.
120. Carter SM, Wilson PR. The effect of die spacing on crown retention. Int J Prosthodont 1996;9:21–29.
121. Wilson AH, Chan DC. The relationship between preparation convergence and retention of extracoronal retainers. J Prosthet Dent 1994;3:74–78.
122. Korioth TW, Waldron TW, Versluis A, Schulte JK. Forces and moments generated at the dental incisors during forceful biting in humans. J Biomech 1997;30:631–633.
123. Morikawa A. Investigation of occlusal force on lower first molar in function [in Japanese]. Kokubyo Gakkai Zasshi 1994;61:250–274.

Dentlearn.ir

124. Wiskott A, Belser U. A rationale for a simplified occlusal design in restorative dentistry: Historical review and clinical guidelines. J Prosthet Dent 1995;75:169–183.
125. Graf H, Geering AH. Rationale for clinical application of different occlusal philosophies. Oral Sci Rev 1977;10:1–10.
126. Caputo AA, Standlee JP. Biomechanics in Clinical Dentistry. Chicago: Quintessence, 1987:128.
127. Jacobsen PH, Wakefieldt AJ, O'Doherty DM, Rees JS. The effect of preparation height and taper on cement lute stress: A three-dimensional finite element analysis. Eur J Prosthodont Restor Dent 2006;14: 151–157.
128. Roudsari RV, Satterthwaite JD. The influence of auxiliary features on the resistance form of short molars prepared for complete cast crowns. J Prosthet Dent 2011;106:305–309.
129. Owen CP. Retention and resistance in preparations for extracoronal restorations. Part 2: Practical and clinical studies. J Prosthet Dent 1986; 56:148–153.
130. Shillingburg HT, Hobo S, Whitsett LD. Fundamentals of Fixed Prosthodontics, ed 2. Chicago: Quintessence, 1981:79–96.
131. Zuckerman GR. Resistance form for the complete veneer crown: Principles of design and analysis. Int J Prosthodont 1988;1:302–307.
132. Eismann HF, Radke RA. Postendodontic restoration. In: Cohen S, Burns RC (eds). Pathways of the Pulp. St Louis: Mosby, 1987:640–683.
133. Sorensen J, Engelman M. Ferrule design and fracture resistance of endodontically treated teeth. J Prosthet Dent 1990;63:529–536.
134. Trabert KC, Cooney JP. The endodontically treated tooth: Restorative concepts and techniques. Dent Clin North Am 1984;28:423–451.
135. Akkayan B. An in vitro study evaluating the effect of ferrule length on fracture resistance of endodontically treated teeth restored with fiber-reinforced and zirconia dowel systems. J Prosthet Dent 2004;92:155–162.
136. Mancebo JC, Jiménez-Castellanos E, Cañadas D. Effect of tooth type and ferrule on the survival of pulpless teeth restored with fiber posts: A 3-year clinical study. Am J Dent 2010;23:351–356.
137. Christensen GJ. Marginal fit of gold inlay castings. J Prosthet Dent 1966;16:297–305.
138. Björn AL, Björn H, Grkovic B. Marginal fit of restorations and its relation to periodontal bone level. I. Metal fillings. Odontol Revy 1969;20:311–321.
139. Björn AL, Björn H, Grkovic B. Marginal fit of restorations and its relation to periodontal bone level. II. Crowns. Odontol Revy 1970;21:337–346.
140. Qualtrough AJ, Piddock V. Dental ceramics: What's new? Dent Update 2002;29:25–33.
141. Belser UC, MacEntee MI, Richter WA. Fit of three porcelain-fused-to-metal marginal designs in vivo: A scanning electron microscope study. J Prosthet Dent 1985;53:24–29.
142. Wright WE. Selection of proper margin configuration. J Calif Dent Assoc 1992;20:41–44.
143. Faucher RR, Nicholls JI. Distortion related to margin design in porcelain-fused-to-metal restorations. J Prosthet Dent 1980;43:149–155.
144. Pascoe DF. Analysis of the geometry of finish lines for full crown restorations. J Prosthet Dent 1978;40:157–162.
145. el-Ebrashi MK, Craig RG, Peyton FA. Experimental stress analysis of dental restorations. 3. The concept of the geometry of proximal margins. J Prosthet Dent 1969;22:333–345.
146. Gardner FM, Tillman-McCombs KW, Gaston ML, Runyan DA. In vitro failure load of metal-collar margins compared with porcelain facial margins of metal-ceramic crowns. J Prosthet Dent 1997;78:1–4.
147. Abbate MF, Tjan AH, Fox WM. Comparison of the marginal fit of various ceramic crown systems. J Prosthet Dent 1989;61:527–531.
148. Gavelis JR, Morency JD, Riley ED, Sozio RB. The effect of various finish line preparations on the marginal seal and occlusal seat of full crown preparations. J Prosthet Dent 1981;45:138–145.
149. Padilla MT, Bailey JH. Marginal configuration, die spacers, fitting of retainers/crowns, and soldering. Dent Clin North Am 1992;36:743–765.
150. Vahidi F, Egloff ET, Panno FV. Evaluation of marginal adaptation of all-ceramic crowns and metal-ceramic

Dentlearn.ir

crowns. J Prosthet Dent 1991;66: 426–431.
151. Donovan TE, Chee WW. Cervical margin design with contemporary esthetic restorations. Dent Clin North Am 2004;48:417–431.
152. Baltzer A. All-ceramic single-tooth restorations: Choosing the material to match the preparation—Preparing the tooth to match the material. Int J Comput Dent 2008;11:241–256.
153. Kois JC. New paradigms for anterior tooth preparation: Rationale and technique. Contemp Esthet Dent 1996;2(1):1–8.
154. Gürel G. The Science and Art of Porcelain Laminate Veneers. Chicago: Quintessence, 2003:246.
155. Sutton AF, McCord JF. Variations in tooth preparations for resin-bonded all-ceramic crowns in general dental practice. Br Dent J 2001;191:677–681.
156. Geminiani A, Lee H, Feng C, Eroli C. The influence of incisal veneering porcelain thickness of two metal ceramic crown systems on failure resistance after cyclic loading. J Prosthet Dent 2010;103:275–282.
157. Aminian A, Brunton PA. A comparison of the depths produced using three different tooth preparation techniques. J Prosthet Dent 2003;89: 19–22.
158. Chiche GJ, Harrison JD. Impression considerations in the maxillary anterior region. Compend Contin Educ Dent 1994;15:318–327.
159. Nemetz H, Donovan TE, Landesman H. Exposing the gingival margin: A systematic approach for the control of hemorrhage. J Prosthet Dent 1984;51:647–650.
160. Benson BW. Tissue displacement methods in fixed prosthodontics. J Prosthet Dent 1986;55:175–181.
161. Nementz E, Seibly W. The use of chemical agents in gingival retraction. Gen Dent 1990;3:104–108.
162. Donovan TE, Gandara BK, Nemetz H. Review and survey of medicaments used with gingival retraction cords. J Prosthet Dent 1985;53: 525–531.
163. Laufer BZ, Baharav H, Ganor Y, Cardash HS. The effect of marginal thickness on the distortion of different impression materials. J Prosthet Dent 1996;76:466–471.
164. Laufer BZ, Baharav H, Cardash HS. The linear accuracy of impressions and stone dies as affected by the thickness of the impression margin. Int J Prosthodont 1994;7:247–252.
165. Aimjirakul P, Masuda T, Takahashi H, Miura H. Gingival sulcus simulation model for evaluating the penetration characteristics of elasto-meric impression materials. Int J Prosthodont 2003;16:385–389.
166. Baharav H, Laufer BZ, Langer Y, Cardish HS. The effect of displacement time on gingival crevice width. Int J Prosthodont 1997;10:248–253.
167. Azzi R, Tsao TF, Carranza FA, Kenney EB. Comparative study of gingival retraction methods. J Prosthet Dent 1983;50:561–565.
168. Harrison JD. Effect of retraction materials on the gingival sulcus epithelium. J Prosthet Dent 1961;11:514–519.
169. Ruel J, Schuessler PJ, Malament K, Mori D. Effect of retraction procedures on the periodontium in humans. J Prosthet Dent 1980;44:508–515.
170. Ciesco JN, William MS, Sandrik JL, Mazur B. Comparison of elastic impression materials used in fixed prosthodontics. J Prosthet Dent 1981;45:89–94.
171. Dounis GS, Ziebert GJ, Dounis KS. A comparison of impression materials for complete-arch fixed partial dentures. J Prosthet Dent 1991; 65:165–169.
172. Lin CC, Ziebert GJ, Donegan SJ, Dhuru VB. Accuracy of impression materials for complete-arch fixed partial dentures. J Prosthet Dent 1988;59:288–291.
173. Federick DR, Caputo A. Comparing the accuracy of reversible hydrocolloid and elastomeric impression materials. J Am Dent Assoc 1997; 128:183–188.
174. Pratten DH, Novetsky M. Detail reproduction of soft tissue: A comparison of impression materials. J Prosthet Dent 1991;65:188–191.
175. Chee WW, Donovan TE. Polyvinyl siloxane impression materials: A review of properties and techniques. J Prosthet Dent 1992;73:419–423.
176. Johnson GH, Lepe X, Aw TC. The effect of surface moisture on detail reproduction of elastomeric impressions. J Prosthet Dent 2003;90:228–234.

Dentlearn.ir

177. Chee WW, Donovan TE, Kahn RL. Indirect inhibition of polymerization of a polyvinyl siloxane impression material: A case report. Quintessence Int 1991;22:133–135.
178. De Camargo LM, Chee WW, Donovan TE. Inhibition of polymerization of polyvinyl siloxanes by medicaments used on gingival retraction cords. J Prosthet Dent 1993;70:114–117.
179. Kahn RL, Donovan TE. A pilot study of polymerization inhibition of poly (vinyl siloxane) materials by latex gloves. Int J Prosthodont 1989;2:128–130.
180. Gordon GE, Johnson GH, Drennon DG. The effect of tray selection on the accuracy of elastomeric impression materials. J Prosthet Dent 1990;63:12–15.
181. Rueda LJ, Sy-Muñoz JT, Naylor WP, Goodacre CJ, Swartz ML. The effect of using custom or stock trays on the accuracy of gypsum casts. Int J Prosthodont 1996;9:367–373.
182. Kurbad A. Impression-free production techniques. Int J Comput Dent 2011;14:59–66.
183. Fasbinder DJ. Digital dentistry: Innovation for restorative treatment. Compend Contin Educ Dent 2010;31(special issue 4):2–11.
184. Ender A, Mehl A. Full arch scans: Conventional versus digital impressions—An in-vitro study. Int J Comput Dent 2011;14:11–21.
185. Zwimpfer M. Color, Light, Sight, Sense. Philadelphia: Schiffer 1988: 1–264.
186. Kim-Pusateri S, Brewer JD, Davis EL, Wee AG. Reliability and accuracy of four dental shade-matching devices. J Prosthet Dent 2009;101:193–199.
187. Lagouvardos PE, Fougia AG, Diamantopoulou SA, Polyzois GL. Repeatability and interdevice reliability of two portable color selection devices in matching and measuring tooth color. J Prosthet Dent 2009;101:40–45.
188. Sorensen JA, Kang SK, Avera SA. Porcelain-composite interface microleakage with various porcelain surface treatments. Dent Mater 1991;7:118–121.
189. Stangel I, Nathanson D, Hsu CS. Shear strength of the composite bond to etched porcelain. J Dent Res 1987;66:1460–1465.
190. Boyer DB, Chan KC. Curing light activated composite cement through porcelain [abstract 1289]. J Dent Res 1989;68:476.
191. Cadenaro M, Navarra CO, Antoniolli F, et al. The effect of curing mode on extent of polymerization and microhardness of dual-cured, self-adhesive resin cements. Am J Dent 2010;23:14–18.
192. Burgess JO, Ghuman T, Cakir D. Self-adhesive resin cements. J Esthet Restor Dent 2010;22:412–419.
193. Cekic I, Ergun G, Lassila LV, Vallittu PK. Ceramic-dentin bonding: Effect of adhesive systems and light-curing units. J Adhes Dent 2007;9:17–23.
194. Bagheri R, Mese A, Burrow MF, Tyas MJ. Comparison of the effect of storage media on shear punch strength of resin luting cements. J Dent 2010;38:820–827.
195. Rosenstiel SF, Gegauff AF. Improving cementation of complete cast crowns: A comparison of static and dynamic seating methods. J Am Dent Assoc 1988;117:845–848.
196. Curtis SR, Richards MW, Meiers JC. Early erosion of glass-ionomer cement at crown margins. Int J Prosthodont 1993;6:553–557.
197. Zhang W, Masumi SI, Song XM. Bonding property of two resin-reinforced glass-ionomer cements to zirconia ceramic. Quintessence Int 2010;41:e132–e140.
198. Borges GA, Caldas D, Taskonak B, Yan J, Sobrinho LC, de Oliveira WJ. Fracture loads of all-ceramic crowns under wet and dry fatigue conditions. J Prosthodont 2009;18:649–655.

Dentlearn.ir



Esthetic Inlays and Onlays

Dennis J. Fasbinder
Gisele Neiva
J. William Robbins

There are several treatment options for conservative posterior esthetic restorations in addition to direct resin composite restorations. This chapter discusses tooth-colored inlays and onlays fabricated in resin composite and in ceramic materials. Restorations fabricated with computer-aided design/computer-assisted manufacture (CAD/CAM) technology will also be discussed. Esthetic inlays and onlays have a number of characteristics in common, whether they are resin, ceramic, or fabricated with CAD/CAM technology.

General Considerations

Preparations

The preparations for ceramic and resin composite inlays and onlays are essentially the same. Preparations for CAD/CAM inlays and onlays do not differ from preparations for laboratory-fabricated inlays and onlays. There is little research to

Dentlearn.ir

support the efficacy of any preparation design over another.[1] However, based on knowledge of the materials and clinical experience, the divergent, relatively nonretentive preparation is most commonly advocated because of ease of placement (Fig 19-1). Resistance form may be incorporated with rounded proximal boxes, but grooves should not be used. Resistance and retention form for the restoration are provided primarily by adhesion to enamel and dentin. Supragingival margin placement is desired to facilitate isolation for the adhesive cementation of the inlay or onlay. The walls and floors of the preparation should be smooth and even, and the

Occlusal reduction should be uniform and of sufficient thickness to ensure strength of the overlying ceramic material to avoid fracture. This equates to at least 1.5 mm in the central fossa and 2.0 mm over functional cusps[2] (Fig 19-2).

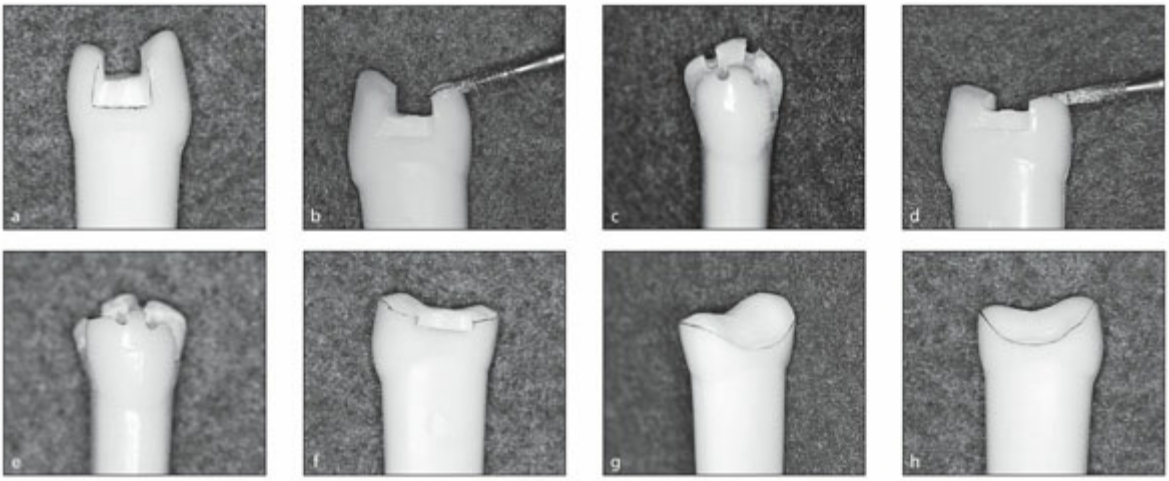

Fig 19-1 Onlay preparation technique. *(a)* Simulation of amalgam preparation after removal of the amalgam. *(b)* Use of a diamond of known diameter to make the first depth cut of 1 mm. *(c)* First depth cuts of 1 mm. *(d)* Use of a diamond of known diameter to make the second depth cuts of 1 mm. *(e)* Second depth cuts of an additional 1 mm. *(f)* Occlusal reduction of 2 mm completed; however, sharp line angles remain in the box area. *(g and h)* Completed smooth, flowing preparation without sharp angles.



Fig 19-2 Inadequate occlusal reduction for a porcelain onlay, resulting in fractured porcelain.

Dentlearn.ir

There is no benefit to the placement of bevels at the occlusal or gingival margins; in fact, bevels should be avoided because thin margins of both resin composite and most ceramics are susceptible to chipping during function.[3,4] A 90-degree butt joint minimizes the chipping problem but may result in a visible demarcation between the tooth and the restoration. Therefore, when the esthetic blend of the restoration and the tooth is important, such as on the facial surface of a maxillary premolar, the entire facial surface of the premolar may be included in the preparation to ensure an optimal shade match with the adjacent teeth (Fig 19-3). A more recent preparation modification has been suggested to enhance the esthetic blend of the facial margin and not involve the entire facial surface of the tooth in the preparation. The cavosurface margin is modified with a football-shaped diamond at a 45-degree angle to the cavosurface margin, creating a blend of porcelain to enamel shading and still maintaining a bulk of ceramic at the margin for physical strength of the ceramic. An in vitro study on ceramic preparations for conservative restoration of endodontically treated teeth reported a significant improvement in the marginal and

both a ferrule and a 90-degree butt-joint margin.[5]

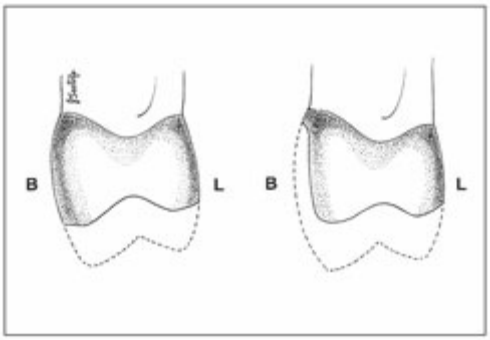

Fig 19-3 Standard onlay preparation *(left)* and modified onlay preparation *(right)* that includes coverage of facial surface to achieve a superior esthetic blend with the natural tooth color. B—buccal; L—lingual.

Bases and liners

The use of bases and liners is somewhat controversial. Initially, glass-ionomer bases were used for dentinal protection and to base the preparation to "ideal" form. However, it has been shown that it is not necessary to protect the dentin from the phosphoric acid etchant.[6] Therefore, glass-ionomer cement is recommended only for routine block-out of undercuts.

Provisional restorations

Dentlearn.ir

Provisional restorations can be a challenge with esthetic inlays and, particularly, onlays because of the nonretentive design of the preparations. Provisional restorations can be made in the usual manner with acrylic resin or resin composite and cemented with temporary cement. It is commonly stated that a eugenol-containing cement should not be used with the provisional restoration when the definitive restoration will be bonded with a resin cement.[1,7] However, the literature is equivocal on the deleterious effect of eugenol. Some studies support the hypothesis that a eugenol-containing provisional cement inhibits the set of resin cements,[1,7,8] while others show that eugenol-containing provisional cements have no impact on bond strengths.[9–14] Because of the nonretentive design of the onlay preparation, the more retentive polycarboxylate cement is the temporary luting cement of choice. Small mechanical undercuts should be placed on the intaglio surface of the provisional restoration to aid in retention. If adjacent teeth are being restored, the provisional restorations can be connected to improve retention.

"spot etched" with phosphoric acid to adhesively bond the provisional restoration in place. A finishing diamond bur may be required to remove the area of bonding once the provisional restoration has been removed to ensure complete removal of the adhesive from the preparation surface prior to delivering the restoration.

For inlay preparations, semiflexible light-cured materials, such as Systemp (Ivoclar Vivadent) or Barricade (Dentsply) may be used. To provide retention and to decrease sensitivity, a dentin primer can be placed in the preparation and air dried, or a small amount of resin-modified glass-ionomer cement liner can be placed on the pulpal floor and polymerized. The preparation is filled with the provisional material, and the patient is instructed to bite into maximum intercuspation to develop the occlusion. Excess material is removed with an explorer, and the provisional restoration is light cured. This technique is recommended only for short-term use in small preparations.[15]

Adhesive cementation

Resin luting cement is the only material recommended for cementing this type of restoration because it bonds to enamel, dentin, and the restorative material. Luting resin cement limits microleakage and enhances the strength of the restoration.[16] It is commonly reported that indirect bonded restorations strengthen the prepared tooth[17,18]; however, this is not universally supported by the literature.[19] Dual-cured luting resin and dual-cured dentin bonding agents, which combine light-curing and

Dentlearn.ir

chemical-curing components, should be used to bond all indirect posterior bonded restorations.[20,21] The light-curing component polymerizes rapidly on exposure to light of the proper wavelength, while the chemical-curing component undergoes a slow polymerization process in those areas to which the light does not penetrate. It is important that the curing light be applied to dual-cured resin for an adequate period of time, because the dual-curing process results in more complete polymerization than that achieved with chemical polymerization alone.[22,23] The shelf life of dual-cured resins is shorter than that of conventional light-cured resin composites. Therefore, expiration dates of adhesive agents and resin luting cements should be monitored carefully. Alternatively, a test batch of dual-cured luting resin can periodically be mixed and allowed to cure in a dark environment to ensure that it will polymerize in the absence of light. Most dual-cured luting resins should polymerize at room temperature in the dark within 10 minutes.

Preparing the restoration for bonding

Adhesion is more reliably achieved to ceramic materials than to resin composite restorations. Ceramics used in these restorations must be etched, creating durable micromechanical retention.[24] The ceramic inlay/onlay is prepared for bonding by the laboratory but may be done chairside instead. Shortly before bonding, a silane coupling agent is applied to the etched surface to enhance wetting by the resin adhesive.[25,26]

Bonding to resin composite restorations is more difficult. The intaglio surface has reliable chemical bond does not form between the inlay and the resin cement.[27–29] Because the resin composite–cement interface may be the weak link, several procedures have been recommended to enhance the bond to resin. With hybrid resin composite, the intaglio surface should be carefully air abraded with 50-µm aluminum oxide or 30-µm silica-modified corundum particles (CoJet Sand, 3M ESPE), avoiding the margins[30] and then cleaned with a steam cleaner or in an ultrasonic bath. The air abrasion provides a rough surface for frictional retention. The cleaned surface should be treated with an agent to allow better wetting by the cement. Silane is generally the preferred wetting agent.[28,31,32] While treatment with hydrofluoric acid has also been recommended to etch the glass particles in the hybrid resin composite, laboratory research does not support the efficacy of this procedure.[27]

Dentlearn.ir

Preparing the tooth for bonding

Ensuring an isolated operating field is a critical step in the adhesive bonding process. Only in a controlled environment can the adhesive bonding materials achieve maximum strength. There are several useful devices. The most cost-effective device is the rubber dam (Fig 19-4a). A number of other commercially available devices, such as an OptraGate (Ivoclar Vivadent) or Isolite[2] (Isolite) (see chapter 8), may be employed if the use of a rubber dam is not feasible or desirable for the clinical case at hand.

Once the restoration is ready for bonding, a decision must be made regarding the type of dentin bonding agent. Three-step etch-and-rinse (fourth-generation) light-cured-only adhesive systems should not be used under indirect posterior bonded restorations. The light-cured adhesive would need to be air thinned prior to polymerization to ensure the absence of pooling of the adhesive, which would prevent complete seating of the restoration. Moreover, it has been shown that air thinning of the light-cured adhesive resin significantly decreases the bond strength.[33] This leaves three-step etch-and-rinse (fourth-generation) dual-cured systems as the adhesive system of choice. However, any adhesive agent that will cure in conjunction with a dual-cured resin luting agent can be selected, regardless of the type of etching system or the number of application steps. Adhesive systems are described in detail in chapter 9.

The technique with the most research support employs the dual-cured, three-step etch-and-rinse (fourth-generation) dentin bonding systems. The enamel is etched for 30 seconds and the dentin for 15 seconds, and the tooth is rinsed for 15 seconds and air dried to enable visual inspection for an adequate enamel etch. The dentin is remoistened with chlorhexidine, and several coats of a hydrophilic resin primer are applied to infiltrate the exposed collagen fibers and form the hybrid layer. Active application of the primer on the dentin may enhance bonding,[34] but the specific instructions of the manufacturer should be followed carefully because they vary from brand to brand. The primer is completely air dried with gentle air pressure. The dual-cured adhesive is placed on the tooth and the previously etched and silanated intaglio surface of the restoration. The dual-cured luting resin is mixed and placed into the preparation and restoration, and the restoration is seated. Excess resin must be completely removed from the proximal-surface gingival margins with floss and interproximal instruments before polymerization of the luting resin. Some clinicians recommend placement of a clear gel, such as glycerin, on the margins before polymerization to prevent the formation of an air-inhibited layer in the luting resin at

Dentlearn.ir

the margin.[35] The margins may be finished with microfine diamonds or multifluted carbide finishing burs and a no. 12 or 12B scalpel blade, and they can be polished with disks, rubber points, or cups. After removal of the rubber dam, the occlusion is adjusted and the surface is polished to a high shine. The final step is rebonding, as described in chapter 11, with an unfilled or lightly filled resin (Figs 19-4b to 19-4g). Figure 19-5 demonstrates luted restorations.



Fig 19-4*(a)* Rubber dam isolation for cementation of a quadrant of porcelain onlays. *(b)* Master cast of a quadrant of porcelain onlay preparations. Note the amount of occlusal reduction. *(c)* Occlusal view of onlay preparations. *(d and e)* Porcelain onlays 2½ years after placement. (Porcelain onlays created by Gilbert Young, CDT, Plano, Texas.) *(f)* Lateral view of the maxillary and mandibular quadrants of porcelain onlays. The esthetic blend on the facial aspect of the maxillary premolars is better because the preparations were taken further gingivally than on the molars. *(g)* Bitewing radiograph taken after 2½ years showing porcelain onlays. Note the different cement radiopacities in the maxillary and mandibular restorations.

Dentlearn.ir



Fig 19-5*(a)* Porcelain onlay preparation, man-dibular first molar. *(b)* Master cast of the prepared mandibular first molar for a porcelain onlay. *(c)* Completed porcelain onlay on the mandibular first molar. *(d)* Buccal view of the completed porcelain onlay on the mandibular first molar. (Porcelain onlay created by Gilbert Young, CDT, Plano, Texas.)

Despite the initial high bond strength of two-step self-etching (sixth-generation) systems and one-step self-etching (seventh-generation) all-in-one systems, these values have been shown to decrease significantly under thermal and mechanical stresses, particularly on enamel; therefore, etch-and-rinse adhesives continue to be the preferred system for dental adhesion.[36,37] Alternative adhesive cementation techniques may be considered by combining a different generation of bonding agent with a dual-cured resin cement. Generally, this results in fewer clinical steps required for the adhesive bonding. However, this is not without a degree of risk. Many two-step etch-and-rinse (fifth-generation) and one-step self-etching (seventh-generation) products are incompatible with dual-cured and autocured luting composites.[38] The clinician must ensure that the selected bonding agent and resin cement will polymerize together.

Maintenance

Maintenance is a very important factor in the longevity of esthetic inlays and onlays. As with all types of restorative dentistry, lack of preventive measures and the resulting caries can cause failure of the finest restoration. Use of devices such as ultrasonic scalers or air-abrasive polishers on these restorations must be avoided because they can cause surface and marginal damage. Calculus should be removed carefully with hand instruments. When scalers are used around a bonded inlay or onlay, care must be taken not to chip the margins. Surface stain may be removed

Dentlearn.ir

from a restoration with aluminum oxide polishing paste or diamond polishing paste on a felt wheel or rubber cup. Because of their ability to etch porcelain, neither acidulated phosphate fluoride nor stannous fluoride solutions or gels should be used intraorally in patients with ceramic restorations. Only neutral sodium fluoride solutions should be used.

The patient should be advised that foods and liquids with a high potential for staining, such as coffee and tea, increase the potential for marginal staining. The patient must also be made aware of the potential for restoration fracture. Activities such as ice chewing and nail biting absolutely must be avoided. When a patient has a history of a parafunctional habit, a protective appliance should be fabricated to protect both the inlay or onlay and the opposing teeth.

Resin Composite Inlays and Onlays

Inlays and onlays made of resin composite are quite popular in Europe but have not gained wide acceptance in the United States. These restorations are typically fabricated on a gypsum cast or die. After polymerization, the restoration is bonded in place with a resin luting cement. Resin composite inlays can be highly esthetic and have certain advantages over direct resin composite and bonded ceramic restorations.

Advantages over direct resin composite restorations

As discussed in chapter 11, inadequate proximal contours and open contacts can be common problems of direct resin composite restorations. These are fewer common problems with resin inlays because contours and contacts can be developed outside of the mouth. If a contact is inadequate, it can easily be corrected prior to cementation.

Several problems associated with direct resin composite restorations are the result of polymerization shrinkage. During polymerization, resin composite shrinks on the order of 2% to 4%,[39–41] often causing a gap to form at the least retentive marginal interface, which is usually the gingival margin. Microleakage and bacterial ingress into the marginal gap may cause pulpal irritation and tooth sensitivity.[42] Current dentin adhesives have lessened, but not eliminated, the problem.[43,44] Polymerization shrinkage can also cause cuspal flexure, which is sometimes associated with craze lines in the enamel and postoperative sensitivity.[45]

Dentlearn.ir

In theory, polymerization shrinkage should be less of a problem with resin inlays because they are polymerized before cementation. The only polymerization shrinkage that occurs at the time of cementation is in the thin layer of resin cement, though this can be considerable (ie, 2% to 7%).[40,41] In fact, polymerization shrinkage stress in thin resin cement layers can be as great as or even higher than in thicker composite increments.[46] Resin inlays are reported to have less microleakage[47–49] and greater strength and hardness[50–52] and result in less postoperative sensitivity than direct resin composite restorations.[53]

While the in vitro data suggest that there are significant advantages to the resin inlay compared with the direct resin composite restoration, this is not corroborated by the in vivo data. In a 5-year clinical study[54] and another 11-year clinical study,[55] no statistically significant difference was found in the success rates for resin inlays compared with direct-placement resin composite restorations. Based on these data, and because of the increased cost of the resin inlay and the frequent need to remove more solid tooth structure for inlays, it is currently difficult to make a strong case in favor of the resin inlay over the direct resin composite restoration.

Secondary polymerization

The superior physical and mechanical properties of resin inlays over direct composite restorations are primarily due to more complete polymerization resulting from secondary polymerization procedures. Directly placed resin composites harden

cases, the polymerization reaction is initiated when a molecule within the resin composite (camphorquinone) forms free radicals when exposed to light of the appropriate wavelength (about 470 nm). The radicals react with a photoreducer (an

As polymerization progresses, the methacrylate chains grow and the material loses its fluidity as a highly cross-linked, rigid network polymer forms. Even with long curing times and powerful lights, incomplete polymerization occurs, particularly at greater depths below the surface because of inadequate light penetration and the immobilization of unreacted molecules within the cross-linked polymer network.[56]

Light-cured resin composite inlays undergo this initial polymerization but then are further polymerized with a combination of intense light, heat, and/or pressure. The postcure can be performed in a postcuring unit specifically made for this purpose, in a toaster oven at approximately 250°F for 7 minutes,[50] or with a curing light or light box. Polymerization under pressure has been shown to increase both diametral

Dentlearn.ir

tensile strength and stiffness of the restoration.[57] These secondary curing procedures are recommended with all indirect resin systems, although they may not be mentioned in all manufacturers' instructions.

Posterior Bonded Ceramic Restorations

Ceramic inlays were introduced in 191358 but did not become popular because of difficulties in fabrication and a high failure rate.[1] In the 1980s, the development of compatible refractory materials made fabrication easier, and the development of adhesive resin cements greatly improved clinical success rates.[2]

The modern generation of bonded porcelain restorations was first described in 1983.[59] When it became clear that the technique had merit in anterior applications, interest developed in the use of bonded porcelain for posterior applications. In 1986, Redford and Jensen[60] described the strengthening effect of porcelain inlays on the fracture resistance of natural teeth. In 1988, Jensen[61] reported excellent clinical success in a 2-year in vivo study. The technique has since been refined to the point that porcelain inlays and onlays are now an accepted operative modality. Box 19-1 details the indirect tooth-colored restoration technique.

Box 19-1	**Indirect tooth-colored onlay technique**
Tooth preparation 1. Select a shade prior to tooth dehydration. 2. Make a stent for fabrication of a provisional restoration. 3. Remove caries and any existing restorative materials. 4. Preparation should be well isolated to ensure success with the adhesive cementation technique. 5. Preparation should allow 2 mm of occlusal clearance for line angles should be rounded and walls divergent occlusally. There should be no grooves or sharp angles. 6. When necessary, retract gingival tissues to expose the preparation margins. Take a final impression. 7. Make a custom provisional restoration	17. Remoisten the dentin preferably with chlorhexidine and actively apply several coats of dentin primer on damp dentin. Air dry the primer, gently at first, until the surface is completely dry, and confirm a uniform shiny surface. 18. Remove the matrix or Teflon tape. 19. Mix and place a dual-curing adhesive, which should not be light cured before placement of the restoration; similarly, dual-curing adhesive must be placed on the inner surface of the restoration. 20. Mix the dual-curing resin composite luting cement and

Dentlearn.ir

using the stent.
Place undercuts in the intaglio surface of the provisional restoration.
8. Cement with a strong provisional cement; because the preparation has minimal resistance form, polycarboxylate cement is the cement of choice for luting the provisional restoration.

Restoration placement
9. Check the restoration on the die for fit, and check for fracture lines with transillumination.
10. Isolate tooth preparation to prevent contamination during the adhesive bonding sequence.
11. Try in the restoration; adjust contours and contacts with appropriate polishing disks and points.
12. Clean the onlay with acetone and air dry.

ceramic restoration with hydrofluoric acid, rinse thoroughly, and air dry. Air abrade the inner surface of the composite inlay with 50-µm alumina or 30-µm silica-modified corundum particles (CoJet Sand).

surface of the onlay and air dry.
15. A matrix band or Teflon tape can be used to protect the adjacent teeth.
16. Etch the tooth with 30% to 40% phosphoric acid etchant gel for 15 to 20 seconds, wash for 5 seconds, and air dry to ensure an adequate enamel etch.
place into the preparation and the inner surface of the restoration with a syringe.
21. Gently place the restoration into the preparation and vibrate with a hand instrument to ensure that it is almost fully seated.
22. Remove excess resin composite luting cement with a brush both occlusally and interproximally.
23. Gently seat the restoration completely with an instrument applied to the occlusal surface, making sure that a bead of composite is expressed at all margins. Confirm correct seating with an explorer at the margins.
24. While the assistant holds the restoration in place, gently clean the interproximal margins with floss, an explorer, and a no. 12 or 12B scalpel blade, being careful not to cause bleeding. The interproximal margins must be completely finished before the resin composite polymerizes. Leave excess composite luting cement on the facial and lingual margins.
25. Cover all accessible interproximal margins with glycerin or with water-soluble lubricant.
26. Complete polymerization by light curing for 90 seconds from the occlusal aspect and 30 seconds each from the facial and lingual aspects in interproximal areas.

Finishing
27. Finish all margins with 12-fluted carbide burs or microfine diamonds, finishing disks, and/or composite polishing points.
28. Adjust the occlusion with articulating paper and a microfine diamond.
29. Complete polishing with appropriate ceramic or composite polishing points.

Indications

The indications for posterior bonded porcelain restorations overlap those for direct

Dentlearn.ir

and indirect posterior resin composite restorations, which have already been described. These restorations are indicated when there is an overriding desire for esthetics and all margins can be placed on enamel. Some clinicians have recommended bonded porcelain rather than indirect resin composite for larger restorations.[2]

Ceramic inlay versus resin composite inlay

Ceramic inlays are reported to leak less than resin composite inlays.[62–64] The marginal fidelity depends on technique and is laboratory dependent.[62] One laboratory study demonstrated better marginal fidelity with ceramic inlays,[64] while another study found better fit with resin inlays.[65] Pressed ceramic inlays have been shown to have an average marginal gap of less than 50 μm.[66] As previously described, adhesion of luting resin is more reliable and durable to etched porcelain material than to prepolymerized resin composite. Therefore, the main advantage of ceramic over composite inlays relates directly to the reliability of the cementation process.

The main advantage of resin composite inlays is that they tend to be more user-friendly, both clinically and in the dental laboratory. The resin inlay can be placed into the preparation with moderate pressure to ensure complete seating without the fear of fracture. Also, if the interproximal contact is removed during the process of adjustment, it can easily be replaced with the addition of light-cured resin composite.

In contrast, the ceramic inlay is quite fragile and subject to fracture during the try-in phase. If the interproximal contact is inadvertently removed during adjustment, it can be replaced by adding low-fusing porcelain, but this step requires refiring the inlay in a porcelain furnace.[67] Once it is removed from the porcelain furnace, the inlay must be re-etched with hydrofluoric acid prior to cementation.

One in vivo study[68] compared the clinical success of these two treatment modalities at 3 years and found that Class 2 ceramic inlays had a significantly higher breakage rate than indirect resin composite inlays. This finding was corroborated in a laboratory study[69] that found lower fracture resistance of ceramic inlays compared with resin inlays. Although a direct composite restoration is recommended over an inlay, as stated previously, there are instances when an inlay could be well recommended. Such situations include a large interproximal distance between teeth leading to difficulty in achieving proper interproximal contact, the need to create a specific occlusal relationship, and defects that extend more than two-thirds of the

Dentlearn.ir

intercuspal width (ie, large isthmus). However, based on the limited data available, resin composite should be considered first for use in two- and three-surface inlay preparations of moderate width.

Ceramic onlay versus resin composite onlay

The ceramic onlay has the same disadvantages as the ceramic inlay. Although some ceramic materials cause wear of opposing enamel,[70] they also provide long-term occlusal stability, which resin composite may not provide in a cuspal-coverage restoration.[71] The stronger bond of resin cement to porcelain is particularly important when cusps are covered. The stronger the bond, the more efficiently forces are transferred through the restoration and the cement and absorbed into the tooth.[16] For these reasons, when even one cusp of a posterior tooth is being covered with an esthetic bonded onlay, the ceramic onlay is preferred.

Ceramic onlays may be used routinely for the esthetic restoration of premolars. They may also be used as cuspal-coverage restorations for molars, although the occlusal forces will be greater in the molar region. Another indication for the ceramic onlay is in the restoration of a molar with a short occlusogingival dimension. In this circumstance, it is difficult to gain axial retention and resistance with a conventional crown preparation. However, the porcelain onlay preparation requires only 2 mm of occlusal reduction and no axial reduction for retention and resistance. The short molar, which would have previously required crown lengthening surgery before placement of a complete-coverage crown, can now be restored more conservatively with the porcelain onlay.

Selection of appropriate patients is of paramount importance in the placement of posterior bonded porcelain restorations. For the greatest long-term predictable success, all margins should be on enamel because of the more reliable bond and seal as compared with dentin. Also, the patient and the tooth to be restored should be amenable to predictably good tissue retraction and isolation from moisture to provide the best environment for bonding the restoration. Ideally, the patient should exhibit no signs of a parafunctional habit. In addition, the restoration should be fabricated so that it contacts in maximum intercuspation position of the mandible but has no contact on the porcelain in mandibular excursive movements.

Shade selection

The shade used for a ceramic inlay or onlay is selected in the same way as for a metal-ceramic crown. Because of the thickness of the occlusal porcelain, the

Dentlearn.ir

underlying tooth color and cement shade have a minimal effect on the shade of the definitive restoration except at the margins. As with porcelain veneers, use of a translucent resin cement is recommended to improve the esthetic blend at the margins.

Fabrication

The most common method of fabrication of ceramic inlays and onlays utilizes a refractory die. After a master die is poured in die stone, a refractory die is made by duplicating the master die or repouring the impression in a refractory material. The porcelain is baked on the refractory die, recovered, and fit to the master die. Variations in the fit of ceramic inlays and onlays are reported to be related more to the ability of the technician than to the type of ceramic material used.[66]

The newer generation of pressed ceramics is fabricated much differently. The restoration is waxed on a stone die in the traditional manner and invested in a special investment. The invested wax pattern is burned out as in the traditional lost-wax technique. An ingot of the pressed ceramic material is heated and pressed into the lost-wax pattern space. After cooling, the investment is removed and the ceramic restoration is retrieved and finished in the same manner as a feldspathic porcelain restoration. Another very popular method for fabricating indirect ceramic restorations is via CAD/CAM systems, which are described in detail later in the chapter.

Isolation

It is universally acknowledged that strict isolation is necessary for bonding posterior adhesive restorations. This is best accomplished with a well-placed rubber dam; however, other techniques can also be used to prevent contamination during the adhesive bonding sequence. If it is not possible to isolate the tooth, an adhesive restoration should not be placed (see Box 19-1).

Resin Composite versus Ceramic

Wear

There are significant differences in the wear characteristics of resin composite and ceramic. Wear i tion,[2] but traditional

Dentlearn.ir

feldspathic porcelain is highly abrasive and can cause significant wear of the opposing dentition. A newer generation of low-fusing porcelains has been shown to cause significantly less wear of enamel than traditional feldspathic porcelain.[72,73] The new class of pressable ceramics, described previously, has become popular, in part because they are less abrasive to opposing teeth. These include Empress (Ivoclar Vivadent), Empress 2, which has been replaced with IPS e.max (Ivoclar Vivadent), Optimal Pressed Ceramic (OPC, Jeneric/Pentron), and Finesse All-Ceramic (Dentsply). The first generation of Empress showed decreased wear of opposing enamel compared with traditional and low-fusing porcelains in vitro.[74] However, the newer generation, Empress 2, has shown almost no wear of opposing enamel, both in vitro[73] and in vivo at 6 months.[75] If long-term clinical studies confirm the low wear of opposing enamel, this will be a significant advance in ceramics.

The data concerning wear of resin composite materials have been somewhat contradictory.[76–78] Enamel is reported to wear at a rate of 30 μm per year in molars and 15 μm per year in premolars.[79] Most modern resin composite materials fall within that range.[78,80] Ferracane[80] reported that the wear of the traditional resin composite, Charisma (Heraeus Kulzer), was lower than that of the indirect composite, Artglass (Heraeus Kulzer). Similarly, Reich et al[81] evaluated the wear of indirect resin composites, Artglass and Targis (Ivoclar Vivadent), to a traditional resin composite, Z100 (3M ESPE). Although Targis demonstrated superior physical and mechanical properties, Z100 had the highest wear resistance. In another laboratory study,[82] the wear of three commercially available indirect resin composite materials was compared with a cast gold control. Targis demonstrated the greatest wear, followed by Artglass; Skulptur FibreKor (Jeneric/Pentron) demonstrated the least wear, which was approximately equal to that of gold. Similarly, the wear rates for Artglass and Targis were evaluated in a two-body wear test.[83] Targis demonstrated wear similar to that of enamel, and Artglass had significantly higher wear than enamel. Another laboratory study[84] reported that the wear resistance of indirect resin composites is similar to that of gold but is significantly more abrasive to antagonistic enamel.

Longevity

Results of short-term clinical studies of composite inlays are encouraging, but there is little long-term data. Bishop[85] reported one failure out of 92 composite inlays that

Dentlearn.ir

had been in place for 7 months to 4 years. A Swedish study[86] reported that 29 of 30 resin inlays were excellent or acceptable at 17 months, while another study[87] reported good marginal integrity at 5 years. Wendt and Leinfelder[88] reported no failures among 60 resin inlays after 3 years, while another study[68] reported that 10 of 145 composite inlays failed at 3 years. A prospective clinical study by Leirskar et al[89] evaluated 64 indirect composite inlays/ onlays over a period of 48 to 75 months with a mean time of 59 months. They reported three failures (5%) because of fractures (two) and caries (one). However, 18 of 64 restorations were rated as less than optimal, mostly because of the change of interproximal contacts over time.

It is still not clear whether the resin inlay offers any advantages in terms of longevity over the direct-placement resin composite restoration. Two clinical studies reported no significant differences between composite inlays and direct resin composite restorations at 5 years[54] and at 11 years.[55] One clinical study[90] of belleGlass (Kerr) reported 5-year results for 24 inlays and onlays. All restorations performed satisfactorily, although 12% had interfacial staining and 58% had slight to moderate marginal degradation. In contrast, another clinical study[91] evaluated 99 composite inlays over a period of 6 to 53 months and reported a success rate of 98%. A recent 36-month clinical study showed 100% success of molar onlays fabricated from two indirect resin composites (Admira and Grandio, Voco), although there was some marginal degradation over the course of the study.[92]

Several clinical studies have evaluated the performance of ceramic inlays or onlays. The clinical success of traditional feldspathic ceramic inlays or onlays has been mixed. A 6-year retrospective study[93] reported a 25.8% failure rate among feld-spathic porcelain onlays with and without metal reinforcement. One 4-year study[94] reported no failures in 50 inlays. Another study reported a 95% success rate after a mean evaluation period of 5.9 years.[95] Other clinical studies, however, have shown significantly higher failure rates. Molin and Karlsson[96] reported that 21 of 145 inlays fractured at 3 years, and their results were comparable with a study by Qualtrough and Wilson[97] that reported 16% failure at 3 years. Still another study[98] reported a 20% failure rate at 8 years, while a similar study[99] reported an 84% success rate with a mean observation time of 6.3 years. If these high failure rates are confirmed by other clinical studies, the long-term prognosis and indication for feldspathic porcelain inlays appear to be questionable.

Clinical results with the leucite-reinforced pressed ceramic restorations have been more promising. Several studies[100–103] have shown excellent clinical success up to 7 years. However, a randomized 5-year clinical evaluation[104] of three ceramic

Dentlearn.ir

inlay systems and gold inlays reported less-promising results: 20% of the leucite-reinforced ceramic inlays failed, and 70% of all of the ceramic inlay systems demonstrated marginal ditching, while there were no failures among the gold inlays. A 3-year study of lithium disilicate (IPS Empress 2) inlays showed 100% success of all 33 restorations available for recall.[105] Krämer and Frankenberger[106] evaluated the clinical outcomes of IPS Empress inlays as well as onlays with cuspal replacement, all with margins that were below the cementoenamel junction, and reported only 8% failures of 96 restorations in 8 years. Stoll et al[107] reported over 96% success over 10 years for a large number (N = 1624) of IPS Empress inlays and partial crowns, with the results being better for vital versus nonvital teeth. A relatively recent review of the clinical success of ceramic restorations for a variety of applications suggests that these materials are very effective.[108]

Failures

Two types of failure are most common with esthetic inlays and onlays: *(1)* bulk fracture (see Fig 19-2) and *(2)* marginal breakdown (Fig 19-6). Bulk fracture sometimes occurs in areas of cus-pal coverage, particularly if the restorative material is less than 2 mm thick (Fig 19-7). It also occurs at the isthmus adjacent to a marginal ridge, where the porcelain is poorly supported by tooth structure.



Fig 19-6 Maxillary first molar with a 7-year-old bonded Dicor (Dentsply) inlay with marginal ditching and a small fracture of the marginal ridge.

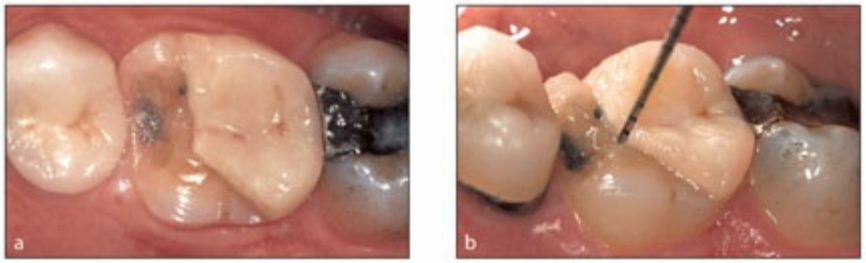

Fig 19-7*(a and b)* Maxillary first molar with a 5-year-old bonded feldspathic porcelain onlay demonstrating bulk fracture.

Dentlearn.ir

Marginal wear is a common finding in esthetic inlays and onlays.[90,104–111] Because resin cements tend not to be heavily filled, they wear more quickly than the adjacent restorations or tooth structure. This is particularly true if the marginal fit is poor.[112,113] Kawai et al[114] demonstrated a linear relationship between wear of resin cement and the horizontal marginal gap. They concluded that reduction of the marginal gap is an important clinical consideration in minimizing the wear of the resin cement. They also found hybrid resin cements to wear faster than microfilled resin cements. Isenberg et al[115] reported 3-year results of a clinical study of 121 CEREC (Sirona Dental) inlay and onlay restorations. None of the restorations exhibited any evidence of interfacial staining, discoloration, or caries, but about 50% of the restorations exhibited gap dimensions large enough to be detected with an explorer. The rate of wear of the resin composite luting agent was linear over the first year, but no further cement wear was noted over the course of the investigation. The depth-to-width ratio of the gap generally did not exceed 50%. However, Hayashi et al[116] reported results of an 8-year clinical study that evaluated marginal wear using an optical laser scanner. They found that marginal deterioration occurred in a sequential three-stage pattern. The initial stage of marginal deterioration occurred rapidly from initial placement to 21 months. In the second stage, the degree of deterioration leveled off and progressed at a much slower rate. The duration of this stage was 21 to 72 months. During the third stage, from year 6 to year 8, the marginal deterioration again accelerated to a much faster rate.

Computerized Dentistry

Computerized dentistry and *digital dentistry* are terms generally used to describe the clinical application of CAD/CAM techniques. There are three features common to CAD/CAM systems.[117] The first is the ability to record the patient's intraoral condition to the computer. This usually involves some sort of intraoral camera to capture a digital file of the dentition. Once the digital file is recorded, a software program is used to design the desired contours of the restoration. This involves control of the usual restoration parameters, such as proximal contacts, emergence profile, and occlusal contacts. Once the design has been completed, a machining device is used to produce the designed restoration. Most commonly, the machining device is a subtractive milling chamber that cuts the definitive restoration from a preformed block of restorative material.

Commercially available computerized dentistry systems that are used in the dental

Dentlearn.ir

office are generally considered to have two applications: *(1)* as a digital impression system and *(2)* as a chairside CAD/CAM system. Digital impression systems focus on the first step of the CAD/CAM process, an accurate recording of the patient's intraoral condition. A data file is created on the system computer, and the patient's dentition is scanned or recorded to the data file. The digital data file is then electronically transmitted via the Internet to a dental laboratory. The dental laboratory has two options for using the patient's data file. One option is to send the electronic data to a processing center to have models fabricated and mounted on an articulator. The articulated models are returned to the dental laboratory, and the restoration can be fabricated by any conventional laboratory process, such as those used for cast gold or porcelain-fused-to-metal restorations. The laboratory also has the option of using a software CAD program to design and produce either a coping or full-contour restoration. The articulated models are used to finish the case, as is done for zirconia or similar restorations[118] (Fig 19-8). The Lava Chairside Oral Scanner (COS) (3M ESPE) and iTero system (Cadent) are the two most common digital impression systems (Figs 19-9 and 19-10).

Dentlearn.ir

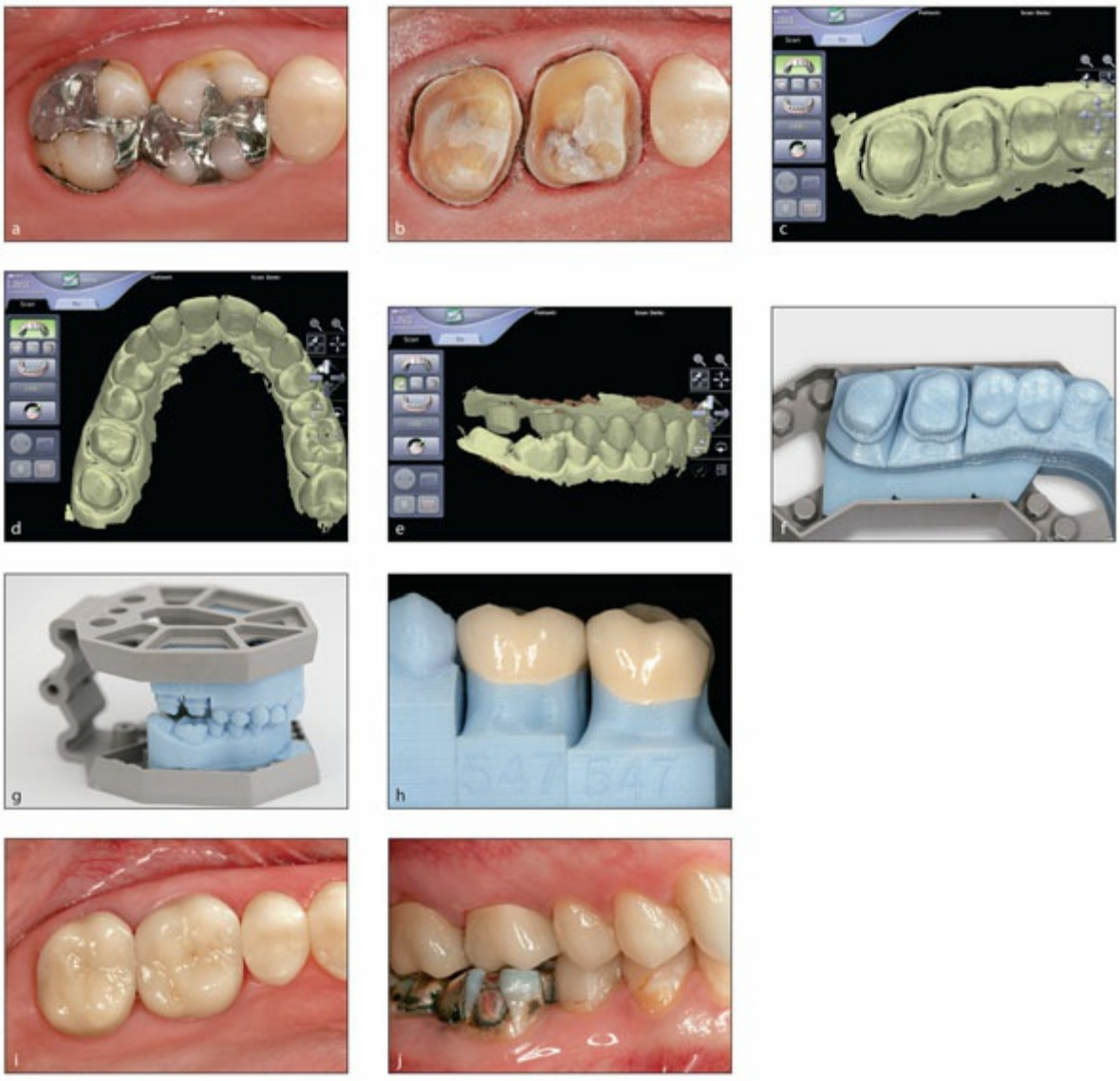

Fig 19-8 The digital impression procedure using the Lava Chairside Oral Scanner (3M ESPE). *(a)* Preoperative occlusal view of the maxillary right first and second molars. *(b)* Crown preparations following tissue retraction and isolation with a fine coating of titanium dioxide powder for digital imaging. *(c)* Digital recording of the crown preparations. *(d)* Digital recording of the full arch. *(e)* Digital models virtually articulated in centric occlusion with the buccal scan. *(f)* Crown preparations on the resin model. *(g)* Articulated resin models from the digital impressions. *(h)* Zirconia crowns (Lava, 3M ESPE) on the resin dies. *(i)* Occlusal view of the cemented Lava crowns. *(j)* Facial view of the cemented Lava crowns.

Dentlearn.ir



Fig 19-9 Lava Chairside Oral Scanner.



Fig 19-10 iTero system.

Chairside CAD/CAM systems can fabricate single-tooth ceramic or composite inlays, onlays, veneers, and crowns. The CEREC Connect system for the CEREC Acquisition Center (AC) unit (Sirona Dental) and the E4D Sky network for the E4D Dentist system (D4D Technologies) are recent upgrades that offer the opportunity to use the chairside systems as purely digital impression systems for cases desired to be fabricated in the dental laboratory[119] (Figs 19-11 and 19-12).



Dentlearn.ir

Fig 19-11 CEREC AC unit with the MC XL and MC milling chambers.



Fig 19-12 E4D Dentist system, consisting of the mobile Design Center and milling unit.

Computerized systems: Cameras

A critical first step in the CAD/CAM sequence is to accurately record the specific teeth and soft tissues to the computer software program. An intraoral camera or scanner becomes the key element for a digital impression. There are significant differences among the cameras and their manners of use in recording the digital impression.

The CEREC AC system has a blue light-emitting diode (LED) camera called the *Bluecam*. It records a series of single images that the software combines into the three-dimensional (3D) virtual model of the dentition. Although a single image is the minimum required to fabricate a restoration, additional images are routinely used to record adjacent teeth, mount the opposing virtual model, or aid in designing the restoration. A titanium dioxide powder is sprayed on the dentition and soft tissues to be recorded to create a uniform reflective surface. The shorter wavelength of the blue light compared with that of a laser allows for greater precision of the optical image.[120] It also uses a telecentric beam that records the tooth surface data from all visible surfaces in a single view.[121] The Bluecam can be used in a manual or automatic mode. The automatic-capture mode prevents recording of data while the camera is moving or shaking. This prevents the capture of blurred images that would be inaccurate.

The E4D Dentist IntraOral Digitizer is a red laser-light camera.[122] It records a series of overlapping single images, rather than a video recording, that the computer calculates into a virtual model. It does not require the use of a reflective powder unless scanning through a thin, transparent aspect of the preparation. In such cases, a

Dentlearn.ir

reflective liquid (E4D Accent) is applied to the surface of the tooth. The operator has the option of manual image capture or automatic image capture with Rapid Scan. A series of nine separate images are recorded from the occlusal, lingual, and facial views for a true 3D capture. Additional images are required to record adjacent teeth.[121] The software immediately indicates the accuracy and usefulness of each scanned image to ensure that all images are properly scanned.[121,122]

The iTero intraoral scanner uses a parallel confocal white light and red laser camera to record a series of images to create a 3D model.[122,123] The scanner emits a beam of light, and only an object at the correct focal length will reflect light back through the filtering device.[124] The scanner captures 100,000 points of laser light and focuses accurately to 300 focal depths spaced 50 μm apart.[121,125] The camera can be placed in contact with the teeth and does not need to be held stationary in space over the teeth. Scanning powder is not required for the camera to accurately record the surface of the teeth. The operator is prompted to record a series of five scans from the occlusal, facial, lingual, mesioproximal, and distoproximal angles of the prepared tooth as well as additional scans of adjacent teeth. The opposing dentition is scanned separately.[125] In addition, angled buccal and lingual views must be taken of the remaining teeth in the arch form.[122] Individual images may be retaken until adequate data is obtained.[121] A total of 15 to 30 scanned images may be required to record the preparation, opposing teeth, and occlusal relationships.[125] Ultimately, the software merges common data from all scans and proposes virtually articulated models.[122]

The Lava COS camera is the only video camera available for digital impressions. It uses "active wavefront sampling" to record up to 20 3D data sets per second and 2,400 3D data sets per arch. A light coating of a titanium dioxide powder is applied to the teeth and soft tissues to enhance the accuracy and efficiency of the scanning process. Three sensors record the clinical situation from varying perspectives and

single-image camera, it captures 3D data in a video process and fabricates the virtual model in real-time on the computer monitor.[126] The virtual model can be switched between a 2D and 3D image as well as visualized with 3D glasses to verify aspects of the recorded models. Another feature of the Lava COS video capture is that the dentition can be recorded in strips or sections and the computer can assemble the strip scans into a real-time single 3D virtual model.[127] The operator has a field of view of approximately 10 mm by 13.5 mm with the camera. The camera has a 5- to 15-mm working depth from the surface being recorded to

Dentlearn.ir

record the dentition. This is sufficiently small to allow recording of the most distal posterior teeth. If the camera is held too close to or too far from the dentition, outside the focal distance, the video recording is automatically paused until the camera is brought back within the focal distance, and recording automatically continues. This prevents inaccurate data from being included in the scan.[122]

Digital impressions

All computerized dentistry systems rely on the ability to accurately record the dentition. Without a precise digital recording, an accurate restoration is not possible.

related to the quality and accuracy of the recorded preparation. This concept is true for both conventional impressions and digital impressions. The definitive restoration can only be as accurate as the quality of the recorded data of the tooth.

There are some guidelines that hold true for all computerized dentistry systems. Digital recordings or scans are as sensitive to moisture contamination and soft tissue retraction problems as traditional impression materials. Moisture, such as saliva or blood, obscures the preparation and prevents an accurate recording of the tooth. Similarly, inadequate retraction of soft tissues may hide the marginal areas from view (Fig 19-13). Digital cameras can only record what is visible and isolated. Careful control of the scanning environment ensures an accurate digital file, which is essential to a well-fitting restoration.



Fig 19-13 There are indistinct margins at the distolingual of the crown preparation for the mandibular first molar in this CEREC virtual model. This is a function of inadequate soft tissue retraction for good visibility of the margins.

Digital impressions offer the clinician excellent immediate feedback on the recorded preparation. The ability to greatly magnify the scanned data on the computer monitor is a significant advantage to ensure an accurate digital impression prior to transmitting the case to the dental laboratory for processing (Fig 19-14). For

Dentlearn.ir

conventional impressions, this level of magnification and critical evaluation may not be possible until the model has been poured and separated and the die trimmed.

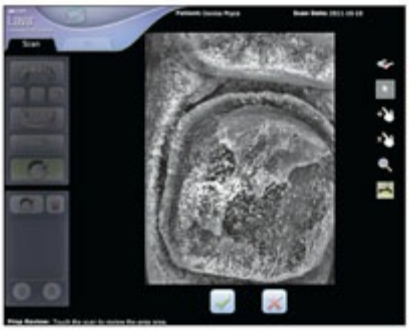

Fig 19-14 High-magnification alternative contrast view of a preparation margin with the Lava COS system allows for critical evaluation of the margins prior to transmitting the case to the dental laboratory.

Digital impressions also provide quantitative data on the preparation relative to the opposing dentition. This is especially helpful in ensuring adequate occlusal clearance for a case based on the specific planned restoration. The software program can provide quantitative data on the occlusal clearance between the models prior to submitting the case to the laboratory for processing (Fig 19-15). Immediate access to the high-magnification images allow for the correction of preparation deficiencies. This avoids discovering the deficiency in the stone models, which would require correction at a second appointment or the deficiency to be worked around by the dental laboratory technician.

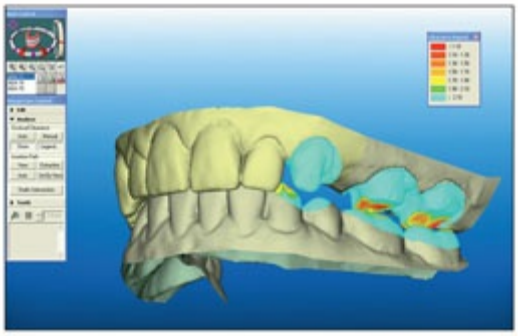

Fig 19-15 Quantitative information on the occlusal clearance is provided with a digital impression from the iTero system. The red-orange areas indicate less than 1.5-mm clearance from the opposing dentition.

Single-image cameras (CEREC AC, E4D, iTero) are line-of-sight cameras that record a series of single images of the dentition. The camera works in a manner similar to our eyes, in that we can see what is directly in our line of vision but not around corners. Each single image must overlap with one or more of the other recorded images to enable the computer to process the single images into a 3D

Dentlearn.ir

virtual model on the software program. Single-image cameras must capture images from a variety of angles to accurately record the dentition below the height of contour. Figure 19-16 shows the facial contour of a virtual model created from a series of single images made from the occlusal aspect of the teeth. Note the straight contours of the adjacent teeth below the height of contour. To accurately record the facial and lingual contours of the teeth, the camera must be angled past the height of contour with two or three images. Note that this is not a problem involving the preparation, as the camera can record all data within the path of insertion of the preparation in a single image.

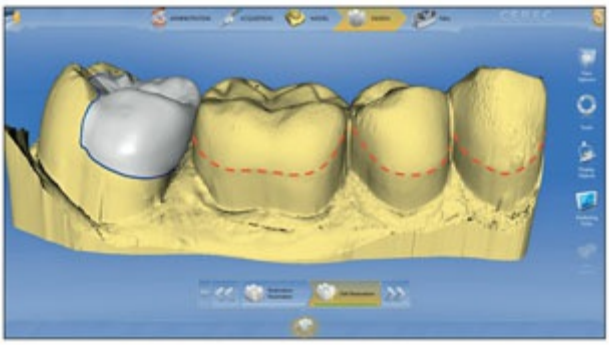

Fig 19-16 The *dotted lines* indicate the facial height of contour of the teeth. Note the flat emergence profile calculated by the software because the images recorded from the occlusal direction were not able to capture data hidden by the height of contour in this angle of recording.

Another important function in making a digital impression is the need to record opposing teeth and occlusal relationships for the planned restoration. Generally, two techniques are employed. One technique is to make a traditional bite registration (eg, with a polyvinyl siloxane bite registration material) of the dentition opposing the prepared teeth. The bite registration is scanned separately from the preparation model, and the software program matches the two models (Fig 19-17). The other technique is to digitally record the opposing model separately. The patient is guided into a closed centric position, and the dentition is scanned from the buccal view. This is referred to as a *buccal scan* (Fig 19-18). The buccal scan records the facial contours of the teeth and soft tissues. The software program uses the buccal scan to align the opposing digital models for accurate recording of the patient's occlusal relationship. No marketed system currently has the ability to digitally record functional lateral movements for mounting. Traditional lateral or protrusive functional registrations are required to mount the case on a semiadjustable articulator to simulate lateral guidance.

Dentlearn.ir

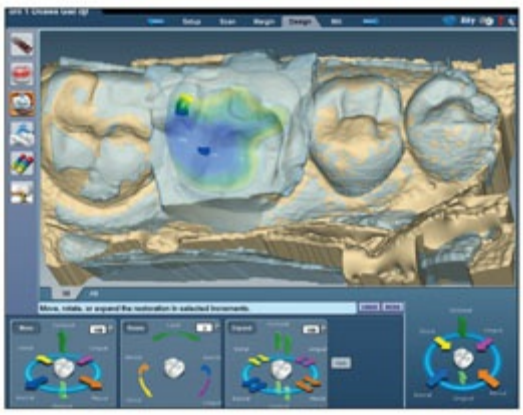

Fig 19-17 Superimposition of the bite registration model over the preparation model and restoration proposal to verify occlusal contacts with the E4D system.

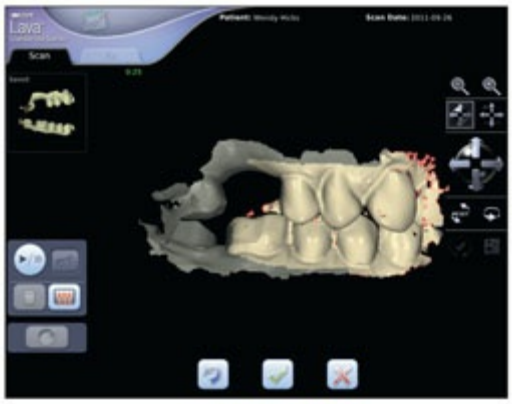

Fig 19-18 Buccal scan mounting of the scanned opposing models with the Lava COS system.

The undisputed key issue with digital impressions is accuracy. The use of conventional impression techniques and materials is the accepted technique for fabricating well-fitting restorations. Without an accurate impression, a well-fitting restoration is not possible regardless of the fabrication process. The starting point for considering digital impression systems is an expectation of at least equal accuracy to conventional impression techniques and materials. Digital impressions have been shown to be equally accurate to conventional impressions.[128,129] Several of the camera systems require the application of a titanium dioxide powder to the surfaces of the teeth and soft tissue to be scanned. The thin, uniform coating creates a uniformly reflective surface on the dentition for accurate data recording. A common misperception is that this thin powder layer limits the accuracy of the definitive restoration. However, even when used incorrectly, excess powder does not affect

fabricated restorations using stone casts. Each of the digital systems has been shown

Dentlearn.ir

equal to conventional fabrication techniques. CEREC has over 25 years of both laboratory and clinical research confirming the predictable outcomes possible with the chairside CAD/CAM system.[130–132] Lava COS has laboratory and clinical research confirming the digital impression technique as a consistently accurate restoration fabrication process.[124,128,129,133] In addition, the more recently introduced

of their restorations.[134,135]

Chairside CAD/CAM ceramic restorations

CAD/CAM technology for the fabrication of ceramic restorations has been a significant development in dentistry. The vast majority of CAD/CAM systems have been designed for use in the dental laboratory. InLab (Sirona Dental), Procera (Nobel Biocare), Lava (3M ESPE), and Cercon (Dentsply/Caulk) are but a few of the CAD/CAM systems dental laboratories are using in an effort to improve efficiency while utilizing modern ceramic materials. There are two currently marketed in-office or chair-side CAD/CAM systems: the CEREC AC driven by the Bluecam camera and the E4D Dentist system. The chairside CAD/CAM systems offer considerable time savings over conventional, laboratory-generated restorations because there is no need for a conventional impression, temporary restoration, or a second appointment; the definitive esthetic restoration is delivered at the same appointment at which the tooth is prepared.[136,137]

The CEREC system was initially marketed as the CEREC 1 system in Europe in 1985, and the first clinical trials took place in 1987.[138] It was introduced in the United States in 1989. Since then, the system has evolved through a series of hardware and software upgrades to reach its present form, the CEREC AC driven by the Bluecam.[139] The E4D Dentist system was introduced in 2008 with its DentaLogic software offering a true 3D virtual model.[140]

Hardware and software

The CEREC AC system consists of an acquisition unit and a milling chamber (see Fig 19-11). The acquisition unit contains a computer with the 3D design software, a liquid crystal display (LCD) monitor, and an intraoral camera for the optical imaging of the cavity preparation. The milling unit houses two motors. Each motor controls a cutting diamond for milling the definitive restoration from prefabricated blocks of restorative material. One motor has a step bur diamond that mills the entire

Dentlearn.ir

tapered cone shape and mills the entire external surface of the restoration. The milling unit also contains a water chamber for distilled water and lubricant additive that is used during the milling procedure to clean and lubricate the diamonds as they mill the restorative material. The acquisition and milling units communicate with each other via a radio transmitter.

The E4D Dentist system has an intraoral laser scanner, a mobile Design Center with DentaLogic software, and a separate milling chamber with a dedicated mill server computer (see Fig 19-12). The milling chamber has two opposing milling motors that can automatically change between three different milling diamonds depending on the specifics of the restoration to be milled. The milling chamber has a dedicated computer server to allow it to operate independently of the Design Center after the case design has been completed and transmitted to the job server.

Inlays/onlays

The tooth preparation will have a major impact on the fit accuracy of the milled restoration. Cavity preparations for CAD/CAM inlays and onlays are similar to those for conventional indirect ceramic inlays and onlays.[141–143] (Fig 19-19). The occlusal aspect of the preparation should be at least 1.5 mm thick in the central fissure and 2.0 mm thick over the cusps to provide adequate strength for the ceramic restoration. All cavosurface margins should be well defined and have a 90-degree butt-joint configuration. This will allow the camera to record an accurate image of the cavosurface margin while providing strength to the restoration. Bevels and knife-edge margins should not be used. The cavity walls of the proximal box should have at least 6 to 8 degrees of divergent taper.[144,145] All preparation floors should be smooth but not necessarily flat. Concavities created by the removal of carious tooth structure or prior restorations may be blocked out with a liner or base, but this is not required to obtain an accurate fit of the restoration.



Fig 19-19 Cavity preparation for a CAD/CAM chairside onlay.

Crowns

Dentlearn.ir

The tooth preparation is the same as described for other all-ceramic crowns (Fig 19-20). The computer graphic design process for a crown is similar to that used for fabrication of an onlay; the milling process is somewhat longer. Many clinicians choose to characterize the monochromatic shade of the ceramic blocks with shade modifiers and a glaze prior to adhesive cementation.[144]



Fig 19-20 Cavity preparation for a CAD/CAM chairside crown.

An additional crown preparation design has been suggested for endodontically treated teeth: the *endocrown* design. This design incorporates the core into the crown as a single restoration (Fig 19-21). This design significantly increases the surface area of the preparation available for adhesive cementation. It is particularly useful in teeth with short clinical crowns. This restoration has not been well evaluated clinically; however, preliminary reports from the University of Zurich, Switzerland, indicate that the cross-sectional area of the tooth may be a factor in retention and may be problematic for premolar teeth.[145]



Fig 19-21 Preparation of an endocrown for an endodontically treated tooth.

Computer-aided design

The process for fabricating a chairside CAD/CAM onlay with the CEREC AC system is illustrated in Fig 19-22. A well-isolated and dry field is necessary to ensure that the preparation is optically scanned with precision and accuracy. It is also critical to clearly isolate the gingival extent of the preparation from the adjacent soft tissues. Following completion of the tooth preparation (see Fig 19-22b), an optical impression is recorded. Because enamel, dentin, bases, and soft tissues do not reflect the Bluecam LED light equally well, the tooth must be coated with a

Dentlearn.ir

uniform reflective material before imaging. The powder should also coat all adjacent structures that may be viewed in the optical scan (see Fig 19-22c). The E4D Dentist IntraOral Digitizer only requires the use of the imaging powder in thinner, more transparent aspects of the preparation.

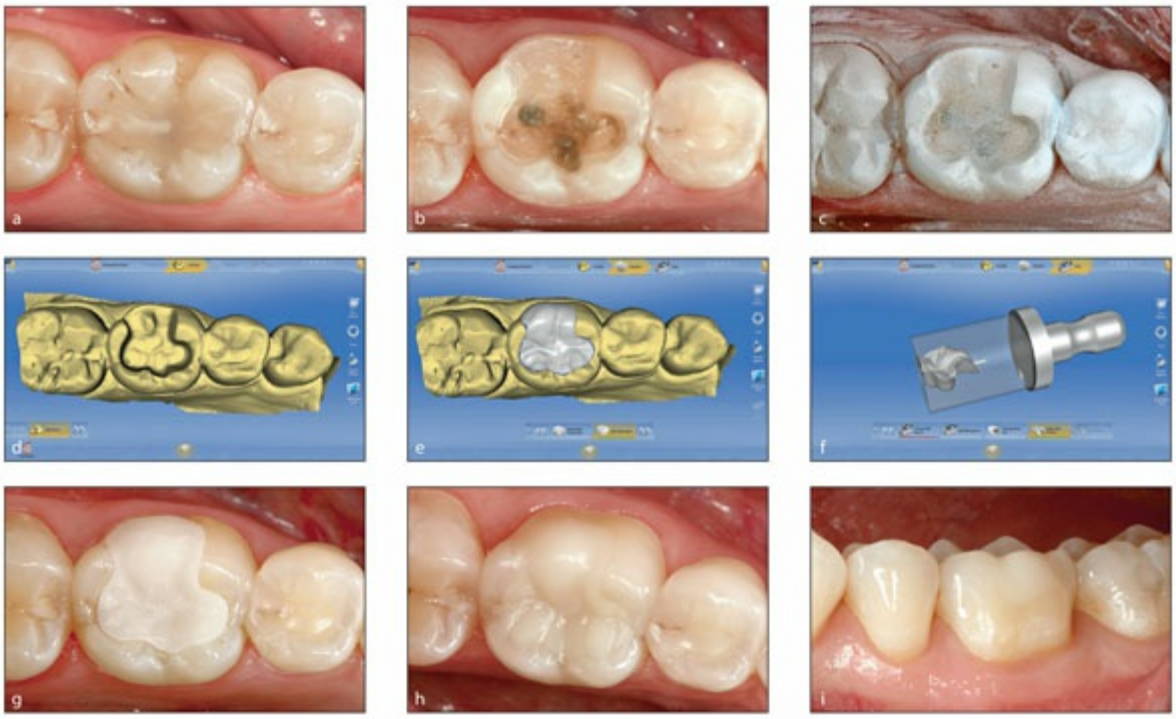

Fig 19-22*(a)* Preoperative view of the mandibular left first molar. *(b)* Onlay preparation for the first molar. *(c)* Preparation and adjacent teeth coated with titanium dioxide powder to record the digital impression. *(d)* Preparation virtual model is calculated for the design of the restoration. *(e)* Computer graphic design of the restoration. *(f)* The milling preview window shows the calculated 3D model of the restoration prior to milling. *(g)* Try-in of the milled Lava Ultimate (3M ESPE) onlay. *(h)* Lava Ultimate onlay is completed following adhesive cementation and polish. *(i)* Facial view of the completed Lava Ultimate onlay.

The camera images are recorded to the software program, where a virtual 3D model is rendered in real time (see Fig 19-22d). All portions of the preparation margins should be visible and distinct from adjacent structures. The camera head must be held motionless to record an accurate image without distortion of the preparation.

The design phase is initiated when the computer renders a virtual 3D model of the cavity preparation from the recorded optical image. The 3D capability of the software (both CEREC and E4D) allows for the preparation model to be rotated in an infinite number of angles and views for design of the restoration. Following identification of the cavity margin by tracing the margin line, the proposed restoration design is shown on the monitor (see Fig 19-22e). A number of editing

Dentlearn.ir

tools are available to customize the contours, anatomy, and occlusal relationship of the restoration.

Computer-assisted manufacture

When the milling function is activated, the software calculates a volume model of the restoration (see Fig 19-22f). Based on the calculated 3D model of the restoration, the computer then requests that the appropriately sized ceramic block be inserted into the milling chamber.

A number of restorative materials are available for use in both chairside CAD/CAM systems. All currently marketed milling materials are available for both systems with the exception of the Vident line of materials, which are restricted to use in the CEREC AC system.[146–148] The restorative material is fabricated in a block form and mounted on a milling stub that can be inserted into the milling chamber. Vita Mark II blocks (Vident) are made of a fine-grained, feldspathic porcelain that has a homogenous structure. The fine grain of the Vita Mark II porcelain is reported to increase hardness of the material but decrease wear of the opposing dentition.[149] Al-Hiyasat et al[150] reported that the Vita Mark II ceramic material was less abrasive and more resistant to wear than conventional aluminous and bonded ceramic materials. The material comes in nine Vita 3D-Master shades (Vident) as well as a bleach shade and an esthetic translucent line of shades. The TriLuxe Forte block (Vident), a multicolor block that simulates the variation in shade from cervical to incisal in a natural tooth, is also available, as well as a RealLife block (Vident) that

Improvements in the software allow for restoration designs to be properly positioned within the multicolor block prior to milling.

The first leucite-reinforced glass ceramic CAD/CAM block was ProCAD (Ivoclar Vivadent), introduced in 1998. It evolved to the current IPS Empress CAD and is a 35% to 45% leucite-reinforced glass ceramic similar to IPS Empress 1 but with a finer particle size of 1 to 5 μm. The excellent clinical success with Empress 1 is expected to be duplicated with the IPS Empress CAD material, as they are essentially the same restorations with different fabrication techniques. Both Vita Mark II and IPS Empress CAD materials can be characterized and glazed in a porcelain oven using stains that are applied chairside.

An innovative resin composite material is also available. Paradigm MZ100 (3M ESPE) is a resin composite with a filler composed of zirconia and silica.[151] The inorganic filler loading is 85% by weight, with an average particle size of 0.6 μm,

Dentlearn.ir

and the material is radiopaque. A study has reported a randomized, longitudinal clinical trial comparing Paradigm MZ100 inlays to Vita Mark II inlays over 3 years of clinical service.[152] A recent study reports the 10-year follow-up of this study as well.[153] The inlays were evaluated using modified US Public Health Service (USPHS) criteria on a yearly basis. The study determined that Paradigm inlays performed equally as well as Vita Mark II inlays at 10 years, with clinical advantages noted in inlay fracture resistance and color match.

A recent material addition for this type of restoration is Lava Ultimate (3M ESPE). Lava Ultimate contains a blend of nanosized silica and zirconia particles (1 to 100 nm) agglomerated into clusters and individual bonded nanosized particles embedded in a highly cross-linked polymer matrix, with approximately an 80% filler load. The material is purported to offer the ease of use of a composite material with a surface gloss and finish retention similar to that of ceramics. To date, no clinical studies have reported on the performance of this material.

Once the ceramic or composite block has been locked in the milling chamber, the unit is ready to mill the restoration. The milling diamonds move in coordination with the movement of the metallic mounting of the ceramic or composite block, which calibrates the position of the milling head. The ceramic or composite block, rotating as it goes, is fed uniformly through the milling process. Milling time is a function of the size and complexity of the restoration and may range from 10 to 20 minutes on average.

Try-in and cementation

Once the ceramic or composite restoration is recovered from the milling chamber, the restoration is tried in. Adjustments to the proximal contacts may have to be made for the restoration to seat completely if the preparation was too sharp or angular. The axiopulpal line angle and the gingival floor of the box are the places most likely for the restoration to require adjustment.[113] Limited to no occlusal adjustment should be done prior to cementation of the restoration; the ceramic is particularly fragile without the support of the luting cement. Should the fit be unacceptable in some area, the design can be reloaded from the computer hard drive and corrected, and a second restoration can be milled quickly.

The ceramic restoration should be etched with hydrofluoric acid and silanated prior to adhesive cementation similar to laboratory ceramic restorations. CAD/CAM composite and nanoceramic materials should be air abraded with CoJet rather than etched prior to silane treatment. Use of a conventional adhesive cementation

Dentlearn.ir

technique and a dual-cured resin cement is recommended.[137,138,154] Contouring and refinement of anatomy can be accomplished after cementation with various microfine diamonds.[155] Finishing and polishing are completed with abrasive rubber points, disks, and cups or brushes with diamond polishing paste as for other ceramic and composite restorations.

Advantages and disadvantages

The main advantages of chairside CAD/CAM technology are the saving of time, service to the patient, and utilization of optimal restorative materials. The technique affords the dentist the opportunity to prepare, design, and fabricate a ceramic restoration in a single appointment, without the need for conventional impressions, provisional restorations, or dental laboratory support. Chairside CAD/CAM technology offers excellent esthetics, durability, and at least short-term strengthening of the tooth. Roznowski et al[156] compared the fracture resistance of molars restored with various adhesive and nonadhesive restorations and reported that teeth restored with mesio-occlusodistal CEREC inlays were as strong as unprepared, unrestored teeth, while nonadhesive restorations weakened teeth.

The chairside CAD/CAM systems are not without their disadvantages. The systems rely on accurate data from the tooth preparation to fabricate the restoration. This requires developing skill in the use of the intraoral scanning device or camera as well as good soft tissue retraction and isolation of the dentition while using the camera. Because the restoration is fabricated without the benefit of a die or articulated casts, development of occlusal relationships may be problematic. The systems have several design options to overcome this apparent limitation. One technique provides the opportunity to record the pretreatment occlusal anatomy, or

E4D DentaLogic program refers to this as *Clone scanning*. The existing occlusal relationships can be maintained in the new restoration. An alternative technique available to the E4D system involves the use of a bite registration to record the occlusal surface of the opposing dentition. The surface data is recorded to the software and superimposed over the design of the new restoration. The CEREC 4.0 program uses a buccal scan technique. This involves recording images of the opposing dentition in a second model catalog and then virtually mounting the opposing models with a scan of the dentition from the facial aspect with the patient closed in centric occlusion position. These techniques offer a degree of control in

Dentlearn.ir

evaluating and developing occlusal relationships in the new restoration. It is not a "virtual articulator" in that it is a static recording and does not record interocclusal relationships in excursive mandibular movements. However, interocclusal relationships in maximum intercuspation position (centric occlusion) of the mandible can be accurately recorded to the system.[157] The milled restoration will require some adjustment after bonding to ensure the absence of interferences in excursive mandibular movements.

A significant training period is required to achieve proficiency with any CAD/CAM system. Participation in a 2-day initial training course is strongly recommended for the chair-side CAD/CAM systems prior to clinical application with the system. This is often followed with a second advanced course after 2 to 4 months of clinical experience. The initial cost of the system is also considerable; however, it is balanced against the minimal per-restoration cost of using the system as compared to laboratory-fabricated ceramic restorations. Generally, the actual cost of the materials for a chairside CAD/CAM restoration to the dentist is about 10% to 15% of the cost of a laboratory-fabricated ceramic restoration.

A major concern about chairside CAD/CAM restorations has been their precementation marginal fit. Several studies have evaluated marginal openings in CAD/CAM restorations. Krejci et al[158] reported precementation marginal openings with CEREC 1 restorations to be in the range of 125 to 175 μm. However, after cementation, they found that more than 90% of enamel-ceramic interfaces had "continuous margins." They found that the quality of the marginal adaptation immediately after cementation does not seem to depend on precementation marginal fit. Peters and Bieniek[159] reported results of a clinical study of 22 CEREC 1 inlays in which the average marginal fit was 121 μm with a range of 60 to 150 μm. Wilder[113] reported the average film thickness of resin cement at the occlusal cavosurface margin with CEREC 1 to be 89 ± 65 μm; the average thickness at the gingival margin was 105 ± 81 μm. By comparison, Christensen[160] reported that gold castings may be fabricated with marginal openings of less than 25 μm. Because of the relatively large precementation marginal gaps, the exposed resin cement was thought to be the weak link in the CEREC 1 restoration.

CEREC system hardware and software improvements have led to improvements in adaptation and marginal fit. Mörmann and Schug[161] evaluated the marginal fit of CAD/CAM inlays fabricated with the improved CEREC 2 unit using the COS 4.01 software program. They reported the overall mean interfacial margin width to be 56 ± 27 μm for CEREC 2 inlays and 84 ± 38 μm for CEREC 1 inlays. They also reported that the mil .4 times greater than

Dentlearn.ir

that of the CEREC 1 unit. Benz et al[162] also reported a mean occlusal interfacial width for CEREC 2 inlays of 48 ± 34 μm, a 35% improvement over the CEREC 1 inlays. Ellingsen and Fasbinder[132] compared the precementation fit of CEREC 2 crowns with that of CEREC 3 crowns. All areas of crown adaptation measured were significantly smaller for the CEREC 3 system compared with the CEREC 2 system except at the axial walls of the preparation. Cavosurface margin gaps of 47.5 ± 19.5 μm were reported for CEREC 3 crowns, and gaps of 97.0 ± 33.8 μm were reported for CEREC 2 crowns. The fit of CEREC 3 crowns is very nearly on par with that of gold castings.

adaptation of CEREC crowns fabricated on virtual models made from the CEREC 3 infrared laser camera and CEREC AC blue LED camera. There was no significant

with the infrared laser camera (Redcam) and the LED camera (Bluecam), with the

Postoperative sensitivity following adhesive restorative procedures is not an uncommon problem. This is often described by the patient as discomfort to cold or to biting pressure. However, clinical studies with chairside CAD/CAM restorations report a low rate of postoperative sensitivity. Sjögren et al[164] reported a higher rate of postoperative sensitivity than that reported in other chairside CAD/CAM studies, with 10 of 72 patients reporting postoperative sensitivity with Vita Mark I or II ceramic inlays. Heymann et al[165] reported no postoperative sensitivity at any recall interval in their 4-year clinical trial of CEREC ceramic inlays. Fasbinder et al[166] reported that 13% of 92 Vita Mark II onlays were rated slightly sensitive at 1 week and 4% at 2 weeks. All sensitivity was resolved by 1 month, and there was essentially no postoperative sensitivity throughout the remainder of the study. Another study by Fasbinder aet al[167] reported that 2 of 62 CEREC onlays cemented with a self-etching cement were sensitive at 1 week, with all sensitivity resolved at 3 weeks without treatment. No restoration was reported as sensitive over the remaining 3 years of the study. Similar postoperative sensitivity was reported in a 10-year randomized clinical trial of chairside CAD/CAM composite and porcelain inlays cemented with an etch-and-rinse concept and a dual-cured resin cement.[153] One of the 80 inlays was reported as sensitive at 1 week, and the sensitivity resolved by 2 weeks without treatment. No other postoperative sensitivity was reported over the remaining 10 years of the study.

The chairside CAD/CAM technique may play a role in minimizing postoperative

Dentlearn.ir

sensitivity. It is imperative to be able to isolate the cavity margins in order to record accurate images of the preparation to fabricate a well-fitting restoration. The ability to deliver the restorations in a single appointment prevents the potential for dentin contamination during the provisional phase. Also, the use of manufactured blocks of porcelain and resin composite significantly restrict the influence of polymerization shrinkage to the composite luting agent, and shrinkage concerns are limited to the thickness of the resin cement.

Longevity/clinical studies

The failure rate of Vita Mark II porcelain inlays made with the CEREC technique has been reported to be very low. Sjögren et al[168] reported 4 fractures among 66 Vita Mark II inlays over 5 years. Pallesen and Van Dijken[169] reported a single fractured Vita Mark II inlay among 16 pairs of CAD/CAM inlays over 8 years. Berg and Dérand[170] reported 3 fractures among 115 Vita Mark II inlays over 5 years. Zimmer et al[171] carried out a retrospective clinical study of 226 CEREC 1 restorations placed in a private practice and evaluated after 10 years. The Kaplan-Meier survival rate reported was 94.7% after 5 years and 85.7% after 10 years. Martin and Jedynakiewicz[172] performed a systematic review of clinical studies on intracoronal CEREC restorations. They reported a mean survival rate of 97.4% over a 4-year period. The primary reasons for failure were reported as fracture of the ceramic material, fracture of the supporting tooth, and postoperative sensitivity. Fracture of the ceramic material was generally a result of occlusal stress or insufficient material thickness. Otto and De Nisco[173] reported an 8% failure rate for ceramic inlays after 10 years of clinical service. Of the failures, 53% were caused by fractures of the ceramic material and 20% were because of tooth fracture. Hickel and Manhart[174] reviewed clinical studies in the dental literature during the 1990s and reported annual failure rates of posterior restorations in stress-bearing areas as 0% to 1⅛% for laboratory-fabricated resin composite inlays, 0% to 7.5% for laboratory-fabricated ceramic inlays, and 0% to 4.4% for CAD/CAM ceramic restorations. They also mentioned bulk fracture as a frequent cause of failure for ceramic inlays.

A significant number of long-term clinical studies have been published on chairside CAD/CAM restorations using all generations of the CEREC system. Zuellig-Singer and Bryant[175] reported results of a 3-year clinical evaluation of CEREC inlays with four different luting agents. One inlay fractured, and 94.6% of the restorations had continuous margins at 3 years. There was no significant

Dentlearn.ir

difference in continuous-margin rates among the different luting materials. The authors also reported less wear with the microfilled luting resins as compared to that of the hybrid composite and glass-ionomer luting materials. Heymann et al,[165] in the previously mentioned clinical study of CEREC 1 inlays, demonstrated no significant changes in the 50 CEREC inlays after 4 years of clinical service. There was no reported postoperative sensitivity, and there were no restoration fractures. Sjögren et al[176] reported a 10-year clinical evaluation of 66 CEREC inlays. They calculated an 11% failure rate after 10 years, with four inlay fractures, one tooth fracture, one restored tooth requiring endodontic treatment, and one inlay replaced because of postoperative symptoms. The survival rate at 10 years was estimated at 89%. They achieved a significantly improved survival rate for CAD/CAM-fabricated inlays cemented with a chemically cured resin composite cement as compared to those cemented with a dual-cured resin cement. Otto and De Nisco[173] reported a 10-year prospective study of 200 CEREC 1 inlays and onlays. The primary failure mechanisms of the 15 failed restorations included restoration fracture (eight cases) and tooth fracture (three cases). Only three of the teeth that had failed restorations required crowns; the remaining restorations were repaired or the initial restoration replaced with another CEREC inlay or onlay. The Kaplan-Meier survival rate was 90.4% at 10 years.

Fasbinder et al[153] reported a 10-year randomized clinical trial of 80 CEREC restorations comparing porcelain inlays with composite inlays. Both restorative materials were cemented with an etch-and-rinse technique and dual-cured resin cement. After 10 years, there was one fractured composite inlay and five fractured porcelain inlays. The composite inlays performed equally as well as the porcelain inlays in all USPHS categories, with significantly better color match and less bulk inlay fracture. In another study, Fasbinder et al[167] reported the results of a randomized, longitudinal clinical trial of 62 CEREC onlays. The leucite-reinforced porcelain and feldspathic porcelain onlays were cemented with a self-etching, self-adhesive resin cement. The onlay preparation extended at least one-half the intercuspal distance, and at least one cusp was not covered with the onlay. Two of the feldspathic porcelain onlays failed during the study. The leucite-reinforced and feldspathic onlays performed similarly well with a self-etching, self-adhesive cement at 3 years with no significant changes observed in any USPHS criteria.

Bindl and Mörmann[177] reported a study comparing CEREC crowns with reinforced ceramic-core crowns. Thirty-six anterior crowns in 24 patients were placed using equal numbers of CEREC and In-Ceram Spinell (Vident) crowns. The crowns were evaluated over a mean service time of 44.9 ± 10.3 months using

Dentlearn.ir

modified USPHS criteria. No significant difference in clinical performance between the two types of ceramic crowns was observed. Fasbinder et al[178] reported a longitudinal clinical trial of 62 lithium disilicate CEREC 3 crowns. No significant difference in the gingival index or plaque index was observed between the test crowns and the control teeth. The percentage of alpha scores for marginal

recall intervals. No surface chipping or fracture was identified on any of the crowns after 2 years. Based on the studies cited above, the performance of the current generation of CAD/CAM-fabricated restorations is expected to be excellent, and the use of this technology is predicted to grow steadily.

References

1. Banks RG. Conservative posterior ceramic restorations: A literature review. J Prosthet Dent 1990;63:619–626.
2. Burke FJ, Qualtrough AJ. Aesthetic inlays: Composite or ceramic? Br Dent J 1994;176:53–60.
3. Qualtrough AJ, Cramer A, Wilson NH, Roulet JF, Noack M. An in vitro evaluation of the marginal integrity of a porcelain inlay system. Int J Prosthodont 1991;4:517–523.
4. Wilson NH, Wilson MA, Wastell DG, Smith GA. Performance of Occlusin in butt-joint and bevel-edged preparations: Five-year results. Dent Mater 1991;7:92–98.

[abstract 1022]. J Dent Res 2012; 91(special issue A).
6. Inokoshi S, Iwaku M, Fusayama T. Pulp response to a new adhesive restorative resin. J Dent Res 1982;61:1014–1019.
7. Nasedkin JN. Porcelain posterior resin-bonded restorations: Current perspectives on esthetic restorative dentistry. Part II. J Can Dent Assoc 1988;54:499–506.
8. Kelsey WP, Blankenau RJ, Latta MA. Resin bond strengths to dentin following placement of an adhere liner [abstract 986]. J Dent Res 1997; 76:137.
9. Bocangel JS, Demarci FF, Turbino ML, et al. Influence of eugenol on the microleakage and bond strength of two bonding agents [abstract 421]. J Dent Res 1997;76:66.
10. Murdoch H, Scrabeck J, Dhuru J. The effect of eugenol on the shear bond strength of composite restorative materials [abstract 1012]. J Dent Res 1999;78;232.
11. Schwartz RS, Davis RD, Mayhew R. The effect of ZOE on the bond strength of resin to enamel. Am J Dent 1990;3:28–30.
12. Schwartz RS, Davis RD, Hilton TJ. Effect of temporary cements on the bond strength of a resin cement. Am J Dent 1992;5:147–150.
13. Sung E, Caputo A, Dail S. The effect of temporary cements on the composite resin bond strength [abstract 1320]. J Dent Res 1998;77:270.
14. Rickert L, Hilton TJ, Ferracane JL. Effects of eugenol concentration in ZOE provisionals on bond strength [abstract 3133]. J Dent Res 2008; 87(special issue B).
15. Burgess JO, Haveman CW, Butzin C. Evaluation of resins for provisional restorations. Am J Dent 1992;5:137–139.
16. Derand T. Stress analysis of cemented or resin-bonded porcelain inlays. Dent Mater 1991;7:21–24.
17. Dalpino P, Francischone C, Ishikiriama A, France E. Fracture resistance of teeth directly and indirectly restored with composite resin and indirectly restored with ceramic materials. Am J Dent 2002;15:389–394.
18. De Freitas C, Miranda M, de Andrade M, Flores V, Vaz L, Guimaraes C. Resistance to maxillary premolar

Dentlearn.ir

fractures after restoration of Class II preparations with resin composite or ceromer. Quintessence Int 2002;33:589–594.
19. St-Georges AJ, Sturdevant JR, Swift EJ Jr, Thompson JY. Fracture resistance of prepared teeth restored with bonded inlay restorations. J Prosthet Dent 2003;89:551–557.
20. Jung H, Friedl KH, Haller A, Schmalz G. Curing efficiency of different polymerization methods through ceramic restorations. Clin Oral Investig 2001;5:156–161.
21. Ferrari M, Dagostin A, Fabianelli A. Marginal integrity of ceramic inlays luted with self-curing resin cements. Dent Mater 2003;19:270–276.
22. Burquieres SH, Burgess JD, Ripps A. Bond strength of resin cement to the dentin varying curing modes and light intensity [abstract 2987]. J Dent Res 1999;78:479.
23. Hilton TJ, Schwartz RS, Ferracane JL. Fifth generation bonding agent application technique effects on bond strength [abstract 214]. J Dent Res 1998;77:132.
24. Bailey L, Bennett R. Two year bond results of Dicor ceramic/LA cement system [abstract 1734]. J Dent Res 1989;68:398.
25. Ozden AN, Akaltan F, Can G. Effect of surface treatments of porcelain in the shear bond strength of applied dual-cured cement. J Prosthet Dent 1994;72:85–88.
26. Thurmond JW, Barkmeler WW, Wilwerding TM. Effect of porcelain surface treatments on bond strengths of composite resin bonded to porcelain. J Prosthet Dent 1994;72:355–359.
27. Imamura GM, Reinhardt JW, Boyer DB, Swift EJ. Enhancement of resin bonding to heat-cured composite resin. Oper Dent 1996;21:249–256.
28. Lutz F. State of the art of tooth-colored restoratives. Oper Dent 1996;21: 237–248.
29. Wendt SL Jr. Microleakage and cusp fracture resistance of heat-treated resin composite inlays. Am J Dent 1991;4:10–14.
30. Latta M, Barkmeier W. Bond strength of a resin cement and a cured composite inlay material. J Prosthet Dent 1993;72:189–193.
31. Ellakwa AE, Shortall AC, Burke FJ, Marquis PM. Effects of grit blasting and silanization on bond strengths of a resin luting cement to Belleglass HP indirect composite. Am J Dent 2003;16:53–57.
32. Tezvergil A, Lassila LV, Yli-Urpo A, Vallittu PK. Repair bond strength of restorative resin composite applied to fiber-reinforced composite substrate. Acta Odontol Scand 2004;62:51–60.
33. Hilton TJ, Schwartz RS. The effect of air thinning on dentin adhesive bond strength [abstract 243]. J Dent Res 1994;73:132.
34. Haws SM, Vargas MA, Guzman S, Cobb DS. Effect of primer application on microleakage of composite resins [abstract 403]. J Dent Res 1997; 76:64.
35. Bergmann P, Noack MJ, Roulet JF. Marginal adaptation with glass ceramic inlays adhesively luted with glycerine gel. Quintessence Int 1991;22:739–744.
36. Erickson RL, Barkmeier WW, Kimmes NS. Fatigue of enamel bonds with self-etch adhesives. Dent Mater 2009;25:716–720.
37. Erickson RL, De Gee AJ, Feilzer AJ. Fatigue testing of enamel bonds with self-etch and total-etch adhesive systems. Dent Mater 2006;22:981–987.
38. Tay F, Carvalho R, Pashley D. Water movement across bonded dentin—Too much of a good thing. J Appl Oral Sci 2004;12(special issue):12–25.
39. Feilzer AJ, de Gee AJ, Davidson CL. Curing contraction of composites and glass ionomer cements. J Prosthet Dent 1988;59:297–300.
40. Osman SA, McCabe JF, Walls AW. Polymerisation shrinkage of luting agents for crown and bridge. Eur J Prosthodont Restor Dent 2008;16:39–44.
41. Kitzumüller K, Graf A, Watts D, Schedle A. Setting kinetics and shrinkage of self-adhesive resin cements depend on cure-mode and temperature. Dent Mater 2011;27:544–551.
42. Brännström M. Infection beneath resin composite restorations: Can it be avoided? Oper Dent 1987;12:158–163.
43. Civelek A, Ersoy M, L'Hotelier E, Soyman M, Say EC. Polymerization shrinkage and microleakage in Class

Dentlearn.ir

II cavities of various resin composites. Oper Dent 2003;28:635–641.
44. Loguercio A, Reis A, Ballester R. Polymerization shrinkage: Effects of constraint and filling technique in composite restorations. Dent Mater 2004;20:236–243.
45. van Dijken J, Horstedt P, Waern R. Directed polymerization shrinkage versus a horizontal incremental filling technique: Interfacial adaptation in vivo in Class II cavities. Am J Dent 1998;11:165–172.
46. Alster D, Feilzer AJ, de Gee AJ, Davidson CL. Polymerization contraction stress in thin resin composite layers as a function of layer thickness. Dent Mater 1997;13:146–150.
47. Hasegawa EA, Boyer DB, Chan DC. Microleakage of indirect composite inlays. Dent Mater 1989;5:388–391.
48. Robinson PB, Moore BK, Swartz ML. Comparison of microleakage in direct and indirect resin composite restorations in vitro. Oper Dent 1987;12:113–116.
49. Shortall AC, Baylis RL, Baylis MA, Grundy JR. Marginal seal comparisons between resin-bonded Class 2 porcelain inlays, posterior composite restorations, and direct composite resin inlays. Int J Prosthodont 1989; 2:217–223.
50. Kanca J. The effect of heat on the surface hardness of light-activated resin composites. Quintessence Int 1989;20:899–901.
51. Wendt SL Jr. The effect of heat used as a secondary cure upon the physical properties of three resin composites. I. Diametral tensile strength, compressive strength, and marginal dimensional stability. Quintessence Int 1987;18:265–271.
52. Wendt SL Jr. The effect of heat used as a secondary cure upon the physical properties of three resin composites. II. Wear, hardness, and color stability. Quintessence Int 1987;18:351–356.
53. Trushkowsky RD. Ceramic optimized polymer: The next generation of esthetic restorations—Part 1. Compend Cont in Educ Dent 1997;18: 1101–1112.
54. Wassell RW, Walls AW, McCabe JF. Direct composite inlays versus conventional composite restorations: Five-year follow-up. J Dent 2000; 28:375–382.
55. Pallesen U, Qvist V. Composite resin fillings and inlays. An 11-year evaluation. Clin Oral Investig 2003;7:71–79.
56. Santos GC Jr, El-Mowafy O, Rubo JH, Santos MJ. Hardening of dual-cure resin cements and a resin cured with QTH and LED curing units. J Can Dent Assoc 2004;70:323–328.
57. Brosh T, Ferstand N, Cardash H, Baharav H. Effect of polymerization under pressure of indirect tensile mechanical properties of light-polymerized composites. J Prosthet Dent 2002;88:381–387.
58. Qualtrough AJ, Wilson NH, Smith GA. The porcelain inlay: A historical review. Oper Dent 1990;15:61–70.
59. Horn HR. A new lamination: Porcelain bonded to enamel. N Y State Dent J 1983;49:401–403.
60. Redford DA, Jensen ME. Etched porcelain resin-bonded posterior restorations: Cuspal flexure, strength, and microleakage [abstract 1573]. J Dent Res 1986;65:334.
61. Jensen ME. A two-year clinical study of posterior etched-porcelain resin-bonded restorations. Am J Dent 1988;1:27–33.
62. Dietschi D, Maeder M, Holz J. In vitro evaluation of marginal fit and morphology of fired ceramic inlays. Quintessence Int 1992;23:271–278.
63. Karaagaclioglu L, Zaimoglu A, Akoren AC. Microleakage of indirect inlays placed on different kinds of glass ionomer cement linings. J Oral Rehabil 1992;19:457–469.
64. Thordrup M, Isidor F, Hørsted-Bindslev P. Comparison of marginal fit and microleakage of ceramic and composite inlays: An in vitro study. J Dent 1994;22:147–153.
65. Soares CJ, Martins LR, Fernandes Neto AJ, Giannini M. Marginal adaptation of indirect composites and ceramic inlay systems. Oper Dent 2003;28:689–694.
66. Audenino G, Bresciano ME, Bassi F, Carossa S. In vitro evaluation of fit of adhesively luted ceramic inlays. Int J Prosthodont 1999;12:342–347.
67. Scherer W, Futter H, Cooper H. Clinical technique for an in-office porcelain modification. J Esthet Dent 1991;3:23–26.
68. Hein DK, Christensen RP, Smith SL. 3 year breakage rate of class 2 tooth colored materials [abstract 1200].

Dentlearn.ir

J Dent Res 1997;76:163.
69. Soares CJ, Martins LR, Pfeifer JM, Giannini M. Fracture resistance of teeth restored with indirect-composite and ceramic inlays. Quintessence Int 2004;35:281–286.
70. Oh W, Delong R, Anusavice K. Factors affecting enamel and ceramic wear: A literature review. J Prosthet Dent 2002;87:451–459.
71. Magne P, Belser UC. Porcelain versus composite inlays/onlays: Effects of mechanical loads on stress distribution, adhesion, and crown flexure. Int J Periodontics Restorative Dent 2003;23:543–555.
72. Metzler KT, Woody RD, Miller AW, Miller BH. In vitro investigation of the wear of human enamel by dental porcelain. J Prosthet Dent 1999;81: 356–364.
73. Sorensen JA, Sultan E, Condon JR. Three-body in vitro wear of enamel against dental ceramics [abstract 909]. J Dent Res 1999;78:219.
74. Imai, Y, Suzuki S, Fukushima S. In vitro enamel wear of modified porcelains [abstract 50]. J Dent Res 1999;78:112.
75. Sorensen JA, Cruz MA, Berge HX. In vivo measurement of antagonist tooth wear opposing ceramic bridges [abstract 232]. J Dent Res 2000; 79(special issue):172.
76. Burgoyne A, Nichols J, Brudvik J. In vitro two-body wear of inlay-onlay resin composite restorations. J Prosthet Dent 1991;65:206–214.
77. Gray W, Suzuki M, Jordan R, et al. Clinical evaluation of indirect composite restorations—3 year results [abstract 633]. J Dent Res 1991;70:344.
78. Walton JN. Esthetic alternatives for posterior teeth: Porcelain and laboratory-processed resin composites. J Can Dent Assoc 1992;58:820–823.
79. Lambrechts P, Braem M, Vuylsteke-Wauters M, Vanherle G. Quantitative in vivo wear of human enamel. J Dent Res 1989;68:1752–1754.
80. Ferracane J. Evaluation of cure, properties, and wear resistance of Art-glass dental composite. Am J Dent 1998;11:214–218.
81. Reich S, Sindel J, Morneburg TH. Wear of prosthetic composites dependent on mechanical matrix properties [abstract 2260]. J Dent Res 1998;77:914.
82. Suzuki S. In vitro wear of indirect resin composite restoratives [abstract 204]. J Dent Res 1998;77:657.
83. Kern M, Strub JR, Lu XY. Wear of composite resin veneering materials in a newly developed chewing simulator [abstract 2154]. J Dent Res 1998;77:901.
84. Suzuki S, Nagai E, Taira Y, Minesaki Y. In vitro wear of indirect composite restoratives. J Prosthet Dent 2002;88:431–436.
85. Bishop BM. A heat and pressure cured composite inlay system: A clinical evaluation. Aust Prosthodont J 1989;3:35–41.
86. Bessing C, Lundqvist P. A 1-year clinical examination of indirect resin composite inlays: A preliminary report. Quintessence Int 1991;22:153–157.
87. van Dijken JW, Horstedt P. Marginal breakdown of 5-year-old direct composite inlays. J Dent 1996;24:389–394.
88. Wendt SL Jr, Leinfelder KF. Clinical evaluation of a heat treated composite inlay: 3-year results. Am J Dent 1992;5:258–262.
89. Leirskar J, Nordbo H, Thoresen NR, Henaug T, von der Fehr FR. A four to six years follow-up of indirect resin composite inlays/onlays. Acta Odontol Scand 2003;61:247–251 [erratum 2003;61:319].
90. O'Neal SJ, Givan DA, Suzuki S. Five year clinical performance of heat and pressure cured indirect composite [abstract 1628]. J Dent Res 1999;78:309.
91. Kukrer D, Gemalmaz D, Kuybulu E, Bozkurt F. A prospective clinical study of ceromer inlays: Results up to 53 months. Int J Prosthodont 2004;17:17–23.
92. Dukic W, Dukic OL, Milardovic S, Delija B. Clinical evaluation of indirect composite restorations at baseline and 36 months after placement. Oper Dent 2012;35:156–164.
93. Smales R, Etemadi S. Survival of ceramic onlays placed with and without metal reinforcement. J Prosthet Dent 2004;91:548–553.

Dentlearn.ir

94. Friedl KH, Schmalz G, Hiller KA, Bey B. In vitro evaluation of a feld-spathic ceramic system: 4 year results. J Dent Res 1997;76:163.
95. Fuzzi M, Rappelli G. Ceramic inlays: Clinical assessment and survival rate. J Adhes Dent 1999;1:71–79.
96. Molin M, Karlsson S. A 3-year clinical follow-up study of a ceramic (OPTEC) inlay system. Acta Odontol Scand 1996;54:145–149.
97. Qualtrough AJ, Wilson NH. A 3-year clinical evaluation of a porcelain onlay system. J Dent 1996;24:317–323.
98. Hayashi M, Tsuchitani Y, Kawamura Y, Miura M, Takeshige F, Ebisu S. Eight-year clinical evaluation of fired ceramic inlays. Oper Dent 2000;25:473–481.
99. Schulz P, Johansson A, Arvidson K. A retrospective study of Mirage ceramic inlays over up to 9 years. Int J Prosthodont 2003;16:510–514.
100. van Dijken JW, Hasselroth L, Ormin A, Olofsson AL. Clinical evaluation of extensive dentin enamel bonded all-ceramic onlays and onlay crowns [abstract 2713]. J Dent Res 1999;78:445.
101. Fradeani M, Aquilano A, Basseyi L. Longitudinal study of pressed glass ceramic inlays for four and a half years. J Prosthet Dent 1997;78:346–353.
102. Frankenberger R, Petschelt A, Kramer N. Leucite-reinforced ceramic inlays and onlays after six years: Clinical behavior. Oper Dent 2000;25:459–465.
103. Studer S, Lehner C, Scharer P. Seven year results of leucite-reinforced glass ceramic inlays and onlays [abstract 1375]. J Dent Res 1998;77:803.
104. Molin MK, Karlsson SL. A randomized 5-year clinical evaluation of 3 ceramic inlay systems. Int J Prosthodont 2000;13:194–200.
105. Fabianelli A, Goracci C, Bertelli E, Davidson CL, Ferrari M. A clinical trial of Empress II porcelain inlays luted to vital teeth with a dual-curing adhesive system and a self-curing resin cement. J Adhes Dent 2006;8:427–431.
106. Krämer N, Frankenberger R. Clinical performance of bonded leucite-reinforced glass ceramic inlays and onlays after eight years. Dent Mater 2005;21:262–271.
107. Stoll R, Cappel I, Jablonski-Momeni A, Pieper K, Stachniss V. Survival of inlays and partial crowns made of IPS empress after a 10-year observation period and in relation to various treatment parameters. Oper Dent 2007;32:556–563.
108. Della Bona A, Kelly JR. The clinical success of all-ceramic restorations. J Am Dent Assoc 2008;139(suppl):8S–13S.
109. Krejci I, Lutz F, Reimer M. Wear of CAD/CAM ceramic inlays: Restorations, opposing cusps, luting cements. Quintessence Int 1994;25:199–207.
110. Krejci I, Guntert A, Lutz F. Scanning electron microscopic and clinical examination of resin composite inlays/onlays up to 12 months in situ. Quintessence Int 1994;25:403–409.
111. Van Meerbeek B, Inokoshi S, Willems G, et al. Marginal adaptation of four tooth-coloured inlay systems in vivo. J Dent 1992;20:18–26.
112. O'Neal SJ, Miracle RL, Leinfelder LF. Evaluating interfacial gaps for esthetic inlays. J Am Dent Assoc 1993;124:48–54.
113. Wilder AD. Clinical considerations of CEREC restorations. In: Mörmann WH (ed). Proceedings of an International Symposium on Computer Restorations. Chicago: Quintessence, 1991:141–149.
114. Kawai K, Isenberg B, Leinfelder KF. Effect of gap dimension on resin composite cement wear. Quintessence Int 1994;25:53–58.
115. Isenberg BP, Essig ME, Leinfelder KF. Three year clinical evaluation of CAD/CAM restorations. J Esthet Dent 1992;4:173–176.
116. Hayashi M, Tsubakimoto Y, Takeshige F, Ebisu S. Analysis of longitudinal marginal deterioration of ceramic inlays. Oper Dent 2004;29:386–391.
117. Beuer F, Schweiger J, Edelhoff D. Digital dentistry: An overview of recent developments for CAD/CAM generated restorations. Br Dent J 2008;204:505–511.
118. Fasbinder DJ. Digital workflow for the Lava COS system. Inside Dent 2009;5(9):114–117.

Dentlearn.ir

119. Levine N. To the sky and beyond. Dent Prod Rep 2009;Oct:116.
120. Mehl A, Ender A, Mormann W, Attin T. Accuracy testing of a new intraoral 3D camera. Int J Comput Dent 2009;12:11–28.
121. Birnbaum NS, Aaronson HB. Dental impressions using 3D digital scanners: Virtual becomes reality. Compend Contin Educ Dent 2008;29: 494–505.
122. Kachalia PR, Geissberger MJ. Dentistry a la carte: In-office CAD/CAM technology. J Calif Dent Assoc 2010;38:323–330.
123. Garg AK. Cadent iTero's digital system for dental impressions: The end of trays and putty? Dent Implant Update 2008;19(1):1–4.
124. Syrek A, Reich G, Ranftl D, Klein C, Cerny B, Brodesser J. Clinical evaluation of all-ceramic crowns fabricated from intraoral digital impressions based on the principle of active wavefront sampling. J Dent 2010; 38:553–559.
125. Henkel GL. A comparison of fixed prostheses generated from conventional and digitally scanned dental impressions. Compend Contin Educ Dent 2007;28:422–431.
126. McMaster D, Cohen B, Spitz SD. Digital workflow. Dent Economics 2008;Aug:30–36.
127. Fasbinder DJ. Digital dentistry: Innovation for restorative treatment. Compend Contin Educ Dent 2010;31(special issue 4):2–11.
128. Ender A, Mehl A. Full arch scans: Conventional versus digital impressions—An in-vitro study. Int J Comput Dent 2011;14:11–21.
129. Ogledzki M, Wenzel K, Doherty E, Kugel G. Accuracy of 3M-Brontes stereolithography models compared to plaster models [abstract 1060]. J Dent Res 2011;90(special issue A).
130. Martin N, Jedynakiewicz NM. Interface dimensions of CEREC-2 MOD inlays. Dent Mater 2000;16:68–74.
131. Estafan D, Dussetschleger F, Agosta C, Reich S. Scanning electron microscope evaluation of CEREC II and CEREC III inlays. Gen Dent 2003;51:450–454 [erratum 2003;51:583].
132. Ellingsen LA, Fasbinder DJ. An in vitro evaluation of CAD/CAM ceramic crowns [abstract 2640]. J Dent Res 2002;81(special issue A):331.
133. Kugel G, Chaimattayompol N, Perry R, et al. Comparison of digital vs conventional impression systems for marginal accuracy [abstract 1119]. J Dent Res 2008;87(special issue A).

all-ceramic crowns [abstract 638]. J Dent Res 2011;90(special issue A).
135. Renne W, McGill ST, VanSickle Forshee K, DeFee MR, Mennito AS. Predicting marginal fit of CAD/CAM crowns based on the presence or absence of common preparation errors. J Prothet Dent 2012;108:310–315.
136. Mörmann WH. Chairside computer-generated ceramic restorations: The CEREC third generation improvements. Pract Periodontics Aesthet Dent 1992;4(7):9–16.
137. Mörmann WH, Brandestini M, Lutz F, Barbakow F. Chairside computer-aided direct ceramic inlays. Quintessence Int 1989;20:329–339.
138. Mörmann WH, Gotsch T, Krejci I, Lutz F, Barbakow F. Clinical status of 94 CEREC ceramic inlays after 3 years in situ. In: Mörmann WH (ed). International Symposium on Computer Restorations. Chicago: Quintessence, 1991:355–363.
139. Mehl A, Hickel R. Current state of development and perspectives of machine-based production methods for dental restorations. Int J Comput Dent 1999;2:9–35.
140. Severance G, Swann L. The Take Care approach to treatment planning, preparation and design for CAD/CAM restorations. Oral Health 2009; 99(3):47–52.
141. Fasbinder DJ. CEREC Operator's Manual. Charlotte, NC: Sirona Dental, 2004.
142. David SB, LoPresti JT. Tooth-colored posterior restorations using CEREC method CAD/CAM–generated ceramic inlays. Compend Contin Educ Dent 1994;15:802–810.
143. Tsotsos S. A historical perspective of tooth preparation for CEREC technology. Oral Health 2009;99(3):55–60.
144. Poticny DJ, Kim J. CAD/CAM in-office technology: Innovations after 25 years for predictable, esthetic outcomes. J Am Dent Assoc 2010;141 (suppl 2):55–95.

Dentlearn.ir

145. Bindl A, Richter B, Mörmann WH. Survival of ceramic CAD/CAM crowns bonded to preparations with reduced macroretention geometry. Int J Prosthodont 2005;18:219–224.
146. Fasbinder DJ. Restorative material options for CAD/CAM restorations. Compend Contin Educ Dent 2002;23:911–920.
147. Fasbinder DJ. Materials for chairside CAD/CAM restorations. Compend Contin Educ Dent 2010;31:702–709.
148. Fasbinder DJ. Chairside CAD/CAM: An overview of restorative material options. Compend Contin Educ Dent 2012;33:50–58.
149. Krejci I. Wear of CEREC and other restorative materials. In: Mörmann WH (ed). Proceedings of an International Symposium on Computer Restorations. Chicago: Quintessence, 1991:245–251.
150. al-Hiyasat AS, Saunders WP, Sharkey SW, Smith G, Gilmour WH. Investigation of human enamel wear against four dental ceramics and gold. J Dent 1998;26:487–495.
151. Rusin RP. Properties and applications of a new composite block for CAD/CAM. Compend Contin Educ Dent 2001;22(6 suppl):35–41.
152. Fasbinder DJ, Dennison JB, Heys DR, Lampe K. The clinical performance of CAD/CAM-generated composite inlays. J Am Dent Assoc 2005;136:1714–1723.
153. Fasbinder DJ, Dennison JB, Heys D. Clinical evaluation of CAD/CAM–generated composite inlays: 10 year report [abstract 379]. J Dent Res 2011;90(special issue A).
154. Mörmann WH. Symposium review. In: Mörmann WH (ed). Proceedings of an International Symposium on Computer Restorations. Chicago: Quintessence, 1991:17–21.
155. Shearer AC, Kusy RP, Whitley JQ, Heymann HO, Wilson NH. Finishing of MGC Dicor material. Int J Prosthodont 1994;7:167–173.
156. Roznowski M, Bremer B, Geurtsen W. Fracture resistance of human molars restored with various filling materials. In: Mörmann WH (ed). Proceedings of an International Symposium on Computer Restorations. Chicago: Quintessence, 1991:559–565.
157. Fasbinder DJ, Poticny DJ. Accuracy of occlusal contacts for crowns with chairside CAD/CAM techniques. Int J Comput Dent 2010;13:303–316.
158. Krejci I, Lutz F, Reimer M. Marginal adaptation and fit of adhesive ceramic inlays. J Dent 1993;21:39–46.
159. Peters A, Bieniek KW. SEM-examination of the marginal adaptation of computer machined ceramic restorations. In: Mörmann WH (ed). Proceedings of an International Symposium on Computer Restorations. Chicago: Quintessence, 1991:365–370.
160. Christensen GJ. Marginal fit of gold inlay castings. J Prosthet Dent 1966;16:297–305.
161. Mörmann WH, Schug J. Grinding precision and accuracy of fit of CEREC 2 CAD/CIM inlays. J Am Dent Assoc 1997;128:47–53.
162. Benz C, Benz B, El Mahdy K, Hickel R. Clinical evaluation of the CEREC II system in comparison to CEREC 1. In: Mörmann W (ed). CAD/CIM in Esthetic Dentistry. Chicago: Quintessence, 1996:516–524.
163. Cook K, Fasbinder DJ. Accuracy of CAD/CAM crown fit with infrared and LED cameras. Int J Comput Dent 2012;15:315–326.
164. Sjögren G, Bergman M, Molin M, Bessing C. A clinical examination of ceramic (CEREC) inlays. Acta Odontol Scand 1992;50:171–178.
165. Heymann HO, Bayne SC, Sturdevant JR, Wilder AD, Roberson TM. The clinical performance of CAD-CAM–generated ceramic inlays: A four-year study. J Am Dent Assoc 1996;127:1171–1181.
166. Fasbinder DJ, Lampe K, Dennison JB, Peters MC, Nematollahi K. Clinical performance of CAD/CIM generated ceramic onlays [abstract 2711]. J Dent Res 1999;78(special issue):444.
167. Fasbinder DJ, Neiva GF, Dennison JB, Heys D. Clinical evaluation of CAD/CAM-generated ceramic onlays [abstract 378]. J Dent Res 2011;90(special issue A).
168. Sjögren G, Molin M, van Dijken JW. A 5-year clinical evaluation of ceramic inlays (CEREC) cemented with a dual-cured or chemically cured resin composite luting agent. Acta Odontol Scand 1998;56:263–267.
169. Pallesen U, van Dijken JW. An 8-year evaluation of sintered ceramic and glass ceramic inlays processed by the CEREC CAD/CAM system. Eur J Oral Sci 2000;108:239–246.

Dentlearn.ir

170. Berg NG, Dérand T. A 5-year evaluation of ceramic inlays (CEREC). Swed Dent J 1997;21:121–127.
171. Zimmer S, Göhlich O, Rüttermann S, Lang H, Raab WH, Barthel CR. Long-term survival of CEREC restorations: A 10-year study. Oper Dent 2008;33:484–487.
172. Martin N, Jedynakiewicz NM. Clinical performance of CEREC ceramic inlays: A systematic review. Dent Mater 1999;15:54–61.
173. Otto T, De Nisco S. Computer-aided direct ceramic restorations: A 10-year prospective clinical study of CEREC CAD/CAM inlays and onlays. Int J Prosthodont 2002;15:122–128.
174. Hickel R, Manhart J. Longevity of restorations in posterior teeth and reasons for failure. J Adhes Dent 2001;3:45–64.
175. Zuellig-Singer R, Bryant RW. Three year evaluation of computer-machined ceramic inlays: Influence of luting agent. Quintessence Int 1998;29:573–582.
176. Sjögren G, Molin M, van Dijken JW. A 10-year prospective evaluation of CAD/CAM-manufactured (CEREC) ceramic inlays cemented with a chemically cured or dual-cured resin composite. Int J Prosthodont 2004;17:241–246.
177. Bindl A, Mörmann W. Survival rate of mono-ceramic and ceramic-core CAD/CAM–generated anterior crowns over 2–5 years. Eur J Oral Sci 2004;112:197–204.
178. Fasbinder DJ, Dennison JB, Heys D, Neiva G. A clinical evaluation of chairside lithium disilicate CAD/CAM crowns: A two-year report. J Am Dent Assoc 2010;141(suppl 2):10S–14S.

Dentlearn.ir



Cast Gold Restorations

Patrice P. Fan
Richard Stevenson
Thomas G. Berry

The cast gold restoration has lessened in popularity over the past 20 years because of the increased emphasis on esthetics, but it remains an excellent restoration with a long history of success. If used with care, gold alloy is considered to have the greatest longevity of any restorative material used in dentistry. This opinion is generally supported by longitudinal studies,[1–3] although it is disputed by other studies.[4–6] Cast gold may be used for intracoronal (inlays) or extra-coronal (complete-coverage crowns) restorations, as well as for restorations that are a combination of both (onlays or partial-coverage crowns) (Fig 20-1).

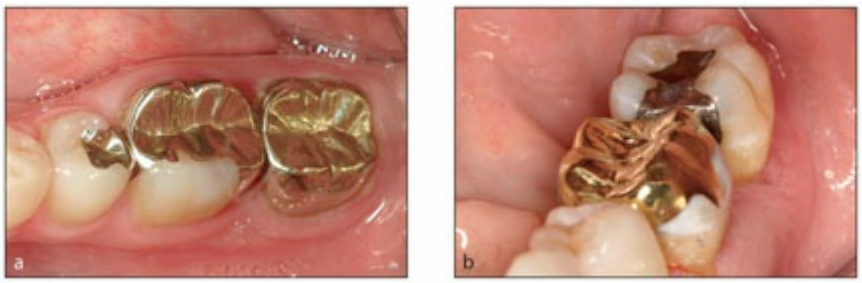

Fig 20-1 *(a)* Inlay, partial-coverage, and complete-coverage cast restorations. *(b)* Partial-coverage cast restoration (mesio-occlusodistal [MOD] onlay).

Dentlearn.ir

Several long-term studies have demonstrated the excellent clinical behaviour of cast gold restorations over time.[7–9] Restoration longevity runs from an average of 10 to 20 years and up to 34 and 52 years in selected practices.[10–12] The survival rate ranges from 87% to 97% at 10 years,[7,9,13] 87% to 90% at 20 years,[9,13] and 73.5% to 98% at 30 years.[8,9,13] Compared with all-ceramic inlays and onlays, cast gold restorations have proven more effective under mechanical stresses such as bruxism.[14]

The failure pattern of these restorations can be divided into biologic and technical reasons. The most prevalent biologic reasons are, in order: secondary caries, tooth fracture, endodontic treatment, primary caries, and periodontal involvement. Loss of retention is the main reason for technical failure, followed by extensive wear.[13,15,16]

Gold castings present several advantages over direct restorative materials such as silver amalgam or resin composite. Because castings are fabricated using an indirect technique, it is possible to achieve nearly ideal contours and occlusion.[17] Gold alloy is a strong material that rarely fractures and, when used as an extracoronal restoration, can provide protection to the tooth.[18–20] Other materials such as titanium and nickel-chrome alloys have shown clinically acceptable results, but gold alloy remains the dental casting material of choice.[21] Gold wears at a rate similar to that of enamel, so it does not cause accelerated wear of the opposing teeth.[22] It casts easily and accurately, and if a type I or II gold is used, marginal adaptation can usually be improved after the restoration is cast. Gold is also resistant to corrosion.[23]

Allergic reactions to gold are relatively rare but have been documented. In a study of 200 patients with persistent oral or cutaneous lesions and suspected gold allergy, 8.5% were found to have a reaction to patch testing with gold salts. Still, gold is considered among the most biocompatible of dental materials.[24]

Gold shows better resistance to at-home vital bleaching agents, such as 10% carbamide peroxide, compared with unpolished amalgam and nickel chrome.[25] However, galvanic corrosion has been shown to cause unpleasant, sometimes painful, transient effects when gold alloy is in direct contact with zinc-containing amalgam restorations. As passivation processes develop, naturally or by actively brushing the new amalgam restoration with tin oxide, side effects subside.[26–28]

The primary drawback to the use of cast gold rather than direct restorations is higher initial cost, because castings require at least two appointments for the patient and have associated laboratory costs. However, the long-term success of cast gold

Dentlearn.ir

restorations offsets this initial investment and decreases frequency of "remakes," preserving tooth structure, pulp vitality, and subsequent expense. For esthetic reasons, gold castings are usually used to restore posterior teeth that are not in the esthetic zone. Preparations for anterior teeth are usually designed so that the gold is not seen during speech and smiling. Esthetics may also be preserved in maxillary posterior teeth when cast gold restorations are used (Figs 20-2 and 20-3). Postoperative tooth sensitivity following insertion of cast gold restorations can usually be prevented with the proper use of sealers, liners, and bases.[29,30] This chapter addresses the indications, materials, and clinical steps for the fabrication of cast gold restorations.



Fig 20-2*(a and b)* Cast gold inlays that preserve tooth structure and are generally not seen during speech and smiling.



Fig 20-3*(a)* Partial-coverage gold restoration. *(b)* When viewed from the anterior, the gold display is minimal, thus satisfying both functional and esthetic demands.

Indications

Traditionally, the indications for a cast gold restoration range from a tooth with a relatively small caries lesion restored with an inlay to a severely weakened and/or malfunctioning tooth restored with a complete-coverage crown. However, direct resin composite or amalgam restorations are more conservative and usually indicated over cast gold for restoration of small caries lesions. While small inlays have been shown to exhibit the highest failure rate of all cast gold restoration types,[9] their long-term clinical success remains excellent. Cast gold restorations may be used to restore teeth with primary caries lesions or to replace existing restorations.

Dentlearn.ir

They are generally indicated for situations in which other, less expensive materials are not suitable for establishing proper proximal and/or occlusal contacts, creating appropriate axial contours, or protecting the remaining tooth structure. A cast gold restoration may also be indicated when gold has been used to restore adjacent and/or opposing teeth to avoid corrosion problems arising from the use of dissimilar metals in close proximity in the same mouth.[31,32] A cast gold restoration may be specifically recommended for posterior areas and for alleviating the deleterious effects of bruxism. Reduction requirements for a full-coverage cast gold crown are more conservative than for any other type of full-coverage restoration, and the wear properties of gold make it an ideal choice when there is opposing intact tooth structure.[22]

The morphology of posterior teeth, the number of carious surfaces, the number of restored surfaces, the width and depth of existing restorations,[33] and the occlusal relationships must be considered when determining the need for a cast restoration. Nonworking-side occlusal contacts can be especially important. Hiatt[34] has shown a significant increase in the number of vertical fractures in teeth with nonworking-side contacts.

Basic Principles of Cast Restorations

While there are many acceptable techniques and designs for cast restorations, certain principles always apply.

Conservation of tooth structure

Preparations should be made as conservatively as possible to maximize the remaining tooth structure, decrease the likelihood of tooth fracture, and lessen the possibility of postoperative sensitivity and pulpal pathosis. Tooth reduction should not exceed the amount that will allow adequate material thickness necessary to resist fracture, deformation, or wear during function. From an anatomical standpoint, nonfunctional cusps (buccal cusps of maxillary teeth, lingual cusps of mandibular teeth) of molars and functional cusps of maxillary premolars possess steep inclines. The enamel is also thinner on nonfunctional cusps. The clinician should keep these elements in mind during treatment planning and cavity preparation.[35–38]

Tooth preservation involves more than simply minimizing the removal of tooth structure. Preparations must be designed to protect remaining tooth structure. This may involve additi tructure, or it may

Dentlearn.ir

necessitate cuspal coverage. Studies have shown that as a cavity preparation gets wider[39,40] and deeper,[41] progressive weakening of the tooth occurs. When an inlay preparation exceeds one-third of the intercuspal (buccal cusp tip to lingual cusp tip) width, an onlay or another extracoronal restoration should be considered to protect the cusps of the tooth. Indeed, a conservative three-surface (mesio-occlusodistal [MOD]) restoration has proven to decrease tooth stiffness by 50% and a large three-surface restoration by as much as 78%.[42] Gold onlays or full-gold cast crowns provide a splinting effect and greater resistance to cuspal movement. They virtually double the resistance to fracture when compared with an intact tooth.[42–44] This reinforcing effect is particularly significant in the maxillary premolars.

Two retrospective studies[19,45] concluded that a significant factor in the prevention of catastrophic failure of endodontical-ly treated teeth was the presence of a full- or partial-coverage restoration. Another 9-year retrospective cohort study[46] demonstrated that endodontically treated teeth with intracoronal restorations were six times more likely to fail catastrophically than teeth restored with full-coverage restorations.[19,45,46] Because extracoronal restorations cover both facial and lingual surfaces, they protect remaining tooth structure and reduce the incidence of tooth fracture.[47]

Retention and resistance form

Retention and resistance form are two separate but related features of a preparation. Correctly incorporated, they resist unseating vertical, lateral, and oblique forces that are placed on the restoration during function or parafunction.[48] *Retention form* resists forces attempting to remove a restoration parallel to the path of insertion. *Resistance form* resists forces attempting to dislodge a restoration obliquely to the path of insertion. Retention form and resistance form are usually closely interrelated and may be difficult to distinguish clinically as separate features. However, they both are affected by four factors. The first is the resulting stress quantified by the ratio of applied force to surface area. The force itself varies in its magnitude, frequency, duration, and direction. The other three factors are the final tooth preparation geometry, the luting material type and thickness, and the tooth and crown surface texturing.[47,49,50]

Retention is gained when two or more walls oppose each other. These walls may be intracoronal, extracoronal, or a combination of the two (Fig 20-4). The amount of retention created by these opposing walls is determined by several factors. The degree of converge alls) or divergence

Dentlearn.ir

toward the occlusal (intracoronal walls) and the length of the walls are the most important factors. One long wall opposed by a short wall provides retention equivalent only to that imparted by the short wall. The longer[51] and more nearly parallel the walls, the greater the retention. The further apart the opposing walls and the greater the surface areas, the more retentive the restoration will be.[52] Certain

Morse taper configuration. In practice, the taper achieved bears little resemblance to that advocated in textbooks (a combined 6 to 12 degrees), and most teeth are prepared with a taper in excess of 12 degrees with clinical success.[53–55] Although a rapid loss of retention occurs as the taper progresses from 5 to 10 degrees for each wall,[56] a total convergence up to 16 degrees still provides adequate retention.[53,54]

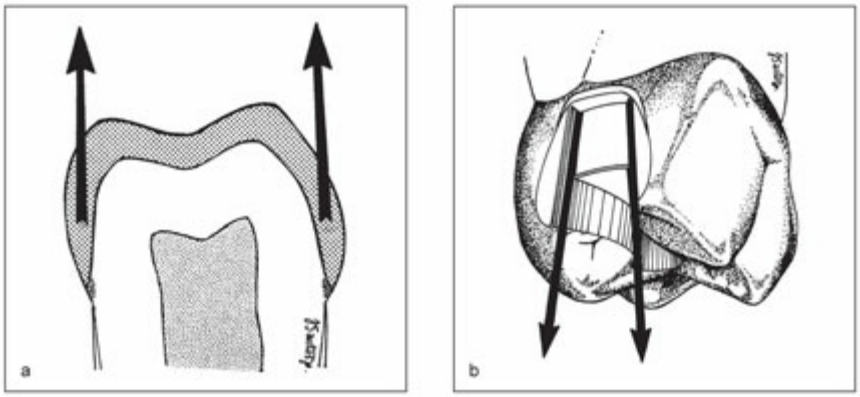

Fig 20-4*(a)* Complete-coverage, or full-veneer, crowns rely on the opposing external walls to provide retention for the restoration. A slight taper of the walls in the occlusal direction provides a

retention.

At a constant taper, retention increases with increasing preparation length, surface area, and preparation diameter and also with the use of a resin-based cement combined with surface treatments.[47,49,50] It is important to note that the retention of a casting prior to cementation is not an indication of its retention postcementation.[57] The addition of intracoronal features has different effects on retention and resistance. The addition of proximal boxes or pins improves both retention and resistance, whereas proximal grooves and slots/potholes mostly enhance resistance form[58] (Figs 20-5 and 20-6). Posterior teeth that are short may present a problem despite their larger diameter. Short, wide preparations do not resist rotational forces well. Adding a groove or a pin will reduce this rotational radius and provide additional resistance.

Dentlearn.ir

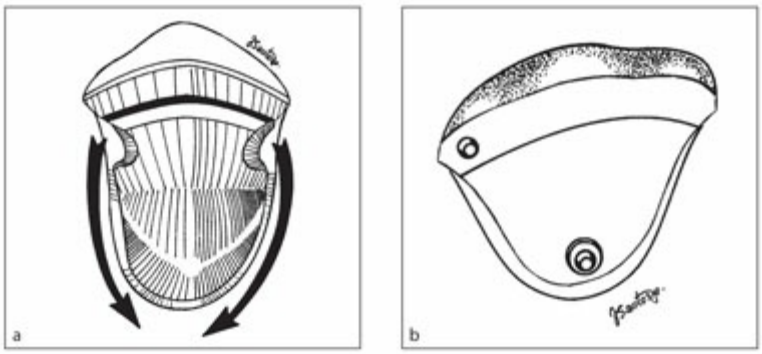

Fig 20-5*(a)* Resistance to lingual and rotational forces may be provided by proximal grooves. *(b)* Pinholes also provide resistance to lingual displacement.



Fig 20-6*(a)* This mandibular molar preparation for a partial-coverage cast gold restoration shows the use of axial grooves and an occlusal dovetail to provide retention and resistance form for the partial-coverage casting. *(b and c)* Note the die and casting showing the same features. *(d)* Definitive restoration.

A recent study[59] demonstrated that the positive influence of grooves or boxes is limited by the height, width, and taper of the existing preparation. The study showed that grooves and boxes seem to possess a limited effect on short, wide, and excessively tapered preparations. The most effective method to improve retention was to decrease the convergence of the preparation's 2.5-mm total height in the cervical 1.5 mm from 20 to 8 degrees. Insufficient retention is a major cause of failure of fixed prostheses, exceeded only by failure due to dental caries and porcelain fracture.[6]

Recent developments in luting agents and techniques of metal conditioning allow bonding of cast restorations to the tooth.[60–62] This greatly improves the resistance to displacement from the preparation. Although less often discussed, the cement's

Dentlearn.ir

compression and shear strength as a function of film thickness, along with the tooth-cement and cement-crown adhesive properties, appear to be essential parameters affecting retention and resistance. However, the long-term effectiveness of bonded castings is not yet known.

Resistance form is essential to providing long-term stability of cemented restorations. Taper has a limited influence. A variation of ± 10% taper increases or decreases resistance by ± 10%.[43,44] Indeed, the rationale for resistance form has evolved from a theoretical model[63,64] to a more clinically relevant idea.[44] The theoretical *self-limiting taper concept*, or "on-off" theory, was defined as a definite convergence angle above which all resistance to lateral force application is lost because of the absence of a cement compression zone on the abutment. However, this has been challenged by the importance of the cement's properties, thickness, and mechanical behavior under compression.[50,64,65] Cement thickness should be kept at the minimum level compatible with seating of the restoration. Texturing the surface of the abutment and crown before cementation increases the resistance to dynamic lateral loading.[50]

Pulpal considerations

Tooth preparation for any cast restoration involves dentin and therefore affects the pulp. Often in situations in which a restoration is indicated, the pulp has already been traumatized by caries and/or previous restorations. Prior to tooth preparation, the pulp should be tested for vitality, and radiographs should be taken. Tooth symptoms and any restorative history should be noted. The additional trauma created by tooth preparation can be enough to cause necrosis of an unhealthy pulp. If the vitality of the pulp is questionable, a reevaluation of the pulpal vitality should be performed 4 to 6 months after the initial evaluation. Endodontic therapy is easier and more predictable and economical for the patient if it is performed before the definitive restoration is placed. Endodontic therapy through an existing restoration is difficult and may lead to decreased crown retention, marginal leakage, and recurrent caries.[66] One study[67] determined that the cast gold restoration presented the lowest rate of bacterial leakage when endodontic access openings were closed with either resin composite or amalgam, compared with other types of full-coverage restorations. Even so, endodontic therapy should be performed prior to preparation.

Pulpal considerations for cast restorations are the same as those for direct restorations. The best pulpal protection is a thick layer of sound dentin. A thorough discussion of the subject can be found in chapter 6. The thinner the dentin, the more

Dentlearn.ir

permeable and susceptible it is to penetration of bacteria and uncured monomers.[68,69] A pulpal reaction will be triggered if the remaining dentinal thickness (RDT) is less than 1 mm (see chapter 6). In situations in which the RDT is very thin, application of a sealer or liner is indicated, followed by an observation period to determine that the tooth remains symptom-free prior to permanent seating the definitive restoration.[70]

Certain anatomical considerations are critical to planning the preparation, especially in younger patients. The pulp horns may be large enough to be exposed during preparation. Examination of preoperative radiographs is imperative to identify potential problems. Because the pulp is narrower in the cervical region of the tooth, pulpal exposures are less likely to occur in this area.

Postcementation thermal sensitivity is sometimes a problem. Several methods to prevent or minimize this problem have been recommended. Some clinicians scrub the preparations with antimicrobial solutions to reduce bacterial contamination, a possible cause of postoperative sensitivity. Other factors affecting pulpal response include RDT and postoperative time.[70–72] Resin varnish and Gluma desensitizer (Heraeus Kulzer) should be avoided in favor of adhesive primers containing an inhibitor of matrix metalloproteinase (MMP), which seems to enhance the bond durability and act as an efficient antibacterial agent.[73–75]

Gingival considerations

When a tooth is prepared for a cast restoration, finish lines (and therefore casting margins) can be placed supragingivally or intracrevicularly.[76] It is well established that supragingival crown margins are compatible with gingival health, but both configurations have their proponents.[77,78] However, there is general agreement that it is only at the completion of the initial periodontal therapy that the decision on the location of finish lines should be made.[79] Should crown lengthening be necessary, the waiting period before final tooth preparation should provide adequate time for healing and tissue stabilization. Each margin location has its indications, as described below.

Supragingival margins present the following advantages:

- Preparation, impression, and temporization are facilitated.
- The restoration can be finished/cemented and cleaned with ease.
- Patient hygiene measures are more effective, and evaluation at recall is facilitated.

Dentlearn.ir

• Incidence of inflammation in adjacent tissues is reduced.

Intracrevicular margins may be warranted in the following situations:

• Existing restorations, caries lesions, or erosion require that the finish line be placed more apically.
• Refinement or modification of an existing finish line is needed.
• Additional retention or resistance form is needed.
• There is a long contact area on a proximal surface.
• The emergence profile requires modification.
• Root sensitivity is unresolved with conservative measures.

Note that esthetics is obviously not a criterion for margin placement in a cast gold restoration.

From a restorative standpoint, subgingival margin placement increases the level of difficulty and reduces predictability. Periodontally, even a well-fitting margin may trigger a pathologic response.[80–83]

The term *subgingival* implies the placement of a restoration margin somewhere between the free gingival margin and the alveolar crest. *Intracrevicular* refers to the placement of a margin within the gingival sulcus and above the junctional epithelium or epithelial attachment (Fig 20-7). Ultimately, the fit, finish, and emergence profile at intracrevicular finish lines may be as significant to gingival health as the location of the finish line in relation to the free gingiva.[84,85]

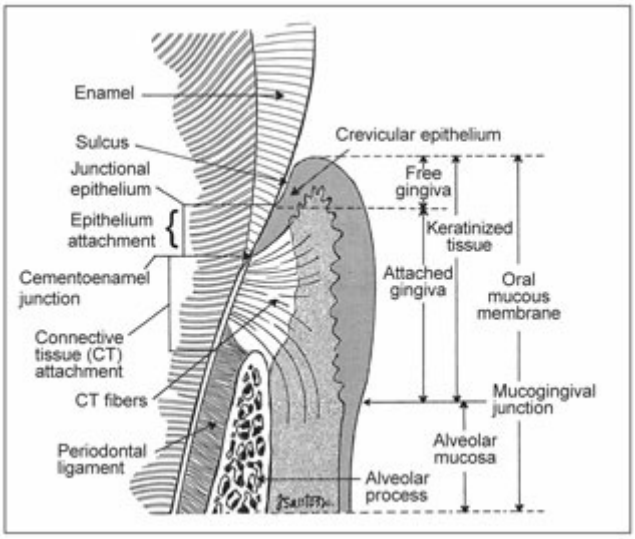

Fig 20-7 Anatomy of the periodontium, illustrating the three zones of the den-togingival junction.[76]

Dentlearn.ir

One other controversial issue pertains to restoration margins impinging on the biologic width. Gargiulo's biologic concept and dimensions have been challenged.[86–88] Of the three components of the biologic width, only the connective tissue attachment seems to be relatively constant. Sulcus depth and epithelial attachment show wide variations. Histologically, the sulcus depth is at 0.5 mm, whereas clinically, it ranges from 1.0 to 4.0 mm and is affected by probing force, tooth position, and tissue health status. The dentogingival complex follows human biologic variability. The most predictable method to assess the patient's specific biologic width is to probe the osseous crest.[87]

Biologic width violation can result in an inflammatory response leading to attachment loss, pocket formation, and osseous resorption. Most studies have been performed on animals, and there is actually very limited data on biologic width.[88]

The consequences of restoration margins impinging on the biologic width remain controversial. A 2-year prospective study failed to correlate the violation of biologic width with bone resorption or gingival recession. On the other hand, a statistically significant increase in probing depth and gingival inflammation was observed, but its clinical significance remains uncertain.[88]

It is important to remember that the bone scallop approximately parallels the cementoenamel junction (CEJ) circumferentially.[86–88] Frequently, a preparation finish line on an anterior tooth does not parallel this osseous scallop, thus inducing an interproximal violation of biologic width.

The interproximal bone in posterior areas has a flat architecture and adequate thickness, so a scallop pattern in the restoration finish line is not as necessary. However, a thin labial or buccal plate over a root prominence is not uncommon, so these areas are at risk.[89] A phenotype characterized by a slender tooth and thin gingival tissue may be prone to gingival recession following a biologically or mechanically aggressive procedure.[90] At least 3.0 mm of height of attached gingiva and free gingiva should be present prior to any restorative procedure in which the finish line approaches gingival tissue.[76]

If possible, finish lines should not be prepared deeper than 0.5 to 1.0 mm into the sulcus[91,92] (no closer than 2.5 mm from the osseous crest) or closer than 1.0 mm to the base of the sul-cus. 76 A more complete discussion of this subject may be found in chapter 1.

Because gingival health may be adversely affected by intracrevicular finish lines,[79,82,93–96] finish lines should be placed supragingivally if the situation permits. When finish lines must be placed within the gingival crevice because of caries

Dentlearn.ir

lesions, existing restorations, fractures, root sensitivity, or short clinical crowns,[97,98] care must be exercised to minimize the damage to gingival tissues. The fragile soft tissue may be reflected by careful placement of a deflection cord (gingival retraction cord), prior to final preparation of the finish line, to avoid soft tissue damage.

Finish lines

The term *finish line* refers to the border of the preparation where the prepared tooth structure meets the unprepared surface of the tooth. The type of finish line depends on the clinical situation. A smooth, well-defined finish line is beneficial, regardless of the design used, to facilitate laboratory procedures and finishing of the restoration. Selection of the type of finish line may be dictated by the shape of the tooth (bell-shaped versus flat) (Fig 20-8), the desired location of the finish line, or operator preference. The most common types of finish lines for cast restorations are knife-edged, chamfer, and shoulder. Both the chamfer and the shoulder configurations may be beveled or unbeveled (Fig 20-9a).

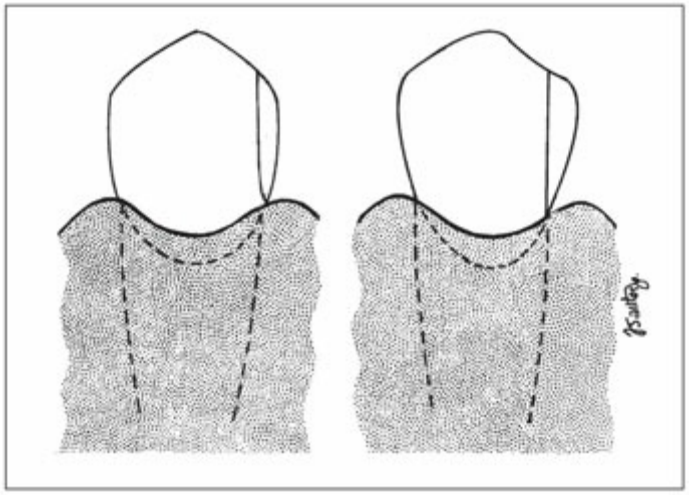

Fig 20-8 Flat proximal surfaces *(left)* allow the easy formation of a chamfered finish line, while bell-shaped anatomy *(right)* makes it difficult to create such a finish line without severe reduction of the proximal surface.

Dentlearn.ir

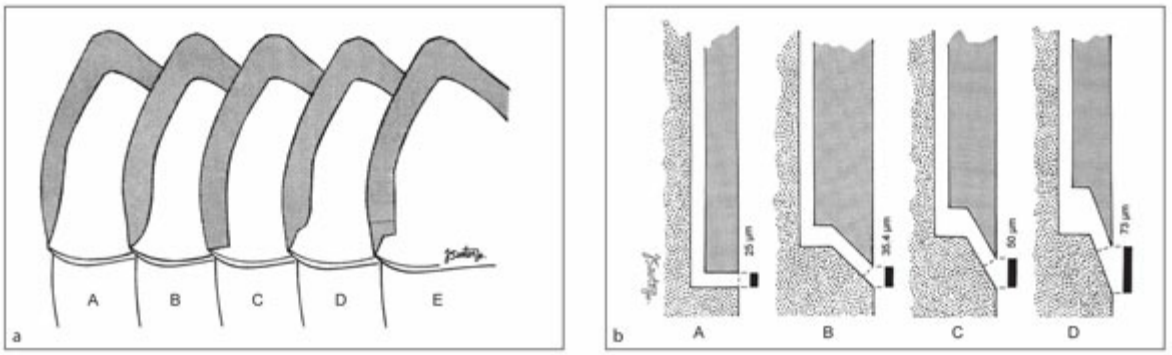

Fig 20-9*(a)* Forms of finish lines: knife-edged (A); chamfer (B); shoulder (C); beveled chamfer (D); beveled shoulder (E). *(b)* Effect of the same cement film thickness on cervical marginal openings, comparing a shoulder marginal configuration with no bevel and beveled shoulders at varied bevel angles: butt margin with a 90-degree cavosurface angle (A); shoulder margin with a 45-degree bevel (B); shoulder margin with a 60-degree bevel (C); shoulder margin with a 70-degree bevel (D). The broken line represents the cement film thickness of 25 μm at the margin. As steepness of the bevel increases, the marginal opening increases.[107]

According to a dental survey, there is no agreement on the ideal finish line.[99] The type of finish line and presence or absence of a bevel will depend on tooth morphology, its location, and the type of restorative material used.

The slip joint versus the butt joint theory

Despite a lack of consensus regarding the maximal allowable marginal gap, a gap between 39 and 120 μm may be considered acceptable.[100–103] It has long been held that the addition of bevels to cast gold preparations helps to reduce marginal gaps.[104] However, this was based on mathematical models that did not take cement thickness into account. As explicitly demonstrated by Ostlund$_{105}$ and supported by others,[106,107] beveling beyond 45 degrees significantly increases the cement-filled opening (Fig 20-9b). Simply put, the steeper the bevel angle, the larger the vertical discrepancy (opening) between the edge of the casting and the finish line. This assumes that the casting is fully relieved, allowing minimum cement thickness. Another study$_{108}$ later demonstrated that crowns with a shoulder finish line configuration had better marginal fit than did those with a beveled finish line configuration. The study did not describe or quantify the amount of difference of laboratory technique, cement material properties, finishing technique, and seating force play important roles in the ultimate finish line fit.[101,109] Research suggests that finish line form and cement do not significantly affect the fit of cemented crowns.

Dentlearn.ir

However, marginal fit varies continuously around the tooth, making an evaluation subjective and arduous.[110–112]

Knife-edged configuration

A knife-edged finish line requires the least amount of tooth reduction. It is sometimes used with a bell-shaped tooth because creation of a heavier margin would require excessive removal of tooth structure. Generally, a knife-edged finish line is not desirable because it is more difficult than other finish lines to discern on a die, and it tends to result in overcontoured restorations. These thin margins are more difficult to wax and cast accurately and are susceptible to distortion under occlusal forces. However, the configuration is commonly used on the mesial aspect of a mesially tipped molar, on the lingual aspects of mandibular molars, and on root surfaces of periodontally involved teeth. It should be noted that excellent results may be obtained with knife-edged finish lines in expert hands coupled with outstanding laboratory support when the gold finish lines are accessible for finishing and are in enamel.[113]

Chamfer configuration

A chamfer is often the preferred finish line for cast gold extra-coronal restorations. It is more conservative than a shoulder finish line and generates less stress at the cement interface.[114] It creates a well-defined and easily identified margin that provides room for adequate thickness of gold without overcon-touring the restoration. Care must be taken not to tilt the bur toward the tooth, because this will increase taper, or away from the tooth, because this will create undercuts.

Shoulder configuration

The shoulder finish line is used primarily when a bulk of material is needed to strengthen the restoration at the margins, such as for all-ceramic or metal-ceramic restorations. It is the least conservative of the finish line types for cast gold. It also has the most critical fit, because there is no bevel present on the restoration that can be burnished against the preparation to reduce marginal opening.

Chamfer or shoulder with a bevel

This design is preferred by clinicians who believe that a beveled margin is easier to detect in an impression and that it makes the margins of the casting more burnishable.

Dentlearn.ir

A bevel is recommended for proximal boxes. However, for full cast crowns, the bevel can increase the risk of encroachment on the epithelial attachment.

Contours

The establishment of proper contours of the restoration depends on proper tooth preparation. An overcontoured casting is often the result of an underprepared tooth. If removal of tooth structure is insufficient, the crown must be overcontoured to obtain sufficient thickness of metal. Overcontoured crowns encourage plaque retention, resulting in gingival inflammation[115,116] (Fig 20-10). Even with overcontoured crowns, however, gingival health can be maintained if the patient practices excellent oral hygiene measures.[117]



Fig 20-10 Overcontoured restorations lead to problems. Note the gingival plaque retention and resultant marginal tissue inflammation as a result of facial overcontouring of this all-gold crown.

Wheeler[118] proposed that convexities be created in the gingival third of artificial crowns to deflect food away from the free gingiva. Herlands et al,[119] however, showed that the maximum bulge in the natural crown at its greatest diameter is no more than 0.5 mm greater than at the CEJ and that the impaction mechanism of gingival injury does not occur. The biologic acceptability of undercontouring is often observed when a provisional crown is lost from a prepared tooth for an extended time without adverse effects on the surrounding gingiva.[117] A natural contour (ie, the exact replacement of the axial and proximal morphology) is the desired form for cast gold restorations when the gingival crest is at a normal level.

When the free gingival margin is apical to the CEJ because of recession or surgery, a flattened contour best reproduces the contour of the root surface.[117] Flat contours are recommended occlusal to furcations to allow access for cleaning.

Stein[120] described the contour of a restoration adjacent to the gingiva as the *emergence profile*. He stated that the proximal emergence profiles of all natural

Dentlearn.ir

teeth are either flat or concave. This natural contour provides an open gingival embrasure that promotes good oral hygiene.

Occlusion

No restoration, no matter how well crafted, will be successful if it does not function correctly. Satisfactory occlusion is required if the restoration is to achieve adequate function and patient comfort.

Establishing biologically acceptable occlusion starts with careful planning. The teeth opposing the one to be restored (whether in a natural or restored state) should be properly aligned and in the desired occlusal plane. Occlusal surfaces should be well formed. If these conditions do not exist, the opposing dentition should be recontoured or restored, if possible. Failure to do so may seriously compromise the occlusal relationships and, in turn, the future health and function of the involved teeth,[121] as well as the patient's comfort.[122,123]

Existing occlusal relationships should be identified with marking tape in maximum intercuspation position (centric occlusion), centric relation, and excursive movements. Tooth fremitus, radiographic evidence of ligament widening, and wear patterns should be noted. It is essential to determine the precise etiology (eg, physiologic forces with compromised periodontal support or pathologic forces on a normal periodontium) of occlusal traumatism. A broken cusp may result from an overload in working or nonworking movements and is often associated with a large existing restoration. Malpositioned teeth, open contacts, and uneven marginal ridges may warrant additional therapy.[121,123]

Acceptable occlusion has several characteristics. Multiple contact points exist between opposing teeth that come into contact simultaneously during closure. The maximum closure position is referred to as *maximum intercuspation*. Ideally, the facial cusps of the mandibular posterior teeth and the palatal cusps of the maxillary posterior teeth contact the opposing teeth in a fossa or on a marginal ridge so that the occlusal contacts stabilize the teeth in both arches. In some cases, contact of mandibular and maxillary anterior teeth separates the posterior teeth during any eccentric movement of the jaw. This occlusal relationship is referred to as *anterior guidance* o r *mutually protected occlusion*.[124,125] Another occlusal relationship, several teeth on the functional side share equally in the contact during lateral movements of the mandible.[126]

A major benefit of indirect fabrication of a restoration is the ability to form the

Dentlearn.ir

wax pattern to the desired occlusal relationships. The wax pattern (and ultimately the restoration) must contact its antagonist(s) in the prescribed contact areas at precisely the instant the other teeth contact. A premature contact or an interference in excursive movements may be uncomfortable, produce loosening or accelerated wear of the restoration or its antagonist, and/or damage the health of the tooth and its supporting structures.[127,128]

Occlusion should be developed with mounted casts on an articulator. For single-unit castings, a simple hinge articulator may be adequate, although it allows accurate reproduction of maximum intercuspation only. Lateral or protrusive interferences must be adjusted in the mouth. In more complicated situations, as for multiple units, use of a more sophisticated semiadjustable articulator may be indicated (Fig 20-11). When casts are mounted on a semiadjustable articulator with a face-bow, the lateral and protrusive movements of the mandible may be simulated with reasonable accuracy.[129]



Fig 20-11 The semiadjustable articulator simulates mandibular movements more closely than the simple hinge articulator.

To verify the accuracy of the relationship of the mounted casts, the patient's occlusal contacts should be checked intraorally with shimstock. If a small discrepancy exists between the patient's occlusal contacts and those on the mounted casts, the casts can be corrected with shimstock, thin articulating paper, and a carving instrument. If the discrepancy is great, it will be necessary to remount the casts. If the casts are mounted accurately and the casting is correctly fabricated, minimal adjustment will be necessary at the placement appointment.

Types of Cast Restorations

The variety of cast r oronal restorations)

Dentlearn.ir

to complete-coverage castings (restorations that cover the entire coronal surface of the tooth) (Fig 20-12). Onlays and partial-coverage castings are hybrids that possess both intracoronal and extracoronal features. The design chosen should be the one that removes the least amount of sound tooth structure while restoring the missing tooth structure and enabling the tooth to withstand functional and parafunctional forces.



Fig 20-12*(a to d)* A variety of designs possible with gold inlay, onlay, partial-coverage, and full-coverage restorations.

Inlay

The gold inlay is a treatment option for moderate-sized Class 1 or Class 2 caries lesions. Although used less frequently than in the past, the inlay has a long history of success. It is not uncommon to see a patient who has multiple inlays that are 30 years old and still clinically serviceable.[9]

Inlays are entirely intracoronal restorations, most commonly with occlusal and proximal extensions (Fig 20-13). When performed with attention to detail and a commitment to skillful execution, inlays can be excellent options for the restoration of caries lesions or defective restorations (Figs 20-14 to 20-16).

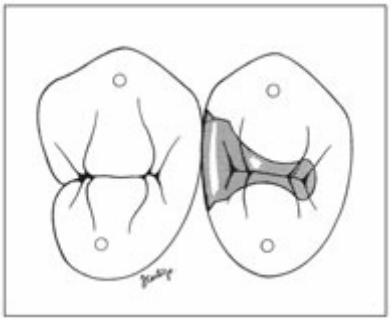

Fig 20-13 An inlay is an intracoronal restoration.

Dentlearn.ir



Fig 20-14 Conservative inlays in the maxilla.



Fig 20-15 Occlusolingual inlay.

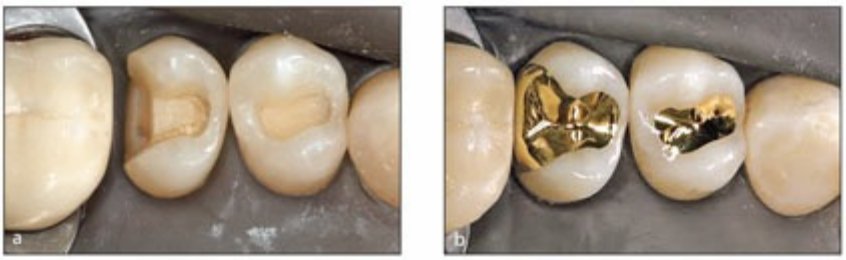

Fig 20-16*(a)* Conservative disto-occlusal and occlusal preparations for cast gold inlays; *(b)* completed restorations after cementation and finishing.

Preparations should be as conservative as possible to maintain tooth strength. If the occlusal width of the preparation exceeds one-third to one-half the buccolingual intercuspal distance, a restoration offering more protection for the cusps, such as an onlay, should be planned.[40] The occlusal contacts should be entirely on gold or enamel, not on a margin of the restoration.

Block-out technique

After the tooth to be treated has been properly diagnosed and treatment planned as requiring a casting, the operative site is isolated, typically with a rubber dam. The existing restoration and caries are removed using carbide burs in a high-speed handpiece for initial depth and outline form, followed by round burs in a low-speed handpiece or spoon excavators for dentinal caries removal. Obtaining a stain-free dentinoenamel junction is a key objective in this step of cavity preparation. The open

Dentlearn.ir

cavity should then be meticulously inspected for cracks, especially for those under cusps or which traverse the tooth mesiodistally or faciolingually. The presence of cracks may require a redesign of the intended restoration to include the coverage of cusps or even the conversion of the preparation and subsequent restoration to a more substantively retentive and resistant restoration, such as an MOD onlay, a three-quarters or seven-eighths crown, or even a full-veneer crown. This flexibility in the operator to change the definitive restorative design demonstrates an appropriate critical-thinking approach to surgical intervention. The next step in the block-out technique is placement of a liner in the deep dentinal areas, followed by filling the cavity nearly to the cavosurface margin with either a composite resin (which may be adhesively bonded) or a reinforced glass-ionomer restorative material. Once the block-out is complete, the operator has a clean start upon which to initiate the following preparation steps. The completed preparation will leave the block-out material only in areas that were previously occupied by dentin, and only for the purpose of avoiding preparation undercuts. All enamel should be supported by dentin, not the block-out material. Figure 20-17 illustrates use of the block-out technique.



Fig 20-17*(a and b)* A completed preparation for a mesio-occlusodistal lingual (MODL) partial onlay showing the use of a block-out material, which serves as a dentin replacement while allowing enamel to be supported by dentin and facilitates a conservative definitive restoration.

The block-out technique provides several additional advantages when used with indirect restorations: *(1)* allows for a more conservative preparation by blocking out dentin undercuts[130]; *(2)* provides the operator with the opportunity to achieve smooth walls of even depth; *(3)* enhances the visibility of all preparation details; and *(4)* improving the seating and fit of the definitive restoration.[131]

Occlusal preparation

Initial entry is made in the central fossa with a tapered fissure bur to establish the pulpal floor (Fig 20-18a). Theoretically, the ideal occlusal depth is 1.0 mm in dentin or 2.5 mm at the triangular ridges. Depth is ultimately determined by the extent of

Dentlearn.ir

existing caries lesions or restorations or the need for additional retention. The occlusal outline is extended mesiodistally along the central groove and stopped just short of the marginal ridge. The bur is held vertically in the long axis of the tooth throughout the preparation. This position and the bur's taper provide the 3- to 5-degree divergence of the facial and lingual walls (total divergence of 6 to 10 degrees) toward the occlusal aspect of the tooth (Fig 20-18b). For two-surface inlays (mesio-occlusal or disto-occlusal), the placement of an occlusal lock or "dovetail" near the marginal ridge will provide a geometry that will resist proximal displacement. The adjacent proximal contact will not provide long-term retention and resistance because teeth move as a result of periodontal ligament compression under normal occlusal loads. When a definite dovetail is not possible because of

incorporated into the preparation design. The placement of either of these auxiliary features will provide the necessary resistance and retention forms to resist proximal displacement.

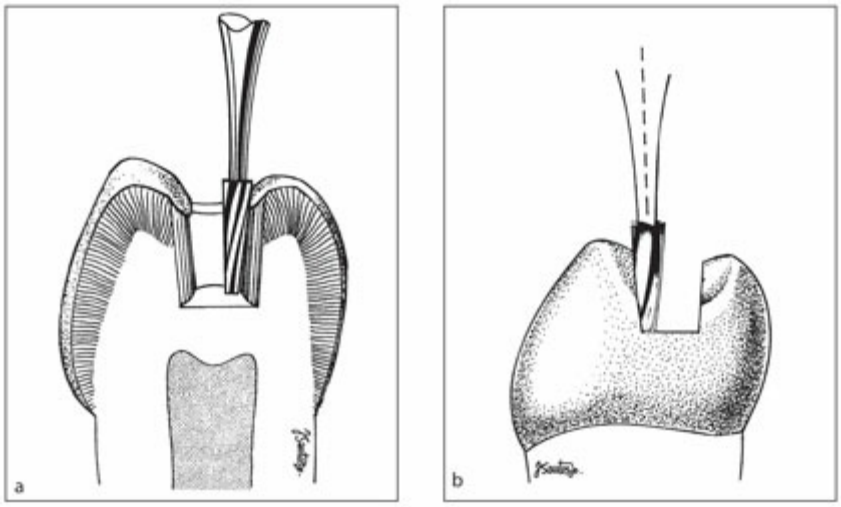

Fig 20-18*(a)* The correct pulpal depth for an inlay is established with a tapered fissure bur. It can

used to help establish the desired occlusal divergence of the walls.

Integral pins and slots

The placement of a pin is a simple two-step process. After identification of an area adjacent to the intact marginal ridge on the pulpal floor, the first step requires the placement of a countersink in dentin with a no. 2 or 4 round bur, to a depth of one-half the bur diameter. This countersink will aid in the placement of the next feature, which is a pinhole. The countersink will also give additional strength to the pin in the finished casting by adding a bulk of gold adjacent to the relatively small integral pin-retentive feature. Pinholes have been historically placed with twist drills of

Dentlearn.ir

various diameters, ranging from 0.5 to 0.7 mm, to a depth of 1.5 to 2.0 mm. The parallel pin technique, developed by Shooshan,[132] required the use of nylon impression pins and slightly smaller nylon castable pins, which were then incorporated into the wax pattern and hence the final casting. Because of the difficulty of obtaining nylon parallel pins today, another technique employs the use of a no. 169L bur, which has the advantage of creating a divergent pinhole, which may be captured in the impression by injecting the hole with impression material and ensuring that no air bubbles are trapped. Air may be vented out of the pinhole during impression taking with the use of a small (30-gauge) anesthetic needle, which is placed in the hole while the impression material is simultaneously injected into the hole. The needle is withdrawn after the material has filled the retentive pinhole.

dentinoenamel junction and are placed in dentin with a no. 169L bur. Slots will typically measure 1.0 to 2.0 mm in width (faciolingually) and are as narrow as the no. 169L bur at a depth of 1.5 to 2.0 mm. They are similar to pins, but they are bulkier and do not require the countersinks described above for pins (Fig 20-19a). Impression taking for slots may utilize the venting technique described above to capture the details of the retentive feature in the impression[133] (Figs 20-19b and 20-19c).



Fig 20-19*(a)* A mesio-occlusal inlay preparation with a slot-retentive feature placed instead of widening the dovetail. *(b)* Use of a 30-gauge needle to vent out the air while simultaneously injecting impression material into the slot. *(c)* Completed impression of a mesio-occlusal premolar inlay with a slot and a distolingual canine inlay with a Shooshan pin.[132]

Dentlearn.ir

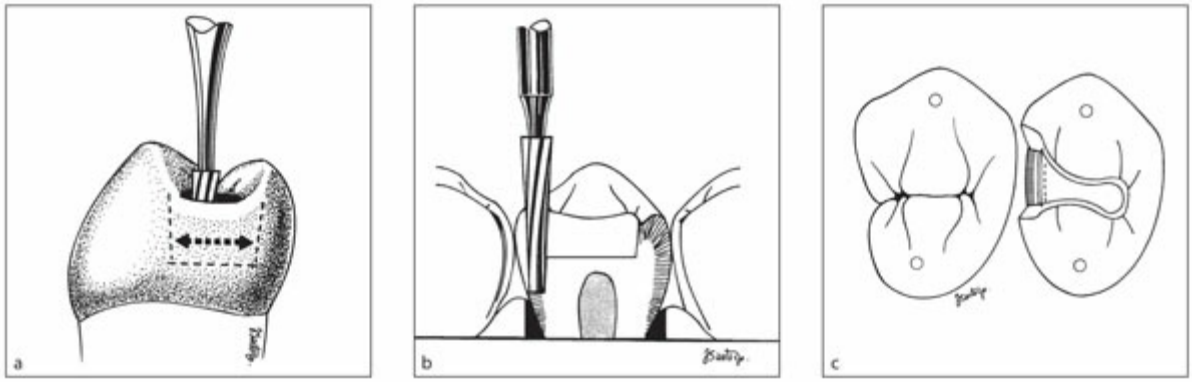

Fig 20-20*(a)* A thin layer of enamel is left on the proximal surface to protect the adjacent tooth while the proximal box is being prepared. *(b)* A flat gingival floor with an axial wall with slight convergence to the occlusal is created. The gingival floor is established occlusal to the gingival tissue, unless otherwise dictated. *(c)* The gingivoaxial line angle is made an even depth into the tooth from the facial to the lingual wall, and the axial wall converges occlusally.

A general guideline for the placement of either slots or pinholes is to place them as far from the primary retentive aspect of the preparation (the proximal box) as possible.[134] It is critical to place integral retentive elements along the line of draw of the preparation, thus avoiding undercuts.

Proximal boxes

The tapered fissure bur is used to create mesial and/or distal proximal boxes. A thin layer of proximal enamel is left to protect the adjacent tooth while the proximal box is formed (Fig 20-20a). The faciolingual dimension is determined by any existing restoration or caries lesion and the relationship of the proximal surface to the adjacent tooth. The gingival floor of the box should have an axial depth of approximately 1.0 to 1.5 mm. Ideally, the gingival extension should be established just apical to the proximal contact (Fig 20-20b). However, the presence of a caries lesion or an existing restoration, or the need for a longer wall to ensure adequate retention, may require extension to a subgingival location. The contour of the axial wall of the box should follow the faciolingual contour of the external surface of the tooth (Fig 20-20c). The box should extend to the facial and lingual borders of the contact area, and the bevels should extend the preparation slightly beyond the box. This extension allows access to the gold margins facially and lin-gually for finishing with a disk.

Refinement

All of the preparation floors and walls should be smooth, all walls except the axial

Dentlearn.ir

walls should be divergent occlusally, the axial walls should be convergent

18). It is critical that no undercut area exists that could interfere with placement and withdrawal. All cavosurface margins must be distinctly defined (Fig 20-21).

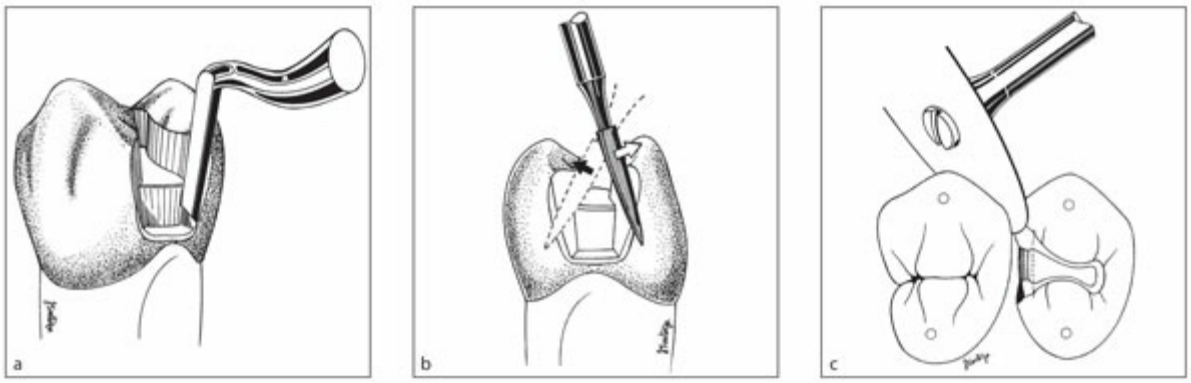

Fig 20-21*(a)* A hand instrument, such as an enamel hatchet, is helpful in smoothing the walls of the preparation. *(b)* The facial and lingual proximal bevels or flares should be established slightly beyond the contact area and blended with the gingival bevel. *(c)* A rotary disk, placed at an angle of 45 degrees, can provide a smooth, flat bevel without undercuts.

Cavosurface bevels

The proximal bevel or flare is established on the facial and lingual walls of the box with a garnet disk, a no. 7901 bur, or a thin, flame-shaped diamond bur (see Figs 20-21b and 20-21c). A finishing bur or diamond bur must be used carefully to avoid developing an undercut in the facial and lingual walls at the faciogingival or linguogingival line angle. An undercut is less likely to occur when a disk is used (see Fig 20-21c). The walls of the preparation should diverge from the gingival floor in the occlusal direction. The proximal bevels should blend smoothly with the gingival and occlusal bevels.

A no. 7901 finishing bur or a thin, flame-shaped diamond bur is used to place 0.5-mm-wide occlusal, proximal, and gingival bevels along the entire cavosurface finish line (Figs 20-22a and 20-22b; see also Fig 20-21b). It may not be possible to place an occlusal bevel if there is a steep incline to the inner cuspal incline. The steep incline may essentially mimic the angle at which the occlusal bevel would normally be placed (Figs 20-22c and 20-22d). A gingival margin trimmer may also be used to place the gingival bevels if access is too limited to use a bur. The bevels should be at an angle of approximately 45 degrees to the external surface of the tooth.

Dentlearn.ir

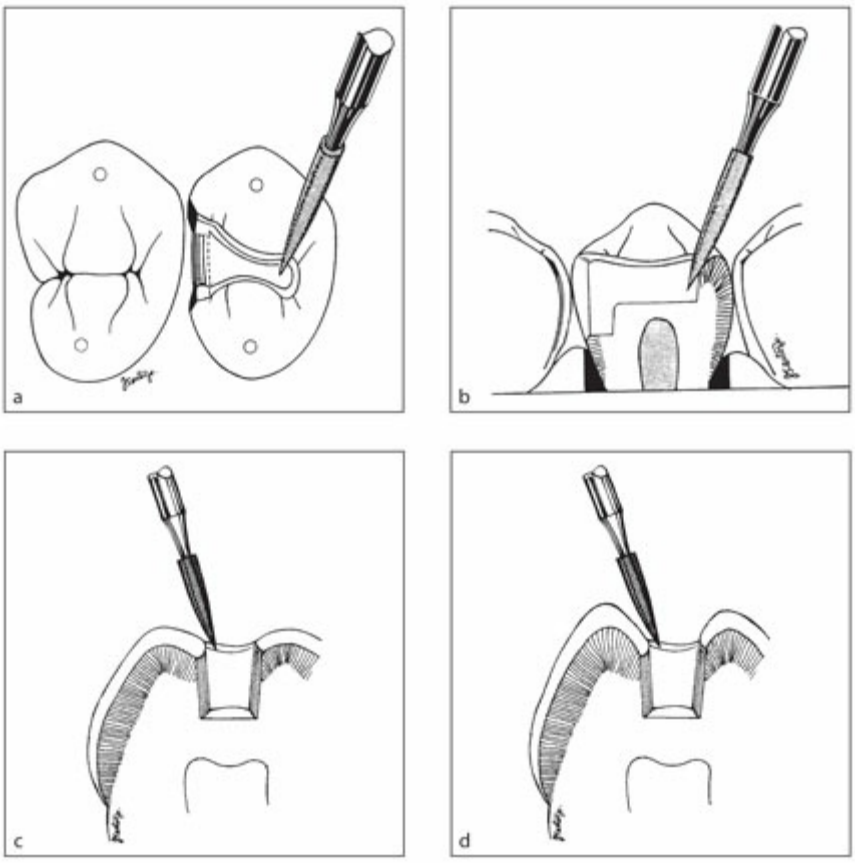

Fig 20-22*(a)* A thin, flame-shaped diamond or finishing bur is used to create a short but distinct bevel at the occlusal finish lines. *(b)* The bevel is extended across the entire occlusal margin and blended with the other bevels. *(c)* An occlusal bevel can be readily placed with a normal or shallow inner cuspal incline. *(d)* It is not possible to place an occlusal bevel with a steep inner cuspal incline because the bevel is essentially parallel to the slope of the cusp.

Retention grooves

If retention grooves are needed to provide additional retention and resistance form, a no. 169 tapered fissure bur is used to place them to bisect the facioaxial and linguoaxial line angles of the box (Fig 20-23). The grooves must diverge toward the occlusal aspect in a facial and lingual direction, and the axial walls should converge occlusally.

Dentlearn.ir

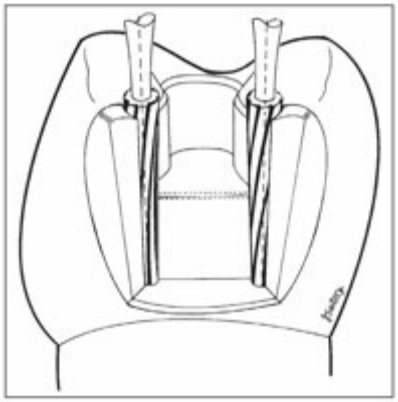

Fig 20-23 The tapered fissure bur (no. 169) is positioned at an angle to give an occlusal divergence for the retentive grooves. The grooves should be at a depth of one-half the diameter of the bur.

Onlay

The onlay is essentially an inlay that covers one or more cusps. A complete onlay covers the entire occlusal surface; a partial onlay covers only a portion of the occlusal surface. The onlay incorporates the principles of both extracoronal and intra-coronal restorations. Although it is generally more conservative than a partial- or complete-coverage crown, it provides the same protection of the remaining tooth structure (Fig 20-24).



Fig 20-24 Onlays on the maxillary premolars provide protection to the facial and lingual cusps while demonstrating minimal display of gold. (Courtesy of Mark Cruz, Monarch Beach, California.)

There are several important features of the preparation. All finish lines are beveled. A bevel or flare creates a second plane designed to allow, with burnishing, close adaptation of the gold to the tooth. A beveled shoulder is used for the centric holding cusps (palatal cusps of maxillary posterior teeth and buccal cusps of mandibular posterior teeth), and a long bevel or chamfer is used for the noncentric cusps. The gingival margin and the facial and lingual walls of the proximal boxes are designed like those for the inlay, with their well-defined bevel or flare. These finish lines are blended to form an uninterrupted finish line around the entire preparation. The gingival floors of the proximal boxes are essentially beveled

Dentlearn.ir

shoulders.

The width and depth of the occlusal portion of the preparation and of the proximal boxes are often dictated by the presence of an old restoration and/or a caries lesion. If additional resistance and retention form are needed, retention grooves may be placed at the axiofacial and axiolingual line angles.

A tapered fissure bur is recommended for preparing the outline form because its taper helps to establish the desired total occlusal divergence of 6 to 10 degrees for

toward the occlusal surface.

Occlusal preparation

The initial entry is made in the central fossa to a depth of approximately 1.0 mm into dentin (total depth of approximately 2.5 mm in the tooth). In some cases, it may be necessary to extend some portions of the preparation to a greater depth because of carious dentin or a previous restoration or for additional retention. The occlusal outline form is extended by moving the bur laterally, cutting with the side of the bur. The occlusal outline form should be as conservative as the caries lesion or old restoration permits. The bur is kept in the long axis of the intended path of insertion so that the taper of the bur provides the desired 3- to 5-degree divergence for each

Proximal boxes

The boxes are created on the proximal surfaces. The facial and lingual walls should exhibit a combined divergence occlus-ally of 6 to 10 degrees from each other as was provided in the occlusal area of the preparation (Fig 20-25a). The faciolingual dimension is likely to be determined by the presence of a restoration, caries lesion, and/or the relationship of the proximal surface to the adjacent tooth (Fig 20-25b). The bevels at the facial and lingual cavosurface angles will extend the preparation slightly beyond the proximal contact area so that the margins of the restoration will be accessible for finishing with a disk (Fig 20-25c).

Dentlearn.ir

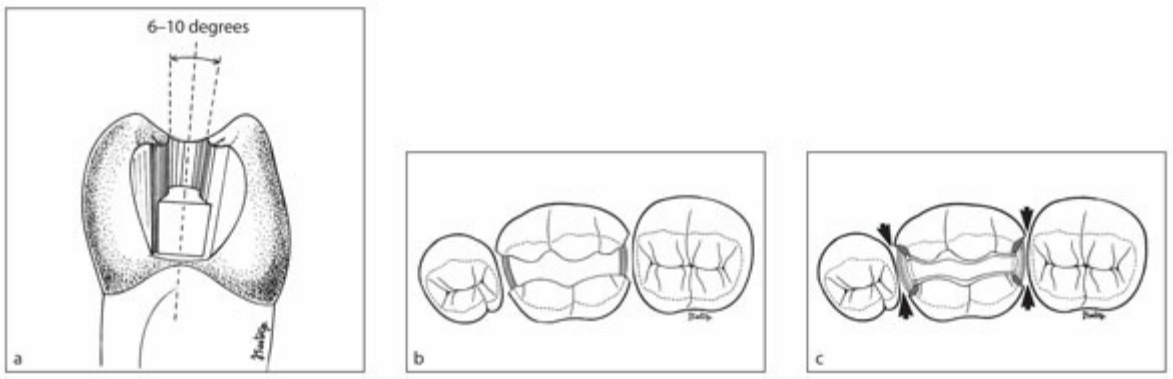

Fig 20-25*(a)* Ideally, opposing walls diverge 6 to 10 degrees for the inlay and onlay preparation. *(b)* The proximal box is extended to or slightly beyond the contact area. Bevels will provide the desired proximal clearance. *(c)* After the bevels are placed, there is access for completing the preparation's finish lines and the margins of the restoration.

Cuspal reduction

A carbide or diamond bur is used to reduce the cusps. Depth cuts of 1.5 to 2.0 mm are made for the centric (vertical holding) cusp(s), and cuts of 1.0 to 1.5 mm are made for the noncentric cusp(s) (Fig 20-26a). A bur with a measured diameter is used to gauge the depth of the cuts. The side of the bur is held parallel to the cuspal inclines to make the depth cuts. After the depth cuts are placed, a uniform reduction of the cusps that parallels the general anatomical contours of the occlusal surface is made. The cuspal heights are reduced to the full extent of the depth cuts (Figs 20-26b and 20-26c). Reduction for the centric holding cusps is generally greater than that for the noncentric cusps because less thickness of the restoration is needed to withstand occlusal forces exerted against a noncentric cusp.

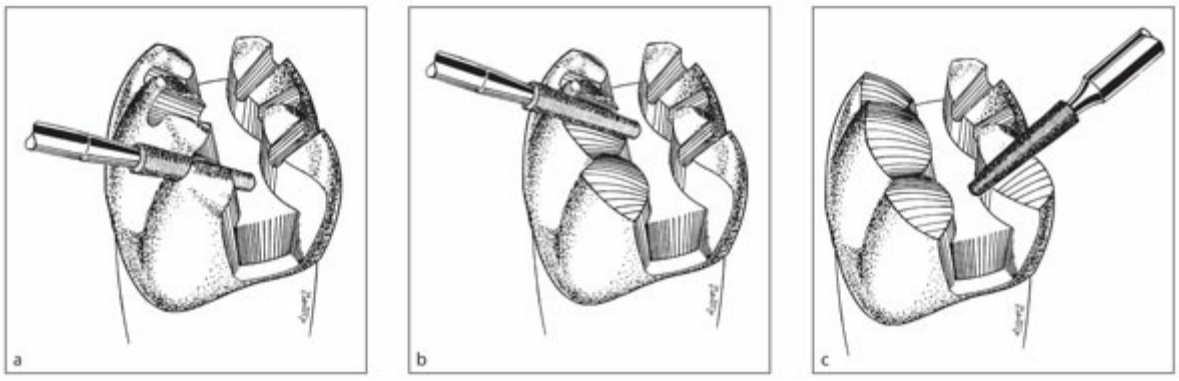

Fig 20-26*(a)* A bur of known diameter is used to establish depth cuts to guide the correct reduction of the cusps: 1.5- to 2.0-mm-deep cuts on centric holding cusps and 1.0- to 1.5-mm-deep cuts in noncentric cusps. *(b)* The buccal cusps are reduced in accordance with the occlusal anatomy of the tooth. *(c)* The lingual cusps of the mandibular teeth require less reduction because they are not holding cusps.

Dentlearn.ir

Shoulder preparation

A shoulder is prepared on the external surface of the centric cusp to provide a band of metal (ferrule) to protect the tooth. The bur is held parallel to the external surface of the tooth to prepare a shoulder about 1.0 mm in height and 1.0 mm in axial depth (Fig 20-27). The finish line should extend gingivally at least 1.0 mm beyond any occlusal contacts. The occlusoaxial line angles are rounded. There must be adequate (1.0- to 1.5-mm) clearance in all eccentric mandibular movements.

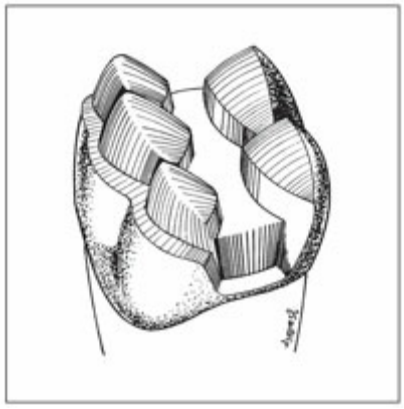

Fig 20-27 The shoulder should have precise line angles.

Noncentric cusp

A chamfer or long bevel may be used instead of a shoulder on the noncentric cusp(s). The bur is positioned at an angle of approximately 45 degrees to the axial surface (Fig 20-28). This provides a ferrule effect for additional protection of the cusp.

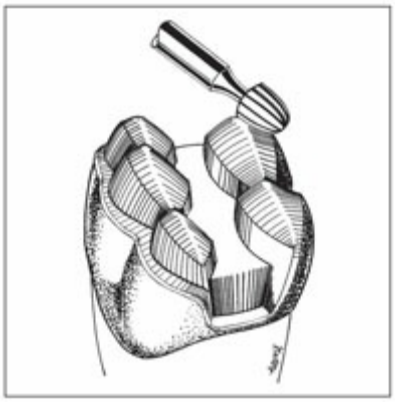

Fig 20-28 A barrel-shaped bur can be used to create the chamfer on the noncentric cusp(s).

Gingival bevel

A smooth and distinct bevel is established on the gingival margins with a no. 7901 finishing bur; a thin, flame-shaped diamond bur; or a gingival margin trimmer. If a

Dentlearn.ir

gingival margin trimmer is utilized, it should be positioned so as to create a 45-degree angle to the blade. This bevel should be approximately 0.5 to 1.0 mm in width and at an angle of approximately 45 degrees to the external surface of the tooth.

Shoulder bevel

A 0.5- to 1.0-mm bevel is placed on the shoulder with a no. 7901 or fine diamond bur. This bevel is blended with the proximal bevels. Any corners or sharp angles at the junction of the various bevels and across the occlusoaxial line angles are eliminated (Fig 20-29).

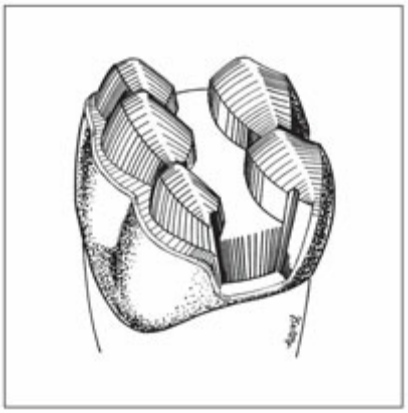

the walls have the correct taper, the grooves are correctly positioned, and the finish lines are smooth and continuous.

Proximal bevels

The proximal bevel or flare is established with a garnet disk; a fine, flame-shaped diamond bur; or a no. 7901 bur. Creation of an undercut during beveling at the faciogingival or linguogingival line angles must be avoided. Divergence is established from the gingival floor occlusally. The proximal bevels should blend smoothly with the gingival bevel and the buccal and lingual bevels.

Retention grooves

If retention grooves are needed, they can be placed in both proximal boxes. A no. 169 bur is used to bisect the facioaxial and linguoaxial line angles. The grooves must diverge toward the occlusal aspect faciolingually and converge toward the

Dentlearn.ir

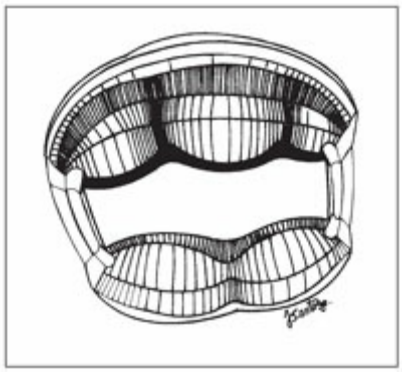

Fig 20-30 The retention grooves are placed at the linguoaxial and facioaxial line angles but do not undermine the enamel.

Partial-coverage crown

The partial-coverage crown, or partial veneer crown, covers only a portion of the outer circumference or axial surfaces of the tooth and completely covers the occlusal surface. For instance, a three-quarters crown has three of the four axial surfaces covered by the restoration, usually leaving the facial axial surface unprepared, except at its occlusal extent; this is to preserve the facial surface for esthetics. A seven-eighths crown, usually used for maxillary molars, covers three and one-half of the four axial surfaces, usually leaving the mesiofacial half of the facial surface of the tooth unprepared. Leaving part of the external surface of the tooth uncovered offers several potential benefits. It conserves tooth structure and avoids potential insult to the periodontium adjacent to the unrestored tooth surface.[95] The uncovered tooth surface allows for pulp testing.[128] Preservation of the facial surface eliminates the need to match the shade of the adjacent teeth with a ceramic material. Because it is not necessary to veneer the casting with a tooth-colored material, the laboratory procedures are simplified.[135]

Retention and resistance of the partial veneer crown are provided by a combination of extracoronal and intracoronal features. The extracoronal retention is created by opposing axial walls on the mesial and distal surfaces that have a combined convergence toward the occlusal of approximately 6 to 10 degrees. This is supplemented with grooves or boxes in the proximal walls that provide not only added retention but also resistance to lingual displacement. A slight overlay of the facial cusp protects it from fracture and provides some resistance form.

The extensions of the proximal and facial portions of the preparation can vary in design according to the specific needs. If the tooth is located so that the facial cusps are readily visible, esthetic concerns may dictate a modification of the standard

Dentlearn.ir

design to conceal the gold. In such cases, the mesial proximal wall is extended toward the facial surface only far enough to barely break contact. Reduction of the mesial incline of the mesiofacial cusp of molars and the mesial incline of the facial cusp of premolars is limited. The distal incline is reduced more to provide protection and the ferrule effect. This more esthetic design is shown in Fig 20-31.

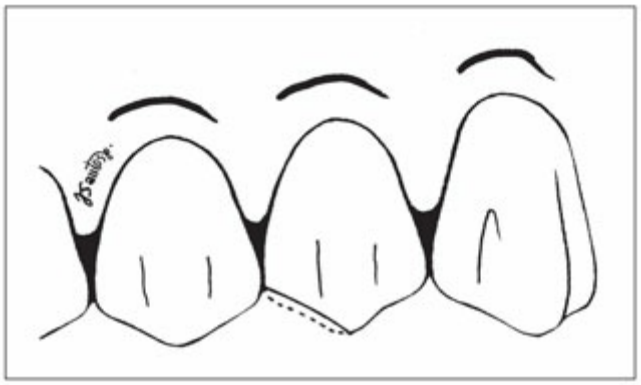

Fig 20-31 Limited reduction of the mesiofacial incline of the facial cusp and greater reduction of the distofacial incline of a maxillary tooth provide some protection to the cusp while limiting the display of gold in a partial-coverage restoration.

Because partial-coverage crowns are infrequently placed on anterior teeth, this section focuses on the posterior teeth.

Occlusal reduction

Depth cuts are made by laying the side of the bur (of measured diameter) against the cuspal inclines (Fig 20-32a) and reducing them to the desired depth (Fig 20-32b). The total reduction of the centric cusp should be 1.5 to 2.0 mm, and that of the non-centric cusp should be 1.0 to 1.5 mm. The remaining occlusal surface is reduced, but the general anatomical contours are maintained (Fig 20-32c). As previously mentioned, less reduction may be desirable in some areas for esthetic reasons. The

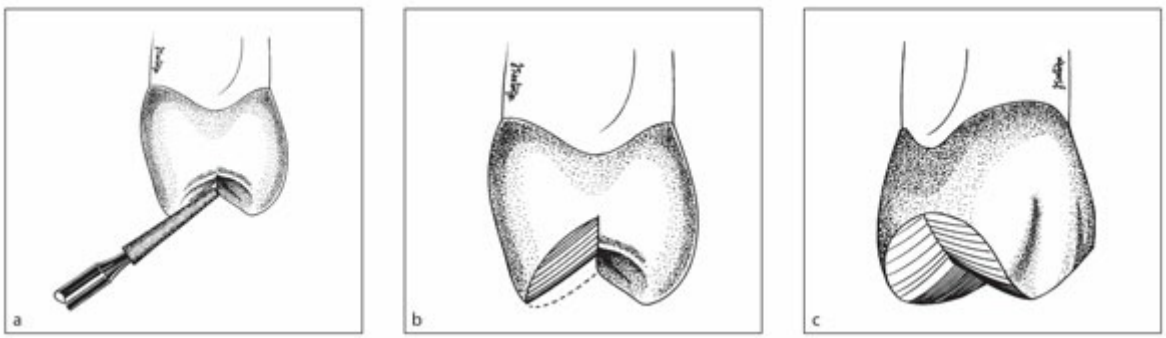

Fig 20-32*(a)* The diamond bur is held at the same angle as the natural slope of the cusp to create an even occlusal reduction for partial-coverage crowns. *(b)* Removal of 1.0 to 1.5 mm of tooth

Dentlearn.ir

structure from the noncentric cusp serves as a guide to reducing the rest of the occlusal surface. *(c)* The occlusal reduction has followed the original contours of the occlusal surface.

Lingual reduction

The axial wall of the lingual surface is reduced with a round-ended tapered diamond bur. Close attention must be paid to the desired path of insertion to establish parallelism. A two-plane reduction of the tooth is needed to maintain natural contours. Because of the anatomical differences in the lingual contours of the maxillary and the mandibular teeth, the second plane on the lingual surface of a maxillary tooth will be more pronounced. The gingival portion of the lingual surface should have a 3- to 5-degree convergence occlusal to the path of insertion (Fig 20-33), and the second plane should be offset about 30 degrees.

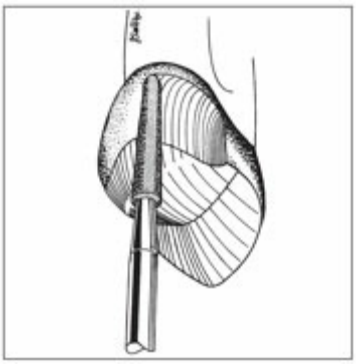

Fig 20-33 The round-ended tapered diamond bur is very effective in creating the proper taper and in creating a chamfer finish line.

Proximal reduction

The proximal surfaces are reduced in one plane. A 3- to 5-degree taper is established from the finish line to the occlusoaxial line angle. Space limitations may require use of a thin tapered diamond bur initially until enough space has been created to use a round-ended tapered diamond bur. The round-ended diamond bur has a more appropriate shape to create a chamfer finish line (Fig 20-34).



Fig 20-34 The lingual contours and finish line should be carried into the proximal surfaces. Lack of access may require use of a thinner diamond bur initially.

Dentlearn.ir

Finish lines

The junction of each proximal wall and the lingual wall is blended so that there is a smooth transition. This procedure is especially important at the finish line. The gingival finish lines are placed slightly coronal to the gingival tissue if possible. The presence of caries lesions or existing restorations may alter the level of finish line placement, but, regardless of where the finish line is located, the transition should be smooth and well defined. For the buccal finish line of partial-coverage crowns for maxillary teeth, several different configurations may be used, balancing the need for resistance form and facial esthetics (Fig 20-35).

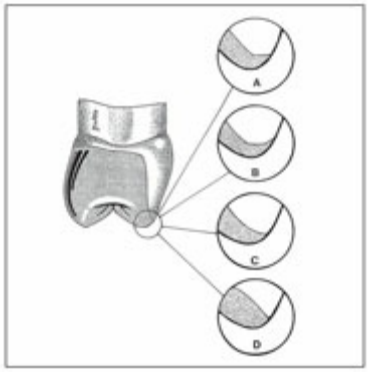

Fig 20-35 Several occlusobuccal finish lines for maxillary partial-coverage crowns—flat bevel (A), contrabevel (B), and knife-edged (C)—are acceptable finish lines. A bevel is not absolutely necessary with adequate enamel support; however, the finish line in D would compromise finish and resistance form with unsupported enamel, making a bevel necessary. (Redrawn from Shillingburg et al,[136] after Ingraham et al[137] and Richter and Ueno.[84])

Proximal grooves

The grooves are initiated in the proximal areas with a no. 170 bur (or a no. 169 bur for a small tooth). The grooves are located as far facially as possible without undermining the facial enamel. It may be helpful to mark the proposed location of the grooves before they are prepared (Fig 20-36). Because the grooves must have a path of draw compatible with each other and with the axial walls, their angulation must be carefully planned before they are begun. As a general rule for posterior teeth, the grooves should be parallel to the long axis of the tooth (Fig 20-37a). The axial walls of the two grooves should converge occlusally. Failure to align the grooves correctly will result in a preparation that does not have an acceptable path of insertion (Figs 20-37b and 20-37c).

Dentlearn.ir

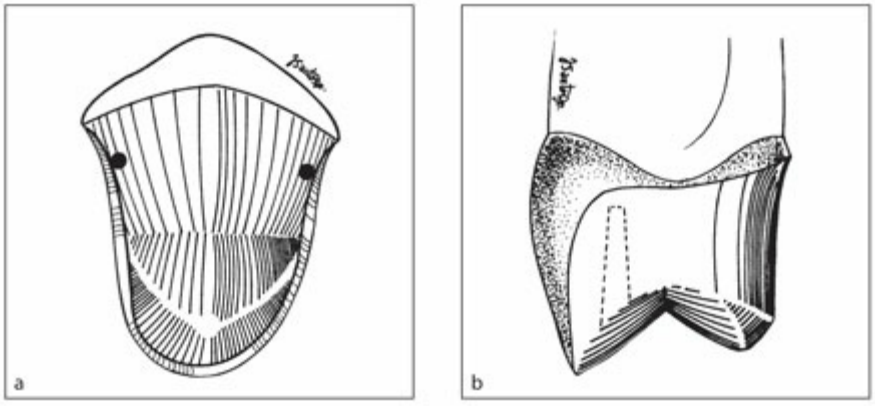

Fig 20-36*(a)* Before the proximal grooves are prepared, their desired location is marked with a pencil or an indentation made by a bur. This aids in obtaining the correct faciolingual location. *(b)* The angulation of the proximal groove is equally important, so visualization is critical.

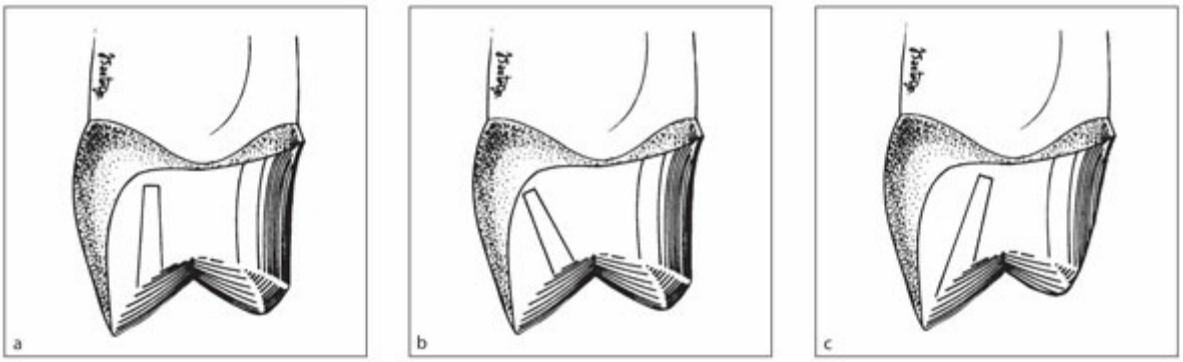

Fig 20-37*(a)* Alignment of the proximal groove with the long axis of the tooth provides the best compatibility with the rest of the preparation design. *(b)* This proximal groove is angulated too much toward the lingual surface and will not provide adequate resistance to lingual rotation. *(c)* This proximal groove is angulated too much toward the facial surface, creating an undercut in relation to the lingual surface of the preparation, thus interfering with the path of insertion.

The axial depth of each groove is made equal to or slightly greater than the diameter of the no. 170 bur. After the first proximal groove is cut, the groove on the opposite side of the preparation is cut in the same fashion so that it aligns with the first groove and with the axial walls (Fig 20-38). The grooves may be enlarged, and

many cases, a box form is present after the removal of an existing restoration. Existing boxes may be modified and incorporated in the preparation in lieu of grooves (Fig 20-39).

Dentlearn.ir

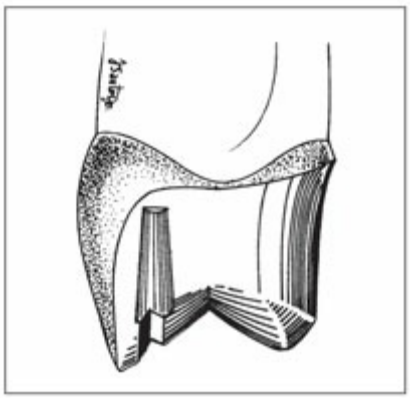

Fig 20-38 Properly designed and placed proximal groove.



Fig 20-39 A groove is located on one proximal surface and a box on the other. Both meet the requirements for occlusal divergence of the facial and lingual walls and convergence of the axial wall toward the opposite proximal wall. The groove has a pronounced lingual wall to enhance resistance to lingual displacement.

In those circumstances where esthetics is a significant consideration, typically for maxillary premolars, less reduction of the facial cusp is desired to reduce the display of gold. This often necessitates that the preparation of the lingual slope of the facial cusp is less than 1.0 mm, with a minimal facial cusp bevel. For this situation, the resistance form and strength of the restoration can be enhanced by preparation of

removed. If not, it may be prepared. A flat-ended tapered carbide or diamond bur is

allows the space for a “staple” of thicker metal in the restoration that resists lingual displacement and helps the restoration resist deformation under pressure (Figs 20-40 and 20-41).

Dentlearn.ir

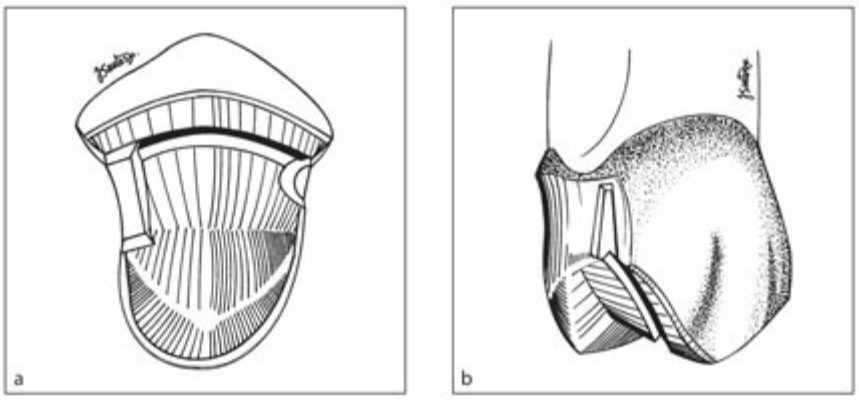

it comes across the occlusal surface to connect to the proximal groove. Also note the small facial bevel.



Fig 20-41 In the mandible, the centric holding cusp requires a facial design similar to that of the onlay preparation.

Facial bevel

Placement of the facial finish line differs in the maxillary teeth and the mandibular teeth. Because the maxillary facial cusp is usually the noncentric cusp, only a 1.0-mm layer of metal, or less, and a short bevel are required to protect the cusp (see Fig 20-40). Placement of a shoulder and a bevel are recommended for the facial cusp in mandibular teeth to help restorations withstand the forces on centric cusps. A shoulder extending 1.0 mm occlusogingivally and 1.0 mm deep axially is placed into the facial surface across the facial cusp with a straight fissure bur held parallel to the external surface of the tooth (see Fig 20-41). A 0.5- to 1.0-mm-wide bevel is placed with a fine diamond or finishing bur. The finish line should be placed gingival to any occlusal contacts.

Final refinement

Dentlearn.ir

All the sharp external angles of the preparation are rounded. Sharp angles make it more difficult to pour the stone into the impression without bubbles. Even if the die is poured without bubbles, it has fragile edges that are easily abraded during laboratory procedures. After all the angles of the preparation are rounded, the surfaces are smoothed with a fine-grit diamond bur. Figure 20-42 illustrates some completed preparations.

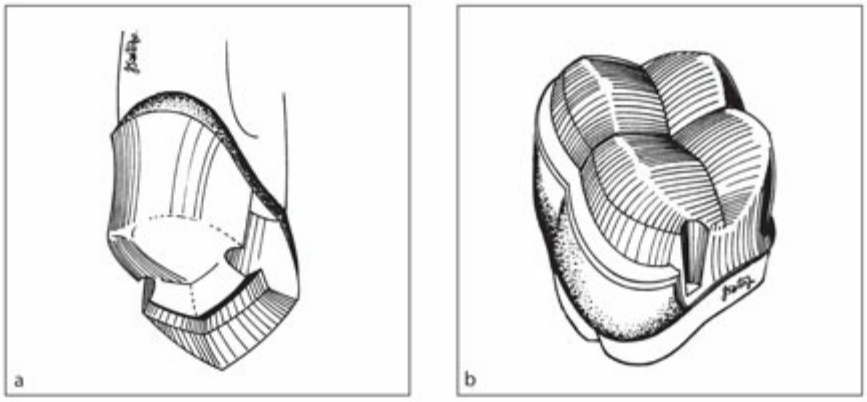

Fig 20-42 Preparations for partial-coverage crowns require the same refinement of walls, floors, and bevels as are needed for inlay and onlay preparations. *(a)* Maxillary premolar preparation. *(b)* Mandibular molar preparation.

Complete-coverage gold castings

As its name implies, the complete-coverage, or full veneer, casting includes coverage of the entire coronal portion of the tooth. Extensive loss of tooth structure is the most common indication for a complete-coverage restoration. For esthetic reasons, this restoration tends to be limited to molars. Because the restoration involves the entire circumference of the tooth, control of occlusal and proximal relationships allows improvements in occlusion and proximal contacts. Correction of tooth positioning is sometimes possible.

Retention is provided primarily or entirely by the extracoro-nal walls. A complete-coverage crown is the most retentive of the casting designs.[138,139] One or more grooves or boxes can be added to the preparation if additional retention and resistance form are needed.

Proximal reduction

A thin tapered carbide or diamond bur is placed at either the facial or lingual embrasure and used to cut proximal tooth structure toward the opposite embrasure (Fig 20-43). The bur should be extended cervically to the desired location of the gingival finish line. Unless a caries lesion, an old restoration, or the need for

Dentlearn.ir

additional retention/resistance features dictates otherwise, the gingival finish line should be established at least 0.5 mm supragingivally. The reduction must be at the expense of the tooth being prepared to avoid damage to the enamel of the adjacent tooth. The reduction, when completed, should taper occlusally 3 to 5 degrees toward the opposing proximal wall. The opposing wall is prepared in the same manner. Once enough space has been created to permit access, a round-ended tapered diamond bur is used to complete the proximal reduction and place a gingival chamfer.

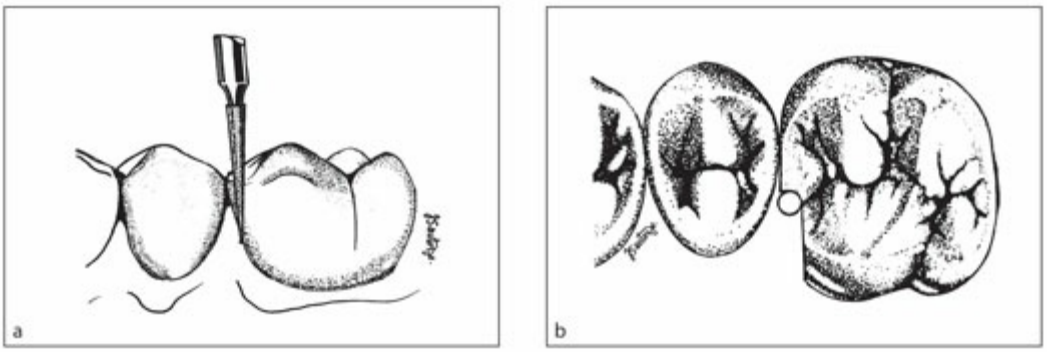

Fig 20-43*(a)* Use of a thin, flame-shaped diamond bur is recommended to initiate the proximal reduction of the preparation for a complete-coverage restoration. *(b)* The reduction is kept within the original contours of the tooth so that abrasion of the adjacent tooth is avoided.

Occlusal reduction

A series of depth cuts is made on the occlusal surface with a diamond or fissure bur. Both the facial and lingual cuspal inclines are cut to a depth of at least 1.5 mm to allow an adequate thickness of metal for strength and wear. An even reduction that follows the original anatomical contours allows the development of the appropriate occlusal anatomy in the restoration.

Facial and lingual reduction

The facial and lingual surfaces are each reduced in two planes to allow reproduction of normal contours in the restoration. The first plane, extending occlusally from the gingival finish line, should have a 3- to 5-degree taper to the path of insertion (Fig 20-44a). The second plane should be angled at 30 to 45 degrees to the first plane to allow desired facial and lingual contours to be reestablished (Figs 20-44b to 20-44d). This second plane should begin at the occlusal third of the wall for the centric cusp and the occlusal fourth for the noncentric cusp. A round-ended tapered diamond bur is used to make these reductions. A modified conservative full-coverage preparation, involving supragingival margins on both lingual and buccal aspects, has

Dentlearn.ir

shown excellent long-term results.[113]

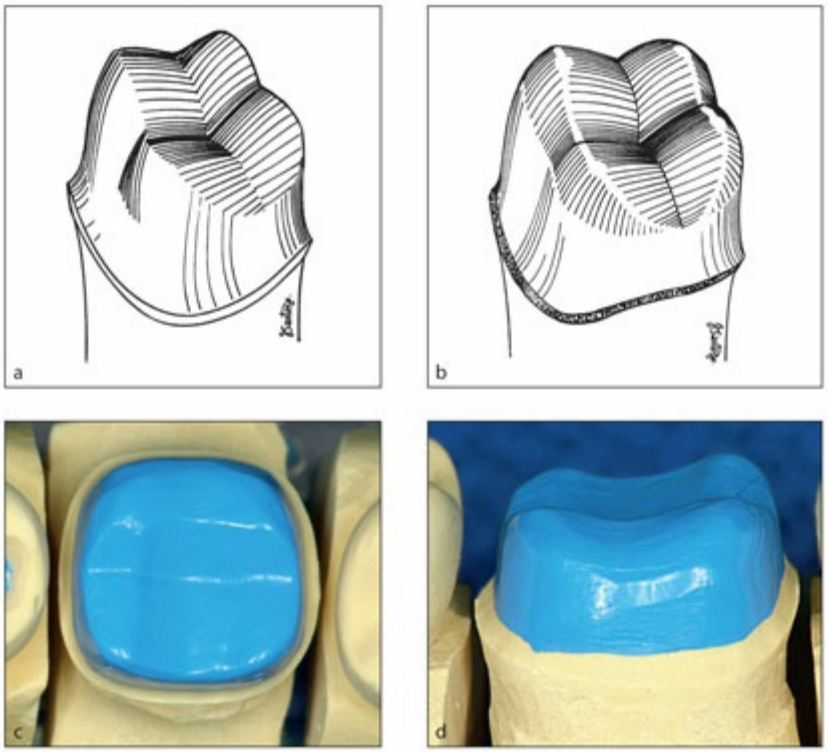

Fig 20-44*(a)* Reduction of the axial walls for a complete-coverage restoration is identical to that for partial-coverage crowns, except the facial wall is also included. At this stage, the facial and lingual walls are each in one plane. *(b)* The second plane is added to the facial and lingual walls. The second plane should be at a 30- to 45-degree angle to the long axis and involves the occlusal third of the centric holding cusp and the occlusal fourth of the noncentric cusp. *(c)* Occlusal view of the die of a full crown preparation (with blue spacer applied) for a mandibular right first molar. *(d)* Facial view of the preparation showing the second plane of reduction.

Refinement

The parts of the preparation are blended to eliminate indefinite areas along the finish line, irregularities in the walls, and sharp corners. A finish line that is distinct around the whole preparation must be established. The facioproximal and linguoproximal line angles often need to be rounded and distinctly defined. All of the sharp corners of the preparation, such as the occlusoaxial line angles, are rounded. The surfaces of the preparation should be relatively smooth. The preparation is viewed carefully from more than one angle to ensure that there are no undercuts within any wall, between the walls, or in relationship to an adjacent tooth.

Try-In

Before the casting is fitted to the prepared tooth, it should be adjusted to fit the

Dentlearn.ir

master die. Research has demonstrated that use of several layers of die spacer can increase the retention of cemented crowns and improve the fit of cemented restorations.[140–142] The intaglio surface of the casting is inspected under magnification for bubbles or other imperfections,[143,144] which can be removed with a small round bur. The die is checked for defects or abraded areas. The casting should not be forced onto the die. If the casting does not seat easily, the die should be sprayed with a disclosing medium, and the crown should then be gently reseated. The disclosing medium should mark areas that are binding on the inside of the casting. These areas can be relieved with a bur (no. 2 or no. 4 round bur). This process is repeated until the casting is fully seated.

Once the casting is fully seated on the die, the interproximal contacts are checked and necessary adjustments made. This is best accomplished on a solid cast, especially if there are multiple castings. The occlusion in maximum intercuspation is adjusted until the restoration holds shimstock equally as well as the adjacent natural teeth. The location and size of the occlusal contacts are marked with articulating paper. A finishing bur, stone, or abrasive disk is used to make any modifications needed. After maximum intercuspation contacts on the restoration are similar to maximum intercuspation contacts on other teeth in the quadrant or arch, if the type of cast articulation is fairly accurate, contacts in excursive movements are marked and

be carefully air abraded with aluminum oxide, avoiding the margins, in preparation for the clinical try-in. Air abrasion provides a dull, matte finish. Any area that binds during intraoral seating of the casting creates a bright, burnished mark. If these steps are accomplished with precision before the patient arrives, minimal chair time should be required for adjustments.

Once adjustments have been made on the cast, the casting is tried on the prepared tooth to determine the fit. Adjustments to the proximal contacts are made if needed.

the casting is reseated. The casting is removed and rein-spected for new shiny spots. This process may need to be repeated several times until the casting is fully seated.

An alternative method to seat castings employs disclosing media. Disclosing media include chloroform and rouge, disclosing pastes or waxes,[145] and impression

the casting, and it is then seated. The casting is removed and inspected for abrasion of the disclosing medium that allows the gold to show through. These areas are adjusted as needed, more disclosing medium is placed, and the casting is reseated. This process is continued until the casting is fully seated.

Dentlearn.ir

The fitting process is completed when the margins are flush against the finish lines of the preparation and there is no binding when the restoration is seated. The casting should fit passively in place. A tight fit usually means the casting is not fully seated. Use of a die spacer medium, painted onto the die to within 0.5 to 1.0 mm of the finish line prior to wax-pattern fabrication, will usually simplify the process of fitting the casting.[146]

Marginal Finishing

Two options exist to complete the finishing of accessible margins of cast gold restorations: *(1)* precementation finishing and *(2)* postcementation finishing.

Precementation finishing

In this option, marginal finishing is done prior to cementation to adapt and polish margins that have already been determined to be satisfactory. The goal is to develop a margin that is adapted to the preparation finish line; extends to, but not beyond, the finish line; and blends with the contours of the tooth.[147] The casting must be fully seated before an attempt can be made to adapt and finish the margins.

Margin location determines whether margin finishing can be done on the tooth. Subgingival and/or interproximal margins are very difficult to reach without damaging the soft tissue, bone, or the tooth itself. For these margins, all finishing must be done on the die. Easily accessible margins can be finished while the casting is seated on the tooth (Fig 20-45). If the margin is tightly adapted but slightly overcontoured or undercontoured, a white stone or abrasive disk can be used in a low-speed handpiece to reduce the protruding surface, whether it is gold or enamel. When finished, the gold margin should be flush with the tooth structure, and adjacent contours of the restoration should be continuous with natural tooth contours.

Dentlearn.ir

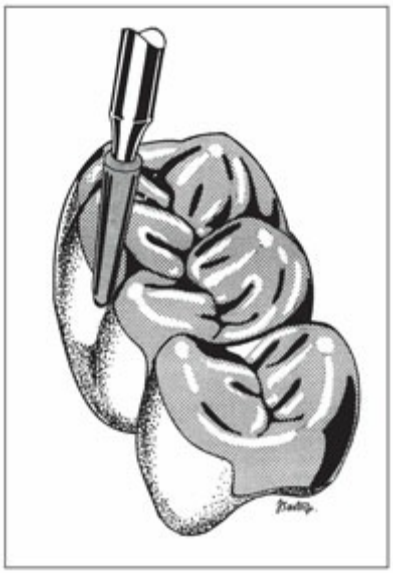

Fig 20-45 A fine diamond bur or finishing stone is held perpendicular to the margin and moved parallel to the margin to reduce small discrepancies in the marginal area.

The best instruments for finishing accessible surfaces are flexible paper disks.[148] Sandpaper disks should not be used to try to close an open margin if the casting is not fully seated. This usually leads to a visible cement line. Rather, the gold casting should be completely seated so that it is brought level to the cavosurface margin. If there is a slightly overextended margin after the casting is completely seated, the use of disks allows the operator to remove the slight vertical excess of gold without creating any gaps or cement lines.[102] The stone or disk should be rotated from the metal to the tooth or parallel to the margin, but never from tooth to gold. Running the rotary instrument from gold to tooth ensures a better seal and prevents the gold margin from being peeled away from the tooth interface. Rubber points or fine-grit abrasive disks may be used to produce a high luster if access permits. Care must be exercised to avoid damage to the soft tissue or abrasion of the tooth surface.

Marginal adaptation can sometimes be improved by hand burnishing, both on the die and on the tooth prior to cementation. Well-controlled pressure is applied with a beavertail or ball burnisher, held adjacent to and moved parallel to the gold margin (Fig 20-46). The burnisher should not be placed directly on the margin. Pressure should be applied with a back-and-forth motion (parallel to the margin) that moves slowly closer to the margin. Because a small area of the burnisher is contacting the gold, a great deal of pressure (force per unit area) is applied. The casting is stabilized during the burnishing process to ensure that it does not change position. It is also critical to have good finger rests to ensure that the burnisher does not slip off the tooth and injure the soft tissue or the tooth itself if the burnishing is done in the

Dentlearn.ir

mouth. Some additional benefit may be achieved by burnishing the margins of the casting on the tooth during the cementation procedure, before the cement sets.[149]



Fig 20-46*(a)* Pressure is applied with the side or tip of the burnisher, which is moved parallel to the marginal area to adapt it more tightly to the tooth. *(b and c)* Mandibular partial-coverage restorations. Note the well-adapted margins that have been burnished.

Cementation

The final step in the process is luting or cementation of the casting. Cement failure has been shown to be the second[150] or third[151] most important factor in the failure of cast restorations. A thin layer of the luting agent (cement) is placed in the casting and on the walls of the preparation, and into any auxiliary retentive features, and the casting is then seated on or in the tooth. Complete seating of the casting should be verified. The cement hardens within a few minutes, and the excess is removed. The luting agent fills the gap between the casting and the tooth to provide retention and to minimize leakage at the margin. Some luting agents, such as zinc phosphate cement, provide retention entirely from frictional resistance to displacement. Others, such as the adhesive resin cements, bond to the tooth and/or the casting to provide adhesion in addition to frictional resistance. It appears that resin cements or resin-modified glass-ionomer cements provide superior retention and have better physical properties than more traditional cements.

However, it is essential to understand that no cement will compensate for inadequate preparation resistance and retention form in the long term. Therefore, when sound preparation design principles can be used, the choice of cement is of little clinical relevance.[152,153] But clinical situations often vary from the ideal, so cement can be of real importance in these cases of compromised resistance/retention form, as suggested by a recent case report of two occlusal onlays, placed on a minimally retentive preparation and cemented with resin-modified glass-ionomer

Dentlearn.ir

cement, that were successfully retained for 6 years.[154] One has to remain prudent as not to draw hasty conclusions that cement will override improper preparation. Sound principles should prevail unless proven otherwise by long-term clinical research.

Postcementation finishing

In this option, a casting that has been determined to be well fitting is cemented and subsequently finished and polished on the tooth itself. The same steps used in the precementation technique are employed after the cement is fully expressed from the casting. This technique affords the operator the advantage of developing a high polish and ideal marginal adaptation simultaneously, without the need to repolish after cementation.

An understanding of the advantages and limitations of each type of cement is relevant and is presented in the following section.

Selection of a luting agent

Options for luting agents today are zinc phosphate, glass-ionomer, polycarboxylate, resin, and resin-modified glass-ionomer cements.[155] Resin cements and resin-modified glass-ionomer cements have gained popularity in recent years, with much of the current research in the area of cements focused on these two materials.

According to surveys,[156,157] there has been a significant shift in routine cement use from zinc phosphate, zinc polycarboxylate, and conventional glass ionomer to resin and resin-modified glass-ionomer cements. More than two-thirds of North American practices have elected resin cements and resin-modified glass-ionomer cements as their first choice. Purportedly, they are superior to zinc phosphate in terms of retention, strength, and solubility and are comparable in terms of film thickness.[158–160]

The type of cement used does not seem to influence the final marginal adaptation. The ease of manipulation and strict adherence to the protocol for each specific luting agent have a more significant impact on the ultimate strength and solubility properties, which, in turn, affect the clinical performance of the definitive restoration.[152,161] Because the indications and procedures for each luting agent are different, they are discussed separately.

Zinc phosphate cement

Dentlearn.ir

Zinc phosphate cement consists of a powder containing 90% zinc oxide and 10% magnesium oxide that is incorporated into a liquid containing approximately 67% phosphoric acid.[31] Among the many luting agents available, zinc phosphate has the longest record (more than 100 years) of successful use.[162] It has good compressive strength and low film thickness, and it is relatively easy to manipulate.[31] Excess cement is easily removed after it has set. Relatively high compressive and tensile strengths make it a good choice for long-span fixed partial dentures.[163] In a study of 48 years, the cement was found to have maintained a stable chemical structure.[164]

Zinc phosphate cement is slightly soluble in oral fluids, allows relatively high levels of microleakage,[165] and is sometimes associated with postoperative sensitivity.[166,167] Despite these drawbacks, it is not unusual to see patients with gold castings that were cemented more than 30 years ago with zinc phosphate cement. In a study of eight restorations that had been in service for 22 years despite positive microleakage tests, no evidence of carious tooth structure, sensitivity, or pulpal degeneration was observed.[168]

Zinc phosphate cement should be mixed on a glass slab that has been chilled, preferably to just above the dew point to avoid water condensation that could contaminate the mix and weaken the set cement. Powder should be mixed into the liquid in small increments over a large area of the glass slab. This method dissipates the heat released during the exothermic setting reaction and provides a longer working time. The slower the mix and cooler the glass slab, the longer the working time. A cool glass slab also allows more powder to be incorporated into the liquid, resulting in improved mechanical properties.[169]From a practical standpoint, refrigerated glass slabs (4şC) always induce water condensation, but the coldness of the slab still allows the incorporation of more powder to the mix, which compensates for the water contamination and leads to improved compressive strength.[170]

Powder is added until the mixed material adheres to the spatula to form a 1-inch string when the spatula is lifted from the glass slab. The mixing should be completed within 90 seconds after initiation. If the mixing is prolonged beyond approximately 90 seconds, the hardening of the cement caused by the setting reaction may be confused with having achieved the proper powder-liquid ratio.[171] Its relatively long working time makes zinc phosphate cement a good choice when multiple castings are luted at the same time. However, because of a lack of a bond to tooth structure and the mixing-technique sensitivity, zinc phosphate is used less frequently now.

Dentlearn.ir

Glass-ionomer cement

Traditional glass-ionomer luting cement is a modification of the glass-ionomer restorative material. It consists of a powder containing aluminum fluorosilicate glass particles that are incorporated into a liquid containing polyalkenoic acids. In some products, these acids are freeze-dried and included in the powder that is mixed with water.[172] It bonds to tooth structure by formation of ionic bonds to hydroxyapatite crystals in enamel and dentin.[172] It is speculated that glass ionomers have the potential to inhibit caries because of fluoride release, but the critical level of fluoride release over time to prevent caries is well beyond the release rate of current glass-ionomer luting cements.[173,174] Glass-ionomer luting cement has a low film thickness (20 to 25 μm) and better mechanical properties than zinc phosphate cement.[31,175,176] However, a glass ionomer may take a significant amount of time before reaching ultimate strength.[177,178] Glass-ionomer cements may be hand-mixed but are also available in preweighed capsules that allow mixing in an amalgamator. Empirical reports of excessive postoperative sensitivity associated with glass-ionomer luting agents have not been borne out in clinical studies.[179–182] Glass-ionomer cements appear to be more technique sensitive than zinc phosphate cements because the surface of the preparation needs to remain moist before cementation and the cement at the margin of the restoration must be isolated from moisture but not desiccated after cementation.[152]

Glass-ionomer cement is very sensitive to early moisture contamination. If exposed to external moisture during the setting reaction (usually 5 minutes), the setting reaction is interrupted, resulting in a cement with high solubility and poor mechanical properties.[183] Therefore, glass-ionomer cement should not be used unless contamination can be prevented. As with glass-ionomer restorative materials, dehydration is also a problem.[184] Excess cement should not be removed from the margins for at least 5 minutes after the crown is seated. Leaving a bead of excess cement in place protects the underlying layers of cement from moisture contamination.[185] Because glass-ionomer cement bonds to the tooth surface, excess cement is somewhat difficult to remove once set, particularly in the interproximal areas.

When glass-ionomer cement is mixed by hand, the pre-measured powder is incorporated into the premeasured liquid in bulk as quickly as possible. A chilled slab has been shown to significantly increase the working time for glass-ionomer cements, as it has for zinc phosphate cements.[186] Most manufacturers now offer an encapsulated form of glass-ionomer luting cement; this results in properly

Dentlearn.ir

proportioned cement that is thoroughly mixed in a few seconds. Glass-ionomer cement has a relatively short working time, so a single mix should be limited to luting no more than two or three units. If additional units have to be luted, a new mix of cement should be used.

Resin-modified glass-ionomer cements

Resin-modified glass-ionomer cements were introduced in the late 1980s. Like resin cements and traditional glass-ionomer cements, resin-modified glass-ionomer cements are modified restorative materials. The combination of resin and glass-ionomer chemistries overcomes some of the problems with moisture contamination and dehydration experienced with glass-ionomer cements[187] and eliminates many of the steps necessary for resin cements.[155] In addition, they release fluoride, providing potential anticaries activity.[188] Resin-modified glass-ionomer cements have physical and mechanical properties between those of conventional glass-ionomer and resin cements.[176] Their adhesive properties to tooth structure are similar to those of traditional glass ionomers,[189] and they have adequately low film thicknesses.[161,190] A recent study showed that both resin cements and resin-modified glass-ionomer cements met the 25-µm film thickness requirement when tested 2 minutes after mixing.[191] However, it is recommended to finish the seating procedure within 10 seconds of the manufacturer's working time to ensure complete seating. A recent study demonstrated that the powder-liquid formulation, as opposed to the paste-paste equivalent, exhibited a significantly better bond to dentin than any of the self-adhesive resin cements.[160]

Resin-modified glass-ionomer cements offer little to no postcementation sensitivity.[192–194]

Finally, resin-modified glass-ionomer cements absorb fluids during and after setting, causing a net expansion.[195,196] One anecdotal clinical report and two in vitro studies[197–199] have linked early resin-modified glass-ionomer formulations with all-ceramic crown fractures. The current generation of resin-modified glass-ionomer cements has apparently overcome this deficiency.[200,201]

Resin luting cements

Resin cements patented since 2002 come either with a separate self-etching bonding agent, such as Panavia F (Kuraray) and Multilink Automix (Ivoclar Vivadent), or with an incorporated self-etching primer, such as RelyX Unicem (3M ESPE) and

Dentlearn.ir

Maxcem (Kerr). These cements have shown low microleakage, high shear bond strength, and adhesive properties to tooth structure. However, they have other additional challenges. First, they are significantly more technique sensitive than traditional luting agents. Most require multiple time-consuming steps and strict moisture control. In addition, resin cements are very difficult to remove from crown margins once they are completely set. Removal of cement flash is made difficult by the relative inaccessibility of crown margins, irregular root topography, and the clear or tooth-colored nature of many resin cements. For these reasons, many clinicians do not use resin cements routinely for posterior applications. However, some circumstances dictate the use of resin cement. Because of their adhesive properties, a resin cement is the material of choice when luting a crown with minimal retention and resistance features. In addition, resin cements must be used when bonding all-ceramic etchable, noncore crowns. As is the case with most dental materials, a clear understanding of the advantages and disadvantages, as well as clinical indications, is essential when making a material selection for a given circumstance.

Resin cements are especially designed for use with bonded ceramic restorations, but they may also be used with cast restorations. They are generally supplied as a dual-paste system in which the two parts are mixed just prior to the cementation process. Polymerization may be initiated by a chemical catalyst or by a combination of a chemical catalyst and a light-activated catalyst, but for cast restorations, chemically cured cements are indicated. Resin cements differ from resin composite restorative materials primarily in their reduced filler content[202]; reduction of the filler content leads to better flow and reduced film thickness, which are desirable properties for a luting cement.[203] Some resin cements contain fillers that are capable of providing fluoride release,[204] although there is questionable therapeutic effect because of the low levels and short duration of fluoride release.[205]

Resin cements have the best mechanical properties of all of the cements.[176,206,207] They are virtually insoluble in oral fluids and have the highest compressive and tensile strengths of all the cements. They also exhibit less microleakage[208] than other luting agents. If used in combination with a dentin adhesive system, they bond to tooth structure and to some metals.[169] For this reason, as previously stated, they are often recommended for less-retentive preparations.[209–211]

There are several potential problems associated with resin cements. There is great variation in the mechanical properties and handling characteristics among resin cements,[190] which can cause confusion for clinicians. The film thickness tends to be

Dentlearn.ir

greater than that of other cements,[173,190,212] so incomplete seating of the casting could be a problem. This is especially true when a dentin adhesive is used, because

require the most clinical steps if used with an adhesive system, so there is more chance for an error in technique to occur. There are no long-term clinical studies to determine if the high retention values and low microleakage are long lasting in castings cemented with resin cements.

Polycarboxylate and zinc oxide–eugenol cements

Polycarboxylate and zinc oxide–eugenol cements are no longer widely used with cast restorations. Their properties are generally inferior to those of the cements previously discussed. Historically, some clinicians have used them if a tooth has had a history of sensitivity. They have also been used as temporary luting agents and with stainless steel crowns.

Preparing the tooth for cementation

Although some materials are more adversely affected by the presence of contaminants than others, no material fares well if used in the presence of oils, debris, saliva, blood, or other significant contamination.[213,214] It is important to ensure that the area is cleaned, free of excess moisture, and well isolated. Bleeding and other significant sources of contamination must be well controlled. Temporary cements leave a layer of debris on the dentin surface[215] that should be removed before cementation. This may be accomplished with hand instruments, pumice, detergents, and/or cleaning agents.

Some clinicians recommend the additional step of disinfecting the preparation with chlorhexidine, ethylenediaminetetraacetic acid (EDTA), or benzylkonium. The rationale is that bacteria are a primary cause of postoperative sensitivity,[71,72] so disinfection of the dentin surface will lower the number of microbes and thus reduce one cause of sensitivity. Another approach is to use desensitizing agents, usually including hydroxyethyl methacrylate (HEMA). These agents can be applied immediately before the final impression. They essentially disinfect the dentin and seal the tubules. Their use does not seem to interfere with crown retention, regardless of the type of luting cement used.[216–218]

In addition to cleaning and isolating the preparation, specific additional steps are recommended to prepare the tooth to receive certain cements. Preparation surface

Dentlearn.ir

texturing obtained either by rotary instruments or sandblasting with 50-μm aluminum oxide has been shown to increase crown retention significantly, regardless of the choice of cement.[202,219,220]

Zinc phosphate cement

Because zinc phosphate cement exhibits the most microleakage of any cement[190] and has been associated with postcemen-tation sensitivity, several methods have been recommended to prevent sensitivity by "sealing" the dentin prior to cementation. Copal varnish has a long history of use for this purpose, with anecdotal reports of success. However, copal varnish does not disinfect the dentin, and its effectiveness has limited duration.[221,222]

More recently, use of dentin primers and adhesives to seal the dentin before cementation has resulted in reports of decreased sensitivity. However, a study has noted a marked (42%) decrease in retention with the application of a resin-based sealer prior to cementation.

Glass-ionomer cements

For glass-ionomer cements, the tooth should be clean and slightly moist.[179] No cavity varnish should be placed that might prevent bonding of this luting agent to the tooth surface. The area should be well isolated to prevent moisture contamination during the luting process and for several minutes following the seating of the restoration.

Resin-modified glass-ionomer cements

One of the advantages of resin-modified glass-ionomer cements is that the cementation procedure is fairly simple. Multiple bonding steps are not necessary, and no special preparation of the tooth surface is performed, other than to make it clean and slightly moist. Removal of excess cement is relatively easy.

Resin cements

Most resin cements have corresponding dentin adhesive systems that are applied immediately before cementation. In most cases, the preparation is etched and a primer and adhesive are placed. Each adhesive system has specific instructions for its use that must be followed precisely to obtain the best results. Failure to follow the specific directions for both the adhesive and the luting resin can mean the

Dentlearn.ir

difference between success and failure. It must be emphasized that excellent isolation is a necessity when a resin cement is used.

A small amount of the cement should be mixed and observed before cementation procedures are started to confirm that the cement will set. Some self-curing resin cements have short shelf lives and lose their ability to polymerize.

Preparing the casting for cementation

After adjustments have been made and the external surface of the casting has been oxide to produce a uniform, slightly roughened finish. Margins must be avoided or cleaned to remove any contaminants, such as polishing compounds. Ammonia, detergents, or various other cleaning solutions may be used in an ultrasonic bath, or the casting can be cleaned with a steam cleaner.

If an adhesive resin cement is used, additional retention can be obtained by tin plating the inside of the casting.[223,224] A number of inexpensive tin-plating systems that can be used to deposit a thin layer of tin on the surface of the gold alloy are commercially available. This simple process can be done in the laboratory or operatory in a few minutes.[223] A newer generation of metal-surface treatments, including the Rocatec[225] (3M ESPE), Silicoater$_{226}$ (Heraeus Kulzer), and CoJet[227] (3M ESPE) systems, all produce a coating that has been shown to significantly increase bond strength of resin to metal. Yet another alternative that has shown promising results is the use of an adhesive system that has an alloy primer.[228]

Seating the casting

With zinc phosphate and glass-ionomer cements, the cement is mixed and placed in the casting. Some clinicians also like to place a layer of the cement on the walls of the preparation for intracoronal restorations. The casting should be half-filled with cement, and all of the margins should be covered. Once the casting is seated with finger pressure, the patient is instructed to bite on an orangewood stick or other seating instrument. If a rubber dam is being used for isolation, two orangewood sticks may be tethered together with dental floss to allow the patient to close on the sticks and not the bow of the rubber dam retainer (clamp). The instrument is moved up and down and then side to side. This technique, called *dynamic seating*, results in more complete seating of the casting.[229] The margins are checked with an explorer

Dentlearn.ir

to determine that complete seating has been accomplished. For small intracoronal castings, such as occlusal and two-surface inlays, a sharpened stick may be placed with heavy force on the casting, along the line of draw of the preparation, with light mallet tapping. This latter technique requires continued tapping with the mallet until no further cement expresses from the marginal areas. The clinician needs to understand how the cement choice relates to finishing technique.

The optimum finishing technique takes place on the die with a final finish applied while the cement is setting. An extremely high luster may be placed on the cemented castings using ribbed (not webbed) polishing cups and a sequence of no. 4 flour of pumice, 15-µm aluminum oxide, and 1-µm aluminum oxide powders, either wet or dry. Use of these agents, particularly dry, can generate a significant temperature increase, and they must be used with light, intermittent pressure.[148]

Recently, a pertinent study explored the marginal adaptation of cast gold inlays with three cements—zinc phosphate, resin-modified glass-ionomer, and self-adhesive modified resin cement—and three finishing techniques.[149] Finishing the casting before and during cementation led to the least marginal opening for all three cements.

The excess cement must be removed with proper timing and care. If removal is attempted before the cement is set, thin strands of cement may be dragged from under the margins, thus creating voids. The beads of extruded cement have been shown to protect the cement at the margin from moisture contamination.[185] Therefore, it is important to check the cement to ensure that it has set before the excess is removed. Excess cement may be removed with an explorer or curette directed parallel or away from accessible margins, and floss or yarn is used to remove interproximal excess cement. The gingival crevice should be flushed with water frequently to remove any loose particles. As a final step, an assistant should supply a continuous stream of air to each margin while the clinician gently reflects the free gingiva with an explorer to check for any remaining cement. Cement left subgingivally can cause tissue inflammation. A knot is tied in the floss and then the floss is pulled back and forth through the gingival embrasure to remove loose pieces of cement from the interproximal areas.

As discussed previously, there are some distinct advantages of adhesive resin luting cements in certain situations, but their use requires different seating procedures than those used for zinc phosphate and glass-ionomer cements. For each resin-based cement, manufacturer instructions should be followed closely. The

retention. Procedure guides accompanying the resin cement should be adhered to.

Dentlearn.ir

Removal of excess adhesive resin cement from exposed areas of the tooth and adjacent teeth can be a bit difficult, so a large amount of excess cement should be avoided. The adhesive and luting materials are mixed and applied according to the manufacturer's instructions, and the casting is seated using procedures similar to those used for other cements. Setting times for these materials vary, and the time to remove excess cement is critical, so, again, instructions must be followed closely.

The occlusion is reevaluated and final adjustments are made, if necessary. An easy technique to adjust high spots is to use a fine egg- or football-shaped carbide bur, followed by abrasive polishers on the adjusted area, to bring the casting back to a smooth surface and high polish. The patient is informed of the possibility of postcementation sensitivity and that a minor additional adjustment of the occlusion may be necessary. The patient is instructed in proper oral hygiene measures to ensure prevention of caries and periodontal problems.

References

1. Bentley C, Drake EW. Longevity of restorations in dental school clinic. J Dent Educ 1986;50:594–600.
2. Marynuik GA. In search of treatment longevity—A 30 year perspective. J Am Dent Assoc 1984;109:739–744.
3. Mjör IA. Placement and replacement of restorations. Oper Dent 1981;6:49–54.
4. Minker JS. Simplified full coverage preparations. Dent Clin North Am 1965;9:355–372.
5. Mjör IA, Jokstad A, Qvist V. Longevity of posterior restorations. Int Dent J 1990;40:11–17.
6. Vanderhaug J. A 15-year clinical evaluation of fixed prosthodontics. Acta Odontol Scand 1991;49:35–40.
7. Stoll R, Sieweke M, Pieper K, Stachniss A, Schulte A. Longevity of cast gold inlays and partial crowns—A retrospective study at a dental clinic. Clin Oral Investig 1999;3:100–104.
8. Erpenstein H, Kerschbaum T, Halfin T. Long term survival of cast gold inlays in a specialized practice. Clin Oral Investig 2001;5:162–166.
9. Donovan T, Simonson RJ, Guentin CT, Tucker RV. Retrospective clinical evaluation of 1,314 cast gold restorations in service from 1 to 52 years. J Esthet Restor Dent 2004;16:194–204.
10. Jokstad A, Mjör IA, Qvist V. The age of restorations in situ. Acta Odontol Scand 1994;52:234–242.
11. Mahmood S, Smales RJ. Longevity of dental restorations in selected patients from different practice environments. Aust Dent J 1994;39:15–17.

Acta Odontol Scand 1992;50:189–192.
13. Studer SP, Wettstein F, Lehner C, Zullo TG, Schärer P. Long-term survival estimates of cast gold inlays and onlays with their analysis of failures. J Oral Rehabil 2000;27:461–472.
14. Beier US, Kapferer I, Burtscher D, Giesinger JM, Dumfahrt H. Clinical performance of all-ceramic inlay and onlay restorations in posterior teeth. Int J Prosthodont 2012;25:395–402.
15. Donly KJ, Jensen ME, Triolo P, Chan D. A clinical comparison of resin composite inlay and onlay posterior restorations and cast-gold restorations at 7 years. Quintessence Int 1999;30:163–168.
16. Mjör IA, Medina JE. Reasons for placement, replacement, and age of gold restorations in selected practices. Oper Dent 1993;18:82–87.
17. Shillingburg HT, Jacobi R, Brackett SE. Fundamentals of Tooth Preparation. Chicago: Quintessence, 1987:112.
18. Salis SG, Hood JA, Stokes A, Kirk E. Patterns of indirect fracture in intact and restored human premolar

Dentlearn.ir

teeth. Endod Dent Traumatol 1987;3:10–14.
19. Sorensen JA, Martinoff JT. Intracoronal reinforcement and coronal coverage: A study of endodontically treated teeth. J Prosthet Dent 1984;51:780–784.
20. Oden A, Tullberg M. Cracks in gold cemented on amalgam restorations. Acta Odontol Scand 1985;43:15–17.
21. Stoll R, Fisher C, Springer M, Stachniss V. Margin adaptation of partial crowns cast in pure titanium and in a gold alloy—An in vitro study. J Oral Rehabil 2002;29:1–6.
22. Delong R, Pintado MR, Douglas WH. The wear of enamel opposing shaded ceramic restorative materials: An in vitro study. J Prosthet Dent 1992;68:42–48.
23. Enderle J, Blanchard S, Bronzino J. Introduction to Biomedical Engineering. San Diego, CA: Academic, 2000:554–557.
24. Laeijendecker R, van Joost T. Oral manifestations of gold allergy. J Am Acad Dermatol 1994;30:205–209.
25. Canay S, Cehreli MC, Bilgic S. In vitro evaluation of the effect of a current bleaching agent on the electrochemical corrosion of dental alloys. J Oral Rehabil 2002;29:1014–1019.
26. Walker RS, Wade AG, Iazzetti G, Sarkar NK. Galvanic interaction between gold and amalgam: Effect of zinc, time and surface treatments. J Am Dent Assoc 2003;134:1463–1467.
27. Meyer RD, Meyer J, Taloumis LJ. Intraoral galvanic corrosion: Literature review and case report. J Prosthet Dent 1993;69:141–143.
28. Willershausen-Zonnchen B, Gross E, Dermann K, Sonnabend E. In vitro study on the corrosion behavior of two amalgams in direct contact to different cast metal alloys [in German]. Dtsch Zahnarztl Z 1991;46:290–292.
29. Johnson GH, Lepe X. Crown retention with the use of a 5% glutaralde-hyde sealer on prepared dentin. J Prosthet Dent 1998;79:671–676.
30. Felton DA, Bergenholtz G, Kanoy BE. Evaluation of the desensitizing effect of Gluma dentin bond on teeth prepared for complete coverage restorations. Int J Prosthodont 1991;4:292–298.
31. Craig RG. Restorative Dental Materials, ed 6. St Louis: Mosby, 1980:57.
32. Phillips RW. Skinner's Science of Dental Materials, ed 9. Philadelphia: Saunders, 1991:296.
33. Lagouvardos P, Sourai P, Douvitsas G. Coronal fractures in posterior teeth. Oper Dent 1989;14:28–32.
34. Hiatt WH. Incomplete crown–root fracture in pulpal periodontal disease. J Periodontol 1973;44:369–379.
35. Eakle WS, Maxwell EH, Braly BV. Fractures of posterior teeth in adults. J Am Dent Assoc 1986;112:215–218.
36. Cavel WT, Kelsey WP, Blankenau RJ. An in vitro study of cuspal fracture. J Prosthet Dent 1985;53:38–42.
37. Cameron CE. Cracked tooth syndrome. J Am Dent Assoc 1976;93:971–975.
38. Gher ME, Dunlap RH, Anderson MH, Kuhl LV. Clinical survey of fractured teeth. J Am Dent Assoc 1987;114:174–177.
39. Larson TD, Douglas WH, Geistfeld RE. Effects of prepared cavities on the strength of teeth. Oper Dent 1981;6:2–5.
40. Vale WA. Cavity preparation. Ir Dent Rev 1956;2:33–41.
41. Blazer PK, Land MR, Cochran RA. Effects of designs of Class 2 preparations on resistance of teeth to fracture. Oper Dent 1983;8:6–10.
42. Reeh ES, Douglas WH, Messer HH. Stiffness of endodontically treated teeth related to restoration technique. J Dent Res 1989;68:1540–1544.
43. Hood JA. Methods to improve fracture resistance of teeth. In: Vanherle G, Smith DC (eds). International Symposium on Posterior Composite Resin Dental Restorative Materials. St Paul, MN: 3M, 1985:443–450.
44. Morin DL, Douglas WH, Cross M, Delong R. Biophysical stress analysis of restored teeth: Experimental strain measurement. Dent Mater 1988; 4:41–48.
45. Cheung GS, Chan TK. Long-term survival of primary root canal treatment carried out in a dental teaching hospital. Int Endod J 2003;36:117–128.
46. Aquilino SA, Caplan DJ. Relationship between crown placement and the survival of endodontically treated teeth. J Prosthet Dent 2002;87: 256–263.
47. Wiskott HW, Nicholls JI, Belser UC. The relationship between abutment taper and resistance of cemented crowns to dynamic loading. Int J Prosthodont 1996;9:117–130.

Dentlearn.ir

48. Graf H, Geering AH. Rationale for clinical application of different occlusal philosophies. Oral Sci Rev 1977;10:1–10.
49. Wiskott HW, Nicholls JI, Belser UC. The effect of tooth preparation height and diameter on the resistance of complete crowns to fatigue loading. Int J Prosthodont 1997;10:207–215.
50. Wiskott HW, Belser UC, Scherrer SS. The effect of film thickness and surface texture on the resistance of cemented extracoronal restorations to lateral fatigue loading. Int J Prosthodont 1999;12:255–262.
51. Gilboe DB, Teteruck WR. Fundamentals of extracoronal tooth preparation. Retention and resistance form. J Prosthet Dent 1974;32:651–656.
52. Jørgensen KD. The relationship between retention and convergence angle in cemented veneer crowns. Acta Odontol Scand 1955;13:35–40.
53. Owen CP. Retention and resistance in preparations for extracoronal restorations. Part II: Practical and clinical studies. J Prosthet Dent 1986; 56:148–153.
54. Ohm E, Silness J. The convergence angle in teeth prepared for artificial crowns. J Oral Rehabil 1978;5:371–375.
55. Mack PJ. A theoretical investigation into the taper achieved on crown and inlay preparations. J Oral Rehabil 1980;7:255–265.
56. Dodge WR, Weed RM, Baez RJ, Buchanan RN. The effect of convergence angle on retention and resistance form. Quintessence Int 1985;16:191–197.
57. Guyer SE. Multiple preparations for fixed prosthodontics. J Prosthet Dent 1970;32:529–553.
58. Weed RM. Determining adequate crown convergence. Tex Dent J 1980; 98:14–16.
59. Proussaefs P, Campagni W, Bernal G, Goodacre C, Kim J. The effectiveness of auxiliary features on a tooth preparation with inadequate resistance form. J Prosthet Dent 2004;91:33–41.
60. Najano K, Tanoue N, Atsuta M, Koizumi H, Matsumura H. Effect of noble metal adhesive systems on bonding between an indirect composite material and a gold alloy. J Oral Sci 2004;46:235–239.
61. Kajihara H, Suzuki S, Minesaki Y, Kurashige H, Tanaka T. The effects of air abrasion on dentin, enamel, and metal bonding. Am J Dent 2004;17:161–164.
62. Pinzón LM, Frey GN, Winkler MM, Tate WH, Burgess JO, Powers JM. Retention of gold alloy crowns cemented with traditional resin cements. Int J Prosthodont 2009;22:351–353.
63. Parker MH, Gunderson RB, Gardner FM, Calverley MJ. Quantitative determination of taper adequate to provide resistance form: Concept of limiting taper. J Prosthet Dent 1988;59:281–288.
64. Zukermann GR. Factors that influence the mechanical retention of the complete crown. Int J Prosthodont 1988;1:196–200.
65. McMullen AF 3rd, Himel VT, Sarkar NK. An in vitro study of the effect endodontic access preparation has upon the retention of porcelain fused to metal crowns of maxillary central incisors. J Endod 1989;15:154–156.
66. Mulvay PG, Abbott PV. The effect of endodontic access cavity preparation and subsequent restorative procedures on molar crown retention. Aust Dent J 1996;41:134–139.
67. Trautmann G, Gutmann JL, Nunn ME, Witherspoon DE, Berry WC, Romero GG. Restoring teeth that are endodontically treated through existing crowns. Part III: Material usage and prevention of bacterial leakage. Quintessence Int 2001;32:27–32.
68. Hamid A, Hume WR. The effect of dentin thickness on diffusion of resin monomers. J Oral Rehabil 1997;24:20–25.
69. Camps J, Tardieu C, Déjou J, Franquin JC, Ladaique P, Rieu R. In vitro cytotoxicity of dental adhesive systems under simulated pulpal pressure. Dent Mater 1997;13:34–42.
70. Camps J, Déjou J, Rémusat M, About I. Factors influencing pulpal response to cavity restorations. Dent Mater 2000;16:432–440.
71. Brännström M, Vojinovic O. Response of the dental pulp to invasion of bacteria around three filling materials. J Dent Child 1976;43:83–89.
72. Cox CF, Suzuki S. Re-evaluating pulp protection: Calcium hydroxide liners vs. cohesive hybridization. J Am Dent Assoc 1994;125:823–831.
73. Külünk S, Saraç D, Külünk T, Karakas O. The effects of different desensitizing agents on the shear bond

Dentlearn.ir

strength of adhesive resin cement to dentin. J Esthet Restor Dent 2011;23:380–387.
74. Boksman LL, Swift EJ Jr. Critical appraisal. Current usage of glutaralde-hyde/ HEMA. J Esthet Restor Dent 2011;23:410–416.
75. Pashley DH, Tay FR, Imazato S. How to increase the durability of resin dentin bonds. Compend Contin Educ Dent 2011;32(7):60–64,66.
76. Wilson RD, Maynard JG. Intracrevicular restorative dentistry. Int J Periodontics Restorative Dent 1981;1:35–49.
77. Valderhaug J. Periodontal considerations and carious lesions following the insertion of fixed prosthesis: A 10-year follow-up study. Int Dent J 1980;30:296–304.
78. Koth DL. Full crown restoration and gingival inflammation in a controlled population. J Prosthet Dent 1982;48:681–685.
79. Waerhaug J. Histologic considerations which govern where the margins of restorations should be located in relation to the gingival. Dent Clin North Am 1960;5:161–176.
80. Renggli HH, Regolati B. Gingival inflammation and plaque accumulation by well-adapted supragingival and subgingival proximal restorations. Helv Odontol Acta 1972;16:99–101.
81. Mörmann W, Regolati B, Renggli HH. Gingival reaction to well-fitted subgingival proximal gold inlays. J Clin Periodontol 1974;1:120–125.
82. Newcomb GM. The relationship between the location of subgingival crown margins and gingival inflammation. J Periodontol 1974;45:151–154.
83. Ericsson I, Lindhe J. Recession in sites with inadequate width of keratin-ized gingiva. An experimental study in the dog. J Clin Periodontol 1984;11:95–103.
84. Richter WA, Ueno H. Relationship of crown margin placement to gingival inflammation. J Prosthet Dent 1973;30:156–161.
85. Ackerman MB. The full coverage restoration in relation to the gingival sulcus. Compend Contin Educ Dent 1997;18:1131–1138,1140.
86. Gargiulo AW, Wentz FM, Orban BJ. Dimensions and relations of the dentogingival junction in humans. J Periodontol 1961;32:261–267.
87. Kois JC. Altering gingival levels: The restorative connection. Part I: Biologic variables. J Esthet Dent 1994;6:3–9.
88. Gunay H, Seeger A, Tschernitschek H, Geurtsen W. Placement of the preparation line and periodontal health —A prospective 2-year clinical study. Int J Periodontics Restorative Dent 2000;20:173–181.
89. Ruben MP, Smukler H, Schulman S, Kon S, Bloom AA. Healing of periodontal surgical wounds. In: Goldman HM, Cohen DW (eds). Periodontal Therapy, ed 6. St Louis: Mosby, 1980:640–754.
90. Koke U, Sander C, Heinecke A, Muller HP. A possible influence of gingival dimensions on attachment loss and gingival recession following placement of artificial crowns. Int J Periodontics Restorative Dent 2003;23:439–445.
91. Dragoo JR, Williams GB. Periodontal tissue reactions to restorative procedures. Int J Periodontics Restorative Dent 1981;1(1):9–23.
92. Mount GJ. Crown and the gingival tissues. Aust Dent J 1970;15:253–258.
93. Jameson LM. Comparison of the volume of crevicular fluid from restored and nonrestored teeth. J Prosthet Dent 1979;41:209–214.
94. Silness J. Periodontal conditions in patients treated with dental bridges. II. The influence of full and partial crowns on plaque accumulation, development of gingivitis and pocket formation. J Periodontal Res 1970;5:219–230.
95. Silness J. Periodontal conditions in patients treated with dental bridges. Part III. The relationship between the location of the crown and margin and the periodontal condition. J Periodontal Res 1970;5:225–229.
96. Reitemeier B, Hansel K, Walter MH, Kastner C, Toutenburg H. Effect of posterior crown margin placement on gingival health. J Prosthet Dent 2002;87:167–172.
97. Kay HB. Esthetic considerations in the definitive periodontal prosthetic management of the maxillary anterior segment. Int J Periodontics Restorative Dent 1982;2(3):45–59.

Dentlearn.ir

98. Nevins M, Skurow HM. The intracrevicular restorative margin, the biologic width, and the maintenance of the gingival margin. Int J Periodontics Restorative Dent 1984;4(3):31–49.
99. Butel EM, Campbell JC, DiFiore PM. Crown margin design: A dental school survey. J Prosthet Dent 1991;65:303–305.
100. Byrne G, Goodacre CJ, Dykema RW, Moore BK. Casting accuracy of high-palladium alloys. J Prosthet Dent 1986;55:297–302.
101. Teteruck WR, Mumford G. The fit of certain dental casting alloys using different investing materials and techniques. J Prosthet Dent 1966; 16:910–927.
102. Christensen GJ. Marginal fit of gold onlays. J Prosthet Dent 1966;16: 297–305.
103. McLean JW, von Fraunhofer JA. The estimation of film thickness by an in vivo technique. Br Dent J 1971;131:107–111.
104. Rosner D. Function, placement and reproduction of bevels for gold casting. J Prosthet Dent 1963;13:1160–1166.
105. Ostlund LE. Cavity design and mathematics: Their effect on gaps at the margins of cast restorations. Oper Dent 1985;10:122–137.
106. Grieve AR. A study of dental cements. Br Dent J 1969;127:405–410.
107. Panno FV, Vahidi F, Gulker I, Ghalili KM. Evaluation of the 45-degree labial bevel with a shoulder preparation. J Prosthet Dent 1986;56:655–661.
108. Pascoe DF. Analysis of the geometry of finish lines for full crown restorations. J Prosthet Dent 1978;40:157–162.
109. Fusayama T, Ide K, Hosoda H. Relief of resistance of cement of full cast crowns. J Prosthet Dent 1964;14:95–105.
110. Byrne G. Influence of finish-line form on crown cementation. Int J Prosthodont 1992;5:137–144.
111. Piemjai M. Effect of seating force, margin design, and cement on marginal seal and retention of cast metal crowns. Int J Prosthodont 2001;14:412–416.
112. Mitchell CA, Pintado MR, Douglas WH. Nondestructive, in vitro qualification of crown margins. J Prosthet Dent 2001;85:575–584.
113. Tucker RV. The full gold crown: An overview. Oper Dent 2000;25:130–133.
114. el-Ebrashi MK, Craig RG, Peyton FA. Experimental stress analysis of dental restorations. 3. The concept of the geometry of proximal margins. J Prosthet Dent 1969;22:333–338.
115. Morris ML. Artificial crown contours and gingival health. J Prosthet Dent 1962;12:1146–1156.
116. Parkinson CF. Excessive crown contours facilitate endemic plaque niches. J Prosthet Dent 1976;35:424–429.
117. Youdelis RA, Weaver JD, Sapkos S. Facial and lingual contours of artificial complete crown restorations and their effect on periodontium. J Prosthet Dent 1973;29:61–66.
118. Wheeler RC. Complete crown form and the periodontium. J Prosthet Dent 1961;11:722–734.
119. Herlands RE, Lucca JJ, Morris HL. Forms, contours, and extensions of full coverage restorations in occlusal reconstruction. Dent Clin North Am 1962;6:147–162.
120. Stein RS. Periodontal dictates for esthetic ceramometal crowns. J Am Dent Assoc 1987;Dec(special issue):63E–75E.
121. Krough-Paulsen WG, Olsson A. Occlusal disharmonies and dysfunction of the stomatognathic system. Dent Clin North Am 1966;10:627–635.
122. Bell WE. Temporomandibular Disorders: Classification/Diagnosis/Management, ed 2. Chicago: Year Book, 1986:219.
123. Schluger S, Yuodelis R, Page RC, Johnson RH. Periodontal Diseases, ed 2. Philadelphia: Lea & Febiger, 1990:125–137.
124. D'Amico A. Functional occlusion of the natural teeth of man. J Prosthet Dent 1961;11:899–915.
125. Ogawa T, Ogimoto T, Koyano K. Pattern of occlusal contacts in lateral positions: Canine protection and

126. Schuyler CH. Considerations of occlusion in fixed partial dentures. Dent Clin North Am 1959;3:175–185.

Dentlearn.ir

127. Kaiser DA, Becker CM, Malone WF. Designs for cast metal restorations. Am J Dent 1998;11:199–201.
128. Kahn AE. Partial versus full coverage. J Prosthet Dent 1960;10:167–172.
129. Gibbs CH, Lundeen HL. Advances in Occlusion. Littleton, MA: PSG, 1982:2–32.
130. McCoy RB. Bases, liners and varnishes update. Oper Dent 1995;20:216.

11 May 2011.
132. Shooshan ED. A pin-ledge casting technique: Its application in periodontal splinting. Dent Clin North Am 1960;4:189–206.
133. Stevenson RG, Refela JA. Conservative and esthetic cast gold fixed partial dentures—Inlay, onlay, and partial veneer retainers, custom composite pontics, and stress breakers: Part II: Utilization of additional retentive features and fabrication of custom pontic facings. J Esthet Restor Dent 2009;21:375–384.
134. Arbo MA. A simple technique for castings with pin retention. Dent Clin North Am 1970;14:19–29.
135. Shillingburg HT. Cast gold restorations. In: Clark JW (ed). Clinical Dentistry. New York: Harper & Row, 1976.
136. Shillingburg HT, Hobo S, Whitsett LD, Jacobi R, Brackett SE. Fundamentals of Fixed Prosthodontics, ed 3. Chicago: Quintessence, 1997:132.
137. Ingraham R, Bassett RW, Koser JR. An Atlas of Cast Gold Procedures, ed 2. Buena Park, CA: Uni-Tro College, 1969:34.
138. Lorey RE, Myers GE. The retentive qualities of bridge retainers. J Am Dent Assoc 1968;76:568–572.
139. Potts RG, Shillingburg HT, Duncanson MG. Retention and resistance of preparations for cast restorations. J Prosthet Dent 1980;43:303–308.
140. Campagni WV, Wright W, Martinoff JT. Effect of die spacer on the seating of complete cast crowns with grooves. J Prosthet Dent 1986;55: 324–328.
141. Marker VA, Miller AW, Miller BH, Swepston JH. Factors affecting the retention and fit of gold castings. J Prosthet Dent 1987;57:425–430.
142. Passon C, Lambert RH, Lambert RL, Newman S. The effect of multiple layers of die spacer on crown retention. Oper Dent 1992;17:42–49.
143. Gerhardt DE. Seating the cast gold restoration. Gen Dent 1987;35:479–481.
144. Ostlund LE. Improving the marginal fit of the cast restorations. J Am Acad Gold Foil Oper 1974;17:56–60.
145. Kaiser DA, Wise HB. Fitting cast gold restorations with the aid of disclosing wax. J Prosthet Dent 1980;43:227–228.

cemented crowns. J Prosthet Dent 1981;45:395–399.
147. Kaiser DA. Anatomy of the cast gold margin. J Prosthet Dent 1983;50: 437–440.
148. Metzler JC, Chandler HH. An evaluation of techniques for finishing margins of gold inlays. J Prosthet Dent 1976;36:523–531.
149. Farrell CV, Johnson GH, Oswald MT, Tucker RD. Effect of cement selection and finishing technique on marginal opening of cast gold inlays. J Prosthet Dent 2008;99:287–292.
150 Schwartz NL, Whitsett LD, Berry TG, Stewart JL. Unserviceable crowns and fixed partial dentures: Life-span and causes for loss of serviceability. J Am Dent Assoc 1970;81:1395–1401.
151. Walton JN, Gardner FM, Agar JR. A survey of crown and fixed partial denture failures: Length of service and reasons for replacement. J Prosthet Dent 1986;56:416–421.
152. Donovan TE, Cho GC. Contemporary evaluation of dental cements. Compend Contin Educ Dent 1999;20:197–199,202–208,210.
153. Zidan O, Ferguson GC. The retention of complete crowns prepared with three different tapers and luted with four different cements. J Prosthet Dent 2003;89:565–571.
154. Brackett MG, Kious AR, Brackett WW. Minimally retentive gold onlays: A six-year case report. Oper Dent 2009;34:352–355.
155. Diaz-Arnold AM, Vargas MA, Haselton DR. Current status of luting agents for fixed prosthodontics. J Prosthet Dent 1999;81:135–141.

Dentlearn.ir

156. Christensen GJ, Christensen R. Use Survey—1990. Clin Res Assoc Newsletter 1990;14:1–3.
157. Christensen GJ, Christensen R. Understanding cement use in 2004. Clin Res Assoc Newsletter 2004;28(10):1–3.
158. Self adhesive resin cements: A replacement or an alternative? Clinicians Rep 2009;2(11):1–3.
159. Piwowarczyk A, Lauer HC. Mechanical properties of luting cements after water storage. Oper Dent 2003;28:535–542.
160. Johnson GA, Lepe X, Zhang H, Wataha JC. Retention of metal-ceramic crowns with contemporary dental cements. J Am Dent Assoc 2009;140:1125–1136.
161. White SN, Yu Z, Tom JF, Sangsurasak S. In vivo marginal adaptation of cast crowns luted with different cements. J Prosthet Dent 1995;74:25–32.
162. Ames WB. A new oxyphosphate for crown seating. Dent Cosmos 1892;34:392–393.
163. Shillingburg HT, Hobo S, Whitsett LD. Fundamentals of Fixed Prosthodontics. Chicago: Quintessence, 1981:376–377.
164. Margerit J, Cluzel B, Leloup JM, et al. Chemical characterization of in vivo aged zinc phosphate dental cements. J Mater Sci Mater Med 1996;7:623–628.
165. White SN, Yu Z, Tom JF, Sangsurasak S. In vivo microleakage of luting cements for cast crowns. J Prosthet Dent 1994;71:333–338.
166. Norman RD, Swartz ML, Phillips RW, Vermani RV. A comparison of the intraoral disintegration of three dental cements. J Am Dent Assoc 1969;78:777–782.
167. White SN, Sorensen JA, Kang SK, Caputo AA. Microleakage of new crown and fixed partial denture luting agents. J Prosthet Dent 1992; 67:156–161.
168. Kydd WL, Nicholls JI, Harrington G. Marginal leakage of cast gold crowns luted with zinc phosphate cement: An in vivo study. J Prosthet Dent 1996;75:9–13.
169. Smith DC. Dental cements. Current status and future prospects. Dent Clin North Am 1983;6:763–792.
170. Jost-Brinkmann PG, Rabe H, Miethke RR. Materials properties of zinc phosphate cements after delayed setting on refrigerated slabs [in German]. Fortschr Kieferorthop 1989;50:1–11.
171. Osborne JW, Wolff MS, Berry JC. Variance in powder-liquid ratio in zinc phosphate cement for luting castings [abstract 468]. J Dent Res 1986;65:778.
172. Katsuyama S, Ishikawa T, Fujii B (eds). Glass Ionomer Dental Cement: The Materials and Their Clinical Use. Diehnelt DE (trans). St Louis: Ishi-yaku EuroAmerica, 1993.
173. Staninec M, Giles WS, Saiku JM, Hattori M. Caries penetration and cement thickness of three luting agents. Int J Prosthodont 1988;1:259–263.
174. Musa A, Pearson GJ, Gelbier M. In vitro investigation of fluoride ion release from four resin modified glass polyalkenoate cements. Biomaterials 1996;17:1019–1023.
175. White SN, Furuichi R, Kyomen SM. Microleakage through dentin after crown cementation. J Endod 1995;21:9–12.
176. White SN, Yu Z. Compressive and diametral tensile strengths of current adhesive luting agents. J Prosthet Dent 1993;69:568–572.
177. Mojon P, Hawbolt EB, MacEntee MI, Ma PH. Early bond strength of luting cements to precious alloy. J Dent Res 1992;71:633–639.
178. Matsuya S, Maeda T, Ohta M. IR and NMR analyses of hardening and maturation of glass ionomer cement. J Dent Res 1996;75:1920–1927.
179. Johnson GH, Powell LV, DeRouen TA. Evaluation and control of post-cementation pulpal sensitivity: Zinc phosphate and glass ionomer cements. J Am Dent Assoc 1993;124:38–46.
180. Jokstad A, Mjör IA. Ten years' clinical evaluation of three luting agents. J Dent 1996;24:309–315.
181. Kern M, Kleimeier B, Schaller HG, Strub JR. Clinical comparison of postoperative sensitivity for a glass ionomer and a zinc phosphate luting cement. J Prosthet Dent 1996;75:159–162.
182. Pameijer CH, Nilner K. Long term clinical evaluation of three luting materials. Swed Dent J 1994;18:59–67.
183. Um CM, Oilo G. The effect of early water contact on glass-ionomer cements. Quintessence Int 1992;23:209–214.

Dentlearn.ir

184. Hornsby PR. Dimensional stability of glass-ionomer cements. J Chem Tech Biotechnol 1980;30:595–601.
185. Curtis SR, Richards MW, Dhuru VB, Meiers JC. Early erosion of glass-ionomer cement at crown margins. Int J Prosthodont 1993;6:553–557.
186. Fricker J, Hirota K, Tamiya Y. The effects of temperature on the setting of glass ionomer (polyalkenoate) cements. Aust Dent J 1991;36:240–242.
187. Wilson AD, Prosser JK, Powis DM. Mechanism of adhesion of polyelectrolyte cements to hydroxyapatite. J Dent Res 1983;62:590–592.
188. Wilson AD. Resin-modified glass-ionomer materials. Int J Prosthodont 1990;3:425–429.
189. Sidhu SK, Watson TF. Resin-modified glass-ionomer materials. Part 1: Properties. Dent Update 1995;22:429–431.
190. White SN, Yu Z. Film thickness of new adhesive luting agents. J Prosthet Dent 1992;67:782–785.
191. Kious AR, Roberts HW, Brackett WW. Film thicknesses of recently introduced luting cements. J Prosthet Dent 2009;101:189–192.
192. Hilton TJ, Hilton DE, Randall R, Ferracane JL. A clinical comparison of two cements for levels of post-operative sensitivity in a practice-based setting. Oper Dent 2004;29:241–248.
193. Chandrasekhar V. Post cementation sensitivity evaluation of glass ionomer, zinc phosphate and resin modified glass ionomer luting cements under class II inlays: An in vivo comparative study. J Conserv Dent 2010;13:23–27.
194. Yoneda S, Morigami M, Suqizaki J, Yamada T. Short-term clinical evaluation of a resin-modified glass-ionomer luting cement. Quintessence Int 2005;36:49–53.
195. Kanchanavasita W, Pearson S, Pearson GJ. Water sorption characteristics of resin-modified glass-ionomer cements. Biomaterials 1997;18: 343–349.
196. Yap AU. Resin-modified glass ionomer cements: A comparison of water sorption characteristics. Biomaterials 1996;17:1897–1900.
197. Miller MB. The reality of nonscience-based newsletters. Quintessence Int 1996;27:655–656.
198. Sindel J, Frankenberger R, Kramer N, Petschelt A. Crack formation of all-ceramic crowns dependent on different core build-up and luting materials. J Dent 1999;27:175–181.
199. Leevailoj C, Platt JA, Cochran MA, Moore BK. In vitro study of fracture incidence and compressive fracture load of all-ceramic crowns cemented with resin-modified glass ionomer and other luting agents. J Prosthet Dent 1998;80:699–707.
200. Duncan JP, Pameijer CH. Retention of parallel-sided titanium posts cemented with six luting agents: An in vitro study. J Prosthet Dent 1998;80:423–428.
201. Snyder MD, Lang BR, Razzoog ME. The efficacy of luting all ceramic crowns with resin-modified glass ionomer cement. J Am Dent Assoc 2003;134:609–612.
202. Jacobson PH, Rees JS. Luting agents for ceramic and polymeric inlays and onlays. Int Dent J 1992;42:145–149.
203. Aquilino SA, Diaz-Arnold AM, Piotrowski TJ. Tensile fatigue limits of prosthodontic adhesives. J Dent Res 1991;70:208–210.
204. Burgess JO, Norling BK, Cardenas HL. Fluoride release and flexural strength of five fluoride releasing luting agents. J Dent Res 1996;75 (special issue):70.
205. McMillen K, Kerby RE, Thakur A, Johnson WM. Fluoride release of resin-based luting agents. J Dent Res 1996;75:68.
206. Shinkai K, Suzuki S, Leinfelder KF, Katch Y. Effect of gap dimensions on wear resistance of luting agents. Am J Dent 1995;8:149–151.
207. White SN, Yu Z. Physical properties of fixed prosthodontic resin composite luting agents. Int J Prosthodont 1993;6:384–389.
208. Blair KF, Koeppen RG, Schwartz RS, Davis RD. Microleakage associated with resin composite–cemented, cast glass ceramic restoration. Int J Prosthodont 1993;6:579–584.
209. Hunsaker JK, Christensen GJ, Christensen RP, et al. Retentive characteristics of dental cementation materials. Gen Dent 1993;44:464–467.

Dentlearn.ir

210. Krabbendam CA, ten Harkel HC, Duijsters PP, Davidson CL. Shear bond strength determinations on various kinds of luting cements with tooth structure and cast alloys using a new testing device. J Dent 1987;15: 77–81.
211. O'Sullivan BP, Johnson PF, Blosser RL, et al. Bond strength of a luting composite to dentin with different bonding systems. J Prosthet Dent 1987;58:171–175.
212. Levine WA. An evaluation of the film thickness of resin luting agents. J Prosthet Dent 1989;62:175–181.
213. Takefu H, Shimoji S, Sugaya T, Kawanami M. Influence of blood contamination before or after surface treatment on adhesion of 4-META/ MMA-TBB resin to root dentin. Dent Mater J 2012;31:131–138.
214. Takimoto M, Ishii R, Iino M, et al. Influence of temporary cement contamination on the surface free energy and dentine bond strength of self-adhesive cements. J Dent 2012;40:131–138.
215. Schwartz RS, Davis RD, Hilton TJ. Effect of temporary cements on the bond strength of a resin cement. Am J Dent 1992;5:147–150.
216. Cobb DS, Reinhardt JW, Vargas MA. Effect of HEMA-containing dentin desensitizers on shear bond strength of a resin cement. Am J Dent 1997;10:62–65.
217. Reinhardt JW, Krell KV. Effect of desensitizers and bonding agents on radicular dentin permeability [abstract 1332]. J Dent Res 1997;76:180.
218. Swift EJ Jr, Lloyd AH, Felton DA. The effect of resin desensitizing agents on crown retention. J Am Dent Assoc 1997;128:195–200.
219. Ayad MF, Rosenstiel SF, Salama M. Influence of tooth surface roughness and type of cement on retention of complete cast crowns. J Prosthet Dent 1997;77:116–121.
220. Tjan AH, Tjan AH, Greive JH. Effects of various cementation methods on the retention of prefabricated posts. J Prosthet Dent 1987;58: 309–313.
221. Tarim B, Suzuki S, Suzuki S, Cox CF. Marginal integrity of bonded amalgam restorations. Am J Dent 1996;9:72–76.
222. Yim NH, Rueggeberg FA, Caughman WF, Gardner FM, Pashley DH. Effect of dentin desensitizers and cementing agents on retention of full crowns using standardized crown preparations. J Prosthet Dent 2000;83:459–465.
223. Imbery TA, Davis RD. Evaluation of tin plating systems for a high-noble alloy. Int J Prosthodont 1993;6:55–59.
224. Olin PS, Hill EM. Tensile strength of air abraded vs tin plated metals luted with three cements [abstract 188]. J Dent Res 1991;70:387.
225. Robin C, Scherrer S, Wiskott H, de Rijk W, Belser U. Weibull parameters of composite resin bond strength to porcelain and noble alloy using Rocatec System. Dent Mater 2002;18:389–395.
226. Vojvodic D, Jerolimov V, Celebic A, Catovic A. Bond strengths of silicoated and acrylic resin bonding systems to metal. J Prosthet Dent 1999;81:1–6.
227. Pilo R, Lewinstein I, Ratzon T, Cardash HS, Brosh T. The influence of dentin and/or metal surface treatment on the retention of cemented crowns in teeth with an increased taper. Dent Mater 2008;24:1058–1064.
228. Yamada Y, Tsubota Y, Fukushima S. Effect of restoration method on fracture resistance of endodontically treated maxillary premolars. Int J Prosthodont 2004;17:94–98.
229. Rosenstiel SF, Gegauff AG. Improving cementation of complete cast crowns: A comparison of static and dynamic seating methods. J Am Dent Assoc 1988;117:845–848.

Dentlearn.ir



Restoration of Endodontically Treated Teeth

James C. Broome
J. William Robbins

Restoring teeth functionally and esthetically after end-odontic treatment often presents a challenge to the dentist. Typically, root canal treatment is initiated because of deep caries or trauma, both of which often result in extensive loss of tooth structure. Additional tooth tissue is removed for endodontic access, cleaning and shaping of the root canal, and post space preparation, further reducing the structural integrity of the tooth and decreasing its resistance to fracture.[1,2] At one time it was believed that endodontically treated teeth are inherently more brittle and susceptible to fracture.[3,4] Subsequent research has shown that the dentin of endodontically treated teeth exhibits mechanical properties equivalent to that of untreated teeth.[5,6]

It has also been proposed that a portion of the sensory feedback mechanism is lost when the neurovas-cular tissue has been removed from the tooth in the course of endodontic therapy, an effect confirmed in an in vivo study.[7] Clinically, this means that the patient can inadvertently bite with more force on an end-odontically treated tooth than on a vital tooth because of the impaired sensory feedback mechanism.

Dentlearn.ir

This may account for the failure of endodontically teeth that would otherwise appear to be fracture resistant (Fig 21-1).

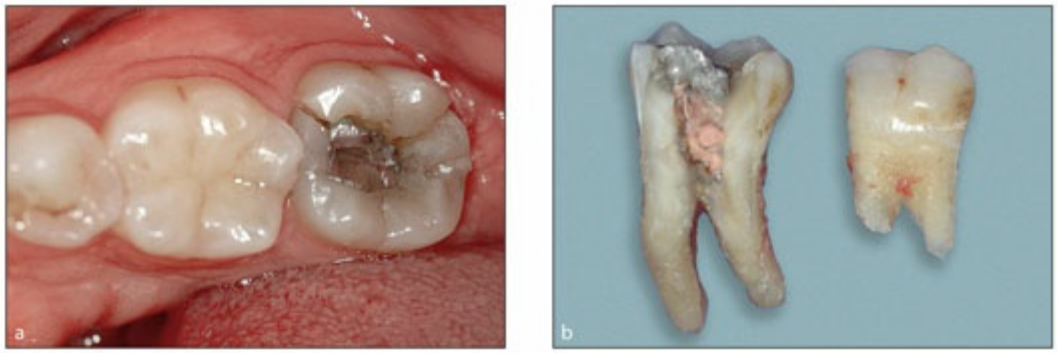

Fig 21-1*(a and b)* Unrestorable, fractured, endodontically treated mandibular second molar with an occlusal amalgam restoration.

While endodontically treated teeth may fail for a variety of reasons—eg, caries, endodontic failure, and periodontal disease, among others—tooth fracture remains a significant factor in the posttreatment extraction of these teeth.[8] The choice of definitive restoration plays an important role in survivability. In selected instances, endodontically treated teeth can be restored with a directly placed restoration, particularly in the anterior region. However, restoring a severely damaged tooth to function and esthetics often requires the use of a full-coverage restoration. Providing adequate resistance and retention form when there is a minimal amount of remaining tooth structure can be problematic. When a moderate amount of tooth structure has been lost, the tooth may be built up with restorative material such as amalgam or composite to provide a *core* to support and retain the crown. When the damage is severe and there is inadequate tooth structure to retain the core, other methods of retention must be employed. This may consist of adhesive bonding techniques, providing auxiliary mechanical retention, and/or placement of a *post* into the root canal that extends into the core and retains it.

The longevity of endodontically treated teeth is difficult to evaluate because of the many possible variables. These include patient factors, such as systemic health, periodontal condition, and caries susceptibility; tooth-related factors, such as function and the amount of tooth structure remaining; as well as material factors, such as the type of post, cement, core, and definitive restoration. While the amount of clinical information grows each year, there are currently insufficient data to predict the effect of each of these factors on the success or failure of an individual tooth. However, analysis of large data sets from insurance companies indicates that endodontic treatment followed by restoration is very successful in terms of tooth retention. Salehrabi and Rotstein[9] analyzed the outcome of endodontic treatment in a

Dentlearn.ir

¼6 million cohort of US patients and found an 8-year survival rate of 97%. Chen et al[10] conducted a similar study on a Taiwanese data set of 1.56 million patients and found a tooth retention rate of 93% after 5 years.

Risk Analysis

The survivability of the individual tooth and its ability to fulfill its intended function must be carefully considered, and the quality of the existing endodontic treatment should be assessed. The absence of symptoms and of periapical pathology, as well as the presence of a radiographically dense and adequately extended obturation, should be confirmed. Periodontal disease should be controlled, and the crown-root ratio should be assessed in view of the position of the tooth in the arch and its anticipated function. Success is enhanced when a restored endodontically treated tooth is in proximal contact on both the mesial and distal.[11] If the root canal filling has been exposed to the oral environment because of leakage or loss of a restoration, contamination of the periapex with bacteria or toxins may occur within days.[12,13] Retreatment should be considered in situations where the root canal filling has been exposed to the oral environment. There are no clinical data available to give specific guidance on how long the root canal filling may be exposed before retreatment should be accomplished, but in vitro studies suggest a range of days to several months.[12,14] Because of the difficulty and expense involved in retreatment after restoration, a conservative approach is recommended. Many clinicians use 2 weeks of exposure as an arbitrary guideline for retreatment. Because of the risk of contamination, coronal sealing of the root canal system should be accomplished as soon as possible after completion of the root canal therapy.[15] A long time span between the endodontic treatment and placement of the definitive restoration leads to a significantly higher failure rate.[16,17]

Perhaps the most important factor related to the survivability of an endodontically treated tooth is the amount of coronal and radicular tooth structure that remains prior to restoration. This factor appears to be of paramount importance and will be considered in detail later in this chapter. The tooth structure that will be available following tooth preparation should be visualized and should be assessed for the provision of adequate retention and resistance form for the subsequent crown. Key to this factor is the presence of an adequate ferrule. The term *ferrule* describes the band of circumferential material that encircles the cervical area of a tooth restored with a crown.[18] As commonly used in dentistry, *ferrule* also refers to the dimension

Dentlearn.ir

of remaining vertical tooth structure from the anticipated margin of the preparation to its coronal extent, which is available for encirclement by the crown. The "ferrule effect" serves to reinforce the remaining tooth structure and helps the restoration withstand lateral forces.[19]

The ferrule provides resistance form and enhances longevity.[20] Ferrule length was found to be more important than post length in increasing fracture resistance to cyclic loading of crowned teeth.[21] Indeed, some authors have noted that the effect of the remaining dentin height is so significant as to make the effect of the type of post and core employed irrelevant with respect to tooth survival.[22] Lack of an adequate ferrule increases the risk of failure because of post-crown dislodgment, post fracture, and root fracture.[23,24] Sorensen and Engelman$_{19}$ noted that a ferrule of only 1.0 mm in vertical height doubles the resistance to fracture of a tooth without remaining coronal tooth structure. Optimal beneficial effect can be expected from a ferrule of at least 1.5 to 2.0 mm of vertical height.[18,25]

Adequate sound tooth structure should be present to allow placement of a restoration margin that will not encroach on the biologic width, which will ensure continued periodontal health. *Biologic width* has been defined as "the dimension of the junctional epithelium and connective tissue attachment to the root above the alveolar crest" and has been estimated to be approximately 2 mm.[26] Violation of this dimension with a restorative margin may result in persistent periodontal inflammation.[27] Given the requirement of a minimal ferrule height of 2 mm, at least 4 mm of sound supra-alveolar tooth structure is necessary for mechanical stability and periodontal health.

If there is insufficient remaining tooth structure to adequately retain a core, the suitability of the existing root canals to receive a post should be assessed. A radiographic assessment of the availability of a sufficient length of straight canal of adequate diameter should be made preoperatively and factored into the prognosis. Periapical radiographs taken from multiple angles are often helpful.

There are few teeth that cannot be endodontically treated and restored to some level of function provided the dentist has the skills and the patient is willing and able to commit the time and resources. Current techniques provide a high degree of success for endodontic treatment. Even teeth with no tooth structure remaining above the osseous crest can be restored if techniques such as forced orthodontic eruption$_{28}$ or crown lengthening surgery are utilized to create more available vertical tooth structure for crown retention. However, these techniques add expense, patient inconvenience, and discomfort and may compromise esthetics and support of

Dentlearn.ir

adjacent teeth.[29] In addition, because roots are tapered, these procedures result in a decrease in the cross-sectional dimension of the final preparation and also decrease the crown-root ratio. With the ever-increasing success and availability of implant treatment, the concept of "restorability" has changed. The tooth may be indeed be restored, but what is the anticipated longevity? A realistic assessment must be made of the long-term prognosis of the restored tooth compared with that of an implant-retained restoration.

The use of osseointegrated implants for the replacement of teeth offers an alternative for teeth with a questionable prognosis. A systematic review of clinical studies assessing the survival rate of single-tooth implants with teeth that had received root canal treatment followed by coronal restoration concluded that there is no difference in the survival outcomes of these two treatment modalities.[30] Fifty-five studies related to single-tooth implants met the criteria for inclusion in the analysis. Success rates ranged from 89% to 100%. The largest study analyzed, a prospective study assessing 2,900 implants, indicated a success rate of 98% at 3 years.[31] Thirteen studies related to the survival of endodontically treated teeth with coronal restorations met the review criteria and were analyzed. Survival ranged from 81% to 100%. The largest study included, with 19,817 teeth, showed a survival rate of 97% at 72 months.[32]

The conscientious practitioner will examine the risk factors associated with the successful endodontic treatment and restoration of a marginal tooth versus extraction and the placement of an implant. This decision involves expertise in implant treatment planning, which is beyond the scope of this text. In making the decision, many factors must be considered, such as the quantity and quality of remaining bone, esthetic and soft tissue considerations, and of course, the desires and medical status of the patient.

Treatment Planning

The type of definitive restoration required for an endodontically treated tooth is primarily determined by the amount of remaining tooth structure, the position of the tooth in the arch, and the functional forces placed on it. An appropriate restoration may range from a direct resin composite in an anterior tooth to a full crown. The greater the amount of tooth structure lost, the greater will be the need for additional retention for the core, often in the form of a post. The ability of a patient to exert heavy occlusal forces, which might displace a core and the crown it supports,

Dentlearn.ir

decreases from the posterior regions of the dental arch to the anterior.[33] However, the direction of the functional forces transitions from primarily vertical (compressive) in the posterior region to lateral (tensile or shear) in the anterior. These tensile forces tend to displace the crown/ core, and therefore the need for additional resistance form is greater in the anterior region, and a post is often required. In the posterior region, although the forces are greater, they are primarily vertical, and sufficient retention and resistance form for the core is often obtained by extending it into the pulp chamber. For these reasons, a post is rarely required in a molar tooth. However, when a restored tooth is to be used as an abutment for a removable or fixed partial denture, greater lateral forces should be anticipated, and the additional resistance form provided by a post should be considered.[34–36] Because of the differences in magnitude of functional forces, direction of forces, and anatomical differences, anterior and posterior teeth present different restorative challenges.

Anterior teeth

In the anterior region, there will frequently be sufficient remaining tooth structure to restore the tooth to function and esthetics with a direct restoration. In cases of traumatically induced pulpal necrosis, the only restoration required is to seal the access preparation (Fig 21-2). In other situations, there may be moderately sized Class 3 cavities in addition to the access. In these cases, neither a post nor a full-coverage restoration is required, and the tooth can be restored with bonded resin composite. When a moderate amount of coronal tooth structure is missing but at least 50% of the coronal enamel remains, the bonded porcelain veneer may be the restoration of choice (Fig 21-3). A tooth conservatively prepared for a porcelain veneer allows for the creation of excellent esthetics without compromising the strength of the remaining tooth structure. Laboratory studies suggest that endodontically treated incisors restored with porcelain veneers have similar resistance to fracture as an intact tooth.[37,38] There is no need for post placement in these situations. Although some laboratory studies[39,40] have indicated that a metallic post strengthens an intact anterior endodontically treated tooth, the majority of studies have suggested that the fracture resistance of these teeth is not affected by placement of a post.[41,42] In addition, placement of a post in an anterior tooth with an intact incisal edge is often complicated by a lack of draw for the post into the canal through the access opening. Removing additional tooth structure in order to place a post is not indicated.

Dentlearn.ir

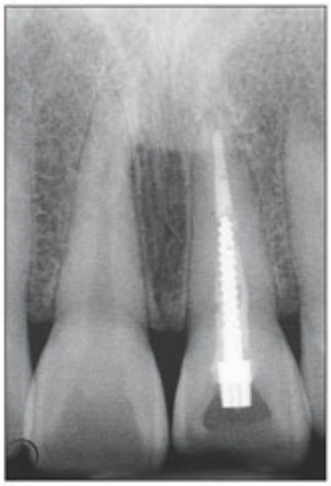

Fig 21-2



Fig 21-3*(a)* Preoperative view of a maxillary right central incisor. *(b)* Preoperative radiograph. *(c and d)* Seven-year postoperative views of the endodontically treated maxillary right central incisor restored with a porcelain veneer.

When the decision has been made to restore the tooth with a crown because of loss of structural integrity or esthetic demand, an assessment must be made as to whether there is sufficient tooth structure remaining to retain the core or whether retention and resistance form must be augmented with a post. Because of the

Dentlearn.ir

predominantly lateral forces that the anterior teeth are subjected to in function, careful consideration should be given to the placement of a post. In some cases, the dentist may wish to defer this decision until after preparing the tooth. An assessment may be made at that time whether sufficient vertical walls remain to resist the lateral forces that the crown will be subjected to without the placement of a post. Because of the size of the canines and the maxillary central incisors, a post can often be avoided in these teeth, and adequate retention and resistance form can be provided by the placement of a core buildup. With maxillary lateral incisors and mandibular central and lateral incisors, providing adequate tooth reduction for the crown often results in very little remaining tooth structure, and the need for a post is clear.

The canals of maxillary and mandibular canines and maxillary central incisors are usually straight and of adequate size and shape for post placement. On the other hand, the canals of mandibular central and lateral incisors, and often maxillary lateral incisors, are small and ribbon shaped and offer variable opportunity for post placement.

Posterior teeth

Clinical studies have demonstrated that a key element in the successful restoration of endodontically treated posterior teeth is the placement of a full coronal cuspal-coverage restoration. In a retrospective study of 1,273 endodontically treated teeth, Sorensen and Martinoff[43] found that a full-coverage restoration increased the success rate of posterior teeth. In another retrospective study, Aquilino and Caplan[44] showed that end-odontically treated molars not crowned after obturation were lost at a rate six times greater than teeth that were crowned. In a systematic review of clinical studies of endodontically treated teeth, Stavropoulou and Koidis[45] determined that the 10-year survival rate of crowned teeth is 81% versus 63% for direct restorations. In a study of molar teeth, Nagasiri and Chitmongkolsuk[46] found that the survival rate of uncrowned teeth was 96% at 1 year, 88% at 2 years, and 36% at 3 years.

Examining the status of the endodontically treated teeth extracted during the period evaluated in two large epidemiologic studies reinforces the importance of cuspal coverage. In the previously cited study by Salehrabi and Rotstein,[9] 85% of extracted teeth had no full coronal coverage. In another study, teeth restored with amalgam or composite showed an incidence of extraction of 6.3%; teeth with full coronal restoration had an incidence of only 2.5%.[32]

Interestingly, despite compelling evidence to crown such teeth, many teeth that

Dentlearn.ir

receive endodontic treatment are not crowned. Scurria et al[47] followed up the restorative outcome of 1,193 endodontically treated teeth through an insurance claims system and reported that the percentage of noncrown restorations placed

Regardless of the seemingly poor performance of direct restoration of endodontically treated posterior teeth, it should be cautiously considered in cases where substantial tooth structure remains. Access preparation has little effect on the stiffness of endodontically treated maxillary premolars, but the removal of the marginal ridges with a larger preparation has a significant effect.[48] The success rate of direct restorations is improved proportionately to the amount of tooth structure remaining$_{46}$ and by using bonded resin composite.[49] A short-term (30-month) clinical evaluation of the use of fiber-reinforced composite (FRC) posts and direct resin composite restorations revealed no failures within that time period.[50] A 3-year clinical study concluded that the clinical success rates of endodontically treated premolars restored with FRC posts and direct composite restorations were equivalent to full coverage with metal-ceramic crowns.[51]

In the face of confusing and contradictory data regarding full-coverage versus direct restoration of endodontically treated teeth, the clinician should take a conservative approach. The preponderance of clinical data suggests that the full coronal coverage restoration is the more predictable and long-lasting restoration. A direct resin composite restoration may be considered when there is substantial remaining tooth structure and lower functional loads are present. However, it should be realized that the strengthening effect of the bonded resin composite may be lost over time. It has been shown that the effect diminishes significantly with both thermal cycling[52] and functional loading[53] of the restoration. Degradation of the resin-dentin bond over time has also been demonstrated in vivo.[54] Therefore, the long-term strengthening effect of the intracoronal bonded restoration must be questioned, and the clinician should choose this treatment option with caution.

Restoration of endodontically treated teeth with amalgam without cuspal overlay has a low clinical success rate and cannot be recommended.[55] However, in the hands of a skilled operator, a cuspal-coverage amalgam restoration may provide a low-cost alternative to a crown (Fig 21-4). In 1980, Nayyar et al[56] described the *amalcore*, or coronal-radicular, restoration. Rather than placement of a post, the pulp chamber and the coronal 2 to 3 mm of each canal are used for retention of the buildup material (Fig 21-5). A post is generally not needed with the amalcore.

Dentlearn.ir

Although some authors have found that placement of a post increases the resistance of the amalcore to fracture,[57,58] others have found no difference.[59] A post is required only when insufficient pulp chamber depth is present to retain the core (Fig 21-6). In a retrospective clinical study of more than 400 coronal-radicular restorations, no failures were noted that could be attributed to the core buildup. If appropriate thickness of occlusal amalgam can be provided and adequate axial contours, proximal contacts, and occlusion can be developed, the amalcore technique can be used to create a long-lasting definitive restoration. A 6-year clinical study demonstrated the effectiveness of complex, cusp-capping amalgam restorations mechanically or adhesively retained.[59]

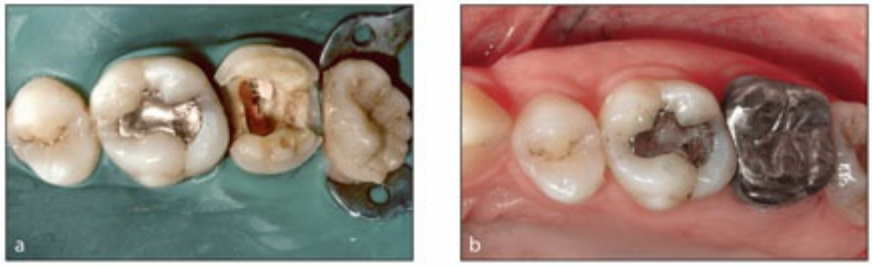

Fig 21-4*(a)(b)*

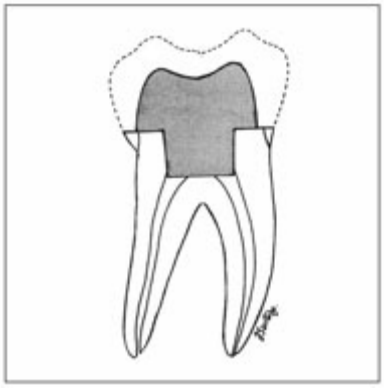

Fig 21-5 Amalcore with adequate chamber retention.



Fig 21-6

Dentlearn.ir

Maxillary premolars are a unique subset of posterior end-odontically treated teeth. Anatomically, the root is often small in diameter relative to the dimensions of the crown to be supported, and there may be little tooth structure to retain the core. The pulp chamber of these teeth is typically small and provides little mechanical retention for the core. A post is indicated in these cases. In addition, these teeth are subjected to a mixture of shear and compressive forces, and the need for a post to provide additional resistance form is often similar to that for an anterior tooth. Similarly, lateral forces exerted on a maxillary premolar functioning as the abutment for a removable partial denture often necessitate a post for additional resistance (Fig 21-7).

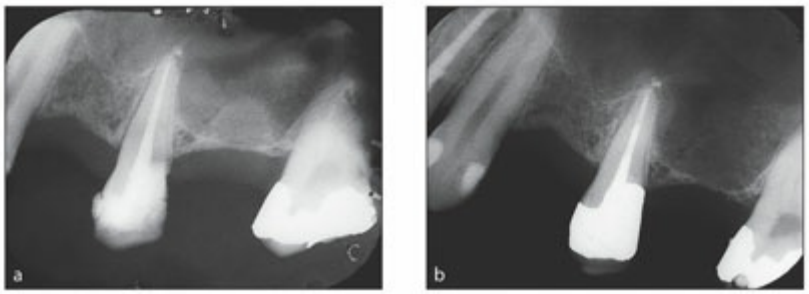

Fig 21-7 *(a)* Preoperative view of an endodontically treated maxillary second premolar. *(b)* Maxillary second premolar after restoration with a tapered prefabricated post and amalgam core. The canal was not enlarged for post placement.

Maxillary premolar roots are often fluted and may be curved, presenting a high risk of strip perforation during preparation of the post space.[60] The palatal root has been shown to have a larger and straighter canal than the buccal and should be utilized for post placement.[61]

For the molar tooth, the decisions are more clear-cut. The forces on posterior teeth are predominately vertical. Therefore, development of additional resistance form to withstand lateral forces is not as commonly needed as in anterior teeth. Because of the morbidity associated with post placement (Fig 21-8), a post is indicated in a posterior tooth only when other more conservative retention and resistance features cannot be used for the core. These features include chamber/canal orifice retention, amalgam pins, and threaded pins, all of which have been shown to be exceedingly effective.[62] When a post is deemed necessary, the palatal canal of maxillary molars and the distal canal of mandibular molars are usually the best choice.

Dentlearn.ir



Fig 21-8 Mandibular molar with post perforation in the mesial concavity of the distal root.

Material Selection

Core material

A core is routinely placed in teeth for which a full-coverage indirect restoration is indicated. The core replaces lost tooth tissue and augments retention, resistance, and support for the crown. Restoring a crown preparation to ideal height through the use of a core increases the ability of the crown to withstand the fatigue forces that might displace it.[63] The core is retained through the use of adhesive bonding, existing mechanical retentive features, a cemented post, or with a combination of methods.

A variety of directly placed restorative materials are available for use as a core with or without a post; amalgam, glass ionomer (both conventional and resin-modified), and resin composite are popular choices. Desirable characteristics of a core material are listed in Box 21-1.

Box 21-1	Characteristics of the ideal core material
• Stability in a wet environment • Ease of manipulation • Rapid, hard set for immediate crown preparation •High compressive strength •High tensile strength •High modulus of elasticity (rigidity) •High fracture toughness •Inert (no corrosion) •Cariostatic properties •Biocompatibility •Low cost	

Dentlearn.ir

Amalgam has numerous advantages as a core material. Its high strength has been confirmed in laboratory studies under both static and dynamic loads.[64,65] The modulus of elasticity of amalgam is three times that of a typical resin composite and thus provides excellent support for all-ceramic crowns.[66] It is easy to place, it is relatively insensitive to moisture contamination, and the color contrast facilitates margin placement. These factors make amalgam an excellent choice when the clinician is faced with placing a core deep within the gingival sulcus. On the other hand, amalgam has a number of disadvantages. Its early strength is low, necessitating a 15- to 20-minute wait until the buildup can be prepared for the crown, even when fast-setting spherical alloy is used. It is messy to prepare and can result in irreversible staining of the marginal gingiva during preparation. Therefore, amalgam should not be used as a core material in a tooth in the esthetic zone.

Conventional glass-ionomer materials have the advantages of fluoride release, ease of manipulation, natural color, biocompatibility, corrosion resistance, and dimensional stability in a wet environment.[67] They are also offered in a metal-reinforced formulation that offers color contrast to tooth structure. However, they have the major disadvantage of brittleness and low resistance to fatigue forces, which makes them unsuitable for use in extensive cores.[64,65] Resin-modified glass-ionomer materials offer improvements over the conventional glass ionomers but still fall short compared with bonded resin composite in terms of fracture toughness, bond strength, and dimensional stability.[68–70]

Resin composite is the most popular core material because of its excellent mechanical properties, bond to tooth structure when used with an adhesive, and ease of use. It is available in light-curing, dual-curing, and self-curing formulations. It is provided as both a tooth-colored material to be used as a core material under anterior all-ceramic restorations and as a color-contrasting material to be used as a core material under metallic or opaque ceramic (alumina or zirconia) restorations. Resin composite has a fracture toughness[68] and transverse strength similar to that of amalgam.[66] Resistance to fatigue loading is intermediate between glass ionomer and amalgam.[64,65] The dimensional stability of resin composite in a wet environment is greater than that of glass-ionomer materials but less than that of amalgam.[70,71] The clinical significance of this property is unclear. One study found that water storage of extracted teeth with composite cores resulted in expansion, which decreased the fit of the subsequent crown. Amalgam was found to be unaffected.[71] Another study found that water storage affected the fit of crowns on preparations of natural tooth as well as composite and that the placement of a well-fitting interim restoration

Dentlearn.ir

improved the fit of both.[72]

In general, the bond of resin composite to the dentin of the pulp chamber is not as strong as that to coronal dentin.[73,74] And, as previously noted, the resin bond may weaken with time and function in the oral environment. For these reasons, the clinician should always strive to create additional mechanical retentive features to retain the resin composite core when possible.

Ribbon reinforcement

The fabrication of an individualized, directly fabricated post and core utilizing adhesively bonded woven polyethylene or glass ribbon and resin composite has been suggested. Examples of these materials include everStick (Stick Tech), which consists of silanated glass fibers impregnated with polymethyl methacrylate (PMMA) and bisphenol glycidyl methacrylate (bis-GMA), and Ribbond (Ribbond), with ultrahigh–molecular weight polyethylene fibers (UHMWP) in a cross-linking lock-stitch leno weave. It has been proposed that these fiber ribbons increase retention and prevent crack propagation through the core.[75] The clinical technique involves embedding the ribbon into resin composite placed in the root canal and within the core and has been described in detail in the literature.[76,77] Newman et al[78] tested the fracture resistance of a variety of post constructs loaded at a 45-degree angle in extracted teeth. When Ribbond and resin composite were used as a post and core in a conservatively prepared root canal, the fracture strength was significantly less than that observed with fiber posts. When tested in flared, thin-walled canals, the fracture strength was equivalent to that with fiber posts.[78] One clinical study showed a high survival rate of teeth restored with this technique.[79] However, a 6-year prospective study showed an overall failure rate of the everStick post and core of 38.7%. This was found to be superior to no post at all but inferior to the 23.4% failure rate seen with a bonded FRC post.[24]

Selection of a post

A wide variety of post designs and materials are available to the clinician (Fig 21-9). Posts may be characterized by manufacturing process (custom-cast versus prefabricated), engagement with root dentin (active versus passive), shape (parallel-sided versus tapered), surface features (smooth versus macroretentive), and material (metallic versus ceramic versus FRC). While each design has its advocates, three fundamental principles should guide selection:

Dentlearn.ir

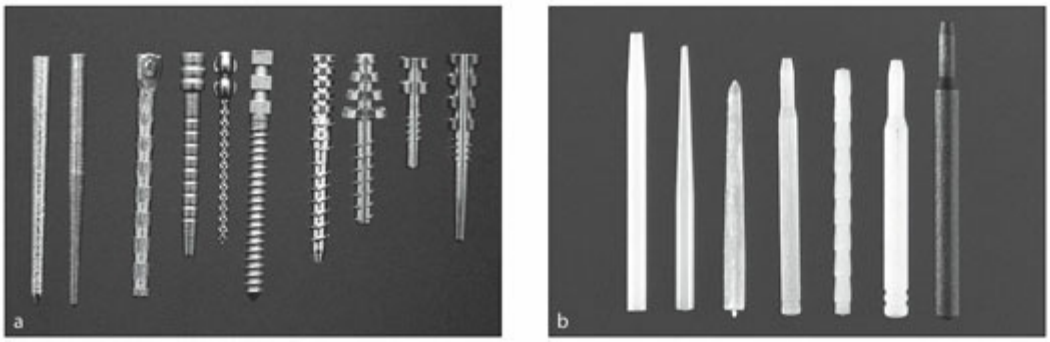

Fig 21-9*(a)* Prefabricated posts. *(left to right)* Passive tapered: Endowel (Star), Filpost (Ivoclar Vivadent); passive parallel: Parapost Plus (Coltène/Whaledent), BCH (3M ESPE), Unity (Coltène/Whaledent), Boston Post (Roydent); active: Flexi-Post (Essential Dental Systems), V-Lock (Brasseler), Radix (Dentsply Maillefer), Cytco (Dentsply Maillefer). *(b)* Nonmetallic posts. *(left to right)* CosmoPost (Ivoclar Vivadent), CeraPost (Brasseler), Luscent Anchor (Dentatus), Light-Post (Bisco), FibreKor Post (Pentron), Aestheti-Plus (Bisco), and C-Post (Bisco).

1. Tooth structure should be preserved to maintain fracture resistance. Ideally, the post should fit the canal shape produced by the endodontic procedure without further removal of tooth structure. Fulfillment of this principle typically necessitates the use of a tapered post.
2. The post should not increase the susceptibility of the tooth to root fracture but rather reduce its incidence, if possible. Selection of a post that fits the canal passively and provides physiologic stress distribution fulfills this requirement.
3. The post should provide adequate retention of the core-crown assembly without compromising the principles of conservation of tooth structure and preservation of root integrity. This principle is satisfied primarily through the use of a post of adequate length and secondarily by the use of adhesive bonding techniques.

No single post system fulfills these principles for all teeth. Clinical judgment must be exercised to select a post system or core-retention method appropriate for each individual situation.

Post Designs and Materials

Cast metal post and core

The custom-cast post and core has a long history of success in restorative dentistry. However, laboratory studies[80–82] have consistently shown that the fracture resistance of teeth restored with custom-cast posts is lower than that of teeth restored with

Dentlearn.ir

many different prefabricated posts. In addition, retrospective clinical studies[23,43] have shown metallic prefabricated parallel-sided posts to have greater clinical success than custom-cast posts. This, coupled with the added expense and extra appointment required to fabricate the custom-cast post, makes its routine use unpopular. In addition, there are concerns about leakage of the interim post crown allowing reinfection of the root canal system during the temporization period.[83]

There are several circumstances in which the custom-cast post is the post of choice:

- When multiple post and core restorations are planned in the same arch, the laboratory-fabricated custom-cast post may be the most time- and cost-efficient method. The teeth are prepared for the posts, and the final crown preparations are completed so that all crown margins are on tooth structure. It is important that the crown preparation be completed before the impression for the post and core is made so that the axial contours of the core can be fabricated correctly.

  An impression is made with an elastomeric impression material used with an injection technique, which allows the impression material to flow into the total length of the prepared canal space (Fig 21-10). This can be best accomplished using one of the following techniques. A 25-gauge needle is placed into the canal before the impression is made. The syringe material is then injected into the canal until it begins to flow out the top of the orifice. While the syringe material is being injected, the needle is slowly removed from the canal. The needle serves as an

  to reproduce the entire length of the canal space. Alternatively, the syringe material may be placed directly into the canal with a needle tube, which is attached to the syringe. The tip of the needle tube must be long enough to extend to the entire length of the prepared canal space. The elastomeric material is injected as the needle tube is slowly removed from the canal. A final technique that can be used to ensure that impression material flows into the entire length of the prepared canal is the use of a lentulo spiral (see Fig 21-13). The syringe impression material is initially injected into the canal until it flows out of the orifice. The lentulo spiral is then introduced into the canal and rotated at low rpm to force the impression material apically. The lentulo spiral should be slowly and gently advanced until the apical aspect of the prepared canal is felt and then slowly removed while it continues to rotate. No reinforcement of the impression material in the canal space is required with the newer impression materials. The impression is poured, and the custom posts are fabricated in the laboratory. At a

Dentlearn.ir

subsequent appointment, the posts are cemented and the final impression for the restorations is made without further tooth preparation.

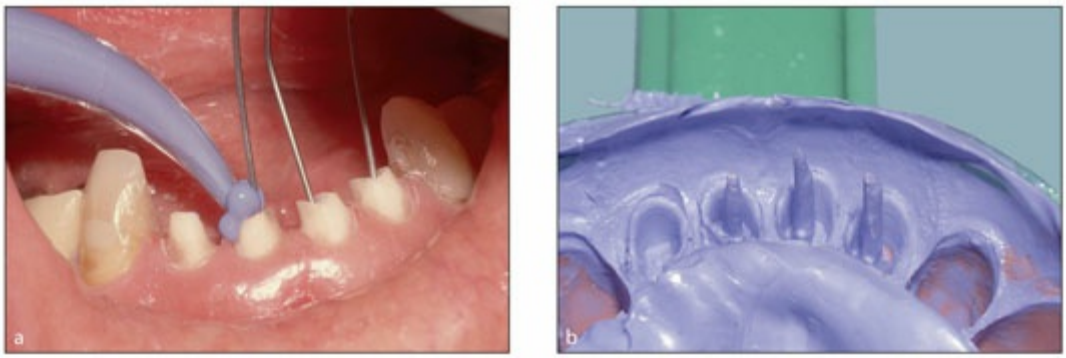

Fig 21-10*(a)* Use of 25-gauge needles to allow air to escape from canals during the impression making to ensure a complete impression of the canal spaces. *(b)* Final impression of canal spaces for laboratory fabrication of custom-cast posts.

- When a small tooth, such as a mandibular incisor, requires a post and core, a prefabricated post may be difficult to use. Commonly, there is minimal space around the post for the core buildup material. In this situation, the custom-cast post serves well.
- Occasionally, the angle of the core in relation to the root must be altered. It is not advisable to bend prefabricated posts; therefore, the custom-cast post and core most successfully fulfills this need (Fig 21-11).

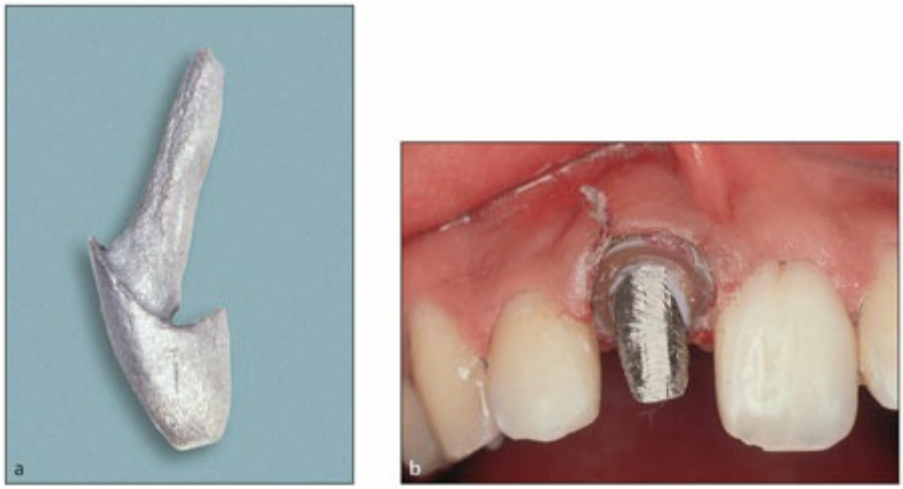

Fig 21-11*(a and b)* Custom-cast post to allow a change in the angle of the core in relation to the post.

Prefabricated metal posts

Prefabricated posts are available in a variety of metallic compositions and styles. They are most commonly manufactured from stainless steel, but many designs are

Dentlearn.ir

also available in titanium alloy. Because stainless steel contains nickel, some clinicians have been concerned about the possible allergenicity of the corrosion products of this metal. Titanium alloy posts were introduced to address this concern. A disadvantage of titanium alloy posts is that they have low radiodensity and may be difficult to detect on radiographs.[84] The passive parallel post, the tapered passive post, and the active post designs will be considered here. The applications for these post types are similar, with certain qualifications as outlined below.

Passive parallel-sided metal post

The prefabricated metallic post by which all other posts are measured has traditionally been the Parapost (Coltène/Whaledent) (see Fig 21-9a). The success of this post style has been demonstrated in the laboratory[21,85,86] as well as clinically.[23,43] Compared with other metallic post designs, the parallel post has been shown to provide the most favorable stress distribution$_{87}$ and exhibits greater retention than the passive tapered post.[88] However, a biologic price must be paid for this increased retention. The naturally tapered canal space must be enlarged to accommodate a parallel post. Enlargement of the canal space is not consistent with the ideal of maintaining as much tooth structure as possible. For this reason, use of the passive parallel post is recommended only when increased retention is needed and the parallel canal preparation will not jeopardize the integrity of the root.

Passive tapered metal post

A goal of all post systems should be minimal removal of tooth structure before post placement. Therefore, the ideal post system requires no further preparation after removal of the gutta-percha. Because the natural shape of the canal is tapered, the passive tapered post best fulfills this criterion. A major advantage of the passive metallic tapered post is that the post can be modified to fit the tapered canal rather than the canal having to be enlarged to fit the post.

The major disadvantage is that the tapered post provides the least retention compared with other post designs. This means that retention must be gained through maximum post length. When the available post space is not long enough to allow for adequate post length, a more retentive post may be indicated. A second commonly stated disadvantage of the tapered post is the alleged wedging effect, which results in increased stress at the apex and possible resultant root fracture.[87,89] This effect has been demonstrated in laboratory studies$_{80}$ with custom-cast tapered post and core restorations. However, this theoretical wedging effect does not appear to be

Dentlearn.ir

valid when a passive tapered post is used in conjunction with an acceptable core material and a crown.[90] A 10-year retrospective study confirmed the clinical durability and retentive ability of smooth tapered posts of appropriate length.[91]

An excellent indication for the passive tapered post is in teeth with small canals and thin, fragile roots, such as maxillary premolars (see Fig 21-7). However, posts of this design may be used routinely in teeth with normal canal configuration and sufficient canal length to provide the necessary retention.

Active metal post

An active post is one that engages (screws into) the dentin of the canal space. There are many active post designs available, including those requiring a tap, self-tapping posts, split-shank posts, and hybrid posts, which contain both active and passive features (see Fig 21-9a). It is difficult to generalize about active posts because of their design differences. In general, it has been reported that the active threaded post has the greatest retention, followed by the parallel post, with the tapered post providing the least retention.[85,86,92] Therefore, the post design should be chosen, in part, by the amount of post retention that the clinical situation requires. If the canal length is adequate and the canal configuration is normal, either the tapered or the parallel post may be selected. However, if the length of post space available is minimal or the canal space is funnel shaped, an active post may be required because of the difficulty in gaining adequate axial retention.

Traditionally, the major concern about active posts has been the potential for vertical fracture of the tooth during placement of the post.[85] In a photoelastic study, stress concentration was noted at each thread of the screw post.[93] However, many laboratory studies support the use of the newer generation of active posts.[94–99] It has been shown that the active post should not be "bottomed out" when it is inserted.[98] After complete seating of an active post, it should be unscrewed one-fourth of a turn. This results in decreased residual stress in the root. It has also been shown that, at shorter lengths, the active post produces less stress than other styles of prefabricated posts.[100] Therefore, active posts are indicated when the canal length is insufficient to gain adequate retention with a passive post. Situations in which an active post may be useful include a short canal space (Fig 21-12) or a canal that is partially occluded by a broken instrument or post.

Dentlearn.ir



Fig 21-12*(a)* Preoperative view of a maxillary lateral incisor with a short canal space. *(b)* The maxillary lateral incisor after restoration with a Brasseler V-Lock active post and amalgam core.

Caution should be used in selecting an active post. In a prospective clinical study, Schmitter et al[101] compared the clinical performance of a metallic screw post with an FRC post over a 5-year period. The survival rate of the teeth restored with a screw post was 50%, while the teeth restored with an FRC post showed a survival

fracture, while the failures with the FRC post were due predominantly to debonding.

Cementation of metal posts. Traditional cements for posts and post and core restorations have been investigated extensively.[85,102–107] These include zinc phosphate, polycarboxylate, and glass-ionomer cements. Both zinc phosphate and glass ionomer have been commonly employed because of their ease of use and their history of clinical success. Traditional cements provide retention for the post primarily through a frictional effect. The cement flows into irregularities in the dentin and post surfaces. On hardening, mechanical retention is created.

The lentulo spiral is an excellent instrument for the placement of the traditional cements (Fig 21-13). The cement may also be placed in the canal with a needle tube, as long as the tip of the tube is inserted to the bottom of the canal space *and* the cement is extruded from the tip as it is slowly removed from the canal. After the cement is placed in the canal, the post is coated with the cement and inserted. The post should be inserted slowly to allow dissipation of hydrostatic forces that might impede complete seating. This is a particular issue with precisely fitting, parallel-sided posts.[108] Many prefabricated posts have a venting mechanism incorporated into their design. Tapered posts are considered "self-venting."[109]

Dentlearn.ir



Fig 21-13 A lentulo spiral is used to place cement into the canal space. This instrument can also be used to enhance impression material adaptation to prepared canal spaces.

Recent trends are toward adhesive cementation of metallic posts, as well as FRC posts, with resin cement. Two adhesive interfaces are involved in this process: the interface of the cement with the dentin and that of the cement with the post. Regarding the cement interface with the metal post, the bond of resin cement has been shown to be improved by air abrasion and by the use of tribochemical coating.[110] Tribochemical coating involves air abrading the post surface with silicate-coated alumina particles followed by chemical silanization. This chair-side process is available commercially as CoJet (3M ESPE). The interface with dentin will be considered in detail later in this chapter.

Ceramic posts

The all-zirconia posts are white, biocompatible,[111] and radiopaque. When used in conjunction with a resin composite core material, a very esthetic post and core can be fabricated. They are strong compared with prefabricated metal and FRC posts, but they are reported to have low resistance to crack propagation.[112] They have an even higher modulus of elasticity than stainless steel,[113] which creates concerns that stress concentration might predispose the tooth to root fracture.[114] However, in vitro studies have shown that failures predominantly involve fractures of the post without root fractures.[115–117] Possibly, the fracture of the ceramic post absorbed most of the energy, thereby saving the remaining root from fracture.[20] While this might be perceived as a beneficial root-preserving effect, fracture of the ceramic post presents a clinical dilemma in that the remaining portion is extremely difficult to remove from the root canal.[112,115] In addition, it has been reported that zirconia posts are manufactured with a wide range of defects, resulting in some posts with very low fracture resistance.[118] Adhesive cementation of a ceramic post within the root canal is problematic because of the difficulty of bonding to the post surface.[119]

Dentlearn.ir

Hydrofluoric acid will not etch the zirconia surface, and air abrasion has variable effects depending on the resin cement used.[110] A variety of chemical primers have been developed and have been shown to enhance the bond to zirconia.[120–122] However, it appears that the bond created with these agents may be susceptible to degradation with aging.[123] Bond strength has also been shown to be improved by

monomer.[125] Because of the susceptibility of zirconia posts to fracture, the increased risk of root fracture, and the difficulties associated with bonding, they cannot be recommended for routine clinical use.

Fiber-reinforced composite posts

Carbon FRC posts

Restoration of endodontically treated teeth with adhesively cemented FRC posts and resin-based composite restorative materials has become increasingly popular in recent years. The trend began in the early 1990s with the introduction of the carbon fiber post. One of the early carbon fiber posts (C-Post, Bisco) consisted of carbon fibers arranged longitudinally in an epoxy matrix. The carbon fiber content constituted approximately 64% of the bulk of the post.[126] It was marketed on the basis of its high strength, its compatibility with adhesive bonding techniques, and a modulus of elasticity comparable with that of dentin. It was postulated that this similarity in stiffness would reduce stress concentration and therefore prevent root fracture.[127] It appeared that the design was effective in this regard. In a 10-year retrospective study, the C-Post showed a success rate of 93%, with no failures due to root fracture.[128] A perceived disadvantage of carbon fiber posts was poor esthetics because of their dark color. With the advent of the glass and quartz FRC posts, carbon FRC posts lack a specific indication and are seldom used.

Glass and quartz FRC posts

Composition. Current FRC posts are fabricated of glass or quartz fibers embedded in a matrix of epoxy or resin composite. When this newer generation of FRC posts was introduced, they were marketed on the basis of improved esthetics because of their white color and translucency. The carbon fiber posts of the previous generation occasionally caused an objectionable dark shadow under highly translucent ceramic restorations. Today, most routinely used ceramic systems utilize a core of opaque

Dentlearn.ir

alumina, zirconia, or lithium disilicate, so the purported esthetic advantage of fiber posts has become less important. However, the potential advantages of a favorable modulus of elasticity and bonding compatibility remain.

FRC posts can be made of different types of glasses. Electrical glass (E-glass) is an amorphous structure composed of silicon dioxide (SiO_2) and other oxides and is the most commonly used type, although high-strength glass (S-glass) is also used. Additionally, some posts are made of quartz—pure silica in a crystalline form.[129] The fibers are often silanated to improve adhesion to the matrix material. They are manufactured by placing a fiber bundle under a load (*pretensing*) and then impregnating it with a liquid resin, which is then cured, often with heat. The load is then released, leaving the fibers under tension, which places the surface of the cured resin in compression to improve resistance to flexural forces.[130] The material is then cut and machined to the desired shape to produce the FRC post. A scanning electron micrography (SEM) image of the head of an FRC post illustrates the surface left by the machining process (Fig 21-14).

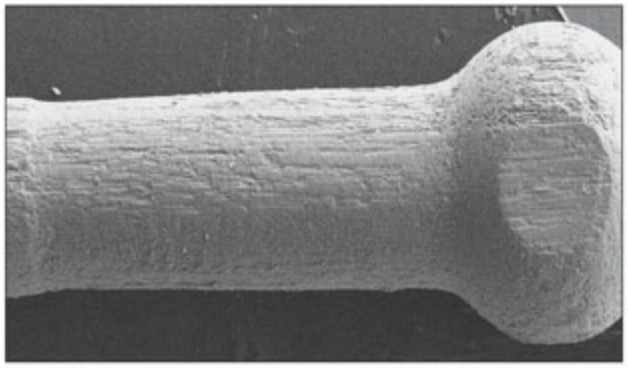

Fig 21-14 Surface characteristics of a machined FRC post are shown in an SEM image (original magnification ×20).

A typical FRC post (DT Light-Post, Bisco) consists of pre-tensed unidirectional 8-μm silanated quartz fibers in an epoxy matrix. The fibers occupy 60% of the volume of the post at a density of 32/mm^2.[75] In contrast, the matrix of another commonly used post (FRC Postec Plus, Ivoclar Vivadent) consists of triethylene glycol dimethacrylate (TEGDMA) and urethane dimethacrylate (UDMA) resins with dispersed silica fibers.[131] A wide variety of FRC post designs are available (see Fig 21-9b).

Strength and fracture resistance. It is difficult to directly compare the strengths of individual FRC post designs because of differences in surface topography (machined retentive features) and tapering, which prevent use of common flexural strength–

Dentlearn.ir

testing methods. However, Stewardson et al[132] tested the flexural properties of post source materials of consistent diameter and length according to International Organization for Standardization (ISO) specification (3597-2:1993, Method 1008B:1996) and determined that the strength of some commonly used fiber post materials exceeded that of gold and stainless steel. FRC posts from different manufacturers vary widely in their ability to withstand fatigue loading, most likely because of differences in manufacturing technique, shape of the post, and fiber density.[130]

Exposure to water and thermocycling has a variable effect on the strength of FRC posts over time, but it is doubtful whether the changes noted are of sufficient magnitude to cause clinical concern.[129,133] Additionally, when sealed inside the root canal, water storage for a 12-month period did not decrease the strength of fiber posts over that of the dry control.[134]

The literature is replete with studies conducted on the fracture resistance of various FRC post and core systems, with many conflicting opinions. Fokkinga et al[20] conducted a structured analysis of the literature on in vitro failure loads and failure modes of fiber, metal, and ceramic post and cores. The structured analysis process for in vitro data is similar to the systematic review, a widely accepted method used to evaluate and summarize the results of randomized controlled clinical trials. An initial MEDLINE search located 1,984 possibly relevant studies. After a series of more rigorous selection criteria were applied, 12 papers were eventually selected, and a multinomial statistical analysis was applied. Most studies described failure loads and modes resulting from static load testing of single-rooted teeth. In general, the prefabricated metal posts were found to have the highest failure loads and the ceramic the lowest. However, FRC posts exhibited more clinically favorable failures with a lower incidence of root fracture. In one study, loading a tooth restored with a steel post resulted in a 30% incidence of root fracture compared

Studies performed with restored extracted teeth are difficult to conduct and interpret because of the great number of variables that must be controlled. High standard deviations are often seen in these studies.

Protection of the root. There are many modes of failure of endodontically treated teeth—caries, periodontal disease, failure of endodontic treatment, or debonding of the post or crown, among others. However, the most catastrophic failure is root fracture. Root fracture often renders a tooth nonrestorable and results in extraction. Figure 21-15 illustrates the effect of the presence of a post schematically. A rigid

Dentlearn.ir

metallic post transmits a laterally applied occlusal force primarily to the cervical area and to the apex of the post. FRC posts have been proposed as a means of reducing the incidence of root fracture by distributing the forces throughout the root. This effect is theoretically achieved through a better match of modulus of elasticity between the dentin and the post.

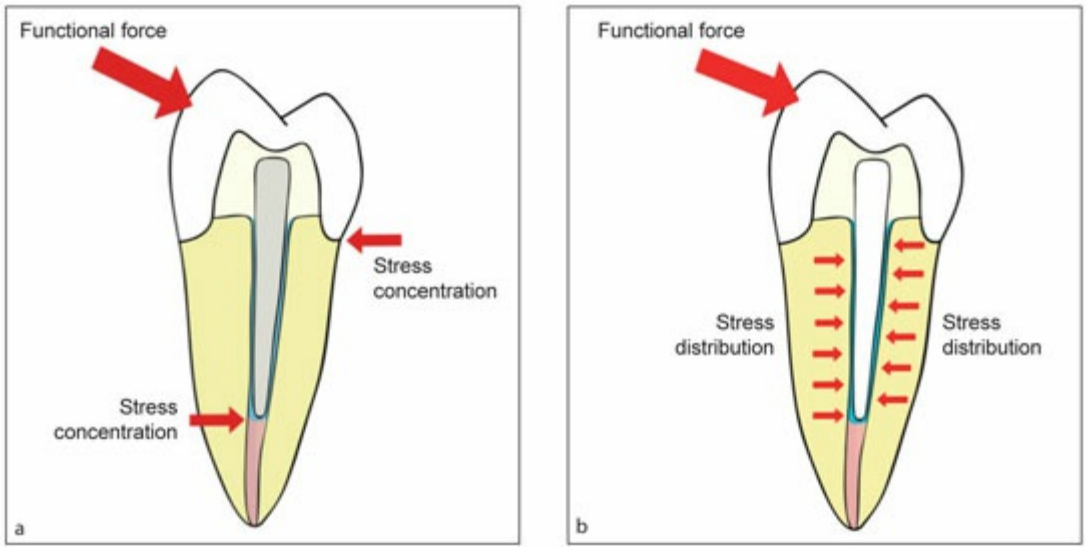

Fig 21-15 Comparative stress distribution within the root: metal post *(a)* versus FRC post *(b)*.

The observed modulus of elasticity of dentin varies depending on testing methodology and on the characteristics of the substrate tested. Regional variations of this dentin modulus also occur, depending on the number and diameter of tubules present. The bulk modulus of dentin has been reported to be in the range of 20 to 25 GPa.[135] Of the materials available for the construction of posts, quartz or silica FRC posts provide the best combination of strength and favorable modulus (Table 21-1).

Table 21-1 **Flexural strength and modulus of restorative materials and dentin**

Material	Type	Elastic modulus (GPa)	Flexural strength (MPa)
Stainless steel[132]		194	743
Carbon fiber[132]	Composipost*	117	1,394
Titanium[132]		110	1,478
Gold[132]	Type IV	87	355
E-glass fiber composite[132]	Postec†	44	1,215
Quartz glass fiber	Light-Post‡	42	1,131

Dentlearn.ir

composite[132]			
Dentin[135]		16	200
Resin composite[136,137]	Z100§	20	139
Resin cement[138]	RelyX Veneer§	8	118
Ceramic[139]	Feldspathic porcelain	70	100

* RTD.
† Ivoclar Vivadent.
‡ Bisco.
§ 3M ESPE.

Predicting clinical performance with in vitro testing is difficult because of the complexity of the system being studied. Success depends on many factors: amount of remaining tooth structure, characteristics of the dentin, quality and effect of endodontic treatment, quality of adhesive bond, and others. Most laboratory studies test only one aspect of restoration behavior.

Finite element analysis (FEA) is a mathematic modeling technique that can be used to calculate stress distribution in structures made from materials with differing moduli and strengths. When applied to endodontically treated teeth, the results have been equivocal. A number of studies have found that use of posts with a stiffness similar to that of dentin results in better stress distribution within the root,[140–142] while others have reported higher stresses in roots restored with lower-modulus posts.[143,144] FEA techniques assume that the materials are homogenous and linearly elastic and that all interfaces are perfectly bonded—conditions that likely do not exist intraorally. Accurate depiction of true clinical conditions would require a level of sophistication not yet seen in the dental literature.

In vitro data tend to support the view that FRC posts have a protective effect on the root compared with metallic posts, but clinical evidence is limited. A Cochran Review published in 2007 identified only one clinical study that achieved the objective of comparing metal with nonmetal posts and also met the data quality criteria.[145] In this retrospective study, Ferrari et al[126] compared the outcomes of restoration with cast gold post and cores with that of FRC posts after 4 years of

root fracture.

Effect of ferrule. As discussed earlier in this chapter, the amount of ferrule, or

Dentlearn.ir

vertical height of the residual dentin above the finish line, is critical to clinical success of endodontically treated teeth. In recent years, a body of literature specific to the effect of ferrule on the performance of teeth adhesively restored with FRC posts has emerged. As with teeth restored with metallic posts conventionally cemented, it is clearly evident from these studies that success of endodontically treated teeth adhesively restored with FRC posts is strongly dependent on the amount of remaining tooth structure.[146] Regardless of restorative methodology used, this factor remains the most consistent predictor of success.[147]

Fatigue testing of extracted teeth restored with FRC posts and ceramic crowns emphasizes the importance of ferrule height. Teeth without a ferrule withstood only 212 load cycles; the presence of a 0.5-mm ferrule raised the mean failure to 155,137 load cycles; and teeth with a 1.0-mm ferrule survived the testing to completion at 250,000 cycles.[148] While it is ideal to have 360 degrees of circumferential axial wall dentin, when there are only partial walls remaining, the location of those walls may affect the prognosis of the restored tooth. As might be predicted by the functional forces applied, the presence of a palatal wall of dentin was found to be critical to the ability of anterior teeth restored with FRC posts to resist crown dislodgment.[149]

The importance of the amount of remaining coronal tooth structure is revealed in the results of clinical studies. In a clinical study of teeth that had been restored with oval-shaped glass fiber posts, Signore et al[150] found that failure increased dramatically when only one or two residual dentin walls greater than 1 mm in height

year clinical study, teeth with a ferrule less than 2 mm in height exhibited a failure rate of 26%. Teeth with a ferrule greater than 2 mm in height had a failure rate of only 7%.[151]

Perhaps the most convincing demonstration of the effect of remaining tooth structure is found in the clinical study by Ferrari et al.[24] A total of 360 teeth were

FRC post, a resin composite core, and porcelain-fused-to-metal crowns. Examination of the results (Table 21-2) reveals a steadily increasing number of failures as the number of remaining walls decreases. This study also demonstrates the contribution of post placement to clinical success. The post does, in part, compensate for a lack of remaining tooth structure, in contrast to previously accepted thought.[152] The Ferrari study also suggests that the presence of a bonded FRC post may provide some degree of reinforcement of the root, as evidenced by the

Dentlearn.ir

observation that teeth without a post exhibited a higher incidence of root fracture than those with a post.[24]

Table 21-2 **Clinical success rates of teeth without a post and with an FRC post according to the amount of remaining tooth structure after 6 years in service[24]**

	4 coronal walls	3 coronal walls	2 coronal walls	1 coronal wall	No walls, ferrule present	No walls, ferrule absent
No post	**100%**	**67%**	**53%**	**29%**	**11%**	**0%**
Crown debond		3	5	6	9	9
Endo failed		3	2	3	3	4
Root fractured			1	3	4	7
DT Light-Post	**100%**	**94%**	**89%**	**78%**	**61%**	**39%**
Post debond		1		3	4	4
Endo failure				1	2	3
Post fracture			1		1	3
Root fracture			1			3

Endo—endodontic treatment.

The dimensions of the ferrule and the number of remaining walls may be considered as primary predictors of clinical success. The previously cited clinical studies make it clear that when a circumferential ferrule of at least 2 mm is not present, the chance of failure increases dramatically.

Adhesion Within the Root Canal

A stated goal of adhesive restoration of endodontically treated teeth is to create a "monoblock" of perfectly bonded components of the same or similar modulus of elasticity—a "structurally and mechanically homogenous complex with dentin."[153] However, as we can see from the summary of clinical studies (Table 21-3), the bond

Dentlearn.ir

of resin cement to dentin in the root canal is far from perfect. The predominant failure mode of teeth restored with bonded FRC posts is consistently debonding of the post/restoration complex.

Advances in adhesive bonding to coronal dentin have led to materials and techniques that are durable and predictable, particularly when three-step etch-and-rinse adhesives are used.[158,159] When measured using comparable methodologies, the bond to root canal dentin appears to be lower than that to coronal dentin.[160,161] There are many reasons why this might be so: There are differences in the characteristics of root versus coronal dentin; there are possible effects from endodontic treatment; the root canal presents a geometry that results in the development of high stresses during resin polymerization; and access and visibility are poor for cleaning and bonding procedures.

Table 21-3 **Clinical studies for glass or quartz FRC posts cemented using an etch-and-rinse adhesive technique***

Authors	Mean study period (Y)	Coronal structure remaining	Teeth treated/ recalled	Tooth type	Definitive restoration	CF (%)	PD (%)	EF (%)	RF (%)	PF (%)
Malferrari et al 2003[154]	2.5	NR	180/NR	All	All-ceramic or metal-ceramic full crown	2	1			
Monticelli et al 2003[155]	2	Two coronal walls	225/NR	Pre-molars	All-ceramic full crown	6	4	3		
Grandini et al 2005[130]	2.5	50% residual tooth structure	100/NR	All	Direct composite	1		1		
Cagidiaco et al 2007[156]	2	0–4 walls	162/162	All	Crowns, direct composite	7	4	3		
Schmitter et al 2011[101]	5	At least 40% of crown destroyed	50/39	NR	Single crowns, FPD or RPD retainers	28	20	3		
		1–								

Dentlearn.ir

Ferrari et al 2012[24]	6	ferrule, no ferrule	120/101	Pre-molars	ceramic full crown	23	11	7	1	
Naumann et al 2012[157]	10	None vs one or more walls	157/1499	All	All-ceramic/ metal-ceramic full crown	37	11	5	3	11

NR–not reported; FPD–fixed partial denture; RPD—removable partial denture; CF–clinical failure; PD–post de
EF–endodontic failure; RF–root fracture; PF–post fracture.
*Numbers may not total correctly due to rounding error.

As a bonding substrate, root dentin is similar to coronal dentin. It was once thought that endodontic treatment led to a decrease in moisture content of the dentin.[3] This assumption has been challenged in recent years, and current thought is that endodontically treated teeth are very similar to untreated teeth in moisture content,[162] mechanical properties, and collagen cross-linking.[163] Some differences do exist. Structurally, root dentin has fewer tubules than coronal dentin and may exhibit tubular sclerosis, particularly in the apical region.[164–166] While these dentin factors may indeed affect in vitro bond strength,[167] with the current state of the art they are probably overshadowed by clinical technique and material issues.

Adhesion within the root canal is typically measured by three different techniques: pull-out tests, microtensile tests, and push-out tests. *Pull-out testing* involves cementing a post within the root of an extracted tooth and then fixing the root into position, gripping the post in the vise of a tensile testing machine, and pulling it out. The force required to remove the post provides an average measurement of the post retention. The pull-out test is difficult to use for FRC posts because the vise grip often crushes the post. *Microtensile testing* is often used for bond strength testing of coronal dentin and can be applied to root dentin. One difficulty with this technique is that the bonded interface is curved because of the shape of the canal, which may make interpretation of the data problematic. The *push-out test* is commonly used to evaluate bond strength within the root canal. With this technique, the FRC post is bonded within the canal of an extracted tooth, and the root is then sectioned into slices perpendicular to its long axis. The cross section of the cemented post within each slice is then loaded to failure, and the bond strength is calculated from the measured surface area of the debonded segment. The push-out test allows determination of bond strength at different levels within the canal and has been found to be more predicta on.[161] See chapter 9

Dentlearn.ir

for more on adhesion testing.

Using the push-out methodology, a number of researchers have reported regional variability in bond strength in the root canal. In general, the bond strength decreases from coronal to apical sites. A consistent decrease in the length and density of resin tags formed during bonding procedures from the coronal to the apical aspect of the canal has also been noted.[168–170] This may be because of the aforementioned increase in tubular sclerosis in the apical region or regional differences in the effectiveness of bonding procedures because of decreased access and visibility.

Effects of polymerization shrinkage and stress

Resin composites shrink approximately 2% to 6% during polymerization.[171] This shrinkage results in contraction forces that may exceed the bond strengths of dentin adhesives.[172] This developing stress may be relieved when there are sufficient free surfaces compared with bonded surfaces in the restoration. The ratio of the bonded to nonbonded surface area is termed the *configuration factor*, or *C-factor,* and is commonly used to describe the severity of the stress challenge on the dentin bond.[172,173] For example, a Class 3 resin composite restoration would have a C-factor of about 1, while a Class 1 restoration might have a C-factor of close to 6. In the root canal, the cement is bonded to an extremely large surface area of dentin and FRC post in comparison with the amount of free surface. It has been estimated that the C-factor of the root canal system may exceed 200.[160] This high-stress state may result in areas of debonding and formation of gaps in the bonded interface. These gaps decrease the overall bond strength occurring within the canal relative to that possible when bonding to a flat surface.[160] The formation of gaps is exacerbated by the conditions of moisture and repetitive occlusal loading found in the oral cavity. The effect of moisture was investigated by Bonfante et al,[174] who found that the percent of continuous dentin interface decreased with 3 months of water storage. Gaps were initially observed in the apical and middle thirds, but these had extended to the cervical area by 3 months. Teeth are continually subjected to fatigue loading in function, and this too can affect the integrity of the bonded dentin interface. Push-out strength decreased for all adhesives tested following thermomechanical loading.[175] The formation of gaps following fatigue loading is dependent on the post material, with FRC posts showing fewer gaps than metallic posts, presumably through the mechanism of better stress distribution.[176] Mannocci et al[177] examined the resin-dentin interface of teeth restored with FRC posts that had been extracted for periodontal reasons after periods of 6 months to 6 years of function. Debonding was

Dentlearn.ir

observed in approximately one-third of the evaluated interfaces. Cyclic fatigue forces are likely a major factor in the observed high proportion of debonding among clinical failures of restored endodontically treated teeth.[178]

Effects of post length and diameter

It is clear that geometric, material, and technical issues result in an imperfectly bonded interface between cement and dentin in the root canal. The relative contribution to post retention of mechanical bonding through hybridization versus purely frictional effects is a subject of debate in the literature.[179–181] It has been previously noted that lower bond strength is found in the apical region than in with the coronal region. Nonetheless, increasing post length does seem to increase post retention.[182,183] Therefore, the principle of increasing length to increase frictional retention, first recommended for metallic posts,[85,92] is also applicable to FRC posts.[141] As a general guideline, Sorensen and Martinoff[184] recommended that the post length should at least equal the crown length. The cervical region of teeth restored with posts is subjected to the highest stress levels,[185] and greater post length allows better distribution of these stresses along the root. When an anterior tooth is experiencing functional forces, the point of approximation of the cervical root with the crest of bone acts as a fulcrum point. Therefore, a more conservative guideline is that the length of the post should be greater than the length of tooth structure extending above the osseous crest.

Three general guidelines may be stated for determining post length:

1. Tooth structure should be preserved. Excessive radicular dentin should not be sacrificed to extend the length of the post.
2. At least 4 mm of gutta-percha should be left apically.
3. The length of the post should be at least equal to the amount of tooth coronal to bone.

Increasing mechanical retention by roughening canal walls with a diamond bur[186] or using specially designed burs to create undercuts in the canal has been proposed, but these techniques are not recommended because removal of additional tooth structure may increase the fracture potential of the root.

It has been reported that increasing the diameter of metallic posts does not significantly contribute to the frictional resistance of the post to displacement[85,187]

Dentlearn.ir

bonded FRC posts, increasing post diameter may have additional deleterious effects. As the diameter increases, so does the load-bearing capacity of the post. For example, a ¼-mm-diameter FRC post was found to have a load-bearing capacity of 85 N, whereas a 2.1-mm-diameter post of the same type has a capacity of 200 N. This increased load-bearing capacity due to increased diameter results in increased rigidity of the post system, which could override the elastic modulus, which is a material property.[20,129] Thus, an increased diameter of post relative to the remaining dentin wall thickness could result in root fracture as a common failure mode, similar to that observed in stiffer metallic or ceramic posts.

Clinical Principles of Adhesive Restoration

Clinical procedures should emphasize preservation of tooth structure, protection of the root, support of the crown, and augmentation of retention and resistance form with adhesive bonding. The first principle, conservation of tooth structure, begins with the endodontic procedure. A minimum of tooth structure should be sacrificed for access and instrumentation of the canal. A post should be placed only when required, because even with careful clinical technique, post space preparation results in the removal of tooth structure, increases the risk of root perforation, and increases time and expense. Optimally, the post should fit the canal as it presents following endodontic treatment. The canal should be occupied to the greatest extent possible with FRC post material, because it is stiffer and stronger than resin-based cements. Similarly, the core should be comprised as much as possible of FRC post material, because its higher stiffness compared with resin composite provides better support for the overlying crown material. An increased core modulus results in greater fracture resistance of ceramic crowns.[138,190,191] The measured modulus of elasticity of an FRC post increases as the load application progresses from 90 degrees to the long axis (as measured and reported in Table 21-1) to a more compressive load as the load becomes normal to the fibers of the post. Therefore, because of the geometry of the post and the direction of occlusal forces, the post material is much stiffer and stronger than the resin composite core material in which it is embedded. Consequently, the FRC post should be left at full length through the placement and buildup procedures and then cut to appropriate length during tooth preparation for the crown. In this way, the FRC post extends to the occlusal or incisal cement layer and provides maximum stiffness and support.

Table 21-1	Flexural strength and modulus of restorative materials and dentin

Dentlearn.ir

Material	Type	Elastic modulus (GPa)	Flexural strength (MPa)
Stainless steel[132]		194	743
Carbon fiber[132]	Composipost*	117	1,394
Titanium[132]		110	1,478
Gold[132]	Type IV	87	355
E-glass fiber composite[132]	Postec†	44	1,215
Quartz glass fiber composite[132]	Light-Post‡	42	1,131
Dentin[135]		16	200
Resin composite[136,137]	Z100§	20	139
Resin cement[138]	RelyX Veneer§	8	118
Ceramic[139]	Feldspathic porcelain	70	100

Therefore, the ideal post design includes a cylindric coronal portion and a conical apical portion.[192] FRC posts that are ovoid in cross section have been developed to better fill the space left by endodontic instrumentation of noncircular canals.[193] Used with ovoid ultrasonic post space preparation instruments, these posts have been found to provide clinically acceptable performance.[150] Conventional FRC posts may be ground to better fit the shape of the canal without loss of surface integrity.[194] However, the procedure is tedious and may be impractical in many situations. When presented with an overly flared canal, the clinician should strive to fill the space around the post with higher-strength/modulus resin composite versus resin cement. FRC "accessory posts" have been developed that may also prove to be useful.[195]

A minimal thickness of the cement layer should be achieved with a properly selected post shape and size. With decreased cement thickness, volumetric shrinkage is reduced.[196] The cement selected should have a low filler loading, because this will result in enhanced flow and adaptation and less shrinkage stress development in the confined canal space compared with more highly filled materials.[197,198]

To summarize, different material requirements exist in different areas of the tooth/restoration construction. The ideal structure would include an FRC post that fills the canal and the space occupied by the core to the greatest extent possible, a

Dentlearn.ir

minimal cement thickness, and a high-strength, high-modulus core material (Fig 21-16).

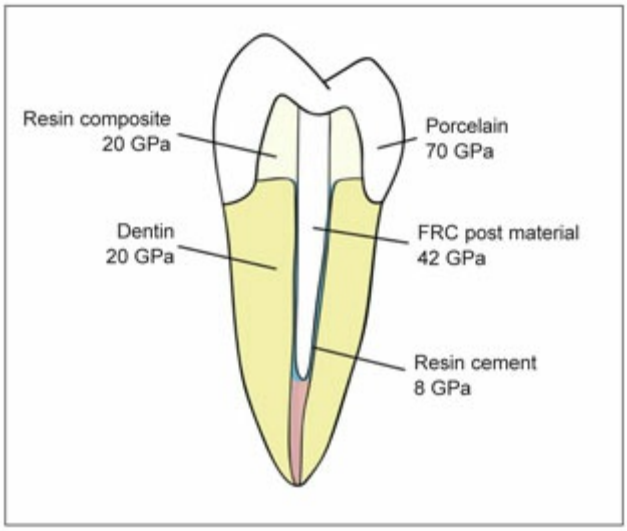

Fig 21-16 A comparison of moduli of elasticity of current restorative materials with that of dentin. The ideal structure would include an FRC post that fills the canal and the space occupied by the core to the greatest extent possible, a minimal cement thickness, and a high-strength, high-modulus core material.

Canal preparation

The root canal dentin of teeth that have been endodontically treated may have been exposed to materials and chemicals that have the potential of altering the dentin structure or interfering with resin polymerization. The canal may have been rinsed with an irrigant such as sodium hypochlorite, hydrogen peroxide, or ethylenediaminetetraacetic acid (EDTA). The dentin may have had extended exposure to sealers or calcium hydroxide. This history must be factored into the canal preparation and selection of adhesive materials.

The inhibitory effect of eugenol on resin polymerization is well known.[139] Eugenol readily diffuses from materials that contain it into adjacent dentin.[199] Eugenol-containing sealers are commonly used in endodontic treatment and have been implicated in decreased bond strength of resin-based adhesives,[200,201] through some researchers have found no effect.[202,203] The key factor seems to be mechanical preparation of the root canal prior to post cementation. Research indicates that this eliminates the effect, presumably by removing the eugenol-contaminated dentin.[204] The use of adhesive techniques incorporating phosphoric acid etchant also appears to restore bond strength.[205,206] The timing of canal preparation also is of concern. Endodontic sealers may exhibit extended setting times. McComb and Smith[207]

Dentlearn.ir

reported the setting time of Roth's 801 (a eugenol-containing material) to be 3.5 hours; the setting time of AH26 (a resin-based, noneugenol sealer) was 10.5 hours. In the case of post space preparation and cementation immediately following endodontic obturation, it may be difficult to clean the unset sealer from the canal walls. Also, even when walls appear to be clean, sealer may be inadvertently spread from the area of the apical seal during the application of adhesive agents via microbrush or paper points. Vano et al[208] reported decreased bond strength with a variety of adhesive techniques when canals were prepared and FRC posts cemented immediately following obturation. When post preparation and cementation was delayed by at least 24 hours, the bond strengths were statistically equivalent with that observed in unobturated roots. Clinicians should exercise caution when using a resin luting agent to cement a post immediately following canal obturation with eugenol-containing sealers.

A canal preparation drill is typically included with FRC post kits, and often the manufacturer's instructions specify preparation limited only to that instrument. Because the drill cross section is circular, and because canals are seldom round, use of this instrument exclusively will undoubtedly result in gutta-percha and sealer remaining in the recesses of oval- and ribbon-shaped canals unless the canal is overprepared. Therefore, canal preparation to receive a bonded FRC post should begin with smaller instruments such as Gates-Glidden burs. The flexibility of the Gates-Glidden bur allows the removal of gutta-percha with minimal risk of perforation. Creation of clean canal walls suitable for bonding can be surprisingly difficult. Even with the use of Peeso reamers prior to use of the post drill, a significant amount of debris remains on canal walls, particularly in the apical region.[209] The presence of this debris results in incomplete hybridization of the dentin in the contaminated areas.[210]

A post should be selected to fit the space created during endodontic treatment without significant further alteration of the canal. The sizing drill should only be used to remove any minor amounts of dentin that act as an impediment to the complete seating of an appropriately selected diameter of post. It should not change the existing anatomical structure of the canal as it presents postendodontically. Heavy apical or lateral forces should be avoided with the post drill. If the canal is properly prepared with the previous instruments, only a light force should be required. Meticulous technique is necessary in post space preparation, and a radiograph prior to cementation (without the post in place) is recommended to help detect any remaining gutta-percha or sealer.

Dentlearn.ir

Selection of bonding agent

A variety of materials and methods for bonding FRC posts are available. These include the traditional etch-and-rinse adhesives used in conjunction with resin cement, self-etching cements, and self-adhesive cements. For coronal dentin bonding, the three-step etch-and-rinse adhesive systems (the so-called fourth-generation bonding agents) involving the use of phosphoric acid etchant, hydrophilic primer, and adhesive remain the gold standard compared with simplified techniques.[158,159] The overwhelming majority of FRC posts in clinical studies were cemented using an etch-and-rinse technique; thus, it is the most clinically proven method. Although controversy exists, in vitro bond-strength studies comparing etching and rinsing with other cementation techniques in root canal dentin generally reflect the clinical results. The three-step etch-and-rinse adhesives are preferred for bonding in the root canal.[211–213]

Unfortunately, the use of etch-and-rinse adhesives within the root canal adds complexity and technique sensitivity to the post cementation process. Overcoming access and visibility constraints requires special techniques to achieve complete coverage of the walls with etchant and to ensure its removal. Similarly, primer application and solvent evaporation can be problematic. Effective etchant application requires the use of a cannula attached to the etchant syringe that will reach the apex of the canal preparation. The tips provided in the various FRC post kits are often inadequate for this purpose. The etchant is injected with a cannula of sufficient length while the tip is withdrawn. If a tip is used that does not reach the complete depth of the canal, a bubble will be formed apical to the point that the gel contacts the canal walls circumferentially, and the gel will go no further (Fig 21-17). If the canal is known to be deeper than the length of the tip, the gel may be carried to the apex with a microbrush. If gel is allowed to remain on the walls, primer penetration will be impeded, and a low-pH environment will be created that may be detrimental to the curing of the dual-curing adhesive that follows.[214] Potesta et al[170] demonstrated the superiority of this technique in a push-out study. The use of an appropriate cannula and technique resulted in higher bond strengths. An air-water syringe was ineffective even when used for periods up to 2 minutes. Rinsing the etchant with the same cannula and a syringe raised the pH level to neutral with as little as 5 ml of water.

Dentlearn.ir



Fig 21-17*(a)* Use of a tip of inadequate length. *(b)* A bubble forms at the point to which the tip extends, and the etchant will go no further. A microbrush must be used to obtain complete coverage. *(c)* Rinsing with an air-water syringe results in incomplete removal of the etchant. *(d)* Etchant remains on the canal walls and will impede bonding. *(e)* A cannula of adequate length is attached to the etchant syringe (Endo-Eze, Ultradent). *(f)* The tip is inserted to the depth of the canal, and the etchant is injected while the tip is withdrawn. *(g)* Complete coverage of the canal with etchant. *(h)* The same tip is attached to an irrigating syringe. *(i)* Complete removal of the etchant.

Care must be taken to ensure uniform application of primer to the canal walls. This is best accomplished through the use of an appropriately sized microbrush.[215,216] There are a number of products on the market that are effective (Fig 21-18). Removal of excess and evaporation of solvent from the primer may be accomplished by repeated insertion and blotting of a microbrush or through the use of paper points. Application of air from the air-water syringe may aid this process. Great care must be used in this step. If excess solvent is allowed to remain, it may inhibit polymerization in the hybrid layer.[217]

Dentlearn.ir

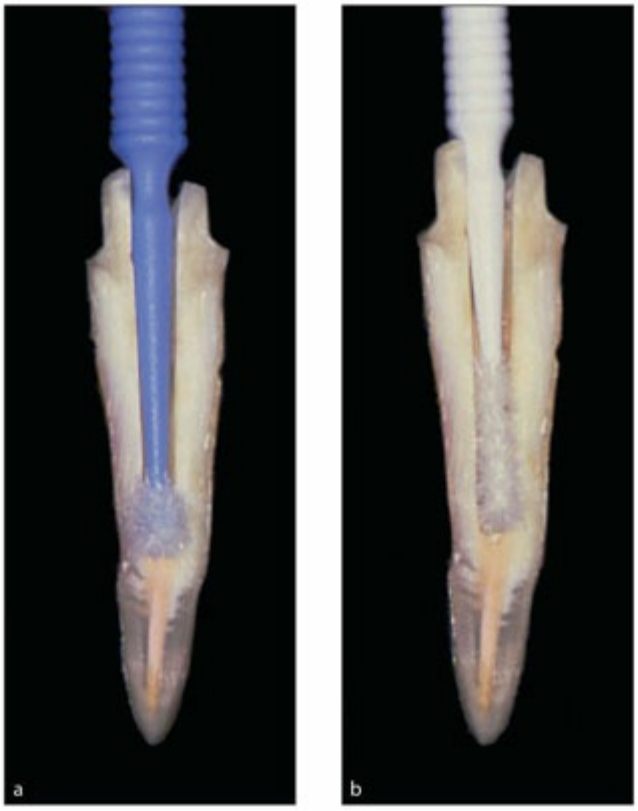

Fig 21-18*(a and b)* Microbrushes for primer application and removal of excess.

A dual-curing adhesive is then applied using a microbrush, and the excess is removed. The dual-curing cement should be applied to the canal using a similar technique. Currently, some manufacturers include tips with their cement that attach to the end of the mixing tip and will reach the apex of most canals (Fig 21-19). If the length of the tip is determined to be insufficient, the cement may be injected into the back of a disposable syringe with a longer cannula attached for delivery into the canal (Fig 21-20).



Fig 21-19 Dual-curing cement with automix tip and 17-mm applicator tip (RelyX Ultimate, 3M ESPE).

Dentlearn.ir



Fig 21-20 Disposable syringe (Skini Syringe, Ultradent) with 22-mm Endo-Eze applicator tip.

Self-etching and self-adhesive cements are marketed as being more convenient to use for post cementation. With self-etching cements, a self-etching primer is applied to the dentin, and the mixed cement is applied to the canal without rinsing. Self-adhesive cements are applied directly to the canal without etching or the use of additional primers or adhesives. While varied results may be found in the literature, they are generally less effective than etch-and-rinse systems.[131,218,219] Low bond-strength values and the lack of long-term clinical data limit the application of recently marketed self-etching and self-adhesive materials for the cementation of FRC posts.[213]

Effect of tag length

In coronal dentin, the majority of the bond strength is derived through hybridization of the intertubular dentin, with a minimal contribution from resin tags formed within the tubules.[220] Within the root canal, the situation appears to be somewhat different. In push-out testing, well-defined tag formation is usually found in areas of high bond strength, while regions with lower adhesion typically exhibit a poorly structured interface.[170,176] Studies show a decrease in tag length and definition from the coronal to apical regions regardless of the adhesive system used.[167,170,210,221] However, the three-step etch-and-rinse adhesives seem to be more effective than simplified systems in creating well-defined resin tags in the apical and middle third.[211] Figure 21-21 illustrates the difference in resin tag formation among a three-step etch-and-rinse adhesive, a self-etching cement, and a self-adhesive cement.[222] Abundant resin tags are noted with the three-step etch-and-rinse adhesive, and it is conceivable that these tags could contribute to frictional retention of the post. In contrast, self-etching and self-adhesive cements exhibit a superficial interaction with root canal dentin. They are not as effective in removing or

Dentlearn.ir

penetrating the thick smear layer produced during canal instrumentation and therefore exhibit poorly defined tag formation.

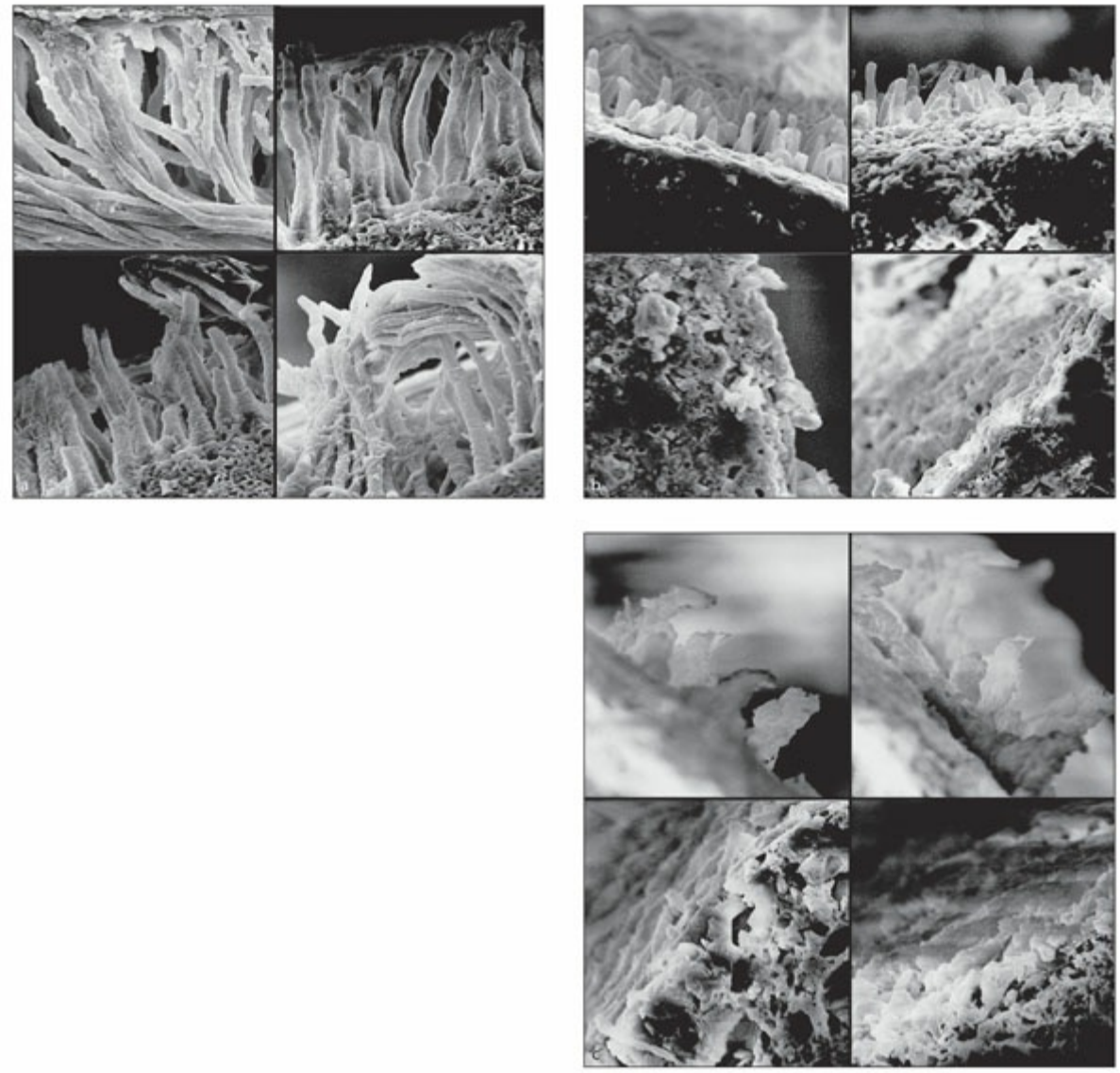

Fig 21-21 *(a)* Resin tag formation with a three-step etch-and-rinse adhesive (Permaflo DC Primers, Ultradent). *(b)* Resin tag formation with a self-etching cement (Panavia F 2.0 with ED Primer, Kuraray). *(c)* Resin tag formation with a self-adhesive cement (RelyX Unicem, 3M ESPE). *(clockwise from upper left)*: coronal dentin, two mid-root locations, apical region.

Bonding to the post

The matrix polymers used in FRC posts typically exhibit a high degree of conversion and are highly cross-linked.[129] The possibility of creating a chemical bond between the luting adhesive and the post is therefore low. However, machining of the post to the desired shape by the manufacturer results in a rough surface, which provides a mechanical interlock for the adhesive (see Fig 21-14).

Dentlearn.ir

A number of methods to improve adhesion to the FRC post have been recommended. Most are intended to remove matrix material from the post to expose the silica-containing fibers. A silane coupling agent is then applied in an attempt to achieve a chemical bond of the silica-containing substrate with the resin cement or resin composite. The use of air abrasion, etching with concentrated hydrogen peroxide,[208] sodium ethoxide,[223] and other agents have been suggested as a means of removing resin matrix from the post surface. Air abrasion must be used with caution, because it can quickly destroy the post if applied for too long. Used appropriately, it has no effect on the mechanical properties of the post.[224] Air abrasion has been found to improve resin retention, with or without silane.[225,226] Treatment of the FRC post with concentrated hydrogen peroxide for as little as 1 minute has also been shown to be effective,[227] as has application of silane to the unetched post surface.[228] The use of hydrofluoric acid$_{208}$ and tribochemical coating$_{229}$ have been evaluated as well but are somewhat cumbersome to use and may damage the surface of the FRC post. The literature regarding the various surface treatments is conflicting, and most are tested after only a short period of water storage and without being subjected to a thermomechanical challenge. Khamverdi et al$_{230}$ evaluated the effect of hydrogen peroxide etching compared with air abrasion on microtensile bond strength to a FRC post after water storage. A steady decrease in bond strength was observed over the storage period, and by 9 months there was no difference between the two treatments. Some post manufacturers recommend application of a bonding agent to the post surface prior to cementation. While not harmful, this has not been shown to increase bond strength.[231]

FRC posts with a machined macroretentive surface are available. While this feature undoubtedly increases mechanical retention at the post-cement interface, it results in a significantly lower fracture resistance than a similar sized post with a smooth surface.[78] Attempting to improve the adhesion beyond that provided by a clean post surface may not be clinically useful. Boschian Pest et al[168] determined the bond strength a variety of adhesives and cements to fiber posts and to dentin. With each combination, the bond to the post was significantly higher than the bond to dentin. The results of most push-out and pull-out bond studies indicate that failure is typically at the dentin interface rather than the post interface.

Box 21-2	**Armamentarium for FRC post cementation**
Restorative setup and routine disposables Boley gauge Post sizing drill	Etchant gel Cannula tip 5-ml syringe

Dentlearn.ir

Fiber post Resin composite restorative material Gates-Glidden burs (nos. 2 to 5) Silicone stops Alcohol wipe	Three-step etch-and-rinse dual-curing adhesive Dual-curing cement with mixing and injection tips Barrier sleeves Microbrushes (3)

Box 21-3	**Clinical steps for FRC post cementation**
1. Administer local anesthesia if necessary. 2. Estimate the length/diameter of the post using the final endodontic radiograph. 3. Isolate the tooth with a rubber dam. 4. Remove existing provisional and any remaining restoration. 5. Set the Gates-Glidden bur to the desired length with a silicone stop and remove the gutta-percha. 6. Set the post sizing drill (corresponding to the post selected) to the established length with a silicone stop and remove any minor obstructions to seating. 7. Take a radiograph to confirm complete gutta-percha removal. 8. Clean the post with an alcohol wipe; set the silicone stop to the established depth of insertion. 9. Attach a cannula tip to the etchant syringe, insert it to the full depth of the canal, and inject the etchant while withdrawing the tip. Coat all radicular and coronal tooth structure to be bonded with etchant. 10. Remove the cannula tip from the etchant syringe and attach it to a 5-ml-syringe loaded with water.	11. Irrigate the canal and surrounding tooth structure with water. 12. Dry with an air syringe; blot the canal with a micro brush. Leave the dentin slightly moist. 13. Apply primer to all dentin surfaces with a microbrush. 14. Evaporate solvent from the coronal dentin with a gentle stream of air. Remove excess primer from the canal by repeated blotting with microbrush. 15. Apply dual-curing adhesive to all dentin surfaces with a microbrush; use a bristle brush to ensure even coating and remove excess from the coronal surfaces. Remove excess adhesive from the canal by repeated blotting with a microbrush. Do not light cure. 16. Attach a new mixing/injection tip to the cement syringe; bleed a BB-sized amount of cement through the tip. 17. Insert the tip to the depth of the canal and inject while withdrawing. Do not overfill. Immediately insert the post and hold it in place with moderate pressure. The post should be inserted slowly to allow dissipation of hydrostatic forces. Remove any excess cement. 18. Light cure for 20 seconds. 19. Proceed with core buildup with resin composite.

Dentlearn.ir

Cement selection

Both light-curing and dual-curing resin cements are available for bonding of FRC posts. Techniques using light-cured adhesives and cements polymerized via light-transmitting posts have been suggested. FRC posts have been presumed to conduct light via the glass or quartz fibers, but these may in fact contribute a relatively small effect compared with the light-transmission capabilities of the resin matrix material.[232] Light-transmitting capabilities vary widely among different posts because of material variations. For all posts, light transmission decreases from coronal to apical. Some FRC posts have been found to transmit no light at all.[233] Relative post translucency affects the degree of conversion of the light-cured cement,[234] but even a highly translucent post exhibits a limited ability to transmit sufficient light to fully cure the resin. In a study assessing the light-transmission capabilities of a translucent fiber post, Galhano et al$_{235}$ found that the microhardness of the resin cement decreased with distance from the light source and that the apical third of the cement remained unpolymerized. Because of uncertainties regarding complete polymerization with the use of light-cured cements, dual-cured materials are recommended. The self-curing mode ensures polymerization at the depths of the canal, and the relatively slow set may allow some stress relief within the cement layer.[236,237] Light curing the dual-curing cement following initial set will stabilize the post to allow the clinician to proceed with the core buildup. It also increases conversion and improves the mechanical properties of the cement.[238–240]

Clinical Technique

From the preceding discussion, it is clear that clinically successful adhesive restoration of endodontically treated teeth requires a detailed understanding of the bonding substrate and materials and scrupulous attention to detail. A suggested armamentarium and procedure for FRC post cementation are shown in Boxes 21-2 and 21-3.

References

1. Wu MK, van der Sluis LW, Wesselink PR. Comparison of mandibular premolars and canines with respect to their resistance to vertical root fracture. J Dent 2004;32:265–268.
2. Tang W, Wu Y, Smales RJ. Identifying and reducing risks for potential fractures in endodontically treated teeth. J Endod 2010;36:609–617.
3. Helfer AR, Melnick S, Schilder H. Determination of the moisture content of vital and pulpless teeth. Oral Surg

Dentlearn.ir

Oral Med Oral Pathol 1972;34:661–670.
4. Carter JM, Sorensen SE, Johnson RR, Teitelbaum RL, Levine MS. Punch shear testing of extracted vital and endodontically treated teeth. J Bio-mech 1983;16:841–848.
5. Huang TJ, Schilder H, Nathanson D. Effects of moisture content and endodontic treatment on some mechanical properties of human dentin. J Endod 1992;18:209–215.
6. Sedgley CM, Messer HH. Are endodontically treated teeth more brittle? J Endod 1992;18:332–335.
7. Randow K, Glantz PO. On cantilever loading of vital and non-vital teeth. An experimental clinical study. Acta Odontol Scand 1986;44:271–277.
8. Zadik Y, Sandler V, Bechor R, Salehrabi R. Analysis of factors related to extraction of endodontically treated teeth. Oral Surg Oral Med Oral Pathol Oral Radiol Endod 2008;106(5):e31–e35.
9. Salehrabi R, Rotstein I. Endodontic treatment outcomes in a large patient population in the USA: An epidemiological study. J Endod 2004;30:846–850.
10. Chen SC, Chueh LH, Hsiao CK, Tsai MY, Ho SC, Chiang CP. An epidemiologic study of tooth retention after nonsurgical endodontic treatment in a large population in Taiwan. J Endod 2007;33:226–229.
11. Naumann M, Blankenstein F, Kiessling S, Dietrich T. Risk factors for failure of glass fiber-reinforced composite post restorations: A prospective observational clinical study. Eur J Oral Sci 2005;113:519–524.
12. Barrieshi KM, Walton RE, Johnson WT, Drake DR. Coronal leakage of mixed anaerobic bacteria after obturation and post space preparation. Oral Surg Oral Med Oral Pathol Oral Radiol Endod 1997;84:310–314.
13. Alves J, Walton R, Drake D. Coronal leakage: Endotoxin penetration from mixed bacterial communities through obturated, post-prepared root canals. J Endod 1998;24:587–591.
14. Magura ME, Kafrawy AH, Brown CE Jr, Newton CW. Human saliva coronal microleakage in obturated root canals: An in vitro study. J Endod 1991;17:324–331.
15. Heling I, Gorfil C, Slutzky H, Kopolovic K, Zalkind M, Slutzky-Goldberg I. Endodontic failure caused by inadequate restorative procedures: Review and treatment recommendations. J Prosthet Dent 2002;87:674–678.
16. Lynch CD, Burke FM, Ní Ríordáin R, Hannigan A. The influence of coronal restoration type on the survival of endodontically treated teeth. Eur J Prosthodont Restor Dent 2004;12:171–176.
17. Willershausen B, Tekyatan H, Krummenauer F, Marroquin BB. Survival rate of endodontically treated teeth in relation to conservative vs post insertion techniques—A retrospective study. Eur J Med Res 2005;10:204–208.
18. Stankiewicz NR, Wilson PR. The ferrule effect: A literature review. Int Endod J 2002;35:575–581.
19. Sorensen JA, Engelman MJ. Ferrule design and fracture resistance of endodontically treated teeth. J Prosthet Dent 1990;63:529–536.
20. Fokkinga WA, Kreulen CM, Vallittu PK, Creugers NH. A structured analysis of in vitro failure loads and failure modes of fiber, metal, and ceramic post-and-core systems. Int J Prosthodont 2004;17:476–482.
21. Isidor F, Brøndum K, Ravnholt G. The influence of post length and crown ferrule length on the resistance to cyclic loading of bovine teeth with prefabricated titanium posts. Int J Prosthodont 1999;12:78–82.
22. Creugers NH, Mentink AG, Fokkinga WA, Kreulen CM. 5-Year follow-up of a prospective clinical study on various types of core restorations. Int J Prosthodont 2005;18:34–39.
23. Torbjörner A, Karlsson S, Ödman PA. Survival rate and failure characteristics for two post designs. J Prosthet Dent 1995;73:439–444.
24. Ferrari M, Vichi A, Fadda G, et al. A randomized controlled trial of end-odontically treated and restored premolars. J Dent Res 2012;91(suppl 1):72S–78S.
25. Zhi-Yue L, Yu-Xing Z. Effects of post-core design and ferrule on fracture resistance of endodontically treated maxillary central incisors. J Prosthet Dent 2003;89:368–373.
26. Sivers JE, Johnson GK. Periodontal and restorative considerations for crown lengthening. Quintessence Int 1985;16:833–836.
27. Fugazzotto PA, Parma-Benfenati S. Preprosthetic periodontal considerations. Crown length and biologic width. Quintessence Int Dent Dig 1984;15:1247–1256.
28. Starr CB. Management of periodontal tissues for restorative dentistry. J Esthet Dent 1991;3:195–208.
29. Gegauff AG. Effect of crown lengthening and ferrule placement on static load failure of cemented cast post-

Dentlearn.ir

cores and crowns. J Prosthet Dent 2000;84:169–179.
30. Iqbal MK, Kim S. For teeth requiring endodontic treatment, what are the differences in outcomes of restored endodontically treated teeth compared to implant-supported restorations? Int J Oral Maxillofac Implants 2007;22(suppl):96–116.
31. Rodriguez AM, Orenstein IH, Morris HF, Ochi S. Survival of various implant-supported prosthesis designs following 36 months of clinical function. Ann Periodontol 2000;5:101–108.
32. Lazarski MP, Walker WA 3rd, Flores CM, Schindler WG, Hargreaves KM. Epidemiological evaluation of the outcomes of nonsurgical root canal treatment in a large cohort of insured dental patients. J Endod 2001;27:791–796.
33. Erhardson S, Sheikholeslam A, Forsberg CM, Lockowandt P. Vertical forces developed by the jaw elevator muscles during unilateral maximal clenching and their distribution on teeth and condyles. Swed Dent J 1993;17:23–34.
34. Sorensen JA, Martinoff JT. Endodontically treated teeth as abutments. J Prosthet Dent 1985;53:631–636.
35. Hatzikyriakos AH, Reisis GI, Tsingos N. A 3-year postoperative clinical evaluation of posts and cores beneath existing crowns. J Prosthet Dent 1992;67:454–458.
36. Goga R, Purton DG. The use of endodontically treated teeth as abutments for crowns, fixed partial dentures, or removable partial dentures: A literature review. Quintessence Int 2007;38:e106–e111.
37. Castelnuovo J, Tjan AH, Phillips K, Nicholls JI, Kois JC. Fracture load and mode of failure of ceramic veneers with different preparations. J Prosthet Dent 2000;83:171–180.
38. Ho HH, Chu FC, Stokes AN. Fracture behavior of human mandibular incisors following endodontic treatment and porcelain veneer restoration. Int J Prosthodont 2001;14:260–264.
39. Kantor ME, Pines MS. A comparative study of restorative techniques for pulpless teeth. J Prosthet Dent 1977;38:405–412.
40. Trabert KC, Caput AA, Abou-Rass M. Tooth fracture—A comparison of endodontic and restorative treatments. J Endod 1978;4:341–345.
41. Guzy GE, Nicholls JI. In vitro comparison of intact endodontically treated teeth with and without endo-post reinforcement. J Prosthet Dent 1979; 42:39–44.
42. Trope M, Maltz DO, Tronstad L. Resistance to fracture of restored end-odontically treated teeth. Endod Dent Traumatol 1985;1:108–111.
43. Sorensen JA, Martinoff JT. Intracoronal reinforcement and coronal coverage: A study of endodontically treated teeth. J Prosthet Dent 1984; 51:780–784.
44. Aquilino SA, Caplan DJ. Relationship between crown placement and the survival of endodontically treated teeth. J Prosthet Dent 2002;87: 256–263.
45. Stavropoulou AF, Koidis PT. A systematic review of single crowns on endodontically treated teeth. J Dent 2007;35:761–767.
46. Nagasiri R, Chitmongkolsuk S. Long-term survival of endodontically treated molars without crown coverage: A retrospective cohort study. J Prosthet Dent 2005;93:164–170.
47. Scurria MS, Shugars DA, Hayden WJ, Felton DA. General dentists' patterns of restoring endodontically treated teeth. J Am Dent Assoc 1995;126:775–779.
48. Reeh ES, Messer HH, Douglas WH. Reduction in tooth stiffness as a result of endodontic and restorative procedures. J Endod 1989;15:512–516.
49. Hansen EK, Asmussen E. In vivo fractures of endodontically treated posterior teeth restored with enamel-bonded resin. Endod Dent Traumatol 1990;6:218–225.
50. Grandini S, Goracci C, Tay FR, Grandini R, Ferrari M. Clinical evaluation of the use of fiber posts and direct resin restorations for endodontically treated teeth. Int J Prosthodont 2005;18:399–404.
51. Mannocci F, Bertelli E, Sherriff M, Watson TF, Ford TR. Three-year clinical comparison of survival of endodontically treated teeth restored with either full cast coverage or with direct composite restoration. J Prosthet Dent 2002;88:297–301.
52. Eakle WS. Effect of thermal cycling on fracture strength and microleakage in teeth restored with a bonded composite resin. Dent Mater 1986;2:114–117.

Dentlearn.ir

53. Fissore B, Nicholls JI, Yuodelis RA. Load fatigue of teeth restored by a dentin bonding agent and a posterior composite resin. J Prosthet Dent 1991;65:80–85.
54. Hashimoto M, Ohno H, Kaga M, Endo K, Sano H, Oguchi H. In vivo degradation of resin–dentin bonds in humans over 1 to 3 years. J Dent Res 2000;79:1385–1391.
55. Hansen EK, Asmussen E, Christiansen NC. In vivo fractures of endodontically treated posterior teeth restored with amalgam. Endod Dent Traumatol 1990;6:49–55.
56. Nayyar A, Walton RE, Leonard LA. An amalgam coronal-radicular dowel and core technique for endodontically treated posterior teeth. J Prosthet Dent 1980;43:511–515.
57. Kern SB, von Fraunhofer JA, Mueninghoff LA. An in vitro comparison of two dowel and core techniques for endodontically treated molars. J Prosthet Dent 1984;51:509–514.
58. Christian GW, Button GL, Moon PC, England MC, Douglas HB. Post core restoration in endodontically treated posterior teeth. J Endod 1981; 7:182–185.
59. Summitt JB, Burgess JO, Berry TG, Robbins JW, Osborne JW, Haveman CW. Six-year clinical evaluation of bonded and pin-retained complex amalgam restorations. Oper Dent 2004;29:261–268.
60. Zillich R, Yaman P. Effect of root curvature on post length in the restoration of endodontically treated premolars. Endod Dent Traumatol 1985;1:135–137.
61. Pilo R, Shapenco E, Lewinstein I. Residual dentin thickness in bifurcated maxillary first premolars after root canal and post space preparation with parallel-sided drills. J Prosthet Dent 2008;99:267–273.
62. Robbins JW, Burgess JO, Summitt JB. Retention and resistance features for complex amalgam restorations. J Am Dent Assoc 1989;118:437–442.
63. Uy JN, Neo JC, Chan SH. The effect of tooth and foundation restoration heights on the load fatigue performance of cast crowns. J Prosthet Dent 2010;104:318–324.
64. Huysmans MC, Peters MC, Plasschaert AJ, van der Varst PG. Failure characteristics of endodontically treated premolars restored with a post and direct restorative material. Int Endod J 1992;25:121–129.
65. Kovarik RE, Breeding LC, Caughman WF. Fatigue life of three core materials under simulated chewing conditions. J Prosthet Dent 1992;68:584–590.
66. Bryant RW, Mahler DB. Modulus of elasticity in bending of composites and amalgams. J Prosthet Dent 1986;56:243–248.
67. Cooley RL, Robbins JW, Barnwell S. Dimensional stability of glass ionomer used as a core material. J Prosthet Dent 1990;64:651–653.
68. Ilie N, Hickel R, Valceanu AS, Huth KC. Fracture toughness of dental restorative materials. Clin Oral Investig 2012;16:489–498.
69. Almuammar MF, Schulman A, Salama FS. Shear bond strength of six restorative materials. J Clin Pediatr Dent 2001;25:221–225.
70. Chutinan S, Platt JA, Cochran MA, Moore BK. Volumetric dimensional change of six direct core materials. Dent Mater 2004;20:345–351.
71. Oliva RA, Lowe JA. Dimensional stability of silver amalgam and composite used as core materials. J Prosthet Dent 1987;57:554–559.
72. Vermilyea SG, Gardner FM, Moergeli JR Jr. Composite dowels and cores: Effect of moisture on the fit of cast restorations. J Prosthet Dent 1987;58:429–431.
73. Kijsamanmith K, Timpawat S, Harnirattisai C, Messer HH. Micro-tensile bond strengths of bonding agents to pulpal floor dentine. Int Endod J 2002;35:833–839.
74. Lopes GC, Cardoso Pde C, Vieira LC, Baratieri LN. Microtensile bond strength to root canal vs pulp chamber dentin: Effect of bonding strategies. J Adhes Dent 2004;6:129–133.
75. Baba NZ, Golden G, Goodacre CJ. Nonmetallic prefabricated dowels: A review of compositions, properties, laboratory, and clinical test results. J Prosthodont 2009;18:527–536.
76. Terry DA, Triolo PT Jr, Swift EJ Jr. Fabrication of direct fiber-reinforced posts: A structural design concept. J Esthet Restor Dent 2001;13:228–240.
77. Deliperi S, Bardwell DN, Coiana C. Reconstruction of devital teeth using direct fiber-reinforced composite resins: A case report. J Adhes Dent 2005;7:165–171.

Dentlearn.ir

78. Newman MP, Yaman P, Dennison J, Rafter M, Billy E. Fracture resistance of endodontically treated teeth restored with composite posts. J Prosthet Dent 2003;89:360–367.
79. Piovesan EM, Demarco FF, Cenci MS, Pereira-Cenci T. Survival rates of endodontically treated teeth restored with fiber-reinforced custom posts and cores: A 97-month study. Int J Prosthodont 2007;20:633–639.
80. Chan RW, Bryant RW. Post-core foundations for endodontically treated posterior teeth. J Prosthet Dent 1982;48:401–406.
81. Lovdahl PE, Nicholls JI. Pin-retained amalgam cores vs. cast-gold dowel-cores. J Prosthet Dent 1977;38:507–514.
82. Newburg RE, Pameijer CH. Retentive properties of post and core systems. J Prosthet Dent 1976;36:636–643.
83. Fox K, Gutteridge DL. An in vitro study of coronal microleakage in root-canal-treated teeth restored by the post and core technique. Int Endod J 1997;30:361–368.
84. Schwartz RS, Robbins JW. Post placement and restoration of endodontically treated teeth: A literature review. J Endod 2004;30:289–301.
85. Standlee JP, Caputo AA, Hanson EC. Retention of endodontic dowels: Effects of cement, dowel length, diameter, and design. J Prosthet Dent 1978;39:400–405.
86. Cooney JP, Caputo AA, Trabert KC. Retention and stress distribution of tapered-end endodontic posts. J Prosthet Dent 1986;55:540–546.
87. Yang HS, Lang LA, Molina A, Felton DA. The effects of dowel design and load direction on dowel-and-core restorations. J Prosthet Dent 2001;85:558–567.
88. Qualtrough AJ, Chandler NP, Purton DG. A comparison of the retention of tooth-colored posts. Quintessence Int 2003;34:199–201.
89. Pérez Moll JF, Howe DF, Svare CW. Cast gold post and core and pin-retained composite resin bases: A comparative study in strength. J Prosthet Dent 1978;40:642–644.
90. Ricker JB, Lautenschlager EP, Greener EH. Mechanical properties of post and core systems. Dent Mater 1986;2:63–66.
91. Weine FS, Wax AH, Wenckus CS. Retrospective study of tapered, smooth post systems in place for 10 years or more. J Endod 1991;17:293–297.
92. Johnson JK, Sakumura JS. Dowel form and tensile force. J Prosthet Dent 1978;40:645–649.
93. Burns DA, Krause WR, Douglas HB, Burns DR. Stress distribution surrounding endodontic posts. J Prosthet Dent 1990;64:412–418.
94. Boyarsky H, Davis R. Root fracture with dentin-retained posts. Am J Dent 1992;5:11–14.
95. Caputo AA, Hokama SN. Stress and retention properties of a new threaded endodontic post. Quintessence Int 1987;18:431–435.
96. Felton DA, Webb EL, Kanoy BE, Dugoni J. Threaded endodontic dowels: Effect of post design on incidence of root fracture. J Prosthet Dent 1991;65:179–187.
97. Greenfeld RS, Roydhouse RH, Marshall FJ, Schoner B. A comparison of two post systems under applied compressive-shear loads. J Prosthet Dent 1989;61:17–24.
98. Ross RS, Nicholls JI, Harrington GW. A comparison of strains generated during placement of five endodontic posts. J Endod 1991;17:450–456.
99. Thorsteinsson TS, Yaman P, Craig RG. Stress analyses of four prefabricated posts. J Prosthet Dent 1992;67:30–33.
100. Standlee JP, Caputo AA, Collard EW, Pollack MH. Analysis of stress distribution by endodontic posts. Oral Surg Oral Med Oral Pathol 1972;33:952–960.
101. Schmitter M, Hamadi K, Rammelsberg P. Survival of two post systems—Five-year results of a randomized clinical trial. Quintessence Int 2011;4 2:843–850.
102. Brown JD, Mitchem JC. Retentive properties of dowel post systems. Oper Dent 1987;12:15–19.
103. Burgess JO, Summitt JB, Robbins JW. The resistance to tensile, compression, and torsional forces provided by four post systems. J Prosthet Dent 1992;68:899–903.
104. Chapman KW, Worley JL, von Fraunhofer JA. Retention of prefabricated posts by cements and resins. J

Dentlearn.ir

Prosthet Dent 1985;54:649–652.
105. Krupp JD, Caputo AA, Trabert KC, Standlee JP. Dowel retention with glass-ionomer cement. J Prosthet Dent 1979;41:163–166.
106. Radke RA, Barkhordar RA, Podesta RE. Retention of cast endodontic posts: Comparison of cementing agents. J Prosthet Dent 1988;59:318–320.
107. Young HM, Shen C, Maryniuk GA. Retention of cast posts relative to cement selection. Quintessence Int 1985;16:357–360.
108. Gross MJ, Turner CH. Intra-radicular hydrostatic pressure changes during the cementation of post-retained crowns. J Oral Rehabil 1983;10: 237–249.
109. Fernandes AS, Shetty S, Coutinho I. Factors determining post selection: A literature review. J Prosthet Dent 2003;90:556–562.
110. Sahafi A, Peutzfeldt A, Asmussen E, Gotfredsen K. Bond strength of resin cement to dentin and to surface-treated posts of titanium alloy, glass fiber, and zirconia. J Adhes Dent 2003;5:153–162.
111. Ichikawa Y, Akagawa Y, Nikai H, Tsuru H. Tissue compatibility and stability of a new zirconia ceramic in vivo. J Prosthet Dent 1992;68:322–326.
112. Asmussen E, Peutzfeldt A, Heitmann T. Stiffness, elastic limit, and strength of newer types of endodontic posts. J Dent 1999;27:275–278.
113. Meyenberg KH, Lüthy H, Schärer P. Zirconia posts: A new all-ceramic concept for nonvital abutment teeth. J Esthet Dent 1995;7:73–80.
114. Akkayan B, Gulmez T. Resistance to fracture of endodontically treated teeth restored with different post systems. J Prosthet Dent 2002;87: 431–437.
115. Cormier CJ, Burns DR, Moon P. In vitro comparison of the fracture resistance and failure mode of fiber, ceramic, and conventional post systems at various stages of restoration. J Prosthodont 2001;10:26–36.
116. Mannocci F, Ferrari M, Watson TF. Intermittent loading of teeth restored using quartz fiber, carbon-quartz fiber, and zirconium dioxide ceramic root canal posts. J Adhes Dent 1999;1:153–158.
117. Maccari PC, Conceicao EN, Nunes MF. Fracture resistance of endodontically treated teeth restored with three different prefabricated esthetic posts. J Esthet Restor Dent 2003;15:25–30.
118. Fischer H, Rentzsch W, Marx R. Elimination of low-quality ceramic posts by proof testing. Dent Mater 2002;18:570–575.
119. Hedlund SO, Johansson NG, Sjögren G. Retention of prefabricated and individually cast root canal posts in vitro. Br Dent J 2003;195:155–158.
120. Magne P, Paranhos MP, Burnett LH Jr. New zirconia primer improves bond strength of resin-based cements. Dent Mater 2010;26:345–352.
121. Attia A, Kern M. Long-term resin bonding to zirconia ceramic with a new universal primer. J Prosthet Dent 2011;106:319–327.
122. Lorenzoni F, Leme V, Santos L, de Oliveira P, Martins L, Bonfante G. Evaluation of chemical treatment on zirconia surface with two primer agents and an alkaline solution on bond strength. Oper Dent 2012; 37:625–633.
123. Silva L, Costa A, Queiroz J, Bottino M, Valandro L. Ceramic primer heat-treatment effect on resin cement/Y-TZP bond strength. Oper Dent 2012;37:634–640.
124. Sahafi A, Peutzfeld A, Asmussen E, Gotfredsen K. Effect of surface treatment of prefabricated posts on bonding of resin cement. Oper Dent 2004;29:60–68.
125. Akgungor G, Sen D, Aydin M. Influence of different surface treatments on the short-term bond strength and durability between a zirconia post and a composite resin core material. J Prosthet Dent 2008;99:388–399.
126. Ferrari M, Vichi A, Garcia-Godoy F. Clinical evaluation of fiber-reinforced epoxy resin posts and cast post and cores. Am J Dent 2000;13(special issue):15B–18B.
127. Torbjörner A, Karlsson S, Syverud M, Hensten-Pettersen A. Carbon fiber reinforced root canal posts. Mechanical and cytotoxic properties. Eur J Oral Sci 1996;104:605–611.
128. Ferrari M, Cagidiaco MC, Goracci C, et al. Long-term retrospective study of the clinical performance of fiber posts. Am J Dent 2007;20:287–291.
129. Lassila LV, Tanner J, Le Bell AM, Narva K, Vallittu PK. Flexural properties of fiber reinforced root canal

Dentlearn.ir

posts. Dent Mater 2004;20:29–36.
130. Grandini S, Goracci C, Monticelli F, Tay FR, Ferrari M. Fatigue resistance and structural characteristics of fiber posts: Three-point bending test and SEM evaluation. Dent Mater 2005;21:75–82.
131. Kececi AD, Ureyen Kaya B, Adanir N. Micro push-out bond strengths of four fiber-reinforced composite post systems and 2 luting materials. Oral Surg Oral Med Oral Pathol Oral Radiol Endod 2008;105:121–128.
132. Stewardson DA, Shortall AC, Marquis PM, Lumley PJ. The flexural properties of endodontic post materials. Dent Mater 2010;26:730–736.
133. Stewardson DA, Shortall AC, Marquis PM. The effect of clinically relevant thermocycling on the flexural properties of endodontic post materials. J Dent 2010;38:437–442.
134. Vichi A, Vano M, Ferrari M. The effect of different storage conditions and duration on the fracture strength of three types of translucent fiber posts. Dent Mater 2008;24:832–838.
135. Sawyer AN, Nikonov SY, Pancio AK, et al. Effects of calcium silicate-based materials on the flexural properties of dentin. J Endod 2012;38: 680–683.
136. Labella R, Lambrechts P, Van Meerbeek B, Vanherle G. Polymerization shrinkage and elasticity of flowable composites and filled adhesives. Dent Mater 1999;15:128–137.
137. Beck P, Broome JC, Jones ZA, Ramp LC. Flexural modulus of composite core materials [abstract 3259]. J Dent Res 2004;83(special issue A).
138. Addison O, Marquis PM, Fleming GJ. Resin elasticity and the strengthening of all-ceramic restorations. J Dent Res 2007;86:519–523.
139. Sakaguchi RL, Powers JM. Craig's Restorative Dental Materials, ed 13. Philadelphia: Elsevier Mosby, 2012:41, 257, 339.
140. Lanza A, Aversa R, Rengo S, Apicella D, Apicella A. 3D FEA of cemented steel, glass and carbon posts in a maxillary incisor. Dent Mater 2005;21:709–715.
141. Boschian Pest L, Guidotti S, Pietrabissa R, Gagliani M. Stress distribution in a post-restored tooth using the three-dimensional finite element method. J Oral Rehabil 2006;33:690–697.
142. Barjau-Escribano A, Sancho-Bru JL, Forner-Navarro L, Rodriguez-Cervantes PJ, Perez-Gonzalez A, Sanchez-Marin FT. Influence of prefabricated post material on restored teeth: Fracture strength and stress distribution. Oper Dent 2006;31:47–54.
143. Asmussen E, Peutzfeldt A, Sahafi A. Finite element analysis of stresses in endodontically treated, dowel-restored teeth. J Prosthet Dent 2005;94:321–329.
144. Santos AF, Meira JB, Tanaka CB, et al. Can fiber posts increase root stresses and reduce fracture? J Dent Res 2010;89:587–591.
145. Bolla M, Muller-Bolla M, Borg C, Lupi-Pegurier L, Laplanche O, Lefores-tier E. Root canal posts for the restoration of root filled teeth [review]. Cochrane Database Syst Rev 2007;(1):CD004623.
146. Cagidiaco MC, Goracci C, Garcia-Godoy F, Ferrari M. Clinical studies of fiber posts: A literature review. Int J Prosthodont 2008;21:328–336.
147. Dietschi D, Duc O, Krejci I, Sadan A. Biomechanical considerations for the restoration of endodontically treated teeth: A systematic review of the literature—Part 1. Composition and micro- and macrostructure alterations. Quintessence Int 2007;38:733–743.
148. Ma PS, Nicholls JI, Junge T, Phillips KM. Load fatigue of teeth with different ferrule lengths, restored with fiber posts, composite resin cores, and all-ceramic crowns. J Prosthet Dent 2009;102:229–234.
149. Ng CC, Dumbrigue HB, Al-Bayat MI, Griggs JA, Wakefield CW. Influence of remaining coronal tooth structure location on the fracture resistance of restored endodontically treated anterior teeth. J Prosthet Dent 2006;95:290–296.
150. Signore A, Kaitsas V, Ravera G, Angiero F, Benedicenti S. Clinical evaluation of an oval-shaped prefabricated glass fiber post in endodontically treated premolars presenting an oval root canal cross-section: A retrospective cohort study. Int J Prosthodont 2011;24:255–263.
151. Mancebo JC, Jimenez-Castellanos E, Canadas D. Effect of tooth type and ferrule on the survival of pulpless teeth restored with fiber posts: A 3-year clinical study. Am J Dent 2010;23:351–356.
152. Dietschi D, Duc O, Krejci I, Sadan A. Biomechanical considerations for the restoration of endodontically

Dentlearn.ir

treated teeth: A systematic review of the literature, Part II (Evaluation of fatigue behavior, interfaces, and in vivo studies). Quintessence Int 2008;39:117–129.
153. Monticelli F, Osorio R, Mazzitelli C, Ferrari M, Toledano M. Limited decalcification/diffusion of self-adhesive cements into dentin. J Dent Res 2008;87:974–979.
154. Malferrari S, Monaco C, Scotti R. Clinical evaluation of teeth restored with quartz fiber-reinforced epoxy resin posts. Int J Prosthodont 2003;16:39–44.
155. Monticelli F, Grandini S, Goracci C, Ferrari M. Clinical behavior of translucent-fiber posts: A 2-year prospective study. Int J Prosthodont 2003;16:593–596.
156. Cagidiaco MC, Radovic I, Simonetti M, Tay F, Ferrari M. Clinical performance of fiber post restorations in endodontically treated teeth: 2-year results. Int J Prosthodont 2007;20:293–298.
157. Naumann M, Koelpin M, Beuer F, Meyer-Lueckel H. 10-year survival evaluation for glass-fiber-supported postendodontic restoration: A prospective observational clinical study. J Endod 2012;38:432–435.
158. De Munck J, Van Landuyt K, Peumans M, et al. A critical review of the durability of adhesion to tooth tissue: Methods and results. J Dent Res 2005;84:118–132.
159. Peumans M, Kanumilli P, De Munck J, Van Landuyt K, Lambrechts P, Van Meerbeek B. Clinical effectiveness of contemporary adhesives: A systematic review of current clinical trials. Dent Mater 2005;21:864–881.
160. Bouillaguet S, Troesch S, Wataha JC, Krejci I, Meyer JM, Pashley DH. Microtensile bond strength between adhesive cements and root canal dentin. Dent Mater 2003;19:199–205.
161. Goracci C, Tavares AU, Fabianelli A, et al. The adhesion between fiber posts and root canal walls. Comparison between microtensile and push-out bond strength measurements. Eur J Oral Sci 2004;112:353–361.
162. Papa J, Cain C, Messer HH. Moisture content of vital vs endodontically treated teeth. Endod Dent Traumatol 1994;10:91–93.
163. Rivera EM, Yamauchi M. Site comparisons of dentine collagen cross-links from extracted human teeth. Arch Oral Biol 1993;38:541–546.
164. Carrigan PJ, Morse DR, Furst ML, Sinai IH. A scanning electron microscopic evaluation of human dentinal tubules according to age and location. J Endod 1984;10:359–363.
165. Mjör IA, Nordahl I. The density and branching of dentinal tubules in human teeth. Arch Oral Biol 1996;41:401–412.
166. Paqué F, Luder HU, Sener B, Zehnder M. Tubular sclerosis rather than the smear layer impedes dye penetration into the dentine of end-odontically instrumented root canals. Int Endod J 2006;39:18–25.
167. Ferrari M, Mannocci F, Vichi A, Cagidiaco MC, Mjör IA. Bonding to root canal: Structural characteristics of the substrate. Am J Dent 2000;13:255–260.
168. Boschian Pest L, Cavalli G, Bertani P, Gagliani M. Adhesive post-end-odontic restorations with fiber posts: Push-out tests and SEM observations. Dent Mater 2002;18:596–602.
169. Perdigao J, Geraldeli S, Lee IK. Push-out bond strengths of tooth-colored posts bonded with different adhesive systems. Am J Dent 2004;17:422–426.
170. Potesta FL, Broome JC, O'Neal SJ, Givan DA, Ramp LC. The effect of etching technique on the retention of adhesively cemented prefabricated dowels. J Prosthodont 2008;17:445–450.
171. Feilzer AJ, De Gee AJ, Davidson CL. Curing contraction of composites and glass-ionomer cements. J Prosthet Dent 1988;59:297–300.
172. Feilzer AJ, De Gee AJ, Davidson CL. Setting stress in composite resin in relation to configuration of the restoration. J Dent Res 1987;66:1636–1639.
173. Carvalho RM, Pereira JC, Yoshiyama M, Pashley DH. A review of polymerization contraction: The influence of stress development versus stress relief. Oper Dent 1996;21:17–24.
174. Bonfante EA, Pegoraro LF, de Goes MF, Carvalho RM. SEM observation of the bond integrity of fiber-reinforced composite posts cemented into root canals. Dent Mater 2008;24:483–491.
175. Bitter K, Perdigao J, Exner M, Neumann K, Kielbassa A, Sterzenbach G. Reliability of fiber post bonding to root canal dentin after simulated clinical function in vitro. Oper Dent 2012;37:397–405.
176. Dietschi D, Ardu S, Rossier-Gerber A, Krejci I. Adaptation of adhesive post and cores to dentin after in

Dentlearn.ir

vitro occlusal loading: Evaluation of post material influence. J Adhes Dent 2006;8:409–419.
177. Mannocci F, Bertelli E, Watson TF, Ford TP. Resin-dentin interfaces of endodontically-treated restored teeth. Am J Dent 2003;16:28–32.
178. Torbjörner A, Fransson B. Biomechanical aspects of prosthetic treatment of structurally compromised teeth. Int J Prosthodont 2004;17: 135–141.
179. Goracci C, Fabianelli A, Sadek FT, Papacchini F, Tay FR, Ferrari M. The contribution of friction to the dislocation resistance of bonded fiber posts. J Endod 2005;31:608–612.
180. Pirani C, Chersoni S, Foschi F, et al. Does hybridization of intraradicular dentin really improve fiber post retention in endodontically treated teeth? J Endod 2005;31:891–894.
181. Sadek FT, Goracci C, Monticelli F, et al. Immediate and 24-hour evaluation of the interfacial strengths of fiber posts. J Endod 2006;32:1174–1177.
182. Braga NM, Paulino SM, Alfredo E, Sousa-Neto MD, Vansan LP. Removal resistance of glass-fiber and metallic cast posts with different lengths. J Oral Sci 2006;48:15–20.
183. Innella R, Autieri G, Ceruti P, Gassino G. Relation between length of fiber post and its mechanical retention. Minerva Stomatol 2005;54:481–488.
184. Sorensen JA, Martinoff JT. Clinically significant factors in dowel design. J Prosthet Dent 1984;52:28–35.
185. Pierrisnard L, Bohin F, Renault P, Barquins M. Corono-radicular reconstruction of pulpless teeth: A mechanical study using finite element analysis. J Prosthet Dent 2002;88:442–448.
186. Christensen GJ. Posts: The best cements and techniques. CRA Newsletter 2011;4(8):1–3.
187. Assif D, Bleicher S. Retention of serrated endodontic posts with a composite luting agent: Effect of cement thickness. J Prosthet Dent 1986;56:689–691.
188. Mattison GD. Photoelastic stress analysis of cast-gold endodontic posts. J Prosthet Dent 1982;48:407–411.
189. Mattison GD, von Fraunhofer JA. Angulation loading effects on cast-gold endodontic posts: A photoelastic stress analysis. J Prosthet Dent 1983;49:636–638.
190. Scherrer SS, de Rijk WG. The fracture resistance of all-ceramic crowns on supporting structures with different elastic moduli. Int J Prosthodont 1993;6:462–467.
191. Lee SK, Wilson PR. Fracture strength of all-ceramic crowns with varying core elastic moduli. Aust Dent J 2000;45:103–107.
192. Lambjerg-Hansen H, Asmussen E. Mechanical properties of endodontic posts. J Oral Rehabil 1997;24:882–887.
193. Coniglio I, Garcia-Godoy F, Magni E, Carvalho CA, Ferrari M. Resin cement thickness in oval-shaped canals: Oval vs. circular fiber posts in combination with different tips/drills for post space preparation. Am J Dent 2009;22:290–294.
194. Plotino G, Grande NM, Pameijer CH, Somma F. Influence of surface remodelling using burs on the macro and micro surface morphology of anatomically formed fibre posts. Int Endod J 2008;41:345–355.
195. Li Q, Xu B, Wang Y, Cai Y. Effects of auxiliary fiber posts on endodontically treated teeth with flared canals. Oper Dent 2011;36:380–389.
196. Tay FR, Loushine RJ, Lambrechts P, Weller RN, Pashley DH. Geometric factors affecting dentin bonding in root canals: A theoretical modeling approach. J Endod 2005;31:584–589.
197. Condon JR, Ferracane JL. Assessing the effect of composite formulation on polymerization stress. J Am Dent Assoc 2000;131:497–503.
198. Ferrari M, Carvalho CA, Goracci C, et al. Influence of luting material filler content on post cementation. J Dent Res 2009;88:951–956.
199. Kielbassa AM, Attin T, Hellwig E. Diffusion behavior of eugenol from zinc oxide-eugenol mixtures through human and bovine dentin in vitro. Oper Dent 1997;22:15–20.
200. Tjan AH, Nemetz H. Effect of eugenol-containing endodontic sealer on retention of prefabricated posts luted with adhesive composite resin cement. Quintessence Int 1992;23:839–844.
201. Aleisa K, Alghabban R, Alwazzan K, Morgano SM. Effect of three end-odontic sealers on the bond strength of prefabricated fiber posts luted with three resin cements. J Prosthet Dent 2012;107:322–326.
202. Schwartz RS, Murchison DF, Walker WA 3rd. Effects of eugenol and noneugenol endodontic sealer

Dentlearn.ir

cements on post retention. J Endod 1998;24:564–567.
203. Hagge MS, Wong RD, Lindemuth JS. Effect of three root canal sealers on the retentive strength of endodontic posts luted with a resin cement. Int Endod J 2002;35:372–378.
204. Boone KJ, Murchison DF, Schindler WG, Walker WA 3rd. Post retention: The effect of sequence of post-space preparation, cementation time, and different sealers. J Endod 2001;27:768–771.
205. Peutzfeldt A, Asmussen E. Influence of eugenol-containing temporary cement on efficacy of dentin-bonding systems. Eur J Oral Sci 1999; 107:65–69.
206. Mayhew JT, Windchy AM, Goldsmith LJ, Gettleman L. Effect of root canal sealers and irrigation agents on retention of preformed posts luted with a resin cement. J Endod 2000;26:341–344.
207. McComb D, Smith DC. Comparison of physical properties of polycarboxylate-based and conventional root canal sealers. J Endod 1976; 2:228–235.
208. Vano M, Cury AH, Goracci C, et al. The effect of immediate versus delayed cementation on the retention of different types of fiber post in canals obturated using a eugenol sealer. J Endod 2006;32:882–885.
209. Serafino C, Gallina G, Cumbo E, Ferrari M. Surface debris of canal walls after post space preparation in endodontically treated teeth: A scanning electron microscopic study. Oral Surg Oral Med Oral Pathol Oral Radiol Endod 2004;97:381–387.
210. Perdigao J, Gomes G, Augusto V. The effect of dowel space on the bond strengths of fiber posts. J Prosthodont 2007;16:154–164.
211. Vichi A, Grandini S, Davidson CL, Ferrari M. An SEM evaluation of several adhesive systems used for bonding fiber posts under clinical conditions. Dent Mater 2002;18:495–502.
212. Valandro LF, Andreatta OD, Valera MC, de Araujo MA. The effect of adhesive systems on the pullout strength of a fiberglass-reinforced composite post system in bovine teeth. J Adhes Dent 2005;7:331–336.
213. Monticelli F, Ferrari M, Toledano M. Cement system and surface treatment selection for fiber post luting. Med Oral Patol Oral Cir Bucal 2008;13:E214–E221.
214. Sanares AM, Itthagarun A, King NM, Tay FR, Pashley DH. Adverse surface interactions between one-bottle light-cured adhesives and chemical-cured composites. Dent Mater 2001;17:542–556.
215. Ferrari M, Vichi A, Grandini S, Geppi S. Influence of microbrush on efficacy of bonding into root canals. Am J Dent 2002;15:227–231.
216. Ferrari M, Grandini S, Simonetti M, Monticelli F, Goracci C. Influence of a microbrush on bonding fiber post into root canals under clinical conditions. Oral Surg Oral Med Oral Pathol Oral Radiol Endod 2002; 94:627–631.
217. Tay FR, Pashley DH, Yoshiyama M. Two modes of nanoleakage expression in single-step adhesives. J Dent Res 2002;81:472–476.
218. Goracci C, Sadek FT, Fabianelli A, Tay FR, Ferrari M. Evaluation of the adhesion of fiber posts to intraradicular dentin. Oper Dent 2005;30:627–635.
219. Amaral M, Santini MF, Wandscher V, Amaral R, Valandro LF. An in vitro comparison of different cementation strategies on the pull-out strength of a glass fiber post. Oper Dent 2009;34:443–451.
220. Gwinnett AJ. Quantitative contribution of resin infiltration/hybridization to dentin bonding. Am J Dent 1993;6:7–9.
221. Scotti N, Rota R, Scansetti M, Migliaretti G, Pasqualini D, Berutti E. Fiber post adhesion to radicular dentin: The use of acid etching prior to a one-step self-etching adhesive. Quintessence Int 2012;43:615–623.
222. Polo C, Broome JC, Burgess JO, Ramp LC. Effect of cementation technique on pushout strength of fiber posts [abstract 1757]. J Dent Res 2008;87(special issue B).
223. Monticelli F, Osorio R, Toledano M, Goracci C, Tay FR, Ferrari M. Improving the quality of the quartz fiber postcore bond using sodium ethox-ide etching and combined silane/adhesive coupling. J Endod 2006;32:447–451.
224. D'Arcangelo C, D'Amario M, Vadini M, De Angelis F, Caputi S. Influence of surface treatments on the flexural properties of fiber posts. J Endod 2007;33:864–867.
225. Balbosh A, Kern M. Effect of surface treatment on retention of glass-fiber endodontic posts. J Prosthet Dent 2006;95:218–223.
226. Choi Y, Pae A, Park EJ, Wright RF. The effect of surface treatment of fiber-reinforced posts on adhesion

Dentlearn.ir

of a resin-based luting agent. J Prosthet Dent 2010;103:362–368.
227. de Sousa Menezes M, Queiroz EC, Soares PV, Faria-e-Silva AL, Soares CJ, Martins LR. Fiber post etching with hydrogen peroxide: Effect of concentration and application time. J Endod 2011;37:398–402.
228. Goracci C, Raffaelli O, Monticelli F, Balleri B, Bertelli E, Ferrari M. The adhesion between prefabricated FRC posts and composite resin cores: Microtensile bond strength with and without post-silanization. Dent Mater 2005;21:437–444.
229. Bitter K, Meyer-Luckel H, Priehn K, Martus P, Kielbassa AM. Bond strengths of resin cements to fiber-reinforced composite posts. Am J Dent 2006;19:138–142.
230. Khamverdi Z, Abbasi S, Habibi E, Kasraei S, Azarsina M, Ebadi S. Effect of storage time on microtensile bond strength between quartz fiber post and composite core after different post surface treatments. J Conserv Dent 2011;14:361–365.
231. Ferrari M, Goracci C, Sadek FT, Monticelli F, Tay FR. An investigation of the interfacial strengths of methacrylate resin-based glass fiber post-core buildups. J Adhes Dent 2006;8:239–245.
232. Le Bell AM, Tanner J, Lassila LV, Kangasniemi I, Vallittu PK. Depth of light-initiated polymerization of glass fiber-reinforced composite in a simulated root canal. Int J Prosthodont 2003;16:403–408.
233. Goracci C, Corciolani G, Vichi A, Ferrari M. Light-transmitting ability of marketed fiber posts. J Dent Res 2008;87:1122–1126.
234. Faria e Silva AL, Arias VG, Soares LE, Martin AA, Martins LR. Influence of fiber-post translucency on the degree of conversion of a dual-cured resin cement. J Endod 2007;33:303–305.
235. Galhano GA, de Melo RM, Barbosa SH, Zamboni SC, Bottino MA, Scotti R. Evaluation of light transmission through translucent and opaque posts. Oper Dent 2008;33:321–324.
236. Braga RR, Ferracane JL, Condon JR. Polymerization contraction stress in dual-cure cements and its effect on interfacial integrity of bonded inlays. J Dent 2002;30:333–340.
237. Feng L, Suh BI. The effect of curing modes on polymerization contraction stress of a dual cured composite. J Biomed Mater Res B Appl Biomater 2006;76(1):196–202.
238. Caughman WF, Chan DC, Rueggeberg FA. Curing potential of dualpolymerizable resin cements in simulated clinical situations. J Prosthet Dent 2001;86:101–106.
239. Hofmann N, Papsthart G, Hugo B, Klaiber B. Comparison of photo-activation versus chemical or dual-curing of resin-based luting cements regarding flexural strength, modulus and surface hardness. J Oral Rehabil 2001;28:1022–1028.
240. el-Badrawy WA, el-Mowafy OM. Chemical versus dual curing of resin inlay cements. J Prosthet Dent 1995;73:515–524.

Dentlearn.ir