50 years

MCDONALD AND AVERY'S DENTISTRY for the CHILD and ADOLESCENT

tenth edition



JEFFREY A. DEAN

ELSEVIER

Dentlearn.ir

McDONALD AND AVERY'S

DENTISTRY for the CHILD and ADOLESCENT

tenth edition

Dentlearn.ir

ELSEVIER evolve

YOU'VE JUST PURCHASED MORE THAN A TEXTBOOK!

Evolve Student Resources for *Dean: McDonald and Avery's Dentistry for the Child and Adolescent, Tenth Edition,* include the following:

- Case Studies
- Videos
- Suggested Readings
- Web Links

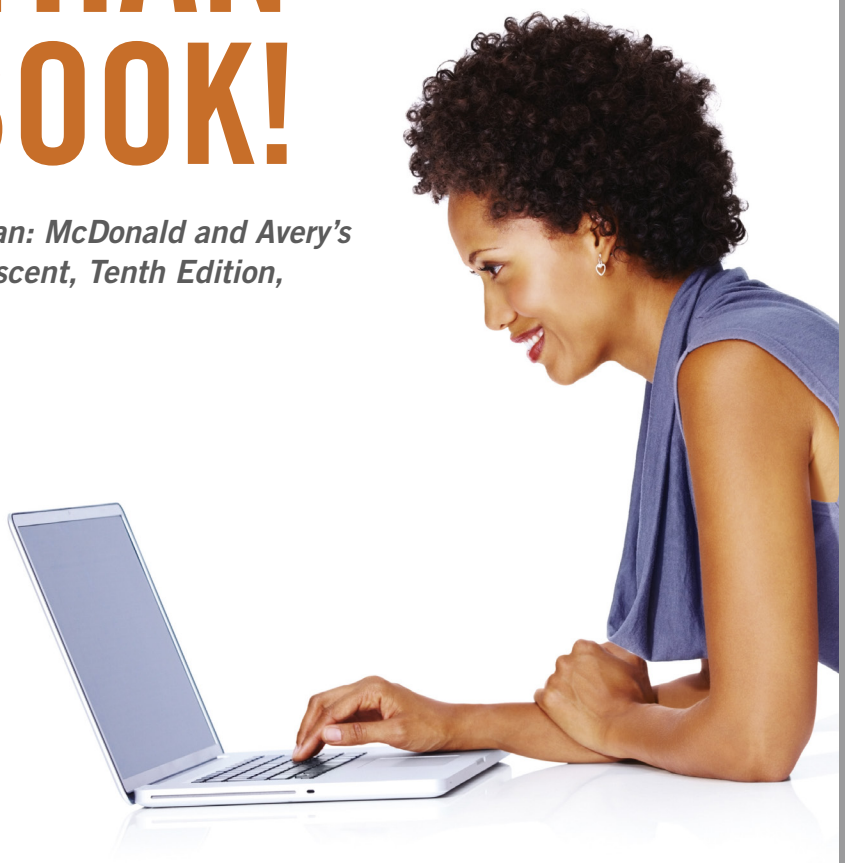

Activate the complete learning experience that comes with each textbook purchase by registering at

REGISTER TODAY!

You can now purchase Elsevier products on Evolve!
Go to evolve.elsevier.com/html/shop-promo.html to search and browse for products.

Dentlearn.ir

tenth edition

McDONALD AND AVERY'S DENTISTRY for the CHILD and ADOLESCENT

Jeffrey A. Dean, DDS, MSD

Chief of Staff, Office of the Chancellor
Indiana University-Purdue University Indianapolis
Ralph E. McDonald Professor of Pediatric Dentistry and Professor of Orthodontics
Indiana University School of Dentistry
Riley Hospital for Children at IU Health
Indianapolis, Indiana

ASSOCIATE EDITORS

James E. Jones, DMD, MSD, EdD, PhD

Professor and Chair
Department of Pediatric Dentistry
Indiana University School of Dentistry
Clinical Professor
Department of Pediatrics
Indiana University School of Medicine
Indianapolis, Indiana

LaQuia A. Walker Vinson, DDS, MPH

Assistant Professor
Pediatric Dentistry
Indiana University,
Indianapolis, Indiana

ELSEVIER

Dentlearn.ir

ELSEVIER

3251 Riverport Lane
St. Louis, Missouri 63043

McDONALD AND AVERY'S DENTISTRY FOR THE CHILD AND ADOLESCENT, TENTH EDITION **ISBN: 978-0-323-28745-6**

No part of this publication may be reproduced or transmitted in any form or by any means,

retrieval system, without permission in writing from the Publisher. Details on how to seek permission, further information about the Publisher's permissions policies and our arrangements with

Publisher (other than as may be noted herein).

Notices

Knowledge and best practice in this field are constantly changing. As new research and experience broaden our understanding, changes in research methods, professional practices, or medical treatment may become necessary.

Practitioners and researchers must always rely on their own experience and knowledge in evaluating and using any information, methods, compounds, or experiments described herein. In using such information or methods they should be mindful of their own safety and the safety of others, including parties for whom they have a professional responsibility.

With respect to any drug or pharmaceutical products identified, readers are advised to check the most current information provided (i) on procedures featured or (ii) by the manufacturer of each product to be administered, to verify the recommended dose or formula, the method and duration of administration, and contraindications. It is the responsibility of practitioners, relying on their own experience and knowledge of their patients, to make diagnoses, to determine dosages and the best treatment for each individual patient, and to take all appropriate safety precautions.

To the fullest extent of the law, neither the Publisher nor the authors, contributors, or editors, assume any liability for any injury and/or damage to persons or property as a matter of products liability, negligence or otherwise, or from any use or operation of any methods, products, instructions, or ideas contained in the material herein.

Library of Congress Cataloging-in-Publication Data

McDonald and Avery's dentistry for the child and adolescent / [edited by] Jeffrey A. Dean, David R. Avery, Ralph E. McDonald. -- Tenth edition.
p. ; cm.
Dentistry for the child and adolescent
Includes bibliographical references and index.
ISBN 978-0-323-28745-6 (hardcover : alk. paper)
I. Dean, Jeffrey A. (Jeffrey Alan), editor. II. Avery, David R., editor. III. McDonald, Ralph E., 1920- , editor. IV. Title: Dentistry for the child and adolescent.
[DNLM: 1. Dental Care for Children. 2. Pediatric Dentistry--methods. WU 480]
RK55.C5
617.6'45--dc23

2015002959

Executive Content Strategist: Kathy Falk
Content Development Manager: Jolynn Gower
Senior Content Development Specialist: Brian Loehr
Publishing Services Manager: Patricia Tannian
Senior Project Manager: Sharon Corell
Book Designer: Ashley Miner

Printed in China.

Last digit is the print number: 9 8 7 6 5 4 3 2 1



Dentlearn.ir

Affectionately dedicated to my wife, Barbara, and to my children, Courtney, Tom, and Austin. As we all know, the time away from family to work on this project can never be gained back, but your patience, love, and support throughout its production are so wonderfully appreciated.

Dentlearn.ir

This page intentionally left blank

Dentlearn.ir

Contributors

Johan K. Aps, DDS, MSc, MSc, PhD
Clinical Associate Professor of Oral and Maxillofacial Radiology
Department of Oral Medicine
University of Washington
Seattle, Washington

Jeffrey D. Bennett, DMD
Professor and Chair
Department of Oral Surgery and Hospital Dentistry
Indiana University School of Dentistry
Indianapolis, Indiana
Diplomate, American Board of Oral and Maxillofacial Surgeons (ABOMS)
Diplomate, National Dental Board of Anesthesiology
Fellow, American Association of Oral and Maxillofacial Surgeons (AAOMS)
Fellow, American Dental Society of Anesthesiology (ADSA)

David T. Brown, DDS, MS
Chair, Department of Restorative Dentistry
Director, Undergraduate Restorative
Professor of Prosthodontics
Indiana University School of Dentistry
Indianapolis, Indiana

Angus C. Cameron, BDS(Hons) MDSc FDSRCS(Eng) FRACDS
Head
Department of Paediatric Dentistry and Orthodontics
Westmead Hospital
Westmead, New South Wales, Australia
Head and Clinical Associate Professor
Department of Paediatric Dentistry
The University of Sydney
Sydney, Australia

Judith R. Chin, DDS, MS
Associate Professor
Department of Pediatric Dentistry
Indiana University School of Dentistry
Indianapolis, Indiana

Jeffrey A. Dean, DDS, MSD
Chief of Staff
Office of the Chancellor
Indiana University-Purdue University Indianapolis
Ralph E. McDonald Professor of Pediatric Dentistry and Professor of Orthodontics
Indiana University School of Dentistry
Riley Hospital for Children at IU Health
Indianapolis, Indiana

Kevin J. Donly, DDS, MS
Professor and Chair
Department of Developmental Dentistry
Professor
Department of Pediatrics
University of Texas Health Science Center at San Antonio
San Antonio, Texas

Burton L. Edelstein, DDS, MPH
Professor of Dentistry and Health Policy and Management
Department of Community Health
College of Dental Medicine
Columbia University Medical Center
New York, New York

John D. Emhardt, MD
Riley Hospital for Children
Indiana University Health
Indianapolis, Indiana

Donald J. Ferguson, DMD, MSD
Dean and Professor of Orthodontics
European University College
Dubai, United Arab Emirates

Elie M. Ferneini, DMD, MD, MHS, MBA, FACS
Oral and Maxillofacial Surgeon
Assistant Clinical Professor, University of Connecticut
Medical Director, Beau Visage Med Spa
Private Practice, Greater Waterbury OMS
Waterbury, Connecticut

Roberto L. Flores, MD
Medical Director
Pediatric Craniofacial Center
NYU Langone Medical Center
New York, New York

Dentlearn.ir

James K. Hartsfield Jr., DMD, MS, MMSc, PhD, FACMG, FACD, FICD, CDABO
Professor and E. Preston Hicks Endowed Chair in Orthodontics and Oral Health Research
Director, Center for the Biologic Basis of Oral/Systemic Diseases Hereditary Genetics/Genomics Core
University of Kentucky
Lexington, Kentucky
Adjunct Professor
Department of Orthodontics and Oral Facial Genetics
Indiana University School of Dentistry
Indianapolis, Indiana
Adjunct Professor
Department of Medical and Molecular Genetics
Indiana University School of Medicine
Indianapolis, Indiana
Adjunct Clinical Professor
Department of Orthodontics
University of Illinois at Chicago College of Dentistry
Chicago, Illinois
Diplomate of the American Board of Orthodontics
Diplomate of the American Board of Medical Genetics
Co-Editor in Chief, Journal of Pediatric Genetics

Roberta A. Hibbard, MD
Professor of Pediatrics
Director Section of Child Protection Programs
Department of Pediatrics
Indiana of University School of Medicine
Indianapolis, Indiana

Randy A. Hock, MD, PhD, MMM
Presbyterian Blume Pediatric Hematology and Oncology Clinic

Charlotte, North Carolina

Donald V. Huebener, DDS, MS, MAEd
Professor, Plastic and Reconstructive Surgery
Department of Surgery, School of Medicine
Washington University, St. Louis, Missouri
Professor, Pediatric Dentistry
School of Dental Medicine
Southern Illinois University
Alton, Illinois

Christopher V. Hughes, DMD, PhD
Professor and Chair
Department of Pediatric Dentistry
Rutgers, The State University of New Jersey
Newark, New Jersey

Vanchit John, DDS, MSD, MDS, BDS
Chairman
Department of Periodontics and Allied Dental Programs
Associate Professor
Indiana University School of Dentistry
Indianapolis, Indiana

James E. Jones, DMD, MSD, EdD, PhD
Professor and Chair
Department of Pediatric Dentistry
Indiana University School of Dentistry
Clinical Professor
Department of Pediatrics
Indiana University School of Medicine
Indianapolis, Indiana

Mathew T. Kattadiyil, BDS, MDS, MS
Professor and Director
Advanced Specialty Education Program in Prosthodontics
Loma Linda University School of Dentistry
Loma Linda, California

Joan E. Kowolik, BDS, LDS, RCS Edin, Dip. Clin. Hyp.
Director of Predoctoral Pediatric Dentistry
Associate Professor of Pediatric Dentistry
Department of Pediatric Dentistry
Indiana University School of Dentistry
Indianapolis, Indiana

John T. Krull, DDS
Assistant Professor
Department of Pediatric Dentistry
Indiana University School of Dentistry
Private Practice of Orthodontics
Indianapolis, Indiana

George E. Krull, DDS
Private Practice, Pediatric Dentistry
Clarkston, Michigan

John J. Manaloor, MD
Assistant Professor of Clinical Pediatrics
Ryan White Center for Pediatric Infectious Diseases and Global Health
Riley Hospital for Children, Indiana University School of Medicine
Indianapolis, Indiana

James L. McDonald Jr., PhD
Emeritus Professor of Oral Biology
Indiana University School of Dentistry
Indianapolis, Indiana

John S. McDonald, DDS, MS
Volunteer Professor
Pediatrics/Oral and Maxillofacial Pathology
Oral and Maxillofacial Surgery/Oral and Maxillofacial Pathology
Anesthesiology/Chronic Head and Neck Pain
University of Cincinnati Neuroscience Institute
Headache and Facial Pain Section
University of Cincinnati College of Medicine
Cincinnati, Ohio

Dentlearn.ir

Edwin T. Parks, DMD, MS
Professor of Diagnostic Sciences
Indiana University School of Dentistry
Indianapolis, Indiana

Jeffrey A. Platt, DDS, MS
Associate Professor of Dental Materials
Department of Restorative Dentistry
Indiana University
Indianapolis, Indiana

Laura Romito, DDS, MS
Associate Professor of Oral Biology
Indiana University School of Dentistry
Indianapolis, Indiana

Brian J. Sanders, DDS, MS
Professor of Pediatric Dentistry
Department of Pediatric Dentistry
Indiana University School of Dentistry
Director, Post Graduate Pediatric Program
Department of Pediatric Dentistry
Riley Hospital for Children
Indianapolis, Indiana

Mark A. Saxen, DDS, PhD
Adjunct Clinical Associate Professor
Department of Oral Pathology, Medicine and Radiology
Indiana University School of Dentistry
Dentist Anesthesiologist
Indiana Office-Based Anesthesia
Indianapolis, Indiana

Amy D. Shapiro, MD
Medical Director
Indiana Hemophilia and Thrombosis Center
Indianapolis, Indiana

Daniel E. Shin, DDS, MSD
Clinical Assistant Professor
Director of Predoctoral Periodontology
Department of Periodontology
Indiana University School of Dentistry
Indianapolis, Indiana

Kenneth J. Spolnik, DDS, MSD
Clinical Professor, Chair and Program Director
Department of Endodontics
Indiana University School of Dentistry
Indianapolis, Indiana
Diplomate, American Board of Endodontics
Co-Founder of Indianapolis Endodontics, P.C.

Jenny I. Stigers, DMD
Associate Professor
University of Kentucky College of Dentistry
Lexington, Kentucky

George K. Stookey, MSD, PhD
Distinguished Professor Emeritus
Indiana University School of Dentistry
Indianapolis, Indiana

Shannon L. Thompson, MD
Assistant Professor of Clinical Medicine
IU Child Protection Programs
Indiana University School of Medicine
Indianapolis, Indiana

Erwin G. Turner, DMD
Associate Professor and Residency Director
Department of Pediatric Dentistry
University of Kentucky College of Dentistry
Lexington, Kentucky

LaQuia A. Walker Vinson, DDS, MPH
Assistant Professor of Pediatric Dentistry
Indiana University
Indianapolis, Indiana

James A. Weddell, DDS, MSD
Associate Professor of Pediatric Dentistry
Department of Pediatric Dentistry
Indiana University School of Dentistry
Indianapolis, Indiana

Julie Weir, BS, CDMP
Founder and Consulting Associate
Julie Weir & Associates Dental Practice Management Consulting
Elizabeth, Colorado

Ghaeth H. Yassen, BDS, MSD, PhD
Visiting Assistant Professor
Department of Restorative Dentistry
Indiana University School of Dentistry
Indianapolis, Indiana

Karen M. Yoder, MSD, PhD
Professor and Director, Civic Engagement and Health Policy
Department of Preventative and Community Dentistry
Indiana University School of Dentistry
Indianapolis, Indiana

Dentlearn.ir

This page intentionally left blank

Dentlearn.ir

Foreword

As we entrust the continuing editions of this textbook to others, we reflect on the many rewards we have realized by our participation in the previous editions. The personal rewards have been many but the more important result is the positive impact that the previous printings have hopefully had on students, colleagues who teach and/or practice pediatric dentistry, and most importantly their patients.

Dental technology has advanced immeasurably in the 50 years that these publications have been available. At that time the efficacy of fluoridated dentifrices had recently been recognized as a safe and effective adjunct to dental caries prevention. Communal water fluoridation was also relatively new. Both of these exceptional caries prevention services were viewed skeptically by many.

Continued



The late Dr. Ralph E. McDonald *(seated)* with Dr. Jeffrey A. Dean *(left)* and Dr. David R. Avery *(right),* pictured with all nine editions of *McDonald and Avery's Dentistry for the Child and Adolescent* displayed on the desktop.

Dentlearn.ir

Today they are accepted by the majority of the scientific community. Only 30 years ago dental amalgam was still the mainstay of restorative dentistry, preformed and festooned stainless steel crowns had just been introduced, and composite resins were in their infancy. Today the crowns and esthetic materials dominate the restorative services provided in pediatric dentistry. Similarly, significant changes in the standards of care and the increased level of our knowledge are reflected in every chapter of this tenth edition.

The senior members of our profession recognize that the technologic advancements and accepted practice norms have dramatically changed our approach to patient care over the past few decades. Virtually every aspect of patient therapy has been affected. We also acknowledge that the advancements are now growing exponentially. However, the ultimate goal of providing the highest quality service to patients remains the same.

Although our publication goal has been to make a positive contribution to our profession and ultimately to its patients, no one has benefited from our efforts more than we have. Regular new editions required us to update our base of knowledge from additions in the scientific literature and from exchanging experiences with our colleagues, including students. Constructive suggestions and criticisms from our colleagues have also strengthened the textbook from one edition to the next. Other noteworthy rewards for us have been the many hugs of appreciation we have received from our own grateful patients as we provided the care that we espoused.

Listing every individual who has helped us over the years of these publications is impractical. Suffice it to say that we are most appreciative to all our colleagues and students, patients, friends, and family who have supported our efforts in myriad ways.

Finally, we wish Godspeed to Drs. Dean, Jones, Vinson, and all other future contributors as they proceed with this work of love. We have the utmost confidence in their abilities to carry on.

Ralph E. McDonald, DDS, MS, LLD*
Dean Emeritus and Professor Emeritus of Pediatric Dentistry
Indiana University School of Dentistry
Indianapolis, Indiana

David R. Avery, DDS, MSD
Ralph E. McDonald Professor Emeritus of Pediatric Dentistry
Indiana University School of Dentistry and
James Whitcomb Riley Hospital for Children
Indianapolis, Indiana

*Unfortunately, Dr. McDonald passed away shortly after the Foreword was written and only months prior to the first printing of the tenth edition. We are all terribly saddened by this loss and will miss him dearly.

Dentlearn.ir

Preface

With this publication of the textbook, we are entering a historic milestone with the first "double digit" edition of the title *Dentistry for the Child and Adolescent*. As I write this, I am holding Dr. Ralph McDonald's very first book entitled *Pedodontics: The Postgraduate Dental Lecture Series*, which he developed early in his career as a professor of pediatric dentistry. This book was published by the CV Mosby Company in 1963 and had 11 chapters, complemany handwritten entries in it. What a treasure!

Although his 1963 first text is known by a different title, it clearly is the foundation of our current series. In fact, all 11 chapter titles in this 1963 edition can be found in some form or another in the current text. As you may have noticed, this therefore represents the 50th celebratory anniversary for this classic pediatric dentistry textbook. Dr. McDonald and Dr. David Avery, who joined him in writing the last seven editions, certainly have left their mark on our specialty with this work, and it's a unique honor and pleasure for me to be able to help continue the series now and hopefully into the future. One can certainly reflect on the perhaps millions of children who these two grand gentlemen were able to directly assist by continuing to provide the latest theories, research, concepts, and techniques to practitioners around the world.

So what changes have we made to this edition? First and foremost is the bowing out of both Drs. McDonald and Avery as editors of the book. While I stayed in regular communications with them during the production, they were not actively engaged in writing or editing. Their involvement was definitely missed by me. In addition, many other contributors have moved on with retirements and other life transitions and are no longer involved. Although we are all sad to see them go, their departure opened up exciting opportunities for new expert contributors to become involved. And I can say, I was very fortunate to successfully recruit wonderful new authors.

In addition to all of the new contributors to the text, as well as the electronic version having questions and answers with each chapter, we have also included a case study or two for each chapter, as well as 10 video vignettes to enhance the learning experience for students. These are significant improvements that we hope you will find most enjoyable. They are available on the Elsevier Evolve website.

Whereas I am very pleased to point out that we have rearranged the text into five major areas of focus, I hope that you will notice that the same excellent chapter titles are promulgated in this tenth edition. The new five areas of focus will help the practitioner and student as they organize their thinking and practice around these concepts. In addition to this new organization, we continue to attempt to replace all illustrations with color and have made significant improvements in this area.

The fundamental essence of the textbook is retained, such that the information contained herein remains relevant to the contemporary science and practice of pediatric dentistry. It is designed to help predoctoral and postdoctoral pediatric dental students provide efficient and superior comprehensive oral health care to infants, children, teenagers, and medically compromised patients. It also provides experienced dentists with reference information regarding new developments and techniques.

Once again, please join me in celebrating the fiftieth anniversary of this textbook series! In assuming the role of editor, I hope I have done justice to the previous work of both Drs. McDonald and Avery. I look forward to receiving feedback from you as you have a chance to peruse the book and as we look forward to continuing the tradition of excellence in pediatric dental education and practice. My sincerest appreciation to all of our past author contributors—and especially to our continuing and our new author contributors—for all of their dedication and work on this anniversary edition!

Jeffrey A. Dean

Dentlearn.ir

This page intentionally left blank

Dentlearn.ir

Acknowledgments

A textbook can be planned and written only with the supportive interest, encouragement, and tangible contributions of many people. Therefore it is a privilege to acknowledge the assistance of others in the preparation of this fiftieth anniversary and tenth edition of the text. First and foremost, of course, I must acknowledge the tremendous contributions and mentorship of both Doctors Ralph McDonald and David Avery. As I mentioned in the preface, their contributions to this edition are missed, but I know that their guidance and mentoring of me during my contributions over the last four editions helped me tremendously as I assumed my new role as chief editor. They both served as tremendous role models and supporters throughout my career.

Next, I wish to acknowledge the contributions of my two associate editors, Dr. James Jones and Dr. LaQuia Vinson. Dr. Jones has contributed to this textbook for many editions, and in particular in this past edition has done anything I've asked to help make sure that we provided a timely and relevant product. Dr. Vinson is a new contributor, brings fresh perspectives, and in particular worked diligently on various aspects of the book. In addition, I'd like to thank Dr. Juan Yepes for taking on the task of making multiple video vignettes that will complement the online version of the textbook.

I would certainly like to take the opportunity to thank the many authors and co-authors who made this tenth edition possible. Specifically, I need to thank and acknowledge the contributions in previous editions by authors who did not participate this time: Drs. Gerald Wright, Dale Miles, David Bixler†, Murray Dock, Keith Moore, Robert Feigal†, Robert Cronin, Charles Goodacre, Thomas Lapp, Ronald Bell†, Michael Sadove, Ann Page Griffin, Jasper Lewis, and Charles Hutton. My hat's off to them for their previous contributions! In addition, special recognition goes to Dr. Rolando DeCastro for his many wonderful illustrations and cover art over the years. Donna Bumgardner once again provided manuscript preparation and valuable editorial assistance for our work, including serving as a bit of a taskmaster to make sure we stayed on track. Mark Dirlam, Kyla Jones, Terry Wilson, and Tim Centers provided assistance with new illustrations. We also gratefully acknowledge the professional staff at Elsevier who has provided valuable assistance and superb guidance in the preparation of this tenth edition, with special thanks to Kathy Falk, executive content specialist; Brian Loehr, senior content development specialist; and Sharon Corell, senior project manager. The faculties of pediatric dentistry and other disciplines at Indiana University have contributed substantially to this work in many ways. We truly appreciate their willingness to share information relevant to scientific accuracy of the manuscripts. Many pediatric dentistry postdoctoral students and auxiliary staff also assisted in numerous ways.

With this special anniversary edition I would like to take the privilege and follow the lead of Dr. McDonald, as he did in his very first edition of this series back in 1963, to thank my family for their patience, love, and support throughout this project and always.

Jeffrey A. Dean

†Deceased

Dentlearn.ir

This page intentionally left blank

Dentlearn.ir

Contents

PART 1 DIAGNOSES

1 Examination of the Mouth and Other Relevant Structures, 1
Jeffrey A. Dean

2 Radiographic Techniques, 17
Edwin T. Parks and Johan K. Aps

3 Acquired and Developmental Disturbances of the Teeth and Associated Oral Structures, 39
James K. Hartsfield Jr. and Angus C. Cameron

4 Development and Morphology of the Primary Teeth, 80
Erwin G. Turner and Jeffrey A. Dean

5 Clinical Genetics for the Dental Practitioner, 87
James K. Hartsfield Jr.

6 Child Abuse and Neglect, 110
Shannon L. Thompson, Brian J. Sanders, and Roberta A. Hibbard

PART 2 CARIES AND PERIODONTOLOGY

7 Mechanical and Chemotherapeutic Home Oral Hygiene, 120
Christopher V. Hughes and Jeffrey A. Dean

8 Nutritional Considerations for the Pediatric Dental Patient, 138
Laura M. Romito and James L. McDonald Jr.

9 Dental Caries in the Child and Adolescent, 155
Judith R. Chin, Joan E. Kowolik, and George K. Stookey

10 Pit-and-Fissure Sealants and Preventive Resin Restorations, 177
Brian J. Sanders

11 Restorative Dentistry, 185
Jeffrey A. Dean and Kevin J. Donly

12 Dental Materials, 206
Jeffrey A. Platt

13 Treatment of Deep Caries, Vital Pulp Exposure, and Pulpless Teeth, 221
Jeffrey A. Dean

14 Gingivitis and Periodontal Disease, 243
Vanchit John, James A. Weddell, Daniel E. Shin, and James E. Jones

PART 3 PAIN CONTROL AND BEHAVIOR GUIDANCE

15 Local Anesthesia and Pain Control for the Child and Adolescent, 274
James E. Jones and Jeffrey A. Dean

16 Nonpharmacologic Management of Children's Behaviors, 286
Jenny I. Stigers

17 Pharmacologic Management of Patient Behavior, 303
Mark A. Saxen

18 Hospital Dental Services for Children and the Use of General Anesthesia, 328
James A. Weddell, James E. Jones, and John D. Emhardt

Dentlearn.ir

PART 4 GROWTH AND DEVELOPMENT

19 Eruption of the Teeth: Local, Systemic, and Congenital Factors That Influence the Process, 349
Jeffrey A. Dean and Erwin G. Turner

20 Growth of the Face and Dental Arches, 375
Donald J. Ferguson and Jeffrey A. Dean

21 Cephalometrics and Facial Aesthetics: The Key to Complete Treatment Planning, 390
John T. Krull, George E. Krull, and Jeffrey A. Dean

22 Managing the Developing Occlusion, 415
Jeffrey A. Dean

23 Multidisciplinary Team Approach to Cleft Lip and Palate Management, 479
LaQuia A. Walker Vinson, Donald V. Huebener, James E. Jones, Roberto L. Flores, and Jeffrey A. Dean

24 Prosthodontic Treatment of the Adolescent Patient, 498
David T. Brown and Mathew T. Kattadiyil

PART 5 MANAGEMENT OF SPECIAL MEDICAL ISSUES AND PRACTICE MANAGEMENT

25 Dental Problems of Children with Special Health Care Needs, 513
James A. Weddell, Brian J. Sanders, and James E. Jones

26 Management of the Medically Compromised Patient: Hematologic Disorders, Cancer, Hepatitis, and AIDS, 540
Brian J. Sanders, Amy D. Shapiro, Randy A. Hock, John J. Manaloor, and James A. Weddell

27 Management of Trauma to the Teeth and Supporting Tissues, 563
James E. Jones, Kenneth J. Spolnik, and Ghaeth H. Yassen

28 Tumors of the Oral Soft Tissues and Cysts and Tumors of Bone, 603
John S. McDonald

29 Oral Surgery for the Pediatric Patient, 627
Elie M. Ferneini and Jeffrey D. Bennett

30 The Child in Context of the Family, Community, and Society, 645
Burton L. Edelstein and Karen M. Yoder

31 Practice Management, 653
Julie Weir

Dentlearn.ir

Video Contents

1 Examination of the mouth

2 Sensor placement: use of direct digital radiology technique in the operating room

11 Restorative techniques

13 Pulp therapy

15 Local anesthetic techniques 1 and 2

17 Airway management in office base anesthesia

18 Throat pack placement

21 Cephalometrics

22 Managing occlusion: delivery of immediate band and loop

25 Use of stabilization

Dentlearn.ir

This page intentionally left blank

Dentlearn.ir

PART 1 DIAGNOSES

CHAPTER 1

Examination of the Mouth and Other Relevant Structures

▲ Jeffrey A. Dean

For additional resources, please visit the evolve website.

CHAPTER OUTLINE

EMERGENCY DENTAL TREATMENT
INITIAL PARENTAL CONTACT WITH THE DENTAL OFFICE
THE DIAGNOSTIC METHOD
PRELIMINARY MEDICAL AND DENTAL HISTORY
CLINICAL EXAMINATION
TEMPOROMANDIBULAR EVALUATION
UNIFORM DENTAL RECORDING
RADIOGRAPHIC EXAMINATION
EARLY EXAMINATION
INFANT DENTAL CARE
DETECTION OF SUBSTANCE ABUSE
Etiologic Factors in Substance Abuse
Specific Substances and Frequency of Use
SUICIDAL TENDENCIES IN CHILDREN AND ADOLESCENTS
INFECTION CONTROL IN THE DENTAL OFFICE
Biofilm
EMERGENCY DENTAL TREATMENT

EMERGENCY DENTAL TREATMENT

A dentist is traditionally taught to perform a complete oral examination of the patient and to develop a treatment plan based on the examination findings. The dentist then makes a case presentation to the patient or parents, outlining the recommended course of treatment. This process should include the development and presentation of a prevention plan that outlines an ongoing comprehensive oral health care program for the patient and establishment of the "dental home."

The plan should include recommendations designed to correct existing oral problems (or halt their progression) and to prevent anticipated future problems. It is essential to obtain all relevant patient and family information, to secure parental consent, and to perform a complete examination before embarking on this comprehensive oral health care program for the pediatric patient. *Anticipatory guidance* is the term often used to describe the discussion and implementation of such a plan with the patient and/or parents. The American Academy of Pediatric Dentistry has published guidelines[1] concerning the periodicity of examination, preventive dental services, and oral treatment for children as summarized in Table 1-1.

Each pediatric patient should be given an opportunity to receive complete dental care. The dentist should not attempt to decide what the child, the parents, or a third-party agent will accept or can afford. If parents reject a portion or all of the recommendations, the dentist has at least fulfilled the obligation of educating the child and the parents about the importance of the recommended procedures. Parents with even moderate income usually find the means to have oral health care performed if the dentist explains that the child's future oral health and even general health are related to the correction of the oral defects.

INITIAL PARENTAL CONTACT WITH THE DENTAL OFFICE

We most often think of parents' first contact with the dental office as being by telephone. This initial conversation between the parent and the office receptionist is very important. It provides the first opportunity for the receptionist to attend to the parents' concerns by pleasantly and concisely responding to questions and by offering an office appointment. The receptionist must have a warm, friendly voice and the ability to communicate clearly. The receptionist's responses should assure the parent that the well-being of the child is the chief concern.

The information recorded by the receptionist during this conversation constitutes the initial dental record for the patient. Filling out a patient information form is a

Dentlearn.ir

Table 1-1

Recommendations for Pediatric Oral Health Assessment, Preventive Services, and Anticipatory Guidance/Counseling

Since each child is unique, these recommendations are designed for the care of children who have no contributing medical conditions and are developing normally. These recommendations will need to be modified for children with special health care needs or if disease or trauma manifests variations from normal. The American Academy of Pediatric Dentistry (AAPD) emphasizes the importance of very early professional intervention and the continuity of care based on the individualized needs of the child. Refer to the text of this guideline for supporting information and references. Refer to the text in the Guidelines on Periodicity of Examinations, Preventive Dental Services, Anticipatory Guidance,

.pdf) for supporting information and references.

	AGE				
American Academy of Pediatric Dentistry	6 to 12 months	12 to 24 months	2 to 6 years	6 to 12 years	12 years and older
Clinical oral examination[1]	•	•	•	•	•
Assesses oral growth and development[2]	•	•	•	•	•
Caries-risk assessment[3]	•	•	•	•	•
Radiographic assessment[4]	•	•	•	•	•
Prophylaxis and topical fluoride[3,4]	•	•	•	•	•
Fluoride supplementation[5]	•	•	•	•	•
Anticipatory guidance/counseling[6]	•	•	•	•	•
Oral hygiene counseling[7]	Parent	Parent	Patient/ parent	Patient/ parent	Patient
Dietary counseling[8]	•	•	•	•	•
Injury prevention counseling[9]	•	•	•	•	•
Counseling for nonnutritive habits[10]	•	•	•	•	•
Counseling for speech/language development	•	•	•	•	•
Assessment and treatment of developing malocclusion			•	•	•
Assessment for pit and fissure sealants[11]			•	•	•
Substance abuse counseling				•	•
Counseling for intraoral/perioral piercing				•	•
Assessment and/or removal of third molars					•
Transition to adult dental care					•

[1]First examination at the eruption of the first tooth and no later than 12 months. Repeat every 6 months or as indicated by child's risk status/ susceptibility to disease. Includes assessment of pathology and injuries.
[2]By clinical examination.
[3]Must be repeated regularly and frequently to maximize effectiveness.
[4]Timing, selection, and frequency determined by child's history, clinical findings, and susceptibility to oral disease.
[5]Consider when systemic fluoride exposure is suboptimal. Up to at least 16 years of age or later in high-risk patients.
[6]Appropriate discussion and counseling should be an integral part of each visit for care.
[7]Initially, responsibility of parent; as child matures, jointly with parent; then, when indicated, only child.
[8]At every appointment; initially discuss appropriate feeding practices, followed by the role of refined carbohydrates and frequency of snacking in caries development and childhood obesity.
[9]Initially for play objects, pacifiers, car seats; then while learning to walk; and then with sports and routine playing, including the importance of mouthguards.
[10]At first, discuss the need for additional sucking: digits vs. pacifiers; then the need to wean from the habit before malocclusion or skeletal dysplasia occurs. For school-aged children and adolescent patients, counsel regarding any existing habits such as fingernail biting, clenching, or bruxism.
[11]For caries-susceptible primary molars, permanent molars, premolars, and anterior teeth with deep pits and fissures; placed as soon as possible after eruption.

convenient method of collecting the necessary initial information. Of course, most dental practices are moving toward online, website-driven information and completion of patient forms for use even before a parent calls an office for an appointment or schedules an appointment online. Practices need to make accommodations to their patient information systems to manage these very productive changes.

THE DIAGNOSTIC METHOD

Before making a diagnosis and developing a treatment plan, the dentist must collect and evaluate the facts associated with the patient's or parents' chief concern and any other identified problems that may be unknown to the patient or parents. Some pathognomonic signs may lead to an almost immediate diagnosis. For example, obvious gingival swelling and drainage may be associated with a single, badly carious primary molar. Although these associated facts are collected and evaluated rapidly, they provide a diagnosis only for a single problem area. On the other hand, a comprehensive diagnosis of all of the patient's problems or potential problems may sometimes need to be postponed until more urgent conditions are resolved. For example, a patient with necrotizing ulcerative gingivitis or a newly fractured crown needs immediate treatment, but the treatment will likely be only palliative, and further diagnostic and treatment procedures will be required later.

The importance of thorough collection and evaluation of the facts concerning a patient's condition cannot be overemphasized. A thorough examination of the pediatric dental patient includes an assessment of the following:

- General growth and health
- Chief complaint, such as pain
- Extraoral soft tissue and temporomandibular joint evaluation
- Intraoral soft tissue
- Oral hygiene and periodontal health
- Intraoral hard tissue
- Developing occlusion
- Caries risk
- Behavior

Additional diagnostic aids are often also required, such as radiographs, study models, photographs, pulp tests, and, infrequently, laboratory tests. In certain unusual cases, all of these diagnostic aids may be necessary before a comprehensive diagnosis can be made. Certainly no oral diagnosis can be complete unless the diagnostician has evaluated the facts obtained by medical and dental history taking, inspection, palpation, exploration (if teeth are present), and often imaging (e.g., radiographs). For a more thorough review of evaluation of the dental patient, refer to the chapter by Glick, Greenberg, and Ship in *Burket's Oral Medicine*.[2]

PRELIMINARY MEDICAL AND DENTAL HISTORY

It is important for the dentist to be familiar with the medical and dental history of the pediatric patient. Familial history may also be relevant to the patient's oral condition and may provide important diagnostic information in some hereditary disorders. Before the dentist examines the child, the dental assistant can obtain sufficient information to provide the dentist with knowledge of the child's general health and can alert the dentist to the need for obtaining additional information from the parent or the child's physician. The form illustrated in Figure 1-1 can be completed by the parent. However, it is more effective for the dental assistant to ask the questions informally and then to present the findings to the dentist and offer personal observations and a summary of the case. The questions included on the form will also provide information about any previous dental treatment.

Information regarding the child's social and psychological development is important. Accurate information reflecting a child's learning, behavioral, or communication problems is sometimes difficult to obtain initially, especially when the parents are aware of their child's developmental disorder but are reluctant to discuss it. Behavior problems in the dental office are often related to the child's inability to communicate with the dentist and to follow instructions. This inability may be attributable to a learning disorder. An indication of learning disorders can usually be obtained by the dental assistant when asking questions about the child's learning process; for example, asking a young school-aged child how he or she is doing in school is a good lead question. The questions should be age-appropriate for the child.

If a young child was hospitalized previously for general anesthetic and surgical procedures, it should be noted. Hospitalization and procedures involving general anesthesia can be a traumatic psychological experience for a preschool child and may sensitize the youngster to procedures that will be encountered later in a dental office.[3] If the dentist is aware that a child was previously hospitalized or that the child fears strangers in clinic attire, the necessary time and procedures can be planned to help the child overcome the fear and accept dental treatment.

Occasionally, when the parents report significant disorders, it is best for the dentist to conduct the medical and dental history interview. When the parents meet with the dentist privately, they are more likely to discuss the child's problems openly, and there is less chance for misunderstandings regarding the nature of the disorders. In addition, the dentist's personal involvement at this early time strengthens the parents' confidence. When an acute or chronic systemic disease or anomaly is indicated, the dentist should consult the child's physician to learn the status of the condition, the long-range prognosis, and the current drug therapy.

When a patient's medical and dental history is recorded, the presence of current illnesses or history of relevant disorders signals the need for special attention. In addition to consulting the child's physician, the dentist may decide to record additional data concerning the child's current physical condition, such as blood pressure, body temperature, heart sounds, height and weight, pulse, and respiration. Before treatment is initiated, certain laboratory tests may be indicated, and special precautions may be necessary. A decision to provide treatment in a

Dentlearn.ir

UNIVERSITY PEDIATRIC DENTISTRY ASSOCIATES
Riley Hospital for Children IU Health | ROC | Pediatric Dentistry
705 Riley Hospital Drive, Room #4205
Indianapolis, IN 46202-5109

x

DOB: EDR:

NA:

LC: DATE:

MEDICAL / DENTAL HISTORY

Patient Name:_____ Birth Date:_____ Gender: ☐Female ☐Male
City & State of Birth:_____ Race:_____ Height:_____ Weight____
Primary Care Physician:_____ Previous Dentist: _____
Physician Address:_____ Dentist Phone:_____
Physician Phone:_____ Last Dental Visit: _____
Date of Last Medical Exam:_____ Last Dental X-rays:_____

Dental History:
What is the primary reason for today's visit? _____
Is patient in pain? ☐YES ☐NO Explain:_____
Has patient had an injury to the mouth, teeth, or jaw? ☐YES ☐NO Explain:_____
What is patient's primary water source: ☐ Private Well ☐ City Water, City Name:_____ ☐Other:_____
Was/is patient ☐ Breastfed or ☐ Bottle-fed Until what age? Breastfed:_____ Bottle-fed:_____
How often does patient brush teeth?_____ ☐With Help ☐Without Help How often does patient floss?_____
Does patient…

Yes / No		Yes / No		Yes / No	
☐	☐ Suck Thumb/Fingers	☐	☐ Bite/Chew Finger Nails	☐	☐ Clench/Grind Teeth
☐	☐ Use Pacifier	☐	☐ Have Speech Issues	☐	☐ Mouth Breather

Medical History:
Is patient currently under the care of a doctor? ☐YES ☐NO Explain:_____
Does patient have allergies? ☐YES ☐NO Explain:_____
Is patient taking medications? ☐YES ☐NO Please list all medications and natural remedies. Additional items may be listed on the back

Medication Name:	Dose:	Frequency of Use:

Has patient had surgery or been hospitalized? ☐YES ☐NO

Hospital Facility:	When:	Reason:

Does patient have / or had any of the following:

Yes / No		Yes / No		Yes / No	
☐	☐ Congenital Heart Defect/Disease	☐	☐ Visual/Hearing Impairment	☐	☐ Failure to Thrive
☐	☐ Heart Surgery	☐	☐ Abnormal Bleeding Issues	☐	☐ Eating Disorders
☐	☐ Heart Murmur	☐	☐ Sickle Cell Trait/Disease	☐	☐ Born Prematurely
☐	☐ High Blood Pressure	☐	☐ Hemophilia	☐	☐ Immunizations
☐	☐ Rheumatic Fever	☐	☐ Anemia	☐	☐ Hepatitis A, B, C
☐	☐ Asthma/Breathing Issues	☐	☐ Kidney Problems	☐	☐ Blood/Blood Product Transfusion
☐	☐ Cerebral Palsy	☐	☐ Liver Problems	☐	☐ HIV/AIDS
☐	☐ Seizures/Convulsions/Epilepsy	☐	☐ Diabetes	☐	☐ Varicella Vaccine / Chicken Pox
☐	☐ Learning/Communication Problems	☐	☐ Muscle/Joint/Bone Problems	☐	☐ TB / Tuberculosis
☐	☐ Autism	☐	☐ Thyroid/Glandular Problems	☐	☐ MRSA
☐	☐ ADD/ADHD	☐	☐ Skin Problems / Hives / Cold Sores	☐	☐ Limited Mobility

I affirm that the information provided above is correct to the best of my knowledge. It will be held in confidence and it is my responsibility to inform this office if there is a change in the health history of this patient. I authorize the release of this information to additional healthcare providers as is necessary for the dental treatments of this patient.

Guardian Signature:_____ Relationship to Patient:_____
Resident Signature: _____ Date:_____ Time:_____

Form #UPDDR217 Rev. 12/2013

Riley Hospital for Children Indiana University Health

INDIANA UNIVERSITY SCHOOL OF DENTISTRY University Pediatric Dentistry Associates

Figure 1-1 Form used in completing the preliminary medical and dental history. (Printed with permission from Indiana University–University Pediatric Dentistry Associates.)

hospital that possibly involves general anesthesia may be appropriate.

The dentist and the staff must also be alert to identify potentially communicable infectious conditions that threaten the health of the patient and others. Knowledge of the current recommended childhood immunization schedule is helpful. It is advisable to postpone nonemergency dental care for a patient exhibiting signs or symptoms of acute infectious disease until the patient recovers. Further discussions of management of dental patients with special medical, physical, or behavioral problems are presented in Parts III and V.

The pertinent facts of the medical history can be transferred to the oral examination record (Fig. 1-2) for easy reference by the dentist. A brief summary of important medical information serves as a convenient reminder to the dentist and the staff, who will refer to this chart at each treatment visit.

The patient's dental history should also be summarized on the examination chart. This should include a record of previous care in the dentist's office and the facts related by the patient and parent(s) regarding previous care, if any, in another office. Information concerning the patient's current oral hygiene habits and previous and current fluoride exposure helps the dentist develop an effective dental disease prevention program. For ex-

sent to a water analysis laboratory to determine the fluoride concentration.

CLINICAL EXAMINATION

Most facts needed for a comprehensive oral diagnosis in the young patient are obtained by thorough clinical and radiographic examination. In addition to examining the oral cavity structures, the dentist may in some cases wish to note the patient's size, stature, gait, or involuntary movements. The first clue to malnutrition may come from observing a patient's abnormal size or stature. Similarly, the severity of a child's illness, even if oral in origin, may be recognized by observing a weak, unsteady gait of lethargy and malaise as the patient walks into the office. All relevant information should be noted on the oral examination record (see Fig. 1-2), which becomes a permanent part of the patient's chart.

The clinical examination, whether the first examination or a regular recall examination, should be all-inclusive. The dentist can gather useful information while getting acquainted with a new patient. Attention to the patient's hair, head, face, neck, and hands should be among the first observations made by the dentist after the patient is seated in the chair.

The patient's hands may reveal information pertinent to a comprehensive diagnosis. The dentist may first detect an elevated temperature by holding the patient's hand. Cold, clammy hands or bitten fingernails may be the first indication of abnormal anxiety in the child. A callused or unusually clean digit suggests a persistent sucking habit. Clubbing of the fingers or a bluish color in the nail beds suggests congenital heart disease, which may require special precautions during dental treatment.

Inspection and palpation of the patient's head and neck are also indicated. Unusual characteristics of the hair or skin should be noted. The dentist may observe signs of problems such as head lice (Fig. 1-3), ringworm (Fig. 1-4), or impetigo (Fig. 1-5) during the examination. Proper referral is indicated immediately, because these conditions are contagious. After the child's physician has supervised treatment to control the condition, the child's dental appointment may be rescheduled. If a contagious condition is identified but the child also has a dental emergency, the dentist and the staff must take appropriate precautions to prevent spread of the disease to others while the emergency is alleviated. Further treatment should be postponed until the contagious condition is controlled.

Variations in the size, shape, symmetry, or function of the head and neck structures should be recorded. Abnormalities of these structures may indicate various syndromes or conditions associated with oral abnormalities.

TEMPOROMANDIBULAR EVALUATION

Okeson[4] published a special report on temporomandibular disorders in children. Okeson indicated that, although several studies included children 5 to 7 years of age, most observations have been made in young adolescents. Studies have placed the findings into the categories of symptoms or signs—those reported by the child or parents and those identified by the dentist during the examination. Prevalence of signs and symptoms increases with age and may occur in 30% of patients.

One should evaluate temporomandibular joint (TMJ) function by palpating the head of each mandibular condyle and by observing the patient while the mouth is closed (teeth clenched), at rest, and in various open positions (Fig. 1-6, *A, B*). Movements of the condyles or jaw that do not flow smoothly or that deviate from the expected norm should be noted. Similarly, any crepitus that may be heard or identified by palpation as well as any other abnormal sounds should be noted. Sore masticatory muscles may also signal TMJ dysfunction. Such deviations from normal TMJ function may require further evaluation and treatment. There is a consensus that temporomandibular disorders in children can be managed effectively by the following conservative and reversible therapies: patient education, mild physical therapy, behavioral therapy, medications, and occlusal splints.[5]

Discussion of the diagnosis and treatment of complex TMJ disorders is available from many sources; we suggest Okeson's *Management of Temporomandibular Disorders and Occlusion* (2013).[6]

The extraoral examination continues with palpation of the patient's neck and submandibular area (see Fig. 1-6, *C, D*). Again, deviations from normal, such as unusual tenderness or enlargement, should be noted and follow-up tests performed or referrals made as indicated.

If the child is old enough to talk, speech should be evaluated. The positions of the tongue, lips, and perioral musculature during speech, while swallowing, and at rest may provide useful diagnostic information.

The intraoral examination of a pediatric patient should be comprehensive. There is a temptation to look first for

Dentlearn.ir

INDIANA UNIVERSITY
SCHOOL OF DENTISTRY
IUPUI

UNIVERSITY PEDIATRIC DENTISTRY ASSOCIATES
Riley Hospital for Children ▪ Outpatient Center ▪ Dental MSA
702 Barnhill Drive, Room #4205
Indianapolis, IN 46202-5200
(317) 274-3865 ▪ (317) 274-9653 Fax

Place Patient Label Here

Patient Name:_____ (Last / First / MI)
OFFICE USE ONLY
DOB_____ Record #: _____

ORAL EXAMINATION RECORD

Address: Same ☐ New ☐ _____ Telephone: Same☐ New☐ _____
**** New address and/or phone number must be noted here and updated in practice software.*

MEDICAL HISTORY SUMMARY
Last History Completed: _____ Update Due: _____ Weight: _____
Current Medication Status & Medication Usage:

DENTAL HISTORY SUMMARY
Date of Last Exam: _____ Last Radiographs: B.W.: _____ A.O.:_____ P.A.:_____ F.M.:_____
Appliances: _____ Last Cemented: _____ Last Replaced: _____
Description of Present Problem:
Summary of Prior Treatment:

EXTRA-ORAL FINDINGS
Head: Neck:
Face: Lips: Hands:

INTRA-ORAL FINDINGS
Palate and Oropharynx: Airway: I II III IV
Tongue and Floor of Mouth: Buccal Mucosa:
Frena: Gingivae and Periodontium:

OCCLUSION REVIEW
Facial Profile: _____

Molar Relationship:

PRIMARY (Terminal Plane):	R	L	PERMANENT:	R	L
Straight	☐	☐	Molar		
Mes. Step	☐	☐	End to End	☐	☐
Dist. Step	☐	☐	Class	___	___
Primate Space	☐	☐	Canine		
Canine Relationship	___	___	Relationship	___	___

Midline: Normal ☐ Deviated ☐
Maxilla _____mm R☐ L☐
Mandible _____mm R☐ L☐
Mandibular:
Shift R☐ L☐ Ant. ☐_____mm

Incisor Relationship:
Overjet _____mm
Overbite _____%
Openbite _____mm

Arch Length: (General Impression)

Maxilla	Mandible
Adequate ☐	Adequate ☐
Inadequate ☐	Inadequate ☐

Eruption Sequence & Timimg:
Normal ☐ Describe ☐
_____
_____

TMJ and Function:
Opening Path: Normal ☐ Deviated ☐
Closing Path: Normal ☐ Deviated ☐
Opening: ____mm Normal ☐ Limited ☐

Joint Sounds:	None	Left	Right
Opening	☐	☐	☐
Closing	☐	☐	☐
Crepitus	☐	☐	☐

Muscle Tenderness:
Tongue Function:
Crossbite:
Oral Habits:
Analysis Recommended: YES☐ NO☐

Supernumerary Teeth/ Congenitally Missing Teeth:
Ectopic Eruption:
Other Anomalies:

Figure 1-2 Chart used to record the oral findings and the treatment proposed for the pediatric patient. (Printed with permission from Indiana University–University Pediatric Dentistry Associates.)

University Pediatric Dentistry Associates 702 Barnhill Drive RM #4205 • Indianapolis IN 46202-5200 • (317) 274-3865 • (317) 274-9653 Fax

ORAL EXAM RECORD

Patient Name: _____

Date of Birth: _____ ACT#: _____

HARD TISSUE EXAMINATION

		Clinical	Radiographic			Clinical	Radiographic
	1				16		
	2				15		
	3				14		
A	4			J	13		
B	5			I	12		
C	6			H	11		
D	7			G	10		
E	8			F	9		
P	25			O	24		
Q	26			N	23		
R	27			M	22		
S	28			L	21		
T	29			K	20		
	30				19		
	31				18		
	32				17		

DIAGNOSTIC SUMMARY

Plaque Score: A B C D F

Prior Score:

Behavior:

Fluoride Status:

Eruption sequence:

Brushing / Flossing:

Occlusion:

Habits:

Periodontal:

Caries:

Periodontal Screening & Recording: _____|_____|_____

Caries Risk Assessment: ☐Low ☐Moderate ☐High

TREATMENT PROPOSED

Upper Right **Upper Left**

Lower Right **Lower Left**

Treatment sequence, additional notations:

1.

2.

3.

4.

5.

Instructions given:

Assistant **Resident** **Faculty Instructor**

Figure 1-2, cont'd

Dentlearn.ir



Figure 1-3 Evidence of head lice infestation. Usually the insects are not seen, but their eggs or nits cling to hair filaments until they hatch. (Courtesy Dr. Hala Henderson.)



Figure 1-4 Lesion on the forehead above the left eyebrow is caused by ringworm infection. Several fungal species may cause lesions on various areas of the body. The dentist may identify lesions on the head, face, or neck of a patient during a routine clinical examination. (Courtesy Dr. Hala Henderson.)

obvious carious lesions. Although controlling carious lesions is important, the dentist should first evaluate the condition of the oral soft tissues and the status of the developing occlusion. If the soft tissues and the occlusion are not observed early in the examination, the dentist may become so engrossed in charting carious lesions and in planning for their restoration that other important anomalies in the mouth are overlooked. In addition, any unusual breath odors and abnormal quantity or consistency of saliva should also be noted.

The buccal tissues, lips, floor of the mouth, palate, and gingivae should be carefully inspected and palpated (Fig. 1-7). The use of the periodontal screening and recording program (PSR) is often a helpful adjunct when working with children. PSR is designed to facilitate early detection of periodontal diseases with a simplified probing technique and minimal documentation. Clerehugh and Tugnait[7] recommend initiation of periodontal screening in children following eruption of the permanent incisors and the first molars. They suggest routine screening in these children at the child's first appointment and at regular recare appointments so that periodontal problems are detected early and treated appropriately. Immunodeficient children are especially vulnerable to early loss of bone support.

A more detailed periodontal evaluation is occasionally indicated, even in young children. Periodontal disorders of children are discussed further in Chapter 14.

The tongue and oropharynx should be closely inspected. Enlarged tonsils accompanied by purulent exudate may be the initial sign of a streptococcal infection, which can lead to rheumatic fever. When streptococcal throat infection is suspected, immediate referral to the child's physician is indicated. In some cases it may be helpful to the physician and convenient for the dentist to obtain a throat culture specimen while the child is still in the dental office, which contributes to an earlier definitive diagnosis of the infection. The diagnosis and treatment of soft tissue problems are discussed throughout this book (see Chapters 3, 27, and 28.)

After thoroughly examining the oral soft tissues, the dentist should inspect the occlusion and note any dental or skeletal irregularities. The dentition and resulting occlusion may undergo considerable change during childhood and early adolescence. This dynamic developmental process occurs in all three planes of space, and with periodic evaluation the dentist can intercept and favorably influence undesirable changes. The patient's facial profile and symmetry; molar, canine, and anterior segment relationships; dental midlines; and relation of arch length to tooth mass should be routinely monitored in the clinical examination. More detailed evaluation and analysis are indicated when significant discrepancies are found during critical stages of growth and development. Diagnostic casts and cephalometric analyses may be indicated relatively early in the mixed-dentition stage and sometimes in the primary dentition. Detailed discussions of analyses of developing occlusions and interceptive treatment recommendations are presented in Chapters 20, 21, and 22.

Finally, the teeth should be inspected carefully for evidence of carious lesions and hereditary or acquired

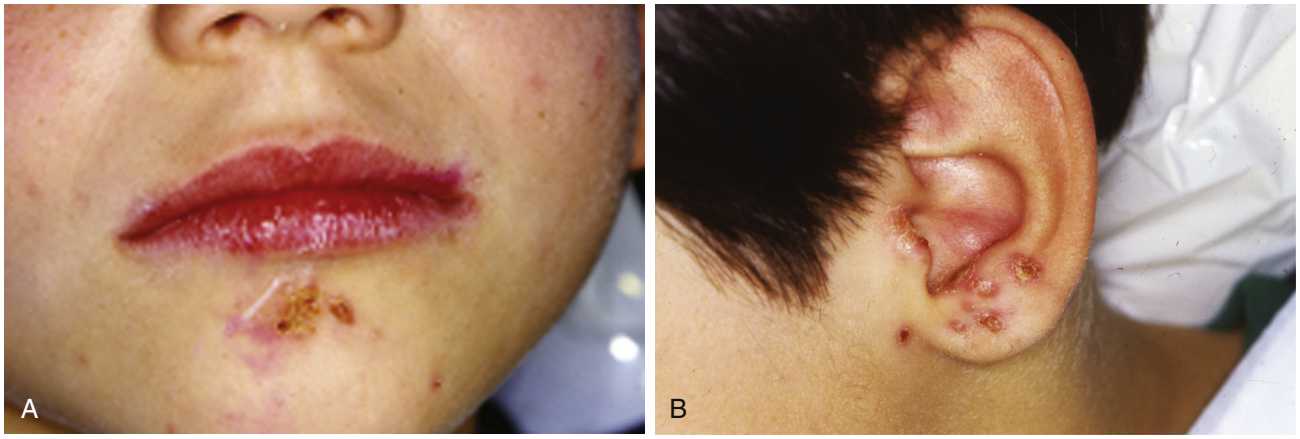

Figure 1-5 Characteristic lesions of impetigo on the lower face **(A)** and on the right ear **(B).** These lesions occur on various skin surfaces, but the dentist is most likely to encounter them on upper body areas. The infections are of bacterial (usually streptococcal) origin and generally require antibiotic therapy for control. The child often spreads the infection by scratching the lesions. (Courtesy Dr. Hala Henderson.)

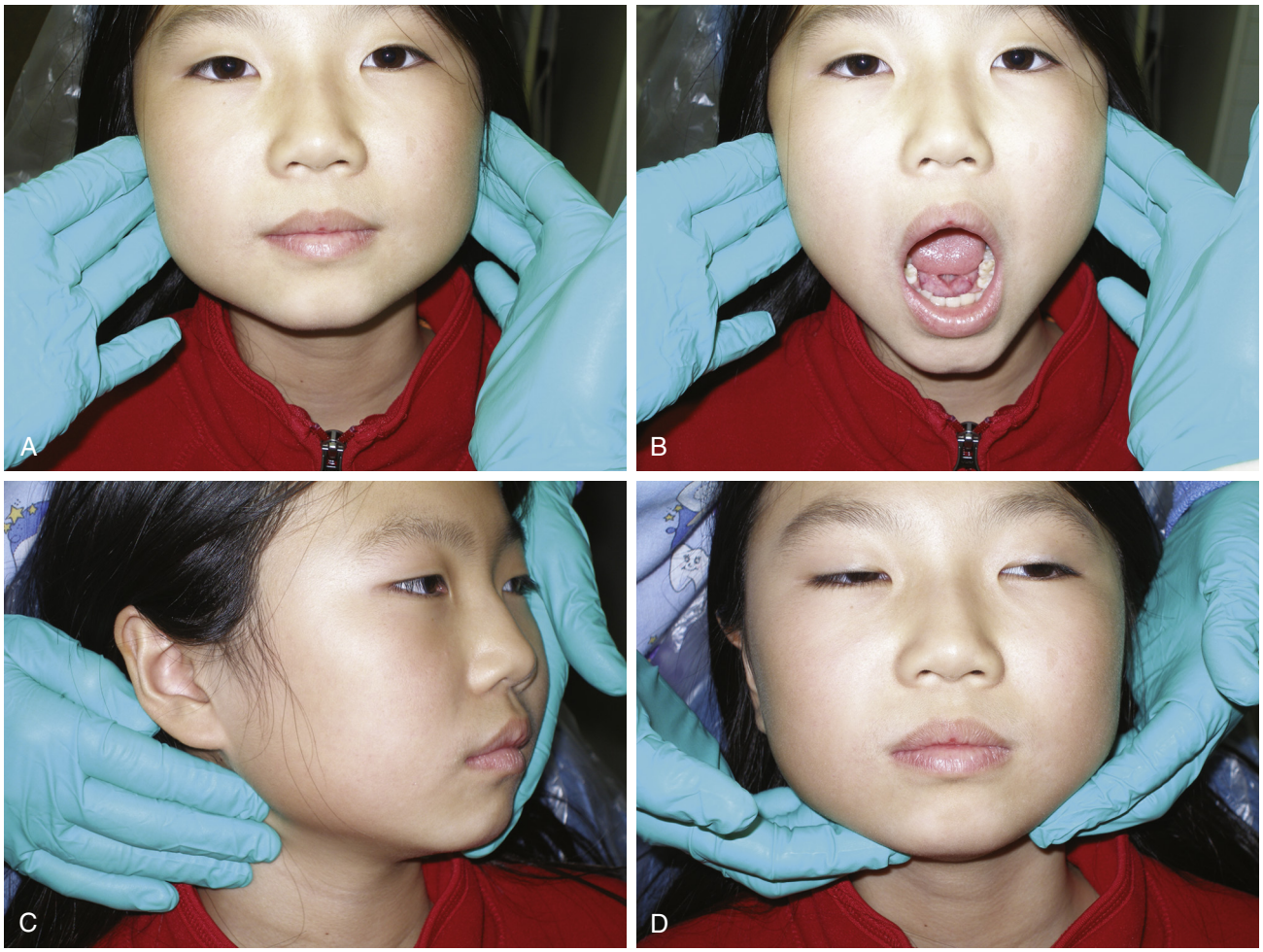

Figure 1-6 **A** and **B,** Observation and palpation of temporomandibular joint function. **C** and **D,** Palpation of the neck and submandibular areas.

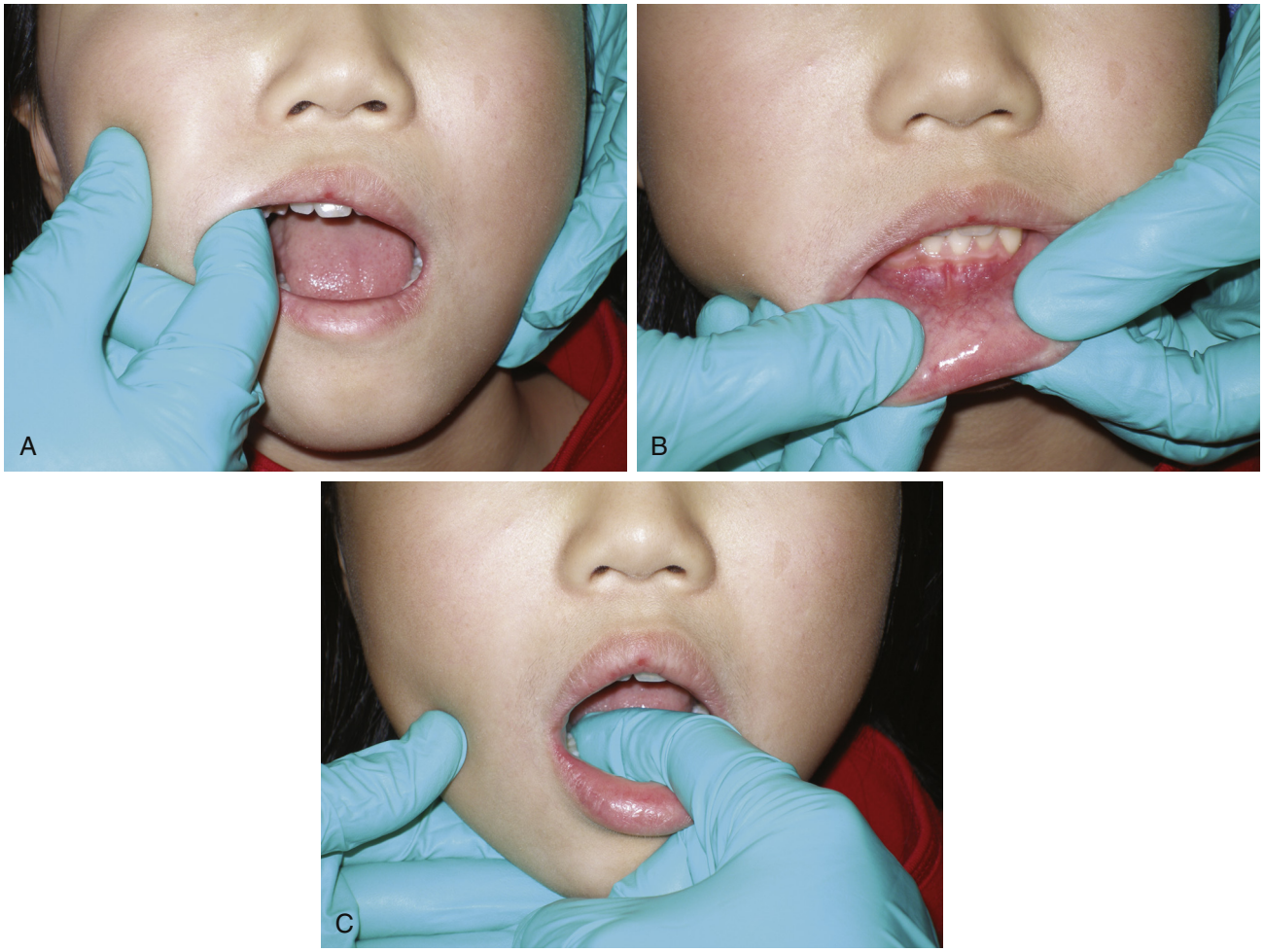

Figure 1-7 Inspection and palpation of the buccal tissues **(A),** the lips **(B),** and the floor of the mouth **(C).**

anomalies. The teeth should also be counted and identified individually to ensure that supernumerary or missing teeth are recognized. Identification of caries lesions is important in patients of all ages but is especially critical in young patients because the lesions may progress rapidly in early childhood if not controlled. Eliminating the etiology of the caries activity, preventive management of the caries process, and restoration of cavitated lesions will prevent pain and the spread of infection and will contribute to the stability of the developing occlusion.

Since it is preferable for the dentist to perform the clinical examination of a new pediatric patient before the radiographic and prophylaxis procedures, it may be necessary to correlate radiographic findings or other initially questionable findings with the findings of a second brief oral examination. This is especially true when the new patient has poor oral hygiene. Detailed inspection and exploration of the teeth and soft tissues cannot be performed adequately until the mouth is free of extraneous debris.

During the clinical examination for carious lesions, each tooth should be dried individually and inspected under a good light. A definite routine for the examination should be established. For example, a dentist may always start in the upper right quadrant, work around the maxillary arch, move down to the lower left quadrant, and end the examination in the lower right quadrant. Morphologic defects and incomplete coalescence of enamel at the bases of pits and fissures in molar teeth can often be detected readily by visual and explorer examination after the teeth have been cleaned and dried. The decision whether to place a sealant or to restore a defect depends on the patient's history of dental caries, the parents' or patient's acceptance of a comprehensive preventive dentistry program (including dietary and oral hygiene control), and the patient's dependability in returning for recare appointments.

In patients with severe dental caries, caries activity tests and diet analysis may contribute to the diagnostic process by helping define specific etiologic factors. These procedures probably have an even greater value in helping the patient and/or parents understand the caries disease process and in motivating them to make the behavioral changes needed to control the disease. The information provided to them should include instruction in plaque control and the appropriate recommendations for fluoride exposure. Dental caries susceptibility, the caries disease process, caries activity tests, diet analysis, and

caries control are discussed in Chapter 9. Plaque control procedures and instructions are detailed in Chapter 7.

The dentist's comprehensive diagnosis depends on the completion of numerous procedures but requires a thorough, systematic, and critical clinical examination. Any deviation from the expected or desired size, shape, color, and consistency of soft or hard tissues should be described in detail. The severity of associated problems and their causes must be clearly identified to the patient or parents before a comprehensive oral health care program can be expected to succeed.

During the initial examination and at subsequent appointments, the dentist and auxiliary staff members should be alert to signs and symptoms of child abuse and neglect. These problems are increasing in prevalence, and the dentist can play an important role in detecting their signs and symptoms; Chapter 6 is devoted to this subject.

UNIFORM DENTAL RECORDING

Many different tooth-charting systems are currently in use, including the universal system illustrated in the hard tissue examination section of Figure 1-2. This system of marking permanent teeth uses the numbers 1 to 32, beginning with the upper right third molar (No. 1) and progressing around the arch to the upper left third molar (No. 16), down to the lower left third molar (No. 17), and around the arch to the lower right third molar (No. 32). The primary teeth are identified in the universal system by the first 20 letters of the alphabet, A through T.

The Fédération Dentaire Internationale's Special Committee on Uniform Dental Recording has specified the following basic requirements for a tooth-charting system:

1. Simple to understand and teach
2. Easy to pronounce in conversation and dictation
3. Readily communicable in print and by wire
4. Easy to translate into computer input
5. Easily adaptable to standard charts used in general practice

The committee found that only one system, the two-digit system, seems to comply with these requirements. According to this system, the first digit indicates the quadrant and the second digit the type of tooth within the quadrant. Quadrants are allotted the digits 1 to 4 for the permanent teeth and 5 to 8 for the primary teeth in a clockwise sequence, starting at the upper right side; teeth within the same quadrant are allotted the digits 1 to 8 (primary teeth, 1 to 5) from the midline backward. The digits should be pronounced separately; thus the permanent canines are teeth one-three, two-three, three-three, and four-three.

In the "Treatment Proposed" section of the oral examination record (see Fig. 1-2), the individual teeth that require restorative procedures, endodontic therapy, or extraction are listed. Gingival areas requiring follow-up therapy are also noted. A checkmark can be placed beside each listed tooth and procedure as the treatment is completed. Additional notations concerning treatment procedures completed and the date are recorded on supplemental treatment record pages.

RADIOGRAPHIC EXAMINATION

When indicated, radiographic examination for children must be completed before a comprehensive oral health care plan can be developed, and subsequent radiographs are required periodically to enable detection of incipient caries lesions or other developing anomalies.

A child should be exposed to dental ionizing radiation only after the dentist has determined that radiography is necessary to make an adequate diagnosis for the individual child at the time of the appointment.

Obtaining isolated occlusal, periapical, or bite-wing films is sometimes indicated in very young children (even infants) because of trauma, toothache, suspected developmental disturbances, or proximal caries. It should be remembered that carious lesions appear smaller on radiographs than they actually are.

As early as 1967, Blayney and Hill[8] recognized the importance of diagnosing incipient proximal carious lesions with the appropriate use of radiographs. If the pediatric patient can be motivated to adopt a routine of good oral hygiene supported by competent supervision, many of these initial lesions can be arrested.

Radiographic techniques for the pediatric patient are described in detail in Chapter 2.

EARLY EXAMINATION

Historically, dental care for children has been designed primarily to prevent oral pain and infection, occurrence and progression of dental caries, premature loss of primary teeth, loss of arch length, and development of an association between fear and dental care. The dentist is responsible for guiding the child and parents, resolving oral disorders before they can affect health and dental alignment, and preventing oral disease. The goals of pediatric dental care are therefore primarily preventive. The dentist's opportunity to conduct an initial oral examination and parental consultation during the patient's infancy is a key element in achieving and maintaining these goals.

Some dentists, especially pediatric dentists, like to counsel expectant parents before their child is born. They consider it appropriate to discuss with expectant mothers the importance of good nutrition during pregnancy and practices that can influence the expected child's general and dental health.

It is also appropriate to inquire about medication that the expectant mother is taking. For example, prolonged ingestion of tetracyclines may result in discolored, pigmented, and even hypoplastic primary teeth.

The expectant mother should be encouraged to visit her dentist and to have all caries lesions restored. The presence of active dental caries and accompanying high levels of *Streptococcus mutans* can lead to transmission by the mother to the infant and may be responsible for the development of caries lesions at a very early age.

It is not intended that the pediatric dentist usurp the responsibility of the expectant mother's physician in recommending dietary practices; rather, the dentist should reinforce good nutritional recommendations provided by medical colleagues.

Dentlearn.ir

INFANT DENTAL CARE

The infant oral health care visit should be seen as the foundation on which a lifetime of preventive education and dental care can be built to help ensure optimal oral health into childhood. Oral examination, anticipatory guidance including preventive education, and appropriate therapeutic intervention for the infant can enhance the opportunity for a lifetime of freedom from preventable oral disease. The 2013 American Academy of Pediatric Dentistry guidelines on infant oral health care included the following recommendations:

1. All primary health care professionals who serve mothers and infants should provide parent/caregiver education on the etiology and prevention of early childhood caries (ECC).
2. The infectious and transmissible nature of bacteria that cause ECC and methods of oral health risk assessment (e.g., Caries Assessment Tool [CAT]), anticipatory guidance, and early intervention should be included in the curriculum of all medical, nursing, and allied health professional programs.
3. Every infant should receive an oral health risk assessment from his or her primary health care provider or qualified health care professional by 6 months of age.
4. Parents or caregivers should establish a dental home for infants by 12 months of age.
5. Health care professionals and all stakeholders in children's health should support the identification of a dental home for all infants at 12 months of age.

Thus it is appropriate for a dentist to perform an oral examination for an infant of any age, even a newborn, and an examination is recommended anytime the parent or physician calls with questions concerning the appearance of an infant's oral tissues. Even when there are no known problems, the child's first dental visit and oral examination should take place by at least 1 year of age. This early dental visit enables the dentist and parents to discuss ways to nurture excellent oral health before any serious problems have had an opportunity to develop. An adequate oral examination for an infant is generally simple and brief, but it may be the important first step toward a lifetime of excellent oral health.

Some dentists may prefer to "preside" during the entire first session with the infant and parents. Others may wish to delegate some of the educational aspects of the session to auxiliary members of the office staff and then conduct the examination and answer any unresolved questions. In either case, it is sometimes necessary to have an assistant available to help hold the child's attention so that the parents can concentrate on the important information being provided.

It is not always necessary to conduct the infant oral examination in the dental operatory, but it should take place where there is adequate light for a visual examination. The dentist may find it convenient to conduct the examination in the private consultation room during the initial meeting with the child and parents. The examination procedures may include only direct observation and digital palpation. However, if primary molars have erupted or if hand instruments may be needed, the examination should be performed in an area where instrument transfers between the dental assistant and the dentist can proceed smoothly.

The parents should be informed before the examination that it will be necessary to restrain the child gently and that it is normal for the child to cry during the procedure. The infant is held on the lap of a parent, usually the mother. This direct involvement of the parent provides emotional support to the child and allows the parent to help restrain the child. Both parents may participate or at least be present during the examination.

The dentist should make a brief attempt to get acquainted with the infant and to project warmth and caring. However, many infants and toddlers are not particularly interested in developing new friendships with strangers, and the dentist should not be discouraged if the infant shuns the friendly approach. Even if the child chooses to resist (which is common and normal), only negligible extra effort is necessary to perform the examination procedure. The dentist should not be flustered by the crying and resistant behavior and should proceed unhurriedly but efficiently with the examination. The dentist's voice should remain unstrained and pleasant during the examination. The dentist's behavior should reassure the child and alleviate the parents' anxiety concerning this first dental procedure.

One method of performing the examination in a private consultation area is illustrated in Figure 1-8, *A*. The dentist and the parent are seated face to face with their knees touching. Their upper legs form the "examination table" for the child. The child's legs straddle the parent's body, which allows the parent to restrain the child's legs and hands (Video 1-1: Examination of the mouth). An assistant is present to record the dentist's examination findings as they are dictated and to help restrain the child if needed. If adequate space is available in the consultation area, the approach illustrated in Figure 1-8, *B*, may be useful. The dental assistant is seated at a desk or writing stand near the child's feet. The dental assistant and the parent are facing the same direction, side by side and at a right angle to the direction that the dentist is facing. The dental assistant is in a good position to hear and record the dentist's findings as they are dictated, even if the child is crying loudly. These positions (see Fig. 1-8) are also convenient for demonstrating oral hygiene procedures to the parents.

The positions of the dentist, parent, child, and dental assistant during the examination at the dental chair are illustrated in Figure 1-9. The dental assistant is seated higher to permit good visibility and to better anticipate the dentist's needs. The assistant is also in a good position to hear and record the dentist's findings. The parent and the dental assistant restrain the child's arms and legs. The child's head is positioned in the bend of the parent's arm. The dentist establishes a chairside position so that not only the dentist's hands but also the lower arms and abdomen may be available for support of the child's head, if necessary.

The infant oral examination may often be performed by careful direct observation and digital palpation. The dentist may need only good lighting for visibility and gauze for drying or debriding tissues. Sometimes a tongue depressor and a soft-bristled toothbrush are useful. At other times, as previously mentioned, the dentist will want the complete

Dentlearn.ir

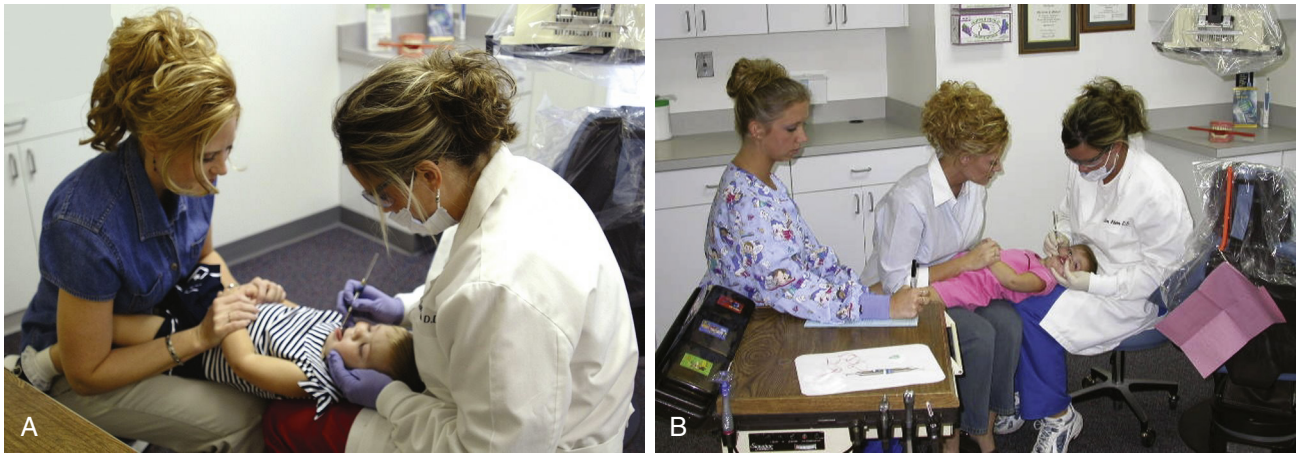

Figure 1-8 **A,** One method of positioning a child for an oral examination in a small, private consultation area. The dental assistant is nearby to record findings. **B,** If space allows three people to sit in a row, this method may make it easier for the dental assistant to hear the findings dictated by the dentist. The dental assistant also helps restrain the child's legs.



Figure 1-9 Oral examination of a very young child in the dental operatory.

operatory available. The examination should begin with a systematic and gentle digital exploration of the soft tissues without any instruments. The child may find this gentle palpation soothing, especially when alveolar ridges in teething areas are massaged. The digital examination may help relax the child and encourage less resistance. If hand instruments are needed, the dentist must be sure to have a stable finger rest before inserting an instrument into the child's mouth.

Although there is little effective communication between the dentist and patient, the child realizes at the conclusion of the examination that nothing "bad" happened and that the procedure was permitted by the parents, who were present and actually helped with the examination. The child will not hold a lasting grudge against anyone, and the experience will not have a detrimental effect on the child's future behavior as a dental patient. On the contrary, our experiences suggest that such early examinations followed by regular recall examinations often contribute to the youngsters' becoming excellent dental patients without fear at very young ages. These children's chances for enjoying excellent oral health throughout life are thus enhanced.

DETECTION OF SUBSTANCE ABUSE

It is within the scope of pediatric dentistry to be concerned with life-threatening habits and illnesses such as alcoholism and drug addiction, which may occur in the older child.

Rosenbaum[9,10] has reported that abusers in the teen years and younger are as common as adult addicts. Drug abuse problems interact directly with the dental care of a patient. Obtaining and maintaining a satisfactory history are important. The office health questionnaire, as presented in this chapter, must be worded to allow the patient or parent to give some indication of a drug problem. It is often difficult to detect addiction from casual observation. Therefore input from the patient giving an indication of addiction is needed. At subsequent visits the dentist must also consider changes in the general health history as well as answers to specific questions.

It is also important to know if the patient is taking drugs at the time of the dental visit because there could be an interaction with drugs, such as nitrous oxide, administered at the dental office. If the patient is under the influence of an abused substance, dental treatment should be postponed until a time when the patient is not "high."

Symptoms of substance abuse may include depression, feelings of inadequacy, frustration, helplessness, immaturity, self-alienation, poor object relations, and major deficiencies in ego structure and functioning. Heavy drug users tend to have poor impulse control and frequently neglect hygiene in general and oral hygiene specifically. In addition, because a patient is taking drugs that affect normal thought processes, the pain from untreated dental conditions may be masked. This combination of factors results in a patient with very little dental interest who is practicing unsatisfactory prevention, leading to increased oral disease.

Identification of substance abusers is difficult, even for an experienced observer. There are specific clues, however. Abrupt changes in behavior are common, as are signs of depression and moodiness. Interest in the opposite sex often decreases. Without any apparent consumption of alcohol, a drug-addicted person can appear intoxicated.

There may be a desperate need for money, as well as loss of weight and appetite. The presence of scars along veins could indicate drug injection. Addicts frequently wear long-sleeved shirts, regardless of the weather, in an effort to cover identifying scars.

Fletcher and colleagues[11] state that the use of illegal drugs and volatile substances is common among young people in developed countries, such as the United States and the United Kingdom. In addition to presenting direct health risks, drug use is associated with accidental injury; self-harm; suicide; and other "problem" behaviors, such as alcohol misuse, unprotected sex, and antisocial behavior. Drug use at an early age is also associated with future use of particularly harmful drugs, such as heroin or cocaine. In turn, dependence on these drugs is associated with high rates of morbidity and mortality, social disadvantage, and crime. It is because of these health and social problems that reducing teenage drug use is a priority.

Their review of the literature, however, suggests that positive ethos and overall levels of strong school relationships and engagement are associated with lower rates of drug use; and that, at the individual level, negative behaviors and attitudes relating to school are also associated with drug use.

MacDonald[12] reports that experimentation is a normal adolescent learning tool, but when combined with normal adolescent curiosity and fearlessness, it may be dangerous. Tobacco smoking is an example of a common teenage experiment. In a study by the National Survey on Drug Use and Health, 12% of adolescents of 12 to 17 years of age had smoked one or more cigarettes in the preceding month; and of those who had never smoked, more than 22% were considered susceptible to start smoking.[13]

ETIOLOGIC FACTORS IN SUBSTANCE ABUSE

Drug abuse in young people can be traced to many causes, the most important of which is considered to be rebellion against parents and society. Other factors may include a need to forget the pressures of daily living, a desire for

the young people want to be associated.[14] Through drugs, young people obtain a momentary feeling of independence and power because they have disobeyed the rules of their parents and society. The satisfaction gained through rebelling against parents can give adolescents a reinforcing motive for persisting in drug abuse.

Children of wealthy parents are increasingly recog-

traits as narcissism, poor impulse control, poor tolerance of frustration, depression, and poor coping ability. Therefore it is not surprising that a large number of children

boredom, anxiety, and depression.

In general, compared to youngsters who do not use drugs, drug users have been found to be less interested in formal education, less involved in organized activities such as athletics, and less likely to have well-defined goals. Adolescents who use drugs heavily have been described as manifesting more psychological problems than do nonusers. Significantly higher percentages of nonusers of drugs reported close relationships with their parents. Children involved in abusing drugs are more often found to have experienced the loss of a parent or to have parents who are divorced.

SPECIFIC SUBSTANCES AND FREQUENCY OF USE

Since 1975, the University of Michigan's Institute for Social Research, funded by the National Institute of Drug Abuse, has collected data on past month, past year, and lifetime drug use among 12th graders. It was expanded in 1991 to include 8th and 10th graders. The most recent report

mtf-overview2013.pdf) says that in the late 20th century, young Americans reached extraordinarily high levels of illicit drug use. In 1975, the majority of young people (55%) had used an illicit drug by the time they left high school. This rose to 66% in 1981, but declined to 41% by 1992—the low point. After 1992, in what the report calls the "relapse phase" of the epidemic, the proportion rose considerably to 55% in 1999 and gradually declined to 47% in 2009 before rising slightly to 50% by 2013.

Suppose the dentist identifies a person who needs help. What can be done? Unless the dentist is exceptionally qualified to handle addiction problems, the answer is direct or indirect referral to a treatment center. If the person expresses a need, the dentist may directly inform that person or the parents about area agencies that provide assistance. However, addicts may react defensively, even with hostility, if a direct approach is used. As with any problem related to general or dental health, preventive efforts must begin with the young. Children at a very young age need to be helped to develop a positive self-image, a sense of self-worth, and a separate identity.

SUICIDAL TENDENCIES IN CHILDREN AND ADOLESCENTS

During the examination of the child, the pediatric dentist should be alert to signs and symptoms of suicidal tendencies. How prevalent is suicide in the young child and adolescent? According to the American Academy of Child and

of teenagers commit suicide each year. It is the sixth leading cause of death in 5- to 14-year-olds and the third leading cause in 15- to 24-year-olds. Suicidal tendencies follow a pattern and background that can be observed by the astute professional or parent. The following excerpt is from the *American Academy of Child and Adolescent Psychiatry*[15]:

> Teenagers experience strong feelings of stress, confusion, self-doubt, pressure to succeed, financial uncertainty, and other fears while growing up. For some teenagers, divorce, the formation of a new family with step-parents and step-siblings, or moving to a new community can be unsettling and can intensify self-doubts. For some teens, suicide may appear to be a solution to their problems and stress.

Depression and suicidal feelings are treatable mental disorders. The child or adolescent needs to have his or her illness recognized and diagnosed, and appropriate treatment plans developed. When parents are in doubt as to whether their child has a serious problem, a psychiatric examination can be helpful. Many of the signs

Dentlearn.ir

and symptoms of suicidal feelings are similar to those of depression.

Parents should be aware of the following signs from adolescents who may attempt suicide:

- Changes in eating and sleeping habits
- Withdrawal from friends, family, and regular activities
- Violent actions, rebellious behavior, or running away
- Drug and alcohol use
- Unusual neglect of personal appearance
- Marked personality change
- Persistent boredom, difficulty concentrating, or a decline in the quality of schoolwork
- Frequent complaints about physical symptoms, often related to emotions, such as stomachaches, headaches, or fatigue
- Loss of interest in pleasurable activities
- Not tolerating praise or rewards

A teenager who is planning to commit suicide may also exhibit the following signs:

- Complain of being a bad person or "feeling rotten" inside
- Give verbal hints with statements such as, "I won't be a problem for you much longer," "Nothing matters," "It's no use," and "I won't see you again."
- Put his or her affairs in order; for example, give away favorite possessions, clean his or her room, or throw away important belongings
- Become suddenly cheerful after a period of depression
- Have signs of psychosis (hallucinations or bizarre thoughts)

Children who say they want to kill themselves should not be ignored, and further expressions of concern and discussion with the child are important. In addition, assistance from a mental health professional should be actively sought. With appropriate counseling and family support, intervention can be successful.

It should be recognized that the pediatric dentist and the orthodontist are in a unique position to recognize early warning signs of adolescent suicide. Loochtan and Cole[16] surveyed 1000 practicing orthodontists and 54 department chairs of postdoctoral programs. Of those surveyed, 50% had at least one patient who had attempted suicide, and 25% had at least one young patient who actually did commit suicide.

INFECTION CONTROL IN THE DENTAL OFFICE

The dental team is exposed to a wide variety of microorganisms in the saliva and blood of their patients. These may include hepatitis B and C, herpes viruses, cytomegalovirus, measles virus, mumps virus, chickenpox virus, human immunodeficiency virus, *Mycobacterium tuberculosis*, streptococci, staphylococci, and other non–vaccine-preventable infections. Because it is impossible to identify all of those patients who may harbor dangerous microorganisms, it is necessary to use standard precautions and practice infection control procedures routinely to avoid spread of disease. The following infection control procedures as described by Miller and Palenik[17] are based on those recommended for dentistry by the Centers for Disease Control and Prevention (CDC) in the Public Health Service of the U.S. Department of Health and Human Services[18]:

- Always obtain (and update) a thorough medical history (as discussed previously in this chapter) and include questions about medications, current illnesses, hepatitis, unintentional weight loss, lymphadenopathy, oral soft tissue lesions, or other infections.
- Clean all reusable instruments in an ultrasonic cleaner or washer/disinfector, and minimize the amount of hand scrubbing. Wear heavy rubber gloves, mask, and protective clothing and eyewear to protect against puncture injuries and splashing.
- Sterilize all reusable instruments that penetrate or come into contact with oral tissues or that become contaminated with saliva or blood. Metal or heat-stable instruments should be sterilized in a steam autoclave, a dry heat oven, or an unsaturated chemical vapor sterilizer. Heat-sensitive items may require up to 10 hours' exposure time for sterilization in a liquid chemical agent approved by the U.S. Food and Drug Administration as a disinfectant/sterilant, followed by rinsing with sterile water. High-level disinfection may be accomplished by submersion in the disinfectant/sterilant chemical for the exposure time recommended on the product label, followed by rinsing with water.
- Monitoring of sterilization procedures should include a combination of process parameters, including mechanical, chemical, and biological. These parameters evaluate both the sterilizing conditions and the procedure's effectiveness. Biological monitoring must occur weekly.
- Dental instruments must be wrapped before sterilization. Unwrapped instruments have no shelf life and must be used immediately after being processed.
- Personal protective equipment (gloves, masks, protective eyewear, and clinical attire) should be worn when treating patients.
- Contamination of clinical contact surfaces with patient materials can occur by direct spray or spatter generated either during dental procedures or by contact with gloved hands. Barrier protection of surfaces and equipment can prevent contamination of clinical contact surfaces, but is particularly effective for those that are difficult to clean. Barriers include clear plastic wrap, bags, sheets, tubing, and plastic-backed paper or other materials impervious to moisture. If barriers are not used, cleaning and disinfection of surfaces between patients should involve use of an EPA-registered hospital disinfectant with a tuberculocidal claim (i.e., intermediate-level disinfectant).
- Hand hygiene (e.g., handwashing, hand antisepsis, or surgical hand antisepsis) substantially reduces potential pathogens on the hands. Evidence indicates that proper hand hygiene is the single most critical measure for reducing the risk of the transmission of organisms. For routine dental examinations and nonsurgical procedures, handwashing and hand antisepsis is achieved by using plain or antimicrobial soap and water. If the hands are not visibly soiled, an alcohol-based hand rub is adequate.
- Regulated medical waste is only a limited subset of waste, constituting 9% to 15% of total waste in hospitals

Dentlearn.ir

and 1% to 2% of total waste in dental offices. Regulated medical waste requires special storage, handling, neutralization, and disposal and is covered by federal, state, and local rules and regulations. Examples of regulated waste found in dental practice settings are solid waste soaked or saturated with blood or saliva (e.g., gauze saturated with blood after surgery), extracted teeth, surgically removed hard and soft tissues, and contaminated sharp items (e.g., needles, scalpel blades, and wires).

- Dental prostheses, appliances, and items used in their fabrication (e.g., impressions, occlusal rims, and bite registrations) are potential sources for cross-contamination and require handling in a manner that prevents exposure of both practitioners and patients.

BIOFILM

The goal of infection control in dentistry is to reduce or eliminate exposure of patients and dental team members to microorganisms. Potential pathogens can usually come from patients and practitioners. Another source, however, could be from the environment, such as via air or water.

Dental unit water lines contain relatively small amounts of water, much of which is in continuous contact with the inner surfaces of the tubing. The water is not in constant motion with extended dormant periods. Movement of water varies, with greatest flow being in the middle of the tubing. Dental unit water lines readily become colonized by a variety of microorganisms, including bacteria, viruses, and protozoa. Water entering dental units usually contains few microorganisms. However, water coming out of the unit is often highly contaminated. Proliferation of microorganisms occurs within biofilms

Current guidelines[19] for the proper treatment of dental unit water lines include the following:

1. Dental line water should contain <200 colony-forming units per mL (CFU/mL).
2. For surgical procedures, use sterile or saline water from a single-use source.
3. Start each day by purging all lines by flushing thoroughly with water.
4. Purge all air and water from high-speed handpieces for 20 to 30 seconds after each patient.
5. Consider separate reservoirs, chemical treatment protocols, and sterile water delivery systems.
6. Use antiretraction valves and terminal flush devices into the dental unit.
7. Drain the water lines at the end of the day.
8. Disinfect dental units attached to hospital main water supplies every 4 months with 500 ppm chlorinated water.

EMERGENCY DENTAL TREATMENT

A patient's initial dental appointment is often prompted by an emergency situation. The diagnostic procedures necessary for an emergency dental appointment were outlined in this chapter previously, but the emergency appointment tends to focus on and resolve a single problem or a single set of related problems rather than provide a comprehensive oral diagnosis and management plan. Once the emergency problem is under control, the dentist should offer comprehensive services to the patient or parents.

The remainder of this book presents information for dentists and dental students to augment their diagnostic and management skills in providing oral health care services to children and adolescents during both emergency and preplanned dental visits.

REFERENCES

1. American Academy of Pediatric Dentistry: Guideline on periodicity of examination, preventive dental services, anticipatory guidance/counseling, and oral treatment for infants, children, and adolescents, *Pediatr Dent* 35:114–121, 2013. [Suppl: Reference manual 2013-2022].
2. Glick M, Greenberg MS, Ship JA: Introduction to oral medicine and oral diagnosis: evaluation of the dental patient. In Greenberg MS, Glick M, Ship JA, editors: *Burket's oral medicine*, ed 11, Hamilton, Ontario, 2008, BC Decker.
3. Fuhrer CT, Weddell JA, Sanders BJ, Jones JE, Dean JA, Tomlin A: Effect on behavior of dental treatment rendered under conscious sedation and general anesthesia in pediatric patients, *Pediatr Dent* 31(7):492–497, 2009.
4. Okeson JP: Temporomandibular disorders in children, *Pediatr Dent* 11(12):325–333, 1989.
5. American Academy of Pediatric Dentistry: Guideline on acquired temporomandibular disorders in infants, children, and adolescents, *Pediatr Dent* 35:262–267, 2013. [Suppl: Reference manual 2013-2014].
6. Okeson JP: *Management of temporomandibular disorders and occlusion*, ed 7, St. Louis, 2012, Mosby.
7. Clerehugh V, Tugnait A: Diagnosis and management of periodontal diseases in children and adolescents, *Periodontology* 26:146–168, 2000-2001.
8. Blayney JR, Hill IN: Fluorine and dental caries, *J Am Dent Assoc* 74:233–302, 1967.
9. Rosenbaum CH: Dental precautions in treating drug addicts: a hidden problem among teens and preteens, *Pediatr Dent* 2:94–96, 1980.
10. Rosenbaum CH: Did you treat a drug addict today? *Int Dent J* 31:307–312, 1981.
11. Fletcher A, Bonell C, Hargreaves J: School effects on young people's drug use: a systematic review of interventional and observational studies, *J Adolesc Health* 42(3):209–220, 2008.
12. MacDonald DI: Drugs, drinking, and adolescence, *Am J Dis Child* 138:117–125, 1984.
13. Centers for Disease Control and Prevention: Racial/ethnic differences among youths in cigarette smoking and susceptibility to start smoking—United States, 2002-2004, *MMWR Morb Mortal Wkly Rep* 55:1275–1277, 2006.

volume=36;issue=1;spage=58;epage=61;aulast=Gopiram.

15. American Academy of Child and Adolescent Psychiatry:

for_Families/Facts_for_Families_Pages/Teen_Suicide_10.aspx, accessed March 2014.

16. Loochtan RM, Cole RM: Adolescent suicide in orthodontics: results of a survey, *Am J Orthod Dentofacial Orthop* 1010: 180–187, 1991.
17. Miller CH, Palenik CJ: *Infection control and hazardous materials management for the dental team*, 5th ed. St. Louis, 2013, Mosby.
18. Centers for Disease Control and Prevention: guidelines for infection control in dental health care settings—2003, *MMWR Morb Mortal Wkly Rep* 52(RR17):1–78, 2003.
19. Garg SK, Mittal S, Kaur P: Dental unit waterline management: historical perspectives and current trends, *J Investig Clin Dent* 3(4):247–252, 2012.

CHAPTER 2

Radiographic Techniques

▲ **Edwin T. Parks** and **Johan K. Aps**

For additional resources, please visit the evolve website.

CHAPTER OUTLINE

RADIATION SAFETY AND PROTECTION
The Basics of Radiation Protection
Protection of the Dental Staff
Protection of the Patient
RADIOGRAPHIC IMAGE RECEPTORS
Analog Film
Photo-Stimulable Phosphor Storage Plates
Solid-State Sensors
Image-Viewing Conditions
RADIOGRAPHIC TECHNIQUES
Intraoral Radiography
Extraoral Radiography
SELECTION CRITERIA AND RADIOGRAPHIC EXAMINATIONS
Criteria for Exposing Children to Ionizing Radiation
Radiographic Exposures in Cases of Dento-Alveolar Trauma
Radiographic Exposures in Special-Needs Patients
INTERPRETATION OF RADIOGRAPHS

Wilhelm Conrad Roentgen's discovery of x-rays on November 8, 1895, initiated the first dental radiographs ever taken, by Otto Walkhoff in January 1896. A new era was born, and ever since, dental radiographs have proven their significant value in dental and maxillofacial diagnosis. For many years, two-dimensional intraoral radiography and extraoral radiography were the only radiographic options; but a little more than two decades ago, three-dimensional imaging in dentistry (cone beam computed tomography, CBCT) became much more readily available. In addition, other advanced imaging modalities, such as multi-slice computed tomography (MSCT), magnetic resonance imaging (MRI), and ultrasound imaging, are also available.

This chapter provides a general overview of the techniques currently used in pediatric dental and maxillofacial radiology and will provide a clear overview of the image receptors, specialized techniques, and the indications and justifications for exposing pediatric patients to ionizing radiation or other imaging modalities.

RADIATION SAFETY AND PROTECTION

THE BASICS OF RADIATION PROTECTION

The three basic principles of radiation protection are as follows:

The Justification Principle

This principle states that one should expose patients to ionizing radiation only if there is no other way to obtain the diagnostic information or if this exposure will positively influence the diagnosis, the treatment, and the patient's health. The principle requires that one should attempt to obtain previously taken images because these contain important information and may negate the need for new radiographs. Special needs patients and children may not always cope well with radiographic procedures. If the cooperation of the patient is unlikely to result in a good-quality image, one should refrain from exposing the patient to ionizing radiation.

The Limitation Principle

This principle states that one should always try to keep the radiation dose as low as reasonably achievable (ALARA). Current selection criteria will assist the clinician in addressing the principle of dose limitation.

The Optimization Principle

Optimization means that one should obtain the best quality images possible, with both previous principles in mind. This can, however, imply the use of a technique that exposes the patient to a higher radiation dose, which can be justified only if the technique offers the greatest benefit for the patient and his/her health outcome.

The purpose for adhering to the above three principles is that x-rays can impart energy to the matter they traverse; if that matter is living tissue, then some biological injury may occur. Although much information is available regarding high levels of radiation (e.g., from cancer radiation treatments and nuclear accidents) and subsequent damage, little is known about the effects of low-energy ionizing radiation (as used in diagnostic radiology and dentistry in particular) on biological systems. Our assumptions of damage are based on extrapolation of data from high to lower levels of radiation. Therefore, two models have been devised to explain these effects: the non-threshold (stochastic) and threshold models. The non-threshold model suggests that any dose of x-rays can cause biological damage, whereas the threshold model suggests

Dentlearn.ir

that no detrimental effects of ionizing radiation occur below a particular level or "threshold" of x-ray exposure. In 2012, White and Mallaya reported that until low-energy ionizing radiation is proven to be risk-free, dental health professionals should protect patients accordingly.

Dental health professionals must be concerned about any risk that the patient may encounter during therapy, with focus on three primary biological effects of low-level radiation: (1) carcinogenesis, (2) teratogenesis (malformations), and (3) mutagenesis. Carcinogenesis and malformations are responses of somatic tissues and, in most instances, are believed to have a threshold response (deterministic effect); that is, a certain amount of radiation is necessary before the response can be seen. Mutations may occur as a response of genetic tissue (gonads) to ionizing radiation and are believed to have no threshold (stochastic effects). In general, younger tissues and organs are more sensitive to ionizing radiation, with the sensitivity decreasing from the period before birth until maturity. Furthermore, far higher doses of radiation can be withstood by localized areas than by the whole body. The annual background radiation for individuals living in the United States is about 3600 microSieverts. It is estimated that, on average, about 20% of that amount results from medical and dental diagnostic imaging. Later in this chapter, radiation doses will be discussed from the perspective of this annual background radiation. This information is important when discussing the potential impact of diagnostic x-ray imaging exposure with patients and parents.

To facilitate the calculation of effective radiation doses from certain diagnostic exposures, the International Commission on Radiological Protection (ICRP) has provided tissue-weighting factors for human tissues (Table 2-1).

Table 2-1

The Tissue-Weighting Factors (WT) as Suggested by the International Commission (Higher WT Equals More Radiation Sensitivity) on Radiological Protection (ICRP, 2005)

Tissue	WT (2005)
Bone marrow	0.12
Breast	0.12
Colon	0.12
Lung	0.12
Stomach	0.12
Bladder	0.05
Esophagus	0.05
Gonads	0.05
Liver	0.05
Thyroid	0.05
Bone surface	0.01
Brain	0.01
Kidneys	0.01
Salivary glands	0.01
Skin	0.01
Remaining tissues	0.10

Some tissues are more vulnerable and susceptible to the effects of ionizing radiation. Table 2-2 shows the estimated risks for the development of a fatal cancer from exposure to diagnostic radiation. It is clear that the use of certain imaging modalities must be well justified. Table 2-3 shows the multiplication factors per age category, highlighting children's increased sensitivity to x-rays.

PROTECTION OF THE DENTAL STAFF

The best method for protecting dental staff from ionizing radiation is the use of shielding. Solid walls (preferably with a lead glass window) are the best protection one can achieve. However, some offices lack such walls, and the

Table 2-2

Estimated Fatal Cancer Risks from Several Radiographic Examinations (Data from Ludlow et al., 2008, *JADA*)

X-Ray Diagnostic Investigation	Estimated Risk of a Fatal Cancer (adult)
Full-mouth x-rays with phosphor storage plates or F-speed analog film and rectangular collimation	2 in 1 million
Full-mouth x-rays with phosphor storage plates or F-speed analog film and circular collimation	9 in 1 million
Full-mouth x-rays with D-speed analog film and circular collimation	21 in 1 million
Two bitewing radiographs with phosphor storage plates or F-speed analog film and rectangular collimation	0.3 in 1 million
Dental panoramic radiograph (solid-state sensor)	0.8 to 1.3 in 1 million
Skull frontal radiograph (phosphor storage plate)	0.3 in 1 million
Lateral skull radiograph (phosphor storage plate)	0.3 in 1 million

Table 2-3

Multiplication Factors Per Age Category for the Estimated Risks of Developing a Fatal Cancer as a Result of Diagnostic Radiographs*

Age Category	Multiplication Factor
<10 years	× 3
10-20 years	× 2
20-30 years	× 1.5
30-50 years	× 0.5
50-80 years	× 0.3
>80 years	× 0

*Whaites E: *Essentials of dental radiography and radiology*, Edinburgh, Churchill Livingstone, 2007.

Dentlearn.ir

radiographer must maintain a safe distance from the x-ray source (Fig. 2-1). Once the x-ray machine is engaged, the patient is to be considered the source of radiation. The radiographer should stand either at 90° to or behind the radiation source; at least 6 feet (2 m) from the radiation source is safe. One should never stand in the path of the primary radiation beam or hold the image receptor or the wall-mounted x-ray machine. If, for whatever reason, insufficient distance is maintained, one should wear a lead apron with thyroid shielding and stand in the appropriate position relative to the radiation source. The 6-foot rule also applies to panoramic and cephalometric imaging.

For CBCT imaging, one should always stand behind a radioprotective barrier.

PROTECTION OF THE PATIENT

In addition to the three basic principles of radiation protection (justification, limitation, and optimization), one can apply the following additional techniques to reduce the radiation burden to the patient:

- Collimation of the x-ray beam
- Correct focus-to-skin distance
- Lead apron with thyroid collar
- More radiation-sensitive image receptors

The use of rectangular collimation limits the surface being irradiated to the size of the image receptor, reducing the radiation dose by about 50%, compared with that achieved with a 2.75-inch-diameter (6 cm) circular collimator (Fig. 2-2). Rectangular collimators are available from different vendors. They are either attached to the tube head or are included in the image receptor holding device. Rectangular collimation also decreases the amount of scatter in the patient's tissues, which in turn results in better image quality.

The focus-to-skin distance is the distance between the x-ray machine's anode (where x-rays are created) and the skin of the patient's cheek or lip. Ideally this should be a minimum of 8 inches (20 cm) to reduce the amount of low-energy x-radiation reaching the patient. Many manufacturers recess the x-ray tube to increase the focus-to-skin distance without increasing the overall length of the tube head.

The utility of a lead apron (as opposed to a thyroid collar) (Fig. 2-3) has been extensively discussed. ICRP guidelines suggest that the use of a lead apron is not necessary with rectangular collimation, short exposure times, adequate x-ray energies, and fast image receptors. Several studies have shown that, with rectangular collimation, the patient is afforded protection from scatter radiation similar to that achieved with a lead apron.

Fast image receptors, which require less exposure time, are advised, since their use will enable the lowest possible radiation dose to be absorbed by the patient. If direct exposure film is used, either E- or F-speed film is recommended. D-speed film requires at least twice the exposure of E-speed film and approximately 70% more exposure than F-speed film. Digital image receptors, either photostimulable phosphor plates (PSPPs) or solid-state sensors, require much less exposure than D-speed film. Thus, digital image receptors and E- or F-speed film are considered to achieve similar lower radiation doses for patients.

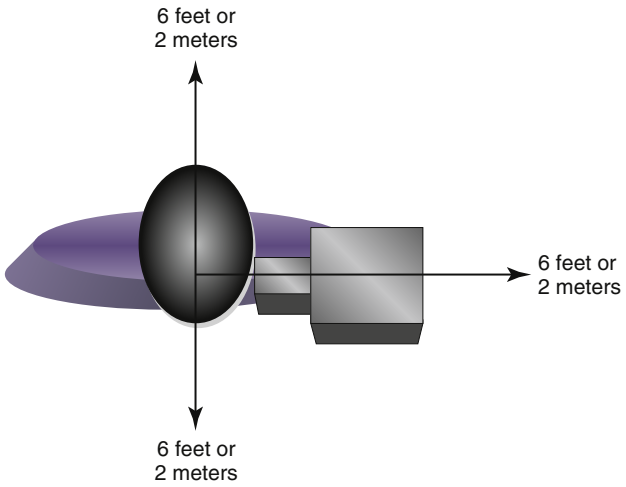

Figure 2-1 Safe locations for the radiographer when obtaining an intraoral radiograph. Bird's eye view of a patient being exposed for a bitewing radiograph. The arrows indicate the safest place for the radiographer to stand: at least 6 feet or 2 meters from the patient.



Figure 2-2 Examples of rectangular collimators. The rectangular end of the beam-indicating device decreases the exposed surface by more than 50%, compared with a 2.75-inch-diameter round collimation. The image on the left shows a non-removable rectangular collimator mounted on an intraoral x-ray machine. The image on the right shows a removable rectangular collimator (DENTSPLY® Universal Collimator) mounted on the circular open-ended beam-indicating device.

Dentlearn.ir



Figure 2-3 An apron containing lead or a material equivalent to lead for dental use.

When a lead apron is used with patients undergoing panoramic imaging, the apron must be placed high in the front, low in the back of the neck, and low over the shoulders. With correct positioning, the apron will not be captured in the panoramic images.

Correct positioning of the patient, image receptor, and tube head as well as appropriate exposure factors will decrease the need for retakes and will help keep the patient's dose as low as reasonably achievable. Darkroom quality assurance is essential if the radiographic imaging is film-based. Adequacy of safe lights, processing chemistry, and equipment maintenance and cleaning should be continuously monitored to maintain the quality and longevity of the film-based image.

From the above, it is clear that there are several actions one can take to minimize absorbed radiation doses and optimize image quality.

RADIOGRAPHIC IMAGE RECEPTORS

ANALOG FILM

Analog film is still used by almost 50% of clinicians in the United States. Some dental professionals have not yet switched to digital radiography or have made only a partial switch (e.g., film for intraoral radiographs and digital for panoramic).

Direct Film

Direct analog film is the film of choice for intraoral radiography. It is called direct because of its high sensitivity to x-rays. Only E- or F-speed film should be used because these require shorter radiation exposure times and hence contribute to a lower radiation burden for the patient. The exposure times needed for E- and F-films are comparable with those for digital image receptors. Direct analog film comes in different sizes (Table 2-4), making it suitable for different patients and tasks. The smallest size is 22 × 35 mm (ISO format 0), which can be used for bitewing radiographs in the primary dentition and for periapical images of individual maxillary or mandibular incisors. Such film is often called "pedo-size" or "child-size." The ISO format 1 size is 24 × 40 mm and can be used for the same purposes as described for size 0. The ISO format 2 size is 31 × 41 mm and is probably the most common size used. It can be used for bitewing images, periapical images in children in a transitional dentition, in adolescents and adults, as well as for occlusal radiographs in the primary dentition. The ISO format 3 size is 27 × 54 mm, which is used only for bitewing images in the transitional or permanent dentition. The largest size is 57 × 76 mm (ISO format 4), typically used for occlusal radiographs of the mandible or maxilla in the mixed and permanent dentition. Film packages contain either single or double film. Since analog film is single-use, packages can be bent if necessary, although this should be minimized to reduce the likelihood of image distortion. Disadvantages of analog film include double exposures and need for sufficient office space to store chemicals, processor, and radiographs.

Table **2-4**

ISO Formats (International Organization for Standardization) of Intraoral Analog Film and Phosphor Storage Plates and their Dimensions

ISO Format	Dimensions (mm)
0	22 × 35
1	24 × 40
2	21 × 41
3	27 × 54
4	57 × 76



Figure 2-4 An opened panoramic cassette (15 × 30 mm) with intensifying screens on both sides (white surfaces) and analog film (blue-purple). A similar cassette, but without intensifying screens, is used for phosphor storage plates.

Indirect Film

Indirect analog film is more sensitive to light than it is to x-rays and should be used only in a cassette with an intensifying screen (Fig. 2-4). Indirect film is usually 15 × 30 cm or



Figure 2-5 The physical appearance of a phosphor storage plate (left) looks very similar to that of analog film (right). The ISO format 2 is shown here.

18 × 24 cm, depending on its application. The intensifying screen converts the x-ray energy into light, which reaches the film and forms the latent image. In dentistry, this type of film is used in panoramic imaging and cephalometric radiography. The use of intensifying screens in cassettes keeps the exposure time as short as possible, but the images are less sharp than those obtained with direct analog film. The cassette should be checked regularly for light-tightness to ensure that no light can cause fogging of the film. The intensifying screens should be kept clean since dust or other particles can cause radiopaque artifacts in the image. One should use only the manufacturer's recommended cleansing agent to clean the intensifying screens.

PHOTO-STIMULABLE PHOSPHOR STORAGE PLATES

PSPPs (Fig. 2-5) appear very similar to analog film and also come in different sizes. This technique is also referred to as indirect digital imaging because the image is captured in an analog format and converted to a digital image when scanned and is not displayed immediately when the radiographic image is captured. The phosphor layer is comprised of europium-activated barium fluorohalide which, when exposed to x-rays, will capture a latent image. The phosphor plate emits a blue fluorescent light when exposed to a red helium laser light inside the PSPP scanner. The blue emissions captured by a photomultiplier are subsequently converted into a visible image. Once the image is generated, the scanner will expose PSPPs to white light to erase the latent image. Because PSPPs are sensitive to white light, the scanner cannot be placed in a brightly lit area, since this will degrade the image once the phosphor plates are freed from the light-tight barrier. PSPPs come in different sizes and can be used for either intraoral or extraoral applications. When used for intraoral radiography, they should be wrapped in a single-use plastic light-tight barrier to avoid both cross-contamination and the toxicity of the phosphor layer. When PSPP is used in a cassette for extraoral radiography, there is no need for it to be wrapped in a plastic barrier. The cassette, however, should be light-tight and should not contain intensifying screens, as is the case with analog indirect film. Because of the various sizes and flexibility of PSPPs, it is acceptable for intraoral radiography in pediatric patients and patients with special needs. The biggest disadvantage of PSPPs is their susceptibility to scratches, bite marks, and creasing, which could damage the phosphor layer (Fig. 2-6). This damage is irreversible and will always be visible as a radiopacity in the image. Just as with analog film, double exposures are possible with this technology.

SOLID-STATE SENSORS

Solid-state sensors (Fig. 2-7) are also known as direct digital receptors because they display the radiographic image instantaneously following exposure. There are two different types of solid-state sensors: charged coupled devices (CCD) and complementary metal oxide semiconductors (CMOS). These sensors differ in how the image is captured but appear similar in both external appearance and image output. Both CCD and CMOS sensors use a scintillation screen (usually gadolinium oxysulfide or cesium iodide) to transform the x-ray energy into visible green light, which is then converted into a visible image. Direct digital sensors are available in sizes 0, 1, and 2. The primary disadvantage of these sensors is that they are relatively bulky and not always easy to position in the patient's mouth (Video 2-1: Sensor placement: use of direct digital radiology technique in the operating room). The majority of direct digital sensors are attached to a computer by a shielded wire cable, which can be damaged by repeated biting. The solid-state sensors are also incorporated into extraoral radiography devices, such as panoramic machines and cephalometric units. The sensors are arranged in a vertical array and capture the x-rays while the panoramic or cephalometric machine scans. The image is formed by vertical lines or columns of pixels. Some manufacturers use a lens in front of the solid-state sensor so that the image from a cephalometric unit can be obtained in one exposure, instead of via a scanning motion from anterior to posterior. This saves time and radiation dose and helps reduce motion artifacts.

Dentlearn.ir

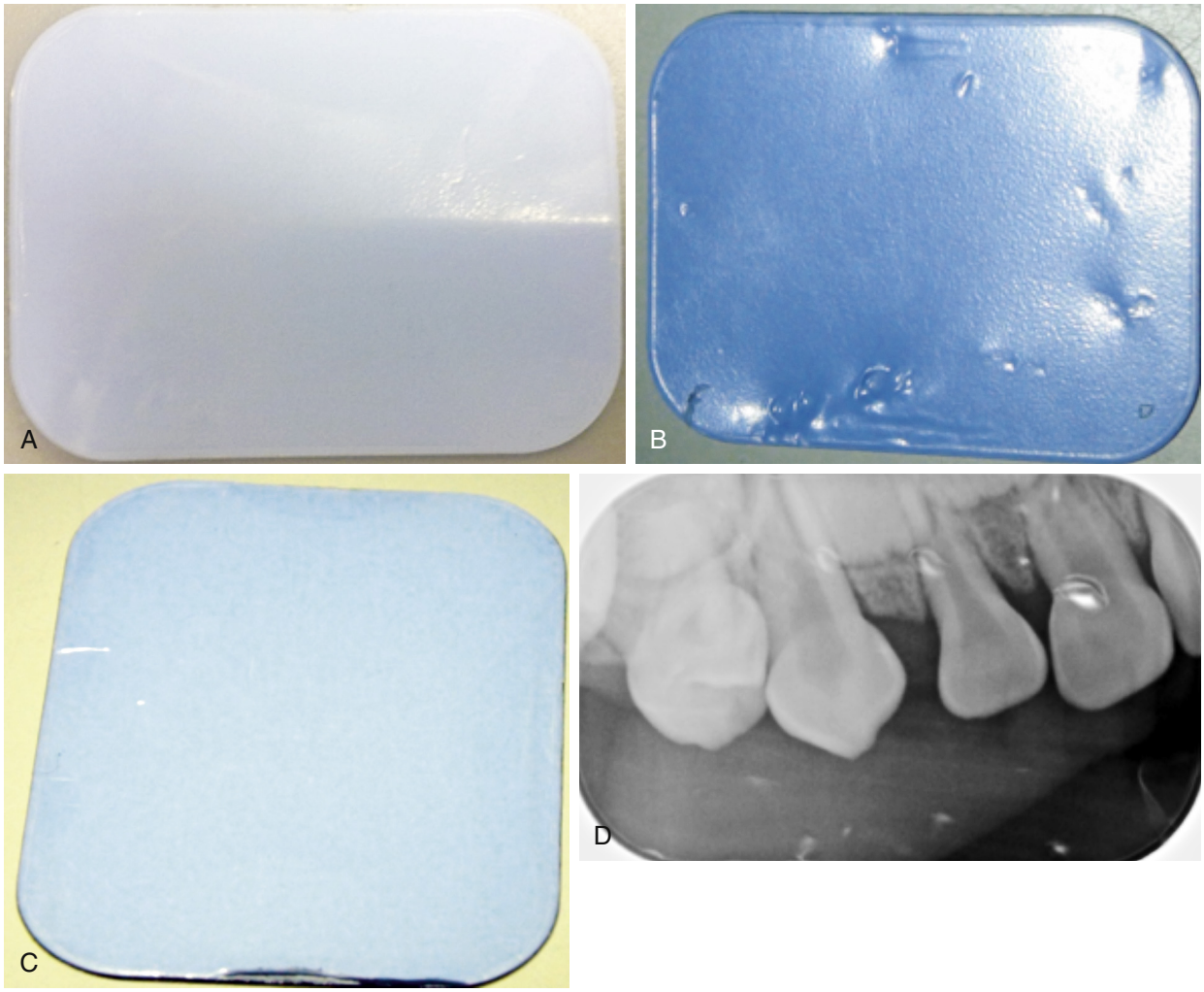

Figure 2-6 **A,** Phosphor plate that has been bent. **B,** Phosphor plate that has been bitten. **C,** Phosphor plate with curling of the phosphor layer on the edge of the short side of the plate. **D,** Phosphor plate image taken with a phosphor plate ISO format 0, with several bitemarks and scratches. The latter will appear on every image that will be taken with this phosphor storage plate.



Figure 2-7 Solid-state sensors, sizes 0, 1, and 2. (Courtesy SIRONA DENTAL SYSTEMS, INC.)

IMAGE-VIEWING CONDITIONS

Analog film should be viewed on a clean and bright view box, with a clean viewing surface and a properly functioning light source. Optimal viewing conditions should allow one to collimate the light, so the light area is restricted to the size of the film. The viewer's eyes should be blocked to surrounding light to ameliorate perception of details. Also, the ambient light in the room should be dimmed so that more details in the radiographic image can be seen. This is not always feasible in a dental office setting, but efforts should be made to place the view box in a dimmed area of the office.

Digital images are viewed on a computer monitor or screen. Ideally, ambient light should be subdued and the monitor calibrated. Some viewing software programs allow for calibration of the computer screen. If they do not, a "monitor calibration screen" can easily be downloaded from the Internet (Fig. 2-8). Monitor performance should be evaluated periodically. The monitor



Figure 2-8 Example of monitor calibration screens.

should be positioned in an area of subdued lighting away from a window or bright light. Touch-screen monitors should not be used since fingerprints can cause image quality to deteriorate. From the literature, it is clear that most computer monitors provide sufficient resolution and contrast for the vast majority of dental diagnostic needs.

A wide range of image receptors can be used in pediatric and special-needs dentistry. It is up to the dental professional to choose the system that works best in his or her practice since technology changes rapidly and image receptors will also change. Perhaps in the near future, technology will be available that makes image capture easier for both the clinician and the patient. Digital image receptors offer the opportunity for the captured image to be enhanced. Common enhancements include density and contrast, magnification, and edge-sharpening. Figure 2-9 demonstrates the effects of density and contrast enhancements.

RADIOGRAPHIC TECHNIQUES

Multiple radiographic techniques must be used to manage the wide range of pediatric and special-needs dental patients. The patient's size and ability to cooperate must be considered when a radiographic technique is selected.

INTRAORAL RADIOGRAPHY

Intraoral tube heads should generate between 60 and 70 kVp to produce adequate diagnostic images. The timer must be accurate to allow for short exposure times. Radiation-sensitive (rapid) image receptors should be used at all times.

Collimation of the radiation beam is advised to reduce the irradiated surface area to the size of the image receptor. There are several types of intraoral radiographs, each of which has specific indications and limitations.

Periapical Radiography

Periapical radiographs should show the crown of the tooth and at least 3 mm beyond the apex of the tooth. To achieve this coverage, one can use either the paralleling technique or the bisecting angle technique. The paralleling technique is preferred because of its accuracy.

Paralleling Technique. This is the most accurate technique for taking intraoral radiographs. The image receptor should be positioned parallel to the long axis of the teeth, while the x-ray beam is directed perpendicular to the image receptor. Ideally, image receptor holders that enable one to aim easily and correctly should be used (Fig. 2-10). This means that the aiming device must firmly grip the image receptor and that there is an extraoral component that allows the x-ray beam to be positioned correctly in both the vertical and horizontal planes. Other holders, such as those displayed in Figure 2-11, do not provide this extraoral component, and can produce either elongation or foreshortening of the image if the vertical angulation is incorrect or overlapping of proximal surfaces if the horizontal angulation is incorrect. Both angulation errors can result in the need for a retake.

Bisecting Angle Technique. In the bisecting angle technique, the image receptor is placed as close to the teeth as possible, and the central x-ray is directed perpendicular to a line that bisects the angle created by the tooth and image receptor (Fig. 2-12). This technique is obviously more prone to geometric errors and should not be regarded as the preferred technique. Elongation or foreshortening (vertical angulation errors) of the image or interproximal overlap (horizontal angulation errors) of the image is often the result of inaccurate aiming.

Bitewing Radiography

Bitewing radiographs are intended to assess interproximal caries and interproximal bone height. Bitewing geometry is based on the paralleling technique, where the image receptor is placed parallel to the teeth and the x-ray beam is aimed perpendicular to the receptor. Overlap of proximal surfaces is minimal with the proper image receptor holders, which assist in directing the x-ray beam through the proximal contacts. However, it is the clinician's evaluation of the receptor placement that determines the accuracy of the image, rather than

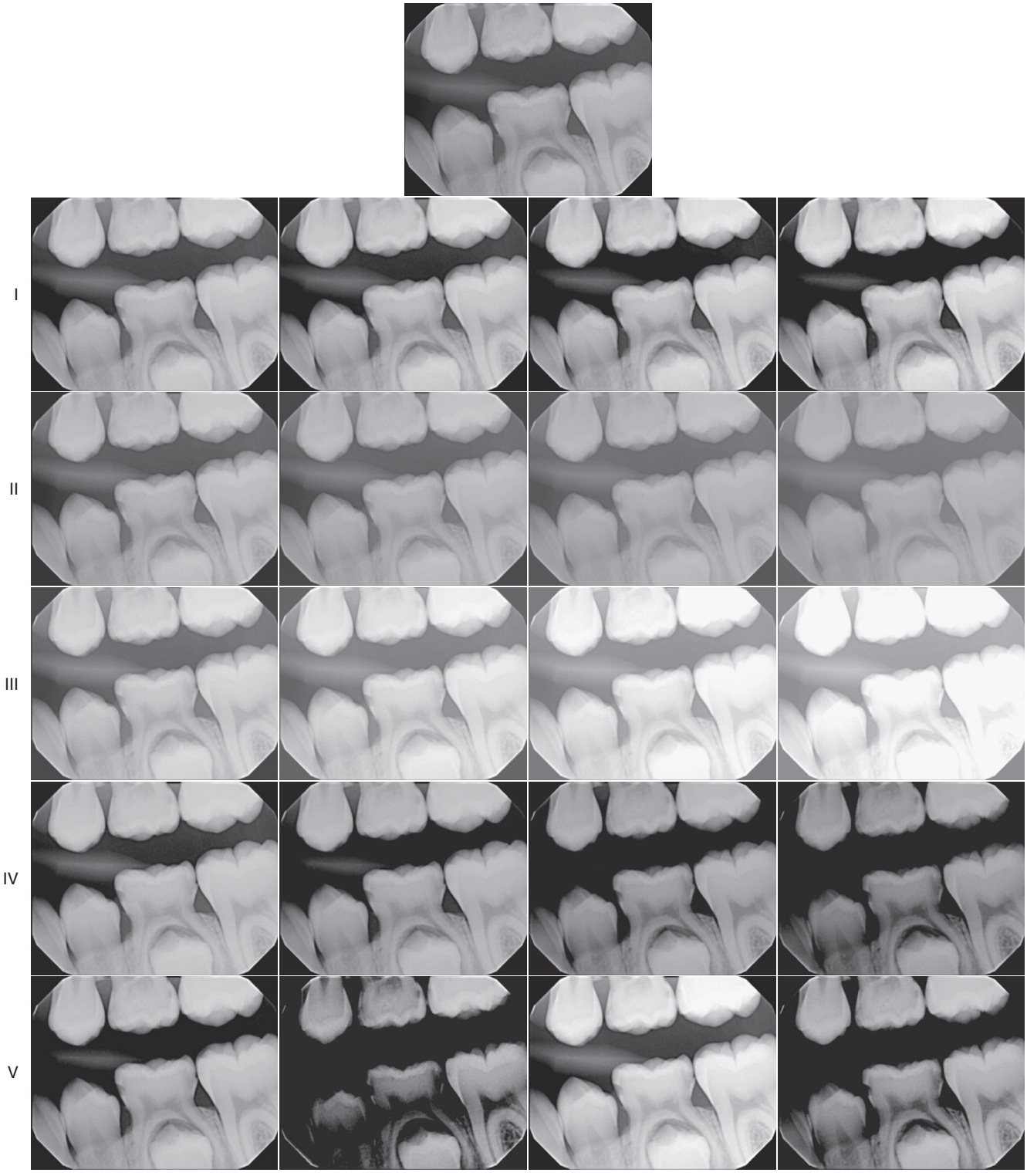

Figure 2-9 This figure shows how adjustments in contrast and density can alter the information in the image one sees on the screen. The image at the top is the original image displayed by the software. The images in the first line have increasing contrast, and those in the second line have decreasing contrast. The images in the third line have decreasing density, and those in the fourth line have increasing density. The bottom line is a combination of changed contrast and density.



Figure 2-10 Illustration of the Rinn® paralleling technique beam-aiming and image receptor holding device. The bite block holds the image receptor firmly and allows for ideal positioning in the patient's mouth. It also allows for the attachment of a metal rod that aids in correct horizontal and vertical aiming of the x-ray beam. The plastic ring (yellow) demonstrates rectangular cut-outs that allow the rectangular collimator/beam-aiming device to be aimed perpendicular to the image receptor. The two images at the bottom are other examples of acceptable image receptor holders/aiming devices.



Figure 2-11 Image receptor holders without extraoral aids. It is obvious that these are not ideal for aiming perfectly perpendicular to the image receptor.

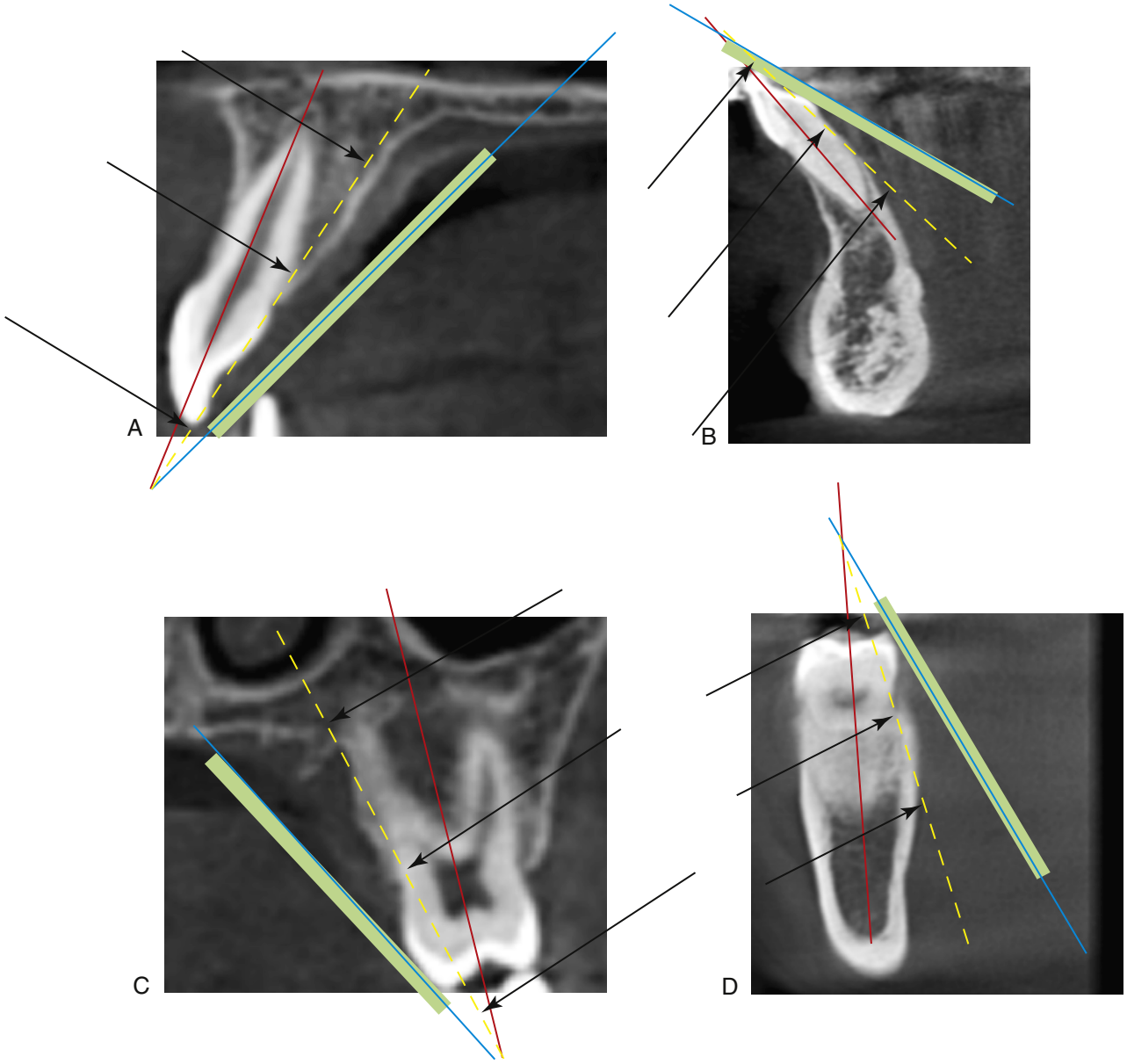

Figure 2-12 The bisecting angle technique illustrated for maxillary and mandibular incisors and for mandibular and maxillary molars. The x-ray beam (black arrows) must be aimed perpendicular to the imaginary bisecting angle (interrupted yellow line) between the long axis of the tooth (red line) and the long axis of the image receptor (blue line).

the receptor holder (Fig. 2-13). Paper tabs, styrofoam tabs, or a device like the Ezee Grip to hold the image receptor in the mouth does not offer extraoral guidance to aim the central x-ray through the proximal contacts.

Anterior Maxillary Occlusal Technique. In the anterior maxillary occlusal technique, the patient's occlusal plane should be parallel to the floor, and the sagittal plane should be perpendicular to the floor (Fig. 2-14). A size 2 image receptor is placed in the patient's mouth so that the long axis of the film runs from left to right, rather than anteroposteriorly, and the midsagittal plane bisects the film. The patient is instructed to bite lightly to hold the receptor; a tongue blade can be attached to PSPP or film receptors (Fig. 2-15), and rigid receptors should be wrapped in gauze to protect the sensor when the patient bites on it. The anterior edge of the receptor should extend approximately 2 mm in front of the incisal edge of the central incisors. The central x-ray is directed to the apices of the central incisors and a centimeter (half-inch) above the tip of the nose and through the midline. The vertical angle is +60°. This receptor is exposed at the usual setting for maxillary incisor periapical films.

Posterior Maxillary Occlusal Technique. In the posterior maxillary occlusal technique, the patient's occlusal plane should be parallel to the floor, and the sagittal plane should be perpendicular to the floor. A size 2 image receptor is placed in the patient's mouth so that the long axis of the film is parallel to the floor. The anterior edge of the receptor should extend just

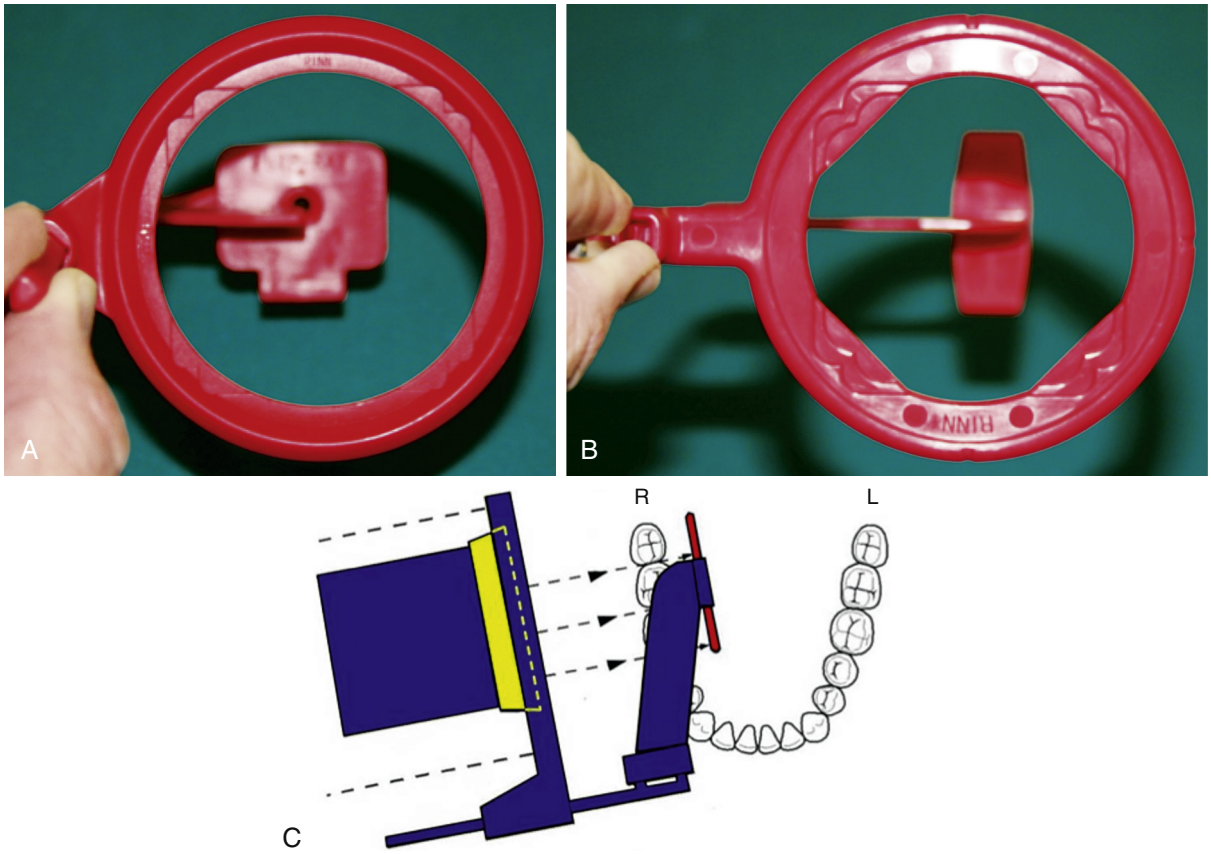

Figure 2-13 Bitewing holders with extraoral aids that allow for proper perpendicular aiming at the image receptor and the teeth. The bottom image represents a schematic view of how a bitewing image should be taken and how the image receptor holder aiming device (e.g., Rinn®) should be used.

mesial to the canine. The outer buccal edge of the receptor should extend approximately 2 mm beyond the primary molar crowns. The patient is instructed to bite lightly to hold the receptor. The central x-ray is directed toward the apices of the primary molars as well as interproximally. The vertical angle is +50°. The receptor is exposed at the usual setting for maxillary premolar periapical projection.

Anterior Mandibular Occlusal Technique. The film placement for the anterior mandibular occlusal technique is identical to that for the anterior maxillary occlusal technique, except that the receptor must be placed so that the tube side faces the x-ray source (Fig. 2-16). In addition, when the patient bites on the receptor, the anterior edge of the receptor is 2 mm beyond the incisal edge of the lower incisors. The patient's head is positioned so that the occlusal plane is at a 45° angle. The cone is then aligned at a –15° vertical angle, and the central x-ray is directed through the symphysis.

Oblique Occlusal Radiography

Oblique occlusal radiography is also based on the bisecting angle technique; it is a good alternative for patients with a severe gag reflex or who cannot tolerate the positioning of the image receptor holder device. It is advisable to tape two wooden tongue depressors around the image receptor to position it in the patient's mouth (see Fig. 2-15). Make sure that the long edge of the film or phosphor plate is visible 1 to 2 mm buccal to the teeth. Position the patient so that the occlusal plane is parallel to the floor. Aim the x-ray beam perpendicular to the bisecting line between the long axis of the tooth and the axis of the occlusal plane. For maxillary images, the patient faces forward. For mandibular images, the patient should turn the head to the opposite side to position the x-ray machine pointing upward, 45° to the mandibular teeth. If the patient faces forward, the tube head will be blocked by the patient's shoulders. The result of these projections should provide a periapical view of the posterior teeth (Fig. 2-17). It is obvious that errors in the vertical or horizontal plane can easily be made, and that foreshortening or elongation and/or overlapping of proximal surfaces can easily occur.

Localization Techniques

One method of localizing embedded or unerupted teeth involves the buccal object rule (also referred to as the parallax technique or the "same lingual opposite buccal" [SLOB] rule), which states that the image of any buccally oriented object appears to move in the opposite direction from a moving x-ray source. Conversely, the image of any lingually oriented object appears to move in the same direction as a moving x-ray source (Fig. 2-18).

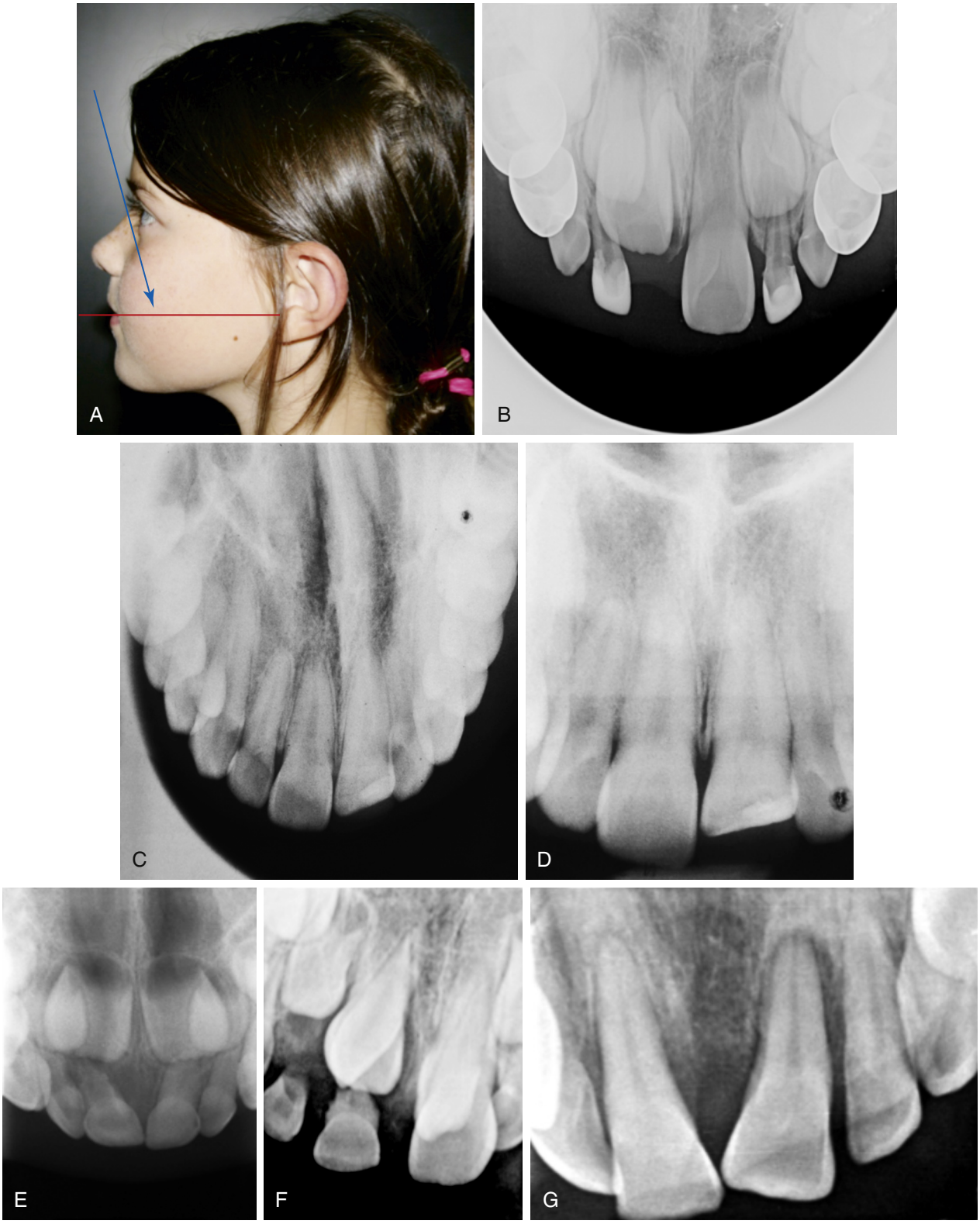

Figure 2-14 An occlusal radiograph in the maxilla should be taken with the patient in an upright position in the chair, with the occlusal plane (red line) horizontal to the floor and the x-ray beam (blue arrow) aimed at 60° to 65° through the bridge of the nose. The radiograph on the right shows the type of image obtained with this technique. The middle image illustrates that this technique does not necessitate the use of size 4 film or phosphor storage plates, but that size 2 will suffice (both images are from the same patient, but taken at different times). The bottom images illustrate the use of this technique in younger patients in the primary dentition and the mixed dentition, and in a special-needs patient with a dento-alveolar trauma (bottom right).

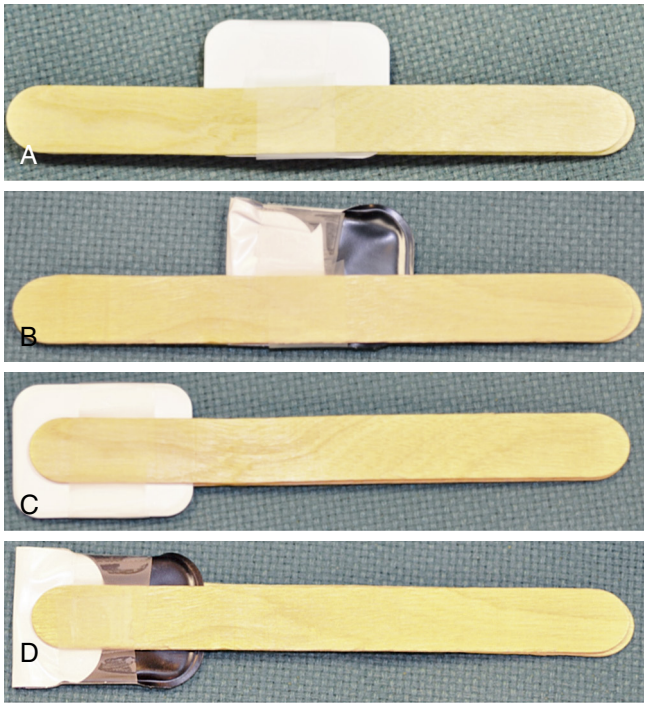

Figure 2-15 Illustration of wooden tongue depressors used to protect the film or phosphor plate from being bitten during positioning and/or exposure. The top two images are for anterior use and the bottom two are for posterior use. The image receptor is taped between two tongue depressors. The patient can bite down on them to avoid permanent damage to a phosphor plate. The tongue depressors provide guidance to the radiographer to assess the level of the occlusal plane or can provide assistance to the caregiver who assists during the radiographic procedure.

Using this principle for localization, the practitioner makes two radiographs of the unerupted tooth. The technique consists of positioning the patient's head so that the sagittal plane is perpendicular to the floor and the ala-tragus line is parallel to the floor. An intraoral periapical film is placed in the mouth and then exposed by the paralleling technique. Subsequently, a second film is placed in the mouth in the same position as the first film, with the patient's head position remaining the same, but with the horizontal angle shifted either anteriorly or posteriorly depending on the site. The object in the projection that moved in the direction opposite that in which the x-ray machine was moved is located more buccally, relative to the object(s) that moved in the same direction as the x-ray machine.

EXTRAORAL RADIOGRAPHY

Panoramic Imaging

The panoramic image is obtained through tomography. This means that only the structures located in the focal trough are captured in focus. Objects or structures outside the focal trough should be interpreted with care. Because of the projection geometry, panoramic images are magnified (by a factor of around 1.3), so measurements taken from a panoramic image will also be magnified.

Most current panoramic machines enable one to take bitewing look-alike images (Fig. 2-19). These images should be interpreted with caution since a standard bitewing projection requires that the image receptor be placed parallel to the teeth, with the x-ray beam directed perpendicular to the receptor. The panoramic bitewing is re-created from the existing panoramic image; nevertheless, it is a very useful alternative when a patient cannot tolerate the intraoral image receptor. However, it should not be used as a standard bitewing projection. Panoramic machines are available with solid-state sensors or with a cassette system. Film-based panoramic cassettes contain intensifying screens that convert x-radiation to visible light. Phosphor plate panoramic cassettes do not contain intensifying screens.

Cephalometric Imaging

This technique is usually used in orthodontics and orthognathic surgery. Some machines will use a single exposure, which minimizes motion errors. In the scanning machines, the exposure takes longer; hence there is a higher risk for motion artifacts in these images. Positioning of the patient in the cephalostat is very important. Remember that digital imaging does not correct or compensate for improper patient positioning.

Oblique Lateral Radiography

This technique offers an excellent alternative to bitewing radiographs, periapical radiographs, or panoramic images, when patients are unable to tolerate these techniques. The technique requires a cassette system (analog film or phosphor storage plate), held parallel to the midsagittal plane of the patient, while the x-ray beam is directed perpendicular to the cassette from behind or below the mandibular body. Figure 2-20 demonstrates the positioning of the patient, image receptor, and tube head. Figure 2-19 provides two examples of oblique lateral projections. This technique should not be regarded as a standard of care for every patient. Special-needs patients and small children can definitely benefit from this technique if a radiographic image is required.

Cone Beam Computed Tomography

This technology has become very popular in the past decade and has found its way into many private practices. This modality is ideal for imaging hard tissues. Artifacts due to beam hardening and motion artifacts are to be avoided (Fig. 2-21). The radiation dose from CBCT is considerably higher than that from a periapical radiograph. It is also very hard to determine the radiation dose in general from CBCT since it depends on exposure settings (kVp, mA, and exposure time), field of view (the size of the volume, which is determined by the size of the cone-shaped x-ray beam), and the resolution of the image (the details). Justification to expose pediatric patients to CBCT should not be taken lightly.

Medical Computed Tomography

Medical CT is responsible for the highest radiation doses a patient can receive from diagnostic imaging. The fan-shaped beam rotates around the patient's body (part) in a helical motion. The space between two rotations of the

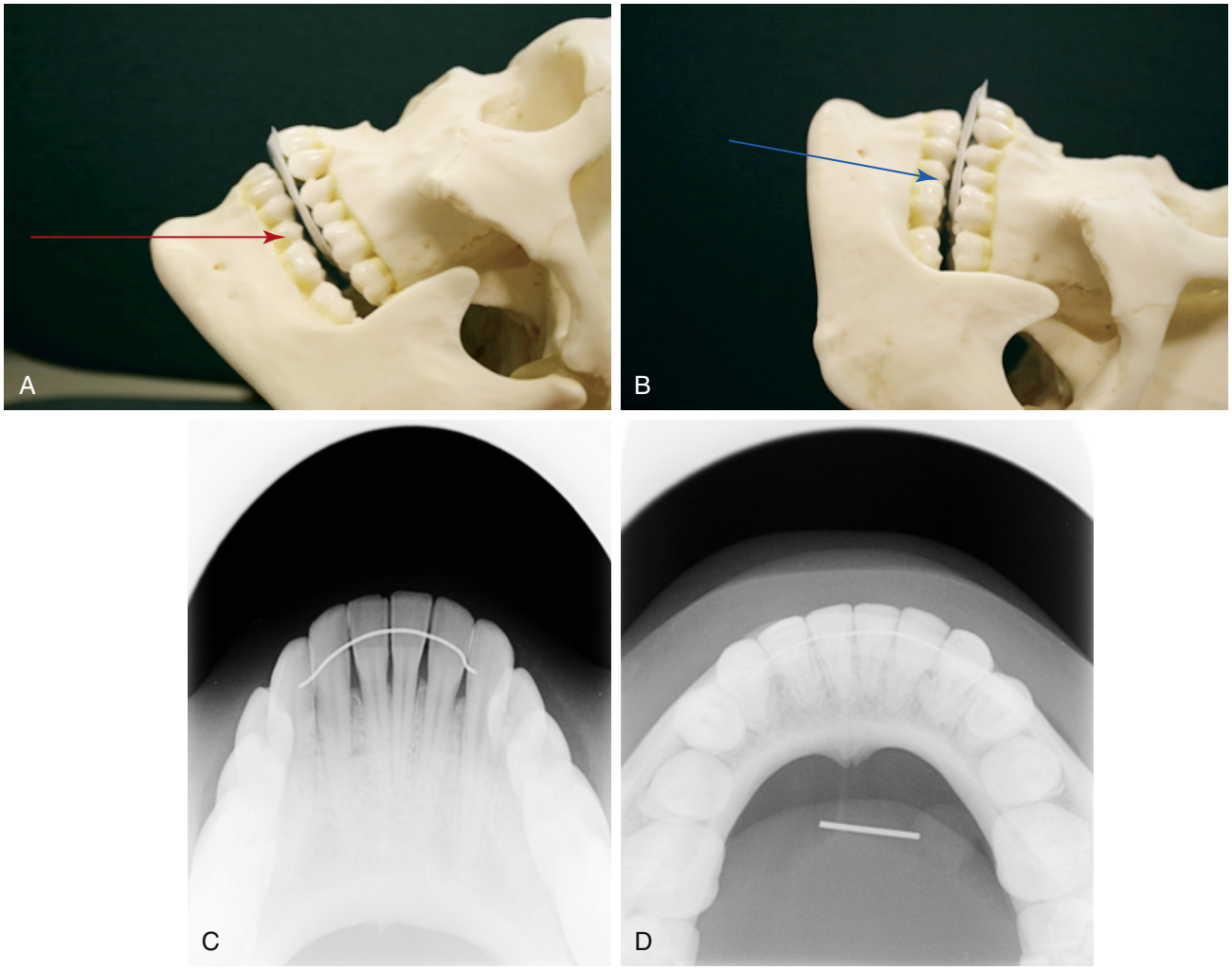

Figure 2-16 The top left image shows the position of the x-ray source (red arrow) 45° occlusal to the mandible. The bottom left shows an example of this projection. The top right image shows the position of the x-ray source (blue arrow) 90° occlusal to the mandible. The bottom right shows an example of this projection (patient with a small piece of a metal rod in the floor of the mouth).

beam (pitch) determines the resolution of the image and hence the radiation dose. Medical CT, also called multislice CT, is useful for the imaging of hard and soft tissues and provides the clinician with the ability to detect very small differences in density in the image (contrast resolution). The technique is usually used to identify malignancies, tumors, and other symptoms of pathology, with or without the use of contrast medium.

Ultrasound Imaging

Most people associate ultrasound imaging with pregnancy, but this technique also is excellent for investigation of soft tissues, such as the floor of the mouth, salivary glands, and lymph nodes in the head and neck region. Since the technique does not involve ionizing radiation, it can be repeated as many times as necessary, without exposing the patient to any risks. Figure 2-22 displays an ultrasonogram of the floor of the mouth as an illustration of an investigation to evaluate swelling or foreign objects in the soft tissues in this region. In addition, this technique is appropriate when fine-needle aspirations are required.

Magnetic Resonance Imaging

Magnetic resonance imaging (MRI) evaluates the hydrogen content of tissues and uses a magnetic field to differentiate among different tissue types. Since there are more hydrogen atoms in soft tissues than in cortical bone, this technique is especially useful with soft tissue. Contraindications for MRI include claustrophobia and the presence of metallic clips or metallic foreign bodies. The most common dental indication for the use of MRI is for imaging the soft tissues of the temporomandibular joint (Fig. 2-23).

SELECTION CRITERIA AND RADIOGRAPHIC EXAMINATIONS

CRITERIA FOR EXPOSING CHILDREN TO IONIZING RADIATION

For all radiographic examinations, the same basic rules apply: justification and professional judgment on an individual patient basis. There are no guidelines per age

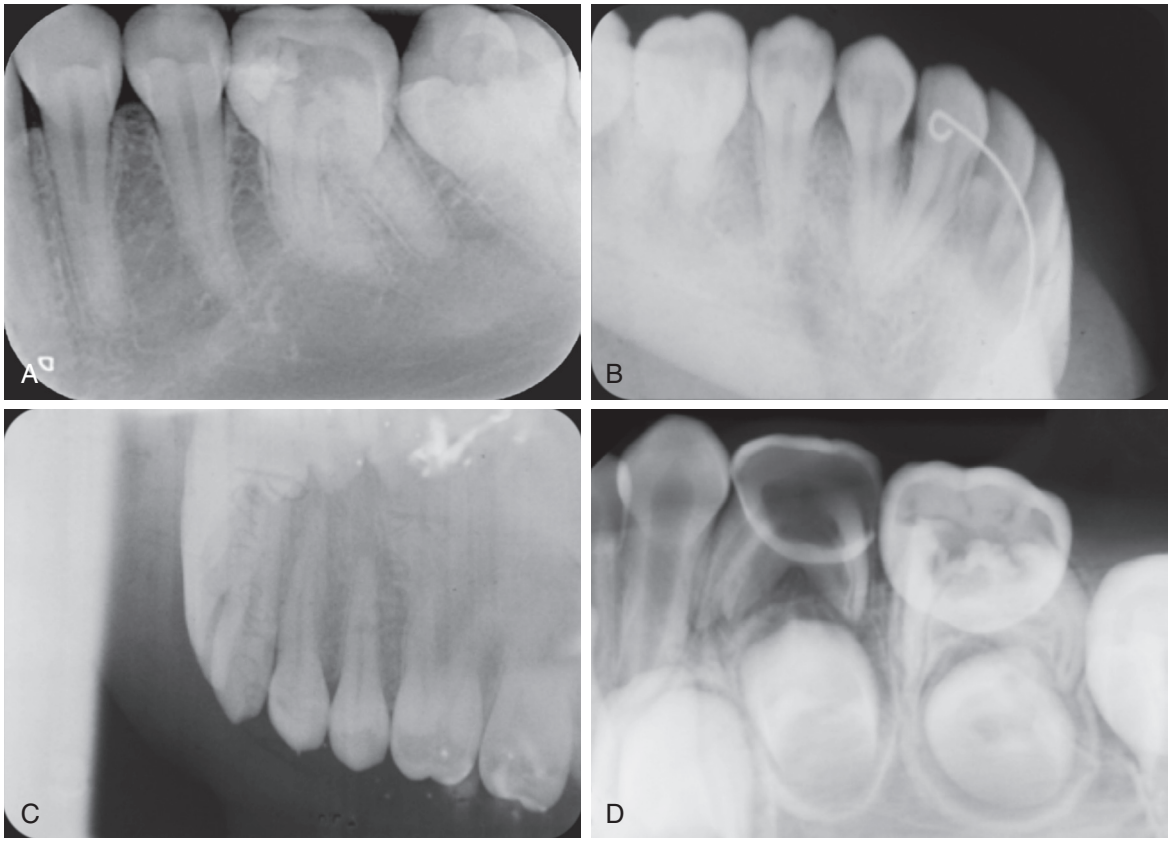

Figure 2-17 Illustrations of radiographs obtained with the oblique occlusal technique in the lateral regions of the dentition in various pediatric patients and patients with special needs.

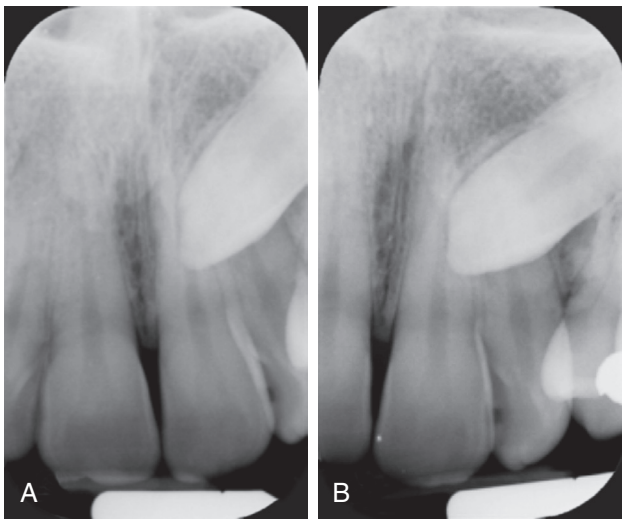

Figure 2-18 The buccal object rule or parallax technique illustrated to determine the position of an impacted maxillary canine. In the left radiograph, the tip of the canine coincides with the mesial wall of the pulp canal of the left central incisor, whereas in the right, it coincides with the distal wall. From the latter, one can conclude that the canine is lingually impacted, since it moved in the same direction as the x-ray source.

Association (ADA), the American Academy for Pediatric Dentistry (AAPD), the European Academy for Pediatric Dentistry (EAPD), and other organizations have published criteria that are meant to guide the dental professional in decision-making regarding appropriate radiographic imaging (Table 2-5). These guidelines clearly state that if the patient cannot cope with the procedure, one should attempt other strategies to handle the situation. The guidelines all acknowledge that, in some cases, radiographs are not possible, in which case, one should balance the benefit against the risk even more carefully. Sometimes it is better to postpone the radiographic exposure until the patient is older or better conditioned. The guidelines also clearly state that if there are no clinical signs of pathology, the need for a radiographic assessment is up to the professional's judgment, and that these decisions have to be made on an individual patient basis. Radiographs are never to be used for economic and screening reasons since they involve a potential health risk for the patient.

Here are some examples of how the guidelines can be interpreted and implemented. A 3-year-old with a sound dentition and open proximal contacts does not need a radiographic assessment. In contrast, for a 3-year-old with only 10 teeth visible in the mouth and no history of dental treatment, the dental professional should make a radiographic assessment. If a 4-year-old shows rampant decay, a radiographic assessment is certainly justifiable and indicated. A 7-year-old with a normal transitional dentition

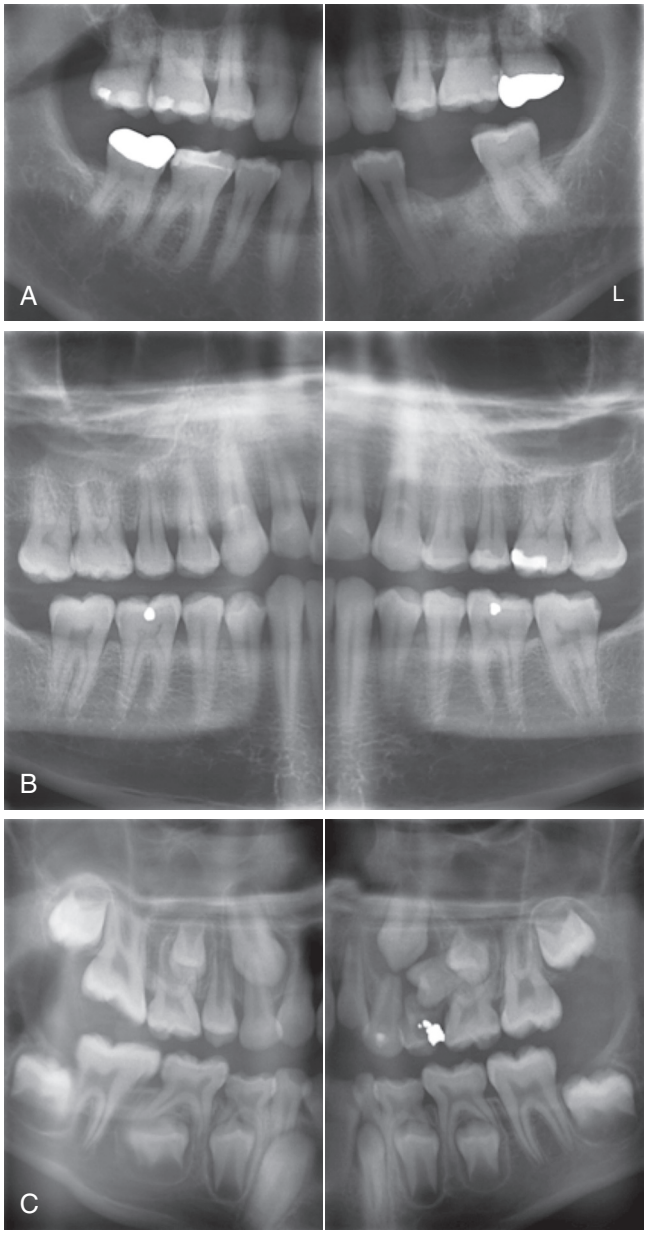

Figure 2-19 Examples of bitewing radiographs taken with a panoramic machine (**A,** Planmeca ProOne; **B,** Planmeca S2 Pan; **C,** Planmeca S3 Promax).

and no caries history, and for whom bitewing images had been taken 12 months prior, does not need a panoramic radiograph. The same 7-year-old, with a complete primary dentition and no clinical signs of tooth mobility, might require a panoramic radiographic assessment. Table 2-5 does not address the use of CBCT or medical CT, but it is obvious that justification and common sense should prevail when these examinations are prescribed for or performed on pediatric patients or patients with special needs.

RADIOGRAPHIC EXPOSURES IN CASES OF DENTO-ALVEOLAR TRAUMA

Dento-alveolar trauma can occur in the primary, mixed, and permanent dentition. Both clinical evaluation and radiographic examination are necessary. Contusions, crown fractures, root fractures, and avulsions are among the many injuries that require radiographic assessment. The number and frequency of radiographs needed, however, are not entirely clear from the literature. Since most accidents involve the maxillary incisors, periapical and occlusal radiographs are likely to be part of the radiographic assessment. This means that x-rays are being aimed at the thyroid gland, which is a radiosensitive organ and should be avoided as much as possible. CBCT is not often needed since periapical radiographs, taken from two different angles, can often provide enough information for a proper diagnosis. However, if a root fracture is suspected, a cone beam image at sufficient resolution (200 µm) can be useful. The potential for motion artifacts in CBCT imaging of pediatric patients must be considered when selecting a radiographic technique. When mandibular fracture is suspected, panoramic radiography is the technique of choice; CBCT might also be worth considering.

RADIOGRAPHIC EXPOSURES IN SPECIAL-NEEDS PATIENTS

diographic assessment. The same selection criteria apply, but the clinician must assess the ability of the patient to cooperate before performing any imaging. Lateral oblique or oblique lateral radiographs and (oblique) occlusal radiographs may prove to be very useful in this patient population. Nevertheless, if the patient cannot tolerate or if the patient cannot cope with the technique required to obtain good-quality images, the clinician may have to pursue an alternative treatment plan and postpone the taking of radiographs until a more suitable moment (e.g., when the patient is under general anesthesia for a medical procedure).

INTERPRETATION OF RADIOGRAPHS

Radiographs should be evaluated under ideal conditions. View boxes or monitors should be clean and positioned in an area of diminished ambient light. Density and contrast enhancements are essential tools for the assessment of digital images. These should be readily accessible so that the clinician can enhance different areas of the image with different enhancement tools. The clinician's ability to enhance the radiographic image dynamically and differentially is a significant advantage over analog film. Software filters can also assist in obtaining better images, but one should never overlook the fact that filtering means loss of information. It is therefore paramount to use all the information contained in the digital image, which should be considered as a database and not merely as an image displayed on the monitor.

As previously mentioned, it is clear that assessing radiographs in a brightly lit dental operatory increases the clinician's potential to miss diagnostically useful information contained in a radiographic image. Despite the fact that the parents and patients appreciate viewing the radiographic images in the operatory, the initial diagnosis should not be made at the chairside monitor, but rather in an area of the office where the light is dimmed.

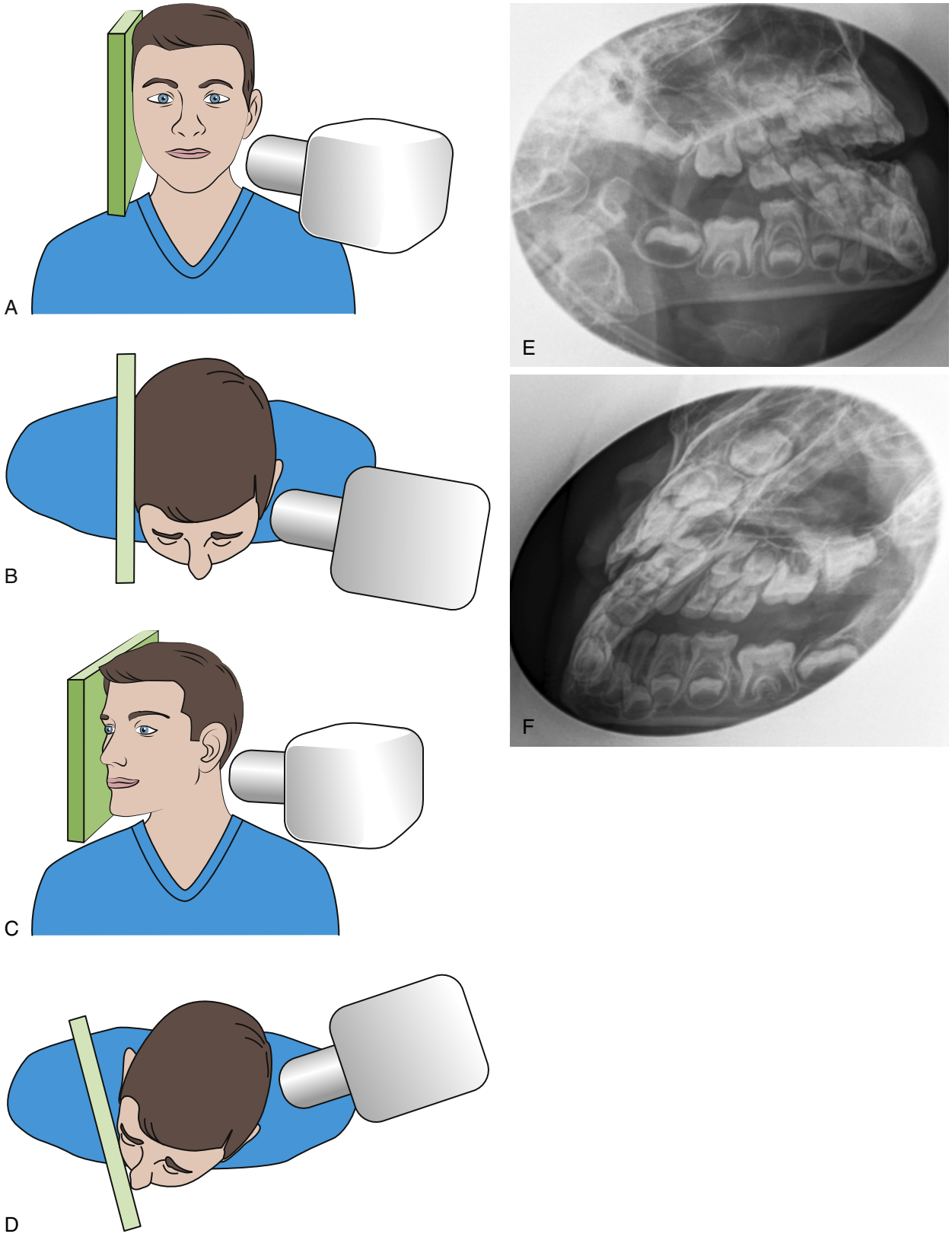

Figure 2-20 Lateral oblique radiographs are taken with a cassette, either containing analog film or a phosphor plate. The patient or caregiver holds the cassette against the patient's cheek. Cassette position is shown in relation to the x-ray source as seen from the front (**A**) and bird's-eye (**B**) view. The nose should then be rotated to touch the cassette, which consequently provides a space between the opposite ramus of the mandible and the cervical spine, from where the x-ray source will be aimed, perpendicular at the cassette (**C** and **D**). Left (**E**) and right (**F**) images obtained with this technique using phosphor plate technology are shown.

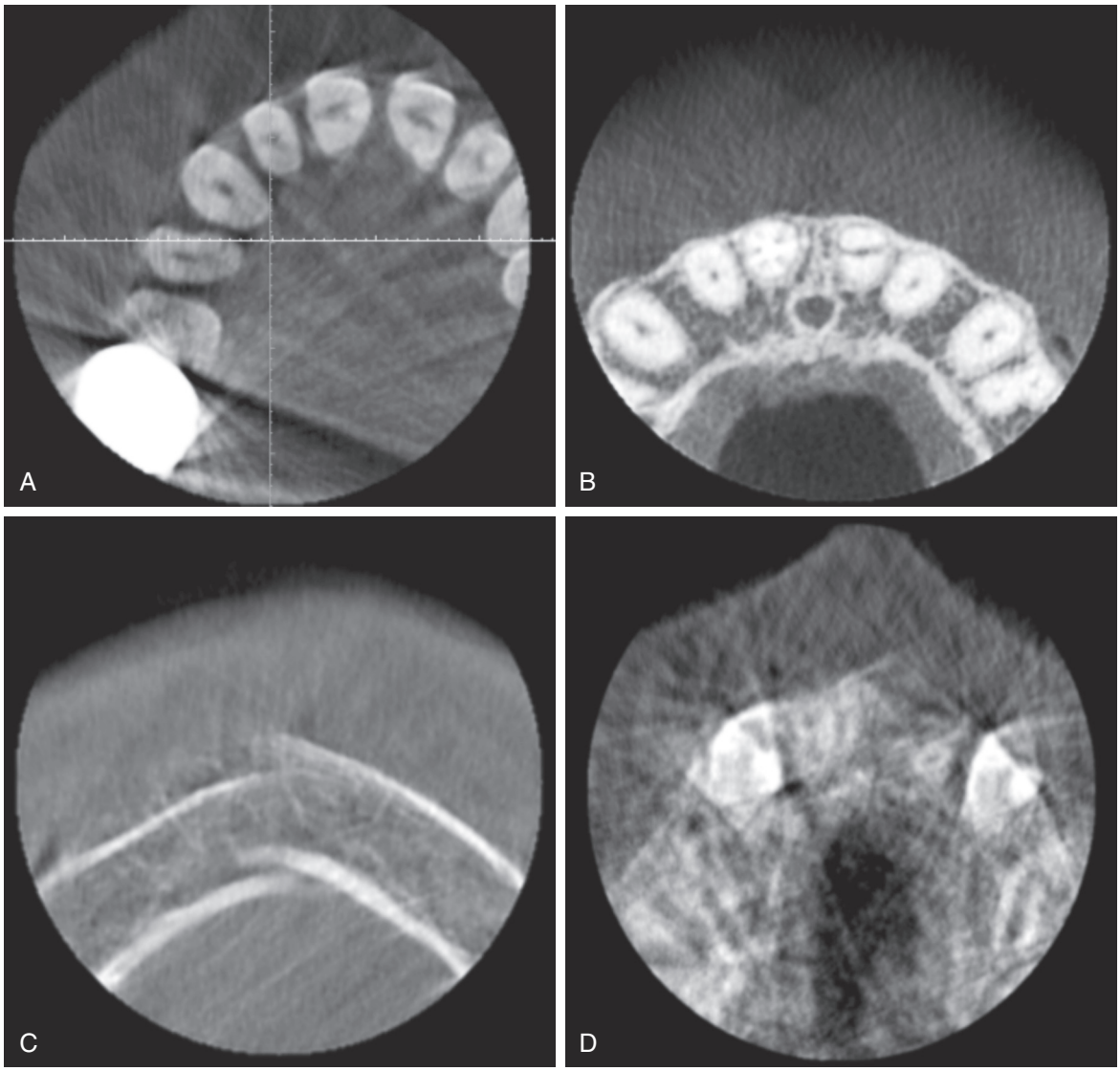

Figure 2-21 Illustration of beam-hardening artifacts. (*top*) Notice the black lines that cross the image and the white streaks near the radiopaque material. (*bottom*) Illustration of patient movement. Notice the apparent broken bone on the left and the non-diagnostic image caused by the patient moving his legs during the exposure in the right image. Cone beam computed tomography images.

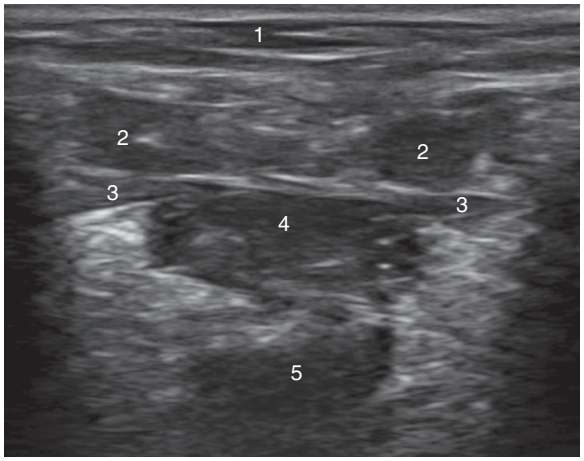

Figure 2-22 Ultrasound image of the floor of the mouth. The top of the image is the skin under the floor of the mouth, and the bottom of the image is the tongue. (1) Skin and platysma. (2) Anterior belly of both digastric muscles. (3) Mylohyoid muscle. (4) Genioglossus and geniohyoid muscles. (5) The tongue.

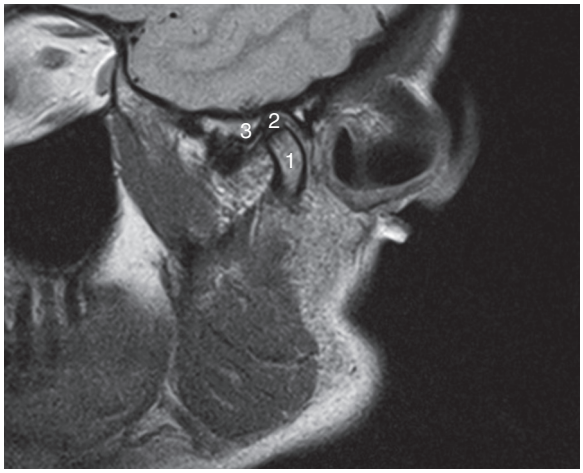

Figure 2-23 Magnetic resonance imaging of the temporomandibular joint: (1) cancellous bone of the condyle (surrounded by a black line, which is the cortical bone); (2) disc of the joint; and (3) articular eminence with the dark line representing the cortical bone, while the white line inferior to that is the fibrous tissue anterior to the articular disc.

In case one has an image that cannot be diagnosed, the assistance of an oral and maxillofacial radiologist may be advisable. These professionals are well trained and can spend more time evaluating the image. The radiologist's report can subsequently be used by the clinician and/or the pathologist and can be of assistance in developing the treatment or follow-up plan for the patient. Oral and maxillofacial radiologists can make recommendations on the need for additional imaging as well as the imaging techniques that should be used.

Table **2-5**

Guidelines for Prescribing Dental Radiographs*

	Patient Age and Dental Developmental Stage				
Type of Encounter	**Child with Primary Dentition** (prior to eruption of first permanent tooth)	**Child with Transitional Dentition** (after eruption of first permanent tooth)	**Adolescent with Permanent Dentition** (prior to eruption of third molars)	**Adult, Dentate or Partially Edentulous**	**Adult, Edentulous**
New patient* being evaluated for dental diseases and dental development	Individualized radiographic exam consisting of selected periapical/occlusal views and/or posterior bitewings if proximal surfaces cannot be visualized or probed. Patients without evidence of disease and with open proximal contacts may not require a radiographic exam at this time.	Individualized radiographic exam consisting of posterior bitewings with panoramic exam or posterior bitewings and selected periapical images.	Individualized radiographic exam consisting of posterior bitewings with panoramic exam or posterior bitewings and selected periapical images. A full mouth intraoral radiographic exam is preferred when the patient has clinical evidence of generalized dental disease or a history of extensive dental treatment.		Individualized radiographic exam, based on clinical signs and symptoms.
Recall patient* with clinical caries or at increased risk for caries**	Posterior bitewing exam at 6-12 month intervals if proximal surfaces cannot be examined visually or with a probe.			Posterior bitewing exam at 6-18 month intervals.	Not applicable
Recall patient* with no clinical caries and not at increased risk for caries**	Posterior bitewing exam at 12-24 month intervals if proximal surfaces cannot be examined visually or with a probe		Posterior bitewing exam at 18-36 month intervals.	Posterior bitewing exam at 24-36 month intervals.	Not applicable
Recall patient* with periodontal disease	Clinical judgment as to the need for and type of radiographic images for the evaluation of periodontal disease. Imaging may consist of, but is not limited to, selected bitewing and/or periapical images of areas where periodontal disease (other than nonspecific gingivitis) can be identified clinically.				Not applicable
Patient for monitoring of growth and development	Clinical judgment as to need for and type of radiographic images for evaluation and/or monitoring of dentofacial growth and development.		Clinical judgment as to need for and type of radiographic images for evaluation and/or monitoring of dentofacial growth and development. Panoramic or periapical exam to assess developing third molars.	Usually not indicated	

Patient with other circumstances including, but not limited to, proposed or existing implants, pathology, restorative/endodontic needs, treated periodontal disease and caries remineralization	Clinical judgment as to need for and type of radiographic images for evaluation and/or monitoring in these circumstances.

*Data from: American Academy of Pediatric Dentistry: Guideline on prescribing dental radiographs for infants, children, adolescents, and persons with special health care needs, *Pediatr Dent* 34(5):189-191, 2012.
Ad Hoc Committee on Pedodontic Radiology. American Academy of Pediatric Dentistry, reference manual, 2012.
The selection of patients for dental radiograph examination, American Dental Association and US Food and Drug Administration, *JADA* 137(9):1304-1312, 2006.

***Clinical situations for which radiographs may be indicated include but are not limited to:**

A. Positive Historical Findings

1. Previous periodontal or endodontic treatment
2. History of pain or trauma
3. Familial history of dental anomalies
4. Postoperative evaluation of healing
5. Remineralization monitoring
6. Presence of implants or evaluation for implant placement

B. Positive Clinical Signs/Symptoms

1. Clinical evidence of periodontal disease
2. Large or deep restorations
3. Deep carious lesions
4. Malposed or clinically impacted teeth
5. Swelling
6. Evidence of dental/facial trauma
7. Mobility of teeth
8. Sinus tract (“fistula”)
9. Clinically suspected sinus pathology
10. Growth abnormalities
11. Oral involvement in known or suspected systemic disease
12. Positive neurologic findings in the head and neck
13. Evidence of foreign objects
14. Pain and/or dysfunction of the temporomandibular joint
15. Facial asymmetry
16. Abutment teeth for fixed or removable partial prosthesis
17. Unexplained bleeding
18. Unexplained sensitivity of teeth
19. Unusual eruption, spacing or migration of teeth
20. Unusual tooth morphology, calcification or color
21. Unexplained absence of teeth
22. Clinical erosion

****Factors increasing risk for caries may include but are not limited to:**

1. High level of caries experience or demineralization
2. History of recurrent caries
3. High titers of cariogenic bacteria
4. Existing restoration(s) of poor quality
5. Poor oral hygiene
6. Inadequate fluoride exposure
7. Prolonged nursing (bottle or breast)
8. Frequent high sucrose content in diet
9. Poor family dental health
10. Developmental or acquired enamel defects
11. Developmental or acquired disability
12. Xerostomia
13. Genetic abnormality of teeth
14. Many multisurface restorations
15. Chemo/radiation therapy
16. Eating disorders
17. Drug/alcohol abuse
18. Irregular dental care

SUGGESTED READINGS

Al Najjar A, Colosi D, Dauer LT, Prins R, et al.: Comparison of adult and child radiation equivalent doses from 2 dental cone beam computed tomography units, *Am J Orthod Dentofacial Orthoped* 143:784–792, 2013. NCRP Report No. 145 Radiation Protection in Dentistry 2003.

American Academy of Pediatric Dentistry: Guideline on prescribing dental radiographs for infants, children, adolescents, and persons with special health care needs, *Pediatr Dent* 34(5):189–191, 2012.

American Dental Association Council on Scientific Affairs: The use of cone beam computed tomography in dentistry: an advisory statement from the American Dental Association Council on Scientific Affairs, *JADA* 143:899–902, 2012.

Amis ES, Butler PF, Applegate KE, Birnbaum SB, et al.: American College of Radiology white paper on radiation dose in medicine, *J Am Coll Radiol* 4:272–284, 2007.

Aps JKM: Cone beam computed tomography in paediatric dentistry: an overview of recent literature, *Eur Arch Paed Dent* 14:131–140, 2013 (doi 10.1007/s40368-013-0029-4).

Aps JKM: Theoretical assessment of the thyroid gland's radiation dose from radiographs taken in dento-alveolar trauma in pediatric patients, *Pediatr Neonatal Care* 1:e104, 2013.

Aps JKM: Three-dimensional imaging in paediatric dentistry; a must-have or you're not up to date? *Eur Arch Paed Dent* 14:129–130, 2013 (doi: 10.1007/s40368-013-0034-7).

Aps JKM, Scott J: Oblique lateral radiographs and bitewings; estimated organ doses in head and neck region with Monte Carlo calculations, *Dentomaxillofac Radiol* 43:20130419, 2014.

Dental Radiographic Examinations: Recommendations for Patient Selection and Limiting Radiation Exposure Revised 2012, ADA Council on Scientific Affairs, US Department of Health and Human Services, Public Health Service, Food and Drug Administration, 2012.

Espelid I, Mejàre I, Weerheijm K: EAPD guidelines for use of radiographs in children, *Eur J Paed Dent* 1:40–48, 2003.

Horner K, Islam M, Flygare L, Tsiklakis K, et al.: Basic principles of use of cone beam computed tomography: consensus guidelines of the European Academy of Dental and Maxillofacial Radiology, *Dentomaxillofac Radiol* 38:187–195, 2009.

Kim S, Yoshizumi TT, Frush DP, Toncheva G, et al.: Radiation dose from cone beam CT in a pediatric phantom: risk estimation of cancer incidence, *Am J Roentgenol* 1:186–190, 2010.

Kullman L, Al Sane M: Guidelines for dental radiography immediately after dento-alveolar trauma, a systematic literature review, *Dent Traumatol* 28:193–199, 2012 (doi: 10.1111/j.6000.9657.2011.01099).

Looe HK, Pfaffenberger A, Chofor N, Eenboom F, et al.: Radiation exposure to children in intraoral dental radiology, *Radiation Protection Dosimetry* 121(4):461–465, 2006.

Ludlow JB, Davies-Ludlow LE, White SC: Patient risk related to common dental radiographic examinations: the impact of 2007 International Commission on Radiological Protection recommendations regarding dose calculation, *JADA* 139:1237–1243, 2008.

McGiff TJ, Danforth RA, Herschaft EE: Maintaining radiation exposures as low as reasonably achievable (ALARA) for dental personnel operating portable hand-held x-ray equipment, *Health Phys* 103(Suppl2):S179–S185, 2012.

Memon A, Godward S, Williams D, Siddique I, et al.: Dental x-rays and the risk of thyroid cancer; a case control study, *Acta Oncol* 49:447–453, 2010.

Parrott LA, Ng SY: A comparison between bitewing radiographs taken with rectangular and circular collimators in UK military dental practices: a retrospective study, *Dentomaxillofacial Radiol* 40:102–109, 2011.

Rush ER, Thompson NA: Dental radiography and equipment: how they influence the radiation dose received at the level of the thyroid gland, *Radiography* 13:214–220, 2007.

Schonfeld SJ, Lee C: Berrington de González A: Medical exposure to radiation and thyroid cancer, *Clin Oncol (R Coll Radiol)* 23:244–250, 2011.

Strakakis J, Damilakis J, Gourtsoyiannis N: Organ and effective dose conversion coefficients for radiographic examinations of the pediatric skull estimated by Monte Carlo methods, *Eur Radiol* 15:1948–1958, 2005.

White SC, Mallaya SM: Update on the biological effects of ionizing radiation, relative dose factors and radiation hygiene, *Austr Dent J* 57(1 Suppl):2–8, 2012.

Zhang W, Abramovitch K, Thames W, Leon I-LK, et al.: Comparison of the efficacy and technical accuracy of different rectangular collimators for intraoral radiography, *Oral Surg Oral Med Oral Pathol Oral Radiol Endod* 108:e22–e28, 2009.

CHAPTER 3

Acquired and Developmental Disturbances of the Teeth and Associated Oral Structures

▲ James K. Hartsfield Jr. and Angus C. Cameron

For additional resources, please visit the evolve website.

CHAPTER OUTLINE

COMMON DISTURBANCES IN CHILDREN
ALVEOLAR ABSCESS
CELLULITIS
DEVELOPMENTAL ANOMALIES OF THE TEETH
- Odontoma
- Fusion of the Teeth
- Gemination
- Dens Invaginatus (Dens in Dente)

EARLY EXFOLIATION OF TEETH
- Hypophosphatasia
- Cherubism (Familial Fibrous Dysplasia)
- Acrodynia
- Hypophosphatemia (Familial or X-Linked Hypophosphatemic Rickets or Vitamin D–Resistant Rickets)
- Cyclic Neutropenia (Cyclic Hematopoiesis)
- Other Disorders

ENAMEL HYPOPLASIA
- Hypoplasia Resulting from Nutritional Deficiencies
- Hypoplasia Related to Brain Injury and Neurologic Defects
- Hypoplasia Associated with Nephrotic Syndrome
- Hypoplasia Associated with Allergies
- Hypoplasia Associated with Lead Poisoning (Plumbism)
- Hypoplasia Caused by Local Infection and Trauma
- Hypoplasia Associated with Cleft Lip and Palate
- Hypoplasia Caused by Ionizing Radiation and Chemotherapy
- Hypoplasia Resulting from Rubella Embryopathy
- Molar-Incisor Hypomineralization (MIH)
- Treatment of Hypoplastic Teeth
- Hypoplasia Caused by Fluoride (Dental Fluorosis)
- Enamel Microabrasion to Remove Superficial Enamel Discolorations

PRE-ERUPTIVE "CARIES" (PRE-ERUPTIVE CORONAL RESORPTION OR PRE-ERUPTIVE INTRACORONAL RADIOLUCENCY)
TAURODONTISM
INHERITED DEFECTS OF DENTIN
- Dentinogenesis Imperfecta (Hereditary Opalescent Dentin)
- Dentin Dysplasia

AMELOGENESIS IMPERFECTA
ENAMEL AND DENTIN APLASIA
AGENESIS OF TEETH
- Anodontia
- Hypodontia (Oligodontia)
- Hypodontia and Palatally Displaced Canines
- Hypodontia (Oligodontia) and Cancer Ectodermal Dysplasias

INTRINSIC DISCOLORATION OF TEETH (PIGMENTATION OF TEETH)
- Discoloration in Hyperbilirubinemia
- Discoloration in Porphyria
- Discoloration in Cystic Fibrosis
- Discoloration in Tetracycline Therapy
- Bleaching of Intrinsic Tooth Discoloration

MICROGNATHIA
ANOMALIES OF THE TONGUE
- Macroglossia
- Ankyloglossia (Tongue-Tie)
- Fissured Tongue and Geographic Tongue (Benign Migratory Glossitis)
- Coated Tongue
- White Strawberry Tongue
- Black Hairy Tongue
- Indentation of the Tongue Margin (Crenation)
- Median Rhomboid Glossitis (Central Papillary Atrophy of the Tongue)
- Trauma to the Tongue, with Emphasis on Tongue Piercing

ABNORMAL LABIAL FRENUM
- Frenectomy

COMMON DISTURBANCES IN CHILDREN

Over the past half century, dental care for children has become more readily available. Caries-preventive programs have become more effective, and there has been a steady decline in the incidence and prevalence of dental caries in both primary and permanent teeth among children worldwide (see Chapter 9). However, according to the first United States Surgeon General's report on oral health in America, published in May 2000, dental caries remains the single most common chronic childhood disease.[1] Periodontal disease is also common; however, this is usually limited to the mild gingivitis that will be experienced by most children. The severe forms of periodontal disease involving bone loss are rare in children and are found only in those with altered immune function. Both caries and periodontal disease are, for the most part, acquired and preventable disturbances of the teeth and jaws. Other chapters of this book are devoted to a more in-depth discussion of the cause, prevention, and management of dental caries (see Chapters 7, 9, 10, 11, and 13) and periodontal disturbances (see Chapter 14). Another large category

Dentlearn.ir

of acquired disturbances is injury to the teeth and supporting tissues (see Chapter 27).

Many children have orthodontic conditions that justify corrective treatment, and for some of them the condition is serious enough to be categorized as deforming or even as a disability. Approximately 1 in 1000 children in the United States is born with a cleft lip or palate. These conditions are primarily developmental disturbances and are discussed in greater detail in Chapters 5 and 23.

ALVEOLAR ABSCESS

An alveolar abscess may be acute or chronic and is associated with pulpal necrosis. In permanent teeth this is usually a well-localized periapical lesion surrounded by a fibrous capsule produced by fibroblasts that differentiate from the periodontal membrane. The primary tooth abscess is usually evident as a more diffuse infection, and the surrounding tissue is less able to isolate or "wall off" the process. The virulence of the microorganisms and the ability of the host to react to the infection probably determine whether the infection will be acute or chronic.

In its early stages the acute alveolar abscess may be diagnosed based on radiographic signs of periodontal ligament space widening. The tooth may be sensitive to percussion and movement, and the patient may be febrile. The symptoms of an acute alveolar abscess can be relieved by antibiotic therapy; however, the main tenet of treatment involves removal of the cause of the infection, namely, the necrotic pulp tissue. Relief of the symptoms is more efficient if drainage is also established (Fig. 3-1) through the pulp chamber of the tooth (in the case of a permanent tooth) and/or the associated gingiva or by extraction of the tooth. If extraction is selected as the best choice of treatment at the emergency appointment and the patient has an unremarkable medical history, concomitant antibiotic therapy is not always necessary. During this acute infection phase, however, it is often difficult or impossible to establish effective anesthesia for tooth extraction. It is also considered unwise to inject local anesthetic solution into inflamed and infected tissue; general anesthesia may be required in severe cases. A significant collection of pus, a spreading infection involving the floor of the mouth, or posterior spread that might involve the orbit and cavernous sinus should be regarded as potentially life-threatening emergencies requiring surgery.

Drainage through the pulp chamber of a primary tooth is almost impossible if subperiosteal pus is present. Drainage through the pulp chamber of a permanent tooth is established by creating a normal but complete, traditional access cavity and instrumenting the canals to permit drainage of the exudate. The endodontic instrument should not pass the root apex. After initial debridement and irrigation the opening to the chamber should be closed unless exudate continues to drain. If pain occurs during the excavation of tooth structure to establish drainage, the discomfort can be lessened if the tooth is stabilized by the dentist's fingers.

A chronic alveolar abscess is less painful and is defined by a more distinct radiographic lesion. Patients who are systemically unwell will also have lymphadenopathy. Draining fistulas are frequently associated with chronic alveolar abscesses. Usually, antibiotic therapy is unnecessary except in patients with an overriding systemic comorbidity (e.g., those patients with organ transplants or who are immunodeficient). Again, drainage and removal of the cause of the infection are necessary through root canal therapy or through extraction. If the lesion has only recently passed the acute stage, there may be an indicative soft-tissue abscess with an accumulation of pus. In this situation, incision and drainage may be indicated in addition to opening the tooth, especially if the tooth is to be treated endodontically. If the lesion is in an advanced chronic stage, drainage may already be established as a natural reaction (Fig. 3-2).

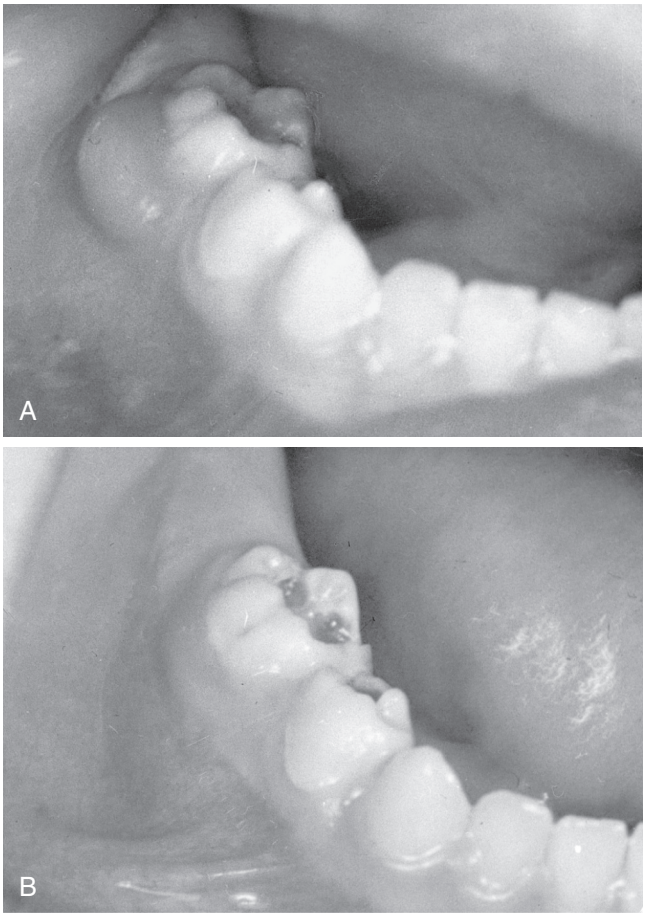

Figure 3-1 **A,** Acute alveolar abscess associated with a pulpless second primary molar. **B,** Removal of the roof of the pulp chamber to allow for drainage resulted in immediate relief of pain. After the swelling is reduced, one can decide whether the tooth is to be treated or extracted.

CELLULITIS

Cellulitis is a diffuse infection of the soft tissues that is seen more frequently in younger children. It is similarly caused by primary or permanent pulpal necrosis and is characterized by considerable swelling of the face or neck due to collateral edema and a spreading fascial infection; the tissue appears dark and brawny.

Cellulitis may be very serious and life threatening. It is usually a result of severe untreated caries in patients who

Dentlearn.ir



Figure 3-2 A pedunculated granulomatous lesion overlying the canine but associated with a chronic draining alveolar abscess of the maxillary right first primary molar.

receive irregular, symptomatic dental care or who may have had dental care only for treatment of dental emergencies. Such children commonly come to the hospital emergency department, where they appear acutely ill and may have a high fever (greater than 40°C) with malaise and lethargy.

If a maxillary tooth is involved, the swelling and redness may involve the eye (Fig. 3-3, *A*) and, if untreated, may spread posteriorly to involve the brain with an abscess or cavernous sinus thrombosis. Cellulitis resulting from an infected mandibular tooth will spread to the floor of the mouth along the fascial planes. An infection involving submandibular, sublingual, and submental spaces is termed *Ludwig's angina*. In this condition the tongue and floor of the mouth become elevated to the extent that the patient's airway is obstructed and swallowing is impossible.

These cases usually require extraction of the primary tooth or the establishment of drainage in permanent teeth, if possible, by opening the pulp chamber of the affected tooth. However, the child may have difficulty opening the mouth to permit the procedure; also, incision of soft tissue to establish drainage is not indicated in the early stages of cellulitis because of the diffuse, poorly localized nature of the infection. Antibiotics are usually indicated in these children.

The cultures isolated from these dental infections are usually of mixed flora, predominantly gram-positive facultative anaerobic microorganisms. They are usually capable of producing hyaluronidase and fibrinolysins, which break down the intercellular cementing substance (hyaluronic acid) and fibrin, thus permitting rapid spread of the infection. A broad-spectrum antibiotic should be prescribed early to reduce the possibility of the infection localizing and draining on the outer surface of the face (see Fig. 3-3, *B*), and penicillin remains the drug of first choice in nonallergic patients. It should be emphasized to the patient or parents that antibiotics will not heal the condition completely and that follow-up treatment of the tooth is essential.

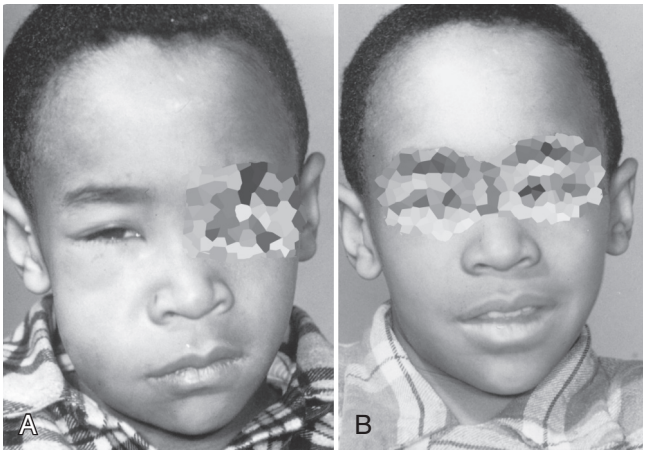

Figure 3-3 **A,** Patient appears to be acutely ill because of an infected permanent molar and resultant cellulitis. **B,** Use of broad-spectrum antibiotics reduced the acute symptoms of the disease and prevented extraoral drainage.

In severe infections, pus or exudate must be taken for culture. Many anaerobic microorganisms will not be identified in such cultures unless specific tests are performed. Nonetheless, if the infection does not respond to the initial antibiotic therapy, a second, more appropriate antibiotic may be selected after the causative organisms have been identified. Molinari has emphasized the continuing emergence of antibiotic-resistant bacterial strains that render many common antimicrobial agents ineffective.[2]

Hospitalization is required for children with severe cellulitis who are systemically unwell, those in whom the clinical signs or symptoms warrant close monitoring, or if there is any question as to whether the patient or parents will follow through with the prescribed treatment. Hospitalization is essential in any case involving a spreading infection of the floor of the mouth, such as Ludwig's angina, because maintenance of a patent airway may require the assistance of medical personnel. In these severe cases, parenteral administration of antibiotics is recommended.

DEVELOPMENTAL ANOMALIES OF THE TEETH

ODONTOMA

Abnormal proliferation of cells of the enamel organ may result in an odontogenic hamartoma, commonly referred to as an *odontoma*. An odontoma may form as a result of altered proliferation of the dental epithelium and budding of the primary tooth germ. Odontomas may be compound, with multiple denticles, or complex, presenting as a single mass of calcified tissue (Figs. 3-4 and 3-5). An odontoma should be surgically removed because it usually interferes with eruption of teeth in the area. The presence of an odontoma should alert the practitioner to inquire about the concurrent presence of dysphagia or a family history of dysphagia, perhaps due to hypertrophy of the smooth muscles of the esophagus as a part of the rare autosomal-dominant odontoma-dysphagia syndrome.[3] Odontomas are discussed in detail in Chapter 28.

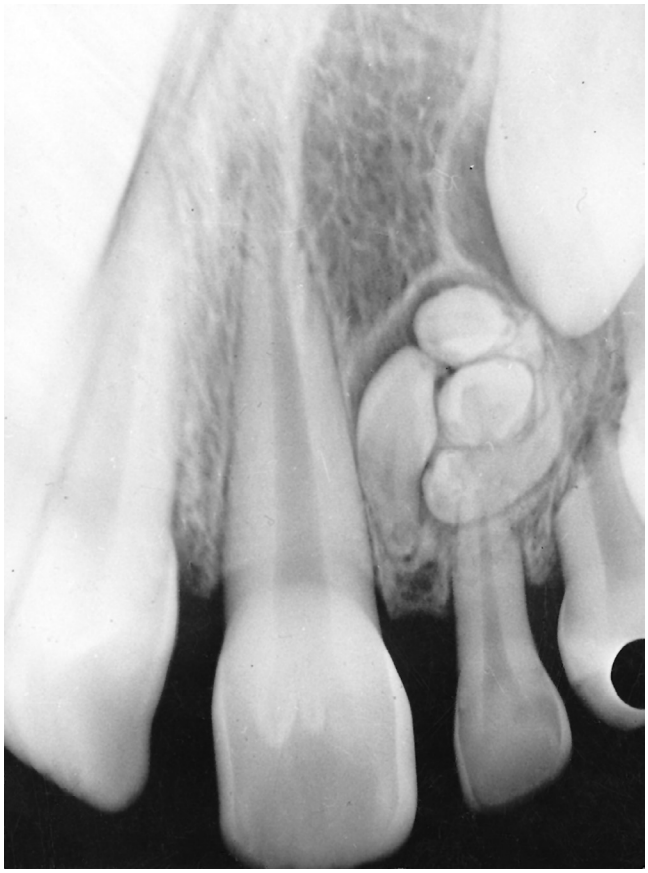

Figure 3-4 Compound composite odontoma. The anomalous structure consists of small structures resembling teeth.

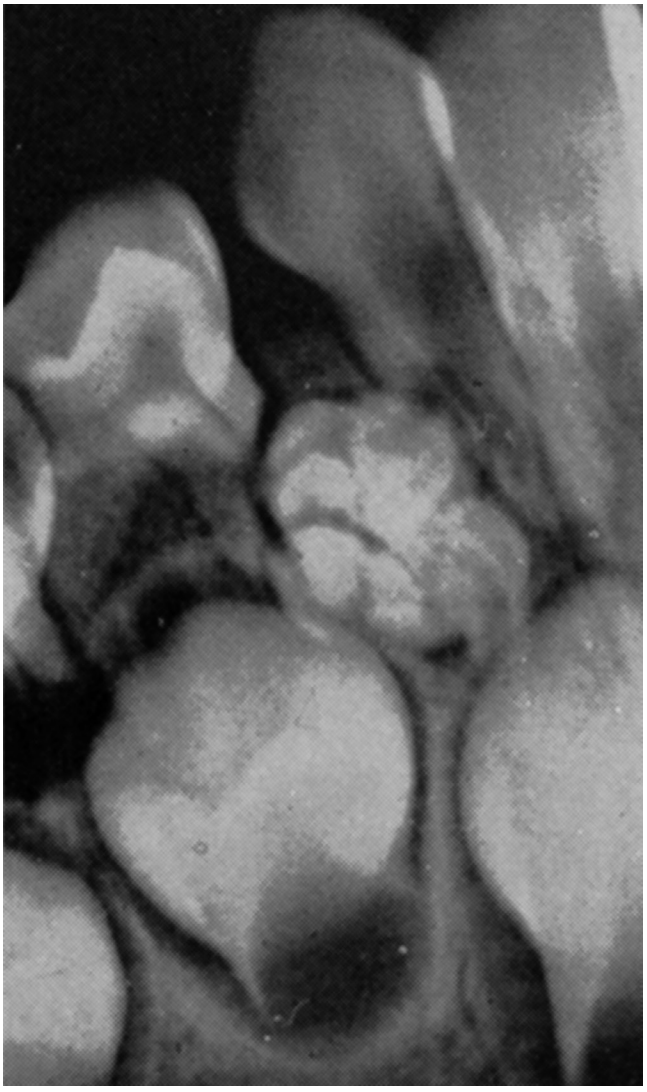

Figure 3-5 Complex composite odontoma.

FUSION OF THE TEETH

Fusion represents the union of two independently developing primary or permanent teeth. The condition is usually limited to the anterior teeth and, like gemination (see the following discussion), may show a familial tendency. Fusion of teeth involving only cementum is termed *concrescence*.

The radiograph may show that the fusion is limited to the crowns and roots. Fused teeth will have separate pulp chambers and separate pulp canals (Fig. 3-6). Dental caries may develop in the line of fusion of the crowns, necessitating the placement of a restoration. A frequent finding in fusion of primary teeth is the developmental absence of one of the corresponding permanent teeth.

Care of such patients requires a multidisciplinary approach involving pediatric dentistry, endodontics, surgery, restorative dentistry, and orthodontics. Surgical sectioning and separation of fused teeth are possible, and, although dentin is exposed, such teeth are easily moved orthodontically without the risk of ankylosis. Diagnosis may be difficult using traditional radiographic techniques due to the superimposition of adjacent structures or other teeth, and cone beam computed tomography is useful in determining the extent and exact location of the fusion. Initially the presence of a single primary and permanent maxillary central incisor may appear to be a product of fusion. However, if the single tooth is in the midline and is symmetric, with normal crown and root shape and size, then it may be either an isolated finding or part of the solitary median maxillary central incisor (SMMCI) syndrome. This is a heterogeneous condition that may include other midline developmental abnormalities of the brain (various degrees of holoprosencephaly) and other structures that can be due to mutation in the sonic hedgehog (*SHH*) gene at 7q36, the *SIX3* gene, or other genetic abnormalities. SMMCI can be a feature of recognized syndromes or a finding in patients with specific chromosomal abnormalities. The development of only one maxillary central incisor is an indication for further evaluation for other anomalies such as short stature with or without growth hormone deficiency, microcephaly, choanal atresia, midnasal stenosis, and congenital nasal pyriform aperture stenosis.[4]

GEMINATION

A geminated tooth must be distinguished from a fused tooth. It represents an attempted division of a single tooth germ by invagination occurring during the proliferation stage of the growth cycle of the tooth, in which case

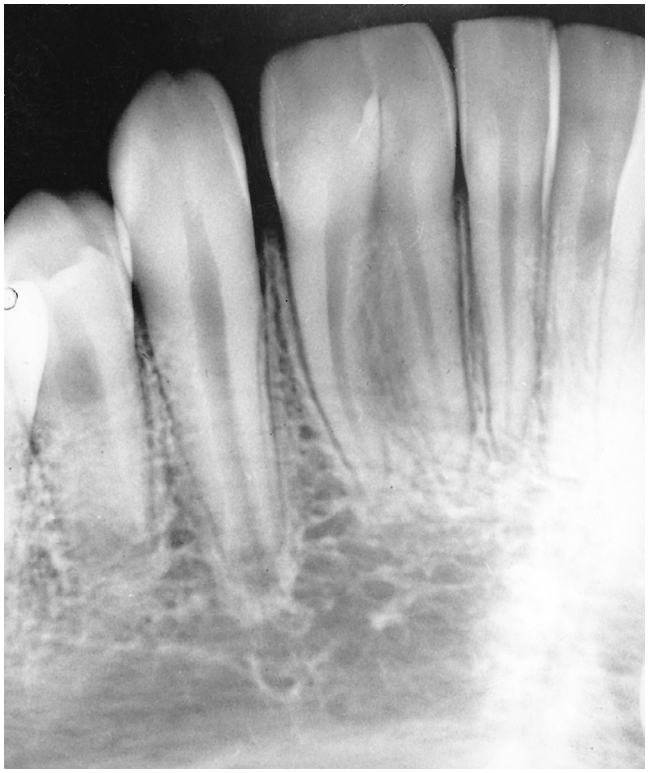

Figure 3-6 Fusion of a permanent central and lateral incisor.

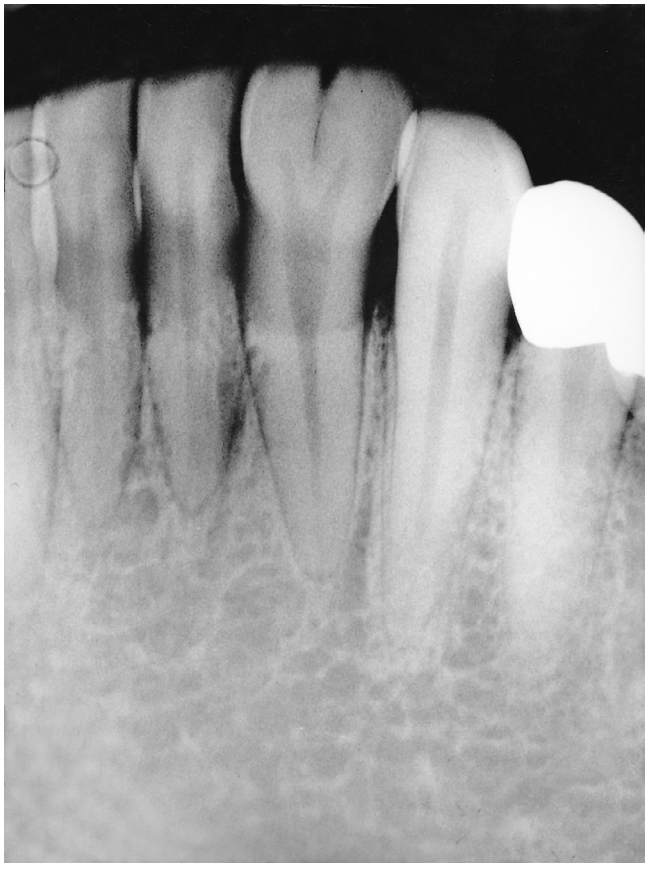

Figure 3-7 Gemination of a mandibular lateral incisor. The crown has a groove on the labial surface and is wider than normal.

the geminated tooth appears clinically as a bifid crown on a single root (Fig. 3-7). The crown is usually wider than normal, with a shallow groove extending from the incisal edge to the cervical region. The anomaly, which may follow a hereditary pattern of occurrence, is seen in both primary and permanent teeth, although it probably appears more frequently in primary teeth.

The treatment of a permanent anterior geminated tooth may involve reduction of the mesiodistal width of the tooth to allow for normal development of the occlusion. Periodic "disking" of the tooth is recommended when the crown is not excessively large, as is eventual preparation of the tooth for restoration if dentin is exposed. However, if the crown is extremely large, the tooth size may be unable to be masked, necessitating removal and a combined orthodontic and prosthodontic approach to rehabilitation.

DENS INVAGINATUS (DENS IN DENTE)

Dens invaginatus (or a tooth within a tooth) can be diagnosed radiographically. This developmental anomaly is a lingual invagination of the enamel, and can occur in primary and permanent teeth. Unusual cases of dens invaginatus have been reported in a mandibular primary canine, a maxillary primary central incisor, and a mandibular second primary molar. It is most often seen in the permanent maxillary lateral incisors, and presence of deep lingual pits should arouse suspicion. Grahnen and colleagues, in a study of 58 families, found that more than one third of the parents of children with dens invaginatus had dens invaginatus or deep lingual pits,[5] indicating autosomal-dominant inheritance with variable expressivity and possibly incomplete penetrance (see Chapter 5 for definitions).

Anterior teeth with dens invaginatus are usually of normal shape and size. In other areas of the mouth, however, the tooth can have an anomalous appearance. A dens invaginatus is characterized by an invagination lined with enamel and the presence of a foramen cecum, with the probability of communication between the cavity of the invagination and the pulp chamber (Fig. 3-8).

Application of sealant or a restoration in the opening of the invagination is the recommended treatment to prevent pulpal involvement. If the condition is detected before complete eruption of the tooth, gingival tissue must be removed to facilitate cavity preparation and restoration. A common presentation may be tooth necrosis, and the child may have an acute abscess. The prognosis of such teeth depends on pulp morphology and restorability of the crown (Fig. 3-9).

EARLY EXFOLIATION OF TEETH

Variations in both the time of eruption and the time of exfoliation of the primary teeth are frequently observed in pediatric patients. A variation of as much as 18 months in the exfoliation time of primary teeth may be considered normal. However, this pattern must be consistent with other aspects of dental development. Exfoliation of teeth in the absence of trauma in children younger than

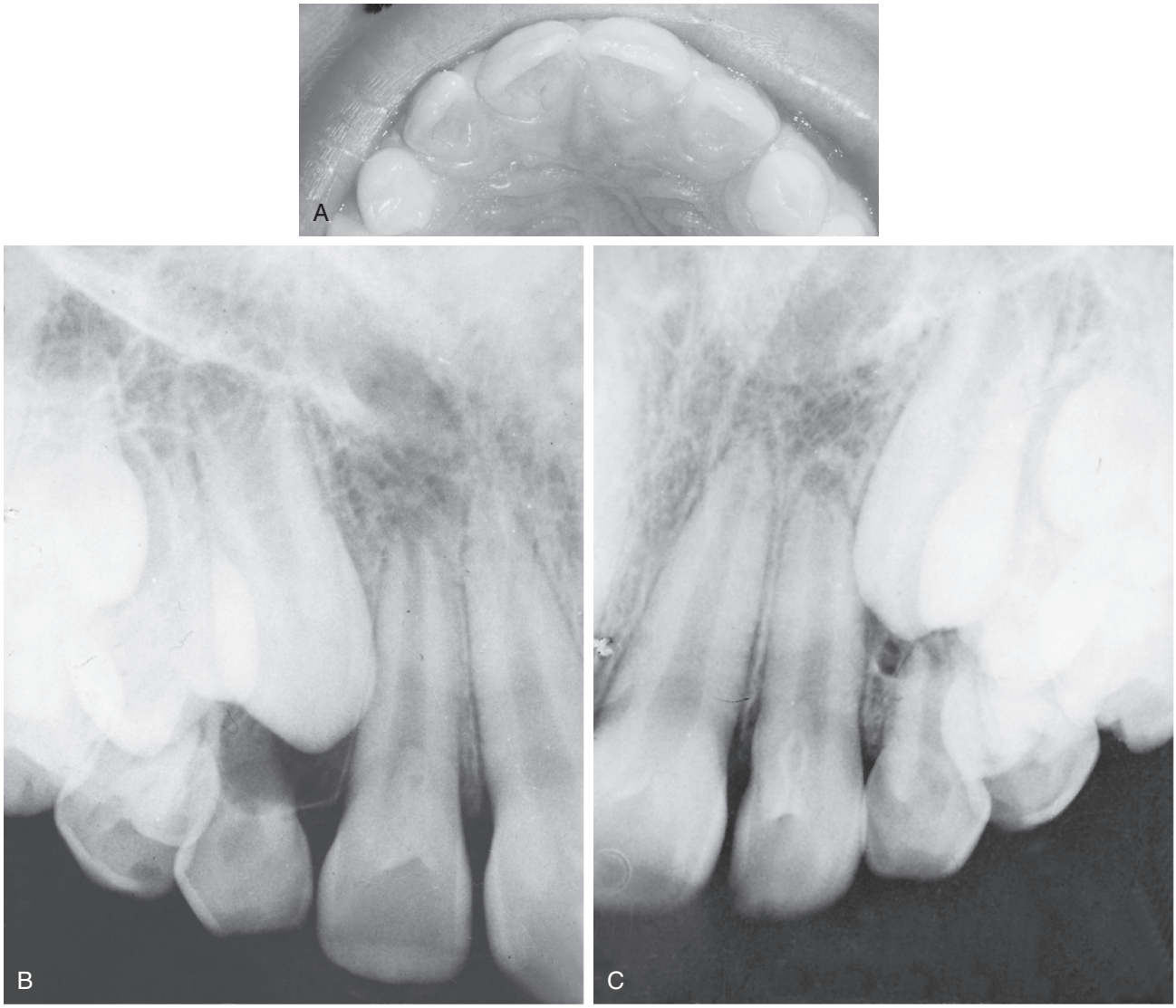

Figure 3-8 **A,** Small, "nonsticky" pits on the lingual surfaces of the maxillary lateral incisors are the only clues to the dens in dente condition of the teeth revealed radiographically in **B** and **C**.

5 years of age merits special attention because it can be related to local or systemic pathology.

Early exfoliation of primary teeth due to periodontitis is uncommon and demands investigation (see Chapters 5 and 14). Along with hypophosphatasia, periodontitis secondary to immune deficiency or dysfunction appears to be the most common cause of premature exfoliation of the primary teeth. The term "aggressive periodontitis" replaced the terms "early-onset," "prepubertal," and "juvenile periodontitis" at a 1999 International Workshop for the classification of periodontal diseases and conditions, where it was decided that the classification terminology should not be age-dependent or require knowledge of rates of progression.[6] Aggressive periodontitis can be formed by a mutation in the *CTSA* gene that codes for cathepsin C. Mutations in *CTSA* can also result in Haim-Munk syndrome or Papillon-Lefèvre syndrome.[7,8]

HYPOPHOSPHATASIA

The clinical dental finding for the diagnosis of hypophosphatasia in children is premature exfoliation of the anterior primary teeth associated with deficient cementum. The loss of teeth in the young child may be spontaneous or may result from a minimal trauma in the absence of gingival inflammation. The loss of alveolar bone may be limited to the anterior region. Hypophosphatasia is characterized by improper mineralization of bone caused by deficient tissue-nonspecific alkaline phosphatase activity in serum, liver, bone, and kidney. Increased levels of urinary phosphoethanolamine and serum pyridoxal-5′-phosphate (vitamin B_6) are also seen since alkaline phosphatase acts in vitamin B_6 metabolism.

Ongoing study into the etiology of hypophosphatasia indicates that the usually lethal autosomal-recessive infantile type (I), the usually autosomal-recessive milder juvenile type (II), and the autosomal-dominant adult type (III) are due to different mutations and heterozygosity vs. homozygosity in the tissue-nonspecific isoenzyme of the alkaline phosphatase (ALPL) gene. Hu and colleagues state that, as a general rule, the earlier the appearance of the disease, the greater its severity.[9] Early exfoliation of the primary teeth is usually



Figure 3-9 Dens in dente in a maxillary lateral incisor. A communication between the invagination and the pulp chamber apparently caused pulpal necrosis.

associated with the juvenile type (II), although such a history may also be present in the adult type (III).[9] Diagnostic tests should include the determination of serum alkaline phosphatase levels in parents and siblings.

Pseudohypophosphatasia, first described by Scriver and Cameron, is a rare disorder in which the child has the phenotype of juvenile hypophosphatasia and elevated levels of urinary phosphoethanolamine, but plasma alkaline phosphatase activity is normal.[10] However, the clinical findings are similar to those of juvenile hypophosphatasia. Pseudohypophosphatasia occurs when there is alkaline phosphatase activity toward artificial substrates, with a lack of activity toward endogenous substrates, resulting in a clinical picture indistinguishable from that of classic hypophosphatasia.

CHERUBISM (FAMILIAL FIBROUS DYSPLASIA)

Cherubism is a rare childhood disease affecting jaw development. The children have "chubby" facies and upturned eyes, giving the condition its name. Cherubism is usually inherited as an autosomal-dominant trait, with somewhat reduced penetrance in females. The expression may be so variable that a parent who appears to be clinically normal may have a history of prominent facial swellings or radiographic evidence of an abnormal bone pattern in the mandible. Although disease progression is expected to stabilize or even regress after puberty, a few very aggressive cases, sometimes producing morbid results, have been reported.[11] At least four cases of nonfamilial cherubism have been reported, suggesting occasional sporadic occurrences from spontaneous mutations. Cherubism may also be associated with the rare, apparently autosomal-recessive, Ramon syndrome (cherubism, eye anomalies, epilepsy, mental deficiency, hypertrichosis, lack of growth, juvenile rheumatoid arthritis, and gingival fibromastosis).[12]

The gene for cherubism has been mapped to chromosome 4p16, and follow-up work by Ueki and colleagues found that mutations in the gene encoding c-Abl–binding protein SH3BP2 on chromosome 4p16.3 cause cherubism.[13] They found several different *SH3BP2* gene mutations in patients with cherubism, which probably resulted in a gain-of-function or dominant-negative effect, although other gene(s) may also cause cherubism in other patients. They postulated that the onset of cherubism and its anatomically circumscribed characteristics may be related to dental developmental processes in children, when signals unique to the mandible and maxilla are transmitted through the extracellular matrix, triggered by the eruption of secondary teeth.

Characteristically there is a symmetric enlargement of the jaws that may be noted at an early age. Radiographically the condition presents multilocular areas of bone destruction (soap-bubble lesions) and thinning of the cortical plate (Fig. 3-10). Teeth in the involved area may exfoliate prematurely because of the loss of support or root resorption or, in permanent teeth, because of interference in the development of roots. Spontaneous loss of teeth may occur, or the child may pull the teeth from the soft tissue. Developing permanent teeth are usually ectopic, being displaced by the growing lesion.

McDonald and Shafer reported a case in which the mandible and maxilla of a 5-year-old girl were symmetrically enlarged.[14] Radiographs showed multilocular cystic involvement of both mandible and maxilla. A complete skeletal survey failed to reveal similar lesions in other bones. Microscopic examination of a segment of bone showed a large number of multinucleated giant cells scattered diffusely throughout a cellular stroma. The giant cells were large and irregular in shape and contained from 30 to 40 nuclei. During a 10-year observation period, the bony lesions had not progressed appreciably.

The patient illustrated in Figure 3-10 was followed into adulthood, and her mouth was restored satisfactorily. A comparison of the full-face photographs in Figures 3-10, *A* and *I*, illustrates that, as the face increases in height, the "cherubic" appearance caused by the bilateral bulging of the bone of the mandible is less apparent. Seven permanent teeth in the upper and lower arches were retained and prepared for Baker attachments. Complete dentures were constructed to restore function and improve appearance.

Pierce and colleagues have reported their 15-year dental management of a mother and two daughters with inherited craniofacial fibrous dysplasia.[15] The daughters exhibited clinical and radiographic appearances similar to those of the patient just described, but the authors consider fibrous dysplasia and cherubism to be separate entities. Their treatment of the daughters, though more aggressive, resulted in nearly complete dentitions. Treatment included surgical autotransplantation of several

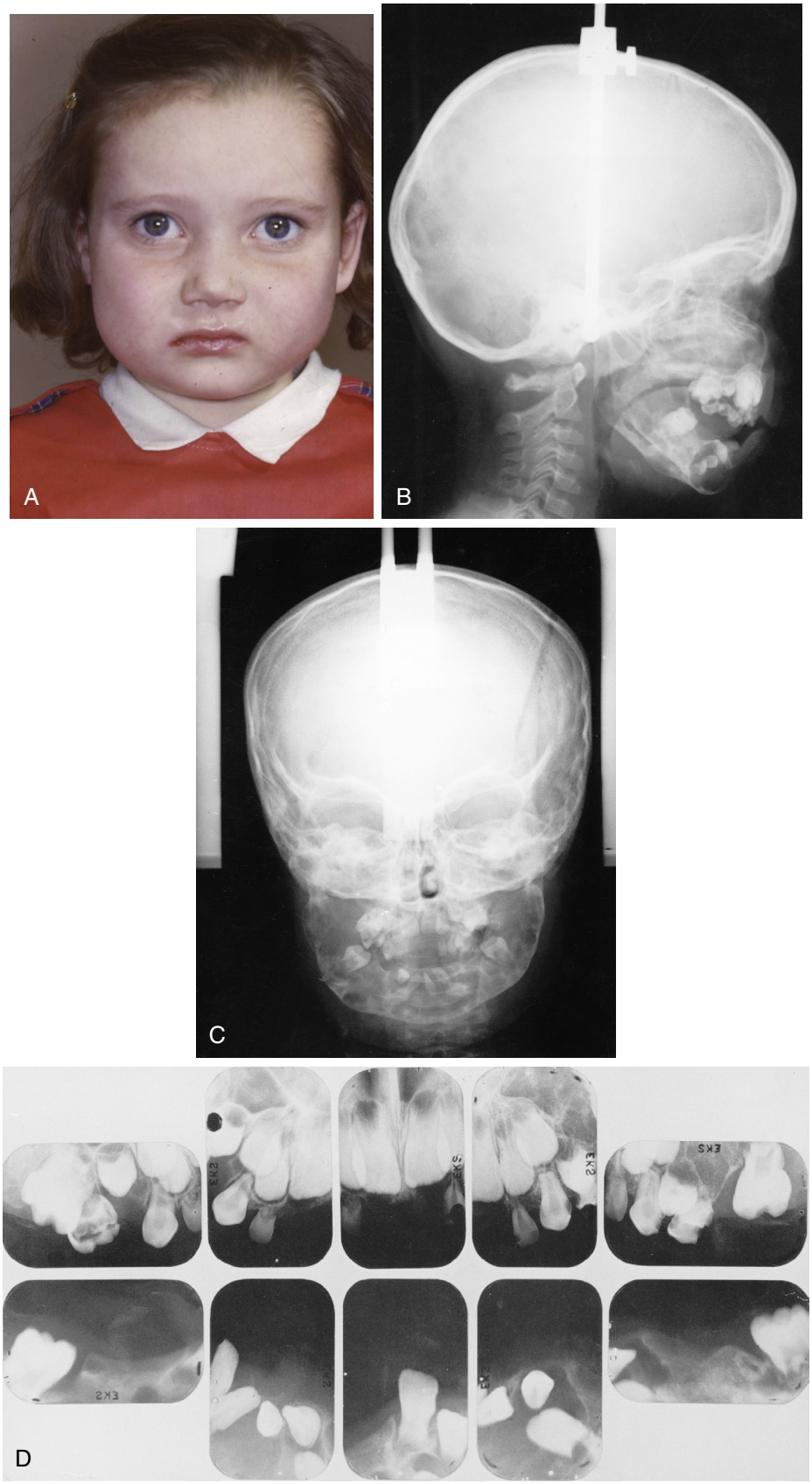

Figure 3-10 **A,** Enlargement of the cheeks caused by bilateral bulging of the bone of the mandible. **B** and **C,** Lateral and anteroposterior cephalometric radiographs. Notice the displacement of the mandibular anterior teeth in a large area of bone destruction, the locular cystic involvement of the mandible and maxillae, and the number of missing teeth. **D,** Full-mouth radiographs demonstrating large areas of bone destruction and several missing teeth.

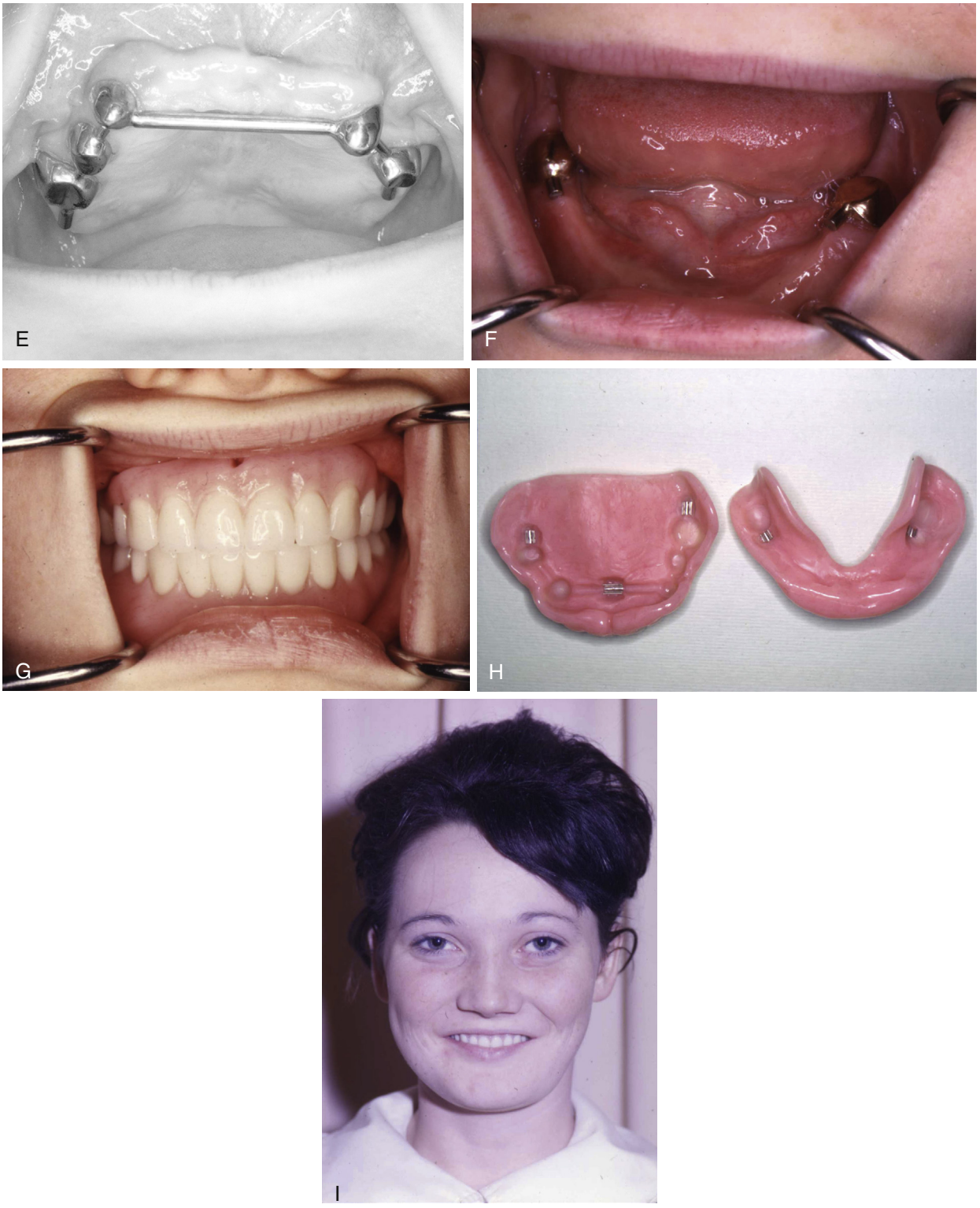

Figure 3-10, cont'd **E** through **H,** When the patient was 18 years of age, the permanent teeth with good support were prepared for Baker attachments, and complete dentures were constructed. **I,** The restored mouth and improved appearance of the adult.

Dentlearn.ir

teeth and bony recontouring. Orthodontic therapy was also provided for one child. Orthodontics was recommended for the other child but was declined; her dental alignment was acceptable 3 years after surgery. Von Wowern published an extensive review of the literature and a 36-year follow-up of families with cherubism.[16]

ACRODYNIA

Acrodynia or pink disease results from the exposure of young children to minute amounts of mercury; ointments and medications are the usual sources of the mercury. Weinstein and Bernstein reported on 20-month-old twin girls who came to a hospital with the classic signs and symptoms of acrodynia.[17] Further investigation revealed that the girls had been receiving once- or twice-weekly doses of a mercury-containing teething powder during the preceding 4 months. Apparently such preparations are still available in some countries. Horowitz and colleagues reported on two young brothers who received a diagnosis of acrodynia after playing repeatedly with a broken sphygmomanometer.[18] Dental amalgam restorations do not cause acrodynia.

The clinical features of the disease include fever, anorexia, desquamation of the soles and palms (causing them to be pink), sweating, tachycardia, gastrointestinal disturbance, and hypotonia. The oral findings include inflammation and ulceration of the mucous membrane, excessive salivation, loss of alveolar bone, and premature exfoliation of teeth.

HYPOPHOSPHATEMIA (FAMILIAL OR X-LINKED HYPOPHOSPHATEMIC RICKETS OR VITAMIN D–RESISTANT RICKETS)

As reported by Hartsfield, hypophosphatemia is the most common inherited abnormality of renal tubular transport.[19] Clinical features become evident in the second year of life and include short stature and bowing of the lower extremities in affected boys. Premature tooth exfoliation is sometimes also a feature. The inheritance pattern of the disease is usually X-linked dominant, and the disorder is twice as common in females as in males. The HYP Consortium of investigators found mutations in the *PHEX* (also called PEX) gene on the X chromosome in patients with this condition.[20]

Other dental manifestations often include periapical radiolucencies, abscesses, and fistulas associated with pulp exposures in the primary and permanent teeth. Pulpal necrosis is caused by abrasion of the thin, hypomineralized enamel, exposing the pulp horns that extend to the dentinoenamel junction or even to the external surface of the tooth. Dental radiographs show rickety bone trabeculations and absent or abnormal lamina dura.

McWhorter and Seale found that 25% of their patients with vitamin D–resistant rickets (VDRR) were affected with abscesses in primary teeth.[21] The results of their study indicated that the presence of one abscess is a predictor of future abscesses in the same patient. The authors suggested that early prophylactic treatment of all posterior primary teeth with pulpotomies and stainless steel crown placement may be the most conservative therapy for a patient with VDRR who develops a spontaneous abscess. However, a follow-up retrospective study by Shroff and colleagues found the success rate for prophylactic pulpotomies in these patients to be only 44%.[22] They concluded that, based on the currently available data, prophylactic pulpotomy therapy cannot be recommended for patients with VDRR. They also suggested that a more aggressive approach involving prophylactic pulpectomy, as previously advocated by Rakocz and colleagues, may be indicated in these patients and encouraged further investigation in this area.[23]

CYCLIC NEUTROPENIA (CYCLIC HEMATOPOIESIS)

Cyclic neutropenia is an autosomal-dominant condition in which affected individuals are at risk for opportunistic infection during intervals of neutropenia that occur in a 21-day cycle concomitant with oscillation in bone marrow blood cell production. Levels of monocytes, platelets, lymphocytes, and reticulocytes also cycle with the same frequency. Although, classically, the cycle has been reported to be 21 days, it has also been reported to occur every 15-35 days in 20 cases from five families.[24] Thus the periodicity of the neutropenia and associated oral ulcerations may be of greater diagnostic significance than the actual length of time between manifestations. Horwitz and colleagues found several different single-base substitutions in the *ELA2* gene encoding neutrophil elastase (also known as leukocyte elastase, elastase 2, and medullasin) in affected individuals and hypothesized that a perturbed interaction between neutrophil elastase and serpins or other substrates may regulate mechanisms governing the clocklike timing of hematopoiesis.[25]

The condition may appear at any age, and numerous cases in children have been reported. The patients have fever, malaise, sore throat, stomatitis, and regional lymphadenopathy as well as headache, cutaneous infection, and conjunctivitis accompanying the neutropenia. Children exhibit severe gingivitis with ulceration. When the neutrophil count returns to normal, the gingiva may return to a nearly normal clinical appearance. Children experiencing repeated insults from the condition have a considerable loss of supporting bone around the teeth. A case report by da Fonseca and Fontes describes a young woman who had suffered from poor oral health throughout her lifetime, and as she approached 21 years of age, all her remaining permanent teeth were finally removed.[26] Soon after the extractions, her blood counts improved to levels not previously seen by her hematologist. In some children, the condition may disappear during adolescence.

OTHER DISORDERS

Premature exfoliation due to periodontal disease may be caused by quantitative neutrophil disorders or qualitative disorders, including acatalasia, Chédiak-Higashi syndrome, or leukocyte adhesion defect (LAD). Early loss of primary teeth is seen in other systemic conditions, such as Coffin-Lowry syndrome, Down syndrome, Ehlers-Danlos syndrome types IV and VIII, Hajdu-Cheney syndrome, hyperpituitarism, hyperthyroidism, juvenile diabetes, Papillon-Lefèvre syndrome, progeria, Singleton-Merten syndrome, Langerhans' cell histiocytosis (see Chapter 28), and the leukemias (see Chapter 26).

Dentlearn.ir

ENAMEL HYPOPLASIA

Amelogenesis occurs in three stages. In the first stage, the enamel matrix is secreted by ameloblasts and in the second stage, it undergoes calcification; a final stage of enamel maturation, with crystal growth and removal of water and protein, continues until eruption. Local or systemic factors that interfere with normal matrix formation cause disorders of tooth quantity with enamel surface defects and irregularities termed *enamel hypoplasia*. Factors that interfere with calcification and maturation of the enamel and are disorders of quality are termed enamel *hypocalcification*.

Enamel hypoplasia may be mild and may result in a pitting of the enamel surface or in the development of a horizontal line across the enamel of the crown. If ameloblastic activity has been disrupted for a long period, gross areas of irregular or imperfect enamel formation occur. Generalized enamel hypoplasia is often seen as a component of many syndromes.

Postnatal hypoplasia of the primary teeth is probably as common as hypoplasia of the permanent teeth, although the former usually does not occur in as severe a form. The hypoplasia of the primary enamel that occurs prior to birth is less common and usually arises from complications of premature birth (Fig. 3-11). In its mildest form, a prenatal disturbance is reflected as an accentuated neonatal ring in the primary tooth. In the severe type of neonatal disturbance, enamel formation is sometimes arrested at birth or during the neonatal period (Fig. 3-12). Postnatal amelogenesis is confined to the portion of the crown located cervically from the enamel area present at birth (Fig. 3-13).

Seow and colleagues have observed that enamel hypoplasia of the primary teeth is common in prematurely born, very-low-birthweight children; its pathogenesis is not understood clearly,[27] but it is likely to occur due to neonatal hypocalcemia or hypoxia. An important local

bation, which usually results in localized enamel hypoplasia involving only the left maxillary anterior teeth. Slayton and colleagues examined 698 well-nourished and healthy children from 4 to 5 years of age and found that 6% had at least one primary tooth with enamel hypoplasia.[28]



Figure 3-11 Prenatal enamel hypoplasia. The medical history revealed that the patient suffered from cerebral palsy as a result of premature birth (gestation, 6 months; birth weight, 2 lb, 5 oz). (Courtesy Dr. Stanley C. Herman.)

HYPOPLASIA RESULTING FROM NUTRITIONAL DEFICIENCIES

Many clinical investigations have been undertaken to determine the relationship between hypoplastic defects of enamel and systemic disabilities. Relatively little importance has been placed on exanthematous fevers, but deficiency states, particularly those related to deficiencies in vitamins A, C, and D, calcium, and phosphorus, can often be related to the occurrence of enamel hypoplasia.

dren who had adequate medical histories, two thirds of the hypoplastic disturbances occurred during infancy (from birth to the end of the first year)[29] (Fig. 3-14). Approximately one third of enamel hypoplasia was found in the portion of teeth formed during early childhood (from 13 to 34 months) (Fig. 3-15). Less than 2% of enamel defects found originated in late childhood (from 35 to 80 months).



Figure 3-12 Neonatal enamel hypoplasia. Only the most cervical parts of the intrinsically stained areas are hypoplastic. The child experienced severe nutritional deficiency during the first month of extrauterine life. (Courtesy Dr. Stanley C. Herman.)

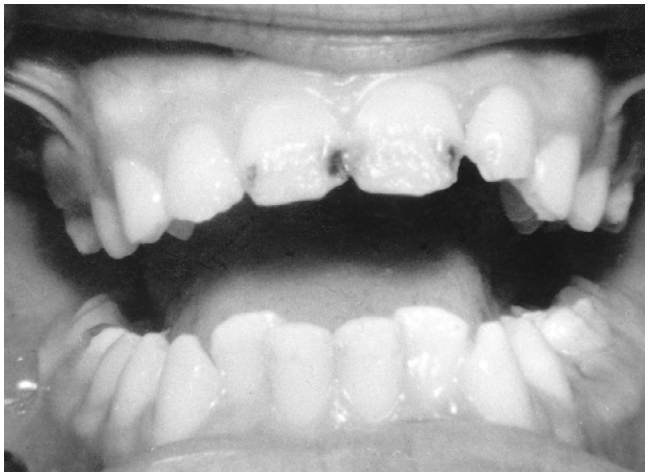

Figure 3-13 Enamel hypoplasia that occurred during infancy. A wide band of pitted enamel is evident on the maxillary and mandibular permanent incisors and first permanent molars. The child was severely affected with pneumonia at 6 months of age. (Courtesy Dr. Stanley C. Herman.)

Dentlearn.ir



Figure 3-14 Enamel hypoplasia that developed as the result of a nutritional deficiency during infancy. The first permanent molars, maxillary central incisors, and mandibular incisors show hypoplastic enamel and dentin.



Figure 3-15 Enamel hypoplasia occurred during early childhood. Enamel formation on the incisal third of the lower incisors and the maxillary central incisors is normal.

Sheldon and colleagues sought to determine whether the defects in enamel were related to the occurrence of systemic ailments.[30] They examined ground sections of 95 teeth from 34 patients for whom detailed medical histories were available. In more than 70% of the individuals, a positive correlation was established between the time of formation of a band of defective enamel and the existence of some systemic disability. However, defects in enamel occurred in 23% of patients who had no history of systemic conditions that might have produced enamel defects. No enamel changes occurred in 6% of patients who had histories of disabilities that had produced enamel changes in other patients. Deficiencies of vitamins A, C, and D, calcium, and phosphorus were the most common causes of defective enamel formation.

Purvis and colleagues, in a study of 112 infants with neonatal tetany, observed that 63 (56%) later showed severe enamel hypoplasia of the primary teeth.[31] Histologic examinations revealed a prolonged disturbance of enamel formation in the 3 months before birth. An inverse relationship was demonstrated between the mean daily hours of bright sunshine in each calendar month and the incidence of neonatal tetany 3 months later. This observation suggested that enamel hypoplasia and neonatal tetany can be manifestations of vitamin D deficiency during pregnancy and are most likely the result of secondary hyperparathyroidism in the mother. A significantly higher mean maternal age and a preponderance of lower social class

In some children a mild deficiency state or systemic condition without clinical symptoms can apparently interfere with ameloblastic activity and can produce a permanent defect in the developing enamel.

HYPOPLASIA RELATED TO BRAIN INJURY AND NEUROLOGIC DEFECTS

Herman and McDonald studied 120 children with cerebral palsy between 2.5 and 10.5 years of age (for whom complete medical records were available) to determine the prevalence of dental hypoplasia, and compared them with 117 age-matched healthy children. [32] They observed enamel hypoplasia in 36% of children with cerebral palsy and in 6% of healthy children. A definite relationship between the time of occurrence of the possible factors that could have caused brain damage and the apparent time of origination of the enamel defect (based on its location in the enamel on the crown of the tooth) was established for 70% of the affected teeth of children with cerebral palsy (see Fig. 3-11). Evidence of enamel hypoplasia is an aid to the clinician and the research worker in determining when brain injury occurred in patients in whom the cause is not clearly defined.

Cohen and Diner observed that enamel defects occurred with greatest frequency in children with low intelligence quotients and a high incidence of neurologic defects.[33] They found that chronologically distributed enamel defects were a valuable aid in neurologic diagnosis because they occur commonly in children with brain damage. In addition, the defects indicate the time of insult to the developing fetus or infant, even when the history is reportedly negative. Martinez and colleagues examined 170 children between 4 and 17 years of age (mean age, 12.03 years) with mental retardation and no history of dental trauma.[34] They found that 37% of these children had dental enamel defects.

HYPOPLASIA ASSOCIATED WITH NEPHROTIC SYNDROME

Oliver and Owings observed enamel hypoplasia in permanent teeth in a high percentage of children with nephrotic syndrome and found a correlation between the time of severe renal disease and the estimated time at which the defective enamel formation occurred.[35] Similarly Koch and colleagues found a high incidence of enamel defects in the primary teeth of children diagnosed with chronic renal failure early in infancy.[36]

HYPOPLASIA ASSOCIATED WITH ALLERGIES

Rattner and Myers discovered a correlation between enamel defects of the primary dentition and the presence of severe allergic reactions.[37] Enamel defects were present in 26 of 45 children with congenital allergies. The enamel

lesions were localized in the occlusal third of the primary canines and first molars.

HYPOPLASIA ASSOCIATED WITH LEAD POISONING (PLUMBISM)

Lawson and Stout observed that in areas of Charleston, South Carolina, where there are very old frame buildings, the incidence of pitting hypoplasia was approximately 100% greater than published standards or the incidence

dentists treating children with unexplained pitting hypoplasia should consider previous exposure to lead as a part of their health evaluation, particularly if the child is from a family in a low economic stratum.

Pearl and Roland have pointed out that the fetus of a mother with lead poisoning can be affected because lead readily crosses the placenta during pregnancy.[39] They observed significant delays in development and eruption of the primary teeth in the child of such a mother. They also listed pica (ingestion of unusual objects to satisfy an abnormal craving) as a common sign of plumbism in children from 1 to 6 years old as well as in their mothers. One mother admitted eating plaster from her apartment walls during several months of pregnancy.

HYPOPLASIA CAUSED BY LOCAL INFECTION AND TRAUMA

Enamel hypoplasia resulting from a deficiency state or a systemic condition will be evident on all the teeth that were undergoing matrix formation and calcification at the time of the insult. The hypoplasia will follow a definite pattern. Individual permanent teeth often have hypoplastic or hypocalcified areas on the crown that result from infection or trauma (Figs. 3-16 and 3-17).

Turner first described this localized type of hypoplasia.[40] He noted defects in the enamel of two premolars and traced the defects to apical infection of the nearest primary molar. Enamel hypoplasia resulting from local infection is called *Turner tooth*.

Bauer concluded, from a study of autopsy material, that the periapical inflammatory processes of primary teeth extend toward the buds of the pertinent permanent teeth and affect them during their prefunctional stage of eruption.[41] The infection fails to stimulate the development of a fibrous wall that would localize the lesion. Instead the infection spreads diffusely through the bone around the buds of the successors and thereby affects the important protective layer of the young enamel, the united enamel epithelium. Bauer found that in some cases the united enamel epithelium was destroyed and the enamel was exposed to inflammatory edema and to granulation tissue. The granulation tissue later eroded the enamel and deposited a well-calcified, metaplastic, cementum-like substance on the surface of the deep excavation.

A traumatic blow to an anterior primary tooth that causes its apical displacement can interfere with matrix formation or calcification of the underlying permanent tooth. The trauma or subsequent periapical infection frequently produces defects on the labial surface of the permanent incisor (Fig. 3-18). The retention of infected primary teeth, even if they are asymptomatic, is unjustifiable.

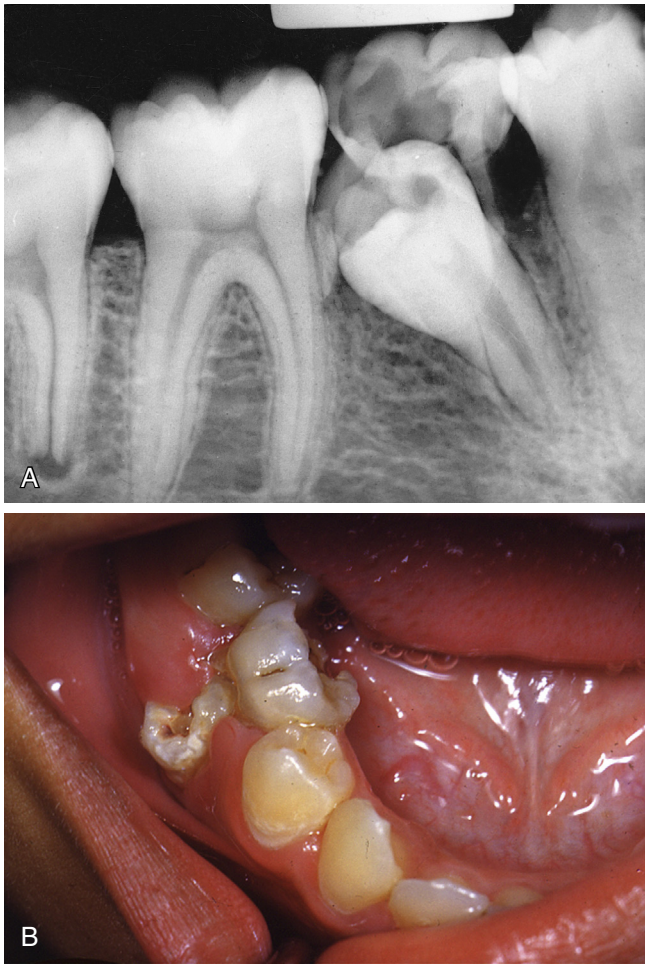

Figure 3-16 **A,** Infected mandibular second primary molar has caused hypoplasia of the second premolar and delayed eruption of the tooth. **B,** Hypoplasia is evident in the occlusal third of the second premolar.

The development of hypoplastic defects on the permanent tooth, its deflection from the normal path of eruption, and even death of the developing tooth may result.

HYPOPLASIA ASSOCIATED WITH CLEFT LIP AND PALATE

Mink studied the incidence of enamel hypoplasia of the maxillary anterior teeth in 98 patients with repaired bilateral and unilateral complete cleft lip and palate; the age of the individuals ranged from 1.5 to 18 years.[42] Among them, 66% with maxillary anterior primary teeth had one or more primary teeth affected with enamel hypoplasia and 92% with erupted maxillary anterior permanent teeth had one or more permanent teeth affected with enamel hypoplasia. Mink concluded that the permanent teeth are in earlier stages of development at the time of the surgical procedure and are more subject to damage. Vichi and Franchi, however, suggested that dental anomalies, including hypoplasia, probably result from multiple causes.[43] They emphasized the difficulty in understanding the role played by genetic factors, postnatal environment, nutrition, and surgical influences in the development of dental anomalies.

Dentlearn.ir

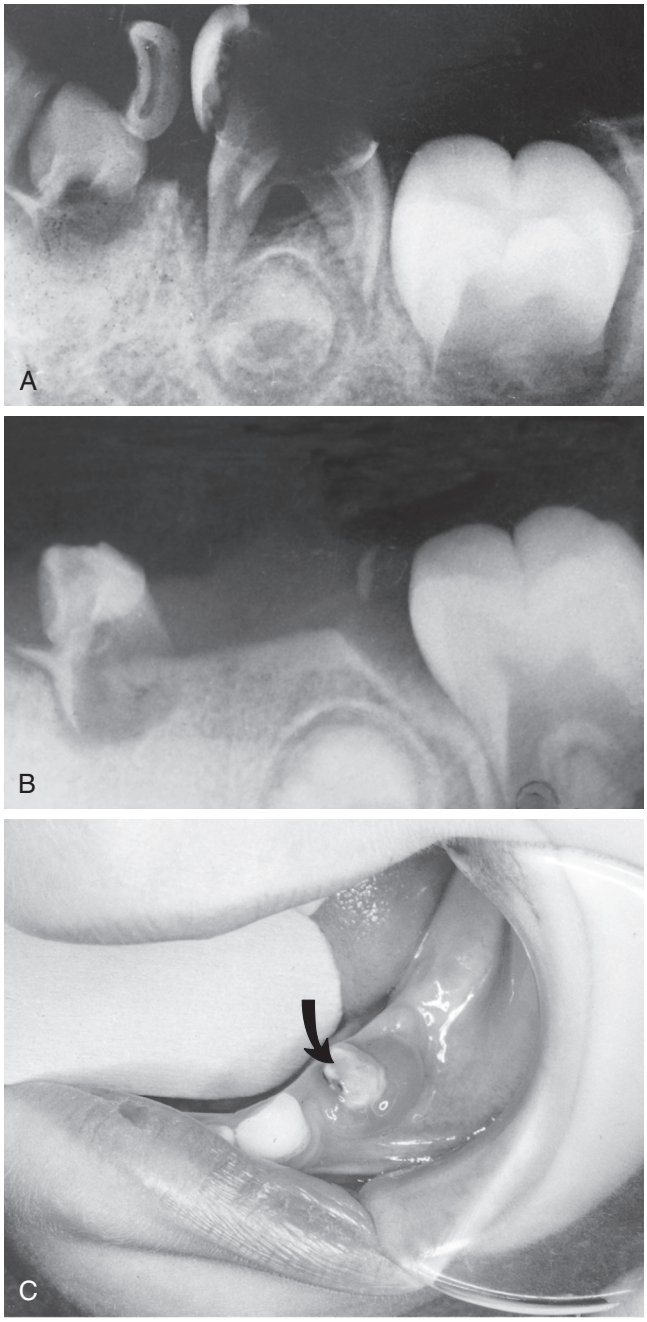

Figure 3-17 **A,** Only a root fragment remains as evidence of a pulpless first primary molar. The infection has affected the development of the first premolar. **B,** The second primary molar has been exfoliated prematurely. The first premolar is malformed as a result of the infection in the area. **C,** The malformed calcified mass *(arrow)* is surrounded by inflamed tissue.

HYPOPLASIA CAUSED BY IONIZING RADIATION AND CHEMOTHERAPY

Numerous dental abnormalities may result in surviving children who receive high-dose radiotherapy and chemotherapy during the time their teeth are forming. Kaste and colleagues reviewed clinical and radiographic records of 423 survivors of acute lymphoblastic leukemia (ALL).[44] Among these patients, they observed root stunting in 24.4%, microdontia in 18.9%, hypodontia in 8.5%, taurodontia in 5.9%, and over-retention of primary teeth in 4%. The patients who were younger than 8 years old at diagnosis or who received cranial irradiation (in addition to chemotherapy) developed more dental abnormalities than those older than 8 years at diagnosis and those who did not receive cranial irradiation. They also noted that the resulting dental defects could affect the survivors' quality of life. The advent of intrathecal chemotherapy has almost eliminated cranial relapse in children with ALL and has reduced the need for cranial irradiation.

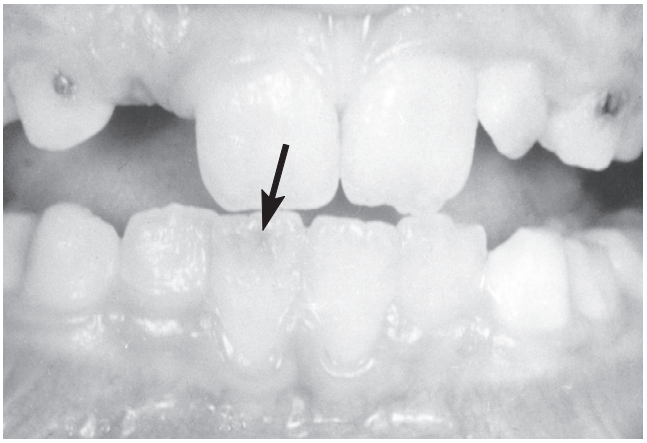

Figure 3-18 Hypoplastic defect on the labial surface of a mandibular permanent central incisor *(arrow)*. There was a history of trauma to the primary tooth.

Maguire and Welbury point out that, as survival rates for children with cancer improve, the emphasis in therapy has moved from saving children at all costs to saving children at the least cost to the child, and therapy protocols are continually reviewed with this goal in mind.[45]

Children who receive high-dose radiotherapy for the treatment of a malignancy are at risk for developing rampant caries in the irradiated area. The main cause is due to reduced or destroyed major salivary gland function.

Ameloblasts are somewhat resistant to x-radiation. However, a line of hypoplastic enamel that corresponds to the stage of development at the time of therapy may be seen (Fig. 3-19). Radiotherapy will have a more severe effect on the development of the dentin, and root formation will be stunted. Occasionally the development of the permanent teeth will be arrested (Fig. 3-20).

HYPOPLASIA RESULTING FROM RUBELLA EMBRYOPATHY

Musselman examined 50 children (average age, 2.5 years) with congenital anomalies attributed to in utero infection with rubella.[46] Enamel hypoplasia was found in 90% of the affected children compared with only 13% of the unaffected children. Tapered teeth also occurred in 78% of the children with a history of rubella (Fig. 3-21). Notched teeth were present in nine of the affected children and none of the unaffected children.

MOLAR-INCISOR HYPOMINERALIZATION (MIH)

It should be noted that interference with dental development at birth, or while the enamel of the permanent first molars and permanent incisors is forming, may result in

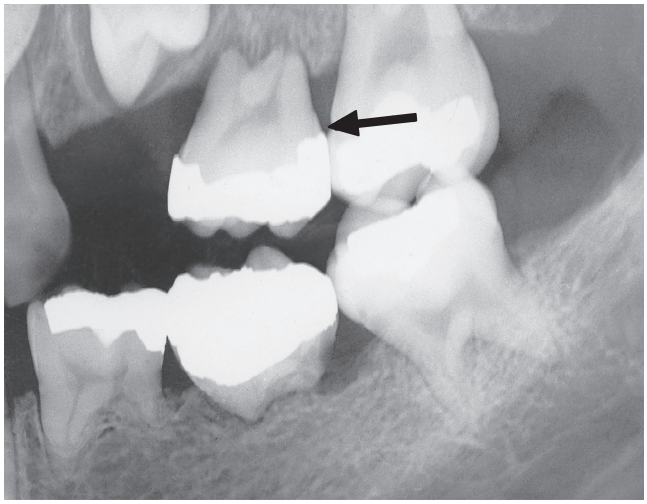

Figure 3-19 X-radiation caused hypoplastic defect on the crown of the first permanent molar *(arrow)* and stunting of root development.



Figure 3-20 Absence of developing premolars and the malformed second permanent molar were caused by excessive x-radiation.

a qualitative effect on the mineralization of one to four of the first permanent molars with or without involvement of the maxillary and mandibular permanent incisors. This has been referred to as molar-incisor hypomineralization (MIH). Although the mechanism(s) remain unclear, possible causes have been reported to include asthma, pneumonia, upper respiratory tract infections, otitis media, antibiotics, dioxins in mother's milk, tonsillitis and tonsillectomy, and exanthematous fevers of childhood.[47]

TREATMENT OF HYPOPLASTIC TEETH

The contention that hypoplastic teeth are more susceptible to dental caries than are normal teeth has little supporting evidence. Carious lesions do develop, however, in the enamel defects and in areas of the clinical crown where dentin is exposed. Small carious and pre-carious areas may be restored with composite resin or a glass ionomer. The restoration is usually confined to the area of involvement. The occlusal third of the first permanent molar often shows gross evidence of hypoplasia, and treatment is necessary before the tooth fully erupts. The most successful restorations for young children are those involving full coverage, namely, stainless steel crowns.

Hypoplastic primary and permanent teeth with large areas of defective enamel and exposed dentin may be



Figure 3-21 The mother of this child had rubella in the eighth week of pregnancy. The primary teeth were tapered and had a rough hypoplastic surface. The child had a patent ductus arteriosus, pulmonary stenosis, and a cognitive disability. There was also a history of difficult feeding and dehydration at 2 months of age. (Courtesy Dr. Robert Musselman.)

sensitive as soon as they erupt. Satisfactory restoration may not be practical at this time. The topical application of fluoride has been found to decrease tooth sensitivity. The application should be repeated as often as necessary to reduce sensitivity to thermal change and acid foods.

HYPOPLASIA CAUSED BY FLUORIDE (DENTAL FLUOROSIS)

Excess ingestion of fluoride can affect ameloblasts during the appositional, calcification, and maturation stages of tooth development, causing the clinical entity called dental fluorosis or mottled enamel. The appearance of enamel affected by excessive fluoride during formation varies considerably. Although the more severe cases of dental fluorosis are associated with a high level of fluoride consumption, there is apparently considerable individual variation. The affected enamel is often limited superficially to the outer 100- to 200-μm layer, with appearance ranging from fine white flecks to brown opaque lesions and/or pitting.

Dental fluorosis is seen most often in permanent teeth, but it has also been observed in primary teeth. Levy and colleagues observed fluorosis of primary teeth in 12.1% of 504 children,[48] most often on second primary molars. The middle of the first year of life seemed to be the most important time with regard to the development of fluorosis in the primary dentition, based on their estimates of fluoride ingested prenatally and during the first year of life in these children. Otherwise, in relation to permanent incisor fluorosis, the exposure to excess fluoride between 18 months and 3 years of age, when the enamel is maturing, is most important. It should be noted that the opacities present are areas of hypomineralization and porosity in the enamel. The surface of newly erupted enamel is subject to abrasion causing pits and stains and is termed posteruptive breakdown.

The existence of a genetic influence on the development of fluorosis is supported by the finding that some

inbred strains of mice are much more susceptible to fluorosis than are other strains that receive the same fluoride dosage under identical conditions. Studies of these differing mouse strains should identify candidate genes for study in human cases of dental and skeletal fluorosis.[49]

ENAMEL MICROABRASION TO REMOVE SUPERFICIAL ENAMEL DISCOLORATIONS

For many years some dentists have advocated the application of hydrochloric acid as an effective method for destaining mottled enamel. McCloskey described a technique, originally advocated by Kane, that used 18% hydrochloric acid on the affected enamel surfaces.[50] Croll has proposed a modified procedure called *enamel microabrasion,* in which a specially prepared abrasive compound (Prema; Premier Dental Products, King of Prussia, Pennsylvania) is applied to the discolored enamel areas, similarly to prophylaxis paste, using a synthetic rubber applicator in a 10:1 gear-reduction handpiece.[51] Frequent rinsing with water and reevaluation of the tooth for color correction are required. The instrumentation is continued until the undesirable coloration is removed or until a noticeable amount of enamel is being removed when the tooth is viewed incisally. Finally the abraded teeth are polished with a fine fluoridated prophylactic paste and given a 4-minute fluoride treatment (Fig. 3-22).

Croll and Helpin have introduced a new delivery system for the microabrasion procedure.[52] A viscous, water-soluble abrasion slurry containing hydrochloric acid and silicon carbide microparticles (Opalustre; Ultradent Products, South Jordan, Utah) is conveniently applied to the tooth surface using a syringe. Bleaching of vital teeth may be used in combination with enamel microabrasion to help remove deeper intrinsic discolorations. (Bleaching is discussed later in this chapter.)

Microabrasion may also be achieved by judicious polishing of the tooth surface with multifluted tungsten carbide burs.

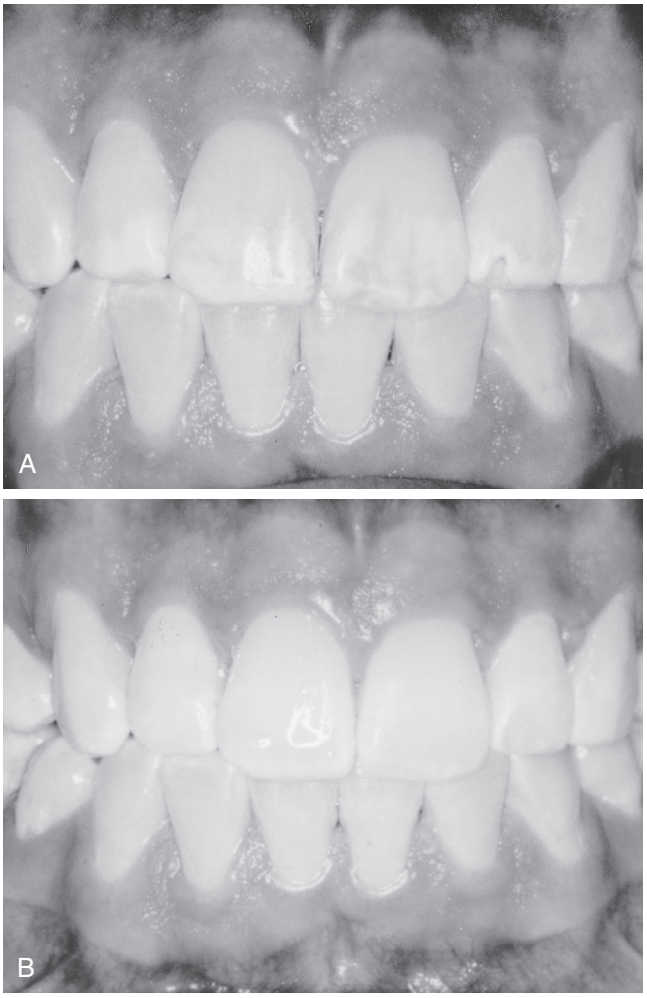

Figure 3-22 **A,** Mottled enamel. Because the brown pigmentation and white splotchy areas were objectionable, the teeth were treated by enamel microabrasion. **B,** Much of the pigment has been removed by enamel microabrasion.

PRE-ERUPTIVE "CARIES" (PRE-ERUPTIVE CORONAL RESORPTION OR PRE-ERUPTIVE INTRACORONAL RADIOLUCENCY)

Occasionally the defects on the crowns of developing permanent teeth are evident radiographically, even though no infection of the primary tooth or surrounding area is apparent (Fig. 3-23). Muhler referred to this condition as pre-eruptive "caries."[53] Such a lesion often does resemble caries when it is observed clinically, and the destructive lesion progresses if it is not restored. As soon as the lesion is reasonably accessible, the tooth should be uncovered by removal of the overlying primary tooth or by surgical exposure. The caries-like dentin is then excavated, and the tooth is restored with a durable temporary or permanent restorative material. In some cases, the lesion may be so extensive that indirect pulp therapy is justified (Fig. 3-24).

Mueller and colleagues reported caries-like, bilateral intra-coronal radiolucencies in mandibular permanent

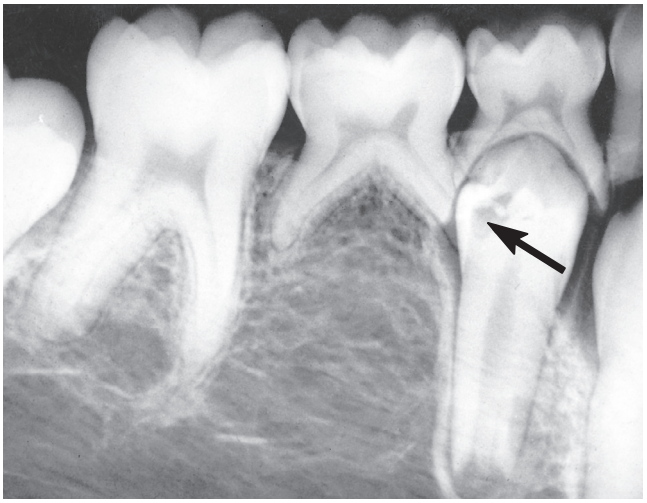

Figure 3-23 Pre-eruptive "caries" on the crown of an unerupted first premolar *(arrow).*

Dentlearn.ir

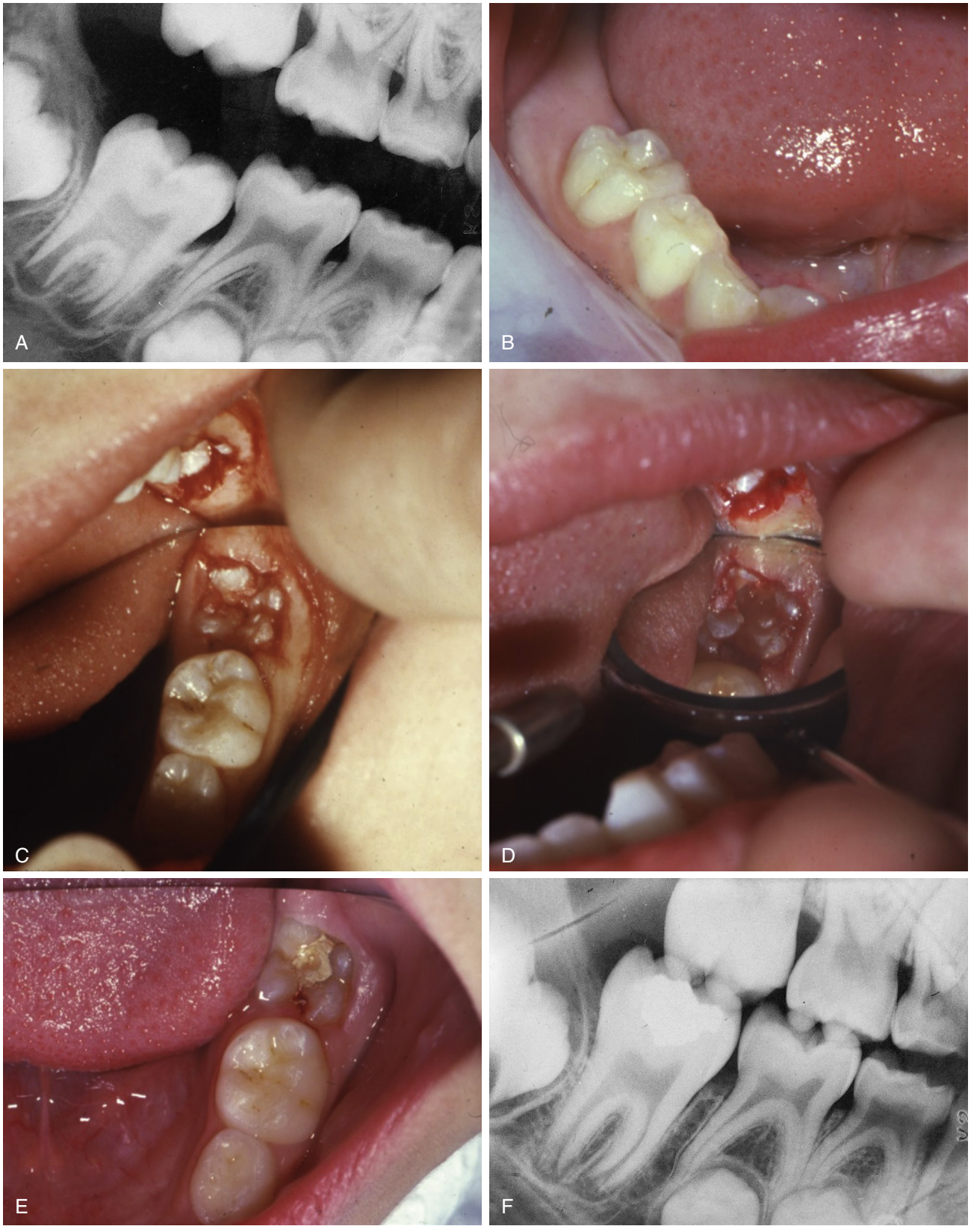

Figure 3-24 **A** and **B,** Pre-eruptive "caries" in a mandibular right first permanent molar that is still unerupted. **C,** Mirror view of the lesion on the occlusal surface of the unerupted tooth. **D,** Mirror view of excavated cavity after gross caries removal. **E,** Mirror view of temporary restoration 1 week postoperatively (dark spot on mesial marginal ridge area is an artifact). **F,** Nine months postoperatively, patient had continued normal root development and eruption of the tooth. The temporary restoration remained 3 months before the tooth was re-entered and restored with amalgam. (Courtesy Drs. George E. Krull and James R. Roche.)

second molars of a 12-year-old patient.[54] Both lesions were successfully treated in a fashion similar to the treatment illustrated in Figure 3-24. Holan and colleagues reported three cases in which similar management of preeruptive tooth defects was successfully performed.[55] Their experience and a review of other reported cases suggest that impacted teeth or teeth delayed in eruption may be at higher risk for developing such lesions.

Seow and associates[56,57] determined the prevalence of pre-eruptive dentin radiolucencies in permanent teeth to be 2% (in 6% of the study population) using bitewing radiographs and 0.5% (in 3% of the study population) using panoramic radiographs. The authors emphasized the importance of careful study of radiographic images of unerupted teeth so that early detection and treatment are possible.

TAURODONTISM

Lysell credits Keith with giving the name to the phenomenon known as *taurodontism*.[58] This anomaly is characterized by a tendency for the body of the tooth to enlarge at the expense of the roots. The pulp chamber is elongated and extends deeply into the region of the roots (Fig. 3-25). A similar condition is seen in the teeth of cud-chewing animals such as the bull (Latin, *taurus*).

Jaspers and Witkop noted that taurodontism is found in about 2.5% of Caucasian adults as an isolated trait as well as in individuals with syndromes such as tricho-dento-osseous syndrome, otodental dysplasia, and X-chromosome aneuploidies.[59] Mena observed a mother and seven children, four of whom showed evidence of taurodontism in the permanent or primary teeth, or both.[60] This was probably the first report of taurodontism of the primary dentition as a definite family trait in children of African heritage. Gedik and Cimen reported taurodontism of six primary molars of a 7-year-old boy who had no syndromes or systemic disease.[61] Other pedigrees have been consistent with autosomal-dominant or autosomal-recessive inheritance. The inheritance may also be polygenic. The clinical significance of the condition becomes apparent only if vital pulp therapy or root canal therapy is necessary.

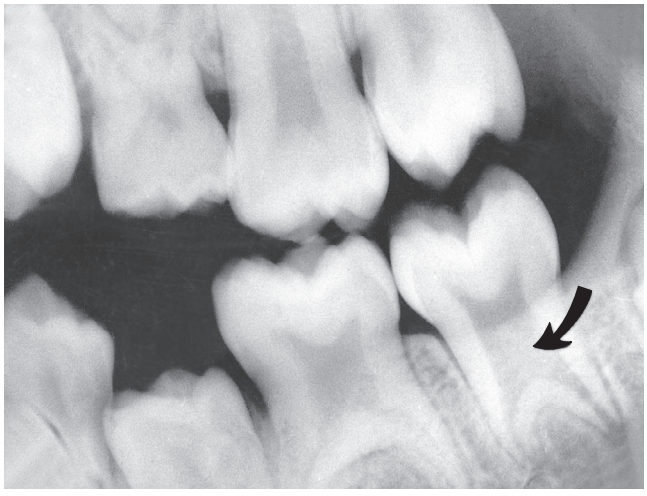

Figure 3-25 Taurodontism. Notice the elongated pulp chamber and short root canals *(arrow)*.

INHERITED DEFECTS OF DENTIN

Two broad categories of heritable dentin defects, dentinogenesis imperfecta and dentin dysplasia, are identifiable, each with distinct subtypes.

DENTINOGENESIS IMPERFECTA (HEREDITARY OPALESCENT DENTIN)

Dentinogenesis imperfecta is inherited as an isolated autosomal-dominant trait ("isolated" in this use means that it occurs without other anomalies). Bixler and colleagues observed this pattern in a six-generation family in which 34 members were studied.[62] There were 100% penetrance and consistent gene expression within a sibship. In a survey of 96,000 Michigan children, Witkop reported a prevalence of 1 in 8000 with the trait.[63] The anomaly may be seen with osteogenesis imperfecta (Fig. 3-26).

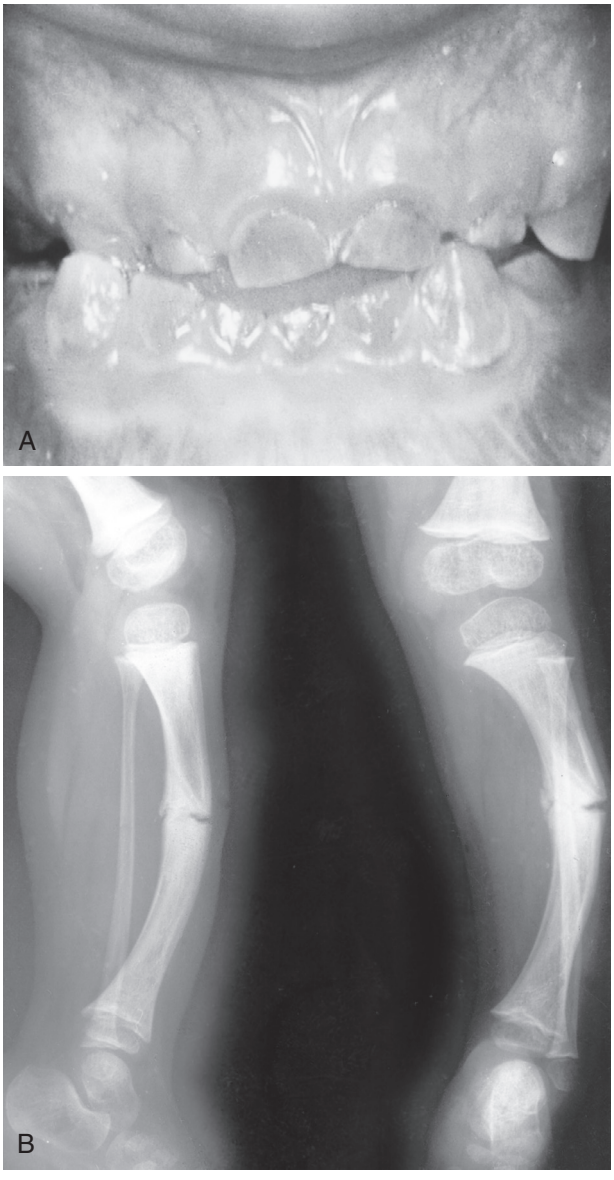

Figure 3-26 **A,** Five-year-old girl with dentinogenesis imperfecta and osteogenesis imperfecta. The child had sustained numerous fractures of the long bones. **B,** A fracture of the tibia is evident in the radiograph.

Dentlearn.ir

A decade later, Witkop suggested that there are two distinct diseases[64] and recommended the terms *dentinogenesis imperfecta* for the disease that occurs in conjunction with osteogenesis imperfecta and *hereditary opalescent dentin* for the disease that occurs as an isolated trait. Shields and colleagues proposed a new classification: (Shields) *type I dentinogenesis imperfecta* and (Shields) *type II dentinogenesis imperfecta*, respectively.[65] In addition, the dentin defects seen in the isolated Brandywine triracial population in southern Maryland were termed (Shields) *type III dentinogenesis imperfecta*. These latter defects consisted of variable expression of the features of (Shields) type I (without osteogenesis imperfecta) and type II, shell-like teeth, and multiple pulp exposures (Fig. 3-27). In this condition, normal dentin formation is confined to a thin layer next to the enamel and cementum, followed by a layer of disorderly dentin containing a few tubules. The roots of shell teeth are short, and the primary teeth may be exfoliated prematurely.

Zhang and colleagues and Xiao and colleagues have found mutations in the *DSPP* gene, which codes for the two major noncollagenous dentin matrix proteins, dentin sialoprotein (DSP) and dentin phosphoprotein (also known as phosphophorin), in patients with (Shields) type II dentinogenesis imperfecta.[66,67] Sreenath and colleagues noted, in the *Dspp* knockout mouse, that the teeth have a widened predentin zone and develop defective dentin mineralization similar in phenotype to that in human (Shields) type III dentinogenesis imperfecta; these findings imply that *Dspp* may also be involved in the latter condition.[68]

The clinical picture of dentinogenesis imperfecta is one in which the primary and permanent teeth are a characteristic reddish-brown to blue-gray opalescent color. Soon after the primary dentition is complete, enamel is worn and often breaks away from the incisal edges of anterior teeth and the occlusal surfaces of posterior teeth. The exposed soft dentin abrades rapidly, occasionally to the extent that the smooth, polished dentin surface is continuous with the gingival tissue (Fig. 3-28). Radiographs show slender roots and bulbous crowns. The pulp chamber is large initially and undergoes obliteration (Fig. 3-29). Periapical rarefaction in the primary dentition is observed only occasionally. However, no satisfactory explanation has been offered, because the condition apparently is not related to pulp exposures and pulpal necrosis. Multiple root fractures are often seen, particularly in older patients. Crowns of the permanent teeth often seem to be of better quality and have less destruction. Occasionally they appear clinically normal



Figure 3-28 Dentinogenesis imperfecta. The primary teeth are severely abraded. Enamel is breaking away from the incisal edge of the lower permanent central incisors.

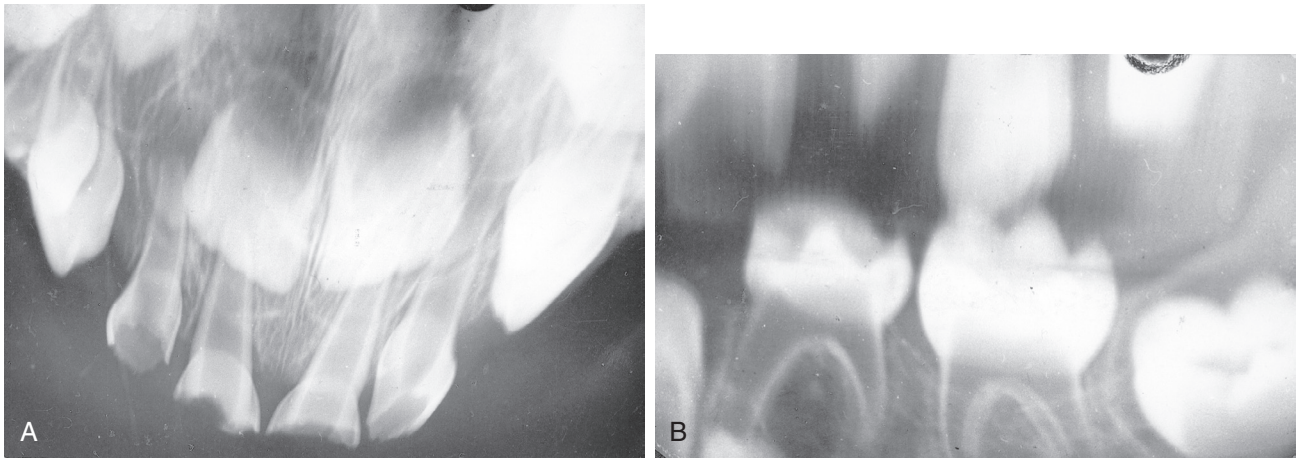

Figure 3-27 Shell teeth. The large size of the pulp cavities indicates the nonexistence of secondary dentin.

Dentlearn.ir

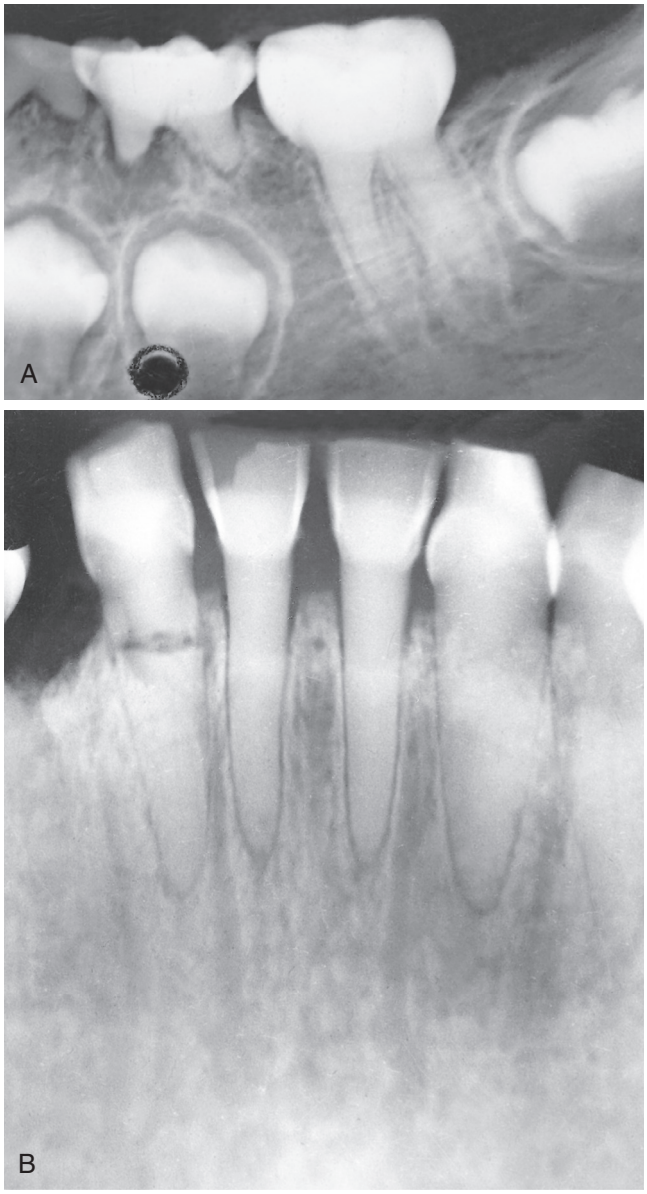

Figure 3-29 **A,** Slender roots with ribbon-like pulp canals and bulbous crowns are characteristic of dentinogenesis imperfecta. The primary molars show periapical rarefaction. **B,** Root fractures are common in older patients.

(Fig. 3-30). There is some evidence of a genotype-phenotype correlation, with Malmgren and colleagues showing one DSPP missense mutation being associated with a more severe phenotype in one family than that seen in another affected family with a different DSPP missense mutation.[69]

The treatment of dentinogenesis imperfecta is difficult in both primary and permanent dentitions. The placement of stainless steel crowns on primary posterior teeth may be considered as a means of preventing gross abrasion of the tooth structure. Full-coverage restorations may be placed on the permanent teeth if the crowns need protection in late adolescence or young adulthood. Bonded veneer restorations on anterior teeth have also been used successfully for aesthetic improvement in patients with

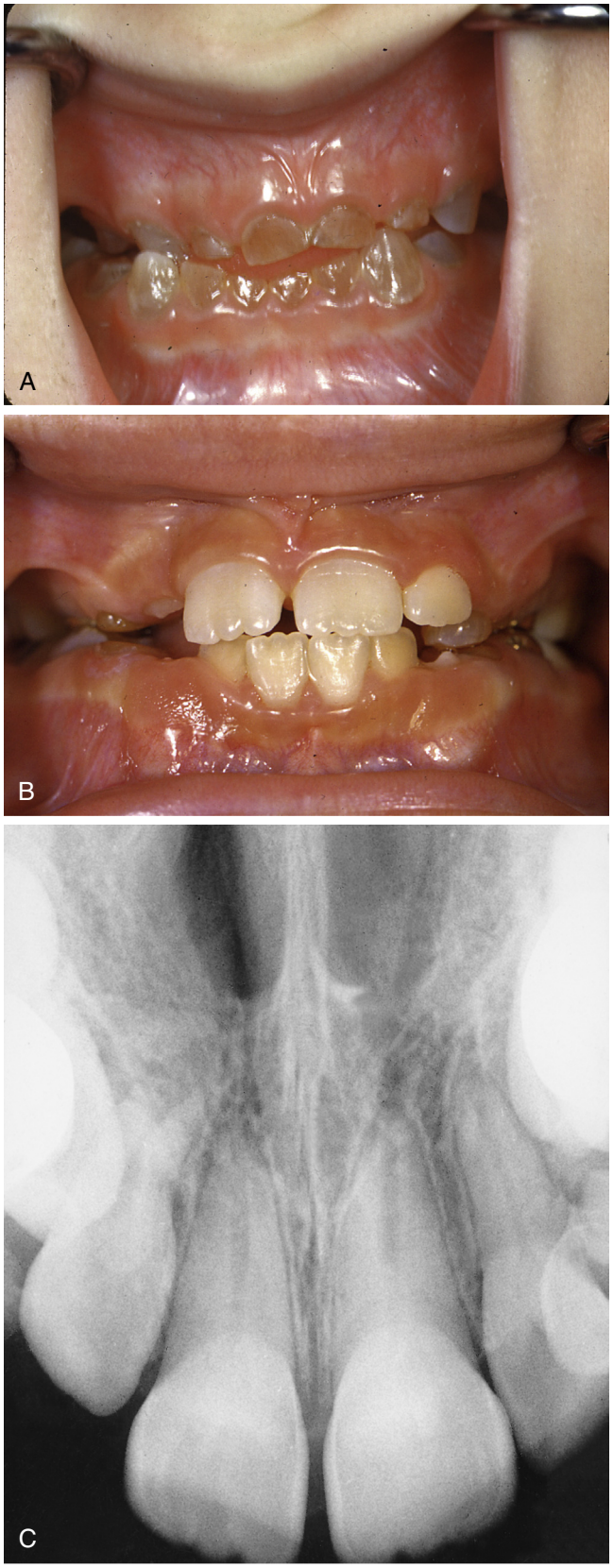

Figure 3-30 **A,** Four-year-old child with dentinogenesis imperfecta. **B,** The permanent teeth, in contrast to the primary teeth, are normal in color. **C,** The radiograph shows typical dentinogenesis imperfecta.

dentinogenesis imperfecta when full-coverage restorations are unnecessary. Unfortunately, the long-term prognosis of these teeth is poor, and, despite best efforts, they are usually lost in early adulthood. A pragmatic approach to treatment planning is required, especially in those patients with osteogenesis imperfecta.

Teeth with periapical rarefaction and root fracture should be removed. Extraction of such teeth is difficult because of the brittleness of the dentin.

DENTIN DYSPLASIA

Dentin dysplasia is a rare disturbance of dentin formation that Shields and colleagues categorized into two types: radicular dentin dysplasia (type I) and coronal dentin dysplasia (type II).[65] Both primary and secondary dentitions are affected in dentin dysplasia type I, which is inherited as an autosomal-dominant trait. Radiographically, the roots are short and may be more pointed than normal. Usually the root canals and pulp chambers are absent except for a chevron-shaped remnant in the crown. The color and general morphology of the crowns of the teeth are usually normal, although they may be slightly opalescent and blue or brown. Periapical radiolucencies may be present at the apices of affected teeth. Investigation of individuals with dentin dysplasia type I associated with extreme microdontia and aberrant crown morphology disclosed homozygosity for a splice-site mutation in the *SMOC2* gene. Since parents and siblings heterozygous for the mutation were not affected, the *SMOC2* gene may not be involved in dentin dysplasia type I without microdontia and aberrant crown morphology.[70] However, it may be involved in the developmental pathway that, with some other alteration, may result in dentin dysplasia type I.

Dentin dysplasia type II is inherited as an autosomal-dominant trait in which the primary dentition appears opalescent and, on radiographs, shows obliterated pulp chambers similar to those in dentinogenesis imperfecta. Unlike dentinogenesis imperfecta, however, in dentin dysplasia type II the permanent dentition has normal color and radiographically exhibits a thistle tube pulp configuration with pulp stones.

Dean and colleagues, noting the phenotypic similarity of dentinogenesis imperfecta, Shields type II, to that in the primary dentition in dentin dysplasia type II, hypothesized that these conditions may be due to different alleles of the same gene.[71] Investigation of a family with 10 of 24 members affected in three generations showed that the candidate region for the dentin dysplasia type II gene overlaps the likely location of the gene for Shields type II dentinogenesis imperfecta. They suggested that a candidate gene for dentinogenesis imperfecta Shields type II and/or III should also be a candidate gene for dentin dysplasia type II. Subsequently, Rajpar and colleagues showed that a DSPP missense mutation was present in a family with dentin dysplasia type II, thereby confirming the hypothesis of Dean and colleagues.[72] Further analysis of the *DSPP* gene in patients with Shields type II dentinogenesis imperfecta or dentin dysplasia type II suggests that these dominant phenotypes result from the disruption of signal peptide processing and/or related biochemical events that interfere with protein processing.[73] This is consistent with the assertion that dentin dysplasia type II and Shields type II dentinogenesis imperfecta are milder and more severe forms, respectively, of the same developmental disease.[74]

AMELOGENESIS IMPERFECTA

As noted in Chapter 5, amelogenesis imperfecta is a developmental defect with a heterogeneous etiology that affects the enamel of both primary and permanent dentition. The anomaly occurs in the general population with an incidence of from 1 in 14,000 to 1 in 16,000. Amelogenesis imperfecta has a wide range of clinical appearances, with three broad categories observed clinically: the hypocalcified type, the hypomaturation type, and the hypoplastic type. Although amelogenesis imperfecta can occur as part of several syndromes, Cartwright and colleagues confirmed that the trait itself could also be associated with a skeletal anterior open bite,[75] although the pathophysiologic relationship between amelogenesis imperfecta and open bite remains unclear.[76]

Progress has been made in unraveling the molecular basis of the myriad clinical forms of amelogenesis imperfecta. Aldred and Crawford discussed the limitations of the existing classification systems and proposed an alternative classification based on the molecular defect, biochemical result, mode of inheritance, and phenotype.[77] They proposed two separate phenotypes, namely, enamel that is predominantly hypoplastic (i.e., enamel that is either uniformly thin, with spacing between adjacent teeth, or irregular, giving rise to pits or grooves) or predominantly hypomineralized (i.e., with soft, poorly formed enamel with altered color and translucency). Hart and colleagues recommended a standardized nomenclature for describing amelogenesis imperfecta that causes alterations at the genomic, complementary DNA, and protein levels.[78,79] Two clinically distinct forms of autosomal-dominant amelogenesis imperfecta—smooth hypoplastic amelogenesis imperfecta and local hypoplastic amelogenesis imperfecta—are associated with mutations in the enamelin (ENAM) gene located at 4q21. In addition, autosomal-dominant amelogenesis imperfecta can be associated with mutation in the Kallikrein-4 (KLK4) gene, and autosomal-recessive pigmented hypomaturation amelogenesis imperfecta with an enamelysin (MMP-20) gene mutation, illustrating the heterogeneity of the condition. An X-linked form (AIH1) has been found to be associated with as many as 14 mutations in the amelogenin (AMELX) gene, located at Xp21.[80] However, at least one family has had the trait linked to another location on chromosome Xq22-q28.[81]

The defective tooth structure is limited to the enamel. On radiographic examination, the pulpal outline appears to be normal, and the root morphology is that of normal teeth. The difference in the appearance and quality of the enamel is thought to be attributable to the state of enamel development at the time the defect occurs. In the hypoplastic type, the enamel matrix appears to be imperfectly formed; although calcification subsequently occurs in the matrix and the enamel is hard, it is defective in amount and has a roughened, pitted surface (Fig. 3-31). In the

Dentlearn.ir



Figure 3-31 Both the primary and permanent teeth are affected by the hereditary anomaly amelogenesis imperfecta. The enamel is pitted but hard.



Figure 3-32 Hypocalcification type of amelogenesis imperfecta. The primary teeth were similarly affected. The enamel surface is soft.

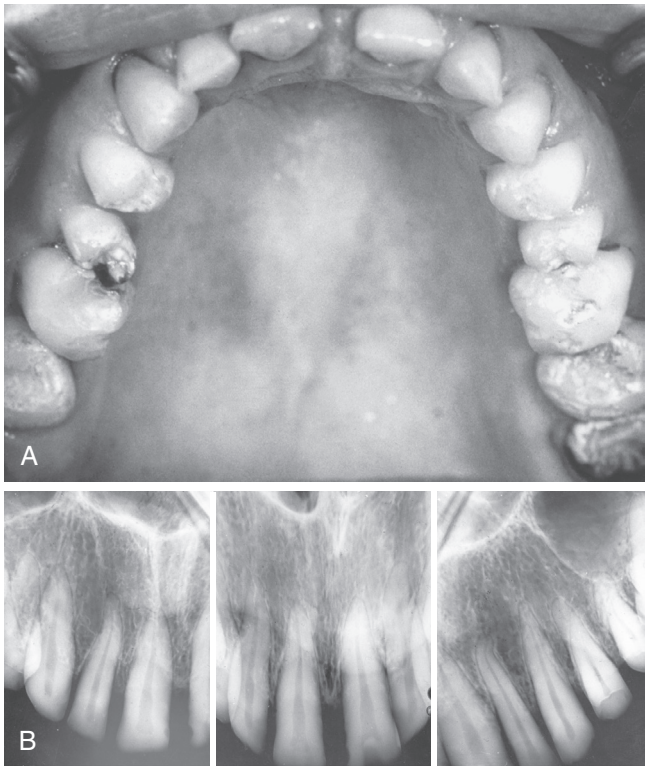

Figure 3-33 **A**, Case diagnosed as amelogenesis imperfecta. The permanent teeth have a thin covering of pigmented enamel. **B**, The radiographs show essentially normal root morphology. The crowns have a thin covering of enamel.

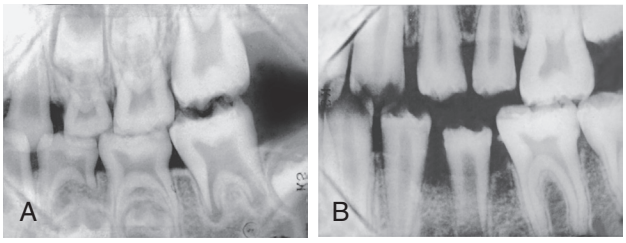

Figure 3-34 **A** and **B,** Left bite-wing radiographs of a patient with amelogenesis imperfecta. Radiograph in **B** was made 6 years after radiograph in **A** and demonstrates the maintenance of a caries-free dentition despite the thin enamel.

hypocalcified type, matrix formation appears to be of normal thickness, but calcification is deficient and the enamel is soft (Fig. 3-32). In both of these more common types of the defect, the enamel becomes stained because of the roughness of the surface and increased permeability.

In still another variant of amelogenesis imperfecta, a thin, smooth covering of brownish-yellow enamel is present. In this type, the enamel does not seem excessively susceptible to abrasion or caries (Figs. 3-33 and 3-34).

Congleton and Burkes reported three cases of amelogenesis imperfecta in which the patients also demonstrated taurodontism.[82] Others have identified cases with the clinical appearance of amelogenesis imperfecta and taurodontism along with strikingly curly hair and increased bone density (especially of the skull), which has been identified as trichodento-osseous syndrome (TDO). Seow has suggested that some cases reported as amelogenesis imperfecta with taurodontism were actually cases of TDO syndrome.[83] Price and colleagues found that this autosomal-dominant condition is caused by a mutation in the distal-less homeobox gene *DLX3*.[84] Even though the taurodontism and amelogenesis imperfecta traits in this condition are fully penetrant in affected individuals, the osseous and hair features are variably expressed even when the same deletion is present in a family—findings that indicate that the variable expression is influenced by other genes and/or environmental factors, although further studies by Price and colleagues indicated that TDO syndrome and amelogenesis imperfecta of the hypomaturation-hypoplastic type with taurodontism are two genetically distinct conditions.[85] Dong and colleagues found that a mutation within the *DLX3* gene homeodomain is associated with amelogenesis imperfecta (hypoplastic-hypomaturation type) with taurodontism (AIHHT). Because a DLX3 mutation outside the homeodomain is associated with TDO syndrome, they suggested that TDO and some forms of AIHHT are allelic.[86]

Amelogenesis imperfecta may also be associated with nephrocalcinosis syndrome, also called enamel-renal syndrome or Lubinsky syndrome. Inheritance appears to be autosomal-recessive. In addition to hypoplastic enamel, the teeth often fail to erupt and undergo resorption due to the disappearance of the reduced enamel epithelium. Histopathology of the gingiva, which may be enlarged, reveals islands of odontogenic calcification.[87,88] Nephrocalcinosis may be the cause of renal impairment but only rarely end-stage renal failure, unless complicated by renal stones and recurrent infections.[89] Since nephrocalcinosis is often asymptomatic and can be associated with impaired renal function, dentists who see children with generalized and thin hypoplastic amelogenesis imperfecta should consider a renal ultrasound scan and referral to a nephrologist, if appropriate. Conversely, children with nephrocalcinosis should also be considered for a dental referral.[88]

The treatment of teeth with amelogenesis imperfecta–like defects depends on the severity of the condition and the demands for aesthetic improvement. When indicated, the teeth can be prepared for full-coverage restorations. For some cases of the hypoplastic types, bonded veneer restorations may offer a more conservative alternative for the management of the aesthetic problem of the anterior teeth. Patel and colleagues have reported successful treatment with porcelain laminate veneer restorations.[90]

ENAMEL AND DENTIN APLASIA

Teeth with characteristics of both dentinogenesis imperfecta and amelogenesis imperfecta have been reported. Chaudhry and colleagues reported such a case and called the condition *odontogenesis imperfecta*.[91] Schimmelpfennig and McDonald observed a similar dentition and termed it *enamel and dentin aplasia*.[92] The primary teeth were essentially devoid of enamel, and the smooth, severely abraded dentin was reddish-brown. Radiographs showed normal alveolar bone around the roots of the teeth. Two teeth had pulp exposure and pulpal degeneration (Fig. 3-35). Radiolucent areas were present at the apices of the two primary teeth, with exposed and degenerated pulps. The pulp chambers and canals in all the primary teeth were extremely large, with no evidence of becoming obliterated. In ground sections of the primary teeth, the dentinal tubules showed little evidence of a normal growth pattern. They were few and irregular, with a tendency toward branching. The cementum appeared normal and was acellular. No evidence of secondary dentin formation was found. A few fragments of enamel adhering to the dentin appeared thinner than normal, and few normal morphologic characteristics were present. The dentinoenamel junction was atypical in that it lacked the characteristic scalloping.

The permanent teeth, when they erupted, were partially covered with a thin, gray, poorly coalesced coating of enamel. Brown dentin could be seen on the labial aspect of the central incisors and at the bases of the fissures of the first permanent molars. Stainless steel crown restorations were placed even before complete eruption to protect the teeth from continued abrasion.

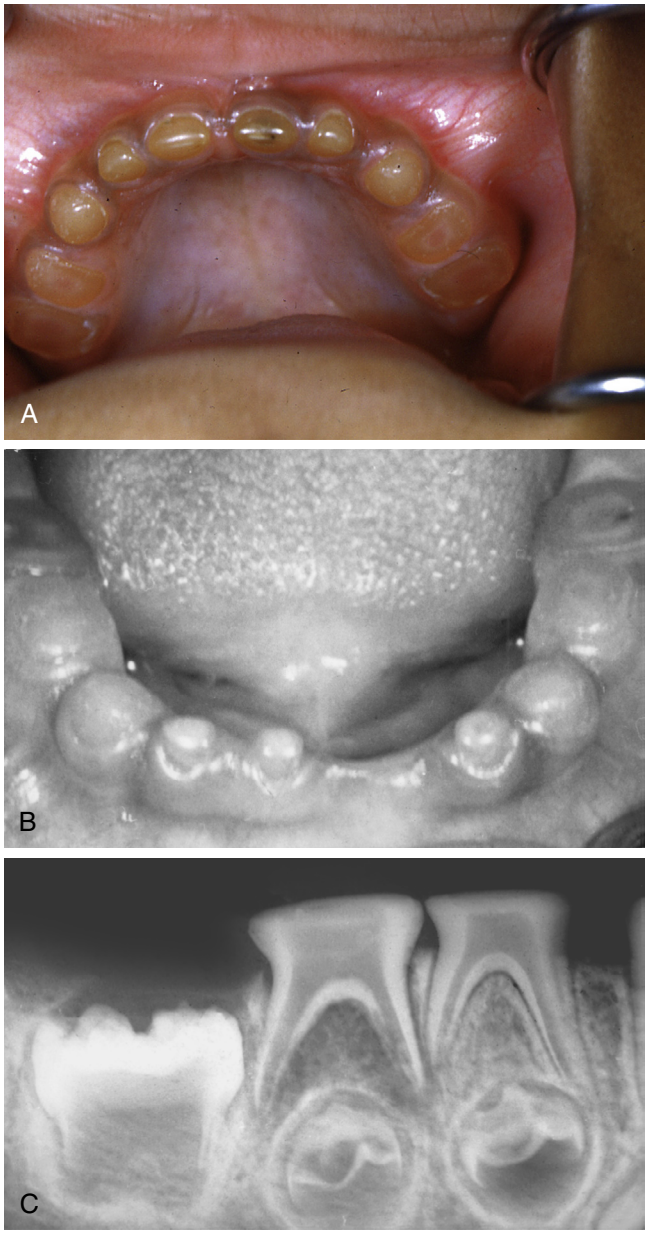

Figure 3-35 **A** and **B,** Severely abraded teeth are almost entirely devoid of enamel. The outline of a large pulp chamber can be seen through a thin covering of dentin. The mandibular second primary molars have pulp exposure. **C,** Radiograph shows large pulp canals and large pulp chambers. Apical rarefaction is associated with pulp exposure of the second primary molar.

AGENESIS OF TEETH

ANODONTIA

Anodontia (i.e., complete failure of the teeth to develop) is rare. Although agenesis of primary and/or permanent teeth is often referred to as *congenital absence,* such teeth would not, of course, be expected in the oral cavity at birth unless they are natal teeth. Gorlin and colleagues noted that, when agenesis occurs as an isolated (nonsyndromic) trait, the primary dentition is not affected, and

Dentlearn.ir

the inheritance is autosomal-recessive.[93] Although dental anomalies, including hypodontia and oligodontia, can occur in many types of ectodermal dysplasia,[94] anodontia is unusual. However, anodontia or oligodontia may be a part of the ectodermal dysplasia also affecting the skin, hair, and nails, called odonto-onycho-dermal dysplasia (OODD), which can be caused by homozygous or compound heterozygous mutations in the *WNT10A* gene.[95,96] Mutations in *WNT10A* are also a significant cause of isolated (nonsyndromic) hypodontia.[97] Thus other factors and/or differences in the specific mutation of the gene can result in syndromic or nonsyndromic selective or complete dental agenesis.

Swallow reported on an 11-year-old boy who had a complete primary dentition but no permanent dentition.[98] Schneider also observed a 7-year-old white female with primary teeth but missing permanent teeth.[99] As is usually the case with presumed autosomal-recessive inheritance, the hereditary background included no known consanguinity in the family or history of anodontia or ectodermal dysplasia in either the maternal or paternal lineage. Although consanguinity increases the likelihood that recessive traits or conditions will be expressed, most affected individuals do not have a family history of inbreeding. An overlay denture, which is often the treatment of choice, was constructed for the patient. A comparable situation is shown in Figure 3-36. Laird reported a similar patient in whom a complete primary dentition was present, but the only permanent teeth were maxillary first permanent molars.[100] Witkop studied two families in which both parents had peg-shaped or missing maxillary lateral incisors, which is an autosomal-dominant trait with incomplete penetrance and variable expressivity, and concluded that agenesis of the permanent teeth can be an expression of the homozygous state of that gene.[101] This hypothesis is also supported by the findings reported by Hoo.[102]



Figure 3-36 A complete primary dentition without evidence of permanent teeth in a 14-year-old girl.

HYPODONTIA (OLIGODONTIA)

Agenesis of some (fewer than 6) teeth (not including the third molars) is referred to as *hypodontia*. The term *partial anodontia* should not be used. *Oligodontia* is used to describe conditions when more than 6 permanent teeth do not develop. Hypodontia is usually familial, although it may occur sporadically (without a family history of hypodontia). It may also be found as part of a syndrome, especially in one of the ectodermal dysplasias, although it usually occurs alone (isolated). Note that *isolated* in this usage means not occurring as part of a syndrome; it may still be familial.

Any of the 32 permanent teeth may be missing. However, there is a propensity for the last tooth in each series to be absent, namely, third molars, mandibular second premolars, maxillary lateral incisors, maxillary second premolars, and mandibular central incisors. This order of frequency has been confirmed in studies by Glenn[103] and by Grahnen.[104] The absence of teeth may be unilateral or bilateral. Glenn observed, during an examination of 1702 children, that 5% had a missing permanent tooth other than a third molar.[103] In 97% of the children, the formation of the second premolar could be detected radiographically at 5.5 years of age and that of the lateral incisor at 3.5 years of age. The most preserved permanent teeth are the maxillary central incisors, the first molars, and the canines.

In addition to the already mentioned autosomal-dominant hypoplasia or agenesis of the maxillary lateral incisors, Vastardis and colleagues found the absence of second premolars in one family showing an autosomal-dominant pattern of inheritance to be caused by a mutation in the *MSX1* gene located at 4p16.1.[105] Hypodontia associated with a heterozygous mutation in the *MSX1* gene, with or without an orofacial cleft, has been referred to as type STHAG1 (selective tooth agenesis 1). Ahmad and colleagues demonstrated that hypodontia inherited in an autosomal-recessive mode and associated with malformation of teeth, enamel hypoplasia, and failure of eruption could be linked to 16q12.1.[113] This type of selective tooth agenesis has been referred to as type STHAG2. Further evidence for the genetic heterogeneity of hypodontia is provided by the finding of a frameshift mutation (resulting in premature termination of translation and a shortened protein) in the human *PAX9* gene in a large family with autosomal-dominant oligodontia.[106] This type of selective tooth agenesis has been referred to as type STHAG3. Hypodontia secondary to the WNT10A mutations already mentioned is referred to as type STHAG4, which is linked to 10q11.2-q21 from analysis of a large Chinese family with dental agenesis ranging from hypodontia to anodontia, and is referred to as "He-Zhao deficiency."[107] STHAG6 oligodontia is caused by an apparently autosomal-recessive mutation in the *LTBP3* gene.[108] Mutations in the X-linked *EDA* gene can cause nonsyndromic oligodontia

Dentlearn.ir

or hypodontia (STHAGX1),[109] or hypohidrotic ectodermal dysplasia,[110] generally affecting males more severely in either case. Animal models of X-linked hypohidrotic ectodermal dysplasia secondary to EDA mutation, including canine models, have shown that postnatal intravenous administration of soluble recombinant EDA significantly corrected the development of the adult teeth, and positively affected other components of the condition.[111] Clinical trials with postnatal intravenous administration of soluble recombinant EDA in humans are in progress.

There are more than 200 syndromes, including many of the ectodermal dysplasias, in which tooth agenesis may be a major feature. Dental agenesis may be associated with other dental anomalies, such as small and short crowns and roots of the teeth that are present, conical crowns, enamel hypoplasia, taurodontism, delayed eruption, prolonged retention of primary teeth, infraocclusion of primary teeth, ectopic eruption, transposition, lack of alveolar bone, reduced vertical dimensions, increased overbite, and tooth impaction (particularly palatally displaced canines).[117]

HYPODONTIA AND PALATALLY DISPLACED CANINES

Impacted or palatally displaced canines occur in 85% of cases with a lack of permanent maxillary canine eruption. In the other 15%, the canines are "ectopic" (buccal). Palatally displaced canines are not typically associated with dental crowding. Palatally displaced canines are frequently, but not always, found in dentitions with various anomalies. These include small peg-shaped or missing maxillary lateral incisors, hypodontia involving other teeth, dentition spacing, and dentitions with delayed development.[118] There is greater likelihood of a palatally displaced canine on the same side of a missing or small maxillary lateral incisor, emphasizing a local environmental effect.[119] There are also cases in which a canine is palatally displaced without an apparent anomaly of the maxillary lateral incisors, and cases in which there are missing lateral incisors without palatal displacement of a canine. Adding to the complexity is the heterogeneity found in studies of cases of both buccally[120] and palatally displaced canines.[119] Wherease the canine eruption theory of guidance by the lateral incisor root cannot explain all instances of palatally displaced canines, it does seem to play a role in some cases.[121]

Maxillary canine impaction or displacement is labial/buccal to the arch in 15% of cases of maxillary canine impaction and, in contrast to palatal displacement associated with small maxillary teeth,[122] is often associated with dental crowding. Because there are various degrees of genetic influence on these anomalies, there has been some discussion about palatally displaced canines themselves also being influenced by genetic factors to some degree. With apparent genetic and environmental factors playing various roles in these cases, the etiology appears to be multifactorial.[123] This is supported by the occurrence of palatally displaced canines occurring in a higher percentage within families than in the general population. Generally, the phenotype is the result of some genetic influences (either or both directly or indirectly, e.g., through a primary effect on development of some or all of the rest of the dentition) interacting with environmental factors. Some of these cases may be examples of how primary genetic influences (which still interact with other genes and environmental factors) affect a phenotypic expression that is a variation in a local environment, such as the physical structure of the lateral incisor in relation to the developing canine.

HYPODONTIA (OLIGODONTIA) AND CANCER

Recently it has been determined that hypodontia may be an indicator of susceptibility to the development of cancer. A striking example of this was reported in a Finnish family in which oligodontia and colorectal cancer were associated with each other and with autosomal-dominant inheritance. The oligodontia and cancer predisposition were caused by a nonsense mutation in the *AXIN2* gene, a Wnt-signaling regulator. Colorectal cancer or precancerous lesions in the family were found only in association with oligodontia and the *AXIN2* mutation, and affected all those of the oldest generation who had the mutation. A different type of de novo mutation (frameshift) in the same gene was found in an unrelated young patient with oligodontia. Both mutations are expected to inactivate the AXIN2 protein function, leading to an increase in Wnt signaling, which may lead to cancer development. This change in AXIN2 protein function also clearly changes the network signaling involved in dental development.[124] Another report found a heterozygous nonsense mutation in *AXIN2* in a three-generation family with autosomal-dominant oligodontia variably associated with colon or gastric polyps, early-onset colorectal and/or breast cancer, and sparse hair and eyebrows.[125]

Further support for the proposition that hypodontia can be developmentally associated with cancer comes from a University of Kentucky report that women with epithelial ovarian cancer (EOC) are 8.1 times more likely to have hypodontia than are women without EOC. In contrast to the oligodontia reported with the specific mutations in the *AXIN2* gene, the severity of hypodontia was in the Kentucky study, with one or two teeth being agenic. Maxillary lateral incisors followed by second premolars were the most frequently affected.[126] In addition, a similar study from Slovenia found a prevalence of hypodontia of 19.2% in women with EOC, and 6.7% in women in the control group. The mean number of missing teeth for women with EOC and women in the control group was 0.6 and 0.1, respectively, and the most frequently affected teeth were lateral incisors, respectively.[127] Sequence analysis of the *MSX1*, *PAX9*, *AXIN2*, *EDA*, *WNT10A*, *BARX*, and *BRCA1* genes from the DNA from participants in the University of Kentucky study led to a conclusion that one half of the dually affected patients had an independent causation of the two conditions, thus significantly reducing the previously estimated ovarian cancer risk for women with congenital tooth agenesis.[128] A study of self-reported family cancer history and analysis of 14 DNA markers in the *AXIN2*, *FGF3*, *FGF10*, and *FGFR2* genes in Brazilian individuals with dental agenesis showed that individuals with tooth agenesis had an increased risk of having a

Dentlearn.ir

family history of cancer (p = 0.00006; OR = 2.7; 95% CI, 1.6-4.4). Tooth agenesis was also associated with variants in the genes studied. It should be noted that although the conglomerate self-reported family history of cancer was significant, a breakdown of types of cancer by "type" (organ or body location) found only brain and nervous system, breast, and prostate to be significant for probands with hypodontia.[129] There was a family history of ovarian cancer in one individual with hypodontia and in one control individual, so there was no significant difference. Although the small number suggests a question of power to exclude this or other types, it does indicate that the risk of ovarian cancer is relatively small if it is associated with hypodontia. These findings are an example of how changes in the protein products of genes can have pleiotropic effects on different parts of the body at different times. Future studies of the family history and genotypes of individuals with hypodontia will help illustrate the potential relative risk of cancer development in individuals or family members with hypodontia compared with that in the general population.

ECTODERMAL DYSPLASIAS

Developmental agenesis of primary teeth is relatively rare. When several primary teeth fail to develop, other ectodermal deficiencies are usually evident. There are more than 170 types of ectodermal dysplasia with various anomalies of ectodermal derivatives, including both primary and permanent teeth, hair, nails, and skin. Children with missing primary and permanent teeth may have some or all of the signs of a type of ectodermal dysplasia and should undergo further evaluation.[130]

One of the more common types of ectodermal dysplasia is X-linked recessive hypohidrotic ectodermal dysplasia (XLHED), also called anhidrotic ectodermal dysplasia and Christ-Siemens-Touraine syndrome. A rare autosomal-recessive form also occurs that is clinically indistinguishable from XLHED. Hypodontia and dental hypoplasia, as well as hypotrichosis, hypohidrosis/anhidrosis, and asteatosis, are characteristic of XLHED. Secondary characteristics include a deficiency in salivary flow, protuberant lips, and a saddle-nose appearance. The skin is often dry and scaly, and there is fissuring at the corners of the mouth. As already noted, mutations in the *EDA* gene have been found in most patients with XLHED.[131]

Because the absence of teeth predisposes the child to a lack of alveolar process growth, the construction of dentures is complicated. However, as might be expected in at least most types of ectodermal dysplasia, skeletal structures are normal. Serial lateral cephalograms obtained during childhood and adolescence have shown that the sagittal development of the jaw is essentially normal. A deficiency in sweat glands predisposes to increased body temperature, and children with hypohidrosis/anhidrosis are extremely uncomfortable during hot weather. Many of them must reside in cool climates. Children with ectodermal dysplasia usually have normal mental capacity and a normal life expectancy. Consanguinity increases the likelihood of expression of an inherited recessive trait or condition (Fig. 3-37) and may be one way a female with a normal karyotype can be affected.

The primary teeth that are present may be normal or reduced in size. The anterior teeth are often conical, which is characteristic of oligodontia associated with many types of ectodermal dysplasia. The primary molars without permanent successors have a tendency to become ankylosed.

The many types of ectodermal dysplasia with different modes of inheritance can be emphasized by describing a "tooth and nail" type of autosomal-dominant ectodermal dysplasia, also called *Witkop syndrome*, reported by Giansanti and associates.[132] This ectodermal dysplasia is characterized by hypoplastic nails and hypodontia. An *MSX1* gene mutation different from that found when only hypodontia is present has been reported by Jumlongras and colleagues in a family with tooth and nail syndrome.[133] In contrast to most nonsyndromic hypodontias, in which premolars and maxillary lateral incisors (excluding third molars) are most often missing, the mandibular incisors, second molars, and maxillary canines are most frequently absent. Overall, the teeth are generally not affected to the extent seen in XLHED, and there is little involvement of the hair and sweat glands.[134]

For children with a large number of missing primary teeth, partial dentures can be constructed at an early age; 2- and 3-year-old children have successfully worn partial dentures. Their ability to masticate food increases, and their nutritional status may improve. A partial denture can be adjusted or remade at intervals to allow for the eruption of permanent teeth. Denture construction at an early age may also reduce the psychological problem of the child's feeling "different" (Fig. 3-38).

If the permanent teeth erupt in good position and in favorable relationship to each other, partial dentures may serve until the child is old enough for implants or a fixed partial denture (described in Chapter 24). Orthodontic and surgical procedures may be necessary before the prosthodontic treatment, however.

Bonding techniques have improved clinicians' ability to provide aesthetic interim restorations and greater function for patients with conical teeth with or without oligodontia or hypodontia. Nunn and colleagues published a series of five papers (monthly, beginning in the March 2003 *British Dental Journal*) that outline the management of patients with hypodontia by a coordinated interdisciplinary team of dentists and demonstrate the advantages of this approach.[135] Several dental specialties are represented on the team. Ideally, the initial responsibility for oversight and coordination of the patient's care begins in infancy with the services of a pediatric dentist. As the patient grows and develops through puberty, a general family practitioner may assume the oversight and coordination responsibilities.

When maxillary lateral incisors are missing, the clinician must analyze the occlusion and arches carefully to determine whether there is sufficient room within the arch to maintain space and to provide fixed bridgework. If space for a normal-sized lateral incisor replacement is insufficient, the clinician may sometimes choose to move the canine forward into the lateral position and reshape it to appear more like a permanent lateral incisor.

Dentlearn.ir

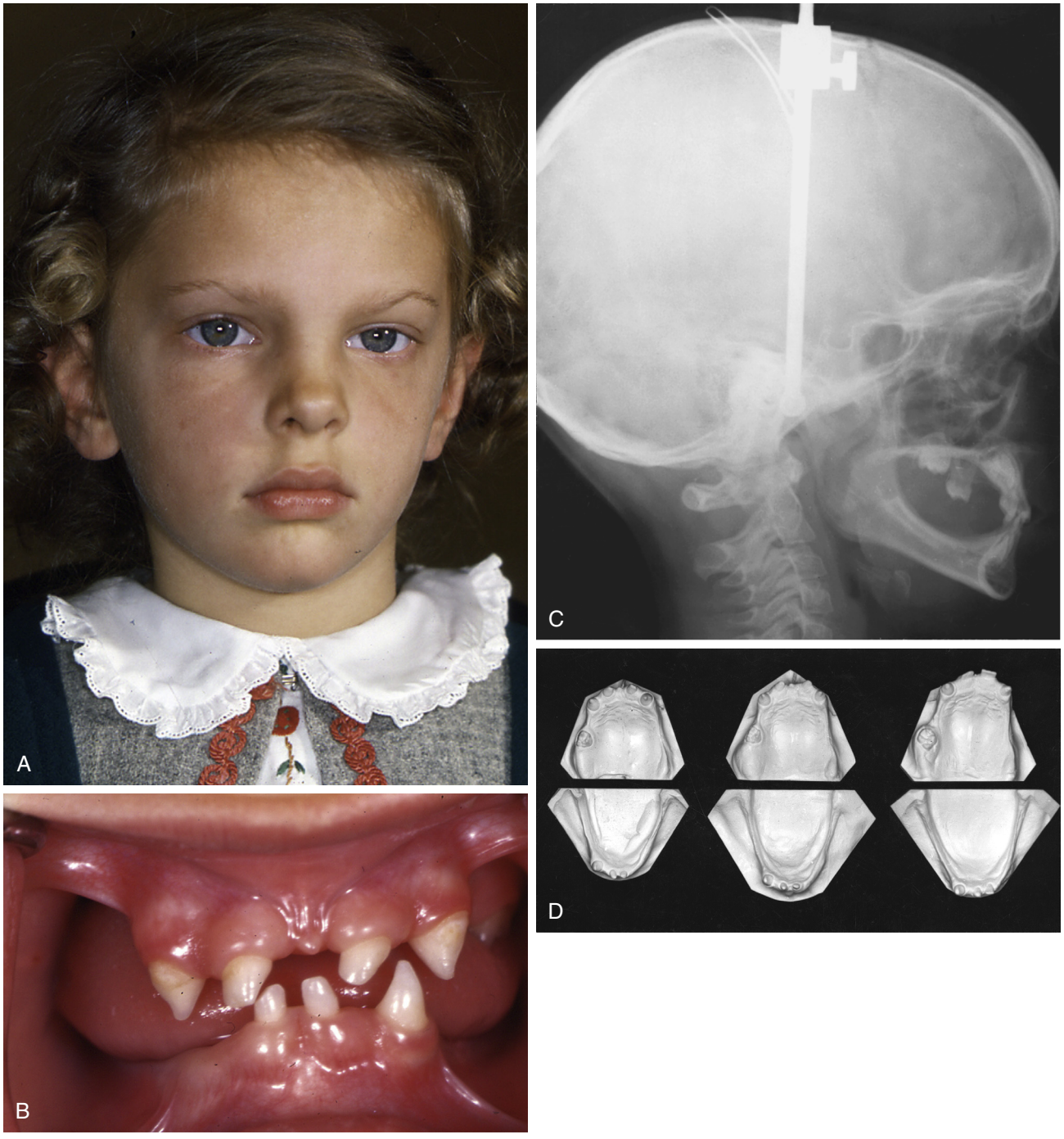

Figure 3-37 **A,** Four-year-old girl with many features of ectodermal dysplasia. There was a history of consanguinity. **B,** The anterior teeth were small and conical. The lack of development of the alveolar process is evident. **C,** The facial pattern was good, even though many primary and permanent teeth were missing. **D,** Partial dentures were constructed, modified, and remade as additional teeth erupted. The models show how growth has occurred in the mandible and maxilla.

INTRINSIC DISCOLORATION OF TEETH (PIGMENTATION OF TEETH)

The primary teeth occasionally have unusual pigmentation. Certain conditions arising from the pulp can cause the entire tooth to appear discolored. Factors causing these conditions include blood-borne pigment, blood decomposition within the pulp, and drugs used in procedures such as root canal therapy. (Color changes in relation to trauma are discussed in Chapter 27.)

DISCOLORATION IN HYPERBILIRUBINEMIA

In several conditions, excess levels of bilirubin are released into the circulating blood.[136] If teeth are developing during periods of hyperbilirubinemia, they may become intrinsically stained. The two most common disorders



Figure 3-38 **A,** Four-year-old boy with characteristics of ectodermal dysplasia. Many primary and permanent teeth are congenitally missing. The skin is dry, and the hair is sparse. **B,** The anterior primary teeth are typically conical. **C** and **D,** A full maxillary overdenture and a partial mandibular denture were constructed.

that cause this intrinsic staining are erythroblastosis fetalis and biliary atresia. Other less common causes are premature birth, ABO blood type incompatibility, neonatal genital hypothyroidism, biliary hypoplasia, tyrosinemia, α1-antitrypsin deficiency, and neonatal hepatitis.

Erythroblastosis fetalis results from the transplacental passage of maternal antibodies against red blood cell antigens of the infant, which leads to an increased rate of red blood cell destruction.[137] Cullen reported on the occurrence of erythroblastosis fetalis produced by Kell immunization.[138] In utero, the maternal antibodies coat the fetal red blood cells and cause hemolysis. The fetus develops anemia, with a resultant increase in the bilirubin content of the amniotic fluid. The newborn appears pale and anemic. Shortly after birth, jaundice occurs as a result of the high bilirubin levels. Despite the development of a method of prevention of maternal isoimmunization by Rh antigens, it remains a significant cause of anemia and jaundice in newborn infants. However, an infant from an Rh-negative mother's first pregnancy rarely develops this disease.

If an infant has had severe, persistent jaundice during the neonatal period, the primary teeth may have a characteristic blue-green color, although in a few instances brown teeth have been observed (Fig. 3-39). The color of the pigmented tooth is gradually reduced. The fading in color is particularly noticeable in the anterior teeth.

DISCOLORATION IN PORPHYRIA

The porphyrias are inherited and acquired disorders in which the activities of the enzymes of the heme biosynthetic pathway are partially or almost completely deficient.[139] As a result, abnormally elevated levels of porphyrins and/or their precursors are produced, which accumulate in tissues and are excreted. Congenital erythropoietic porphyria (Günther disease) is a rare autosomal-recessive form of the disease.

Children with congenital erythropoietic porphyria have red-colored urine, are hypersensitive to light, and develop subepidermal bullous lesions when their skin is exposed to sunlight. Their primary teeth are purplish-brown



Figure 3-39 Characteristic blue-green discoloration of the primary teeth in an infant who suffered from persistent jaundice in the neonatal period.

as a result of the deposition of porphyrin in the developing structures. The permanent teeth also show evidence of intrinsic staining but to a lesser degree.

DISCOLORATION IN CYSTIC FIBROSIS

Cystic fibrosis is an inherited, chronic, multisystem, life-shortening disorder characterized primarily by poor digestion and obstruction and infection of the airways. It is autosomal-recessive and is caused by mutations in both copies of the cystic fibrosis transmembrane regulator gene (CFTR). Zegarelli and colleagues have suggested that tooth discoloration in persons with cystic fibrosis is a result of either the disease alone, or therapeutic agents, especially tetracyclines, or a combination of the two factors.[140] The possibility that there is, at least in part, an intrinsic developmental enamel abnormality secondary to the disease is supported by the investigations of Wright and associates, who found abnormal enamel in the incisors of homozygous CFTR knockout mice.[141] Further studies by Arquitt and colleagues also strongly suggest that CFTR plays an important role in enamel formation.[142]

Although many patients with cystic fibrosis who lived during the latter half of the twentieth century endured unsightly discolorations of their teeth because they received tetracycline therapy during a period when their tooth crowns were forming, modern physicians rarely, if ever, prescribe tetracyclines for patients during their tooth-forming years. During the era when tetracycline therapy for children was common, Primosch reported on tetracycline tooth discolorations, enamel defects, and dental caries in 86 young patients with cystic fibrosis.[143] The incidence of dental caries in these patients was compared with that in control individuals matched for gender, race, exposure to optimally fluoridated water, chronologic age, and dental age. The findings indicated a high prevalence of tooth discolorations and enamel defects but a significantly reduced caries experience in the patients with cystic fibrosis who had received tetracycline drugs.



Figure 3-40 Pigmentation in tetracycline therapy. The permanent incisors that have erupted appear yellowish-brown.

DISCOLORATION IN TETRACYCLINE THERAPY

Dentists and physicians have observed that children who received tetracycline therapy during the period of calcification of the primary or permanent teeth show a degree of pigmentation of the clinical crowns of the teeth. As van der Bijl and Pitigoi-Aron pointed out, because the tetracyclines chelate calcium salts, the drugs are incorporated into bones and teeth during calcification.[144] The crowns of affected teeth are discolored, ranging from yellow to brown and from gray to black (Fig. 3-40). At present most, if not all, infections in children can be treated effectively with antibiotics that do not cause tooth discoloration. Consequently, this previously common problem is now rare.

Tetracycline is deposited in the dentin and, to a lesser extent, in the enamel of teeth that are calcifying during the time the drug is administered. The location of the pigment in the tooth can be correlated with the stage of development of the tooth and the time and duration of drug administration. The tetracyclines, which are yellow, fluoresce under ultraviolet light. When tetracyclines in the dental structures darken from yellow to brown, the fluorescence diminishes because of the destruction of the fluorophores.

The exposure of the teeth to light results in slow oxidation, with a change in color of the pigment from yellow to brown. The larger the dose of drug relative to body weight, the deeper the pigmentation. The duration of exposure to the drug may be less important than the total dose relative to body weight.

Because tetracyclines can be transferred through the placenta, the crowns of the primary teeth may also show noticeable discoloration if tetracyclines are administered during pregnancy. Moffitt and colleagues have observed that the critical period for tetracycline-related discoloration in the primary dentition is 4 months in utero to 3 months postpartum for maxillary and mandibular incisors and 5 months in utero to 9 months postpartum for maxillary and mandibular canines.[145]

The sensitive period for tetracycline-induced discoloration in the permanent maxillary and mandibular

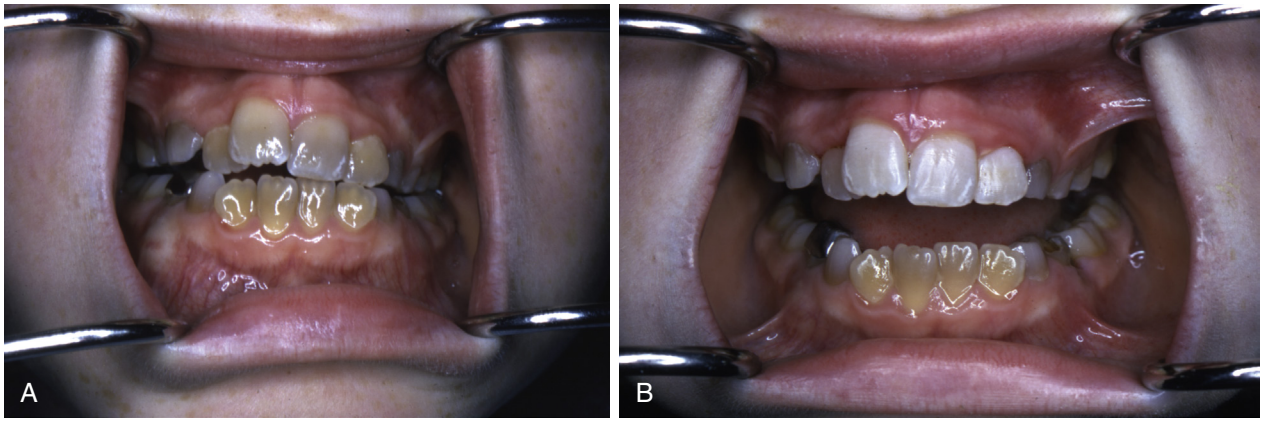

Figure 3-41 **A,** Tetracycline-pigmented teeth. **B,** The maxillary incisors have been bleached; the lower mandibular incisors are untreated.

incisors and canines is approximately 3 months to 7 years of age. The maxillary lateral incisors are an exception because they begin to calcify at 10 to 12 months postpartum.

In addition to fluoride and tetracyclines (including minocycline), ciprofloxacin has been associated with intrinsic staining. Medications that have been reported to cause extrinsic staining include chlorhexidine, oral iron salts, co-amoxiclav, and essential oils.[146]

BLEACHING OF INTRINSIC TOOTH DISCOLORATION

Vital bleaching of intrinsically discolored teeth became a popular dental cosmetic procedure during the late twentieth century (Fig. 3-41), and several safe techniques are available. The accepted procedures incorporate the use of a peroxide compound placed on the tooth surface that bleaches the intrinsic tooth pigments to a lighter hue. Adding energy to the peroxide compound, as in the form of heat, light, or laser radiation, may accelerate this process.

Although many diluted tooth-bleaching products are available over the counter, the most efficient and effective systems are provided or prescribed by a dentist. To be safe, bleaching procedures must be carefully performed and monitored. Although these procedures are usually performed on permanent teeth, Brantley and associates reported successfully bleaching discolored primary teeth in a 4-year-old girl.[147]

Refer to current textbooks on endodontics or cosmetic dentistry for more information on bleaching techniques. Another valuable resource with considerable detailed information is the Special Supplement of the *Journal of the American Dental Association*, volume 128, April 1997. This supplement provides reports presented by numerous recognized bleaching experts during an international symposium on the subject of nonrestorative treatment of discolored teeth.

If the tooth discoloration is severe and bleaching does not adequately improve the condition, the dentist may consider masking the visible surfaces with bonded veneer restorations similar to those discussed in Chapter 11. Bleaching and enamel microabrasion may be used in combination for certain types of discoloration, and these procedures may also be used as adjunctive steps before placement of veneer restorations.

MICROGNATHIA

Micrognathia is usually congenital, but it may be acquired in later life. The mandible is most often affected (Fig. 3-42). The etiology of congenital micrognathia appears to be heterogeneous. Deficient nutrition of the mother and intrauterine injury resulting from pressure or trauma have been suggested as possible causes. In addition, micrognathia may be part of the Robin sequence, which also includes cleft palate (especially in the posterior with a rounded distal edge) and glossoptosis. Although this developmental sequence may be sporadic, it is often the pleiotropic expression of a gene for a condition such as Stickler syndrome or velocardiofacial syndrome and warrants a clinical genetic evaluation.[148,149]

Infants with mandibular micrognathia have difficulty breathing and experience episodes of cyanosis; they must be kept in a ventral position as much as possible. The anterior portion of the mandible is positioned so that the tongue has little if any support and can fall backward, causing an obstruction.

Based on longitudinal growth studies, Pruzansky and Richmond reported that, in most instances of congenital micrognathia, the increment in mandibular growth relative to total facial growth during infancy and early childhood is sufficient to overcome the extreme recessiveness of the chin at birth.[150] This is often referred to as "catch-up growth." Daskalogiannakis and colleagues performed 29 cephalometric measurements, taken at three different ages, on 96 patients with Robin sequence and compared them with similar measurements in 50 patients with isolated clefting of the palate (con-

quence had mandibles significantly smaller than those

age to 17 years of age. This finding suggests that the mandibles of patients with Robin sequence do not really grow proportionately more than those in others not affected by the disorder.

Dentlearn.ir



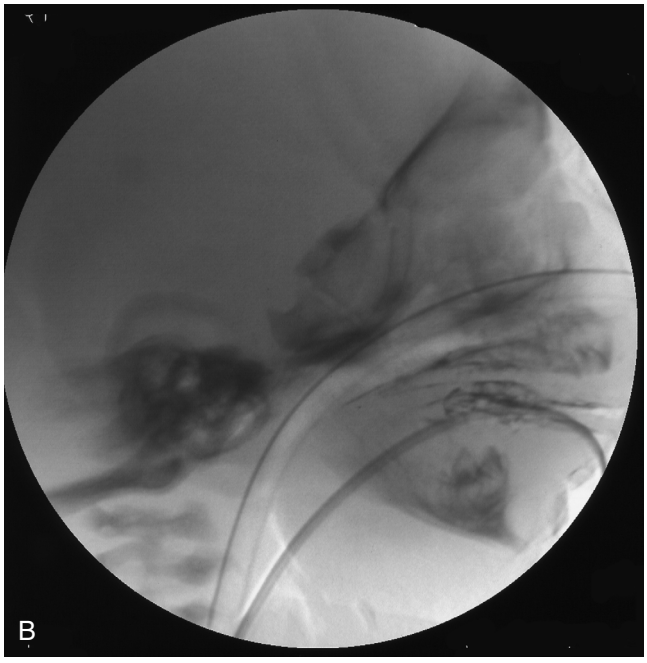

Figure 3-42 **A,** Micrognathia in a girl 1 month of age. The chin is noticeably recessive. **B,** The radiograph shows the extent of the development of the dentition at birth. When the patient was 1 year of age, the micrognathia was less noticeable.

The nursing bottle may be used in the treatment of congenital micrognathia to help promote adequate function of the mandible. Because the infant should be made to reach for the nipple of the nursing bottle, the bottle should never be allowed to rest against the mandible. The parent is instructed to sit the infant on his or her lap in an upright position and place gentle forward pressure on the child's ramus with the thumb and fingers while offering the bottle. Thus the infant must extend the mandible to feed. Mandibular advancement by orthopedic force is sometimes recommended, as well as surgical mandibular reconstruction.

Hotz and Gnoinski have described the use of a special palatal obturator appliance to help infants born with Robin sequence.[152] In addition to providing coverage to seal the cleft palate, the appliance includes a posterior extension to simulate the missing soft palate structures, including the uvula. The appliance seems to stimulate the infant to maintain a more normal tongue position. The improved tongue position significantly reduces the tendency for the infant to experience life-threatening apneic episodes. Dean and colleagues also reported successful use of similar appliances in infants with Robin sequence,[153] including 22 infants with severe airway obstruction. Their results supported the use of the obturator, but they also concluded that further study of treatment with these appliances was needed.

Acquired micrognathia may develop gradually and may not be evident until children reach 4 to 6 years of age. This anomaly in growth is usually related to heredity. Ankylosis of the jaw caused by a birth injury or trauma in later life may result in an acquired type of micrognathia. Infection in the temporomandibular joint area can also cause arrested growth at the head of the condyle and lead to development of the acquired pattern of micrognathia. In cases of true ankylosis of the mandible, arthroplasty should be recommended.

ANOMALIES OF THE TONGUE

Pediatric patients with unremarkable medical histories rarely complain of symptomatic tongue lesions. However, the tongue should be inspected carefully during the examination. Several benign conditions may be evident that should be brought to the attention of the parents.

Burket described four main types of papillae of the tongue.[154] From 10 to 15 large circumvallate papillae may be found on the posterior border of the dorsum. These papillae have a blood supply and are the site of numerous taste buds. Fungiform (mushroom-shaped) papillae may be distributed over the entire dorsum of the tongue; however, they are present in greater numbers at the tip and toward the lateral margins of the tongue. Inflammatory and atrophic changes occurring on the dorsum of the tongue may involve the vascularized fungiform papillae. The most numerous papillae of the tongue are the filiform papillae, which are thin and hairlike, and evenly distributed over the dorsal surface. The filiform papillae are without a vascular core, and their continuous growth is slight. The foliate papillae represent a fourth type and are arranged in folds along the lateral margins of the tongue; the taste sensation is associated with these papillae.

MACROGLOSSIA

Macroglossia refers to a larger-than-normal tongue size and may be either congenital or acquired. Congenital macroglossia, which is caused by an overdevelopment of the lingual musculature or vascular tissues, becomes increasingly apparent as the child develops.

An abnormally large tongue is characteristic of hypothyroidism, in which case the tongue is fissured and may extend from the mouth. Macroglossia is also commonly observed with type 2 glycogen-storage disease, neurofibromatosis type 1, and Beckwith-Wiedemann syndrome. It can be an isolated and sporadic (nonfamilial) trait or a familial (autosomal-dominant) trait, as studied by Reynoso and colleagues.[155] Macroglossia has also been cited as a characteristic of Down syndrome. Occasionally an allergic reaction causes a transitory enlargement of the tongue (angioneurotic edema). Both allergic reaction and injury can cause such severe enlargement of the tongue that a tracheotomy is necessary to maintain a patent airway.

A disproportionately large tongue may cause both an abnormal growth pattern of the jaw and malocclusion. Flaring of the lower anterior teeth and an Angle Class III malocclusion are occasionally the result of macroglossia. The treatment of macroglossia depends on its cause and severity. Surgical reduction of a portion of the tongue is occasionally necessary.

ANKYLOGLOSSIA (TONGUE-TIE)

In ankyloglossia a short lingual frenum extending from the tip of the tongue to the floor of the mouth and onto the lingual gingival tissue limits movements of the tongue and causes speech difficulties (Fig. 3-43). Stripping of the lingual tissues may occur if the tongue-tie is not corrected. Surgical reduction of the abnormal lingual frenum is indicated if it interferes with the infant's nursing (lingual frenectomy, frenotomy, or frenuloplasty). In the older child, a reduction of the frenum should be recommended only if local conditions or speech problems warrant the treatment. Studies of nonsyndromic ankyloglossia have suggested both autosomal-dominant and X-linked inheritance, although in one of the studies 47% of those affected had no family history of ankyloglossia.[156,157] Familial cleft palate with or without ankyloglossia is caused by mutation in the *TBX22* gene.[158]

Ayers and Hilton reported a case of ankyloglossia in a 7-year-old boy who had been evaluated at his school for a speech problem.[159] The patient had previously undergone routine dental examinations, but no treatment had been suggested by the dentist. Tongue mobility and speech patterns improved greatly after the frenum attachment was released surgically. The patient and parents reported very little postoperative discomfort. This history and the results are similar to those of the 6-year-old girl with ankyloglossia illustrated in Fig. 3-44. Messner and Lalakea, after studying 30 one- to 12-year-old children with ankyloglossia, concluded that tongue mobility and speech improved significantly after frenuloplasty.[160]

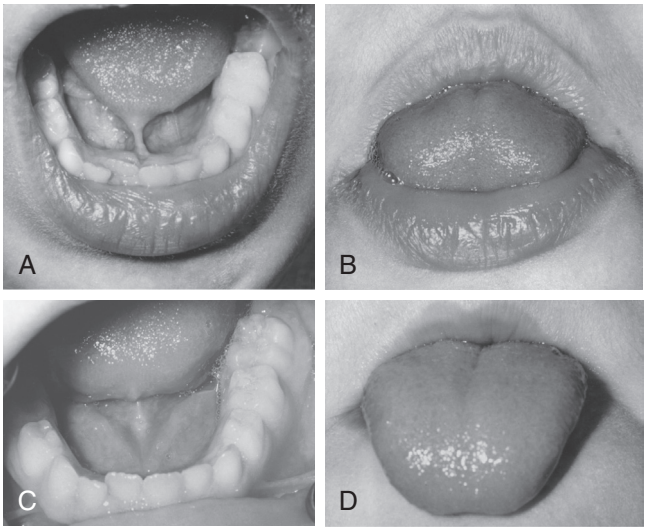

Figure 3-44 **A,** Ankyloglossia in a 6-year-old girl. **B,** Patient had limited tongue mobility and speech problems. **C,** Two weeks after surgical release. **D,** Tongue mobility and speech improved spontaneously.

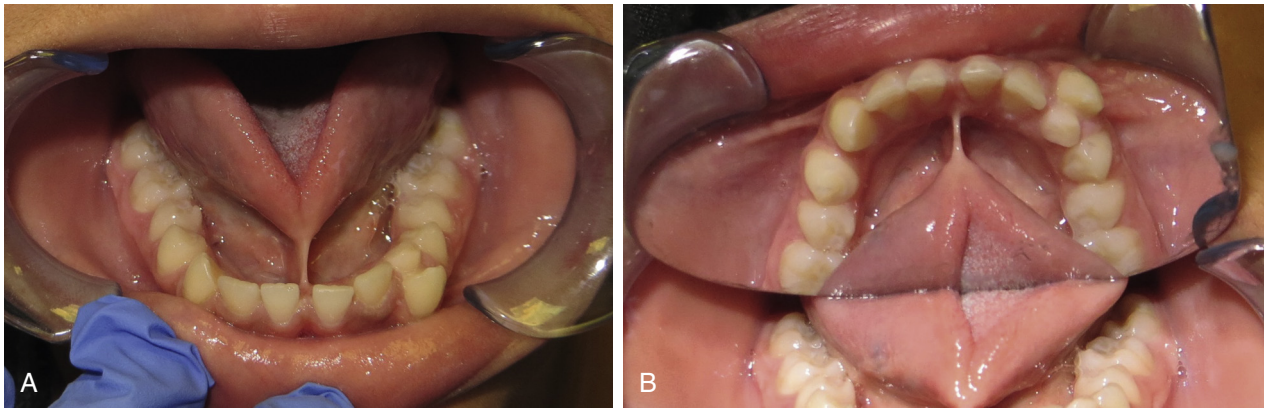

Figure 3-43 **A,** Ankyloglossia (tongue-tie). A short, heavy lingual frenum extends from the top of the tongue to the floor of the mouth and onto the lingual tissue. **B,** A mirror view of the abnormal frenum.

Dentlearn.ir

FISSURED TONGUE AND GEOGRAPHIC TONGUE (BENIGN MIGRATORY GLOSSITIS)

A fissured tongue is seen in a small number of children and may be of no clinical significance, although it is sometimes associated with hypothyroidism and Down syndrome. The fissures on the dorsum of the tongue usually have a symmetric pattern and may be longitudinal or at right angles to the margin of the tongue. Vitamin B–complex deficiency may be associated with the fissuring. Treatment of the fissured tongue is generally unnecessary unless a mild inflammation develops at the base of the fissures from an accumulation of food debris. Brushing of the tongue and improved oral hygiene aid in reducing the inflammation and soreness.

A wandering type of lesion and probably the most common tongue anomaly is known as *geographic tongue*. Prevalence rates from 1% to as high as 14% have been reported. Kullaa-Mikkonen studied the inheritance of fissured tongue in 31 families and concluded that fissured tongue with smooth-surfaced papillae is transmitted as an autosomal-dominant trait with incomplete penetrance and is preceded by geographic tongue.[161] The severity of fissured tongue increased with age. Tongue fissuring with normal-appearing filiform papillae was found not to be familial and was not associated with geographic tongue.

Geographic tongue is often detected during routine dental examination of pediatric patients who are unaware of the condition. Red, smooth areas devoid of filiform papillae appear on the dorsum of the tongue. The margins of the lesions are well developed and slightly raised. The involved areas enlarge and migrate by extension of the desquamation of the papillae at one margin of the lesion and regeneration at the other (Fig. 3-45). Every few days, a change can be noted in the pattern of the lesions. The condition is self-limiting, however, and no treatment is necessary.

Bánóczy and colleagues have indicated that gastrointestinal disturbances associated with anemia may be related to migratory glossitis.[162] In addition, a psychosomatic disorder should be considered as a possible etiologic factor. Histologically the process appears to be superficial, with desquamation of the keratin layers of papillae and inflammation of the corium.

COATED TONGUE

A white coating of the tongue is usually associated with local factors. The amount of coating on the tongue varies with the time of day and is related to oral hygiene and the character of the diet. The coating consists of food debris, microorganisms, and keratinized epithelium found on and around the filiform papillae (Fig. 3-46).

Children who have a congenital or acquired deficiency in salivary flow may have a coated tongue, occasionally to the extent that a dry crust appears on the dorsum of the tongue. Frequent rinsing with artificial saliva palliates the condition. Systemic disease with associated fever and dehydration may also cause a coating, which is usually white but may become stained with foods or drugs. Increased ingestion of liquid is appropriate to alleviate this situation. Brushing the

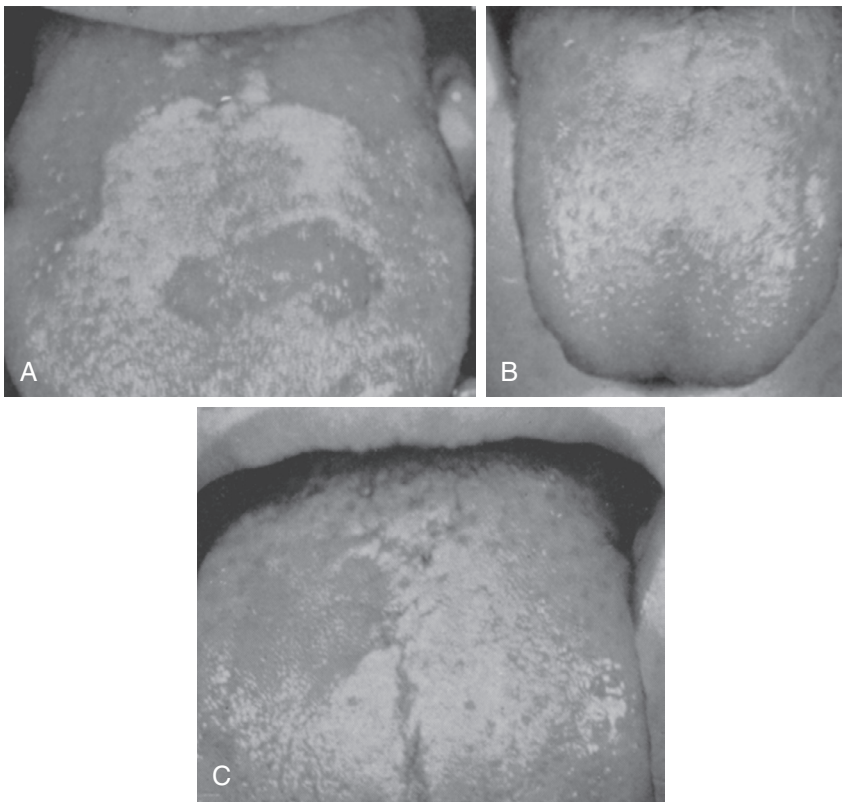

Figure 3-45 **A,** Geographic tongue. The smooth areas are devoid of filiform papillae. **B,** The pattern observed at the initial visit is indistinguishable 4 weeks later. **C,** In 1 year a new pattern is developing on the dorsum of the tongue.

Dentlearn.ir

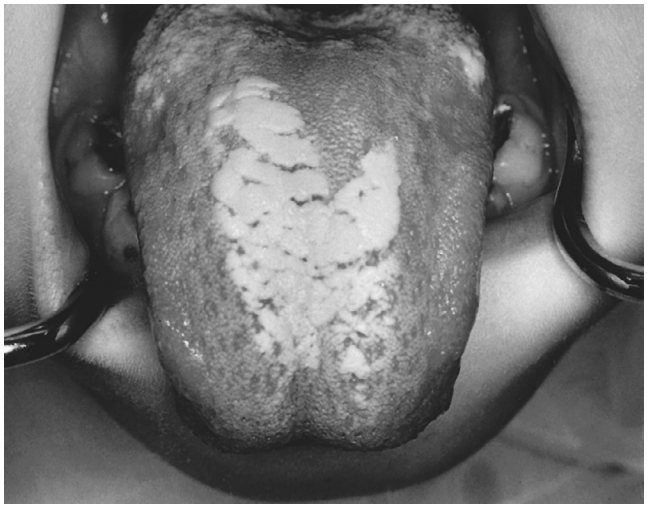

Figure 3-46 White coating of the tongue is usually associated with local factors.

tongue with a toothbrush and dentifrice reduces the coating.

WHITE STRAWBERRY TONGUE

An enlargement of the fungiform papillae extending above the level of the white desquamating filiform papillae gives the appearance of an unripe strawberry. The condition has been observed in cases of scarlet fever and Kawasaki disease in young children. During the course of scarlet fever and other acute febrile conditions, the coating disappears and the enlarged red papillae extend above a smooth, denuded surface, which gives the appearance of a red strawberry or raspberry. The tongue returns to normal after recovery from the systemic condition.

BLACK HAIRY TONGUE

Black hairy tongue is rarely seen in children but occurs in young adults and has been related to the oral and systemic intake of antibiotics, smoking, and excessive ingestion of dark drinks such as coffee and tea (Fig. 3-47). Accumulations of keratin on the filiform papillae in the middle third of the tongue become elongated into hairlike processes, sometimes as long as 2.5 cm (1 inch). Neville and colleagues note that the cause is uncertain but that an apparent increase in keratin production or a decrease in normal keratin desquamation results.[136] It is a benign condition with no serious sequelae. Rigorous hygienic procedures such as brushing and scraping the tongue may help control it. When the condition appears during antibiotic therapy, it usually disappears again without specific treatment after the antibiotics are discontinued.

INDENTATION OF THE TONGUE MARGIN (CRENATION)

During the examination of the pediatric patient, the dentist may notice a scalloping or crenation along the lingual periphery. Careful examination will reveal the markings to be caused by the tongue's position against the lingual surfaces of the mandibular teeth. Although usually no significance can be attached to these crenations, they have been related to pressure habits, macroglossia, vitamin B–complex deficiency, and systemic disease that causes reduced muscle tone.



Figure 3-47 Black hairy tongue. This condition usually has no clinical significance.

MEDIAN RHOMBOID GLOSSITIS (CENTRAL PAPILLARY ATROPHY OF THE TONGUE)

Median rhomboid glossitis is an oval, rhomboid, or diamond-shaped reddish patch on the dorsal surface of the tongue immediately anterior to the circumvallate papillae. Flat, slightly raised, or nodular, it stands out distinctly from the rest of the tongue because it has no filiform papillae. This atrophic area is usually asymptomatic. Long believed to be a developmental anomaly, the condition is now recognized almost exclusively to represent a chronic, localized, and mild candidal infection, as proposed by Cooke.[163]

Although median rhomboid glossitis occurs more often in adults, it is sometimes seen in teenagers and even occurs infrequently in younger children. Barasch and colleagues have observed it with high prevalence in HIV-positive children.[164] Treatment with topical antifungal agents is appropriate.

TRAUMA TO THE TONGUE, WITH EMPHASIS ON TONGUE PIERCING

A child may bite his or her tongue as a result of a traumatic blow or fall. The dentist may inadvertently traumatize the tongue with a cutting instrument during operative procedures. Deep laceration of the tongue requires suturing to minimize scarring and to aid in hemorrhage control. In cases of severe injury, the tongue should be examined carefully for the detection of any enlargement that might interfere with the maintenance of an open airway.

Tongue piercing, a deliberate trauma, is one of the popular types of body piercing occurring in all parts of the world today, especially among teenagers and young adults (Fig. 3-48). Tongue piercing is of particular interest

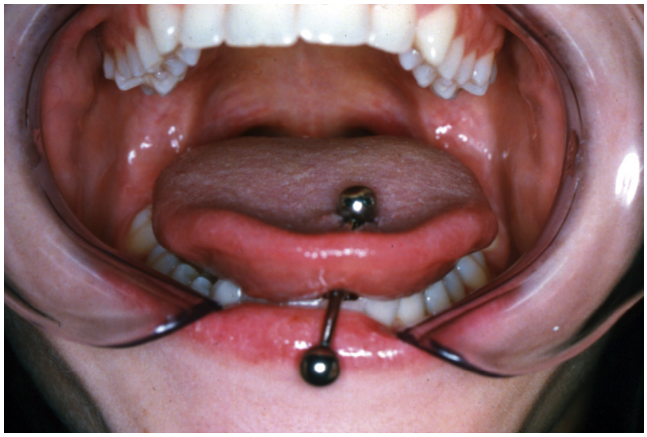

Figure 3-48 Tongue ornaments are popular among teenagers and young adults.

in dentistry because it carries a high risk of adverse intraoral sequelae and can have significant systemic effects. The scientific literature has exploded with documented cases of complications following piercing procedures. Fractured teeth, dental abrasion, and gingival recession are reported to be common sequelae. Other observed complications with life-threatening potential include brain abscess,[165] cephalic tetanus,[166] endocarditis,[167] Ludwig angina,[168] and upper airway compromise.[169] Whenever appropriate, dentists should counsel their patients and other members of the community about the serious risks associated with this form of body art. If patients insist on wearing tongue ornaments and other body jewelry, they should be advised to remove them at least during athletic activities in which the risk of injury is high.

ABNORMAL LABIAL FRENUM

A maxillary midline diastema is frequently seen in preschool children and in those in the mixed-dentition stage. It is important to determine whether the diastema is normal for that particular time of development or is related to an abnormal maxillary labial frenum.

A midline diastema may be considered normal for many children during the time of eruption of the permanent maxillary central incisors. When the incisors first erupt, they may be separated by bone, and the crowns incline distally because of the crowding of the roots. With the eruption of the lateral incisors and the permanent canines, the midline diastema is reduced, and in most cases normal contact between the central incisors develops.

Insufficient tooth mass in the maxillary anterior region, the presence of peg-shaped lateral incisors, or the congenital absence of lateral incisors may cause a diastema. Other factors and anomalies, including a midline supernumerary tooth, an oral habit, macroglossia, and abnormally large mandibular anterior teeth, should be considered as possible causes (in addition to an abnormal labial frenum) of the midline diastema.

The labial frenum is composed of two layers of epithelium enclosing a loose vascular connective tissue. Muscle fibers, if present, are derived from the orbicularis oris muscle.



Figure 3-49 Abnormal labial frenum. There is blanching of the free marginal tissue between the central incisors and of the palatine papilla. A frenectomy is indicated.

The origin of the maxillary frenum is at the midline on the inner surface of the lip. The origin is often wide, but the tissue of the frenum itself narrows in width and is inserted in the midline into the outer layer of periosteum suture and the alveolar process. The exact attachment site is variable. It can be several millimeters above the crest of the ridge or on the ridge, or the fibers may pass between the central incisors and attach to the palatine papilla.

Many dentists delay considering an abnormal labial frenum as the cause of a diastema until all the maxillary permanent anterior teeth, including the canines, have erupted. This approach may be considered generally correct. However, other diagnostic points should be kept in mind.

One can carry out a simple diagnostic test for an abnormal frenum during mid- to late-mixed dentition by observing the location of the alveolar attachment when intermittent pressure is exerted on the frenum. If a heavy band of tissue with a broad, fanlike base is attached to the palatine papilla and produces blanching of the papilla, it is safe to predict that the frenum will unfavorably influence the development of the anterior occlusion (Fig. 3-49).

The abnormal labial frenum, in addition to causing a midline diastema, can produce other undesirable clinical conditions. The heavy band of tissue and low attachment can interfere with toothbrushing by making it difficult to place the brush at the proper level in the vestibule to brush in the conventional manner. If fibers of the frenum attach to the free marginal tissue, stretching of the lip during mastication and speech may cause stripping of the tissue from the neck of the tooth. Such attachment may also cause the accumulation of food particles and eventual pocket formation. The abnormal frenum may restrict movements of the lip, may interfere with speech, and may produce an undesirable cosmetic result (Fig. 3-50).

FRENECTOMY

The decision regarding treatment of the labial frenum should be made only after a careful evaluation to determine whether the result will be undesirable if the condition is allowed to remain.

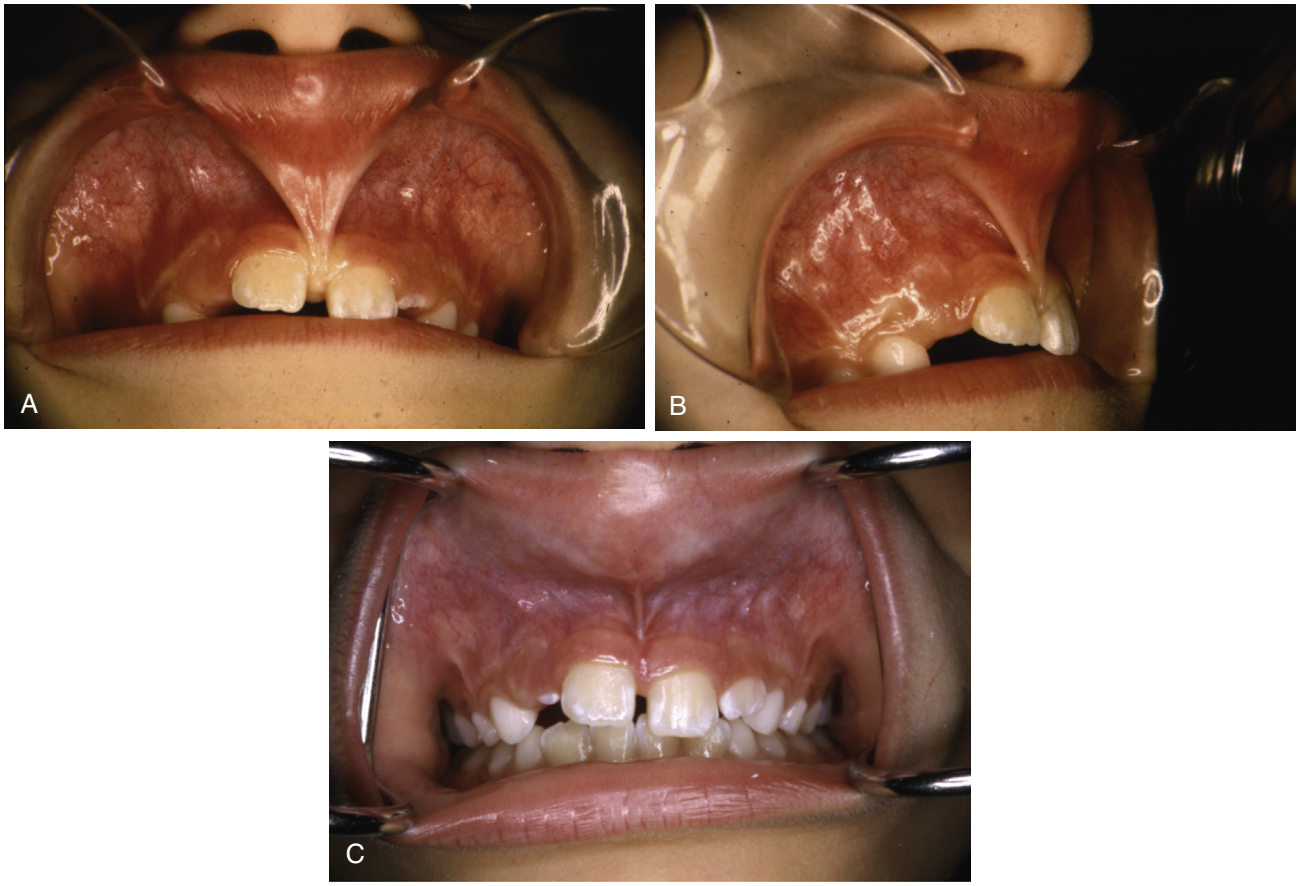

Figure 3-50 **A,** Abnormal labial frenum in an 8-year-old child. The heavy, fan-shaped band of tissue interfered with speech and had an undesirable appearance. **B,** An oblique view of the abnormal frenum. **C,** A much more desirable appearance is observed 6 months after the frenectomy.

In the surgical technique, a wedge-shaped section of tissue is removed, including the tissue between the central incisors and the tissue extending palatally to the nasal palatine papilla (Figs. 3-50 and 3-51). Lateral incisions are made on either side of the frenum to the depth of the underlying bone. The free marginal tissue on the mesial side of the central incisors should not be disturbed. The wedge of tissue can be picked up with tissue forceps and excised with tissue shears at an area close enough to the origin of the frenum to provide a desirable cosmetic effect. Sutures are placed inside the lip to approximate the free tissue margins. It is generally unnecessary to suture or pack the tissue between the incisors.

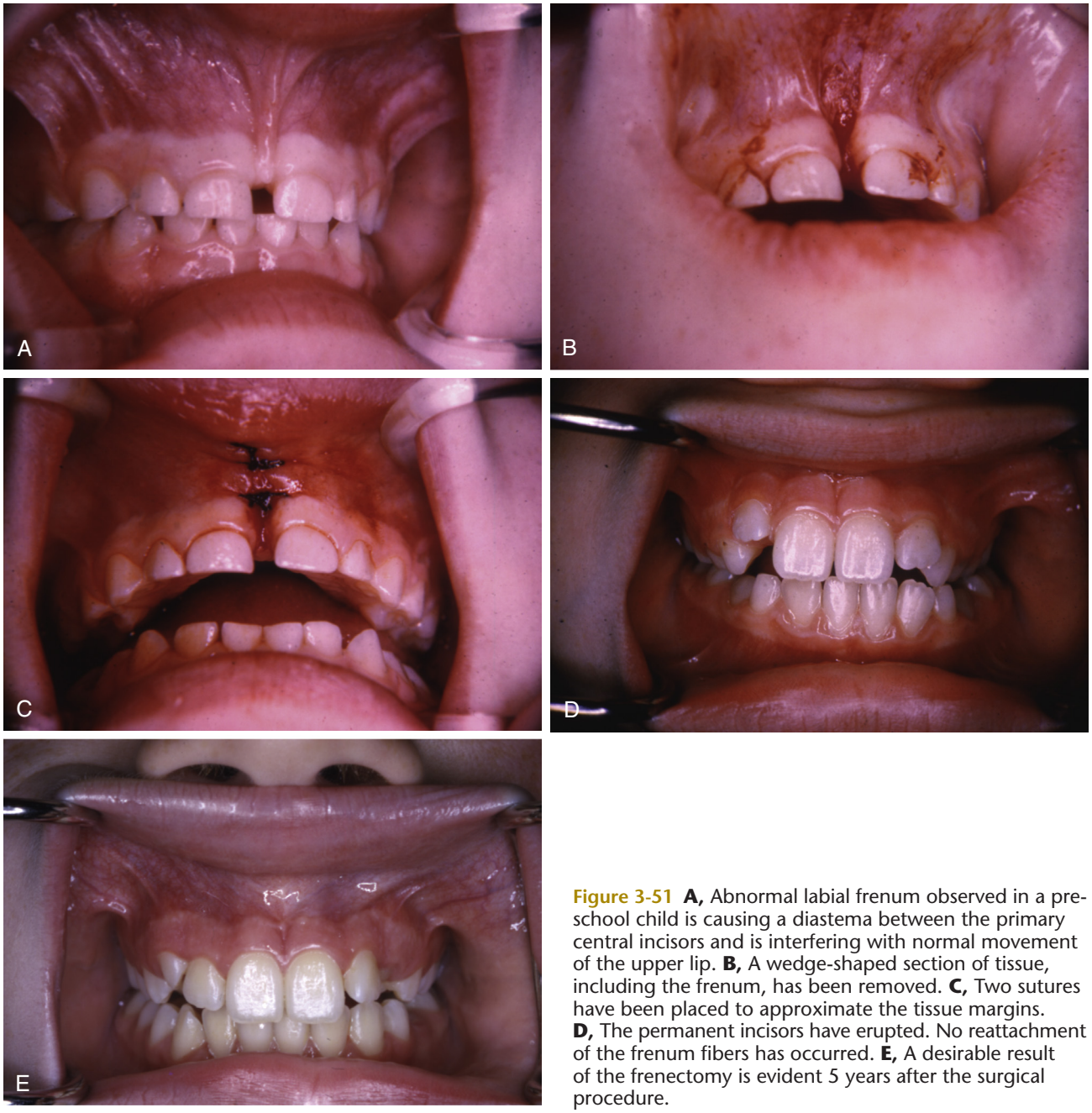

Figure 3-51 **A,** Abnormal labial frenum observed in a preschool child is causing a diastema between the primary central incisors and is interfering with normal movement of the upper lip. **B,** A wedge-shaped section of tissue, including the frenum, has been removed. **C,** Two sutures have been placed to approximate the tissue margins. **D,** The permanent incisors have erupted. No reattachment of the frenum fibers has occurred. **E,** A desirable result of the frenectomy is evident 5 years after the surgical procedure.

REFERENCES

1. US Department of Health and Human Services. Oral health in America: a report of the Surgeon General. Rockville, Md, US Department of Health and Human Services, National Institute of Dental and Craniofacial Research, National Institutes of Health, 2000.
2. Molinari JA: Microbial disease trends and acquired antibiotic resistance: Part 1, *Compend Contin Educ Dent* 18(2):106–108, 1997.
3. Bader G: Odontomatosis (multiple odontomas), *Oral Surg Oral Med Oral Pathol* 23(6):770–773, 1967.
4. Nanni L, et al.: SHH mutation is associated with solitary median maxillary central incisor: a study of 13 patients and review of the literature, *Am J Med Genet* 102(1):1–10, 2001.
5. Grahnen H, Lindahl B, Omnell KA: Dens invaginatus. I. A clinical, roentgenological and genetical study of permanent upper lateral incisors, *Odont Rev* 10:115–137, 1959.
6. Armitage GC: Development of a classification system for periodontal diseases and conditions, *Ann Periodontol* 4:1–6, 1999.
7. Hart TC, Hart PS, Michalec MD, Zhang Y, Firatli E, Van Dyke TE, Stabholz A, Zlotogorski A, Shapira L, Soskolne WA: Haim-Munk syndrome and Papillon-Lefèvre syndrome are allelic mutations in cathepsin, *C J Med Genet* 37:88–94, 2000. Erratum: J Med Genet 38:79, 2001.
8. Hewitt C, McCormick D, Linden G, Turk D, Stern I, Wallace I, Southern L, Zhang L, Howard R, Bullon P, Wong M, Widmer R, et al.: The role of cathepsin C in Papillon-Lefèvre syndrome, prepubertal periodontitis, and aggressive periodontitis, *Hum Mutat* 23:222–228, 2004.

9. Hu CC, et al.: A clinical and research protocol for characterizing patients with hypophosphatasia, *Pediatr Dent* 18(1):17–23, 1996.
10. Scriver CR, Cameron D: Pseudohypophosphatasia, *N Engl J Med* 281(11):604–606, 1969.
11. Kalantar Motamedi MH: Treatment of cherubism with locally aggressive behavior presenting in adulthood: report of four cases and a proposed new grading system, *J Oral Maxillofac Surg* 56(11):1336–1342, 1998.
12. Parkin B, Law C: Axenfeld anomaly and retinal changes in Ramon syndrome: follow-up of two sibs, *Am J Med Genet* 104:131–134, 2001.
13. Ueki Y, et al.: Mutations in the gene encoding c-Abl-binding protein SH3BP2 cause cherubism, *Nat Genet* 28(2):125–126, 2001.
14. McDonald RE, Shafer WG: Disseminated juvenile fibrous dysplasia of the jaws, *Am J Dis Child* 89(3):354–358, 1955.
15. Pierce AM, et al.: Fifteen-year follow-up of a family with inherited craniofacial fibrous dysplasia, *J Oral Maxillofac Surg* 54(6):780–788, 1996.
16. Von Wowern N: Cherubism: a 36-year long-term follow-up of 2 generations in different families and review of the literature, *Oral Surg Oral Med Oral Pathol Oral Radiol Endod* 90(6):765–772, 2002.
17. Weinstein M, Bernstein S: Pink ladies: mercury poisoning in twin girls, *CMAJ* 168(2):201, 2003.
18. Horowitz Y, et al.: Acrodynia: a case report of two siblings, *Arch Dis Child* 86(6):453, 2002.
19. Hartsfield JK Jr: Premature exfoliation of teeth in childhood and adolescence, *Adv Pediatr* 41:453–470, 1994.
20. Francis F, Hennig S, Korn B, et al.: A gene (PEX) with homologies to endopeptidases is mutated in patients with X-linked hypophosphatemic rickets. The HYP Consortium, *Nat Genet* 11(2):130–136, 1995.
21. McWhorter AG, Seale NS: Prevalence of dental abscess in a population of children with vitamin D-resistant rickets, *Pediatr Dent* 13(2):91–96, 1991.
22. Shroff DV, McWhorter AG, Seale NS: Evaluation of aggressive pulp therapy in a population of vitamin D-resistant rickets patients: a follow-up of 4 cases, *Pediatr Dent* 24(4):347–349, 2002.
23. Rakocz M, Keating J 3rd, Johnson R: Management of the primary dentition in vitamin D-resistant rickets, *Oral Surg Oral Med Oral Pathol* 54(2):166–171, 1982.
24. Morley AA, Carew JP, Baikie AG: Familial cyclical neutropenia, *Br J Haematol* 13:719–738, 1967.
25. Horwitz M, et al.: Mutations in ELA2, encoding neutrophil elastase, define a 21-day biological clock in cyclic haematopoiesis, *Nat Genet* 23(4):433–436, 1999.
26. da Fonseca MA, Fontes F: Early tooth loss due to cyclic neutropenia: long-term follow-up of one patient, *Spec Care Dentist* 20(5):187–190, 2000.
27. Seow WK, et al.: Mineral deficiency in the pathogenesis of enamel hypoplasia in prematurely born, very low birthweight children, *Pediatr Dent* 11(4):297–302, 1989.
28. Slayton RL, et al.: Prevalence of enamel hypoplasia and isolated opacities in the primary dentition, *Pediatr Dent* 23(1):32–36, 2001.
29. Sarnat BG, Schour I: Enamel hypoplasia (chronological enamel aplasia) in relation to systemic disease: a chronologic, morphologic and etiologic classification, *J Am Dent Assoc* 29:67–75, 1942.
30. Sheldon M, Bibby BG, Bales MS: Relationship between microscopic enamel defects and infantile disabilities, *J Dent Res* 24:109–116, 1945.
31. Purvis RJ, et al.: Enamel hypoplasia of the teeth associated with neonatal tetany: a manifestation of maternal vitamin-D deficiency, *Lancet* 2(7833):811–814, 1973.
32. Herman SC, McDonald RE: Enamel hypoplasia in cerebral palsied children, *J Dent Child* 30:46–49, 1963.
33. Cohen HJ, Diner H: The significance of developmental dental enamel defects in neurological diagnosis, *Pediatrics* 46(5):737–747, 1970.
34. Martínez A, et al.: Prevalence of developmental enamel defects in mentally retarded children, *ASDC J Dent Child* 69(2):151–155, 2002.
35. Oliver WJ, et al.: Hypoplastic enamel associated with the nephrotic syndrome, *Pediatrics* 32:399–406, 1963.
36. Koch MJ, et al.: Enamel hypoplasia of primary teeth in chronic renal failure, *Pediatr Nephrol* 13(1):68–72, 1999.
37. Rattner LJ, Myers HM: Occurrence of enamel hypoplasia in children with congenital allergies, *J Dent Res* 41:646–649, 1962.
38. Lawson BF, et al.: The incidence of enamel hypoplasia associated with chronic pediatric lead poisoning, *S C Dent J* 29(11):5–10, 1971.
39. Pearl M, Roland NM: Delayed primary dentition in a case of congenital lead poisoning, *ASDC J Dent Child* 47(4): 269–271, 1980.
40. Turner JG: Two cases of hypoplasia of enamel, *Br J Dent Sci* 55:227–228, 1912.
41. Bauer WH: Effect of periapical processes of deciduous teeth on the buds of permanent teeth, *Am J Orthod* 32:232–241, 1946.
42. Mink JR: Relationship of enamel hypoplasia and trauma in repaired cleft lip and palate. Indiana School of Dentistry, Indianapolis, 1961, Indiana University.
43. Vichi M, Franchi L: Abnormalities of the maxillary incisors in children with cleft lip and palate, *ASDC J Dent Child* 62(6):412–417, 1995.
44. Kaste SC, et al.: Dental abnormalities in children treated for acute lymphoblastic leukemia, *Leukemia* 11(6):792–796, 1997.
45. Maguire A, Welbury RR: Long-term effects of antineoplastic chemotherapy and radiotherapy on dental development, *Dent Update* 23(5):188–194, 1996.
46. Musselman RJ: *Dental defects and rubella embryopathy: a clinical study of fifty children*, Indianapolis, 1968, Indiana School of Dentistry. Indiana University.
47. Willmott NS, Bryan RAE, Duggal MS: Molar-incisor-hypomineralisation: a literature review, *Eur Arch Paediatr Dent* 9(4):172–179, 2008.
48. Levy SM, et al.: Primary tooth fluorosis and fluoride intake during the first year of life, *Commun Dent Oral Epidemiol* 30(4):286–295, 2002.
49. Everett ET, et al.: Dental fluorosis: variability among different inbred mouse strains, *J Dent Res* 81(11):794–798, 2002.
50. McCloskey RJ: A technique for removal of fluorosis stains, *J Am Dent Assoc* 109(1):63–64, 1984.
51. Croll TP: Enamel microabrasion: observations after 10 years, *J Am Dent Assoc* 128(Suppl):45–50, 1997.
52. Croll TP, Helpin ML: Enamel microabrasion: a new approach, *J Esthet Dent* 12(2):64–71, 2000.
53. Muhler JC: Effect of apical inflammation of the primary teeth on dental caries in the permanent teeth, *J Dent Child* 24:209–210, 1957.
54. Mueller BH, et al.: "Caries-like" resorption of unerupted permanent teeth, *J Pedod* 4(2):166–172, 1980.
55. Holan G, Eidelman E, Mass E: Pre-eruptive coronal resorption of permanent teeth: report of three cases and their treatments, *Pediatr Dent* 16(5):373–377, 1994.
56. Seow WK, Wan A, McAllan LH: The prevalence of pre-eruptive dentin radiolucencies in the permanent dentition, *Pediatr Dent* 21(1):26–33, 1999.
57. Seow WK, Lu PC, McAllan LH: Prevalence of pre-eruptive intracoronal dentin defects from panoramic radiographs, *Pediatr Dent* 21(6):332–339, 1999.

58. Lysell L: Taurodontism: a case report and a survey of the literature, *Odontol Rev* 13(2):158–174, 1962.
59. Jaspers MT, Witkop CJ Jr: Taurodontism, an isolated trait associated with syndromes and X-chromosomal aneuploidy, *Am J Hum Genet* 32(3):396–413, 1980.
60. Mena CA: Taurodontism, *Oral Surg Oral Med Oral Pathol* 32(5):812–823, 1971.
61. Gedik R, Cimen M: Multiple taurodontism: report of case, *ASDC J Dent Child* 67(3):216–217, 2000.
62. Bixler D, Conneally PM, Christen AG: Dentinogenesis imperfecta: genetic variations in a six-generation family, *J Dent Res* 48(6):1196–1199, 1969.
63. Witkop CJ Jr: *Genetics and dental health*, New York, 1961, McGraw-Hill.
64. Witkop CJ Jr: Manifestations of genetic diseases in the human pulp, *Oral Surg Oral Med Oral Pathol* 32(2):278–316, 1971.
65. Shields ED, Bixler D, el-Kafrawy AM: A proposed classification for heritable human dentine defects with a description of a new entity, *Arch Oral Biol* 18(4):543–553, 1973.
66. Zhang X, et al.: DSPP mutation in dentinogenesis imperfecta Shields type II, *Nat Genet* 27(2):151–152, 2001.
67. Xiao S, et al.: Dentinogenesis imperfecta 1 with or without progressive hearing loss is associated with distinct mutations in DSPP, *Nat Genet* 27(2):201–204, 2001.
68. Sreenath T, et al.: Dentin sialophosphoprotein knockout mouse teeth display widened predentin zone and develop defective dentin mineralization similar to human dentinogenesis imperfecta type III, *J Biol Chem* 278(27):24874–24880, 2003.
69. Malmgren B, et al.: Clinical, histopathologic, and genetic investigation in two large families with dentinogenesis imperfecta type II, *Hum Genet* 114(5):491–498, 2004.
70. Bloch-Zupan A, Jamet X, Etard C, et al.: Homozygosity mapping and candidate prioritization identify mutations, missed by whole-exome sequencing, in SMOC2, causing major dental developmental defects, *Am J Hum Genet* 89:773–781, 2011.
71. Dean JA, et al.: Dentin dysplasia, type II linkage to chromosome 4q, *J Craniofac Genet Dev Biol* 17(4):172–177, 1997.
72. Rajpar MH, et al.: Mutation of the signal peptide region of the bicistronic gene DSPP affects translocation to the endoplasmic reticulum and results in defective dentine biomineralization, *Hum Mol Genet* 11(21):2559–2565, 2002.
73. McKnight DA, et al.: A comprehensive analysis of normal variation and disease-causing mutations in the human DSPP gene, *Hum Mutat* 29(12):1392–1404, 2008.
74. Beattie ML, et al.: Phenotypic variation in dentinogenesis imperfecta/dentin dysplasia linked to 4q21, *J Dent Res* 85(4):329–333, 2006.
75. Cartwright AR, Kula K, Wright TJ: Craniofacial features associated with amelogenesis imperfecta, *J Craniofac Genet Dev Biol* 19(3):148–156, 1999.
76. Ravassipour DB, et al.: Variation in dental and skeletal open bite malocclusion in humans with amelogenesis imperfecta, *Arch Oral Biol* 50(7):611–623, 2005.
77. Aldred MJ, Crawford PJ: Amelogenesis imperfecta—towards a new classification, *Oral Dis* 1(1):2–5, 1995.
78. Hart PS, et al.: A nomenclature for X-linked amelogenesis imperfecta, *Arch Oral Biol* 47(4):255–260, 2002.
79. Hart PS, et al.: Identification of the enamelin (g.8344delG) mutation in a new kindred and presentation of a standardized ENAM nomenclature, *Arch Oral Biol* 48(8):589–596, 2003.
80. Stephanopoulos G, Garefalaki ME, Lyroudia K: Genes and related proteins involved in amelogenesis imperfecta, *J Dent Res* 84(12):1117–1126, 2005.
81. Aldred MJ, et al.: Genetic heterogeneity in X-linked amelogenesis imperfecta, *Genomics* 14(3):567–573, 1992.
82. Congleton J, Burkes EJ Jr: Amelogenesis imperfecta with taurodontism, *Oral Surg Oral Med Oral Pathol* 48(6):540–544, 1979.
83. Seow WK: Taurodontism of the mandibular first permanent molar distinguishes between the tricho-dento-osseous (TDO) syndrome and amelogenesis imperfecta, *Clin Genet* 43(5):240–246, 1993.
84. Price JA, et al.: A common DLX3 gene mutation is responsible for tricho-dento-osseous syndrome in Virginia and North Carolina families, *J Med Genet* 35(10):825–828, 1998.
85. Price JA, et al.: Tricho-dento-osseous syndrome and amelogenesis imperfecta with taurodontism are genetically distinct conditions, *Clin Genet* 56(1):35–40, 1999.
86. Dong J, et al.: DLX3 mutation associated with autosomal dominant amelogenesis imperfecta with taurodontism, *Am J Med Genet A* 133A(2):138–141, 2005.
87. Hall RK, Phakey P, Palamara J, McCredie DA: Amelogenesis imperfecta and nephrocalcinosis syndrome: case studies of clinical features and ultrastructure of tooth enamel in two siblings, *Oral Surg Oral Med Oral Pathol Oral Radiol Endod* 79:583–592, 1995.
88. Martelli-Júnior H, Santos Neto PE, Aquino SN, Santos CC, Borges SP, Oliveira EA, Lopes MA: Coletta RD: Amelogenesis imperfecta and nephrocalcinosis syndrome: a case report and review of the literature, *Nephron Physiol* 118:62–65, 2011.
89. Vervaet BA, Verhulst A, D'Haese PC, De Broe ME: Nephrocalcinosis: new insights into mechanisms and consequences, *Nephrol Dial Transplant* 24:2030–2035, 2009.
90. Patel RR, et al.: X-linked (recessive) hypomaturation amelogenesis imperfecta: a prosthodontic, genetic, and histopathologic report, *J Prosthet Dent* 66(3):398–402, 1991.
91. Chaudhry AP, et al.: Odontogenesis imperfecta. Report of a case, *Oral Surg Oral Med Oral Pathol* 14:1099–1103, 1961.
92. Schimmelpfennig CB, McDonald RE: Enamel and dentine aplasia; report of a case, *Oral Surg Oral Med Oral Pathol* 6(12):1444–1449, 1953.
93. Gorlin RJ, Herman NG, Moss SJ: Complete absence of the permanent dentition: an autosomal recessive disorder, *Am J Med Genet* 5(2):207–209, 1980.
94. Salinas CF, Jorgenson RJ, Wright JT, DiGiovanna JJ, Fete MD: 2008 International Conference on Ectodermal Dysplasias Classification: conference report, *Am J Med Genet* 149A:1958–1969, 2009.
95. Adaimy L, Chouery E, Megarbane H, Mroueh S, Delague V, Nicolas E, Belguith H, de Mazancourt P, Megarbane A: Mutation in WNT10A is associated with an autosomal recessive ectodermal dysplasia: the odonto-onycho-dermal dysplasia, *Am J Hum Genet* 81:821–828, 2007.
96. Ohring A, Stamm T, Spaich C, Haase C, Spree K, Hehr U, Hoffmann M, Ledig S, Sel S, Wieacker P, Ropke A: WNT10A mutations are a frequent cause of a broad spectrum of ectodermal dysplasias with sex-biased manifestation pattern in heterozygotes, *Am J Hum Genet* 85:97–105, 2009.
97. van den Boogaard M-J, Creton M, Bronkhorst Y, van der Hout A, Hennekam E, Lindhout D, Cune M, Ploos van Amstel HK: Mutations in WNT10A are present in more than half of isolated hypodontia cases, *J Med Genet* 49:327–331, 2012.
98. Swallow JN: Complete anodontia of the permanent dentition, *Br Dent J* 107:143–145, 1959.
99. Schneider PE: Complete anodontia of the permanent dentition: case report, *Pediatr Dent* 12(2):112–114, 1990.
100. Laird GS: Congenital anodontia, *J Am Dent Assoc* 51:722, 1955.

101. Witkop CJ Jr: Agenesis of succedaneous teeth: an expression of the homozygous state of the gene for the pegged or missing maxillary lateral incisor trait, *Am J Med Genet* 26(2):431–436, 1987.
102. Hoo JJ: Anodontia of permanent teeth (OMIM # 206780) and pegged/missing maxillary lateral incisors (OMIM # 150400) in the same family, *Am J Med Genet* 90(4):326–327, 2000.
103. Glenn FB: A consecutive six-year study of the prevalence of congenitally missing teeth in private practice of two geographically separated areas, *J Dent Child* 31:269–270, 1964.
104. Grahnen H: Hypodontia in the permanent dentition, *Dent Abstr* 3:308–309, 1957.
105. Vastardis H, et al.: A human MSX1 homeodomain missense mutation causes selective tooth agenesis, *Nat Genet* 13(4):417–421, 1996.
106. Stockton DW, et al.: Mutation of PAX9 is associated with oligodontia, *Nat Genet* 24(1):18–19, 2000.
107. Liu W, Wang H, Zhao S, Zhao W, Bai S, Zhao Y, Xu S, Wu C, Huang W, Chen Z, Feng G, He L: The novel gene locus for agenesis of permanent teeth (He-Zhao deficiency) maps to chromosome 10q11.2, *J Dent Res* 80:1716–1720, 2001.
108. Noor A, Windpassinger C, Vitcu I, Orlic M, Rafiq MA, Khalid M, Malik MN, Ayub M, Alman B, Vincent JB: Oligodontia is caused by mutation in LTBP3, the gene encoding latent TGF-beta binding protein 3, *Am J Hum Genet* 84:519–523, 2009.
109. Han D, Gong Y, Wu H, Zhang X, Yan M, Wang X, Qu H, Feng H, Song S: Novel EDA mutation resulting in X-linked non-syndromic hypodontia and the pattern of EDA-associated isolated tooth agenesis, *Eur J Med Genet* 51:536–546, 2008.
110. Vincent MC, Biancalana V, Ginisty D, Mandel JL, Calvas P: Mutational spectrum of the ED1 gene in X-linked hypohidrotic ectodermal dysplasia, *Eur J Hum Genet* 9:355–363, 2001.
111. Casal ML, Lewis JR, Mauldin EA, Tardivel A, Ingold K, Favre M, Paradies F, Demotz S, Gaide O, Schneider P: Significant correction of disease after postnatal administration of recombinant ectodysplasin A in canine X-linked ectodermal dysplasia, *Am J Hum Genet* 81:1050–1056, 2007.
112. Erpenstein H, Pfeiffer RA: [Sex-linked-dominant hereditary reduction in number of teeth], *Humangenetik* 4(3):280–293, 1967.
113. Ahmad W, et al.: A locus for autosomal recessive hypodontia with associated dental anomalies maps to chromosome 16q12.1, *Am J Hum Genet* 62(4):987–991, 1998.
114. Bennett CG, Ronk SL: Congenitally missing primary teeth: report of case, *ASDC J Dent Child* 47(5):346–348, 1980.
115. Shashikiran ND, Karthik V, Subbareddy VV: Multiple congenitally missing primary teeth: report of a case, *Pediatr Dent* 24(2):149–152, 2002.
116. Fleming P, Nelson J, Gorlin RJ: Single maxillary central incisor in association with mid-line anomalies, *Br Dent J* 168(12):476–479, 1990.
117. Cobourne MT: Familial human hypodontia—is it all in the genes? *Br Dent J* 203(4):203–208, 2007.
118. Becker A, Sharabi S, Chaushu S: Maxillary tooth size variation in dentitions with palatal canine displacement, *Eur J Orthod* 24(3):313–318, 2002.
119. Becker A, Gillis I, Shpack N: The etiology of palatal displacement of maxillary canines, *Clin Orthod Res* 2(2):62–66, 1999.
120. Chaushu S, Sharabi S, Becker A: Tooth size in dentitions with buccal canine ectopia, *Eur J Orthod* 25(5):485–491, 2003.
121. Becker A: In defense of the guidance theory of palatal canine displacement, *Angle Orthod* 65(2):95–98, 1995.
122. Paschos E, et al.: Investigation of maxillary tooth sizes in patients with palatal canine displacement, *J Orofac Orthop* 66(4):288–298, 2005.
123. Peck S, Peck L, Kataja M: The palatally displaced canine as a dental anomaly of genetic origin, *Angle Orthod* 64(4): 249–256, 1994.
124. Lammi L, et al.: Mutations in AXIN2 cause familial tooth agenesis and predispose to colorectal cancer, *Am J Hum Genet* 74(5):1043–1050, 2004.
125. Marvin ML, Mazzoni SM, Herron CM, Edwards S, Gruber SB, Petty EM: AXIN2-associated autosomal dominant ectodermal dysplasia and neoplastic syndrome, *Am J Med Genet* 155A:898–902, 2011.
126. Chalothorn LA, et al.: Hypodontia as a risk marker for epithelial ovarian cancer: a case-controlled study, *J Am Dent Assoc* 139(2):163–169, 2008.
127. Fekonja A, Čretnik A, Takac I: Hypodontia prevalence and pattern in women with epithelial ovarian cancer. *Angle Orthod*

    876.1.
128. Bonds J, Pollan-White S, Xiang L, Mues G, D'Souza R: Is there a link between ovarian cancer and tooth agenesis? *Eur J Med Genet* 57(5):235–239, 2014.
129. Küchler EC, Lips A, Tannure PN, Ho B, Costa MC, Granjeiro JM, Vieira AR: Tooth agenesis association with self-reported family history of cancer, *J Dent Res* 92(2):149–155, 2013.
130. Salinas CF, Jorgenson RJ, Wright JT, DiGiovanna JJ, Fete MD: 2008 International Conference on Ectodermal Dysplasias Classification: conference report, *Am J Med Genet* 149A:1958–1969, 2009.
131. Monreal AW, Zonana J, Ferguson B: Identification of a new splice form of the EDA1 gene permits detection of nearly all X-linked hypohidrotic ectodermal dysplasia mutations, *Am J Hum Genet* 63(2):380–389, 1998.
132. Giansanti JS, Long SM, Rankin JL: The "tooth and nail" type of autosomal dominant ectodermal dysplasia, *Oral Surg Oral Med Oral Pathol* 37(4):576–582, 1974.
133. Jumlongras D, et al.: A nonsense mutation in MSX1 causes Witkop syndrome, *Am J Hum Genet* 69(1):67–74, 2001.
134. Hudson CD, Witkop CJ: Autosomal dominant hypodontia with nail dysgenesis. Report of twenty-nine cases in six families, *Oral Surg Oral Med Oral Pathol* 39(3):409–423, 1975.
135. Nunn JH, et al.: The interdisciplinary management of hypodontia: background and role of paediatric dentistry, *Br Dent J* 194(5):245–251, 2003.
136. Neville BW, et al.: *Oral and maxillofacial pathology*, 2nd ed., Philadelphia, 2002, WB Saunders.
137. Stoll BJ, Kliegman RM: Hemolytic disease of the newborn (erythroblastosis fetalis). In Behrman RE, Kliegman RM, Jenson HB, editors: *Nelson textbook of pediatrics*, Philadelphia, 2004, WB Saunders.
138. Cullen CL: Erythroblastosis fetalis produced by Kell immunization: dental findings, *Pediatr Dent* 12(6):393–396, 1990.
139. Sassa S: The porphyrias. In Behrman RE, Kliegman RM, Jenson HB, editors: *Nelson textbook of pediatrics*, Philadelphia, 2004, WB Saunders.
140. Zegarelli EV, et al.: Discoloration of the teeth in a 24-year-old patient with cystic fibrosis of the pancreas not primarily associated with tetracycline therapy. Report of a case, *Oral Surg Oral Med Oral Pathol* 24(1):62–64, 1967.
141. Wright JT, Hall KI, Grubb BR: Enamel mineral composition of normal and cystic fibrosis transgenic mice, *Adv Dent Res* 10(2):270–274, 1996.
142. Arquitt CK, Boyd C, Wright JT: Cystic fibrosis transmembrane regulator gene (CFTR) is associated with abnormal enamel formation, *J Dent Res* 81(7):492–496, 2002.

143. Primosch RE: Tetracycline discoloration, enamel defects, and dental caries in patients with cystic fibrosis, *Oral Surg Oral Med Oral Pathol* 50(4):301–308, 1980.
144. van der Bijl P, Pitigoi-Aron G: Tetracyclines and calcified tissues, *Ann Dent* 54(1-2):69–72, 1995.
145. Moffitt JM, et al.: Prediction of tetracycline-induced tooth discoloration, *J Am Dent Assoc* 88(3):547–552, 1974.
146. Tredwin CJ, Scully C, Bagan-Sebastian JV: Drug-induced disorders of teeth, *J Dent Res* 84(7):596–602, 2005.
147. Brantley DH, Barnes KP, Haywood VB: Bleaching primary teeth with 10% carbamide peroxide, *Pediatr Dent* 23(6): 514–516, 2001.
148. Gorlin RJ, Cohen MM Jr, Hennekam RCM: *Syndromes of the head and neck*, 4th ed., New York, 2001, Oxford University Press.
149. Hartsfield JK Jr: The benefits of obtaining the opinion of a clinical geneticist regarding orthodontic patients. In Krishnan V, Davidovitch Z, editors: *Integrated clinical orthodontics*, Oxford, 2012, Wiley-Blackwell, pp 109–131.
150. Pruzansky S, Richmond JB: Growth of mandible in infants with micrognathia; clinical implications, *Am J Dis Child* 88(1):29–42, 1954.
151. Daskalogiannakis J, Ross RB, Tompson BD: The mandibular catch-up growth controversy in Pierre Robin sequence, *Am J Orthod Dentofacial Orthop* 120(3):280–285, 2001.
152. Hotz M, Gnoinski W: Clefts of the secondary palate associated with the "Pierre Robin syndrome." Management by early maxillary orthopaedics, *Swed Dent J Suppl* 15:89–98, 1982.
153. Dean JA, et al.: Prevention of airway obstruction in Pierre Robin sequence via obturator use, *Pediatr Dent* 24:173–174, 2002. (abstract).
154. Burket LW: *Oral medicine: diagnosis and treatment*, 7th ed., Philadelphia, 1977, JB Lippincott.
155. Reynoso MC, et al.: Autosomal dominant congenital macroglossia: further delineation of the syndrome, *Genet Couns* 5(2):151–154, 1994.
156. Keizer D: Casuistische mededelingen dominant erfeljik ankyloglosson, *Nederl T Geneesk* 96:2203–2205, 1952.
157. Klockars T, Pitkaranta A: Inheritance of ankyloglossia (tongue-tie), *Clin Genet* 75:98–99, 2009. (letter).
158. Braybrook C, Doudney K, Marcano ACB, Arnason A, Bjornsson A, Patton MA, Goodfellow PJ, Moore GE, Stanier P: The T-box transcription factor gene TBX22 is mutated in X-linked cleft palate and ankyloglossia, *Nature Genet* 29: 179–183, 2001.
159. Ayers FJ, Hilton LM: Treatment of ankyloglossia: report of case, *ASDC J Dent Child* 44(3):237–239, 1977.
160. Messner AH, Lalakea ML: The effect of ankyloglossia on speech in children, *Otolaryngol Head Neck Surg* 127(6): 539–545, 2002.
161. Kullaa-Mikkonen A: Familial study of fissured tongue, *Scand J Dent Res* 96(4):366–375, 1988.
162. Bánóczy J, Szabo L, Csiba A: Migratory glossitis. A clinical-histologic review of seventy cases, *Oral Surg Oral Med Oral Pathol* 39(1):113–121, 1975.
163. Cooke BE: Median rhomboid glossitis. Candidiasis and not a developmental anomaly, *Br J Dermatol* 93(4):399–405, 1975.
164. Barasch A, et al.: Oral soft tissue manifestations in HIV-positive vs. HIV-negative children from an inner city population: a two-year observational study, *Pediatr Dent* 22(3):215–220, 2000.
165. Martinello RA, Cooney EL: Cerebellar brain abscess associated with tongue piercing, *Clin Infect Dis* 36(2):e32–e34, 2003.
166. Dyce O, et al.: Tongue piercing. The new "rusty nail?" *Head Neck* 22(7):728–732, 2000.
167. Akhondi H, Rahimi AR: *Haemophilus aphrophilus* endocarditis after tongue piercing, *Emerg Infect Dis* 8(8):850–851, 2002.
168. Perkins CS, Meisner J, Harrison JM: A complication of tongue piercing, *Br Dent J* 182(4):147–148, 1997.
169. Keogh IJ, O'Leary G: Serious complication of tongue piercing, *J Laryngol Otol* 115(3):233–234, 2001.

CHAPTER 4

Development and Morphology of the Primary Teeth

▲ **Erwin G. Turner** and **Jeffrey A. Dean**

For additional resources, please visit the evolve website.

CHAPTER OUTLINE

LIFE CYCLE OF THE TOOTH
- Initiation (Bud Stage)
- Proliferation (Cap Stage)
- Histodifferentiation and Morphodifferentiation (Bell Stage)
- Apposition
- Calcification

EARLY DEVELOPMENT AND CALCIFICATION OF THE ANTERIOR PRIMARY TEETH

EARLY DEVELOPMENT AND CALCIFICATION OF THE POSTERIOR PRIMARY TEETH AND THE FIRST PERMANENT MOLAR

MORPHOLOGY OF INDIVIDUAL PRIMARY TEETH
- Maxillary Central Incisor
- Maxillary Lateral Incisor
- Maxillary Canine
- Mandibular Central Incisor
- Mandibular Lateral Incisor
- Mandibular Canine
- Maxillary First Molar
- Maxillary Second Molar
- Mandibular First Molar
- Mandibular Second Molar

MORPHOLOGIC DIFFERENCES BETWEEN PRIMARY AND PERMANENT TEETH

SIZE AND MORPHOLOGY OF THE PRIMARY TOOTH PULP CHAMBER

This chapter presents a brief review of the development of the teeth. An accurate chronology of primary tooth calcification is of clinical significance to the dentist. It is often necessary to explain to parents the time sequence of calcification in utero and during infancy. The common observations of tetracycline pigmentation, developmental enamel defects, and generalized hereditary anomalies can be explained if the calcification schedule is known. A brief discussion of the morphology of the primary teeth is also appropriate before restorative procedures are considered for children.

A complete review is available in the reference texts on oral histology, dental anatomy, and developmental anatomy listed at the end of the chapter. Furthermore, contemporary scientists are rapidly gaining knowledge of tooth development at the molecular level. We suggest that readers with a special interest in the molecular events of tooth development study the listed references by Smith[1] and by Miletich and Sharpe.[2]

LIFE CYCLE OF THE TOOTH

INITIATION (BUD STAGE)

Evidence of development of the human tooth can be observed as early as the sixth week of embryonic life. Cells in the basal layer of the oral epithelium proliferate at a more rapid rate than do the adjacent cells. The result is an epithelial thickening in the region of the future dental arch that extends along the entire free margin of the jaws. This thickening is called the *primordium* of the ectodermal portion of the teeth and what results is called the *dental lamina*. At the same time, 10 round or ovoid swellings occur in each jaw in the position to be occupied by the primary teeth.

Certain cells of the basal layer begin to proliferate at a more rapid rate than do the adjacent cells (Fig. 4-1, *A*). These proliferating cells contain the entire growth potential of the teeth. The permanent molars, like the primary teeth, arise from the dental lamina. The permanent incisors, canines, and premolars develop from the buds of their primary predecessors. The congenital absence of a tooth is the result of a lack of initiation or an arrest in the proliferation of cells. The presence of supernumerary teeth is the result of continued budding of the enamel organ.

PROLIFERATION (CAP STAGE)

Proliferation of the cells continues during the cap stage. As a result of unequal growth in the different parts of the bud, a cap is formed (Fig. 4-1, *B*). A shallow invagination appears on the deep surface of the bud. The peripheral cells of the cap later form the outer and inner enamel epithelium.

As with a deficiency in initiation, a deficiency in proliferation results in failure of the tooth germ to develop and in fewer than the normal numbers of teeth. Excessive proliferation of cells may result in epithelial rests. These rests may remain inactive or become activated due to an irritation or stimulus. If the cells become partially differentiated or detached from the enamel organ in their partially differentiated state, they assume the secretory functions common to all epithelial cells, and a cyst develops. If the cells become more fully differentiated or detached from the enamel organ, they produce enamel and dentin, which results in an odontoma (Fig. 3-5) or a supernumerary

Dentlearn.ir

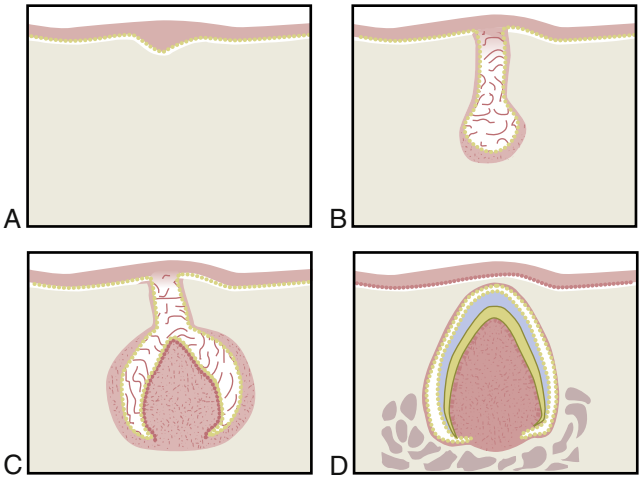

Figure 4-1 Life cycle of the tooth. **A**, Initiation (bud stage). **B**, Proliferation (cap stage). **C**, Histodifferentiation and morphologic differentiation (bell stage). **D**, Apposition and calcification. (Adapted from Bath-Balogh M, Fehrenbach MJ: *Illustrated dental embryology, histology, and anatomy*, ed 2, Philadelphia, 2006, Saunders.)

tooth. The degree of differentiation of the cells determines whether a cyst, an odontoma, or a supernumerary tooth develops (Fig. 22-52).

HISTODIFFERENTIATION AND MORPHODIFFERENTIATION (BELL STAGE)

The epithelium continues to invaginate and deepen until the enamel organ takes on the shape of a bell (Fig. 4-1, *C*). It is during this stage that the cells of the dental papilla differentiate into odontoblasts and those of the inner enamel epithelium differentiate into ameloblasts.

Histodifferentiation marks the end of the proliferative stage as the cells lose their capacity to multiply. This stage is the forerunner of appositional activity. Disturbances in the differentiation of the formative cells of the tooth germ result in abnormal structure of the dentin or enamel. One clinical example of the failure of ameloblasts to differentiate properly is amelogenesis imperfecta (Figs. 3-32 and 3-33). The failure of the odontoblasts to differentiate properly, with the resultant abnormal dentin structure, results in dentinogenesis imperfecta (Fig. 3-31).

In the morphodifferentiation stage, the formative cells are arranged to outline the form and size of the tooth. This process occurs before matrix deposition. The morphologic pattern of the tooth becomes established when the inner enamel epithelium is arranged so that the boundary between it and the odontoblasts outlines the future dentino-enamel junction. Disturbances and aberrations in morphodifferentiation lead to abnormal forms and sizes of teeth, resulting in conditions such as peg teeth, other types of microdontia, and macrodontia.

APPOSITION

Appositional growth is the result of a layer-like deposition of a nonvital extracellular secretion in the form of a tissue matrix. This matrix is deposited by the formative cells, ameloblasts, and odontoblasts, which line up along the future dentino-enamel and dentinocemental junction at the stage of morphodifferentiation. These cells deposit the enamel and dentin matrix in a definite pattern and at a definite rate. The formative cells begin their work at specific sites that are referred to as *growth centers* as soon as the blueprint, the dentino-enamel junction, is completed (Fig. 4-1, *D*).

Any systemic disturbance or local trauma that injures the ameloblasts during enamel formation can cause an interruption or an arrest in matrix apposition, which results in enamel hypoplasia (Fig. 3-16). Hypoplasia of the dentin is less common than enamel hypoplasia and occurs only after severe systemic disturbances (Fig. 3-15).

CALCIFICATION

Calcification (mineralization) takes place following matrix deposition and involves the precipitation of inorganic calcium salts within the deposited matrix. The process begins with the precipitation of a small nidus, and further precipitation occurs around it. The original nidus increases in size by the addition of concentric laminations. There is an eventual approximation and fusion of these individual calcospherites into a homogeneously mineralized layer of tissue matrix. If the calcification process is disturbed, there is a lack of fusion of the calcospherites. These deficiencies are not readily identified in the enamel, but in the dentin they are evident microscopically and are referred to as interglobular dentin.

EARLY DEVELOPMENT AND CALCIFICATION OF THE ANTERIOR PRIMARY TEETH

Kraus and Jordan found that the first macroscopic indication of morphologic development occurs at approximately 11 weeks in utero.[3] The maxillary and mandibular central incisor crowns appear identical at this early stage as tiny, hemispheric, moundlike structures.

The lateral incisors begin to develop morphologic characteristics between 13 and 14 weeks. There is evidence of the developing canines between 14 and 16 weeks. Calcification of the central incisor begins at approximately 14 weeks in utero, with the maxillary central incisor slightly preceding the mandibular central incisor. The initial calcification of the lateral incisor occurs at 16 weeks and that of the canine at 17 weeks.

The developmental dates listed precede by 3 to 4 weeks the dates that appear in the chronology of the human dentition as developed by Logan and Kronfeld.[4] This observation has been confirmed by Lunt and Law.[5]

EARLY DEVELOPMENT AND CALCIFICATION OF THE POSTERIOR PRIMARY TEETH AND THE FIRST PERMANENT MOLAR

The maxillary first primary molar appears macroscopically at 12½ weeks in utero. Kraus and Jordan[3] observed that, as early as 15½ weeks, the apex of the mesiobuccal cusp may undergo calcification. At approximately 34 weeks

the entire occlusal surface is covered by calcified tissue. At birth, calcification includes roughly three fourths of the occlusal gingival height of the crown.

The maxillary second primary molar also appears macroscopically at about 12½ weeks in utero. There is evidence of calcification of the mesiobuccal cusp as early as 19 weeks. At birth, calcification extends occlusogingivally to include approximately one fourth of the height of the crown.

The mandibular first primary molar initially becomes evident macroscopically at about 12 weeks in utero. Calcification may be observed as early as 15½ weeks at the apex of the mesiobuccal cusp. At birth, a completely calcified cap covers the occlusal surface.

The mandibular second primary molar also becomes evident macroscopically at 12½ weeks in utero. According to Kraus and Jordan, calcification may begin at 18 weeks.[3] At the time of birth, the five centers have coalesced, and only a small area of uncalcified tissue remains in the middle of the occlusal surface. There are sharp conical cusps, angular ridges, and a smooth occlusal surface, all of which indicate that calcification of these areas is incomplete at birth. Thus there is a calcification sequence of central incisor, first molar, lateral incisor, canine, and second molar.

The work of Kraus and Jordan indicates that the adjacent second primary and the first permanent molars undergo identical patterns of morphodifferentiation but at different times, and the initial development of the first permanent molar occurs slightly later. Their research has also shown that the first permanent molars are uncalcified before 28 weeks of age; calcification may begin at any time thereafter. Some degree of calcification is always present at birth. In addition, Marita and others,[6] using first permanent and second primary molars, reported that their patterns of cusp shape variability differ from each other and that temporal factors contribute to the patterns of size variability, while shape variability is influenced more by topographic factors.

MORPHOLOGY OF INDIVIDUAL PRIMARY TEETH

MAXILLARY CENTRAL INCISOR

The mesiodistal width of the crown of the maxillary central incisor is greater than the cervico-incisal length. Developmental lines are usually not evident in the crown; thus the labial surface is smooth. The incisal edge is nearly straight even before abrasion becomes evident. There are well-developed marginal ridges on the lingual surface and a distinctly developed cingulum (Figs. 4-2 and 4-3). The root of the incisor is conical with tapered sides.

MAXILLARY LATERAL INCISOR

The outline of the maxillary lateral incisor is similar to that of the central incisor, but the crown is smaller in all dimensions. The length of the crown from the cervical to the incisal edge is greater than the mesiodistal width. The root outline is similar to that of the central incisor but is longer in proportion to the crown.

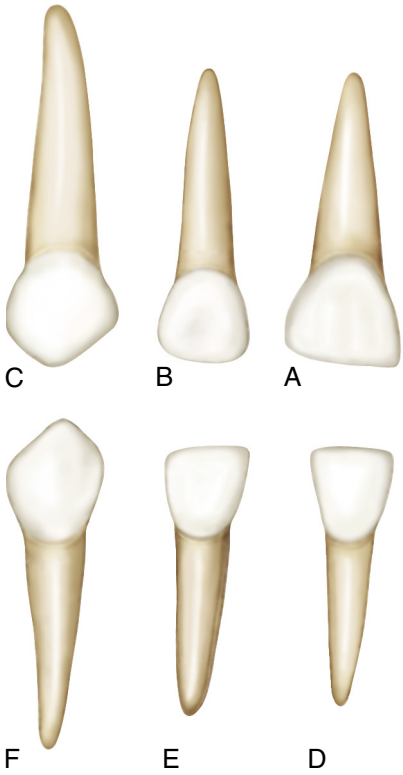

Figure 4-2 Primary right anterior teeth, labial aspect. **A**, Maxillary central incisor. **B**, Maxillary lateral incisor. **C**, Maxillary canine. **D**, Mandibular central incisor. **E**, Mandibular lateral incisor. **F**, Mandibular canine. (From Nelson SJ: *Wheeler's dental anatomy, physiology, and occlusion*, ed 9, Philadelphia, 2010, WB Saunders.)

MAXILLARY CANINE

The crown of the maxillary canine is more constricted at the cervical region than are the incisors, and the incisal and distal surfaces are more convex. There is a well-developed sharp cusp rather than a relatively straight incisal edge. The canine has a long, slender, tapering root that is more than twice the length of the crown. The root is usually inclined distally, apical to the middle third.

MANDIBULAR CENTRAL INCISOR

The mandibular central incisor is smaller than the maxillary central incisor, but its labiolingual measurement is usually only 1 mm less. The labial aspect presents a flat surface without developmental grooves. The lingual surface presents marginal ridges and a cingulum. The middle third and the incisal third on the lingual surface may have a flattened surface level with the marginal ridges, or there may be a slight concavity. The incisal edge is straight and bisects the crown labiolingually. The root is approximately twice the length of the crown.

MANDIBULAR LATERAL INCISOR

The outline of the mandibular lateral incisor is similar to that of the central incisor but is somewhat larger in all dimensions except labiolingually. The lingual surface may have greater concavity between the marginal ridges. The incisal edge slopes toward the distal aspect of the tooth.

Dentlearn.ir

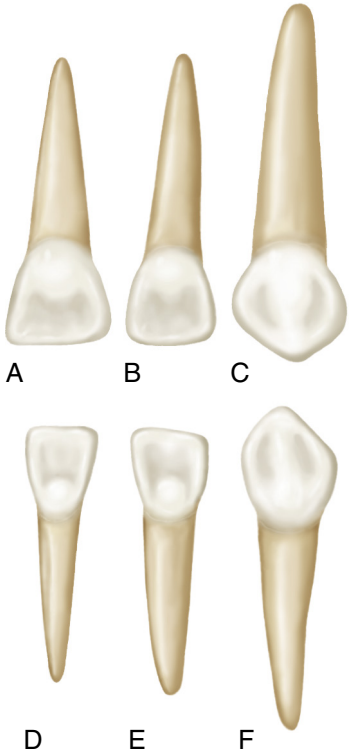

Figure 4-3 Primary right anterior teeth, lingual aspect. **A**, Maxillary central incisor. **B**, Maxillary lateral incisor. **C**, Maxillary canine. **D**, Mandibular central incisor. **E**, Mandibular lateral incisor. **F**, Mandibular canine. (From Nelson SJ: *Wheeler's dental anatomy, physiology, and occlusion*, ed 9, Philadelphia, 2010, WB Saunders.)

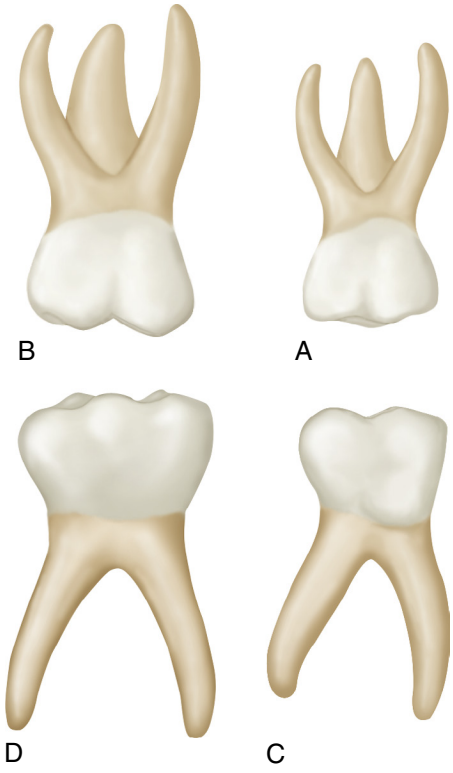

Figure 4-4 Primary right molars, buccal aspect. **A**, Maxillary first molar. **B**, Maxillary second molar. **C**, Mandibular first molar. **D**, Mandibular second molar. (From Nelson SJ: *Wheeler's dental anatomy, physiology, and occlusion*, ed 9, Philadelphia, 2010, WB Saunders.)

MANDIBULAR CANINE

The form of the mandibular canine is similar to that of the maxillary canine, with a few exceptions. The crown is slightly shorter, and the root may be as much as 2 mm shorter than that of the maxillary canine. The mandibular canine is not as large labiolingually as its maxillary counterpart.

MAXILLARY FIRST MOLAR

The greatest dimension of the crown of the maxillary first molar is at the mesiodistal contact areas, and from these areas the crown converges toward the cervical region (Figs. 4-4, 4-5, and 4-6).

The mesiolingual cusp is the largest and sharpest. The distolingual cusp is poorly defined, small, and rounded. The buccal surface is smooth, with little evidence of developmental grooves. The three roots are long, slender, and widely spread.

MAXILLARY SECOND MOLAR

There is a considerable resemblance between the maxillary second primary molar and the maxillary first permanent molar. There are two well-defined buccal cusps, with a developmental groove between them. The crown of the second molar is considerably larger than that of the first molar.

The bifurcation between the buccal roots is close to the cervical region. The roots are longer and heavier than those of the first primary molar, and the lingual root is

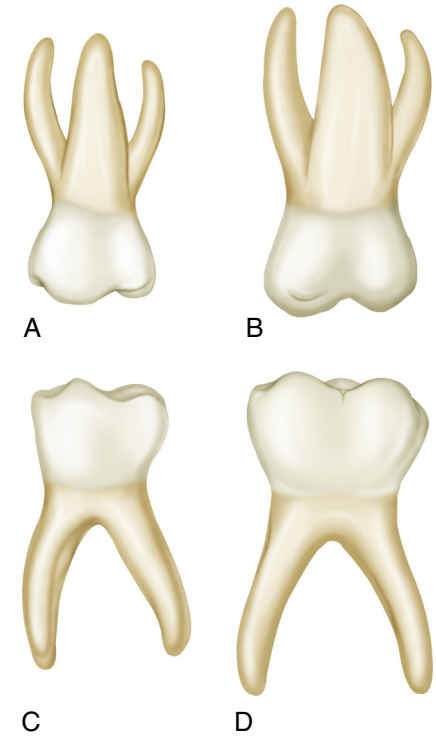

Figure 4-5 Primary right molars, lingual aspect. **A**, Maxillary first molar. **B**, Maxillary second molar. **C**, Mandibular first molar. **D**, Mandibular second molar. (From Nelson SJ: *Wheeler's dental anatomy, physiology, and occlusion*, ed 9, Philadelphia, 2010, WB Saunders.)

Dentlearn.ir

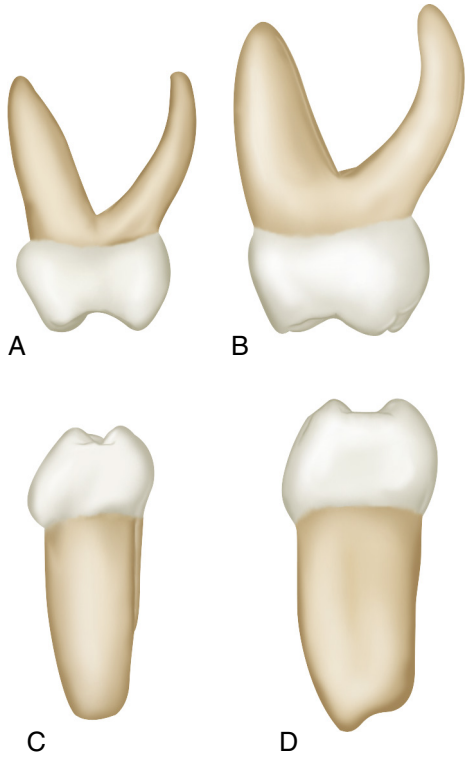

Figure 4-6 Primary right molars, mesial aspect. **A**, Maxillary first molar. **B**, Maxillary second molar. **C**, Mandibular first molar. **D**, Mandibular second molar. (From Nelson SJ: *Wheeler's dental anatomy, physiology, and occlusion*, ed 9, Philadelphia, 2010, WB Saunders.)

large and thick compared with the other roots (Figs. 4-4 and 4-5).

The lingual surface has three cusps: a mesiolingual cusp that is large and well developed, a distolingual cusp, and a third and smaller supplemental cusp (the cusp of Carabelli). A well-defined groove separates the mesiolingual cusp from the distolingual cusp. On the occlusal surface a prominent oblique ridge connects the mesiolingual cusp with the distobuccal cusp (Fig. 4-7).

MANDIBULAR FIRST MOLAR

Unlike the other primary teeth, the first primary molar does not resemble any of the permanent teeth. The mesial outline of the tooth, when viewed from the buccal aspect, is almost straight from the contact area to the cervical region. The distal area of the tooth is shorter than the mesial area.

The two distinct buccal cusps have no evidence of a distinct developmental groove between them; the mesial cusp is the larger of the two.

There is a pronounced lingual convergence of the crown on the mesial aspect, with a rhomboid outline present on the distal aspect. The mesiolingual cusp is long and sharp at the tip; a developmental groove separates this cusp from the distolingual cusp, which is rounded and well developed. The mesial marginal ridge is well developed, to the extent that it appears as another small cusp lingually. When the tooth is viewed from the mesial aspect, there is an extreme curvature buccally at the cervical third. The crown length is greater in the mesiobuccal area than in the mesiolingual area; thus the cervical line slants upward from the buccal to the lingual surface.

The longer slender roots spread considerably at the apical third, extending beyond the outline of the crown. The mesial root, when viewed from the mesial aspect, does not resemble any other primary root. The buccal and lingual outlines of the root drop straight down from the crown, being essentially parallel for more than half their length. The end of the root is flat and almost square.

MANDIBULAR SECOND MOLAR

The mandibular second molar resembles the mandibular first permanent molar, except that the primary tooth is smaller in all its dimensions. The buccal surface is divided into three cusps that are separated by mesiobuccal and distobuccal developmental grooves. The cusps are almost equal in size. Two cusps of almost equal size are evident on the lingual surface and are divided by a short lingual groove.

The primary second molar, when viewed from the occlusal surface, appears rectangular with a slight distal convergence of the crown. The mesial marginal ridge is developed to a greater extent than the distal marginal ridge.

One difference between the crown of the primary molar and that of the first permanent molar is in the distobuccal cusp; the distal cusp of the permanent molar is smaller than the other two buccal cusps.

The roots of the primary second molar are long and slender, with a characteristic flare mesiodistally in the middle and apical thirds.

MORPHOLOGIC DIFFERENCES BETWEEN PRIMARY AND PERMANENT TEETH

Cleghorn and others[7] state that the morphology of the primary dentition is different in many respects from that of the permanent dentition, and not only in the sizes of the crowns and roots. They have outlined these morphologic differences (Box 4-1).

SIZE AND MORPHOLOGY OF THE PRIMARY TOOTH PULP CHAMBER

Considerable individual variation exists in the sizes of the pulp chambers and pulp canals of the primary teeth. Immediately after tooth eruption, the pulp chambers are large and generally follow the outline of the crown. They decrease in size as age increases and under the influence of both function and abrasion of the occlusal and incisal surfaces of the teeth.

No attempt is made here to describe in detail each pulp chamber outline; rather, it is suggested that the dentist examine critically the bitewing radiographs of the child before undertaking operative procedures. Just as there are individual differences in the calcification and eruption times of teeth, so are there individual differences in the morphology of the crowns and the size of the pulp chamber. However, radiographs do not demonstrate completely the extent of the pulp horn into the cuspal area.

Dentlearn.ir

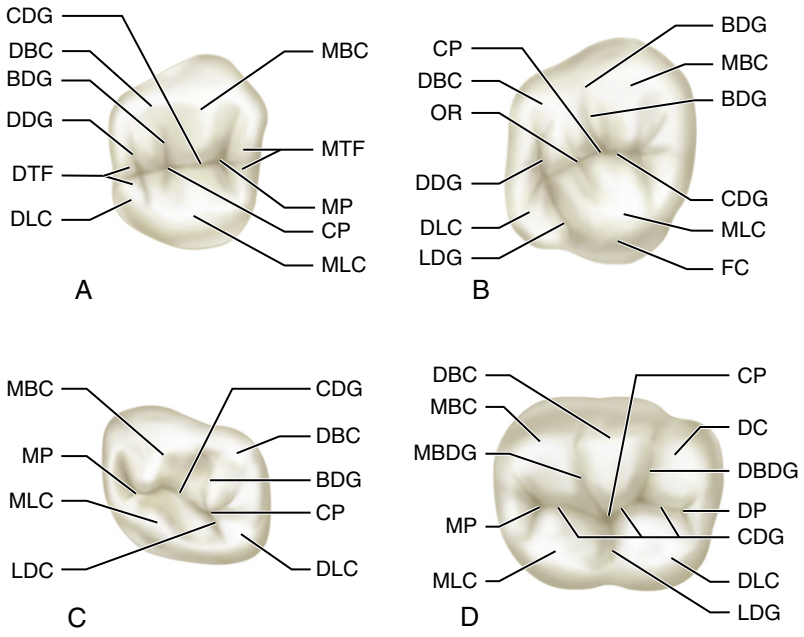

Figure 4-7 Primary right molars, occlusal aspect. **A**, Maxillary first molar. **B**, Maxillary second molar. **C**, Mandibular first molar. **D**, Mandibular second molar. BDG, Buccal developmental groove; CDG, central developmental groove; CP, central pit; DBC, distobuccal cusp; DBDG, distobuccal developmental groove; DC, distal cusp; DDG, distal developmental groove; DLC, distolingual cusp; DP, distal pit; DTF, distal triangular fossa; FC, fifth cusp; LDG, lingual developmental groove; MBC, mesiobuccal cusp; MBDG, mesiobuccal developmental groove; MLC, mesiolingual cusp; MP, mesial pit; MTF, mesial triangular fossa; OR, oblique ridge. (From Nelson SJ: *Wheeler's dental anatomy, physiology, and occlusion*, ed 9, Philadelphia, 2010, WB Saunders.)

Box 4-1

Characteristics of Teeth in the Primary Dentition

Crowns

The crowns in the primary dentition are shorter relative to the length of the root (i.e., smaller crown: root ratio).

The occlusal tables of primary molars are constricted buccolingually and much narrower mesiodistally when compared with those of the permanent molars.

Enamel and dentin are thinner compared with permanent teeth.

The thickness of the enamel and dentin of primary teeth is approximately half that of permanent teeth.

The enamel rod direction in the cervical area is angled occlusally compared with the apical direction in permanent teeth.

Crowns of primary teeth are characterized by significant cervical constriction in both the mesiodistal and faciolingual dimensions.

The primary molars have a pronounced buccal cervical bulge.

The contact areas of primary molars are flat and very broad buccolingually compared with the permanent molars.

The crown color of the primary teeth is whiter and a lighter shade.

Roots

The roots of the primary molars have a greater flare, which accommodates the developing crowns of the succedaneous permanent premolars of the permanent dentition.

The mesiodistal width of the roots of primary anterior teeth is much narrower than the crown when compared with those of the permanent anterior teeth.

The primary molar roots are relatively longer and more slender, i.e., mandibular molar roots are narrower mesiodistally, maxillary MB and DB roots are narrower mesiodistally, and maxillary palatal roots are narrower buccolingually.

Pulp and Root Canal Systems

The size of the pulp relative to the crown is larger in the primary teeth.

Pulp horns are higher in proportion and are located closer to the DEJ and to the outer surface of the crown.

Mesial pulp horns are higher than distal pulp horns.

Pulp chambers are shaped comparably with the shape of the outline of the crown from an occlusal view.

Pulp horns are present under each cusp of the primary molars.

The pulp chambers of primary mandibular molar teeth are normally larger than the pulp chambers of primary maxillary molars.

The root canal system of fully developed primary molars is extremely tortuous and complex.

Used with permission from Cleghorn BM, Boorberg NB, Christie WH. Primary human teeth and their root canal systems, Endodontic Topics *23:6-33, 2010.*

In addition, the cemento-enamel junction of primary teeth presents three interesting morphologic relationships, in which the cementum is over enamel, the cementum and enamel are edge to edge, or there is a gap between the cementum and enamel with dentin exposure. This irregularity in the cemento-enamel junction may indicate the need for care during restorative and other procedures to avoid damage.[8]

REFERENCES

1. Smith CE: Cellular and chemical events during enamel maturation, *Crit Rev Oral Biol Med* 9:128–161, 1998.
2. Miletich I, Sharpe PT: Normal and abnormal dental development, *Hum Mol Genet* 12:R69–R73, 2003.
3. Kraus BS, Jordan RE: *The human dentition before birth*, Philadelphia, 1965, Lea & Febiger.
4. Logan WHG, Kronfeld R: Development of the human jaws and surrounding structures from birth to the age of fifteen years, *J Am Dent Assoc* 20:379–427, 1933.
5. Lunt RC, Law DB: A review of the chronology of calcification of deciduous teeth, *J Am Dent Assoc* 89:599–606, 1974.
6. Morita W, Yano W, Nagaoka T, et al.: Size and shape variability in human molars during odontogenesis, *J Dent Res* 93:275–280, 2014.
7. Cleghorn BM, Boorberg NB, Christie WH: Primary human teeth and their root canal systems, *Endodontic Topics* 23:6–33, 2012.
8. Francischone LA, Consolaro A: Morphology of the cemento-enamel junction of primary teeth, *J Dent Child* 75:252–259, 2008.

SUGGESTED READINGS

Chiego D: *Essentials of oral histology and embryology*, ed 4, St. Louis, 2013, Mosby.
Nanci A: *Ten Cate's oral histology*, ed 8, St. Louis, 2013, Mosby.
Nelson SJ: *Wheeler's dental anatomy, physiology, and occlusion*, ed 9, Philadelphia, 2010, WB Saunders.
Schour I, Massler M: Studies in tooth development: the growth pattern of human teeth, *J Am Dent Assoc* 27:1778–1793, 1940.

CHAPTER 5

Clinical Genetics for the Dental Practitioner

▲ James K. Hartsfield Jr.

For additional resources, please visit the evolve website.

CHAPTER OUTLINE

REVIEW OF GENETIC PRINCIPLES
CELL DIFFERENTIATION AND DEVELOPMENTAL BIOLOGY
CHROMOSOMES
HEREDITARY TRAITS IN FAMILIES
DEVELOPMENTAL BIOLOGY OF ENAMEL
AUTOSOMAL-DOMINANT INHERITANCE
AUTOSOMAL-RECESSIVE INHERITANCE
X-LINKED OR SEX-LINKED INHERITANCE
  X-Linked Dominant
  X-Linked Recessive
VARIATION IN GENE EXPRESSION
  Penetrance
  Expressivity
  Epigenetics
MULTIFACTORIAL INHERITANCE
  Multifactorial (Complex) Inheritance in Human Diseases
INFLUENCE OF GENETIC FACTORS ON MAJOR CRANIOFACIAL, ORAL, AND DENTAL CONDITIONS
GENETICS AND DENTAL CARIES
GENETICS AND PERIODONTAL DISEASE
  Aggressive (Early-Onset) Periodontitis
GENETICS OF MALOCCLUSION
EXTERNAL APICAL ROOT RESORPTION
GENETICS OF CLEFT LIP AND PALATE

The purpose of this chapter is twofold: to review genetic principles and to mention a few examples of the influence of genetic factors on major craniofacial, oral, and dental conditions. As the basis for relatively rare developmental dysplasias, diseases, and syndromes that show a genetic cause or marked genetic influence becomes known, increasing attention is being paid to those genetic factors that influence (or are associated with) more common conditions. An increased appreciation of how genetic factors interact with environmental (nongenetic) factors to influence growth and pathology will lead to an increased understanding of pathogenesis and the susceptible or that they may respond differently to treatment. Further information may be found online in the Genetics Home Reference—Your Guide to Understanding

REVIEW OF GENETIC PRINCIPLES

The *genome* contains the entire genetic content of a set of chromosomes present within a cell or an organism. Within the genome are genes that represent the smallest physical and functional units of inheritance that reside in specific sites (called *loci* or locus for a single location). A *gene* can be defined as the entire DNA sequence necessary for the synthesis of a functional polypeptide molecule (production of a protein via a messenger RNA intermediate) or RNA molecule (transfer RNA and ribosomal RNA). *Genotype* generally refers to the set of genes that an individual carries and, in particular, usually refers to the specific pair of alleles (alternative forms of a particular gene) that a person has at a given location (locus) of his/her total collection of DNA, called that individual's *genome*. In contrast, *phenotype* is the observable properties and physical characteristics of an individual, as determined by the individual's genotype and the environment in which the individual develops over a period of time.

Remarkable advances in the biochemical techniques used to study cell molecular biology and DNA have taken researchers to the threshold of understanding the regulation of cell functions. To illustrate, not so long ago, DNA analyses were performed on minute amounts (picograms) of DNA. This limitation was necessary because there was vestigators discovered the DNA polymerase enzyme that could replicate DNA through the polymerase chain reac- disappeared. This advance facilitated the completion of the human genome project, which resulted in not only the definition of a single human genome sequence composed of overlapping parts from many humans but also an expanding catalogue of more than one million sites of variation in the human genome sequence. These variations (or polymorphisms) may be used as markers for genetic analysis (including analysis of genetic-environmental interaction) in human beings. The genome varies from one individual to the next, most often in terms of single base changes of DNA, called *single nucleotide polymorphisms* (SNPs, pronounced "snips"). The main use of this human SNP map will be to determine the contributions of genes to diseases (or nondisease phenotypes) that have complex, multifactorial bases (Fig. 5-1).

Dentlearn.ir

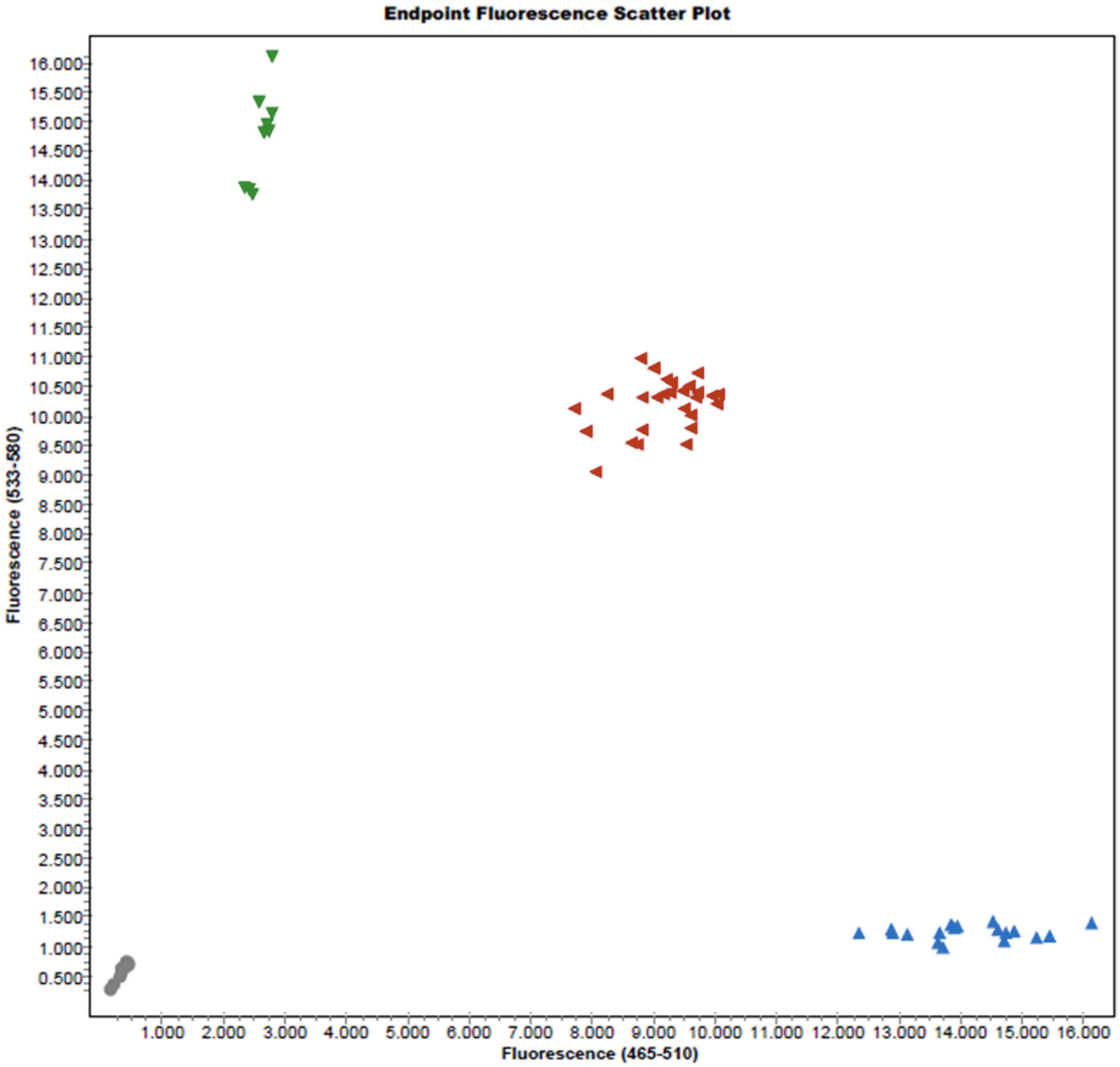

Figure 5-1 Single nucleotide polymorphism (SNP) genotyping endpoint fluorescence scatter plot. Each triangle is an individual located in an area that is homozygous for one of the gene variants (alleles), or homozygous for the other gene variant (allele), or has one of each (heterozygous). The individual's genotype for that specific SNP can be determined by the location of the symbol for that person on the scatter plot. For example, this is a plot for the catechol *O*-methyltransferase gene SNP, which is important in pain perception. The individuals indicated by the green triangles are GG, the individuals marked by the red

tion following orthodontic separator placement and COMT haplotype. *J Dent Res* 93(Spec Iss B): abstract number 1674, 2014

Information about genetic influences on clinical questions is starting to accelerate due to what is referred to as next-generation or "deep" sequencing. Compared with the methods used in the human genome project over 10 years ago, modern sequencers are 50,000-fold faster, and therefore proportionately cheaper (Fig. 5-2). Although costs are decreasing, generating high coverage across the entire genome (referred to as whole genome sequencing, or WGS) is still expensive. So, a common alternative is to

for sequences in the exons of coding genes (known as the "exome"), resulting in whole exome sequencing (WES).[1] Determination of the genes responsible for still-unknown Mendelian (single-gene) and complex diseases and traits presents an immediate opportunity for this technology to be used to move from approaches based on only partial

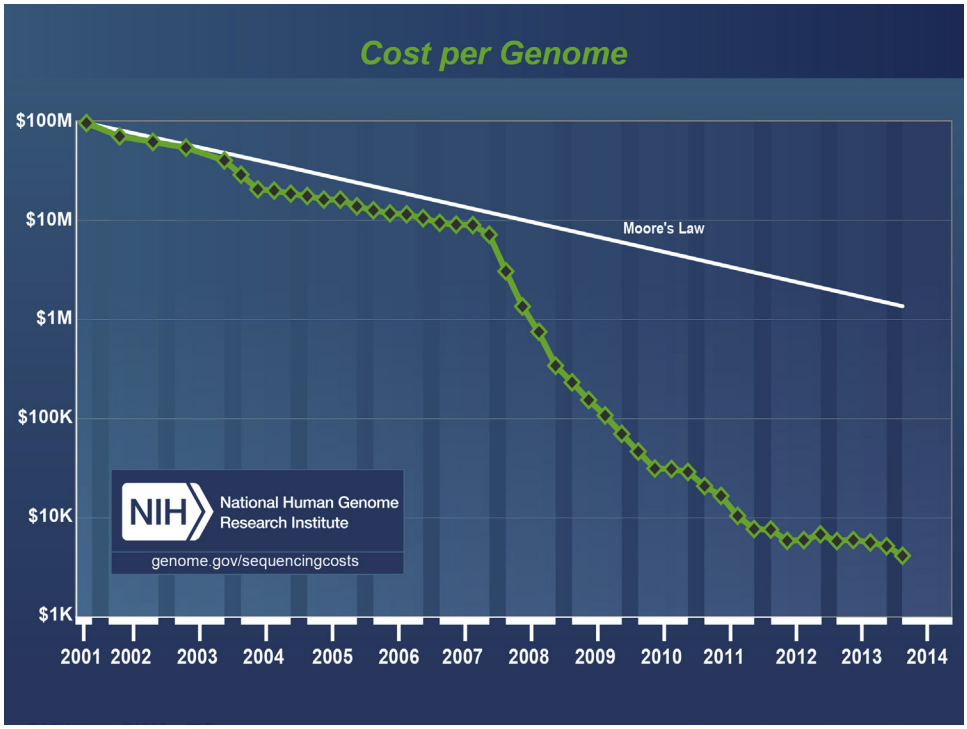

Figure 5-2 Genome sequencing cost in USD as estimated by the National Human Genome Research Institute. In comparison with hypothetical data reflecting Moore's law, which describes a long-term trend in the computer hardware industry that involves the doubling of "compute power" every 2 years, the progress in decreasing the costs of genomic sequencing has been spectacular. [From Wetterstrand KA: DNA sequencing costs: data from the NHGRI Genome Sequencing Program (GSP);

information (genetic linkage and genome-wide association studies, GWAS) to complete analysis of the relationship between genomic variation and phenotype.[2]

CELL DIFFERENTIATION AND DEVELOPMENTAL BIOLOGY

It is fascinating that a single fertilized ovum contains within itself the potential for development of the incredibly complicated human organism. Cellular differentiation is a critical component of this developmental process and, aside from the development of antibody diversity, typically occurs in the absence of genetic alteration or mutation. Different types of cells gain their specific identities from a particular subset of the approximately 30,000 or more genes present within the genome. The types of polypeptides that a cell can synthesize include: enzymes, which catalyze various activities of cellular metabolism and homeostasis; structural proteins, which form the intracellular and extracellular scaffolding or cellular matrix; and regulatory proteins, which convey signals from the outside of the cell to the nucleus and modulate or control specific gene expression. In a developing embryo, cells reside in a three-dimensional environment and respond to signals from themselves (autocrine), from nearby sources (paracrine), and from anatomically distant sources (endocrine). Many of these signals are mediated by soluble molecules (either peptide or nonpeptide in origin) that bind to specific receptors (proteins) present on the surface or on the inside of cells. In addition to signals from soluble factors, cells can respond to cell-to-cell or cell-to-extracellular matrix signals.[3]

The action of "turning on" or "turning off" specific genes, referred to as *regulation of gene expression*, is carefully orchestrated and remains a critical element in the determination of cell specificity and tissue morphogenesis. Transcription factors bind to DNA and either facilitate or suppress initiation of gene transcription, the most common control point of gene expression. In the development of the craniofacial complex, there is increasing evidence for the role of homeobox-containing gene families that encode transcription factors. These then are critical for the control of complex interactions between and among genes that are subsequently expressed during development.

In summary:

1. The genetic message lies in the DNA itself, which is coded and transmitted from cell generation to cell generation when these DNA molecules are replicated (or duplicated).
2. A given cell type and function are defined by the specific RNA molecules made from the DNA master. These RNA molecular copies direct protein synthesis in the cell.
3. Transcription factors determine which genes are expressed through the production of the RNA and subsequent protein.
4. Environmental factors can influence the modification of gene expression through the addition or removal of

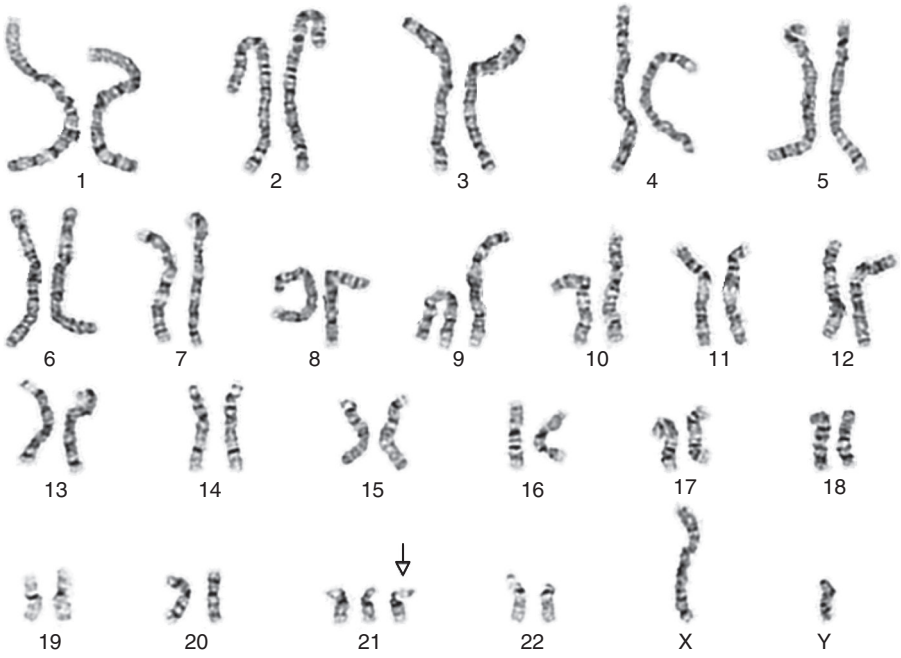

Figure 5-3 Banded karyotype of a male with trisomy of chromosome 21 (Down syndrome). (Courtesy Cytogenetic Laboratories, Indiana University School of Medicine, Indianapolis.)

to the DNA or supporting structures, referred to as epigenetics. If present in the germ line, these changes can be inherited along with the DNA sequence.

5. Development occurs through the action of specific transcription factors and other regulators of protein production on specific genes that need to be expressed next in time.

CHROMOSOMES

have 46 chromosomes that contain an estimated 30,000 genes, including numerous duplicates. Of the 46 chromosomes, the *sex chromosomes* are the X and Y and the remaining 44 chromosomes are referred to as *autosomes*. Each autosome has a paired mate that is referred to as its *homologue*. Therefore, with the exception of some of the genes on the X and Y chromosomes in males, there are at least two copies of each gene unless a piece of DNA is deleted. Thus the human chromosome complement consists of 23 pairs of chromosomes (one pair of sex chromosomes and 22 pairs of autosomes).

Lejeune and colleagues demonstrated that the fundamental cause of Down syndrome is the presence of an extra specific chromosome (number 21) in the affected individual's cells.[4] When an entire extra chromosome is present, the condition is called a *trisomy* of the chromosome in question; for example, trisomy 21 for Down syndrome. Figure 5-3 shows the karyotype of a male who has Down

21 and number 22 chromosomes is readily apparent.

Since this report in 1959, many disease states have been shown to be associated with an incorrect chromosome complement. By using first the microscopic study of chromosome structure, and now the chromosomal microarray approach with considerable refinement, it was shown that alterations in the fine structure of chromosomes, as well as in their number, could be present. Monosomy of an autosome, or a missing autosomal chromosome, had not been believed to be compatible with life, but several monosomies in live-born children have now been reported. Monosomy of the sex chromosomes can be compatible with life and typically affects develop-

individuals. The best-known example of this is Turner syndrome, which occurs in approximately 1 in every 5000 live female births. These persons are phenotypic females who are usually missing one of the X chromosomes and are chromosomally designated as 45, X. Other aberrations of the X chromosome may also cause Turner syndrome. Affected individuals are typically short of stature, lack secondary gender characteristics, and are sterile. Table 5-1 lists common chromosomal aberrations that produce clinical disease, including examples of translocations (the attachment of a broken piece from one chromosome to another, but not homologous, chromosome) and deletions (the absence of a piece of a chromosome).

Chromosome abnormalities are an important cause of spontaneous abortion. About 15% of all recognized pregnancies end in spontaneous abortion, and the incidence of chromosome abnormalities in such abortions is greater than 50%. Only 0.3% to 0.5% of all live-born infants have a chromosome abnormality that is detectable with standard microscopic karyotyping. Microdeletions and microduplications of DNA, not visible by routine chromosome karyotype analysis, are a major cause of human malformation and mental retardation. A complementary analysis called *comparative genomic hybridization* (CGH) or *chromosomal microarray* (CMA) can improve the diagnostic detection rate of these small chromosomal abnormalities. The technology

Dentlearn.ir

Table **5-1**

Common Chromosomal Aberrations

Type	Specific Alteration	Clinical Result
Aneuploidy	Trisomy 21	Down syndrome
	Trisomy 18	Edwards syndrome
	Trisomy 13	Patau syndrome
	Extra X chromosomes	In females: XXX, XXXX, XXXXX syndromes
		In males: Klinefelter syndrome—XXY, XXXY, and XXXXY
	Monosomy, autosomal	Usually nonviable
	Monosomy, X chromosome	In females: Turner syndrome, 45, X
		In males: nonviable, 45, Y
Translocation	14/21, 21/21 or 21/22	Translocation carrier (normal phenotype) or Down syndrome
Deletion	Ring chromosome	Variable
	Short arm chromosome No. 5	Cri du chat syndrome
	Philadelphia chromosome (No. 22)	Chronic myeloid leukemia

has advanced so that CMA is now the American College of Medical Genetics and Genomics' recommended first-tier diagnostic test for individuals with multiple congenital anomalies, developmental delay/intellectual disability, and autism spectrum disorders.[5] Although chromosomal microarray has been extensively shown to provide a higher diagnostic yield than conventional cytogenetic methods, some health insurers refuse to provide coverage for this test, claiming that it is experimental and does not affect patients' clinical management. In contrast to this claim, there are data demonstrating the clinical utility of CMA.[6]

HEREDITARY TRAITS IN FAMILIES

Heritability is the proportion of the total phenotypic vari-

On an individual basis for a binary trait (i.e., a disease or trait that an individual either has or does not have), heritability is not the proportion of disease or the trait attributable to, or caused by, genetic factors. For a quantitative trait, heritability is not a measure of the proportion of an individual's score attributable to genetic factors.[7] A trait with a heritability of 1 is said to be expressed without any environmental influence, whereas a trait with a heritability of 0.5 has half its variability (from individual to individual) influenced by environmental factors and half by genotypic factors. Values greater than 1 may occur because the methodology provides an estimate of heritability under several simplifying assumptions that may be incorrect.

There is the common perception that knowing a trait's heritability will somehow affect how a patient should be treated (e.g., for malocclusion) or that it will define the limits of tooth movement or the manipulation of jaw growth. This is not true. The ability of the patient to respond to changes in the environment (including treatment), which has nothing to do with heritability, defines these limits. Heritability estimates imply nothing about trait size or treatment limits based on a presumed genetic "predetermination."[8] Even so, the estimation of heritability can provide an indication of the relative importance of genetic factors on a trait in a

of genetic influence on a trait is a preliminary step to performing further specific genetic linkage studies (with DNA markers) to determine areas of the genome that appear to be associated with the characteristics of a given trait.

When hereditary traits in families are to be studied, it is convenient to think of three classes of genetically influenced traits: (1) monogenic, (2) polygenic, and (3) multifactorial. Recently, the polygenic and multifactorial classes have often been combined into what are referred to as *complex traits* rather than Mendelian traits.[9] Monogenic traits are produced and regulated by a single gene locus. Usually they are relatively rare in the general population (occurrence in fewer than 1 per 1000 individuals). However, if the appearance of an affected person is striking, there may be instant recognition of the disease, as with patients having albinism, achondroplasia, or neurofibromatosis. Monogenetic conditions often occur in families and show transmission characteristics of the Mendelian (dominant or recessive) traits.

Polygenic traits, too, are hereditary and typically exert influence over common characteristics such as height, skin, and intelligence. This influence takes place through many gene loci collectively asserting their regulation of the trait. Although each gene involved has a minimal effect by itself, the effect of all the genes involved is additive. The associated phenotype is rarely discrete and is most commonly continuous or quantitative. Because these traits show a quantitative distribution of their phenotypes in a population, they do not show Mendelian inheritance patterns. It is important to note that the very nature of their influence (multiple genes, each with a small additive effect) dictates that their environment may readily influence them. Monogenic traits are not readily amenable to large-scale environmental modification, although there can be variations, presumably secondary to other genetic and environmental factors. By contrast, one can easily think of a dozen environmental factors known to influence height and intelligence quotient.

Finally, multifactorial traits or conditions are influenced by multiple genes but differ significantly from polygenic traits in that the influence is achieved through an interaction of multiple genes and environmental factors and occurs when a liability threshold is exceeded. Although typically the number of genes involved is many, occasionally a few genes, sometimes only two or three, influence the trait. The effect of these genes on the phenotype is therefore a net effect, not necessarily a simple additive one. Furthermore, phenotypic expression approaches that of a discrete Mendelian trait and therefore cannot be readily classed as a quantitative trait. Likewise, the effect of a gene influencing the phenotype may not be as great as that of a gene associated with a monogenic trait, but the gene may be referred to as having a major effect. Among the well-known hereditary types of conditions designated as multifactorial are many of the severe nonsyndromic congenital malformations such as cleft lip and palate (CLP), neural tube defects such as spina bifida, anencephaly, and hip dislocation. Multifactorial complex inheritance is discussed later.

The investigation of human heritable traits usually involves the observation of specific features in a family and the study of that family's pedigree. In a family, the affected individual who first brings that family to the attention of the geneticist is called the *proband* or *propositus*. This individual is the index case. Brothers and sisters of the proband are *siblings* or sibs. Thus a sibship consists of all the brothers and sisters in a nuclear family unit (parents and their offspring). The clinical appearance in an individual of a given trait, such as eye color or height, is that individual's phenotype, whereas the specific genetic makeup that influences or is associated with the phenotype is the genotype.

In an earlier section, the point is made that the human chromosome complement has 22 homologous pairs of autosomes and one pair of sex chromosomes. Because of homologue pairing (excluding the X and Y chromosomes in the male), there are at least two copies of each gene, one located at the same position (locus) on each member of the homologous pair. Genes at the same locus on a pair of homologous chromosomes are *alleles*. When both members of a pair of alleles are identical, the individual is *homozygous* for that locus. When the two alleles at a specific locus are different, the individual is *heterozygous* for that locus.

A gene that results in the expression of a particular phenotype in single dose (i.e., heterozygous) is a dominant gene. If the gene must be present in double dose (homozygous) to express the phenotype, it is a recessive gene. It is actually the phenotype that is dominant or recessive and not the gene itself. The terms *dominant gene* and *recessive gene*, though, are commonly used to describe these types of inherited traits in families.

Construction of a pedigree, which is a shorthand method of classifying the family data, conveniently summarizes these data for the study of inherited traits. The symbols used in constructing a pedigree are shown in Figure 5-4. The observable inheritance patterns followed by such monogenic traits within families are determined by (1) whether the trait is dominant or recessive, (2) whether the gene is autosomal (on one of the autosomes) or X-linked (on the X chromosome), and (3) the chance distribution in the offspring of those genes passed from parents in their gametes (sperm and ova). Pedigree construction is a valuable tool for the clinician who is concerned with the diagnosis of and counseling regarding hereditary traits. Every dentist should be able to construct and interpret a pedigree because it is a certainty that patients will come to the dentist's office with heritable oral diseases that must be diagnosed before treatment can begin.

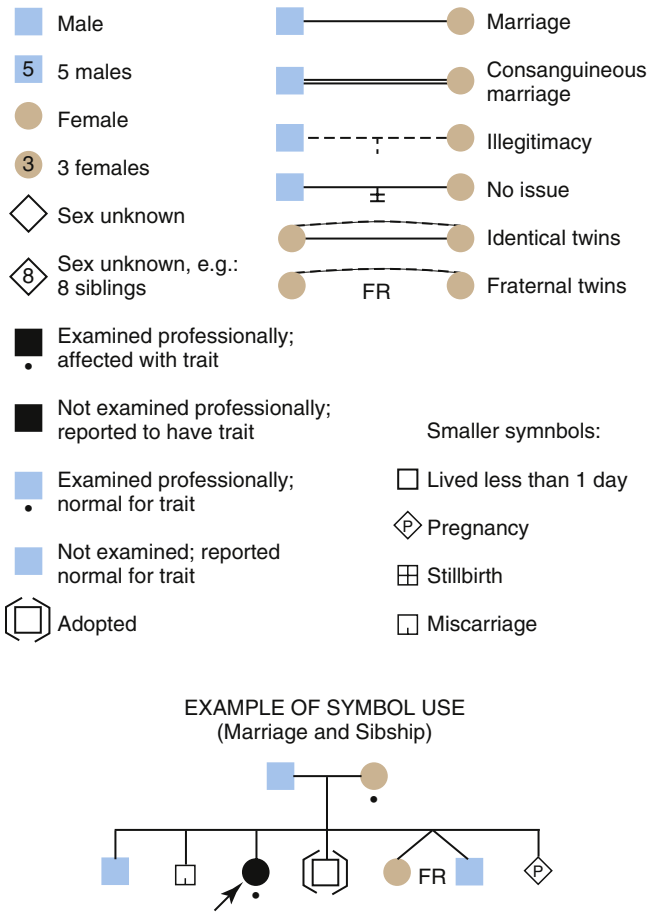

Figure 5-4 Pedigree symbols used in family studies.

The simple patterns of monogenic inheritance seen in families are described in the following discussion. Because all the Mendelian modes of inheritance are found in the amelogenesis imperfecta (AI) disorders, these are used to illustrate basic genetic principles.

DEVELOPMENTAL BIOLOGY OF ENAMEL

Tucker and Sharpe have provided a review of how molecular biologists are studying the genetic factors involved in dental development.[10] The two developmentally different cell layers involved in dentinogenesis, inner enamel epithelium (enamel) and neural crest (dentin), are separated by an extracellular matrix.[11] Specific tooth development is then mutually dependent on reciprocal cell-to-cell signaling between these two developmentally different cell layers.[12] The genes involved in the development of these

Dentlearn.ir

tissues are candidates for DNA mutation analysis, especially if they are in a chromosome location that has been associated with or linked to an inherited defect of enamel or dentin. The most intriguing dental research today is focused on (1) the attempt to localize the genes for these proteins to specific loci and (2) the biochemical identification of a specific defect in the protein that prevents it from functioning normally. The following is a discussion of genetic principles best exemplified by the heritable disorders of enamel. (Further discussion of the molecular basis of the heritable disorders of dentin and enamel appears in Chapter 3.)

Based on clinical appearance, radiographic characteristics, and microscopic features, oral pathologists have recognized three major types of inherited enamel defects: hypoplasia, hypocalcification, and hypomaturation.

These terms also provide the general description of the disease phenotypes. For example, in type 1, enamel hypoplasia, the enamel is hard and well calcified but defective in amount, so the teeth appear small. Two types of deficient enamel phenotypes are seen: generalized (all the enamel) and localized (pits and grooves in specific areas). Type 2, hypocalcification disorders, are those in which the enamel matrix is so drastically altered that normal calcification cannot occur, with the result that the clinical phenotype is soft, mushy enamel that easily wears away. Type 3 defect, hypomaturation, involves the process of maturation of the enamel crystal. This occurs after an essentially normal enamel matrix has been established. The enamel is of normal thickness (not hypoplastic) and relatively normal hardness (slightly hypocalcified) with reduced radiographic density and discoloration.

From this collection of enamel diseases we can now select four examples of AI that illustrate the four major Mendelian modes of inheritance: autosomal dominant (AD), autosomal recessive (AR), X-linked dominant (XLD), and X-linked recessive (XLR).

One characteristic of inherited dental defects is that both dentitions (primary and permanent) are affected. Occasionally the defect is expressed differently in the two dentitions, as in the case of dentin dysplasia type II.[13] However, it is much more common to see the same clinical and radiographic picture in both dentitions. Both dentitions are affected in AI disorders.

AUTOSOMAL-DOMINANT INHERITANCE

From pedigrees such as that shown in Figure 5-5, the following criteria for AD inheritance may be deduced:

1. The phenotype occurs in successive generations, that is, it shows vertical inheritance.
2. On average, 50% of the offspring of an affected parent will also be affected.
3. Normal parents have normal offspring. The following causes of exceptions to this rule are worth noting:

- Nonpenetrance of the trait (defined later).
- A mutation in either the sperm or egg.
- Germinal mosaicism. This is an increasingly invoked explanation for this situation. In this case, one of the parents is mosaic in the germ cell line, and the sperm or eggs are of two types—one cell line with and one cell line without the mutation. Chance determines which sperm cell line will be selected. However, as the molecular basis of genetic traits becomes evident, mutation analysis may show that a parent believed to be unaffected may actually also have the somatic mutation found in affected children.
- Nonpaternity. Although this is not strictly a genetic problem, the illegitimacy rate in the U.S. population is high enough to make this a likely explanation when a normal couple has a child affected with a completely penetrant dominant trait.

4. Males and females are equally likely to be affected.

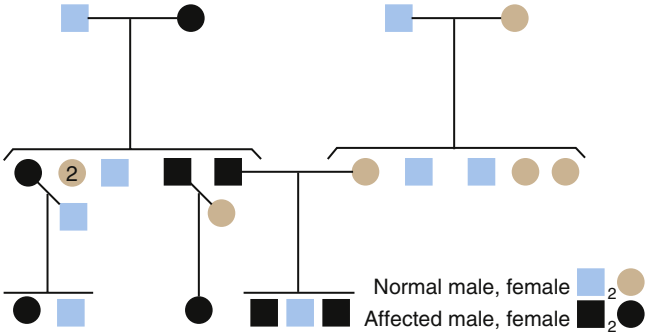

Figure 5-5 Autosomal-dominant inheritance in hypocalcified amelogenesis imperfecta.

The hypocalcification type of AI provides an excellent example of AD inheritance. For diagnosis of this trait, several criteria are used. First, enamel matrix is susceptible to abrasion. The clinical picture is typical—gross accumulation of plaque on teeth that are hypersensitive because of the exposed dentin. Second, radiographs show enamel of various interproximal thicknesses but with a Swiss cheese appearance because of loss of mineral. Thus severe abrasion of this soft enamel is common.

AUTOSOMAL-RECESSIVE INHERITANCE

Recessively inherited traits require that both genes of a given pair at a single locus code for defective proteins. Thus, of the two alleles at this genetic locus for AI, both must be mutants to show the trait. The following three gene pairs are recognized: AA, normal; Aa, heterozygote, showing an unaffected phenotype; and aa, homozygous, affected phenotype. The most common genetic situation producing an affected child is that in which both parents are heterozygous at this genetic locus (Fig. 5-6).

The following significant points about recessive inheritance must be noted:

1. The concept of a gene carrier is used here. The carrier is heterozygous for a recessive gene, and this single gene has only subtle, if any, expression. Parents of an affected child are typically heterozygous (carriers) and are then interpreted as being normal. Sometimes the carrier state can be detected, as in the case of phenylketonuria or Tay-Sachs disease. In these conditions a test is available for carrier identification to detect the presence of the single mutant gene. This greatly improves the precision of genetic counseling.

Dentlearn.ir

2. The rarer the recessive gene, the more likely it is that normal parents who have an affected child will be blood relatives. This is consanguineous mating. Given that both parents who produce an AR-affected child are heterozygotes, it is easy to see that only one of the four possible combinations of parents' genes results in the homozygous-affected genotype. Hence, the recurrence risk for an affected child in this case is 25%. Note that transmission of the phenotype in a pedigree is horizontal (typically present only in sibs) and not vertical as with a dominant trait.

Of several AR types of AI, the one chosen for discussion here is the pigmented hypomaturation form. In this instance, the genetic defect probably lies in the protein needed in late tooth development to produce mature, hard, and dense enamel. The defective enamel present is softer than normal but not nearly as soft and easily abraded as in the hypocalcification defect. Remarkably, a brown pigment is found in these outer layers of enamel that are formed last, imparting a dark brown, unsightly appearance that necessitates restorative treatment. A pedigree illustrating AR inheritance of this hypomaturation defect is shown in Figure 5-6.

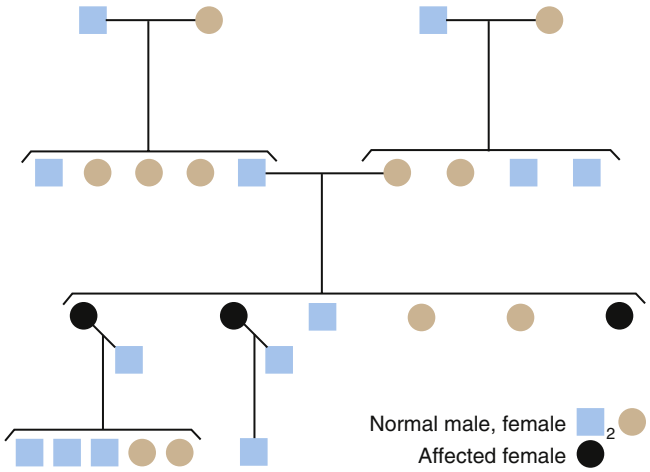

Figure 5-6 Autosomal-recessive inheritance in pigmented amelogenesis imperfecta.

X-LINKED OR SEX-LINKED INHERITANCE

Genes on the sex chromosomes are unequally distributed to males and females. This inequality is the result of the following facts: (1) males have one X and one Y chromosome, whereas females have two X chromosomes; and (2) the genes active on the Y chromosome are essentially concerned with the development of the male reproductive system. For these reasons, then, males are hemizygous for X-linked genes, meaning that they have only half (or one each) of the X-linked genes. Because females have two X chromosomes, they may be either homozygous or heterozygous for X-linked genes, just as with autosomal genes.

Interesting genetic combinations are made possible by the male hemizygous condition. Because only one gene locus of each kind in the X chromosome is represented in the male, all recessive genes in single dose express themselves phenotypically and thereby behave as though they were dominant genes. Conversely, XLR genes must be present in double dose (homozygous) in females to fully express themselves. Consequently, full expression of rare XLR diseases in practice is restricted to males and is seen infrequently in females.

To this point we have considered heritable defects in two of the three major types of enamel disorders. The third type—AI, hypoplastic type—shows both autosomal and X-linked modes of inheritance, but only one X-linked type is described here.

X-LINKED DOMINANT

Figure 5-7 is the pedigree of a family with an XLD form of AI, hypoplastic type.[14] The clinical features are diagnostic and in some females can be quite striking.

Once again, both dentitions are affected similarly. The surface defect has been described as being granular, lobular, or even pitted. Conceivably, all these different forms of expression are the result of the action of a single gene (or at least its alleles). The enamel is hard but because of its thinness is more susceptible to fracture and abnormal wear. Under the appropriate conditions, this trait resembles a hypocalcification defect. However, radiographs quickly resolve this diagnostic problem and show enamel of normal density but with greatly reduced thickness.

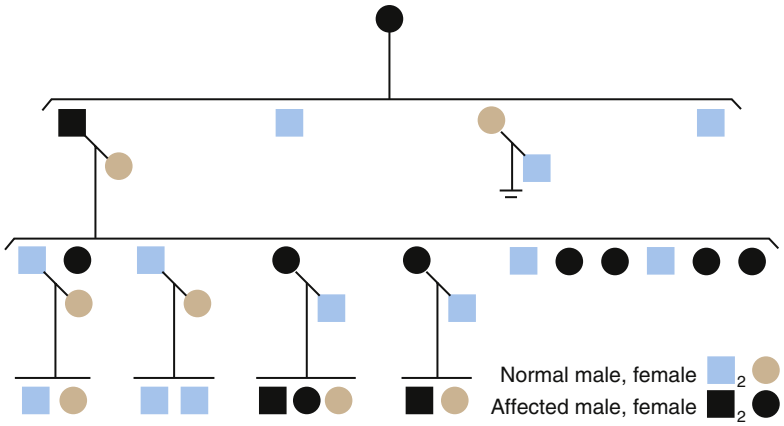

Figure 5-7 X-linked dominant inheritance in hypoplastic amelogenesis imperfecta.

X-LINKED RECESSIVE

A pedigree of a family with the X-linked recessive form of enamel hypomaturation is shown in Figure 5-8. The genetic criteria for diagnosing an XLR trait are summarized as follows:

1. Because the gene cannot be passed from father to son, affected fathers almost never have affected sons. A son could be affected if the mother is a carrier of the XLR trait.
2. All daughters of an affected male receive his X-linked genes. Therefore, affected males transmit the trait to their grandsons if they are affected through their daughters.
3. The incidence of the trait is much higher in males than in females. This is typified by the disease hemophilia, which is also caused by an XLR gene.

The clinical features of XLR hypomaturation-type AI are most striking. The enamel has a somewhat reduced hardness but is not soft. However, the crowns of the teeth look like mountains with snow on them; hence the name "snow-capped teeth." Radiologically, the enamel is hypomature; it shows a lack of contrast between enamel and dentin even though the enamel is of normal thickness.

It should be noted that heterozygous females occasionally show significant clinical expression of a single XLR gene. The reason for this apparent contradiction is the process of X inactivation, termed *lyonization,* after geneticist Mary Lyon. This occurs only in females. All normal female cells have two X chromosomes, but most of the genes on one of the two X chromosomes are inactivated at approximately the blastula stage of development. This has the effect of making the total number of active, X-linked genes about the same in both males and females. If the female is heterozygous for an X-linked trait, two populations of cells result. One cell population has genes on one X chromosome that are active, while the other cell population has genes on the other X chromosome that are active. When by chance the X chromosome with the deleterious gene is active in a significant proportion of the cells, its expression may be observed in that female. Chance dictates that this imbalance does not occur frequently, but because all females are, by definition of lyonization, mosaic with regard to X-linked traits, phenotypic expression of heterozygous genes may occur in them.

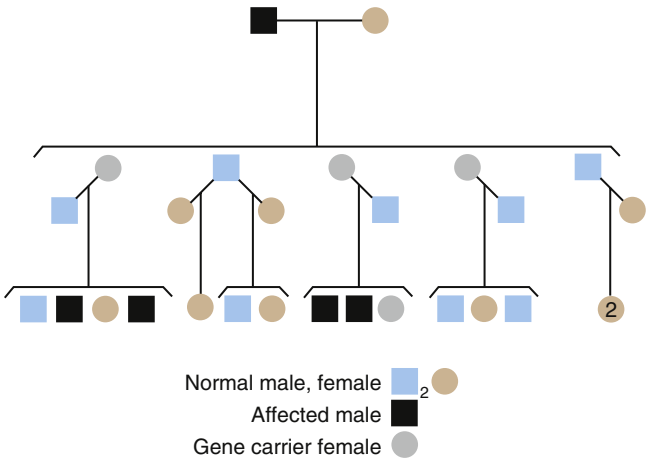

Figure 5-8 X-linked recessive inheritance in hypomaturation amelogenesis imperfecta.

The previous statements concerning the distribution of XLR genes in males and females apply equally as well to XLD genes. The principal difference lies in the fact that when the gene is dominant, more females than males will show the trait (see pedigree in Fig. 5-8). Because all XLR genes behave as dominant genes in males, no new criteria are made for their inheritance in males. The following criteria distinguish an XLD trait in families:

1. Affected males must transmit the trait to all of their daughters (as with XLR traits), and all of them are affected because fathers give their X chromosome to their daughters and their Y chromosome to their sons.
2. Affected males cannot transmit the trait to their sons (just as with XLR traits).
3. Heterozygous females transmit the trait to, on average, 50% of their children of both genders, whereas homozygous-affected females will have only affected children. The latter situation is exceptionally rare for a dominant trait and is practically never observed. Thus all females affected with a dominantly inherited X-linked trait are considered to be heterozygotes until proven otherwise.

Two points are emphasized here. First, transmission of XLD genes by females follows a pattern indistinguishable from that of autosomal transmission. Thus these two types of dominant inheritance can be differentiated only by observation of the offspring of affected males. Second, it was noted that XLR disorders are much less common in females than in males. The reverse is true for XLD traits. An XLD trait should appear about twice as often in females as in males because females have twice as many X chromosomes as males.

Amelogenesis Imperfecta and Nephrocalcinosis Syndrome

Although amelogenesis imperfecta usually occurs as an isolated trait and not as part of a syndrome, many syndromes include amelogenesis imperfecta as part of their pattern of anomalies.[15] One that is rare, but of clinical importance due to its potential medical significance, is amelogenesis imperfecta with nephrocalcinosis, also called enamel-renal syndrome. This AR condition is caused by mutations in the *FAM20A* gene. In addition to the hypoplastic enamel, other dental findings include pulp stones, delayed or failed eruption of secondary dentition, and gingival overgrowth. Since nephrocalcinosis is often asymptomatic and can be associated with impaired renal function, dentists who see children with generalized and thin hypoplastic amelogenesis imperfecta should consider referral to a nephrologist for a renal ultrasound scan. Likewise, children and adults with nephrocalcinosis should be referred to a dentist.[16] Follow-up may be indicated since blood chemistry analyses are typically normal, and the nephrocalcinosis may not appear on renal ultrasound until later in life.[17]

Dentlearn.ir

VARIATION IN GENE EXPRESSION

The patterns of inheritance shown in traits determined by genes at a single locus are usually easy to recognize. However, many factors may modify the expression of a gene in a family in such a way that a typical monogenic pattern of inheritance is not discernible. Two concepts related to modification of gene action are discussed here: penetrance and expressivity.

PENETRANCE

When a person with a given genotype fails to demonstrate the phenotype characteristic for the genotype, the gene is said to show reduced penetrance. This is a situation most commonly seen with dominant traits. Dentinogenesis imperfecta, an AD trait, is practically 100% penetrant because all individuals who carry that gene show its phenotype. Conversely, osteogenesis imperfecta shows incomplete penetrance because pedigree studies demonstrate individuals who must carry the gene but who do not appear to be affected. Another relevant example is found in the CLP trait. Consider the following family history: a grandfather and his grandson both have CLP but the boy's mother (also the grandfather's daughter) does not. The probability is very high that her son's cleft liability came from his grandfather and therefore was passed through the mother without being expressed as an overt cleft. Possibly the subtle action or predisposition of a clefting gene or genes may be found in measurements of facial structures, or variation in other structures such as the orbicularis oris muscle may be identified. This could increase the power of linkage analysis of the predisposing genotype. With the spectacular advances in the understanding of the human genome, we may be able to locate a gene that regulates clefting before its action at the molecular level is known or shows this action as a clinical trait.

EXPRESSIVITY

If a single gene trait can show different phenotypes in the affected members of kindred, it shows variable expressivity. Osteogenesis imperfecta also provides an illustration of variable gene expression. The cardinal signs of this disease are (1) multiple fractures, (2) blue sclera, (3) dentinogenesis imperfecta, and (4) otosclerosis, which results in a hearing deficit. Affected persons in a single family may show any one or a combination of these signs, which illustrates the considerable variation in gene expression. The minimum expression of the gene observed in a family might then be only a blue color to the sclera, which could be unnoticed by the clinician. In this case, highly variable gene expression may fade into nonpenetrance.

The craniosynostosis syndromes are AD traits associated with single gene mutations. They also provide good examples of how, even with the strong influence of a single gene, the phenotype can vary markedly. Although it was once thought that a particular mutation in a given gene would always result in a specific syndrome, several identical mutations in the fibroblast growth factor receptor 2 (FGFR2) gene have been found in patients diagnosed with the three different clinical craniosynostosis syndrome entities of Crouzon, Pfeiffer, and Jackson-Weiss syndrome.[18,19]

Another example of the individual variability of these single-gene-mutation AD phenotypes occurred when two individuals in the same family had the classic phenotypes of Pfeiffer and Apert syndromes. In addition, seven other family members had unusually shaped heads and facial appearance reminiscent of Crouzon syndrome.[20] The phenotype may be so variable that the individual may appear to be clinically normal, yet have the same gene mutation associated with Crouzon syndrome in three of his children and two of his grandchildren. Only through the analysis of radiographic measurements was a minimal expression of features suggestive of Crouzon syndrome evident.[21]

EPIGENETICS

The influence of one or more modifying genes through their protein products in reducing or enhancing the effect of another gene has been referred to as *epigenetics*, but is now commonly referred to as *epistasis*. *Epigenetics* now refers to changes in gene expression that are inherited but not caused by alteration in the sequence of the gene. Examples of epigenetics include gene expression that is altered by methylation or acetylation, and by inhibition of messenger RNA expression by interfering RNA or microRNA binding.[22] Although monozygotic (identical) twins are epigenetically indistinguishable during the early years of life, older monozygous twins exhibit remarkable differences in their overall content and genomic distribution of 5-methylcytosine DNA and histone acetylation, which can create differences in gene expression between the twin pairs.[23] These epigenetic factors can help explain the relationship between an individual's genetic background, the environment, aging, and disease. It can do so because the epigenetic state varies among tissues and during a lifetime, whereas the DNA sequence remains es-

and external environment, epigenetic mechanisms can "remember" these changes in the normal programming and reprogramming of gene activity.[24] This is leading to a new way of thinking about how the genome and environment interact, with a tremendous impact on the study of developmental biology, cancer, and other diseases.

MULTIFACTORIAL INHERITANCE

The following features typify multifactorial inheritance in contrast to monogenic inheritance: (1) multiple genes (polygenes) at different loci are involved in expressing the phenotype, and (2) the phenotype produced is a summation of the effects of polygenes interacting with their environment. The phenotypic result is often a continuously varying spectrum of that trait (e.g., height) rather than presentation as a discrete (trait present or absent) phenotype.

Many common diseases, such as dental caries, have continuous variation with no sharp distinction between normal (average) and abnormal (extremes). However, there may be a specific measurement point beyond which that disease is arbitrarily regarded by the clinician as abnormal.

Dentlearn.ir

Multifactorial inheritance is troublesome to analyze genetically; in fact, geneticists often arrive at a diagnosis of multifactorial inheritance for a given trait only after the monogenic forms of inheritance have been considered and found to be unlikely. Certain techniques for studying it have been developed. The simplest is the method of resemblance between relatives, which states that the more closely related two individuals are, the more closely they resemble each other concerning the specific trait in question. It is important to stress, though, the continuous phenotypic variation that is characteristic of inheritance patterns resulting from polygenes.

This issue of continuous variation is emphasized because the most common diseases with which the dentist must deal (i.e., periodontal disease, dental caries, and malocclusion) are multifactorial traits. Only the extremes of variation are readily apparent to the dentist, such as in the child with rampant caries or the adult who is caries-free. In this latter instance, if one did not understand the concept of multifactorial inheritance, one might conclude that such individuals represent a discrete phenotype influenced by a single gene in a Mendelian manner. This is frequently not the case.

A most important feature of traits produced by polygenes is that they are susceptible to environmental modification. A phenotype resulting from the concerted action of 100 genes is much more likely to be altered and modified by the existing environment than a trait controlled by only one or even several genes. Even so, this does not mean that a trait resulting from only one or even several genes cannot be influenced by environmental factors. The change in phenotype depends on the individual's ability to respond to the environmental factor, which may be heavily influenced by the same gene(s) originally influencing the phenotype or by other genes.

An example of a polygenic trait that is markedly influenced by environmental factors is dental caries, which is the interaction product of three essential factors: a cariogenic diet, a caries-producing bacterial flora, and a susceptible tooth. These three factors encompass a variety of biologically complicated entities, such as saliva, plaque, tooth matrix formation, and crystallization. It should be easy to see that the development of these complex elements must involve a great many genes. Environmental modification, such as properly timed systemic fluoride supplementation, produces a considerable alteration in the phenotype without changing the genetic constitution of the individual. The reader can probably think of additional environmental modifications that can produce a greatly altered dental caries experience without changing an individual's genes. Some conditions that are attributed to a multifactorial inheritance because they tend to occur in particular families may be greatly influenced by a gene or genes that predispose to the condition, depending on the other genetic or environmental factors involved.

MULTIFACTORIAL (COMPLEX) INHERITANCE IN HUMAN DISEASES

For many common disorders, such as diabetes and hypertension, and even for the major common congenital malformations (i.e., spina bifida, hydrocephalus, and CLP), there is a definite familial tendency. This is shown by the fact that the proportion of affected near-relatives is greater than the incidence in the general population. However, this proportion is much lower than that expected for a monogenic trait, and the explanation most commonly offered for major congenital malformations is that they are multifactorial traits. As previously stated, one definition of a complex trait is that it represents the summation of the effects of many genes (polygenes) interacting with the environment, which is why it has also been termed multifactorial. Environment is defined as those nongenetic circumstances that render an individual more or less susceptible to a disease state. In contrast to so-called simple monogenic traits, whose characteristics have been summarized in preceding paragraphs, multifactorial complex diseases show the following characteristics:

1. Each person has a liability for a given disease, and that liability represents a sum of the genetic and environmental liabilities.
2. The multifactorial-threshold model is a mathematical way of expressing these liabilities. For polygenic traits, the model is simply a gaussian curve. As already noted, for multifactorial traits, a threshold must be added to allow the continuous polygenic model to be used in describing noncontinuous or discrete traits. For many human congenital malformations, a multifactorial model with threshold is appropriate for describing discrete traits such as CLP. Such a threshold means that all persons with sufficient gene dosage and environmental interaction will be above the threshold of expression and show the cleft lip. Those with less will not show a cleft lip. A graphic representation of this idea is shown in Figure 5-9.
3. Because of the different dosages of polygenes in the overall incidence of this trait will vary in near-relatives of those affected. For example, a dominantly inherited trait has a gene dosage of 1 in 2 (50%). Assuming that several polygenes may be involved in CLP, this figure decreases at least tenfold to about 1% to 5%. The incidence in a random population is even lower—about 1 per 1000. Therefore, increasing gene dosage for a multifactorial complex trait in a family is associated with an increased incidence of that trait in

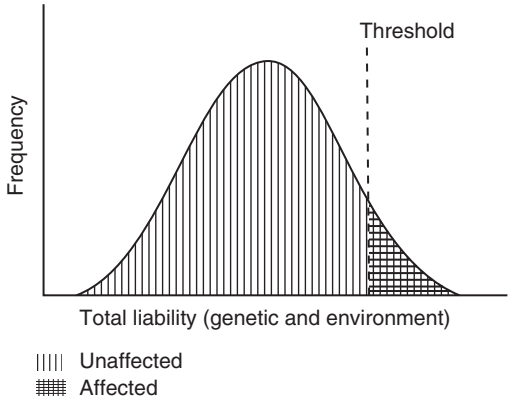

Figure 5-9 Multifactorial model for inheritance of cleft lip and palate.

Dentlearn.ir

near-relatives of the affected individuals. The nature of this system with a threshold permits large numbers of persons at risk for showing that phenotype (CLP) to carry the liability for clefting without expressing it clinically. Based on current research findings regarding traits that are multifactorial with a threshold, it appears that it will be difficult to relate these mathematical observations to cellular biological function.

Toward the end of the nineteenth century, Galton recognized that twins could be useful for evaluating the nature-nurture argument that was raging at that time. Interest in the twin method for study of the relative importance of heredity and environment in humans has been increasing. One explanation for this interest is that many human traits are complex and susceptible to environmental modification, and are therefore difficult to study by conventional methods. The twin method allows such traits to be studied based on the principle that human twins are of two basic types: monozygotic (or identical) twins, resulting from a single ovum fertilized by a single sperm, and dizygotic (or fraternal) twins, resulting from fertilization of two ova by two sperms. It is axiomatic that monozygotic twins have identical genotypes, whereas dizygotic twins are no more closely related to each other than are any two siblings. It also follows that differences between monozygotic twins result from environmental differences (although, as previously mentioned, epigenetics could be a factor), whereas those between dizygotic twins result from differences in both heredity and environment.

To use the twin method, one must distinguish between the two types of zygosity. If both twins are identical for the trait in question (regardless of their zygosity), they are described as *concordant*. If they are unlike for the trait, evaluated. For example, monozygous twins show a 33% concordance for CLP, whereas dizygous twins show only a 5% concordance.

Another method to estimate the heritability of a trait and to evaluate evidence of linkage of a phenotype with DNA polymorphisms is by sib-pair analysis. Heritability estimates can be generated from within- and between-sibship variance quantified by generalized linear models, with confounding factors controlled for where indicated. Polymorphic DNA markers may be tested for genetic linkage (proximity) to a gene influencing a particular phenotype by testing whether the magnitude of the phenotypic difference between two siblings is correlated with the alleles they share that are identical by descent (IBD). An allele is considered to be IBD if both members of a sibling pair inherited the same marker allele from the same parent. If a marker is linked to a gene contributing to the phenotype in question, then siblings with a similar (if quantitative) or the same (if discrete) phenotype would be expected to share more alleles IBD, whereas siblings with widely differing phenotypes would be expected to share few if any alleles IBD near any gene(s) influencing the phenotype.[25] In addition, another method of looking for DNA markers is by linkage disequilibrium or association analysis. In its simplest terms, this refers to a nonrandom association of alleles at two or more loci. It was found that some sections of DNA do not tend to change through generations, in what are called *haplotype blocks*. Because of this, testing one SNP within each block for significant association with a disease or trait is possible when an influencing locus for that disease or trait is located in or at least close to that haplotype block.[26] Partly because these haplotype blocks occur in populations, these analyses can be performed on unrelated individuals (affected and controls), as opposed to linkage analyses.

However, if the control individuals are from a different genetic background than the affected individuals, there may be a bias. One way to deal with that problem is to use the quantitative transmission disequilibrium test. This analysis calculates the difference between the value of the quantitative trait in the offspring and the average value of the quantitative trait in all offspring in all families studied, while simultaneously considering the allele transmission from parent to offspring.[27] Thus, whereas the sib-pair linkage analysis involves two or more siblings, the quantitative transmission disequilibrium test involves trios of parents and one or more siblings.

INFLUENCE OF GENETIC FACTORS ON MAJOR CRANIOFACIAL, ORAL, AND DENTAL CONDITIONS

GENETICS AND DENTAL CARIES

It is clear from many dietary studies that variation in susceptibility to dental caries exists even under identical, controlled conditions. This implies that, because of genetic differences, certain environmental factors are potentially more cariogenic for some people than for others. This is not to say that dental caries is an inherited disease; rather, genetic influences may modify the overt expression of this disease in the individual.

Fifty years ago, dental caries was presented to dental students as a disease that was so common that more than 99% of the general population was afflicted with it. Although it is still recognized as a common disease, the use of systemic and topical fluorides and persistence by organized dentistry to bring about changes in dietary habits and oral hygiene practices have contributed significantly to a remarkable decrease in the prevalence of this disorder, especially noted in children. Currently, it is not unusual for a prepubertal child to be caries-free. However, there are individual variations in caries that are not fully explained by hygiene or fluoride exposure.

Three essential interacting elements comprise the model system for dental caries that is most commonly used to discuss its etiology: microorganisms, substrate (fermentable carbohydrates), and host factors such as tooth anatomy. It is in the last area—host factors—that genetics exerts a major influence on dental caries initiation.

Several investigators have studied the genetic aspects of dental caries in humans, using both twin and family pedigree approaches. Because dental caries is an age-dependent process, much of the reported data cannot be compared because of age differences in the various

Dentlearn.ir

servations by Klein and Palmer[28] and Klein[29] are worth noting. Their findings indicated that children have a caries experience remarkably similar to that of their parents when the susceptibility of both parents is the same (either high or low). However, when caries susceptibility of the two parents is dissimilar, the children's susceptibility tends to be more like that of the mother than that of the father. This finding was particularly evident in daughters.

Because dental caries is an infectious communicable disease, however, familial clustering may, to some degree, reflect familial environmental contact, with transmission of cariogenic bacteria to children at certain ages. Li and Caufield found that mothers are the principal source of mutans streptococci in their infants, with a greater rate of transmission to female than male infants.[30] In addition, the association of maternal salivary bacterial challenge (mutans streptococci and lactobacilli) from pregnancy through 24 months postpartum is associated with not only oral infection among children but also their caries incidence (≥1 cavitated or restored teeth) at 36 months.[31] The more common a genetic trait is, the more difficult it is to demonstrate its genetic character. Several authors have attempted to do this for dental caries by the study of twins. Book and Grahnen attempted to maximize differences in caries experience within families by selecting caries-free 20-year-old men and comparing caries experience within their families.[32] Results showed that parents and siblings of caries-free propositi had significantly lower rates of decayed, missing, and filled teeth than did the control families. The authors concluded that the observed differences are hereditary and probably polygenic.

Studies of twins conducted by Dahlberg and Dahlberg,[33] Mansbridge,[34] Horowitz and colleagues,[35] Caldwell and Finn,[36] and Bretz and colleagues[37] indicated that genetic factors make a significant contribution to individual differences in caries susceptibility. However, most authors agree that this genetic component of dental caries is overshadowed by the overall effect of environmental factors in most individuals. Although it appears that genetic factors significantly contribute to the colonization of specific oral bacteria,[38] or to the levels of *Streptococcus mutans* specifically,[39] the conclusion from clinical twin and familial correlation studies and estimations from heritability studies regarding the degree of genetic influence on caries may be confounded by familial factors such as oral hygiene habits, diet, and the already-mentioned transmission of cariogenic bacteria within the family.

The foundation for seeking different individual susceptibilities to caries is based on animal studies. Hunt and colleagues succeeded in establishing caries-resistant and caries-susceptible strains of rats using inbreeding techniques.[48] Although the resistant strain was challenged by oral inoculation of cariogenic bacteria, the resistant phenotype was maintained. These were the first studies to confirm the presence of important genetic elements influencing dental caries susceptibility.

A review of inherited risks for susceptibility to caries found evidence of an association between altered dental enamel development in defined populations and an increased risk of caries, as well as a relationship between host immune complex genes and different levels of cariogenic bacteria and enamel defects.[40] This is further supported by the finding of a significant interaction between tuftelin SNP genotypes and *S. mutans* levels,[41] and by variation in the amelogenin gene and caries susceptibility.[42] Thus the individual's genotype may influence the likelihood of intraoral colonization of cariogenic bacteria, which further exemplifies the complexity of caries development. Genetics studies on well-characterized populations with clearly defined caries experience will help define those host factors with the greatest influence on the incidence of caries.[32]

For example, GWAS for dental caries focused on the primary dentition in children aged 3 to 12 years old and implicated several novel genes*: ACTN2, EDARADD, EPHA7, LPO, MPPED2, MTR,* and *ZMPSTE24.* Subsequent investigation has corroborated the influence of the *MPPED2* and *ACTN2* genes on caries risk. The role of *ACTN2* in organizing ameloblasts during amelogenesis supports the hypothesis of its involvement in caries risk, although the functional role of *MPPED2* in caries is currently unknown.[43] The enamelin gene (ENAM) has also been implicated as a factor in caries susceptibility.[44] An indication that different genes may influence caries activities across the surfaces of the permanent dentition was found by a GWAS suggesting *BCOR* and *INHBA* to be factors in pit-and-fissure caries, while *BCORL1, CXCR1,* and *CXCR2* are factors in smooth-surface caries.[45,46] Further studies to define the genes involved, which may be related, for example, to salivary flow, plaque formation, and diet preferences, are in progress. Bretz and colleagues found that genetic factors contributed independently to both dental caries and sucrose sweetness preference,[47] although it is likely that an increased preference for sweets would affect the caries rate.

In summary, susceptibility to human dental caries is influenced to a significant but variable degree by genetic factors in most individuals. This genetic influence control is undoubtedly complex and strongly implies considerable environmental influence. However, there are likely individuals in whom the genetic susceptibility is markedly greater than that in most of the population. Specific types of dental caries susceptibility representing the extreme variations of this trait may ultimately prove to be monogenic or major gene traits, but at present the evidence is insufficient for a clear statement of such inheritance.

GENETICS AND PERIODONTAL DISEASE

The periodontal disease state is often described as a local inflammatory disease with possible underlying systemic factors. This disease is so widespread in human populations and has such widely varying clinicohistopathologic features that it seems certain that multiple diseases with multiple causes are being lumped together as a single entity. Periodontists suggest that there is evidence for the existence of several variant types of periodontal disease,

bone loss, oral hygiene status, and the presence or absence of local factors. One might visualize a continuum of disease expression ranging from localized gingivitis to

Dentlearn.ir

generalized periodontitis with severe bone and tooth loss. Such a complex disease shows both inflammatory and degenerative pathologic features.

It is easy to understand why genetics studies of this common problem have been neglected. As is true for dental caries, periodontal disease is common; occurs with a continuum of expressivity; and is greatly influenced by environmental conditions, such as diet, occlusion, and oral hygiene habits. All of these features fit the description of a complex type of disease or at least of disease susceptibility.

Most genetics studies of a trait make use of families with multiple affected individuals or twins. A carefully designed study of twins with periodontal disease was reported by Ciancio and colleagues in 1969.[49] Using the Ramfjord index, which evaluates gingival inflammation, calculus formation, tooth mobility, and tooth loss in all four quadrants of the mouth, the authors examined seven monozygotic and 12 dizygotic pairs of teenaged twins. They concluded that there was no evidence in these twins for significant heritability of any of these dental parameters.

Alternatively, Michalowicz and colleagues published a large study (63 monozygotic and 33 dizygotic pairs) of adult twins (mean age, 40 years).[50] Using elements of the Ramfjord index as criteria for diagnosis, they calculated heritability estimates. The authors state that from 38% to 82% of the periodontal disease identified in these twins was attributable to genetic factors.

Investigation by Kornman and colleagues into the association of different polymorphisms of inflammation-mediating genes and periodontal disease in adult nonsmokers indicated that interleukin 1α and 1β (IL-1α and IL-1β) genotypes may be a risk factor.[51] The IL-1β polymorphism was IL-1β + 3953 and the IL-1α polymorphism was IL-1α -889. Nonsmokers aged 40 to 60 carrying the "2" allele (in either the homozygous or the heterozygous state) at both loci were observed to have nearly 19 times the risk of developing severe periodontitis as did those homozygous for the "1" allele at either or both of these loci. However, this association has been seen in other,[53] but not all, populations.[52-55] Greenstein and Hart noted that the relationship of specific IL-1 genotypes and the level of crevicular fluid IL-1β is not clear, and that the ability of the genetic susceptibility test for severe chronic periodontitis, based on the findings of Kornman and colleagues, to forecast which patients will develop increased bleeding on probing, periodontitis, loss of teeth, or need for dental implants is ambiguous.[56] This illustrates the complexity of genetic association studies, and genetic counseling is based on a marker that accounts for only a portion of phenotypic variations.

A genome-wide scan for chronic periodontitis found suggestive evidence of association for six genes, including *NIN, NPY,* and *WNT5A* for severe chronic periodontitis, and *NCR2, EMR1,* and chromosome location 10p15 for moderate chronic periodontitis. Inclusion of smoking data along with the genetic analysis increased the heritable variance in severe chronic periodontitis from 18% to 52%, confirming smoking as an environmental causative factor that may act in addition to inherited susceptibility genes.[57]

Early-onset periodontitis has been the subject of most family studies. Because several forms of early-onset periodontitis (e.g., localized prepubertal periodontitis, localized juvenile periodontitis [JP], and generalized JP) can be found in the same family, the expression of the underlying genetic etiology appears to have the potential to be influenced by other genetic factors.[58]

Progress has been made in the study of rare genetic conditions or syndromes that can predispose to periodontal disease or have periodontal disease as a relatively consistent component of their pleiotropic effect. For example, leukocyte adhesion deficiency (LAD), type I and type II, are AR disorders of the leukocyte adhesion cascade.[59] LAD type I has abnormalities in the integrin receptors of leukocytes resulting from mutations in the β2 integrin chain (ITGβ2) gene, leading to impaired adhesion and chemotaxis, which result in increased susceptibility for severe infections and early-onset (prepubertal) periodontitis.[60,61] LAD type II is also an AR disorder secondary to mutation in the *SLC35C1* gene encoding a GDP-fucose transmembrane transporter (FucT1) located in the Golgi apparatus. The infectious episodes and the severity are much milder than those observed in LAD type I, and the only persistent clinical symptom is chronic severe periodontitis. The exact defect in the system is absence of the sialyl Lewis x (SleX) structure antigens, which are important ligands for selectin on the leukocyte, which leads to a profound defect in leukocyte rolling, the first step in the adhesion cascade. This causes a marked decrease in chemotaxis, accompanied by pronounced neutrophilia. Apart from the leukocyte defect, these patients suffer from severe growth and mental retar-

Ehlers-Danlos syndrome (EDS) is a collection of 10 types distinguished on the basis of clinical symptoms and inheritance patterns. In addition to consistent early-onset periodontal disease, patients with EDS type VIII have variable hyperextensibility of the skin, ecchymotic pretibial lesions, minimal bruising, minimal to moderate joint hypermobility of the digits, and "cigarette paper" scars. Inheritance is AD. Early-onset periodontal disease may also be found in patients with EDS type IV. These individuals are usually characterized by type III collagen abnormalities with hyperextensibility of the skin, ecchymotic pretibial lesions, easy bruisability, cigarette paper scars, joint hypermobility of digits, pes planus, and, of greatest concern, arterial and intestinal ruptures. Individuals with type IV, like those with type VIII, also have AD inheritance.[62] The presence or absence of type III collagen abnormalities has been taken to be a differentiating factor between the two types, with EDS type IV showing abnormal type III collagen. The considerable overlap in phenotype of these two types warrants careful family and clinical evaluation, and biochemical studies of collagen when a patient with features of EDS and periodontal disease is evaluated.[63]

Chédiak-Higashi syndrome has frequently been linked with severe periodontitis. This rare AR disorder is characterized by oculocutaneous hypopigmentation, severe immunologic deficiency with neutropenia and lack of natural killer cells, a bleeding tendency, and neurologic abnormalities. It is caused by mutations in the *CHS1/LYST* gene.[64]

Dentlearn.ir

Papillon-Lefèvre syndrome and Haim-Munk syndrome are two of the many different types of palmoplantar keratoderma, differing from the others by the occurrence of severe early-onset periodontitis with premature loss of the primary and permanent dentition. In addition, Haim-Munk syndrome is characterized by arachnodactyly, acroosteolysis, and onychogryphosis.[65] Hart and colleagues[66] have shown that both of these AR syndromes are due to different mutations in the cathepsin C (*CTSC*) gene. A possible role for a mutation in this gene has also been reported in patients with generalized nonsyndromic aggressive periodontitis.[67]

AGGRESSIVE (EARLY-ONSET) PERIODONTITIS

Early-onset periodontitis may occur in the primary dentition (prepubertal periodontitis), may develop during puberty (JP), or may be characterized by exceedingly rapid loss of alveolar bone (rapidly progressive periodontitis). Along with hypophosphatasia, prepubertal periodontitis appears to be the most commonly encountered cause of premature exfoliation of the primary teeth, especially in girls (Fig. 5-10).[62]

JP has the following features:

1. An early onset of the breakdown of periodontal bone. This bone loss is of two types: chronic periodontitis in a generalized form affecting any dental area and a localized form in which the molar or incisor regions of bone are the most severely affected.
2. Bone destruction that is rapid and vertical, with specific microorganisms associated with the periodontal lesion.
3. Familial aggregation, especially in the molar and incisor types. It seems probable that the generalized and localized types represent two different aspects of the same disorder; this discussion considers them as a complex entity called *familial JP*.

Evaluation of the same IL-1α and IL-1β polymorphisms found by Kornman and colleagues[51] to be associated with periodontitis in adult nonsmokers was performed by Diehl and colleagues in black and white families with two or more members affected with early-onset periodontitis.[68] Interestingly, they found the IL-1 alleles associated with high risk of early-onset periodontitis to be the ones suggested previously to be correlated with low risk for severe adult periodontitis. They concluded that early-onset periodontitis is a complex, oligogenic disorder (i.e., involving a small number of genes), with IL-1 genetic variation having an important but not exclusive influence on disease risk. Aggressive periodontitis-1 is caused by mutation in the *CTSC* gene, which is also involved in Papillon-Lefèvre syndrome and Haim-Munk syndrome, while aggressive periodontitis-2 has been mapped to a different chromosomal location (1q25).[69-71]

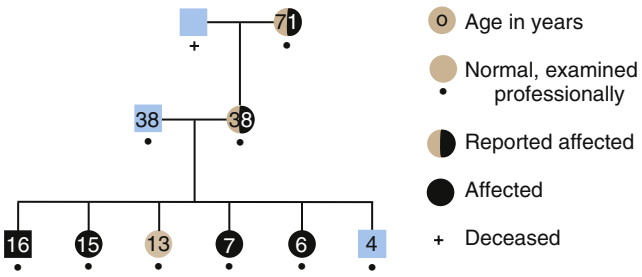

Figure 5-10 Pedigree of family with juvenile periodontitis, a dominant trait.

GENETICS OF MALOCCLUSION

The study of occlusion pertains to relationships between teeth in the same dental arch, as well as between the two dental arches when the teeth come together. Many factors are involved in the definition of normal occlusion. Some of the most important orofacial parameters of occlusion are airway function, soft tissue anatomy and function, size of the maxilla, size of the mandible (both rami and body), arch form, anatomy of teeth (including malformation), agenesis of teeth, and rotation of teeth. All of these important elements must be included in the concept of occlusion.

Malocclusion is perhaps somewhat easier to define. One may simply say that malocclusion is a significant deviation from normal occlusion. However, this description is useful only if one considers the multiple aspects implicit in such a definition. Normal occlusion and malocclusion are dynamic concepts that involve the interrelationships of many factors, not a few of which have been shown to be influenced by genetic factors. Genetic influences on each occlusal trait are rarely due to only a single gene, which would be necessary for malocclusion to be due to the simple inheritance of discrete skeletal and dental characteristics. Instead, malocclusions are often polygenic with the potential for environmental influence and are therefore complex traits. Even though we will focus on genetic factors, it should always be remembered that malocclusion can be greatly or even predominantly influenced by environmental factors, particularly for occlusal variables. It has been suggested that the rapid increase in malocclusion in indigenous Australian people was produced by dietary factors concurrent with industrialization, emphasizing the importance of environmental influences on occlusal variation and the variability of apparent genetic determinants with respect to the environment or population in which they are measured.[72-74] Likewise Kawala et al., after studying the concordance of malocclusion in twins, showed that the distribution of within-pair malocclusions depended upon the gender of the individuals, and supported the impact of environmental factors.[75]

Theoretically, there are two general ways in which predisposing or causative factors for malocclusion could be due to heritable characteristics. One would be inheritance of a disproportion between the size of the teeth and the jaws, resulting in crowding or spacing issues. Posterior and/or anterior Bolton discrepancies are defined as a disproportion among the sizes of individual teeth between the two arches. To achieve good occlusion with the ideal overbite and overjet, the maxillary and mandibular teeth must be proportional in their mesial-distal dimensions. If some teeth are not proportional, then there could be crowding, spacing issues, and/or an effect on overbite and or overjet, even if the arches are in a favorable relationship.

Dentlearn.ir

Certainly hypodontia, as well as the often-associated smaller size of teeth that are often agenic, or other teeth, can contribute to malocclusion. This is particularly evident in patients with hypodontia or even oligodontia, which may occur spontaneously or be part of a syndrome such as hypohidrotic ectodermal dysplasia (HED), which can be caused by mutations in the *EDA* gene. Other mutations in the same gene may cause nonsyndromic dental agenesis, and, in a Hong Kong Chinese Class I malocclu-

its receptor, *XEDAR*, have been associated with dental crowding greater than 5 mm.[76] Several other genes in addition to *EDA* and *XEDAR*, associated with syndromic or nonsyndromic hypodontia/oligodontia, including *MSX1*, *PAX9*, *AXIN2*, *WNT10A*, and *LTBP3* (see Chapter 3), could also contribute to variations in tooth size in general or for specific teeth.

The other general way in which predisposing or causative factors for malocclusion could be due to heritable characteristics would be inheritance of a disproportion in the position, size, or shape of the mandible and maxilla. Note that the influence on bony morphology could be secondary to heritable effects, including those on cartilage, collagen, muscle fibers, other connective tissue components, and growth factors. For example, in a study conducted by Yamaguchi and colleagues on the association of the Pro561Thr (P56IT) variant in the growth hormone receptor (*GHR*) gene with craniofacial measurements on lateral cephalometric radiographs, it was found that individuals without the *GHR* P56IT allele had a significantly greater mandibular ramus length (condylion-gonion) than did those with the *GHR* P56IT allele in a normal

mandibular ramus height in those with the *GHR* P56IT allele was 4.65 mm shorter than that in those without the *GHR* P56IT allele. This significant correlation between the *GHR* P56IT allele and shorter mandibular ramus height was confirmed in an additional 80 women.

Class III malocclusion morphology is heterogeneous, with various degrees of incidence among different ethnic

sult in the condition.[78,79] There is a strong heritable component in Class III malocclusion in general, with modes of inheritance being reported to be polygenic,[80] AD in

The variations in ethnic incidence, as well as variations in morphology that we lump together into the category of Class III malocclusion, may also reflect variations in genes involved in "different" Class III malocclusions. This concept of genetic heterogeneity influencing the range of subphenotypes or subtypes in what we call a Class III malocclusion is supported by genetic linkage and association studies finding several different genes or genetic markers to be significant for Class III malocclusion among differ-

other Class III malocclusion genes or markers possibly

vast majority of Class III malocclusion genetics studies had been completed in Asian populations and implicated multiple chromosomal regions including 1p35, 1p36, 4p16.1, 6q25, 12q13, 14q24.3, and 19p13.2.[83-89] A study of Class III malocclusion in Colombia yielded significant genetic linkage to 1p22.1, 3q26.2, 11q22, 12q13.13, and 12q23 in patients primarily with maxillary hypoplasia.[90] Another study of Class III malocclusion in Colombian and Brazilian families, primarily with mandibular prognathism in the presence or absence of maxillary hypoplasia, found linkage to the chromosome.[91] Another genetic

patients from the United States, consisting mostly of Caucasian individuals, was race-, age-, and gender-matched with Class I/orthognathic control individuals, with genetic markers used for a set of candidate genes. There was a significant ($p = 0.02$) association of the Class III malocclusion with the marker rs10850110 located upstream of the myosin 1H gene (MYO1H) on chromosome 12q24.11.[92]

The influence of muscle on skeletal morphology is further supported by research in myosin gene expression, muscle fiber type differences, and skeletal malocclusions. Gene expression evaluation in masseter muscle from individuals undergoing orthognathic surgery for skeleton-based malocclusions found a trend for increased *MYO1H* and *MYO1C* expression in Class III malocclusion compared with Class II malocclusion. There were significant correlations ($p < 0.05$) between *MYO1C* expression and fiber-type percent occupancy in masseter muscle from individuals with normal and deep-bite malocclusions. Significant correlations were also identified between *MYO1C* and *MHC* (myosin heavy chain) gene expression. The mechanism of how the *MYO1H* and *MYO1C* genes and their protein products influence the Class III phenotype, however, remains unknown. It has been postulated that altered glucose transport during condylar cartilage growth may be one of the cellular mechanisms that promotes mandibular prognathism, as well as development of open and deep-bite skeletal malocclusions through masseter muscle fiber-type differences.[93] Analysis of the DNA sequences from an Estonian family recently uncovered a rare heterozygous missense mutation associated with Class III skeletal malocclusion in the dual-specificity phosphatase 6 (DUSP6) gene (c.545C>T; p.Ser182Phe; rs139318648). Affected individuals in this family were largely characterized as having a straight profile with maxillary deficiency. This rare variant co-segregated with the disease and followed an AD pattern of inheritance with incomplete penetrance. The *DUSP6* gene encodes a cytoplasmic dual-specificity phosphatase that acts as a negative regulator of the MAP kinases, ERK1/2. This protein is involved in some fundamental signaling processes that occur at the early stages of skeletal development, and can be transcriptionally upregulated via the fibroblast growth factor (FGF)/FGF receptor signaling pathway.[94] (For further details on the genetics of Class III malocclusion, see "Family History and Genetics of Mandibular Prognathism."[95])

The studies previously mentioned dealt with differences in jaw morphology. What about differences in growth velocity during puberty? Certainly, increased accuracy in the estimation of pubertal facial growth would be of great benefit prior to the utilization of different therapeutic modalities including orthodontics, orthopedic

Dentlearn.ir

growth modification, and surgery. The pubertal growth spurt response is mediated by the combination of sex steroids; growth hormone; insulin-like growth factor (IGF-I); and other endocrine, paracrine, and autocrine factors. Testosterone and estradiol in mice have a direct, gender-specific stimulatory activity on male- and female-derived chondroprogenitor cell proliferation. Testosterone stimulated growth and local production of IGF-I and IGF-I-R in chondrocyte cell layers of an isolated organ culture of the mouse mandibular condyle.[96] Administration of low doses of testosterone in boys with delayed puberty accelerates not only their statural growth rate but also their

mones involved in growth and development.[98]

Aromatase (also known as estrogen synthetase, encoded by the *CYP19A1* gene) is a key cytochrome P450 enzyme involved in estrogen biosynthesis.[99] This steroidogenic enzyme catalyzes the final step of estrogen biosynthesis by converting testosterone and androstenedione to estradiol and estrone, respectively.[100] Regulation of this gene's transcription is critical for the testosterone/estrogen (T/E) ratio in the body since aromatase plays an important role in the conversion of androgens to estrogens. Some studies have shown that the T/E ratio is critical in the development of gender-indexed facial characteristics such as the growth of cheekbones, the mandible, and chin; the prominence of eyebrow ridges; and the lengthening of the lower face.[101,102] The difference in the average sagit-

with different *CYP19A1* alleles with the greatest differences in growth per year was just over 1.5 mm per year during treatment for the maxilla, and 2.5 mm per year for the mandible. There was no statistically significant difference for the particular *CYP19A1* alleles in females. It is particularly interesting that at the beginning of treatment there was no statistically significant difference among the males based on the *CYP19A1* genotype. The difference expressed itself only over the time of treatment during the cervical vertebral stage associated with increased growth velocity.[103,104] Interestingly, the same result was found

gesting that this variation in the *CYP19A1* gene may be a multiethnic marker for sagittal facial growth.[105] Although the difference in average annual sagittal mandibular and maxillary growth based on this *CYP19A1* genotype were significant, as one factor in a complex trait (sagittal jaw growth), it accounts for only part of the variation seen, and therefore, by itself, has little predictive power.[106] King and colleagues noted that many studies that estimate the heritability of craniofacial structures may have a bias, because they have generally involved individuals who had not undergone orthodontic treatment, and that those judged to have an extreme malocclusion were often excluded. They found that, in contrast to the relatively high heritability of cephalometric variables and low heritability of occlusal variables in individuals with naturally occurring good occlusion, the heritability estimates for craniofacial skeletal variables in those with overt malocclusions were significantly lower and the heritability estimates for occlusal variations were significantly higher. This observation supports the idea that everyone does not react to specific environmental factors in the same manner, although those who are related are more likely to react similarly. To quote King and colleagues[108]:

> We propose that the substantive measures of intersib similarity for occlusal traits reflect similar responses to environmental factors common to both siblings. That is, given genetically influenced facial types and growth patterns, siblings are likely to respond to environmental factors (e.g., reduced masticatory stress, chronic mouth breathing) in similar fashions. Malocclusions appear to be acquired, but the fundamental genetic control of craniofacial form often diverts siblings into comparable physiologic responses leading to development of similar malocclusions.

Although we have some information about genetic influence on specific traits (e.g., missing teeth, occlusal patterns, tooth morphology, and even mandibular prognathism), these cases are exceptions; we do not have sufficient information to make accurate predictions about the development of occlusion simply by studying the frequency of its occurrence in parents or even siblings. Admittedly, family patterns of resemblance are frequently obvious, but predictions must be made cautiously because of the genetic and environmental variables and their interaction, which are unknown and difficult to evaluate.

Currently the results of studies on the genetic and environmental factors that influence the development of

not necessarily of any particular individual. In addition, the extent to which a particular trait is influenced by genetic factors may have little, if any, effect on the success of environmental (treatment) intervention. Even so, it may be that genetic factors that influenced a trait will also influence the response to intervention to alter that trait, or other genetic factors may be involved in the response. Therefore, the possibility of altering the environment to gain a more favorable occlusion theoretically exists, even in individuals in whom the malocclusion has a relatively high genetic influence. However, the question of how environmental and genetic factors interact is most relevant to clinical practice because it may explain why a particular alteration of the environment (treatment) may be successful in one compliant patient and not in another.[109]

Multiple factors and processes contribute to individual responses to treatment. Some patients exhibit unusual untreated growth patterns, treatment outcomes, or reactions to medications linked to polymorphic genes. Analysis of overall treatment response requires a systems analysis based on informatics for integration of all relevant information. The influence of genetic factors on treatment outcome must be studied and understood in quantitative terms for it to be applied effectively for each patient. Conclusions from retrospective studies must be evaluated by prospective testing for a true evaluation of their value in practice. Genetics studies are necessary to further the evidence base for practice. Only then will we begin to truly understand how nature (genetic factors) and nurture (environmental factors, including treatment) together affect treatment of our patients.

Dentlearn.ir

EXTERNAL APICAL ROOT RESORPTION

Basic descriptors of root resorption are based on the anatomic region of occurrence; that is, designations are *internal root resorption* and *external root resorption* (cervical root resorption and external apical root resorption [EARR]). EARR is a frequent iatrogenic outcome associated with orthodontic treatment and may also occur in the absence of orthodontic treatment.[110,111] Although orthodontic treatment is associated with some maxillary central incisor EARR in most patients, and more than one third of those treated experience greater than 3 mm of loss, severe EARR (>5 mm) occurs in 2% to 5% of cases.[112,113]

Currently, there are no reliable markers to predict either who will develop EARR or its severity following orthodontic tooth movement, although the shape of the root does appear to be associated with the likelihood of EARR and is best examined on periapical rather than panoramic radiographs. Even when duration of treatment is a factor, along with several significant dentofacial structural measurements (e.g., overjet), it does not account for enough of the observed variability to be useful as a predictor of EARR.[113]

Although orthodontic tooth movement, or *biomechanics*, has been found to account for approximately one tenth to one third of the total variation in EARR, Owman-Moll and colleagues showed that individual variation overshadowed the force magnitude and the force type in defining the susceptibility to histologic root resorption associated with orthodontic force.[114] Individual variations were considerable regarding both extension and depth of histologic root resorption within individuals, and these were not correlated to the magnitude of tooth movement achieved.[115]

The degree and severity of EARR associated with orthodontic treatment are multifactorial, involving host and environmental factors,[116] with genetic factors accounting for at least 50% of the variation overall and approximately two thirds of the variation seen in maxillary central incisor EARR.[117,118] In addition, studies in a panel of different inbred mice also supported a genetic component involving multiple genes in histologic root resorption.[119,120]

The potential for IL-1β to have an effect on root resorption was supported by the increase in orthodontically induced histologic root resorption in the absence of the IL-1β cytokine in a knockout mouse model[122,123] and a P2rx7 knockout mouse model,[124,125] because a lack of the P2rx7 receptor results in a lack of IL-1β. In both of these models, there was no difference at baseline between the histologic root resorption in wild-type ("normal") and knockout mice, whereas the application of force resulted in a significant increase in histologic root resorption in the wild-type mice. In addition, there was a significant ($p < 0.02$) increase in histologic root resorption in both types of knockout mice compared to the respective wild-type mice when the same force was applied in all the mice. Thus, there was a significant interaction between the genotype and environment (orthodontic force) in histologic root resorption.

There have been at least seven clinical studies of whether the +3953/4 (G/A) SNP rs1143634 DNA marker variation in the *IL-1B* gene is associated with variation in EARR concurrent with orthodontia. Three studies of cohorts from the United States (Caucasian),[121] Brazil,[126] and Spain[127] found a significant association, whereas four others, from Japan,[128] Germany,[129] Portugal,[130] and the Czech Republic,[131] did not find a significant association. In addition, a meta-analysis of studies investigating the IL-1B +3953/4 polymorphism and EARR concurrent with orthodontic treatment found no publication bias or association. Other DNA markers for other genes have been investigated as well, with some finding a significant association and others none.[132] Most of these studies investigated only one, or possibly two, genetic markers, and sometimes clinical factors such as length of treatment and extraction of premolars are also included in the analysis. Since from the beginning of these studies it was appreciated that EARR concurrent with orthodontia is a complex trait, future studies should endeavor to study as many genetic and treatment factors as possible in as many orthodontic patients as possible to gain a better understanding of this phenomenon.

GENETICS OF CLEFT LIP AND PALATE

Studies of the CLP phenotype in twins indicate that monozygous twins have a 35% concordance rate, whereas dizygous twins show less than 5% concordance.[133] Information from two sources (families and twins) establishes a genetic basis for CLP, but despite many extensive investigations, no simple pattern of inheritance has been demonstrated. This has led to proposals for a variety of genetic modes of inheritance for CLP, including dominance, recessiveness, and gender linkage, and has led ultimately to the documentation of modifying conditions that may be present, such as incomplete penetrance and variable gene expressivity.[134] There are three important reasons for the failure to resolve the question of a hereditary basis for clefts: (1) some clefts are of a nongenetic origin and should not be included in a genetic analysis (such cases are seldom recognized and are difficult to prove); (2) individuals who have increased genetic liability for having a child with CLP often fail to be recognized, but because they do not have CLP themselves, they cannot be identified with certainty (this latter situation defines the problem of nonpenetrance for genes that control CLP)[107]; and (3) CLP, although sometimes appearing to be relatively simple in origin, is undoubtedly a complex of diseases with different etiologies lumped together because of clinical disease resemblance (they all show clefting).

cally different clefts: cleft lip either with or without cleft palate, CL(P), and isolated cleft palate (cleft palate only, CPO). These two entities, CL(P) and CPO, can occur as both single and multiple cases in a family. In the former they are called *sporadic*, and in the latter they are called *familial* or *multiplex*. Some researchers refer to multiplex cases as those individuals with findings in addition to an oral cleft, even if a specific syndrome is not recognized. It should also be noted that CPO that occurs without a cleft of the lip is different from the palatal cleft that occurs as a part of CL(P). The embryology and developmental

Dentlearn.ir

timing are different, and CPO is more commonly part of a syndrome than is CL(P). CPO is less common, with a prevalence of approximately 1 per 1500 to 2000 births in Caucasians, whereas CL(P) is more common, with 1 or 2 per 1000 births. The prevalence of CPO does not vary in different racial backgrounds, but the prevalence of CL(P) varies considerably, with Asians and Native Americans having the highest rate and Africans the lowest. There are also gender ratio differences, with more males having CL(P) and more females having CPO. Except in a small number of syndromes such as Van der Woude syndrome, families with one type of clefting segregating in the family do not have the other cleft type occurring at a rate higher than the population prevalence.

for CL(P) and three for CPO. These three for each type

proximately 30% of CL(P) and 50% of CPO patients have one of the more than 400 syndromes described.[135]

As noted earlier, it is probable that minor and subtle facial changes are more likely to produce the best-correlated phenotype needed to pinpoint the cleft genotype. Part of the reason for this view is the suspicion that certain facial shapes are more predisposed to developing CL(P) than others,[136,137] and that subepithelial defects of the upper lip musculature are part of the phenotypic spectrum of oral clefts and may represent an occult, subclinical manifestation of the anomaly.[138] Although this approach seems best for producing an accurately generated clefting phenotype, further study of the developmental anatomy of the head and face is needed.

The published data on nonsyndromic cleft populations come from around the world (Japan, China, Hawaii, Denmark, Sweden, the United Kingdom, and North America). These studies make it clear that both CL(P) and CPO are heterogeneous diseases; that is, there are multiple causes for the single phenotypes. The generally accepted hereditary basis for CL(P) and CPO can be summarized as follows: Single, nonsyndromic cases of CL(P) and CP, or sporadic clefts, are believed to be the result of a complex interaction between multiple genetic and environmental factors. Hence, their etiology is multifactorial in the true sense of the word, and the chance that these multiple factors would interact to produce a cleft phenotype in relatives is small, probably less than 1%.

cases of clefts that occur in a single family. These are called familial (or multiplex) and have been viewed by researchers as the "true" genetic cases. Familial occurrences of CL(P) and CPO seem most likely to be attributed to the action of a single major gene, but the influence of multifactorial (complex) trait factors is difficult to rule out. Thus we are left with the idea that both multifactorial and single major gene elements may have a role in producing sporadic and familial cases of CL(P) and CPO. (For an overview of genetic and other factors in orofacial clefting, the reader is referred to the paper by Leslie and Marazita.[139])

An example of an environmental (dietary) factor associated with a decrease in neural tube defects such as spina bifida, as well as orofacial clefting, is the maternal intake of folate (folic acid), now a common component in prenatal vitamins. To be effective, such vitamins or other dietary supplements must be used at least around the time of conception because of the embryologic timing of neural tube closure, and lip and palate formation. Because of the public health importance and critical need before a woman may realize that she is pregnant, folic acid fortification of grains in the United States became mandatory January 1, 1998, specifically to reduce the occurrence of neural tube defects, which has been successful. This has also, to a lesser degree, reduced the occurrence of orofacial clefting. Interestingly, however, it did not decrease the occurrence of orofacial clefting in children whose mothers smoke cigarettes.[140]

Although some genetic and environmental risk factors for CL(P) have been identified, many nonsyndromic clefts are not linked to any of these factors. Furthermore, there is a paucity of information available on the long-term consequences for children born with CL(P) or CPO. To address these concerns, the National Center on Birth Defects and Developmental Disabilities at the Centers for Disease Control and Prevention conducted a workshop entitled "Prioritizing a Research Agenda for Orofacial Clefts." Experts in the fields of epidemiology, public health, genetics, psychology, speech pathology, dentistry, health economics, and others participated in this workshop to review the state of knowledge on orofacial clefts, identify knowledge gaps that need additional public health research, and create a prioritized public health research agenda based on these gaps. Their report is recommended to the reader as an excellent summary of the current knowledge and future research priorities for orofacial clefting.[141]

REFERENCES

1. Bamshad MJ, Ng SB, Bigham AW, et al.: Exome sequencing as a tool for Mendelian disease gene discovery, *Nat Rev Genet* 12:745–755, 2011.
2. Kilpinen H, Barrett JC: How next-generation sequencing is transforming complex disease genetics, *Trends Genet* 29: 23–30, 2013.
3. Everett ET, Hartsfield JK Jr: Mouse models for craniofacial anomalies. In *Biological mechanisms of tooth movement and craniofacial adaptation*, Boston, 2000, Harvard Society for the Advancement of Orthodontics.
4. Lejeune J, Turpin R, Gautier J: Le mongolisme; premier exemple d'aberration et autosomique humaine, *Ann Genet* 1:41–49, 1959.
5. Manning M, Hudgins L: Professional Practice and Guidelines Committee. Array-based technology and recommendations for utilization in medical genetics practice for detection of chromosomal abnormalities, *Genet Med* 12:742–745, 2010.
6. Henderson LB, Applegate CD, Wohler E, et al.: The impact of chromosomal microarray on clinical management: a retrospective analysis, *Genet Med* 16:657–664, 2014.
7. Hopper JL: *Heritability in biostatistical genetics and genetic epidemiology*, New York, 2002, Wiley.
8. Harris EF: Interpreting heritability estimates in the orthodontic literature, *Semin Orthod* 14:125–134, 2008.

9. Abass S, Hartsfield JK Jr: Investigation of genetic factors affecting complex traits using external apical root resorption as a model, *Semin Orthod* 14:115–124, 2008.
10. Tucker A, Sharpe P: The cutting-edge of mammalian development; how the embryo makes teeth, *Nat Rev Genet* 5(7):499–508, 2004.
11. Croissant R, Guenther H, Slavkin H: How are embryonic pre-ameloblasts instructed by odontoblasts to synthesize enamel? In Slavkin HC, Greulich RC, editors: *Extracellular matrix influences on gene expression*, New York, 1975, Academic Press.
12. Sharpe PT: Neural crest and tooth morphogenesis, *Adv Dent Res* 15:4–7, 2001.
13. Dean JA, et al.: Dentin dysplasia, type II linkage to chromosome 4q, *J Craniofac Genet Dev Biol* 17(4):172–177, 1997.
14. Schulze C, Lenz F: Uber Zahnschmelzhypoplasie von unvollstandig dominatem geschlechtgebundened Erbang, *Z Mensch Vererb Konstitutionsl* 31:104–114, 1952.
15. Hartsfield JK Jr: The benefits of obtaining the opinion of a clinical geneticist regarding orthodontic patients. In *Integrated Clinical Orthodontics,* Krishnan V, Davidovitch Z, editors, Oxford, 2012, Wiley-Blackwell.
16. Martelli-Junior H, Santos Neto P, Aquino S, et al.: Amelogenesis imperfecta and nephrocalcinosis syndrome: a case report and review of the literature, *Nephron Physiol* 118: 62–65, 2011.
17. Wang S, Aref P, Hu Y, et al.: FAM20A mutations can cause enamel-renal syndrome (ERS), *PLoS Genet* 9:e1003302, 2013.
18. Mulvihill JJ: Craniofacial syndromes: no such thing as a single gene disease, *Nat Genet* 9(2):101–103, 1995.
19. Park WJ, Bellus GA, Jabs EW: Mutations in fibroblast growth factor receptors: phenotypic consequences during eukaryotic development, *Am J Hum Genet* 57(4):748–754, 1995.
20. Escobar V, Bixler D: On the classification of the acrocephalosyndactyly syndromes, *Clin Genet* 12(3):169–178, 1977.
21. Everett ET, et al.: A novel FGFR2 gene mutation in Crouzon syndrome associated with apparent nonpenetrance, *Cleft Palate Craniofac J* 36(6):533–541, 1999.
22. Rosenberg RN, Stuve O, Eagar T: 200 years after Darwin, *JAMA* 301(6):660–662, 2009.
23. Fraga MF, et al.: Epigenetic differences arise during the lifetime of monozygotic twins, *Proc Natl Acad Sci U S A* 102(30): 10604–10609, 2005.
24. Feinberg AP: Epigenetics at the epicenter of modern medicine, *JAMA* 299(11):1345–1350, 2008.
25. Kruglyak L, Lander ES: Complete multipoint sib-pair analysis of qualitative and quantitative traits, *Am J Hum Genet* 57(2):439–454, 1995.
26. Slatkin M: Linkage disequilibrium—understanding the evolutionary past and mapping the medical future, *Nat Rev Genet* 9(6):477–485, 2008.
27. Abecasis GR, Cardon LR, Cookson WO: A general test of association for quantitative traits in nuclear families, *Am J Hum Genet* 66(1):279–292, 2000.
28. Klein H, Palmer CE: Studies of dental caries. V. Familial resemblance in caries experience in siblings, *Public Health Rep* 53:1353–1364, 1938.
29. Klein H: The family and dental disease. IV. Dental disease (DMF) experience in parents and offspring, *J Am Dent Assoc* 33:735–743, 1946.
30. Li Y, Caufield PW: The fidelity of initial acquisition of mutans streptococci by infants from their mothers, *J Dent Res* 74(2):681–685, 1995.
31. Chaffee B, Gansky S, Weintraub J, et al.: Maternal oral bacterial levels predict early childhood caries development, *J Dent Res* 93:238–244, 2014.
32. Book JA, Grahnen H: Clinical and genetical studies of dental caries. II. Parents and sibs of adult highly resistant (caries-free) proposition, *Odontol Rev* 4:1–53, 1953.
33. Dahlberg G, Dahlberg B: Uber Karies und andere Zahnveranderungen bei Zwillingen, *Uppsala Lakerf Forh* 47:395–416, 1942.
34. Mansbridge JN: Heredity and dental caries, *J Dent Res* 38(2): 337–347, 1959.
35. Horowitz SL, Osborne RH, DeGeorge FV: Caries experience in twins, *Science* 128(3319):300–301, 1958.
36. Caldwell RC, Finn SB: Comparisons of the caries experience between identical and fraternal twins and unrelated children, *J Dent Res* 39:693–694, 1960.
37. Bretz WA, et al.: Dental caries and microbial acid production in twins, *Caries Res* 39(3):168–172, 2005.
38. Corby PM, et al.: Heritability of oral microbial species in caries-active and caries-free twins, *Twin Res Hum Genet* 10(6):821–828, 2007.
39. Corby PM, Bretz WA, Hart TC, et al.: *Mutans* streptococci in preschool twins, *Arch Oral Biol* 50(3):347–351, 2005.
40. Shuler CF: Inherited risks for susceptibility to dental caries, *J Dent Educ* 65(10):1038–1045, 2001.
41. Slayton RL, Cooper ME, Marazita ML: Tuftelin, mutans streptococci, and dental caries susceptibility, *J Dent Res* 84(8):711–714, 2005.
42. Deeley K, Letra A, Rose EK, et al.: Possible association of amelogenin to high caries experience in a Guatemalan-Mayan population, *Caries Res* 42(1):8–13, 2008.
43. Stanley B, Feingold E, Cooper M, et al.: Genetic association of *MPPED2* and *ACTN2* with dental caries, *J Dent Res* 93(7):626–632, 2014.
44. Chaussain C, Bouazza N, Gasse B, et al.: Dental caries and enamelin haplotype, *J Dent Res* 93:360–365, 2014.
45. Zeng Z, Shaffer J, Wang X, et al.: Genome-wide association studies of pit-and-fissure-and smooth-surface caries in permanent dentition, *J Dent Res* 92(5):432–437, 2013.
46. Vieira AR, Marazita ML, Goldstein-McHenry T: Genome-wide scan finds suggestive caries loci, *J Dent Res* 87(5):435–439, 2008.
47. Bretz WA, Corby PM, Melo MR, et al.: Heritability estimates for dental caries and sucrose sweetness preference, *Arch Oral Biol* 51(12):1156–1160, 2006.
48. Hunt HR, Hoppert CA, Rosen S: Genetic factors in experimental rat caries. In Sognnaes RF, editor: *Advances in experimental caries research*, Washington, DC, 1995, American Associates for the Advancement of Science.
49. Ciancio SG, Hazen SP, Cunat JJ: Periodontal observations in twins, *J Periodontal Res* 4(1):42–45, 1969.
50. Michalowicz BS, Aeppli D, Virag G, et al.: Periodontal findings in adult twins, *J Periodontol* 62(5):293–299, 1991.
51. Kornman KS, Crane A, Wang HY, et al.: The interleukin-1 genotype as a severity factor in adult periodontal disease, *J Clin Periodontol* 24(1):72–77, 1997.
52. Wagner J, Kaminski WE, Aslanidis C, et al.: Prevalence of OPG and IL-1 gene polymorphisms in chronic periodontitis, *J Clin Periodontol* 34(10):823–827, 2007.
53. Sakellari D, Katsares V, Gerogiadou M, et al.: No correlation of five gene polymorphisms with periodontal conditions in a Greek population, *J Clin Periodontol* 33(11):765–770, 2006.
54. Fiebig A, et al.: Polymorphisms in the interleukin-1 (IL1) gene cluster are not associated with aggressive periodontitis in a large Caucasian population, *Genomics* 92(5):309–315, 2008.
55. Nikolopoulos GK, et al.: Cytokine gene polymorphisms in periodontal disease: a meta-analysis of 53 studies including 4178 cases and 4590 controls, *J Clin Periodontol* 35(9): 754–767, 2008.

56. Greenstein G, Hart TC: Clinical utility of a genetic susceptibility test for severe chronic periodontitis: a critical evaluation, *J Am Dent Assoc* 133(4):452–459; quiz 492–453, 2002.
57. Divaris K, Monda KL, North KE, et al.: Exploring the genetic basis of chronic periodontitis: a genome-wide association study, *Hum Molec Genet* 22:2312–2324, 2013.
58. Schenkein HA: Inheritance as a determinant of susceptibility for periodontitis, *J Dent Educ* 62(10):840–851, 1998.
59. Etzioni A, Tonetti M: Leukocyte adhesion deficiency II—from A to almost Z, *Immunol Rev* 178:138–147, 2000.
60. Arnaout MA, et al.: Point mutations impairing cell surface expression of the common beta subunit (CD18) in a patient with leukocyte adhesion molecule (Leu-CAM) deficiency, *J Clin Invest* 85(3):977–981, 1990.
61. Meyle J, Gonzales JR: Influences of systemic diseases on periodontitis in children and adolescents, *Periodontol* 2000(26):92–112, 2001.
62. Hartsfield JK Jr: Premature exfoliation of teeth in childhood and adolescence, *Adv Pediatr* 41:453–470, 1994.
63. Hartsfield JK Jr, Kousseff BG: Phenotypic overlap of Ehlers-Danlos syndrome types IV and VIII, *Am J Med Genet* 37(4):465–470, 1990.
64. Nagle DL, et al.: Identification and mutation analysis of the complete gene for Chediak-Higashi syndrome, *Nat Genet* 14(3):307–311, 1996.
65. Hart TC, et al.: Genetic studies of syndromes with severe periodontitis and palmoplantar hyperkeratosis, *J Periodontal Res* 32(1 Pt 2):81–89, 1997.
66. Hart TC, et al.: Haim-Munk syndrome and Papillon-Lefèvre syndrome are allelic mutations in cathepsin C, *J Med Genet* 37(2):88–94, 2000.
67. Noack B, et al.: Cathepsin C gene variants in aggressive periodontitis, *J Dent Res* 87(10):958–963, 2008.
68. Diehl SR, et al.: Linkage disequilibrium of interleukin-1 genetic polymorphisms with early-onset periodontitis, *J Periodontol* 70(4):418–430, 1999.
69. Hart TC, Hart PS, Michalec MD, et al.: Haim-Munk syndrome and Papillon-Lefèvre syndrome are allelic mutations in cathepsin, *J Med Genet* 37:88–94, 2000. Note: Erratum: *J Med Genet* 38:79, 2001.
70. Hewitt C, McCormick D, Linden G, et al.: The role of cathepsin C in Papillon-Lefèvre syndrome, prepubertal periodontitis, and aggressive periodontitis, *Hum Mutat* 23:222–228, 2004.
71. Li Y, Xu L, Hasturk H, et al.: Localized aggressive periodontitis is linked to human chromosome 1q25, *Hum Genet* 114:291–297, 2004.
72. Corruccini RS: An epidemiologic transition in dental occlusion in world populations, *Am J Orthod* 86:419–426, 1984.
73. Corruccini RS: Australian aboriginal tooth succession, interproximal attrition, and Begg's theory, *Am J Orthod Dentofacial Orthop* 97:349–357, 1990.
74. Corruccini RS, Townsend GC, Richards LC, et al.: Genetic and environmental determinants of dental occlusal variation in twins of different nationalities, *Hum Biol* 62:353–367, 1990.
75. Kawala B, Antoszewska J, Necka A: Genetics or environment? A twin-method study of malocclusions, *World J Orthod* 8:405–410, 2007.
76. Ting TY, Wong RW, Rabie AB: Analysis of genetic polymorphisms in skeletal Class I crowding, *Am J Orthod Dentofacial Orthop* 140:e9–e15, 2011.
77. Yamaguchi T, Maki K, Shibasaki Y: Growth hormone receptor gene variant and mandibular height in the normal Japanese population, *Am J Orthod Dentofacial Orthop* 119(6):650–653, 2001.
78. Singh GD: Morphologic determinants in the etiology of class III malocclusions: a review, *Clin Anat* 12(5):382–405, 1999.
79. Bui C, King T, Proffit W, et al.: Phenotypic characterization of class III patients, *Angle Orthod* 76(4):564–569, 2006.
80. Litton SF, Acermann LV, Isaacson RJ, et al.: A genetic study of Class 3 malocclusion, *Am J Orthod* 58(6):565–577, 1970.
81. El-Gheriani AA, Maher BS, El-Gheriani AS, et al.: Segregation analysis of mandibular prognathism in Libya, *J Dent Res* 82(7):523–527, 2003.
82. Cruz RM, Krieger H, Ferreira R, et al.: Major gene and multifactorial inheritance of mandibular prognathism, *Am J Med Genet A* 146A(1):71–77, 2008.
83. Yamaguchi T, Park SB, Narita A, et al.: Genome-wide linkage analysis of mandibular prognathism in Korean and Japanese patients, *J Dent Res* 84:255–259, 2005.
84. Jang JY, Park EK, Ryoo HM, et al.: Polymorphisms in the Matrilin-1 gene and risk of mandibular prognathism in Koreans, *J Dent Res* 89:1203–1207, 2010.
85. Xue F, Wong RW, Rabie AB: Genes, genetics, and Class III malocclusion, *Orthod Craniofacial Res* 13:69–74, 2010.
86. Li Q, Zhang F, Li X, et al.: Genome scan for locus involved in mandibular prognathism in pedigrees from China, *PLoS*

.pone.0012678.
87. Li Q, Li X, Zhang F, et al.: The identification of a novel locus for mandibular prognathism in the Han Chinese population, *J Dent Res* 90:53–57, 2011.
88. Xue F, Rabie A, Luo G: Analysis of the association of COL2A1 and IGF–1 with mandibular prognathism in a Chinese population, *Orthod Craniofacial Res* 17:144–149, 2014.
89. Yamaguchi T, Park SB, Narita A, et al.: Genome-wide linkage analysis of mandibular prognathism in Korean and Japanese patients, *J Dent Res* 84(3):255–259, 2005.
90. Frazier-Bowers S, Rincon-Rodriguez R, Zhou J, et al.: Evidence of linkage in a Hispanic cohort with a class III dentofacial phenotype, *J Dent Res* 88(1):56–60, 2009.
91. Falcão-Alencar G, Ortero LM, Cruz RM, et al.: *Evidence for genetic linkage of the Class III craniofacial phenotype with human chromosome 7 in 36 South American families (abstract/program #975)*, Washington, DC, November 3, 2010, Presented at the 60th Annual Meeting of The American Society of Human Genetics.
92. Tassopoulou-Fishell M, Deeley K, Harvey EM, et al.: Genetic variation in myosin 1H contributes to mandibular prognathism, *Am J Orthod Dentofacial Orthop* 141:51–59, 2012.
93. Raoul G, Desh H, Gray SL, et al.: Expression of unconventional type-1 myosins (1H/1C) in masseter muscle influence the development of skeletal malocclusion in orthognathic surgery subjects, *Int J Oral Maxillofacial Surg* 42:1335, 2013.
94. Nikopensius T, Saag M, Jagomägi T, et al.: A missense mutation in DUSP6 is associated with class III malocclusion, *J Dent Res* 92:893–898, 2013.
95. Otero L, Morford LA, Falcão-Alencar G, et al.: Family history and genetics of mandibular prognathism. In Ngan PW, Deguchi T, Roberts WE, editors: *Orthodontic treatment of Class III malocclusion (eBook)*, Bentham Science, Beijing, China, 2014, Bentham eBooks, pp 3–24.
96. Maor G, Segev Y, Phillip M: Testosterone stimulates insulin-like growth factor-I and insulin-like growth factor-I-receptor gene expression in the mandibular condyle—a model of endochondral ossification, *Endocrinology* 140:1901–1910, 1999.
97. Verdonck A, Gaethofs M, Carels C, et al.: Effect of low-dose testosterone treatment on craniofacial growth in boys with delayed puberty, *Eur J Orthod* 21(2):137–143, 1999.

98. Honjo H, Tamura T, Matsumoto Y, et al.: Estrogen as a growth factor to central nervous cells: estrogen treatment promotes development of acetylcholinesterase-positive basal forebrain neurons transplanted in the anterior eye chamber, *J Steroid Biochem Mol Biol* 41:633–635, 1992.
99. Bulun SE, Sebastian S, Takayama K, et al.: The human CYP19 (aromatase P450) gene: update on physiologic roles and genomic organization of promoters, *J Steroid Biochem Mol Biol* 86:219–224, 2003.
100. Guo Y, Xiong DH, Yang TL, et al.: Polymorphisms of estrogen-biosynthesis genes CYP17 and CYP19 may influence age at menarche: a genetic association study in Caucasian females, *Hum Molec Genet* 15:2401–2408, 2006.
101. Schaefer K, Fink B, Mitteroecker P, et al.: Visualizing facial shape regression upon 2nd to 4th digit ratio and testosterone, *Collegium Antropologicum* 29:415–419, 2005.
102. Schaefer K, Fink B, Grammer K, et al.: Female appearance: facial and bodily attractiveness as shape, *Psych Sci* 48:187–204, 2006.
103. Hartsfield JK Jr, Zhou J, Chen S: The importance of analyzing specific genetic factors in facial growth for diagnosis and treatment planning. In McNamara JA, Kapila SD, editors: *Surgical enhancement of orthodontic treatment*, Ann Arbor, 2010, University of Michigan.
104. McNamara JA, Kapila SD: *Monograph 47, Craniofacial Growth Series, Department of Orthodontics and Pediatric Dentistry and Center for Human Growth and Development*, Ann Arbor, 2010, The University of Michigan. 267–281.
105. He S, Hartsfield JK Jr, Guo Y, et al.: Association between CYP19A1 genotype and pubertal sagittal jaw growth, *Am J Orthod Dentofacial Orthop* 142:662–670, 2012.
106. Hartsfield JK Jr, Morford LA, Otero LM: Genetic factors affecting facial growth. Chapter 6. In Bourzgui F, editor: *Orthodontics—basic aspects and clinical considerations*, pp 125–152, articles/show/title/genetic-factors-affecting-facial-growth.
107. Harris JE: Genetic factors in the growth of the head. Inheritance of the craniofacial complex and malocclusion, *Dent Clin North Am* 19(1):151–160, 1975.
108. King L, Harris EF, Tolley EA: Heritability of cephalometric and occlusal variables as assessed from siblings with overt malocclusions, *Am J Orthod Dentofacial Orthop* 104(2):121–131, 1993.
109. Hartsfield JK Jr: Development of the vertical dimension: nature and nurture, *Semin Orthod* 8:113–119, 2002.
110. Harris EF, Butler ML: Patterns of incisor root resorption before and after orthodontic correction in cases with anterior open bites, *Am J Orthod Dentofacial Orthop* 101(2):112–119, 1992.
111. Harris EF, Robinson QC, Woods MA: An analysis of causes of apical root resorption in patients not treated orthodontically, *Quintessence Int* 24(6):417–428, 1993.
112. Killiany DM: Root resorption caused by orthodontic treatment: an evidence-based review of literature, *Semin Orthod* 5(2):128–133, 1999.
113. Taithongchai R, Sookkorn K, Killiany DM: Facial and dentoalveolar structure and the prediction of apical root shortening, *Am J Orthod Dentofacial Orthop* 110(3):296–302, 1996.
114. Owman-Moll P, Kurol J, Lundgren D: Continuous versus interrupted continuous orthodontic force related to early tooth movement and root resorption, *Angle Orthod* 65(6):395–401, 1995.
115. Kurol J, Owman-Moll P, Lundgren D: Time-related root resorption after application of a controlled continuous orthodontic force, *Am J Orthod Dentofacial Orthop* 110(3):303–310, 1996.
116. Ngan DC, Kharbanda OP, Byloff FK, et al.: The genetic contribution to orthodontic root resorption: a retrospective twin study, *Aust Orthod J* 20(1):1–9, 2004.
117. Harris EF, Kineret SE, Tolley EA: A heritable component for external apical root resorption in patients treated orthodontically, *Am J Orthod Dentofacial Orthop* 111(3):301–309, 1997.
118. Hartsfield JK Jr, Everett ET, Al-Qawasmi RA: Genetic factors in external apical root resorption and orthodontic treatment, *Crit Rev Oral Biol Med* 15(2):115–122, 2004.
119. Al-Qawasmi RA, Harsfield JK Jr, Everett ET, et al.: Root resorption associated with orthodontic force in inbred mice: genetic contributions, *Eur J Orthod* 28(1):13–19, 2006.
120. Abass SK, Hartsfield JK Jr, Al-Qawasmi RA, et al.: Inheritance of susceptibility to root resorption associated with orthodontic force in mice, *Am J Orthod Dentofacial Orthop* 134:742–750, 2008.
121. Al-Qawasmi RA, et al.: Genetic predisposition to external apical root resorption, *Am J Orthod Dentofacial Orthop* 123(3):242–252, 2003.
122. Al-Qawasmi RA, et al.: Root resorption associated with orthodontic force in IL-1beta knockout mouse, *J Musculoskelet Neuronal Interact* 4(4):383–385, 2004.
123. Hartsfield JK Jr: Pathways in external apical root resorption associated with orthodontia, *Orthod Craniofac Res* 12:236–242, 2009.
124. Viecilli RF, Katona TR, Chen J, et al.: Three-dimensional mechanical environment of orthodontic tooth movement and root resorption, *Am J Orthod Dentofacial Orthop* 133(6):791, 2008. e711–e726.
125. Viecilli RF, et al.: Orthodontic mechanotransduction and the role of the P2X7 receptor, *Am J Orthod Dentofacial Orthop* 135:694, 2009. 135(6):694.e1–e16.
126. Bastos Lages EM, Drummond AF, Pretti H, et al.: Association of functional gene polymorphism IL-1β in patients with external apical root resorption, *Am J Orthod Dentofacial Orthop* 136:542–546, 2009.
127. Iglesias-Linares A, Yañez-Vico R, Ballesta-Mudarra S, et al.: Postorthodontic external root resorption is associated with IL1 receptor antagonist gene variations, *Oral Dis* 18:198–205, 2012.
128. Tomoyasu Y, Yamaguchi T, Tajima A, et al.: External apical root resorption and the interleukin-1B gene polymorphism in the Japanese population, *Orthod Waves* 68:152–157, 2009.
129. Gülden N, Eggermann T, Zerres K, et al.: Interleukin-1 polymorphisms in relation to external apical root resorption (EARR), *J Orofac Orthop* 70:20–38, 2009.
130. Pereira S, Lavado N, Npgieora L, et al.: Polymorphisms of genes encoding P2X7R, IL-1B, OPG and RANK in orthodontic-induced apical root resorption, *Oral Dis online*, 2013.
131. Linhartova P, Cernochova P: Izakovicova Holla L: IL1 gene polymorphisms in relation to external apical root resorption concurrent with orthodontia, *Oral Dis* 19:262–270, 2013.
132. Al-Qawasmi RA, Hartsfield JK Jr, Everett ET, et al.: Genetic predisposition to external apical root resorption in orthodontic patients: linkage of chromosome-18 marker, *J Dent Res* 82(5):356–360, 2003.
133. Shields ED, Bixler D, Fogh-Andersen P: Facial clefts in Danish twins, *Cleft Palate J* 16(1):1–6, 1979.
134. Fogh-Andersen P: *Incidence of harelip and cleft palate*, Copenhagen, 1942, Nyt Nordisk Forlag.
135. Lidral AC, Moreno LM, Bullard SA: Genetic factors and orofacial clefting, *Semin Orthod* 14:103–114, 2008.

136. Ward RE, Moore ES, Hartsfield JKJ: Morphometric characteristics of subjects with oral facial clefts and their relatives. In Wyszynski DF, editor: *Cleft lip and palate from origin to treatment*, New York, 2002, Oxford University Press.
137. Weinberg SM, Neiswanger K, Richtsmeier JT, et al.: Three-dimensional morphometric analysis of craniofacial shape in the unaffected relatives of individuals with nonsyndromic orofacial clefts: a possible marker for genetic susceptibility, *Am J Med Genet A* 146A(4):409–420, 2008.
138. Weinberg SM, Brandon CA, McHenry TH, et al.: Rethinking isolated cleft palate: evidence of occult lip defects in a subset of cases, *Am J Med Genet A* 146A(13):1670–1675, 2008.
139. Leslie EJ, Marazita ML: Genetics of cleft lip and cleft palate, *Am J Med Genet C Semin Med Genet* 163:246–258, 2013.
140. Yazdy MM, Honein MA, Xing J: Reduction in orofacial clefts following folic acid fortification of the U.S. grain supply, *Birth Defects Res A Clin Mol Teratol* 79(1):16–23, 2007.
141. Yazdy MM, Honein MA, Rasmussen SA, et al.: Priorities for future public health research in orofacial clefts, *Cleft Palate Craniofac J* 44(4):351–357, 2007.

CHAPTER 6

Child Abuse and Neglect

▲ Shannon L. Thompson, Brian J. Sanders, and Roberta A. Hibbard

For additional resources, please visit the evolve website.

CHAPTER OUTLINE

DEFINING CHILD ABUSE
- Physical Abuse
- Sexual Abuse
- Neglect
- Emotional or Psychological Abuse
- Medical Child Abuse

THE VICTIMS OF ABUSE

POSSIBLE INDICATORS OF CHILD ABUSE
- Physical Indicators
- Behavioral Indicators

EVALUATING SUSPECTED CASES OF CHILD ABUSE
- History-Taking
- Communication with the Patient
- Physical Examination

MANAGING SUSPECTED CASES OF CHILD ABUSE
- Treatment
- Documentation
- Reporting
- Parental Concerns

UNDERSTANDING THE LEGAL REQUIREMENTS
- Obligation of the Dentist

CONCLUSION

Child abuse and neglect affect millions of children in the United States each year and are found in all ethnic, cultural, and socioeconomic sections of our society. The long-term effects resulting from child maltreatment are deleterious and often involve physical, cognitive, and emotional impairments in childhood that clearly correlate with morbidity in adulthood. It has been reported that orofacial trauma is present in approximately 50% to 75% of all reported cases of physical abuse.[1] Many of the injuries common to abuse in children are thus within the scope of dentistry and are easily observed by the dental professional.[1] This places dental professionals in a unique position to identify victims of child maltreatment. Dentists must therefore be knowledgeable of their responsibilities in the recognition, documentation, treatment, and reporting of suspected child abuse cases. To intervene appropriately, dental professionals must first be willing to consider the possibility of abuse or neglect when faced with unusual injuries; otherwise it cannot be diagnosed.[2] "The public and the profession are best served by dentists who are familiar with identifying the signs of abuse and neglect and knowledgeable about the appropriate intervention resources …" (statement by ADA's Council on Ethics, Bylaws, and Judicial Affairs, April 2000). This chapter includes a discussion of the types of child maltreatment frequently encountered, the clinical presentation and management of suspected child abuse, and the documentation and reporting required in these cases.

DEFINING CHILD ABUSE

Child abuse and neglect encompass a variety of experiences that are threatening or harmful to the child and are the result of acts of commission or omission on the part of a responsible caretaker. Child maltreatment can present in many forms and may be divided into the categories of physical abuse, sexual abuse, emotional or psychological abuse, and neglect (Table 6-1).[3] Although maltreatment is not always willful, meaning that the harm or injury inflicted is not always intended, it can nonetheless result in significant damage to the child and, in too many cases, death. Professionals from multidisciplinary backgrounds working together are in the best position to identify, treat, and intervene on the behalf of this vulnerable population. Dental professionals also have an opportunity to take a proactive role in helping these victims by recognizing child abuse in its many forms.

PHYSICAL ABUSE

Physical abuse can be defined as a nonaccidental inflicted physical injury (ranging from minor bruises to severe fractures or death) that occurs as a result of harming a child by a parent, caregiver, or other person who has responsibility for the child.[4] It is often the most easily recognized form of child maltreatment. The *battered child syndrome* was initially described by Kempe and colleagues in 1962 and was further elaborated by Kempe and Helfer in 1972 as the clinical picture of physical trauma in which the explanation of injury was not consistent with the severity and type of injury observed.[5,6] Physical abuse is usually recognized by the pattern of injury and/or its inconsistency with the related history. Bruises, welts, fractures, burns, and lacerations are examples of commonly inflicted physical injuries. Studies have consistently shown that head, face, and neck injuries that can easily be recognized by the dentist occur in more than half the cases of child abuse,[7] and 25% of physical abuse injuries occur in or around the mouth.

Dentlearn.ir

Table **6-1**

Types of Child Maltreatment[3]

Types of Abuse	Description
Physical abuse	Any nonaccidental injury or trauma to the body of a child by a parent or caregiver.
Sexual abuse	Any sexual behavior or activity with a minor or the exploitation of a minor, by an adult, for the sexual pleasure of someone else.
Neglect	Occurs when an adult knowingly permits a child to endure pain or suffering or fails to provide the basic needs for proper development. Categorized as physical, medical, educational, and emotional.
Emotional abuse	A pattern of behavior that impedes a child's development and self-esteem by constant criticizing or belittling or failing to provide love and/or appropriate guidance.

SEXUAL ABUSE

Sexual abuse is defined by the Federal Child Abuse Prevention and Treatment Act (CAPTA) as "the employment, use, persuasion, inducement, enticement, or coercion of any child to engage in, or assist any other person to engage in, any sexually explicit conduct or simulation of such conduct for the purpose of producing a visual depiction of such conduct; or the rape, and in cases of caretaker or inter-familial relationships, statutory rape, molestation, prostitution, or other form of sexual exploitation of children, or incest with children."[4] Sexual abuse essentially includes any sexually stimulating activity that is inappropriate for the child's age, level of cognitive development, or role within the family. Sexually abusive acts can include activities such as exhibitionism, kissing, fondling, intercourse, child pornography, child prostitution, and rape. Oral findings of trauma to the mouth from sexual contact or lesions from sexually transmitted infections can readily be identified by dentists who maintain a high index of suspicion when faced with these findings. Some states include age criteria or an age differential in their statutes defining some forms of sexual abuse. Practitioners should be aware that there are differences in state definitions.

NEGLECT

Neglect is the failure of a parent, guardian, or other caregiver to provide for a child's basic needs. It can be further categorized as physical (e.g., failure to provide necessary food or shelter, lack of appropriate supervision), medical (e.g., failure to provide necessary medical or mental health treatment), educational (e.g., failure to educate a child or attend to special education needs), or emotional (e.g., inattention to a child's emotional needs, failure to provide psychological care, or permitting the child to use alcohol or other drugs).[4] Whereas physical abuse tends to be episodic, neglect tends to be chronic and more insidious and may present through failure to take the child for appropriate dental care, which may be just one manifestation of a larger picture of neglect.[8] The American Academy of Pediatric Dentistry defines dental neglect as the "willful failure of a parent or guardian to seek and follow through with treatment necessary to ensure a level of oral health essential for adequate function and freedom from pain and infection,"[9] and is the most frequent type of abuse seen by dentists.[10] Factors that can play a role in failure to seek adequate dental care can include family isolation, lack of finances, parental ignorance, or lack of perceived value of oral health.[7] Dentists should be aware of these factors and attempt to assist families in overcoming these barriers when possible. The level of medical and dental care, adequate nutrition, and adequate food and clothing must be considered in light of cultural and religious differences, poverty, and community requirements and standards and the impact of such neglect on the physical well-being of the child.

EMOTIONAL OR PSYCHOLOGICAL ABUSE

Emotional abuse can be defined as a pattern of behavior that impairs a child's emotional development or sense of self-worth, which may include constant criticism, threats, or rejection, as well as the withholding of love, support, or guidance.[4] It has been a concern for many years, but standards for identifying and proving such abuse have been extremely difficult to establish. Demonstrating the direct or causal link between the emotional and verbal abuse and the harm to the child can be difficult. Harm to the child generally occurs in various ways over a prolonged period of time and usually manifests as abnormal behaviors, high-risk–taking behaviors, or mental health problems that are multifactorial in origin. Continuous isolation, rejection, degradation, terrorization, corruption, exploitation, and denial of affection are examples of behaviors that frequently have significant damaging effects on the child.

MEDICAL CHILD ABUSE

Perhaps the most difficult form of child maltreatment to identify and treat is a factitious disorder. Initially called *Munchausen syndrome by proxy*, and then *pediatric condition falsification*, the problem is one of child abuse in the medical setting. It occurs when a perpetrator (usually the mother) fabricates or exaggerates signs and/or symptoms of illness, or induces illness or signs and/or symptoms of illnesses in the child, causing unnecessary and harmful or potentially harmful testing, procedures, and treatments to be performed on the child. This form of abuse is different from all other forms of child maltreatment in that the medical community is unwittingly a part of the abuse. Because health care providers are often dependent on the parental history of the child's illness, it takes some time for the practitioner to realize the inconsistencies and possibly fabricated or exaggerated nature of the complaints. These children often present with persistent and recurrent illnesses that cannot be explained and signs and symptoms that do not clinically make sense.

The motivation of the perpetrators of this form of abuse can be multifactorial (e.g., to gain medical attention, as a result of parental psychosis, or to obtain money or services) but is not considered in the making of a diagnosis of medical child abuse. The bizarre nature of many of these cases makes them almost unbelievable to the professionals involved, which can unfortunately lead to failure to protect the child.

THE VICTIMS OF ABUSE

Children from all walks of life can be victims of child abuse or neglect—no age, race, gender, or socioeconomic level is spared. Each year millions of children are reported to children's protective services or law enforcement authorities as suspected victims of abuse.[3] According to the National Child Abuse and Neglect Data System (NCANDS), child protective service agencies received an estimated 3.4 million referrals involving approximately 6.3 million children in 2012.[11] Statistics on child abuse reflect only those cases known or suspected, and all studies struggle with the component of the unknown. The Child Maltreatment 2012 report (NCANDS) noted that, of the victims reported, more than 75% (78.3%) suffered neglect, more than 15% (18.3%) suffered physical abuse, and fewer than 10% (9.3%) suffered sexual abuse.[11] As is often the case, children may be the victim of more than one type of maltreatment. These statistics reflect a child counted once for each maltreatment type.

Sociodemographic characteristics of maltreated children vary somewhat by the type of abuse or neglect. According to the Child Maltreatment 2012 report, victims in their first year of life had the highest rate of victimization, at 21.9 per 1000 children of the same age in the national population. Boys accounted for 48.7% and girls accounted for 50.9% of victims, and the majority of victims consisted of three races or ethnicities—White (44.0%), Hispanic (21.8%), and African-American (21.0%).[11] Child fatalities are clearly the most tragic consequence of maltreatment. Based on NCANDS 2012 data, a nationally estimated 1640 children died from abuse and neglect, of whom nearly three quarters (70.3%) were younger than 3 years of age and 85.5% were comprised of the three aforementioned ethnicities—White (38.3%), African-American (31.9%), and Hispanic (15.3%).[11]

Most episodes of child abuse and neglect take place within the child's family and are symptomatic of the family's dysfunction.[3] Characteristics that are overrepresented among families of maltreated children, and therefore considered risk factors, include the presence of multiple children in the home, lower socioeconomic status, interpartner violence, substance abuse, and illness and financial stresses. Children living in violent homes are increasingly recognized as victims of maltreatment. Infants and young children are more likely to be abused because of their defenselessness, physical fragility, and inability to escape an angry parent or caregiver, whereas adolescents often trigger violent responses from their caregivers by challenging parental authority.[12] Risk factors certainly play a role, but ultimately every child is a potential victim.

POSSIBLE INDICATORS OF CHILD ABUSE

As stated earlier, child abuse and neglect cannot be identified if they are not considered as a diagnostic possibility. The dental professional must be willing to consider the diagnosis of abuse to make the diagnosis. Dentists who have been educated to recognize the signs of child maltreatment are 5 times more likely to make a report than dentists who have not.[13] Indicators of child abuse and neglect are those signs or symptoms that should raise one's suspicions to the possibility of child maltreatment. The presence of such indicators is not diagnostic of maltreatment but should lead dentists to be more thoughtful in their consideration when faced with concerning injuries/illnesses. Child abuse should be included in the differential diagnosis. Many of the signs and symptoms are nonspecific and may be present for a variety of reasons, child abuse being only one of those reasons. Indicators of abuse and neglect often depend on the child's age and developmental level, and may vary with the child's experiences and resiliency.

PHYSICAL INDICATORS

There are numerous common physical signs that should alert one to the possibility of physical abuse and/or neglect. Some physical indicators of physical abuse include unexplained bruises, fractures, burns, lacerations, and abrasions. Although many injuries are accidental, dental professionals should always maintain a high index of suspicion for any traumatic injury, especially those in which there is either no explanation given or the explanation is not consistent with or plausible for the injury seen.

Unexplained bruises, abrasions, welts, or lacerations in places not routinely subject to the child's rough-and-tumble lifestyle are those that should be considered suspicious for abusive injury. For example, bruises on the shins and forehead or overlying bony prominences are expected in normal healthy active toddlers, whereas those seen on the neck, upper arms, or abdomen are not. Bruising in any infant who is not yet ambulating or cruising is suspicious. Unexplained injuries on the face, especially the cheeks; clusters of bruises or bruises that appear patterned, reflecting the shape of an article; and scattered significant bruises on different surface areas appearing to be at various stages of healing are all suspicious. The study by Pierce et al. on bruising characteristics of abused children versus accidental injuries found clear evidence that the following should be considered a red flag and serve as a sign for possible physical abuse: bruising without a clear confirmatory history for any infant not cruising and bruising to the torso-ear-neck (TEN) region of a child younger than 4 years of age (TEN-4 guideline).[13] Trauma resulting in injuries to the teeth, mouth, lips, tongue, or cheeks inconsistent with an accident is an indicator that should be readily identified by the dental professional.[1] Any unexplained fracture, especially in children younger than 2 years of age, multiple fractures in various stages of healing, or injuries to the growth centers of bones should raise real concern. While all such injuries can be accidental, a clear and plausible explanation must be sought. For example, a simple linear skull fracture may result from a short-height

Dentlearn.ir

fall (less than 3 to 4 feet). However, such a fall would not explain a skull fracture accompanied by intracranial hemorrhage (e.g., subdural hematoma) and brain injury with severe multilayer retinal hemorrhages; this would be much more characteristic of abusive head trauma. Burns are another form of recognizable child abuse. Intentional cigarette (Fig. 6-1) and immersion burns are readily distinguishable from accidental splash burns in that they typically have a uniform depth and clear lines of demarcation and can be symmetric. Suspicious burn patterns require a careful history and scene investigation to determine the etiology. Another physical indicator of physical abuse is evidence of delayed or inappropriate treatment of injuries. There are also physical indicators of neglect, which can include abandonment, consistent lack of appropriate supervision, unattended medical or dental needs, a distended abdomen, an emaciated appearance, poor hygiene, or being inappropriately or inadequately dressed for conditions. Indicators of dental neglect include untreated extensive caries that could easily be detected by a layperson; untreated pain, infection, bleeding, or trauma affecting the orofacial region; or lack of continuity of care in the presence of identified dental disease.[3]

BEHAVIORAL INDICATORS

Significant behavioral changes often linked to the various forms of child maltreatment include withdrawal, depression, poor school performance, regression in developmentally appropriate behavior, acting out, clinginess, and somatic complaints. Young maltreated children may show inappropriate affection toward others or may be extremely wary and distant in social interactions. Many abused children will still demonstrate affection toward an abusive parent, which should not be construed as evidence against maltreatment. Children who express fear of going home, appear frightened by their parents, show a lack of spontaneous smiling, or avoid eye contact with their parents are displaying behavioral indicators for maltreatment. Any child who reports injury by caretakers should be taken seriously. Extensive lists can be found describing behavioral indicators of possible maltreatment. These should be considered in light of the child's entire clinical history and presentation and not in isolation. When other explanations for such behaviors are not found, maltreatment is an appropriate consideration.



Figure 6-1 Intentional cigarette burn. (From Zitelli BJ, Davis HW: *Atlas of pediatric physical diagnosis*, ed 5, Philadelphia, 2008, Mosby.)

Behavioral indicators for physical abuse may also be present in caretakers. These include both a lack of concern and inappropriately high levels of concern in relation to the severity of the child's injury, defensiveness or hostility when questioned, and refusal of needed further evaluation and care for the child. Other behavioral indicators include an explanation that is inconsistent with the pattern of injury or the child's abilities or an explanation that changes when the perpetrator realizes that the first story was not believed. Poor judgment, jealousy or extreme protectiveness, excessive watchfulness or vigilance, child abandonment, violent behavior, and erratic behavior (suggesting substance abuse or mental illness) are other clues to possible maltreatment by caretakers. Indications of possible medical child abuse can include doctor or emergency department "shopping" or excessive use of medical care for an apparently well child. A child who is seen for repeated ingestions of harmful substances or has repeated hospitalizations for the same or similar constellation of symptoms with largely negative diagnostic testing is also concerning.

Like pediatricians, dental professionals have a continuing relationship with their pediatric patients and their families, since it is often necessary for a patient to be seen several times a month.[8] This provides the dental professional with ample opportunity to recognize any concerning physical and behavioral indicators of physical abuse and neglect and to intervene when necessary to protect potential victims of abuse.

EVALUATING SUSPECTED CASES OF CHILD ABUSE

Trauma to the orofacial structures is a frequent manifestation of child abuse: it is present in as many as 50% to 75% of all reported cases of child physical abuse.[1] Because abusive parents do not always show the same caution when visiting the dentist as when visiting the physician, the dental practitioner may be the first person to identify the abused child. The dentist must therefore learn to screen for maltreatment as a basic part of any clinical examination performed on a child[14] and complete a thorough history as well as a thorough dental and general physical examination. The dentist must learn to recognize an abused child and make the appropriate referrals.[15]

HISTORY-TAKING

A certain combination of information is what influences or creates the suspicion of possible child maltreatment.

Dentlearn.ir

Historical information should include a complete dental and medical history. Details regarding any trauma should be complete and obtained separately from more than one source (e.g., parent and child), if possible, and in the presence of another staff member to act as a witness.[14] The use of open-ended questions is favored, and "yes" or "no" questions should be avoided. Often, the best question is, "What happened?" The dentist need ask only for a level of detail that would be indicative of a suspicion for reportable abuse or neglect. Such details might include who witnessed the injury and who was with the child at the time of the injury; where the child and supervising adults were at the time of the injury; and details about what, how, and when the incident occurred. A description of present and past injuries, as well as the child's developmental abilities, is usually helpful. Situations raising the strongest suspicions are those in which the pattern of injury is not consistent with the account offered to explain it. The history should be consistent with the injury as it relates to the mechanism of the injury, the timing of the injury, and the developmental level of the child. For example, a 3-month-old (nonambulatory) infant cannot sustain a spiral femur fracture from crawling. A bruise in the shape of a handprint on the cheek does not result from a fall down the stairs (Fig. 6-2). Conflicting accounts from two or more individuals (e.g., parents or a parent and child) or historical accounts that change over time should raise concerns. Additionally, any significant injury that is reportedly "unwitnessed" is reasonable cause for suspicion.



Figure 6-2 Bruise in the shape of a handprint on the cheek.

COMMUNICATION WITH THE PATIENT

In most circumstances, professionals who are identifying and reporting suspected child maltreatment will have to talk to children to clarify a possible suspicion. They should not, however, be conducting investigative interviews of children to learn explicit details or sort out the truthfulness of comments. The goal of questioning should be limited to obtaining the information needed to care appropriately for the child and help inform opinions about suspicions of child maltreatment. If, based on this information, including one's own knowledge and experience, there is reason to believe that the child may have been abused or neglected, a report should be made to the appropriate child protection agency, whose job it is to investigate such concerns. It is appropriate to listen to and provide support for the child who is talking and wants to disclose more.

PHYSICAL EXAMINATION

The examination of the patient by a dentist should include a careful and thorough intraoral and perioral exam in addition to exposed areas of the body that can be examined without undressing the child. The examination should be completed before any treatment is initiated. Observations should be assessed in the context of the age, developmental level, and known history of the child, and should include the patient's posture, gait, and clothing. Dental staff should also be trained in recognizing abuse and neglect so that they may alert the dentist if they have concerns. Inappropriate dress may be cause for concern. For example, a child who appears with a long-sleeved shirt in the middle of the hot summer may be dressed in this manner to cover old injuries.

The dentist should start the examination at the top, beginning with careful visual examination and palpation of the head, including hair, scalp, facial bones, and mouth, and systematically work down. Findings that may be of concern include alopecia, which without an underlying medical cause may be an indicator of malnutrition or hair pulling. Subgaleal hematoma can be the result of trauma to the scalp from direct trauma or violent hair pulling. Periorbital ecchymosis, subconjunctival hemorrhages, ptosis, and deviated or unequal pupils may indicate significant facial trauma. A nasal fracture, deviated septum, and clotted blood are nasal findings that may be of concern and indicate previous trauma. Bruising inside and behind the ears is worrisome for inflicted trauma. Tympanic membrane damage can be of concern. Other common orofacial injuries include lacerations, burns, abrasions, or bruises to the lips or corners of the mouth; labial (maxillary) or lingual frenum tears; burns or lacerations of the gingiva, tongue, palate, or floor of the mouth; and past or present fractures to the facial bones, condyles, ramus, or symphysis of the mandible, which can result in malocclusion.[3] Burns can be the result of forced ingestion of hot or caustic substances. A torn maxillary frenum on a child who is immobile may indicate possible trauma to the mouth from a slap, fist

Dentlearn.ir

blow, or forced feeding, and a torn lingual frenum could indicate sexual abuse or forced feeding (Figs. 6-3 and 6-4). The mandible should be examined for any deviation on opening, range of motion, trismus, and occlusion at rest. The maxilla should also be examined for any mobility indicating a facial fracture. Bleeding under the tongue may indicate a fracture of the body of the mandible. Examination of the teeth and their supporting structures may also reveal concerns for abusive injury and may be present in the form of missing teeth or previously traumatized teeth (avulsions, luxations, intrusions, or fractures). Physical exam findings of a child with dental neglect may reveal a child with extensive, untreated dental caries, untreated infection, or dental pain.



Figure 6-3 Torn frenulum from blunt force trauma to the mouth. Upon further investigation, this child was found to have 17 fractures.



Figure 6-4 Sublingual hemorrhage in an infant with signs of genital and abdominal trauma.

Any bruise in the shape of an object, such as a belt, looped cord, handprint, or hanger, should alert the practitioner to inflicted trauma. Though bruising cannot be aged by its appearance, various colors of bruises can be indicative of the several stages of resolution and may suggest ongoing trauma. The neck should be examined for evidence of ligature marks or bruises (Fig. 6-5) with associated facial petechiae that may indicate attempted strangulation. Physical trauma to the child's chest or ribs may elicit a painful response from the child if a lifting motion is used to slide the child up to the top of the dental chair and may warrant further examination.

Bite marks should be suspected when bruising, abrasions, or lacerations are found in an elliptical or ovoid pattern.[7] Bite marks can occur anywhere, but most commonly are found on the facial cheeks, back, sides, arms, buttocks, and genitalia.[3] Human bites tend to compress flesh, whereas animal bites typically result in tears and avulsions of the flesh.[7] The presence of adult bite marks (Fig. 6-6) is usually associated with physical or sexual abuse[3] and can help



Figure 6-5 Attempted strangulation marks on the neck of an adolescent. (From Hobbs CJ, Wynne JM: *Physical signs of child abuse: a colour atlas*, ed 2, London, 2001, WB Saunders/Harcourt Publishers.)

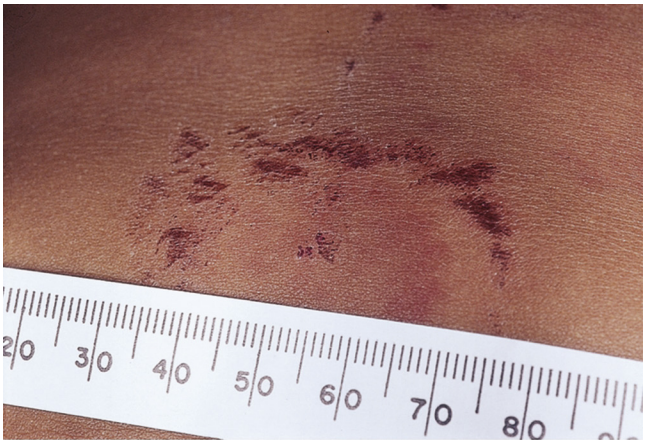

Figure 6-6 The presence of an adult bite mark may be a sign of physical or sexual abuse or neglect. (From Shah BR, Laude TA: *Atlas of pediatric clinical diagnosis*, Philadelphia, 2000, WB Saunders.)

Dentlearn.ir

identify the abuser. An intercanine distance (linear distance between the central points of the cuspid tips) measuring more than 3.0 cm is suspicious for an adult bite.[7] A forensic odontologist or pathologist should be consulted as soon as possible when adult bite marks are suspected. These injuries should be clearly documented with detailed information about their pattern, size, contour, and color. They should be photographed, if possible, when they are first observed because they tend to fade rapidly. Photographs should include a patient identification tag and a scale marker. Photographs should be taken so that the angle of the camera lens is directly over the bite and perpendicular to the plane of the bite, to avoid distortion.[7] The American Board of Forensic Odontology has developed a special photographic scale for this purpose, which can also be used in the documentation of other injuries (ABFO No. 2 reference scale, Lightening Powder Company Inc., Salem, OR, USA).[7] Most law enforcement agencies will dispatch a photographer if requested in child abuse cases.

Dentists are not as involved as other health professionals in the diagnosis of sexual abuse; however, there are certain signs and symptoms for which they should remain alert.[3] Bruising, erythema, or petechiae at the junction of the soft and hard palates may indicate forced oral penetration (Fig. 6-7). Oral manifestations of sexually transmitted infections can be apparent in sexually abused children. Gonorrhea may appear symptomatically as anything from erythema to ulcerations and from vesiculopustular to pseudomembranous lesions on the lips, tongue, palate, and/or pharynx.[3] Syphilis may manifest as a papule on the lip or skin at the site of inoculation, which later ulcerates to form the classic chancre in primary syphilis, and as a generalized maculopapular rash in secondary syphilis.[3] Condylomata acuminata (Human papilloma virus, HPV) can appear as single or multiple raised pedunculated, cauliflower-like lesions in the oral cavity, as well as genital and anal areas.[3] Herpes simplex virus (HSV) presents as oral or perioral painful erythematous eruptions with grape-like clusters of vesicles that rupture to form crusted-over lesions. HPV and HSV do not necessarily indicate sexual abuse as they have both vertical (mother-to-child transmission in utero or during birth) and horizontal (person-to-person or to self, transmission via direct physical contact, airborne, or environmental contact) modes of transmission. Their presence should raise the question of, but not be used as diagnostic for, sexual abuse. This is unlike gonorrhea or syphilis, which are both diagnostic of sexual abuse. Pregnancy in a child under the age of sexual consent (varies by state, but generally 12 to 13 years) is also diagnostic of sexual abuse and should be reported. It is the combination of a complete history and physical examination that should form one's basis for the suspicion of child maltreatment, all while considering the differential diagnosis. The primary goal of detection is to prevent further injury to the child.



Figure 6-7 Palatal hemorrhage from oral-genital contact.

MANAGING SUSPECTED CASES OF CHILD ABUSE

Clinical and medicolegal management of suspected child abuse and neglect involves several basic steps: appropriate medical and dental treatment, complete and objective documentation (including photographs), and reporting. There are numerous reports in the dental literature in which dentists initially suspected abuse-based orofacial injuries, many of which were instances of severe child abuse resulting in hospitalization or death.[16] As health care professionals, dentists should be especially sensitive to the need for protecting children from abuse and neglect and should adopt routine protocols for the management of these cases when suspicion exists.

TREATMENT

Any medical or dental treatment that is indicated by the child's condition should be provided. The dentist can ensure that a child receives the immediate necessary attention. In cases of child abuse or neglect, if the dentist feels competent and the problem or injury is restricted to the mouth, definitive dental/medical care should be initiated. More extensive trauma (e.g., fractures, lacerations, serious injuries to the head) should be referred to the appropriate medical and dental specialists.[3] For example, a maxillofacial surgeon may be best qualified to provide treatment for instances of severe trauma to the jaw, alveoli, or intraoral soft tissues.[16] A plastic surgeon may be best qualified to treat facial lacerations requiring extensive suturing.[16] In cases of suspected head trauma, the child should be

Dentlearn.ir

referred to a pediatrician or neurosurgeon familiar with child abuse as soon as possible. Referral to a local ER/hospital may be indicated for other trauma involving the body, head, or extremities. Additionally, some cases may require referral to the child's primary care provider or a child abuse pediatrician who can assist in considering the complete differential diagnosis, identify medical conditions that can mimic or be confused with child abuse, and perform any additional medical evaluation necessary.[17] The dentist should always notify the specialist or hospital/ER regarding his/her concern of maltreatment so that these individuals may also be sensitive and helpful in assessing the possibility of abuse.[3,16] Referral to a physician does not eliminate the dentist's obligation to make a report to authorities if maltreatment is suspected. If the treatment is within the scope of the dentist's mandate, definitive care should be given, followed by a discussion with the caregiver regarding the treatment provided, the prognosis, and any necessary follow-up care prior to any discussion of the suspicion of child abuse.[16]

DOCUMENTATION

All data collected in the medical history and physical examination must be documented in a complete and objective manner. Pertinent positive and negative findings should be included. Findings should be documented with a detailed description of the injuries and the history obtained for how they occurred. Actual comments in quotations should be recorded whenever possible. Behaviors should also be objectively noted, and opinions about those behaviors should be avoided. If possible, photographs of any visible injuries should be obtained, with the child's name and date of the photograph included in the picture. Most law enforcement officials will take photographs if requested to do so when suspected child abuse is reported. Also document why maltreatment is suspected. When suspected maltreatment is reported to authorities, the time, date, and method of reporting (telephone or written report) should also be documented in the medical and dental record.

REPORTING

Dentists must be informed about their responsibilities in relation to child maltreatment as outlined by the American Dental Association. The dentist is obligated by law to report suspected findings of child abuse to child protective service agencies and/or law enforcement officials. Reports of suspected child maltreatment to local authorities mandated to investigate allegations are allowable without parental consent under Health Insurance Portability and Accountability Act regulations. Underreporting is a concern among all health professionals and is not unique to dentists.[18] Health care professionals are likely to underreport cases of suspected abuse because of their own values and attitudes toward abuse,[18] due to concerns about making false accusations,[1] or because of a lack of adequate training or education in the recognition of child maltreatment.[16] With increased public awareness and the inclusion of courses on child abuse in the dental curriculum, ignorance of the laws regarding child abuse is not an acceptable excuse. Health professionals who fail to report reasonable suspicions of abuse may be subject to civil or criminal charges. Those who report in good faith are protected from civil and criminal liability.

Reporting is initiated simply with a telephone call to the appropriate child protective service or law enforcement agency, depending on local statutes. The telephone call initiates a response by professionals trained in investigating and recognizing child abuse. The reasons for the suspicion, with supporting documentation, should be communicated both verbally and in writing. Dentists are mandated to report based on "reasonable suspicion" and are not responsible for any further investigation. If the concern is dental neglect, the dentist must work with the authorities to educate them on the diagnosis and need for care and then establish and follow through on a plan of treatment. While it is possible to report suspected child abuse anonymously in most states, it is preferred that one provide one's contact information to help the agency understand the concerns. There should be no reluctance on the part of the dentist to report suspected child abuse due to concerns that it will require a great deal of time. In most cases once the initial report has been filed, no further involvement is necessary on the part of the dentist, and few cases require a court appearance. Detailed documentation in the dental record may lessen the likelihood of the need for a personal appearance.

PARENTAL CONCERNS

In most situations parents should be told about concerns of possible child abuse or neglect and the legal requirement to report it to local authorities. This can help maintain the relationship with the patient and family. It can also be helpful to ask the parent if there has ever been a concern that someone might have hurt the child. Health care professionals should take care not to make any accusations about who may have caused the harm. One may consider using the following simple and direct statement: "Because of an injury like this in a child of this age, we have to think about all of the possible causes. Whenever we are faced with this, I am required by law to make a report to Child Protective Services." When the dentist's action is presented to parents as motivated by concern for the child and by an attitude of partnership in an effort to figure out what has happened, many parents are eventually appreciative and will continue to seek support and care from the reporting professional.

In situations in which a child is suspected to have been significantly harmed in the home, in which the parent is expected to be violent, or in which possible retribution against the child for having made a disclosure about abuse is a concern, it may be more prudent to contact the authorities first and have them present to protect the child before parents are informed about suspicions of abuse. Discussion about the severity of the situation with the authorities will aid in determining a plan about the disposition of the child (e.g., whether you should release the child from the office or await the arrival of the authorities). The dental professional has no legal obligation to inform parents that abuse or neglect is suspected or will be reported. Decisions about this should be tailored to the specific situation. The welfare of the patient should be at the forefront

Dentlearn.ir

of all decision making, and any concerns about losing a patient from a practice should be secondary.

UNDERSTANDING THE LEGAL REQUIREMENTS

There are mandates in all fifty states requiring that suspected child abuse and neglect be reported to proper state authorities by dental professionals.[18] These statutes may vary somewhat from state to state regarding detailed definitions of child abuse and neglect, but there is no variance in the identification of all health care professionals as mandated reporters. It is important to emphasize that one is required to report reasonable suspicions of child maltreatment, not proven allegations of abuse. Once suspicions have been reported, it is the responsibility of social and legal authorities to determine the needs of the child and family, whether maltreatment has occurred, and what intervention or service is legally allowable or necessary.

OBLIGATION OF THE DENTIST

Dental professionals are mandated reporters under state law and may face criminal sanctions for failing to report cases. They also have a defined ethical duty to report, and may be subject to private civil malpractice lawsuits if they fail to notify state child protection agencies when appropriate.[18] Some state statutes allow the mandated reporter to be held liable for proximate damages caused by the failure to report. The privileged quality of communication between the caretakers or the patient and the practitioner is not grounds for excluding evidence in a judicial proceeding that either results from a report or results from failure

of records should always be maintained. Reports and any other information obtained in reference to a report are

the juvenile code to examine them.

Again, it must be understood that absolute proof is not required when making reports about suspicions of abuse. It is the responsibility of child protective service agencies and law enforcement officials to investigate suspicions and determine whether intervention is necessary. The health care professional can provide invaluable assistance by giving as much information as possible through communication and coordination. Investigating professionals cannot do their jobs if the health care professional does not share detailed information regarding why the suspicions exist. Health care professionals who are unhappy with the outcome of system intervention (e.g., nothing was done) are usually those who would not or did not provide the information available that would have assisted authorities in making the best-informed decisions. If the health care professional believes that a bad decision is being made, a follow-up telephone call to the assigned case worker or case worker's supervisor to clarify concerns and interventions is appropriate. Many misperceptions exist about what interventions are possible legally. Clear communication and coordination can improve everyone's knowledge and understanding about a child's needs and what can be done to meet them.

In cases of dental neglect, the dentist should determine whether the failure to provide dental care is willful or due to a lack of awareness, lack of finances, or lack of perceived value of health care prior to filing a report with proper authorities. Taking a good medical and dental history and making repeated attempts to obtain appropriate treatment for the child can help sort out these issues. Dentists must be aware of these factors and attempt to assist families to overcome any identified barriers as well as provide clear explanations regarding the disease and its implications.[7] A call to a child protective service agency is indicated if repeated attempts to address the cause of the dental neglect are not met with success, since the manifestations of dental neglect (e.g., dental caries, periodontal disease) can cause significant pain, infection, and loss of oral function if left untreated. This can result in adverse effects on learning, communication, nutrition, and other activities necessary for normal growth and development.[7]

CONCLUSION

Consequences of child abuse can be devastating, often manifesting in emotional problems, cognitive impairments, mental health disturbances, and long-term physical problems.[3] Society is also adversely affected by child abuse through the substantial direct costs resulting from the investigation, prosecution, and resulting health care costs.[3] It is known that, of the abused children who are returned to the same environment without intervention, many will be seriously reinjured or killed. It is thus imperative that health care professionals appropriately recognize and report suspected victims of child maltreatment to prevent further injury and/or death to the child. Dental professionals and offices can be instrumental in prevention efforts as well by facilitating community awareness of child abuse through the provision of resource materials in waiting rooms, participation in organizations concerned with ending violence, and ensuring that all office staff become familiar with the signs of abuse and be encouraged in the pursuit of continuing education on the subject.[14]

REFERENCES

1. Santos JF, et al.: Primary identification of an abused child in dental office: a case report, *J Indian Soc Pedodont Prev Dent* 25(4):191–193, 2007.
2. Jones R, et al.: Clinicians' description of factors influencing their reporting of suspected child abuse: report of the child

   112(2):259–266, 2008.
3. Jessee S, Deinard S: Child abuse and neglect: implications for the dental professional, Crest Oral-B at dentalcare.com, Continuing Education Course, Revised November 30, 2012.
4. Child Information Gateway Factsheet: *What is child abuse*

   welfare.gov.
5. Kempe CH, et al.: The battered child syndrome, *J Am Med Assoc* 181:17–24, 1962.
6. Kempe C, Helfer R: *Helping the battered child and his family*, Philadelphia, 1972, JB Lippincott.
7. American Academy of Pediatric Dentistry: *Guideline on oral and dental aspects of child abuse and neglect,* AAP Committee on Child Abuse and Neglect and AAPD, Council on Clinical Affairs, Adopted, 1999, Revised 2005, Reaffirmed 2010.

8. Kiran K, Kamala BK: Child abuse and the role of a dental professional – the Indian scenario, *Child Abuse Negl* 35:157–158, 2011.
9. American Academy of Pediatric Dentistry: Definition of dental neglect, *Pediatr Dent* 35(6):13, 2013-2014.
10. Kilpatrick NM, et al.: Child protection: a survey of experience and knowledge within the dental profession of New South Wales, Australia, *Int J Ped Dent* 9:153–159, 1999.
11. U.S. Department of Health and Human Services: Administration for Children and Families, Administration on Children, Youth and Families, Children's Bureau, *Child*

programs/cb/research-data-technology/statistics-research/child-maltreatment.
12. Da Fonesca M, et al.: Dental aspects of 1248 cases of child maltreatment on file at a major county hospital, *Pediatr Dent* 14(3):152–157, 1992.
13. Pierce MC, et al.: Bruising characteristics discriminating physical child abuse from accidental trauma, *Pediatrics* 125:67–74, 2010.
14. Tsang A, Sweet D: Detecting child abuse and neglect – are dentists doing enough? *J Can Dent Assoc* 65:387–391, 1999.
15. Harris JC, Sidebotham PD, Welbury RR: Safeguarding children in dental practice, *Primary Care Dent* 34:508–517, 2007.
16. Needleman HL: Orofacial trauma in child abuse: types, prevalence, management and the dental profession's involvement, *Pediatr Dent* 8(1 spec iss):71–80, 1986.
17. Kellogg N: AAP Committee on Child Abuse and Neglect: Oral and dental aspects of child abuse and neglect, *Pediatrics* 116(6):1565–1568, 2005.
18. Katner DR, Brown C: Mandatory reporting of oral injuries indicating possible child abuse, *J Am Dent Assoc* 143(10): 1087–1091, 2012.

SUGGESTED READINGS

American Dental Association Council on Dental Practice: *The dentist's responsibility in identifying and reporting child abuse*, Chicago, 1987, The Association.

Bross DC: Managing pediatric dental patients: issues raised by the law and changing views of proper child care, *J Pediatr Dent* 26(2):125–130, 2004.

Croll TP, et al.: Rapid neurologic assessment and initial management for the patient with traumatic dental injuries, *J Am Dent Assoc* 100:530–534, 1980.

Davis MJ, Vogel L: Neurological assessment of the child with head trauma, *J Dent Child* 62:93–96, 1995.

Golden MH, Samuels MP, Southall DP: How to distinguish between neglect and deprivational abuse, *Arch Dis Child* 88:105–107, 2003.

Sheridan MS: The deceit continues: an updated literature review of Munchausen syndrome by proxy, *Child Abuse Negl* 27:431–451, 2003.

Sidebotham P, Golding J: ALSPAC Study Team: Child maltreatment in the "children of the nineties." A longitudinal study of parental risk factors, *Child Abuse Negl* 25:1177–1200, 2001.

PART 2 CARIES AND PERIODONTOLOGY

CHAPTER 7

Mechanical and Chemotherapeutic Home Oral Hygiene

▲ Christopher V. Hughes and Jeffrey A. Dean

For additional resources, please visit the evolve website.

CHAPTER OUTLINE

MICROBIAL ASPECTS OF ORAL HYGIENE AND PLAQUE FORMATION
MECHANICAL METHODS OF PLAQUE CONTROL
- Manual Toothbrush
- Floss
- Powered Mechanical Plaque Removal
- Dentifrices
- Disclosing Agents
- Other Adjuncts for Plaque Control
- Techniques
- Visual-Motor Skill Mastery
- Time Considerations

CHEMOTHERAPEUTIC PLAQUE CONTROL
- Antiseptic Agents
- Enzymes, Plaque-Modifying Agents, and Plaque Attachment Interference Agents
- Sugar Substitutes

AGE-SPECIFIC HOME ORAL HYGIENE INSTRUCTIONS
- Prenatal Counseling
- Infants (Birth to 1 Year Old)
- Toddlers (1 to 3 Years Old)
- Preschoolers (3 to 6 Years Old)
- School-Aged Children (6 to 12 Years Old)
- Adolescents (12 to 19 Years Old)
- In-Office Oral Hygiene Programs

As the technological level of health care increases, it is important not to lose sight of the basics of patient care. In dentistry, this means establishing and maintaining effective preventive habits in our patients. No matter how sophisticated our dental techniques and procedures have become, preventive dentistry is the foundation on which all oral health care must be built. In 1960 McDonald discussed how pediatric medicine had changed in the previous 30 years (since 1930) from 90% treatment and 10% prevention to just the reverse.[1] He stated that preventive measures for dentistry were available and remained to be applied, as they had been in pediatrics. With this preventive philosophy, dentistry, particularly dentistry for children, has come a long way toward reaching this ratio of 90% prevention to 10% treatment.

At the core of this preventive foundation are home oral hygiene and plaque control. The area of oral hygiene has undergone recent developments that have turned a mundane subject into a field of surprising growth and research. Modern biology has made new inroads into the area of plaque control and will continue to exert a strong influence on how we look at oral hygiene and plaque in the future. The traditional focus of oral hygiene has been and will continue to be the control of the two most prevalent oral diseases: caries and periodontal disease. Although plaque control is essential to oral hygiene, unlike with periodontal disease, no clear relationship exists between plaque control and the prevention of caries. As discussed in Chapter 9 the complex etiology of decay centers on the following factors: tooth susceptibility, bacterial plaque, refined carbohydrates, and time. Many other variables, such as oral sugar clearance, salivary flow, and pH and immune factors, add to the complexity of this process. This may help explain the difficulty in demonstrating a relationship between oral hygiene practices and caries prevention.

Despite this ambiguity, plaque control remains an essential element in oral health. Although Marsh has shown that the natural oral microflora confers several benefits on the host, in the absence of oral hygiene, dental plaque accumulates, which leads to shifts in bacterial populations away from those associated with health.[2] Treatment should therefore be designed to control rather than to eliminate dental plaque.

Dentlearn.ir

Not only have there been advances in biology, but the public's consciousness regarding home oral hygiene also has been raised to new levels by the advertising of home health care products. The global oral care market is estimated to exceed $36 billion by 2017. Health and cosmetic awareness by patients is possibly at an all-time high; the patients are willing to pay for the best in health products.

This chapter addresses the broad area of home oral hygiene for the child and adolescent, from the biology of plaque development to plaque removal techniques and patient motivation. Dental health care professionals need to make home oral hygiene the core of their preventive foundation.

MICROBIAL ASPECTS OF ORAL HYGIENE AND PLAQUE FORMATION

Although Miller proposed, in the late nineteenth century, that microorganisms play a role in dental disease,[3] definitive evidence of the microbial etiology of dental caries and periodontal diseases did not appear until three fourths of a century later, with the work of Keyes[4] and Löe and colleagues.[5] Since these seminal studies, a major focus of dental research has been to define the specific microorganisms in dental plaque that mediate these diseases. Although great progress has been made in identifying these pathogens, our primary tools for preventing dental diseases remain mechanical removal of plaque and promotion of the remineralization of the tooth surface. Therefore the following brief review of the timing, mechanisms, and biology of plaque formation provides a scientific rationale for any clinical program of oral hygiene and prevention.

The development of anaerobic culturing techniques and, more recently, genetic techniques that allow for the detection of uncultivable species has identified more than 700 bacterial species and numerous distinct bacterial habitats in the mouth. Interestingly, only limited numbers of species are found in high numbers in dental plaque.[6-8] These species are uniquely suited to this habitat. The formation of plaque on the tooth surface is characterized by progression from a limited number of pioneer species (mainly streptococci and other gram-positive organisms) to the complex flora of mature dental plaque. This maturation involves initial adherence of bacteria to the salivary pellicle and subsequent formation of a complex multispecies biofilm. Most oral bacteria have evolved specific adherence mechanisms that enable them to colonize the tooth surface. In addition, bacteria undergo numerous phenotypic changes as they initiate the formation of a biofilm. The molecular mechanisms that underlie these processes have been intensively studied. Kolenbrander and Kuramitsu have provided recent reviews of these areas.[8-10] Although their reports offer the possibility of new methods of plaque control, mechanical plaque removal with supplementation by chemotherapeutic agents currently offers the most practical method of controlling plaque.

Not only do microbial changes occur as plaque matures on the tooth surface but also do mature dental plaques associated with oral diseases appear to differ from those associated with oral health. Many studies have demonstrated that, in dental caries, the pathogenicity of plaque is related to the numbers of *mutans streptococci* and other cariogenic species present.[11,12] In contrast, the plaques associated with gingival inflammation are characterized by a predominance of gram-negative bacteria rather than the predominantly gram-positive flora found in oral health. This transition seems to coincide with inflammatory changes that occur at the gingival margin. Culture-independent studies using genetic techniques have expanded the range of disease-associated bacteria in both dental caries and periodontal diseases.[6] Regardless, plaque control efforts should be directed toward two goals: (1) limiting the numbers of mutans streptococci and other cariogenic organisms in dental plaques for the prevention of caries by mechanical elimination of supragingival plaque and limitation of dietary sucrose and (2) maintaining the predominantly gram-positive flora associated with gingival health by mechanical removal of plaque from the subgingival area on a regular basis. The use of chemotherapeutic agents, particularly chlorhexidine, can also play a role in the maintenance of gingival health. The incorporation of these methods into the daily routines of patients and their parents is perhaps the greatest challenge facing the dentist.

MECHANICAL METHODS OF PLAQUE CONTROL

Mechanical methods of plaque control are the most widely accepted techniques for plaque removal. Toothbrushing and flossing are the essential elements of these mechanical methods; adjuncts include disclosing agents, oral irrigators, and tongue scrapers.

MANUAL TOOTHBRUSH

The toothbrush is the most common method for removing plaque from the oral cavity. Several variables enter into the design and fabrication of toothbrushes, including the bristle material; length, diameter, and total number of fibers; length of brush head; trim design of brush head; number and arrangement of bristle tufts; angulation of brush head to handle; and handle design. In addition, many features, such as the use of neon colors or familiar cartoon caricatures, are designed to attract the attention of potential purchasers (Fig. 7-1).



Figure 7-1 Features such as neon colors or cartoon characters on toothbrushes are designed to attract the attention of purchasers.

Dentlearn.ir

Today most commercially available toothbrushes are manufactured with synthetic (nylon) bristles. Park and colleagues identify the bristle and head of the toothbrush as the most important part of the toothbrush, noting that the length of most bristles is 11 mm.[12a] Toothbrushes are

of these bristles. The diameter ranges for these classifications are 0.16 to 0.22 mm for soft, 0.23 to 0.29 mm for medium, and 0.30 mm and above for hard. In addition to the bristle diameter, the bristle end has been studied to determine the most beneficial type for plaque control. Of the three types of bristle ends (Figs. 7-2, *A-C*), coarse-cut, enlarged bulbous, and round, the round end is the bristle type of choice because it is associated with a lower incidence of gingival tissue irritation. However, even the coarse-cut bristles round off eventually with normal use (see Fig. 11-2, *D*).

The soft brush is preferable for most uses in pediatric dentistry because of the decreased likelihood of gingival tissue trauma and increased interproximal cleaning ability. In evaluating the best toothbrush head and handle for children, Updyke concludes that it is best to use a

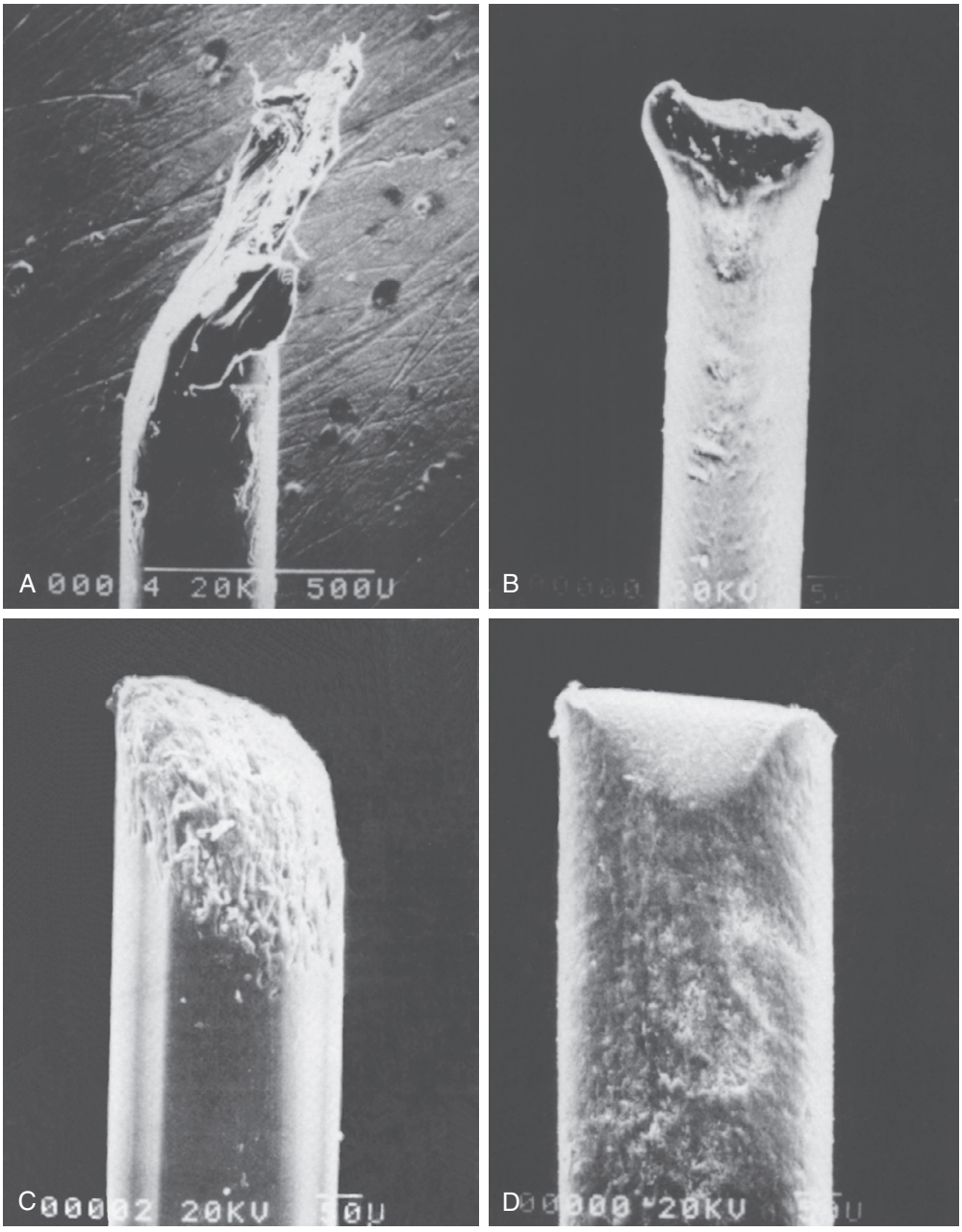

Figure 7-2 Scanning electron micrographs of toothbrush bristles manufactured by different processes. **A**, Coarse-cut bristle end, probably the result of an incomplete single-blade cut. **B**, Slightly enlarged, bulbous nylon bristle end, resulting from a double-blade or scissors cut. **C**, Tapered or round-end nylon toothbrush bristle produced by heat or a mechanical polishing process. **D**, Scrubbing, mechanical action of a toothbrush wear machine has rounded off this bristle removed from a brush that was originally coarse-cut. (From Park KK, Matis BA, Christen AG: Choosing an effective toothbrush, *Clin Prev Dent* 7:5-10, 1985.)

Dentlearn.ir

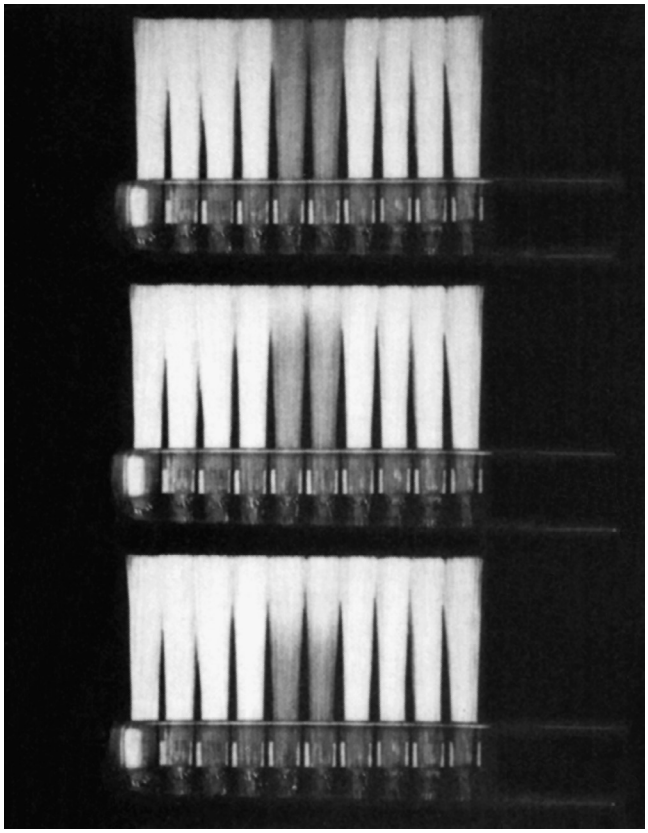

Figure 7-3 Blue dye in the center bristle tufts of this toothbrush fades down from the end with use. When the dye reaches the halfway point *(bottom),* the manufacturer suggests replacing the toothbrush.

toothbrush with a smaller head and a thicker handle than an adult-size toothbrush, for better access to the oral cavity and to facilitate the child's grip of the handle.[13] However, no single toothbrush design has been scientifically proven to be superior for the removal of plaque,[14] although some evidence exists that an angled bristle tuft configuration is more effective.[15,16] Multiple variables influence a toothbrush's ability to remove plaque; therefore the practitioner should make recommendations only after assessing a patient's individual needs.

Wear rates of toothbrush bristles and their subsequent ability to remove plaque raise another concern. Numerous studies suggest that toothbrushes remain effective even after wear is noticeable to the patient.[17] With time, of course, there is an inevitable decline in efficiency. Studies suggest that this occurs by the fourth month of continued use, especially at approximal sites.[18] The cleansing effectiveness of toothbrushes is maintained until pronounced toothbrush wear has occurred. This implies that patients are much more likely to dispose of a brush well before its clinical usefulness actually ends than to continue to use a toothbrush that no longer cleans effectively. In this regard, one manufacturer claims that its commercial toothbrush (Oral-B Indicator; Oral-B Laboratories, Inc., Belmont, California, United States) indicates when the brush should be replaced by means of centrally located tufts of bristles dyed with food colorant. When the

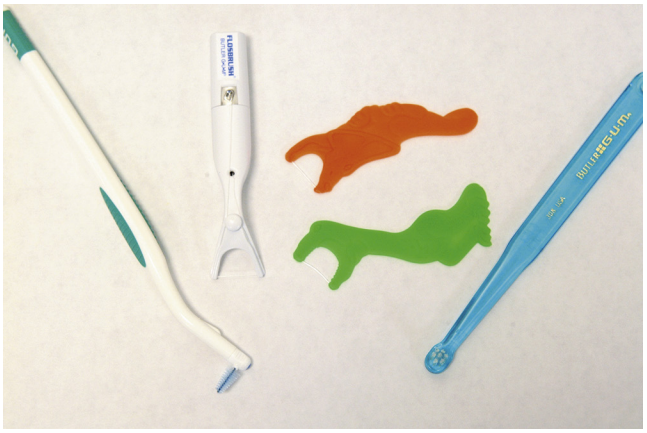

Figure 7-4 Several different methods for interproximal cleaning. Left to right, interdental brush, Y-shaped floss-holder, disposable floss-holders, and end-tuft brush.

blue band fades to halfway down the bristle, it is time to replace the brush (Fig. 7-3). The company states that this occurs, on average, after 3 months, but that the time varies depending on the individual's brushing habits.

Parents frequently ask how often they should change a child's toothbrush. It is best to replace the toothbrush when it appears well worn. This can present some problems for parents because some children, especially toddlers, chew their brushes when brushing, which rapidly gives the bristles a well-worn appearance.

FLOSS

Although toothbrushing is the most widely used method of mechanical plaque control, toothbrushing alone cannot adequately remove plaque from all tooth surfaces. In particular, it is not efficient in removing interproximal plaque, which means that interproximal cleaning beyond brushing is necessary. Many studies have compared the short-term benefits of flossing and toothbrushing with those of toothbrushing alone. Surprisingly, these studies show minimal or modest differences between the two

caries.[19,20] The short-term nature of most studies limits their ability to detect differences. However, Corby and colleagues did find differences in the microbial composition of dental plaques following flossing. After a 2-week study period of 12- to 21-year-old well-matched twins, they found that tooth and tongue brushing plus flossing significantly decreased the abundance of microbial species associated with periodontal disease and dental caries.[21] Many devices have been suggested for the interproximal removal of plaque, such as interdental brushes, floss-holders and floss, and end-tuft brushes (Fig. 7-4). According to Mauriello and associates, there appears to be no substantial difference among these devices in their ability to remove plaque and their tendency to reduce gingival inflammation when they are used properly; however, floss is the standard device with which other devices are most often compared.[22] The other devices are more often recommended in certain unique circumstances; for example, the interdental brush may be recommended

Dentlearn.ir



Figure 7-5 Dental floss. Thin *(top),* tape *(middle),* and meshwork *(bottom).*

for orthodontic patients. Unfortunately, regular flossing does not occur daily in most households. Chen and Rubinson demonstrated that daily flossing was practiced by only 20% of mothers, 12% of fathers, and 6% of children within families.[23] In addition, 28% of mothers, 45% of fathers, and 48% of children never floss their teeth. Technical difficulties with flossing in children may account for low compliance.[24]

Several different types of floss are available: flavored and unflavored; waxed and unwaxed; and thin, tape, and meshwork (Super Floss; Oral-B Laboratories, Inc., Belmont, California, United States) (Fig. 7-5). Almost all commercially available floss is made of nylon, although floss made of Teflon material (polytetrafluoroethylene) (Glide; W.L. Gore and Associates, Inc., Flagstaff, Arizona, United States) is also available. The manufacturer claims that, because the material has a lower coefficient of friction than nylon, this floss does not shred, slides easily between tight contacts, and minimizes snapping of the floss.

Based on the work of Bass, unwaxed nylon-filament floss has generally been considered the floss of choice because of the ease of passing the floss between tight contacts, the lack of a wax residue, the squeaking sound produced by moving the floss over a clean tooth, and the fiber spread, which results in increased surface contact and greater plaque removal.[25]

However, more recent work clearly indicates that individual patient needs and preferences should be taken into account before floss selection recommendations are made. Clinical studies have shown little difference in cleaning efficacy, comfort of use, or ease of use among the available floss types.[26,27]

With these results in mind, it may help when making floss recommendations to parents for their children to consider both the parent's and the child's preferences and individual needs. From the perspective of patient acceptance, flavored waxed floss may be most effective. In addition, many parents complain that their fingers are too large for their child's mouth. Floss-holding devices

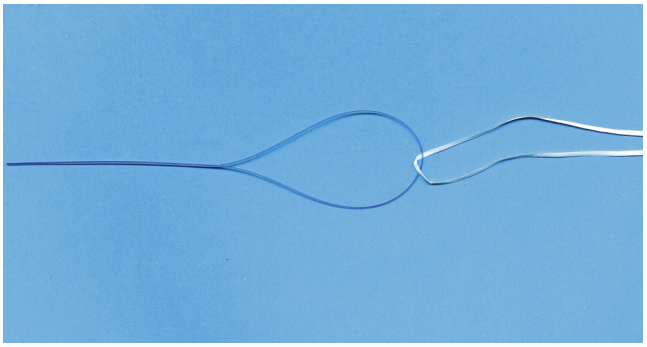

Figure 7-6 Floss-threading device with segment of thin floss attached.

(see Fig. 11-4) are an excellent alternative for parents when this complaint is voiced or when the dexterity of the parent or child prevents handholding of floss. For orthodontic patients, the use of Super Floss or a floss-threader (Fig. 7-6) helps in negotiating the floss under the archwires to allow for interproximal cleaning. For orthodontic patients, flossing is a tedious process but is nonetheless essential to the maintenance of oral health.

POWERED MECHANICAL PLAQUE REMOVAL

The use of powered or electric toothbrushes has received considerable attention since the 1960s. The rationale for using powered brushes is that many patients remove plaque poorly because they lack adequate manual dexterity to manipulate the brush. The powered brushes should decrease the need for dexterity by automatically including some movement of the toothbrush head. However, initial studies into the plaque removal effectiveness of powered toothbrushes failed to demonstrate greater efficacy for powered than for manual toothbrushes. Although improvement was seen initially, over time the level of cleaning achieved with powered toothbrushes declined to the same level as that obtained with manual toothbrushes. Kerlinger refers to this as the *Hawthorne effect*: almost any change or experimental manipulation will induce an improvement in behavior, apparently because of a novelty effect.[28] The introduction of powered toothbrushes caused an initial increase in use, and therefore plaque and gingivitis were controlled. Over time, however, the results were comparable with those achieved with manual toothbrushes.

Use of the latest powered toothbrushes, such as the Sonicare (Philips Oral Healthcare, Inc., Snoqualmie, Washington, United States) or the Braun Oral-B Kids' Power Toothbrush (D10) (Oral-B Laboratories, Inc., Belmont, California, United States), however, may prove to be more beneficial than the use of other toothbrushes.

The Sonicare uses sonic technology in the form of acoustic energy to improve the plaque removal ability of traditional toothbrush bristles. The brush has an electromagnetic device that drives the bristles' motions at 261 Hz, or 31,320 brush strokes per minute. Ho and Niederman found that the Sonicare toothbrush was significantly more effective than the manual toothbrush in reducing the plaque index, gingival index, percentage of sites that bled when probed, pocket depth, and total gram-negative

Dentlearn.ir

leagues have demonstrated a 40% improvement in the debris index component of the Simplified Oral Hygiene Index in children aged 4 to 9 years who were using the Braun Oral-B Kids' Power Toothbrush (D10).[30] Studies by Grossman and Proskin[31] and by Jongenelis and Wiedemann[32] also compared the effectiveness of electric vs. manual toothbrushes when the toothbrushes were specifically designed for children. Both studies concluded that the powered toothbrushes removed significantly more plaque than the manual toothbrushes for children. Finally, Heanue and associates performed a meta-analysis showing that powered toothbrushes with a rotation-oscillation action design removed more plaque and reduced gingivitis more effectively than manual brushes in both the short and the long term.[33] No other powered toothbrush designs were consistently superior to manual toothbrushes. Subsequent meta-analyses have continued to demonstrate a modest superiority of the rotation-oscillation action design, although its clinical significance is unclear.[34,35]

The Toothbrush Acceptance Program Guidelines of the American Dental Association (ADA) Council on Scientific Affairs list several requirements for both manual and powered toothbrushes.[36] Perhaps the main difference in requirements for the two is that powered toothbrushes must have been subjected to an examination by and met the requirements of an appropriate technical safety laboratory such as Underwriters Laboratories, Inc., because of their electrical power supply.

DENTIFRICES

Dentifrices serve multiple functions in oral hygiene through the inclusion of a variety of agents. They act as plaque- and stain-removing agents through the use of abrasives and surfactants. Pleasant flavors and colors encourage their use. They have tartar control properties because of the addition of pyrophosphates. Finally, dentifrices have anticaries and desensitization properties through the action of fluoride and other agents. Recently, numerous toothpastes have been marketed that contain additional remineralizing agents such as amorphous calcium phosphate-casein phosphopeptide. A growing body of evidence supports their use, especially in high-risk patients.[37,38] A child's dentifrice should contain fluoride, rank low in abrasiveness, and carry the ADA seal of acceptance. In 2014 50 different fluoride-containing dentifrices were listed as accepted dental therapeutic products by the ADA Council on Scientific Affairs. Many of the 50 dentifrices are specifically designed and flavored to appeal to children.

These formulations are useful because a child is more likely to practice oral hygiene procedures if the tools to be used are pleasing. Although the caries-preventive efficacy of fluoride toothpastes in children has been well documented, the impact of dentifrices on children's total fluoride intake must be considered. Adair and associates confirmed that children tend to use larger amounts of dentifrice, brush for a longer period, and rinse and expectorate less when using a children's dentifrice than when using an adult dentifrice.[39] Levy and Zarei-M studied toothbrushing habits and quantities of toothpaste used on toothbrushes in children from birth through 6 years of age. Figure 7-7 shows their results.[40] This study did not quantify the amount of toothpaste, and therefore of fluoride, ingested from the use of a certain amount of toothpaste on the brush. However, the investigators suggest that ingestion was likely a substantial source of systemic fluoride for these children during the years when a risk of dental fluorosis is present. It is interesting to note that many toothpaste advertisements show children with large amounts of toothpaste on their brushes. Clearly, this is not the perception dentists want the public to have regarding the use of fluoridated toothpastes in young children.

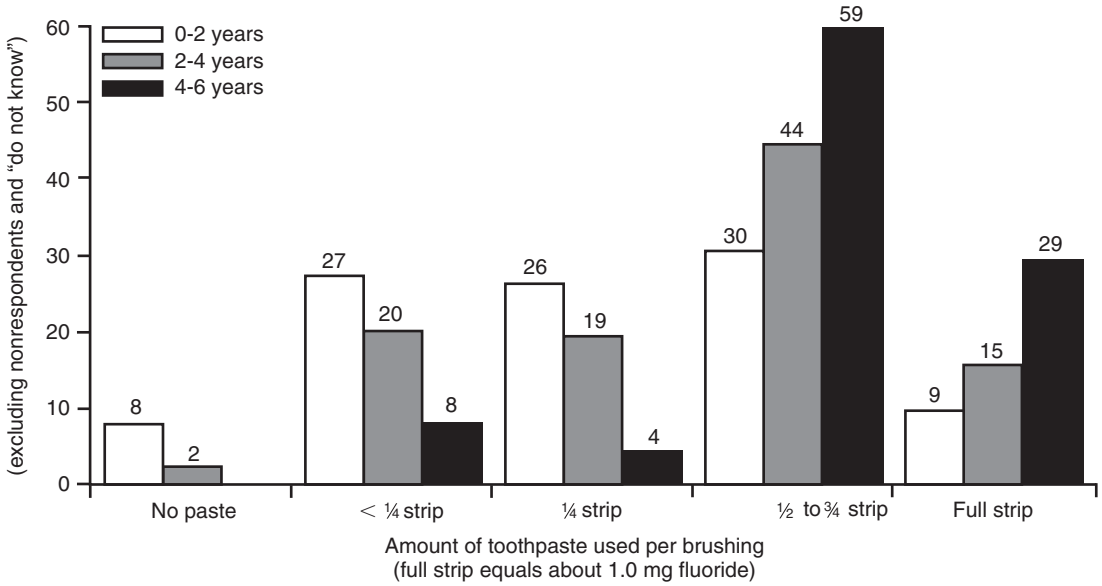

Figure 7-7 Quantity of toothpaste used by children from birth to 6 years of age. (From Levy SM, Zarei-M Z: Evaluation of fluoride exposures in children, *J Dent Child* 58:467-473, 1991.)

Dentlearn.ir

Simard and colleagues concluded, from their study of 12- to 24-month-old children, that 20% of the children ingested more than 0.25 mg of fluoride per day by toothbrushing alone.[41] To reduce the chance of dental fluorosis in children secondary to toothpaste ingestion, they suggested the following. Manufacturers should market a low-fluoride dentifrice for infants or reduce the diameter of the tube orifice. Parents should be advised to delay the use of fluoride dentifrices until the child is older than 36 months and to use pea-sized quantities of toothpaste. Pediatricians should take into consideration all sources of fluoride before prescribing supplements. However, recent reviews conclude that the relationship between the risk of fluorosis and toothpaste ingestion has been overestimated.[42] Given the benefits of fluoride, the judicious use of fluoridated toothpaste, even in young children, should be encouraged.[42-44]

DISCLOSING AGENTS

To increase the patient's ability to remove plaque, several agents have been developed to allow for patient visualization of plaque. These include iodine, gentian violet, erythrosin, basic fuchsin, fast green, food dyes, fluorescein, and a two-tone disclosing agent. Use of these agents is particularly helpful in teaching children toothbrushing techniques and educating them on the rationale for oral hygiene. FDC red No. 28 is a plaque-disclosing agent commonly used either as a liquid to be dabbed onto the teeth with a cotton swab or in the form of a chewable tablet (Fig. 7-8). Unfortunately, this dye stains the oral soft tissues and dental pellicle, as well as the plaque, leaving an objectionable pink discoloration that lasts up to several hours after use. Most younger children do not appear to be bothered by the discoloration, but as children approach adolescence, it can become a problem. Fluorescein-disclosing agents were developed to address this problem, because fluorescein is not visible under normal light. Their use, however, does require special equipment.

In a study by Lim and colleagues, four different techniques were compared for clinically detecting plaque in patients using different dietary regimens.[45] Individuals in the study population, ranging in age from 18 to 27 years, had their plaque levels assessed using a caries probe, a plaque-detection probe, erythrosin, and a two-tone disclosing agent at 3, 6, and 18 hours after their teeth had been thoroughly cleaned. Thirty-eight patients were assigned to a sucrose-restricted (SR) diet in the first part of the study and thirty-two to a sucrose-supplemented (SS) diet in the second part of the study. At 3 hours, plaque was detectable on more than 12% of sites in those consuming the SR diet and up to 23% in those on the SS diet. After 18 hours the proportion of plaque-covered surfaces had increased to between 52% (SR diet) and 73% (SS diet). For minimal amounts of plaque, the disclosing solutions were found to be the most sensitive assessment techniques. For moderate and abundant plaque deposits, however, the probe techniques were more sensitive.



Figure 7-8 Plaque-disclosing procedure. **A,** Two common forms of FDC red No. 28 disclosing agent: a liquid that is dabbed on with a cotton swab and a chewable tablet. **B,** Mixed dentition in a patient before oral hygiene and use of a disclosing agent. **C,** Patient before oral hygiene but after use of a disclosing agent. **D,** Patient after oral hygiene and use of a disclosing agent.

Dentlearn.ir

The clinical significance of these data is that, in measuring a patient's oral hygiene abilities, one must assess plaque deposits immediately after the patient has cleaned his or her teeth. Otherwise, allowances must be made for factors such as the time elapsed since the teeth were cleaned and the patient's diet. If a patient is seen several hours after the teeth have been cleaned, the quality of plaque control may be deemed unsatisfactory regardless of the quality of the patient's performance. Disclosing agents can be valuable adjuncts for both clinical and at home use.

OTHER ADJUNCTS FOR PLAQUE CONTROL

Several other devices, such as oral irrigators and tongue scrapers, have been suggested for routine oral hygiene. Oral irrigators use pulsed water or chemotherapeutic agents to dislodge plaque from the dentition. Tongue scrapers, which are flat, flexible plastic sticks, are used to remove bacterial and food deposits that accumulate within the rough dorsal surface of the tongue. In addition, gauze or special dental washcloths are useful in infants to massage the gums and to remove plaque on newly erupted teeth. Although these adjuncts add to our basic hygiene tools, toothbrushes and floss remain the most effective means of mechanical plaque removal. Professional recommendation of these adjuncts should be to suggest them as supplements to and not substitutes for the basic tools and should take into consideration the patient's and caregiver's individual needs, abilities, and preferences.

TECHNIQUES

As with toothbrush design, several different types of toothbrushing techniques for children have been advocated over the years. The more predominant techniques are the roll method, the Charters method, the horizontal scrubbing method, and the modified Stillman method.[46] Anaise, in his study of the effectiveness of these four techniques in children from 11 to 14 years of age, describes them as follows.[47]

Roll Method

The brush is placed in the vestibule, the bristle ends directed apically, with the sides of the bristles touching the gingival tissue. The patient exerts lateral pressure on the sides of the bristles, and the brush is moved occlusally. The brush is placed again high in the vestibule, and the rolling motion is repeated. The lingual surfaces are brushed in the same manner, with two teeth brushed simultaneously.

Charters Method

The ends of the bristles are placed in contact with the enamel of the teeth and the gingiva, with the bristles pointed at about a 45° angle toward the plane of occlusion. A lateral and downward pressure is then placed on the brush, and the brush is vibrated gently back and forth a millimeter or so.

Horizontal Scrubbing Method

The brush is placed horizontally on buccal and lingual surfaces and moved back and forth with a scrubbing motion.

Modified Stillman Method

The modified Stillman method combines a vibratory action of the bristles with a stroke movement of the brush in the long axis of the teeth. The brush is placed at the mucogingival line, with the bristles pointed away from the crown, and moved with a stroking motion along the gingiva and the tooth surface. The handle is rotated toward the crown and vibrated as the brush is moved.

Anaise concluded that the horizontal scrubbing method exhibited a more significant plaque-removing effect than the roll, Charters, and modified Stillman methods.[46] This finding supports the work done by McClure[48] and by Sangnes and colleagues.[49]

The horizontal scrub technique removes as much or more plaque than the other techniques, regardless of the child's age and whether the brushing is performed by the parent or the child. In addition, it is the technique most naturally adopted by children. Therefore in most situations the horizontal scrubbing method can be recommended for brushing children's teeth, regardless of the brushing method.[50] By following a systematic approach, as shown in Figure 7-9, the child or parent can help ensure

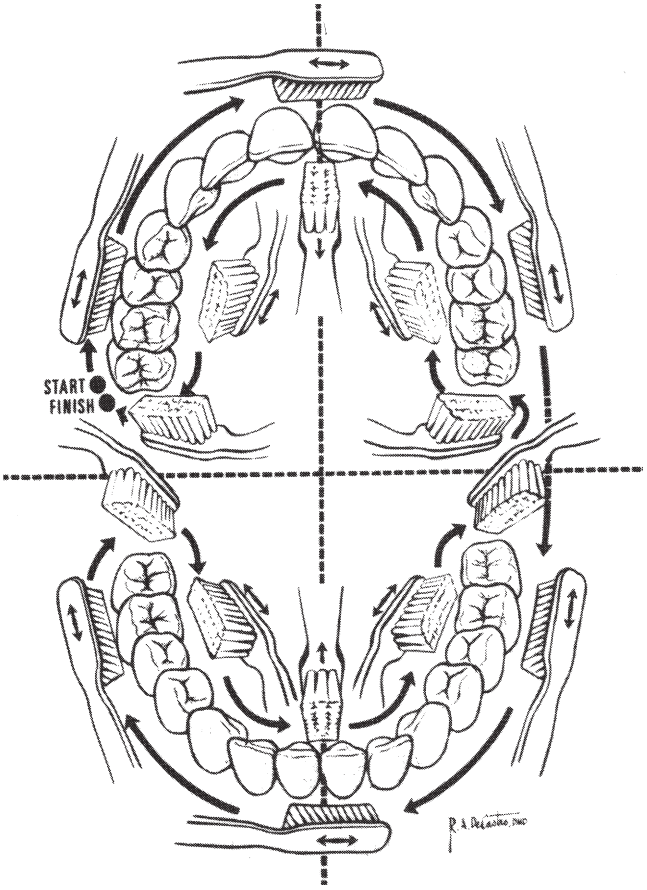

Figure 7-9 Systematic approach to brushing the teeth begins with the buccal aspects of the teeth in the maxillary right quadrant and follows the arrows. Bristles are held at 45° to the long axis of the teeth and are directed to the gum line. Short back-and-forth strokes are used, allowing bristles to remain in the same place. The handle of the brush is placed parallel to the biting surfaces except when one is brushing the lingual aspects of the anterior teeth and the posterior aspects of the last tooth in each quadrant, when a heel-toe direction of brushing is used. (Courtesy of Dr. Paul Starkey.)

Dentlearn.ir

that all areas of the mouth are cleaned. Notice also on this figure the positioning of the brush head on the lingual surfaces of the anterior teeth and on the distal aspect of the most posterior tooth in each quadrant.

For flossing, the following technique is recommended (Fig. 7-10):

1. A 46- to 61-cm (18- to 24-inch) length of floss is obtained, and the ends are wrapped around the patient's or parent's middle fingers. Floss should be long enough to allow the thumbs to touch each other when the hands are laid flat.
2. The thumbs and index fingers are used to guide the floss as it is gently "sawed" between the two teeth to be cleaned. Care must be taken not to snap the floss down through the interproximal contacts, to avoid gingival trauma.
3. The floss is then manipulated into a C shape around each tooth and moved in a cervical-occlusal reciprocating motion until the plaque is removed. In between the cleaning of each pair of teeth, the floss is repositioned on the fingers so that fresh, unsoiled floss is used at each new location.

Learning a flossing technique is difficult and takes some practice. Some children and their parents prefer to make a loop of floss. Tying the two ends of the floss together, instead of wrapping it around their fingers, assists them in holding and controlling the floss. However, Rodrigues and colleagues demonstrated that, even when the looped floss technique is used, a training program is required for children from 6½ to 7½ years of age if a significant reduction is to be achieved in proximal surface dental plaque indices.[51]

VISUAL-MOTOR SKILL MASTERY

Several attempts have been made to develop specific recommendations for when children can begin performing oral hygiene procedures themselves with adequate effectiveness. Terhune stated that the variables of age, gender, and eye-hand coordination could not precisely predict when particular children were ready to learn an effective dental flossing technique.[52] However, all 8- to 11-year-old children in his study learned how to use dental floss effectively within 10 days. Mescher and associates found that hand function was an age-related factor in children's ability to perform sulcular toothbrushing, but that hand function test scores were not accurate predictors of an individual's toothbrushing ability.[53]

Preisch, however, using a visual-motor integration developmental test, did find a significant relationship between developmental age and oral hygiene scores.[54]

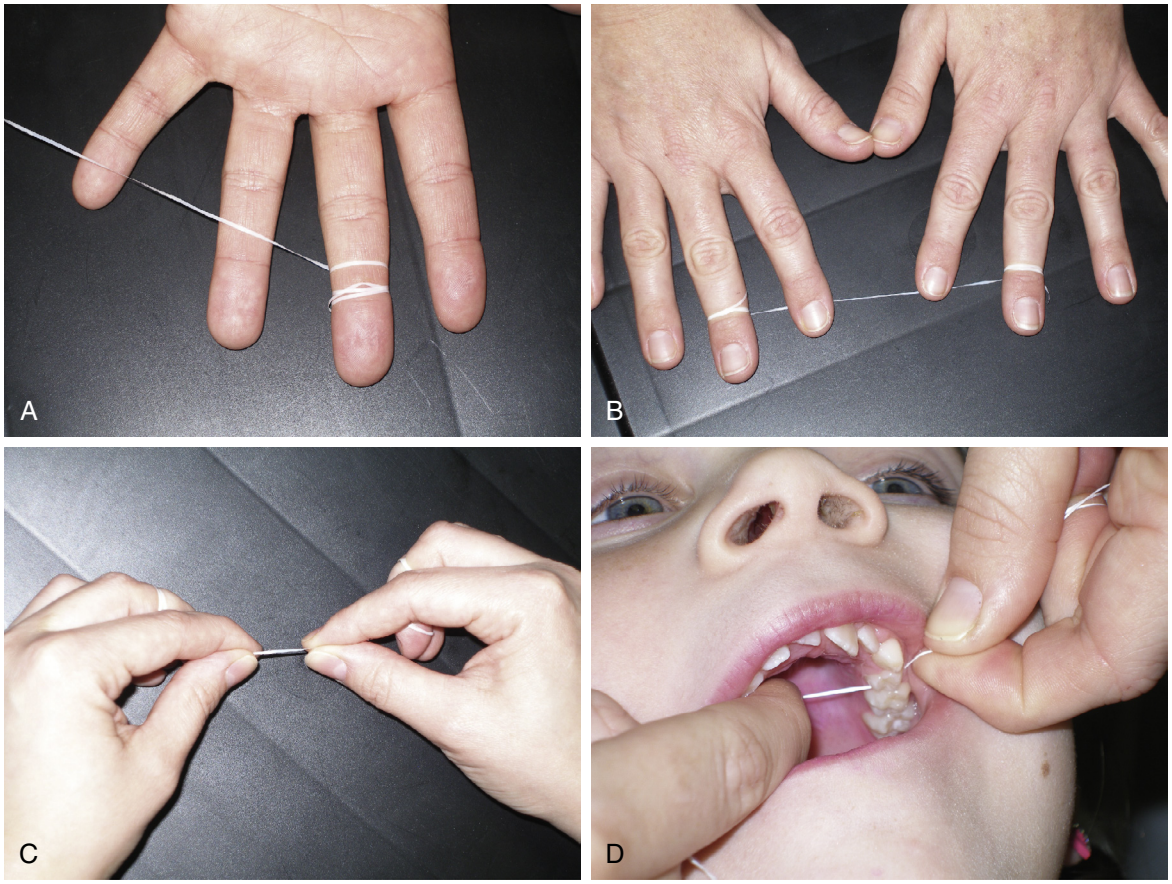

Figure 7-10 Flossing technique. **A**, The length of floss is wrapped around the middle fingers of each hand. **B**, Enough floss should be left between the middle fingers to allow the thumbs to touch when the hands are laid flat. **C**, The index fingers and thumbs are used to manipulate the floss. **D**, The floss is carefully placed in a C shape between the interproximal contacts and gently "sawed" up and down until each tooth surface is clean.

Dentlearn.ir

Significant correlations were shown between the child-achievement and motor skill level. Higher levels of thinking and behavior require integration among sensory inputs and motor action. A child can have well-developed visual and motor skills but may be unable to coordinate the two. Although both chronologic and developmental ages were found to be predictors of plaque removal ability, only developmental age demonstrated statistically significant predictive power. Because of the complexity of this test, however, we are left without a practical method for making recommendations to parents as to when their child can begin brushing unsupervised. As Preisch laments, many dentists use anecdotal accounts and tell parents to supervise their children's brushing until the children can color within the lines, tie their own shoelaces, or cut through a tough piece of meat.[54] However, this may still be our best practical recommendation.

TIME CONSIDERATIONS

Another of the important questions regarding home oral health care involves time considerations in oral hygiene practices. How often and for how long should patients brush and floss their teeth? In discussing frequency of oral hygiene procedures, Löe suggests that oral cleanliness should be regarded as a defined state in which all surfaces of all teeth are plaque-free.[55] He states that it may not be surprising to find that complete removal of plaque once daily or every second day, or possibly even once every third day, is more valuable in preventing dental disease than performing two or three inadequate brushings per day. Indeed, Lang and colleagues observed that completion of effective oral hygiene procedures at intervals of up to 48 hours is compatible with gingival health.[56] Studies addressing the relation between the frequency of hygiene procedures and caries experience in children have yielded inconclusive results.

In addition to optimal brushing frequency, the most efficacious length of brushing time has been investigated. In a study by Hodges and colleagues, 84 children from 5 to 15 years of age brushed their teeth with a fluoridated dentifrice for 30, 60, 120, or 180 seconds.[57] The results of the study suggested that, statistically, a 1-minute brushing period provides the greatest plaque removal benefit of all time periods tested. Indeed, Honkala and colleagues concluded that time spent toothbrushing was more important than the frequency of brushing.[58]

The following recommendations are made based on the preceding information. In children, thorough oral hygiene procedures should be performed at least once daily, preferably twice, with parental supervision. Teeth should be brushed for at least 1 minute with a fluoridated dentifrice; flossing and other plaque removal activities are added to this time. If oral hygiene is accomplished only once per day, it should be the last thing the child does before bedtime at night. Because the flow of saliva and its buffering capacity are reduced during sleep, it is advantageous to remove plaque before bedtime. In addition, the development in children of a learned behavior performed at a specific time of day, each and every day, will be helpful throughout childhood and into adulthood.

CHEMOTHERAPEUTIC PLAQUE CONTROL

Although the use of mechanical therapy for plaque control can provide excellent results, it is clear that many patients are unable, unwilling, or untrained to practice routine effective mechanotherapy. In addition, certain patients with dental diseases (e.g., periodontitis) or medical diseases (e.g., immunocompromised conditions) require additional assistance beyond mechanotherapy to maintain a normal state of oral health. Because of this, chemotherapeutic agents have been developed as adjuncts in plaque control.

Van der Ouderaa has stated that the ideal chemotherapeutic plaque control agent should have the following characteristics[59]:

- Specificity only for the pathogenic bacteria
- Substantivity—the ability to attach to and be retained by oral surfaces and then be released over time without loss of potency
- Chemical stability during storage
- Absence of adverse reactions, such as staining or mucosal interactions
- Toxicologic safety
- Ecologic safety so as not to alter the microbiotic flora adversely
- Ease of use

No agent has yet been developed that has all of these characteristics.

There are several main routes of administration of antiplaque agents designed for home use. They are mouthwashes, dentifrices, gels, irrigators, floss, chewing gum, lozenges, and capsules. All of these are designed for local, supragingival administration, except the irrigator and capsule delivery methods. The irrigators can provide both supragingival and subgingival delivery. The capsules are designed for systemic distribution.

Both van der Ouderaa,[59] Mandel,[60] and Gunsolley[61] provided excellent reviews of the various chemotherapeutic agents and their uses. Box 7-1 is adapted from those reviews. Space does not allow for a complete discussion of the agents listed in this box; however, a few pertinent subjects are addressed. Recent systematic reviews provide additional insight into the effectiveness of chemotherapeutic agents, their mechanisms of action, and their suitability for clinical practice.[61-63]

ANTISEPTIC AGENTS

The antiseptic agents used in chemotherapeutic plaque control have been shown to exhibit little or no oral or systemic toxicity in the concentrations used. Virtually no drug resistance is induced, and in most instances these agents have a broad antimicrobial spectrum. Chlorhexidine, a positively charged organic antiseptic agent, has received considerable attention and study because of its ability to reduce plaque and gingivitis scores. It has strong substantivity, binding well to many sites in the oral cavity and maintaining an ongoing antibacterial presence. Chlorhexidine binds with anionic glycoproteins and phosphoproteins on the buccal, palatal, and labial mucosa, and the tooth-borne pellicle. Its antibacterial effects include binding well to bacterial cell membranes, increasing

Dentlearn.ir

Box 7-1

Chemotherapeutic Plaque Control Agents

ANTISEPTIC AGENTS
Positively Charged Organic Molecules: Quaternary ammonium compounds—cetylpyridinium chloride
Pyrimidines—hexedine
Bis-biguanides—chlorhexidine, alexidine
Noncharged Phenolic Agents: Listerine (thymol, eucalyptol, menthol, and methylsalicylate), triclosan, phenol, and thymol
Oxygenating Agents: Peroxides and perborate
Bis-Pyridines: Octenidine
Halogens: Iodine, iodophors, and fluorides
Heavy Metal Salts: Silver, mercury, zinc, copper, and tin

ANTIBIOTICS
Niddamycin, kanamycin sulfate, tetracycline hydrochloride, and vancomycin hydrochloride

ENZYMES
Mucinases, pancreatin, fungal enzymes, and protease

PLAQUE-MODIFYING AGENTS
Urea peroxide

SUGAR SUBSTITUTES
Xylitol, mannitol

PLAQUE ATTACHMENT INTERFERENCE AGENTS
Sodium polyvinylphosphonic acid, perfluoroalkyl

their permeability, initiating leakage, and precipitating intracellular components.

An abundance of clinical trials supports its efficacy in reducing plaque and gingivitis scores in conjunction with routine oral hygiene. Van Strydonck and colleagues recently reviewed 30 clinical trials comparing the use of chlorhexidine mouthrinses with that of placebo/control mouthrinses or oral hygiene for greater than 4 weeks. Meta-analysis of studies with a low risk of author-estimated bias showed a 33% reduction in plaque with chlorhexidine and a 26% reduction in gingivitis relative to control. CHX

cal trials specifically targeting children have also shown significant reductions in plaque and gingivitis scores.[65,66] The benefits of chlorhexidine mouthrinses and varnishes with respect to caries prevention are inconclusive, especially in children with regular fluoride exposure.[67,68] Children with low fluoride exposure may benefit from chlorhexidine varnish application (Fig. 7-11).[67]

Chlorhexidine spray has stimulated interest regarding its use in populations with disabilities because of its effectiveness and ease of administration. Burtner and colleagues demonstrated a 35% reduction in plaque levels with use of the spray compared with placebo use in a study of 16 institutionalized adult males with severe and profound mental retardation.[69] Chikte and colleagues conducted a 9-week, double-blind, randomized, crossover clinical trial involving 52 institutionalized individuals from 10 to 26 years of age and with mental disabilities. By

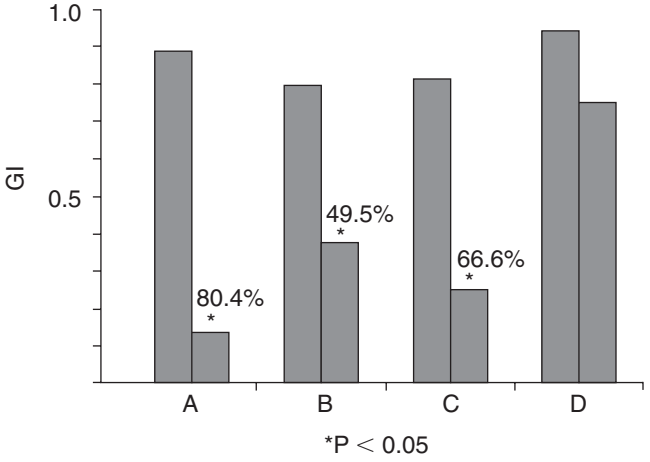

schoolchildren rinsing with chlorhexidine digluconate (CHX) or placebo solution for 6 months under supervision. Clear bars, before treatment; screened bars, after treatment.

placebo 6 times weekly. (From Lang NP et al: Effects of supervised chlorhexidine mouthrinses in children, *J Periodontal Res* 17:101-111, 1982.)

the end of the trial, plaque and gingival indices had been

with chlorhexidine spray, reductions in plaque and gingival indices were 75% and 78%, respectively.

In addition to its use in institutionalized patients with mental retardation, chlorhexidine has been studied for its use in immunocompromised patients. Clinical trials of its efficacy in preventing or ameliorating oral mucositis have produced conflicting results.[71,72] A recent evidence-based analysis suggested that the evidence for its use in immunocompromised children for the prevention of mucositis is equivocal, and therefore its use could not be recommended.[73] The use of positively charged antiplaque agents has been hampered by adverse reactions such as staining of teeth, impaired taste sensation, and increased supragingival calculus formation. Different attempts have been made to decrease these side effects, such as alteration of dietary habits, increase in mechanical plaque removal efforts, and use of hydrogen peroxide solutions in conjunction with the antiseptic agent. Continued research is needed to find methods to limit these adverse reactions.

The most widely known noncharged phenolic antiseptic agent is Listerine (Pfizer Warner Lambert Division, Morris Plains, New Jersey, United States). It has demonstrated a long history of efficacy and was among the original antiseptic agents studied by W.D. Miller in 1890.[3] In addition, it was the first over-the-counter mouthrinse to be accepted by the ADA Council on Dental Therapeutics for its help in controlling plaque and gingivitis.[36] Despite its long history of use, most studies have shown chlorhexidine to be significantly more effective than Listerine in reducing plaque and gingivitis indices.[61-63] Listerine tends to give patients a burning sensation, and it has a bitter

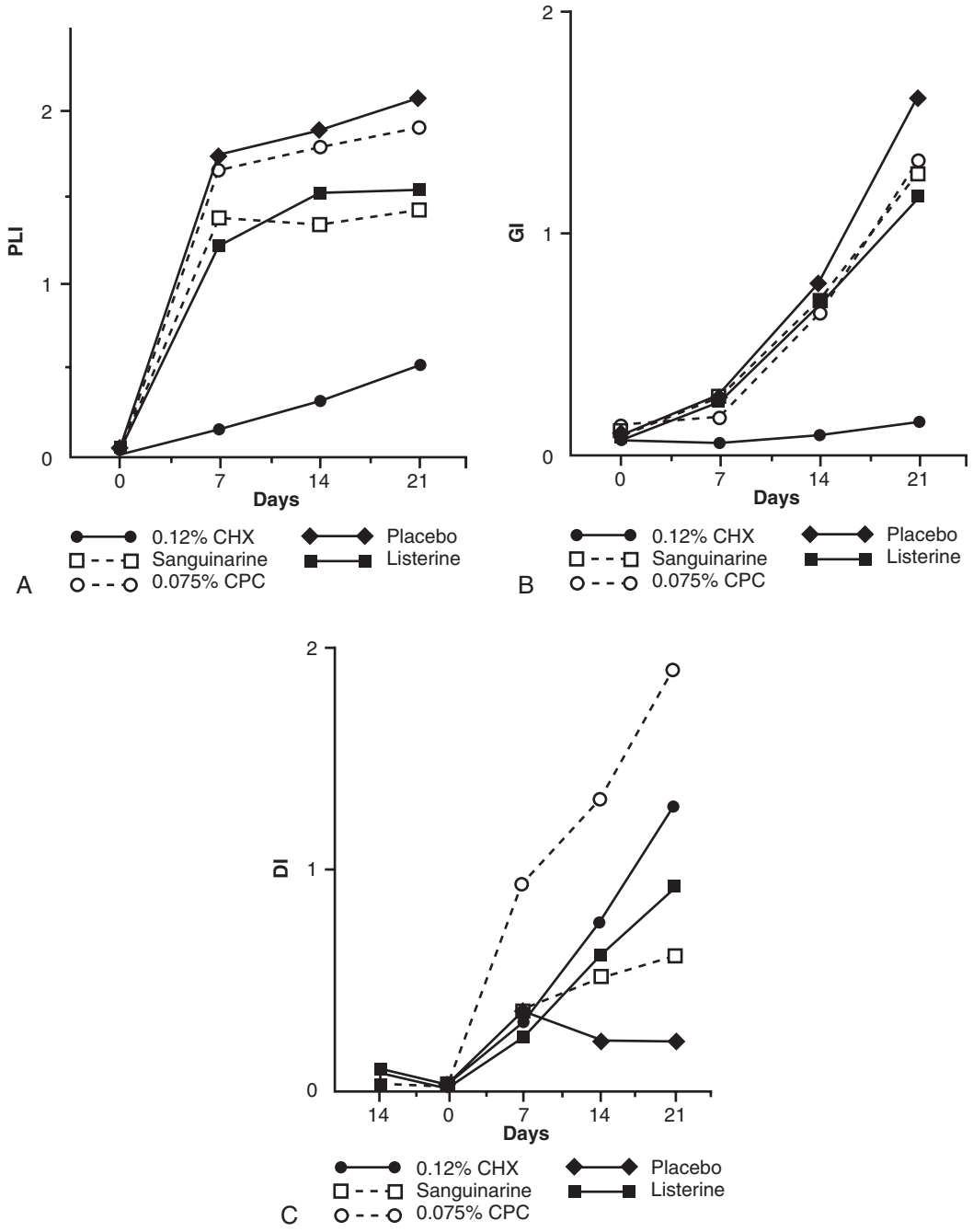

chlorhexidine digluconate (CHX), 0.075% cetylpyridinium chloride (CPC), Listerine, sanguinarine, or placebo. **A,** Mean plaque index (PLI). **B,** Mean gingival index (GI). **C,** Mean discoloration index (DI). (From Lang NP, Brecx MC: Chlorhexidine digluconate: an agent for chemical plaque control and prevention of gingival inflammation, *J Periodontal Res* 16 [Suppl 21]:74-89, 1986.)

taste. Lang and Brecx have summarized the changes in plaque index, gingival index, and discoloration index scores resulting from the use of four well-known chemotherapeutic plaque control agents (Fig. 7-12).[74] The effects of two daily 10-mL rinses with 0.12% chlorhexidine digluconate, the quaternary ammonium compound cetylpyridinium chloride, the phenolic compound Listerine, or the plant alkaloid sanguinarine were compared with those of rinses with a placebo. All rinses were supervised by registered dental hygienists during these 21-day studyindividuals each and were instructed to refrain from oral hygiene during the 21 days. Although the sanguinarine, Listerine, and cetylpyridinium chloride inhibited plaque formation to some extent, they did not prevent gingivitis significantly more than did the placebo. The chlorhexidine, however, maintained the preexperimental gingival index scores throughout the 21 days. Unfortunately, all of

Dentlearn.ir

the antiseptics demonstrated higher discoloration index scores than the placebo. As can be seen in Figure 11-12, *C*, chlorhexidine had the second highest discoloration score of the four agents. Not surprisingly, studies have shown improvement in plaque and gingivitis when antiseptic rinses are used in conjunction with dentifrices compared with dentifrice use alone.[75,76]

Listerine has one of the highest alcohol contents of any mouthwash at approximately 25%. The alcohol content of some mouthwashes has been the cause for some concern. Although the development of oral and pharyngeal cancer with long-term mouthwash use has been investigated, alcohol intoxication is more relevant to pediatric dentistry. In addition, the relationship of alcohol-containing mouthwashes to oral carcinomas is equivocal. Alcohol intoxication of children and adolescents from mouthwashes is a concern because of the products' availability. Most parents do not recognize the potential harm from these rinses. Selbst and associates reported the case of a 4-year-old boy who died after consuming approximately 12 ounces of a 10% alcohol mouthwash.[77] They advocated for stronger legislation that would restrict the level of alcohol in substances that might be available to children and for continued education of practitioners and parents regarding the potential lethality of most mouthwashes so that accidental ingestions are prevented. One for cough and cold products with 12% alcohol to have child-resistant tops when some mouthwashes with even higher alcohol content have "designer" shot-glass tops. The ADA Council on Dental Therapeutics requires any mouthrinses that carry the ADA seal of acceptance and contain more than 5% ethyl alcohol to be packaged in bottles with child-resistant caps. Since 1995 such products in the United States have been legally required to have child-resistant packaging, with a documented reduction in these events.[78]

Chitosans are another cationic antimicrobial finding their way into oral health care. They are derived from the shells of shrimp and other crustaceans and appear to reduce biofilm viability.[79]

A few comments regarding the use of fluoride as a halogen antiseptic plaque control agent are appropriate here, although its use in dentistry is discussed in other portions of the text. The fluoride ion inhibits the carbohydrate use of oral organisms by blocking enzymes involved in the glycolytic pathway; however, at preventive-use levels it probably does not alter the plaque ecosystem. As mentioned earlier, stannous fluoride can produce reductions in plaque and gingivitis scores approaching those of chlorhexidine, but this effect is caused by the tin content of this salt, not the fluoride content. It is interesting to note that two antiseptic agents, chlorhexidine and triclosan, have been incorporated into dentifrice formulations.[67]

ENZYMES, PLAQUE-MODIFYING AGENTS, AND PLAQUE ATTACHMENT INTERFERENCE AGENTS

Enzyme systems intended to alter plaque architecture and adherence, as well as enzymes designed to generate antibacterial products, have been investigated. However, problems associated with the long-term stability of enzyme molecules in environments with potentially high concentrations of alcohol or surfactants have yet to be addressed. The use of urea peroxide as a plaque-modifying agent has been investigated because of its increased stability over hydrogen peroxide and the protein denaturation effect of urea. Only limited success has been demonstrated. The use of agents designed to interfere with the initial adherence of bacteria to the salivary pellicle or the subsequent accumulation by growth and interbacterial adherence seems encouraging. Delmopinol, derived from orpholinoethanol, exerts its effects by binding to salivary proteins and altering the cohesive and adhesive properties of the films formed.

Although these areas may hold promise for future chemotherapeutic control of plaque, additional research is needed.

SUGAR SUBSTITUTES

The use of sugar substitutes such as xylitol, mannitol, sucralose, and aspartame has been advocated. Although Park and colleagues have shown that sugar substitutes can have a positive influence on plaque pH, the intrinsic antiplaque activity is much lower than that of other plaque control agents.[80] These agents have been suggested for use in chewing gum to decrease plaque accumulation and pH. Advocating the use of chewing gum as a preventive technique is not without controversy, however. Hoerman and colleagues demonstrated that, in a no-oral-hygiene environment, plaque accumulation was lower when gum with sucrose or sorbitol was chewed than when gum was not chewed.[81] In addition, Isokangas and associates carried out a 2-year study of 11- and 12-year-old children with moderate and decreasing caries prevalence.[82] They demonstrated that the combination of xylitol gum chewing and fluoride use resulted in a significantly lower incidence of caries than that achieved with fluoride use alone. Research into the use of sugar substitutes as plaque control agents continues.[83]

One final comment is in order. Because of conflicting results published on the effectiveness of the commercially available prebrushing rinse containing sodium benzoate, it is not included in the list of chemotherapeutic plaque control agents. In addition, it is not accepted by the ADA. O'Mullane suggests that the positive results found for this prebrushing rinse may stem purely from the advantage of rinsing with water before brushing.[84] The idea of using water to help remove plaque is not new. The "swish-and-swallow" method of removing material from the mouth immediately after eating in circumstances where brushing is impractical has been advocated for a long time. Ciancio recommends that, when a product is selected for a patient, consideration be given to necessity, efficacy, adverse effects, and cost-effectiveness.[85]

AGE-SPECIFIC HOME ORAL HYGIENE INSTRUCTIONS

The appropriateness and effectiveness of home oral hygiene procedures change throughout childhood. Specific age-related home oral hygiene recommendations are described in the following sections. It is necessary to involve

Dentlearn.ir

the parent at some level in the oral hygiene procedure for each of the age categories.

PRENATAL COUNSELING

The best time to begin counseling parents and establishing a child's dental preventive program is actually before the birth of the child. This is beneficial for numerous reasons. For an expectant couple, particularly if the child is their first, this is a time in their lives when they are most receptive to preventive health recommendations. These parents-to-be become acutely aware of their child's dependence on them for all nurturing and health care needs. Parents have a strong instinct to provide the best that they can for their child. Counseling them on their own hygiene habits and the effect they can have on their children as role models will aid in improving both the parents' and the child's oral health. Discussing pregnancy gingivitis with the mother-to-be and dispelling some of the myths about childbirth and dental health can be beneficial. In addition, a review of infant dental care is useful for the expectant parents.

INFANTS (BIRTH TO 1 YEAR OLD)

It is important that a few basic home oral hygiene procedures begin during the child's first year of life. There is general agreement that plaque removal activities should begin when the first primary teeth erupt. Some practitioners recommend cleaning and massaging of the gums before this, to help in establishing a healthy oral flora and to aid in teething. This early cleaning must be done totally by the parent. It can be accomplished by wrapping a moistened gauze square or washcloth around the finger and gently massaging the teeth and gingival tissues. The child can be positioned in numerous ways during this procedure, but cradling the child with one arm while massaging the teeth with the hand of the other may be the simplest and provides the infant with a strong sense of security (Fig. 7-13). This procedure should be performed once daily. Generally, other plaque removal techniques are not necessary. The introduction of a moistened, soft-bristled, child- or infant-sized toothbrush during this age is advisable only if the parent feels comfortable using the brush. The use of a dentifrice is neither necessary nor advised, as the foaming action of the paste tends to be objectionable to the infant. Because fluoride ingestion is possible, however, use of a nonfluoridated tooth and gum cleanser may be beneficial.



Figure 7-13 Arm-cradled position of child for effective cleansing of the oral cavity. This figure shows the use of a gauze square for wiping the child's dentition and gingival tissues.

The child's first visit to the dentist should take place during this period. The American Academy of Pediatric Dentistry recommends that parents or caregivers establish a dental home for infants by 12 months of age.[86] When the child has special dental needs, such as medical problems or trauma, this visit can be sooner. Several objectives are accomplished at this visit. Certainly, instruction of the parents in the use of the oral hygiene practices mentioned herein is necessary. In addition, an infant dental examination and fluoride status review should be accomplished, dietary issues related to nursing and bottle caries, as well as other health concerns, should be addressed, anticipatory guidance should be provided, and caries risk assessment should be accomplished. These subjects are discussed in more detail in other sections of this text. These first dental visits are also a time for the child to become familiar with the dental environment and the dental staff and the dentist, which makes any future dental treatment less anxiety-provoking.

TODDLERS (1 TO 3 YEARS OLD)

During "toddlerhood," the toothbrush should be introduced into the plaque removal procedure if this was not accomplished previously. Because of the inability of the potential for fluoride ingestion, careful and minimal (a "smear" of toothpaste on the brush) introduction of fluoridated dentifrice can be used in 2- and 3-year-olds. Most children enjoy imitating their parents and will readily practice toothbrushing. Adequate plaque removal is not usually accomplished by the child alone, however. Although the child should be encouraged to begin rudimentary brushing, the parent remains the primary caregiver in these hygiene procedures. The use of additional instruments for plaque control is generally unnecessary, although flossing may be needed if any interproximal contacts are closed. The use of a flossing aid may also be indicated.

Positioning of the child and parent is again important. Although most children enjoy brushing their own teeth, many are resistant to allowing anyone else to do the brushing. Several positions can be used by the parent, but the lap-to-lap position, as shown in Figure 7-14, allows one adult to control the child's body movements while the other adult brushes the teeth. Notice how the child's arms and legs are controlled with the hands and elbows of the adult responsible for body movements. The parents should be encouraged to make this a special time for the child and to praise the child as much as possible. For single-parent households, a one-adult position often becomes necessary. In this situation the parent sits on the floor with his or her legs stretched out in front, and the

Dentlearn.ir

child is positioned between the legs. The child's head is placed between the thighs of the parent, with the child's arms and legs carefully controlled by the legs of the parent. This position is a little awkward, but for a young child resistant to oral hygiene, it does allow these procedures to be accomplished.

PRESCHOOLERS (3 TO 6 YEARS OLD)

Although children in the preschool age range begin to demonstrate significant improvements in their ability to manipulate the toothbrush, it is still the responsibility of the parent to be the primary provider of oral hygiene



Figure 7-14 Lap-to-lap position of child. Two adults sit with knees touching, using their laps as a table on which to rest the child. The adult on the right holds the child's legs and arms, while the adult on the left performs the oral hygiene procedures.



Figure 7-15 Only a smear of fluoride toothpaste (size of a rice grain, *left*) should be used for children under age 3 years of age, and no more than a pea size of fluoride toothpaste should be used for children from 3 to 6 years of age *(right).*

procedures. All too often, parents of these children feel that the child has adequately achieved the skills necessary to clean the teeth. It is important to stress to the parents that they must continue to brush their child's teeth. Although fluoride ingestion remains a concern for this age

to expectorate toothpaste adequately. Until this occurs, it is important for parents to use only a pea-sized amount of toothpaste on the child's brush (Fig. 7-15). In addition, it is during this age that flossing is most likely to begin. As mentioned previously, if the interproximal contacts are closed, the parent must begin flossing procedures. In the primary dentition, the posterior contacts may be the only areas where flossing is needed. The closure of the spaces between the primary molars tends to occur somewhere near the start of this age range. If any interproximal area has tooth-to-tooth contact, however, daily flossing of that area becomes necessary.

Proper positioning of the child continues to be useful

od advocated is that in which the parent stands behind the child and both face the same direction. The child rests his or her head back into the parent's nondominant arm. With the hand of this arm, the parent can retract the child's cheeks and use the other hand to brush. This position is also appropriate for flossing. To brush their child's teeth, many parents use a frontal approach, which is awkward and provides little head support. This positioning technique should be discouraged.

It is also during this stage that fluoride gels and rinses for home use may be introduced. Because of the risk of ingestion, however, these agents should be used in small quantities, and their use should be limited to those patients demonstrating a moderate to high risk of caries. The use of other chemotherapeutic plaque control agents is generally not recommended.

SCHOOL-AGED CHILDREN (6 TO 12 YEARS OLD)

The 6- to 12-year stage is marked by acceptance of increasing responsibilities by the children. The need to assume responsibility for homework and household chores tends to occur during this time. In addition, the child can begin to assume more responsibility for oral hygiene. Parental involvement is still needed. However, instead of performing the oral hygiene, parents can switch to active supervision. By the second half of this stage, most children can provide their basic oral hygiene (brushing and flossing). Parents may find they need to brush or floss their child's teeth only in certain difficult-to-reach areas of the mouth or if there is a compliance problem. Parents do need to actively inspect their child's teeth for cleanliness on a regular basis. One helpful adjunct is the use of a disclosing agent. After the child has brushed, flossed, and used the disclosing agent on his or her teeth, the parent can easily visualize any remaining plaque and assist the child in removing it.

By this age, ingestion of fluoridated materials, such as dentifrices, gels, or rinses, is not as pronounced a concern because these children are able to expectorate well. Certainly the use of fluoridated dentifrices is essential; however, fluoridated gels and rinses can be reserved for

those children at risk for caries. In addition, the use of chlorhexidine or Listerine can be introduced to those at risk for periodontal disease and caries, although some children who might benefit from these chemotherapeutic agents will find their use objectionable.

Because early treatment of malocclusions has in-

ment and experienced its accompanying increased risk for caries and periodontal disease. Special attention to oral hygiene is necessary for these patients. Increased frequency and adequacy of brushing and flossing become necessary. Although fluoridated dentifrices provide cost-efficient fluoride exposure, the use of fluoridated gels or rinses is strongly encouraged. In addition, as with other patients at risk for caries and periodontal disease, the use of chemotherapeutic agents and adjuncts such as oral irrigators is recommended. Feil and colleagues published an interesting study on the intentional use of the Hawthorne effect to improve oral hygiene compliance in orthodontic patients.[87] Forty adolescent orthodontic patients with histories of poor oral hygiene were assigned

were presented with a situation that stimulated participation in an experiment, whereas the control individuals had no knowledge of study participation. Although there were no statistically significant differences between the

plaque scores at 3 months and again at 6 months. The experimental participants had significantly improved oral hygiene, which suggests that the Hawthorne effect (participating in an "experimental study") caused the adolescent patients to pay more attention to oral hygiene and therefore to do a better job.

ADOLESCENTS (12 TO 19 YEARS OLD)

Although the adolescent patient usually has developed the skills for adequate oral hygiene procedures, compliance is a major problem during this age period. Griffen and Goepferd point out that motivating an adolescent to assume responsibility for personal oral hygiene may be complicated by reactions of rebellion against external authority and some incapacity to appreciate long-term consequences.[88] Macgregor and Balding's survey of 4075 children 14 years old suggests a positive relationship between self-esteem and toothbrushing behavior and motivation for mouth care in adolescents.[89] Because self-esteem declines between the ages of 11 and 14 and then shows a gradual improvement into adulthood, it is not hard to understand why plaque control in these patients declines. In addition, poor dietary habits and pubertal hormonal changes increase adolescents' risk for caries and gingival inflammation.

Therefore it is important for practitioners and parents to continue to help and guide adolescents as they progress through this difficult stage. Stressing the children's increased responsibility as young adults without appearing authoritarian can aid them in accepting their new role. The parents must be ready to adapt to their child's changing personality and to continue to reinforce the need for oral health care and hygiene. Increasing the adolescents' knowledge regarding plaque control and oral diseases, as well as appealing to their appearance, may also help in motivating these patients.

IN-OFFICE ORAL HYGIENE PROGRAMS

Preventive dentistry is the foundation on which all oral health care must be built. In establishing this foundation for their patients, practitioners must first look at themselves and their office environment. Each practice must establish a preventive philosophy that is evident throughout the patient's encounter with the dental office. This means that the dentist, the staff, and the practice systems and design must reflect this concept. All staff members must have a personal understanding and appreciation of the importance of this basic concept. This must be evident in their personal hygiene and in their routine interactions with patients.

After this introspective look and adjustment the practitioner can turn to the patient directly. Ong discusses several basic concepts for developing a plaque control program in the dental office.[90] Gathering information from the child and parent is necessary for the practitioner to understand their concerns and to let them know that he or she understands these concerns. By discussing the patient's and parents' needs, and listening to and observing their reactions, the practitioner can gauge their readiness to begin the plaque control program. Dental education of the parent and child should be accomplished next, with tailoring to the patient's individual problem. Describing exactly why oral hygiene is important in the patient's particular case can help with motivation. The information should be delivered in simple terms and with enthusiasm and conviction. It also needs to be conveyed to the child in age-appropriate language.

When specific age-appropriate oral hygiene instructions are given, it is important to be positive and reassuring, not critical. Use phrases like "Let me show you how to improve," rather than saying, "You're doing it all wrong." Be gentle but firm, and enlist the parents' and patient's help in the treatment plan and therapy. Setting goals and complimenting achievements will assist in keeping the parents' and patient's attitudes positive. It is very useful to be open to parental and patient feedback regarding their priorities and progress. As with many long-term commitments, cyclic participation can be expected and accepted to a certain extent. However, the parents and patient must know the consequences of neglect. Finally, establishment of a regular maintenance schedule is imperative. Along with prophylaxis, reinstruction and remotivation in the plaque control program are necessary elements for success. Recare intervals should be personalized to the individual patient's needs, with consideration of factors such as: caries and periodontal disease risk; restorative, orthodontic, and prosthetic concerns; and individual patient and parental dental education and skill levels. It is the responsibility of every dental practitioner to make oral hygiene and prevention the core of his or her practice. By listening to, educating, adapting to, and motivating our patients and their parents, we can make our preventive practices successful and enjoyable.

Dentlearn.ir

REFERENCES

1. McDonald RE: Pediatrics allied with pedodontics, *Pediatr Herald* 1(5):1, 1960.
2. Marsh PD: Contemporary perspective on plaque control, *Br Dent J* 212(12):601–606, 2012.
3. Miller WD: *Microorganisms of the human mouth*, Philadelphia, 1890, SS White Dental Manufacturing.
4. Keyes PH: The infectious and transmissible nature of experimental dental caries, *Arch Oral Biol* 1:304–320, 1960.
5. Löe H, Theilade E, Jensen SB: Experimental gingivitis in man, *J Periodontol* 35:177–187, 1965.
6. Wade WG: The oral microbiome in health and disease, *Pharmacolog Res* 69:137–143, 2012.
7. Aas JA, et al.: Defining the normal bacterial flora of the oral cavity, *J Clin Microbiol* 43:5721–5732, 2005.
8. Kuramitsu HK, et al.: Interspecies interactions with oral microbial communities, *Microbiol Mol Biol Rev* 71:653–670, 2007.
9. Jakubovics NS, Kolenbrander PE: The road to ruin: the formation of disease-associated oral biofilms, *Oral Dis* 16:729–739, 2010.
10. Kolenbrander PE, et al.: Bacterial interactions and successions during plaque development, *Periodontol 2000* 42:47–79, 2006.
11. Balakrishnan M, Simmonds RS, Tagg JR: Dental caries is a preventable infectious disease, *Aust Dent J* 45(4):235–245, 2000.
12. Bradshaw DJ, Lynch RJM: Diet and the microbial aetiology of dental caries: new paradigms, *Int Dent J* 63(Suppl 2):64–72, 2013.

12a. Park KK, Matis BA, Christen AG: Choosing an effective toothbrush, *Clin Prev Dent* 7(4):5–10, 1985.

13. Updyke JR: A new handle for a child's toothbrush, *J Dent Child* 46:123–125, 1979.
14. Voelker MA, et al.: Catalogue of tooth brush head designs, *J Dent Hyg* 87(3):118–133, 2013.
15. Sharma NC, et al.: Plaque removal efficacy and safety of the next generation of manual toothbrush with angled bristle technology; results from three comparative clinical studies, *Am J Dent* 18:3–7, 2005.
16. Slott DE, et al.: The efficacy of manual toothbrushes following a brushing exercise: a systematic review, *Int J Dent Hyg* 10:187–197, 2012.
17. Tan E, Daly C: Comparison of new and 3-month-old toothbrushes in plaque removal, *J Clin Periodontol* 29:645–650, 2002.
18. Conforti NJ, et al.: An investigation into the effect of three months' clinical wear on tootbrush efficacy: results from two independent studies, *J Clin Dent* 14(2):29–33, 2003.
19. Drisko CL: Periodontal self-care: evidence-based support, *Periodontol* 62:243–255, 2013.
20. Sambunjak D, et al.: Flossing for the management of periodontal diseases and dental caries in adults, *Cochrane Database Syst Rev* 12:CD008829, 2011.
21. Corby PM, et al.: Treatment outcomes of dental flossing in twins: molecular analysis of the interproximal microflora, *J Periodontol* 79(8):1426–1433, 2008.
22. Mauriello AM, et al.: Effectiveness of three interproximal cleaning devices, *Clin Prev Dent* 9(3):18–22, 1987.
23. Chen MS, Rubinson L: Preventive dental behavior in families: a national survey, *J Am Dent Assoc* 105:43–46, 1982.
24. Ashkenazi M, Bidoosi M, Levin L: Factors associated with reduced compliance of children to dental preventive measures, *Odontology* 100:241–248, 2012.
25. Bass CC: An effective method of personal oral hygiene. Part II, *J La State Med Soc* 106:100, 1954.
26. Carr MP, et al.: Evaluation of floss types for interproximal plaque removal, *Am J Dent* 13(4):212–214, 2000.
27. Terezhalmy GT, Bartizek RD, Biesbrock AR: Plaque-removal efficacy of four types of dental floss, *J Periodontol* 79:245–251, 2008.
28. Kerlinger FN: *Foundations of behavioral research, educational and psychological injury*, New York, 1965, Holt, Rinehart and Winston.
29. Ho HP, Niederman R: Effectiveness of the Sonicare toothbrush on reduction of plaque, gingivitis, probing pocket depth and subgingival bacteria in adolescent orthodontic patients, *J Clin Dent* 8:15–19, 1997.
30. Nowak AJ, et al.: A practice based study of a children's power toothbrush: efficiency and acceptance, *Compendium* 23(Suppl 2):25–32, 2002.
31. Grossman E, Proskin H: A comparison of the efficacy and safety of an electric and a manual children's toothbrush, *J Am Dent Assoc* 128:469–474, 1997.
32. Jongenelis AP, Wiedemann W: A comparison of plaque removal effectiveness of an electric versus a manual toothbrush in children, *J Dent Child* 64:176–182, 1997.
33. Heanue M, et al.: Manual versus powered toothbrushing for oral health, *Cochrane Database Syst Rev* 1:CD002281, 2003.
34. Robinson P, et al.: Manual versus powered toothbrushing for oral health [review], *Cochrane Database Syst Rev* 2:CD002281, 2005.
35. Deacon SA, et al.: Different powered toothbrushes for plaque control and gingival health [review], *Cochrane Database Syst Rev* 12:CD004971, 2010.
36. American Dental Association: Council on Scientific Affairs: *Acceptance Program Guidelines—Toothbrushes*, Chicago, 2012, American Dental Association.
37. Cochrane NJ, et al.: New approaches to enhanced remineralization of tooth enamel, *J Dent Res* 89(11):1187–1197, 2010.
38. Cochrane NJ, Reynolds EC: Calcium phosphopeptides—mechanisms of action and evidence for clinical efficacy, *Adv Dent Res* 24:41–47, 2012.
39. Adair SM, Picitelli WP, McKnight-Hanes C: Comparison of school children, *Pediatr Dent* 19:99–103, 1997.
40. Levy SM, Zarei-M Z: Evaluation of fluoride exposures in children, *J Dent Child* 58:467–473, 1991.
41. Simard PL, et al.: Ingestion of fluoride from dentifrices by children aged 12 to 24 months, *Clin Pediatr* 30:614–617, 1991.
42. Cury JA, Tenuta LMA: Evidence-based recommendation on toothpaste use, *Braz Oral Res* 1:1–7, 2014.
43. Wong MCM, et al.: Cochrane Reviews on the benefits/risks of fluoride toothpastes, *J Dent Res* 90(5):573–579, 2011.
44. Wright JT, et al.: Fluoride toothpaste efficacy and safety in children younger than 6 years: a systematic review, *J Am Dent Assoc* 145(2):182–189, 2014.
45. Lim LP, et al.: A comparison of four techniques for clinical detection of early plaque formed during different dietary regimes, *J Clin Periodontol* 13:658–665, 1986.
46. Harris NO, Garcia-Godoy F, Nathe CN: *Primary preventive dentistry*, ed 8, Pearson Education, Saddle River, NJ, 2014.
47. Anaise JZ: The toothbrush in plaque removal, *J Dent Child* 42:186–189, 1975.
48. McClure DB: A comparison of toothbrushing technics for the preschool child, *J Dent Child* 33:205–210, 1966.
49. Sangnes G, Zachrisson B, Gjermo P: Effectiveness of vertical and horizontal brushing techniques in plaque removal, *J Dent Child* 39:94–97, 1972.
50. Starkey P: Instructions to parents for brushing the child's teeth, *J Dent Child* 28:42–47, 1961.
51. Rodrigues CR, et al.: The effect of training on the ability of children to use dental floss, *J Dent Child* 63:39–41, 1996.
52. Terhune JA: Predicting the readiness of elementary school children to learn an effective dental flossing technique, *J Am Dent Assoc* 86:1332–1336, 1973.

53. Mescher KD, Brine P, Biller I: Ability of elementary school children to perform sulcular toothbrushing as related to their hand function ability, *Pediatr Dent* 2:31–36, 1980.
54. Preisch JW: The relationship between visual motor integration and oral hygiene in children [Master's thesis], Bloomington, Indiana, 1984, Indiana University.
55. Löe H: How frequently must patients carry out effective oral hygiene procedures in order to maintain gingival health? *J Periodontol* 42:312–313, 1971.
56. Lang NP, et al.: Toothbrushing frequency as it relates to plaque development and gingival health, *J Periodontol* 44:396–405, 1973.
57. Hodges CA, Bianco JG, Cancro LP: The removal of dental plaque under timed intervals of toothbrushing, *J Dent Res* 60:425, 1981. [abstract 460].
58. Honkala E, et al.: Effectiveness of children's habitual toothbrushing, *J Clin Periodontol* 13(1):81–85, 1986.
59. van der Ouderaa FJ: Anti-plaque agents: rationale and prospects for prevention of gingivitis and periodontal disease, *J Clin Periodontol* 18:447–454, 1991.
60. Mandel ID: Chemotherapeutic agents for controlling plaque and gingivitis, *J Clin Periodontol* 15:488–498, 1988.
61. Gunsolley JC: Clinical efficacy of antimicrobial mouthrinses, *J Dent* 38:S6–S10, 2010.
62. Stoeken JE, Paraskevas S, van der Weijden GA: The long-term effect of a mouthrinse containing essential oils on dental plaque and gingivitis: a systematic review, *J Periodontol* 78(7):1218–1228, 2007.
63. Gunsolley JC: A meta-analysis of six-month studies of antiplaque and antigingivitis agents, *J Am Dent Assoc* 137(12): 1649–1657, 2006.
64. Van Strydonck DAC, et al.: Effect of a chlorhexidine mouthrinse on plaque, gingival inflammation and staining in gingivitis patients: a systematic review, *J Clin Periodontol* 39:1042–1055, 2012.
65. Lang NP, et al.: Effects of supervised chlorhexidine mouthrinses in children, *J Periodontal Res* 17:101–111, 1982.
66. de la Rosa M, Sturzenberger OP, Moore DJ: The use of chlorhexidine in the management of gingivitis in children, *J Periodontol* 59(6):387–389, 1988.
67. Twetman S: Antimicrobials in future caries control? A review with special reference to chlorhexidine treatment, *Caries Res* 38:223–229, 2004.
68. James P, Parnell C, Whelton H: The caries-preventive effect of chlorhexidine varnish in children and adolescents: a systematic review, *Caries Res* 44:333–340, 2010.
69. Burtner AP, et al.: Effects of chlorhexidine spray on plaque and gingival health in institutionalized persons with mental retardation, *Spec Care Dentist* 11(3):97–100, 1991.
70. Chikte UM, et al.: Evaluation of stannous fluoride and chlorhexidine sprays on plaque and gingivitis in handicapped children, *J Clin Periodontol* 18:281–286, 1991.
71. Ferretti GA, et al.: Control of oral mucositis and candidiasis in marrow transplantation: a prospective, double-blind trial of chlorhexidine gluconate oral rinse, *Bone Marrow Transplant* 3:483–493, 1988.
72. Raether D, et al.: Effectiveness of oral chlorhexidine for reducing stomatitis in a pediatric bone marrow transplant population, *Pediatr Dent* 11:37–42, 1989.
73. Qutob AF, et al.: Prevention of oral mucositis in children receiving cancer therapy: a systematic review and evidence-based analysis, *Oral Oncol* 48:102–107, 2013.
74. Lang NP, Brecx MC: Chlorhexidine digluconate: an agent for chemical plaque control and prevention of gingival inflammation, *J Periodontal Res* 16(Suppl 21):74–89, 1986.
75. Sharma N, et al.: Adjunctive benefit of an essential oil-containing mouthrinse in reducing plaque and gingivitis in patients who brush and floss regularly: a six-month study, *J Am Dent Assoc* 135(4):496–504, 2004.
76. White DJ, Barker ML, Klukowska M: In vivo antiplaque efficacy of combined antimicrobial dentifrice and rinse hygiene regimens, *Am J Dent* 21(3):189–196, 2008.
77. Selbst AM, DeMaio JG, Boenning D: Mouthwash poisoning, *Clin Pediatr* 24:162–163, 1985.
78. Mrvos R, Krenzelok EP: Child-resistant closures for mouthwash. Do they make a difference? *Pediatr Emerg Care* 23: 713–715, 2007.
79. Busscher HJ, et al.: Influence of a chitosan on oral bacterial adhesion and growth in vitro, *Eur J Oral Sci* 116(5):493–495, 2008.
80. Park K, et al.: Comparison of plaque pH response from a variety of sweeteners, *J Dent Res* 71(Spec Iss):269, 1992 [AADR abstract].
81. Hoerman KC, et al.: Effect of gum chewing on plaque accumulation, *J Clin Dent* 2(1):17–21, 1990.
82. Isokangas P, et al.: Xylitol chewing gum in caries prevention: a field study in children, *J Am Dent Assoc* 117:315–320, 1988.
83. Milgrom P, et al.: Clinical evidence for polyol efficacy, *Adv Dent Res* 24(2):112–116, 2012.
84. O'Mullane D: New agents in the chemical control of plaque and gingivitis: reaction paper, *J Dent Res* 71:1455–1456, 1992.
85. Ciancio SG: Agents for the management of plaque and gingivitis, *J Dent Res* 71:1450–1454, 1992.
86. American Academy of Pediatric Dentistry: *Guidelines on Infant Oral Health Care, Reference Manual*. Chicago, 2014.
87. Feil PH, et al.: Intentional use of the Hawthorne effect to improve oral hygiene compliance in orthodontic patients, *J Dent Educ* 66(10):1129–1135, 2002.
88. Griffen AL, Goepferd SJ: Preventive oral health care for the infant, child, and adolescent, *Pediatr Clin North Am* 38(5):1209–1226, 1991.
89. Macgregor ID, Balding JW: Self-esteem as a predictor of toothbrushing behavior in young adolescents, *J Clin Periodontol* 18:312–316, 1991.
90. Ong G: Practical strategies for a plaque-control program, *Clin Prev Dent* 13(3):8–11, 1991.

CHAPTER 8

Nutritional Considerations for the Pediatric Dental Patient

▲ Laura M. Romito and James L. McDonald Jr.

For additional resources, please visit the evolve website.

CHAPTER OUTLINE

MYPLATE FOOD GUIDANCE SYSTEM
DIETARY INTAKE PATTERNS
- Eating Out
- Portion Sizes
- Meal Pattern and Frequency

MALNUTRITION AND FOOD INSECURITY
PEDIATRIC UNDERNUTRITION
- Iron
- Zinc
- Calcium
- Vitamin D
- Vitamin B_{12}

PEDIATRIC OVERNUTRITION
- Health Impact of High Salt Intake

FEEDING AND EATING DISORDERS
- Anorexia Nervosa
- Bulimia
- Binge-Eating Disorder

Q & A CONCERNING PEDIATRIC NUTRITION ISSUES

This chapter focuses on healthful dietary and nutritional practices for dental patients presented within the framework of a Pediatric Dentistry textbook. It is obvious that eating nutritiously promotes not only healthy teeth and gums but also a healthy body. Contemporary research continues to demonstrate that pursuing nutritious eating behaviors is essential in maximizing health, vitality, and longevity.

Heart disease and cancer top the list of the leading causes of death in the United States, with chronic obstructive pulmonary disease and stroke filling the 3rd and 4th spots, respectively.[1] However, three major lifestyle choices are the underlying causes of these diseases: using tobacco products, leading a sedentary lifestyle, and making poor dietary choices. Clearly, both what we eat and what we do not eat are major factors affecting the length and quality of our lives. The basis of our dietary choices is established early in life, and these food choices and dietary patterns will affect our health and well-being at every stage of life. There are many ways in which health professionals can promote the health of their patients. One means is to educate them and their caregivers regarding proper eating behaviors.

Research studies show that individuals who live in countries bordering the Mediterranean Sea live longer and are less prone to a variety of diseases than are those residing in other countries. This is often attributed to the consumption of a diet rich in fruits, vegetables, nuts, whole grains, legumes, and olive oil and low in red meat, sugar, and saturated fat. Eating in this manner provides many health benefits, especially when these dietary patterns are combined with regular physical activity. Although a cause-effect relationship has not been conclusively demonstrated, an association does exist between consumption of the Mediterranean diet and good health outcomes.[2] Eating a Mediterranean diet results in better control of body weight and blood pressure and assists in the more effective regulation of blood sugar and cholesterol levels. The Mediterranean dietary pattern also provides protection against cardiovascular diseases, Parkinson's disease, Alzheimer's, type 2 diabetes, and certain types of cancer. It is enlightening to compare life expectancy data between the United States and several of the countries located in the vicinity of the Mediterranean Sea (Table 8-1) to determine how those who regularly consume such a diet compare with those who do not.[3]

Although several factors may contribute to these differences in life expectancy, the United States ranks behind four Mediterranean countries in this regard. On average, American men live 3.3 fewer years than do their Italian counterparts, with American women some 3.6 years behind Italian women. Although not conclusive, analysis of the data (see Table 12-1) supports the potential value of

Table **8-1**

Life Expectancy Comparison

COUNTRY	MEAN LIFE EXPECTANCY (IN YEARS) AT BIRTH BY GENDER	
	Men	Women
Italy	79.2	84.5
France	78.2	84.8
Spain	78.2	84.4
Greece	77.4	82.7
United States	75.9	80.9

Dentlearn.ir

Table **8-2**

***Healthy People 2020* selected nutritional goals**

Objective	Baseline	Target
NWS-1 Increase the number of States with nutrition standards for foods and beverages provided to preschool-aged children in child care	24	34
NWS-2.1 Increase the proportion of schools that do not sell or offer calorically sweetened beverages to students	9.3%	21.3%
NWS-2.2 Increase the proportion of school districts that require schools to make fruits or vegetables available whenever other food is offered or sold	6.6%	18.6%
NWS-3 Increase the number of States that have State-level policies that provide incentives to food retail outlets to provide foods that are encouraged by the Dietary Guidelines for Americans	8	18
NWS-10.4 Reduce the proportion of children and adolescents aged 2 to 19 years who are considered obese	16.1%	14.5%
NWS-12 Eliminate very low food security among children (% of households)	1.3%	0.2%
NWS-14 Increase the contribution of fruits to the diets of the population aged 2 years and older; *cup equivalent per 1000 calories	0.5*	0.9*
NWS-15.1 Increase the contribution of total vegetables to the diets of the population aged 2 years and older; *cup equivalent per 1000 calories	0.8*	1.1*
NWS-20 Increase consumption of calcium in the population aged 2 years and older	1119 mg	1300 mg

the Mediterranean style of eating as an important factor in promoting health and longevity.

In the United States, the Healthy People 2020 document provides evidence-based goals and 10-year benchmarks to guide national health promotion and disease prevention efforts to improve the health of all Americans in the upcoming decade. Released in 2010 by the U.S. Department of Health and Human Services,[4] it builds on the accomplishments of three decades of previous Healthy People initiatives. Objectives under the topic of *Nutrition and Weight Status* support consumption of a healthful diet and maintenance of a healthy body weight, and recognize that factors that are critical to the adoption of healthy lifestyles include individual suggestions as well as the policies and environments that support such behaviors. Table 8-2 summarizes key objectives related to pediatric nutrition.

The 2010 Dietary Guidelines for Americans promulgated by the U.S. Department of Agriculture (USDA) support the objectives in the *Healthy People* documents and emphasize the following major goals for Americans:

- Balance calories with physical activity to manage weight
- Consume more of certain foods and nutrients such as fruits, vegetables, whole grains, fat-free and low-fat dairy products, and seafood
- Consume fewer foods with sodium (salt), saturated fats, transfats, cholesterol, added sugars, and refined grains

The 2015 Dietary Guidelines for Americans are currently being developed. More information on these guidelines[5] can be found at the following website: http://

MYPLATE FOOD GUIDANCE SYSTEM

The MyPlate Food Guidance System is a pictorial representation of the USDA's daily food recommendations. Released in 2012, MyPlate replaced the nation's previously well-known nutrition education tool, MyPyramid (2005).

vegetables, proteins, dairy, and grains) is depicted proportionally according to the current recommendations. In addition, the website ChooseMyPlate.gov offers numerous educational resources and practical guidance for consumers, educators, and health professionals in building a healthful diet. For example, one can develop an individualized nutrition plan based on personal factors such as age, gender, and physical activity by utilizing the online tools, such as SuperTracker, and the Daily Food Plan and

several food plans for special populations, such as vegetarians, moms, and preschoolers. The SuperTracker tool can help plan, analyze, and track one's diet, weight, and physical activity; it can also be further personalized by using the goal setting, virtual coaching, and journaling features. Health and nutrition information for children over the age of 5 years is also provided on the site and includes activities, coloring pages, and interactive games as well as tips for caregivers concerning children's nutrition and meal planning (Fig. 8-1).

DIETARY INTAKE PATTERNS

Trends in U.S. dietary intake patterns reflect changes in several factors, including the consumption of low-nutrient, high-calorie foods and beverages (empty calories), as well as changes in the average portion size, snacking habits, and eating away from home.[7] National surveys measuring nutritional status and dietary patterns of children and adolescents revealed that the total caloric intake of U.S. children increased from the 1970s to the 1990s; these results reflect an increased consumption of soft drinks, grain products, fried potatoes, noncitrus juices, cheese,

Dentlearn.ir



Figure 8-1 Choose My Plate. (Courtesy of USDA's Center for Nutrition and Policy Promotion.)

candy, and fruit drinks.[8,9] Conversely, over this time period, decreases were found in intakes of milk in general, whole milk, vegetables and legumes, beef, pork, and eggs. Less than half of children consumed the recommended intakes of discretionary fat and added sugar were much higher than recommended.

Using data from the National Health and Nutrition Examination Survey (NHANES), researchers have continued to monitor dietary trends among American children and adolescents. For example, in evaluating beverage consumption for children from birth to 5 years of age, Fulgoni found that although milk remains the primary beverage, intakes have declined. From the 1970s through the 1990s, approximately 85% of preschoolers consumed some form of milk, but by 2000-2006, milk consumption had declined to 77%.[10] Conversely, fruit juice consumption increased dramatically over the same time period. While fruit juice can be an important source of vitamin C, potassium, and magnesium, it may also replace other nutritious foods, including those with calcium. From 1976 to 2006, preschoolers' consumption of fruit drinks, which contain less than 10% fruit juice but generous amounts of added sugars, remained relatively stable at approximately 35-37% of this population.[10] At least one third of preschoolers regularly consumed soft drinks, and the consumed amounts increased with child age. Han and Powell[11] reported that in the United States, regular soda was the major form of sugar-sweetened beverage consumed by young people, particularly teenagers, and those from low socioeconomic backgrounds. However, while consumption of soda has decreased in recent years, the prevalence of sports/energy drink consumption has tripled. This is concerning because, along with the well-known risk for dental caries, there is evidence that high intakes of sweetened beverages are associated with increased caloric intake, weight gain, and obesity.[12,13] Furthermore, an increased intake of sugar-sweetened beverages among children aged 3-11 years has been associated with a decrease in HDL cholesterol levels and increases in waist circumference and C-reactive protein, a known marker of inflammation and cardiometabolic disease.[14]

From 1989 to 2004, there was an appreciable rise in daily calories consumed among U.S. children and teenagers.[15] One study found that in individuals aged 2-18 years, empty calories accounted for nearly 40% of daily energy intake.[16] The increase in calories during this period was attributed to an increased intake of the following foods: sugar-sweetened beverages, pizza, full-fat milk, grain-based desserts, breads, pasta, and savory snacks. However, from 2003 to 2010, along with an increase in fruit consumption, total caloric intake in U.S. children declined, as did their consumption of many of the aforementioned foods. However, this trend did not occur among preschool-aged children and those of low socioeconomic status; compared with 1989-1991, their total energy intakes remained significantly higher in 2009-2010.[15] In preschoolers, from 1989 to 2008, there was an increase in foods with high levels of added sugar and fat such as savory snacks, pizza, calzones, Mexican dishes, sweet snacks/candy, and fruit juice.[17]

Although current trends may indicate a shift toward improved dietary intake, consumption of excess calories and foods with added fat and sugar negatively affects the overall quality of children's diets. In the National Growth and Health Study, Moore et al. found that the aforementioned excesses contributed to inadequate intakes of essential vitamins and minerals, as well as to intakes of dairy foods, fruits, and vegetables that fell short of recommended levels in more than 90% of teenage girls.[18] Similarly, Ionotti et al. determined, from a 10th graders, that only 25% of the children consumed the highest proportions of daily vegetables and fruits and the smallest intake of energy-dense, low-nutrient foods.[19]

In 2013 over 13 million children participated in the School Breakfast Program (SBP) and over 30 million participated in the National School Lunch Program (NSLP). These federally funded programs evolved as efforts to assist children in low-income households. Children from households with incomes at or below the poverty level are eligible for free meals; those with higher incomes may be eligible for reduced-price meals.[20] Because school meal programs can have a significant impact on children's health, their ability to meet nutritional quality standards is important. An analysis of a nationally representative that, compared with meals eaten at home, school lunches provided lower-calorie, higher-quality food; in addition, NSLP participants ate fewer calories from sugar-sweetened beverages at school than did nonparticipants, but obtained more calories from low-nutrient, energy-dense solid foods such as fries and higher-fat baked goods in secondary schools. Overall, compared with nonparticipants, school lunch participants' dietary intake at school was lower in calories.[21]

However, Clark and Fox reported that while the majority of U.S. public schoolchildren obtained nutritionally adequate diets from school meals, 80% consumed excess saturated fat and 92% consumed excess sodium.[22] High sodium intakes may increase dietary intake of sugary beverages.[23] A survey of school principals from a nationally

participation in the federal school nutrition program, Fresh Fruits and Vegetable Program, increased the availability of fresh fruits during school lunch meals.[24] Likewise, a systematic review and meta-analysis by Evans et al. found that from 1989 to 2009, school-based nutrition programs generated a modest improvement on children's fruit consumption but had no impact on vegetable intake.[25] Clearly, there is room for improvement.

EATING OUT

Children and teenagers continue to obtain more of their meals outside of the home, often from fast-food establishments. From the late 1970s through the mid-2000s, the percentage of daily calories consumed in fast-food restaurants by children aged 2-18 years grew from 2% to 13%, while full-service restaurants' contribution to their daily caloric intake increased from 1% to 5%.[26,27] From 2000 to 2008, fast-food and full-service restaurant meal consumption by children and teenagers was associated with increased calories, particularly for adolescents and those

of soda and sugar-sweetened drinks. Fast-food intake in-

sodium and protein for teenagers.[28] However, the type of restaurant may be a moderating factor. Larson et al. found that compared with "burger and fries" establishments, those serving primarily sandwiches/subs were associated with fewer markers of poor diet quality and had no relationship with body weight.[29] Likewise, recent systematic reviews examining the association among eating out, dietary intake, and weight concluded that eating away from home is a risk factor for higher fat and calorie intakes and lower consumption of micronutrients[30] but remain less conclusive about weight gain, especially in young populations.[31]

PORTION SIZES

Along with an increase in eating outside the home, there is a trend toward expanded food-serving sizes. Most marketplace portions of foods exceed standard serving sizes by at least a factor of 2 (e.g., bagels and sodas) and sometimes by a factor of 8 (e.g., cookies).[32] Fast-food chains offer larger sizes of hamburgers, sodas, and fries. The current serving sizes are often two to five times larger than the size originally marketed. These changes in dietary patterns parallel the progressive increase in obesity seen in the United States. Based on this information, eating away from home is associated with a compromised quality of nutritional intake and may increase the risk for chronic diseases. An analysis of the dietary patterns of U.S. children and adolescents from 2003 to 2006 found that, compared with younger children, teenagers are more susceptible to distorted portion sizes and that high-calorie, low-nutrient foods such as sugar-sweetened beverages, fries, and pizza for a significant portion of their diet.[33]

MEAL PATTERN AND FREQUENCY

Although from 2000 to 2011 U.S. kids and teenagers had increased intakes of high-calorie, low-nutrient snacks, an association between snacking behavior and obesity remains unclear.[34] However, Koletzko et al. found that a higher meal frequency among children was associated with a decreased risk of obesity, which led the authors to suggest that children should consume 5 nutritious meals per day.[35]

Eating dinner at home in a dining area and helping to prepare meals were associated with a decreased body mass index (BMI) in children.[36] Furthermore, in teenagers, Berge et al. found that positive interpersonal communications with family members at the dinner table was associated with lower BMI and greater vegetable consumption.[37] However, from 1999 to 2010, a widening gap in family meals based on socioeconomic status was noted by a Minnesota study. Youth in the lowest socioeconomic status showed a decrease from 4 to 3.6 family meals per week over the time period, while those in upper socioeconomic

not bode well for low-income youth, who have greater risk of poor health outcomes.

MALNUTRITION AND FOOD INSECURITY

Malnutrition includes undernutrition (inadequate intake of nutrients that potentially leads to deficiency diseases) and overnutrition (excessive dietary intake of energy, fat, or cholesterol that predisposes individuals to chronic diseases). While the latter excessive consumption pattern may be quantitatively more relevant to overall mortality and morbidity rates in contemporary U.S. society than are nutrient deficiencies, malnutrition from dietary insufficiency has not been eradicated.

Chronic malnutrition as measured by low weight for age and low growth rates has decreased; some of this decline has been attributed to better nutrition. Today, the proportion of mothers receiving early prenatal care is at a record high. Data released in 2012 by the U.S. Department of Health and Human Services reported that as of 2011, the overall rate at which infants die before their first birthday was 6.05 deaths per 1000 live births. However, infant death rates are disproportionately higher in

and Native Americans, with 13.3 and 9.2 deaths per 1000 live births, respectively. Furthermore, the U.S. infant mortality rate continues to rank among the highest of the industrialized nations. More than 16 million children in the United States live in poverty, and some estimates indicate that children in approximately 10% of households experience hunger or the risk of hunger.[39]

Knol and colleagues evaluated the dietary patterns of low-income children from 2 to 3 years of age and from 4 to 8 years of age and found that the predominant eating

diet as described by national recommendations. Rather, the diets mimicked those of adults, with high intakes of

Dentlearn.ir

added sugars and discretionary fats as a percentage of daily calories.[40] Thus children of low socioeconomic status are at risk for the long-term consequences of malnutrition.

According to USDA, food security is generally defined as "access by all people at all times to enough food for an active, healthy life." Conversely, food insecurity describes a "household-level economic and social condition of limited or uncertain access to adequate food." Hunger is an individual-level physiological condition that may result from food insecurity, and refers to "a potential consequence of food insecurity that, because of prolonged, involuntary lack of food, results in discomfort, illness, weakness, or pain that goes beyond the usual uneasy sensation."[41,42] Thus food insecurity is considered a risk factor for malnutrition.

Data regarding the food security of U.S. households are obtained by USDA from federally sponsored national surveys. The food security status of each household is categorized according to the following labels.

- *High food security*: Households had no problems or anxiety about consistently accessing adequate food.
- *Marginal food security*: Households had problems at times, or anxiety about, accessing adequate food, but the quality, variety, and quantity of their food intake were not substantially reduced.
- *Low food security*: Households reduced the quality, variety, and desirability of their diets, but the quantity of food intake and normal eating patterns were not substantially disrupted.
- *Very low food security*: At times during the year, eating patterns of one or more household members were disrupted and food intake reduced because the household lacked money and other resources for food.

USDA reported that in 2012, 85.5% of U.S. households were food secure; however, 14.5% of households (17 million individuals) reported being food insecure, with 5.7% reporting very low food security. Prevalence of food insecurity was greater in metropolitan areas, poor households, households with children headed by single women or single men, and African-American and Hispanic households.

Because food-insecure households are eligible to receive assistance from federally funded programs such as the Supplemental Nutrition Assistance Program (formerly the Food Stamp Program), research has been ongoing to understand the impact of these programs on food insecurity and nutrition. In addition, studies are seeking to clarify the relationships between food insecurity and nutritional status, health risks, and reduced quality of life, especially in children. Ryu and Bartfield analyzed household food security data from a nationally representative

1998 through eighth grade in 2007. More than one fifth of the children resided in a food-insecure home during the 9-year timeframe, which, in many cases, was a transient situation. Nevertheless, results suggested poorer health status for children living with persistent household food insecurity.[43] Food insecurity has also been associated with increased mental and substance abuse disorders in adolescents.[44]

A recent literature review found that there is a growing body of evidence supporting the association between food insecurity and obesity in teenagers, but the relationship remains unclear in children.[45] For example, a longitudinal study of the relationship of food insecurity on obesi-

low-income children participating in the Massachusetts Special Supplemental Nutrition Program for Women, Infants, and Children, found that, compared with children in food-secure homes, those experiencing persistent household food insecurity had 22% greater odds of being obese.[46] However, this finding was moderated by maternal prepregnancy weight status, with obesity more common among children of underweight and obese women. Clearly, more research is needed in this area to improve understanding of these relationships.

PEDIATRIC UNDERNUTRITION

Undernutrition is the insufficient consumption of essential nutrients, resulting in health problems. Failure to thrive is a concern sometimes observed among infants and children. This term refers to individuals whose current body weight or rate of weight gain falls significantly below that of other children of similar age and gender. These children are much smaller and shorter than their counterparts, and may lack mental and social skills as well as physical abilities such as rolling over, sitting, standing, and walking. Although there are numerous potential environmental and medical causes of failure to thrive, poor eating habits, such as not having formal mealtimes or chronically eating in front of the television, may play a role.

Typically, in mild but chronic undernutrition, weight loss with normal height and head circumference is seen. If the situation continues, growth will slow, and head circumference and height will be below age- and gender-related standards. Severe lack of caloric intake results in a wasting condition known as marasmus. Adequate intake of calories with insufficient protein can produce kwashiorkor, a condition characterized by increased susceptibility to infections and edema. However, these latter two conditions are primarily seen in areas plagued with famine and are rarely seen in the United States.

The Third School Nutrition Dietary Assessment Study[47] assessed the quality and contributions of the National School Lunch Program and the School Breakfast Program to children's nutritional health. Both are longstanding government programs designed to bring nutritious food to America's children. The results indicate that the majority of U.S. schoolchildren consume nutritionally adequate diets, though many may have deficient fiber intake, with excessive consumption of saturated fat and sodium. Nevertheless, 15% of children still showed inadequate intakes of vitamin A, vitamin C, vitamin E, phosphorus, and magnesium. These inadequacies were greatest among female adolescents. Elementary schoolchildren showed excessive intakes of calories, but this was not observed among high school students. Since these three vitamins and two minerals seem to be an issue among some children, a short consideration of each follows.

Dentlearn.ir

Vitamin A has two fundamental forms in foods: retinoids found in animal foods and carotenoids present in plant foods. Since both plant and animal food are good sources, true dietary deficiencies are generally not likely to be a problem in Westernized societies. In contrast, vitamin C, which is required for wound healing and healthy blood vessels, is found only in fruits and vegetables, and if these foods are not regularly eaten, suboptimal deficiencies of this vitamin can occur. Vitamin E represents a collection of chemically similar vitamins that provide important resistance to oxidative stress in the body. Richest dietary sources are nuts, seeds, fruits, fish, and plant oils. Supplements of this vitamin are quite popular, but food sources are likely a safer and more effective choice.

Phosphorus is an essential mineral nutrient required for strong bones and teeth. It is found in practically every food item in the human diet. As a result, a dietary deficiency is extremely unlikely. Magnesium is another mineral with important roles in human metabolism and is widespread in animal and plant foods alike. Richest sources are green leafy vegetables, nuts and seeds, fish, legumes, and whole grains.

Nutrient undernutrition may have several causes, only one of which is an inadequate dietary intake. Some cases may be secondary to poor socioeconomic status, lack of education, perceived allergies/food intolerances, and child neglect or abuse. Historically, iron, calcium, and zinc are three minerals sometimes ingested only at marginal levels by many youth. Vitamins D and B_{12} have also been found difficult to ingest at recommended levels among children and adolescents in research studies.[48,49]

IRON

Iron fulfills its primary role in the body as a component of blood hemoglobin and muscle myoglobin, by providing cells with a constant supply of oxygen. It also functions as a co-factor for many enzymatic reactions in the body and is important for proper functioning of the immune system. Although the prevalence of iron deficiency has declined in recent years, it remains an enormous problem globally and an important pediatric public health problem even in the United States. Many of the adverse consequences of iron deficiency are associated with its most severe form, iron-deficiency anemia. However, iron deficiency without anemia is associated with poor cognition and lower scholastic achievement in children and adolescents.[50] Clinical signs of iron-deficiency anemia may include weakness, fatigue, pallor, and numbness and tingling of the extremities. Common oral manifestations are glossitis and fissures at the corners of the mouth (angular cheilitis). The papillae of the tongue may be atrophied, which gives the tongue a smooth, shiny, red appearance. In addition, pallor of the oral mucosa or lips may be observed. Affected individuals may also be at increased risk for fungal infections, such as candidiasis.

Iron needs are higher during growth stages, and those most vulnerable to iron deficiency include preterm and low-birthweight infants, older infants and toddlers, teenage girls, and women of child-bearing age. Iron deficiency early in life appears related to behavioral problems in infants who score significantly lower on various tests measuring intellectual and motor functioning. An assessment of iron deficiency prevalence in U.S. children from 1 to 3 years of age during 1976-2002 showed no significant changes during this period, with overall prevalence ranging from 8% to 10%. Iron deficiency prevalence decreased from 22% to 9% in toddlers in low-income households, but remained at 7% in toddlers from households above the poverty level. During this 26-year period, iron deficiency prevalence in African-American toddlers decreased from 16% to 6%, but remained unchanged in both Hispanic and white children at 13% and 6%, respectively. Prolonged bottle feeding for up to 48 months of age was positively correlated with increased prevalence of iron deficiency and may account for the higher prevalence seen in Hispanic toddlers.

Somewhat surprisingly, overweight toddlers have a significantly higher prevalence of iron deficiency than do comparable normal-weight or underweight peers. This has also been observed in older children and adolescents. Possible explanations for this association include a greater intake of foods high in calories, but low in iron, an alteration in iron absorption or metabolism, and a reduced level of physical activity among the overweight children. Additionally, overweight girls may grow faster and mature earlier than normal-weight peers, making it more difficult to meet their iron requirements. To prevent iron deficiency, vulnerable populations should be encouraged to eat iron-rich foods and breast-feed or use iron-fortified formula for infants. Iron is found primarily in meat, poultry, and fish. However, other foods such as beans, lentils, fortified cereal grain products, and certain vegetables can also contribute to dietary intake of iron.

ZINC

The trace mineral zinc has important roles in growth and development, sexual maturation, immune function, and wound healing; it also has a role in taste and smell acuity. Recently, it has become a popular medicament for treating the common cold (Box 8-1).

Severe zinc deficiency in children is common in developing countries, but far less so in the United States. Chronic low dietary zinc intakes may produce a deficiency, as may low bioavailability, and/or adverse interactions with other nutrients. Iron and zinc share many common food sources, so individuals at risk for iron deficiency may also be at risk for zinc deficiency. Zinc is present in foods that are high in protein, such as beef, eggs, poultry, and legumes, as well as in whole grains, fortified, ready-to-eat cereals, and dark green and yellow vegetables. However, as is the case with iron, zinc from plant food sources is

Box 8-1

Zinc Study[51,52]

Two studies conducted with a study population of schoolchildren have suggested that taking zinc-containing lozenges can ease the symptoms of the common cold and shorten its duration.

Dosages tested were 10-15 mg zinc sulfate daily.

Dentlearn.ir

not as well absorbed as that found in animal foods. Briefel and colleagues[53] assessed zinc intakes from food and supplements in the U.S. population between 1988 and 1994 using NHANES III data. Results indicated that in children younger than 10 years, boys and girls had similar zinc intakes, but in those older than 10, boys' intakes exceeded those of girls. Eighty-one percent of 1- to 3-year-olds and 48 percent of 4- to 6-year-olds had inadequate zinc intake, defined as less than 77% of the 1989 Recommended Dietary Allowance. In addition, roughly 61% of adolescent girls had inadequate intake compared with 38% of adolescent boys.[53]

One of the first clinical manifestations of severe zinc deficiency in children is stunted growth. Other signs and symptoms include abnormal immune responses, decreased reproductive development and function, and skeletal abnormalities. Oral manifestations include impaired wound healing, alterations of the oral epithelium, xerostomia, reduced or altered sense of taste or smell, and reduced appetite. During tooth formation, children with zinc deficiency may be at increased risk for dental caries. In addition, because of its impact on immune function, zinc deficiency may increase the risk of oral infections such as periodontal disease and candidiasis.

CALCIUM

Calcium and vitamin D work together to maximize the mineralization of bones and teeth. Calcium is also needed for proper nerve and muscle activity, blood clotting, and transport of ions across cell membranes. Individuals at risk for inadequate calcium intake include those who dislike milk and other food sources of calcium, as well as those with milk allergies, lactose intolerance, and malabsorptive disorders. Inadequate calcium intake over time can increase the risk of bone demineralization and osteoporosis.

Osteoporosis is a bone disease of older individuals and is most commonly diagnosed in postmenopausal women. It is characterized by a reduction in the quantity of skeletal tissue and thus is often considered to be a geriatric disorder. Education for its prevention, however, is legitimately within the domain of pediatricians and pediatric dentists. Childhood and adolescence are crucial times for development of the skeletal system, and the dietary requirement for calcium peaks during the teenage years. The Food and Nutrition Board of the Institute of Medicine recommends an intake of 1300 mg per day of calcium during adolescence. This equals roughly the amount of calcium present in 4 ⅓ cups of milk, so this is not an easy recommendation to meet.

Achieving a high peak bone mass is the first line of defense against osteoporosis. Low calcium intake, particularly in combination with low levels of physical activity, may compromise the attainment of optimal peak bone mass. This is a particularly important consideration for adolescent girls, because almost half of the adult skeletal mass is formed during the second decade of life, and calcium accumulation normally triples during the pubertal

that is at highest risk for low calcium intakes. Only 30% of adolescent girls reach 75% of the recommended daily allowance for calcium, and its intake appears to be declining among 6- to 11-year-olds. This problem may be alleviated by educating youth to select more calcium-rich foods (e.g., cheese, yogurt, fortified breakfast cereals, fortified orange juice concentrates) or to consider using calcium supplements. Calcium carbonate has a good absorption rate and has been characterized as a relatively inexpensive supplement containing a high percentage level of calcium. The concept that dental alveolar bone height loss is associated with osteoporosis is supported by research; therefore strategies for reducing osteoporosis risk may also help retard alveolar bone loss. Dental professionals can help improve both the oral and systemic health of their pediatric patients over the long term by guiding them in meeting calcium intake recommendations.[54]

VITAMIN D

Vitamin D is a fat-soluble vitamin that promotes the absorption of calcium from foods in the gastrointestinal tract, leading to proper mineralization of bones and teeth. As a result, having adequate stores of this vitamin is crucial for proper skeletal and dental development. Vitamin D also acts in concert with parathyroid hormone to maintain tight control of blood calcium levels. A slight reduction in blood calcium concentration stimulates secretion of parathyroid hormone, which mobilizes calcium and phosphorus from the skeleton to reestablish calcium homeostasis in the blood. Vitamin D seems to play a role in immune function; in addition, lack of this vitamin may contribute to several diseases, including hypertension, multiple sclerosis, and certain cancers. It has recently been suggested to be a factor in serotonin synthesis in the brain and to perhaps play a role in autism.[55]

Vitamin D deficiency is increasingly being recognized as pandemic. The problem is threefold:

1. There is a lack of appreciation that exposure to sunlight is a significant source of the vitamin.
2. Few foods naturally contain vitamin D.
3. Foods that are fortified with vitamin D are often not consumed in sufficient amounts to meet the requirement.

of 6- to 21-year-olds in the northeastern United States, more than half the individuals were found to have low serum vitamin D concentrations; the prevalence of deficiencies increased with advancing age, and also during the winter months, especially in African-American children.[56] In a different study of nearly 400 healthy infants and toddlers, 12% of the children had suboptimal serum levels of vitamin D, and a third of these children exhibited radiographic evidence of bone demineralization. Predictors of vitamin D deficiency included breast-feeding without supplementation in the infants and low milk intake among the toddlers. Cushman and colleagues[57] evaluated the effects of subclinical vitamin D deficiency on bone mineral density (BMD) and bone turnover in healthy adolescent boys and girls. Even though no relation between BMD and vitamin D status was observed in boys, the 12- to 15-year-old girls with high vitamin D status had significantly greater bone density, lower serum parathyroid hormone, and lower bone turnover markers than girls with low vitamin D status.

Dentlearn.ir

Exposure to sunlight is the major source of vitamin D for most people. Ultraviolet rays from the sun trigger vitamin D synthesis in the skin from its chemical precursor, 7-dehydrocholesterol. Natural sources of this vitamin are fatty fish such as salmon, mackerel, and herring, as well as fish oil, including cod liver oil. In the United States, although some juices, breads, yogurts, and cheeses are enriched with vitamin D, fortified milk is considered as the primary dietary source of the vitamin.

Because vitamin D is an essential nutrient for proper skeletal development, children who receive too little may develop rickets—a bone disease characterized by bone deformities, poor muscle development, abnormal spinal curvature, and bowed legs. The latter manifestation occurs because the skeleton cannot support the body weight of the child. In addition, enlarged joints and delayed closure of the skull bones may be present. The presence of rickets during tooth development may result in enamel and dentin hypoplasia, incomplete development, or delayed tooth eruption.

During the first half of the twentieth century, thousands of cases of nutritional rickets were reported in the United States, particularly in the northern climates during the winter months, when exposure to sunlight was minimal. This disease was virtually eradicated once vitamin D began to be added to milk. In recent years, however, a resurgence of rickets has occurred, particularly in African-American breast-fed babies. There appear to be two major reasons for this resurgence. First is the increase in breast-feeding. Breast-feeding is the preferred method of infant nutrition, but by itself does not supply adequate amounts of vitamin D. Second, endogenously produced vitamin D via effective sun exposure has decreased; it can vary with time of exposure, amount of skin exposed, degree of air pollution and cloud cover, the time of day, latitude, season, sunscreen use, and skin pigmentation. Time spent indoors watching television or playing electronic games does not provide sun exposure.

Compared with individuals possessing a lighter complexion, those with heavily pigmented skin are less efficient in synthesizing vitamin D from sunlight. In addition, some African Americans are unable to digest the lactose in milk efficiently, which leads to a significant reduction in milk intake and consequently in vitamin D levels. The increase in reported cases of nutritional rickets prompted the American Academy of Pediatrics to issue new guidelines in 2003 recommending supplemental vitamin D for all breast-fed infants. However, this recommendation has not been universally adopted by pediatricians, which leaves concerns about the continued risks of vitamin D–dependent rickets in U.S. children.[58]

VITAMIN B_{12}

Vitamin B_{12} is one of the B-complex vitamins, and cobalt is present within the molecule, classifying it as the only vitamin containing a mineral element. Vitamin B_{12} is essential in producing red blood cells in the bone marrow and for myelin synthesis in the nervous system. B_{12} is thought to be present only in animal foods (meat, fish, eggs, and dairy products), and as a result, strict vegetarians are considered to be at risk for a dietary deficiency. Those suffering from anorexia nervosa and bulimia are also considered to be vulnerable to a deficiency.

Neurologic impairment resulting from a vitamin B_{12} deficiency has been reported in two children breast-fed by vegetarian mothers. In one of these cases, the diagnosis was made at 15 months, and vitamin B_{12} therapy was initiated. At age 28 months, the child's developmental skill levels ranged from 9 months for fine motor skills to 18 months for gross motor skills. Her expressive language was at a 10-month level.[59] Health care providers should be alert to the possibility of B_{12} deficiency under these circumstances. Plant foods fortified with this vitamin, such as selected cereals, meat analogues, soy or rice beverages, and nutritional yeast, can be reliable and regular sources.

Chronic vitamin B_{12} deficiency can result from a lack of the vitamin in the diet, and it can also be due to an autoimmune reaction in which intrinsic factor, a stomach protein required for the absorption of B_{12}, is not produced. The lack of intrinsic factor can result in a vitamin B_{12} anemia known as pernicious anemia, which is characterized by large, immature blood cells. Additional signs and symptoms of deficiency of this vitamin include pallor, dizziness, fatigue, weight loss, confusion, hypotension, and peripheral nerve degeneration. Oral manifestations of vitamin B_{12} deficiency include soreness of the soft tissues and atrophic glossitis.[60]

PEDIATRIC OVERNUTRITION

For the majority of children and adolescents in the United States today, negative health outcomes brought on by malnutrition are far more likely to be related to overconsumption of food, sodium, and calories than to deficiencies brought on by underconsumption of food and nutrients. In other words, the risk of a child suffering from type 2 diabetes related to obesity is considerably greater than that of getting scurvy brought on by insufficient vitamin C intake.

Perhaps the greatest current public health threat for our country is the increasing prevalence of overweight and obesity, which have ballooned during the last 3 decades of the twentieth century. This issue invariably leads to a lifelong struggle with body weight control issues, and the attendant increased risk for heart disease, cancer, and stroke. Until recently, this epidemic appeared to be continuing unabated.[61]

Simply stated, obesity results from a chronic imbalance between energy intake and energy expenditure, in which the former exceeds the latter. However, its increasing incidence is related to a complex array of genetic, environmental, psychosocial, biological, and economic factors. Obesity is traditionally defined as the excessive accumulation of fat in the body, whereas overweight means weighing more than is considered normal. These terms are often defined based on BMI. BMI is calculated by dividing the individual's weight in kilograms by the square of the height in meters. When BMI is plotted on age- and gender-appropriate growth charts, overweight individuals can be identified as those between the 85th and 95th percentiles for age and gender. It is clear that this mathematical calculation is rather complex and can best be determined online by means of a BMI calculator

values in children are shown in Table 8-3.

Dentlearn.ir

Table **8-3**

BMI values and standards for children

Value	Standard
<5th percentile	Underweight
5th to <85th percentile	Normal weight
85th to <95th percentile	Overweight
≥95th percentile	Obese

A major focus of the nationwide health promotion and disease prevention agenda in Healthy People 2010 was to reduce the proportions of children and adolescents who are overweight or obese. Unfortunately, current estimates are that 36% of U.S. adults are obese, whereas the corresponding value for children and adolescents is 17%.[63] This latter figure translates to roughly 12.5 million young individuals. The prevalence of overweight among children ages 6 to 11 has more than doubled in the past 20 years; the rate among adolescents has more than tripled.

However, several recent reports, including an article in the *Journal of the American Medical Association,*[64] have reported a significant reduction in obesity among 2- to 5-year-old children over the past decade. In this latter study, obesity was defined in children as a BMI > the 95th percentile of the gender-specific CDC BMI-for-age growth charts. In adults, obesity was defined as a BMI of 30 and above. A 43% drop in the obesity rate among 2- to 5-year-old children was an unexpected finding.

Several theories have been proposed to help explain this observation:

1. Children are consuming fewer calories provided as sugary beverages than they did 10 years ago.
2. More women are breast-feeding their infants, which is associated with a lower risk of obesity.
3. There has been a slight overall drop in calories ingested per capita in the past decade.
4. Some combination of state, local, and federal programs designed to reduce obesity is beginning to bear fruit.

Regarding the latter idea, First Lady Michelle Obama led an effort to alter young people's eating and exercise behaviors in a healthier direction. Some 10,000 child-care centers across the country have signed on, and numerous cities have also been striving to fight obesity by reducing sugary beverage ingestion and the use of transfats in restaurants. It is encouraging to see progress against obesity being demonstrated in 2- to 5-year-olds, since reversing unhealthy eating habits at a later age is difficult. However, a note of caution is necessary. Very young children comprise only a small fraction of the American population declines in obesity rates. For example, women over 60 years of age have shown an increase in obesity during the past decade. Nevertheless, if this trend continues in young children in America, and expands to the adult population, we can be more optimistic about ultimately reversing the obesity epidemic.

There are many consequences of obesity, both short- and long-term. An estimated 61% of overweight youth have at least one additional risk factor for heart disease, such as high cholesterol or high blood pressure. Overweight children are at greater risk for bone and joint problems, as well as obstructive sleep apnea, which has been observed in as many as one in six obese children. The latter condition can lead to daytime somnolence, neurocognitive abnormalities, and impaired learning. Because obese children tend to become obese adults, the potential impact of childhood obesity on the health care system is enormous. It has been suggested that the increased medical care costs associated with obesity may be greater than those associated with smoking and drinking alcohol.[65]

As overweight young people grow older, they are at increased risk for heart disease, type 2 diabetes mellitus, stroke, several types of cancer, and osteoarthritis. The current epidemic of type 2 diabetes escalating in children and adolescents is associated with obesity and a persistently elevated BMI. Roughly one of four obese children (aged 4 to 10 years) has been reported as glucose-intolerant.[66] This condition is a precursor to diabetes and is a generic term referring to metabolic conditions resulting in higher than normal (hyperglycemia) blood glucose levels. A sedentary lifestyle and obesity are associated with glucose intolerance.

Severe obesity has long been thought to reduce life expectancy. A recent report states that 20-year-old white men with a BMI greater than 45 (extreme obesity) are estimated to lose 13 years of life because of their body weight.[67] In spite of several decades of public health efforts to educate the population regarding the dangers of obesity, the trend toward progressively increasing body weight has not abated.

Aside from the obvious health risks associated with obesity in childhood and adolescence, there are also significant psychological and quality-of-life issues to be considered. Ackard and associates reported that objective overeating with loss of control in adolescents was associated with lower scores on measures of body satisfaction and self-esteem and higher scores regarding depressive mood.[68] Overeating was also associated with elevated risk of suicide. Thus objective overeating among adolescents is linked to several adverse behaviors and negative psychological experiences. It remains to be determined whether objective overeating is an early warning sign of psychological distress or, rather, a potential consequence of compromised psychological health.

Schwimmer and colleagues compared the health-related quality of life of obese children and adolescents with that of both their healthy (non-obese) counterparts and a cohort of children and adolescents diagnosed with cancer.[69] Quality-of-life ratings of severely obese children and adolescents were lower than those of healthy children and adolescents and similar to those of children and adolescents with cancer. An impaired self-image and perception of low quality of life in this population are not surprising, because obesity is one of the most stigmatizing and least socially acceptable conditions in childhood. These and similar findings emphasize how critical it is for health professionals, teachers, and parents to be aware of not only the medical risks of obesity in children but also the potential psychological significance of this condition.

The eating environment existing in contemporary America often promotes the intake of convenient, relatively inexpensive, highly palatable foods served in large portions.[70] As previously mentioned, this type of eating pattern from childhood through adult life contributes to obesity as well as diabetes, hypertension, coronary heart disease, and certain types of cancer. Regrettably, the factors contributing to future obesity are thought to begin in infancy and early childhood.[71] Since these diseases only become evident during adulthood, in spite of having their origins in childhood and adolescence, they provide the health care professional with a potential avenue for preventive medicine. Early intervention approaches ing patterns. Atherosclerotic heart disease is such a case. Modifiable risk factors can be identified and addressed in the pediatric population, with the goal of preventing or ameliorating heart disease in later life. Thus prevention of coronary heart disease is a pediatric health issue, as is prevention of the other diseases mentioned earlier.

Epidemiologic studies have identified a web of factors that can contribute to the obesity epidemic in U.S. children and adolescents. These influences exist at the individual, family, community, and societal levels. They include changing meal environments, increased TV viewing and video game playing, food availability, less parental leisure time, changes in suburbia that discourage physical activity, increased concern over neighborhood safety, increased advertising and availability of high-fat, calorie-dense fast food, changes in parental work patterns, increased need for child care, and increased utilization of labor-saving devices (e.g., cars, computers, smart phones, etc.). Because the problem is multifactorial, solutions should target multiple factors. An extensive review of the literature by Wofford clearly identified the preschool years as a critical time to intervene in obesity prevention. Parental involvement and a role by health care practitioners in emphasizing recommendations were vital to successful interventions. In addition, prevention strategies should focus on building positive, healthy behaviors that produce more satisfactory long-term results than do strategies that focus on limiting behaviors.[72]

A classic research study showed that the prevalence of obesity is lowest among children watching less than one hour of television a day and highest among those watching 4 or more hours a day.[73] Not only will sedentary children expend less energy, but they will also invariably be increasing their consumption of high-fat, high-sugar, high-calorie snack foods during these sedentary periods.[74] Research from roughly two decades ago indicates that food (typically a sweet snack) is consumed or referred to 3-5 times per half hour on prime-time programming.[75] Additionally, the majority of commercials shown during children's programming promote foods with low nutritional value, including candy, soft drinks, sugared cereals, and potato chips, as well as other high-salt, high-fat snacks.[76]

Any effort to attack the obesity problem should focus not only on making better food choices but also on increasing physical activity levels, which increases energy use and helps achieve a healthy weight. Exercise promotes both physical health and emotional well-being. How much and how often you exercise is a major determinant of both morbidity and mortality. It has been identified as a national priority area for promoting the health of the U.S. population.[77] However, many children and adolescents do not meet the recommendations for physical activity. This fact is particularly sobering because the adolescent years are thought to be the period during which adult health-related behaviors such as dietary and physical activity patterns are being shaped. Childhood is likely to be a critical time for promoting physical activity. In 2005 the Centers for Disease Control and Prevention reported that only 27.8% of high school girls and 43.8% of high school boys participated in at least 60 minutes of physical activity per day. A comparable report for 2011[78] showed that this figure had fallen to 18.5% for girls and 38.3% for boys.

Walking as a means of transportation is a component of an active lifestyle associated with a reduced risk of chronic diseases and an increased sense of well-being; however, time spent walking has declined among U.S. children. One of the objectives of Healthy People 2010 was to increase the proportion of walking trips to school from 31% to 50% among children and adolescents. In 1969 approximately half of all U.S. schoolchildren walked or biked to and from school; of those living within 1 mile of school, 87% walked or biked to school. By 2004 fewer than 15% of children used an active mode of transportation. In 2004 the CDC reported the results of a Consumer Styles survey of parents that cited distance to school as the most common barrier to walking to school, followed by traffic-related dangers.[79] The reduction in total physical activity that occurs from mid- to late adolescence appears to be related more to a reduction in the number of activities in which adolescents choose to participate than to a decline in the time spent on each activity.[80] This finding supports other evidence that physical activity declines during adolescence.

According to the Dietary Guidelines for Americans, 2010, it is recommended that children and adolescents participate in at least 60 minutes of moderately intense physical activity most days of the week, preferably daily. For youth, regular physical activity has beneficial effects on weight, muscular strength, cardiorespiratory fitness, bone mass, blood pressure, anxiety, and self-esteem. Walking programs are being increasingly promoted for youth in selected school systems. Many of these programs are using pedometers to register the number of steps being taken. These small units, which clip onto waistbands, resemble tiny pagers and are reasonably accurate in counting all the steps taken over a given period of time. For some programs, the goal is to reach 12,000 steps per day, but for all the programs, a general objective is to motivate the person wearing the pedometer to progressively increase the step count over time and to maintain a minimally acceptable level of steps per day.

HEALTH IMPACT OF HIGH SALT INTAKE

When we consider the issue of overnutrition and how it might relate to health problems, sodium intake generally emerges as an important topic for consideration. More

Dentlearn.ir

specifically, we question whether children and adolescents are consuming too much sodium from dietary salt and initiating a behavior of eating that will be problematic during their lifetime. According to a recent study,[81] the answer is likely to be "yes." This team of researchers monitored the eating habits of more than 760 high school adolescents for a week. They observed that these teenagers were ingesting as much dietary salt as were their adult counterparts, an amount far exceeding guidelines for good health. On average, the teenagers were taking in almost 3300 mg sodium each day, an amount more than double the 1500 mg currently recommended by the American Heart Association.[82]

An additional finding of the research was that a direct link existed between the high levels of salt intake and an increased risk for overweight and obesity. Previous studies[83,84] have shown that salt typically promotes the desire to drink more sugary sodas and consume more calories, thereby providing a potential mechanism for weight gain.

An elevated sodium intake has often been cited as being associated with an increase in blood pressure, raising hypertension rates and the risk for heart disease and early death.[85] It has also been suggested that by significantly reducing the average daily intake of sodium, the general population could enjoy improved health.

From a dental health perspective, the increased desire for sugary beverage consumption, triggered by a high-salt diet, could contribute to dental caries and other harmful effects. Several strategies to offset these kinds of adverse oral effects from high-salt diets would be to read food labels carefully and not choose those with high sodium content, not to add salt to food via the saltshaker, and to select fresh fruits and vegetables as food choices whenever possible.

FEEDING AND EATING DISORDERS

Physical appearance is of prime importance for most teenagers, and for some adolescent girls in particular, getting "thin enough" can become an obsession. It is estimated that 20 million women and 10 million men suffer from a clinically significant eating disorder such as anorexia nervosa, bulimia nervosa, or binge-eating disorder at some point during their lifetime.[86] Because women and men are often secretive about their eating disorders, existing epidemiologic studies may underestimate the true prevalence of these conditions.[87] Some personality traits, such as perfectionism and obsession with weight and body dissatisfaction, may cluster in families of women with eating disorders. Perfectionism may be an environmental or genetic factor.[88,89]

Disordered eating is a term that includes a full spectrum of unhealthy eating behaviors from inappropriate dieting to clinical eating disorders.[90] The mass media are viewed by many as major contributors in influencing disordered eating behaviors in young people through the presentation of often unattainable physical images and emphasis on the "thin ideal."[91]

Analyses of body measurements of 500 models listed on modeling agency websites and in adult magazines over a 12-year period showed that nearly all the centerfolds and three fourths of the models had BMIs that approximated the American Psychological Association's criteria for anorexia nervosa.[92] Although boys may be increasingly influenced by the portrayals of muscular men in the media, most research has focused on the effects of media portrayals on girls' eating and dietary habits. Teenage girls are most at risk for developing eating disorders as they struggle with bodies that are getting larger in a culture that simultaneously attempts to sell them junk food and tells them that they should be thin. A study by Field found that more than 10% of adolescent girls and 3% of boys binge-eat or purge at least once a week. Risk factors for these disordered eating behaviors included frequent dieting, concerns about weight, and in girls younger than 14 years, maternal history of an eating disorder.[93]

Research has shown that being overweight in childhood is a risk factor for disordered eating, and both are risk factors for full-syndrome eating disorders. Shape and weight concerns appear to be elevated in overweight children and teenagers, especially in white girls. Up to 79% of overweight youth report unhealthy weight control behaviors, and up to 17% report extreme weight control behaviors such as self-induced vomiting or laxative or diuretic abuse.[94]

A study of risk factors for eating disorders, conducted

adolescent girls, found that body dissatisfaction, nega-

ideal, and dieting were significant predictors of eating disorder development. Findings indicated that although eating disorders tend to manifest in late adolescence, most of these risk factors assessed are present much earlier, and that body dissatisfaction appears to present in advance of any perceived pressure to achieve an ideal thinness.[95] Unlike the findings of others,[96] this study determined that BMI was not a predictor for eating disorder development up to age 21, which led the authors to suggest that subjective dissatisfaction with body shape and size, rather than actual levels of adiposity, might be a more important factor in the appearance of eating disorders.[95] Likewise, analysis of data from the National Longitudinal Study of Adolescent Health, a large nationally representa-

dieting, depression, and body image distortion were associated with eating disorders in young adulthood. Prevalence of eating disorders among the males and females in

mon being binge eating. Dieting was reported by 27% of females and 11% of the males.[97]

Considering the high prevalence of weight-related concerns and body dissatisfaction among young people in the United States, it would be prudent to aim appropriate interventions at all youth.

ANOREXIA NERVOSA

Preoccupation with appearance and body weight during adolescence may lead to anorexia nervosa, a condition of self-induced starvation. Anorexia may be of the restrictive type, in which food intake is severely limited, or of the binge-eating/purging type, in which individuals engage in self-induced vomiting or the misuse of laxatives,

Dentlearn.ir

diuretics, or enemas. This illness, which is much less common in males and is also less common than bulimia nervosa, is characterized by self-imposed weight loss, amenorrhea, and a distorted attitude toward eating and body weight. In some instances this behavior is used as a means of establishing a sense of identity and control. Anorexia nervosa has captured the interest of psychoanalysts, behavior therapists, family therapists, nutritionists, and endocrinologists alike because of the interplay among the powerful psychological, environmental, genetic, and physiologic components of the disease. Anorexia nervosa rarely begins before puberty and probably is manifest across a wide range of severity levels. Affected individuals often lack the ability to recognize that their emaciated bodies are too thin. Despite their advanced state of wasting, they may continue to believe that they are overweight. According to DSM-5, the three diagnostic criteria for anorexia nervosa are the following[98,99]:

- Persistent restriction of energy intake leading to significantly low body weight (in context of what is minimally expected for age, gender, developmental trajectory, and physical health)
- Either an intense fear of gaining weight or of becoming fat, or persistent behavior that interferes with weight gain (even though significantly low in body weight)
- Disturbance in the way one's body weight or shape is experienced, undue influence of body shape and weight on self-evaluation, or persistent lack of recognition of the seriousness of the current low body weight

A wide range of complications, including many of the consequences of starvation, is possible in anorexia nervosa. Fat depletion is the most obvious physical consequence. Qualitative deficiencies in the diet may lead to anemia, hypoproteinemia, and sometimes vitamin deficiencies. Serious electrolyte imbalances, notably hypokalemia, can occur when vomiting or laxative or diuretic abuse is practiced. Anorexia may be accompanied by enlargement of the parotid glands, edema of the legs, increased facial hair, and reductions in blood pressure and pulse rate. Nutritional deficiencies may lead to glossitis, gingivitis, a reduction in the amount and pH of the saliva, and an increase in dental caries susceptibility. Dental erosion may be evident on the palatal aspects of anterior and posterior teeth (perimolysis) secondary to the use of sports drinks, caffeinated/carbonated drinks, wine, vinegar, and lemon juice used to quell sensations of hunger. Anorexics who engage in self-induced vomiting may exhibit epithelial erosion, gingivitis, and dental erosion on the palatal surfaces of the maxillary anterior teeth.[98]

Long-term studies have demonstrated diverse outcomes ranging from full recovery to chronicity and death. Outpatient treatment is preferred for most individuals. Treatment is typically multidisciplinary and involves medical, nutritional, social, and psychological components.[100] If the illness is severe and family and environmental circumstances are too damaging, or if there is little response to outpatient treatment, then hospitalization is indicated. Fluoxetine hydrochloride appears to help control the obsessive-compulsive behavior involved in both anorexia nervosa and bulimia. This drug raises the brain levels of serotonin, and as a consequence, the urge to binge and the preoccupation with food appear to lessen.

BULIMIA

Another eating disorder, bulimia nervosa, is characterized by binge eating and invariably by self-induced vomiting. It also is more prevalent in young women and is more common than is anorexia nervosa. It usually begins during late adolescence or early adult life. Its prevalence among males is probably vastly underestimated because of underreporting. The American Psychiatric Association's diagnostic criteria for bulimia nervosa are the following[99]:

- Eating, in a discrete period of time (e.g., within any 2-hour period), an amount of food that is definitely larger than what most individuals would eat in a similar period of time under similar circumstances
- A sense of a lack of control over eating during the episode (e.g., a feeling that one cannot stop eating or control what or how much one is eating)
- Recurrent inappropriate compensatory behaviors to prevent weight gain, such as self-induced vomiting; misuse of laxatives, diuretics, or other medications; fasting; or excessive exercise
- The binge-eating and compensatory behaviors both occur, on average, at least once a week for 3 months.
- Self-evaluation is unduly influenced by body shape and weight.
- The disturbance does not occur exclusively during episodes of anorexia nervosa.

Although it is more medically benign than anorexia nervosa, bulimia nervosa is associated with significant health consequences. Approximately half of patients with this disorder have fluid and electrolyte abnormalities. Hypokalemia develops in a small percentage. Enlargement of the parotid glands, esophagitis, and gastric necrosis may also occur. Because of the exposure of the tooth surfaces to the highly acidic regurgitated gastric contents, enamel erosion is common among patients with bulimia nervosa. The degree of enamel damage can be extensive. Although unanimity of opinion does not exist, the suggestion has been made that toothbrushing after vomiting actually promotes enamel loss and that, instead, patients should be instructed to rinse with an alkaline solution such as sodium bicarbonate dissolved in water. Other suggestions include the use of liquid sugar-free antacids, water, or milk. A fluoride treatment should be considered because of its potential for remineralizing previously demineralized areas of the dentition. Daily rinses with 0.5% sodium fluoride and administration of a 1.1% neutral fluoride gel in custom trays can be recommended.

Most bulimic patients can be treated effectively as outpatients. Although antidepressant medications may be useful in some cases, a multidisciplinary approach to treatment is often indicated.[100] There is some evidence that individuals, particularly girls, who have family meals in a positive atmosphere are at lower risk for bulimia.

Dentlearn.ir

Family meals may serve a protective function against disordered eating as well as other problems by acting as a forum for working through various issues.[101]

BINGE-EATING DISORDER

Within the *Diagnostic and Statistical Manual,* Fifth Edition (DSM-5), released in 2013, binge-eating disorder achieved official diagnostic recognition. The essential feature of binge-eating disorder is recurrent episodes of binge eating that must occur, on average, at least once per week for three months. It is defined by the consumption of excessive amounts of food along with the sensation of loss of control. The following are the DSM-5[99] criteria for this disorder:

- Recurrent episodes of binge eating. A recurrent episode is characterized by both of the following:
  - Eating in a discrete period of time (e.g., within any 2-hour period) an amount of food that is definitely larger than what most people would eat in a similar period of time and under similar circumstances.
  - A sense of a lack of control over eating during the episode (e.g., a feeling that one cannot stop eating or control what or how much one is eating).
- The binge-eating episodes are associated with three or more of the following:
  - Eating much more rapidly than normal
  - Eating until feeling uncomfortably full
  - Eating large amounts of food when not feeling hungry
  - Eating alone because of feeling embarrassed by how much one is eating
  - Feeling disgusted with oneself, depressed, or very guilty afterward
- Marked distress regarding binge eating is present.
- The binge eating occurs, on average, at least once a week for 3 months.
- The binge eating is not associated with the recurrent use of inappropriate compensatory behavior as in bulimia nervosa and does not occur exclusively during the course of bulimia nervosa or anorexia nervosa.

Patients with binge-eating disorder may be treated as outpatients in a multidisciplinary manner. In overweight patients with binge-eating disorder, the goals include achieving a sustainable weight loss and abstaining from binge eating. Pharmacotherapy with antidepressants and selective serotonin reuptake inhibitors has been used. Other classes of medications, such as antiobesity drugs and anticonvulsants, have also been studied and have shown some success. Psychotherapy in the form of cognitive-behavioral therapy has been a popular approach, and other modalities, such as exercise, self-help, and virtual reality therapy, have also been tried as adjunctive therapies for binge-eating disorder. Furthermore, some studies indicate that there may be a benefit to combined behavioral therapy and pharmacotherapy in the treatment of binge-eating disorder; however, more research is needed for a better understanding of the long-term effects of these treatments. As health care professionals deal with eating disorders in their patients, they recognize that primary prevention combined with early detection and treatment clearly helps reduce morbidity and mortality in affected youth.[100]

Q & A CONCERNING PEDIATRIC NUTRITION ISSUES

Why is a nutritious breakfast important to begin the day?

Examined from a nutrient density perspective (nutrients provided per calorie), breakfast is generally the most important meal of the day; however, 40% of children and teenagers in America are thought to skip breakfast. Those who skip it are literally on an unintended 36-hour fast until lunchtime, and are observed to suffer from more physical, intellectual, and behavioral problems compared with those who eat a nutritious breakfast. Eating a healthy breakfast is associated with improved cognitive function, memory, reduced tardiness, and improved mood.

Is a vegetarian diet healthy for children?

Since plant-based foods are generally quite nutritious, a vegetarian diet can be healthful if well planned. An important question is what food items will replace the meat. If primarily legumes, beans, nuts, and soy products, there should be no protein inadequacy. If primarily cheese and whole milk, then there may be concerns over excess calories and saturated fat intake. Planning exclusively vegetarian diets will require careful consideration on how to receive adequate intakes of protein, iron, and vitamin B_{12}.

Are changes in store for food and nutrition labeling practices?

The Food and Drug Administration is proposing significant changes in food and nutrition labels for the first time since such labels became mandatory some 20 years ago. If the modifications are accepted, calories will appear in larger and bolder type, the consumer will be able to discern if the food product contains added sugar, and serving sizes will be adjusted upward to reflect more accurately the amounts that Americans are actually consuming. These changes are scheduled in the future and are being considered because current food labeling is thought by many as both outdated and difficult to understand.

Why is healthy eating so important in childhood and adolescence?

Ingesting nutritious foods early in life initiates an eating behavior that conveys protection against obesity, diabetes, and dental caries currently and later in life. Continuing to follow these patterns of eating over a lifetime is associated with a reduction in risk for heart disease, cancer, osteoporosis, hypertension, stroke, and early death. There are emotional and psychological benefits to be gained as well.

What are the major concerns regarding unhealthy eating during childhood?

Eating too few nutrients and calories in childhood will ultimately negatively affect growth, performance in school, cognitive development, and overall health. In contrast, overconsumption of fast food, processed snack foods, and sugar-sweetened beverages will invariably lead to weight gain, overweight, obesity, and an increased risk of diabetes, and may increase the risk for dental caries.

What would a child's ideal dinner plate look like?

Ideally, half the food on a child's plate would be fruits and vegetables. Protein would be provided largely by lean meats, nuts, and eggs. High-fiber whole-grain breads and cereals would be served in lieu of refined grains. Fried

Dentlearn.ir

foods would be limited, and milk and water would be offered instead of sugary fruit drinks and sodas. Of course, many children would not select such a plate voluntarily. This is where parents or guardians must help guide the children's food selections in a logical and loving manner.

What are harmful dietary fats?

Researchers agree that there are two major types of fat detrimental to health: saturated fat and fats containing transfatty acids. Saturated fat comes primarily from animal foods such as meat, poultry, and certain dairy products. A high intake of this kind of fat increases LDL cholesterol levels and elevates the risk for cardiovascular disease. Most transfatty acids in our diet come as a result of a food manufacturing process known as hydrogenation, in which unsaturated fat is partially hydrogenated to enhance consumer properties. These latter fatty acids also increase blood levels of LDL cholesterol and increase the risk for cardiovascular disease. The U.S. Food and Drug Administration has recently proposed a regulatory change that would essentially ban artificial transfats from the American diet by no longer considering them as "generally recognized as safe."

What are considered as healthful dietary fats?

Monounsaturated fat is found in vegetable oils, fruits, nuts, legumes, and fish, and has been reported to lower blood cholesterol and help reduce the risk of heart diseases. This type of fat may also help regulate blood insulin and glucose levels and be of benefit for persons with type 2 diabetes. Polyunsaturated fat is primarily found in plant-based foods such as vegetable oils. These oils are thought to improve blood cholesterol levels, thereby lessening the risk of heart disease. Omega-3 fatty acids appear to be of particular benefit in preventing heart disease. These healthful fatty acids are primarily found in fatty, cold water fish and fish oils. They are present in plant oils as well, but it is less certain if that source is as effective in promoting heart health as are fish oils. Omega-3 fatty acid supplements are not thought to be as beneficial as those from natural food sources.

Do healthy children need vitamin supplements?

Foods that we consume contain essential vitamins, minerals, protein, fiber, phytochemicals, and other beneficial chemicals whose roles in human nutrition have not yet been fully identified. Nutritional supplements do not contain this range of essential nutrients present within the natural environment of a food substance. Vitamin and other supplements are not intended to serve as food substitutes. Children should be encouraged and helped to receive their nutrients from foods, rather than from nutritional supplements.

Are there foods that fight flu and colds?

There are neither specific foods nor nutrients that can either prevent or cure a cold or influenza. However, some evidence suggests that there are strategies to help strengthen the immune system and aid in resisting these illnesses. Examples include getting plenty of sleep, participating in regular exercise, keeping well hydrated, and minimizing stress. The foods that may help in this endeavor by contributing protective substances include green leafy vegetables, highly pigmented vegetables and fruits, citrus fruits, vegetable oils, nuts, whole grains, and seafood. This diverse collection of foods provides high levels of nutrients such as beta-carotene, vitamin A, vitamin C, vitamin E, assorted other antioxidants, and the minerals zinc and selenium, all of which may fortify the immune system.

Are fruit drinks and juices healthy for children?

Most children enjoy the taste of fruit juices but may drink them in excess to the exclusion of other more nutritious foods. Many fruit drinks are high in added sugar and calories, and even 100% fruit and vegetable juices are often highly acidic. The outcome of this may be the intake of too much sugar and calories, thus contributing to such problems as poor overall nutritional quality of the diet, obesity, as well as enamel erosion and dental caries. Far more acceptable dietary choices than fruit drinks and juices are whole fruits, low-fat dairy, or water.

Are meal replacement shakes and smoothies good snack choices for children and adolescents?

The consumption of fruit-/vegetable- or protein-based smoothies and shakes has become popular in recent years. These products are often high in acid, sugar, and fermentable carbohydrates. If kids and teenagers are consuming such meal replacement beverages multiple times per day as snacks, the amount of time the oral cavity is exposed to a reduction in pH is increased, which increases the risk of demineralization, enamel erosion, and dental caries. More healthful choices would include non-cariogenic snacks of solid foods such as nuts, cheese, popcorn, milk, yogurt, and raw vegetables.

Are diet sodas and sports/energy drinks harmful to children and adolescents?

Diet sodas are popular among children and teenagers and are perceived as healthier than sugared beverages; in addition, they are often used by youth concerned about gaining weight. Sports and energy drinks are also marketed as "healthy" alternatives to regular soda and as a means to obtain better physical performance or maintain alertness. The American College of Sports Medicine recommends consumption of adequate food and fluids before, during, and after exercise to help maintain blood glucose during exercise, maximize performance, and improve recovery time; consumption of sport drinks containing carbohydrates and electrolytes during intense exercise periods lasting longer than 1 hour may be helpful in refueling muscles and decreasing the risk of dehydration. However, for shorter exercise periods, consumption of plain water is recommended. The so-called energy drinks are often high in caffeine, and adverse cardiovascular events have been reported with their use in some individuals. Moreover, these beverages are often highly acidic and can cause dissolution of tooth enamel.

Additionally, although diet sodas do not contain sugar, sports and energy drinks often do, and whether they contain sugar or not, excessive consumption of any of these beverages can be harmful to oral health. These beverages contain acids such as phosphoric and citric acid, which can contribute to enamel erosion and dental caries, particularly if the consumer sips on these products throughout the day.

How common are food allergies?

It is estimated that 3% to 4% of the American population is affected by food allergies, generally affecting the digestive or respiratory system or the skin. True food allergies have

Dentlearn.ir

a sudden onset and occur whenever the offending food is eaten. The most common culprits are nuts, fish or shellfish, milk, eggs, soy, and wheat, with symptoms ranging from mild to potentially life threatening. They are caused by an allergic response by the immune system to a food component, mistakenly thought to pose a threat to the body. The resulting biologic reaction against the allergen produces the symptoms. In contrast, food intolerances have a more gradual onset, are generally less severe, and do not have a fatal outcome. These food sensitivities are usually produced by stomach irritation and improper food digestion. Lactose-intolerance is probably the most common food intolerance. Gluten may produce either an allergic response or a sensitivity reaction. Once the offending food allergen has been identified, the primary treatment is to remove that item from the diet permanently. Food intolerances can be treated more easily. Simply reducing the quantity of the offending food that is eaten, and also the frequency of its ingestion, can alleviate most symptoms.

Is the gluten in foods a common problem for children and adolescents?

Gluten is a mixture of proteins found in foods processed from wheat and other grains. Roughly 1% of the U.S. population suffers from celiac disease, which is an autoimmune disease of the small intestine in which the individual is intolerant to gluten in the diet. Those affected generally exhibit a broad range and severity of intestinal symptoms. Perhaps 6% of the population may be affected by non-celiac gluten intolerance/sensitivity, which is usually a less severe gastrointestinal condition and does not fall into the conventional autoimmune disease category. These ailments are often helped by avoiding gluten in the diet, which is sometimes a difficult task to accomplish in view of the rather ubiquitous distribution, albeit at low concentrations, of gluten in a variety of food products. An important first step for sufferers is to receive an accurate diagnosis from a physician to determine the best treatment approach.

Are there any "addictive" foods?

An addiction is simply defined as a powerful and harmful need to have regular access to something (such as a drug) or participate in an activity (such as gambling). The definition becomes less clear when applied to food addictions. Some scientists feel that certain foods behave similarly to addictive drugs and cause a release of "feel good" chemicals in the brain when they are eaten. Others disagree, insisting that overeating is basically an emotional problem, not one of an addiction. A few studies have identified chocolate, sugar, and cheese as likely suspects in the addictive foods category. All three have been demonstrated at times to promote the release of opiate-like substances that stimulate the brain's pleasure center and promote the eating of these foods frequently and compulsively.

REFERENCES

1. Hoyert D, et al.: Deaths: Preliminary Data for 2011, *National Vital Statistics Reports* 61(6):1–51, Oct 10, 2012.
2. Samieri C, et al.: The association between dietary patterns at midlife and health in aging, *Ann Intern Med* 159(9): 584–591, 2013.
3. *CIA World Fact Book*, World Life Expectancies, 2011.
4. U.S. Department of Health and Human Services: Nutrition

   default.aspx, 2014.
5. U.S. Department of Health and Human Services. Office of Dis-

   .health.gov/dietaryguidelines/2010.asp.
6. United States Department of Agriculture (USDA). http://choosemyplate.gov.
7. Briefel RR, Johnson CL: Secular trends in dietary intake in the United States, *Annu Rev Nutr* 24:401–431, 2004.
8. ADA Reports: Position of the American Dietetic Association: dietary guidance for healthy children ages 2-11 years, *J Am Diet Assoc* 104(4):660–667, 2004.
9. Enns CW, Mickle SJ, Goldman JD: Trends in food and nutrient intakes by children in the United States, *Fam Econ Nutr Rev* 14(2):56–68, 2002.
10. Fulgoni EL, Quann EE: National trends in beverage consumption in children from birth to 5 years: analysis of NHANES across three decades, *Nutr J* 31:11–92, 2012 Oct.
11. Han E, Powell LM: Consumption patterns of sugar-sweetened beverages in the United States, *J Acad Nutr Diet* 113(1):43–53, 2013.
12. Dubois L, et al.: Regular sugar-sweetened beverage consumption between meals increases risk of overweight among preschool-aged children, *J Am Diet Assoc* 107(6):924–935, 2007.
13. Hu FB: Resolved: there is sufficient scientific evidence that decreasing sugar-sweetened beverage consumption will reduce the prevalence of obesity and obesity-related diseases, *Obes Rev* 14(8):606–609, 2013.
14. Kosova EC, Auinger P, Bremer AA: The relationships between sugar-sweetened beverage intake and cardiometabolic markers in young children, *J Acad Nutr Diet* 113(2): 219–227, 2013.
15. Slining MM, Mathias KC, Popkin BM: Trends in food and beverage sources among US children and adolescents: 1989-2010, *J Acad Nutr Diet* 113(12):1683–1694, 2013.
16. Reedy J, Krebs-Smith SM: Dietary sources of energy, solid fats, and added sugars among children and adolescents in the United States, *J Am Diet Assoc* 110(10):1477–1484, 2010.
17. Ford CN, Slining MM, Popkin BM: Trends in dietary intake among US 2- to 6-year-old children, 1989-2008, *J Acad Nutr Diet* 113(1):35–42, 2013.

    equacy in adolescent girls, *Nutrients* 4(11):1692–1708, 2012.
19. Iannotti RJ, Wang J: Trends in physical activity, sedentary behavior, diet, and BMI among US adolescents, 2001-2009, *Pediatrics* 132(4):606–614, 2013.
20. USDA: Food and Nutrition Service National School Lunch

    /default/files/NSLPFactSheet.pdf Accessed March 2014.
21. Briefel RR, Wilson A, Gleason PM: Consumption of low-nutrient, energy-dense foods and beverages at school, home, and other locations among school lunch participants and nonparticipants, *J Am Diet Assoc* 109(2 Suppl):S79–S90, 2009.
22. Clark MA, Fox MK: Nutritional quality of the diets of US public school children and the role of the school meal programs, *J Am Diet Assoc* 109(2 Suppl):S44–S56, 2009.
23. Grimes CA, et al.: Dietary sodium intake is associated with total fluid and sugar-sweetened beverage consumption in US children and adolescents aged 2-18 y: NHANES 2005-2008, *Am J Clin Nutr* 98(1):189–196, 2013.
24. Ohri-Vachaspati P, Turner L, Chaloupka FJ, Fruit Fresh, Vegetable: Program participation in elementary schools in the United States and availability of fruits and vegetables in school lunch meals, *J Acad Nutr Diet* 112(6):921–926, 2012.

25. Evans CE, et al: Systematic review and meta-analysis of school-based interventions to improve daily fruit and vegetable intake in children aged 5 to 12 y, *Am J Clin Nutr* 96(4):889–901. Epub 2012 Sep 5.
26. Guthrie JF, Lin BH, Frazao E: Role of food prepared away from home in the American diet, 1977-78 versus 1994-96: changes and consequences, *J Nutr Educ Behav* 34(3):140–150, 2002.
27. Poti JM, Popkin BM: Trends in energy intake among US children by eating location and food source, 1977-2006, *J Am Diet Assoc* 111(8):1156–1164, 2011.
28. Powell LM, Nguyen BT: Fast-food and full-service restaurant consumption among children and adolescents: effect on energy, beverage, and nutrient intake, *JAMA Pediatrics* 167(1):14–20, 2013.
29. Larson N, et al.: Eating breakfast and dinner together as a family: associations with sociodemographic characteristics and implications for diet quality and weight status, *J Acad Nutr Diet* 113(12):1601–1609, 2013.
30. Lachat C, et al.: Eating out of home and its association with dietary intake: a systematic review of the evidence, *Obes Rev* 13(4):329–346, 2011.
31. Bezerra IN, Curioni C, Sichieri R: Association between eating out of home and body weight, *Nutr Rev* 70(2):65–79, 2012.
32. Young L, Nestle M: Expanding portion sizes in the U.S. marketplace: implications for nutrition counseling, *J Am Diet Assoc* 103(2):231–234, 2003.
33. Piernas C, Popkin BM: Increased portion sizes from energy-dense foods affect total energy intake at eating occasions in US children and adolescents: patterns and trends by age

    Am J Clin Nutr 94(5):1324–1332, 2011.
34. Larson N, Story M: A review of snacking patterns among children and adolescents: what are the implications of snacking for weight status? *Child Obes* 9(2):104–115, 2013.
35. Koletzko B, Toschke AM: Meal patterns and frequencies: do they affect body weight in children and adolescents? *Crit Rev Food Sci Nutr* 50(2):100–105, 2010.
36. Wansink B, van Kleef E: Dinner Rituals that correlate with child and adult BMI, *Obesity (Silver Spring)*, 22(5):E91–E95, 2014. (doi: 10.1002/oby.20629). Epub 2013 Dec 19.
37. Berge JM, et al.: Structural and interpersonal characteristics of family meals: associations with adolescent body mass index and dietary patterns, *J Acad Nutr Diet* 113(6):816–822, 2013.
38. Neumark-Sztainer D, et al.: Changes in the frequency of family meals from 1999 to 2010 in the homes of adolescents: trends by sociodemographic characteristics, *J Adolesc Health* 5(2):201–206, 2012.

    .org/programs/health/healthtipsmalnutrition.htm. Accessed March 10, 2013.
40. Knol LL, Haughton B, Fitzhugh EC: Dietary patterns of young, low-income US children, *J Am Diet Assoc* 105(11):1765–1773, 2005.
41. United States Department of Agriculture Economic Re-

    .gov/topics/food-nutrition-assistance/food-security-in-the-us.aspx#.Ux87hoWwXwo. Accessed March 8, 2014.
42. Coleman-Jensen A, Nord M, Singh A: Household Food Security in the United States in 2012, Table 1B.USDA ERS,

    facts/child-hunger-facts.aspx#_edn10.
43. Ryu JH, Bartfeld JS: Household food insecurity during childhood and subsequent health status: the early childhood longitudinal study—kindergarten cohort, *Am J Public Health* 102(11):e50–e55, 2012.
44. McLaughlin KA, et al.: Food insecurity and mental disorders

    Adolesc Psychiatry 51(12):1293–1303, 2012.
45. Franklin B, et al.: Exploring mediators of food insecurity and obesity: a review of recent literature, *J Community Health* 37(1):253–264, 2012.
46. Metallinos-Katsaras E, Must A, Gorman K: A longitudinal study of food insecurity on obesity in preschool children, *J Acad Nutr Diet* 112(12):1949–1958, 2012.
47. The Third School Nutrition Dietary Assessment Study: Findings and Policy Implications for Improving the Health of U.S. Children, *J Am Diet Assoc* 109(Suppl):S1–S136, 2009.
48. Kids and Vitamin D Deficiency: American Academy of Pediatrics, Online publication, Oct 17, 2012.
49. Black M: Effects of vitamin B_{12} and folate deficiency on brain development in children, *Food Nutr Bull* 29(2 Suppl): S126–S131, 2008. NIH Public Access.
50. Baker R, Greer F: Diagnosis and prevention of iron deficiency and iron-deficiency anemia in infants and children (0-3 years of age), *Pediatrics* 126(5):1040–1050, 2010.
51. Kurugol Z, et al.: The prophylactic and therapeutic effectiveness of zinc sulphate on common colds in children, *Acta Paediatr* 95(10):1175–1181, 2006.
52. Singh M: Zinc for the common cold, *Cochrane Database Syst Rev* 6:CD001364, 2013.
53. Briefel R, et al.: Zinc intake of the US population: findings from the third national health and nutrition examination survey, 1988-1994, *J Nutr* 130(5 Supplement):1367–1373S, 2000.
54. Keye E: Bone health and oral health, *J Sch Health* 77(10): 701–705, 2007.
55. Patrick R, Ames B: Vitamin D hormone regulates serotonin synthesis. Part 1: relevance for autism, *FASEB J* Online pub, Feb 20, 2014.
56. Weng F, et al.: Risk factors for low serum 25-hydroxyvitamin D concentrations in otherwise healthy children and adolescents, *Am J Clin Nutr* 86(1):150–158, 2007.
57. Cushman K, et al.: Low vitamin D status adversely affects bone health parameters in adolescents, *Am J Clin Nutr* 87(4):1039–1044, 2008.
58. Vitamin D: Supplements for Infants, American Academy of Pediatrics, March, 2010. On-line reference.
59. Neurologic impairment in children associated with maternal dietary deficiency of cobalamin—Georgia, 2001, *MMWR Morb Mortal Wkly Rep* 52(4):61–64, 2003.
60. Palmer C: Vitamins today. In *Diet and nutrition in oral health*, ed 2, New Jersey, 2007, Prentice Hall. (Chapter 9.)
61. Centers for Disease Control and Prevention. 1600 Clifton Road Atlanta, GA 30329-4027, USA.
62. Centers for Disease Control and Prevention, National Center for Health Statistics. Centers for Disease Control and Prevention 1600 Clifton Road Atlanta, GA 30329-4027 USA.
63. Centers for Disease Control and Prevention 1600 Clifton Road Atlanta, GA 30329-4027 USA. Available at: http://

64. Ogden CL, et al.: Prevalence of childhood and adult obesity in the United States, 2011-2012, *J Am Med Assoc* 311(8): 806–814, 2014.
65. Sturm R: The effects of obesity, smoking, and drinking on medical problems and costs: obesity outranks both smoking and drinking in its deleterious effects on health and health costs, *Health Aff (Millwood)* 21(2):245–253, 2002.
66. Sinha R, et al.: Prevalence of impaired glucose tolerance among children and adolescents with marked obesity, *N Engl J Med* 346(11):802–810, 2002.

67. Fontaine K, et al.: Years of life lost due to obesity, *J Am Med Assoc* 289(2):187–193, 2003.
68. Ackard DM, et al.: Overeating among adolescents: prevalence and associations with weight-related characteristics and psychological health, *Pediatrics* 111(1):67–74, 2003.
69. Schwimmer JB, Burwinkle TM, Varni JW: Health-related quality of life of severely obese children and adolescents, *J Am Med Assoc* 289(14):1813–1819, 2003.
70. Rolls B, Morris E, Roe L: Portion size of food affects energy intake in normal-weight and overweight men and women, *Am J Clin Nutr* 76(6):1207–1213, 2002.
71. Savage J, et al.: Parental influence on eating behavior, *J Law Med Ethics* 35(1):22–34, 2007.
72. Wofford L: Systematic review of childhood obesity prevention, *J Ped Nurs* 23(1):5–19, 2008.
73. Crespo CJ, et al.: Television watching, energy intake, and obesity in U.S. children: results from the third National Health and Nutrition Examination Survey, 1988-1994, *Arch Pediatr Adolesc Med* 155(3):360–365, 2001.
74. Vader AM, et al.: Television viewing and snacking behaviors of fourth- and eighth-grade school children in Texas, *Prev Chronic Dis* 6(3):489, 2009. On-line reference.
75. Story M, Faulkner P: The prime time diet: a content analysis of eating and food messages in television content and commercials, *Am J Public Health* 80(6):738–740, 1990.
76. Taras HL, Gage M: Advertised foods on children's television, *Arch Pediatr Adolesc Med* 149(6):649–652, 1995.
77. CDC: Youth Risk Behavior Surveillance–United States, 2011, *MMWR Morb Mortal Wkly Rep* 61:2012.
78. Pate R, O'Neill J: Physical activity guidelines for young children, *JAMA Pediatrics* 166(12):1095–1096, 2012.
79. Centers for Disease Control: Barriers to children walking to or from school–United States, 2004: *MMWR Morb Mortal Wkly Rep* 54(38):949–952, 2005.
80. Aaron DJ, et al.: Longitudinal study of the number and choice of leisure time physical activities from mid to late adolescence: implications for school curricula and community recreation programs, *Arch Pediatr Adolesc Med* 156(11):1075–1080, 2002.
81. Zhu H, et al.: Dietary sodium, adiposity and inflammation in healthy adolescents, *Pediatrics* 133(3):e635–e642, 2014.
82. American Heart Association Advisory Recommendation: Consume no more than 1500 mg of sodium a day, Jan 13, 2011.
83. He F, et al.: Salt intake, hypertension, and obesity in children, *Hypertension* 51(3):629–634, 2008.
84. Grimes C, et al.: Dietary salt intake, sugar-sweetened beverage consumption, and obesity risk, *Pediatrics* 131(1):14–21, 2013.
85. Mugavero K, et al.: Reducing sodium intake at the community level: the Sodium Reduction in Communities program, *Prev Chronic Dis* 9:E168, 2012 (doi: 10.5888/pcd9.120081).
86. Wade TD, Keski-Rahkonen A, Hudson J: Epidemiology of eating disorders. In Tsuang M, Tohen M, editors: *Textbook in psychiatric epidemiology*, ed. 3, New York, 2011, Wiley, pp 343–360.
87. Faine MP: Recognition and management of eating disorders in the dental office, *Dent Clin North Am* 47(2):395–410, 2003.
88. Woodside D, et al.: Personality, perfectionism, and attitudes toward eating in parents of individuals with eating disorders, *Int J Eat Disord* 31(3):290–299, 2002.
89. Keel PK, Forney KJ: Psychosocial risk factors for eating disorders, *Int J Eat Disord* 46(5):433–439, 2013.
90. Sherman RT, Thompson RA: The female athlete triad, *J Sch Nurs* 20(4):197–202, 2004.
91. Fernandez S, Pritchard M: Relationships between self-esteem, media influence and drive for thinness, *Eat Behav* 13(4):321–325, 2012.
92. Brown JK, Witherspoon EM: The mass media and American adolescents' health, *J Adolesc Health* 31(Suppl 66):153–170, 2002.
93. Field EM, et al.: Family, peer, and media predictors of becoming eating disordered, *Arch Pediatr Adolesc Med* 162(6):574–579, 2008.
94. Goldschmidt A, et al.: Disordered eating attitudes and behaviors in overweight youth, *Obesity* 16(2):257–264, 2008.
95. Rohde P, Stice E, Marti CN: Development and predictive effects of eating disorder risk factors during adolescence: implications for prevention efforts, *Int J Eat Disord*, Mar 6, 2014 (doi: 10.1002/eat.22270). [Epub ahead of print].
96. Micali N et al: Frequency and patterns of eating disorder symptoms in early adolescence, *J Adolesc Health* 2014 May; 54(5):574-581 (doi: 10.1016/j.jadohealth). 2013. 10.200. Epub 2013 Dec 17.
97. Liechty JM, Lee MJ: Longitudinal predictors of dieting and disordered eating among young adults in the U.S., *Int J Eat Disord* 46(8):790–800, 2013.
98. Lo Muzio L, et al.: Eating disorders: a threat for women's health. Oral manifestations in a comprehensive review, *Minerva Stomatolog* 56(5):281–292, 2007.
99. Attia E, et al.: Feeding and eating disorders in DSM-5, *Am J Psychiatry* 170(11):1237–1239, 2013.
100. Treasure J, Claudino AM, Zucker N: Eating disorders, *Lancet* 375(9714):583–593, 2010.
101. Neumark-Sztainer DR, et al.: Shared risk and protective factors for overweight and disordered eating in adolescents, *Am J Prev Med* 33(5):359–369, 2007.

CHAPTER 9

Dental Caries in the Child and Adolescent

▲ Judith R. Chin, Joan E. Kowolik, and George K. Stookey

For additional resources, please visit the evolve website.

CHAPTER OUTLINE

DENTIST'S ROLE IN THE CARIES CONTROL PROGRAM
ETIOLOGY OF DENTAL CARIES
CARIES PREVALENCE IN PRESCHOOL CHILDREN
CARIES PREVALENCE IN SCHOOLCHILDREN
RAMPANT DENTAL CARIES
EARLY CHILDHOOD CARIES, SEVERE EARLY CHILDHOOD CARIES, NURSING CARIES, BABY BOTTLE TOOTH DECAY
ADDITIONAL FACTORS KNOWN TO INFLUENCE DENTAL CARIES
- Saliva
- Socioeconomic Status
- Anatomic Characteristics of the Teeth
- Arrangement of the Teeth in the Arch
- Presence of Dental Appliances and Restorations
- Hereditary Factors

EARLY DETECTION OF DISEASE ACTIVITY
PREDICTION OF PATIENTS' RISK FOR FUTURE DISEASE (RISK ASSESSMENT)
CONTROL OF DENTAL CARIES
- Control of All Active Caries Lesions
- Reduction in the Intake of Freely Fermentable Carbohydrates
- Reduction of Dental Plaque (and Microorganisms) with Good Oral Hygiene Procedures
- Use of Fluorides and Topical Antimicrobial Agents

DIAGNOSTIC TOOLS
- Infrared Laser Fluorescence (DIAGNOdent)
- Digital Imaging Fiberoptic Transillumination
- Quantitative Light Fluorescence

OTHER PREVENTIVE THERAPIES
- Chlorhexidine and Thymol
- Povidone-Iodine
- Xylitol
- Caries Vaccine
- Dental Caries Activity Tests

DENTIST'S ROLE IN THE CARIES CONTROL PROGRAM

DENTIST'S ROLE IN THE CARIES CONTROL PROGRAM

Good oral health is an integral component of good general health. This would include a Dental Home, which is defined as "the ongoing relationship between the dentist and team and the patient, inclusive of all aspects of oral health care delivered in a comprehensive, continuously accessible, coordinated, and family-centered way. Establishment of a dental home begins no later than 12 months of age and includes referral to dental specialists when appropriate."[1-3] Children should receive their first dental examination between 6 and 12 months of age. In a comprehensive report prepared for the Oral Health Subcommittee of the Healthy Mothers–Healthy Babies Coalition, Ripa states, "Priority needs to be given to a major national educational program directed toward educating the public about nursing caries."[4,5] The educational program must involve direct contact with pregnant women, parents, and other caregivers in population

Although enjoying good oral health includes more than just having healthy teeth, many children have inadequate oral and general health because of active and uncontrolled dental caries. According to the United States Surgeon General's report on oral health in America, published in May 2000, dental caries is the single most common chronic childhood disease.[2] Over the last 60 years, we have seen the meaning of oral health evolve from a narrow focus on teeth and gingiva to the recognition that the mouth is the center of vital tissues and functions that are critical to total health and well-being across the life span. The mouth is a mirror of health or disease, which acts as an accessible model for the study of other tissues and organs. The mouth is the potential source of pathology, which may affect other systems and organs, but also provides the impetus for extensive future research.[2] Dental caries is five times more common than asthma and seven times more common than hay fever. These statistics continue and were reaffirmed by the United States Surgeon General's report in 2010.[3] Furthermore, as Edelstein and Douglass noted, dental caries is not self-limiting, like the common cold, nor amenable to treatment with a simple course of antibiotics, like an ear infection.[4] After analyzing the National Health Interview Survey data from 1993 through 1996, Newacheck and colleagues concluded that dental care is the most prevalent unmet health need among American children.[6] Although effective methods are known for prevention and management of dental disease, the unmet need for treatment, especially in children, does not seem to be diminishing.[7] Gift has estimated that 51 million school hours per year are lost in the United States because of dental-related illness.[8]

Dentlearn.ir

ETIOLOGY OF DENTAL CARIES

The development of dental caries may be considered as a continuous dynamic process involving repeating periods of demineralization by organic acids of microbial origin and subsequent remineralization by salivary components (or therapeutic agents), but in which the overall oral environment is imbalanced toward demineralization. Several factors influence the degree of vulnerability of the tooth.[9]

Today all experts on dental caries generally agree that it is an infectious and communicable disease and that multiple factors influence its initiation and progression. The disease is recognized to require a host (tooth in the oral environment), a dietary substrate, and aciduric bacteria.[9] The saliva (also considered a host component), the substrate, and the bacteria form a biofilm (plaque) that adheres to the tooth surface. Over time the presence of the substrate serves as a nutrient for the bacteria, and the bacteria produce acids that can demineralize the tooth. The flow, dilution, buffering, and remineralizing capacity of saliva are also recognized to be critical factors that affect, and in some ways regulate, the progression and regression of the disease. If the oral environment is balanced and favorable, saliva can contribute to strengthening of the tooth by supplying the components known to help build strong apatite structure. If the oral environment is unfavorable (too much acid is produced too often), an adequate flow of saliva can help dilute and buffer the acid, and thus slow the rate of damage to the tooth or even repair it. The critical pH for dissolution of enamel has been shown to be about 5.5. Once the process reaches dentin, dissolution can occur at a considerably higher pH. In addition, we know of many anatomic, behavioral, dietary, genetic, social, cultural, socioeconomic, and therapeutic variables that can significantly influence the level of caries activity favorably or unfavorably.[10]

Dental caries is a preventable disease; it typically begins in enamel and progresses slowly in its early stages. Rampant caries is an exception to the typical course and is discussed later. Cavitation of the tooth structure is a late-stage development of the disease. Before cavitation, the progress of the disease may be arrested or reversed if a favorable oral environment can be achieved. Even after cavitation occurs, if the pulp is not yet involved and if the cavitated area is open enough to be self-cleansing (plaque-free), the caries process can halt and the lesion can become "arrested." Arrested lesions typically exhibit much coronal destruction, but the remaining exposed dentin is hard and usually very dark, there is no evidence of pulpal damage, and the patient has no pain. We also must emphasize that treating a caries-affected tooth by providing a restoration does not cure the disease. If the unfavorable oral environment that caused the cavity persists, so will the disease, and more restorations will be required in time. Treating the oral infection by reducing the number of cariogenic microorganisms and establishing a favorable oral environment to promote predominantly remineralization of tooth structure over time will arrest the caries process and limit the disease. Arresting the disease currently requires modifications by the patient or caregiver and relies on the individual's compliance in making the necessary modifications.

Many microorganisms can produce enough acid to demineralize tooth structure, particularly aciduric streptococci, lactobacilli, diphtheroids, yeasts, staphylococci, and certain strains of sarcinae. The mutans streptococci (MS) has been implicated as among the major and most virulent of the caries-producing organisms. Consequently, MS has been targeted in a large share of research. Loesche conducted an extensive review of the literature regarding the etiology of caries.[11] He concluded that the evidence suggests that MS, possibly *Streptococcus sobrinus*, and lactobacilli are human odontopathogens. He stated that aciduricity appears to be the most consistent attribute of MS and is associated with its cariogenicity. He also observed that other aciduric species, such as *S. sobrinus*, may be more important in smooth-surface decay and are perhaps associated with rampant caries. Loesche concluded the review with the suggestion that treatment strategies that interfere with the colonization of MS may have a profound effect on the incidence of caries in humans.[11]

Wan and colleagues published a series of three papers that report on 111 infants whom they observed to 2 years of age. They found MS colonization in infants as young as 3 months, and more than 50% of the predentate infants were infected by 6 months of age. By 24 months of age, 84% of the children harbored the bacteria.[12-14] Investigations by Davey and Rogers[15] and by Berkowitz and Jones[16] have confirmed that MS is transmitted orally from mother to infant, whereas Brown and colleagues[17] have demonstrated a relationship between the numbers of MS present in mothers and those in their infants. Research by Kohler and colleagues demonstrated that reducing the numbers of oral MS in mothers delayed the colonization of the organisms in the mouths of their children.[18] Their findings also showed that 52% of the children who carried mutans streptococci at 3 years of age had caries, whereas only 3% of the children without demonstrable MS had caries at the same age. Caufield and colleagues suggested the possibility of a "window of infectivity" between 19 and 33 months of age during which most children acquire the cariogenic organisms.[19] The mother was the most common source of transmission of the bacteria to the child.

Mohan and colleagues found oral MS colonization in 20% of the children younger than 14 months of age.[20] In addition, logistic regression models that controlled for both age and number of teeth indicated that children who consumed sweetened beverages in their baby bottles were four times more likely to have MS than were children who consumed only milk. All experts agree that the earlier transmission occurs, the higher the caries risk.

The acids that initially demineralize the enamel have a pH of 5.5 to 5.2 or less and are formed in the plaque biofilm material, which firmly attaches to the tooth structure. This biofilm, which exists primarily in the susceptible areas of the teeth (i.e., occlusal and facial surfaces), has received a great deal of attention. Considerable emphasis is currently being given to plaque and its relationship to oral disease. Methods of chemical plaque control are being investigated. The acids involved in the initiation of the caries process are normal metabolic byproducts of the microorganisms and are generated by the metabolism of

Dentlearn.ir

carbohydrates. Because the outer surface of enamel is far more resistant to demineralization by acid than is the deeper portion of enamel, the greatest amount of demineralization occurs 10 to 15 μm beneath the enamel surface (Fig. 9-1). The continuation of this process results in the formation of an incipient subsurface enamel lesion that is first observed clinically as a so-called white spot. Unless the demineralization is arrested or reversed (remineralization), the subsurface lesion continues to enlarge, with the eventual collapse of the thin surface layer and the formation of a cavitated lesion.[21,22]

Remineralization of incipient subsurface lesions may occur as long as the surface layer of the enamel remains intact. Saliva, which is supersaturated with calcium and phosphate and has acid-buffering capability, diffuses into plaque, where it neutralizes the microbial acids and repairs the damaged enamel. The time required for remineralization to replace the hydroxyapatite lost during demineralization is determined by the age of the plaque, the nature of the carbohydrate consumed, and the presence or absence of fluoride. For example, it has been suggested that, in the presence of dental plaque that has developed for 12 hours or less, the enamel demineralization resulting from a single exposure to sucrose will be remineralized by saliva within about 10 minutes. In contrast, a period of at least 4 hours is required for saliva to repair the damage to enamel resulting from a similar exposure to sucrose in the presence of dental plaque that is 48 or more hours old. The presence of fluoride has a profound effect on the remineralization process; fluoride not only greatly enhances the rate of remineralization of enamel by saliva but also results in the formation of fluorohydroxyapatite during the process, which increases the resistance of the remineralized enamel to future attack by acids. Fluoride also has antimicrobial effects.[21]

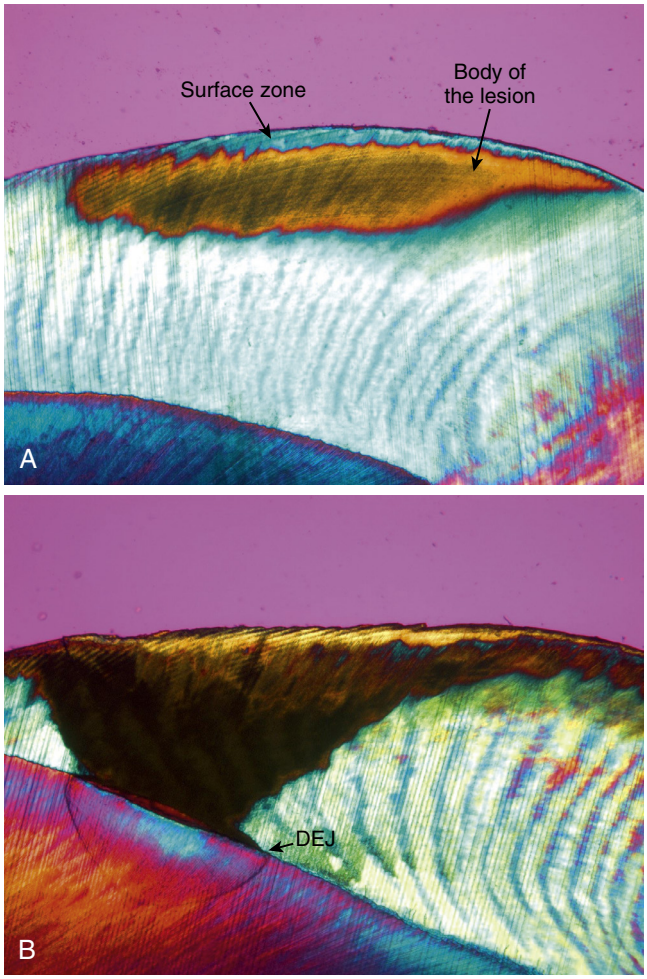

Figure 9-1 Polarized light appearance of natural subsurface caries lesion. **A,** Blue/green line represents surface zone; yellow/brown represents the most demineralized area, the body of the lesion. **B,** More advanced natural subsurface lesion reaching the dentino-enamel junction (DEJ). This would be a white-spot lesion. (Courtesy Dr. James Wefel.)

CARIES PREVALENCE IN PRESCHOOL CHILDREN

Edelstein and Tinanoff found that 30.5% of 200 preschool children had caries detectable by visual or radiographic examination.[23] These children were recruited from a private pediatric dental office and ranged in age from 5 months to 5 years 11 months (mean, 3 years 8 months). Several other studies in the United States report caries prevalence in children age 4 years and under as ranging from 38% to 49%.[7,24,25] In general, other reports of caries prevalence among children in various parts of the world show rates that seem to be comparable with those cited here. Another common element of caries prevalence in the United States and throughout the world is that children from

greater caries prevalence than their peers from families at a higher socioeconomic level. Vargas and colleagues

2 to 5 years of age had at least one decayed or filled pri-

of individuals included in the third National Health and Nutrition Examination Survey (NHANES III, 1988-1994).

male, with an ethnic distribution of 64.1% non-Hispanic white, 16.0% black, 9.5% Mexican American, and 10.4% other ethnicities. The family incomes for these children

In a longitudinal evaluation of caries patterns in 317 children followed up for an average of 7.8 years in private dental practices, Greenwell and colleagues made several noteworthy discoveries.[27] They found that 84% of the children who were caries-free in the primary dentition remained caries-free in the mixed dentition. Children with pit-and-fissure caries in the primary dentition were more likely to develop smooth-surface caries of primary teeth than were the caries-free children. Fifty-seven percent of the children with proximal lesions in primary molars in the primary dentition developed additional primary molar proximal lesions in the mixed dentition. Children with faciolingual decay (nursing caries) were at

caries lesions. These investigators also discovered levels of

Dentlearn.ir

caries susceptibility in children that can be characterized as caries-free, pit-and-fissure caries, and proximal molar caries patterns.

CARIES PREVALENCE IN SCHOOLCHILDREN

The report by Vargas and colleagues provides additional representative data for schoolchildren as well.[26] Their re-

to 12 years of age had at least one decayed or filled pri-

from 6 to 14 years of age, 40% had at least one decayed or filled permanent tooth. Of the 1383 children from 15 to 18 years of age, 89.8% had at least one decayed or filled permanent tooth. The ethnic and family income

were comparable with those outlined in detail for the preschool children. This information, along with that in many other published reports, clearly indicates that managing the disease of dental caries among children remains a formidable task, despite the advances made in various preventive programs.

RAMPANT DENTAL CARIES

The disease process referred to as *rampant caries* is, in terms of human history, relatively new. Rampant caries has been defined by Massler as a "suddenly appearing, widespread, rapidly burrowing type of caries, resulting in early involvement of the pulp and affecting those teeth usually regarded as immune to ordinary decay."[28]

There is no evidence that the mechanism of the decay process is different in rampant caries or that it occurs only in teeth that are malformed or inferior in composition. On the contrary, rampant caries can occur suddenly in teeth that were previously sound for many years. The sudden onset of the disease suggests that an overwhelming imbalance of the oral environment has occurred, and some factors in the caries process seem to accelerate it so that it becomes uncontrollable; it is then referred to as *rampant caries*.

When a patient has what is considered an excessive amount of tooth decay, one must determine whether that person actually has a high susceptibility and truly rampant caries of sudden onset or whether the oral condition represents years of neglect and inadequate dental care. Young teenagers seem to be particularly susceptible to rampant caries, although it has been observed in both children and adults of all ages (Fig. 9-2).

There is considerable evidence that emotional disturbances may be a causative factor in some cases of rampant caries. Repressed emotions and fears, dissatisfaction with achievement, rebellion against a home situation, a feeling of inferiority, a traumatic school experience, and continuous general tension and anxiety have been observed in children and adults with rampant dental caries. Because adolescence is often considered to be a time of difficult adjustment, the increased incidence of rampant caries in

disturbance may initiate an unusual craving for sweets or the habit of snacking, which in turn might influence the incidence of dental caries. On the other hand, a noticeable salivary deficiency is not an uncommon finding in patients receiving radiation therapy to the head and neck and may place patients at high risk for severe caries development.

EARLY CHILDHOOD CARIES, SEVERE EARLY CHILDHOOD CARIES, NURSING CARIES, BABY BOTTLE TOOTH DECAY

The American Academy of Pediatric Dentistry (AAPD) defines early childhood caries (ECC) as the presence of one or more decayed (noncavitated or cavitated), missing (as a result of caries), or filled tooth surfaces in any primary tooth in a child 71 months of age or younger. AAPD also specifies that, in children younger than 3 years of age, any sign of smooth-surface caries is indicative of severe early childhood caries (S-ECC).[29]

Research shows that human breastfeeding in infants has many advantages and has not been epidemiologically associated with caries in the absence of other factors such as poor oral hygiene or a carbohydrate diet. Frequent nighttime bottle feeding with milk is associated with, but not consistently implicated in, S-ECC. Breastfeeding more than seven times daily after 12 months of age is associated with increased risk for ECC.[30,31] Nighttime bottle feeding with juice, repeated use of a sippy or no-spill cup, and frequent between-meal consumption of sugar-containing snacks or drinks (e.g., juice, formula, soda) will increase the risk of caries.[32,33] The clinical appearance of the teeth in S-ECC in a child 2, 3, or 4 years of age is typical and follows a definite pattern.[34] There is early carious involvement of the maxillary anterior teeth, the maxillary and mandibular first primary molars, and sometimes the mandibular canines (Fig. 9-3). The mandibular incisors are usually unaffected. A discussion with the parents often reveals an inappropriate feeding pattern: the child has been put to bed at afternoon nap time and/or at night with a bottle holding milk or a sugar-containing beverage. The child falls asleep, and the liquid becomes pooled around the teeth (the lower anterior teeth tend to be protected by the tongue). The carbohydrate-containing liquid provides an excellent culture medium for acidogenic microorganisms. Salivary flow is also decreased during sleep, and clearance of the liquid from the oral cavity is slowed.

AAPD endorses the policy statement of the American Academy of Pediatrics (AAP) on breastfeeding and the use of human milk.[35] The AAP statement includes the acknowledgment that "breast-feeding ensures the best possible health as well as the best development and psychosocial outcomes for the infant." However, both organizations discourage extended or excessive frequency of feeding times (from the breast or bottle) and encourage appropriate oral hygiene measures for infants and toddlers.

There is considerable scientific evidence from experiments in vitro and in animal models to suggest that some dairy products such as bovine milk and cheese, as well as human breast milk, are not cariogenic and may actually

Dentlearn.ir



Figure 9-2 **A,** Early childhood caries (ECC). **B,** Occlusal ECC in mandible. **C,** Occlusal and interproximal ECC in maxilla (mirror image). **D,** Rampant dental caries and evidence of dental neglect in a preschool child. **E,** Palatal caries on maxillary incisor teeth.

be protective to tooth structure and promote remineralization under certain conditions. Similar experiments show that many infant formulas, with refined food additives, do promote caries. There is much still to learn about caries progression in both the more typical disease and this rampant form. It is prudent to counsel parents to practice good oral hygiene measures for the child and to avoid inappropriate feeding habits that are associated with S-ECC.[30]

ADDITIONAL FACTORS KNOWN TO INFLUENCE DENTAL CARIES

SALIVA

Although saliva was identified in the etiology section earlier as part of the host component and thus a primary part of the caries process, the role of saliva overall is unique. Further discussion is warranted regarding its influence on

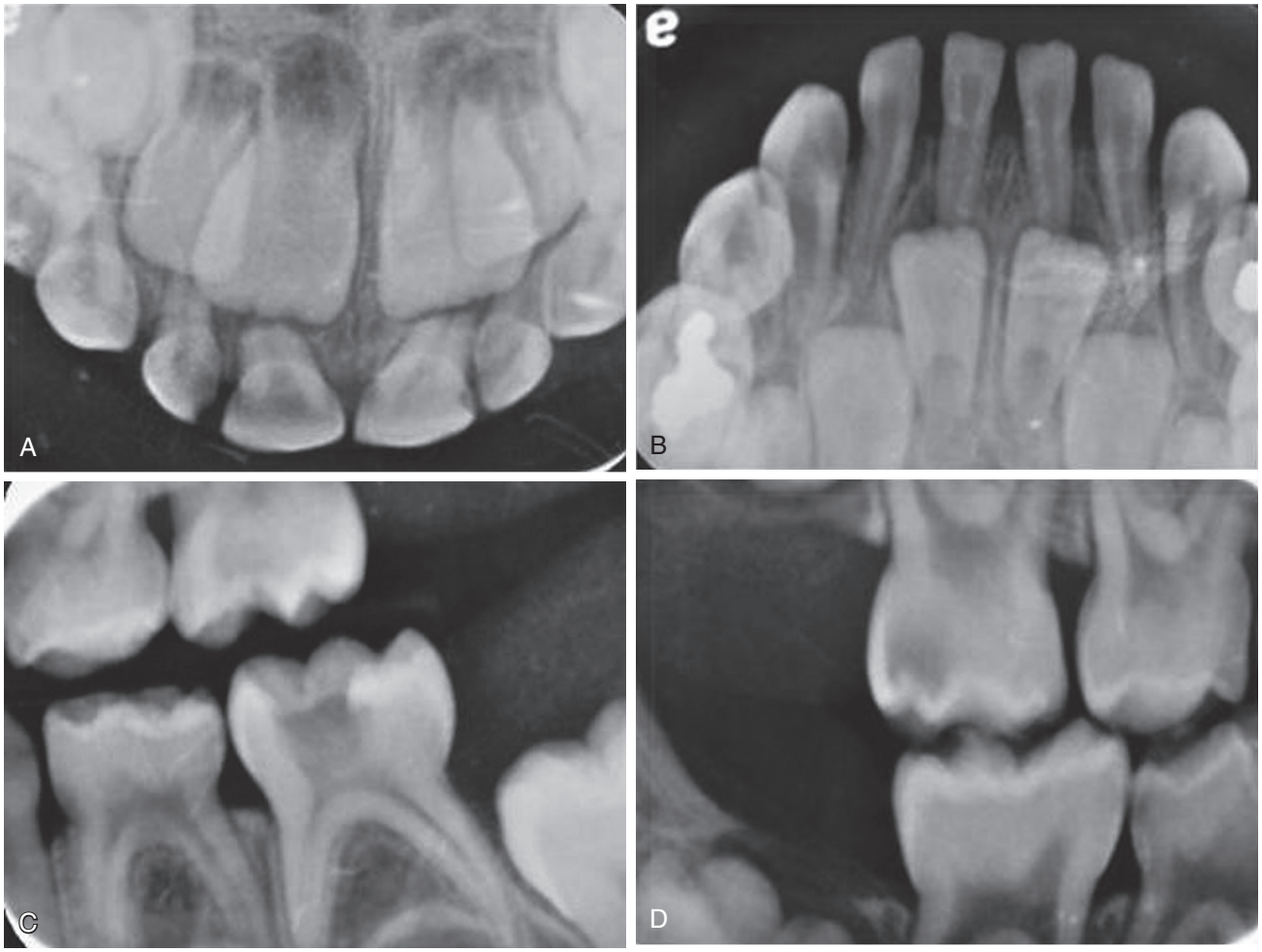

Figure 9-3 Radiographs illustrating early childhood caries. **A,** Maxillary incisors (interproximal). **B,** Mandibular incisors. **C,** Deep caries in mandibular molar. **D,** Maxillary molar distally and on mandibular first molar.

several aspects of the caries process that may help produce favorable environments to combat the process. Any patient with a salivary deficiency, from any cause, is at a higher risk for caries activity.

It is generally accepted that the dental caries process is controlled to a large extent by a natural protective mechanism inherent within the saliva. Many properties of saliva have been investigated for their possible role in the caries process. Considerable importance has been placed on the salivary pH; the acid-neutralizing power; and the calcium, fluoride, and phosphorus content. It has long been suggested that, in addition to these properties, the rate of flow and the viscosity of saliva may influence the development of caries. The normal salivary flow aids in the solution of food debris on which microorganisms thrive. In addition, the saliva manifests a variety of antibacterial and other antiinfectious properties. All known characteristics of saliva seem somehow relevant to the process of dental caries.[21]

Saliva is secreted by three paired masses of cells—the submandibular, sublingual, and parotid glands. Small accessory glands are also scattered over the oral mucous membranes. Each of these has its own duct. The salivary glands are under the control of the autonomic (involuntary) nervous system, receiving fibers from both its parasympathetic and sympathetic divisions. Stimulation of either the parasympathetic (chorda tympani) fibers or the sympathetic fibers to the submandibular or sublingual gland causes a secretion of saliva. In most animals the secretion resulting from parasympathetic stimulation is profuse and watery. Sympathetic stimulation, however, causes a scanty secretion of a thick, mucinous juice. Stimulation of the parasympathetic fibers to the parotid gland causes a profuse, watery secretion, but stimulation of the sympathetic fibers causes no secretion.[21]

Salivary Deficiency

A reduction in the salivary flow may be temporary or permanent. When the quantity is only moderately reduced, the oral structures may appear normal. A pronounced reduction or complete absence of saliva, however, results in an acidic environment with rampant caries (Fig. 9-4). In addition to the rapid destruction of the teeth, there may be dryness and cracking of the lips, with fissuring at the corners of the mouth, burning and soreness of the mucous membranes, crusting of the tongue and palate, and sometimes paresthesia of the tongue or mucous membrane.

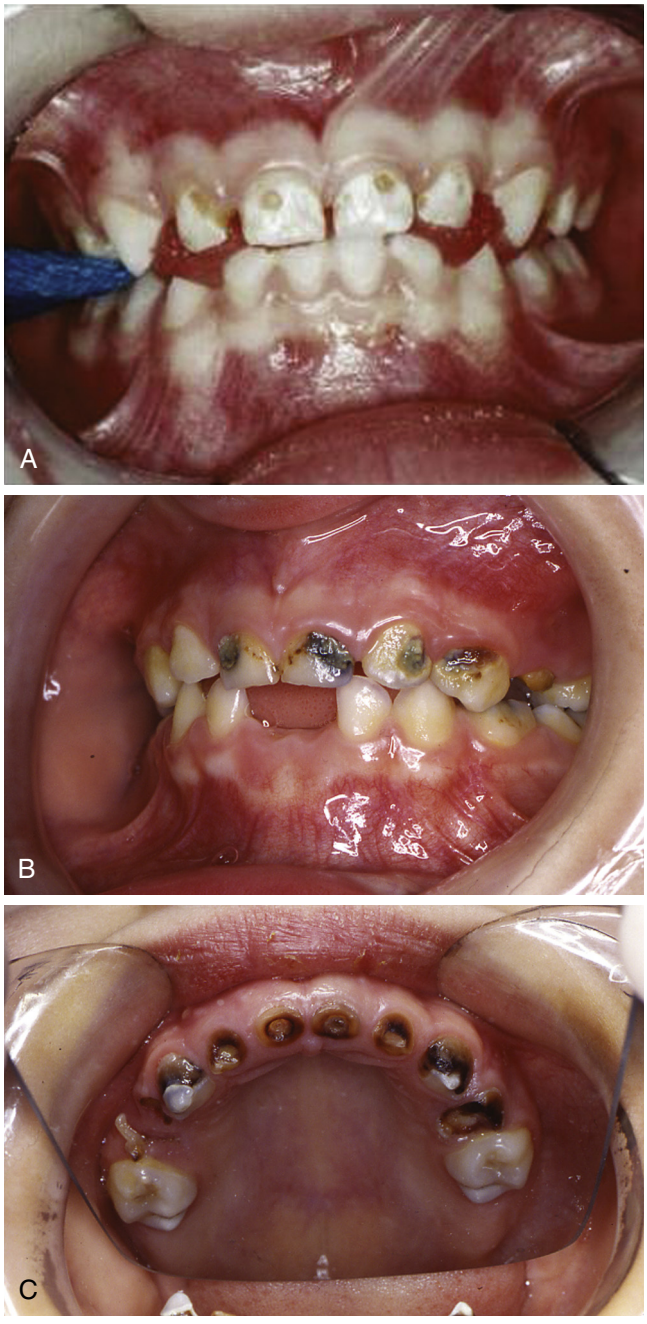

Figure 9-4 Progression of early childhood caries illustrated in three different children. **A,** Restorable with resins. **B,** Restorable with crown forms (possibly). **C,** Nonrestorable.

There are many reasons for a reduction in salivary flow. Acquired salivary dysfunction may be the result of a psychological or emotional disturbance and, again, may be either temporary or permanent. During the acute stages, mumps may cause a temporary reduction in salivary flow. Immune disorders, such as Sjögren syndrome, and genetic conditions, such as hypohidrotic ectodermal dysplasia, often exhibit chronic xerostomia (dry mouth). Many oncology patients receive head and neck or total-body irradiation that also results in salivary gland dysfunction. Patients with deficient salivary flow often have excessive or rampant caries. In contrast, patients with greater than average salivary flow are usually relatively free from dental caries.[36]

If a patient has no known existing conditions that may cause hyposalivation, and if the clinician notices a small pool of saliva in the floor of the mouth during oral examination, it is not unreasonable to assume that the patient has adequate salivary quantity and flow. Little information is available about salivary flow rates in children, but Crossner reported that in children from 5 to 15 years of age, the rate of mixed whole stimulated saliva increases with age, and boys have consistently higher rates than girls.[37] Saliva substitutes, as well as fluoride and chlorhexidine rinses, are reported to enhance remineralization and promote resistance to demineralization of tooth surfaces, and may help prevent radiation-induced caries.[36]

Salivary Viscosity

It has long been suggested that the viscosity of saliva is related to the rate of dental decay. Both thick, ropy saliva and thin, watery saliva have been blamed for rampant dental caries. Previous work has shown a statistically significant direct relationship between the viscosity of saliva and the number of decayed, missing, and filled teeth.[38] This relationship held true for all members of the observer saliva invariably had poor oral hygiene. The teeth were covered with stain or plaque, and the rate of dental caries ranged from greater than average to rampant.

No evidence exists that viscosity changes with age under normal conditions. This property of the saliva is governed not only by the particular set of glands stimulated but also by the type of nervous stimulation and the amount of mucin (glycoprotein) present. Some genetic abnormalities affect the viscosity of saliva; most notably, patients with cystic fibrosis often have thick, ropy saliva and salivary dysfunction.

SOCIOECONOMIC STATUS

The Surgeon General's report of 2010[3] indicated that one in four American children is born into poverty.[2] The report notes that children and adolescents living in poverty suffer twice as much tooth decay as their more affluent peers, and that their disease is more likely to go untreated. The report also mentioned that, although continuing reductions of dental caries in permanent teeth have been achieved, caries prevalence in primary teeth has stabi-

Census Bureau report published in March 2003 showed that the poverty rate for children in the United States rose in 2002, whereas it dropped for people 65 years and older.[39] Nearly half of the 35 million people living in poverty were children. These are alarming data, calling attention to a huge unmet oral health care need in the United States.

Following the report of the Surgeon General, Edelstein pointed out that, paradoxically, children living in poverty also have the highest rates of dental insurance coverage, largely through the Medicaid program and the State Children's Health Insurance Program.[40] Yet Medicaid-eligible children who have cavities have twice the number of

caries-affected teeth and twice the number of visits for pain relief but fewer total dental visits than do children in families with higher incomes. He also noted that these disparities continue into adolescence and young adulthood, albeit to a lesser degree. Because practitioners have the opportunity to assess the oral health of poor children individually, they will identify some patients at low risk for dental caries. However, the available data confirm that, from a demographic perspective, economically poor children are at high risk for dental caries.

ANATOMIC CHARACTERISTICS OF THE TEETH

Certain teeth of many patients, particularly permanent teeth, seem vulnerable to dental caries as they emerge, and, in caries-active mouths, they may show evidence of the attack almost coincident with their eruption into the oral cavity. Because enamel calcification is incomplete at the time of eruption of the teeth and an additional period of about 2 years is required for the calcification process to be completed by exposure to saliva, the teeth are especially susceptible to caries formation during the first 2 years after eruption. Permanent molars often have incompletely coalesced pits and fissures with or without hypoplasia that allows the dental plaque material to be retained at the base of the defect, sometimes in contact with exposed dentin. These defects or anatomic characteristics can readily be seen if the tooth is dried and the debris and plaque removed. In addition to occlusal surfaces, lingual pits on the maxillary permanent molars, buccal pits on the mandibular permanent molars, and lingual pits on the maxillary permanent lateral incisors are vulnerable areas in which the process of dental caries may proceed rapidly.[41]

ARRANGEMENT OF THE TEETH IN THE ARCH

Crowded and irregular teeth are not readily cleansed during the natural masticatory process. It is likewise difficult for the patient to clean the mouth properly with a toothbrush and floss if the teeth are crowded or overlapped. This condition therefore may contribute to the problem of dental caries.[42]

PRESENCE OF DENTAL APPLIANCES AND RESTORATIONS

Space maintainers and orthodontic appliances often encourage the retention of food debris and plaque material and have been shown to result in an increase in the bacterial population.[42] Few patients keep their mouths meticulously clean, and even those who make an attempt may be hampered by the presence of dental appliances that retain plaque material between brushings. Rosenbloom and Tinanoff evaluated the MS levels of patients before, during, and after orthodontic treatment.[43] MS levels were significantly elevated during active treatment. When of treatment, however, the microbial levels were found to have decreased significantly to levels comparable with those of untreated children.

Dentists have known for many years that the tooth structure at the interface with restorative material is especially vulnerable to recurrent caries. Clinical studies suggest that dentists and their patients should not expect successful restorative treatment to reduce a patient's risk for future development of caries lesions. Tinanoff and colleagues found higher numbers of salivary MS in patients after they received restorative treatment.[44] Wright and colleagues observed significant reductions in the numbers of MS and lactobacilli immediately after restoration; however, MS returned to prerestoration levels in many of the study participants.[45] Gregory and colleagues observed that postoperative counts of salivary streptococci essentially equaled the preoperative counts after all restorative work had been completed in their patients.[46] Effective prevention programs are required to protect the patient from additional caries and to better justify the investment in restorative care.

HEREDITARY FACTORS

Although parents of children with excessive or rampant caries tend to blame the condition on hereditary factors or tendencies, and some scientific evidence (as reviewed in Chapter 5) acknowledges certain genetic influences on the caries process, most authors agree that genetic influences on dental caries are relatively minor in comparison with the overall effect of environmental factors. The fact that children acquire their dietary habits, oral hygiene habits, and oral microflora from their parents makes dental caries more an environmental than a hereditary disease. Although several hereditary factors (see Chapter 5) may be influential in promoting or preventing dental caries activity, available effective preventive therapies along with proper dietary and plaque control measures can override the hereditary factors that contribute to caries development.

EARLY DETECTION OF DISEASE ACTIVITY

Traditionally, dentists have relied upon a visual-tactile-radiographic procedure for the detection of dental caries. This procedure involves the visual identification of demineralized areas (typically white spots) or suspicious pits or fissures and the use of the dental explorer to determine the presence of a loss of continuity or breaks in the enamel and to assess the softness or resilience of the enamel. Caries lesions located on interproximal tooth surfaces have generally been detected with the use of bitewing radiographs. These procedures have been used routinely in virtually every dental office in the United States for the past 50 years. Tactile probing with an explorer is no longer used for caries detection in most European countries, and this protocol has now been adopted by many U.S. dental schools. The primary concerns that led to the discontinuation of the probing procedure were as follows: (1) the insertion of the explorer into the suspected lesion inevitably disrupts the surface layer covering very early lesions, thereby eliminating the possibility for remineralization of the decalcified area; (2) the probing of lesions and suspected lesions results in the transport of cariogenic bacteria from one area to another; and (3) frank lesions requiring restoration are generally apparent visually without the need for probing. The clinical caries detection procedures commonly used in Europe have been described by several clinical investigators.[47-52]

Dentlearn.ir

The reversal of the caries process depends on an intact surface layer of the lesion. The use of the dental explorer to routinely probe enamel is no longer recommended.

Caries lesions are detected visually on the basis of their location (mineralization can occur only in areas where dental plaque may accumulate regularly) and the presence of enamel opacities with or without staining. The state of activity is determined by the visual appearance of an opacity, the color of the area (i.e., presence of white or tan stain), and the roughness of the enamel surface as assessed by dragging of the explorer across the surface. Again the only use of the dental explorer as a probe is to remove plaque or debris from tooth surfaces.[52]

While this visual examination procedure for clinically detecting dental caries maintains the integrity of the enamel surface over the demineralized area and the possibility for the remineralization of the area, there remain some practical limitations to this caries detection procedure. The detection process requires the visual detection of demineralized areas as so-called white spots. First, these areas are relatively small, and tooth surfaces must be carefully air-dried during the visual examination. By the time these areas can be detected visually as white spots, the demineralization will have progressed through at least one third of the outer portion of the enamel.[53] Mineralization of this magnitude requires longer time periods and a greater number of treatments to remineralize completely.

Lesions detected on radiographs have generally progressed to the initial involvement of dentin. The increased desire of dental professionals and patients for more conservative restorative procedures and the implementation of measures to control and reverse the caries process led to significant efforts to develop technologies for the early detection of dental caries. Dental scientists have explored other measures to assist with the detection of caries at an earlier stage of the formation process, which resulted in the development and evaluation of a variety of instruments.[51]

PREDICTION OF PATIENTS' RISK FOR FUTURE DISEASE (RISK ASSESSMENT)

In contemporary health care practices, caries-risk assessment and management are now recognized as an important component in providing appropriate dental care for infants, children, and adolescents. AAPD supports that appropriate oral health assessment should begin within 6 months of the eruption of the first tooth and certainly by the first birthday. This assessment should continue as appropriate by the same dentist and dental team providing the child with a Dental Home. With the very young infant, the caries risk focuses on the parents' and caregiver's oral health habits. The habits of the parents and caregiver greatly influence the oral health of the child. These caregivers are asked questions that help guide oral health education for the infant, including the following questions[1]:

1. When did they last have dental care and treatment?
2. What are their eating habits, including sugar, soda, juice, and energy drink consumption?
3. How often do they brush and floss their teeth?

The education and training required to achieve optimal oral health must be provided to the adults who care for the child. Only once the child has grown and will have more input into his/her eating and toothbrushing habits should the focus move to the child. With the older child, especially with the adolescent, caries-risk assessment tools become more useful.

In 2003 when discussing caries risk and introducing the "Cariogram," Petersson repeated the complex nature of dental caries and the difficulties in predicting the development of the disease in any one patient.[54] Over the years these difficulties have not decreased. There are several tools for predicting dental caries development. In 2012 Tellez conducted a systematic review of caries-risk assessment tools and concluded, "There is an urgent need to develop valid and reliable methods for caries risk assessment that are based on best evidence for prediction and disease epidemiology management rather than opinions of experts." In this review the four most commonly used caries-risk assessment tools were reviewed (Cariogram, Caries Management by Risk Assessment [CAMBRA], American Dental Association, and the American Academy of Pediatric Dentistry) and were found to be of equal value. The Cariogram has been evaluated and found to be more predictive in permanent teeth than with preschool children.[55]

The "Cariogram" is a computer caries-risk program that records several data points including past caries experience, diet, oral hygiene habits, fluoride exposures, and analysis of saliva. The program then produces the results as a colored graph. This was well described by Gonzalez and Okunseri in 2010.[56] The different colors are as follows: red for bacteria, dark blue for diet, light blue for susceptibility-related factors, and yellow for circumstances; green represents the chance of avoiding caries. This pictorial presentation with the associated personal plan may be good for patients or parents, although students in this study did not support the usefulness of the tool in the academic setting. The Cariogram has been validated in several clinical studies and has been demonstrated to be successful in predicting caries risk. While assessment of caries risk undoubtedly is benefiting from emerging science and technologies, AAPD believes that sufficient evidence exists to support the creation of a framework for classifying caries risk in infants, children, and adolescents based on a set of physical, environmental, and general health factors. It has also been documented that the caries-risk tools commonly used for adults do not support future risk for children.[57-59] AAPD has published guidelines on caries-risk assessment and management and the caries-risk assessment tool (CAT) (Tables 9-1 and 9-2).

Of course, accurate caries-risk assessments of patients can guide clinicians and health care facilities toward better allocation of their time and resources for their high-risk patients. As our accuracy and efficiency in identifying patients with active disease or high potential to develop disease improve, and as parents, patients, and health care insurance plans accept this newer approach to care, the standard "6-month recall visit" for children may change to a more customized plan for in-

are at low risk for caries and who do not have other oral conditions that need frequent monitoring may not

Dentlearn.ir

Table **9-1**

Caries-Risk Assessment Form for Children 6 Years Old or Younger

(FOR DENTAL PROVIDERS)

Factors	High Risk	Moderate Risk	Low Risk
Biological			
Patient is of low socioeconomic status	Yes		
Patient has >3 between meal sugar-containing snacks or beverages per day	Yes		
Patient has special health care needs		Yes	
Patient is a recent immigrant		Yes	
Protective			
Patient receives optimally-fluoridated drinking water			Yes
Patient brushes teeth daily with fluoridated toothpaste			Yes
Patient receives topical fluoride from health professional			Yes
Patient receives additional home measures (e.g., xylitol, MI paste, antimicrobial)			Yes
Patient has dental home/regular dental care			Yes
Clinical Findings			
Patient has >1 interproximal lesions	Yes		
Patient has active white spot lesions or enamel defects	Yes		
Patient has low salivary flow	Yes		
Patient has defective restorations		Yes	
Patient is wearing an intraoral appliance		Yes	

Circling those conditions that apply to a specific patient helps the practitioner and patient/parent understand the factors that contribute to or protect from caries. Risk assessment categorization of low, moderate, or high is based on preponderance of factors for the individual. However, clinical judgment may justify the use of one factor (e.g., ≥1 interproximal lesions, low salivary flow) in determining overall risk.

Overall assessment of the dental caries risk: High ❒ Moderate ❒ Low ❒

From Council on Clinical Affairs: Guideline on Caries-risk Assessment and Management for Infants, Children, and Adolescents, American Academy of Pediatric Dentistry, Reference Manual 36(6), 127-134, 2014.

require oral health care visits as often as those at high risk (with or without active disease), whereas compliant high-risk patients may, at times, require frequent visits and multiple forms of caries control therapies in addition to their voluntary modification of caries-promoting dietary and behavioral habits.

CONTROL OF DENTAL CARIES

Many practical measures for the control of dental caries are applicable to private practice. Most practitioners have tried control measures with various degrees of success. One cannot emphasize too strongly, however, that no single measure for the control of dental caries will be entirely satisfactory. All possible preventive measures and approaches must be considered in the hope of successfully controlling and preventing the caries process. None of these preventive approaches can have any hope for success without the regular and full cooperation and commitment from the caregiver and patient, with home-care vigilance.

Pediatric dentists who see patients on a referral basis may hear a parent remark, "My child has so many cavities that my dentist doesn't know where to start." Although it is true that the problem may at first seem overwhelming, a systematic, understanding approach often results in a gratifying response. Following a discussion of the oral problems with the parents, an outline of procedures for the control of active or rampant caries in the cooperative and communicative patient is explained. With this approach and with patient cooperation, the problem can usually be explained and brought under control. The successful management of active dental caries, however, depends on the parents' or patient's interest in maintaining the patient's teeth and their cooperation in a customized and specific caries control program.

CONTROL OF ALL ACTIVE CARIES LESIONS

When rampant caries occurs, the first steps are to initiate treatment of all caries lesions to stop or at least slow the progression of the disease and to identify the most important causes of the existing condition. Next, or even simultaneously, if possible, the practitioner begins working with the patient and/or parents to achieve the appropriate behavioral modifications required to prevent recurrence. The problem may then be approached in a systematic manner. Invariably, modifications in oral hygiene procedures and dietary habits are necessary. Often, achieving patient compliance with the recommended modifications is the greatest challenge of all.

If the initial restorative treatment is to be done in one appointment with the patient under general anesthesia

Table **9-2**

Example of a Caries Management Protocol for Children 6 Years Old or Younger

	INTERVENTIONS				
Risk Category	**Diagnostics**	**Fluoride**	**Diet**	**Sealants**	**Restorative**
Low risk:	• Recall every six to 12 months • Radiographs every 12 to 24 months	• Twice daily brushing with fluoridated toothpaste[μ]	No	Yes	• Surveillance[χ]
Moderate risk: patient/parent engaged	• Recall every six months • Radiographs every six to 12 months	• Twice daily brushing with fluoridated toothpaste[μ] • Fluoride supplements[δ] • Professional topical treatment every six months	• Counseling	Yes	• Active surveillance[ε] of incipient lesions • Restoration of cavitated or enlarging lesions
Moderate risk: patient/parent not engaged	• Recall every six months • Radiographs every six to 12 months	• Twice daily brushing with toothpaste[μ] • Professional topical treatment every six months	• Counseling, with limited expectations	Yes	• Active surveillance[ε] of incipient lesions • Restoration of cavitated or enlarging lesions
High risk: patient/parent engaged	• Recall every three months • Radiographs every six months	• Brushing with 0.5 percent fluoride • Fluoride supplements[δ] • Professional topical treatment every three months	• Counseling • Xylitol	Yes	• Active surveillance[ε] of incipient lesions • Restoration of cavitated or enlarging lesions
High risk: patient/parent not engaged	• Recall every three months • Radiographs every six months	• Brushing with 0.5 percent fluoride • Professional topical treatment every three months	• Counseling, with limited expectations • Xylitol	Yes	• Restore incipient, cavitated, or enlarging lesions

α, Salivary mutans streptococci bacterial levels; *ϕ,* interim therapeutic restoration; *γ,* parental supervision of a "pea-sized" amount of toothpaste; *β,* parental supervision of a "smear" amount of toothpaste; *λ,* indicated for teeth with deep fissure anatomy or developmental defects; χ, periodic monitoring for signs of caries progression; δ, need to consider fluoride levels in drinking water; ε, careful monitoring of caries progression and prevention program; μ, less concern about the quantity of toothpaste.
From Council on Clinical Affairs: Guideline on Caries-risk Assessment and Management for Infants, Children, and Adolescents, American Academy of Pediatric Dentistry, Reference Manual 36(6), 127-134, 2014.

or in one or two appointments with sedation, control of the existing lesions will be definitive at that time. If the restorative care is to be performed over several visits in the outpatient setting, gross caries excavation as an initial approach in the control of rampant dental caries has several advantages. The removal of the superficial caries and the filling of the cavity with a glass-ionomer material or zinc oxide–eugenol cement (IRM, Intermediate Restorative Material; LD Caulk Co., Milford, DE, USA) will at least temporarily arrest the caries process and prevent its rapid progression to the dental pulp. Gross caries removal can usually be accomplished easily in one appointment. If there are many extensive caries lesions, however, a second appointment may be necessary.

An alternative approach for some compliant children (with compliant parents) old enough to rinse and expectorate, and for compliant adolescents, is to initiate intensive and multiple antimicrobial and topical fluoride therapies in conjunction with the necessary behavioral lifestyle modifications and then to proceed systematically with restorations and other indicated therapies.

REDUCTION IN THE INTAKE OF FREELY FERMENTABLE CARBOHYDRATES

Excellent studies have shown a relationship between diet and dental caries. As a result of these studies, considerable emphasis has been placed on this phase of the caries control program. There is also much evidence to confirm that between-meal snacking and the frequency of eating and drinking are related to dental caries incidence.

Gustafsson and colleagues conducted a well-controlled study of dental caries, now considered a classic, and obfat, low in carbohydrates, and practically free of sugar had low caries activity.[60] When refined sugar was added to the diet in the form of a mealtime supplement, there

Dentlearn.ir

was still little or no caries activity. However, when caramels were given between meals, a statistically significant increase in the number of new caries lesions occurred. It was concluded from these studies that dental caries activity could be increased by the consumption of sugar if the sugar was in a form easily retained on the tooth surface. The more frequently this form of sugar was consumed between meals, the greater was the tendency for an increase in dental caries.

Weiss and Trithart reported additional evidence for the relationship between the incidence of dental caries

children it was found that most between-meal snacks were of high sugar content or were high in adhesiveness. The children who did not eat between meals had 3.3 decayed, extracted, or filled primary teeth (deft), whereas those who ate four or more items between meals had a deft value of 9.8.

As mentioned earlier, sweetened liquids provided to young children in nursing bottles can have enormous cariogenic potential. Likewise, carbonated soft drinks, juices, sweetened drinks, and energy drinks are popular with older children and adolescents and are readily available. Frequent ingestion of these drinks is another form of snacking that can promote and accelerate caries progression.

Investigations by Schachtele and Jensen[62] and by Park and colleagues[63] have indicated that the acidity of plaque located in interproximal areas, which generally have less exposure to saliva, may remain below the critical pH for periods in excess of 2 hours after carbohydrate ingestion. Because foods containing sugars in solution and retentive sugars are included in the dietary analysis, 20 minutes may be considered the minimal time each exposure permits acid concentrations to be available in the bacterial plaque.

The following can be used in explaining the dental caries process to a parent or child:

Fermentable carbohydrate + Oral bacteria within plaque → Acid within plaque

Acid + Susceptible tooth → Tooth decay

REDUCTION OF DENTAL PLAQUE (AND MICROORGANISMS) WITH GOOD ORAL HYGIENE PROCEDURES

Chapter 14 discusses the importance of good oral hygiene in more detail, but it must be mentioned here as a critically important component of any caries control program. Berenie and colleagues studied the relationships between frequency of toothbrushing, oral hygiene, gingival health, and caries in 384 children, from 9 to 13 years of age, who resided in a fluoride-deficient western New York community.[64] Of the children studied, 37% brushed their teeth once a day, 37% brushed twice a day, and 13% brushed less than once a day. The remaining children in

or more times each day. A trend toward decreased scores for decayed, missing, or filled permanent teeth (DMFT) and decayed, missing, or filled permanent tooth surfaces (DMFS) accompanied increased daily brushing. The increased frequency of daily toothbrushing had its most significant positive effect on the level of oral hygiene.

Beal and colleagues studied the caries incidence and gingival health of children who were 11 to 12 years old at the start of the study.[65] The children's dental cleanliness was evaluated at yearly examinations for a 3-year period. The children whose dental cleanliness was consistently good had lower caries increments than those whose dental cleanliness was consistently bad. Horowitz and colleagues have demonstrated the benefits of a school-based plaque removal program in a 3-year study of children in grades 5 to 8.[66] At the end of the study, the adjusted mean DMFS scores were 13% lower in the supervised plaque re-

ference in affected mesial and distal surfaces, a figure that approached statistical significance ($p = 0.07$). Similarly, Tsamtsouris and colleagues demonstrated that supervised toothbrushing with instruction produces significantly and consistently lower plaque scores, even in preschool children, than were achieved through a control test of the same children when they were neither supervised nor instructed.[67] The investigators concluded that constant reinforcement is necessary to maintain effective plaque control in preschool children.

Wright and colleagues conducted a clinical study to evaluate the effect of frequent interdental flossing on the incidence of proximal dental caries.[68] Schoolchildren from a fluoride-deficient area were studied after clinical and radiographic examinations were performed. Based on the observations of this study, the authors concluded that frequent interdental flossing resulted in a 50% reduction in the incidence of proximal caries in primary teeth during a 20-month period. The longer the period of interdental flossing, the greater the benefit; however, there was little residual effect after flossing was discontinued.

USE OF FLUORIDES AND TOPICAL ANTIMICROBIAL AGENTS

Without doubt, the repeated use of fluorides is of critical importance for the control and prevention of dental caries in both children and adults. Numerous controlled clinical investigations have consistently demonstrated the cariostatic properties of fluoride provided in a variety of forms. As a topically applied therapeutic agent, fluoride is effective in preventing future lesion development, in arresting or at least slowing the progression of active cavitated lesions, and in remineralizing active incipient lesions. Topical fluoride also has some antimicrobial properties.[69]

Existing evidence indicates that the cariostatic activity of fluoride involves several different mechanisms. The ingestion of fluoride results in its incorporation into the dentin and enamel of unerupted teeth; this makes the teeth more resistant to acid attack after eruption into the oral cavity. Although it is present in very low concentrations, ingested fluoride is secreted into saliva and is accumulated in plaque, where it decreases microbial acid production and enhances the remineralization of the underlying enamel. Fluoride from saliva is also topically incorporated into the enamel of newly

Dentlearn.ir

erupted teeth, thereby enhancing enamel mineralization (frequently called *enamel maturation*), which decreases caries susceptibility. The exposure of the teeth to fluoride through professional application of fluoride varnishes, gels, foams, and solutions, in addition to exposure from dentifrices, engages almost all of the foregoing mechanisms except the pre-eruptive incorporation into enamel. Numerous studies have shown that the presence of fluoride greatly enhances the rate of remineralization of demineralized enamel and dentin. Moreover, tooth structure remineralized in the presence of fluoride contains increased concentrations of fluorohydroxyapatite, which makes the remineralized tissue more resistant to future attack by acids than was the original structure. In view of fluoride's multiple mechanisms of action, it is not surprising that treatment with fluoride through multiple delivery systems has additive benefits. This supports the recommendation that frequent exposure to fluoride is beneficial for maximal caries prevention and control.

Communal Water Fluoridation

Research studies continue to support fluoridation of the communal water supply as the most effective method of reducing the dental caries problem in the general population.[70] In 1998 Stookey noted that approximately half of the population of the United States enjoys the benefits of fluoridated community water supplies.[71]

Murray reviewed 113 studies conducted in 23 countries to help clarify various reports on the benefits to primary teeth of communal water fluoridation.[72] A thorough review of the data clearly showed that water fluoridation provides protection for primary teeth against dental caries but to a somewhat lesser degree for permanent teeth. The caries reduction benefits to primary teeth ranged between 40% and 50%, whereas the range for permanent teeth was between 50% and 60%.

Carmichael and colleagues[73] and Rock and colleagues[74] have reported data in separate studies comparing the caries incidence in children living in two fluoridated communities with that in children living in two nonfluoridated communities in England. The role of fluoridation in reducing dental caries is obvious in both studies. The study by Carmichael and colleagues also demonstrated that children in lower social classes gain an even greater caries-preventive benefit than children in higher social

lower social classes have a higher prevalence of proximal caries lesions, and proximal tooth surfaces derive the greatest benefit from fluoridation.

The protection afforded by the ingestion of fluoridated water persists throughout the lifetime of the person. Several studies have shown that the continuous ingestion of fluoridated water during adulthood decreases the prevalence of dental caries by about the same magnitude as that observed in children.[75,76] In addition, Stamm and Banting have reported a 56% decrease in the prevalence of root-surface caries in adults who lived continuously in a fluoridated community.[77]

The posteruptive benefits associated with the ingestion of fluoridated water have also been demonstrated. The posteruptive ingestion of fluoridated water can result in decreases in caries prevalence up to 30%.[78,79] Similarly, Hardwick and colleagues have reported a 27% reduction in caries prevalence after 4 years of ingestion of fluoridated water by teenagers who were 12 years of age when fluoridation was initiated.[80] These observations are consistent with the multiple mechanisms of the action of fluoride cited earlier and support the significant contribution of the exposure of the teeth to fluoride even in the very low concentrations present in fluoridated drinking water.

Several studies concerning the reduced prevalence of dental caries associated with the presence of fluoride in communal water supplies have demonstrated appreciably lesser benefits, typically ranging between 18% and 30%.[81-83] This decrease in attributable benefit is due to the so-called halo effect associated with the preparation of numerous foods and beverages in fluoridated communities and their consumption in nonfluoridated communities. Reports have attempted to quantify this halo effect by measuring the fluoride intake of children residing in communities that do not have a fluoridated communal water supply and have shown that fluoride ingestion is nearly 70% of that by residents of optimally fluoridated communities.[84,85] Thus it is not surprising that only modest differences in caries prevalence rates are noted between children residing in fluoridated and nonfluoridated communities.

When fluoridation is discontinued in a community, an increase in the dental caries incidence follows. Way has reported that, after a 2-year lapse in drinking fluoride-free water in Galesburg, Illinois, children experienced as much as a 38% increase in tooth decay.[86] Lemke and colleagues have reported that in Antigo, Wisconsin, a city of 9600, tooth decay rose 92% among kindergarten children, 183% among second graders, and 100% among fourth graders when fluoridation was discontinued.[87]

Eichenbaum and colleagues reported interesting information related to the long-term impact of communal fluoridation on the private practice of pediatric dentistry.[88] A survey conducted from 1948 to 1950 showed that 86% of the pediatric patients in a private pediatric dental practice needed restorative treatment, and nearly half of these children required pulp therapy. The results of this survey encouraged the city health officials to implement dental health education and preventive programs that included communal water fluoridation. A survey of the same practice almost 30 years later (1977 to 1979) revealed a dramatic change in the restorative needs of the children. The majority of children needed no restorations, and the number of teeth with pulp involvement was negligible.

In 1986 Smith estimated that the average annual cost of fluoridating communal water supplies was approximately $0.25 per person.[89] Gish pointed out in 1979 that the annual cost varied with the size of the community, ranging from approximately $1.50 per person in very small communities to as low as $0.10 per person in larger metropolitan areas.[90] These estimates are still valid, with only upward adjustment for inflation. Communal water fluoridation remains by far the most cost-effective caries-preventive measure available.

In 2001 the Task Force on Community Preventive Services of the CDC strongly recommended community

Dentlearn.ir

water fluoridation and school-based or school-linked pit-and-fissure sealant delivery programs for the prevention and control of dental caries.[91]

Fluoride-Containing Dentifrices

Extensive research initiated in the early 1950s ultimately resulted in the identification of the first fluoride-containing dentifrice (Crest; Procter & Gamble, Cincinnati, Ohio, USA) capable of decreasing the incidence of dental caries. This dentifrice contained stannous fluoride (SnF_2) in combination with calcium pyrophosphate as the cleaning and polishing system; and in 1964, based on more than 20 clinical trials, it was accepted by the Council on Dental Therapeutics of the American Dental Association (ADA) as the first therapeutic dentifrice. The significance of this original development has been profound; in fact a review by Jenkins concluded that the general decline in caries prevalence in Great Britain and other developed countries appears to be attributable in large part to the widespread use of effective fluoride-containing dentifrices.[92] Meta-analyses of more than 70 randomized or quasi-randomized controlled clinical trials have shown that fluoride toothpaste is efficacious in reducing the prevalence of dental caries in permanent teeth. The effect was increased in children with higher baseline levels of caries who used a higher concentration of fluoride in the toothpaste, had greater frequency of use, and brushed under supervision.[93]

Caregivers should be counseled based on the child's age and caries-risk status.[69] A smear of fluoridated toothpaste for children less than 2 years of age at increased risk for dental caries may decrease risk of fluorosis. A "pea-sized" amount of toothpaste is appropriate for children aged two through 5 years (Fig. 9-5).[94,95] A Cochrane review found that the effect of fluoride toothpaste increases with higher frequency of use. There were statistically significant associations between estimates of DMFS-prevented fractions and frequency of use, with a 14% increase in preventive fractions (95% CI: 6% to 22%) with twice-daily brushing vs once-daily brushing. Children should brush twice a day.[96]



Figure 9-5 Toothbrush with pea-sized amount of toothpaste.

Before 1981, attempts to identify a fluoride dentifrice system significantly more effective than the original stannous fluoride formulation were unsuccessful. However, in 1981 the results of two clinical studies demonstrated the superiority of a sodium fluoride composition.[97,98] A 3-year clinical study was conducted by Beiswanger and colleagues[97] to determine the effect of a sodium fluoride–silica abrasive dentifrice on dental caries. The dentifrice, containing 0.243% sodium fluoride,

of 1824 schoolchildren from 6 to 14 years of age in Indiana cities where water supplies were fluoride deficient (containing less than 0.35 ppm fluoride). After 3 years

had significantly lower DMFT and DMFS increments

dentifrice. Two independent examiners found that the reductions were 14.8% and 10.5% for DMFT and 16.4% and 13.1% for DMFS. These results are consistent with those reported by Zacherl in which the sodium fluoride dentifrice resulted in a 40.7% decrease in DMFS compared with a 23.4% decrease observed with the stannous fluoride dentifrice.[98] Similarly, studies conducted by Gerdin[99] and by Edlund and Koch[100] indicated that the use of sodium fluoride dentifrices by children resulted in significantly less caries than the use of dentifrices containing sodium monofluorophosphate.

Topical Fluorides in the Dental Office

Fluoride-containing varnishes have been widely used in Europe and other parts of the world for approximately 40 years but were not available in the United States until 1994. The first fluoride varnish was introduced in Europe in 1964 and contained 5.0% sodium fluoride (or 2.26% fluoride, equivalent to 22,600 ppm). A second product was introduced in Europe in 1975 and contained 0.9% silane fluoride (or 0.1% fluoride). Much more research has been conducted on the sodium fluoride system, and it is the most widely accepted.

Petersson,[101] Horowitz and Ismail,[102] and Petersson and colleagues[103] have reviewed the numerous controlled clinical trials of fluoride varnishes and concluded that these materials are equally as effective as professional topical fluoride applications for the prevention of dental caries in children. Seppä and colleagues investigated the effect of the sodium fluoride varnish in children with previously high caries experience and found that this measure resulted in numerically fewer new caries lesions than was achieved with semiannual applications of an acidulated phosphate fluoride (APF) gel during a 3-year study period.[104] These investigators also noted that the data for use of this varnish satisfied the criteria of the ADA for the claim of being "at least as good as" professionally applied topical fluoride gels. Helfenstein and Steiner performed a meta-analysis of the data from several clinical trials and found that use of the sodium fluoride varnish resulted in an overall reduction of 38% in caries of the permanent teeth.[105]

The periodic professional topical application of more concentrated fluoride solutions, gels, foams, or varnishes has been repeatedly demonstrated to result in

Dentlearn.ir

a significant reduction in the incidence of dental caries in both children and adults, as well as in the arrest of incipient lesions.[106] As a result, professional topical fluoride applications are recommended for all children and adolescents at moderate to high caries risk. Even in the absence of dental caries activity, topical fluoride applications for children are recommended as a means of raising the fluoride content of the enamel of newly erupted teeth, thereby increasing the resistance of these teeth to caries formation. Historically the periodic topical application of fluoride was first demonstrated in the early 1940s to be effective for the prevention of dental caries. Since that time, many hundreds of publications have provided additional data to confirm the efficacy of professionally applied topical fluoride treatments for caries prevention.[106]

A 4-minute treatment time has been typically recommended for professionally applied topical fluoride solutions, gels, or foams. They are less effective than fluoride varnish.[106] Some manufacturers recommend only a 1-minute application. Most of the fluoride uptake in the enamel occurs during the first minute after application. However, measurable benefits do continue to accrue for approximately 4 minutes if the topical preparation remains in contact with the teeth. Therefore the 4-minute application is recommended whenever possible. If gel or foam is applied with a tray technique, the trays should be about one-third full for gel and one-half full for foam. Usually both upper and lower trays are inserted at once to complete the topical fluoride treatment in one 4-minute application. Some trays are supplied as a connected double set. The patient sits in an upright position with his/her head tipped slightly forward to allow excess saliva and fluoride to flow toward the lips. With a saliva ejector inside the patient's mouth, the tip is moved to help control drooling and the swallowing of fluoride. The dentist or appropriate office staff should supervise the treatment and provide assistance as needed. Patients requiring assistance also often need positive reinforcement during the procedure. Extra caution and special application techniques are required when topical solutions, gels, or foams are placed in the mouths of children. For children 4 years of age and younger, trays may be challenging to use.

The results of independent clinical trials have raised serious questions about the need for dental prophylaxis before the topical application of fluoride. Ripa and colleagues compared the caries incidence during a 3-year period in children given semiannual topical applications of fluoride after different cleaning procedures.[107] Before each fluoride treatment the children received conventional prophylaxis with a nonfluoride prophylactic paste, performed supervised toothbrushing and flossing, or rinsed their mouths with water. Caries increments after 3 years were essentially identical in all cleaning the teeth before the fluoride treatment may not influence the cariostatic activity of the fluoride applications. Similarly designed clinical trials were conducted by Houpt and colleagues,[108] Katz and colleagues,[109] and Bijella,[110] with results comparable with those observed by Ripa and colleagues.[107,110] Collectively these studies indicate that prophylaxis before a topical fluoride application may be an optional procedure with regard to caries reduction.

Beginning with reports by Ekstrand and colleagues[111] and LeCompte and Whitford,[112] several investigators have expressed concern regarding the amount of fluoride swallowed by children during a topical fluoride application. These reports indicated that, depending on the manner of application, 15 to 31 mg of fluoride may be swallowed during the treatment. Stookey and colleagues explored the feasibility of permitting patients to rinse after a topical fluoride application as a means of reducing fluoride ingestion.[113] However, they observed that rinsing with water significantly decreased fluoride deposition in incipient caries lesions. The patient should be encouraged not to eat, drink, or rinse for 30 minutes after the treatment, to maximize fluoride uptake in enamel.

The sodium fluoride varnish (Fig. 9-6) is particularly recommended for use in children because of its ease of application and equal efficacy to APF systems.[71] The varnish is applied with a soft brush, with reapplications recommended at 3- to 6-month intervals depending on caries-risk assessment. A more intensive annual treatment regimen consisting of three applications within a 10-day period was investigated and was observed to be as effective as applications every 4 months.[114-116] Furthermore, single annual applications have been found to be without clinical benefit. Because less than a milliliter of varnish is used for a professional treatment in children, the amount of fluoride that will ultimately be ingested when the varnish is lost from the tooth surfaces is less than 3 mg. Thus there are no practical concerns regarding safety, and this procedure is frequently recommended for use in children in place of the traditional topical fluoride gel application.

Topical Fluorides for the General Anesthesia Patient

The application of fluoride to the teeth of children receiving dental care under a general anesthetic, after the placement of restorations, is certainly recommended. Thorough prophylaxis should precede the placement of



Figure 9-6 Application of white fluoride varnish.

Dentlearn.ir

the rubber dam for a quadrant of restorations. The fluoride should be applied after the restorative work has been completed.

Over-the-Counter Fluoride Mouthrinses and Gels

The use of dilute oral fluoride rinses and gels as an additional dental caries control measure has become another helpful adjunct. Children younger than 4 years of age may not have full control over their swallowing reflexes; therefore caution should be exercised when these products are

some small children can expectorate rinses quite reliably under proper supervision, or the parent can brush on the gel and wipe away the excess.

Radike and colleagues observed schoolchildren who rinsed their mouths once each school day for 2 school years with a stannous fluoride mouthrinse containing 250 ppm fluoride (about 0.1% stannous fluoride).[117] There was a significant reduction in dental caries at the end of the first and second school years. Two independent examiners found caries reductions of 33% and 43% in DMFS scores. The anticaries benefit from the stannous fluoride mouthrinse was especially encouraging because the children were already receiving the optimum benefit of water fluoridation.

Extensive field research has been conducted on the use of fluoride mouthrinses. Most studies incorporate the use of a 0.2% sodium fluoride rinse once weekly or a 0.05% sodium fluoride rinse once daily. As does the work previously summarized, these other studies show unquestionable caries-preventive benefits of the regular use of self-administered fluoride rinses when properly supervised. These benefits accrue to primary and permanent teeth, and seem to be helpful both in fluoridated areas and in areas with nonfluoridated water. The studies by Heifetz[118] and by Ripa and Leske[119] are cited in the references listed at the end of this chapter as good examples of clinical research with fluoride rinses. Studies supporting the use of the dilute gels are not as numerous as those for the rinses, but some gels have been approved.

Prescription Home-Use Fluoride Mouthrinses, Toothpastes, and Gels

Additional at-home topical fluoride treatments involving increased concentrations of fluoride should be considered for children at high risk for caries. These may include over-the-counter or prescription-strength formulations.[120] A meta-analysis of permanent teeth indicated that there is a statistically significant reduction in caries with the use of prescription-strength fluoride mouthrinses (0.09% fluoride, equivalent to 900 ppm) compared with placebo, no treatment, or Oral Hygiene Instruction (OHI) and prophylaxis. By frequency of use, daily and weekly rinsing showed statistically significant effects, while biweekly rinsing showed no[106] significant improvement.

The primary difference between gels and toothpastes (0.5% fluoride, equivalent to 5000 ppm) is that pastes contain a small amount of an abrasive component. Two meta-analyses, one for primary teeth and another for permanent teeth, showed a statistically significant reduction of dental caries with prescription-strength 0.5% fluoride toothpaste or gel compared with no treatment, placebo, or a 0.125% to 0.145% fluoride toothpaste.[106]

Dietary Fluoride Supplements

A review of the literature on the value of fluorides administered during pregnancy failed to disclose any valid evidence to support such use, even in nonfluoridated areas.

Participants in a symposium concerning the use of prenatal fluorides agreed that transfer of fluoride does occur from the mother to the fetus through the placenta.[121] A study by Katz and Muhler suggested that the effect of fluoride on primary teeth is mainly topical, posteruption, and postnatal.[122,123] In a study to determine the effect of waterborne fluoride on dental caries in primary teeth, investigators examined 890 children from 4 to 7 years of age in one Indiana city having a communal water supply with only 0.05 ppm fluoride and in three cities having a supply with a concentration of 1 ppm fluoride. Children living in the cities with 1 ppm fluoride in the water had between 35% and 65% fewer dental caries lesions in their primary teeth than those living in the fluoride-deficient city. Comparisons of dental caries incidence in the primary teeth of children living in the same city and who were exposed either prenatally or postnatally or exclu-

The natural fluoride content of the water should first be determined. Fluoride supplements should be prescribed only for children who are at high risk of developing caries and after all other sources of fluoride (toothpaste, fluoride in water, infant formula, etc.) have been evaluated. When the primary source of drinking water is deficient in fluoride and the child is at high risk for caries, careful consideration of systemic fluoride supplements (drops, lozenges, beads) should be given before fluoride supplements are prescribed. If the natural fluoride content is 0.4 ppm or higher, supplements should not be administered.[124] If the fluoride content is below 0.4 ppm, the administration of fluoride supplements should be considered only after a review of all other types of fluoride sources, and if the child is at moderate to high risk for caries.[124]

Several studies have reported the caries-preventive effects of adding fluoride to a variety of foods and beverages. Fluoride in countries outside the United States has been used as a caries-preventive additive in salt, milk, and even sugar.[125] Numerous reports show that these products can have measurable and favorable results when used as intended. Such products are designed for use by specific

Combinations of Fluoride Therapies

There is considerable evidence to suggest that using combinations of therapeutic fluoride agents often produces additive anticariogenic effects. The evidence also indicates that the earlier fluoride therapy is initiated in children, the more effective the caries control will be. However, one must use caution in prescribing multiple therapies in children, to avoid excessive fluoride ingestion.

Fluorosis

Fluoride is the most effective caries-preventive agent commercially available today. Except in a patient with

Dentlearn.ir

a fluoride allergy (very rare), it is considered completely safe when properly used. Fluorosis is associated with cumulative fluoride intake during enamel development, with the severity dependent on the dose, duration, and timing of systemic fluoride ingestion.[70] The ingestion of high concentrations can lead to nausea, vomiting, dental fluorosis (mottling), or, in extreme cases, even death, especially in children. Sources of dietary fluoride may include drinking water from home, day care, and school; beverages such as soda, juice, and infant formula; prepared food; and toothpaste. Infant formulas, especially powdered formulas that have been reconstituted with fluoridated water, have been associated with an increased risk of fluorosis.[126] Extreme care must be used to safeguard the agents from inappropriate or inadvertent ingestion. It is imperative that the dental profession have full awareness of the hazards accompanying its use and yet be prepared to use it to the patient's maximum advantage through careful consideration of each patient's individual situation.

DIAGNOSTIC TOOLS

Caries detection is entering a new era, with technologies capable of both detecting lesions at an earlier stage of development and quantifying the impact of noninvasive professional fluoride treatments such as fluoride varnishes. There are several different instruments available on the market that may be able to assist with the early detection of caries. Each of these instruments must be used in combination with a detailed clinical examination and review of caries risk for each child. There is insufficient scientific evidence for diagnostic accuracy regarding fiberoptic methods and quantitative light-induced fluorescence. The electrical methods and laser fluorescence could be useful adjuncts to visual-tactile and radiographic examinations, especially on occlusal surfaces in permanent and primary molars, but evidence is graded as limited. No conclusions can be drawn regarding the cost-effectiveness of these detection methods. Early identification will provide evidence to guide the dental professional in implementing various measures for the reversal and control of these caries lesions.[127,128]

INFRARED LASER FLUORESCENCE (DIAGNOdent)

DIAGNOdent is an instrument designed to facilitate the detection and quantification of dental caries on occlusal and smooth surfaces (Kaltenbach & Voigt GmbH & Co., Biberach/Riss, Germany) (Fig. 9-7). It uses a diode laser light source and a fiberoptic cable that transmits the light to a handheld probe with a fiberoptic eye in the tip. The light is absorbed and induces infrared fluorescence by organic and inorganic material. The emitted fluorescence is collected at the probe tip, transmitted through ascending fibers, and processed and presented on a display window as an integer between 0 and 99. Increased fluorescence reflects potential caries-affected tooth substance. The identity of the material responsible for the fluorescence is still under investigation, but it appears to be bacterial metabolites, particularly the porphyrins.[128]



Figure 9-7 Infrared laser fluorescence diagnostic machine.

Many in vitro studies and a few in vivo (clinical) studies of the performance of this instrument have been reported. The results of the various in vitro studies have indicated that DIAGNOdent is capable of detecting relatively advanced caries lesions, and DIAGNOdent readings show a very good correlation with histologic evidence of caries, but not with the depths of the lesions in dentin. However, the results of the in vitro studies have also indicated that the readings are influenced by several variables, including the type of restoration present on the tooth, degree of dehydration of the lesion, presence of dental plaque, and presence of various types of stain in occlusal fissures. An example of this is that readings would be very high for resins and sealants, indicating caries where there may be none.[127,128]

The results of clinical investigations have shown significant differences in readings between different DIAGNOdent instruments with regard to the extent of occlusal caries, which raises questions regarding the selection of a value of 20 or 25 to indicate the presence of caries. Instrument readings higher than 20 or 25 suggest the presence of caries, and higher readings generally reflect more extensive lesion progression, although there does not appear to be a linear relationship between the readings and the extent of the lesion. Prudent use of the instrument could identify early lesions that should be considered for preventive rather than restorative treatment.[127,128]

DIGITAL IMAGING FIBEROPTIC TRANSILLUMINATION

Conventional clinical caries examinations routinely use transillumination to identify lesions located on the interproximal surfaces of the anterior teeth. For at least 30 years a fiberoptic transillumination (FOTI) instrument has been available for clinical use. It provides an intense light beam that is transmitted through a fiberoptic cable to a specially designed probe to permit the use of transillumination on the proximal surfaces of posterior teeth.

Dentlearn.ir

Repeated improvements have been made in the instrument so that it may be used on occlusal and proximal tooth surfaces and the instrument is commonly used, often in place of radiographs, in private practices in Europe. Digital imaging fiber optic transillumination (DIFOTI) (Electro-Optical Sciences, Inc., Irvington, New York, USA) is a further advancement of this technology, in which the visually observed images are captured with the use of a digital charge-coupled device (CCD) camera and sent to a computer for analysis with dedicated algorithms.

QUANTITATIVE LIGHT FLUORESCENCE

The most extensively investigated technique available for the early detection of dental caries is quantitative light fluorescence (QLF). Numerous additional in vitro and in situ studies have confirmed this important correlation between the amount of observed fluorescence and the mineral content of the lesions, and have made it possible to develop a system that could truly assess changes in either the progression or regression of caries lesions.

The fluorescent filtered images are captured with a color CCD camera. From these clinical studies, it is apparent that QLF enhances the early detection of dental caries and is uniquely useful in monitoring the progression or regression of lesions.

Numerous investigations have demonstrated the practical usefulness of QLF for the early detection of dental caries on occlusal and smooth tooth surfaces, and for the quantification of lesion changes related to treatment procedures and environmental factors such as oral hygiene. The only significant limitation to this instrument is its inability to detect or monitor interproximal lesions.[127,128]

OTHER PREVENTIVE THERAPIES

CHLORHEXIDINE AND THYMOL

As an oral antimicrobial, chlorhexidine has been used in oral rinses, dentifrices, chewing gum, varnish, and gel. In the United States, it is used most often in the form of a prescription oral rinse. Many children object to the taste of these products, but they have been shown to be effective against the microorganisms causing both caries and periodontal disease. Additionally, most chlorhexidine mouthrinses contain a high concentration of alcohol; thymol has also been included with chlorhexidine in some varnish preparations. To date, these products have not shown superior caries-preventive results when compared with multiple fluoride therapies, and they may require more frequent application to be effective.

POVIDONE-IODINE

Considerable data exist from laboratory and animal studies to confirm the dramatic suppression of MS by iodine. Several studies in humans have been conducted, but there is insufficient evidence that the use of iodine lowers the incidence of caries. Short-term reductions of MS have been noted, but long-term reductions have not been reported.[131]

XYLITOL

Xylitol is a sweetener that inhibits the growth of MS. Numerous studies seem to confirm its anticariogenic capability. Clinically effective levels of xylitol show MS strains with reduced adhesion to the teeth and other reduced virulence properties, such as less acid production.[129] Xylitol has been tested as an additive to a variety of foods and to dentifrices. However, the vast majority of published data come from studies in which xylitol was incorporated into chewing gum. Mäkinen has reported numerous studies on the topic, most of them performed with many different co-workers in different parts of the world. In 2000 he published a concise summary entitled, "The Rocky Road of Xylitol to Its Clinical Application."[130] A recent evidence-based review concluded that there is insufficient evidence that the use of xylitol gum, chlorhexidine varnish or gel, or calcium supplementation in mothers lowers the incidence of caries in their children. Clinicians may consider recommending xylitol use to moderate- or high-caries-risk patients. Those recommending xylitol should be familiar with the product labeling and recommend age-appropriate products. They should routinely reassess a child for changes in caries-risk status and adjust recommendations accordingly.[129,131]

CARIES VACCINE

A vaccine to prevent the disease of dental caries has been an anticipated scientific breakthrough since at least the early 1940s. Research efforts assume that MS is the principal etiologic organism of dental caries, and the development of a method of immunization specifically targeted at neutralizing MS has been a major thrust of caries vaccine research. Bowen reported that monkeys remained caries-free for more than 6 years after the animals received intraoral injections of killed MS, even though the monkeys were fed highly cariogenic diets and had severe malocclusion that would predispose them to caries.[132] Most current research is being directed toward a greater understanding of the immune system and specifically of immune responses to MS. The route of administration of the vaccine is usually mucosal absorption by intraoral or intranasal tissues.

DENTAL CARIES ACTIVITY TESTS

For the larger part of a century, dental scientists have been trying to develop a convenient method for quantitatively measuring the degree of dental caries activity in individual patients. Techniques requiring laboratory procedures to determine oral bacterial counts or their aciduric potential have been developed and used. More recently, convenient paper test strips to gauge salivary microbial density in patients have been tested. No truly convenient and efficient test method has yet been developed that has sufficient accuracy to be a reliable caries activity indicator. Research continues in this area, because having an accurate, convenient, and efficient test to measure early caries activity and its level of potential, especially in young children, would be a very useful diagnostic tool for private practitioners and public health assistance providers.[133]

Dentlearn.ir

DENTIST'S ROLE IN THE CARIES CONTROL PROGRAM

The success of a dental caries control program depends to a great extent on the interest and cooperation of the patient and the patient's caregivers. Rampant caries should not be viewed as a hopeless problem. Diagnostic, therapeutic, and preventive measures are available to control it. In the clinical management of rampant caries, the dentist's role consists of seeking and eliminating the cause to the extent possible. This includes trying to correct inappropriate habits or deficiency states that may be contributing factors, restoring the salvageable teeth to good form and function, and, finally, making use of all available therapeutic preventive and control measures in an established, ongoing manner.

Successful management of all active dental caries problems also requires careful diagnosis, complete dental and medical history-taking, the initiation of a comprehensive preventive program, the application of sound principles of restorative dentistry, and the establishment of a regular recall schedule for maintenance and reemphasis of the preventive procedures. The recall appointment should be set at each visit based on the clinician's judgment of the patient's caries risk for future disease at that time.[134]

REFERENCES

1. American Academy of Pediatric Dentistry: Definition of a dental home, *Pediatr Dent* 35(6):12, 2014. [Special issue: Reference manual 2013-2014].
2. US Department of Health and Human Services: *Oral health in America: a report of the Surgeon General*, Rockville, MD, 2000, US Department of Health and Human Services, National Institute of Dental and Craniofacial Research, National Institutes of Health.
3. Benjamin RM: Surgeon General's perspectives, *Public Health Rep* 125:2010, 2010.
4. Edelstein BL, Douglass CW: Dispelling the myth that 50 percent of U.S. schoolchildren have never had a cavity, *Public Health Rep* 110:522–530, 1995.
5. Ripa LW: Nursing caries: a comprehensive review, *Pediatr Dent* 10:268–282, 1988.
6. Newacheck PW, et al.: The unmet health needs of America's children, *Pediatrics* 105:989–997, 2000.
7. Pew Charitable Trusts: In search of dental care, *Public Health*

   loadedFiles/PCS_Assets/2013/In_search_of_dental_care.pdf. March 25, 2014.
8. Gift HC: Oral health outcomes research—challenges and opportunities. In Slade GD, editor: *Measuring oral health and quality of life*, Chapel Hill, NC, 1997, University of North Carolina Department of Dental Ecology.
9. Keyes P, Fitzgerald RJ: Dental caries in the Syrian hamster, *Arch Oral Biol* 7:267–277, 1962.
10. American Academy of Pediatric Dentistry Policy on Early Childhood Caries (ECC): Classifications, consequences, and preventive strategies, *Pediatr Dent* 35(6):47–49, 2014. [Special issue: Reference manual 2013-2014].
11. Loesche WJ: Role of Streptococcus mutans in human dental decay, *Microbiol Rev* 50:353–380, 1986.
12. Wan AK, et al.: Association of Streptococcus mutans infection and oral developmental nodules in pre-dentate infants, *J Dent Res* 80:1945–1948, 2001.
13. Wan AK, et al.: Oral colonization of Streptococcus mutans in six-month-old predentate infants, *J Dent Res* 80:2060–2065, 2001.
14. Wan AK, et al.: A longitudinal study of Streptococcus mutans colonization in infants after tooth eruption, *J Dent Res* 82:504–508, 2003.
15. Davey AL, Rogers AH: Multiple types of the bacterium Streptococcus mutans in the human mouth and their intrafamily transmission, *Arch Oral Biol* 29:453–460, 1984.
16. Berkowitz RJ, Jones P: Mouth-to-mouth transmission of the bacterium Streptococcus mutans between mother and child, *Arch Oral Biol* 30:377–379, 1985.
17. Brown JP, Junner C, Liew V: A study of Streptococcus mutans levels in both infants with bottle caries and their mothers, *Aust Dent J* 30:96–98, 1985.
18. Kohler B, Andreen I, Jonsson B: The effect of caries-preventive measures in mothers on dental caries and the presence of the bacteria Streptococcus mutans and lactobacilli in their children, *Arch Oral Biol* 29:879–883, 1984.
19. Caufield PW, Cutter GR, Dasanayake AP: Initial acquisition of mutans streptococci by infants: evidence for a discrete window of infectivity, *J Dent Res* 72:37–45, 1993.
20. Mohan A, et al.: The relationship between bottle usage/content, age, and number of teeth with mutans streptococci colonization in 6–24-month-old children, *Community Dent Oral Epidemiol* 26:12–20, 1998.
21. Nyvad B, Fejerskov O: Assessing the stage of caries lesion activity on the basis of clinical and microbiological examination, *Community Dent Oral Epidemiol* 25:69–75, 1997.
22. CDC: Recommendations for using fluoride to prevent and control dental caries in the United States, *MMWR Recomm Rep* 50(RR-14):1–42, 2001.
23. Edelstein B, Tinanoff N: Screening preschool children for dental caries using a microbial test, *Pediatr Dent* 11:129–132, 1989.
24. Douglass JM, et al.: Dental caries experience in a Connecticut Head Start program in 1991 and 1999, *Pediatr Dent* 24:309–314, 2002.
25. Tang JM, et al.: Dental caries prevalence and treatment levels in Arizona preschool children, *Public Health Rep* 112:319–331, 1997.
26. Vargas CM, Crall JJ, Schneider DA: Sociodemographic distribution of pediatric dental caries: NHANES III, 1988-1994, *J Am Dent Assoc* 129:1229–1238, 1998.
27. Greenwell AL, et al.: Longitudinal evaluation of caries patterns from the primary to the mixed dentition, *Pediatr Dent* 12:278–282, 1990.
28. Massler JN: Teen-age caries, *J Dent Child* 12:57–64, 1945.
29. American Academy of Pediatric Dentistry: Policy on early childhood caries (ECC): unique challenges and treatment options, *Pediatr Dent* 33(Suppl 6):50–51, 2014. [Special issue: Reference manual 2013-2014].
30. Iida H, et al.: Association between infant breastfeeding and early childhood caries in the United States, *Pediatrics* 120(4):944–952, 2007.
31. Mohebbi SZ, et al.: Feeding habits as determinants of early childhood caries in a population where prolonged breastfeeding is the norm, *Community Dent Oral Epidemiol* 36(4):363–369, 2008.
32. Feldens CA, et al.: Early feeding practices and severe early childhood caries in four-year-old children from southern Brazil: a birth cohort study, *Caries Res* 44(5):445–452, 2010.
33. Tinanoff NT, Kanellis MJ, Vargas CM: Current understanding of the epidemiology, mechanism, and prevention of dental caries in preschool children, *Pediatr Dent* 24(6):543–551, 2002.

34. American Academy of Pediatric Dentistry: Policy on early childhood caries (ECC): classifications, consequences and preventive strategies, *Pediatr Dent* 30(Suppl 7):40–43, 2008. [Special issue: Reference manual 2008-2009].
35. American Academy of Pediatric Dentistry: Policy on dietary recommendations for infants, children, and adolescents, *Pediatr Dent* 30(Suppl 7):L47–L48, 2008. [Special issue: Reference manual 2008-2009].
36. Tinanoff NT: The oral cavity. In Kliegman RM, Stanton BF, St Geme J, et al.: *Nelson textbook of pediatrics*, ed 19, Philadelphia, 2011, Elsevier (Saunders), p 1257.
37. Crossner CG: Salivary flow rate in children and adolescents, *Swed Dent J* 8:271–276, 1984.
38. McDonald RE: *Human saliva: a study of the rate of flow and viscosity and its relationship to dental caries [thesis]*, Indianapolis, 1951, Indiana University School of Dentistry.
39. US Census Bureau: *Poverty in the United States: 2002*, Washington, DC, March 10, 2003, US Department of Commerce, Economics and Statistics Administration, US Census Bureau.
40. Edelstein BL: Disparities in oral health and access to care: findings of national surveys, *Ambul Pediatr* 2(Suppl):141–147, 2002.
41. Weerheijm KL: Molar incisor hypomineralisation (MIH), *Eur J Paediatr Dent* 4(3):114–120, 2003.
42. Hafez HS, et al.: Dental crowding as a caries risk factor: a systematic review, *Am J Orthod Dentofacial Orthop* 142(4): 443–450, 2012.
43. Rosenbloom RG, Tinanoff N: Salivary Streptococcus mutans levels in patients before, during and after orthodontic treatment, *Am J Orthod Dentofacial Orthop* 100:35–37, 1991.
44. Tinanoff N, Siegrist B, Lang NP: Safety and antibacterial properties of controlled release SnF2, *J Oral Rehabil* 13: 73–81, 1986.
45. Wright JT, et al.: Effect of conventional dental restorative treatment on bacteria in saliva, *Community Dent Oral Epidemiol* 20:138–143, 1992.
46. Gregory RL, El-Rahman AMA, Avery DR: Effect of restorative treatment on mutans streptococci and IgA antibodies, *Pediatr Dent* 20:273–277, 1998.
47. Pitts NB: Clinical diagnosis of dental caries. A European perspective, *J Dent Educ* 65:973–980, 2001.
48. Pitts NB: Modern concepts of caries measurement, *J Dent Res* 83:43–47, 2004.
49. Pitts NB: Are we ready to move from operative to non-operative/preventive treatment of dental caries in clinical practice? *Caries Res* 38:294–304, 2004.
50. Ekstrand KR: Improving clinical visual detection—potential for caries clinical trials, *J Dent Res* 83(Spec Iss):C67–C71, 2004.
51. Nyvad B, Machiulskiene V, Baelum V: The Nyvad criteria for assessment of caries lesion activity. In Stookey GK, editor: *Clinical Models Workshop: remin-demin, precavitation, caries*, Indianapolis, 2005, Proceedings of the 7th Indiana Conference.
52. Ekstrand K, Qvist V, Thylstrup A: Light microscope study of the effect of probing in occlusal surfaces, *Caries Res* 21: 363–374, 1987.
53. Pitts NB, Stamm J: International Consensus Workshop on Caries Clinical Trials (ICW-CCT) final consensus statements: agreeing where the evidence leads, *J Dent Res* 83:125–128, 2004.
54. Petersson GH: Assessing caries risk–using the Cariogram model, *Swed Dent J Suppl* 158:1–65, 2003.
55. Tellez M, et al.: Evidence on existing caries risk assessment systems: are they predictive of future caries? *Community Dent Oral Epidemiol* 41:67–78, 2013.
56. Gonzalez CD, Okunseri C: Senior dental students' experience with Cariogram in a pediatric dentistry clinic, *J Dent Educ* 74(2):123–129, 2010.
57. ADA Council on Scientific Affairs: Fluoride toothpaste use for young children, *JADA* 145(2):190–191, 2014.
58. Tellez M, et al.: Evidence on existing caries risk assessment systems: are they predictive of future caries? *Community Dent Oral Epidemiol* 41(1):67–78, 2013.
59. Dean JA, et al.: Progression of interproximal caries in primary dentition, *J Clin Pediatr Dent* 22(1):59–62, 1997.
60. Gustafsson BE, et al.: The Vipeholm dental caries studies: the effect of different levels of carbohydrate intake on caries activity in 436 individuals observed for five years (Sweden), *Acta Odontol Scand* 11:232–364, 1954.
61. Weiss RL, Trithart AH: Between-meal eating habits and dental caries experience in preschool children, *Am J Public Health* 50:1097–1104, 1960.
62. Schachtele CG, Jensen ME: Comparison of methods for monitoring changes in the pH of human dental plaque, *J Dent Res* 61:1117–1125, 1982.
63. Park KK, Ashmore RW, Stookey GK: Prolonged response period for indwelling plaque pH studies, *J Dent Res* 65(Spec Iss):282, 1986 (abstract).
64. Berenie J, Ripa LW, Leske G: The relationship of frequency of toothbrushing, oral hygiene, gingival health, and caries experience in schoolchildren, *J Public Health Dent* 33:160–171, 1973.
65. Beal JF, et al.: The relationship between dental cleanliness, dental caries incidence and gingival health, *Br Dent J* 146:111–114, 1979.
66. Horowitz AM, et al.: Effects of supervised daily plaque removal by children after 3 years, *Community Dent Oral Epidemiol* 8:171–176, 1980.
67. Tsamtsouris A, White GE, Clark ER: The effect of instruction and supervised toothbrushing on the reduction of dental plaque in kindergarten children, *J Dent Child* 46:204–209, 1979.
68. Wright GZ, Banting DW, Feasby WH: The Dorchester dental flossing study: final report, *Clin Prev Dent* 1(3):23–26, 1979.
69. Wright JT, et al.: Fluoride toothpaste efficacy and safety in children younger than 6 years: a systematic review, *J Am Dent Assoc* 145(2):182–189, 2014.
70. Centers for Disease Control and Prevention: Recommendations for using fluoride to prevent and control dental caries in the United States, *MMWR Recomm Rep* 50(RR-14):1–42, 2001.
71. Stookey GK: Caries prevention, *J Dent Educ* 62:803–811, 1998.
72. Murray JJ: Efficacy of preventive agents for dental caries. Systemic fluorides: water fluoridation, *Caries Res* 27(Suppl 1):2–8, 1993.
73. Carmichael CL, et al.: The effect of fluoridation upon the relationship between caries experience and social class in 5-year-old children in Newcastle and Northumberland, *Br Dent J* 149:163–167, 1980.
74. Rock WP, Gordon PH, Bradnock G: Dental caries experience in Birmingham and Wolverhampton schoolchildren following the fluoridation of Birmingham water in 1964, *Br Dent J* 150:61–66, 1981.
75. Russell AL, Elvolve E: Domestic water and dental caries. VIII. A study of the fluoride-dental caries relationship in an adult population, *Public Health Rep* 66:1389–1401, 1951.
76. Englander HR, Reuss RC, Kesel RG: Dental caries in adults who consume fluoridated versus fluoride-deficient water, *J Am Dent Assoc* 68:14–19, 1964.

77. Stamm JW, Banting DW: Adult root caries survey of two similar communities with contrasting natural water fluoride level, *J Am Dent Assoc* 120:143–149, 1990.
78. Arnold FA, et al.: Effect of fluoridated public water supplies on dental caries prevalence. Tenth year of the Grand Rapids-Muskegon study, *Bull Am Assoc Public Health Dent* 17:32–38, 1957.
79. Hayes RL, Littleton NW, White CL: Posteruptive effects of fluoridation on first permanent molars of children in Grand Rapids, Michigan, *Am J Public Health* 47:192–199, 1957.
80. Hardwick JL, Teasdale J, Bloodworth G: Caries increments over 4 years in children aged 12 at the start of water fluoridation, *Br Dent J* 153:217–222, 1982.
81. Brunelle JA, Carlos JP: Recent trends in dental caries in U.S. children and the effect of water fluoridation, *J Dent Res* 69:723–727, 1990.
82. Clark DC, et al.: Effects of lifelong consumption of fluoridated water or use of fluoride supplements on dental caries experience, *Community Dent Oral Epidemiol* 23:20–24, 1995.
83. Newbrun E: Effectiveness of water fluoridation, *J Public Health Dent* 49:279–289, 1989.

lected from adolescents, *J Dent Res* 77(Spec Iss):143, 1998 (abstract).
85. Jackson RD, et al.: The fluoride content of foods and beverages from negligibly and optimally fluoridated communities, *Community Dent Oral Epidemiol* 30:382–391, 2002.
86. Way RM: The effect on dental caries of a change from a naturally fluoridated to a fluoride-free communal water, *J Dent Child* 31:151–157, 1964.
87. Lemke CW, Doherty JM, Arra MC: Controlled fluoridation: the dental effects of discontinuation in Antigo, Wisconsin, *J Am Dent Assoc* 80:782–786, 1970.
88. Eichenbaum IW, Dunn NA, Tinanoff N: Impact of fluoridation in a private pedodontic practice: thirty years later, *J Dent Child* 48:211–214, 1981.
89. Smith CE: *Personal communication*, 1986.
90. Gish CW: The dollars and cents of prevention, *J Indiana Dent Assoc* 58(2):12–14, 1979.
91. Centers for Disease Control and Prevention: Promoting oral health: interventions for preventing dental caries, oral and pharyngeal cancers, and sports-related craniofacial injuries. A report on the recommendations of the task force on community preventive services, *MMWR Recomm Rep* 50(RR-21):1–13, 2001.
92. Jenkins GN: Recent changes in dental caries, *Br Med J* 291:1297–1298, 1985.
93. Walsh T, et al.: Fluoride toothpastes of different concentrations for preventing dental caries in children and adolescents, *Cochrane Database Syst Rev* 1: CD007868, 2010.
94. Scottish Intercollegiate Guideline Network: *Dental interventions to prevent caries in children* (#138)1–52, March 2014. Available at
Accessed March 25, 2014.
95. Maternal Child Health Bureau Expert Panel: *Topical fluoride recommendations for high-risk children*, Washington, DC, 2007, Maternal Child Health Bureau. Available at http://

cessed March 25, 2014.
96. Marinho VC, et al.: Fluoride toothpastes for preventing dental caries in children and adolescents, *Cochrane Database Syst Rev* (1):CD002278 2003.
97. Beiswanger BB, Gish CW, Mallatt ME: A three year study of the effect of a sodium fluoride-silica abrasive dentifrice on dental caries, *Pharmacol Ther Dent* 106:9–16, 1981.
98. Zacherl WA: A three-year clinical caries evaluation of a sodium fluoride-silica abrasive dentifrice, *Pharmacol Ther Dent* 6:1–7, 1981.
99. Gerdin PO: Studies in dentifrices. VI. The inhibitory effect of some grinding and non-grinding fluoride dentifrices on dental caries, *Swed Dent J* 65:521–532, 1972.
100. Edlund D, Koch G: Effect on caries of daily supervised toothbrushing with sodium monofluorophosphate and sodium fluoride dentifrices, *Scand J Dent Res* 85:41–45, 1977.
101. Petersson LG: Fluoride mouthrinses and fluoride varnishes, *Caries Res* 27(Suppl 1):35–42, 1993.
102. Horowitz HS, Ismail AI: Topical fluorides in caries prevention. In Fejerskov O, Ekstrand J, Burt BA, editors: *Fluoride in dentistry*, ed 2, Copenhagen, 1996, Munksgaard.
103. Petersson LG, et al.: *Fluoride varnish for community based caries prevention in children*, Geneva, 1997, World Health Organization. WHO/NCD/ORH/FV/97.1.
104. Seppä L, et al.: Fluoride varnish versus acidulated phosphate fluoride gel: a 3-year clinical trial, *Caries Res* 27:327–330, 1995.
105. Helfenstein U, Steiner M: Fluoride varnishes (Duraphat): a meta-analysis, *Community Dent Oral Epidemiol* 22:1–5, 1994.
106. Weyant RJ, et al.: Topical fluoride for caries prevention: executive summary of the updated clinical recommendations and supporting systematic review. American Dental Association Council on Scientific Affairs Expert Panel on Topical Fluoride Caries Preventive Agents, *J Am Dent Assoc* 144(11):1279–1291, 2013.
107. Ripa LW, et al.: Effect of prior toothcleaning on bi-annual professional acidulated phosphate fluoride topical fluoride gel-tray treatments: results after three years, *Caries Res* 18:457–464, 1984.
108. Houpt M, Koenigsberg S, Shey Z: The effect of prior toothcleaning on the efficacy of topical fluoride treatment: two-year results, *Clin Prev Dent* 5(4):8–10, 1983.
109. Katz RV, et al.: Topical fluoride and prophylaxis: a 30-month clinical trial, *J Dent Res* 63(Spec Iss):256, 1984 (abstract).
110. Bijella MFTB, et al.: Comparison of dental prophylaxis and toothbrushing prior to topical APF applications, *Community Dent Oral Epidemiol* 13:208–211, 1985.
111. Ekstrand J, et al.: Pharmacokinetics of fluoride gels in children and adults, *Caries Res* 15:213–220, 1981.
112. LeCompte EJ, Whitford GM: Pharmacokinetics of fluoride from APF gels and fluoride tablets in children, *J Dent Res* 61:469–472, 1982.
113. Stookey GK, et al.: The effect of rinsing with water immediately after a professional fluoride gel application on fluoride uptake in demineralized enamel: an in vivo study, *Pediatr Dent* 8:153–157, 1986.
114. Petersson LG, et al.: Caries-inhibiting effect of different modes of Duraphat varnish reapplication: a three-year radiographic study, *Caries Res* 25:70–73, 1991.
115. Petersson LG, Westerberg I: Intensive fluoride varnish program in Swedish adolescents: economic assessment of a 7-year follow-up study on proximal caries incidence, *Caries Res* 28:59–63, 1994.
116. Skold L, et al.: Four-year study of caries inhibition of intensive Duraphat application in 11–15-year-old children, *Community Dent Oral Epidemiol* 22:9–12, 1994.
117. Radike AW, et al.: Clinical evaluation of stannous fluoride as an anticaries mouth rinse, *J Am Dent Assoc* 86:404–408, 1973.
118. Heifetz SB: Evaluation of the comparative effectiveness of fluoride mouthrinsing, fluoride tablets, and both procedures in combination: interim findings after two years, *Pediatr Dent* 9:121–125, 1987.

119. Ripa LW, Leske G: Effect on the primary dentition of mouthrinsing with a 0.2 percent neutral NaF solution: results from a demonstration program after four school years, *Pediatr Dent* 3:311–315, 1981.
120. American Academy of Pediatric Dentistry: Guideline on fluoride therapy, *Pediatr Dent* 33(Suppl 6):153–155, 2014. [Special issue: Reference manual 2013-2014].
121. Symposium: Perspectives on the use of prenatal fluorides, *J Dent Child* 48:100–133, 1981.
122. Katz S, Muhler JC: Prenatal and postnatal fluoride and dental caries experience in deciduous teeth, *J Am Dent Assoc* 76:305–311, 1968.
123. Hennon DK, Stookey GK, Muhler JC: The clinical anticariogenic effectiveness of supplementary fluoride-vitamin preparation: results at the end of three years, *J Dent Child* 33:3–12, 1966.
124. Rozier RG, et al.: Evidence-based clinical recommendations on the prescription of dietary fluoride supplements for caries prevention: a report of the American Dental Association Council on Scientific Affairs, *J Am Dent Assoc* 141(12): 1480–1489, 2010.
125. Espelid I: Caries preventive effect of fluoride in milk, salt and tablets: a literature review, *Eur Arch Paediatr Dent* 10(3):149–156, 2009.
126. Hujoel PP, et al.: Infant formula and enamel fluorosis. A systematic review, *J Am Dent Assoc* 140(7):841–854, 2009.
127. Pereira AC, et al.: Validity of caries detection on occlusal surfaces and treatment decisions based on results from multiple caries-detection methods, *Eur J Oral Sci* 117(1):51–57, 2009.
128. Twetman S, et al.: Adjunct methods for caries detection: a systematic review of literature, *Acta Odontol Scand* 71: 388–397, 2013.
129. American Academy of Pediatric Dentistry: Guideline on xylitol use in caries prevention, *Pediatr Dent* 35(6):157–159, 2014. [Special issue: Reference manual 2013-2014].
130. Mäkinen KK: The rocky road of xylitol to its clinical application, *J Dent Res* 79:1352–1355, 2000.
131. Rethman MP, et al.: Nonfluoride caries-preventive agents: executive summary of evidence-based clinical recommendations. American Dental Association Council on Scientific Affairs Expert Panel on Nonfluoride Caries-Preventive Agents, *J Am Dent Assoc* 142(9):1065–1071, 2011.
132. Bowen WH: Relevance of caries vaccine investigations in rodents, primates, and humans: critical assessment, *Immunology* 11–20, 1976 (abstract; special suppl).
133. Bader JD, Shugars DA, Bonito AJ: Systematic reviews of selected dental caries diagnostic and management methods, *J Dent Educ* 65(10):960–968, 2001.
134. American Academy of Pediatric Dentistry: Guideline on pediatric restorative dentistry, *Pediatr Dent* 35(6):205–211, 2014. [Special issue: Reference manual 2013-2014].

CHAPTER 10

Pit-and-Fissure Sealants and Preventive Resin Restorations

▲ Brian J. Sanders

For additional resources, please visit the evolve website.

CHAPTER OUTLINE

CLINICAL TRIALS
RATIONALE FOR USE OF SEALANTS
SELECTION OF TEETH FOR SEALING
SEALANT TECHNIQUE
Cleaning
Isolation
Etching
Washing
Application of Sealant
Check of Occlusal Interferences
Reevaluation
PREVENTIVE RESIN RESTORATION (SEALED COMPOSITE RESIN RESTORATION)

In 1955 Buonocore described the technique of acid-etching as a simple method of increasing the adhesion of self-curing methyl methacrylate resin materials to dental enamel.[1] He used 85% phosphoric acid to etch enamel for 30 seconds. This produces a roughened surface at the microscopic level, which allows for the mechanical bonding of low-viscosity resin materials.

The first materials used experimentally as sealants were based on cyanoacrylates but were not marketed. By 1965 Bowen had developed the bis-GMA resin, which is the chemical reaction product of bisphenol A and glycidyl methacrylate.[2] This is the base resin used in most of the current commercial sealants. Urethane dimethacrylate and other dimethacrylates are alternative resins used in sealant materials.

For chemically cured sealants, a tertiary amine (activator) in one component is mixed with another component containing benzoyl peroxide, and their reaction produces free radicals, which initiate polymerization of the sealant material.

The other sealant materials are activated by an external energy source. The early light-activated sealants were polymerized by the action of ultraviolet rays (which are no longer used) on benzoin methyl ether or higher-alkyl benzoin ethers to activate the peroxide curing system. The visible light–curing sealants have diketones and aromatic ketones, which are sensitive to visible light in the wavelength region of 470 nm (blue region). Some sealants contain filler, usually silicon dioxide microfill or even quartz.

Sealant materials may be transparent or opaque. Opaque materials are available in tooth color or white. Transparent sealants are clear, pink, or amber. The clear and tooth-colored sealants are aesthetic but are difficult to detect at recall examinations. Advances in sealant technology include light-activated coloring agents that allow for color change during and/or after polymerization. These compositional changes do not affect the sealant but offer the benefit in the recognition of sealed surfaces.

The cariostatic properties of sealants are attributed to the physical obstruction of pits and grooves. This prevents colonization of pits and fissures with new bacteria and also prevents fermentable carbohydrates from reaching any bacteria remaining in the pits and fissures, so that the remaining bacteria cannot produce acid in cariogenic concentrations.

CLINICAL TRIALS

Many clinical studies have reported the success of pit-and-fissure sealants with respect to caries reduction. As the longevity of the sealant increases, the retention rate becomes a determinant of its effectiveness as a caries-preventive measure.

In 1983 a National Institutes of Health Consensus Panel considered the available information on pit-and-fissure sealants and concluded that "the placement of sealants is a highly effective means of preventing pit and fissure caries. […] Expanding the use of sealants would substantially reduce the occurrence of dental caries in the population beyond that already achieved by fluorides and other preventive resources."[3]

participants in a sealant study recalled after 15 years.[4]

surfaces were sound 15 years after a single sealant application, whereas 31% were carious or restored. In the

residence, 17% of the surfaces were sound, whereas 83% were carious or restored. He also estimated that a pit-and-fissure surface on a permanent first molar is 7.5 times more likely to be carious or restored after 15 years if it is not sealed with a single application of pit-and-fissure sealant.

The use of glass ionomer as a sealant material has the advantage of continuous fluoride release; in addition, it is hydrophilic and its preventive effect may continue

Dentlearn.ir

with the visible loss of the material. Glass ionomer may be useful as a sealant material in deeply fissured primary molars that are difficult to isolate due to the child's precooperative behavior and in partially erupted permanent molars that the clinician believes are at risk for developing decay. Antonson and colleagues concluded that glass-ionomer sealants had greater success in the sealing of partially erupted teeth and combating potential salivary contamination.[5] In such cases, glass-ionomer materials must be considered a provisional sealant to be reevaluated and probably replaced with resin-based sealants when better isolation is possible. Further long-term research is necessary before such materials are recommended as routine pit-and-fissure sealant materials.

A systematic review of evidence regarding the effectiveness of sealants in stabilizing or reducing bacterial levels in carious lesions found that sealants were effective in reducing total bacteria, and this number continued to decrease with the time of sealant placement. The findings of these investigators continue to support the notion that a retained sealant can deprive bacteria of access to nutrients and therefore can be effective in reducing caries progression.[6-8]

Wendt and Koch annually followed 758 sealed occlusal surfaces in first permanent molars for 1 to 10 years.[9] At the end of their study, evaluation of the surfaces that had been sealed 10 years previously revealed that only 6% showed caries or restorations. Romcke and associates annually monitored 8340 sealants placed on high-risk (for caries) first permanent molars during a 10-year period.[10] Maintenance resealing was performed as indicated during the annual evaluations. One year after the sealants were placed, 6% required resealing; thereafter, 2% to 4% required resealing annually. After 8 to 10 years 85% of the sealed surfaces remained caries-free.

Retrospective studies based on billing data from large third-party databases reveal that sealant use is still surprisingly low, even in populations for whom sealants are a covered benefit.[11,12] In addition, these studies show that the effectiveness of sealants in preventing the need for future restorative care on the sealed surfaces declines after the first 3 years following sealant treatment. These data argue again for the importance of vigilant recall and upkeep of sealants after placement.

Another concern is the placement of sealants immediately after topical fluoride application. Clinical and in vitro studies have shown that topical fluoride does not interfere with the bonding between the sealant and enamel.[13,14]

RATIONALE FOR USE OF SEALANTS

In 2008 the report on "Evidence Based Clinical Recommendations for the Use of Pit and Fissure Sealants" by the American Dental Association's Council on Scientific Affairs concluded that sealants are effective in caries prevention and can prevent the progression of early noncavitated caries lesions.[15]

The American Academy of Pediatric Dentistry's Pediatric Restorative Dentistry Consensus Conference[16] confirmed support for sealant use and published these recommendations:

1. Bonded resin sealants, placed by appropriately trained dental personnel, are safe, effective, and underused in preventing pit-and-fissure caries on at-risk surfaces. Effectiveness is increased with good technique and appropriate follow-up and resealing as necessary.
2. Sealant benefit is increased by placement on surfaces judged to be at high risk for, or surfaces that already exhibit, incipient caries lesions. Placing sealant over minimal-enamel caries has been shown to be effective at inhibiting lesion progression. As with all dental treatment, appropriate follow-up care is recommended.
3. The best evaluation of risk is made by an experienced clinician using indicators of tooth morphology, clinical diagnostics, past caries history, past fluoride history, and present oral hygiene.
4. Caries risk, and therefore potential sealant benefit, may exist in any tooth with a pit or fissure, at any age, including primary teeth of children and permanent teeth of children and adults.
5. Sealant placement methods should include careful cleaning of the pits and fissures without removal of any appreciable enamel. Some circumstances may indicate use of a minimal-enameloplasty technique.
6. Placement of a low-viscosity, hydrophilic material-bonding layer as part of or under the actual sealant has been shown to enhance its long-term retention and effectiveness.
7. Glass-ionomer materials have been shown to be ineffective as pit-and-fissure sealants but can be used as transitional sealants.
8. The profession must be alert to new preventive methods effective against pit-and-fissure caries. These may include changes in dental materials or technology.

SELECTION OF TEETH FOR SEALING

To gain the greatest benefit, the clinician should determine the caries risk; thus the term risk-based sealant treatment has come into use. In risk-based sealant treatment, the practitioner takes into account prior caries experience, fluoride history, oral hygiene, and fissure anatomy in determining when sealant should be applied.

Good professional judgment should be used in the selection of teeth and patients. The use of pit-and-fissure sealants is contraindicated when rampant caries or interproximal lesions are present. Occlusal surfaces that are already carious with involvement of the dentin require restoration.

All caries-susceptible surfaces should be carefully evaluated, because caries is unlikely in well-coalesced pits and fissures. In this case sealants might be unnecessary or, at least, not cost-effective. Finally, although sealant application is relatively simple, the meticulous technique requires patient cooperation and should be postponed for uncooperative patients until the procedures can be properly executed.

Dentlearn.ir

While the cost-effectiveness of sealing permanent teeth is well established, it has not been well studied for primary teeth. Chi and colleagues attempted to address this question by analyzing the cost-effectiveness comparing two primary molar sealing strategies, always seal or never seal, with the standard care for Medicaid-enrolled children.[17] Using Iowa Medicaid claims data, they found that:

1. Primary molar sealants prevent dental disease.
2. Primary molar sealants lead to higher costs, although sealants for children at increased risk for tooth decay would be one cost-reducing strategy.
3. Compared with standard care, the incremental cost and treatment avoided for always sealing primary molars are less than the incremental cost and treatment avoided for never sealing primary molars.

SEALANT TECHNIQUE

After selection the tooth is washed and dried, and the deep pits and fissures are reevaluated (Fig. 10-1, *A*). If caries is present, restoration or a combination of restoration and sealing may be indicated (see later).

Marking centric stops with articulating paper provides information so that excess sealant does not interfere with occlusion. This is not necessary when the tooth has just erupted but is helpful in a well-established occlusion.

CLEANING

Adequate retention of the sealant requires that the pits and fissures be clean and free of excess moisture (see Figs. 10-1, *B* and 10-1, *C*). Acid-etching completely removes the enamel pellicle, and a dental prophylaxis (even with a dental explorer) does not increase the retention of sealants. From a practical standpoint, in cases of poor oral hygiene, fissure cleansing with a rotating dry bristle brush may be beneficial.

Pope and colleagues found, in a laboratory study, that the use of a quarter round bur produced the greatest penetration of the sealant into the etched enamel.[18] The use of an aluminum oxide air abrasion system enables sealant penetration greater than that achievable by the use of pumice or a dry bristle brush alone. It is not known if the increased depth of sealant penetration will result in greater sealant retention. When pumice or aluminum oxide is used, particulate matter is left in the deep recesses of the pits, the impact of which has not been determined.

Hatibovic-Kofman and colleagues measured the mi-

teeth.[19] The teeth received conventional (etch), quarter round bur, or air abrasion surface preparation. Teeth prepared with the bur exhibited the least microleakage. The amount of microleakage in the conventional and air abra-

The routine procedure of fissure eradication is probably not necessary. In fact, inappropriate or aggressive use of fissure opening or enameloplasty often removes the last of the enamel overlying the dentin at the bottoms of fissures, which leaves the tooth more susceptible to future caries in case of sealant loss. Good sealant methodology and proper sealant volume are probably more beneficial than enameloplasty.

ISOLATION

The tooth (or quadrant of teeth) to be sealed is first isolated. Rubber dam isolation is ideal but may not be feasible in certain circumstances. Cotton rolls, absorbent shields, and high-volume evacuation with compressed air may also be used effectively.

Eidelman and associates reported comparable retention results with the use of a rubber dam and cotton rolls for the isolation of teeth to be sealed.[20]

ETCHING

Microporosities in the enamel surface are created by the acid-etching technique. This facilitates the application of a low-viscosity resin that penetrates the roughened surface and produces a mechanical lock of resin tags when cured.

Various phosphoric acid solutions have been evaluated for the etching procedure. Zidan and Hill tested the amount of surface loss of the enamel after 60 seconds of etching with different phosphoric acid concentrations ranging from 0.5% to 80%.[21] They reported that the maximum loss of the enamel was produced by the 35% concentrations, whereas the bond strengths were not significantly different after being etched with 2%, 5%, and 35% concentrations. Generally, from 30% to 50% acid solutions or gels are recommended.

The etchant in solution should be placed on the enamel with a brush, small sponge, cotton pellet, or applicator provided by the manufacturer. The etchant should be placed widely across the surface to be sealed, so that there is no chance that resin placement and polymerization will occur over an unetched enamel area. If a solution is used, one should gently agitate and replenish it, making an effort to avoid rubbing and breaking the enamel rods.

Occasionally a viscous gel etchant may show a "skipping" effect, which occurs when the etchant does not completely and uniformly wet the entire enamel surface, and unetched areas are evident after washing and drying. If this occurs, reetching is necessary.

Generally a 20-second etching time is recommended. Enamel rich with fluorhydroxyapatite may be resistant to etching and may need to be exposed for longer periods. Primary teeth may also sometimes be resistant to etching and may require a longer etching time. Redford and colleagues reported no increase in bond strength with 120-second etching on primary teeth compared with 15-, 30-, and 60-second etching times.[22] Their in vitro study showed that the etch depth increased between 60 and 120 seconds, but there was no corresponding increase in bond strength.

Some advocate preparing the enamel for sealant application with an aluminum oxide air abrasion system or a laser system approved for hard-tissue procedures. To date, studies indicate that additional acid-etching is needed after each of these techniques to allow for adequate resin bonding to the enamel.

Dentlearn.ir

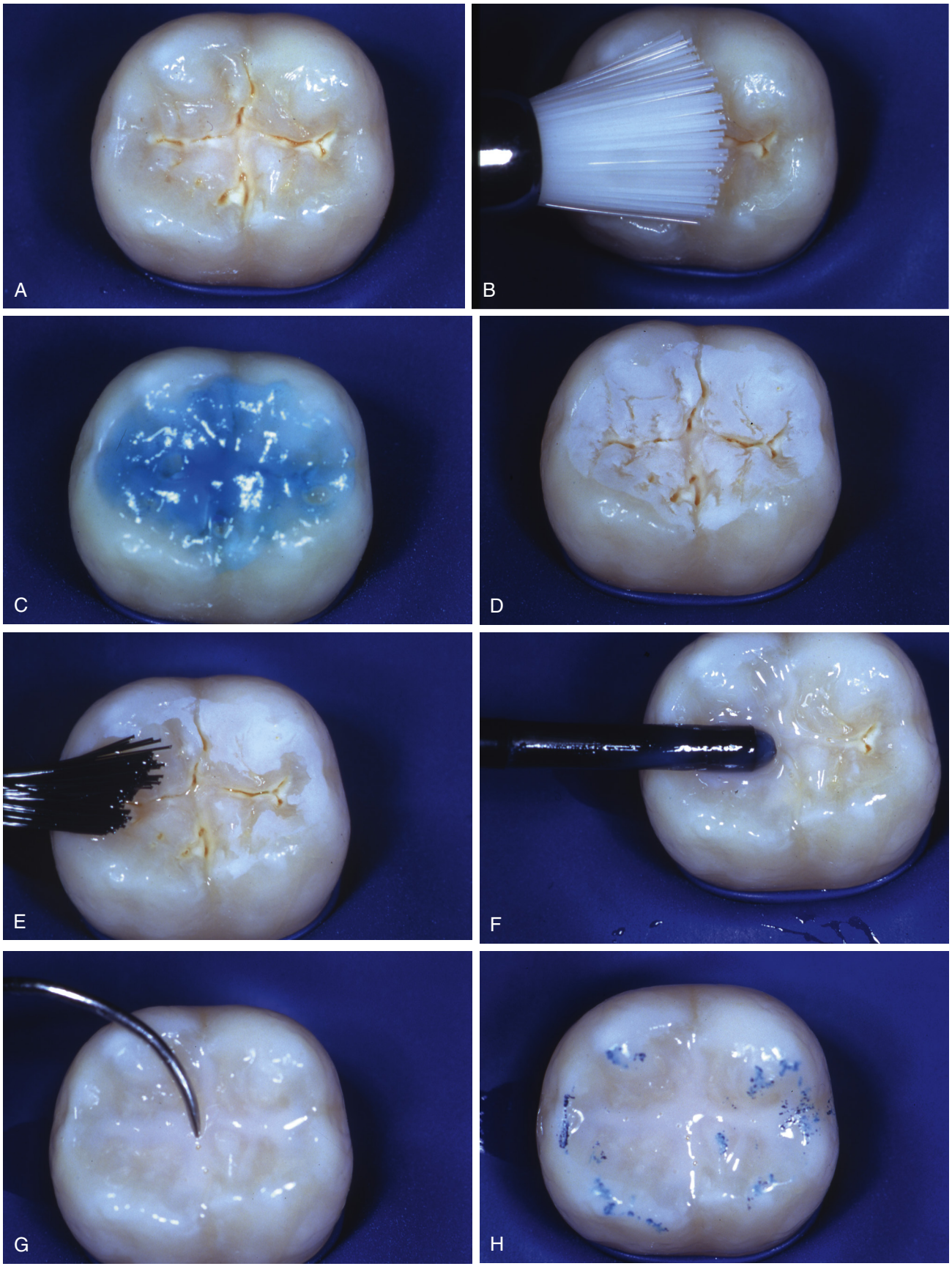

Figure 10-1 **A**, An occlusal view of a molar with susceptible pits and fissures. **B**, The tooth is cleaned with a rotary brush. **C**, The tooth is etched. **D**, The tooth appears frosty after being etched, washed, and dried. **E**, The bonding agent is placed on the tooth. **F,** The sealant is applied to the tooth. **G**, The sealant is checked for polymerization voids and excess. **H**, The occlusion is adjusted as necessary.

WASHING

Most manufacturers' instructions advocate a thorough washing and drying of the etched tooth surface but do not specify a time interval. Phillips advocated a 40-second washing time,[23] and Norling advocated 20 seconds.[24]

The etched enamel is dried with a compressed air stream that is free of oil contaminants. The dry etched enamel should exhibit a characteristic frosty appearance (see Fig. 10-1, *D*).

Feigal and colleagues found that the use of a dentin-bonding agent increased sealant retention in teeth even when salivary contamination occurred.[25] Choi and colleagues have reported corresponding findings in vitro on moisture-contaminated bovine enamel.[26] In a later extensive review article, Feigal recommended routine placement of bonding agents before all sealant applications.[27]

Although the recommendation is still to avoid moisture contamination whenever possible during sealant application, the use of a dentin-bonding agent as part of the technique appears to be warranted (see Fig. 10-1, *E*). Furthermore, the use of a dentin-bonding agent is definitely recommended in clinical situations that do not lend themselves to strict isolation—for example, when newly erupted teeth are sealed or when patient cooperation is not ideal. The use of a dentin-bonding agent is also advantageous on the buccal surfaces of molars, which traditionally have shown a lower retention rate than the occlusal surfaces of teeth.[28] When used, the bonding agent must be thoroughly air-dried across the surface to be sealed to avoid a thick layer of adhesive residue.

APPLICATION OF SEALANT

Chemically Cured Sealant

The manufacturer's instructions should be followed. Precise mixing without vigorous agitation can help prevent the formation of air bubbles.

The addition of the catalyst to the base immediately begins the polymerization of the material, and this should be kept in mind so that no time is lost in carrying the material to the etched and dried tooth. Working time is limited with a chemically cured sealant.

Visible Light–Cured Sealant

The curing of a light-polymerized sealant is not completed without the exposure of the material to the curing light, but the operating light and ambient light can also affect the material over a period of time, and so material should be dispensed only when it is time to place it on the tooth. The working time is longer than with chemically cured sealant. The method of placement varies with the different applicators provided by the manufacturers. The sealant is applied to the prepared surface in moderation and then gently teased with a brush or probe into the pits and grooves (see Figs. 10-1, *F* and 10-1, *G*). With careful application, incorporation of air bubbles is avoided. Care should also be taken to avoid applying large amounts of the sealant material.

If a light-curing material is used, the intensity of the light should be considered. If a large surface area requires polymerization, place the light directly over each area of the occlusal surface for the recommended time.

With light-cured sealants there is less chance for the incorporation of air bubbles, because no mixing of materials is required. After the material has been cured and while the treated teeth are still isolated, the unpolymerized surface layer should be removed by washing and drying, to avoid an unpleasant taste.

CHECK OF OCCLUSAL INTERFERENCES

Articulating paper should be used to check for occlusal interferences, and the occlusion be adjusted if necessary (see Fig. 10-1, *H*). All centric stops should be on the enamel.

If a filled sealant has been used, it is essential to adjust the occlusion before the patient is dismissed.

Other excess sealant that may have flowed over the marginal ridge or toward the cervical area should also be removed. If the tooth is isolated with a rubber dam, the excess should be removed before the rubber dam is detached. A small round bur at slow speed will remove the excess effectively. If etchant has been well localized, excess sealant may be removed with a sharp instrument from the unetched tooth enamel without removing sealant from the etched groove areas.

REEVALUATION

It is important to recognize that sealed teeth should be observed clinically at periodic recall visits so that the effectiveness of the sealant can be determined. Periodic recall and reapplication of sealants are necessary, because it is estimated that between 5% and 10% of sealants need to be repaired or replaced yearly. If a sealant is partially or completely lost, any discolored or defective old sealant should be removed and the tooth reevaluated. A new sealant can be applied using the method previously described.

PREVENTIVE RESIN RESTORATION (SEALED COMPOSITE RESIN RESTORATION)

The preventive resin restoration is an alternative procedure for restoring young permanent teeth that require only minimal tooth preparation for caries removal but also have adjacent susceptible fissures.

Simonsen and Stallard described the technique of removing only the carious tooth structure in small class I cavities.[29] A resin restoration was then placed, and the adjacent pits and fissures were sealed at the same time.

Henderson and Setcos described the sequence of the preventive resin restoration that is particularly applicable for young patients with recently erupted teeth and minimally carious pits and fissures.[30] They pointed out that this preparation requires a meticulous technique that involves more time than the traditional occlusal amalgam restoration. This type of restoration was advocated for carefully selected non–stress-bearing areas to minimize anatomic wear.

Occlusal surfaces often have small carious pits. For minimal caries, restorations are not likely to be subjected to substantial stresses that might lead to wear of resin materials. Figure 10-2 shows diagrams illustrating the principles of the sealant-composite combination. In this case

Dentlearn.ir

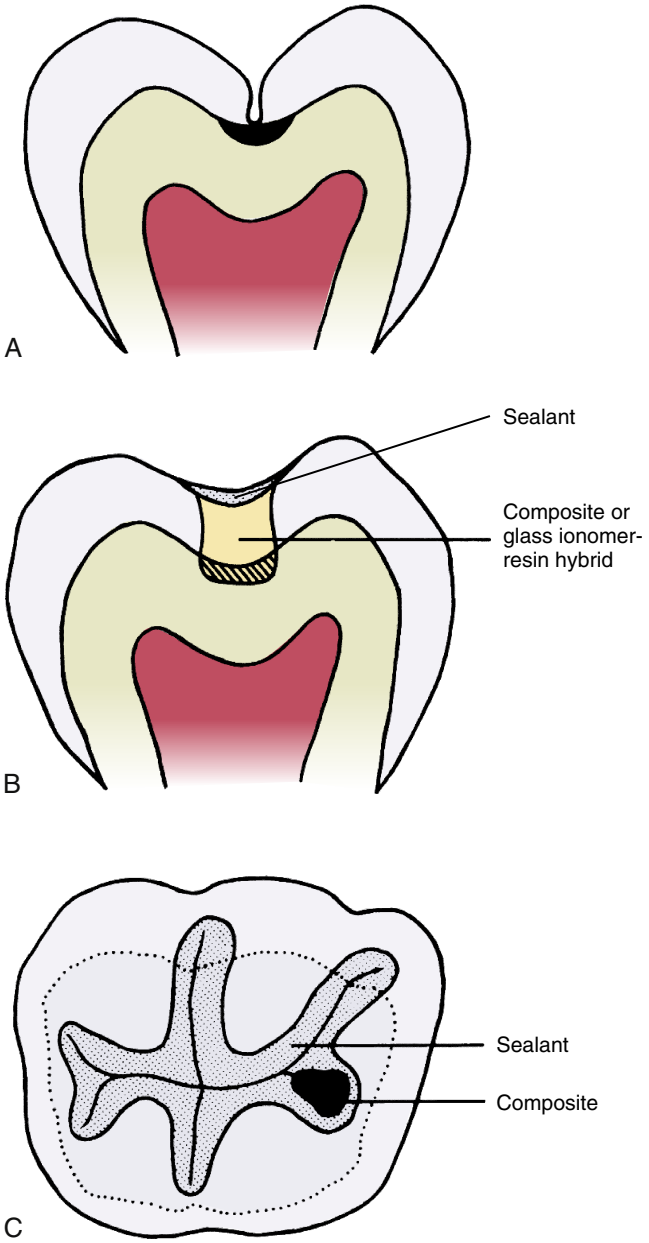

Figure 10-2 Diagrams illustrating the sealed composite resin restoration. **A**, A cross-section showing caries extending to the dentin. **B**, A cross-section through a preparation with a glass-ionomer or composite restoration and a sealant. **C**, An occlusal view of the outline of a small restoration where a pit-and-fissure sealant illustrates the extension-for-prevention principle of cavity preparation.

a small caries lesion has penetrated the dentin. In general, bitewing radiographs should indicate no interproximal caries.

A clinical series showing the sequence for this conservative preparation and restoration is portrayed in Figure 10-3. Caries is identified by careful visual examination of a dry occlusal tooth surface with the use of a sharp explorer, a mirror, and a light (see Fig. 10-3, *A*). Articulating paper marks on the tooth would indicate the points of occlusal contact.

The tooth is anesthetized if necessary, isolated, and reexamined so that the extent of the caries process can be determined. A No. 329 bur or a laser system approved for hard tissue can be used to gain access to the depth of the lesion and to complete caries removal (see Fig. 10-3, *B*). The preparation, which should not extend to the occlusal contact marks, is washed, dried, and examined.

The cavity and the enamel beside the susceptible grooves are etched (see Fig. 10-3, *C*). A gel or liquid form of 37% phosphoric acid is commonly used for 20 seconds. Surface preparation with aluminum oxide air abrasion or a laser system approved for hard tissue may not substitute for acid-etching. If these cleaning methods are used, etchant must still be applied to provide adequate resin-bonding enamel. The lingual grooves of maxillary molars and the buccal grooves of mandibular molars are also commonly etched and sealed. The tooth is thoroughly washed for approximately 30 to 40 seconds and completely dried.

A thin layer of bonding agent is applied to the cavity (see Fig. 10-3, *D*). A stream of air must be used to thin the bonding agent and to prevent pooling of bonding agent in the cavity.

The cavities are filled with a light-curing composite or resin-modified glass ionomer, which may be cured at this time (see Fig. 10-3, *E*). A light-curing sealant is placed over the remaining susceptible areas and brushed into the pits and grooves (see Fig. 10-3, *F*). The materials are polymerized with visible light in accordance with the manufacturer's instructions.

The rubber dam is removed, and the occlusal contacts are checked. A small-particle diamond rotary instrument can be used to remove excess sealant and ensure centric stops on the enamel (see Figs. 10-3, *G* and 10-3, *H*).

A meticulous technique is used in the selection, preparation, and restoration of minor pit-and-fissure caries with the preventive resin restoration.

The long-term effectiveness of the bonded restoration with sealant overlay has been proven. The restorations have success equivalent to or better than that of amalgam restorations. Once again, however, success is dependent upon whether the sealant remains intact.

The use of flowable composite systems is also gaining in popularity because they are easy to apply and because evidence shows that less microleakage occurs with these systems than when teeth are restored with condensable composite resins, such as sealant materials that have slightly more filler than filled sealants. Therefore the practical results of sealing with a flowable or a filled sealant should not differ.

There is no single perfect conservative restoration. Each dentist must decide, on an individual basis, the appropriate type of procedure. The restoration described can be very effective in carefully selected cases.

Walker and associates reported on preventive resin restorations placed in patients from 6 to 18 years of age and observed for up to 6.5 years.[31] Of the 5185 restorations, 83% did not require further intervention. Those requiring intervention included 37% that needed sealant alone and 21% that required treatment because of the development of an interproximal lesion. Houpt and associates reported complete retention of 54% of their preventive resin

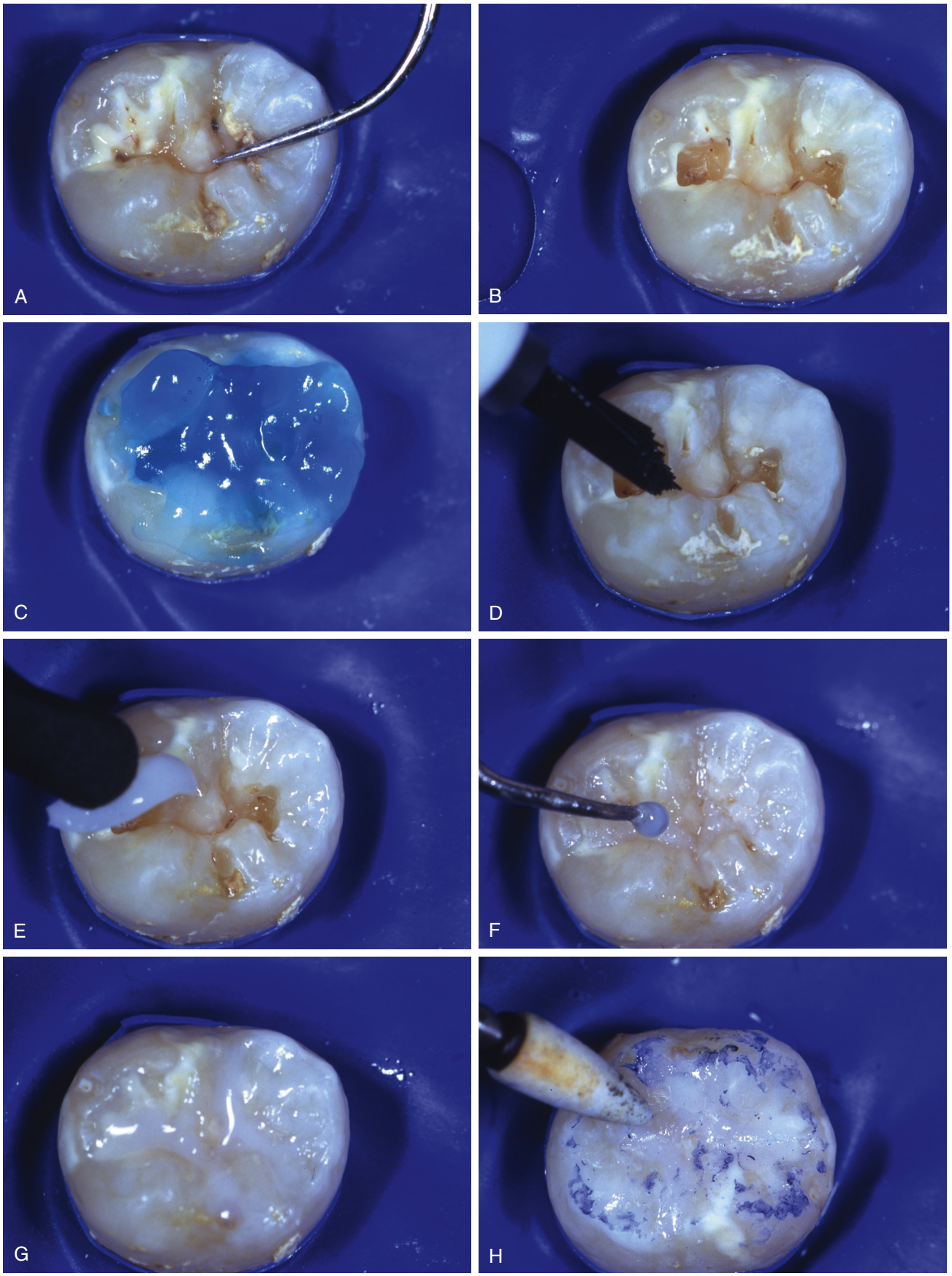

Figure 10-3 **A**, Occlusal caries identified with susceptible pits and grooves. **B**, Caries is removed from the dentin. **C**, The tooth is etched. **D**, The bonding agent is placed. **E**, Composite resin is placed. **F**, Sealant is placed over resin. **G**, Polymerized preventive resin restoration. **H,** The occlusion is adjusted.

restorations, partial loss of sealant in 25%, and complete loss of sealant in 20% after 9 years.[32] Caries occurred in 25% of the teeth that had sealant loss, and 88% of the restored surfaces remained caries-free 9 years after treatment. These researchers concluded that preventive restorations produce excellent long-term results. Conservative cavity preparation with sealing for prevention is a successful approach for treating selected decayed teeth.

REFERENCES

1. Buonocore MG: A simple method of increasing the adhesion of acrylic filling materials to enamel surfaces, *J Dent Res* 34:849–853, 1955.
2. Bowen RL: Method of preparing a monomer having phe-
3. Dental sealants in the prevention of tooth decay: Proceedings of the National Institutes of Health Consensus Development Conference, *J Dent Educ* 48:4–131, 1984.
4. Simonsen RJ: Retention and effectiveness of dental sealant after 15 years, *J Am Dent Assoc* 122:34–42, 1991.
5. Antonson SA, et al.: Twenty-four month clinical evaluation of fissure sealants on partially erupted permanent first molars, *J Am Dent Assoc* 143(2):115–122, 2012.
6. Griffin SO, et al.: The effectiveness of sealants in managing caries lesions, *J Dent Res* 87(2):169–174, 2008.
7. Azarpazhooh A, et al.: Pit and fissure sealants in the prevention of dental caries in children and adolescents: a systematic review, *J Can Dent Assoc* 74(2):171–177, 2008.
8. Oong EM, et al.: The effect of dental sealants on bacteria levels in caries lesions, *J Am Dent Assoc* 139(3):271–278, 2008.
9. Wendt L, Koch G: Fissure sealant in permanent first molars after 10 years, *Swed Dent J* 12:181–185, 1988.
10. Romcke RG, et al.: Retention and maintenance of fissure sealants over 10 years, *J Can Dent Assoc* 56:235–237, 1990.
11. Dennison JB, et al.: Effectiveness of sealant treatment over five years in an insured population, *J Am Dent Assoc* 131:597–605, 2000.
12. Robison VA, et al.: A longitudinal study of school children's experience in the North Carolina dental Medicaid program, 1984 through 1992, *Am J Public Health* 88:1669–1673, 1998.
13. Koh SH, et al.: Effects of topical fluoride treatment on tensile bond strength of pit and fissure sealants, *Gen Dent* 46:278–280, 1998.
14. Warren DP, et al.: Effect of topical fluoride on retention of pit and fissure sealants, *J Dent Hyg* 75:21–24, 2001.
15. Beauchamp J, et al.: Evidence based clinical recommendations for the use of pit and fissure sealants, *J Am Dent Assoc* 139:257–268, 2008.
16. Papers from the Pediatric Restorative Dentistry Consensus Conference. San Antonio, Texas, April 15-16, 2002. *Pediatr Dent* 24(5):374–516, 2002.
17. Chi DL, et al.: Cost-effectiveness of pit-and-fissure sealants on primary molars in Medicaid-enrolled children, *Am J Pub Health* 104(3):555–561, 2014.
18. Pope BD, et al.: Effectiveness of occlusal fissure cleansing methods and sealant micromorphology, *J Dent Child* 63:175–180, 1996.
19. Hatibovic-Kofman S, et al.: Microleakage of sealants after conventional, bur, and air-abrasion preparation of pits and fissures, *Pediatr Dent* 20:173–176, 1998.
20. Eidelman E, et al.: The retention of fissure sealants: rubber dam or cotton rolls in a private practice, *J Dent Child* 50:259–261, 1983.
21. Zidan O, Hill G: Phosphoric acid concentration: enamel surface loss and bonding strength, *J Prosthet Dent* 55:388–391, 1986.
22. Redford DA, et al.: The effect of different etching times on the sealant bond strength, etch depth, and pattern in primary teeth, *Pediatr Dent* 8:111–115, 1986.
23. Phillips RW: *Personal communication*, 1986.
24. Norling BK: Bonding. In Anusavice KJ, editor: *Phillips' science of dental materials*, ed 11, St. Louis, 2003, Saunders.
25. Feigal RJ, et al.: Retaining sealants on salivary contaminated enamel, *J Am Dent Assoc* 124:88–96, 1993.
26. Choi JW, et al.: The efficacy of primer on sealant shear bond strength, *Pediatr Dent* 19:286–288, 1997.
27. Feigal RJ: Sealants and preventive restorations: review of effectiveness and clinical changes for improvement, *Pediatr Dent* 20:85–92, 1998.
28. Feigal RJ, et al.: Improved sealant retention with bonding agents: a clinical study of two-bottle and single-bottle systems, *J Dent Res* 79:1850–1856, 2000.
29. Simonsen RJ, Stallard RE: Sealant-restorations utilizing a diluted filled composite resin: one year results, *Quintessence Int* 8(6):77–84, 1977.
30. Henderson HZ, Setcos JC: The sealed composite resin restoration, *J Dent Child* 52:300–302, 1985.
31. Walker J, et al.: The effectiveness of preventive resin restorations in pediatric patients, *J Dent Child* 63:338–340, 1996.
32. Houpt M, et al.: The preventive resin (composite resin/sealant) restoration: nine-year results, *Quintessence Int* 25:155–159, 1994.

CHAPTER 11

Restorative Dentistry

▲ Jeffrey A. Dean and Kevin J. Donly

For additional resources, please visit the evolve website.

CHAPTER OUTLINE

STATUS OF COMMON RESTORATIVE MATERIALS
MAINTENANCE OF A CLEAN FIELD
- Armamentarium for Rubber Dam Placement
- Selection of a Clamp

ISOLITE SYSTEM
MORPHOLOGIC CONSIDERATIONS
BASIC PRINCIPLES IN CAVITY PREPARATION IN PRIMARY TEETH
CAVITY PREPARATION IN PRIMARY TEETH
- Incipient Class I Cavity in a Very Young Child
- Pit or Fissure Class I Cavity
- Deep-Seated Class I Cavity
- Class II Cavity
- Class III Cavity
- Modified Class III Cavity Preparation

RESTORATION OF PROXIMAL INCISAL CARIES IN PRIMARY ANTERIOR TEETH
- Aesthetic Resin Restoration
- Stainless Steel Crowns
- Direct Resin Crowns

PREPARATION OF CAVITIES IN YOUNG PERMANENT TEETH
- Interim Restoration for Hypoplastic Permanent Molars

STAINLESS STEEL CROWNS FOR POSTERIOR TEETH
- Preparation of the Tooth
- Selection of Crown Size
- Contouring of the Crown (When Necessary)

COSMETIC ZIRCONIA CROWNS
ALTERNATIVE RESTORATIVE TREATMENT
COSMETIC RESTORATIVE PROCEDURES FOR YOUNG PERMANENT ANTERIOR TEETH
- Bonded Composite Veneer Restorations (Resin-Based Composite Bonding)
- Bonded Laminate Veneer Restorations (Dental Laminates or Laminate Veneers)

CONTROVERSIES IN PEDIATRIC RESTORATIVE DENTISTRY
- Laser Use
- Minimalist Approach to Restorative Care

Advances in preventive dentistry and their application in the private dental office, the widespread acceptance of communal fluoridation, and greater emphasis on dental health education have dramatically changed the nature of dental practice. Today the dentist devotes more time to preventive procedures and less time to the routine restoration of caries-affected teeth.

Nevertheless, restoration of caries lesions in primary and young permanent teeth continues to be among the important services that pediatric dentists and general practitioners provide for the children in their practices. Patients and fellow practitioners often judge dentists on the effectiveness of their preventive programs and the skill with which they perform routine operative procedures.

The *Reference Manual* of the American Academy of Pediatric Dentistry (AAPD) includes a Guideline on Pediatric Restorative Dentistry (revised in 2012) that states the following, in part[1]:

Restorative treatment is based on the results of an appropriate clinical examination and is ideally part of a comprehensive treatment plan. The treatment plan should consider the following:

1. The developmental status of the dentition
2. A caries-risk assessment
3. Patient's oral hygiene
4. Anticipated parental compliance and likelihood of timely recall
5. Patient's ability to cooperate for treatment

The restorative treatment plan must be prepared in conjunction with an individually tailored preventive program. Restoration of primary teeth differs significantly from restoration of permanent teeth, due in part to the differences in tooth morphology.

In 2002 AAPD, with financial assistance from the American Society of Dentistry for Children, held a pediatric restorative dentistry consensus conference in San Antonio, Texas. Sixteen literature review and position papers were presented at the conference, and numerous consensus statements about appropriate pediatric restorative materials and procedures were developed. The papers and consensus statements are compiled in the September/October 2002 issue of *Pediatric Dentistry*.

STATUS OF COMMON RESTORATIVE MATERIALS

Advances in the development of improved biomaterials for dental restorations have been rapid, and they continue to occur at a fast pace. This fact creates a significant challenge for dentists striving to remain at the cutting edge of dental technology. The more common restorative materials used in pediatric dentistry are composite and other resin systems, glass ionomers, silver amalgam alloys, and stainless steel alloys. Porcelain, zirconia, and cast metal alloy materials are also used in pediatric

Dentlearn.ir

restorative dentistry but less frequently than those listed in the previous sentence.

Resin-based composites, glass ionomers, or some combination of the two are being used progressively more and silver amalgam progressively less in pediatric restorative dentistry; many pediatric dentistry practices do not use silver amalgam at all; instead, some form of resin-based composite or glass ionomer is used. These materials have bonding capability. Glass ionomers may be considered pharmacologically therapeutic because they release fluoride over time; they also have minimal shrinkage during setting. Resin-based composites possess durability and superior aesthetic qualities. When managed properly, both materials are capable of providing excellent marginal sealing at the tooth–restorative material interface. The manufacturers of these materials have also combined them in an effort to join the primary advantages of each type of material. Berg has suggested that we think of these materials and their combinations on a continuum, with glass ionomer on the left, resin-based composite on the right, and the combined materials somewhere in between, depending on the relative amounts of each material in the mix. Two major categories on the continuum are described as "resin-modified glass ionomer" (or "hybrid ionomer" or "light-cured glass ionomer") and "compomers" (or "polyacid-modified composite resin" or "glass-ionomer–modified resin-based composite"). A fifth formulation has been added on the right side of the continuum in the form of "flowable resin-based composite." Berg points out that knowing the particular strengths and weaknesses of each type of material on the continuum will enhance the clinician's ability to make the best choices for each individual restorative situation.[2] Use of any of these restorative materials generally requires more effort and time than those needed for corresponding conventional amalgam restorations.

Despite its declining use, silver amalgam remains one of the most durable and cost-effective restorative materials. Success in the use of this filling material depends on adherence to certain principles of cavity preparation that do not always apply when materials on the glass-ionomer–composite-resin continuum are used. Some renewed interest in silver amalgam has occurred because of the development of "bonded amalgams." Bonded amalgams are silver amalgam restorations that have been condensed into etched cavity preparations lined with a dentin-bonding agent and some material on the glass-ionomer–composite-resin continuum. Bonded amalgams require considerable extra effort and expense to place compared with conventional amalgam restorations. The improvements in tooth support and marginal integrity gained with these restorations have been demonstrated in many studies. Some longer-term studies, however, suggest that the advantages of bonded amalgams may be transient and relatively short-lived, possibly 1 year or less.[3,4] In general, the use of bonded amalgams seems difficult to justify for the routine restoration of primary teeth, because traditional silver amalgam should provide comparable quality more efficiently and cost-effectively in most situations.

Stainless steel alloy is another commonly used pediatric restorative material. It is used extensively for full coronal coverage restorations of primary teeth. Stainless steel crowns have undoubtedly preserved the function of many primary teeth that otherwise would have been unrestorable. In addition, stainless steel crowns are often used to restore all posterior teeth in young patients with high risk for caries who exhibit multiple proximal lesions that could otherwise be restored with silver amalgam or aesthetic materials. Crowns are used instead simply because they better protect all posterior tooth surfaces from developing additional caries and because the posterior crown restoration has proven to be the most durable and cost-effective in the primary dentition. Anterior and posterior stainless steel crowns may have labial and/or occlusal resin or porcelain veneers to enhance aesthetics.

MAINTENANCE OF A CLEAN FIELD

The maintenance of a clean operating field during cavity preparation and placement of the restorative material helps ensure efficient operation and development of a serviceable restoration that will maintain the tooth and the integrity of the developing occlusion.

The rubber dam aids in the maintenance of a clean field. It is generally agreed that the use of the rubber dam offers the following advantages:

1. *Saves time.* The dentist who has not routinely used the rubber dam needs only to follow the routine presented later in this chapter or a modification of it for a reasonable period to be convinced that operating time can be appreciably reduced. The time spent in placing the rubber dam is negligible, as long as the dentist works out a definite routine and uses a chairside assistant. Heise reported an average time of 1 minute and 48 seconds to isolate an average of 2.8 teeth with the rubber dam in 302 cases.[5] These applications of the rubber dam, placed with the aid of a capable dental assistant, were for routine operative dentistry procedures. The minimum time recorded for placing a rubber dam was 15 seconds (single-tooth isolation), and the maximum time was 6 minutes. Many of the applications ranged 25 to 50 seconds. Heise also observed that approximately 10 seconds are required to remove the rubber dam. The elimination of rinsing and spitting by the pediatric patient will invariably make up for the time required for the placement of the rubber dam and may save additional time.
2. *Aids management.* A few explanatory words and reference to the rubber dam as a "raincoat" for the tooth or as a "Halloween mask" help allay the child's anxiety. It has been found through experience that apprehensive or otherwise uncooperative children can often be controlled more easily with a rubber dam in place. Because the rubber dam efficiently controls the patient's tongue and lips, the dentist has greater freedom to complete the operative procedures.
3. *Controls saliva.* Control of saliva is an extremely important consideration when one is completing an ideal cavity preparation for primary teeth. The margin of error is appreciably reduced when a cavity is prepared in a primary tooth that has a large pulp and extensive caries involvement. Small pulp exposures may be more easily detected when the tooth is

Dentlearn.ir

well isolated. It is equally important to observe the true extent of the exposure and the degree and type of hemorrhage from the pulp tissue. Thus the rubber dam aids the dentist in evaluating teeth that are being considered for vital pulp therapy.

4. *Provides protection.* The use of the rubber dam prevents foreign objects from coming into contact with oral structures. When filling material, debris, or medicaments are dropped into the mouth, salivary flow is stimulated and interferes with the operative or restorative procedure. A rubber dam also prevents the small child in a reclining position from swallowing or aspirating foreign objects and materials.
5. *Helps the dentist educate parents.* Parents are always interested in the treatment that has been accomplished for their child. While the rubber dam is in place, the dentist can conveniently show parents the completed work after an operative procedure. The rubber dam creates the feeling that the dentist has complete control of the situation and that a conscientious effort has been made to provide the highest type of service.

ARMAMENTARIUM FOR RUBBER DAM PLACEMENT

The armamentarium consists of 5 × 5-inch sheets of medium latex, a rubber dam punch, clamp forceps, a selection of clamps, a flat-blade instrument, dental floss, and a rubber dam frame. If one visualizes an approximately 1¼-inch square in the center of a sheet of rubber dam, each corner of the square indicates where the punch holes for the clamp-bearing tooth in each of the four quadrants of the mouth are to be made (Fig. 11-1). As experience is gained in applying the dam, the dentist and assistant will soon learn the proper location for punching the holes. If the holes are punched too far apart, the dam will not readily fit between the contact areas. In addition, the greater bulk of material between the teeth will greatly increase the possibility that the rubber will become a barrier to proximal surface preparation. Conversely, if the holes are punched too close together, salivary leakage will contaminate the operating field. In general, the holes should be punched the same distance apart as the holes on the cutting table of the rubber dam punch.

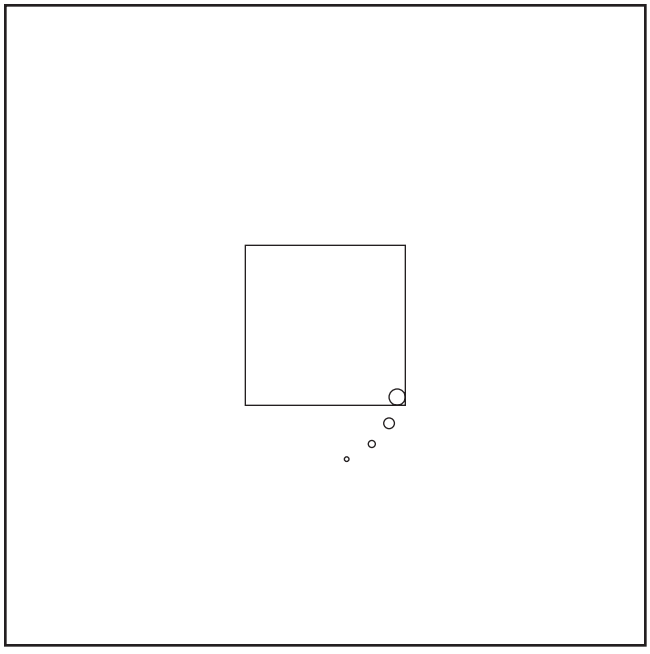

Figure 11-1 The corners of the square represent points where punch holes should be made for the clamp-bearing tooth.

The large punch hole is used for the clamp-bearing tooth and for most permanent molars, the medium-sized punch hole generally is used for the premolars and primary molars, the second smallest hole is used for maxillary permanent incisors, and the smallest hole is adequate for the primary incisors and lower permanent incisors.

SELECTION OF A CLAMP

The operator will soon develop a personal preference for specific clamps to use to secure the dam in isolating different areas in the mouth. Unless the clamp is firmly anchored to the tooth, the tension of the stretched rubber will easily dislodge it. Therefore proper selection of a clamp is of utmost importance. It is recommended that the clamp be tried on the tooth before the rubber dam is placed, to ascertain that the clamp can be securely seated and will not be easily dislodged by the probing tongue, lip, or cheek musculature. An 18-inch length of dental floss should be doubled and securely fastened to the bow of the clamp. The floss will facilitate retrieval in the unlikely event that the clamp slips and falls toward the pharynx (Fig. 11-2).

The following procedure is recommended for rubber dam application (Fig. 11-3). The previously selected and ligated clamp is placed in the rubber dam. The dentist grasps the clamp forceps with the clamp engaged. The assistant, seated to the left of the patient (the dentist is right-handed in this example), grasps the upper corners of the dam with the right hand and the lower left corner between the left thumb and index finger. The dam is moved toward the patient's face as the dentist carries the clamp to the tooth while holding the lower right portion of the dam. After securing the clamp on



Figure 11-2 An Ivory No. 3 clamp has been trial-fitted to the second primary molar. The clamp will be removed and placed in the rubber dam.

Dentlearn.ir

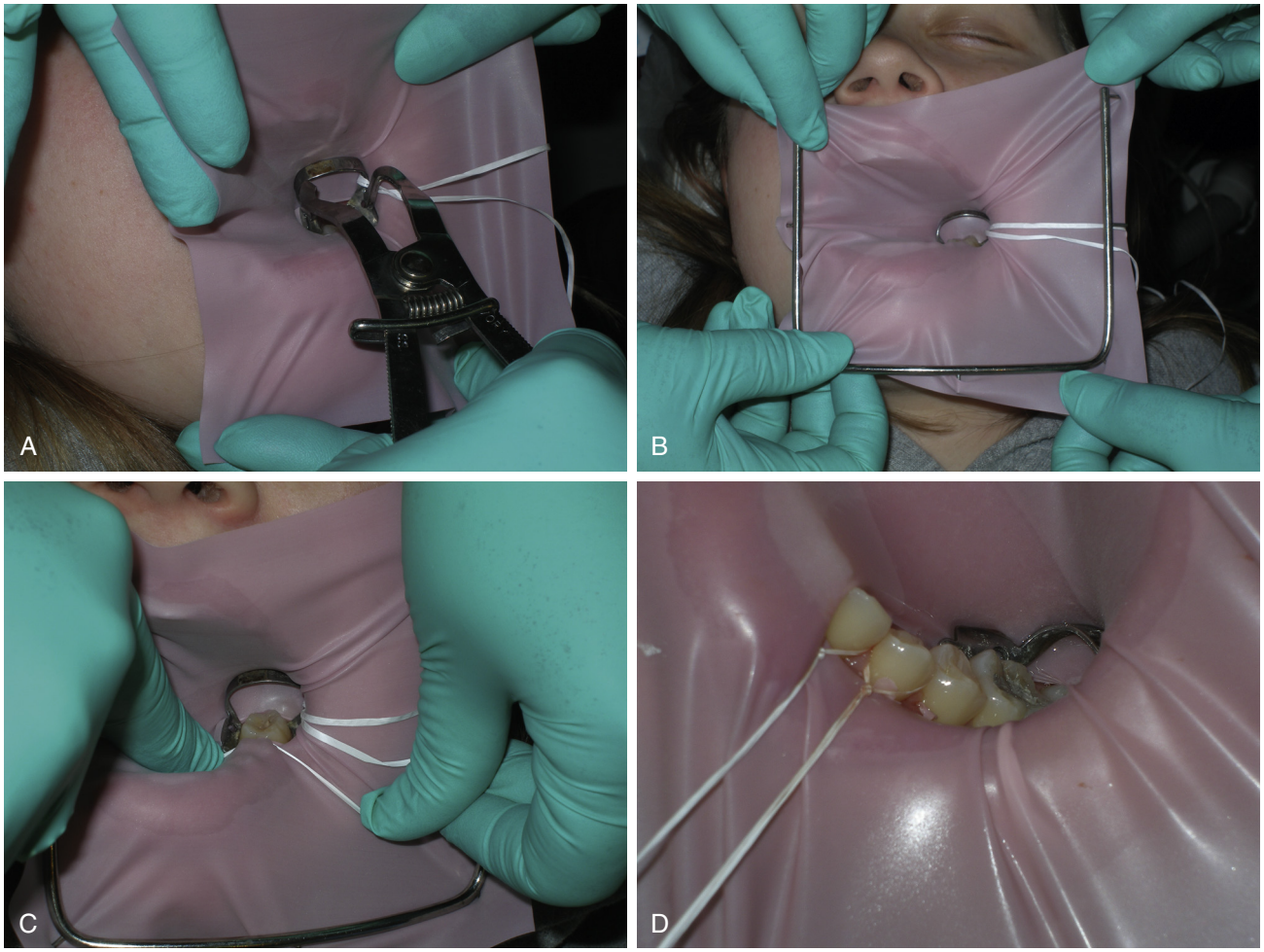

Figure 11-3 **A,** The dental assistant holds the top and lower right corners of the rubber dam as the dentist holds the lower left corner and carries the clamp to the tooth. **B,** The assistant and dentist attach the corners of the rubber dam to the frame. **C,** Dental floss is used to carry the rubber dam between the teeth. **D,** The teeth are isolated and ready for the operative procedure. (**A, B,** and **C** Courtesy of Dr. Richard Troyer.)

the tooth, the dentist transfers the clamp forceps to the assistant, who receives it while continuing to hold the upper corners of the dam with the right hand. The dentist then places the frame over the rubber dam. Together the assistant and dentist attach the corners of the dam to the frame. The flat blade of a plastic instrument or a right-angle explorer may be used to remove the rubber dam material from the wings of the clamp and to complete the seal around the clamped tooth. If necessary, light finger pressure may seat the clamp securely by moving it cervically on the tooth. If additional teeth are to be isolated, the rubber is stretched over them, and the excess rubber between the punched holes is placed between the contact areas with the aid of dental floss. The most anterior tooth and others, if necessary, are ligated to aid in the retention of the dam and prevention of cervical leakage. The free ends of the floss are allowed to remain because they may aid in further retraction of the gingival tissue or the patient's lip during the operative procedure. At the end of the operative procedure, the length of floss will also aid in removing the ligature.

When a quadrant of restorations in the primary dentition is planned and no pulp therapy is anticipated, Croll recommends the "slit-dam method."[6] One long opening is made in the dam, and the entire quadrant is isolated without interseptal dam material between the teeth.

It is unwise to include more teeth in the rubber dam than are necessary to isolate the working area adequately. If the first or second permanent molar is the only tooth in the quadrant that exhibits caries and if it requires only an occlusal preparation, it is often desirable to punch only one hole in the dam and isolate the single tooth (Fig. 11-4). This procedure will require only seconds and will save many minutes.

Due to an increase in latex allergies, latex-free rubber dams are available and used in the same manner already described.

ISOLITE SYSTEM

The Isolite system has also been recommended for achieving an isolated field. This dental isolation device is designed to function as a vacuum suction and to provide intraoral illumination. The system helps retract the tongue and has an integrated six-foot-long vacuum/power

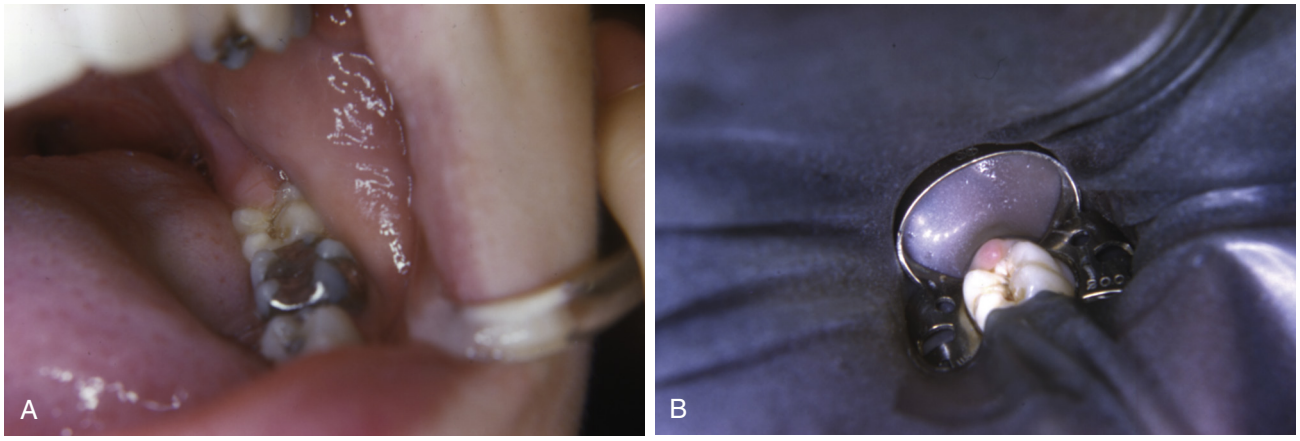

Figure 11-4 **A,** The second permanent molar requires an occlusal restoration. It is not necessary to isolate more than a single tooth. **B,** A No. 200 clamp has been selected to hold the rubber dam in place. The rubber dam has retracted the tissue that extended over the distal marginal ridge.

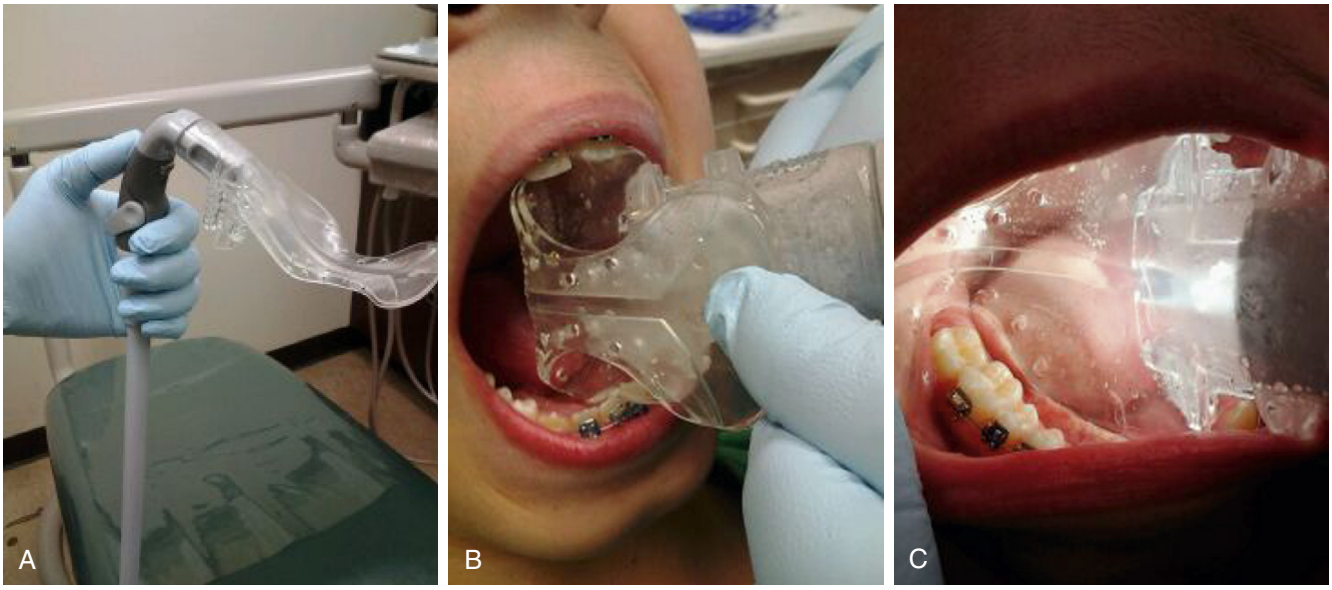

Figure 11-5 **A,** The Isolite system attached to the unit's vacuum. **B,** The isolation system folded for insertion into the oral cavity. **C,** The isolation system position intraorally.

silicone hose that connects easily to most standard high-volume ports (Fig. 11-5).[7]

MORPHOLOGIC CONSIDERATIONS

The crowns of the primary teeth are smaller but more bulbous than those of the corresponding permanent teeth, and the molars are bell-shaped, with a definite constriction in the cervical region. The characteristic sharp lingual inclination occlusal to the facial surfaces results in the formation of a distinct faciogingival ridge that ends abruptly at the cemento-enamel junction. The sharp constriction at the neck of the primary molar necessitates special care in the formation of the gingival floor during class II cavity preparation. The buccal and lingual surfaces of the molars, sharply converging occlusally, form a narrow occlusal surface or food table; this is especially true of the first primary molar.

The pulpal outline of the primary teeth follows the dentino-enamel junction more closely than that of the permanent teeth. The pulpal horns are longer and more pointed than the cusps would indicate. The dentin also has less bulk or thickness, so the pulp is proportionately larger than that of the permanent teeth. The enamel of the primary teeth is thin but of uniform thickness. The enamel surface tends to be parallel to the dentino-enamel junction.

BASIC PRINCIPLES IN CAVITY PREPARATION IN PRIMARY TEETH

Traditional cavity preparations for class I and class II lesions include areas that have caries involvement and areas that retain food and plaque material and may be considered areas of potential caries involvement. A flat pulpal floor is generally advocated. However, a sharp angle

between the pulpal floor and the axial wall of a two-surface preparation should be avoided. Rounded angles throughout the preparation will result in less concentration of stresses and will permit better adaptation of the restorative material into the extremities of the preparation.

Although the traditional class I cavity preparation and restoration may occasionally be the most practical treatment for a tooth in certain circumstances, such treatment is currently obsolete for most class I lesions. The traditional treatment has been replaced, for the most part, by conservative caries excavation and restoration with a combination of bonding restorative and sealant materials (see Chapter 10).

Likewise, the traditional class II cavity preparation and restoration, although not yet considered obsolete, are currently used less frequently as steadily improving restorative materials with therapeutic and bonding capability are developed. In the traditional class II cavity preparation for amalgam, the buccal and lingual extensions should be carried to self-cleansing areas. The cavity design should have greater buccal and lingual extension at the cervical area of the preparation to clear contact with the adjacent tooth. This divergent pattern is necessary because of the broad, flat contact areas of the primary molars and because of the distinct buccal bulge in the gingival third. Ideally the width of the preparation at the isthmus should be approximately one-third the intercuspal dimension. The axiopulpal line angle should be beveled or grooved to reduce the concentration of stresses and to provide greater bulk of material in this area, which is vulnerable to fracture.

Because many occlusal fractures of amalgam restorations are caused by sharp opposing cusps, it is advisable to identify these potentially damaging cusps with articulating paper before cavity preparation. The slight reduction and rounding of a sharp opposing cusp will reduce the number of such fractures.

CAVITY PREPARATION IN PRIMARY TEETH

The steps in cavity preparation in a primary tooth are not difficult, but they do require precise operator control. Many authorities advocate the use of small, round-ended carbide burs in the high-speed handpiece to establish the cavity outline and perform the gross preparation. For efficiency and convenience, all necessary high-speed instrumentation for a given preparation may be completed with a single bur in most situations. Therefore the dentist should select the bur that is best designed to accomplish all the high-speed cutting required for the procedure being planned. Figure 11-6 illustrates four high-speed carbide burs designed to cut efficiently and yet allow for conservative cavity preparations with rounded line angles and point angles. Alternatively, cavity preparations may be made with aluminum oxide air abrasion systems or with laser systems approved for hard-tissue procedures, when indications allow.

INCIPIENT CLASS I CAVITY IN A VERY YOUNG CHILD

During the routine examination of a child younger than 2 years of age, the dentist may occasionally discover a small but definite caries lesion in the central fossa of one or two first primary molars, with all other teeth being sound. Thus restorative needs are present but minimal. Because of the child's psychological immaturity and because it is usually impossible to establish effective communication with the child, the parent should hold the child on his or her lap in the dental chair. This helps the child feel more secure and provides a better opportunity to restrain the child's movement during the operative procedure. The small-cavity preparation may be made without the aid of a rubber dam or local anesthetic. A No. 329 or No. 330 bur is used to open the decayed area and extend the cavosurface margin only to the extent of the caries lesion. If the patient is resistant (usually), completing the preparation with an air abrasion or laser system would be inconvenient. The preparation can be completed in just a few seconds. Restoring the tooth with amalgam or a resin-modified glass ionomer arrests the decay and at least temporarily prevents further tooth destruction without a lengthy or involved dental appointment for the child. If the child is cooperative, a preventive resin restoration, preceded by application of a dentin-bonding agent, may be used.



Figure 11-6 Round-ended, high-speed carbide burs No. 329, No. 330, No. 245, and No. 256, which may be used for cutting cavity preparations.

PIT OR FISSURE CLASS I CAVITY

The preparation and restoration of a pit or fissure class I cavity are discussed in the section on preventive resin restoration in Chapter 10.

DEEP-SEATED CLASS I CAVITY

If an amalgam restoration is planned, the first step in the preparation of an extensive class I cavity is to the enamel that overhangs the extensive caries lesion. Then the cavity preparation should be extended throughout the remaining grooves and anatomic occlusal defects. The caries-affected dentin should next be removed with large, round burs or spoon excavators. If a caries exposure is not encountered, the cavity walls should be finished as previously

Dentlearn.ir

described. With deep caries lesions and near pulp exposures, the depth of the cavity should be covered with a biocompatible base material to provide adequate thermal protection for the pulp.

If a resin-based composite and/or glass-ionomer restoration is planned, any disease-free pits and grooves may be sealed as part of the bonded restoration. The restorative material also provides thermal insulation to the pulp.

CLASS II CAVITY

Proximal lesions in a preschool child indicate excessive caries activity; a preventive and restorative program should be undertaken immediately.

Small Lesions

Very small incipient proximal lesions may be chemically restored with topical fluoride therapy provided by the dentist, along with the judicious use of fluoride products designed for topical application at home. If this treatment regimen is accompanied by improved diet and improved oral hygiene, some incipient proximal lesions may remineralize or remain in an arrested state indefinitely. However, the parents should be informed of the incipient lesions, and emphasis should be placed on the need to continue practicing the recommended procedures and to bring the child back for periodic examinations. If the parents and the patient do not follow the instructions properly, subsequent bitewing radiographs will reveal advancement of the lesion, and restorative procedures should be initiated before the defects become extensive caries lesions.

As bonded restorations have improved, especially those restorations capable of fluoride release, more conservative cavity preparation designs have also been advocated. In otherwise sound teeth free of susceptible pits and fissures, accessing small class II caries lesions via small openings in the marginal ridges or in the facial surfaces of the teeth is becoming a popular technique (Fig. 11-7). Gaining access to the lesion with openings only large enough to allow caries excavation is the goal. Caries is removed by pendulous motions of small burs or by tilting of the air abrasion tip laterally and pulpally at the initial opening. This technique is particularly useful in cooperative patients who have one or two affected primary molars and who are judged to be at relatively low risk for additional caries activity. Suwatviroj and colleagues have shown in vitro that various tooth-colored restorations placed in box-only preparations did not differ in fracture resistance from those placed in dovetail preparations.[8] However, resin-modified glass-ionomer restorations placed in box-only preparations were more likely to show adhesive failure than those placed in dovetail preparations.

Other researchers, Croll[9] and Vaikuntam,[10] have also advocated conservative preparations and restorations with fluoride-releasing restorative materials. Our experience has shown that local anesthesia is usually unnecessary to make the preparation. When this short procedure is performed in cooperative patients, rubber dam isolation is often optional, especially on maxillary teeth. Use of resin-modified glass-ionomer materials results in excellent restorations for this conservative procedure (Fig. 11-8).

Marks and associates[11] and Welbury[12] and colleagues (who also restored class I preparations) have reported satisfactory results using conservative class II preparations and compomers to restore primary molars in studies of 36 and 42 months' duration, respectively. In a 3-year study, Hubel and Mejàre reported the successful performance of conservative class II resin-modified glass-ionomer restorations in primary molars.[13]



Figure 11-7 Approximating conservative preparations to remove small class II caries lesions in primary molars. **A,** Marginal ridge access. **B,** Facial surface access.

Lesions with Greater Dentin Involvement

The first step in the traditional preparation of a class II cavity in a primary tooth for an amalgam or an aesthetic restoration involves opening the marginal ridge area. Extreme care must be taken when breaking through the marginal ridge to prevent damage to the adjacent proximal surface.

Amalgam

The gingival seat and proximal walls should break contact with the adjacent tooth. The angle formed by the axial wall and the buccal and lingual walls of the proximal box should approach a right angle. The buccal and lingual walls necessarily diverge toward the cervical region, following the general contour of the tooth (Fig. 11-9). The occlusal extension of the preparation should include any caries-susceptible pits and fissures. If the occlusal surface is sound and not caries-susceptible, then a minimal occlusal dovetail is still often needed to enhance the cavity retention form. If caries-affected tooth structure remains after the preparation outline is established, it should be removed next. The appropriate liner or intermediate base, if indicated, and a snug-fitting matrix should be placed before the amalgam is inserted.

Dentlearn.ir



Figure 11-8 **A,** Conservative class II preparation. **B,** Resin-modified glass-ionomer restoration. **C,** Preoperative radiograph (top) and 17-month postoperative film.

Aesthetic Materials

Because of improvements in the properties of resin-based composites, many dentists use them routinely for posterior restorations. More recently the use of glass-ionomer restoratives (or other materials on the glass-ionomer–composite-resin continuum) has also been advocated. The preparation and restoration may be similar to those described earlier for amalgam when significant caries exists on both the occlusal and proximal surfaces. However, little or no occlusal preparation may be required when the occlusal pits and fissures are caries-susceptible but sound or incipient. The proximal restoration may then be combined with the application of an occlusal sealant (with or without enameloplasty). Whenever composite restorative materials are used, enamel beveling, etching, and application of bonding agents are recommended.

Clinical trials of restorations of primary molars, reported by Paquette and colleagues[14] and by Oldenburg and associates,[15] revealed that traditional preparations modified only by beveling of enamel margins and restored with bonded resin-based composites yielded highly successful results during 12- and 24-month observation periods. Tonn and Ryge also reported acceptable 2-year results for primary molars restored with bonded resin-based composites in traditional cavity preparations modified only by the beveling of enamel margins.[16]

Dilley and colleagues have demonstrated that the placement and finishing of posterior composite restorations are

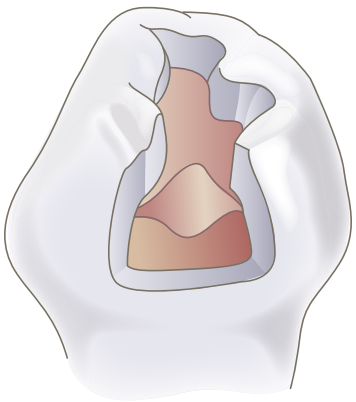

Figure 11-9 Traditional class II cavity preparation for a primary molar. The preparation includes diverging proximal walls and a beveled and grooved axiopulpal line angle.

significantly more time consuming than those for comparable amalgam restorations.[17] In addition to increasing the cost of care, the extra time required for treatment may complicate patient management for some young patients.

After 3 years of observation Donly and associates have reported successful results for class II resin-modified glass-ionomer restorations in primary molars.[18] In an interesting study by dos Santos and colleagues, class I and II preparations in primary molars were restored with either a resin-modified glass ionomer, a polyacid-modified

composite, or a traditional resin-based composite. After 24 months no statistically significant differences were found among the materials, although, not too surprisingly, the class I restorations showed higher survival rates than did the class II restorations.[19] The dentist's sound professional judgment is the key to selecting the restoration that will best serve the patient in each situation.

Resin Infiltrate

Recently introduced to the marketplace is a resin infiltrate (icon-DMG, Hamburg, Germany) designed to infiltrate subsurface lesions, preventing lesion advancement. Enamel is etched with hydrochloric acid prior to the placement of the resin. The resin can be placed on facial or lingual tooth surfaces and proximal lesions. An applicator specifically designed to allow proximal flow of the resin is provided by the manufacturer. The resin is tooth-colored but not radiopaque.

In a 1-year clinical study involving 42 children (mean age, 7.17 years), a resin infiltrate and 5% sodium fluoride varnish were placed on two subsurface enamel lesions. After 1 year 31% of the lesions treated with resin infiltrate had progressed compared with 67% of the lesions treated with 5% sodium fluoride varnish.[20] In another clinical trial with 22 adults, 29 lesion pairs, where the lesion was located in the inner half of enamel to the outer third of dentin, had either a resin infiltrate or no treatment provided. After 3 years 4% of the lesions treated with resin infiltrate had progressed, and 42% of lesions that received no treatment had progressed.[21] Another clinical trial with 39 adults with three proximal lesions in the outer third of dentin received a resin infiltrate, a sealant, and one lesion was left untreated (control). After 3 years there was no significant difference in the progression of the lesions treated with the resin infiltrate or sealant; however, both the resin infiltrate and sealant were significantly better at inhibiting lesion progression than was the untreated control.[22] Analysis of future clinical data will provide further information on the effectiveness of and indications for resin infiltrate in pediatric dentistry.

CLASS III CAVITY

Caries lesions on the proximal surfaces of anterior primary teeth sometimes occur in children whose teeth are in contact and in children who have evidence of arch inadequacy or crowding. Caries involvement of the anterior primary teeth, however, may be interpreted as evidence of excessive caries activity requiring a comprehensive preventive program.

If the caries lesion has not advanced appreciably into the dentin and if removal of the caries will not involve or weaken the incisal angle, a small conventional class III cavity may be prepared and the tooth may be restored with the dentist's choice of bonding materials (Fig. 11-10).

Mandibular primary incisors with small proximal caries lesions may not require conventional restorations at all. Enameloplasty of the affected proximal surface (usually described as "disking") to open the proximal contact and remove most, if not all, of the cavitation, followed by topical treatments with fluoride varnish, will often suffice until the teeth exfoliate naturally. Extraction is usually indicated when mandibular primary incisors have extensive caries.

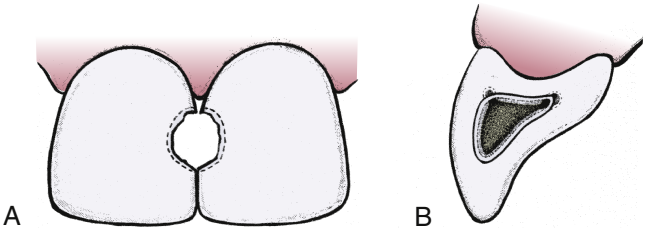

Figure 11-10 **A,** Schematic drawing of caries lesions on the mesial surfaces of maxillary primary central incisors that do not undermine the mesial angles of the teeth. The dotted line indicates the proposed labial outline of the class III cavity preparation. **B,** Proximal view illustrates that the class III preparation is limited to the cervical two thirds of the primary incisor. (From Roche JR: Restorative dentistry. In Goldman HM et al, eds. *Current therapy in dentistry*, vol 4, St. Louis, 1970, Mosby.)

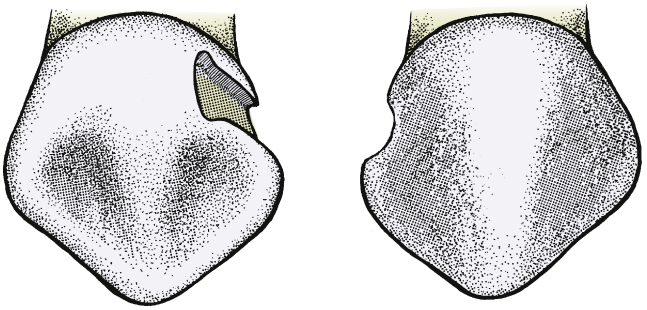

Figure 11-11 Lingual and labial views of a modified class III preparation for a maxillary primary canine. The dovetail improves the retention form of the preparation and allows access for placement of the restorative material to ensure adequate contact with the adjacent tooth.

MODIFIED CLASS III CAVITY PREPARATION

The distal surface of the primary canine is a frequent site of caries attack in patients at high risk for caries if the canine is in proximal contact with the first molar. The position of the tooth in the arch, the characteristically broad contact between the distal surface of the canine and the mesial surface of the primary molar, and the height of the gingival tissue sometimes make it difficult to prepare a typical class III cavity and restore it adequately. The modified class III preparation uses a dovetail on the lingual or occasionally on the labial surfaces of the tooth. A lingual lock is normally considered for the maxillary canine, whereas a labial lock may be more conveniently prepared on the mandibular teeth, for which the aesthetic requirement is not as important (Figs. 11-11 and 11-12). The preparation allows for the additional retention and access necessary for proper insertion of the restorative material.

Trairatvorakul and Piwat compared 31 paired slot preparations with dovetail class III preparations in primary anterior teeth in a well-controlled clinical study in children from 2 years 6 months to 5 years 3 months of age.[23] All teeth were restored with composite and evaluated for marginal adaptation, anatomic form, secondary caries, and marginal discoloration at 6, 12, and 24 months. Twenty-two pairs of restorations were available at the end

Dentlearn.ir

able. There was no statistically significant difference between more conservative slot preparation may often be preferred.

RESTORATION OF PROXIMAL INCISAL CARIES IN PRIMARY ANTERIOR TEETH

AESTHETIC RESIN RESTORATION

One type of preparation used for the aesthetic restoration of primary incisors in which dental caries approximates or involves the incisal edge of the teeth is illustrated in Figure 11-13. As with other operative procedures for the pediatric patient, the use of the rubber dam aids in maintenance of a dry field, provides better vision for the clinician, and facilitates control of the patient's lips and tongue.

The preparation includes a proximal reduction through the incisal angle and the caries lesion, and ends at the established cervical seat. Labial and lingual locks are then prepared in the cervical third of the tooth. The remaining caries is removed, the tooth is etched, and a bonding agent is applied.

A properly placed matrix tightly wedged at the cervical seat aids the operator in placing, shaping, and holding the resin-based composite during the curing process. A good matrix also simplifies the finishing procedures.

McEvoy described a similar preparation and restoration for primary incisors, except that the retentive locking component is placed on the labial surface only in the gingival third of the tooth.[24] The lock extends minimally across two thirds of the labial surface and may extend even farther to include decalcified enamel in the cervical area. We also recommend beveling the enamel margins slightly before etching, to further improve the marginal bonding of the restoration.

Initial shaping of the restoration may be accomplished with a flame-shaped finishing bur. The excess resin is removed, and the contour of the restoration is established. The gingival margins may be finished with a sharp scalpel blade. Final polishing may be accomplished with the rubber cup and a fine, moist abrasive material or one of the composite polishing systems (Fig. 11-14).

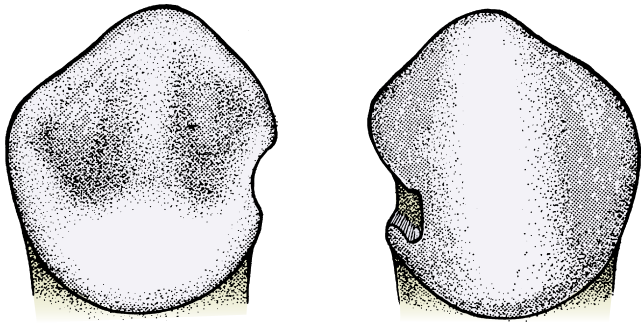

Figure 11-12 Lingual and labial views of a modified class III preparation for a mandibular primary canine.

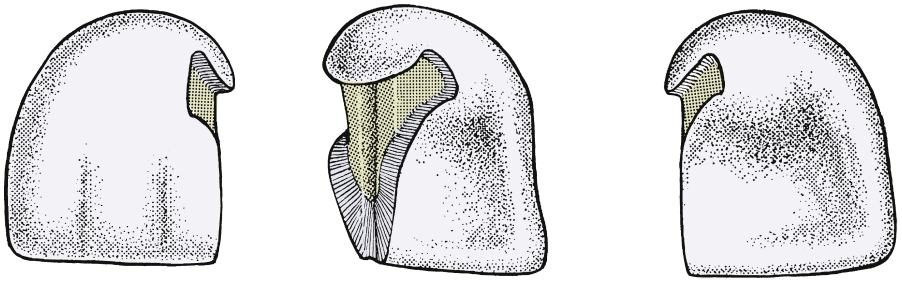

Figure 11-13 Labial, proximolingual, and lingual views of a preparation for an aesthetic resin restoration in a primary incisor. The preparation includes a proximal reduction and the establishment of a definitive cervical seat that extends to labial and lingual locks in the cervical third of the tooth.

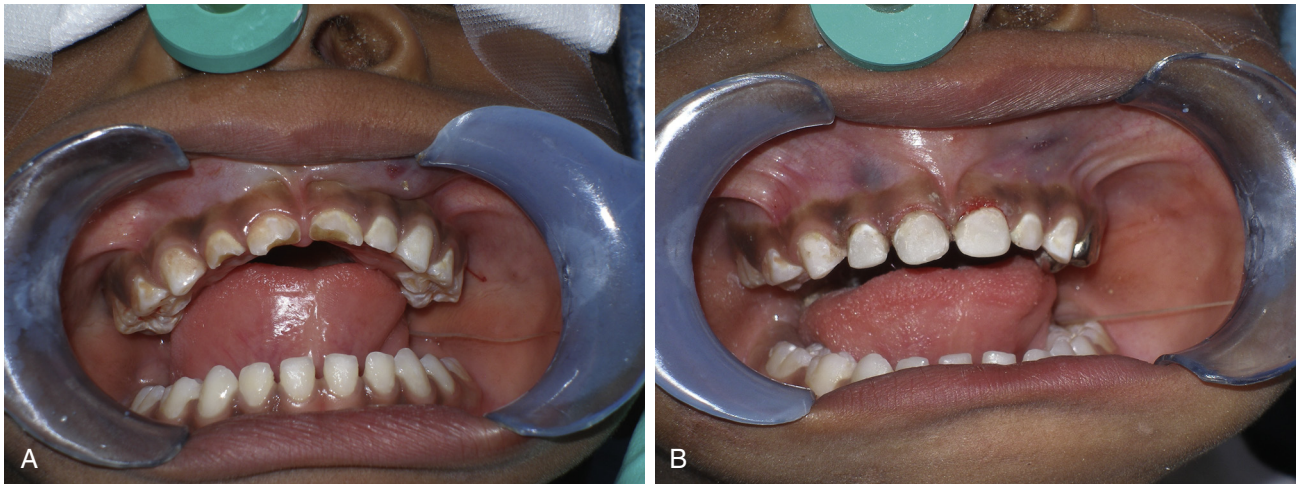

Figure 11-14 **A,** Extensive caries lesions of the maxillary right central, left central, and lateral incisors of a 3½-year-old patient. **B,** Postoperative view of the restored teeth. The restorations are retained with labial and lingual locks incorporated into the preparations. The maxillary lateral preparation was designed as illustrated in Fig. 7-13.

Dentlearn.ir

STAINLESS STEEL CROWNS

Primary incisors or canines that have extensive proximal lesions involving the incisal portion of the tooth may be restored with stainless steel crowns.

A stainless steel crown of appropriate size is selected, contoured at the cervical margin, polished, and cemented into place. (The crown technique is discussed in detail later in this chapter.) Although the crown will be well retained even on teeth that require removal of extensive portions of caries-affected tooth structure, the aesthetic requirements of some children may not be met by this type of restoration.

Most of the labial metal may be cut away, leaving a labial "window" that is then restored with resin-based composite (Fig. 11-15). This restoration is called an open-face stainless steel crown.

Several brands of stainless steel crowns with aesthetic facings preveneered to the labial surfaces are also available to restore primary anterior teeth (Fig. 11-16). Such crowns are available for direct adaptation to the prepared teeth and have had a significant amount of success. One retrospective study of 226 crowns has shown that an overall 91% of crowns retained good to excellent clinical appearance.[25] Alternatively the restorations may be completed in two appointments, with the labial veneers added in the laboratory after the bare stainless steel crowns are adapted to the teeth but before final cementation.

Croll recommends that an anterior alginate impression be made before the restorative appointment.[26] The crown preparations can then be simulated on a stone model,

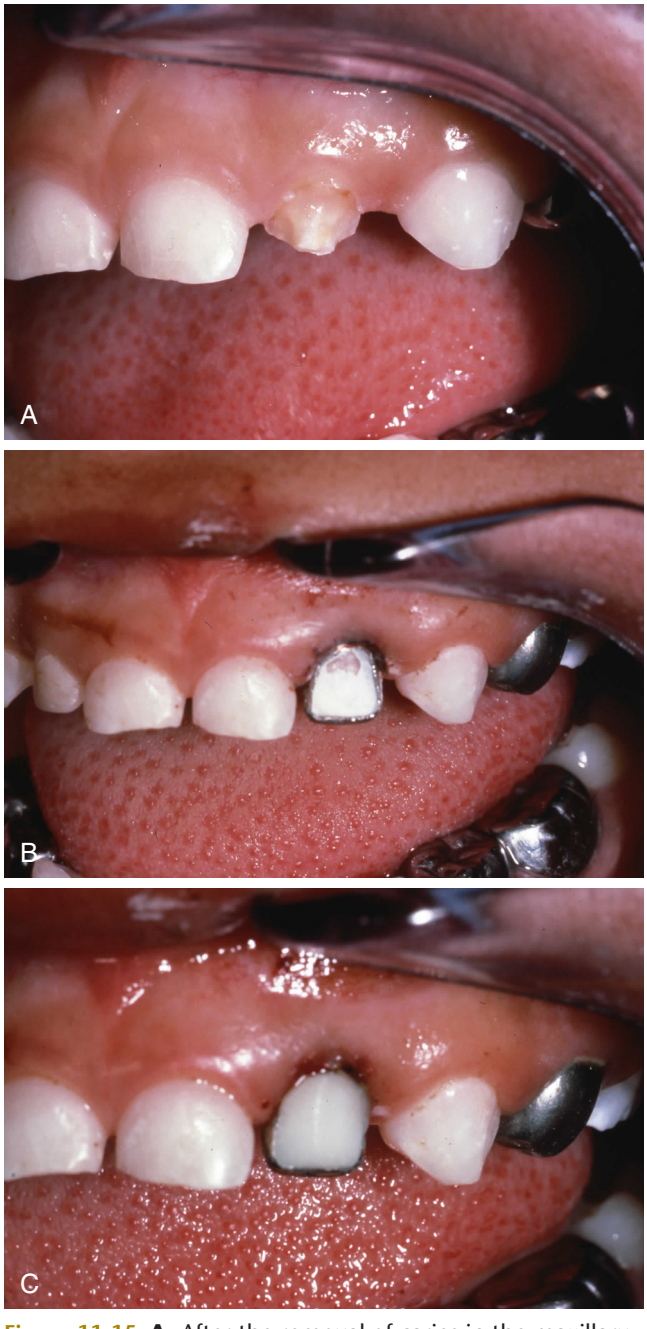

Figure 11-15 **A,** After the removal of caries in the maxillary left primary lateral incisor and preparation of the tooth, a stainless steel crown was fitted to the tooth and, **B,** the labial portion of the stainless steel crown was removed. **C,** The facial surface was then restored with resin.



Figure 11-16 **A,** Extensive caries involving the maxillary primary incisors. **B,** Resin-faced stainless steel crowns following cementation with a glass-ionomer cement.

Dentlearn.ir

and most of the crown adaptation can be achieved in advance. This procedure enables the clinician to cement the crowns in the same appointment at which the preparations are made (rather than waiting for laboratory veneering of the adapted bare crowns). Croll's technique also gives the clinician a better opportunity to focus on fitting the crowns so that optimal tooth alignment will result, which further enhances the aesthetic outcome.

DIRECT RESIN CROWNS

Webber and associates[27] described the resin crown technique wherein the tooth is restored with resin-based composite with a celluloid crown form used as a matrix. They point out that very little finishing of the restoration is required when the celluloid crown has been properly fitted.

The jacket crown technique illustrated in Figure 11-17 incorporates the use of a celluloid crown form and resin-based composite as advocated by Webber and associates[23] and today is commonly called a "strip crown." In a retrospective study by Kupietzky and others, strip crowns were shown to perform well for restoring primary incisors with large or multisurface caries for periods of more than 3 years. There was an 80% overall retention rate for the 145 restorations.[28]

Celluloid crown forms are also available for primary posterior teeth. These crown forms are useful matrices for some posterior bonded restorations. A good example of an indication for the use of such a crown form is to provide a bonded crown buildup for temporary reestablishment of arch integrity and occlusion of an ankylosed (submerged) primary molar.

PREPARATION OF CAVITIES IN YOUNG PERMANENT TEETH

Many of the caries management procedures presented in this textbook also often apply to young permanent teeth. Entire textbooks are devoted to operative dentistry

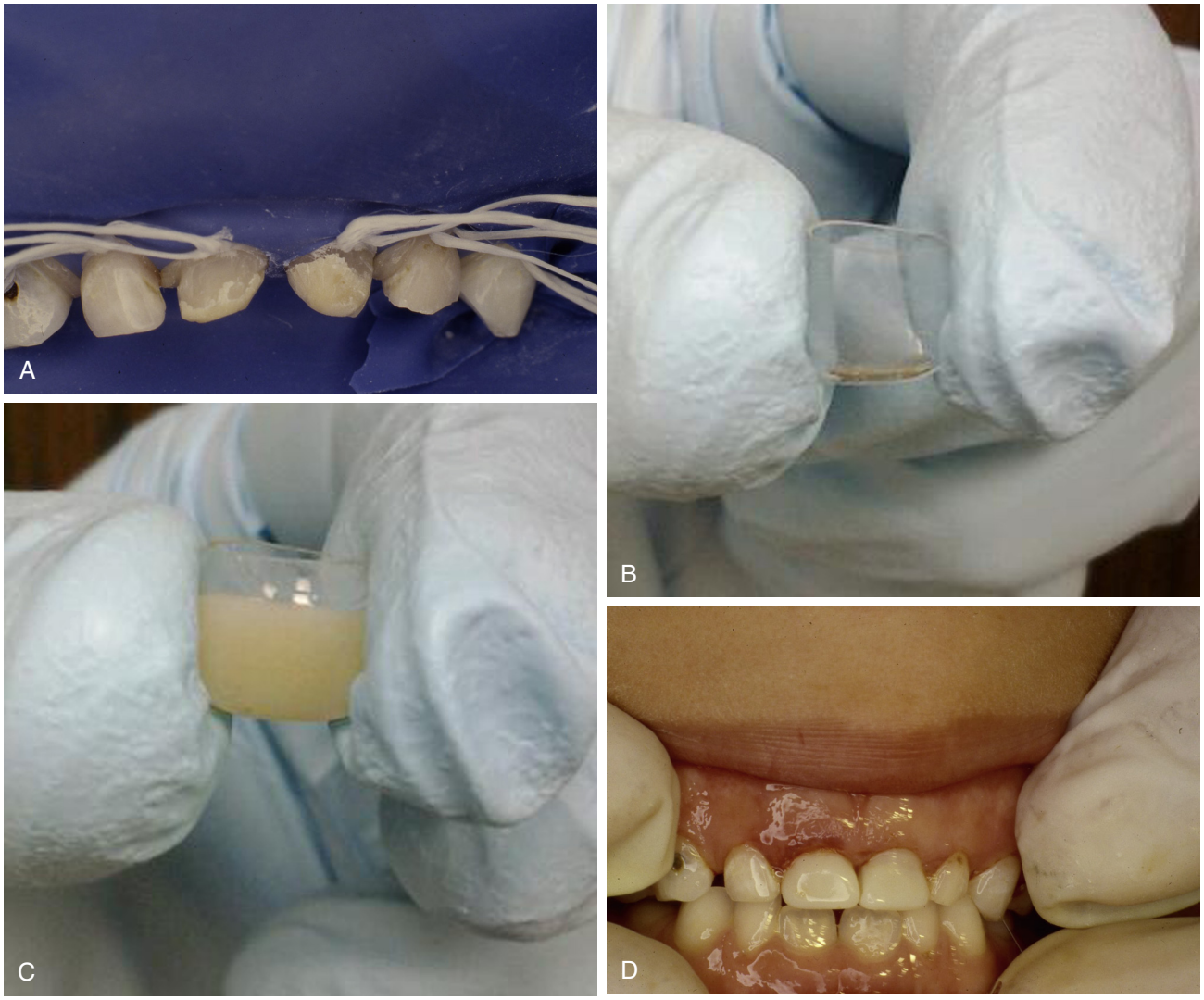

Figure 11-17 **A,** Extensive caries of the primary maxillary right central, left central, and left lateral incisors of a 4-year-old patient. **B,** Fitted celluloid crown forms were trimmed to just cover the cervical margins of the prepared teeth. **C,** Two-thirds filled with a heavily filled resin-based composite, seated over the prepared teeth, with excess resin being removed from the cervical margins and light polymerization. **D,** Polishing.

Dentlearn.ir

procedures, and the primary focus of these books is restoration of permanent teeth. Repeating all of that information (or portions thereof) in this chapter is impractical and unrealistic. For detailed information about the various cavity preparation designs for permanent teeth and the matrix systems to facilitate the placement and contour of restorations, please consult a standard textbook of operative dentistry listed in the references, such as the text by Roberson and colleagues.[29]

INTERIM RESTORATION FOR HYPOPLASTIC PERMANENT MOLARS

The dentist who routinely treats children occasionally faces a difficult restorative problem when severely hypoplastic first permanent molars erupt. Often the teeth are so defective that they require restoration at a very early stage of eruption. Many of these teeth have been saved by early restoration with stainless steel crowns as an interim procedure. However, this procedure may require sacrificing sound tooth surfaces to provide adequate space for the crown. Such full-coverage restorations are sometimes difficult to fit.

The composite materials have proved to provide a more satisfactory interim restoration for many of these teeth. Such a bonded composite build-up restoration allows for the preservation of all sound tooth structure and depends on the presence of some enamel surfaces to provide bonded retention for the restorative material. Any soft defective areas are excavated, but little or no additional tooth preparation is done. Usually even undermined enamel surfaces are preserved for additional retention and support of the restorative material. In some cases gingivoplasty around the erupting tooth may first be necessary to allow for adequate access to and isolation of the defective areas. Even if the restoration requires occasional repair, it still often provides a more satisfactory interim result than the stainless steel crown. Some of the newer restorative materials on the glass-ionomer–composite-resin continuum may provide an even better interim restoration for hypoplastic teeth because of their ability to release fluoride and to bond to hypoplastic enamel.

In situations where a stainless steel crown is required to restore a young permanent molar, Radcliffe and Cullen have noted the importance of conservative tooth preparation to preserve better options for future restoration of the same tooth.[30] They advocate a preparation similar to that described in the following section.

STAINLESS STEEL CROWNS FOR POSTERIOR TEETH

Chrome steel crowns, as introduced by Humphrey in 1950, have proved to be serviceable restorations for children and adolescents and are now commonly called stainless steel crowns.[31] The indications for the use of stainless steel crowns in pediatric dentistry include the following:

1. Restorations for primary or young permanent teeth with extensive and/or multiple caries lesions (Fig. 11-18)
2. Restorations for hypoplastic primary or permanent teeth that cannot be adequately restored with bonded restorations
3. Restorations for teeth with hereditary anomalies, such as dentinogenesis imperfecta or amelogenesis imperfecta
4. Restorations for pulpotomized or pulpectomized primary or young permanent teeth when there is increased danger of fracture of the remaining coronal tooth structure
5. Restorations for fractured teeth
6. Restorations for primary teeth to be used as abutments for appliances
7. Attachments for habit-breaking and orthodontic appliances

Randall published an extensive review of the literature that reports on the use of preformed metal crowns for primary and permanent molars.[32] She found five clinical studies that compared the performance of crown restorations with that of multisurface amalgam restorations. The five studies included a total of 1210 crowns and 2201 amalgams that were followed from a minimum of 2 years to a maximum of 10 years. The findings in all five studies were in agreement that the crown restorations were superior to the amalgam restorations in the treatment of multisurface cavities in primary molars. Randall's review was followed by a position paper prepared by Seale that included additional scientific evidence favoring the use of stainless steel crown restorations, especially in children at high risk for caries.[33] Seale's published abstract states the following:

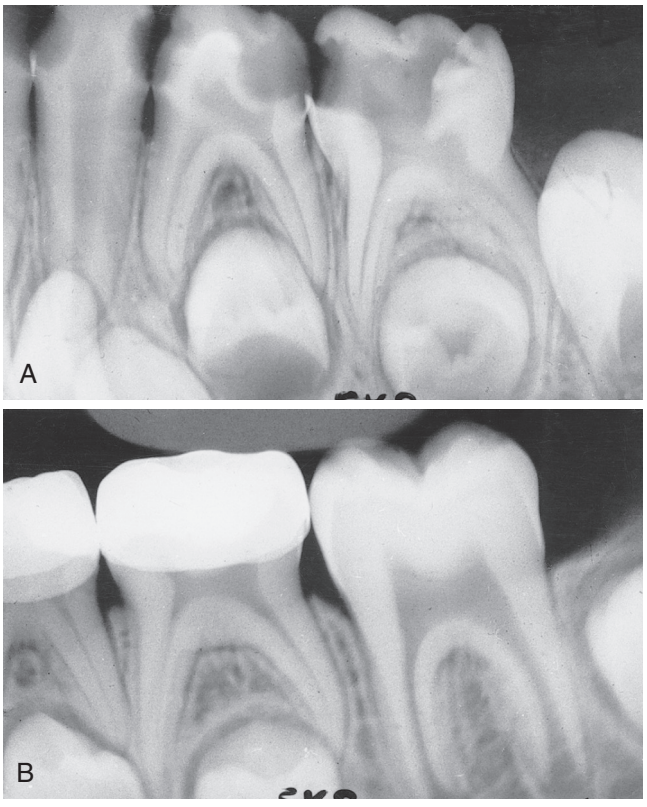

Figure 11-18 **A,** Primary molars with extensive caries lesions. **B,** Adequately contoured stainless steel crowns have maintained function and the relationship of the primary teeth in the arch.

Dentlearn.ir

The stainless steel crown (SSC) is an extremely durable restoration. Children with extensive decay, large lesions or multiple surface lesions in primary molars should be treated with stainless steel crowns. Because of the protection from future decay provided by their feature of full coverage and their increased durability and longevity, strong consideration should be given to the use of SSCs in children who require general anesthesia. Finally, a strong argument for the use of the SSC restoration is its cost effectiveness based on its durability and longevity.

PREPARATION OF THE TOOTH

A local anesthetic should be administered and a rubber dam placed as for other restorative procedures. The proximal surfaces are reduced using a No. 69L bur at high speed (Fig. 11-19). Care must be taken not to damage adjacent tooth surfaces during the proximal reductions. A wooden wedge may be placed tightly between the surface being reduced and the adjacent surface to provide a slight separation between the teeth for better access. Near-vertical reductions are made on the proximal surfaces and carried gingivally until the contact with the adjacent tooth is

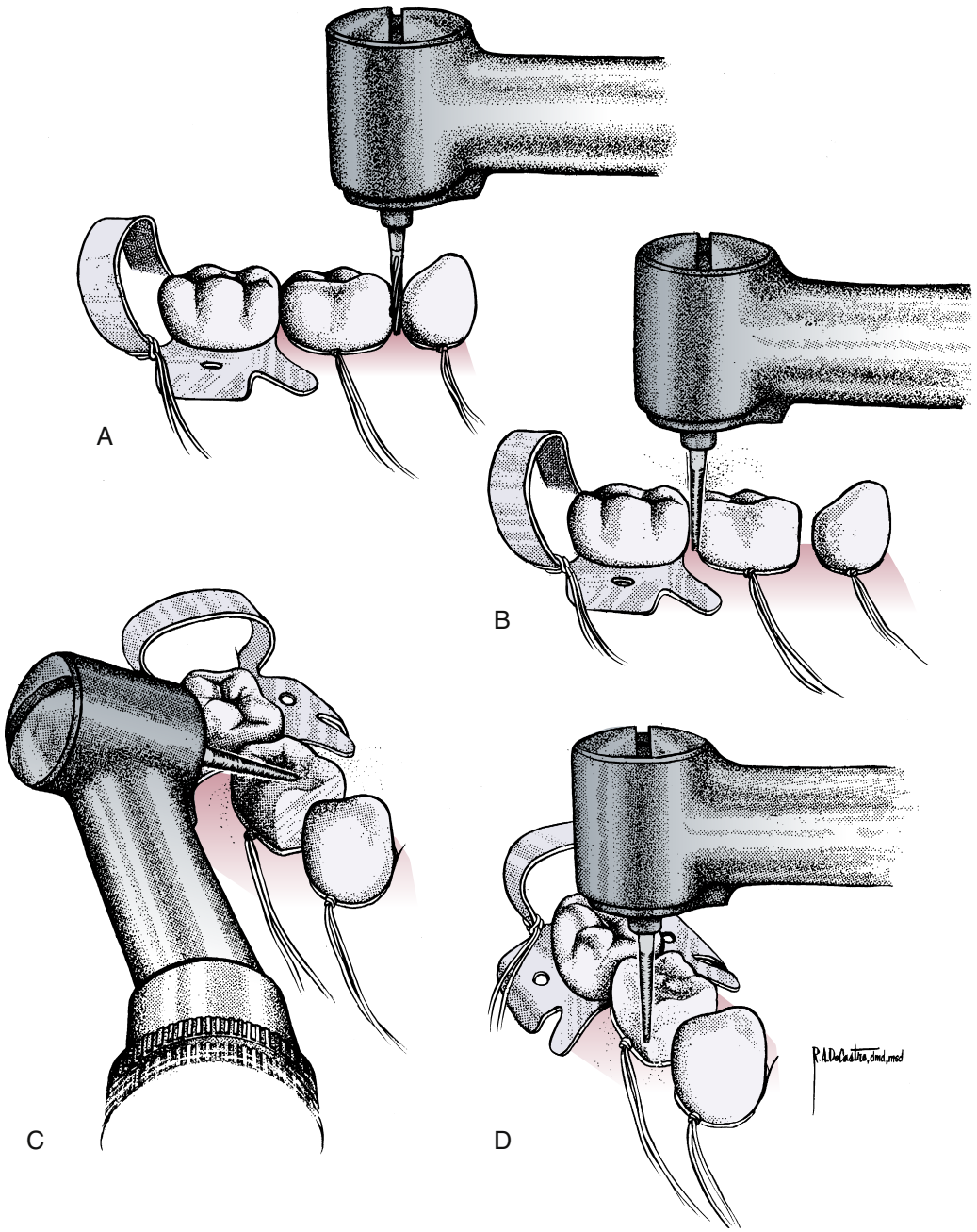

Figure 11-19 Steps in the preparation of a primary molar for a stainless steel crown restoration with a No. 69L bur in the high-speed handpiece. **A,** Mesial reduction. **B,** Distal reduction. **C,** Occlusal reduction. **D,** Rounding of the line angles.

Dentlearn.ir

broken and an explorer can be passed freely between the prepared tooth and the adjacent tooth. The gingival margin of the preparation on the proximal surface should be a smooth feathered edge with no ledge or shoulder present. The cusps and the occlusal portion of the tooth may then be reduced with a No. 69L bur revolving at high speed. The general contour of the occlusal surface is followed, and approximately 1 mm of clearance with the opposing teeth is required.

The No. 69L bur at high speed may also be used to remove all sharp line and point angles. It is usually not necessary to reduce the buccal or lingual surfaces; in fact, it is desirable to have an undercut on these surfaces to aid in the retention of the contoured crown. In some cases, however, it may be necessary to reduce the distinct buccal bulge, particularly on the first primary molar.

If any caries-affected dentin remains after these steps in crown preparation are completed, it is excavated next. In the event that a vital pulp exposure is encountered, a pulpotomy procedure is usually carried out.

SELECTION OF CROWN SIZE

The smallest crown that completely covers the preparation should be chosen. Spedding has advocated adhering to two important principles that will help to produce well-adapted stainless steel crowns consistently.[34] First, the operator must establish the correct occlusogingival crown length; and second, the crown margins should be shaped circumferentially to follow the natural contours of the tooth's marginal gingivae. The crown should be reduced in height, if necessary, until it clears the occlusion and is approximately 0.5 to 1 mm beneath the free margin of the gingival tissue. The patient can force the crown over the preparation by biting an orangewood stick or a tongue depressor. After making a scratch mark on the crown at the level of the free margin of the gingival tissue, the dentist can remove the crown and determine where additional metal must be cut away with No. 11B curved shears or a rotating stone (Fig. 11-20).

With curved-beak pliers, the cut edges of the crown are redirected cervically, and the crown is replaced on the preparation. The child is again directed to bite on an orangewood stick to seat the crown forcibly so that the gingival margins may be checked for proper extension.

The precontoured and festooned crowns currently available often require very little, if any, modification before cementation.

CONTOURING OF THE CROWN (WHEN NECESSARY)

Crown-contouring pliers with a ball-and-socket design are used at the cervical third (if loosely fitting, start at the middle third) of the buccal and lingual surfaces to help adapt the margins of the crown to the cervical portion of the tooth. The handles of the pliers are tipped toward the center of the crown, so that the metal is stretched and curled inward as the crown is moved toward the pliers from the opposite side. Curved-beak pliers are used to further improve the contour on the buccal and lingual surfaces (Fig. 11-21). The curved-beak pliers may also be used to contour the proximal areas of the crown and develop desirable contact with adjacent teeth. Many clinicians prefer to complete the crown-contouring procedures with crown-crimping pliers (Fig. 11-22). If necessary, solder may be added to the proximal surfaces of the crown to improve the proximal contacts and contour. Trimming and contouring are continued until the crown fits the preparation snugly and extends under the free margin of the gingival tissue.

The crown should be replaced on the preparation after the contouring procedure to ensure that it snaps securely into place. The occlusion should be checked at this stage to ensure that the crown is not opening the bite or causing a shifting of the mandible into an undesirable relationship with the opposing teeth (Fig. 11-23).

The final step before cementation is to produce a beveled gingival margin that may be polished and that will be well tolerated by the gingival tissue. A rubber abrasive wheel can be used to produce the smooth margin.

On occasion, the best-fitting crown may need to be modified to produce a more desirable adaptation to the prepared cervical margin. Mink and Hill have referred to methods of modifying stainless steel crowns for primary and permanent teeth.[35] The oversized crown may be cut as illustrated in Figure 11-24 and the cut edges overlapped. The crown is replaced on the tooth to ensure that it now fits snugly at the cervical region, and a scratch is made at the overlapped margin. The crown is removed from the tooth, and the overlapped material is repositioned and welded. A small amount of solder is allowed to flow over the outside margin. The crown is finished in the previously recommended manner and cemented to the prepared tooth.

If the dentist encounters a tooth that is too large for the largest crown, a similar technique may be helpful. The crown may be cut on the buccal or lingual surface. After the crown has been adapted to the prepared tooth, an additional piece of 0.004-inch stainless steel band material may be welded into place. A small amount of solder should be added to the outer surfaces of the margins. The crown may then be contoured in the usual manner, polished, and cemented into place (Video 11-1: Restorative techniques).

Finally, just as with crowns for anterior teeth, preveneered stainless steel crowns for posterior primary teeth have been developed. These crowns require considerably more crown preparation than conventional stainless steel crowns, but Yilmaz and Kocogullari have reported success rates as high as 80%.[36]

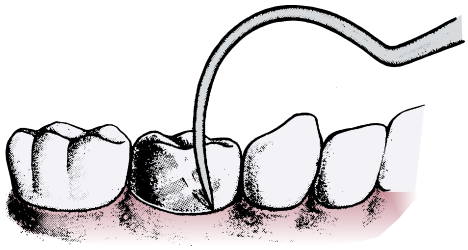

Figure 11-20 A scratch is made at the level of the free margin of the gingival tissue as an aid in determining where additional metal must be removed.

Dentlearn.ir







Figure 11-21 **A,** Crown-contouring pliers are used to contour the buccal and lingual surfaces of the crown. The crown is held firmly with the pliers, and pressure is exerted with the finger from the opposite side of the crown to bend the surface inward. **B,** The curved-beak pliers are "walked" completely around the cervical margins of the crown to direct all margins inward with smooth, flowing contour. **C,** The crown on the right was the same size and shape as the crown on the left before it was contoured. This illustrates the effectiveness of the contouring procedures with the pliers as described.

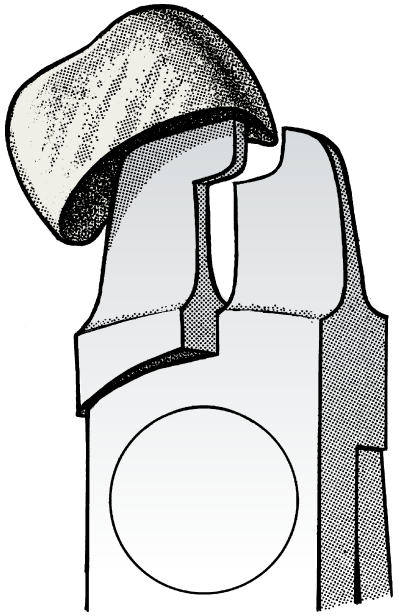

Figure 11-22 Crown-crimping pliers may also be used for crown contouring.

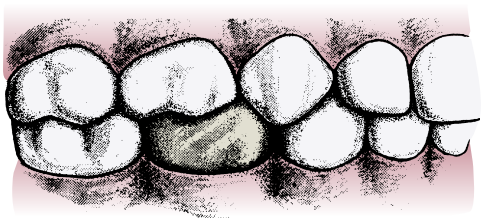

Figure 11-23 Final adaptation of the crown should result in good occlusion before cementation.

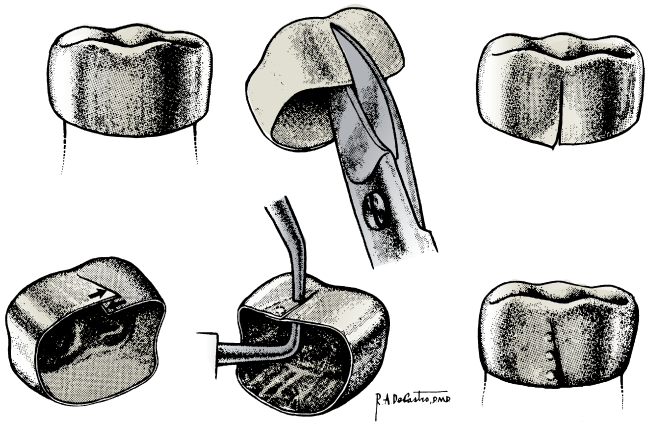

Figure 11-24 Technique for adapting an oversized crown to a prepared tooth.

COSMETIC ZIRCONIA CROWNS

Zirconia crowns are now marketed for the aesthetic restoration of primary anterior (Fig. 11-25) and posterior teeth (Fig. 11-26). These crowns offer a very aesthetic appearance while providing a durable crown. An in vitro study has demonstrated that natural teeth opposing zirconia

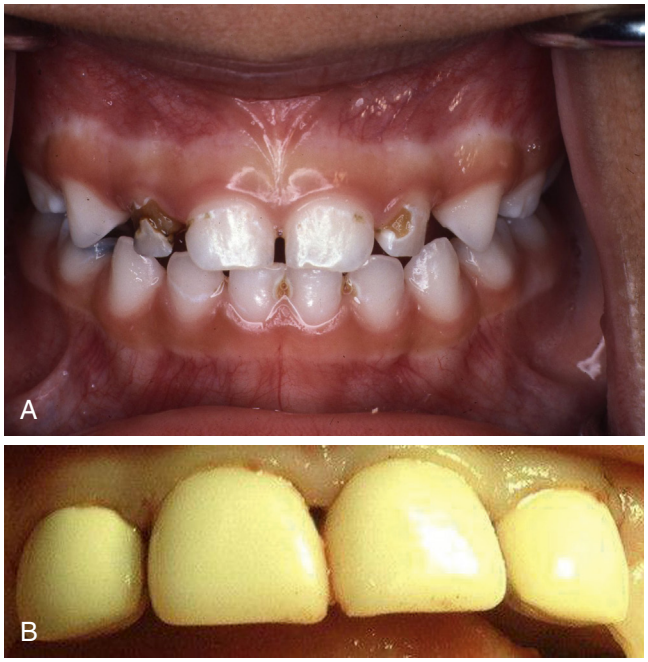

Figure 11-25 **A,** Extensive caries of the maxillary primary lateral incisors, with caries involving the lingual surfaces of the central incisors. **B,** The lateral incisors restored with resin-faced crowns and the central incisors restored with zirconia crowns.

crowns have much more favorable wear than natural teeth opposing porcelain crowns. Further use of these crowns and clinical research will offer additional information for these crowns in the future.[37]

ALTERNATIVE RESTORATIVE TREATMENT

Alternative or atraumatic restorative treatment (ART) has become a popular descriptive term to describe a conservative method of managing both small and large caries lesions when treating the disease by more traditional restorative procedures is impossible or impractical for many reasons, including lack of access to traditional dental settings. This method may prevent pain and preserve teeth in individuals who do not have access to regular and conventional oral health care. ART may be performed with only hand instruments when no other dental equipment is available, but it may be useful sometimes in the conventional dental setting as well. ART does not require complete excavation of dentinal caries before placement of the restorative material. This is not a totally new concept in dentistry, but it has enjoyed renewed recognition as a viable restorative approach because of the development of the more durable fluoride-releasing glass-ionomer and resin-modified glass-ionomer restorative materials. (The principles validating this technique are discussed in the section Treatment of the Deep Caries Lesion in Chapter 13)

This technique is promoted and endorsed by the World Health Organization with the goals of preserving tooth structure, reducing infection, and avoiding discomfort. Recognizing the technique as a means of restoring and preventing dental caries, the International Association for

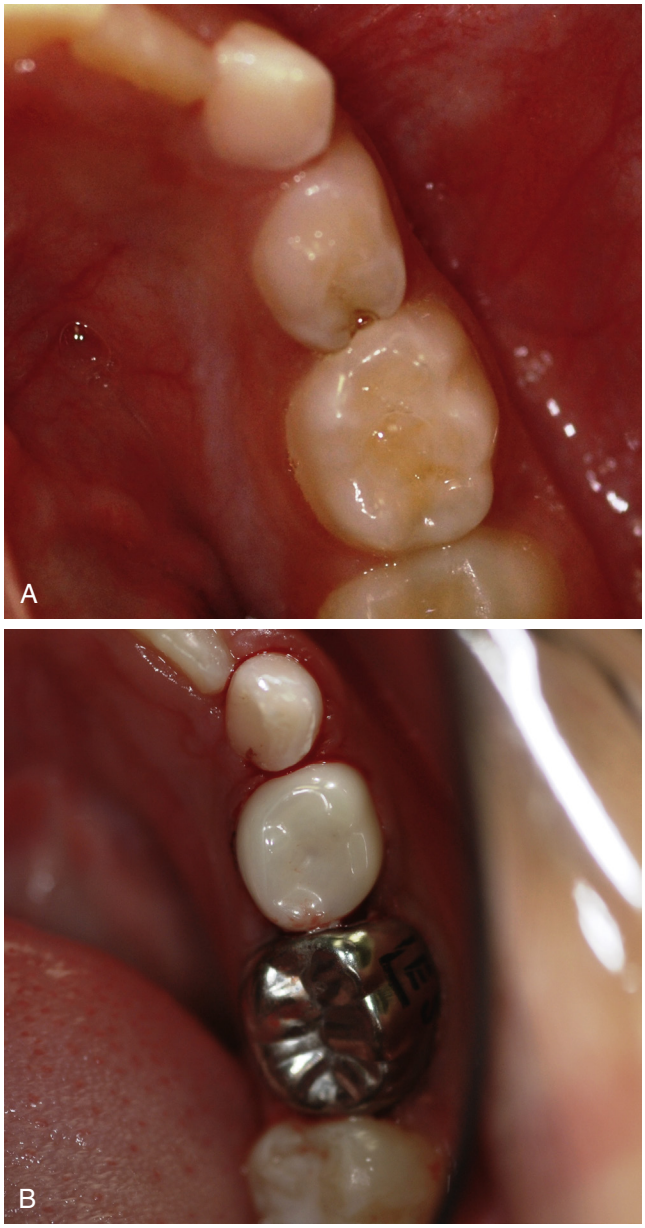

Figure 11-26 **A,** A mandibular first primary molar exhibiting occlusodistal caries. **B,** A posterior primary molar zirconia crown cemented with resin cement.

Dental Research held a symposium on ART in June 1995. The procedure does not require a traditional dental setting. Preventive measures to control the bacterial infection and the causative agents of the disease should also be used for optimal results following treatment.

In 2008 AAPD added the term *interim therapeutic restorative technique (ITR)*. The reference manual differentiates ART from ITR as follows[1]:

> Because circumstances do not allow for follow-up care, ART has been mistakenly interpreted as a definitive restoration. ITR utilizes similar techniques, but has different therapeutic goals. ITR more accurately describes the procedure used in contemporary dental practice.

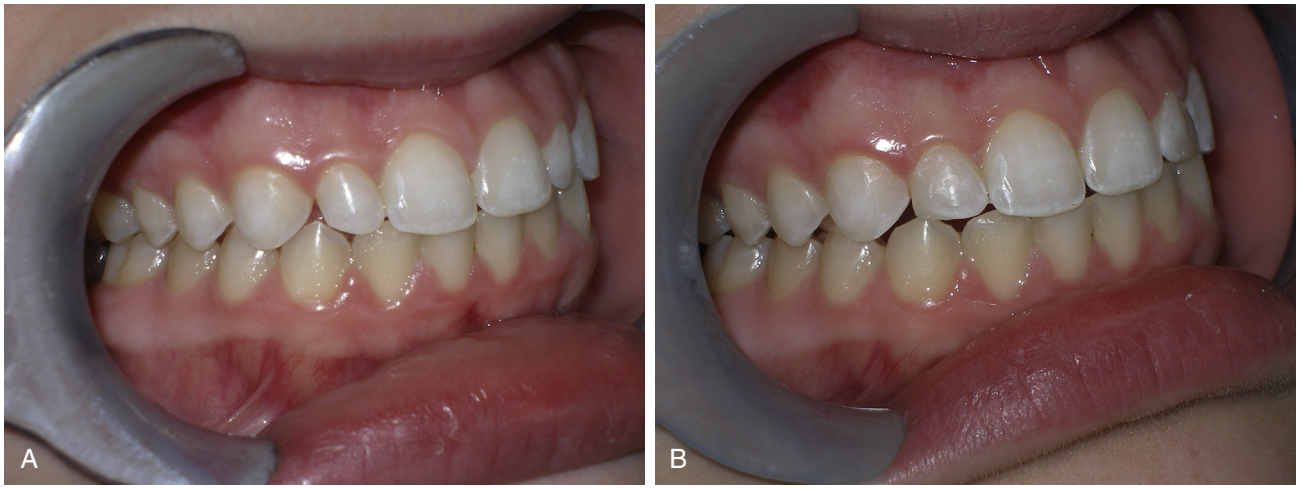

Figure 11-27 **A,** Undersized maxillary right lateral incisor in a young patient. **B,** Improved appearance of tooth after restoration with a bonded laminate veneer restoration.

COSMETIC RESTORATIVE PROCEDURES FOR YOUNG PERMANENT ANTERIOR TEETH

A common problem confronting dentists who treat children is the aesthetic management of anterior teeth that are discolored, developmentally undersized or malformed, malposed, or fractured. Dentists recognize that aesthetic impairments of the teeth often adversely affect the social and psychological development of the growing child. Aesthetic restorative systems and bonding techniques are usually used when restorations are indicated in these situations. Although bonding procedures are also applicable to primary tooth restorations (as described earlier in this chapter), the following discussion applies primarily to permanent anterior teeth simply because few indications are encountered in the primary dentition. However, Aron has reported the successful use of bonded porcelain veneers for primary incisors in a young patient.[38]

The following discussion assumes that one understands dental bonding principles and has a working knowledge of the process. These principles and procedures are similar for sealants, restorative resins, and resin luting agents (see Chapter 10). Some tooth preparation confined to enamel (as much as possible) is often indicated, although not always required, before cosmetic bonding procedures are performed.

BONDED COMPOSITE VENEER RESTORATIONS (RESIN-BASED COMPOSITE BONDING)

Resin-based composite restoratives (and bonding agents) are frequently applied directly to etched enamel. The restorative resin simply becomes a veneer to improve tooth color or contour. Restorative resin-bonding techniques are particularly useful for restoring anterior crown fractures (see Chapter 27) and for cosmetically increasing the mesial-distal widths of young permanent anterior teeth (Fig. 11-27). Bonded composite veneers are also useful for restoring small hypoplastic or discolored areas on visible tooth surfaces. Many dentists also use this type of restoration to mask intrinsic discolorations by veneering the entire labial surfaces of the discolored anterior teeth (Fig. 11-28). This approach may provide satisfactory cosmetic restorations for teeth with mild to moderate discolorations that will not respond to the bleaching or microabrasion procedures discussed in Chapter 3.

BONDED LAMINATE VENEER RESTORATIONS (DENTAL LAMINATES OR LAMINATE VENEERS)

The use of thin, prefitted porcelain facings (laminate veneers) that are bonded to enamel surfaces has become commonplace in cosmetic dentistry. Interest in laminate veneer restorations has grown steadily since their introduction by Faunce and Faunce.[39] Such restorations for maxillary anterior teeth are recognized as conservative, aesthetically satisfactory restorations, especially in children and young adults. Laminate veneer restorations have also been used successfully on mandibular anterior teeth.

The laminate veneer technique offers aesthetic improvement because the restored teeth simulate the natural hue and appearance of normal, healthy tooth structure. When properly finished, the laminate restorations are well tolerated by the gingival tissues, even though their contour may be slightly excessive. Immaculate oral hygiene is essential, but experience has shown that the maintenance of gingival health around the restorations is certainly possible in cooperative patients (Fig. 11-29).

The luting materials are tooth-colored resin systems designed for use in bonding techniques. If the teeth being treated are severely discolored, tinting or opaquing agents may also be required. The laminate veneer procedure is not complicated, but it requires meticulous attention to detail for success.

The bonding procedure for a laminate veneer restoration requires proper preparation of the inside laminate surface and proper etching of the outer enamel surface. The inside of the porcelain laminate surface is etched with a hydrofluoric acid etchant and then coated with

Dentlearn.ir



Figure 11-28 Resin-based composite bonding. **A,** Preoperative appearance of a 15-year-old girl who said, "I don't like my teeth." **B,** A heavily filled resin-based composite restorative material bonded to teeth 9, 10, and 11 with a chamfer preparation placed. **C,** Postoperative appearance of finished restorations after placement of a microfilled resin-based composite.

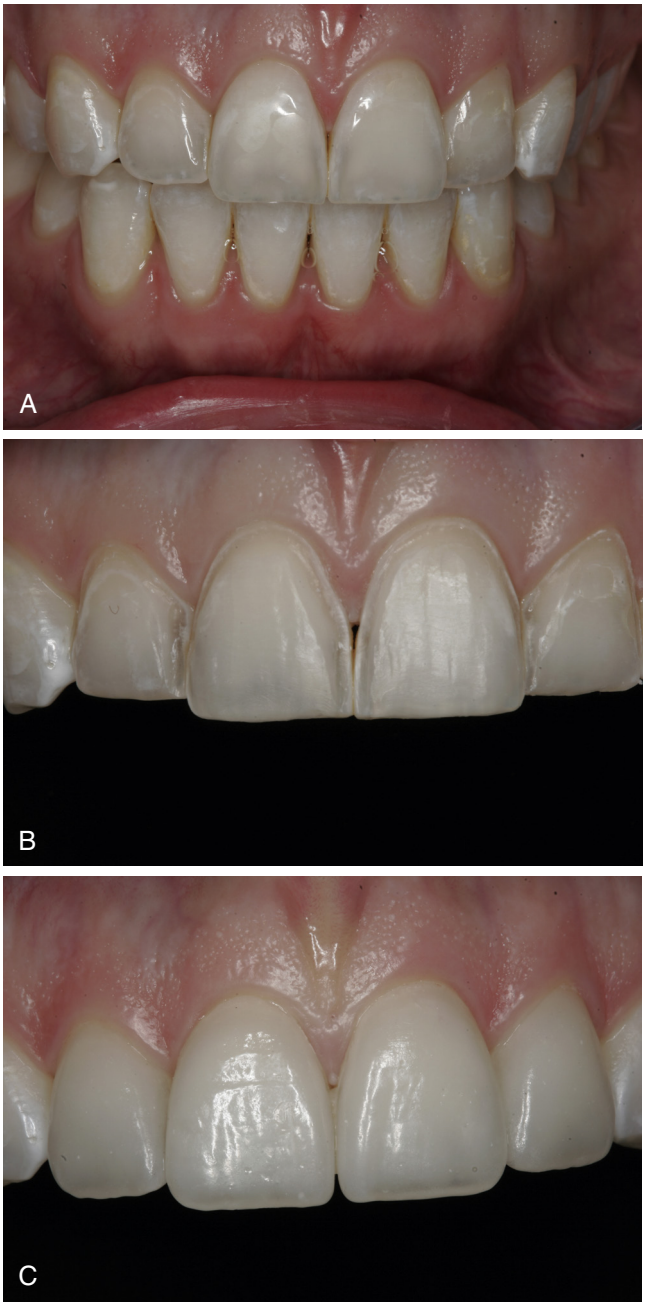

Figure 11-29 **A,** Anterior teeth of a teenaged patient after the removal of bonded orthodontic appliances. The hypoplastic defects are obvious on the canines and lateral incisors, and the central incisors are mildly affected as well. **B,** Photograph of same patient after completion of the intraenamel preparations. **C,** Bonded resin veneer restorations. (Courtesy of Dr. Nasser Barghi.)

silane, which results in a bond with the resin luting agent similar to that achieved on etched enamel but also enhanced chemically by the silane. Excellent bond strengths to the porcelain surface have been reported by Lee and colleagues.[40]

The intraenamel preparation includes removal of 0.5 to 1 mm of facial enamel, tapering to about 0.25 to 0.5 mm at the cervical margin. This margin is finished in a well-defined chamfer with the crest of the gingival margin not more than 0.5 mm subgingivally. The incisal margin may end just short of the incisal edge, or it may include the entire incisal edge ending on the lingual surface. It is better not to place incisal margins where direct incising forces occur. Bonded porcelain techniques have significant value in cosmetic dental procedures (Fig. 11-30).



Figure 11-30 **A,** Severe tooth "pitting" and discoloration in a teenager. **B,** The teeth are prepared for porcelain-bonded veneer restorations. **C,** Final porcelain veneer restorations. (Courtesy of Dr. Nasser Barghi.)

Refer to the text by Nixon[41] for additional information on the many varieties of materials and techniques available for dental cosmetic procedures.

CONTROVERSIES IN PEDIATRIC RESTORATIVE DENTISTRY

LASER USE

In 2013 AAPD released its first policy statement on the use of lasers for pediatric dental patients. While lasers are recognized as a viable alternative to traditional preparation tools in restorative dentistry, as with any tool there are advantages and limitations, and perhaps laser use is best viewed as an alternative and complementary method. Less heat generation, the necessity for little or no local anesthesia, and removal of caries with minimal involvement of surrounding tooth structure are among several advantages of lasers. Limitations include high start-up costs,



Figure 11-31 **A,** Adjacent interproximal lesions on teeth E and F. **B,** Sluiceway opened up with a high-speed handpiece to allow for direct fluoride varnish application and easier cleansing with brushing. No restoration was placed.

the need for different equipment for different applications, and the need for additional practitioner training in the methodology. However, despite acknowledging that cavity preparation with a laser takes longer and smells unpleasant, one study[42] has recently shown that adolescents prefer the laser to conventional preparation because they found it more comfortable. For a more thorough review, see Olivi and colleagues'[43] user guide entitled *Pediatric Laser Dentistry*.

MINIMALIST APPROACH TO RESTORATIVE CARE

Many of us are familiar with the technique demonstrated in Figure 11-31, where adjacent interproximal lesions have been managed by simply opening up the contact between the two teeth with a high-speed handpiece, applying fluoride varnish, and having the parents use focused toothbrushing in the area to slow or arrest the decay. This is used particularly with lower primary incisor tooth interproximal decay. However, an article by Kidd[44] stretches the boundaries of options for management of caries in primary teeth by suggesting the following:

- No caries removal, but opening the lesion to allow for cleaning (as above)
- Sealing techniques with no caries removal (the Hall technique)
- Partial caries removal and restoration (the atraumatic restorative technique)
- Complete caries removal and restoration
- Not restoring or opening the tooth, but leaving it as is

The Hall technique involves restoration of nonpulpally–involved, significantly decayed primary molars with stainless steel crowns luted with glass-ionomer cement, but without caries removal. While preliminary studies[45] seem optimistic, this technique remains controversial, raises concerns such as gingival health around the crowns, and begs the need for prospective, randomized, controlled clinical trials.

REFERENCES

1. American Academy of Pediatric Dentistry: *Reference Manual 35:06*, Chicago, 2012-2013, AAPD pp 226–234.
2. Berg JH: The continuum of restorative materials in pediatric dentistry: a review for the clinician, *Pediatr Dent* 20:93–100, 1998.
3. Bonilla E, White SN: Fatigue of resin-bonded amalgam restorations, *Oper Dent* 21:122–126, 1996.
4. Mahler DB, et al.: One-year clinical evaluation of bonded amalgam restorations, *J Am Dent Assoc* 127:345–349, 1996.
5. Heise AL: Time required in rubber dam placement, *J Dent Child* 38:116–117, 1971.
6. Croll TP: Restorative dentistry for preschool children, *Dent Clin North Am* 39:737–770, 1995.
7. Collette J, Wilson S, Sullivan D: A study of the Isolite system during sealant placement: efficacy and patient acceptance, *Pediatr Dent* 32:146–150, 2010.
8. Suwatviroj P, et al.: The effects of cavity preparation and lamination on bond strength and fracture of tooth-colored restorations in primary molars, *Pediatr Dent* 25(6):534–540, 2003.
9. Croll TP: Lateral-access class II restoration using resin-modified glass-ionomer or silver-cermet cement, *Quintessence Int* 26: 121–126, 1995.
10. Vaikuntam J: Resin-modified glass ionomer cements (RM GICs): implications for use in pediatric dentistry, *J Dent Child* 64:131–134, 1997.
11. Marks LA, et al.: Dyract versus Tytin class II restorations in primary molars: 36 months evaluation, *Caries Res* 33: 387–392, 1999.
12. Welbury RR, et al.: Clinical evaluation of paired compomer and glass ionomer restorations in primary molars: final results after 42 months, *Br Dent J* 189:93–97, 2000.
13. Hubel S, Mejàre I: Conventional versus resin-modified glass-ionomer cement for class II restorations in primary molars. A 3-year clinical study, *Int J Paediatr Dent* 13:2–8, 2003.
14. Paquette DE, et al.: Modified cavity preparations for composite resins in primary molars, *Pediatr Dent* 5:246–251, 1983.
15. Oldenburg TR, Vann Jr WF, Dilley DC: Composite restorations for primary molars: two-year results, *Pediatr Dent* 7: 96–103, 1985.
16. Tonn EM, Ryge G: Two-year clinical evaluation of light-cured composite resin restorations in primary molars, *J Am Dent Assoc* 111:44–48, 1985.
17. Dilley DC, et al.: Time required for placement of composite versus amalgam restorations, *J Dent Child* 57:177–183, 1990.
18. Donly KJ, et al.: Clinical performance and caries inhibition of resin-modified glass ionomer cement and amalgam restorations, *J Am Dent Assoc* 130:1459–1466, 1999.
19. dos Santos MPA, et al.: A randomized trial of resin-based restorations in class I and class II beveled preparations in primary molars, *J Am Dent Assoc* 140(2):156–166, 2009.
20. Ekstrand KR, Bakhshandeh A, Martignon S: Treatment of proximal superficial caries lesions on primary molar teeth with resin infiltration and fluoride varnish only: efficacy after 1 year, *Caries Res* 44:41–46, 2010.
21. Myer-Lueckel H, Bitter K, Paris S: Randomized controlled clinical trial on proximal caries infiltration: three-year follow-up, *Caries Res* 46:544–548, 2012.
22. Martignon S, et al.: Infiltrating/sealing proximal caries lesions: a 3-year randomized clinical trial, *J Dent Res* 91(3): 288–292, 2012.
23. Trairatvorakul C, Piwat S: Comparative clinical evaluation of slot versus dovetail class III composite restorations in primary anterior teeth, *J Clin Pediatr Dent* 28(2):125–130, 2004.
24. McEvoy SA: A modified class III cavity preparation and composite resin filling technique for primary incisors, *Dent Clin North Am* 28:145–155, 1984.
25. MacLean JK, et al.: Clinical outcomes for primary anterior teeth treated with preveneered stainless steel crowns, *Pediatr Dent* 29(5):377–381, 2007.
26. Croll TP: Primary incisor restoration using resin-veneered stainless steel crowns, *J Dent Child* 65:89–95, 1998.
27. Webber DL, et al.: A method of restoring primary anterior teeth with the aid of a celluloid crown form and composite resins, *Pediatr Dent* 1:244–246, 1979.
28. Kupietzky A, et al.: Long-term photographic and radiographic assessment of bonded resin composite strip crowns for primary incisors: results after 3 years, *Pediatr Dent* 27(3): 221–225, 2005.
29. Roberson TM, et al.: *Sturdevant's art & science of operative dentistry*, ed 5, St. Louis, 2006, Mosby.
30. Radcliffe RM, Cullen CL: Preservation of future options: restorative procedures on first permanent molars in children, *J Dent Child* 58:104–108, 1991.
31. Humphrey WP: Uses of chrome steel in children's dentistry, *Dent Surv* 26:945–949, 1950.
32. Randall RC: Preformed metal crowns for primary and permanent molar teeth: review of the literature, *Pediatr Dent* 24:489–500, 2002.
33. Seale NS: The use of stainless steel crowns, *Pediatr Dent* 24:501–505, 2002.
34. Spedding RH: Two principles for improving the adaptation of stainless steel crowns to primary molars, *Dent Clin North Am* 28:157–175, 1984.
35. Mink JR, Hill CJ: Modification of the stainless steel crown for primary teeth, *J Dent Child* 38:61–69, 1971.
36. Yilmaz Y, Kocogullari ME: Clinical evaluation of two different methods of stainless steel esthetic crowns, *J Dent Child (Chic)* 71(3):212–214, 2004.
37. Jung YS, et al.: A study on the in-vitro wear of the natural tooth structure by opposing zirconia or dental porcelain, *J Adv Prosthodont* 2:111–115, 2010.
38. Aron VO: Porcelain veneers for primary incisors: a case report, *Quintessence Int* 26:455–457, 1995.
39. Faunce FR, Faunce AR: The use of laminate veneers for restoration of fractured or discolored teeth, *Tex Dent J* 93(8):6–7, 1975.
40. Lee JG, et al.: Bonding strengths of etched porcelain discs and three different bonding agents, *J Dent Child* 53:409–414, 1986.
41. Nixon RL: Masking severely tetracycline-stained teeth with ceramic laminate veneers, *Pract Periodontics Aesthet Dent* 8:227–235, 1996.
42. Hjertton PM, Bagesund M: Er:YAG laser or high-speed bur for cavity preparation in adolescents, *Acta Odontol Scand* 71:610–615, 2013.
43. Olivi G, Margolis FS, Genovese MD: *Pediatric laser dentistry, a user's guide*, Chicago, 2011, Quintessence Publishing Co., Inc.
44. Kidd E: Should deciduous teeth be restored? Reflections of a cariologist, *Dent Update* 39:159–166, 2012.
45. Innes NPT, Evans DJP: Modern approaches to caries management of the primary dentition, *Br Dent J* 214(11):559–566, 2013.

CHAPTER 12

Dental Materials

▲ Jeffrey A. Platt

For additional resources, please visit the evolve website.

CHAPTER OUTLINE

REGULATORY CONSIDERATIONS
THE TOOTH-RESTORATION INTERFACE
TREATMENT OF THE CAVITY PREPARATION
TEMPORARY AND PERMANENT RESTORATIONS
RESTORATIVE RESINS
Conventional Composites
Microfilled Composites
Hybrid Composites
Light-Cured Composites
Posterior Composite Restoration
Resin Inlays
Dental Adhesives
AMALGAM
Selection of the Alloy
High-Copper Alloys
Mercury/Alloy Ratio
Trituration
Mechanical Amalgamators
Condensation
Moisture
Marginal Breakdown and Bulk Fracture
Bonded Amalgam Restorations
Mercury Toxicity
CERAMICS
CEMENTS
Luting Cements

REGULATORY CONSIDERATIONS

Providing surgical therapy for initial and recurrent caries remains an integral part of the pediatric dental practice. Because the incidence of caries is not declining in some segments of our population and in conjunction with the restorative challenges involved with trauma cases and developmental defects, the demand for high-quality restorative materials remains strong. The global desire to see the reduction and potential elimination of dental amalgam continues to stimulate improvement of more aesthetic restorative options. However, material fracture, solubility, dimensional change, and discoloration continue to plague many of the composite materials in use today. Furthermore, some public concern remains about the potential negative biological impact of resin monomers.

The development of materials to meet the challenging needs of restorative dentistry is accomplished under the guidance of a series of standards that provide thresholds for different properties considered to be important for clinical success. These standards have become international in scope, providing more global consistency for the profession. The standards are often used to show suitability for the marketplace when marketing approval is sought from the Food and Drug Administration in the United States or from similar organizations in other countries.

Sidebar: *The organizations that govern materials property standards in the United States. Other countries have similar entities.*

American Dental Association (ADA) Council on Scientific Affairs
ADA Standards Committee on Dental Products
American National Standards Institute
International Standards Organization (ISO)

Concerns about infection control and ease of delivery have resulted in many materials being supplied in unit dose packaging. Eliminating bulk packaging has greatly reduced chairside disinfection concerns.

Another area of concern involves the safety of individuals working with restorative materials. The Occupational Safety and Health Administration is responsible for developing and enforcing standards deemed necessary to ensure workplace safety. Most countries have similar oversight entities. Many dental materials contain hazardous materials and create a risk for an adverse biological response. Material Safety Data Sheets are supplied by manufacturers and provide important precautionary information to minimize exposure risks and treatment guidance for inappropriate exposures. The American Dental Association provides a *Regulatory Compliance Manual* to assist the dentist/owner in meeting regulatory requirements.

THE TOOTH-RESTORATION INTERFACE

A critical component in the success of an "ideal" restorative material involves the control of leakage that occurs along the tooth-restoration interface. Multiple investigations seem to indicate that the presence of a clinically intact interface can prevent the progression of caries. Maintaining a sealed interface is challenged by the oral environment.

Sidebar: *Some factors affecting tooth-restoration interface stability.*

Changes in temperature
Mechanical stress
Cariogenic biofilms
Poor material adaptation during placement

Loss of interface integrity and subsequent microleakage may be the precursors of secondary caries, marginal

Dentlearn.ir

discoloration, postoperative sensitivity, and pulp pathology. Microleakage poses a particular concern for teeth in the pediatric patient, because the floor of the cavity preparation may be close to the pulp. The added insult to the pulp caused by the seepage of irritants that penetrate around the restoration and through the thin layer of dentin, or a microscopic pulpal exposure, may produce irreversible pulp damage. There is a lack of strong evidence that microleakage laboratory testing correlates with clinical performance of materials. However, there is significant clinical evidence that providing a good seal inhibits caries progression under a restoration. This makes the formation of a good tooth-restoration interface a significant concern.

One approach to bonding substances together is entirely mechanical. A liquid adhesive is used that will flow into and then solidify in irregularities in the bonding surfaces. In dentistry, acid etching is commonly used to accomplish bonding of a restorative resin to enamel by the formation of resin tags in the etched enamel.

For true adhesion to occur, bonding takes place at a molecular level and involves a chemical interaction between the molecules of the adhesive and the solid surface. Dental materials that are based on polyacrylic and other polyalkenoic acids, such as the glass-ionomer cements, are current examples of this potential for true adhesion to tooth structure and have an established clinical record of success.

Although advancements have been made in surface chemistry and the development of adhesives for all types of unusual applications, dental substrates remain a difficult challenge. Tooth structure possesses numerous undesirable characteristics as a substrate for bonding of an adhesive. It is rough, inhomogeneous in composition, covered with a tenacious layer of surface debris, and wet. These factors discourage adhesion. Furthermore, the reactivity (surface energy) of enamel and dentin is fairly low, and therefore the surface does not easily attract other molecules. When fluoride is included in the mineral structure of the tooth, the surface energy is further reduced.

On the other hand, the surface energy of most restorative materials, particularly metallic ones, is higher than that of normal intact tooth structure. Therefore debris accumulates on the surfaces of restorations more than on the adjoining enamel. In addition, biofilms form readily on methacrylate-based materials. This could contribute to the high incidence of secondary caries associated with most restorative materials. Debris accumulation can promote marginal deterioration by the loss of tooth structure or restorative material at the interface. Such deterioration would be expected to increase microleakage and its associated negative outcomes.

Marginal leakage has been a more acute problem with resins than with any other restorative material. Amalgam restorations tend to counteract the microleakage phenomenon by the formation of corrosion products along the tooth-restoration interface. Other restorative materials may provide a mechanism for resisting secondary caries attributable to microleakage, such as the fluoride released from glass-ionomer cement (GIC). With most direct restorative resins, however, there is no inherent resistance to the dangers of marginal penetration of deleterious agents. Thus the dentist will find it difficult to maintain good adaptation of the resin restoration material to the tooth surface under oral conditions.

TREATMENT OF THE CAVITY PREPARATION

Various materials have been advocated for use on the cavity preparation prior to placement of the final restoration. In preparations that do not approach the pulp, the method of cavity surface preparation is dependent upon the final restorative material. For resin composite restorations, the preparation is treated with a dental adhesive prior to placement of the restorative material. For glass-ionomer restorations, the smear layer is removed with a polyacrylic acid-based dentin conditioner, followed by placement of the glass-ionomer material directly onto the dentin.

When the preparation approaches the pulp tissue, a hard-setting calcium hydroxide formulation has long been used as a therapeutic aid associated with dentin bridge formation between the material and remaining vital pulp tissue. When placed directly on the pulp, this material causes necrosis of the superficial pulp tissue, followed by odontoblast activity and subsequent dentin formation. Early versions of calcium hydroxide liners were very susceptible to dissolution and had poor mechanical properties. Newer versions have been improved, but calcium hydroxide does not seal the dentin. Glass-ionomer cement or resin-modified glass-ionomer cement liners have been placed over calcium hydroxide to provide a level of protection from future bacterial penetration. Dental adhesives used with resin composite restorations can provide this protection, more predictably when the restoration margins are all in enamel.

Newer approaches to pulp-capping and pulpotomy methodologies include the use of materials containing calcium silicate and calcium aluminate. Mineral trioxide aggregate (MTA) is a mixture of dicalcium and tricalcium silicates, tricalcium aluminate, gypsum, and tetracalcium aluminoferrite. Calcium silicates have been modified with light-activated resins to form lining materials with enhanced dentin interaction when compared with that of calcium hydroxide.

TEMPORARY AND PERMANENT RESTORATIONS

The temporary restoration should possess good biological characteristics; have minimal solubility; and be rigid, strong, and resistant to abrasion. The relative importance of each of these properties depends on the degree of permanence desired. For example, in the caries-affected mouth, it is often desirable to remove some or all of the caries immediately and place temporary restorations which are subsequently replaced with more permanent restorative materials. In such situations the temporary restoration may need to serve for several months or longer. Strength and resistance to abrasion and dissolution are of paramount importance in these cases. In most cases, however, temporary restorations need to remain in place

Dentlearn.ir

only for days. For short-duration restorations, emphasis may be placed on the biological properties when the restorative material is selected.

For intermediate restorations, zinc oxide–eugenol cement has been commonly used because of its excellent tissue tolerance and ability to minimize initial microleakage. The strength, rigidity, and resistance to abrasion of the conventional zinc oxide–eugenol mixture have been improved by the addition of polymers and by the surface treatment of the zinc oxide powder.

Type II GICs or the newer resin-modified GICs are also useful as long-term, temporary restoratives—for example, in the restoration of eroded areas in teeth with exposed areas of cementum and dentin. Because of its desirable biological and adhesive characteristics, GICs can be used to restore these lesions without the need for a retentive cavity preparation. If conventional GICs are used as restorative materials, they must be protected from exposure to moisture in the early stages of setting and from dehydration for a very long time, preferably the entire time the restoration will serve. In general, a resin-modified glass ionomer is a better choice, for reasons given previously.

GIC formulations that include enhanced filler composition to improve their mechanical properties have higher viscosity and are advocated for atraumatic restorative treatment applications and for class I and class II restorations in the primary dentition. Improvements in the mechanical properties of these "reinforced" GICs have shown promise in some clinical trials. Whether their mechanical properties, such as fracture toughness, are adequate to resist masticatory stress for long periods of time is yet to be shown.

RESTORATIVE RESINS

CONVENTIONAL COMPOSITES

The term *composite material* refers to a multiphase material with a distinct interface separating the components. When properly constructed, the combination of materials results in properties that could not be obtained with any of the components alone. (Examples of natural composites are bone, tooth enamel, and wood.) In a resin composite dental restorative material, inorganic filler is added to a resin (organic) matrix in such a way that the properties of the matrix have been improved.

Several filler characteristics have a pronounced influence on the ultimate composite properties. The shape, size, orientation, concentration, and distribution of the filler are very important. The filler size has been used as one method of classifying these materials (Table 12-1).

Likewise, the composition of the resin matrix has a significant impact on the properties. The resin matrix of most of the currently available composite materials is based on combinations of bisphenol A–glycidyldimethacrylate (bis-GMA), urethane dimethacrylate, and triethylene glycol dimethacrylate, which is a low-viscosity resin added as a diluent. Among the materials used for macrofillers are ground particles of fused silica; crystalline quartz; and soft glasses such as barium, strontium, and zirconium silicate glass. These particles, which make up

Table 12-1

Classification of Direct Restorative Resin Composites

By Filler Size and Content	By Use or Characteristic	By Activation Mechanism
Hybrid	Multipurpose	Light-cured
Microhybrid	Bulk-fill	Chemically cured
Microfill	Flowable	Dual-cured
Nanohybrid	Core	
Nanocomposite	Provisional	

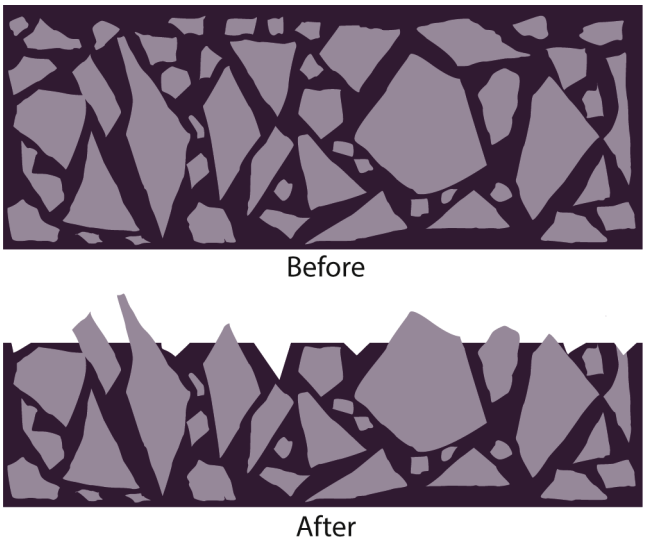

Figure 12-1 Schematic drawing of a conventional composite resin with macrofiller *(black areas)* before and after finishing or wear. (Redrawn from Phillips RW: *Science of dental materials*, ed 9, Philadelphia, 1991, WB Saunders.)

70% to 80% of the material by weight of multipurpose composites, enhance the physical and mechanical properties of the material. When compared with an unfilled acrylic resin, the composite resins demonstrate increased stiffness and hardness, a reduced coefficient of thermal expansion, and reduced polymerization shrinkage.

The filler and the resin matrix may be chemically bonded together with a coupling agent on the surface of the filler. If this bonding is not accomplished, the particles may be easily dislodged, water sorption at the filler-matrix interface may take place, and stress transfer between matrix and filler may not occur. The filler particles are coated with a reactive silane product. Despite use of this coupling system, the filler particles do become dislodged during cutting and finishing and under abrasive action such as toothbrushing or occlusal contact. This abrasive action likely affects the softer resin matrix, which can erode and expose the filler particles. When enough of the filler particle is exposed, it will break free of the resin. This process continually leaves a rough surface (Figs. 12-1 and 12-2). Because the composites are 70% to 80% filled, this surface roughness is clinically noticeable.

Dentlearn.ir



Figure 12-2 Scanning electron micrograph showing generalized wear of a packable composite exposing the enamel margin.

Based on clinical experience, there has been a definite preference for use of smaller filler particles. In the early resin composites, it was common for the particle size to approach 100 μm; now the coarsest particles would not exceed 30 μm. The average mean particle size of the fillers in conventional composites is in the 8- to 12-μm range. So-called nanohybrid composites and nanocomposites contain fillers as small as 0.002 μm.

MICROFILLED COMPOSITES

Efforts to improve the surface smoothness and polishability of composite resins led to the development of the microfilled composite. These composites are based on the use of an extremely small silica filler particle, whose size is from 0.02 to 0.04 μm; hence they are called microfine, microfilled, or polishable resins. The particles may be dispensed directly into the paste, but the amount that can be added in this manner is very limited. Addition of amounts in excess of 20% results in a paste too viscous for the dentist to use.

Matrix resin monomer can be heavily filled with microfine silica and polymerized in the manufacturing process. The resulting composite is ground to filler particle sizes comparable with those of the inorganic filler in conventional composite. This "organic" filler with additional colloidal silica is then added to the resin monomer to form the composite resin paste. The structure of such a resin is illustrated in Figure 12-3.

The appealing characteristic of these microfilled resins is their ability to be finished to an extremely smooth surface, which was a major problem with the conventional composites. When microfilled resins are finished, the polymerized resin filler particles cut at the same rate as the matrix, which results in a much smoother surface, as shown in Figure 12-3. Even if some of the very small silica particles are dislodged, the surface irregularities cannot be detected visually.



Figure 12-3 Structure of a microfilled resin showing microfiller *(dots)* and prepolymerized macrofiller particles before and after being finished. (Redrawn from Phillips RW: *Science of dental materials,* ed 9, Philadelphia, 1991, WB Saunders.)

Because of the small silica particle size, the filler has a very large surface area, and the total amount of filler that can be incorporated is reduced to about 50% by weight compared with a filler loading of 70% to 80% for conventional composites. Thus the microfilled composite has higher resin matrix content. As a result, such resins are softer and have a slightly higher coefficient of thermal expansion, higher water absorption, more polymerization shrinkage, and somewhat lower mechanical properties. Because of this tradeoff in properties, microfilled resins should be used where aesthetics is the principal consideration and where undue stress will not be placed on the restoration, such as in class III or class V restorations. When the restoration is subject to stress, such as the incisal margin of a class IV restoration, a composite having better physical properties is preferred. The development of different types of hybrid composites has significantly reduced the use of microfilled composites.

HYBRID COMPOSITES

The conventional macrofilled composite is no longer in common use. Filler sizes have been continuously reduced to approach the surface smoothness of the microfilled resin but retain the filler levels and physical properties of the conventional composite. Hybrid composites are a recent step toward smaller particle size. They contain radiopaque glass particles with an average size of 0.6 to 1.0 μm in addition to 10% to 20% colloidal silica. The total filler level is significantly higher than in a microfill resin, at 70% to 80%. Because these combine two types of fillers, the result is called a *hybrid composite.*

Although the surfaces of hybrid resins are not as smooth as those of microfilled resins, these resins find extensive anterior use if they are carefully polished. In addition, one of the primary motivations in the development of these hybrid materials was to find a material that could compare favorably with dental amalgam in wear resistance in class I and II restorations. (The use of composites

Dentlearn.ir

in such situations is discussed in the section on posterior composite restorations.) The most recent trend in resin composites has been the marketing of multipurpose restorative materials for use in either anterior or posterior applications.

Flowable composites have become popular for small restorations and are used as liners. Filler content is decreased or matrix monomers changed to decrease the viscosity of the resin composite. This generally comes with a sacrifice of mechanical properties. Some flowable composites are marketed for use as pit-and-fissure sealants.

Nanoparticles are now included in the nanocomposite and nanohybrid composite materials. These particles range from 0.002 μm to 0.075 μm and are formed from sols of silica or zirconia. It is apparent that much of this size range was present in the microfill resins, making the nomenclature somewhat misleading. However, the improved filler manufacturing techniques have resulted in filler levels approaching 80% for these materials. Their polishability and relatively good mechanical properties have made them popular clinical choices for many applications.

LIGHT-CURED COMPOSITES

Originally, composite resins were chemically activated, which required the mechanical mixing of two pastes to initiate the chemical reaction. Light-cured or light-activated composites have largely supplanted the chemically activated composites. Light-activated resins do not differ significantly in composition from the chemically activated resins except for the polymerization activation mechanism. However, light curing provides an advantage in working time and other handling characteristics. The dentist has complete control over the working time and is not confined to the rather short working time of the chemically activated systems. This is particularly beneficial when large restorations such as class IV restorations are placed.

Most currently available visible light-cured resins contain the photosensitive initiator camphorquinone, which absorbs visible light at wavelengths between 450 and 500 nm (blue light) and forms free radicals that activate an amine accelerator. Because of the yellow color of camphorquinone, other photoinitiators, such as phenylpropanedione and 2,4,6-trimethylbenzoyldiphenylphosphine oxide, have also been used in some lighter-shade composites.

One major disadvantage of light-cured composites must be emphasized. Polymerization will occur only if the resin is exposed to light of sufficient intensity for an adequate length of time. The top surface of a restoration, which is nearly in direct contact with the light source, will always be cured if the light and resin are serviceable. However, the curing of the portion of the restoration farthest removed from the light is less certain. Normally this portion of the restoration is not accessible for any kind of probing to test its hardness. If the cure is incomplete on the bottom side of the resin compared with the top surface, the physical properties will be reduced and a color shift may occur in time. Likewise, unpolymerized monomer may increase the potential for pulpal irritation. Microleakage is another potential scenario. For maximum polymerization to be ensured, the end of the light source should be within 1 mm of the surface of the resin and the depth of resin to be cured should not exceed 2.5 mm. Furthermore, the curing time should match the manufacturer's recommendation for the type of light unit and resin shade. Larger restorations and dark shades of resin require an incremental placement technique.

Dual-activated resins are available that combine both light and chemical activation. In situations in which light access to parts of the restoration is problematic, a dual-activated material may be preferred. Bulk-fill composites have recently been introduced that provide a 4- to 5-mm depth of cure through the use of highly sensitive photoinitiators or very light resin shades.

Sidebar: *Light-curing technique.*

Position the patient for maximum control

Stabilize the light guide during the curing cycle

Be sure the end of the light guide is clean and not damaged

Begin the polymerization with the guide about 1 mm away from the resin surface

After 1 second, move the guide as close to the resin surface as possible

Wear eye protection to allow for visual monitoring of the curing cycle

When visible light-curing systems were first introduced into dentistry, considerable emphasis was placed on the claim that the light output of the unit remained constant with use, unlike the previously used ultraviolet light units. Unfortunately this statement is only partially true. Numerous factors do influence the light output of a visible light-curing unit, such as power line variations, aging of the filters, aging of the lamp, damage to the light-conducting pipe or optic fiber, and resin buildup on the end of the light tip. Many visible light activation units have built-in meters to verify adequate light intensity. Inexpensive meters are available for this purpose and should be used regularly. If such a device is not available, a simple curing light usage test should be performed to ensure adequate light intensity. Place a mass of light-curing resin that is about the thickness of a nickel over a Mylar matrix strip on a sheet of white paper. Cover this mass with a Mylar matrix strip. Holding the curing light within 1 mm of the top surface, cure the resin for the length of time normally used. Remove the Mylar matrix strips and probe both the top and bottom resin surfaces with an explorer. There should be no noticeable difference in hardness or scratch resistance. Dark shades of composite resin may require longer curing times or curing of a thinner layer according to the manufacturer's instructions. If a comparable cure on both top and bottom cannot be achieved, the combination of resin and curing light is unsatisfactory for clinical use.

The original visible light activation units incorporated a quartz-tungsten-halogen (QTH) lamp as a light source. This light is filtered to retain the wavelengths between 400 and 500 nm (blue light). In an effort to accomplish more rapid polymerization of a greater thickness of resin, manufacturers have marketed other light sources, such as plasma arc lamps and lasers. Both are significantly more expensive

Dentlearn.ir

than the QTH units, and there is evidence that more rapid polymerization may increase polymerization shrinkage stresses at the tooth-resin interface. A popular type of activation unit uses blue light–emitting diodes (LED). LEDs are nearly 100% efficient at generating light over a relatively narrow wavelength band (often from 460 to 480 nm). The diodes are commonly made of indium, gallium, and nitride. Variations in concentrations of these elements within the diode can shift the spectral output of the light, and some lights now contain multiple diodes. These lights are often self-contained, rechargeable, battery-powered activation lights that generate less heat than QTH units do. (More than 95% of the electrical energy delivered to a QTH light becomes heat and light at wavelengths longer than 500 nm.) Unlike QTH lamps, an LED should maintain a constant output throughout its lifetime. High output LED units can provide enough energy to burn tissue and should not be held against mucosa for long periods of time.

The total power delivered in the 400- to 500-nm band from LED lights was initially much lower than that of QTH units. Recently marketed LED lights have significantly improved power output, and the useful light intensity for some LED units exceeds that of the best QTH units. A significant advantage of the LED lights appears to be convenience because they do not require a power cord fixed to a base unit (Fig. 12-4). Because of the risk of retinal damage to the operator, protective glasses or shields are recommended to protect the eyes from the glare of the intense blue light produced by visible-spectrum curing lights.

POSTERIOR COMPOSITE RESTORATION

Composite resins were originally used for anterior or non–stress-bearing locations such as class III, IV, and V restorations. They are now widely used for class I and II restorations. Early attempts with conventional macrofilled composites failed because of unacceptable wear on the occlusal surface. Only in the case of conservative restorations in primary dentition was any success observed. A major goal of composite resin research has been to develop properties adequate for use as alternatives to dental amalgam.

The improved strength, hardness, and modulus of elasticity of newer composite resins, with their low thermal conductivity and superior aesthetics, indicate that they may serve in the restoration of occlusal and proximal surfaces in posterior teeth (class I and II restorations). Extensive clinical testing has been done to compare the performance of these new resins with that of amalgam. Resin composites now exist with documented clinical wear of less than 20 μm/yr over a 5-year period. The patient and guardian should be cautioned that the performance of these restorations over long periods (5 to 10 years or longer) should be monitored for wear and occlusal relationships.



Figure 12-4 Rechargeable battery-powered light-emitting-diode–type visible light activation unit.

The dentist needs to be aware of two additional factors when choosing resin composites for posterior occlusal service. Although the microleakage problems with anterior composite restorations have been significantly reduced by the development of the acid-etch enamel-bonding technique (discussed later), posterior class II restorations often have gingival margins in dentin or cementum. Furthermore, the class II restoration presents a proximal surface with poor, if any, direct access to the curing light. (As mentioned under the heading "Light-Cured Composite" earlier in this chapter, exposure to light of adequate intensity is essential to cure a light-cured composite.) Various solutions have been suggested, including the use of light-conducting interproximal wedges. Probably the best general procedures are to utilize incremental buildup and pay careful attention to the light-curing technique.

Another problem with posterior restorations is related to the curing shrinkage pattern. Most composite resins exhibit linear shrinkage of 2% or more during curing. The light-cured composite hardens first on the surface immediately adjacent to the curing light tip. As a consequence, the direction of shrinkage is toward the curing light and well-bonded interfaces and away from the floor of the preparation or the gingival margin. This places the largest stresses from curing shrinkage on the sections of resin that are the least well-cured and whose bond to tooth structure may be the poorest. Increased microleakage may be the result. Recent developments have resulted in the marketing of new resin matrix systems with very low polymerization shrinkage. Analysis of laboratory data shows that these materials minimize polymerization stresses at the resin interface. The use of liners with a lower modulus of elasticity also reduces these stresses. Long-term clinical data, however, are not available to fully substantiate the importance of these laboratory observations.

Resin composites are greatly compromised by moisture contamination during placement, so effective isolation of the operative field is essential. Operative techniques as described in Chapter 11 can reduce this risk.

Knowledge about the safety of composite resins is important. A resin monomer often used in restorative resin composites is bis-GMA. This monomer is the reaction product of bisphenol A and a dimethacrylate. Bisphenol A is chemically similar to synthetic estrogen. Because of this, concerns have been raised about the potential for promoting certain types of malignancies. Complete conversion of the bisphenol A during the synthesis of bis-GMA resin monomers does not occur, and very small trace amounts can be found in dental composites. Although bisphenol A is commonly used in many commercial polymers for nondental uses, certain jurisdictions, including the State of California,

Dentlearn.ir

have promulgated severe restrictions on its use in food or drink containers and, in particular, in resin baby bottles. Components used in the light activation of polymerization initiation are very reactive. Traces of these components remain after the resin has hardened. Moreover, enzymes in saliva and in oral tissues may promote degradation of dental resins, which could release reactive species. It is important that the dental consumer, who may be the parent of a pediatric patient, be aware of the risks and benefits of the dental materials used in a proposed treatment plan.

The clinical application of pit-and-fissure sealants is discussed in a separate chapter; however, some comments about these materials are relevant to the discussion of light-activated resin composites. Clinicians often tend to assume that a sealant is so thin that if the surface is hard, the material is properly polymerized. Cross-sections through extracted molar teeth show that thicknesses exceeding 2 mm are common in occlusal pits. Deep developmental grooves may have exposed dentin at the bottom, and if the bottom of the sealant is not adequately polymerized, the dentin is in contact with reactive components of the resin. The geometry of the occlusal surface may result in reduced light intensity because of the distance of the tip from the occlusal grooves. Use of a large-diameter curing tip further reduces the intensity. Opaque sealants are popular, but the opacity also reduces the light transmitted to the bottom of the sealant. Adequate polymerization is a function of the energy delivered to the entire mass of the resin. Radiant exposure is the product of light intensity and the activation time. Good light-curing of opaque sealants requires meticulous attention to detail.

RESIN INLAYS

Some of the shortcomings of composite resins, particularly the difficulties involving placement and light-curing (discussed previously), can be minimized with the use of direct or indirect resin inlay restorations. The indirect inlay restoration is fabricated in the laboratory on a die poured from an impression of the prepared tooth—similar to a wax pattern for a cast restoration—whereas the direct resin inlay is fabricated in the operatory. In the latter instance a separating medium is applied to the prepared tooth prior to the placement and light-curing of the resin. Then the direct inlay is removed from the mouth and subjected to additional curing procedures. Finally the finished inlay is cemented in the mouth with resin cement.

Both techniques allow better access for light-curing the composite, and the finished restoration can be subjected to additional curing under intense light, heat, pressure, or some combination of these. In theory the properties of the resulting composite are maximized, and the presence of unreacted monomer is minimized. More importantly the polymerization shrinkage occurs outside the mouth. The stresses at the tooth-restoration interface should be much lower than in direct-placement resin restorations.

DENTAL ADHESIVES

Enamel Bonding

The acid-etch technique is one of the most satisfactory methods for mechanical bonding of resin to enamel. First, the enamel is etched with a solution of phosphoric acid (usually about 35%) for approximately 15 to 20 seconds. Gels, created by the addition of colloidal silica or polymer beads to the acid, result in a material that is more easily handled during placement.

The next critical step in the technique is the use of a water rinse to remove the debris produced during etching. If this debris is not flushed off the enamel surface, the resin will not wet the etched surface. A minimum wash time of 30 seconds is usually recommended. If an enamel adhesive or pit-and-fissure sealant is being placed, the etched surface must be dried for at least 15 seconds before the resin is placed.

Any film of moisture on this cleaned surface will inhibit resin penetration into the etched enamel. If the surface is accidentally contaminated by saliva, the salivary film cannot be completely removed by being washed. Rather the surface should be re-etched for 10 seconds, then washed and dried.

An etched enamel surface is shown in Figure 12-5, *A*. The acid cleans the enamel to provide better wetting of the resin and creates pores into which the resin flows to produce "tags" that greatly increase retention (see Fig. 12-5, *B*). The resulting bond should reduce the possibility of marginal staining, which is the invariable result of microleakage. In addition to providing a seal between the resin and tooth, the acid-etch technique results in mechanical retention. Resin shear bond strengths to etched enamel range from 16 to 22 MPa.

Dentin Bonding

As an adjunct to the acid-etch technique, manufacturers formerly supplied enamel-bonding agents. The bonding agent consisted of bis-GMA resin matrix material diluted with a low-viscosity methacrylate monomer. After the enamel was acid-etched the bonding agent was applied. The composite resin was then immediately inserted, and it in turn bonded to the intermediate layer of the resin-bonding agent. The resulting bond to tooth structure was strictly mechanical. Some orthodontic bonding resins and pit-and-fissure sealants resemble these early bonding agents.

Providing successful bonding to dentin has gone through multiple generations of development. Early efforts to etch dentin and apply enamel-bonding agents were not successful. The structure of dentin is far more complex, and it has a lower concentration of inorganic material. Because of the microstructural organization of dentin, the regular etch patterns seen with enamel are not produced. Due to the organic component of dentin and the permeability that results from the dentinal tubules, the dentin surface has low surface energy and is constantly wet. This presents the ultimate challenge for adhesion. For many years research has focused on the development of agents that will bond adhesively to dentin. This has led to the introduction of dentin-bonding agents, which are either chemically activated or light-cured. They are applied to the dentin before placement of the composite.

The chemistry of the different products is complex and varied. Some agents rely on mechanical retention, whereas there is some evidence that others form chemical bonds to the organic or inorganic portions of the dentin.

Dentlearn.ir

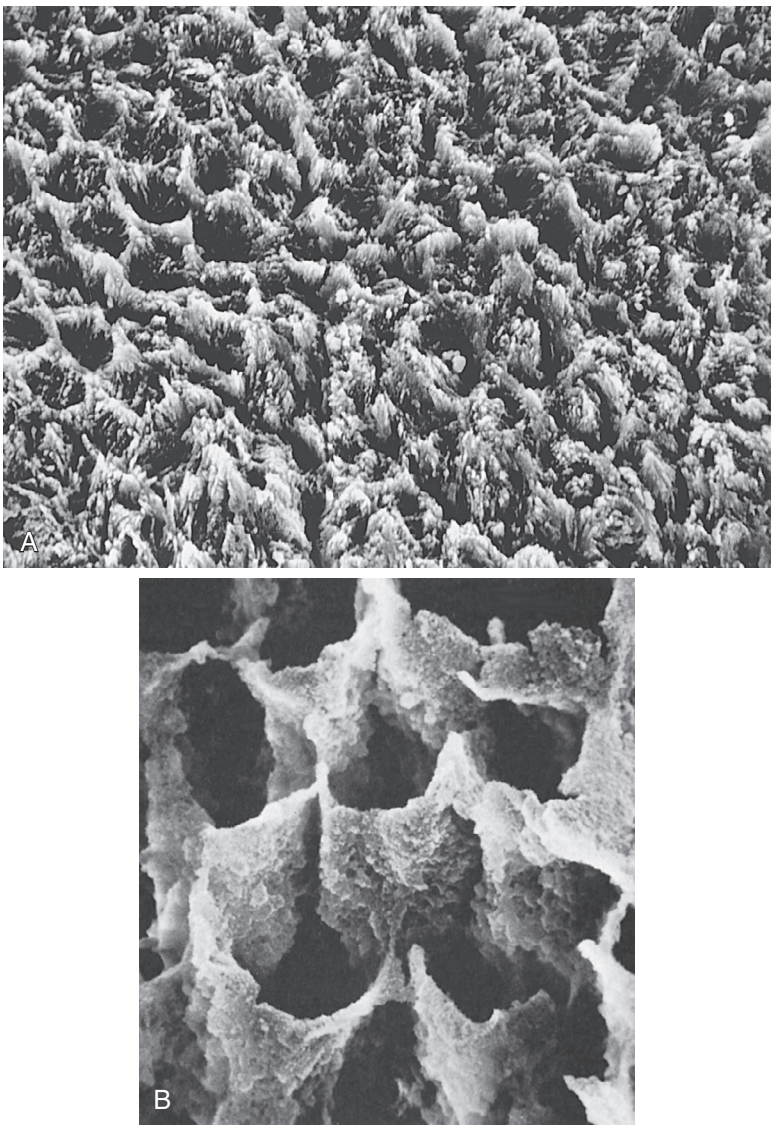

Figure 12-5 Effects of acid etching. **A,** Scanning electron micrograph of enamel surface etched with phosphoric acid. **B,** Scanning electron micrograph of resin tags formed by penetration of resin into etched enamel surface (5000x). (**A** and **B** from Anusavice KJ: *Phillips' Science of dental materials*, ed 11, St. Louis, 2003, WB Saunders; courtesy of K.J. Söderholm.)

However, little convincing evidence exists that, as a whole, the dentin-bonding agents currently marketed form significant chemical bonds to dentin. It is more likely that the primary bonding mechanism is micromechanical. Performance is often asserted by reports of bond strengths to dentin. Tensile bond strengths appear to provide better clinical relevance than shear bond strengths. Often the bond strengths measured in vitro decrease markedly with time, exposure to water, and thermocycling. The presence of matrix metalloproteinases and collagenases in etched dentin appears to contribute to bond degradation.

Sidebar: *Types of Dental Adhesives*.
Etch-and-rinse, 3-step
Etch-and-rinse, 2-step
Self-etch, 2-step
Self-etch, 1-step
Self-etch, universal
Glass-ionomer cement

The dentin-bonding systems that first exhibited good bond strengths involved removal of the dentin smear layer and decalcification of the outer layer of intact dentin with an acid. A hydrophilic primer component carried by a volatile solvent that displaces water was then applied. This resulted in creation of a so-called hybrid layer between the intact dentin and the resin adhesive because resin components in the primer penetrate the decalcified dentin, reacting with and modifying the remaining dentin structure. High in vitro bond strengths are generally reported for these systems, along with good short-term clinical performance. Unlike the enamel-bonding acid-etch technique, when systems with hydrophilic primers are used, it is important that the etched dentin surface not be desiccated before application of the primer.

Current advances have focused on the development of delivery systems that simplify the steps involved in the use of dentin-bonding systems. Acidic primers that are

self-etching have been introduced. These simultaneously demineralize and penetrate the smear layer and underlying dentin. Other systems combine the primer and the resin adhesive into one component. These simplified systems mix the acidic primer and resin adhesive before they are placed on the tooth surface. Even though these newer systems use fewer separate components, their application still requires that several steps be performed with great attention to detail. Use of these materials remains extremely technique-sensitive. The status of these agents remains controversial, particularly with regard to their long-term stability in the oral cavity. Until these matters are resolved, it would be prudent not to deviate too far from accepted restorative procedures. One should assume that the dentin adhesive will not eliminate the need for the use of traditional methods for retention of the resin restoration, such as acid-etching of the enamel and retentive cavity preparations in dentin or cementum.

Analysis of laboratory data has shown incompatibility between some of the newer dental bonding systems and restorative resins or resin cements that are activated by chemical or dual means. Many of the resins used for crown buildup as core materials fall into these categories. It appears that the use of acidic primers may interfere with the chemical activation of these resin materials unless a separate resin adhesive is placed over the primer and light-activated before the core material or cement is placed. The simplified adhesive systems are also relatively hydrophilic and act as a permeable membrane, allowing water to move through the adhesive layer and interfere with the bond to the overlying resin, particularly if curing is delayed.

Current dental adhesives are to be used with both dentin and enamel. Bond strengths reported for etched enamel usually equal those for the original enamel-bonding agents that have largely disappeared. Regardless of whether an auxiliary resin-bonding agent is used, adequate etching of the enamel is an important step in securing mechanical bonding of any restorative resin to enamel. Some of the systems that use self-etching primers or acids other than phosphoric acid do not routinely yield enamel-bond strengths as high as expected with conventional acid-etching. Questions exist about the effectiveness of dental bonding systems with self-etching primers when these are used in place of phosphoric acid treatment for bonding orthodontic appliances and pit-and-fissure sealing.

Conventional phosphoric acid etchants can be used to ensure etching of the enamel margins of a cavity preparation. This selective etching technique has led to a new terials are intended for use on all tooth structures, whether or not phosphoric acid has been applied. Some of these adhesives also include active molecules for interaction with ceramic and metallic surfaces.

In the context of dental bonding, one should not ignore the polyacrylic acid systems. GIC has been recommended as a dentin-bonding agent in the so-called sandwich technique. Fast-setting GICs are available as cavity-lining materials (type III GIC and light-cured GIC). The enamel is not covered with GIC; rather, it is acid-etched in the conventional manner. A resin-bonding agent is then applied and a composite resin placed. The ionomer bonds adhesively to the tooth, whereas the bonding agent bonds mechanically to the ionomer and the enamel. This adds yet another dimension to dentin-bonding technology, particularly for class II restorations.

Dental resins are no more or less irritating to the pulp than are several other commonly used restorative materials. Whenever the cavity preparation is deep, the same precautions should be taken with resins as with other restorative materials.

AMALGAM

Controversy regarding the safety of the dental amalgam restoration has existed since the material was introduced to the profession more than 150 years ago. Periodically this controversy surfaces in the news media and becomes a matter for public and professional debate. In 2012 the inclusion of dental amalgam in the United Nations Environment Program Mercury Treaty brought heightened awareness to dentistry's impact on the environment. As a result, the dentist who uses dental amalgam can expect questions to be raised by patients and their guardians and can expect requests for replacement of intact amalgam restorations with other materials.

Amalgam is no longer the most commonly used material for restoring posterior caries lesions. Tooth-colored restorative materials are increasingly being used. The popularity of dental amalgam likely will continue to decline as these other materials demonstrate their longevity and their suitability as general amalgam replacements in the permanent dentition.

The unique clinical success of amalgam during 150 years of use has been associated with many characteristics. It is likely that its excellent clinical service, even under adverse conditions, is related to the tendency for its microleakage to decrease as the restoration ages in the oral cavity. Although amalgam does not bond to tooth structure, and the margins of an amalgam restoration may appear open, the restoration-tooth interface immediately below the exposed margin becomes filled with relatively insoluble corrosion products that inhibit leakage. Amalgam is unique from this standpoint. The microleakage around other restorative materials usually increases with time. Amalgam is the least technique-sensitive of all current direct restorative materials. Another unique property of amalgam as a direct filling material is its lack of dimensional change during hardening. The ADA specification for dental amalgam limits maximum acceptable dimensional change to ± 0.2%. If this is compared with a common value of 2% or higher for the polymerization shrinkage of a resin matrix composite material, the potential impact on microleakage is obvious.

Nevertheless, failures of amalgam restorations are observed. These may occur in the form of recurrent caries, fracture (either gross or severe marginal breakdown), dimensional change, or involvement of the pulp or periodontal membrane. More significant than the type of failure is its cause. Two factors that lead to such clinical failures are improper design of the prepared cavity and

Dentlearn.ir

faulty manipulation. In other words, the deterioration of amalgam restorations can often be associated with the clinician's neglect in observing the fundamental principles of cavity design or abuse in preparing and inserting the material. Another factor involved is the choice of the alloy used.

SELECTION OF THE ALLOY

Several criteria are involved in the selection of an amalgam alloy. The first criterion is that the alloy should meet the requirements of ADA Specification No. 1 or ISO Specification 24234.

The manipulative characteristics of dental amalgam are extremely important and a matter of subjective preference. Rate of hardening, smoothness of the mix, and ease of condensation and finishing vary with the alloy. For example, the resistance felt with lathe-cut amalgams during condensation is entirely different from that with spherical amalgams. The alloy selected must be one with which the dentist feels comfortable because the operator variable is a major factor influencing the clinical lifetime of the restoration. Use of alloys and techniques that encourage standardization in the manipulation and placement of the amalgam enhances the quality of the service rendered. Coincident with this is the delivery system provided by the manufacturer—its convenience, expediency, and ability to reduce human variables.

Obviously, the physical properties should be reviewed in the light of claims made for the superiority of one alloy over competing products. Ideally such a list of properties should be accompanied by documented clinical performance in the form of well-controlled clinical studies. Although the cost of the alloy is a factor, this criterion should not be overemphasized when balanced against the alloy's ability to render maximum clinical service. The dentist should always consider the fractional costs of any material compared with the overall total charges for a dental procedure when making price comparisons among brands, particularly when comparing a brand with documented clinical performance against a generic brand of material.

Dental amalgam alloys generally are available as either small filings called lathe-cut alloys or spherical particles called spherical alloys. Spherical alloys tend to amalgamate readily. Therefore amalgamation can be accomplished with smaller amounts of mercury than required for lathe-cut alloys, and the material gains strength more rapidly. Also, the condensation pressure and technique used by the dentist in placing the restoration are somewhat less critical in achieving the same properties of the amalgam. This is an advantage in difficult clinical situations in which optimal access for condensation is limited. Spherical amalgam alloys have a somewhat different feel during condensation and require less condensation pressure than do lathe-cut alloys. The dentist and auxiliary personnel should familiarize themselves with the handling characteristics of a new alloy before placing clinical restorations.

HIGH-COPPER ALLOYS

The original dental amalgam alloys were of silver and tin with a maximum of 6% copper. When significantly more copper is available, improved laboratory properties and clinical performance have been demonstrated. This improvement has been attributed to the displacement of the tin-mercury reaction product with a copper-tin phase during the amalgamation reaction. Alloys that contain enough copper to eliminate the formation of the tin-mercury phase (from 11% to 30%) are called high-copper amalgam alloys. The first such alloy of this type was an admixed system. Small spherical particles of a silver-copper alloy were added to filings of a conventional silver-tin alloy. High-copper alloys can also be made with single-composition particles. Each of these alloy particles has the same chemical composition, usually silver, copper, and tin. Amalgams made from high-copper alloys have low creep. Creep is the tendency of a material to deform continuously under a constant applied stress and has been associated with the marginal breakdown (ditching) of amalgam restorations. Creep of modern high-copper amalgam alloys is less than 1%. Choice of amalgam alloy today should be limited to high-copper alloy systems.

Regardless of the alloy used, manipulation plays a vital role in controlling the properties and the clinical performance of the restoration.

MERCURY/ALLOY RATIO

Most of the properties of amalgam restorations have been shown to depend on the relative amount of mercury contained in the finished restoration (the residual mercury). One variable that controls the final mercury content is the amount of mercury required to mix the amalgam.

Amalgam alloy is sold in the form of prefilled, disposable mixing capsules containing the proper amounts of alloy and mercury. This delivery system provides several advantages. The alloy/mercury ratio is accurately preproportioned. The need for disinfection procedures is minimized because the capsule system is discarded after use. Most importantly, exposure of dental personnel and environmental contamination by mercury vapor are minimized. These prefilled capsules are usually available for mixes of different sizes, often called single- or double-spill capsules.

TRITURATION

The second manipulative variable that controls the residual mercury content is trituration. Trituration time can significantly influence both consistency and working time of the mixed amalgam. These in turn relate to the ability to bring excess mercury to the surface during condensation. The correct trituration time varies depending on the composition of the alloy, the mercury/alloy ratio, the size of mix, and other factors. The best practice is to acquire an appreciation for the appearance of a proper mix and then to adjust the trituration time accordingly. The most serious error in amalgamation is generally undertrituration. An undertriturated mix appears dry and sandy and does not cohere into a single mass. Such an amalgam will set too rapidly, which results in high residual mercury content, reduced strength, and the increased likelihood of fracture or marginal breakdown. Properly mixed amalgam is a shiny, coherent mass that can be readily removed from the capsule.

Dentlearn.ir

MECHANICAL AMALGAMATORS

When first introduced, mechanical amalgamators for dental amalgam operated at a single speed that was usually below 3000 cpm. High-copper alloys in prefilled, self-activating capsules are designed for shorter trituration times at higher trituration speeds. Failure to activate these capsules reliably results in undertrituration and is a common problem with the use of older single-speed amalgamators. Because amalgamators also deteriorate with time, replacement of an older unit with a new high-speed amalgamator is desirable. A unit that allows multiple speeds of operation should be selected because numerous other products such as dental cements are now marketed in capsules to be mixed in a dental amalgamator. The trituration times suggested by the amalgam alloy supplier are starting points. Amalgamators may vary in operating speed even within the same brand, and a unit's performance may vary with line voltage or the number of times it is used in rapid succession. Trituration speed and time significantly influences the rate at which some amalgams harden (Fig. 12-6).

CONDENSATION

The purpose of condensation is to adapt the amalgam to the walls of the cavity preparation as closely as pos-

to express excess mercury from the amalgam. Within reasonable limits, the greater the condensation pressure, the lower the amount of residual mercury left in the restoration and the greater the strength of the restoration. The selection of the condenser and the technique of "building" the amalgam should be designed to achieve those objectives, as described in detail in textbooks of operative dentistry, and should be tailored to the handling characteristics of the type of amalgam alloy chosen.

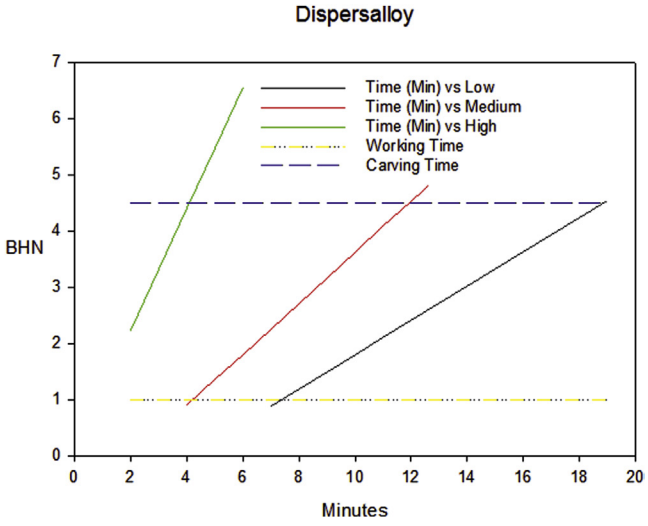

Figure 12-6 The influence of amalgamator speed (low-medium-high) on the hardening rate of a high-copper amalgam alloy, as measured by the Brinell hardness number (BHN). BHN = 1.0 indicates the working time, and BHN = 4.5 indicates the carving time. (Redrawn from Brackett W. Master's thesis. Indianapolis, 1986, Indiana University School of Dentistry.)

MOISTURE

Moisture contamination of an amalgam restoration can promote failure. If zinc is present in the alloy, it will react with water, and hydrogen gas will be formed. As this gas builds up within the amalgam, a significant delayed expansion can occur and may cause protrusion of the amalgam from the cavity preparation, which enhances the possibility of fracture at the margins.

Such moisture contamination can result from failure to maintain a dry field during the placement of the restoration. Exposure to saliva after the amalgam has been completely condensed is not harmful. It is only moisture incorporated within the amalgam as it is being prepared or inserted that must be avoided.

Zinc-free alloys are available, and their physical properties are generally comparable with those of their zinc-containing counterparts. A zinc-free, high-copper alloy should be used when the dentist operates in a field where moisture control is difficult.

MARGINAL BREAKDOWN AND BULK FRACTURE

Because dental amalgam is a brittle material, a commonly observed type of amalgam failure is the restoration in which the marginal areas have become severely chipped. The exact mechanisms that produce this breakdown of the amalgam or the adjoining tooth structure are not established, but it is likely that the deterioration is precipitated by manipulation and the finishing technique rather than by dimensional changes during setting.

If the restoration is improperly finished by the dentist, a thin ledge of amalgam may be left that extends slightly over the enamel at the margins. These thin edges of such a brittle material cannot support the forces of mastication. In time they fracture, leaving an opening at the margins.

Bulk fracture of amalgam is much less common with high-copper amalgam alloys. Those cases that do occur likely have one of two causes. Poor cavity design resulting in an insufficient bulk of material across the isthmus can lead to failure of even a high-strength alloy, as illustrated in Figure 12-7. The other reason for bulk fracture is

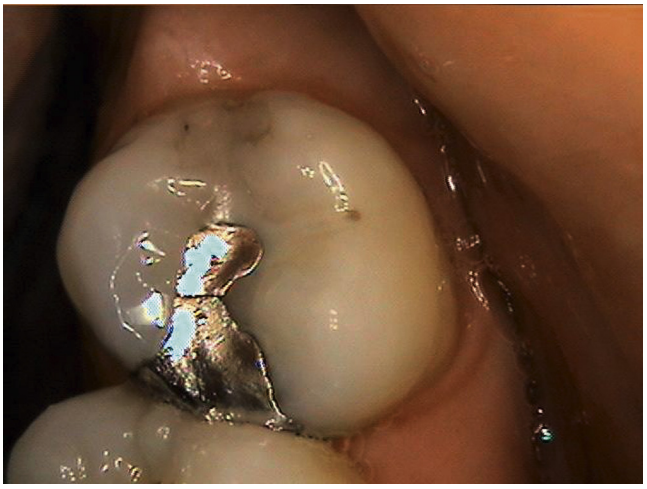

Figure 12-7 Bulk fracture of an amalgam restoration. Such failure may occur from improper cavity design or premature occlusal loading.

Dentlearn.ir

premature loading of the restoration. Unlike a resin matrix composite, amalgam gains strength slowly over the first 24 hours. Premature loading can result in minute fractures that are not apparent for weeks or even months. The use of a rapid-setting amalgam with a high 1-hour compressive strength should be considered during the treatment of a pediatric patient in whom compliance with instructions to refrain from biting down hard on the freshly placed amalgam is in question.

BONDED AMALGAM RESTORATIONS

Because dental amalgam does not adhere to tooth structure, it must be retained mechanically by the design of the cavity preparation and/or mechanical devices such as pins. The placement of an amalgam does not strengthen the compromised remaining tooth structure, and subsequent fracture may occur, particularly in molar teeth with relatively large mesio-disto-occlusal amalgam restorations. The use of dental adhesive systems, as described in detail in the section related to resin composites, as lining materials for amalgam to create a "bonded amalgam restoration" has been suggested. Several products are marketed specifically for this purpose. In general, they are chemically activated dentin-bonding systems over which the amalgam is condensed before the resin adhesive has hardened. This results in an intermixing of the unset resin and the plastic amalgam at the interface and forms a mechanical bond as both materials harden. It is important to distinguish this application from the use of a dental adhesive to seal the dentin surface and reduce early microleakage as previously discussed. When dental adhesives are used to seal the dentin surface, the adhesive should be polymerized before the amalgam is placed.

Bond strengths reported in laboratory studies between amalgam and dentin are lower than the maximum reported for resin composite bonded to dentin. In vitro studies also show that teeth restored with bonded amalgams are more resistant to fracture than those in which amalgam is placed without a bonding adhesive. These are relatively short-term laboratory studies. Even though longer-term clinical data are available, little is known about the potential influence of embedding the resin into the bulk of the amalgam on the long-term properties of the restoration. At present, amalgam bonding should be considered only as an adjunct for conventional, accepted practices of cavity preparation and mechanical retention of amalgam.

MERCURY TOXICITY

The amalgam restoration is possible only because of the unique characteristics of mercury. Mixing this liquid metal with the alloy powder provides a plastic mass that can be inserted into the tooth and then hardens rapidly to a structure that resists the rigors of the oral environment. As the restoration hardens, mercury reacts with silver and tin to form stable, intermetallic compounds. Most of the public controversy about the safety of dental amalgam has focused on the hazards associated with elemental mercury and some of its organic compounds. Many substances commonly regarded as quite safe contain extremely dangerous elemental ingredients. No one would ever consider human ingestion of elemental sodium or chlorine, but ordinary table salt, which is the compound sodium chloride, is an important dietary substance. From the time of the earliest use of amalgam, it has been asked whether mercury in a dental restoration can produce local or systemic toxic effects in humans. It is periodically conjectured that mercury toxicity from dental restorations is the cause for numerous illnesses of unknown etiology.

The possibility of toxic reactions by the patient to traces of mercury penetrating the tooth or sensitization from mercury dissolving from the surface of the amalgam is remote. The danger has been evaluated in numerous studies. The patient's encounter with mercury vapor during insertion of the restoration is brief, and the total amount of mercury vapor is small. Furthermore, the amount of mercury released from the amalgam in service is small compared with that released from other sources of mercury from air, water, and food. Metallic mercury in the human digestive track is apparently not converted to lethal organo-mercury compounds and is excreted by the body.

Both the National Institutes of Health and the FDA have examined the evidence for risk of dental restorative materials to the patient. The conclusion was that, except for the very small fraction of the population with a true allergic reaction to mercury or other constituents of amalgam, the dental amalgam restoration remains a safe and effective treatment. No evidence was found that related the presence of amalgam restorations to disorders such as arthritis, multiple sclerosis, or other diseases in which amalgam has been implicated. It should be noted that no currently available restorative material is completely risk-free, and that patients should be informed of the relative risks associated with all dental treatment alternatives.

The question about the replacement of existing serviceable amalgams with other materials remains one of professional judgment. Both the ADA and some state dental licensing boards have found that a dentist who recommends replacement of amalgam restorations with other materials based on the claim that this will improve the physical health of the patient may be acting unethically and may be subject to sanctions by licensing bodies and to suits for civil damages. Patients who believe that they have medical problems related to the presence of any dental restorative material should be referred to a physician for diagnosis and treatment recommendations.

What about dental office personnel? Restorative dentists and their office personnel are potentially exposed daily to mercury, even in offices in which amalgam restorations are not being placed. Although metallic mercury can be absorbed through the skin or by ingestion, the primary risk to dental personnel is from inhalation. A potential hazard exists for both the dentist and the staff from long-term inhalation of mercury vapor in the dental clinic, although the few actual incidents reported have been related to poor mercury-handling technique. The maximum level considered safe for occupational exposure is 0.1 mg of inorganic mercury per cubic meter of air averaged over a standard 8-hour workday. Mercury at room temperature has a vapor pressure almost 400 times the maximum level considered safe. This vapor has no color, odor, or taste and cannot be readily detected by

Dentlearn.ir

simple means at the level of maximum safe exposure. Because liquid mercury is almost 14 times more dense than water, a small spill can be significant. Eliminating the use of bulk mercury by the use of prefilled, disposable capsules significantly reduces exposure to mercury vapor.

The dental operatory should be well ventilated. All mercury waste and amalgam scrap removed during the placement or removal of amalgam restorations should be collected and stored in well-sealed containers. When amalgam is cut, water spray and high-speed evacuation should be used. More detailed recommendations can be obtained from the *Regulatory Compliance Manual* published by the ADA. The risk to dental personnel from mercury exposure cannot be ignored. However, adherence to simple hygienic procedures will ensure a safe working environment.

Waste materials containing mercury or amalgam scrap should be disposed of responsibly in accordance with the regulations of the local Environmental Protection Agency. These materials should not be incinerated or subjected to heat sterilization. Biologically contaminated wastes containing mercury, including extracted teeth, should be cold sterilized with a chemical agent before disposal. The most significant threat to the continued use of dental amalgam will likely be from government regulations on environmental waste discharge. In Japan use of amalgam has been discontinued because it is not feasible for a dental office using amalgam to meet restrictions on mercury discharge into sewers. Amalgam-mercury separators on dental clinic wastewater discharge lines are now required in several countries in Europe and are considered best practice by the American Dental Association. Local and state authorities should be consulted about limitations on the discharge of mercury into wastewater from a dental practice.

CERAMICS

Increased demands for aesthetic restorations and the encouraging performance of all-ceramic restorations in the permanent dentition have led to significant advances in dental ceramics. Glass ceramics used in all-ceramic restorations now provide highly aesthetic results, but their relatively low mechanical properties and brittle nature prohibit their predictable use in high-stress applications unless supported by a high-strength substrate. Polycrystalline ceramics, such as yttria-stabilized zirconia, are marketed for use as all-ceramic preformed crowns in pediatric applications. Because of the brittle nature of the material, these crowns cannot be crimped or adapted to a preparation. Retention is largely dependent on bonding to the preparation. Further evidence is needed to understand the clinical importance of this new treatment option.

CEMENTS

LUTING CEMENTS

Cements are used for luting applications and as restorative materials. Luting cements are used to fill the space between the tooth structure and restorations or appliances made outside of the mouth. Restorative applications of cements include temporary and permanent restorations and bases under other restorative materials. In addition, at least one cement is used as a pit-and-fissure sealant. The similar. Changes are made in formulation to enhance the viscosity of luting cements and the strength of restorative cements.

Sidebar: *Cements with Pediatric Interest.*
Zinc Oxide–Eugenol
Polycarboxylate
Glass Ionomer
Resin-Modified Glass Ionomer
Self-Adhesive Resin
Resin

Different applications are associated with different requirements for luting cements. When an indirect restoration such as a stainless steel crown is luted, the ideal characteristics of the cement would include low solubility, the ability to bond to tooth structure, and enough strength to resist dislodgement during function. When an orthodontic band that needs to be retrieved at some point is luted, the cement needs to be weak enough to be broken during band removal and must be easily cleansed from the tooth surface. Zinc phosphate cement was used historically for broad application. It finds very little use in today's pediatric practice.

Restorative cements are of lower strength than other direct restorative materials. This limits their use to temporary and low-stress permanent applications.

Zinc Oxide–Eugenol

The acid-base reaction between zinc oxide and eugenol results in a cement that can be used as both a luting and a restorative material. Because of its low strength and high oral solubility, zinc oxide–eugenol is not recommended as a permanent luting cement. However, because of its exceptionally kind biological behavior, it is often used as a base material, as a temporary luting cement, and as a temporary restorative material. Eugenol is an inhibitor for addition-polymerization resins and can interfere with subsequent use of resin cements, restorative materials, and even some impression materials.

Zinc Phosphate Cement

Formerly, zinc phosphate cement was the most widely used luting agent. Composed essentially of phosphoric acid liquid that is mixed with zinc oxide powder, the cement has excellent handling characteristics such as setting time, fluidity, and film thickness. Furthermore, this type of cement has a long history of successful applications for permanent cementation. It does not have an anticariogenic effect, does not adhere to tooth structure, and does demonstrate a moderate degree of intraoral solubility.

Because of the phosphoric acid liquid, zinc phosphate cement is an irritant, and proper pulp protection is recommended. When experience indicates that sensitivity and pulp response are likely to be problems, the use of cement that is more biologically compatible, such as polycarboxylate cement, is recommended.

Dentlearn.ir

Polycarboxylate Cement

When zinc polycarboxylate cement is used, the bond occurs

acid and the calcium in the tooth structure. The powder of the cement is essentially zinc oxide. This cement continues to maintain some presence in the marketplace because it offers good biocompatibility with pulp tissue.

Because the ultimate properties are affected by changes in the water content of the liquid, the cement liquid should not be dispensed until just before the mix is to occur. Increases in the powder/liquid ratio make the cement less adherent to the tooth; decreases in the ratio result in increased solubility. The powder is quickly added to the liquid and the mix completed within 30 seconds. If the surface of the cement is not glossy in appearance, the mix should be discarded and a new one prepared. The gloss is

required for cement-tooth bonding.

Glass-Ionomer Cement

Glass-ionomer cement (GIC) is another type of cement that is based on polyacrylic acid. Type 1 GIC is used for luting applications. Because of their fluoride release and potential for adherence to the calcium in the tooth, GIC formulations have been prepared for use as restorative materials (type II) and as base and liner materials (type III).

Like zinc polycarboxylate cement, the glass-ionomer liquid is a polyacrylic or other alkenoic acid, such as itaconic or maleic, with tartaric acid added to improve handling properties. The acid has the potential for bonding to calcium in the manner described for polycarboxylate. This chemical bond provides retention of the cement to the tooth.

The powder is a fluoroaluminosilicate glass and displays fluoride release patterns that change over time. Analysis of data from glass-ionomer restorations of class V erosion lesions for periods of more than 7 years indicates that GIC shows resistance to secondary caries. The desirability of the GIC system should be readily apparent: it has a potential for adherence to tooth structure and possesses anticariogenic potential.

The material is supplied as a powder and liquid and is commonly preproportioned in a disposable capsule to be mixed in an amalgamator. With type I GIC, the liquid acid may be freeze-dried and combined in the powder. When this powder is mixed with water, the acid reconstitutes, which results in the same setting reaction. The freeze-dried products have better shelf life and somewhat lower viscosity, which are important characteristics for luting cements.

The mix can be made either on a disposable, moisture-resistant paper pad or on a glass slab. For minimal contamination of the mix from abraded metal, a plastic spatula is preferred to a metal one. As with polycarboxylate cement, the polyacrylic-acid–based liquid is not dispensed until just before the start of the mix. GICs are mixed in a manner similar to polycarboxylate cements: large increments of the powder are rapidly incorporated into the liquid, and the mix should be completed within 40 seconds. The working time is short, usually no more than 3 minutes from the start of the mix. If the mix has lost its gloss or a skin has formed on the surface, the material should be discarded.

After setting, the material is more brittle than polycarboxylate cement. It can be trimmed and finished in much the same manner as zinc phosphate cement. Before the patient is dismissed, all the accessible margins should be covered with the varnish or protective resin supplied by the manufacturer. This protects the cement from oral fluids and dehydration during the next few hours as the setting reaction continues.

Instances of postoperative sensitivity have been reported when GIC is used as a luting agent, particularly in deep preparations with minimal remaining dentin. This is possibly attributable to the low initial pH of the cement and its relatively slow set. As a guard against potential irritation, a liner such as calcium hydroxide should be placed in very deep areas. The cut dentin surface can be cleaned mechanically with pumice, but the smear layer should not be removed. After being cleaned the dentin should be rinsed and dried but not desiccated. A slightly damp surface appears to help minimize sensitivity and does not interfere with the setting reaction.

Glass-ionomer luting cements have lower intraoral solubility and mechanical properties similar to those of zinc phosphate cements. Because of their potential for fluoride release and adhesion to tooth structure, they have been popular for the luting of metallic restorations.

In addition to its use as a luting agent for metallic restorations, GIC has been used for luting orthodontic bands to posterior teeth and for bonding orthodontic brackets to acid-etched enamel. GIC has cohesive strength lower than that of the resin orthodontic adhesives, but the fluoride release from GIC should minimize the white spotting and decalcification sometimes seen around orthodontic brackets or bands.

Resin-Modified Glass-Ionomer Cements

Resin monomers have been added to GIC to make *resin-modified GIC*. These cements, also referred to as *hybrid glass ionomers* or *light-cured glass ionomers,* are created by the addition of resin monomers or a co-monomer of acrylic acid and a methacrylate such as hydroxyethyl methacrylate to the glass-ionomer formulation. The known disadvantages of conventional glass ionomers (short working time, slow development of ultimate properties, sensitivity to both moisture exposure and dehydration during setting, and, when compared with resin cements, lower cohesive strength) have been largely addressed in the resin-modified GIC. The resin component hardens immediately on exposure to the light, which results in an initial set of the cement. The material then continues to undergo the acid-base GIC setting reaction that occurs more slowly than that of a conventional GIC, resulting in a much longer working time for the resin-modified glass ionomer. The rapid set after light exposure yields a material that is much less sensitive to dehydration or moisture. Type I resin-modified GIC luting cements have gained wide acceptance when used with metallic restorations; in this case the resin component is either chemically activated or dual-activated (chemically and light). Resin-modified GIC type II restorative materials appear to exhibit the advantages of conventional GIC and have gained in popularity because they facilitate decreased treatment times.

Resin Cements

Derived from the composite resin systems used for restorative materials, resin luting cements may be viewed as

Dentlearn.ir

lightly filled composites. The resin matrix systems used are the same as, or closely related to, those used for restorative resins. Although these materials are not new to dentistry, they are becoming more extensively used. Their first major clinical application was in direct bonding of orthodontic attachments to acid-etched enamel, for which they quickly became the materials of choice. Similar formulations were developed with pit-and-fissure sealants, which are discussed in Chapter 10. The resin-bonded bridge, such as the "Maryland" bridge, is another application in which resin cements came to the forefront. The demand for dentistry has resulted in extensive use of both resin and ceramic veneers. Here, too, resin cements are the cements of choice. In addition, new technology for fabricating all-ceramic crowns and inlays has greatly increased the use of these restorations. Because resin cements have high strength, low film thickness, very low oral solubility, and can be bonded to etched enamel, ceramics, resins, and etched or treated metal surfaces, they are the cements of choice for veneers and all-ceramic crowns. With the advent of dentin adhesives, resin cements provide the possibility of bonded, indirect restorations.

Resin cements are usually available in different shades for color matching beneath translucent restorations, and opaque cements are made for masking metal substructure or discolored tooth structure. The first resin cements were two-component, chemically activated curing systems. Visible light–activated, single-component systems are now available and are popular when used with translucent restorative materials. Dual-activated materials, which are both chemically and light-activated, are recommended for use beneath thick restorations and in locations where geometry may limit access to the curing light.

Self-adhesive resin cements have become popular choices for luting applications. In principle, these materials are similar to the self-etch dental adhesives. They are acidic, do not require a separate adhesive, and form a thin

these materials do not have the same level of mechanical properties as traditional resin cements.

SUGGESTED READINGS

General

Anusavice KJ: *Phillips' science of dental materials*, ed 12, Philadelphia, 2013, WB Saunders.

O'Brien WJ: *Dental materials and their selection*, ed 4, Chicago, 2008, Quintessence Publishing.

Sakaguchi RL, Powers JM: *Craig's restorative dental materials*, ed 13, Philadelphia, 2012, Elsevier Mosby.

Adhesion

Buonocore MG: *The use of adhesives in dentistry*, Springfield, IL, 1975, Charles C. Thomas.

Garcia-Godoy F, Donly KJ: Dentin/enamel adhesives in pediatric dentistry, *Pediatr Dent* 24:462–464, 2002.

Gerdolle DA, Mortier E, Droz D: Microleakage and polymerization shrinkage of various polymer restorative materials, *J Dent Child* 75:125–133, 2008.

Heintze SD: Clinical relevance of tests on bond strength, microleakage and marginal adaptation, *Dent Mater* 29:59–84, 2013.

Heintze SD, Ruffieux C, Rousson V: Clinical performance of cervical restorations—a meta-analysis, *Dent Mater* 26:993–1000, 2010.

Mertz-Fairhurst EJ, et al.: Ultraconservative and cariostatic sealed restorations: results at year 10, *J Am Dent Assoc* 129:55–66, 1998.

Peumans M, et al.: Clinical effectiveness of contemporary adhesives: a systematic review of current clinical trials, *Dent Mater* 21:864–881, 2005.

Van Meerbeek B, et al.: Relationship between bond-strength tests and clinical outcomes, *Dent Mater* 26:e100–121, 2010.

Amalgam

Batchu H, et al.: Evaluating amalgam separators using an international standard, *J Am Dent Assoc* 137:999–1005, 2006.

Browning WD, Johnson WW, Gregory PN: Clinical performance of bonded amalgam restorations at 42 months, *J Am Dent Assoc* 131:607–611, 2000.

Mahler DB, Engle JH: Clinical evaluation of amalgam bonding in Class I and II restorations, *J Am Dent Assoc* 131:39–43, 2000.

Mahler DB, et al.: Corrosion sealing of amalgam restorations in vitro, *Oper Dent* 34:312–320, 2009.

Marshall GW, Marshall SJ, Letzel H: Mercury content of amalgam restorations, *Gen Dent* 37:473–477, 1989.

Osborne JW, Summitt JB, Roberts HW: The use of dental amalgam in pediatric dentistry: review of the literature, *Pediatr Dent* 24:439–447, 2002.

Summit JB, et al.: The performance of bonded vs. pin-retained complex amalgam restorations: a five-year clinical evaluation, *J Am Dent Assoc* 132:923–931, 2001.

Cements

Chadwick BL, Evans DJ: Restoration of class II cavities in primary molar teeth with conventional and resin modified glass ionomer cements: a systematic review of the literature, *Eur Arch Paediatr Dent* 8:14–21, 2007.

Kloukos D, Pandis N, Eliades T: Bisphenol-A and residual monomer leaching from orthodontic adhesive resins and polycarbonate brackets: a systematic review, *Am J Orthod Dentofacial Orthop* 143:S104–S112, 2013.

Mickenautsch S, Yengopal V: Caries-preventive effect of glass ionomer and resin-based fissure sealants on permanent teeth: an update of systematic review evidence, *BMC Research Notes* 4:22, 2011.

Roberts HW, et al.: Mineral trioxide aggregate material use in endodontic treatment: a review of the literature, *Dent Mater* 24:149–164, 2008.

Yengopal V, Mickenautsch S: Caries-preventive effect of resin-modified glass-ionomer cement (RM-GIC) versus composite resin: a quantitative systematic review, *Eur Arch Paediatr Dent* 12:5–14, 2011.

Composites

Braga RR, Ballester RY, Ferracane JL: Factors involved in the development of polymerization shrinkage stress in resin-composites: a systematic review, *Dent Mater* 21:962–970, 2005.

Bücher K, et al.: Longevity of composite restorations in patients with early childhood caries (ECC), *Clin Oral Investig* 18:775–782, 2014.

Margeas R: Versatile composite resins simplifying the practice of restorative dentistry, *Compend Contin Educ Dent* 35:52–55, 2014.

Moore BK, et al.: Depth of cure of dental resin composites: ISO 4049 depth and microhardness of types of materials and shades, *Oper Dent* 33:408–412, 2008.

Platt JA, Clark H, Moore BK: Curing of pit and fissure sealants using light emitting diode curing units, *Oper Dent* 30:764–771, 2005.

Price RB, Shortall AC, Palin WM: Contemporary issues in light curing, *Oper Dent* 39:4–14, 2014.

Toh SL, Messer LB: Evidence-based assessment of tooth-colored restorations in proximal lesions of primary molars, *Pediatr Dent* 29:8–15, 2007.

Dentlearn.ir

CHAPTER 13

Treatment of Deep Caries, Vital Pulp Exposure, and Pulpless Teeth

▲ Jeffrey A. Dean

For additional resources, please visit the evolve website.

CHAPTER OUTLINE

DIAGNOSTIC AIDS IN THE SELECTION OF TEETH FOR VITAL PULP THERAPY
- History of Pain
- Clinical Signs and Symptoms
- Radiographic Interpretation
- Pulp Testing
- Physical Condition of the Patient

EVALUATION OF TREATMENT PROGNOSIS BEFORE PULP THERAPY

TREATMENT OF THE DEEP CARIES LESION
- Indirect Pulp Treatment (Gross Caries Removal or Indirect Pulp Therapy)

VITAL PULP EXPOSURE
- Size of the Exposure and Pulpal Hemorrhage

VITAL PULP THERAPY TECHNIQUES
- Direct Pulp Capping
- Pulpotomy

NONVITAL PULP TREATMENT WITH IRREVERSIBLE PULPITIS OR NECROTIC PULP
- Pulpectomy

SUMMARY OF PULP THERAPY

RESTORATION OF THE PULPALLY INVOLVED TOOTH

REACTION OF THE PULP TO VARIOUS CAPPING MATERIALS
- Zinc Oxide–Eugenol
- Calcium Hydroxide
- Preparations Containing Formalin
- Ferric Sulfate
- Mineral Trioxide Aggregate
- Other Capping Materials and Methods
- Summary of Pulp-Capping Materials

FAILURES AFTER VITAL PULP THERAPY
- Alveolar Abscess

EARLY EXFOLIATION OR OVER-RETENTION OF PRIMARY TEETH WITH PULP TREATMENTS

It is well recognized that maintenance of the primary teeth has many of the same goals as maintenance of the permanent dentition. Primary teeth aid in maintaining the integrity of the dental arch, thereby preventing malocclusion, allowing for proper speech and mastication, preventing aberrant tongue habits, and providing esthetics.[1] Primary teeth have the additional goal of guiding the eruption of the permanent teeth. Therefore treating primary teeth that have been afflicted by disease or trauma is imperative. However, the treatment of the dental pulp exposed by the caries process, by accident during cavity preparation, or even as a result of injury and fracture of the tooth has long presented a challenge. As early as 1756, Pfaff reported placing a small piece of gold over a vital exposure in an attempt to promote healing.

Although it has been established that the pulp is capable of healing, there is still much to learn regarding the control of infection and inflammation in the vital pulp. Current methods of diagnosing the extent of pulpal injury are inadequate. More effective methods of pulp therapy are still needed, and more research is necessary.

DIAGNOSTIC AIDS IN THE SELECTION OF TEETH FOR VITAL PULP THERAPY

HISTORY OF PAIN

The history of either the presence or the absence of pain may not be as reliable in the differential diagnosis of the condition of the exposed primary pulp as it is in permanent teeth. Degeneration of primary pulp even to the point of abscess formation without the child recalling pain or discomfort is not uncommon. Nevertheless, the history of a toothache should be the first consideration in the selection of teeth for vital pulp therapy. A toothache coincident with or immediately after a meal may not indicate extensive pulpal inflammation. The pain may be caused by an accumulation of food within a caries lesion, by pressure, or by a chemical irritation to vital pulp protected by only a thin layer of intact dentin.

A severe toothache at night usually signals extensive degeneration of the pulp and calls for more than conservative pulp therapy. A spontaneous toothache of more than momentary duration occurring at any time usually

Dentlearn.ir

means that pulpal disease has progressed too far for treatment, even with a pulpotomy.

CLINICAL SIGNS AND SYMPTOMS

A gingival abscess or draining fistula associated with a tooth with a deep caries lesion is an obvious clinical sign of an irreversibly diseased pulp. Such infections can be resolved only by successful endodontic therapy or extraction of the tooth.

Abnormal tooth mobility is another clinical sign that may indicate a severely diseased pulp. When such a tooth is evaluated for mobility, the manipulation may elicit localized pain in the area, but this is not always the case. If pain is absent or minimal during manipulation of the diseased mobile tooth, the pulp is probably in a more advanced and chronic degenerative condition. Pathologic mobility must be distinguished from normal mobility in primary teeth near exfoliation.

Sensitivity to percussion or pressure is a clinical symptom suggestive of at least some degree of pulpal disease, but the degenerative stage of the pulp is probably of the acute inflammatory type. Tooth mobility or sensitivity to percussion or pressure may be a clinical sign of other dental problems as well, such as a high restoration or advanced periodontal disease. However, when this clinical information is identified in a child and is associated with a tooth having a deep caries lesion, the problem is most likely to be caused by pulpal disease and possibly by inflammatory involvement of the periodontal ligament.

RADIOGRAPHIC INTERPRETATION

A recent x-ray film must be available to examine for evidence of periradicular or periapical changes, such as thickening of the periodontal ligament or rarefaction of the supporting bone. These conditions almost always rule out treatment other than an endodontic procedure or extraction of the tooth. Radiographic interpretation is more difficult in children than in adults. The permanent teeth may have incompletely formed root ends, giving an impression of periapical radiolucency, and the roots of the primary teeth undergoing even normal physiologic resorption often present a misleading picture or one suggestive of pathologic change.

The proximity of caries lesions to the pulp cannot always be determined accurately in the x-ray film. What often appears to be an intact barrier of secondary dentin protecting the pulp may actually be a perforated mass of irregularly calcified and carious material. The pulp beneath this material may have extensive inflammation (Fig. 13-1). Radiographic evidence of calcified masses within the pulp chamber is diagnostically important. If the irritation to the pulp is relatively mild and chronic, the pulp will respond with inflammation and will attempt to eliminate the irritation by blocking (with irregular dentin) the tubules through which the irritating factors are transmitted. If the irritation is intense and acute, and if the caries lesion is developing rapidly, the defense mechanism may not have a chance to lay down the reparative dentin barrier, and the disease process may reach the pulp. In this instance the pulp may attempt to form a barrier at some distance from the exposure site. These calcified masses are sometimes evident in the pulp horn or even in the region of the pulp canal entrance. A histologic examination of these teeth shows irregular, amorphous masses of calcified material that are not like pulp stones (Fig. 13-2). The masses bear no resemblance to dentin or to a dentinal barrier and are always associated with advanced degenerative changes of the coronal pulp and inflammation of the tissue in the canal.



Figure 13-1 **A,** First primary molar appears to have an intact dentinal barrier beneath the caries lesion. **B,** Histologic section shows a perforation of the barrier with necrotic material at the exposure site. There is advanced inflammation of the pulp tissue, which is likely to evoke a spontaneous pain response.

Dentlearn.ir

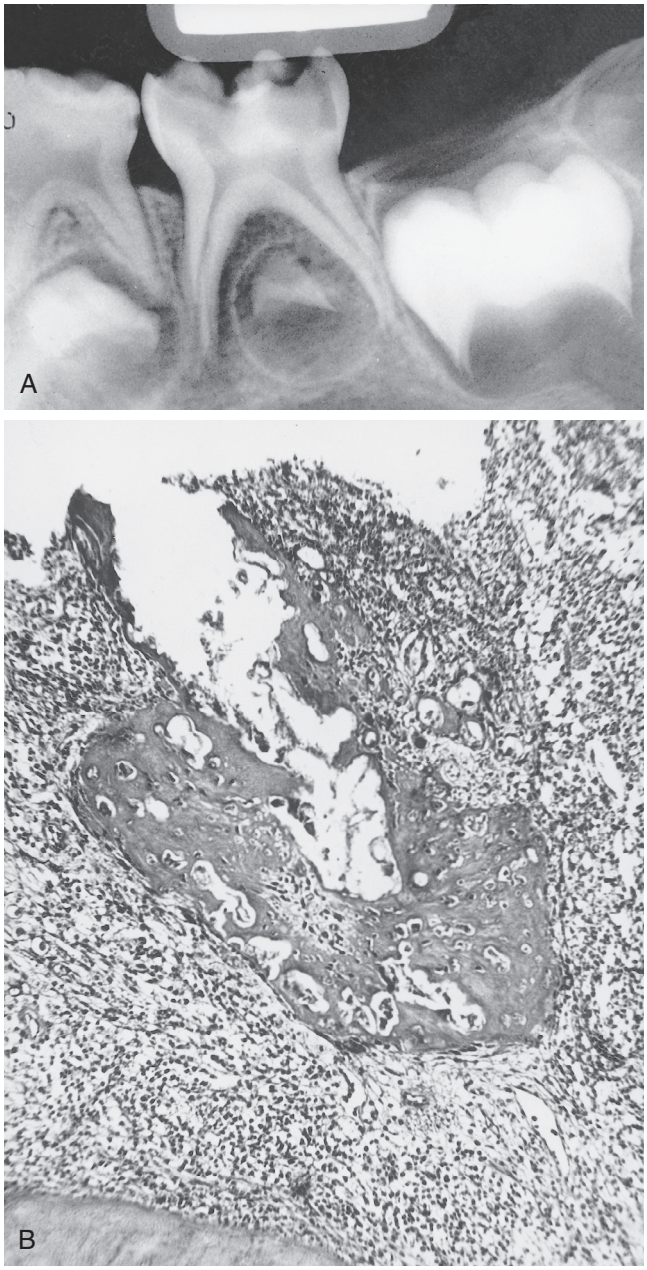

Figure 13-2 **A,** Calcified mass in the pulp chamber beneath the exposure site is associated with extensive inflammation of the pulp in the coronal area and in the pulp canals. **B,** The amorphous mass is surrounded by pulp tissue with advanced inflammation.

PULP TESTING

Historically the value of the electric pulp test in determining the condition of the pulp of primary teeth has been viewed as questionable. Although it will give an indication of whether the pulp is vital, the test does not provide reliable evidence of the degree of pulpal inflammation. A complicating factor is the occasional positive response to the test in a tooth with a necrotic pulp if the content of the canals is liquid. The reliability of the pulp test for the young child can also be questioned sometimes because of the child's apprehension associated with the test itself.

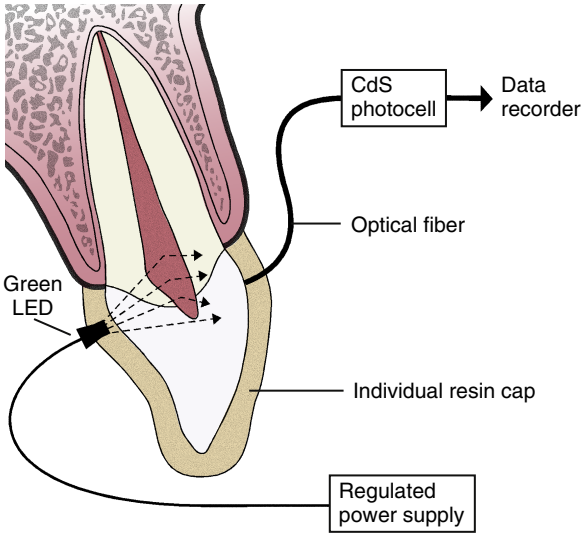

Figure 13-3 Schematic drawing of transmitted-light photoplethysmography. LED, light-emitting diode. (Adapted from Miwa Z et al: Pulpal blood flow in vital and nonvital young permanent teeth measured by transmitted-light photoplethysmography: a pilot study, *Pediatr Dent* 24:594-598, 2002.)

Thermal tests also have reliability problems in the primary dentition. The lack of reliability is possibly related to the young child's inability to understand the tests. However, Hori and colleagues[2] have found the electric pulp test to be reliable in diagnosing the pulp status in primary teeth. Comparing the electric pulp test with thermal testing, they found the highest accuracy for the former, followed by heat and then cold tests.

Several noninvasive techniques have been developed and advocated for recording the blood flow in human dental pulp. Two of these methods include the use of a laser Doppler flowmeter and transmitted-light photoplethysmography. As shown in the schematic in Figure 13-3, these methods essentially work by the transmission of a laser or light beam through the crown of the tooth; the signal is picked up on the other side of the tooth by an optical fiber and photocell. A distinct advantage of this technique is its noninvasive nature, particularly in comparison with electric pulp testing. Not only is there inaccuracy in the response of the pulp to electric stimuli but also the electric pulp tester may elicit pain. Because the testing may be uncomfortable for young patients, further dental treatment may be affected. A study by Miwa and colleagues suggested that the transmitted-light technique can detect pulpal blood flow in young permanent teeth and is thus applicable to the assessment of pulp vitality.[3] Recent research has looked at the use of pulse oximetry measured oxygen saturation levels of the dental pulp. Although the technique may not be ready for routine clinical use, it is a promising new area of study.

PHYSICAL CONDITION OF THE PATIENT

Although local observations are of extreme importance in the selection of cases for vital pulp therapy, the dentist must also consider the physical condition of the patient. In seriously ill children, extraction of the involved tooth after

proper premedication with antibiotics, rather than pulp therapy, should be the treatment of choice. Children with conditions that render them susceptible to subacute bacterial endocarditis or those with nephritis, leukemia, solid tumors, idiopathic cyclic neutropenia, or any condition that causes cyclic or chronic depression of granulocyte and polymorphonuclear leukocyte counts should not be subjected to the possibility of an acute infection resulting from failed pulp therapy.[4] Occasionally, pulp therapy for a tooth of a chronically ill child may be justified, but only after careful consideration is given to the prognosis of the child's general condition, the prognosis of the endodontic therapy, and the relative importance of retaining the involved tooth.

EVALUATION OF TREATMENT PROGNOSIS BEFORE PULP THERAPY

The diagnostic process of selecting teeth that are good candidates for vital pulp therapy has at least two dimensions. First, the dentist must decide that the tooth has a good chance of responding favorably to the pulp therapy procedure indicated. Second, the advisability of performing the pulp therapy and restoring the tooth must be weighed against extraction and space management. For example, nothing is gained by successful pulp therapy if the crown of the involved tooth is nonrestorable or the periodontal structures are irreversibly diseased. By the same rationale, a dentist is likely to invest more time and effort to save a pulpally involved second primary molar in a 4-year-old child with unerupted first permanent molars than to save a pulpally involved first primary molar in an 8-year-old child.

Other factors to consider include the following:

1. The level of patient and parent cooperation and motivation in receiving the treatment
2. The level of patient and parent desire and motivation in maintaining oral health and hygiene
3. The caries activity of the patient and the overall prognosis of oral rehabilitation
4. The stage of dental development of the patient
5. The degree of difficulty anticipated in adequate performance of the pulp therapy (instrumentation) in the particular case
6. Space management issues resulting from previous extractions, preexisting malocclusion, ankylosis, congenitally missing teeth, and space loss caused by the extensive carious destruction of teeth and subsequent drifting
7. Excessive extrusion of the pulpally involved tooth resulting from the absence of opposing teeth

These examples, in any combination, illustrate the almost infinite number of treatment considerations that could be important in an individual patient with pulpal pathosis.

TREATMENT OF THE DEEP CARIES LESION

Children and young adults who have not received early and adequate dental care and optimal systemic fluoride and do not have adequate oral hygiene often develop deep caries lesions in the primary and permanent teeth. Many of the lesions appear radiographically to be dangerously close to the pulp or to actually involve the dental pulp. Approximately 75% of the teeth with deep caries have been found from clinical observations to have pulpal exposures. Well over 90% of the asymptomatic teeth with deep caries lesions can be successfully treated by indirect pulp therapy techniques, without pulp exposure. This procedure is described herein.

If a carious exposure discovered at the time of the initial caries excavation could be routinely treated with consistently good results, a major problem in dentistry would be solved. Unfortunately, the treatment of vital exposures, especially in primary teeth, has not been entirely successful. Therefore clinicians prefer to avoid pulp exposure during the removal of deep caries whenever possible.

INDIRECT PULP TREATMENT (GROSS CARIES REMOVAL OR INDIRECT PULP THERAPY)

The procedure in which only the gross caries is removed from the lesion and the cavity is sealed for a time with a biocompatible material is referred to as indirect pulp treatment (Fig. 13-4). Indirect pulp treatment is not a new procedure but has attracted renewed interest. Laboratory studies and favorable clinical evidence justify its routine use. Teeth with deep caries that are free of symptoms of painful pulpitis are candidates for this procedure.

The clinical procedure involves removing the gross caries but allowing sufficient caries to remain over the pulp horn to avoid exposure of the pulp. The walls of the cavity are extended to sound tooth structure because the presence of carious enamel and dentin at the margins of the cavity will prevent the establishment of an adequate seal (extremely important) during the period of repair. The remaining thin layer of caries at the base of the cavity is covered with a radiopaque biocompatible base material and sealed with a durable interim restoration (Fig. 13-5). Some interim restorative materials may also serve as the base material. While waiting 6 to 8 weeks for the placement of a final restoration has been suggested in the past (a two-step process), there is no conclusive evidence that this is necessary. Therefore it is common for clinicians to place a definitive final restoration that seals the tooth from microleakage.

If the decision is made to reenter the tooth after 6 to 8 weeks, careful removal of the remaining carious material,

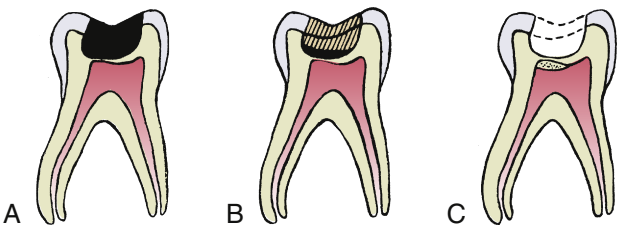

Figure 13-4 Indirect pulp therapy. **A,** A primary or permanent tooth with deep caries. **B,** The gross caries has been removed and the cavity sealed with durable biocompatible cement or restorative material. **C,** Six to eight weeks later, the cavity is reopened and the remaining caries excavated. A sound dentin barrier protects the pulp, and the tooth is ready for final restoration. (Courtesy of Dr. Paul E. Starkey.)

Dentlearn.ir

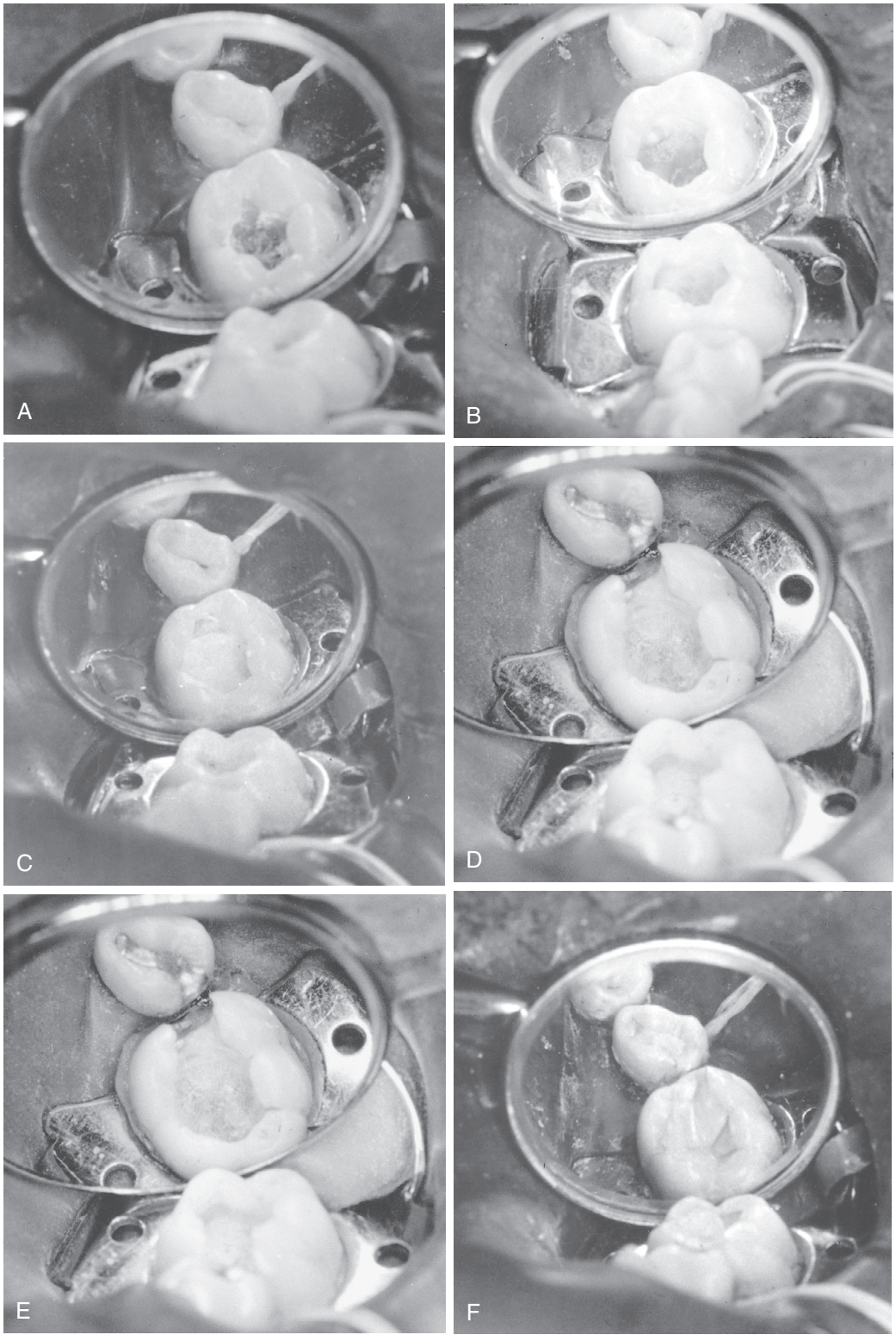

Figure 13-5 **A,** Second primary molar with deep occlusal caries. Because the tooth was free of symptoms of painful pulpitis, indirect pulp therapy was completed. **B,** The gross caries has been removed. A small amount of soft carious dentin remains at the base of the cavity. **C,** Calcium hydroxide has been placed over the remaining caries. The cavity may be sealed with a durable intermediate restorative material. **D,** After 6 to 8 weeks, the intermediate restorative material is removed. The caries in the base of the cavity appears arrested and dry. **E,** The remaining caries has been removed. **F,** After placement of a biocompatible base, the primary second molar has been restored with amalgam.

now somewhat sclerotic, may reveal a sound base of dentin without pulp exposure. If a sound layer of dentin covers the pulp, the tooth is restored in the conventional manner (Fig. 13-6). Al-Zayer and associates reported that the use of a base over the calcium hydroxide liner, in addition to a stainless steel crown, dramatically increases the success rate.[5] If a small pulp exposure is encountered, a different type of treatment, based on the clinical signs and symptoms and local conditions, must be used.

Nirschl and Avery performed indirect pulp therapy on 38 carefully selected primary and young permanent teeth.[6] Gross caries removal under rubber dam isolation was accomplished, calcium hydroxide was used in each tooth as a sedative base, and the teeth were restored with amalgam. Successful treatment occurred in 32 (94.1%) of the 34 teeth that were available for the 6-month evaluation procedure. In all cases of successful treatment, the base material and the residual carious dentin were observed to be dry on reentry and clinical examination. Of the successfully treated teeth, only four had residual carious dentin that felt somewhat soft when probed with an explorer; in the remainder, the dentin felt hard. Pinto and colleagues showed similar dentin consistency results, as well as significantly decreased bacterial counts at the end of treatment.[7]

VITAL PULP EXPOSURE

Although the routine practice of indirect pulp therapy in properly selected teeth will significantly reduce the number of direct pulp exposures encountered, all dentists who treat severe caries in children will be faced with treatment decisions related to the management of vital pulp exposures.

The appropriate procedure should be selected only after a careful evaluation of the patient's symptoms, results of diagnostic tests, and conditions at the exposure site. The health of the exposed dental pulp is sometimes difficult to determine, especially in children, and there is often lack of conformity between clinical symptoms and histopathologic condition.

SIZE OF THE EXPOSURE AND PULPAL HEMORRHAGE

The size of the exposure, appearance of the pulp, and amount of bleeding are valuable observations for diagnosing the condition of the primary pulp. Therefore the use of a rubber dam to isolate the tooth is extremely important; in addition, with the rubber dam the area can be kept clean and the work can be done more efficiently.

The most favorable condition for vital pulp therapy is the small pinpoint exposure surrounded by sound dentin. However, a true carious exposure, even of pinpoint size, will be accompanied by inflammation of the pulp, the degree of which is usually directly related to the size of the exposure (Fig. 13-7).

A large exposure—the type that is encountered when a mass of leathery dentin is removed—is often associated with a watery exudate or pus at the exposure site. These conditions are indicative of advanced pulp degenera-

In addition, excessive hemorrhage at the point of carious

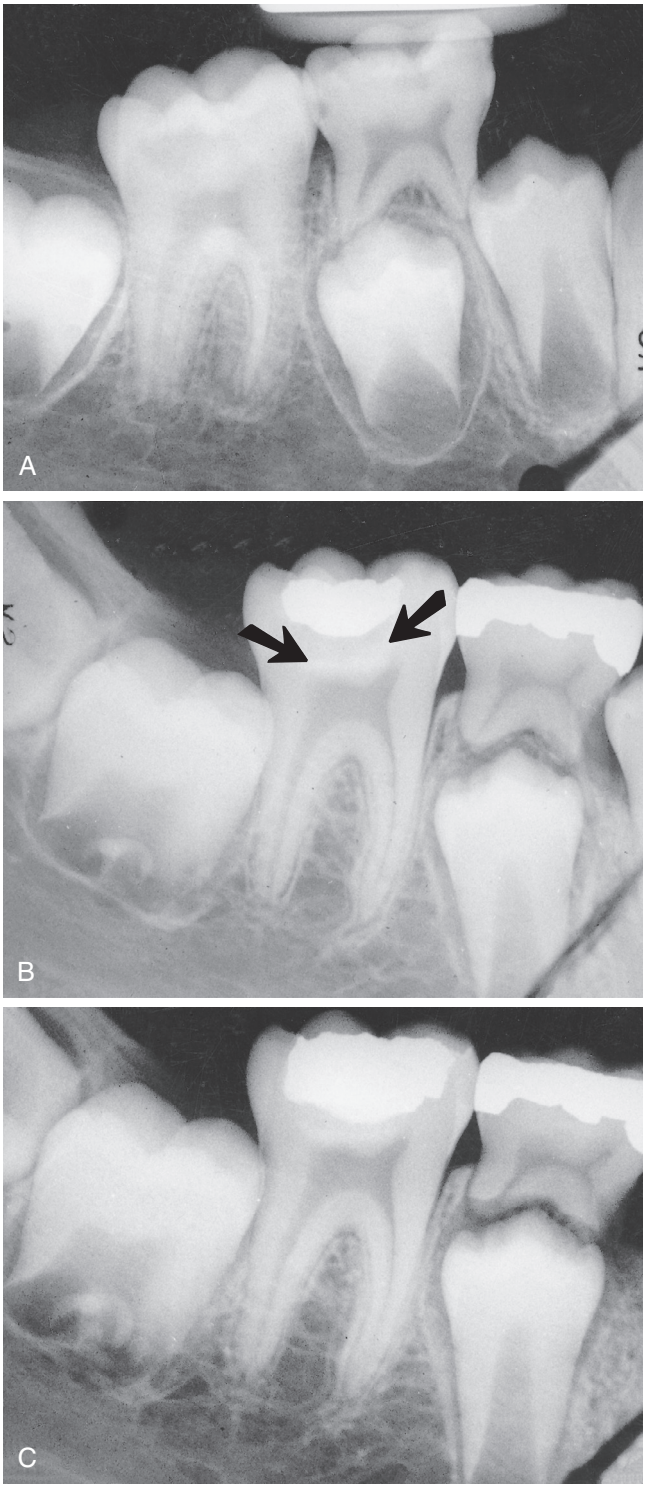

Figure 13-6 **A,** Radiograph of the first permanent molar revealed a deep caries lesion. Gross caries was removed, and calcium hydroxide was placed over the remaining caries. The tooth was restored with amalgam and was not reentered for complete caries removal for 3 months. **B,** Sclerotic dentin can be seen beneath the remaining caries and the covering of calcium hydroxide *(arrows)*. **C,** The tooth was reentered, and the remaining caries was removed. A sound dentin barrier was observed at the base of the cavity. A new amalgam restoration was placed after complete caries removal.

Dentlearn.ir



Figure 13-7 Pulp exposed by caries will show inflammation at the exposure site. Fragments of necrotic dentin will be introduced into the pulp during excavation of the caries.

exposure or during pulp amputation is invariably associated with hyperemia and generalized inflammation of the pulp. When the latter is observed, endodontic therapy or extraction of the tooth is the treatment of choice.

VITAL PULP THERAPY TECHNIQUES

For many centuries, and probably from almost the beginning of time for humans, there has been a search for the best (safe and effective) methods of managing pulpal disease and traumatic pulpal exposure. These efforts have generated considerable controversy and debate as proponents of specific materials and methods attempt to justify their chosen techniques. Despite many impressive scientific advancements, these controversies remain unsettled here in the twenty-first century. The identification of the best formulations of ingredients and techniques for producing predictable pulpal healing remains elusive. To complicate this issue further, the predominant belief is that pulp therapies appropriate for permanent teeth may not always be equally effective in treating similar conditions in primary teeth.

It is generally agreed that the prognosis after any type of pulp therapy improves in the absence of contamination by pathogenic microorganisms. Thus biocompatible neutralization of any existing pulpal contamination and prevention of future contamination (e.g., microleakage) are worthy goals in vital pulp therapy. If the treatment material in direct contact with the pulp also has some inherent quality that promotes, stimulates, or accelerates a true tissue-healing response, so much the better; however, vital pulp tissue can recover from a variety of insults spontaneously in a favorable environment.

The techniques and procedures discussed in the following pages represent the standards as we perceive them at this writing. Some go back to the time when treatment decisions were made empirically. Their effectiveness has been proved over time, if not by science, and they represent the benchmarks against which newer techniques are compared. We look forward to having more effective, biologically compatible, and scientifically sound methods in the future.

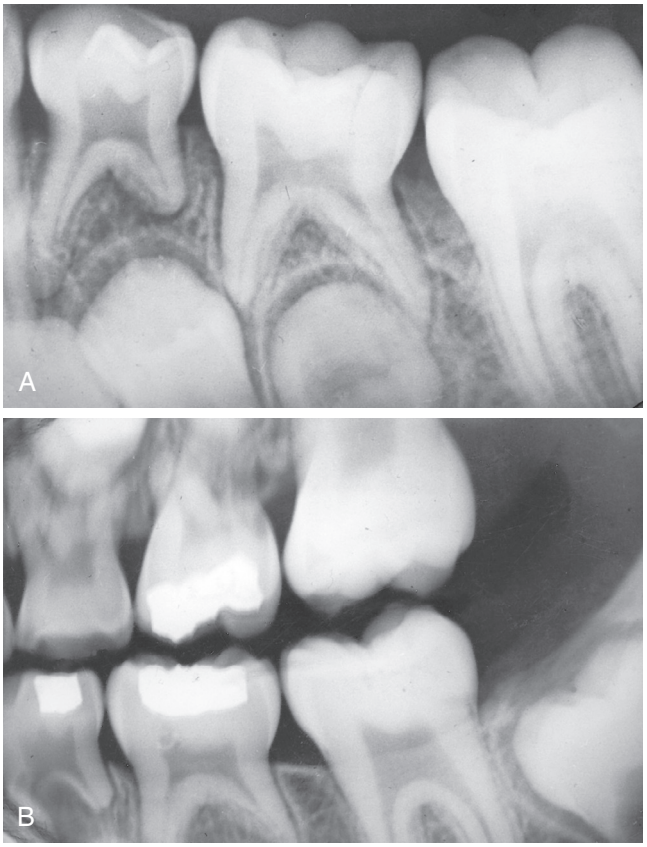

Figure 13-8 **A,** Mesial pulp horn of the mandibular second primary molar accidentally exposed during cavity preparation was covered with calcium hydroxide. **B,** Dentinal bridge across the mesial pulp horn is evidence of pulp healing.

DIRECT PULP CAPPING

The pulp-capping procedure has been widely practiced for years and is still the favorite method of many dentists for treating vital pulp exposures. Although pulp capping has been condemned by some, others report that, if the teeth are carefully selected, excellent results can be obtained.

It is generally agreed that pulp-capping procedures should be limited to small exposures produced accidentally by trauma or during cavity preparation or to true pinpoint carious exposures that are surrounded by sound dentin (Figure 13-8). Pulp capping should be considered only for teeth in which there is an absence of pain, with the possible exception of discomfort caused by the intake of food. In addition, there should be either no bleeding at the exposure site, as is often the case in a mechanical exposure, or bleeding in an amount that would be considered normal in the absence of a hyperemic or inflamed pulp.

All pulp treatment procedures should be carried out with sterile instruments in clean conditions. Use of the rubber dam will help keep the pulp free of external contamination. All peripheral carious tissue should be excavated before excavation is begun on the portion of the carious dentin most likely to result in pulp exposure. Thus most of the bacterially infected tissue will have been removed before actual pulp exposure occurs. The work of

Kakehashi and colleagues[9] and of Walshe,[10] which is described later in this chapter, supports the desirability of using a surgically clean technique to minimize bacterial contamination of the pulpal tissue.

Calcium hydroxide remains the standard material for pulp capping of normal vital pulp tissue; it can possibly stimulate the repair reaction. A hard-setting calcium hydroxide capping material should be used. If the tooth is small (such as a first primary molar), hard-setting calcium hydroxide may also be used as the base for the restoration. Some studies have shown successful results with direct capping of exposed pulps with adhesive bonding agents, whereas others have reported pulpal inflammation and unacceptable results with this technique.[11] In addition, the use of mineral trioxide aggregate (MTA) has shown promise, but further research would be helpful.[12]

PULPOTOMY

The removal of the coronal portion of the pulp is an accepted procedure for treating both primary and permanent teeth with carious pulp exposures. The justification for this procedure is that the coronal pulp tissue, which is adjacent to the carious exposure, usually contains microorganisms and shows evidence of inflammation and degenerative change. The abnormal tissue can be removed, and the healing can be allowed to take place at the entrance of the pulp canal in an area of essentially normal pulp. Even the pulpotomy procedure, however, is likely to result in a high percentage of failures unless the teeth are carefully selected.

In the pulpotomy procedure, the tooth should first be anesthetized and isolated with the rubber dam. A surgically clean technique should be used throughout the procedure. All remaining dental caries, as well as the overhanging enamel, should be removed to provide good access to the coronal pulp. Pain during caries removal and instrumentation may be an indication of faulty anesthetic technique. More often, however, it indicates pulpal hyperemia and inflammation, which makes the tooth a poor risk for vital pulpotomy. If the pulp at the exposure site bleeds excessively after complete removal of caries, the tooth is also a poor risk for vital pulpotomy.

The entire roof of the pulp chamber should be removed. No overhanging dentin from the roof of the pulp chamber or pulp horns should remain. No attempt is made to control the hemorrhage until the coronal pulp has been amputated. Funnel-shaped access to the entrance of the root canals should be created. A sharp discoid spoon excavator, large enough to extend across the entrance of the individual root canals, may be used to amputate the coronal pulp at its entrance into the canals. The pulp stumps should be excised cleanly, with no tissue tags extending across the floor of the pulp chamber. The pulp chamber should then be irrigated with a light flow of water from a water syringe and evacuated. Cotton pellets moistened with water should be placed in the pulp chamber and allowed to remain over the pulp stumps until a clot forms (Fig. 13-9).

Laboratory and clinical observations indicate that a different technique and capping material are necessary in the treatment of primary teeth than in the treatment of permanent teeth. As a result of these observations, two specific pulpotomy techniques have evolved and are in general use.

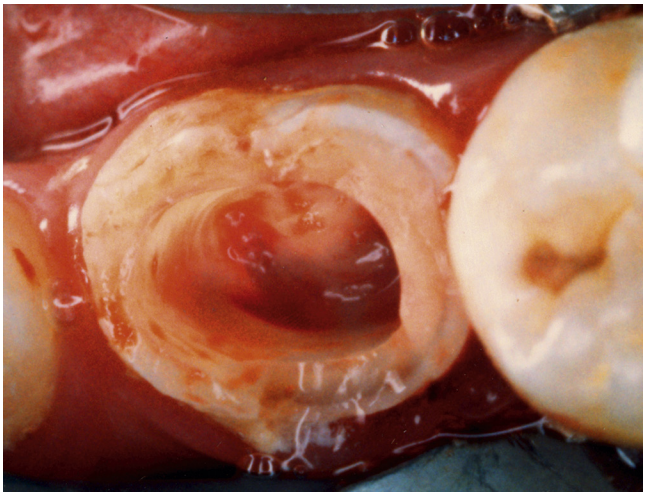

Figure 13-9 Cleanly excised pulpal stumps with no tissue tags across the floor or along the walls of the chamber. The hemorrhage has been controlled. Notice also that the roof of the pulp chamber has been completely removed to provide total access to the pulp canals.

Pulpotomy Technique for Permanent Teeth

The use of either calcium hydroxide or MTA can be recommended in the treatment of permanent teeth with carious pulp exposures when there is a pathologic change in the pulp at the exposure site.[13,14] This procedure is particularly indicated for permanent teeth with immature root development but with healthy pulp tissue in the root canals. It is also indicated for a permanent tooth with a pulp exposure resulting from crown fracture when the trauma has also produced a root fracture of the same tooth. The procedure is completed during a single appointment. Only teeth free of symptoms of painful pulpitis are considered for treatment. The procedure involves the amputation of the coronal portion of the pulp as described, the control of hemorrhage, and the placement of the capping material over the pulp tissue remaining in the canals (Fig. 13-10). A protective layer of hard-setting cement is placed over the calcium hydroxide to provide an adequate seal. The tooth is subsequently prepared for full-coverage restoration. However, if the tissue in the pulp canals appears hyperemic after the amputation of the coronal tissue, a pulpotomy should no longer be considered. Endodontic treatment is indicated if the tooth is to be saved.

After 1 year a tooth that has been treated successfully with a pulpotomy should have a normal periodontal ligament and lamina dura, radiographic evidence of a calresorption or pathologic resorption. The treatment of permanent teeth by the pulpotomy method has resulted in a higher rate of success when the teeth are selected carefully based on existing knowledge of diagnostic techniques.

Dentlearn.ir

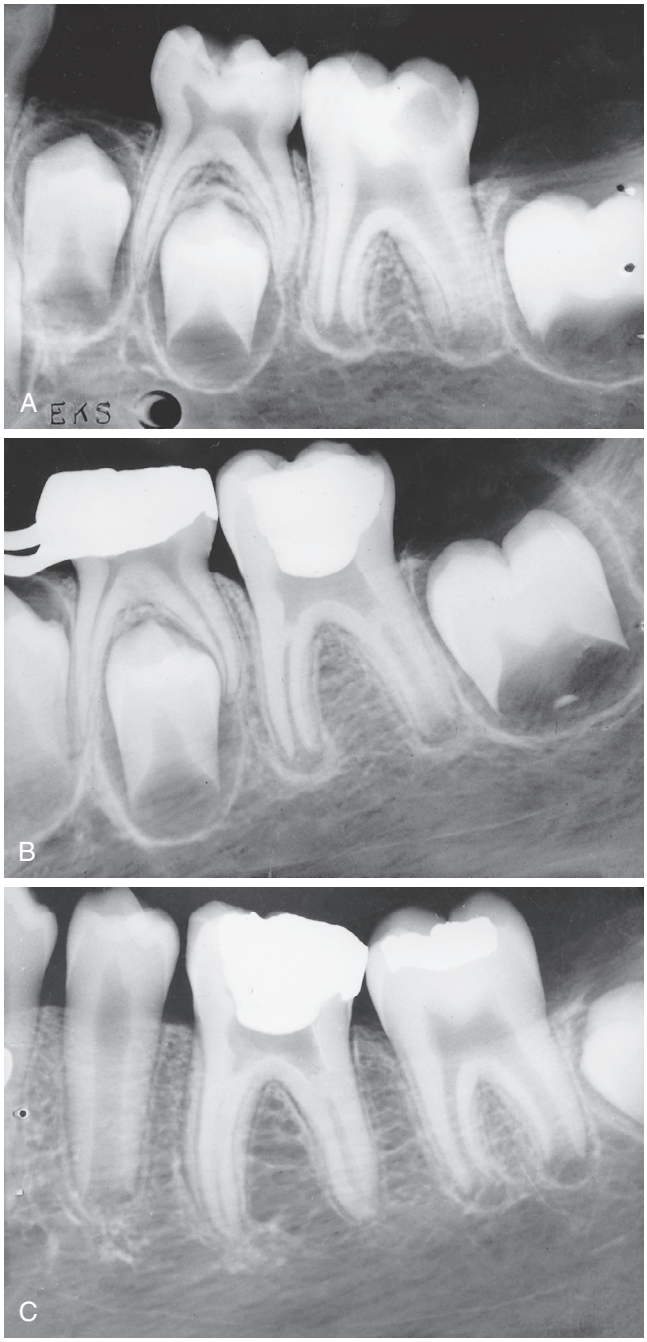

Figure 13-10 **A,** Pulp of the first permanent molar was exposed by caries. The tooth was considered a candidate for the calcium hydroxide pulpotomy technique. **B,** Calcified bridge has formed over the vital pulp in the canals. **C,** Continued root development and pulpal recession are indicative of continuing pulpal vitality. The crown should be supported with a full-coverage restoration.

Pulpotomy Technique for Primary Teeth

The same diagnostic criteria recommended for the selection of permanent teeth for the pulpotomy procedure should be used in the selection of primary teeth for this procedure. The treatment is also completed during a single appointment. A surgically clean technique should be used. The coronal portion of the pulp should be amputated as described previously, the debris should be removed from the chamber, and the hemorrhage should be controlled. If there is evidence of hyperemia after the removal of the coronal pulp, which indicates that inflammation is present in the tissue beyond the coronal portion of the pulp, the technique should be abandoned in favor of pulpectomy or the removal of the tooth. If the hemorrhage is controlled readily and the pulp stumps appear normal, it may be assumed that the pulp tissue in the canals is normal, and it is possible to proceed with pulpotomy.

Although the formocresol pulpotomy technique has been recommended for many years as the principal method for treating primary teeth with carious exposures, a substantial shift away from use of this medicament has occurred because of concerns about its toxic effects. Many alternatives, including MTA, sodium hypochlorite, ferric sulfate, electrosurgery, and lasers, have been investigated to replace formocresol as the medicament of choice for pulpotomy. Despite this, formocresol continues to be a very commonly used pulpotomy medicament.[15] Indeed, Milnes' reevaluation of earlier and more recent research about formaldehyde metabolism, pharmacokinetics, and carcinogenicity led him to suggest that there is an inconsequential risk associated with the use of formocresol in pediatric pulp therapy.[16] The pulp chamber is dried with sterile cotton pellets. Next, a pellet of cotton moistened with a 1:5 concentration of Buckley's formocresol and blotted on sterile gauze to remove the excess is placed in contact with the pulp stumps and allowed to remain for 5 minutes. Because formocresol is caustic, care must be taken to avoid contact with the gingival tissues. The pellets are then removed, and the pulp chamber is dried with new pellets. A thick paste of hard-setting zinc oxide–eugenol is prepared and placed over the pulp stumps. The tooth is then restored with a stainless steel crown (Fig. 13-11).

Although the recommendation is that the blotted cotton pellet moistened with a 1:5 concentration of formocresol be applied to the pulp stumps for 5 minutes, the 5-minute application time has been determined somewhat arbitrarily. Few data are available to verify the optimal application time, although García-Godoy and colleagues have suggested that, based on their limited work with pulpotomies in dogs, a 1-minute application time may be adequate and perhaps superior to the recommended 5 minutes.[17]

Buckley's original formula for formocresol calls for equal parts of formaldehyde and cresol (Sultan Chemists, Inc., Englewood, New Jersey, United States). The 1:5 concentration of this formula is prepared by, first, thoroughly mixing three parts of glycerin with one part of distilled water, and then adding four parts of this diluent to one part of Buckley's formocresol, followed again by thorough mixing.

Despite the continuing common use of formocresol, other materials and techniques have been studied and are used regularly in practice. An excellent prospective randomized clinical trial was conducted by Fernandez and others,[18] comparing the use of formocresol, MTA, sodium hypochlorite, and ferric sulfate. They used a pulpotomy technique and formocresol application similar to

that described above. The use of the other 3 medicaments was as follows:

- MTA: the pulp stumps were covered with an MTA paste made by mixing of the MTA powder with sterile saline at a ratio of 3:1
- Ferric sulfate: 20% ferric sulfate solution was used to burnish the pulp stumps for 15 seconds with a syringe applicator
- Sodium hypochlorite: a 5% NaOCl-saturated cotton pellet was placed on the pulp stumps for 30 seconds

Both the ferric sulfate and sodium hypochlorite solutions were rinsed off with water to verify that no blood

mer-reinforced zinc oxide–eugenol material was placed in the pulp chamber, and the teeth were restored with stain-

and at the end of 24 months of follow-up, of the teeth available for study, no statistically significant difference

NONVITAL PULP TREATMENT WITH IRREVERSIBLE PULPITIS OR NECROTIC PULP

PULPECTOMY

A pulpectomy may be performed on primary teeth when the coronal pulp tissue and the tissue entering the pulp canals are vital but show clinical evidence of hyperemia (Fig. 13-12) or if the root canals show evidence of necrosis (suppuration). It is unwise to maintain untreated infected primary teeth in the mouth. They may be opened for drainage and often remain asymptomatic for an indefinite period. However, they are a source of infection and should be treated or removed. The morphology of the root canals in primary teeth makes endodontic treatment difficult and often impractical. Mature first primary molar canals are often so small that they are inaccessible even to the smallest barbed broach. If the canal cannot be properly cleansed of necrotic material, sterilized, and adequately filled, endodontic therapy is more likely to fail.

Hibbard and Ireland studied the primary root canal morphology by removing the pulp from extracted teeth, forcing acrylic resin into the pulp canals, and dissolving the covering of tooth structure in 10% nitric acid.[19] It was apparent that, initially, only one root canal was present in each of the mandibular and maxillary molar roots. The subsequent deposition of secondary dentin throughout the life of the teeth caused a change in the morphologic pattern of the root canal, producing variations and eventual alterations in the numbers and sizes of the canals. The variations included lateral branching, connecting fibrils, apical ramifications, and partial fusion of the canals. The use of micro-computed tomography has produced some exquisite views of the anatomy of primary molars (Figs. 13-13 and 13-14). These findings explain the complications often encountered in root canal therapy.

Endodontic procedures for the treatment of primary teeth are indicated if the canals are accessible and if there is evidence of essentially normal supporting bone. Aminabadi and colleagues have demonstrated that while primary second molars are more accessible than first molars, all of them are negotiable.[20] In addition, other studies have investigated ultrasonic instrumentation[21] and root apex locators[22] in the root canal treatment of primary teeth. If the supporting bone is also compromised, the likelihood of successful endodontic therapy is lower.

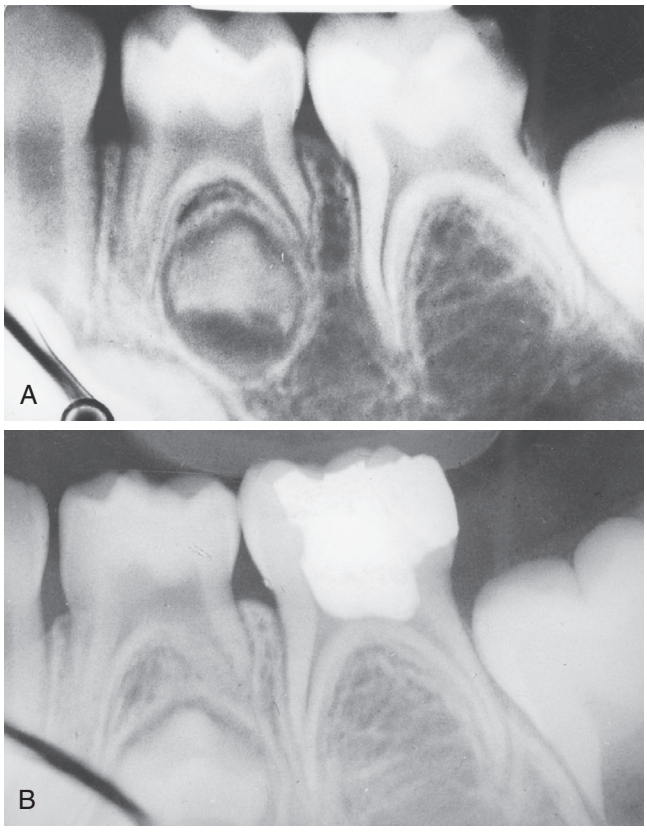

Figure 13-11 **A,** Formocresol pulpotomy technique was completed. **B,** Normal appearance of the supporting tissues is indicative of a successful treatment. The tooth should now be restored with a stainless steel crown.

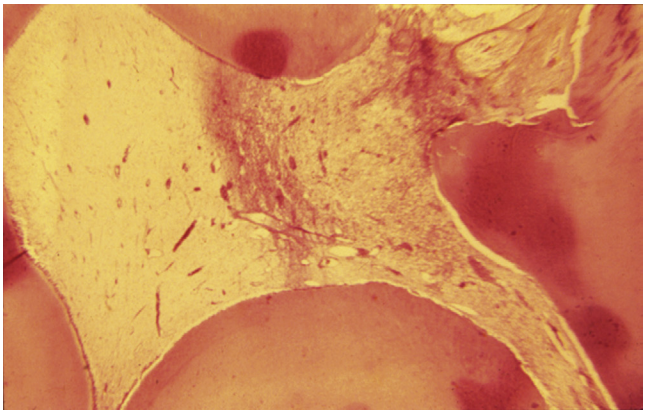

Figure 13-12 Histologic section of a second primary molar with a carious pulp exposure. There was clinical evidence of hyperemia and inflammation of the pulp. Inflammation is evident in half the coronal pulp and in the pulp canal. This condition should be treated by the pulpectomy technique.

If the second primary molar is lost before the eruption of the first permanent molar, the dentist is confronted with the difficult problem of preventing the first permanent molar from drifting mesially during its eruption. Special effort should be made to treat and retain the second primary molar, even if it has a necrotic pulp. Similarly, longer-than-normal retention of a second primary molar may be desired when the succedaneous second premolar is congenitally missing (Fig. 13-15).

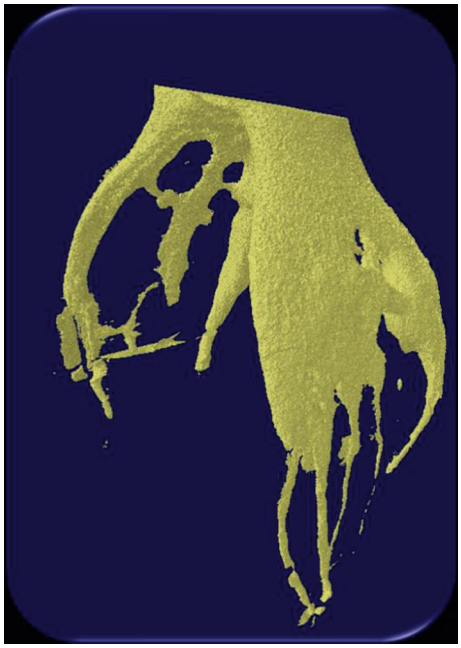

Figure 13-13 Micro-computed tomography of a mandibular second primary molar root canal system. (Courtesy of Dr. Ashraf Al-Hosainy, Mansoura University School of Dentistry, Egypt.)

Many dentists prefer to use root canal instruments placed in a special rotary handpiece and nickel titanium files for root canal debridement. Root canal instrumentation may be facilitated with the judicious use of this mechanical technique, especially in canals that are difficult to negotiate with hand instruments. Cautious manipulation is important, however, to prevent breaking the file or overinstrumentation of the canal and apical tissues.

After the pulp tissue has been removed from the canals, a syringe is used to irrigate them with 3% hydrogen peroxide followed by sodium hypochlorite. The canals should then be dried with sterile paperpoints. When hemorrhage is controlled and the canals remain dry, a thin mix of filling paste may be prepared. Small Kerr files may be used to apply the paste to the walls. The excess thin paste may be removed with paperpoints and Hedström files. A thick mix of the treatment paste should then be prepared, rolled into a point, and carried into the canal. Root canal pluggers may be used to condense the filling material into the canals. Alternatively a Lentulo spiral file can be placed on an endodontic handpiece to spiral the filling material into the canals. An x-ray film may be necessary to allow the success in filling the canals to be evaluated (Fig. 13-16). Further condensation may be carried out if required. The tooth should be restored with full coverage.

Although zinc oxide–eugenol paste has been viewed as the traditional root canal filling material for primary teeth, results from multiple studies[23-28] suggest that KRI paste (Pharmachemie AG, Zürich, Switzerland) may be preferable. Excellent results have been observed in many cases. The primary components of KRI paste are zinc oxide and iodoform. The main advantages of KRI paste over zinc oxide–eugenol paste are that KRI paste resorbs in synchrony with primary roots and is less irritating to surrounding tissues if a root is inadvertently overfilled.

Another popular root canal filling material for prima-

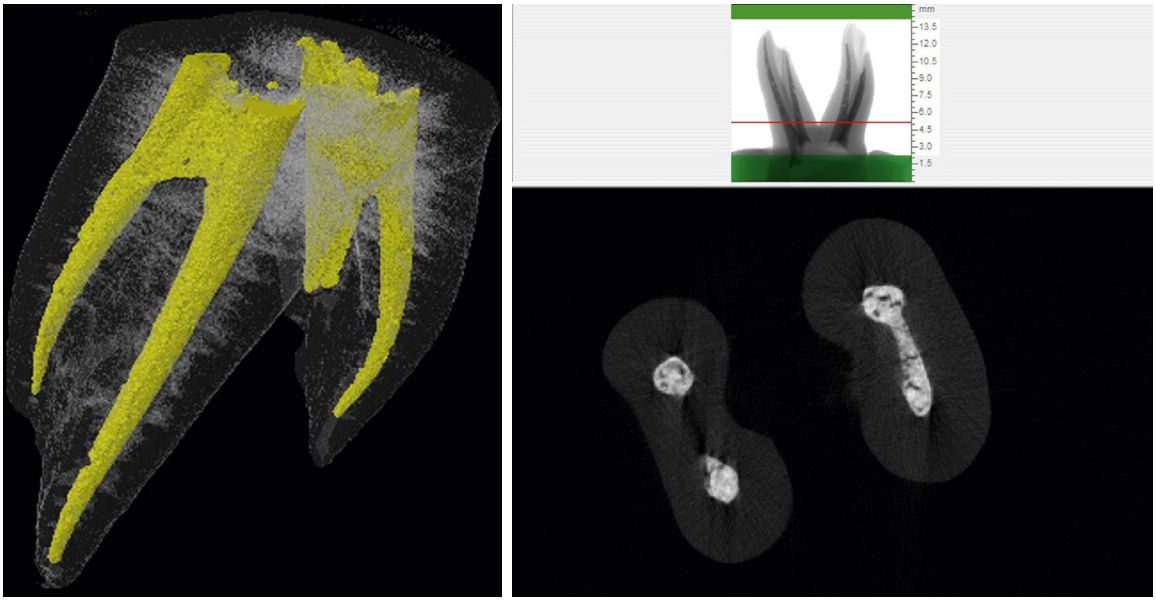

Figure 13-14 Three views of micro-computed tomographs of a mandibular second primary molar root canal system obturated with Vitapex. (Courtesy of Dr. Ashraf Al-Hosainy, Mansoura University School of Dentistry, Egypt.)

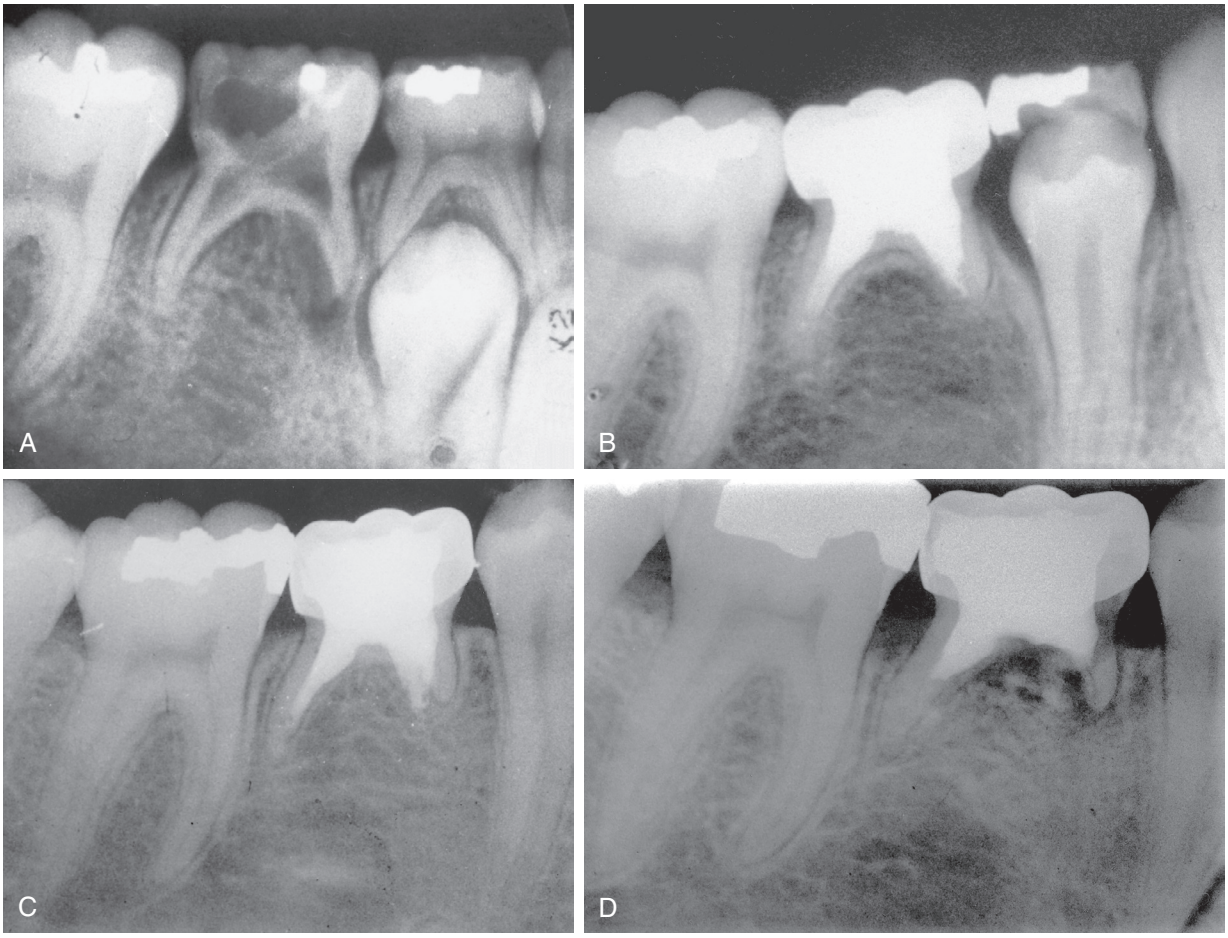

Figure 13-15 **A,** Necrotic tooth resulting from a carious exposure of the pulp of the second primary molar. Because the succedaneous second premolar was congenitally missing, a decision was made to attempt to save the tooth as a functional space

B, Radiograph made 1 year and 7 months after the pulp canals were treated and filled. The mesial canal was treated with complete pulpectomy; the distal canal was treated with partial pulpectomy. **C,** Six years and seven months after treatment, the tooth is asymptomatic; the supporting tissues appear normal, but some root resorption has occurred. **D,** Fourteen years and six months postoperatively, the tooth was extracted because of the development of symptoms and loss of bone support. At this time, the patient was a young adult, and a fixed bridge was made.

Vancouver, British Columbia, Canada), a product that has received many favorable reports about its successful use in infected primary teeth. The primary components of Vitapex are calcium hydroxide and iodoform. Vitapex may be at least as effective as KRI paste, and Nurko and García-Godoy[26,29] have published some reports of studies in humans.

Currently, pulpectomies in primary teeth are commonly completed in a single appointment. If the tooth has painful necrosis with purulence in the canals, however, completing the pulpectomy procedure over two or three visits should improve the likelihood of success.

SUMMARY OF PULP THERAPY

The preceding discussion of various pulp therapies conforms, in principle, to the Guidelines for Pulp Therapy for Primary and Young Permanent Teeth as published by the American Academy of Pediatric Dentistry (AAPD).[30]

In cases of clinical problems that will likely require pulp therapy to return the patient to satisfactory oral health, treatment decisions are not always clear-cut. Proper diagnosis of the pulpal problem is important to allow the dentist to select the most conservative treatment procedure that offers the best chance of long-term success with the least chance of subsequent complications. The dentist should think of the possible treatment options in a progressive manner that takes into account both treatment conservatism (e.g., a pulpotomy is more conservative than a pulpectomy) and posttreatment problems (Fig. 13-17). The most conservative treatment possible may not always be the indicated procedure after the dentist also weighs the risks of posttreatment failure in a particular case (Video 13-1: Pulp therapy).

RESTORATION OF THE PULPALLY INVOLVED TOOTH

It has been a common practice for some dentists to delay for weeks or months the permanent restoration of a tooth that has undergone vital pulp therapy, to allow time to determine whether the treatment procedure will be

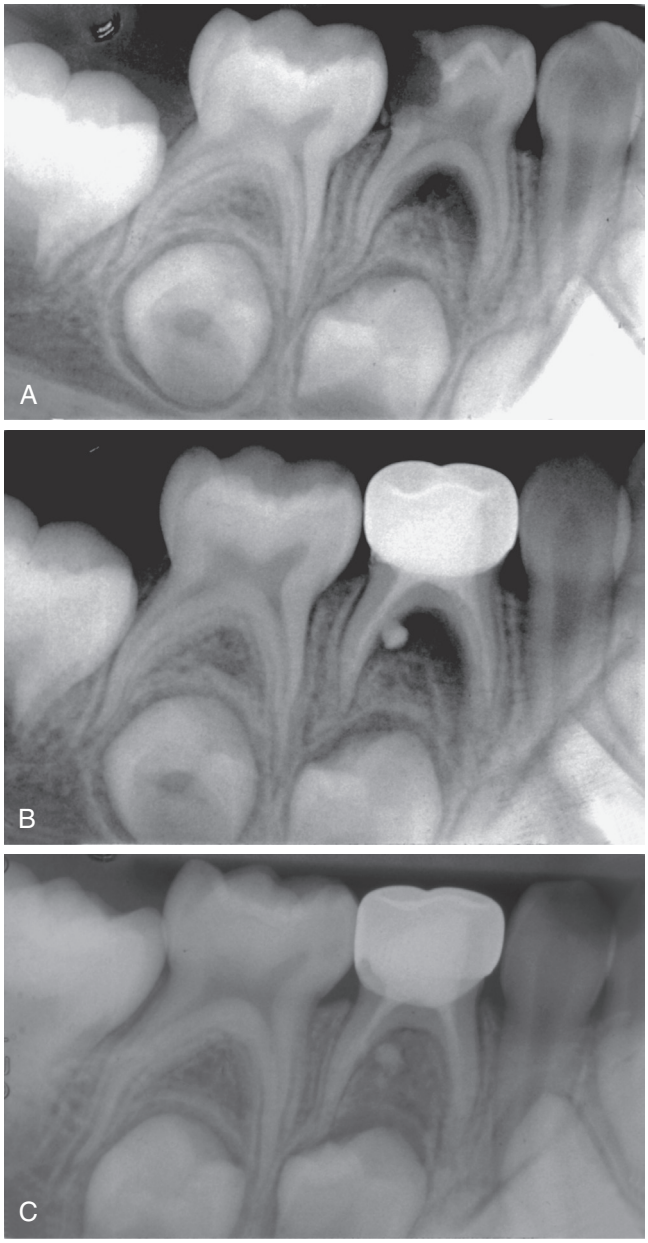

Figure 13-16 Successful single-appointment pulpectomy. Note extrusion of zinc oxide–eugenol into furcal area from distal root accessory canal, but adequate subsequent healing. **A,** Pretreatment. **B,** Immediately after treatment. **C,** Ten months after treatment.

successful. However, failures in pulp therapy are usually not evident for many months. Rarely does a failure in pulp therapy or an endodontic procedure on a primary tooth cause the child to experience acute symptoms. Failures are usually evidenced by pathologic root resorption or rarefied areas in the bone and are discovered during regular recall appointments.

Primary and permanent molars that have been treated by the pulpotomy or pulpectomy technique have a weak, unsupported crown that is liable to fracture. Failure of the buccal or lingual plate often occurs below the gingival attachment or even below the crest of the alveolar bone.

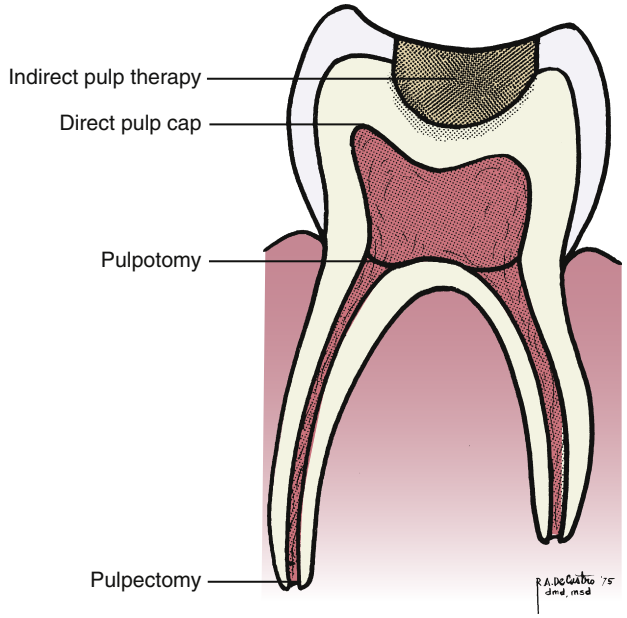

Figure 13-17 Pulp therapy progression.

This type of fracture makes subsequent restoration of the tooth impractical. Also, a delay in restoring the tooth with a material that will adequately seal the tooth and prevent the ingress of oral fluids is one cause for failure of pulp therapy. Application of a layer of hard-setting cement over the capping material, followed by a substantial restoration, will adequately protect the pulp against contaminating oral fluids during the healing process.

An amalgam, composite resin, or glass-ionomer restoration may serve as the immediate and often the final restoration for teeth with pulp caps and well-supported crowns. As soon as it is practical, however, other pulpally treated posterior teeth should be prepared for stainless steel crowns. Pulp treatment of a primary molar is typically followed by placement of a stainless steel crown restoration during the same appointment.

REACTION OF THE PULP TO VARIOUS CAPPING MATERIALS

So many different materials have been proposed that a brief review of several popular agents is valuable for an understanding of the various reactions of the pulp. In addition to this section, Chen and Jorden present a well-written article on the present and future of materials for primary tooth pulp treatment.[31]

ZINC OXIDE–EUGENOL

Before calcium hydroxide came into common use, zinc oxide–eugenol was used more often than any other pulp-capping material. Although dentists have apparently had good clinical results with the use of zinc oxide–eugenol, it is not recommended as a direct pulp-capping material.

CALCIUM HYDROXIDE

Herman first introduced calcium hydroxide as a biological dressing.[32] Because of its high alkalinity (pH 12), it is

so caustic that when it is placed in contact with vital pulp tissue, the reaction produces a superficial necrosis of the pulp. The irritant qualities seem to be related to its ability to stimulate development of a calcified barrier. The superficial necrotic area in the pulp that develops beneath the calcium hydroxide is demarcated from the healthy pulp tissue below by a new, deeply staining zone comprised of basophilic elements of the calcium hydroxide dressing. The original proteinate zone is still present. However, against this zone is a new area of coarse fibrous tissue likened to a primitive type of bone. On the periphery of the new fibrous tissue, cells resembling odontoblasts appear to be lining up. One month after the capping procedure, a calcified bridge is evident radiographically. This bridge continues to increase in thickness during the next 12 months (Fig. 13-18). The pulp tissue beneath the calcified bridge remains vital and is essentially free of inflammatory cells.

Many studies have reported on the use of calcium hydroxide as a pulp-capping material; a few are included in the references for this chapter. Investigators who evaluate experimental pulp-capping agents commonly compare their results with the agent being tested with the results they can obtain with calcium hydroxide under similar conditions. Thus calcium hydroxide currently serves as the standard or control material for experimentation related to pulp-capping agents.

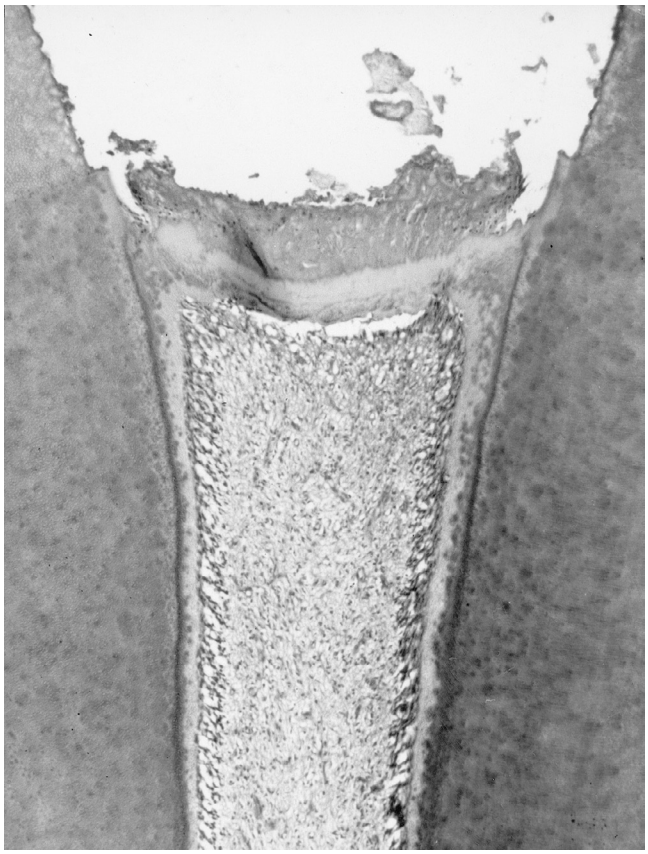

Figure 13-18 Calcified bridge covering an amputated pulp that was capped with calcium hydroxide.

PREPARATIONS CONTAINING FORMALIN

The belief that exposing the pulp to formocresol or capping it with materials that contain formocresol will promote pulp healing or even maintain the pulp in a healthy state has not been adequately substantiated. Some studies have indicated that the formocresol pulpotomy technique may be applied to permanent teeth, but its use in permanent teeth remains an interim procedure, to be followed by conventional endodontic therapy. The clinical success experienced in the treatment of primary pulps with these materials is possibly related more to the drug's germicidal action and fixation qualities than to its ability to promote healing.

Doyle and associates compared the success of the full-strength formocresol pulpotomy technique with the success of the calcium hydroxide pulpotomy technique.[33] Experimental pulpotomies were performed on 65 normal human primary teeth, many of which could later be extracted for histologic examination. The formocresol technique was used on 33 teeth, and the calcium hydroxide technique was used in the treatment of the other 32. Under the conditions of this study, the formocresol pulpotomy technique yielded outcomes superior to those of the calcium hydroxide technique for at least the first 18 months after treatment. Formocresol did not stimulate the healing response of the remaining pulp tissue but rather tended to fix essentially all the remaining tissue (Figs. 13-19 and 13-20). The use of calcium hydroxide was associated with the formation of a dentin bridge and the complete healing of the amputated primary pulp in 50% of the cases that were available for histologic study.

FERRIC SULFATE

Considerable interest and research have been devoted to investigating the effectiveness of ferric sulfate to treat the surface of the remaining pulp tissue after pulpotomy of primary teeth. Ferric sulfate agglutinates blood proteins and controls hemorrhage in the process without clot formation.

favorable data from an animal study and a longer-term clinical human study (mean observation period, 20.5 months).[34,35] Their success rates for ferric sulfate pulpotomies were very similar to those for diluted formocresol pulpotomies (control condition). More long-term clinical studies are needed, but currently it appears that ferric sulfate could be a better choice for treating primary teeth needing pulpotomy (results equal to those achieved with diluted formocresol but with less toxicity). Ferric sulfate is available in a 15.5% solution under the trade name of Astringedent (Ultradent Products, Inc., South Jordan, Utah, United States).

A study by Casas and colleagues compared the outcome of ferric sulfate pulpotomy with that of primary tooth root canal therapy (pulpectomy) on cariously exposed vital pulps of primary molars.[36] Although their study showed that root canal therapy had produced more acceptable treatment outcomes than ferric sulfate pulpotomy in vital pulp treatment of primary molars at a 2-year follow-up visit, the survival rates for the two

Dentlearn.ir

techniques were not statistically different. There was no clinical evidence of pathosis in 96% of the ferric sulfate pulpotomies and 98% of the molars undergoing root canal therapy. They suggest that, for clinicians who wish to avoid aldehydes in vital molar pulp therapy for children, either of these two alternatives is feasible. Of course, the main advantage of the ferric sulfate pulpotomy over a pulpectomy for dentists working with children is the considerably faster speed with which a pulpotomy can be performed.

MINERAL TRIOXIDE AGGREGATE

MTA is emerging as a popular product for pulpotomies secondary to a variety of factors. Originally developed as a root-end filling material, its main components are tricalcium silicate, tricalcium aluminate, tricalcium oxide, and silicate oxide.[37] The positive properties of MTA are biocompatibility, good sealing properties, antimicrobial activity, and the ability to set in the presence of moisture and blood. The negative attributes include difficulty of handling and the exceptional cost. In addition, along with formocresol and ferric sulfate, MTA can cause pulp canal obliteration. Despite this, it seems to come closest to our goal of formation of a natural dentinal bridge across the exposed pulpal tissue.

OTHER CAPPING MATERIALS AND METHODS

Pulp-capping experiments in animals have tested a variety of antibiotics and corticosteroids, alone or in combination with calcium hydroxide; in the 1970s interest in pulp-capping research shifted to other experimental materials.

Dickey and associates[38] tested a crystalline form of pure calcium hydroxyapatite, and Ibarra[39] evaluated an experimental synthetic hydroxyapatite used in combination with either chlorhexidine gluconate solution or distilled water as vehicles. None of these was as satisfactory as calcium hydroxide as a pulp-capping material. In addition, they were somewhat difficult to manipulate.

In other investigations in search of improved pulp-capping materials, agents that showed at least promising preliminary results have included freeze-dried bone, chlorhexidine, feracrylum, calcium phosphate ceramics, tetracalcium phosphate cement, dentin-bonding agents in combination with bonded resin or glass-ionomer materials, and bone morphogenetic proteins.[40-51]

In an excellent review on pulpotomies in primary teeth, Ranly suggested that pulpotomy modalities can be classified by treatment objective into three categories: devitalization, preservation, and regeneration.[52] He noted that

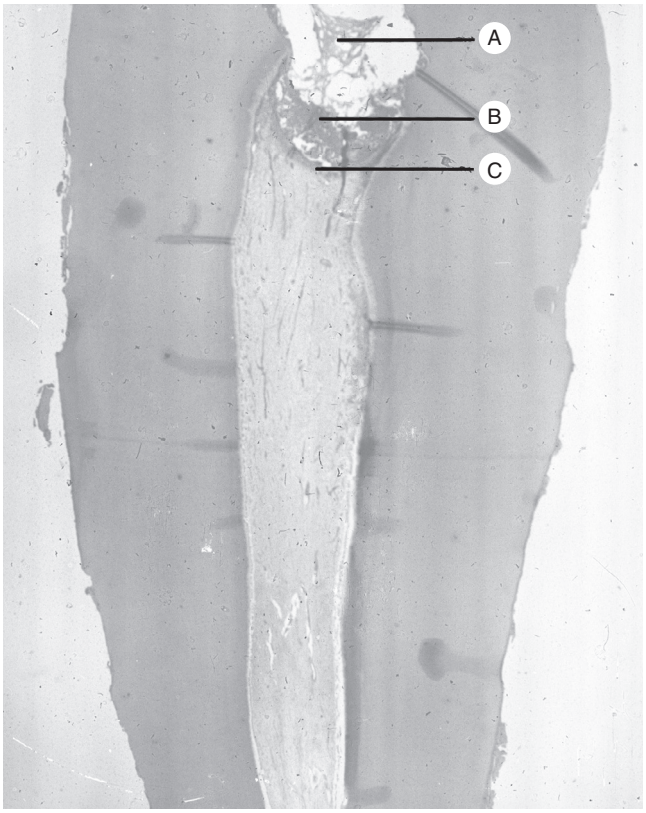

Figure 13-19 Histologic section of a primary pulp exposed to formocresol for 4 days. The medicament came into contact with the pulp at *A,* the debris and blood clot are evident at *B,* and a noticeably eosinophilic, compressed line is evident at *C*. The underlying pulp was a pale, homogeneously stained tissue with a loss of basophilic nuclei. (Courtesy of Dr. Walter A. Doyle.)

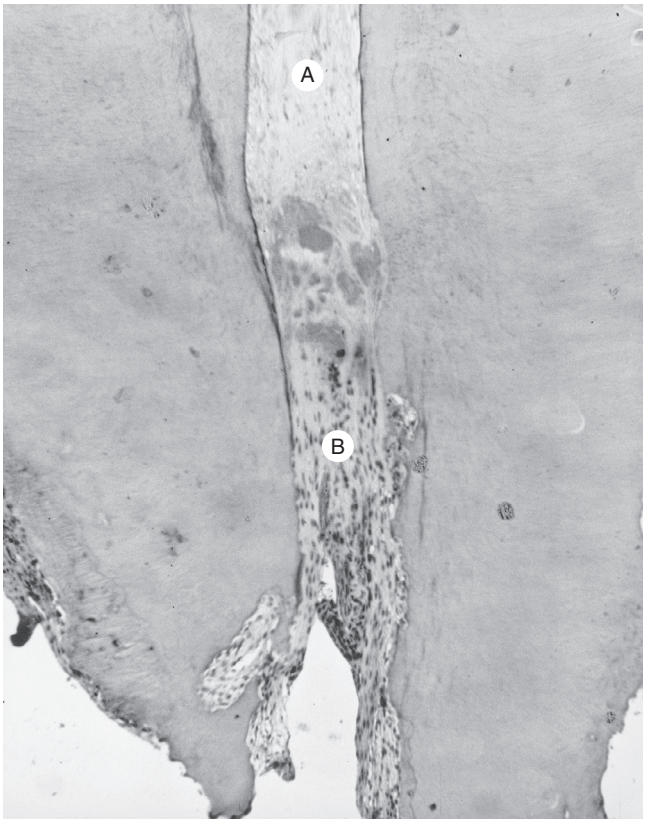

Figure 13-20 Histologic section of a primary pulp exposed to formocresol for 41 days. The pulp, *A,* appeared pale and pink, and there was a loss of cellular definition. Vital tissue can be seen in the apical portion, *B.* (Courtesy of Dr. Walter A. Doyle.)

the treatment objective of an ideal pulpotomy agent is to leave the radicular pulp vital and healthy and completely enclosed within an odontoblast-lined dentin chamber. The regeneration modality most closely resembles this ideal. Through the use of a family of bone morphogenetic proteins, it may be possible to induce reparative dentin formation with recombinant dentinogenic proteins similar to the native proteins of the body. Fuks suggests that because the specificity of growth factors such as transforming growth factor β and bone morphogenetic protein in inducing reparative processes is not clear, further studies are required for a full understanding of the kinetics of growth factor release and the sequence of growth factor–induced reparative dentinogenesis.[11] Commercially available recombinant human bone morphogenetic proteins for pulp therapy are now available for experimentation and clinical trials. In addition, Sabbarini and others have demonstrated the effective use, both histologically and clinically, of an enamel matrix derivative as a pulpotomy agent in primary teeth.[53,54]

Ruemping and associates compared the pulp response to formocresol with electrosurgical coagulation after

was not large, and the observation periods were relatively short (maximum was 2 months after the operation), but the results of their histologic study showed the electrosurgical technique to be as favorable as the full-strength formocresol technique. Shaw and associates have also demonstrated favorable results lasting up to 6 months with electrosurgical pulpotomies in monkeys.[56]

Mack and Dean reported the results of a retrospective human study of electrosurgical pulpotomies performed on primary molars.[57] The mean postoperative observation time for the 164 teeth studied was 2 years and 3 months. They reported a 99.4% success rate (one failure) for this pulpotomy technique. In addition, Dean and colleagues demonstrated no statistically significant difference between the electrosurgical and formocresol pulpotomy techniques in a prospective clinical study involving 50 children requiring at least one pulpotomy.[58] The children were ran-

electrosurgical technique and 25 undergoing the formocresol technique. The mean age at treatment was 63.6 months, and the mean postoperative observation time was 10.9 months. The clinical and radiographic success rates were 96% and 84%, respectively, for the electrosurgical

between results for the two techniques, although the elec-

concluded that the results of their study support the use of electrosurgical pulpotomy as a viable alternative to formocresol pulpotomy. Rivera and colleagues[59] obtained results similar to those of Dean and associates; however, Fishman and colleagues[60] found considerably lower success rates with the use of electrosurgical pulpotomy.

Shoji and colleagues reported the results of some preliminary studies on the treatment of amputated pulps (pulpotomies) in dogs by CO_2 laser radiation.[61] Wilkerson and colleagues reported favorable pulpal responses of healing and repair in swine following pulpotomies involving an argon laser.[62] Moritz and associates applied 200 direct pulp caps in adult patients after mechanical pulp exposures.[63]

calcium hydroxide pulp cap. The other half (experimental

going CO_2 laser radiation until the "exposed pulps were completely sealed." The teeth were monitored monthly. One year after treatment, the success rate for teeth in the

cal and the laser techniques seem to be favorable areas for further research in pulp therapy, a systematic review by De Coster and others states that, given the paucity and heterogeneity of high-quality articles, general recommendations for the clinical use of the laser in pulpotomies for primary teeth cannot yet be made.[64]

SUMMARY OF PULP-CAPPING MATERIALS

Clarity does seem to be developing regarding some research results that should allow for the use of successful alternatives to formocresol.[65] In fact the network meta-analyses by Lin and others led them to suggest that MTA is the first choice for primary molar pulpotomies, unless cost is an issue.[66] In that case they suggest that ferric sulfate may be the choice (Table 13-1, Fig. 13-21).

However, the following survey conclusions by Dunston and Coll[67] show that we continue to lack uniformity in agreement:

Conclusions from 2005 vs 1997 surveys of U.S. dental schools and diplomates of the American Board of Pediatric Dentistry:

1. For indirect pulp therapy, there was significantly more use of glass ionomer and fewer zinc oxide–eugenol or calcium hydroxide liners; most did not reenter a tooth following indirect pulp therapy.
2. Formocresol remained the preferred pulpotomy medicament, but ferric sulfate use had increased. Zinc oxide–eugenol remained the base of choice after a pulpotomy.
3. Slightly less pulpectomy therapy was advocated for abscessed teeth. When such therapy was performed, more dentists advocated combined iodoform and calcium hydroxide paste fillers. Few advocated a two-appointment pulpectomy procedure.
4. Disagreements continue, and the AAPD pulp therapy guidelines and results of pulpal research were not always applied.
5. Diplomates tended to practice pulpal therapy similar to that taught by program directors.

FAILURES AFTER VITAL PULP THERAPY

Failure in the formation of a calcified bridge across the vital pulp has often been related to the age of the patient, degree of surgical trauma, sealing pressure, improper choice of capping material, low threshold of host resistance, and presence of microorganisms with subsequent infection. Kakehashi and colleagues studied the effects of surgical exposures of dental pulps in germ-free and conventional laboratory rats.[9] The injured pulpal tissue contaminated

Dentlearn.ir

Table **13-1**

Failure Odds Ratio of Network and Standard Meta-Analysis for Clinical and Radiographic Outcome for Primary Molar Pulpotomy after 18-24–Month Follow-Up

	CLINICAL OUTCOME				RADIOGRAPHIC OUTCOME			
	Network Meta-Analysis		Standard Pair-Wise Meta-Analysis		Network Meta-Analysis		Standard Pair-Wise	
	Estimates	95% CI	Estimates	95% CI	Estimates	95% CI	Estimates	95% CI
FS vs FC	0.90	(0.48, 1.65)	1.00	(0.88, 1.12)	1.02	(0.60, 1.78)	1.0	(0.91, 1.11)
$Ca(OH)_2$ vs FC	1.94	(1.11, 3.25)*	1.20	(1.05, 1.37)*	2.97	(1.78, 4.99)*	1.40	(1.19, 1.65)*
MTA vs FC	0.90	(0.61, 1.32)	0.91	(0.79, 1.05)	0.66	(0.45, 0.98)*	0.83	(0.73, 0.96)*
Lasers vs FC	3.38	(1.37, 8.61)*	1.35	(1.14, 1.60)*	2.54	(1.32, 4.76)*	1.38	(1.15, 1.66)*
$Ca(OH)_2$ vs FS	2.16	(1.12, 4.31)*	1.22	(1.04, 1.42)*	2.90	(1.56, 5.54)*	1.37	(1.13, 1.67)*
MTA vs FS	1.00	(0.54, 1.86)	0.91	(0.70, 1.19)	0.64	(0.35, 1.22)	0.88	(0.66, 1.18)
Lasers vs FS	3.73	(1.27, 11.67)*	1.13	(0.92, 1.39)	2.47	(1.11, 5.23)*	1.27	(1.00, 1.62)*
MTA vs $Ca(OH)_2$	0.47	(0.26, 0.83)*	0.80	(0.52, 1.23)	0.22	(0.12, 0.41)	0.58	(0.33, 1.00)
Lasers vs $Ca(OH)_2$	1.72	(0.62, 4.98)	0.89	(0.68, 1.16)	0.86	(0.40, 1.72)	0.79	(0.56, 1.12)
Lasers vs MTA	3.76	(1.39, 10.08)*			3.88	(1.85, 8.05)*		

Reprinted with permission from Lin P-Y et al: Primary molar pulpotomy: a systematic review and network meta-analysis. *J Dent*, 42(9): 1060-77, 2014.
*p <0.05
vs, versus; CI, credible interval; FC, formocresol; FS, ferric sulfate; MTA, mineral trioxide aggregate.

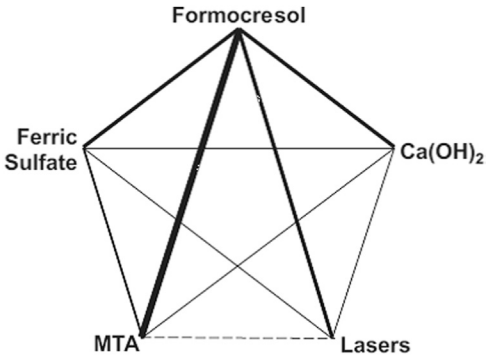

Figure 13-21 Network for the comparisons among different medicaments for primary molar pulpotomy. Dotted lines refer to those comparisons that have not been tested directly in clinical trials. The width of the solid lines is in proportion to the amount of evidence available in the literature. (Reprinted with permission from Lin P-Y et al: Primary molar pulpotomy: a systematic review and network meta-analysis, *J Dent*, 42(9):1060-77, 2014.)

with microorganisms failed to show evidence of repair; especially lacking were matrix formation and attempted dentinal bridging. In the germ-free animals, bridging began in 14 days and was complete in 28 days regardless of the severity of the exposure. The major determinant in the healing of exposed rodent pulps appeared to be the presence or absence of microorganisms. These findings were later corroborated by Watts and Paterson.[68]

Walshe provided further evidence that the success of vital pulp therapy depends on adherence to a surgically aseptic technique. In his experiment, the teeth of monkeys were capped with bovine dentin mixed with methylcellulose, and histologic observations were made 42 days postoperatively.[10] Approximately half the teeth capped with the experimental material were successfully repaired with atubular dentin (Fig. 13-22). The remaining teeth showed various degrees of inflammation and repair. The Brown and Bren staining technique demonstrated the presence of microorganisms in the pulp of the teeth that failed to repair (Figs. 13-23 and 13-24). The stain also revealed microorganisms between the dentin walls and the filling material. The microorganisms were apparently introduced at the time of the pulp-capping procedure, or leakage of the restoration allowed them to gain entrance to the pulp chamber. This study likewise supports the need for a good surgical technique and the placement of a restoration that will provide the best possible seal.

within the pulp canal several months after the pulpotomy procedure is the most frequently seen evidence of an

resorption is a destructive process generally believed to be caused by odontoclastic activity, and it may progress slowly or rapidly. Occasionally, secondary repair of the resorbed dentinal area occurs.

No satisfactory explanation for the postpulpotomy

demonstrated, however, that with a true carious exposure of the pulp, an inflammatory process will be present to some degree. The inflammation may be limited to the exposure site, or it may be diffused throughout the coronal portion of the pulp. Amputation of all pulp showing the

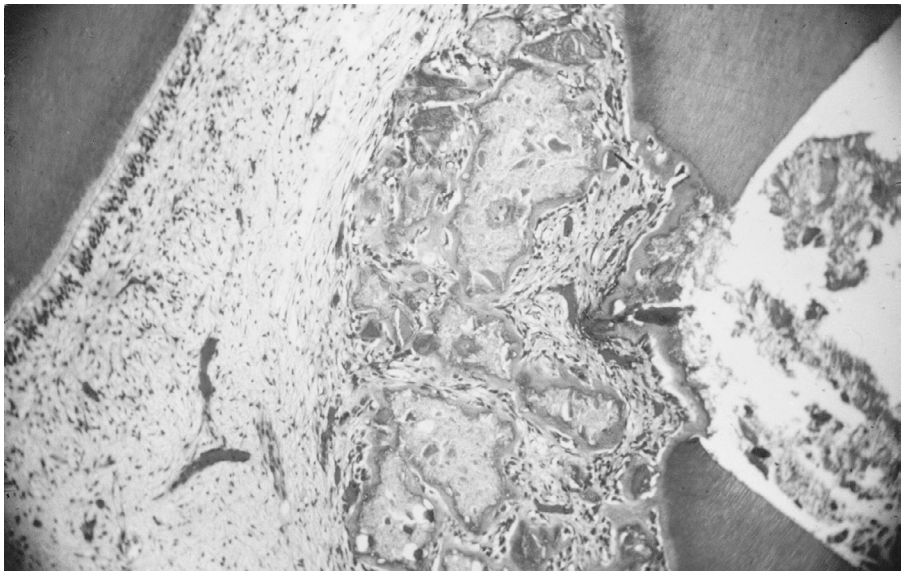

Figure 13-22 Surgical exposure of the pulp of a monkey was capped with powdered bovine dentin. Atubular dentin bridging the exposure site was evident 42 days postoperatively.

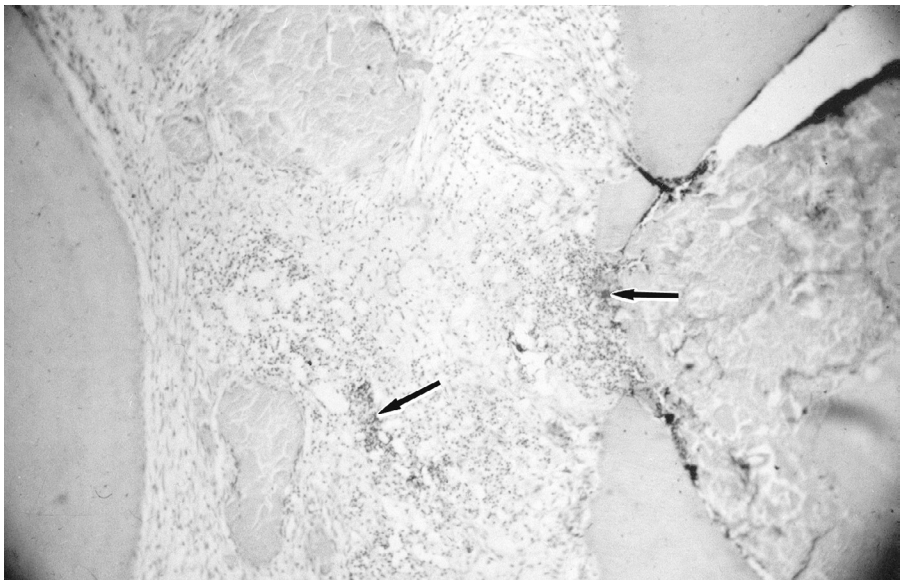

Figure 13-23 Pulps capped with bovine dentin failed to undergo calcific repair and demonstrated microorganisms *(arrows)* in the pulp. (Courtesy of Dr. Martin Walshe.)

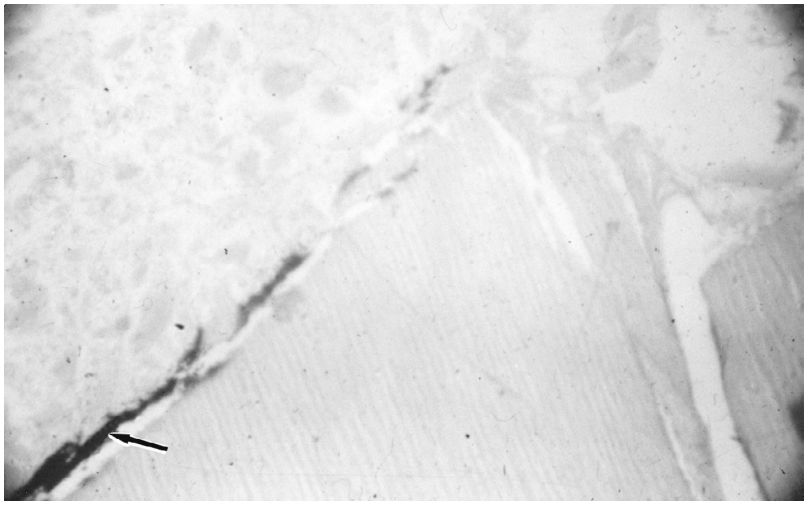

Figure 13-24 Microorganisms *(arrow)* may be seen between the dentin walls and the filling material. (Courtesy of Dr. Martin Walshe.)

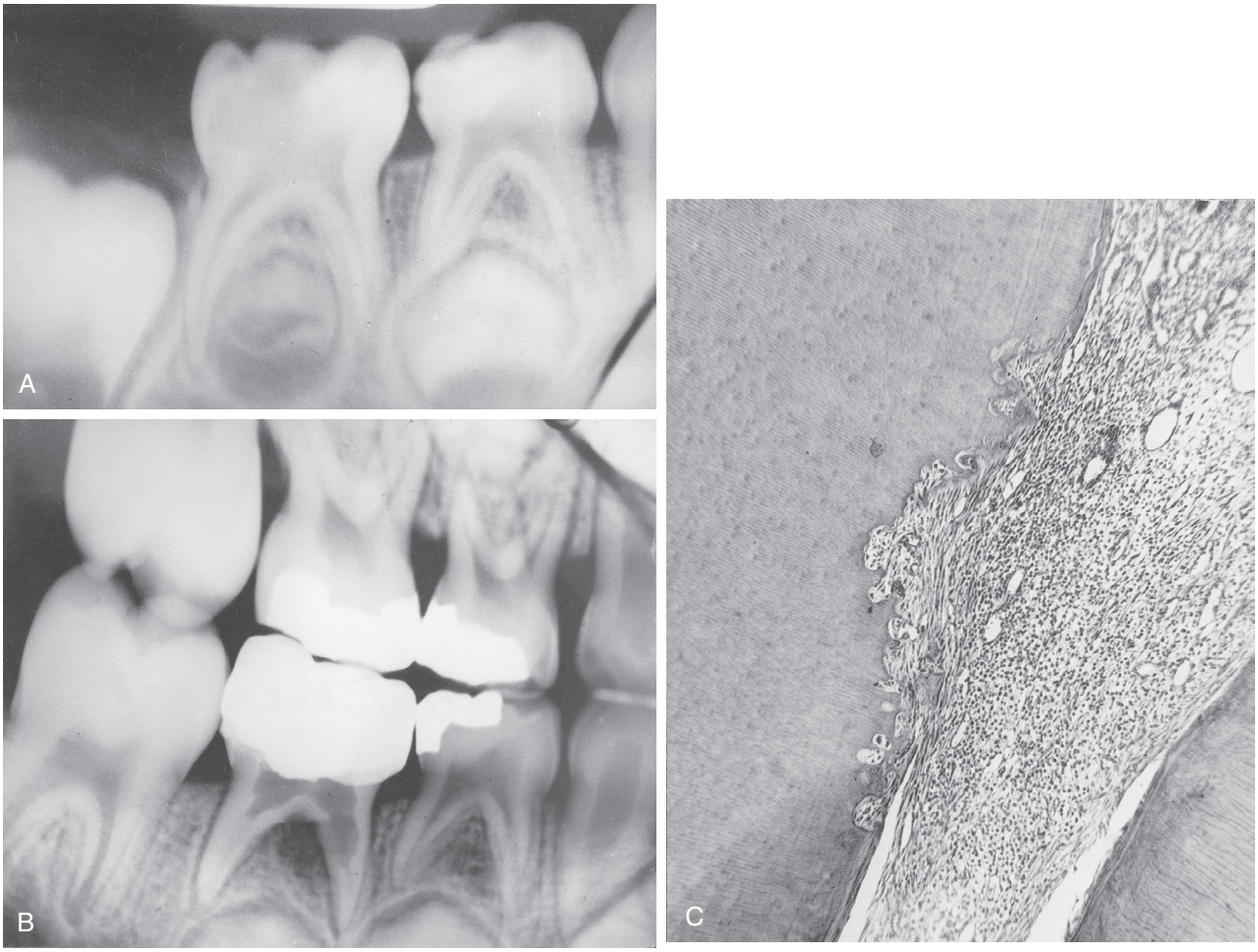

Figure 13-25 **A,** Preoperative radiograph of a second primary molar treated with the calcium hydroxide pulpotomy technique.

inflammatory change may be difficult or impossible, and abnormal pulp tissue may be allowed to remain. If the inflammation extended to the entrance of the pulp canal, odontoclasts may have been attracted to the area; if it were possible to examine the tooth histologically, small bays of resorption would be evident. This condition may exist at the time of pulp therapy, although there is no way to detect it. The only indication would be the clinical evidence of a hyperemic pulp.

Inflammatory cells drawn to the area as a result of the placement of an irritating capping material might well attack the pulp is normal at the time of treatment. Because the roots of primary teeth are undergoing normal physiologic resorption, vascularity of the apical region is increased. Odontoclastic activity present in the area may predispose of a pulp-capping material is placed on the pulp.

ALVEOLAR ABSCESS

An alveolar abscess occasionally develops some months after pulp therapy has been completed. The tooth usually remains asymptomatic, and the child is unaware of the infection, which may be present in the bone surrounding the root apices or in the area of the root bifurcation. A fistulous opening may be present, which indicates the chronic condition of the infection. Primary teeth that show evidence of an alveolar abscess should be removed. Permanent teeth that have previously been treated by pulp capping or by pulpotomy and later show evidence of pulpal necrosis and apical infection may be considered for endodontic treatment.

EARLY EXFOLIATION OR OVER-RETENTION OF PRIMARY TEETH WITH PULP TREATMENTS

Occasionally a pulpally treated tooth previously believed to be successfully managed will loosen and exfoliate (or require extraction) prematurely for no apparent reason. It is believed that such a condition results from low-grade, chronic, asymptomatic, localized infection. Usually, abnormal and incomplete root resorption patterns of the affected teeth are also observed. When this occurs, space management must be considered.

Another sequela requiring close observation is the tendency for primary teeth undergoing successful

Dentlearn.ir

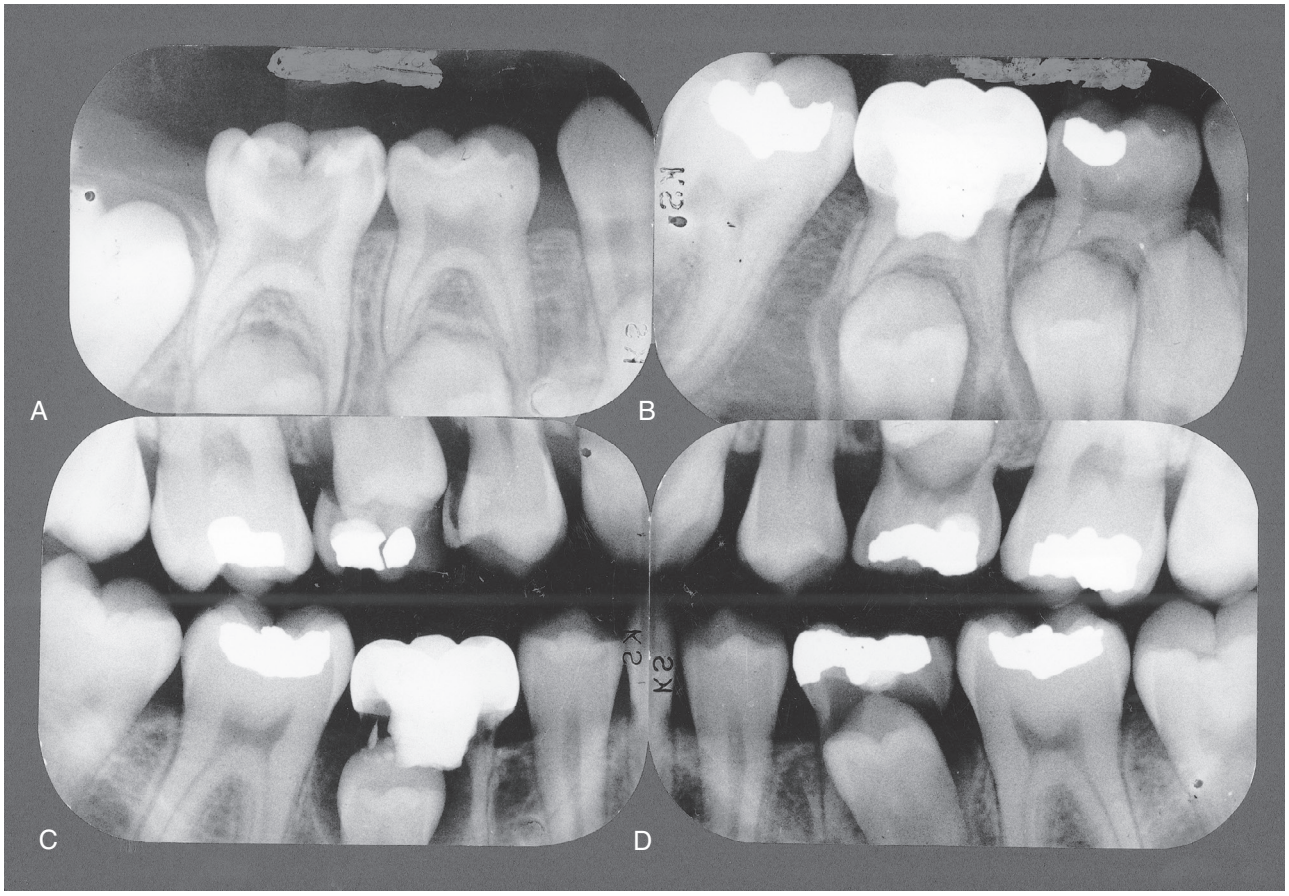

Figure 13-26 **A,** A pulpally involved second primary molar was successfully treated with a formocresol pulpotomy and restored with a stainless steel crown. **B,** This 4-year posttreatment radiograph reveals long-term successful management. **C** and **D,** Bilateral bitewing radiographs for the same patient 7 years after the pulpotomy reveal that the resorption of the pulpotomized molar is falling behind compared with its antimere. The eruption of the permanent second premolar is also being delayed. The pulpally treated tooth should be extracted at this time. (Courtesy of Dr. Wayne A. Moldenhauer.)

pulpotomies or pulpectomies to be over-retained. This situation may have the untoward result of interfering with the normal eruption of permanent teeth and adversely affecting the developing occlusion. Close periodic observation of pulpally treated teeth is necessary to intercept such a developing problem. Extraction of the primary tooth is usually sufficient. This phenomenon may occur when normal physiologic exfoliation is delayed by the bulky amount of cement contained in the pulp chamber. Even though the material is resorbable, its resorption is slowed significantly when large quantities are present (Fig. 13-26).

REFERENCES

1. Waterhouse PJ, et al.: Pediatric endodontics, in *Cohen's pathways of the pulp*. In Hargreaves KM, Cohen S, editors: ed 10, St. Louis, 2011, Mosby-Elsevier, pp 808–857.
2. Hori A, et al.: The ability of pulp sensibility tests to evaluate the pulp status in primary teeth, *Int J Paediatr Dent* 21(6):441–445, 2011.
3. Miwa Z, et al.: Pulpal blood flow in vital and nonvital young permanent teeth measured by transmitted-light photoplethysmography: a pilot study, *Pediatr Dent* 24(6):594–598, 2002.
4. Dunlop RM, et al.: Pulp therapy in pediatric patients with congenital heart disease: survey of American Academy of Pediatric Dentistry members, *J Dent Child* 80(3):139–144, 2013.
5. Al-Zayer MA, et al.: Indirect pulp treatment of primary posterior teeth: a retrospective study, *Pediatr Dent* 25(1):29–36, 2003.
6. Nirschl RF, Avery DR: Evaluation of a new pulp capping agent in indirect pulp therapy, *J Dent Child* 50:25–30, 1983.
7. Pinto AS, et al.: Clinical and microbiological effect of calcium hydroxide protection in indirect pulp capping in primary teeth, *Am J Dent* 19(6):382–386, 2006.
8. Reference deleted in proofs.
9. Kakehashi S, et al.: The effects of surgical exposure of dental pulps in germ-free and conventional laboratory rats, *Oral Surg* 20:340–349, 1965.
10. Walshe MJ: *Pulp reaction to anorganic bovine dentin [Master's thesis]*, Indianapolis, 1967, Indiana University School of Dentistry.
11. Fuks AB: Current concepts in vital primary pulp therapy, *Eur J Paediatr Dent* 3(3):115–120, 2002.
12. Caicedo R, et al.: Clinical, radiographic and histological analysis of the effects of mineral trioxide aggregate used in direct pulp capping and pulpotomies of primary teeth, *Aust Dent J* 51(4):297–305, 2006.
13. Chailertvanitul P, et al.: Randomized control trial comparing calcium hydroxide and mineral trioxide aggregate for partial pulpotomies in cariously exposed pulps of permanent molars, *Int Endod J* 47(9):835–842, 2014.

14. Witherspoon DE, Small JC, Harris GZ: Mineral trioxide aggregate pulpotomies: a case series outcomes assessment, *J Am Dent Assoc* 137(5):610–618, 2006.
15. Walker LA, et al.: Current trends in pulp therapy: a survey analyzing pulpotomy techniques taught in pediatric dental residency programs, *J Dent Child* 80(1):31–35, 2013.
16. Milnes AR: Is formocresol obsolete? A fresh look at the evidence concerning safety issues, *Pediatr Dent* 30(3):237–246, 2008.
17. García-Godoy F, et al.: Pulpal response to different application times of formocresol, *J Pedod* 6:176–193, 1982.
18. Fernandez CC, et al.: Clinical and radiographic outcomes of the use of four dressing materials in pulpotomized primary molars: a randomized clinical trial with 2-year follow-up, *Int J Paed Dent* 23:400–407, 2013.
19. Hibbard ED, Ireland RL: Morphology of the root canals of the primary molar teeth, *J Dent Child* 24:250–257, 1957.
20. Aminabadi NA, et al.: Study of root canal accessibility in human primary molars, *J Oral Sci* 50(1):69–74, 2008.
21. da Costa CC, et al.: Endodontics in primary molars using ultrasonic instrumentation, *J Dent Child* 75(1):20–23, 2008.
22. Bodur H, et al.: Accuracy of two different apex locators in primary teeth with and without root resorption, *Clin Oral Invest* 12(2):137–141, 2008.
23. Holan G, Fuks AB: A comparison of pulpectomies using ZOE and KRI paste in primary molars: a retrospective study, *Pediatr Dent* 15:403–407, 1993.
24. Ranly DM, García-Godoy F: Current and potential pulp therapies for primary and young permanent teeth, *J Dent* 28:153–161, 2000.
25. Ritwik P: A review of pulp therapy for primary and immature permanent teeth, *Calif Dent Assoc J* 41:585–594, 2013.
26. García-Godoy F: Evaluation of an iodoform paste in root canal therapy for infected primary teeth, *J Dent Child* 54:30–34, 1987.
27. Rifkin A: A simple, effective, safe technique for the root canal treatment of abscessed primary teeth, *J Dent Child* 47: 435–441, 1980.
28. Rifkin A: The root canal treatment of abscessed primary teeth—a three to four year follow-up, *J Dent Child* 49: 428–431, 1982.
29. Nurko C, García-Godoy F: Evaluation of the calcium hydroxide/iodoform paste (Vitapex) in root canal therapy for primary teeth, *J Clin Pediatr Dent* 23:289–294, 1999.
30. American Academy of Pediatric Dentistry: Special issue: reference manual 2013-2014, *Pediatr Dent* 35(6 suppl):235–242, 2013.
31. Chen JW, Jorden M: Materials for primary tooth pulp treatment: the present and the future, *Endo Topics* 23:41–49, 2012.
32. Herman B: *Organic Root Canal Treatment*, Frankfurt, Germany, 1936, W Kramer.
33. Doyle WA, et al.: Formocresol versus calcium hydroxide in pulpotomy, *J Dent Child* 29:86–97, 1962.
34. Fuks AB, et al.: Pulp response to ferric sulfate, diluted formocresol and IRM in pulpotomized primary baboon teeth, *J Dent Child* 64:254–259, 1997.
35. Fuks AB, et al.: Ferric sulfate versus dilute formocresol in pulpotomized primary molars: long-term follow-up, *Pediatr Dent* 19:327–330, 1997.
36. Casas MJ, et al.: Two-year outcomes of primary molar ferric sulfate pulpotomy and root canal therapy, *Pediatr Dent* 25(2):97–102, 2003.
37. Celik B, et al.: A randomized trial of mineral trioxide aggregate cements in primary tooth pulpotomies, *J Dent Child* 80(3):126–132, 2013.
38. Dickey DM, et al.: Pulp reactions to a calcium hydroxyapatite in monkeys, *J Dent Res* 59(Spec Iss A):360, 1980 (abstract 371).
39. Ibarra AJ: *Pulp reactions to a synthetic hydroxyapatite and chlorhexidine in monkeys [Master's thesis]*, Indianapolis, 1980, Indiana University School of Dentistry.
40. Fadavi S, et al.: Freeze-dried bone in pulpotomy procedures in monkeys, *J Pedod* 13:108–122, 1989.
41. Thomas GP, et al.: Histologic study of pulp capping using chlorhexidine in dogs, *NDA J* 46:17–20, 1995.
42. Prabhu NT, Munshi AK: Clinical, radiographic and histological observations of the radicular pulp following "feracrylum" pulpotomy, *J Clin Pediatr Dent* 21:151–156, 1997.
43. Higashi T, Okamoto H: Influence of particle size of calcium phosphate ceramics as a capping agent on the formation of a hard tissue barrier in amputated dental pulp, *J Endod* 22: 281–283, 1996.
44. Yoshimine Y, Maeda K: Histologic evaluation of tetracalcium phosphate–based cement as a direct pulp-capping agent, *Oral Surg Oral Med Oral Pathol Oral Radiol Endod* 79:351–358, 1995.
45. Cox CF, et al.: Biocompatibility of primer, adhesive and resin composite systems on non-exposed and exposed pulps of non-human primate teeth, *Am J Dent* 11(Spec Iss):S55–S63, 1988.
46. Cox CF, Suzuki S: Re-evaluating pulp protection: calcium hydroxide liners vs. cohesive hybridization, *J Am Dent Assoc* 125:823–831, 1994.
47. Pameijer CH, Stanley HR: The disastrous effects of the "total etch" technique in vital pulp capping in primates, *Am J Dent* 11(Spec Iss):S45–S54, 1988.
48. Ford TR, et al.: Using mineral trioxide aggregate as a pulp capping material, *J Am Dent Assoc* 127:1491–1494, 1996.
49. Rutherford B, Fitzgerald M: A new biological approach to vital pulp therapy, *Crit Rev Oral Biol Med* 6:218–229, 1995.
50. Jepsen S, et al.: Recombinant human osteogenic protein-1 induces dentin formation: an experimental study in miniature swine, *J Endod* 23:378–382, 1997.
51. Calland JW, et al.: Human pulp cells respond to calcitonin gene–related peptide in vitro, *J Endod* 23:485–489, 1997.
52. Ranly DM: Pulpotomy therapy in primary teeth: new modalities for old rationales, *Pediatr Dent* 16:403–409, 1994.
53. Sabbarini J, et al.: Histological evaluation of enamel matrix derivative as a pulpotomy agent in primary teeth, *Pediatr Dent* 29(6):475–479, 2007.
54. Sabbarini J, et al.: Comparison of enamel matrix derivative versus formocresol as pulpotomy agents in the primary dentition, *J Endod* 34(3):284–287, 2008.
55. Ruemping DR, et al.: Electrosurgical pulpotomy in primates—a comparison with formocresol pulpotomy, *Pediatr Dent* 5:14–18, 1983.
56. Shaw DW, et al.: Electrosurgical pulpotomy: a 6-month study in primates, *J Endod* 13:500–505, 1987.
57. Mack RB, Dean JA: Electrosurgical pulpotomy: a retrospective human study, *J Dent Child* 60:107–114, 1993.
58. Dean J, et al.: Comparison of electrosurgical and formocresol pulpotomy procedures in children, *Int J Paediatr Dent* 12:177–182, 2002.
59. Rivera N, et al.: Pulpal therapy for primary teeth: formocresol vs electrosurgery: a clinical study, *J Dent Child* 70(1):71–73, 2003.
60. Fishman SA, et al.: Success of electrofulguration pulpotomies covered by zinc oxide and eugenol or calcium hydroxide: a clinical study, *Pediatr Dent* 18:385–390, 1996.
61. Shoji S, et al.: Histopathological changes in dental pulps irradiated by CO_2 laser: a preliminary report on laser pulpotomy, *J Endod* 11:379–384, 1985.

62. Wilkerson MK, et al.: Effects of the argon laser on primary tooth pulpotomies in swine, *J Clin Laser Med Surg* 14:37–42, 1996.
63. Moritz A, et al.: The CO_2 laser as an aid in direct pulp capping, *J Endod* 24:248–251, 1998.
64. De Coster P, et al.: Laser-assisted pulpotomy in primary teeth: a systematic review, *Int J Paediatr Dent* 23:389–399, 2013.
65. Fuks AB: Vital pulp therapy with new materials for primary teeth: new directions and treatment perspectives, *Pediatr Dent* 30(3):211–219, 2008.
66. Lin P-Y, et al.: Primary molar pulpotomy: a systematic review and network meta-analysis, *J Dent* 42(9):1060–1077, 2014.
67. Dunston B, Coll JA: A survey of primary tooth pulp therapy as taught in US dental schools and practiced by diplomates of the American Board of Pediatric Dentistry, *Pediatr Dent* 30(1):42–48, 2008.
68. Watts A, Paterson RC: Bacterial contamination as a factor influencing the toxicity of materials to the exposed dental pulp, *Oral Surg* 64:466–474, 1987.

CHAPTER 14

Gingivitis and Periodontal Disease

▲ Vanchit John, James A. Weddell, Daniel E. Shin, and James E. Jones

For additional resources, please visit the evolve website.

CHAPTER OUTLINE

ERUPTION GINGIVITIS
DENTAL PLAQUE–INDUCED GINGIVITIS
ALLERGY AND GINGIVAL INFLAMMATION
ACUTE GINGIVAL DISEASE
- Herpes Simplex Virus Infection
- Recurrent Aphthous Ulcer (Canker Sore)
- Necrotizing Ulcerative Gingivitis (Vincent Infection)
- Acute Candidiasis (Thrush, Candidosis, Moniliasis)
- Acute Bacterial Infections

CHRONIC NONSPECIFIC GINGIVITIS
CHLORHEXIDINE AS A THERAPEUTIC PLAQUE CONTROL AGENT
GINGIVAL DISEASES MODIFIED BY SYSTEMIC FACTORS
- Gingival Diseases Associated with the Endocrine System
- Gingival Lesions of Genetic Origin
- Phenytoin-Induced Gingival Overgrowth
- Ascorbic Acid Deficiency Gingivitis (Scorbutic Gingivitis)

PERIODONTAL DISEASES IN CHILDREN
- Aggressive Periodontitis (Early-Onset Periodontitis)
- Generalized Aggressive Periodontitis
- Localized Aggressive Periodontitis (Localized Juvenile Periodontitis)
- Treatment of Aggressive Periodontitis

PERIODONTITIS AS A MANIFESTATION OF SYSTEMIC DISEASE
- Premature Bone Loss in the Primary Dentition
- Papillon-Lefèvre Syndrome
- Gingival Recession
- Self-Mutilation
- Abnormal Frenum Attachment
- Frenotomy and Frenectomy
- Techniques for Mandibular Frenectomy and Vestibular Depth Increase
- Free Gingival Autograft Procedure
- Lasers

CLINICAL ASSESSMENT OF ORAL CLEANLINESS AND PERIODONTAL DISEASE
- Plaque Control Record
- Periodontal Screening and Recording

EXTRINSIC STAINS AND DEPOSITS ON TEETH
- Green Stain
- Orange Stain
- Black Stain
- Removal of Extrinsic Stains
- Pigmentation Caused by Stannous Fluoride Application

CALCULUS

The gingiva is the part of the oral mucous membrane that covers the alveolar processes and the cervical portions of the teeth. It has been traditionally divided into free and attached gingiva. The free gingiva is the tissue coronal to the bottom of the gingival sulcus. The attached gingiva extends apically from the free gingival groove to the mucogingival junction.

The gingival tissues are normally light pink, although the color may be related to the complexion of the person, the thickness of the tissue, and the degree of keratinization. The gingival color of the young child may be more reddish due to increased vascularity and thinner epithelium. The surface of the gingiva of a child appears less stippled or smoother than that of an adult. In the healthy adult, the marginal gingiva has a sharp, knifelike edge. During the period of tooth eruption in the child, however, the gingivae are thicker and have rounded margins due to the migration and cervical constriction of the primary teeth.

Delaney reports probing depths around primary teeth to be approximately 2 mm, with the facial and lingual probe sites shallower than the proximal sites.[1] The periodontal ligament in children is wider than that in adults. The width of the attached gingiva is narrower in the mandible than in the maxilla, and both widths increase with the transition from the primary to permanent dentition in the child. The alveolar bone surrounding the primary dentition demonstrates fewer trabeculae, less calcification, and larger marrow spaces.

Recent recognition that periodontal disease may have its origins in childhood has led dentists to be more aggressive in treatment. Studies confirm a high prevalence of gingival inflammation in children. Periodontal conditions that progress rapidly and result in the loss of primary and permanent teeth have been noted with increased frequency.[2] Therefore the American Academy of Pediatric Dentistry's recommendations for children and adolescents include placing greater emphasis on the prevention, early diagnosis, and treatment of gingival and periodontal disease in children.[3] By the establishment of excellent oral hygiene habits in children, which will carry over to adulthood, the risk of periodontal disease is lowered.

Gingivitis is inflammation involving only the gingival tissues surrounding the tooth. Microscopically, it is

Dentlearn.ir

characterized by the presence of an inflammatory exudate and edema, some destruction of collagenous gingival fibers, and ulceration and proliferation of the epithelium facing the tooth and attaching the gingiva to it. Numerous studies indicate that marginal gingivitis is the most common form of periodontal disease and starts in early childhood.

Severe gingivitis is relatively uncommon in children, although numerous surveys have shown that a large portion of the pediatric population has mild gingivitis. The major etiologic factors associated with gingivitis and more significant periodontal disease are uncalcified and calcified bacterial plaque. However, gingivitis rarely progresses to periodontitis in the preschool and grade school child.

Bacterial plaque, which is composed of soft bacterial deposits that adhere firmly to the teeth, is considered to be a complex, metabolically interconnected, highly organized bacterial system consisting of dense masses of microorganisms embedded in an intermicrobial matrix (biofilm). In sufficient concentration it can disturb the host-parasite relationship and cause dental caries and periodontal disease.

Eastcott and Stallard have observed that plaque begins to form within 2 hours after the teeth are brushed.[4] Coccal forms of bacteria appear first on a thin fenestrated pellicle (organic bacteria-free film deposited on the tooth surface). The surface is completely covered with a smooth material 3 hours after teeth are brushed. Within 5 hours, plaque microcolonies develop, apparently by cell division. Between 6 and 12 hours the covering material becomes thinner and is reduced to discontinuous small scattered areas. About 30% of the cocci are in various stages of division by 24 hours. Rod-shaped bacteria appear for the first time in the 24-hour-old plaque. Within 48 hours the surface of the plaque is covered with a mass of rods and filaments.

Dental calculus, which is considered to be a calcified dental plaque, is discussed later in the chapter. It is classified as supragingival or subgingival, depending on its location on the tooth. Supragingival calculus presents as hard, firmly adherent masses on the enamel of teeth, whereas subgingival calculus is found as a concretion on the tooth in the confines of the periodontal pocket. The surface of dental calculus is always covered by an uncalcified plaque. Calculus is an important factor in the development of gingival and periodontal disease.

Suomi and colleagues, in a study of approximately 1700 children from 9 to 14 years of age, found that a relatively

calculus (both supragingival and subgingival).[5] From 56% to 85% of the children in the various age, gender, and

ings of this study indicated that most children from 9 to 14 years of age who are of low socioeconomic status would benefit from inclusion in a preventive periodontal disease program based on the improvement of oral hygiene.

ERUPTION GINGIVITIS

A transitory type of gingivitis is often observed in young children when the primary teeth are erupting. This gingivitis, often localized and associated with difficult eruption, subsides after the teeth emerge into the oral cavity.

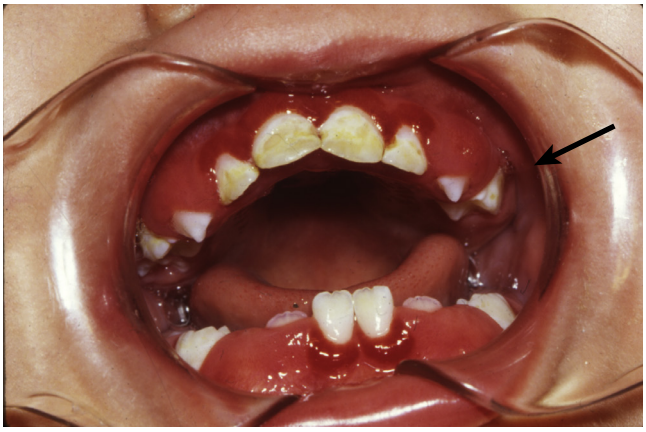

Figure 14-1 Mild inflammation *(arrow)* is evident in the tissue partially covering the crown of the erupting first permanent molar.

Weddell and Klein conducted a study to determine the

6 and 36 months of age.[6] The children, patients of pediatricians in the Indianapolis area, had been born in the area, which has a fluoridated water supply. Among 299 white children, gingivitis was present in 13% of those from 6 to 17 months of age, 34% of those in the 18- to 23-month

study because of the inconsistency of their gingival colors. The gingivitis observed by Weddell and Klein was, for the most part, eruption gingivitis. Nevertheless, their findings support the view that an oral hygiene program should be initiated by parents when the child is very young.

The greatest increase in the incidence of gingivitis in

the permanent teeth begin to erupt. This increase in gingivitis apparently occurs because the gingival margin receives no protection from the coronal contour of the tooth during the early stage of active eruption, and the continual impingement of food on the gingivae exacerbates the inflammatory process.

Food debris, materia alba, and bacterial plaque often collect around and beneath the free gingival tissue, partially cover the crown of the erupting tooth, and cause the development of an inflammatory process (Fig. 14-1). This inflammation is most commonly associated with the eruption of the first and second permanent molars, and the condition can be painful and can develop into pericoronitis or a pericoronal abscess. Mild eruption gingivitis requires no treatment other than improved oral hygiene. Painful pericoronitis may be helped when the area is irrigated with a counterirritant, such as Peroxyl (Colgate-Palmolive Co., New York, New York, United States). Pericoronitis accompanied by swelling and lymph node involvement should be treated with antibiotic therapy.

DENTAL PLAQUE–INDUCED GINGIVITIS

The degree of dental cleanliness and the condition of the gingival tissues in children are related. Horowitz and associates observed significant improvements in the gingivitis

Dentlearn.ir



Figure 14-2 Gingivitis resulting from poor oral hygiene and reduced function in the area. A painful second primary molar has interfered with normal function on this side of the mouth.

scores of schoolchildren after the initiation of a supervised daily plaque removal program.[7] Children in grades 5 to 8 participated in the program, and successful results were maintained during three school years. The mean gingivitis scores were reduced 40% among girls and 17% among boys during the program period, whereas the children in the con-

for the period of the study. Adequate mouth hygiene and cleanliness of the teeth are related to frequency of brushing and the thoroughness with which bacterial plaque is removed from the teeth. Favorable occlusion and the chewing of coarse, detergent-type foods, such as raw carrots, celery, and apples, have a beneficial effect on oral cleanliness.

In a study of 2876 children residing in a naturally fluoridated area, Murray confirmed the high prevalence of gingivitis in the young population.[8] He observed that inflammation of one or more papillae or margins associated with the incisor and canine teeth occurred in 90% of children from 8 to 18 years of age. He also pointed to the importance of a good standard of oral cleanliness in reducing gingivitis and, thereby, in preventing the progression of the disease in later life.

Gingivitis associated with poor oral hygiene is usu-

Early gingivitis is quickly reversible and can be treated with good oral prophylactic treatment and instruction in toothbrushing and flossing techniques to keep the teeth free of bacterial plaque (Figs. 14-2 and 14-3, *A* and *B*). Gingivitis is generally less severe in children than in adults with similar plaque levels.

ALLERGY AND GINGIVAL INFLAMMATION

Matsson and Moller studied the degree of seasonal variation of gingival inflammation in children with allergies to birch pollen.[9] Thirty-four children who were allergic were examined during two successive spring seasons and the one intervening fall. Age- and gender-matched controls were also examined in the fall. Gingival inflammation and the presence or absence of plaque were recorded, and



Figure 14-3 **A,** Localized gingival inflammation and recession associated with minimal plaque accumulation on mandibular right central incisor. **B,** Gingival health was greatly improved after a thorough plaque removal regimen was initiated at home.

a bleeding/plaque ratio was calculated for each child. The results indicated an enhanced gingival inflammatory reaction in the allergic children during the pollen seasons. Although the authors acknowledge that the significance of gingival reaction during short allergy seasons is difficult to assess, they speculate that patients with complex allergies who have symptoms for longer periods may be at higher risk for more significant adverse periodontal changes.

ACUTE GINGIVAL DISEASE

HERPES SIMPLEX VIRUS INFECTION

Herpes virus causes one of the most widespread viral infections. The primary infection usually occurs in a child younger than 6 years of age who has had no contact with the type 1 herpes simplex virus (HSV-1) and who therefore has no neutralizing antibodies. It is believed that 99% of all primary infections are of the subclinical type. The infection may also occur in susceptible adults who have not had a primary infection (Fig. 14-4).

In some preschool children the primary infection may be characterized by only one or two mild sores on the oral mucous membranes, which may be of little concern to the child or may go unnoticed by the parents. In other children the primary infection may be manifested by acute symptoms (acute herpetic gingivostomatitis). The active

Dentlearn.ir



Figure 14-4 Ulcerated stage of primary herpes in a young adult. Notice the circumscribed confluent areas of inflammation.



Figure 14-5 **A,** Acute herpetic gingivostomatitis on the tongue in a child. **B,** Fiery red gingival tissues are characteristic findings.

symptoms of the acute disease can occur in children with clean mouths and healthy oral tissues. The symptoms of the disease develop suddenly and include, in addition to the fiery red gingival tissues, malaise, irritability, headache, and pain associated with the intake of food and liquids of acidic content. A characteristic oral finding in the acute primary disease is the presence of yellow or white liquid-filled vesicles. In a few days the vesicles rupture and form painful ulcers, 1 to 3 mm in diameter, which are covered with a whitish gray membrane and have a circumscribed area of inflammation (Fig. 14-5, *A* and *B*). The ulcers may be observed on any area of the mucous membrane, including buccal mucosa, tongue, lips, hard and soft palate, and the tonsillar areas. Large ulcerated lesions may occasionally be observed on the palate or gingival tissues or in the region of the mucobuccal fold. This distribution makes the differential diagnosis more difficult. An additional diagnostic criterion is a fourfold rise of serum antibodies to HSV-1. The lesion culture also shows positive results for HSV-1.

Treatment of acute herpetic gingivostomatitis in children, which runs a course of 10 to 14 days, should include specific antiviral medication and provision for the relief of the acute symptoms so that fluid and nutritional intake can be maintained. The application of a mild topical anesthetic, such as dyclonine hydrochloride (0.5%) (Dyclone), before mealtime temporarily relieves the pain and allows the child to eat soft food. Another topical anesthetic, lidocaine (Xylocaine Viscous), can be prescribed for the child who can hold 1 teaspoon of the anesthetic in the mouth for 2 to 3 minutes and then expectorate the solution. Schaaf recommends, as an alternative to the anesthetic, a mixture of equal parts of diphenhydramine (Benadryl) elixir and Kaopectate.[10] This material can be compounded by the pharmacist or mixed by the parent. Diphenhydramine has mild analgesic and anti-inflammatory properties, whereas the kaolin-pectin compound coats the lesions. Because fruit juices are usually irritating to the ulcerated area, ingestion of a vitamin supplement during the course of the disease is indicated.

Although the treatments described may be useful, they are only palliative. The mainstay of definitive therapy is regular doses of specific systemic antiviral medication combined with systemic analgesics (acetaminophen or ibuprofen) during the course of the disease. The antiviral medications currently available are acyclovir, famciclovir, and valacyclovir. These medications inhibit viral replication in cells infected with the virus. Acyclovir (Zovirax; GlaxoSmithKline, Inc., Research Triangle Park, North Carolina, United States) should be administered in five daily doses to equal 1000 mg per day for 10 days. Acyclovir is available in capsules or suspension. Acyclovir therapy has been successfully used in infants and children.[11] Famciclovir (Famvir; Novartis Pharmaceuticals Corporation, East Hanover, New Jersey, United States) and valacyclovir (Valtrex; GlaxoSmithKline, Inc.) are newer and possibly more effective antiviral agents, but their use in pediatric populations has not yet been studied. The Food and Drug Administration (FDA)-approved treatment for recurrent herpes simplex labialis (RHL) in children 12 years of age and older is valacyclovir 2 g, initially, and 2 g 12 hours later. Famciclovir (one 1500-g dose) with prodrome (at the earliest sign of the lesions) is an FDA-approved treatment for herpes simplex labialis in adults, but it has not been studied in children. Bed rest and isolation from other children in the family are also recommended. Hale and colleagues reported an outbreak of herpes simplex infec-

orphanage.[12] The children ranged in age from 11 to 35 months. In three of the children, a mild fever of brief duration and small oral lesions were the only signs of infection; these might easily have been missed in a situation different from that of an institutional study. The remaining children had symptoms of acute infection.

After the initial primary attack during early childhood, the herpes simplex virus becomes inactive and resides in sensory nerve ganglia. The virus often reappears later as the familiar cold sore or fever blister, usually on the outside of the lips (Fig. 14-6, *A-C*). Thus the disease has been commonly referred to as *recurrent herpes labialis* (RHL). However, approximately 5% of recurrences are intraoral. With the recurring attacks, the sores develop in essentially the same area. Kleinman and colleagues published the results of a national survey of 39,206 schoolchildren aged from 5 to 17 years.[13] A history of RHL was reported by 33% of the children.

The recurrence of the disease has often been related to conditions of emotional stress and lowered tissue resistance resulting from various types of trauma. Excessive exposure to sunlight may be responsible for the appearance of the recurrent herpetic lesions on the lip. Use of sunscreen can prevent sun-induced recurrences. Lesions on the lip may also appear after dental treatment and may be related to irritation from rubber dam material or even routine daily procedures.

The most effective treatment for these recurrences is the use of the specific systemic antiviral medications already discussed in connection with the treatment of the primary herpetic infection (acyclovir, famciclovir, and valacyclovir). The medication should be taken immediately after the prodromal symptom of recurrence. The daily dosages are the same as those for the primary infection, but the course of treatment is usually 5 days instead of 10. One-day therapy for RHL is a total of 4 g valacyclovir given in two divided doses: 2 g initially with the prodrome, followed 12 hours later with another 2 g. This regimen has been approved for children 12 years of age and older. Another topical antiviral agent, penciclovir cream (Denavir; Novartis Consumer Health, Inc., Parsippany, New Jersey, United States), may be applied to perioral lesions but should not be applied to intraoral lesions. The penciclovir cream and systemic antivirals should not be prescribed for concurrent use. The penciclovir cream can be applied for 4 days, every 2 hours while the patient is awake, and it is approved for use in children 12 years of age and older. Topical 5% acyclovir cream may be prescribed for use 5 times daily for 4 days in children 12 years of age and older.

Other remedies for herpes simplex infection also include the amino acid lysine. The oral therapy is based on lysine's antagonistic effect on another amino acid, arginine. Griffith and associates conducted an initial study in which 250 patients were given daily lysine doses of 1000 mg and were told to avoid eating arginine-rich foods, such as chocolate and nuts.[14] The lysine therapy was continued until the patients had been lesion-free for 6 months. L-Lysine monohydrochloride is available commercially in capsule form or in tablets containing 100 or 312 mg of L-Lysine (General Nutrition Corp., Pittsburgh, Pennsylvania, United States). The patients reported that pain disappeared overnight in virtually every instance. New vesicles failed to appear, and a majority considered the resolution of the lesions to be more rapid than in the past. There was also a reduction in frequency of occurrences in some patients. Griffith and colleagues concluded that improper food selection may make adequate lysine intake precarious for some persons.[14] Ingestion of cereals, seeds, nuts, and chocolate would produce a high arginine/lysine ratio and favor the development of herpetic lesions. Similar results are obtained when arginine is

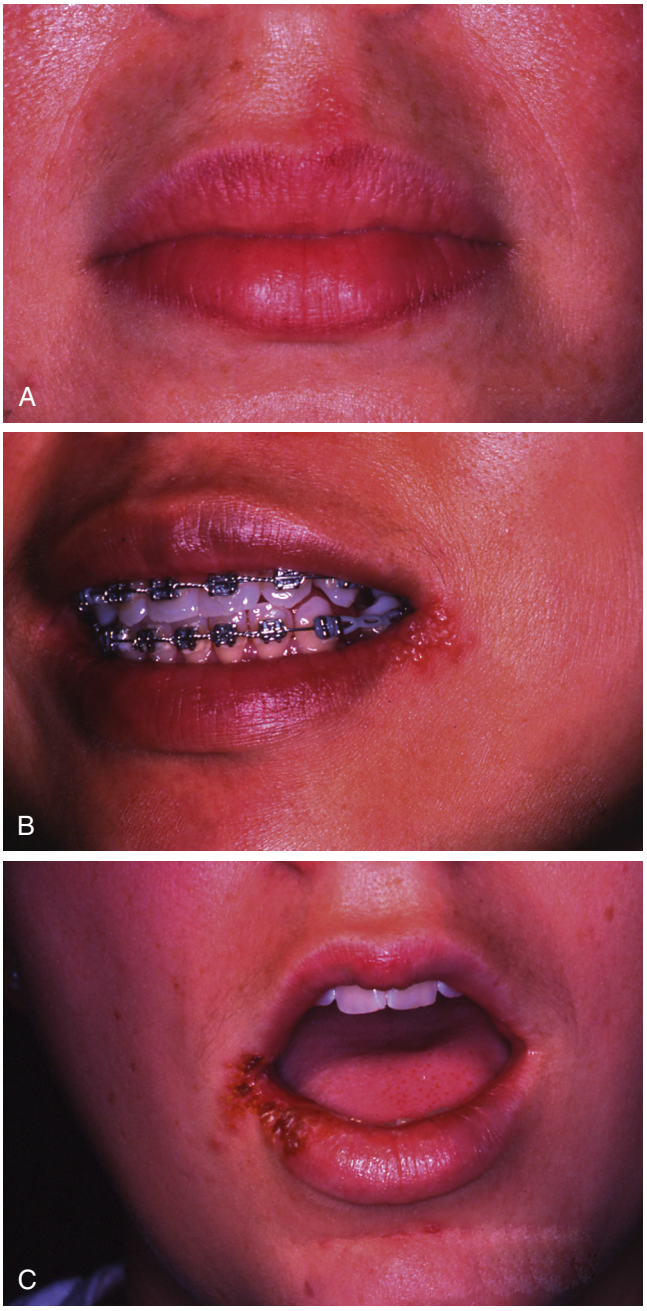

Figure 14-6 Recurrent herpes labialis. **A,** Early vesicular lesions. **B,** Mature vesicular lesion. **C,** Appearance of herpes labialis after rupture of vesicles and crusting of the lesion. (Courtesy of Dr. Susan L. Zunt.)

Dentlearn.ir



Figure 14-7 Primary herpetic infection involving the dorsal surface of the thumb of a 3-year-old child. An acute primary infection was present in the mouth.



Figure 14-8 Evidence of the development of a recurrent aphthous ulcer in the mucobuccal fold above the primary canine. An area of inflammation and vesicle formation is apparent (*arrow*).

added to the medium in the laboratory to induce herpes proliferation. The avoidance of these foods, coupled with the selection of foods with adequate lysine, such as dairy products and yeast, should discourage herpes infection. These authors postulate that this may explain the low incidence of herpes in infants before they are weaned from a predominantly milk diet. Prophylactic lysine is apparently useful in managing selected cases of RHL if serum lysine is maintained at adequate concentrations.

Brooks and associates have reported that dentists are frequently exposed to HSV-1.[15] They evaluated the risk of infection with the virus by assessing disease experience, comparing the individual's history with the results of a complement fixation or antibody titration test, or both. dental faculty members, and 23 staff members. Although almost all of those with a history of herpetic infection showed antibodies to HSV-1, only 57% of those lacking such a history had neutralizing antibody titers of 1:10 or higher. This finding suggests that a significant number of practicing dentists risk primary herpetic infection. Consequently, dentists and dental auxiliaries without a history of herpetic lesions might benefit from serologic testing. Considering the occupational disability that often accompanies HSV-1 infection of the finger or eye, effective barrier protection for health professionals is important.

Primary herpetic infection has been observed on the dorsal surface of the thumb of a pediatric patient (Fig. 14-7). The child was a thumb sucker, and the acute primary infection was present in the mouth. The dorsal surface of the thumb, which rested on the mandibular incisor teeth, apparently became irritated, and an inoculation of the virus took place. The oral condition and the lesions on the thumb subsided in 2 weeks.

RECURRENT APHTHOUS ULCER (CANKER SORE)

The recurrent aphthous ulcer (RAU)—also referred to as recurrent aphthous stomatitis (RAS)—is a painful ulceration on the unattached mucous membrane that occurs in school-aged children and adults. The peak age for RAU is between 10 and 19 years of age. It has been reported to be the most common mucosal disorder in people of all ages and races in the world. This disorder, according to definitions adopted in the epidemiologic literature, is characterized by recurrent ulcerations on the moist mucous membranes of the mouth, in which both discrete and confluent lesions form rapidly in certain sites and feature a round to oval crateriform base, raised reddened margins, and pain. They may appear as attacks of minor or single, major or multiple, or herpetiform lesions. They may or may not be associated with ulcerative lesions elsewhere.[16] In the national survey reported by Kleinman and colleagues, a history of RAU was reported by 37% of the schoolchildren and occurred approximately three times more often in white than in African-American schoolchildren.[13] Ship and colleagues reported the prevalence estimates of RAU to range between 2% and 50%, with most estimates between 5% and 25% (among medical and dental students, estimated prevalence is between 50% and 60%).[17] Lesions persist for 4 to 12 days and heal uneventfully, leaving scars only rarely and only in cases of unusually large lesions. The description of RAU frequently includes the term *canker sores* (Fig. 14-8). The major form (RAS) is less common and has been referred to as *periadenitis mucosa necrotica recurrens* and *Sutton disease*. RAS has been associated with other systemic diseases: PFAPA (periodic fever, aphthous stomatitis, pharyngitis, adenitis), Behçet disease, Crohn disease, ulcerative colitis, celiac disease, neutropenia, immunodeficiency syndromes, Reiter's syndrome, systemic lupus erythematosus, and MAGIC (mouth and genital ulcers with inflamed cartilage) syndrome.

The cause of RAU is unknown. Local and systemic conditions along with a genetic predisposition and immunologic and infectious microbial factors have been identified as potential causes. The condition may be caused by a delayed hypersensitivity to the L form of *Streptococcus sanguis,* which is a common constituent of the normal oral microbiota of humans. It is also possible that the lesions are caused by an autoimmune reaction of the oral epithelium. Epidemiologic studies by Ship and colleagues provide evidence for this hypothesis.[17] Analysis of these data

Dentlearn.ir

indicates that both RHL and RAU may be produced by the same mechanism, despite the known infectious agent of RHL and the absence of any known virus for RAU. Scully and Porter reported strong associations with interleukin genotypes.[16]

Local factors include trauma, allergy to toothpaste constituents (sodium lauryl sulfate), and salivary gland dysfunction. In a review of the clinical problem, Antoon and Miller suggested that minor trauma is a common precipitating factor, accounting for as many as 75% of the episodes.[18] Injuries caused by cheek biting and minor facial irritations are probably the most common precipitating factors. Nutritional deficiencies are found in 20% of persons with aphthous ulcers. The clinically detectable deficiencies include deficiencies of iron, vitamin B_{12}, and folic acid. Stress may prove to be an important precipitating factor in students in professional schools and military personnel.

According to Greenspan and colleagues, either nonspecific factors (trauma, food allergy) or specific factors (bacterial or viral infection) may trigger a temporary imbalance in various cell subpopulations.[19] This imbalance could then upset immune regulation and result in local destruction of the oral epithelium and thus ulceration. Ship and colleagues also suggested herpes simplex virus, human herpesvirus type 6, cytomegalovirus, Epstein-Barr virus, and varicella-zoster virus as possible causes of RAS.[17] Current treatment is focused on promoting ulcer healing, reducing ulcer duration and patient pain, maintaining the patient's nutritional intake, and preventing or reducing the frequency of recurrence of the disease.

Numerous treatments have been recommended for RAU, but a completely successful therapy has not been found. Topical anti-inflammatory and analgesic medicines and/or systemic immunomodulatory and immunosuppressive agents have been used for RAU. The primary line of treatment uses topical gels, creams, and ointments as anti-inflammatory agents. Currently, a topical corticosteroid (e.g., 0.5% fluocinonide, 0.025% triamcinolone, or 0.5% clobetasol) is applied to the area with a mucosal adherent (e.g., isobutyl cyanoacrylate, Orabase). For example, the application of triamcinolone acetonide (Kenalog in Orabase) to the surfaces of the lesions before meals and before sleeping may also be helpful. Binnie and colleagues reported that an anti-inflammatory and antiallergic medication in the form of a topical paste is effective in reducing pain and accelerating healing of RAU ulcers.[20] The active ingredient in the paste is 5% amlexanox (Aphthasol; Access Pharmaceuticals, Dallas, Texas, United States). The paste is applied to the ulcer 4 times daily, after meals and at bedtime, until the ulcer heals. Zilactin (Zila Pharmaceuticals, Phoenix, Arizona, United States), a topical paste with hydroxypropyl cellulose film, has also been used to adhere to the mucosa and cover the ulcer while providing pain relief for an extended period of time. Occlusive topical 2-otylcyanoacrylate adheres for 6 hours. Aloe vera freeze-dried gel extract adheres and forms an occlusive protective patch. In severe cases oral prednisone has been prescribed.

Topical rinses have also been helpful for the relief of RAU. Sucralfate has proved useful by its property of coating the affected area. The topical application of tetracycline to the ulcers is often helpful in reducing the pain and in shortening the course of the disease. A mouthwash containing suspension of one of the tetracyclines has been helpful to some, but the mouthwash should not be swallowed. Chlorhexidine (CH) mouthwash has also been known to alleviate the symptoms of RAU. Dexamethasone elixir when swished is useful to treat ulcerations in areas of the mouth that are difficult to access. Meiller and associates have reported that the duration and severity of RAU lesions can be significantly reduced by vigorous twice-daily rinsing with an antimicrobial mouthwash (Listerine Antiseptic; Pfizer Warner Lambert Division, Morris Plains, New Jersey, United States).[21]

NECROTIZING ULCERATIVE GINGIVITIS (VINCENT INFECTION)

The infectious disease commonly referred to as acute necrotizing ulcerative gingivitis (NUG) is rare among preschool children in the United States. The condition occurs occasionally in children from 6 to 12 years old, and is more commonly seen in young adults.

NUG can be easily diagnosed because of the involvement of the interproximal papillae and the presence of a pseudomembranous necrotic covering of the marginal tissue (Fig. 14-9). *Prevotella intermedia*, *Fusobacterium*, *Treponema*, and *Selenomonas* species are several predominant microorganisms that have been found in the microflora of NUG lesions. The clinical manifestations of the disease include inflamed, painful, bleeding gingival tissue, poor appetite, temperature as high as 40°C (104°F), general malaise, and a fetid odor.

The disease responds dramatically within 24 to 48 hours to subgingival curettage, debridement, and the use of mild oxidizing solutions. If the gingival tissues are acutely and extensively inflamed when the patient is first seen, antibiotic therapy is indicated. Improved oral hygiene, the use of mild oxidizing mouthrinses after each meal, and twice-daily rinsing with CH will aid in overcoming the infection.

There should be no difficulty in distinguishing NUG from acute herpetic gingivostomatitis, although the two are sometimes confused. Round ulcers with red areolae on the lips and cheeks are characteristic of herpetic gingivostomatitis. Therapeutic prophylaxis and debridement bring about a favorable response in cases of NUG but not in acute herpetic gingivostomatitis. A therapeutic trial of antibiotics reduces the acute symptoms in NUG but not in the viral infection. Acute herpetic gingivostomatitis is most frequently seen in preschool children, and its onset is rapid, whereas, as stated earlier, NUG rarely occurs

period, usually in a mouth in which irritants and poor oral hygiene are present. On the other hand, acute oral infections initially diagnosed as NUG have frequently been found later to be an oral manifestation of one of the xanthomatoses. The early stages of conditions such as Hand-Schüller-Christian disease and Langerhands cell histiocytosis are associated with many of the symptoms of NUG.

Dentlearn.ir



Figure 14-9 **A,** A rare example of necrotizing ulcerative gingivitis in an 8-year-old boy. **B,** Local treatment and improved oral hygiene produced a dramatic recovery from the infection.

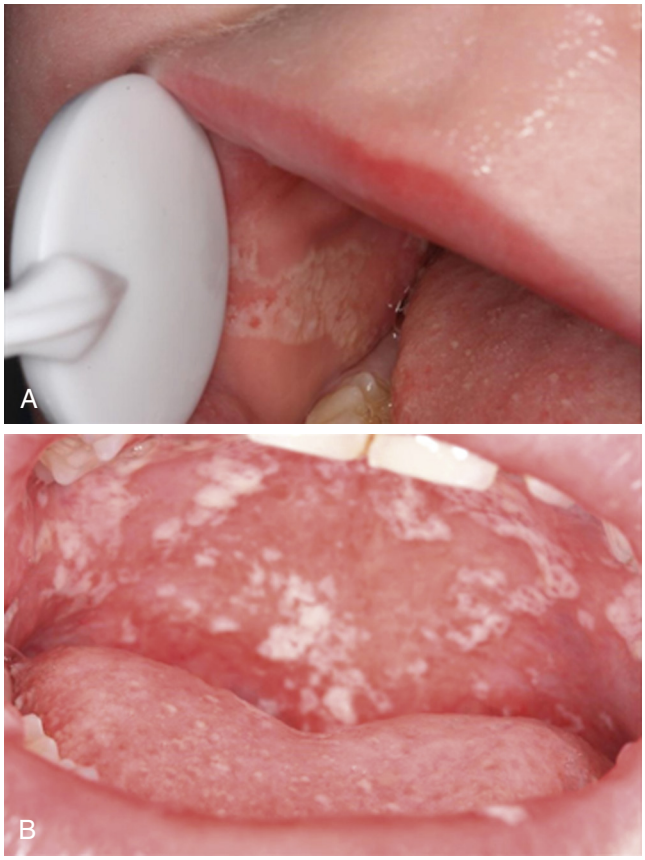

Figure 14-10 **A,** The characteristic appearance of acute candidiasis on the upper and lower lips of a young patient. **B,** The hard and soft palates were also severely affected. The infection was controlled with a 7-day regimen of nystatin.

ACUTE CANDIDIASIS (THRUSH, CANDIDOSIS, MONILIASIS)

Candida (Monilia) albicans is a common inhabitant of the oral cavity but may multiply rapidly and cause a pathogenic state when host resistance is lowered. Young children sometimes develop thrush after local antibiotic therapy, which allows the fungus to proliferate. The lesions of oral candidiasis appear as raised, furry white patches, which can be removed easily to produce a bleeding underlying surface (Fig. 14-10, *A* and *B*). Neonatal candidiasis, contracted during passage through the vagina and erupting clinically during the first 2 weeks of life, is a common occurrence. This infection is also common in immunosuppressed patients (see Chapter 26).

Antifungal antibiotics control thrush. For infants and very young children, a suspension of 1 mL (100,000 units) of nystatin (Mycostatin) may be dropped into the mouth for local action 4 times a day. Nystatin is nonirritating and nontoxic. Clotrimazole suspension (10 mg/mL), 1 to 2 mL applied to affected areas 4 times daily, is an effective antifungal medication. Systemic fluconazole suspension (10 mg/mL) is safe to use in infants at a total dosage of up to 6 mg/kg/day. For children old enough to manage solid medications allowed to dissolve in the mouth, clotrimazole troches or nystatin pastilles are recommended because the therapeutic agent remains in the saliva longer than with the liquid medication. For children old enough to swallow, systemic fluconazole (100-mg tablets) in a 14-day course may be prescribed when the infection has not responded to topical antifungal agents.

ACUTE BACTERIAL INFECTIONS

The prevalence of acute bacterial infection in the oral cavity is unknown. Acute streptococcal gingivitis is an example of this type of infection. It is characterized by enlarged papilla, gingival abscesses, and painful, erythematous gingiva that bleed easily. Cultures show a predominance of hemolytic streptococci. Acute infections of this type may be more common than was previously realized. The diagnosis is difficult to make, however, without extensive laboratory tests. Broad-spectrum antibiotics are recommended if the infection is believed to be bacterial in origin. Improved oral hygiene is important in treating the infection. As with any acute microbial oral infection, CH mouthrinses are also appropriate.

CHRONIC NONSPECIFIC GINGIVITIS

A type of gingivitis commonly seen during the preteenage and teenage years is often referred to as *chronic nonspecific gingivitis*. The chronic gingival inflammation may be localized to the anterior region, or it may be more generalized. Although the condition is rarely painful, it may persist for long periods without much improvement (Fig. 14-11).



Figure 14-11 Chronic nonspecific gingivitis. The cause of this type of gingivitis is complex, and it often persists for prolonged periods without significant improvement.



Figure 14-12 Fiery red gingival lesions essentially limited to the anterior labial tissues. Only minimum local deposits

Glauser and colleagues observed an unusual gingivitis in Navajo Indians between 12 and 18 years of age, similar to that seen in Figure 14-12, in which the fiery red gingival lesion was not accompanied by enlarged interdental labial papillae or closely associated with local irritants.[22] The gingivitis showed little improvement after a prophylactic treatment. The age of the patients involved and the prevalence of the disease in girls suggested a hormonal imbalance as a possible factor. Histologic examination of tissue sections and the use of special stains ruled out a bacterial infection. Inadequate oral hygiene, which allows for food impaction and the accumulation of materia alba and bacterial plaque, is undoubtedly the major cause of this chronic type of gingivitis.

The cause of chronic gingivitis is complex and is considered to be based on a multitude of local and systemic factors. Because dietary inadequacies are often found in

nonspecific type.

vey described in Chapter 8 is an important diagnostic aid. Insufficient quantities of fruits and vegetables in the diet, leading to a subclinical vitamin deficiency, may be an important predisposing factor. An improved dietary intake of vitamins and the use of multiple-vitamin supplements will improve the gingival condition in many children.

Malocclusion, which prevents adequate function, and crowded teeth, which make oral hygiene and plaque removal more difficult, are also important predisposing factors in gingivitis. Caries lesions, with irritating sharp margins and faulty restorations with overhanging margins (both of which cause food accumulation) also favor the development of the chronic type of gingivitis. Therefore the placement of dental restorations to restore adequate function and contour of defective teeth after the reduction of acute symptoms is an equally important treatment consideration.

A wide variety of local irritants can produce a hyperplastic type of gingivitis in children and young adults. The irritation to the gingival tissue produced by mouth breathing is often responsible for the development of the chronic hyperplastic form of gingivitis, particularly in the maxillary arch. All these factors should be considered contributory to chronic nonspecific gingivitis and should be corrected in the treatment of the condition. The importance of thorough daily oral hygiene must be emphasized repeatedly to the patients.

CHLORHEXIDINE AS A THERAPEUTIC PLAQUE CONTROL AGENT

CH is a cationic bisbiguanide with broad antimicrobial activity that acts by rupturing cell membranes. It has been used commonly as an antiseptic skin and wound cleanser for presurgical preparation of the patient and as a handwash and surgical scrub for health care personnel. It has also been added as a preservative to

very dilute concentrations in the peritoneal cavity and urinary bladder. In addition to its broad antimicrobial activity, CH exhibits a unique property known as substantivity, which allows the agent to bind to proteins in human tissues. From there, the agent is slowly released, thereby resulting in a prolonged antimicrobial activity against gram-positive bacteria, gram-negative bacteria, and fungi.

In dentistry, CH has been studied for control of smooth surface caries, for use as a denture disinfectant, and as a plaque control agent. Its use in controlling dental plaque accumulations has received the most attention in dental research. Numerous studies have demonstrated that CH reduces plaque by 50-55% and gingivitis by up to 45%.[23,24] Mouthrinses containing CH have been popular as therapeutic agents in several countries for some time, and in 1986 CH was approved for use in the United States. Two products under the trade names Peridex (Colgate-Palmolive Co.) and PerioGard (Zila Pharmaceuticals) have received FDA approval as prescription agents. These mouthrinses contain 0.12% CH gluconate as the active ingredient. Outside of the United States, CH is offered as a 0.2% solution. However, in a double-blinded, randomized, cross-over study comparing the two different concentrations' antimicrobial effects and clinical efficacies in reducing de novo plaque formation, Quirynen et al. did not find any statistically significant differences between the two.[25]

The widespread use of CH mouthrinses over many years, especially in Europe, has established an excellent safety record. Few adverse side-effects have been reported with CH mouthrinses, but their use has been linked to mouth dryness and burning sensations in some persons due to the alcohol base. An alcohol-free product is marketed under the trade name Gum® Paroex® (Sunstar Americas, Inc., Chicago, Illinois, United States). Generalized staining over long-term use and taste alterations have has been reported. Poorly defined desquamative lesions have been observed after the mouthrinse was used. Allergic reactions to CH are rare. If the rinse is inadvertently swallowed, it has essentially little systemic effect due to poor absorption in the gastrointestinal system.

Löoe and Schiöott reported highly significant inhibition of plaque formation and the prevention of gingivitis with the use of an aqueous solution of 0.2% CH digluconate as a mouthrinse twice daily with swishing for 1 minute.[26] Yankell and associates have shown that dental stain from CH mouthrinse can be significantly reduced with regular use of a tartar-control dentifrice.[27]

It is important to recognize that the beneficial use of CH as a therapeutic mouthrinse should be considered adjunctive to the practice of sound conventional plaque control measures as presented in Chapter 7 and elsewhere in this text. A study by Brecx and colleagues regarding the efficacy of Listerine, Meridol, and CH mouthrinses found CH to be the most effective to supplement habitual mechanical oral hygiene.[28] They also found that a combination of habitual self-performed and nonsupervised oral hygiene with Listerine or Meridol is more beneficial for plaque control than the use of mechanical oral hygiene alone. Its adjunctive use would also seem most appropriate for therapy in cases in which attaining adequate plaque control is more difficult, such as during illness or convalescence after serious injuries.

The rationale to include the use of a daily antimicrobial mouthrinse to the child's and adolescent's oral hygiene regimens when inadequate plaque control exists to control and prevent periodontal disease and deliver antimicrobial agents to mucosal sites harboring bacteria throughout the mouth, thereby complementing plaque control, is widely accepted.[29]

GINGIVAL DISEASES MODIFIED BY SYSTEMIC FACTORS

GINGIVAL DISEASES ASSOCIATED WITH THE ENDOCRINE SYSTEM

Puberty gingivitis is a distinctive type of gingivitis that occasionally develops in children in the prepubertal and pubertal period. Cohen, in a study of 270 boys and girls



Figure 14-13 **A,** Puberty gingivitis. The enlargement of the gingival tissues was limited to the mandibular anterior region. **B,** Local treatment resulted in only a slight improvement of the condition. A persistence of the hyperplastic enlargement would indicate the need for gingivoplasty.

largement in the anterior segment occurred with regularity in the prepubertal and premenarcheal period, as well as in pubescence.[30] The gingival enlargement was marginal in distribution and, in the presence of local irritants, was characterized by prominent bulbous interproximal papillae far greater than gingival enlargements associated with local factors. Nakagawa and colleagues found a statistically significant increase in gingival inflammation, sex hormones, and the occurrence of *Prevotella intermedia* in adolescents during puberty.[31]

17 years of age revealed an initially high prevalence of gingivitis that tended to decline with age.[32] In both genders, the prevalence of gingivitis tended to decrease with age. Initially, 89% of 11-year-olds and 92% of 12-year-olds were affected.

The enlargement of the gingival tissues in puberty gingivitis is confined to the anterior segment and may be present in only one arch. The lingual gingival tissue generally remains unaffected (Fig. 14-13, *A* and *B*). Treatment of puberty gingivitis should be directed toward improved oral hygiene, removal of all local irritants, restoration of carious teeth, and dietary changes necessary to ensure an adequate nutritional status. Cohen observed a sharp improvement in gingival inflammation and enlargement after the oral administration of 500 mg of ascorbic acid.[30] However, the improvement did not occur until the vitamin had been taken for approximately 4 weeks.

Diabetes is another endocrine disorder that can adversely affect gingival health. Studies have demonstrated

Dentlearn.ir

that patients with diabetes tend to develop a more pronounced plaque-induced gingival inflammation than do those without diabetes. In a cross-sectional investigation comparing the gingival health of 85 adolescents with insulin-dependent diabetes (IDDM) and 38 healthy controls, De Pommereau and colleagues found that IDDM adolescents suffered significantly more gingival inflammation than did healthy controls, despite having similar plaque scores. A definitive reason for this finding could not be reached; however, the investigators recommended close periodontal monitoring of IDDM children and adolescents.[33]

Severe cases of hyperplastic gingivitis that do not respond to local or systemic therapy should be treated by gingivoplasty. Surgical removal of the thickened fibrotic marginal and interproximal tissue has been found effective. Recurrence of any hyperplastic tissue will be minimal if adequate oral hygiene is maintained.

GINGIVAL LESIONS OF GENETIC ORIGIN

Hereditary gingival fibromatosis (HGF) is characterized by a slow, progressive, benign enlargement of the gingiva. Clinically, the HGF-gingival enlargement is characterized as being of normal color, firm consistency, non-hemorrhagic, and asymptomatic with an equal gender predilection. HGF, which is the most common genetic form of gingival enlargement, usually has an autosomal-dominant mode of inheritance. This rare type of gingivitis has been referred to as *elephantiasis gingivae* or *hereditary hyperplasia* of the gums. The gingival tissues appear normal at birth but begin to enlarge with the eruption of the primary teeth. Although mild cases are observed, the gingival tissues usually continue to enlarge with eruption of the permanent teeth until the tissues essentially cover the clinical crowns of the teeth (Figs. 14-14, *A* and *B*). The dense fibrous tissue often causes displacement of the teeth and malocclusion. The condition is not painful until the tissue enlarges to the extent that it partially covers the occlusal surfaces of the molars and becomes traumatized during mastication.

Zackin and Weisberger described fibromatosis histologically as a moderate hyperplasia of the epithelium, with hyperkeratosis and elongation of the rete pegs.[34] The increase in tissue mass is primarily the result of an increase and thickening of the collagenous bundles in the connective tissue stroma. The tissue shows a high degree of differentiation, and a few young fibroblasts are present (Fig. 14-14, *C*).

Surgical removal of the hyperplastic tissue achieves a more favorable oral and facial appearance. However, hyperplasia can recur within a few months and can return to the original condition within a few years. Although the tissue usually appears pale and firm, the surgical procedure is accompanied by excessive hemorrhage. Therefore quadrant surgery is usually recommended. Brown and colleagues have reported a case in which apically positioned flap surgery and CO_2 laser evaporation were used to reduce the gingival tissue.[35] The importance of excellent plaque control should be stressed to the patient because this delays the recurrence of the gingival overgrowth.

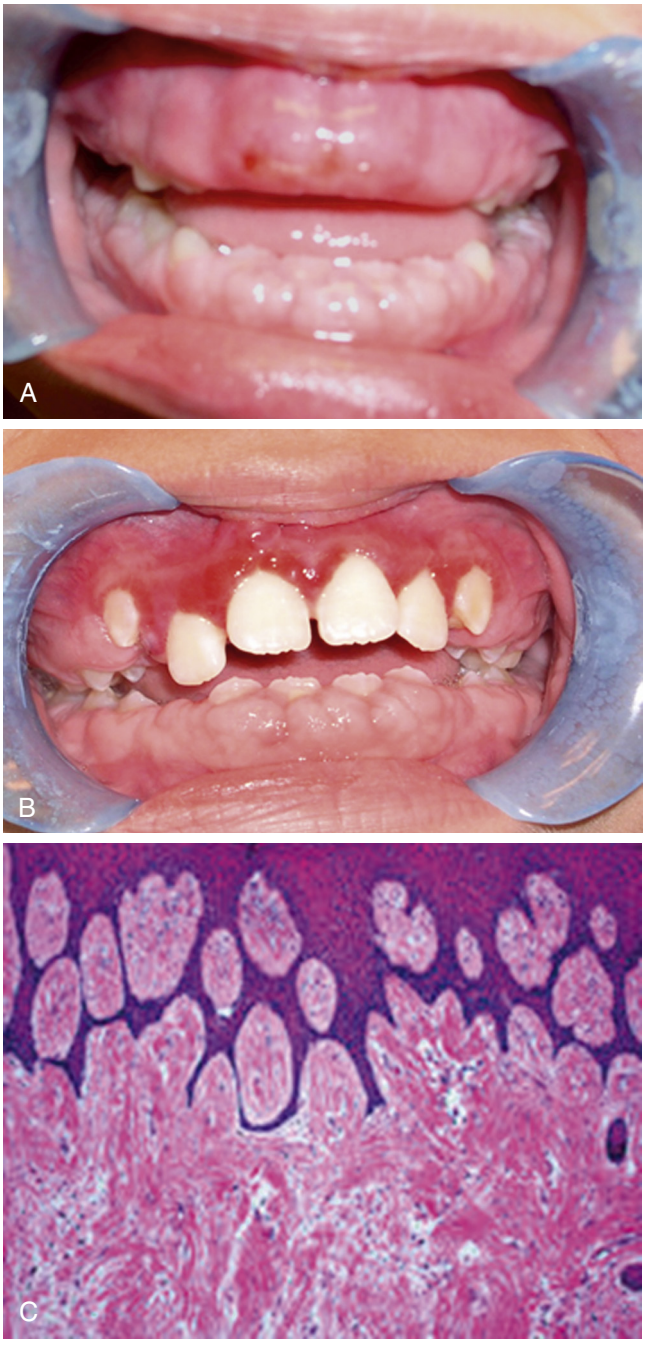

Figure 14-14 **A,** Hereditary gingival fibromatosis in an 11-year-old female. The maxillary anterior gingival tissues completely covered the crowns of teeth #6, 7, 8, 9, 10, and 11. **B,** Clinical presentation approximately 6 weeks after the maxillary teeth were surgically exposed by removal of excessive tissue. Although oral hygiene still needs to improve, the results of the surgical procedure were dramatic. **C,** Histologic specimen of HGF. Note the moderate hyperplasia of the epithelium with elongated rete pegs. The underlying connective tissue is composed of thick, irregularly arranged collagen fibers. (**C,** From Coletta RD, Graner E: Hereditary gingival fibromatosis: a systematic review, *J Periodontol* 77:753-764, 2006.)

Dentlearn.ir

PHENYTOIN-INDUCED GINGIVAL OVERGROWTH

Phenytoin (Dilantin, or diphenylhydantoin), a major anticonvulsant agent used in the treatment of epilepsy, was first introduced in the late 1930s, with common side effects of various degrees of gingival hyperplasia first described by Kimball in 1939.[36] He reported that 57% of 119 patients taking phenytoin for the control of seizure activity experienced some degree of gingival overgrowth.

Today an estimated two million people use this medication because of its comparative safety and broad therapeutic range. The incidence of phenytoin-induced gingival overgrowth (PIGO) in patients undergoing long-term phenytoin therapy has been reported as ranging between 0% and 95%, with numerous investigators reporting figures at the 40% to 50% level.[37]

Early research showed an increase in the number of fibroblasts in patients receiving Dilantin; thus the condition was termed *Dilantin hyperplasia*. Now the term *phenytoin-induced gingival overgrowth* is preferred because Hassell and colleagues found true hyperplasia not to exist.[38] Neither was there excessive collagen accumulation per unit of tissue nor did the fibroblasts appear abnormal in number or size.

The influence of serum and salivary levels of phenytoin on the development of PIGO has also been investigated. Some authors report a positive relationship between the level of phenytoin in serum and saliva and the severity of PIGO in some cases.[39,40,41] Other investigators have reported that no such correlation exists.[42,43] It is generally agreed that a relationship exists between dosage and PIGO when the level of phenytoin per unit body weight or actual serum level is considered. Sasaki and Maita reported a significant correlation between the degree of gingival overgrowth and a high level of basic fibroblast growth factor in serum.[44] No such correlations were observed for patient age, daily or total phenytoin dose, duration of therapy, or serum phenytoin level.

Most investigators agree on the existence of a close relationship between oral hygiene and PIGO. PIGO can be decreased or prevented by scrupulous oral hygiene and dental prophylaxis. The relationship between plaque, local irritants, and PIGO is also supported by the observation that patients without teeth almost never develop PIGO.

PIGO, when it does develop, begins to appear as early as 2 to 3 weeks after the initiation of phenytoin therapy and peaks at 18 to 24 months. The initial clinical appearance is painless enlargement of the interproximal gingiva. The buccal and anterior segments are more often affected than the lingual and posterior segments (Figs. 14-15 and 14-16, *A*). The affected areas are isolated at first but can become more generalized later. Unless secondary infection or inflammation is present, the gingiva appears pink and firm and does not bleed easily when probed. As the interdental lobulations grow, clefting becomes apparent at the midline of the tooth. With time, the lobulations coalesce at the midline, forming pseudopockets and covering more of the crown of the tooth. The epithelial attachment level usually remains constant. In some cases the entire occlusal surface of the tooth becomes covered. These lesions may remain purely fibrotic or may be combined with a noticeable inflammatory component.



Figure 14-15 Phenytoin gingivitis of the severe generalized type in an 11-year-old child. The enlarged gingival tissue covers a significant portion of the clinical crowns of the maxillary and mandibular surfaces of the anterior dentition.



Figure 14-16 **A,** Phenytoin gingivitis of the severe generalized type. **B,** Surgical removal of the overgrowth of hyperplastic gingival tissue results in temporary improvement of the condition. Excellent oral hygiene is essential in controlling the gingival enlargement.

PIGO may impose problems of aesthetics, difficulty in mastication, speech impairment, delayed tooth eruption, tissue trauma, and secondary inflammation leading to periodontal disease.[45] No cure exists, and treatment is often symptomatic. Antihistamines, topical corticosteroids,

Dentlearn.ir

ascorbic acid (vitamin C) supplements, topical antibiotics, and alkaline mouthwashes are considered to be ineffective.

Steinberg and Steinberg describe the recommended dental treatment based on clinical oral signs and symptoms.[46] Patients with mild PIGO (i.e., less than one third of the clinical crown is covered) require daily meticulous oral hygiene and more frequent dental care. For patients with moderate PIGO (i.e., one to two thirds of the clinical crown is covered), meticulous oral home care and the judicious use of an irrigating device may be needed. Use of an antiplaque mouthrinse (0.12% chlorhexidine gluconate) in the device further helps control bacterial growth. Initially, a series of four consecutive weekly office visits for prophylaxis and topical stannous fluoride application is recommended. The fifth week is used to evaluate the gingivae and note any change in size. Phenytoin levels should be checked (normal therapeutic range is 10 to 15 mg/mL). If there has been no change, consultation with the patient's physician concerning the possibility of using a different anticonvulsant drug may be helpful. If no improvement occurs, surgical removal of the overgrowth may be recommended. For patients with severe PIGO (i.e., more than two thirds of the tooth is covered) who do not respond to the previously mentioned therapeutic regimens, surgical removal is necessary. As in any periodontal surgery, scaling and root planing before surgery and meticulous oral hygiene after surgery are essential to minimize the overgrowth, which can occur as early as 3 to 4 weeks after surgery (Fig 14-16, *B*). Donnenfeld and colleagues found no PIGO recurrence for as long as 9 months postoperatively.[47] If surgery is required a second time and the patient has a history of rapid recurrence, a pressure appliance should be considered as an adjunct to home oral care. If the patient has multiple gingivectomies, clinical management becomes one of postponing repeat surgery for as long as possible.

Specific surgical approaches for PIGO include gingivectomy with periodontal knives, laser, or electrosurgery, and

allows the tissue to heal more quickly, but more operative and postoperative bleeding occurs, and the procedure requires more time and patient cooperation. Electrosurgery is less time-consuming, decreases blood loss, improves visibility, allows for superior control in areas of limited access, is self-sterilizing, and does not always require the use of periodontal packs. Disadvantages include its contraindication in patients with cardiac pacemakers, unpleasant odor, delayed healing, and the potential for error in application that results in undesired bone or tissue loss. Advantages of the surgical laser include the following: lack of hemorrhage, which yields a dry field; noncontact during surgery; sterilization of the surgical area; prompt healing; minimal postoperative discomfort; and minimal time spent in performance of the procedures. Disadvantages include cost and size of equipment, necessity for hospitalization, potential for delayed healing of some tissues, greater degree of expertise required, loss of tactile feedback, requirement for eye protection, ability of the laser to ignite a plastic or rubber endotracheal tube, and a need to cover the nonsurgical field with moist sponge shields to prevent

has some advantages over the previously mentioned treat-

healing (stimulates primary healing), controls postoperative bleeding, minimizes postoperative pain, and allows for the optional use of a periodontal pack. The choice of surgical approach must be left to the operator and is based on patient cooperation and compliance, the degree of gingival overgrowth, and operator expertise. Healing is usually rapid with all these modalities.

The surgical removal of severely overgrown tissue in PIGO and good oral hygiene after surgery are generally considered to be the most effective treatment. However, even these procedures have often been followed by a gradual recurrence of the fibrous tissue.

A preliminary study of the use of a pressure appliance for PIGO hyperplasia has been reported by Davis and colleagues.[48] Immediately after the surgical removal of hyperplastic tissue, an impression was taken and a positive-pressure splint was constructed. Periodontal dressings were removed at the end of 1 week, and the positive-pressure appliance was inserted. Seven of the

rence of gingival hyperplasia, one had a slight recurrence, and one had a moderate recurrence. The natural rubber, mouth-protector type of appliance and the type with a cast chromium-cobalt framework lined with soft plastic were equally effective. The appliance is generally used only at night but may be worn night and day if such a schedule is required. Sheridan and Reeve also reported success in controlling gingival overgrowth with positive-pressure appliances.[49]

Steinberg suggested that use of a series of pressure appliances may help reduce the size of the gingival overgrowth without surgery.[50] He reported one case in which existing systemic conditions contraindicated surgical removal of the gingival tissue. After oral hygiene was improved, pressure appliances were made on stone casts of the patient's maxillary and mandibular arches after 2 mm of the stone were trimmed away in the gingival overgrowth areas. The patient wore the appliance about 12 hours each day for 4 weeks, after which a new pressure device was made. Steinberg observed a pronounced decrease in the sizes of the gingival lesions after 8 weeks of therapy. He suggested that a series of such appliances could succeed in gradually reducing gingival overgrowth to clinically tolerable limits. He also pointed out that this therapeutic approach is not practical for the average patient but that it may prove valuable for patients for whom oral surgery is contraindicated.

Drew and colleagues[51] and Bäckman and associates[52] have reported that patients with PIGO or patients at risk for developing it may benefit from receiving folate therapy. Their work demonstrated a reduction in the severity of PIGO in patients who received systemic folic acid supplementation. The work of Drew and colleagues further demonstrated that twice-daily oral rinsing with a topical folic acid solution resulted in tissue responses significantly better than those achieved with systemic folic acid therapy.[51] Their studies suggest that folic acid therapy may inhibit PIGO and that additional related studies are indicated.

Dentlearn.ir



Figure 14-17 **A,** Severe scorbutic gingivitis in a 16-month-old child. Large hematomas were evident in the maxillary arch. The condition was initially incorrectly diagnosed as Vincent infection. **B,** Daily administration of 400 mg of ascorbic acid resulted in a dramatic recovery.

Other drugs that have been reported to induce gingival overgrowth in some patients include cyclosporin, tal. As with all disorders affecting periodontal tissues, the maintenance of excellent oral hygiene is the primary key to successful therapy.

ASCORBIC ACID DEFICIENCY GINGIVITIS (SCORBUTIC GINGIVITIS)

Scorbutic gingivitis is associated with vitamin C deficiency and differs from the type of gingivitis related to poor oral hygiene. The involvement is usually limited to marginal tissues and papillae. The child with scorbutic gingivitis may complain of severe pain. Spontaneous hemorrhage may be evident. Aside from dietary deficiencies, ascorbic acid deficiency gingivitis can be seen in both pediatric and adult cancer patients undergoing radiotherapy and/or chemotherapy where the mucosal linings of the intestinal walls are affected and the absorption of nutrients is impaired.

Severe clinical scorbutic gingivitis is rare in children. However, it may occur in children allergic to fruit juices when provision of an adequate dietary supplement of vitamin C is neglected (Fig. 14-17, *A*). When blood studies indicate a vitamin C deficiency and exclude other possible systemic conditions, the gingivitis responds dramatically to the daily administration of 250 to 500 mg of ascorbic acid (Fig. 14-17, *B*). Older children and adults may require 1 g of vitamin C for 2 weeks to speed recovery.



Figure 14-18 **A,** Scorbutic gingivitis in a 13-year-old girl. The diet was almost entirely lacking in foods containing vitamin C. **B,** An improved diet, supplemental amounts of fresh fruit juices, and toothbrushing instruction resulted in an improved gingival condition in 2 weeks.

A less severe type of gingivitis resulting from vitamin C deficiency is probably much more common than most dentists realize. Inflammation and enlargement of the marginal gingival tissue and papillae in the absence of local predisposing factors are possible evidence of scorbutic gingivitis (Fig 14-18, *A* and *B*). Questioning the child and parents regarding eating habits and using the 7-day diet survey frequently reveal that the child is receiving inadequate amounts of foods containing vitamin C. Complete dental care, improved oral hygiene, and supplementation with vitamin C and other water-soluble vitamins will greatly improve the gingival condition.

PERIODONTAL DISEASES IN CHILDREN

Periodontitis, an inflammatory disease of the gingiva and deeper tissues of the periodontium, is characterized by pocket formation and destruction of the supporting alveolar bone. Bone loss in children can be detected in bitewing radiographs by comparison of the height of the alveolar bone with that of the cemento-enamel junction. Distances between 2 and 3 mm indicate questionable

Dentlearn.ir

bone loss, and distances greater than 3 mm indicate definite bone loss.

Periodontal probing for attachment loss and bitewing radiography are often used for the clinical confirmation of the diagnosis. Bone loss is usually between the primary first and second molars.

In its classification of periodontitis, the American Academy of Periodontology categorized the early-onset form under Aggressive Periodontitis.[53]

AGGRESSIVE PERIODONTITIS (EARLY-ONSET PERIODONTITIS)

Aggressive periodontitis is used as a generic term to describe in younger individuals who may or may not be otherwise healthy. Aggressive periodontitis can be viewed as two categories of periodontitis that may have overlapping etiologies and clinical presentations: (1) a localized form (localized aggressive periodontitis [LAP]) and (2) a generalized form (generalized aggressive periodontitis [GAP]). Albandar and colleagues, using data from a 1986-1987 survey, estimated the prevalence of aggressive periodontitis in adolescent schoolchildren in the United States to be 10% in African Americans, 5% in Hispanics, and 1.3% in whites.[54]

Löe and Brown have reported observations from a periodontal assessment of 1107 adolescents aged from 14 to 17 years.[55] Approximately 0.53% were estimated to have LAP, 0.13% to have GAP, and 1.61% to have incidental loss of attachment. Boys were more likely to have GAP than were girls (ratio, 4.3:1).

Aggressive periodontitis of the primary dentition can occur in a localized form but is usually seen in the generalized form. LAP is localized attachment loss and alveolar bone loss only in the primary dentition in an otherwise healthy child. The exact time of onset is unknown, but it appears to arise around or before 4 years of age, when the bone loss is usually seen on radiographs around the primary molars and/or incisors. Abnormal probing depths with minor gingival inflammation, rapid bone loss, and minimal to various amounts of plaque have been demonstrated at the affected sites of the child's dentition. Abnormalities in host defenses (e.g., leukocyte chemotaxis), extensive proximal caries facilitating plaque retention and bone loss, and a family history of periodontitis have been associated with LAP in children.[56] As the disease progresses, the child's periodontium shows signs of gingival inflammation, with gingival clefts and localized ulceration of the gingival margin.

GENERALIZED AGGRESSIVE PERIODONTITIS

The onset of GAP is during or soon after the eruption of the primary teeth. It results in severe gingival inflammation and generalized attachment loss, tooth mobility, and rapid alveolar bone loss with premature exfoliation of the teeth (Fig. 14-19). The gingival tissue may initially demonstrate only minor inflammation with plaque accumulation at a minimum. It often affects the entire dentition. Alveolar bone destruction proceeds rapidly, and the primary teeth may be lost by 3 years of age. Because of its wide distribution and rapid rate of alveolar bone destruction, the GAP was previously known as *generalized juvenile periodontitis*, *severe periodontitis,* and *rapidly progressive periodontitis*. Chronic cases display the presence of clefting and pronounced recession with associated acute inflammation.

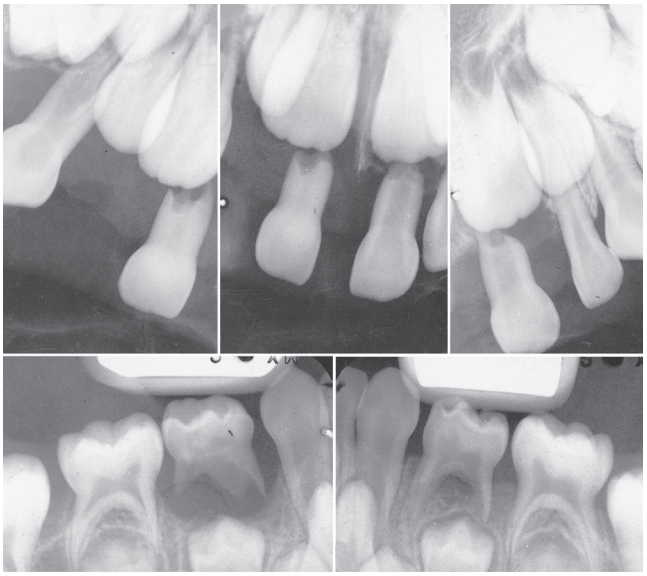

Figure 14-19 Radiographs of prepubertal periodontitis in a 4 1/2-year-old girl. A generalized loss of alveolar bone can be seen in the radiographs.

Affected teeth harbor more nonmotile, facultative, anaerobic, gram-negative rods (especially *Porphyromonas gingivalis*) in GAP than in LAP. Microorganisms predominating in the gingival pockets include *Aggregatibacter actinomycetemcomitans* (*Aa*), *Porphyromonas (Bacteroides) gingivalis (Pg), Bacteroides melaninogenicus, Prevotella intermedia, Capnocytophaga sputigena,* and *Fusobacterium nucleatum*. Findings of Asikainen and associates suggest that the major periodontal pathogens are transmitted among family members.[57] The past medical history of the child often reveals a history of recurrent infections (e.g., otitis media, skin infections, upper respiratory tract infections).

LAP and GAP are distinctly different radiographically and clinically. Neutrophils in GAP patients have suppressed chemotaxis. Individuals with GAP exhibit marked periodontal inflammation and have heavy accumulations of plaque and calculus. Testing may reveal a high prevalence of leukocyte adherence abnormalities and an impaired host response to bacterial infections.

[See the later section on Premature Bone Loss in the Primary Dentition.]

LOCALIZED AGGRESSIVE PERIODONTITIS (LOCALIZED JUVENILE PERIODONTITIS)

The term for the previously described condition of localized juvenile periodontitis has also been replaced by the term *localized aggressive periodontitis*. This condition presents a classic pattern and occurs in otherwise healthy children and adolescents without clinical evidence of systemic disease. It is characterized by the rapid and severe loss of alveolar bone around more than one permanent tooth, usually the first molars and incisors

Dentlearn.ir

(Fig. 14-20, Fig 14-21, *A* and *B*). It appears self-limiting, and analysis of retrospective data obtained from LAP patients suggests that bone loss around the primary teeth can be an early finding in this disease. Reported estimates of the prevalence of LAP range from 0.1% to 1.5%, with a bilaterally symmetric pattern of bone loss in a geographically diverse adolescent population. The prevalence in the African-American population is greater—2.5%. Clinically, LAP patients have less tissue inflammation and very little supragingival dental plaque or calculus. However, they do present with evidence of subgingival plaque accumulation, both tissue-associated and tooth-associated. Progression of bone loss is three to four times faster than in chronic periodontitis.

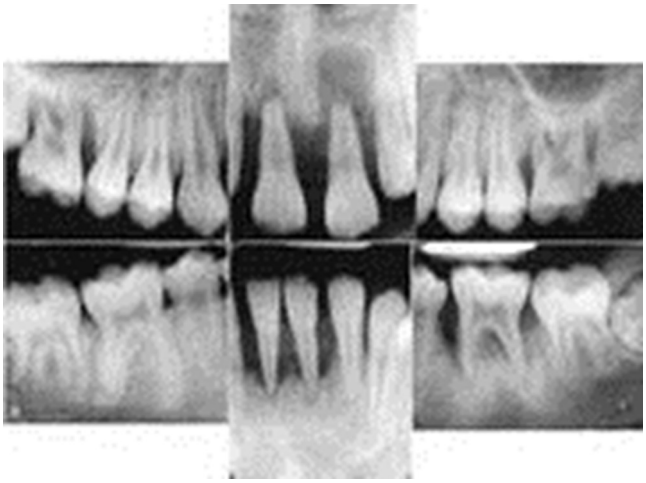

Figure 14-20 Radiographs of a 12-year-old boy with the localized form of early-onset periodontitis. The films revealed loss of support in the incisor and first permanent molar areas. The maxillary central incisors, mandibular incisors, and first permanent molars were removed. Partial dentures were constructed.

LAP is not thought to be a single disease entity. The probable causative microbial species are *Aa* or *Aa* in combination with *Porphyromonas*-like species. A variety of neutrophil defects has been reported in patients with LAP. According to Page and colleagues, most patients with LAP manifest abnormalities in peripheral blood neutrophil (polymorphonuclear leukocyte) chemotaxis and, in some cases, in monocyte chemotaxis.[58] Also, anomalies of phagocytosis, bacterial activity, leukotriene B_4 generation, and other defects have been reported. Page and colleagues suspect a hereditary basis for LAP; some believe that the mode of transmission is autosomal recessive, but others have provided evidence that the pattern is typical of an X-linked–dominant mode.

TREATMENT OF AGGRESSIVE PERIODONTITIS

Successful treatment of aggressive periodontitis depends on early diagnosis, the use of antibiotics against the infecting microorganisms, and the provision of an infection-free environment for healing. Treatment of aggressive periodontitis, both LAP and GAP, includes oral hygiene

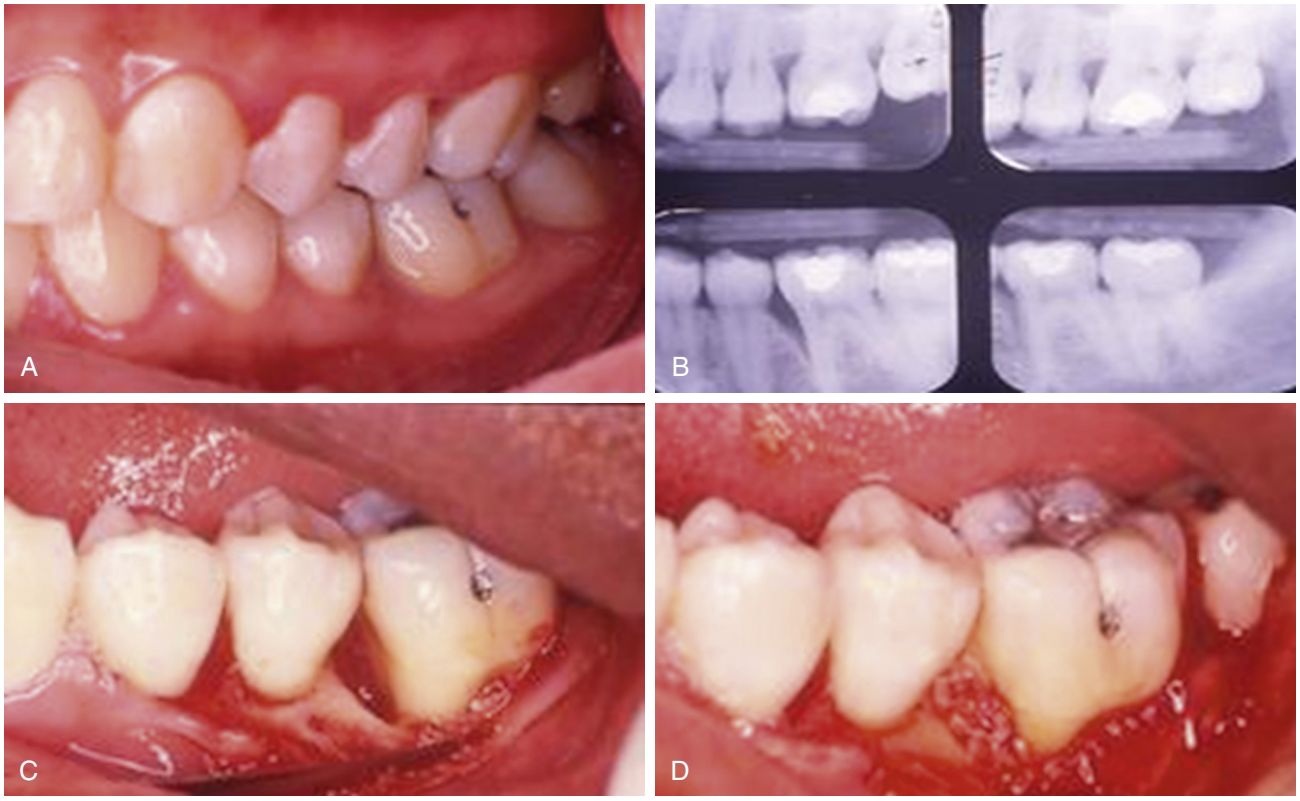

Figure 14-21 **A,** Localized aggressive periodontitis. **B,** Radiographic evidence of vertical bone loss on the mesial surfaces of tooth #14 and especially tooth #19. **C,** Clinical evidence of the vertical bone loss of tooth #19. **D,** Guided Tissue Regeneration as a treatment option using a bone allograph and a membrane.

Dentlearn.ir

instructions, consultation with the patient's physician if necessary, and mechanical removal of supragingival and subgingival microbial agents via nonsurgical and/or surgical treatment modalities with adjunctive antimicrobial therapy (Fig. 14-21, *C* and *D*). Adjunctive antimicrobial therapy should be used to aid in the elimination of any *Aa* organisms that have penetrated the microscopic ulcerations of the crevicular epithelium. A combination regimen of amoxicillin and metronidazole over 1 to 2 weeks has been found to eliminate *Aa* and suppress *Pg* significantly. On the other hand, the use of tetracyclines to treat aggressive periodontitis in the pediatric population should be avoided because this could cause discoloration of teeth. Likewise, tetracyclines should not be prescribed to pregnant mothers because these antibiotics are classified as FDA Pregnancy Category D agents. In a study of deep periodontal lesions, Christersson and colleagues demonstrated that scaling and root planing alone were ineffective for the elimination of *Aa*.[59]

Microdentex manufactures the DMDx (Microdentex, Fort Myers, Florida, United States) test, a DNA test kit for periodontal pathogens. The test aids in establishing the risk of aggressive periodontitis and confirms whether the child has responded favorably to the use of adjunctive antibiotics. Retesting in 4 to 6 weeks after the completion of antibiotic therapy determines the patient's response to the treatment. The test involves collection of a plaque specimen by the insertion of a paper point provided in the kit into a periodontal pocket for 10 seconds. The paper point is placed in a test vial and returned for microbial testing. Although the Pedo Probe test provides a detailed analysis only for *Aa*, the laboratory will also perform a more detailed microbial analysis.

Treatment of GAP is often less predictable. Alternative antibiotics directed at the specific pathogenic flora may be required when there is no response to traditional therapies. The multidisciplinary approach combines clinical laboratory evaluation with conventional periodontal therapeutic methods for the diagnosis and treatment of severe GAP cases.

PERIODONTITIS AS A MANIFESTATION OF SYSTEMIC DISEASE

In 1999 the American Academy of Periodontology introduced a new classification, classifying periodontitis as a manifestation of systemic disease as a separate category. Several of these conditions are identified in the pediatric population:

A. Associated with hematological disorders
   1. Acquired neutropenia
   2. Leukemias
   3. Other

B. Associated with genetic disorders
   1. Familial and cyclic neutropenia
   2. Down syndrome
   3. Leukocyte adhesion deficiency syndromes
   4. Papillon-Lefèvre syndrome
   5. Chédiak-Higashi syndrome
   6. Histiocytosis syndromes
   7. Glycogen storage disease
   8. Infantile genetic agranulocytosis
   9. Cohen syndrome
   10. Ehlers-Danlos syndrome (types IV and VIII)
   11. Hypophosphatasia
   12. Other

C. Not otherwise specified (NOS)

PREMATURE BONE LOSS IN THE PRIMARY DENTITION

Advanced alveolar bone loss associated with systemic disease occurs in children and adolescents, as well as in adults. In the primary dentition, this is rare. Although most premature tooth loss from non-systemic disease results from trauma or caries, the cause of advanced alveolar bone loss is often not readily apparent. Local factors (periodontitis, trauma, and infection secondary to caries) account for the majority of cases of premature bone loss. Goepferd reports that bony destruction in the primary dentition in the absence of local factors is highly suggestive of systemic disease.[60] Many possibilities exist, including hypophosphatasia, Papillon-Lefèvre syndrome, histiocytosis X, agranulocytosis, leukocyte adherence deficiency, neutropenias, leukemias, diabetes mellitus, scleroderma, fibrous dysplasia, acrodynia, Down syndrome, and Chédiak-Higashi syndrome. The defect in immune and neutrophil cell function associated with these diseases is thought to increase patient susceptibility to periodontitis causing alveolar bone loss and to other infections.

PAPILLON-LEFÈVRE SYNDROME

Coccia and colleagues observed Papillon-Lefèvre syndrome (precocious periodontosis) in a 2 1/2-year-old child.[61] The syndrome is rare, and the cause unknown. However, in the families of affected children (1 to 4 per 1,000,000) in which a familial predisposition to the disorder is noted, an autosomal-recessive mode of inheritance has been identified.[62] There is no racial or gender predominance.



Figure 14-22 Intraoral condition of a 2½-year-old child with Papillon-Lefèvre syndrome. Inflammatory gingival engorgement and accumulated accretions were present, especially in the mandibular incisor area.

Dentlearn.ir



Figure 14-23 Hyperkeratosis of the plantar surfaces of the feet *(arrows)*.

The observations made in the young child (Fig. 14-22) are typical of those reported by Gorlin and associates.[63] The primary teeth erupted at the normal time. However, as early as 2 years of age, the child rubbed the gingival tissues and acted as if they were painful. There was a tendency toward gingival bleeding when the teeth were brushed. Hyperkeratosis of the palms and soles was present (Fig. 14-23); the first evidence was erythema and scaliness noted initially at 8 months of age. Delaney noted that hyperkeratotic lesions of the elbows and knees may be observed.[1] Repeated laboratory tests, including complete blood count, urinalysis, and micro serum calcium and phosphorus determinations, yielded essentially normal results.

At 2½ years of age, all the primary teeth showed looseness, and full-mouth radiographs revealed severe horizontal bone resorption (Fig. 14-24). Because of gingival inflammation, patient discomfort, and the presence of infected periodontal pockets, all the primary teeth were removed by 3 years of age. Histologic sections of the teeth displayed a premature resorption pattern with essentially normal pulp tissue. Cementum was apparently normal and covered the root structure. An accumulation of adherent basophilic plaque, made up of a mass of filamentous microorganisms, was noted on almost the entire length of the root surface. Periodontal pathogens (*Aggregatibacter actinomycetemcomitans, Fusobacterium nucleatum, Capnocytophaga species,* and *Eikenella corrodens*) have been isolated in the dental plaque of patients with Papillon-Lefèvre syndrome, according to Tinanoff and colleagues.[64]

Complete dentures were constructed 3 months after the removal of the primary teeth. The child tolerated the dentures well, both functionally and psychologically (Fig. 14-25, *A* and *B*). The first permanent molars and mandibular central incisors erupted at the expected time, and the denture base was adjusted to allow for the emergence of the teeth. Although previous reports have indicated that the permanent dentition will also be affected, the child whose history is reported here has been followed into young adulthood, and the dentition, including the supporting tissues, appears normal (Fig. 14-26). In addition, the patient has successfully undergone orthodontic treatment.

Reports of the effectiveness of tetracycline therapy as an adjunct to meticulous subgingival debridement in the management of periodontal disease prompted McDonald to reinvestigate the history in the reported case of Papillon-Lefèvre syndrome. The father, a physician, reported that tetracyclines were given to the child repeatedly for ear infections between 3 and 6 years of age. This regimen may have been responsible for eliminating pathogens and preventing the destructive process from being carried into the permanent dentition. However, attempts at conventional therapy have been unsuccessful in preventing tooth loss. Delaney reports that periodontal treatment for these young children includes identification of specific pathogens, specific antibiotic therapy against these organisms, and full-mouth extractions early enough to provide an edentulous period before permanent tooth eruption.[3]

GINGIVAL RECESSION

Gingival recession is often observed in children. Several factors predispose patients to gingival recession. These factors include the presence of a narrow band of attached or keratinized gingiva, alveolar bony dehiscence, toothbrush trauma, tooth prominence, impinging frenum attachment, soft tissue impingement by opposing occlusion, orthodontic tooth movement, use of impression techniques including subgingival tissue retraction, oral habits, periodontitis, pseudorecession (extrusion of teeth), and intraoral piercings, such as tongue piercings. Recession is dealt with conservatively by elimination of the etiology if possible, while excellent oral hygiene is maintained in the affected areas. If the recession of the affected area remains unchanged (nonprogressive) or improves, continued periodic monitoring is recommended. If the recession has progressed after a 4- to 8-week period of observation, other periodontal procedures may be required based on the identified predisposing factor.

SELF-MUTILATION

Although there has been infrequent reference to self-mutilation in the dental literature, occasionally children purposely traumatize their oral structures. Plesset reported observing a 9-year-old girl of apparently normal intelligence who worked her maxillary primary canine and mandibular permanent incisors loose from their supporting tissues and removed them.[65] In another case Leksell and Edvardson reported on a 4-year-old female child who presented to her pediatric dentist for self-luxation of teeth caused by oral motor tics. Further investigation revealed that the patient's oral self-injurious behavior was associated with a previously undiagnosed Tourette syndrome.[66]

Self-mutilation probably occurs more frequently than is realized because relatively few children will admit to the act unless they are observed practicing it. Therefore the self-inflicted lesions may be incorrectly diagnosed. Dentists should be aware of the possibility of this condition and should approach the problem in the same manner as they do thumb sucking. An attempt should be made to determine the cause. If it is found to be the result of local dental factors, it can be corrected. However, in the majority

Dentlearn.ir

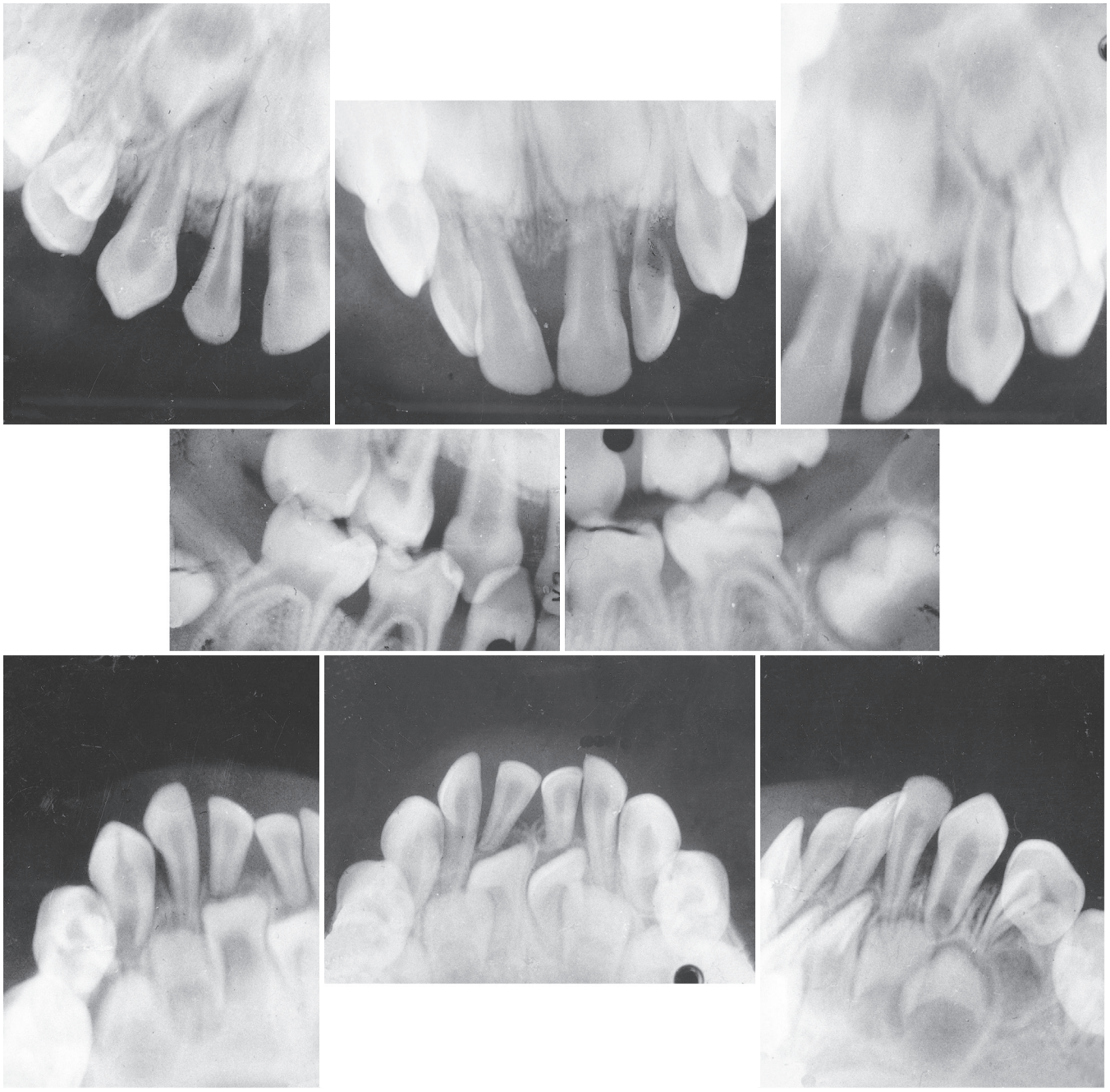

Figure 14-24 Full-mouth and bitewing radiographs of a 2½-year-old child with Papillon-Lefèvre syndrome. Severe horizontal bone resorption is readily detected in all four quadrants. The incisor areas display extreme alveolar bone loss to the extent that only the apical third of the root remains supported. All primary teeth were extracted by 3 years of age, and dentures were constructed.

of children an emotional problem is involved, and the family must be directed to competent counseling services.

Children as young as 4 years of age have been observed who have traumatized the free and attached gingival tissues with a fingernail, occasionally to the extent that the supporting alveolar bone has been destroyed. In a case report, Krejci reported on an 8-year-old African-American male who presented with gingival swelling along the facial marginal gingiva of the maxillary right central incisor. Investigation revealed that the patient had a positive history of fingernail chewing and a habit of sliding the cleaved fingernails underneath the gingival margins of his maxillary central incisors. As a result, surgical intervention and counseling were recommended (Fig. 14-27, *A-E*).[67] A 14-year-old girl produced unilateral stripping of the buccal tissue in the maxillary canine area (Fig. 14-28, *A* and *B*) with her fingernail. The condition can be successfully treated surgically once the habit is stopped.

Traumatic gingival recession in infants resulting from a dummy (pacifier) sucking habit has been observed by

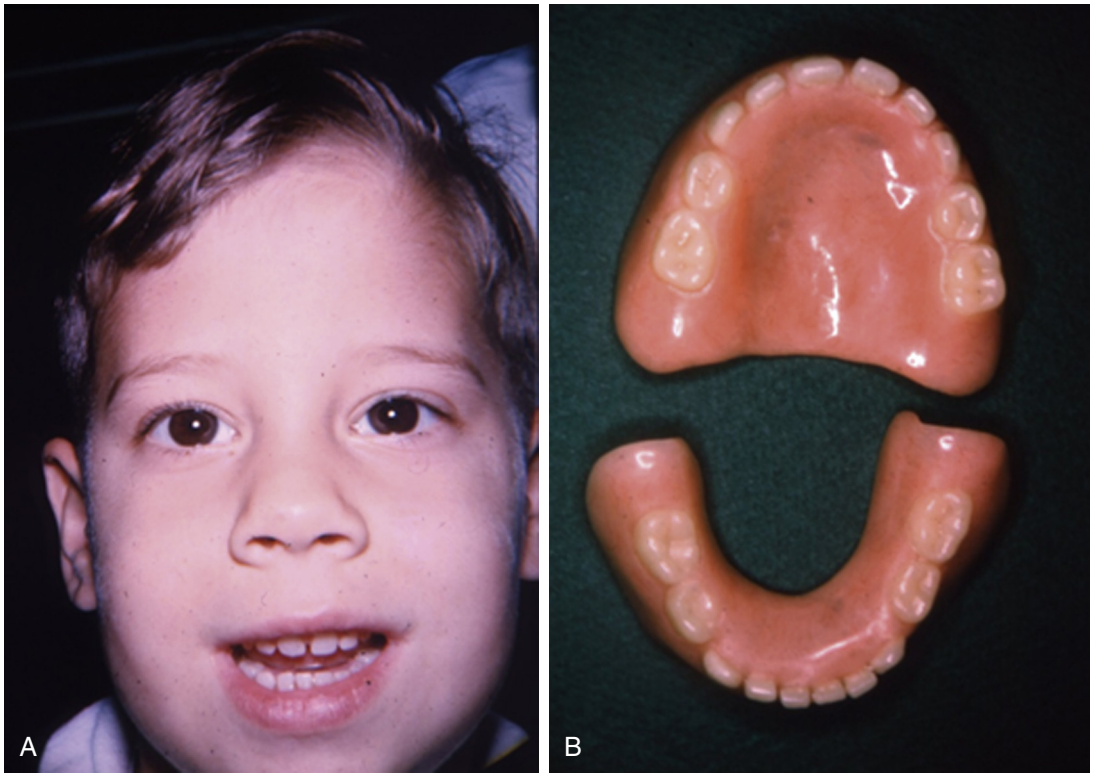

Figure 14-25 **A,** Three-year-old child with complete dentures. **B,** Constructed complete dentures, which were later modified to allow for eruption of the mandibular incisors and the first permanent molars.

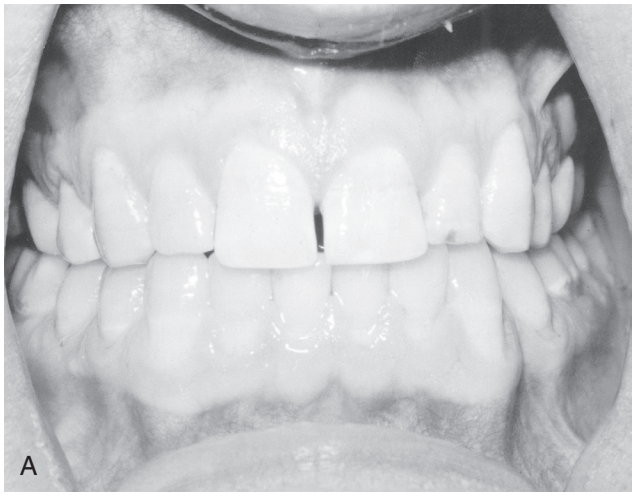

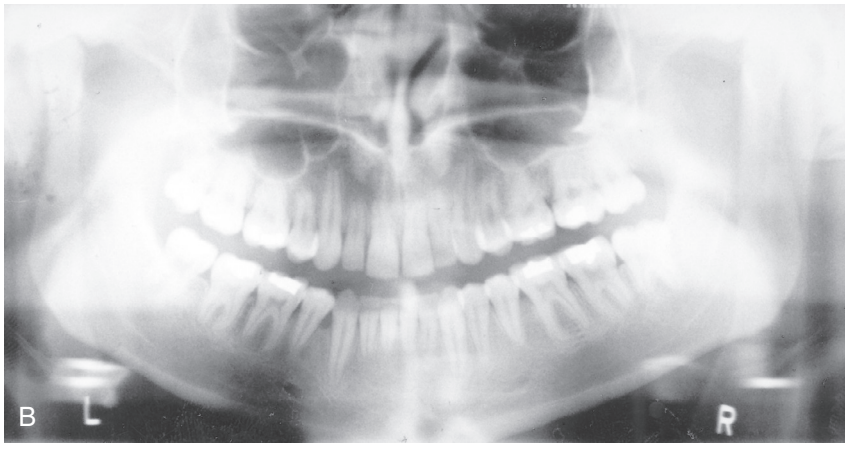

Figure 14-26 **A,** Anterior intraoral view. **B,** Panorex of the patient noted in Figures 14-24 and 14-25 at 15 years of age. The survey revealed normal alveolar bone. Some apical root resorption related to orthodontic treatment can be seen in the mandibular incisors.

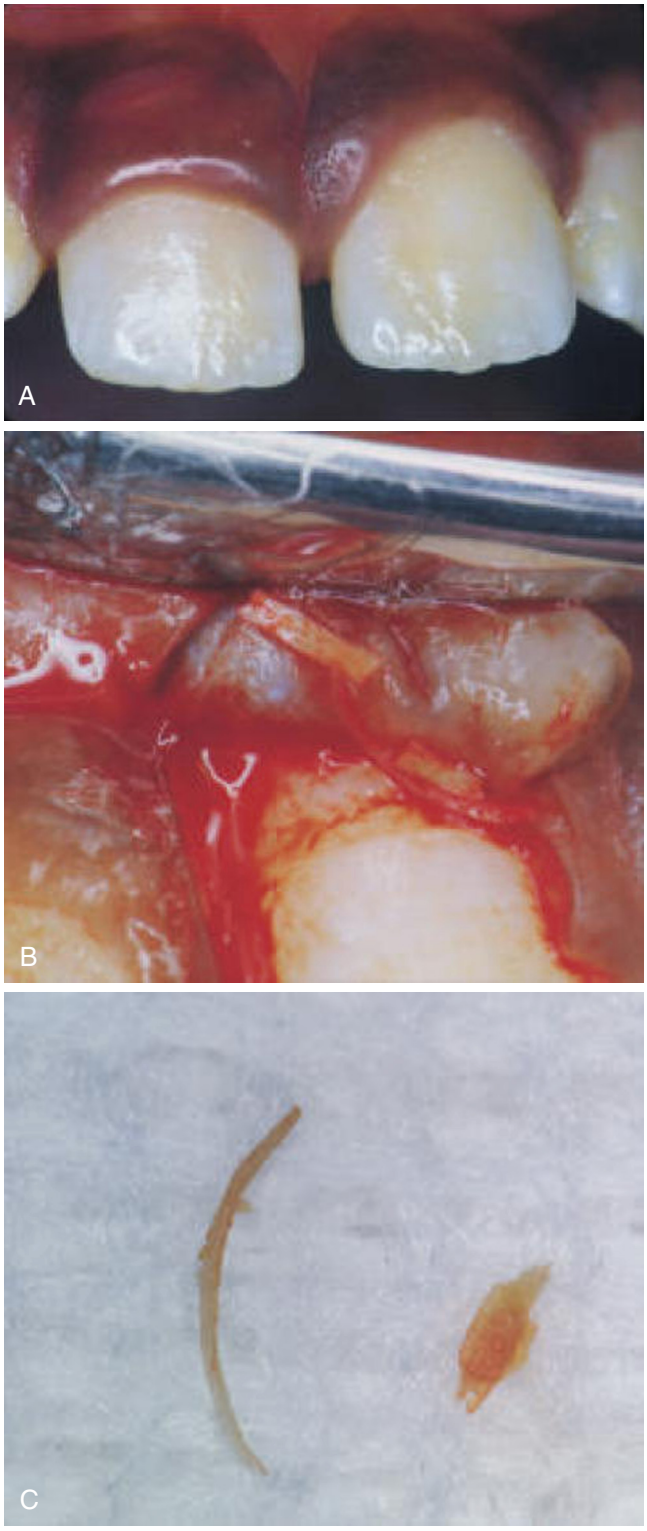

Figure 14-27 **A,** An 8-year-old African American with gingival swelling along the maxillary right central incisor. **B,** Surgical intervention reveals fragments of embedded fingernail in the gingiva. **C,** Fingernail remnants removed during surgical procedure.



Figure 14-28 **A,** Stripping of the free and attached tissue from the buccal side of a cuspid and exposure of the root surface secondary to constant scraping with a fingernail. **B,** After a surgical procedure and the cessation of scraping, adequate healing had occurred.

Stewart and Kernohan.[68] In the unconventional sucking habit, a segment of the plastic shield is embraced by the infant's lower lip so that the inner surface of the shield bears against the labial aspect of the incisors and the gingival tissues. If the shield is held in this position, the edge of the shield moves with an abrasive action during sucking, leading to gingival injury, recession, and loss of alveolar bone.

Self-mutilation by biting has been associated with severe emotional disturbances such as Lesch-Nyhan syndrome, congenital insensitivity to pain, and autism. Friedlander and colleagues report autistic children with facial bruising, abrasions, and intraoral traumatic ulcerations that are most often the result of self-injurious behaviors rather than abuse by parents or caretakers.[69] Management requires a choice between the initial use of protective appliances vs. surgical procedures. Littlewood and Mitchell report that mouthguards are helpful for

children with congenital indifference to pain until they are mature enough to appreciate and avoid self-mutilating behaviors, a learning process normally acquired by painful experiences.[70] Cusumano and colleagues report that the use of carbamazepine may be beneficial for children with Lesch-Nyhan syndrome.[71]

ABNORMAL FRENUM ATTACHMENT

A frenum is a membranous fold that joins two parts and restricts the individual movement of each. Henry and colleagues describe a frenum as a mucous membrane fold containing epithelium and connective tissue fibers but no muscle.[72] In contrast, Ross and colleagues histologically analyzed 40 frenal biopsy specimens and found that 37.5% of the specimens contained skeletal or striated muscle.[73] A normal frenum attaches apically to the free gingival margin so as not to exert a pull on the zone of the attached gingiva, usually terminating at the mucogingival junction. Although a wide variety of aberrant positions occurs, commonly observed locations of frena in the child are on the facial gingival surface of the anterior midline of the maxilla, on the facial and lingual gingival surfaces of the anterior midline of the mandible, and on the mandibular and maxillary premolar facial area. Some frena have bifid and trifid attachments to the alveolar process.

An abnormal or high frenum is present when there is inadequate attached gingiva in the terminal insertion area. A frenum attached too closely to the gingival margin may interfere with proper toothbrush placement, may cause opening of the gingival crevice during function, or may interfere with speech. High frenum attachments may also be associated with isolated gingival recessions and diastemas, although a cause-and-effect relationship may or may not exist.

An abnormally short lingual frenum and the inability to extend the tongue constitute a congenital condition known as ankyloglossia (tongue-tie).[74] Normal function can occur with this mild form, and the frenum may lengthen with normal growth and maturation of the child.

A mandibular anterior frenum occasionally inserts into the free or marginal gingival tissue and causes subsequent recession and pocket formation. The abnormal frenum attachment is most often observed in the central incisor area (Fig. 14-29), although it may involve the labial tissue in the canine areas. The abnormal attachment is frequently associated with a vestibular trough that is more shallow than normal throughout the anterior region.

Movements of the lip cause the abnormal frenum to pull on the fibers inserting into the free marginal tissue. Food accumulates, causing inflammation and eventually the development of a pocket between the labial surface of the tooth and the vestibular mucosa. Early treatment of the abnormal frenum attachment is indicated to prevent continued stripping of the labial tissue, subsequent loss of alveolar bone, and possible eventual loss of the tooth. Although traumatic occlusion and poor oral hygiene are occasionally associated with the gingival stripping condition, the abnormal frenum attachment is more often the offender.



Figure 14-29 Abnormal attachment of the frenum. The fibers can be seen extending to the papilla between the central incisors, with branching auxiliary fibers inserting into the marginal tissue.

The maxillary anterior frenum connects the upper lip to the suture line areas between the central incisors. The importance of a frenum that prevents aesthetic contact of the central incisors has been the subject of debate. The literature indicates that a diastema may be considered normal as the maxillary central incisors erupt and can be expected to close as the other permanent front teeth erupt. Seldom has any correlation been found between a maxillary frenum problem and recession.

FRENOTOMY AND FRENECTOMY

A frenotomy involves an incision of the periosteal fiber attachment and possibly suturing of the frenum to the periosteum at the base of the vestibule. It is associated with less postoperative discomfort than a frenectomy and will usually suffice. A frenectomy involves complete excision of the frenum and its periosteal attachment. A frenectomy is indicated when large, fleshy frena are involved. The need for a frenectomy or frenotomy should be based on the individual's ability to maintain gingival health. The surgical management of the abnormal maxillary labial frenum is presented in Chapter 3 (see Figs. 3-50 to 3-52).

Indications for treating a high frenum include the following:

1. A high frenum attachment associated with an area of persistent gingival inflammation that has not responded to root planing and good oral hygiene
2. A frenum associated with an area of recession that is progressive
3. A high maxillary frenum and an associated midline diastema that persist after complete eruption of the permanent canines
4. A mandibular lingual frenum that inhibits the tongue from touching the maxillary central incisors. This would interfere with the child's ability to make /t/, /d/, and /l/ sounds. As long as the child has enough range of motion to raise the tongue to the roof of the mouth, no surgery would be indicated. Most children cannot normally make these sounds until after 6 or 7 years of age. Speech therapy may be indicated (see Fig. 7-45).

Dentlearn.ir

If a high frenum is associated with an area of no or minimal keratinized gingiva and a frenotomy or frenectomy is indicated, a gingival graft or vestibular extension should be used to augment the procedure. Under these circumstances, a frenotomy or frenectomy often does not create stable long-term results. Bohannan indicated that, if there is an adequate band of attached gingiva, high frena and vestibular depth do not pose a problem.[75-77] Use of the latter procedures to accomplish elimination of the frenum pull is considered a more standard approach.

TECHNIQUES FOR MANDIBULAR FRENECTOMY AND VESTIBULAR DEPTH INCREASE

Bohannan has published a series of reports of his studies in the alteration of vestibular depth and frenectomy.[75-77] Three different surgical procedures, which he refers to as complete denudation, periosteum retention, and vestibular incision, were studied as methods to produce increased vestibular depth and frenum alteration.

Complete Denudation

The complete denudation procedure is preceded by a routine gingivectomy extending laterally to the first premolars. By blunt dissection, the periosteum and adherent fibrous tissue are detached apically, and the labial plate is exposed to a depth of approximately 12 mm. The resulting soft-tissue flap is removed by excision. A rapid-setting dressing is placed directly over the osseous tissue and is changed at 7-day intervals for 4 weeks.

Periosteum Retention

The periosteum retention procedure, as carried out by Bohannan, does not always result in maintenance of the desirable amount of vestibular depth.[76] The procedure is essentially the same as that described previously, except that the periosteum is retained.

Vestibular Incision

The vestibular incision method (mandibular frenectomy) is a surgical procedure that has been used with success. The elimination of the abnormal frenum should remain the objective of the procedure, although it is often desirable to alter the vestibular depth also. However, the frenum is the primary etiologic factor in the stripping of the gingival tissue and labial pocket formation.

A preliminary prophylactic procedure should be performed to remove hard deposits, debris, and plaque material from the teeth. The surgical procedure should be more extensive than a conservative incision of the frenum. Such a procedure would allow the muscle fibers to reattach, with resultant scar tissue formation, and would perhaps make the condition more severe (Fig. 14-30, *A-C*).

A local anesthetic is given before the surgical procedure. Administration of a right and a left inferior alveolar injection is the method of choice. Some dentists prefer to inject the local anesthetic solution throughout the operative field. However, caution should be exercised because the anesthetic may distend the tissue, which makes it more difficult to find landmarks during the surgical procedure.

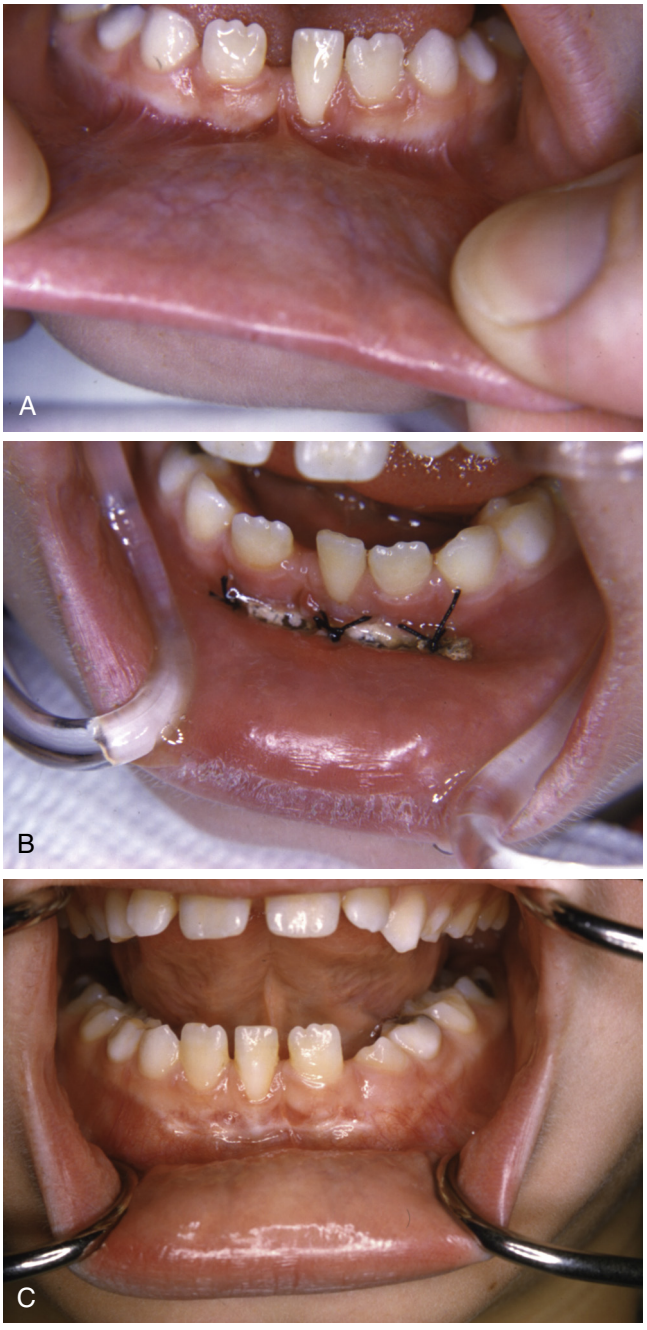

Figure 14-30 **A,** Tissue has been stripped and a pocket formed on the labial surface of the right central incisor. A frenectomy procedure to increase the depth of the vestibular trough is indicated. **B,** An incision has been made and a pack has been placed and secured with three sutures. **C,** Three months after the operation, improvement in the health of the gingival tissue in the mandibular anterior region is evident.

The lower lip should be stretched outward and downward, and an incision approximately 1 cm in depth beyond the level of the vestibular trough should be made at a right angle to the underlying bone. The incision is made at the junction of the mucobuccal fold and attached

Dentlearn.ir



Figure 14-31 **A,** Stripping of the tissue and loss of alveolar bone from the labial aspect of the mandibular right central incisor are related to an abnormal frenum attachment and shallow vestibule. **B,** An incision has been made, and the connective tissue and muscle attachments have been freed by blunt dissection. **C,** One week after the operation, there is evidence of granulation tissue. **D,** An improvement is evident in the gingival contour of the tissue surrounding the right central incisor.

gingiva, and should extend at least two teeth on either side of the attachment. If the abnormal attachment is on the incisor area, an incision is often made from an area opposite one canine to the canine on the other side of the mouth. The connective tissue and muscle attachments are then freed by blunt dissection with a periosteal elevator (Fig. 14-31, *A-C*). No attempt is made to strip the underlying periosteum.

A periodontal pack or some type of splint must be used to prevent reattachment of the tissue and to allow granulation to occur at a greater depth. A piece of rubber tubing 2 to 3 mm in diameter and the exact length of the incision can be coated with surgical paste and sutured in the trough. The patient is seen 24 hours postoperatively, and any granulation tissue that has developed over the ends of the tubing is removed. The pack is normally removed after 4 or 5 days, and the wound is irrigated as necessary until healing occurs.

As an alternative method of encouraging healing at a new depth, the entire surgical wound is filled with a stiff periodontal dressing of the zinc oxide–eugenol type. The pack, which extends over the labial surfaces of the anterior teeth, may be covered with dry foil and allowed to remain for 3 to 4 weeks with only weekly changes. Some dentists ligate an acrylic splint to the teeth after surgery to aid in the reestablishment of the new sulcular depth.

FREE GINGIVAL AUTOGRAFT PROCEDURE

The free gingival autograft procedure (FGG) may be considered for children and young adults when there is a prominent tooth position that is complicated by the absence of attached gingiva, a shallow vestibular fornix, and a high midline frenum attachment (Fig. 14-32). FGG is also indicated when there are areas of root exposure that are of aesthetic concern to the patient, when the labial gingivae of some teeth require subgingival crown margins, when teeth are clasped by a removable partial denture having a narrow zone of gingiva, and when teeth that have no labial keratinized gingiva need orthodontic movement, which makes them more prominent in the arch. When these indications are kept in mind, it will be apparent to the clinician that FGG is not always the best procedure. There may be an aesthetic concern with the surrounding gingiva because the autograft will remain the same color and texture as the palatal donor site (Fig. 14-33). If root coverage and esthetics is the goal, the connective tissue graft, laterally positioned pedicle graft, and coronally positioned flap procedures are preferrable. When the amount of attached gingiva is adequate, FGG is not indicated. If pocket elimination is a concern, an apically repositioned flap should be a choice.

In FGG the receptor site is first prepared. When a high frenum attachment has contributed to the mucogingival

Dentlearn.ir

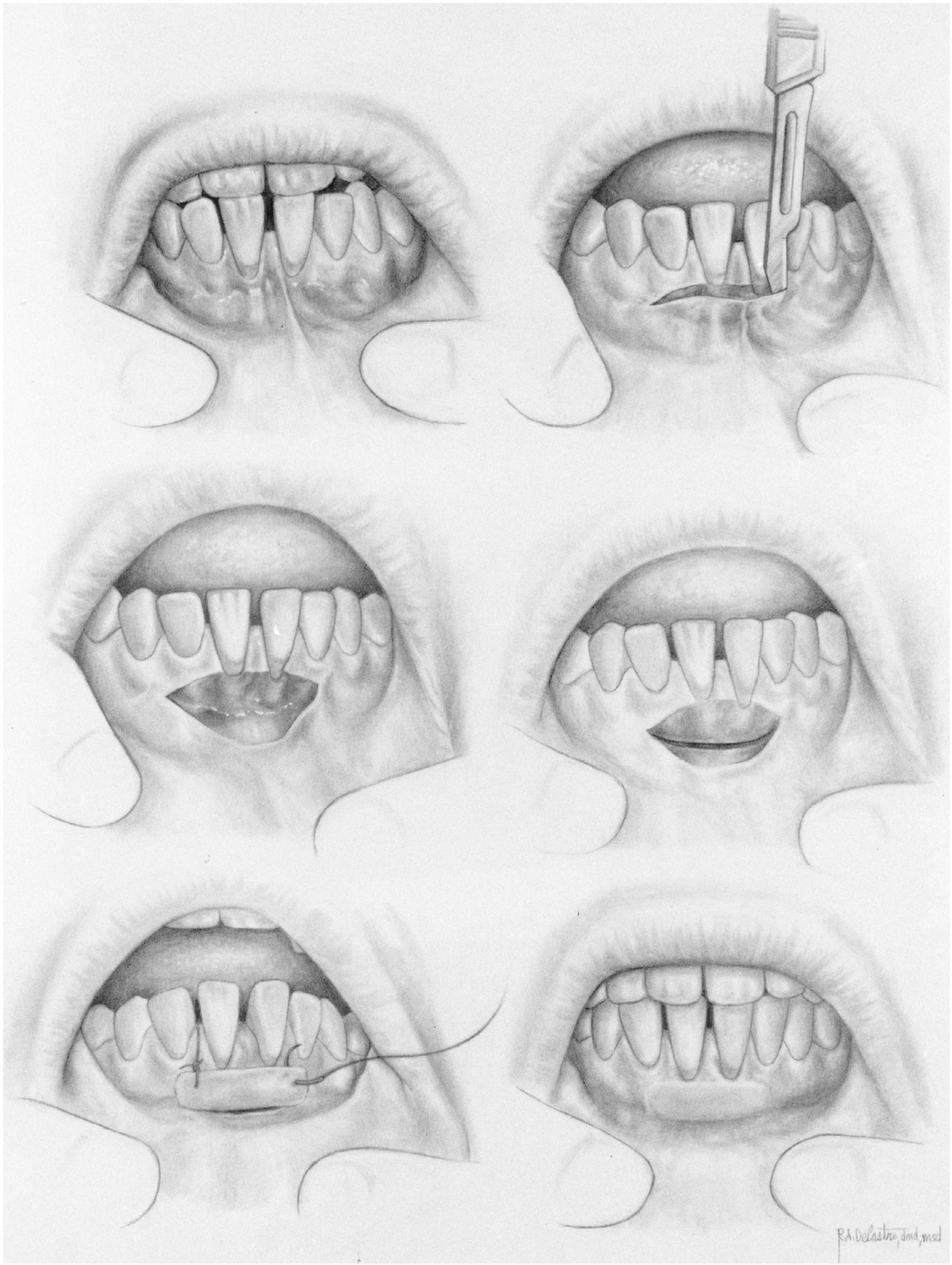

Figure 14-32 The free gingival graft procedure may be considered for children and adults when there is a shallow vestibular fornix and a high midline frenum attachment.



Figure 14-33 Two-year clinical postoperative appearance of a free gingival graft. Note the color mismatch of the free gingival graft with the surrounding soft tissue.

problem, tension is placed on the lower lip to activate the frenum and trace its insertion into the marginal tissue. A horizontal incision is made at the mucogingival junction, including the attachment of the frenum to the gingiva. The mucosa is displaced apically by blunt dissection, and a non-movable receptor site is left consisting of periosteum and a thin covering of firm connective tissue. Any gingival epithelium coronal to the primary incision is trimmed away, which leaves a receptor bed of connective tissue with an adequate blood supply.

The next step is to fenestrate the periosteum to help prevent mobility of the graft after healing. To do this, two horizontal incisions, 1 mm apart, are made through the periosteum at the apical boundary of the displaced mucosa. The isolated periosteum between the two horizontal incisions is peeled away so that the facial cortical plate of bone is exposed. A template of adhesive foil slightly larger than the mandibular receptor site is made, and the palatal donor site is anesthetized. The template is placed on the anesthetized tissue and is outlined with a shallow incision. The graft is freed from the underlying submucosa by sharp dissection. The operator should strive to secure an intermediate-thickness graft (approximately 1 mm thick).

After the graft is removed from the palate, the connective tissue side is inspected to ensure that no fatty tissue remains on it (adherent fatty tissue would prevent revascularization of the graft from the connective tissue of the receptor site). If present, the fatty tissue is carefully dissected from the graft. The graft is carried to the receptor site, and any final trimming is done to secure an approximation of the donor tissue to the receptor site. The graft is stabilized onto the recipient site using a thin non-resorbable or resorbable suture with an atraumatic (taper) needle. Multiple sling sutures, horizontal sutures, and interrupted sutures are routinely needed to secure and immobilize the graft over the recipient site. Depending on the case, a periodontal dressing may be placed over the graft to protect it. When the patient returns 7 to 10 days after surgery, the dressing (if previously applied) is removed, the area is debrided and irrigated, and the sutures are removed.

By 7 to 10 days, the graft should be firmly fixed to the underlying receptor site, and the epithelial covering should be continuous with that of the contiguous gingiva and oral mucosa. The patient is instructed to gently clean away any debris from the area with a cotton ball soaked in warm water and to continue the interdental flossing routine. Normal brushing can usually be reintroduced between 21 and 25 days after the graft is placed.

LASERS

Within the last few decades, lasers have been accepted as a novel treatment modality for a wide array of intraoral procedures, including, but not limited to: preparation of teeth for restorative purposes, pulpotomies, and obtaining incisional or excisional soft-tissue biopsies. The term "laser" stands for "light amplification by stimulated emission of radiation." The "light" is not limited to visible light but also refers to electromagnetic radiation of any frequency—infrared, ultraviolet, x-ray, etc. "Light" is amplified when "an active element undergoes stimulated quantum transitions that create the energy beam."[78] This energy beam, in turn, is a monochromatic (light of one wavelength), unidirectional, highly collimated, tightly focused beam that is directed against the targeted area. Upon absorption of the laser wavelength, the light energy is converted into thermal energy (heat) in the affected tissue, thereby triggering a photothermal effect. In other words, as heat builds up in the affected tissue, the targeted area will undergo physical and biological changes: coagulation at 65°C to 90°C, protein denaturation at 90°C to 100°C, or vaporization over 100°C.[79]

In biology, numerous biological tissues and molecules have absorption spectra in the ultraviolet, infrared, and visible wavelengths. This is important because a laser's biological effect is dependent on the targeted tissue's affinity to a specific wavelength of laser energy.[78] For instance, a CO_2 laser wavelength (10,600 nm) is readily absorbed by tissue that has high water content. Because over 75% of the soft tissue is composed of water, the energy beam emitted from a CO_2 laser is readily absorbed by soft tissue. This makes a CO_2 laser ideal in soft-tissue excisional procedures, such as frenectomies, operculum removal, or soft-tissue lesion biopsies. In comparison, an Nd:YAG laser emits an energy beam at 1064 nm and is also absorbed by tissue high in water content but not as readily as a CO_2 laser. However, unlike a CO_2 laser, an Nd:YAG laser is readily absorbed by pigmented soft tissue. This makes an Nd:YAG laser practical in cases where pigmented tissues, pigmented lesions, or hemorrhagic lesions need to be excised. Additionally, the heating effect of the Nd:YAG laser is ideal in stimulating coagulation because small capillaries and small venules have a high affinity for this wavelength. A diode laser (819 nm) is similar to the Nd:YAG laser in its affinity for pigmented tissues and hemorrhagic tissues. In contrast, an Er:YAG laser (2940 nm) and Er,Cr:YSGG laser (2780 nm) emit wavelengths that have a strong affinity for tissue with high water content and/or high hydroxyapatite content. Because of this, Er:YAG and Er,Cr:YSGG lasers are more appropriate for soft-tissue removal procedures, removal of osseous tissue, and cavity preparations.

A laser procedure known as LANAP (i.e., "laser-assisted new attachment procedure") has been introduced as an

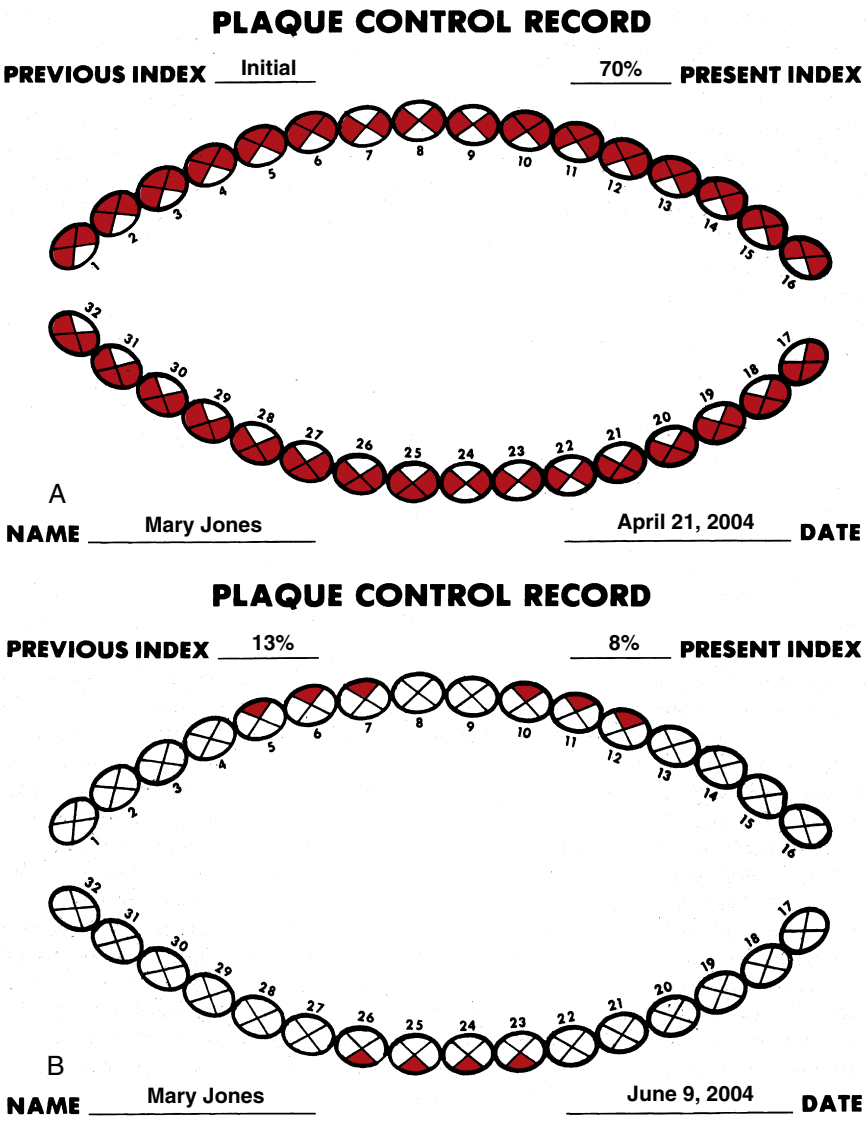

Figure 14-34 **A,** Plaque accumulations recorded at the initial control appointment. **B,** Plaque accumulations recorded at the fifth session.

alternative to conventional periodontal therapy for the treatment of chronic periodontitis.[80] The key feature of LANAP is the Nd:YAG laser, which is used to deliver a highly focused and intense beam of energy to the targeted tissue. This has several advantages. First, because the Nd:YAG laser emits an energy beam that is readily absorbed by inflamed, hemorrhagic tissue, the diseased pocket epithelium is ablated while healthy tissue is preserved. Second, because the Nd:YAG laser is attracted to pigment, the laser wavelength is readily absorbed by pathogenic black-pigmented bacteria (such as *Porphyromonas* and *Prevotella* spp), thereby inducing a bactericidal effect. Third, because the Nd:YAG is readily absorbed by blood vessels, coagulation is achieved at the treated site. The thermal fibrin clot, in turn, creates a physical barrier that prevents epithelial downgrowth and creates conditions within the subgingival environment that favor periodontal regeneration. Yet although LANAP shows great potential, evidence to support the use of lasers to treat periodontitis is scarce and inconclusive.[81] Further research is still necessary to determine the effectiveness and predictability of lasers to treat periodontitis.

CLINICAL ASSESSMENT OF ORAL CLEANLINESS AND PERIODONTAL DISEASE

PLAQUE CONTROL RECORD

O'Leary and colleagues developed the plaque control record to give the dentist, hygienist, and dental educator a simple method of recording the presence of plaque on individual tooth surfaces (mesial, distal, facial, and lingual).[82]

At the initial appointment, a suitable disclosing solution, such as Bismarck brown, is painted on all exposed tooth surfaces. After the patient has rinsed, the operator, using an explorer, examines each stained surface for soft accumulations at the dentogingival junction. When found, these accumulations are recorded by making a dash in the appropriate spaces on the record form. Figure 14-34, *A* shows a

Dentlearn.ir

form completed at the patient's first appointment for learning plaque control. No attempt is made to differentiate among the various amounts of plaque on tooth surfaces.

After all teeth are examined and scored, an index can be derived when the number of plaque-containing surfaces is divided by the total number of available surfaces. The same procedure is carried out at subsequent appointments to determine the patient's progress in learning and carrying out the prescribed oral hygiene procedures. Figure 14-34, *B* shows a patient's progress from the initial assessment to the point (fifth session) at which plaque control is deemed satisfactory.

[A detailed approach to the teaching of toothbrushing, flossing, and plaque control is described in Chapter 7.)

PERIODONTAL SCREENING AND RECORDING

As noted in Chapter 1, it is recommended to use the periodontal screening and recording (PSR) method to facilitate the early detection of periodontal diseases in children. Clerehugh and Tugnait recommend using PSR for pediatric dental patients following the eruption of the permanent incisors and first molars.[83] They suggest routine screening for new pediatric patients and at regular re-care appointments so that periodontal problems are detected early and treated appropriately. Immunodeficient children are especially vulnerable to early loss of bone support.

Although PSR was originally designed for use in adults, it has been found to be an effective method of detecting early signs of periodontal disease among certain children who may be at higher risk. PSR is not a substitute for a comprehensive periodontal examination, but it should help the clinician efficiently identify the few child or adolescent patients who need a comprehensive periodontal evaluation. In addition, the possibility of false readings caused by gingival pseudo pocketing must be considered because pseudo pocketing is more frequent in young patients.

For purposes of recording the results of PSR, the dentition is divided into six areas (sextants): two anterior sextants (maxillary and mandibular) and four posterior sextants (right and left maxillary and mandibular). The gingival sulcus depth of each tooth or implant is measured in at least six areas (three facial and three lingual areas) by gentle probing with a periodontal probe in the standard manner. Each sextant is scored for periodontal health based on a code number from 0 to 4 as follows:

- Code 0 indicates that all sulcus depths in the sextant are 3.5 mm or less, and no calculus is present and no gingival bleeding occurred from the gentle probing.
- Code 1 indicates that all sulcus depths are 3.5 mm or less, and no calculus is present but some bleeding occurred from the gentle probing.
- Code 2 indicates that all sulcus depths are 3.5 mm or less, and some calculus is present. Supra or subgingival calculus and/or defective margins are detected.
- Code 3 indicates that one or more sulcus depths are between 3.5 and 5.5 mm.
- Code 4 indicates that one or more sulcus depths are more than 5.5 mm.

In addition to the code number, an asterisk (*) may accompany the code score to indicate furcation involvement, abnormal tooth mobility, muco-gingival problems, or significant gingival recession.

Appropriate preventive care, oral hygiene instruction, and therapy (plaque and calculus removal) are indicated, as required, for patients who receive PSR code scores of 2, 1, or 0. Patients receiving code scores of 3 or 4 require more comprehensive periodontal evaluation and treatment.

EXTRINSIC STAINS AND DEPOSITS ON TEETH

Previous work regarding the staining of children's teeth has been related primarily to studies of orange and green stain of the extrinsic type. It has been generally accepted that this stain is of microbial origin, although some reports have indicated that oral iron preparations or other medications may be responsible for an additional type of extrinsic staining. The accumulation of dental deposits and stains is affected by salivary composition and flow rates, poor oral hygiene, enamel defects, and aging with exposed extrinsic factors (medications, coffee, tea, tobacco, and intrinsic physiological changes). Extrinsic stains are identified by color, distribution, and tenaciousness along with age, gender, and home care.

Staining is generally believed to be caused by extrinsic agents, which can be readily removed from tooth surfaces with an abrasive material. The agents responsible for staining are deposited in enamel defects or become attached to the enamel without bringing about a change in its surface. Pigmentation, in contrast to extrinsic staining, is associated with an active chemical change in the tooth structure, and the resulting pigment cannot be removed without alteration of the tooth structure.

GREEN STAIN

The cause of green stain, which is most often seen on the teeth of children, is unknown, although it is believed to be the result of the action of chromogenic bacteria on the enamel cuticle. Boys are more frequently affected than girls. The color of the stain varies from dark green to light yellowish-green. This tenacious deposit is seen most often in the gingival third of the labial surfaces of the maxillary anterior teeth. The stain collects more readily on the labial surfaces of the maxillary anterior teeth in mouth breathers. It tends to recur even after careful and complete removal. The enamel beneath the stain may be roughened or may have undergone initial demineralization. The roughening of the surface is believed to be related to the frequency of recurrence of the stain (Fig. 14-35). Fungi (*Penicillium* and *Aspergillus*) and fluorescent bacteria have been associated with the discoloration.

ORANGE STAIN

The cause of orange stain is likewise unknown. Orange stain occurs less frequently and is more easily removed than green or brown stain. The stain is most often seen in the gingival third of the tooth and is associated with poor oral hygiene (Fig. 14-36).

Dentlearn.ir



Figure 14-35 Dark green stain is evident on maxillary anterior teeth. Papillary and marginal gingivitis is also present. The patient had poor oral hygiene and was a mouth-breather.



Figure 14-36 Orange stain is evident in the gingival half of the maxillary left posterior teeth.

BLACK STAIN

A black stain occasionally develops on the primary or permanent teeth of children, but it is much less common than the orange or green type (Fig. 14-37). A thin black line of dots or band of stain may be seen following the gingival contour or it may be apparent in a more generalized pattern on the clinical crown, particularly if there are roughened or pitted areas. The black stain is difficult to remove, especially if it collects in pitted areas. It has been reported more frequently in females. Many children who have black stain are relatively free of dental caries and have excellent oral hygiene. The chromogenic bacterium primarily associated with this stain is *Actinomyces*.[84]

REMOVAL OF EXTRINSIC STAINS

Extrinsic stains can be removed by polishing with a rubber cup and flour pumice. If the stain is resistant and difficult to remove, the excess water should be blotted from the pumice and the teeth should be dried before the polishing procedure is performed. Because stains are most often seen in a mouth in which there is poor oral hygiene, improving the oral hygiene minimizes the recurrence of the stain.



Figure 14-37 Black stain is evident on the primary teeth. The stain is difficult to remove, particularly when it collects in roughened areas of the tooth.

PIGMENTATION CAUSED BY STANNOUS FLUORIDE APPLICATION

During the first clinical trials involving the topical application of an 8% stannous fluoride solution, certain areas of the tooth became discolored. A characteristic pigmentation of both caries and pre-caries lesions has been found to be associated with exposure to stannous fluoride.

CALCULUS

Calculus is not often seen in preschool children, and even in children of grade-school age, it occurs with much lower frequency than in adult patients. A low caries incidence is related to high calculus incidence. Bhat reported findings in 14- to 17-year-old children who participated in the 1986-1987 National Survey of Oral Health.[85] Supragingival calculus was observed in nearly 34% of the children and subgingival calculus in approximately 23%. Both types showed a predilection for molars in the maxilla and incisors and canines in the mandible. Children with mental retardation often have accumulations of calculus on their teeth. This accumulation may be related to abnormal muscular function, a soft diet, poor oral hygiene, and stagnation of saliva.

The observations reported by Turesky and colleagues regarding early calculus formation in children and adults substantiate those of others and indicate that calculus begins as a soft, adherent, bacteria-laden plaque that undergoes progressive calcification.[86] They observed calculus formation on cellulose acetate strips that were fixed in children's mouths. Plaque material that accumulated on the strips underwent progressive hardening. A soft plaque material consisted, for the most part, of bacteria appearing as a dense meshwork of diffusely distributed gram-negative cocci with occasional rod forms. Filamentous or thread-shaped organisms were scarce. Leukocytes and epithelial cells were also scattered within the amorphous matrix.

Supragingival deposits of calculus occur most frequently and in greater quantity on the buccal surfaces of the maxillary molars and the lingual surfaces of the mandibular anterior teeth. These areas are near the openings of the major salivary glands. Local factors are unquestionably important in the initiation of calculus formation.

REFERENCES

1. Delaney JE: Periodontal and soft-tissue abnormalities, *Dent Clin North Am* 39:837–850, 1995.
2. Armitage G: Development of a classification system for periodontal disease and conditions, *Ann Periodontol* 4:1–6, 1999.
3. American Academy of Pediatric Dentistry: Reference manual 2013-2014, *Pediatr Dent* 35(6 Suppl):338–345, 2013.
4. Eastcott AD, Stallard RE: Sequential changes in developing human dental plaque as visualized by scanning electron microscope, *J Periodontol* 44:218–224, 1973.
5. Suomi JD, et al.: Oral calculus in children, *J Periodontol* 42:341–345, 1971.
6. Weddell JA, Klein AI: Socioeconomic correlation of oral disease in 6- to 36-month children, *Pediatr Dent* 3:306–310, 1981.
7. Horowitz AM, et al.: Effects of supervised daily dental plaque removal by children after 3 years, *Community Dent Oral Epidemiol* 8:171–176, 1980.
8. Murray JJ: The prevalence of gingivitis in children continuously resident in a high fluoride area, *J Dent Child* 41:133–139, 1974.
9. Matsson L, Moller C: Gingival inflammatory reactions in children with rhinoconjunctivitis due to birch pollinosis, *Scand J Dent Res* 98:504–509, 1990.
10. Schaaf JE: Non-dental pharmacotherapeutics, *Alumni Bull Sch Dent Indiana Univ Spring* 48–53, 1984.
11. Faden H: Management of primary herpetic gingivostomatitis in young children, *Pediatr Emerg Care* 22(4):268, 2006.
12. Hale BD, et al.: Epidemic herpetic stomatitis in orphanage children, *Dent Abst* 8:556, 1963.
13. Kleinman DV, et al.: Epidemiology of oral mucosal lesions in United States schoolchilden: 1986-87, *Community Dent Oral Epidemiol* 22:243–253, 1994.
14. Griffith RS, Norins AL, Kagan C: A multicentered study of lysine therapy in herpes simplex infection, *Dermatologica* 156:257–267, 1978.
15. Brooks SL, et al.: Prevalence of herpes simplex virus disease in a professional population, *J Am Dent Assoc* 102:31–34, 1981.
16. Scully C, Porter S: Oral mucosal disease: recurrent aphthous stomatitis, *Br J Oral Maxillofac Surg* 46:198–206, 2008.
17. Ship JA, et al.: Recurrent aphthous stomatitis, *Quintessence Int* 31:95–112, 2000.
18. Antoon JW, Miller RL: Aphthous ulcers: a review of the literature on etiology, pathogenesis, diagnosis, and treatment, *J Am Dent Assoc* 101:803–808, 1980.
19. Greenspan JA, et al.: Lymphocyte function in recurrent aphthous ulceration, *J Oral Pathol* 14:592–602, 1985.
20. Binnie WH, et al.: Amlexanox oral paste: a novel treatment that accelerates the healing of aphthous ulcers, *Compendium Contin Educ Dent* 18:1116-1118, 1120-1122, 1124–1126, 1997.
21. Meiller TF, et al.: Effect of an antimicrobial mouth rinse on recurrent aphthous ulcerations, *Oral Surg Oral Med Oral Pathol* 72:425–429, 1991.
22. Glauser RO, et al.: An unusual gingivitis among Navajo Indians, *Periodontics* 1:255–259, 1963.
23. Grossman E, Reiter G, Sturzenberger OP: Six-month study of the effects of chlorhexidine mouthrinse on gingivitis in adults, *J Periodontal Res* 21:33, 1986.
24. Banting D, Bosma M, Bollmer B: Clinical effectiveness of a 0.12% chlorhexidine mouthrinse over two years, *J Dent Res* 68:1716, 1989.
25. Quirynen M, et al.: Effect of different chlorhexidine formulations in mouthrinses on de novo plaque formation, *J Clin Periodontol* 28:1127–1136, 2001.
26. Löe H, Schiött CR: The effect of mouthrinses and topical application of chlorhexidine on the development of dental plaque and gingivitis in man, *J Periodontal Res* 5:79–83, 1970.
27. Yankell SL, et al.: Laboratory and clinical stain removal evaluations of two tartar control dentifrices, *J Clin Dent* 6:207–210, 1995.
28. Brecx M, et al.: Efficacy of Listerine, Meridol and chlorhexidine mouthrinses as supplements to regular tooth-cleaning measures, *J Clin Periodontol* 19:202–207, 1992.
29. Barnett ML: The rationale for the daily use of an antimicrobial mouthrinse, *J Am Dent Assoc* 137(7 Suppl):16S–21S, 2006.
30. Cohen MM: The effect of large doses of ascorbic acid on gingival tissue at puberty, *J Dent Res* 34:750–751, 1955 (abstract).
31. Nakagawa S, et al.: A longitudinal study from prepuberty to puberty of gingivitis, *J Clin Periodontol* 21:658–665, 1994.
32. Sutcliffe P: A longitudinal study of gingivitis and puberty, *J Periodontal Res* 7:52–58, 1972.
33. De Pommereau V, et al.: Periodontal status in insulin-dependent diabetic adolescents, *J Clin Periodontol* 19: 628–632, 1992.
34. Zackin SJ, Weisberger D: Hereditary gingival fibromatosis: report of a family, *Oral Surg Oral Med Oral Pathol* 14:825–835, 1961.
35. Brown RS, et al.: Treatment of a patient with hereditary gingival fibromatosis: a case report, *Spec Care Dentist* 15:149–153, 1995.
36. Kimball OP: Treatment of epilepsy with sodium diphenylhydantoinate, *J Am Med Assoc* 112:1244–1245, 1939.
37. Castetta I, et al.: Phenytoin-induced gingival overgrowth, a community-based cross-sectional study in Ferrara, Italy, *Neuroepidemiology* 16:296–303, 1997.
38. Hassell T, et al.: Diphenylhydantoin (Dilantin) gingival hyperplasia: drug-induced abnormality of connective tissue, *Proc Natl Acad Sci USA* 73:2909–2912, 1976.
39. Addy V, et al.: Risk factors in phenytoin-induced gingival hyperplasia, *J Periodontol* 54:373–377, 1983.
40. Kapur RN, et al.: Diphenylhydantoin-induced gingival hyperplasia: its relationship to dose and serum level, *Dev Med Child Neurol* 15:483–487, 1973.
41. Little RM, et al.: Diphenylhydantoin-induced gingival hyperplasia: its response to changes in drug dosage, *Dev Med Child Neurol* 17:421–424, 1975.
42. Livingston S, et al.: The medical treatment of epilepsy: managing side effects of antiepileptic drugs, *Pediatr Ann* 8:261–266, 1979.
43. Ciancio SG, et al.: Gingival hyperplasia and diphenylhydantoin, *J Periodontol* 43:411–414, 1972.
44. Sasaki T, Maita E: Increased BfGF level in the serum of patients with phenytoin-induced gingival overgrowth, *J Clin Periodontol* 25:42–47, 1998.
45. Jones JE, et al.: Incidence and indications for surgical management of phenytoin-induced gingival overgrowth in a cerebral palsy population, *J Oral Maxillofac Surg* 46:385–390, 1988.
46. Steinberg SC, Steinberg AD: Phenytoin-induced gingival overgrowth control in severely retarded children, *J Periodontol* 53:429–433, 1982.
47. Donnenfeld OW, et al.: A nine-month clinical and histological study of patients on diphenyl hydantoin following gingivectomy, *J Periodontol* 45:547–557, 1974.

48. Davis RK, et al.: A preliminary report on a new therapy for Dilantin gingival hyperplasia, *J Periodontol* 34:17–22, 1963.
49. Sheridan PJ, Reeve CM: Effective treatment of Dilantin gingival hyperplasia, *Oral Surg Oral Med Oral Pathol* 35:42–46, 1973.
50. Steinberg AD: Clinical management of phenytoin-induced gingival overgrowth in handicapped children, *Pediatr Dent* 3(Spec Iss):130–136, 1981.
51. Drew HJ, et al.: Effect of folate on phenytoin hyperplasia, *J Clin Periodontol* 14:350–356, 1987.
52. Bäckman N, et al.: Folate treatment of diphenylhydantoin-induced gingival hyperplasia, *Scand J Dent Res* 97:222–232, 1989.
53. American Academy of Periodontology: Parameter on aggressive periodontitis, *J Periodontol* 71(Suppl):867, 2000.
54. Albandar JM, et al.: Clinical features of early-onset periodontitis, *J Am Dent Assoc* 128:1393–1399, 1997.
55. Löe H, Brown LJ: Early onset of periodontitis in the United States of America, *J Periodontol* 62:608–616, 1991.
56. Deas DE, et al.: Systemic disease and periodontitis: manifestations of neutrophil dysfunction, *Periodontol 2000* 32:82, 2003.
57. Asikainen S, et al.: Can one acquire periodontal bacteria and periodontitis from a family member? *J Am Dent Assoc* 128:1263–1270, 1997.
58. Page RC, et al.: Clinical and laboratory studies of a family with a high prevalence of juvenile periodontitis, *J Periodontol* 56:602–610, 1985.
59. Christersson LA, et al.: Microbiological and clinical effects of surgical treatment of localized juvenile periodontitis, *J Clin Periodontol* 12:465–476, 1985.
60. Goepferd SJ: Advanced alveolar bone loss in the primary dentition: a case report, *J Periodontol* 52:753–757, 1981.
61. Coccia CT, et al.: Papillon-Lefèvre syndrome: precocious periodontosis with palmar-plantar hyperkeratosis, *J Periodontol* 37:408–414, 1966.
62. Canger EM, et al.: Intraoral findings of Papillon-Lefevre syndrome, *J Dent Child* 75:99–103, 2008.
63. Gorlin RJ, et al.: The syndrome of palmar-plantar hyperkeratosis and premature periodontal destruction of the teeth, *J Pediatr* 65:895–908, 1964.
64. Tinanoff N, et al.: Dental treatment of Papillon-Lefèvre syndrome: 15-year follow-up, *J Clin Periodontol* 22:609–612, 1995.
65. Plesset DN: Auto-extraction, *Oral Surg Oral Med Oral Pathol* 12:302–303, 1959.
66. Leksell E, Edvardson S: A case of Tourette syndrome presenting with oral self-injurious behaviour, *Int J Paediatr Dent* 15(5):370–374, 2005.
67. Krejci CB: Self-inflicted gingival injury due to habitual fingernail biting, *J Periodontol* 71:1029–1031, 2000.
68. Stewart DJ, Kernohan DC: Traumatic gingival recession in infants: the result of a dummy sucking habit, *Br Dent J* 135:157–158, 1973.
69. Friedlander AH, et al.: The neuropathology, medical management and dental implications of autism, *J Am Dent Assoc* 137:1517–1527, 2006.
70. Littlewood SJ, Mitchell L: The dental problems and management of a patient suffering from congenital insensitivity to pain, *Int J Paediatr Dent* 8:47–50, 1998.
71. Cusumano FJ, et al.: Prevention of self-mutilation in patients with Lesch-Nyhan syndrome: review of literature, *J Dent Child* 68:175–178, 2001.
72. Henry SW, et al.: Histologic features of the superior labial frenum, *J Periodontol* 47:25–28, 1976.
73. Ross, et al.: Histologic survey of the frena of the oral cavity, *Quintessence Int* 20:233–347, 1990.
74. Suter V, Bornstein MM: Ankyloglossia: facts and myths in diagnosis and treatment, *J Periodontol* 80(8):1204–1219, 2009.
75. Bohannan HM: Studies in the alteration of vestibular depth. I, Complete denudation, *J Periodontol* 33:120–128, 1962.
76. Bohannan HM: Studies in the alteration of vestibular depth. II, Periosteum retention, *J Periodontol* 33:354–359, 1962.
77. Bohannan HM: III: Vestibular incision, *J Periodontol* 34: 209–215, 1963.
78. Cobb C: AAP-Commissioned Review: Lasers in periodontics: a review of the literature, *J Periodontol* 77(4):545–564, 2006.
79. American Academy of Periodontology Academy Report: Lasers in periodontics, *J Periodontol* 73(10):1231–1239, 2002.
80. Gregg RH, McCarthy D: Laser periodontal therapy for bone regeneration, *Dent Today* 21:54–59, 2002.
81. American Academy of Periodontology: Statement on the efficacy of lasers in non-surgical treatment of inflammatory periodontal disease, *J Periodontol* 82(4):513–514, 2011.
82. O'Leary TJ, et al.: The plaque control record, *J Periodontol* 43:38, 1972.
83. Clerehugh V, Tugnait A: Periodontal diseases in children and adolescents: I. Aetiology and diagnosis, *Dent Update* 28: 222–230, 232, 2001.
84. Slots J: The microflora of black stain on primary teeth, *Scand J Dent Res* 82:484–490, 1974.
85. Bhat M: Periodontal health of 14- to 17-year-old US schoolchildren, *J Public Health Dent* 51:5–11, 1991.
86. Turesky S, et al.: Histologic and histochemical observations regarding early calculus formation in children and adults, *J Periodontol* 32:7–14, 1961.

PART 3 PAIN CONTROL AND BEHAVIOR GUIDANCE

CHAPTER 15

Local Anesthesia and Pain Control for the Child and Adolescent

▲ James E. Jones and Jeffrey A. Dean

For additional resources, please visit the evolve website.

CHAPTER OUTLINE

TOPICAL ANESTHETICS
JET INJECTION
LOCAL ANESTHESIA BY CONVENTIONAL INJECTION
ANESTHETIZATION OF MANDIBULAR TEETH AND SOFT TISSUE
- Inferior Alveolar Nerve Block (Conventional Mandibular Block)
- Lingual Nerve Block
- Long Buccal Nerve Block
- Infiltration Anesthesia for Mandibular Primary Molars
- Infiltration for Mandibular Incisors
- Mandibular Conduction Anesthesia (Gow-Gates Mandibular Block Technique)

ANESTHETIZATION OF MAXILLARY PRIMARY AND PERMANENT INCISORS AND CANINES
- Supraperiosteal Technique (Local Infiltration)

ANESTHETIZATION OF MAXILLARY PRIMARY MOLARS AND PREMOLARS
ANESTHETIZATION OF MAXILLARY PERMANENT MOLARS
ANESTHETIZATION OF THE PALATAL TISSUES
- Nasopalatine Nerve Block
- Greater (Anterior) Palatine Injection

SUPPLEMENTAL INJECTION TECHNIQUES
- Infraorbital Nerve Block and Mental Nerve Block
- Periodontal Ligament Injection (Intraligamentary Injection)
- Intraosseous Injection, Interseptal Injection, and Intrapulpal Injection
- Computer-Controlled Local Anesthetic Delivery System (Wand)

COMPLICATIONS AFTER A LOCAL ANESTHETIC
- Anesthetic Toxicity
- Trauma to Soft Tissue

REVERSAL OF DENTAL ANESTHESIA
ANALGESICS

It is generally agreed that one of the most important aspects of child behavior guidance in the dental office is the control of pain during dental procedures. If children experience pain during restorative or surgical procedures, their future as dental patients may be damaged. Therefore it is important at each visit to reduce discomfort to a minimum and to control painful situations. There are many pharmacologic pain control strategies to help children cope with these situations, both preoperatively and postoperatively. Most of these strategies involve the use of local anesthetics or analgesics.

Because there is usually some discomfort associated with the procedure, use of a local anesthetic is generally indicated when operative work is to be performed on the permanent teeth, and the same is true of cavity preparations in primary teeth. Dental procedures can be carried out more effectively if the child is comfortable and free of pain. The local anesthetic can prevent discomfort that may be associated with placing a rubber dam clamp, ligating teeth, and cutting tooth structure. Even the youngest child treated in the dental office normally has no contraindications for the use of a local anesthetic.

Investigators have found that injection is the dental procedure that produces the greatest negative response in children. Responses become increasingly negative over a series of four or five injections. Venham and Quatrocelli[1] have reported that a series of dental visits sensitized children to the stressful injection procedure while reducing their apprehension toward relatively nonstressful procedures. Thus dentists should anticipate the need for continued efforts to help the child cope with dental injections.

TOPICAL ANESTHETICS

Topical anesthetics reduce the slight discomfort that may be associated with the insertion of the needle before the

Dentlearn.ir

injection of the local anesthetic. Some topical anesthetics, however, present a disadvantage if they have a disagreeable taste. Also, the additional time required to apply them may increase the child's apprehension concerning the approaching procedure.

Topical anesthetics are available in gel, liquid, ointment, and pressurized spray forms. However, the pleasant-tasting and quick-acting liquid, gel, or ointment preparations seem to be preferred by most dentists. These agents are applied to the oral mucous membranes with a cotton-tipped applicator. Numerous anesthetic agents have been used in topical anesthetic preparations, including ethyl aminobenzoate, butacaine sulfate, cocaine, dyclonine, lidocaine, and tetracaine.

Ethyl aminobenzoate (benzocaine) liquid, ointment, or gel preparations are probably best suited for topical anesthesia in dentistry. They offer a more rapid onset and longer duration of anesthesia than other topical agents. They are not known to produce systemic toxicity as oral topical anesthetics, but a few localized allergic reactions have been reported from prolonged or repeated use. Examples of commercially available products are Hurricaine (Beutlich L.P. Pharmaceuticals, Inc., Chicago, Illinois, United States), Topicale (Premier Dental Products, Inc., Plymouth Meeting, Pennsylvania, United States), and Gingicaine (Gingi-Pak, Inc., Camarillo, California, United States). All three products are available in gel form. Gingicaine is also available in liquid and spray forms, Hurricaine as a liquid, and Topicale in ointment and patch forms. All products are supplied in a variety of flavors.

The mucosa at the site of the intended needle insertion is dried with gauze, and a small amount of the topical anesthetic agent is applied to the tissue with a cotton swab. Topical anesthesia should be produced in approximately 30 seconds.

During the application of the topical anesthetic, the dentist should prepare the child for the injection. The explanation should not necessarily be a detailed description but simply an indication that the tooth is going to be put to sleep so that the treatment can proceed without discomfort.

JET INJECTION

The jet injection instrument is based on the principle that small quantities of liquids forced through very small openings under high pressure can penetrate mucous membrane or skin without causing excessive tissue trauma. One jet injection device, the Syrijet Mark II (Keystone Industries, Cherry Hill, New Jersey, United States), holds a standard 1.8-mL cartridge of local anesthetic solution. It can be adjusted to expel 0.05 to 0.2 mL of solution under 2000 psi pressure.

Jet injection produces surface anesthesia instantly and is used instead of topical anesthetics by some dentists. The method is quick and essentially painless, although the abruptness of the injection may produce momentary anxiety in the patient. This technique is also useful for obtaining gingival anesthesia before a rubber dam clamp is placed for isolation procedures that otherwise do not require local anesthetic. Similarly, soft-tissue anesthesia may be obtained before band adaptation of partially erupted molars or for the removal of a very loose (soft-tissue–retained) primary tooth. O'Toole has reported that the Syrijet may be used instead of needle injections for nasopalatine, anterior palatine, and long buccal nerve blocks.[2]

A more recently developed jet injection device, reported by Duckworth and colleagues, delivers a dose of dry powdered anesthetic to the oral mucosa.[3] In this study—an initial trial with 14 adult participants—successful topical analgesia without tissue damage was reported. More clinical trials are required before substantial claims can be made regarding the efficacious of this technique and whether its routine use for topical anesthesia is warranted.

LOCAL ANESTHESIA BY CONVENTIONAL INJECTION

Wittrock and Fischer[4] and later Trapp and Davies[5] demonstrated that human blood can be readily aspirated with the smaller-gauge needles. Trapp and Davies reported positive aspiration through 23-, 25-, 27-, and 30-gauge needles without a clinically significant difference in resistance to flow. Malamed recommends the use of larger-gauge needles (i.e., 25 gauge) for injection into highly vascular areas or areas where needle deflection through soft tissue may be a factor.[6] Regardless of the size of the needle used, it is generally agreed that the anesthetic solution should be injected slowly, and that the dentist should watch the patient closely for any evidence of an unexpected reaction. The injections that are most commonly used in the treatment of children are described in the following sections.

ANESTHETIZATION OF MANDIBULAR TEETH AND SOFT TISSUE

INFERIOR ALVEOLAR NERVE BLOCK (CONVENTIONAL MANDIBULAR BLOCK)

In general, when deep operative or surgical procedures are undertaken for the mandibular primary or permanent teeth, the inferior alveolar nerve must be blocked. The supraperiosteal injection technique may sometimes be useful in anesthetizing primary incisors, but it is not as reliable for complete anesthesia of the mandibular primary or permanent molars.

Olsen reported that the mandibular foramen is situated at a level lower than the occlusal plane of the primary teeth of the pediatric patient.[7] Therefore the injection must be made slightly lower and more posteriorly than for an adult patient. An accepted technique is one in which the thumb is laid on the occlusal surface of the oblique ridge and the ball of the thumb resting in the retromolar fossa. Firm support during the injection procedure can be given when the ball of the middle finger is resting on the posterior border of the mandible. The barrel of the syringe should be directed on a plane between the two primary molars on the opposite side of the arch. It is advisable to inject a small amount of the solution as soon as the tissue is penetrated and to continue to inject minute quantities as the needle is directed toward the mandibular foramen.

Dentlearn.ir

The depth of insertion averages about 15 mm but varies with the size of the mandible and its changing proportions, depending on the age of the patient. Approximately 1 mL of the solution should be deposited around the inferior alveolar nerve (Figs. 15-1 and 15-2).

LINGUAL NERVE BLOCK

One can block the lingual nerve by bringing the syringe to the opposite side with the injection of a small quantity of the solution as the needle is withdrawn. If small amounts of anesthetic are injected during insertion and withdrawal of the needle for the inferior alveolar nerve block, the lingual nerve will invariably be anesthetized as well.

LONG BUCCAL NERVE BLOCK

For the removal of mandibular permanent molars or sometimes for the placement of a rubber dam clamp on these teeth, it is necessary to anesthetize the long buccal nerve. A small quantity of the solution may be deposited in the mucobuccal fold at a point distal and buccal to the indicated tooth (Fig. 15-3).



Figure 15-1 The mandible is supported by the thumb and middle finger, while the needle is directed toward the inferior alveolar nerve.



Figure 15-2 Anesthetic solution is deposited around the inferior alveolar nerve.

All facial mandibular gingival tissue on the side that has been injected will be anesthetized for operative procedures, with the possible exception of the tissue facial to the central and lateral incisors, which may receive innervation from overlapping nerve fibers from the opposite side.

INFILTRATION ANESTHESIA FOR MANDIBULAR PRIMARY MOLARS

To test the hypothesis that dental pain control by infiltration/intrapapillary injection was less effective than inferior alveolar block/long buccal infiltration anesthesia in children, Naidu and colleagues[8] conducted study comparing two local anesthesia techniques using 2% lidocaine, 1:100,000 epinephrine. They studied 101 healthy children, aged 5 to 8 years, who had no contraindication for local anesthetic and who needed a pulpotomy treatment and stainless steel crown placement in a mandibular primary molar. All children were given 40% nitrous oxide. Children self-reported pain using the Color Analogue Scale (from 1, indicating "no pain," to 10, indicating "most pain"). The overall pain levels reported by the children were low, and there were no differences between conditions at any point in the procedure. Mean self-reported pain reports for clamp placement were 2.8 for block/long buccal and 1.9 for infiltration/intrapapillary ($p = 0.1$). Pain reports for drilling were 2.0 for block/long buccal and 1.8 for infiltration/intrapapillary ($p = 0.7$). Supplementary local anesthetic was required by 9% of the children (4 of 0.07). There was no difference in pain control effectiveness between infiltration/intrapapillary injection and inferior alveolar block/long buccal infiltration by 2% lidocaine with 1:100,000 epinephrine when mandibular primary molars received pulpotomy treatment and stainless steel crowns.

Oulis and associates[9] reported similar results when comparing the effectiveness of mandibular infiltration anesthesia with that of mandibular block anesthesia



Figure 15-3 In anesthetization of the long buccal nerve, a small quantity of the solution may be deposited in the mucobuccal fold adjacent to the first permanent molar.

Dentlearn.ir

in children 3 to 9 years of age requiring the same type of treatment on contralateral mandibular molars. The half-mouth study design was used. Dental procedures included class I and II amalgam restorations, stainless steel crowns, formocresol pulpotomies, and extractions. Evaluations of pain and behavior for each anesthetic technique and type of treatment were made based on sounds, motor, and ocular changes indicating pain and on the Frankl behavior rating scale. Evaluations were made upon probing, rubber dam placement, and during tooth preparation and extraction. Study results reported that no statistically significant difference was found between the two anesthetic techniques for either behavior pain during amalgam or stainless steel crown restorations ($p = 0.05$). Mandibular infiltration was less effective than mandibular block for pulpotomy and extraction ($p = 0.05$). No significant relationship between effectiveness and age, as determined by primary or mixed dentition, was noticed.

In 1976 a new local anesthetic, articaine, was introduced in Europe, and by 1983 it was in use in Canada. It was not available in the United States until 2000, by which time the preservative had been removed from the formulation, and it received Food and Drug Administration (FDA) approval. Articaine (Septocaine), manu-

underwent several research studies to test its reliability and effectiveness, and it became readily available and widely used. Articaine is unique among local anesthet-

an amide intermediate chain) that is metabolized in the

metabolism via pseudocholinesterase, which purportedly increases the rate of breakdown and reduces toxicity. This difference in metabolism gives articaine the advantage of having a 30-minute half-life; lidocaine, for example, has a 90-minute half-life.[10-14]

Sharaf[15] demonstrated that behavior in young children can be adversely affected by the painful mandibular block. It is well known that articaine has a high bone-penetrating ability, which suggests that it may be more successful as a locally injected infiltration. From these reports, one may infer that mandibular infiltration anesthesia may produce adequate anesthesia in mandibular deciduous molars for most restorative procedures (Video 15-1: Local anesthetic techniques 1 and 2).

INFILTRATION FOR MANDIBULAR INCISORS

The terminal ends of the inferior alveolar nerves cross over the mandibular midline slightly and provide conjoined innervation of the mandibular incisors. A single inferior alveolar nerve block may not be adequate for operative or surgical procedures on the incisors, even on the side of the block anesthesia. The labial cortical bone overlying the mandibular incisors is usually thin enough for supraperiosteal anesthesia techniques to be effective.

If only superficial caries excavation of mandibular incisors is needed or if the removal of a partially exfoliated primary incisor is planned, infiltration anesthesia alone may be adequate. Incisor infiltration is most useful as an adjunct to an inferior alveolar nerve block when total anesthesia of the quadrant is desired. In this case the infiltration injection is made close to the midline on the side of the block anesthesia, but the solution is deposited labial to the incisors on the opposite side of the midline.

MANDIBULAR CONDUCTION ANESTHESIA (GOW-GATES MANDIBULAR BLOCK TECHNIQUE)

In 1973 Gow-Gates introduced a new method of achieving mandibular anesthesia, which he referred to as *mandibular conduction anesthesia*.[16] This approach uses external anatomic landmarks to align the needle so that anesthetic solution is deposited at the base of the neck of the mandibular condyle. This technique is a nerve block procedure that anesthetizes virtually the entire distribution of the fifth cranial nerve in the mandibular area, including the inferior alveolar, lingual, buccal, mental, incisive, auriculotemporal, and mylohyoid nerves. Thus with a single injection, the entire right or left half of the mandibular teeth and soft tissues can be anesthetized, except possibly the mandibular incisors, which may receive partial innervation from the incisive nerves of the opposite side. Gow-Gates suggested that, once the technique is learned properly, it rarely fails to produce good mandibular anesthesia.[16] He used the technique in practice more than 50,000 times. The technique has become increasingly popular and is often referred to as the *Gow-Gates technique*.

The external landmarks to help align the needle for this injection are the tragus of the ear and the corner of the mouth. The needle is inserted just medial to the tendon of the temporal muscle and considerably superior to the insertion point for conventional mandibular block anesthesia. The needle is also inclined upward and parallel to a line from the corner of the patient's mouth to the lower border of the tragus (intertragic notch). The needle and the barrel of the syringe should be directed toward the injection site from the corner of the mouth on the opposite side (Fig. 15-4).



Figure 15-4 Barrel of the syringe is aligned with a line from the corner of the mouth to the intertragic notch.

Dentlearn.ir

ANESTHETIZATION OF MAXILLARY PRIMARY AND PERMANENT INCISORS AND CANINES

SUPRAPERIOSTEAL TECHNIQUE (LOCAL INFILTRATION)

Local infiltration (supraperiosteal technique) is used to anesthetize the primary anterior teeth. The injection should be made closer to the gingival margin than in the patient with permanent teeth, and the solution should be deposited close to the bone. After the needle tip has penetrated the soft tissue at the mucobuccal fold, it needs little advancement before the solution is deposited (2 mm at most) because the apices of the maxillary primary anterior teeth are essentially at the level of the mucobuccal fold. Some dentists prefer to pull the upper lip down over the needle tip to penetrate the tissue rather than advancing the needle upward. This approach works quite well for the maxillary anterior region (Figs. 15-5 to 15-7).

In the anesthetization of the permanent central incisor teeth, the puncture site is at the mucobuccal fold so that the solution may be deposited slowly and slightly above and close to the apex of the tooth. Because nerve fibers may be extending from the opposite side, it may be necessary to deposit a small amount of the anesthetic solution adjacent to the apex of the other central incisor to obtain adequate anesthesia in either primary or permanent teeth. If a rubber dam is to be applied, it is advisable to inject a drop or two of anesthetic solution into the lingual free marginal tissue to prevent the discomfort associated with the placement of the rubber dam clamp and ligatures.

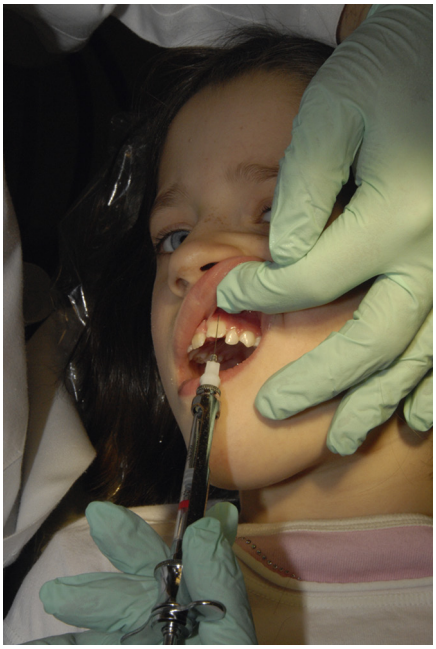

Figure 15-5 Anesthetization of a central incisor. The supraperiosteal injection should be close to the bone and adjacent to the apex of the tooth.

Before extraction of the incisors or canines in either the primary or permanent dentition, it is necessary for the palatal soft tissues to be anesthetized. The nasopalatine injection provides adequate anesthesia for the palatal tissues of all four incisors and at least partial anesthesia of the canine areas. Nerve fibers from the greater (anterior) palatine nerve usually extend to the canine area as well. If only a single anterior tooth is to be removed, adequate palatal anesthesia may also be obtained when anesthetic solution is deposited in the attached palatal gingiva adjacent to the tooth to be removed. If it is observed that the patient does not have profound anesthesia of anterior teeth during the operative procedures with the supraperiosteal technique, a nasopalatine injection is advisable.

ANESTHETIZATION OF MAXILLARY PRIMARY MOLARS AND PREMOLARS

Traditionally, dentists have been taught that the middle superior alveolar nerve supplies the maxillary primary molars, the premolars, and the mesiobuccal root of the first permanent molar. There is no doubt that the middle superior alveolar nerve is at least partially responsible for

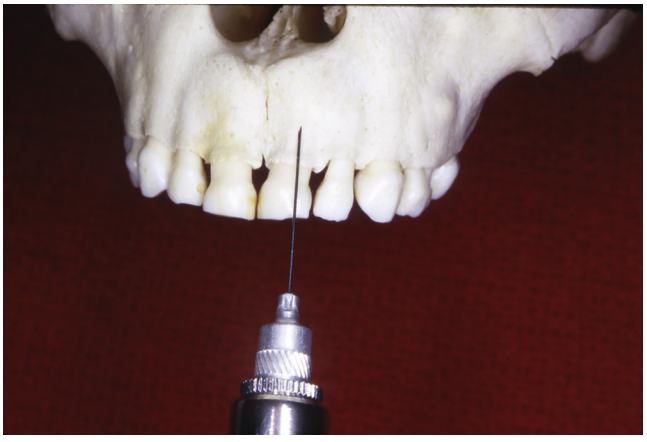

Figure 15-6 Needle point is opposite the apex of the maxillary primary incisor.



Figure 15-7 Position of the needle for anesthetization of a maxillary primary canine.

Dentlearn.ir

the innervation of these teeth. However, Jorgensen and Hayden, during child cadaver dissections, have demonstrated plexus formation of the middle and posterior superior alveolar nerves in the primary molar area.[17] The role of the posterior superior alveolar nerve in innervating the primary molar area has not previously received adequate attention. In addition, Jorgensen and Hayden have demonstrated maxillary bone thickness approaching 1 cm overlying the buccal roots of the first permanent and second primary molars in the skulls of children.[17]

The bone overlying the first primary molar is thin, and this tooth can be adequately anesthetized by injection of anesthetic solution opposite the apices of the roots (Figs. 15-8 and 15-9). However, the thick zygomatic process overlies the buccal roots of the second primary and first permanent molars in the primary and early-mixed dentition. This thickness of bone renders the supraperiosteal injection at the apices of the roots of the second primary molar much less effective; the injection should be supplemented with a second injection superior to the maxillary tuberosity area to block the posterior superior alveolar nerve, as has been traditionally taught for permanent molars (Fig. 15-10). This supplemental injection helps compensate for the additional bone thickness and the posterior middle superior alveolar nerve plexus in the area of the second primary molar, which compromise the anesthesia obtained by injection at the apices only.

For anesthetization of the maxillary first or second premolar, a single injection is made at the mucobuccal fold to allow the solution to be deposited slightly above the apex of the tooth. Because of the horizontal and vertical growth of the maxilla that has occurred by the time the premolars erupt, the buccal cortical bone overlying their roots is thin enough to permit good anesthesia with this method. The injection should be made slowly, and the solution should be deposited close to the bone; these recommendations hold true for all supraperiosteal and block anesthesia techniques in dentistry.

Before operative procedures for maxillary primary molars and maxillary premolars are undertaken, the appropriate injection techniques for the buccal tissues, as described, should be performed. If the rubber dam clamp impinges on the palatal tissue, injection of a drop or two of the anesthetic solution into the free marginal tissue lingual to the clamped tooth alleviates the discomfort and is less painful than the true greater (anterior) palatine injection. The greater palatine injection is indicated if maxillary primary molars or premolars are to be extracted or if palatal tissue surgery is planned.



Figure 15-8 Injection of the anesthetic solution to anesthetize the maxillary second primary molar for operative procedures.

ANESTHETIZATION OF MAXILLARY PERMANENT MOLARS

To anesthetize the maxillary first or second permanent molars, the dentist instructs the child to partially close the mouth to allow the cheek and lips to be stretched laterally. The tip of the dentist's left forefinger (for a right-handed dentist) will rest in a concavity in the mucobuccal fold and is rotated to allow the fingernail to be adjacent to the mucosa. The ball of the finger is in contact with the posterior surface of the zygomatic process. Bennett suggests that the finger be on a plane at right angles to the occlusal surfaces of the maxillary teeth and at 45° to the patient's sagittal plane.[18] The index finger should point in the direction of the needle during the injection.



Figure 15-9 Anesthetic solution is injected opposite the apices of the buccal roots of the first primary molar.



Figure 15-10 Posterior superior alveolar injection for maxillary permanent molars and second primary molar.

Dentlearn.ir

The puncture point is in the mucobuccal fold above and distal to the distobuccal root of the first permanent molar. If the second molar has erupted, the injection should be made above the second molar. The needle is advanced upward and distally, depositing the solution over the apices of the teeth. The needle is inserted for a distance of approximately 2 cm in a posterior and upward direction; it should be positioned close to the bone, with the bevel toward the bone (see Fig. 15-10).

For complete anesthesia of the first permanent molar for operative procedures, the supraperiosteal injection is made by insertion of the needle in the mucobuccal fold and deposition of the solution at the apex of the mesiobuccal root of the molar.

ANESTHETIZATION OF THE PALATAL TISSUES

Anesthesia of the palatal tissues can be one of the more exquisitely painful procedures performed in dentistry. Ramirez and colleagues discuss methods for achieving profound anesthesia with minimal pain in the palatal and lingual aspects.[19] After buccal infiltration they suggest interdental (interpapillary) infiltration, with slow injection of the anesthetic solution as the needle is penetrating the papilla. The interdental infiltration allows for diffusion of the anesthetic to the palatal aspect via the craterlike area of the interproximal oral mucosa joining the lingual and buccal interdental papillae, known as the *col*. Blanching of the area indicates sufficient anesthesia of the superficial soft tissues; however, additional palatal infiltration may be given as needed.

NASOPALATINE NERVE BLOCK

Blocking the nasopalatine nerve anesthetizes the palatal tissues of the six anterior teeth. If the needle is carried into the canal, it is possible to anesthetize the six anterior teeth completely. However, this technique is painful and is not routinely used before operative procedures. If the patient experiences incomplete anesthesia after supraperiosteal injection above the apices of the anterior teeth on the labial side, it may be necessary to resort to the nasopalatine injection. The path of insertion of the needle is alongside the incisive papilla, just posterior to the central incisors. The needle is directed upward into the incisive canal (Fig. 15-11). The discomfort associated with the injection can be reduced by deposition of the anesthetic solution in advance of the needle. When anesthesia of the canine area is required, it may be necessary to inject a small amount of anesthetic solution into the gingival tissue adjacent to the lingual aspect of the canine to anesthetize overlapping branches of the greater palatine nerve.

GREATER (ANTERIOR) PALATINE INJECTION

The greater palatine injection anesthetizes the mucoperiosteum of the palate from the tuberosity to the canine region and from the median line to the gingival crest on the injected side. This injection is used with the middle or posterior alveolar nerve block before surgical procedures. The innervation of the soft tissues of the posterior two thirds of the palate is derived from the greater and lesser palatine nerves.



Figure 15-11 The needle is directed upward into the incisive canal when the nasopalatine nerve is anesthetized.



Figure 15-12 Greater palatine injection is used in conjunction with the middle or posterior alveolar nerve block before removal of a maxillary primary molar.

Before the injection is made, it is helpful to bisect an imaginary line drawn from the gingival border of the most posterior molar that has erupted to the midline. Approaching from the opposite side of the mouth, the dentist makes the injection along this imaginary line and distal to the last tooth (Figs. 15-12 and 15-13). In the child in whom only the primary dentition has erupted, the injection should be made approximately 10 mm posterior to the distal surface of the second primary molar. It is not necessary to enter the greater palatine foramen. A few drops of the solution should be injected slowly at the point where the nerve emerges from the foramen.

Dentlearn.ir

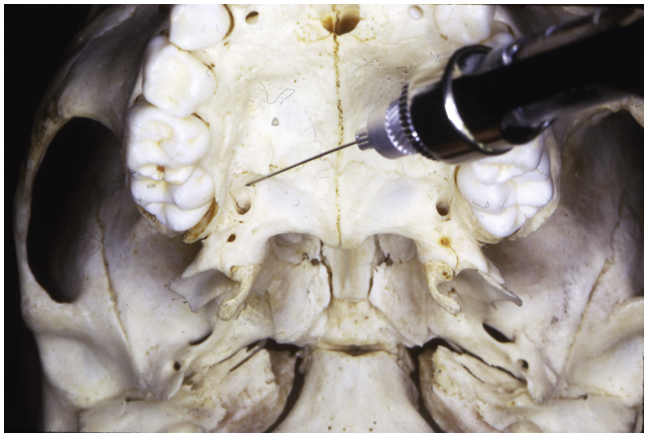

Figure 15-13 The needle is inserted approximately 10 mm posterior to the distal surface of the second primary molar.

SUPPLEMENTAL INJECTION TECHNIQUES

INFRAORBITAL NERVE BLOCK AND MENTAL NERVE BLOCK

The infraorbital nerve block and mental nerve block are two additional local anesthetic techniques used by many dentists. The infraorbital nerve block anesthetizes the branches of the anterior and middle superior alveolar nerves. It also affects innervation of the soft tissues below the eye, half of the nose, and the oral musculature of the upper lip on the injected side of the face. This leaves the child with a feeling of numbness above the mouth similar to that below the mouth when an inferior alveolar nerve is blocked. In addition, there is temporary partial oral paralysis. These effects do not contraindicate use of the technique when it is truly needed. However, its use can be difficult to justify in routine operative and extraction procedures for teeth innervated by the anterior and middle superior alveolar nerves because the supraperiosteal techniques are more localized and just as effective. The infraorbital block technique is preferred when impacted teeth (especially canines or first premolars) or large cysts are to be removed, when moderate inflammation or infection contraindicates use of the supraperiosteal injection site, or when longer duration or a greater area of anesthesia is needed.

The mental nerve block leaves the patient with essentially the same feelings of numbness as the inferior alveolar nerve block. Blocking the mental nerve anesthetizes all mandibular teeth in the quadrant except the permanent molars. Thus the mental nerve block makes it possible for routine operative procedures to be performed on all primary teeth without discomfort to the patient. However, the inferior alveolar nerve block should be favored unless there is a specific contraindication to its use at the inferior alveolar nerve injection site. The mental nerve block is no more comfortable for the patient, and the technique puts the syringe in clear view of the patient, whereas the inferior alveolar nerve block may be performed with the syringe out of the child's direct vision.

Refer to the textbook by Malamed for more detailed information concerning the infraorbital block, the mental block, and other local anesthetic techniques.[6]

PERIODONTAL LIGAMENT INJECTION (INTRALIGAMENTARY INJECTION)

The periodontal ligament injection has been used for many years as an adjunctive method of obtaining more complete anesthesia when supraperiosteal or block techniques failed to provide adequate anesthesia. This technique has also gained credibility as a good method of obtaining primary anesthesia for one or two teeth.

The technique is simple, requires only small quantities of anesthetic solution, and produces anesthesia almost instantly. The needle is placed in the gingival sulcus, usually on the mesial surface, and is advanced along the root surface until resistance is met. Approximately 0.2 mL of anesthetic is then deposited into the periodontal ligament. For multirooted teeth, injections are made both mesially and distally. Considerable pressure is necessary to express the anesthetic solution.

A conventional dental syringe may be used for this technique. However, the great pressure required to express the anesthetic makes it desirable to use a syringe with a closed barrel, to offer protection in the unlikely event that the anesthetic cartridge breaks. Some syringes are equipped with a metal or Teflon sleeve that encloses the cartridge and provides the necessary protection in case of breakage.

Syringes designed specifically for the periodontal ligament injection technique have been developed. One syringe, the Peri-Press (Universal Dental Implements, Fanwood, New Jersey, United States), is designed with a lever-action "trigger" that enables the dentist to deliver the necessary injection pressure conveniently. The Peri-Press syringe has a solid metal barrel and is calibrated to deliver 0.14 mL of anesthetic solution each time the trigger is completely activated.

There are some possible psychological disadvantages to the use of the periodontal ligament injection technique, especially for the inexperienced pediatric patient. The technique provides the patient with an opportunity to see the syringe and to watch the administration of the anesthetic. This may not be a significant problem for the experienced, well-adjusted dental patient, but it may contribute to the anxiety reaction of the new or anxiety-prone patient. In addition, the very design of the Peri-Press (which resembles a handgun) probably has some adverse psychological effects.

There are two types of syringes designed specifically for intraligamentary injections: gun-like and pen-like. They both have the additional disadvantage of being quite expensive compared with good, conventional aspirating syringes. The pen-like syringe would be preferred in pediatric dentistry, but it is even more expensive than the gun-like instrument. Nevertheless, the periodontal ligament injection technique seems to offer a valuable adjunctive method of achieving dental anesthesia.

Malamed has reported a clinical study in which impressive results were obtained for certain procedures when the periodontal ligament injection technique was used.[20]

Dentlearn.ir

pointed out that additional research was warranted. However, seven periodontal procedures (curettage and root planing) were performed with 100% effective anesthesia, and two teeth were extracted with 100% effective anesthesia (injections were administered to the mesial, distal, buccal, and lingual areas for these procedures). Seventy-one routine restorative procedures were performed under periodontal ligament anesthesia, with 91.5% effectiveness. Because of the confined space and the limited blood circulation at the injection site for the periodontal ligament technique, the use of vasoconstrictors as an additive to the anesthetic solution may not be warranted. In fact, vasoconstrictors might conceivably contribute to ischemia of the periodontal ligament, which could at least add to localized postoperative discomfort or possibly cause more serious damage to the periodontal ligament. Walton and Abbott have also reported a clinical evaluation of the technique that showed a 92% success rate.[21]

The periodontal ligament injection offers the following advantages for either primary or adjunctive anesthesia:

1. It provides reliable pain control rapidly and easily.
2. It provides pulpal anesthesia for 30 to 45 minutes, long enough for many single-tooth procedures without an extended period of postoperative anesthesia.
3. It is no more uncomfortable than other local anesthesia techniques.
4. It is completely painless if used adjunctively.
5. It requires very small quantities of anesthetic solution.
6. It does not require aspiration before injection.
7. It may be performed without removal of the rubber dam.
8. It may be useful in patients with bleeding disorders that contraindicate use of other injections.
9. It may be useful in young or disabled patients in whom the possibility of postoperative trauma to the lips or tongue is a concern.

INTRAOSSEOUS INJECTION, INTERSEPTAL INJECTION, AND INTRAPULPAL INJECTION

Intraosseous, interseptal, and intrapulpal injection techniques have been known for many years. The intrapulpal injection is an adjunctive anesthesia technique designed to obtain profound pulpal anesthesia during direct pulp therapy when other local anesthesia attempts have failed. The intrapulpal injection often provides the desired anesthesia, but the technique has the disadvantage of being initially painful, although the onset of anesthesia is usually rapid.

Intraosseous injection techniques (of which the interseptal injection is one type) require the deposition of local anesthetic solution in the porous alveolar bone. One may do this by forcing a needle through the cortical plate and into the cancellous alveolar bone, or a small, round bur may be used to create access in the bone for the needle. A small, reinforced intraosseous needle may be used to penetrate the cortical plate more easily. This procedure is not particularly difficult in children because their cortical bone is less dense than that of adults. The intraosseous techniques have been advocated for both primary anesthesia and adjunctive anesthesia when other local injections have failed to produce adequate anesthesia. These techniques have been reported by Lilienthal to produce profound anesthesia.[22] They do not seem to offer any advantages over the periodontal ligament injection except when use of the latter is contraindicated by infection in the periodontal ligament space.

COMPUTER-CONTROLLED LOCAL ANESTHETIC DELIVERY SYSTEM (WAND)

Reports by Friedman and Hochman[23] and by Krochak and Friedman[24] emphasize the advantages of a computer-controlled local anesthetic delivery system known as the Wand (Milestone Scientific, Livingston, New Jersey, United States). The system includes a conventional local anesthetic needle and a disposable wand-like syringe held by a pen grasp when used for oral local anesthetic injections. A microprocessor with a foot control regulates the delivery of anesthetic solution through the syringe at a precision-metered flow rate, constant pressure, and controlled volume. The system includes an aspiration cycle for use when necessary. Block, infiltration, palatal, and periodontal ligament injections are all reported to be more comfortable for the patient with the Wand than with conventional injection techniques. In a randomized clinical trial comparing the Wand with the traditional anesthetic delivery system, Allen and associates demonstrated that use of the Wand led to significantly fewer disruptive behaviors ($p < 0.01$) in preschool-aged children.[25] None of the preschool-aged children exposed to the Wand required restraint during the initial interval, whereas nearly half of the children receiving a traditional injection required some type of immediate restraint.

COMPLICATIONS AFTER A LOCAL ANESTHETIC

ANESTHETIC TOXICITY

Systemic toxic reactions from anesthetics are rarely observed in adults. However, young children are more likely to experience toxic reactions because of their lower body weight. Young children are also often sedated with pharmacologic agents before the treatment. The potential for toxic reactions increases when local anesthetics are used in conjunction with sedation medications. Aubuchon found a direct linear relationship between the number of cartridges of local anesthetic administered and the frequency of severe reactions.[26] It is most important for dentists who treat children to be acutely aware of the maximum recommended dosages of the anesthetic agents they use because allowable dosages are based on the patient's weight (Table 15-1). For example, the toxic dose of lidocaine would be attained if hardly more than 1.5 cartridges (3 mL) of 2% lidocaine with 1:100,000 epinephrine were injected at one time in a patient weighing 14 kg (30 lb). Yet 5.5 cartridges of the same anesthetic agent would be required to reach the toxic level in an adolescent patient weighing 46 kg (100 lb).

Another simple alternative for calculating maximum safe doses of local anesthetics is offered by Moore and

Dentlearn.ir

Table **15-1**

Maximum Recommended Doses of Local Anesthetics

Dose	Name	Percent of Local Anesthetic	Vasoconstrictor	Duration of Anesthetic	Maximum Recommended Dose
Lidocaine	Xylocaine	2	Epinephrine 1:100,000	Pulpal: 60 min Soft tissue: 3-5 h	4.4 mg/kg
Mepivacaine	Carbocaine	3		Pulpal: 20-40 min Soft tissue: 2-3 h	4.4 mg/kg
Prilocaine	Citanest Forte	4	Epinephrine 1:200,000	Pulpal: 60-90 min Soft tissue: 3-8 h	6.0 mg/kg
Articaine	Septocaine	4	Epinephrine 1:100,000	Pulpal: 60-75 min Soft tissue: 180-360 min	7 mg/kg

Adapted from Malamed SF: *Handbook of local anesthesia*, ed 6, St. Louis, 2012, Elsevier.

Hersh,[27] who suggest that it is the most conservative guideline that can be applied to all anesthetic formulations used in dentistry. "The rule of 25" states that for healthy patients, a dentist can safely use 1 cartridge of anesthetic for every 25 pounds of patient weight; that is, 1 cartridge for a patient weighing 25 pounds, 2 cartridges for a patient weighing 50 pounds, 3 cartridges for a patient weighing 75 pounds, and 6 cartridges for a patient weighing 150 pounds or greater.

Because there is the possibility of toxic reaction to local anesthetic in some children, Wilson and colleagues have studied and reported on the clinical effectiveness of 1% and 2% lidocaine.[28] They found that 1% and 2% lidocaine were equally effective for minor procedures on primary molars.[27] The 1% lidocaine had a slightly lower effectiveness for major procedures, including pulpotomies and extractions.

TRAUMA TO SOFT TISSUE

Parents of children who receive regional local anesthesia in the dental office should be warned that the soft tissue in the area will be without sensation for 1 hour or more. These children should be observed carefully so that they will not purposely or inadvertently bite the tissue. Children who receive an inferior alveolar injection for routine operative procedures may bite the lip, tongue, or inner surface of the cheek. Sometimes a parent calls the dentist's office an hour or two after a dental appointment to report an injury to the child's oral mucous membrane. The parent may wonder if the accident occurred during the dental appointment; in all probability the child has chewed the area, and the result 24 hours later is an ulceration, often termed a traumatic ulcer (Fig. 15-14). Complications after a self-inflicted injury of this type are rare. However, the child should be seen in 24 hours, and a warm saline mouthrinse is helpful in keeping the area clean.

In a prospective study, College and colleagues evaluated unilateral vs. bilateral mandibular nerve block anesthesia with regard to postoperative soft-tissue trauma and other complications in a pediatric population.[29] Their results showed that after unilateral and bilateral blocks, 13% of patients experienced postoperative soft-tissue trauma, with the younger patients (younger than 4 years of age) experiencing more than twice as many problems as the older patients (older than 12 years of age). Interest-



Figure 15-14 Child who has chewed his lip after an inferior alveolar nerve block for operative procedures.

age 4, patients receiving the unilateral nerve blocks had a significantly higher incidence of trauma than patients receiving the bilateral nerve blocks (35% vs. 5%). Although the use of bilateral mandibular nerve blocks has been discouraged in the past, College and colleagues concluded that there is no contraindication to the use of bilateral mandibular block anesthesia in pediatric patients.

REVERSAL OF DENTAL ANESTHESIA

With the granting of marketing approval by the FDA in May 2008, OraVerse (Septodont, Inc., Louisville, Colo-

maceuticals, Inc., San Diego, California, United States,

came the first pharmaceutical agent indicated for the reversal of soft-tissue anesthesia—that is, anesthesia of the lip and tongue, and the associated functional deficits resulting from an intraoral submucosal injection of a local anesthetic containing a vasoconstrictor.

In randomized, double-blind, controlled phase 3 studies, following the administration of local anesthetics and completion of the dental procedure, patients were given either OraVerse or the control treatment. OraVerse

Table **15-2**

Common Medications and Dosages for Oral Pediatric Postoperative Pain Management

Medication	Availability	Dosage
Acetaminophen	Elixir: 160 mg/5 mL Tablets: 325 mg Chewable: 160 mg	10-15 mg/kg/dose given at 4-to 6-hour intervals
Ibuprofen	Suspension: 100 mg/5 mL Tablets: 200, 300, 400, 600, 800 mg	4-10 mg/kg/dose given at 6- to 8-hour intervals
Tramadol	Tablets: 50, 100 mg	1-2 mg/kg/dose given at 4- to 6-hour intervals – maximum 100 mg
Codeine and acetaminophen	Suspension: 12 mg/5 mL 12 mg codeine/120 mg acetaminophen/5 mL	0.5-1.0 mg/kg/dose given at 4- to 6-hour intervals
Hydrocodone and acetaminophen	Suspension: 7.5 mg hydrocodone/325 mg acetaminophen/15 mL Tablets: 5 mg hydrocodone/325 mg acetaminophen	0.3 mL/kg/dose given at 4- to 6-hour intervals <50 kg 0.135 mg/kg

Partially adapted from Tate AR, Acs G: Dental postoperative pain management in children, *Dent Clin North Am* 46:707-717, 2002.

reduced the median time to recovery of normal sensation in the lower lip (as measured by standardized lip-tapping procedures) by 85 minutes compared with the control. OraVerse reduced the median time to recovery of normal sensation in the upper lip by 83 minutes. Within 1 hour after administration of OraVerse, 41% of the patients reported normal lower lip sensation, compared with 7% in tional pediatric patients (from 6 to 11 years of age) have been recently reported.[30]

In all OraVerse clinical trials, no serious adverse events were reported. The most common adverse reaction was transient injection site pain. Although tachycardia and cardiac arrhythmia may occur with the parenteral use of alpha-adrenergic blocking agents, such events are uncommon after the submucosal administration of OraVerse. Currently, OraVerse is not recommended for use in children younger than 6 years of age or in those who weigh less than 15 kg (33 lb). Clinical trials are being conducted in the U.S. for children from 2 to 5 years of age. These trials are being conducted under the FDA's Pediatric Research

valprocess/developmentresources/ucm049867.htm).

ANALGESICS

In addition to local administration of anesthetics, systemic administration of analgesics is occasionally necessary to help control pain. These analgesics may be needed in instances of moderate to severe pain associated with trauma or infectious processes such as abscessed teeth, or they may be administered preoperatively or postoperatively in association with a dental procedure that may cause pain for the child. The rationale for the preoperative administration of analgesics draws on the theory that giving the drug before the procedure provides effective analgesia because it precedes the inflammatory response and subsequent pain incurred during the operative procedure. This theory is not without controversy, however, and there are conflicting reports within the literature as to the efficacy of this technique.

Tate and Acs suggest that the selection and dosages of analgesics vary because of the changes in body weight and composition that occur throughout childhood.[31] The first choice in most cases is the least potent analgesic with the fewest side effects. Table 15-2 provides common pediatric pain management agents and their appropriate dosage schedules. Rarely does the recommended dosage of acetaminophen or nonsteroidal anti-inflammatory drugs fail to control the dental pain, and in such cases, the combination of codeine and acetaminophen provides the needed pain relief. Finally, in cases of severe pain in which codeine and acetaminophen are not effective, hydrocodone and acetaminophen may be indicated.

REFERENCES

1. Venham L, Quatrocelli S: The young child's response to repeated dental procedures, *J Dent Res* 56:734–738, 1977.
2. O'Toole TJ: Administration of local anesthesia. In Snawder KD, editor: *Handbook of clinical pedodontics*, St. Louis, 1980, Mosby.
3. Duckworth GM et al.: Oral PowderJect: a novel system for administering local anaesthesia to the oral mucosa, *Br Dent J* 185:536–539, 1998.
4. Wittrock JW, Fischer WE: The aspiration of blood through small-gauge needles, *J Am Dent Assoc* 76:79–81, 1968.
5. Trapp LD, Davies RO: Aspiration as a function of hypoderlimb, *Anesth Prog* 27:49–51, 1980.
6. Malamed SF: *Handbook of local anesthesia*, ed 6, St. Louis, 2012, Elsevier Mosby.
7. Olsen NH: Anesthesia for the child patient, *J Am Dent Assoc* 53:548–555, 1956.
8. Naidu S et al.: A randomized controlled trial comparing mandibular local anesthesia techniques in children receiving nitrous oxide-oxygen sedation, *Anesth Prog* 51:19–23, 2004.
9. Oulis CJ, Vadiakas GP, Vasilopoulou A: The effectiveness of mandibular infiltration compared to mandibular block anesthesia in treating primary molars in children, *Pediatr Dent* 18:301–305, 1996.
10. Oertel R, Rahn R, Kirch W: Clinical pharmacokinetics of articaine, *Clin Pharmacokinet* 33(6):417–426, 1997.

11. Ortel R et al.: The concentration of local anesthetics in the dental alveolus, comparative studies of lidocaine and articaine in the mandible and maxilla, *Schweiz Monatsschr Zahnmed* 104(8):952–955, 1994.
12. Vree TB, Gielen MJ: Clinical pharmacology and the use of articaine for local regional anaesthesia, *Best Pract Res Clin Anaesthesiol* 19(2):293–308, 2005.
13. Claffey E et al.: Anesthetic efficacy of articaine for inferior alveolar nerve blocks in patients with irreversible pulpitis, *J Endodont* 30(8):568–571, 2004.
14. Kanaa MD et al.: Articaine and lidocaine mandibular buccal infiltration anesthesia: a prospective randomized double blind cross-over study, *J Endodont* 32(4):296–298, 2006.
15. Sharaf AA: Evaluation of mandibular infiltration versus block anesthesia in pediatric dentistry, *J Dent Child* 64:276–281, 1997.
16. Gow-Gates GAE: Mandibular conduction anesthesia: a new technique using extraoral landmarks, *Oral Surg* 36:321–328, 1973.
17. Jorgensen NB, Hayden J Jr: *Sedation, local and general anesthesia in dentistry*, ed 3, Philadelphia, 1980, Lea & Febiger.
18. Bennett CR: *Monheim's local anesthesia and pain control in dental practice*, ed 7, St. Louis, 1984, Mosby.
19. Ramirez K et al.: Painless pediatric local anesthesia, *Gen Dent* 49(2):174–176, 2001.
20. Malamed SF: The periodontal ligament (PDL) injection: an alternative to inferior alveolar nerve block, *Oral Surg* 53:117–121, 1982.
21. Walton RE, Abbott BJ: Periodontal ligament injection: a clinical evaluation, *J Am Dent Assoc* 103:571–575, 1981.
22. Lilienthal B: A clinical appraisal of intraosseous dental anesthesia, *Oral Surg* 39:692–697, 1975.
23. Friedman MJ, Hochman MN: A 21st century computerized injection system for local pain control, *Compend Contin Educ Dent* 18:995–1000, 1002–1004, 1997.
24. Krochak M, Friedman N: Using a precision-metered injection system to minimize dental injection anxiety, *Compend Contin Educ Dent* 19:137–143, 146–150, 1998.
25. Allen KD et al.: Comparison of a computerized anesthesia device with a traditional syringe in preschool children, *Pediatr Dent* 24(4):315–320, 2002.
26. Aubuchon RW: Sedation liabilities in pedodontics, *Pediatr Dent* 4:171–180, 1982.
27. Moore PA, Hersh EV: Local anesthetics: pharmacology and toxicology, *Dent Clin North Am* 54:587–599, 2010.
28. Wilson TG et al.: Clinical effectiveness of 1 and 2% lidocaine in young pediatric dental patients, *Pediatr Dent* 12:353–359, 1990.
29. College C et al.: Bilateral versus unilateral mandibular block anesthesia in a pediatric population, *Pediatr Dent* 22(6): 453–457, 2000.
30. Tavares M et al.: Reversal of soft-tissue local anesthesia with phentolamine mesylate in pediatric patients, *J Am Dent Assoc* 139:1095–1104, 2008.
31. Tate AR, Acs G: Dental postoperative pain management in children, *Dent Clin North Am* 46(4):707–117, 2002.

SUGGESTED READINGS

Berde CB, Sethna NF: Drug therapy: analgesics for the treatment of pain in children, *N Engl J Med* 347(14):1094–1103, 2002.
Blanton PL, Jeske AH: The key to profound local anesthesia: neuroanatomy, *J Am Dent Assoc* 134:753–760, 2003.

CHAPTER 16

Nonpharmacologic Management of Children's Behaviors

▲ Jenny I. Stigers

For additional resources, please visit the evolve website.

CHAPTER OUTLINE

PEDIATRIC DENTAL PATIENTS
- Variables Influencing Children's Dental Behaviors
- Classifying Children's Cooperative Behavior
- The Functional Inquiry

PARENTS OF PEDIATRIC PATIENTS

STRATEGIES OF THE DENTAL TEAM
- Preappointment Behavior Modification
- Fundamentals of Behavior Guidance
- Communicating with Children
- Behavior Shaping
- Retraining
- Aversive Conditioning
- Practical Considerations
- Limitations

The foundation of practicing dentistry for children is the ability to guide them through their dental experiences. In the short term, this ability is a prerequisite to providing for their immediate dental needs. More long-lasting beneficial effects also can result when the seeds for future dental health are planted early in life. For many years the process of leading a child through a dental appointment had been termed behavior management. In 2003 the American Academy of Pediatric Dentistry (AAPD) sponsored a national symposium on behavior management that focused on clinical techniques and the changing environment of and trends in contemporary pediatric dental practices. Following this conference, AAPD introduced the term *behavior guidance* in its clinical guidelines to emphasize that the goals are not to "deal with" a child's behavior but rather to enhance communication and partner with the child and parent to promote a positive attitude and good oral health. Wright and Kupietzky recently reported that *behavior management* continues to be the preferred term globally.[1]

A professional goal is to promote positive dental attitudes and improve the dental health of society. Logically, children are keys to the future. A major difference between the treatment of children and the treatment of adults is the relationship. Treating adults generally involves a one-to-one relationship, that is, a dentist-patient relationship. Treating a child, however, usually relies on a one-to-two relationship among the dentist, the patient, and parents or caregivers. Figure 16-1 illustrates this relationship, known as the *pediatric dentistry treatment triangle*.[1] Because these individuals and their relationships cannot be segregated from external influences, the triangle is encircled by society. Management methods acceptable to society and the litigiousness of society have been factors influencing treatment modalities. Juntgen et al. found that obstacles to incorporating previously unused techniques into pediatric dental practices include legal concerns, parental acceptance to change, and limited resources.[2] Note that the child is at the apex of the triangle and is the focus of attention of both the family and the dental team. Although mothers' attitudes have been shown to significantly affect their children's behaviors in the dental office, the roles of families have been changing, and the entire family environment must be considered. Because changes are constantly occurring within each personality, one must remember that there is an ever-changing, dynamic relationship among the corners of the triangle—the child, the family, and the dental team. The arrows placed on the lines of communication remind us that communication is reciprocal.

The importance of this unifying concept will become evident as behavior guidance techniques are described. However, this concept also serves as the basis of organization for this chapter, the goal of which is to discuss nonpharmacologic approaches to guiding children's behavior in dentistry.

PEDIATRIC DENTAL PATIENTS

Child development involves the study of all areas of human development from conception through young adulthood. It involves more than physical growth, which often implies only an increase in size. *Development* implies a sequential unfolding that may involve changes in size, shape, function, structure, or skill.

Over the years, numerous child development theories have evolved. These have helped explain physical, cognitive, language, motor, and social/emotional development. Recently fields such as *behavior genetics* and *social epigenetics* have focused on the influences of both nature and nurture on health outcomes. Considerable development occurs in utero and during the early years of life. Boyce reported that being reared in poverty or disadvantaged settings affects brain development both structurally and functionally.[3]

Dentlearn.ir

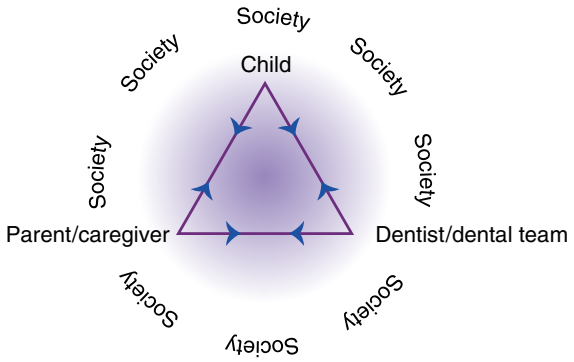

Figure 16-1 The pediatric treatment triangle illustrates basic relationships in pediatric dentistry. (Modified from Wright GZ, Kupietzky A. Introductory remarks. In Wright GZ, Kupietzky A, eds. *Behavior management in dentistry for children,* 2nd ed, 2014, Wiley Blackwell, 3-9.)

He described a neurobiologic susceptibility to social contexts that can jeopardize development. The convergence of social-environmental conditions and genetically derived differences in vulnerability is a rapidly expanding area of research, one that is important to oral health care for children. Although there may be expectations for children's skills based upon chronological age, the practitioner must assess the individual child's understanding and be familiar with the family environment. Differences in genetics, personality, and experience influence the way the child engages with his surroundings. If influences are in harmony, healthy development of the child can be expected; if they are dissonant, behavioral problems are almost sure to ensue. Key to a practitioner's interaction with a child is remembering that each child is unique and exists in the context of his family.

Early child development study linked changes to specific chronologic ages. The initial work gathered age norms for physiologic developmental tasks. Eventually, personality description principles also evolved. One of the pioneers was at Yale University. Typical personality characteristics related to specific chronologic ages that have relevance to dentistry are listed in Box 16-1.[4] These can help in the development of behavioral guidance strategies. For example, if the dentist knows the limitations of a 2-year-old's vocabulary, it becomes apparent that communication must occur through the sense of touch and voice modulation rather than through the spoken word. Recognizing also the close symbiotic relationship with parents, dentists generally try to keep the parent-child pair intact.

Relating personality characteristics to chronologic ages has led to some interesting labeling. For example, a noncompliant 2-year-old is often referred to as being in the stage of the "terrible twos." Dentists sometimes refer to such children as being in the *precooperative stage*. Unfortunately, this has led, in some instances, to use of the age of the child, rather than the child's ability, as a reason for noncompliance.

The broad area of physical development involves changes that occur in children's size, strength, motor coordination, functioning of body systems, and so forth. Thus the child's total physical growth and efficiency from the moment of conception until adulthood are together termed *physical development*. Because a child's physical development is relatively independent of other major areas of development, subareas of physical development must be relatively independent. Neither can a child's coordination be judged by physical size nor is physical strength related to dental development.

Relating key aspects of development to chronologic ages has led to the establishment of developmental milestones as a means of assessing individual children. Selected developmental, cognitive, and psychosocial milestones are listed in Table 16-1. There is a normal range of ages at which motor and language skills are acquired; a general principle is that the earlier a skill emerges, the narrower is the range. On the other hand, developmental tasks tend to occur with wider ranges of normality as age increases. For the dentist, this holds practical importance. For example, consider the task of teaching children how to floss their teeth. Because the ability to floss occurs later in life (9 to 12 years of age), there is a wide performance range. Knowing the general developmental principle reminds the clinician to consider the ability or readiness of the individual to perform a given task.

Another area that has received great attention from psychologists is the socialization of children. As with physical development, age-specific skills have been derived

Box 16-1

Age-Related Psychosocial Traits and Skills for 2- to 5-Year-Old Children

TWO YEARS
Geared to gross motor skills, such as running and jumping
Likes to see and touch
Very attached to parent
Plays alone; rarely shares
Has limited vocabulary; shows early sentence formation
Becoming interested in self-help skills

THREE YEARS
Less egocentric; likes to please
Has very active imagination; likes stories
Remains closely attached to parent

FOUR YEARS
Tries to impose powers
Reaches out—expansive period
Shows many independent self-help skills
Knows "thank you" and "please"

FIVE YEARS
Undergoes a period of consolidation; deliberate
Takes pride in possessions
Relinquishes comfort objects, such as a blanket or thumb
Plays cooperatively with peers

(Based on the work of Dr. A. Gesell.[4])

Table **16-1**

Developmental, Cognitive, and Psychosocial Stages of Children

Age	Social/Emotional	Language/Communication	Cognitive	Movement/Physical Development
6 Months	• Knows familiar faces and begins to know if someone is a stranger • Likes to play with others, especially parents • Responds to other people's emotions and often seems happy • Likes to look at self in a mirror	• Responds to sounds by making sounds • Strings vowels together when babbling ("ah," "eh," "oh") and likes taking turns with parent while making sounds • Responds to own name • Makes sounds to show joy and displeasure • Begins to say consonant sounds (jabbering with "m," "b")	• Looks around at things nearby • Brings things to mouth • Shows curiosity about things and tries to get things that are out of reach • Begins to pass things from one hand to the other	• Rolls over in both directions (front to back, back to front) • Begins to sit without support • When standing, supports weight on legs and might bounce • Rocks back and forth, sometimes crawling backward before moving forward
12 Months	• Is shy or nervous with strangers • Cries when mom or dad leaves • Has favorite things and people • Shows fear in some situations • Hands you a book when he wants to hear a story • Repeats sounds or actions to get attention • Puts out arm or leg to help with dressing • Plays games such as "peek-a-boo" and "pat-a-cake"	• Responds to simple spoken requests • Uses simple gestures, like shaking head "no" or waving "bye-bye" • Makes sounds with changes in tone (sounds more like speech) • Says "mama" and "dada" and exclamations like "uh-oh!" • Tries to say words you say	• Explores things in different ways, like shaking, banging, throwing • Finds hidden things easily • Looks at the right picture or thing when it's named • Copies gestures • Starts to use things correctly; for example, drinks from a cup, brushes hair • Bangs two things together • Puts things in a container, takes things out of a container • Lets things go without help • Pokes with index (pointer) finger • Follows simple directions like "pick up the toy"	• Gets to a sitting position without help • Pulls up to stand, walks holding on to furniture ("cruising") • May take a few steps without holding on • May stand alone

Table **16-1**

Developmental, Cognitive, and Psychosocial Stages of Children—cont'd

Age	Social/Emotional	Language/Communication	Cognitive	Movement/Physical Development
24 Months	• Copies others, especially adults and older children • Gets excited when with other children • Shows more and more independence • Shows defiant behavior (doing what he has been told not to) • Plays mainly beside other children, but is beginning to include other children, such as in chase games	• Points to things or pictures when they are named • Knows names of familiar people and body parts • Says sentences with 2 to 4 words • Follows simple instructions • Repeats words overheard in conversation • Points to things in a book	• Finds things even when hidden under two or three covers • Begins to sort shapes and colors • Completes sentences and rhymes in familiar books • Plays simple make-believe games • Builds towers of 4 or more blocks • Might use one hand more than the other • Follows two-step instructions such as "Pick up your shoes and put them in the closet." • Names items in a picture book such as a cat, bird, or dog	• Stands on tiptoe • Kicks a ball • Begins to run • Climbs onto and down from furniture without help • Walks up and down stairs holding on • Throws ball overhand • Makes or copies straight lines and circles
36 Months	• Copies adults and friends • Shows affection for friends without prompting • Takes turns in games • Shows concern for a crying friend • Understands the idea of "mine" and "his" or "hers" • Shows a wide range of emotions • Separates easily from mom and dad • May get upset with major changes in routine • Dresses and undresses self	• Follows instructions with 2 or 3 steps • Can name most familiar things • Understands words like "in," "on," and "under" • Says first name, age, and sex • Names a friend • Says words like "I," "me," "we," and "you" and some plurals (cars, dogs, cats) • Talks well enough for strangers to understand most of the time • Carries on a conversation using 2 to 3 sentences	• Can work toys with buttons, levers, and moving parts • Plays make-believe with dolls, animals, and people • Does puzzles with 3 or 4 pieces • Understands what "two" means • Copies a circle with pencil or crayon • Turns book pages one at a time • Builds towers of more than 6 blocks • Screws and unscrews jar lids or turns door handle	• Climbs well • Runs easily • Pedals a tricycle (3-wheel bike) • Walks up and down stairs, one foot on each step

Continued

Dentlearn.ir

Table **16-1**

Developmental, Cognitive, and Psychosocial Stages of Children—cont'd

Age	Social/Emotional	Language/Communication	Cognitive	Movement/Physical Development
48 Months	• Enjoys doing new things • Plays "Mom" and "Dad" • Is more and more creative with make-believe play • Would rather play with other children than by himself • Cooperates with other children • Often can't tell what's real and what's make-believe • Talks about what she likes and what she is interested in	• Knows some basic rules of grammar, such as correctly using "he" and "she" • Sings a song or says a poem from memory such as "Itsy Bitsy Spider" or "Wheels on the Bus" • Tells stories • Can say first and last name	• Names some colors and some numbers • Understands the idea of counting • Starts to understand time • Remembers parts of a story • Understands the idea of "same" and "different" • Draws a person with 2 to 4 body parts • Uses scissors capital letters • Plays board or card games • Tells you what he thinks is going to happen next in a book	• Hops and stands on one foot up to 2 seconds • Catches a bounced ball most of the time • Pours, cuts with supervision, and mashes own food
60 Months	• Wants to please friends • Wants to be like friends • More likely to agree with rules • Likes to sing, dance, and act • Is aware of gender • Can tell what's real and what's make-believe • Shows more independence (for example, may visit a next-door neighbor by himself [adult supervision is still needed]) • Is sometimes demanding and sometimes very cooperative	• Speaks very clearly • Tells a simple story using full sentences • Uses future tense; for example, "Grandma will be here." • Says name and address	• Counts 10 or more things • Can draw a person with at least 6 body parts • Can print some letters or numbers • Copies a triangle and other geometric shapes • Knows about things used every day, like money and food	• Stands on one foot for 10 seconds or longer • Hops; may be able to skip • Can do a somersault • Uses a fork and spoon and sometimes a table knife • Can use the toilet on her own • Swings and climbs

Data from Shelov S. and Altman TR: *Caring for your baby and young child: birth to age 5,* 5th edition, 2009 by the American Academy of Pediatrics; and Hagan J. Shaw JS, and Duncan PM: *Bright futures: guidelines for health supervision of infants, children, and adolescents,* 3rd edition, Elk Grove Village, IL: 2008, American Academy of Pediatrics. This milestone checklist is not a substitute for a standardized, validated developmental screening tool.)

Dentlearn.ir

for social development; these take into account both interpersonal relationships and independent functioning skills. An important process for dentists is the child's growth toward independent functioning. For their survival, infants are dependent on others to clothe, feed, and nurture them. As children grow and their ability to care for themselves improves, they gain social independence. Recognizing that the change from functional dependency to functional autonomy is a normal process in social development can assist the dentist. Many young children want to brush their own teeth but lack sufficient digital dexterity. Parents, on the other hand, understand the lack of digital skills and often insist on attending to their children's oral health care. Appreciating that this tug-of-war is a normal part of social maturation allows the dentist to intercede and make appropriate conciliatory recommendations.

Intellectual development is probably the area most comprehensively studied, beginning in the early 1900s with the work of Alfred Binet.[5] The method that he employed quantified mental abilities in relation to chronologic age. It led to the concept of the intelligence quotient (IQ), which was measured by tasks examining memory, spatial relationships, reasoning, and a variety of other primary mental skills. By determining the average age required to pass each task, he derived age norms. This enabled an examiner to determine a child's mental age based on performance.

Quantification of intelligence has led to various classification guides. Since the time of Binet, more than 300 tests have been devised to measure intellectual development. The best-known and most frequently used of these tests are the Wechsler intelligence scales. These are indi-

of the test are available for preschoolers (Wechsler Preschool and Primary Scale of Intelligence, or WPPSI), children (Wechsler Intelligence Scale for Children-Revised, or WISC-R), and adults (Wechsler Adult Intelligence Scale, or WAIS).

Intellectual functioning is measured by assessment with one or more standardized, individually administered intelligence tests such as the Wechsler Intelligence Scales for Children or the Revised Stanford-Binet. Generally, an IQ test has a median raw score of 100 and a standard deviation of 15. Performance classifications such as "very superior" or "borderline" have been used over the years; other terms such as "upper extreme" and "lower extreme" have been suggested to reflect deviations from the norm while being more value-neutral.

Those with an IQ test score of around 70 (approximately two standard deviations below the mean) may have a limitation in intellectual functioning. However, *intellectual disability* would not be diagnosed in an individual with an IQ of less than 70 without significant limitations in adaptive functioning in areas such as communication, self-care, social/interpersonal skills, and adaptation to home living. A measure of adaptive functioning is obtained from a developmental and medical history and one or more reliable collateral sources (e.g., caregiver, educator). Scales have been designed to quantify adaptive functioning, such as the Vineland Adaptive Behavior Scales, whose measures provide a composite score reflective of subscores in several adaptive skill domains.

Scores from tests, even the highly standardized ones, are only estimates and may not be a fair appraisal for a given child on a given day. The younger the child, the less reliable the test scores. The more delayed the child, the less reliable the test scores. The more an individual's cultural and educational opportunities differ from the norm, the less reliable and valid that test is for that individual. However, the information from psychometric assessments can alert a dentist to the possibility that a child may need an individualized approach in the dental office, as well as elsewhere. Individuals with intelligence deficiency or intellectual disability may require special behavior guidance.

VARIABLES INFLUENCING CHILDREN'S DENTAL BEHAVIORS

The responses of children to the dental environment are diverse and complex. Children present for treatment with differences in age, maturity, temperament, experience, family background, culture, and oral health status. Klingberg and Broberg,[6] in a review of literature from 1982 to 2006, reported that dental fear/anxiety and dental behavior management problems were relatively common for pediatric dental patients, each affecting 9% of children and adolescents. Girls exhibited more dental anxiety and dental behavior management problems than did boys. Dental fear/anxiety was more closely associated with temperamental traits such as shyness, inhibition, and negative emotionality, whereas behavioral problems were connected with activity and impulsivity. Blomqvist et al. found a significant correlation between dental fear and anxiety and verbal IQ, but not any other cognitive index, in a population of children with behavior and learning problems.[7]

Most dentists readily recognize children with dental behavior management problems, whereas dental fear and anxiety may be more subtle. Fear is best understood in the context of personal, environmental, and situational influences. It can be a normal reaction for young children, especially in unfamiliar situations where they lack control or perceive the potential for pain. As children age, with increasing ability to anticipate, understand, and control impulses, fears may be expected to decline. But if fear or anxiety is disproportionate to the situation, an unpleasant experience is likely and the child may become uncooperative and display disruptive behavior.

Dental fear/anxiety is not synonymous with dental behavior management problems. In a study of more than 3200 Swedish children, Klingberg and Berggren[8] found that 27% of patients with dental behavior management problems showed dental fear/anxiety, whereas 61% of those with fear/anxiety reacted with behavioral problems. The key to successful outcomes (i.e., compliance, relief of anxiety, completion of quality care, development of a trusting relationship) is an appropriate assessment of the child and family to prepare them to participate actively in a positive manner in the child's oral health care. Dentistry has had some difficulty identifying the stimuli that lead to misbehavior in the dental office, although several variables in children's backgrounds have been related to it.

Dentlearn.ir

Parental Anxiety

With few exceptions, investigations indicate a significant correlation between maternal anxiety and a child's cooperative behavior at the first dental visit. High anxiety on the part of parents tends to affect their children's behavior negatively. Parents can and do convey their fears to their children. Although analysis of the scientific data reveals that children of all ages can be affected by their mothers' anxieties, the effect is greatest with those younger than four years of age. This might be anticipated because of the child-parent symbiosis that begins in infancy and gradually diminishes.

Toxic Stress

Stress is first experienced in utero and will recur throughout life. Although stress produces some minor physiologic changes, it is normal and necessary for survival. Many stresses, such as receiving immunizations and beginning daycare, are short-lived. Parents offer support to young children experiencing these stressors, but children ultimately must learn how to cope with challenges they encounter. Stress that continues over a prolonged period and has lifelong effects is termed *toxic stress*. Toxic stressors include child abuse/neglect, chronic exposure to drugs or violence in the home, and parental depression or mental illness. Economic hardship is a stressor experienced recently by many families. Long summarized the influence of economic hardship on children and parents.[9] Parental support, discipline, and caregiving suffer. The child, in turn, may develop behavioral and emotional adjustment problems.

Medical Experiences

The importance of medical experiences, a highly complex variable, has been debated over the years. There is general agreement, however, that children who view medical experiences positively are more likely to be cooperative with the dentist. The emotional quality of past visits rather than the number of visits is significant. The behavior of children with special health care needs may differ from that of healthy children. Those with chronic medical conditions (without developmental delay) can become "adultified."[10] Because of recurring medical experiences, they may become accustomed to the health care setting and behave "better" than expected.

Pain during previous health care visits is another consideration in a child's medical experiences. The pain may have been moderate or intense, real or imaginary. Nonetheless, parental beliefs about past medical pain are significantly correlated with their children's cooperative behavior in the dental environment. Studies have also shown that previous surgical experiences adversely influence behavior at the first dental visit, but this was not the case in subsequent visits.

Awareness of Dental Problem

Some children may approach their dentist knowing that they have a dental problem. The problem may be as serious as a chronic dental abscess or as simple as extrinsic staining of the dentition. However, there is a tendency toward negative behavior at the first dental visit when the child believes that a dental problem exists. Concern about the presence of caries may also lead to missed appointments. Such considerations provide the dentist with greater motivation for educating the parents about the value of establishing a dental home early—before any dental problems develop. Early, regular dental visits decrease a child's risk of preventable oral disease, help a child develop appropriate coping mechanisms, and enhance a positive attitude for future visits.

General Behavior Problems

Klingberg and Broberg[6] found some support for a relationship between general behavioral problems and dental behavior management problems. Children who have difficulty focusing attention and/or adjusting activities in their general environment have increased problems complying with behavioral expectations in the dental environment. General fears can be important etiologic factors in the development of dental fears. Some children, however, have behavioral problems only in the dental environment; this may be due to previous negative experiences with dental care.

CLASSIFYING CHILDREN'S COOPERATIVE BEHAVIOR

Numerous systems have been developed for classifying children's behavior in the dental environment. An understanding of these systems holds more than academic interest. Such knowledge can be an asset to the dentist in several ways: assisting in directing the behavior guidance approach, providing a means for the systematic recording of behaviors, and assisting in evaluating the validity of current research.

Wright's clinical classification places children in one of three categories[11]:

- Cooperative
- Lacking in cooperative ability
- Potentially cooperative

When a child is being examined, his/her cooperative behavior is taken into account because it is a key to the rendering of treatment. Most children seen in the dental office cooperate. Cooperative children are reasonably relaxed. They have minimal apprehension and may even be enthusiastic. They can be treated by a straightforward, behavior-shaping approach. When guidelines for behavior are established, these children perform within the framework provided.

In contrast is the child lacking in cooperative ability. This category includes very young children with whom communication cannot be established and of whom comprehension cannot be expected. Because of their age,

who lack cooperative ability is those with specific debilitating or disabling conditions. The severity of the child's condition prohibits cooperation in the usual manner. At times, special behavior guidance techniques are used for these children. Although their treatment can be carried out, immediate major positive behavioral changes cannot be expected. Characteristically the nomenclature applied to a potentially cooperative child is "behavior problem." This type of behavior differs from that of children lacking

Dentlearn.ir

cooperative ability because these children have the capability to perform cooperatively. This is an important distinction. When a child is characterized as potentially cooperative, clinical judgment is that the child's behavior can be modified; that is, the child can become cooperative.

The dental literature is filled with descriptions of potentially cooperative patients. Moreover, the adverse reactions have been given specific labels, such as uncontrolled, defiant, timid, tense-cooperative, and whining. Dentists often use these labels because they convey, in as few words as possible, the essence of the child's response to the dental care.

Another system that has been used in behavioral science research is the Frankl behavior rating scale.[12] A description of the scale, which divides observed behavior into four categories, follows:

- *Rating 1: Definitely negative*. Refusal of treatment, forceful crying, fearfulness, or any other overt evidence of extreme negativism
- *Rating 2: Negative.* Reluctance to accept treatment, uncooperativeness, some evidence of negative attitude but not pronounced (sullen, withdrawn)
- *Rating 3: Positive.* Acceptance of treatment; cautious behavior at times; willingness to comply with the dentist, at times with reservation, but patient follows the dentist's directions cooperatively
- *Rating 4: Definitely positive*. Good rapport with the dentist, interest in the dental procedures, laughter and enjoyment

The Frankl method of classification has been a popular research tool, and it also lends itself to a shorthand form that can be used for recording children's behavior in the dental office: positive cooperative behavior can be jotted down as "+" or "+ +" and uncooperative behavior as "–" or "– –." A shortcoming of this method is that the scale does not communicate sufficient clinical information regarding uncooperative children. If a child is judged as "–," the user of this classification system must qualify and categorize the reaction. If "–, tearful" is recorded, a better description of the clinical response is made.

THE FUNCTIONAL INQUIRY

Before the dentist treats a child, medical, dental, and social histories are essential. However, a functional inquiry, from a behavioral viewpoint, should also be conducted. During the inquiry, there are two primary goals: (1) to learn about patient and parental concerns and (2) to gather information to enable a reliable estimate of the cooperative ability of the child. Coupling the findings from the functional inquiry with the clinical experience, the dentist is in a much better position to meet the patient's needs and to apply appropriate behavior guidance strategies to treat individual pediatric patients than by simply proceeding inadequately informed.

Usually, functional inquiries are conducted in two ways: (1) by a paper-and-pencil questionnaire completed by the parent and (2) by direct interview of child and parent. In some offices, one method may predominate, whereas in others both techniques are used. Each method has specific merits.

Box 16-2

Clinically Relevant Questions That Can Be Added to History Forms

(CIRCLE ONE)	
How do you think your child has reacted to past medical procedures?	Very well Moderately well Moderately poorly Very poorly
How would you rate your own anxiety (fear, nervousness) at this moment?	High Moderately high Moderately low Low
Does your child think there is anything wrong with his or her teeth, such as a chipped tooth, decayed tooth, or gum boil?	Yes No
How do you expect your child to react in the dental chair?	Very well Moderately well Moderately poorly Very poorly

Written questionnaires can be important tools for gaining information because probing questions can uncover critical facts about child-rearing practices in the home, a child's school experiences, or the patient's developmental status. Four questions with clinical relevance that can be added to history forms are listed in Box 16-2.

The responses to these questions, originally from behavioral science research, can alert the clinician to a potential behavioral problem. If a parent responds negatively to more than one question, the chance of encountering a behavior problem rises considerably. An unlimited list of questions could be prepared for paper-and-pencil questionnaires, but from the dentist's viewpoint, a lengthy list is impractical.

Most practicing dentists recognize the merits of personal contact with parents. For the personal interview to serve as an efficient functional inquiry tool, a structured framework is necessary. The paper-and-pencil questionnaire is a starting point. It provides general information or clues that help guide the personal interview. Consider the following question:

Do you consider your child to be (check one):
___ advanced in learning?
___ progressing normally?
___ a slow learner?

If the parent has indicated that the child is a slow learner, more factual information is necessary. A leading question in the personal interview might be, "Does your child receive special services at school?" A child may receive support services through an individualized education progam or attend a special classroom or school. Knowledge of the child's educational plan or special academic environment can offer a clue about the functional level of the patient. There is no limit to the depth of the personal interview, but if it is to be efficient, questioning

Dentlearn.ir

must be thoughtful. Other avenues that can be explored include rewards and consequences used in the home environment. These provide insight into the type of behavior guidance techniques that would be acceptable to a parent.

PARENTS OF PEDIATRIC PATIENTS

From the moment of their children's birth, parents shape children's behaviors by selective encouragement and discouragement of particular behaviors, by their disciplinary techniques, or lack thereof, and by the amount of freedom they allow. In early years, at least historically, it is mainly from parents that children learn what they are supposed to do and what behavior is forbidden. Single-parent families, blended families, families with same-sex parents, and multigenerational households all have their special sets of circumstances. Furthermore, societal changes in recent years have created dynamics that can indirectly affect the behavior of children in dental offices. For example, when children are brought to dental offices by caregivers or child care workers unfamiliar with the children's histories, and to whom the children have little attachment, insecurity may interfere with the child's ability to communicate effectively with the dentist. When providing dental care for children, it is important that dentists understand parents' expectancies. In dentist-parent relationships, a difficult question is, "What does a parent or caregiver consider an acceptable behavioral guidance technique?" Considering societal changes and that North America is a cultural mosaic with many parents having dental attitudes deeply rooted in their heritage, it is not an easy question to answer. Because some ethnic minorities rely on family elders in health care decision-making, it may be wise to ask whether anyone besides the presenting parent should be included in treatment planning discussions.[13]

Despite the acknowledged importance of the parental role in the pediatric treatment triangle and the necessity of gaining parental cooperation, it is only recently that the dental literature has provided dentists with advice for collaborating with parents. When the parent is confused and the confusion goes unrecognized by the dentist, compliance with health behaviors suffers. Bidirectional communication is critical. Three notable works on parental acceptance are by Murphy and colleagues,[14] Lawrence and associates,[15] and Eaton and co-workers.[16] The three studies are similar in design: Parents are shown videotapes of different behavioral guidance methods and instructed to indicate their acceptability of them on a rating scale. The studies span two decades, provide interesting information, and show how parental attitudes change. In the earliest study,[14] 10 techniques were videotaped. Four of the techniques found to be acceptable were tell-show-do, positive reinforcement, voice control, and use of a mouth prop. Six techniques found to be unacceptable involved restraint methods, sedation, and general anesthesia.

The latter two studies[15,16] used the same videotape and demonstrated eight behavior guidance methods. All studies reported tell-show-do as the most acceptable technique. In the latter two studies, nitrous oxide sedation was found to be the next most acceptable technique. All studies were able to establish a hierarchy of parental acceptance based upon the mean ratings of parent responses, allowing for the observation of two interesting changes. Hand-over-mouth became the least accepted technique, whereas general anesthesia became the third most accepted method for behavior guidance.

Caution must be exercised when the results of these investigations are applied to clinical practice. Eaton[16] noted considerable variability in parental attitudes to all techniques. The studies also require replication with the same videotapes in different locales. Do New England parents, Spanish-speaking parents in Florida or New Mexico, Native American parents, and West Coast parents all hold the same views as do parents in the American Midwest, where these studies were performed?

There is not complete agreement as to what formulates parental attitudes. Eaton and colleagues[16] found that parental gender, age, and social status were unrelated to attitudes. However, an earlier study by Fields and coworkers[17] showed that social status correlated negatively with general anesthesia. Those parents in the higher

Again, this illustrates how things have changed over two decades, in that the Eaton study showed much greater acceptance of general anesthesia.

Casamassimo et al. surveyed diplomates of the American Board of Pediatric Dentistry regarding parenting styles and the impact on dental practice.[18] Most diplomates indicated that there has been a change in parental demographics. There are more single parents, increased mobility, and more dual-income families. The findings from this report determined that children's behaviors in dental offices were strongly related to parenting styles, preferences, and demands. Failure of parents to set limits on their children's behaviors was the main parental child-rearing problem. The investigators also found that parental expectations were often unattainable.

Dentists in practice must anticipate these types of problems and learn to contend with them. The diplomates suggested several methods of coping with parent's and children's behaviors; however, one recommendation dwarfed all others in frequency—the improvement of communication. Communication can mean many things, but in this instance it refers to the dentist's getting his or her message across to the parents and having them work with the dentist. All messages should be communicated in a manner that is respectful of the family's values, beliefs, and behaviors. Building rapport is critical in gaining both parental and patient cooperation and compliance. Motivational interviewing is one technique for the assessment of parental beliefs and underlying social determinants that can be effective in altering health behaviors.[19]

STRATEGIES OF THE DENTAL TEAM

A primary objective during dental procedures is to lead children step by step so that they develop a positive attitude toward dentistry. Fortunately, most children progress easily and pleasantly through their dental visits,

Dentlearn.ir

without undue pressure on themselves or the dental team. These successes can be attributed to several factors, such as a child's confident personality, a parent's proper preparation of the child for the appointment, or a dental team's excellent communicative skills. In contrast, some children's dental office experiences cause anxiety and the beginning of a negative dental attitude. Sometimes these controllable but apprehensive children are managed without medication, as long as appropriate nonpharmacologic psychologic techniques are used.

Because behavior guidance techniques are used daily and come naturally to many persons, their importance sometimes is overlooked or taken for granted. This increases the potential for avoidable behavior problems. However, a full understanding and conscious implementation of strategies can lead to recognizable improvements in child management skills. Although this section heightens the awareness of various techniques commonly used in dental offices today, it should be regarded as only a start to the study of behavior guidance strategies.

PREAPPOINTMENT BEHAVIOR MODIFICATION

Psychologists have developed many techniques for modifying patients' behaviors by using the principles of learning theory. These techniques are called *behavior modification*. Usually they are thought about in conjunction with dentist-patient intraoperatory relationships. However, preappointment behavior modification, as it is used here, refers to anything that is said or done to have a positive influence on the child's behavior before the child enters a dental operatory. The merit of this strategy is that it prepares the pediatric patient and eases the introduction to dentistry. It has received a great deal of attention because the first dental visit is crucial in the formation of the child's attitude toward dentistry. If the first visit is pleasant, it paves the road for future successes.

Several methods of preappointment behavior modification are recognized. Films or videotapes have been developed to provide a model for the young patient. The goal is for the patient to reproduce behavior exhibited by the model. On the day of the appointment, or perhaps at a previous visit, the new pediatric patient views the presentation.

Most modeling studies indicate that there is merit in introducing children to dentistry in this way, but not all studies show statistically improved cooperative behavior on the part of the children. The lack of replication may be the result of differences in experimental design, dental teams, or videotapes or films. It suggests a necessity for careful videotape or film selection for office use.

Preappointment behavior modification can also be performed with live patient models such as siblings, other children, or parents. Many dentists allow young children into the operatory with parents to preview the dental experience. Because the observing child likely will be initiated into dental care with a dental examination, a parent's recall visit offers an excellent modeling opportunity. On these occasions, many young children climb into the dental chair after their parents' appointments. These previews should be selected carefully. Young children are sometimes frightened by loud noises, as from a high-speed handpiece.

The merits of modeling procedures, commonly involving audiovisual or live models, are recognized by psychologists. Rimm and Masters[20] summarized them as follows: (1) stimulation of new behaviors, (2) facilitation of behavior in a more appropriate manner, (3) disinhibition of inappropriate behavior due to fear, and (4) extinction of fears. These procedures offer the practicing dentist some interesting ways to modify children's behavior before their dental visit.

Another behavior modification method involves preappointment parental education via mailings, prerecorded messages, or customized web pages. Precontact with the parent can provide directions for preparing the child for an initial dental visit, explain office procedures, and answer questions. Setting expectations for the first visit can increase the likelihood of a successful appointment. Beneficial effects of preappointment mailings were demonstrated in a controlled study by Wright et al.[21] Children seemed better prepared by their mothers, and the dentist saw more cooperative pediatric patients. Almost all parents understood the letter's contents, acknowledged the dentist's thoughtfulness, and welcomed the concern for the proper presentation to their children. A similar letter is shown in Figure 16-2. Dentists using preappointment educational materials should be selective. Overpreparation could confuse a parent or provoke unnecessary anxiety.

FUNDAMENTALS OF BEHAVIOR GUIDANCE

Behavior guidance involves the total dental health team. Indeed, many dental auxiliaries are invaluable when it comes to providing care for children. All personnel have a stake in guiding a child through the dental experience.

Over the years, behavior guidance has meant different things to different people. In 1895 McElroy wrote, "Although the operative dentistry may be perfect, the appointment is a failure if the child departs in tears."[22] This was the first mention in dental literature of measuring the success or failure of a child's appointment by anything other than technical proficiency. Pediatric dentistry has progressed since that time, and one definition is the following:

> Behavior guidance is the means by which the dental health team effectively and efficiently performs treatment for a child and, at the same time, instills a positive dental attitude.

Effectively in this definition refers to the provision of high-quality dental care. Efficient treatment is a necessity in private practice today. Quadrant dentistry, or perhaps half-mouth dentistry, utilizing auxiliary personnel is vital in the delivery of efficient service to children. Finally, the development of a pediatric patient's positive attitude is an integral part of this definition. In the past, many practitioners have considered "getting the job done" to be behavior management. The current definition suggests a great deal more.

What has been omitted from the definition of behavior guidance is interesting. There is no mention of any

Dentlearn.ir

Dear Parent:

Children who have pleasant dental appointments when they are very young are likely to have a favorable outlook toward dental care throughout life. The first appointment is very important in this attitude formation. That is the reason I am writing to you.

At our first appointment we will examine your child's teeth and gums and take any necessary x-ray films. For most children this will be an interesting and even happy occasion. All the people on our staff enjoy children and know how to work with them, but you, parents, play an important role in getting children started with a good attitude toward dental care. One of the useful things that you can do is to be completely natural and easygoing when you tell your child about the appointment with the dentist. This approach enables children to view their dental visit as an opportunity to meet some new people who want to help them stay healthy.

Your cooperation is appreciated. Remember, good general health depends partly on the development of good habits, such as sensible eating, sleeping routines, and exercise. Dental health also depends on good habits, such as proper toothbrushing, regular dental visits, and a good diet. We will have a chance to further discuss these points during your child's appointment.

Sincerely,

Figure 16-2 Letter to assist parents in preparing children for first dental visit. (Adapted from Wright GZ, Alpern GD, Leake JL: The modifiability of maternal anxiety as it relates to children's cooperative dental behavior, *J Dent Child* 40:265-271, 1973.)

specific techniques or modalities of treatment. The definition allows for the exercise of individuality. The challenge to the dentist is to satisfy the elements of the definition as frequently as possible and as safely as possible for each child in a dental practice.

Although various methods in managing pediatric dental patients have evolved over the years, certain practices and concepts remain fundamental to successful behavior guidance. These are basic to the establishment of good dental team–pediatric patient relationships. These practices increase the chances for success in the provision of care for children. They should be considered inviolate. The following fundamentals of behavior guidance center on the attitude and integrity of the entire dental team.

Positive Approach

There is general agreement that the attitude or expectations of the dentist can affect the outcome of a dental appointment. The child will respond with the type of behavior expected. In essence, the child fulfills the dentist's prophecy. Thus positive statements increase the chances of success with children. They are more effective than thoughtless questions or remarks. To obtain success with children, it is important that the dentist anticipate success.

Team Attitude

Personality factors such as warmth and interest that can be conveyed without a spoken word are critical when children are treated. A pleasant smile tells a child that an adult cares. Children respond best to a natural and friendly attitude. Often this can be conveyed immediately to the pediatric patient through a casual greeting. Children also can be made to feel comfortable in the dental office by the use of nicknames, which can be placed on a patient's record. Noting school accomplishments or extracurricular activities such as scouting, baseball, gymnastics, or other hobbies helps in initiating future conversations and demonstrates a friendly, caring attitude to a pediatric patient.

Organization

Plans in the dental office have many dimensions, beginning, for example, with the reception area. Who summons the new patient? The dentist, the dental assistant, the dental hygienist, or the receptionist? If a child creates a disturbance in the reception area, who will address the problem? Each dental office must devise its own contingency plans, and the entire office staff must know in advance what is expected of them and what is to be done. Such plans are key features of many pediatric dental offices because they increase efficiency and contribute to successful dental staff–pediatric patient relationships. Also, a well-organized, written treatment plan must be available for the dental office team. Delays and indecisiveness can build apprehension in young patients.

Truthfulness

Unlike adults, most children see things as either "black" or "white." The shades between are difficult for them to discern. To youngsters, the dental health team is either truthful or not. Because truthfulness is extremely important in building trust, it is a fundamental principle in caring for children. Recognizing and acknowledging a patient's fear and anxiety can strengthen that trust. Empathizing with, rather than denying, such emotions helps provide assurance that the dentist appreciates the patient as an individual.

Tolerance

Tolerance level, a seldom-discussed concept, varies from person to person. It refers to the dentist's ability to cope rationally with misbehaviors while maintaining composure. Recognizing individual tolerance levels is especially important in the treatment of children. In addition to varying from person to person, tolerance levels fluctuate for a given individual. For example, an upsetting experience at home can affect the clinician's mood in the dental office. Some people are in a better frame of mind early in the morning, whereas the coping abilities of others improve as the day progresses. Thus afternoon people should instruct receptionists not to book children with behavior problems the first thing in the morning. Learning to recognize factors that overtax tolerance levels is another fundamental because it prevents loss of self-control.

Flexibility

Because children lack maturity, the dental team must be prepared to change its plans at times. A child may begin fretting or squirming in the dental chair after half an hour, and the treatment intended for that day may have to be divided into multiple appointments. On the other hand, a dentist may plan a step-wise indirect pulp treatment, but because the child is difficult, the indirect pulp procedure may have to be completed during a single session. Many dentists, following accepted four-handed dentistry practices, work at the 11 o'clock or 12 o'clock position. Treatment of small children may demand a change in operating position. Thus the dental team must be as flexible as the situation demands.

COMMUNICATING WITH CHILDREN

Several effective communication techniques can be suggested. These key points are guidelines and not inflexible rules, because in the unpredictable world of pediatric health care, one must always be prepared to improvise.

Establishment of Communication

Previous editions of this textbook have stated that the first objective in the successful management of the young child is to establish communication. Involving a child in a conversation not only enables the dentist to learn about the patient but also may relax the child. There are many ways of initiating verbal communication, and the effectiveness of these approaches differs with the age of the child. Generally, verbal communication with younger children is best initiated with complimentary comments, followed by questions that elicit an answer other than "yes" or "no."

Establishment of the Communicator

Members of the dental team must be aware of their roles when communicating with a pediatric patient. Generally, the dental assistant talks with the child during the transfer from reception room to the operatory and during preparation of the child in the dental chair. When the dentist arrives, the dental assistant usually assumes a more passive role, because the child can listen to only one person at a time. It is important that communication occur from a single source. When both dentist and dental assistant provide directions, the result may be a response that is undesirable simply because the child becomes confused. The same holds true when parents are present in the operatory. The communication must be primarily bidirectional, between the dentist and the child.

Message Clarity

Communication is a complex, multisensory process. It includes a transmitter, a medium, and a receiver. The dentist or dental health team is the transmitter, the spoken word frequently is the medium, and the pediatric patient is the receiver. The message must be understood in the same way by both the sender and the receiver.

Very often, to improve the clarity of messages to young patients, dentists use euphemisms to explain procedures. For pediatric dentists, euphemisms or word substitutes are like a second language. Examples of word substitutes that can be used to explain procedures to children are given in Box 16-3.

It is important to be careful in selecting words and phrases used to indoctrinate the new pediatric dental patient because for the young child, language labels are the basis for many generalizations. The classic example is the language label for "doctor," which confuses many youngsters. This is known as *mediated generalization*. Eventually, as a result of experiences, the child learns that the "dentist doctor" is different from the "physician doctor" and that the physician's office and the dentist's office are different environments. The process of sorting out such differences is referred to as *discrimination*.

Voice Control

Throughout the dental literature, reference is made to voice control. It is difficult to describe this effective communicative technique using the written word. Sudden and firm commands are used to get the child's attention or to stop the child's undesirable behavior. Another form of voice control is a slow and deliberate cadence that can function like music to set a mood. In both cases, how it is said is more important than what is said because the

Box 16-3

Word Substitutes for Explaining Procedures to Children

DENTAL TERMINOLOGY	*WORD SUBSTITUTES*
Rubber dam	Rubber raincoat
Rubber dam clamp	Tooth button
Rubber dam frame	Coat rack
Sealant	Tooth paint
Fluoride varnish	Tooth vitamins
Air syringe	Wind gun
Water syringe	Water gun
Suction	Vacuum cleaner
Alginate	Pudding
Study models	Statues
High speed	Whistle
Low speed	Motorcycle

Dentlearn.ir

dentist is attempting to influence behavior directly, not through understanding.

Although dentists have long recognized the merits of employing voice control when children's behaviors have been disruptive, Greenbaum and colleagues have given it scientific credence.[23] Considering the use of loud commands as a punishment technique, they compared the effects of loud and normal voice commands given to 40 children with potential behavior problems. Their findings demonstrated that loud commands reduced disruptive behaviors.

Chambers' theory is that voice control is most effective when used in conjunction with other communications.[24] A sudden command of "Stop crying and pay attention!" may be a necessary preliminary measure for future communication. The same message spoken in a foreign language probably would be equally effective in stopping disruptive patient behavior that was preventing communication. Used properly in correct situations, voice control is an effective behavior guidance tool. However, because parents may find voice control to be an aversive technique, discussing this technique with parents prior to its use may decrease the risk for misunderstanding.[25]

Multisensory Communication

In verbal communications, the focus is on what to say or how it is said. However, nonverbal messages can also be sent to patients or received from them. Body contact can be a form of nonverbal communication. The dentist's simple act of placing a hand on a child's shoulder while sitting on a chairside stool conveys a feeling of warmth and friendship. Greenbaum and colleagues found that this type of physical contact helped children to relax, especially those from 7 to 10 years of age.[23]

Eye contact is also important. The child who avoids it often is not fully prepared to cooperate. Apprehension can be conveyed without a spoken word. Detecting a rapid heartbeat or noticing beads of perspiration on the face are observations that alert the dentist to a child's nervousness. When the dentist talks to children, every effort should be made not to tower above them. Sitting and speaking at eye level allow for friendlier and less authoritative communications.

Problem Ownership

In difficult situations, dentists sometimes forget that they are guiding the behavior of children. They begin by sending "you" messages, for example, "You stop that immediately!" or "If you don't stay still, we will have to hold your hands." "You" messages have been termed *roadblocks to communication*; instead of gaining cooperation, they only undermine the rapport between a pediatric patient and dentist. Nash discussed that "you" messages may impugn a child's character, depreciate him as a person, shatter his self-esteem, underscore his inadequacies, and cast judgment.[26] They are more likely to provoke conflict and rebellion than "I" messages. "I" messages reflect the practitioner's experience and disclose the focus of the problem, such as "I can't fix your teeth if you don't open your mouth wide." They are honest, clear, and inarguable. This self-disclosing assertiveness is one technique that is particularly well suited to increase the flow of information between the dentist and the pediatric patient.

A technique that encourages the use of "you" is *attending*. Attending describes the desirable conduct to help shape compliance.[10] For example, "You are staying so still" reinforces the specific cooperative behavior that is necessary for the treatment to be completed. Positive attention to discrete behaviors confirms to children that they are doing what was requested and can nurture the relationship between patients and providers.

Active Listening

Listening is important in the treatment of children. Children express their feelings by word and by action. Listening to the spoken words may be more important in establishing rapport with the older child, whereas attention to nonverbal behavior is often more crucial in guiding the behavior of a younger child. Active listening mirrors the communicated emotion. Whether the child says "I'm scared" or hesitates in opening his mouth, the dentist needs to acknowledge, not ignore, what the child is feeling. Sensitivity to the expressed emotions can reassure the child and encourage genuine communication. The patient is stimulated to express feelings, and the dentist does the same, as necessary processes in communication.

Appropriate Responses

Another principle in communicating with children is that the response should be appropriate to the situation. The appropriateness of the response depends primarily on the extent and nature of the relationship with the child, the age of the child, and evaluation of the motivation of the child's behavior. An inappropriate response would be a dentist's displaying extreme displeasure with an anxious young child on the first visit, when there has been insufficient time to establish a good rapport. On the other hand, if a dentist has made inroads with a child, who then displays unacceptable behavior, a dentist may well express disapproval without losing personal control. The response is then appropriate.

BEHAVIOR SHAPING

Behavior shaping is a common nonpharmacologic technique. It is a form of behavior modification; hence, it is based on the established principles of social learning. By definition, it is that procedure which very slowly develops behavior by reinforcing successive approximations of the desired behavior until the desired behavior occurs. Proponents of the theory hold that most behavior is learned and that learning is the establishment of a connection between a stimulus and a response. For this reason, it is sometimes called stimulus-response (S-R) theory.

When shaping behavior, the dental assistant or dentist is teaching a child how to behave. Young children are led through these procedures step by step. Patients have to be communicative and cooperative to absorb information that may be complex for them. The following is an outline for a behavior-shaping model:

Dentlearn.ir

1. State the general goal or task to the child at the outset.
2. Explain the necessity for the procedure. A child who understands the reason is more likely to cooperate.
3. Divide the explanation for the procedure. Children cannot always grasp the overall procedure with a single explanation; consequently, they have to be led through the procedure slowly.
4. Give all explanations at a child's level of understanding. Use euphemisms appropriately.
5. Use successive approximations. Since its introduction in 1959, tell-show-do has remained a cornerstone of behavior guidance. It is a series of successive approximations, and it should be used routinely by all members of the dental team who work with children. Dental assistants, dental hygienists, and dentists should demonstrate various instruments step by step before their application by telling, showing, and doing. When the dentist works intraorally, a pediatric patient should be shown as much of the procedure as possible. Only when the child has a view of the procedures being undertaken are successive approximations being performed properly (Fig. 16-3).
6. Reinforce appropriate behavior. Be as specific as possible because specific reinforcement is more effective than a generalized approach. Immediate and specific reinforcements can reduce children's fear-related behaviors.

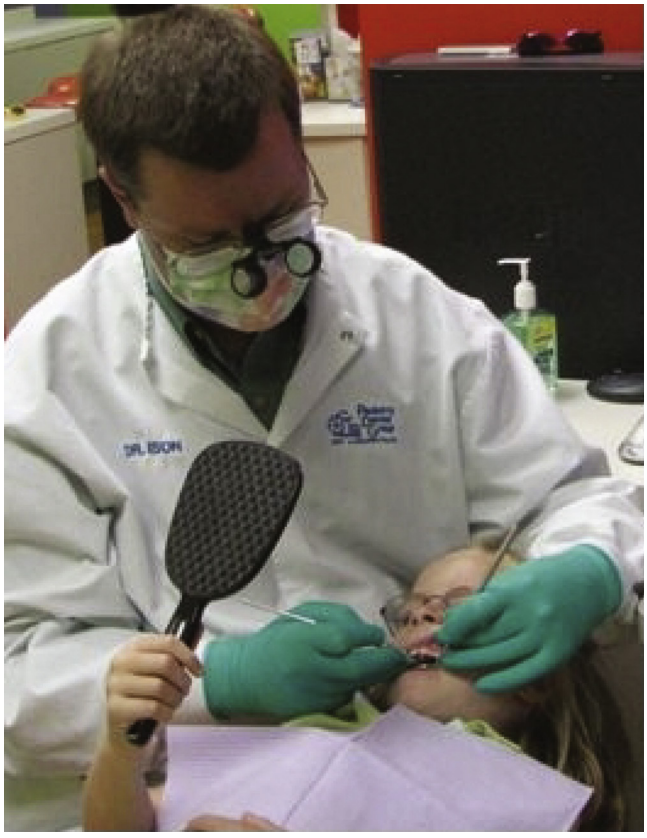

Figure 16-3 Child views intraoral procedure with hand mirror. If mirror blocks light to oral cavity, smaller mirror is used. With fiberoptic handpieces, blockage of light is not a problem.

7. Disregard minor inappropriate behavior. Ignored minor misbehavior tends to extinguish itself when not reinforced.

Behavior shaping is regarded as a learning model. The most efficient learning models are those that follow the learning theory model most closely. Deviations from the model create less efficiency in terms of learning. One way to improve consistency in this area is for the dental team to record various clinical sessions with pediatric patients and then to review the recordings, keeping in mind the basics of the behavior-shaping learning model.

Although tell-show-do is similar to behavior shaping, the two differ. In addition to demanding the reinforcement of cooperative behavior, behavior shaping also includes the need for steps to be retraced if misbehavior occurs. For example, if a child is shown an instrument and looks away, the dentist must go back to the explanatory portion of the procedure. Behavior shaping requires that the "desired behavior" be observed along the way. If the dentist proceeds along the sequential steps and begins performing treatment when the desired behavior is not present, there is deviation from the learning model and a greater likelihood of increased misbehavior.

RETRAINING

Children who require retraining approach the dental office displaying considerable apprehension or negative behavior. The demonstrated behavior may be the result of a previous dental visit or the effect of improper parental or peer orientation. Determining the source of the problem is helpful because the undesirable behavior can then be avoided through another technique or deemphasized, or a distraction can be used. These ploys begin the retraining program, which eventually leads to behavior shaping.

When encountering negative behavior, the dentist should always remember that an objective is to build a new series of associations in the child's mind. If a child's expectation of being hurt is not reinforced, a new set of expectations is learned. The dentist can be trusted! The child develops a new perception of the dental office and a new relationship to dentistry. Unacceptable behavior previously learned extinguishes. It is critical to remember that the stimulus must be altered to elicit a change in the response.

Individuals respond to stimuli to which they have been preconditioned. If the original stimulus and the new one are very similar, then the response will be similar. This is known as *stimulus generalization*. If a child has had an unpleasant experience in the dental office and then is taken to a different office where there is a different dentist and an entirely different staff and surroundings, the child still tends to generalize that an unpleasant event will occur in this new dental office. There are enough similar stimuli to produce this response. To offset the generalization, the dental team must demonstrate a "difference." This is one of the reasons why the use of nitrous oxide–oxygen sedation often works when retraining children. It offers a difference.

AVERSIVE CONDITIONING

The behavior modification method of aversive conditioning is also known as hand-over-mouth exercise (HOME).[27] Its purpose is to gain the attention of a highly oppositional

Dentlearn.ir

child so that communication can be established and cooperation obtained for a safe course of treatment. The technique fits the rules of learning theory: maladaptive acts (screaming, kicking) are linked to restraint (hand over mouth), and cooperative behavior is related to removal of the restriction and the use of positive reinforcement (praise). It is important to stress that aversive conditioning should not be used routinely but as a method of last resort, usually with children from three to six years of age who have appropriate communicative abilities.

Over the years, attitudes toward HOME have changed. Surveys of pediatric dentistry diplomates in 1972 and 1981 demonstrated acceptance by a substantial portion of the profession. In both instances, more than 80% of the pediatric dentists indicated that they used aversive therapy at times. However, Adair[28] reported that HOME was used by a distinct minority of pediatric dentists. The greatest frequency of use was by older men, likely reflecting attitudes and training during their residency programs. Oeuis and colleagues surveyed pediatric dentists in 2007, following the removal of HOME from AAPD's clinical practice guidelines.[29] Interestingly, this survey found a greater usage of HOME (44%), with half believing HOME to be an acceptable technique. The authors noted that this could be due to response bias. That said, 32% of practitioners believed that it may cause psychological harm to the child. Inquiring into acceptance of the technique by dental educators, Adair[28] found that 54% thought the technique was unacceptable, and 18% did not teach it at all. Some parents, too, have disapproved of the technique (Eaton[17] found it the only technique rated unacceptable by parents), and another concern has been a legal one. The acceptance of aversive conditioning by the dental professional is not an absolute assurance of the legality of the technique. Aversive conditioning can be a safe and effective method of managing a child with an extremely difficult behavior problem. However, any departure from the accepted application of aversive conditioning may expose the dentist to liability. Those dentists or dental students who contemplate using it should consult detailed writings in advance. Dentists should be aware of the acceptability of the technique in their practice location. Bross cautioned that once a technique is found to be legally unacceptable in one instance, a legal risk arises if full consent is not gained or if the procedure is used.[30]

PRACTICAL CONSIDERATIONS

Some procedural aspects of dental practice help guide children successfully through their dental experiences. Like many of the techniques described previously, they have evolved over the years without being experimentally tested. Nevertheless, these practical considerations form an integral part of present-day dental practice. They also would be fruitful areas for future research.

Scheduling

Children are bundles of energy. Lacking the patience of adults, many children become restless and tired when faced with long delays in a reception area. This should be taken into account when designing an office schedule. A good general rule is that a child should not be kept waiting in the reception area and that every effort should be made to be on time.

Morning appointment times have been suggested for children. It is a practice that has guided scheduling in many dental offices because children are more alert and the dental team is fresher in the morning. Many dentists (preschoolers in the morning and older children in the children serving as models for each other. Another advantage is that the dental office may run more smoothly with less psychological change of pace.

Sometimes expediency rather than a realistic evaluation of a child's behavior may predispose the dentist toward morning appointments for preschool children. Frequently, it is easier to persuade parents to take younger children out of nursery school or kindergarten than to arrange morning appointments for elementary or junior high school children. From a behavioral standpoint, other factors seem important when appointment times are determined. Patient-related concerns include patient age, presence of a handicapping condition, and need for any sedation. The dentist's attitude is also important. Some dentists avoid seeing children with behavior problems first thing in the morning. A policy regarding scheduling should be formulated by the dentist, and scheduling should not be left to chance.

Another scheduling concern has been appointment length. Historically, writers have agreed that the nature of childhood precludes giving the sustained attention that may be required for long dental visits. Generally, a long visit is defined as any period in excess of half an hour. Most of these views were expressed more than 35 years ago, and appointments have increased in duration. Improved technology, the application of time and motion studies by efficiency experts, and the current trend toward quadrant or half-mouth dentistry have altered contemporary practices. Because evidence of the effect of appointment duration on patient cooperation is divided, this remains a question for researchers. Appointment duration should not be extended beyond a patient's tolerance level solely for the practice's convenience.

Parent-Child Separation

Years ago, parents did not expect to enter the operatory. Today's parents actively participate in health care services through the process of informed consent, and increasingly want to accompany their children during their health care experiences. Having parents stay with their child can streamline informed consent and communication into the normal office flow. Adair and colleagues[31] found that a clear majority of pediatric dentists in all age/gender a variety of procedures. In addition to increasing communication efficiency, parental presence can reassure both the child and the parent. Parents can witness the dentist's compassionate approach and hear the educational instructions provided to the children. At the same time, the dentist obtains rapid feedback on parental attitudes and beliefs.

Dentlearn.ir

A parent can be a major asset in supporting and communicating with a child who has a disability, often providing important information and interpretation. Because of the close symbiotic relationship that very young children (those who have not reached the age of understanding and full verbal communication) have with their parents, they often remain together. Excluding the parent from the operatory could be justified for many reasons, including parental interference and limitations on dentist-child interactions. With older children, an independent experience may contribute toward development of confidence and appropriate coping mechanisms and, ultimately, a positive attitude on the part of the child. Another reason for advocating a separation policy is that the dentist may be more relaxed and comfortable when the parent remains in the reception area, so as not to be perceived as "performing." As a consequence of this more relaxed manner, the dentist's actions are likely to have a more positive effect on the child's behavior.

The separation procedure warrants serious consideration. The dentist must develop an office policy, inform the office staff, and assume responsibility to train office personnel in reception room strategies. In this age of accountability, the dentist may also have to explain the policy to a parent. Establishment of the policy should therefore be based on a rationale that takes into account the benefits and drawbacks resulting from separation, the benefits to the individual child, and the dental team's personal comfort level. Because some dentists become tense when parents are present and others enjoy having parents in the operatory, an office policy becomes, to some extent, an individual decision.

Tangible Reinforcements

Giving gifts to children has become a fact of commercial life in North America. There is general agreement on the merit of this practice in the dental office; gift-giving can serve as a reward. If the gift has a dental significance (e.g., a toothbrush kit), so much the better. In these situations the gift is also used to reinforce the importance of oral health.

Various trinkets in a toy chest should be used as tokens of affection for children, not as bribes. The gift-giving practice can have spectacular results. Many children who seem tense during operative procedures suddenly perk up when the procedures are completed and scurry for a gift. These gifts provide a pleasant reminder of the appointment.

LIMITATIONS

Today's children differ from those of past generations. They begin school earlier. Through the media, they are more aware than children were years ago. We hear more of children facing poverty, experiencing learning disorders, and developing poor coping skills, and are more aware of children with eating disorders and drug use. Children also have legal and social advocates who have influenced management techniques. Limitations on the dentist exist today that were unheard of previously.

Parenting also has changed. Much of the behavioral science research was done with traditional families in the 1960s and 1970s. Single-parent homes were less common, and terms such as *reconstituted families* and *same-sex marriages* were unknown. What about the child-rearing practices in these families? Decades ago, when "father" came to the office, it usually meant that the child had a behavior problem and "father" was the enforcer. With both parents working or with single-parent families, it is not unusual for a father to accompany a child to the dental office. Have parental expectations changed in the dental office? Yes. This chapter discusses the reasons why parents might be excluded from the operatory, but it also urges periodic review of the policy. Many parents insist on their right to accompany their child. Societal changes influence our management methods, and there is a need to review past research carefully and assess its applicability to the present.

Dentists also face societal limitations, and they are changing their approaches to management. Years ago, the HOME technique might have been used to subdue a 3-year-old so that the dentist could perform an examination. This chapter does not describe the technique in detail because it is not used by most of today's dentists. Parental influences, as well as legal and ethical concerns, have resulted in a decreased or discontinued use of controversial techniques like HOME. Dental students rarely have the opportunity to observe or use the technique.

The corners of the pediatric treatment triangle have been changing rapidly, which influences the practice of dentistry for children. Recognizing these changing times, the Council on Clinical Affairs of AAPD has produced guidelines for behavior guidance.[25] The techniques recommended in this chapter conform to these guidelines. However, there are limitations to written standards; these standards change. Dental students and dentists must remember to keep abreast of the times in this highly dynamic area.

REFERENCES

1. Wright GZ, Kupietzky A: Introductory remarks. In Wright GZ, Kupietzky A, editors: *Behavior management in dentistry for children*, ed 2, Wiley Blackwell, Ames, Iowa, 2014, pp 3–9.
2. Juntgen LM, Sanders BJ, Walker LA, et al.: Factors influencing behavior guidance: a survey of practicing pediatric dentists, *Pediatr Dent* 35:539–545, 2013.
3. Boyce WT: The lifelong effects of early childhood adversity and toxic stress, *Pediatr Dent* 36:102–108, 2014.
4. Gesell A, Ilg FL: *Child development: an introduction to the study of human growth*, New York, NY, 1949, Harper & Row.
5. Binet A: New methods for the diagnosis of the intellectual level of subnormals, *L'Année Psychologique* 12:191–244, 1905.
6. Klingberg G, Broberg AG: Dental fear/anxiety and dental behaviour management problems in children and adolescents: a review of prevalence and concomitant psychological factors, *Int J Paediatr Dent* 17:391–406, 2007.
7. Blomqvist M, Ek U, Fernell E, Homberg K, Westerlund J, Dahllöf G: Cognitive ability and dental fear and anxiety, *Eur J Oral Sci* 121:117–120, 2013.
8. Klingberg G, Berggren U, Carlsson SG, Norén JG: Child dental fear: cause-related factors and clinical effects, *Eur J Oral Sci* 103:405–412, 1995.
9. Long N: Stress and economic hardship: the impact on children and parents, *Pediatr Dent* 36:109–114, 2014.

10. Fisher-Owens S: Broadening perspectives on pediatric oral health care provision: social determinants of health and behavior management, *Pediatr Dent* 36:115–120, 2014.
11. Wright GZ: *Behavior management in dentistry for children*, Philadelphia, 1975, WB Saunders.
12. Frankl SN, Shiere FR, Fogels HR: Should the parent remain in the operatory? *J Dent Child* 29:150–163, 1962.
13. Goleman J: Cultural factors affecting behavior guidance and family compliance, *Pediatr Dent* 36:121–127, 2014.
14. Murphy ML, Fields Jr HW, Machen JB: Parental acceptance of pediatric dentistry behavior techniques, *Pediatr Dent* 6: 193–198, 1984.
15. Lawrence SM, McTigue DM, Wilson S, et al.: Parental attitudes toward behavior management techniques in pediatric dentistry, *Pediatr Dent* 13:151–155, 1991.
16. Eaton JJ, McTigue DJ, Fields Jr HW, Beck M: Attitudes of contemporary parents toward behavior management techniques used in pediatric dentistry, *Pediatr Dent* 27:107–113, 2005.
17. Fields Jr HW, Machen JB, Murphy MG: The acceptability of various behavior management techniques relative to types of treatment, *Pediatr Dent* 6:199–203, 1984.
18. Casamassimo P, Wilson S, Gross L: Effects of changing US parenting styles on dental practice: perceptions of diplomates of the American Board of Pediatric Dentistry, *Pediatric Dent* 2:18–22, 2002.
19. Watt RG: Motivational interviewing may be effective in dental setting, *Evid Based Dent* 11:13, 2010.
20. Rimm DC, Masters JC: *Behavior therapy: techniques and empirical findings*, New York, 1974, Academic Press.
21. Wright GZ, Alpern GD, Leake JL: The modifiability of maternal anxiety as it relates to children's cooperative dental behavior, *J Dent Child* 40:265–271, 1973.
22. McElroy CM: Dentistry for children, *Calif Dent Assoc Trans* 85, 1895.
23. Greenbaum PE, Lumley MA, Turner C, Melamed BG: Dentist's reassuring touch: effects on children's behavior, *Pediatr Dent* 15:20–24, 1993.
24. Chambers DW: Behavior management techniques for pediatric dentists: an embarrassment of riches, *J Dent Child* 44:30–34, 1977.
25. American Academy of Pediatric Dentistry: Guideline on Behavior Guidance for the Pediatric Dental Patient, *Pediatr Dent* 35(Spec Issue):175–187, 2014.
26. Nash DA: Engaging children's cooperation in the dental environment through effective communication, *Pediatr Dent* 28:455–459, 2006.
27. Levitas TC: HOME—Hand over mouth exercise, *J Dent Child* 41:178–182, 1974.
28. Adair SM, et al.: A survey of members of the American Academy of Pediatric Dentistry on their use of behavior management techniques, *Pediatr Dent* 26:159–166, 2004.
29. Oueis HS, Ralstrom E, Miriyala V, et al.: Alternatives for hand over mouth exercise after its elimination from the clinical guidelines of the American Academy of Pediatric Dentistry, *Pediatr Dent* 32:223–228, 2010.
30. Bross DC: Managing pediatric dental patients: issues raised by the law and changing views of proper child care, *Pediatr Dent* 26:125–130, 2004.
31. Adair SM, Schafer TE, Waller JL, Rockman RA: Age and gender differences in the use of behavior management techniques by pediatric dentists, *Pediatr Dent* 29:403–408, 2007.

CHAPTER 17

Pharmacologic Management of Patient Behavior

▲ Mark A. Saxen

For additional resources, please visit the evolve website.

CHAPTER OUTLINE

DEFINITION OF TERMS
- Pharmacologic Management
- The Continuum of Anesthesia and Sedation

FUNDAMENTAL CONCEPTS
- Anatomic and Physiologic Differences
- Routes of Drug Administration
- Drugs and Agents Used for Sedation
- Nitrous Oxide
- Antihistamines
- Benzodiazepine Agonists and Antagonists
- Opioid Agonists and Antagonists
- Other Sedative-Hypnotics

NITROUS OXIDE ADMINISTRATION
- Objectives
- Equipment
- Technique
- Monitoring and Documentation

ENTERAL SEDATION TECHNIQUE

COMBINATIONS OF METHODS AND AGENTS

FACILITIES AND EQUIPMENT

DOCUMENTATION

PATIENT SELECTION AND PREPARATION
- Indications
- Preoperative Evaluation
- Informed Consent
- Instructions to Parents

MONITORING
- Intraoperative Monitoring
- Postoperative Monitoring

CONCLUDING THOUGHTS

DEFINITION OF TERMS

PHARMACOLOGIC MANAGEMENT

Pharmacologic management is a broad term that describes the use of drugs to manage the behavior of pediatric patients undergoing dental procedures. The types of drugs used include inhaled gases, oral medications, drugs administered via intravenous infusion, intramuscular injection, and other routes of administration. Pharmacologic management is further divided into two subcategories, sedation and general anesthesia.[1] This chapter will focus on minimal and moderate sedation (formerly termed "conscious sedation"), as administered by the dentist while simultaneously performing dental procedures in the dental office.

Dentists often think of sedation as a limited form of anesthesia that falls within the broader realm of behavior management (Fig. 17-1). In contrast, anesthesiologists view sedation as part of a broader physiologic continuum that ranges from an awake, relaxed, conscious state to unconscious with no responsiveness. The level of sedation often changes during the course of medical and dental procedures, and the distinction between different levels of sedation and general anesthesia is not always well defined (Fig. 17-2). When sedation is administered to children, respiratory depression and loss of protective reflexes may occur rapidly and unexpectedly, regardless of the intended level of sedation. Furthermore, maintaining a sustained level of moderate sedation can be difficult. Dr. Charles Cote, the well-known pediatric anesthesiologist and educator, maintains that the term "conscious sedation" is an oxymoron when applied to young children. "When caring for young children, particularly when they have to remain quiet for any length of time, one must induce pharmacologic coma" (deep sedation/general anesthesia).[2]

Incorporating sedation into a dental practice requires knowledge and skills beyond the scope of many predoctoral education programs. Very few dentists pursue the advanced residency training required to administer general anesthesia in a dental office. Pediatric dental residency programs provide training that allows pediatric dentists to administer minimal and moderate sedation in their practices. Professional and state standards usually require additional trained staff to be present when sedation is administered to dental patients.[3] Taken together, these reasons illustrate why the term *pharmacologic management* remains nebulous and may explain why it is not commonly and universally practiced by pediatric dentists.[4] In spite of these issues, pharmacologic management provides a valuable component to the pediatric dental practice. Safe and effective practice of this skill requires a broad understanding of the pharmacology, physiology, current professional standards, and relevant outcomes.

THE CONTINUUM OF ANESTHESIA AND SEDATION

The concept of a spectrum of anesthesia is essential to a proper understanding of anesthesia and sedation. It is the basis for the American Dental Association's Guidelines for the Use of Sedation and General Anesthesia by Dentists and provides a framework for many state dental board regulations, hospital privileges, and professional liability insurance policies. Although the levels of anesthesia exist

Dentlearn.ir

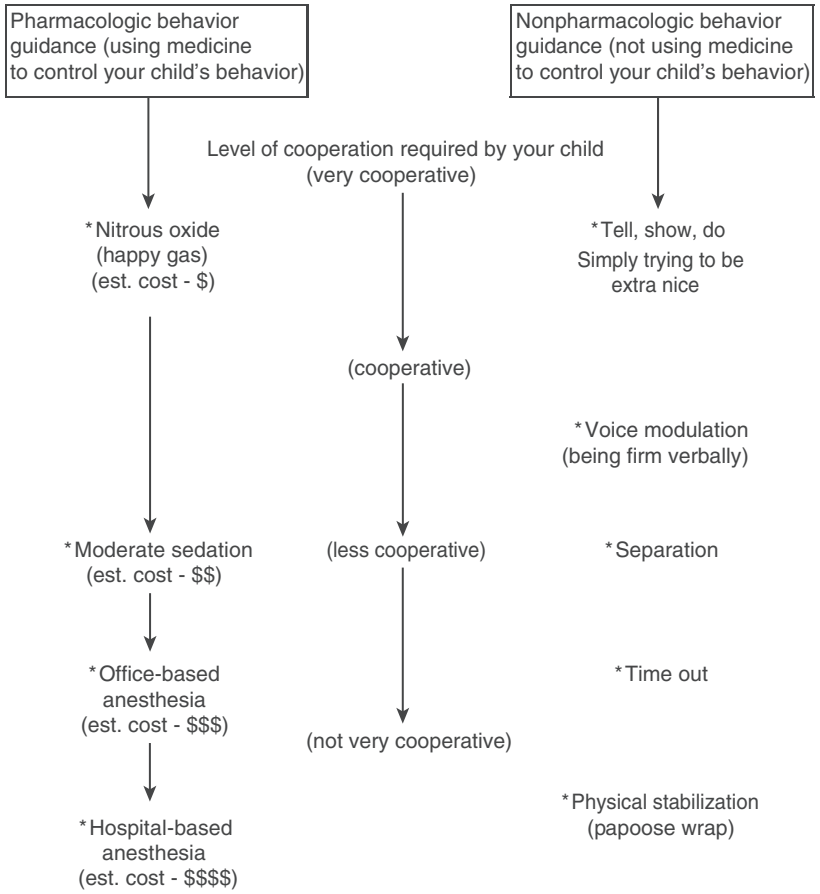

Figure 17-1 Behavior Guidance Flowchart. (Adapted from the private practice of Dr. Matthew Pate, Kokomo, Indiana.)

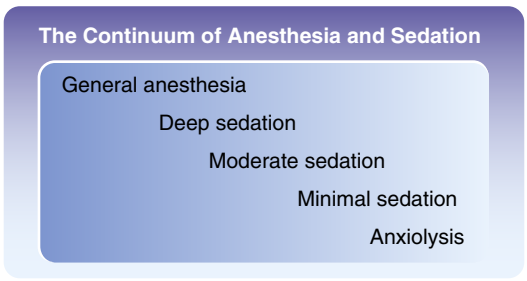

Figure 17-2 Clinical assessment of the level of sedation is usually not as straightforward as the definitions of various levels of anesthesia imply. There is considerable overlap among the levels of sedation, and a patient's level of sedation may easily change throughout the course of a procedure. For this reason, proper vigilance and monitoring are essential for the safe administration of sedation and anesthesia.

on a continuum, the spectrum defines the various levels of sedation and anesthesia as follows.

Minimal sedation – a minimally depressed level of consciousness, produced by a pharmacologic method that retains the patient's ability to maintain an airway independently and continuously and respond normally to tactile stimulation and verbal commands. Although cognitive function and coordination may be modestly impaired, ventilatory and cardiovascular functions are unaffected. When the intent is minimal sedation for adults, the appropriate initial dosing of a single enteral drug is no more than the maximum recommended dose (MRD) of a drug that can be prescribed for unmonitored home use.

Moderate sedation – a drug-induced depression of consciousness during which patients respond purposefully to verbal commands, either alone or accompanied by light tactile stimulation. No interventions are required to maintain a patent airway, and spontaneous ventilation is adequate. Cardiovascular function is usually maintained. Repeated dosing of an agent before the effects of previous dosing can be fully appreciated may result in a greater alteration of the state of consciousness than the dentist intends.

A patient whose only response is reflex withdrawal from a painful stimulus is not considered to be in a state of minimal or moderate sedation. Drugs used to produce a state of minimal or moderate sedation should carry a margin of safety sufficiently wide to avoid unintended loss of consciousness.

Deep sedation – a drug-induced depression of consciousness during which patients cannot be easily aroused but respond purposefully following repeated or painful stimulation. The ability to maintain ventilatory function independently may be impaired. Patients may require assistance in maintaining a patent airway, and spontaneous ventilation may be inadequate. Cardiovascular function is usually maintained.

General anesthesia – a drug-induced loss of consciousness during which patients are not arousable, even by painful

stimulation. The ability to maintain ventilatory function independently is often impaired. Patients often require assistance in maintaining a patent airway, and positive pressure ventilation may be required because of depressed spontaneous ventilation or drug-induced depression of neuromuscular function. Cardiovascular function may be impaired.

Because sedation and general anesthesia are on a continuum, practitioners intending to produce minimal or moderate sedation should be able to diagnose and manage the physiologic consequences of patients whose level of sedation becomes deeper than initially intended. The term "rescue" is often used to describe this management, and refers to steps taken to return the patient to the initially desired level of sedation.[5]

It is important to note the absence of any mention of routes of administration in these definitions. Prior to the twenty-first century, it was common for many state dental boards and other institutions to delineate privileges and guidelines for "intravenous sedation" or "oral sedation." These terms are inherently misleading, because the level of sedation is completely independent of the route of administration. For example, one is capable of producing general anesthesia with oral medications, and a state of minimal sedation can easily be obtained through an intravenous route. Similarly, the term "conscious sedation," a term originally coined to describe the sedation of dental patients, is purposefully avoided in these definitions, because consciousness is not clearly defined and is always limited to a particular level of sedation. Although terms like "oral sedation," "IV sedation," and "conscious sedation" continue to be used in dentistry today, they are anachronistic, potentially misleading, and should be avoided.[6]

FUNDAMENTAL CONCEPTS

The goals of sedation for the pediatric patient are (1) to guard the patient's safety and welfare; (2) to minimize physical discomfort and pain; (3) to control anxiety, minimize psychological trauma, and maximize the potential for amnesia; (4) to control behavior or movement so that the procedure can be completed safely; and (5) to return the patient to a physiologic state in which safe discharge, as determined according to recognized criteria, is possible.[7]

Having a systematic routine to follow during sedation is an essential element of safe practice. The sedation routine should be reflected in the documentation an office uses for every step of the process. This includes preoperative evaluation, physical assessment, intraoperative and postoperative notes, and follow-up notes. The simple process of following a well-conceived procedural checklist has been demonstrated to reduce preventable errors in all areas of health care.[8]

Outcomes assessment is also a critical element of safe sedation practice. The practice of obtaining follow-up data and recording outcomes in a systematic database is not currently as strong in dentistry as it is in medicine, yet it is no less critical. Analysis of data derived from follow-up phone calls and other postoperative assessments helps the dentist identify previously unappreciated treatment sequelae and also gauge the appropriateness of his/her discharge criteria, an area previously underappreciated by many sedation practitioners.[9,10]

ANATOMIC AND PHYSIOLOGIC DIFFERENCES

The adage "children are not small adults" is well appreciated by clinicians who treat children on a regular basis. Physiologic systems grow and develop at different rates, particularly in children under the age of 8 years. A sound understanding of the anatomic and physiologic differences of children is crucial to the safe practice of pharmacologic management, which is most typically used to manage preschool-aged children.

Central Nervous System

Although the brain of a full-term newborn accounts for approximately 10% of the total body weight, only 25% of the neuronal cells of an adult are present at birth. Growth in the CNS of a newborn is extremely rapid, with brain weight doubling by the age of 6 months and tripling by 12 months. By 12 months, brain stem and cortex neuronal cell development is nearly complete; however, myelination lags behind and is not complete until the third year of life.

In the last decade, research performed in nonhuman primates has suggested that several anesthetic and sedative drugs may be toxic to developing neurons, leading to concern about the possible damaging effects of sedation and anesthesia on infants and young children. While the relevance of these studies to humans remains unknown, two large-scale studies are currently under way to determine the clinical relevance of these findings. The Pediatric Anesthesia and Neurodevelopment Assessment study (PANDA) is a multicenter study investigating the neurodevelopment of children in the United States who have undergone general anesthesia prior to age three. The General Anesthesia Spinal study (GAS) is a worldwide, multinational comparison of children who have undergone either general anesthesia or spinal anesthesia.[11] With an estimated 10 million anesthetic procedures performed on children aged three and under in the United States each year, the importance of research in this area cannot be overestimated.[12]

Cardiovascular System

Autonomic control of the heart is a balance between the sympathetic and parasympathetic nervous systems; however, these two systems develop at different rates. The parasympathetic system controls heart rate in utero and is fully intact at birth, whereas the sympathetic control begins shortly after birth and continues to develop in the first several months of life. Wide variations in heart rate can continue for several months and even appear in young children as a result of variations in autonomic tone.[13]

The heart of a newborn infant is characterized by an immature left ventricle and myocardium. In contrast to fully mature hearts, the infant heart cannot use changes in myocardial contractility to increase cardiac output in times of stress. Heart rate is the major determinant of cardiac output of a young child's heart. Myocardial contractility continues to develop in the toddler, reaching near-adult levels of contractility by the age of 8 years. This rate dependency of the pediatric heart is reflected in normal heart rate values, which drop from a rate of 120 ± 20 in a 6-month-old infant to 90 ± 10 in a 5-year-old and 70 ± 17

Dentlearn.ir

Table **17-1**

Vital Signs at Various Ages

Age (yr)	Heart Rate (beats/min)	Blood Pressure (mm Hg)	Respiratory Rate (breaths/min)
1-3	70-110	90-105/55-70	20-30
3-6	65-110	95-110/60-75	20-25
6-12	60-95	100-120/60-75	14-22
12	55-85	110-135/65-85	12-18

Adapted from Behrman RE et al: *Nelson textbook of pediatrics*, 19 ed, Philadelphia, 2011, Elsevier Science.

in a 12-year-old child.[14] In contrast, blood pressure rises rapidly in the first days to weeks (Table 17-1).

Respiratory System

As with the heart, the lungs of a newborn are immature. Growth in the number of alveoli occurs mainly after birth and continues to the age of 8 years, whereas the sizes of alveoli continue to increase until the growth of the chest wall is complete. As the number of alveoli increase, blood vessels proliferate in the gas exchange areas, primarily in the first 5 years of life. The development of alveolar smooth muscle begins after birth and continues into late childhood and adolescence. Conditions that disturb the flow of blood in the lungs, particularly congenital heart lesions, may disturb normal growth and development of the pulmonary vasculature.[15] A higher metabolic rate is present in infants and children, resulting in a rate of alveolar ventilation that is two to three times greater than that in adults. Functional reserve capacity (FRC) is also significantly smaller in children than in adults. FRC acts as a buffer to maintain consistent alveolar ventilation during inspiration and expiration. In the adult, the ratio of alveolar ventilation to FRC is 1.5 to 1, whereas in the infant, it is 5 to 1. Placing a patient in the supine position, as is commonly done during dental treatment, decreases FRC by 20% to 30%. One can therefore appreciate why hypoxemia can develop so rapidly in the pediatric dental patient when normal respiratory function is diminished.[16,17]

The characteristic anatomic differences of the pediatric airway must also be appreciated. In general, children have proportionately larger heads and shorter necks. The larynx is more cephalad and anterior in the child, being located at the level of C3-4, as compared with C4-5 in the adult. The relatively narrow nasal passages, large tongues, and large tonsils and adenoids contribute to the tendency of the upper airway to be blocked by secretions or edema. In addition, the relatively vascular and fragile nature of tonsils adds an additional risk factor in patients with large tonsils undergoing procedures in the airway, particularly when the tonsils are inflamed. As a general rule, patients with tonsillar tissue that occupies more than 50% of the pharyngeal space are not good candidates for pharmacologic management[17] (Fig. 17-3).

Body Size and Composition

Obesity is an important, but often underappreciated, risk factor for pharmacologic management. According to estimates from the Centers for Disease Control and Prevention, 1 of 3 children in the United States is obese or overweight by the time he/she reaches his/her fifth birthday.[18] The risk is increased in children living in low-income families.[19] Obesity affects the delivery of all levels of sedation and anesthesia in many ways. Increased adiposity may affect the ability of a sedated child to maintain a patent airway and complicate airway management. Obstructive sleep apnea, which occurs in up to 60% of obese children, may complicate both procedural sedation and the recovery of patients after sedation.[20] Venous access may be more difficult, complicating resuscitation in the event of an emergency. Obesity may affect the pharmacokinetic properties of certain sedative drugs, which may distribute preferentially to fatty tissues. Dose calculations for certain sedative drugs may need to be adjusted to avoid inadvertent oversedation. Normal vital signs, such as blood pressure, may be affected.[21] Obesity may also complicate the management of older children, should rescue or resuscitation be required. Members of the dental team must be confident that they are capable of moving and handling an obese child should unconsciousness occur.

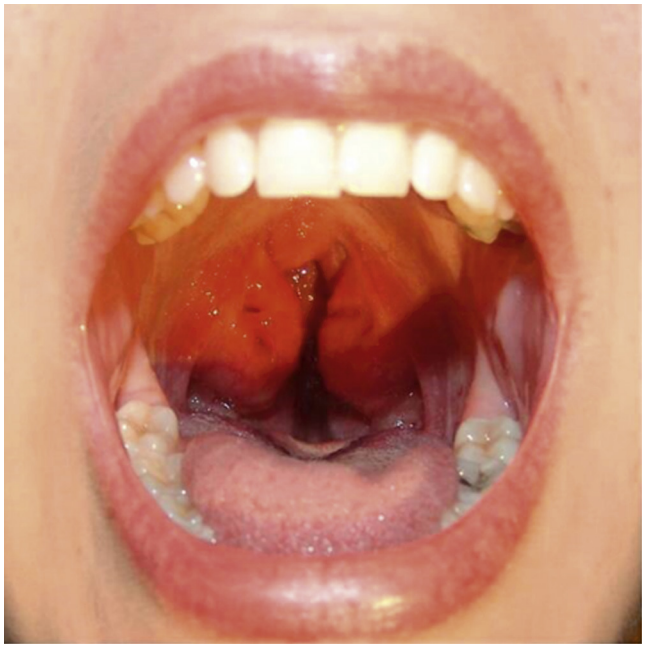

Figure 17-3 Enlarged tonsils, particularly when inflamed, increase the risk of airway complications during sedation.

ROUTES OF DRUG ADMINISTRATION

Pharmacokinetics is the study of the absorption, distribution, metabolism, and excretion of a drug and its metabolites. This information helps determine how much drug is made available to the actual site where the drug binds and takes effect. The route of administration describes where and how the drug is initially absorbed by the body. A given dose of a drug, administered via different routes, can have very different effects. For example, the analgesia and side effects following intravenous administration of meperidine differ dramatically from those seen following oral

Dentlearn.ir

administration.[22] This is due primarily to differences in the pharmacokinetic properties of these two forms of the drug.

Inhalational Route

The inhalational route is a highly effective route of administration, allowing nonirritating gases and volatile drugs to be inhaled and absorbed directly through the pulmonary epithelium and mucous membranes of the respiratory tract into the circulation. The almost instantaneous absorption of agents delivered through this route is due to the large surface area of the lung. Equilibrium is quickly established among the partial pressure of the drug in the alveolar gas space, serum, and target tissues in the brain. As a result, inhaled anesthetic gases are easily titrated by adjustment of the amount of inhaled gas, provided the rate and depth of ventilation are adequately controlled.

Enteral Route

Enteral sedation is achieved by drugs that are swallowed and absorbed through the digestive or enteric system. Although this form of drug delivery is simple and relatively inexpensive, the effects are not produced as reliably as those of drugs delivered through parenteral routes—that is, routes that do not involve the digestive tract. Disadvantages of the oral route include limited absorption of some drugs due to physiochemical factors, destruction by digestive enzymes or gastric pH, and metabolism from enzymes in the liver (termed first-pass metabolism).[23] Dosing discrepancies may also occur during swallowing by an uncooperative patient. Once swallowed, medication may be broken down by gastric enzymes in the stomach; however, no absorption occurs until the drug enters the small intestine. Differences in drug formulation may result in some drugs being broken down more completely in the stomach than others. Because high sympathetic nervous system tone inhibits gastric emptying time, anxious patients may demonstrate a longer time to the onset of sedation than predicted. Once absorbed in the small intestine, drugs pass through the hepatic portal system, where they are metabolized to various degrees by hepatic enzymes. The amount and activity of hepatic enzymes vary significantly among patients, with as much as an eightfold difference noted among populations of normal individuals. This effect, known as the first-pass effect, may account for large discrepancies between the amount of drug present in the initial drug formulation and the amount of drug that remains active after first-pass metabolism (Fig. 17-4, *A*). The onset, peak, and duration of drug effects may still be affected by numerous factors once they bind to their effect site in the brain; however, as a general rule, most clinically useful agents will display an onset approximately 30 minutes after administration, with peak effect noted by 60 minutes. The duration of effect is usually proportional to the elimination half-life of the drug.

Although the enteral route of administration is better accepted by pediatric patients over injections, not all patients will readily accept orally administered drugs. The taste may be quite objectionable, especially to very young children. This can usually be overcome when the drug is mixed with a palatable liquid (e.g., flavoring drops). The use of a syringe to deliver oral medication to uncooperative children is sometimes used, but caution must be exercised with this technique to avoid inadvertent aspiration of the drug.[24] Enteral drugs should only be administered to patients while under supervision by trained personnel. The practice of having parents administer oral medications to children prior to arrival at the office should be avoided.[25]

Intramuscular Route

Intramuscular administration relies upon the high vascularity of muscle tissue to achieve a moderately rapid onset of action, usually within 5 to 10 minutes. When properly administered, intramuscular injection provides a more rapid onset and offset as compared with enteral techniques (see Fig. 17-4, *B*). As with enteral techniques, practitioners are limited to a single dose of medication; however, the onset of sedation is more predictable than is the onset of oral techniques. For pediatric dental sedation, injections are typically performed in the vastus lateralis or deltoid muscle. Aqueous solutions are well absorbed following intramuscular injection. Care should be taken to prepare the solution in a volume that is appropriate for the size of the injected muscle because excessive volume may cause pain and/or tissue damage and hinder absorption. The most common error in the delivery of intramuscular injections is failure of the injected solution to be deposited deep in the muscle bed, where maximum absorption can take effect. Misplaced or superficial injections result in deposition of the solution in fascia or subcutaneous tissue, resulting in slower, less predictable onset.

As with local anesthetic techniques, knowledge of the anatomy of the injection site is mandatory for safe and effective delivery. The vastus lateralis muscle on the ventral thigh is often preferred due to its larger size and relative easy access in small children. The upper outer quadrant of the gluteus maximus muscle and the middle of the deltoid muscle are other acceptable sites as long as muscle development is adequate. Once the medication has been injected, if the desired effect is not achieved within 25 to 30 minutes, termination should be considered. As with oral agents, additional intramuscular injections are not advisable, and may create unintended sequelae for a prolonged period of time.

Submucosal and Subcutaneous Routes

Submucosal sedation involves the deposition of the drug beneath the oral mucosa. Its use is almost exclusively the province of dentistry. It is analogous to subcutaneous injection, with the solution being deposited below the intraoral mucosa. From a pharmacologic perspective, there is little advantage of the submucosal route over the subcutaneous route. From a practical perspective, it is often harder to administer a well-controlled intraoral injection as opposed to an intramuscular injection. Details of this technique may be found in earlier editions of this text.

Intravenous Route

The intravenous route of administration shares most of the desirable pharmacokinetic and pharmacodynamic features of inhalational anesthetics. Drugs delivered through the intravenous route circulate directly to the brain, with onset occurring within 20 to 40 seconds. The

Dentlearn.ir

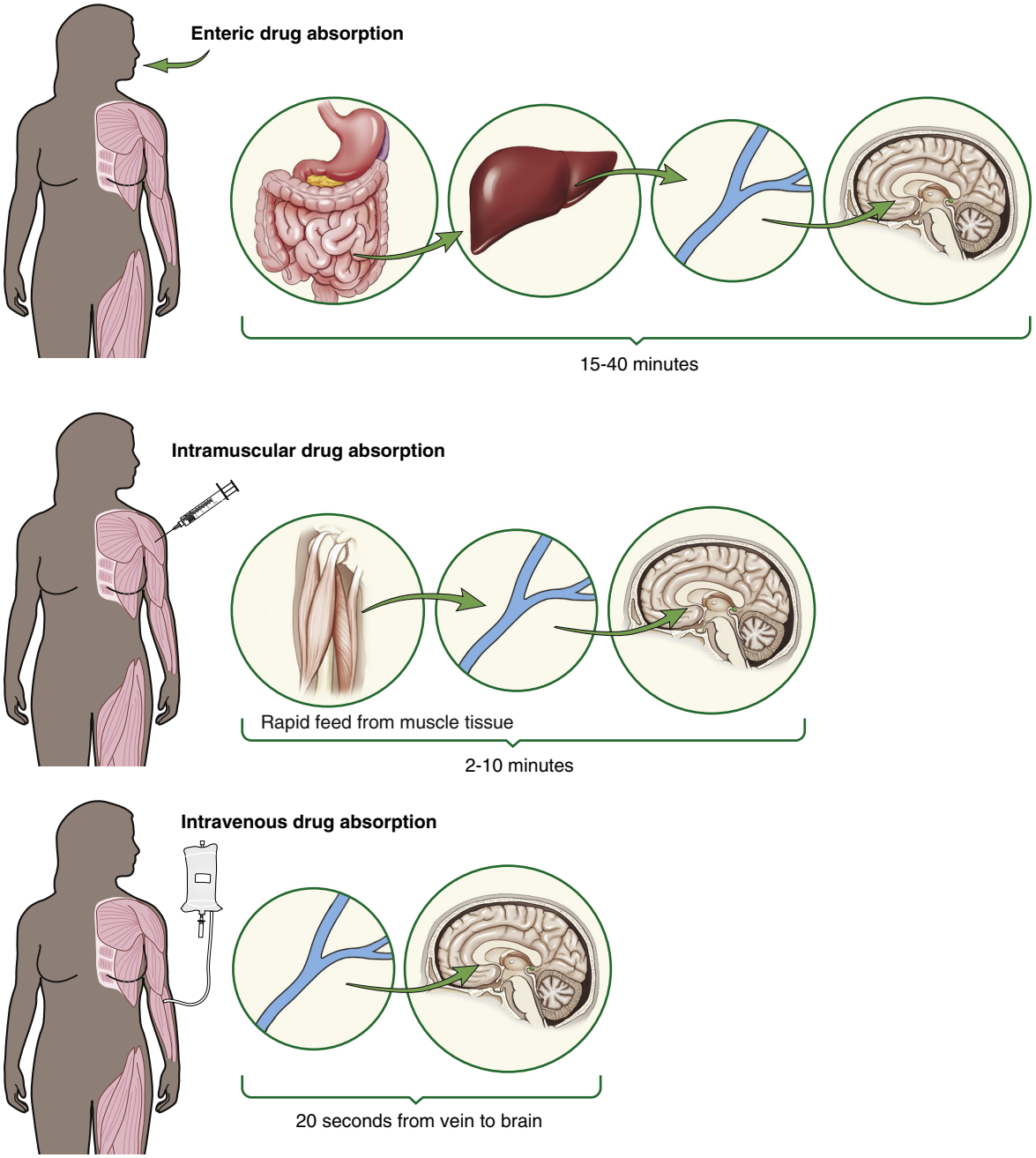

Figure 17-4 Comparison of drug absorption and distribution to the brain through the enteral, intramuscular, and intravenous routes.

level of sedation or anesthesia is readily titrated and can be sustained for extended periods of time. Recovery from intravenously administered drugs is often more rapid than that from drugs delivered through the oral or intramuscular route. Multiple doses can be administered through an intravenous infusion, with a high degree of versatility and control. The intravenous route also requires the most training and experience to perform because drug-related complications often arise very rapidly, with increased potential for severe consequences.

Despite the clear advantages of the intravenous route of administration, it is often difficult to achieve sustained moderate sedation through the intravenous route in the pediatric patient. The reasons for this have less to do with the route of administration and more to do with how easy it is to achieve a state of general anesthesia when attempting to provide moderate sedation to children during dental procedures. Advanced training for intravenous and other parenteral administration techniques is required.[3] Dentists with limited parenteral moderate sedation permits will often find this modality best suited to older children and adolescents for a combination of behavioral, pharmacologic, and practical reasons.

Rectal Route

Rectal administration of sedative drugs with suppositories has a limited history in pediatric dentistry. Drugs administered through this route are absorbed through two different vascular systems, one of which delivers agents to the liver while the second bypasses the liver. As a result, wide variations of bioavailability are seen after rectal administration. References report that 50% of a drug delivered by the rectal route undergoes first-pass metabolism in the liver, but this is a broad approximation, and absorption is often irregular and incomplete. For this reason, and because of the tendency toward mucosal irritation from drugs delivered via this route, rectal administration is not recommended for pediatric sedation.[26]

DRUGS AND AGENTS USED FOR SEDATION

NITROUS OXIDE

Eighty-five percent of pediatric dentists use inhalation of nitrous oxide and oxygen to sedate patients, making it the most frequently used pediatric sedation technique today. Nitrous oxide is a slightly sweet-smelling, colorless, inert gas. It is compressed in cylinders as a liquid that vaporizes on release. The gas is nonflammable but will support combustion.

The pharmacokinetic properties of nitrous oxide are well suited to producing moderate sedation. The small molecular size and low solubility allow for rapid alveolar uptake and distribution through the arterial circulation to the brain. Within 3 to 5 minutes of the patient inhaling a fixed concentration of nitrous oxide, equilibrium is reached among the concentrations in the alveolar gas, blood, and target sites in the brain. There is good correlation between the mixture set with the flowmeter and the observed effect. The nitrous oxide machine feeds a steady, consistent mixture, making it relatively easy for the dentist to achieve a steady state of moderate sedation in a patient whose rate and depth of breathing and level of procedural stimulation remain reasonably constant consistently. The lack of significant biotransformation in the liver or other sites allows for an equally rapid recovery. Excretion occurs almost entirely through the lungs; only very small amounts may be excreted in body fluids and intestinal gas.

The mechanism through which nitrous oxide produces its clinical effects remains undefined. Current evidence suggests an interaction with the endogenous opioid system, because its effects are abolished by the administration of the opioid antagonist, naloxone. The strongest evidence suggests that nitrous oxide stimulates the release of enkephalins, which trigger descending noradrenergic pathways. The most common estimate of analgesic efficacy suggests that 30% nitrous oxide delivered by full mask is equivalent to 10 to 15 mg of morphine. This interaction with the endogenous opioid system may account, in part, for the abuse potential that has been attributed to nitrous oxide.

Nitrous oxide is the weakest of all inhalational agents, with a minimum alveolar concentration (MAC) of 105. The MAC of an inhalational agent is a measure of its anesthetic potency; it is defined as the concentration required to produce immobility in 50% of patients upon surgical skin incision. Most commonly used inhalational general anesthetics today have MAC values between 1% and 6% (Table 17-2). The exceedingly high MAC value of nitrous oxide precludes the use of an inhalational agent as the sole means of producing general anesthesia; however, it possesses very useful clinical effects when delivered at subanesthetic concentrations far below MAC value.

Table 17-2

MAC Values for Common Inhaled Anesthetics

Minimum Alveolar Concentration (MAC)	%
Nitrous oxide	104
Desflurane	6.0
Sevoflurane	2.0
Isoflurane	1.2
Halothane	0.75

Adapted from Nickalls RW, Mapleson WW: Age-related iso-MAC charts for isoflurane, sevoflurane and desoflurane in man, *Br J Anaesth* 31:170-174, 2003.

A nitrous oxide concentration between 30% and 50% (roughly 0.3 to 0.5 MAC) will produce a relaxed, somnolent, and sometimes euphoric patient who may appear dissociated and easily susceptible to suggestion. Amnesia may occur in some patients, but there is little alteration of learning or memory. The concentration of nitrous oxide should not routinely exceed 50% in clinical dental practice because concentrations in this range increase the likelihood of nausea, vomiting, and disorientation. At concentrations greater than 60%, patients may experience ataxia, giddiness, dysphoria, and increased sleepiness. Like all inhaled agents, nitrous oxide can be titrated, allowing the doctor to adjust the level of sedation to match the level of surgical stimulation.

Nitrous oxide reduces the ventilatory response to hypoxemia but has minimal effect on the hypercapnic respiratory drive when delivered in concentrations less than 50%. It should be avoided, however, in patients who rely significantly on hypoxia-driven ventilation. When combined with other agents that depress respiration, nitrous oxide may diminish the body's normal response to low oxygen tension. These effects are usually negligible, however, because of the high concentration of oxygen administered in combination with nitrous oxide. Nitrous oxide slightly increases the respiratory minute volume. As the patient becomes more relaxed from the effects of nitrous oxide, the respiratory rate may decrease slightly. The gas is nonirritating to the respiratory tract and can be given to patients with asthma without fear of bronchospasm. Caution must be exercised when nitrous oxide is used with central nervous system depressants because it may enhance those actions.

Nitrous oxide–oxygen has an excellent safety record with few adverse effects. Nausea and vomiting are the most common adverse effects, occurring in 1% to 10% of patients. The incidence of adverse effects increases with concentrations in excess of 50%, rapid fluctuations

Dentlearn.ir

of concentrations, and rapid induction and reversal. The likelihood of nausea and vomiting also increases with the length of the procedures, beginning at durations of approximately 20 minutes. Fasting is not required for nitrous oxide–oxygen sedation.

Nitrous oxide will become entrapped in gas-filled spaces such as the middle ear, sinuses, and gastrointestinal tract. Middle ear pressure will increase significantly, and although it is of little significance in a patient with normal patency of Eustachian tubes, it can induce pain in patients with acute otitis media and should be avoided. Other contraindications include severe behavioral problems and emotional illness, uncooperativeness, claustrophobia, maxillofacial deformities that prevent nasal hood placement, nasal obstruction (e.g., upper respiratory infection, nasal polyps, deviated septum), chronic obstructive pulmonary disease, pregnancy, and situations in which high oxygenation is inadvisable (e.g., bleomycin therapy).

When medical-quality nitrous oxide and oxygen are used properly, there is little to no risk of toxicity for the dental patient. The greatest concern regarding toxicity centers on the exposure of dental personnel to high ambient air levels of the gas when it is used for patient sedation. Chronic exposure to nitrous oxide, including recreational abuse, can produce neurotoxicity, sexual and reproductive problems, hepatotoxicity, and renal dysfunction. The rate of spontaneous abortion is known to be higher in operating room personnel and in the spouses of operating room personnel. In addition, individuals exposed over the long term may experience a decrease in fertility. An increase in hepatic disease was found in dentists and dental personnel exposed to high levels of nitrous oxide for periods longer than 3 hours per week.[27] In light of these findings, leakage from open nitrous oxide delivery systems, such as those used in the dental office, should be reduced as much as possible. This can be accomplished by limiting the amount of mouth breathing by the patient and the use of an efficient scavenging system. The office location as well as office personnel should be periodically monitored for exposure to ambient nitrous oxide. Numerous units are available that use infrared spectrophotometry to measure levels of unscavenged nitrous oxide in the dental operatory environment. These machines can detect levels as low as 1 ppm and are particularly useful for uncovering leaks around tanks and flowmeters. A less costly and more practical approach is the use of dosimetry badges that are worn by office personnel when using nitrous oxide. These units are generally worn for an 8-hour period and report exposure as time-weighted averages. Methods to limit exposure to ambient nitrous oxide are listed in Box 17-1.

Box 17-1

Recommendations for Minimizing Occupational Exposure to N_2O

- Use scavenging systems that remove N_2O during patient's exhalation.
- Ensure that exhaust systems adequately vent scavenged air and gases to the outside of the building and away from fresh air intake vents.
- Where possible, use outdoor air for dental operatory ventilation.
- Implement careful, regular inspection and maintenance of the nitrous oxide/oxygen delivery equipment.
- Carefully consider patient selection criteria (i.e., indications and contraindications) prior to administering N_2O.
- Select a properly fitted mask size for each patient.
- During administration, visually monitor the patient and titrate the flow/percentage to the minimal effective dose of N_2O.
- Encourage patients to minimize talking and mouth breathing during N_2O administration.
- Use rubber dam and high-volume dental evacuator when possible during N_2O administration.
- Administer 100% oxygen to the patient for at least 5 minutes after terminating nitrous oxide use, to replace the N_2O in the gas delivery system.

Data from the American Academy of Pediatric Dentistry Policy on Minimizing Occupational Health Hazards Associated with Nitrous Oxide Reference Nitrous.pdf.

ANTIHISTAMINES

Hydroxyzine (Atarax, Vistaril)

Hydroxyzine is an antihistamine with weak sedative, anticholinergic, and antiemetic properties. It produces sedation by inhibiting the hypothalamic H-1 histamine receptors involved in governing the sleep-wake cycle in humans.[28] The antimuscarinic action of hydroxyzine inhibits the flow of saliva, resulting in various degrees of xerostomia. Although clinical anxiolysis is sometimes reported with hydroxyzine, this effect is most likely related to the production of drowsiness and is not linked to specific actions on the neural substrates involved in anxiety. In normal doses, it has no cardiovascular or respiratory depressant effects. Absorption through the gastrointestinal tract is relatively rapid, with the onset of action occurring in 15 to 30 minutes. Peak levels occur at 2 hours. Recovery is slow by modern standards, reflected by the mean half-life of 3 hours. It is available in two forms, hydroxyzine hydrochloride (Atarax) and hydroxyzine pamoate (Vistaril).

Preparation: tablets, elixir

Dosage: 0.5 to 1.0 mg/kg

Side effects: prolonged drowsiness, ataxia, dry mouth. In children, paradoxical reactions may occur at sedative doses.

Promethazine (Phenergan)

of drugs characterized by a wide range of clinical effects. Phenothiazines bind to a variety of receptors in the central nervous system, including histaminic, alpha adrenergic, muscarinic, serotonergic, and dopaminergic receptors.[29] As a class, phenothiazines are most commonly used as antipsychotics, antiemetics, and sedatives. Promethazine lacks antipsychotic effects, but has strong anticholinergic,

Dentlearn.ir

antiemetic, and antihistaminic effects. It has been used in clinical practice in the United States since 1946, most commonly as an antiemetic and sedative agent. It continues to be used as a sedative in pediatric dentistry, although its use has been supplanted by newer sedative agents with better pharmacokinetic properties.

Like hydroxyzine, promethazine is readily absorbed by the GI tract, with onset of action noted at 20 minutes and peak effect occurring within 2 to 3 hours.[30] It is highly bound to plasma proteins and has a serum half-life of 7 to 14 hours.[31] The long half-life may be seen as beneficial in terms of its antiemetic effects but may also contribute to prolonged drowsiness, particularly when used in combination with other sedative drugs. Promethazine is rapidly degraded by first-pass metabolism, resulting in limited bioavailability after oral or rectal administration. Promethazine has been associated with an enhanced risk of sudden infant death syndrome (SIDS) and worsening of sleep apnea. Although the mechanisms remain unclear, relaxation of the oral pharyngeal musculature may be a contributing factor in patients with compromised airways or a history of SIDS.[32]

Preparation: tablets, rectal suppository

Dosage: 0.5 to 1 mg/kg to a maximum single dose of 50 mg

Side effects: blurred vision, prolonged drowsiness, ataxia

Diphenhydramine (Benadryl)

Along with hydroxyzine, diphenhydramine is the most commonly used antihistamine for procedural sedation and antiemetic therapy in children. When compared with other antihistamines, diphenhydramine is noted for its pronounced tendency to produce sedation and its strong antimuscarinic effects. It is approved by the Food and Drug Administration (FDA) for over-the-counter use as a sleep aid and therapeutic for motion sickness. It is well absorbed through the gastrointestinal tract but undergoes significant first-pass metabolism in the liver, resulting in a bioavailability of 40% to 60%. The peak clinical effect occurs at approximately 1 hour. The half-life of diphenhydramine ranges from 2 to 8 hours. It is metabolized by the liver and is completely excreted in 24 hours.

Preparation: tablets, elixir, capsules, injectable

Dosage: oral, intramuscular, or intravenous—1.0 to 1.5 mg/kg; maximum single dose is 50 mg

BENZODIAZEPINE AGONISTS AND ANTAGONISTS

Benzodiazepines are the most commonly used drugs for procedural sedation in medicine and dentistry today. The popularity of this class of drugs is due to its wide therapeutic index, shallow dose-response curve, and its specific effects on the GABAnergic neurons of the central nervous system. GABA is the major inhibitory neurotransmitter in the brain, and GABA receptors are found in high concentrations in the cerebral cortex, midbrain, hippocampus, and other sites involved in the neural processing of awareness, anxiety, and learning.[33]

Benzodiazepines have five major clinical effects: anxiolysis, hypnosis, amnesia, muscle relaxation, and anticonvulsant activity.[34] Each of the clinically available benzodiazepine drugs is characterized by the relative degree to which it produces each of these five major effects. Despite having marked effects on awareness and memory, benzodiazepines have negligible effects on cardiovascular or respiratory function when used as single agents. Members of this class of drugs also lack analgesic activity, although they are believed to play a role in the prevention of hyperalgesia from surgical trauma.

Diazepam (Valium)

Introduced in 1963, diazepam is the oldest benzodiazepine in use for clinical sedation and is often considered the standard with which all other benzodiazepines are compared. It is rapidly absorbed from the GI tract, reaching peak serum levels in as little as 15 to 30 minutes in children. Due to its high lipid solubility, diazepam redistributes rapidly to other tissues. It is metabolized into two principal metabolites, desmethyldiazepam and oxazepam. Desmethyldiazepam is only slightly less potent than its parent compound diazepam and is believed to be the chief cause of secondary drowsiness, or resedation, which may happen hours after the initial dose. Enterohepatic recirculation also contributes to the long elimination half-life of this drug, which ranges from 21 to 37 hours.[35] When compared with newer, more potent benzodiazepines, diazepam is distinguished by its ability to produce rapid and sustained anxiolysis. The prolonged recovery period poses a potential for resedation and airway obstruction in the postprocedural phases of treatment, especially in obese children and in cases where opioid agents had been coadministered during the procedure. Side effects most commonly include ataxia and prolonged sedation.

Dosage: oral—0.2 to 0.5 mg/kg to a maximum single dose of 10 mg; intravenous—0.25 mg/kg

Supplied: tablets—2, 5, and 10 mg; suspension—5 mg/mL

Midazolam (Versed)

Midazolam was introduced into U.S. medical and dental practice in 1985 as the first water-soluble benzodiazepine. This property accounts for its stability in aqueous solutions, making it nonirritating to tissues following intravenous or intramuscular administration. When administered orally, it undergoes rapid absorption, but from 50% to 65% of the dose is lost to first-pass metabolism. The onset of sedation occurs within 20 to 30 minutes, allowing an average of 30 minutes of working time for the dentist. After binding to receptor sites in the brain, the drug is rapidly redistributed to other tissues or metabolized. Although biotransformation of midazolam in the liver produces one active metabolite, it is of negligible clinical importance. The elimination half-time of midazolam is 1 to 4 hours, which is significantly shorter than that of diazepam. Cognitive testing in adults shows return of normal mental function within 4 hours.[36]

Midazolam is much more potent than diazepam, as predicted by its greater affinity to bind benzodiazepine receptors in the brain.[37] The clinical potency of midazolam is estimated to be 2 to 5 times the potency of diazepam. Part of the reason for this discrepancy is the difference in dose-response relationships of the two drugs. Diazepam is characterized by a more gradual increase in effects with dose,

Dentlearn.ir

whereas midazolam shows greater potency with increasing dose.[38] This difference in potency was not fully appreciated in the late 1980s, when midazolam was first introduced and commercially prepared in the same concentrations as diazepam. Early reports of hypoxia associated with midazolam were almost entirely due to lack of appreciation for the difference in potency between the two drugs.[39] This difference may also explain the differences in cognitive effects seen when midazolam and diazepam are compared. Midazolam produces more consistent anterograde amnesia during moderate sedation than does diazepam, whereas diazepam is more likely to produce anxiolysis with less amnesia. Both effects are dose-dependent, and precise ranges for enteral sedation techniques are difficult to define, because nearly all clinical examinations of these effects were performed with intravenous or intramuscular administration.[40,41] It is worth noting that amnesia may not be desirable for all types of sedation in pediatric practice. Older children and adolescents with a desire to cooperate may tolerate procedures better with anxiolysis as compared with deeper levels of sedation and accompanying amnesia.

Midazolam is available as a premixed suspension; however, independent studies have reported superior bioavailability, shorter onset, and better sedation scores with a mixture of a standard parenteral midazolam preparation with Syrpalta®, a commercial syrup.[42,43]

Preparation: syrup, parenteral injection solution

Dosage: oral—0.25 to 1.0 mg/kg to a maximum single dose of 20 mg; intramuscular—0.1 to 0.15 mg/kg to a maximum dose of 10 mg

Flumazenil (Romazicon)

Flumazenil is a direct, specific reversal agent used in clinical practice to treat benzodiazepine overdose. Pharmacologically it acts as a competitive antagonist at the benzodiazepine receptor sites in the central nervous system. In selected situations the drug is capable of rescuing patients from the effects of benzodiazepine overdose. It is included by several state boards, institutions, and organizations as a required drug when sedation with benzodiazepines is performed. Unfortunately, the use of this drug has been misinterpreted, leading to practices that undermine its intended purpose and effective use in an emergency.

Flumazenil is approved by FDA for intravenous administration. Effective and safe reversal in adults is achieved by titration, by the injection of 0.2-mg doses every 3 to 5 minutes up to a total dosage of 1 mg. When an adequate dose is achieved, reversal of effects occurs within 2 minutes; however, the duration of reversal is short, lasting only 20 to 45 minutes. The manufacturer states that "conscious sedation is reversed in most patients with cumulative doses between 0.6 mg and 1.0 mg. For children, an initial intravenous dose of 0.01 mg/kg (maximum dose: 0.2 mg) given over 15 seconds is recommended, with repeat 0.01 mg/kg (maximum dose: 0.2 mg) after 45 seconds, and then every minute to a maximum total cumulative dose of 0.05 mg/kg or 1 mg, whichever is lower; usual total dose: 0.08 to 1 mg (mean: 0.65 mg)."

Alternate routes of administration via intraoral submucosal injection in the sublingual area have been described; however, the onset of action is slower, and accurate titration is not possible outside of the intravenous route.[44] Practitioners using this route must estimate the appropriate dose or use the recommended starting dose for a single injection. Furthermore, there is no support for the practice of routinely administering flumazenil at the end of sedation in an attempt to accelerate recovery. In a study of adults undergoing moderate sedation with benzodiazepines, Hosaka et al. found that a single dose of 0.2-mg flumazenil was inadequate to reverse the effects of a typical enteral sedation with triazolam. They concluded that reversal for the purpose of discharging the patient early is neither appropriate nor safe.[45]

A more insidious issue with flumazenil is a misunderstanding of its role in sedation emergencies. Respiratory events account for the greatest share of sedation-related morbidity and mortality. Sedation with a benzodiazepine is a common practice in children, and one may be led to believe that the administration of flumazenil is an appropriate first step for the management of hypoventilation or apnea during benzodiazepine sedation. Proper and effective airway management is always the first step undertaken when respiratory distress is encountered. Delaying airway management for the purpose of administering flumazenil may cause delays resulting in hypoxia, serious morbidity, or death.

Dosage: intravenous—as described

Supplied: 5- and 10-mL multiple-use vials containing 0.1 mg/mL in boxes of 10

OPIOID AGONISTS AND ANTAGONISTS

Opioids are drugs that bind to receptors in the endogenous opioid system (EOS), a collection of neurons with diverse connections throughout the central and peripheral nervous system. Although EOS is most commonly appreciated for its ability to diminish or block the sensation of painful sensory stimulation, it is also involved in numerous homeostatic functions, such as breathing, digestion, movement control, airway reflexes, and modulation of the stress response. Opioids are most useful during moderate sedation for their ability to suppress the cough reflex, provide analgesia, and produce a sensation of well-being; however, direct scientific evidence for their utilization in pediatric dental sedation is extremely limited. They are also closely linked with several important side effects, including respiratory depression, nausea and vomiting, delayed gastric emptying, constipation and urinary retention, and itching.

Opioids differ from the benzodiazepines in several critical ways that are relevant to the clinician seeking to provide moderate sedation. They produce analgesia by raising the threshold for perceiving painful stimulation, whereas benzodiazepines have no significant effect on pain perception. At sedative doses, opioids produce analgesia while not affecting awareness and memory, whereas benzodiazepines produce profound, dose-dependent amnesia. All opioid agonists produce dose-dependent respiratory depression through direct action on the ventilatory control center in the medulla and blunt the response to hypercarbia and hypoxia. The effects of opioids on the response to hypercarbia are particularly relevant to clinical sedation because they raise the apneic threshold, i.e., the point at which patients stop breathing (Fig. 17-5). Under these conditions, the accumulation of carbon

Dentlearn.ir

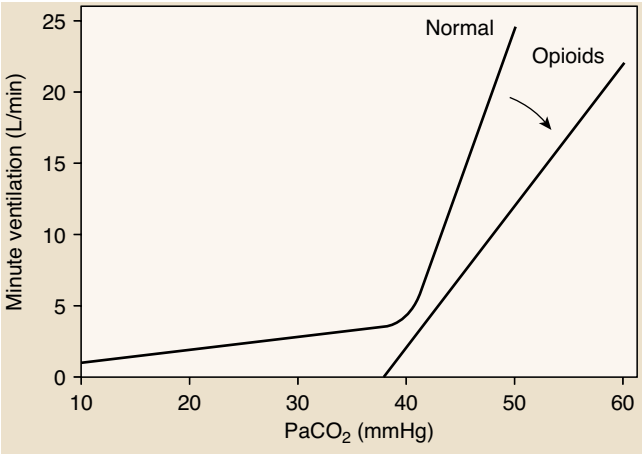

Figure 17-5 The effects of opioids on the ventilatory response to hypercarbia.

dioxide secondary to airway obstruction may not increase the rate of ventilation, leading to acute hypoxia. Because the rate and depth of ventilation may already be reduced during sedation, changes in breathing may be subtle. Continuous and careful observation of the rate and depth of breathing should accompany the use of any opioid.

Opioids also induce nausea and vomiting through direct action on the chemoreceptor trigger zone in the medulla. In comparison, benzodiazepines do not depress ventilation at sedative doses and are not associated with the production of nausea and vomiting. Tolerance, dependence, and abuse potential are associated with repeated dosing of both agents. While these phenomena are not generally induced by a single exposure of the patient to these drugs during a sedative procedure, practitioners may find patients under therapy with these drugs to be refractory to moderate sedation. Although most opioids are readily absorbed through the gastrointestinal (GI) tract, bioavailability is limited by significant first-pass metabolism. In general, the parenteral administration of opioids is more effective and reliable than oral administration.

For the purposes of this chapter, discussion will be limited to fentanyl, meperidine, and naloxone.

Fentanyl (Sublimaze)

Fentanyl is a potent synthetic opiate agonist. A dose of 0.1 mg is approximately equivalent to 10 mg of morphine or 75 mg of meperidine. Fentanyl acts rapidly, and after intramuscular injection the onset occurs in 7 to 15 minutes; duration of effects is 1 to 2 hours. The drug is metabolized by the liver and is excreted in the urine. Fentanyl produces little histamine release and has a much lower emetic effect than does morphine or meperidine. Fentanyl can be administered by the intramuscular, intravenous, or submucosal route.

Supplied: 0.05 mg/mL in 2- and 5-mL ampules

Dosage: 0.002 to 0.004 mg/kg

Meperidine (Demerol)

Meperidine is a synthetic opiate agonist, closely related to fentanyl in chemical structure. It is water-soluble but is incompatible with many other drugs in solution. Meperidine may be administered through either enteral or parenteral administration; however, oral administration is only about half as effective as intramuscular injection. It is rapidly and well absorbed from the GI tract, reaching peak effect in about 60 minutes. Approximately 90% of an oral dose undergoes biotransformation via first-pass metabolism to normeperidine and meperidinic acid. Normeperidine is an active metabolite with approximately 50% of the analgesic activity as the parent compound, and manifests an elimination half-life of 15 to 40 hours. Normeperidine also possesses CNS stimulation and can become proconvulsant with prolonged accumulation of the metabolite. Its use is contraindicated in patients with a history of hepatic disease, renal disease or dysfunction, or seizure disorders.

Supplied: oral tablets—50 and 100 mg; oral syrup—50 mg/5 mL; parenteral solution—25, 50, 75, and 100 mg/mL

Dosage: oral, subcutaneous, or intramuscular—1.0 to 2.2 mg/kg, not to exceed 100 mg when given alone or 50 mg when in combination with other CNS depressants

Naloxone (Narcan)

A semisynthetic opioid receptor antagonist used to reverse the effects of opioid drug overdose, naloxone is a pure antagonist, with no intrinsic agonist activity. Following subcutaneous or intramuscular injection, reversal begins within 2 to 5 minutes, as compared with 30 seconds to 2 minutes following intravenous administration. Reversal persists for approximately 45 minutes via either route. Excessive or too rapid reversal may result in adverse reactions including nausea, vomiting, sweating, hypotension, hypertension, ventricular tachycardia and fibrillation, and pulmonary edema. Therefore naloxone should be titrated judiciously, with the intravenous route used whenever possible. As with benzodiazepine reversal discussed earlier, the administration of naloxone should never take precedence over basic airway management and resuscitative measures.

Dosage: intravenous, subcutaneous, intramuscular—initial dose: 0.01 mg/kg; subsequent doses: 0.1 mg/kg (2 mg maximum) every 2 to 3 minutes

Supplied: parenteral solution—0.02, 0.4, 1.0 mg/kg

OTHER SEDATIVE-HYPNOTICS

Prior to the modern era, many drugs with nonspecific mechanisms of action were introduced into clinical medical and dental practice for the purpose of producing sleep or sedation. These include paraldehyde, chloral hydrate, ethchlorvynol, meprobamate, and others. The effects of all of these drugs resemble those of barbiturate drugs, in that they produce profound hypnosis with little or no effect upon pain perception. Like barbiturates, they are characterized by a limited therapeutic window and possess a significant risk of respiratory depression and other toxic effects when doses exceed clinically accepted ranges. The last of these agents to be used routinely in clinical practice was chloral hydrate, which was used by many pediatric dentists until it was discontinued in 2012. The discussion of these agents in this chapter will be limited to chloral hydrate.

Chloral Hydrate

Chloral hydrate is an aldehyde compound that is metabolized by alcohol dehydrogenase in the liver to its active metabolite, trichloroethanol. In vitro studies have suggested

that trichloroethanol acts upon GABA receptors in a manner similar to barbiturates and benzodiazepines.[46] It is a chemical irritant to the skin and mucous membranes and is associated with a high rate of nausea and vomiting, particularly when administered on an empty stomach. After oral administration, the drug was characterized by a slow onset time (30 to 60 minutes) and had a duration of action of 4 to 8 hours, with an elimination half-life of 8 to 11 hours.

Children given chloral hydrate would often enter a period of disinhibition resulting in excitement and irritability before reaching a level of clinically useful sedation. Large doses sensitize the myocardium to the effects of epinephrine, resulting in arrhythmias.[47,48] The lethal dose of chloral hydrate is stated to be 10 g in adults, yet ingestion of 4 g has been associated with a fatal outcome.[49]

Chloral hydrate is no longer available commercially in the United States, but is included here because of its history in pediatric dentistry and references in the pediatric dentistry literature.

NITROUS OXIDE ADMINISTRATION

OBJECTIVES

The objectives of nitrous oxide sedation, as stated by the American Academy of Pediatric Dentistry,[50] include the following:

- Reducing or eliminating anxiety
- Reducing untoward movement and reaction to dental treatment
- Enhancing communication and patient cooperation
- Raising the pain threshold
- Increasing tolerance for longer appointments
- Aiding in the treatment of a patient with mental and/or physical disabilities or a medically compromised patient
- Reducing gagging
- Potentiating the effects of sedatives

Disadvantages of nitrous oxide–oxygen inhalation may include:

- Lack of potency
- Dependence on psychological reassurance
- Interference of the nasal hood with injection to the anterior maxillary region
- Need for the patient to be able to breathe through the nose
- Nitrous oxide pollution and potential occupational exposure health hazards

EQUIPMENT

Several manufacturers produce machines for the safe delivery of nitrous oxide–oxygen sedation in the dental office. All newly installed facilities that include nitrous oxide–oxygen delivery systems must be inspected for proper gas delivery and intact safety features prior to use. Acceptable machines must possess a high-flow oxygen flush valve and be capable of delivering 100% oxygen at a flow rate appropriate for pediatric emergency management. Fail-safe mechanisms include nitrous oxide–oxygen proportioning systems that do not allow oxygen concentrations to drop below 30%. If systems are used that allow more than 70% nitrous oxide and less than 30% oxygen, an inline oxygen analyzer must be used. An acceptable scavenging system must be demonstrated to minimize the risk of occupational exposure and room contamination.[27] The double-mask type is the most efficient type of scavenger[51] (Fig. 17-6). These systems send exhaust into the vacuum waste system, which should be vented to the outside to prevent dispersal of gases to other areas of the office or building. Nasal hoods should be of good design and should be available in pediatric and adult sizes to ensure adequate fit, which further reduces leakage.

An additional safety feature for all nitrous oxide systems, mobile or fixed, is the pin-index yoke system. Gas tanks will align only at right angles, and produce a normal coupling when gas-specific pins are properly aligned (Fig. 17-7). Although it seems highly unlikely that gas tanks could be mistakenly attached to the wrong line with a pin-index system in place, such errors have occurred. Gas tank crossover errors are more likely to occur when office renovations are done and when fittings wear with age and use.

TECHNIQUE

After a thorough inspection of the equipment, the mask should be introduced to the patient with an explanation delivered at the appropriate level of understanding, and then the mask should be carefully placed over the patient's nose. Traditional behavior guidance techniques should be used because the effectiveness of nitrous oxide–oxygen sedation is closely linked to psychological reassurance. The delivery tubes are tightened behind the chair back with the patient in a comfortable position. The bag is filled with 100% oxygen and delivered to the patient for 1 or 2 minutes at an appropriate flow rate, typically between 4 and 6 L/min. With an appropriate flow rate, movement covering one quarter to one half of the breathing bag should be observed with each inhalation and exhalation. With too high a flow rate, the bag will be overinflated, movement will not be seen with each breath, and leakage will occur from around the mask. In this instance, the flow rate should be adjusted downward. Too low a flow rate will deplete the bag of mixed gases. Once the proper flow rate is achieved, the nitrous oxide can be introduced by slowly increasing the concentration in increments of 10% to 20% until the desired level is achieved.

The dentist should encourage the patient to breathe through the nose with the mouth closed. It is helpful to explain the sensations as the patient begins to experience the effects of the gas. Effects are often described as a floating, giddy feeling with tingling of fingers and toes. The appearance of ptosis (sagging of the eyelids) is used by many as an objective marker of when local anesthetic should be administered. Once this is completed, the concentration can be reduced to approximately 30% nitrous oxide/70% oxygen or lower. The level of moderate sedation can then be maintained throughout the procedures with minor adjustments of the oxygen and nitrous gas proportion. The dentist and staff should communicate with the patient throughout the procedure, paying particular attention to the rate and depth of breathing.

Dentlearn.ir

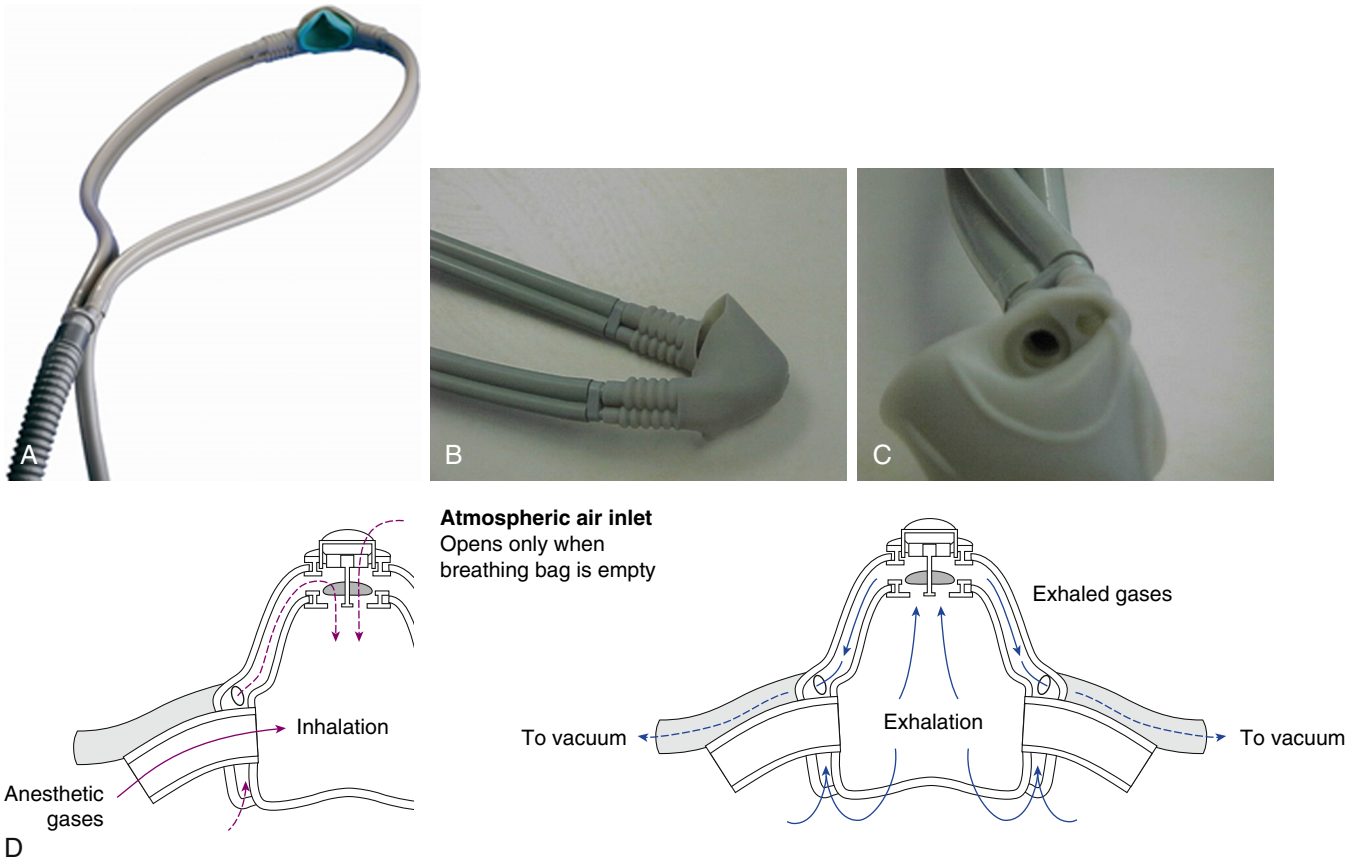

Figure 17-6 Example of a double-mask scavenger breathing circuit. **A** shows the "mask within a mask design," whereas **B** through **D** show the combination of fresh inhalation and exhalation lines within the mask. (Photos courtesy of Porter Instrument Co., Hatfield, Pennsylvania, United States.)

This should be recorded for future reference. An emesis basin should be readily available; if vomiting does occur, the patient's head should be rotated to the side. However, the laryngeal reflex is not obtunded with nitrous oxide when used at proper concentrations, so aspiration of vomitus is unlikely.[52]

Recovery can be achieved quickly by reverse titration. Once the flow of nitrous oxide is reduced to zero, the patient should be allowed to breathe 100% oxygen for 3 to 5 minutes. The patient should be allowed to remain in the sitting position for a brief period to ensure against dizziness upon standing. The patient is then ready for discharge.

Diffusion hypoxia refers to conditions in which inhalation of high concentrations of nitrous oxide is abruptly discontinued, resulting in the quick reversal of the nitrous oxide concentration gradient between the gases in the lung and alveolar circulation. Under these conditions, nitrous oxide rapidly dilutes the oxygen in the alveoli, creating the conditions for hypoxemia. Many dentists provide the patient with 100% oxygen during the first few minutes following discontinuation of nitrous oxide to counteract the development of hypoxemia; however, this concern may be more theoretical than clinical. Studies have shown that hypoxemia is significant for only a few minutes and has been documented only when high concentrations (>70%) have been delivered by full mask or by endotracheal tube. These conditions cannot be met with the use of conventional dental nitrous oxide machines with nasal masks, and any tendency for diffusion hypoxia in the dental setting is likely to be trivial.

One must be cautious when attempting to extrapolate concentrations quoted from the anesthesia literature on nitrous oxide delivered through a full face mask or endotracheal tube and applying them to a dental office setting. The typical dental unit is constructed very differently from standard anesthesia machines. Loosely fitting nasal hood masks, dead space in large-bore tubing, and escape of nitrous oxide through the mouth of a spontaneously breathing patient dilute the intended concentration of nitrous oxide in the typical dental unit. Machines set to deliver 70% nitrous oxide, for example, may be delivering only from 30% to 50% nitrous oxide to the patient's alveoli due to the factors described above (Fig. 17-8).

MONITORING AND DOCUMENTATION

Clinical observation and intermittent assessment of the level of sedation must occur throughout the procedure. This must include the patient's responsiveness, color, and assessment of respiratory rate and rhythm. In addition, the percent of nitrous oxide used, flow rate, duration of the procedure, and posttreatment oxygenation must be documented. Informed consent along with the indication for the use of nitrous oxide/oxygen must be documented

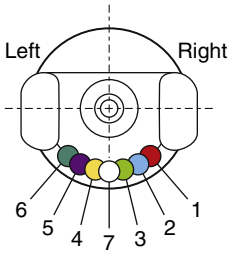

Gas	Index pins	CGA connection number
Oxygen	2-5	870
Nitrous oxide	3-5	910
Cyclopropane	3-6	920
O_2-CO_2 (CO_2<7.5%)	2-6	880
O_2-CO_2 (CO_2>7.5%)	1-6	940
O_2-HE (HE>80.5%)	4-6	930
O_2-HE (HE<80.5%)	2-4	890
Air	1-5	950
Nitrogen	1-4	960
N_2O-O_2 (N_2O 47.5-52.5%)	7	965

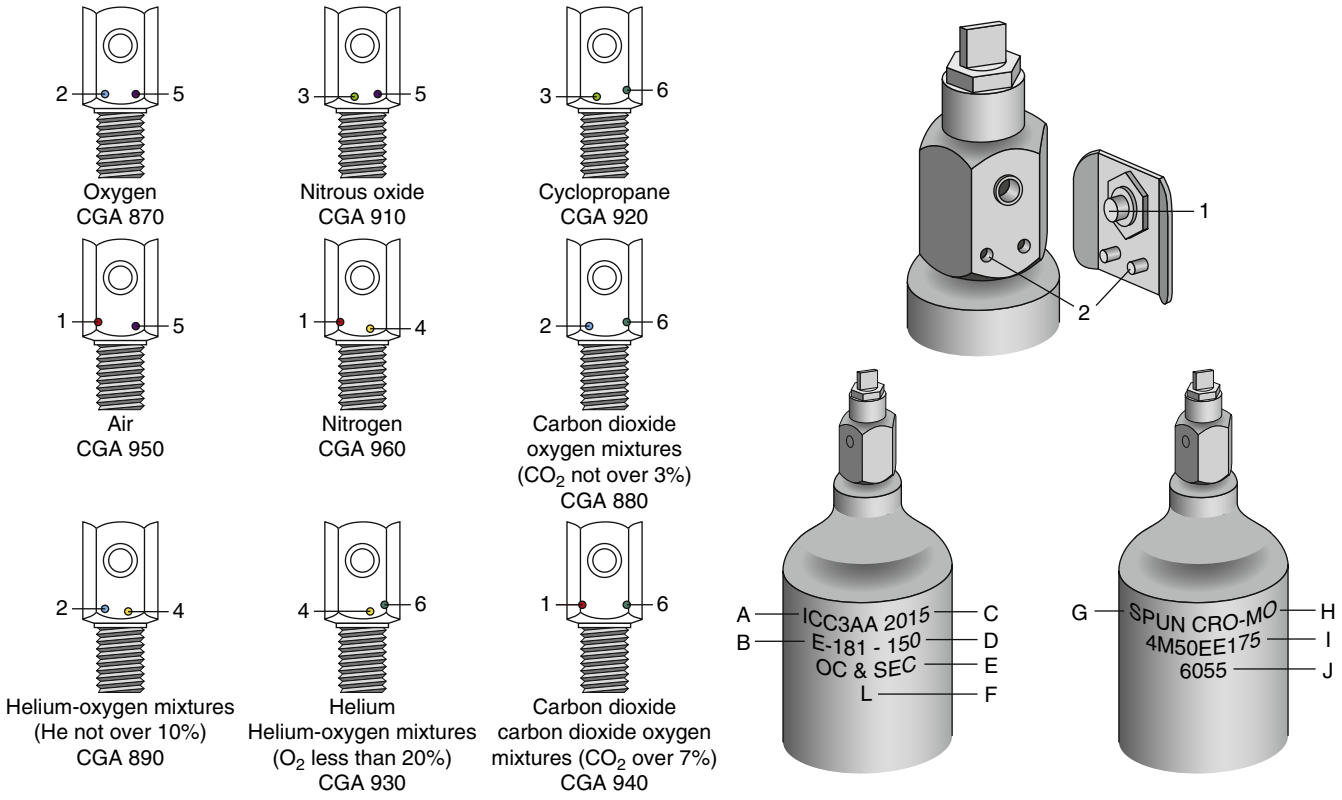

Figure 17-7 The pin-index system is used universally to minimize the chance of inadvertent connection of a medical gas to the wrong supply system.

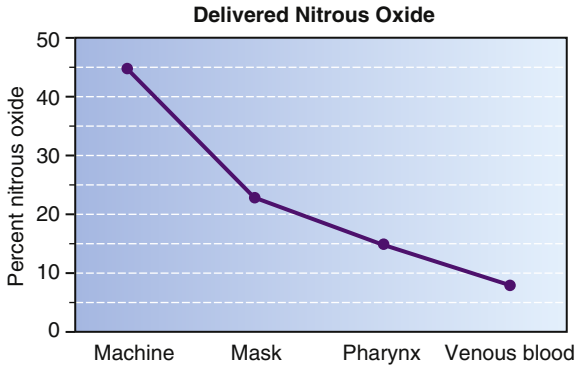

Figure 17-8 The concentration of nitrous oxide that reaches the blood is often significantly less than the concentration indicated on the flowmeter.

in the record. A dedicated section or form, apart from the general consent to dental treatment, should be used.

ENTERAL SEDATION TECHNIQUE

After the sedative agents have been selected, the proper dose of medication is calculated for the child. Once the sedative is administered, the patient should be kept in an area of the office that allows for continuous monitoring. When the desired effect is observed (usually after 30 to 60 minutes), the patient is transferred to the chair. Protective restraint devices, such as a papoose board (Fig.17-9, *A*), are often helpful to control potentially harmful movements in a sedated child. When such devices are used, the arms, legs, and pelvis should be aligned and secured, leaving the chest and diaphragm unrestrained, so that



Figure 17-9 **A**, Papoose board. **B**, Shoulder roll placement. The shoulder roll functions to keep the head rolled up and back, which allows for a more patent airway.

spontaneous breathing is not hindered. A shoulder roll, placed carefully beneath the upper part of the scapulae, will often help maintain airway patency during procedures (see Fig.17-9, *B*). Nitrous oxide and oxygen may be started at this time to improve oxygenation and provide small adjustments to the level of sedation as needed. If the patient is not adequately sedated to the point that treatment can be accomplished, the attempt should be aborted. If the patient enters a level of deep sedation or general anesthesia, and the dentist does not possess comprehensive training in general anesthesia, the procedure should be stopped and the patient returned to the appropriate level of sedation (usually moderate sedation). If the dentist is unable to manage the patient after using the maximum amount of oral medication and nitrous oxide, the procedure should be terminated. Adding an additional enteral drug to deepen the level of sedation is often unpredictable, prolongs recovery, and may place the child at risk for resedation after discharge, when professional supervision is unavailable.

Timing is the most critical factor for successful treatment with enteral sedation techniques, yet practitioners have little ability to control the depth and duration of enteral sedation. Enteral sedation techniques are best suited for short procedures that can be accomplished within the expected working time of the sedative drug. Properly administered local anesthesia will enhance any level of anesthesia, but it is particularly useful in maximizing the effectiveness of minimal and moderate sedation. The patient should be monitored carefully during the procedure, to ensure responsiveness. Discharge to the parent should occur only after minimal discharge criteria have been met (Box 17-2). Full oral and written instructions on postsedation care should be carefully reviewed with the caregiver, and the written information should be given to that person for easy reference at home (Box 17-3).

Box 17-2

Discharge Criteria

1. Cardiovascular function and airway patency are satisfactory and stable.
2. Patient is easily arousable, and protective reflexes are intact.
3. The patient can talk (if age-appropriate).
4. Patient can sit unaided (if age-appropriate).
5. For a young child or a child with disabilities, incapable of the usual expected responses, the presedation level of responsiveness or a level as close as possible to the normal level for that child should be achieved.
6. The state of hydration is adequate.

Box 17-3

Minimum Elements of Post-Sedation Discharge Instructions

1. Dietary guidelines
2. Instructions for taking medications
3. Description of any restrictions in activity
4. Identification of a responsible adult who will accompany and observe the patient after discharge
5. Contact information, including a phone number, and instructions to follow in the event of postoperative complications or an emergency

COMBINATIONS OF METHODS AND AGENTS

Pain is a complex process consisting of several interrelated components. The most basic component of pain is nociception, the unconscious, reflexive neuronal response to actual or potential tissue damage. Nociception, in turn, elicits other involuntary responses such as stimulation of the sympathetic nervous system, reflex withdrawal from the stimulus, and various neuroendocrine responses in both the central nervous system and the peripheral tissues. Consciousness awareness of the event adds another layer to response, resulting in the *experience* of pain. Anxiety, the learned anticipation of pain acquired from previous experiences, may also modify present and future experiences of pain. Each of these responses possesses its own neurologic substrate in the nervous system.

No single drug available to the pediatric dentist for moderate sedation will neutralize all of the components of the pain process. For example, opioid drugs raise the threshold for nociception but, when used alone, do not usually eliminate the dental patient's awareness of the procedure. Benzodiazepines have specific anxiolytic, amnesia-producing, and muscle-relaxant effects that minimize or eliminate awareness of the procedure but do not affect nociception. If sedative drugs are chosen and dosed appropriately, drug combinations can be more effective than single drugs in a given situation, because more components of the pain and anxiety response are neutralized with the drug combination. The practice of using drug combinations must be judicious and thoughtful, however, because the potential for adverse outcomes is likely to increase when three or more sedative drugs are administered during pediatric sedation.[53] This is because each sedative drug has side effects in addition to the intended action; drugs interact with each other to produce new, unanticipated effects, and the chances of unintended consequences increase with the complexity of the drug combination.

Local anesthetics block the nociceptive process, preventing both the immediate sensation of pain and secondary disruption of sedation caused by autonomic and neuroendocrine responses. Local anesthesia is an integral part of levels of dental sedation and is often the most appropriate first choice of drugs to combine with other sedative agents to enhance the efficacy of moderate sedation.[54] Evidence shows that the use of local anesthetics improves the intraoperative and recovery phases of dental rehabilitation under general anesthesia.[55] In many instances the apparent lack of local anesthetic efficacy during pediatric sedation is due to inattention to the expected onset, depth, and duration of local anesthesia. For most anesthetics, profound pulpal anesthesia exists for a much smaller window of time than the numbness produced in the surrounding soft tissue[56] (Fig. 17-10). Operators should time local anesthetic administration so that the expected peak pulpal anesthesia coincides with the execution of known painful procedures, such as tooth extraction, pulpotomy, and surgical operations.

Inhalational sedation with nitrous oxide and oxygen is the next most frequently used agent in combination techniques. The onset, duration, and offset of oral sedative agents are relatively slow and beyond the control of the dentist once the drug is swallowed. In contrast, nitrous oxide is characterized by rapid onset and offset, is highly controllable, and is easily titrated. Nitrous oxide is well suited to the making of intraoperative adjustments to the level of sedation provided by an oral agent. In contrast to the nonrecommended practice of dose-stacking (adding additional doses of oral sedatives in an attempt to deepen sedation), nitrous oxide provides rapid enhancement of the sedation level while allowing for equally rapid reversal of its effects should the enhanced level of sedation prove to be beyond the intended level of sedation.

Oral sedative combinations have a long history in pediatric dentistry. Given the rapid expansion of our knowledge of central nervous system physiology and pharmacology over the past 50 years, it is not surprising that our clinical criteria for oral sedative combinations have evolved as well. The current concept of an ideal oral sedative combination calls for drugs with well-described mechanisms of actions, a wide margin of safety, and evidence to support their use in pediatric dentistry. These criteria are difficult to fulfill with many of the traditional techniques that used drugs with nonspecific mechanisms of actions and few documented outcome data. In an analysis of 53 studies of enteral sedation techniques

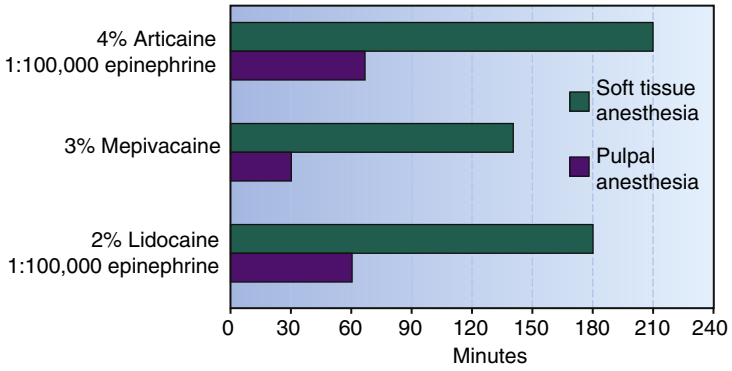

Figure 17-10 Producing high-quality local anesthesia is a fundamental component of successful moderate sedation. The peak effect of local anesthesia should ideally correspond to the peak surgical stimulation produced by the dental procedure. The use of a clock is useful for timing the appropriate administration of local anesthetic during sedation.

Dentlearn.ir

published between 1996 and 2005, Robb was unable to identify differences in the efficacy of drug combinations used for pediatric dentistry, due to poor reporting practices and the lack of a standard scoring system.[57] A more recent analysis of 36 more recent studies of pediatric dental sedations showed weak evidence for the efficacy of oral midazolam and nitrous oxide.[58] Chowdhury and Vargus compared a chloral hydrate, meperidine, and hydroxyzine combination with oral midazolam and concluded that the chloral hydrate combinations showed significantly more effective sedation than midazolam.[59] A comparison of hydroxyzine/midazolam with hydroxyzine and chloral hydrate/hydroxyzine by Torres-Perez et al. concluded that regimens of midazolam or chloral hydrate mixed with hydroxyzine represented excellent choices for conscious sedation.[60]

Chloral hydrate became unavailable in the United States after February 2012. Prior to its discontinuance, certain chloral hydrate combinations had a reputation for being effective, yet remained controversial. A retrospective chart review of 195 cases showed that 50 mg/kg chloral hydrate combined with either meperidine or hydroxyzine was judged to be satisfactory in 72% of cases.[61] Higher doses of chloral hydrate with nitrous oxide were also judged as effective; however, the risk of airway compromise, respiratory depression, and exceeding moderate sedation increased significantly with increasing doses.[62,63] Despite the apparent success of these combinations, concerns surfaced in several reports about the use of chloral hydrate. In a review of poor outcomes associated with chloral hydrate in medical and dental practice, Cote et al. found that 5 of 13 cases of death or permanent brain damage were dental patients.[64] Incorrect dosing, poor communication among dental staff, and failure to rescue patients from deeper than intended levels of sedation have been cited as major factors leading to the poor outcomes in dental settings.[65]

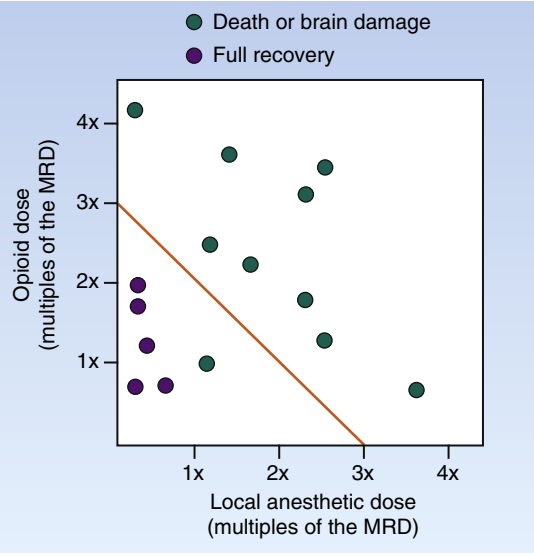

Figure 17-11 Caution must be exercised when local anesthetics are used together with opioids during pediatric sedation.

One recent attempt to identify an alternative to chloral hydrate combinations has been the use of midazolam in combination with meperidine and hydroxyzine. Sheroan et al. found no difference in behavioral outcomes or physiologic parameters when this combination was compared with chloral hydrate, meperidine, and hydroxyzine.[66] Further investigation of the safety and efficacy of this and similar combinations is needed, particularly regarding the continued use of opioids in such combinations. A dose-dependent increase in untoward outcomes, including hypoxia, has been demonstrated for meperidine.[67] Opioids have also been associated with significant local anesthetic toxicity when both have been used as part of a pediatric sedation regimen.[68,69] The interaction results in a lowering of the convulsant threshold for local anesthetic toxicity. Although the mechanism is multifaceted, opioids may produce a mild respiratory acidosis that decreases the binding of local anesthetics to serum albumin, permitting more free drug to circulate to the CNS. In a review of adverse drug interactions in dental practice, an expert panel rated this interaction as highly significant, particularly with the combination of meperidine and mepivacaine[70] (Fig. 17-11).

FACILITIES AND EQUIPMENT

Although not necessary, a comfortable, single-patient, "quiet room" is helpful. It isolates the sedation in progress from the activity of a typical pediatric dental practice and reduces noise and other distractions that may compromise the ability of the doctor and staff to focus fully on the patient. The facility should also be equipped with adequate suction, monitoring devices, and a positive-pressure oxygen delivery system that is capable of sustaining greater than 90% oxygen at a flow of 10 L/min for at least 60 minutes (650-L E cylinder). When a self-inflating bag-valve-mask device is used for delivering positive-pressure oxygen, a 15-L/min flow is recommended. A functional suction apparatus with appropriate suction catheters and a sphygmomanometer with cuffs of appropriate size for pediatric patients must be immediately available. All equipment must be adaptable to children of all ages and sizes.[2]

As previously stated, all inhalational sedation equipment must have the capability for immediate delivery of 100% oxygen with a minimum delivery of 30%. The apparatus must have a fail-safe system that accomplishes complete shutdown when the oxygen supply drops below the 30% level. If nitrous oxide–oxygen delivery equipment capable of delivering more than 70% nitrous oxide and less than 30% oxygen is used, an in-line oxygen analyzer must be used. This system must be checked and calibrated annually.

Timely and effective airway management is the most important factor. In the emergency airway armamentarium, drugs and equipment needed to resuscitate an apneic, unconscious patient must be fresh and close at hand. An adequate positive-pressure device, such as an Ambu bag or a modified Jackson-Rees circuit, should be kept in the quiet room to provide immediate positive-pressure ventilation should a patient become apneic (Fig. 17-12). Although ventilation with an Ambu bag and insertion of

Dentlearn.ir

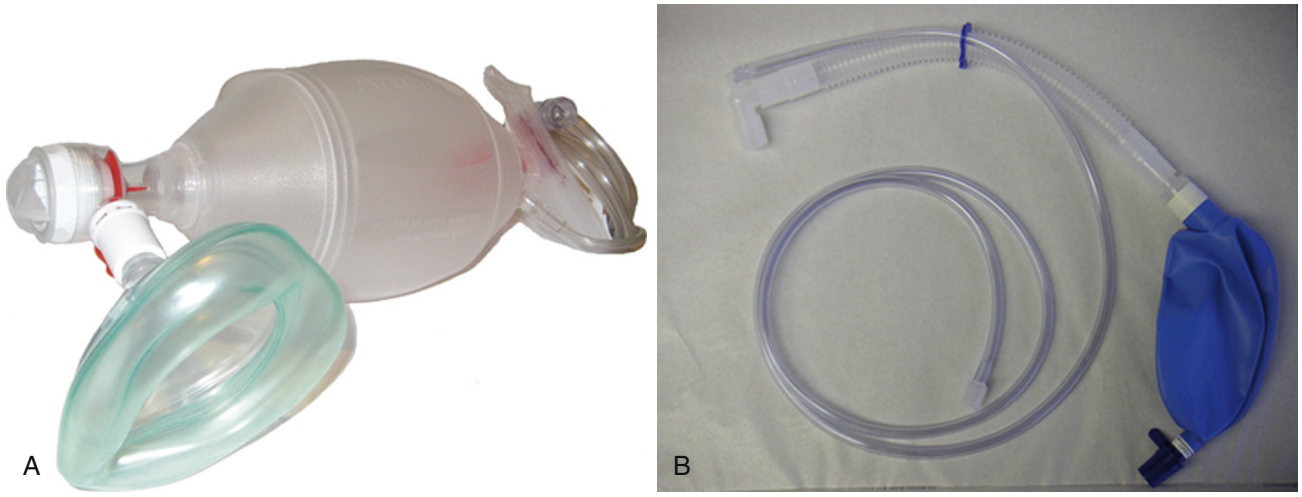

Figure 17-12 Nitrous oxide delivery systems are designed to provide a sedative mixture of gas to patients breathing spontaneously. They are not designed to deliver positive-pressure ventilation in an emergency. Dentists should have an adequate emergency breathing circuit, such as an Ambu bag, **A,** or modified Jackson-Rees circuit, **B,** which can be used to deliver positive-pressure oxygen when indicated.

Table **17-3**

Continuum of Depth of Sedation: Definition of General Anesthesia and Levels of Sedation/Analgesia

	Minimal Sedation Anxiolysis	Moderate Sedation/Analgesia ("conscious sedation")	Deep Sedation/Analgesia	General Anesthesia
Responsiveness	Normal response to verbal stimulation	Purposeful response to verbal or tactile stimulation	Purposeful response following repeated or painful stimulation	Unarousable even with painful stimulus
Airway	Unaffected	No intervention required	Intervention may be required	Intervention often required
Spontaneous ventilation	Unaffected	Adequate	May be inadequate	Frequently inadequate
Cardiovascular function	Unaffected	Usually maintained	Usually maintained	May be impaired

July 30, 2014.)

a supraglottic emergency airway device are part of the current Basic Life Support guidelines offered by the American Heart Association, the use of these devices should be reviewed in regular emergency drills in offices that provide sedation to pediatric patients.

DOCUMENTATION

Clear and complete documentation of the sedation procedure is essential for many reasons. Good records enable a practitioner to address postoperative concerns after discharge, evaluate problems or concerns discovered on follow-up or subsequent appointments, and participate in continuous quality improvement practices (CQI). Preprocedural records should document: (1) adherence to food and liquid intake restrictions; (2) preoperative health evaluation, including the patient's health history and a complete physical assessment along with the patient's current weight, age, and baseline vital signs; (3) name and address of the physician who usually cares for the child; (4) a note as to why the particular method of management was selected; (5) documentation of informed consent; and (6) the delivery of instructions to the caregiver. Before the procedure is undertaken, a "time out" should be performed to confirm the patient's name, the procedure to be performed, and the site of the procedure.

Intraoperatively, the appropriate vital signs should be recorded as they are assessed (Table 17-3). Timed notations regarding the patient's appearance and significant intraoperative events should be included. The type of drug, dose administered, route and site of administration, and time of administration should be clearly indicated. If a note as to what was prescribed should also be a part of the permanent record.

After treatment is completed, the patient should be observed in a recovery area equipped with suction and the capability to provide positive-pressure ventilation. Vital signs should be recorded at specific intervals. If the patient is not fully alert, oxygen saturation and heart rate should be continuously monitored until discharge criteria are met. The doctor administering the sedation is responsible for determining when fitness for discharge is achieved.

PATIENT SELECTION AND PREPARATION

INDICATIONS

No single agent, drug combination, or technique should be expected to be successful every time. The dentist should choose the agent and technique that best fit the patient type as well as the nature of what needs to be accomplished. Pediatric dentists have often found behavioral or anxiety-assessment profiles to be helpful in determining the most appropriate form of behavioral management for a child.[71,72] As the practitioner gains experience, equal or greater value will be placed on his/her intuition and judgment.

PREOPERATIVE EVALUATION

A thorough review of the medical history is required to determine whether a patient is a good candidate for sedation. This review may also include a recent medical history and physical examination from another qualified provider, as indicated. The review of medical history, along with a focused physical assessment, enables the dentist to arrive at a physical status classification.

The physical status classification system of the American Society of Anesthesiologists is the most commonly used method of determining the physical status for patients undergoing any form of anesthesia (Box 17-4). Following a review of the medical history and physical

quently considered appropriate candidates for minimal,

ASA class II may also benefit from appropriate procedural sedation; however, consultation with an anesthesiologist or appropriate medical specialist is often desired. Chil-

with special needs, and those with anatomic airway abnormalities or extreme tonsillar hypertrophy require additional medical consultation as part of the preoperative evaluation, and are often better managed by a physician anesthesiologist or dentist anesthesiologist.

The medical history should include the following information:

1. Allergies and previous allergic or adverse drug reactions.
2. Current medications, including dosage, time, route, and site of administration for prescription, over-the-counter, herbal, or illicit drugs. Many drugs, including herbal agents (e.g., St. John's Wort, Echinacea, kava, valerian), may alter drug pharmacokinetics, prolonging the effects of sedative agents.
3. Diseases or abnormalities in the patient, including pregnancy status of adolescents and neurologic impairment that might increase the potential for airway obstruction, such as a history of snoring or obstructive sleep apnea.
4. Previous hospitalizations, including the date, purpose, and hospital course.
5. History of general anesthesia or sedation and any associated complication.
6. Family history of diseases and sedation or anesthetic complications.
7. Review of body systems.
8. Age (in years and months) and weight.
9. Name, address, and contact information of the child's medical home.

The physical evaluation should include the following:

1. Height and weight.
2. Vital signs, including heart, respiratory rates, blood pressure, and temperature. If determination of baseline vital signs is prevented by the patient's physical resistance or emotional condition, the reason(s) should be documented.
3. Evaluation of airway patency, to include tonsillar size and anatomic abnormalities that may increase the risk of airway obstruction (e.g., mandibular hypoplasia, large, short neck, limited mandibular range of motion).
4. Physical abnormalities or conditions that may affect routine intraoperative monitoring (e.g., recent orthopedic injuries to arms or legs, active skin rashes).

Dentists should also assess the degree to which behavioral abnormalities will affect the ability for the child to be assessed during sedation. The child's failure to respond appropriately to verbal interaction places a greater degree of responsibility upon the dentist for determining and maintaining an appropriate level of sedation.

Box 17-4

American Society of Anesthesiologists' Physical Status Classification System

ASA Physical Status 1 - A normal healthy patient
ASA Physical Status 2 - A patient with mild systemic disease
ASA Physical Status 3 - A patient with severe systemic disease
ASA Physical Status 4 - A patient with a severe systemic disease that is a constant threat to life
ASA Physical Status 5 - A moribund patient who is not expected to survive without the operation
ASA Physical Status 6 - A patient who has been declared brain dead and whose organs are being removed for donor purposes

INFORMED CONSENT

The parent or legal guardian must consent to the use of sedation for the child. These individuals are entitled to receive complete information regarding the reasonably foreseeable risks and the benefits associated with the particular technique and agents being used, as well as any alternative methods available. Therefore the explanation

Dentlearn.ir

should be in clear, concise terms that are familiar to them. Informed consent forms should contain the parent's or guardian's signature and the date upon which informed consent was obtained, as well as the date upon which the sedation is planned. If informed consent is obtained prior to the date of the procedure, consent should be reaffirmed on the day of surgery prior to the start of treatment. The doctor must be satisfied that the parent or legal guardian has the capacity to understand the risks and benefits of the procedure and is able to provide voluntary consent that is free of coercion.[73] Because sedation is not considered a routine part of every dental visit, this consent should be separate and distinct from permission to treat the patient.

INSTRUCTIONS TO PARENTS

Information in written form should be reviewed with the person caring for the child and given to this person along with the notice of the scheduled appointment. This information should include a 24-hour contact number for the practitioner.

The American Academy of Pediatric Dentistry specifies the following preoperative dietary instructions:

1. Clear liquids: water, fruit juices without pulp, carbonated beverages, clear tea, or black coffee up to 2 hours before the procedure.
2. Breast milk up to 4 hours before the procedure.
3. Infant formula up to 6 hours before the procedure.
4. Nonhuman milk up to 6 hours before the procedure.
5. A light meal up to 6 hours before the procedure. A light meal typically consists of toast and clear liquids. Meals that include fried or fatty foods or meat may prolong gastric emptying times and should be avoided.
6. It is permissible for routine necessary medications to be taken with a sip of water on the day of the procedure.

The reasons for these recommendations are twofold. First, emesis during or immediately after a sedative procedure is a potential complication that can result in the aspiration of stomach contents, leading to laryngospasm or severe airway obstruction. Aspiration may have serious sequelae, including aspiration pneumonitis and potentially fatal pulmonary damage. Second, the uptake of sedative agents administered by the oral route is maximized when the stomach is empty.

The parent or guardian should also be advised that he or she will be expected to remain in the area of the office during the sedation appointment. With regard to transportation, the instructions should request that a second person accompany the parent so that the person caring for the child may be free to attend to the child's needs during the trip home.

The caregiver should be advised that, on arriving home, the child may sleep, feel drowsy, or display irritability. It is important to stress the need for frequent observation of the child for an appropriate period of time. The dentist should consider the types of agents used and the expected duration of drug effects when advising the caregiver on the length of time a child should be closely supervised at home. Inappropriate or inaccurate postoperative instructions may cause caregivers to question their credibility or dismiss other postoperative instructions.

Many pediatric dentists recommend that children first be offered clear liquids after sedation and advance to solid foods as tolerated. Once solids are tolerated, there are no dietary restrictions other than those imposed as a result of the dental procedure performed. This practice is based on concern that premature feeding may contribute to nausea, thus prolonging the reintroduction of solid foods. There are several causes of nausea and vomiting after sedation. Risk factors include the use of nitrous oxide or opioid medications, swallowing of blood, relative hypoxia, premature ambulation, inadequate pain control, and procedures lasting over 30 minutes.[74] Dentists should carefully consider additional factors to maximize the prevention of postoperative nausea and vomiting. Verbal and written instructions should be provided to the parent or guardian before the patient is discharged from the office (Box 14-2). The time at which the dentist determined fitness for discharge should be noted, along with a notation that oral and written discharge instructions were provided.

MONITORING

INTRAOPERATIVE MONITORING

Intraoperative monitoring must include an assessment of oxygenation, ventilation, and circulation. The depth of sedation dictates the degree and frequency of monitoring required.[75]

As the treatment progresses, the state of consciousness should be evaluated frequently by verbal communication with the patient. For those patients incapable of communication, either because of age or disability, some means of evoking a response should be used. Another area of assessment is the patient's external appearance. The oral mucosa, the nail beds, and the complexion of the skin provide indications of perfusion of the patient. This should be done at intervals throughout the procedure and documented in the record. If restraining devices that cover the patient are used, a hand or foot should be exposed. These devices should be carefully applied to the sedated patient to ensure that there is no restriction of the chest.

The heart and respiratory rates can be continuously monitored with a pretracheal stethoscope (Fig. 17-13). The bell of the stethoscope is secured in the suprasternal notch, where breath and heart sounds are easily auscultated. This instrument allows for continuous monitoring of the rate and depth of breathing. These devices are manufactured with a variety of amplification schemes, including a remote earpiece and a wireless speaker that transmits the patient's breath sounds throughout the entire operatory. Additional ventilatory monitoring should include observation of chest excursions. The common dental team habit of using the patient's chest as an ad hoc instrument table, or completely covering the chest with towels or other barriers, interferes with the observation of chest excursions and should be avoided when possible.

Although it is acceptable to measure physiologic parameters using the basic methods of auscultation and an aneroid sphygmomanometer with a manually inflated

Dentlearn.ir



cators of ventilation. **A,** Proper placement of chest piece on patient. **B,** Wireless system. (**B,** Courtesy of Sedation Resource.)

cuff, numerous automatic, continuous-monitoring blood pressure devices are available. In all instances, the cuff should be of the appropriate size for the patient. Pulse oximetry probes are available that attach to the finger or earlobe and produce both visual and audible signals. The pulse oximeter and automatic blood pressure cuff are often bundled together in a single monitor that may also include additional physiologic monitoring devices (Fig. 17-14).

In 1981 the introduction of pulse oximetry to health care providers created a revolution in patient safety monitoring. By 1987 it had become part of the standard monitoring armamentarium for anesthesia providers and is used in many other locations where the monitoring of the *effectiveness* of a patient's breathing is desired. The device measures the extent to which hemoglobin is saturated with oxygen while simultaneously monitoring the peripheral pulse rate. A probe consisting of an optical diode sensor and a second, light-emitting diode is applied to a digit on the hand or foot, or to the earlobe. The light-emitting diode emits both red and infrared wavelengths of light, and the light-detecting diode detects light transmitted through the tissue. Red wavelengths are absorbed primarily by oxygenated hemoglobin, whereas infrared wavelengths are absorbed primarily by deoxygenated hemoglobin. The ratio of deoxygenated hemoglobin to oxygenated hemoglobin is determined and displayed. One shortcoming of the pulse oximeter is a processing delay of approximately 20 to 40 seconds. This is particularly pertinent for pediatric dentists because children may begin to experience oxygen desaturation within 10 to 20 seconds after the onset of breathlessness (Video 17-1: Airway management in office base anesthesia). For this reason, it is important that the pulse oximeter be appreciated as a monitor of oxygenation, not of ventilation. Several conditions can also lead to inaccurate oximeter readings, including (1) failure to place diodes directly opposite each other, (2) interference from ambient light, (3) placement of diodes on the same limb as a blood pressure cuff, (4) fingernail polish on the digit to which the sensor is attached, (5) cold limbs, (6) profound tissue pigmentation, (7) reuse of disposable sensors, and (8) motion artifacts. Sensor displacement is the most common cause for false readings in children and can be minimized by the use of a sensor with adhesive tabs rather than a clip-on sensor. Securing the sensor with additional tape and using a toe rather than a finger may also help minimize displacement.

The correlation between the percent oxygen saturation of hemoglobin (Sa_{O_2}) and oxygen tension in arterial blood (Pa_{O_2}) must be appreciated when oxygen saturation is interpreted. The relationship between the two parameters is plotted on the oxyhemoglobin dissociation curve (Fig. 17-15). Unbound oxygen dissolved in blood produces the oxygen tension (Pa_{O_2}) required to supply oxygen to peripheral tissues. When a patient stops breathing, hypoxemia begins when oxygen saturation drops to 95%, corresponding to an oxygen tension of 80 mm Hg. Once the arterial saturation levels drop to 90% (Pa_{O_2} = 60 mm Hg), the patient will begin to desaturate rapidly if effective ventilation is not immediately restored. Awareness of the peripheral oxygen saturation from moment to moment is important during the administration of sedation because hypoxia is almost always the initial event in morbidity and mortality related to sedation.[76]

Ventilation, i.e., the mechanical act of moving air throughout the respiratory system, must be evaluated independently from oxygenation. Methods used to monitor ventilation include visual monitoring for chest wall movement, listening for breath sounds with a precordial stethoscope, determination of respiratory rate, and capnography. Capnography is the most sensitive of these methods, providing direct confirmation of apnea within seconds after breathing is interrupted. When possible, the provides the optimal strategy for monitoring the adequacy of breathing during the course of pediatric sedation. The capnograph (Fig. 17-16, *A*) detects both the presence and the quality of ventilation by analyzing the concentration of carbon dioxide in the exhaled gases through differential infrared absorption. The end-tidal carbon dioxide concentration is the concentration of carbon dioxide measured at the terminal portion of the exhalation

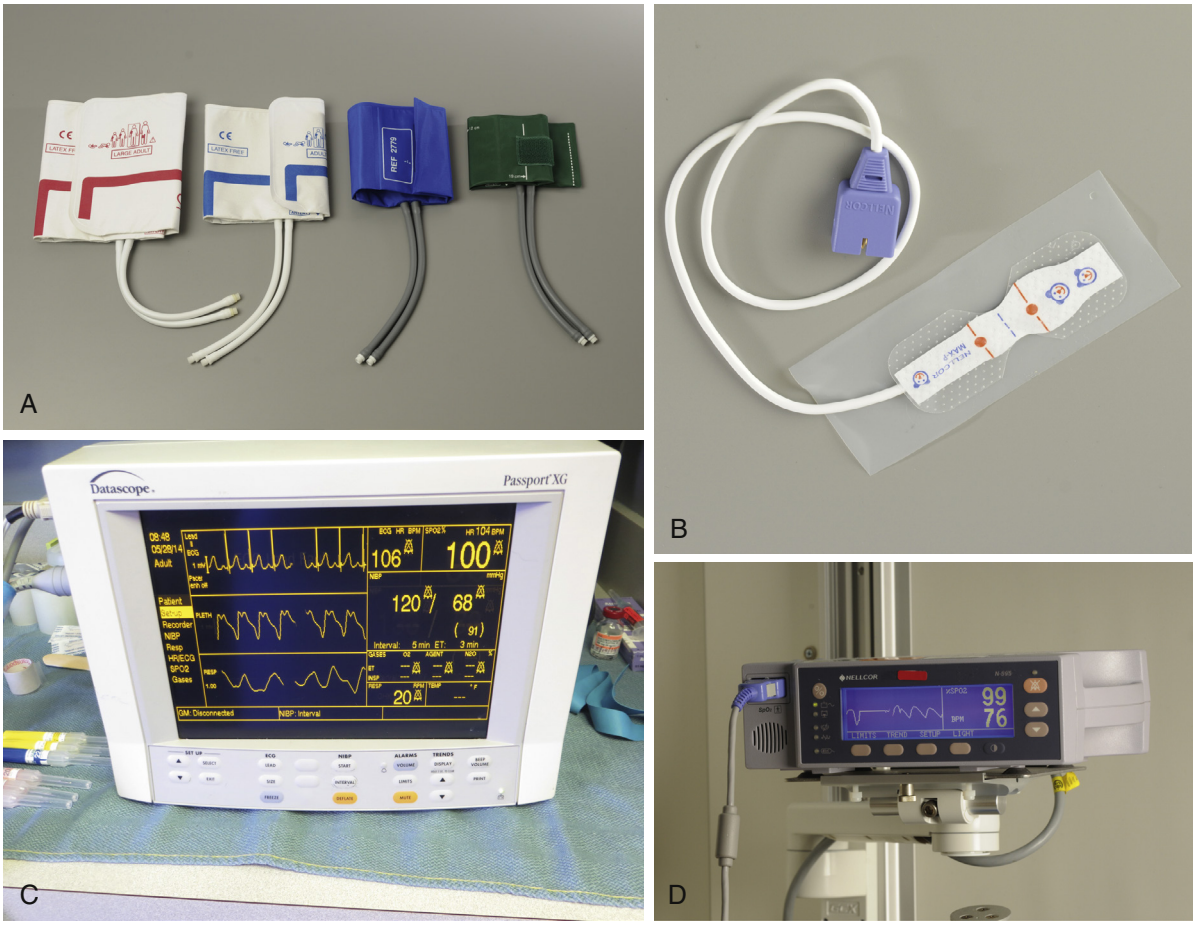

Figure 17-14 Physiologic monitoring should be chosen to conform to basic standards of intraoperative monitoring while matching the needs of the pediatric dentist. Devices should be appropriately sized for pediatric patients. A wide variety of monitors exists. **A,** Blood pressure cuffs in various sizes. **B,** Pulse oximetry probes with and without adhesive tabs. **C,** Automated vital signs monitor. **D,** Pulse oximeter.

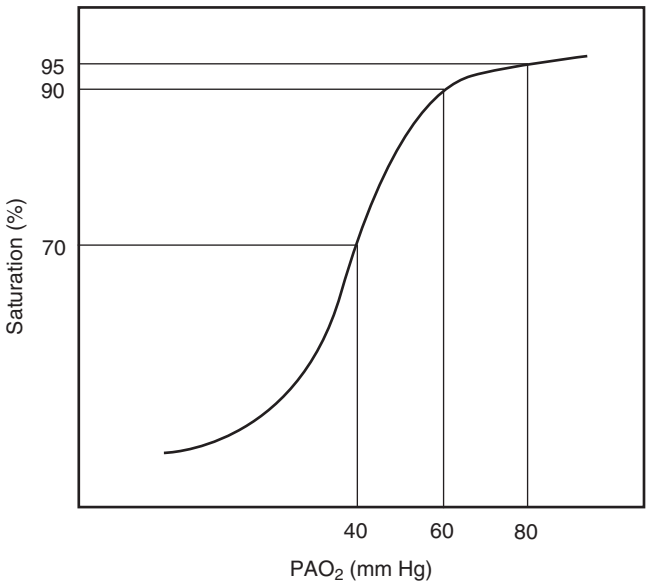

Figure 17-15 Oxyhemoglobin dissociation curve, which shows the saturation of hemoglobin with oxygen (Sao_2) relative to oxygen tension (Pao_2). Hypoxemia is defined as Pao_2 below 80 mm Hg (95% Sao_2). (From Dionne R, Phero, J, Becker D. *Management of pain and anxiety in the dental office,* Philadelphia, 2002, WB Saunders.)

curve (see Fig. 17-16, *B*).[18] The sampling line is placed either in the nostril or in close approximation to the nose or mouth and allows for sampling of exhaled air into the unit. There are limitations to the accuracy of readings, especially when the device is used in children. Head movement, mouth breathing, crying, and tube blockage by mucous all result in inaccurate readings. In 2014 the American Association of Oral and Maxillofacial Surgeons mandated the use of capnography whenever possible during moderate sedation as part of its standard of care.[77]

POSTOPERATIVE MONITORING

Determining fitness for discharge is a critical part of the sedation process because it marks the point at which supervision of the child is relinquished from the professional staff to the parents. The child must be reasonably alert, able to talk, ambulating with minimal assistance, and sitting unaided. The child should be able to remain awake for at least 20 minutes, unstimulated, before discharge. For the very young patient or a patient with disabilities, either of whom might be incapable of the usually expected responses, a level of awareness that is as close to the usual state as possible for that person must be achieved before discharge. Fitness for discharge is the responsibility of the doctor and must be documented.[53]



Normal capnogram

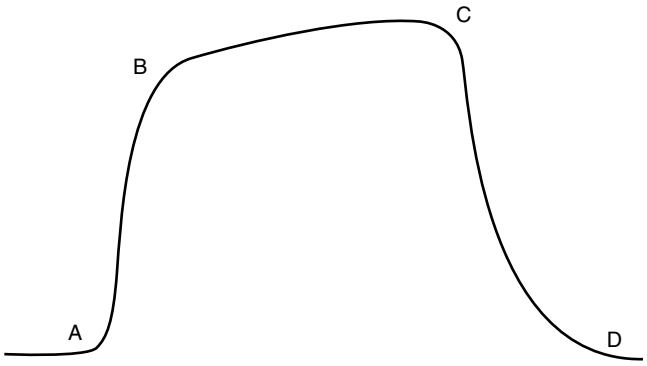

A: Exhalation begins
B-C: Plateau = outflow of alveolar gas
D: End-tidal CO_2

B

Figure 17-16 Capnography. **A**, The monitor produces a waveform by the continuous analysis of expired gas for carbon dioxide. **B**, The presence of a waveform implies exhalation of gases from the lungs. The end-tidal carbon dioxide concentration (point C) corresponds to the concentration of alveolar gas, which correlates closely with the arterial partial pressure of carbon dioxide. (**A,** Courtesy of Capnocheck by Smiths Medical ASD, Inc., St. Paul, Minnesota; **B,** from Anderson J, Vann W. Respiratory monitoring during pediatric sedation: pulse oximetry and capnography, *Pediatr Dent* 10:94-101, 1988.)

CONCLUDING THOUGHTS

The American Academy of Pediatric Dentistry and the American Dental Association have published several guidelines to assist the dentist in performing moderate sedation. Items from these guidelines have been referenced in several places throughout this chapter. In addition to these valuable sets of guidelines, three principles are offered here for dentists undertaking moderate sedation for children:

1) *Primum non nocere* is the Latin phrase translated as "first, do no harm." It is the guiding bioethical principle for all health care providers and is based on the Hippocratic Oath. Prior to undertaking any pediatric sedation, the dentist must be satisfied that the potential benefits of treatment outweigh potential risks, and that the decision is founded on appropriate information.
2) *Airway management supersedes pharmacologic management.* The maintenance of adequate ventilation and oxygenation must be ensured throughout all phases of pharmacologic management. Where there is doubt, the sedation protocol should be modified or abandoned.
3) *Appreciate the limits of moderate sedation.* Patient responsiveness is inherent in moderate sedation. Sometimes the responsiveness of the patient will interfere with dental treatment, causing treatment to be modified or abandoned. When treatment cannot be accomplished with moderate sedation, alternative strategies, such as general anesthesia performed by appropriately trained providers, should be considered.

REFERENCES

1. Wilson S: Pharmacological management of the pediatric dental patient, *Ped Dent* 26:131–134, 2004.
2. Cote C: Commentary on article by Vlade et al., *Am J Roentgenol* 165:910–912, 1995.
3. Boynes S: *Dental anesthesiology: a guide to the rules and regulations of the USA* 5th Edition. 2013 No-No Orchard Publishing, USA, pp 52–1024.
4. Hicks CG, et al.: Demand in pediatric dentistry for sedation and general anesthesia by dentist anesthesiologists: a survey of directors of dentist anesthesiologists and pediatric dentistry residencies, *Anesth Prog* 59:3–11, 2012.
5. Excerpted from Continuum of Depth of Sedation: Definition of General Anesthesia and Levels of Sedation/Analgesia, 2004, of the American Society of Anesthesiologists (ASA).

   Northwest Highway, Park Ridge, IL 60068–62573.
6. Green SM: Procedural sedation: moving beyond conscious sedation, *Anal Emerg Med* 39:433–435, 2002.
7. Cote C, Wilson S: Guidelines for the monitoring and management of pediatric patients during and after sedation for diagnostic and therapeutic procedures, *Pediatrics* 118:2587–2603, 2006.
8. Haynes AB, et al.: A surgical safety checklist to reduce morbidity and mortality in a global population, *New Engl J Med* 360:491–499, 2009.
9. Cote C: Discharge criteria for children sedated by nonanesthesiologists, *Anesthesiology* 100:207–209, 2004.
10. Lee H, et al.: Trends in death associated with pediatric dental sedation and general anesthesia, *Pediatr Anesth* 23:741–746, 2013.
11. Perouansky M, Hemmings HC: Neurotoxicity of general anesthetics: cause for concern? *Anesthesiology* 111:1365–1371, 2009.
12. Sun L: Early childhood general anaesthesia exposure and neurocognitive development, *Br J Anaesth* 105(Suppl 1):i61–i68, 2010.
13. Southall DP, et al.: Study of cardiac rhythm in healthy newborn infants, *Br Heart J* 41:382, 1979.
14. Katz J, Steward DJ: *Anesthesia and uncommon diseases*, ed 4, Philadelphia, 1998, WB Saunders.
15. Hislop A, et al.: Postnatal growth and function of the preacinar airways, *Thorax* 27:265–274, 1972.
16. Giovannitti JA: Dental anesthesia and pediatric dentistry, *Anesth Prog* 42:95–99, 1995.
17. Cote CJ, et al.: *A practice of anesthesia for infants and children*, ed 4, Philadelphia, 2009, WB Saunders, p 662.
18. 2009 Pediatric Nutrition Surveillance System data (PedNSS),
19. *Childhood Obesity Facts*, last accessed January 23, 2015. http://
20. Narang I, Mathew JL: Childhood obesity and obstructive sleep apnea, *J Nutrition Metab* 8, 2012. 2012: ID 134202.
21. Sorof J, Daniels S: Obesity hypertension in children: a problem of epidemic proportions, *Hypertension* 40:441–447, 2002.

22. Stambaugh JE, et al.: The clinical pharmacology of meperidine – comparison of routes of administration, *J Clin Pharmacol* 16:245–256, 1976.
23. Pharmacokinetics In: *Goodman and Gilman's The pharmacological basis of therapeutics*. In Brunton L, Chabner B, Knollman E, editors, 12 ed. New York, 2001, McGraw-Hill, p 20.
24. Granoff DM, et al.: Cardiorespiratory arrest following aspiration of chloral hydrate, *Am J Dis Child* 122:170–171, 1971.
25. Guidelines for the use of sedation and anesthesia by dentists: *American Dental Association*, Last accessed January 23, 2015.
26. Pharmacokinetics In: Goodman and Gilman's *The pharmacological basis of therapeutics*. In Brunton L, Chabner B, Knollman E, editors, 12 ed. New York, 2001, McGraw-Hill, p 22.
27. Cohen EN, et al.: Occupational disease in dentistry and exposure to trace anesthetic gases, *J Am Dent Assoc* 101:21–31, 1980.
28. Thallar M: Histamine in the regulation of wakefulness, *Sleep Med Rev* 15:65–74, 2011.
29. Richelson E: Neuroleptic affinities for human brain receptors and their use in predicting adverse effects, *J Clin Psychiatr* 45:331–336, 1984.
30. Paton D, Webster D: Clinical pharmacokinetics of H1 receptor antagonists, *Clin Pharmacokinetics* 10:477–479, 1985.
31. Taylor G, et al.: Determination of promethazine in biological fluids, *Anal Lett* 12:1435–1442, 1979.
32. Hickson GB, et al.: Should promethazine in liquid form be available without prescription? *Pediatrics* 86:221–225, 1990.
33. Ghoneim MM, Mewaldt SP: Benzodiazepines and human memory: a review, *Anesthesiology* 72:926–938, 1990.
34. Charney DS, Mihic SJ, Harris RA: Hypnotics and sedatives. In Brunton L, Chabner B, Knollman E, editors, 12 ed. Goodman and Gilman's *The pharmacological basis of therapeutics*, New York, 2001, McGraw-Hill.
35. Stoelting RK: Benzodiazepines. In: *Pharmacology and physiology in anesthetic practice*, ed 4, New York, 2006, Lippincott.
36. Reeves JG, et al.: Midazolam: pharmacology and uses, *Anesthesiology* 62:310–324, 1985.
37. Mohler H, Okada T: Benzodiazepine receptor: demonstration of the central nervous system, *Science* 198:849–851, 1977.
38. White PF, et al.: Comparison of midazolam and diazepam for sedation during plastic surgery, *Plast Reconstr Surg* 81:703–712, 1988.
39. Bailey PL, et al.: Frequent hypoxia and apnea after sedation with midazolam and fentanyl, *Anesthesiology* 73:826–830, 1990.
40. Miller DR: Midazolam and awareness with recall during total intravenous anesthesia, *Can J Anaesth* 43:946–953, 1996.
41. Miller R: Duration of amnesia associated with midazolam/fentanyl intravenous administration, *J Oral Maxillofac Surg* 47:155–158, 1989.
42. Brosius KK, Bannister CF: Midazolam premedication in children: a comparison of two dosage formulations on sedation score and plasma levels, *Anesth Analg* 96:392–395, 2003.
43. Khalil SN, et al.: A paediatric trial comparing midazolam/Syrplata mixture with premixed midazolam syrup (Roche), *Paediatr Anaesth* 13:205–209, 2003.
44. Heniff MS, et al.: Comparison of routes of flumazenil administration to reverse midazolam-induced respiratory depression in a canine model, *Acad Emerge Med* 4:1115–1118, 1997.
45. Hosaka K, et al.: Flumazenil reversal of sublingual triazolam: a randomized controlled clinical trial, *J Am Dent Assoc* 140:559–566, 2009.
46. Lovinger DM, et al.: Trichloroethanol potentiates synaptic transmission mediated by gamma aminobutyric acid receptors in hippocampal neurons, *J Pharmacol Exp Ther* 264:1079–1103, 1993.
47. Bowyer K, Glasser SP: Chloral hydrate overdose and cardiac arrhythmias, *Chest* 77:232–235, 1980.
48. Brown AM, Cade JF: Cardiac arrhythmias after chloral hydrate overdose, *Med J Aust* 1:28–29, 1980.
49. Gerretsen M, de Groot G, van Heijst ANP, Maes RA: Chloral hydrate poisoning: its mechanism and therapy, *Vet Hum Toxicol* 21(Suppl):53–56, 1979.
50. Guidelines for the use of nitrous oxide for pediatric dental patients, *Am Acad Pediatr Dent Ref Man* 35:13–14, last accessed G_Nitrous.pdf.
51. Chrysikopoulou A, et al.: Effectiveness of two nitrous oxide scavenging nasal hoods during routine pediatric dental treatment, *Pediatr Dent* 28:242–247, 2006.
52. Allen GD, et al.: The efficacy of the laryngeal reflex in conscious sedation, *J Am Dent Assoc* 96:901–903, 1977.
53. Cote CJ, et al.: Adverse sedation events in pediatrics: analysis of medications used for sedation, *Pediatrics* 106:633–644, 2000.
54. American Dental Association: *Guidelines for the use of sedation and general anesthesia by dentists*, Last accessed January 24,
55. Townsend JA, et al.: The use of local anesthesia during dental rehabilitation: a survey of AAPD members, *Pediatric Dent* 35:422–425, 2013.
56. Yagiela I: Local anesthetics, *Anesth Prog* 38:128–141, 1991.
57. Robb ND: Which is the most effective drug or method of sedation used for anxious children? What are the most effective techniques for the use of conscious sedation behavior management in paediatric dentistry? *Evid Based Dent* 6(3):71, 2005.
58. Lourenco-Matharu L, et al.: Sedation of children undergoing dental treatment, Cochrane Database Syst Rev 14(3):77–79, 2012.
59. Chowdhury J, Vargas KG: Comparison of chloral hydrate, meperidine and hydroxyzine to midazolam regimens for oral sedation of pediatric dental patients, *Pediatr Dent* 27:191–197, 2005.
60. Torres-Perez J: Comparison of three conscious sedation regimens for pediatric dental patients, *J Clin Pediatr Dent* 31: 183–186, 2007.
61. Leelataweedwud P, Vann WF: Adverse events and outcomes of conscious sedation for pediatric patients: study of an oral sedation regimen, *J Am Dent Assoc* 132:1531–1539, 2001.
62. Littman R, et al.: Chloral hydrate sedation: the additive respiratory depressant effects of nitrous oxide, *Anesth Analg* 86:724–728, 1998.
63. Moore PA, et al.: Sedation in pediatric dentistry: a practical assessment procedure, *J Am Dent Assoc* 109:564–569, 1984.
64. Cote C, et al.: Adverse sedation events in pediatrics: analysis of medications used for sedation, *Pediatrics* 106:633–642, 2000.
65. Hayden J: Chloral hydrate as a sedative in dentistry, *J Colo Dent Assoc* 61:3–4, 1982.
66. Sheroan MM: A prospective study of 2 sedation regimens in children: chloral hydrate, meperidine and hydroxyzine versus midazolam, meperidine and hydroxyzine, *Anesth Prog* 53:83–90, 2006.
67. McKee KC, et al.: Dose response characteristics of meperidine in preschool children, *Pediatr Dent* 12:222–227, 1990.
68. Goodson JM, Moore PA: Life-threatening reactions following pedodontic sedations: an assessment of narcotic, local anesthetic and antiemetic drug interactions, *J Am Dent Assoc* 107:239–245, 1983.
69. Moore PA, Goodson JM: Risk appraisal of narcotic sedation for children, *Anesth Progr* 32:129–139, 1985.

70. Moore PM: Adverse drug interactions in dental practice: interactions associated with local anesthetics, sedatives and anxiolytics, *J Am Dent Assoc* 130:541–554, 1999.
71. Venham LL, et al.: Interval rating scales for children's dental anxiety and uncooperative behavior, *Pediatr Dent* 2:195–202, 1980.
72. Frankl SN, et al.: Should the parent remain with the child in the dental operatory? *J Dent Children* 29:150–163, 1962.
73. Beauchamp TL, Childress J: *Principles of biomedical ethics*, 4 ed, New York, 1994, New Oxford University Press.
74. Kovac AL: Management of postoperative nausea and vomiting in children, *Pediatr Drugs* 91:47–69, 2007.
75. American Academy of Pediatric Dentistry: Guidelines for monitoring and management of pediatric patients during and after sedation for diagnostic and therapeutic procedures, *Pediatr Dent* 29:134–143, 2008.
76. Cote C, et al.: Adverse sedation events in pediatrics: a critical incident analysis of contributing factors, *Pediatrics* 105: 805–814, 2000.
77. American Association of Oral and Maxillofacial Surgeons:

uary 24, 2015.

CHAPTER 18

Hospital Dental Services for Children and the Use of General Anesthesia

▲ James A. Weddell, James E. Jones, and John D. Emhardt

For additional resources, please visit the evolve website.

CHAPTER OUTLINE

OBTAINING HOSPITAL STAFF PRIVILEGES
INDICATIONS FOR GENERAL ANESTHESIA IN THE TREATMENT OF CHILDREN
PSYCHOLOGICAL EFFECTS OF HOSPITALIZATION ON CHILDREN
OUTPATIENT VERSUS INPATIENT SURGERY
MEDICAL HISTORY AND PHYSICAL EXAMINATION
ADMISSION TO THE HOSPITAL
OPERATING ROOM PROTOCOL
PROPERTIES OF INHALATION GENERAL ANESTHETICS
ANESTHETIC PREPARATION OF THE CHILD
Time-Out Protocol
PERIORAL CLEANING, DRAPING, AND PLACEMENT OF PHARYNGEAL THROAT PACK
RESTORATIVE DENTISTRY IN THE OPERATING ROOM
COMPLETION OF THE PROCEDURE
End Time-Out Protocol
POSTANESTHESIA CARE UNIT
POSTOPERATIVE CARE

Dentists can provide essential services to patients within an operating room setting in addition to providing consultative and emergency services. Staff membership is necessary. National commissions such as the Joint Commission (formerly the Joint Commission on Accreditation of Healthcare Organizations [JCAHO]) issue the standards for hospital governance for all hospital services. Ambulatory surgery centers (ASCs) also offer operating room facilities and may be accredited by organizations focused solely on outpatient care, such as the Accreditation Association for Ambulatory Health Care (AAAHC). Staff membership is required as well.

In recent years, with the increasing number of general practice residencies and postdoctoral specialty programs, the qualified dentist finds that staff privileges in a facility offering operating room resources are a necessity. Active involvement in hospital dentistry has added a rewarding component to the practices of many dentists. Many hospitals have incorporated not only dental specialties but also general dental services, providing a comprehensive health care facility in which to serve the community.

OBTAINING HOSPITAL STAFF PRIVILEGES

Requirements for obtaining hospital staff privileges vary among institutions. The dentist must fulfill the following three basic requirements to become a hospital staff member:

1. The applicant must have graduated from an accredited dental school.
2. The applicant must be licensed to practice dentistry in the state in which the facility is located.
3. The applicant must have high moral and ethical standards.

Additional requirements may have to be met to obtain staff privileges. Many hospitals ask staff members to sign a "Delineation of Privileges" form indicating the procedures that staff members are qualified to perform and that are accepted by the governing body of the hospital. The applicant must show proof of professional liability insurance, and, in many hospitals, specialty board certification is required.

In a children's hospital, dentists might be required to have adequate advanced training to treat and manage children in the hospital. The requirements may include a dental residency of 1 to 3 years in a teaching hospital in which the dentist (1) gains experience in recording and evaluating the medical history and current medical status of children; (2) receives instruction in physical examination techniques and in recognition of conditions that may influence dental treatment decisions; (3) learns to initiate appropriate medical consultations when a problem arises during treatment; (4) learns the procedure for admitting, monitoring, and discharging children; and (5) develops proficiency in operating room protocol. A rotation in which the dental resident was actively involved in administering general anesthesia to children is highly desirable. Current certification in basic cardiopulmonary resuscitation should be maintained by all members of the hospital's professional staff, including dentists. It is highly desirable to have participated in a pediatric advanced life support (PALS) course as well.

As active members of the hospital staff, dentists should be aware of the hospital's bylaws, rules, regulations, and

easy reference. Fully understanding the responsibilities of staff membership will enable dentists to treat their

Dentlearn.ir

patients within the established protocol of the institution. Full participation in the active staff includes willing participation in necessary committee work, such as credentialing or operations committees, so that the pediatric dentist will be well informed as to the needs and expectations of his/her colleagues. Most important, dentists should endeavor to provide the highest-quality care within the specialty area for which they are trained. The American Academy of Pediatric Dentistry encourages the participation of pediatric dentistry practitioners on hospital medical-dental staffs, recognizes the American Dental Association as a corporate member of the Joint Commission, and encourages hospital member pediatric dentists to maintain strict adherence to the rules and regulations of the policies of the hospital medical staff.

INDICATIONS FOR GENERAL ANESTHESIA IN THE TREATMENT OF CHILDREN

The use of general anesthesia for dental care in children is sometimes necessary for safe, efficient, and effective care. Depending on the patient, this will be done in an ambulatory care setting or inpatient hospital setting. It should be only one component of the dentist's overall treatment regimen. Oral hygiene and preventive care must be implemented at the onset of treatment with parents or guardians and patients in order to eliminate the cause of the dental problem.

The safety of the patient and practitioner, as well as the need to diagnose and treat, must justify the use of general anesthesia. All available management techniques, including acceptable restraints and sedation, should be considered before the decision is made to use a general anesthetic. Crespi and Friedman cite several authors who agree in recommending that at least one or two attempts be made using conventional behavior management techniques or conscious sedation before general anesthesia is considered.[1] Patient restraints should be used only after consideration of the possibility for psychological trauma. In the event that conscious sedation is necessary, a qualified and credentialed sedation team must be utilized. Parental or guardian written consent must be obtained before administering general anesthesia. Documentation regarding dental treatment needs, unmanageability in the dental setting, and contributory medical problems must be included in the patient's hospital record. Records must be clearly written so others are able to read and understand them. The introduction of the electronic medical record has improved the issue of legibility of written notes; however, the simple retrieval of pertinent medical information or the writing of required orders may be more difficult with such a system. The practitioner must be able to appropriately utilize the medical record system of the institution. Review organizations examine dental admissions for proper documentation in the hospital chart for insurance payment and quality assurance purposes.

Patients for whom general anesthesia has been the management technique of choice include the following:

1. Patients unable to cooperate due to a lack of psychological or emotional maturity and/or those who have a physical, mental, or medically compromising disability that precludes conscious sedation.
2. Patients with dental restorative or surgical needs for whom local anesthesia is ineffective because of acute infection, anatomic variations, or allergy.
3. The extremely uncooperative, fearful, anxious, physically resistant, or uncommunicative child or adolescent with substantial dental needs for whom there is no expectation that the behavior will soon improve.
4. Patients who have sustained extensive orofacial or dental trauma and/or require significant surgical procedures.
5. Patients requiring immediate, extensive comprehensive oral or dental needs.
6. Patients requiring dental care for whom the use of general anesthesia may protect the developing psyche and/or reduce medical risks.

If the benefits of the procedure outweigh the risk of anesthesia, there are few if any contraindications to general anesthesia. However, when a concern about the medical condition exists, consultation with an anesthesiologist would be desirable. Patients for whom general anesthesia is usually contraindicated include those with a medical contraindication to general anesthesia and healthy and cooperative patients with minimal dental needs.

PSYCHOLOGICAL EFFECTS OF HOSPITALIZATION ON CHILDREN

Hospitalization is a frequent source of anxiety for children. According to King and Nielson, 20% to 50% of children demonstrate some degree of behavioral change after hospitalization.[2] Separation of the child from the parent appears to be a significant factor in posthospitalization anxiety, although other causes are also documented. Allowing the parent to stay with the child during the hospitalization, and especially to be present when the child leaves for and returns from surgery, can reduce anxiety for the child and parent alike.

According to Camm and colleagues, postoperative behavioral changes in children who received dental treatment with general anesthesia in a hospital were similar to those observed in children who received treatment under conscious sedation in a dental clinic.[3] Mothers of children receiving dental treatment with general anesthesia in a hospital setting were found to experience more stress during the procedure. Ways to decrease these stresses include the following: providing a prior tour of the operating room facility, informing the parents of the status of the child during the procedure, and letting them know that "everything is all right." Seventy-five percent of the children receiving general anesthesia exhibited some type of behavioral change. Positive changes included less fuss about eating, fewer temper tantrums, and better appetite. Negative changes included biting the fingernails, becoming upset when left alone, being more cautious or avoiding new things, staying with the parent more, needing more attention, and being afraid of the dark. Ways to minimize negative changes include (1) involving the child in the operating room tour, (2) allowing the child to bring along

Dentlearn.ir

a favorite doll or toy, (3) giving preinduction sedation, (4) providing a nonthreatening environment, (5) giving postprocedure sedation as needed, and (6) allowing parents to rejoin their children as early as possible in the recovery area.

Some centers allow parents to be present at the induction of anesthesia. Usually the anesthesia is induced when the child breathes anesthetic gases such as sevoflurane and/or nitrous oxide through a face mask. As the child becomes anesthetized, the parent is encouraged to provide calm, loving reassurance until the child is unaware of the parent's presence. For this technique to be effectively utilized, it is mandatory that the operating room team be comfortable with the parent's presence and prepared to care for the parent if he/she were to become distressed. It is also critical that the parent be educated as to what to expect as the child is anesthetized, including the possibility that the child may not readily accept the mask, that the child's breathing may become obstructed or "snory," or that the child's eyes may display abnormal movements as he/she enters the excitement stage of anesthesia. Parental presence can be especially helpful with the child with autism spectrum disorder or with a child who refuses or is resistant to oral sedation such as midazolam.

Another similar technique utilizes certified child life therapists skilled in the application of distraction techniques and play therapy. These personnel must also be educated as to their responsibilities during the induction of anesthesia. Utilization of parental presence or child life therapists can markedly reduce the requirement for oral sedation and thus enhance facility throughput by avoiding any delays in medication administration, emergence from anesthesia, or postoperative observation time required to meet discharge criteria.

To limit the severity and duration of psychological disturbances, the dentist should strive to reduce parental apprehension concerning the operative procedure. Because children often sense apprehension in their parents, effectively reducing the parents' anxiety will put the child more at ease. Thoroughly explaining the procedure, describing the normal postanesthetic side effects, and familiarizing the child and parents with the hospital can reduce postoperative anxiety.

Peretz and colleagues concluded that children treated for early childhood caries under general anesthesia or under conscious sedation at a very young age behaved similarly or better in a follow-up examination approximately 14 months after treatment than at their pretreatment visit, as measured by the Frankl scale and by the "sitting pattern."[4] Fuhrer and colleagues found that children were more likely to exhibit positive behavior at their 6-month recall appointment following dental treatment for childhood caries under general anesthesia compared with those treated under oral conscious sedation.[5]

OUTPATIENT VERSUS INPATIENT SURGERY

During the past 30 years, the popularity of outpatient anesthesia and surgery has continued to increase. Currently, more than 70% of all pediatric surgical and diagnostic procedures are performed on an outpatient basis. The criteria for and advantages of ambulatory general anesthesia procedures are well recognized. The increasing cost of inpatient hospital care, advances in anesthetic management, and quality assessment of patient care have led to changes in preoperative and postoperative management of many surgical procedures done under general anesthesia that were previously assumed to be possible only on an inpatient basis. Ambulatory care is more expeditious, better tolerated by both family and hospital teams, and less traumatic for the patient. Development of freestanding ambulatory care surgical centers (i.e., same-day surgery centers) and hospital ambulatory surgical care areas has decreased health care costs for consumers and third-party providers. The advances in perioperative anesthesia care are related to the wider availability of more highly qualified anesthesia care providers (board-certified anesthesiologists with pediatric subspecialty training) and the availability of modern, safer, short-acting anesthetic and adjuvant drugs and monitoring equipment. Several studies have reported a significant decrease in anesthesia-related morbidity and mortality in children over the past 2 decades.

Good patient selection is an important criterion for a successful outpatient surgery program. A young child or adolescent who requires a general anesthetic and is free of any significant medical disorders (i.e., is categorized as class I or II on the American Society of Anesthesiologists [ASA] physical status classification—see Box 17-4) can be considered a candidate for outpatient surgery. Certain patients with well-controlled chronic systemic diseases such as asthma, diabetes, and congenital heart disease can also be considered for outpatient anesthesia following prior consultation with an anesthesiologist.

When outpatient surgery is planned, the child undergoes a complete preoperative evaluation, including a comprehensive medical history and physical examination, anesthesia assessment, and limited hematologic evaluation. Many medical facilities allow this preadmission preparation to be performed outside of the medical outpatient treatment facility. Biery and associates suggest that routine laboratory tests, such as urinalysis and complete blood count with indices and electrolyte levels, are neither cost-effective nor necessary for patients in whom the prior complete medical history and physical examination were unremarkable.[6] Current recommendations for preoperative laboratory examination are indicated only if required for a patient's comorbidities. ASA no longer suggests required preoperative laboratory examination in a patient without medical comorbidity.

As an outpatient, the child should be brought by the parents to the hospital at least 1½ hours before the dental surgery. The nursing staff will verify that all preoperative instructions have been followed and that the appropriate laboratory tests have been performed. Several hours after the procedure is completed, the patient is released to the parent or guardian. Postoperative instructions are given, and a follow-up appointment is scheduled.

The dentist will be more responsible for team communication, physical assessment, management, and postoperative evaluation for outpatient procedures performed

Dentlearn.ir

under general anesthesia than for inpatient procedures. To qualify for treatment, pediatric outpatient general anesthesia patients must have reliable parents or guardians. For example, the parents must have transportation available to return the child to the hospital in case postoperative complications develop at home.

In some cases the management of the child in an outpatient facility will be precluded by the patient's comorbidities. Accreditation guidelines from AAAHC do not permit scheduling a case in an outpatient center when it is certain that the patient will require postoperative observation in an outpatient facility. Some outpatient facilities have resources permitting a prolonged observation period such as 23 hours, but many do not. In this case the procedure would best be scheduled in a facility with the resources for postoperative inpatient hospitalization. The child should be treated as an inpatient if a medical condition exists that requires close follow-up, if the child lives outside the general area of the hospital, or if the parents demonstrate questionable ability to comply with preoperative or postoperative instructions. In many instances, patients with medical or developmental disabilities and/or with multiple problems requiring lengthy dental treatment are not good candidates for ambulatory care with general anesthesia. However, even some of these patients can be managed in an ambulatory setting when they are properly assessed and when no postoperative complications are anticipated. Conditions such as those listed in Table 18-1 commonly preclude an outpatient procedure.

MEDICAL HISTORY AND PHYSICAL EXAMINATION

Once the decision has been made that a general anesthetic would be preferable for a pediatric patient, the dentist should evaluate the child's medical history, the current medical status, and the possibility of complications resulting from the procedure. This process is discussed in Chapter 17 and the patient-classification categories are shown in Box 17-4. The parents should be told of any potential complications, and their informed consent must be obtained (Fig. 18-1).

Intraoperative medical complications of dental patients with and without disabilities undergoing general anesthesia have been reported at 0% to 1.4%. In a survey of 200 pediatric dental general anesthesia cases, Enger and Mourino indicated that the most common postoperative complications following general anesthesia in children younger than the age of 5 years were vomiting, fever, and sore throat.[7] Treatment consisted of antiemetic medications for nausea with vomiting, ice chips for sore throat, and acetaminophen (Tylenol) for fever. Common minor reversible complications include pain, swelling, bleeding, separation anxiety, sleepiness, and iatrogenic trauma (such as minor abrasion, burn, or laceration). A majority of these will resolve within 2 weeks after the procedure. Bradley and Lynch found that no significant long-term complications resulting from anesthesia or operative procedures were observed in 100 patients with and without disabilities.[8]

Table 18-1

Comorbidities Possibly Necessitating Postoperative Hospital Observation

Respiratory:
Airway
History of difficult intubation or mask management
Craniofacial abnormality
Hypoplastic or retrognathic mandible
Apnea
Asthma, poorly controlled
Mediastinal lymphoma or mass
Cardiac:
Congenital heart disease, especially those with single ventricle physiology
Cardiac transplant
Congestive heart failure
Pacemaker or implantable defibrillator
Reduced ejection fraction on echocardiography
Stenotic valve lesions (e.g., aortic stenosis)
Neurologic:
Chronic neuromuscular disease
Seizure disorder
Metabolic:
Diabetes, poorly controlled
Inborn errors of metabolism
Malignant hyperthermia
Mitochondrial myopathy
Morbid obesity
Coagulopathy:
Hemophilia
Von Willebrand's
Medication or herbal therapy induced (aspirin is not a contraindication)
Cancer:
ASA status greater than 3 (a patient with a severe systemic disease)

Patients with cardiac lesions repaired previously and/or appropriately managed by a cardiologist may still be candidates for outpatient management. These patients' cases should be discussed with an anesthesiologist.

The Joint Commission requires that all patients admitted to a hospital or treated under general anesthesia as outpatients have a physical examination performed by a physician or qualified dentist. The child's physician must therefore be consulted for the completion of a comprehensive medical history and physical examination (Box 18-1). If the physician is not a member of the hospital staff, a staff physician should complete the medical history and physical examination before the child is admitted. The dentist should perform a thorough intraoral examination and submit a record of the findings together with a

Dentlearn.ir

102869
CH-7841 (SEP 13)
Effective 2012

ROC SURGERY, LLC

CONSENT FOR PROCEDURE

By signing this form, I agree to the procedure(s) listed here:

Any necessary dental treatment under general anesthesia including: examination, radiographs, prophylaxis, periodontal therapy, restorations, extractions, pulpal therapy, space maintainers, fluoride treatment, and photographs

to be done by: University Pediatric Dentistry Associates **, member of the ROC Surgery, LLC medical staff and other appropriate licensed personnel.**

The exceptions to my consent are as follows: NONE

From this point on all procedures will be called the "procedure;" and the persons performing the procedure will be called "treating practitioner."

I understand and agree to the following items:

- **Residents and students may help with my care.**
- **Medical staff other than the treating practitioner may do part of my procedure.**
- **Health care Industry representatives may be in the room to consult during my procedure.**
- **The treating practitioner may do other procedures not listed here if they are needed.**
- **An unexpected outcome may occur. An unexpected outcome does not mean care was not appropriate.**
- **I may be given local anesthetics or sedation that the Treating Practitioner believes appropriate. I have been told about the risks of these medications. These include injury to my teeth, dentures, throat, mouth, surrounding structures, and death.**
- **Parts of my body taken out during surgery can be thrown away or used for research so long as I am not identified.**
- **Pictures may be taken and used for teaching as long as I am not identified.**
- **I have talked with the Treating Practitioner about the procedure and why I need it, the expected outcome and risks, and the chances of success. We have also discussed other possible treatment(s) including the risks and benefits, and what could happen if I do not have the procedure. I have been told additional choices, including not having the procedure, other procedures, medicine, and therapy.**
- **I have been told about the risk of the procedure, which include but are not limited to bleeding, infection, injury, scarring, and/or damage to parts of my body, and death. Other risks:**

Common: sore throat, nausea, vomiting, fever, pain, bleeding, swelling, separtion anxiety, sleepiness, iatrogenic trauma (minor abraision, laceration, burn)

Uncommon: aspiration/foreign body, idiosyncratic drug reaction, dental trauma

Rare: heart and lung complications, cardiac depression and arrest

Patient/Guardian Signature (or Surrogate, if incapacitated/minor)

Patient/Guardian Name *(please print)*:

Date: _____ **Time:** _____

If signed by Surrogate: Relationship to Patient:

Healthcare Professional Witness

Witness Signature:

Witness Name *(please print)*:

Date: **Time:**

TREATING PRACTITIONER USE ONLY

I have discussed with the patient the nature of the proposed care, treatment, services, medications, interventions, or procedures; the potential benefits, risks, or side effects, including potential problems related to recuperation; the likelihood of achieving care, treatment, and service goals; the reasonable alternatives to the proposed care, treatment, and service; the relevant risks, benefits and side effects related to alternatives, including the possible results of not receiving care, treatment and services; and when indicated, any limitations on the confidentiality of information learned from or about the patient.

Signed:

Date: **Time:**

CONSENT FOR PROCEDURE
(Page 1 of 1)

Medical Record Copy

M-1

general anesthesia. (Courtesy of Indiana University Health, Riley Outpatient Center Surgery, LLC.)

SIGNATURES REQUIRED

1. If the patient is an adult (age 18 or over) – signature of patient; or, if the patient is incompetent, the guardian's signature.
2. Minor patient (under age 18) – if emancipated (providing own support and living apart from the parents) patient's signature.

   If married, signatures of patient and spouse are required.

   Otherwise, signature of parent or guardian is required.
3. In an emergency threatening the life or well-being of the patient, and if signatures as required above are not available, there should be an entry in the chart documenting the emergency nature of the procedure and the need for prompt action, attested by the signatures of two physicians. Also, the signature of the closest adult relative should be obtained, if available.

Figure 18-1, cont'd.

Box 18-1

Components of the Pediatric Medical History and Physical Examination for Admission to the Hospital

A. Pediatric History

1. Identification: age, gender, racial-ethnic profile
2. Informant and estimate of reliability
3. Problem leading to admittance
4. History of present illness: date of onset, chronologic description of illness, presence or absence of previous similar episodes, treatment given prior to admittance
5. Medical survey
   a. Immunization against diphtheria, pertussis, tetanus, polio, measles, mumps, rubella
   b. Previous hospitalizations, operations, major illnesses, or injuries
   c. Allergies, including allergies to food and drugs
   d. Dietary history (younger than 2 years of age)
   e. Current medications
6. Developmental status
   a. Infants younger than 2 years: statement regarding motor and language development
   b. Preschool children: general statement regarding development
   c. Children in school: statement regarding school performance
7. Family history
   a. Coagulation abnormalities
   b. Anesthesia complications

B. Physical Examination

1. Vital signs: temperature, pulse, respiration, blood pressure, oxygen saturation
2. Measurements: weight, height, or length
3. General observations: nutrition, color, distress
4. Head: size and shape, description of fontanel if present
5. Eyes: pupils, extraocular movements
6. Ears: position and shape
7. Airway: size of mouth and degree of opening, mobility of cervical spine and TMJ, size of mandible, Mallampati score
8. Nose: patency, secretions
9. Mouth: teeth, tongue, pharynx, and tonsils
10. Neck: masses, lymphadenopathy, range of motion
11. Lungs: auscultation
12. Cardiovascular system: heart sounds, rate, rhythm, murmurs; pulses
13. Abdomen: masses, distention
14. Genitalia: male testes, female introitus
15. Skin: rashes, bruises, lacerations
16. Lymph nodes
17. Skeleton: joints, spine, history of fractures
18. Nervous system: state of consciousness, gait (if walking)
19. Summary list of problems on tentative diagnosis

summary of the child's dental history and the reason for admission (Box 18-2). The hospital must be notified to reserve an appropriate surgical suite and a bed for the child. Two weeks before admission or an outpatient dental surgery appointment, a letter containing general instructions concerning the procedure, results of the dental examination, and pertinent dates and times should be mailed to the parents.

In the event that a child is expected to be admitted for hospital observation, it may be inappropriate to utilize an ASC. AAAHC requires that a patient be cared for in the ASC only if it is intended that the patient will be discharged to home from the center. If hospital admission following a procedure is anticipated or considered likely, that patient should be cared for in a facility with the resources available for prolonged postoperative observation.

A dental procedure may be canceled before the administration of general anesthesia due to patient illness; productive cough, rhinitis, or wheezing; failure to comply with preoperative instructions such as abstention from

eating or drinking; or risks related to coexisting diseases. Issues identified on preoperative contact with parents may require a general anesthetic case to be rescheduled. The risks of morbidity from the anesthesia must be weighed against the risk of postponement.

ADMISSION TO THE HOSPITAL

Some patients presenting for elective surgery are brought in on the day of surgery as an "AM admit." In this instance the child may come to the hospital the same day as the operative procedure and stay postoperatively until the next morning or longer. The parents must complete the necessary forms for admission to the hospital. The dentist must write the child's admission orders, which give the nursing staff the preliminary information needed and outline the basic care procedures for the child. Modern hospital practice includes consultation and discussion with the hospitalist regarding the reasons for admission and the potential postoperative concerns. This conversation should include the dentist, anesthesiologist, and hospitalist and/or team who will be caring for the child postoperatively. The nursing staff will explain standard hospital procedures to the parents and make any recommendations needed to foster a comfortable experience for the patient.

During this time, the child will be visited by the anesthesiologist involved in the anticipated procedure. The anesthesiologist will assess the child's present state of health and review the past and present hospital records, focusing on prior exposures to general anesthetics and any complications that may have occurred. The anesthesiologist will explain the procedures involved during his or her part of the procedure and answer any questions that the child or parent might have. The decision regarding the length of time the child should refrain from consuming solid foods and liquids before the procedure is also determined by the anesthesiologist; time may vary for younger patients, to prevent hypoglycemia (Fig. 18-2).

Before surgery, the dentist can answer any questions the parents or the child might have. The dentist should also evaluate the preoperative laboratory data so that appropriate consultations can be initiated if any abnormal values are found. The dentist should record an admitting note in the medical chart to provide the supporting staff with a concise record of the child's medical history, current medical and oral status, diagnosis, and proposed treatment (Box 18-3). With the onset of paperless charting, abbreviations are not as common when information is recorded in the medical chart. Modern hospital care discourages the use of abbreviations because of the risk of ambiguity. However, Box 18-4 is a list of common abbreviations one may encounter with medical chart review. Thirty minutes before the dental procedure, the dentist and the staff should be in the operating room area.

Box 18-2

Components of the Dental History and Intraoral Examination to be Completed before Hospitalization

1. Past dental history
2. Head and neck physical examination
   a. General
   b. Head
   c. Neck
   d. Face
   e. Lateral facial profile
3. Intraoral examination
   a. Lips
   b. Tongue
   c. Floor of mouth
   d. Buccal mucosa
   e. Hard and soft palates
   f. Oropharynx
   g. Periodontium
4. Teeth
   a. Caries
   b. Eruption sequence
   c. Occlusion molar, cuspid, overbite, overjet, and midline
5. Oral habits
6. Behavior
7. Recommendations

Outpatient NPO Guidelines*

Over one year of age
• Clear liquids permitted until 3 hours prior to scheduled surgery
• Breast milk until 4 hours prior to surgery
• Formula, fortified breast milk, and solid food stopped at midnight** **if the procedure is not to be done until after noon, dry cereal or toast and juice permitted until 0600
• Clear liquids include water, apple juice, Gatorade, and Sprite. No Jello or broth after midnight.
• A clear recipe specifying what foods or liquids are acceptable can minimize confusion on the day of the procedure.

*These guidelines are utilized by the Riley Outpatient Center in Indianapolis, Indiana. These are based on factors unique to the surgery center, permit some leeway in the case of changes in the schedule, and are consistent with recommendations of the American Society of Anesthesiologists (Anesthesiology 2011; 114:495-511).

Figure 18-2 Nothing by mouth (nil per os [NPO]), times according to age. (Courtesy of Indiana University Health, Riley Outpatient Center Surgery, LLC.)

Box 18-3

Components of Dentist's Admitting Note on the Medical History-Physical: Progress Note Form

1. Name, age, gender, race, chief complaint, and rationale for admission
2. History of the present illness
3. Past medical history
4. Present medications (list all with dosages and times given)
5. Results of current laboratory tests
6. Documentation of informed consent and physical examination
7. Impression of case (intraoral examination, diagnosis, and prognosis)
8. Plan for treatment
9. Dentist's signature

OPERATING ROOM PROTOCOL

All persons involved in the care of patients in the operating room must follow Occupational Safety and Health Administration (OSHA) guidelines. They must wear appropriate attire designed to prevent contamination of the surgical suite, hallways, and recovery room. This generally consists of a shirt, pants or skirt, and coverings for the face, head, and feet. A hood is used to cover all unshaven facial hair. Eyeglasses, goggles, or a face shield must be used to protect the surgeon's eyes, and a mask must cover the mouth and nose. Hand hygiene measures must be followed. These include alcohol-based hand-rubbing before and after any patient contact.

The dentist and staff should be familiar with the standard scrub technique for sterile procedures. Neither the medical nor the dental literature documents that a sterile technique is more advantageous than a modified sterile, or clean, technique for restorative dental procedures. Therefore intraoral dental procedures are generally considered

Box 18-4

Abbreviations Commonly Used in the Hospital

a.c.	Before meals (ante cibos)
ad lib.	At liberty or at pleasure
anom	Anomalies
AP	Anteroposterior
aq.	Aqueous, water
BP	Blood pressure
BRP	Bathroom privileges
BUN	Blood urea nitrogen
bx	Biopsy
c	With (cum)
C	Celsius (formerly centigrade)
Caps.	Capsule
CBC	Complete blood count
CC	Chief complaint
CNS	Central nervous system
cong	Congenital
CP	Cerebral palsy
CV	Cardiovascular
d/c	Discontinue
Dent	Dental
Diff	Differential blood count
disch	Discharge
D5W	5% dextrose in water
Dx	Diagnosis
ECG	Electrocardiogram (also EKG)
Elix	Elixir
ER	Emergency room
FHx	Family history
FUO	Fever of unknown origin
Fx	Fracture
GA	General anesthesia or (gen an)
ging	Gingiva
Hr	Hour
Hct	Hematocrit
HEENT	Head, eyes, ears, nose, and throat
Hg	Mercury
Hx	History
HPI	History of present illness
h.s.	Just before sleep (hora somni)
I&D	Incision and drainage
IM	Intramuscular
I&O	Intake and output
IV	Intravenous
kg	Kilogram
Mand	Mandible
Max	Maxilla
M	Molar, in moles
MCH	Mean corpuscular hemoglobin
MCHC	Mean corpuscular hemoglobin concentration
MCV	Mean corpuscular volume
Med	Medication
norm	Normal
neg	Negative
N_2O	Nitrous oxide
NPO	Nothing by mouth (nil per os)
NSA	No significant abnormality
n/v	Nausea and vomiting
op	Operation
OPD	Outpatient department
OR	Operating room
PA	Posteroanterior
p.c.	After meals (post cibos)
PE (or Px)	Physical examination
Ped	Pediatric
PH	Past history
PMH	Past medical history
p.o.	By mouth (per os)
postop	Postoperative
preop	Preoperative

Continued

Box 18-4

Abbreviations Commonly Used in the Hospital—cont'd

prep	Prepare	Hep	Hepatitis
prn	As required (pro re nata)	S/P	Status post
pro Time	Prothrombin time	Stat	At once (statim)
Pt	Patient	rect	Rectal
PT	Physical therapy	surg	Surgery
PTT	Partial thromboplastin time	Sx	Signs and symptoms
Px	Physical examination	tbsp	Tablespoon
q	Every (quaque)	TPR	Temperature, pulse, and respiration
qs	Sufficient quantity (quantum sufficit)	Tx	Treatment
R/O	Rule out	UA	Urinalysis
ROS	Review of symptoms	WBC	White blood count
RR	Respiratory rate	WD	Well developed
RR	Recovery room	W/F	White female
RSR	Regular sinus rhythm	W/M	White male
Rx	treatment (or prescription)	WN	Well nourished
s	Without (sine)	WNL	Within normal limits
SBE	Subacute bacterial endocarditis	w/o	Without
Subq	Subcutaneous		
SH	Social history		

clean procedures rather than sterile procedures. However, the dentist should wear sterile gloves. A sterile gown is worn at the discretion of the dentist. The barrier technique should be followed to prevent cross-contamination between and among patients in the hospital.

PROPERTIES OF INHALATION GENERAL ANESTHETICS

All inhalation anesthetic agents produce anesthesia by depressing specific areas of the brain. The magnitude of depression is proportional to the partial pressure of the inhalation agents reaching specific sites in the central nervous system (CNS) after entering through the lungs and being distributed by the circulation to the tissues. The resulting physiologic signs of CNS depression produced by general anesthetic agents have been described by Guedel and modified by Roberts as stages of anesthesia with ether (Fig. 18-3).[9,10] Guedel's classification of the stages of anesthesia is largely of historical interest, however. Modern inhaled anesthetics are extremely potent. Induction of anesthesia occurs quickly, and passage through the stages of anesthesia is quite rapid.

Techniques of inhalation anesthesia vary with the type of equipment used (i.e., reservoir bag, directional valves), chemical absorption of expired carbon dioxide, and rebreathing of expired gases. The techniques range from insufflation to open or nonbreathing systems, semiopen systems, semiclosed systems, and closed systems. The semiclosed "circle" system is most often used in modern anesthesia. Exhaled gases mingle with fresh gas and are rebreathed after all the carbon dioxide is removed by a chemical absorber. Inhaled gases are humidified, and a reservoir bag or ventilator allows for assisted respiration. Reduced loss of body heat and water vapor, increased

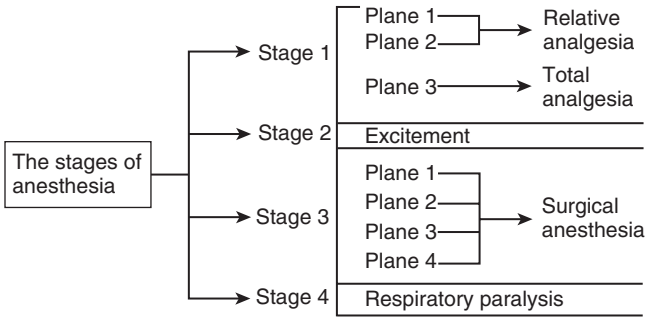

Figure 18-3 Stages of anesthesia observed with ether. (Adapted from Roberts GJ: Relative analgesia in clinical practice. In Coplans MD, Green RA, eds. *Anaesthesia and sedation in dentistry,* vol 12, Amsterdam, 1983, Elsevier Science.)

economy of flow, and decreased environmental contamination are advantages of the low-flow semiclosed system.

An anesthetic's potency is defined as the concentration of the agent required to inhibit response to a standard surgical stimulus. The potency is expressed in terms of the minimal alveolar concentration (MAC) value for the agent. The MAC of a given agent will abolish the response to stimulus in 50% of patients. Expressed as a number, MAC values are additive when different agents are used in combination. MAC is useful in that it provides an estimate of the anesthetic requirement for each patient. Fine adjustment of anesthetic administration can then be made by monitoring the patient's physiologic responses (e.g., heart rate, blood pressure, and respiratory rate). Commonly used inhalation anesthetics in children include nitrous oxide, isoflurane, desflurane, and sevoflurane. Each of these is useful in different applications. Nitrous oxide is the least soluble of the anesthetic gases that

Dentlearn.ir

promote a rapid onset and offset of effect. It is odorless and also the least potent. The other anesthetic gases are modern, nonflammable halogenated ethers. Desflurane is the least soluble halogenated volatile anesthetic. It has a rapid onset and offset; however, its utility is limited by its noxious odor. Sevoflurane is also quite insoluble but not as much as desflurane. It is widely used because its odor is non-noxious and it can be safely used to induce an anesthetic in an awake patient. Isoflurane is the oldest and most soluble of the halogenated anesthetic vapors in clinical use. It is more noxious than sevoflurane and has a slower onset and offset compared with those of the other gases. Its utility is mainly in the area of maintenance of anesthesia.

In children, to avoid the trauma of establishing intravenous access while awake, anesthesia is commonly induced by inhalation of a halogenated volatile anesthetic via a face mask. Due to its non-noxious odor, halothane (a halogenated alkane) has enjoyed widespread popularity for decades as an induction agent in children. Sevoflurane became available in 1995; in comparison with halothane, it is less soluble (producing more rapid induction and emergence) and is associated with less myocardial depression and fewer and less significant respiratory problems when used for inhalational induction. Like halothane, it has a non-noxious odor. As a result, sevoflurane has become the agent of choice for inhalational induction. (Halothane is still used in other parts of the world, but is not in wide clinical use in the United States.) Following induction of anesthesia, intravenous access is established. For maintenance of anesthesia, sevoflurane, isoflurane, and desflurane are all acceptable.

Intraoperative and postoperative anesthetic management is best accomplished by dentist-administered local anesthesia in addition to the general anesthesia. By the use of appropriate local anesthesia, the postoperative pain medication requirements will be lessened, thus minimizing potential opioid-induced side effects. Because general anesthesia is associated with a significant incidence of postoperative emesis, antiemetic agents such as ondansetron and dexamethasone may be administered intraoperatively to prevent this occurrence.

ANESTHETIC PREPARATION OF THE CHILD

TIME-OUT PROTOCOL

After donning operating room attire, the dentist should report to the surgical suite and inform the anesthesiologist of any special requests concerning the procedure before the induction of anesthesia. When the patient enters the operating room, the mandatory "time-out protocol" initiated by the circulating nurse identifies the patient, allergies, planned medications, and proposed treatment to the dentist and anesthesiologist before induction, for the child's safety (Fig. 18-4). Nasotracheal intubation is preferred to ensure good access to the oral cavity. However, a history of epistaxis or certain medical comorbidities may make nasotracheal intubation relatively contraindicated. One technique for nasal endotracheal intubation utilizes a latex-free red rubber catheter to serve as an atraumatic dilation device to prevent the passage of the hollow-pointed endotracheal tube through the nasopharyngeal tissues.[11] This typically is done without the instillation of a topical vasoconstrictor such as neosynephrine. Oral tracheal intubation is not contraindicated, however, and can be used in a dental case with minimal restorative needs. In this event the anesthesiologist will typically place the endotracheal tube to the least-affected side of the oral cavity first and then move it to the other side after treatment of disease not obscured by the tube is completed. One must recognize that complications related to the administration of general anesthesia (i.e., laryngospasm, tooth avulsion or aspiration, traumatic intubation, compromised airway, malignant hyperthermia) are possible and may require expert management by the anesthesiologist.

The anesthesiologist is responsible for starting intravenous fluids, securing the necessary monitoring equipment, performing the intubation, and stabilizing the endotracheal tube. The anesthesiologist will select the type of intravenous fluid, calculate the estimated fluid replacement and fluid deficit volumes, and perform a physical assessment of dehydration. The monitoring equipment should include (1) an automatic sphygmomanometer, (2) electrocardiographic leads, (3) a temperature-monitoring device, (4) a pulse oximeter, and (5) a capnography device. The anesthesiologist must confirm that the child is in stable condition prior to the onset of the dental operation (Fig. 18-5).

Special care is taken to protect the child's eyes (Fig. 18-6). In addition, a shoulder roll is placed, padding is added to the patient's pressure points, the endotracheal tube and head are stabilized, heating or cooling blankets are used as needed, and the safety belt is secured. The dentist has the table positioned to conduct dental procedures, and the anesthesiologist administers any preoperative intravenous medications requested.

Before scrubbing, the dentist should obtain any necessary preoperative radiographic studies. All persons involved in the radiologic procedure should wear protective lead apparel. Radiographs of excellent quality can be made while a patient is under general anesthesia without exposing the patient or staff to unnecessary radiation (Fig. 18-7). Digital radiographs are advantageous because radiation exposure is decreased and image feedback is immediate.

PERIORAL CLEANING, DRAPING, AND PLACEMENT OF PHARYNGEAL THROAT PACK

Before the dental procedure is begun, the perioral area is cleansed with sterile 4 × 4-inch gauze pads. The first gauze pad is saturated with a bacteriostatic cleansing agent and the second with sterile water. Alcohol is not used in the operating room because it is a potential fire hazard (Fig. 18-8). This procedure is intended not to sterilize the area but only to remove gross debris (Fig. 18-9). A surgical sheet is then positioned over the remainder

Dentlearn.ir

102887
CH-7859 (JUL 12)
Page 1 of 1

ROC SURGERY, LLC

ASC Universal Protocol Checklist

- to be initialed by a licensed professional

Patient Sticker

Procedures: _____

_____

Assessment/Prep Area	Yes	No	N/A
Correct patient verified using 2 patient identifiers			
Allergies validated			
Current History & Physical ***(dated within 30 days)***			
Current Clinical Note (N/A if H&P completed today)			
Consent form is accurate and signed ***(dated/timed within 60 days)***			
Diagnostic, radiology and lab results are available: ☐EKG ☐H/H ☐ Glu ☐ Preg ☐K+ ☐ PTT/INR ☐ Other_____			
Patient/Surrogate questions for Treating Practitioner answered			
Driver/Caretaker availability confirmed			
Site marked 'YES' by Treating Practitioner			
Parent/Guardian band on			

Handoff	Yes	No	N/A
Correct patient verified using 2 patient identifiers			
Allergies validated			
Current History & Physical ***(dated within 30 days)***			
Current Clinical Note (N/A if H&P completed today)			
Consent form is accurate and signed ***(dated/timed within 60 days)***			
Diagnostic, radiology and lab results are available: ☐EKG ☐H/H ☐ Glu ☐ Preg ☐K+ ☐ PTT/INR ☐ Other_____			
Site marked 'YES' by Treating Practitioner			
Implants/Devices or special equipment available			

First Time Out	Yes	No	N/A
Allergies verified			
Verbalized procedure(s) match consent			
Verbal acknowledgement by all procedure team members present			

Second Time Out	Yes	No	N/A
Correct patient verified using 2 patient identifiers			
Correct site confirmed with Informed Consent and marked			
Verbal congruency from ALL team members that site matches consent			
Relevant images displayed/labeled with correct pt. identifiers			
Antibiotic administered			
Fluids/medications labeled appropriately on sterile field			
DVT/VTE prophylaxis			
Verbal acknowledgement by all procedure team members present			

Final Time Out	Yes	No	N/A
Consent reviewed – all procedures have been documented			
Specimens addressed, labeled and identified			
All foreign bodies not intended for implantation have been removed			
Counts addressed			
Verbal acknowledgement by all procedure team members present			

Initials	Signature	Initials	Signature

UNIVERSAL PROTOCOL CHECKLIST (Page 1 of 1)
Please Place Behind Consent In Chart

Intra-OP Records
M-22

Figure 18-4 Universal protocol checklist. (Courtesy of Indiana University Health, Riley Outpatient Center Surgery, LLC.)



Figure 18-5 Patient is in a stable anesthetic condition and ready for the dental procedure. Notice the position of the precordial stethoscope, blood pressure cuff, and orotracheal tube.



Figure 18-6 Special eye guard protects the patient's eyes during the procedure.

of the child's body. This helps maintain body temperature and provides a clean field during the procedure. The head is draped with three towels arranged to form a triangular access space for the mouth. The towels are secured in place with towel clamps or hemostats. The mouth should be fully exposed (Fig. 18-10). The anesthesiologist may request that part of the nasotracheal tube remain exposed so that all connections can be easily monitored. The assistants then place all supporting carts and stands around the table in positions that the dentist finds comfortable and efficient (Fig. 18-11).

The patient's mouth is opened with the aid of a molt mouth prop. Care should be taken not to impinge on the lips or tongue with the prop (Fig. 18-12). The mouth is thoroughly aspirated. The pharyngopalatine area is sealed off with a strip of moist 3-inch sterile gauze approximately 12 to 18 inches long (Fig. 18-13). Written documentation of throat pack placement and removal is required on the physical history form of the medical chart. This packing reduces the escape of anesthetic agents and prevents any material from entering the pharynx. The gauze should be tightly packed around the tube so that a good seal is ensured (Video 18-1: Throat pack placement). Once the pack is in place, a thorough intraoral examination is performed, followed by dental prophylaxis. The dentist should then evaluate any new radiographic studies that have been obtained and formulate a final treatment plan.

RESTORATIVE DENTISTRY IN THE OPERATING ROOM

Instruments used for restorative dental procedures in the operating room are the same as those for procedures in the dental operatory. Local anesthesia may be used to minimize pain and bleeding. The use of local anesthesia can decrease the anesthetic requirements or need for postoperative opiate analgesia and thus decrease postoperative side effects such as nausea. The use of quadrant isolation with a rubber dam is preferred (Fig. 18-14). After the completion of all dental procedures, a topical fluoride varnish should be applied before the throat pack is removed. Documentation of dental procedures, extracted teeth, sutures, blood loss, and hydration in the medical chart is required.

Restorative dental care under general anesthesia allows for excellent patient compliance and the easy achievement of a well-lighted field, and therefore increases the quality and quantity of dental care while decreasing the anxiety level for the clinician and patient during dental treatment. Spiro and Burns found that they were able to treat seven teeth per hour in children under general anesthesia compared with only three teeth per hour in children of similar age in a clinic setting.[12] Eidelman and associates reported that the quality of restorative treatment performed was better under general anesthesia than under conscious sedation.[13]

The dentist should place restorations that will provide the greatest longevity with the least amount of maintenance, for example, full-coverage stainless steel crowns rather than large amalgam restorations on posterior primary teeth. In a 3-year study of comprehensive dental cases treated under general anesthesia, O'Sullivan and Curzon found stainless steel crowns to be significantly more successful (3% failure rate) than amalgam or composite restorations (29% failure rate).[14] A 6-month retrospective study by Tate and colleagues to assess the failure

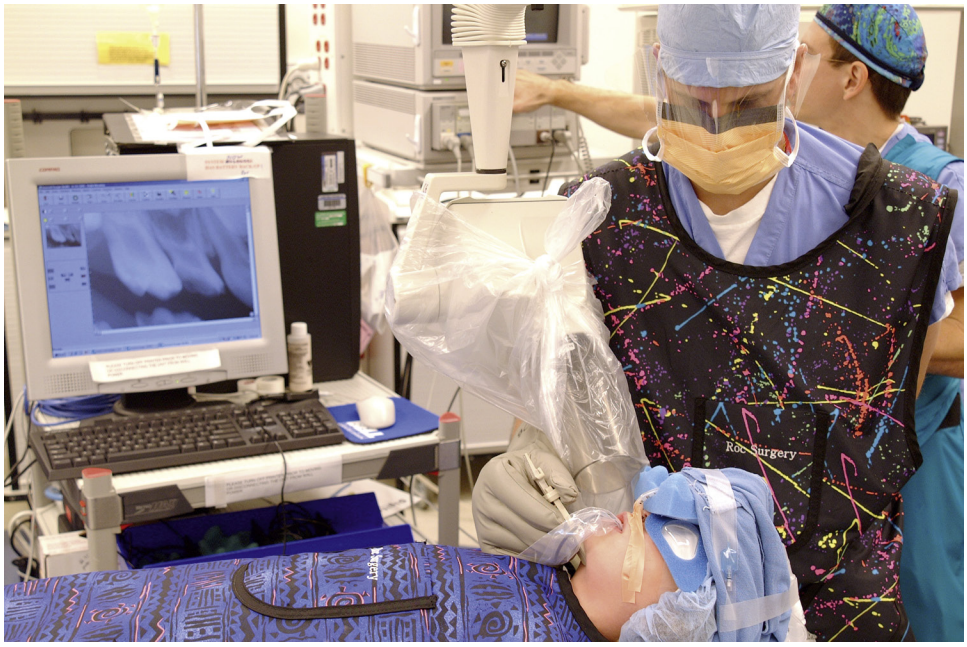

Figure 18-7 Obtaining diagnostic radiographs. Notice the use of protective lead gloves, gown, and apron.



Figure 18-8 Materials required for perioral cleaning. Clockwise from upper left: pharyngeal throat pack, towel clamps, patient drapes, bacteriostatic cleaning agent, sterile water, and alcohol.

rates of dental restorative procedures performed under general anesthesia by pediatric dental residents found stainless steel crowns to be best (8%), followed by amalgam (21%) and composite (30%); composite strip crowns (51%) had the lowest successful restorative treatment rate.[15] In a 6- to 27-month postoperative period following general anesthesia, Al-Eheideb et al. reported similar values, with stainless steel crowns (95.5%) being more successful than amalgams or composite restorations (50%). In their review, pulpotomies had an extremely high success rate (97.1%), whereas sealants were retained only 68.3% of the time.[16] In a 30-month longevity study of over 1000 composite restorations completed in the operating room, Bücher and colleagues noted a high success rate (81.5%).[17] In another study of composite strip crowns, Kupietzky and co-workers found them to be aesthetic and durable, with an 88% overall retention rate after 6 months.[18]



Figure 18-9 Special care must be taken during perioral cleaning to prevent materials from entering the oral cavity.

Intraoperative anesthesia complications (e.g., dislodged or obstructed endotracheal tube; intravenous infiltrates or disconnects; nasal bleeding or edema; abrasion; laceration of the tongue, lips, or mucosa; and arrhythmias) and extraoral complications (e.g., perioral abrasions, swellings, or lacerations) rarely occur. Care should be taken by the dentist not to displace the endotracheal tube and to minimize contact with the perioral tissues when possible. Priority is given by the dentist to the anesthesiologist to treat any adverse event quickly, even to the point of stopping treatment and removing rubber dams to allow access.

COMPLETION OF THE PROCEDURE

END TIME-OUT PROTOCOL

The anesthesiologist should be notified 10 minutes before the completion of the procedure so that the child can begin to be aroused and preparations can be made for extubation. The recovery room personnel are notified that the child will soon be arriving so that they can begin preparations. On completion of the dental procedure, the oral cavity is thoroughly debrided, and the throat pack is removed carefully to prevent aspiration of any materials that might be lodged against it. The "end time-out protocol" is called by the circulating nurse to identify any patient safety concerns (see Fig. 18-4). The dentist verbalizes a needle-and-sponge count and removal of the throat pack to the nurse. The anesthesiologist then brings the patient through emergence, and the trachea is extubated. The dentist should remain in the operating room during the extubation process to assist the anesthesiologist if necessary. When the child is transported to the recovery



Figure 18-10 Placement of the surgical sheet and triangular draping of the oral cavity area. The nasotracheal tube is exposed to allow for easy monitoring of its connections.

room, the dentist should accompany the anesthesiologist and provide assistance during the transportation.

POSTANESTHESIA CARE UNIT

When the child arrives in the postanesthesia care unit or recovery room, the dentist should inform the nursing staff of the procedures accomplished and of any special requests or instructions. If teeth have been removed, the nurse should be specifically instructed how and where to apply gauze packs for hemostasis. The nurses and other medical staff are available to deal with immediate postoperative complications (e.g., fever, nausea, vomiting, croup, hypoxia, bleeding, and laryngospasm) if they occur. After the dentist has confirmed that the airway is patent and the vital signs are stable, and after the anesthesiologist is confident the child is recovering well, the dentist should meet with the parents or guardian to provide a brief report of the child's condition and a review of the treatment. The parents or guardian of inpatients should be informed of the approximate time the child will be reunited with them. The parents or guardian of outpatients should be informed if events have occurred indicating that the child should be observed in the hospital. Prescriptions may be written for pain control agents (e.g., acetaminophen with hydrocodone, ibuprofen suspension), antibiotics (e.g., amoxicillin, clindamycin), or antiemetics for nausea (e.g., prochlorperazine, ondansetron [Zofran]). It should be noted that codeine is not routinely prescribed because of an association with death in patients at risk for postoperative airway obstruction or apnea. Codeine has also been found to be ineffective in a significant part of the population because of an enzyme deficiency that prevents its metabolism to the active form.

POSTOPERATIVE CARE

Postoperative orders and the operative note for the staff should be completed by the dentist and recorded in the medical chart while the child is in the postanesthesia care unit (Figs. 18-15 and Box 18-5). Transfer orders may be used for individuals requiring more specialized care than the pediatric dentist usually provides (see Fig. 18-15, *C*). The operative report should be dictated as soon after the completion of the procedure as possible (Box 18-6).

If the child was treated as an outpatient, once the child is awake and alert, displays appropriate behavior, maintains his or her own airway, has stable vital signs, has no uncontrolled bleeding or pain, is voiding, and has no retention of liquids, the child could be discharged rather than kept overnight for further evaluation. The facility may have a list of discharge criteria to facilitate this decision (Fig. 18-16). If the child is to be kept for a 23-hour

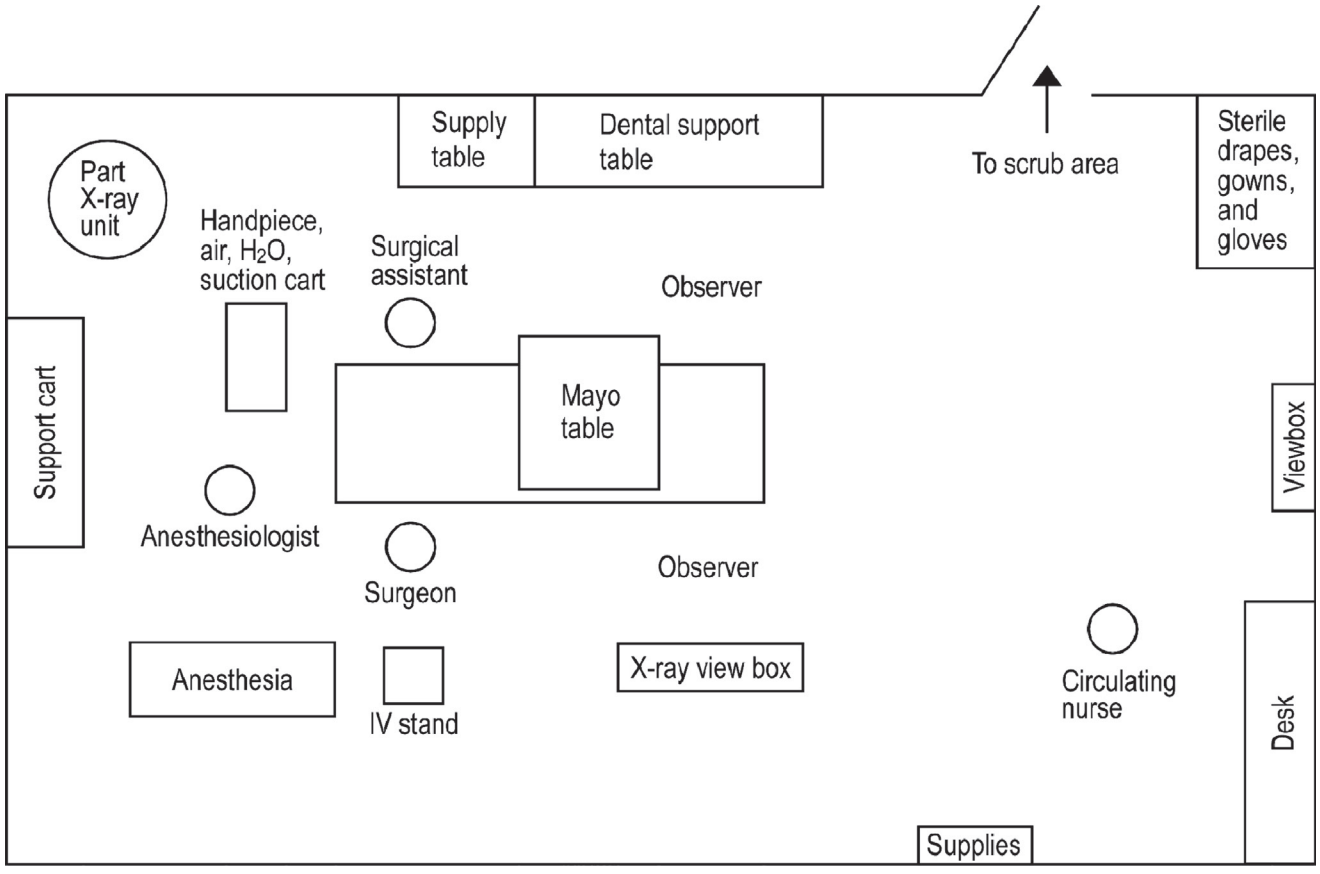

A

Figure 18-11 **A,** Schematic drawing of one example of the positioning of personnel and equipment in the operating room. IV, intravenous.

Continued



Figure 18-11, cont'd **B,** Operating room positions of the staff while performing the necessary dental procedures. From left: Dental assistant, dental surgeon, anesthesiologist, assistant dental surgeon, and circulating nurse. **C,** Sitting position in operating room. From left: Dental surgeon, dental assistant (anesthesiologist is out of the picture to the left).

observation, an appropriate note is recorded in the medical chart, and a discharge summary is dictated (Box 18-7) after the child is released. Postoperative instructions and necessary prescriptions are given to the parents or guardian, and a predischarge observation appointment for the child is arranged. The dentist must be available that evening (a contact number must be given) in the event the parents or guardian needs assistance in caring for the child after returning home. These instructions and prescriptions help the patient deal with common complications after discharge, such as fever, nausea, vomiting, pain, and bleeding.

Effective communication is essential at this time to reaffirm the parents' or guardian's cooperation in performing oral health care and in keeping follow-up observation appointments and recall appointments. Enger and Mourino reported that only 57% of dental patients undergoing a treatment in the operating room returned

Dentlearn.ir



Figure 18-12 Positioning of a mouth prop. Special care is taken not to impinge on the lips or tongue with the prop.



Figure 18-13 Placement of the pharyngeal throat pack.

for 6-month recall visits,[7] and suggested that procedures requiring monitoring (i.e., space maintenance) be postponed if the patient's return is unlikely. In a study of patients needing repeat dental treatment in the operating room, Sheller et al. found the best outcomes to result from aggressive treatment of caries, active patient follow-up, and education of parents.[19] Common patient characteristics included the following: 100% with carious involvement of maxillary central incisors, most central incisors were nonrestorable, the child was still using a bottle at the time of the operating room procedure, the child is responsible for brushing his/her own teeth, the child showed poor cooperation in medical/dental setting, the child had a difficult personality as described by the parent, the social situation was dysfunctional, and follow-up care was lacking.

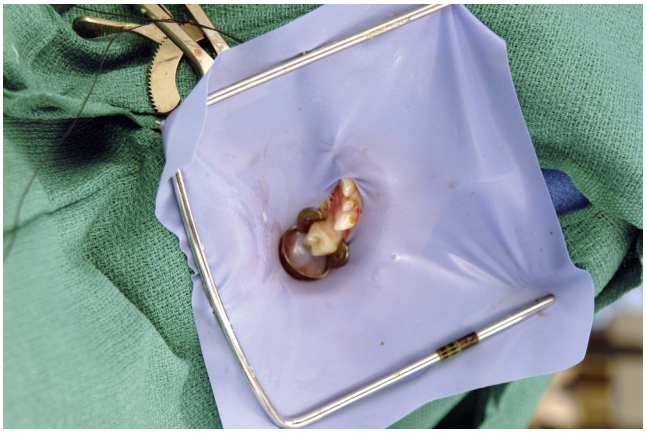

Figure 18-14 Rubber dam isolation of the maxillary left quadrant.

A study by Almeida et al. of future caries susceptibility in children with early childhood caries (ECC) following dental treatment under general anesthesia found that, despite implementation of increased preventive measures for these children, they were still highly predisposed to greater caries incidence in later years.[20] The researchers concluded that more aggressive preventive therapies may be required in children who experience ECC.

There are several categories of dental problems in children who cannot be handled well in the office setting and are best managed in the hospital or outpatient surgery center. The ability to treat children in the hospital environment and to provide comprehensive dental care using a general anesthetic for such children is a valuable part of the dentist's treatment regimen. Granting hospital staff privileges to qualified dentists has become routine at many hospitals seeking to provide comprehensive health care for the community. The dentist who uses the hospital or outpatient surgery center for the care of patients often finds it to be a rewarding component of practice. Following dental treatment under general anesthesia, Anderson et al. found that dental patient complaints of pain, problems with eating, sleeping, and behavioral concerns showed significant improvement, thereby improving their quality of life.[21]

Outpatient Orders

1. PACU care per protocol.
2. Discontinue IV when released from PACU.
3. Begin clear liquids in day surgery.
4. Pain medication: Acetaminophen _____mg po q4h prn pain (10-15 mg/kg/ standard dose. Hydrocodone (7.5 mg with acetaminophen 325 mg/15mL solution), po q6h for moderate to severe pain (typical dose 0.15 mg/kg).
5. Antibiotics (if indicated); amoxicillin__mg if not allergic to penicillins, clindamycin__mg, if allergic to penicillins.
6. Call dental house officer at _____ if questions.
7. Release from day surgery when discharge criteria are met.
8. Return appointment.
9. Call if problems arise.

Officer number _____
Pager number _____
Signature_____

A

Inpatient Orders

1. Admit to _____ to Dr. _____ Service.
2. Allergies.
3. Vital signs q2h x 2, then q4h x 2, then q8h.
4. Continuous pulse oximetry x 24h.
5. Head of bed elevated 30 degrees.
6. Protective stabilization, if needed.
7. Encourage oral fluids.
8. Advance to soft diet as tolerates.
9. Medications: list all meds, dosage, times given.
10. Pain medication: Acetaminophen _____mg po q4h prn pain (typical dose 10-15 mg/kg).
    Hydrocodone (7.5mg with acetaminophen 325 mg/15mL solution), po q6h for moderate to severe pain (typical dose 0.15 mg/kg).
11. Nausea medication (if indicated): Ondansetron____mg po or IV prn nausea (0.1-0.2 mg/kg, max dose 4 mg).
12. IV fluids: D5 1/2 ns + 20 meq KCL or Lactated Ringer's (LR) solution at___ (typical maintenance fluid rate = 4 mL/kg for patients <10kg for patients >30 kg).
13. Antibiotics (if indicated); amoxicillin___mg if not allergic to penicillins, clindamycin___mg, if allergic to penicillins.
14. Apnea monitor, if indicated.
15. For oral swelling–apply ice pack to area for 30 minutes.
16. Check for oral bleeding q15 min x 1 hr. If needed, apply moist 4 x 4 sterile gauze to area with pressure.
17. Call if needed.

Officer number _____
Pager number _____
Signature_____

B

Transfer Medical Orders

1. Transfer to pediatric medical service: Dr. _MD____ pager number_____.
2. Vital signs per PACU protocol.
3. Change intravenous fluids per pediatric medical service.
4. Encourage clear liquids.
5. Advance to soft diet as tolerated.
6. Monitor for oral hemorrhage for 24 hours. Apply moist sterile gauze and pressure, if necessary. Call dentist for excessive hemorrhage or swelling.
7. Medications per pediatric medical service.
8. Continue additional medications per prescription:
   i.e., mild pain—acetaminophen or ibuprofen suspension;
   moderate pain—hydrocodone with acetaminophen elixir
   Antibiotic—amoxicillin; allergy clindamycin
   Nausea—ondansetron.
9. Give and review appropriate home care instructions, and return appointment with family prior to discharge.
10. For dental questions contact: Dr. _____ pager number_____.

_____
Dentist Signature

C

Figure 18-15 Components of the dentist's postoperative orders for a patient. **A,** Inpatient orders. **B,** Outpatient orders. **C,** Transfer medical orders.

Box 18-5

Components of the Dentist's Operative Note

1. Title of dental procedure
2. Type of intubation and anesthesia used
3. Teeth restored
4. Teeth extracted
5. Other procedures completed
6. Dental prophylaxis and topical fluoride used
7. Summary (e.g., length of procedure, how the child tolerated the procedure, blood loss, complications)
8. Prognosis
9. Dentist's signature

Box 18-6

Components of the Dentist's Operative Report

1. Doctor's and assistants' names
2. Patient's name and hospital number
3. Preoperative diagnosis
4. Postoperative diagnosis
5. Title of the operative procedure
6. Preparation for anesthesia (preoperative medications, type of intubation, and anesthetic agents used)
7. Surgical procedure
   a. Radiographs taken
   b. Description of scrub, draping procedure, and throat pack
   c. Number of teeth restored and type of restorations
   d. Number of teeth receiving pulp therapy
   e. Teeth extracted (name each)
   f. Gingival therapy procedures
   g. Band(s) for appliance(s) and impression(s)
   h. Dental prophylaxis and fluoride applied
   i. Types and amounts of intraoperative fluids used
   j. Other information (if indicated)
8. Estimated blood loss and hemostasis
9. Condition of the patient at the conclusion of the surgical procedure (complications incurred if indicated)
10. Condition of the patient on arrival in the recovery room
11. Prognosis

Box 18-7

Components of the Dentist's Discharge Summary Statement

1. Patient's name and hospital number
2. Date of admission
3. Date of discharge
4. Date of dictation
5. Preoperative diagnosis
6. Postoperative diagnosis
7. Age, race, and gender of patient
8. Reason for admission and treatment using general anesthetic
9. Results of preoperative history and physical examination (medical and dental) and present medications
10. Name of the physician completing the history and physical examination
11. Complete description of the surgical procedure (see Box 15-6)
12. Patient's tolerance in the recovery room and ward
13. Condition of patient on discharge
14. Individual to whom patient is discharged
15. Home care instructions given to parents or guardian and medications prescribed (dosage and times to be given)
16. Patient's next appointment
17. Copies of discharge summary sent to patient's physician and referring dentist or physician

ROC SURGERY LLC
Perioperative Care Center
Riley Outpatient Surgery Center (ROC)

Discharge Criteria to the Care of a Responsible Adult

Policy

Readiness for discharge from the Day Surgery Unit is based on nursing assessment and meeting pre-set discharge criteria.

Criteria for Discharge from SDS (or PACU) to Home

Assess the patient's readiness for discharge based on the following criteria:

1. Heart rate, respiratory rate, and blood pressure are within 10% of preoperative values. SaO_2 is >95 or at preoperative value. Owing to the nature of the pediatric patient, many patients may be upset upon admission to the point that vital signs are not representative of their baseline. In this situation, the first set of vital signs from the OR will be used.
2. Respirations are unlabored and breath sounds are equal and consistent with the preoperative examination.
3. Dressing is intact with minimal or no drainage present and/or incision is free of fresh drainage.
4. Patient is tolerating oral fluids with no nausea or vomiting unless physician has made an exception to this.
5. Patient is alert when awake or at preoperative level of function.
6. Older child is able to speak clearly or at preoperative level and infant has a clear cry.
7. Pain is controlled.
8. Patient's motor function has returned to baseline or is at an expected level consistent with the surgical or anesthetic management.
9. All postoperative orders have been addressed and completed where applicable.
10. Return appointments have been made if applicable.
11. Anesthesiologist has been notified of and/or has examined any child with prolonged emesis or croup.
12. Patient has discharge order signed by surgeon and anesthesiologist.

Figure 18-16 Discharge criteria for post-OR dental patient. (Courtesy of Indiana University Health, Riley Outpatient Center Surgery, LLC.)

REFERENCES

1. Crespi P, Friedman RB: Hospitalization for the pediatric dental patient: an update on admission indications and third party review, *N Y State Dent J* 52(2):40–43, 1986.
2. King KJ, Nielson RR: Dental treatment in the hospital utilizing general anesthesia. In Nowak AJ, editor: *Dentistry for the handicapped patient*, St. Louis, 1976, Mosby.
3. Camm JH, et al.: Behavioral changes of children undergoing dental treatment using sedation versus general anesthesia, *Pediatr Dent* 9(2):111–117, 1987.
4. Peretz B, et al.: Children with baby bottle tooth decay treated under general anesthesia or sedation: behavior in a follow-up visit, *J Clin Pediatr Dent* 24(2):97–101, 2000.
5. Fuhrer CT, et al.: Effect on behavior of dental treatment rendered under conscious sedation and general anesthesia in pediatric patients, *Pediatr Dent* 31:492–497, 2009.
6. Biery KA, Shamaskin RG, Campbell RL: Analysis of preoperative laboratory values prior to outpatient dental anesthesia, *Anesth Prog* 34:58–60, 1987.
7. Enger DJ, Mourino AP: A survey of 200 pediatric dental general anesthesia cases, *J Dent Child* 52(1):36–41, 1985.
8. Bradley GS, Lynch S: Safety of hospital dental treatment for the high-risk patient, *Spec Care Dentist* 4(6):253–260, 1984.
9. Guedel AE: *Inhalation anesthesia*, New York, 1937, Macmillan.
10. Roberts GJ: Relative analgesia in clinical practice. In Coplans MD, Green RA, editors: *Anaesthesia and sedation in dentistry*, vol. 12. Amsterdam, 1983, Elsevier Science.
11. Ray TL, Tobias JD: An alternative technique for nasotracheal intubation, *South Med J* 96(10):1039–1041, 2003.
12. Spiro SR, Burns J: Current concepts of premedication and anesthesiological management for the pediatric dental patient who is hospitalized for dento-oral rehabilitation, *J Hosp Dent Pract* 14(1):35–39, 1980.
13. Eidelman E, Faibis S, Peretz B: A comparison of restorations for children with early childhood caries treated under general anesthesia or conscious sedation, *Pediatr Dent* 22:33–37, 2000.
14. O'Sullivan EA, Curzon MEJ: The efficacy of comprehensive dental care for children under general anesthesia, *Br Dent J* 171:56–58, 1991.
15. Tate AR, et al.: Failure rates of restorative procedures following dental rehabilitation under general anesthesia, *Pediatr Dent* 24(1):69–71, 2002.
16. Al-Eheideb AA, Herman NG: Outcomes of dental procedures performed on children under general anesthesia, *J Clin Pediatr Dent* 27:181–183, 2003.
17. Bücher K, et al.: Longevity of composite restorations in patients with early childhood caries (ECC), *Clin Oral Investig* 18(3):775–782, 2013.
18. Kupietzky A, Waggoner WF, Galea J: The clinical and radiographic success of bonded resin composite strip crowns for primary incisors, *Pediatr Dent* 25:577–581, 2003.
19. Sheller B, et al.: Reasons for repeat dental treatment under general anesthesia for the healthy child, *Pediatr Dent* 25: 546–552, 2003.
20. Almeida A, et al.: Future caries susceptibility in children with early childhood caries following treatment under general anesthesia, *Pediatr Dent* 22(4):1–5, 2000.
21. Anderson HK, et al.: Changes in aspects of children's oral health related quality of life following dental treatment under general anesthesia, *Int J Paediatr Dent* 14(5):317–325, 2004.

SUGGESTED READINGS

American Academy of Pediatric Dentistry: Special Issue: Reference manual 2013-2014, *Pediatr Dent* 35(7 suppl):84–85, 86, 181–184, 2013.

American Society of Anesthesiologists: Practice Guidelines for Preoperative Fasting and the Use of Pharmacologic Agents to Reduce the Risk of Pulmonary Aspiration; Application to Healthy Patients Undergoing Elective Procedures, *Anesthesiology* 114:495–511, 2011.

Herlich A, et al.: Anesthesia for pediatric dentistry. In *Smith's Anesthesia for Infants and Children*, ed 8, St. Louis, 2011, Mosby.

VanCleave AM, et al.: Factors involved in dental surgery fires: a review of the literature, *Anesth Prog* 61:21–25, 2014.

VanCleave AM, et al.: The effect of intraoral suction on oxygen-enriched surgical environments: a mechanism for reducing the risk of surgical fires, *Anesth Prog* 61:155–161, 2014.

PART 4 GROWTH AND DEVELOPMENT

CHAPTER 19

Eruption of the Teeth: Local, Systemic, and Congenital Factors That Influence the Process

▲ **Jeffrey A. Dean** and **Erwin G. Turner**

For additional resources, please visit the evolve website.

CHAPTER OUTLINE

CHRONOLOGIC DEVELOPMENT AND ERUPTION OF THE TEETH
- Influence of Premature Loss of Primary Molars on Eruption Time of Their Successors
- Variations in Sequence of Eruption

LINGUAL ERUPTION OF MANDIBULAR PERMANENT INCISORS

TEETHING AND DIFFICULT ERUPTION
- Eruption Hematoma (Eruption Cyst)
- Eruption Sequestrum
- Ectopic Eruption

NATAL AND NEONATAL TEETH

EPSTEIN PEARLS, BOHN NODULES, AND DENTAL LAMINA CYSTS

LOCAL AND SYSTEMIC FACTORS THAT INFLUENCE ERUPTION
- Ankylosed Teeth
- Ankylosis of Primary Molars with Absence of Permanent Successors
- Ankylosed Permanent Teeth
- Trisomy 21 Syndrome (Down Syndrome)
- Cleidocranial Dysplasia
- Hypothyroidism
- Hypopituitarism
- Achondroplastic Dwarfism
- Other Causes

CHRONOLOGIC DEVELOPMENT AND ERUPTION OF THE TEETH

A variety of developmental defects that are evident after eruption of the primary and permanent teeth can be related to systemic and local factors that influence matrix formation and the calcification process. Thus it is important that the dentist be able to explain to the parents the time factors related to the early stages of tooth calcification both in utero and during infancy.

Past classic studies and reviews of the literature involving calcification of the primary teeth have compared their findings with the values in Table 19-1 showing the Logan and Kronfeld chronology of the human dentition, which has been the accepted standard for many years.[1] Their findings offered revisions that established earlier ages than those previously accepted for initial calcification and later ages at which the primary teeth erupt.

These studies and reviews concluded that Table 19-1 should be modified and that the sequence of calcification of the primary teeth should be changed to central incisor, first molar, lateral incisor, canine, and second molar. They determined that the times of initial calcification of the primary teeth are 2 to 6 weeks earlier than those given in Table 19-1, and they also concluded that the maxillary teeth are generally ahead of the mandibular teeth in development. Exceptions are the second molars, which generally are advanced in the mandible, and the lateral incisors and canines, which at times may be ahead in the mandible.

These studies also propose that the lateral incisor, first molar, and canine tend to erupt earlier in the maxilla than in the mandible, compared with the Logan and Kronfeld table, which suggests that eruption in the mandible is generally ahead of that in the maxilla. The ages at which primary teeth erupt are 2 or more months later than suggested in the Logan and Kronfeld table. The study by Hernandez and colleagues provides confirmation that more recent studies in different white populations have findings similar to those from these classic studies on eruption

Dentlearn.ir

Table **19-1**

Chronology of the Human Dentition

Tooth	Hard Tissue Formation Begins	Amount of Enamel Formed at Birth	Enamel Completed	Eruption	Root Completed
Deciduous dentition					
Maxillary					
Central incisor	4 mo in utero	Five sixths	1½ mo	7½ mo	1½ yr
Lateral incisor	4½ mo in utero	Two thirds	2½ mo	9 mo	2 yr
Cuspid	5 mo in utero	One third	9 mo	18 mo	3¼ yr
First molar	5 mo in utero	Cusps united	6 mo	14 mo	2½ yr
Second molar	6 mo in utero	Cusp tips still isolated	11 mo	24 mo	3 yr
Mandibular					
Central incisor	4½ mo in utero	Three fifths	2½ mo	6 mo	1½ yr
Lateral incisor	4½ mo in utero	Three fifths	3 mo	7 mo	1½ yr
Cuspid	5 mo in utero	One third	9 mo	16 mo	3¼ yr
First molar	5 mo in utero	Cusps united	5½ mo	12 mo	2¼ yr
Second molar	6 mo in utero	Cusp tips still isolated	10 mo	20 mo	3 yr
Permanent dentition					
Maxillary					
Central incisor	3-4 mo		4-5 yr	7-8 yr	10 yr
Lateral incisor	10-12 mo		4-5 yr	8-9 yr	11 yr
Cuspid	4-5 mo		6-7 yr	11-12 yr	13-15 yr
First bicuspid	1½-1¾ yr		5-6 yr	10-11 yr	12-13 yr
Second bicuspid	2-2¼ yr		6-7 yr	10-12 yr	12-14 yr
First molar	At birth	Sometimes a trace	2½-3 yr	6-7 yr	9-10 yr
Second molar	2½-3 yr		7-8 yr	12-13 yr	14-16 yr
Third molar	7-9 yr		12-16 yr	17-21 yr	18-25 yr
Mandibular					
Central incisor	3-4 mo		4-5 yr	6-7 yr	9 yr
Lateral incisor	3-4 mo		4-5 yr	7-8 yr	10 yr
Cuspid	4-5 mo		6-7 yr	9-10 yr	12-14 yr
First bicuspid	1¾-2 yr		5-6 yr	10-12 yr	12-13 yr
Second bicuspid	2¼-2½ yr		6-7 yr	11-12 yr	13-14 yr
First molar	At birth	Sometimes a trace	2½-3 yr	6-7 yr	9-10 yr
Second molar	2½-3 yr		7-8 yr	11-13 yr	14-15 yr
Third molar	8-10 yr		12-16 yr	17-21 yr	18-25 yr

From Kronfeld R: *Bur* 35:18-25, 1935 (based on research by WHG Logan and R Kronfeld); adapted by Kronfeld R, Schour I: *J Am Dent Assoc* 26:18-32, 1939; further adapted by McCall JO, Wald SS: *Clinical dental roentgenology: technic and interpretation including roentgen studies of the child and young adult,* Philadelphia, 1940, WB Saunders.

chronology.[2] Their findings are further substantiated by the recent study conducted by Hu et al.[3] An example of these modifications to the Logan and Kronfeld table may be found in the Dental Growth and Development section of the American Academy of Pediatric Dentistry Reference Manual.[4]

The time of eruption of both primary and permanent teeth varies greatly. Variations of 6 months on either side of the usual eruption date may be considered normal for a given child. A study by Parner and colleagues compared the well-known general acceleration of the physical development of children over the past century with their own observations of the emergence of permanent teeth.[5] They found that the emergence of permanent teeth has not been subject to a similar acceleration; in fact, the mean age of eruption has increased slightly, but only by a few days per year. They conclude that the age of eruption of the permanent teeth is a much more stable phenomenon than other aspects of physical development in children.

Numerous in vivo animal experiments and human radiographic studies have been done to better understand the process of tooth eruption. Although many theories have been advanced, the factors responsible for the eruption of the teeth are not fully understood. The factors that have been related to the eruption of teeth include elongation of the root, forces exerted by the vascular tissues around and beneath the root, growth of the alveolar bone, growth of dentin, growth and pull of the periodontal

membrane, hormonal influences, presence of a viable dental follicle, pressure from the muscular action, and resorption of the alveolar crest.

A series of experiments by Cahill and Marks established that a viable dental follicle is required for tooth eruption.[6] Further studies by Marks and Cahill resulted in the conclusion that "tooth eruption is a series of metabolic events in alveolar bone characterized by bone resorption and formation on opposite sides of the dental follicle and the tooth does not contribute to this process."[7]

Tooth eruption is influenced by pituitary growth hormone and thyroid hormone, and parathyroid hormone–related protein is required for tooth eruption.

Each tooth starts to move toward occlusion at approximately the time of crown completion, and the interval from crown completion and the beginning of eruption until the tooth is in full occlusion is approximately 5 years for permanent teeth.

Many investigators have observed that tooth emergence appeared to be more closely associated with the stage of root formation than with the chronologic or skeletal age of the child. By the time of clinical emergence, approximately three fourths of root formation has occurred, with the teeth reaching occlusion before the root development is complete.

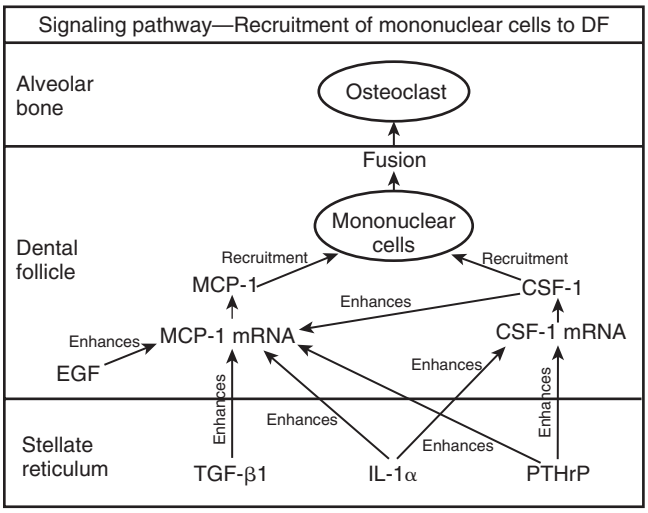

Figure 19-1 Paracrine signaling between the stellate reticulum and dental follicle (DF) results in the synthesis and secretion of chemotactic molecules, colony-stimulating factor 1 (CSF-1), and monocyte chemotactic protein 1 (MCP-1) for recruitment of mononuclear cells. EGF, Epidermal growth factor; IL-1α, interleukin 1α; PTHrP, parathyroid hormone–related peptide; mRNA, messenger RNA; TGF-β1, transforming growth factor β1. (From Wise GE et al: *Crit Rev Oral Biol Med* 13(14):323-355, 2002.)

5437 radiographs from a homogeneous (French-Cana-

the gender differences in the development of permanent mandibular teeth from the early stages of calcification to closure of the apex. The analysis of the developmental curves of individual teeth shows a common pattern, namely, the similarity in timing between the genders for the early stages of development. For the first stages of crown formation, which they refer to as A, B, and C, there was no difference between boys and girls in the chronology of dental calcification in the majority of teeth. For the fourth stage, D, which represents the completion of crown development, girls were more advanced than boys by an average of 0.35 year for four teeth. For the stages of root development, the mean difference between the genders for all teeth was 0.54 year; the largest difference was for the canine (0.90 year). Analysis of the data from Demirjian and Levesque show the importance of sexual dimorphism during the period of root development rather than during the period of crown development.[8]

The tooth eruption process is clearly complex, and many different mechanisms are undoubtedly involved. Some of the leading scientists who are contributing to a better understanding of the tooth eruption process have written review articles to help consolidate the facts and theories associated with this process. A review article by Wise and colleagues focuses on the molecular signals that initiate tooth eruption.[9] The researchers state that tooth eruption is a complex and tightly regulated process that involves cells of the tooth organ and the surrounding alveolus. Mononuclear cells (osteoclast precursors) must be recruited into the dental follicle before the onset of eruption. These cells, in turn, fuse to form osteoclasts that resorb alveolar bone, creating an eruption pathway for the tooth to exit its bony crypt. In recent years, knowledge of the biology of tooth eruption has greatly increased. What has emerged is the realization that interactions of osteoblasts, osteoclasts, and dental follicles involve a complex interplay of regulatory genes that encode various transcription factors, proto-oncogenes, and soluble factors. For the clinician faced with treating both simple and complex dental complications arising from abnormal tooth eruption, knowledge of the basic molecular mechanisms involved is essential (Fig. 19-1). Finally, an extensive review by Marks and Schroeder analyzes experimental data to identify the basic principles of tooth eruption and offers their guiding theories of the process.[10] For more information about the details of the tooth eruption process, refer to these review articles.

INFLUENCE OF PREMATURE LOSS OF PRIMARY MOLARS ON ERUPTION TIME OF THEIR SUCCESSORS

After reviewing the records of children in the Burlington study who had undergone unilateral extraction of primary molars, Posen came to the following conclusions: Eruption of the premolar teeth is delayed in children who lose primary molars at 4 or 5 years of age and before.[11] If extraction of the primary molars occurs after the age of 5 years, there is a decrease in the delay of premolar eruption. At 8, 9, and 10 years of age, premolar eruption resulting from premature loss of primary teeth is greatly accelerated. Hartsfield stated that premature loss of teeth associated with systemic disease usually results from some change in the immune system or connective tissue.[12]

Dentlearn.ir

The most common of these conditions appears to be hypophosphatasia and early-onset periodontitis.

VARIATIONS IN SEQUENCE OF ERUPTION

The mandibular first permanent molars are often the first permanent teeth to erupt. They are quickly followed by the mandibular central incisors. Previous studies found little or no clinical significance to the eruption of the incisors before the molars.

After analyzing serial records of 16,000 children in Newburgh and Kingston, New York, Carlos and Gittelsohn concluded that the average eruption time of the mandibular central incisors was earlier than that of the first molars by about 1½ months in both boys and girls.[13] Of considerable interest was the gender difference in the eruption sequence of permanent teeth. The mandibular canine erupted before the maxillary and mandibular first premolars in girls. In boys, the eruption order was reversed—the maxillary and mandibular first premolars erupted before the mandibular canine.

Moyers stated that the most common sequence of eruption of permanent teeth in the mandible is first molar, central incisor, lateral incisor, canine, first premolar, second premolar, and second molar.[14] The most common sequence for the eruption of the maxillary permanent teeth is first molar, central incisor, lateral incisor, first premolar, second premolar, canine, and second molar (Fig. 19-2). He identified these common sequences in each arch to be favorable for maintaining the length of the arches during the transitional dentition.

It is desirable that the mandibular canine erupt before the first and second premolars. This sequence aids in maintaining adequate arch length and in preventing lingual tipping of the incisors, which not only causes a loss of arch length but also allows an increased overbite to develop. An abnormal lip musculature or an oral habit that causes a greater force on the mandibular incisors than can be compensated for by the tongue allows the anterior segment to collapse. For this reason, use of a passive lingual arch appliance is often indicated when the primary canines have been lost prematurely or when the sequence of eruption is undesirable.

A deficiency in arch length can occur if the mandibular second permanent molar develops and erupts before the second premolar. Eruption of the second permanent molar first encourages mesial migration or tipping of the first permanent molar and encroachment on the space needed for the second premolar. The importance of maintaining the second primary molar until its replacement by the second premolar is discussed in Chapter 22. In the maxillary arch, the first premolar ideally should erupt before the second premolar, and they should be followed by the canine. The untimely loss of primary molars in the maxillary arch, which allows the first permanent molar to drift and tip mesially, results in the permanent canine's being blocked out of the arch, usually to the labial side.

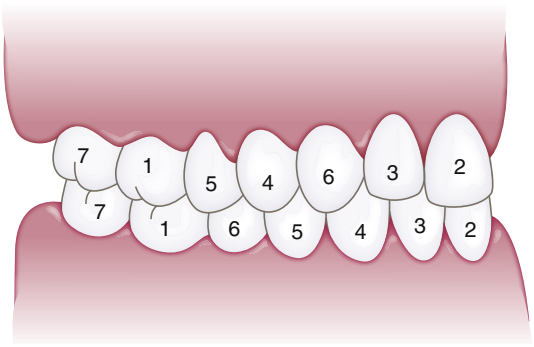

Figure 19-2 Desirable eruption sequence for the permanent teeth.

The position of the developing second permanent molar in the maxillary arch and its relationship to the first permanent molar should be given special attention. Its eruption before the premolars and canine can cause a loss of arch length, just as in the mandibular arch. The eruption of the maxillary canine is often delayed because of an abnormal position or deviations in the eruption path. This delayed eruption should be considered along with its possible effect on the alignment of the maxillary teeth. The significance of the sequence of the eruption of permanent teeth is considered further in Chapter 22.

Finally, deviations from accepted norms of eruption time are often observed in clinical practice. Premature eruption has been noted, but delayed tooth eruption is the most commonly encountered deviation from normal eruption time.[15]

LINGUAL ERUPTION OF MANDIBULAR PERMANENT INCISORS

The eruption of mandibular permanent incisors lingual to retained primary incisors is often a source of concern for parents. The primary teeth may have undergone extensive root resorption and may be held only by soft tissues. In other instances, the roots may not have undergone normal resorption and the teeth remain solidly in place. It is common for mandibular permanent incisors to erupt lingually, and this pattern should be considered essentially normal. It is seen both in patients with an obvious arch length inadequacy (Fig. 19-3) and in those with a desirable amount of spacing of the primary incisors (Fig. 19-4). In either case the tongue and continued alveolar growth seem to play important roles in influencing the permanent incisors into a more normal position with time. Although there may be insufficient room in the arch for the newly erupted permanent tooth, its position will improve over several months. In some cases there is justification for removal of the corresponding primary tooth. Extraction of other primary teeth in the area is not recommended, however, because it will only temporarily relieve the crowding and may even contribute to the development of a more severe arch length inadequacy.

Gellin has emphasized the anxiety created when parents discover a double row of teeth. He suggested that if the condition is identified before 7½ years of age, it is unnecessary to subject the child to the trauma of removing the primary teeth, because the problem almost always self-corrects within a few months.[16] However, he warned

Dentlearn.ir

that when lingually erupted permanent mandibular incisors are seen in an older child and the radiograph shows no root resorption of the primary teeth, self-correction has not been achieved and the corresponding primary teeth should be removed.

Gellin and Haley conducted a clinical study to determine whether removal of the corresponding primary tooth is necessary when the lingual eruption pattern of the mandibular permanent incisor is identified.[17] They monitored 57 lingually positioned mandibular permanent central or lateral incisors in 44 children (22 boys and 22 girls). The children were selected for the study if they had one or more permanent mandibular incisors erupting immediately lingual to the corresponding primary incisor. Other inclusion criteria were the presence of both primary mandibular canines, the absence of any other anomalies of the mandibular primary or permanent incisors, and the absence of severe crowding of the permanent mandibular incisors characterized by eruption of the lateral incisors directly behind the central incisors. The mean age of the children at their first observation was 6 years 4 months (range, 4 years 10 months to 8 years 8 months). Of the permanent teeth studied, 47 were central incisors and 10 were lateral incisors.

In all cases, labial migration occurred naturally and extraction of the corresponding primary incisor was unnecessary. Gellin and Haley reported that spontaneous correction of lingually erupted mandibular permanent central incisors occurred by age 8 years 2 months in 95% of the cases that met the criteria of their study.[17] They also observed that spontaneous correction of lingually erupted lateral incisors occurred by at least 8 years 4 months of age.

for specific conclusions to be drawn, correction occurred in all cases and central incisors migrated labially at an earlier age. Gellin and Haley recommended a conservative approach of waiting and periodic observation to spare the child a surgical procedure. They suggested that if labial migration of the permanent incisor has not occurred by 8 years 2 months for central incisors and 8 years 4 months for lateral incisors, over-retention of the primary incisor should be suspected, and removal of the primary tooth considered. However, they recommended removal only if the primary incisor remained firm and the root had failed to resorb. These findings and suggestions were further substantiated by the study conducted by Aminabadi et al.[18]

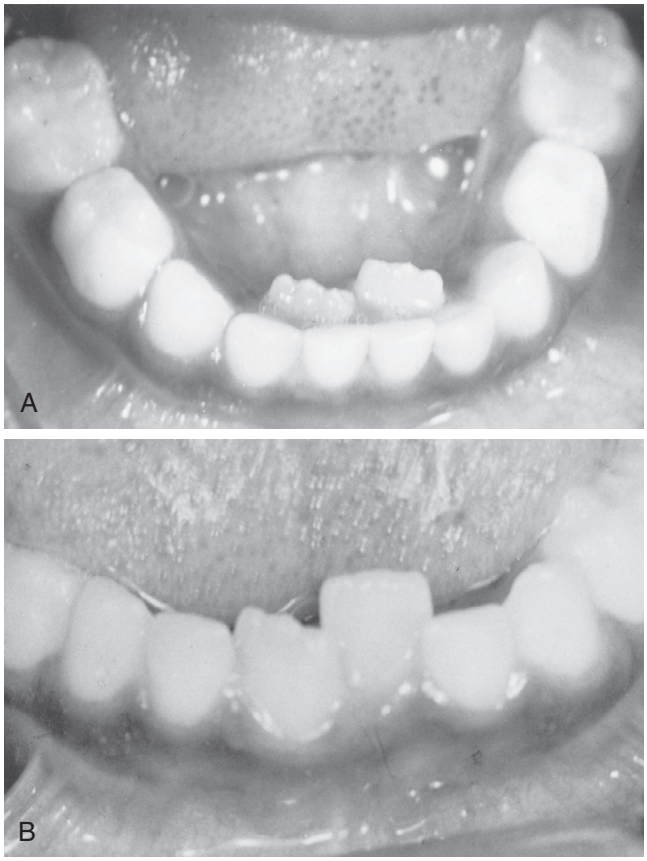

Figure 19-3 **A,** The permanent central incisors are erupting lingual to the retained primary central incisors, which were extracted. **B,** The arch length is inadequate to accommodate the permanent incisors. However, they have moved forward into a more favorable position as a result of the force exerted on them by the tongue.

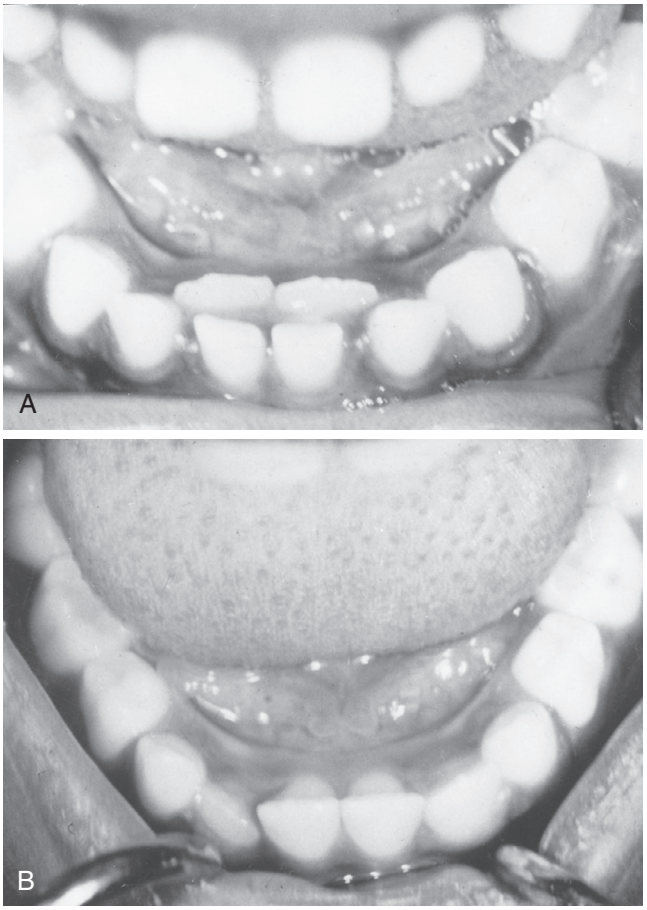

Figure 19-4 **A,** Primary teeth are desirably spaced with sufficient room for the permanent central incisors. However, the permanent teeth erupted lingually to the primary teeth. **B,** Extraction of the primary central incisors resulted in a desirable positioning of the permanent teeth, but given enough time this condition probably would have been self-correcting.

We recognize that spontaneous correction of lingually erupted permanent incisors is likely to occur given enough time, particularly in cases in which there is not severe crowding. A watchful waiting approach may be justified, especially when the patient is first seen in the dentist's office for this specific problem. Removal of a tooth during the first dental appointment of a child 6 to 8 years old probably compromises the dentist's ability to develop rapport with the child. However, the extraction procedure in such cases is quite simple, and we believe there may be many times when it is appropriate. The parents' feelings should not be ignored in the decision; even a 95% chance that correction will occur may not satisfy all parents. The dentist may find that some dental patients prefer to have the primary tooth extracted and the problem laid to rest. Although monitoring the condition without extraction is acceptable under the conditions outlined by Gellin and Haley, we know of no significant contraindications to early removal of the offending primary incisor even in spaced dentitions, if specific conditions warrant its consideration.

Even when mandibular permanent incisors erupt uneventfully, they often appear rotated and staggered in position. The molding action of the tongue and the lips improves their relationship within a few months.

TEETHING AND DIFFICULT ERUPTION

In most children the eruption of primary teeth is preceded by increased salivation, and the child will want to put the hand and fingers into the mouth—these observations may be the only indication that the teeth will soon erupt.

Some young children become restless and fretful during the time of eruption of the primary teeth. Many conditions, including croup, diarrhea, fever, convulsions, primary herpetic gingivostomatitis, and even death have been incorrectly attributed to eruption. In the nineteenth century, complications from teething were believed to be a frequent cause of infant mortality. Several previous studies have reported that, in 1839, 5016 deaths in England and Wales were attributed to teething.

Illingworth made a thorough search of the world literature and failed to produce evidence that teething causes fever, convulsions, bronchitis, or diarrhea.[19] His findings are supported by Tasanen's unique study of teething, in which 192 tooth eruptions were observed in 126 infants and 107 control children.[20] All the babies were seen on the day of tooth eruption, and records were kept of the temperature, incidence of infection, erythrocyte sedimentation rate, white blood cell count, behavior (including sleep), color of the mucosa, sensitivity of the tissue covering the erupting tooth, and pain resulting from pressure on the tooth. Tasanen concluded that teething does not increase the incidence of infection, does not cause any rise in temperature, erythrocyte sedimentation rate, or white blood cell count, and does not cause diarrhea, cough, sleep disturbance, or rubbing of the ear or cheek, but that it does cause daytime restlessness, an increase in the amount of finger sucking or rubbing of the gum, an increase in drooling, and possibly some loss of appetite. In one third of the children, there was no change in the color of the mucosa in the area of the erupting tooth; in one third, the change was slight; and in the remaining third, there was a pronounced change in the mucosa, often with small hemorrhages.

A later study of 46 healthy infants conducted by Jaber and colleagues demonstrated a small increase in body temperature in 20 (43%) of the infants on the day of emergence of their first tooth.[21] However, the authors emphasized a danger in attributing fever to teething. Macknin and colleagues have confirmed these results.[22] Serious mistakes have been made in the health care of infants and toddlers when their symptoms were ascribed to teething without a thorough diagnostic evaluation, which resulted in the overlooking of significant systemic disturbances. Swann observed 50 children who were hospitalized after parents or physicians initially attributed their symptoms to teething.[23] After a careful medical evaluation, an organic cause of illness was identified in 48 of the 50 patients.

Because the eruption of teeth is a normal physiologic process, the association with fever and systemic disturbances is not justified. A fever or respiratory tract infection during this time should be considered coincidental to the eruption process rather than related to it.

Inflammation of the gingival tissues before complete emergence of the crown may cause a temporary painful condition that subsides within a few days. The surgical removal of the tissue covering the tooth to facilitate eruption is not indicated. If the child is having extreme difficulty, the application of a nonirritating topical anesthetic may bring temporary relief. The parent can apply the anesthetic to the affected tissue over the erupting tooth three or four times a day. Several low-dose products specifically formulated for infants are available without prescription. Caution must be exercised, however, when one is prescribing topical anesthetics, especially for infants, because systemic absorption of the anesthetic agent is rapid, and toxic doses can occur if the product is misused. The parent must clearly understand the importance of using the drug only as directed. The eruption process may be hastened if the child is allowed to chew on a piece of toast or a clean teething object.

ERUPTION HEMATOMA (ERUPTION CYST)

A bluish-purple elevated area of tissue, commonly called an eruption hematoma, occasionally develops a few weeks before the eruption of a primary or permanent tooth. The blood-filled cyst is most frequently seen in the primary second molar or the first permanent molar region. This fact substantiates the belief that the condition develops as a result of trauma to the soft tissue during function (Fig. 19-5). Usually the tooth breaks through the tissue within a few days, and the hematoma subsides. Because the condition is almost always self-limiting, treatment of an eruption hematoma is rarely necessary. However, surgical uncovering of the crown may occasionally be justified.

When the parents discover an eruption hematoma, they may fear that the child has a serious disease such as a malignant tumor. The dentist must be understanding and sensitive to their anxiety while reassuring them that the lesion is not serious.

Dentlearn.ir

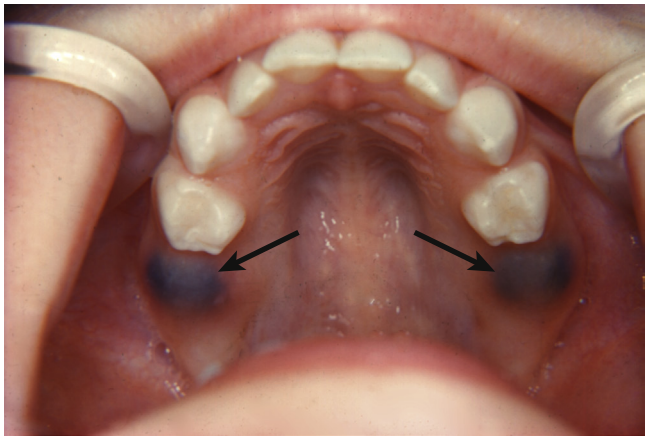

Figure 19-5 Eruption hematomas *(arrows)* have developed before the eruption of the second primary molars.

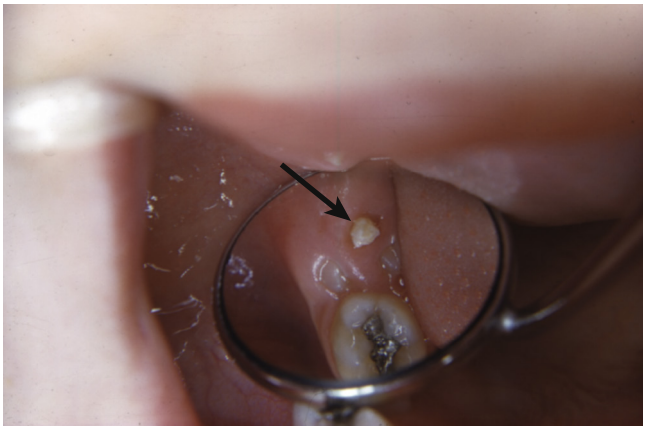

Figure 19-6 Arrow points to an eruption sequestrum in a girl 5 years, 11 months of age. It appears clinically as a white spicule of hard tissue overlying the central fossa of a mandibular first permanent molar, which is just beginning to erupt through the mucosa. (Courtesy Drs. Paul E. Starkey and William G. Shafer.)

ERUPTION SEQUESTRUM

The eruption sequestrum is occasionally seen in children at the time of the eruption of the first permanent molar (Figs. 19-6 and 19-7). Starkey and Shafer have described the sequestrum as a tiny spicule of nonviable bone overlying the crown of an erupting permanent molar just before or immediately after the emergence of the tips of the cusps through the oral mucosa.[24] Case studies have reported that eruption sequestra are composed of dentin and cementum as well as a cementum-like material formed within the follicle. These findings have been confirmed by the work of Alexandra de Queiroz and associates.[25] Maki and colleagues also report that the ratio of calcium to phosphorus in their case report was higher than that seen in normal osseous tissue.[26] These various reports suggest that eruption sequestra may develop from either osteogenic or odontogenic tissue. Regardless of its origin, the hard tissue fragment is generally overlying the central fossa of the associated tooth, embedded, and contoured within the soft tissue. As the tooth erupts and the cusps emerge, the fragment sequestrates.

Eruption sequestra are usually of little or no clinical significance. It is probable that some of these sequestra spontaneously resolve without noticeable symptoms. However, after an eruption sequestrum has surfaced through the mucosa, it may easily be removed if it is causing local irritation. The base of the sequestrum is often still well embedded in gingival tissue when it is discovered, and application of a topical anesthetic or infiltration of a few drops of a local anesthetic may be necessary to avoid discomfort during removal.

ECTOPIC ERUPTION

Arch length inadequacy, tooth mass redundancy, or a variety of local factors may influence a tooth to erupt or try to erupt in an abnormal position. Occasionally this condition may be so severe that actual transposition of teeth takes place. Several problems associated with the ectopic eruption of teeth and the management of these problems are presented in Chapter 22.

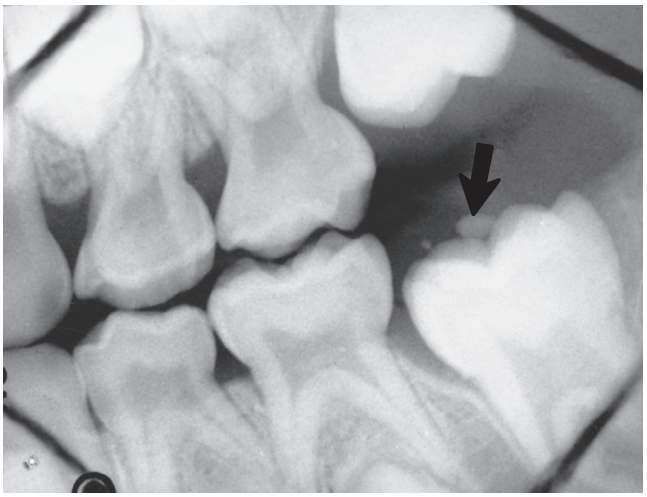

Figure 19-7 Radiographic appearance of an eruption sequestrum *(arrow)* in a child 6 years, 9 months of age. No treatment is required unless symptoms develop. (Courtesy Drs. Paul E. Starkey and William G. Shafer.)

NATAL AND NEONATAL TEETH

The prevalence of natal teeth (teeth present at birth) and neonatal teeth (teeth that erupt during the first 30 days) is low. Leung conducted a retrospective study of hospital records of 50,892 infants born in Calgary, Alberta (Canada).[27] These records identified 15 infants found to have natal teeth, a prevalence of 1 in 3392 births. In another survey Kates and colleagues found the calculated prevalence of natal teeth to be 1 in 3667 among 11,000 infants when the survey information was obtained indirectly; the prevalence was found to be 1 in 716.[28]

Zhu and King conducted an extensive review of the literature of reported cases of natal and neonatal teeth.[29] They found that about 85% of natal or neonatal teeth are mandibular primary incisors, and only small percentages

are supernumerary teeth. It is common for natal and neonatal teeth to occur in pairs. Natal and neonatal molars are rare: Zhu and King found only 20 reported cases dating from 1897. They also reported that most premature tooth eruption seems to occur in otherwise normal infants, with or without a family history of the condition. In some infants, however, the presence of such teeth may be a localized manifestation of various environmental causes or an underlying syndrome, with the most common being Ellis-van Creveld syndrome, Hallermann-Streiff syndrome, Pierre Robin syndrome, and Sotos syndrome. This underscores the importance of thorough diagnostic evaluations of infants with natal or neonatal teeth. It has been reported that less than 10% of neonatal teeth are supernumerary.[30]

Spouge and Feasby believe that the terms *natal teeth* and *neonatal teeth* constitute a relatively artificial distinction and should be further qualified to provide a more practical clinical meaning.[31] They have suggested that the terms *mature* and *immature* are more in keeping with the various prognoses associated with such teeth.

Most studies suggest that the etiology for the premature eruption or the appearance of natal and neonatal teeth is multifactorial. A possible factor involving the early eruption of primary teeth seems to be familial, due to inheritance as an autosomal-dominant trait.

Many parents volunteer the information that their teeth erupted early, and studies have found that from 10 to 15% of the children with natal or neonatal teeth had parents, siblings, or other near relatives with a history of such teeth.

A radiograph should be made to determine the amount of root development and the relationship of a prematurely erupted tooth to its adjacent teeth. One of the parents can hold the x-ray film in the infant's mouth during the exposure.

Most prematurely erupted teeth (immature type) are hypermobile because of limited root development. Some teeth may be mobile to the extent that there is danger of displacement of the tooth and possible aspiration, in which case the removal of the tooth is indicated. In some cases the sharp incisal edge of the tooth may cause laceration of the lingual surface of the tongue (Riga-Fede disease), and the tooth may have to be removed.

Zhu and King were unable to find any reported cases of aspirated natal or neonatal teeth. Extraction of such a tooth, if necessary, is a simple procedure but is emotionally difficult for the parents.[29] After the tooth is removed, careful curettage of the socket is indicated in an attempt to remove any odontogenic cellular remnants that may otherwise be left in the extraction site. Such retained remnants may subsequently develop atypical toothlike structures that require additional treatment.

The preferable approach, however, is to leave the tooth in place and to explain to the parents the desirability of maintaining this tooth in the mouth because of its importance in the growth and uncomplicated eruption of the adjacent teeth. Within a relatively short time the prematurely erupted tooth will become stabilized, and the other teeth in the arch will erupt (Fig. 19-8).

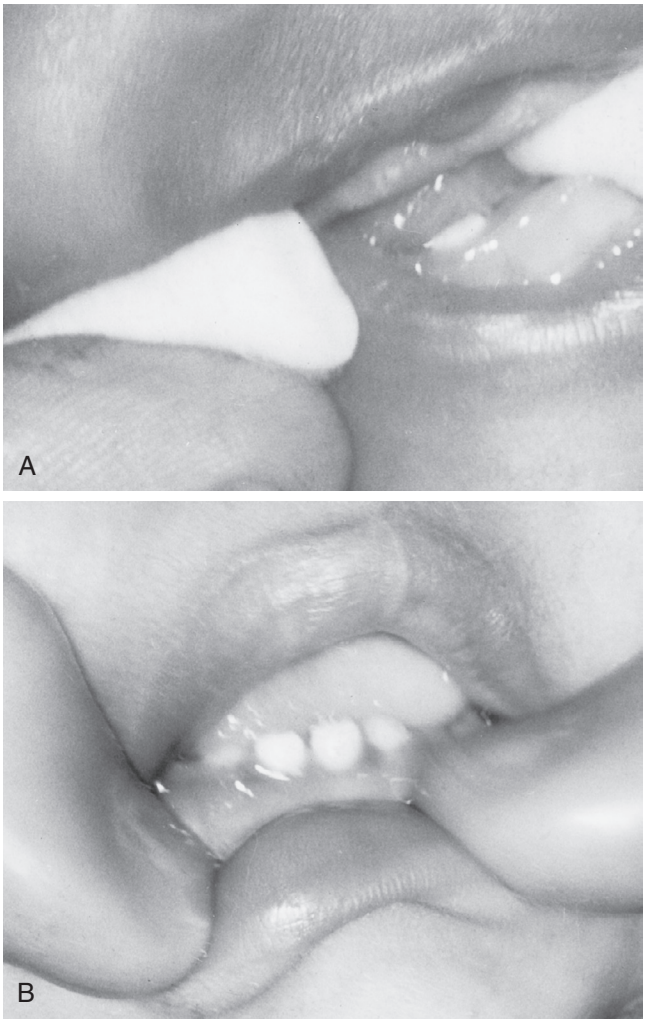

Figure 19-8 **A,** Natal tooth in a 3-day-old infant. Because the tooth was not excessively mobile, there was no reason to recommend its removal. **B,** Within 2 months other teeth in the mandibular anterior region erupted. The ungloved fingers in the photographs are those of the infant's parent.

Eruption of teeth during the neonatal period presents less of a problem. These teeth can usually be maintained even though root development is limited (Figs. 19-9 and 19-10).

A retained natal or neonatal tooth may cause difficulty for a mother who wishes to breast-feed her infant. If breast-feeding is too painful for the mother initially, the use of a breast pump and bottling of the milk are recommended. However, the infant may be conditioned not to "bite" during suckling in a relatively short time if the mother persists with breast-feeding. It seems that the infant senses the mother's discomfort and learns to avoid causing it.

EPSTEIN PEARLS, BOHN NODULES, AND DENTAL LAMINA CYSTS

On rare occasions, small, white or grayish-white lesions on the alveolar mucosa of the newborn may be incorrectly diagnosed as natal teeth. The lesions are usually multiple

Dentlearn.ir

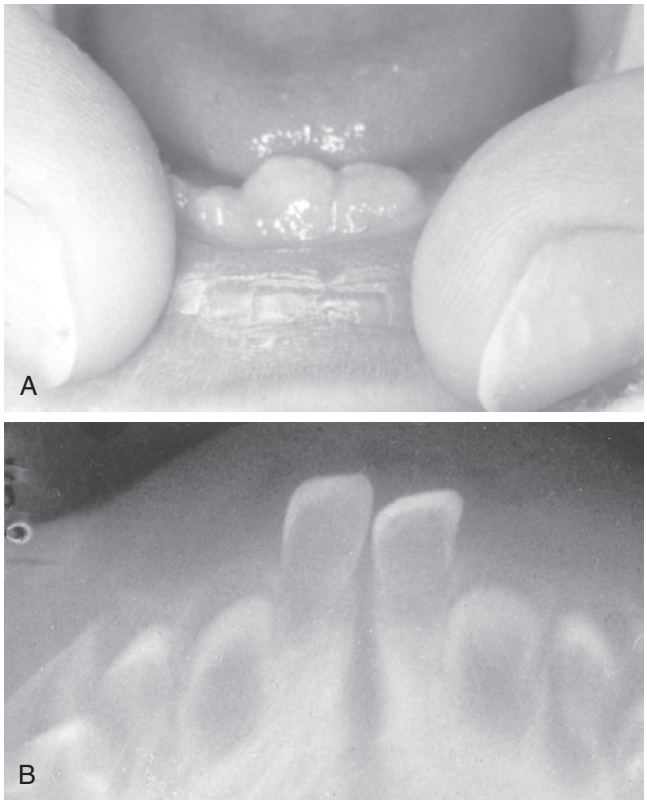

Figure 19-9 **A,** Parents of a 3-week-old infant were concerned about the elevated mass of tissue on the mandibular ridge. **B,** Radiograph revealed two primary central incisors that would soon erupt. The ungloved fingers in the photograph are those of the infant's parent.

but do not increase in size (Fig. 19-11). No treatment is indicated because the lesions are spontaneously shed a few weeks after birth.

Fromm reported that clinically visible cysts were found in 1028 of 1367 newborn infants.[32] He noted and classified the following three types of inclusion cysts:

1. Epstein pearls are formed along the midpalatine raphe. They are considered remnants of epithelial tissue trapped along the raphe as the fetus grew.
2. Bohn nodules are formed along the buccal and lingual aspects of the dental ridges and on the palate away from the raphe. The nodules are considered remnants of salivary gland tissue and are histologically different from Epstein pearls.
3. Dental lamina cysts are found on the crests of the maxillary and mandibular dental ridges. The cysts apparently originated from remnants of the dental lamina.

These findings are supported by the work of Neville and associates.[33]

LOCAL AND SYSTEMIC FACTORS THAT INFLUENCE ERUPTION

ANKYLOSED TEETH

The problem of ankylosed primary molars deserves much attention by dentists. Application of the term *submerged molar* to this condition is inaccurate, even though the tooth may appear to be submerging into the mandible or maxilla. This misconception results from the fact that the ankylosed tooth is in a state of static retention, whereas in the adjacent areas eruption and alveolar growth continue. The term *infraocclusion*, although commonly used today, is not preferable to ankylosis, in the authors' opinions.

Henderson noted that ankylosis should be considered an interruption in the rhythm of eruption and that a patient who has one or two ankylosed teeth is more likely to have other teeth become ankylosed.[34]

The mandibular primary molars are the teeth most often observed to be ankylosed (Figs. 19-12 and 19-13). In unusual cases all the primary molars may become firmly attached to the alveolar bone before their normal exfoliation time. Such a case is illustrated in this chapter (see Fig. 19-17). Ankylosis of the anterior primary teeth does not occur unless there has been a trauma.

The cause of ankylosis in the primary molar areas is unknown, but at least three theories have been proposed. The observation of ankylosis in several members of the same family lends support to the theory that it follows a familial pattern. Studies have reported that the condition occurs more frequently among siblings of children with the characteristics. The occurrence is noted to have a familial tendency and is probably a non-gender-linked trait. Investigators have observed the prevalence of ankylosis to be much lower among black children than among white children.

dren with 108 ankylosed teeth, 21 of the affected primary teeth had no permanent successors.[35] Others also reported a higher prevalence of developmentally absent premolar teeth in patients with ankylosis, suggesting that there is a relationship between the congenital absence of permanent teeth and ankylosed primary teeth. Steigman and co-workers have discounted this relationship.[36] Based on observation and a careful review of the literature, they reported that there appears to be no causal relationship between ankylosed precursors and the congenital absence of their successors.

Normal resorption of the primary molar begins on the inner or lingual surfaces of the roots. The resorption process is not continuous but is interrupted by periods of inactivity or rest. A reparative process follows periods of resorption. In the course of this reparative phase, a solid union often develops between the bone and the primary tooth. This intermittent resorption and repair may explain the various degrees of firmness of the primary teeth before their exfoliation. Extensive bony ankylosis of the primary tooth may prevent normal exfoliation and the eruption of the permanent successor.

Ankylosis of the primary molar to the alveolar bone does not usually occur until after its root resorption begins. If ankylosis occurs early, eruption of the adjacent teeth may progress enough that the ankylosed tooth is far below the normal plane of occlusion and may even be partially covered with soft tissue (Fig. 19-14). An epithelium-lined track, however, will extend from the oral cavity to

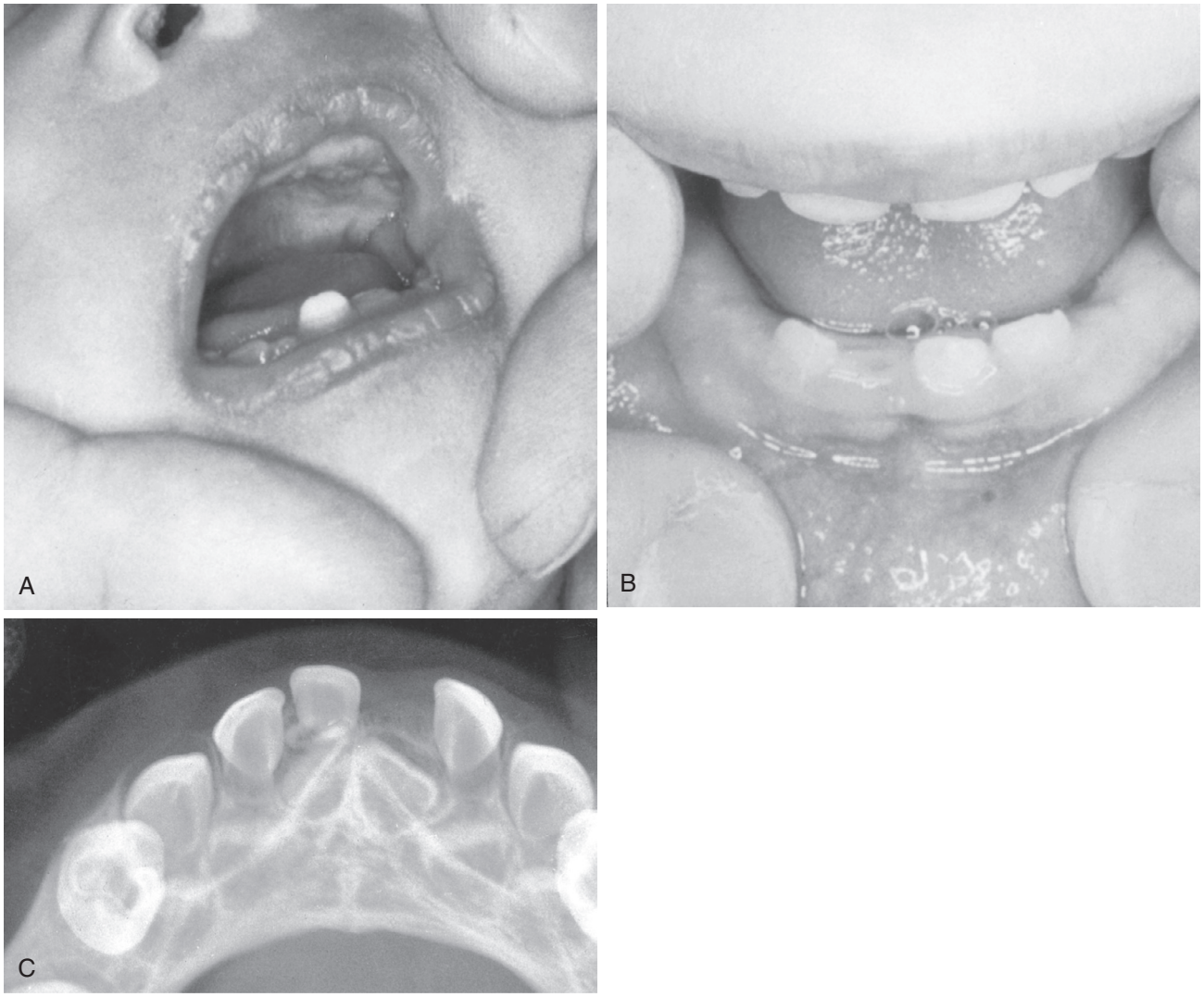

Figure 19-10 **A,** Eruption of one of the primary central incisors occurred at 4 weeks of age. The tooth was mobile because of limited root formation, but it was not extracted. **B,** One of the prematurely erupted central incisors was subsequently lost as the result of a fall, but the other was retained. **C,** Dilacerated root formation on one of the neonatal teeth. The ungloved fingers in the photographs are those of the infant's parent.

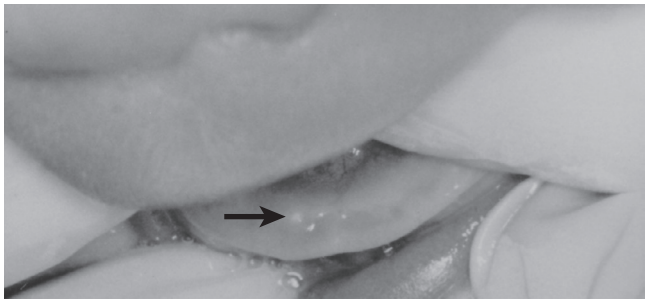

Figure 19-11 Dental lamina cyst *(arrow)*. No treatment is indicated; such lesions disappear within a few weeks after birth.

the tooth. Ankylosis may occasionally occur even before the eruption and complete root formation of the primary tooth (Fig. 19-15). Tsukamoto and Braham reported a case of apparent early ankylosis of a mandibular second primary molar that was not diagnosed until the patient was 10 years of age, at which time the succedaneous second premolar was lying malposed but occlusal to the unerupted primary molar.[37] Ankylosis can also occur late in the resorption of the primary roots and even then can interfere with the eruption of the underlying permanent tooth (Fig. 19-16).

The diagnosis of an ankylosed tooth is not difficult to make. Because eruption has not occurred and the alveolar process has not developed in normal occlusion, the opposing molars in the area seem to be out of occlusion. The ankylosed tooth is not mobile, even in cases of advanced root resorption. Ankylosis can be partially confirmed by tapping the suspected tooth and

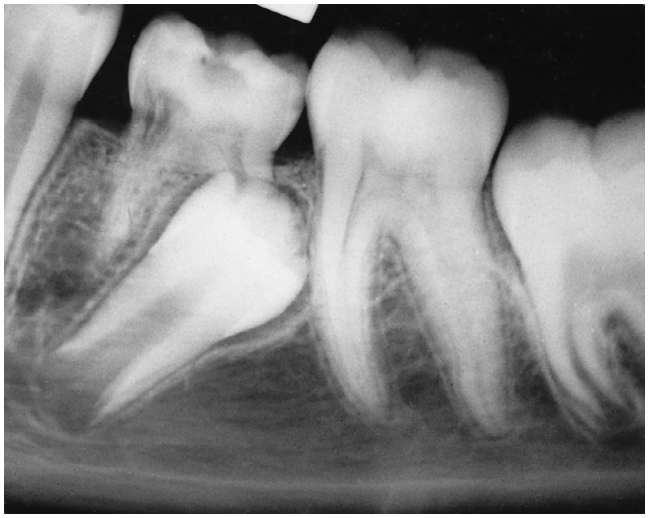

Figure 19-12 The second primary molar is ankylosed and below the normal plane of occlusion. There is evidence of root resorption and deposition of bone into the resorbed areas.

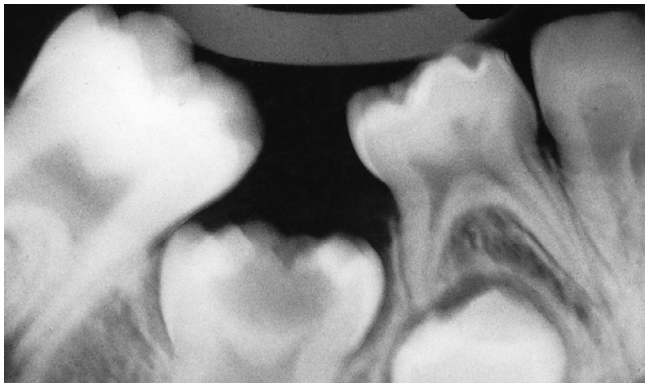

Figure 19-14 Ankylosed second primary molar with a caries lesion in the occlusal surface. This tooth probably became ankylosed soon after root resorption began.

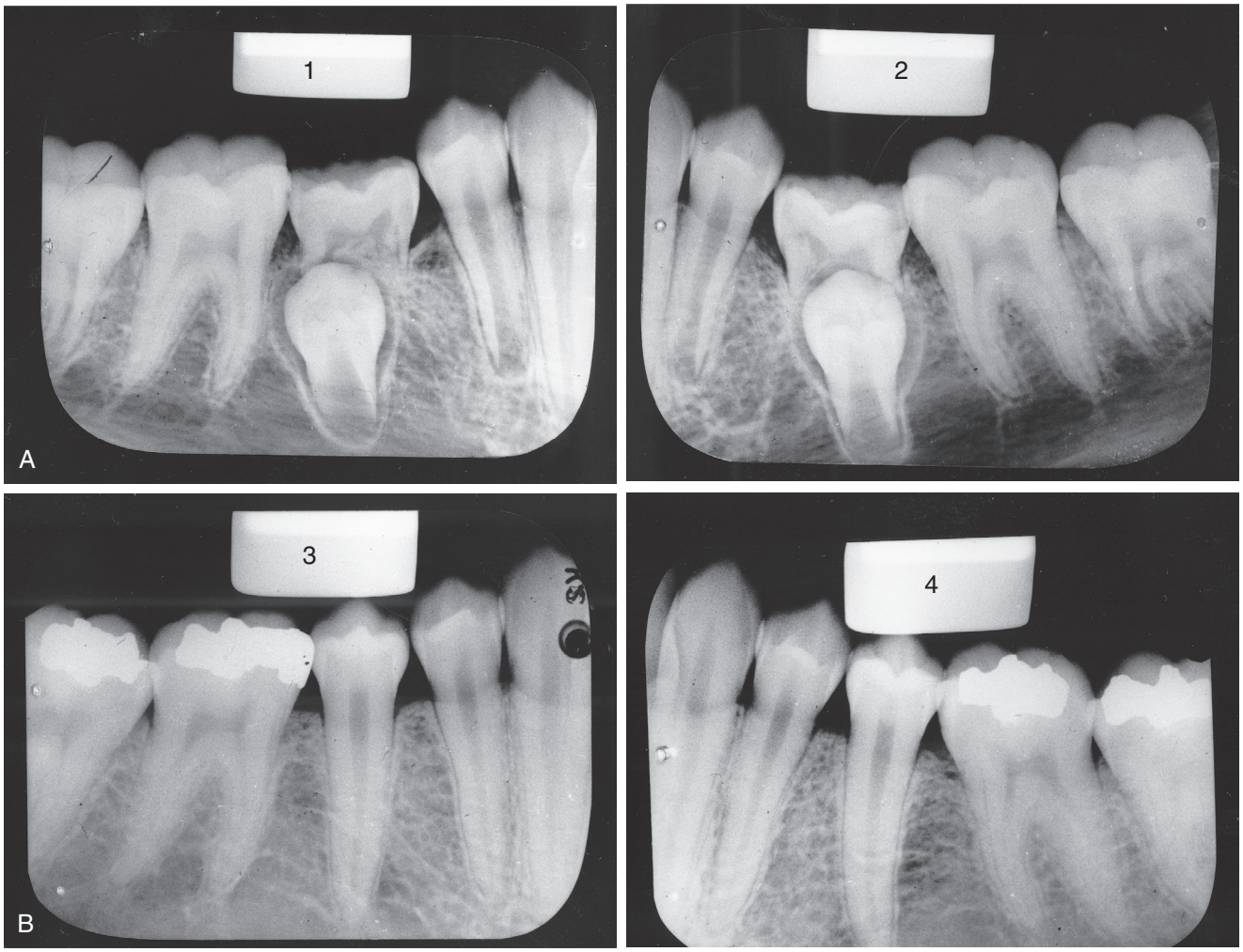

Figure 19-13 **A,** Bilateral ankylosis of second primary molars. **B,** The ankylosed molars were eventually shed, and the second premolars erupted into good occlusion. Frequently, the ankylosed teeth must be removed surgically.

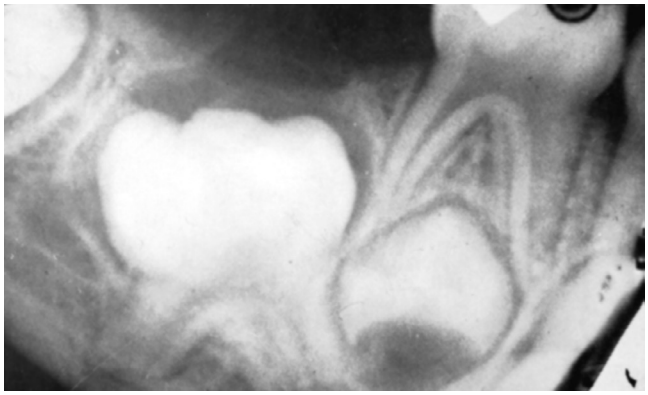

Figure 19-15 An ankylosed, deeply embedded second primary molar. Surgical removal of this tooth is indicated.

an adjacent normal tooth with a blunt instrument and comparing the sounds. The ankylosed tooth will have a solid sound, whereas the normal tooth will have a cushioned sound because it has an intact periodontal membrane that absorbs some of the shock of the blow.

The radiograph is often a valuable diagnostic aid. A break in the continuity of the periodontal membrane, indicating an area of ankylosis, is often evident radiographically.

In the management of an ankylosed tooth, early recognition and diagnosis are extremely important. The eventual treatment may involve surgical removal (Fig. 19-17). However, unless a caries problem is unusual or loss of arch length is evident, the dentist may choose to keep the tooth under observation. A tooth that is definitely ankylosed may at some future time undergo root resorption and be normally exfoliated. When patient cooperation is good and recall periods are regular, a watchful waiting approach is best.

Belanger and colleagues reported a case in which early ankylosis of even a mandibular second primary molar spontaneously resolved.[38] The tooth was discovered to be unerupted in an otherwise complete primary dentition in occlusion at 3 years of age. The tooth remained in its ankylosed condition until the adjacent first permanent molar began erupting through the gingival tissue. By 6 years 9 months of age, the primary molar had erupted into functional occlusion, and a normal-appearing periodontal ligament space could be seen radiographically even though no space was previously apparent in the furcation. Tieu and others present an excellent systematic review of the management of ankylosed primary molars with premolar successors.[39]

ANKYLOSIS OF PRIMARY MOLARS WITH ABSENCE OF PERMANENT SUCCESSORS

Kurol and Thilander emphasize the importance of the presence of a permanent successor for normal exfoliation of a primary molar. In their longitudinal study, no ankylosed primary molars without permanent successors were found to exfoliate spontaneously. However, very slow root resorption was observed for most of the ankylosed teeth.[40]

Messer and Cline observed that failure to carry out timed extraction of severely infraoccluded molars results in reduced alveolar bone support for the premolars.[41] However, Kurol and Olson suggest that infraocclusions

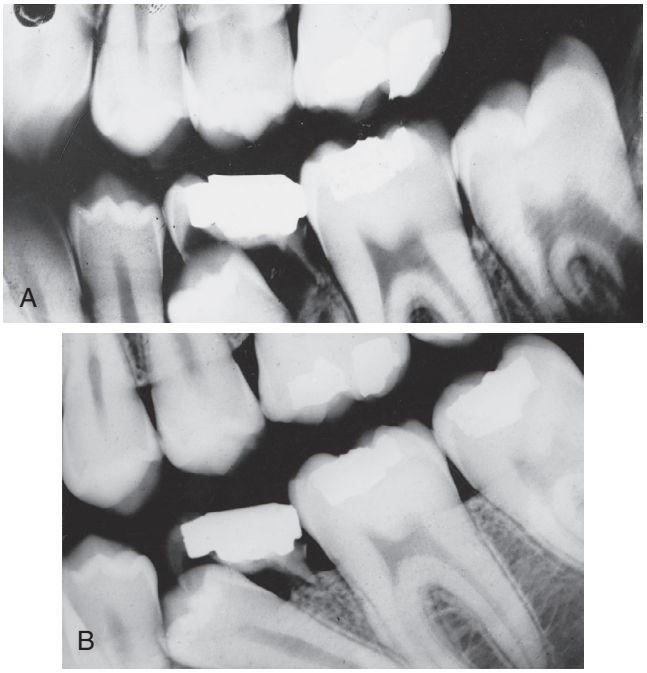

Figure 19-16 **A,** A small spicule of root of the primary tooth is ankylosed to the alveolar bone. This was overlooked at the time of the routine examination. **B,** One year later, the second primary molar is still retained, and the second premolar has moved into a more unfavorable position.

and ankylosis of primary molars do not constitute a general risk for future alveolar bone loss mesial to the first permanent molars.[42] In their study of 119 infraoccluded primary molars next to permanent first molars, all but two of the first permanent molars showed a normal alveolar bone level mesially. Therefore the general treatment recommendation to await normal exfoliation and eruption of successors remains valid in their opinion. They suggest that, in patients in whom there is an abnormality associated with a succedaneous tooth (e.g., agenesis, ectopic eruption), early intervention is most likely required. In situations in which permanent successors of ankylosed primary molars are missing, attempts have been made to establish functional occlusion using stainless steel crowns, overlays, or bonded composite resins on the affected primary molars. Currently, bonded restorations would be the preferred choice. This treatment is successful only if maximum eruption of permanent teeth in the arch has occurred. If the adjacent teeth are still in a state of active eruption, they will soon bypass the ankylosed tooth (Fig. 19-18).

ANKYLOSED PERMANENT TEETH

The incomplete eruption of a permanent molar may be related to a small area of root ankylosis. The removal of soft tissue and bone covering the occlusal aspect of the crown should be attempted first, and the area should be packed with surgical cement to provide a pathway for the developing permanent tooth (Fig. 19-19). If the permanent tooth is exposed in the oral cavity and at a lower occlusal plane than the adjacent teeth, ankylosis is the probable cause. Both Biederman and Skolnick have

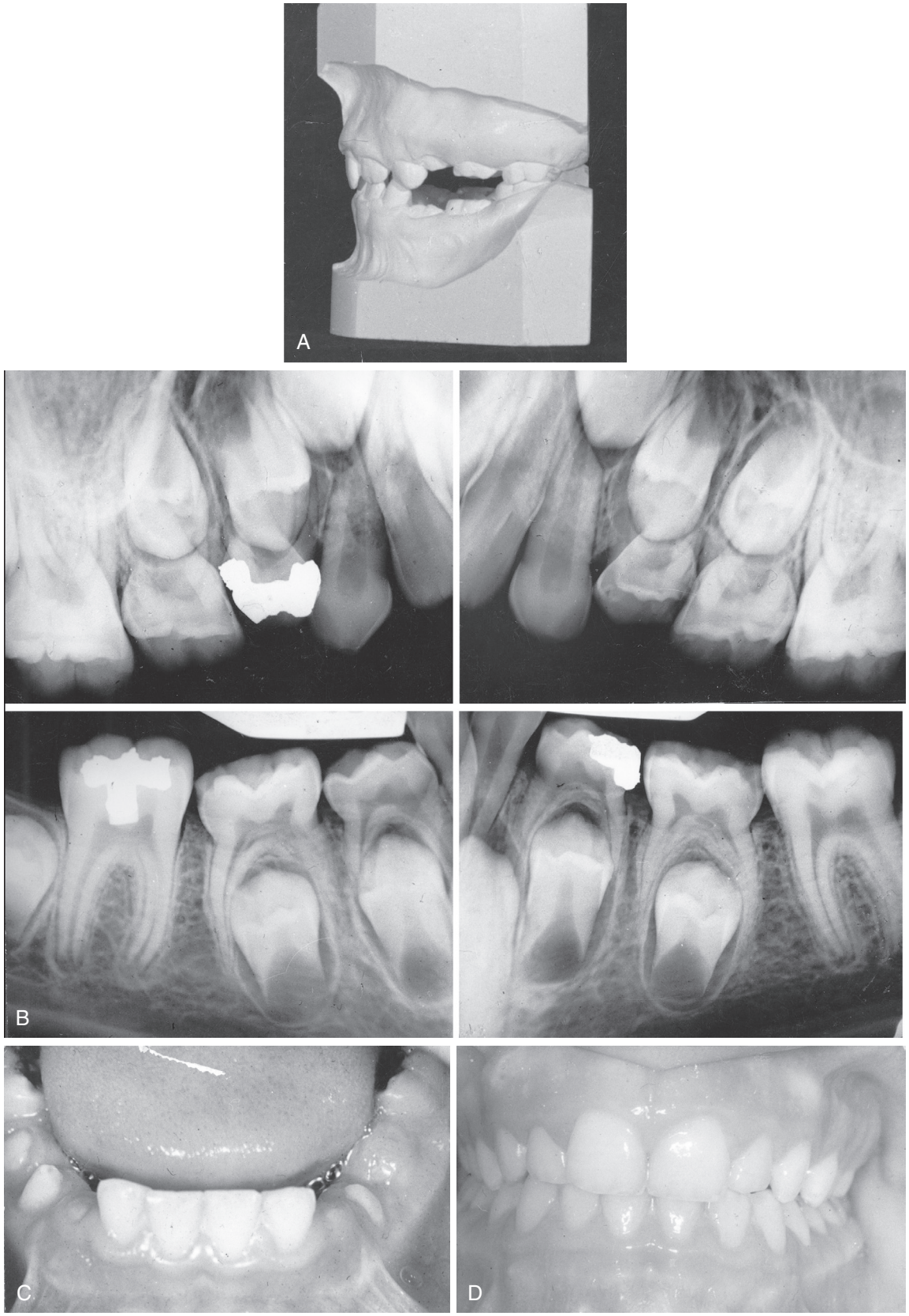

Figure 19-17 **A,** All eight of the primary molars were ankylosed. Continuing eruption of the adjacent teeth has caused a loss of arch length. **B,** Radiographs aided in the diagnosis of the ankylosed primary molars. The recommended treatment was surgical removal of the ankylosed teeth. **C,** Space maintainers were constructed after removal of the ankylosed teeth and were worn until the permanent teeth erupted. **D,** Ideal occlusion was achieved as a result of early diagnosis and the removal of the ankylosed teeth at the proper time.

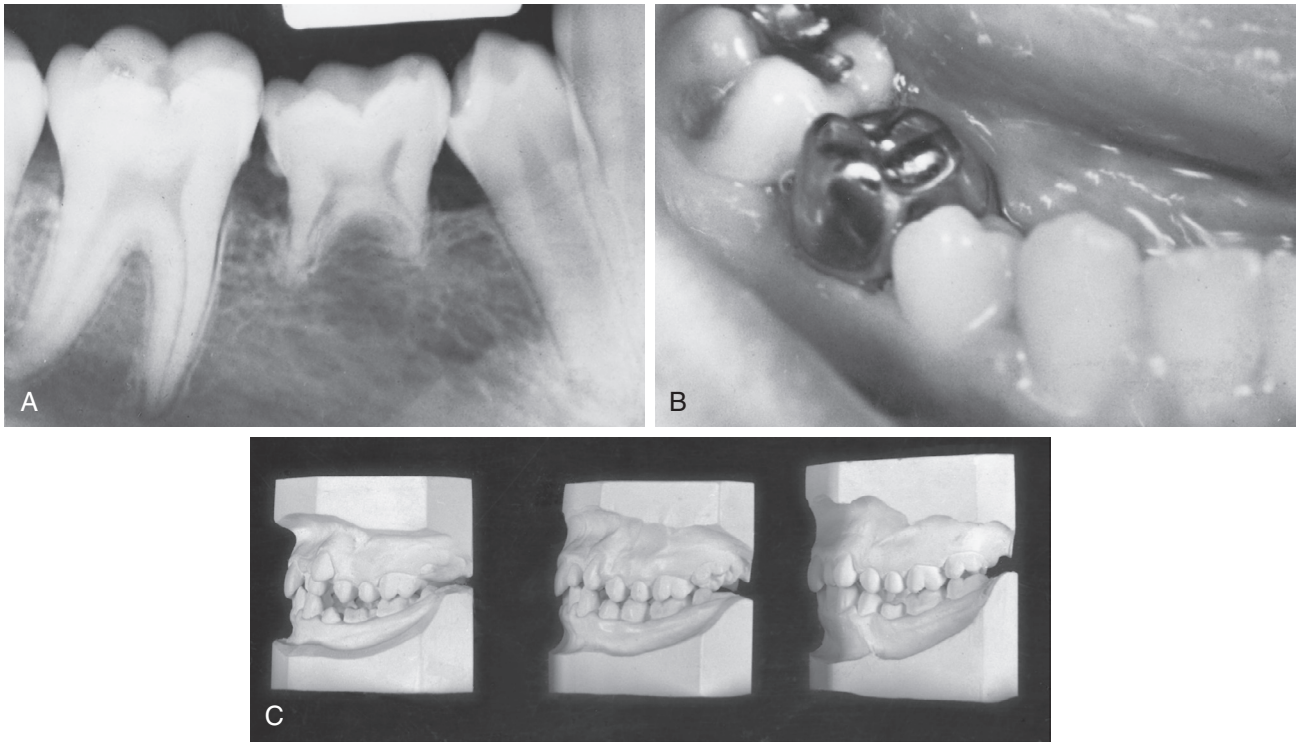

Figure 19-18 **A,** Ankylosed primary molar without a permanent successor. **B,** Mesiodistal width of the primary molar was reduced to allow the premolar to erupt, and an overlay was constructed to establish occlusion with the opposing teeth. **C,** Models at the left show the original condition. Center models show the occlusion at the time the overlay was placed on the ankylosed tooth. Models at the right show the continued eruption of the adjacent teeth that occurred in the subsequent 18-month period.

described a luxation technique effective in breaking the bony ankylosis.[43,44] If the rocking technique is not immediately successful, it should be repeated in 6 months. A delay in treatment may result in a permanently ankylosed molar (Fig. 19-20).

Unerupted permanent teeth may become ankylosed by inostosis of enamel. According to Franklin, the process follows the irritation of the follicular or periodontal tissue resulting from chronic infection.[45] The close association of an infected apex with an unerupted tooth may give rise to the process. In the unerupted tooth, enamel is protected by enamel epithelium. The enamel epithelium may disintegrate as a result of infection (or trauma), the enamel may subsequently be resorbed, and bone or coronal cementum may be deposited in its place. The result is solid fixation of the tooth in its unerupted position (Fig. 19-21).

TRISOMY 21 SYNDROME (DOWN SYNDROME)

Trisomy 21 syndrome (Down syndrome [DS])—that is, the presence of three number 21 chromosomes rather than the normal two (diploid)—is one of the congenital anomalies in which delayed eruption of the teeth frequently occurs. The first primary teeth may not appear until 2 years of age, and the dentition may not be complete until 5 years of age. The eruption often follows an abnormal sequence, and some of the primary teeth may be retained until 15 years of age. In a study of 127 males and 128 females with DS, Ondarza and colleagues found that, on average, six primary teeth were delayed in eruption in boys and 11 primary teeth were delayed in girls.[46] A similar study conducted by Jara and colleagues in 116 males and 124 females with DS showed delayed eruption of 13 permanent teeth in boys and eight permanent teeth in girls.[47] These studies seem to confirm that delayed tooth eruption is common but sporadic in children with DS.

Earlier literature refers to DS as *mongolism*, but the use of this term is inappropriate, and it may be insulting to the affected families. DS occurs very early in embryonic development, possibly during the first cell divisions. Anomalies of the eye and external ear are seen, and congenital heart defects are often present. The occurrence of DS is frequently related to maternal age. Various sources report the frequency of DS to be approximately 0.9 per 1000 births when the mother is less than 33 years of age, 2.8 per 1000 when the mother is 35 to 38 years old, and 38 per 1000 when the mother is 44 years or older, with certain populations reporting a high of 91 per 1000 in

The diagnosis of DS in a child is not usually difficult to make because of the characteristic facial pattern (Fig. 19-22). The orbits are small, the eyes slope upward, and the bridge of the nose is more depressed than normal. In a study of 194 children with DS, Cohen reported that 54% demonstrated anomalies in the formation of the external ear, characterized by outstanding "lap" ear with flat or absent helix.[48] Mental retardation is another characteristic finding, with most children in the mild to moderate range of disability (see Table 16-2).

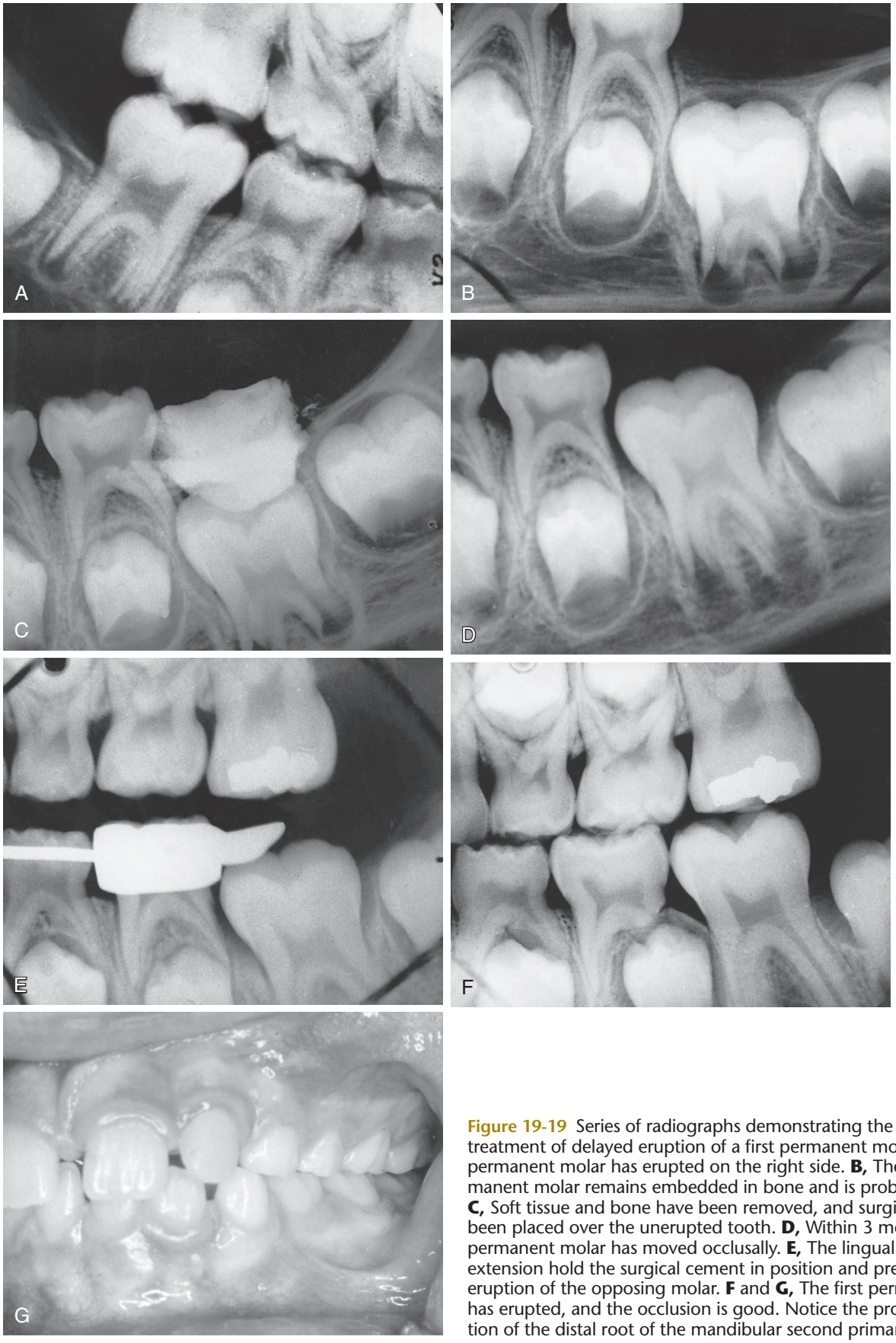

Figure 19-19 Series of radiographs demonstrating the successful treatment of delayed eruption of a first permanent molar. **A,** The first permanent molar has erupted on the right side. **B,** The left first permanent molar remains embedded in bone and is probably ankylosed. **C,** Soft tissue and bone have been removed, and surgical cement has been placed over the unerupted tooth. **D,** Within 3 months, the first permanent molar has moved occlusally. **E,** The lingual arch and distal extension hold the surgical cement in position and prevent continued eruption of the opposing molar. **F** and **G,** The first permanent molar has erupted, and the occlusion is good. Notice the progressive resorption of the distal root of the mandibular second primary molar.



Figure 19-20 Ankylosed first permanent molar.

Landau made a cephalometric comparison of children with DS and their normal siblings.[49] Retardation in the growth of the maxillae and mandible was evident in those with DS. Both the maxillae and mandible were positioned anteriorly under the cranial base. The upper facial height was found to be significantly smaller. The midface was also found to be small in the vertical and horizontal dimensions. The smaller jaws contribute to a tendency for protrusion of the tongue and dental crowding, both of which may compromise the development of good occlusion. The tongue also tends to be larger than normal.

Many children with DS have chronic inflammation of the conjunctiva and a history of repeated respiratory tract infections. The use of antibiotics has reduced the incidence of chronic infection and has resulted in fewer deaths from infection.

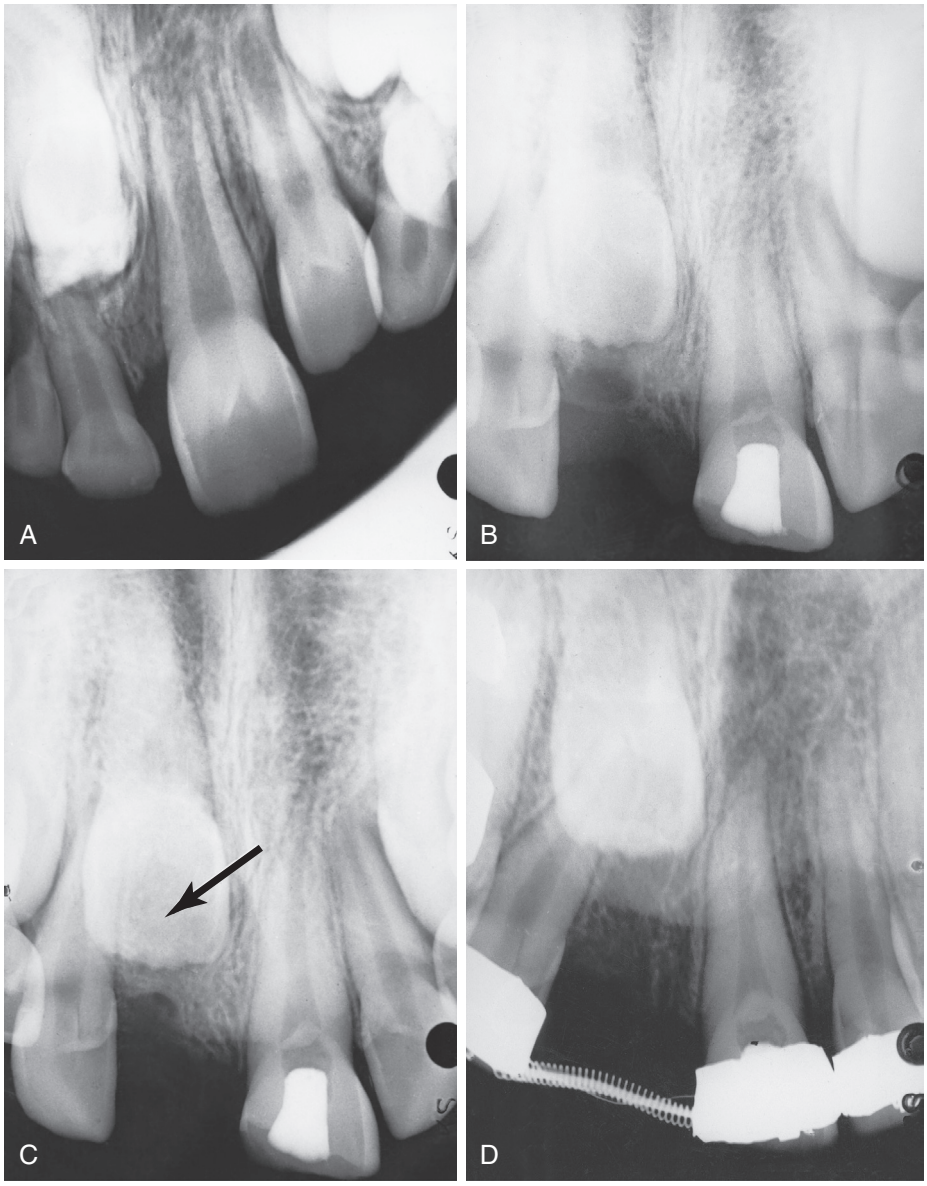

Figure 19-21 Ankylosis by inostosis. **A,** A mesiodens has delayed the eruption of the maxillary right permanent central incisor. **B,** The primary incisors and the mesiodens were removed. During the surgical removal of the mesiodens, there was apparently damage to the enamel epithelium. **C,** There is evidence of resorption of the enamel of the unerupted incisor and ankylosis of the tooth. **D,** The left central incisor crown sustained a fracture and pulp exposure. A calcium hydroxide pulpotomy was successfully performed, which resulted in continued root development.

After a literature review, Cichon and colleagues concluded that individuals with DS have a higher prevalence of periodontal disease than otherwise normal, age-matched and of similar age distribution.[50] Furthermore, the reports of exaggerated immunoinflammatory responses of the tissues in patients with DS cannot be explained by poor oral hygiene alone and may be the result of impaired cell-mediated and humoral immunities and deficient phagocytic systems. Cichon and colleagues' study of 10 patients with DS and aged 20 to 31 years demonstrated that young age of onset, severe destruction, and pathogenesis of disease in the periodontal tissues were consistent with a juvenile periodontitis disease pattern.

conducted gingival health assessments of 75 individuals with DS and aged 2 to 18 years.[51] The extent of gingival inflammation and the antibody titers of the individuals with DS suggested that colonization of certain pathogenic organisms for periodontal disease had occurred before 5 years of age. The prevalence and extent of gingivitis were significantly higher than in normal children. The antibody titers also suggested that colonization of additional pathogenic organisms increased with age. The authors believe that there are abnormalities in the systemic defenses that are responsible for the early onset of disease in the individuals with DS. Similarly, Carlstedt and colleagues have demonstrated significantly higher oral colonization with *Candida albicans* in children with DS compared with that abnormalities of the immune response in children with DS are responsible for their greater susceptibility to oral mucosal disease.

Dental caries susceptibility is usually low in those with DS. This finding has been reported by Lee and associates, who noted a much lower dental caries incidence in both the primary and the permanent dentitions.[53] Shapira and Stabholz successfully demonstrated caries reduction and improved periodontal health during a 30-month period after initiating a comprehensive preventive oral health program for 20 children with DS.[54]

Seagriff-Curtin and associates believe that although some children with low cognitive ability are unmanageable for dental procedures, most are pleasant, cheerful, affectionate, and well behaved.[55] They can often be managed in the dental office in a conventional manner. The possibility of reduced resistance to infection should be considered in the dental management of the child with DS.



Figure 19-22 Child with Down syndrome, at 1 and 5 years of age.

CLEIDOCRANIAL DYSPLASIA

A rare congenital syndrome that has dental significance is cleidocranial dysplasia (CCD), which has also been referred to as *cleidocranial dysostosis, osteodentin dysplasia, mutational dysostosis,* and *Marie-Sainton syndrome*. Transmission of the condition is by either parent to a child of either gender, so that the disorder thus follows a true Mendelian dominant pattern. CCD can also occur sporadically with no apparent hereditary influence and with no predilection for race. The diagnosis is based on the finding of an absence of clavicles, although there may be remnants of the clavicles, as evidenced by the presence of the sternal and acromial ends. The fontanels are large, and radiographs of the head show open sutures, even late in the child's life. The sinuses, particularly the frontal sinus, are usually small.

Richardson and Deussen performed cephalometric analyses of 17 patients with CCD.[56] They found that, on average, the patients exhibited mandibular prognathism caused by increased mandibular lengths and short cranial bases. The maxillae tended to be short vertically but not anteroposteriorly. Somewhat similar findings have been reported by Jensen and Kreiborg in their study of 22 children with CCD.[57]

The development of the dentition is delayed. Complete primary dentition at 15 years of age, resulting from delayed resorption of the deciduous teeth and delayed eruption of the permanent teeth, is not uncommon (Fig. 19-23).

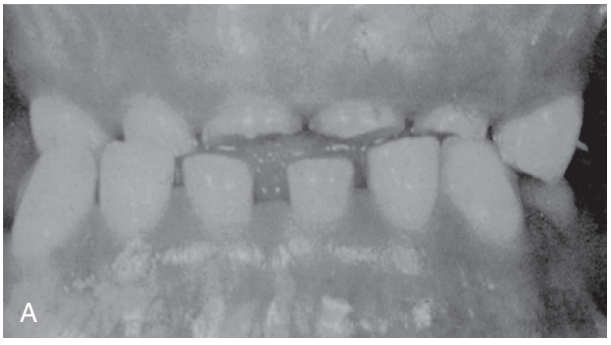

Figure 19-23 Cleidocranial dysplasia. **A,** A Primary dentition is still present at 15 years of age.

Continued

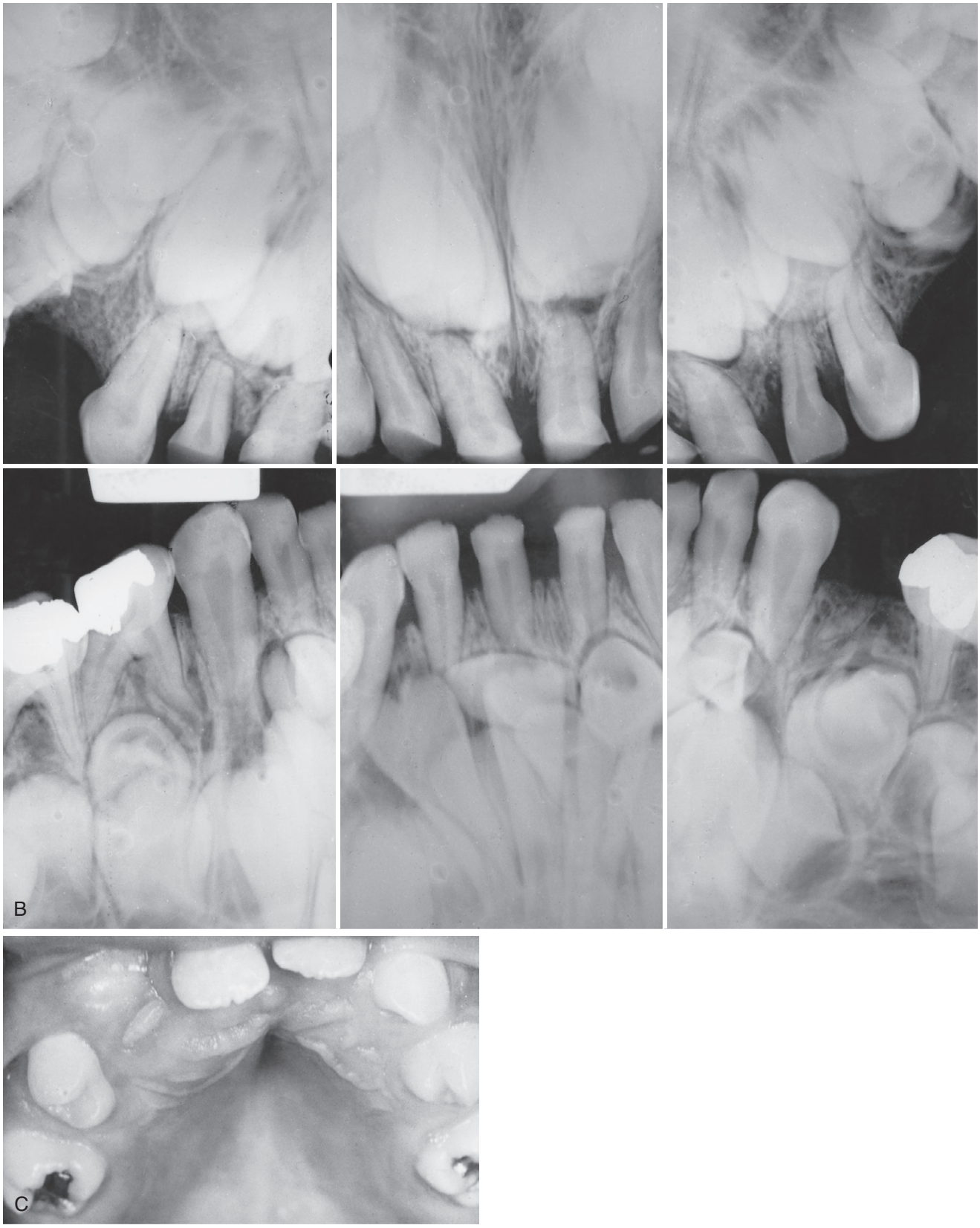

Figure 19-23 cont'd **B,** Delayed dentition and the presence of many supernumerary teeth. **C,** Removal of supernumerary teeth in the maxillary arch caused irregular and delayed eruption of some of the permanent teeth.

Dentlearn.ir

One of the important distinguishing characteristics is the presence of supernumerary teeth. Some children may have only a few supernumerary teeth in the anterior region of the mouth; others may have a large number of extra teeth throughout the mouth. Even with removal of the primary and supernumerary teeth, eruption of the permanent dentition, without orthodontic intervention, is often delayed and irregular. Other reports by Jensen and Kreiborg, based on their experiences and longitudinal study of 19 patients with CCD, provide information to help clinicians predict the location and time of onset of formation of supernumerary teeth. This information should help the clinician develop an optimal surgical treatment plan.[58,59]

Hutton and colleagues have reported the successful dental management of a patient with CCD over a 15-year period.[60] The patient was first seen at 2 years of age. Treatment consisted of timed extractions of primary and supernumerary teeth and conservative uncovering of the permanent teeth. The surgical procedures were planned according to progressive radiographic evidence of the development of the permanent teeth. This management results in a nearly normal but slightly delayed eruption sequence. Orthodontic treatment was begun at 14 years of age, and by 16 years of age the patient displayed acceptable occlusion and normal vertical dimension, root development, and periodontal bone support.

Learning from their experiences with the long-term management of 16 patients with CCD, Becker and colleagues advocate cooperative efforts by clinicians from the disciplines of pediatric dentistry, oral and maxillofacial surgery, and orthodontics and dentofacial orthopedics.[61] The pediatric dentist serves as the coordinator of overall oral health care and disease prevention during an extended treatment regimen that usually includes two surgical interventions and three stages of orthodontic surgery.

Delayed eruption has also been reported in other forms of osteopetroses.

HYPOTHYROIDISM

Hypothyroidism is another possible cause of delayed eruption. Patients in whom the function of the thyroid gland is extremely deficient have characteristic dental findings.

Congenital Hypothyroidism (Cretinism)

Hypothyroidism occurring at birth and during the period of most rapid growth, if undetected and untreated, causes mental deficiency and dwarfism. In earlier medical and dental literature, this condition was referred to as *cretinism*. Congenital hypothyroidism is the result of an absence or underdevelopment of the thyroid gland and insufficient levels of thyroid hormone (Fig. 19-24). Today it is routinely diagnosed and corrected at birth because of mandatory blood screening of newborn infants. An inadequately treated child with congenital hypothyroidism is a small and disproportionate person, with abnormally short arms and legs. The head is disproportionately large, although the trunk shows less deviation from the norm. Obesity is common.

Without adequate hormonal therapy, the dentition of the child with congenital hypothyroidism is delayed in all stages, including eruption of the primary teeth, exfoliation of the primary teeth, and eruption of the permanent teeth. The teeth are normal in size but are crowded in jaws that are smaller than normal. The tongue is large and may protrude from the mouth. The abnormal size of the tongue and its position often cause an anterior open bite and flaring of the anterior teeth. Tooth crowding, malocclusion, and mouth breathing cause a chronic hyperplastic type of gingivitis.

Although untreated congenital hypothyroidism is rare, even in developing countries, Loevy and colleagues published a case report documenting the condition discovered in a 19-year-old boy.[62] The patient presented with a complete caries-free primary dentition and partially erupted maxillary first permanent molars. All primary teeth showed some abrasion. At a subsequent oral examination 1 year and 9 months after appropriate l-thyroxine therapy was initiated, several primary teeth had exfoliated, permanent incisors and first molars had erupted, and radiographs showed additional development of other permanent teeth.

Juvenile Hypothyroidism (Acquired Hypothyroidism)

Juvenile hypothyroidism results from a malfunction of the thyroid gland, usually between 6 and 12 years of age. Because the deficiency occurs after the period of rapid growth, the unusual facial and body patterns characteristic of a person with congenital hypothyroidism are not present. However, obesity is evident to a lesser degree. In untreated juvenile hypothyroidism, delayed exfoliation of the primary teeth and delayed eruption of the permanent teeth are characteristic. A child with a chronologic age of 14 years may have a dentition in a stage of development comparable with that of a child 9 or 10 years of age (Fig. 19-25).

HYPOPITUITARISM

A pronounced deceleration of the growth of the bones and soft tissues of the body will result from a deficiency in secretion of the growth hormone. Pituitary dwarfism is the result of an early hypofunction of the pituitary gland. Again, early diagnosis is routine because of the mandatory blood screening of newborn infants for congenital hypothyroidism.

An individual with pituitary dwarfism is well proportioned but resembles a child of considerably younger chronologic age (Fig. 19-26). The dentition is essentially normal in size.

Delayed eruption of the dentition is characteristic. In severe cases the primary teeth do not undergo resorption but instead may be retained throughout the life of the person. The underlying permanent teeth continue to develop but do not erupt. Extraction of the deciduous teeth is not indicated because eruption of the permanent teeth cannot be ensured. Some degree of cognitive disability often occurs.

Dentlearn.ir



Figure 19-24 **A,** Greatly delayed dentition of a 24-year-old patient with congenital hypothyroidism. **B,** With the administration of thyroxine, the eruption of the permanent teeth was accelerated. (Courtesy Dr. David F. Mitchell.)

ACHONDROPLASTIC DWARFISM

Achondroplastic dwarfism, also diagnosed at birth, demonstrates a few characteristic dental findings. Growth of the extremities is limited because of a lack of calcification in the cartilage of the long bones. Stature improvements have been reported with surgical lengthening of the limbs and also with growth hormone therapy. The head is disproportionately large, although the trunk is normal in size. The fingers may be of almost equal length, and the hands are plump. The fontanels are open at birth. The upper face is underdeveloped, and the bridge of the nose is depressed.

Although the etiology of achondroplastic dwarfism is unknown, it is clearly an autosomal-dominant disorder, although sporadic spontaneous mutations occur. There is some evidence that the condition is more likely to occur when the ages of the parents differ significantly. In contrast to DS, the increased age of the father may be related to the occurrence of the condition.

Deficient growth in the cranial base is evident in many individuals with achondroplastic dwarfism. The maxilla may be small, with resultant crowding of the teeth and a tendency for open bite. Chronic gingivitis is usually present. However, this condition may be related to the malocclusion and crowding of the teeth. In the patient shown in Figure 19-27, the development of the dentition was slightly delayed.

OTHER CAUSES

Delayed eruption of the teeth has been linked to other disorders, including fibromatosis gingivae (see Chapter 14),



Figure 19-25 **A,** A 14-year-old girl with juvenile hypothyroidism. **B,** The occlusion was essentialy normal but was delayed in its development. **C,** Delayed development of the teeth in juvenile hypothyroidism. The maxillary midline supernumerary tooth is a coincidental finding.

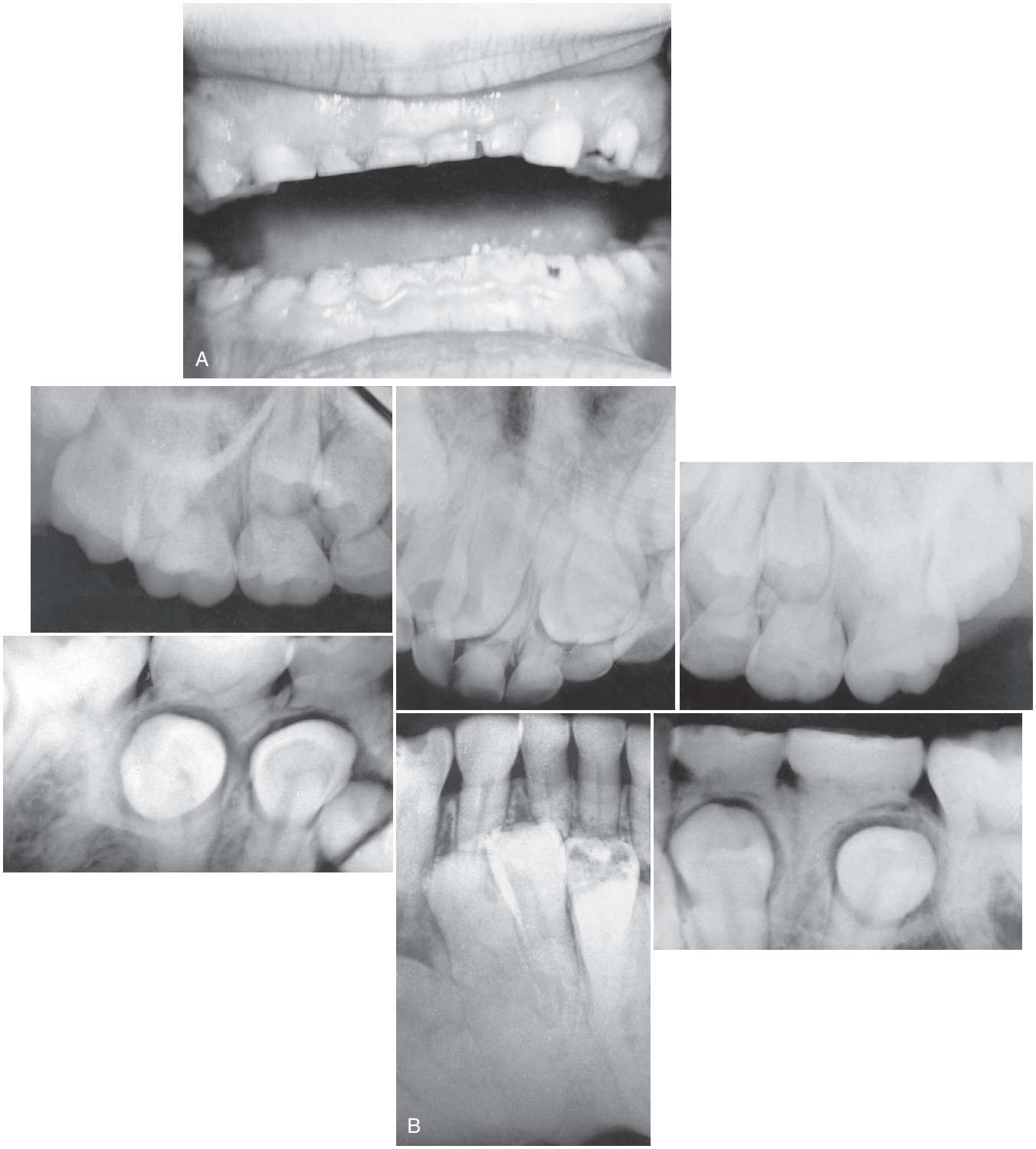

Figure 19-26 A 28-year-old woman diagnosed as having hypopituitary dwarfism. **A,** Complete primary dentition at 28 years of age. The first permanent molars have erupted. **B,** The roots of the primary teeth have not been resorbed to an appreciable degree, although some permanent teeth show complete development.

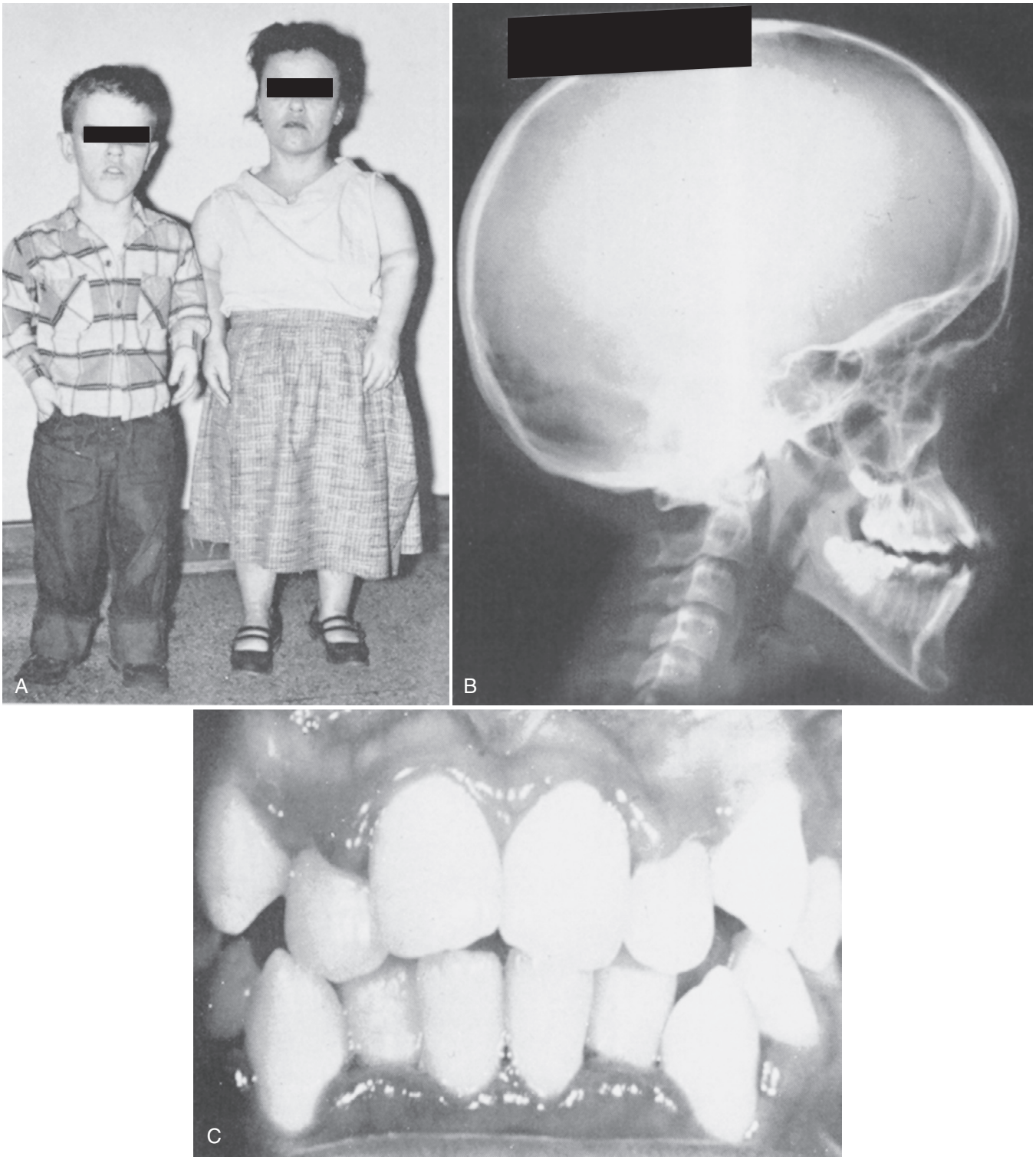

Figure 19-27 **A,** A 14-year-old boy with achondroplastic dwarfism and his mother. Growth of the extremities is limited in both. **B,** The upper face is greatly underdeveloped. **C,** The arch length is inadequate, and the teeth are crowded. (**A** and **B,** courtesy Dr. Ralph E. McDonald. **C,** from Shafer W, Hine MK, Levy BM: *A textbook of oral pathology,* Philadelphia, 1958, WB Saunders.)

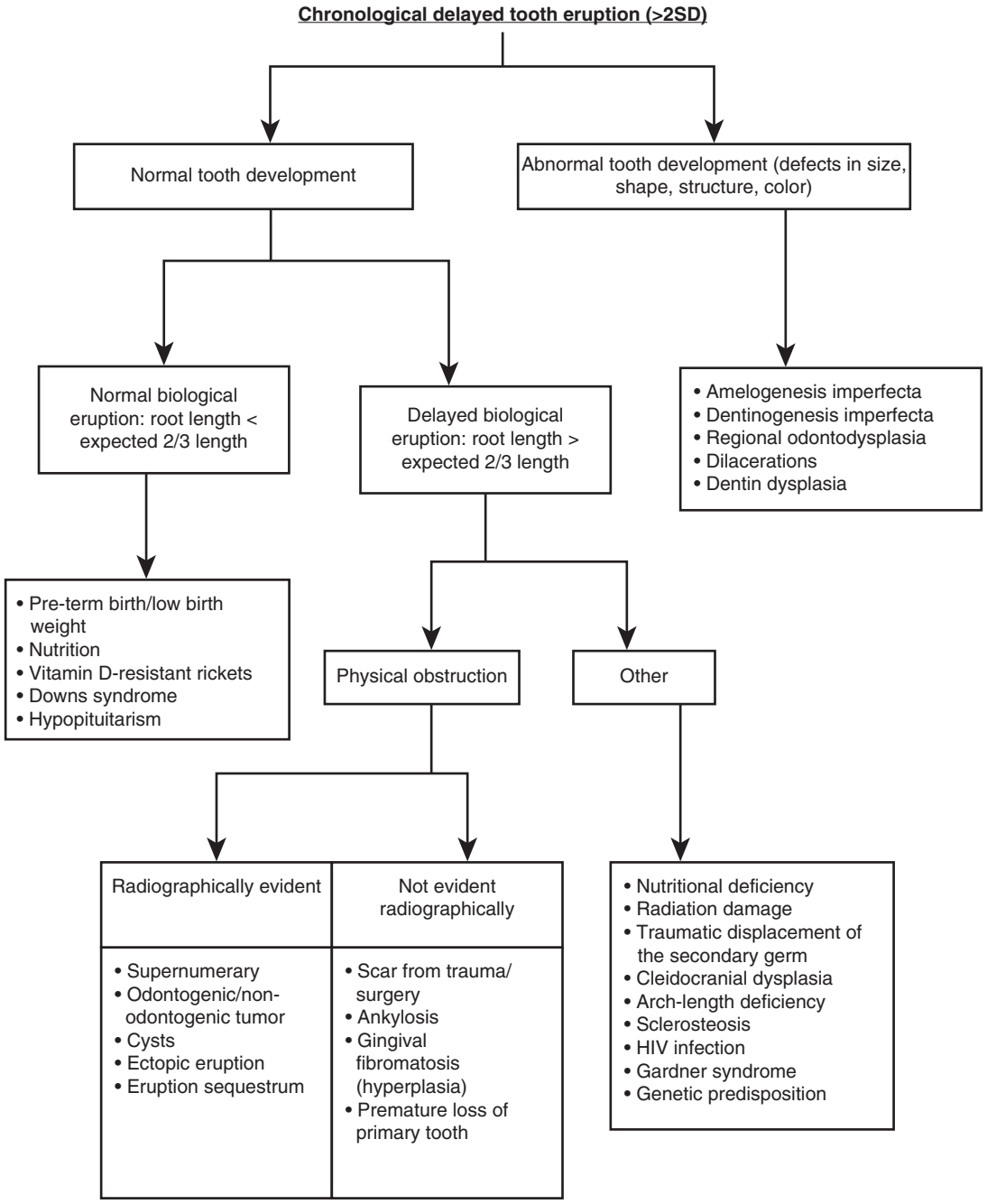

Figure 19-28 Diagnostic algorithm of delayed tooth eruption. (From Suri L, Gagari E, Vastardis H: Delayed tooth eruption: pathogenesis, diagnosis, and treatment. A literature review, *Am J Orthod Dentofacial Orthop* 126:435, 2004.)

Albright hereditary osteodystrophy, chondroectodermal dysplasia (Ellis-van Creveld syndrome), de Lange syndrome, frontometaphyseal dysplasia, Gardner syndrome, Goltz syndrome, Hunter syndrome, incontinentia pigmenti syndrome (Bloch-Sulzberger syndrome), Maroteaux-Lamy mucopolysaccharidosis, Miller-Dieker syndrome, progeria syndrome (Hutchinson-Gilford syndrome), and familial hypophosphatemia.

Of additional interest is the effect of bisphosphonate therapy on children with osteogenesis imperfecta. Bisphosphonates inhibit the ability of osteoclasts to resorb bone. Indeed, one study demonstrated that children with osteogenesis imperfecta treated with bisphosphonates had an associated mean delay of 1.67 years in tooth eruption.[63] Finally, a well-laid-out diagnostic algorithm for delayed tooth eruption is shown in Figure 19-28.

REFERENCES

1. Logan WHG, Kronfeld R: Development of the human jaws and the surrounding structures from birth to the age of 15 years, *J Am Dent Assoc* 20:379–427, 1933.
2. Hernandez M, Espasa E, Boj JR: Eruption chronology of the permanent dentition in Spanish children, *J Clin Pediatr Dent* 32:347–350, 2008.

3. Hu X, et al.: Precise chronology of differentiation of developing human primary dentition, *Histochem Cell Biol* 141: 221–227, 2014.
4. American Academy of Pediatric Dentistry Reference Manual 35:362, 2013/14.
5. Parner E, et al.: A longitudinal study of time trends in the eruption of permanent teeth in Danish children, *Arch Oral Biol* 46:425–431, 2001.
6. Cahill DR, Marks SC: Tooth eruption: evidence for the central role of the dental follicle, *J Oral Pathol* 9:189–200, 1980.
7. Marks SC, Cahill DR: Experimental study in the dog of the non-active role of the tooth in the eruptive process, *Arch Oral Biol* 29:311–322, 1984.
8. Demirjian A, Levesque GY: Sexual differences in dental development and prediction of emergence, *J Dent Res* 59:1110–1122, 1980.
9. Wise GE, et al.: Cellular, molecular, and genetic determinants of tooth eruption, *Crit Rev Oral Biol Med* 12(4): 323–335, 2002.
10. Marks SC, Schroeder HE: Tooth eruption: theories and facts, *Anat Rec* 245:373–374, 1996.
11. Posen AL: The effect of premature loss of deciduous molars on premolar eruption, *Angle Orthod* 35:249–252, 1965.
12. Hartsfield J: Premature exfoliation of teeth in childhood and adolescence, *Adv Pediatr* 41:453–470, 1994.
13. Carlos JP, Gittelsohn AM: Longitudinal studies of the natural history of caries. I. Eruption patterns of the permanent teeth, *J Dent Res* 44:509–516, 1965.
14. Moyers RE: *Handbook of orthodontics*, ed 4, Chicago, 1988, Mosby.
15. Suri L, et al.: Delayed tooth eruption: pathogenesis, diagnosis, and treatment. A literature review, *Am J Orthod Dentofacial Orthop* 126:432–445, 2004.
16. Gellin ME: Indications and contraindications for the removal of primary teeth, *Dent Clin North Am* 13:899–911, 1969.
17. Gellin ME, Haley JV: Managing cases of overretention of mandibular primary incisors where their permanent successors erupt lingually, *J Dent Child* 49:118–122, 1982.
18. Aminabadi NA, et al.: Lingual eruption of mandibular permanent incisors: a space correlated phenomenon, *J Contemp Dent Pract* 10(1):25–32, 2009.
19. Illingworth RS: Teething, *Dev Med Child Neurol* 11:376–377, 1969.
20 Tasanen A: General and local effects of the eruption of deciduous teeth, *Ann Paediatr Fenn* 14(Suppl 29):1–40, 1968.
21. Jaber L, Cohen IJ, Mor A: Fever associated with teething, *Arch Dis Child* 67:233–234, 1992.
22. Macknin M, et al.: Symptoms associated with infant teething: a prospective study, *Pediatrics* 105(4):747–752, 2000.
23. Swann IL: Teething complications: a persisting misconception, *Postgrad Med J* 55:24–25, 1979.
24. Starkey PE, Shafer WG: Eruption sequestra in children, *J Dent Child* 30:84–86, 1963.
25. de Queiroz AM, et al.: Eruption sequestrum – case report and histopathological findings, *Braz Dent J* 23(6):764–767, 2012.
26. Maki K, et al.: Eruption sequestrum: x-ray microanalysis and microscopic findings, *J Clin Pediatr Dent* 29(3):245–247, 2005.
27. Leung AK: Natal teeth, *Am J Dis Child* 140:249–251, 1986.
28. Kates GA, Needleman HL, Holmes LB: Natal and neo-natal teeth: a clinical study, *J Am Dent Assoc* 109:441–443, 1984.
29. Zhu J, King D: Natal and neonatal teeth, *J Dent Child* 62: 123–128, 1995.
30. Adekoya-Sofowora CA: Natal and neonatal teeth: a review, *Niger Postgrad Med J* 15(1):38–41, 2008.
31. Spouge JD, Feasby WH: Erupted teeth in the newborn, *Oral Surg* 22:198–208, 1966.
32. Fromm A: Epstein's pearls, Bohn's nodules and inclusion cysts of the oral cavity, *J Dent Child* 34:275–287, 1967.
33. Neville BW, et al.: *Oral and maxillofacial pathology*, ed 3, Philadelphia, 2009, Saunders.
34. Henderson HZ: Ankylosis of primary molars: a clinical, radiographic, and histologic study, *J Dent Child* 46:117–122, 1979.
35. Darling AI, Levers BG: Submerged human deciduous molars and ankylosis, *Arch Oral Biol* 18:1021–1040, 1973.
36. Steigman S, Koyoumdjisky-Kaye E, Matrai Y: Submerged deciduous molars and congenital absence of premolars, *J Dent Res* 52:842, 1973.
37. Tsukamoto S, Braham RL: Unerupted second primary molar positioned inferior to the second premolar: clinical report, *J Dent Child* 53:67–69, 1986.
38. Tieu LD, et al.: Management of ankylosed primary molars with premolar successors: a systematic review, *J Am Dent Assoc* 144(6):602–611, 2013.
39. Belanger GK, Strange M, Sexton JR: Early ankylosis of a primary molar with self-correction: case report, *Pediatr Dent* 8:37–40, 1986.
40. Kurol J, Thilander B: Infraocclusion of primary molars with aplasia of the permanent successor: a longitudinal study, *Angle Orthod* 54:283–294, 1984.
41. Messer LB, Cline JT: Ankylosed primary molars: results and treatment recommendations from an eight-year longitudinal study, *Pediatr Dent* 2:37–47, 1980.
42. Kurol J, Olson L: Ankylosis of primary molars—a future periodontal threat to first permanent molars? *Eur J Orthod* 13(5):404–409, 1991.
43. Biederman W: Etiology and treatment of tooth ankylosis, *Am J Orthod* 48:670–684, 1962.
44. Skolnick IM: Ankylosis of maxillary permanent first molar, *J Am Dent Assoc* 100:558–560, 1980.
45. Franklin CD: Ankylosis of an unerupted third molar by inostosis of enamel, *Br Dent J* 133:346–347, 1972.
46. Ondarza A, et al.: Sequence of eruption of deciduous denti-

Biol 42:401–406, 1997.
47. Jara L, et al.: The sequence of eruption of the permanent den-

Biol 38:85–89, 1993.
48. Cohen MM: Variability of facial and dental characteristics in trisomy G, *South Med J* 64:51–55, 1971.
49. Landau MJ: *A cephalometric comparison of children with Down's syndrome and their normal siblings [thesis]*, Indianapolis, 1966, Indiana University School of Dentistry.
50. Cichon P, Crawford L, Grimm WD: Early-onset periodontitis associated with Down's syndrome: clinical interventional study, *Ann Periodontol* 3:370–380, 1998.
51. Morinushi T, Lopatin DE, Van Poperin N: The relationship between gingivitis and the serum antibodies to the microbiota associated with periodontal disease in children with Down's syndrome, *J Periodontol* 68:626–631, 1997.
52. Carlstedt K, et al.: Oral carriage of *Candida* species in children and adolescents with Down's syndrome, *Int J Paediatr Dent* 6:95–100, 1996.
53. Lee SR, et al.: Dental caries and salivary immunoglobulin A in Down syndrome children, *J Paediatr Child Health* 40:530–533, 2004.
54. Shapira J, Stabholz A: A comprehensive 30-month preventive dental health program in a pre-adolescent population with Down's syndrome: a longitudinal study, *Spec Care Dentist* 16:33–37, 1996.
55 Seagriff-Curtin P, Pugliese S, Romer M: Dental considerations for individuals with Down syndrome, *N Y State Dent J* 72:33–35, 2006.

56. Richardson A, Deussen FF: Facial and dental anomalies in cleidocranial dysplasia: a study of 17 cases, *Int J Paediatr Dent* 4:225–231, 1994.
57. Jensen BL, Kreiborg S: Craniofacial growth in cleidocranial dysplasia—a roentgencephalometric study, *J Craniofac Genet Dev Biol* 15:35–42, 1995.
58. Jensen BL, Kreiborg S: Development of the dentition in cleidocranial dysplasia, *J Oral Pathol Med* 19:89–93, 1990.
59. Jensen BL, Kreiborg S: Dental treatment strategies in cleidocranial dysplasia, *Br Dent J* 172:243–247, 1992.
60. Hutton CE, Bixler D, Garner LD: Cleidocranial dysplasia—treatment of dental problems: report of a case, *J Dent Child* 48:456–462, 1981.
61. Becker A, et al.: Cleidocranial dysplasia. Part II. Treatment protocol for the orthodontic and surgical modality, *Am J Orthod Dentofacial Orthop* 111:173–184, 1997.
62. Loevy HT, Aduss H, Rosenthal IM: Tooth eruption and craniofacial development in congenital hypothyroidism: report of case, *J Am Dent Assoc* 115:429–431, 1987.
63. Kamoun-Goldrat A, Ginisty D, Le Merrer M: Effects of bisphosphonates on tooth eruption in children with osteogenesis imperfecta, *Eur J Oral Sci* 116:195–198, 2008.

CHAPTER 20

Growth of the Face and Dental Arches

▲ Donald J. Ferguson and Jeffrey A. Dean

For additional resources, please visit the evolve website.

CHAPTER OUTLINE

THE NATURE OF GROWTH
- Basic Concepts of Human Growth
- Craniofacial Growth Principles
- Basic Concepts of Craniofacial Growth

CRANIOFACIAL PATTERN
- Ideal Paradigms for Dentofacial Pattern

GROWTH AND FACIAL PATTERN
- Consistency in Pattern Maturation
- Ideal Frontal Facial Pattern
- Ideal Facial Profile Pattern
- Maintenance of Overall Pattern
- Facial Growth Emulates General Somatic Growth

GROWTH AND PATTERN OF OCCLUSION
- Consistency in Pattern Development
- Primary Dentition Terminus
- Opposing First Molars at Initial Contact
- Ideal Static Occlusion Pattern
- Maintenance of Overall Pattern

GROWTH AND DENTAL ARCH PATTERN
- Similar Stage Sequencing
- Ideal Dental Arch Pattern
- Tooth Size/Arch Size Ratio as Pattern Determinant
- Computation of Tooth Size/Arch Size Balance
- Compensations in Dental Arch Development
- Maintenance of Overall Pattern
- Effects of Environmental Factors on Dental Arch Pattern

SUMMARY

Historically, patient care in medicine and dentistry has been oriented toward the elimination of disease and the resolution of debilitating conditions. Competent care in dentistry today includes issues related not only to disease and functional disability but also to the patient's well-being. The appearance of the face and dentition is recognized with increasing frequency as a major factor in human psychosocial health.[1]

This chapter is about dental and facial malocclusion—the recognition and anticipation of malocclusion during the growing years. The dentofacial pattern can be easily and accurately assessed at chairside. In clinical terms, pertinent growth issues are discussed in relation to how growth changes the pattern of the face, occlusion, and dental arches. Knowledge of pattern appraisal and growth can be integrated into efficacious clinical decisions about a young patient. This chapter enhances the reader's diagnostic and treatment planning skills with reference to malocclusion in the pediatric patient.

The clinician treating malocclusion is primarily interested in the growth and development of craniofacial tissues as they result in facial and dentoalveolar patterns. Attanasio and colleagues have demonstrated that our understanding of how genes express their influence on facial shape and dentofacial pattern, and how environment influences gene expression, has advanced at a remarkable pace.[2] How molecular mechanisms are implicated at a clinically relevant level, however, has yet to be elucidated. Mao pointed out that what we understand about induced treatment effects at the macroscopic phenotype level has been described in moderate detail at the cellular level but is only beginning to be described at the level of protein and peptide production.[3] For this reason, this chapter discusses dentofacial growth and development at a macroscopic level, from the perspective of the practicing clinician.

THE NATURE OF GROWTH

Growth refers to an increase in anatomic size. Three parameters commonly used in growth literature to assess craniofacial size increase are magnitude, velocity, and direction. Magnitude refers to the linear dimension overall or the dimension of a part. Direction means the vector of size increase as might be described on a three-dimensional coordinate system. Velocity is defined as the amount of change per unit of time.

Size increase is typically illustrated in one of two ways. When growth is measured periodically and measurements are plotted as percentages of total growth, the result is a cumulative or distance curve (Fig. 20-1). A human postnatal cumulative curve is characterized by two plateaus and one period of accelerated growth. A second method of graphically demonstrating growth change is by use of an incremental or velocity growth curve (Fig. 20-2). A velocity curve plots growth increments (e.g., centimeters per year) as a function of time. Characteristic of an incremental human growth curve is rapid accelerating prenatal growth, rapid decelerating

Dentlearn.ir

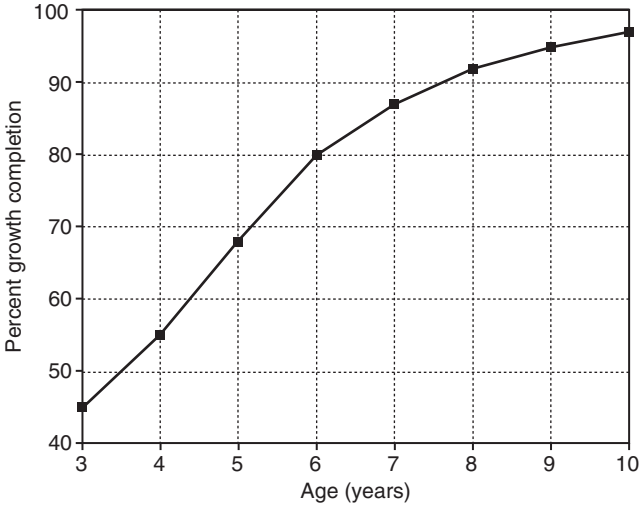

Figure 20-1 Cumulative (distance) growth curve.

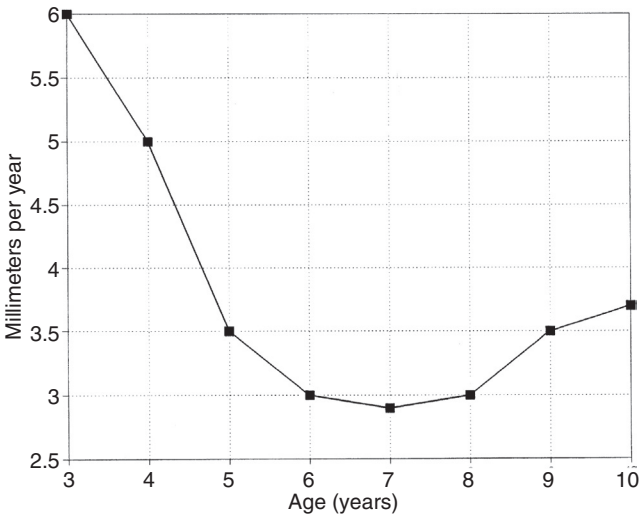

Figure 20-2 Incremental (velocity) growth curve.

postnatal growth for the first 2 or 3 years, and a period of relatively slow incremental growth during childhood, followed by growth acceleration for 2 or 3 years during pubertal adolescence.

Three observations are central to a clinically relevant understanding of growth. First, growth implies change, a transition from one condition to another. This broader meaning of growth helps define growth as a concept. Conceptual growth refers to a passage from one anatomic form (i.e., size and shape) to another. Transitions in functional stage or activity refer to development. Development, in biologic literature, usually means increased specialization or a higher order of organization and also connotes an interaction of functioning parts. Development means increased organization or specialization of functioning (physiologic) parts.

Growth is more readily understood when a physical pattern is used to describe the effects of growth change. Growth, by nature, is a relational concept. Without reference to a structural model, growth has little clinical utility or meaning. This chapter discusses growth with reference to "ideal" facial, occlusion, and dental arch paradigms.

Growth is a complex phenomenon. There is a large volume of information available on craniofacial growth. Moreover, there is little consensus in the literature as to which data or combination of data is most useful to the practitioner committed to making competent decisions about direct patient care. In light of these prevailing circumstances, the following concepts and principles about craniofacial growth are presented in a way that should be clinically useful and difficult to refute. These postulates are derived and adapted in part from the widely held tenets about general human growth and development presented by Valadian and Porter.[4] The discussion of general craniofacial principles is followed by application of the principles to three areas of craniofacial growth: the face, occlusion, and dental arches. The goal of this chapter is to integrate growth principles into patient appraisal to enhance diagnostic and treatment planning efficacy.

BASIC CONCEPTS OF HUMAN GROWTH

1. Growth disposition is similar for all healthy individuals. Healthy individuals go through growth stages that are the same for everyone, according to Valadian and Porter.[4] The prenatal period, from conception to birth, averages 40 weeks in length. Infancy includes the first 2 years of life after birth, and childhood ranges from 2 to 10 years for girls and from 2 to 12 years for boys. The length of adolescence is the same for both genders but is comprised of different years, from 10 to 18 years for females and from 12 to 20 years for males (Fig. 20-3).

   Each growth stage is unique. Rate of size increase is most remarkable during the prenatal period and declines substantially during infancy. Generally, growth velocity plateaus during childhood and increases again during adolescence. All healthy individuals experience these growth cycles, although the various basic tissues and body parts are affected differently.
2. Different body parts increase in length at different rates. From birth to adulthood, the head increases about twice in length, the trunk about three times, the arms about four times, and the legs about five times. Different parts of the body grow at different times and at different rates. For example, the head increases in size very early in life, and its rate of increase is very rapid during the prenatal and early postnatal periods.
3. The overall potential for growth is determined primarily by intrinsic or genetic factors. Genetic endowment is the main determinant of growth potential. Intrinsic factors are also those conditions and events that occur from conception to birth. Maternal nutrition or disease can modify child development before birth. Some tissues tend to demonstrate high genetic predilection. Neural and primary cartilage tissue growth seems genetically predisposed in size and growth timing. Tooth size appears to be under strict genetic control.[5,6]
4. The extent to which an individual attains his or her potential for growth is determined predominantly by extrinsic or environmental factors. Extrinsic factors

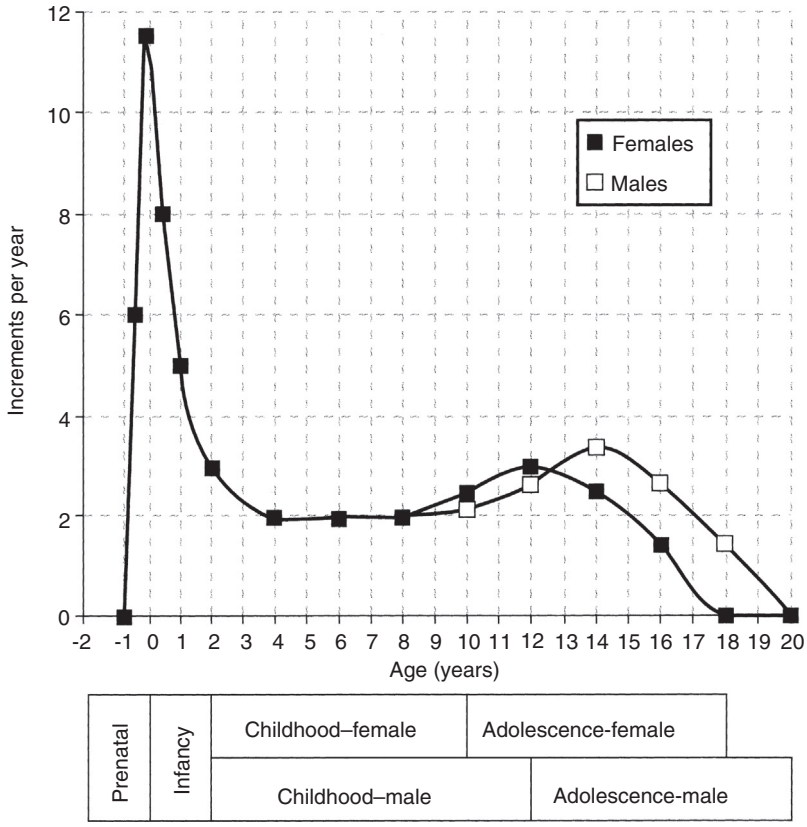

Figure 20-3 Incremental growth curve illustrating growth stages.

include all postnatal environmental conditions, such as nutrition, illness, exercise, and climate. Environmental factors of particular interest to the dental clinician are oral habits, pathology, caries, premature loss of teeth, and metabolic disease. In the absence of detrimental extrinsic factors, the dentofacial complex will tend to attain its maximum potential in growth.

CRANIOFACIAL GROWTH PRINCIPLES

1. The basic tissue types and functioning spaces that comprise the head and face are subject to growth timing differences. The human head is composed of a variety of basic tissue types; the relative percentages of these types, at any given age, depend on the timing of their growth. Neural tissue completes its growth at an early age. By contrast, general somatic tissues, such as muscle, bone, and connective tissue, mature at a slower rate. Neural tissue has attained about 60% to 70% of adult size by birth, and its growth is about 95% completed by middle childhood. This is in sharp contrast to growth of other craniofacial soft tissues (Fig. 20-4). Muscle tissue is only 40% to 45% of its adult size by birth, and its growth is approximately 70% completed by 7 years of age. The size of craniofacial lymphoid tissue (tonsils and adenoids) is about 125% of adult size at 5 years of age and decreases gradually to adulthood. Linder-Aronson and Leighton have shown that functional pharyngeal space increases in relation to decreased tonsillar-adenoid mass.[7]

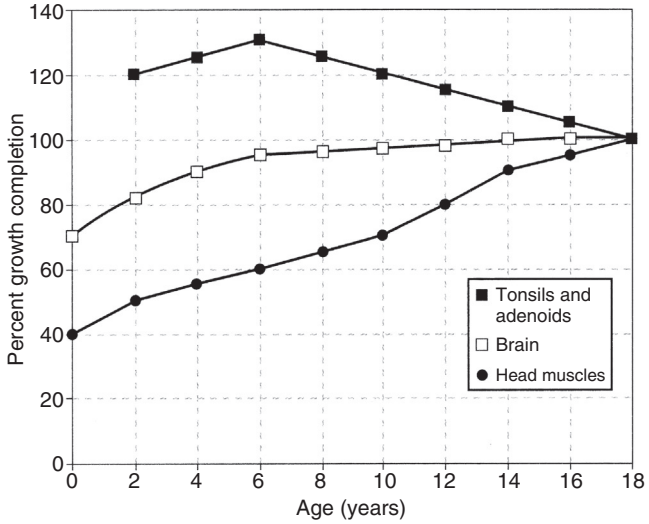

Figure 20-4 Cumulative growth curve for craniofacial neural, muscle, and lymphoid tissues. (From Linder-Aronson S, Leighton BC: A longitudinal study of the development of the posterior nasopharyngeal wall between 3 and 6 years of age, *Eur J Orthod* 5:47-58, 1983.)

The growth timing of skeletal tissues also demonstrates variation. Craniofacial bone growth is about 45% completed by birth and 70% completed by 7 years of age. In contrast, primary cartilage of the head and face has achieved approximately 75% of adult size by birth and 95% by 7 years of age (Fig. 20-5). The small

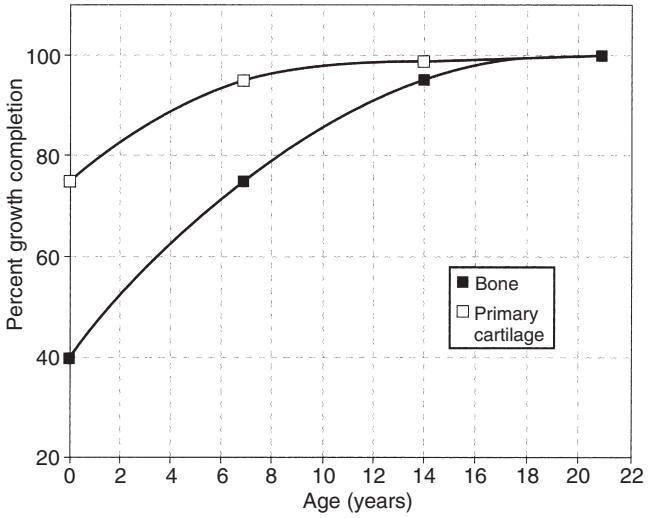

Figure 20-5 Cumulative growth curve for craniofacial bone and primary cartilage.

amount of primary cartilage remaining in the head and face after middle childhood, however, continues to grow through puberty.

2. Growth of primary cartilage and functioning spaces has a directing influence on craniofacial pattern change. Primary cartilage is a tissue of particular interest to craniofacial growth theorists. According to Enlow and Hans, it is singular in form; has the capacity to grow from within (interstitial growth); is pressure-tolerant, noncalcified, flexible, and nonvascular; and does not require a covering nutrient membrane for survival.[8] Primary cartilage found in the head and face is identical to the growth plate cartilage of long bones. Scott contends that primary cartilage is genetically predisposed, acts during growth as an autonomous tissue, and is able to directly influence the craniofacial pattern.[9]

   Sperber documents that primary cartilage first appears in the head during the fifth prenatal week.[10] By the eighth prenatal week, a cartilaginous mass called the *chondrocranium* is present and is the precursor to the adult cranial base and nasal and otic structures. By middle childhood, most primary cartilage is replaced by bone in a process called *endochondral bone formation*.

   The overall growth-directing influence of primary cartilage on craniofacial pattern change is most profound in early life. By birth, cartilage constitutes a substantial portion of the nasal septum and cranial base. Interstitial expansion of primary cartilage probably has a direct influence on the position of the maxilla by way of the septopremaxillary suspensory ligament, as suggested by Latham[11] and later contended by Gange and Johnston.[12] The maxilla is most likely thrust downward and forward during infancy and early childhood. The contributions to midface growth of primary cartilage are greatly diminished after middle childhood.

   The development of functioning spaces has also received considerable attention as a key concept among craniofacial growth theories.[13] The head carries out numerous functions. Some functions are more essential than others, but all require the development and maintenance of spaces. Neural integration is a critical function, and space is required for the brain and central and peripheral nervous system expansion. Respiration and deglutition are also essential to life and require development of nasal, pharyngeal, and oral spaces. Sight, olfaction, hearing, and speech are important but less critical craniofacial functions that also require development of functioning spaces for operation.

   According to Moss and Salentijn, a likely craniofacial growth scenario of functioning space development in head and facial patterns includes the following sequence of events.[14] Rapid size increase of the brain during prenatal and early postnatal life thrusts the calvarial bony plates outward and the midface forward. Birth invokes a set of functional processes previously not essential for life (i.e., breathing and swallowing). Repositioning of the mandible and tongue takes place to ensure patency of nasal-oral-pharyngeal spaces. The mandible is depressed and thrust forward for these functions to be supported and maintained.

3. Mandibular condylar cartilage, craniofacial sutures, and appositional-resorptive bone change facilitate pattern growth of the head and face. Koski identifies the mandibular condyles, once considered growth centers with directive capacity, as an adaptive growth mechanism.[15] Cartilage found at the head of the condyle is a secondary, fibrous cartilage and differs significantly from the primary, growth plate cartilage considered to be under high genetic control.[16] During craniofacial growth, the mandible is repositioned continuously to its best functional advantage. Reposturing alters the anatomic position of the condyle relative to that of the glenoid fossa. Compensatory growth of secondary condylar cartilage is one mechanism that facilitates the maintenance of mandibular position.

   Koski also points out that craniofacial sutures are important growth sites that serve to facilitate calvarial and midface growth.[15] Calvarial sutures close by 5 years of age, but some facial sutures remain patent through puberty. Craniofacial bones are thrust apart by primary cartilage, and functioning space increases. Sutures enable osseous deposition to occur at bone edges, which allows bones of the face and skull to adapt.

   Enlow and Hans have shown that bone, unlike primary cartilage, is subject to environmental controls.[17] Bone may assume many forms during growth; it is pressure-sensitive, calcified, vascular, and relatively inflexible, and requires a covering membrane for survival. The craniofacial skeleton increases in size by way of surface addition only and increases in shape through differential appositional-resorptive bone growth. This differential growth process accounts for a considerable amount of size increase after middle childhood.

   Growth theorists Moss and Salentijn[13] believe that the general somatic tissues (i.e., bone, muscle, and connective tissue) demonstrate growth change as a consequence of supporting the functioning operations of the head. Indeed, the research evidence of Linder-Aronson[18] and of Harvold and associates[19] is

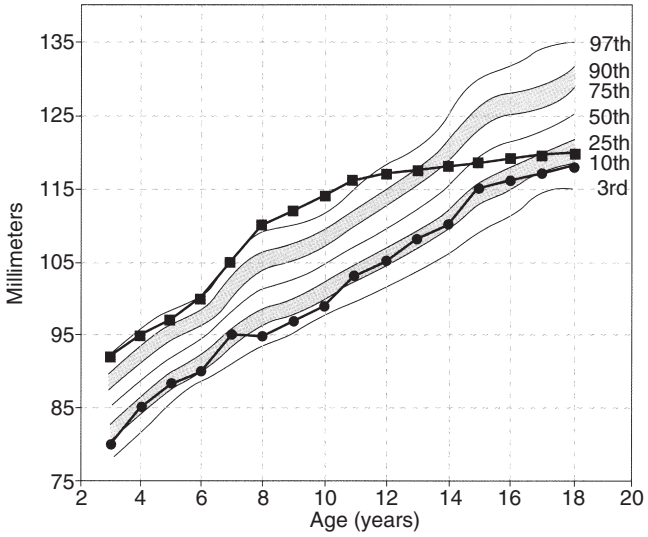

Figure 20-6 Cumulative growth chart for male face height (hard tissue nasion to menton), illustrating seven percentile levels. • Relatively normal growth; ■ deviation of several percentile levels during growth, suggestive of abnormalcy. (From Broadbent BH et al: *Bolton standards of dentofacial developmental growth,* St. Louis, 1975, Mosby.)

convincing in that bone and muscle, as basic tissues, are adaptive and compensatory. Understanding bone and muscle growth may come through understanding the temporal development of functioning spaces and the effects of interstitial cartilage expansion on surrounding tissues.

4. Growth of the head and face tends to demonstrate relative equivalency. Humans tend to grow with relative consistency. A percentile growth chart is a valuable instrument for assessing growth consistency over a time period (Fig. 20-6). Percentile charts are customarily divided into the following seven percentile levels: 97th, 90th, 75th, 50th, 25th, 10th, and 3rd. Healthy children tend to maintain a similar percentile level through successive stages of development. Deviations during growth of more than two percentile levels may indicate developmental problems, such as illness or disease.

   Attributes (craniofacial parts) that are structurally related also maintain a consistent relationship throughout successive stages of growth after infancy. Enlow and Hans[17] identify the dental arches of the maxilla and mandible as an example of a structural part-counterpart relationship. An Angle Class II skeletal pattern at 3 years of age is maintained into adulthood without corrective therapy. Both dental arches in healthy individuals tend to increase in size at about the same rate. Hence, balanced or equivalent growth tends to maintain architecturally related structures of any craniofacial pattern that is present after 2 years of age.

BASIC CONCEPTS OF CRANIOFACIAL GROWTH

1. Different parts of the craniofacial complex grow at different times. The head takes on appearance characteristics unique to each particular growth stage. Different parts of the face experience differences in growth timing as well. The infant has a disproportionately large calvaria and forehead compared with the adult because growth of the neural tissue takes place earlier in life than does facial growth.

   Size increase of the face and calvaria in the three spatial planes is a differential growth process. Scott,[20] Meredith,[21] and Ranly[22] have contributed to an understanding of this process. By birth, the cranial height dimension has attained about 70% of its adult status; cranial width, 65%; and cranial length or depth, 60% (Fig. 20-7). In contrast, only 40% of facial height and 45% of facial length (depth) have been achieved by birth. Face width (i.e., bizygomatic and bigonial), on the other hand, has attained about 60% of adult stature. Growth in face width actually falls between the classic neural and general somatic growth curves.

   After birth, a pattern in facial growth timing emerges. The anterior cranial base completes most of its growth during infancy and early childhood, but frontal and nasal bones continue outward expansion through appositional-resorptive bone growth.[23] Growth magnitude and duration are greater for the anterior maxilla than for the forehead but less than for the anterior mandible. The posterior face demonstrates the greatest incremental growth during late puberty.

2. Differences in growth size, direction, velocity, and timing are observed among individuals. Bergersen has also noted large variations in growth patterns among individuals and has shown that any measured attribute will demonstrate a range of expression about a central tendency.[24] Incremental growth curves for healthy males and females will demonstrate the same general disposition but may show marked differences in maturation timing (Fig. 20-8). Generally, females mature 2 years earlier than males, but Valadian and Porter have indicated that variations are so great that an early-maturing boy may mature earlier than a late-maturing girl.[4] Males tend to grow larger in size than females.

3. The heads and faces of no two humans are exactly the same. Brodie pointed out that no two humans are exactly the same.[25] This fact is no more clearly evident than when one compares, at any given age, a measured attribute shared by healthy individuals. Most attributes have a range of expression that can be graphically illustrated by a normal distribution curve (Fig. 20-9).

   If the same attribute was measured in a population of individuals, the most frequently occurring value (mode), middle value in the series (median), or arithmetic average of all the measured values combined (mean) would represent the central tendency of the population. Central tendency is often referred to as *normalcy*. Another way to describe attribute distribution is by using percentile equivalents. The 50th percentile indicates the center of the distribution, the 25th percentile the lower one fourth, and so on.

   A third statistical parameter often used in growth literature to indicate distribution is the standard deviation. A standard deviation (SD) of ± 1 includes about 68% of the entire population; ± 2 SD and ± 3 SD are equivalent to approximately 95% and 99% of the

Dentlearn.ir

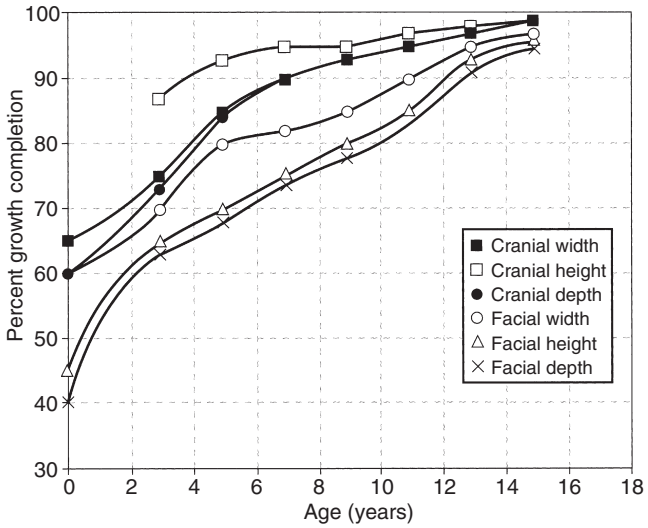

Figure 20-7 Cumulative growth curve for calvaria and face in width, height, and depth. (From Scott JH: The growth of the human face, *Proc R Soc Med* 47:5, 1954; Meredith HV: Changes in form of the head and face during childhood, *Growth* 24:215-264, 1960; Ranly DM: *A synopsis of craniofacial growth,* New York, 1980, Appleton & Lange.)



Figure 20-8 Incremental growth curves for early- and late-maturing males and females.

distribution, respectively. The mean values and SDs for a normative population are invaluable aids in describing a patient's condition. By comparing a patient's value to a population value for the same trait, the clinician can make statements about relative largeness or smallness. Generally, measurements beyond ± 2 SD are considered clinically important because those values fall outside 95% of the population on which the normative value is based.

In the remainder of this chapter, references are made to craniofacial growth principles and concepts in discussing growth of the face, occlusion, and dental arches.

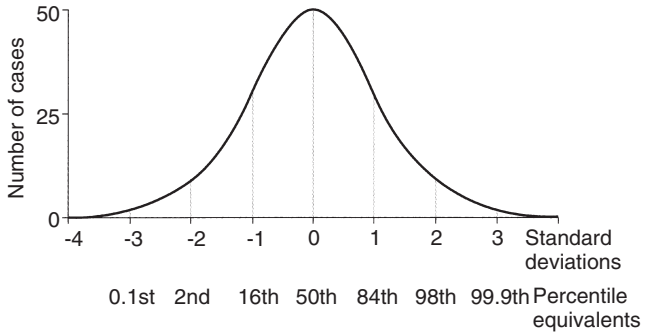

Figure 20-9 Normal distribution curve illustrating standard deviations and percentile equivalents.

CRANIOFACIAL PATTERN

In clinical assessment and treatment planning for the young patient, information about growth is often not considered to the degree that it should be. Craniofacial growth issues can be made more central to patient care concerns when a physical model is used to help visualize growth effects. For this reason, a particularly strong effort is made here to define physical craniofacial pattern.

There are two methods commonly used in dentistry to gather information about craniofacial pattern. One method is to examine the patient physically at chairside. Information collected in this fashion is based on criteria contrived and established in the practitioner's mind. The second method is to analyze dental records. Historically, cephalometric analysis has been a particularly useful tool for collecting objective information about craniofacial patterns. Generally, the patient's radiographic values measured on the cephalogram are compared with normative values derived from a population database. In this way, degrees of normalcy can be estimated by the clinician. One database is unique in its composition in that only individuals presenting with optimal or ideal craniofacial pattern were included in the study.[26] This unique conceptual approach to defining craniofacial pattern enables the practitioner to make assessments about patient optimality. Patient-measured values are compared with values from cephalograms that have relatively ideal patterns. Cephalometric analysis is discussed in Chapter 21. Darwis and colleagues suggest that using a combination of methods, such as three-dimensional facial morphometry and Fourier analysis, can provide a more comprehensive knowledge of growth and development of craniofacial structures and thus may allow for the improved prediction of clinical outcomes.[27] Fourier analysis is a mathematical curve-fitting procedure that can represent boundaries so that the outlines of objects can be addressed.

IDEAL PARADIGMS FOR DENTOFACIAL PATTERN

Standards for chairside facial appraisal have been offered by Ackerman and Proffit,[28] Angle,[29] Bell and colleagues,[30] Cox and van der Linden,[31] Lucker and co-workers,[1] and Patterson and Powell.[32] Most of these physical appraisal models refer to the adult face. Horowitz and Hixon[33] describe idealized facial pattern as "the way things ought to be." Models available for examining the face espouse an assessment

of proportion, balance, and harmony—concepts that help define overall facial attractiveness. The concept of an ideal face can be a useful clinical tool if it is used properly and its limitations are acknowledged. The first limitation is the fact that an ideal has little or no biological basis. Biological data can neither refute nor support the contention that the face should be ideal. Second, faces do not need to be ideal to work properly; ideal pattern, for the most part, has little connection with physiologic function. Third, an ideal model is simply a mental construct, a fiction. The words *ideal paradigm* mean "perfect example."

A perfect example, on the other hand, can be a powerful diagnostic and treatment-planning tool. The patient's facial pattern can be compared with criteria for idealness, the differences noted, and hence a problem list constructed. Criteria for an ideal face can help organize a vast array of information that is readily available to the clinician through physical observation. An ideal facial paradigm can serve as a treatment planning tool as well. Although the concept of an ideal face is fictitious and biologically unsupported, it can serve as a guide by providing an example toward which treatment may be directed. Ideal paradigms for dental occlusion and dental arch pattern are also represented in the dental literature; good examples may be found in the works of Angle,[29] Andrews,[34] and Roth.[35] The purposes served by these paradigms are the same as for ideal facial models; they are powerful diagnostic and treatment-planning aids.

GROWTH AND FACIAL PATTERN

CONSISTENCY IN PATTERN MATURATION

Following birth, the face increases in size to a greater extent than does the calvaria. Bell and associates propose that, by adulthood, the ideal face should be equally proportioned in forehead, midface, and lower face heights.[30] Enlow demonstrated that the facial profile flattens as the face ages. Nose and chin become more prominent, and lips become less pronounced[36] (Fig. 20-10). Every healthy individual, regardless of the overall craniofacial pattern, experiences profile flattening and face height increases relative to the cranium.

IDEAL FRONTAL FACIAL PATTERN

Criteria for facial idealness are age-dependent. Because the face elongates and the profile becomes less convex with maturity, ideal criteria appropriate for the adult face would not necessarily apply to the younger face. The ideal frontal facial pattern for a 7-year-old child might include the following criteria (Fig. 20-11):

1. Right and left face halves are symmetrical.
2. Glabella (midpoint between eyebrows) to subnasale (point where columella merges with upper lip) equals subnasale to menton (inferior aspect of chin).
3. Subnasale to lower border of upper lip represents one-third the distance from subnasale to menton.
4. The upper central incisor edge is 2 mm inferior to the lower border of the upper lip.
5. Alar base width equals inner canthal width.



Figure 20-10 Graphic illustration of facial profile flattening from 6 years of age *(solid line)* to 18 years of age *(broken line)*.

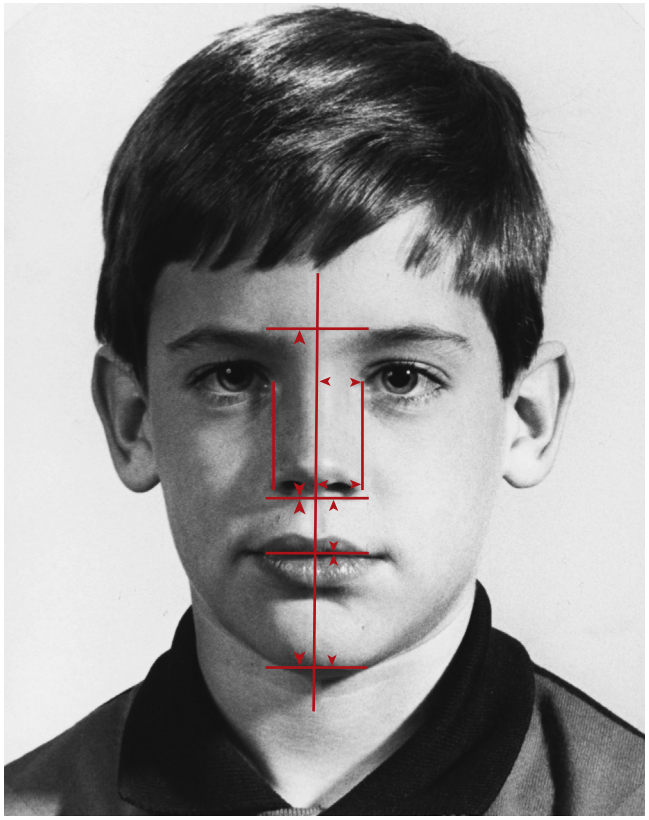

Figure 20-11 Ideal frontal facial pattern for a 7-year-old child.

IDEAL FACIAL PROFILE PATTERN

Use of a reference plane is very helpful for evaluation of the facial profile at chairside. The Frankfort horizontal plane is an anthropometric reference line frequently

Dentlearn.ir

used for analysis of the lateral face. It is defined by Farkas as the superior limit of the external auditory meatus and the palpated border of the infraorbital bony rim.[37] A second reference line constructed perpendicular to the Frankfort horizontal plane and through the glabella (FHP) has been used in lateral profile assessment by Legan and Burstone.[38]

The ideal profile pattern for a 7-year-old child might include the following criteria (Fig. 20-12):

1. Chin 5 mm behind FHP
2. Most anterior aspect of lower lip on FHP
3. Most anterior aspect of upper lip 5 mm ahead of FHP
4. Nasolabial angle of 100 degrees
5. No more than 2 mm lip separation when relaxed

MAINTENANCE OF OVERALL PATTERN

The overall pattern presented by the individual at an early age will be maintained into adulthood. Although every individual experiences profile flattening and facial elongation as the face matures, Enlow and colleagues demonstrated that the magnitude of these changes is not great enough to offset disharmonies in overall facial structure.[39] Martinez-Maza and associates examined facial bone modeling behaviors and confirmed that the skeletal components of the craniofacial complex maintain functional and structural balance integrity while increasing in size during growth.[40] Discrepancies between the positions of the maxilla and mandible persist throughout life unless clinical therapy is used to rectify the disharmonies.

At chairside, disharmony between the maxilla and the mandible can be simply and readily identified. A list of differences can be formulated by comparison of the patient's facial measurements with the criteria of an ideal face. The differences serve as a patient problem list. Adding average growth change (i.e., magnitude, direction, and velocity) to the pattern presented by the individual will give an estimate of how facial patterns will look at a later age. This growth scheme is known as a *mean-change-expansion scheme*.[33] Balbach demonstrated it to be the most useful way to predict the effects of growth on facial pattern.[41] The mean-change-expansion scheme is useful for evaluation of almost all patients routinely seen in the dental office. Balanced or average growth affecting all aspects of the head and face relatively equally, however, cannot be assumed for all patients. The heads and faces of individuals who have some craniofacial congenital anomalies, hypoplastic defects, or acquired deformities that alter primary or compensatory craniofacial growth mechanisms do not grow in a typical manner.

Because growth change in healthy children affects the face in a relatively consistent and predictable way, the key to facial diagnosis and treatment planning is the clinician's ability to identify and diagnostically describe facial pattern. Identification of balanced, proportional facial pattern, as well as recognition of facial imbalance, should be routine during patient assessment. The use of criteria related to ideal facial pattern can be helpful.

The goal in treating facial imbalance in children is to establish architectural balance in the facial pattern. If corrective measures include compensation for the effects from treatment rebound or relapse, the facial pattern established by therapy will be maintained. As the face continues to grow and increase in size, all structurally related parts of the treated face will undergo relative growth equality.

Correction of facial imbalance in the child is achieved through clinical manipulation of the means by which adaptive, compensatory facial growth occurs. Some sutures of the upper face remain patent into adolescence. Application of forces through orthopedic headgear, controlled in direction and amount, can result in an alteration of maxillary growth direction and, ultimately, of maxillary position. Also, maxillary transverse size can be increased by judicious expansion of the palatal suture. The secondary cartilage of the mandibular condyle remains responsive to mechanical stimulation throughout life, but appositional response of this fibrocartilage decreases with age, as shown by McNamara and Carlson.[42] Facial bones respond to changes in microenvironmental stress and strain by changing form. Patterns of osseous deposition and resorption can be altered by the use of appliances that carefully load bone with physiologically compatible biomechanical forces.

Successful treatment of a child with facial imbalance secondary to mandibular retrognathia, for example, involves manipulation of several growth mechanisms. Mandibular anterior repositioning with a functional appliance probably affects many sites. Graber and Swain[43] believe that modification of the dentofacial complex occurs by the following means:

1. Condylar growth (secondary cartilage growth)
2. Glenoid fossa adaptation (apposition-resorption bone growth)
3. Elimination of functional retrusion
4. More favorable mandibular growth direction
5. Withholding of downward and forward maxillary arch movement (apposition-resorption bone growth)
6. Differential upward and forward eruption of the lower buccal segment (apposition-resorption bone growth)
7. Orthopedic movement of the maxilla and upper dentition (maxillary suture system growth)

FACIAL GROWTH EMULATES GENERAL SOMATIC GROWTH

The degree to which the facial pattern can be altered through biomechanical therapy depends on the amount of growth potential remaining. In general, the magnitude of facial pattern alteration possible is inversely proportional to age: the older the individual, the less the facial pattern can be therapeutically modified. The opportunity to alter compensatory, adaptive growth mechanisms is also greater in a rapidly growing individual. Mellion and colleagues report that the adolescent growth spurt is characterized by increased growth velocity onset and peak at about 9.6 and 11.5 years of age for girls and 12 and 14.3 years of age for boys.[44] The maximum velocity or peak height velocity of growth is attained approximately 2 years after pubertal onset. Cumulative facial growth closely parallels general somatic growth (Fig. 20-13). Analysis of skeletal hand development can be

Dentlearn.ir

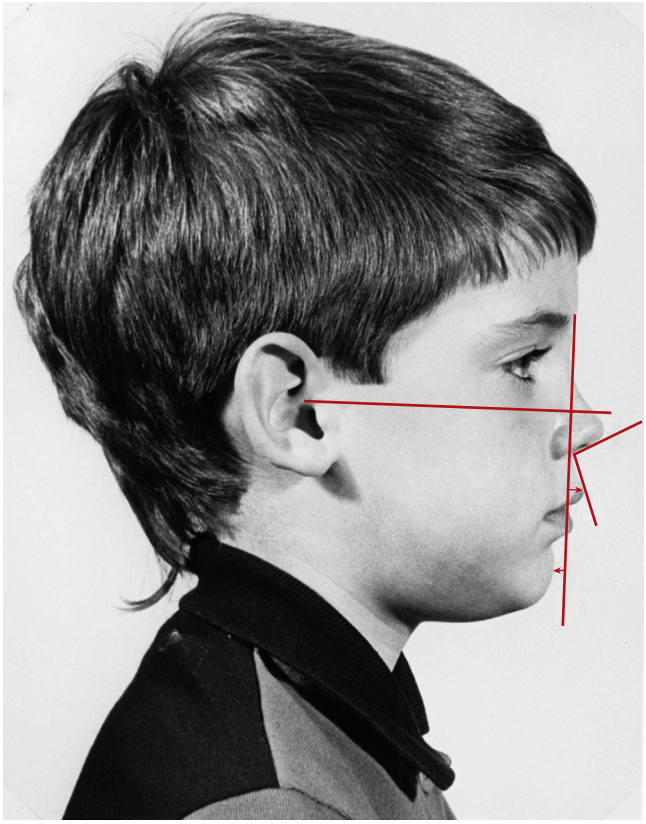

Figure 20-12 Ideal profile facial pattern for a 7-year-old child.

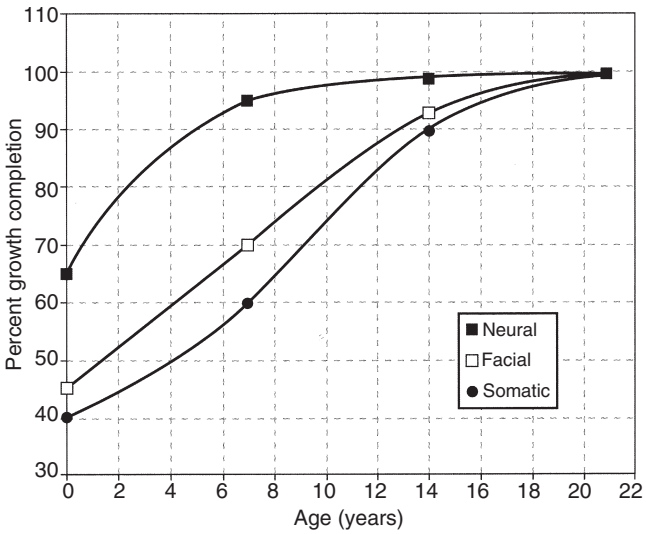

Figure 20-13 Cumulative growth curves for neural, facial, and general somatic tissues.

helpful in estimating general skeletal maturation and, hence, facial skeletal maturation. It is relevant to evaluate a child's maturity in direct relation to the child's own pubertal growth spurt to assess whether maximum pubertal growth is imminent, has been reached, or has been passed.

GROWTH AND PATTERN OF OCCLUSION

CONSISTENCY IN PATTERN DEVELOPMENT

Usually, no teeth are clinically visible at birth. Leighton has shown that the upper anterior gum pad (intercuspid width) is typically wider than the lower anterior pad, and the upper anterior gum pad protrudes (overjet) about 5 mm relative to the lower anterior gum pad.[45] The upper anterior gum pad usually overlaps (overbite) the lower anterior pad by about 0.5 mm. In the first 6 months of postnatal life, there is marked palatal width increase, and the overjet decreases rapidly.

PRIMARY DENTITION TERMINUS

By 3 years of age, the occlusion of 20 primary teeth is usually established. The relationship of the distal terminal planes of opposing second primary molar teeth can

flush terminal plane (flush terminus) means that the anterior-posterior positions of the distal surfaces of opposing primary second molars are in the same vertical plane. A mesial-step terminus is defined as a lower second primary molar terminal plane that is mesial to the maxillary primary terminus. The distal-step terminal plane is a situation in which the mandibular second primary molar terminus is distal to the upper second primary molar terminus.

Statistical studies of primary terminal plane status report that 49% of the time, the terminal plane of the lower primary second molar is mesial to the upper terminus (mesial step); the lower terminus is flush with the upper terminus 37% of the time; and the distal-step primary terminus is seen in approximately 14% of cases. These data are derived from studies reported by Arya and associates[46] and by Carlsen and Meredith.[47]

OPPOSING FIRST MOLARS AT INITIAL CONTACT

The permanent first molars are clinically visible at about 6 years of age and are the first permanent teeth to emerge. The relationship of permanent first molars when initial occluding contact occurs during eruption may be represented by one of four categories (see Fig. 20-14). A Class I relationship means that the mesial-buccal (m-b) cusp of the upper permanent molar is in contact at or very near the buccal groove of the lower permanent first molar. This occurs approximately 55% of the time. An end-on relationship means that m-b cusps of both molars oppose one another. The incidence of this situation is about 25%. A Class II relationship, occurring 19% of the time, is one in which an upper m-b cusp is anterior to the lower m-b cusp. Class III represents the situation in which an upper m-b cusp is distal to the lower buccal groove. This occurs in only 1% of the population.[47] Table 20-1 shows the incidence of medial-step, flush, and distal-step primary terminus and end-on, Class I, Class II, and Class III permanent first molar occlusions during the three stages of occlusion development.[46-48]

IDEAL STATIC OCCLUSION PATTERN

The concept of ideal occlusion development has been described by Friel[49] and by Lewis and Lehman.[50] Sanin and

Savara have also shown that, to a considerable extent, ideal occlusion at a young age predisposes to an ideal adult occlusion.[51] The most desirable occlusion in the permanent dentition is a Class I interdigitation, and certain features in the primary and mixed dentitions, if observed accurately, can provide clinical clues as to whether a Class I relationship of the dentition will eventually develop.

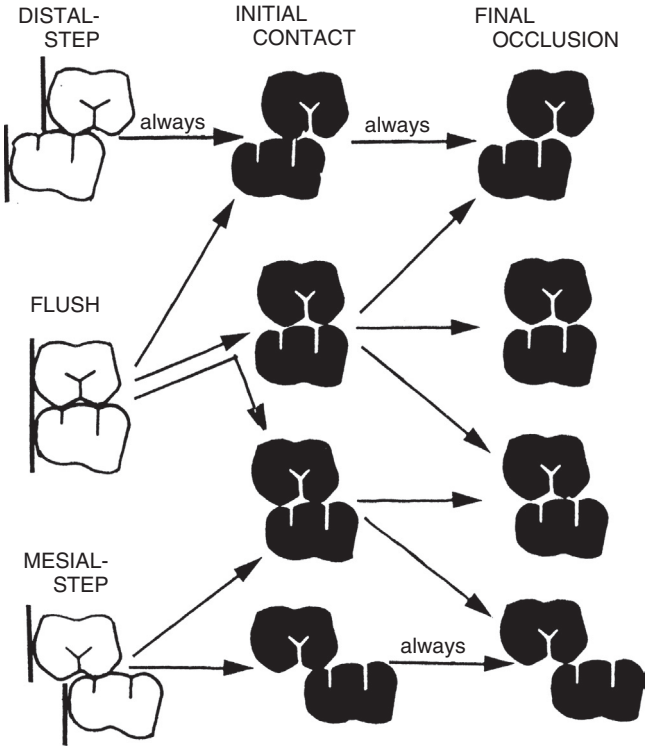

Figure 20-14 Graphic illustration of permanent first molar occlusion development. Outlined crown images represent three terminal plane relationships of primary second molars at about 5 years of age. Darkened images represent various permanent first molar relationships at initial occluding contact (about 6½ years of age) and at full occlusion contact (about 12 years of age). (From Arya BS et al: Prediction of first molar occlusion, *Am J Orthod* 63:610-621, 1973; Carlsen DB, Meredith HV: Biologic variation in selected relationships of opposing posterior teeth, *Angle Orthod* 30:162-173, 1960; Moyers RA: *Handbook of orthodontics*, ed 3, Chicago, 1973, Mosby.)

The major difference between ideal adult and child occlusions is the teeth present. By 7 years of age, the primary central and lateral incisors have been or are in the process of being replaced by their permanent successors, and the permanent first molars have already erupted. The primary dentition remaining usually includes the canine and first and second molars of both arches. Criteria for ideal dental occlusion for a 7-year-old child might include the following:

1. Class I molar and canine interdigitation
2. 2-mm anterior and posterior overjet
3. 2-mm anterior overbite
4. Coincident dental midlines

MAINTENANCE OF OVERALL PATTERN

Gum pad relationships at birth cannot be used as reliable diagnostic criteria for predicting subsequent arch relationship. The primacy of life-supporting functions (i.e., respiration and swallowing) is so great at birth that major unpredictable adjustments in maxillary and mandibular positions take place in the first few years of life. By 3 years of age, however, the relationship of maxilla to mandible is well established, and the overall maxillomandibular pattern does not change significantly thereafter.

One key diagnostic feature regarding future occlusion status is the relationships of the primary terminal planes. The likelihood of a Class I relationship developing in the permanent dentition is greatest when a mild mesial-step terminus exists during the primary dentition stage (see Fig. 20-14). If an exaggerated mesial step exists, a Class III permanent molar relationship will develop. The possibility that a Class I relationship will develop from a distal-step primary terminus is virtually nonexistent. Hence, the presence of a distal step is highly predictive of a developing Class II permanent molar relationship.

Another important diagnostic feature that is predictive of later occlusion status is the relationships of the first permanent molars during initial occluding contact. The first permanent molars erupt between 5 and 7 years of age. The chance that a Class I interdigitation of the dentition will evolve is best when a Class I relationship is represented at initial permanent first molar occluding contact. A Class II first permanent molar occlusion at initial occluding contact will predictably remain a Class II occlusion into the complete adult dentition. Also indicative of

Table **20-1**

Incidence of Terminal Molar Relationships at Three Stages of Occlusion Development

Primary Terminal Plane at Age 5 Years	Initial Permanent First Molar Occlusion at Age 6½ Years	Final Occlusion at About Age 12 Years
	1% Class III	3% Class III
49% Class I (ms)	27% Class I	59% Class I
37% Flush	49% End-on	
14% Class II (ds)	23% Class II	39% Class II

ms, medial step; ds, distal step.

Arya BS et al: Prediction of first molar occlusion, *Am J Orthod* 63:610-621, 1973.

Carlsen DB, Meredith HV: Biologic variation in selected relationships of opposing posterior teeth, *Angle Orthod* 30:162-173, 1960.

HEW reports on occlusion: summary and discussion, *J Clin Orthod* 12:849-862, 1978.

a developing malocclusion are some initially occluding end-to-end relationships. Three quarters of initially contacting end-on first molar occlusions will shift toward a Class I during the transition dentition phase. However, 25% of these end-on relationships will shift into a Class II relationship. A Class III occlusion at initial contact will predictably lead to a future Class III molar relationship. This discussion regarding diagnostic and predictive information is based on the work of Arya and associates,[46] Carlsen and Meredith,[47] and Moyers.[52]

The development of the transitional-phase occlusion and malocclusion is graphically illustrated in Figure 20-14. Note that distal-step terminus always leads to Class II initial contact and final permanent first molar occlusions. The probability that a Class III final first permanent molar relationship will develop from a Class III initial contact occlusion is also very high. Development of the occlusion from flush terminus, end-on, and Class I initial contact molar relationships is highly variable.

The occlusion relationship of upper to lower dentition remains nearly the same throughout the growing period.[53] Exceptions are cases in which environmental factors, such as premature loss of primary teeth, are superimposed on the developing occlusion, as shown by Northway and associates.[54] Carlsen and Meredith demonstrated that, 70% of the time, the lower permanent first molars move mesially relative to the upper permanent first molars during the transition occlusion phase.[47] The magnitude of this shift, however, typically does not compensate for a permanent first molar malocclusion. Overall occlusion pattern is maintained during growth.

GROWTH AND DENTAL ARCH PATTERN

SIMILAR STAGE SEQUENCING

The stage sequence of dental arch development is the same for everyone. According to Nery and Oka, the crowns of primary teeth begin calcification between 3 and 4 months prenatally.[55] The calcification of mandibular teeth usually precedes that of the maxillary dentition; the central incisors typically show first evidence of calcification and the second molars last. Boys typically begin calcification before girls.

The first primary tooth to erupt is the central incisor at about 7½ months, and the last to erupt is the second primary molar at about 2½ years. Closure of the root apex occurs at 3 years for the second primary molar. The usual sequence of primary dentition eruption is the central incisor (in Palmer notation, designated by the letter A), the lateral incisor (B), the first primary molar (C), and the canine (D), followed by the second primary molar (E). Hence, the typical eruption sequence is A-B-D-C-E.

Calcification of the permanent teeth does not begin until after birth.[55] The first permanent molar is the first to show evidence of calcification, which takes place during the second postnatal month. The third molar is the last to begin calcification, which occurs at about 9 years.

The typical eruption sequence for the mandibular arch is as follows: first molar (in Palmer notation, designated by the number 6), central incisor (1), lateral incisor (2), canine (3), first premolar (4), second premolar (5), and second molar (7), followed by the third molar (8). For the maxillary arch, the usual sequence of eruption for the permanent teeth is as follows: 6-1-2-4-5-3-7-8. Eruption timing in girls generally precedes that in boys by an average of 5 months.

Eruption times for permanent teeth can vary considerably depending on the specific tooth. According to Garn, eruption time for the lower incisor varies the least; 90% of lower permanent incisors erupt within a span of 3 years. In contrast, eruption time varies the most for the lower second permanent premolar, which shows a 6½-year span.[5]

Dimensional changes for dental arch length, circumference, and intermolar and intercanine widths during childhood and adolescence have been compiled by Moorrees.[56,57] Average dimensional dental arch changes from ages 6 to 18 years for maxillary and mandibular arches are as follows:

Lower Arch

Arch width:	Bicanine: 3-mm increase Bimolar: 2-mm increase
Arch length:	1-mm decrease because of the uprighting of incisors
Arch circumference:	Decrease of 4 mm

Upper Arch

Arch width:	Bicanine: 5-mm increase Bimolar: 4-mm increase
Arch length:	Slight decrease because of the uprighting of incisors
Arch circumference:	Increase of 1 mm

IDEAL DENTAL ARCH PATTERN

Development of dental arch malocclusion is predictable. Likewise, development of a clinically acceptable dental arch can be predicted. The status of the dental arch at mid-adolescence is contingent on clinical features that can be easily recognized during the transition phase dentition. The simplest method of evaluating the dental arch for factors predisposing to malocclusion is to compare the patient's mixed dentition dental arch with an ideal dental arch pattern.

For the dental arch, the ideal pattern for a 7-year-old child might meet the following criteria:

1. Tight proximal contacts
2. No rotations
3. Specific buccal-lingual axial inclinations
4. Specific mesial-distal axial inclinations
5. Even marginal ridges vertically
6. Flat occlusal plane
7. Excess (positive) leeway space

Ethnic background can make a difference in the dentition and occlusal development. An interesting study by Anderson[58] showed that the primary dental arch dimensions of African-American children were significantly larger than those of European-American children in arch width, length, perimeter, and interdental space.

Dentlearn.ir

TOOTH SIZE/ARCH SIZE RATIO AS PATTERN DETERMINANT

Tooth size and alveolar size are the primary factors that determine the status of the permanent dental arch. If tooth size and arch size are not balanced, the effect on the permanent dental arch is crowding or spacing. Crowding is the most common feature of dental arch malocclusion. Only when the combined size of the permanent teeth is balanced with the size of the alveolar apical area is an ideal dental arch possible.

Van der Linden referred to the alveolar bone surrounding the dental apex regions as the *apical area*.[59] Ten Cate reported evidence that the alveolus probably forms as a result of inductive action from cells of the dental follicle.[60] The size of alveolar bone is influenced by the many environmental factors that affect intramembranous bone growth. It is possible to clinically increase or decrease the size of the alveolar apical area during growth. Fränkel has demonstrated that alveolar arch size can be increased dramatically during childhood and that the increases are stable into adulthood.[61]

Tooth size, for the purpose of discussing dental arch development, refers to the mesial-distal dimensions of each tooth. According to Garn[5] and Potter and colleagues,[6] mesial-distal tooth size is determined primarily by genetic factors. Four chromosomal gene loci appear to be responsible for mesial-distal maxillary tooth size, and the mandibular dentition seems to be under the genetic control of six loci. Tooth size is polygenically determined and continuously variable (i.e., a wide range of individuality exists in terms of the width of any single tooth). Dental size is expressed through X-linked inheritance, and racial differences are known. The upper lateral incisor shows the most variability in tooth size.

Tooth size and alveolar apical area size are the most pertinent factors in the determination of the intraarch component of malocclusion. Therefore, it is relevant to consider these factors at length. The alveolar apical area will respond to biomechanical stimulation from orthodontic appliances because intramembranous bone is adaptive and compensatory. Crown size, on the other hand, cannot be predictably influenced during growth by clinical therapy.

The clinical crowns of all permanent teeth, except for the third molar, are completely formed by middle childhood. Mesial-distal crown widths will not change after crown formation unless affected by factors such as caries. Hence, mesial-distal crown dimension is a stable factor in the tooth size/arch size ratio. In an attempt to exploit the clinical usefulness of crown dimension stability, tooth size relationships are examined.

Comparison of primary and permanent mesial-distal tooth sizes is one such consideration. Studies by Moorrees revealed that there is little about primary dentition size that predicts permanent dentition size.[57] Correlation coefficient (r) values ranging from r = 0.2 to r = 0.6 are indicative of the poor predictive relationship between primary mesial-distal tooth sizes and the sizes of their permanent successors. Correlation coefficients of r = 0.8 or higher are required to make predictions for the individual patient at chairside.[32] The combined mesial-distal sizes of all primary teeth and the combined sizes for the permanent teeth show a correlation of r = 0.5. Hence, Moorrees concluded that the sizes of the primary teeth are of little predictive value in estimating the sizes of their permanent successors.[56]

The strength of the size relationships among the permanent teeth, however, is clinically important for some comparisons. Potter and Nance demonstrated that the size of an individual tooth is highly correlated with the size of the contralateral tooth in the same arch, as reflected in an r value of around 0.9.[62] The combined mesial-distal dimensions of contralateral quadrants of teeth show a slightly higher correlation of r = 0.95. Intraarch size of the lower incisors vs. mesial-distal sizes of the lower canine and premolars combined, show only moderate correlation (r = 0.6) and therefore are not clinically useful.[63]

COMPUTATION OF TOOTH SIZE/ARCH SIZE BALANCE

The primary reason for dental arch malocclusion is imbalance between tooth size and alveolar apical size. In the transition (mixed) dentition, it is possible to accurately determine if combined mesial-distal tooth size will be balanced with alveolar arch size in later life. This process of determination is called *mixed dentition space analysis*. Many methods of mixed dentition space analysis are available.[64,65] Common to all of these methods is the attempt to determine the combined mesial-distal size of the unerupted permanent canine and first and second premolars. According to Horowitz and Hixon, the lower dental arch is the focus for space analysis and the basis of orthodontic diagnosis and treatment planning.[33] The mandibular alveolar base can be modified less therapeutically than can the upper alveolus and therefore restricts treatment possibilities. The mandibular arch also undergoes less growth change than does the upper arch.

Efficacy studies by Gardner,[66] Kaplan and colleagues,[67] and Staley and colleagues[68-70] revealed one method to be the most accurate in predicting the combined size of the unerupted canine and premolars during the mixed dentition. This method, originally devised by Hixon and Oldfather,[63] has been refined by Bishara and Staley.[71] In summary, the analysis involves the following steps:

1. Measure the combined width of the lower lateral and central incisors on one side.
2. Measure (directly from the radiograph) the crown sizes of the unerupted 4-5 on the same side.
3. Add the incisor and the premolar sizes.
4. Refer to the prediction chart to determine the sizes of the unerupted 3-4-5.

Techniques of mixed dentition space analysis allow for estimation of the sizes of the unerupted canine and premolars on the lower arch. This size estimate must then be compared with a measurement of the arch space available between the mesial aspect of the lower molar and the distal aspect of the lateral incisor in the same quadrant. The difference between the combined width of the three

Dentlearn.ir

unerupted permanent teeth and this arch space has been called *leeway space*.

The most favorable dental arch pattern is one in which leeway space is excessive (i.e., combined size of unerupted canine and premolars is smaller than arch space available). If leeway space is deficient, dental arch crowding predictably results. Average growth changes in the dental arch are not great enough to compensate for leeway deficiencies.

COMPENSATIONS IN DENTAL ARCH DEVELOPMENT

Tooth size/arch size imbalances result in dental arch conditions that are less than ideal. When combined mesial-distal tooth size exceeds alveolar arch size, compensatory adjustments occur, resulting in dental arch crowding, excessive curve of Spee, or deviant axial tooth inclinations. Dental spacing results when alveolar arch size exceeds the combined mesial-distal size of the teeth.

Competent treatment planning during the mixed dentition must account not only for differences between the size of unerupted canine and premolars and the space available for them, but also for compensating dental factors. Ideal dental arch status provides a model for such planning. Each compensating factor (i.e., crowding, spacing, excess occlusal curve, or deviant axial tooth position) can be appraised relative to an ideal dental arch. Alteration of a crowded arch to an ideally aligned arch is not possible without creating extra space to resolve the crowding. Consequently, a competent dental arch treatment plan must specify the manner in which space will be clinically created. Several means are available for creating dental arch space:

1. Move molars distally.
2. Decrease the mesial-distal dimension of the teeth present in the arch.
3. Increase the buccal-lingual axial inclination of the incisors.
4. Reduce the number of teeth in the arch by extraction.

Resolution of an excessive occlusal curve also requires more space. Merrifield indicated that, generally, for each millimeter of excessive occlusal curve, 1 mm of arch length space is required.[72] For labially inclined incisors to be uprighted, arch length space is also required. In contrast, more arch length is created when retroclined incisors are proclined through therapy; the length of the arch is increased by repositioning the incisal edges from a lingual to a more labial position.

MAINTENANCE OF OVERALL PATTERN

Space analysis combined with evaluation of the impact of compensating factors on dental arch status is the means by which overall space requirements for the lower arch can be determined during the mixed dentition phase. Overall space appraisal during the mixed dentition is highly indicative of future arch status. The condition presented during the mixed dentition will, to a high degree, be maintained in the permanent dental arch. For this reason, a nonideal adult arch status can be anticipated early, and many undesirable conditions can be resolved during the transition from the primary to the permanent dental arch.

Overall space appraisal is typically expressed as millimeters of arch length space excess or deficiency. Dental arch space excess (1 to 2 mm) is a relatively ideal situation. Clinically, little intervention is usually required because mesial drifting of the permanent teeth often results in little or no crowding or residual spacing. Space excess exceeding 3 to 4 mm, however, can lead to dental arch problems. For example, congenital absence of one or more teeth can leave so much arch space that mesial drifting cannot compensate. Decisions favoring retention of primary teeth as long as possible, extraction of primary teeth and retention of space for later restorative prosthesis, or extraction followed by space closure must be made as long-term planning decisions.

Space deficiencies less than -2 mm can usually be managed with a lower lingual holding arch. Arch space deficiencies of from -3 to -6 mm should be scrutinized carefully. Typically, a space-regaining lower lingual arch or arch length expansion treatment measure is indicated. Arches with deficiencies in excess of -6 mm are candidates for aggressive space-regaining techniques, dental arch expansion treatment, or one of several serial extraction sequences. The clinical approach to various conditions of space excess and deficiency is based on overall space appraisal (space analysis plus compensating factors), as shown in Table 20-2.

Table **20-2**

Clinical Disposition Guidelines for Various Dental Arch Space Conditions Resulting from Overall Mixed Dentition Space Appraisal

Overall Appraisal	mm	Clinical Disposition
Large space excess	Greater than +3	Long-term planning
Space excess	Less than +3 to 0	No action; observation
Equivalency	0	Careful observation
Deficiency	Less than -3 to 0	Lower lingual holding arch
Moderate deficiency	-3 to -6	Space regaining or arch expansion
Large deficiency	Greater than -6	Space regaining, arch expansion, or extraction

Dentlearn.ir

EFFECTS OF ENVIRONMENTAL FACTORS ON DENTAL ARCH PATTERN

The primary determinant of dental arch malocclusion is mesial-distal tooth size/arch size imbalance. Nevertheless, secondary factors can dramatically influence the disposition of the dental arch during childhood. Dental arch status is subject to the ravaging effects of environmental factors that can include early loss of primary teeth, interproximal caries, pathology, ankylosis of primary teeth, oral habits, trauma, and early eruption of permanent second molars.

The environmental factors most commonly affecting dental arch status are probably caries and premature loss of primary teeth. Early primary tooth loss and caries can have a profound effect on dental arch status. Caries and early loss of the primary first molars (D), second molars (E), or both (D + E) result in a decrease in dental arch length. A study by Northway and colleagues[54] showed the following specific details:

1. E loss had the most deleterious effect on dental arch length.
2. Early posterior primary loss resulted in space closure of 2- to 4-mm per quadrant in both arches.
3. Space loss was age-related in the upper but not in the lower arch.
4. Upper D loss typically resulted in blocked-out canines; upper E loss usually led to an impacted second permanent premolar.
5. The greatest space loss was caused by mesial molar movement.
6. More space was lost in the first year after premature tooth loss than in successive years.
7. No recovery of space was demonstrated during growth in the upper arch, and little was found in the lower arch.

SUMMARY

This chapter integrates basic growth principles with patient appraisal to enhance diagnostic and treatment-planning efficacy. Merging growth principles with dentofacial pattern brings to light specific growth features pertinent to clinical patient-care decision-making. This chapter focused on growth events germane to a better understanding of malocclusion as it affects the face, occlusion, and dental arches. Two themes were consistent throughout the chapter. First, overall pattern is maintained from early childhood until growth completion. Growth change affects architecturally equivalent structures in a balanced way. For this reason, craniofacial pattern can be predicted to a great extent. The best estimation of future status is obtained by taking the pattern present at an early age and adding the average growth change. Second, dentofacial pattern changes regionally as an individual matures, and these maturation changes are common in all healthy individuals. Regional variation introduced by the maturing process, however, is not great enough to alter the overall dentofacial pattern.

REFERENCES

1. Lucker GW, et al.: Psychological aspects of facial form, Monograph No. 11, *Craniofacial growth series,* Ann Arbor, 1980, University of Michigan.
2. Attanasio C, et al.: Fine tuning of craniofacial morphology by distant-acting enhancers, *Science* 342:12410061–12410068, 2013.
3. Mao JJ: Mechanobiology of craniofacial sutures, *J Dent Res* 81:810–816, 2002.
4. Valadian I, Porter D: *Physical growth and development: from conception to maturity*, Boston, 1977, John Wright-PSG.
5. Garn SM: Genetics of dental development. In McNamara JA Jr, editor: *The biology of occlusal development*, Monograph No. 7, *Craniofacial growth series,* Ann Arbor, 1977, University of Michigan.
6. Potter RH, et al.: A twin study on dental dimension. II, Independent genetic determinants, *Am J Phys Anthropol* 44: 397–412, 1976.
7. Linder-Aronson S, Leighton BC: A longitudinal study of the development of the posterior nasopharyngeal wall between 3 and 6 years of age, *Eur J Orthod* 5:47–58, 1983.
8. Enlow DH, Hans MG: *Essentials of facial growth*, Philadelphia, 1996, WB Saunders.
9. Scott JH: The nasal septum, *Br Dent J* 95:37, 1953.
10. Sperber GH: *Craniofacial embryology*, ed 3, Boston, 1981, John Wright-PSG.
11. Latham RA: Maxillary development and growth: the septopremaxillary ligament, *J Anat* 107:471, 1974.
12. Gange RJ, Johnston LE: The septopremaxillary attachment and midfacial growth, *Am J Orthod* 66:71–81, 1979.
13. Moss ML, Salentijn L: The primary role of functional matrices in facial growth, *Am J Orthod* 55:566–577, 1969.
14. Moss ML, Salentijn L: The capsular matrix, *Am J Orthod* 56:474–490, 1969.
15. Koski KL: Cranial growth centers: facts or fallacies? *Am J Orthod* 54:566–583, 1968.
16. Dixon AD, et al.: *Fundamentals of craniofacial growth*, Boca Raton, FL, 1997, CRC Press, pp 121–124.
17. Enlow DH, Hans MG: *Handbook of facial growth*, Philadelphia, 1996, WB Saunders.
18. Linder-Aronson S: Effects of adenectomy on dentition and nasopharynx, *Am J Orthod* 65:1–15, 1974.
19. Harvold EP, et al.: Primate experiments on oral respiration, *Am J Orthod* 79:359–372, 1981.
20. Scott JH: The growth of the human face, *Proc R Soc Med* 47:5, 1954.
21. Meredith HV: Changes in form of the head and face during childhood, *Growth* 24:215–264, 1960.
22. Ranly DM: *A synopsis of craniofacial growth*, New York, 1980, Appleton & Lange.

Scand 17:239, 1959.
24. Bergersen EO: The directions of facial growth from infancy to adulthood, *Angle Orthod* 36:18–43, 1960.
25. Brodie AG: Facial patterns: a theme on variation, *Angle Orthod* 16:75–87, 1946.
26. Broadbent BH Sr, et al.: *Bolton standards of dentofacial developmental growth*, St. Louis, 1975, Mosby.
27. Darwis WE, et al.: Assessing growth and development of the facial profile, *Pediatr Dent* 25:103–108, 2003.
28. Ackerman JL, Proffit WR: The characteristics of malocclusion: a modern approach to classification and diagnosis, *Am J Orthod* 56:443–454, 1969.
29. Angle EH: *Treatment of malocclusion of the teeth*, ed 7, Philadelphia, 1907, SS White Dental Mfg.

30. Bell WH, et al.: *Surgical correction of dentofacial deformities*, Vol. 1, Philadelphia, 1980, WB Saunders.
31. Cox NH, van der Linden F: Facial harmony, *Am J Orthod* 60:175–183, 1971.
32. Patterson CN, Powell DG: Facial analysis in patient evaluation for physiologic and cosmetic surgery, *Laryngoscope* 84:1004–1019, 1979.
33. Horowitz SL, Hixon EH: *The nature of orthodontic diagnosis*, St. Louis, 1966, Mosby.
34. Andrews LF: Six keys to normal occlusion, *Am J Orthod* 62:296–309, 1972.
35. Roth RH: Functional occlusion for the orthodontist. Part III, *J Clin Orthod* 15:174, 1981.
36. Enlow DH: A morphogenetic analysis of facial growth, *Am J Orthod* 52:283–299, 1966.
37. Farkas LG: *Anthropology of the head and face in medicine*, New York, 1981, Elsevier.
38. Legan HL, Burstone CJ: Soft tissue cephalometric analysis for orthognathic surgery, *J Oral Surg* 38:744–752, 1980.
39. Enlow DH, et al.: A procedure for the analysis of intrinsic facial form and growth, *Am J Orthod* 56:6–23, 1969.
40. Martinez-Maza C, et al.: Postnatal changes in the growth dynamics of the human face revealed from bone modelling patterns, *J Anat* 223:228–241, 2013.
41. Balbach DR: The cephalometric relationship between the morphology of the mandible and its future occlusal position, *Angle Orthod* 39:29–41, 1969.
42. McNamara JA, Carlson DS: Quantitative analysis of temporomandibular joint adaptations to protrusive function, *Am J Orthod* 76:593–611, 1979.
43. Graber TM, Swain BF: *Orthodontics: current principles and techniques*, St. Louis, 1985, Mosby.
44. Mellion ZJ, et al.: The pattern of facial skeletal growth and its relationship to various common indexes of maturation, *Am J Orthod Dentofacial Orthop* 143:845–854, 2013.
45. Leighton BC: Early recognition of normal occlusion. In McNamara JA, editor: *The biology of occlusion development*, Monograph No. 7, *Craniofacial growth series*, Ann Arbor, 1977, University of Michigan.
46. Arya BS, et al.: Prediction of first molar occlusion, *Am J Orthod* 63:610–621, 1973.
47. Carlsen DB, Meredith HV: Biologic variation in selected relationships of opposing posterior teeth, *Angle Orthod* 30: 162–173, 1960.
48. HEW reports on occlusion: summary and discussion, *J Clin Orthod* 12:849–862, 1978.
49. Friel S: Occlusion: observations on its development from infancy to old age, *Int J Orthod* 13:322–341, 1927.
50. Lewis SJ, Lehman IA: Observations of the growth changes in the teeth and dental arches, *Dent Cosmos* 70:480, 1929.
51. Sanin C, Savara BS: The development of excellent occlusion, *Am J Orthod* 61:345–352, 1972.
52. Moyers RA: *Handbook of orthodontics*, ed 3, Chicago, 1973, Mosby.
53. da Silva LP, Gleiser R: Occlusal development between primary and mixed dentitions: a 5-year longitudinal study, *J Dent Child* 75:287–294, 2008.
54. Northway WM, et al.: Effects of premature loss of deciduous molars, *Angle Orthod* 54:295–329, 1984.
55. Nery EB, Oka SW: Developmental stages of the human dentition. In Melmich M, et al.: eds. *Clinical dysmorphology of orofacial structures*, Boston, 1982, John Wright-PSG.
56. Moorrees CFA: *The dentition of the growing child*, Cambridge, MA, 1959, Harvard University Press.
57. Moorrees CFA: Growth studies of the dentition: a review, *Am J Orthod* 55:600–616, 1969.
58. Anderson AA: The dentition and occlusal development in children of African American descent, *Angle Orthod* 77: 421–429, 2007.
59. Van der Linden FPGM: Transition of the human dentition, Monograph No. 13, *Craniofacial growth series*, Ann Arbor, 1982, University of Michigan.
60. Ten Cate AR: Formation of supporting bone in association with periodontal ligament organization in the mouse, *Arch Oral Biol* 20:137–138, 1975.
61. Fränkel R: Decrowding during eruption under the screening influence of vestibular shields, *Am J Orthod* 65:372–406, 1974.
62. Potter RH, Nance WE: A twin study on dental dimension. *Anthropol* 44:391–395, 1976.
63. Hixon EH, Oldfather RE: Estimation of the sizes of unerupted cuspid and bicuspid teeth, *Angle Orthod* 28:236–240, 1958.
64. Melgaco CA, et al.: Mandibular permanent first molar and incisor width as predictor of mandibular canine and premolar width, *Am J Orthod Dentofacial Orthop* 132:340–345, 2007.
65. Durgekar SC, Naik V: Evaluation of Moyers mixed dentition analysis in school children, *Indian J Dent Res* 20:26–30, 2009.
66. Gardner RB: A comparison of four methods of predicting arch length, *Am J Orthod* 75:387–398, 1979.
67. Kaplan RG, et al.: An analysis of three mixed dentition analyses, *J Dent Res* 56:1337–1343, 1977.
68. Staley RN, Kerber PE: A revision of the Hixon and Oldfather mixed dentition prediction method, *Am J Orthod* 78: 296–302, 1980.
69. Staley RN: Prediction of the widths of unerupted canines and premolars, *J Am Dent Assoc* 108:185–190, 1984.
70. Staley RN, et al.: Prediction of lower canine and premolar widths in the mixed dentition, *Am J Orthod* 76:300–309, 1979.
71. Bishara SE, Staley RN: Mixed-dentition mandibular arch length analysis: a step-by-step approach using the revised Hixon-Oldfather prediction method, *Am J Orthod* 86: 130–135, 1984.
72. Merrifield LL: Differential diagnosis with total space analysis, *J Charles Tweed Foundation* 6:10–15, 1978.

CHAPTER 21

Cephalometrics and Facial Aesthetics: The Key to Complete Treatment Planning

▲ John T. Krull, George E. Krull, and Jeffrey A. Dean

For additional resources, please visit the evolve website.

CHAPTER OUTLINE

RADIOGRAPHIC TECHNIQUE
- Lateral Head Film
- Frontal (Posteroanterior) Film

CEPHALOMETRIC TRACING TECHNIQUE

REFERENCE POINTS FOR LATERAL TRACING

REFERENCE LINES, ANGLES, AND PLANES

INTERPRETATION OF MEASUREMENTS

LATERAL CEPHALOMETRIC ASSESSMENT
- Maxillary Skeletal
- Maxillary Dental
- Mandibular Skeletal
- Mandibular Dental
- Vertical
- Soft Tissue

FRONTAL (POSTEROANTERIOR) CEPHALOMETRIC ASSESSMENT

DIRECTIONS OF GROWTH

COMPUTERIZED CEPHALOMETRIC DIAGNOSIS AND TREATMENT PLANNING
- Digital Imaging

ANTEROPOSTERIOR INTERARCH DISCREPANCIES
- Class I
- Class II Division I
- Class II Division II
- Class III

FACIAL TYPES
- Mesofacial Pattern
- Dolichofacial Pattern
- Brachyfacial Pattern

VERTICAL ARCH DISCREPANCIES
- Open Bite
- Deep Bite

ANGLE CLASSIFICATION OF OCCLUSION
- Descriptive Skeletal and Dental Evaluation

EVALUATION OF FACIAL AESTHETICS
- Frontal View
- Profile View

In studying a case of malocclusion, give no thought to the methods of treatment or appliances until the case variations from the normal in type, occlusion, and facial lines have been thoroughly comprehended. Then the requirements and proper plan of treatment become apparent.

—Edward H. Angle

Cephalometrics, the assessment of craniofacial dimensions, particularly the ethnographic determination of cranial morphology, is an ancient skill practiced by anthropologists for centuries.

Beauty and harmony are the traditional guiding principles used to assess facial proportions, although the definition of beauty may change as civilizations change. Greek sculpture during the golden age of art (fourth century BC) shows facial proportions very similar to those found desirable today. Basic facial features of Greek male and female figures appear to be depicted identically, with most sculpture angles within 5° of contemporary standards; the exceptions are a more acute mentolabial sulcus and nasofacial angle for the ancient Greek ideal.

In the early twentieth century, dentistry began to include the concepts of facial harmony and balance in the theory and practice of cephalometrics. In 1922 Simon introduced this modern era with the development of gnathostatics, a photographic technique that related the teeth and their respective bony bases to each other and to specific craniofacial structures. Although Racini and Carrera obtained the first x-ray films of the skull by the standard lateral view in 1926, it was not until the introduction of the cephalometer by Broadbent in 1931 that the science of cephalometrics became standardized. This sophisticated form of radiography enabled the practitioner to identify specific problem areas of craniofacial disproportion and devise detailed therapeutic interventions. Through the contributions of investigators such as Brodie, Downs, Reidel, Steiner, Tweed, and Ricketts, the clinical application of cephalometrics has developed the techniques that permit the observation of discrepancies observed in the mandible, maxilla, dental units, and soft-tissue profile.

The primary aim of cephalometric analysis is to localize malocclusion within a tracing of facial bone and soft-tissue structures. The analysis is performed by using standardized cephalometric landmarks to construct lines, angles, and imaginary planes, which permits the linear and angular assessment of dental and facial relationships as seen on radiographic films of the head and face. These findings are compared with established normal values,

Dentlearn.ir

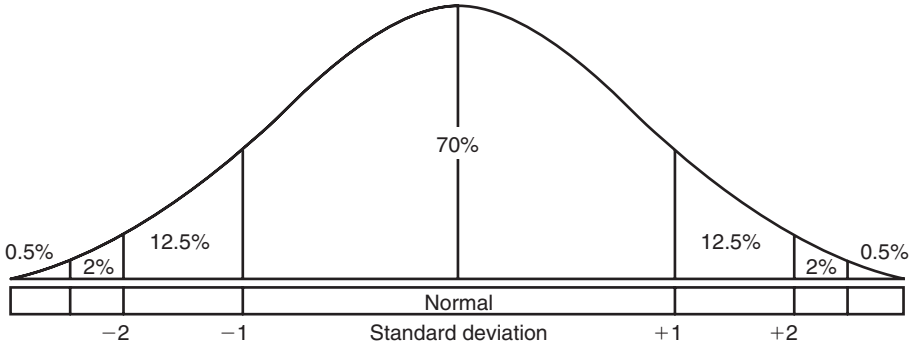

Figure 21-1 Bell-shaped curve illustrating the approximate distribution of biologic variables in the general population.

and an individualized treatment protocol is developed for orthopedic, orthodontic, and orthognathic therapies.

The science of cephalometrics has often been referred to as a "numbers game" and has the reputation of being difficult to master. There appears to be a universal search one to an accurate diagnosis. Such a search is futile because all cephalometric measurements may at times lead one to an erroneous conclusion. However, an accurate, in-depth analysis provides one with an assessment of dentofacial and craniofacial morphology. A cephalometric radiograph furnishes one with a static analysis, whereas subsequent films allow the clinician to follow the growth patterns of the adolescent patient on a longitudinal basis. In addition, comparison of serial cephalograms of the same patient may allow some developmental predictions to be made.

The use of cephalometrics serves to confirm the diagnosis and makes it possible to include the morphology of the cranium when alternative treatment modalities are considered. In patient care, cephalometrics can provide valuable data when treatment is first initiated and can serve a monitoring function during the course of orthodontic care. On completion of treatment, cephalometric radiology enables one to assess the relative degree of posttreatment stability and evaluate treatment results produced by various mechanical and appliance selections.

Cephalometric numbers or central tendencies have been developed to serve as guidelines in evaluation of the patient. Dentists must keep in mind that they are treating individuals, not averages, and that the numbers merely help or guide in the formulation of an accurate diagnosis and treatment plan. Because of individual anatomic, biological, and environmental variations, it is imperative that the clinician consider several factors to achieve a comprehensive case analysis. Any attempt to simplify the analysis is likely to lead to an erroneous conclusion.

The norm is commonly referred to as the *mean* or *average*. However, the norm, as it is applied in cephalometrics, is not a set of averages. The average patient in any given population will generally deviate from the norm because dental occlusions of the Class I variety.

Most biological variables are randomly distributed in the population and can be graphically illustrated by a bell-shaped curve (Fig. 21-1). Within this curve, approximately 70% of any given population lies within one standard deviation of the mean and 95% of the population falls within two standard deviations. Throughout this chapter, the statistical concept of standard deviation is referred to as *clinical deviation* (CD).

As a general rule, the goal in treatment planning is to treat in the direction of cephalometric norms. The clinical advantages include the following:

1. A more favorable and predictable aesthetic result
2. Greater posttreatment stability
3. Improved function and periodontal health

RADIOGRAPHIC TECHNIQUE

The technique used in cephalometric radiology has been standardized to permit the comparison of initial and subsequent films for the same patient so that growth can be assessed and treatment progress monitored.

This standardization requires that the equipment include a headholder (cephalostat) and an x-ray tube positioned at a distance of 60 inches from the midsagittal plane of the subject and that the distance from the midsagittal plane of the patient to the film be approximately 7.5 inches (Fig. 21-2). The cephalostat maintains a reproducible spatial relationship with respect to the position of the patient's head, the film, and the x-ray source. The most common device uses a counterbalanced beam with the radiographic tube on one end and the cephalostat on the other. This entire unit can be adjusted vertically to compensate for variations in patient height.

The patient is positioned in the cephalostat by means of laterally adjusted ear rods and a vertically adjusted nasal piece (Fig. 21-3). The nasal piece allows the clinician to orient the patient's head so that the Frankfort horizontal plane (a plane extending from the tragus of the ear to the inferior border of the orbital rim) is parallel to the floor. The ear posts should be centrally aligned to the source of radiation so that a transporionic axis is established.

LATERAL HEAD FILM

For a lateral head radiograph, the patient is first positioned so that the left side of the face is tangent to an 8 × 10-inch film cassette, which permits less magnification and less distortion of the left-sided structures (Fig. 21-4).

The film cassette should be positioned as closely as possible to the patient to minimize the effects of magnification, maximize resolution, and standardize the technique. The distance from the film cassette to the patient's midsagittal plane should be recorded to allow for comparison

Dentlearn.ir



Figure 21-2 Wall-mounted, counterbalanced cephalometer. (Courtesy Dr. William W. Merow.)



Figure 21-3 Patient positioned in the cephalostat.

of serial films. Generally, the film is obtained with the mandible in its most retruded position and the lips in repose. Use of additional positions may be indicated. Once the patient has been positioned, the x-ray beam should enter through the ear rods perpendicular to the film.

Grids and intensifying screens are accessories used to improve the quality of the radiographic image. Rare-earth

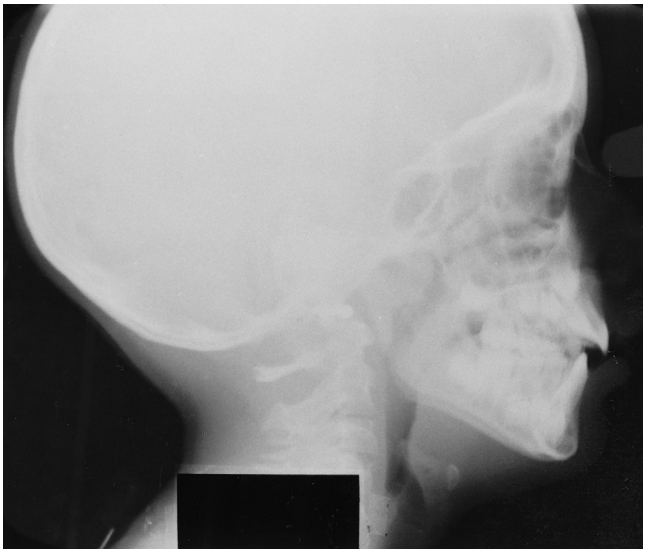

Figure 21-4 Lateral cephalometric film.

intensifying screens allow for a reduction of radiographic exposure while increasing the clarity of the radiographic image. Because the film range does not provide for sharp skeletal and soft-tissue contrast, a movable aluminum screen attached to the cassette must be used over the soft-tissue profile area to reduce the radiation and provide a better differential contrast between the two tissue types.

FRONTAL (POSTEROANTERIOR) FILM

Most diagnostic features related to vertical and anteroposterior (AP) problems are evident from the lateral film; however, severe maxillary transverse deficiencies or facial asymmetries may be better diagnosed using a posteroanterior (PA) film (Fig. 21-5). The patient is oriented facing the film cassette, with the ear rods and nasion piece positioning the patient so that the midsagittal and Frankfort planes are at right angles to the film cassette. After the patient's head is positioned so that the central x-ray beam



Figure 21-5 Frontal (posteroanterior) cephalometric film. (Courtesy Dr. William W. Merow.)

passes through the head at the level of the transporionic axis and at its midpoint, the film cassette is moved into contact with the patient's nose. Because more radiation is required for this view, the milliamperage must be increased over that used in the lateral film technique.

CEPHALOMETRIC TRACING TECHNIQUE

Precise localization of the anatomic landmarks used in cephalometric analysis requires adequate knowledge of the radiographic and anatomic appearance of the facial bones and their relationships to adjacent structures. Various features are discernible: lines, shadows, the projections of bony structures, and contours of various densities. All of these make it difficult for the clinician to interpret and identify the anatomic relationships. A clear understanding of craniofacial structures and their relative spatial relationships is imperative before a lateral head film is traced.

Figure 21-6 depicts a lateral cephalometric tracing. The lateral tracing should include the soft-tissue outline, bony profile, outline of the mandible, posterior and anterior cranial base, odontoid process of the axis, anterior lip of the foramen magnum, clivus, planum orbitale, sella turcica, orbit, pterygomaxillary fissure, floor of the nose, roof of the palate, and body of the hyoid bone.

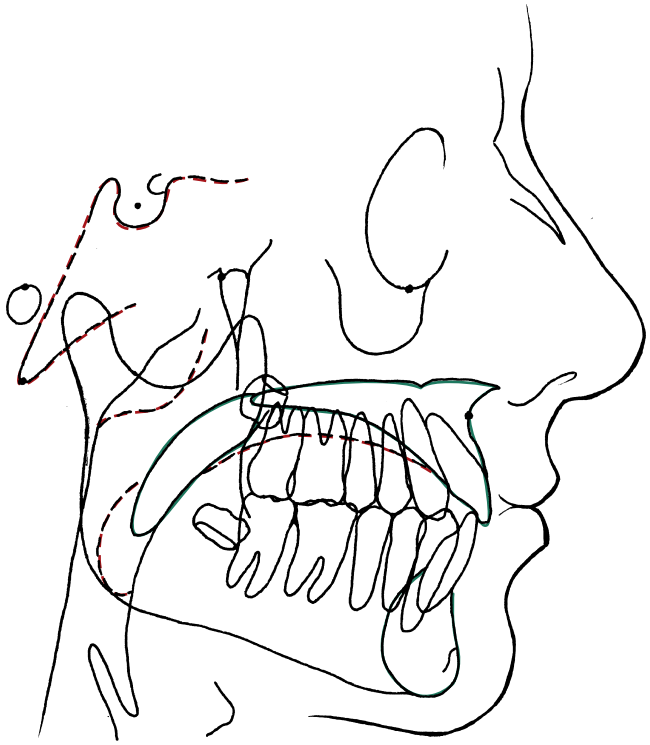

Figure 21-6 Lateral cephalometric tracing.

In addition to the bony tissues, at least the first permanent molars and the most anterior maxillary and mandibular incisors are commonly included. In certain situations it may be desirable to trace other teeth or the complete dentition, as shown in Figure 21-6.

For the tracing to be made, the radiograph is placed on a view box with the facial profile to the right side. Acetate tracing paper (0.003 matte) is then placed over the radiograph with the matte side up. With a sharp No. 2 or 3H drawing pencil, all the necessary structures are traced (Video 21-1: Cephalometrics). Because all x-rays become divergent once they emanate from the collimator, magnification of the subject will result, and a double-image effect will occur along the inferior border of the mandible and the area of the posterior teeth. All paired structures will produce double images on the head films. Because left-sided structures are magnified less by the radiographic beam and are considered more accurately rendered, the outline of these structures can be traced, although some prefer to make the tracing lines bisect bilateral images.

A PA cephalometric radiograph, as illustrated in Figure 21-5, can be of significant diagnostic value in cases demonstrating mandibular displacement, facial asymmetry, severe posterior crossbite, or other types of bony dysplasia. Cephalometric analysis and a thorough and systematic clinical examination of these patients often reveal malocclusions accompanied by mandibular shifts when the patient is in maximum occlusion.

The PA radiograph is traced in the same manner as the lateral film. Figure 21-7 illustrates the important skeletal and dental structures that must be traced for an accurate and complete analysis. Even though many practitioners are trained in cephalometrics using the manual tracing

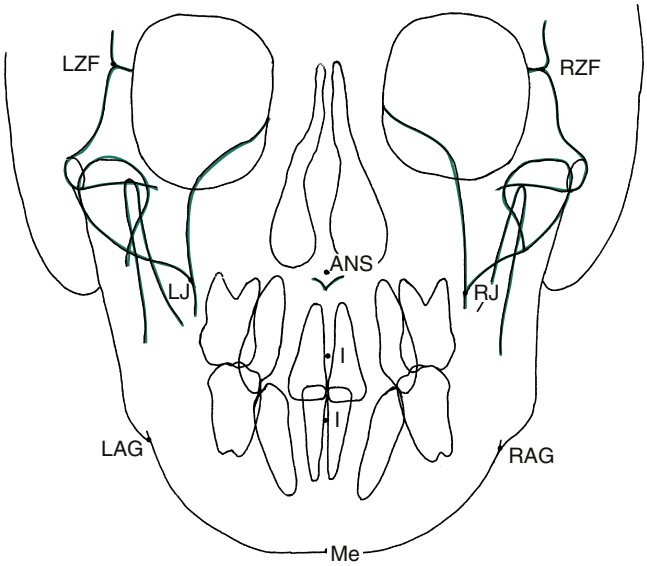

Figure 21-7 Frontal (posteroanterior) cephalometric tracing (see also Fig. 21-10). *ANS,* Anterior nasal spine; *I, I* (incisor) point; *LAG,* left antegonial notch; *LJ,* left jugal process of maxillary tuberosity; *LZF,* left zygomaticofrontal suture; *Me,* menton; *RAG,* right antegonial notch; *RJ,* right jugal process of maxillary tuberosity; *RZF,* right zygomaticofrontal suture.

methodology, contemporary cephalometric tracing is now most often done digitally with a computer software program on a digital cephalogram. The principles of the tracing are the same; only the tools are different.

REFERENCE POINTS FOR LATERAL TRACING

The ultimate diagnostic value of the cephalometric analysis is dependent on the initial accurate identification and localization of anatomic and anthropologic points (Fig. 21-8). These landmarks are used to construct the lines, angles, and planes used to make a two-dimensional assessment of the patient's craniofacial and dental relationships. Although each analysis is completed in two dimensions, when the lateral and PA analyses for the same patient are considered together, a three-dimensional simulation emerges to contribute to the overall diagnosis and treatment plan. The following reference points are used in this chapter (see Fig. 21-8):

Sella turcica (S, or sella). The midpoint of the hypophyseal fossa. This is the ovoid area of the spheroid bone that contains the pituitary gland.

Nasion (N). The external junction of the nasofrontal suture in the median plane. If the suture is not visible, this point is located at the deepest concavity of the two bones.

Orbitale (O). The most inferior point on the external border of the orbit.

Condylion (Cd). The most superior point on the articular head of the condyle.

Anterior nasal spine (ANS). The most anterior projection of the anterior nasal spine of the maxilla in the median plane.

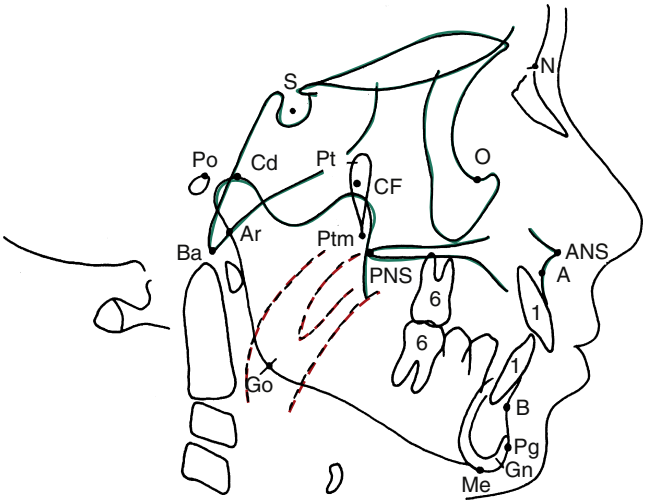

Figure 21-8 Lateral tracing with cephalometric reference points. (Adapted from Dr. William W. Merow.)

A point (subspinale, or A). The deepest point of the curvature of the anterior maxilla between the ANS and the alveolar crest. Although the A point may change with treatment, it represents the most forward point of the maxilla.

B point (supramentale, or B). The most posterior point on the outer curve of the mandibular alveolar process between the alveolar crest and the bony chin. The B point delineates the most anterior point of the mandible in the median plane.

Pogonion (Pg). The most anterior point on the midsagittal mandibular symphysis.

Menton (Me). The most inferior point of the mandibular symphysis.

Gnathion (Gn). A constructed point that is formed by the intersection of the facial and mandibular planes.

Gonion (Go). Another constructed point that is represented by the intersection of the lines tangent to the posterior margin of the ascending ramus and the mandibular plane.

Articulare (Ar). The point of intersection of the posterior margin of the ascending ramus and the outer margin of the cranial base.

Porion (Po). A point located at the most superior point of the external auditory meatus or the superior aspect of the metal ring that is a component of the left ear rod of the cephalostat.

Basion (Ba). The most inferior posterior point on the occipital bone that corresponds to the anterior margin of the foramen magnum.

Pterygomaxillary fissure (Ptm). A teardrop-shaped fissure, the posterior wall of which is created by the anterior borders of the pterygoid plates of the sphenoid bone; the anterior wall represents the posterior border of the maxilla (maxillary tuberosity). The tip of this fissure denotes the posterior extent of the maxilla.

Posterior nasal spine (PNS). The tip of the posterior spine of the palatine bone. This landmark is usually not visible even on well-exposed lateral head films; therefore it is a constructed point that is represented by the

intersection of a continuation of the anterior wall of the pterygopalatine fossa and the floor of the nose. It also denotes the posterior limit of the maxilla.

Pt point (Pt). The intersection of the inferior border of the foramen rotundum with the posterior wall of the Ptm.

CF point (center of face). The cephalometric landmark formed by the intersection of the Frankfort horizontal plane and a perpendicular line through Pt.

REFERENCE LINES, ANGLES, AND PLANES

Linear assessment is derived when two reference points are connected. Angular measurements are possible when three points are used. Planes (and some lines) are actually imaginary when the cephalometric tracing is viewed because the planes are at right angles to the tracing and can be seen only as a line on the two-dimensional tracing (Fig. 21-9). In cephalometric analysis the dentist must become accustomed to thinking in three dimensions while viewing a two-dimensional representation. Therefore a point on the tracing may not only be a point but also may represent a line (or axis). A line on the tracing may actually be a line (or axis) or it may represent a plane.

Several lines or planes are used in different cephalometric analyses, although one line or plane generally serves as the major reference on which the entire analysis is based. Two common references are the sella-nasion plane (anterior cranial base) and the Frankfort horizontal plane.

The basic units of cephalometric analysis are angles and distances (lines). Measurements may be treated as absolute values, or they may be related to one another and expressed as relative proportions. These measurements and interrelationships provide the basic framework for describing craniofacial abnormalities. The following definitions help explain the planes of reference used in this chapter (see Fig. 21-9).

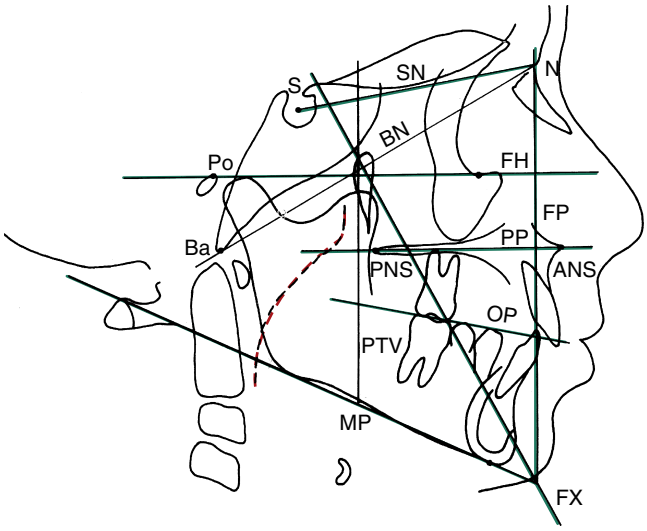

Figure 21-9 Cephalometric reference lines and planes. (Adapted from Dr. William W. Merow.)

Frankfort horizontal plane (FH). This plane is constructed from the porion (Po) to the orbitale (O) and represents the basic horizontal plane of the head.

Sella-Nasion plane (SN). This plane is represented by a line connecting the sella (S) and the nasion (N). It denotes the AP extent of the anterior cranial base. This reference plane is of questionable diagnostic value in true mandibular prognathism.

Occlusal plane (OP). This plane separates the maxillary and mandibular permanent molars (or, in younger patients, the primary second molars) and passes through the contact between the most anterior maxillary and mandibular incisors. If the incisors are not in contact, the line passes midway between the incisal edges. Ideally, the OP is nearly parallel to both the palatal plane (PP) and the FH.

Facial plane (FP). A line constructed through the nasion (N) perpendicular to the FH represents this plane.

Mandibular plane (MP). The mandibular plane is constructed as a tangent to the inferior border of the mandible.

Pterygoid vertical plane (PTV). This plane is represented by a line perpendicular to the FH through the Pt point. Studies have shown that the intersection of the FH and the PTV is extremely stable because growth has little effect on this point. An overall view of patient growth may be gained by evaluation of serial cephalometric films on which the FH and the PTV are superimposed. The PTV represents a basic vertical reference plane.

Basion-Nasion plane (BN). This plane passes through the basion (Ba) and nasion (N). The plane represents the cranial base and is the dividing plane between the cranium and the face.

Facial axis (FX). This line is constructed from the Pt point through the gnathion. The FX ideally crosses the BN at a right angle.

Palatal plane (PP). This plane extends through the anterior nasal spine (ANS) and posterior nasal spine (PNS). The relationship of this plane to the FH is useful in evaluation of the treatment changes occurring in the maxilla.

INTERPRETATION OF MEASUREMENTS

The objectives of cephalometric interpretation are summarized as follows:

1. To define both the skeletal and facial types
2. To evaluate the relationship between the maxillary and mandibular basal bones
3. To assess the dental relationships (the spatial relationships between the teeth, maxilla, mandible, and cranial base)
4. To locate the malocclusion within the dentofacial complex and analyze its origin (skeletal or dentoalveolar)
5. To study the facial soft-tissue contours with respect to the cause of the malocclusion
6. To consider the impact of the various options for correcting the malocclusion on the facial contours and on the skeletal and dental components
7. To facilitate selection of a treatment plan
8. To evaluate the results of various soft-tissue surgical procedures

Dentlearn.ir

LATERAL CEPHALOMETRIC ASSESSMENT

MAXILLARY SKELETAL

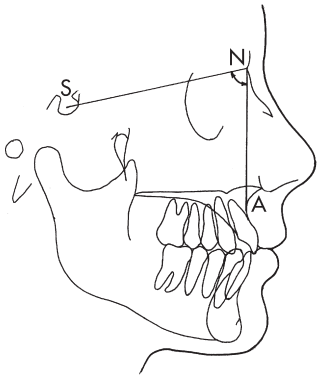

SNA

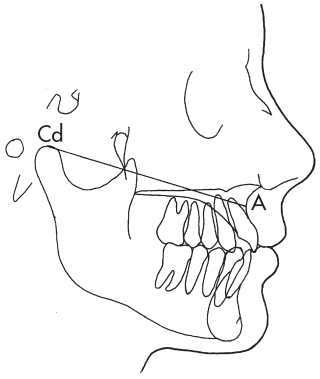

MAXILLARY LENGTH

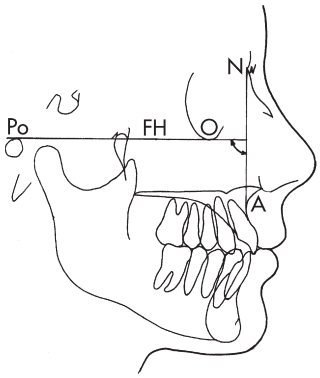

MAXILLARY DEPTH

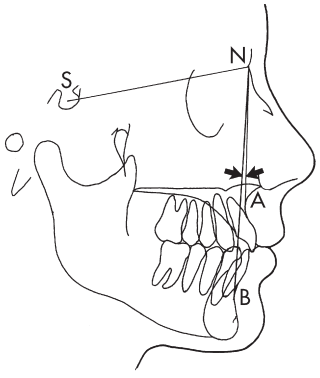

ANB

SNA: The angle between SN and N–A point line

Clinical norm: 82°

Clinical deviation: 2°

Interpretation: Establishes horizontal location of the maxilla. Deviation in cranial base (SN, angulation, or length) or vertical maxillary excess proves that this measurement is unreliable. Therefore reduced emphasis should be given in these instances.

Maxillary depth: The angle formed by the intersection of the FH and N–A point planes

Clinical norm: 90°

Clinical deviation: 3°

Interpretation: Indicates horizontal position of maxilla. Class II skeletal patterns caused by a prognathic maxilla show values exceeding 90°. Chronic thumb-suckers generally demonstrate large values.

Maxillary length: The measurement of the line extending from Cd to A point

Clinical norm: 85 mm (female), 87 mm (male)

Clinical deviation: 6 mm

Interpretation: Increases 1 mm per year until adult size is attained (95 to 100 mm). This measurement determines if the Class II or Class III skeletal pattern is attributable to a long or short maxilla, respectively.

ANB: The difference between the SNA and SNB angles

Clinical norm: +2°

Clinical deviation: 2°

Interpretation: Indicates the horizontal relationship between maxilla and mandible. Positive values indicate that the maxilla is forward of the mandible, whereas negative values indicate a Class III skeletal relationship.

MAXILLARY DENTAL

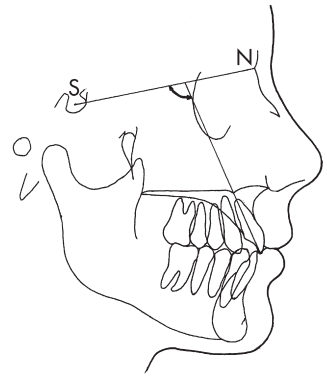

MAXILLARY INCISOR ANGULATION

Dentlearn.ir

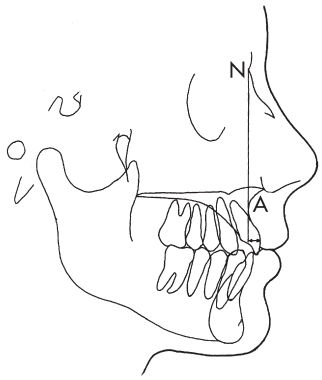

MAXILLARY INCISOR
(ANTERIOR-POSTERIOR) POSITION

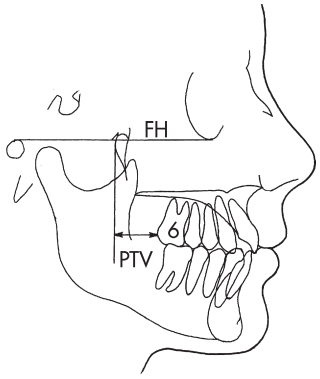

UPPER MOLAR POSITION

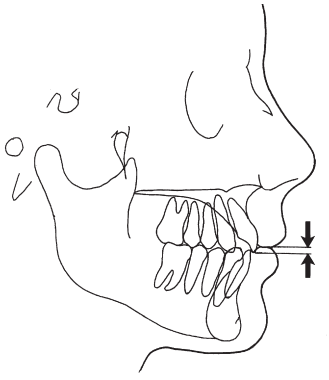

MAXILLARY INCISOR TO UPPER LIP

Maxillary incisor angulation: The angle formed by SN and the incisor long axis

Clinical norm: 102°

Clinical deviation: 3°

Interpretation: Relates the upper incisor angulation to the upper and middle face. Values well above 102° indicate angular incisor protrusion, whereas values significantly less than that demonstrate angular retrusion. It is also important to take into consideration that the incisal two thirds of the maxillary central incisor crown is narrower and relatively flat. The labial surface has its greatest height at the center of the gingival margin and curves to the incisal edge. Ideally, the incisal two thirds should be parallel to the facial plane (FP).

Maxillary incisor AP position: The horizontal distance from the facial surface of the maxillary central incisors to the N–A point line

Clinical norm: 4 mm

Clinical deviation: 2 mm

Interpretation: Indicates horizontal position of the maxillary incisors. Values in excess of 6 mm indicate anterior dental protrusion, whereas values 1 mm or less show dental retrusion.

Upper molar position: The horizontal distance from PTV to the distal surface of the maxillary first molar

Clinical norm: Chronologic age of the patient + 3 mm (e.g., a 10-year-old has a clinical norm of 10 + 3 = 13 mm). The growth change is approximately 1 mm per year through the years of active growth.

Clinical deviation: 3 mm

Interpretation: Determines if the dental malocclusion is caused by the AP position of the maxillary molar. It is important in treatment planning considerations involving distal movement of the maxillary molars.

Maxillary incisor to upper lip: The vertical distance between the inferior border of the upper lip and the incisal edge of the maxillary incisor

Clinical norm: 3 mm

Clinical deviation: 1 mm

Interpretation: Gives an evaluation of the amount of upper incisor in repose. Values of 5 mm or more may be associated with vertical maxillary excess. This value must be compared with upper lip length. Patients with short upper lips will show more incisor at rest.

MANDIBULAR SKELETAL

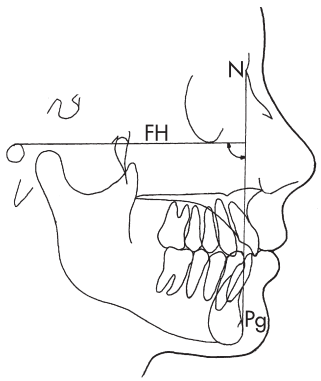

FACIAL ANGLE

Dentlearn.ir

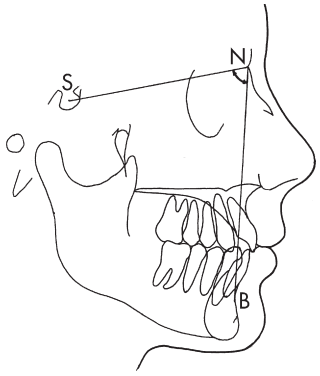

SNB

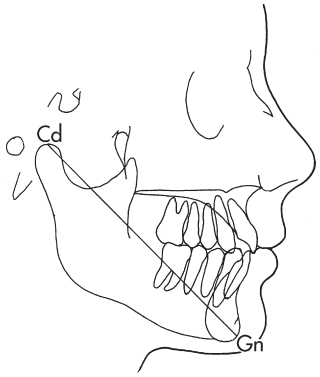

MANDIBULAR LENGTH

SNB: The angle formed between the SN and N–B point planes

Clinical norm: 80°

Clinical deviation: 2°

Interpretation: Indicates horizontal location of the mandible. Abnormal cranial base angulation and vertical facial excess will adversely affect the reliability of this measurement.

Facial angle (depth): The angle formed between the N-Pg and FH planes

Clinical norm: 87° at 9 years of age. Increases 0.33° per year.

Clinical deviation: 3°

Interpretation: Locates the horizontal position of the chin. Determines if the skeletal Class II or Class III relationship is attributable to a retrognathic or a prognathic mandible.

Mandibular length: The absolute distance between Cd and Gn

Clinical norm: 105 mm at 9 years of age with yearly growth increments of 2 to 2.5 mm, reaching a maximum of 120 to 130 mm. Generally 2 mm less in females than in males at 9 years of age.

Clinical deviation: 6 mm

Interpretation: Determines whether the skeletal Class II or Class III relationship is attributable to a small or large mandible.

MANDIBULAR DENTAL

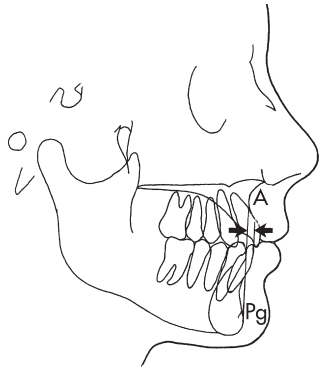

MANDIBULAR INCISOR PROTRUSION

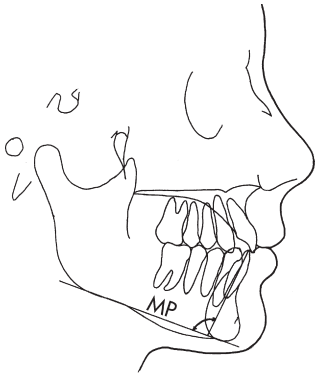

IMPA

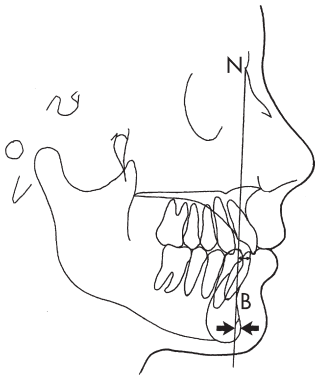

HOLDAWAY RATIO

Mandibular incisor protrusion: The horizontal distance from the tip of the mandibular incisor to the A point–Pg line

Clinical norm: +2 mm

Clinical deviation: 2.3 mm

Interpretation: Defines the AP position of the mandibular dental unit and quantifies the reciprocal relationship of the maxillary and mandibular dental units. Not only

Dentlearn.ir

is this a key aesthetic relationship, but it also needs to be correlated with a functional arch length analysis.

Incisor mandibular plane angle (IMPA): The inner angle between the long axis of the mandibular incisor and MP

Clinical norm: 90°

Clinical deviation: 4°

Interpretation: Gives an evaluation of the angular position of the incisor to the mandibular basal bone.

Holdaway ratio: The ratio of the mandibular incisor and Pg to the N–B point line

Clinical norm: 1:1

Clinical deviation: 2 mm

Interpretation: The AP position of the mandibular incisor and Pg should project equally from the N–B point line for good facial balance.

VERTICAL

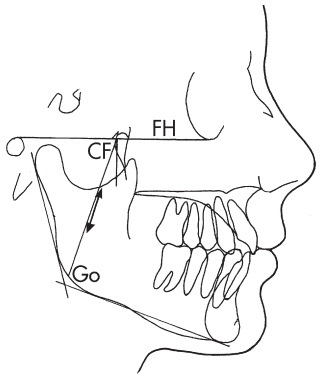

POSTERIOR FACIAL HEIGHT

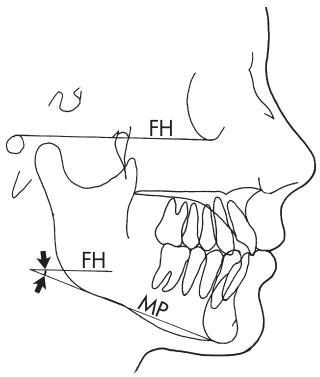

FMA

Posterior facial height: The linear distance between Go and the CF point

Clinical norm: 55 mm for the average-sized patient at 8.5 years of age. Increases 1 mm per year.

Clinical deviation: 3.3 mm

Interpretation: Measures vertical growth of the ramus and can therefore be of value in predicting clockwise or counterclockwise growth patterns. Values less than 51 mm represent a leaning toward dolichofacial patterns,

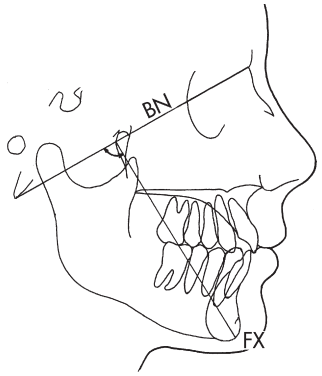

FACIAL AXIS ANGLE

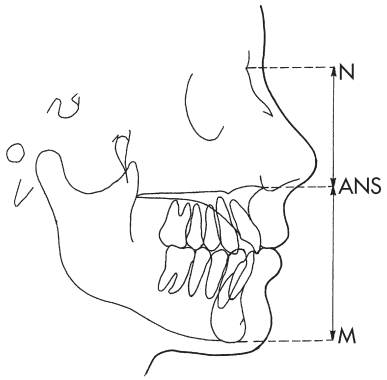

FACIAL HEIGHT

whereas values in excess of 59 mm may indicate brachyfacial or counterclockwise growth trends.

Mandibular plane angle (FMA): The angle formed by the intersection of FH and MP

Clinical norm: 26°. Decreases 1° every 4 years during normal growth.

Clinical deviation: 4°

Interpretation: Values in excess of 31° may indicate clockwise growth with dolichofacial growth trends, whereas values less than 21° imply vertical deficiency as often seen in brachyfacial growth patterns.

Facial axis angle: The angle between FX and BN

Clinical norm: 90°

Clinical deviation: 3.5°. Changes 1° every 3 years in the average patient.

Interpretation: Expresses the ratio of facial height to depth and thus indicates the direction of growth of the chin. Values in excess of 94° may indicate counterclockwise growth and those less than 85° may imply clockwise growth in brachyfacial and dolichofacial facial types, respectively.

Facial height: The vertical relationship between upper and lower facial height (N-ANS:ANS-M)

Clinical norm: Upper, 53 mm; lower, 65 mm

Interpretation: More important than the absolute value is the ratio between upper and lower facial height, which should be approximately 5:6 for a well-balanced face.

Dentlearn.ir

SOFT TISSUE

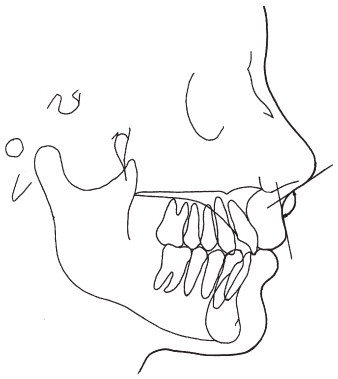

NASOLABIAL ANGLE

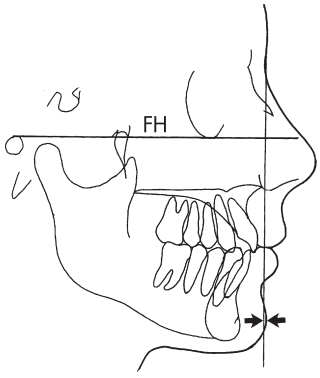

ZERO MERIDIAN

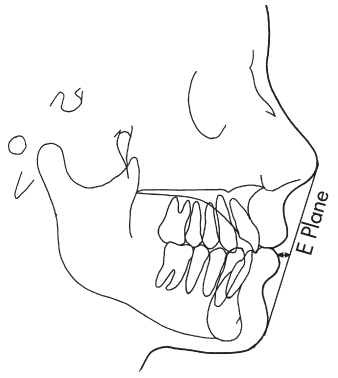

LIP PROTRUSION

Nasolabial angle: The angle formed by the intersection of the lines tangent to the columella of the nose and the upper lip

Clinical norm: 90° to 110°

Interpretation: Provides an assessment of the nose-to-upper lip relationship. Values in excess of 114° may indicate upper lip retrusion, whereas values of 96° or less may be associated with dental protrusion.

Zero meridian: The horizontal distance from the chin to a line perpendicular to FH and tangent to the soft-tissue nasion

Clinical norm: 0 mm

Clinical deviation: 2 mm

Interpretation: May be helpful in assessment of the projection of the chin relative to FH.

Interlabial distance: The vertical distance between the inferior aspect of the upper lip and the superior surface of the lower lip with the patient in repose

Clinical norm: 1.9 mm

Clinical deviation: 1.2 mm

Interpretation: High values indicate lip incompetence and are often associated with hyperactivity of the mentalis muscle. Low values may be associated with overclosure.

Lip protrusion: The horizontal distance between the lower lip and the aesthetic plane (E plane). The aesthetic plane is a line connecting the tip of the nose and the most anterior point on the soft-tissue chin.

Clinical norm: –2 mm at 8.5 years of age; decreases 0.2 mm per year. The values tend to decrease with age until adult values of –5 mm are reached.

Clinical deviation: 2 mm

Interpretation: Indicates soft-tissue balance between lips and profile (nose-chin). This measurement is important because it takes into account the variability in thickness of the soft-tissue chin.

FRONTAL (POSTEROANTERIOR) CEPHALOMETRIC ASSESSMENT

Frontal cephalometric points and planes are used to evaluate the overall relationships of the cranium, maxilla, mandible, and denture from a frontal view. Figure 21-10 is a graphic representation of the points, lines, and planes used in frontal cephalometric analysis.

Dental midline: The horizontal distance between the maxillary and mandibular incisor midlines

Clinical norm: 0 mm

Clinical deviation: 1.5 mm

Interpretation: Determines dental midline asymmetry.

Maxillomandibular width: The horizontal distance between the jugal process of the maxilla and the frontal facial plane

Clinical norm: 10 mm for patient of average size at 8½ years of age. Needs to be corrected for size.

Interpretation: Determines if a crossbite is skeletal in nature. Large values are associated with skeletal lingual crossbites, whereas lesser values indicate skeletal buccal crossbites.

Maxillomandibular midline: The angle formed by the ANS-Me plane through ANS and perpendicular to the zygomatic frontal suture plane

Clinical norm: 0 mm

Clinical deviation: 2 mm

Interpretation: Determines whether facial asymmetry is attributable to total size discrepancy or a functional shift of the mandible.

Denture to jaw midlines: The horizontal distance between the midlines of the mandibular incisors and maxilla and mandible

Clinical norm: 0 mm

Clinical deviation: 1.5 mm

Interpretation: Aids differential diagnosis between denture shift and mandibular shift.

Dentlearn.ir

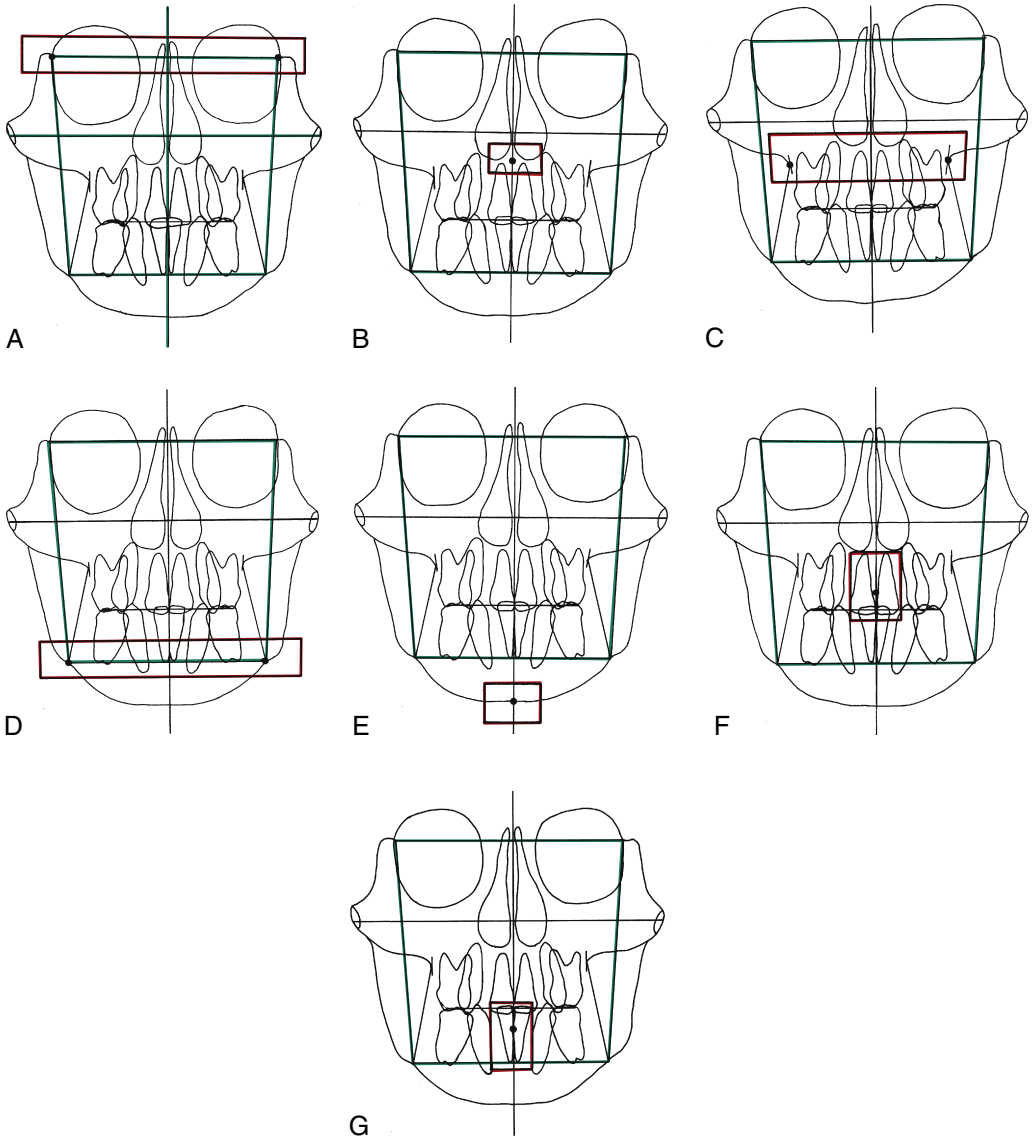

Figure 21-10 Frontal reference points (see also Fig. 21-7). **A,** LZF/RZF, bilateral points on the medial aspect of the zygomaticofrontal sutures at the intersections of the orbits. **B,** ANS, tip of anterior nasal spine. **C,** LJ/RJ, bilateral points on the jugal processes and the intersection of the maxillary tuberosities and the zygomatic buttresses. **D,** LAG/RAG, points at the lateral inferior margin of the antegonial protuberances of the mandible. **E,** Me, menton, point of the inferior border of the mandibular symphysis directly inferior to the mental protuberance. **F,** I point, a point selected at the interdental papilla of the upper incisors at the junction of the crowns and gingiva. **G,** I point, a point selected at the interdental papilla of the lower incisors at the junction of the crowns and gingiva.

Occlusal plane tilt: Measures the degree of parallelism between the occlusal plane and a line through the zygomatic frontal sutures

Clinical norm: 0 mm

Clinical deviation: 2 mm

Interpretation: A skeletal asymmetry in addition to a tilt in occlusal plane is usually a signal of possible temporomandibular joint dysfunction.

Maxillary width: The horizontal distance between the jugal processes of the maxilla

Clinical norm: 61.9 mm at 9 years of age. Increases 0.6 mm per year.

Clinical deviation: 3 mm

Interpretation: Indicates the width of the maxilla. The change in value is useful in cases involving sutural expansion of the palate.

DIRECTIONS OF GROWTH

The constructed gonial angle is formed by the intersection of the ascending ramus and the body of the mandible. This angle can be used as an initial assessment of future mandibular growth. The direction of growth is very important in the selection of a functional appliance if that method of treatment is indicated. In cases such as mandibular prognathism, the information

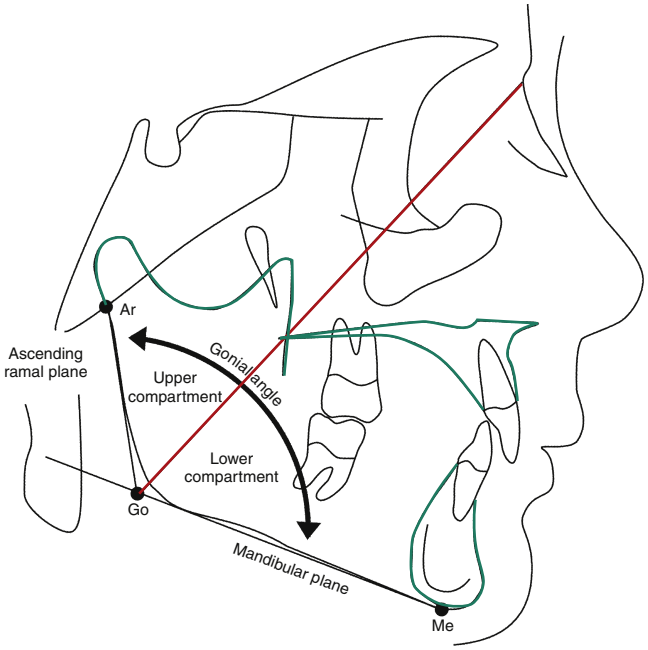

Figure 21-11 Facial growth vector assessment and the gonial angle.

would lead one to the conclusion that treatment might best be delayed due to the possibility of latent mandibular growth.

The gonial angle is divided into two parts for determination of the angular relationship between the ascending ramus and the body of the mandible. A line is constructed between the nasion and the constructed gonial angle (facial depth line), dividing the gonial angle into upper and lower compartments. As a general rule, the upper angle, with a normal range of 52° to 55°, indicates horizontal or counterclockwise growth. The lower angle, with a range of 70° to 75°, is an indicator of vertical or clockwise growth. The astute clinician needs to keep in mind that growth rarely occurs in a straight line but rather exhibits more of a curve (Fig. 21-11).

A larger upper angle would indicate a more forward growth, whereas a larger lower angle would indicate downward growth. Conversely, a small upper angle would indicate clockwise growth and a small lower angle would suggest counterclockwise growth.

Another method of assessing the direction of growth is to divide the upper angle by the lower angle, resulting in a percentage. The numerical value can then be compared with the numbers in the following list to give an idea of the growth vector. A more in-depth analysis may be indicated in more difficult musculoskeletal discrepancies.

Ideal growth: 70% to 78%
Clockwise tendency: 69.9% to 68.1%
Clockwise growth: ≤68%
Excessive clockwise growth: <60%
Counterclockwise tendency: 78.1% to 79.9%
Counterclockwise growth: ≥80%
Excessive counterclockwise growth: >88%

COMPUTERIZED CEPHALOMETRIC DIAGNOSIS AND TREATMENT PLANNING

The availability of inexpensive and powerful computers in the dental office has made comprehensive cephalometric software a reliable tool for the practitioner. These computer programs, in addition to providing accurate models of the skeletal and soft-tissue anatomy, allow for an accurate prediction of aesthetic results by the evaluation of the soft-tissue changes secondary to orthodontic and orthopedic alterations in the hard tissues. One can also evaluate multiple treatment plans and examine the changes that would result relative to the soft tissue before actually initiating a specific treatment plan.

DIGITAL IMAGING

Imaging has been an important aspect of dental care since the early 1900s. The x-ray was discovered by Wilhelm Conrad Roentgen in late 1895. This discovery resulted in a method whereby dental anatomy could be evaluated. Dr. Otto Walkoff took the first dental radiographs in 1896, with an exposure time of 25 minutes. Later that same year, advances were made in the field such that the exposure time was reduced to 9 minutes. The first dental radiographs were obtained in the United States that same year by the Eastman Kodak Company. Finally, in 1919 Kodak produced the first dental x-ray films designed for direct exposure. The F-speed film introduced in 2000 required 1/60th of the radiation of the 1919 films.

Over the years, dentistry has been on the cutting edge of radiology. Dentistry entered a new era of diagnostic imaging when French dentist Francis Mouyen introduced digital imaging in 1987. This method creates images with the use of a computer. In recent years, cone-beam computed tomography (CT) has come into play. This digital imaging system can produce both two- and three-dimensional images.

Digital imaging provides high-resolution images and compared with conventional radiography, the patient is exposed to reduced radiation. Additionally, digitally generated images provide an accurate and reproducible method of analysis. Digital radiographs used in conjunction with the appropriate software can generate three-dimensional images and allow for an accurate evaluation of anatomic structures. Improved image sharpness in, for example, the central incisor region can be accomplished by digital elimination of the shadows cast by the cervical vertebrae. A more relevant image results in a more accurate diagnosis.

In 2001 the TOM OR-DVT-9000, the first dentomaxillofacial dedicated cone-beam CT machine, was developed in the United States. Virtually every practitioner can benefit from this new technology. In the past few years, image centers have been established that allow clinicians in larger cities to have access to these facilities. Stand-alone software packages placed at office workstations enable dentists to view a full range of sophisticated images. Soft-

the CT machines.

Dentlearn.ir

ANTEROPOSTERIOR INTERARCH DISCREPANCIES

CLASS I

A Class I occlusion is one in which the mesiobuccal cusp tip of the maxillary first molar aligns with the buccal groove of the mandibular first molar (Fig. 21-12). Because of this sagittal relationship, most Class I occlusions demonstrate reasonably normal skeletal and soft-tissue profiles.

CLASS II DIVISION I

In Class II division I malocclusion, the mesiobuccal cusp tip of the maxillary first molar is positioned anterior to the buccal groove of the mandibular first molar (Fig. 21-13). The sagittal molar relationship of these patients is referred to as a *disto-occlusion* as opposed to a neutro-occlusion in patients with Class I occlusion. The exact reason for this relationship may be skeletal, dental, or a combination of the two. The nature of the problem can be more accurately determined by the use of cephalometric analysis. This type of malocclusion is often characterized by excessive overjet in the anterior region. Unlike the patient with Class I occlusion, these patients often exhibit more downward growth, abnormal muscle pressure, and a convex soft- and hard-tissue profile.

In vertical growth patterns in which the upper molars are erupting along the facial axis and the upper incisors are erupting in a protruded direction, space between the upper molars and incisors is increased, which results in the typical dental characteristics of the Class II division I malocclusion.

CLASS II DIVISION II

The molar position observed in patients with Class II division II malocclusion is similar to that of those with Class II division I malocclusion, although the excessive overjet associated with the latter is not seen (Fig. 21-14). The anterior relationship of a Class II division II malocclusion is characterized by lingual tipping of the central incisors and labial flaring of the lateral incisors. Whereas patients with Class II division I malocclusion show a weak chin, patients with division II malocclusion tend to have a square jaw, skeletal deep bite, and a short lower facial height. Class II division II malocclusions demonstrate strong growth patterns in which the upper molar grows down the facial axis, whereas the upper incisor moves down with a retroclination. In this case there is a diminution of space between the molar and incisor. This results in a pinching or closing of the arch, which gives the characteristic flaring of the upper lateral incisors and linguoversion of the central incisors. In severe cases an hourglass-shaped upper arch form may result.

CLASS III

In Class III malocclusion, the mesiobuccal cusp tip of the maxillary first permanent molar is posterior to the buccal groove of the mandibular first permanent molar (Fig. 21-15). The most common cause of Class III malocclusions is excessive growth of the mandible. The molar position of these patients is referred to as *mesio-occlusion*, whereas the anterior relationship shows a negative overjet. Many

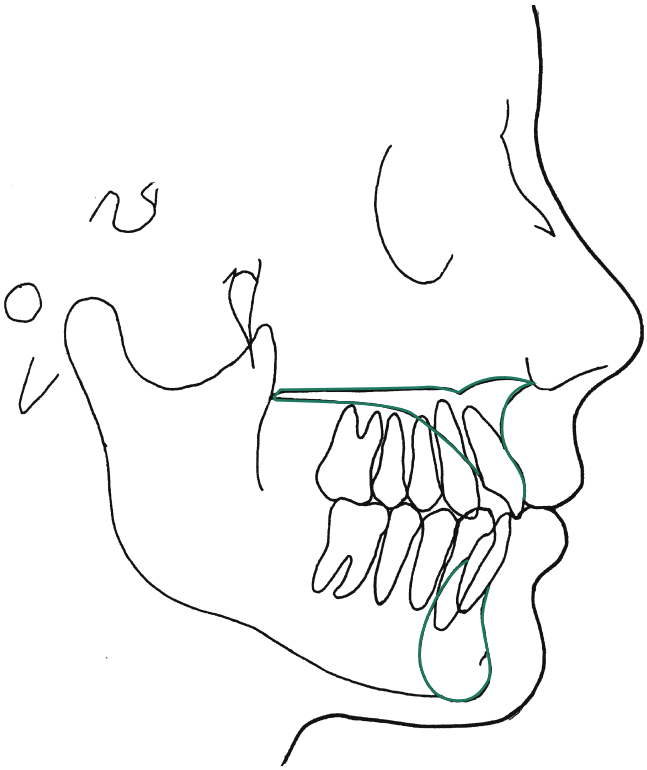

Figure. 21-12 **Class I occlusion.**

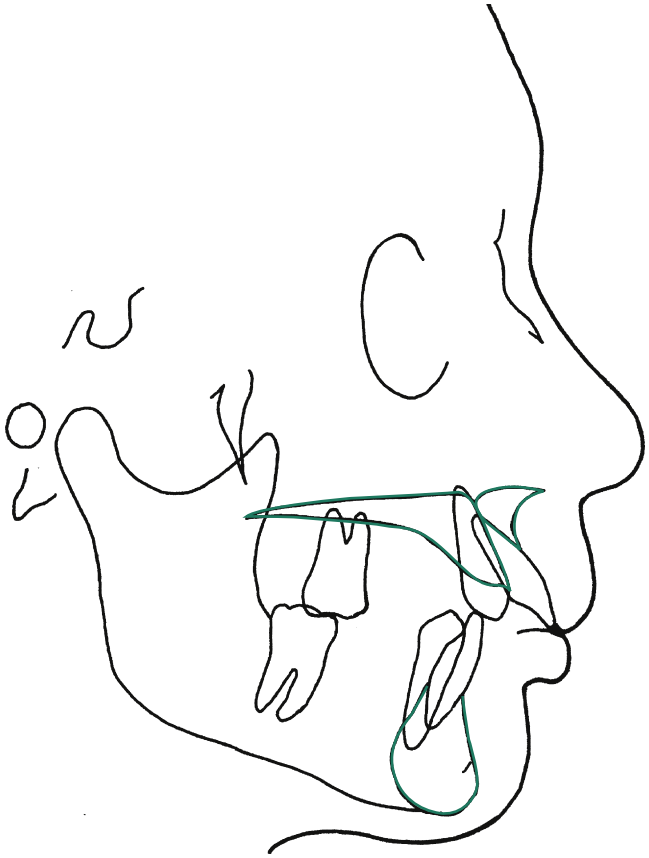

Figure 21-13 **Class II division I occlusion.**

Dentlearn.ir

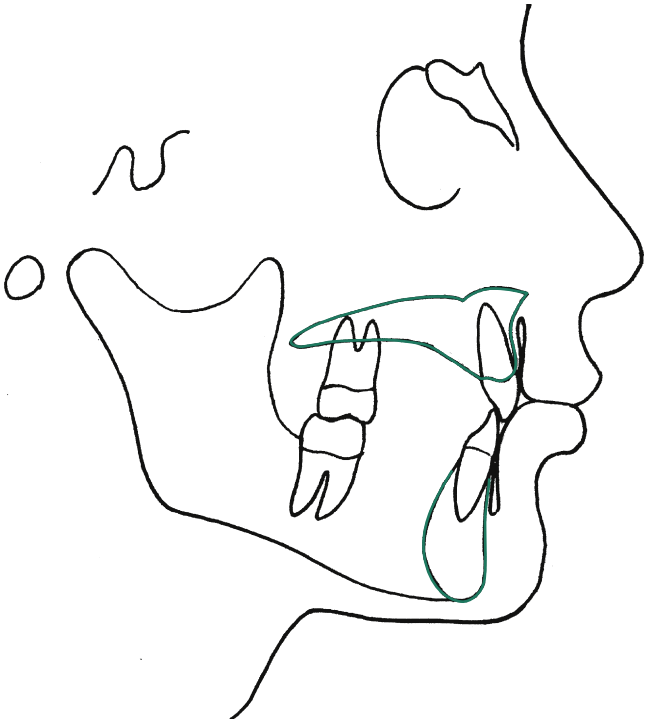

Figure 21-14 Class II division II occlusion.

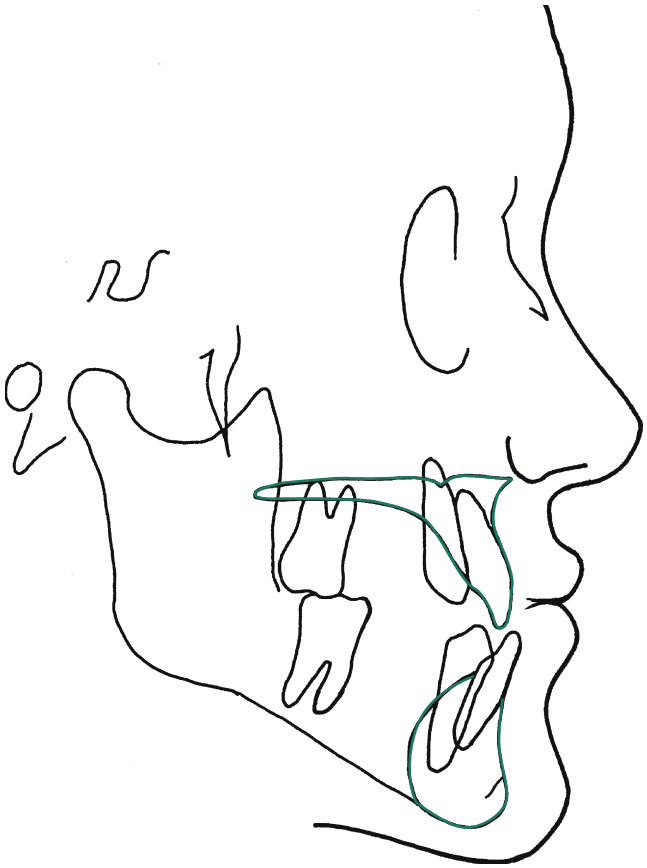

Figure 21-15 Class III occlusion.

cases demonstrate dental compensations in which the maxillary incisors are excessively flared and the mandibular incisors are severely tipped lingually. These patients typically show concave facial profiles and steep mandibular plane angles attributable, in part, to an obtuse gonial angle.

FACIAL TYPES

The three basic facial types or patterns are dolichofacial (vertical), mesofacial (ideal), and brachyfacial (horizontal). The determination of the patient's facial pattern is important in growth prediction and treatment planning, even though no definitive correlation between malocclusion and facial types has been demonstrated. It should be obvious that the prognosis for a pleasing facial result in the treatment of a Class II malocclusion associated with a retrognathic mandible would be more uncertain than that in the treatment of a Class II malocclusion occurring with an orthognathic mandible. Therefore one of the first assessments necessary for an accurate craniofacial diagnosis is classification of the patient's facial type.

Although all facial types may be observed in association with different malocclusions, a significantly higher incidence of specific types does occur with certain types of malocclusion, such as the association of Class II malocclusions with retrognathic mandibles and of Class III malocclusions with prognathic mandibles. On the other hand, an orthognathic facial type is not always associated with an ideal Class I occlusal relationship. As the clinician becomes more familiar with the different types of malocclusion, it will become obvious that certain facial patterns are commonly associated with each classification of malocclusion.

MESOFACIAL PATTERN

The mesofacial pattern is most often associated with Class I occlusions because these patients are characterized by a relatively normal maxillary and mandibular relationship that results in good facial balance (Fig. 21-16).

DOLICHOFACIAL PATTERN

The faces of patients with the dolichofacial pattern are usually long and of weak musculature because of the tendency for vertical growth. The molar occlusion is often of the Class II division I variety. The protruded dentition of these patients often results in facial grimacing and disharmony. Reduction of the interincisal angle will result in a more pleasing facial profile (Fig. 21-17).

BRACHYFACIAL PATTERN

The short faces and wide, square mandibles of patients with a brachyfacial pattern are most often associated with Class II division II malocclusions. The mandibular growth of these patients is usually forward rather than downward. Consequently, these patients typically exhibit excessive anterior overbites and strong chins (Fig. 21-18). Aesthetically, the brachyfacial patient can generally accommodate a fuller dentition with a more acute interincisal angle. The fuller dentition helps balance the strong chin and the shorter lower facial height by giving more forward projection to the midfacial region.

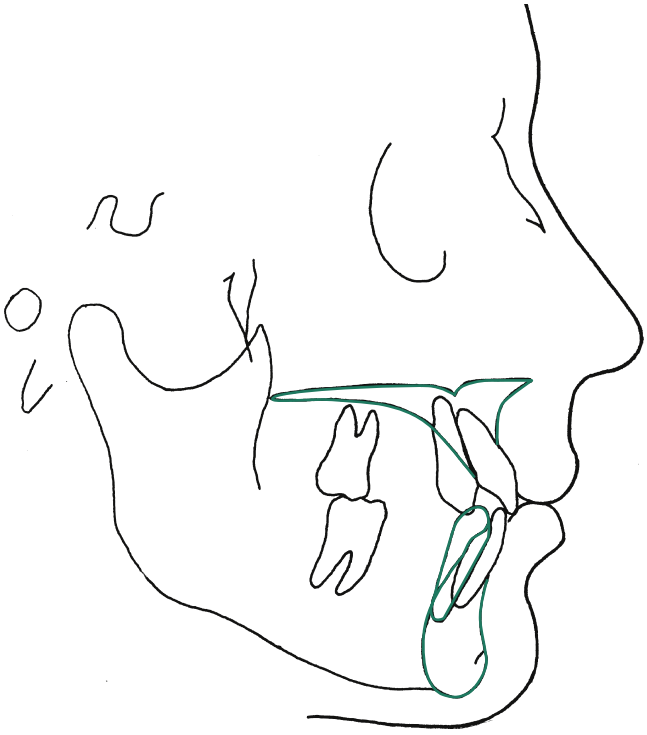

Figure 21-16 **Mesofacial pattern.**

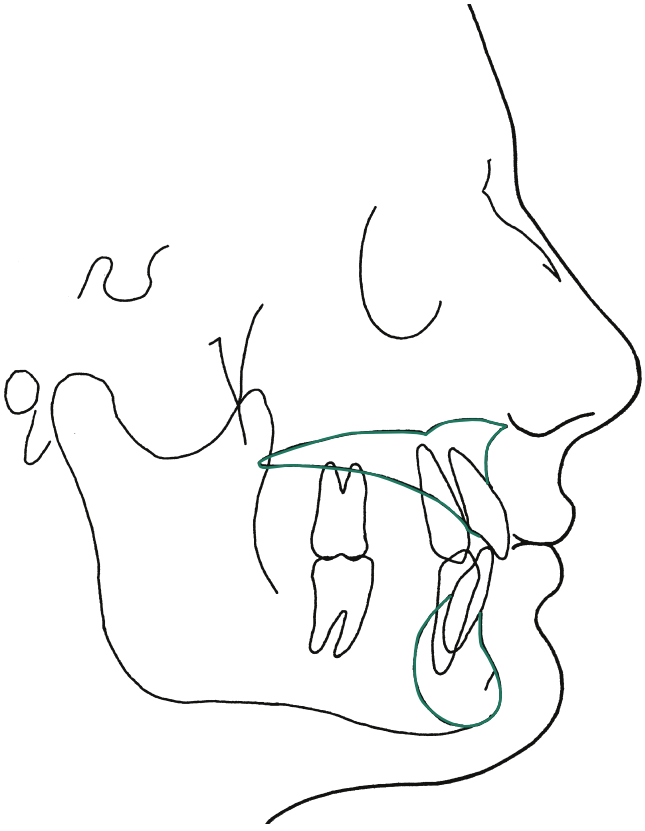

Figure 21-18 **Brachyfacial pattern.**

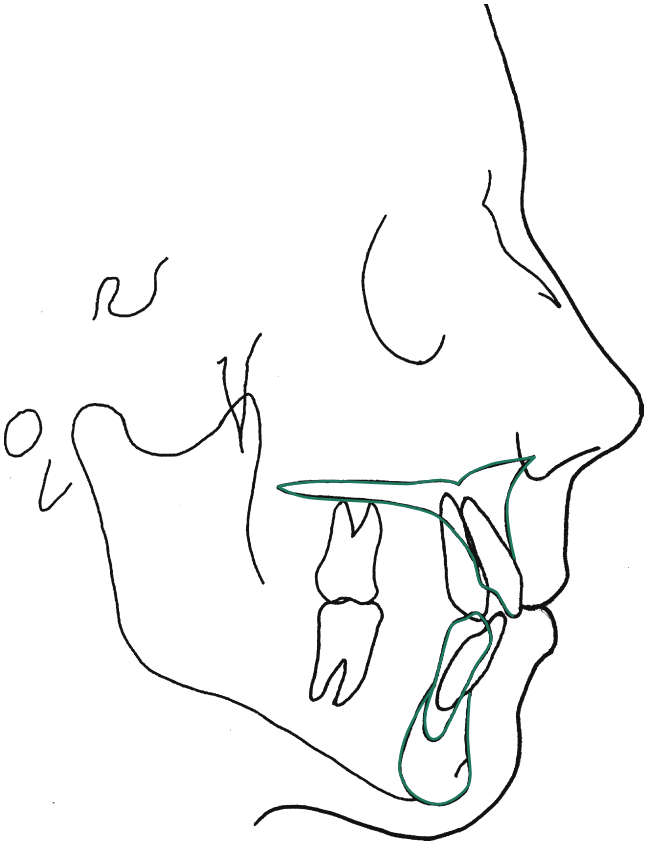

Figure 21-17 **Dolichofacial pattern.**

VERTICAL ARCH DISCREPANCIES

OPEN BITE

Open-bite relationships are characterized by failure of the teeth in both arches to meet properly (Fig. 21-19). Open bites may be observed in the anterior or posterior region and may be attributable to supraeruption of the adjacent teeth or infraeruption of the teeth in the area of question. Open bites may be caused by abnormal habits, deviant growth patterns, or an abnormal tongue position.

DEEP BITE

Deep bites are most often observed in Class II division I malocclusion in which, because of the excessive overjet, the mandibular incisors supraerupt until they come into contact with the hard palate (Fig. 21-20). The Class II division II malocclusion is also associated with a deep bite, although in these patients the cause may be infraeruption of the posterior teeth or supraeruption of the maxillary anterior teeth. In many deep-bite cases the condition results in overclosure of the mandible, leading to labial movement of the upper incisors and, in some cases, generalized spacing of the maxillary anterior teeth. The correction leading to opening of the bite is determined by the type of malocclusion, the aesthetic goals, and the philosophical approach of the clinician. A comprehensive case analysis is therefore necessary to define the etiologic factors.

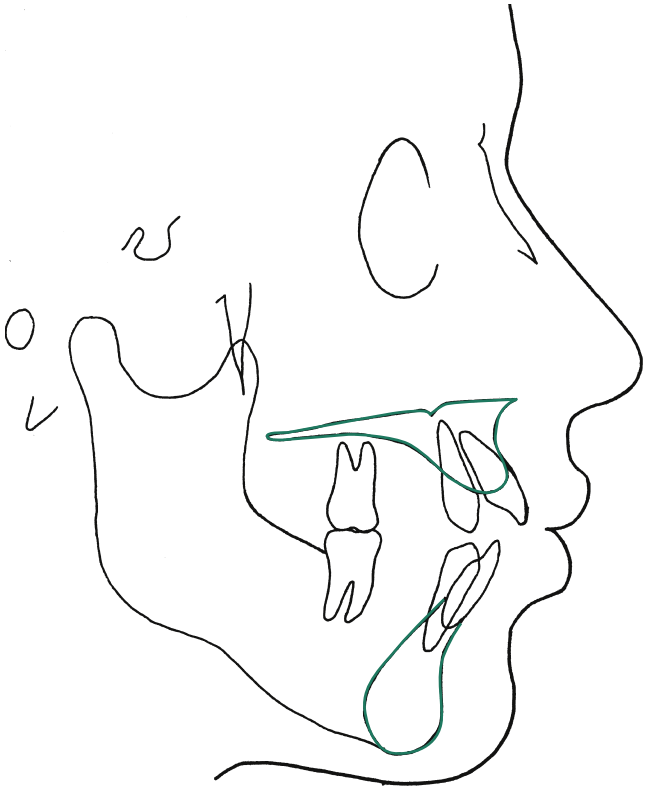

Figure 21-19 **Open-bite pattern.**

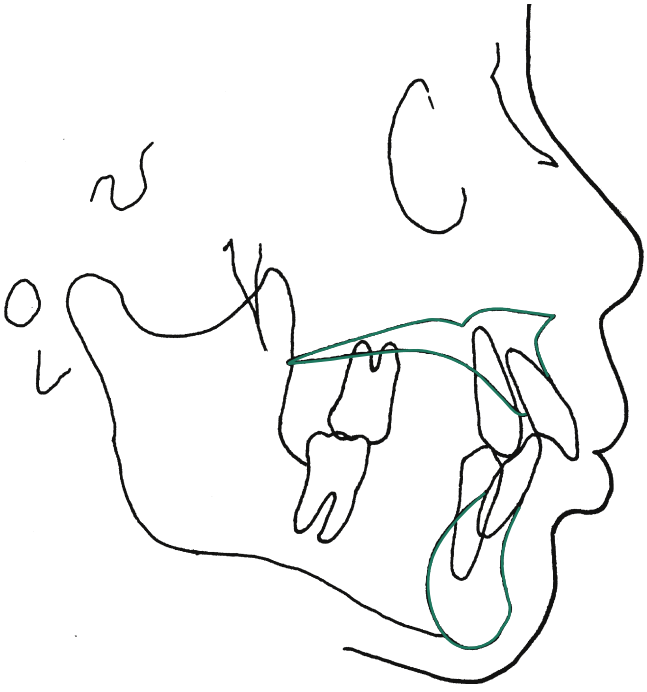

Figure 21-20 **Deep-bite pattern.**

ANGLE CLASSIFICATION OF OCCLUSION

Orthodontists are concerned with facial form, function, oral health, and beauty. The primary criteria for classifying the occlusion were developed in 1899 by Edward Angle, the father of modern orthodontics, to evaluate the sagittal relationship of the canines and molars. Angle was a nonextractionist who considered the bust of Apollo Belvedere to be the epitome of facial balance, and consequently it served as a guide to his treatment objectives. Angle contended that dental arch expansion was necessary for proper orthodontic treatment. With this method of treatment, Dr. Angle rarely removed teeth. Insightful orthodontists such as Charles Tweed, Hays Nance, and P. R. Begg refuted Angle's approach to treatment, which often resulted in poor facial aesthetics, instability, and periodontal problems. These latter orthodontists often recommended the removal of teeth to improve facial aesthetics and avoid double protrusion. Over the years the pendulum has swung back and forth between extraction and nonextraction. The fear of creating a "dished-in" profile has been reported. The statement has been made that the removal of premolars in orthodontic therapy will result in flat facial profiles and temporomandibular joint dysfunction. A study carried out at Washington University evaluated 160 extraction cases. The study findings indicate that, if proper diagnostic criteria are used in the treatment evaluation, the removal of teeth is not detrimental to good facial balance. The Angle system of classification (described earlier) is a simple analysis that allows one to classify a patient's occlusion into one of three different categories (Class I, II, or III). Although this system allows for ease of understanding and communication, it should be augmented with further data to develop an appreciation of facial form. It has been the authors' experience that better and more gratifying results are achieved when the original diagnosis and treatment plan correlate the sagittal, dental, and skeletal relationships with facial form.

The Angle description of the sagittal relationship of the maxillary and mandibular dental units does not take into account their spatial orientation with respect to the patient's facial type. For example, Figures 21-21 and 21-22 show examples of two patients who both demonstrate Angle Class III malocclusion. From the photographs it is apparent that the overall relationship of the bony bases and the teeth to the face are quite dissimilar, even though both examples are given the same Angle classification. Figure 21-21 depicts an example of maxillary deficiency (retrognathism), whereas Figure 21-22 represents a case demonstrating mandibular prognathism. Even though the Angle relationship is the same, the comprehensive diagnosis and treatment plan should be quite different if the most favorable result for each patient is to be achieved. Therefore, further supplementation of the Angle system of classification is in order.

DESCRIPTIVE SKELETAL AND DENTAL EVALUATION

Before the basic steps involved in comprehensive analysis are outlined, five descriptive terms must be defined and clearly understood. They are as follows:

Orthognathism. A skeletal term indicating the ideal balance among the cranial base, the maxilla, and the mandible from a sagittal view.

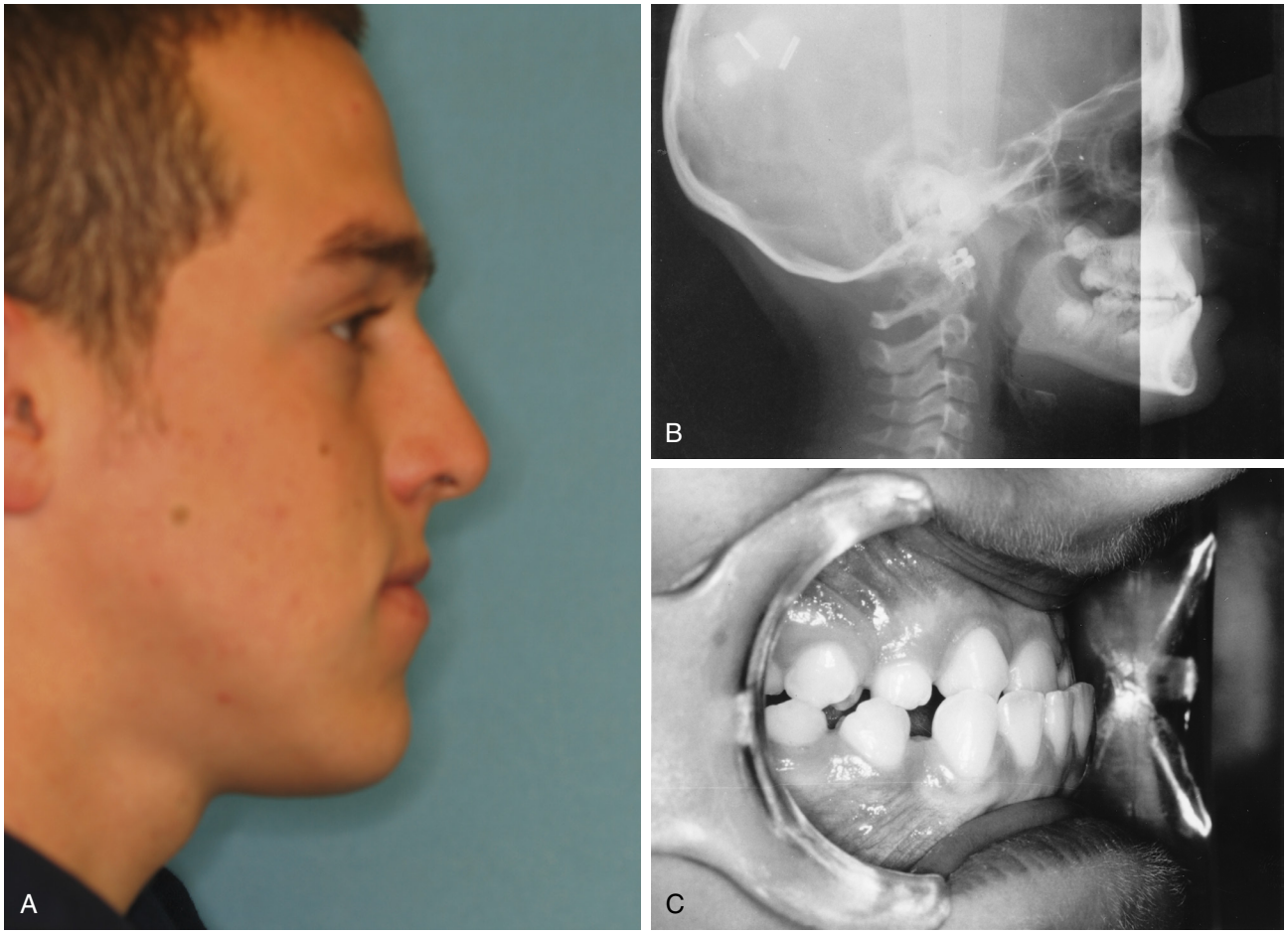

Figure 21-21 **A**, Maxillary retrognathism (clinical appearance). **B**, Maxillary retrognathism (cephalometric radiograph). **C**, Class III occlusion.

Prognathism. The anterior positioning of either one or both bony jaws relative to the facial skeleton and soft tissues. Hence the following entities may exist: maxillary prognathism, mandibular prognathism, or bimaxillary (maxillary and mandibular) prognathism.

Retrognathism. The posterior placement of either one or both jaws relative to the face. Similar entities can be demonstrated as mentioned in the previous category.

Protrusion. A forward positioning of the dental units (teeth) relative to their bony base. Again, protrusion may occur with maxillary or mandibular teeth or both.

Retrusion. A posterior placement of either one or both dentoalveolar units relative to their respective bony bases.

Although the terms *prognathism* and *retrognathism* describe improper skeletal relationships of the jaws and the face, protrusion and retrusion simply indicate the relation of the dentoalveolar unit with respect to its supporting jaw.

Thus four components exist that can occur in any one of three possible sagittal positions (anterior, posterior, and ideal). These constitute 81 possible combinations.

By supplementing the Angle classification with additional analyses to determine the relative maxillary and mandibular skeletal, dental, and facial relationships, the clinician can obtain a more detailed diagnosis. The specific components of the craniofacial complex responsible for the discrepancy are also more clearly identified. Cephalometric analysis also must be correlated and compared with other diagnostic records and clinical findings because the former cannot be expected to provide all the information necessary for an accurate treatment analysis.

The accuracy of the diagnosis is dependent on a thorough and systematic evaluation of several of the morphologic components in combination; individual measurements are of little value by themselves. Isolated measurements may demonstrate clinical deviation from the norm, but when these dimensions are combined with others, they may show collective compensation yielding a normal occlusal relationship. In contrast, a malocclusion may also be the result of dimensions that, individually, are considered within normal limits yet in combination result in an abnormal arrangement.

Any cephalometric measurement may be misleading. accuracy. It is important to realize that the fewer factors used in the analysis, the greater the risk of misdiagnosis.

It is the borderline cases that often require a more detailed analysis. Obvious cases involving severe skeletal



Figure 21-22 **A**, Mandibular prognathism (clinical appearance). **B**, Mandibular prognathism (cephalometric radiograph). **C**, Class III occlusion.

dysplasia can often be diagnosed based on relatively few factors.

To properly analyze a cephalometric tracing, one must evaluate the interarch and the patient's facial characteristics.

EVALUATION OF FACIAL AESTHETICS

A thorough and systematic evaluation of a patient's facial structures forms the basis for an accurate diagnosis and subsequent treatment. Too often the lateral cephalometric radiograph and diagnostic casts are used as substitutes for a complete clinical examination of the patient's facial characteristics. Most of us have been taught to focus on the lateral cephalometric radiograph in our diagnosis. In the process, we have migrated away from the clinical examination and the art of the soft-tissue diagnosis. It is imperative that we reintroduce the fundamental concepts of art and beauty that were fundamental in Angle School of Orthodontia. Over the years, advancements in orthodontic technology have resulted in a shift from the art in orthodontic diagnosis and treatment planning to a dependency on cephalometric measurements. The clinical examination has taken a back seat to the typical orthodontic records, which include the lateral cephalometric radiograph and study models. Orthodontic treatment goals based entirely on cephalometric numbers may result in excessive retraction of the maxillary and mandibular incisors. There is much more to modern-day orthodontics than just an excellent occlusion. It has been stated



Figure 21-23 Patient's head positioned with the Frankfort horizontal plane parallel to the floor.



Figure 21-24 Frontal facial thirds.

that hard-tissue analysis alone is inadequate in treatment planning and may result in a compromised soft-tissue profile. Lines, angles, and numbers should not be used as the only diagnostic tools, but rather should be viewed as an adjunct to what the clinician visually assesses about the patient's facial form. To develop the clinical ability to observe variations from the normal facial structure, the practitioner must have a firm grasp of what constitutes an ideal face (complete with ideal variations). This section deals with the facial examination of the ideal face. The guidelines are directed at the adolescent and teenaged patient and do not have complete application to patients from 5 to 10 years of age, because facial proportions generally change with the approach of puberty.

To evaluate the patient properly, the clinician should have the patient stand in a relaxed position. The patient's head should be positioned with the Frankfort horizontal plane parallel to the floor (Fig. 21-23). Patients should not be asked to simply "look straight ahead," because patients tend to place the head in the position that is habitually preferred. It is also important to position the patient's occlusion in centric relation rather than centric occlusion. The patient's lips should be in repose during the examination. Patients frequently mask lip incompetence by forcing their lips together.

FRONTAL VIEW

The evaluation begins with the frontal view. This is the view people most often see of themselves. The balance among the upper, middle, and lower thirds of the face is analyzed (Fig. 21-24). The upper third is bounded by the hairline (when combed back) and glabellar area. This area is least informative and is not the area to which corrections would normally be directed. More emphasis is placed on the proportions and symmetry of the middle third (from the glabellar region to subnasale) and the lower third (from the subnasale to menton).

In the middle third of the face, when the patient is looking straight ahead, the sclera of the eye is not seen superior or inferior to the pupil. Normal intercanthal distance is 30 to 32 mm (CD, ± 2 mm). Normal interpupillary distance is 60 to 65 mm. The inner and outer canthal tendons should fall close to a straight horizontal axis through the palpebral fissures (the fissures created when the eyelids are closed). The distance between the semilunar folds in the intercanthal area should approximate the alar base width (Fig. 21-25). Deviations from these general guidelines could indicate some deformity of the middle facial third.

Evaluation of the lower facial third is then carried out. The ratio of the middle to lower facial thirds in vertical height should be approximately 5:6. The upper lip and its relationship to the teeth are noted with the lips in repose and also during smiling. The distance between the medial limbus of the eyes should equal the width of the mouth when it is relaxed (Fig. 21-26). Interlabial distance is measured with the lips at rest; up to 3.5 mm of interlabial distance is considered acceptable. The upper lip length from subnasale to stomion (lip commissure) should represent one third of the lower third facial height (see Fig. 21-24). Normal upper lip length should be 22 mm (CD, ± 2 mm)

Dentlearn.ir



Figure 21-25 Comparison of the intercanthal distance and alar base width.



Figure 21-26 Comparison of the medial limbus width and the width of the mouth.



Figure 21-27 Ideal smile pattern.

in males and 20 mm (CD, ± 2 mm) in females. Ideally, with the lips in repose, 2 to 4 mm of the upper incisor should be visible. More than this amount could indicate a vertical maxillary excess. One important characteristic that is often missed is that the incisal edges should approximate the lower lip line.

Next, the patient's smile is assessed. Another important aspect of a well-balanced smile is the height, uniformity, and contour of the gingival margins. Grafts and gingival recontouring may be an important treatment modality in selected cases. In addition, the facial surfaces of the anterior teeth should converge toward the facial midline; the long axis (direction of the anterior teeth) in an aesthetic smile also follows a progression as the teeth move away from the midline. The separations between the maxillary anterior teeth help to define an attractive smile. The spaces between the edges of the teeth are known as embrasure spaces. These spaces follow a pattern that begins between the central incisors and progresses as one moves away from the dental midline. Smile patterns vary with individuals, but aesthetically, when a person smiles, the upper lip vermilion should rest on or near the cervicogingival margin of the incisors (Fig. 21-27).

The smile analysis would not be complete without an evaluation of the buccal corridors, which are defined as the spaces between the buccal surfaces of the maxillary posterior teeth and the inner commisures (see Fig. 21-27). Generally, smile attractiveness is improved as the buccal corridor is decreased. In other words, small



Figure 21-28 **Excessive eversion of the lower lip.**



Figure 21-29 **Hyperactive mentalis muscle during forced lip closure. Patient has lip incompetence.**

buccal corridors are considered to be significantly more attractive than large buccal corridors. The position of the lower lip is also noted. Excessive eversion of the lower lip is seen in patients with mandibular retrognathism (Fig. 21-28). The mentalis muscle can be hyperactive during forced closure of the lower lip (Fig. 21-29); such muscle hyperactivity is frequently seen in patients with mandibular retrognathia, vertical maxillary excess, apertognathia (open-bite deformity), and lip incompetence.

The last evaluation of the full face is that of facial symmetry. The face is divided in half by a line that bisects the glabella, nasal tip, upper lip, and chin (Fig. 21-30). The face is also divided vertically into equal fifths (Fig. 21-31).

PROFILE VIEW

The patient is next evaluated from the profile view. The examination considers many of the same features noted in the frontal examination. The face is divided into thirds (Fig. 21-32). A comparison of the vertical facial heights and the AP relationship of the facial thirds constitutes the initial assessment. The vertical relationships are the same in the profile view as they are in frontal views.

The upper facial third profile establishes the relationship between the forehead and superior orbital rim. The further the forehead protrudes beyond the superior orbital rim, the less aesthetically acceptable it is. The globe of the eye and its relationship to the superior orbital rim are assessed. The superior orbital rim is normally 8 to 16 mm anterior of the globe.



Figure 21-30 **Facial symmetry.**

Dentlearn.ir



Figure 21-31 Vertical facial fifths.

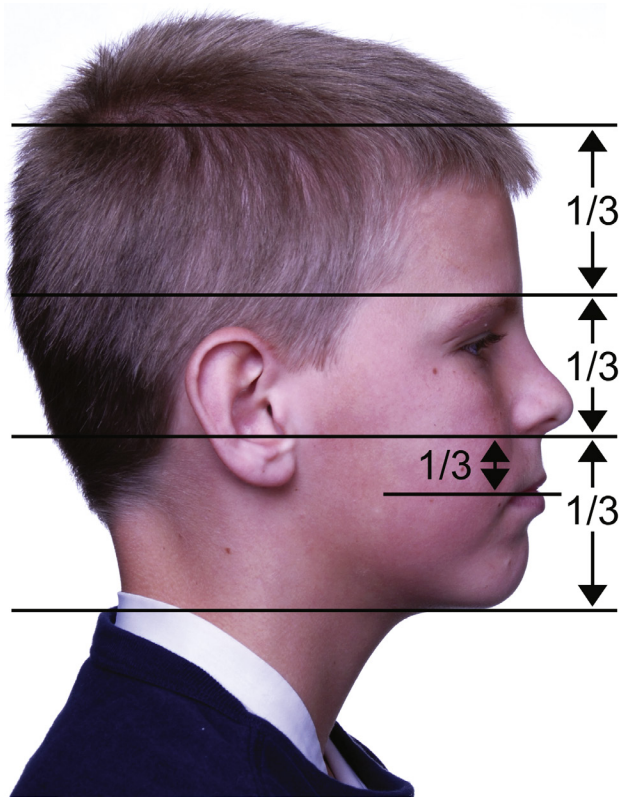

Figure 21-32 Profile facial thirds.

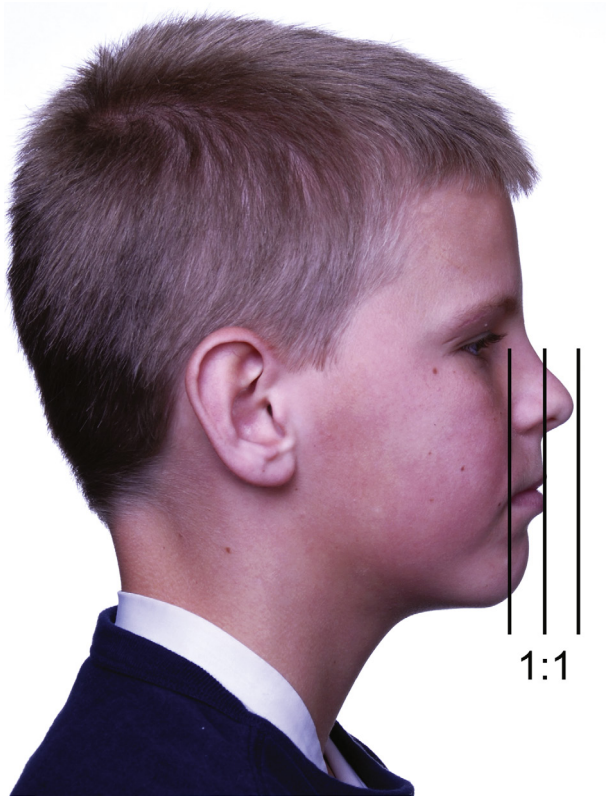

Figure 21-33 Ratio shows 1:1 relationship from nasolabial fold to subnasale, and from subnasale to tip of the nose.

The evaluation of the middle facial third involves an assessment of the relationship among the globes, inferior orbital rims, cheekbones, nose, and upper lip. The nasal bridge should project anterior to the globe by 5 to 15 mm. A reference line dropped from the most anterior projection of the globe and perpendicular to the Frankfort horizontal plane should fall on, or slightly behind, the soft tissue of the cheek.

In evaluation of the lower facial third, the vertical dimensions as described in the frontal view need to be considered. In addition, AP assessments are done. Projection of the upper lip is clinically evaluated by measuring from the nasolabial fold to the subnasale and comparing that numeric value with the distance from the subnasale to the tip of the nose. Ideally this ratio should be 1:1 (Fig. 21-33). The relationship of the nose and upper lip is determined by measuring the nasolabial angle (Fig. 21-34). This value can range from 90° to 110°.

The lower facial third is compared with the middle and upper thirds. The zero meridian is a straight line constructed by placing a line through the soft-tissue nasion, perpendicular to the Frankfort horizontal plane. The lips and chin should fall near this line (Fig. 21-35). During the profile evaluation of the lower facial third, any AP discrepancies between the maxilla and mandible (i.e., prognathism and retrognathism) are noted. The upper and lower lip positions are also assessed. The shape and size of the chin button are appraised. In some cases apparent mandibular retrognathism is in reality a flat or deficient chin button (microgenia). Conversely, too prominent a

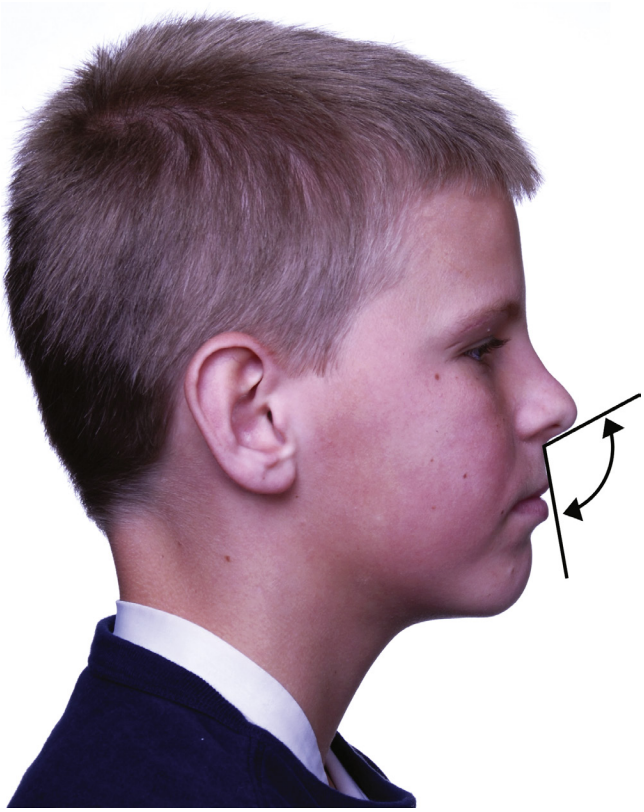

Figure 21-34 **Nasolabial angle.**



Figure 21-35 **Zero meridian.**

Lateral View

1. Frankfort Horizontal Plane: (FH)
   This plane is constructed from superior porion: (Po) to inferior orbitale (O) and represents the basic horizontal plane of the head.

2. Zero Meridian:
   The horizontal distance from the chin to a line perpendicular to (FH) and tangent to soft tissue nasion.

3. Maxillary Depth:
   The angle formed by the intersection of (FH) and N–A point planes.

4. Nasolabial Angle:
   The angle formed by the intersection of the lines tangent to the columella of the nose and the upper lip.

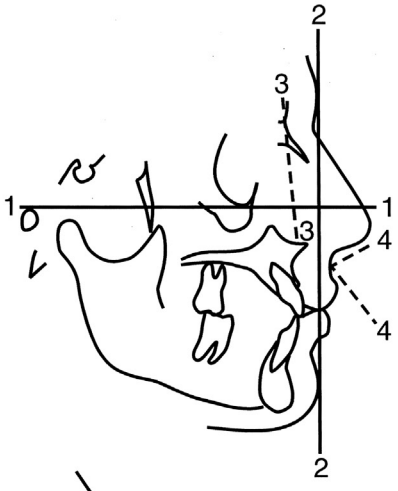

Lateral View Lip Measurements

1. Interlabial Gap:
   0-3.5 mm with lips in repose.

2. Upper Lip Length:
   Measured from (SN) to the inferior border of the upper lip.

3. Upper Incisor relative to the Upper Lip:
   The amount of upper incisor relative to the inferior border of the upper lip in repose.

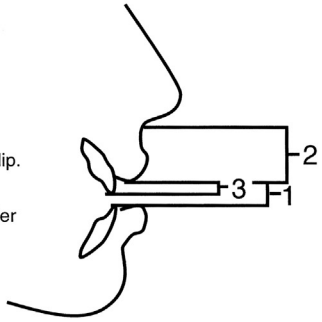

Figure 21-36 **Summary of lateral dentofacial measurements.**

chin may be visualized as a pseudoprognathism and may be aesthetically unacceptable.

The evaluation of the patient's face constitutes an important portion of the initial diagnosis and treatment plan phase of orthodontics. A systematic approach to examining the face is essential (Fig. 21-36). Basic guidelines of facial form have been reviewed. The values discussed are normal values for whites, but these must be used as relative guidelines only. The clinician must look at the patient's face and assess the overall harmony that exists. When deviations from normal facial form are detected, variations in treatment modalities must be considered to achieve better facial harmony. The main treatment objective is always to provide the patient with the best functional and aesthetic result possible.

SUGGESTED READINGS

Ackerman MB, Ackerman J: Smile analysis and design in the digital era, *J Clin Orthod* 36:221–236, 2002.

Angle EH: Classification of malocclusion, *Dent Cosmos* 41:248-264, 350–357, 1899.

Arnett GW: Facial keys to diagnosis and treatment planning—part I, *Am J Orthod Dentofacial Orthop* 103:299–312, 1993.

Arnett GW: Facial keys to diagnosis and treatment planning—part II, *Am J Orthod Dentofacial Orthop* 103:395–411, 1993.

Baek GW, et al.: Skeletodental factors affecting chin point deviation in female patients with Class III malocclusion and facial asymmetry: a three-dimensional analysis using computed tomography, *Oral Surg Oral Med Oral Pathol Oral Radiol Endod* 104:628–639, 2007.

Bell WH, Proffit WR, White RP: *Surgical correction of dentofacial deformities*, vol 1, Philadelphia, 1980, WB Saunders.

Boley JC: Serial extraction revisited: 30 years in retrospect, *Am J Orthod Dentofacial Orthop* 112:575–577, 2002.

Braun S: Diagnosis driven vs appliance driven treatment outcomes. In Sachdeva RCL, editor: *Orthodontics for the next millennium*, Glendora, CA, 1997, Ormco, pp 32–45.

Broadbent BH: A new x-ray technique and its application to orthodontia, *Angle Orthod* 1:45–66, 1931.

Broadbent BH: The face of the normal child, *Angle Orthod* 7:183–208, 1937.

Brodie AG, et al.: Cephalometric appraisal of orthodontic results: a preliminary report, *Angle Orthod* 8:261–351, 1938.

Burstone CJ: Lip posture and its significance in treatment planning, *Am J Orthod* 53:262–284, 1967.

Cheong YV, Lo LJ: Facial asymmetry: etiology, evaluation, and management, *Chang Gung Med J* 34:341–351, 2011.

Dickens S, Sarver DM, Proffit WR: The dynamics of the maxillary incisor and the upper lip: a cross-sectional study of resting and smile hard tissue characteristics, *World J Orthod* 3:313–320, 2003.

Downs WB: Variations in facial relationships: their significance in treatment and prognosis, *Am J Orthod* 34:812–840, 1948.

Dugoni SA, et al.: Early mixed dentition treatment: posttreatment evaluation of stability and relapse, *Angle Orthod* 65:311–332, 1995.

Gracco A, et al.: The smile buccal corridors: aesthetic value for dentists and laypersons, *Prog Orthod* 7:56–65, 2006.

Havens DC, et al.: The role of the posed smile in overall facial esthetics, *Angle Orthod* 80:322–328, 2010.

James RD: A comparative study of facial profiles in extraction and nonextraction treatment, *Am J Orthod Dentofacial Orthop* 114:265–276, 1998.

Katz MI: Angle classification revisited. Is current use reliable? *Am J Orthod Dentofacial Orthop* 102:173–179, 1992.

Klocke A, Nanda RS, Kahl-Nieke B: Skeletal class II patterns in the primary dentition, *Am J Orthod Dentofacial Orthop* 112:596–601, 2002.

Lines PA, Lines RR, Lines CA: Profilemetrics and facial esthetics, *Am J Orthod* 73:648–657, 1978.

Long RE, McNamara JA: Facial growth following pharyngeal flap surgery: skeletal assessment on serial lateral cephalometric radiographs, *Am J Orthod* 87:187–196, 1985.

McLeod C, et al.: Esthetics and smile characteristics evaluated by lay-person, *Angle Orthod* 81:198–205, 2011.

McNamara JA: Influence of respiratory pattern on craniofacial growth, *Angle Orthod* 51:269–300, 1981.

Moore T, et al.: Buccal corridors and smile esthetics, *Am J Orthod Dentofacial Orthop* 127:208–213, 2005.

Morley J: The role of cosmetic dentistry in restoring a youthful appearance, *J Am Dent Assoc* 30:1166–1172, 1999.

Owen AH 3rd: Diagnostic block cephalometrics, part 1, *J Clin Orthod* 18:400–422, 1984.

Owen AH 3rd: Clinical interpretation of diagnostic block cephalometric analysis, *J Clin Orthod* 20:710–715, 1986.

Parekh SM, et al.: Attractiveness of variations in the smile arc and buccal corridor space as judged by orthodontists and laymen, *Angle Orthod* 76:557, 2006.

Reidel RA: The relation of maxillary structures to cranium in malocclusion and in normal occlusion, *Angle Orthod* 22:142–145, 1952.

Ricketts RM: Cephalometric analysis and synthesis, *Angle Orthod* 31:141–156, 1961.

Ricketts RM, Schulhof RJ, Bagha L: Orientation—sella-nasion or Frankfort horizontal, *Am J Orthod* 69:648–654, 1976.

Ritter DE, et al.: Analysis of the smile photograph, *World J Orthod* 7:279–285, 2006.

Rody WJ Jr, Araujo EA: Extraction decision-making Wigglegram, *J Clin Orthod* 36:510–519, 2002.

Sarver DM: Video cephalometric diagnosis (VCD): a new concept in treatment planning? *Am J Orthod Dentofacial Orthop* 110:128–136, 1996.

Schulhof RJ: When S-N is abnormal, *J Clin Orthod* 11:343, 1977.

Severt TR, Proffit WR: The prevalence of facial asymmetry in the dentofacial deformities population at the University of North Carolina, *Int J Adult Orthod Orthognath Surg* 12:171–176, 1997.

Simon PW: *Fundamental principles of a systematic diagnosis of dental anomalies*, Boston, 1926, The Stratford.

Steiner C: Cephalometrics for you and me, *Am J Orthod* 39:729–755, 1953.

Tucker S, et al.: Comparison of actual surgical outcomes and 3-dimensional surgical simulations, *J Oral Maxillofac Surg* 68:2412–2421, 2010.

Tweed CH: The Frankfort-mandibular incisor angle (FMIA) in orthodontic diagnosis, treatment planning and prognosis, *Angle Orthod* 24:121–169, 1954.

You KH et al.: Three-dimensional computed tomography analysis of mandibular morphology in patients with facial asymmetry and mandibular prognathism, *Am J Orthod Dentofacial Orthop* 138:540.e1–8, 2010.

Dentlearn.ir

CHAPTER 22

Managing the Developing Occlusion

▲ Jeffrey A. Dean

For additional resources, please visit the evolve website.

CHAPTER OUTLINE

DEVELOPMENT OF OCCLUSION AND TIMING OF INTERVENTIONS
- Primate Spaces
- Mesial Molar Shift
- Leeway Space
- Intervention Considerations

EARLY LOSS OF TEETH AND SPACE MAINTENANCE
- Needs Assessment
- Specific Tooth Loss Strategies

ORAL HABITS IN CHILDREN
- Bruxism
- Digit Sucking
- Tongue-Thrust Swallowing

ANTERIOR CROSSBITE IN PRIMARY AND MIXED DENTITIONS
- Tongue Blade/Popsicle Stick Therapy
- Lower Inclined Plane
- Palatal-Spring Appliances (Removable Hawley or Fixed Palatal Wire)
- Fixed Transpalatal Wires with Springs

POSTERIOR CROSSBITE IN PRIMARY AND MIXED DENTITIONS
- Selective Equilibration
- Maxillary Expansion

ERUPTION PROBLEMS AND ERUPTION "GUIDANCE"
- Ectopic Eruption of First Permanent Molars
- Eruption Guidance in the Lower Incisor Segment
- Eruption Guidance in the Mandibular Canine and Premolar Segment
- Eruption Guidance in the Maxillary Canine and Premolar Segment

OBSTRUCTIVE SLEEP APNEA AND ORTHODONTICS

COMPREHENSIVE ORTHODONTICS FOR THE DEVELOPING OCCLUSION
- Primary to Mid-Mixed Dentition (Ages 4 to 10 Years)
- Mid- to Late Mixed Dentition (Ages 10 to 12 Years)
- Early Permanent Dentition (Ages 12 to 16 Years)

It should be the goal of every practitioner providing oral health care for children and adolescents to assess and guide the developing occlusion toward optimal outcomes. The Clinical Guidelines of the American Academy of Pediatric Dentistry[1] on "Management of the Developing Dentition and Occlusion in Pediatric Dentistry" illustrate this responsibility with the following statement:

> Guidance of eruption and development of the primary, mixed and permanent dentitions is an integral component of comprehensive oral healthcare for all pediatric dental patients. Such guidance should contribute to the development of a permanent dentition that is in a stable, functional, and esthetically acceptable occlusion. Early diagnosis and successful treatment of developing malocclusions can have both short-term and long-term benefits while achieving the goal of occlusal harmony, function, and dental facial esthetics.

Ngan and colleagues[2] illustrate this responsibility regarding contemporary practice in stating, "Pediatric dentistry has increasingly shifted from a conservative-restorative approach toward a concept of total pediatric patient care. Thus all aspects of oral health care including diagnosis, prevention, oral medicine, restoration, and correction of malocclusion are increasingly the responsibility of the pediatric dentist." In the context of these statements, clinical decisions are presented daily that challenge pediatric practitioners in affecting outcomes in management of the developing occlusion. As defined by Moyers,[3] space supervision is "when the judgment of the dentist determines that the individual patient's occlusion will have a better chance of obtaining optimum development through supervised intervention of the transitional dentition than without clinician directed intervention." Space supervision encompasses procedures such as preventive orthodontics, guidance of eruption, interceptive orthodontics, and phased "early" orthodontic treatment that should be understood in terms of its diagnostic parameters, treatment basis, and clinical applications.

DEVELOPMENT OF OCCLUSION AND TIMING OF INTERVENTIONS

PRIMATE SPACES

A review of studies by Baume,[4] Moorrees,[5,6] Bishara and colleagues,[7] and Moyers and Wainwright[8] provides an understanding of the biogenetic course of the primary, transitional, and permanent dentitions that is critical to management of the developing dentition. Evaluating study models of the primary dentitions of 30 children

Dentlearn.ir

obtained sequentially at various developmental stages, Baume[4] reported two consistent morphologic arch forms of the primary dentition: either generalized spaces between the teeth were present (type I) or the teeth were in proximal contact without spacing (type II). The arch form in both types appears congenital rather than developmental because the original pattern exhibited upon eruption was maintained from ages 3 to 6 years. Spaced arches frequently exhibit two distinct diastemas—referred to as *primate spaces*—one between the mandibular canine and first primary molar and the other between the maxillary lateral incisor and primary canine. Baume[4] observed that until the eruption of the permanent first molars, the sagittal dimension of the primary dental arches remained essentially unchanged, with the possible exception of a slight decrease as the result of the development of dental caries on the proximal surfaces of the molar teeth. Only minor changes in the transverse dimension of the primary dental arches occurred during 3 to 6 years of age unless negatively influenced by deleterious functional patterns. Given these findings, orthodontic intervention during the primary dentition up to 6 years of age is mostly directed toward maintaining inherent arch dimensions and arch integrity with preventive and restorative services. Space maintainers, when primary teeth are lost prematurely, are the next major consideration in maintaining arch dimensions. Control of functional problems such as elimination of deleterious thumb-sucking habits and correction of functional crossbites may also receive attention during the primary dentition years. While desirable, treatments for these factors are often deferred depending upon the cooperation of the child with appliance protocols.

MESIAL MOLAR SHIFT

The early-mixed dentition (6 to 9 years of age) is a period much more prone to localized factors that may result in severe malocclusion problems if undetected. In addition to a continuation of basic preventive and space maintenance issues, problems encountered in this period include dentoalveolar anterior crossbites, ectopic eruption of permanent incisors and/or first permanent molars, posterior crossbites, open bite and flared maxillary incisors associated with deleterious oral habits, and developmental anomalies (e.g., ankylosis, supernumerary teeth, and missing teeth). Baume[4] compared models of 60 children before and after eruption of the permanent molars and found three distinct kinds of molar adjustment (Fig. 22-1). "Early" mesial shift during first permanent molar eruption occurs at the expense of any posterior spacing that might have been present to include breakdown spaces resulting from interproximal caries. Moyers,[8] agreeing that the pattern of transition involving the straight terminal plane is normal, suggested that the occlusion forming a mesial step (distal surface of the lower second primary molar is mesial to the same surface of the maxillary molar) is most ideal for Class I development. A distal step (distal surface of lower second primary molar is distal to the same surface of the maxillary molar) indicates a developing Class II malocclusion. Proper permanent molar occlusion was achieved from a straight terminal plane by a second mesial shift of the molars as second primary molars are exfoliated. This "late" shift of

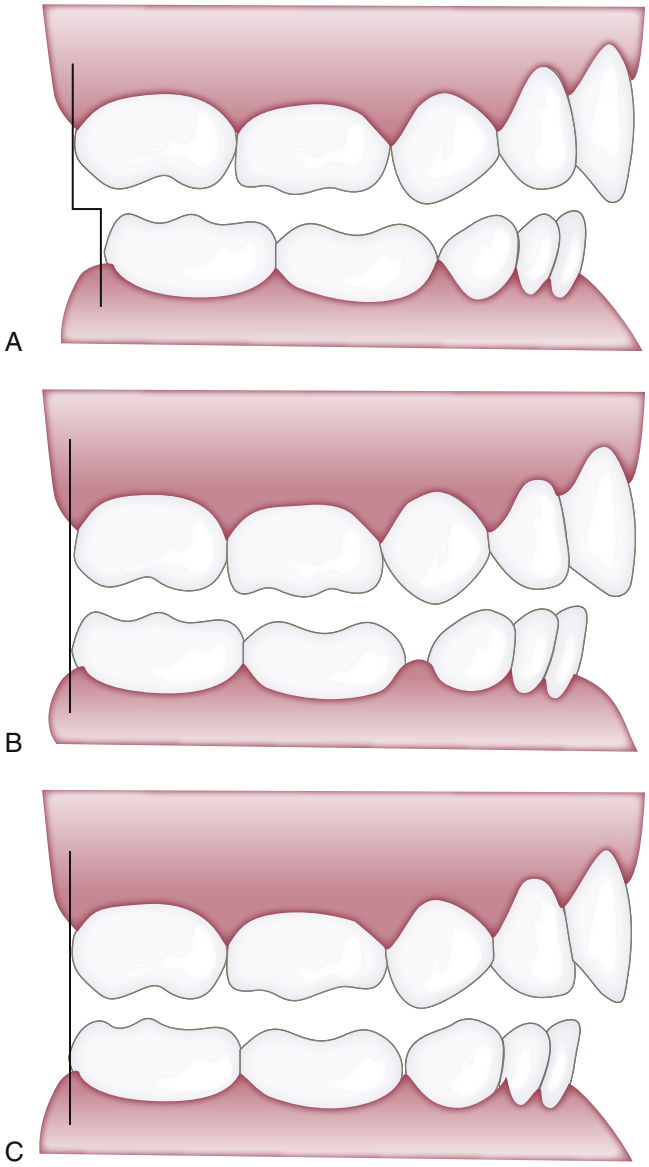

Figure 22-1 **A,** Diagram showing mesial step terminal plane that allows the first permanent molar to erupt directly into proper Class I occlusion. **B,** Straight terminal plane with primary spacing. "Early mesial shift" of mandibular molars closing primary spaces will help establish proper first permanent molar occlusion. **C,** Straight terminal plane without primary spacing. Permanent molars erupt into end-on position in the mixed dentition. Proper first permanent molar occlusion may be attained when the second primary molars exfoliate and a "late mesial shift" of the mandibular first permanent molar occurs.

the mandibular first molar, often under the additional influence of the emerging second permanent molar, occurs at the expense of the leeway space with a decrease in attendant arch length of 2 to 3 mm on average.

Further evaluation by Baume indicated that a transverse widening of the intercanine width of the upper and lower dental arches occurred during eruption of the permanent incisors. The increase represented a physiologic widening by lateral and frontal alveolar growth

Dentlearn.ir

to provide space for the erupting permanent incisors and their greater mesiodistal widths. The mean increase in intercanine width was greater in the maxillary arch (3 to 4 mm) than in the mandibular arch (2 to 3 mm). In the mandibular arch, the greatest tendency to increased width was during eruption of the lower lateral incisors, whereas in the maxillary arch it occurred primarily during eruption of the maxillary central incisors. Whereas the increase was slightly greater in nonspaced primary arches than in spaced arches, the arches with spaces generally resulted in favorable alignment of the permanent incisors. About 40% of the arches without primary dental spacing resulted in crowded anterior segments. Moorrees reported similar dimensional changes concurrent with incisor transitional periods.[5]

Bishara and colleagues[7] also reported arch dimensional changes in their studies of patients from 6 weeks to 45 years of age, noting that (1) significant maxillary and mandibular arch width increases occurred between 6 weeks and 2 years of age; (2) the mandibular intercanine width was established by 8 years of age (i.e., after eruption of the four incisors); and (3) although arch width increased between 3 and 13 years of age, there was a slight decrease in width, more in the intercanine than in the intermolar area, after complete eruption of the permanent teeth. In sum, incisor alignment patterns and intercanine arch dimensions are essentially established by age 8 years of age. Interceptive procedures receive significantly more emphasis in this period to allow for a harmonious transition directed toward achieving alignment of the permanent incisors and 6-year molars with symmetric arch development and coincident midlines. Additionally, early recognition and elimination of deleterious oral habits or deviant functional patterns should enhance normal patterns of development while diminishing the long-term effects of atypical growth.

LEEWAY SPACE

In addition to malocclusion factors identifiable during first molar and incisor transition, corrective measures to align and position the erupting buccal segments come into play during the late mixed dentition (9 to 12 years of age), when primary canines and molars are exfoliating in conjunction with eruption of the permanent canines and premolars. Epidemiologic studies demonstrate that crowding and malalignment become significantly more prevalent and exhibit greater severity between the mixed-dentition period (6 to 12 years of age) and the adolescent young permanent dentition (12 to 18 years of age). This suggests that normal transitional changes do not compensate for anterior malalignment and crowding, in that late mesial shift of the buccal segments upon exfoliation of second primary molars results in decreased arch length and arch circumference. Nance[9] observed that in the average patient's mandibular arch, a leeway size difference of +1.7 mm per side exists, with the combined mesiodistal widths of the primary canine, first primary molar, and second primary molar being larger than the mesiodistal widths of the corresponding permanent canine and premolars. The difference between the total width of the corresponding three primary teeth in the maxillary arch compared with the three permanent teeth that succeed them is +0.9 mm per side of leeway space. The control of this leeway space in terms of arch dimensional change through space supervision may offer opportunities for significant improvement in tooth size–arch size adjustments for the relief of typical levels of crowding. Gianelly[10,11] and others have shown that the control of leeway space will accommodate typical levels of lower incisor crowding in approximately 75% of mixed-dentition patients presenting for orthodontic treatment. As applied to the late mixed dentition, a positive excess leeway space to an overall deficiency of less than 2 mm per quadrant may be considered potential situations for space supervision programs. Lower arch length deficiencies of more than 2 to 3 mm per quadrant should be considered a discrepancy beyond simple guidance procedures. However, there is a drawback: Sonis and Ackerman have shown a significant increase in mandibular second permanent molar impaction with this approach when compared with historic controls.[12] There is a positive predictive value in measurement of the pretreatment intermolar angulation between the first and second permanent mandibular molars.

In keeping with supervision of leeway space as a fundamental concept, the vast majority of patients should be evaluated around the time of the clinical emergence of the lower canine, lower first premolars, and upper first premolars. These teeth erupt about 1 to 1½ years ahead of the final buccal segment transition. This leaves time for the practitioner to assess overall dimensional needs and plan treatment interventions for the relief of crowding, manage space to minimize future permanent tooth extractions, coordinate the transverse widths of the dental arches, and guide teeth into favorable positions that provide more stable long-term results. A second advantage for this timing in diagnosis and treatment planning is that it precedes the pubertal growth spurt in females, which in turn is approximately 2 years ahead of the pubertal growth spurt in males. If a skeletal malocclusion is noted, the opportunity for growth modification with dentofacial orthopedics, to take advantage of peak growth velocities, is available for positively influencing skeletal discrepancies, arch development, and facial balance. Consultation with an orthodontist is critical for children in whom skeletal considerations, severe growth problems, extensive crowding with pronounced tooth mass–arch length discrepancies, and dental anomalies are present that significantly compromise the child's orofacial development. Coordination will lead to more accurate identification of problems, aid in appropriate treatment decisions, and offer the potential for optimal results without having to resort to compromised treatment options in the full permanent dentition. Psychological aspects of treatment in terms of patient motivation, improved and dramatic dentofacial change, a social desire for treatment, well-being for the child and parents are good practice-builders with timely coordinated management.

INTERVENTION CONSIDERATIONS

One should recognize that certain disadvantages involved in "early" treatment must be factored into the equation on whether to intervene in an individual patient. These include

Dentlearn.ir

the reality that overall treatment time is likely prolonged, multiple problems often arise in individual patients, untoward responses may occur given the variability of growth dynamics, there is potential for iatrogenic damage to the developing teeth, some children cannot cope with treatment demands, and patient and parent burnout often occur given that overall management is rarely a one-shot operation. Parents must have realistic perspectives of treatment goals and be willing to assume the financial and appointment obligations involved in treatment. While things happen slowly during the development of the occlusion, timing is critical for certain procedures, in that there are many problems that can occur and jeopardize successful outcome. In the decision-making process for an individual patient, the clinician involved in early orthodontic procedures should ask two key questions, each with its own subset of questions:

1. *What is the specific problem?* How did it happen? Is the etiology resolved? What will happen without treatment? Will it stay the same, get worse, or go away on its own? Simply put, not every child can or should be treated with interceptive procedures. Roughly half of patients fall into an area of real or absolute need in requiring corrective treatment for functional and aesthetic problems that will potentially lead to deterioration of the occlusion if untreated. Even though some children may benefit from interceptive treatments, there should be understanding that later comprehensive treatments will be necessary to achieve acceptable results.
2. *What will the likely result of interceptive treatment be?* The remaining estimate of up to 50% of children is

   orthodontic interventions in the developing occlu-

   in which treatment intervention will potentially eliminate or minimize the need for future orthodontic treatment. At the least, interceptive treatments should enhance long-term treatment options and outcomes without compromising future needs. So a subset of questions should be asked. Is treatment justified in terms of improvement in aesthetics and function while eliminating or minimizing the need for future treatment? Will the intervention correct a problem at the optimal time to enhance later options and outcomes? Can treatment methods be used to advantage such that the skill and experience of the clinician intersect with patient needs? Does treatment meet socioeconomic issues? Does the treatment present an outcome that can be easily realized in conjunction with later comprehensive care that will be required anyway?

For these questions to be answered, a thorough clinical examination supported by appropriate diagnostic records should be obtained before treatment interventions are initiated. The clinical examination should assess the patient's overall health status, extraoral facial patterns (profile, facial symmetry, area of discrepancy), occlusion from an aesthetic and functional standpoint, temporomandibular joint function, neuromuscular patterns, growth patterns, and nasopharyngeal airway patterns. A form similar to the one depicted in Figure 22-2 is helpful in composing clinical findings and formulating the patient's diagnosis, problem list, and treatment plan summary. In terms of diagnostic records beyond clinical findings, necessary records may range from simple photos or study models for the treatment of a functional posterior crossbite to a complete set of orthodontic records for a patient with a skeletal malocclusion or severe crowding. More comprehensive records may include an eight-film series of extraoral and intraoral photographs, appropriately trimmed orthodontic study models, a full-mouth series or panoramic radiographs, lateral and anteroposterior cephalograms, and, when indicated, temporomandibular diagnostic views such as corrected axis tomograms or magnetic resonance imaging. Supplemental diagnostic procedures can also include a detailed tooth size–arch size space analysis (Chapter 19) and a cephalometric analysis (Chapter 20). Finally, cone-beam computed tomography should be considered in special cases, such as patients with impacted teeth or craniofacial anomalies.

EARLY LOSS OF TEETH AND SPACE MAINTENANCE

If arch integrity is disrupted by early loss of primary teeth, problems may arise that affect the alignment of the permanent dentition. Opposing teeth can supraerupt, more distal teeth can drift and tip mesially, and more forward teeth can drift and tip distally (Figs. 22-3 and 22-4). Altered tooth positions may include a "symptomatic" space deficiency with loss of arch length and circumference, blocked or deflected eruption of permanent teeth, unattractive appearance, food impaction areas, increased caries and periodontal disease, and other negative aspects of malocclusion. The altered occlusal relationships may evidence traumatic interference and untoward jaw relationships. When early primary tooth loss occurs, corrective measures such as passive space maintenance, active tooth guidance with space regained, or a combination of both may be needed to optimize the normal process of occlusal development.

Miyamoto and colleagues[13] observed the effects of the early loss of primary teeth by measuring crowding and malalignment in the permanent dentition of 255 schoolchildren aged 11 years or older. Children who had premature loss of one or more primary canines or molars were more likely to receive orthodontic treatment in the permanent dentition, with the need being more than 3 times greater in children who had lost one or more prima-

Premature loss of primary molars was especially associated with major malalignment of permanent teeth. No differences were observed in effects between loss of first and second primary molars. Crowding of anterior teeth was directly affected by the premature loss of primary canines.

NEEDS ASSESSMENT

Owen's review of the clinical literature[14] revealed the following general factors that should be considered in assessing the implications of premature loss of primary teeth for arch development, the development of a malocclusion, and the need for a space maintainer.

1. *Incidence of space loss.* Almost all cases of early primary molar loss show some decrease in arch length (i.e., mesial movement of permanent molars, distal

Dentlearn.ir

ORTHODONTIC DIAGNOSIS, TREATMENT, AND MECHANICS PLAN

Name _____ Race ____ Sex ____ Birthdate _____ Age ____ Chart No. _____

Resident's Name: _____ Records Date: _____

1. Patient History

A. Significant Medical History: _____

_____

B. Patient's and/or Parents' Chief Complaint: _____

_____

C. Attitude Toward Treatment: _____

_____

2. Clinical Examination

A. Soft Tissue

Profile _____ Lip Competence _____ Lip/Incisor at Rest _____ Smiling _____

Oral Hygiene _____ Periodontal Status _____ Other _____

B. Occlusion Class: I II III Division: I II

Overjet _____ mm Overbite _____ mm Midline _____ mm

Crossbite _____

Molar Relation: Left _____ Right _____

Cuspid Relation: Left _____ Right _____

C. Dental Development Stage and Eruption Sequence:

D. Habits and/or Other Significant Clinical Findings:

E. TMJ and Function:

Opening Path: Normal Deviated: _____

Closing Path: Normal Deviated: _____

Range of Motion: Vertical _____ mm Protrusion: _____ mm

Left Deviation: _____ mm Right Deviation: _____ mm

Joint Sounds:	None	Left	Right
	Opening	_____	_____
	Closing	_____	_____
	Crepitus	_____	_____

Muscle Tenderness: None _____

Tongue Function: Normal _____

3. Model Analysis **Static Tanaka and Johnston Analysis (JADA 1974)**

Total M-D Width of Upper Incisors _____ mm "A"

Maxillary Arch Length Discrepancy (From $\underline{6}|$ to $|\underline{6}$)

Total Predicted Tooth Mass:

[("B" ÷ 2) + 11 mm] × 2 + "A" = _____ mm

Total Measured Arch Length = _____ mm

Difference _____ mm

Total M-D Width of Lower Incisors _____ mm "B"

Mandibular Arch Length Discrepancy (From $\overline{6}|$ to $|\overline{6}$)

Total Predicted Tooth Mass:

[("B" ÷ 2) + 10.5 mm] × 2 + "B" = _____ mm

Total Measured Arch Length = _____ mm

Difference _____ mm

A

Figure 22-2 "Orthodontic Diagnosis and Treatment Plan" form. **A,** Front side.

continued

4. Attach computerized cephalometric tracing and appropriate analysis.

5. Diagnostic and Arch Length Analysis Summary and Problem List

6. Treatment Plan or Objective Sequence

7. Mechanics Plan–Appliance Selection—Retention

8. Projected Treatment Time (with Good Compliance), Treatment Fees

9. Faculty Authorization to Start Treatment:

Signature Date

B

Figure 22-2, cont'd B, Back side. Indiana University Department of Pediatric Dentistry.

Dentlearn.ir

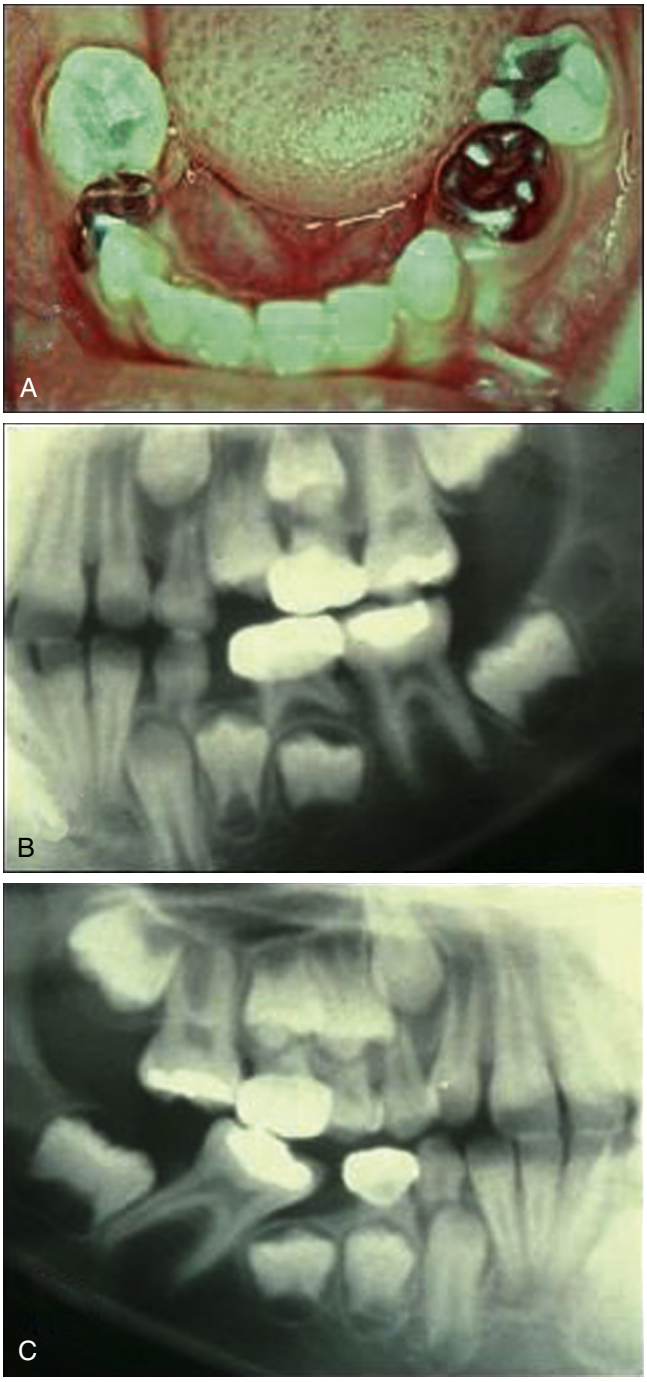

Figure 22-3 **A,** Space loss and occlusal changes associated with early loss of lower primary molars. **B,** Radiograph of left segment with loss of first primary molar. Note some distal movement of primary canine. **C,** Radiograph of right segment with loss of mandibular second primary molar and associated space loss approximating 4 to 6 mm. Note pronounced mesial tipping of permanent first molar crown without notable bodily movement.

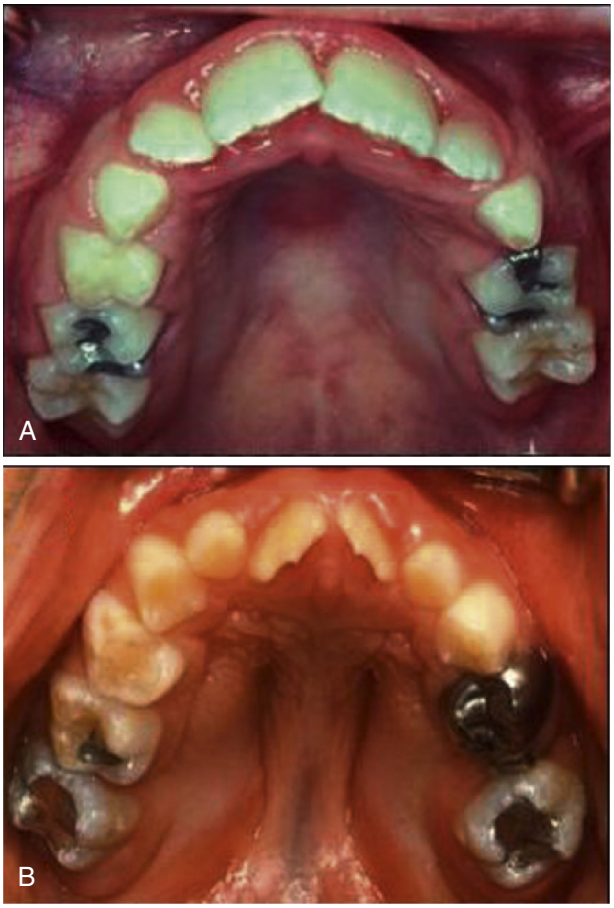

Figure 22-4 Loss of upper primary molars in association with eruption of first permanent molars and space loss. **A,** Loss of upper left first primary molar with space loss approximating 4 to 6 mm. **B,** Loss of upper left second primary molar with space loss approximating 6 to 8 mm. Note rotation of first molar in conjunction with more bodily movement.

movement of anterior teeth). The amount of closure is affected by numerous variables (e.g., tooth involved, time of loss).

2. *Time elapsed since loss.* Most of the space loss usually takes place during the first 6 months after the primary tooth is lost, and space closure tends to occur more rapidly in the maxillary arch than in the mandible. Thus when a primary tooth is removed and factors indicate need for space maintenance, it is best to insert an appliance as soon as possible after the extraction.
3. *Stage of development/dental age of the patient.* In general, more space loss is likely to occur if teeth are actively erupting adjacent to the area left by the premature loss of the primary tooth. Significant space loss is most influenced by the stage of eruption of the first permanent molars, with the potential particularly high if a primary molar is lost just before or during eruption of the first permanent molars. The amount of space closure is usually less if the permanent molars are fully erupted into occlusal interdigitation at the time of primary tooth loss. A similar situation exists if the first primary molar has been lost prematurely and the permanent lateral incisor is in an active state of eruption. The eruption of the permanent lateral incisor may result in distal movement of the primary canine and encroachment on space available. This condition is frequently accompanied by a shift in

the midline toward the area of the loss. In the mandibular arch, a lingual "collapse" of the anterior segment may occur, with a resulting increased overbite. Another factor is in terms of available abutments for securing a space maintainer at the time of the primary tooth loss. A second primary molar lost at 5 years of age requires different abutment considerations than one lost during the mixed dentition when first permanent molars have erupted. Also, teeth actively erupting adjacent to the edentulous area have a greater effect on the amount of space lost than do fully erupted teeth. For example, if the first primary molar is lost during the time of active eruption of the first permanent molar, a strong forward force will be exerted on the second primary molar that causes it to tip into the space required for eruption of the first premolar. Changes may extend anteriorly with shift of the dental midline and retrusion of the anterior segment after early loss of a first primary molar.

4. *Amount of space closure.* Loss of maxillary second primary molars results in the greatest amount of closure, up to 8 mm of space loss in a quadrant (see Fig. 22-4, *B*). Loss of mandibular second primary molars shows the next greatest amount—up to 4 mm in a quadrant (see Fig. 22-3, *A* and *C*). Loss of upper or lower first primary molars shows almost equal amounts of space closure when compared with one another; the amount is most affected by timing of the first primary molar loss (see Fig. 22-4, *A*). Space loss potential is particularly high if the primary molar loss occurs in approximation to first permanent molar eruption, irrespective of which primary molar is lost and in which arch the loss occurs. After first permanent molars have erupted into occlusion, loss of second primary molars may still result in significant space closure. Loss of a first primary molar with retention of the second primary molar shows minimal amounts of space closure because the second primary molar serves to buttress first permanent molar positions after occlusion is established.
5. *Direction of closure.* Maxillary posterior spaces close predominantly by mesial bodily movement and mesiolingual rotation around the palatal root of the first permanent molars. Only minimal mesial crown-tipping of the first molar is usually noted. In contrast, mandibular spaces close primarily by mesial tipping of the first permanent molars, along with distal movement and retroclination of teeth anterior to the space (see Fig. 22-3, *C*). Bodily movement of first molars is not typically notable in the lower arch as seen in the upper arch. Lower molars also tend to roll lingually in conjunction with their mesial crown-tipping during space loss movements.
6. *Eruption timing of permanent successors.* Grøn,[15] in evaluating the emergence of permanent teeth, found that teeth normally erupt when three fourths of the root is developed, regardless of the child's chronologic age. However, the eruption timing of a permanent successor may be delayed or accelerated after premature loss of a primary tooth, depending on the developmental status, bone density of the area, and nature of the primary tooth loss. Very early loss before significant root formation of the permanent successor usually results in delayed eruption timing that may alter normal transitional adjustments in arch length, arch width, and arch circumference. Several studies have indicated that loss of a primary molar before 7 years of age leads to delayed emergence of the succedaneous tooth, whereas loss after 7 years of age leads to early emergence. The magnitude of any timing change in eruption is affected by age at time of tooth loss; if a primary molar is lost at 4 years of age, the emergence of the premolar could be delayed by as much as 1 year, with emergence occurring at root completion. If the loss occurs at 6 years of age, a delay of about 6 months is more likely, with emergence seen when root development approaches completion. Primary tooth loss within 6 to 12 months of normal exfoliation time may result in acceleration in eruption timing of the underlying permanent tooth.
   Individual permanent teeth are often observed to be delayed in their development and, consequently, in their eruption timing. Impacted permanent teeth or deviations in eruption paths may be reflected in abnormally delayed eruption times. In cases of this type, it is generally necessary to extract the primary tooth, construct a space maintainer, and allow the permanent tooth to erupt and assume its normal position (Fig. 22-5). The exact timing of permanent tooth eruption is less important in overall occlusal development compared with its greater significance relative to sequencing, site of eruption, and adequate space for subsequent eruption.
7. *Amount of bone covering the nonerupted tooth.* Prediction of eruption based on timing of primary tooth loss and stage of root development is not reliable if the bone covering the permanent tooth has been destroyed by infection. Emergence is then usually accelerated. If there is bone covering the tooth, it can be predicted that eruption will not readily occur. A guide is that premolars usually require about 4 to 6 months to move through 1 mm of bone, as measured on bitewing radiographs.
8. *Abnormal oral musculature.* Strong mentalis muscle patterns may have a pronounced negative effect after loss of mandibular primary molars or canines, with collapse of the arch and the distal drifting of the anterior segment that is often exhibited. Thumb or finger habits may similarly produce abnormal forces in initiating collapse of the dental arches after untimely loss of primary teeth.
9. *Congenital absence of the permanent tooth.* Before space maintenance, the presence of a normal successor must be ensured before space maintenance through radiographic evaluation. Should the succedaneous tooth be congenitally absent or significantly malformed, the decision is a challenging one, whether to hold the space for many years until a permanent prosthesis can be provided or to allow space closure with the likelihood of orthodontic treatment to achieve proper alignment.
   When utilized, a space maintainer must fulfill the fundamental role of preventing untoward mesial migration of buccal segments and lingual collapse of anterior

Dentlearn.ir

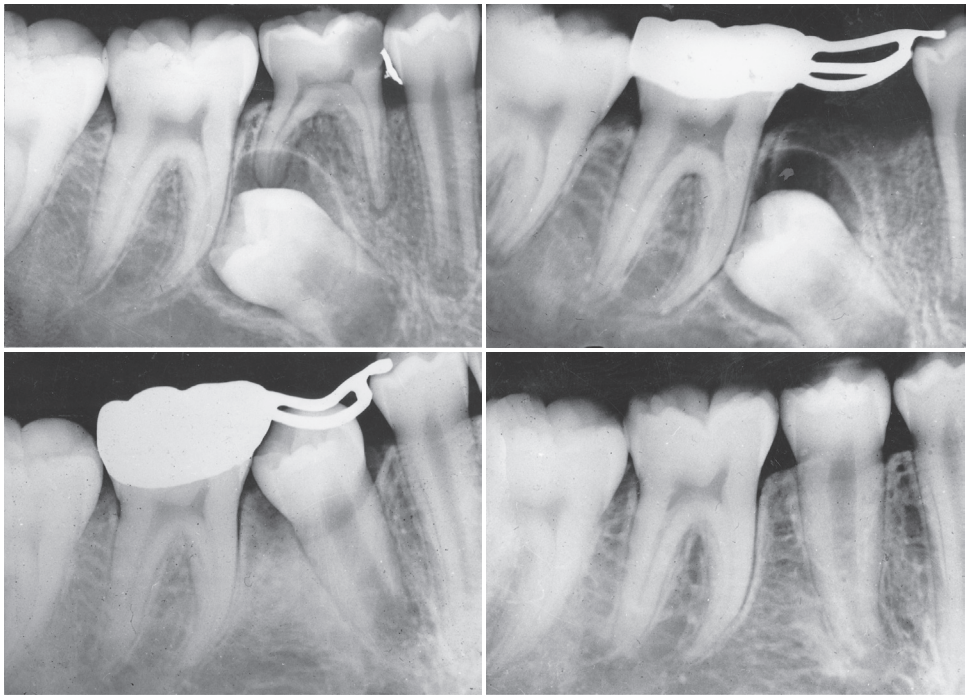

Figure 22-5 Extraction of the second primary molar and space maintenance were indicated because of prolonged retention of the primary tooth and impaction of the second premolar. The second premolar eventually erupted into its normal position.

segments in maintaining the mesiodistal dimensions of the prematurely lost primary tooth. The appliance should not interfere with masticatory function, nor should it inhibit or deflect normal growth changes. It should be simple to construct and maintain; durable, strong, and stable; passive in not imposing pressures on remaining teeth that might affect orthodontic movements; and easily cleanable without enhancing dental caries or soft-tissue pathology. Beyond these fundamental roles, space maintainers may be designed to prevent supraeruption of teeth opposing the space, improve esthetics, and assist in speech (i.e., anterior space maintainers in control of oral habits).

When a primary tooth is lost prematurely, a space maintainer need not be automatically necessary or desirable. The decision to place a space maintainer and the choice of design to use are affected by the following: the specific tooth that was lost, from which arch, at what time, whether the permanent successor is present and developing normally, the patient's overall oral health status and motivation, and the status of existing arch length to accommodate the permanent teeth. If analysis indicates a positive arch length or deficiency of less than 1 to 2 mm per quadrant, a space maintainer may be beneficial in holding tooth positions. If the space is not held, the total arch length may be further decreased and lead to possible premolar extraction requirements. Holding the space may allow the permanent premolars and canines to erupt and utilize leeway space to alleviate anterior crowding. However, if the arch length deficiency is 2 to 3 mm or more per quadrant, a significant discrepancy exists where space regaining, serial extraction, and/or comprehensive orthodontic treatment may be indicated. If there is no question that permanent teeth will have to be removed to obtain a favorable occlusion, space maintenance may not be desirable because the space would need to be closed during orthodontic treatment anyway. In less obvious extraction cases, holding the space to allow teeth to erupt and prevent impactions can be a valuable service. As related to the premature loss of specific primary teeth, the arch involved, and developmental timing, the following recommendations are made with regard to placement and design of space maintainers.

SPECIFIC TOOTH LOSS STRATEGIES

Loss of Primary Incisors

Early loss of lower primary incisors is generally due to ectopic eruption of the permanent incisors in reflecting excessive incisor liability. Given the potential for increased intracanine width during permanent incisor eruption, the clinician should monitor development in the lower incisor area and generally not intervene. Individual circumstances may indicate extraction of the antimere primary incisor to enhance incisor positioning and midline symmetry. The loss of lower incisors in other circumstances, such as trauma, advanced caries, or extraction of a neonatal tooth, may result in anterior space loss if it occurs before primary canine stabilization is realized.

Premature loss of maxillary primary incisors does not generally result in decreased upper intracanine dimensions if the incisor loss occurs after the primary canines have erupted into occlusion at approximately 2 years of age. The support of the mandibular occlusion "holds" the maxillary anterior intracanine width dimensions. Baume type I spaced primary dentitions have significant latitude to resist arch dimensional changes. If the anterior primary teeth were in contact before the loss or there is evidence



Figure 22-6 **A,** Child with some loss of space in the primary incisor area that was observed at the time of the first examination. **B,** Space closure continued and was accompanied by drifting of teeth throughout the anterior area, including the canines.

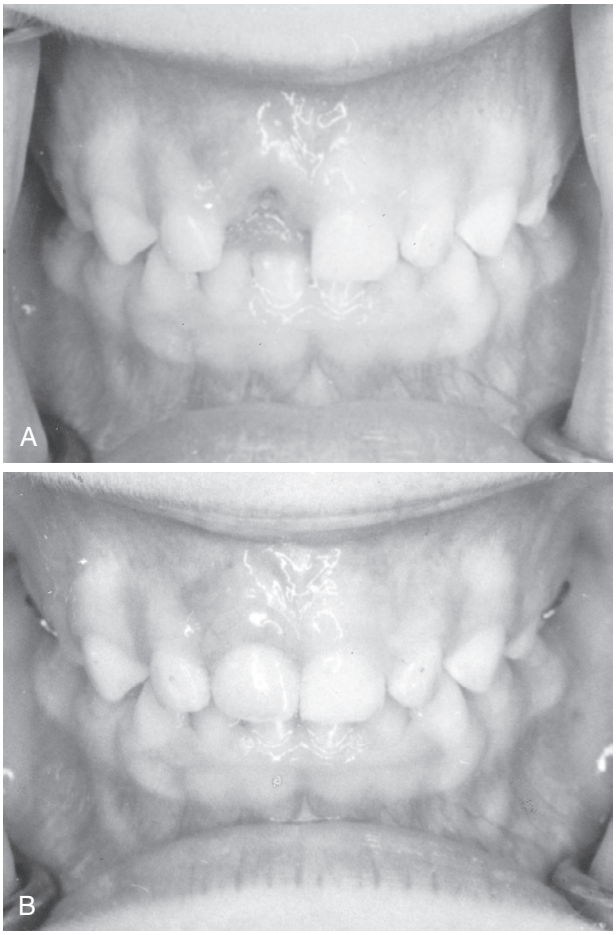

Figure 22-7 **A,** This 3½-year-old child has lost a primary incisor as the result of trauma. **B,** A removable palatal retainer with a primary central incisor pontic has been constructed to prevent space closure and to restore normal appearance.

of an arch length inadequacy in the anterior region, space adjustments in alignment after the loss of one of the primary incisors is a potential factor in space maintenance (Fig. 22-6). The major consequence of early loss of maxillary primary incisors is most likely delayed eruption timing of the permanent successors as reparative bone and dense connective tissue cover the site. In addition, unattractive appearance and potential development of deleterious habits (e.g., tongue-thrust swallow, forward resting posture of the tongue, improper pronunciation of fricative sounds such as "s" and "f") may be of concern following premature loss of primary maxillary incisors. An anterior appliance incorporating artificial primary teeth may be considered to satisfy aesthetic and functional needs. Acrylic partial dentures have been successful in the replacement of single (Fig. 22-7) and multiple (Fig. 22-8) maxillary primary incisors. Given the demands of cooperation in wear and frequent appliance loss or damage, such removable appliances can be problematic in preschool-age children.

A fixed option using primary incisor denture teeth secured from a rigid stainless steel wire (0.036- or 0.040-inch) extended to bands or stainless steel crowns on the primary molars, a so-called "Hollywood" bridge, may be a more predictable option (Fig. 22-9). One can obtain additional stabilization in keeping the wire from flexing by placing an occlusal rest on the first primary molar, using a Nance button, or by covering the ridge with acrylic resin. Use of such an appliance incorporating artificial primary anterior teeth is an option for addressing primarily aesthetic demands rather than specific space management concerns.

Loss of Primary Canines

Most often due to ectopic eruption of permanent lateral incisors, early loss of a mandibular primary canine is a significant indicator of a tooth size–arch size discrepancy. Unilateral loss of a lower primary canine is frequently followed by a shift in the dental midline toward the side of loss, lingual collapse of the incisor segment, and possibly deepening of the bite (Figs. 22-10, *A* and *B*). The asymmetric disruption in arch integrity complicates normal eruption of the permanent canines and premolars toward the affected side. If ectopic eruption involves bilateral loss of both lower primary canines, pronounced lingual inclination and distal drifting of the permanent incisors, deepening of the overbite, increased overjet, and significant loss of arch perimeter are likely to be the alignment results (see Figs. 22-10, *C* and *D*).

Dentlearn.ir

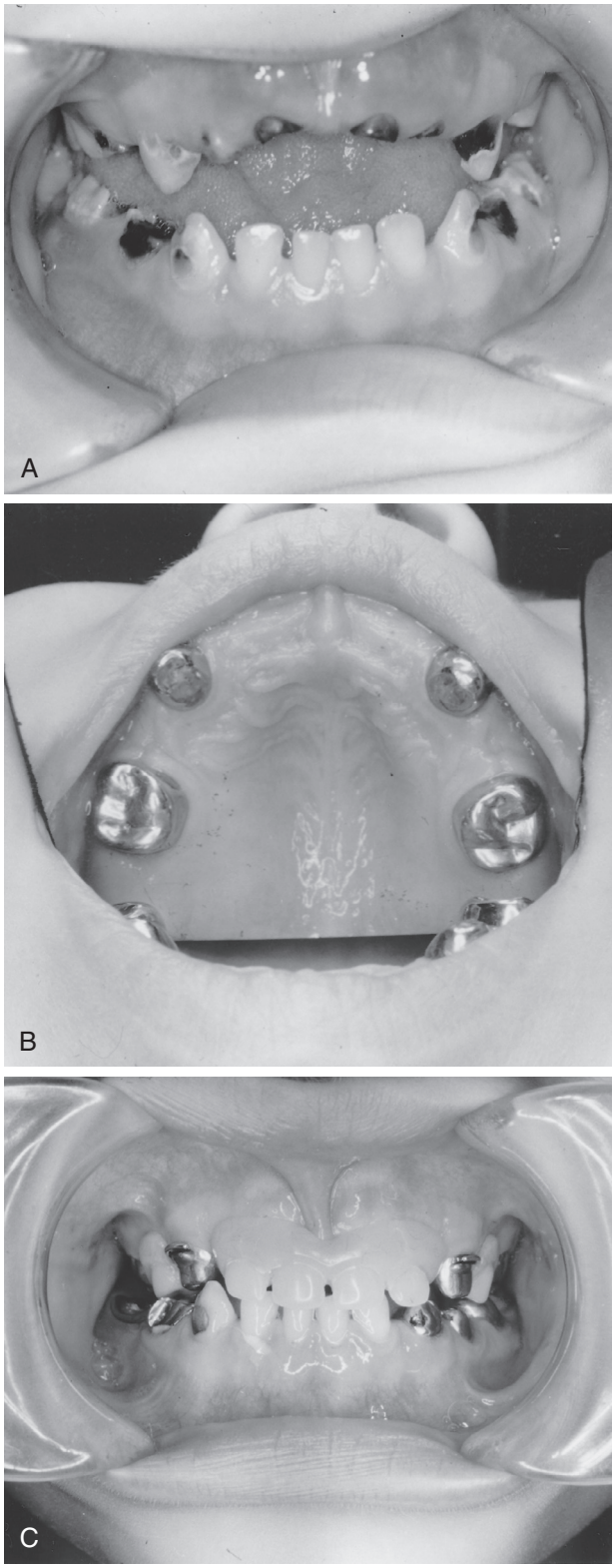

Figure 22-8 **A,** This 4-year-old child required removal of nonrestorable maxillary primary incisors and first primary molars. **B,** Stainless steel crowns were placed on the primary canines and second molars. **C,** A maxillary removable partial retainer with incisor pontics maintains space, improves appearance, and reduces the possibility of a tongue-thrust.

If one primary canine is lost during incisor eruption, it may be desirable to extract the contralateral primary canine to help maintain arch symmetry. Although extraction of the contralateral primary canine may improve the appearance of incisor alignment and midline integrity, crowding problems requiring such intervention strongly indicate a significant arch length deficiency that will likely become grossly evident upon permanent canine and premolar eruption. Some clinicians recommend a lingual holding arch with spur attachments to control incisor positioning and prevent encroachment on permanent canine eruption positions when primary canines are lost prematurely. Even though this may be feasible in some cases, the asymmetric positioning and displacement of the incisors typically contradict simple placement of a lingual holding arch at this stage without first aligning the incisors with active appliance therapy. The inherent questionable prognosis relative to arch length–tooth size considerations brings into question simple appliance therapy at this point in development. Regardless of the individual decision, the prognosis related to ectopic loss of primary canines is generally not good concerning the status of long-range occlusion.

The ectopic loss of maxillary primary canines occurs less frequently than does mandibular loss, given more favorable space adjustments for incisor liability. When it occurs, ectopic loss of a maxillary primary canine typically reflects a very distal eruptive displacement of the permanent lateral incisor and not necessarily a significant tooth mass problem. Atypical upper anterior alignment may occur, with resultant crowding and blockage of the permanent canine because it erupts so late in normal transition. Early loss of maxillary primary canines is an indicator for early orthodontic treatment with an understanding that the child is a definite candidate for comprehensive orthodontic intervention.

Loss of First Primary Molars

The effect of premature loss of first primary molars in both arches is mostly dependent on the state of eruption of the first permanent molars. If the primary first molar is lost during the primary dentition from ages 3 to 5 years, there should be little or no space loss associated with mesial movement of the second primary molar. However, as first permanent molars erupt at ages 5 to 7 years, a strong force is exerted that pushes the second primary molar forward into the first primary molar space (see Fig. 22-3, *B*). This results in a loss of posterior arch length within the quadrant that can lead to crowding as the canines and premolars erupt in later stages. In addition to posterior effects, mandibular arch length may be further compromised by distal and lingual shifting of anterior teeth toward the side of first primary molar tooth loss. Therefore the loss of a first primary molar in either arch, approximating eruption of first permanent molars, indicates that the use of a space maintainer is generally desirable to stabilize second primary molar and canine positioning.

If the first primary molar is lost after first permanent molars have erupted into occlusion and the second primary molar is still in position, minimal space loss should be evidenced in either arch. This is particularly applica-

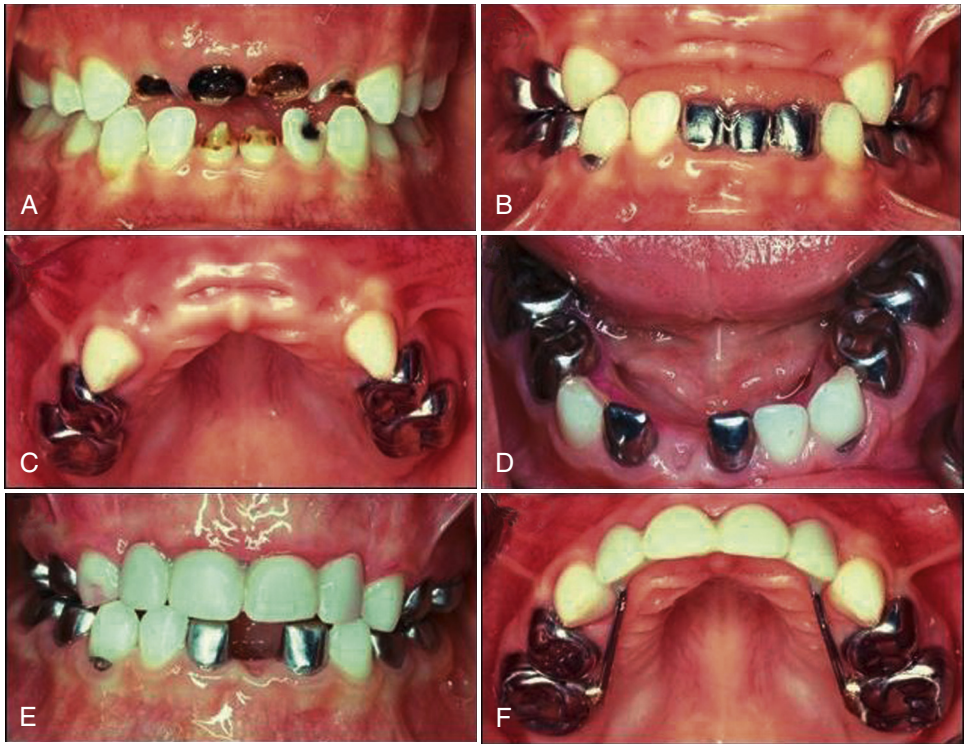

Figure 22-9 Early loss of maxillary primary incisors in 4½-year-old child. **A,** Pretreatment caries with nonrestorable maxillary primary incisors. **B, C,** and **D,** Postrestorative appearance with multiple stainless steel crowns. While interdigitation should hold anterior intercanine space, the parents and patient requested cosmetic incisor replacement. **E** and **F,** A fixed space maintainer with a "Hollywood" bridge fulfills aesthetic demands as an elective treatment. Appliance used one-size-larger crowns fitted over restorative crowns on second primary molars as abutments.

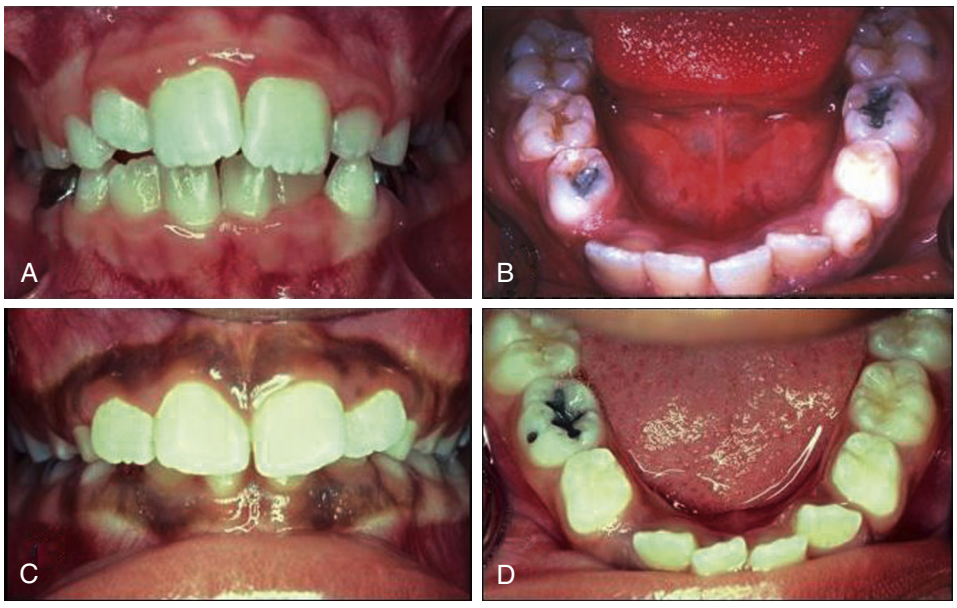

Figure 22-10 Ectopic loss of lower primary canines in association with permanent lateral incisor eruption. **A** and **B,** Unilateral canine loss results in asymmetric arch dimensions as the incisors shift toward the side of loss and lingualize their positioning. **C** and **D,** Bilateral ectopic loss of canines allows for maintenance of arch symmetry, but results in significant lingual retroclination and supraeruption of lower incisors, increased overjet, deepened overbite, and reduction in lower arch dimensions.

ble when first permanent molars are positioned in a full Class I or Class II cuspal interdigitation. If first permanent molars are in an end-to-end relationship, the location, by arch, of the missing first primary molar may be a factor in potential molar adjustments. If loss of the first primary molar occurs in the upper arch, untoward shifting from the end-to-end occlusion may result in Class II molar positioning. To ensure that this does not happen, a space maintainer for the upper arch may be considered. If the first primary molar loss occurs in the lower arch,

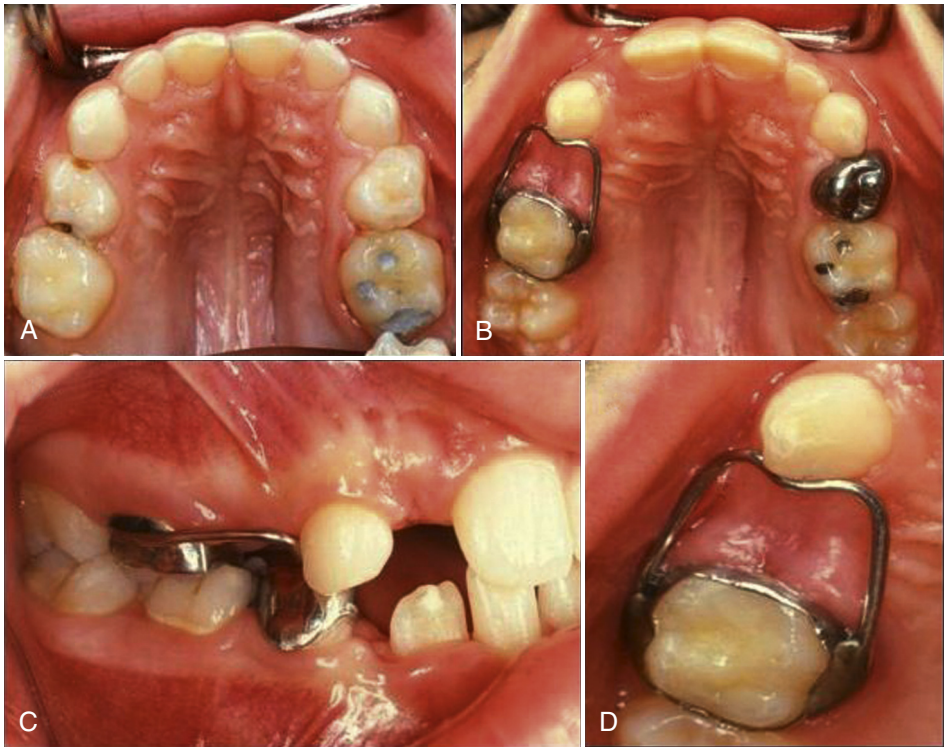

Figure 22-11 **A** and **B,** Pretreatment at 4½ years of age and follow-up at 7 years showing value of properly fitted and designed band-and-loop appliance to hold space for an extracted first primary molar. **C,** Buccal occlusion showing proper relationship of erupted first permanent molars. **D,** Close-up of design shows that loop is sufficiently large to allow for the eventual eruption of the permanent tooth.

any molar shift would be in the direction of a Class I relationship. Space maintenance would be less likely unless absolute preservation of leeway space was indicated until permanent canines and premolars erupt.

A unilateral fixed space maintainer called a *band* or *crown and loop* is usually the appliance of choice for early loss of first primary molars (Video 22-1: Managing occlusion: delivery of immediate band and loop). The appliance incorporates a band or crown on the second primary molar with a soldered wire-loop extension extending forward to come into contact with the distal-cervical surface of the primary canine in the quadrant (Fig. 22-11). The loop uses 0.036- or 0.040-inch stainless steel wire strong enough to withstand biting forces while ensuring a rigid abutment contact in stopping forward movement of the second primary molar and distal movement of the primary canine. Wire design approximates the gingival contour of the extraction space to avoid occlusal interference and is wide enough to allow the permanent tooth to erupt. A modification of the design is use of a single-wire extension "arm" rather than a full loop from the posterior abutment to come into contact with the anterior abutment (Fig. 22-12). The single arm of 0.036- or 0.040-inch stainless steel wire is rigid enough to hold the space while reducing by half possible interference with eruption of the underlying tooth. Neither the loop nor the arm design restores chewing function or prevents eruption of opposing teeth, a possible consideration in some cases. In addition, the wire may inhibit primary canine distolateral movement as permanent incisors erupt, particularly in association with lower lateral incisor eruption. For this reason, the status of permanent incisor eruption sequencing,

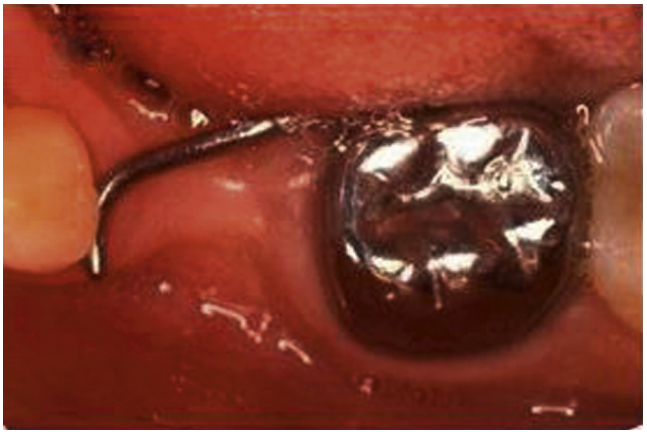

Figure 22-12 Close-up of unilateral crown and arm space maintainer.

symmetry, and positioning should be monitored and guidance steps taken to optimize normal incisor eruption. The clinician must recognize these limitations and prepare for modifications in the overall space supervision planning.

The use of a band as the abutment attachment makes it easy and economical to construct, takes little chair time, and adjusts readily to accommodate the changing dentition. The use of a stainless steel crown as the abutment base (Fig. 22-13) offers the advantage of increased stability and retention. A crown is used if the second primary molar has extensive caries or if the tooth has had vital pulp therapy. The steel crown should be prepared as described in Chapter 11: an impression is made, the crown

Dentlearn.ir

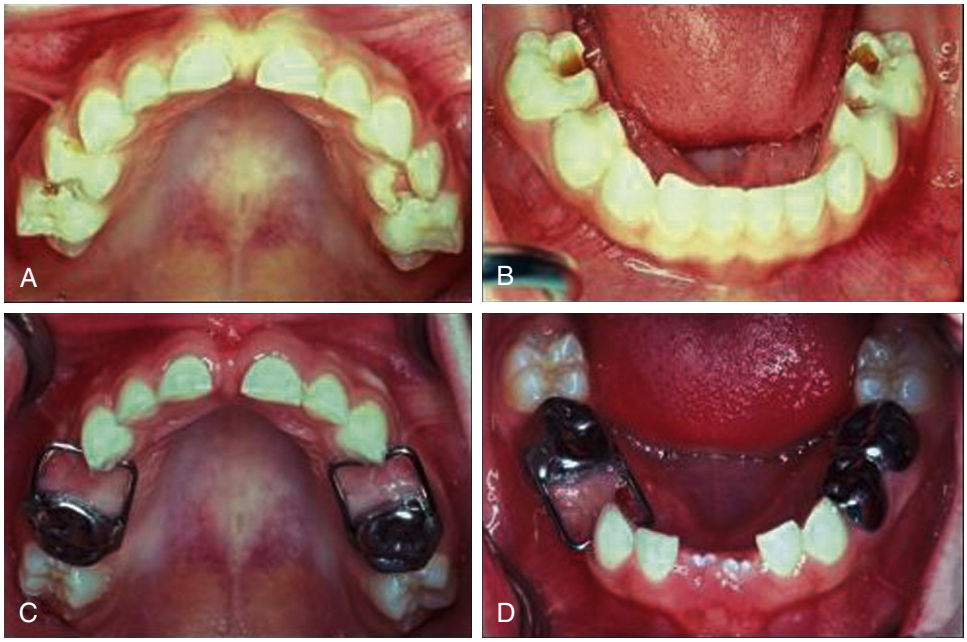

Figure 22-13 **A** and **B,** Pretreatment of upper and lower arches with caries and pulp involvement of primary molars. **C** and **D,** Same upper and lower arches with crowns and loops placed for early loss of three first primary molars. Note erupted first permanent molars with proper positioning.

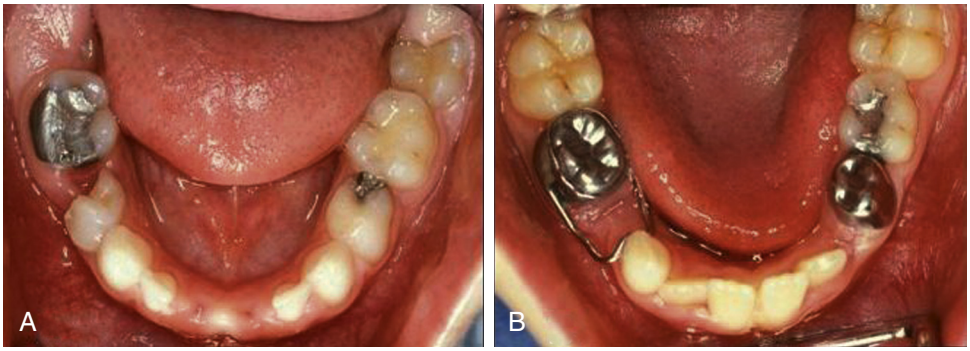

Figure 22-14 **A,** Pretreatment of lower arch with caries and pulp involvement of primary molars. **B,** Same lower arch with band and loop placed over a restored crown on the second primary molar for early loss of right first primary molars. The band was fabricated from the next-larger-sized crown by removing the occlusal surface and shortening the cervical portion of the crown. Note erupted first permanent molars with proper positioning.

removed from the tooth and seated in the impression, and a working model prepared on which to fabricate the loop. Because it is difficult to remove the crown (converted to a band) to make adjustments, adapting a band or one-size-larger crown over a cemented crown restoration or constructing a conventional band-and-loop appliance is another alternative to address unilateral space maintenance (Fig. 22-14).

If first primary molars are lost bilaterally within a lower arch and the second primary molars are retained, two separate unilateral loop appliances are generally indicated until first permanent molar and incisor eruption is complete. Bilateral lingual holding arch designs should not be placed before eruption of the permanent incisors because the lingual wire may interfere with incisor positioning during eruption. Additionally, primary incisors as anterior stops do not offer sufficient anchorage to prevent loss of arch length in most cases. Either of the loop or arm designs is relatively effective as long as the clinician realizes that the appliances are dependent on abutment teeth that may exfoliate before the need for space maintenance is complete. After the permanent incisors have fully erupted and as the primary canines and molars exfoliate, a second appliance that stabilizes final permanent molar position and arch length may be necessary to prevent subsequent space loss.

Loss of Second Primary Molars

If a second primary molar is lost in a child 2 to 5 years of age, no space loss should occur while the first permanent molar is in basal bone. The options for managing such early loss are very limited due to lack of retention elements for fixed appliances and difficulties with patient cooperation in the use of appliances at this age. As first

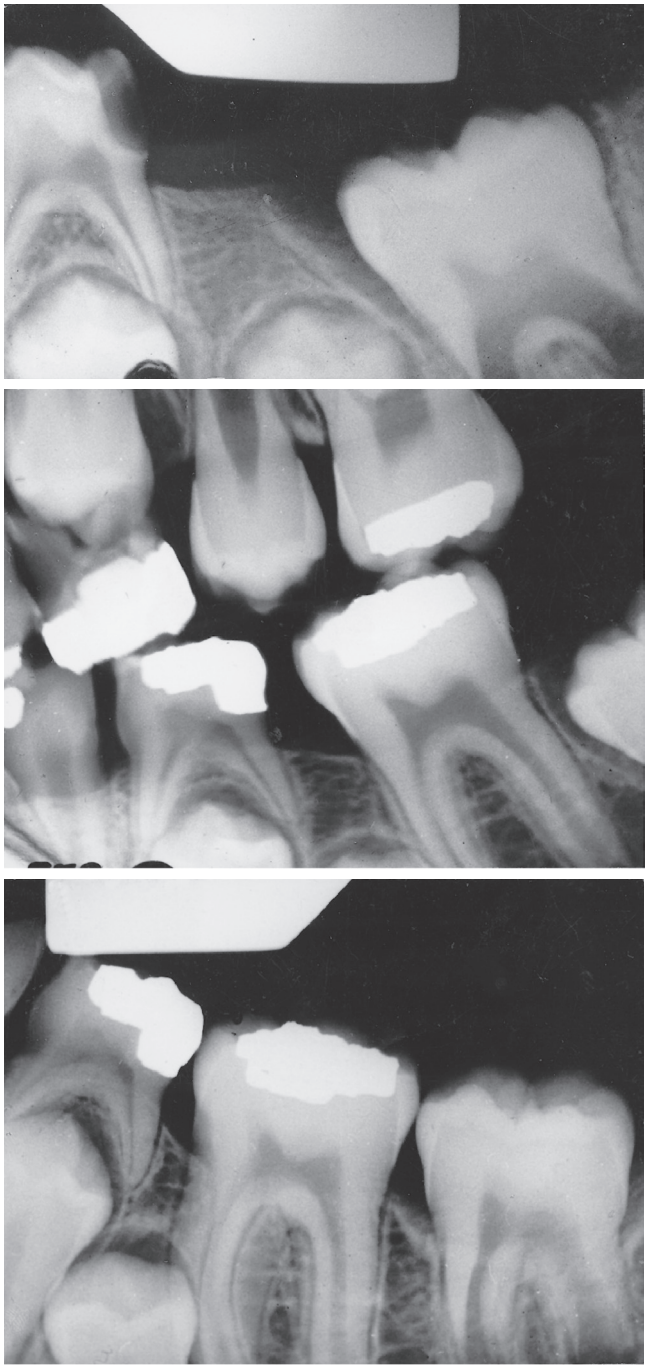

Figure 22-15 A sequence of three radiographs showing early loss of a lower second primary molar and mesial movement of the first permanent molar before eruption. Eventually there was complete closure of the space needed for the second premolar.

permanent molars erupt, however, considerable loss in arch length can occur if no second primary molar is present as an eruptive guide (Fig. 22-15). Space loss of as much as 8 mm in a maxillary quadrant has been documented as the first permanent molar displaces forward through bodily crown-root movement and mesiolingual rotation around the palatal root. Early loss of lower second primary molars in conjunction with first permanent molar eruption timing results in up to 4 to 6 mm of space loss during transition. The lower first molars move forward by pronounced mesial tipping of the crown, with more modest bodily tooth movement expressed in molar adjustments. Distal movement and retroclination of teeth anterior to the space are also a likely consequence of early loss in the lower arch. If the loss of the second primary molar occurs after the first permanent molars have fully erupted and normal cuspal interdigitation has been established, the degree of space loss should be less dramatic than earlier during molar transition, regardless of the arch involved. However, mesial movement of the permanent molar through lack of buttressing support from the missing second primary molar usually results in space loss that may be significant. Quadrant space loss of 2 to 3 mm without the buttressing support of the second primary molar may be realized—easily enough to compromise positioning of the permanent canines and premolars.

Given the findings regarding space loss with second primary molars, a space maintainer is generally indicated in most patients to control permanent molar positions. If the loss occurs just before eruption of the first permanent molar, that is, when the first molar crown is still covered with oral mucosa and a thin partial covering of bone, a space maintainer to guide the positioning of the first permanent molar into normal occlusion is desirable. The appliance of choice is a distal shoe for both the maxillary (Fig. 22-16) and mandibular arches. The appliance incorporates a posterior wire-loop extension from the first primary molar that supports a vertical tissue blade positioned to come into contact with and guide the erupting permanent molar into normal position. The depth of the intragingival extension should be about 1.0 to 1.5 mm beyond the mesial marginal ridge of the molar, to "capture" the surface as the tooth erupts vertically. Gauged in length to represent the missing second molar, accurate placement is critical to ensure that the distal shoe does not extend too far distally over the first molar and block its eruption, nor be too short and not maintain the space occupied by the lost second primary molar. It has been observed that the soft tissue tolerates the blade extension well, although a small metallic "tattoo" in the gingiva may result.

The first primary molar is first prepared with a stainless steel crown or well-adapted band that provides a retentive base for the distal shoe. An impression is made to prepare a working model. If the primary second molar has not yet been extracted, it is cut off the model and a hole made with a bur that simulates the position of the distal root of the tooth. If the second primary molar has been removed previously, the positioning of the tissue extension may be determined with measurements on bitewing or periapical radiographs or by measurement of the mesiodistal width of the contralateral second molar. The extension blade is contoured and extended distally into the prepared opening on the model, and the loop is soldered to the band or crown. An alternative design is the use of an adjustable Gerber extension involving a trombone-type attachment with the sleeve portion tach-welded or soldered to the band or crown (see Fig. 22-16). The sliding extension can be positioned into the tube sleeve and the posterior length

Dentlearn.ir

adjusted to the proper spacing with the blade extension positioned directly into the extraction space or a surgical incision made just at the mesial contact area of the erupting first permanent molar. Crimping of the sleeve tube holds the length of the established extension loop. Ideally, the tach-welded area should be supported with additional solder to reinforce the appliance's resistance to occlusal forces. Before final placement, a radiograph of the distal shoe in position should be made to determine whether the extension is in proper relationship with the unerupted first permanent molar. Final adjustments in length and contour may be made to ensure that mesial contact of the first permanent molar is provided. Brill,[16] in describing chair-side fabrication procedures, presents the distal shoe as an efficient and cost-effective appliance for guiding the unerupted permanent first molar into position, with success rates relatively equal to those reported from studies of the longevity of other space maintainers.

Several conditions contraindicate the use of distal shoe appliances. Given the extent of caries involvement, there may be lack of abutments to support a cemented appliance. Poor oral hygiene or lack of patient and parental cooperation greatly reduces the possibility of a successful clinical result. Histologic studies show that the distal shoe does not become lined with epithelium and is associated with a chronic inflammatory response. Therefore certain medical conditions such as blood dyscrasias, immunosuppression, congenital heart defects, history of rheumatic fever, and diabetes contraindicate the use of the appliance. If the distal shoe is contraindicated, two possibilities for treatment exist: (1) allow the tooth to erupt and regain space later, or (2) use a removable or fixed appliance that does not penetrate the tissue but places pressure on the ridge mesial to the unerupted permanent molar (Fig. 22-17). Carroll and Jones[17] reported on a pressure-type appliance successfully used to guide the permanent molar as it erupted. Given the fact that the first permanent molars are guided in their eruption by the distal-cervical aspect of the second primary molar, the acrylic or pressure extension usually serves as an ineffective guide for eruptive positioning. The removable extension is more likely to work in the lower arch if the eruption bulge area of the first permanent molar can be engaged with the acrylic. If several teeth are missing, the removable appliance can serve to restore function and prevent supereruption of opposing teeth.

After the first permanent molar has been guided into position, a distal shoe is usually indicated for replacement with a different appliance. Continued vertical development will usually result in tipping of the permanent first molar over the top of the blade extension, with resulting space loss and tissue complications. One option is to remove the intragingival extension and replace it with a

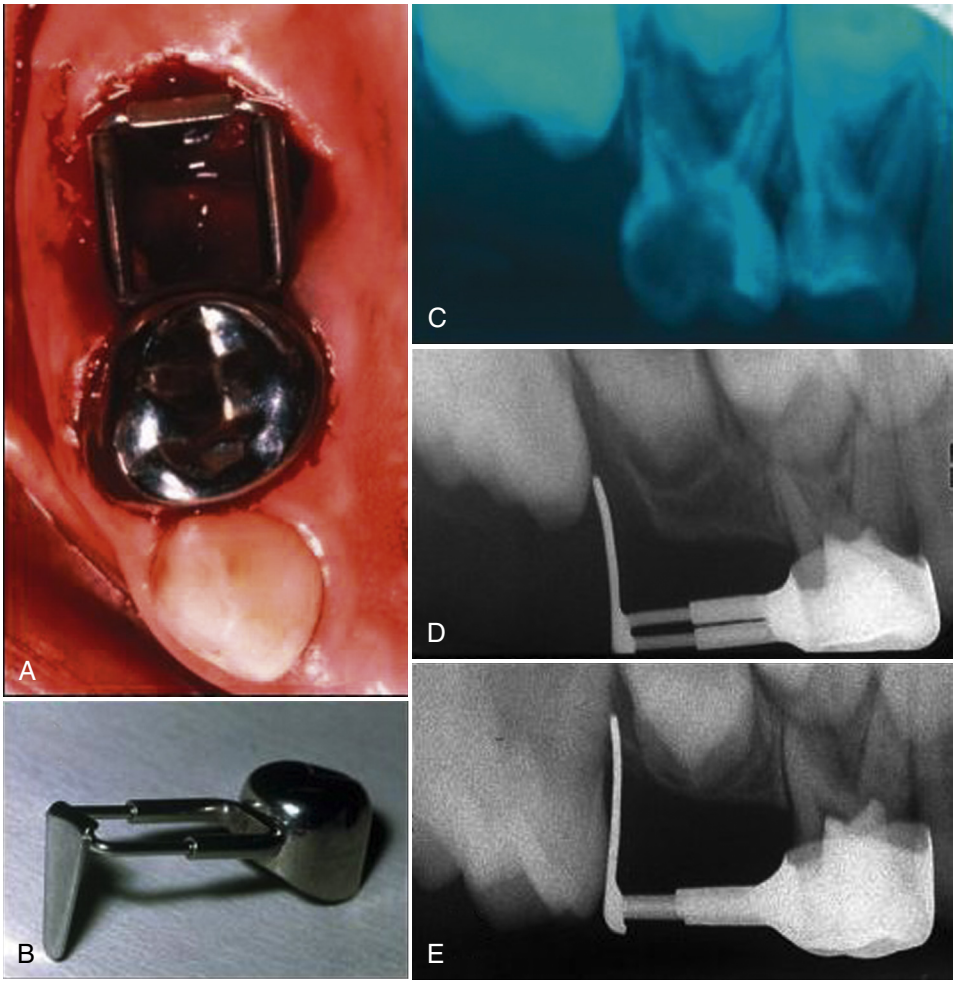

Figure 22-16 **A,** The second primary molar is nonrestorable and must be extracted. A crown with a distal shoe extension to help guide the first permanent molar has been placed. **B,** Picture of a prefabricated crown with Gerber-type distal shoe extension as used in the case. **C, D,** and **E,** Progress can be seen on radiographs in guiding the eruption of the permanent molar over 12 months.

reverse band and loop, using an occlusally directed extension to prevent the molar from tipping over the wire. Exfoliation of the first primary molar as an abutment may also occur before eruption of the second premolars. Therefore once the first permanent molars have erupted sufficiently to be banded, a more preferred option for the replacement of a distal shoe is the use of a bilateral space maintainer such as a mandibular lingual holding arch, maxillary transpalatal bar, or maxillary Nance appliance. These same bilateral space maintainers are the method of choice to provide stability to first permanent molar positions whenever the second primary molars are lost and first permanent molars have erupted into occlusion. Even after first permanent molar occlusion is established, the loss of second primary molars will potentially result in significant amounts of closure without the buttressing effect of the primary second molar.

The classic bilateral mixed-dentition space maintainer in the mandibular arch is the soldered lingual holding arch (Fig. 22-18). With bands fitted to the first permanent molars, a 0.036- or 0.040-inch stainless steel wire is contoured to the arch and extended forward to make contact with the cingulum area of the incisors (Fig. 22-19). The design stabilizes lower molar positions from moving mesially and incisor relationships from retroclining lingually in sustaining the canine-premolar segment space (i.e., leeway space). The lingual wire must simply be contoured not to interfere with normal eruption paths and provide an anterior arch form so that the incisors have an opportunity for alignment. In the mixed dentition, the soldered lingual holding arch should present minimal problems with breakage, minimal oral hygiene concerns, minimal interference in eruptive movements of permanent canines and premolars, and no concerns about whether the child is wearing the appliance. Importantly, the bilateral design and use of permanent teeth as abutments allow for application during the full transitional dentition period of the buccal segments. As stated earlier, lower lingual arches should not be placed before the eruption of the permanent incisors because of their frequent lingual eruption path. The lingual wire may interfere with normal incisor positioning if the appliance is in position before lateral incisor eruption. Additionally, abutting against primary incisors as anterior stops does not offer sufficient anchorage to prevent significant loss of arch length.

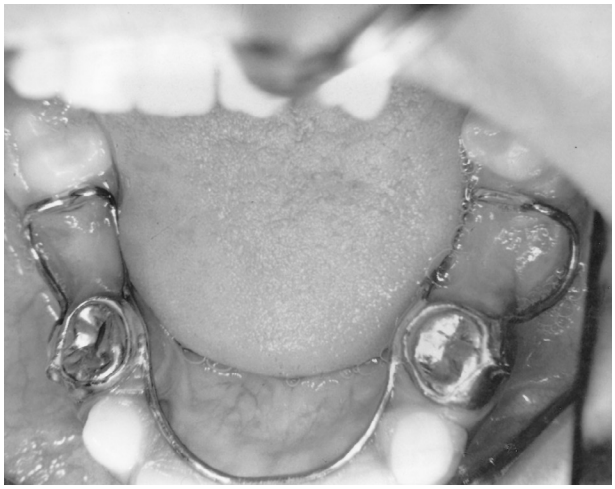

Figure 22-17 A modified distal shoe "pressure" appliance to provide bilateral space maintenance and eruption guidance for the first permanent molars. The permanent molars are erupting properly, and the intragingival extensions may be removed.

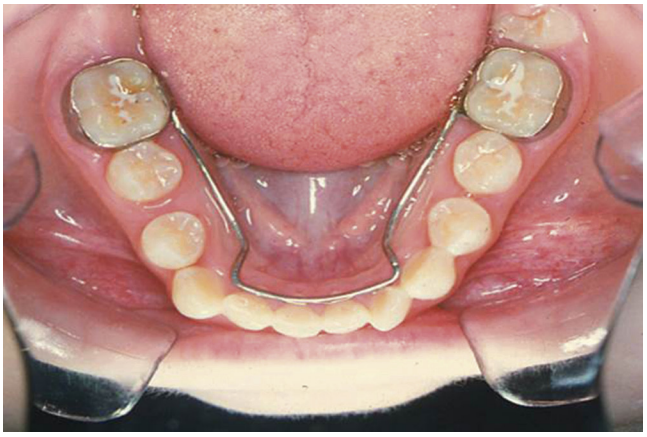

Figure 22-19 Proper design of a passive mandibular soldered lingual holding arch positioned with wire contact at the cingulum area of the permanent incisors. The wire offsets and contours to position the wire away from the eruption path of buccal segment teeth and to avoid tongue irritation. Note the excess "leeway" space in the premolar area secondary to the appliance, preventing a late mesial shift of the permanent molars.



Figure 22-18 Lingual holding arch for bilateral space maintenance and guidance of buccal segment eruption patterns. **A,** Initial appliance placement in conjunction with primary molar extractions. **B,** Eruption transition at 6 months after extractions. **C,** Eruption status at 1 year. Note improvement in anterior and buccal segment alignment.

Used in the maxillary arch to stabilize molar positions bilaterally, the soldered transpalatal bar incorporates a transverse palatal wire of 0.036- or 0.040-inch stainless steel wire soldered to molar abutments (Fig. 22-20, *A*). The rigid transverse wire prevents the two main space loss patterns of upper first permanent molars: mesiobuccal rotation and anterior bodily displacement. While the appliance may allow some minor mesial tipping of the upper molars, this is generally considered insignificant in terms of overall space loss in the maxillary arch. The simple transpalatal contour of the connector wire offers the main argument for this appliance: It is easy to fabricate and offers minimal irritation to the palatal tissue or tongue. The Nance appliance uses a contoured rigid wire with an acrylic "button" in contact with the palatal shelf as an anterior stop for bilateral molar stabilization in the maxillary arch (see Fig. 22-20, *B*). Providing the same molar rotation and bodily movement control as transpalatal bars, the added bracing of the acrylic button against the anterior palatal vault offers some additional resistance against forward tipping movements of the molars. Although the bilateral stability of the transpalatal appliance appears adequate in most situations, the resistance of the Nance with its acrylic palatal stop is preferred by some clinicians. Tissue irritation beneath the button does not appear to be a clinical problem in most cases if proper hygiene is performed.

The fixed space maintainers as described have the distinct advantage that they are stable, not easily broken, and wear is not dependent on the child. Ensuring that the appliance is passive and does not cause unwanted tooth movement is generally the greatest concern. Proper design should minimize eruption interference and the effects of unfavorable abutment loss or impingement of soft tissues. Poor band fit or defective cement may serve as a locus for debris accumulation and subsequent decalcification. Steps to prevent this include adapting a band that contours tightly to the tooth surface and extends beneath the gingival margins, providing a thorough prophylaxis before cementation, keeping the tooth thoroughly dry during cementation, using glass-ionomer cements, and teaching the child and parent proper oral hygiene practices to include the use of fluoride rinses. Closely checking the appliance at 6-month intervals to monitor potential problems is the standard protocol.

Areas of Multiple Primary Molar Loss

Loss of multiple primary molars may lead to mutilation of the developing dentition unless an appliance is constructed to maintain relationships of the remaining teeth and to guide eruption of the developing teeth. In addition to arch dimension concerns, reduced masticatory function is undesirable from a nutritional standpoint. Removable acrylic partial dentures have been used successfully in either arch after the loss of multiple teeth. If artificial teeth are included, an essentially normal degree of function and acceptable aesthetics can be restored. The disadvantages lie in their unpredictability outside the clinician's control because the appliances require patient cooperation and can be easily lost or broken during wear. During the transitional stages of exfoliation and eruption, stability of removable appliances is often difficult to sustain with the loss of abutments. The wire clasps and resin contact areas may present "food traps" for plaque accumulation, with increased potential for soft-tissue irritation and dental caries.

If the loss of one or both of the second primary molars occurs a short time before the eruption of the first permanent molars, the acrylic removable appliance may be considered in preference to one of the distal shoe maintainers described previously. An acrylic partial denture with a distal extension may be used to guide first permanent molars into position (Fig. 22-21). The teeth to be extracted are cut away from the stone cast, and a depression is cut into the stone model to allow for fabrication of the acrylic extension. The acrylic will extend into the alveolus after removal of the primary teeth. The extension may be removed after eruption of the permanent tooth. It is occasionally necessary to recommend extraction of all the primary teeth in a preschool child. Although this was more common in the prefluoridation era, some children even today must have all of their teeth removed because of widespread oral infection and because the teeth are nonrestorable. Preschool children can wear complete dentures successfully before the eruption of permanent teeth (Fig. 22-22).

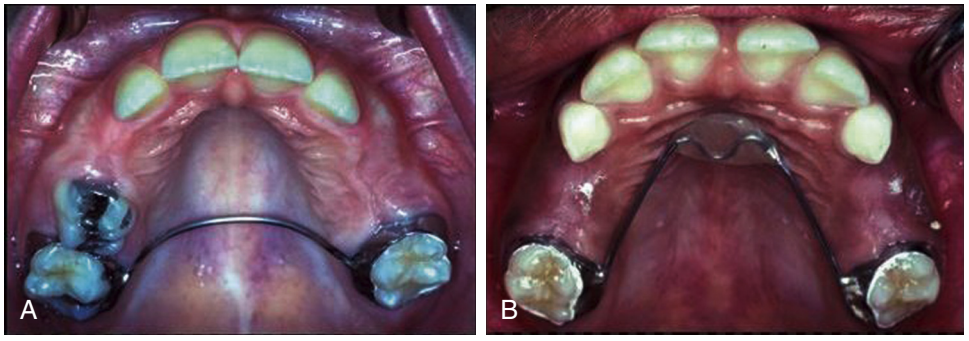

Figure 22-20 Bilateral fixed space maintainers for maxillary molar control. **A,** Soldered transpalatal bar with 0.036-inch stainless steel wire contoured to traverse the palatal contour. The appliance prevents forward bodily movement and rotation of molars around palatal roots. **B,** Nance appliance incorporates a 0.036-inch stainless steel wire that traverses the arch with a midline acrylic button positioned against the anterior palatal contour. The design prevents molars from forward bodily movement, rotation around the palatal roots, and mesial tipping.

Dentlearn.ir

Loss of First Permanent Molars

The first permanent molar is unquestionably the most important unit of mastication and is essential in the development of a functionally desirable occlusion. A caries lesion may develop rapidly in the first permanent molar and occasionally progress from an incipient lesion to a pulp exposure in a 6-month period. The loss of a first permanent molar in a child can lead to changes in the dental arches that can be traced throughout the child's life. Unless appropriate corrective measures are instituted, these changes include diminished local function, drifting of teeth, and continued eruption of opposing teeth.

The second molars, even if unerupted, start to drift mesially after the loss of the first permanent molar. A greater degree of forward bodily movement will occur with loss of the first permanent molar in 8- to 12-year-old children. In older children, if the loss occurs after eruption of the second permanent molar, more exaggerated mesial

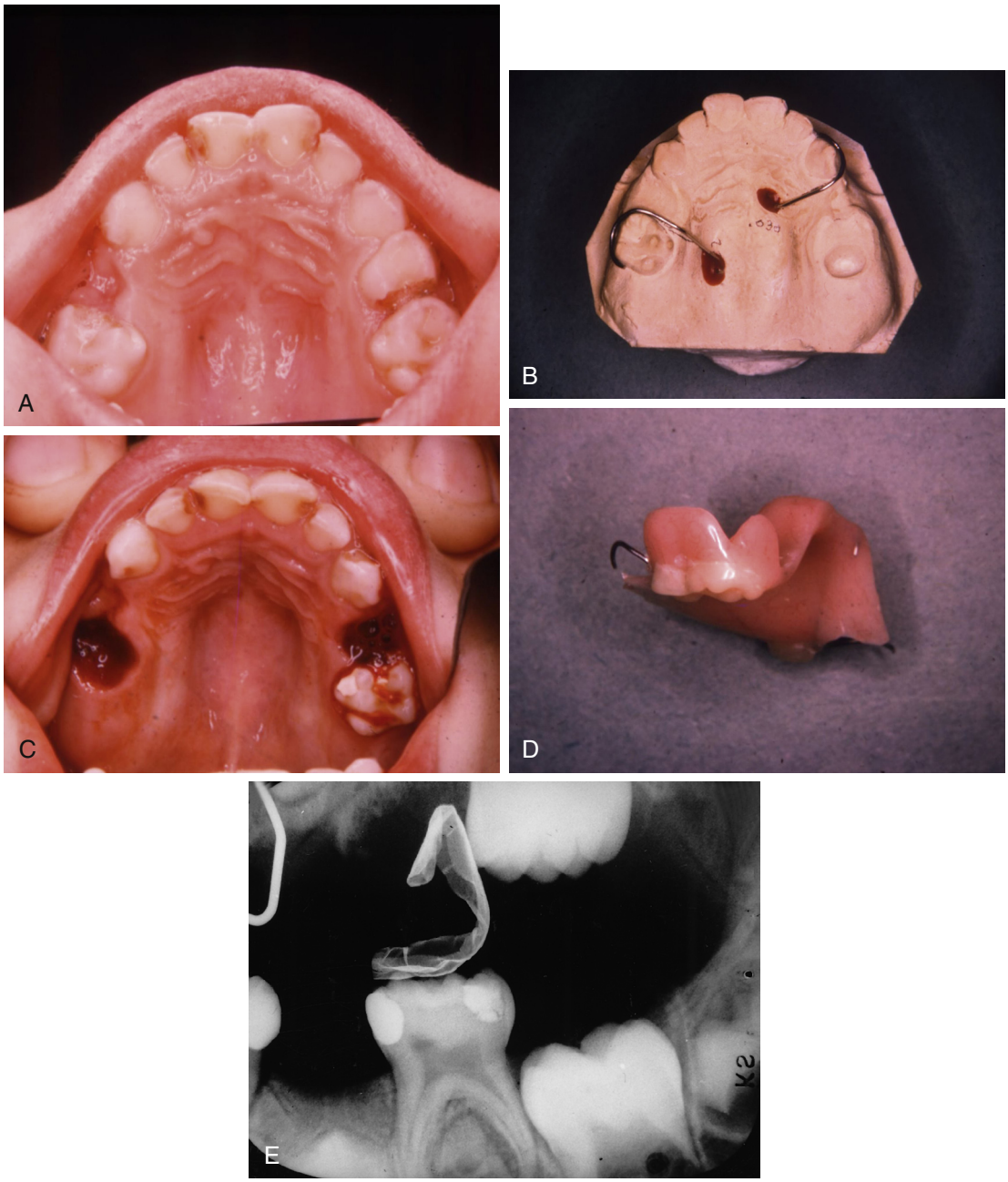

Figure 22-21 **A,** Clinical and radiographic examination revealed need for extraction of both maxillary first primary molars and the left second primary molar at age 6 years. **B,** The teeth indicated for extraction are cut away from the stone model, and a depression is made in the second molar area for an acrylic distal shoe-type extension. **C,** The primary teeth have been extracted in preparation for the placement of the partial denture. **D,** The acrylic distal shoe extension. **E,** Lead foil has been placed over the tissue extension to determine, with the aid of a radiograph, whether the acrylic is positioned properly to guide the eruption of the first permanent molar. (Courtesy Dr. Paul E. Starkey.)

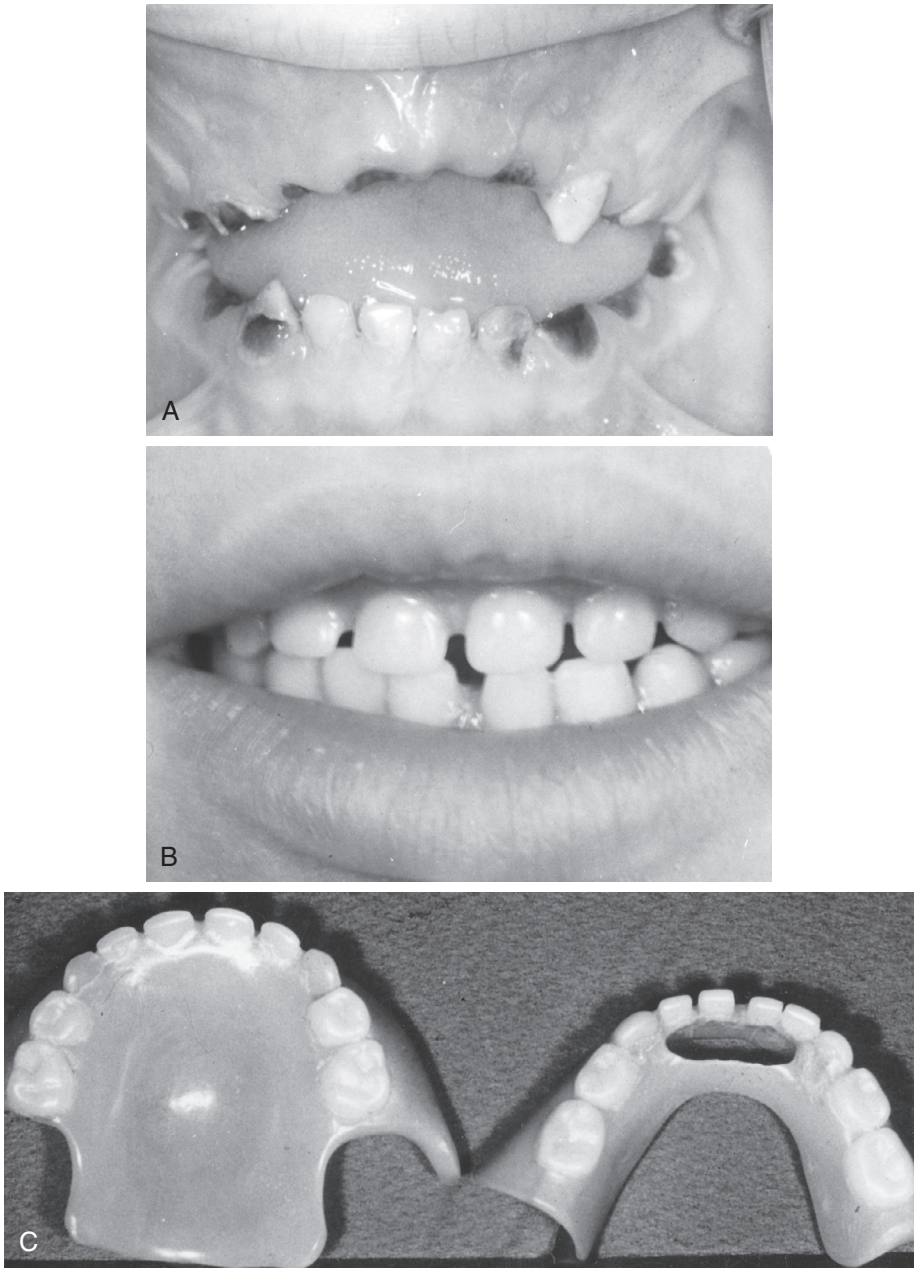

Figure 22-22 **A,** Primary teeth with rampant gross caries and pulpal involvement. **B,** Complete dentures in place after the extraction of all primary teeth. **C,** Modification of the dentures after eruption of upper first permanent molars and lower permanent incisors.

tipping of the second molar can be the expected outcome. Although the premolars undergo the greatest amount of distal drifting, all the teeth anterior to the space, including the central and lateral incisors on the side where the loss occurred, may show evidence of movement. Contacts open and the premolars, in particular, rotate as they fall distally. There is a tendency for the maxillary premolars to move distally in unison, whereas those in the lower arch may move separately. When the maxillary first permanent molar loses its opponent, it erupts at a faster rate than the adjacent teeth. The alveolar process is also carried along with the molars and causes problems when prosthetic replacements are needed. The treatment of patients with the loss of first permanent molars must be approached on an individual basis. A superimposed existing malocclusion, abnormal musculature, or the presence of deleterious oral habits can affect the result, as in the case of the premature loss of primary molars.

Loss of a first permanent molar before the eruption of the second permanent molar presents problems in both anteroposterior space control and vertical eruption control of opposing molars. Although it is possible to prevent overeruption of a maxillary first permanent molar by placing a lower partial denture, there is no completely effective way to influence the path of eruption of the developing second permanent molar other than the use of an acrylic distal shoe extension on a partial denture as described previously. The second molar drifts mesially before eruption when the first permanent molar has been extracted. Repositioning this tooth orthodontically is possible after its eruption. However, the child must

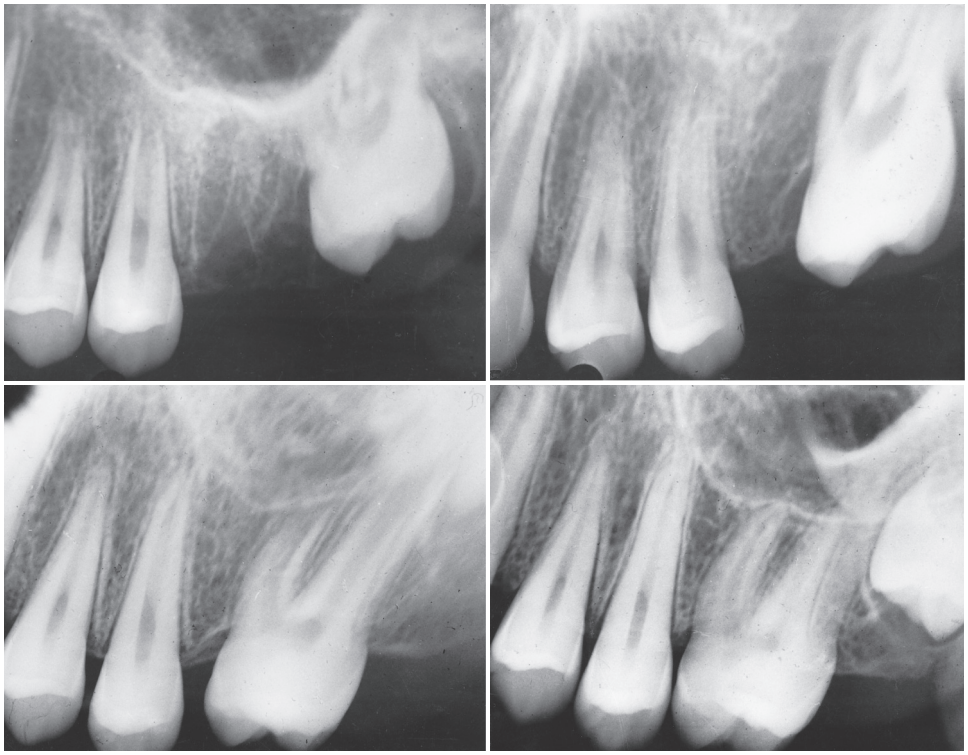

Figure 22-23 Radiographs taken at 6-month intervals after a maxillary first permanent molar was lost before the eruption of the second permanent molar.

then be considered for prolonged space maintenance until the time when a more permanent tooth replacement can be inserted. The removal of the opposing first permanent molar, even when the tooth appears to be sound and caries-free, is sometimes recommended in preference to allowing it to extrude or to subjecting the child to prolonged space maintenance and eventual fixed replacement.

If the first permanent molars are removed several years before eruption of the second permanent molars, there is an excellent chance that the second molars will erupt in an acceptable position (Fig. 22-23). However, the axial inclination of the second molars, particularly in the lower arch, may be greater than normal.

The decision whether to allow the second molar to drift mesially or to guide it forward in an upright position may be influenced by the presence of a third molar of normal size. If there is a question regarding the favorable development of a third molar on the affected side, repositioning the drifted second molar and holding space for a replacement prosthesis are usually the treatment of choice.

When the first permanent molar is lost after the eruption of the second permanent molar, orthodontic evaluation is indicated, and the following points should be considered: Is the child in need of corrective treatment other than in the first permanent molar area? Should the space be maintained for a replacement prosthesis? Should the second molar be moved forward into the area formerly occupied by the first molar? The latter choice is often the more satisfactory, even though there will be a difference in the number of molars in the opposing arch. A third molar can often be removed to compensate for the difference. Without treatment, the second molar will tip forward within a matter of weeks (Fig. 22-24).

Another option to consider is autotransplantation of a third molar into the first molar position (Fig. 22-25).[18] According to Bauss and colleagues, autotransplantation has become a well-established treatment modality in cases of early tooth loss or aplasia.[19] For third molars with partly developed roots, transplantation success rates have been reported to range from 74% to 100%.

ORAL HABITS IN CHILDREN

BRUXISM

Defined as nonfunctional grinding or gnashing of teeth, bruxism has been reported in up to 15% of children and young adults. Usually occurring at night, bruxism can result in significant abrasion of primary and permanent teeth if continued over a prolonged period (Fig. 22-26). A vinyl bite-guard that covers occlusal surfaces of all teeth can be worn at night to prevent continued abrasion. The occlusal surface of the bite-guard should be flat to avoid occlusal interference. A mouth guard of the type described in Chapter 24 may also help in overcoming the habit. Ramfjord[20] believes that occlusal interference may trigger bruxism if combined with nervous tension. Therefore occlusal equilibration can be used to help the problem if obvious interference is present. Sheppard[21] recommends construction of an anterior bite plate that allows for continued eruption of the posterior teeth if they have been abraded by the habit. When bruxism continues into adulthood, periodontal disease and/or temporomandibular joint disturbances can result.

Dentlearn.ir

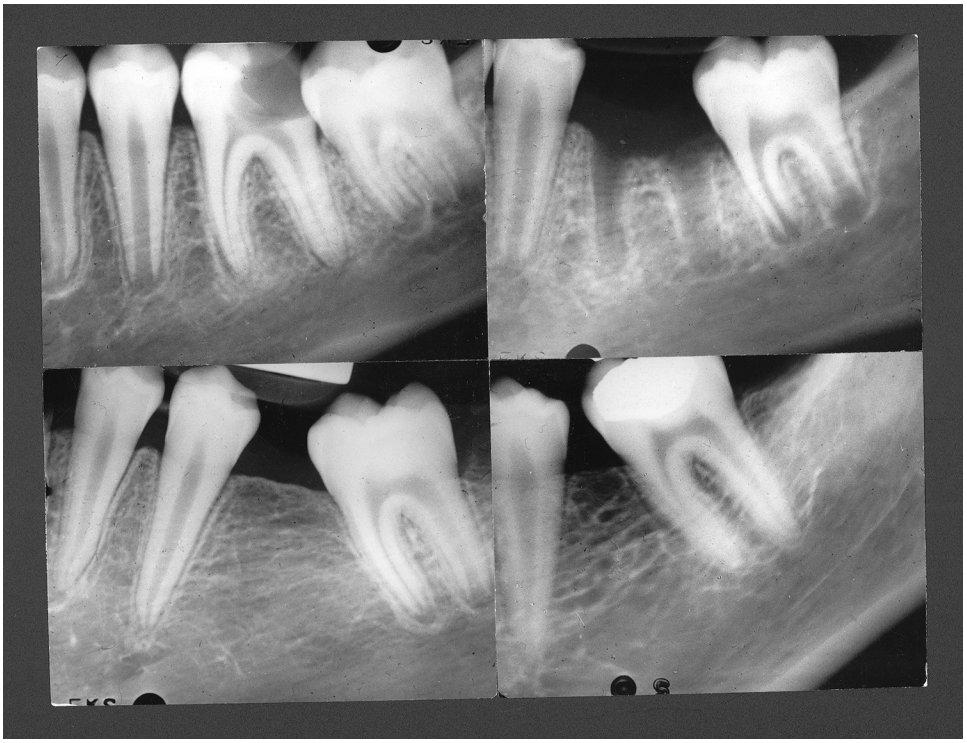

Figure 22-24 Radiographs taken at 6-month intervals after the loss of a mandibular first permanent molar. Notice the degree of tipping of the second molar and distal drifting of the premolars.

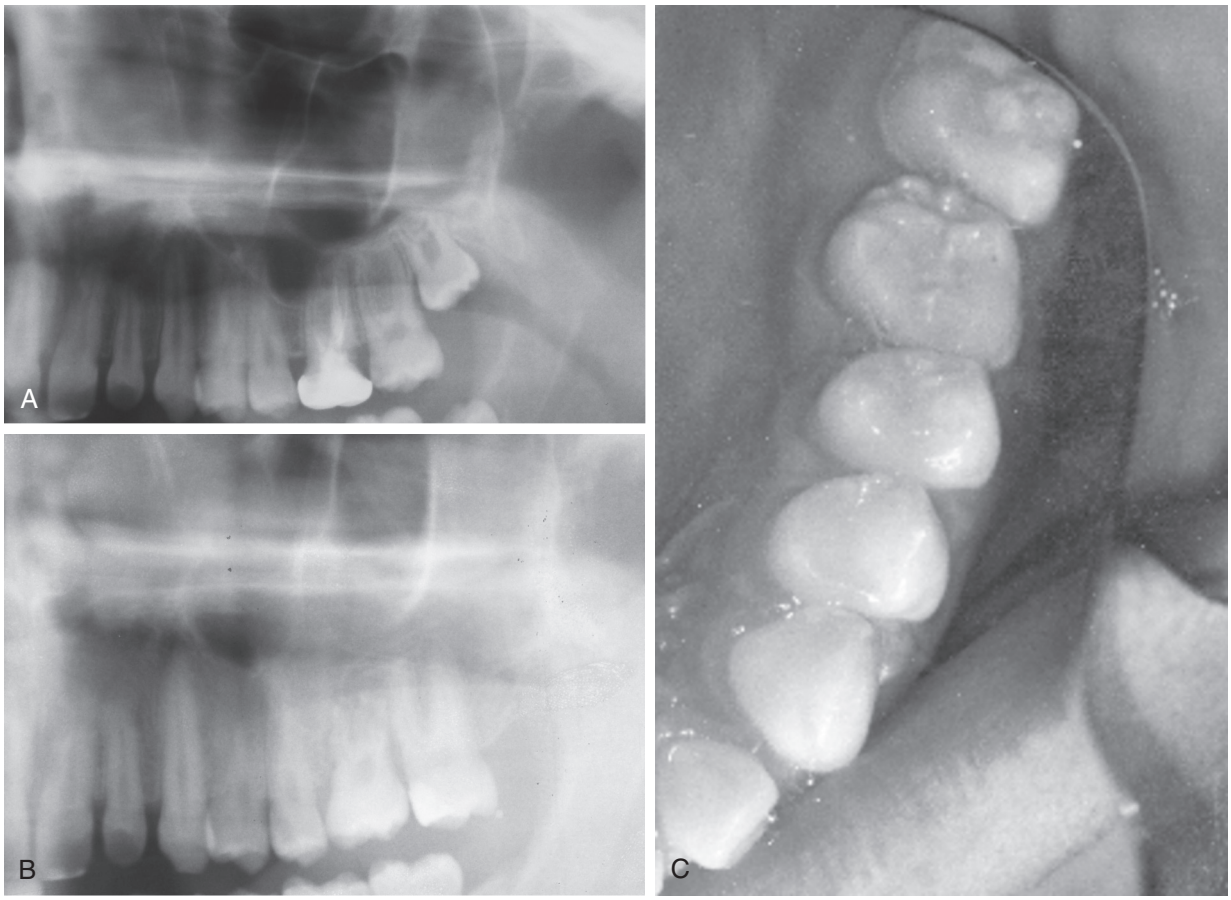

Figure 22-25 Third molar autotransplantation. **A,** Radiograph showing failed attempt at maintaining first permanent molar and minimal root development of third permanent molar. Radiographic **(B)** and clinical views **(C)** of third molar 15 months after autotransplantation. Note continued root development.

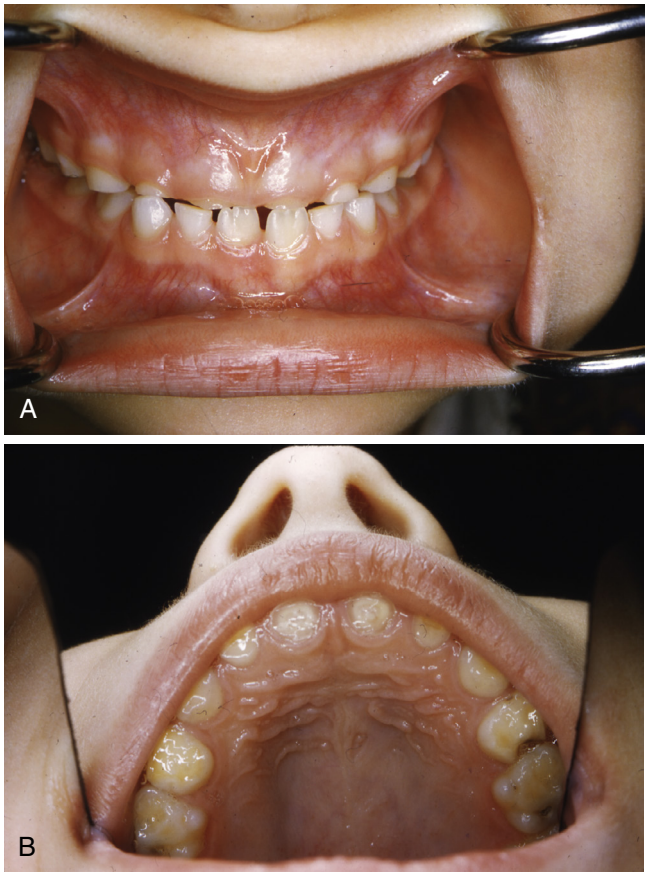

Figure 22-26 Bruxism resulting in severe abrasion of the maxillary primary anterior teeth. **A,** Frontal view. **B,** Occlusal view.

DIGIT SUCKING

Many children suck their thumbs or fingers for short periods during infancy or early childhood, with the habit considered normal during the first 2 years of life. If present at such an early age, parents should be advised to periodically observe the nature and intensity of the habit. If the child demonstrates gradually diminishing activity, it is probable that the habit will cease without intervention. Traisman and Traisman[22] reported that the average age at which digit sucking stopped was 3.8 years, although other studies indicate a persistent incidence of up to 20% at age 4 years. These studies indicate that changes in the anterior occlusion caused by digit sucking are temporary, with little likelihood of long-term effects if the habit is discontinued by the age of 3 to 4 years.

If the intensity of the habit persists or increases and adverse dental and skeletal changes are noted beyond age 4 years, corrective measures may be needed to avoid undesirable occlusal problems (Fig. 22-27). By the age of 6 to 7 years, estimates indicate that approximately 10% to 15% of children have a persistent digit-sucking habit that runs the gamut from incidental sucking at bedtime to pronounced habits that seems to be almost constant. Almost all authorities recognize that persistent digit-sucking habits extending into the incisor transition period can cause a malocclusion or aggravate an already existing one. Pressure generated from the habit can produce changes in the anterior segments of the dental arches, with labial flaring and protrusive spacing of maxillary anterior teeth and increased overjet. Remodeling of the maxillary alveolar process and vertical displacement of the maxillary anterior teeth can result in an open-bite relationship.

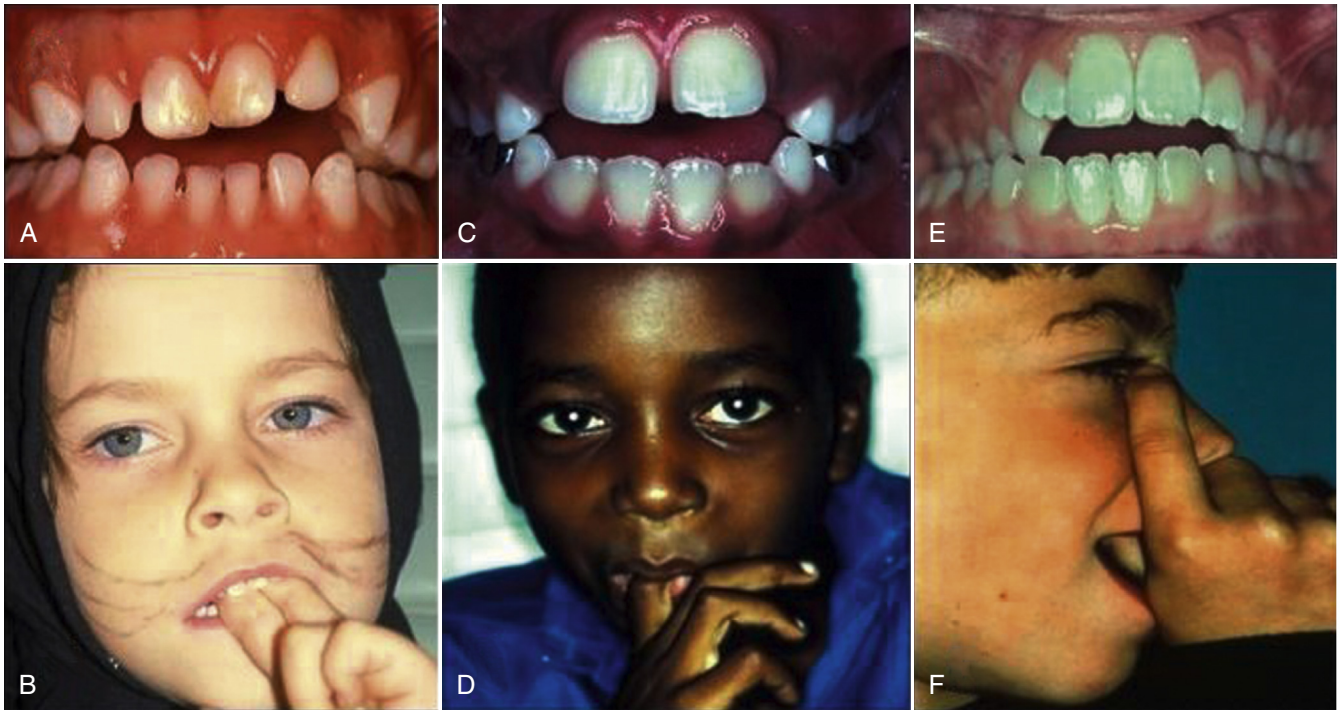

Figure 22-27 Occlusion of three children with different patterns of digit-sucking habits. **A** and **B,** An open bite in the primary dentition caused by the child placing two fingers between the anterior teeth. **C** and **D,** An open bite with flared maxillary incisors in the mixed dentition caused by an index-finger-sucking habit. **E** and **F,** An open bite with maxillary constriction produced by thumb-sucking as presented. The maxillary constriction resulted in a posterior crossbite with a functional shift of the mandible on closure.

In addition, the digit positioning can interfere with eruption of the lower incisors, to exaggerate the open-bite appearance in the incisor segment. Intense patterns may contribute to pronounced lingual inclination of the mandibular incisors, which further increases the overjet situation. The increased open bite and overjet may lead to abnormal muscle activities where the tongue protrudes during swallowing as an adaptation to the anterior space. Subtelny,[23,24] in evaluating 34 digit-sucking children by cineradiography, reported that 82% exhibited tongue-thrust activity during swallowing. Dental findings included protruded maxillary incisors, anterior open bite, and increased maxillary arch length as a result of atypical muscular forces from the thumb, the perioral musculature, and forward positioning of the tongue. The child with a persistent digit-sucking habit that results in an open bite typically exhibits a convex profile with hypotonic upper lip, lower lip hypertonicity with marked mentalis muscle activity, and tongue-thrusting. These patterns maintain and possibly intensify the developing anterior open bite and overjet discrepancy.

The effect of prolonged digit sucking on posterior relationships is less clear. Strong muscle contractions of the circumoral musculature with the highest force levels approximating the maxillary canine area have been documented with extraoral habits. These may result in a relative constriction in maxillary arch width that has been associated with an increased development of functional posterior crossbites in children whose habits persist past the age of 4 to 5 years. While not as profound, associations between distal-step primary molars and Class II permanent molars have been suggested in children whose habits extend into the transitional dentition period. Popovich and Thompson[25] observed 1258 children at the Burlington Growth Centre, representing approximately 90% of the pediatric population of Burlington, Ontario. Many of the children were seen annually from 3 to 12 years of age, with their oral habits and occlusal status recorded at 3, 6, 9, and 12 years of age. There was a significant association between the prevalence of Class II malocclusion and persisting digit sucking in the different

at 3 and 4 years of age to 41.9% at 12 years of age, and the probability of a Class II malocclusion increased as the duration of the habit increased. If the habit was stopped before 6 years of age, the effects on occlusion were often transitory. In contrast, no child who stopped a habit after 6 years of age had a normal occlusion at age 12. An interesting observation was that children who had used a pacifier had a significantly lower rate of digit sucking. However, Zardetto and others[26] point out that similar occlusal and myofunctional alterations have been detected among children who have prolonged pacifier habits (either conventional or physiologic pacifiers), when compared with those with no sucking habits. Children who used a pacifier were significantly more likely to show open bite, posterior crossbite, increased overjet, and alteration in cheek mobility than were habit-free children.

Interceptive treatments to stop a digit-sucking habit depend upon the patient's age, emotional and psychological state, cooperative motivation of the parents and child, nature of occlusal changes, and associated functional adaptations. An age-based approach provides a foundation for treatment, although individual patient findings may result in a more aggressive approach to intervention or, more likely, may cause greater caution and actually delay or defer treatment. These age-based concepts are as follows:

Before age 4 If one accepts the premise that a digit-sucking habit will usually stop by age 4 years, and that the effects on the occlusion are probably not permanent, then direct intervention before this age has questionable merit. Additionally, the child's level of understanding complicates cooperation with any of the intervention options.

ward systems may help some children to cease digit suck-

dentist discusses the problem and its effect on the teeth. The child is asked to keep a daily record of each episode of digit sucking and to report on his/her progress in stopping the habit. A decrease in the number of times the habit is practiced is evidence of progress and indicates that the child will likely discontinue the habit. A positive approach involves cooperation of the parents, who are often overanxious about the habit. This anxiety may result in nagging or punishment, which often creates greater tension and may even intensify the habit. The parents should consent to disregard the habit and not mention it to the child for a more successful outcome. A timed reward system may help. For each day the child refrains from the habit, a star is placed on a calendar. In month 1, the child receives some reward or prize predetermined by the parent if the monthly calendar has 28 stars (i.e., two "bad" days allowed). In month 2, the goal is 29 stars to receive a reward. Month 3 should present a calendar completely filled with stars. The prizes are progressively enhanced in value for the child. If the child ceases the habit for 3 months, the long-term chances of stopping the habit and enhancing occlusal development are good (Fig. 22-28).

Negative reinforcers such as mittens, bandages, and bitter-tasting medicaments applied directly to the offending digit can occasionally effect a stoppage of the habit. Many practitioners have been successful using "thumb-guard" gadgets that the child wears on the thumb as a reminder not to use the thumb. These approaches meet greater success in children who express a desire to quit and just need a little help—the "reinforcers" are viewed as reminders rather than punishment.

The school-age years Although reward techniques may work in some children aged 6 years or older, the persistent habit may be so ingrained as to present unlikely successful stoppage with such ploys. This is the child who has "tried to stop, but just cannot get it done." The transition of the permanent incisors and the ingrained nature of the habit often require direct appliance therapy, not only to stop the habit but also to enhance proper tooth eruption and alignment by influencing any acquired muscular patterns. A palatal crib appliance that prevents the offending digit from being placed in the sucking position and acts to restrain the tongue from forward positioning is a valuable adjunct in habit therapy during the mixed-dentition years (Fig. 22-29). Palatal crib designs generally

Dentlearn.ir

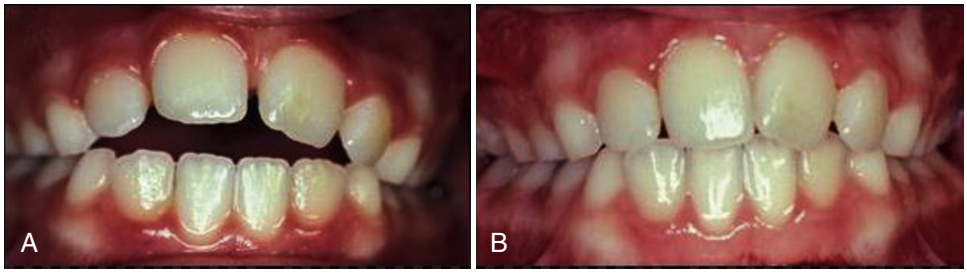

Figure 22-28 **A,** Open bite with some maxillary constriction evident in the mixed dentition of an 8-year-old child with a persistent thumb-sucking habit. **B,** The child was encouraged to discontinue the habit through a positive rewards system. There was self-correction of the open bite and transverse relationships by 9 years of age, when the dysfunctional habit was discontinued.

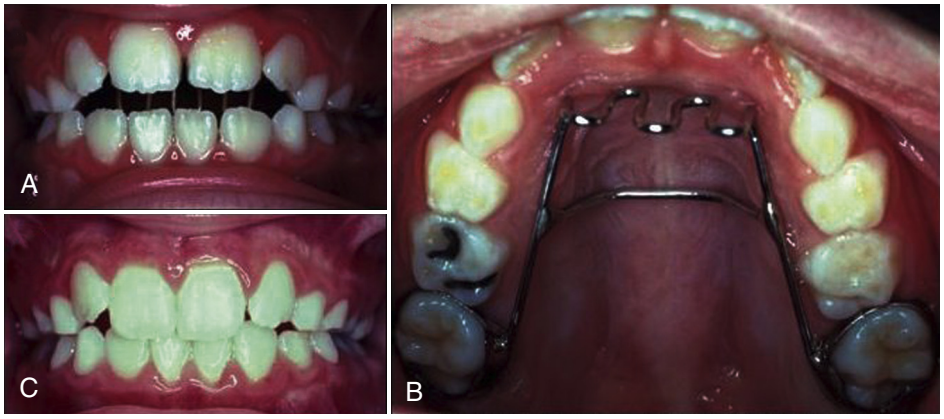

Figure 22-29 Palatal crib appliance in the mixed dentition to help the child stop a thumb-sucking habit, control forward tongue positioning, and allow for eruptive "self-correction" of the anterior open bite. **A,** Pretreatment incisor open bite at time of appliance placement. Note crib appliance's vertical extension to level of lower incisors. **B,** Palatal crib appliance of 0.040-inch stainless steel. **C,** Posttreatment closure of open bite after 6 months of crib therapy. The habit stopped within 1 week of appliance placement.

use the first permanent molars as anchorage abutments with a major connecting wire of standard 0.040-inch stainless steel orthodontic wire, ensuring a strong and stable appliance that is resistant to both digit and tongue pressures. The crib approximates the cross-arch level of the upper canines, with the "fence" extending vertically to about the level of and just lingual to the lower incisors. Positioning should ensure no occlusal interference in all functional excursions and allow clearance for upper incisors to lingualize into normal inclinations. The posterior transpalatal wire provides further rigidity and prevents constriction of maxillary intermolar width through pressures placed on the "fence" by the tongue or digit.

Palatal crib appliances are particularly effective in promoting a favorable environment for self-correction of incisor open bite if applied when incisors are in active eruption phases. Labial flaring of the incisors should be reduced by the action of the upper lip when the digit and the tongue are no longer acting as opposing forces. Most children accommodate to the palatal crib in a short time, and rarely are any problems lasting ones. Haryett and associates[27,28] reported that, upon insertion of palatal crib appliances, nearly 80% of patients stopped sucking their thumbs within 7 days after insertion of the appliance. They also reported that if the appliance was removed 3 months after insertion, the chance of the habit recurring was likely. The best chance of lasting success occurred when the appliance was left in place for 6 to 10 months. Therefore it is recommended that the fixed palatal crib be treatment-planned to be worn for a period of 6 to 8 months.

The child's cooperation should be obtained when a palatal crib appliance is placed. The function of the appliance is to "help" and to "remind" the patient—the appliance cannot break the habit by itself without the child's cooperation. Failure to gain at least tacit cooperation will usually result in failure because the child resorts to new habit postures, complains, and causes such a commotion that the parent demands removal or the child even physically removes or distorts the appliance deliberately. Because cooperation and motivation are critical to success, the child should be told that the appliance is being used to help him/her to stop sucking the thumb that has affected the position of the teeth. Some temporary difficulty with speech and eating should also be anticipated upon placement, with most children accommodating in a short time. Some patients present with palatal irritation of the crib at about a month into appliance wear. This is usually attributable to pressures from the tongue pushing the appliance upward and is more common if second primary molars are used as anchorage abutments. Simple adjustment with intraoral three-pronged pliers can be used to bend the anterior crib away from the tissue. This adjustment is usually necessary only at the initial first-month

check because the tongue soon adapts and "reprograms" from forward positioning.

Positive changes in open bite and overjet should be notable by 3 months into treatment, and self-correction should be achieved by the sixth month of the appliance protocol. If protrusion of the maxillary incisors and anterior open bite have not "self-corrected" after the habit and tongue-thrust are controlled, the discrepancy should be reevaluated to ensure that other problems (e.g., lip sucking) are not factors. In these situations, additional orthodontic treatment may be indicated to align the protruded and flared incisors into normal overbite and overjet positions. Older children in the late mixed or young permanent dentition stage, with more established occlusal relationships, prolonged atypical functional patterns, and less eruptive potential, are less likely to demonstrate self-correction. They usually require corrective orthodontic treatment with Edgewise techniques.

Variations of the palatal crib, ranging from simple wires contoured to the palate without vertical extensions, to appliances incorporating reminder aspects (e.g., rollers on the Bluegrass appliance, a removable Hawley-type appliance), to the use of "rakes," "spurs," or "spikes" extending from the crib-wire or bands, have been advocated by various clinicians. A removable partial retainer with a series of smooth loops placed lingual to the incisors has proved successful in helping a child overcome a habit (Fig. 22-30). However, because a child may have a strong physical and emotional urge to continue the habit and not a strong resolve to quit, the use of a removable crib appliance is much less likely to succeed when compared with a fixed-crib approach. The Bluegrass appliance (Fig. 22-31) incorporates a modified, six-sided roller constructed to spin around a 0.045-inch stainless steel wire when rolled by the tongue. Haskell and Mink[29] reported successful stoppage of thumb-sucking in children using the appliance with a program of positive reinforcement. The use of rakes and spurs in habit therapy has also been reported with success, although Haryett and associates[27,28] found that 27% of children wearing a "rake" had transitory sleep disturbances compared with only 8% of children wearing a palatal crib. They also found that 14 (21.2%) of 66 children being treated developed mannerisms that persisted even after appliance therapy was discontinued. These included nail biting, chewing of hair or clothing, scratching of the body, and cracking of knuckles, but no enuresis. Davidson and associates[30] reported that 36% of thumb-sucking children who received no treatment and were still actively thumb-sucking also developed other mannerisms. Thus there was no greater substitution of mannerisms when a habit was treated with an appliance than when a habit was not treated. With no significant advantages in treatment effectiveness seen by other designs in the context of early intervention, the basic palatal crib appliance remains the recommended appliance design of choice for treating digit-sucking habits in the transitional dentition.

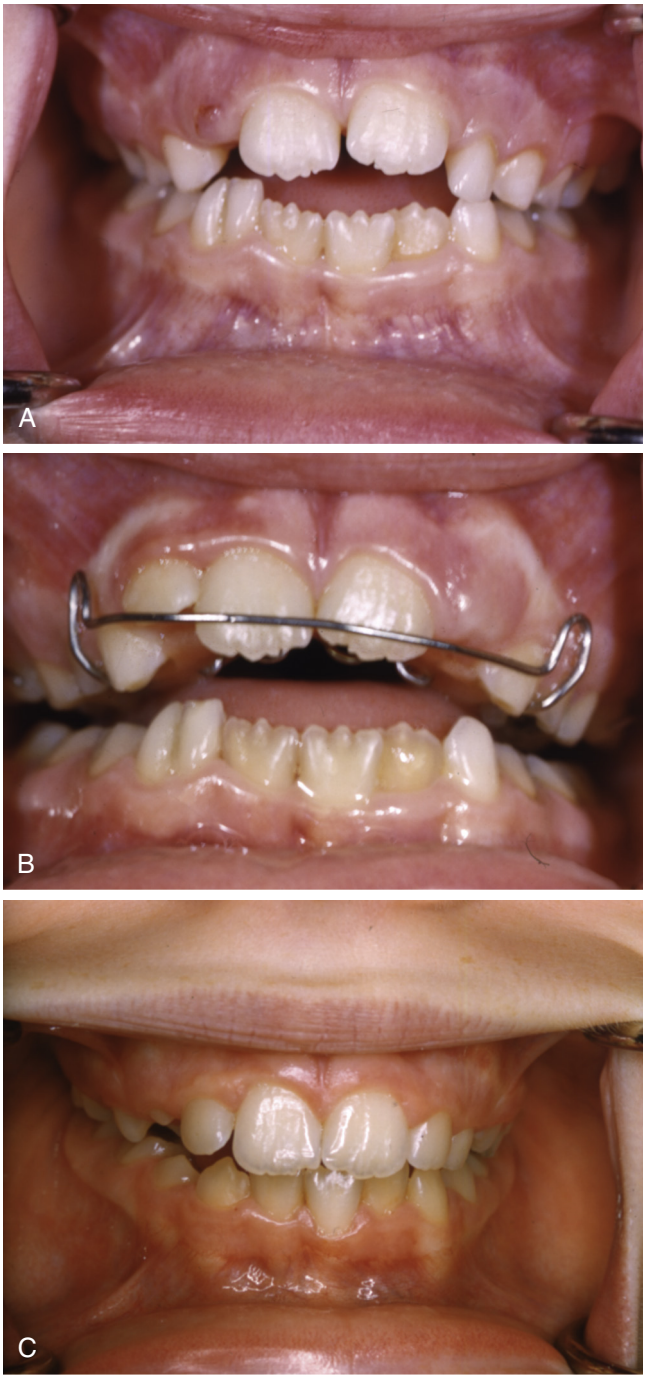

Figure 22-30 **A,** Anterior open bite caused by a thumb-sucking habit. **B,** A Hawley-type reminder appliance was constructed after other problems in the patient's life were recognized and treated. **C,** The occlusion 18 months after the child had overcome the habit.

TONGUE-THRUST SWALLOWING

Three major problems are usually associated with abnormal forward tongue positioning—anterior open bite, protrusion of the incisors, and lisping. Proffit[31] suggests two major reasons for a relatively high prevalence of anterior tongue positioning in children, related to physiology (maturation) and to anatomy (growth). Infants normally position the tongue forward and down in the mouth at rest and during swallowing to help establish an airway for respiration. An infant's swallow is characterized by strong lip activity, placement of the tongue tip against the lower

Dentlearn.ir

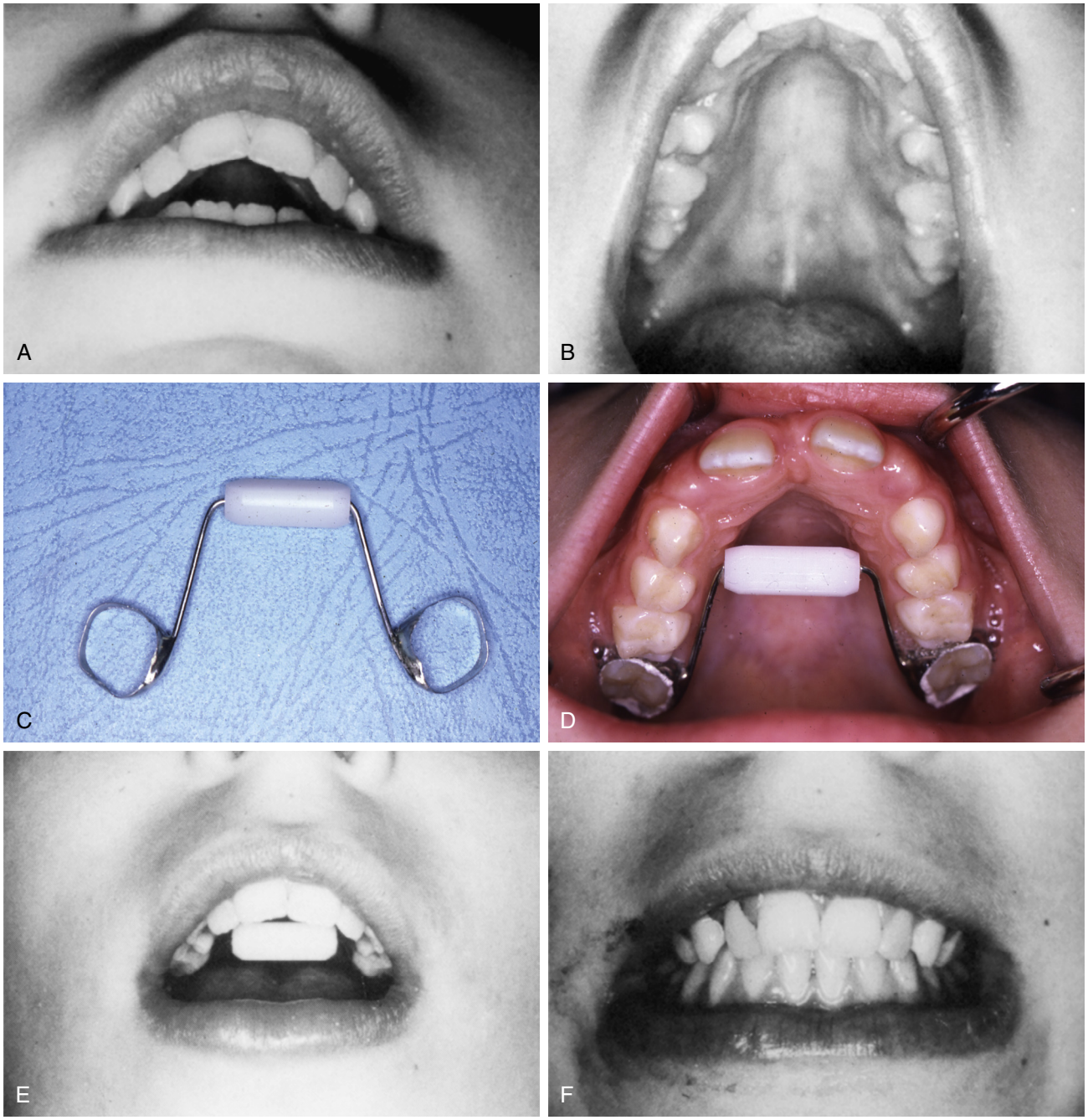

Figure 22-31 **A** and **B,** Anterior open bite and palatal configuration in the mixed dentition associated with a thumb-sucking habit. **C,** Bluegrass appliance with occlusal view of the appliance in place. **D,** Anterior view of the appliance in place. **E,** Frontal view of appliance in place. **F,** Correction of the anterior open bite. (Courtesy Dr. John R. Mink.)

lip, and relaxation of the elevator muscles of the mandible. Physiologic transitions in swallowing patterns begin during the first year of life as teeth erupt and continue over the next several years as oral function matures. There is a gradual activation of the elevator muscles of the mandible in swallowing so that a mature swallowing pattern is characterized by relaxation of the lips, placement of the tongue behind the maxillary incisors, and elevation of the mandible until posterior teeth come into contact in occlusion. This is usually observed before a child is 4 or 5 years of age.

An abnormal swallowing pattern prolonged into the mixed and permanent dentitions is characterized by protrusion of the tongue between the anterior dentition, lack of molar contact, and excessive circumoral muscle activity. Studies have shown the prevalence of tongue-thrust to be much greater than the prevalence of anterior open bite. Using cineradiography, Subtelny[21,22] demonstrated that tongue-thrust activity between the incisors with incomplete contact of the molars during swallowing occurs in as many as 40% of adults with clinically acceptable occlusion. Fletcher[32] reported that, in 1615 children from

ages 6 to 18 years, 52.3% of the 6- and 7-year-old children thrust their tongue. The incidence rates were reduced to 34% at age 10 years, whereas almost 25% of the 16- to 18-year-olds showed tongue-thrust patterns. Hanson and Cohen[33] found a similar incidence and age distribution of the tongue protruding between the teeth during swallowing. Despite these high numbers for tongue-thrust pat-

an overall open-bite incidence of 5.7 % in U.S. schoolchildren. African Americans have a much higher prevalence than whites of an open bite greater than 2 mm (9.6% to 1.4%, respectively). From the data, it becomes obvious that tongue thrust does not necessarily coincide with open-bite malocclusion, and deviations from "normal" swallowing are not necessarily detrimental to the occlusion.

Given the high percentages of tongue-thrust in chil-

the lack of direct cause-and-effect relationships with open-bite malocclusions, it seems reasonable to conclude that most tongue-thrust patterns are normal transitional occurrences. The adaptation to the more typical adult swallowing pattern appears to be related to an increase in the functional space for tongue activity during adolescent growth changes. The mandible follows skeletal growth patterns that allow space for a downward and backward accommodation of the tongue. Concurrently, tonsillar and adenoid lymphoid tissue mass is reduced to allow greater oropharyngeal air space. Vertical growth of the dentoalveolar structures of the mandible and maxilla contributes to an increase in oropharyngeal space that allows the tongue to assume a more posterior position as the child proceeds through puberty.

Transition toward adult swallowing patterns appears to be affected by a prolonged digit-sucking habit or by a skeletal malocclusion in which anterior open bite or incisor protrusion exists between the dental arches (e.g., Class II division 1). In these individuals, continued functional tongue protrusion during deglutition is viewed as an adaptation that maintains the anterior open bite and is not a primary etiological factor in causing the open bite. Studies by Profitt[34] and others have shown that there is no "equal balance" of forces on the dentition produced by the tongue vs. the lip musculature during functional activity. The expansive forces of the tongue are significantly greater than and not balanced by the containing forces of the lips. The shape of the dental arches and position of the teeth do not appear to be overwhelmingly influenced by the horizontally directed pressures of the lips and tongue during normal functional activities such as swallowing and speaking. Profitt[34] reported that tongue pressures decrease as the size of the arch increases, patients with protruding incisors have fewer lingual tongue pressures than do those with normal occlusion, and when incisors are retracted, the tongue pressures increase to normal values. These findings are the reverse of what would be expected if tongue pressure had pushed the teeth into protruded positions. However, stronger relationships with the patient's arch form and the resting pressures of the tongue and lips have been found. An anteriorly positioned tongue "at rest" can impede vertical eruption of the teeth and result in an open bite. This may be reflected in the findings that most habit-related open bites are self-correcting when digit sucking is eliminated and tongue positioning is controlled.

The controversy concerning tongue-thrust swallowing extends into treatment approaches that include palatal crib-type appliances, full orthodontic therapy, myofunctional therapy, or combinations of the above. The occurrence of an open bite is often initially related to a thumb- or finger-sucking habit and then retained by the tongue being thrust forward or the tongue merely occupying the space. In appliance therapy for digit-sucking habits, a vertical crib "fence" helps modify forward tongue positioning associated with the anterior open bite. With stoppage of the habit, the tongue assumes more normal swallowing patterns as muscular functions reflect adaptation to the corrected anterior open bite. But what about the child who presents with an anterior open bite and does not have a history of a digit-sucking habit? Will this child benefit from a palatal crib appliance to restrain the tongue? Or should other approaches be taken in managing the open bite? The answer lies in understanding our previous discussion on normal swallowing patterns and the implications of tongue-thrust to occlusion. In the school-age child without a documented digit-sucking habit, palatal crib therapy directed specifically toward tongue-thrust swallowing as a "causative" factor seems questionable. This is based on the reasoning that, without a documented extraoral habit, the most likely causative factors would be either a significant airway obstruction with habitual mouth breathing or a skeletal open-bite pattern. Both of these situations require a much more comprehensive approach than simple interceptive appliance therapy. In fact, placement of a tongue-restricting palatal crib appliance could exacerbate airway problems by forcing the child to keep the mandible open to accommodate the appliance. The palatal crib design could actually make things worse. The same applies to a skeletal open bite with the usual implications of a vertical growth pattern. In addition, the variability of normal swallowing patterns in relation to malocclusion, coupled with the spontaneous improvement in tongue-thrusting patterns and anterior open bite that is evidenced in 80% of children by the age of 12 years, argues against tongue-thrust-directed therapy as a stand-alone treatment for open bite.

Myofunctional therapy is the conscious retraining of the tongue and strengthening of the lip muscles through a specially designed exercise program. Promoted with the expectation that training muscles to function properly will reduce abnormal pressures, successive steps in the training program include acquainting the patient with the abnormal swallowing pattern, teaching the correct pattern of swallowing using various exercises, and reinforcing the correct patterns. Training exercises involve proper tongue-tip placement against the roof of the mouth and not between the teeth, masseter muscle isometrics to ensure swallowing with the molar teeth in contact, and lip exercises to correct mentalis and facial muscle activities. One technique has the patient practice swallowing correctly 20 times before each meal. Holding a glass of water in one hand and facing a mirror, the child takes a sip of water, closes the teeth into occlusion,

Dentlearn.ir

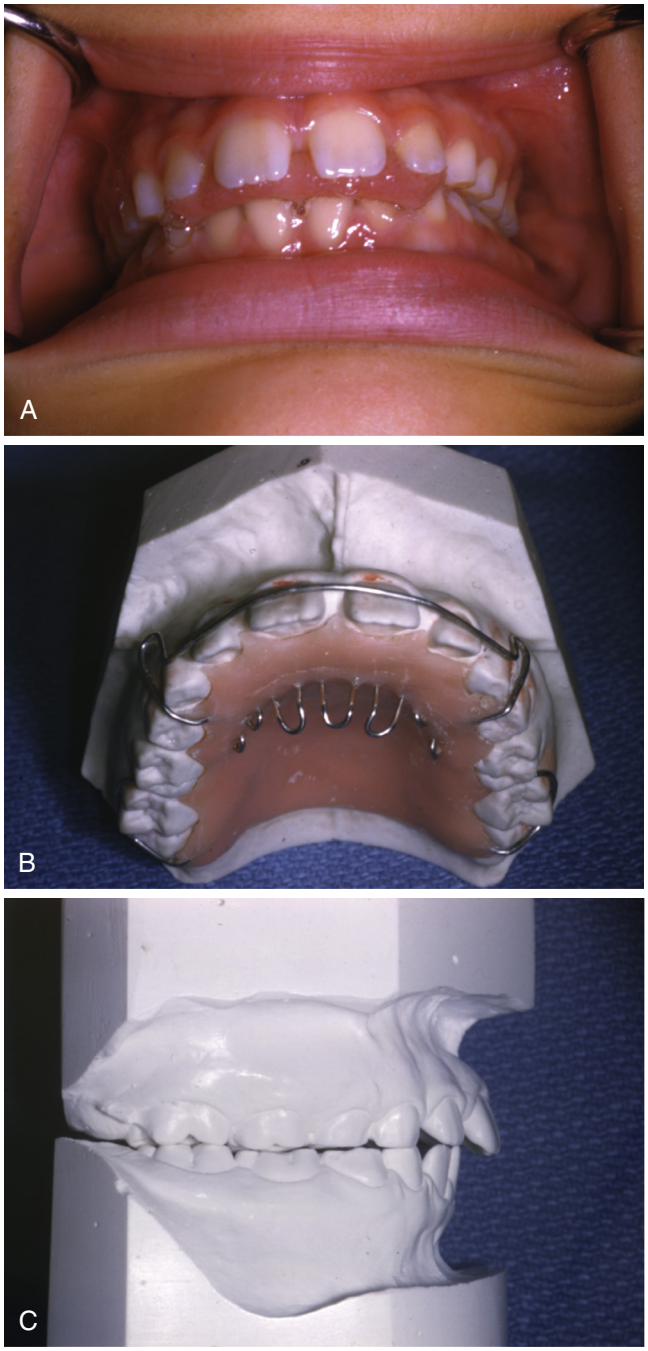

Figure 22-32 **A,** Anterior open bite resulting from a tongue-thrust swallowing pattern. **B,** A removable retainer with a crib-like component helped "retrain" the tongue from being thrust forward during the swallowing process. **C,** The tongue-thrust pattern has been overcome and the occlusion is greatly improved.

places the tip of the tongue against the incisive papilla, and swallows. This is repeated, followed each time by the relaxation of the muscles until the swallowing progresses smoothly. The use of a sugarless mint may also help in muscle training. The child is instructed to use the tip of the tongue to hold a mint against the roof of the mouth until it melts. As the mint is held, saliva flows and makes it necessary for the child to swallow. Treatments are usually programmed to take 7 to 10 weeks of exercises until the oral environment is stabilized. Most therapists prefer to wait until the child is about 9 years of age before beginning treatment because normal developmental changes occurring around this same time allow for more favorable positioning of the tongue. After the patient has trained the tongue and muscles to function properly during swallowing, an acrylic palatal retainer with a "fence" may be constructed as a reminder to position the tongue properly during swallowing (Fig. 22-32).

In patients with tongue-thrust swallowing and a speech problem, referral to a speech therapist is the most appropriate course of action. If a malocclusion is also present, the coordinated use of myofunctional therapy by the speech therapist and orthodontic treatment may be undertaken to take advantage of each service. Generally, any therapy aimed at altering the tongue positions during swallowing and speech should be done in conjunction with or after the orthodontic treatment rather than preceding it. If mouth-breathing postures are identified with clinical symptoms of airway blockage, the dentist should refer the child to an otolaryngologist for appropriate medical consideration. Patients who are obligate mouth breathers secondary to hypertrophic adenoid tissue or allergic conditions can have corresponding poor postural relationships that can influence the developing skeletal face. With proper diagnosis and management, the airway interference may be reduced or eliminated to influence occlusal development and orofacial musculature in a positive direction. In patients with tongue-thrust alone and no malocclusion, speech, or airway problems, there is no reason to recommend any interceptive orthodontic treatment.

ANTERIOR CROSSBITE IN PRIMARY AND MIXED DENTITIONS

Dentoalveolar anterior crossbite represents a linguoversion of one or more maxillary anterior teeth with resultant "locking" behind the opposing mandibular teeth in full closure (Fig. 22-33). The anterior crossbite is usually an acquired malocclusion resulting from local etiological factors (e.g., over-retained primary incisors) that interfere with the normal eruptive positioning of the maxillary anterior teeth. In some cases during closure movements, premature contacts due to the lingual malpositioning may result in a forward mandibular deviation to effect full closure that "locks" the anterior segment in a crossbite posture involving multiple teeth. Such an acquired muscular pattern is referred to as a pseudo-Class III malocclusion as the mandible shifts from Class I to Class III relationships during closure (Fig. 22-34). In most cases localized dentoalveolar anterior crossbites with or without mandibular displacement should be treated as soon as they are discovered. Delayed treatment can lead to serious complications such as loss of arch dimensions and asymmetric midlines, traumatic occlusion with stripping of gingival tissue on the labial aspect of the lower tooth, wear facets on involved incisors, and untoward growth patterns if a functional shift is involved. Importantly, at later developmental stages, not only does differential

Dentlearn.ir



Figure 22-33 Examples of dentoalveolar anterior crossbites with lingually locked maxillary central incisors. The malpositioning with traumatic occlusion results in forward displacement of the lower incisor and stripping of the gingival tissues.



Figure 22-34 Lingually displaced central incisors may produce occlusal interference on closure that results in a functional anterior shift of the mandible (pseudo-Class III malocclusion). **A,** Maximum intercuspation after anterior shift of mandible. **B,** First contact with edge-to-edge incisor interference. **C,** Maxillary incisors malpositioned lingual to arch form.

diagnosis become more difficult but also do the mechanics for correction become more complex with less predictable results. Simple appliance designs are usually adequate to achieve correction of dentoalveolar anterior crossbites. Diagnoses should be made with consideration of the following clinical findings.

1. *Number of teeth involved*. Involvement of one or two incisors usually represents a dental crossbite, although the chance of functional displacement is increased as more teeth are involved. Suspicion of a skeletal malocclusion grows in proportion to the number of teeth in crossbite.
2. *Inclinations of maxillary and mandibular incisors*. Dentoalveolar and functional crossbites usually exhibit lingual inclination of the maxillary incisors and normal to slight labioversion of the lower incisors in response to incisal interference. In a true skeletal Class III malocclusion, lower incisors are retroclined, whereas maxillary incisors usually exhibit normal to proclined inclinations.
3. *Mandibular closure pattern and facial profile*. In a dentoalveolar crossbite, the facial profile and buccal occlusion should present a neutroclusion at rest, first contact, and full closure, with the soft tissues masking the dental malpositioning. Any displacement of the mandible should be observable as a shift from neutroclusion to Class III buccal patterns "worsens" a normative profile at rest to an apparent prognathism in full closure. If the child can readily bite to an edge-to-edge incisor position without directed jaw manipulation, evidence of a forward shift of the mandible is confirmed. A Class III skeletal malocclusion should close in a smooth pattern without anteroposterior disruption. A mesiocclusion of molar positioning and prognathism of the profile should persist at all times.
4. *Familial appearance*. If similar dentofacial conditions exist, the probability increases that the case involves a skeletal problem that is genetic in origin rather than a localized malocclusion.
5. *Cephalometric analysis*. Assessment of lateral cephalograms can usually confirm impressions of the clinical examination (see Chapter 21). Realizing that anterior displacement may demonstrate cephalometric measurements indicating mandibular prognathism when the cephalogram is obtained in full occlusion, the clinician should analyze centric relation cephalograms or overlay analysis of rest position and full occlusal tracings to determine true skeletal relationships. The inclination patterns of the upper and lower incisors are key factors in this assessment.

Diagnosed in the transitional dentition, dentoalveolar anterior crossbites with or without mandibular displacement are usually approached from the viewpoint that the primary discrepancy involves one or more maxillary anterior teeth in linguoversion. Any labial inclination of lower incisors is in response to the upper malpositioning. This simplifies treatment, in that correction is directed toward labial movement of displaced maxillary incisors to "jump" the bite. After normal maxillary incisor positions are achieved, the proclination of lower incisors is usually self-correcting with the establishment of normal overbite and overjet. Studies have shown that gingival recession in the lower anterior segment improves spontaneously after crossbite correction. In most cases removal of the traumatic occlusion allows normal attachment levels to be sustained without the need for specific periodontal treatment procedures. If it can be assumed that local etiologic factors such as over-retained primary incisors have been eliminated, one of several treatment methods may be

selected. This is done after an evaluation of biomechanical decision factors such as the following:

1. *Incisor positioning and available space.* If space is available, options can be directed toward simple labially directed tipping movements of involved maxillary incisors. This particularly applies if the root of the lingual tooth is in the same relative position as it would occupy in normal occlusion. If space is not available or with greater bodily tooth displacement, Edgewise appliances may be required to create space and provide controlled orthodontic movements.
2. *Stage of eruption.* If the displaced maxillary incisor is in active eruption, the treatment may use simple leveraging techniques to redirect the tooth forward into acceptable position. If the tooth is fully erupted, the forces of occlusion will usually not allow simple leveraging of eruption paths. Directed forces to effect labial repositioning of the involved maxillary anterior teeth will be required.
3. *Degree of overbite.* During treatment, occlusal bite planes are often proposed to remove overbite interference during labial movement. Whereas this is desirable in the use of removable appliances and those incorporating labial bracketing of involved teeth, the 3- to 4-mm freeway space at rest position and the use of directed lingual applied forces from fixed appliances negate the need for bite-opening to achieve successful labial movement in most clinical situations. Exceptions involve cases exhibiting more than 5 mm of overbite extending beyond freeway space. The overbite has greater impact on retention, in that positive overbite will maintain positioning of the incisors once corrected.

In addition to these factors, cooperation of the patient and parent and personal preference of the clinician are considerations in treatment mechanics. Treatment approaches are of two general types: (1) passive incisal guides that, during mandibular closure, redirect or "leverage" maxillary anterior inclinations in a labial orientation; and (2) active appliances that use directed orthodontic forces to achieve labial repositioning of the maxillary anterior teeth.

TONGUE BLADE/POPSICLE STICK THERAPY

Cooperative children can often correct a localized anterior crossbite using the wedging effect of a tongue blade or popsicle stick (Fig. 22-35). Teeth in initial eruption with a minimal degree of locking can often be repositioned within 24 to 72 hours. The child is instructed to place the stick behind the locked tooth and, using the chin as a fulcrum, exerts pressure on the tooth in the labial direction. The procedure is done in 15- to 30-minute increments at a time for at least several hours of engagement. The obvious advantage of the technique is that "self-correction" avoids the expense and time involved with appliance therapy. The technique is highly dependent upon the frequency, duration, and accuracy with which the child uses the leverage stick against an erupting incisor. While it is still possible to correct an established crossbite with intense tongue blade therapy, the treatment is very unlikely if the tooth is erupted into full crossbite.

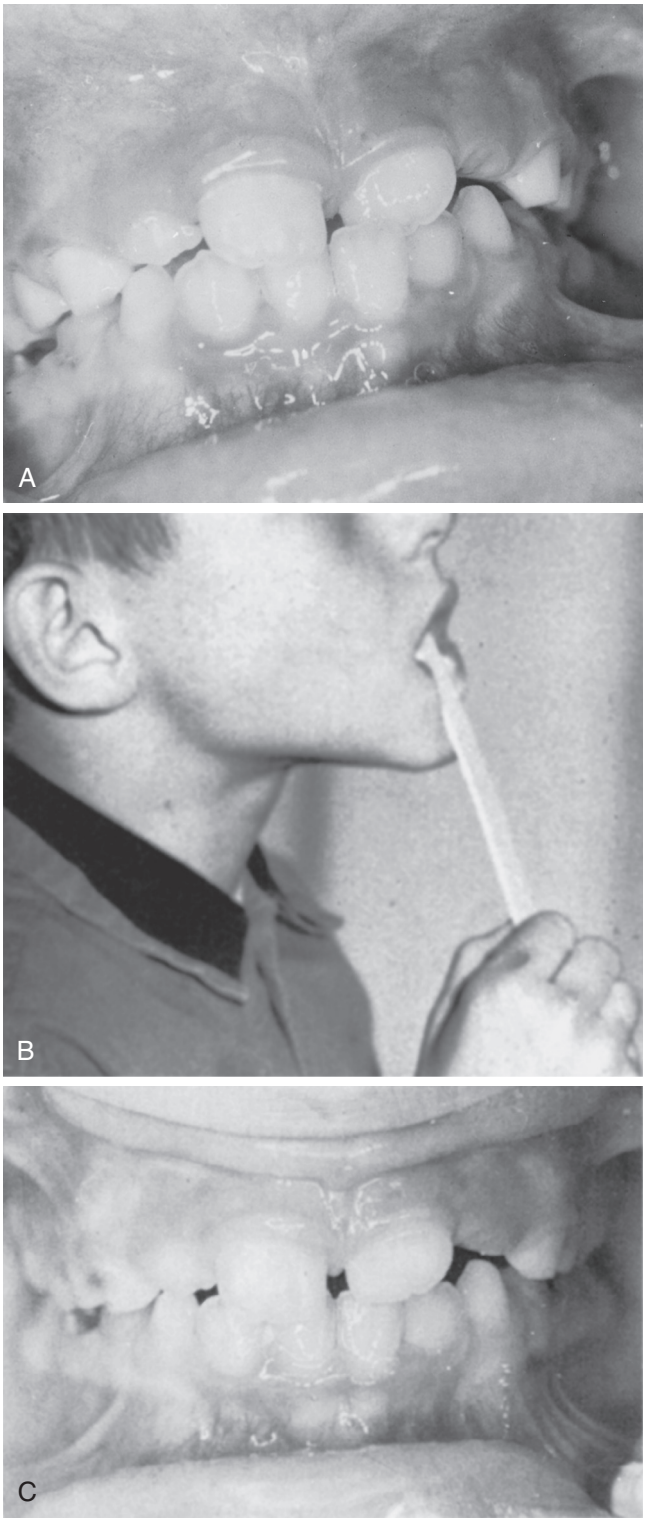

Figure 22-35 **A,** Partially erupted central incisor with a minimal degree of overbite and lingual locking. **B,** A tongue blade was used to exert labially directed pressure on the lingually locked incisor. **C,** Correction of the crossbite accomplished with the tongue blade.

Dentlearn.ir

LOWER INCLINED PLANE

An acrylic extension from the lower anterior teeth designed to engage the incisal edges of lingual displaced maxillary teeth during closure applies pressure upon patient closure that will direct the engaged tooth labially into normal bite position (Fig. 22-36). Prerequisites for an inclined plane are adequate space in the maxillary arch, a normal or excessive overbite, and sufficient mandibular teeth for retention of the acrylic. The inclined plane is constructed using self-curing resin on a working model to enclose the lower canine-to-canine anterior segment. This maximizes stability while preventing excessive lingual movement of the lower incisors. The acrylic should engage only the upper tooth or teeth in crossbite and incorporate approximately a 45° incline to the long axis of the lower incisors. The incline portion should extend about ¼ inch posteriorly such that the patient cannot readily bite behind the inclined plane.

At placement, the inclined plane is tried in the child's mouth before cementation to ensure that only the locked upper incisor is in contact with the acrylic and the plane does not touch palatal tissue. The posterior "bite-opening" should be slightly beyond rest position (not more than 2 to 3 mm), to avoid excessive muscle fatigue. This bite-opening limits the time the appliance can be worn because eruption of posterior teeth may occur within 2 weeks and a tendency to an anterior open bite may result. The physical activities of children with bite planes should be restricted, to minimize the possibility of avulsion or luxation of the teeth that occlude on the plane from a blow to the chin. Follow-up should be made at 1 week, with adequate bite-jumping usually achieved within this time. If not "jumped" after 1 week, the inclined plane may be continued no more than an additional week. The appliance design and upper spacing should be evaluated for any interference to correction before the therapy is continued. The inclined plane should not be applied beyond this 2-week period due to the danger of overeruption of the posterior teeth and opening of the bite. If the situation is not corrected in this time, either the original diagnosis may be in error or more controlled mechanics are indicated. Once correction is achieved, the appliance should be carefully removed to allow for final positional adjustments with the natural vertical overlap providing retention of the corrected positions.

The advantages of the inclined plane lie in ease of fabrication, simplicity of action, rapid correction time, and possible use when there is insufficient eruption to engage active appliances. Disadvantages include discomfort associated with forced bite-opening, poor aesthetics, limitations on diet, potential for gingival irritation, possibility of creating an open bite, and, of particular concern,

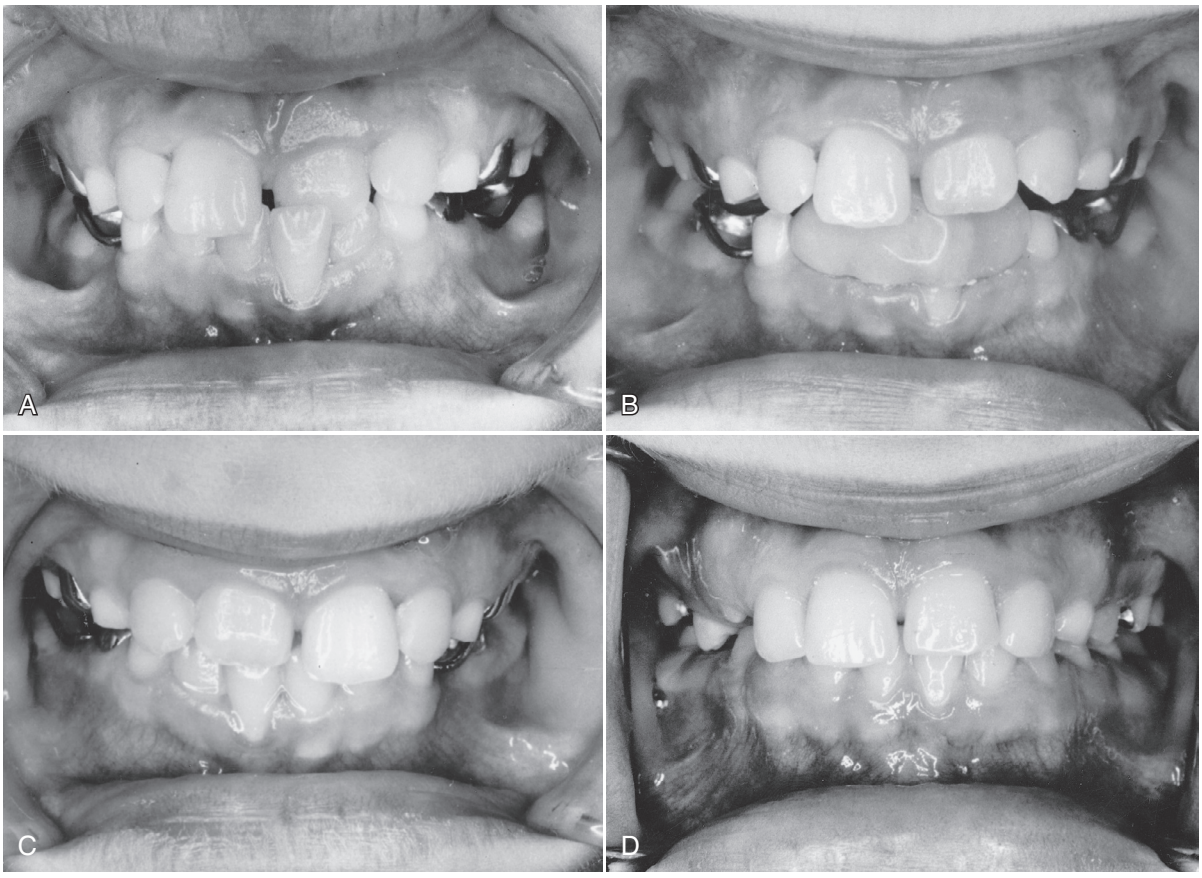

Figure 22-36 **A,** Essentially normal occlusion except for the central incisor crossbite. **B,** A lower cemented acrylic bite plane was used to reposition the lingually locked incisor. **C,** The tooth has moved into correct position with sufficient overbite to maintain the new relationship. **D,** Four years after the correction of the crossbite. Notice improvement in the appearance of the tissue on the labial surface of the lower left central incisor.

Dentlearn.ir

the risk of traumatic injury if the child hits his/her chin while the inclined plane is positioned in the mouth. In addition, the inclined plane may be dislodged by occlusal stress and require recementation. Given these disadvantages and the availability of other options that are more predictable and safer, the use of acrylic inclined planes is generally to be avoided except when other options are simply not feasible.

PALATAL-SPRING APPLIANCES (REMOVABLE HAWLEY OR FIXED PALATAL WIRE)

A fixed or removable appliance incorporating palatal springs provides the best option for dental anterior crossbites that are not amenable to tongue blade guidance. Properly oriented springs exert targeted labially directed pressures against the teeth from the palatal side and are not affected by the reverse overjet. The major disadvantages are technical: the finesse needed in engaging the spring to the involved tooth or teeth, adjustments if breakage occurs, modification for retention if overbite is not adequate, and untoward movements. These disadvantages may be readily overcome with proper fabrication and management of the appliance.

A removable Hawley-type retainer modified with auxiliary springs can reduce lingual displacement of maxillary incisors, with correction usually achieved in 6 to 12 weeks (Fig. 22-37). A conventional Hawley retainer incorporating a labial bow and Adams clasps on the molars provides the base for the spring component. Although usually not necessary, the use of full posterior occlusal coverage enhances the effectiveness of a removable approach by minimizing any overbite interference to labial movement. Appliance action is enhanced if the appliance is seated when teeth are in occlusion, to engage the finger-spring more fully in counterbalancing the displacement effects of spring engagement.

With a helical loop finger-spring of 0.020- or 0.022-inch stainless steel wire, activation should represent 2 to 3 mm of helical loop closing from passive spring positioning that approximates the incisal edge of the contacted tooth. When activated, the spring tends to slide along the sloping lingual surface of the incisor to exaggerate tipping



Figure 22-37 Removable Hawley-type finger-spring appliance. **A** and **B,** Lingual locked permanent lateral incisor with retained primary lateral incisor and insufficient space for the lateral to move forward. **C,** A removable Hawley-type appliance with finger-spring designed to correct the condition. Note that the retained primary incisor was extracted and the mesial surface of the primary canine was disked to allow space for tooth movement. Activation of the spring with engagement under the lingual composite "button" resulted in labial movement of the tooth. **D,** The corrected occlusion at the time the appliance was discontinued. **E** and **F,** Same patient 3 years later without any intervening retention or other treatments. Bands have just been placed in preparation for phase 2 braces.

Dentlearn.ir

effects. This problem can be overcome by the bonding of a small "button" of flowable composite on the lingual surface to create a retentive undercut for maintaining a cervical orientation of the spring. This optimizes labial movement with less tipping by orienting the force vector closer to the center of rotation of the engaged tooth. The composite should not interfere with vertical closure after the malposed tooth is moved out of crossbite (i.e., not placed too far incisally), while ensuring spring engagement by extending the mesiodistal width of the tooth.

FIXED TRANSPALATAL WIRES WITH SPRINGS

A transpalatal connector wire of 0.036- or 0.040-inch stainless steel soldered to banded molars that incorporates a helical loop spring of 0.020-inch stainless steel wire provides a very effective method to labialize maxillary incisors involved in anterior crossbite (Fig. 22-38). The orientation of the spring essentially mirrors the procedures outlined for the removable Hawley appliance. With the lingual composite button used to engage the spring, the increased stability and rigidity of the fixed anchorage system dramatically enhance directed forces toward the center of rotation of the engaged incisors. The fixed approach results in significantly less tooth-tipping in offering a more bodily applied tooth movement and provides continuous force application that is not dependent on the child's cooperation. These factors combine to effect correction of dental anterior crossbites by means of a fixed-spring approach with average treatment times ranging from 1 to 3 weeks.

Abutment support may be from either second primary molars or first permanent molars, depending on developmental and eruptive status, condition of the crown, and clinician choice. After bands are fitted to selected abutments and a working model is prepared, the anchor wire is bent to approximate the palatal arch form about 5 mm lingual to the anterior teeth in crossbite. This positioning provides accurate space for bending a compact double-helical loop spring as the active component. The maxillary incisors to be engaged should be cut off horizontally on the working model at the cingulum level to create a "table" to position the spring horizontally with proper length. Passively, the helical loop extends from the anchor wire to rest on the cut-off incisal table, with the free end of the spring at the labial surface. The original positioning of the palatal anchor wire about 5 mm behind the crossbite teeth provides this distance in a double-helical design. Careful soldering of the spring to the palatal wire completes the appliance in preparation for polishing.

Labial Edgewise Archwires

Edgewise brackets and labial archwire mechanics are used when multiple incisors are in crossbite, palatal displacement and rotations are severe, and adjacent tooth movements are needed to adjust anterior spacing. While the clinician who wisely applies Edgewise techniques can achieve greater control in tooth positioning, their use presents major disadvantages in the early-mixed dentition, when most anterior crossbites are corrected. Disadvantages include increased chair time in placement, adjustment, and removal; need for special equipment and supplies; increased soft-tissue irritation; decalcification of teeth; risk of injury to developing teeth with excessive



Figure 22-38 Fixed palatal finger-spring appliance. **A,** Lingual locked permanent central incisor with significant overbite. **B,** Fixed palatal appliance at delivery with double-helical loop finger-spring designed to labialize the single incisor. Initial activation of the spring from a passive position at the labial surface to engage the lingual composite "button" resulted in directed movement of the tooth. **C,** The corrected occlusion at 17 days' treatment time. **D,** The appearance of the spring at completion with the incisor out of crossbite. The lingual composite had been removed at 10 days' treatment time to eliminate vertical interference with positioning.

Dentlearn.ir

biomechanical movements; and the expectations and expenses associated with "braces." Discussion of Edgewise archwire techniques falls beyond the concepts of interceptive management and is illustrated in the section on Comprehensive Orthodontics.

Finally, it is worth mentioning that an interesting study by Rosa et al. showed 84% spontaneous correction of anterior crossbites in conjunction with rapid palatal expansion treatment in the mixed dentition.[35] This occurred whether or not the patients had an existing posterior crossbite because all 50 patients studied exhibited maxillary crowding but only 20 had a posterior crossbite.

POSTERIOR CROSSBITE IN PRIMARY AND MIXED DENTITIONS

Before treatment, the type of posterior crossbites in children must be determined—whether the discrepancy is a localized problem in tooth eruption (dental crossbite), a gross basal disharmony between the maxilla and mandible (skeletal crossbite), or a transverse discrepancy in upper to lower arch width that produces a lateral shift of the mandible on closure (functional crossbite).

Dental posterior crossbites involve atypical eruption and alignment with localized displacement of individual teeth into crossbite configurations. Most often involving isolated permanent maxillary first molars or premolars, dental crossbites are usually corrected in conjunction with comprehensive Edgewise orthodontics. Within an interceptive context, isolated first permanent molar crossbites can be corrected by the use of cross-arch elastics (Fig. 22-39). A hook or button (either bonded to enamel or welded onto bands) on the lingual surface of the upper molar and the buccal surface of the lower molar is used to secure elastics. The elastics should be changed by the child or parent each day until the crossbite has been corrected. Typically, a crossbite involving isolated first molars can be corrected with cross-arch elastics in 4 to 8 weeks. If either of the opposing molars is in correct alignment before treatment, an anchorage appliance (lower lingual arch or upper Nance/Transpalatal Bar) may help prevent movement of that tooth. The corrected cuspal interdigitation usually holds the teeth in their new relationship, so there is no need for a retentive appliance.

Skeletal posterior crossbites present as gross discrepancies in basal relationships of the maxilla and mandible, usually presenting a full bilateral crossbite with severe constriction of the maxilla (Fig. 22-40). Midlines are generally coincident to the facial midline in occlusion, with no functional deviations observed on closure. The skeletal dysplasia is often complicated by other factors such as crowding of the maxillary teeth, anterior open bite, and environmental factors that impede normal growth patterns (e.g., severe airway problems, cleft palate). Kurol and Berglund[36] found 4 of 86 crossbites in children, a relatively low frequency, presenting as full bilateral crossbite. Modéer and associates[37] reported a similar 2% incidence of bilateral crossbites in children.

Functional posterior crossbites involve a lateral shift of the mandible during closure in response to transverse occlusal interference between the maxillary and mandibular

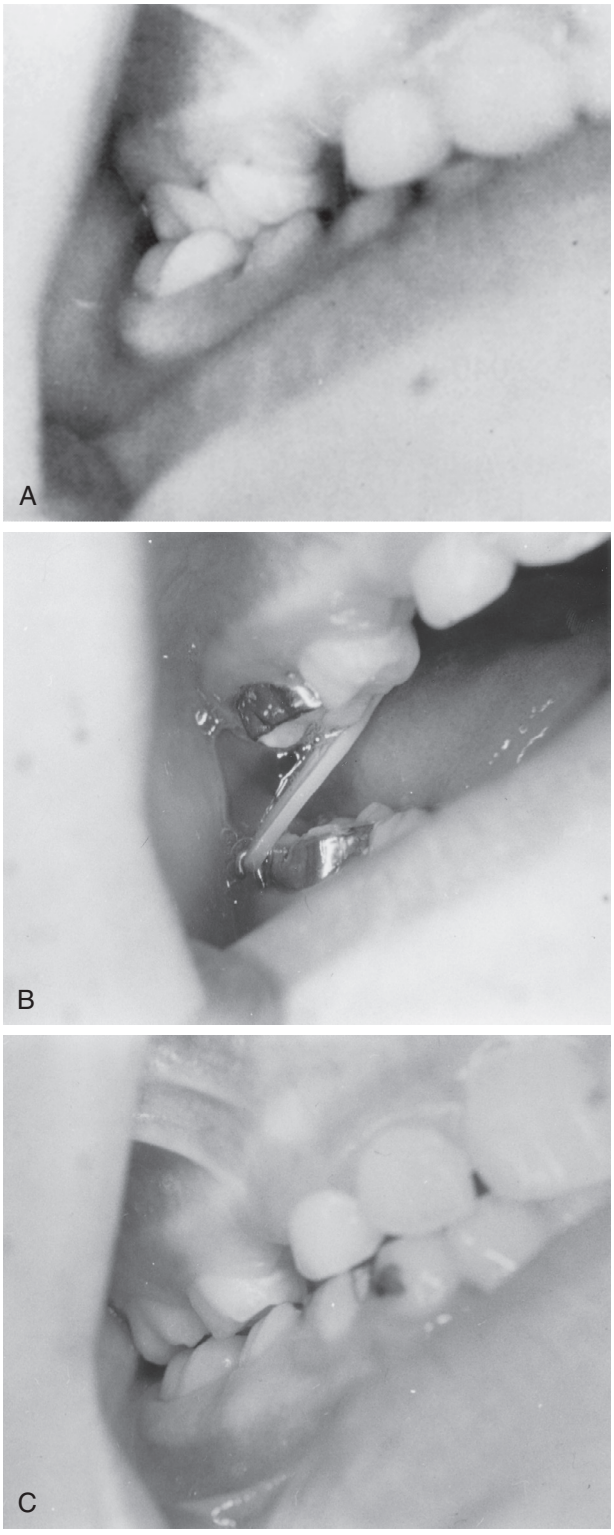

Figure 22-39 **A,** Buccal crossbite limited to the first permanent molars on the right side. **B,** Molar bands with hooks and cross-arch elastics from lingual side of upper to buccal side of lower are used to correct the crossbite. **C,** The crossbite has been corrected in a 4-week period.

Dentlearn.ir



Figure 22-40 An acrylic jackscrew rapid palatal expander (Haas RPE) in the mixed dentition with bands on the permanent first molars and bonded composite on the primary canines. **A** and **B,** The pretreatment bilateral posterior crossbite with constricted and tapering maxillary arch form. **C** and **D,** The rapid palatal expansion appliance appearance at cementation and after expansion involving 32 turns on a once-a-day schedule. **E,** The occlusion at 3 months with the appliance maintained for retention. **F,** The occlusion 1 year after appliance removal.

arch widths. The deviation of the mandible presents as a unilateral crossbite in centric occlusion involving multiple posterior teeth on one side, normal buccolingual occlusion of the contralateral side, and a deviation of the lower midline and chin toward the crossbite side (Figs. 22-41 and 22-42). While presenting a unilateral appearance in occlusion, functional posterior crossbites show cusp-to-cusp transverse contacts bilaterally, with a constricted maxillary arch of insufficient width to enclose the lower dentition at initial contact. Factors contributing to constriction in maxillary width include upright primary canine interference, thumb and finger habits, and mouth-breathing/airway problems. Studies demonstrate a direct linear progression between prolonged digit and pacifier habits beyond the age of 4 years and a higher incidence of posterior crossbites.

Functional posterior crossbites are among the more common occlusal problems observed in the primary and mixed dentitions, with an incidence rate of 5% to 8% of children. Lindner and Modéer,[38] documenting patterns in 76 children with primary dentition, reported that three or more teeth (canines back) were involved in 85% of the crossbites, with two thirds extended to include the primary lateral incisors. A lateral shift of the mandible was seen in 97% of the children, resulting in a lower midline discrepancy of about 2 mm on average. Other studies support the impression that more than 90% of posterior crossbites in children exhibit functional shifting of the mandible on closure as a component of the crossbite pattern. As a result of the functional shift, dental, skeletal, and neuromuscular adjustments likely result in further constriction of the maxillary arch, maldistribution of erupting teeth and alveolar bone, and asymmetric growth of the contralateral sides. Kutin and Hawes,[39] in a study of 35 children with posterior crossbite in the primary dentition followed into the mixed dentition, reported that 32 of the children showed persistent crossbite of the first permanent molars after their eruption. Other studies have also suggested that posterior crossbites are generally not self-correcting because consistent incidence rates have been shown in children at 3, 6, 8, 10, and 12 years of age. It appears that less than 10% of posterior crossbites present in the primary dentition self-correct into the mixed dentition.

In conjunction with functional posterior crossbites, asymmetric condylar positioning has been demonstrated on tomograms and transcranial radiographs. Hesse and colleagues[40] documented condylar positioning using temporomandibular joint tomograms in 22 functional posterior crossbite patients corrected with maxillary expansion at a mean age of 8.5 years. The condyle on the noncrossbite side was positioned more anteriorly before treatment and moved posteriorly and superiorly after treatment. The condylar position was similar at pretreatment and posttreatment stages on the crossbite side. Importantly, correction of the crossbite with maxillary

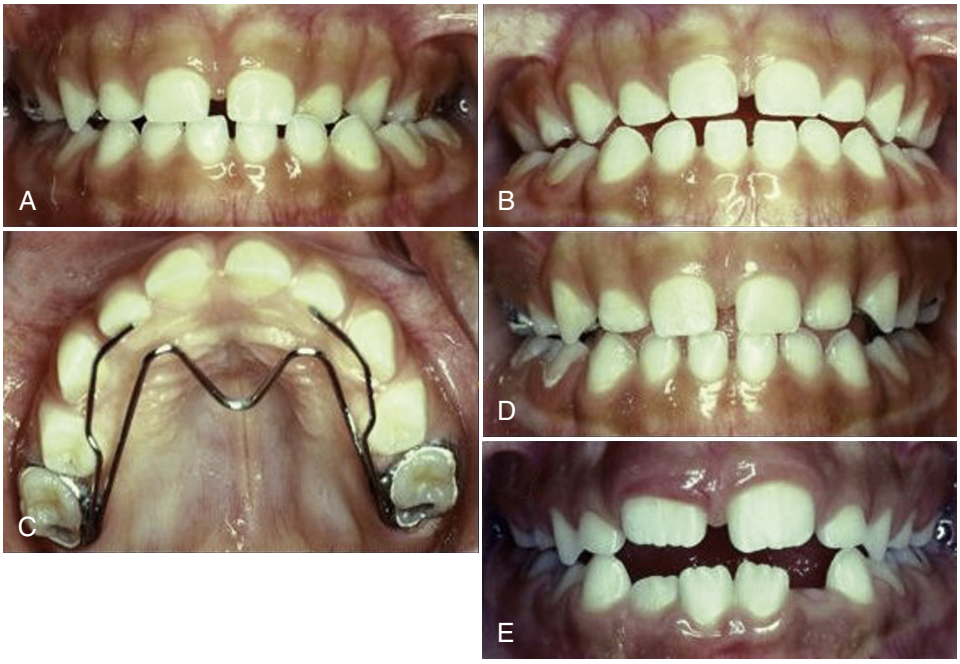

Figure 22-41 W-arch appliance. **A,** Functional posterior crossbite in the primary dentition in maximum intercuspation occlusion. Crossbite extends through buccal segment from the lateral incisor with a 2.5-mm mandibular midline shift to the affected side. **B,** In rest to first contact position, the dental midlines are normal with the posterior segments edge-to-edge bilaterally in transverse width. **C,** Soldered W-lingual arch appliance at cementation. **D,** The crossbite was corrected in 6 weeks with 2- to 3-mm overexpansion; the appliance was left in place for 3 months. Notice that the dental midlines are properly aligned with the functional shift eliminated. **E,** Two years posttreatment, the transverse posterior widths are in proper relationship with no mandibular shift evident during closure.

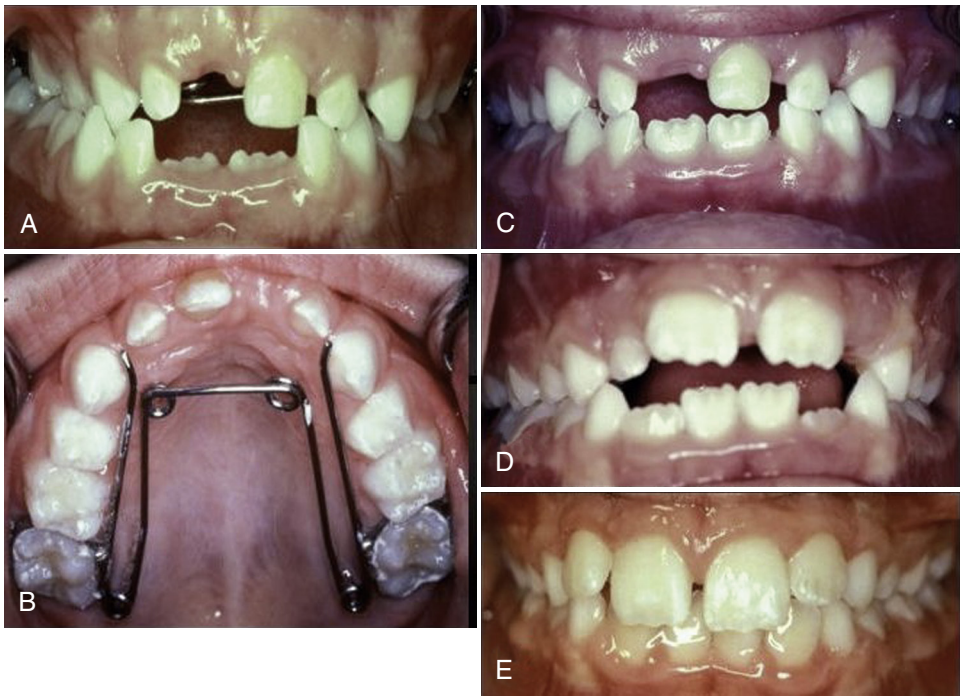

Figure 22-42 Quad-helix appliance. **A,** Functional posterior crossbite in the early transitional dentition in maximum intercuspation occlusion. Crossbite extends through buccal segment with a 1.5-mm mandibular midline shift to the affected side. **B,** Soldered quad-helix appliance at cementation. Note symmetric and horizontal loop design for optimum expansion with minimal buccal tipping of molars. **C,** Occlusion 2 weeks after appliance removal. The crossbite was corrected in 4 weeks, and the appliance was left in place for 2 months. Dental midlines are properly aligned with the functional shift eliminated. **D,** Six months posttreatment, the transverse posterior widths remain in proper relationship with no mandibular shift evident during closure. **E,** Two years after treatment into mid-mixed dentition with proper transverse relationships and no functional shift of mandible noted.

expansion established symmetry of condylar relationships in all planes of space. Myers and associates[41] similarly reported that joint spaces were asymmetric before treatment of children with functional crossbite, and correction led to symmetry of condylar joint spaces. Pirtiniemi and colleagues,[42] comparing condylar path and mandibular length in nine children with unilateral posterior crossbite treated with maxillary expansion between

with untreated crossbites into young adulthood, reported that the condylar path evidenced asymmetry in both treated and untreated individuals, with greater steepness and condylar rotation on the crossbite side. The eminence

as mandibular length was shorter on the crossbite side. The degree of mandibular asymmetric length was twice as great in untreated children vs. those with treated posterior crossbites. Other studies confirm that displacement of the mandible in growing children produces asymmetric mandibular length, with the crossbite side shorter than the noncrossbite side. The mandibular rotation also results in a sagittal asymmetry of contralateral sides, with the crossbite side expressing a more distal step–Class II relationship and the noncrossbite side a more Class I to Class III pattern. Even though correction with maxillary expansion improves molar positioning toward Class I positions on the crossbite side and reduces the midline discrepancy, full establishment of symmetric relationships after correction is not a consistent finding. The continuation of some degree of asymmetry after correction suggests that unbalanced growth occurred up to the time of correction, more balanced symmetry of the growth patterns was expressed after correction, and any acquired pretreatment morphological asymmetry remained after correction.

Early correction of posterior crossbites has been shown to enhance developmental patterns by redirecting teeth into more normal positions, correcting asymmetries of condylar position, allowing for normal vertical closure without functional deviations, making beneficial dentoskeletal changes during periods of dynamic growth, and eliminating factors detrimental to dentofacial development. Early treatment also allows for simplified approaches that are less complex, less time consuming, and more physiologically tolerable to structural tissues than are treatment demands in older patients. Delaying correction until the permanent dentition requires more complex mechanics to achieve basal arch corrections and may necessitate surgical approaches to achieving maxillary expansion.

SELECTIVE EQUILIBRATION

Selective equilibration of deflective interference, usually the primary canines, may enhance differences between intercanine widths and offer some potential for functional crossbite correction without appliances. The equilibration involves selective reduction (i.e., slanting) of the lingual aspects of the upper primary canines and labial reduction of the lower primary canines. Selective grinding, according to Lindner,[43] is successful when the maxillary intercanine width difference is larger than the mandibular intercanine width by a positive 2 to 3 mm before the selective grinding. When the upper-to-lower intercanine width approximates the same width or the lower is greater, selective grinding is not effective and upper canine expansion is required. In most full primary or mixed-dentition cases, equilibration procedures alone are insufficient to eliminate a functional discrepancy associated with a constricted maxillary dentoalveolar width.

MAXILLARY EXPANSION

Appliances used for maxillary expansion in the correction of posterior crossbites include fixed palatal wire designs (e.g., W-arch, quad-helix), fixed jackscrew expanders (e.g., Hyrax, Rapid Palatal Expander [RPE] of Haas), and removable split-acrylic plate appliances (e.g., Schwarz Plate). Success rate for treatments during the primary and mixed dentitions have been documented at greater than 90% for the fixed approaches success rate and 70% for removable appliances. Dimensional changes have documented that early expansion techniques to correct posterior crossbites in children require an average final overall increase of about 3 to 4 mm in intramolar width and 2 to 3 mm of intracanine width change for successful correction. The clinical reports further indicate that expansion protocols, regardless of the appliance used, should incorporate an overexpansion of about 2 to 3 mm beyond these final desired increments during the active phase in order to accommodate settling adjustments after treatment.

Transverse expansion of the maxillary arch is directed at a combination of dentoalveolar expansion and orthopedic separation of the midpalatal suture. It is considered desirable to optimize the opening of the midpalatal suture in order to provide more stable basal arch expansion than orthodontically oriented lateral expansion. In the consideration of appliance options, the nature of orthodontic and orthopedic movements is closely related to the rate of expansion, the magnitude of force application, and the patient's developmental stage. Fixed palatal jackscrew appliances, such as the RPE of Haas (see Fig. 22-40) and the Hyrax (Fig. 22-43), are applied bilaterally to maxillary posterior teeth, with the midline screw generally expanded at a rate of one or two turns per day (one turn equals 0.25 mm of screw widening) during an active treatment time of 1 to 4 weeks. Single activations of fixed jackscrews produce high magnitude forces in the 3- to 10-pound range that maximize orthopedic separation by overwhelming suture tissues before substantial orthodontic movement can occur. The relative skeletal and dental components produced by rapid palatal expansion have been evaluated with standardized nonanatomic reference points (e.g., implants) and frontal cephalograms. Krebs[44] reported average arch width increases of 6 mm (range, 0.5 to 10.3 mm) for 23 individuals aged 8 to 19 years, with a total dental arch increase twice that of the skeletal segments. Analyzing the Krebs data, Hicks[45] estimated that skeletal separation accounted for approximately one half of increased arch width in 8- to 12-year-olds and about one third of the increase in 13- to 19-year-olds. Three- to six-month retention periods involving fixed appliances (e.g., expanded appliance, transpalatal bar) are recommended to allow for reorganization and stabilization of rapidly expanded maxillary sutures.

Dentlearn.ir

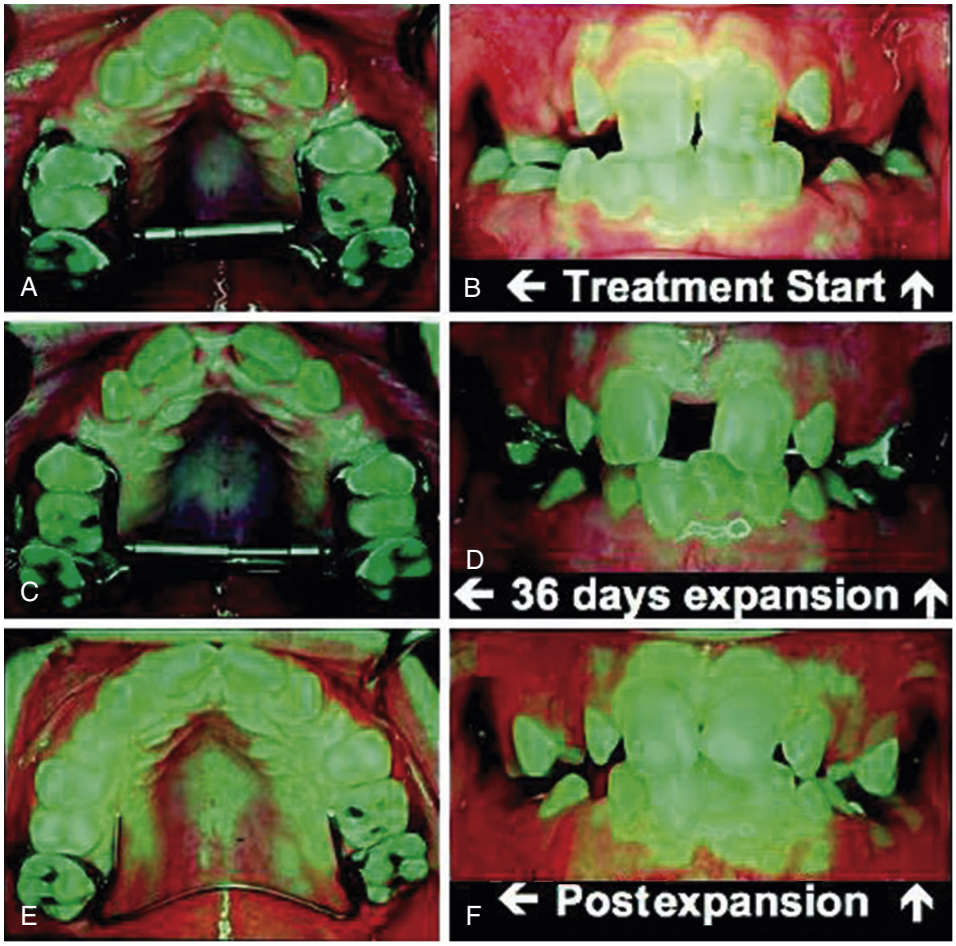

Figure 22-43 Hyrax appliance in late-transitional dentition with bands on the permanent first molars and first premolars. **A,** The Hyrax appliance at cementation. **B,** The pretreatment bilateral posterior crossbite with symmetric but constricted maxillary arch form. **C** and **D,** Appliance and occlusal appearance after expansion involving 36 turns on a once-a-day schedule. The large midline diastema reflects orthopedic separation of the mid-palatal suture. **E** and **F,** The occlusion at 6 months postexpansion. The Hyrax was maintained for 5 months, and then replaced with the fixed transpalatal appliance for retention.

Compared with the jackscrew appliances, fixed palatal wire appliances (e.g., W-arch, quad-helix) accomplish maxillary expansion following "low-force" and "slow-expansion" procedures. Thomas and colleagues[46] determined that W-arch (see Fig. 22-41) and quad-helix (see Fig. 22-42) designs with 6 to 8 mm of expansion produced lateral forces in the range of 400 to 600 g (approximating 1 pound) at the molar positions and 200 to 300 g at the canine level. Some degree of sutural separation has been documented during the primary and mixed-dentition stages with forces in these ranges. Using forces of less than 2 pounds to achieve maxillary arch width increases from 3.8 to 8.7 mm during treatment, Hicks estimated that skeletal changes represented 24% to 30% of the total arch width increase in 10- to 11-year-old children and 16% in 14- to 15-year-old patients. Although they did not document the relative ratios of orthopedic vs. orthodontic change, Harberson and Myers[47] reported radiographic evidence of suture opening during the deciduous and early-mixed dentition in 8 of 10 posterior crossbites successfully corrected with a W-arch appliance. Bell and Lecompte[48] reported suture separation on each of 10 children (mean age, 6 years 9 months) by means of quad-helix appliances with mean increases of maxillary intermolar width of +5.3 mm and maxillary intercanine width of +4.1 mm in successfully correcting functional posterior crossbites. The conceptual model of fixed palatal wire appliances in the primary and mixed dentitions is that favorable orthopedic and orthodontic ratios of expansion are realized with less disruption than with rapidly expanded sutures. Because of the "physiologic" nature of the expansion, the integrity of tissue elements is sustained to allow for enhanced stabilization of the changes, with retention periods of up to 3 months appearing adequate.

The palatal wire W-arch and quad-helix designs offer the advantages of increased molar rotational ability, relative comfort, minimal effect on speech and deglutition, reduced soft-tissue irritation, and removal of adjustment responsibility from the patient-parent. Posterior crossbites in the full primary dentition are usually treated with banding of the deciduous second molars at ages 4 to 5 years. In the mixed-dentition period (i.e., ages 6 to 11 years), the first permanent molars are generally banded for posterior crossbite correction. During the active eruption stage of the first permanent molars, from about 6 months before emergence until opposing occlusion is established, maxillary expansion procedures should usually be delayed. The first permanent molars may not be affected by expansion of the deciduous dentition during this transitional stage and may erupt into crossbite, thus requiring additional treatment. Delaying expansion until the first permanent molars are in occlusion results in no significant technical problems related to treatment. The Hyrax jackscrew appliance becomes the priority choice for maxillary expansion

when gross discrepancies in basal relationships present as full bilateral crossbites, when there is pronounced maxillary constriction with severe crowding of the maxillary teeth, and when other factors suggest the use of a rapid palatal expansion to exaggerate orthopedic over orthodontic movements. True bilateral posterior crossbites require twice as much incremental expansion as needed in functional crossbites, bringing into play the greater increments achievable with fixed jackscrew appliances. Given an increasing resistance to sutural separation, older patients with late mixed or young permanent dentition (i.e., 10- to 16-year-olds) require higher force systems of rapid palatal expanders. Additionally, the transitional status of exfoliating primary and erupting permanent teeth in the late mixed dentition may complicate anchorage options in the use of palatal wire appliances. The Hyrax is used until growth is complete (girls, 16 to 17 years; boys, 18 to 21 years), with sutural separation anticipated during the earlier stages of this developmental period. After retention, regardless of whether jackscrew or palatal wire-type appliances were used in treatment, the laterally tipped dental elements will upright. This dental relapse must be factored into the active expansion and retention phases.

The soldered W-arch uses a 0.036- or 0.040-inch stainless steel wire contoured to the arch from bands on the most distal teeth involved in the crossbite. The wire is expanded to the bilateral width of the central fossae of the banded molars before cementation, such that the appliance must be compressed 2 to 3 mm bilaterally for placement on the banded teeth. It is reactivated by being removed for additional adjustment every 3 or 4 weeks if necessary until the crossbite has been corrected (see Fig. 22-41). The appliance may be used as a retainer for 3 to 6 months after active treatment. The soldered W-arch is very stable, with its primary use in situations that require 4 to 5 mm of maxillary buccal expansion such as typically required in functional posterior crossbites. Some palatal expansion may occur with the W-arch.

The quad-helix appliance, by incorporating four helical loops into the W-arch design, provides refined adjustment capability for a longer range of force application (see Fig. 22-42). For that reason, quad-helix treatment is emphasized, although the basic W-arch design follows similar protocols. The quad-helix is fabricated from 0.036-inch stainless steel wire with the loops equal in size to optimize symmetric expansion and the "cosmetic" look of the appliance. The anterior loops should be at the level of the canines and approximate the palatal width to minimize the space between the crossbar and the palatal contour. All loops should be as horizontal as possible, with the anterior loops circling toward the palate at the level of the primary canines and the posterior loops away from the palate. This places the helical loop section and the lateral expansion forces in a more palatal position for enhanced expansion effects. The posterior loops should extend approximately 2 to 3 mm distal to the molar bands for enhanced molar rotation and expansion.

The progress of expansion is followed as described for the W-arch appliance, with a 2- to 3-week appointments interval. Adjustments are made only when progress between successive appointments is static and the amount of increased arch width is inadequate. Expansion is considered adequate when the occlusal aspect of the maxillary lingual cusps comes into contact with the occlusal slope of the mandibular buccal cusps in representing approximately 2 to 3 mm of overexpansion to compensate for later uprighting of laterally tipped teeth once appliances are removed. Successful expansion with slight overcorrection is usually achieved in 4 to 6 weeks. If an adjustment is necessary, the appliance should be removed for activations to ensure appropriate expansion increments in both amount and location. Activations consist of, again, opening with finger "accordion"-type action or incorporating strategic bends along the wire-lengths to increase lateral expansion. Bends can be done intraorally but tend to create compensating adjustments such that multiple intraoral activations frequently produce untoward movements. The appliance is left in the expanded position to serve as a retainer with a recommended minimum retention period of at least 3 months. Longer periods are suggested if the patient has a history of oral habits (e.g., thumb-sucking, mouth breathing, tongue-thrusting) or exhibits continued functional inconsistencies in mandibular closure. While using the appliance as its own retainer is convenient, the possibility of continued expansion into buccal crossbite must be realized. Thus supervision during "retention" with a monthly monitoring schedule is desirable. Heat-annealing of the appliance may also be considered, or the clinician may use a follow-up Hawley-type retainer.

Fixed Hyrax jackscrews are preferred for bilateral posterior crossbites with pronounced maxillary constriction that require 6 to 8 mm of expansion to correct the transverse discrepancy, and in older patients in whom sutural integrity requires greater force magnitudes to achieve basal arch changes (see Fig. 22-43). Expansion effects with the Hyrax appliance are closely related to the rigidity of the appliance, positioning of the jackscrew relative to the palatal arch form, and resistance of the maxillary complex. Banded designs reinforced with buccal and lingual connector wires between multiple abutments demonstrate the most rigidity in design. If such a design is used in the mixed dentition, the first permanent molars and second primary molars provide excellent anchorage for the appliance. In the adolescent dentition, anchorage usually involves first permanent molars and either first or second premolars. These appliances have been shown to generate the greatest orthopedic response when positioned high in the palatal contour and as far posteriorly toward molar positions as possible. Given the force levels generated, an activation rate of one turn per day is advised to achieve expansion on the order of 6 to 8 mm (24 to 32 turns) during an active treatment time approximating 1 month. After sufficient expansion is obtained, the appliance is left in place for 6 months to allow for reorganization of the expanded suture and enhanced stability of the arch width achieved.

ERUPTION PROBLEMS AND ERUPTION "GUIDANCE"

Abnormal eruption patterns with resultant ectopic displacement, asymmetry of alignment, disruption in arch integrity, and crowding are all benchmarks of a tooth

Dentlearn.ir

size–arch size discrepancy. In addition, local factors such as supernumerary teeth, congenital absence or malformation of permanent successors, necrosis or dystrophic calcification of a primary tooth secondary to trauma or caries, and ankylosis of primary molars may present barriers to normal eruption and alignment. The watchword for evaluation should be in monitoring the sequence and symmetry of eruption patterns, with a basic rule that the transition should be about the same for contralateral segments.

ECTOPIC ERUPTION OF FIRST PERMANENT MOLARS

First permanent molars may be positioned too far mesially in their eruption path, with resultant ectopic resorption of the distal root of the second primary molar. Bjerklin and Kurol[49] distinguished two types of ectopic eruption—reversible and irreversible. In the reversible type, the molar frees itself from the ectopic position and erupts into normal alignment, with the second primary molar remaining in position (Fig. 22-44). Most permanent molars in children with reversible patterns had freed themselves by 7 years of age. In the irreversible type, the maxillary first molar remains unerupted and in contact with the cervical root area of the second primary molar (Fig. 22-45). By the ages of 7 and 8 years, any ectopic eruption of a permanent first molar should be considered irreversibly locked. Young[50] observed that ectopic eruption of first permanent molars occurred 52 times in 1619 children (3%), with the problem seen more frequently in boys (33 times) than in girls (19 times). The ectopic molar often occurred in more than one quadrant and was most often observed in the maxilla (only two ectopic lower first molars were noted). Young further observed that two thirds of ectopic molars erupted into their essentially normal positions without corrective treatment (reversible). Bjerklin and Kurol also reported that children with irreversible ectopic eruption patterns had significantly larger permanent first molars, a more pronounced mesial angle path of eruption, and a tendency toward a shorter maxilla in relation to the cranial base. No significant differences in these variables were found between sides with reversible ectopic eruption and sides with normal eruption. Ectopic molars also show a significant familial tendency, with a prevalence of 19.8% in affected siblings vs. the overall 2% to 3% general occurrence. A frequent occurrence rate of ectopic first permanent molars at 25% in children with cleft lip and cleft palate again implicates maxillary positioning and basal arch size as etiologic factors.

Irreversible ectopic molars that remain locked, if untreated, can lead to premature loss of the primary second molar with a resultant decrease in quadrant arch length, asymmetric shifting of the upper first molar toward Class II positioning, and supraeruption of the opposing molar with distortion of the lower curve of Spee and potential occlusal interference. Early assessment with intraoral or panoramic films approximating the timing of first permanent molar eruption is thus critical to identification of the problem and provides an opportunity to intercept potential sequelae. If the problem is detected at 5 to 6 years of age, an observation approach of "watchful waiting"

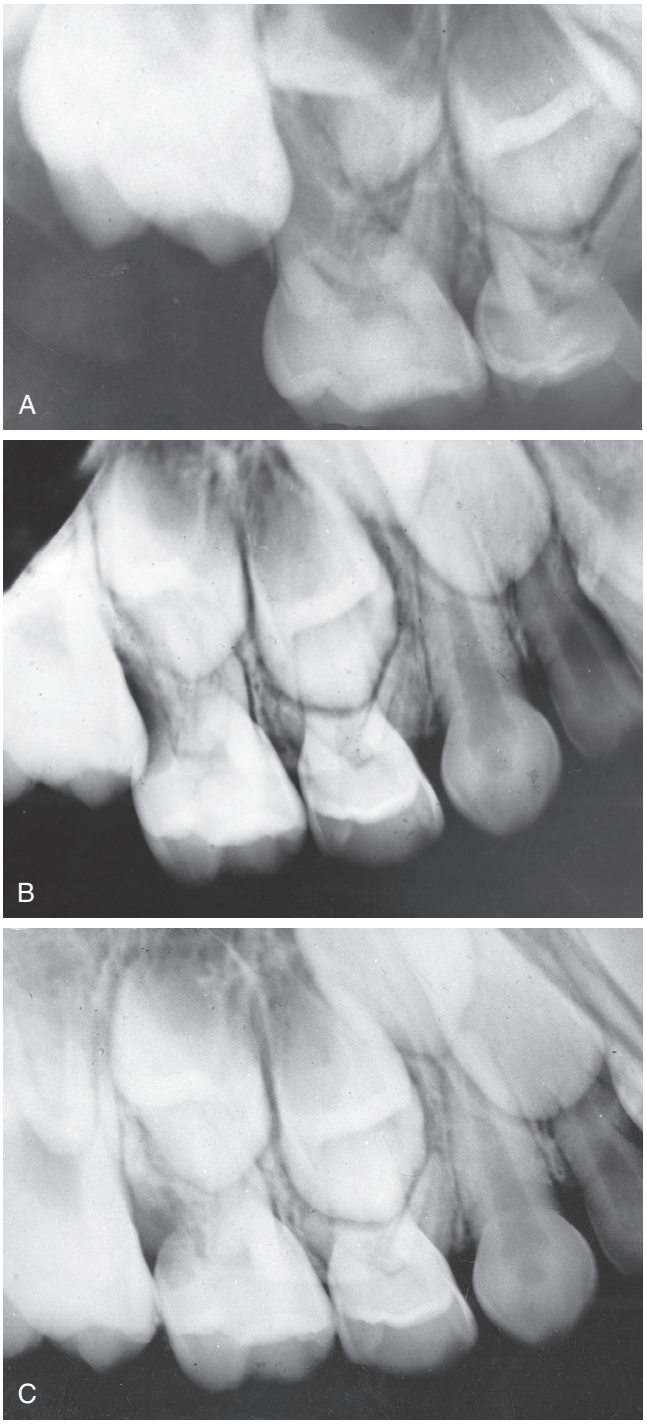

Figure 22-44 **A,** Ectopic eruption of a maxillary first permanent molar with evidence of resorption of the distal buccal tooth of the second primary molar. **B** and **C,** Subsequent radiographs show continued resorption of the primary molar, but "self-corrective" eruptive positioning of the first permanent molar. Approximately two thirds of ectopic molars are reported to exhibit such a "reversible" pattern.

Dentlearn.ir

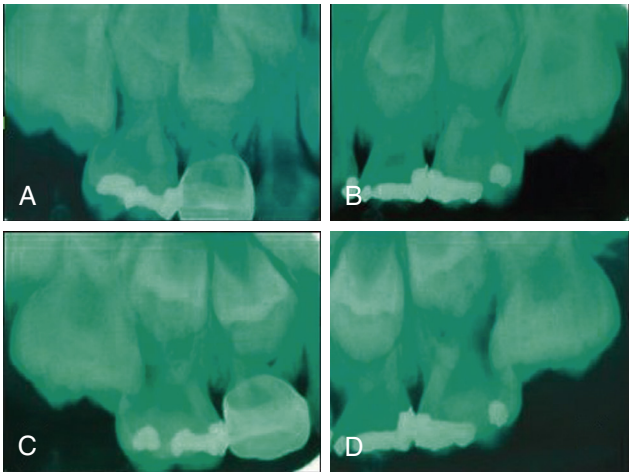

Figure 22-45 **A** and **B,** Periapical radiographs demonstrating bilateral ectopic eruption of maxillary first permanent molars with resorption of the distal aspect of the second primary molars. **C** and **D,** Subsequent radiographs obtained at 6-month recall showing "irreversible" pattern of ectopic eruption with continued resorption of the primary molars and greater mesial displacement of the first permanent molars.

with appropriate monitoring may be indicated, given the two-thirds potential for self-correction. With self-correction being unlikely as the child approaches 7 years of age, continued "locking" of the first molar with advanced resorption of the primary second molar usually warrants intervention. Another timing clue is that when the opposing molar reaches the level of the lower occlusal plane, intervention is indicated to establish proper vertical control and prevent supraeruption. Because the anomaly often occurs bilaterally in conjunction with a tooth mass discrepancy, the finding should result in careful examination of other areas for similar conditions.

Interceptive correction involves guidance of the ectopic molar into normal position, retention of a favorable eruption sequence, and maintenance of arch length. Importantly, the resorptive process of the primary molar generally stops once the ectopic positioning is corrected and the tooth remains to stabilize arch integrity. One option is to restore the second primary molar with pulpotomy and a stainless steel crown supplemented with band material extending subgingivally to rest mesially to the ectopic molar. Designed to serve as a guide for eruption positioning, the extension must be carefully placed so as not to exaggerate molar entrapment. The technique seems simple but is actually very difficult to do and should generally be avoided. Several other corrective procedures have been reported, with treatments varied by the extent of blockage, degree of primary tooth resorption, direction of displacement, timing, arch length status, and patient cooperation. Approaches include separators and distalizing appliances.

Orthodontic elastic separators are the first choice if access is sufficient to allow insertion for engagement in the contact areas of entrapment. The first placement is the most difficult and often requires a modified separator and floss engagement. This is done by looping floss through the separator, passing the floss through the contact area, pulling the doubled separator into the cervical area of contact, and then pulling one side of the separator through the contact with the floss. Progressive use of larger separators placed conventionally—from smaller, "stretchier" elastic types to more rigid plastic types—at subsequent visits facilitates this approach. Replacement at 1- to 2-week intervals usually accomplishes correction within 2 months. Separating springs can also be used provided sufficient eruption for insertion between the contact areas. However, separating springs tend to impinge upon tissues and are easily displaced, raising concerns for swallowing or aspiration. If springs are used, insertion is most easily achieved by the use of How or Weingart pliers to grasp the active arm of the spring. Floss looped through the helix serves as a safety device if the spring slips out of the pliers. The head of the spring is placed on the marginal ridge, while the active arm is directed below the contact point of the teeth. The spring may be inserted from the buccal or lingual side (whichever provides the greater access); the buccal approach is usually easier. The spring is left in place until the tooth is freed from contact with the adjacent tooth and is erupting. The patient should be seen every 2 to 3 weeks for evaluation of eruption progress and reactivation of the spring.

Brass ligature wire threaded between the contact areas of the affected teeth may facilitate distal movement of the permanent molar through periodic tightening of the looped wire as a separating force. The wire should be twisted or a new one placed at approximately 3- to 5-day intervals until the desired separation is achieved. Brass wire usage is uncomfortable and local anesthetic is often required; the brass wire usually has to be replaced one or more times before correction is achieved, relapses easily, and, in essence, is vastly overrated. Treatment with any of the separator techniques requires that only a minimal lock be evidenced and that minimal resorption of the primary second molar has occurred. Of the three, elastic separators are much easier to use and are much less problematic for minimal locks than are either separating springs or brass wire.

Irreversible ectopic eruptions may require the use of distally directed forces from the second primary molars to disengage and allow eruption of the first permanent molar. The Humphrey appliance uses a distally directed S-shaped loop that is actively engaged on the occlusal surface of the ectopically erupting permanent molar (Fig. 22-46). In original usage, it was often necessary to remove the appliance for activations of the loop, and a restoration was required in the first molar after correction. The advantages were stability and ability for severe locks of the 6-year molar to be corrected. Subsequent modifications to the original Humphrey design include the use of helical springs (0.018- to 0.022-inch wire) to provide more continual force and easier reactivations, added stability by the anchoring of banded molars bilaterally with a palatal wire, using springs from buccal and lingual aspects to minimize rotations of the permanent molar, and using bonded composite resins to engage the distalizing springs. Problems in activation and adjustment of the spring, possible occlusal interference distorting the wire,

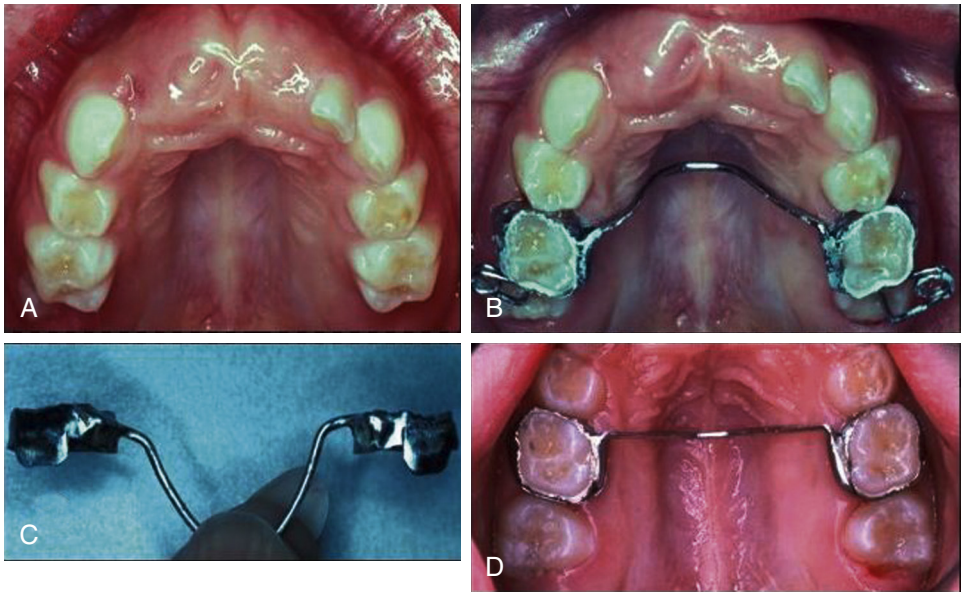

Figure 22-46 Distalizing spring (Humphrey) appliance. **A,** Bilateral ectopic eruption of the maxillary first permanent molars. **B,** A Humphrey-type banded appliance with distalizing springs has been fabricated to reposition the ectopic first permanent molar. The ectopic molars were uncovered at the time of band fitting. At placement, composite ridges were bonded to the occlusal surfaces for spring engagement. **C** and **D,** After distal repositioning of the first permanent molar was achieved, the appliance was removed, springs were cut off, and band material was tach-welded to provide extensions to maintain first permanent molar eruption into favorable positions.

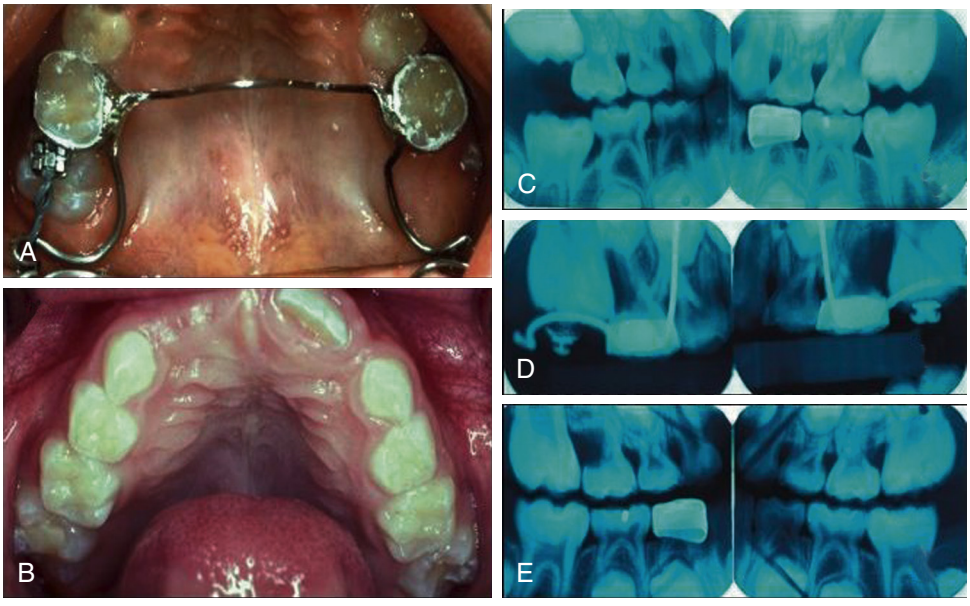

Figure 22-47 Fixed maxillary Halterman appliance. **A,** Bands on second primary molars with distal engagement arms for engaging elastomeric chains to bonded attachments on bilateral ectopic first permanent molars. **B,** The first permanent molar has erupted into a favorable position after 6 weeks' treatment time. Radiographs showing distal repositioning of the first permanent molar from pretreatment **(C),** at 2 weeks of treatment **(D),** to 1 year posttreatment **(E).**

need for access to the occlusal surface of the first permanent molar, and possible reciprocal movement of primary molars are all disadvantages. Once distalized, the spring needs to be removed to allow for vertical eruption of the molar to ensure correction. To prevent relapse of the molar into the undermined area, band extensions are tack-welded to the distal aspect of the band and the appliance is recemented.

The Halterman appliance uses elastomeric chains rather than springs as the distalizing force (Fig. 22-47). With a rigid 0.036-inch stainless steel wire "hook" extended distally from the lingual aspect of bands on the second primary molars, stretching of elastomeric chains from bonded buttons on the ectopic molar essentially "slingshots" the molar distally. Extending the wire from the lingual side of the primary molar avoids wire impingement

with the anterior border of the ramus during opening. The wire should approximate the palatal contour with the hook positioned horizontally to approximate the buccolingual midpoint of the desired molar location and about 5 mm beyond the distal marginal ridge of the involved permanent molar. This position provides adequate stretch of the elastic forces in a vertical and parallel orientation to normal arch alignment. An occlusal button, cleat, or bracket is bonded to the central fossae area of the ectopic first molar as far mesially as accessible. Clinician-preferred (i.e., self- or light-cured) resin bonding is used with success, depending on avoidance of moisture contamination. Hybrid glass-ionomer cements that allow moisture exposure and do not require acid-etching are an alternative if isolation is compromised. In placement, the elastomeric chain should already be secured to the button during the bonding process to ensure that composite material does not extend into undercut areas and block elastic engagement. After the button is bonded, the appliance is cemented and the elastomeric chain is stretched to the distal hook. A closed-loop chain is recommended for enhanced force application. Being relatively simple to apply as well as predictable and effective, the Halterman distalizing technique is currently the preferred method when elastic separators are not applicable.

ERUPTION GUIDANCE IN THE LOWER INCISOR SEGMENT

Developmental patterns often find permanent lower incisors erupting into a lingual position behind the primary incisors as a "double row" of teeth. The majority of these cases self-correct via eventual exfoliation; however, if the problem does not self-correct by age 8 years, extraction of the primary incisors may be necessary (see Chapter 19). The tongue usually positions the permanent incisor forward into normal alignment. In conjunction with eruption of lower lateral incisors, there is a normative increase in lower intercanine width of 2 to 3 mm (range, 0 to 5 mm). This "growth" in lower anterior space helps compensate for the inherent tooth mass liability. After the lower permanent incisor transition is complete, by 7 to 8 years of age, the "normative" finding presents almost 2 mm of incisor crowding. Studies document that no future increase in lower intercanine width for relief of crowding will occur after this stage of incisor eruption is complete. However, extra space is available within the overall arch, as represented by the size difference between the primary canines and primary molars vs. the permanent canines and premolars. This "leeway space" represents a +1.7 mm, on average, in each lower quadrant and provides potential for the relief of lower incisor crowding. Gianelly,[11] reporting on 100 consecutive mixed-dentition children presenting for orthodontic needs, found that 85 of them had lower incisor crowding, with an average crowding discrepancy of –4.4 mm, a discrepancy significantly greater than population averages of approximately 2 mm. When leeway space was calculated into a space analysis, adequate room to accommodate an aligned dentition was indicated in 72% of the individuals with crowding. Given this potential, if an overall space analysis indicates that a child's arch perimeter is adequate to accommodate or be within 2 to 3 mm of relieving any incisor malalignment, the clinician should consider options to facilitate adjustments through guidance of eruption and timely use of the available leeway space.

A first option when incisor crowding is less than 3 to 4 mm involves "disking" the primary canines on their mesiolingual surfaces. Timely disking provides a "sluice-way" for lingual displaced incisors to slide forward toward the anterior arch form under the muscular pressure of the tongue (Fig. 22-48). Bilateral disking can provide up to 2 to 3 mm of space for "unraveling" of lingually displaced incisors. With proper slicing of the mesiolingual corner at the gingival contact area, there is actually no measurable encroachment on overall leeway space in the individual quadrant. Movement of the incisors under tongue pressure potentially increases midline arch length and overall arch circumference as the arch is rounded out in a forward direction. In the case of labial malpositioned incisors, while disking may provide additional room for alignment, the lips are a more significant factor in the balance between muscular forces. The result is lingual flattening of the anterior segment and a decrease in overall arch space. Disking must involve slicing the canine subgingivally to completely free the contact area. Disking just the crown is not enough. The use of a tapered bur of a size to allow access without injury to adjacent permanent teeth is required (#699 or #169). Local anesthesia or nitrous oxide support is frequently required because dentin exposure and periodontal insult are necessary to disk primary canines adequately. Placement of a wedge is sometimes necessary to protect the lateral incisor. Timing is critical to allow for optimal tooth positioning and ease of access. Given normative intercanine width increases of 2 to 3 mm during lateral incisor eruption, disking should be delayed until eruptive "wedging" effects of the incisors are realized. If indicated, disking of lower primary canines is therefore recommended at around 7 to 8 years of age, near completion of lateral incisor eruption.

While excessive incisor liability may result in ectopic loss of lower primary canines (reviewed earlier in this chapter), more often the primary canines remain and the permanent incisors erupt significantly malpositioned. If disking of the canines is not an option due to the level of crowding or positioning of the incisors, elective extraction of the primary canines to maintain arch symmetry, coincident midlines, and incisor integrity may be considered (Fig. 22-49). Such intervention becomes more viable when the incisor liability and crowding are greater than 4 mm in the anterior segment. However, the clinician must remember that early loss of lower primary canines will likely result in significant lower arch collapse. Therefore the extraction of primary canines should not be undertaken without parental understanding of the consequences and, ideally, orthodontic consultation. Given the long-term implications, such intervention goes beyond a first step in guidance of eruption and actually represents the start of either a phased early treatment program or a serial extraction program.

Dentlearn.ir

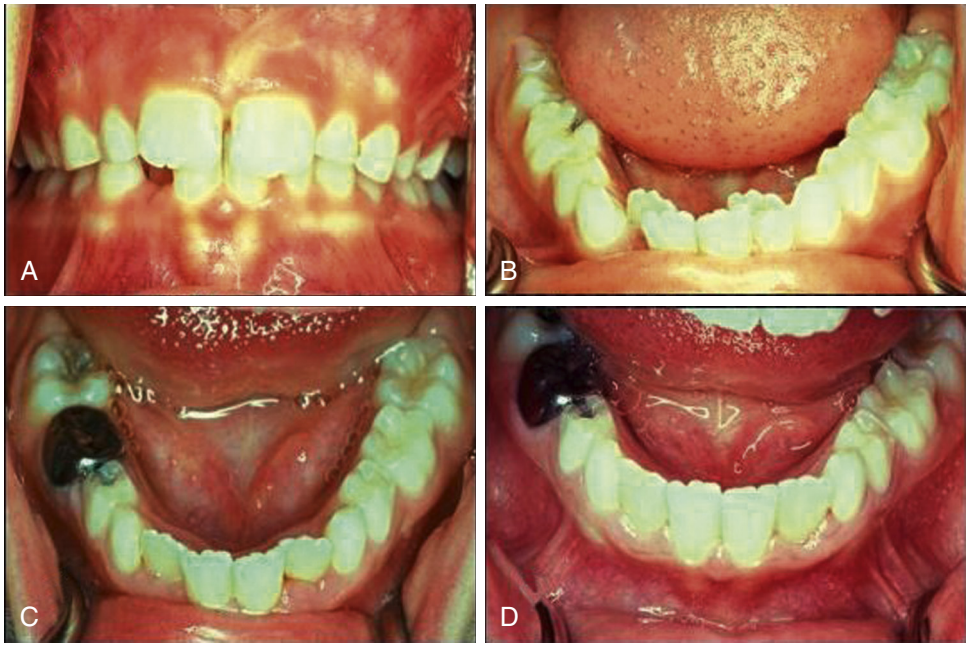

Figure 22-48 Incisor guidance with disking of lower primary canines. **A** and **B,** Presentation of approximately 4.5 mm of lower incisor crowding with lingual malpositioning of lateral incisors, retained lower left primary lateral, and 80% overbite. Given significant overbite and positioning of incisors, the decision was made to disk the lower primary canines bilaterally in conjunction with restorative appointments. **C,** Same patient at 6-month recall appointment after disking. Slight additional disking of canines was done at recall. **D,** Same patient at 1 year from start of first disking. Arch form is established as tongue pressure positioned the lingually displaced incisors forward into the spaces created by disking.

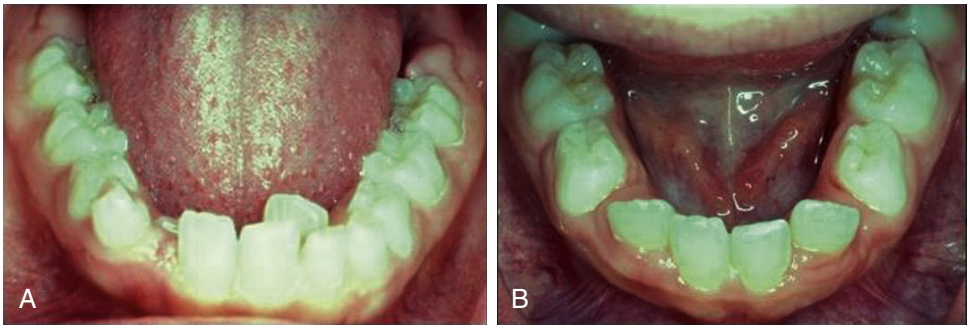

Figure 22-49 Elective extraction of lower primary canines. **A,** Significant lower incisor crowding and malpositioning evidenced by advanced lower right primary canine resorption with ectopic positioning of adjacent lateral incisor, lower dental shifting toward right, and retained lower left primary lateral. Due to imminent loss of the lower right canine and malpositioning, a decision was made to extract the primary canines bilaterally. **B,** Same patient 1 year later with symmetry and integrity of lower incisor alignment. Patient is on course for either serial extraction protocol or setup for arch development, depending upon other variables.

ERUPTION GUIDANCE IN THE MANDIBULAR CANINE AND PREMOLAR SEGMENT

For a child between 10 and 12 years of age, radiographic evaluation of the buccal segments provides particular consideration in eruption guidance relative to primary resorption patterns, eruption sequencing, molar adjustments to achieve Class I relationships, and usage of leeway space. Because the lower canine and first premolar often erupt nearly concurrently and are larger than their primary predecessors, they often take a mesial eruption path, with the canine overlapping the lateral incisors. To minimize such malpositioning, their timely transition along with concurrent disking of the mesial surface of the second primary molar may provide up to 2 to 3 mm of space for their distal positioning (Fig. 22-50). The second premolars usually erupt about a year later, frequently taking a path of eruption along the distal root of the second primary molar. Extraction of the second primary molar is sometimes indicated to allow for normal eruption of the second premolar if such an atypical pattern is noted. In addition to assessing eruption of the second premolars, the clinician should consider placement of a lingual holding arch concurrent with removal or exfoliation of the second primary molars (see Fig. 22-18). If the available buccal segment space is tight, the optimal use of leeway space for crowding is desirable, and/or the second

permanent molars are erupting before the second premolars, the lingual arch may be a critical element in controlling overall arch dimensions.

Treatment-based articles have documented positive alignment effects in the use of passive lingual holding arches for control of leeway space when used in the late mixed dentition. DeBaets and Chiarini[51] reported on arch changes in 39 mixed-dentition cases with lower anterior crowding treated with passive lingual arch therapy and selected removal of primary molars over a 4-year period as compared with arch similar crowding. In untreated children, lower canine and premolar mesial displacement occurred, with overlap of already crowded lower incisors. In contrast, children with lingual arches showed an average decrease in lower anterior crowding of 3 to 4 mm by the time of second permanent molar eruption. The permanent canines and premolars erupted with an average of 1.5 mm more distal positioning per side in children with lingual arches than in control children. Dugoni and associates[52] published similar findings in 25 mixed-dentition patients with reductions in lower incisor crowding of greater than 3 mm after placement of passive lingual arches and selected primary molar extractions. After an average postretention period of 10 years, 19 of the 25 patients continued to show clinically satisfactory lower anterior alignment. When compared with 10-year follow-up studies of orthodontically aligned patients, these results suggest that stability of the alignment with lingual arch therapy was greater than or at least equal to that of active orthodontic treatments. Reballato et al.,[53] using cephalograms, study models, and tomograms of the mandibular body, reported dimensional changes in 14 mixed-dentition patients with incisor crowding of 3 mm or more who were treated with passive lingual arches in comparison with 16 untreated control individuals. In lingual arch patients, arch length did not measurably change through eruption of the succedaneous teeth, compared with an average arch length decrease of 2.5 mm per side in the untreated control individuals. Arch-length changes were related to first molars moving forward uprighting of incisors in the controls reduced arch length 0.65 mm. In sum, the lingual arch reduced mesial molar migration and incisor lingual movement in controlling arch length, with concurrent relief of 3 to 4 mm of lower incisor crowding in the treatment population. Brennan and Gianelly[54] quantified dimensional changes in 107 consecutive mixed-dentition patients treated with passive lingual arches through eruption of all succedaneous teeth, with occasional extraction of second primary molars being the only other intervention. Arch length decreased an average of 0.4 mm, whereas width increased slightly in lingual arch patients. The resultant average +4.4 mm of total available leeway space produced an average decrease in lower incisor crowding from a pretreatment of –4.8 mm to +0.2 mm of space after treatment. The space adjustments were enough to resolve incisor crowding completely in 65 individuals (roughly 60%). An additional 16 individuals (1 in 6) had a final discrepancy of less than 1 mm, and 13 (1 in 10) had a final discrepancy of less than 2 mm. Only 14 patients (13%) had crowding greater than 2 mm after full buccal segment eruption was complete. Of note, the majority of patients with higher levels of postlingual arch crowding presented

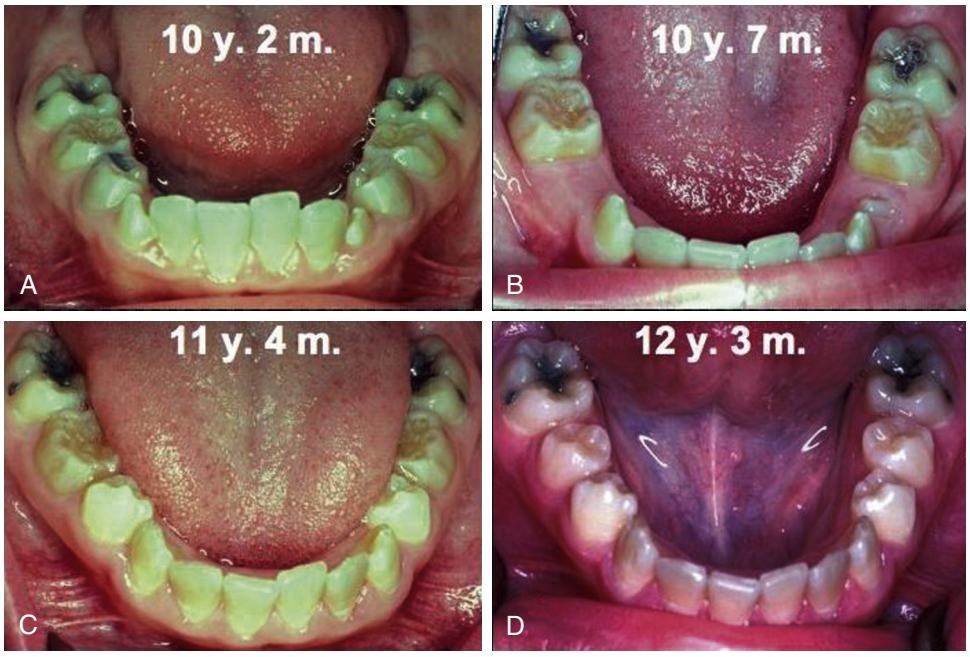

Figure 22-50 Eruption guidance with sequential disking and selective extraction of primary teeth. **A,** Pretreatment alignment with mesial eruption path of permanent canines to overlap incisors. **B,** Alignment at 5 months after elective extraction of primary first molars and disking of the mesial surfaces of the second primary molars. **C,** Permanent canines and first premolars have erupted in distal orientation with reduction in anterior crowding. **D,** After eruption of second premolars, good arch form is established, with overall adequate space and easily correctible minor rotations.

with initial ectopic loss of the lower primary canines. In sum, a passive lingual arch with selected removal of primary teeth provided adequate space and eruption guidance to relieve significant lower incisor crowding in 105 of the 107 individuals.

These studies consistently confirmed that arch length remains relatively constant or decreases minimally in patients treated with a passive lingual arch by reducing forward movement of molars and lingual movement of lower incisors. Timely treatment not only maintains arch length, but also allows for distal eruptive positioning of canines and premolars as a positive influence on relief of mixed-dentition crowding in the 2- to 4-mm range, enough to relieve lower crowding in about two thirds to three fourths of patients.

ERUPTION GUIDANCE IN THE MAXILLARY CANINE AND PREMOLAR SEGMENT

In the 7- to 8-year-old child, maxillary permanent canine positioning approximates the distal aspect of the root of the lateral incisor. This is associated with a normative distal tipping of the lateral incisor crowns under the fulcrum pressure of the canine at the lateral root area. The maxillary canine then normally deflects with a more vertical positioning toward the primary canine root area as eruption continues, with a concurrent more labial orientation of the canine. This labial orientation can be noted clinically by bulging in the vestibular aspect of the alveolar process. As resorption of the primary canine proceeds in normal patterns, the adjacent maxillary lateral incisor crown should tip mesially as vertical eruption of the permanent canine continues down the primary canine root length. With exfoliation of the primary canine, the maxillary permanent canines typically emerge with a slight labial orientation that tends to lingualize into the arch form as eruption proceeds under the balancing forces of the perioral tissues.

Given this tortuous and long journey, permanent maxillary canine eruption disturbances resulting in severe displacement and/or impaction are reported in 2% of the population, with females affected three times more frequently than males. As the final succedaneous tooth to erupt in the maxilla, mesiolabial displacement of the permanent canine is usually due to an arch length deficiency as the canine assumes whatever space is left over in the quadrant. In contrast to labial displacement, arch length deficiency appears to be less of a factor in palatal impactions, because 85% demonstrate adequate arch length in the involved quadrant. An etiologic factor in true palatal impactions may actually be excessive space in the canine area rather than a lack of arch length. When maxillary lateral incisors are absent, peg-shaped, or smaller than the lower incisors, palatally displaced maxillary canines are noted in approximately 40% to 45% of patients. When the ectopic permanent canine is close to the root of the lateral incisor, notable displacement of the incisor and idiopathic root resorption of the incisor may occur. The resorption is often difficult to diagnose because most of the lesions are located palatally toward the middle and apical thirds of the incisor, with the overlapping canine crown concealing radiographic visualization of the resorptive process. It has been reported that up to 12.5% of ectopic palatally positioned canines cause resorption of the adjacent incisors. In about half of the cases analyzed, the resorption extends into the pulp of the involved teeth, with the degree of resorption ranging from loss of one fourth of the root to almost complete loss of root structure. The actual percentage of resorption occurrence may be much higher than reported due to inherent limitations of the two-dimensional radiographs used by most clinicians.

Screening for potential displacement and impaction of maxillary canines should start at 10 to 11 years of age with clinical and radiographic examinations, to include evaluation of eruption trajectory, symmetry of positioning, status of root development, and orientation to the adjacent lateral incisor and primary canine. In cases of mesially displaced maxillary canines with overlap of adjacent permanent lateral incisor roots beyond age 10 years, timely removal of the adjacent primary canines, and often simultaneously the first primary molars, greatly enhances the possibility for more distal and vertical eruptive directions (Fig. 22-51). This timing coincides with when

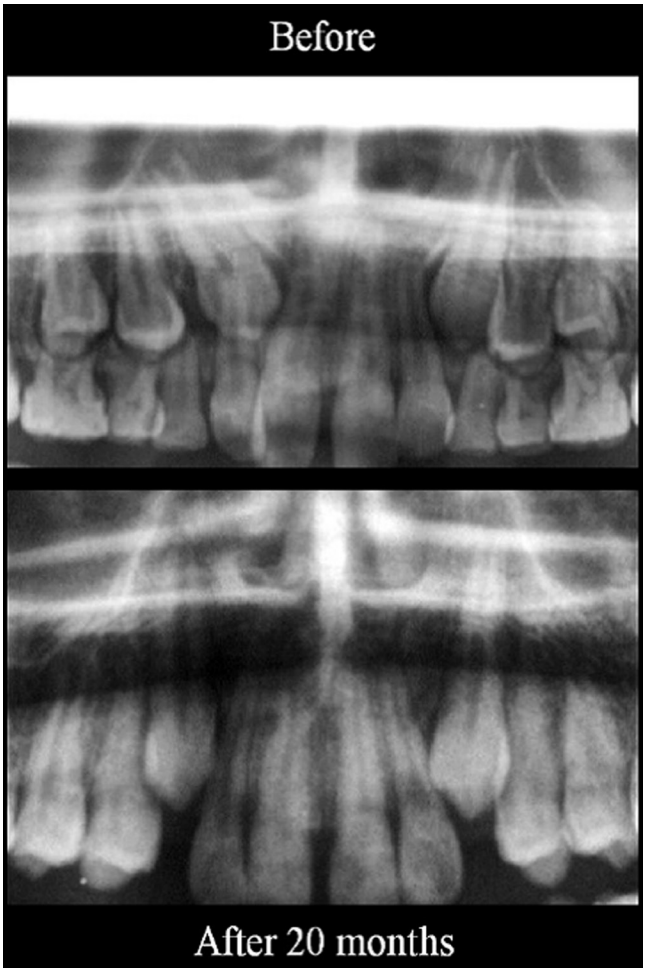

Figure 22-51 Example of bilateral impaction of the maxillary permanent canines corrected by bilateral extraction of the primary canines and first molars; before and after extractions. (Giulio AB et al: Double vs single primary teeth extraction approach as prevention of permanent maxillary canines ectopic eruption, *Pediatr Dent* 32:407-412, 2010.)

Dentlearn.ir

eruptive forces are optimal as the permanent canine attains approximately two-thirds root development. Once the apices of the canine are three-fourths or more formed, the eruptive force is reduced and the tooth will more likely have to be actively moved into the mouth. The clinical examination should involve palpation of the buccal aspect of the alveolar bone in the canine region slightly above the primary canine. A canine bulge should be evident, indicating the presence of the canine in a normal path of eruption at this stage of development. Although the presence of the buccal bulge does not necessarily preclude the possibility of impaction, the absence of such a clinical indicator by 10 to 11 years of age should warrant exploration. A major clinical clue to significant canine malpositioning involves excessive distal and labiolingual tipping of the lateral incisor crown. This suggests that the erupting canine is placing fulcrum-type pressure on the lateral root, "pushing" the root mesially to tip the crown in a distal direction. If the lateral crown is tipping labially, the permanent canine is probably displaced in front of the lateral root. If the lateral crown is tipping in a lingual direction, the canine crown is more likely to be displaced behind the lateral root. Other clinical signs include delayed eruption of the canine beyond 13 to 14 years of age, with prolonged retention of primary canines, and soft-tissue bulging either too high in the vestibule or palatally.

Radiographic evaluation of the maxillary canine area should be particularly emphasized when lateral incisor inclinations are pronounced (as noted before), when small maxillary (pegged) lateral incisors are present, when primary canines are not appropriately mobile, and when the eruptive bulging of the canines is atypical. Although excessive mesial inclination resulting in overlap of the canine crown with the lateral incisor roots, as observed on radiographs, may suggest potential impaction, this prognostic sign can be applied reliably only if the overlapping is present after root development of the lateral incisors is almost complete and the canine has attained approximately two-thirds root development (i.e., around 10 to 11 years of age). At that point, the degree of overlap of the canine crown with the lateral incisor root and the resorption pattern of the primary canine and first primary molars are key indicators for potential canine impaction and for the prognosis of successful interceptive guidance. Localization of the labial or lingual positioning of the tooth by special radiographic techniques is essential. (The procedure described in Chapter 2 helps in this localization.) Studies indicate that if the displaced permanent canine overlap of the adjacent permanent lateral incisor is not beyond the midline long axis of the lateral (still toward the "distal" half of the root), the chances for the canine repositioning and erupting into normal position after primary canine extraction show roughly 85% to 90% success. If the canine overlap is beyond the lateral incisor's long axis (toward the mesial half of the root or beyond), successful repositioning drops to approximately 60% of cases, with extraction of the primary canine.

Follow-up at 1 year after the primary canine extraction should find significant improvement in canine positioning. If not improved, the canine is probably positioned toward the palate and will require complicated treatment options, including surgical exposure with removal of obstructing structures to allow "hoped-for" passive eruption, surgical exposure with active orthodontic traction to move the tooth into position, autotransplantation of the impacted canine into the proper position, or extraction of the impacted canine and substitution by the first premolars. Surgical exposure that allows for natural eruption is dependent on the displaced tooth having a reasonable axial inclination and incomplete root development to achieve eruptive potential. When conditions for "passive" eruption are not met, an active approach involving surgical exposure followed by active orthodontic traction applied to the tooth may be necessary. Orthodontic traction involves complex biomechanical force parameters of direction, duration, amount, and method of activation in positioning the tooth, which are beyond the scope of our discussion.

Maxillary Anterior Diastemas

Parents are often concerned about anterior spacing that presents during eruption of the maxillary dentition. Unless there is a valid reason to intervene early, active treatment should be postponed until the complete eruption of the permanent canines, because anterior spaces often close spontaneously as the lateral incisors and particularly the permanent canines erupt. After the canines erupt, the condition can be reevaluated and appropriate treatment taken as needed. Figure 22-52 shows a patient whose parent wanted the diastema closed and was concerned about the high position of the canines. No treatment was begun. The 24-month follow-up image shows that diastema closed, with the canines in reasonably good alignment.

Valid reasons for early closure of excess maxillary spaces may be in consideration of atypical or asymmetric eruption patterns. Lateral incisors may be erupting lingually without sufficient space to be aligned labially into the arch. The maxillary incisors may be excessively flared and "splayed," with lip interpositioning that puts the teeth at risk for traumatic injury. Adjusting the symmetry of alignment, consolidating spaces, and retracting excessively proclined incisors may be indicated to facilitate long-term development. An extremely heavy labial frenum may prevent natural closure of a diastema. If orthodontic closure is advocated, it should occur before the frenectomy to reduce the chance of scar tissue impeding tooth movement. If there is sufficient arch space for the eruption of incisors and canines, it is best to delay frenum surgery until these teeth have fully erupted.

Supernumerary Teeth

Supernumerary teeth can be associated with delayed eruption of permanent teeth, overretention of primary teeth, deflection of roots with unusual inclinations, displacement of teeth, diastemas, abnormal root resorption, and formation of follicular or dentigerous cysts (Fig. 22-53). Occurring approximately eight times more frequently in the maxilla than in the mandible, supernumerary permanent teeth have been reported in up to 3.6% of children. The occurrence of supernumerary teeth in several members of the same family has been observed, indicating a familial pattern. The most frequent site is the maxillary

Dentlearn.ir

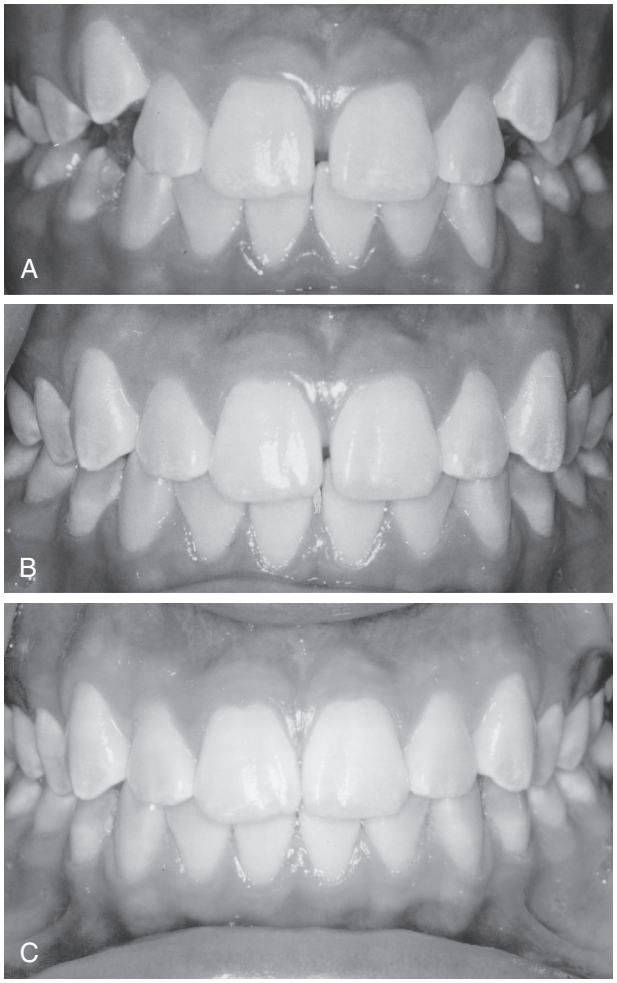

Figure 22-52 **A,** Patient with midline diastema and highly positioned canines. No treatment was instituted. **B,** Twenty-four months later, the diastema has closed significantly and the canines are erupting into a more favorable position. **C,** Thirty-six months later, the diastema has closed completely, and the canines have assumed a near-ideal position.

anterior segment, where atypically shaped accessory teeth of a conical tuberculated form, known as *mesiodens*, occur between the maxillary central incisors (Fig. 22-54). Reported in boys twice as often as in girls, 80% of mesiodens have a single occurrence, whereas 20% have two or more supernumerary teeth. The mesiodens usually presents a peg- or cone-shaped crown with a single root. More than 90% are palatally positioned. Approximately three of four mesiodens remain unerupted and commonly need surgical removal at some point during treatment because they often prevent eruption of adjacent permanent teeth or cause their ectopic eruption. Supernumerary primary teeth (Fig. 22-55) are apparently less common than supernumerary permanent teeth.

If a supernumerary tooth is identified through radiographic techniques (see Chapter 2), the decision whether to intervene surgically or keep the tooth under observation must be made. If the supernumerary tooth is not interfering with the symmetric development of adjacent teeth and there is no evidence of cyst formation, the

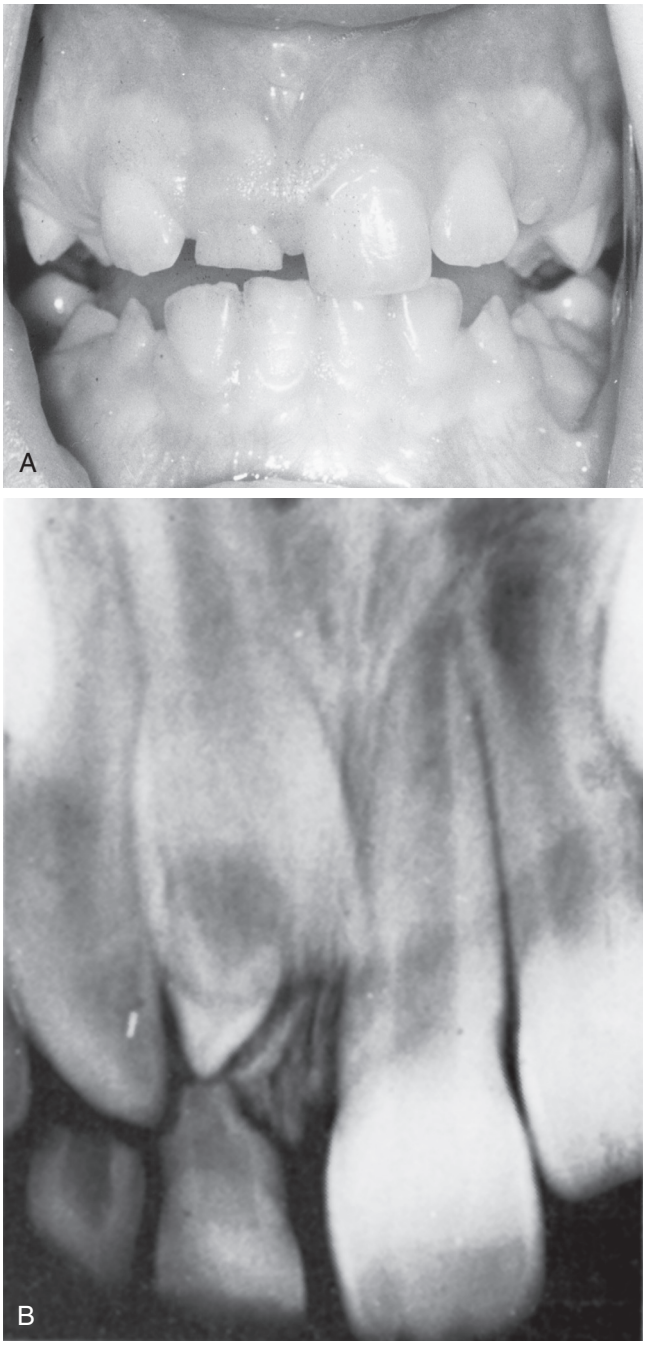

Figure 22-53 **A,** Patient with an unerupted maxillary permanent central incisor and retained primary central incisor. Permanent laterals are erupting. **B,** Radiograph shows a supernumerary tooth (mesiodens), which has delayed the eruption of the permanent incisor.

correct decision may be to observe the tooth until the child is old enough to better tolerate the surgical procedure. Watchful waiting until the development of the permanent incisors reaches approximately two-thirds to three-quarters root formation allows for less risk to the incisor development in the surgical procedures. Possible eruption of the supernumerary tooth and avoidance of surgical exposure are also potential benefits in delaying intervention. However, in the case of severe exfoliation

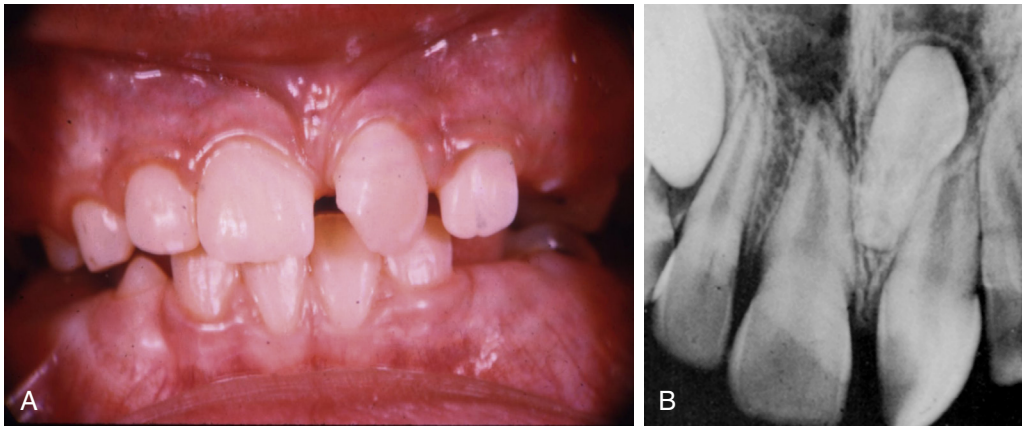

Figure 22-54 **A,** Rotation and labioversion of a maxillary central incisor with midline diastema. **B,** Radiographic assessment revealed a well-developed midline supernumerary tooth (mesiodens) with an inverted eruption path. Surgical removal of the tooth is indicated.



Figure 22-55 Supernumerary maxillary right primary lateral incisor positioned distal to the lateral incisor. There may be corresponding supernumerary permanent teeth. The teeth should be counted at the time of the clinical examination so that erupted supernumerary teeth will not be overlooked.

and eruption irregularities, earlier removal of a supernumerary tooth and the over-retained primary teeth may be desirable to lessen potential sequelae. The clinician must still consider the status of the adjacent permanent teeth and may prefer to wait until root development is preferably two-thirds established before surgically removing the supernumerary tooth.

When surgical removal is accomplished, exposure of the unerupted permanent tooth or teeth with provision

Reports suggest that up to 80% of permanent maxillary teeth will spontaneously erupt after the supernumerary is removed. During surgery, the bone and soft tissue should be removed from the incisal third of the tooth or teeth that are delayed in their eruption. If the permanent teeth are positioned extremely high, a prolonged period of watchful waiting may be necessary until they have migrated within the bone to a position that would allow for surgical intervention. An open pathway should be maintained, if possible, to hasten the eruption of the delayed tooth. A thin covering of dense scar tissue can delay eruption indefinitely. Ultimately, orthodontic treatment is often necessary to make adequate room for the unerupted tooth and to position it properly in the arch. Because of these considerations and the frequency with which supernumerary teeth are observed, radiographic surveys that include maxillary anterior views are essential for children at 5 to 7 years of age, to allow for early detection and planning.

Congenitally Missing Teeth

Studies have reported that congenitally missing permanent teeth (excluding third molars) occur in 2.3% to 9.6% of the population, with no significant gender differences. Oligodontia affects two or more teeth in about one half of cases, frequently in a symmetric pattern involving antimeres. The most frequently missing permanent teeth are third molars (one to four wisdom teeth are absent in up to one third of the population), mandibular second premolars, maxillary lateral incisors, and maxillary second premolars. Morphologic changes such as cone-shaped teeth are characteristically seen in association with missing permanent teeth—agenesis and peg-shaped maxillary lateral incisors approximate a 1:1 ratio. The congenital absence of primary teeth has a much lower prevalence than does absence in the permanent dentition. The prevalence of missing primary teeth ranges between 0.1% and 0.7%, with absence usually located in the maxillary or mandibular incisor areas. When several primary teeth fail to develop, other ectodermal deficiencies are usually evident (e.g., ectodermal dysplasia). If the absence is localized to only one or two primary teeth, no specific treatment is generally needed. However, the long-term implications are significant because the analogue of the permanent tooth is derived from the primary tooth bud. Therefore a missing primary tooth almost always means that the associated permanent tooth will be missing, with attendant occlusal factors.

The management of congenitally missing permanent teeth requires a thorough evaluation of arch length, occlusion, and facial growth patterns, given the long-term consequences to aesthetic and functional arch alignment in terms of which specific tooth is missing, adjacent teeth



Figure 22-56 Surgical removal of supernumerary incisors with uncovering of blocked permanent incisors allows for normative eruption positioning of the involved incisors. **A,** Radiograph showing two mesiodens associated with retained primary central incisors and delayed eruption of permanent central incisors at age 9 years and 6 months. The primary incisors were extracted at this time. **B** and **C,** Same patient at age 11 years and 10 months. **D, E,** and **F,** Surgical removal of two mesiodens with uncovering of unerupted incisor. **G,** One week after surgery. **H** and **I,** Same patient at age 13 years and 1 month. One year after surgical uncovering, no orthodontic appliances.

drifting into the space, the distribution of the space, and supraeruption of opposing teeth. Early consultation with the orthodontist and prosthodontist is important in determining appropriate care. If one or both of the permanent maxillary lateral incisors are missing, the dentist must decide whether to hold space for prosthetic replacements or to encourage the permanent canine to erupt mesially into the lateral incisor position. In the latter instance, the mesial eruption path of the adjacent permanent canines may erupt fully forward into the lateral space and naturally compensate for the missing lateral incisors. This pattern of "canine replacement" is particularly beneficial when the patient presents with excessive maxillary overjet and dental protrusion or a significant tooth size discrepancy that would benefit from an extraction protocol. Consolidation of the maxillary arch form with canine "replacement" leads to reduction of the protrusive overjet and compensation for a tooth mass discrepancy. Orthodontic treatment is generally needed to place the canine in the correct axial inclination before the crown is reshaped to resemble the lateral. In some instances, the shape of the canine may not be favorable to use as a lateral, even with extensive recontouring. In contrast, a patient with Class I or Class III relationships and more normal alignment spacing usually benefits from having the canines in their normal A-P positions and restoration of the missing lateral incisors with prosthodontic treatment (Fig. 22-57). If the canines are erupting too far forward from their normal positions in this case, timely removal of the primary canines may enhance a more distal eruption path toward normal canine positions. However, with the advent of implants for replacement of lateral incisors, that recommendation has changed. According to Kokich,[55] the ideal situation is to encourage the canine to erupt adjacent to the permanent central incisor. After it has erupted, it can be moved distally into its normal position. By distal movement of the tooth, bone is maintained in forming an alveolar ridge with adequate buccal lingual width to facilitate proper implant placement.

When one or more permanent premolars, usually the second premolars, are congenitally missing, should the space be maintained for fixed prostheses later or should it be closed? Many factors influence the decision whether to retain or extract the overlying second primary molar,

Dentlearn.ir

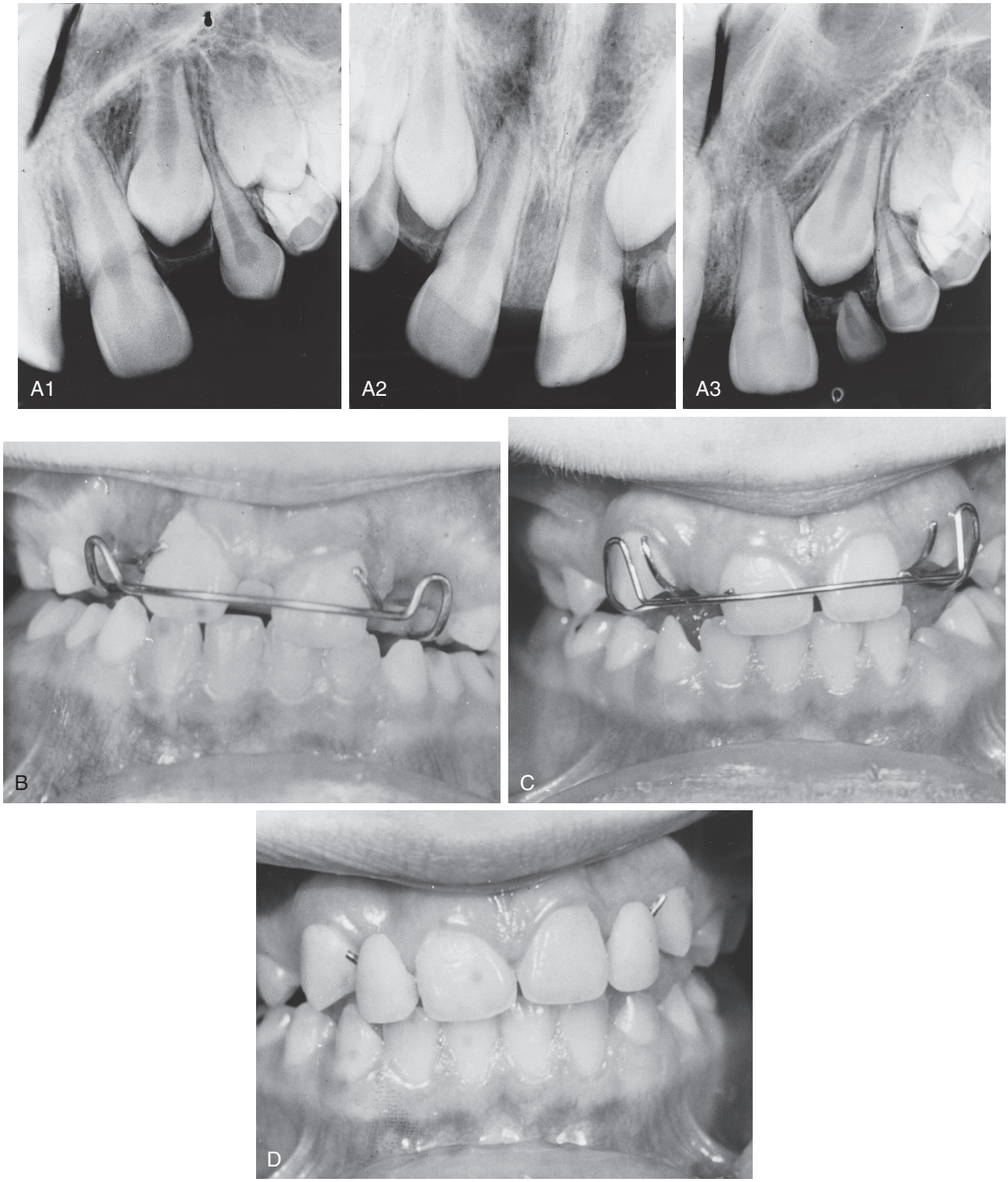

Figure 22-57 **A,** Congenital absence of permanent lateral incisors shown on periapical radiographs. **B,** The primary canines were extracted to encourage a more distal eruption path of the permanent canines. A Hawley-type appliance with springs was constructed to close the diastema between the central incisors. **C,** Auxiliary wires were added to the appliance to guide the permanent canines into a more favorable position. **D,** Space has been regained for eventual fixed prostheses to replace the lateral incisors. Meanwhile the removable retainer with lateral pontics is worn.

including the degree of arch length deficiency, facial and skeletal patterns, molar relationships, vertical aspects of the malocclusion, anteroposterior incisor positioning, and stage of transitional dentition. For example, if just one premolar is absent and the rest of the occlusion is aesthetically and functionally sound, long-term retention of the primary molar is usually encouraged until growth is complete and prosthodontics can be used to replace the missing premolar. However, the larger mesiodistal width of the primary molar may cause incorrect occlusal relationships with the permanent teeth. Slicing the mesial and/or distal surfaces of the primary molar may allow for improved interdigitation, but often the bulbous, divergent roots of the primary molar prevent mesial movement of the permanent molar. Also, the roots of the primary molar may be resorbed, and the tooth may be lost eventually. To summarize, if the primary molar is maintaining vertical occlusion and arch length stability, then it should be retained for alveolar bone integrity and to allow for future implant prosthetics. An exception would be in a child with a significant tooth size–arch size discrepancy where a serial extraction protocol would provide successful aesthetic and functional outcomes. Early extraction would provide positive alignment factors without compromising long-term results because later orthodontic tooth movements will bring alveolar bone support.

The general concept of the primary molar being maintained when the underlying premolar is missing applies except when the retained primary molar exhibits significant ankylosis. Restorative coverage (i.e., composite buildups, stainless steel crowns) of the ankylosed primary molar may help maintain occlusal harmony if the vertical discrepancy is not extreme. In most cases, however, early extraction of the affected primary molar may enhance occlusal outcomes by avoiding excess vertical collapse and the loss of alveolar bone height that occurs secondary to early ankylosis. Even in cases of ankylosed second primary molars over missing premolars where future prosthetic replacement is planned, early extraction of the primary molar may be advisable. The consequence of leaving severely displaced ankylosed primary molars when the premolars are absent will likely result in vertically compromised alveolar heights of adjacent teeth, because there is no erupting premolar to maintain alveolar ridge integrity. For these reasons, the early extraction of ankylosed second primary molars when the second premolars are congenitally absent should be an early treatment planning decision and is usually desirable. If such teeth are extracted early, the majority of alveolar ridge reduction secondary to the extraction will occur in the first year after removal, will represent about an overall one-third loss in width, and is not progressive. Adjacent tooth movements usually maintain adequate alveolar width for subsequent implant placement and establish better arch length adjustments for proper occlusion. Planning must also consider whether to hold the space for future prosthetic replacement or allow "driftodontics" to start closing the space of the missing premolar. Early extraction is particularly indicated if the case can be handled long-term with a premolar extraction protocol and where multiple premolars are absent symmetrically. Given long-term considerations, the treatment options available, and the multiple disciplines potentially involved, the clinician must take the lead role in coordinating treatment and utilizing the expertise of specialists.

OBSTRUCTIVE SLEEP APNEA AND ORTHODONTICS

An evolving area of interest to dentistry is the management of obstructive sleep apnea in children. While the etiology for obstructive sleep apnea is multi-factorial, it seems clear that moderate to severe mandibular retrognathia may play a significant role for some patients. While orthodontic interventions are not mentioned in the 2012 American Academy of Pediatrics Guidelines for Diagnosis and Management of Childhood Obstructive Sleep Apnea Syndrome, they are considered by some sleep medicine experts to be an alternative treatment option.[56]

As discussed by De Luca Canto and colleagues, sleep-disordered breathing is of significant relevance to practicing dentists because it has been associated with a variety of oral and craniofacial problems including chin retrusion, Class II malocclusion, vertical growth direction, and sleep bruxism.[57] While it seems clear that dentistry has an opportunity to contribute in this significant problem area for children, comprehensive diagnosis and management are more than just placement of mandibular advancement appliances, such as those described in the following section. Therefore it seems reasonable that the team approach—involving a pediatrician, dental practitioners, sleep disorder centers that can provide definitive diagnostic techniques such as a polysomnogram, and others—is important to ensure that the problem is diagnosed and managed appropriately.

COMPREHENSIVE ORTHODONTICS FOR THE DEVELOPING OCCLUSION

Comprehensive orthodontics can be defined as an in-depth evaluation of a patient's entire orofacial complex and the corrective treatments necessary to achieve optimal dental aesthetics, facial aesthetics, skeletal balance, and functional harmony. Comprehensive orthodontic treatment recognizes more broadly based malocclusion factors than those cited in interceptive orthodontics and guidance of eruption. Diplomates of the American Board of Orthodontics (ABO) listed the correction of skeletal Class II and Class III malocclusions, excess vertical development, and severe tooth size–arch size discrepancies presenting displaced permanent teeth as complex problems indicated for comprehensive levels of early treatment intervention.[58] The achievement of functional and aesthetic harmony requires the coordination of a multitude of factors, from the fine details of tooth positioning to the relationships of the maxilla and mandible. Since "normality" encompasses a variable range, the fundamental goals of comprehensive orthodontic management of the occlusion may be delineated as the possession of:

1. *Dental aesthetics*. The tooth alignment and arch form are generally consistent with orthognathic Class I molar positioning, normal anterior overbite and overjet,

Dentlearn.ir

integrity of dentitional alignment, and symmetric arches positioned over basal bone. The details of these dental aesthetic descriptors are best defined in the context of the "six keys of occlusion," as delineated by Andrews,[59] to include proper molar relationship, proper crown angulation and inclination, no rotations, tight contacts, and a flat occlusal plane.

2. *Facial aesthetics*. Balanced facial profile and frontal symmetry with harmonious relationships among the jaws, teeth, and soft tissues are realized within the context of normal facial developmental patterns relative to patient age, ethnic/racial differences, and growth patterns.
3. *Optimally functional occlusion*. The interplay of gnathologic factors allows for comfortable and efficient actions of the orofacial components in a harmonious neuromuscular environment without deleterious stress on the teeth, periodontal structures, and temporomandibular joints.
4. *Stability of occlusion*. When applied to postorthodontic treatment, the interrelationships of the teeth, jaws, and soft tissues should not only meet the aesthetic and functional goals of treatment but also be sustained with long-lasting stability and retention of achieved goals.

Comprehensive orthodontic treatment usually requires complete fixed Edgewise appliances to achieve final positioning of all or nearly all of the permanent teeth into optimal aesthetic and functional harmony within the alveolar basal bone. If a practitioner decides to initiate comprehensive levels of orthodontic care, it is important that he or she accept responsibility to provide the treatment to full completion standards. It is not appropriate to provide only one phase of treatment with the intention of referring the patient for the final and definitive phases of care unless the separate treatments were predetermined between consulting providers. If the practitioner recognizes the need for, but is unwilling or unable to provide, comprehensive care, it is appropriate to refer the patient to a practitioner able to address all of the orthodontic needs.

The interventions necessary to achieve comprehensive goals may be accomplished in one single phase or in specifically planned phases of treatment. To determine the approach in most patients, the preferred time for evaluating comprehensive orthodontic needs and implementing treatment is from the transitional mixed dentition into the young permanent (adolescent) dentition. The ABO Diplomates have stated that there are numerous advantages for both the patient and the practitioner in terms of early orthodontic treatment and, importantly, that the final results of early treatment tend to be better. The basis for these statements lies in the fact that the clinician has the ability, with mixed-dentition timing, to control arch length adjustments in terms of leeway space and late mesial molar shifts for the relief of most levels of crowding, to utilize space-gaining and arch-expansion procedures in reducing extraction needs, to control incisor and buccal segment eruption patterns for adjustments in overbite, open bite, and leveling of the curve of Spee, to control deleterious habits and functional deviations in occlusion, and to use growth modification with dentofacial orthopedics for skeletal discrepancies. Most of the January 1998 and June 2002 issues of the *American Journal of Orthodontics and Dentofacial Orthopedics* are dedicated to a broad range of topics related to the rationale for common procedures used in early orthodontic treatment. These issues serve as excel-

A convenient way to look at comprehensive orthodontics in the context of "early" treatment is to relate it in terms of the developmental stage of the dentition. The dental stages in which comprehensive treatments are considered for growing patients involve the full primary to the mid-mixed dentition through transitional eruption of the first molars and incisors (4 to 10 years of age), the mid- to late mixed dentition overlapping the transition of the buccal segments (10 to 12 years of age), and the early permanent dentition (12 to 16 years of age). The general scope of interceptive orthodontic interventions in these stages is outlined earlier in this chapter. They serve as a focus for the presentation of case examples that illustrate the more comprehensive treatments necessary to address more complex needs in growing patients.

PRIMARY TO MID-MIXED DENTITION (AGES 4 TO 10 YEARS)

If not corrected early, abnormal dental, skeletal, and functional relationships that are notable in the primary dentition may have profound effects on orofacial growth patterns. They can become increasingly difficult to correct as the child transitions toward the permanent dentition. Some of the more significant problems that can be treated effectively in the primary dentition involve functional and bilateral posterior crossbites along with deleterious oral habits. As illustrated in earlier sections, significant orthodontic and orthopedic changes can be affected with various "interceptive" appliances in this period. A further example of primary dentition intervention that potentially extends into more comprehensive concepts is shown in Figure 22-58 with correction of a pseudo-Class III malocclusion. Without such early treatment, the functional aspects of the malocclusion could carry over into much more complex skeletal problems, as growth continues to compensate for the deviations. It is not necessarily the intent of an early-phased treatment to prevent the need for full Edgewise appliances in the permanent dentition. The goal is to establish normal vertical, transverse, and sagittal relationships of the dentition with functional perioral balance. However, as illustrated in this interceptive case, it is possible to establish such a harmonious relationship of the dental units that further treatment is unnecessary. Such an outcome is also illustrated in Figure 22-59, where more involved early treatment mechanics were used. Each of these cases supports the idea that the real goal of such treatment in developmental stages should be to minimize or eliminate the amount of orthodontic treatment needed in the permanent dentition, with more ideal outcomes. The remaining cases presented involve just such comprehensive treatments, where Edgewise appliances were used to finish the treated occlusion toward optimal functional and aesthetic outcomes.

Dentlearn.ir

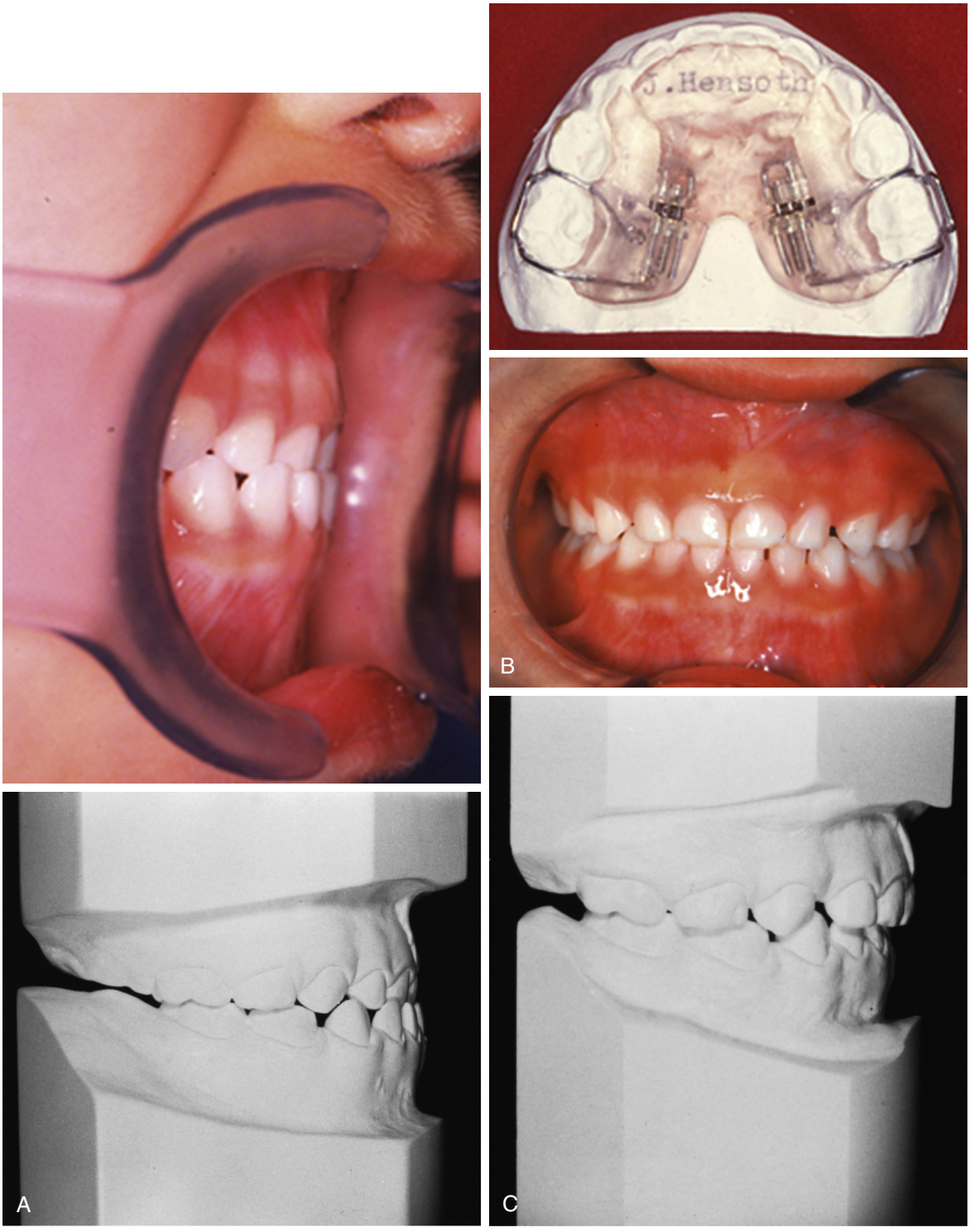

Figure 22-58 Primary dentition anterior crossbite with functional shift of mandible. **A,** Pretreatment clinical and model view of occlusion. **B,** Anterior sagittal appliance designed to labialize the primary incisors. **C,** Posttreatment clinical and model view of occlusion.

Correction of Class II skeletal relationships in the primary and early-mixed dentition stages with functional appliances and extraoral headgear has been reported in the literature. In contemporary practice, however, Class II malocclusions are generally managed from the mid- to the late mixed dentition, extending on into the young permanent dentition, with positive outcomes. This later timing coincides with the pubertal growth period for enhanced dentofacial orthopedics and the transition of the buccal dentition to optimally affect sagittal dentoalveolar corrective changes. In addition, later timing simplifies retention considerations of any

achieved correction by reducing the time between the early treatment phase, the full Edgewise phase, and the completion of growth. In contrast, skeletal Class III relationships should ideally be addressed in the primary and incisor transition periods to establish normative overbite and overjet relationships into the mixed and permanent dentitions. Class III corrections in this time frame have been consistently shown to present efficient and effective treatment outcomes compared with later treatment timing. This particularly applies if the Class III pattern involves a retruded maxillary complex as the causative factor or if the anteroposterior discrepancy is the result of a functional anterior displacement of the mandible (pseudo-Class III). If the major component of the Class III pattern is a severe skeletal overgrowth of the mandible, attempts at correction are more variable and often require retreatment as the lower jaw outgrows the correction. This is especially true if there is a strong genetic/familial component to the mandibular prognathia.

Vertical growth abnormalities can also be successfully managed in this early transitional period. Patients with

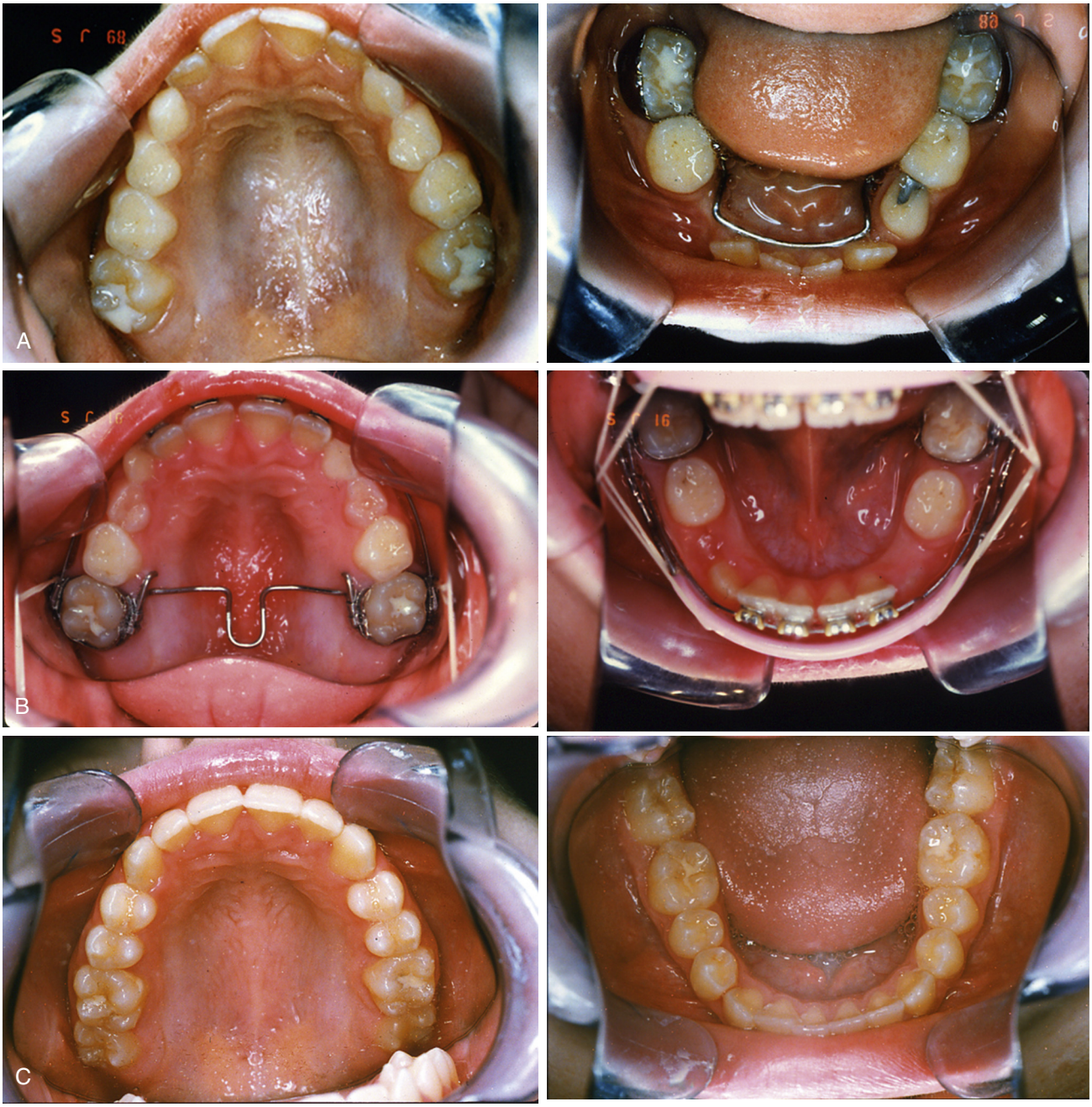

Figure 22-59 Patient treated with phase I orthodontics only. **A,** Pretreatment occlusal views; note tapered maxillary arch and arch length insufficiency in the mandibular arch. **B,** Phase I treatment with fixed 2 × 4 Edgewise appliances, maxillary transpalatal bar, and mandibular lip bumper. Note arch length development, particularly in the lower arch. **C,** Posttreatment occlusal views in permanent dentition without additional full Edgewise bracketing.

deep overbites and a horizontal growth pattern (low mandibular plane angle) may benefit from a removable anterior bite plane to allow for supraeruption of the posterior dentition.

Because the permanent incisors and first molars have erupted by ages 8 to 9 years in both arches, fixed Edgewise appliances can be placed in a segmental fashion to accomplish specific dental orthodontic movements. Molar-to-incisor bracketing treatments (2 × 4 setup) generally last 6 to 12 months and are designed to correct severe and detrimental displacements in establishing normative overbite and overjet of the incisor segments. After the 2 × 4 mechanics, the patient is typically placed in a resting retention phase until full eruption of the permanent dentition is established around ages 12 to 13 years. A first-phase approach involving a 2 × 4 setup with a transpalatal bar for anchorage to help correct a Class II division 2 deep-bite malocclusion at age 9 years and 4 months is presented in Figure 22-60. Lower arch development was enhanced with a mandibular lip bumper during the upper retention phase. Full Edgewise appliances followed in the permanent dentition to finalize alignments (age, 12 years and 10 months).

MID- TO LATE MIXED DENTITION (AGES 10 TO 12 YEARS)

Given that the majority of patients present with Class I skeletal relationships and that any malocclusion requiring treatment most likely involves crowding, the incorporation of space supervision concepts with the control of leeway space is a major component of treatment

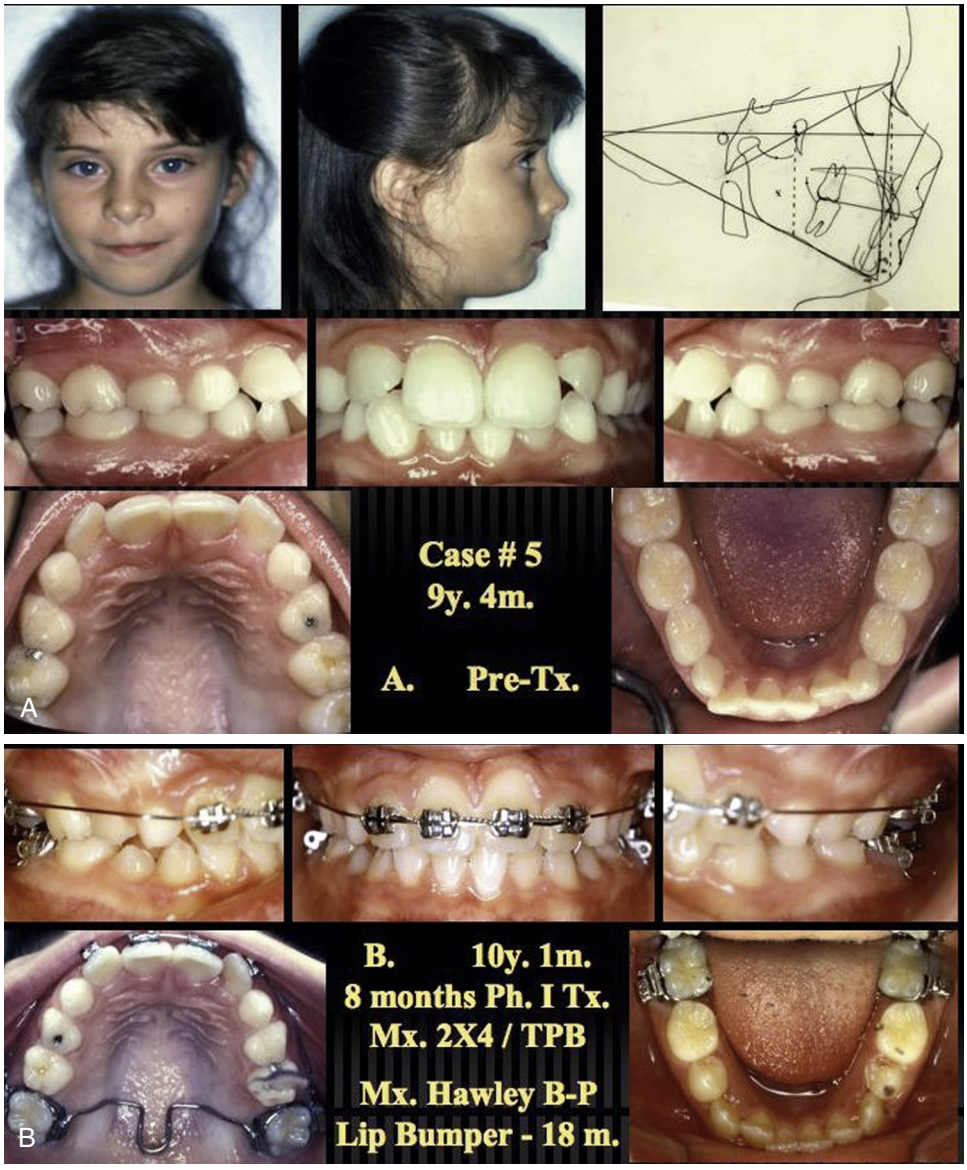

Figure 22-60 **A,** Class II division 2 deep-bite malocclusion in a child aged 9 years and 4 months with mesofacial growth pattern, retrognathic mandible, ANB = +6 degrees, moderate incisor crowding. **B,** A maxillary 2 × 4 with a transpalatal bar was used along with a mandibular lip bumper for 8 months of phase I treatment. The upper was retained with a Hawley bite plane; the lip bumper was continued for an additional 18 months.

Continued

Dentlearn.ir

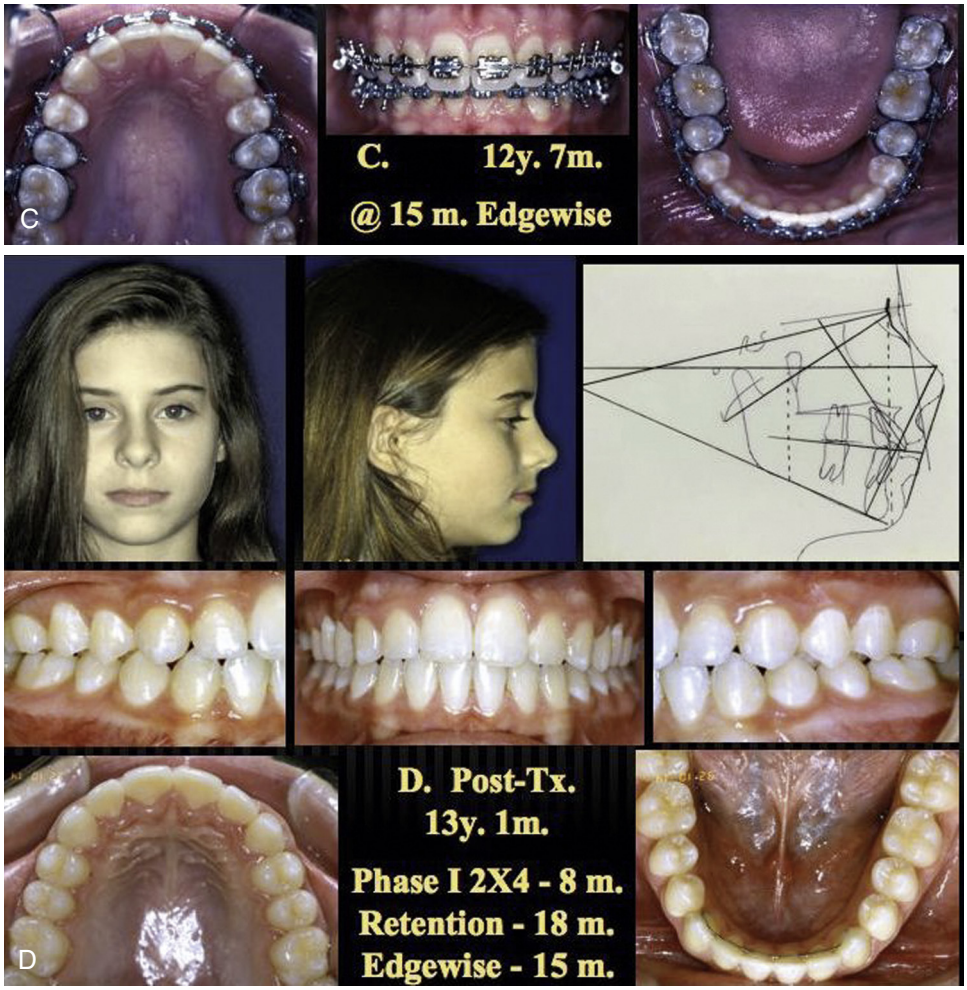

Figure 22-60, cont'd **C,** Patient started second Edgewise phase that continued for a total of 15 months until age 12 years and 7 months. **D,** Final records obtained 3 months after removal of Edgewise appliances at age 12 years and 10 months.

in the late mixed dentition. Addressed in a sequential consideration of guidance in an earlier section of this chapter, Figure 22-61 illustrates the value of a mandibular lingual holding arch in the relief of lower anterior crowding at 11 years and 8 months of age in controlling leeway space. Class I molar relationships were maintained with the lingual arch and selective primary extractions over 18 months of space supervision. Seventeen months of full Edgewise appliances completed the alignment (15 years and 5 months).

Patients who present with skeletal Class II malocclusions often benefit from dentofacial orthopedics involving directed extraoral headgear mechanics and/or mandibular advancement (functional) appliances during the late mixed dentition period. The growth modification appliances, timed with pubertal growth, enhance maxillary to mandibular skeletal and dental relationships in preparation for full Edgewise appliances to finish and detail final alignment.

Mid- to late dentition treatments in managing the occlusion, with full Edgewise appliances to follow in the permanent dentition, typically involve:

Space supervision. To hold lower leeway space (lingual holding arch), hold upper leeway space, and derotate permanent first molars (transpalatal bar).

Expansion appliances. Transpalatal arch bars, Hyrax, lip bumpers.

Fixed Edgewise appliances and archwires. Banded molars and bracketed incisors for 2 × 4 mechanics. Allows for molar derotation and uprighting, incisor leveling, incisor alignment, and incisor protraction or retraction.

Extraoral headgear. Directed cervical-pull, high-pull, or protraction reverse-pull headgear applications, with selection dependent on the vertical and sagittal facial growth patterns as well as the stage of development. Often used with anterior bite planes.

Functional appliances. Removable (e.g., Bionator) and fixed (e.g., Herbst) mandibular advancement appliances serve as examples of many options for Class II problems. Reverse-pull facemasks and maxillary and mandibular miniplates with orthopedic traction are examples for Class III problems. The type of functional appliance and its design vary significantly depending on the facial growth pattern.

Selected extractions. Timely removal of both primary teeth and selected permanent teeth in guidance

Dentlearn.ir

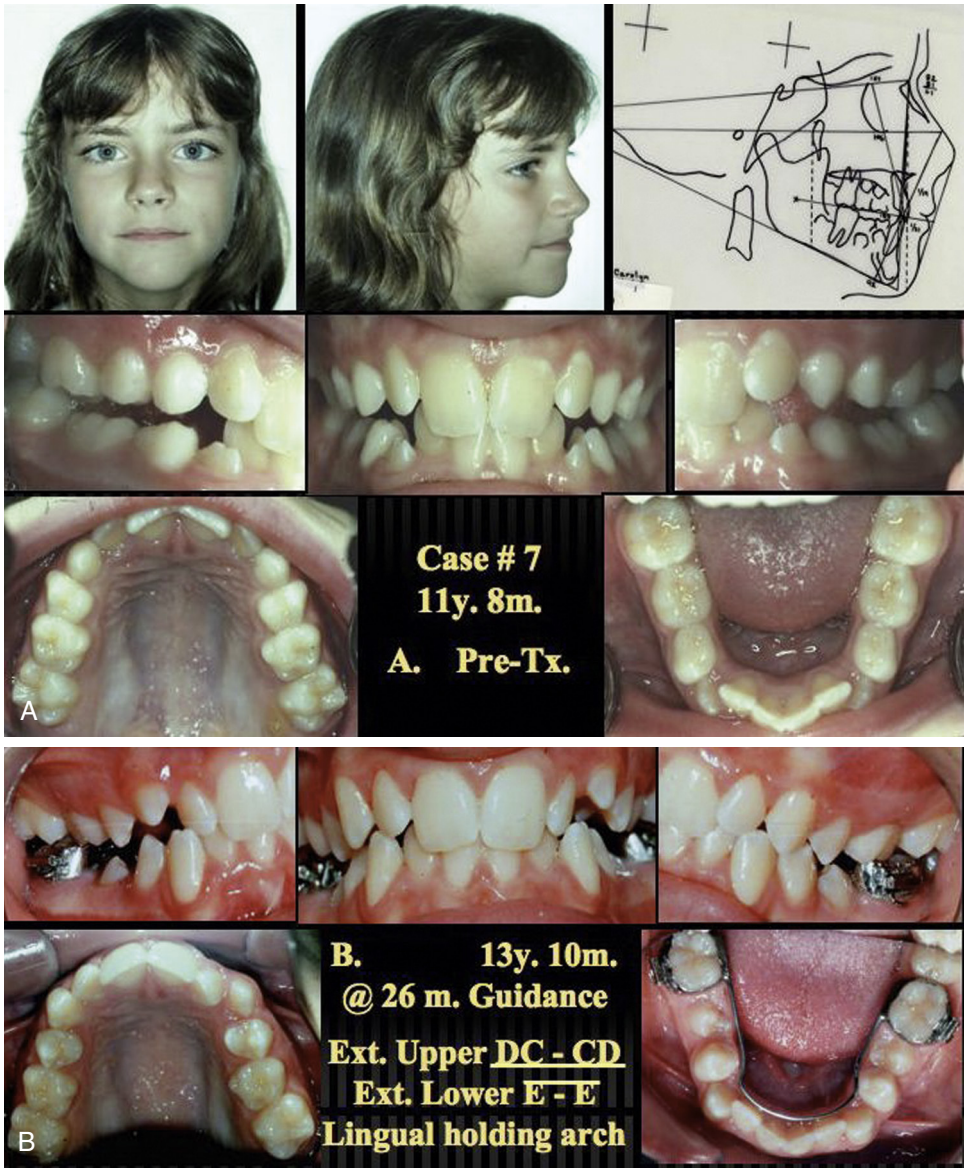

Figure 22-61 **A,** Class I mixed dentition in a patient aged 11 years and 8 months with notable anterior crowding, delayed dental developmental timing, mesofacial growth pattern, and bilateral ankylosed lower primary molars. **B,** Patient at age 13 years and 10 months after 26 months' guidance with selective extraction of upper primary canines and first molars, lower first and second primary molars, and passive lingual holding arch.

Continued

and serial extraction protocols optimizes the use of available space. The patient's diagnosis influences which "early" treatment modalities would be appropriate. One pervasive philosophy in early orthodontic treatment is that the simplest biomechanics necessary to achieve the desired treatment outcome is the best.

EARLY PERMANENT DENTITION (AGES 12 TO 16 YEARS)

Comprehensive orthodontic care in the adolescent permanent dentition again includes both orthopedic and orthodontic components. Orthopedic components might involve continued applications of palatal expanders, headgears, and functional appliances. Figure 22-62 illustrates the correction of a Class II malocclusion with a functional appliance in the permanent dentition. An activator for mandibular advancement worn in combination with a high-pull headgear for restraint of maxillary growth addressed the skeletal Class II problem. The orthodontic component included full fixed Edgewise appliances to establish occlusal relationships as near to "ideal" as possible. Extraction of a single maxillary first premolar was used in the full Edgewise phase to camouflage the midline asymmetry in finishing with a good buccal occlusion.

Localized tooth displacements such as maxillary canine impactions and significant genetic tooth size–arch size discrepancies not manageable with space supervision procedures are also commonly addressed in this period.

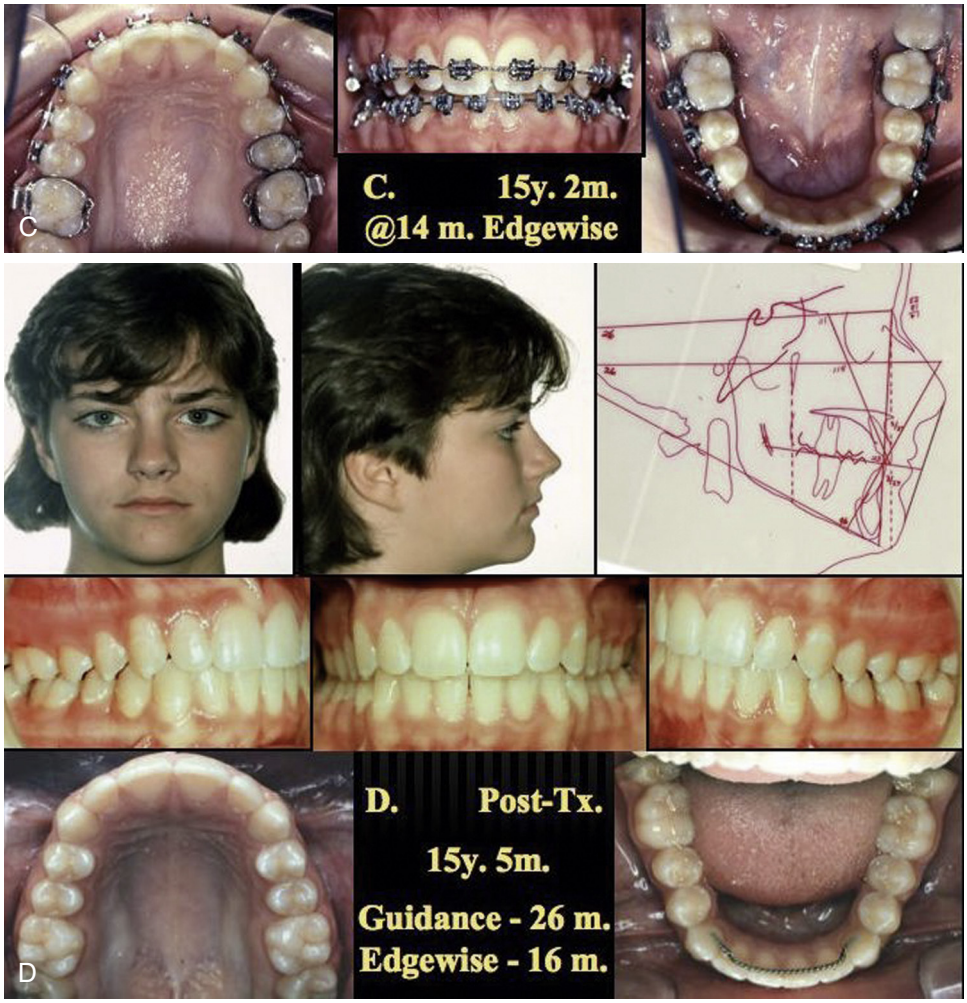

Figure 22-61, cont'd **C,** Full upper and lower Edgewise appliances were used for a total of 15 months. **D,** Final records obtained after removal of Edgewise appliances at age 15 years and 5 months.

The removal of selected permanent teeth in cases of significant tooth size–arch size discrepancies with severe tooth displacements or to camouflage Class II or Class III dental malocclusions often offers good options as part of a comprehensive treatment plan.

If a patient has undergone an earlier phase of treatment successfully, the Edgewise phase of treatment might take as little as 12 to 18 months and, it is hoped, will involve few, if any, orthopedic needs. However, if this is the start of comprehensive care, more treatment time will likely be needed. Treatment with full Edgewise appliances includes leveling and alignment of the dentition, space consolidation, transverse coordination of upper to lower arch forms, sagittal arch coordination (Class II or III elastic wear), establishment of root parallelism over basal bone, finishing and detailing of intra- and interarch positioning (i.e., first-, second-, and third-order archwire bends), and buccal or anterior segmental finishing procedures to establish maximum interdigitation between arches. In selected patients, the Edgewise treatment may be more limited, unnecessary as determined by the dental practitioner, or unwanted as determined by the patient and/or parent. Limited treatment can involve segmented arch therapy in which only the teeth or arch needing attention is addressed. Occasionally the practitioner may be so satisfied with the result after an earlier phase that no further treatment is recommended. However, this is fairly uncommon. A more likely occurrence is that the patient and/or parents decide that they are satisfied with the result, even though some finishing details are needed. It is critical to stress to parents before initiating early treatments that most children will benefit from a final period of full orthodontic appliances (phase II) to optimize aesthetic and functional outcomes. It is particularly important to allow for final tooth positioning of the permanent second molars.

Retention following the definitive stage of comprehensive Edgewise treatment should involve the philosophy of "retention for a lifetime." There are many different types of retention schemes. Although no perfect retention scheme has been developed and periodic observation is warranted for all, the following retention schedule seems to provide for stable results:

Dentlearn.ir

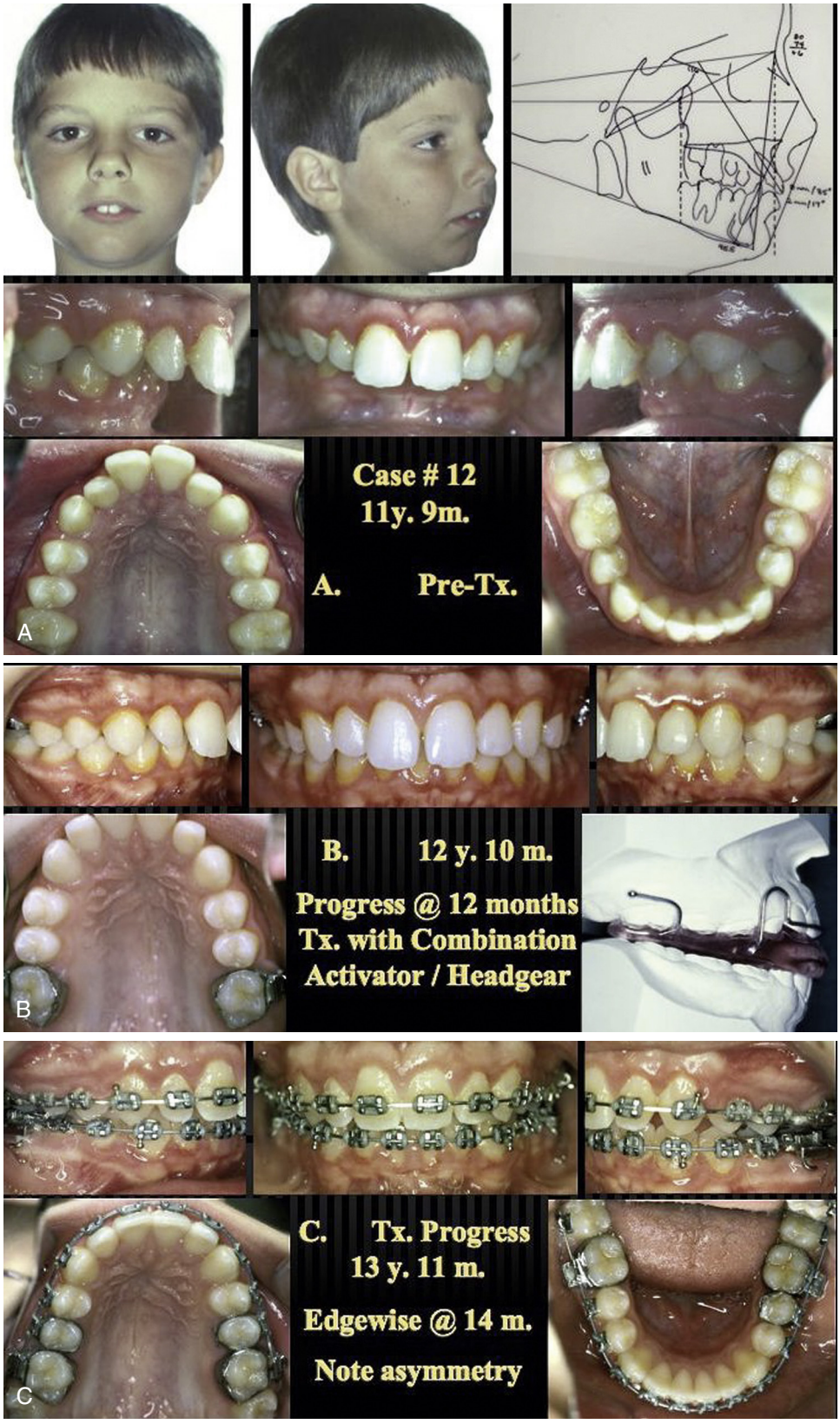

Figure 22-62 **A,** Class II division 1 mixed dentition with convex profile, lip interpositioning, mesofacial growth patterns, ANB = +10 degrees, mandibular retrognathia, and maxillary dental protrusion in a patient aged 11 years and 9 months. **B,** Patient after 12 months of wearing a mandibular functional advancement appliance (i.e., Activator) and cervical-pull headgear in combination with following a regimen of 12 to 14 hours of wear per day. **C,** Patient started full Edgewise phase at age 12 years and 10 months. The treatment progress at 14 months of Edgewise use illustrates midline asymmetry with Class I right and Class II left buccal occlusion.

Continued

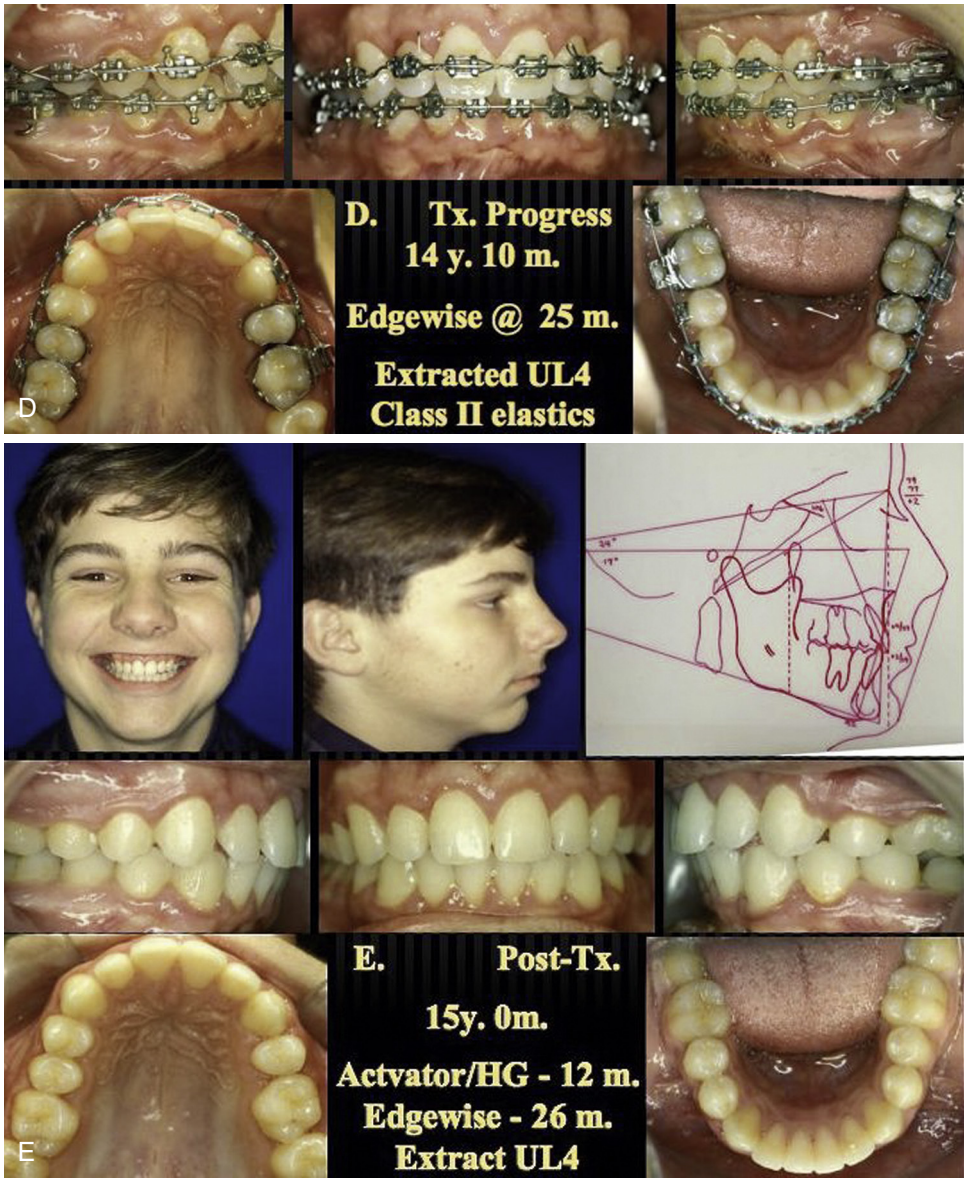

Figure 22-62, cont'd **D,** Treatment progress at 25 months of Edgewise treatment illustrates midline symmetry attained in conjunction with selective extraction of the upper left first premolar. **E,** Final records obtained at age 15 years and 0 months after 12 months of growth modification and 26 months of Edgewise appliances.

1. Maxillary and mandibular Hawley retainers worn 24 hours a day for 4 to 6 months, followed by 6 to 8 months of at-night-only wear.
2. After 1 year, reassess if wear can be reduced to 1 or 2 nights per week with the patient increasing wear as needed if the retainers become tight from tooth movement.
3. Continue wear as above for "retention for a lifetime" or, at an absolute minimum, until age 21 years, at which time the craniofacial growth rate has been reduced to that of an adult.

The use of a backup set of thin acrylic overlay retainers is a useful way of inexpensively giving the patient an emergency set of retainers if the Hawley retainers are lost or damaged. As an added benefit, they can be used for home bleaching of the teeth for those patients who are interested. Fixed retention may be necessary in special circumstances. A lower canine-to-canine fixed, bonded wire can be helpful for severe rotations, and an upper lateral-to-lateral fixed, bonded wire is useful to prevent space opening for patients with initial diastemas.

One final thought that seems of particular interest to parents regards the effect of extraction of third molars on late lower incisor crowding. Although more studies will be necessary to corroborate the results, a nicely done prospective randomized controlled clinical trial of orthodontic patients who had early extraction of third molars vs. those who did not showed no clinically significant difference in incisor crowding between the two. The authors concluded that removal of third molars to reduce or prevent incisor crowding was not justified.[60]

Dentlearn.ir

REFERENCES

1. American Academy of Pediatric Dentistry. Reference manual: Guideline management of the developing dentition and oc-

   Policies_Guidelines/G_DevelopDentition.pdf, accessed September 1 2014.
2. Ngan PW, et al.: Orthodontic treatment in the primary dentition, *J Am Dent Assoc* 116:336–340, 1988.
3. Moyers RE: *Handbook of Orthodontics*, ed 4, Chicago, 1988, CV Mosby.
4. Baume LJ: Physiological tooth migration and its significance for the development of occlusion, *J Dent Res* 29: 123-132(331-348): 440–447, 1950.
5. Moorrees CFA: Growth changes of the dental arches: a longitudinal study, *J Can Dent Assoc* 24:449–457, 1958.
6. Moorrees CFA: *Dentition of the Growing Child*, Cambridge, 1959, Harvard University Press.
7. Bishara SE, et al.: Arch width changes from 6 weeks to 45 years of age, *Am J Orthod Dentofacial Orthop* 111:401–409, 1997.
8. Moyers RE, Wainwright RL: Skeletal contributions to occlusal development. In McNamara JA, editor: *The Biology of Occlusal Development, Craniofacial Growth Series,* Monograph, 1977, pp 89–111. University of Michigan, Ann Arbor, Michigan.
9. Nance HN: The limitations of orthodontic treatment. I. Mixed dentition diagnosis and treatment, *Am J Orthod* 33:177–223, 1947.
10. Gianelly AA: Crowding—timing of treatment, *Angle Orthod* 64:414–418, 1994.
11. Gianelly AA: Leeway space and the resolution of crowding in the mixed dentition, *Semin Orthod* 1:188–194, 1995.
12. Sonis A, Ackerman M: E-space preservation: is there a relationship to mandibular second molar impaction? *Angle Orthod* 81(6):1045–1049, 2011.
13. Miyamoto W, et al.: Effect of premature loss of deciduous canines and molars on malocclusion of the permanent dentition, *J Dent Res* 55:584–590, 1976.
14. Owen DG: The incidence and nature of space closure following the premature extraction of deciduous teeth—a literature survey, *Am J Orthod* 59:37–49, 1971.
15. Grøn AM: Prediction of tooth emergence, *J Dent Res* 41: 573–585, 1962.
16. Brill WA: The distal shoe space maintainer: chairside fabrication and clinical performance, *Pediatr Dent* 24:561–565, 2002.
17. Carroll CE, Jones JE: Pressure-appliance therapy following premature loss of primary molars, *J Dent Child* 49:347–351, 1982.
18. Waldon K, et al.: Indications for the use of auto-transplantation of teeth in the child and adolescent, *Eur Arch Paediatr Dent* 13(4):210–216, 2012.
19. Bauss O, et al.: Autotransplantation of immature third molars: influence of different splinting methods and fixation periods, *Dent Traumatol* 18(6):322–328, 2002.
20. Ramfjord SP: Bruxism: a clinical and electromyographic study, *J Am Dent Assoc* 62:21–44, 1961.
21. Sheppard IM: The treatment of bruxism, *Dent Clin North Am* 207–213, 1960.
22. Traisman AS, Traisman HS: Thumb- and finger-sucking: a study of 2,650 infants and children, *J Pediatr* 52:566–572, 1959.
23. Subtelny JD: Oral habits—studies in form, function, and therapy, *Angle Orthod* 43:349–383, 1973.
24. Subtelny JD: Oral respiration: facial maldevelopment and corrective dentofacial orthopedics, *Angle Orthod* 50:147–164, 1980.
25. Popovich F, Thompson GW: Thumb and finger sucking—its relation to malocclusion, *Am J Orthod* 63:148–155, 1973.
26. Zardetto CG, et al.: Effects of different pacifiers on the primary dentition and oral myofunctional structures of preschool children, *Pediatr Dent* 24:522–560, 2002.
27. Haryett RD, et al.: Chronic thumb-sucking: psychologic effectiveness of various methods of treatment, *Am J Orthod* 53:569–585, 1967.
28. Haryett RD, et al.: Chronic thumb-sucking—a second report on treatment and its psychologic effects, *Am J Orthod* 57:164–178, 1970.
29. Haskell BS, Mink JR: An aid to stop thumb sucking—the "Bluegrass" appliance, *Pediatr Dent* 13:83–85, 1991.
30. Davidson PO, et al.: Thumb-sucking: habit or symptom? *J Dent Child* 34:252–259, 1967.
31. Proffit WR: *Contemporary Orthodontics*, ed 5, St. Louis, 2013, Mosby.
32. Fletcher BT: Etiology of finger-sucking: review of literature, *J Dent Child* 42:293–298, 1975.
33. Hanson ML, Cohen MS: Effects of form and function on swallowing and the developing dentition, *Am J Orthod* 64:63–74, 1973.
34. Profitt WR: Equilibrium theory revisited—factors influencing position of the teeth, *Angle Orthod* 48:175–185, 1978.
35. Rosa M, et al.: Spontaneous correction of anterior crossbite by RPE anchored on deciduous teeth in the early mixed dentition, *Eur J Paed Dent* 13(3):176–180, 2012.
36. Kurol J, Bergland L: Longitudinal study and cost-benefit analysis of the effect of early treatment of posterior crossbites in the primary dentition, *Eur J Orthod* 14:173–179, 1992.
37. Modéer T, et al.: Sucking habits and their relation to posterior crossbite in 4 year old children, *Scand J Dent Res* 90: 323–328, 1982.
38. Lindner A, Modéer T: Relation between sucking habits and dental characteristics in preschool children with unilateral crossbite, *Scand J Dent Res* 97:278–283, 1989.
39. Kutin G, Hawes RR: Posterior cross-bites in the deciduous and mixed dentitions, *Am J Orthod* 56:491–504, 1969.
40. Hesse K, et al.: Changes in condylar position and occlusion associated with maxillary expansion for correction of functional unilateral posterior crossbite, *Am J Orthod Dentofac Orthop* 111:410–418, 1997.
41. Myers DR, et al.: Condylar position in children with functional posterior crossbites before and after correction, *Pediatr Dent* 2:190–194, 1980.
42. Pirtiniemi P, et al.: Relationship between craniofacial and condyle path asymmetry in unilateral crossbite patients, *Eur J Orthod* 12:408–413, 1990.
43. Lindner A: Longitudinal study on the effect of early interceptive treatment in 4-year-old children with unilateral crossbite, *Scand J Dent Res* 197:432–441, 1989.
44. Krebs AA: Rapid expansion of mid-palatal suture by fixed appliance. An implant study over a 7- year period, *Trans Eur Orthod* 131–132, 1964.
45. Hicks EP: Slow maxillary expansion—a clinical study of skeletal versus dental response to low magnitude force, *Am J Orthop* 73:121–141, 1979.
46. Thomas GG, et al.: Experimentally determined forces of maxillary lingual arch expansion appliances, *J Pedod* 7(1):3–7, 1982.
47. Harberson VA, Myers DR: Mid-palatal suture opening during functional posterior crossbite correction, *Am J Orthod* 74(3):310–313, 1978.
48. Bell RA, Lecompte EJ: The effects of maxillary expansion using a quad-helix appliance during the deciduous and mixed dentitions, *Am J Orthod* 79:152–157, 1981.

49. Bjerklin K, Kurol J: Ectopic eruption of the maxillary first permanent molar: etiologic factors, *Am J Orthod* 84:147–155, 1983.
50. Young DH: Ectopic eruption of the first permanent molar, *J Dent Child* 24:153–162, 1957.
51. DeBaets J, Chiarini M: The pseudo class I: a newly defined type of malocclusion, *J Clin Orthod* 29:73–88, 1995.
52. Dugoni SA, et al.: Early mixed dentition treatment—post-retention evaluation of stability and relapse, *Angle Orthod* 65:311–320, 1995.
53. Rebellato J, et al.: Lower arch perimeter preservation using the lingual arch, *Am J Orthod Dentofac Orthop* 112:449–456, 1997.
54. Brennan MM, Gianelly AA: The use of the lingual arch in the mixed dentition to resolve incisor crowding, *Am J Orthod Dentofac Orthop* 117:81–85, 2000.
55. Kokich VG: Congenitally missing teeth—orthodontic management in the adolescent patient, *Am J Orthod Dentofac Orthop* 121:594–595, 2002.
56. Trosman I: Childhood obstructive sleep apnea syndrome: a review of the American Academy of Pediatrics Guidelines, *Pediatr Ann* 42(10):195–199, 2013.
57. De Luca Canto G, et al.: Capability of questionnaires and clinical examinations to assess sleep-disordered breathing in children: a systematic review and meta-analysis, *J Am Dent Assoc* 145(2):165–178, 2014.
58. Bishara SE, et al.: Proceedings of the workshop discussions on early orthodontic treatment. College of Diplomates of the American Board of Orthodontics, *Am J Orthod Dentofac Orthop* 113:5–6, 1998.
59. Andrews LF: The six keys to normal occlusion, *Am J Orthod* 62:296–309, 1972.
60. Harradine NW, Pearson MH, Toth B: The effect of extraction of third molars on late lower incisor crowding: a randomized controlled trial, *Br J Orthod* 25(2):117–122, 1998.

SUGGESTED READINGS

Bacetti T, Franchi L, McNamara JA: Treatment and post-treatment craniofacial changes after rapid maxillary expansion and facemask therapy, *Am J Orthod Dentofac Orthop* 118:404–413, 2000.

Bishara SE: Impacted maxillary canines, *Am J Orthod Dentofac Orthop* 101:159–171, 1992.

De Clerck HJ, et al.: Orthopedic traction of the maxilla with miniplates: a new perspective for treatment of midface deficiency, *J Oral Maxillofac Surg* 67(10):2123–2129, 2009.

Dincer M, et al.: Space maintainer effects on intercanine arch width and length, *J Clin Pediatr Dent* 21:47–50, 1996.

Ericson S, Kurol J: Resorption of incisors after ectopic eruption of maxillary canines—a CT study, *Angle Orthod* 70:415–423, 2000.

Foley TF, Wright GZ, Weinberger SJ: Management of lower incisor crowding in the early mixed dentition, *J Dent Child* 63:169–174, 1996.

Halterman CW: A simple technique for the treatment of ectopically erupting permanent first molars, *J Am Dent Assoc* 105:1031–1033, 1982.

Humphrey WP: A simple technique for correcting an ectopically erupting first permanent molar, *J Dent Child* 29:176–178, 1962.

Kennedy DB, Turley PK: Clinical management of ectopically erupting first permanent molars, *Am J Orthod Dentofac Orthop* 96:336–345, 1987.

Kluemper GT, Beeman CS, Hicks EP: Early orthodontic treatment—what are the imperatives? *J Am Dent Assoc* 131:613–620, 2000.

Koroluk LD, Tulloch JF, Phillips C: Incisor trauma and early treatment for Class II Division I malocclusion, *Am J Orthod Dentofacial Orthop* 123:117–126, 2003.

Moorrees CFA, Chadha JM: Available space for the incisors during dental development: a growth study based on physiologic age, *Angle Orthod* 35:12–24, 1965.

Moorees CFA, et al.: Growth studies of the dentition—a review, *Am J Orthod* 55:600–613, 1969.

Ngan P, Alkire RG, Fields H: Management of space problems in the primary and mixed dentitions, *J Am Dent Assoc* 130:1330–1339, 1999.

Pancherz H, et al.: Thirty-two year follow-up study of Herbst therapy: a biometric dental cast analysis, *Am J Orthod Dentofacial Orthop* 145(1):15–27, 2014.

Rajab LD: Clinical performance and survival of space maintainers—evaluation over a period of five years, *J Dent Child* 69:156–160, 2002.

Tulloch JF, et al.: Outcomes in a 2-phase randomized clinical trial of early Class II treatment, *Am J Orthod Dentofac Orthop* 125:657–667, 2004.

Vargo J, et al.: Treatment effects and short-term relapse of maxillomandibular expansion during the early to mid-mixed dentition, *Am J Orthod Dentofac Orthop* 131:456–463, 2007.

Vizzotto MB, et al.: The Quad-helix appliance in the primary dentition—orthodontic and orthopedic measurements, *J Clin Pediatr Dent* 32(2):165–170, 2007.

CHAPTER 23

Multidisciplinary Team Approach to Cleft Lip and Palate Management

▲ LaQuia A. Walker Vinson, Donald V. Huebener, James E. Jones, Roberto L. Flores, and Jeffrey A. Dean

For additional resources, please visit the evolve website.

CHAPTER OUTLINE

CLASSIFICATION OF CLEFT LIP AND PALATE
MULTIDISCIPLINARY CLEFT LIP AND PALATE TEAM
GENERAL RESPONSIBILITIES OF TEAM MEMBERS
Dental Specialties
Medical and Allied Health Specialties
MULTIDISCIPLINARY SEQUENCING OF TREATMENT IN CLEFTS
Stage I (Infant Appliance Stage: Birth to 18 Months of Age)
Stage II (Primary Dentition Stage: 18 Months to 5 Years of Age)
Stage III (Late Primary or Early Mixed Dentition Stage: 6 to 10 or 11 Years of Age)
Stage IV (Permanent Dentition Stage: 12 to 18 Years of Age)

Cleft lip and palate, the most common of the craniofacial anomalies, are severe congenital anomalies with a global incidence of 0.28 to 3.74 per 1000 live births. In the United States, cleft lip and palate occur in approximately 1 in 940 newborns.[1] The incidence varies widely among races: about 1 in 800 white newborns, 1 in 2000 black newborns, and 1 in 500 Japanese or Navaho Indian newborns. Isolated cleft palate occurs in about 1 in 2000 newborns and demonstrates less racial variation. Cleft lip and palate together account for approximately 50% of all cases, whereas isolated cleft lip and isolated cleft palate each occurs in about 25% of cases. Some of these congenital anomalies appear to be genetically determined, although the majority are of unknown cause or are attributable to teratogenic influences (see Chapter 5).

CLASSIFICATION OF CLEFT LIP AND PALATE

There is a tendency to conceptualize cleft lip and palate as a homogenous anomaly. If that were true, a treatment plan applicable to all cases could be formulated. However, the reality is that clefts vary widely in their clinical presentations.

According to Harkins, to standardize the reporting of cleft lip and palate, the Nomenclature Committee of the American Association of Cleft Palate Rehabilitation devised a classification system that later was adopted by the Cleft Palate Association.[2] The complexity of this system, however, has made its acceptance less than overwhelming. Veau in 1931 proposed the most frequently used system:

- Class I—a unilateral notching of the vermilion not extending into the lip
- Class II—a unilateral notching of the vermilion border, with the cleft extending into the lip but not including the floor of the nose
- Class III—a unilateral clefting of the vermilion border of the lip extending into the floor of the nose
- Class IV—any bilateral clefting of the lip, whether it be incomplete notching or complete clefting

Veau divided palatal clefts into four classes as follows (Fig. 23-1):

- Class I—involves only the soft palate
- Class II—involves the soft and hard palates but not the alveolar process
- Class III—involves both soft and hard palates and the alveolar process on one side of the premaxillary area
- Class IV—involves both soft and hard palates and continues through the alveolus on both sides of the premaxilla, leaving it free and often mobile

Veau did not include submucous clefts of the palate in his classification system. Submucous clefts may frequently be diagnosed by the following physical findings: bifid uvula, palpable notching at the posterior portion of the hard palate, and a zona pellucida (thin, translucent membrane). Submucous clefts of the palate may be associated with an incomplete velopharyngeal mechanism or eustachian tube dysfunction.

MULTIDISCIPLINARY CLEFT LIP AND PALATE TEAM

Children born with cleft lip and palate have many problems that need to be solved for successful habilitation. The complexity of these problems requires that numerous health care practitioners cooperate in providing the

Dentlearn.ir

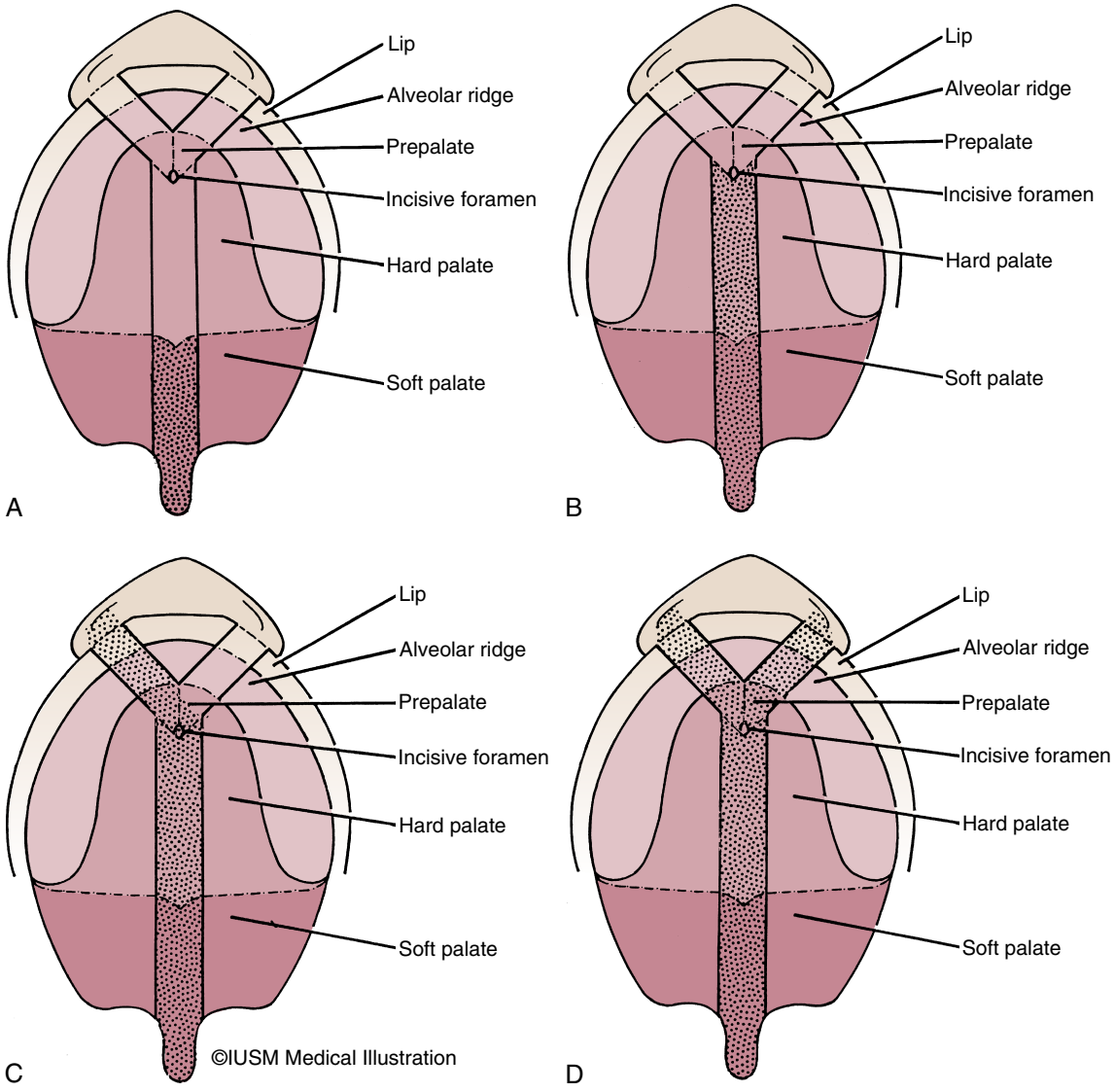

Figure 23-1 Veau's classification of cleft lip and palate. Shaded area, extent of the cleft. **A,** Class I cleft of the soft palate only. **B,** Class II cleft of the soft and hard palates but not involving the alveolar process. **C,** Class III unilateral complete cleft of the lip and palate. **D,** Class IV bilateral complete cleft of the lip and palate.

specialized knowledge and skills necessary to ensure comprehensive care. The multidisciplinary cleft lip and palate team concept has evolved from that need.

To address the many treatment regimens and different care protocols, the American Cleft Palate–Craniofacial vened a consensus conference on recommended practices for the care of patients with craniofacial anomalies. This conference produced the document "Parameters for Evaluation and Treatment of Patients with Cleft Lip/Palate or Other Craniofacial Anomalies."[4] This serves as a guide for implementing the multidisciplinary approach to cleft and craniofacial care and is used by teams in the United States and Canada.

Because optimal care is best achieved by multiple types of clinical expertise, the teams may be composed of individuals in (1) dental specialties (orthodontics, oral surgery, pediatric dentistry, and prosthodontics), (2) medical specialties (genetics, otolaryngology, pediatrics, plastic surgery, and psychiatry), and (3) allied health care fields (audiology, nursing, psychology, social work, and speech pathology).

These care providers assess the patient's medical status and general development, dental development, facial aesthetics, psychological well-being, hearing, and speech development. Team members must communicate effectively among themselves, with the child and parents, and with the primary care physician and dentist. Individuals on the team must respect one another's opinions and be flexible in planning and carrying out therapy. Periodic evaluation is necessary to assess the effect of previous therapy and to determine whether an alternative approach may be necessary. A team conference immediately after patient examination is a desirable way to discuss current problems and plan timely therapy.

Whitehouse describes the clinical team as a "close, cooperative, democratic, multiprofessional union devoted to a common purpose—the best treatment of the fundamental needs of the patient."[5]

GENERAL RESPONSIBILITIES OF TEAM MEMBERS

DENTAL SPECIALTIES

The pediatric dentist is responsible for the overall dental care of the patient. Numerous dental anomalies and malocclusions occur with a cleft lip or palate. These may be attributed to the congenital clefting itself or may be secondary to the surgical correction of the primary defects. A high correlation is found between the number and severity of dental problems and the type and severity of the cleft.

The pediatric dentist should discuss with the patient and parents the traditional dental problems associated with clefting. Any one, or several, of the following conditions may occur with a significantly greater frequency than in the general population:

1. If there is a natal or neonatal tooth observed in a patient with a complete unilateral or bilateral cleft palate, it is usually a maxillary central incisor (Fig. 23-2).
2. There is a high incidence of congenitally absent teeth, especially the primary or permanent lateral incisor, adjacent to the alveolar cleft. There is also an increased incidence of congenitally missing second premolars.
3. There is a significant increase in the frequency of supernumerary teeth (Fig. 23-3), which are often seen in children with complete unilateral or bilateral clefts. Occasionally, there can be supernumerary teeth and congenitally missing teeth in patients with cleft lip only, with or without notching of the alveolus.
4. It is common to find ectopic primary lateral incisors located palatally, adjacent to, or within the cleft site. In the permanent dentition, canines on the side of the complete alveolar cleft may erupt palatally into the cleft.
5. Various anomalies of tooth morphology are frequently seen in association with complete unilateral and bilateral clefts of the palate. These include enamel hypoplasia, microdontia or macrodontia, fused teeth, and aberrations in crown shape. The teeth most often affected are the primary and permanent maxillary incisors.
6. Permanent teeth that erupt adjacent to a cleft alveolar ridge usually have a deficiency of supporting alveolar bone about the root surfaces. These teeth are susceptible to premature loss. A decrease in alveolar bone support may be accentuated when periodontal disease is present or when orthodontic appliance therapy is used indiscriminately.
7. Permanent central incisors adjacent to an alveolar cleft frequently erupt in a rotated position and with deviations of axial root inclination.
8. Patients with a complete cleft palate and alveolus do not have a contiguous maxillary arch. External forces applied to the maxilla (e.g., by muscles of mastication or by the contraction of scar tissue after surgical repair of the cleft palate) can result in medial collapse of the posterior segments. A posterior crossbite may be observed unilaterally or bilaterally.



Figure 23-2 Neonatal maxillary central incisor in a newborn infant with a bilateral complete cleft lip and palate.

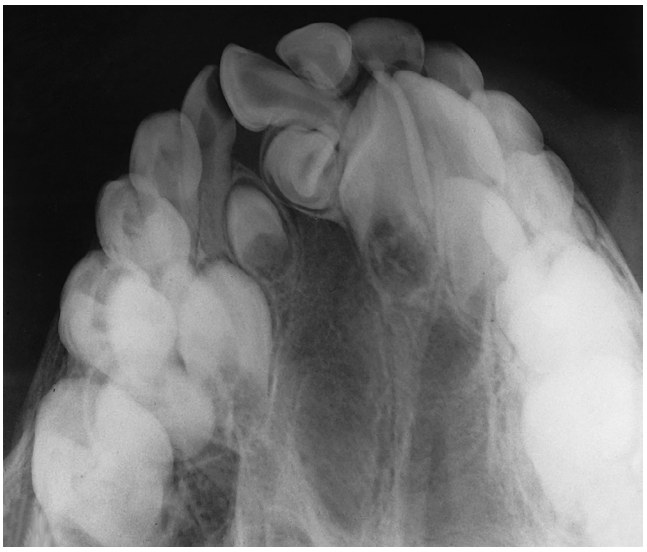

Figure 23-3 Maxillary occlusal radiograph demonstrating supernumerary maxillary central incisors.

9. In an infant with a complete bilateral cleft lip and palate, the premaxilla is often protuberant and mobile. There may be a greater than 100% overbite, with subsequent stripping of the labially attached gingiva overlying the mandibular incisors (Fig. 23-4). Traumatic anterior end-to-end occlusion, or an anterior crossbite, is also common.
10. In a patient with a complete unilateral or bilateral cleft palate, the lateral facial profile may appear noticeably convex (Fig. 23-5). This may become more perceptible as the child grows older. The appearance may be attributed to a true mandibular or pseudomandibular prognathism. In pseudomandibular prognathism, the maxilla is in spatial disharmony with the mandible. This may be caused by a retrognathic maxilla or an attenuation of the anteroposterior and vertical growth of the maxilla.

Pediatric Dentist

Preventive dental care is extremely important in these cases. Parents are often overwhelmed by other aspects of

Dentlearn.ir



Figure 23-4 Bilateral complete cleft lip and palate demonstrating a greater than 100% overbite. Stripping of the labially attached gingiva of the mandibular central and lateral incisors is common in this presentation.



Figure 23-5 Lateral facial profile of an adolescent boy with a repaired bilateral complete cleft lip and palate. Maxillary hypoplasia, secondary to the cleft defect, often produces a greatly concave lateral facial profile.

the cleft deformity and may give dental care a low priority or even neglect it altogether. The intact dental occlusion is the foundation upon which future orthodontic therapy takes place. For this reason, optimum dental health is essential for the total habilitation of the patient. Any compromise will lead to a less than optimal result. Routine prophylaxis and fluoride treatments are mandatory. Referral for preventive dental care should be made during the first year of life. Fluoride supplements, dentifrices, and rinses are indicated if the patient lives in a nonfluoridated community. The parents and patient should be instructed in proper dental hygiene techniques, especially around the defect. Close communication between the primary care dentist and the cleft team is important to ensure the continuity of care necessary during the extended treatment of such patients. Routine periodic reports from the cleft team should be forwarded to the child's primary care dentist, especially during orthodontic or surgical treatment. Pediatric dentists are often involved in the presurgical and postsurgical treatment phases of maxillary orthopedics. Both active and passive appliances are used to bring the cleft segments into a more ideal alignment and thereby promote a more favorable initial surgical outcome.

Orthodontist

The orthodontist plays a key role in the diagnosis and treatment of a cleft condition by obtaining the records necessary for diagnosis and treatment planning. These include cephalometric and panoramic radiographs, study models, and diagnostic photographs. Analysis of these records enables the orthodontist to describe and quantitate the facial skeleton and soft-tissue deformities. Using expertise in the growth and development of the facial skeleton, this specialist can identify problem areas and, with some limitations, predict growth and development. Many team members depend on the orthodontist's analysis and quantitations of the cleft anomaly for treatment planning.

The orthodontist also provides comprehensive orthodontic care for patients. Most orthodontic care can be considered conventional, but for difficult dental configurations, innovation and imagination are required for treatment. If surgical treatment is indicated, the orthodontist works closely with the surgeon to plan the most appropriate procedure. Immediate postoperative function, aesthetic result, and long-term stability are factors considered before surgery.

Oral and Maxillofacial Surgeon

The ability to surgically alter skeletal relationships of the maxillomandibular complex is the basis for participation by the oral and maxillofacial surgeon on the cleft team. This specialist evaluates all patients for facial form and function and jaw position. Many patients have significant skeletal malocclusions that cannot be treated by conventional orthodontics and require surgical correction.

The surgical placement of alveolar cleft bone grafts is another important role of the oral and maxillofacial surgeon. These grafts aid in dental habilitation. The grafted bone supports the teeth adjacent to the cleft site and provides bone through which teeth may erupt. A detailed discussion of these grafts follows later in this chapter.

Prosthodontist

The maxillofacial prosthodontist replaces, restores, or rehabilitates orofacial structures that may be congenitally missing or malformed. Nonliving materials are used to restore and enhance form and anatomy. There is a special



Figure 23-6 **A,** Bilateral complete cleft lip and palate in which the maxillary six permanent anterior teeth have been removed. **B,** Removable prosthodontic appliance providing acceptable occlusal and aesthetic results.

commitment to the oral cavity because this specialist fabricates prosthetic appliances to rehabilitate mastication, deglutition, speech, and oral aesthetics.

Many patients with clefts have congenitally missing teeth or malformed teeth that may need to be removed. In these cases masticatory function, speech, and orofacial aesthetics are compromised, and successful habilitation dictates that the missing teeth be replaced to achieve as nearly normal a condition as possible (Fig. 23-6). The maxillofacial prosthodontist may do this with fixed or removable appliances or with a combination of the two.

Occasionally, patients demonstrate aberrant speech patterns caused by failure of the soft palate to elevate properly. If surgical soft palate reconstruction and revision are unsuccessful, a palatal lift appliance can be fabricated to aid the speech mechanism. In other cases the maxillofacial prosthodontist may fabricate a speech bulb prosthesis to aid or augment the velopharyngeal mechanism. In patients with considerable escape of air through persistent palatal fistulas, the fistulas can be surgically repaired or obturated (Fig. 23-7).

MEDICAL AND ALLIED HEALTH SPECIALTIES

The patient care coordinator arranges appointments, maintains patient records, and monitors the interaction of the patient and family with the various team members.

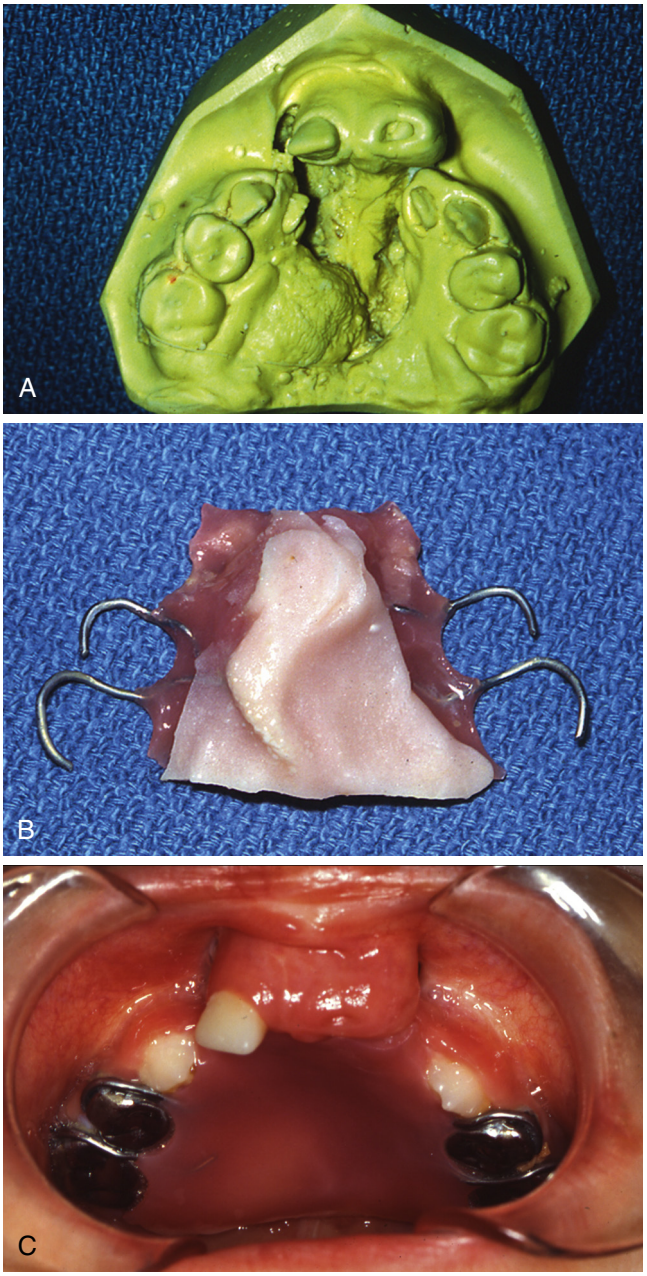

Figure 23-7 **A,** Diagnostic maxillary model of a bilateral complete cleft lip and palate. Notice the large patent oronasal fistula that resulted after several attempts to close the defect surgically. **B,** Maxillary prosthesis constructed for the patient to obturate the palatal defect. **C,** Palatal prosthesis in place. This closure provides a reduction in the amount of fluids and foods that enter the nasal cavity during eating. The closure also facilitates more normal speech production.

The coordinator corresponds with health and school personnel near the patient's home to help provide continuity of care for the cleft patients within the community. The coordinator is the most convenient point of contact with team members for the patients, their families, and health care practitioners outside the medical center complex.

The pediatrician, often the patient's own pediatrician or family physician, is responsible for maintenance of the patient's overall health. This specialist performs complete

Dentlearn.ir

physical evaluations and helps assess the patient's physiologic status. Close attention is also directed to growth status and other developmental milestones.

The medical geneticist examines the patient to find characteristics of syndromes associated with cleft lip and palate. Consideration is given to the genetic basis for the anomaly, and this information is related to the parents. Genetic counseling is a very important function of the geneticist. Parents are vitally interested in risk assessment relative to future offspring, and other family members who may be at risk are often counseled (see Chapter 5).

The role of the plastic and reconstructive surgeon begins with a determination of the timing and method of lip closure. In addition, the plastic surgeon is responsible for cleft palate repair and secondary surgery to correct velopharyngeal incompetence and/or palatal fistulas. Internal and external cleft nasal deformities are corrected by the plastic surgeon.

The social worker acts as the patient's advocate in many cases and aids in psychosocial assessment. This team member assists the family by making referrals to persons or agencies at the local, county, and state levels for guidance regarding financial resources for medical care. During hospitalization, the social worker provides supportive counseling and facilitates communication between the family and medical or hospital personnel. The focus is on helping the family cope with stress during and after surgery and on dealing with emotional factors involved in forming realistic expectations of surgical outcomes and in adapting to problems of body image.

The psychiatrist and psychologist evaluate the patient for strengths and weaknesses in cognitive, interpersonal, emotional, behavioral, and social development. Emphasis is placed on the patient's ability to cope with the emotional and physical stress created by the cleft defect. Consultation with the parents and school regarding educational or behavioral management occurs when indicated.

The speech pathologist functions essentially as a monitor of speech output. All speech sounds are analyzed to determine deviations from normal, and the cause of any deviation is evaluated. To the extent that anatomic variations are corrected, the speech pathologist offers therapeutic options to enhance maturation of speech or to achieve satisfactory compensation in motor production for optimal speech.

The audiologist performs tests to identify any hearing difficulties. When neither the child nor the parents recognize hearing problems, the result can be a delay in speech and language development and poor performance in school. When hearing tests or impedance measures are abnormal, a referral is made to an otolaryngologist for an ear examination. The otolaryngologist coordinates audiology tests and any special studies that may be needed to evaluate middle ear structures. Any middle ear surgery that is to be done is performed by this member of the team. He or she may also perform a nasopharyngoscopic examination in coordination with the speech pathologist.

Nurses provide various functions that are valuable to the cleft lip and palate team. They actively communicate with other disciplines in relaying information regarding the special needs of each child and family. Nurses emphasize total family involvement and not just treatment of the patient. They prepare patients and families for either outpatient or inpatient surgery and assist in the overall management process. Above all, they are extremely important in assessing the initial feeding issues and advising parents about ongoing nutritional concerns.

The presence of more complex craniofacial anomalies, such as Crouzon syndrome, Treacher-Collins syndrome, or hemifacial microsomia, requires additional specialists on the team. Some of these care providers include anesthesiologists, diagnostic medical imaging radiologists, neurologists, neurosurgeons, and ophthalmologists in addition to those cleft team providers already mentioned.

MULTIDISCIPLINARY SEQUENCING OF TREATMENT IN CLEFTS

The following discussion focuses on major treatment procedures performed by members of the cleft team. For convenience, the treatment is divided into four stages, which generally correspond to stages in the child's dental development.

STAGE I (INFANT APPLIANCE STAGE: BIRTH TO 18 MONTHS OF AGE)

Management of the patient with a cleft begins with immediate attention to the needs of the newborn. Feeding problems are often associated with cleft anomalies, particularly clefting of the palate, which make it difficult for the infant to maintain adequate nutrition. These problems include insufficient suction to pull milk from the nipple, excessive air intake during feeding (requiring several burpings), choking, nasal discharge, and excessive time required to take nourishment. The clinical nurse specialist on the cleft team or the feeding specialist is contacted to assess the feeding issues and offer advice and support. Various feeding techniques as well as feeding bottles/supplies have been advocated for use by infants with clefts.[6]

In the past, McNeil[7,8] and other authors since then have advocated various prosthetic appliances, both active and passive, for the treatment of infants born with unilateral and bilateral clefts of the lip and palate. One such prosthesis, an intraoral maxillary obturator, has proved beneficial by providing an artificial palate. The advantages of this prosthetic therapy include the following:

1. Provides a false palate against which the infant can suck, reduces the incidence of feeding difficulties in newborns, and helps maintain adequate nutrition
2. Provides maxillary cross-arch stability and prevents arch collapse after definitive cheiloplasty (surgical closure of the lip)
3. Provides maxillary orthopedic molding of the cleft segments into approximation before primary alveolar cleft bone grafting

In a study by Jones, maxillary obturators were constructed to facilitate feeding for 51 infants with unilateral or bilateral cleft lip and palate.[9] From birth, each infant had continuously experienced feeding difficulties before obturator therapy. After the infants had worn the obturator for at least 8 months, parents reported that they were more comfortable while feeding their infants and

Dentlearn.ir

that nasal discharge was reduced. The time required for feeding and the difficulty experienced by the parents were also reduced. Of particular importance was the reported reduction of parental apprehension during feeding. All parents recommended the obturator for others who have infants with cleft lip and palate. It was also reported that the weights of the infants at 1, 3, and 6 months of age consistently remained at, or above, the 50th percentile compared with normative growth data. No fluctuation in weight was noted even after primary lip closure at about 3 months of age.

Impression Technique and Feeding Obturator Construction

As soon as possible (usually within 2 weeks of birth), an impression is made of the infant's maxillary arch for construction of an intraoral obturator. An alginate impression of the infant's maxillary arch is made with a modified stock tray. Ideally, this is accomplished as soon after birth as possible. The infant is held upright during the impression process to prevent aspiration of excess material (Fig. 23-8). Appropriate emergency equipment, including forced oxygen, suction, and standard airway management equipment, should be available. The impression should exhibit good anatomic detail with coverage of the entire maxillary arch (Fig. 23-9). A stone model is then produced. The steps in obturator construction are as follows:

1. Block out excessive undercuts with modeling dough or wax. Modeling dough is preferred because it is easy to remove from the finished prosthesis.
2. Apply a tinfoil substitute over the entire surface of the maxillary model and let it dry.
3. If necessary, place a dam of modeling dough on the back of the model to hold the resin in the palatal defect while it cures.
4. Pour a mixture of soft, autopolymerizing acrylic resin into the cleft to the level of the palate. This provides retention for the prosthesis by gently contouring into the available undercuts (Fig. 23-10).
5. Place the model in a warm, moist environment to cure for 20 minutes.



Figure 23-8 Maxillary impression for obturator construction on a newborn with a cleft lip and palate. The infant is held in an upright position to prevent aspiration of excess material.

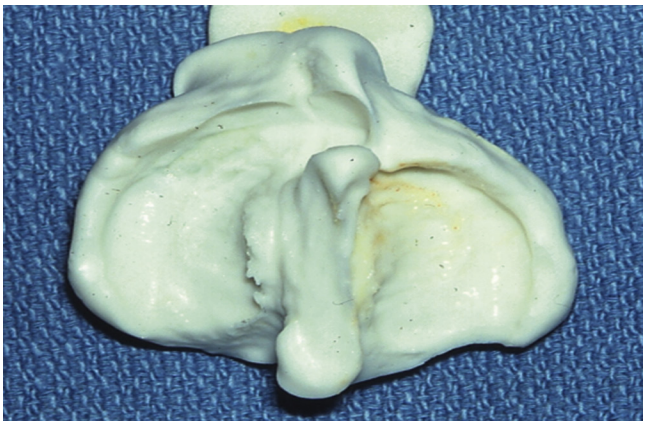

Figure 23-9 Final impression of the infant's maxillary arch. Notice the extension of the material into the cleft defect, as well as the roll produced in the buccal fold. Attention to such detail ensures an excellent reproduction of the intraoral architecture for obturator construction.

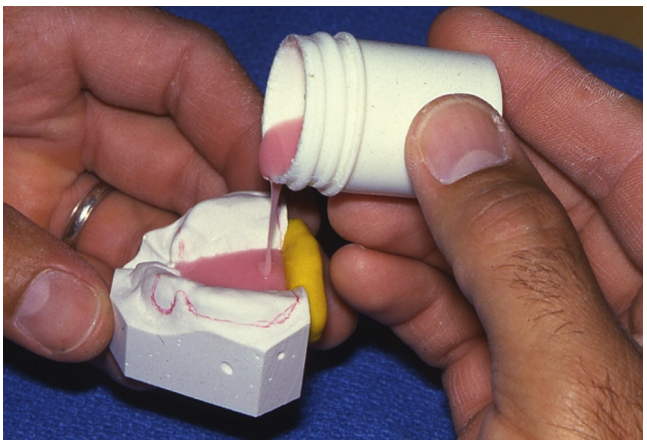

Figure 23-10 Application of soft, autopolymerizing resin into the cleft to the level of the palate. This material provides increased retention of the obturator by contouring into the cleft. Notice the dam of modeling dough, which aids in the placement of the resin.

Dentlearn.ir

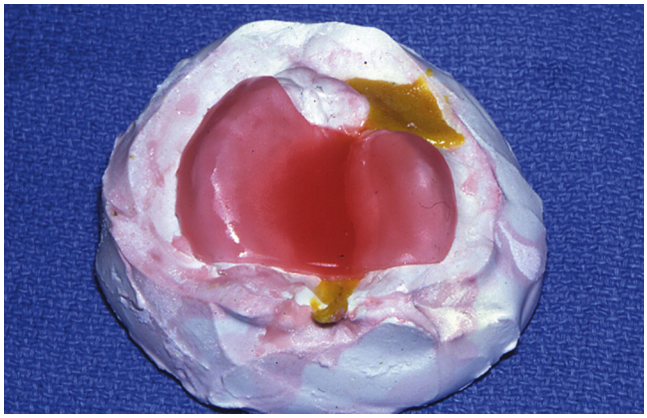

Figure 23-11 Maxillary model at the completion of the application of autopolymerizing acrylic resin. The obturator is allowed to cure for 20 minutes and then is trimmed and polished. Notice the extension of the resin into the mucobuccal fold. This extension further increases the retention of the prosthesis.

6. Add autopolymerizing acrylic resin to the palate using a "salt and pepper" method, making sure the acrylic resin extends well into the mucobuccal fold area (Fig. 23-11).
7. Remove the appliance from the model, and rinse the wax and modeling dough off with hot water. Then trim and polish the appliance.

Clinical Management of Initial Obturator Therapy

The appliance is positioned in the infant's mouth (Fig. 23-12). Areas of excessive pressure exerted by the acrylic resin on any intraoral tissues are identified by observation and then reduced. Care is taken to keep the acrylic resin from impinging on muscle attachments or extending to the depth of the buccal vestibule. Parents are instructed in placement and removal of the appliance and its daily cleaning. Infants are usually seen for adjustments 2 days after appliance delivery. After delivery of the obturator, the infant is allowed to become accustomed to the appliance for 1 week. Monthly observations are then scheduled. In most cases, this appliance will serve until the time of initial lip closure at approximately 3 months of age. The major advantage of obturator use during this stage is to enhance the child's ability to obtain nourishment.

Not all clinicians who work with infants with cleft lip and palate advocate the use of prosthetic feeding appliances. Some believe that such appliances are not effective in facilitating feeding. Pashayan and McNab recommend using a standard nipple that has been crosscut.[10] This enlarged cut provides improved ejection of the milk into the infant's mouth with a minimum of effort. Although this recommendation is appropriate for many infants born with cleft lip and palate, obturator construction may be indicated for children born with more severe facial deformities. This is especially important in consideration of the maxillary orthopedic molding of the alveolar segments after surgical closure of the lip.



Figure 23-12 Obturator in place on the infant's maxillary arch. Notice the extension of the soft resin into the cleft defect, which provides increased retention. (From Jones JE, Kerkhof RL: Obturator construction for maxillary orthopedics in cleft lip and palate infants, *Quintessence Dent Technol* 8:583-586, 1984.)

Presurgical Orthopedics

In some cases of bilateral cleft lip and palate, the infant has a premaxillary segment positioned severely anterior to the maxillary arch segments or deviated laterally to one side of the cleft defect (Fig. 23-13). This presents a difficult clinical challenge for the surgeon before surgical closure of the lip. If lip surgery is undertaken with the premaxilla in such an abnormal position, the chances of lip dehiscence (i.e., lip separation caused by increased pressure at the suture lines) are increased. As early as 1686, Hofman described the use of a head cap and premaxillary strap to reposition the premaxilla.[11] Methods of presurgical orthopedics include lip taping across the upper lip.[12] The advantages of this method are its ease of use; however, it does not afford the same control of the force direction and therefore cannot be used in all instances. Newer methods include DynaCleft®, which is a premade topical approximation device that has been successfully used to mold the upper lip and alveolus and to support the developing nasal tissues prior to cleft lip repair.[13]

Some researchers have recommended the use of active appliances for the normalization of cleft alveolar segments before initial lip surgery in infants. Latham and colleagues used a dentomaxillary advancement appliance to bring unilateral cleft segments into approximation.[14] In bilateral clefts, they expanded collapsed lateral cleft segments and actively retracted the premaxilla into a more ideal arch form. They postulated that such presurgical maxillary orthopedic procedures make lip surgery easier and result in less soft-tissue tension following closure. In addition, gingivoperiosteoplasty (GPP) can be facilitated at the time of cleft lip repair. This procedure will be discussed later in the chapter.

More recently, Grayson and Cutting have promoted the use of a nasoalveolar molding (NAM) appliance with a nasal labial extension to shape the nasal cleft cartilage.[15] The objective of this presurgical effort is to reduce the severity of the cleft deformity, approximate the alveolar and lip segments, decrease the nasal base width, elongate the columella, and attempt to achieve symmetry of the nasal cartilages (Fig. 23-14). They demonstrated that the

Dentlearn.ir

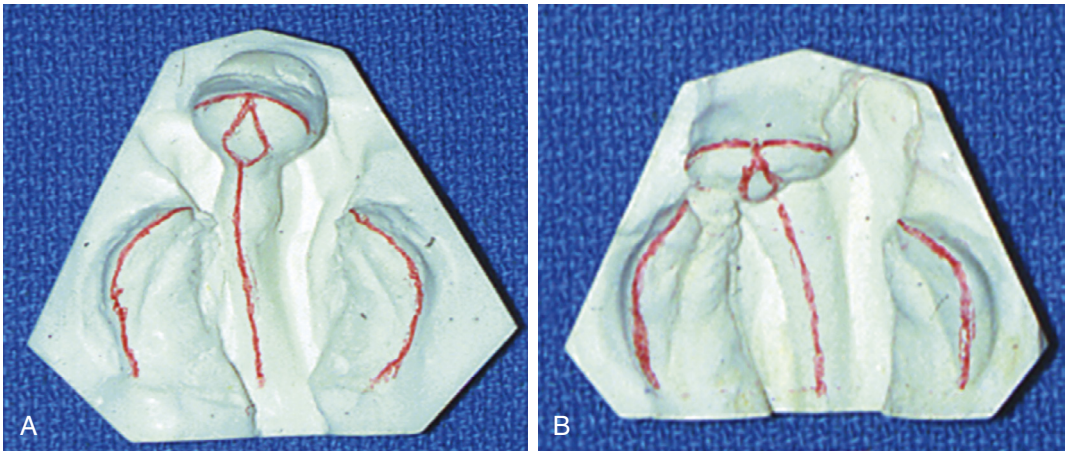

Figure 23-13 Representative diagnostic models of two clinical presentations in bilateral complete cleft lip and palate. **A,** Severe anteroposterior protrusion of the premaxillary segment. **B,** Severe anteroposterior protrusion of the premaxillary segment with a lateral deviation.



Figure 23-14 **A,** A 6-week-old infant with a bilateral cleft lip and palate. There is complete bilateral clefting of the palate, an incomplete cleft lip on the right side, and a complete cleft lip on the left side. The premaxilla is displaced anteriorly and to the right side. **B,** A nasoalveolar molding (NAM) that has a left nasal extension designed to give better shaping to the left nares. The acrylic portion that fits over the palate and premaxilla is designed to bring the premaxilla to the center and back into alignment with the right and left alveolar segments. This is accomplished with selective addition and removal of acrylic. **C,** The infant with the NAM appliance in place and active at almost 3 months of age. **D,** The infant after lip repair. The premaxilla has been brought into good arch alignment with the alveolar segments. (Photos courtesy of Jennifer Kugar, DDS, MSD, James Whitcomb Riley Hospital for Children, Craniofacial Anomaly Team.)

aesthetic and functional outcome of the primary lip and nose surgery is more favorable when NAM is used.[16] Critics point out that NAM is labor-intensive and therefore not a feasible option for many patients and centers. The benefit of columellar lengthening for patients with bilateral cleft palate is a critical advantage of NAM to nasal reconstruction. With the use of bilateral nasal stints and taping techniques, the almost absent columella in bilateral clefts can be nonsurgically elongated before initial lip and nose surgery. Finally, NAM facilitates GPP at the time of cleft lip repair. This can be of particular advantage in patients with complete bilateral cleft lip and palate because osseous union of the premaxilla with the lesser segment can prevent further descent of the premaxilla or collapse of the lesser segments during subsequent facial development.

Airway Obstruction

Infants with airway obstruction secondary to Pierre Robin sequence (micrognathia, glossoptosis, and cleft palate) may require intervention to aid breathing (Fig. 23-15, *A*). An obturator with a posterior palatal extension may be used to reposition the tongue downward and forward out of the cleft site (see Fig. 23-15, *B*). Prone positioning, supplemental oxygen, nasopharyngeal tubes, and continuous positive airway pressure (CPAP) may also be helpful. If a nonsurgical approach is unsuccessful, lip-to-tongue adhesion, mandibular distraction, or tracheostomy may be necessary.

Cheiloplasty

The appearance of an unrepaired wide cleft lip can be distressing. Some parents feel anxiety, depression, guilt, or rejection. Lip surgery will significantly improve the infant's appearance and may thereby relieve parental apprehensions and enhance their acceptance of the child.

Cleft lip repair is typically performed in infants at approximately 3 months of age. Primary nasal reconstruction is commonly performed at the time of lip repair. Prior to the start of surgery, when the infant is under general anesthesia, if an obturator has been necessary, an impression is made of the maxillary arch for construction of a new obturator. This is necessary to accommodate craniofacial growth during the first few months of life.

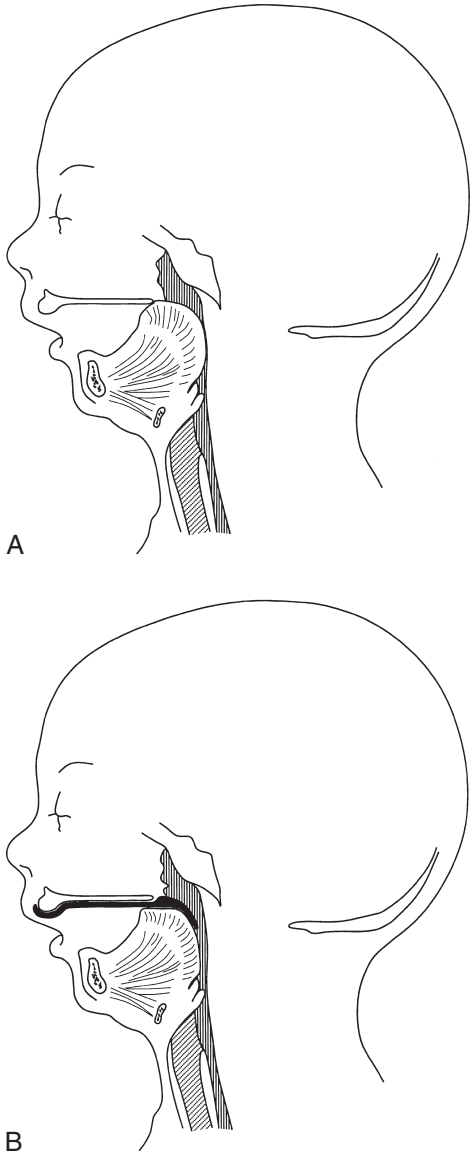

Figure 23-15 **A,** Infant with airway obstruction secondary to Pierre Robin sequence. Notice the closure of the oral airway related to the retroposition of the tongue. **B,** Infant with obturator in position. Notice the anterior placement of the tongue, which allows the oral airway to remain open.

Maxillary Orthopedics

After definitive lip closure, maxillary arch collapse in the unilateral or bilateral complete cleft may occur. This is attributed to the increased tension placed on the segments by the repaired lip. To prevent this collapse, an obturator may be used to provide cross-arch stability and support. As pressure is exerted on the anterior segments of the maxilla by the repaired lip, orthopedic molding of the segments can be achieved. In unilateral cases, the force applied to the greater segment by the intact lip molds that segment around to approximate the lesser segment (Fig. 23-16). This molding is facilitated by the obturator, which provides a fulcrum around which the anterior portion of the greater segment rotates. At the same time the appliance resists any tendency for the greater and lesser segments to collapse toward the midline. In bilateral cleft cases the repaired lip provides further retraction at the premaxilla, positioning it between the two lateral maxillary segments. When the maxillary segments are in good alignment and abut across the cleft sites, a primary cleft bone graft can be considered.

Bone Grafting of Alveolar Cleft Defects

Bone grafting of alveolar cleft defects has been a confusing issue to many patients and practitioners. This stems in part from the lack of unanimity concerning terminology and technique. The following definitions, which have been reasonably accepted by practitioners, will be used in this discussion.

Dentlearn.ir

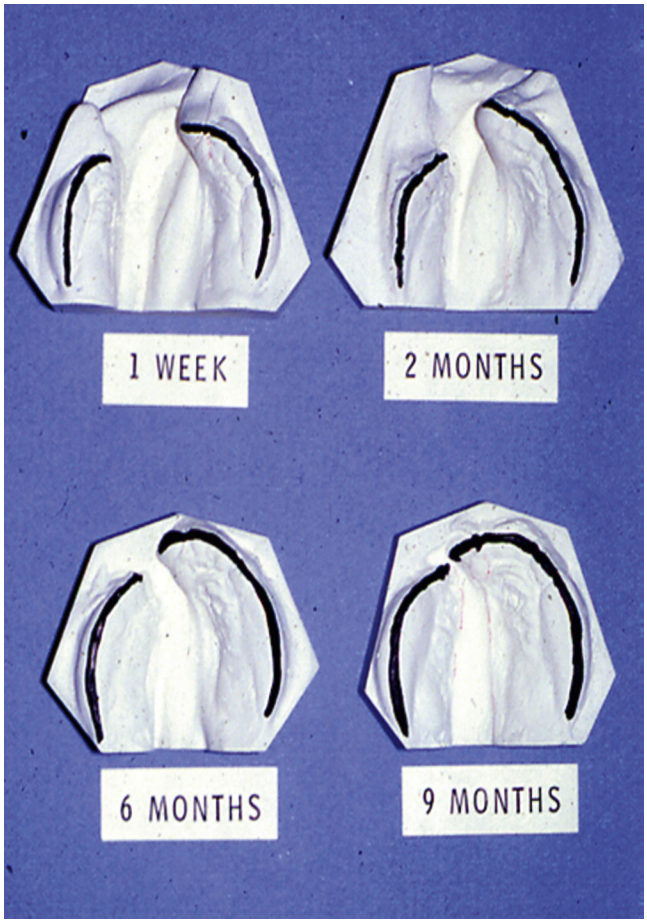

Figure 23-16 Sequential maxillary arch dental models demonstrating maxillary orthopedic molding in an infant with a unilateral complete cleft lip and palate. Notice that, as the cleft defect closes with time, lateral arch dimension is maintained, which produces optimal maxillary arch symmetry. (From Jones JE et al: Maxillary arch expansion in cleft lip and palate infants prior to primary autogenous alveolar bone graft surgery, *Quintessence Int* 17:245-248, 1986.)

Primary bone grafting refers to bone-grafting procedures involving alveolar cleft defects in children younger than 2 years of age; this term implies nothing about technique. Secondary bone grafting is usually performed in the mixed dentition stage, between 9 and 12 years of age.

Primary Alveolar Cleft Bone Grafting

Primary alveolar cleft bone grafting is controversial. The concept fell into disfavor in the early 1970s amid numerous reports of significant attenuation in midfacial growth. Use of a primary alveolar cleft bone graft does not necessarily preclude a later secondary alveolar cleft bone graft if it is indicated. The objectives of a secondary cleft bone graft can be somewhat different, as will be seen. Although a recent survey of cleft and craniofacial teams conducted by the American Cleft Palate–Craniofacial Association reported that only 3% of teams perform primary alveolar cleft bone grafting, continued critical evaluation of early alveolar bone grafting and outcomes from cleft centers utilizing this technique is necessary. A different approach to normalizing the cleft alveolar segment relationships has been advocated by Huebener and Marsh.[17] In their treatment protocol, which uses the forces created by either lip adhesion or primary lip closure, a passive alveolar molding appliance similar to that used by Rosenstein is used.[18] The passive appliance does not have an acrylic extension over the alveolar ridges, and it is placed on the day of the lip surgery. The tension created by lip closure acts over time on the anterior alveolar cleft segments (in both unilateral and bilateral clefts) and shapes these cleft segments around the anterior portion of the molding appliance. The appliance is worn by the infant until palatoplasty. Usually at that time the cleft segments are abutting and the torqued maxillary frenum has returned to the midsagittal plane. In this protocol, no primary alveolar bone grafting is performed.

Another technique that has gained favor in some cleft centers is gingivoperiosteoplasty (GPP). This technique takes advantage of the osteogenic properties of infants rather than grafts to bridge the bony cleft of the alveolus. Originally described by Skoog,[19] GPP has the potential of restoring the alveolar arch at the time of infancy through "boneless bone grafting." Mucoperiosteal flaps are raised, usually at the time of cleft lip repair, and then sealed over the alveolar cleft without the use of a primary bone graft. This procedure requires closure of the nasal floor at the time of cleft lip repair and anatomic realignment of the alveolar segments by presurgical orthopedics prior to reconstruction. Although bone formation is possible through GPP, the consistency of bone formation and the avoidance of secondary bone grafting remain areas of active debate. Furthermore, the potential detriment to facial growth and tooth formation has not been entirely elucidated. Despite these limitations, GPP has been embraced in several institutions, and this technique remains an area of active research.

Palatoplasty

Closure of the palate is accomplished by 1 year of age, primarily to facilitate the acquisition of normal speech because this correlates with the age at which most children begin to talk. The procedure may also improve hearing and swallowing by aligning the cleft palatal musculature. Dedicated speech therapy is critical in the years following surgery to optimize palatal function.

After primary closure of the cleft palate, some patients may demonstrate velopharyngeal insufficiency requiring secondary surgery. A persistent inability to close the nasopharynx may result in unsatisfactory speech (nasality and articulation problems), regurgitation of fluids from the nose, and facial grimacing. At Indiana University, of the various surgical approaches to correct velopharyngeal insufficiency, the pharyngeal flap is most commonly used. Velopharyngeal insufficiency is definitely diagnosed by

before the child begins school.

Dental Care

One of the most important aspects of cleft lip and palate care is infant oral health care. It is during this time that the American Academy of Pediatric Dentistry advocates the "age one" dental visit.[20] During this visit, the pediatric

Table **23-1**

Oral Health Risk Factors for Children with Oral Facial Clefting[21]

Caries Risk Factors	Periodontitis Risk Factors
Enamel defects (hypoplasia) of teeth adjacent to the cleft site	Poorly developed osseous supports and lack of proper connective attachment of teeth associated with the cleft
Parents who are overwhelmed with numerous medical needs of the child such that oral health has a comparatively low priority	Abnormalities of size, shape, and number and malalignment of teeth associated with the cleft
Use of an acrylic obturator	Inadequate oral hygiene
Longer oral clearance times	Orthodontic appliances
Permissive parenting, which may allow a highly cariogenic diet and less-than-adequate oral hygiene home care	Subgingival restorations
Orthodontic appliances, which impede adequate hygiene	Discontinuous and infrequent periodontal maintenance
Significant lip scarring and/or malalignment of teeth, which make the cleft area more difficult to clean	
Oral aversion and/or fear of toothbrushing	
Cognitive or motor impairment, which may lead to ineffective oral hygiene	

dentist examines the oral cavity, notes any abnormalities in the soft and hard tissues, and provides anticipatory guidance to the parents regarding oral health care. Also, during this visit, emphasis is placed on the prevention of oral disease. In particular, this first visit offers parents an opportunity to discuss the many developmental issues unique to the cleft deformity (Table 23-1).

STAGE II (PRIMARY DENTITION STAGE: 18 MONTHS TO 5 YEARS OF AGE)

Treatment during the primary dentition stage of dental development is initially focused on establishing and maintaining oral health. Meticulous daily oral hygiene for the child, with emphasis on direct assistance from the parents, is established to reduce the possibility of the development of dental caries. Ectopic eruption of the primary maxillary anterior dentition is common around the cleft defect.

Special care should be taken to keep these teeth free from caries because food is often lodged in and around the cleft defect. An increase in the frequency of periodic recall examinations, possibly to 3- to 4-month intervals, enables the dentist to intercept areas of decalcification. This preventive regimen is continued throughout all subsequent stages in the management of the cleft.

In some extensive cases of unilateral and bilateral complete clefts of the lip and palate, surgical closure is postponed beyond the usual 12 months of age. In these cases, because of the development of speech at this age, maxillary prosthetic appliances are constructed to provide normal maxillary arch integrity (Fig. 23-17). As the child grows, more tissue will become available to close the palate.

STAGE III (LATE PRIMARY OR EARLY MIXED DENTITION STAGE: 6 TO 10 OR 11 YEARS OF AGE)

Many problems encountered during the late primary and mixed dentition stages of dental development arise from ectopically erupting permanent central and lateral incisors or crossbites of the posterior dental segments. Treatment therefore concentrates on correction of a developing traumatic occlusion and posterior segmental alignment. Interceptive correction of a traumatic occlusion is essential to prevent destruction of enamel in the involved dentition (Fig. 23-18). Maxillary expansion to correct posterior segmental collapse is accomplished by routine palatal expansion (Fig. 23-19). This is especially important in patients who have not undergone primary alveolar cleft bone grafting. Once the condition is corrected, retention can be maintained by passive holding appliances.

Secondary Alveolar Cleft Bone Graft

A successful alveolar cleft bone graft satisfies several objectives. In addition to giving bony support for the teeth adjacent to the cleft and providing bone through which teeth can erupt, it offers maxillary arch continuity and aids in closure of the oronasal fistula. It also supports the alar base of the nose.

Conceptually the technique is not difficult, but technically it can be tedious. There are several approaches to developing the required soft-tissue flaps, but all seem to be variations of the technique described by Boyne and Sands.[22] The soft tissue in and adjacent to the cleft side is incised and elevated so that labial and palatal mucosal leaflets are everted to obtain labial and palatal closure. The tissues lining the cleft are elevated and inverted into the nose for nasal floor closure. Particulate marrow and cancellous bone harvested from the iliac crest are placed into the cleft defect, filling it from the piriform rim to the alveolar crest before closure of the labial tissues (Fig. 23-20).

Providing bony support to teeth adjacent to the cleft site is of paramount importance (Fig. 23-21). In most cases bone should be grafted into the cleft before orthodontic tooth alignment is begun. When the cleft is filled with normal, viable bone, the orthodontist can proceed with tooth alignment without fear of exposing a root surface into the cleft site. In fact, after a 2-month healing period, a tooth can be moved into the newly grafted bone with the expectation that the bone will respond to the tooth movement as any normal bone would. Any tooth movement undertaken before the graft is placed could jeopardize the bony support of the teeth adjacent to the cleft.

Dentlearn.ir

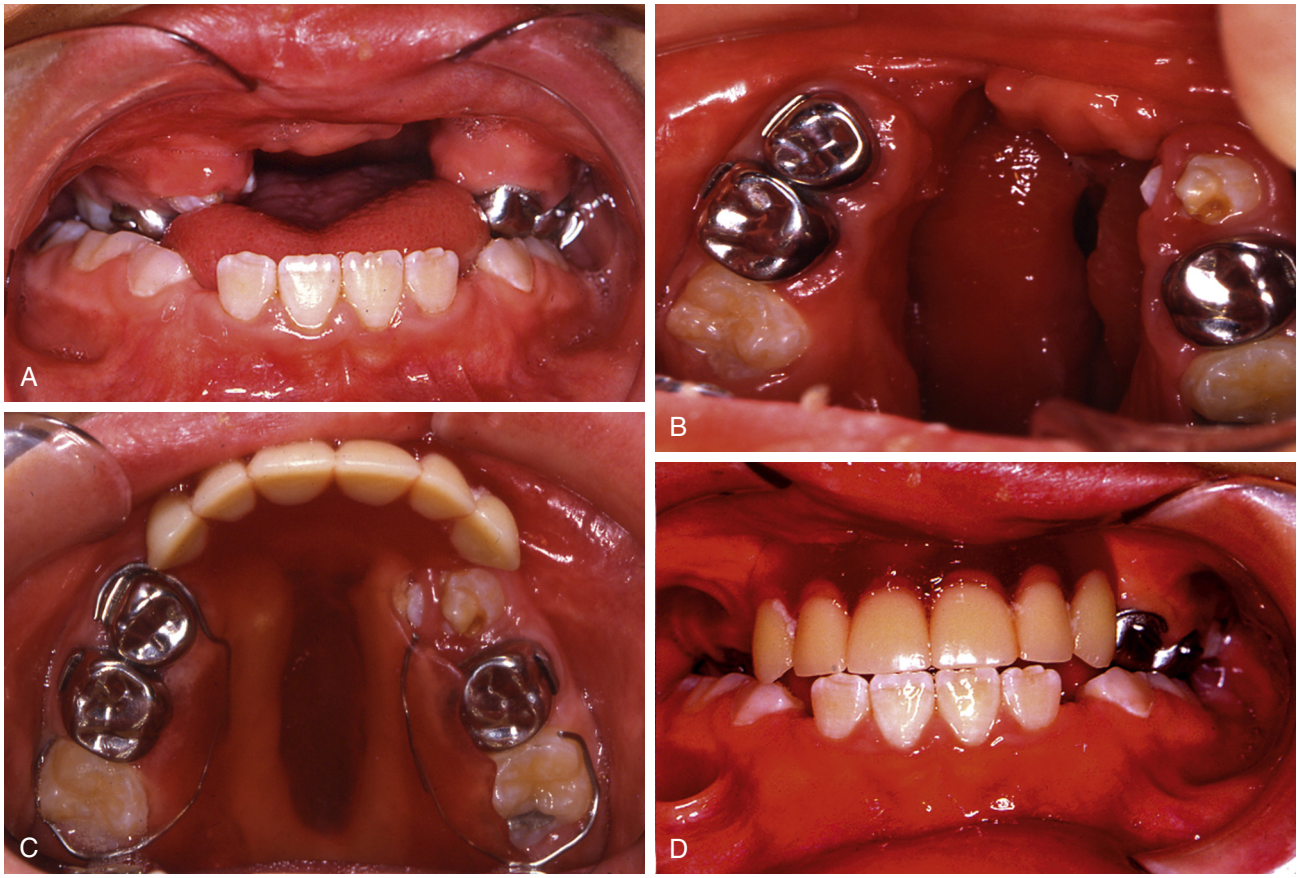

Figure 23-17 **A,** Intraoral view of a unilateral complete cleft lip and palate. Because of the extensive cleft of the hard and soft palates, the treatment of choice was prosthodontic obturation of the defect until growth was sufficient to allow for definitive surgical closure. **B,** Maxillary arch demonstrating extensive cleft palate requiring an interim prosthesis. **C,** Interim maxillary prosthesis in place. This effectively closes the oral cavity from the nasal cavity and facilitates mastication and speech. The appliance is removed daily for cleaning. **D,** Interim prosthesis in occlusion. The prosthetic anterior teeth provide support of the upper lip and improve aesthetics.

As a related consideration, grafted bone that obliterates the alveolar cleft also provides bone through which teeth can erupt. When canines and, in some cases, central incisors are allowed to erupt before bone grafting, they often lack adequate periodontal bone support. When the bone graft precedes permanent tooth eruption, compromised periodontal situations can often be prevented. El Deeb and colleagues studied the eruption patterns of canines through grafted bone in alveolar cleft defects.[23] They found that canine teeth erupted spontaneously through the grafted bone but that this eruption may be later than normal and takes longer. In their study, 27% of the canines erupted spontaneously. The remainder required surgical uncovering and orthodontic forces to accomplish eruption and alignment in the arch. Turvey and associates found the rate of spontaneous eruption to be 95%, which represents a significant difference.[24] However, the point is that canines can and do erupt through the grafts. If eruption seems greatly delayed, surgical and orthodontic intervention is appropriate.

El Deeb and colleagues have recommended that the graft be placed between 9 and 12 years of age, when the canine root is one quarter to half formed.[23] They reported that the canine subsequently has normal root development and that morphologic conditions will be unaffected by the surgical procedure.

Restoring maxillary arch continuity and stabilizing the maxillary segments represent other major objectives. In the case of a bilateral cleft, the premaxilla is stabilized as the bone grafts are incorporated between the premaxilla and the lateral maxillary segments. In the process, the alveolar ridge contour is restored so that the ability to provide a stable, aesthetic prosthesis is enhanced. There is often some degree of collapse of the maxillary arch form. It is possible to expand the arch after grafting, as pointed out by Boyne and Sands[25]; however, it is preferable to expand these collapsed segments to as optimal an arch form as possible before grafting. Pregraft expansion also widens the cleft site, which allows better access for nasal floor closure. After the arch expansion has occurred, the bone graft can be placed. After the graft has been incorporated, it can be expected to maintain a good arch form.

Closure of the oronasal fistula is often the most significant result of bone graft surgery, according to patients, who often experience fluid regurgitation into the nose and mucus drainage from the nose into the oral cavity



Figure 23-18 Interceptive correction, in the mixed dentition, of a full maxillary left crossbite in a complete unilateral cleft lip and palate. **A,** Diagnostic models for a unilateral complete cleft lip and palate. Notice the presence of a crossbite extending from the maxillary left central incisor to the maxillary first permanent molar. **B,** Occlusal views of maxillary and mandibular models. Notice the pronounced asymmetry of the maxillary arch. **C,** Occlusion with fixed appliances in place on the maxillary arch. **D,** Occlusal view demonstrating removable W-arch to correct the posterior segmental crossbite. **E,** Occlusal view demonstrating correction of posterior crossbite and improved alignment of the maxillary anterior segment. Notice the improved maxillary arch symmetry. **F,** Occlusion at the end of interceptive therapy. Notice the correction of the anterior and posterior crossbites. At this time, the patient is ready for secondary alveolar bone grafting (see text for the description of secondary bone-grafting procedure).

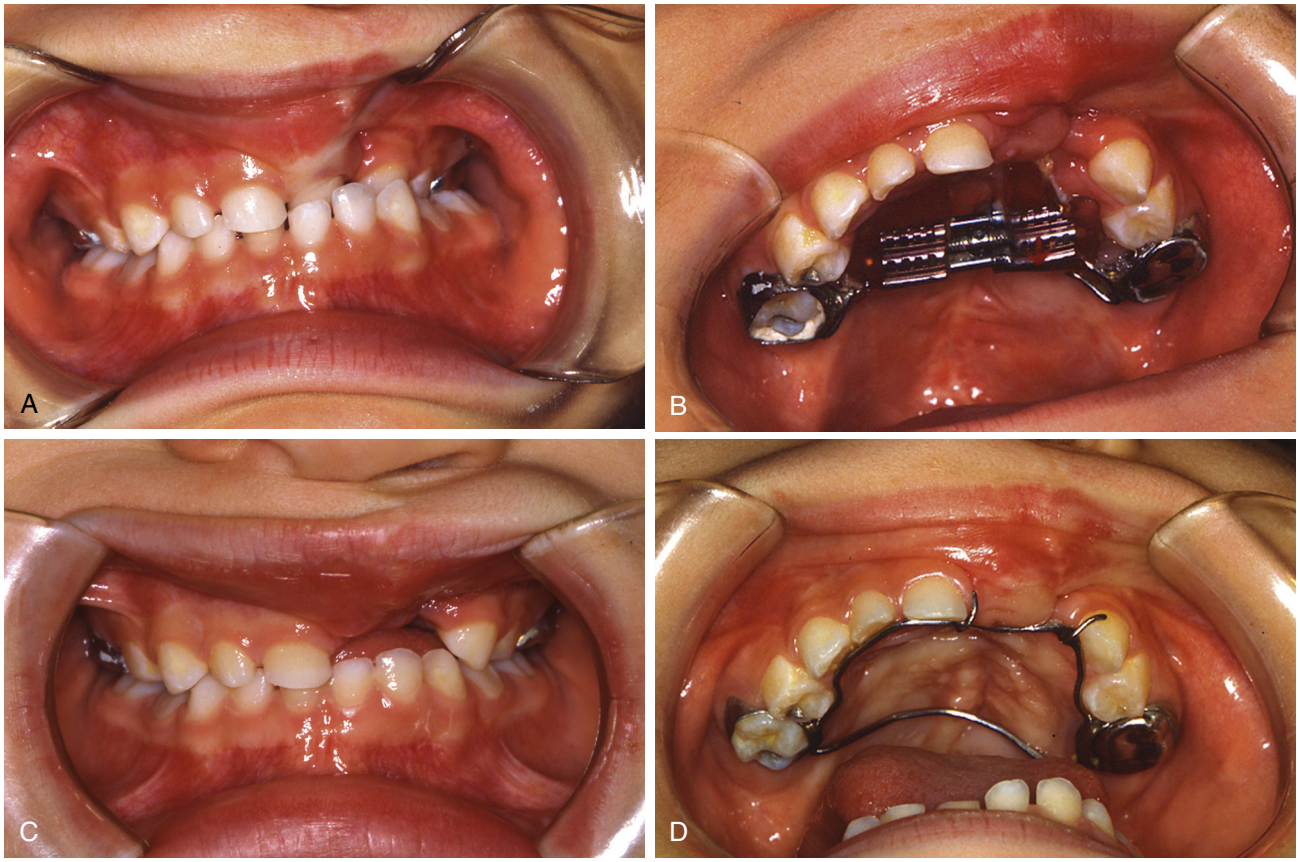

Figure 23-19 Interceptive correction, in the primary dentition, of a full maxillary left crossbite in a complete unilateral cleft lip and palate. **A,** Occlusion demonstrating a crossbite from the maxillary left primary incisor extending to the second primary molar. **B,** Fixed palatal expander in place on the maxillary arch at the completion of expansion. The left primary central incisor, loosened by traumatic occlusion before initiation of therapy, exfoliated during treatment. **C,** Occlusion at the completion of interceptive therapy. Notice the correction of the posterior crossbite. **D,** Placement of a passive maxillary arch-holding appliance to maintain optimal arch symmetry until the time of secondary alveolar bone grafting.

through the fistula. Depending on its size, the fistula can produce significant speech problems because air escapes when the patient phonates. Although closure of this fistula can be affected with only soft-tissue closure, Enemark and associates have indicated that closure is more successful when combined with a bone graft.[26]

With a cleft maxilla, the cleft extends through the piriform rim beneath the alar base of the nose. As a result, the alar base on the cleft side is often depressed because of lack of underlying bony support. Filling the cleft with bone provides underlying bony support that often elevates the alar base of the nose. Although this may not entirely correct any existing nasal deformity, it does provide good support over which nasal reconstructive and revision surgery can be accomplished.

Secondary alveolar cleft bone grafting has been widely accepted. According to several researchers,[25,27-31] success rates are generally around 90%. Morbidity includes pain in the donor site, dehiscence of mucosal flaps, and partial or complete loss of grafted bone. Infection in the donor or recipient sites has been rare. There has been increasing interest in many cleft centers in decreasing the morbidity of secondary alveolar grafts by replacing iliac bone with growth factors such as bone morphogenetic protein combined with cadaveric bone or other nonautogenous implants.[32,33] The advantages to function and decreasing morbidity are topics of active debate. The potential morbidity of placing bone growth factors in the growing dental arch has prevented many surgeons from embracing this treatment option.[34] Secondary alveolar cleft bone grafting is an important procedure that greatly facilitates total habilitation. Not only is speech improved but dental, aesthetic, and psychosocial benefits are also to be gained. It is necessary, again, to emphasize the different objectives of primary and secondary grafting and to reiterate that they are not mutually exclusive procedures. The primary graft, over time, may satisfy some or all the objectives of secondary grafting. However, due to risks to future facial growth and aesthetics, primary grafting has been abandoned by most cleft centers in favor of secondary grafting only.

Effect of Facial Aesthetics on Self-Concept

Appearance helps determine how an individual interacts with society and, in turn, how society perceives and accepts that individual. Facial aesthetics is especially important to the development of self-concept. A child born with a serious congenital facial anomaly may find adaptation difficult. For example, Striker and

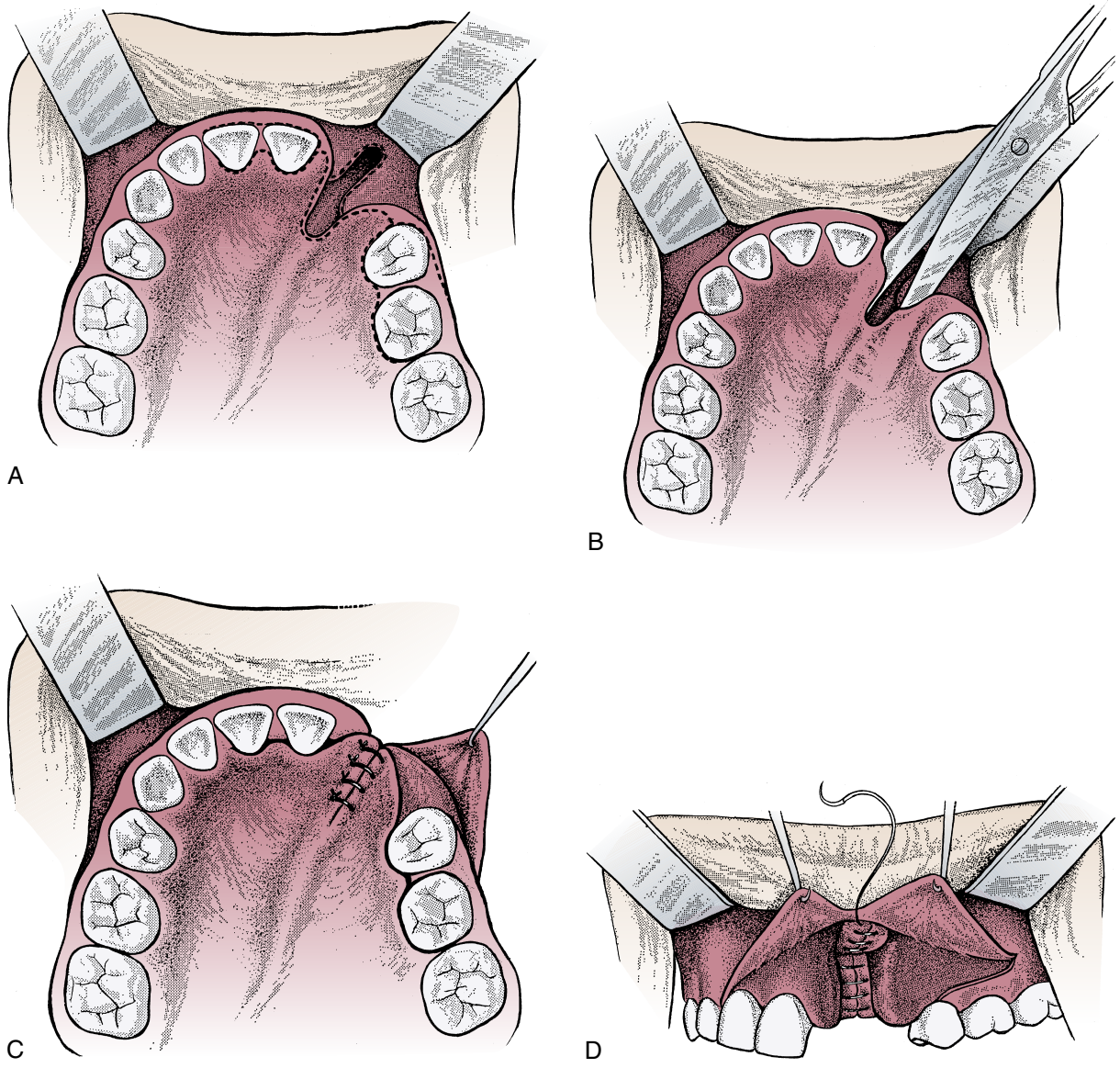

Figure 23-20 Technique for secondary alveolar cleft bone graft. **A,** Mucosal incisions outlined. **B,** Development of palatal mucoperiosteal flap. **C,** Closure of palatal mucosa. **D,** Closure of nasal mucosa within cleft site.

continued

associates have stated that the psychological sequelae of cleft lip and palate may have as great an impact on the individual as the physical aspects.[34] MacGregor stressed that, because of society's emphasis on physical attractiveness and conformity, the role of the face in interactions with others is such that many problems associated with cleft lip and palate involve considerations of mental health.[35] Revisional surgery to the lip and nose can be considered at this time to assist in psychosocial development.

Of special importance in the comprehensive dental management of cleft lip and palate is the dentist's ability to provide the young patient with interim prostheses to improve facial appearance (Fig. 23-22). These can be periodically adjusted to allow for eruption of the developing dentition. Such treatment, when possible, should begin before the child starts formal education.

STAGE IV (PERMANENT DENTITION STAGE: 12 TO 18 YEARS OF AGE)

The majority of persons with cleft lip and palate require some degree of orthodontic management and can be treated conventionally. Some patients with clefts, however, will require a combined orthodontic-surgical approach in the permanent dentition to achieve optimal outcome. Before initiating the indicated therapy, the orthodontist completes a full diagnostic examination to determine the status of the patient's craniofacial development.

Most orthognathic surgical procedures involving the maxilla and mandible are deferred until the teenage years, when maximum growth of the jaws has been attained and all permanent teeth except the third molars have erupted. In boys, surgeons usually delay osteotomies until approximately 17 to 18 years of age; in girls,

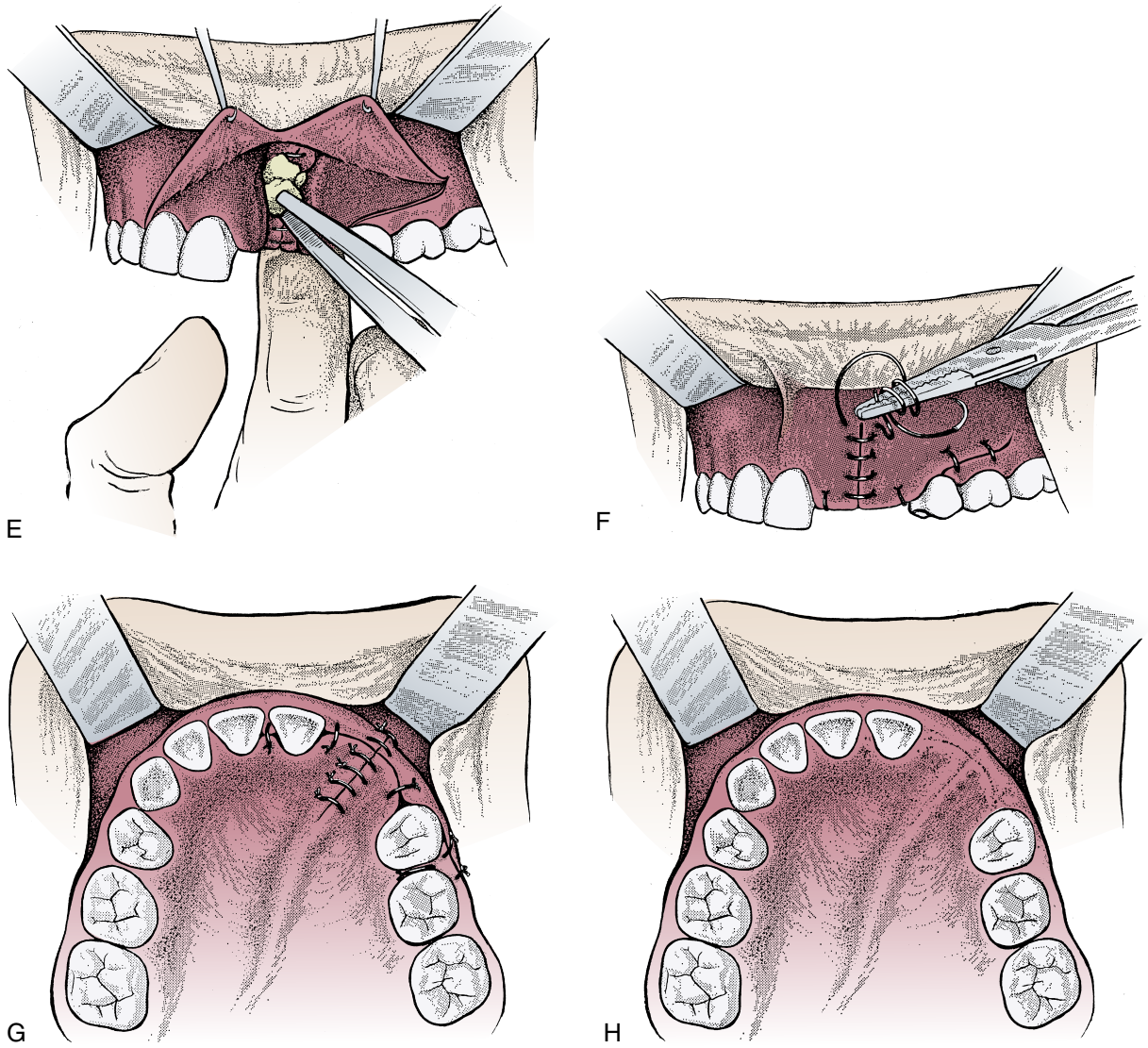

Figure 23-20, cont'd **E,** Placement of fresh autogenous bone into the cleft defect. **F** and **G,** Reapproximation and closure of mucoperiosteal flaps. **H,** The reconstructed maxillary alveolus.

because of earlier maturation, surgery after 15 years of age is possible. The manner in which the maxilla and mandible relate to each other spatially after growth is frequently difficult to predict based on the patient's appearance as a child. An example is the patient with a complete bilateral cleft lip and palate who has a protuberant premaxilla at birth. In childhood, the lateral profile may appear severely convex, and the initial impression is that the patient will require a premaxillary segment surgical setback. This could be an erroneous assumption, and corrective surgery could be potentially deleterious if it is performed at an early age. With time, many of these persons acquire an essentially normal lateral facial profile. By the time maximum growth has been attained, a surprising number of these persons acquire a more normal convex profile.

In some instances children with a cleft with a severely retrusive maxilla cannot undergo orthodontic correction with conventional therapy. In these cases the surgical procedure often used is the LeFort I maxillary advancement with or without setback of the lower jaw. This procedure is not technically feasible until the patient has a full complement of permanent dentition. The horizontal cuts to free the maxilla must necessarily be made above the apexes of the permanent dentition. At times the maxilla will require partition into two or three segments to achieve full dental restoration. Unerupted cuspids or bicuspids would make this procedure impractical. Therefore surgery must be deferred until the permanent dentition has erupted.

Cosmetic Surgery

Major nasal bone surgery may be deferred until the patient is in the early teens and after orthognathic surgery. These procedures help restore projection, symmetry, refinement, and airflow to the nose. However, cartilaginous nasal tip asymmetries may be corrected at any time. Additional tip-cartilage revisions may be performed as needed.

Dentlearn.ir

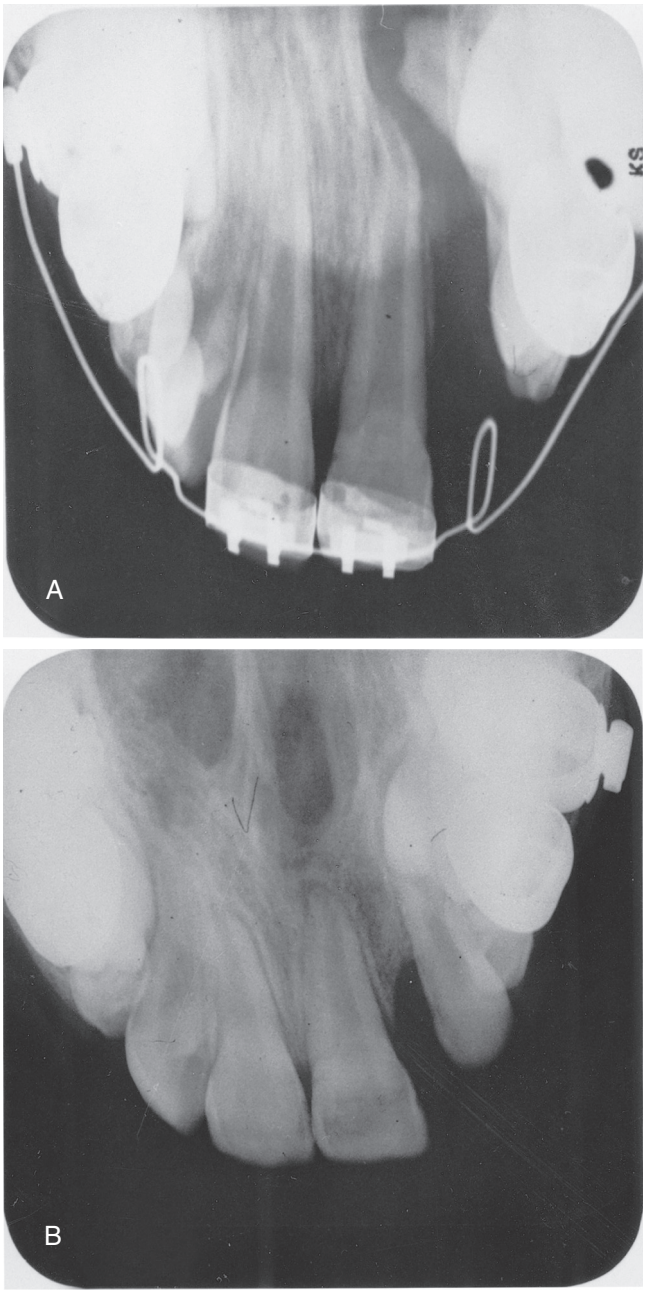

Figure 23-21 **A,** Pregraft maxillary occlusal radiograph demonstrating cleft defect with thin layer of bone over the distal root surface of the maxillary left central incisor. The canine has not started to erupt. **B,** Postgraft maxillary occlusal radiograph demonstrating consolidation of bone across the cleft defect. Preliminary orthodontic alignment has been completed. The canine can be expected to erupt through the grafted area. (From Nelson CL et al: Indiana's craniofacial anomalies team: dentists play an important role, *J Indiana Dent Assoc* 65(6):9-13, 1986.)

Common secondary deformities of the repaired unilateral or bilateral cleft lip include an upper lip that is too long or short, a tight upper lip, a deficiency of the vermilion tissue, and residual clefts (or notching) of the lip. Final surgical revision is frequently deferred until the mid to late teens, to eliminate the variable of future



Figure 23-22 **A**, Plaster model of patient's maxillary arch ready for construction of the interim denture. **B,** Transitional maxillary complete overdenture. Such appliances may be used several years without replacement. **C,** Transitional maxillary overdenture in place. The patient's self-esteem is greatly enhanced by his essentially normal facial aesthetics.

facial growth on the surgical result. It is also prudent to defer final lip revisions until the completion of any surgical or orthodontic treatment that will change the osseous or dental support of the upper lip.

REFERENCES

1. Parker SE, et al.: Updated National Birth Prevalence estimates for selected birth defects in the United States, 2004-2006, *Birth Defects Res A Clin Mol Teratol* 88(12):1008–1016, 2010.
2. Harkins CS, et al.: A classification of cleft lip and palate, *Plast Reconstr Surg* 29:31–39, 1962.
3. Veau V: Treatment of the unilateral harelip, *Int Dent Congress 8th Trans* Paris:126–131, 1931.
4. American Cleft Palate-Craniofacial Association: Parameters for the evaluation and treatment of patients with cleft lip/palate or other craniofacial anomalies, *Cleft Palate–Craniofac J* 30(Suppl 1): 2000, revised 2007.
5. Whitehouse FA: Treatment as a dynamic system, *Cleft Palate J* 2:16–27, 1965.
6. Chibbaro P, Barzilai J, Breen M: Nursing care of the patient with a cleft lip and palate. In Loose J, Kirschner R, editors: *Comprehensive cleft care*, New York, 2009, McGraw-Hill, pp 150–167.
7. McNeil CK: *Oral and facial deformity*, London, 1954, Pittman.
8. McNeil CK: Congenital oral deformities, *Br Dent J* 101:191–198, 1956.
9. Jones JE: *The use and clinical effectiveness of the maxillary obturator appliance in cleft lip and palate infants: birth through six months of age [Doctoral dissertation]*, San Jose, Costa Rica, 2003, Empresarial University.
10. Pashayan HM, McNab M: Simplified method of feeding infants with cleft palate with or without cleft lip, *Am J Dis Child* 133:145–147, 1979.
11. Hofman JP: *De labiis leoporinis/von Hasen-Scharten*, Heidelberg, 1686, Bergmann.
12. Pool R, Farnworth TK: Preoperative lip taping in the cleft lip, *Ann Plast Surg* 32(3):243–249, 1994.
13. Monasterio L, et al.: Comparative study of nasoalveolar molding methods: nasal elevator plus DynaCleft® versus NAM-Grayson in patients with complete unilateral cleft lip and palate, *Cleft Palate Craniofac J* 50(5):548–554, 2013.
14. Latham RA, et al.: An extraorally activated expansion appliance for cleft palate infants, *Cleft Palate J* 13:253–261, 1976.
15. Grayson BH, Cutting CB: Presurgical nasoalveolar orthopedic molding in primary correction of the nose, lip, and alveolus of infants born with unilateral and bilateral clefts, *Cleft Palate Craniofac J* 38:193–198, 2001.
16. Barillas I, et al.: Nasoalveolar molding improves long-term nasal symmetry in complete unilateral cleft lip-cleft palate patients, *Plast Reconstr Surg* 123:1002–1006, 2009.
17. Huebener DV, Marsh JL: A survey of early management of cleft lip and palate—the first 18 months, *Unpublished data presented at the American Cleft Palate–Craniofacial Annual Meeting*, 2002.
18. Rosenstein SW: Orthodontic and bone grafting procedures in a cleft lip and palate series: an interim cephalometric evaluation, *Angle Orthod* 45:227–237, 1975.
19. Skoog T: The use of periosteum and Surgicel for bone restoration in congenital clefts of the maxilla, *Scand J Plast Surg* 1:113–130, 1967.
20. American Academy of Pediatric Dentistry: Guideline on infant oral health care, In *American Academy of Pediatric Dentistry Reference Manual 2008-9*, Chicago, 2009, American Academy of Pediatric Dentistry, pp 90–92.
21. Wells M: Oral health status of children with craniofacial anomalies, *Pediatr Dent* 35(3):E79–E86, 2013.
22. Boyne PJ, Sands NR: Secondary bone grafting of residual alveolar and palatal clefts, *J Oral Surg* 30:87–92, 1972.
23. El Deeb M, et al.: Canine eruption into grafted bone in maxillary alveolar cleft defects, *Cleft Palate J* 19:9–16, 1982.
24. Turvey TA, et al.: Delayed bone grafting in the cleft maxilla and palate: a retrospective multidisciplinary analysis, *Am J Orthod* 86:244–256, 1984.
25. Boyne PJ, Sands NR: Combined orthodontic surgical management of residual palato-alveolar cleft defects, *Am J Orthod* 70:20–37, 1976.
26. Enemark H, et al.: Secondary bone grafting in unilateral cleft lip and palate patients: indications and treatment procedure, *Int J Oral Surg* 14:2–10, 1985.
27. Bertz JE: Bone grafting of alveolar clefts, *J Oral Surg* 39: 874–877, 1981.
28. Hall HD, Posnick JC: Early results of secondary bone grafts in 106 alveolar clefts, *J Oral Maxillofac Surg* 41:289–294, 1983.
29. Kortebein MJ, Nelson CL, Sadove AM: Retrospective analysis of 135 secondary alveolar cleft bone grafts, *J Oral Maxillofac Surg* 49:493–498, 1991.
30. Kwon HJ, et al.: The management of alveolar cleft defects, *J Am Dent Assoc* 102:848–853, 1981.
31. Troxell JB, Fonseca RJ, Osbon DB: A retrospective study of alveolar cleft grafting, *J Oral Maxillofac Surg* 40:721–725, 1982.
32. Canan LW Jr, et al.: Human bone morphogenetic protein-2 use for maxillary reconstruction in cleft lip and palate patients, *J Craniofac Surg* 23(6):1627–1633, 2012.
33. Dickinson BP, et al.: Reduced morbidity and improved healing with bone morphogenic protein-2 in older patients with alveolar cleft defects, *Plast Reconstr Surg* 121(1):209–217, 2008.
34. Striker G, et al.: Psychosocial aspects of craniofacial disfigurement: a "state of the art" assessment conducted by the Craniofacial Anomalies Program Branch, the National Institute of Dental Research, *Am J Orthod* 76:410–422, 1979.
35. MacGregor FC: Social and psychological implications of dentofacial disfigurement, *Angle Orthod* 40:231–233, 1970.

CHAPTER 24

Prosthodontic Treatment of the Adolescent Patient

▲ David T. Brown and Mathew T. Kattadiyil

For additional resources, please visit the evolve website.

CHAPTER OUTLINE

RESTORATION OF SINGLE MALFORMED, DISCOLORED, OR FRACTURED TEETH
- All-Ceramic and Metal-Ceramic Crowns
- Teeth with Pulpal Involvement

FIXED PARTIAL DENTURES
- Resin-Bonded Retainers
- Complete Crown Retainers
- Fixed Partial Denture Pontics

REMOVABLE PARTIAL DENTURES
OVERDENTURES
IMPLANT PROSTHESES
- Implant Usage Before Growth Completion
- Implants for Orthodontic Anchorage

RECARE PROGRAM
PROTECTIVE MOUTHGUARDS

Scientific advancements in the areas of preventive dentistry, access to and use of dental services, water fluoridation, topical application of fluorides, and new commercial preventive dentistry products have led to substantial reductions in the incidence of dental diseases in developed countries. However, Caplan and Weintraub determined that adolescents are still affected by caries, particularly those who are minorities, are rural inhabitants, have minimal fluoride exposure, and are from less educated and less affluent families.[1] Results of a health and nutrition survey reported by Vargas and colleagues also support a higher caries prevalence among lower-income children and minorities.[2] Assessments of periodontal health by Barmes and Leous[3] show a decrease in the severity of periodontal disease.

Dental trauma continues to be a significant problem among adolescents, as supported by Gift and Bhat's assessment of orofacial injury[4] and by Bader and colleagues' estimates of the incidence and consequences of tooth fracture.[5] In addition, bulimia, anorexia, and dietary habits have led to an increase in the erosion of tooth structure among teenagers, particularly in girls.

Some of the aesthetic treatment needs resulting from these conditions can be managed with resin-bonding procedures and porcelain laminate veneers, and, whenever possible, these should be considered as first-choice treatments. When these procedures have not provided a satisfactory result or when teeth are missing, then prosthodontics such as single crowns, fixed partial dentures, implant prostheses, or removable prostheses are indicated.

Because adolescents are often affected psychologically by the unacceptable appearance of diseased, damaged, or missing teeth, one should not allow chronologic age to preclude performance of whatever treatment is necessary to provide proper function and aesthetics.[6] If the teeth involved are fully erupted, have achieved complete root formation, and may be prepared without causing irreversible damage to the pulp, successful prosthodontic treatment can often be provided for patients as young as 12 to 14 years of age. Patient cooperation, however, is mandatory during and after treatment. Adolescent patients must be able to tolerate long appointments and remain still for extended periods while teeth are being prepared and impression materials are setting. Also, they must be able to achieve and maintain good oral hygiene around both the provisional and definitive restorations, as well as in the rest of the mouth. All these conditions make it highly desirable for the necessary treatment to be performed as expeditiously as possible. Finally, it must be understood that an adolescent is more likely to sustain trauma to the oral structures than is an adult; thus there is greater risk of damage to restorations and prostheses than in an adult patient.

Prosthodontic treatment of the adolescent patient often requires highly intricate procedures that go beyond the scope of this chapter. The goal of this chapter is to offer the reader an opportunity to develop a better appreciation of the achievable and available solutions for the young patient with a prosthodontic need. The interested reader should consult the prosthodontic literature and current textbooks on fixed, removable, and implant prosthodontics for more detailed information in this area of dentistry.

RESTORATION OF SINGLE MALFORMED, DISCOLORED, OR FRACTURED TEETH

ALL-CERAMIC AND METAL-CERAMIC CROWNS

Crowns are indicated only when more conservative treatments cannot be performed or have proven to be unsuccessful. All-ceramic crowns are the most aesthetic full coverage crown restorations currently available in dentistry. The achievement of optimal longevity with all-ceramic

Dentlearn.ir

crowns requires normal tooth preparation form because the prepared tooth must provide support for the restoration. Therefore, if a large portion of tooth structure is missing because of trauma or caries or if previous restorations become dislodged during tooth reduction, then a separate restoration that is well retained in remaining tooth structure should be placed to establish an ideal preparation form (Fig. 24-1). Also, the fracture resistance of all-ceramic crowns is enhanced when other characteristics are present. Occlusal forces should be average or below average. The centric occlusal contacts should ideally be located over the concave lingual portion of the prepared tooth and not cervical to the cingulum, where fracture of the crown is more likely to occur. The prepared tooth should possess average or greater incisocervical length and should not be short, round, or overtapered.

The tooth preparation for an all-ceramic crown (Fig. 24-2) should possess a well-defined, smooth finish line that is 0.8 mm deep around the entire tooth, with the axial surfaces reduced to a depth of 0.8 mm. The lingual reduction for occlusal clearance should be 1 mm. An incisal edge reduction of 1.5 to 2 mm is required and is biologically acceptable even in the presence of large pulps. The use of resin cement and associated dentin bonding is recommended because crown strength is significantly improved. Both chamfer and shoulder finish lines can be used in conjunction with resin cement without compromising restoration strength. If zinc phosphate or glass-ionomer cement is used, however, then a shoulder finish line should be used to optimize crown strength.

When the ideal tooth preparation form is seriously compromised or the magnitude of occlusal forces contraindicates restoration with an all-ceramic crown, use of the stronger metal-ceramic crown is indicated. The tooth preparation design and reduction depths for a metal-ceramic crown are shown in Figure. 24-3. When cervical aesthetics must be optimized in a metal-ceramic restoration, one can use a collarless design that eliminates facial cervical metal and uses a porcelain facial margin (Figs. 24-4 and 24-5).

Whenever possible, cervical margins should not be extended into the gingival sulcus of an adolescent patient. If oral hygiene is inadequate, subgingival margins may produce accelerated gingival recession or interfere with the normal cervical relocation of the gingival tissues as the patient matures. Both occurrences produce an aesthetic liability (Figs. 24-6 and 24-7).

TEETH WITH PULPAL INVOLVEMENT

When tooth fracture or caries involves the pulp and root development is complete, a routine pulpectomy and gutta-percha root canal filling should be completed. Because posts and cores do not strengthen endodontically treated teeth, their use is indicated only when the remaining coronal tooth structure does not provide adequate retention for definitive restoration. Restorations that do not use a post should be used whenever possible to replace missing tooth structure and serve as a retentive foundation. It is particularly important that the teeth in the mouths of accident-prone adolescents or in whom athletic trauma has previously occurred be restored without a post, if possible.



Figure 24-1 **A,** Traumatically injured central and lateral incisors that have been restored with bonded resins and then prepared to receive all-ceramic crowns. **B,** All-ceramic crowns have been cemented.

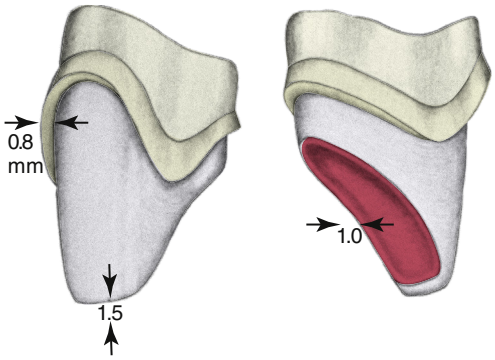

Figure 24-2 Two views of all-ceramic (porcelain jacket crown) preparation showing recommended reduction depths and shoulder finish line.

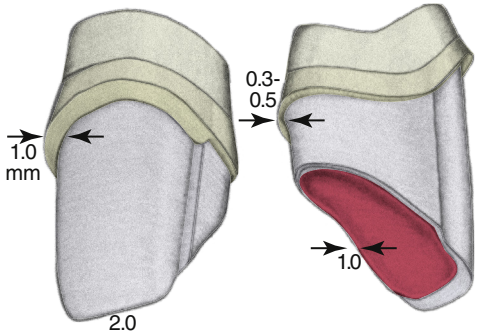

Figure 24-3 Two views of metal-ceramic crown preparation showing minimal facial reduction and shoulder finish line, minimal incisal reduction, lingual axial reduction depth and chamfer finish line, and lingual reduction for occlusal clearance.

Dentlearn.ir

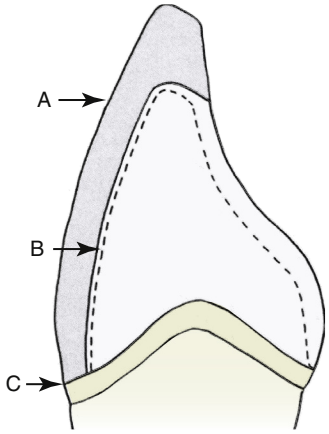

Figure 24-4 Collarless metal-ceramic framework design that eliminates visible cervical metal. *A* indicates porcelain; *B* indicates the underlying metal framework that does not cover shoulder finish line; and *C* is the margin where porcelain comes into contact only with the prepared tooth.



Figure 24-5 **A,** The maxillary lateral incisor was traumatically injured, resulting in loss of the incisal one third and much of the lingual surface. The tooth has been prepared for a metal-ceramic crown with a porcelain margin (collarless metal-ceramic crown). **B,** The lateral incisor crown has been cemented.



Figure 24-6 Gingival contour in 25-year-old patient resulting from placement of subgingival crown on maxillary right central incisor at 8 years of age. The gingival crest is not positioned as far apically on the restored central incisor, and its form is rounded and thick rather than the normal form of the gingival margin, which is thinner and sharper.



Figure 24-7 Accelerated gingival recession around maxillary left central incisor resulting from metal-ceramic crown with subgingival margins placed at a young age. The gingiva is edematous and red, and the gingival margin is rounded and thick.

This practice helps avoid irreparable damage in the form of root fracture in case the restored tooth is once again subjected to trauma. Even though trauma may result in restoration dislodgement or perhaps even fracture of the tooth, the tooth will have survived at least one more traumatic experience.

In the case of pulpal involvement when the root is incompletely formed, a pulpotomy followed by placement of an appropriate restoration is indicated. Subsequently, when root formation is completed, a pulpectomy is performed, followed by placement of the definitive restoration or crown, if needed.

FIXED PARTIAL DENTURES

When a tooth is lost, space maintenance should be provided immediately after extraction to prevent tipping, tilting, or rotation of the abutment teeth or eruption of the opposing teeth. Space maintenance should be continued until the fixed prosthesis is completed. If the abutment teeth are malaligned and pulp size does not permit the amount of tooth reduction necessary to align the preparations, orthodontic repositioning of the abutment teeth should be initiated.

The use of conventional fixed partial dentures, requiring complete crown tooth preparations, is decreasing in adult patients due to the use of dental implants and occurs only sparsely in adolescents. Contemporary treatment planning more frequently indicates that an interim fixed or removable prosthesis be used until such time as growth is completed and dental implants can be placed. When an interim fixed prosthesis is needed, resin-bonded fixed partial dentures are a good choice. When implants will not be used or have not been successful, fixed partial dentures become an appropriate definitive treatment. These fixed partial dentures can use conventional complete crown retainers, or they can use resin-bonded retainers designed for long-term service.

RESIN-BONDED RETAINERS

For reasons of pulpal and periodontal health and conservation of tooth structure, resin-bonded retainers are

frequently used to replace missing teeth when dental implants are not being used (Fig. 24-8). Retention and resistance form is achieved through tooth preparations, terminating in enamel, coupled with acid-etching of the enamel and fixation with resin cement. The conservative approach of using resin-bonded retainers, however, does require that the abutment teeth be intact or minimally restored, with substantial enamel present for bonding procedures. To produce an adequate area for resin bonding, the existing crown should be of average or greater length. A maximal amount of the invisible portions of the lingual and proximal surfaces should be covered by the retainers to increase bonding surface area. The existing crown form, color, and axial alignment must be satisfactory because this prosthesis design does not permit the incorporation of changes in the facial enamel of abutment teeth. When abutment crown contours or color requires aesthetic changes, then complete crown retainers may produce a superior result.

These prostheses can be successful for many years, but suitable attention must be paid to four factors: (1) appropriate diagnosis and treatment planning, (2) correct tooth preparation, (3) good-fitting castings, and (4) meticulous adherence to the required resin-bonding procedures.

Several factors important to diagnosis and treatment planning have been identified. Prostheses with only one pontic have much higher success rates, so the use of long-span prostheses should be avoided. Multiple splinted retainers are associated with higher failure rates. The use of resin-bonded cantilevered prostheses (with only one retainer) has been reported, and analysis of data from Hussey and associates[7] and Leempoel and colleagues[8] indicates that this type of design can be used successfully in certain situations such as a missing maxillary lateral incisor (Fig. 24-9).

Preparation of abutment teeth for resin-bonded prostheses is not recommended for prostheses that will be used only on an interim basis. However, when long-term service is needed, tooth preparation has been found to substantially reduce debonding of retainers.

Barrack and Bretz determined that the successful use of resin-bonded prostheses requires establishment of retention and resistance form through tooth preparation (see Fig. 24-9, *B* and Fig. 24-10).[9] Because the tooth preparation is limited principally to enamel, these retainers can be used without pulpal damage and the teeth can often be prepared without anesthesia. The proximal surfaces adjacent to the edentulous area should be reduced to remove interproximal undercuts and to provide parallel surfaces that aid retention. One or two proximal grooves must be placed to enhance the resistance and retention form (see Fig. 24-10, *A*). Proximal grooves have been identified as a key factor in the resistance to debonding.[10] The tooth preparation should include a small peripheral chamfer finish line (see Fig. 24-10, *B*) formed with the tip of a rounded-end diamond instrument. The lingual surfaces of anterior teeth are reduced to create occlusal clearance with the opposing teeth. The minimal occlusal clearance space for short-span (three-unit) prostheses with normal occlusal forces is 0.5 mm. It may not be necessary to reduce the abutment teeth lingually when there is existing occlusal clearance, whereas reduction of opposing teeth



Figure 24-8 **A,** Congenitally missing maxillary lateral incisors. **B,** Resin-bonded prostheses were used instead of conventionally cemented prostheses to preserve as much tooth structure as possible on the central incisor and canine abutments.

may be necessary when occlusal contact occurs over broad areas of the lingual surfaces. Multiple ledges, prepared across the reduced lingual surface (see Fig. 24-10, *C*), increase the casting rigidity and, along with the proximal grooves, aid in retention and resistance form and in orientation of the casting during cementation.

The preparation of posterior abutment teeth should include reduction of the proximal surfaces to eliminate undercuts and to produce minimal occlusal convergence for retention and resistance form. The reduction should also include lingual surfaces and at least 180° of circumferential reduction, as determined by Creugers and colleagues.[11] One or two proximal grooves are placed, one or two occlusal rest seats are prepared,[9] and a small chamfer finish line is formed. The use of an inlay-like occlusal rest has been advocated to increase resistance and retention form. The occlusal aspect of the lingual cusp can also be slightly reduced and covered with metal to increase the bonding area and prosthesis retention (Fig. 24-11).

A metal-ceramic alloy is used for the prosthesis framework, which allows porcelain to be bonded over the visible facial surfaces of pontics to meet aesthetic requirements. Several design variations are used for the retainer castings, differing in the manner in which the resin mechanically

Dentlearn.ir



Figure 24-9 **A,** Congenitally missing maxillary lateral incisor. **B,** Incisal view of the bonded two-unit prosthesis where the lateral incisor pontic has been cantilevered from the maxillary canine. **C,** Facial view of the completed prosthesis.

interlocks with the surface of the casting that comes into contact with the prepared teeth.

The first prosthesis design featured retainer castings that were perforated lingually, which allowed resin to encompass the casting. Subsequently, a technique was introduced that used a base metal alloy and thereby took advantage of the ability of the alloy to be acid-etched to provide microscopic areas of retention (Fig. 24-12). This technique is not suitable for use with gold-containing alloys because they cannot be etched in this manner.

An alternative method of treating the metal surface to provide retention for the resin is to subject the bonding surface to airborne-particle abrasion with 50-μm aluminum oxide. This method provides retention comparable with that of chemically etched metal and can be used with any casting alloy.[12]

The completed prosthesis is first trial-seated so that any required adjustments of form, color, occlusion, and glaze can be completed. The prosthesis should then be cleaned ultrasonically to remove debris that may be present in the retentive areas and dried thoroughly with clean, dry, compressed air.

Cementation of the prosthesis with the acid-etching and resin procedure requires optimal moisture control, which is best obtained with use of a rubber dam. Composite resins specially designed for cementation of this type of prosthesis are used. After isolation of the prepared teeth (Fig. 24-13), the enamel is acid-etched in the usual manner, rinsed, and dried. The resin is applied to the casting and the prosthesis seated (see Fig. 24-13, *B*). Excess cement is quickly removed, and the prosthesis is held motionless until polymerization is complete. Resin cement left in interproximal undercut areas until hard can be very difficult to remove.

Opaque resins can be used to help mask the metal when abutment teeth are very translucent. This procedure helps reduce the darkening effect of lingual metal showing through the incisal aspect of a tooth. Also, when adequate bonding area is present lingually, it may be possible to reduce the area of retainer coverage by cutting away lingual metal before cementation so that none is located behind thin translucent areas of the tooth.

Fiber-reinforced composite-resin fixed partial dentures have also proved to be a predictable aesthetic treatment alternative to metal-ceramic resin-bonded retainers and are worthy of consideration as interim long-term restorations when aesthetics is a priority.[13]

COMPLETE CROWN RETAINERS

When a resin-bonded retainer cannot be used because of the tooth condition, crown form, crown length, axial alignment, occlusal forces, or conditions requiring maximal retention and resistance form, use of complete crown retainers is indicated.

Cast metal retainers should be used posteriorly wherever aesthetically possible because they require less tooth reduction than a metal-ceramic retainer. When short clinical crowns are encountered, it may be necessary to use auxiliary grooves or boxes in the axial surfaces to achieve the required degree of retention and resistance form. It may also be necessary to perform a gingivoplasty so that more tooth structure is exposed.

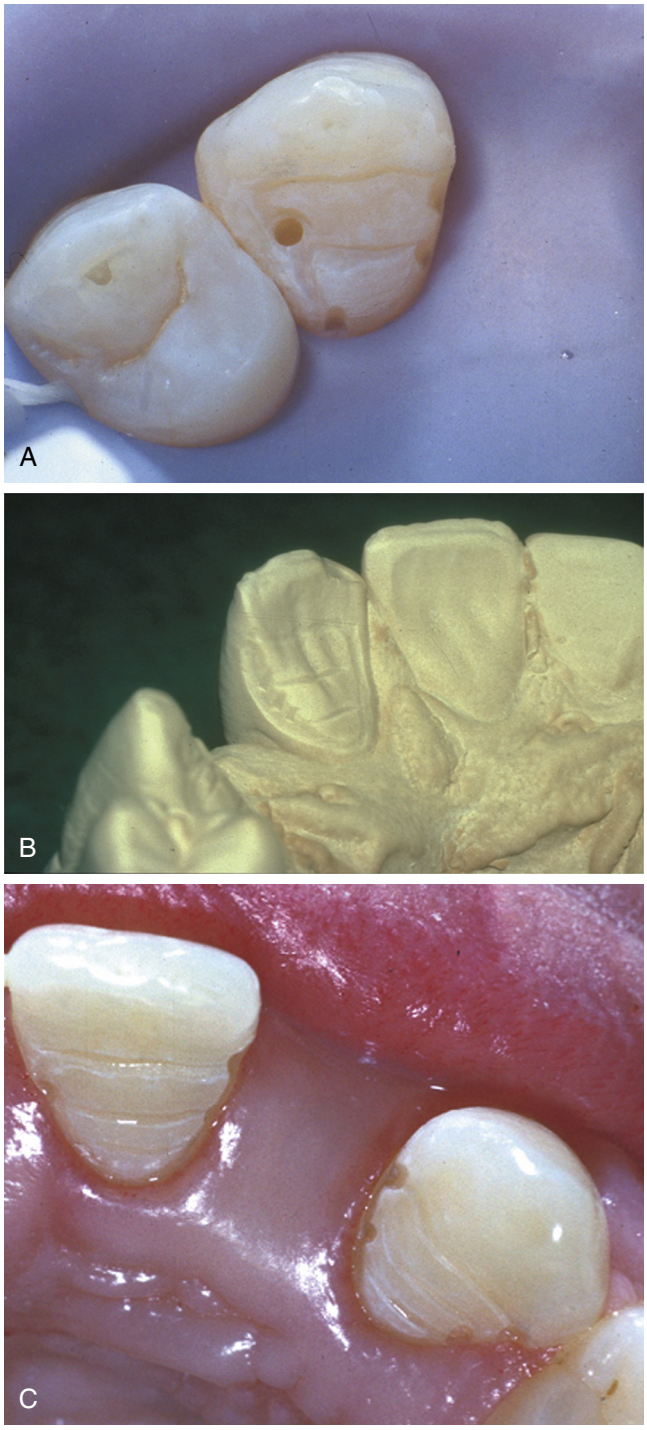

Figure 24-10 **A,** The maxillary canine has been isolated for prosthesis cementation with the use of a rubber dam, which affords a good view of the well-defined proximal grooves. **B,** Cast of prepared maxillary central incisor and canine. Note the small peripheral chamfer, the lingual ledges, and the small proximal grooves. **C,** Another patient in whom the maxillary central incisors and canine have been prepared with multiple lingual ledges and multiple proximal grooves.

When aesthetic requirements demand and pulp size permits, metal-ceramic restorations are indicated. When complete crown retainers are indicated but pulp size allows only minimal reduction, an all-resin fixed prosthesis may be the best choice. The all-resin restoration offers good aesthetics initially and requires only minimal axial tooth reduction (0.5 mm), but because it has less wear resistance, strength, and color stability than porcelain, it must be replaced periodically. All-resin prostheses rarely last more than a few years without significant wear, color change, or fracture. If the casts and records are retained, however, additional replacement prostheses can be made and several additional years of service obtained. Subsequent treatment may permit the use of metal-ceramic retainers because enough pulpal recession may have occurred facilitating safe additional tooth reduction. The development of new resins and fiber reinforcement may extend the longevity of such prostheses.

Complete crown retainers can also be used in conjunction with cantilevered prostheses so that tooth preparation is limited to one tooth. Schwartz and associates[14] and Foster[15] have shown use of the cantilever design to be a viable treatment alternative. The absence of a maxillary lateral incisor, which is encountered in adolescents because of congenital abnormality, is a situation well suited to this design. A two-unit fixed prosthesis can be fabricated with a lateral incisor pontic cantilevered from the canine retainer. The positional stability of the canine is important to the success of this design. The canine should not be mobile, and the arch form should be stable (i.e., teeth have not shifted and are not shifting position). The canine should not have recently undergone orthodontic repositioning that involved significant rotation. A final note: While these are for the primary dentition, the availability of commercially available pre-veneered aesthetic stainless steel crowns has added an additional potential restorative option when aesthetics is a concern and full coverage is necessary.[16,17]

FIXED PARTIAL DENTURE PONTICS

Pontics are usually of an all-metal or metal-ceramic design, depending on the aesthetic requirements. The metal-ceramic pontic is a highly versatile replacement, combining the aesthetic benefits of porcelain with the strength of metal, and is widely adaptable to edentulous spaces of various sizes.

Pontic design must include meticulous attention to the amount of ridge coverage; the area of contact must be minimized, and the embrasures must be as large as possible while meeting aesthetic demands. These procedures are mandatory to provide soft-tissue access for oral hygiene aids.

REMOVABLE PARTIAL DENTURES

When the number of missing teeth prevents use of a fixed partial denture, a removable partial denture becomes a restoration of necessity. Indications for a removable partial denture include excessive span length, the inability to achieve adequate retention for a fixed prosthesis, congenital malformations that result in only a few widely spaced



Figure 24-11 **A,** Congenitally missing maxillary lateral incisor. **B,** Mirror view of the canine and first premolar, which have been prepared for a resin-bonded prosthesis. The lingual cusp of the premolar has been reduced so the retainer can be bonded over the cusp. **C,** Mirror view of bonded prosthesis showing coverage of the premolar lingual cusp. **D,** Facial view of completed prosthesis.

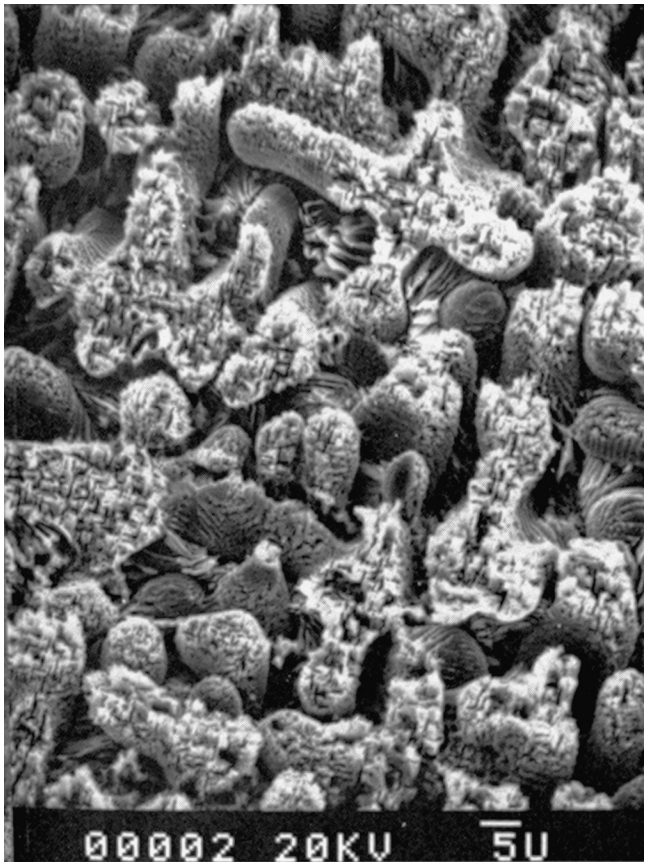

Figure 24-12 Scanning electron micrograph of etched base metal (×1000). (Courtesy of B. K. Moore.)

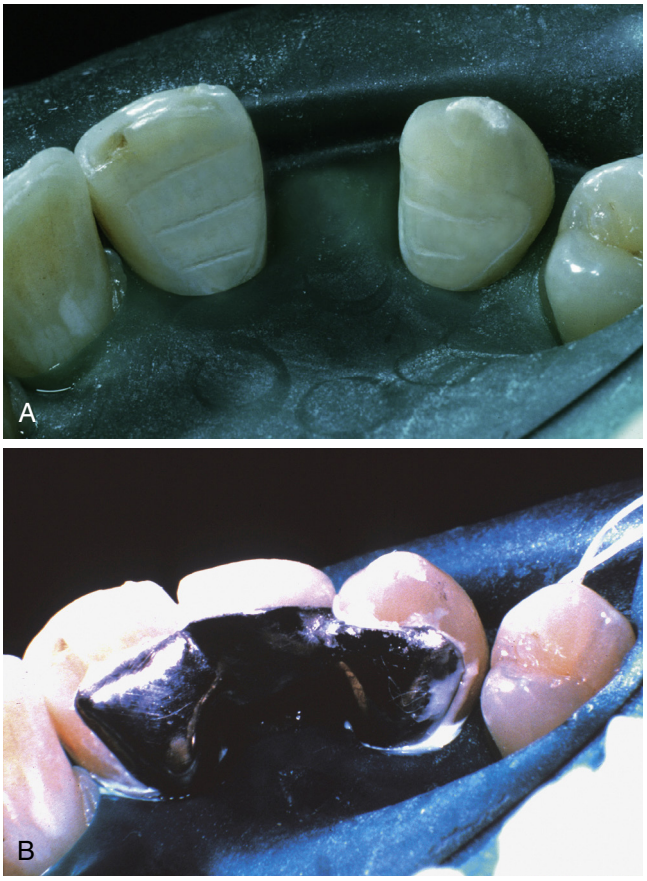

Figure 24-13 **A,** Teeth isolated with rubber dam in preparation for resin-bonding procedures. **B,** Prosthesis bonded with resin.

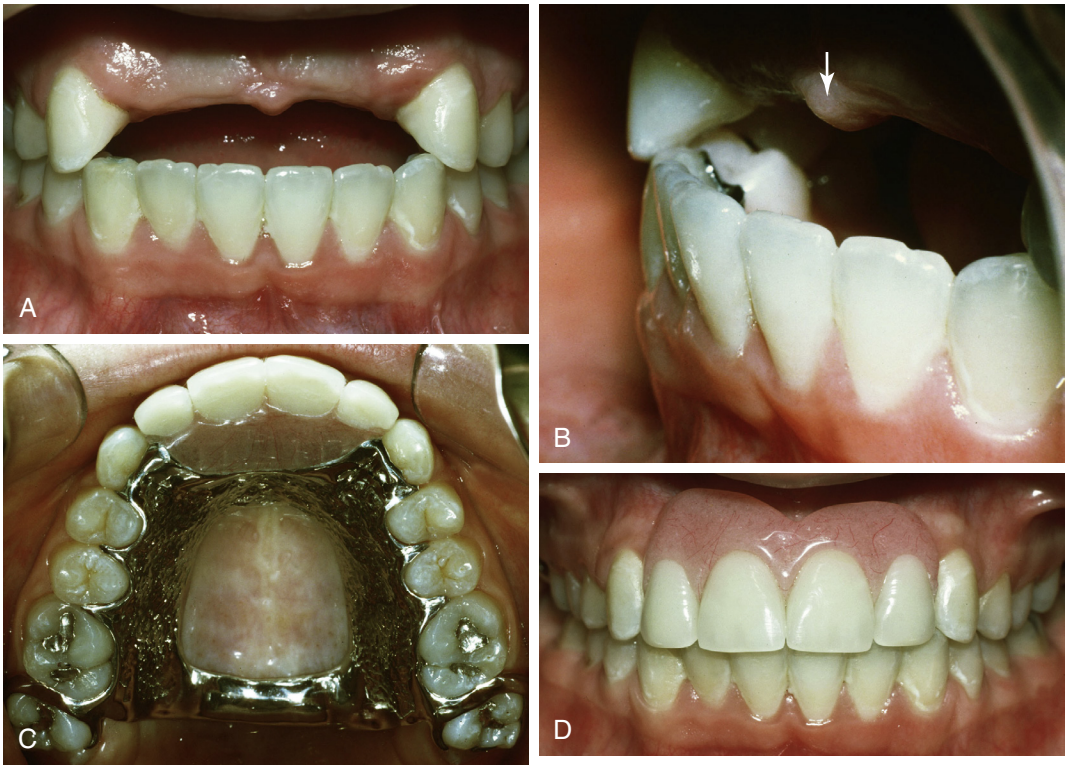

Figure 24-14 **A,** The four maxillary incisors have been lost as a result of traumatic injury. Note the long span, short clinical crowns, and facial flare to the canines, which make retention and resistance form difficult to achieve for a conventional fixed partial denture. **B,** Lateral view showing the relationship of the mandibular incisors to the residual alveolar ridge. The trauma caused substantial bone loss, and the ridge is located lingual to the mandibular incisors (*arrow* indicates the position of the incisive papilla on the crest of the residual alveolar ridge), which necessitates the use of a removable partial denture base for lip support and proper aesthetics. **C,** Occlusal view of maxillary removable partial denture. **D,** Facial view of completed prosthesis.

permanent teeth, and injuries that have caused multiple teeth and often alveolar bone to be lost (Fig. 24-14).

When treatment is planned for an adolescent patient who needs a removable partial denture, there are three major objectives: (1) the restoration of the functions of mastication and speech, (2) the restoration of dental and facial aesthetics, and (3) the preservation of the remaining teeth and their supportive tissues.

The function of mastication can be restored when correct, harmonious, and nondestructive occlusal relationships are provided between the supplied teeth and the opposing remaining natural dentition. The development of proper speech can be ensured if the parts of the partial denture are given correct form, dimension, and position in their relationships to the tongue, cheek, and lips.

The restoration of aesthetics is often the most important personal consideration for adolescent patients. Artificial teeth of compatible color, size, and form, naturally arranged and positioned, enhance dental aesthetics. In addition, the form and size of the base of a partial denture must be correct to ensure the restoration of normal facial contours.

The preservation of the remaining teeth and their supportive tissues is the most important objective of all but will not be achieved without adequate mouth preparation, correct partial denture design, accurate fabrication of that design, periodic professional follow-up care, and continued proper home care by the patient.

Additional dental procedures may be required to create an oral environment that will furnish proper support and retention for the removable partial denture and that will prevent the development of forces or processes that are harmful to the remaining teeth and their supportive tissues. These preparatory procedures may involve all phases or branches of dentistry. Adolescents may require periodontal procedures, particularly to increase crown length for crown or fixed partial denture retention or to improve tissue contours so that more ideal results can be achieved.

Orthodontic procedures can be used to reposition severely malpositioned teeth that would otherwise require extraction and particularly for malpositioned teeth that are vital to an adequate treatment plan.

OVERDENTURES

Occasionally, congenital abnormalities or trauma results in the loss of multiple teeth, and the resulting interarch relationship does not allow a conventional removable partial denture to reestablish proper occlusion with opposing teeth. This situation may necessitate fabrication of a prosthesis that overlays all or part of the remaining teeth so that proper function and facial aesthetics can be established (Fig. 24-15, *A* and *B*).[18]

Dentlearn.ir

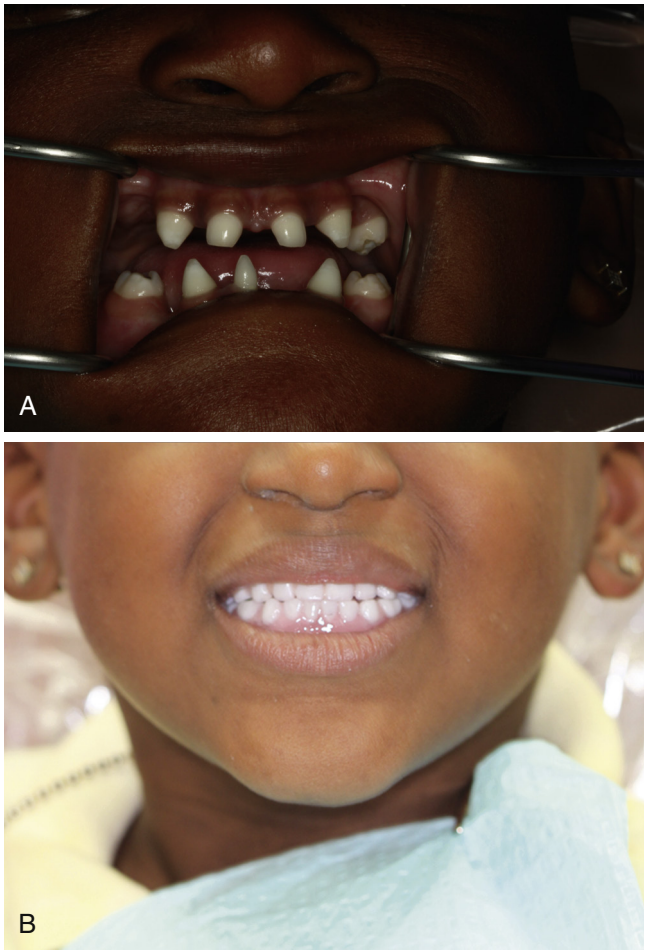

Figure 24-15 **A,** Facial view of maxillary and mandibular teeth showing significant malformation and spacing in a patient with ectodermal dysplasia. **B,** Facial view of maxillary and mandibular overdentures showing improved aesthetics. (Photos courtesy of Dr. Adriana Diaz Backer.)

IMPLANT PROSTHESES

An understanding of dental development and craniofacial growth is certainly a prerequisite for anyone anticipating the use of dental implants in growing patients. Growth and development in the maxilla and mandible are quite different, as are growth and development in the specific areas of each arch.[19-21] In the maxilla, growth is intimately associated with the growth of the cranial base in early childhood, whereas later growth occurs primarily by enlargement of the maxilla. This growth is extremely variable and can be observed as vertical growth, transverse growth, and anteroposterior growth. Transverse growth occurs primarily at the midpalatal suture of the maxilla. The sutural growth site is extremely important and poses a risk to the placement of an implant-supported prosthesis that crosses this suture and could limit its growth potential. The maxilla also grows vertically by passive displacement as well as by alveolar appositional growth. It is the vertical component of maxillary growth that causes the most concern in the long-term positional stability of the individual implant and its effect on restorative function and aesthetics.

Mandibular growth differs greatly from the complex growth in the maxilla. Not closely associated with major cranial passive growth, mandibular growth is primarily downward and forward, mediated by appositional condylar growth. This growth is not purely linear but can be rotational secondary to the precise direction of condylar growth patterns. The appositional growth is also refined by certain areas of resorption, primarily seen on the anterior aspect of the ramus. As the mandible increases in length, it also increases in width, secondary to the flaring of posterior growth direction. This allows the mandible to accommodate to the increased maxillary width caused by the growth in the palatal suture area. Anterior stabilization is accomplished by the early closure of the mandibular symphysis. Although less dynamic than maxillary growth, mandibular growth can create many complexities that could place dental implants at positional risk, especially in the posterior mandible, secondary to vertical changes and resorptive processes.

In addition to understanding growth and development, the clinician must also comprehend the dynamics of the positional relationship between the dental implant and its biological environment in the growing patient. A wealth of dental literature from in vivo evidence-based studies attests to the long-term success of dental implants and their associated prostheses in adults. Such a wealth of knowledge does not exist, however, for the growing patient. The behavior of an osseointegrated dental implant essentially resembles that of an ankylosed tooth, and the latter therefore provides an accurate model of the behavior of an implant in a growing patient. Two facets of the relationship of ankylotic teeth to their actively growing environment must be understood. First, the ankylotic tooth, lacking the adaptive mechanisms of a healthy tooth, does not erupt normally and becomes buried. Second, failing to participate in vertical growth, it often creates severe malocclusions secondary to tipping and associated growth changes in normal teeth adjacent to the affected ankylotic tooth. It seems logical that an osseointegrated implant placed prematurely could elicit the same negative growth effects.

The routine successful use of osseointegrated dental implants in total or partial support of prostheses in adults has heightened interest in their use in younger patients. Adolescents are frequently seen who have congenital anomalies, have undergone ablative surgical procedures or radiation therapy, or have experienced traumatic tooth loss, and the use of dental implants would greatly assist prosthesis support (Figs. 24-16 and 24-17). Replacement of congenitally missing teeth with implants can often be accomplished in an aesthetic manner that preserves the integrity of adjacent teeth. However, dental and skeletal growth is a major confounding variable related to the use of dental implants in adolescent patients.[22]

There are two primary concerns related to the placement of implants before growth is completed: (1) the

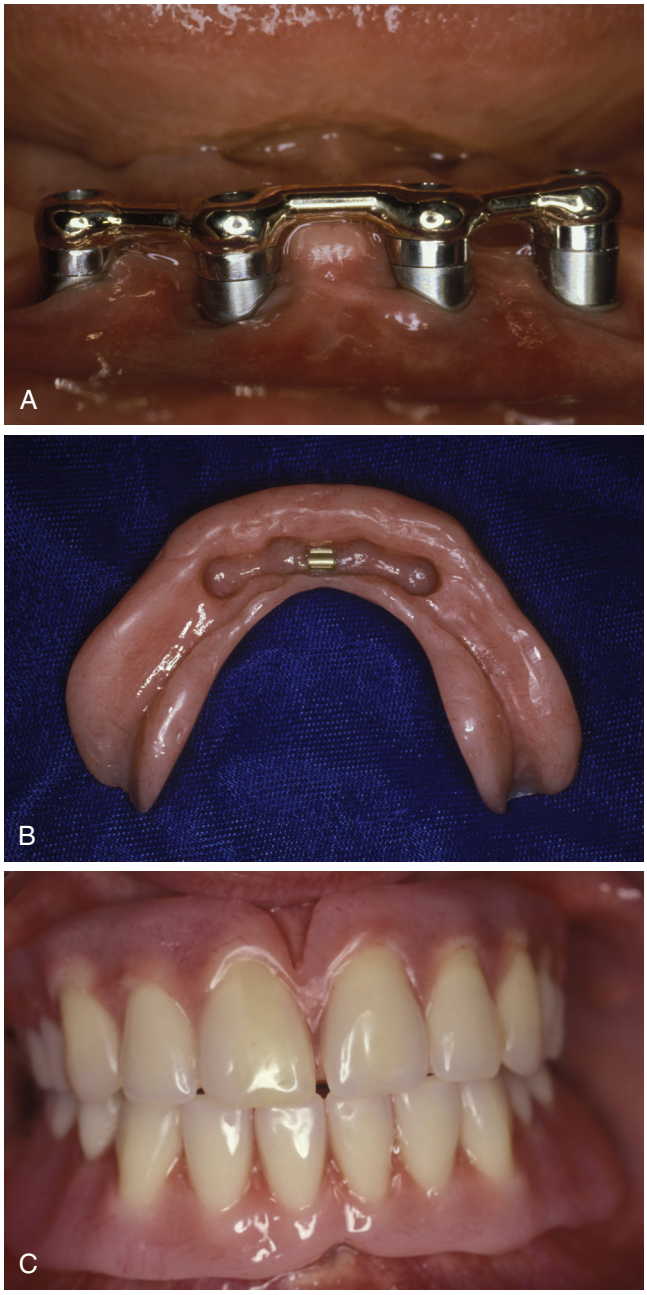

Figure 24-16 **A,** A congenital condition resulted in extensive and aggressive bone changes and loss of the teeth. Four implants were placed in this patient at the age of 12 years. This treatment greatly enhances prosthesis stability and will help preserve the remaining mandibular anterior bone. Because the mandibular symphysis fuses at birth or shortly thereafter, early implant placement in this area is less affected by future growth. **B,** Mandibular overdenture prosthesis that will be supported by the four implants and bar. **C,** Facial view of the completed prosthesis.

effect of growth on the long-term relative position of the dental implant, and (2) the effect of the implant-supported prosthesis on future dental and skeletal growth.

An understanding of dental and skeletal growth and development and its variability in the male and female adolescent population elucidates the serious concerns regarding premature placement of implants. Refer to Chapter 19 for a more in-depth discussion of this topic.

IMPLANT USAGE BEFORE GROWTH COMPLETION

Although it is best to wait until maxillary and mandibular growth is completed before placing osseointegrated implants, dentists are constantly faced with apparent indications for implant treatment. The clinician must understand the disadvantages of early placement and weigh those factors against the functional and aesthetic advantages afforded by implants. If a determination is made that implants are needed before growth completion, it is more predictable to restore larger edentulous areas with implants than to place a single implant-supported crown in a growing patient (Figs. 24-18 and 24-19). The successful use of implant-assisted prostheses in patients with multiple missing teeth has been reported.[23-26] Implants have been placed in the anterior mandible in patients as young as 5 years of age (Fig. 24-20). Often, the placement of implants in this area diminishes the residual alveolar resorption anticipated from many years of removable prosthesis wear. Unfortunately, one of the most frequently encountered implant indications is treatment of the traumatic loss or congenital absence of a single anterior maxillary tooth. The placement of dental implants in this area should not be attempted until the accelerated phase of peripubertal growth is close to complete.

IMPLANTS FOR ORTHODONTIC ANCHORAGE

Osseointegrated implants have been used as valuable adjuncts to orthodontic treatment when there is a need for anchorage but no conventional tooth anchorage is available.[27-31] Because the implants act as ankylosed teeth and are incapable of being moved by orthodontic or orthopedic forces, they serve as ideal anchorage units. Their use has produced tooth movements that otherwise would not be possible, particularly when a great many teeth are missing as a result of trauma or congenital anomalies. Implants are especially valuable when their postorthodontic positioning permits them to be used to support a future prosthesis.

RECARE PROGRAM

The prosthodontic treatment of an adolescent does not end with the placement of the prosthesis. Periodic recare appointments for inspection, maintenance, repair, or replacement are a necessity. For patients who have removable partial dentures, relining or rebasing should be performed when indicated. When all-ceramic crowns or metal-ceramic restorations are used in an adolescent patient, replacement may be needed periodically as the gingival tissue assumes its adult position. Patients with fixed partial dentures should be examined periodically for soft-tissue health, evidence of occlusal wear, and responses of the supportive tissues to the added stress loads. Patients with implant-assisted restorations should be evaluated frequently to ensure the health of the osseointegrated implant and its surrounding tissue, as well as to assess the

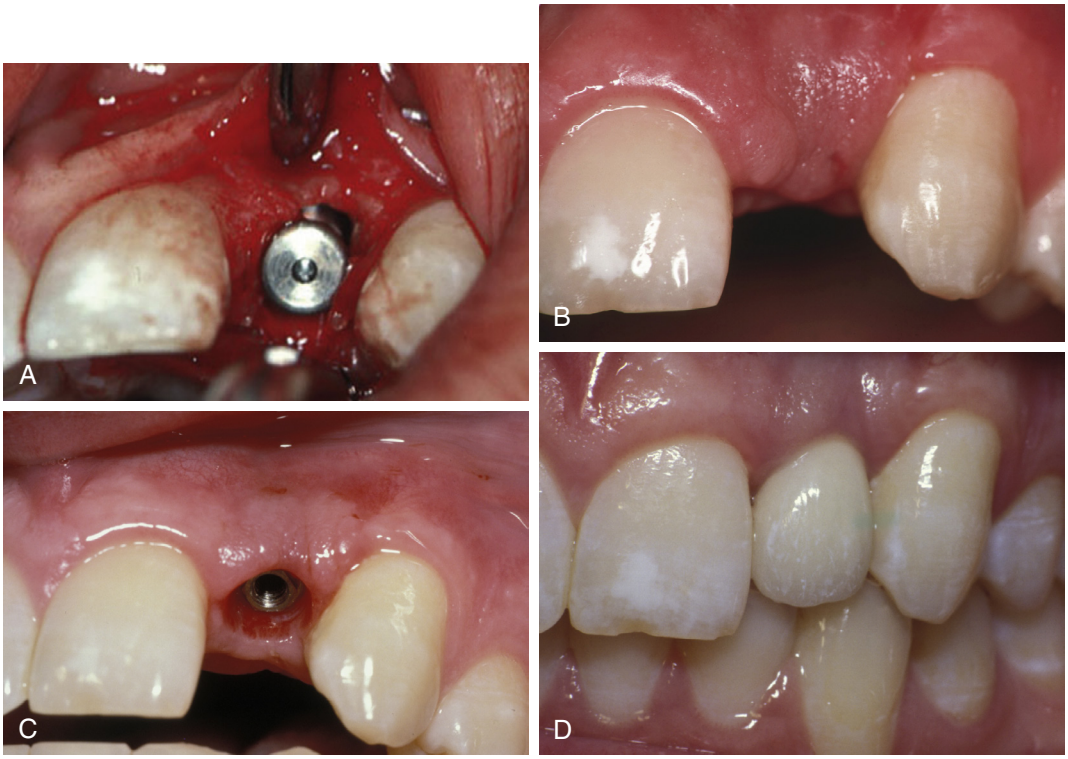

Figure 24-17 **A,** A 16-year-old boy traumatically fractured the maxillary left lateral incisor, rendering it nonrestorable. An implant is being placed in the socket immediately after extraction. **B,** Edentulous ridge following implant placement. **C,** Incisal view of the implant after appropriate bone and soft-tissue healing has occurred. **D,** Completed metal-ceramic restoration.

effect of the implant-supported prosthesis on the overall growth and development of the patient. The use of dental implants to assist in the support of a prosthesis necessitates an extremely vigilant recare program.

Every adolescent patient must be taught proper oral hygiene and home care for his or her prosthodontic restorations and must be motivated until adequate performance is routinely achieved. Each patient with fixed or implant-supported prostheses should be taught the use of aids such as the floss threader and interproximal brush to enhance oral hygiene efforts. Only with regular recare programs can maximum longevity of service be realized.

PROTECTIVE MOUTHGUARDS

Although this chapter is concerned with the prosthodontic treatment of adolescents, emphasis should always be placed on the prevention of oral disease and injury. The number and severity of injuries to the teeth and jaws can be significantly reduced through the faithful use of protective mouthguards by athletes who are engaged in contact sports.[32,33]

A recent evidence-based review of the prevention of dental injuries noted, however, that there are only a few epidemiological studies on protectiveness of mouthguards, and that most of them have a low level of evidence.[34]

Effective and relatively inexpensive prefabricated mouthguards are available at sporting goods stores. A custom-made mouthguard can be fabricated, however, by vacuum-molding a sheet of thick, clear material over a stone cast of the maxillary arch. Seals and Dorrough have reviewed the advantages of custom-made mouth protectors.[35]

Studies comparing custom-made (laboratory) mouthguards with standard (manufactured) or intraorally formed mouthguards have shown that the custom-made mouthguards provide better fit and comfort, are less likely to affect the player's speech adversely, and are less likely to become loose.[36] Several materials have been suggested for use in mouthguards, including poly(vinyl acetate-ethylene) copolymer thermoplastic, polyurethane, and laminated thermoplastic.[37] Chaconas and colleagues demonstrated that the laminated thermoplastic underwent significantly less dimensional change compared with other materials.[38] McGlumphy et al. have recently evaluated the use of three-dimensional imaging to assess the strain and deformation of mouthguard materials.[39]

Because a custom-made mouthguard accurately fits individual tooth and arch form, it affords maximal resistance to dislodgement. The technique of fabrication involves placing the mouthguard material (Fig. 24-21, *A*) in a molding machine, which softens the material by heat (see Fig. 24-21, *B*) and closely adapts it to a dry stone cast by vacuum (see Fig. 24-21, *C*). After the adapted material has cooled, the guard is removed from the cast and the excess peripheral material is trimmed off with scissors (see Fig. 24-21, *D*). The borders are rounded when the material is trimmed with a resin-trimming bur and flamed with a

Dentlearn.ir

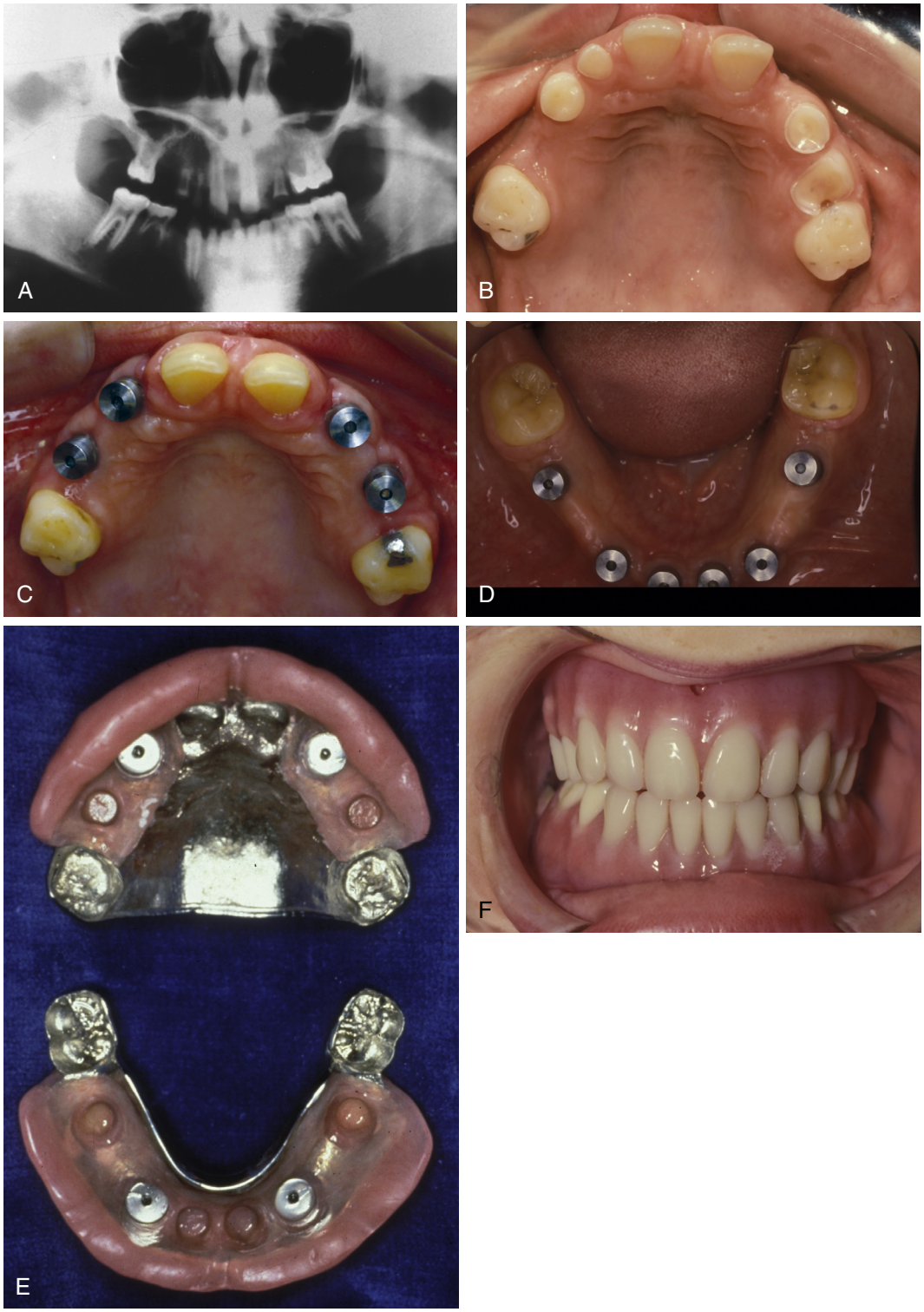

Figure 24-18 **A,** Panoramic radiograph of a 12-year-old with partial anodontia of unknown origin. **B,** Occlusal view of maxillary arch showing primary teeth that will be extracted. **C,** Four maxillary implants have been placed. **D,** Six mandibular implants have been placed to provide prosthesis stability and preserve bone. **E,** Maxillary and mandibular overdentures with magnets to augment stability and retention. **F,** Facial view of completed overdentures.

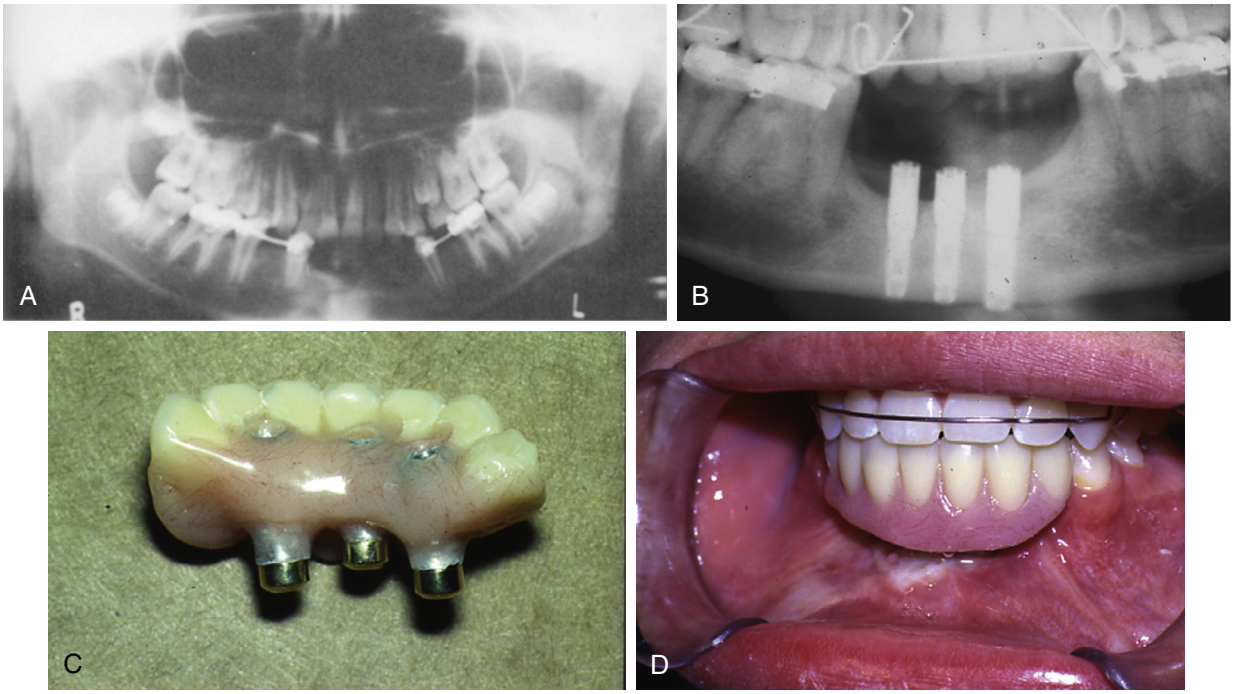

Figure 24-19 **A,** Panoramic radiograph of a 13-year-old patient after removal of a giant cell granuloma from the anterior mandible. **B,** Radiograph showing ridge defect and the location of the three implants. **C,** Fixed prosthesis that will be attached to the three implants. **D,** Prosthesis in place.

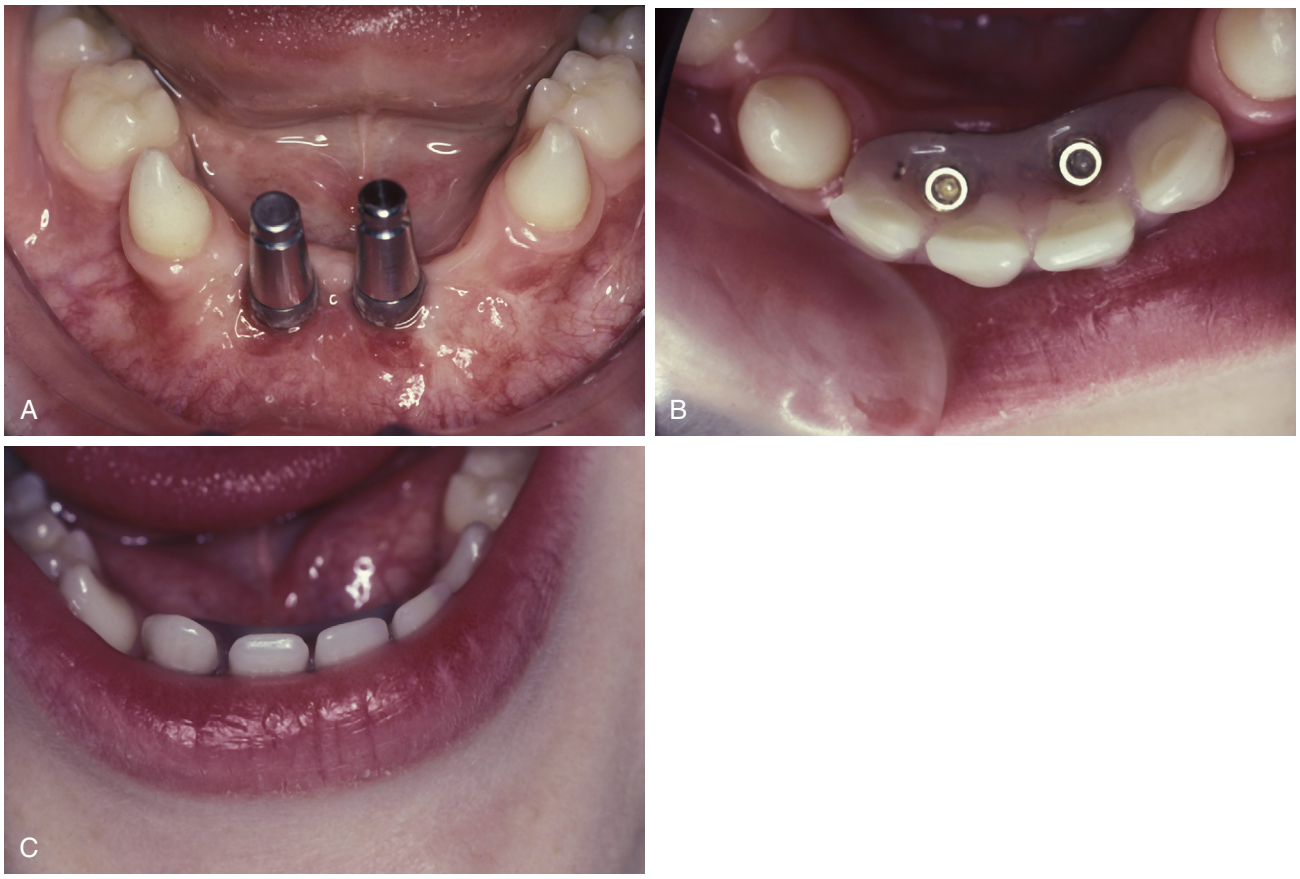

Figure 24-20 **A,** Two implants placed in a 5-year-old patient with partial anodontia resulting from ectodermal dysplasia. Impression copings have been attached for the impression procedure. Because of the early fusion of the mandibular symphysis, future bone growth will be minimally affected. **B,** Incisal view of the retrievable prosthesis showing two lingually located screws. A retrievable design permits the prosthetic teeth to be replaced to accommodate future growth. **C,** Facial view of completed prosthesis.



Figure 24-21 **A,** Clear material (0.150 inch) used to fabricate a mouthguard. **B,** Material clamped in machine and heated until it softens and droops. **C,** Material vacuum-adapted to dry stone cast. **D,** Guard being trimmed with scissors. **E,** Appearance of borders after being trimmed with acrylic bur and polished with pumice. **F,** Completed mouthguard on cast.

torch or polished with wet pumice on a rag wheel (see Fig. 24-21, *E*).

Maximum retention is obtained when the entire hard palate is covered. If the guard interferes with speech, however, a portion of the palatal area of the guard can be removed.

The successful use of mouthguards by many young athletes has proven that they can be worn with comfort and serve as effective safeguards against injuries to the teeth.[40,41]

REFERENCES

1. Caplan DJ, Weintraub JA: The oral health burden in the United States: a summary of recent epidemiologic studies, *J Dent Educ* 57(12):853–862, 1993.
2. Vargas CM, et al.: Sociodemographic distribution of pediatric dental caries: NHANES III, 1988-1994, *J Am Dent Assoc* 129:1229–1238, 1998.
3. Barmes DE, Leous PA: Assessment of periodontal status by CPITN and its applicability to the development of long-term goals on periodontal health of the population, *Int Dent J* 36:177–181, 1986.
4. Gift HC, Bhat M: Dental visits for orofacial injury: defining the dentist's role, *J Am Dent Assoc* 124:92–98, 1993.
5. Bader JD, et al.: Preliminary estimates of the incidence and consequences of tooth fracture, *J Am Dent Assoc* 126: 1650–1654, 1995.
6. Oliveira BH, et al.: Biannual fluoride varnish application and caries incidence in preschoolers: a 24-month follow-up randomized placebo-controlled clinical trial, *Caries Res* 48: 228–236, 2014.
7. Hussey DL, et al.: Performance of 400 adhesive bridges fitted in a restorative dentistry department, *J Dent* 19:221–225, 1991.
8. Leempoel PJ, et al.: The survival rate of bridges: a study of 1674 bridges in 40 Dutch general practices, *J Oral Rehabil* 22:327–330, 1995.

9. Barrack G, Bretz WA: A long-term prospective study of the etched-cast restoration, *Int J Prosthodont* 6:428–434, 1993.
10. Hansson O, Bergström B: A longitudinal study of resin-bonded prostheses, *J Prosthet Dent* 76:132–139, 1996.
11. Creugers NHJ, et al.: Clinical performance of resin-bonded bridges: a 5 year prospective study. Part II: influence of patient dependent variables, *J Oral Rehabil* 16:521–527, 1989.
12. Atta MO, Smith BGN: The bond strength of a new adhesive bridge cement to sand-blasted nickel-chromium alloy compared with composite to acid-etched alloy, *J Dent Res* 65(Spec Iss):496(abst no 74), 1986.
13. Spinas E, Aresu M, Canargiu F: Prosthetic rehabilitation interventions in adolescents with fixed bridges: a 5-year observational study, *Eur J Paediatr Dent* 14(1):59–62, 2013.
14. Schwartz NL, et al.: Unserviceable crowns and fixed partial dentures: life-span and causes for loss of serviceability, *J Am Dent Assoc* 81:1395–1401, 1970.
15. Foster LV: Failed conventional bridge work from general dental practice: clinical aspects and treatment needs of 142 cases, *Br Dent J* 168:199–201, 1990.
16. Leith R, O'Connell AC: A clinical study evaluating success of 2 commercially available preveneered primary molar stainless steel crowns, *Pediatr Dent* 33:300–306, 2001.
17. Beattie S, et al.: Fracture resistance of 3 types of primary esthetic stainless steel crowns, *J Can Dent Assoc* 77:b90, 2011.
18. Vergo TJ: Prosthodontics for pediatric patients with congenital/developmental orofacial anomalies: a long-term follow-up, *J Prosthet Dent* 86:342–347, 2001.
19. Cronin RJ, Oesterle LJ: Implant use in growing patients: treatment planning concerns, *Dent Clin North Am* 42(1): 1–34, 1998.
20. Cronin RJ, et al.: Mandibular implants and the growing patient, *Int J Oral Maxillofac Implants* 9:55–62, 1994.
21. Oesterle LJ, et al.: Maxillary implants and the growing patient, *Int J Oral Maxillofac Implants* 8:377–387, 1993.
22. Bergendal B, et al.: Implant failure in young children with ectodermal dysplasia: a retrospective evaluation of use and outcome of dental implant treatment in children in Sweden, *Int J Oral Maxillofac Implants* 23(3):520–524, 2008.
23. Guckes AD, et al.: Using endosseous dental implants for patients with ectodermal dysplasia, *J Am Dent Assoc* 122:59–62, 1991.
24. Ledermann PD, et al.: Osseointegrated dental implants as alternative therapy to bridge construction or orthodontics in young patients: seven years of clinical experience, *Pediatr Dent* 15:327–333, 1993.
25. Westwood RM, Duncan JM: Implants in adolescents: a literature review and case reports, *Int J Oral Maxillofac Implants* 11:750–755, 1996.
26. Aydinbelge M, et al.: Implants in children with hypohidrotic ectodermal dysplasia: an alternative approach to esthetic management: case report and review of the literature, *Pediatr Dent* 35(5):441–446, 2013.
27. Kokich VG: Managing complex orthodontic problems: the use of implants for anchorage, *Semin Orthod* 2:153–160, 1996.
28. Upadhyay M, et al.: Mini-implant anchorage for en-masse retraction of maxillary anterior teeth: a clinical cephalometric study, *Am J Orthod Dentofacial Orthop* 134(6):803–810, 2008.
29. Iseri H, et al.: Ten-year follow-up of a patient with hemifacial microsomia treated with distraction osteogenesis and orthodontics: an implant analysis, *Am J Orthod Dentofacial Orthop* 134(2):296–304, 2008.
30. Upadhyay M, et al.: Mini-implants for en masse intrusion of maxillary anterior teeth in a severe Class II division 2 malocclusion, *J Orthod* 35(2):79–89, 2008.
31. Garfinkle JS, et al.: Evaluation of orthodontic mini-implant anchorage in premolar extraction therapy in adolescents, *Am J Orthod Dentofacial Orthop* 133(5):642–653, 2008.
32. Matalon V, et al.: Compliance of children and youngsters in the use of mouthguards, *Dent Traumatol* 24(4):462–467, 2008.
33. Knapik JJ, et al.: Mouthguards in sport activities: history, physical properties and injury prevention effectiveness, *Sports Med* 37:117–144, 2007.
34. Sigurdsson A: Evidence-based review of prevention of dental injuries, *Pediatr Dent* 35:184–190, 2013.
35. Seals RR, Dorrough BC: Custom mouth protectors: a review of their applications, *J Prosthet Dent* 51:238–242, 1984.
36. Stokes ANS, et al.: Comparison of laboratory and intraorally formed mouth protectors, *Endod Dent Traumatol* 3:255–258, 1987.
37. Geary JL, Kinirons MJ: Post thermoforming dimensional changes of ethylene vinyl acetate used in custom-made mouthguards for trauma prevention—a pilot study, *Dent Traumatol* 24(3):350–355, 2008.
38. Chaconas SJ, et al.: A comparison of athletic mouthguard materials, *Am J Sports Med* 13:193–197, 1985.
39. McGlumphy KC, et al.: Pilot study of 3D image correlation photogrammetry to assess strain and deformation of mouthguard materials, *Dent Traumatol* 30(3):236–239, 2014 Jun.
40. Gawlak D, et al.: Comparison of usability properties of custom-made and standard self-adapted mouthguards, *Dent Traumatol* 30(4):306–311, 2014 Aug.
41. Tuna EB, Ozel E: Factors affecting sports-related orofacial injuries and the importance of mouthguards, *Sports Med* 44(6):777–783, 2014 Jun.

PART 5 MANAGEMENT OF SPECIAL MEDICAL ISSUES AND PRACTICE MANAGEMENT

CHAPTER 25

Dental Problems of Children with Special Health Care Needs

▲ James A. Weddell, Brian J. Sanders, and James E. Jones

For additional resources, please visit the evolve website.

CHAPTER OUTLINE

DENTAL ACCESS
FIRST DENTAL VISIT
RADIOGRAPHIC EXAMINATION
PREVENTIVE DENTISTRY
- Home Dental Care
- Diet and Nutrition
- Fluoride Exposure
- Preventive Restorations
- Regular Professional Supervision

MANAGEMENT OF A CHILD WITH SPECIAL HEALTH CARE NEEDS DURING DENTAL TREATMENT
- Protective Stabilization

INTELLECTUAL DISABILITY
- Dental Treatment of a Person with Intellectual Disability

DOWN SYNDROME (TRISOMY 21 SYNDROME)
LEARNING DISABILITIES
FRAGILE X SYNDROME
FETAL ALCOHOL SPECTRUM DISORDER
AUTISM SPECTRUM DISORDER
CEREBRAL PALSY
SPINA BIFIDA AND LATEX ALLERGY
RESPIRATORY DISEASES
- Asthma (Reactive Airway Disease)
- Bronchopulmonary Dysplasia
- Cystic Fibrosis

HEARING LOSS
VISUAL IMPAIRMENT
HEART DISEASE
- Congenital Heart Disease
- Acquired Heart Disease
- Dental Management
- Cardiac Surgery Patients

Approximately 54 million children and adults in the United States have a disabling condition.[1] The American Academy of Pediatric Dentistry defines individuals with special health care needs (SHCN) as those with "any physical, developmental, mental, sensory, behavioral, cognitive, or emotional impairment or limiting condition that requires medical management, health care intervention, and/or use of specialized services or programs."[2] Individuals with SHCN are at increased risk for oral disease.[3]

Many children with SHCN are best managed initially by a multidisciplinary team in which a dentist is available to evaluate the child's extraoral and intraoral findings. A diagnosis is then established, and an impression is gained of the child's strengths and weaknesses and the team's recommendations for future care. The child may then be "mainstreamed" to a dental practitioner, whom the family chooses, if a preference is indicated. The team is available to help the family practitioner or pediatric dentist treat the child and prepare the family for the child's future treatment needs, because oral health is a vital part of the child's well-being and general health.[3]

Children with SHCN may present challenges that require special preparation before the dentist and office staff can provide acceptable care. In addition, parental anxiety concerning the problems associated with a child's SHCN frequently delays dental care until significant oral disease has developed. Also, some dentists feel uncomfortable providing treatment for children with SHCN, which results in a loss of greatly needed services. Kane and colleagues reported failure to obtain routine medical care as well as income below 400% of federal poverty guidelines as barriers to the receipt of dental care for children with SHCN.[4] Financing and reimbursement issues are other barriers for families of children with SHCN and for dental practitioners. Nonfinancial barriers such as language and psychosocial, structural, and cultural considerations also interfere with access to oral care.[5]

This chapter discusses disabling pediatric conditions that dentists sometimes encounter in practice. If a dentist becomes familiar with the SHCN of a child and with the parents' concerns, the dental management of the child can be gratifying.

Dentlearn.ir

DENTAL ACCESS

Improving access to oral health care for those deprived of needed services should be of great concern to the dental profession. Large segments of the population do not have access to dental care. Children with SHCN, such as those who are chronically ill, homebound, and have developmental disabilities and emotional impairments, fall into

receive needed medical and dental services, 24% report at least one unmet need. Preventive dental care is the most common of those unmet needs.[6] In addition, these

20% of the U.S. population who exhibit 80% of all caries.

The rapid expansion of the elderly population, the presence of children with SHCN, and the emergence of legislative guidelines for people of all ages with SHCN are three important factors that should prompt dentists to address cost-efficient ways to make their office facilities and operatory areas accessible for persons with SHCN. In August 1984 another federal-level cornerstone was laid for barrier-free facility access with the passage of the Uniform Federal Accessibility Standards.[7] Enacted in 1990, the Americans with Disabilities Act defines the dental office as a place of public accommodation.[8] Dental consumer populations are becoming more sensitive to the service needs and desires of people with SHCN by improving family conditions and public education. Failure to accommodate patients with SHCN could be considered discrimination and a violation of state or federal law. Table 25-1 lists common minimum requirements needed to gain access.

In the dental operatory, doorways should be 4 inches (10 cm) wider than normal. In the dental suite, where floor circulation space is at a premium, aisle passage in the operatory area should be planned with the dimensions

Table **25-1**

Accessibility Guidelines

Building Features	Gradient	Length	Width	Surface, Other Specifics
Parking space	1:50 max slope	Standard	Auto: 96 inches Van: 144 inches	Nonskid, paved, sign-posted, adjacent to walkway
Walkway	1:12 max slope	Not applicable	36 inches	Nonskid, no obstructions, overhangs, smooth
Passenger loading zone	Flat	20 feet	60 inches	Same as above
Curb ramps	1:12 max slope		36 inches	Nonskid, side flair <1:10 slope
Door	5-foot entrance and exit platform area	Standard	32-inch minimum; preferably 36 inches	Away from prevailing winds, lever with 10-lb pull, auto-assisted door available, kick plate
Interior ramp	1:20 max slope	72-inch minimum length if rise >6 inches	36 inches	Nonskid, handrails
Wheelchair lift	Bilevel	8-foot max drop	36 × 48 inches	Nonskid, dependent on specific chair
Corridor		Standard	48 inches/64 inches	New facility, no obstacles
Flooring	Flat, firm carpet	Not applicable	½-inch maximum thickness	No doormats, level thresholds
Signs	Braille, raised letters	Above 5 feet	Readable	Near latch of office door
Waiting room	Flat	Standard	36-inch aisle; one cleared area: 36 × 52 inches	No carpet pad, well-insulated, minimum low-frequency background noise
Restrooms	Flat		32-inch stall min., preferably 36 inches	Nonskid, magnetic catch door
Public telephone	No higher than 4 feet	3 feet above floor	26-inch clearance	Phone directory near phone, adjustable volume control
Elevator	Flat		54 × 68 inches	Nonskid, call and control box 48 inches high, include Braille or incised letters
Operatory	Flat 8 × 10 feet	Standard	32- to 36-inch door	Nonskid, rotating or movable chair, drill, and suction

Adapted from Bill DJ, Weddell JA: Dental office access for patients with disabling conditions, *Spec Care Dentist* 6:246-252, 1986.

Dentlearn.ir

shown in Figure 25-1. The required wheelchair turning space and top space under furniture and fixtures may be more readily accommodated if one operatory is specifically designed with a movable dental chair, instrument control unit, and suction system. Movable equipment should enhance the opportunity for the patient's wheelchair to be backed into the operatory, thus reducing the need for more wheelchair-turning space. If possible, a wider radius for turning space is desirable to accommodate the wheelchair extensions and adaptations that are required for some persons. Dental chairs should be adjustable for height to match different wheelchair designs.

FIRST DENTAL VISIT

Many people avoid dental treatment for themselves or their children because of their fear that dental visits are routinely painful. Dental professionals should use every opportunity to help patients or parents overcome this barrier to the mainstream of effective dental care and establish a "dental home" with them (see Chapter 1).

Upon scheduling an appointment, the dental receptionist should determine the presence and nature of any SHCN, identify the family's medical provider, and alert the dentist so that adequate time can be allowed. The initial dental examination for a child with SHCN is like the initial examination described in Chapter 1. Special attention should be given to obtaining a thorough medical and dental history. The names and addresses of medical or dental personnel who have previously treated the patient are necessary for consultation purposes. Consultation with these specialists is common; this helps provide insight in case management and planning and avoids unwanted outcomes. Health Insurance Portability and Accountability Act compliance is mandatory throughout this process.

The first dental appointment is very important and can set the stage for subsequent appointments. As previously noted, parental anxiety about a child's dental treatment may be a significant factor. In many situations, parents or guardians do not realize the importance of this visit and desire treatment immediately. By scheduling the patient at a designated time (early in the day) and allowing sufficient time to talk with the parents (or the guardian) and the patient before initiating any dental care, a practitioner can establish an excellent relationship with them. Sending a letter before the appointment explaining the first visit to the family and sending another letter afterward letting them know how helpful they were are beneficial. This initial demonstration of sincere interest in the child often proves advantageous and saves time throughout the entire treatment process. Obtaining an informed consent is imperative. Many times, dental treatment must be delayed until an informed consent is obtained through a guardian or court petition when no parents are legally accountable.

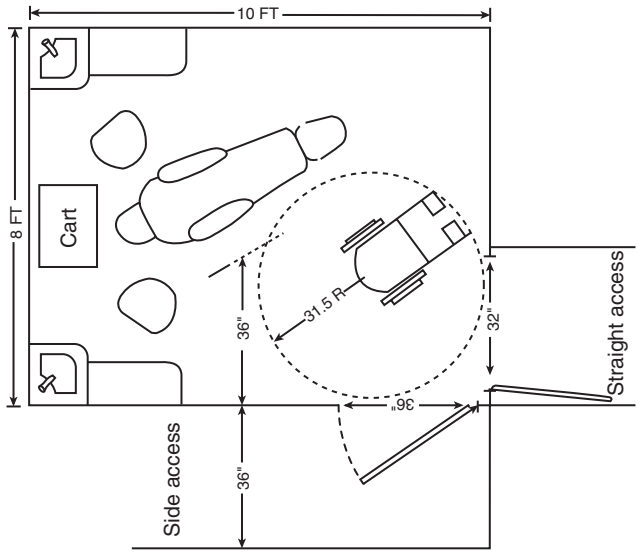

Figure 25-1 An accessible dental operatory floor plan designed for either a straight or side access doorway. (From Bill DJ, Weddell JA: Dental office access for patients with disabling conditions, *Spec Care Dentist* 6:246-252, 1986.)

RADIOGRAPHIC EXAMINATION

Adequate radiographic records are often necessary in planning dental treatment for the child with SHCN. Through appropriate behavior management of the child, a dentist can usually perform a complete radiographic examination of the teeth when indicated. Occasionally, assistance from the parent and dental auxiliaries and the use of immobilization devices may be necessary to obtain the films. Better cooperation may be elicited from some children by delaying radiographs until the second visit, when they are familiar with the dental office and have found it a friendly place.

For patients with limited ability to control film position, intraoral films with bitewing tabs are used for all bitewing and periapical radiographs. An 18-inch (46-cm) length of floss is attached through a hole made in the tab (Fig. 25-2) to facilitate retrieval of the film if it falls toward the pharynx. Hardwired digital sensors have reduced this risk, although they may be difficult to tolerate by the patient. Regardless of the types of radiographs to be made, the patient should wear a lead apron with a thyroid shield, and anyone who helps hold the patient and the film or sensor steady should wear a lead-lined apron and gloves (Fig. 25-3).

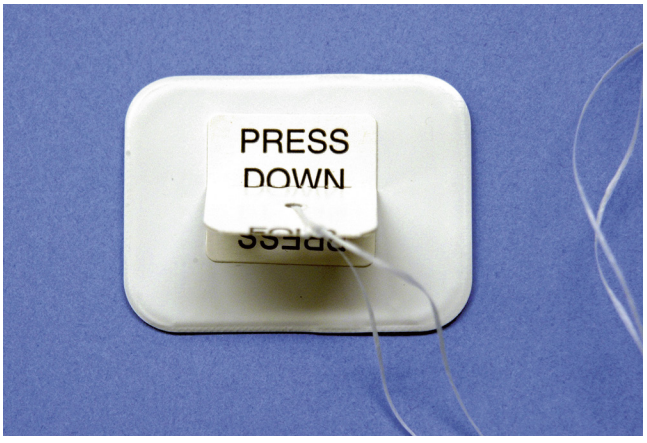

Figure 25-2 Bitewing radiographic film secured with floss.

Dentlearn.ir



Figure 25-3 Extra assistance in holding the patient's head steady to prevent movement while a radiograph is being made.

PREVENTIVE DENTISTRY

Preventing oral disease before it starts is the most desirable way of ensuring good dental health for any dental patient. An effective preventive dentistry program is important for a child with SHCN because of the predisposing factors that make restorative dental care harder to obtain when it is necessary, and those who make preventive dental visits will have fewer unmet needs.[9] Dental diagnosis and treatment planning will necessitate an accurate, up-to-date medical history at each visit. After the diagnosis, the dentist should determine the patient's needs, assume the responsibility for formulating an individual program for the child, and adequately communicate to the parents and patient how such a program can be affected. Use of a Caries-Risk Assessment Tool (CAT) to integrate these dental risk factors may result in a more aggressive approach to the individual's dental treatment plan. A clear perception of the situation by everyone involved is essential for a successful preventive program; adequate communication is vital.

HOME DENTAL CARE

Dental education of parents/guardians/caregivers is important to ensure that children with SHCN do not jeopardize their overall health by neglecting their oral health. The parents (or the guardian) are initially responsible for establishing good oral hygiene in the home. Reinforcement of good home dental care is provided through mass media (e.g., newspapers, radio, television, and Internet), communication with other people, and school activities (e.g., health classes, parent-teacher association meetings, and observation of National Dental Health Month). This supplementary support relieves the dentist of having sole responsibility for explaining the need for home dental care and reinforces the receptivity of the parent and child to such a program. The dentist or the hygienist is responsible for consulting with the caregiver of the child with SHCN (i.e., parent, guardian, or nursing home attendant) when continued oral hygiene problems occur. Regular follow-up supervision at home and in the dental office is essential for effective implementation of the preventive dental treatment plan.

Home dental care should begin in infancy; the dentist should teach the parents to gently cleanse the incisors daily with a soft cloth or an infant toothbrush. For older children who are unwilling or physically unable to cooperate, the dentist should teach the parent or guardian to clean teeth twice a day using correct toothbrushing techniques, safely immobilizing the child when necessary. Figure 25-4 shows several positions for toothbrushing that permit firm control and support of the child, adequate visibility, and convenient positioning of the adult, with reasonable comfort for both adult and child (also see Chapter 7). Positions most commonly used for children requiring oral care assistance are as follows:

- The standing or sitting child is placed in front of the adult so that the adult can cradle the child's head with one hand while using the other hand to brush the teeth.
- The child reclines on a sofa or bed with the head angled backward on the parent's lap. Again, the child's head is stabilized with one hand while the teeth are brushed with the other hand.
- The parents face each other with their knees touching. The child's buttocks are placed on one parent's lap, with the child facing that parent while the child's head and shoulders lie on the other parent's knees; this allows the first parent to brush the teeth.
- The extremely difficult patient is isolated in an open area and reclined in the brusher's lap. The patient is then immobilized by an extra attendant while the brusher institutes proper oral care. If a child cannot be adequately immobilized by one person, then both parents and perhaps siblings may be needed to complete the home dental care procedures.
- The standing and resistive child is placed in front of the caregiver so that the adult can wrap his or her legs around the child to support the torso while using the hands to support the head and brush the teeth.



Figure 25-4 Common positions for plaque removal. **A,** Standing. **B,** Upright wheelchair. **C**, Reclining on couch. **D,** Reclining in bed. **E,** "Leg-lock" position. **F,** Reclining on floor.

If a child with SHCN is institutionalized, the staff should be instructed in the proper dental care regimen for the child. Wrapped tongue blades may be of benefit in helping to keep a child's mouth open while plaque is being removed. Stabilization of the child's head prevents unnecessary trauma from sudden movements. Follow-up observation is carried out by the dentist or the hygienist, and it is appropriate to offer in-service training sessions and to check with the staff periodically to identify and solve the problems associated with an oral hygiene program in the institution.

Some parents and health centers have encouraged children with SHCN to assume the responsibility for their own oral hygiene, but the results are usually poor. Although independent brushing is not contraindicated, parents and staff should be aware that, without their follow-up, unsupervised oral hygiene procedures in children with SHCN can have serious dental consequences. The amount of supervision and assistance provided by the parents or staff should depend on the child's willingness to cooperate and ability to maintain good oral hygiene twice a day.

A plaque control program is essential in monitoring oral hygiene in the child with SHCN and determining the level of success achieved by each patient. The brushing technique for patients with SHCN who have fine or gross motor deficiencies limiting their ability to brush should be effective and yet simple for the person performing the brushing. One technique often recommended is the horizontal scrub method because it is easy to perform and can yield good results. This technique consists of performing gentle horizontal strokes on cheek, tongue, and biting surfaces of all teeth and gums. Other patients with SHCN without such motor problems can use the age-appropriate techniques previously discussed in Chapter 7. A soft, multitufted nylon brush should be used.

Figure 25-5 illustrates some modifications that may be made to a toothbrush to help persons with poor fine motor skills improve their brushing techniques. Although many types of grips are available, using the patient's hand to custom-design a handle has often had good results (Fig. 25-6). Electric toothbrushes have also been used effectively by children with SHCN. The vibration and noise tend to desensitize the patient for future dental appointments if followed by positive reinforcement, while the design and color are motivational for the child. Also, commercial toothbrush products are available with suction abilities built into the brush (Sage Products, .ca/products/oral-hygiene/nonSuction.cfm?section=Non-Suction%20Products). The suction is advantageous because of the excess saliva often found in patients with SHCN. Daily flossing, with supervision or the use of flossholders, is essential to maintain optimal gingival health.

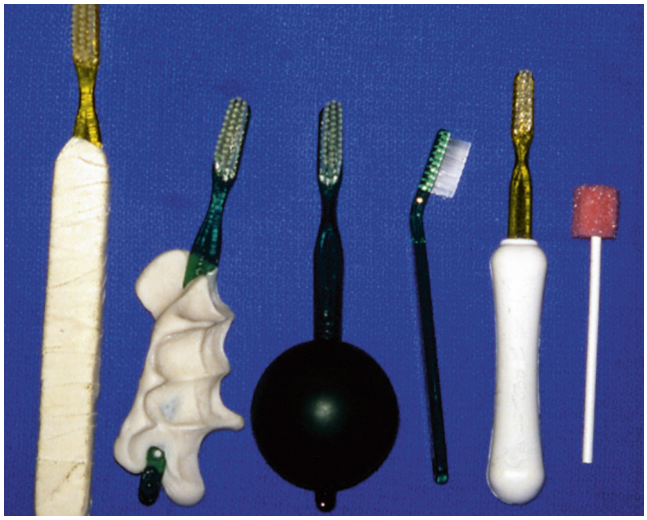

Figure 25-5 Various toothbrush handle modifications.

DIET AND NUTRITION

Diet and nutrition influence dental caries by affecting the type and virulence of the microorganisms in dental plaque,

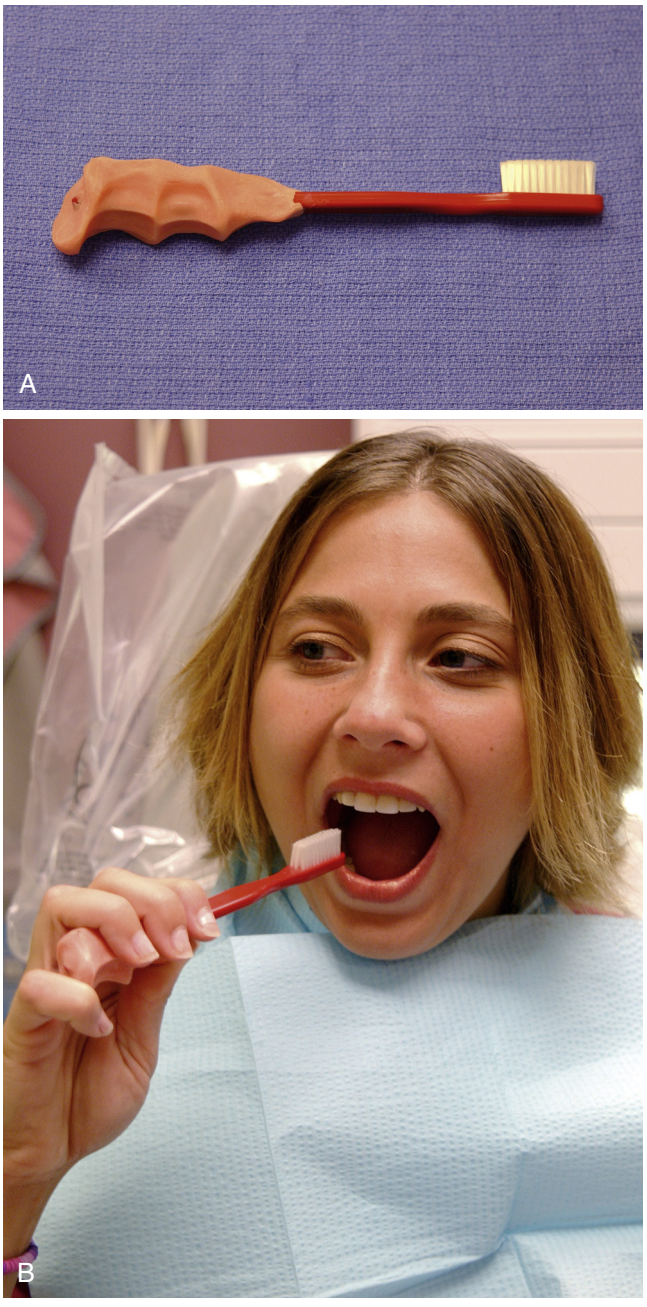

Figure 25-6 **A,** Custom-designed acrylic handle. **B,** Patient using the custom-handle toothbrush.

Dentlearn.ir

the resistance of teeth and supporting structures, and the properties of saliva in the oral cavity. A proper noncariogenic diet, as outlined in Chapter 8, is essential to a good preventive program for a child with SHCN. As discussed in Chapter 9 one should assess the diet by reviewing answers on a diet survey with the parent, realizing that allowances must be made for certain conditions for which dietary modifications are required. For example, conditions associated with difficulty in swallowing, such as severe cerebral palsy, may require that the patient be on a pureed diet. Patients with certain metabolic disturbances or syndromes, such as phenylketonuria, diabetes, or Prader-Willi syndrome, have diets that restrict specific foods or total caloric consumption. Whatever the special circumstances, any dietary recommendations should be made individually after proper consultation with the patient's primary physician or dietitian, along with early intervention and aggressive preventive care based on the child's caries risk.[10] The oral side effects of the child's medications should be reviewed with the parents or guardians at each visit to identify specific concerns, for example, of increased caries or gingival overgrowth, to prevent or minimize these problems. Particular emphasis should be placed on discontinuation of the nursing bottle by 12 months of age and cessation of at-will breast-feeding after teeth begin to erupt, to decrease the likelihood of early childhood caries.

FLUORIDE EXPOSURE

The judicious use of systemic fluoride is important in the comprehensive management of any dental patient. Special emphasis should be placed on ensuring adequate systemic fluoride for patients with disabilities. The dentist should first determine the concentration of fluoride in the patient's daily water supply. If the level of fluoride is between 0.7 and 1 ppm, no supplementation is normally required. If the dentist is not sure of the fluoride level of the patient's drinking water or fluoride acquired from other sources, an analysis is indicated. Once the level has been documented, a determination of the need for fluoride supplementation can be made. The amount of systemic fluoride supplementation necessary, along with the various forms available (i.e., drops, tablets, and rinses), is outlined in Chapter 9.

Whether the patient lives in an area with a fluoridated or nonfluoridated water supply, a topical fluoride should be applied after a regularly scheduled professional prophylaxis. Also, 5% neutral sodium fluoride varnishes have been shown to be beneficial.[11] An American Dental Association–accepted dentifrice containing a therapeutic fluoride compound should also be used daily. Some clinicians treating patients with SHCN who have chronically poor oral hygiene and high decay rates suggest a daily regimen of rinsing with 0.05% sodium fluoride solution. Nightly application of a 0.4% stannous fluoride or 1.1% sodium fluoride brush-on gel has also been successfully used to decrease caries in children.

PREVENTIVE RESTORATIONS

Pit-and-fissure sealants have been shown to reduce occlusal caries effectively. Sealants are appropriate in patients with SHCN. For a patient who requires dental work under general anesthesia, deep occlusal pits and fissures should be restored with amalgam or long-wearing composites to prevent further breakdown and decay. Patients with severe bruxism and interproximal decay may need their teeth restored with stainless steel crowns to increase the longevity of the restorations.

REGULAR PROFESSIONAL SUPERVISION

Close observation of caries-susceptible patients and regular dental examinations are important in the treatment of patients with SHCN. Although most patients are seen semiannually for professional prophylaxis, examination, and topical fluoride application, certain patients can benefit from recall examinations every 2, 3, or 4 months. This is particularly true of patients who are confined to institutions in which dental health programs are inadequate. Transferring the "dental home" of an adult patient with SHCN to a knowledgeable general dentist is recommended when dental care needs go beyond the scope of a pediatric dentist. If necessary, the pediatric dentist may refer the patient for "specialized care" (e.g., oral surgeon, orthodontist, periodontist).

MANAGEMENT OF A CHILD WITH SPECIAL HEALTH CARE NEEDS DURING DENTAL TREATMENT

The principles of behavior management discussed in Chapter 16 are even more important in the treatment of a child with SHCN. Because hospital visits or previous appointments with a physician frequently result in the development of apprehension in the patient, additional time must be spent with the parent and the child to establish rapport and dispel the child's anxiety. If patient cooperation cannot be obtained, the dentist must consider alternatives such as protective stabilization, conscious sedation, or general anesthesia to allow the necessary dental procedures to be performed.

PROTECTIVE STABILIZATION

Partial or complete protective stabilization of the patient is sometimes a necessary and effective way to diagnose and deliver dental care to patients who need help controlling their extremities, such as infants or patients with certain neuromuscular disorders. Protective stabilization is also useful for managing combative, resistant patients so that the patient, practitioner, and/or dental staff may be protected from injury while care is being provided. This can be performed by the dentist, staff, or parent, with or without the aid of a stabilization device.

The parents, guardian, or patient (if an adult) must be informed and must give consent, and the consent must be documented before protective stabilization is used. These individuals should have a clear understanding of the type of stabilization to be used, the rationale, and the duration of use. In many cases this information should be included in the explanation of the overall management approach for the child during the initial examination and conference with the parents.

In October 1990 the Omnibus Budget Reconciliation Act of 1987 became effective. It provided recommended guidelines to reduce the risk of injury and death from the use of patient restraints.

Dentlearn.ir

The American Academy of Pediatric Dentistry's *Behavior Guidance for the Pediatric Dental Patient Reference Manual 2014-15* indicates that the need to diagnose and treat, as well as to protect the safety of the patient, parent, staff, and practitioner, must justify the use of stabilization.[12] This decision should take into consideration a careful review of the patient's emotional development, physical and medical conditions (e.g., asthma-compromised respiratory function), dental needs, other alternative behavioral modalities, and quality of dental care. Although the benefits and importance of protective stabilization have been documented, the use of behavioral management or sedation, as discussed in Chapter 17 can reduce the amount of stabilization required. This is only one means of behavior control that can be used to achieve an adequate level of dental treatment (Video 25-1: Use of stabilization).

The use of protective stabilization is indicated in the following situations:

- A patient requires immediate diagnosis and/or limited treatment and cannot cooperate because of lack of maturity or mental or physical disability.
- A patient requires diagnosis or treatment and does not cooperate after other behavior management techniques have failed.
- The safety of the patient, staff, parent, or practitioner would be at risk without the use of protective stabilization.

The use of stabilization is contraindicated in the following situations:

- A cooperative nonsedated patient.
- Patients who cannot be safely stabilized due to medical or physical conditions.
- Patients who have experienced previous physical or psychological trauma from protective stabilization (unless no other alternatives are available).
- Nonsedated patients with nonemergent treatment requiring lengthy appointments.

Protective stabilization should not be used as punishment and should not be used solely for the convenience of the staff. The patient's record should display an informed consent, the indications for use, the type of stabilization used, and the duration of application. The tightness and duration of stabilization must be monitored and reassessed at regular intervals; stabilization around the extremities or chest must not actively restrict circulation or respiration. Stabilization should be terminated as soon as possible in a patient who is experiencing severe stress or hysterics to prevent possible physical or psychological trauma.

Common mechanical aids for maintaining the mouth in an open position are shown in Figure 25-7. Padded and wrapped tongue blades are easy to use, disposable, and inexpensive. Frequently, parents of a child with disabilities are given wrapped tongue blades or Open Wide (Specialized Care Co., Hampton, New Hampshire, United



Figure 25-7 Protective stabilization aids to keep the patient's mouth open. **A,** Wrapped tongue blades. **B,** Open Wide (Specialized Care Co.,) disposable mouth prop in proper position. **C,** Molt Mouth Prop (Hu-Friedy) in proper position. **D,** McKesson bite blocks.

Dentlearn.ir

States) disposable mouth props to aid with home dental care. The Open Wide mouth prop has a durable foam core on the end of a tongue depressor. It is also easy to use, disposable, and available in two sizes, but it is slightly more expensive than wrapped tongue blades. The Molt Mouth Prop (Hu-Friedy, Chicago, Illinois, United States) can be very helpful to manage a difficult patient for a prolonged period. It is made in both adult and child sizes, allows access to the opposite side of the mouth, and operates by a "reverse scissors" action. Its disadvantages include the possibility of lip and palatal lacerations and luxation of teeth if not used correctly. Caution must be exercised to prevent injury to the patient, and the prop should not be allowed to rest on anterior teeth. The patient's mouth should not be forced beyond its natural limits because patient discomfort and panic will result, which will cause further resistance and perhaps airway compromise.

Rubber bite blocks can be purchased in various sizes to fit on the occlusal surfaces of the teeth and stabilize the mouth in an open position. The bite blocks should have floss attached for easy retrieval if they become dislodged in the mouth.

Body control is gained through a variety of methods and techniques. For children who have a severe intellectual disability or are very young, parents and dental assistants can help control movements during dental procedures (Fig. 25-8). Usually, however, for a child who has a severe intellectual disability, better working conditions and a more predictable patient response are obtained through the combined use of psychological management techniques, parental assistance, pharmacologic aids, and stabilization.

The following are commonly used for protective stabilization:

Body

Papoose Board (Olympic Medical Corp., Seattle, Washington, United States)

Triangular sheet



Figure 25-8 Assistance for protective stabilization. **A,** Parental aid during an examination. **B,** Additional assistance during the dental procedure.

Dentlearn.ir

Pedi-Wrap (The Medi-Kid Co., Hemet, California, United States)
Beanbag dental chair insert
Safety belt
Extra assistant

Extremities

Posey straps (Posey Co., Arcadia, California, United States)
Velcro straps
Towel and tape
Extra assistant

Head

Forearm-body support
Head positioner
Plastic bowl
Extra assistant

The Papoose Board (Fig. 25-9) has several advantages. It is simple to store and use, reusable, and available in sizes to hold both large and small children and has attached head stabilizers. It does not always fit the contours of a dental chair, however, and sometimes a supporting pillow is needed. Because it covers the patient's diaphragm, a pretracheal stethoscope is necessary to monitor respiration if the board is used in combination with sedation. An extremely resistant patient may develop hyperthermia if immobilized too long, and, of course, any restrained patient requires constant attendance and supervision.

The triangular sheet technique can be utilized to control an extremely resistant child (Fig. 25-10, *A*). This economical method allows the patient to sit upright during radiographic examinations. Its disadvantages include the frequent need for straps to maintain the patient's position in the chair, the difficulty of its use with small patients, and the possibility of airway impingement if the patient slips downward unnoticed. Hyperthermia may be another problem during long periods of stabilization. Again, the need for constant supervision is emphasized so that these problems may be avoided.

The Rainbow Stabilizing System (Specialized Care Co.; see Fig. 25-10, *B*), which is available with or without the backboard, also comes in various sizes and allows the patient some movement while still being confined. Its mesh fabric permits better ventilation, lessening the chances of the patient developing hyperthermia. It, too, requires straps to maintain body position in the dental chair and constant supervision to prevent the patient from rolling out of the chair.

The beanbag dental chair insert was developed to help comfortably accommodate hypotonic and severely spastic persons who need more support and less stabilization in a dental environment (see Fig. 25-10, *C*). It is reusable and washable, and one size fits most people. Many patients with SHCN relax more in this setting.

The child's arms and legs can be stabilized with help from the parent or the dental assistant, with Posey straps, or with a towel and adhesive tape (Fig. 25-11). If movement of the extremities is the only problem, having a dental assistant stabilize the child is very helpful. Posey straps fasten to the arms of the dental chair and allow limited movement of the patient's forearm and hand. This limited movement frequently prevents overaction by resistant or combative patients. Wrapping a towel around the patient's forearms and fastening it with adhesive tape (without impeding circulation) is often helpful for an athetoid-spastic cerebral palsy patient who tries desperately but without success to control body movements. Protective stabilization actually encourages relaxation and prevents undesired reflexes by keeping the patient's arms in the midline of the body.

A patient's head position can usually be successfully maintained through the use of forearm-body pressure by the dentist. Other options include the presence of an additional assistant to stabilize the child's head or use of a Papoose Board head positioner or a plastic bowl (doggie bowl) to provide position guidance (Fig. 25-12).

An explanation of the benefits of protective stabilization should be presented by the dentist before use if communication with the patient is possible. The mouth prop can be identified as a "tooth chair," the Pedi-Wrap as a "safety robe," and a stabilization strap as a "safety belt," which allows the patient to feel secure rather than threatened. The parents should be given a careful explanation about how protective stabilization allows the needed dental work to be done while minimizing the possibility of accidental injury to the patient, parent, staff, or dentist. If a child requires extensive dental treatment and cooperation cannot be achieved by routine psychological, physical, or pharmacologic measures, the use of general anesthesia in a controlled atmosphere, as discussed in Chapter 18, is recommended.

INTELLECTUAL DISABILITY

Intellectual disability is a general term used when an individual's intellectual development is significantly lower than average and his or her ability to adapt to the environment is consequently limited.[13] The condition varies in severity and cause. A classification of intellectual disability is presented in Table 25-2. Intellectual disability has been identified in approximately 3% of the U.S. population. For many years the potential abilities of people with intellectual disabilities were poorly understood, and such individuals were often treated as inferior. They were described using the terms *idiot* (IQ [intelligence quotient] below 25), *imbecile* (IQ from 25 to 50), and *moron* (IQ from 50 to 70). With the formation of the President's Committee on Mental Retardation in 1968, emphasis was placed on education of individuals with intellectual disabilities to increase their social and civic responsibilities, motor skills, and independence within society.

Although a child who scores 2 standard deviations below the mean on the Stanford-Binet Intelligence Scale or the Wechsler Intelligence Scale for Children may have some degree of retardation, a diagnosis of intellectual disability is not made based on IQ alone. Both inadequate adaptive functioning and intellectual deficiency are required to fulfill a diagnosis of intellectual disability.

A child with mild intellectual disability is one who, because of low intelligence, requires special supports in the school environment. In the academic environment, these children may be eligible for special education services for students with mild intellectual disability. Educational

Dentlearn.ir



Figure 25-9 **A,** The Olympic Papoose Board (Olympic Medical Corp.) secured to a dental chair. **B,** Patient being placed in Papoose Board. **C,** Papoose Board in use.



Figure 25-10 Protective stabilization for control of body and extremities. **A,** Patient confined in a triangular sheet with leg straps. **B,** Patient in a Pedi-Wrap. **C,** Patient lying in a beanbag dental chair insert. (**C,** Courtesy Dr. Priscilla John Bond.)

programs for such children are generally simplified versions of regular school programs and usually lead to literacy and attainment of skills necessary for employment.

mately 80% of all persons with intellectual disability, will function acceptably as adults.

Children who are capable of some education and partial independence but who are not expected to experience full independence as adults may be eligible for special education services for students with moderate intellectual disability. Classroom activities may focus on attainment of daily living skills. Classrooms are often designed and furnished like a home, and the curriculum includes dressing, grooming, cooking, table setting, feeding, and cleaning. Individuals with moderate intellectual disability can be expected to master many vocational, leisure, and self-help skills within a supportive environment with trained personnel who help them with problems with which they may not be able to cope on their own.

A child with severe or profound intellectual disability

in special education programs. A student with severe to profound intellectual disability can achieve success with self-help, leisure, and some vocational skills given

can allow individuals with severe to profound intellectual disability a measure of independence while providing sufficient support for safety and continuing reinforcement.



Figure 25-11 Protective stabilization for the extremities. **A,** Posey strap (Posey Co.) on wrist. **B,** Towel and tape on forearm.

DENTAL TREATMENT OF A PERSON WITH INTELLECTUAL DISABILITY

Children with intellectual disability may have a higher incidence of poor oral hygiene, gingivitis, malocclusion, and untreated caries. As the severity of intellectual disability increases, typical oral signs of clenching, bruxing, drooling, pica, trauma, missing teeth, and self-injurious behaviors increase. Providing dental treatment for a person with intellectual disability requires adjusting to social, intellectual, and emotional delays. A short attention span, restlessness, hyperactivity, and erratic emotional behavior may characterize patients with intellectual disability undergoing dental care. The dentist should assess the degree of intellectual disability by consulting the patient's physician for frequent medical assessment and coordinate care when appropriate.

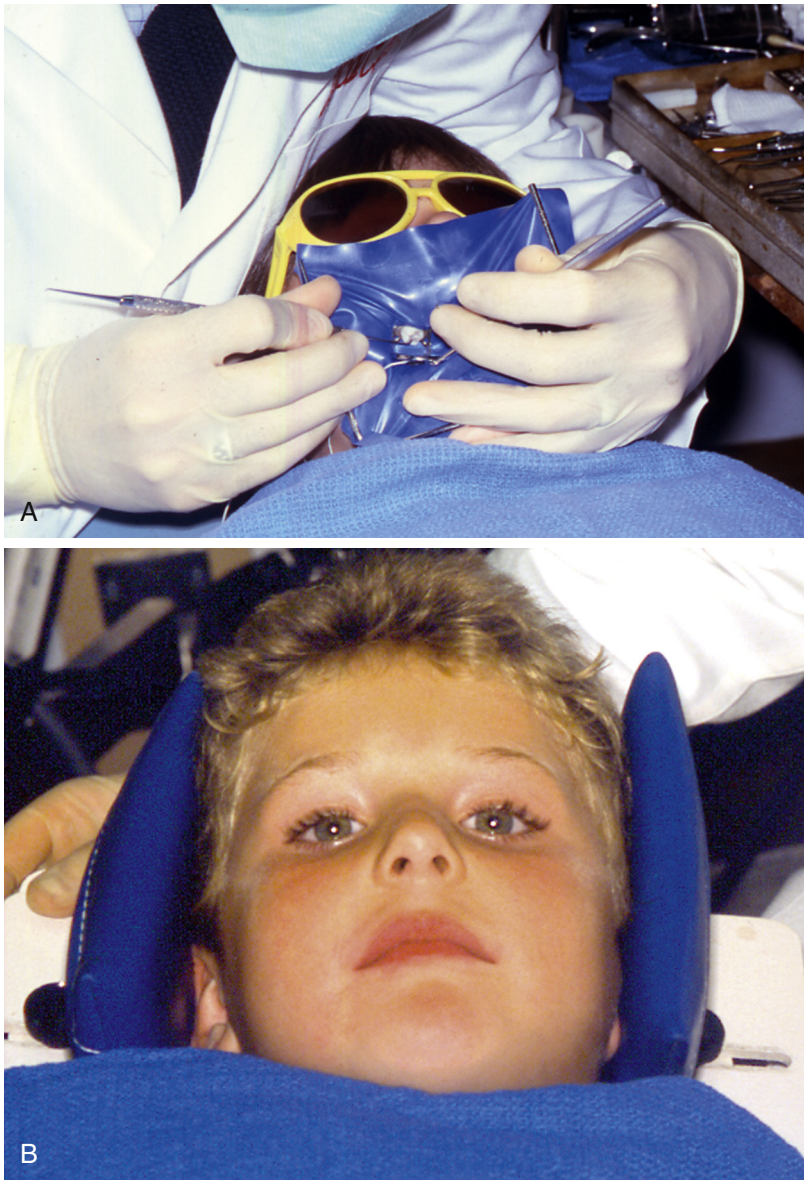

Figure 25-12 Protective stabilization aids for the head. **A,** Proper positioning of the dentist's hands, forearm, and body. **B,** Use of the Olympic Papoose Board head positioner.

The following procedures have proved beneficial in establishing dentist-patient-parent-staff rapport and reducing the patient's anxiety about dental care:

1. Give the family a brief tour of the office before attempting treatment. Introduce the patient and family (parent/caretaker/guardian) to the office staff. This will familiarize the patient with the personnel and facility and reduce the patient's fear of the unknown. Allow the patient to bring a favorite item (stuffed animal, blanket, or toy) to hold for the visit.
2. Be repetitive; speak slowly and in simple terms. Make sure explanations are understood by asking the patient if there are any questions. If the individual has an alternative communication system, such as a picture board or electronic device, be sure it is available to assist with dental explanations and instructions.
3. Give only one instruction at a time. Reward the patient with compliments after the successful completion of each procedure.
4. Actively listen to the patient. People with intellectual disability often have trouble with communication, and the dentist should be particularly sensitive to gestures and verbal requests.
5. Invite the parent/guardian into the operatory for assistance and to aid in communication with the patient when helpful.
6. Keep appointments short. Gradually progress to more difficult procedures (e.g., anesthesia and restorative dentistry) after the patient has become accustomed to the dental environment.
7. Schedule the patient's visit early in the day, on a lightly scheduled day, when the dentist, the staff, and the patient will be less fatigued.

Table **25-2**

Classification of Intellectual Disability

Degree of Mental Disability	SB-IV	WISC-III	Communication	Special Requirements for Dental Care
Mild	67-52	69-55	Should be able to speak well enough for most communication needs	Treat as normal child; mild sedation or nitrous oxide–oxygen analgesia may be beneficial
Moderate	51-36	54-40	Has vocabulary and language skills such that the child can communicate with others at a basic level	Mild to moderate sedation may be beneficial; use restraints and positive reinforcement; general anesthesia may be indicated in cases of severe, generalized, dental decay
Severe or profound	35 and below	39 and below	Mute or communicates in grunts; little or no communication skills	Same as for moderately intellectually disabled

SB-IV, Stanford-Binet Intelligence Scale, 4th ed; WISC-III, Wechsler Intelligence Scale for Children, 3rd ed.

With adequate preparation, the dentist and the staff can provide a valuable service. By thoroughly understanding the patient's degree of intellectual disability and abilities, and by exercising patience and understanding, the dentist should have no significant problems in delivering dental care. When cooperation does not exist, sedation or general anesthesia may be an option.

DOWN SYNDROME (TRISOMY 21 SYNDROME)

Down syndrome is the best-known chromosomal dis-

chromosome 21(trisomy 21). Medical conditions that occur more frequently in infants and children with Down syndrome and increase the mortality of these individuals include cardiac defects, leukemia, and upper respiratory infections. The incidence of congenital cardiac defects is about 40%, and because of these patients' high susceptibility to periodontal disease, knowledge of a heart condition is essential for dental treatment. Children with Down syndrome have a 10- to 20-fold greater incidence of leukemia during infancy compared with the general population. This increased incidence of leukemia is not maintained later in life.

Skeletal findings are an underdeveloped midface, creating a prognathic occlusal relationship. Oral findings include mouth breathing, open bite, appearance of macroglossia, fissured lips and tongue, angular cheilitis, delayed eruption times, missing and malformed teeth, oligodontia, small roots, microdontia, crowding, and a low level of caries. Children with Down syndrome experience a high incidence of rapid, destructive periodontal disease, which may be related to local factors such as tooth morphology, bruxism, malocclusion, and poor oral hygiene. Certain systemic factors are also believed to contribute to periodontal disease, including poor circulation and decreased cellular motility of gingival fibroblasts,[14] decreased humoral response, general physical deterioration at an early age, and genetic influences. Bell and colleagues reported that severity of tooth wear (both attrition and erosion) was significantly greater in children with Down syndrome than in children without the syndrome.[15]

Many children with Down syndrome are affectionate and cooperative, and dental procedures can be provided without compromise if the dentist works at a slightly slower pace. Emphasis should be placed on preventive dental care with frequent follow-up visits to monitor oral hygiene. A recent study by Cheng and colleagues documented periodontal healing responses in adult patients with Down syndrome using nonsurgical periodontal therapy in conjunction with the use of chlorhexidine rinse twice a day and chlorhexidine gel and monthly recalls.[16] Comprehensive dental care is an overall goal with alteration based on the individual's level of functioning. Light sedation and immobilization may be indicated in those children who are moderately apprehensive. Severely resistive patients may require general anesthesia.

Delayed tooth eruption frequently occurs in children with Down syndrome. For this reason, additional discussion of this disorder is presented in Chapter 19.

LEARNING DISABILITIES

Learning disabilities are neurological conditions that interfere with the individual's ability to store, process, or produce information. They can affect a person's ability to read, write, count, speak, or reason. In addition, they may affect memory, attention, coordination, social skills, and emotional maturity. Learning disabilities affect between 3% and 15% of the population. They occur four times more frequently among boys than among girls.

Learning disabilities may run in families, indicating a possible genetic factor, and are sometimes confused with

intellectual disabilities, autism, deafness, and behavioral disorders. They include conditions that have been referred to as perceptual handicaps, brain injury, minimal brain dysfunction, dyslexia, and developmental aphasia. The cause of learning disabilities remains unclear. Physiologic factors, such as minimal brain injury or damage to the central nervous system, have been implicated. The possibility exists that severe emotional disturbances can develop as a result of learning disabilities. This potential has prompted the early diagnosis and treatment of affected persons.

Most children with learning disabilities accept dental care and cause no unusual management problems for the dentist. If a child is resistant, behavioral management and conscious sedation techniques may be used with success.

FRAGILE X SYNDROME

Fragile X is an X-linked developmental disorder. It accounts for 30% to 50% of cases of X-linked mental disability. The defect is an abnormal gene on the terminal portion of the long arm of an X chromosome. Males are more vulnerable because they have only one X chromosome and are more significantly affected than females. Numerous studies have investigated fragile X syndrome in males, but fragile X syndrome in females has not been investigated as extensively because the physical and cognitive deficits in females are usually less severe. It is one of the most common genetic causes of learning disability, but because it is less phenotypically recognizable, reports of orofacial findings are limited.

A history of developmental delay and hyperactivity, and physical features such as prominent ears, long face, prominent jaw, flattened nasal bridge, hyperextensible joints, flat feet, mitral valve prolapse (MPV), simian creases of the palms, and postadolescent macroorchidism in males should be considered potential indicators for fragile X syndrome. A higher incidence of malocclusions including an open bite and crossbites has been reported.

Behavioral features such as hand slapping, hand biting, and poor eye contact are frequently seen. Fragile X syndrome may be diagnosed in individuals with another diagnosis such as Down syndrome or cerebral palsy.

Treatment of children with fragile X syndrome is multidisciplinary, and speech, language, and occupational therapy is required to address the cognitive, language, and sensory integration problems. Medical intervention can be useful in decreasing the hyperactivity and improving the attention span. Females with fragile X syndrome have a more favorable outcome with appropriate intervention than do males with fragile X syndrome.

The mode of dental treatment depends on the level of developmental delay, cognitive ability, and degree of hyperactivity. Children with mild cases may be treated by scheduling short appointments and using immobilization and/or conscious sedation. Severely affected individuals must be treated in the operating room under general anesthesia.

FETAL ALCOHOL SPECTRUM DISORDER

Fetal alcohol spectrum disorder (FASD) is an umbrella term that describes the range of effects that may occur with maternal consumption of alcohol during pregnancy. It occurs in about 40,000 babies per year, and it is likely that the alcohol affects the normal development of the neural crest cells. The Centers for Disease Control and Prevention requires three facial findings, growth deficits, and central nervous system abnormalities to make the diagnosis, but even in the absence of the characteristic findings, FASD should be suspected in children with growth deficits, central nervous system abnormalities, and a history of prenatal alcohol exposure. Physical findings may include moderate to severe growth retardation with persistent microcephaly. There are often eye abnormalities, short palpebral fissures, a smooth philtrum, and a thin vermilion border. Cardiac malformations include ventricular septal defects, pulmonary artery hypoplasia, and interruption of the aortic arch. Hearing and vestibular problems are also seen, and because the development of speech is dependent upon an intact hearing apparatus, children with FASD may have slurred speech and poor receptive and language skills. The vestibular damage may result in postural disturbances. Other associated abnormalities such as skeletal, urinary, and immune system impairment have also been reported.

Craniofacial features include midface underdevelopment, small teeth, absent teeth, high arched palate, delayed dental development, enamel anomalies, cleft lip or palate, crowded incisors, excessive maxillary overjet, and open bite. The dentist must be aware of the physical, emotional, and mental conditions, because these may affect dental management and treatment planning.

AUTISM SPECTRUM DISORDER

Autism spectrum disorder (ASD) includes three neurodevelopmental disorders: autism disorder, Asperger syndrome, and pervasive development disorder (PDD). The prevalence is estimated to be 6 per 1000 children. The rise in the rates of ASD has been attributed to increased awareness and better diagnostic tools. It occurs with greater frequency in boys than girls.

The exact cause of ASD is not completely known, although genetic factors and environmental factors may play a role. Although the majority of cases are idiopathic, a small percent have a known inheritance such as fragile X syndrome, tuberous sclerosis, Rett syndrome, and Angelman syndrome. Many children with ASD present with a typical developmental period followed by regression in the second year.

There are three levels of impairment noted. The first notable impairment is social, which, in some cases is extreme, with lack of eye contact and not responding to one's name. The second is an impairment in communication, which can result in the delay or complete lack of spoken language. Children with Asperger syndrome do not have a general delay in language or cognitive development; however, they often have communication difficulties, especially in sustaining conversations.

The third area of impairment in ASD is repetitive behaviors. They may include staring, floppy hands, an odd interest in or preoccupation with specific objects. There is great variability in presentation in children with ASD,

Dentlearn.ir

and the diagnosis is made based upon the number of symptoms involved.

Children with ASD have multiple medical and behavioral problems that may make dental treatment difficult. These children often have poor muscle tone, poor coordination, drooling, a hyperactive knee jerk, and strabismus; 30% eventually develop epilepsy. Children with ASD may have strict routines and prefer soft foods and sweetened foods. Because of poor tongue coordination, children with ASD tend to "pouch" food instead of swallowing. This habit, combined with the desire for sweetened foods, leads to increased susceptibility to caries.

Because of their tendency to adhere to routines, children with ASD may require several dental visits to acclimate to the dental environment. The use of a Papoose Board or Pedi-Wrap and preappointment conscious sedation may be necessary and in some instances has a calming effect on the child.

CEREBRAL PALSY

Cerebral palsy is one of the primary handicapping conditions of childhood. The incidence of cerebral palsy in the United States, for all ages, is 1.5 to 3 cases per 1000 individuals. One newborn in approximately 200 live births will be affected with this condition. Cerebral palsy is not a specific disease entity but rather a collection of disabling disorders caused by insult and permanent damage to the brain in the prenatal and perinatal periods, during which time the central nervous system is still maturing. This disability might involve muscle weakness, stiffness, or paralysis, poor balance or irregular gait, and uncoordinated or involuntary movements.

Although many recognized conditions result in damage to the motor centers of the brain, in at least one third of the cases of cerebral palsy, no discernible cause is found. It has been well established that any factor contributing to decreased oxygenation of the developing brain can be responsible for brain damage. In addition, causal relationships have been established between cerebral palsy and complications of labor or delivery; infections of the brain, such as meningitis and encephalitis; toxemias of pregnancy; congenital defects of the brain; kernicterus; poisoning with certain drugs and heavy metals; and accidents resulting in trauma to the head. There is a high correlation between premature birth and cerebral palsy. (Approximately one third of all infants born prematurely have a demonstrable nervous system abnormality.)

There are various types of cerebral palsy, which are distinguished according to the neuromuscular dysfunctions observed and the extent of anatomic involvement. Some persons may have almost imperceptible symptoms. Others are severely disabled, with no appreciable use of the muscles of their limbs and other voluntary muscles. It is imperative to keep in mind that two patients with the same type of cerebral palsy may show very disparate symptoms. The following terms are commonly used to designate involved areas of the body:

1. Monoplegia—involvement of one limb only
2. Hemiplegia—involvement of one side of the body
3. Paraplegia—involvement of both legs only
4. Diplegia—involvement of both legs with minimum involvement of both arms
5. Quadriplegia—involvement of all four limbs

The following outline provides a classification of cerebral palsy according to the type of neuromuscular dysfunction and lists a few of the basic characteristics of each type:

I. Spastic (approximately 70% of cases)
   A. Hyperirritability of involved muscles, resulting in exaggerated contraction when stimulated
   B. Tense, contracted muscles (e.g., spastic hemiplegia affects one third of all children with cerebral palsy. The hand and arm are flexed and held in against the trunk. The foot and leg may be flexed and with circumduction of the affected leg.)
   C. Limited control of neck muscles, which results in head rolling
   D. Lack of control of the muscles supporting the trunk, which results in difficulty in maintaining upright posture
   E. Lack of coordination of intraoral, perioral, and masticatory musculature; possibility of impaired chewing and swallowing, excessive drooling, persistent spastic tongue-thrust, and speech impairments
II. Dyskinetic (athetosis and choreoathetosis) (approximately 15% of cases)
   A. Constant and uncontrolled motion of involved muscles
   B. Succession of slow, twisting, or writhing involuntary movements (athetosis) or quick, jerky movements (choreoathetosis)
   C. Frequent involvement of neck musculature, which results in excessive movement of the head (Hypertonicity of these muscles may cause the head to be held back, with the mouth constantly open and the tongue positioned anteriorly or protruded.)
   D. Possibility of frequent, uncontrolled jaw movements, causing abrupt closure of the jaws or severe bruxism
   E. Frequent hypotonicity of perioral musculature, with mouth breathing, tongue protrusion, and excessive drooling
   F. Facial grimacing
   G. Chewing and swallowing difficulties
   H. Speech problems
III. Ataxic (approximately 5% of cases)
   A. Inability of involved muscles to contract completely so that voluntary movements can be only partially performed
   B. Poor sense of balance and uncoordinated voluntary movements (e.g., stumbling or staggering gait or difficulty in grasping objects)
   C. Possibility of tremors and an uncontrollable trembling or quivering when attempting voluntary tasks
IV. Mixed (approximately 10% of cases)
   A. Combination of characteristics of more than one type of cerebral palsy (e.g., mixed spastic-athetoid quadriplegia)

Two additional forms of cerebral palsy have been described but occur infrequently. In hypotonia, the muscles are flaccid (i.e., there is an inability to elicit muscle activity on volitional stimulation). In rigidity, the muscles are

Dentlearn.ir

in a constant state of contraction. The condition is characterized by prolonged periods in which the muscles of the extremities or trunk remain rigid, resisting any effort to move them.

In many patients with cerebral palsy, certain neonatal reflexes may persist long after the age at which they normally disappear. These primitive reflexes are usually modified or are progressively replaced as the subcortical dominance of the infant's behavior is suppressed by higher centers of the maturing central nervous system. Three of the most common reactions, which a dentist should recognize, are the following:

1. *Asymmetric tonic neck reflex*. If the patient's head is suddenly turned to one side, the arm and leg on the side to which the face is turned extend and stiffen. The limbs on the opposite side flex.
2. *Tonic labyrinthine reflex*. If the patient's head suddenly falls backward while the patient is supine, the back may assume the position known as *postural extension*; the legs and arms straighten out, and the neck and back arch.
3. *Startle reflex*. This reflex, which is frequently observed in persons with cerebral palsy, consists of sudden, involuntary, often forceful bodily movements. This reaction is produced when the patient is surprised by stimuli, such as sudden noises or unexpected movements by other people.

Because the motor involvement in cerebral palsy results from irreversible damage to the developing brain, other symptoms of organic brain damage may also be present. The fact that these other symptoms are frequently seen underscores the premise that cerebral palsy does not denote one specific disease entity. Rather, it is a complex of disabling conditions, the clinical manifestations of which depend on the extent and location of damage to the brain. The following are some common manifestations:

1. *Intellectual disability*. Approximately 60% of persons with cerebral palsy demonstrate some degree of intellectual disability.
2. *Seizure disorders*. Seizures are an accompanying condition in 30% to 50% of cases; they occur primarily during infancy and early childhood. Most seizures can be controlled with anticonvulsant medications.
3. *Sensory deficits or dysfunctions*. Impairment of hearing is more common than in the normal population, and eye disorders affect approximately 35% of persons with cerebral palsy. The most common visual defect is strabismus.
4. *Speech disorders*. More than half of patients with cerebral palsy have some speech problem—usually dysarthria, an inability to articulate well because of lack of control of the speech muscles.
5. *Joint contractures*. Persons with spasticity and rigidity demonstrate abnormal limb postures and contractures during growth and at maturity, primarily because of cerebral palsy. Often the patient will not be physically able to brush or floss adequately. When oral hygiene measures must be provided for the person by another individual, they may be performed infrequently and inadequately. Diet may also be significant; children who have difficulty chewing and swallowing tend to eat soft foods, which are easily swallowed and are high in carbohydrates. Patients with cerebral palsy and who take phenytoin to control seizure activity will generally have a degree of gingival hyperplasia.

No intraoral anomalies are unique to persons with cerebral palsy. However, several conditions are more common or more severe than in the general population. These conditions are as follows:

1. *Periodontal disease*. Periodontal disease and poor oral hygiene occur with great frequency in persons with
2. *Dental caries*. The data are conflicting regarding the incidence of dental caries in patients with cerebral palsy compared with its incidence in the general population. Except among institutionalized patients, the incidence of caries does not seem to be significantly greater among persons with cerebral palsy.
3. *Malocclusions*. The prevalence of malocclusions in patients with cerebral palsy is approximately twice that in the general population. Commonly observed conditions include noticeable protrusion of the maxillary anterior teeth, excessive overbite and overjet, open bites, and unilateral crossbites. A primary cause may be a disharmonious relationship between intraoral and perioral muscles. Uncoordinated and uncontrolled movements of jaws, lips, and tongue are observed with greater frequency in patients with cerebral palsy. This may result in impaired chewing and swallowing, excessive drooling, tongue-thrust, and speech impairment.
4. *Bruxism*. Bruxism is commonly observed in patients with athetoid cerebral palsy. Severe occlusal attrition of the primary and permanent dentition may be noted, with the resulting loss of vertical interarch dimension. Temporomandibular joint disorders may be sequelae of this condition in adult patients.
5. *Trauma*. Persons with cerebral palsy are more susceptible to trauma, particularly to the maxillary anterior teeth. This situation is related to the increased tendency to fall, along with a diminished extensor reflex to cushion such falls, and the frequent increased flaring of the maxillary anterior teeth. Susceptibilities also include aspiration and ingestion of a foreign body.

To an uninformed dentist, a person with cerebral palsy who has involuntary movements of the limbs and head might be perceived as an uncooperative and unmanageable patient. In addition, patients who have unintelligible speech, uncontrollable jaw movements, and spastic tongue are often erroneously assumed to be intellectually delayed. A clinician who is not knowledgeable about cerebral palsy and other physically and intellectually disabling conditions may feel uncomfortable about treating such patients and may refuse to do so.

In providing treatment for children with cerebral palsy, it is imperative that a dentist evaluate each patient thoroughly in terms of personal characteristics, symptoms, and behavior and then proceed as conditions and needs dictate.

The dentist should never make assumptions about the degree of a child's physical or intellectual impairments without first acquiring the facts. Taking a thorough medical and dental history is very important, and the parent

Dentlearn.ir

or guardian should be interviewed before the initiation of any treatment. It may also be beneficial to consult the patient's physician regarding the patient's medical status.

A patient with cerebral palsy and who has involuntary head movements may be cognizant of the need to minimize these movements while receiving dental care. Paradoxically the patient's own endeavors to control these movements may only exacerbate the problem. Therefore it is imperative that all dental personnel be empathic about the fears and frustrations that such a person experiences. The importance of maintaining a calm, friendly, and professional atmosphere cannot be overemphasized.

The following suggestions are offered to the clinician as being of practical significance in treating a patient with cerebral palsy:

1. Consider treating a patient who uses a wheelchair in the wheelchair. Many patients express such a preference, and it is frequently more practical for the dentist. For a young patient, the wheelchair may be tipped back into the dentist's lap.
2. If a patient is to be transferred to the dental chair, ask about a preference for the mode of transfer. If the patient has no preference, the two-person lift is recommended.
3. Make an effort to stabilize the patient's head throughout all phases of dental treatment.
4. Try to place and maintain the patient in the midline of the dental chair, with arms and legs as close to the body as feasible.
5. Keep the patient's back slightly elevated to minimize difficulties in swallowing. (It is advisable not to have the patient in a completely supine position.)
6. When the patient has been placed in the dental chair, determine the patient's degree of comfort and assess the position of the extremities. Do not force the limbs into unnatural positions. Consider the use of pillows, towels, and other measures for trunk and limb support.
7. Use stabilization judiciously to control flailing movements of the extremities.
8. For control of involuntary jaw movements, choose from a variety of mouth props. Patient preference should weigh heavily because a patient with cerebral palsy may be very apprehensive about the ability to control swallowing. Such appliances may also trigger the strong gag reflex that many of these patients possess. Allow frequent time-outs for the patient to
9. To minimize startle reflex reactions, avoid presenting stimuli such as abrupt movements, noises, and lights without forewarning the patient.
10. Introduce intraoral stimuli slowly to avoid eliciting a gag reflex or to make it less severe.
11. Consider the use of the rubber dam, a highly recommended technique, for restorative procedures.
12. Work efficiently and quickly and minimize patient time in the chair to decrease fatigue of the involved muscles.
13. Sedation or general anesthesia may be an option for more complex patients.

SPINA BIFIDA AND LATEX ALLERGY

Although the etiology of spina bifida is unknown, it is thought to be the result of a genetic predisposition whose manifestation is triggered by the environment. There are two common forms of this neural tube defect, spina bifida occulta and myelomeningocele. Spina bifida occulta (i.e., closed) presents with skin covering an area where tissue protrudes through a bony cleft in the vertebral column. These children may develop foot weakness or bowel and bladder sphincter disturbances. Myelomeningocele (spina bifida aperta, i.e., open) is the most severe because the spinal cord, spinal fluid, and membranes protrude in a sac through the defect. These children can suffer from hydrocephalus, paralysis, orthopedic deformities, and genitourinary abnormalities. If the mother takes folic acid during the first 6 weeks of pregnancy, over 50% of neural tube defects can be prevented.

Children with neural tube defects are at higher risk for caries secondary to poor hygiene, poor nutritional intake, and long-term drug therapy. They are also at higher risk for latex allergy because they are frequently exposed to latex as a result of undergoing procedures in which latex products are used. Therefore Nettis and colleagues[17] recommend that all patients be screened for conditions such as spina bifida and exposure to recurrent surgical procedures, and for a history of atopy, cross-reactive food allergies (i.e., allergies to banana, avocado, kiwi, and chestnuts, which may sensitize allergic patients to latex exposure), and previous reactions to natural rubber latex.

For all patients with a latex allergy or latex allergy risk factors, all equipment that comes in intimate contact with the patient should be made of nonlatex substitutes. Nettis and colleagues[17] suggest avoiding handling of nonlatex products while wearing latex gloves or with unwashed hands to prevent the transfer of latex allergens to nonlatex products. They suggest that the ideal time to schedule dental appointments for such individuals is at the beginning of a working session, such as in the morning or after a vacation when the office has been closed. This will allow for settling of airborne latex particles. Another good scheduling time is after the office has been professionally vacuumed and cleaned to remove latex-tainted cornstarch. Mild irritant reactions to latex can be managed with immediate removal of the rubber object and administration of an antihistamine. However, acute systemic reactions (anaphylaxis) require immediate treatment with epinephrine injection 1:1000 USP and may necessitate emergency resuscitation (call 911).

RESPIRATORY DISEASES

ASTHMA (REACTIVE AIRWAY DISEASE)

Asthma is a common childhood disease, affecting 1 in 10 children. Although often thought of as acute respiratory distress brought on by environmental factors, asthma is a chronic airway disease characterized by inflammation, increased mucus production, and bronchial constriction.

Asthma is a diffuse obstructive disease of the airway caused by edema of the mucous membranes, increased

Dentlearn.ir

mucous secretions, and spasm of smooth muscle. It is twice as common in prepubertal boys but affects both genders equally during adolescence and adulthood. The etiology includes biochemical, immunologic, infectious, endocrine, and psychological factors. The typical symptoms of asthma are coughing, wheezing, chest tightness, and dyspnea. The clinical onset of an episode may occur over minutes (acute) or hours and days. An acute attack is associated with exposure to irritants such as cold air, fumes, or dust, and it may develop in minutes. An attack developing over days is usually precipitated by a viral respiratory infection. Severe bronchial obstruction results in labored breathing, wheezing, tachypnea, profuse perspiration, cyanosis, hyperventilation, tachycardia, and sometimes chest pain. A dental procedure constitutes an acute irritant to the airways of the asthmatic child and may precipitate an attack.

Fortunately, three fourths of childhood asthma is mild, with minimal daily symptoms and short-lived exacerbations. Before initiating dental treatment, the dentist should know what are the frequency and severity of the attacks, what are the triggering agents, when the patient was hospitalized and/or in the emergency department, when the last attack occurred, what medications the patient takes, and what limitations on activity the patient may have. Patients taking systemic corticosteroids and those who were hospitalized or in the emergency department in the preceding year should be treated with caution because they are at higher risk of morbidity and mortality. Sometimes, deferring the dental visit until the patient's asthma is controlled is the best approach.

Patients who use bronchodilators should take a dose before their appointment, and they should bring their inhalers or nebulizers into the dental office in case trouble arises. Acute symptoms may be prevented by the use of the child's bronchodilator (inhaled β2 receptor agonist such as albuterol). Behavioral methods are used to reduce anxiety, and nitrous oxide–oxygen analgesia may be helpful. Hydroxyzine hydrochloride (Vistaril) and diazepam (Valium) have been successful in alleviating anxiety. Barbiturates and narcotics are not indicated because of their potential for histamine release, leading to a bronchospasm. Aspirin compounds and nonsteroidal anti-inflammatory agents are contraindicated because about 4% of patients experience wheezing after taking these drugs. Acetaminophen is recommended. Positioning a child with mild asthmatic symptoms in an upright or semiupright position for the dental procedure may be beneficial.

Oral findings of children with moderate to severe asthma include higher caries rates, decreased salivary rates, increased prevalence of oral mucosal changes characteristic of chronic mouth breathers, and increased levels of gingivitis. Increased incidence of orofacial abnormalities such as high palatal vault, more posterior crossbites, greater overjets, and increased facial height is also seen.

Dental goals are similar to those for other patients, with care taken to avoid the potential for dental materials and products to exacerbate the asthma. The patient's pulmonary function, propensity for developing an attack, immune status, and adrenal status should be evaluated prior to dental treatment. Emergency treatment for a person with asthma and who is in respiratory distress requires discontinuing the dental procedure, reassuring the patient, and opening the airway. Staff should administer 100% oxygen while placing the patient in an upright or comfortable position. Keeping the airway open, administer the patient's β_2 agonist with an inhaler or nebulizer. If there is no improvement, administer subcutaneous epinephrine (0.01 mg/kg of 1:1000 solution) and obtain medical assistance immediately.

BRONCHOPULMONARY DYSPLASIA

Bronchopulmonary dysplasia is a chronic lung disease usually resulting from the occurrence during infancy of respiratory distress syndrome that requires prolonged ventilation with a high concentration of inspired oxygen. Chronic lung changes are more likely to occur in the premature infant. The incidence is approximately 60% in infants weighing less than 1000 g at birth. With the increased survival of low-birthweight infants, the prevalence of bronchopulmonary dysplasia has increased. The lung pathology of children with bronchopulmonary dysplasia shows evidence of bronchial ulceration, necrosis with plugging of bronchiolar lumina, and inflammatory cells. This bronchiolar injury compromises further lung development. Inflammatory changes and bronchiolar fibrosis lead to increased airway resistance and contribute to the hypoxemia seen in infants with bronchopulmonary dysplasia. Some children with bronchopulmonary dysplasia develop right ventricular hypertrophy (cor pulmonale). Other significant pulmonary complications include tracheal stenosis, upper airway obstruction secondary to subglottic cysts, and hoarseness because of partial or complete vocal cord paralysis. About 20% of infants with bronchopulmonary dysplasia die within the first year of life. The major causes of death are cor pulmonale, respiratory infections, and sudden death.

An increased oxygen supply must be provided to prevent hypoxic pulmonary vasoconstriction and to decrease the work of breathing. The nasal cannula provides continuous oxygen delivery, which results in fewer fluctuations in oxygen tension. Weaning the child off oxygen is possible with improved lung function and lung size. Children who develop cor pulmonale may require diuretic therapy to prevent congestive heart failure.

Dental care for children with bronchopulmonary dysplasia requires more chair time than usual. These children often spend a significant part of their early lives in the hospital and exhibit significant oral defensiveness.

After the initial dental evaluation, consultation with a pulmonologist is beneficial to plan safe dental treatment for the patient. If the dental patient is taking oxygen continuously via a nasal cannula, short appointments with frequent breaks are necessary to prevent the development of pulmonary vasoconstriction. Parents of children with bronchopulmonary dysplasia may need to provide additional oral hygiene for their children when these children are required to eat frequent small meals to maintain the proper caloric intake. Any nonemergent dental care should be avoided when the patient is not doing well medically.

Dentlearn.ir

CYSTIC FIBROSIS

Cystic fibrosis is an autosomal-recessive disorder occurring in 1 of every 2000 births. It is the most common lethal genetic disorder affecting whites. The genetically altered protein affects exocrine gland function. The defective exocrine gland function leads to microobstruction of the pancreas, which results in cystic degeneration of the pancreas and, ultimately, a digestive enzyme deficiency producing malabsorption of nutrients.

The defective gene products cause abnormal water and electrolyte transport across epithelial cells, which results in a chronic disease of the respiratory and gastrointestinal system, elevated levels of electrolytes in sweat, and impaired reproductive function.

In the lungs, retention of mucus occurs, which causes obstructive lung disease and increased frequency of infections. As the progressive lung disease develops, there is an increase in chest diameter, clubbing of the fingers and toes, decreased exercise tolerance, and a chronic productive cough. Before advances in antibiotic therapy, physical therapy, and nutritional supplementation, these individuals rarely survived childhood. The median life expectancy has been increased to 39 years for women and 41 years for men. Death is most frequently the result of pneumonia and anoxia after a long period of respiratory insufficiency. Cystic fibrosis–related diabetes is becoming more common as patients live longer.

Children with cystic fibrosis have a high incidence of tooth discoloration when systemic tetracyclines are taken during tooth formation. With the advent of alternative antibiotics, the incidence of tooth discoloration is decreasing. The incidence of dental caries in children with cystic fibrosis is low secondary to long-term antibiotic therapy, buffering capacity of excess calcium in the saliva, and pancreatic enzyme replacement therapy. There is a high incidence of mouth breathing and open-bite malocclusion associated with chronic nasal and sinus obstruction. Patients with cystic fibrosis may prefer to be treated in a more upright position to allow them to clear secretions more easily. The use of sedative agents that interfere with pulmonary function should be avoided, and the patient's physician should be contacted before nitrous oxide–oxygen sedation is used in a patient exhibiting evidence of severe emphysema.

HEARING LOSS

Hearing loss (deafness) is a disability that is often overlooked because it is not obvious. Total hearing loss affects 1.8 million people, and there are 14 million hearing-impaired individuals in the United States. About 1 in 600 neonates has a congenital hearing loss. During the neonatal period, many more acquire hearing loss from other associated conditions. Almost inevitably, speech is affected. If an impairment is severe enough that dentist and child cannot communicate verbally, the dentist must use sight, taste, and touch to communicate and to allow the child to learn about dental experiences. Table 25-3 shows how speech and psychological problems relate to various degrees of hearing loss. Many times, mild hearing losses are not diagnosed, which leads to management problems because of the child's misunderstanding of instructions;

Table **25-3**

Implications of Auditory Disability Relative to International Standards Organization (ISO) Reference Levels*

ISO (DB)	Disability	Speech Comprehension	Psychological Problems in Children
0	Insignificant	Little or no difficulty	None
25	Slight	Difficulty with faint speech; language and speech development within normal limits	Child may show a slight verbal deficit.
40	Mild-moderate	Frequent difficulty with normal speech at 3 feet (91.4 cm); language skills are mildly affected	Psychological problems can be recognized.
55	Marked	Frequent difficulty with loud speech at 3 feet (91.4 cm); difficulty understanding with hearing aid in school situation	Child is likely to be educationally retarded, with more pronounced emotional and social problems than in children with normal hearing.
70	Severe	May understand only shouts or amplified speech at 1 foot (30.5 cm) from ear	The prelingually deaf show pronounced educational retardation and evident emotional and social problems.
90	Extreme	Usually no understanding of speech even when amplified; child does not rely on hearing for communication.	The prelingually deaf usually show severe intellectual disability and emotional underdevelopment.

*Reference levels are in decibels relative to threshold in young patients with normal hearing.
Adapted from Goetzinger CP: The psychology of hearing impairment, In: Katz J, ed. *Handbook of clinical audiology*, ed 2, Baltimore, 1978, Williams & Wilkins.

Dentlearn.ir

children with more severe hearing losses already have psychological and social disturbances that make dental behavior management more complex. Parents may suspect profound hearing loss if their infant does not respond to ordinary sounds or voices. Early identification and correction of hearing loss are essential for the normal development of communication skills. No abnormal dental findings are associated with hearing loss.

The following are known causes of hearing loss:

- Prenatal factors
- Viral infections, such as rubella and influenza
- Ototoxic drugs, such as aspirin, streptomycin, neomycin, kanamycin
- Congenital syphilis
- Heredity disorders (e.g., Alport, Arnold-Chiari, Crouzon, Hunter, Klippel-Feil, Stickler, Treacher Collins, and Waardenburg syndromes)
- Perinatal factors
- Toxemia late in pregnancy
- Prematurity
- Birth injury
- Anoxia
- Erythroblastosis fetalis
- Postnatal factors
- Viral infections, such as mumps, measles, chickenpox, influenza, poliomyelitis, meningitis
- Injuries

The following should be considered in the treatment of a hearing-impaired patient:

1. Prepare the patient and parent before the first visit with a welcome letter describing what is to be done and including a medical history form.
2. Let the patient and parent determine, during the initial appointment, how the patient desires to communicate (i.e., interpreter, lip reading, sign language, note writing [for child who can read], or a combination of these). Look for ways to improve communication. It is useful to learn some basic sign language. Face the patient and speak slowly at a natural pace and directly to the patient without shouting. Exaggeration of facial expressions and the use of slang make lip reading difficult. Even the best lip-readers comprehend only 30% to 40% of what is said.
3. Assess speech, language ability, and degree of hearing impairment when taking the patient's complete medical history. Identify the age of onset, type, degree, and cause of hearing loss, and determine whether any other family members are affected.
4. Enhance visibility for communication. Watch the patient's expression. Make sure the patient understands what the dental equipment is, what is going to happen, and how it will feel. Have the patient use hand gestures if a problem arises. If appropriate, write out and display information.
5. Reassure the patient with physical contact; hold the patient's hand initially, or place a hand reassuringly on the patient's shoulder while the patient maintains visual contact. Without visual contact, the child may be startled. Explain to the patient if you must leave the room.
6. Use the tell-show-feel-do approach. Use visual aids and allow the patient to see the instruments, and demonstrate how they work. Hearing-impaired children may be very sensitive to vibration.
7. Display confidence; use smiles and reassuring gestures to build up confidence and reduce anxiety. Allow extra time for all appointments.
8. Avoid blocking the patient's visual field, especially with a rubber dam.
9. Adjust the hearing aid (if the patient has one) before the handpiece is in operation because a hearing aid amplifies all sounds. Many times the patient will prefer to have it turned off.
10. Make sure the parent or patient understands explanations of diagnosis, treatment, and payment. Deaf persons have different levels of skill with English. Use of an interpreter is extremely helpful.

VISUAL IMPAIRMENT

Total visual impairment (blindness) affects more than 30 million people. The list that follows gives some of the known causes of visual impairment; however, in more than 35% of those affected, the cause is either unknown or unreported. Blindness is not an all-or-nothing phenomenon; a person is considered to be affected by blindness if the visual acuity does not exceed 20/200 in the better eye with corrective lenses, or if the acuity is greater than 20/200 but is accompanied by a visual field of no greater than 20 degrees.

The following are known causes of visual impairment:

- Prenatal causes
- Optic atrophy
- Microphthalmos
- Cataracts
- Colobomas
- Dermoid and other tumors
- Toxoplasmosis
- Cytomegalic inclusion disease
- Syphilis
- Rubella
- Tuberculous meningitis
- Developmental abnormalities of the orbit
- Postnatal causes
- Trauma
- Retrolental fibroplasia
- Hypertension
- Premature birth
- Polycythemia vera
- Hemorrhagic disorders
- Leukemia
- Diabetes mellitus
- Glaucoma

Visual impairment may be only one aspect of a child's disability. For example, a patient with congenital rubella may have deafness, mental retardation, congenital heart disease, and dental defects, as well as blindness resulting from congenital cataracts. Total visual impairment is one disorder that may result in frequent hospitalizations, separation from family, and slow social development. Because the capabilities of a child with blindness are difficult to assess, the child may be considered developmentally delayed.

Consideration must be given to every developmental aspect of a child with blindness. Early in development, the parents may experience guilt and either overprotect

Dentlearn.ir

or reject the child; this can result in a lack of development of self-help skills and delayed development in general, which is often misinterpreted as intellectual disability. Assessment of parental attitudes is of primary importance in behavioral management. In addition, children with blindness may exhibit self-stimulating activities, such as eye pressing, finger flicking, rocking, and head banging. Therefore assessment of the child's socialization is useful in the management of dental behavior.

A distinction should be made between children who at one time had sight and those who have not and thus cannot form visual concepts. More explanation is needed for children in the latter category to help them perceive the dental environment. Dentists should realize that congenitally visually impaired children need a greater display of affection and love early in life and that they differ intellectually from children who are not congenitally visually impaired. Although explanation is accomplished through touching and hearing, reinforcement takes place through smelling and tasting. The modalities of listening, touching, tasting, and smelling are extremely important in helping these children learn coping behavior. Reports indicate that, once speech is developed, the other senses assume heightened importance and other development can occur that is comparable with that in children with sight.

Reports also reveal that motor activity affects the development of language and perception. Visually impaired children tend to have more accidents than other children during the early years while they are acquiring motor skills.

Hypoplastic teeth and trauma to the anterior teeth have been reported to occur with greater than average frequency in visually impaired children. Such children are also more likely to have gingival inflammation because of their inability to see and remove plaque. Other dental abnormalities occur with the same frequency as in the general population.

Before initiating dental treatment for a visually impaired child, the dentist should keep the following points in mind:

1. Determine the degree of visual impairment. (Can the patient tell light from dark?)
2. If the patient is accompanied by a companion, find out if the companion is an interpreter. If he or she is not, address the patient.
3. Establish rapport; afterward offer verbal and physical reassurance. Avoid expressions of pity or references to visual impairment as an affliction.
4. In guiding the patient to the operatory, ask if the patient desires assistance. Do not grab, move, or stop the patient without verbal warning. Encourage the parent to accompany the child.
5. Paint a picture in the mind of the visually impaired child by describing the office setting and treatment. Always give the patient adequate descriptions before performing treatment procedures. It is important to use the same office setting for each dental visit to allay the patient's anxiety.
6. Introduce other office personnel very informally.
7. When making physical contact, do so reassuringly. Holding the patient's hand often promotes relaxation.
8. Allow the patient to ask questions about the course of treatment and answer them, keeping in mind that the patient is highly individual, sensitive, and responsive.
9. Allow a patient who wears eyeglasses to keep them on for protection and security.
10. Rather than using the tell-show-feel-do approach, invite the patient to touch, taste, or smell, recognizing that these senses are acute. Avoid sight references.
11. Describe in detail the instruments and objects to be placed in the patient's mouth. Demonstrate a rubber cup on the patient's fingernail.
12. Because strong tastes may be rejected, use smaller quantities of dental materials with such characteristics.
13. Some patients may be photophobic. Ask parents about light sensitivity and allow these patients to wear sunglasses.
14. Explain the procedures of oral hygiene and then place the patient's hand over yours as you slowly but deliberately guide the toothbrush.
15. Use audiocassette tapes and braille dental pamphlets explaining specific dental procedures to supplement information and decrease chair time.
16. Announce exits from and entrances to the dental operatory cheerfully. Keep distractions to a minimum, and avoid unexpected loud noises.
17. Limit providers of the patient's dental care to one dentist whenever possible.
18. Maintain a relaxed atmosphere. Remember that your patient cannot see your smile.

The provision of dental care to a visually impaired child is facilitated by an in-depth understanding of the patient's background. A team approach by all health professionals involved in the care of the child is ideal. Disease prevention and continuity of care are of utmost importance.

HEART DISEASE

Heart disease can be divided into two general types: congenital and acquired. Because individuals with heart disease may require special precautions during dental treatment, such as antibiotic coverage for prevention of infective endocarditis (IE), a dentist should closely evaluate the medical histories of all patients to ascertain their cardiovascular status. In April 2007 the American Heart Association presented recommendations to conserve the use of antibiotics for the prevention of IE to minimize the risk of developing resistance to current regimens.[18]

CONGENITAL HEART DISEASE

The incidence of congenital heart disease is approximately 9 in 1000 births. The following is the relative incidence of congenital heart defects (Toronto Heart Registry):

Defect	Percent
Ventricular septal defect	22
Patent ductus arteriosus	17
Tetralogy of Fallot	11
Transposition of the great vessels	8
Atrial septal defect	7
Pulmonary stenosis	7
Coarctation of the aorta	6
Aortic stenosis	5
Tricuspid atresia	3
All others	14

The cause of a congenital heart defect is obscure. Generally it is a result of aberrant embryonic development of a

Dentlearn.ir

normal structure or the failure of a structure to progress beyond an early stage of embryonic development. Only rarely can a causal factor be identified in congenital heart disease. Maternal rubella and chronic maternal alcohol abuse are known to interfere with normal cardiogenesis. If a parent or a sibling has a congenital heart defect, the chances that a child will be born with a heart defect are about 5 to 10 times greater than average. Congenital heart disease can be

Acyanotic Congenital Heart Disease

Acyanotic congenital heart disease is characterized by minimal or no cyanosis and is commonly divided into

cause left-to-right shunting of blood within the heart.

septal defect. Clinical manifestations of these defects can include congestive heart failure, pulmonary congestion, heart murmur, labored breathing, and cardiomegaly.

obstruction (e.g., aortic stenosis and coarctation of the aorta). The clinical manifestations can include labored breathing and congestive heart failure.

Cyanotic Congenital Heart Disease

Cyanotic congenital heart disease is characterized by right-to-left shunting of blood within the heart. Cyanosis is often observed even during minor exertion. Examples of such defects are tetralogy of Fallot, transposition of the great vessels, pulmonary stenosis, and tricuspid atresia. Clinical manifestations can include cyanosis, hypoxic spells, poor physical development, heart murmurs, and clubbing of the terminal phalanges of the fingers (Fig. 25-13).

ACQUIRED HEART DISEASE

Rheumatic Fever

Rheumatic fever is a serious inflammatory disease that occurs as a delayed sequela to pharyngeal infection with

agnosed cause of acquired heart disease in patients un-

A Streptococcus strains initiate the disease is unknown. The infection can involve the heart, joints, skin, central nervous system, and subcutaneous tissue. In general the incidence of rheumatic fever is decreasing. However, the incidence after exudative pharyngitis in epidemics is approximately 3%. (The incidence is much lower when the streptococcal pharyngitis is less severe.)

Although rheumatic fever can occur at any age, it is rare in infancy. It appears most commonly in children between the ages of 6 and 15 years. Rheumatic fever is most prevalent in temperate zones and at high altitudes and is more common and severe in children who live in substandard conditions. The clinical symptoms of rheumatic fever vary.

Cardiac involvement is the most significant pathologic sequela of rheumatic fever; carditis develops in approximately 50% of patients. Cardiac involvement can be fatal during the acute phase or can lead to chronic rheumatic heart disease as a result of scarring and deformity of heart valves.



Figure 25-13 The hand of a 9-year-old boy with tetralogy of Fallot. Clubbing of the terminal phalanges is apparent.

Infective Endocarditis

Infective Endocarditis (IE) is one of the most serious infections of humans. It is characterized by microbial infection of the heart valves or endocardium in proximity to congenital or acquired cardiac defects. IE has been classically divided into acute and subacute forms. The acute form is a fulminating disease that usually occurs when microorganisms of high pathogenicity attack a normal heart, causing erosive destruction of the valves. Microorganisms associated with the acute form include *Staphylococcus,*

subacute IE usually develops in persons with preexisting congenital cardiac disease or rheumatic valvular lesions. Surgical placement of prosthetic heart valves can also predispose a patient to IE; heart valve infections occur in 1% to 2% of such patients. The subacute form is commonly caused by viridans streptococci, microorganisms common to the flora of the oral cavity.

Embolization is a characteristic feature of IE. Microorganisms introduced into the bloodstream may colonize the endocardium at or near congenital valvular defects, valves damaged by rheumatic fever, or prosthetic heart valves. These vegetations, composed of microorganisms and fibrous exudate, may separate and, depending on whether the endocarditis involves the left or right side of the heart, be propelled into the systemic or pulmonary circulation.

The clinical symptoms of IE include low, irregular fever (afternoon or evening peaks) with sweating, malaise, anorexia, weight loss, and arthralgia. Inflammation of the endocardium increases cardiac destruction, and murmurs subsequently develop. Painful fingers and toes and skin lesions are also important symptoms. Laboratory findings can include leukocytosis and neutrophilia and normocytic, normochromic anemia. The erythrocyte sedimentation rate is rapid.

Infective Endocarditis Prophylaxis

Transient bacteremia is an important initiating factor in IE. Procedures known to precipitate transient bacteremias

Dentlearn.ir

Box 25-1

Dental Procedures for Which Endocarditis Prophylaxis Is Reasonable for Highest Risk Patients

All dental procedures that involve manipulation of gingival tissue or the periapical region of teeth or perforation of the oral mucosa*

*PRN prophylaxis: routine anesthetic injections through noninfected tissue, taking dental radiographs, placement of removable prosthodontic or orthodontic appliances, adjustment of orthodontic appliances, placement of orthodontic brackets, shedding of deciduous teeth, and bleeding from trauma to the lips or oral mucosa.

From Wilson W et al: Prevention of infective endocarditis: guidelines from American Heart Association, *Circulation* 116:1736-1754, 2007. Reprinted with permission © 2007, American Heart Association, Inc.

Box 25-2

Cardiac Conditions Associated with the Highest Risk of Adverse Outcome from Endocarditis for Which Prophylaxis with Dental Procedures Is Reasonable

Prosthetic cardiac valve or prosthetic material used for cardiac valve repair

Previous infective endocarditis

Congenital heart disease (CHD)*

Unrepaired cyanotic CHD, including palliative shunts and conduits

Completely repaired congenital heart defect with prosthetic material or device, whether placed by surgery or by catheter intervention, during the first 6 months after the procedure†

Repaired CHD with residual defects at the site or adjacent to the site of prosthetic patch or prosthetic device (which inhibits endothelialization)

Cardiac transplantation recipients who develop cardiac valvulopathy

*Except for the conditions listed above, antibiotic prophylaxis is no longer recommended for any other form of CHD.

†Prophylaxis is reasonable because endothelialization of prosthetic material occurs within 6 months after the procedure.

From Wilson W et al: Prevention of infective endocarditis: guidelines from American Heart Association, *Circulation* 116:1736-1754, 2007. Reprinted with permission © 2007, American Heart Association, Inc.

in dentistry and for which IE prophylaxis is or is not recommended are included in Box 25-1.

Certain heart conditions are associated with the highest risk of adverse outcomes from IE (Box 25-2). Any dental patient who has a history of congenital heart disease or rheumatic heart disease or who has a prosthetic heart valve should be considered susceptible. The American Heart Association's antibiotic recommendations for the prevention of bacterial endocarditis are presented in Box 25-3.

The recent AHA revision concluded that only a small number of cases of IE might be prevented by antibiotic prophylaxis for dental procedures, even if such prophylactic therapy were 100% effective. IE prophylaxis for invasive dental procedures involving the manipulation of gingival tissue or the periapical region of teeth or perforation of the oral mucosa is only for patients with the highest risk of adverse outcome (see Box 23-2). Prophylaxis is not recommended.[18]

DENTAL MANAGEMENT

Parents of patients with cardiac risks typically lack knowledge about IE even after being informed during routine cardiology visits. Hayes and Fasules[19] report a deficiency of knowledge among dentists regarding the indications for prophylaxis and the antibiotic regimen required to prevent IE. Before initiating care, the dentist should obtain a thorough medical and dental history, perform a physical examination, formulate a complete treatment plan, and discuss the treatment with the child's physician or cardiologist. Behavior management techniques are useful, and conscious sedation and nitrous oxide–oxygen analgesia have also been proven beneficial in reducing anxiety in such patients. Conscious sedation monitoring and cardiopulmonary resuscitation equipment should be readily available during the appointment. If general anesthesia is indicated, the dental procedures should be completed in a hospital setting, where adequate supportive care is available if needed.

Other considerations are especially important in treating patients who are susceptible to IE:

- Pulp therapy is not recommended for primary teeth with a poor prognosis because of the high incidence of associated chronic infection. Extraction of such teeth with appropriate fixed-space maintenance is preferred.
- Endodontic therapy in the permanent dentition can usually be accomplished successfully if the teeth to be treated are carefully selected and the endodontic therapy is adequately performed.
- A dentist who feels uncomfortable in treating patients who are susceptible to IE has a responsibility to refer them to someone who will adequately care for them.

CARDIAC SURGERY PATIENTS

Patients who are to undergo cardiac surgery should first have a careful dental evaluation so that oral infections can be properly diagnosed and treated. This practice, along with an implemented preventive dental program, will decrease the incidence of postoperative IE from oral sources, improve surgical outcomes, and improve the patient's overall health.[20]

After dental radiographs are obtained and an evaluation is performed, a consultation with the patient's cardiologist is in order to plan required dental treatment before surgery. The cardiologist will indicate the specific desired antibiotic prophylaxis needed before the dental treatment. The dental examination and preventive dental program should be implemented before the child reaches 6 months of age when possible. Ideally, dental treatment should be completed within 3 or 4 weeks of the planned surgery to allow for healing and the return of normal flora.

Dentlearn.ir

Box 25-3

Regimens for a Dental Procedure

		REGIMEN: SINGLE DOSE 30 TO 60 MINUTES BEFORE PROCEDURE	
SITUATION	**AGENT**	**ADULTS**	**CHILDREN**
Oral	Amoxicillin	2 g	50 mg/kg
Unable to take oral medication	Ampicillin OR Cefazolin or ceftriaxone	2 g IM or IV 1 g IM or IV	50 mg/kg IM or IV 50 mg/kg IM or IV
Allergic to penicillins or ampicillin—oral	Cephalexin *† OR Clindamycin OR Azithromycin or clarithromycin	2 g 600 mg 500 mg	50 mg/kg 20 mg/kg 15 mg/kg
Allergic to penicillin or ampicillin and unable to take oral medication	Cefazolin or ceftriaxone† OR Clindamycin	1g IM or IV 600 mg IM or IV	50 mg/kg IM or IV 20 mg/kg IM or IV

IM, intramuscular; IV, intravenous.
*Or other first- or second-generation oral cephalosporin in equivalent adult or pediatric dosage.
†Cephalosporins should not be used in an individual with a history of anaphylaxis, angioedema, or urticaria with penicillins or ampicillin.

REFERENCES

1. US Department of Health and Human Services: *Delivering on the promise: self-evaluation to promote community living for people with disabilities: report to the President on Executive Order 13217*, Washington, DC, 2002, US Department of Health and

   final/hhs.html. Accessed March 19, 2014.
2. American Academy of Pediatric Dentistry: Guideline on management of dental patients with special health care needs, *Pediatr Dent (Suppl Issue: Ref. Manual, 2013-14)* 35:6, 2013.
3. US Department of Health and Human Services: *Oral health in America: a report of the Surgeon General, Rockville, MD: US Dept of Health and Human Services, National Institute of Dental and Craniofacial Research*, Bethesda, 2000, National Institutes of Health.
4. Kane D, et al.: Factors associated with access to dental care for children with special health care needs, *J Am Dent Assoc* 139:326–333, 2008.
5. Chen AY, Newacheck PW: Insurance coverage and financial burden for families of children with special health care needs, *Ambul Pediatr* 6(4):204–209, 2006.
6. National survey of children with special health care needs: NS-CSHCN 2009.10. Data query from the Child and Adolescent Health Measurement Initiative, Data Resource Center for Child and Adolescent Health website. Retrieved

7. Uniform Federal Accessibility Standards, part II, *Fed Reg* 153(49): 31528–31613, 1984.
8. US Department of Health and Human Services: Health Insurance Portability and Accountability Act (HIPAA). Available

   Feb. 17, 2009.
9. Van Cleave J, Davis MM: Preventive care utilization among children with and without special health care needs: associations with unmet need, *Ambul Pediatr* 8(5):305–311, 2008.
10. Moursi AM, et al.: Nutrition and oral health considerations in children with special health care needs: implication for oral health care providers, *Pediatr Dent* 32(4):333–342, 2010.
11. Beltran-Aguilar E, Goldstein J: Fluoride varnishes: a review of their clinical use, cariostatic mechanisms, efficacy, and safety, *J Am Dent Assoc* 131:589–596, 2000.
12. American Academy of Pediatric Dentistry: Behavior guidance for the pediatric dental patient, *Pediatr Dent* 36, 2014-15 (6 Suppl Issue: Ref. Manual 179–193).
13. Schalock RL, et al.: The renaming of mental retardation: understanding the change to the term intellectual disability, *Intellect Dev Disabil* 45(2):116–124, 2007.
14. Murakami J, et al.: Cellular mobility of Down syndrome gingival fibroblasts is susceptible to impairment by *Porphyromonas gingivalis* invasion, *J Periodontol* 79(4):721–727, 2008.
15. Bell EJ, et al.: Tooth wear in children with Down syndrome, *Aust Dent J* 47:30–35, 2002.
16. Cheng RH, et al.: Non-surgical periodontal therapy chlorhexidine use in adults with Down syndrome, *J Periodontol* 79(2): 379–385, 2008.
17. Nettis E, et al.: Reported latex allergy in dental patients, *Oral Surg Oral Med Oral Pathol Oral Radiol Endod* 93(2):144–148, 2002.
18. Wilson W, et al.: Prevention of infective endocarditis: guidelines from American Heart Association, *Circulation* 116: 1736–1754, 2007.
19. Hayes PA, Fasules J: Dental screening of pediatric cardiac surgical patients, *J Dent Child* 68:255–258, 2001.
20. Yasney JS, White J: Dental considerations for cardiac surgery, *J Cardiac Surg* 24(1):64–68, 2009.

SUGGESTED READINGS

Abman SH, Mourani PM, Sontag M: Bronchopulmonary dysplasia: a genetic disease, *Pediatrics* 122(3):658–659, 2008.

Aps JK, Van Maele GO, Martens LC: Oral hygiene habits and oral health in cystic fibrosis, *Eur J Paediatr Dent* 3(4):181–187, 2002.

Barnett ML: Dental treatment program for patients with mental retardation, *Ment Retard* 26:310, 1988.

Barnett ML, et al.: The prevalence of periodontitis and dental caries in the Down syndrome population, *J Periodontol* 57:288–293, 1986.

Behrman RE, et al.: *Nelson textbook of pediatrics*, ed 18, Philadelphia, 2007, WB Saunders.
Bill D, Weddell JA: Dental office access for the disabled, *Spec Care Dentist* 7:246–252, 1987.
Clark CA, et al.: Dental treatment for deaf patients, *Spec Care Dentist* 6:102–106, 1986.
Fernald GW, et al.: Cystic fibrosis: a current review, *Pediatr Dent* 12:72–77, 1990.
Hagerman GW, et al.: Girls with fragile X syndrome: physical and neurocognitive status and outcome, *Pediatrics* 89: 395–400, 1992.
Hennequin M, et al.: Accuracy of estimation of dental treatment need in special care patients, *J Dent* 28:131–136, 2000.
Hudson M: Dental surgery in pediatric patients with spina bifida and latex allergy, *AORN J* 74(1):56–78, 2001.
Itthagarun A, et al.: Fetal alcohol syndrome: case report and review of the literature, *Oral Surg Oral Med Oral Pathol Oral Radiol Endod* 103:e20–e25, 2007.
Jaber MA: Dental caries experience, oral health status and treatment needs of dental patients with autism, *J Appl Oral Sci* 19(3):212–217, 2011.
McCrindle BW, et al.: An evaluation of parental concerns and misconceptions about heart murmurs, *Clin Pediatr* 34:25–31, 1995.
Morsey SL: Communicating with and treating the blind child, *Dent Hyg* 65:288–290, 1980.
Newschaffer CJ, et al.: The epidemiology of autism spectrum disorders, *Annu Rev Public Health* 28:235–258, 2007.
Pope JEC, Curzon MEJ: The dental status of cerebral palsied children, *Pediatr Dent* 13(3):156–162, 1991.
Rosenberg DJ, et al.: Estimating treatment and treatment times for special and nonspecial patients in hospital ambulatory dental clinics, *J Dent Educ* 50:665–672, 1986.
Sanders BJ, et al.: Managing patients who have seizure disorders: dental and medical issues, *J Am Dent Assoc* 126:1641–1647, 1995.
Sant'Anna LB, Tosello DO: Fetal alcohol syndrome and developing craniofacial and dental structures: a review, *Orthod Craniofac Res* 9:172–185, 2006.
Shelhart WC, et al.: Oral findings in Fragile X syndrome, *Am J Med Genet* 23:179–187, 1986.
Simko A, et al.: Fragile X: recognition in young children, *Pediatrics* 83:547–551, 1989.
Steinbacher DM, Glick M: The dental patient with asthma: an update and oral health consideration, *J Am Dent Assoc* 132:1229–1239, 2001.
Stensson M, et al.: Oral health in preschool children with asthma, *Int J Paediatr Dent* 18(4):243–250, 2008.
Terzian EC, Schneider RE: Management of the patient with cystic fibrosis in oral and maxillofacial surgery, *J Oral Maxillofac Surg* 66(2):349–354, 2008.
Tesini DA, Fenton SJ: Oral health needs of persons with physical or mental disabilities, *Dent Clin North Am* 38:483–498, 1994.
Waldman BH, et al.: Children with mental retardation and epilepsy: demographics and general concerns, *J Dent Child* 67:274–268, 2000.
Wandera A, Conry JP: Aspiration and ingestion of a foreign body during dental examination by a patient with spastic quadriparesis: case report, *Pediatr Dent* 15:362–363, 1993.
Zhu J, et al.: Dental management of children with asthma, *Pediatr Dent* 18:363–370, 1996.

Dentlearn.ir

CHAPTER 26

Management of the Medically Compromised Patient: Hematologic Disorders, Cancer, Hepatitis, and AIDS

▲ **Brian J. Sanders, Amy D. Shapiro, Randy A. Hock, John J. Manaloor,** and **James A. Weddell**

For additional resources, please visit the evolve *website.*

CHAPTER OUTLINE

HEMOPHILIA
- Disorders of Hemostasis
- Procoagulant Classification
- Treatment
- Women with Bleeding Disorders
- Complications of Bleeding Disorders
- Risks to Dental Staff
- Development of a Treatment Plan
- Use of Antifibrinolytic Agents
- Pain Control
- Dental Management

VIRAL HEPATITIS
- Sickle Cell Anemia

ACQUIRED IMMUNODEFICIENCY SYNDROME
- Oral Manifestations of HIV Infection

LEUKEMIA
- Oral Manifestations of Leukemia
- Dental Management of Patients with Leukemia

HEMATOPOIETIC STEM CELL TRANSPLANTATION
- Oral Complications of Bone Marrow Transplantation
- Graft-Versus-Host Disease
- Pretransplantation Preparation
- Admission and Nursing Interventions
- Remission Phase

SOLID TUMORS

To achieve optimal oral health for the medically compromised patient, the dentist and physician must establish a close working relationship. The complexity of many of these medical conditions may require additional treatment time for adequate services to be provided. To minimize the risk for potential complications that may affect the health of medically compromised patients, the health care team must develop a proactive aggressive prevention-oriented program. Each patient presents individual challenges to the dentist; achieving a successful outcome can be a rewarding experience. This chapter discusses a variety of medical conditions and their dental management.

HEMOPHILIA

DISORDERS OF HEMOSTASIS

The hemophilias are disorders of hemostasis, resulting from a deficiency of a clotting factor that promotes formation of a fibrin clot, termed procoagulants. Hemophilia is an inherited bleeding disorder affecting approximately 1 in 5000 males.[1] Hemophilia A, or *classic hemophilia*, is a deficiency of factor VIII, also known as *antihemophilic factor*. It is the most common form of hemophilia and is inherited as an X-linked recessive trait. Therefore males are affected, females are carriers, and there is no male-to-male transmission. If a normal male has children with a carrier of hemophilia, there is a 50% chance that hemophilia will occur in each male offspring and a 50% chance that each female offspring will be a carrier. If a male with hemophilia has children with a normal female, all male offspring will be normal, and all female offspring will be carriers. Hemophilia B, or *Christmas disease*, is caused by a deficiency of factor IX (plasma thromboplastin component) and is also inherited as an X-linked recessive trait. Factor IX deficiency is one fourth as prevalent as factor VIII deficiency.[2]

Factor XI (plasma thromboplastin antecedent) deficiency, referred to as *hemophilia C* or *Rosenthal's disease*, is inherited as an autosomal-recessive trait, with male and female offspring equally affected. This disorder is most frequently observed in those of Ashkenazi Jewish descent, but it is found in many other populations. Other factor deficiencies, such as factors II, V, and XIII (one case per 1 million population) and factor VII (one case per 500,000 population), are rare and are inherited as autosomal-recessive traits.[3,4]

Von Willebrand disease (VWD) is a hereditary bleeding disorder resulting from an abnormality of the von Willebrand factor (VWF) found in plasma, platelets, megakaryocytes, and endothelial cells. VWF circulates in conjunction with factor VIII, protecting it from proteolytic degradation, and is important in platelet adhesion to the subendothelium via collagen and therefore the formation of the primary platelet plug. In VWD, VWF may have a quantitative or qualitative abnormality. VWF is composed of subunits called *multimers*. VWD is divided

Dentlearn.ir

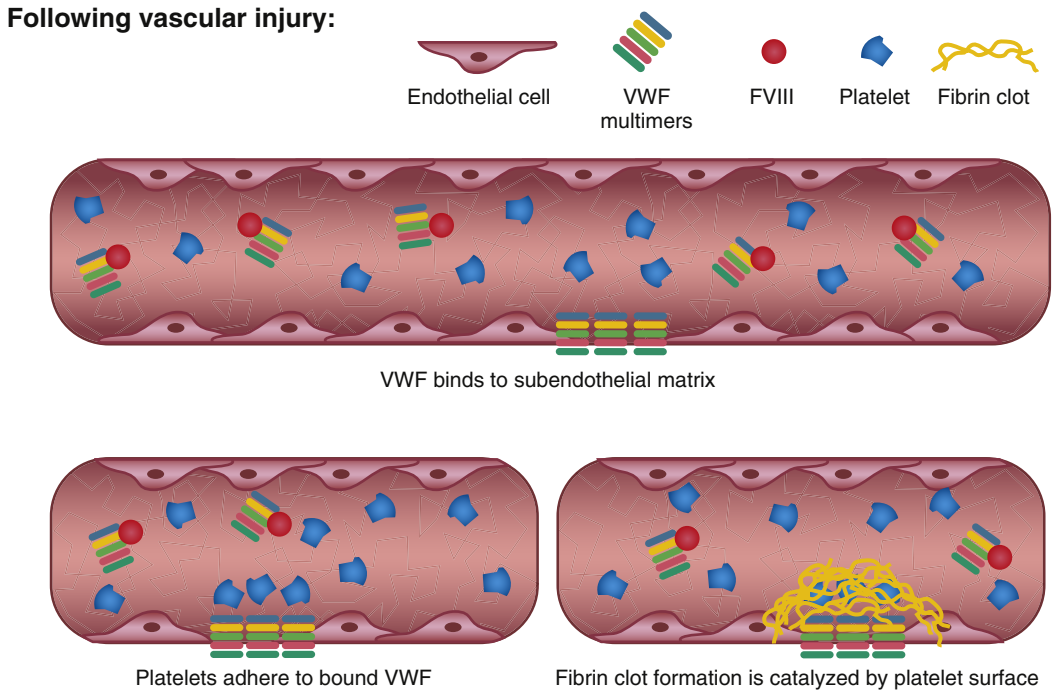

Figure 26-1 Primary hemostatic response to vascular injury with evolution into secondary hemostasis. This figure shows the primary hemostatic response to vascular injury involving the endothelial cell and platelet; primary hemostasis leads to and is an integral part of secondary hemostasis involving coagulation factors, including von Willebrand factor and factor VIII, culminating in the generation of fibrin. (With permission from CSL Behring and Robert Montgomery.)

into subtypes based on the plasma multimers of VWF, the amount of VWF present, and ratios between VWF laboratory analyses. Optimal treatment of this disorder is dependent upon the subtype.[5-7]

Impaired formation of the primary platelet plug results in bleeding from the skin and mucosa, bruising, epistaxis, prolonged bleeding after surgical procedures, and menorrhagia (Fig. 26-1). This is in contrast to hemophilia involving deficiencies of factors VIII and IX, where the hallmark bleeding events include muscles and joints (Fig. 26-2).[8]

PROCOAGULANT CLASSIFICATION

Factors VIII and IX deficiencies are subcategorized based on the level of the procoagulant present; normal levels range from 55% to 100%:

- Severe deficiency: levels less than 1%
- Moderate deficiency: levels between 1% and 5%
- Mild deficiency: levels greater than or equal to 5% to less than 50%

Patients with severe deficiency may experience frequent bleeding episodes, often occurring 2 to 4 times per month. Bleeding episodes are often spontaneous, without a specific history of injury or trauma. Common sites of bleeding include joints, muscles, and skin. Hemarthroses (joint hemorrhages) are frequently observed, with symptoms including pain, stiffness, and limited range of motion. Repeated episodes of hemarthroses or muscle hemorrhage result in chronic musculoskeletal disease and culminate in debilitating painful arthritis and disability. Commonly affected joints include knees, elbows, ankles, hips, and shoulders.[2] Pseudotumors (hemorrhagic pseudocysts) may occur in several locations including the jaw, in which case curettage is indicated.[9,10]

Patients with moderate deficiency experience less frequent bleeding episodes occurring approximately 4 to 6 times per year. However, if a target joint (a joint with repeated episodes of bleeding) develops in a patient with moderate deficiency, spontaneous bleeding may occur. Patients with mild deficiency bleed infrequently and only in association with surgery or injury. The diagnosis of a mild deficiency may occur with an abnormal screening coagulation test performed as part of a presurgical evaluation, or when bleeding occurs in association with surgery or trauma. The dental care provider may be the first health care provider to identify a patient with mild deficiency, since interventions or injury in the oral cavity may unmask a previously undiagnosed individual.

Mouth lacerations are a common cause of bleeding in children with all severities of hemophilia. Sonis and Musselman evaluated 132 patients with factor VIII–deficient hemophilia and noted that "persistent oral bleeding resulted in the diagnosis of 13.6% of all cases of hemophilia."[11] Approximately 29% of cases of mild hemophilia observed were discovered as a result of bleeding from the oral cavity. Of the cases diagnosed secondary to oral bleeding, 78% were the result of bleeding from the maxillary frenum and 22% resulted from tongue bleeds. Thus initial diagnosis of hemophilia,

Dentlearn.ir

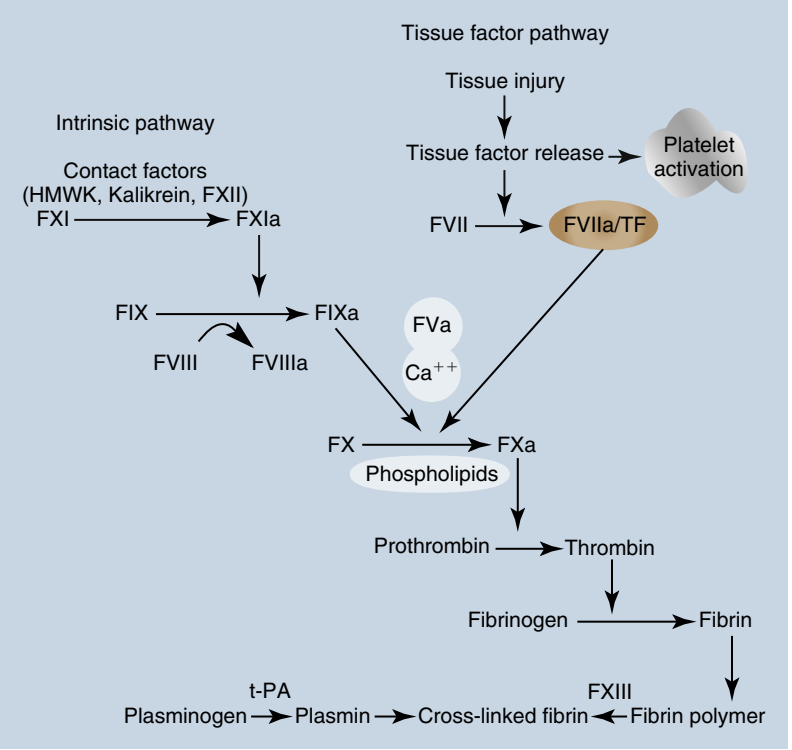

Figure 26-2 Coagulation cascade. This figure shows the complex interplay between plasma coagulation factors and fibrinolytic pathway (plasminogen and end enzyme plasmin) responsible for clot lysis after healing. The importance of the role of the tissue factor pathway and cellular systems (platelets) in initiating physiologic hemostasis is highlighted. The factors deficient in hemophilia A and B (factors VIII and IX, respectively) are shown in relationship to their role in the coagulation pathway. (Courtesy Anjali Sharathkumar.)

especially in moderate or mild disease, may directly involve the dentist.[12]

TREATMENT

The mainstay of therapy for hemophilia is replacement of the deficient coagulation factor through the use of purified concentrates either manufactured through recombinant technology or from pooled plasma. In the past, whole blood, plasma, or cryoprecipitate was used; but at present, genetically engineered products represent the main source of replacement therapy.[13] Factor concentrates are advantageous as they are generally accessible, easily handled and stored, and virally inactivated and result in consistent hemostatic results. The dosage, frequency of administration, and duration of therapy depend on the activity level required, half-life of the procoagulant, intervention or procedure contemplated, or location and severity of the bleeding episode. The half-life of factor VIII is approximately 12 hours, whereas that for factor IX is approximately 18 hours.[2,14]

New therapies currently in clinical trials and approaching the marketplace have utilized strategies to prolong the half-lives of both factor VIII and factor IX. As these products become clinically available, their individual half-lives will be used to determine the appropriate dosing interval. In general, factor IX–modified long-lasting products have achieved an increase in factor IX half-life of 3 to 5 times the native protein, whereas factor VIII–modified long-lasting products are within 1.5 times the native protein due to factor VII's association with and limitation of VWF half-life in plasma.[15]

Hemophilia A

Factor VIII concentrate is used to treat hemophilia A. Vials of factor concentrate are labeled with the number of international activity units contained, where 1 IU is the amount of activity of the procoagulant present in 1 mL of normal plasma. For routine hemorrhagic episodes, such as early joint, soft-tissue, and oral bleeds, an initial correction to an approximate level of 40% to 50% commonly achieves hemostasis and resolution of the bleeding episode. However, some care providers use higher doses for initial treatment and follow-up doses, especially in hemarthroses.[16] For mild factor VIII deficiency, DDAVP (1-deamino-8-D-arginine vasopressin) (Sanofi-Aventis, Bridgewater, New Jersey, United States) may be used for minor hemorrhagic episodes to achieve hemostasis. DDAVP (desmopressin acetate) is a synthetic analogue of the natural pituitary hormone 8-arginine vasopressin (antidiuretic hormone) that affects renal water conservation. This drug, when given intravenously, subcutaneously, or intranasally (Stimate), causes a rise in activities of factor VIII and VWF through release from stored sites in endothelial cells. An appropriate rise in factor VIII activity to hemostatic levels should be documented for any given patient before therapeutic use of this agent as responses vary among individuals. Peak levels are obtained approximately 1 hour after intravenous or subcutaneous administration and 90 minutes after intranasal administration. The intranasal form used to treat bleeding disorders is a more concentrated form of DDAVP than the preparation used to treat diabetes insipidus or enuresis. Therefore the concentrated preparation should be written for a brand name only or in conjunction with the stated concentration of 1.5 mg/mL of DDAVP. Repeated administration of DDAVP may result in tachyphylaxis, a reduction in expected response with sequential dosing due to depletion

of storage sites. Use of DDAVP to treat hemorrhagic disorders may also be associated with water retention, hyponatremia, and, rarely, seizures; therefore monitoring of electrolytes may be required in some circumstances, especially in surgical situations.[17-19]

Hemophilia B

Factor IX deficiency is treated with purified coagulation factor IX concentrate (monoclonal and recombinant). In the past, less pure products in the class of prothrombin complex concentrates (PCCs) were used. PCCs contained other vitamin K–dependent coagulation factors in addition to factor IX and some activated forms of these procoagulants. Individuals who require high doses or repeated PCC infusions are at risk for development of disseminated intravascular coagulation and thrombosis. The minimal desired level for hemostasis is the same for factor IX as for factor VIII (~40%); however, the number of units required to achieve this level is different as the volume of distribution of factor IX (minimally ~1.0) is greater than that for factor VIII (0.5). The volume of distribution of recombinant factor IX is greater than that of plasma-derived factor IX (estimated minimum volume of 1.2 compared with 1, respectively, whereas in infants and young children a minimum volume of distribution of 1.4 should be used for dose calculation). Because interindividual variability in the volume of distribution is wide, measurement of activity levels may be required to document a hemostatic level.[2,13,20]

Treatment Regimens

Clotting factor concentrates are administered in different regimens depending on the patient's level of severity, number of bleeding episodes, and physician's recommendations. Treatment regimens may be divided into replacement therapy administered after a bleeding episode has occurred (on-demand therapy) or as therapy administered on a regularly scheduled basis to prevent or suppress bleeding episodes (prophylaxis). Prophylactic regimens are further subdivided into primary and secondary. Primary prophylaxis is a long-term treatment for prevention of joint disease instituted before or after minimal hemarthrosis has occurred; secondary prophylaxis may be long or short term, but is instituted after hemarthrosis has occurred or to interrupt a bleeding pattern to rest a joint. Primary prophylactic therapy has been shown in a prospective randomized study to be the most effective regimen to prevent joint disease in patients with severe hemophilia and is now considered the standard of care for these patients.[21] Therefore dental care providers should schedule dental evaluations and interventions on regularly planned infusion days, whereas patients treated with on-demand regimens require discussion regarding the need for replacement therapy to be administered, specifically for dental interventions. Patients using regimens of prophylaxis may have a central venous catheter placed for frequent venous access. The use of antibiotic prophylaxis to protect the central venous access device may be considered, although it is not recommended by the Centers for Disease Control and Prevention (see Antibiotic Prophylaxis in the section on Dental Management).[22]

Von Willebrand Disease

Patients with VWD should undergo subtyping to determine optimal therapy. DDAVP may be used to achieve hemostasis in most patients with type I VWD, where type I VWD represents a quantitative VWF deficiency with intact multimers. When DDAVP is used, a test dose should be administered to document an adequate hemostatic response. For patients with less common subtypes of VWD, patients who do not respond to DDAVP, or patients for whom DDAVP is contraindicated, or in bleeding events where DDAVP is contraindicated, other therapeutic modalities may be required, including replacement with exogenous intact VWF through the use of a concentrate. Interventions and therapeutic approaches should be discussed with a hemophilia-comprehensive treatment center.[6,7,23,24]

WOMEN WITH BLEEDING DISORDERS

Female carriers of hemophilia A and B may have decreased levels of factors VIII and IX, respectively, with levels in the mild deficiency range. It is recommended that, to determine bleeding risk, all carriers of hemophilia be evaluated to determine their baseline factor activity level specific to the type of hemophilia carried. Women who are carriers of hemophilia should be treated as potential mild-deficient patients, and their hematologist should be contacted to determine the baseline factor activity level and need for treatment before or after specific dental interventions.[25,26]

As previously discussed, VWD is inherited as an autosomal-dominant trait, with males and females equally affected. In addition, very rare bleeding disorders such as factors VII, IX, XIII etc. are autosomal-recessive, with females and males equally affected. Therefore females with bleeding disorders are not uncommon. An appropriate personal and family history is required to determine if individuals are or could be affected.[23]

COMPLICATIONS OF BLEEDING DISORDERS

Inhibitors are antibodies, commonly IgG, that are directed against and neutralize the replaced coagulation factor. Inhibitors are one of the most severe complications for patients with hemophilia. Inhibitors may develop in approximately 30% of patients with severe factor VIII deficiency and in 3% to 5% of patients with severe factor IX deficiency.[27] The key to successful treatment of patients with inhibitors is accurate knowledge of the inhibitor classification (high- vs. low-responding) and current inhibitor level. Patients with inhibitors are divided into two

past peak anamnestic titer. Inhibitor levels are measured in Bethesda units (BU), a measurement that reflects the ability of the antibody to neutralize a specific amount of procoagulant.[27,28] Low responders have peak levels at any time less than 5 BU and may continue to be treated with factor concentrate at higher than normal doses, whereas high responders have peak titers greater than or equal to 5 BU and require use of bypassing products (activated PCC or recombinant factor VIIa). Hemophilic patients

Dentlearn.ir

with inhibitors pose considerable treatment challenges and should be managed only in conjunction with a hemophilia-comprehensive treatment center, as hemostasis is often difficult to achieve or maintain and patient response to therapy is variable.

Another important complication of hemophilia includes arthritis—a degenerative joint disease—and resultant disability secondary to recurrent bleeding.[29] Blood-borne viral infections have previously represented an important treatment complication of these disorders and may have been transmitted via required blood or blood-derived concentrates prior to effective viral inactivation methods. Hepatitis B and C have been a significant source of morbidity and mortality in this patient population.[30] The human immunodeficiency virus (HIV) has also been a major source of morbidity and mortality since approximately 1979. Before 1985 there was no antibody test for HIV and no consistent effective viral inactivation in the manufacture of plasma-derived factor concentrates. Therefore between 1979 and 1985, factor concentrates and blood products may have been contaminated with HIV. Approximately 90% of hemophilic patients with severe factor VIII deficiency, and 30% of those with severe factor IX deficiency who received plasma concentrates during the at-risk period may have become infected with HIV. HIV infection is a sensitive issue for these individuals, who may now bear the burden of two chronic conditions.[31] Currently available treatments of factor concentrates made through recombinant technology or pooled plasma have effectively eliminated transmission of HIV and hepatitis B and C. Nevertheless, universal precautions should be followed in the treatment of all hemophilic patients with a history of receiving factor concentrates.

RISKS TO DENTAL STAFF

Virtually all surgical trainees will experience at least one needle-stick injury, and nurses are at significant risk for multiple needle-stick injuries, given their frequent handling of sharps. The risk for acquiring hepatitis B (HBV), hepatitis C (HCV), or human immunodeficiency (HIV) virus infections following an accidental needle stick are 30%, 3%, and 0.3%, respectively.[32] Although there is now evidence for the transmission of HIV when infected mothers premasticate food for their children, the quantifiable risk of HIV transmission via saliva alone is lower than that from a needle-stick injury.[33,34]

A study by Klein and colleagues demonstrated a quantifiable occupational risk for HCV infection among dental professionals, with higher rates among oral surgeons when compared with rates among conventional dentists.[35] Investigators at a dental teaching hospital report that exposures occur while sharps are cleared away after direct patient care.[36,32] These data warrant that dental personnel be vaccinated against HBV and adopt appropriate universal precautions during and after all patient encounters, especially since many patients do not know their status relative to these blood-borne infections.

DEVELOPMENT OF A TREATMENT PLAN

With recent advances in treatment, most patients with bleeding disorders receive outpatient dental care routinely. With a thorough understanding of the patient's hemostatic disorder, the dentist, in conjunction with the hematologist, is able to make safe and appropriate treatment decisions.

The dentist must be aware of the procedures that can be safely performed and those in which complications may arise. The dentist should confer with the patient's physician and hematologist to formulate an appropriate treatment plan. The dentist should know the specific type of bleeding disorder, severity, frequency of and treatment for bleeding episodes, as well as the patient's inhibitor status. Many individuals with hemophilia self-administer infusion products at home and are therefore able to treat themselves as required. The dentist should be prepared to discuss with the hematologist the type of anesthetic anticipated to be administered, invasiveness of the dental procedure, amount of bleeding anticipated, and time involved in oral wound-healing in order to help establish an appropriate treatment plan, including the need for replacement and adjunctive therapies.[37]

USE OF ANTIFIBRINOLYTIC AGENTS

Antifibrinolytic agents are an adjunctive therapy for dental management of patients with bleeding disorders and are important for the prevention or treatment of oral bleeding. These agents include ε-aminocaproic acid (Amicar; Xanodyne Pharmaceuticals, Florence, Kentucky, United States) and tranexamic acid (Lysteda; Ferring Pharmaceuticals, Parsippany, New Jersey, United States and Cyklokapron; Pfizer, New York, New York, United States). Hemophilic patients form loose, friable clots that are easily dislodged or rapidly dissolved, especially in the oral cavity, where local fibrinolysis is increased. Antifibrinolytics prevent clot lysis within the oral cavity and are often used as an adjunctive therapy to factor concentrates. For some dental procedures in which minimal bleeding is anticipated, antifibrinolytics may be recommended as the sole hemostatic agent.

Dosages

In children ε-aminocaproic acid is given immediately before dental treatment in an initial loading dose of 100 to 200 mg/kg by mouth up to a maximum total dose of 10 g. Subsequently, 50 to 100 mg/kg per dose up to a total maximum dose of 5 g is administered orally every 6 hours for 5 to 7 days. Alternatively, for patients of approximately adult size or heavier than 30 kg, a regimen of 3 g by mouth 4 times daily without a loading dose may be used. The advantage of ε-aminocaproic acid for children is that it is available in both tablet and liquid form.

The maximum oral dose of tranexamic acid is 25 mg/kg; for a 60 kg adult, the dose is 1500 mg every 8 hours. Doses of 10 to 15 mg/kg/kg body weight have been reported to be effective depending on the location and severity of bleeding. Dosing is continued every 8 hours for 5 to 7 days. In the United States, the oral preparation of tranexamic acid is available and approved only for use in cyclic menorrhagia; however, physicians have utilized this agent off-label for bleeding in other areas, including dental procedures or oral bleeding. In addition, the

Dentlearn.ir

intravenous formulation is available in the United States and may be administered orally if required.[37,38]

Side effects

The common side effects associated with the use of antifibrinolytics include headache, nausea, and dry mouth. These side effects are usually tolerable and, unless severe, do not require discontinuation of the medication. Other less common side effects have been reported. To avoid thrombosis, antifibrinolytics should not be used when renal or urinary tract bleeding is present or when there is evidence of disseminated intravascular coagulation. Repeated use of a PCC in patients with inhibitors should also be avoided during a course of antifibrinolytic therapy as this combination may predispose to thrombotic episodes.

PAIN CONTROL

Analgesia

If patient apprehension is significant, sedation or nitrous oxide–oxygen inhalation analgesia may be considered. Hypnosis has also proved beneficial for some individuals. Intramuscular injections of hypnotic, tranquilizing, or analgesic agents are contraindicated especially in patients who have not received replacement therapy or in patients with inhibitors, due to the risk of hematoma formation. Analgesics containing aspirin or anti-inflammatory agents (e.g., ibuprofen) may affect platelet function and should be avoided. Acute pain of moderate intensity is frequently managed with acetaminophen (Tylenol; McNeil Pharmaceuticals, Washington, Pennsylvania, United States). Darvon Compound-65 contains aspirin and should be avoided. For severe pain, narcotic analgesics may be required and are not contraindicated in the patient with a bleeding disorder.

Local Anesthesia

In the absence of factor replacement, periodontal ligament (PDL) injections may be used. The anesthetic is administered along the four axial surfaces of the tooth by placement of the needle into the gingival sulcus and the PDL space. Infiltration anesthesia can generally be administered without pretreatment with either ε-aminocaproic acid or replacement therapy. However, if the infiltration injection is into loose connective tissue or a highly vascularized area, then factor concentrate replacement to achieve a level of approximately 30% to 40% activity is required.

One must proceed with caution when considering block anesthesia. The loose, connective, nonfibrous, and highly vascularized tissue at the sites of inferior alveolar nerve injection and posterior superior alveolar injections is predisposed to development of a dissecting hematoma, which may cause airway obstruction and result in a life-threatening bleeding episode. Therefore a minimum of a 40% factor correction is mandatory with block anesthesia. The dentist must carefully aspirate to ensure that the needle has not entered a blood vessel. If bloody aspirate is present, further factor replacement may be required, and the attending hematologist should be notified immediately following the operative procedure. All patients should be observed for development of a hematoma and immediately referred for treatment in cases where hematomas develop after the administration of local anesthesia.

DENTAL MANAGEMENT

Most patients with bleeding disorders are recommended to receive routine regular outpatient dental care. Appointments should be arranged so that maximum treatment is accomplished per visit in order to minimize the need for unscheduled factor infusions and resultant increased cost.[37-39] Patients with inhibitors are best treated at a center with experience in dealing with this complication. Dental procedures utilized to treat a patient with a bleeding disorder do not differ significantly from those used for unaffected individuals.

Prevention of Dental Disease

A program that includes toothbrushing, flossing, appropriate topical fluoride exposure, adequate systemic fluoride administration, consumption of a proper diet, and professional examination at regular intervals is an effective approach to the prevention of dental problems. Rubber cup prophylaxis and supragingival scaling may be safely performed without prior factor replacement therapy. Minor bleeding is often controlled with local measures, such as direct pressure with a moistened gauze square. If bleeding persists for several minutes, the topical application of recombinant thrombin (RECOTHROM; ZymoGenetics, Inc., Seattle, Washington, United States),* microfibrillar collagen (Avitene; Darvol Inc., subsidiary of C.R. Bard, Inc., Warwick, Rhode Island, United States), and local fibrin glue may be of value.

Periodontal Therapy

Patients who require deep scaling due to gross calculus should initially undergo supragingival scaling. The tissue should be allowed to heal for 7 to 14 days, during which time the gingiva recedes as edema and hyperemia diminish. Subsequent treatments to remove calculus and irritants therefore incur decreased bleeding risk from the tissue. If subgingival scaling is planned, replacement therapy may be considered, depending on the amount of anticipated bleeding and the severity of the factor deficiency. It is imperative that periodontal patients be placed on a maintenance schedule for proper management.[37,40,41]

An abnormal frenum attachment may cause gingival recession and pocket formation. Early treatment is indicated to prevent continued gingival recession and alveolar bone loss. All appropriate frenectomy techniques are surgically acceptable for patients with bleeding disorders; both factor concentrate replacement and antifibrinolytic therapy are required before frenum or other periodontal surgery. If a large amount of bleeding is anticipated, these procedures should be performed in a hospital environment, with the requisite preparation. The hematologist or attending physician must be contacted to determine the

*Although not reported in the dental literature, bovine thrombin–induced acquired factor V deficiency—a rare, acquired coagulopathy—has been reported; therefore recombinant thrombin is recommended.

Dentlearn.ir

appropriate factor correction required and the possible need for subsequent hospital or outpatient management.

Restorative Procedures

Patients with bleeding disorders should be allowed to consider all restorative procedures. Most restorative procedures on primary teeth are successfully completed, without factor concentrate replacement, by PDL injections of local anesthesia or local infiltration. Small lesions may be restored under nitrous oxide–oxygen inhalation analgesia alone. The use of acetaminophen with codeine may also decrease discomfort in the child.

Most operative procedures for adults may also be completed under local anesthesia, a procedure that usually does not require factor concentrate replacement. If a mandibular block or a posterior superior alveolar injection is anticipated, factor concentrate replacement to a level of 40% and antifibrinolytic therapy are required before injection. If factor concentrate replacement is required, all possible restorative treatment should be completed in one visit to minimize the number of infusions required to complete the restorative treatment plan.

A rubber dam should be used to isolate the operating field and retract and protect the cheeks, lips, and tongue. These soft tissues are highly vascular, and accidental laceration may present a difficult management problem. A thin rubber dam is preferred, since there is a decreased tendency to torque the rubber dam retainer and cause gingival tissue abrasion. The retainer should be placed carefully so that it is stable. If a retainer slips, it may lacerate the gingival papilla. Retainers with subgingival extensions should be avoided.

Wedges and matrices can be used conventionally. During proximal preparation, the wedge retracts the papilla, thus protecting it. A properly placed matrix should not cause bleeding.

High-speed vacuum and saliva ejectors must be used with caution to prevent sublingual hematomas. Care must also be used in the placement of intraoral radiographic films, particularly in highly vascular sublingual tissues.

The preparation of a tooth for a cast crown requires caution in gingival preparation, as does placement of retraction cord and impression material. Periphery wax is used on the impression tray to prevent possible intraoral laceration during tray placement. Undue trauma should be avoided in cementing or finishing a crown.

Pulpal Therapy

At times pulp exposures in primary and permanent teeth may be avoided if carious dentin is not entirely removed in one procedure (indirect pulp therapy). A pulpotomy or pulpectomy is preferable to extraction. The extraction of a tooth in an individual with a bleeding disorder involves more complicated treatment and expense. Most vital pulpotomy and pulpectomy procedures can be successfully completed with local infiltration anesthesia. Nitrous oxide–oxygen inhalation analgesia may also help alleviate discomfort. If the pulp of a vital tooth is exposed, an intrapulpal injection may be used safely to control pain. Bleeding from the pulp chamber does not present a significant problem, in that it is readily controlled with pressure from cotton pledgets. If pulp tissue is necrotic, local anesthetic is usually unnecessary.

Oral Surgery

Preoperative evaluation and postoperative management of the patient with a bleeding disorder and undergoing extractions must be coordinated with the hematologist. The dentist should discuss the surgical procedure with the hematologist, including the anesthetic technique, degree of anticipated surgical trauma, and expected duration for healing. The hematologist then determines the amount and duration of factor concentrate replacement and adjunctive therapies required for surgery and postoperative management. Today it is possible for oral surgery to be performed in the patient with a bleeding disorder on an outpatient basis.[42,43] Requirements include an experienced dentist and hematologist, a facility available for the patient to receive infusions if home infusion is not performed, and a coagulation laboratory capable of timely needed laboratory evaluations. Patients with inhibitors should be treated only in a safe setting by those experienced in their management.

For simple extractions of erupted permanent teeth and multirooted primary teeth, a 30% to 40% factor correction is administered within 1 hour before dental treatment. Antifibrinolytic therapy should be started immediately before or after the procedure and should be continued for 5 to 10 days. The patient should be placed on a clear liquid diet for the first 72 hours. For the next week, a soft, pureed diet is recommended. During this period, the patient should not use straws, metal utensils, pacifiers, or bottles. After 10 days the patient may begin to consume a more normal diet. Specific postoperative instructions should be provided to the patient and parent. Factor concentrate is extremely costly; therefore all extractions should be completed in one appointment if possible.

After extractions are completed, direct topical application of hemostatic agents, such as thrombin or microfibrillar collagen hemostat (Avitene; Darvol Inc.), may assist with local hemostasis. The socket should be packed with an absorbable gelatin sponge (e.g., Gelfoam; Pharmacia and Upjohn Co., Kalamazoo, Michigan, United States). Microfibrillar collagen or topical thrombin or fibrin glue may then be placed in the wound. Direct pressure with gauze should then be applied to the area.

Stomahesive (ConvaTec Inc., Skillman, New Jersey, United States) may be placed over the wound for additional protection from the oral environment. In general, the use of sutures should be avoided unless suturing is expected to markedly enhance healing, in which case resorbent sutures are recommended. The patient must be given specific and thorough postoperative instructions.

For surgical extractions of impacted, partially erupted, or unerupted teeth, a higher factor activity level may be targeted before surgery due to the increased likelihood of surgical trauma and a longer healing period. This should be discussed with the hematologist, who may also elect to administer factor replacement to the patient postoperatively. Antifibrinolytic therapy should be started immediately before or after the procedure and continue for 7 to 10 days.

Dentlearn.ir

For simple extractions of single-rooted primary teeth (i.e., incisors and canines), the amount of root development present must be evaluated to determine whether factor replacement therapy is required. If there is complete root development, factor replacement therapy is likely required, whereas if there is only partial root formation, antifibrinolytic therapy along with local hemostatic agents may be all that is required.

The normal exfoliation of primary teeth does not usually result in bleeding or require factor replacement. Bleeding in these circumstances can generally be controlled with direct finger and gauze pressure maintained for several minutes. The direct topical application of an adjunctive agent may also help with local hemostasis. If there is continuous slow bleeding, antifibrinolytic therapy may be initiated. In rare circumstances, most commonly when the gingival tissue is repeatedly traumatized during exfoliation, use of factor replacement therapy may be required. In this circumstance, dental evaluation should be performed and consideration given to removal of the exfoliating tooth if repeated trauma cannot be avoided.

Surgical Complications

Despite all precautions, bleeding may occur 3 to 4 days postoperatively when the clot begins to resorb. Both systemic and local treatment should be used for hemostatic control when bleeding occurs. Sufficient replacement factor should be administered to control recurrent bleeding.[44]

It is not prudent to protect a loose abnormal clot. The typical clot in this situation is characterized as a "liver clot" and is dark red, usually protruding from the surgical site, and often covers the surfaces of several teeth. Following adequate replacement with factor concentrate, usually to a 30% to 40% activity level, the abnormal clot should be removed and the area cleansed to help isolate the source of bleeding. The socket should then be repacked, and the use of antifibrinolytic agents considered.

Antibiotic Prophylaxis

Total joint replacement, usually of the hip or knee, is often performed in adult patients with severe hemophilia to restore function and alleviate pain associated with degenerative arthritis due to recurrent hemarthroses.The American Dental Association and American Academy of Orthopedic Surgeons advocate in favor of antibiotic prophylaxis for patients with artificial joints before invasive dental procedures. Although there is limited evidence to support this recommendation,[45,46] the dentist should consult with the orthopedic surgeon prior to dental treatment. The American Heart Association recommendations for bacterial endocarditis prophylaxis, last updated in 2007, are commonly followed.[47] Antibiotic prophylaxis is no longer recommended for patients with central venous access devices, although each hematologist's preference and particular patient's circumstance should be considered. If the patient is immunocompromised because of HIV infection, antibiotic prophylaxis may be considered in coordination with the HIV specialist.

Orthodontic Treatment

Early recognition of an orthodontic problem is important because selective guidance can diminish or eliminate complex orthodontic problems. Both interceptive and full-banded orthodontics may be performed if required. Care must be taken in the adaptation and placement of bands and in the avoidance of protruding sharp edges and wires to prevent laceration of oral mucosa. Bleeding caused by an accidental scratch or minor laceration of the gingiva usually responds to applied pressure for 5 minutes. The use of preformed orthodontic bands and brackets, which can be bonded directly to the teeth, almost totally eliminates contact of orthodontic appliances with gingiva during placement. Longer-acting wires and springs require less frequent adjustment of orthodontic appliances. Oral hygiene is particularly important to avoid inflamed, edematous, and hemorrhagic gingival tissues. A water-irrigating device may be helpful for home dental care.

Dental Emergencies

Oral trauma is a common occurrence during childhood. Management of bleeding injuries, including hematomas, in the oral cavity of the patient with a bleeding disorder may require a combination of factor replacement and antifibrinolytic therapy, as well as treatment with local hemostatic agents. Blood loss from the oral cavity is easily underestimated or overestimated. The patient's hemoglobin should be checked to ensure that anemia has not developed in these circumstances.

VIRAL HEPATITIS

Infection by the various strains of viral hepatitis causes inflammation of the liver parenchyma, which may lead to necrosis or cirrhosis. Acute hepatitis classically presents with lethargy, loss of appetite, nausea, vomiting, and abdominal pain, but may not be recognized until jaundice ultimately develops.

Acute viral hepatitis may be caused by any of the following: hepatitis A virus (HAV), HBV, hepatitis delta virus (HDV), HCV, or hepatitis E virus (HEV).

HAV infection results in an acute febrile illness with jaundice, anorexia, nausea, and malaise. Most HAV infections in infants and children cause mild, nonspecific symptoms without jaundice. HAV is spread by the fecal-oral route and is endemic in developing areas. Spread occurs readily in households and day-care centers, where symptomatic illness occurs primarily among adult contacts with children. No HAV carrier state exists, and the presence of immunoglobulin G–anti-HAV indicates past infection and lifelong immunity to HAV. The risk for transmission in a dental setting is low. A two-dose vaccination series separated by 6 months can be given to anyone older than 1 year of age.

HBV transmission is of major concern to the dentist. Members of the dental profession assume a risk for acquiring HBV that may be 10 times greater than that of the general population.[48] An additional concern is the potential of becoming an asymptomatic yet infectious carrier of HBV and of having the capability of transmitting the disease to patients and dental staff members and family.

Dentlearn.ir

HBV is transmitted from person to person by parenteral, percutaneous, or mucous membrane inoculation. It can be transmitted by the percutaneous introduction of blood, administration of certain blood products, or direct contact with secretions contaminated with blood containing HBV. Infection may also result from inoculation of mucous membranes, including sexual transmission. Wound exudates contain HBV, and open-wound to open-wound contact can transmit infection. There can also be vertical transmission from an infected mother to her baby, which frequently leads to chronic infection.

A medical history is unreliable in identifying patients who have HBV infection, because approximately 80% of all HBV infections are undiagnosed. However, the medi-

are at higher risk of being undiagnosed carriers. Among populations at high risk for HBV infection are patients undergoing hemodialysis, patients requiring frequent large-volume blood transfusions or administration of clotting factor concentrates, residents of institutions for those with mental disabilities, and users of illicit injectable drugs.

In 2011 an estimated 18,000 people in the United States became infected with HBV, and an estimated 700,000 to 1.4 million chronically infected people live in the United States. Overall, chronic hepatitis B claims nearly 1800 lives per year in the United States.[49] Chronic active hepatitis develops in more than 25% of carriers and often progresses to cirrhosis. Furthermore, HBV carriers have a 12 to 300 times higher risk of developing primary liver cancer than uninfected individuals.

For detection of acute or chronic HBV infection, the serologic test for hepatitis B surface antigen (HBsAg) is most commonly used. The antibody to surface antigen (anti-HBs) is protective and indicates a resolved natural infection or successful vaccination. Antibody to the core antigen (anti-HBc) indicates exposure to natural HBV but can be present in either resolved or chronic infection. The hepatitis B "e" antigen (HBeAg) is a useful marker for infectivity. Patients who test positive for anti-HBe and HBsAg are most likely to transmit the disease. If the patient still shows a positive test result for HBsAg 6 months after an acute HBV infection, the patient is considered to be chronically infected. Chronic infection is less likely the older the patient at the time of exposure; hence the mandate to vaccinate children shortly after birth.

The availability of a safe, effective hepatitis B vaccine affords the dentist and staff additional protection against acquiring HBV infection. HBV vaccine is recommended for all health care personnel. The vaccine is derived using recombinant DNA and therefore does not have the potential to transmit the disease. When administered in a three-dose injection regimen (0, 1, 6 months), the recombinant DNA vaccine induces protective antibody (anti-HBs) in 95% to 100% of adults.

A fulminant type of hepatitis occurs with infection by HDV but only with coexisting or simultaneous infection with HBV. HDV is defective in that it requires HBV for outer coat proteins (HBsAg), as well as for replication. Transmission is similar to that of HBV—by parenteral, percutaneous, or mucous membrane inoculation.

HCV, against which there is no available immunization, is of similar concern for the dentist because of its transmission via exposure to infectious body fluids. Patients at risk for hepatitis C include those who received blood transfusions or organ transplants before 1992, those who received clotting factors before 1987, those on long-term dialysis, and most commonly those who have experimented with illicit intravenous drugs, regardless of how many times or how long ago. Infection associated with injection drug use accounts for more than 50% of the new cases in the United States. Of those infected, chronic infection develops in 70% to 85%, and chronic liver disease develops in about 70%. Although only 3% of infected people die of liver failure, hepatitis C is the leading reason for liver transplantation in adults in the United States.[50]

In 1989 parenterally transmitted non-A non-B (NANB) was identified as HCV. Subsequently, six genotypes have been identified. Diagnosis is made by detection of antibody to HCV (anti-HCV) in the serum and can be confirmed by radioimmunoblot assay. Polymerase chain reaction (PCR) testing can be done qualitatively to confirm diagnosis or quantitatively to assess response to treatment. Treatment historically included administration of interferon or pegylated interferon with or without ribavirin, with response rates varying based on the viral genotype. Newer agents such as simeprevir, a NS3/4A protease inhibitor, and sofosbuvir, a nucleotide analogue NS5B polymerase inhibitor, have been shown to be effective agents in combination, and are transforming care for patients with HCV, especially for those not eligible for interferon.[51] In 2011 the Centers for Disease Control and Prevention estimated that there were 16,500 new cases of infection with hepatitis C in the United States, down from 240,000 per year in the 1980s.[52] There are nearly 4 million people infected with hepatitis C in the United States (1.6%). Of the chronically infected, some 16,000 patients die per year. Enterically transmitted NANB has been identified as the hepatitis E virus. Transmission is by the fecal-oral route. Large, well-documented outbreaks have been seen worldwide and can be found in the returning traveler.[53] There appear to be a 6- to 8-week incubation period and a low incidence of carrier state after infection. However, a high fatality rate (10% to 20%) is seen in women who contract this virus in their third trimester of pregnancy.[54] There is no immunization available against this pathogen.

SICKLE CELL ANEMIA

Sickle cell anemia (SCA) is composed of sickle cell trait, which is benign and does not restrict medical or dental treatment, and sickle cell disease (SCD). Patients with SCD have an autosomal-recessive hemolytic disorder that occurs predominantly in persons of African descent but is also found among Italian, Arabian, Greek, and Indian people.[55]

Patients with SCD produce hemoglobin S instead of the normal hemoglobin A. Hemoglobin S has a decreased oxygen-carrying capacity. Decreased oxygen tension causes sickling of cells. These patients are susceptible to recurrent acute infections, which result in an "aplastic

Dentlearn.ir

crisis" caused by decreased red blood cell production and in subsequent joint and abdominal pain with fever. Over time, there is a progressive deterioration of cardiac, pulmonary, and renal function.

Many factors can precipitate a sickle cell crisis, including acidosis, hypoxia, hypothermia, hypotension, stress, hypovolemia, dehydration, fever, and infection. Patients with SCD have hemoglobin levels of 6 to 9 g/dL (normal, 12 to 18 g/dL). Patients with SCD are treated with hydroxyurea (HU) in an attempt to increase their fetal hemoglobin and prevent the formation of the HbS polymer. Hematopoietic stem cell transplantation is the only available curative therapy.[55]

Radiographic changes are associated with SCD, in particular, a generalized radiolucency and loss of trabeculae with prominent lamina dura, caused by increased erythropoietic demands that result in expansion of the marrow spaces. Bone growth may be decreased in the mandible, resulting in retrusion, and the teeth may be hypomineralized. There is a high incidence of malocclusions in patients with SCD. There is an increased incidence of overjet, higher angulation, and diastames secondary to the compensating expansion of their bone marrow.[56] Occasionally, patients with SCD have infarcts in the jaw, which may be mistaken for a toothache or osteomyelitis. The patients experience dental pain with absence of pathology.

Dental appointments should be short to reduce potential stress on the patient. The importance of an aggressive preventive program cannot be understated, and such a program should have the goal of maintaining excellent oral health and decreasing the possibility of oral infection. Dental treatment should not be initiated during a sickle cell crisis. If emergency treatment is necessary during a crisis, only treatment that will make the patient more comfortable should be provided. Patients with SCD may have skeletal changes that make orthodontic treatment beneficial. Special care must be taken to avoid tissue irritation, which may induce bacteremias, and the disease process may compromise the proposed treatment. Careful monitoring is a necessity when elective orthodontic treatment is proposed for patients with SCD.

Many patients with SCD have defective spleen function or undergo a splenectomy, which leaves them more vulnerable to infection because immunoglobulin production is decreased and phagocytosis of foreign antigens is thus impaired. Most patients with SCD are taking low-dose daily prophylactic antibiotics, and the need for additional antibiotics for dental procedures is debatable. Some authors have recommended the use of antibiotics for all dental procedures, whereas others recommend the administration of additional antibiotics when there is obvious dental or periodontal infection. The selection of an antibiotic is usually similar to that in cases of heart defect.

The use of local anesthetics with a vasoconstrictor is not contraindicated in patients with SCD. Some textbooks do recommend against the use of vasoconstrictors, although there is no evidence to support this practice. Similarly, the use of nitrous oxide is not contraindicated in these patients. Care must be taken in treating patients with SCD to avoid diffusion hypoxia at the completion of the dental procedure.

The restoration of teeth, including pulpotomies, is preferable to extraction. Pulpectomy in a nonvital tooth is reasonable if the practitioner is fairly confident that the tooth can remain noninfected. If the tooth is likely to persist as a focus of infection, then extraction is indicated.

The use of general anesthesia for dental procedures must be approached cautiously in consultation with the hematologist and anesthesiologist. Previously, the standard protocol was to perform a direct transfusion (immediate introduction of whole blood or blood components) or an exchange transfusion (repetitive withdrawal of small amounts of blood and replacement with donor blood until a large portion of the patient's blood has been exchanged) before general anesthesia. The goal of the transfusion is to increase the patient's hemoglobin level to higher than 10 g/dL and to decrease the hemoglobin S level below 40%. Transfusions do not provide complete protection against venous complications, but they may temporarily improve the patient's condition and reduce the hazards of surgery.

The current thinking is to weigh the risks associated with transfusion prior to anesthesia induction. Suggested guidelines for performing a prophylactic transfusion before general anesthesia have been proposed. Patients with a hemoglobin level of less than 7 g/dL and a hematocrit of less than 20% may require a transfusion. Pediatric patients are usually less likely to have posttransfusion complications than are adults. A high frequency of hospitalizations is indicative of a more severe anemia, and such patients may require transfusion before surgery. Minor surgeries may not require a transfusion.

ACQUIRED IMMUNODEFICIENCY SYNDROME

Acquired immunodeficiency syndrome (AIDS) is a clinically defined condition caused by infection with HIV type 1 or, much less commonly, type 2. In 2011 it was estimated that nearly 1.2 million people in the United States are infected with HIV and approximately 15% of them do not know their status.[57]

The period of time from HIV infection to the appearance of symptoms consistent with AIDS can be approximately a decade in many adults. Consequently, HIV-infected individuals can unknowingly spread the virus to their sexual or needle-sharing partners or, in the case of infected mothers, to their children.

HIV infects cells of the immune system, specifically lymphocytes and macrophages. These leukocytes contain the greatest number of CD4 cell-surface receptors (glycoproteins), which permit attachment with viral surface proteins (GP120). Under the control of the HIV *pol* gene, the virus produces the enzyme reverse transcriptase, which is essential for incorporating viral RNA into host nuclear DNA. The viral genome is integrated into the host-cell genome and leads to progressive and eventually irreversible immunosuppression by producing more virus and further killing the CD4 lymphocytes that are important modulators of the immune system. The subsequent immunodeficiency results in a variety of opportunistic infections, malignancies (e.g., Kaposi sarcoma and lymphoma), and

Dentlearn.ir

autoimmune diseases. Diagnosis is made by screening the serum for antibodies to HIV and is confirmed by a second methodology such as Western blot analysis or PCR. Ongoing management is guided by the patient's $CD4^+$ cell count and viral load as measured by PCR. The former is an indication of the patient's immune status, whereas a higher viral load is associated with a more accelerated disease. The current antiretroviral drugs target the virus at several steps: (1) the adhesion of the virus to the chemokine receptor CCR5, (2) the fusion of the virus to the host cell (fusion inhibitors), (3) the integration of viral genes into the target cell (integrase inhibitors), (4) the transcription of DNA from viral RNA by reverse transcriptase (nucleoside, nonnucleoside, and nucleotide reverse transcriptase inhibitors), and (5) the cleavage of viral proteins by the viral protease enzyme (protease inhibitors). The most effective treatment strategies use a combination of several drugs to inhibit the virus at several steps.

In the United States, nearly two thirds of newly infected men diagnosed in 2010 acquired HIV through homosexual contact, infection from illicit drug use accounted for 12% of new cases, and 16% of infections were acquired through heterosexual contact.[58] Among infected women in the United States, 80% acquired HIV through heterosexual contact and 19% through intravenous drug use. Almost 30% of newborns of untreated HIV-infected mothers can acquire HIV through vertical transmission. However, treatment of pregnant women with antiretroviral medications, including azidothymidine (AZT), has decreased the rate of transmission by 70%. The onset of symptoms is shortened in children who have acquired their infection prenatally and go untreated. Only 75% of untreated babies survive to age 5 years, and by that age 50% have severe symptoms. Now individuals infected with HIV are treated with highly active antiretroviral therapy (HAART), providing a combination of agents to target different stages of the viral life cycle concomitantly, making what was once a terminal diagnosis into a manageable infection.[59]

Infants and children with AIDS have clinical findings similar to those in adults. Early manifestations of untreated HIV infection include weight loss and failure to thrive, hepatomegaly or splenomegaly, generalized lymphadenopathy, and chronic diarrhea. Unlike in adults, recurrent and severe bacterial infections are more common in pediatric patients with untreated HIV infection, especially *Pneumocystis jirovecii*.

ORAL MANIFESTATIONS OF HIV INFECTION

The types of oral lesions seen in HIV infection may be caused by fungal, viral, or bacterial infections, as well as neoplastic and idiopathic processes. HIV infection predisposes this population of patients to a greater severity of conventional periodontal problems. On review of the charts of some 2500 adult patients living with HIV, Fox and her collaborators found that a slim majority had not received dental care in more than 2 years, and that at the time of dental care, nearly half had an unmet oral need and had detectable viral loads despite having been connected with HIV specialists.[60] Antibacterial therapy and, even more so, antifungal therapy should be discussed with HIV specialists, with the understanding that these therapeutics, though indicated, may be detrimental to HAART efficacy.[61,62]

Fungal Infection

Pindborg stated that the most common HIV-associated infection of the mouth is caused by the fungus *Candida albicans*.[63] Oral candidiasis is frequently present and may lead to esophageal or disseminated candidiasis. There are four major types of oral candidiasis: (1) pseudomembranous, (2) hyperplastic, (3) erythematous (atrophic), and (4) angular cheilotic.

The pseudomembranous lesion is characterized by the presence of creamy white or yellow plaque that can easily be removed from mucosa, leaving a red, bleeding surface. The most common locations for these lesions are the palate, buccal and labial mucosa, and dorsum of the tongue.

The hyperplastic lesion is characterized by white plaque that cannot easily be removed. The most common location is the buccal mucosa. The erythematous (atrophic) lesion is characterized by a red appearance. Common locations are the palate and the dorsum of the tongue. The lesions may also appear as spotty areas on the buccal mucosa. Angular cheilitis is characterized by fissures radiating from the commissures of the mouth, often associated with small, white plaque.

The treatment of *C. albicans* infection can be either systemic or topical. Topical therapy involves the use of nystatin (Mycostatin) rinses (100,000 U, 3 to 5 times daily) or clotrimazole (Mycelex) troches for 1 to 2 weeks. Systemic therapy calls for ketoconazole (Nizoral), 200 or 400 mg daily with food, or fluconazole (Diflucan), 100 mg daily. Amphotericin B and its lipid preparations, azoles such as fluconazole (administered intravenously), and echinocandins are used for systemic infection.

Oropharnygeal candidal infections are common and can frequently recur.[64] Therefore patients may remain on antifungal medication indefinitely. As an adjunctive measure, mouthrinses with Peridex (0.12% chlorhexidine digluconate; Zila Pharmaceuticals, Phoenix, Arizona, United States) may be used. Chronic oral candidiasis, given the available armamentarium of HAART agents, may be a poor prognostic sign indicating a phase of more rapid decline of immune function to the terminal phase of AIDS.

Viral Infection

In the same way that fungi can cause oral disease because of the immune dysfunction induced by HIV infection, several viruses can produce lesions in the mouth following colonization or reactivation. According

papillomaviruses.[65]

Oral warts may be seen in the HIV-infected patient, with human papillomavirus as the etiologic agent. Some warts have a raised, cauliflower-like appearance, whereas others are well circumscribed, have a flat surface, and almost disappear when the mucosa is stretched.

Herpes simplex virus (HSV) can produce recurrent episodes of painful ulceration. Intraorally, the lesions appear most commonly on the palate. Typically these lesions present as vesicles that break open to form ulcers. However, they may also have an atypical appearance as slitlike

Dentlearn.ir

lesions on the tongue or may mimic other diseases. Diagnosis can be made from culture, PCR, or fluorescent antibody testing.

Herpetic lesions may be treated with oral acyclovir and its relatives, valacyclovir and famciclovir. Acyclovir may also be administered intravenously (750 mg/m^2 in divided doses 3 times a day until lesions clear) in individuals with more severe oropharyngeal lesions or in those unable to swallow.

Herpes zoster (shingles) is caused by varicella-zoster virus (VZV), the chickenpox virus. Varicella-zoster virus can produce oral ulcerations, which are usually accompanied by skin lesions generally restricted to one side of the face. These lesions are also treated with acyclovir.

Oral hairy leukoplakia (HL) is a white lesion that does not rub off, located on the lateral margins of the tongue. The surface may be smooth, corrugated, or markedly folded. HL is seen only in patients who are HIV-infected. HL is a virally induced lesion caused by the Epstein-Barr virus. Treatment may include the use of high-dose acyclovir. However, the lesions usually recur.

Bacterial Infections, Gingivitis, and Periodontitis

Progressive and premature periodontal disease is seen relatively frequently in HIV-infected individuals and may even be the first sign of HIV infection. Unlike conventional periodontal disease, these lesions do not respond effectively to standard periodontal therapy. There may be a rapid progression from mild gingivitis to advanced, painful, spontaneously bleeding periodontal disease in a few months. Treatment includes aggressive curettage, Peridex (0.12% chlorhexidine digluconate) rinses 3 times daily, and possibly antibiotic treatment.

Bacteria causing oral lesions may include *Mycobacterium avium-intracellulare* and *Klebsiella pneumonia,* among others. Well-described conditions include linear gingival erythema (LGE) and necrotizing ulcerative periodontitis (NUP), which likely represent dysbiosis of the microflora. Many of the oral lesions seen in association with HIV infection are not new entities; rather, they are known diseases that either follow an atypical course or show an unusual response to treatment. This is frequently the case with neoplasms as well.

Neoplasms

Kaposi sarcoma, secondary to transformation induced by human herpes virus-8 infection, is the most common malignancy seen in AIDS and, according to Silverman, occurs in 15% to 20% of adult patients with AIDS.[66] Intraoral lesions may occur alone or along with skin, visceral, and lymph node lesions. The first lesions of Kaposi sarcoma often appear in the mouth. They may be red, blue, or purple, flat or raised, and solitary or multiple. The most common oral site is the hard palate, although lesions may be found on any part of the oral mucosa. Treatment for aggressive lesions involves radiation, laser surgery, or chemotherapy. Conventional surgery may be appropriate for small lesions.

ing the fastest among patients with AIDS is the lymphomas, most commonly the non-Hodgkin lymphomas. The first manifestation may be a firm, painless swelling in the mouth. Biopsies of these growths are indicated to establish a diagnosis. Treatment includes multidrug chemotherapy and radiation. Less than 20% of patients survive 2 years; the mean survival time is approximately 6 months from diagnosis.

Oral squamous cell carcinomas also occur more frequently in the HIV-infected population. In patients with HIV/AIDS who develop malignancies, their HAART should be optimized while definitive oncologic therapy is pending.[59]

Idiopathic Lesions

Greenspan described oral ulcers of unknown etiology that are being reported with increasing frequency in people with HIV infection.[65] The ulcers resemble aphthous lesions, appearing as well-circumscribed ulcers with an erythematous margin. Patients sometimes exhibit extremely large and painful necrotic ulcers that may persist for several weeks. These ulcers are more common among pediatric patients. The serum and oral secretions, if screened by PCR for human herpes viruses (EBV, HHV6, HHV7), are not uncommonly positive, but this more likely represents asymptomatic shedding rather than identification of an untreated coinfection. In the patient on appropriate HAART therapy, topical steroids are reasonable and safe.

Salivary gland swelling has been seen in both adults and children with HIV infection. The cause of the swelling is unknown and may be combinational. It usually involves the parotid glands and is also accompanied by xerostomia. These patients may be best evaluated with fine-needle aspiration, especially if there is a focal mass.

HIV-infected patients may develop oral manifestations of autoimmune disorders, including immune thrombocytopenic purpura. Oral lesions appear as small, blood-filled purpuric lesions or petechiae. Spontaneous gingival bleeding may also occur.

LEUKEMIA

Malignancy is second only to accidents as the leading cause of death in children. Leukemias are hematopoietic malignancies in which abnormal leukocytes (blast cells) proliferate in the bone marrow, replacing normal cells, and disseminate into the peripheral blood, accumulating in other tissues and organs of the body.

the predominant abnormal leukocytes in the bone marrow (Table 26-1). These types are further categorized as acute or chronic, depending on the clinical course and the degree of differentiation, or maturation, of the predominant abnormal cells.

In the United States, about one of every 6000 children under the age of 20 years is diagnosed each year with cancer. Acute leukemia is the most common malignancy in children and adolescents, with about 4000 new cases diagnosed annually in the United States. Thus acute leukemia accounts for about one third of all childhood malignancies; of these, approximately 75% are lymphocytic (acute lymphocytic leukemia, or ALL) and 25% are acute

Dentlearn.ir

Table **26-1**

Childhood Leukemias

Type	Age and White Blood Cell Count (WBC) at Onset	Prognosis	Treatment
Acute lymphocytic (ALL)	Peak age, 3-6 years	>94% remission induction, varies with age and presenting WBC count	Vincristine, L-asparaginase, prednisone, dexamethasone, 6-mercaptopurine, methotrexate, daunomycin, doxorubicin, cytosine arabinoside [araC], cyclophosphamide
Standard risk	1-9 years with WBC <50,000/mm^3	80%-90% EFS at 60 months	
Poor risk	>10 years or any age with WBC >50,000/mm^3	50%-60% EFS at 60 months	
Infants	<1 year, any WBC	20%-30% EFS at 60 months	
Acute myelogenous (AML)		80% remission induction; 40% EFS at 36 months; >95% EFS in children with Down syndrome younger than 2 years of age	Cytosine arabinoside, daunomycin, VP-16, 6-thioguanine, idarubicin, dexamethasone; hematopoietic stem cell transplantation*
Myelocytic (AML)	Older children and adolescents	Presence of (t8;21) cytogenetic abnormality yields better outcome ~70% survival, whereas abnormalities of 11q23, monosomy 5 or 7 portend poor prognosis (20%)	
Monocytic or myelomonocytic (AmoL; AMML)	Infants and young children more common	Presence of cytogenetic abnormality (inv 16) yields better outcome ~70% survival	
Promyelocytic (APL)	Uncommon; seen in older children	Presence of cytogenetic abnormality (t15;17) yields better outcome ~70% survival	Responds to all trans-retinoic acid and arsenic trioxide
Erythroleukemia	Very rare	Generally very poor	
Megakaryocytic leukemia	Very rare	Generally very poor, in young Down syndrome patients—excellent prognosis	
Chronic myelocytic (CML)			
Juvenile, Philadelphia chromosome-negative	Infants and toddlers, very rare	Median survival <9 months	Hematopoietic stem cell transplantation†
Adult, Philadelphia chromosome-positive	Older children and adolescents	Chronic phase about 2-4 years, then death in blast cell crisis, usually of AML, which is resistant to therapy; great improvement with imatinib	Imatinib (Gleevec), hydroxyurea; interferon alpha; hematopoietic stem cell transplantation†
Chronic lymphocytic	Not seen in children		

*Sibling HLA-matched hematopoietic stem cell transplantation (HSCT) is considered the treatment of choice for most subtypes of acute myelogenous leukemia. Each sibling has one chance in four of being a perfect match. The patient is put into remission by standard chemotherapy before bone marrow transplantation. Of AML patients undergoing transplantation in first remission, 60% show no evidence of disease after 2 years.
†Hematopoietic stem cell transplantation has been the treatment of choice for adult and juvenile chronic myelocytic leukemia. Response to standard chemotherapy is generally poor. Imatinib, a selective inhibitor of tyrosine kinase at the breakpoint cluster region on the *ABL* gene (causative abnormality in CML), is highly effective and well tolerated in all phases of CML when taken orally. Because long-term oral imatinib has been successful in children, the role and timing of HSCT are somewhat controversial in the treatment of childhood Philadelphia chromosome-positive CML. Transplantation for adult-type CML in first chronic phase using a matched sibling donor gives 60% disease-free survival at 2 years.
EFS, Event-free survival.
Courtesy Dr. Randy Hock and Dr. Alexandra Cheerua.

myelogenous leukemia (AML). Chronic leukemia in children is rare, accounting for less than 2% of all cases.

The peak incidence of childhood leukemia is at between 2 and 5 years of age. Although the cause of leukemia is unknown, ionizing radiation, certain chemical agents, and genetic factors have been implicated. For example, children with chromosomal abnormalities (Down syndrome and Bloom syndrome), children with an identical twin who has leukemia, and children with immunologic disorders have an increased risk for leukemia. In the United States, leukemia rates for white children are about 1.5 times those for black children.[67]

The clinical manifestations of acute leukemia are caused by the infiltration of leukemia cells into tissues and organs. Infiltration and proliferation of leukemia cells in the bone marrow lead to anemia, thrombocytopenia, and granulocytopenia. Because these cytopenias develop gradually, the onset of the disease is frequently insidious. The history at presentation may reveal increased irritability, lethargy, persistent fever, vague bone pain, and easy bruising. Some of the more common findings on initial physical examination are pallor, fever, tachycardia, adenopathy, hepatosplenomegaly, petechiae, cutaneous bruises, gingival bleeding, and evidence of infection.

In approximately 90% of the cases of acute leukemia, a peripheral blood smear reveals anemia and thrombocytopenia. In about 65% of cases the white blood cell count is low or normal, but it may be greater than 50,000 cells/mm^3.

When a new case of leukemia is diagnosed, the patient is hospitalized and therapy is directed toward stabilizing the patient physiologically, transfusing blood products to correct anemia and control bleeding, identifying and eliminating infection, evaluating renal and hepatic functions, and preparing the patient for chemotherapy. These interventions proceed while the definitive studies to determine the exact type of leukemia are undertaken, including a bone marrow aspiration for microscopic analysis, special cytochemical staining, immunophenotyping by flow cytometry, and cytogenetic analysis. The goal of treatment is to induce and maintain a complete remission, which is defined as resolution of the physical findings of leukemia (e.g., adenopathy, hepatosplenomegaly, petechiae) and normalization of peripheral blood counts and bone marrow (less than 5% blast cells).

The term *minimal residual disease* (MRD) has been applied when multiple-parameter flow cytometry and sometimes PCR technology are used to denote that less than 0.1% blast cells are found. Remission with MRD is a better prognostic factor than the old definition of remission.

The basic principle of treatment of ALL is substantially different from that for AML or nonlymphocytic leukemia (ANLL). In general, the treatment of ANLL is very intense and results in profound bone marrow hypoplasia, but the treatment duration is usually short (less than 1 year). For ALL, the treatment is less intense but more prolonged (2.5 to 3.5 years).

Overall, the treatment regimens vary considerably, depending on prognostic factors and the parameters being

induction, incorporates the use of a combination of antileukemic drugs at staggered intervals during a 4-week regimen (Table 26-2). This combination of drugs should rapidly destroy the leukemic cells yet maintain the regenerative potential of the nonmalignant hematopoietic cells within the bone marrow. About 95% of patients with ALL will be in complete remission at day 28 of therapy. The second phase, *consolidation*, attempts to consolidate remission and intensify prophylactic central nervous system (CNS) treatment. Prevention of CNS relapse uses intrathecally administered chemotherapy (methotrexate with or without cytosine arabinoside and hydrocortisone) to destroy leukemic cells within CNS. Methotrexate is instilled directly into the lumbar spinal fluid, because most antileukemic drugs do not readily cross the blood-brain barrier. Intensive intrathecal chemotherapy to prevent CNS relapse has replaced cranial irradiation for patients

However, both cranial irradiation and intrathecal chemotherapy are still used to prevent CNS relapse in high-risk ALL patients. The third phase, *interim maintenance*, uses a combination of agents that are relatively nontoxic and requires only monthly visits to the outpatient clinic. In most cases a fourth phase, *delayed intensification*, follows interim maintenance. This serves to intensify antileukemic therapy again after a short period of less intensive therapy. The addition of a late phase of intensive therapy substantially improves survival in patients with ALL. Following delayed intensification, therapy continues for 2 years for girls and 3 years for boys (maintenance phase), with chemotherapeutic agents given as in interim maintenance.

The prognosis for a child with acute leukemia has improved dramatically over the past several decades. Thirty-five years ago, there would have been little need to discuss dental treatment for a child with leukemia because the disease was invariably fatal—in most cases within 6 months of diagnosis. Today with the development of new and better antileukemia drugs, use of intensive combination drug therapy, selective incorporation of radiation therapy for certain patients, and improvements in diagnostic techniques and general supportive care, the overall survival for all children with ALL is now about 85%.

Pretreatment prognostic factors identify patients who are likely to benefit from either standard or more intensive therapy. Factors that identify patients who are likely to benefit from the type of therapy just outlined, which causes relatively minimal toxicity, are patient age between 1 and 10 years, a white blood cell count of less than 50,000/mm^3, lymphoblast morphology that is not of the Burkitt type, and the absence of certain cytogenetic abnormalities [t(4;11); t(9;22)] (also known as the Philadelphia chromosome) or hypoploidy in the lymphoblasts. The presence of either the TEL-AML1 fusion [t(12;21)(p13;q22)] or the simultaneous trisomies of chromosomes 4, 10, and 17 in the lymphoblasts correlates with an improved prognosis and may qualify these children for less strenuous therapy.

Children with ALL who are at particularly high risk are those who are younger than 1 year of age at diagnosis, have a high initial white blood cell count, or have the

Dentlearn.ir

Table **26-2**

Major Chemotherapeutic Agents and Their Side Effects

Agent	Nausea*	Bone Marrow Suppression	Hair Loss	Stomatitis/ Ulcers	Renal	Neurologic
Alkylating Agents						
Carboplatin	Yes	Yes	Yes	No	No	No
Cisplatin	Yes (severe)	Yes	Yes	No	No	Peripheral neuropathy
Cyclophosphamide	Yes	Yes	Yes	No	No	Seizures (rare)
Ifosfamide	Yes	Yes	Yes	No	No	Somnolence
Antibiotics						
Actinomycin D	Yes	Yes	Yes	Yes	No	No
Vincristine†	No	No	Yes	No; jaw pain	No	Peripheral neuropathy, seizures (rare)
Daunomycin‡	Yes	Yes	Yes	Yes	No	No
Doxorubicin‡	Yes	Yes	Yes	Yes	No	No
Idarubicin‡	Yes	Yes	Yes	Yes	No	No
Antimetabolites						
Cytosine arabinoside (araC)	Yes	Yes	Yes	Yes	No	Cerebellar dysfunction
Methotrexate	Yes	Yes	Yes	Yes	Yes	Leukoence-phalopathy§
6-Mercaptopurine	Yes	Yes	Mild	Rare	No	No
Plant alkaloids						
Etoposide	Yes	Yes	Yes	No	No	No
Miscellaneous						
Dexamethasone	No	No	No	No	No	Pseudotumor; psychoses
Prednisone	No	No	No	No	No	Pseudotumor; psychoses
L-Asparaginase¶	No	No	No	No	No	Seizures (rare), thrombosis

*Nausea is substantially alleviated by the judicious use of antiemetics.
†These agents cause severe skin burns if they extravasate from the vein.
‡High cumulative doses may result in cardiac toxicity.
§Leukoencephalopathy is usually seen with methotrexate in conjunction with whole-brain radiation.
¶L-Asparaginase may cause pancreatitis and diabetes.

cytogenetic abnormalities mentioned above, or have a persistence of identified disease after induction therapy. More intrusive treatment regimens are used for these patients.

The early response to induction chemotherapy is also a strong predictor of outcome for patients with ALL.[68,69] Current clinical trials in leukemia are using flow cytometry and molecular techniques to detect blast cells not visible morphologically in bone marrow aspirates. Quantification of this MRD is being used as an additional tool to direct therapy so that children can receive risk-based adjusted therapy.

The prognosis for children with AML has improved significantly over the past several years, with event-free survivals of approximately 50% (at 3 years) for children receiving chemotherapy and somewhat higher percentages for patients undergoing allogeneic hematopoietic stem cell transplantation from a matched sibling after achieving remission with chemotherapy.[70] The treatment regimens are intrusive and result in profound bone marrow suppression. These patients have severe prolonged neutropenia, necessitating long hospitalizations. They often have serious infections and severe mucositis.

ORAL MANIFESTATIONS OF LEUKEMIA

Pathologic changes in the oral cavity as a result of leukemia occur frequently. Oral signs or symptoms suggestive of leukemia have been reported in as many as 75% of adults and 29% of children with leukemia. The lower incidence of oral manifestations in children can be attributed in part to the early age at diagnosis and the high per-

of ALL peaks at 3 years of age, when preexisting inflammatory and degenerative changes are comparatively less frequent.



Figure 26-3 Several small ecchymoses on the dorsal surface of the tongue in a 10-year-old girl with acute lymphocytic leukemia. (Courtesy Dr. Bruce W. Vash.)



Figure 26-4 Petechia along the gingival sulcus in a 14-year-old female with acute lymphocytic leukemia. (Courtesy Dr. Bruce W. Vash.)

Abnormalities in or around the oral cavity occur in all pathologies are more commonly observed in acute leukemias than in chronic leukemias. Oral findings suggestive of leukemia are also more common in AML than in ALL.

The most frequently reported oral abnormalities attributed to the leukemic process include regional lymphadenopathy, mucous membrane petechiae and ecchymoses, gingival bleeding, gingival hypertrophy, pallor, and nonspecific ulcerations. Manifestations seen occasionally are cranial nerve palsies, chin and lip paresthesias, odontalgia, jaw pain, loose teeth, extruded teeth, and gangrenous stomatitis. Each of these findings has been reported in all types of leukemia. Regional lymphadenopathy is the most frequently reported finding. Gingival abnormalities, including hypertrophy and bleeding, are more common in patients with AML, whereas petechiae and ecchymoses are more common in those with ALL.

Like the systemic manifestations of leukemia, oral changes can be attributed to anemia, granulocytopenia, and thrombocytopenia, all of which result from the replacement of normal bone marrow elements by undifferentiated blast cells or direct invasion of tissue by these leukemic cells. Very high circulating white blood cell numbers in the peripheral blood can lead to stasis results in areas of necrosis and ulceration that can readily become infected by opportunistic oral microorganisms in patients with neutropenia. A person with severe thrombocytopenia, having lost the capacity to maintain vascular integrity, is likely to bleed spontaneously. Clinical manifestations are petechiae or ecchymoses of the oral mucosa or frank bleeding from the gingival sulcus (Figs. 26-3 and 26-4). The propensity for gingival bleeding is greatly increased in persons with deficient oral hygiene because accumulated plaque and debris are significant local irritants.

Direct invasion of tissue by an infiltrate of leukemic cells can produce gingival hypertrophy. Such gingival changes can occur despite excellent oral hygiene. Inresult in strangulation of pulpal tissue and spontaneous abscess formation as a result of infection or focal areas of liquefaction necrosis in the dental pulp of clinically and radiographically sound teeth. In a similar fashion the teeth may rapidly loosen as a result of necrosis of PDL.

Skeletal lesions caused by leukemic infiltration of bone are common in childhood leukemia. The most common finding is a generalized osteoporosis caused by enlargement of the Haversian and Volkmann canals. Osteolytic lesions resulting from focal areas of hemorrhage and necrosis and leading to loss of trabecular bone are also common.

Evidence of skeletal lesions is visible on dental radiographs in up to 63% of children with acute leukemia. Manifestations in the jaws include generalized loss of trabeculation, destruction of the crypts of developing teeth, loss of lamina dura, widening of the PDL space, and displacement of teeth and tooth buds (Fig. 26-5). Because none of the oral changes is a pathognomonic sign of leukemia and all can be associated with numerous local or systemic disease processes, a diagnosis of leukemia cannot be based on oral findings alone. Such changes should, however, alert the clinician to the possibility of malignancy as the underlying cause.

DENTAL MANAGEMENT OF PATIENTS WITH LEUKEMIA

Before any dental treatment is administered to a child with leukemia, the child's hematologist/oncologist or primary care physician should be consulted. The following information should be ascertained:

1. Primary medical diagnosis
2. Anticipated clinical course and prognosis
3. Present and future therapeutic modalities
4. Present general state of health
5. Present hematologic status

It is also important to establish, by consultation with the patient's physician, when dental treatment may be most propitious and to schedule the patient's treatment accordingly. The proposed procedures should be discussed to determine if they are appropriate.

Dentlearn.ir

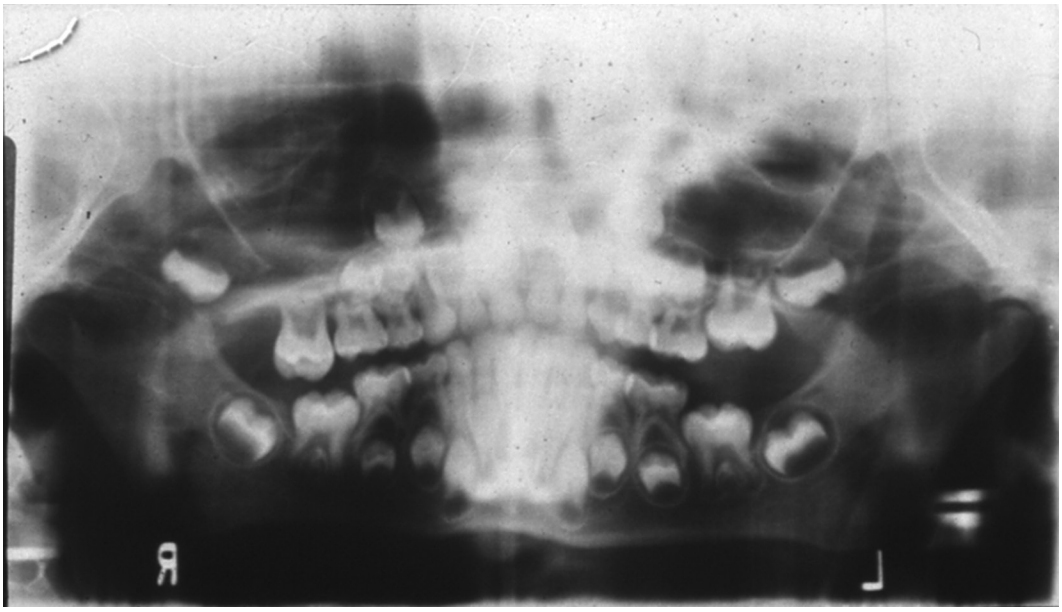

Figure 26-5 Panoramic radiograph of a patient with acute myelocytic leukemia resulting in the displacement of the maxillary right permanent molar. (Courtesy Dr. Bruce W. Vash.)

For a child whose first remission has not yet been attained or one who is in relapse, all elective dental procedures should be deferred. However, it is essential that potential sources of systemic infection within the oral cavity be controlled or eradicated whenever they are recognized (e.g., immediate extraction of carious primary teeth with pulpal involvement).

Routine preventive, restorative, and surgical procedures can usually be provided for a patient who is in complete remission yet is undergoing chemotherapy. The time when such procedures may be completed without complications will depend on the specific agents administered and the time of administration. Before the appointment—preferably the same day—a blood cell profile (complete blood count) and platelet count should be obtained to confirm that the patient is not unexpectedly at undue risk for hemorrhage or infection. A patient who has been in complete remission for at least 2 years and no longer requires chemotherapy may be treated in an essentially normal manner. A preappointment blood workup is not necessary.

Pulp therapy on primary teeth is contraindicated in any patient with a history of leukemia. Endodontic treatment for permanent teeth is not recommended for any patient with leukemia who may have a chronic, intermittent suppression of granulocytes. Even with the most exacting technique, an area of chronic inflammatory tissue may remain in the periapical region of endodontically treated teeth. An area of low-grade, chronic inflammation in a healthy patient is generally well tolerated, but in an immunosuppressed, neutropenic patient the same area can act as an anachoretic focus with devastating sequelae. The decision to perform an endodontic procedure on a patient who has been in prolonged complete remission and who is not undergoing chemotherapy must be made by the dentist.

Table **26-3**

Clinical Importance of Platelet Count*

Count (cells/mm³)	Significance
150,000-400,000	Normal
50,000-150,000	Bleeding time is prolonged, but patient would tolerate most routine procedures
20,000-50,000	At moderate risk for bleeding; defer elective surgical procedures
<20,000	At significant risk for bleeding; defer elective dental procedures

*An absolute indication for platelet transfusion is significant bleeding. If the count is <20,000 to 30,000 cells/mm³, the patient should probably be given prophylactic platelet transfusion before dental procedures. Indiscriminate use of platelet therapy may lead to the development of antiplatelet antibodies.
Courtesy Dr. Thomas D. Coates.

A platelet level of 100,000/mm³ is adequate for most dental procedures (Table 26-3). Routine preventive and restorative treatment, including nonblock injections, may be considered when the platelet count is at least 50,000/mm³. With inadequate oral hygiene, unhealthy periodontal tissues, and the presence of local irritants, hemorrhage from the gingival sulcus may be observed when platelet counts are between 20,000 and 50,000/mm³. Such hemorrhaging is usually noted only after manipulation of the tissues, such as during toothbrushing. If the platelet count is lower than 20,000/mm³, all the intraoral mucosal tissues may show clinical evidence of spontaneous hemorrhaging (e.g., petechiae, ecchymoses, or frank hemorrhage). No dental treatment should be performed

Table **26-4**

Clinical Importance of White Blood Cell Count

ANC*	Significance
>1500	Normal
500-1000	Patient at some risk for infection; defer elective procedures that could induce significant transient bacteremia
200-500	Patient must be admitted to hospital if febrile and given broad-spectrum antibiotics; at moderate risk for sepsis; defer all elective dental procedures
<200	At significant risk for sepsis

*ANC, absolute neutrophil count; it is computed as follows:
ANC = (% of polymorphonuclear leukocytes + % of bands) × total white count ÷ 100
Courtesy Dr. Thomas D. Coates.

at such a time without a preceding prophylactic platelet transfusion. Good oral hygiene must be maintained while the platelet count is at this level, but it may be necessary to discontinue the use of a toothbrush and to substitute cleaning with moist gauze wipes, supplemented by frequent saline rinses.

The absolute neutrophil count (ANC) is an indicator of the host's ability to suppress or eliminate infection. It is calculated by the following formula:

$$\text{ANC} = (\%\ \text{of neutrophils} + \%\ \text{of bands}) \times \text{total white count} \div 100$$

The clinical significance of ANC is presented in Table 26-4. If ANC is less than 1000/mm^3, elective dental treatment should be deferred. A leukemic patient with a low ANC may require prophylactic broad-spectrum antibiotic therapy before certain dental procedures. The patient's physician should be consulted regarding the appropriate drugs and dosages.

Infection and hemorrhage are the primary causes of death other than resistant disease or relapse in children with leukemia. Therefore the primary objective of dental treatment in a child with leukemia should be the prevention, control, and eradication of oral inflammation, hemorrhage, and infection.

Frequently, initial oral manifestations of bleeding or infection are observed in association with an unhealthy periodontium. In patients with leukemia who are neutropenic or who are being treated with corticosteroids, the true degree of periodontal inflammation or infection may be masked, because the cardinal signs of inflammation may not be apparent. There is a much greater propensity for gingival bleeding when the periodontium is unhealthy. When oral hygiene is neglected and local irritants are present, spontaneous hemorrhaging from the gingival sulcus may be observed if the patient is thrombocytopenic.

It is imperative that a patient who is diagnosed as having leukemia be enrolled in a good preventive dental care program in which special emphasis is placed on the initiation and maintenance of a comprehensive oral hygiene regimen. The use of a soft nylon toothbrush for the removal of plaque is recommended, even if the patient is thrombocytopenic. As long as the gingiva remains in a healthy state and its manipulation by brushing does not induce significant hemorrhage, it is not appropriate to discontinue the use of a toothbrush because of the platelet level alone. The practicality of flossing must be assessed on an individual basis.

It is important that significant local irritants, including orthodontic appliances, be removed. Scaling and subgingival curettage should not necessarily be perceived as elective dental treatment in all patients. This is especially true if the anticipated clinical course may place the patient at high risk for hemorrhage and infection. Patients with classic leukemic gingivitis experience various degrees of discomfort. The use of warm saline rinses several times each day may assist in the relief of symptoms.

Erosive or ulcerative lesions are common in children with leukemia. These lesions are often associated with the use of certain chemotherapeutic agents (see Table 26-2), especially methotrexate and the anthracycline antibiotics daunomycin and doxorubicin. The lesions may be an early indicator of drug toxicity. After administration of the drug is discontinued and ANC has recovered, these lesions usually disappear within a few days. Treatment is directed toward the relief of discomfort (Table 26-5).

In a patient who is granulocytopenic, trauma may result in the occurrence of ulcerative lesions, especially along the lateral border of the tongue and buccal mucosa. The clinical course of these ulcerations is generally benign, although the time necessary for healing may be prolonged. Use of topical obtundents for pain may be the only treatment indicated.

Infrequent, deep lesions will bleed spontaneously or as a result of trauma. Local measures, such as the topical application of either bovine thrombin or Avitene and the placement of an oral adhesive for protection, may be beneficial.

In a patient who is physically debilitated or who is in relapse, septic, and severely granulocytopenic, ulcerative lesions require close observation. Such lesions may serve as a nidus for the proliferation of microorganisms, which can lead to potentially fatal viral, fungal, or bacterial infection. Therefore specimens from these ulcerative lesions should be cultured and subsequent sensitivity testing performed, and antibiotic therapy should be initiated or modified accordingly.

Candidiasis is common in children with leukemia. They are especially susceptible to this fungal infection because of (1) general physical debilitation, (2) immunosuppression, (3) prolonged antibiotic therapy, (4) chemotherapy, and (5) poor oral hygiene. The following topical use of nystatin can be particularly beneficial:

- Nystatin oral suspension, 100,000 U/mL

Dentlearn.ir

Table **26-5**

Topical Obtundents for Oral Pain (Frequently Used at James Whitcomb Riley Hospital for Children and St. Vincent Children's Hospital)

Combination	Administration	Indications
Benacort-Tetrastat (Mary's Magic Potion)		
Hydrocortisone powder 60 mg Tetracycline 1.5 g Nystatin suspension 100,000 U/mL 60 mL Benadryl elixir qs 240 L	Swish 5-10 mL for 1 minute; then expectorate	Generalized stomatitis and mild discomfort
Philadelphia Mouthwash*		
Benadryl elixir 90 mL Maalox suspension 90 mL Viscous lidocaine 2% 90 mL Distilled water 180 mL Cherry or vanilla flavoring to taste	Swish 5-10 mL for 1 minute; then expectorate	Generalized stomatitis and mild discomfort
Orabase with benzocaine, or viscous lidocaine 2%, or dyclonine HCl 0.5%	Apply locally to lesions with cotton swab	Discrete, painful lesions

*Use should be supervised to prevent lidocaine toxicity.

- Swish 5 mL for 5 minutes and then swallow
- Repeat every 6 hours; continue for 48 hours after lesions disappear

In more resistant cases of oral candidiasis, fluconazole may be useful, administered once daily either orally or intravenously (in young children, 6 mg/kg on day 1, then 3 mg/kg to a maximum of 12 mg/kg per day; in older children and adults, 200 mg on day 1, then 100 mg).

For patients who are thrombocytopenic or at risk for intermittent episodes of thrombocytopenia because of chemotherapy or active disease, the dentist should avoid prescribing drugs that may alter platelet function, such as salicylates (aspirin) and nonsteroidal anti-inflammatory drugs.

HEMATOPOIETIC STEM CELL TRANSPLANTATION

The transplantation of hematopoietic stem cells can be curative for a variety of disorders, including aplastic anemia, thalassemia, and severe combined immunodeficiency. Stem cell transplantation has also been shown to be effective as rescue therapy for patients undergoing extremely aggressive treatment for leukemia in which both lethal doses of chemotherapy and total-body irradiation are used to destroy all bone marrow elements, including normal marrow cells. Intensive chemotherapy, total-body irradiation, and stem cell rescue are being used in experimental treatment protocols for children with very aggressive malignancies (e.g., advanced neuroblastoma and Ewing sarcoma).

As with any organ transplantation, hematopoietic stem cell transplantation candidates must have a compatible donor. Suitable stem cell donors may include HLA-compatible siblings or matched unrelated donors. In some situations, placental cord blood can be used. In certain cases autologous transplantation is performed in which the patient's own bone marrow or peripheral blood stem cells are harvested, stored, and then returned to the patient after intensive treatment and after remission has been achieved.

In almost all organ transplantation procedures, host rejection of the transplanted organ and infection are prime reasons for treatment failure. An additional complication in allogeneic hematopoietic stem cell transplantation is graft-versus-host disease (GVHD), in which immunocompetent donor lymphocytes attack the recipient host cells.

During and after hematopoietic stem cell transplantation, the most common cause of serious morbidity and mortality is infection. The risk for infection from exogenous sources is reduced by good handwashing. Despite multiple-agent antibacterial, antifungal, and antiviral therapy, endogenous opportunistic organisms are usually the cause of life-threatening infection in hematopoietic stem cell transplantation patients, who, because of ablated bone marrow function, are unable to mount protective inflammatory and immune responses before engraftment of donor bone marrow.

ORAL COMPLICATIONS OF BONE MARROW TRANSPLANTATION

The oral complications of bone marrow transplantation differ from those seen during conventional therapy for malignant disease only in degree and duration. Oral ulceration, mucositis, and transient salivary gland dysfunction are frequent consequences of stomatotoxic chemotherapy and total-body irradiation. Minor trauma to atrophic mucous membranes often results in self-induced ulceration of the buccal mucosa, lips, and tongue. Thrombocytopenic gingival bleeding

and bleeding from oral ulcerations are also frequently encountered.

Oral bleeding responds well to platelet transfusions and intravenous aminocaproic acid (Amicar). Topical application of Avitene (bovine corium collagen hydrochloride), powdered thrombin, and pressure are often effective for control of localized bleeding and often must be relied on in those cases in which the patient fails to respond to transfused platelets.

Oral ulceration and mucositis are common sequelae of cancer treatment, and they resolve with the return of bone marrow function and rising absolute neutrophil counts. Interim treatment is directed toward palliation and the prevention of secondary infection. An expert panel has recently reviewed and evaluated basic oral care interventions and management approaches to prevent and treat oral mucositis in cancer patients.[71,72] The conclusions were that there is evidence to support the use of basic oral care protocols for all patients receiving radiation and/or chemotherapy. The evidence does not support the use of chlorhexidine for the prevention of mucositis in patients receiving head and neck radiotherapy. Moreover, recommendations were developed against the topical use of antimicrobials and sucralfate for the prevention of radiation or chemotherapy mucositis. This same expert panel could not develop guidelines for the use of mixed-medication mouthwashes (such as Mary's Magic Potion; see Table 26-5). However, many clinicians believe that using these customized medication mouthwashes can provide comfort. Any of the topically applied obtundent solutions or topical local anesthetics mentioned previously may be used. The efficacy of each will vary among patients, and in some cases only potent systemic analgesics will provide relief. In all cases, however, infection must be suspected, and specimens from all lesions should be cultured and growing organisms tested for antibiotic susceptibility.

GRAFT-VERSUS-HOST DISEASE

A major problem of allogeneic bone marrow transplantation is the development of GVHD. This disorder appears to result from an interaction between donor immunocompetent cells and recipient cells that display disparate antigens. The acute form of the disease involves the lymphoid system, skin, liver, and gastrointestinal tract. Cutaneous and oral mucosal involvement in chronic GVHD is common and is manifested as painful overt mucosal erythema, reticular or lichenoid eruptions, or desquamation and ulceration. Treatment with dexamethasone oral rinses may be helpful in cases of severe mucosal involvement in chronic GVHD. Mucosal involvement may be accompanied by salivary gland dysfunction with xerostomia, dysphagia, and dysgeusia.

Treatment of both acute and chronic GVHD is directed at correcting, masking, or preventing disordered immune regulation. Therapies with low- and high-dose steroids (prednisone, dexamethasone), antithymocyte globulin, cyclosporin, azathioprine, or methotrexate have been attempted with mixed results. Although severe acute GVHD can be rapidly fatal, chronic GVHD is usually transient and controllable with systemic therapy. The goals of therapy for mucosal and salivary gland manifestations, which relies on abundant rinses, are palliation and the prevention of secondary infection.

Of note, the positive side of GVHD is an associated graft-vs.-leukemia effect. In both acute and chronic GVHD, the immune response associated with GVHD appears to affect leukemia cells in that there is an inverse relationship between the severity of GVHD and the incidence of relapse.

PRETRANSPLANTATION PREPARATION

Bone marrow transplantation programs place a high priority on pretransplantation dental care and daily mouth care in the transplant unit. The primary goal of this oral health care protocol is to prevent, reduce in severity, or palliatively relieve oral problems involved in the oral care of patients receiving oncologic therapy. The integrity of the oral cavity is maintained by keeping the oral structures, both hard and soft tissues, clean, moist, and free of infection. The resultant decrease in septic episodes in the oral cavity should diminish the patient's morbidity and mortality, because the mouth is the most common source of infection in these patients.

Four weeks before bone marrow transplantation, all candidates for this procedure should receive a thorough clinical and radiographic oral examination during the workup phase initiated from the oncology physician's consult. The resultant dental treatment plan, along with the primary goals of oral health care, is discussed with the patient's oncologist, the patient, and the parents. Each patient is also informed of all potential oral complications of bone marrow transplantation and GVHD.

Along with professional preventive dental care, each patient should receive instruction in daily mouth care, including brushing and flossing. The daily use of self-applied topical fluoride gel and Peridex rinse (every 12 hours) is recommended. Dental appointments are scheduled for any necessary periodontal, restorative, or oral surgery treatment, if indicated, to eliminate and control oral infections or conditions that may lead to episodic problems. Potential foci of infection or bleeding, such as pulpally involved teeth, periodontally involved teeth, partially erupted teeth, exfoliating primary teeth and carious teeth, or teeth with defective restorations, must be treated before the patient's admission to the transplant unit. Recommended treatment should ideally be completed at least 2 weeks before admission to allow for healing of violated tissues and the reestablishment of optimal oral hygiene.

Unfortunately, there are times when the patient's medical status necessitates admission for transplantation before all dental treatment can be completed. Therefore the minimum preadmission dental requirement is a mouth free of foci of acute infection and free of physical irritants. Each patient must receive thorough supragingival and subgingival scaling and prophylaxis; open caries lesions and caries lesions approaching the pulp must be restored, and abscessed teeth, teeth with severe periodontal involvement, and exfoliating primary teeth causing gingival irritation must be removed.

Dentlearn.ir

Box 26-1

Treatment of Mucositis and Candidiasis (Guidelines for Nursing Staff)

MILD MUCOSITIS
- Continue same oral regimen and add 2% sodium bicarbonate.
- Chart condition of oral cavity each shift; notify doctor of any change from the previous day or shift.

MODERATE OR SEVERE MUCOSITIS
- Obtain order for pain medication to be administered either before oral care or as a continuous drip (i.e., morphine sulphate); may require bolus administration in addition to continuous drip.
- Follow same regimen as with mild mucositis, using both 2% sodium bicarbonate and Peridex with Toothette.
- Use Peridex every 4 hours; if patient is having difficulty rinsing with full-strength Peridex, dilute Peridex 1:1 with sterile water.

CANDIDA *INFECTION*
- Contact dentist to examine and obtain a culture specimen. Hold one dose of Peridex and nystatin until culture is obtained.
- Patient must be started on additional antifungal therapy once culture results show evidence of yeast infection.
- If oral candidiasis is documented by culture, nystatin should be applied with a Toothette, swished for 30 to 60 seconds, then swallowed.
- Chart condition of oral cavity; each shift should notify doctor of any change from the previous day shift.

ADMISSION AND NURSING INTERVENTIONS

Peridex has been shown to be effective in minimizing the septic episodes in the oral cavity when used with other chemotherapeutic agents. On admission, the patient should be instructed to brush his or her teeth 3 times a day with a Peridex-soaked ultrasoft toothbrush (e.g., Sensodyne Gentle, GlaxoSmithKline Consumer Healthcare, Bentford, U.K.). When the platelet count is below 20,000/mm^3 and gum bleeding is apparent, a Toothette (Toothette, Sage Products LLC, Cary, IL) may be used in place of a toothbrush. The patient may not eat or drink for 1 hour following the use of Peridex. Surgilube may be applied to the lips following each rinse session and every 4 hours for dryness.

Allogeneic and autologous transplant patients are started on antifungal prophylaxis with fluconazole (5 mg/kg per day by mouth, maximum dose 200 mg per day). The condition of the oral cavity should be monitored and charted on each shift. Doctors should be notified of any change in the oral cavity from the previous day or shift.

The treatment of mucositis is described in Box 26-1. Mild mucositis is defined as mild erythema, no mucosal ulcerations, and no pain; the patient is able to swallow, and no local analgesia is required. Moderate mucositis is defined as moderate erythema and multiple mucosal ulcerations with pain that may or may not require analgesics; the patient can swallow but it may be painful. Severe mucositis is defined as erythema, multiple ulcerations, severe pain requiring analgesia, and difficulty in swallowing or inability to swallow. Although the regimens shown are not always successful in cases of moderate or severe mucositis, consistent follow-through minimizes many signs and symptoms.

The presence of white patches (i.e., candidal infection) may occur. Care must be taken in obtaining culture specimens and providing specific antifungal therapy.

REMISSION PHASE

During the remission phase of post–bone marrow transplantation therapy, consistent oral hygiene should be provided by the patient or parent. For the first 90 days, the dental staff should provide maintenance oral evaluations and preventive oral care reinforcement for the patient during periodic hospital oncologic evaluations.

Afterward, the patient should be referred to his or her private dentist for continuity of oral health care. If the patient has no dentist, referral should be made to a dental diagnostic clinic at the patient's medical center for dental health status evaluation and dental care.

SOLID TUMORS

Solid tumors account for approximately half of the cases of childhood malignancy. The most common tumors include brain tumors, lymphoma, neuroblastoma, Wilms' tumor, osteosarcoma, and rhabdomyosarcoma. Because many of the malignancies can involve bone marrow and their treatment with chemotherapy and radiation can suppress marrow function, many of the complications seen in acute leukemia are also seen with these patients. Bleeding diatheses and the propensity to infection are the most notable medical complications seen. In general, the dental management of patients with solid tumors is similar to that of patients with acute leukemia.

REFERENCES

1. Soucie JM, et al.: Occurrence of hemophilia in the United States. The Hemophilia Surveillance System Project Investigators, *Am J Hematol* 59(4):288–294, 1998.
2. Berntorp E, Shapiro AD: Modern haemophilia care, *Lancet* 379(9824):1447–1456, 2012.
3. Peyvandi F, et al.: Rare bleeding disorders, *Haemophilia* 14(Suppl 3):202–210, 2008.
4. Duga S, Salomon O: Congenital factor XI deficiency: an update, *Semin Thromb Hemost* 39(6):621–631, 2013.
5. Nichols WL, et al.: Von Willebrand disease (VWD): evidence-based diagnosis and management guidelines, the National Heart, Lung, and Blood Institute (NHLBI) Expert Panel report (USA), *Haemophilia* 14(2):171–232, 2008.
6. Berntorp E, et al.: Third Åland Islands conference on von Willebrand disease, 26-28 September 2012: meeting report, *Haemophilia* 19(Suppl 3):1–18, 2013.

7. Berntorp E, et al.: von Willebrand's disease: a report from a meeting in the Åland Islands, *Haemophilia* 18(Suppl 6):1–13, 2012.
8. Seligsohn U: Treatment of inherited platelet disorders, *Haemophilia* 18(Suppl 4):161–165, 2012.
9. Srinivasan K, et al.: Magnetic resonance imaging of mandibular hemophilic pseudotumor associated with factor IX deficiency: report of case with review of literature, *J Oral Maxillofac Surg* 69(6):1683–1690, 2011.
10. Throndson RR, et al.: Pseudotumor of hemophilia in the mandible of a patient with hemophilia A, *Oral Surg Oral Med Oral Pathol Oral Radiol* 113(2):229–233, 2012.
11. Sonis AL, Musselman RJ: Oral bleeding in classic hemophilia, *Oral Surg* 53:363–366, 1982.
12. Israels S, et al.: Bleeding disorders: characterization, dental considerations and management, *J Can Dent Assoc* 72(9):827, 2006.
13. Escobar MA: Advances in the treatment of inherited coagulation disorders, *Haemophilia* 19(5):648–659, 2013.
14. MASAC Recommendation #218: MASAC recommendation concerning products for the treatment of hemophilia and other bleeding disorders; Table 1: Products licensed in the US to treat

    StaticPages/menu0/menu5/menu57/masa190tables.pdf
15. Gupta S, Shapiro AD: New recombinant factor concentrates, *Int Monitor Hemophilia* 21:3–8, 2013.
16. Simpson ML, Valentino LA: Management of joint bleeding in hemophilia, *Expert Rev Haematol* 5(4):459–468, 2012.
17. Gill JC, et al.: Evaluation of high concentration intranasal and intravenous desmopressin in pediatric patients with mild hemophilia A or mild-to-moderate type 1 von Willebrand disease, *J Pediatr* 140(5):595–599, 2001.
18. Castaman G: Desmopressin for the treatment of haemophilia, *Haemophilia* 14(Suppl 1):15–20, 2008.
19. Rodeghiero F, et al.: How to estimate bleeding risk in mild bleeding disorders, *J Thromb Haemost* 5(Suppl 1):157–166, 2007.
20. Björkman S, et al.: Pharmacokinetics of recombinant factor IX in relation to age of the patient: implications for dosing in prophylaxis, *Haemophilia* 7(2):133–139, 2001.
21. Manco-Johnson MJ, et al.: Prophylaxis versus episodic treatment to prevent joint disease in boys with severe hemophilia, *N Engl J Med* 357(6):535–544, 2007.
22. Wilson W, et al.: Prevention of infective endocarditis: guidelines from the American Heart Association: a guideline from the American Heart Association Rheumatic Fever, Endocarditis, and Kawasaki Disease Committee, Council on Cardiovascular Disease in the Young, and the Council on Clinical Cardiology, Council on Cardiovascular Surgery and Anesthesia, and the Quality of Care and Outcomes Research Inter-

    2007. *Erratum in Circulation* 116(15):e376–e377, 2007.
23. Byams VR: Women with bleeding disorders, *J Womens Health* 16(9):1249–1251, 2007.
24. Federici AB, Mannucci PM: Management of inherited von Willebrand disease in 2007, *Ann Med* 39(5):346–358, 2007.
25. Plug I, et al.: Bleeding in carriers of hemophilia, *Blood* 108(1):52–56, 2006.
26. Street AM, et al.: Management of carriers and babies with haemophilia, *Haemophilia* 14(Suppl 3):181–187, 2008.
27. DiMichele DM: Inhibitor treatment in haemophilias A and B: inhibitor diagnosis, *Haemophilia* 12(Suppl 6):37–41, 2006.
28. Astermark J: Overview of inhibitors, *Semin Hematol* 43(2 Suppl 4):3–7, 2006.
29. Mauser-Bunschoten EP, et al.: Co-morbidity in the ageing haemophilia patient: the down side of increased life expectancy, *Haemophilia* 15(4):853–863, 2009.
30. Goedert JJ, et al.: Human immunodeficiency and hepatitis virus infections and their associated conditions and treatments among people with haemophilia, *Haemophilia* 10(Suppl 4):205–210, 2004.
31. Evatt BL: The tragic history of AIDS in the hemophilia population, 1982-84, *J Thromb Haemost* 4(11):2295–2301, 2006.
32. Wicker S, et al.: Determination of risk of infection with blood-borne pathogens following a needlestick injury in hospital workers, *Ann Occup Hyg* 52(7):615–622, 2008.
33. *MMWR Morbid Mortal Wkly Rep* 60(9):273–275, 2011.
34. Laheij AM, et al.: Healthcare-associated viral and bacterial infections in dentistry, *J Oral Microbiol* 4:17659, 2012.
35. Klein RS, et al.: Occupational risk for hepatitis C virus infection among New York City, *Lancet* 338:159–142, 1991.
36. Hughes A, et al.: Adverse incidents resulting in exposure to body fluids at a UK dental teaching hospital over a 6-year period, *Infect Drug Resist* 5:155–161, 2012.
37. Anderson JA, et al.: Guidance on the dental management of patients with haemophilia and congenital bleeding disorders, *Br Dent J* 215(10):497–504, 2013.
38. Lee AP, et al.: Effectiveness in controlling haemorrhage after dental scaling in people with haemophilia by using tranexamic acid mouthwash, *Br Dent J* 198(1):33–38, 2005.
39. Delati MH, et al.: Bleeding disorders seen in the dental practice, *Dent Update* 39(4):266–268, 270, 2012.
40. Azhar S, et al.: Periodontal status and IOTN interventions among young hemophiliacs, *Haemophilia* 12(4):4011–4014, 2006. *Erratum* in Haemophilia 12(5):559, 2006.
41. Correa ME, et al.: Clinical impact of oral health indexes in dental extraction of hemophilic patients, *J Oral Maxillofac Surg* 64(5):785–788, 2006.
42. Brewer AK: Advances in minor oral surgery in patients with congenital bleeding disorders, *Haemophilia* 14(Suppl 3): 119–121, 2008.
43. Piot B, et al.: Management of dental extractions in patients with bleeding disorders, *Oral Surg Oral Med Oral Pathol Oral Radiol Endod* 93(3):247–250, 2002.
44. Reich W, et al.: Bleeding complications after oral surgery in outpatients with compromised haemostasis: incidence and management, *Oral Maxillofac Surg* 13(2):73–77, 2009.
45. American Dental Association: American Academy of Orthopedic Surgeons: Antibiotic prophylaxis for dental patients with total joint replacements, *J Am Dent Assoc* 134:895–898, 2003.
46. Olsen I, et al.: Should patients with hip joint prosthesis receive antibiotic prophylaxis before dental treatment? *J Oral Microbiol* 2:5265, 2010.
47. Lockhart PB, et al.: Acceptance among and impact on dental practitioners and patients of American Heart Association recommendations for antibiotic prophylaxis, *J Am Dent Assoc* 144(9):1030–1035, 2013.
48. Araujo MW, Andreana S: Risk and prevention of transmission of infectious diseases in dentistry, *Quintessence Int* 33(5):376–382, 2002.

    06/06/2014).
50. Razavi H, et al.: Chronic hepatitis C virus (HCV) disease burden and cost in the United States, *Hepatology* 57(6):2164–2170, 2013.

52. Centers for Disease Control and Prevention: Viral hepatitis.

    c/fact.htm (accessed 06/06/2014).
53. Herrera JL: Hepatitis E as a cause of acute non-A, non-B hepatitis, *Arch Intern Med* 153(6):773–775, 1993.
54. Borkakoti J, et al.: Does high viral load of hepatitis E virus influence the severity and prognosis of acute liver failure during pregnancy? *J Med Virol* 85(4):620–626, 2013.

55. da Fonseca MA: Dental and oral care for chronically ill children and adolescents, *General Dent* 58(3):204–207, 2010.
56. Alves AC, et al.: Malocclusion and treatment in children and adolescents with sickle cell disease, *Angle Orthod* Vol. 84(3):467–472, 2014.

cessed 06/06/2014).

Report_vol_23.pdf.
59. Panel on Antiretroviral Guidelines for Adults and Adolescents: Guidelines for the use of antiretroviral agents in HIV-1-infected adults and adolescents. Department of Health and

tentfiles/Ivguidelines/AdultandAdolescentGI.pdf. (accessed 06/06/2014).
60. Fox JE, et al.: Increasing access to oral health care for people living with HIV/AIDS in the U.S: baseline evaluation results of the Innovations in Oral Health Care Initiative, *Public Health Rep* 127(Suppl 2):5–16, 2012.
61. Lacovou E, et al.: Diagnosis and treatment of HIV-associated manifestations in otolaryngology, *Infect Dis Rep* 4(1):e9, 2012.
62. Reznik DA: Oral manifestations of HIV disease, *Top HIV Med* 13(5):143–148, 2005 Dec-2006 Jan.
63. Pindborg JJ: Oral candidiasis in HIV infection. In Robertson PB, Greenspan JS, editors: *Perspectives on oral manifestations of AIDS. Diagnosis and management of HIV-associated infections*, Littleton, MA, 1988, PSG Publishing.
64. Patton LL: Oral lesions associated with human immunodeficiency virus disease, *Dent Clin N Am* 57:673–698, 2013.
65. Greenspan D: Oral manifestations of HIV infection. In Robertson PB, Greenspan JS, editors: *Perspectives on oral manifestations of AIDS. Diagnosis and management of HIV-associated infections*, Littleton, MA, 1988, PSG Publishing.
66. Silverman S, AIDS: HIV infection and dentistry. Part I: Epidemiology, pathogenesis and transmission. Part II: Oral manifestations, diagnosis and management. In *Fairfax (VA), California, and American Dental Institutes for Continuing Education*, Vol 7. 1991.
67. Howlader N, et al. editors: *SEER Cancer Statistics Review*, 1975-2011, National Cancer Institute, Bethesda, MD, http://seer.cancer.gov.csr/1975_2011/, (based on November 2013 SEER data submission, posted to the SEER website, April 2014.
68. Schultz KR, et al.: Risk- and response-based classification of childhood B-precursor acute lymphoblastic leukemia: a combined analysis of prognostic markers from the Pediatric On-

Blood 109:926–935, 2007.
69. Borowitz MJ, et al.: Clinical significance of minimal residual disease in childhood acute lymphoblastic leukemia and its relationship to other prognostic factors: a Children's Oncol-

70. Meschinchi S, Arceci RJ: Prognostic factors and risk-based therapy in acute myeloid leukemia, *Oncologist* 12:341–355, 2007.
71. McGuire DB, et al.: Systemic review of basic oral care for the management of oral mucositis in cancer patients, *Support Care Cancer* 21:3165–3177, 2013.
72. Saunders DP, et al.: Systematic review of antimicrobials, mucosal coating agents, anesthetics, and analgesics for the management of oral mucositis in cancer patients, *Support Care Cancer* 21:3191–3207, 2013.

CHAPTER 27

Management of Trauma to the Teeth and Supporting Tissues

▲ James E. Jones, Kenneth J. Spolnik, and Ghaeth H. Yassen

For additional resources, please visit the evolve website.

CHAPTER OUTLINE

HISTORY AND EXAMINATION
- History of the Injury
- Clinical Examination
- Radiographic Examination

EMERGENCY TREATMENT OF SOFT-TISSUE INJURY

EMERGENCY TREATMENT AND TEMPORARY RESTORATION OF FRACTURED TEETH WITHOUT PULP EXPOSURE
- Fragment Restoration (Reattachment of Tooth Fragment)
- Temporary Bonded Resin Restoration

TREATMENT OF VITAL PULP EXPOSURES
- Direct Pulp Cap
- Pulpotomy
- Pulpectomy with Endodontic Treatment

THERAPY TO STIMULATE ROOT GROWTH AND APICAL REPAIR IN IMMATURE TEETH WITH PULPAL NECROSIS
- Apexification
- Regenerative Endodontic Procedures

REACTION OF THE TOOTH TO TRAUMA
- Pulpal Hyperemia
- Calcific Metamorphosis of the Dental Pulp (Progressive Canal Calcification or Dystrophic Calcification)
- Peripheral (External) Root Resorption
- Pulpal Necrosis
- Ankylosis

RESTORATION OF FRACTURED TEETH
- Aesthetic Bonded Composite Resin Restoration

REACTION OF PERMANENT TOOTH BUDS TO INJURY
- Hypocalcification and Hypoplasia
- Reparative Dentin Production
- Dilaceration

DISPLACEMENT OF PRIMARY AND PERMANENT ANTERIOR TEETH (LUXATION)
- Intrusion and Extrusion of Teeth
- Avulsion and Replantation
- Management of Root Fractures
- Other Displacement Injuries of Teeth Requiring Stabilization

MANAGEMENT OF ORAL BURNS
- Nature of the Injury
- Treatment

TRAUMA PREVENTION

Injuries to the teeth of children or adults present unique problems in diagnosis and treatment. The diagnosis of the extent of the injury after a blow to a tooth, regardless of loss of tooth structure, is difficult and often inconclusive. Trauma to a tooth is invariably followed by pulpal hyperemia, the extent of which cannot always be determined by available diagnostic methods. Congestion and alteration in the blood flow in the pulp may be sufficient to initiate irreversible degenerative changes which, over time, can cause pulpal necrosis. In addition, the apical vessels may have been severed or damaged enough to interfere with the normal reparative process. Treatment of injuries causing pulp exposure or tooth displacement is particularly challenging because the prognosis of the involved tooth is often uncertain.

The treatment of fractured teeth, particularly in young patients, is further complicated by the often difficult but extremely important restorative procedure. Although the dentist may prefer to delay the restoration because of a questionable prognosis for the pulp, often a malocclusion can develop within a matter of days as a result of a break in the normal proximal contact with adjacent teeth. Adjacent teeth may tip into the area created by the loss of tooth structure. This loss of space will create a problem when the final restoration is contemplated. There must often be a compromise of an ideal aesthetic appearance, at least in the initial restoration, because the prognosis is questionable or because the tooth is young and has a large pulp or is still in the stage of active eruption.

The likelihood of success often depends on the rapidity with which the tooth is treated after the injury, regardless of whether the procedure involves protecting a large area of exposed dentin or treating a vital pulp exposure. Several factors can be considered common to all types of injury to the anterior teeth. These important considerations should become a checklist that is used consistently by the dentist in the diagnosis of and treatment planning for traumatic injuries.

The International Association of Dental Traumatology reports that one of every two children sustains a dental injury, most often between the ages of 8 and 12 years. They suggest that, in most cases of dental trauma, a rapid and appropriate treatment can lessen its impact from both an oral and an aesthetic standpoint. To that end the association has developed guidelines for the evaluation and management of traumatic dental injuries

HISTORY AND EXAMINATION

The routine use of a clinical evaluation sheet for injured anterior teeth is helpful during the initial examination and subsequent examinations of an injured tooth (Fig. 27-1). The

Dentlearn.ir

ASSESSMENT OF ACUTE TRAUMATIC INJURIES	**PATIENT NAME:** _____ **DATE OF BIRTH:** _____
DATE: **TIME:**	**REFERRED BY:**

HISTORY

MEDICAL HISTORY:	
ALLERGIES:	DATE OF LAST TETANUS INNOCULATON:
DATE AND TIME OF INJURY:	TIME LAPSED SINCE INJURY:
WHERE INJURY OCCURRED:	
HOW INJURY OCCURRED:	

Check if present and describe	**MANAGEMENT PRIOR TO EXAM**
☐ Nondental injuries	By whom:
☐ Loss of consciousness	Describe:
☐ Altered orientation/mental status	
☐ Hemorrhage from nose/ears	
☐ Headache/nausea/vomiting	
☐ Neck pain	
☐ Spontaneous dental pain	
☐ Pain on mastication	
☐ Reaction to thermal changes	
☐ Previous dental trauma	
☐ Other complaints	

EXTRAORAL EXAM

Check if present and describe	**OTHER FINDINGS/COMMENTS:**
☐ Facial fractures	
☐ Lacerations	
☐ Contusions	
☐ Swelling	
☐ Abrasions	
☐ Hemorrhage/drainage	
☐ Foreign bodies	
☐ TMJ deviation/asymmetry	

INTRAORAL EXAMINATION

Check if injured and describe	**DIAGRAM OF INJURIES**
☐ Lips	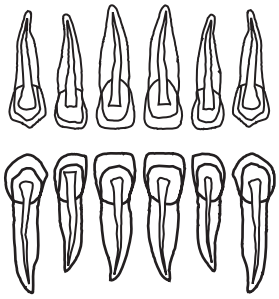
☐ Frenae	
☐ Buccal mucosa	
☐ Gingivae	
☐ Palate	
☐ Tongue	
☐ Floor of mouth	
Occlusion	
☐ Molar classification **R**___ **L**___	
☐ Canine classification **R**___ **L**___	
☐ Overbite (%)_____	
☐ Overjet (mm)_____	
☐ Crossbite **Y** **N**	
☐ Midline deviation **Y** **N**	
☐ Interferences **Y** **N**	

Figure 27-1 Assessment of acute traumatic injuries. (Adapted from American Academy of Pediatric Dentistry, *Pediatr Dent* 24 (7 suppl): 95-96, 2002.)

DENTAL INJURIES	**TOOTH NUMBER**					
	AVULSION — Extraoral time					
	Storage medium					
	INFRACTION					
	CROWN FRACTURE					
	PULP EXPOSURE — Size					
	Appearance					
	COLOR					
	MOBILITY (mm)					
	PERCUSSION					
	LUXATION — Direction					
	Extent					
	PULP TESTING — Electric					
	Thermal					
	CARIES/PREVIOUS RESTORATIONS					
RADIOGRAPHS	PULP SIZE					
	ROOT DEVELOPMENT					
	ROOT FRACTURE					
	PERIODONTAL LIGAMENT SPACE					
	PERIAPICAL PATHOLOGY					
	ALVEOLAR FRACTURE					
	FOREIGN BODY					
	DEVELOPMENTAL ANOMALY					
	OTHER					

TREATMENT

Check if performed and describe

- ☐ Soft-tissue management
- ☐ Medication
- ☐ Pulp therapy
- ☐ Repositioning
- ☐ Stabilization
- ☐ Restoration
- ☐ Extraction
- ☐ Prescription
- ☐ Referral
- ☐ Other

INSTRUCTIONS AND DISPOSITION

Check if discussed

- ☐ Diet
- ☐ Hygiene
- ☐ Pain
- ☐ Swelling
- ☐ Infection
- ☐ Prescription
- ☐ Complications:
  - ☐ Damage to developing teeth
  - ☐ Abnormal position/ankylosis
  - ☐ Tooth loss
  - ☐ Pulp damage to injured teeth
- ☐ Other:
- ☐ Follow-up:
- ☐ Other

SUMMARY

Subsequent visit No. 1 Date_____

1. Pulpal response 7 8 9 10 □□|□□
2. Radiographic exam □□|□□ 26 25 24 23
3. Treatment and comments: _____

Subsequent visit No. 2 Date_____

1. Pulpal response 7 8 9 10 □□|□□
2. Radiographic exam □□|□□ 26 25 24 23
3. Treatment and comments: _____

Subsequent visit No. 3 Date_____

1. Pulpal response 7 8 9 10 □□|□□
2. Radiographic exam □□|□□ 26 25 24 23
3. Treatment and comments: _____

Subsequent visit No. 4 Date_____

1. Pulpal response 7 8 9 10 □□|□□
2. Radiographic exam □□|□□ 26 25 24 23
3. Treatment and comments: _____

Figure 27-1, cont'd

Dentlearn.ir

form, which becomes a part of the patient's record, serves as a checklist of important questions that must be asked and observations that must be made by the dentist and the auxiliary personnel during the examination of the child.

HISTORY OF THE INJURY

The time of the injury should first be established. Unfortunately, many patients do not seek professional advice and treatment immediately after an injury. Occasionally the accident is so severe that dental treatment cannot be started immediately because other injuries have higher priority. Davis and Vogel emphasized that a force strong enough to fracture, intrude, or avulse a tooth is also strong enough to result in cervical spine or intracranial injury. The dentist must be particularly alert to such potential problems, be prepared ahead of time to make a neurologic assessment, and make appropriate medical referral when indicated without delay.[1] The patient should be assessed for nausea, vomiting, drowsiness, or possible cerebral spinal fluid leakage from the nose and ears, which would indicate a skull fracture. In addition, the patient should be evaluated for lacerations and facial bone fractures. Obtaining a baseline temperature, pulse, blood pressure, and respiratory rate should be considered as information to be gathered before addressing the dental needs of the patient. Finally, Davis[2] recommends a quick cranial nerve evaluation involving the following four areas:

1. Extraocular muscles are intact and functioning appropriately; that is, the patient can track a finger moving vertically and horizontally through the visual field with the eyes remaining in tandem.
2. Pupils are equal, round, and reactive to light with accommodation.
3. Sensory function is normal as measured through light touch to various areas of the face.
4. Symmetry of motor function is present, as assessed by having the patient frown, smile, move the tongue, and perform several voluntary muscular movements.

The prognosis of an injured tooth depends logically, often to a great extent, on the time that has elapsed between the occurrence of the accident and the initiation of emergency treatment. This is particularly true in cases of pulp exposure, for which pulp capping or pulpotomy would be the procedure of choice. Rusmah treated 123 traumatized permanent incisors and monitored them over a 24-month period. His findings suggest that the interval between trauma and emergency treatment is directly related to the severity of the injury and the dental awareness of the patients.[3] Furthermore, the prognosis of the injured teeth maintaining pulp vitality diminished when treatment was delayed. The loss of vitality of some injured teeth occurred as early as 3 months and as late as 24 months after the injury, which justifies a long follow-up period after injury.

For practical and especially economic reasons, Andreasen and colleagues have attempted to classify pulpal and periodontal healing of traumatic dental injuries based on the effect of treatment delay.[4] They developed three major categories of treatment timing: acute treatment (i.e., within a few hours), subacute treatment (i.e., within the first 24 hours), and delayed treatment (i.e., after the first 24 hours). Unfortunately, there is limited knowledge available in the literature of the effect of treatment delay on wound healing.

Taking a complete dental history can help the dentist learn of previous injuries to the teeth in the area. Repeated injuries to the teeth are not uncommon in children with protruding anterior teeth and in those who are active in athletics. In these patients the prognosis may be less favorable. The dentist must rule out the possibility of a degenerative pulp or adverse reaction of the supporting tissues as a result of previous trauma.

The patient's complaints and experiences after the injury are often valuable in determining the extent of the injury and in estimating the ability of the injured pulp and supporting tissues to overcome the effects of the injury. Pain caused by thermal change is indicative of significant pulpal inflammation. Pain occurring when the teeth are brought into normal occlusion may indicate that the tooth has been displaced. Such pain could likewise indicate an injury to the periodontal and supporting tissues. The likelihood of eventual pulpal necrosis increases if the tooth is mobile at the time of the first examination. The greater the mobility, the greater the chance of pulpal death.

Trauma to the supporting tissues may cause sufficient inflammation to initiate external root resorption. In instances of severe injury, teeth can be lost as a result of pathologic root resorption and pulpal degeneration.

CLINICAL EXAMINATION

The clinical examination should be conducted after the teeth in the area of injury have been carefully cleaned of debris. When the injury has resulted in a fracture of the crown, the dentist should observe the amount of tooth structure that has been lost and should look for evidence of pulp exposure. With the aid of a good light, the dentist should carefully examine the clinical crown for cracks and craze lines, the presence of which could influence the type of permanent restoration used for the tooth. With light transmitted through the teeth in the area, the color of the injured tooth should be carefully compared with that of adjacent uninjured teeth. Severely traumatized teeth often appear darker and reddish, although not actually discolored, which indicates pulpal hyperemia (Fig. 27-2). This appearance suggests that at some later time the pulp may undergo degenerative change, terminating in pulpal necrosis.

Diangelis and colleagues have advocated the following classification of crown fractures in describing the extent of damage to the crown of the tooth[5]:

Crown fracture–uncomplicated: an enamel fracture or an enamel-dentin fracture that does not involve the pulp.

Crown fracture–complicated: an enamel-dentin fracture with pulp exposure.

A vitality test of the injured tooth should be performed, and the teeth in the immediate area, as well as those in the opposing arch, should be tested. The best prediction of continued vitality of the pulp of a damaged or traumatized tooth is the vital response to electric pulp testing at the time of the initial examination. A negative response, however, is not a reliable evidence of pulp death because some teeth that give such a response soon after the injury may recover vitality after a time. When the electric pulp tester is used, the dentist should first determine the normal

Dentlearn.ir



Figure 27-2 The reddish appearance of the exposed dentin is evidence of severe hyperemia within the pulp tissue. The prognosis for retaining vitality of the pulp is poor.

reading by testing an uninjured tooth on the opposite side of the mouth and recording the lowest number at which the tooth responds. If the injured tooth requires more current than does a normal tooth, the pulp may be undergoing degenerative change, whereas if it required less current, pulpal inflammation is usually indicated.

Many practitioners question the need for the electric vitality test immediately after the injury. Because the electrical stimulus has been shown to produce negligible additional pulpal irritation, its use is not contraindicated on this basis. However, the patient's measured responses to the test may be almost meaningless. The reliability of the electric pulp test depends on eliciting valid responses from the patient. The mere presence of this new, unknown instrument may create anxiety in children that hampers their ability to respond accurately to the test. Because an unscheduled emergency appointment for treatment of an injury is a new experience, it seems reasonable to introduce the child to the instrument during the first emergency visit, when the child does not know what to expect. This gives the dentist an opportunity to allay the child's anxiety about the instrument during a time when the responses are not as important as they will be on subsequent visits. Furthermore, the electric pulp test is frequently unreliable, even on normal teeth when apices are incompletely formed.

The thermal test is also somewhat helpful in determining the degree of pulpal damage after trauma. Although there are difficulties with the thermal test, it is probably more reliable than the electric pulp test in testing primary incisors in young children. Failure of a tooth to respond to heat indicates pulpal necrosis. The response of a tooth to a lower degree of heat than is necessary to elicit a response in adjacent teeth is an indication of inflammation. Pain occurring when ice is applied to a normal tooth will subside when the ice is removed. A more painful and often lingering reaction to cold indicates a pathologic change within the pulp, the nature of which can be determined when the reaction is correlated with other clinical observations.

Failure of a recently traumatized tooth to respond to the pulp test is not uncommon and may indicate a previous

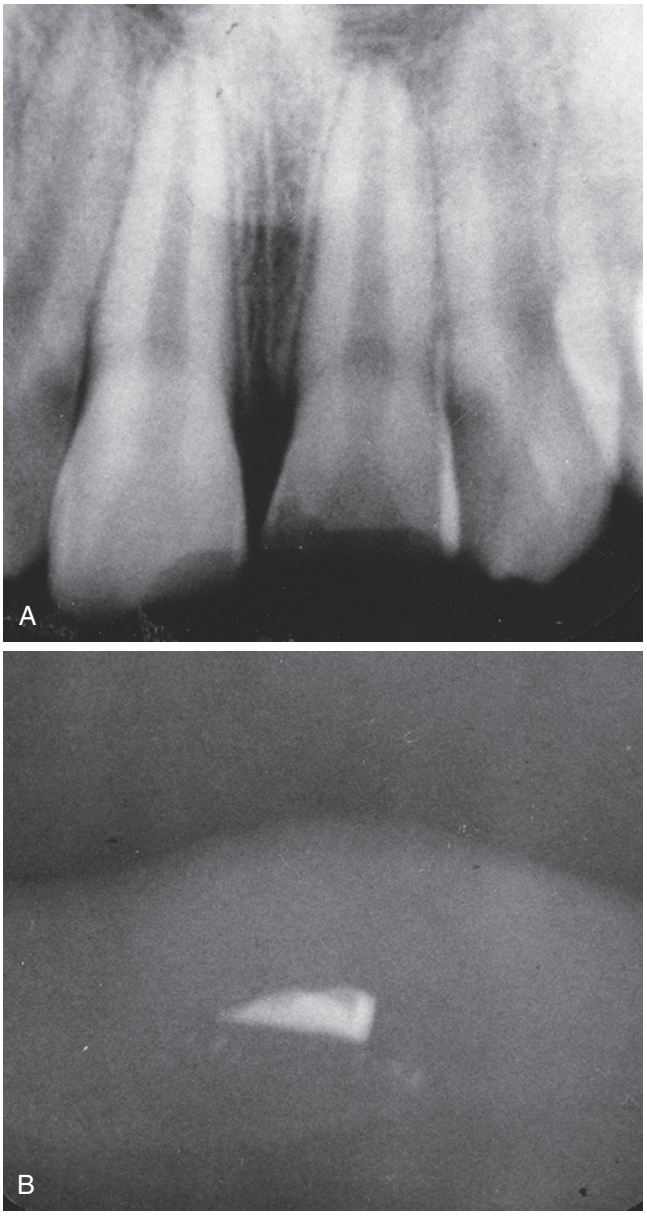

Figure 27-3 **A,** Radiograph of fractured teeth. **B,** Radiograph with a reduced exposure time (25% of the usual time) was useful for detection of the location of this fractured tooth fragment within the patient's lip.

injury with a resulting necrotic pulp. However, the traumatized tooth may be in a state of shock and as a result may fail to respond to the accepted methods of determining pulp vitality. The failure of a pulp to respond immediately after an accident is not an indication for endodontic therapy. Instead, emergency treatment should be completed, and the tooth should be retested at the next follow-up visit.

RADIOGRAPHIC EXAMINATION

The examination of traumatized teeth cannot be considered complete without a radiograph of the injured tooth, the adjacent teeth, and sometimes the teeth in the opposing arch. In search of a fractured tooth fragment, it may even be necessary to obtain a radiograph of the soft tissue

surrounding the injury site (Fig. 27-3). The relative sizes of the pulp chamber and canal should be carefully examined. Irregularities or an inconsistency in the size of the chamber or canal compared with that of adjacent teeth may be evidence of a previous injury. This observation is important in determining the immediate course of treatment. In young patients, the stage of apical development often indicates the type of treatment, just as the size of the coronal pulp and its proximity to the area of fracture influence the type of restoration that can be used. A root fracture as a result of the injury or one previously sustained can be detected by a careful examination of the radiograph. However, the presence of a root fracture may not influence the course of treatment, particularly if the fracture line is in the region of the apical third. Teeth with root fractures in this area rarely need stabilization, and a fibrous or calcified union usually results. If teeth have been discernibly dislocated, with or without root fracture, two or three radiographs of the area at different angles may be needed to clearly define the defect and aid the dentist in deciding on a course of treatment.

Another value of the radiograph is that it provides a record of the tooth immediately after the injury. Frequent, periodic radiographs reveal evidence of continued pulp vitality or adverse changes that take place within the pulp or the supporting tissues. In young teeth in which the pulp recovers from the initial trauma, the pulp chamber and canal decrease in size coincident with the normal formation of secondary dentin. After a period of time an inconsistency in the true size or contour of the pulp chamber or canal compared with that of adjacent teeth may indicate a developing pathologic condition.

When more complex facial injuries have occurred or jaw fractures are suspected, extraoral films may also be necessary to identify the extent and location of all injury sequelae. Oblique lateral jaw radiographs and panoramic films are often useful adjuncts to this diagnostic process.

EMERGENCY TREATMENT OF SOFT-TISSUE INJURY

Injury to the teeth of children is often accompanied by open wounds of the oral tissues, abrasion of the facial tissues, or even puncture wounds. The dentist must recognize the possibility of the development of tetanus after the injury and must carry out adequate first-aid measures.

Children with up-to-date active immunization are protected by the level of antibodies in their circulation, produced by a series of injections of tetanus toxoid. Primary immunization is usually a part of medical care during the first 2 years of life. However, primary immunization cannot be assumed—it must be confirmed by examination of the child's medical record.

When the child who has had primary immunization receives an injury from an object that is likely to have been contaminated, the antibody-forming mechanism may be activated with a booster injection of toxoid. An unimmunized child can be protected through passive immunization or serotherapy with tetanus antitoxin (tetanus immune globulin, or TIG).

The dentist examining the child after an injury should determine the child's immunization status, carry out adequate debridement of the wound, and, when indicated, refer the child to the family physician. Tetanus is often fatal, and preventive measures must be taken if there is a possibility that an injured child is not adequately immunized.

Debridement, suturing, and/or hemorrhage control of open soft-tissue wounds should be carried out as indicated. Working with an oral and maxillofacial surgeon or a plastic surgeon may also be indicated.

EMERGENCY TREATMENT AND TEMPORARY RESTORATION OF FRACTURED TEETH WITHOUT PULP EXPOSURE

A trauma to a tooth that causes a loss of only a small portion of enamel should be treated as carefully as one in which greater tooth structure is lost. The emergency treatment of minor injuries in which only the enamel is fractured may consist of no more than smoothing the rough, jagged tooth structure. However, without exception, a thorough examination should be conducted as previously described. The patient should be reexamined at 2 weeks and again at 1 month after the injury. If the tooth appears to have recovered at that time, continued observation at the patient's regular recall appointments should be the rule.

Sudden injuries with a resultant extensive loss of tooth structure and exposed dentin require an immediate temporary restoration or protective covering, in addition to the complete diagnostic procedure. In this type of injury, initial pulpal hyperemia and the possibility of further trauma to the pulp by pressure or by thermal or chemical irritants must be reduced. In addition, if normal contact with adjacent or opposing teeth has been lost, temporary restoration or protective covering can be designed to maintain the arch integrity. Because providing an adequate permanent restoration may depend on maintaining the normal alignment and position of teeth in the area, this part of the treatment is as important as maintaining the vitality of the teeth. Several restorations that will satisfy these requirements can easily be fabricated.

FRAGMENT RESTORATION (REATTACHMENT OF TOOTH FRAGMENT)

Occasionally the dentist may have the opportunity to reattach the fragment of a fractured tooth using resin and bonding techniques. Successful reattachment of tooth fragments has been reported to be stable and is an option to be considered by the dentist.[6,7]

This procedure is atraumatic and seems to be the ideal method of restoring the fractured crown. Sealing the injured tooth and aesthetically restoring its natural contour and color are accomplished simply and constitute an excellent service to the patient. The procedure provides an essentially perfect temporary restoration that may be retained a long time in some cases.

It is not often that the fractured tooth fragment remains intact and is recovered after an injury, but when this happens, the dentist may consider the reattachment procedure. The tooth requires no mechanical preparation because

Dentlearn.ir

retention is provided by enamel etching and bonding techniques. If little or no dentin is exposed, the fragment and the fractured tooth enamel are etched and reattached with bonding agents and materials. Farik and colleagues have tested the use of the new single-bottle dentin adhesives with and without unfilled resins in the fragment-bonding technique.[8] Their hypothesis was that the amount of resin in single-bottle dentin adhesives might not be sufficient to secure an adequate fragment bond. The results of their study showed that all but one of the seven dentin adhesive systems tested should be used with an additional unfilled resin when fractured teeth are restored by reattachment.

For cases in which considerable dentin is exposed or a direct pulp cap is indicated, some controversy exists about the best treatment to enhance the likelihood of maintaining pulp vitality. Some believe that the meticulous use of bonding agents and materials to directly cap the exposed dentin and the pulp, if exposed, (i.e., the *total-etch technique*) is best, whereas others believe that calcium hydroxide should be applied to the exposed dentin and pulp before the bonding procedure is completed.

Figure 27-4 illustrates the successful management of an uncomplicated fracture of the maxillary right central incisor in a 6-year-old boy who was treated approximately 1 hour after the injury. After the fragment was trial-seated to confirm a precise fit, the exposed dentin of the fractured tooth was covered with a thin layer of hard-setting calcium hydroxide that was allowed to remain as a sedative dressing between the tooth and restored fragment. A portion of the dentin in the fragment was removed to provide space for the calcium hydroxide. The fragment was then soaked in etchant, and the fractured area of the tooth was also etched well beyond the fracture site. After thorough rinsing and drying of all etched enamel, the fragment and the etched portion of the tooth were painted with a light-curing sealant material. Although no bonding agent was used here, its use is currently recommended. The selected shade of composite resin was used to fill the prepared void in the fragment, and it was then carefully seated into its correct position and held firmly while the material was light-cured. Subsequent radiographs and vitality tests indicated that the tooth had probably responded favorably. Kanca reported reattachment of a fragment that successfully capped the pulp using the total-etch technique.[9] The restoration was more than 5 years old (replaced once) and was still in place at the time of the report.

Ludlow and LaTurno have reported the success of a fragment restoration for a 13-year-old patient in whom essentially the entire clinical crown of a maxillary incisor was fractured away (class IV fracture).[10] The remaining tooth was first treated with a root canal filling, and then the pulp canal of the tooth and the enlarged pulp chamcavities to strengthen the reattached crown.

TEMPORARY BONDED RESIN RESTORATION

The excellent marginal seal and retention derived from the application of aesthetic restorative materials to etched enamel surfaces have revolutionized the approach to the restoration of fractured anterior teeth. These bonding techniques are highly successful and versatile in many situations involving anterior trauma.

It may not be advisable to restore an extensive crown fracture with a finished aesthetic resin restoration on the day of the injury because it is usually best not to manipulate the tooth more than is absolutely necessary to make a diagnosis and provide emergency treatment. Also, such emergencies are usually treated at unscheduled appointments, and this treatment should be carried out as efficiently as possible to prevent significant disruption of the dentist's scheduled appointments. A temporary restorative resin restoration can be placed efficiently and is often the treatment of choice.

Conventional bonding procedures are used for application of the restorative resin material as a protective covering at the fracture site. As a short-term temporary restoration, it requires little or no finishing and does not need to restore the tooth to normal contour. However, the restoration should cover the fractured surfaces and maintain any natural proximal contacts the patient may have had before the injury (Fig. 27-5). After an adequate recovery period an aesthetic resin restoration may be completed, often without removal of all the temporary resin material. However, the outer surfaces of the temporary restoration should be removed superficially before the new material is applied. The margins of the new restoration should extend beyond the margins of the temporary restoration and onto newly etched enamel. The aesthetic bonded resin restoration is discussed and illustrated later in this chapter.

TREATMENT OF VITAL PULP EXPOSURES

Injury resulting in an exposure of the pulp in young patients often presents a challenge in diagnosis and treatment even greater than that of a pulp exposed by caries. In addition to treating the pulp at the exposure site, the dentist must keep in mind that, as a result of the blow, conditions may be present for many unpredictable reactions in the pulp or supporting tissues. The immediate objective in treatment, however, should be the selection of a procedure designed to maintain the vitality of the pulp whenever possible. In the management of vital pulp exposure, at least three choices of treatment are available: direct pulp cap, pulpotomy, and pulpectomy with endodontic therapy.

DIRECT PULP CAP

If the patient is seen within an hour or two after the injury, if the vital exposure is small, and if sufficient crown remains to retain a temporary restoration to support the capping material and prevent the ingress of oral fluids, the treatment of choice is direct pulp capping (Fig. 27-6). If the final restoration of the tooth will require the use of the pulp chamber or pulp canal for retention, a pulpotomy or a pulpectomy is the treatment of choice.

Even though the pulp at the exposure site has been exposed to oral fluids for a period of time, the tooth should be isolated with a rubber dam, and the treatment procedure should be completed in a surgically clean environment. The healthy pulp may survive and repair small injuries even in the presence of a few bacteria, the same as any other connective tissue. The crown and the area of

Dentlearn.ir

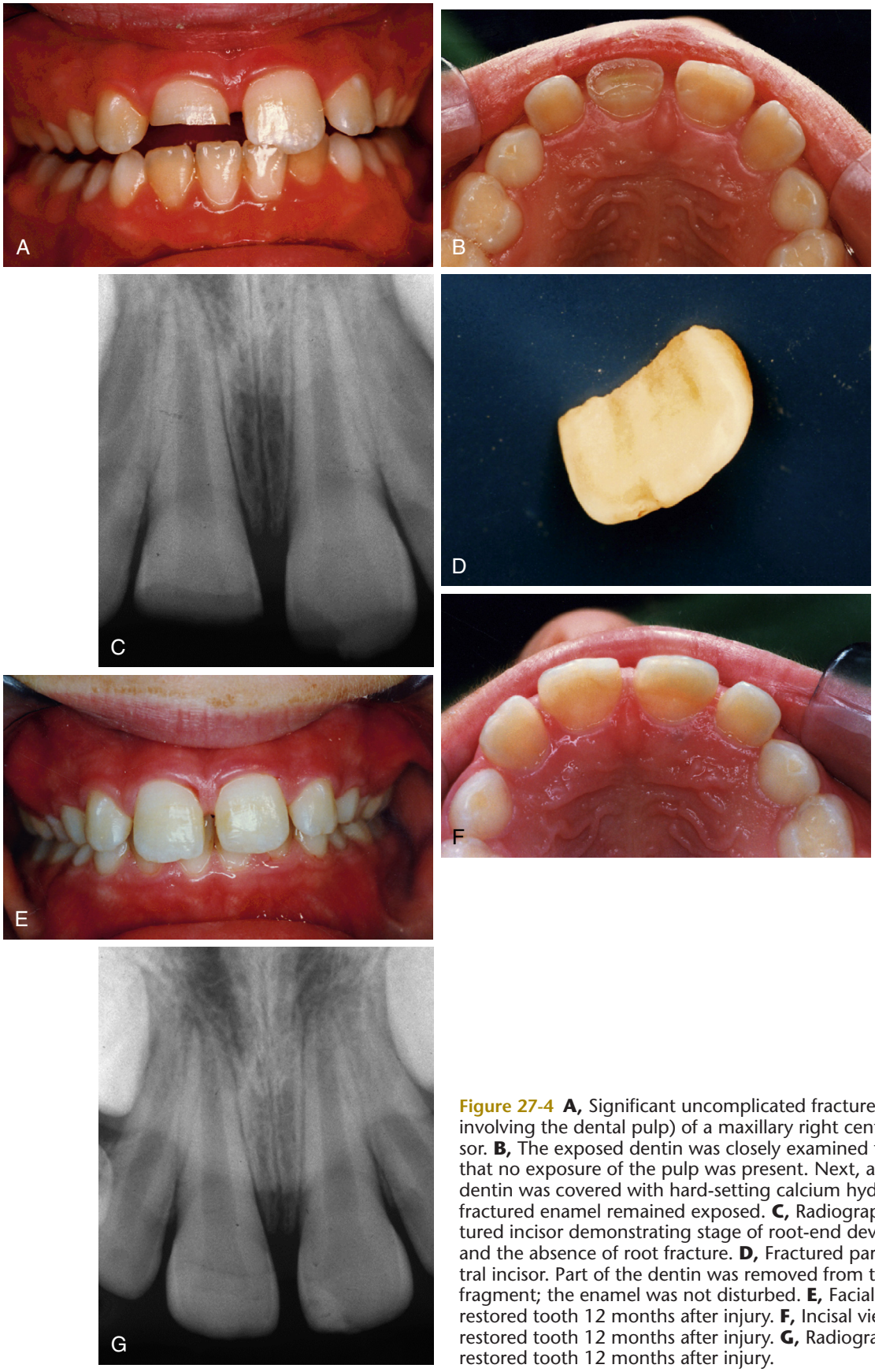

Figure 27-4 **A,** Significant uncomplicated fracture (not involving the dental pulp) of a maxillary right central incisor. **B,** The exposed dentin was closely examined to ensure that no exposure of the pulp was present. Next, all exposed dentin was covered with hard-setting calcium hydroxide; all fractured enamel remained exposed. **C,** Radiograph of fractured incisor demonstrating stage of root-end development and the absence of root fracture. **D,** Fractured part of central incisor. Part of the dentin was removed from the tooth fragment; the enamel was not disturbed. **E,** Facial review of restored tooth 12 months after injury. **F,** Incisal view of the restored tooth 12 months after injury. **G,** Radiograph of the restored tooth 12 months after injury.



Figure 27-5 **A,** Uncomplicated crown fracture (not involving the dental pulp) of maxillary right central incisor and of the maxillary left central incisor. **B,** Radiograph obtained after the traumatic incident. **C,** Maxillary occlusal view of traumatized central incisors. The maxillary left central incisor has been minimally prepared for a temporary restoration. Note that no pulpal exposure is evident. **D,** Calcium hydroxide has been applied, covering all exposed dentin. **E,** Etchant is being applied, per manufacturer's instructions, to the involved teeth. **F,** Involved teeth after the etching process. Note the etched "snow-capped" appearance of the enamel. **G,** Involved teeth after application of the temporary restoration. The occlusion has been checked to make sure that there is no contact with the opposing dentition. After an appropriate amount of observation time, a more aesthetic restoration will be completed.



Figure 27-6 Complicated crown fracture (involving the dental pulp) to a permanent central incisor. A small pulp exposure is evident that should be capped and protected with a bonded restoration.

the actual exposure should be washed free of debris, and the pulp should be kept moist before the placement of the pulp-capping material.

As mentioned in Chapter 13, numerous pulp-capping materials have been studied. Pulp capping with conventional bonding materials is now accepted by many, although the procedure is also considered inadvisable by others. Reports of the use of both mineral trioxide aggregate (MTA) and bone morphogenetic proteins are significant not only for pulp capping but also for general use in endodontic therapy for vital and nonvital teeth.

The prime requisite of pulpal healing is an adequate seal against oral fluids. Therefore a restoration should be placed immediately to protect the pulp-capping material until the healing process is well advanced. A thin layer of dentin-like material should cover the vital pulp tissue in at least 2 months.

If the injured tooth presents a good indication for direct pulp capping, there is a definite advantage in providing this treatment. The pulp will remain functional and reparative, and dentin will develop and allow the tooth to be restored without loss of normal pulp vitality.

PULPOTOMY

If the pulp exposure in a traumatized, immature permanent (open apex) tooth is large, if even a small pulp exposure exists and the patient did not seek treatment until several hours or days after the injury, or if there is insufficient crown remaining to hold a temporary restoration, the immediate treatment of choice is a shallow pulpotomy or a conventional pulpotomy (Fig. 27-7). A shallow or partial pulpotomy is preferable if coronal pulp inflammation is not widespread and if a deeper access opening is not needed to help retain the coronal restoration.[11] Pulpotomy is also indicated for immature permanent teeth if necrotic pulp tissue is evident at the exposure site with inflammation of the underlying coronal tissue, but a conventional or cervical pulpotomy would be required. Yet another indication is trauma to a more mature permanent (closed apex) tooth that has caused both a pulp exposure and a root fracture. In addition, a shallow pulpotomy may be the treatment of choice for a complicated fracture of a tooth with a closed apex when definitive treatment can be provided soon after the injury (Fig. 27-8).

The exposure site should be conservatively enlarged, and 1 to 2 mm of coronal pulp tissue should be removed for the shallow pulpotomy or all pulp tissue in the pulp chamber should be removed for the conventional pulpotomy. When pulp amputation has been completed to the desired level, the pulp chamber should be thoroughly cleaned with copious irrigation. No visible dentin chips or pulp tissue tags should remain. If the remaining pulp is healthy, hemorrhage will be easy to control with a pledget of moist cotton lightly compressed against the tissue. The pulp should also have a bright reddish-pink color and a concave contour (meniscus). A deeper amputation may be necessary if the health of the pulp is questionable. A dressing of calcium hydroxide is gently applied to the vital pulp tissue so that it is in passive contact with the pulp. The remaining access opening is filled with a hard-setting, biocompatible material with excellent marginal sealing capability. The crown may then be restored with a separate bonding procedure.

Some experts on pulp therapy recommend conventional pulpectomy and root canal fillings for all teeth treated with calcium hydroxide pulpotomies soon after the root apices close. They view the calcium hydroxide pulpotomy as an interim procedure performed solely to achieve normal root development and apical closure. They justify the pulpectomy and root canal filling after apical closure as necessary to prevent an exaggerated calcific response that may result in total obliteration of the root canal (calcific metamorphosis or calcific degeneration).

We have observed this calcific degenerative response and agree that it should be intercepted with root canal therapy if possible after apical closure. However, long-term successes can be achieved after calcium hydroxide pulpotomy in which no calcific metamorphosis has been observed. If healthy pulp tissue remains in the root canal, if the coronal pulp tissue is cleanly excised without excessive tissue laceration and tearing, if the calcium hydroxide is placed gently on the pulp tissue at the amputation site without undue pressure, and if the tooth is adequately sealed, there is a high probability that long-term success can be achieved without follow-up root canal therapy.[12,13]

PULPECTOMY WITH ENDODONTIC TREATMENT

One of the most challenging endodontic procedures is the treatment and subsequent filling of the root canal of a tooth with an open apex. The lumen of the root canal of such an immature tooth is largest at the apex and smallest in the cervical area and is often referred to as a *blunderbuss canal*. Hermetic sealing of the apex with conventional endodontic techniques is usually impossible without apical surgery. This surgical procedure is traumatic for the young child and should be avoided if possible.

In instances of complicated fractures of young permanent teeth with incomplete root growth and a vital pulp, the pulpotomy technique (as just described) is the procedure of choice. The successful pulpotomy allows the pulp in the root canal to maintain its vitality and also allows the apical portion to continue to develop (apexogenesis). For complicated fractures, the eventual restoration may require a post in the root canal. Before this type

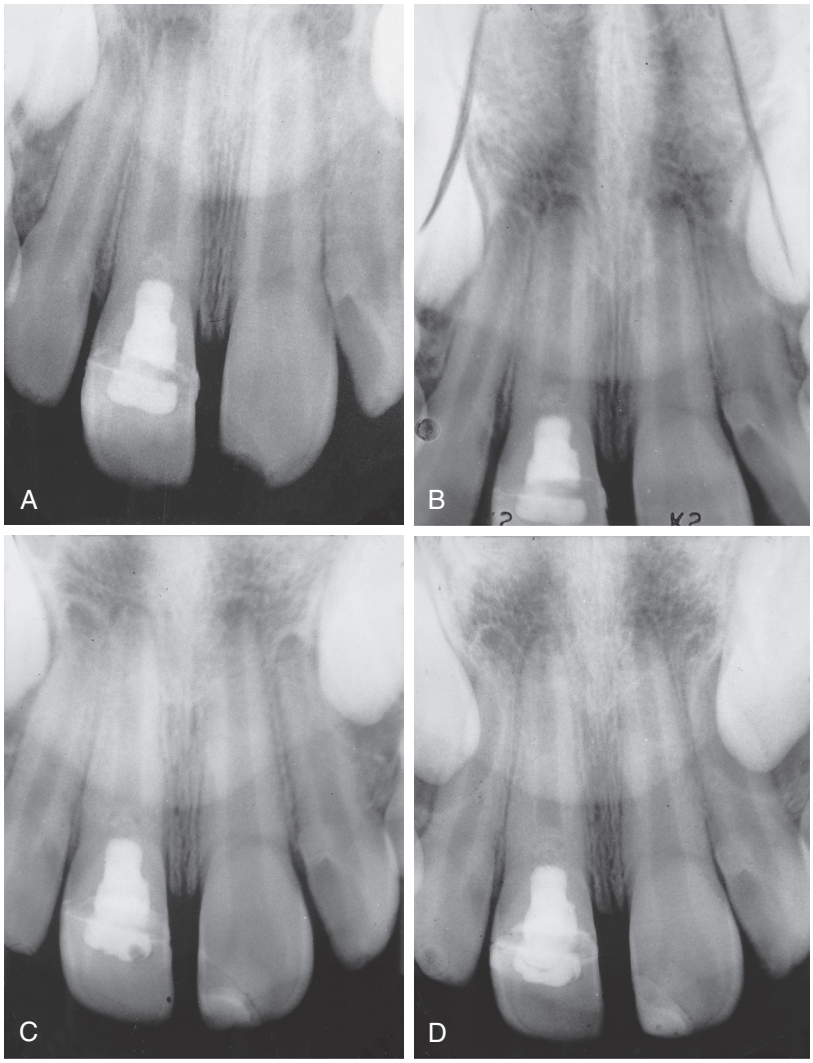

Figure 27-7 **A,** Radiographic appearance of the restored maxillary right central incisor 10 days after a complicated crown fracture occurred and the calcium hydroxide pulpotomy was performed. A fragment restoration was also used to restore the class II fracture of the maxillary left central incisor at this same appointment, but after this radiograph was obtained. **B,** This radiograph, made 7½ weeks after the pulpotomy, shows evidence of a calcified bridge developing at the level of the pulpal amputation. **C,** Eight months after initial treatment, it appears that root development is progressing normally for both maxillary central incisors. **D,** Root completion has been achieved on both maxillary central incisors 20 months after the original injury. The root canals exhibit normal anatomic configuration.

of restoration is completed, the dentinal bridge that has formed after the pulpotomy can be perforated and routine endodontic procedures can be undertaken in a now completely developed root canal.

Occasionally a patient has an acute periapical abscess associated with a traumatized tooth. The trauma may have caused a very small pulp exposure that was overlooked, or the pulp may have been devitalized as a result of injury or actual severing of the apical vessels. A loss of pulp vitality may have caused interrupted growth of the root canal, and the dentist is faced with the task of treating a canal with an open apex.

If an abscess is present, it must be treated first. If there is acute pain and evidence of swelling of the soft tissues, drainage through the pulp canal will give the child almost immediate relief. A conventional endodontic access opening should be made into the pulp chamber. If pain is caused by the pressure required to make the opening into the pulp, the tooth should be supported by the dentist's fingers. Antibiotic therapy is also generally indicated.

THERAPY TO STIMULATE ROOT GROWTH AND APICAL REPAIR IN IMMATURE TEETH WITH PULPAL NECROSIS

APEXIFICATION

The conventional treatment of pulpless anterior teeth usually requires apical surgery if the teeth have open apices. Many young teeth have been saved in this manner. However, a less traumatic endodontic therapy called *apexification* has been found to be effective in the management of immature, necrotic permanent teeth. The apexification



Figure 27-8 **A,** Severe complicated fracture of the maxillary right central incisor. The trauma occurred approximately 60 minutes earlier. **B,** Maxillary periapical radiograph of traumatized incisor. Note the apical closure of the root tip. **C,** After appropriate infiltration of local anesthesia (no local anesthesia was injected into the pulp tissue at the fracture site), approximately 2 mm of pulpal tissue at the fracture was removed by means of a number 4 round diamond with gentle water irrigation. This created an undercut in tooth structure, facilitating retention of calcium hydroxide to be placed later during the procedure. Note the excellent hemostasis of the amputated pulp tissue. **D,** A cotton pellet, moistened with sterile saline, was placed over the pulpal tissue for 5 minutes. **E,** After verification of excellent hemostasis following use of the moistened cotton pellet, calcium hydroxide was used to fill the area created during pulp removal. **F,** Maxillary radiograph after placement of the calcium hydroxide. **G,** Clinical picture of incisor 3 months after the traumatic event. Normal responses to both electric and cold pulp-testing were obtained at 1-, 2-, and 3-month observation intervals. A permanent restoration is planned.

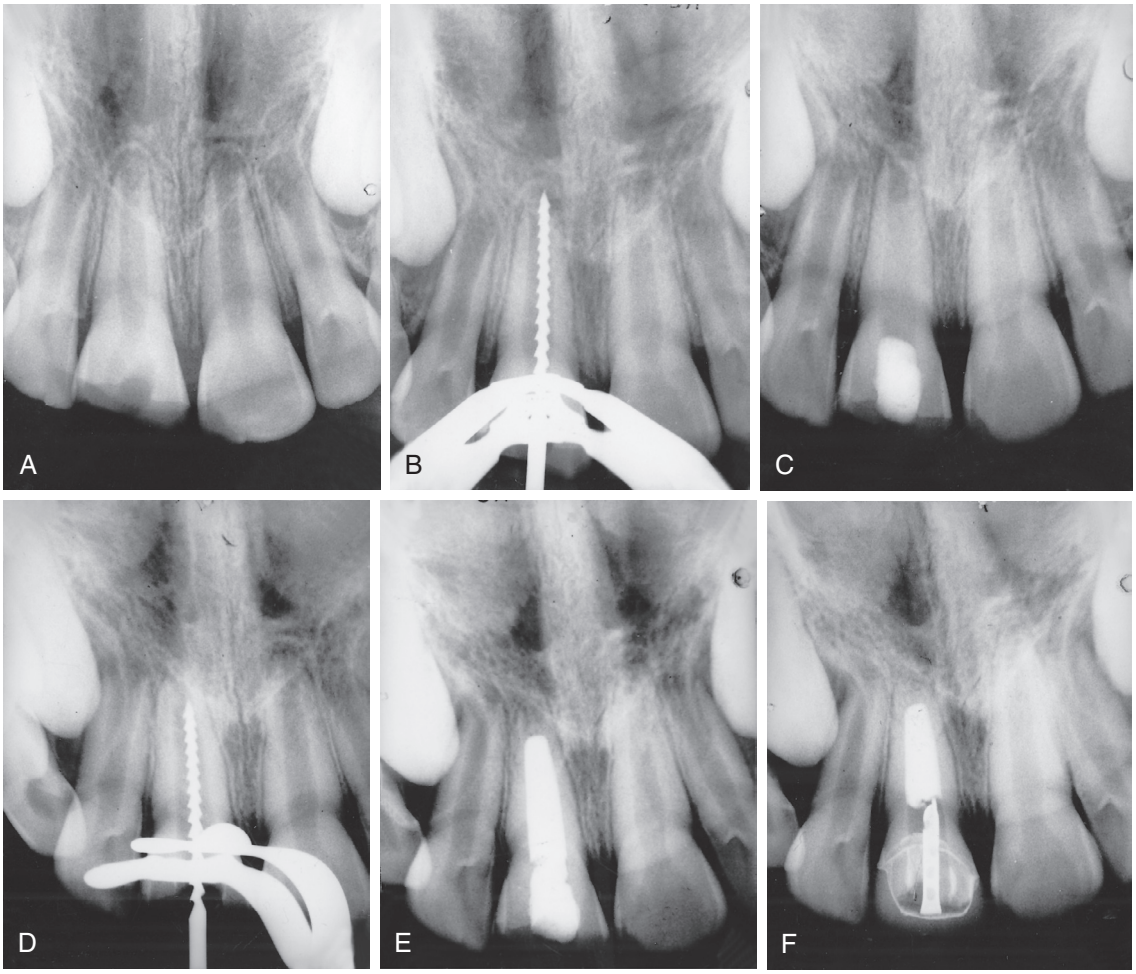

Figure 27-9 Series of radiographs demonstrating treatment to stimulate root-end development of a pulpless young anterior permanent central incisor. **A,** An injury several months before had resulted in a pulp exposure. An acute abscess was present at the beginning of treatment. An opening to the pulp chamber was made to allow for drainage. **B,** Four days after the initial treatment, the canal length was established. Files were used to clean the canal. After cleansing and irrigation of the canal, calcium hydroxide and camphorated mono-parachlorophenol were used to fill the canal. **C,** One month after initial treatment. **D,** Six months after initial treatment, a definite calcified stop was encountered when the file was introduced. The canal was cleansed thoroughly, and gutta-percha was used to fill the canal. **E,** Five months after the placement of the gutta-percha canal filling. **F,** A 6-month postoperative radiograph. A tube and resin core was placed, and the tooth was restored with a jacket crown. Currently, an aesthetic bonded composite resin restoration (or a fragment restoration if possible) would probably be the preferred interim restoration until the patient has attained adulthood. (Courtesy Drs. Paul E. Starkey and Joe Camp.)

procedure should precede conventional root canal therapy in the management of teeth with irreversibly diseased pulps and open apices.

Frank described a technique based on the normal physiologic pattern of root development that brings about the resumption of apical development so that the root canal can be obliterated by conventional canal-filling techniques.[14] The procedure has been demonstrated to be successful in repeated clinical trials stimulating the process of root end development, which was interrupted by pulpal necrosis, so that it continues to the point of apical closure (Fig. 27-9).[14] Often a calcific bridge develops just coronal to the apex. When the closure occurs, or when the calcific "plug" is observed in the apical portion, routine endodontic procedures may be completed; the possibility of recurrent periapical pathosis is thus prevented.

The following steps are included in the technique:

1. The affected tooth is carefully isolated with a rubber dam, and an access opening is made into the pulp chamber.
2. A file is placed in the root canal, and a radiograph is made to establish the root length accurately. It is important to avoid placing the instrument through the apex, which might injure the epithelial diaphragm.
3. After the remnants of the pulp have been removed using barbed broaches and files, the canal is flooded with hydrogen peroxide to aid in the removal of debris. The canal is then irrigated with sodium hypochlorite and saline.
4. The canal is dried with large paper points and loose cotton.
5. A thick paste of calcium hydroxide is transferred to the canal. An endodontic plugger may be used

Dentlearn.ir

to push the material to the apical end, but excess material should not be forced beyond the apex.
6. A cotton pledget is placed over the calcium hydroxide, and the seal is completed with a layer of reinforced zinc oxide–eugenol cement.

Weine recommends that the apexification procedure be completed in two appointments.[15] After instrumentation, irrigation, and drying of the canal during the first appointment, he advises sealing a sterile, dry, cotton pellet in the pulp chamber for 1 to 2 weeks. Placing a calcium hydroxide dressing in the canal is optional at the first appointment. During the second appointment, the debridement procedures are repeated before the canal is filled with a thick paste of calcium hydroxide and camphoric p-monochlorophenol (CMCP) or calcium hydroxide in a methylcellulose paste.

Whether the tooth is filled in one or two appointments (or more) should be determined to a large extent by the clinical signs and symptoms present and to a lesser extent by operator convenience. All signs and symptoms of active infection should be eliminated before the canal is filled with the treatment paste. Absence of tenderness to percussion is an especially good sign before the canal is filled. Because of the wide-open access to periapical tissues, it is not always possible to maintain complete dryness in the root canal. If the canal continues to weep but other signs of infection seem to be controlled after two or three appointments, the dentist may elect to proceed with the calcium hydroxide paste treatment.

As a general rule, the treatment paste is allowed to remain for 6 months. The root canal is then reopened to determine whether the tooth is ready for a conventional gutta-percha filling, as determined by the presence of a "positive stop" when the apical area is probed with a file. Often there is also radiographic evidence of apical closure. Frank has described four successful results of apexification treatment[14]: (1) continued closure of the canal and apex to a normal appearance, (2) a dome-shaped apical closure with the canal retaining a blunderbuss appearance, (3) no apparent radiographic change but a positive stop in the apical area, and (4) a positive stop and radiographic evidence of a barrier coronal to the anatomic apex of the tooth.

If apical closure has not occurred in 6 months, the root canal is retreated with the calcium hydroxide paste. If weeping in the canal was not controlled before the canal was filled, retreatment is recommended 2 or 3 months after the first treatment.

Ideally, the postoperative radiographs should demonstrate continued apical growth and closure as in a normal tooth. However, any of the other three previously described results is considered successful. When closure has been achieved, the canal is filled in the conventional manner with gutta-percha.

Currently, there seems to be a trend away from the incorporation of antibacterial agents, such as CMCP, into the calcium hydroxide treatment paste. It is generally agreed that calcium hydroxide is the major ingredient responsible for stimulating the desired calcific closure of the apical area. Calcium hydroxide is also an antibacterial agent. It may be that CMCP does not enhance the repair; on the other hand, its use as described here has not been shown to be detrimental. Certainly more than one treatment paste has been employed with success. Giuliani and associates have demonstrated the use of MTA to form an apical plug for apexification in three clinical cases[16] (Fig. 27-10). The root canals of central incisors that had suffered premature interruption of root development as a consequence of trauma were rinsed with 5% sodium hypochloride. Calcium hydroxide was then placed in the canals for 1 week. Following this, the apical portion of the canal (4 mm) was filled with MTA and the remaining portions of the root canals were closed with thermoplastic gutta-percha. At the 6-month and 1-year follow-ups, the clinical and radiographic appearance of the teeth showed resolution of the periapical lesions. These researchers suggest that MTA is a valid option for apexification. They also suggest that long-term outcome studies are needed to test whether this treatment modality will be successful in

Teeth treated by the apexification method are susceptible to fracture because of the brittleness that results from nonvitality and from the relatively thin dentinal walls of the roots. In addition, another important problem with the calcium hydroxide apexification technique is the duration of therapy, which often lasts many months.

REGENERATIVE ENDODONTIC PROCEDURES

Regenerative Endodontic Procedures (REPs) can be defined as biologically based procedures designed to replace damaged structures, which include dentin, root structures, and cells of the pulp–dentin complex.[17] These procedures provide a biological alternative to induce continuous root development and reduce the risk of fracture associated with traditional treatments of immature teeth with necrotic pulps, such as calcium hydroxide or MTA apexification, where the root remains thin and weak (Fig. 27-11). The premise of endodontic regeneration was suggested in 1961, when Nygaard-Østby evaluated the role of blood clots in endodontic therapy.[18] In 1971 Nygaard-Østby and Hjørtdal discussed the use of growth-promoting substances to help in the healing process after partial root canal filling.[19] Following this, endodontic regenerative procedures were largely ignored for 30 years, until the first clinical case of contemporary REPs was published by Iwaya and colleagues in 2001.[20] In the last two decades numerous case reports and retrospective clinical studies have demonstrated notable improvements in some clinical outcomes after REP treatment of immature teeth with pulpal necrosis. These improvements include healing of periapical pathology, continued development of the root apex, and increased thickness of the root canal wall.

Nakashima and Akamine described three key ingredients for tissue engineering: stem cells, scaffolds, and growth factors.[21] Stem cells are undifferentiated cells that continuously divide. Numerous types of multipotent adult stem cells have been identified from teeth and were hypothesized to play an important role in endodontic regeneration, such as stem cells from apical papilla, dental pulp stem cells, and periodontal ligament stem cells. The second key element is the scaffold, which provides a matrix for cell organization, proliferation, differentiation, and revascularization. Contemporary REPs have used dentin and blood clots to provide scaffolds in the

Dentlearn.ir

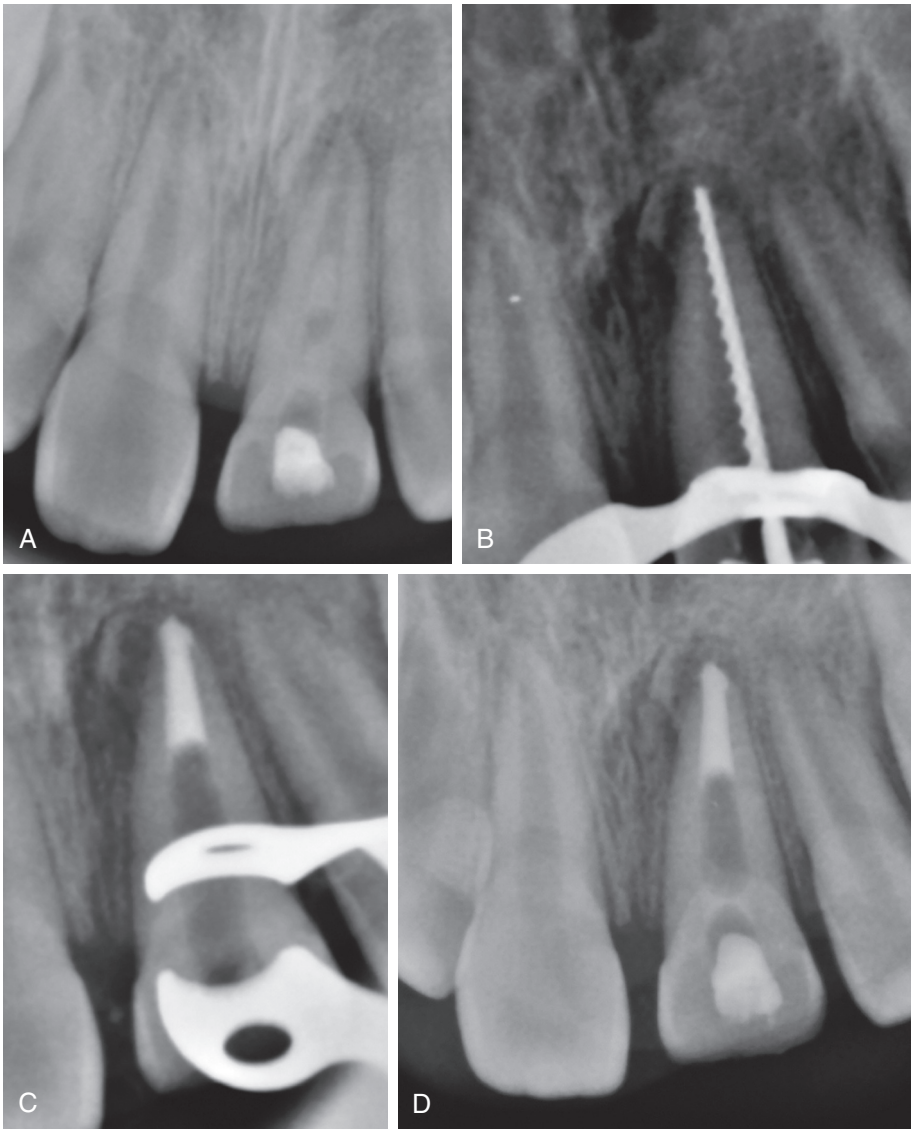

Figure 27-10 **A,** Maxillary right central incisor with periapical pathology secondary to trauma. The canal has been opened, rinsed with 5% sodium hypochlorite, dried, and filled with calcium hydroxide. **B,** Approximately 7 days after initial treatment with calcium hydroxide, the incisor was instrumented to remove all remaining tissue before further treatment. **C,** The apical 4 to 5 mm of the incisor root has been filled with mineral trioxide aggregate (MTA). **D,** The incisor has completed initial treatment with MTA. A temporary restoration has been placed to seal the canal opening. It was thought that several months of observation would be desirable before the final gutta-percha placement on top of the MTA apical seal. (Courtesy Dr. Joseph Legan.)

root canal. However, various scaffolds made of natural or synthetic materials have been proposed in an attempt to create more controlled three-dimensional scaffolds inside the root canal.[22] The third key element is growth factors. These are biological signaling proteins that regulate cellular proliferation, differentiation, and maturation. Current REPs rely mainly on the ability of root canal dentin to release important signaling molecules that may play an important role in regenerative procedures.

Most contemporary REPs rely on the chemical debridement of the root canal as there is minimal or no mechanical instrumentation. The main objective of chemical debridement is the elimination of microorganisms and necrotic tissues from the root canal system, and this step has been suggested to be the essential factor in successful REPs. Root canal irrigation with sodium hypochlorite has been suggested to disinfect the root canal and to eliminate the necrotic organic materials from the canal system during REPs. However, higher concentrations of sodium hypochlorite have harmful effects on the differentiation and survival of dental pulp stem cells.[23] Therefore 1.5% sodium hypochlorite has been suggested for use in REPs due to its minimal toxic effects on dental pulp stem cells. On the other hand, root canal irrigation with 17% ethylenediaminetetraacetic acid (EDTA) has been recommended as a final irrigation step during REPs. EDTA was suggested to condition the superficial root canal walls, expose the dentin protein matrix, and improve dental

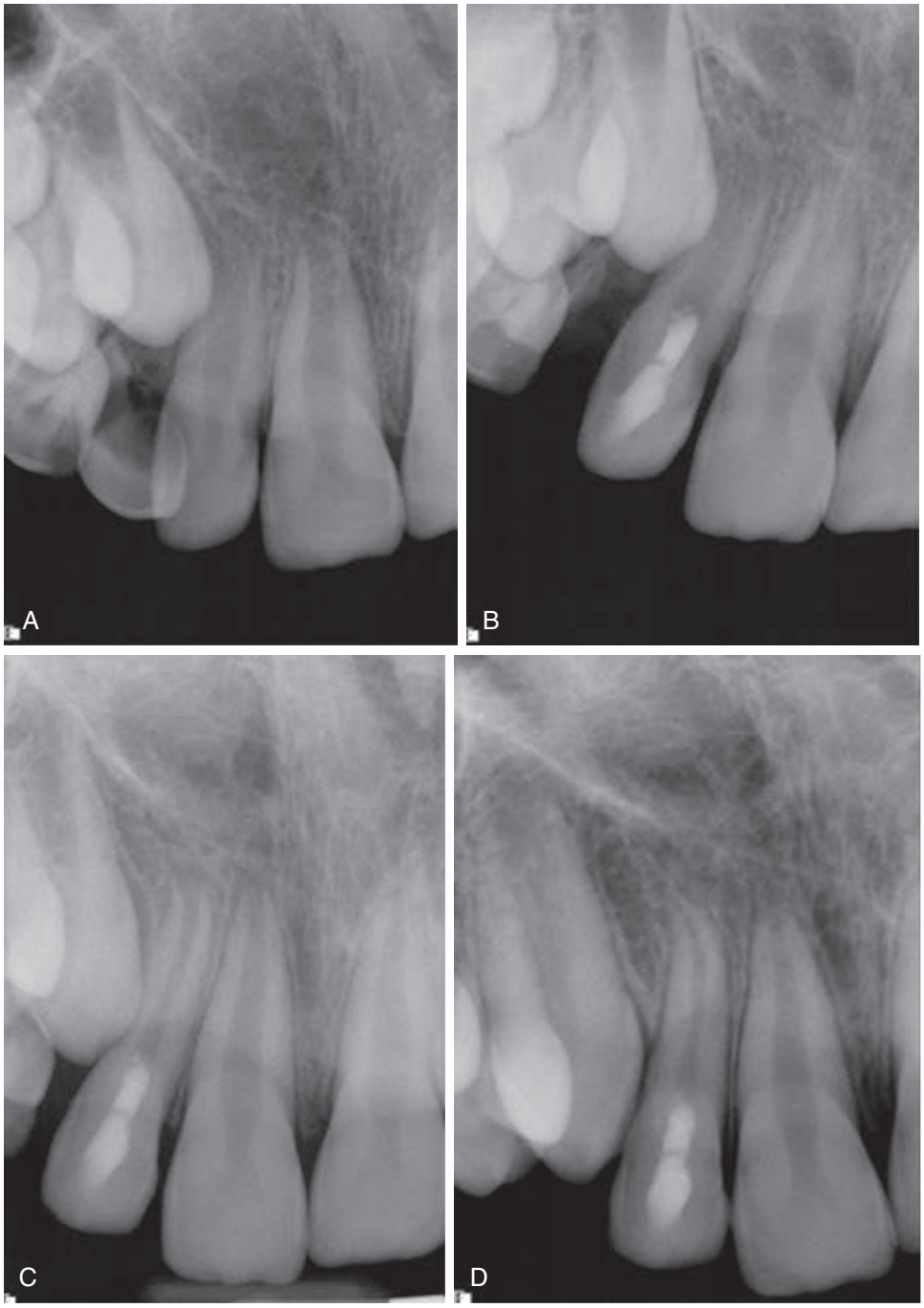

Figure 27-11 Series of radiographs demonstrating the case of an immature necrotic tooth treated with the endodontic regeneration approach according to the recent guidelines of the American Association of Endodontists. **A,** Immature permanent upper right lateral incisor with pulpal necrosis and periapical abscess secondary to dental trauma. The pulp chamber was accessed, canal length was established, and pus was drained from the canal via small capillary tubes connected to high-speed suction. The canal was rinsed with 20 mL of 1.5% sodium hypochlorite, followed by 20 mL of sterile saline, and dried with paper points. Triple antibiotic paste composed of clindamycin, ciprofloxin, and metronidiazole was prepared and placed into the canal by means of a special syringe. **B,** Four weeks after the initial treatment, no negative clinical signs and symptoms were observed. The canal was accessed, irrigated with 17% EDTA, and dried with paper points. A size 60 endodontic file was used to lacerate the apical papilla and induce bleeding into the canal up to the cemento-enamel junction. A small piece of Colla Tape was placed over the clot, and 3 mm of white MTA was applied to seal the access opening, followed by a composite resin permanent restoration. **C,** Six-month follow-up radiograph shows the start of root maturation with an increase in root length. **D,** Thirteen-month follow-up radiograph indicates complete root formation with an increase in length and thickness of the root.

pulp stem cell proliferation. However, intracanal medicaments used in REPs, such as various antibiotic mixtures and calcium hydroxide, have also been suggested to have a role in exposing various dentinal proteins.[24] The application of intracanal medicaments has been adopted in all suggested REPs. The most widely used intracanal medicament in endodontic regeneration is the triple antibiotic paste described by Hoshino et al.,[25] which is a mixture of water and equal parts of metronidazole, ciprofloxacin, and minocycline. However, significant tooth discoloration after the application of triple antibiotic paste has been reported to occur due to staining of the dentin by the minocycline present in the paste. Sealing the pulp chamber with flowable composite resin before the triple antibiotic paste application and maintaining the paste below the cemento-enamel junction have been suggested to minimize the staining effect of the paste.[26] Other authors proposed eliminating the minocycline and keeping only metronidazole and ciprofloxacin in the antibiotic paste or substituting the minocycline with another antibiotic, such as clindamycin, cefaclor, or amoxicillin.[23] Recent in vitro studies raised some concerns regarding the cytotoxic effects of various antibiotic combinations used in REPs on the dental pulp stem cells. Therefore lower concentrations of these antibiotic mixtures (0.1 mg/mL) have been recommended to avoid stem cell toxicity.[27] It is noteworthy that the short-term application of calcium hydroxide paste has also been successfully used in REPs.[28] Indeed, the effects of calcium hydroxide paste were found to be less detrimental to stem cells of the apical papillae, as compared with various antibiotic mixtures.[27] A biocompatible disinfection protocol utilizing both irrigation solutions and intracanal medicament to effectively eradicate a root canal infection and create an environment conducive to the proliferation and differentiation of dental pulp stem cells is an important aim to improve the outcomes of REPs.

Currently, there is no standardized clinical protocol regarding REPs. Indeed, several variations of REPs have been suggested. The American Association of Endodontists has recommended the following treatment protocol based on the best evidence level from clinical case studies and preclinical translational investigations (see Fig. 27-11).[29]

First Appointment

1. After administration of adequate local anesthesia, the affected tooth is carefully isolated with a rubber dam, and an access opening is made into the pulp chamber.
2. A file is placed 1 mm from the root end in the root canal, and a radiograph is made to establish the root length accurately.
3. Each root canal is slowly irrigated with 20 mL of 1.5% sodium hypochlorite for 5 minutes followed by irrigation with 20 mL of saline for 5 minutes. A closed-end needle or the EndoVac negative pressure irrigation system should always be used to deliver the irrigation solutions during REP, to minimize the possibility of extrusion of irrigants into the periapical space.
4. The canal is dried with large paper points.
5. Antibiotic or calcium hydroxide paste is applied into the canal via a lentulo spiral or Centrix syringe. For antibiotic paste, mix equal portions of metronidazole, ciprofloxacin, and minocycline with sterile water to create a pasty consistency. However, a lower concentration of antibiotics is preferable (0.1 mg/mL).
6. Seal the root canal with 3 to 4-mm Cavit, followed by a temporary restorative material, and dismiss the patient for 1 to 4 weeks.

Second Appointment

1. Evaluate the affected tooth response to initial treatment. If there are no clinical signs or symptoms of persistent infection, proceed with step 2. If there is evidence (e.g., sinus tract, percussion sensitivity), consider additional treatment with NaOCl irrigation and the antibiotic intracanal medicament and recall the patient after 1 to 4 weeks.
2. After administration of adequate local anesthesia, 3% mepivacaine (no epinephrine), the affected tooth is isolated with a rubber dam.
3. The root canal is accessed, and the intracanal paste is removed by gentle irrigation with 20 mL of 17% EDTA followed by normal saline, using a closed-end needle or the EndoVac system.
4. The canal is dried with large paper points.
5. Bleeding is induced into the root canal by overinstrumentation with an endodontic file.
6. Bleeding is stopped 3 mm from the cemento-enamel junction.

merdental.com/Products/Regenerative) is placed at 3 mm below the cemento-enamel junction.

8. A 3- to 4-mm layer of white MTA is placed, followed by reinforced glass ionomer and permanent coronal restoration. Glass ionomer may be a potential alternative to MTA in cases where crown discoloration is a potential aesthetic concern.

Cases treated with REPs need to be followed up at 3 months, 6 months, and annually thereafter for 4 years. Absence of signs and symptoms of pathosis, as well as radiographic evidence of bony healing within 2 years of treatment, should be expected. However, the clinical expectations for REPs are not well defined. Geisler[30] suggested that the degree of success of REPs can be measured by the achievement of a primary goal, which is the absence of symptoms and radiographic evidence of periapical healing. Secondary desirable yet not essential goals are increases in the thickness of the root walls and/or increases in the length of the immature root. Tertiary goals, indicating a high level of success, include regaining the vitality of the tooth. Clinical signs and symptoms after REPs, such as swelling, pain, or an increase in radiolucency, indicate failure of REPs, and more traditional treatment modalities should be initiated, such as MTA apexification.

REACTION OF THE TOOTH TO TRAUMA

PULPAL HYPEREMIA

The dentist must be cognizant of the inadequacies of present methods of determining the initial pulpal reaction

Dentlearn.ir



Figure 27-12 Maxillary left primary central incisor became discolored within 2 weeks after trauma. A pulp test indicated that the pulp was vital.

to an injury and of the difficulty in predicting the long-range reaction of the pulp and supporting tissues to the insult. A trauma of even a so-called minor nature is immediately followed by pulpal hyperemia.

Congestion of blood within the pulp chamber a short time after the injury can often be detected in the clinical examination. If a strong light is directed to the labial surface of the injured tooth and the lingual surface is viewed in a mirror, the coronal portion of the tooth will often appear reddish compared with the adjacent teeth. The color change may be evident for several weeks after the accident and often indicates a poor prognosis.

The dentist will occasionally observe temporary discoloration of a tooth after injury. Hyperemia and increased pressure may cause the rupture of capillaries and the escape of red blood cells, with subsequent breakdown and pigment formation. The extravasated blood may be reabsorbed before gaining access to the dentinal tubules, in which case little if any color change will be noticeable and what does appear will be temporary (Fig. 27-12). In more severe cases there is pigment formation in the dentinal tubules. The change in color is evident within 2 to 3 weeks after the injury, and although the reaction is reversible to a degree, the crown of the injured tooth retains some of the discoloration for an indefinite period. In cases of this type, there is some chance that the pulp will retain its vitality, although the likelihood of vitality is apparently low in primary teeth with dark-gray discoloration. Croll and colleagues found that 33 of 51 traumatized teeth (65%) with gray-black discoloration were necrotic.[31] Holan and Fuks conducted a retrospective study of 88 pulpectomized primary incisors, 48 of which met their nine clinical and radiographic criteria for further investigation.[32] Briefly, their criteria included dark-gray coronal discoloration as the primary diagnostic sign before pulpectomy. The remaining criteria were indicative of normal conditions or conditions only somewhat suggestive of a pulpal problem. They found that 47 (98%) of the teeth included in the study were either necrotic (37, or 77%) or partially necrotic (10, or 21%). Because all of these teeth were previously determined to need pulpectomy, the 98% confirmation is not surprising. However, the fact remains that all the teeth

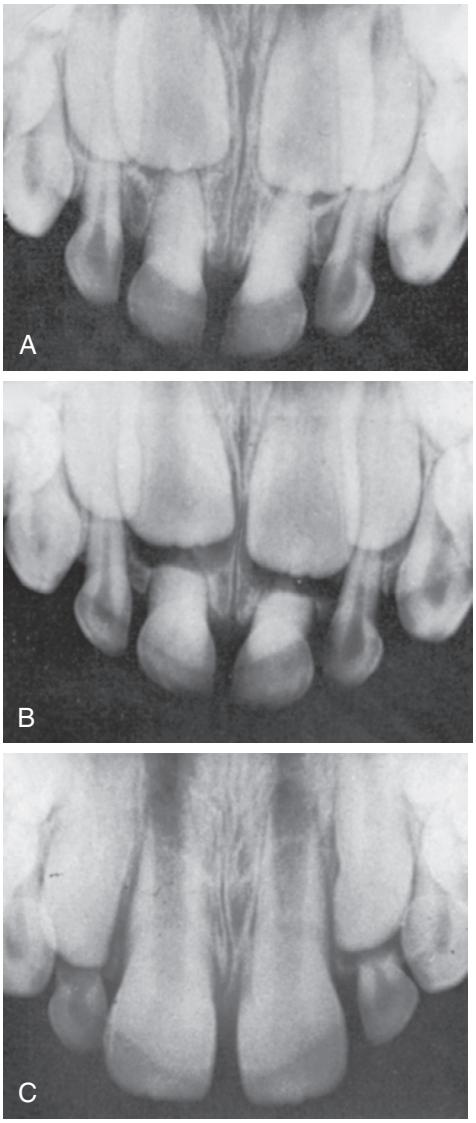

Figure 27-13 **A,** Radiograph demonstrates almost complete obliteration of the pulp chambers and canals. **B,** Normal root resorption of the primary incisors has occurred. **C,** The permanent incisors have erupted.

exhibited dark-gray discoloration and few, if any, other minor signs or symptoms of a problem. Discoloration that becomes evident for the first time months or years after an accident, however, is evidence of a necrotic pulp.

CALCIFIC METAMORPHOSIS OF THE DENTAL PULP (PROGRESSIVE CANAL CALCIFICATION OR DYSTROPHIC CALCIFICATION)

A frequently observed reaction to trauma is the partial or complete obliteration of the pulp chamber and canal (Fig. 27-13). Although the radiograph may give the illusion of complete obliteration, an extremely fine root canal and remnants of the pulp will persist.

The crowns of teeth that have undergone this reaction may have a yellowish, opaque color. Primary teeth demonstrating calcific metamorphosis will usually undergo normal root resorption, although Peterson and colleagues

Dentlearn.ir



Figure 27-14 Trauma occurred 10 years before acute symptoms developed in the left central incisor. An apical lesion area may be seen. The right central incisor was lost at the time of the injury.

have reported observing one patient who exhibited calcific metamorphosis of a maxillary primary central incisor that subsequently showed evidence of significant internal resorption in the root.[33] They emphasize the need for careful monitoring of traumatized teeth that have undergone calcific metamorphosis.

Permanent teeth will often be retained indefinitely. However, a permanent tooth showing signs of calcific changes as a result of trauma should be regarded as a potential focus of infection. A small percentage of such teeth demonstrate pathologic change many years after the injury (Fig. 27-14).

believed to be caused by odontoclastic action. It may be observed radiographically in the pulp chamber or canal within a few weeks or months after an injury. The destructive process may progress slowly or rapidly. If progression is rapid, it may cause a perforation of the crown or root within a few weeks (Fig. 27-15). Mummery described this condition as "pink spot" because when the crown is affected, the vascular tissue of the pulp shines through the remaining thin shell of the tooth.[34] He referred to the occurrence of a perforation as "perforating hyperplasia of the pulp." If evidence of

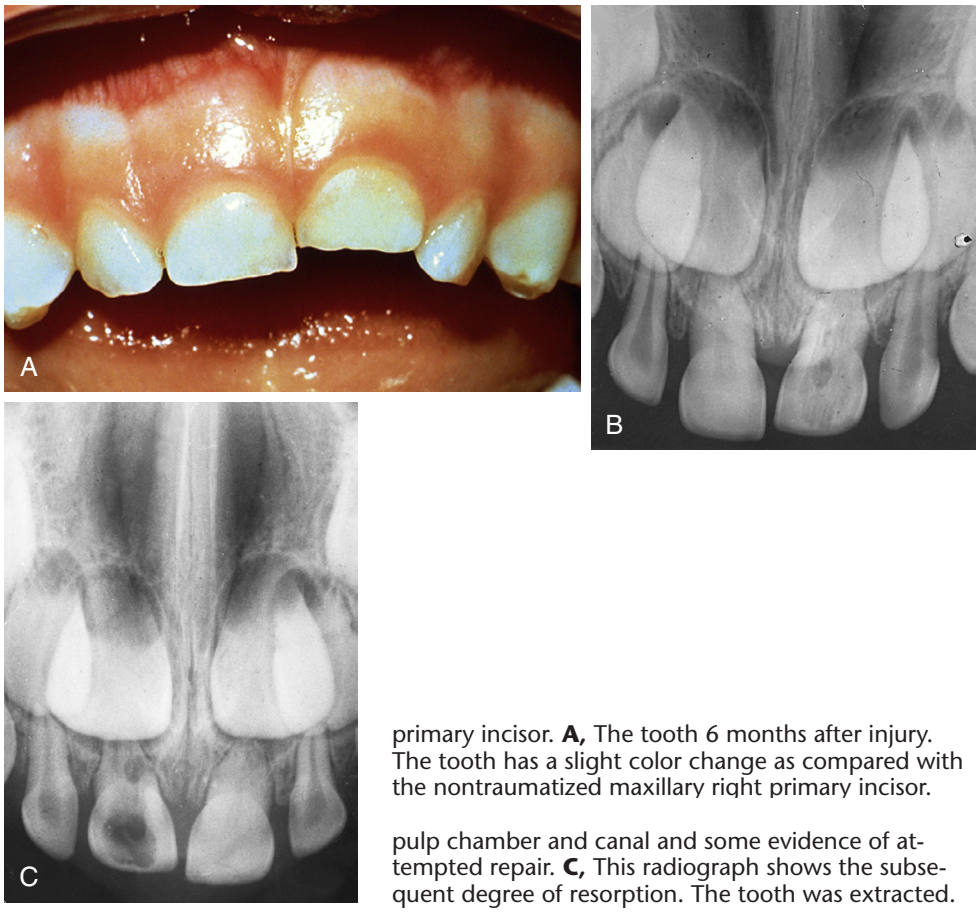

primary incisor. **A,** The tooth 6 months after injury. The tooth has a slight color change as compared with the nontraumatized maxillary right primary incisor.

pulp chamber and canal and some evidence of attempted repair. **C,** This radiograph shows the subsequent degree of resorption. The tooth was extracted.

Dentlearn.ir

extensive with resulting perforation, the tooth may possibly be retained when endodontic procedures are instituted.

PERIPHERAL (EXTERNAL) ROOT RESORPTION

Trauma with damage to the periodontal structures may cause peripheral root resorption (Fig. 27-16). This reaction starts from without, and the pulp may not become involved. Usually the resorption continues unabated until gross areas of the root have been destroyed. In exceptional cases the resorption may become arrested, and the tooth may be retained. Peripheral root resorption is most often observed in cases of severe trauma in which there has been some degree of displacement of the tooth.

PULPAL NECROSIS

Little relationship exists between the type of injury to the tooth and the reaction of the pulp and supporting tissues. A severe blow to a tooth causing displacement often results in pulpal necrosis. The blow may cause a severance of the apical vessels, in which case the pulp undergoes autolysis and necrosis. In a less severe type of injury, the hyperemia and slowing of blood flow through the pulpal tissue may cause eventual necrosis of the pulp. In some cases the necrosis may not occur until several months after the injury.

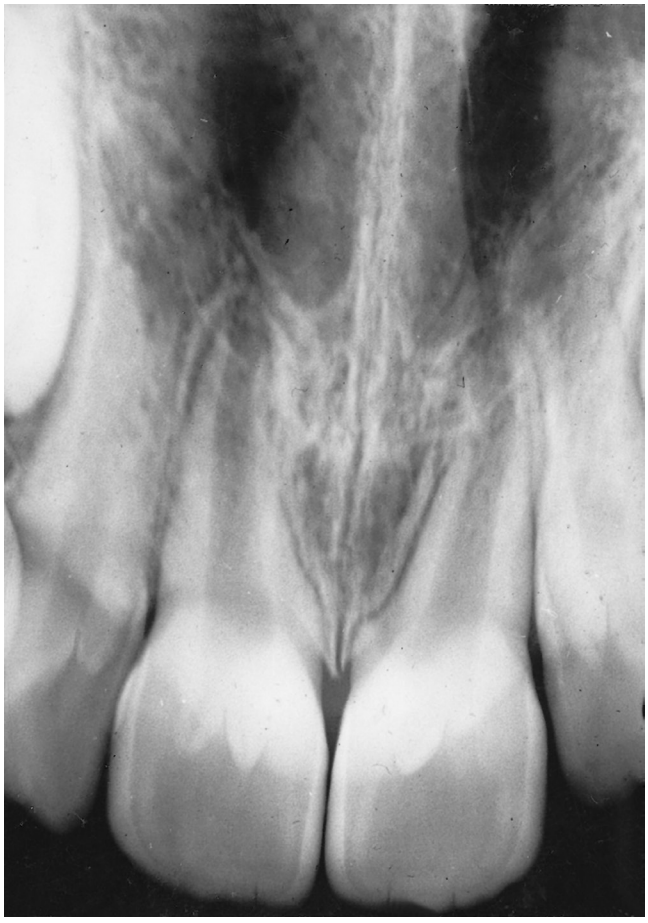

Figure 27-16 Radiographic evidence of peripheral root resorption. In these teeth the pulp vitality was retained and root resorption did not continue.

A tooth receiving an injury that causes coronal fracture may have a better pulpal prognosis than a tooth that sustains a severe blow without fracturing the crown. Part of the energy of the blow dissipates as the crown fractures, rather than all of the energy's being absorbed by the tooth's supporting tissues. Thus the periodontium and the pulp of the injured tooth sustain fewer traumas when the crown fractures. The prognosis for long-term retention of the tooth and for maintenance of pulp vitality may then improve. However, because some teeth do not recover from traumatic blows that seem relatively minor, all injured teeth should be closely monitored.

Injured teeth with subsequent pulpal necrosis are commonly asymptomatic, and the radiograph is essentially normal. It should be realized, however, that these teeth are probably infected and that acute symptoms and clinical evidence of infection will inevitably develop at a later date. The tooth with a necrotic pulp should therefore be extracted or treated with endodontic procedures, whichever is indicated.

A necrotic pulp in an anterior primary tooth may be successfully treated if no extensive root resorption or bone loss has occurred (Fig. 27-17). The treatment technique is essentially the same as that for permanent teeth. However, trauma to the periapical tissues during canal instrumentation must be carefully avoided. After the canal has been properly prepared via a facial access in this example, it is filled with slow-setting zinc oxide–eugenol. The canal walls are first lined with a thin mix of the canal-filling material. A thicker mix should then be placed in the pulp chamber. Over this is placed a pledget of cotton, and the material is forced into the canal with a small amalgam plugger.

ANKYLOSIS

Another reaction observed after trauma to anterior primary or permanent teeth is ankylosis, a condition caused by injury to the periodontal ligament and subsequent inflammation, which is associated with invasion by osteoclastic cells. The result is irregularly resorbed areas on the peripheral root surface. In histologic sections, repair can be seen that may cause a mechanical lock or fusion between alveolar bone and the root surface. Clinical evidence of ankylosis is seen as a difference in the incisal plane of the ankylosed tooth and adjacent teeth. The adjacent teeth continue to erupt, whereas the ankylosed tooth remains fixed in relation to surrounding structures. The radiograph may show an interruption in the periodontal membrane of the ankylosed tooth, and often the dentin may appear to be continuous with alveolar bone.

The ankylosed anterior primary tooth should be removed if there is evidence of its causing delayed or ectopic eruption of the permanent successor. If ankylosis of a permanent tooth occurs during active eruption, eventually a discrepancy between the position of this tooth and its adjacent ones will be obvious. The uninjured teeth will continue to erupt and may drift mesially, with a loss of

Dentlearn.ir



Figure 27-17 **A,** Evidence of dark crown for the maxillary left central incisor, demonstrating possible pulpal necrosis. A pulp test indicated that the pulp was nonvital. **B,** A conservative facial access was used to enter the pulp chamber. This access helped maintain tooth structure for the final restoration. **C,** The canal was instrumented to remove all necrotic tissue. Special care was taken not to traumatize the periapical tissue during instrumentation. **D,** A paper point was used to dry the canal thoroughly before placement of the filling material. **E,** A slow-setting zinc oxide–eugenol mix was gently spun into the canal by rotary instrumentation. **F,** Postoperative radiograph showing excellent filling of the canal to the apex of the tooth. **G,** Final restoration after the necrotic pulp was addressed. A facial composite restoration was used as a conservative restoration in this clinical presentation. (Courtesy Dr. James Weddell.)

arch length. Therefore either surgical repositioning or the removal of a permanent tooth that becomes ankylosed is often necessary, especially if the ankylosis occurs during the preteen or early teen years.

RESTORATION OF FRACTURED TEETH

The restoration of a fractured tooth is as important as the emergency treatment designed to aid in the recovery of the pulp after the trauma. Several restorations have been advocated, and although the dentist has a wide choice of techniques and types of restorations, the circumstances surrounding the case often dictate the type of restoration for a given patient. The prognosis of pulp healing, the amount of tooth structure remaining, the stage of eruption of the tooth and adjacent teeth, the size of the dental pulp and degree of root closure, the normalcy of the occlusion, and the wishes of the patient must all be considered in the selection of a temporary restoration, an intermediate restoration, or the permanent restoration. In the young patient, although it is often desirable to wait for continued eruption of the tooth or to determine the outcome of a vital pulp procedure, a delay of even a few weeks is often sufficient to allow the tipping of adjacent teeth, overeruption of opposing teeth, or other undesirable changes in the occlusion.

AESTHETIC BONDED COMPOSITE RESIN RESTORATION

The feathered-edge restorative technique without mechanical tooth preparation is appropriate in some situations, but it requires excessive contour in the restoration. It offers the advantage of creating less irritation to the pulp because little or no enamel modification is required. In some cases the excess contour is relatively insignificant, but it may be more significant if the restoration is large (50% or more of the crown) or the fracture extends near or below gingival tissue. Excessive contour on the lingual surface of a maxillary anterior tooth may interfere with normal occlusion.

A beveled preparation affords the dentist the opportunity to reduce the amount of overcontouring of larger restorations, and it reduces contour in areas where the occlusion prohibits overcontouring. The dentist may elect the feathered-edge technique (no preparation) on the labial tooth surface and the beveled preparation on the proximal or lingual surface, or both. Both techniques are described in the following discussion.

When a beveled preparation is desired, the bevel is made in the enamel around the entire circumference or the selected part of the fracture (Fig. 27-18). The bevel should be about 1 to 2 mm incisocervically and about halfway (or more) through the thickness of the enamel at the fracture margins. The labial enamel margin should be irregular to provide a better aesthetic blending of the resin with the tooth structure. This sequence may be altered if the practitioner uses some of the latest-generation bonding adhesive systems.

The exposed dentin from a recent injury may be covered with a calcium hydroxide liner. Dilute phosphoric

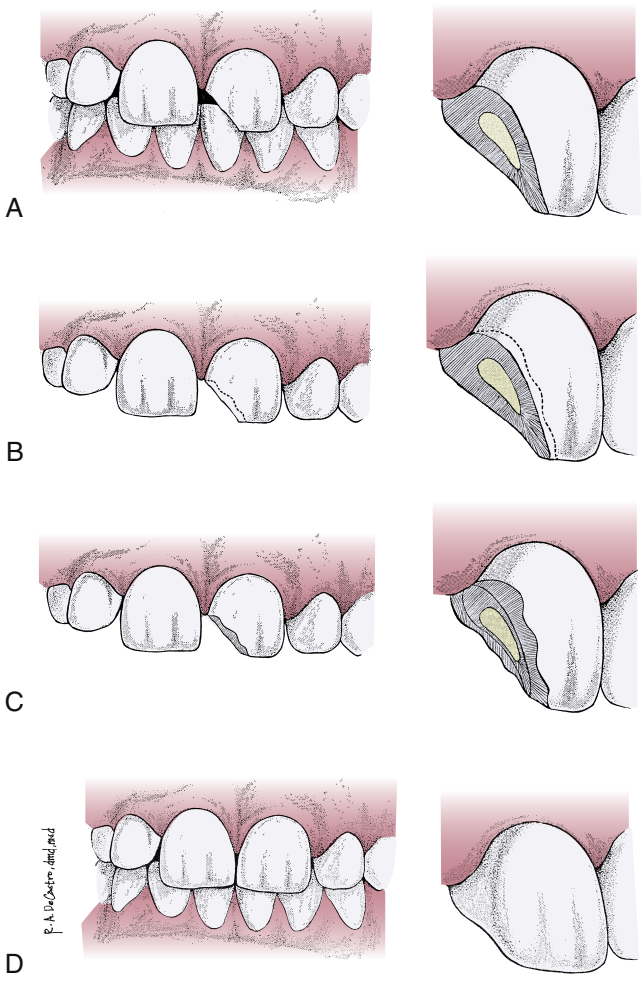

Figure 27-18 **A,** Typical uncomplicated crown fracture of a permanent incisor. **B,** Dotted line represents the approximate location of the irregular enamel margin to be placed on the labial surface in the bevel preparation. **C,** Bevel preparation complete and ready for etching. **D,** Bonded composite material restored natural contour and color.

acid (etchant or tooth conditioner) is applied to the enamel surface of the preparation for about 20 seconds (longer for primary teeth). The tooth is then thoroughly flushed with water, and excess moisture is removed with air. The etched area should appear frosty and opaque. Alternatively, the total-etch technique may be used. In either case a bonding agent is applied to all etched tooth structures. Again, this sequence may be altered with the use of some of the latest bonding adhesive systems.

A celluloid matrix strip may be placed interproximally and wedged for close adaptation at the gingival margin. In large restorations a custom-cut celluloid crown form matrix may be used to help contour the restoration.

Often, little or no mechanical preparation of the fractured incisor is necessary with the feathered-edge technique. Instead, the resin margins are allowed to overlap the fractured edges to become feathered-edge margins

Dentlearn.ir

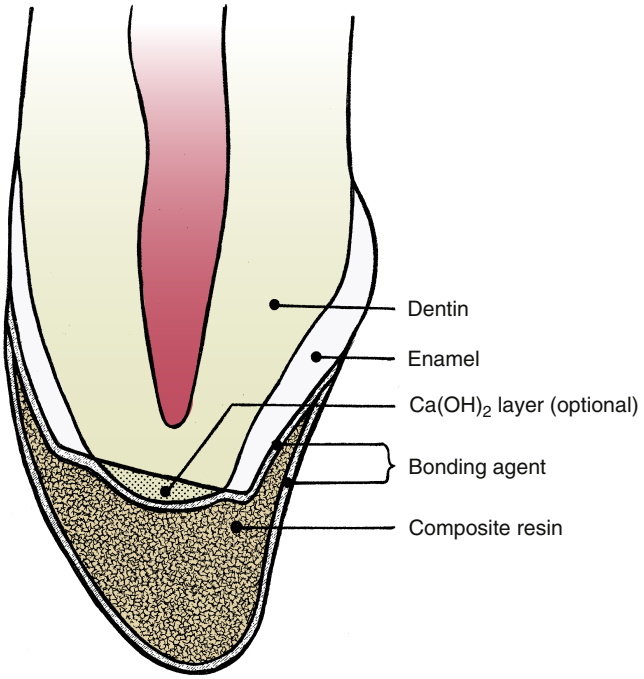

Figure 27-19 This sagittal drawing illustrates the application of a feathered-edge restoration on a fractured incisor. Little or no tooth preparation is required before calcium hydroxide (optional) is placed on the exposed dentin and the tooth is etched. Slight beveling of the fractured enamel margins is suggested. The drawing also illustrates the need for overcontouring of the labial and lingual surfaces with the feathered-edge restoration.

on the etched sound enamel cervical to the fracture (Fig. 27-19). This procedure requires a slightly overcontoured restoration and therefore has limitations. The dentist should be alert to potential undesirable changes in gingival health or the creation of traumatic occlusion. Slight beveling of the fractured enamel margins is usually recommended with the feathered-edge technique to remove loose enamel rods and ensure a fresh surface for etching. The exposed dentin may be protected with a layer of hard-setting calcium hydroxide, and etching should extend 2 or 3 mm beyond the fracture to allow an adequate surface for feather-edging of the resin restorative materials. Most manufacturers supply a kit, which usually includes an etchant, a bonding agent, the restorative materials, and a shade guide. The bonding agent is applied to the etched surfaces.

The light-polymerized materials offer the advantage of allowing the clinician to build or sculpt the restoration in small increments and minimize finishing time. Clinical studies have confirmed that excellent and durable restorations may be obtained. Finishing disks and large, round finishing burs or diamonds may be used to contour the labial and lingual surfaces.

REACTION OF PERMANENT TOOTH BUDS TO INJURY

The dentist who provides emergency care for a child after an injury to the anterior primary teeth must be aware of the possibility of damage to the underlying developing permanent teeth.



Figure 27-20 Skull of a 5-year-old child demonstrating the relationship between the position of the roots of the primary central and lateral incisors and the crowns of their permanent successors (see *arrows*).

Andreasen and colleagues have reported on the effects of injuries to primary teeth on their permanent successors.[35] In a clinical and radiographic study of 213 teeth, these investigators reported that more than 40% of their young patients had changes in the permanent teeth that could be traced to injury to the primary dentition. The close anatomic relationship between the apices of primary teeth and their developing permanent successors explains why injuries to primary teeth may involve the permanent dentition (Fig. 27-20).

The dentist and the physician should also be aware of the possibility of trauma to permanent tooth buds from other unusual injuries so that parents may be informed of the possibility of defective permanent tooth development. Some injuries to the face and jaws may not appear to have caused any dental injuries initially, but the problem may be noticed several months or years later (Fig. 27-21).

HYPOCALCIFICATION AND HYPOPLASIA

Cutright's experiments with miniature pigs have shown many lesions similar to those seen in permanent human teeth as a result of trauma, infection, or both.[36] He observed small areas that showed destruction of the ameloblasts and a pitted area where a thin enamel layer had been laid down before the injury. In other teeth there was evidence of destruction of the ameloblasts before any enamel had been laid down, resulting in hypoplasia that clinically appeared as deep pitting.

Dentlearn.ir

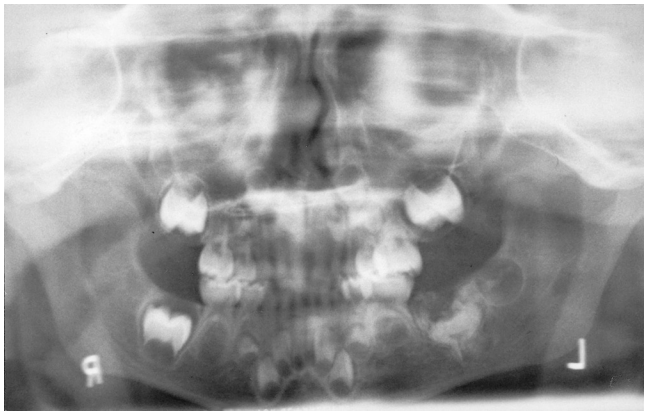

Figure 27-21 This radiograph of a 4-year-old child reveals improper formation of the mandibular left first permanent molar. At 18 months, the child had been viciously attacked by a dog. There had been a severe puncture wound of the lower left jaw from the dog's canines, although it was not known then that the injury involved the permanent molar tooth bud. The calcified lesion was removed and microscopically diagnosed as a developing tooth with displaced enamel matrix into follicular tissue. Early removal enhanced the potential of the normally developing second permanent molar to eventually acquire an acceptable first permanent molar position.

Permanent teeth in humans may show a variety of these defects, including gross malformations of the crown (Fig. 27-22). The presence of a small, pigmented hypoplastic area has been referred to as *Turner tooth*. Small hypoplastic defects may be restored by the resin-bonding technique.

REPARATIVE DENTIN PRODUCTION

In cases in which the injury to the developing permanent tooth is severe enough to remove the thin covering of developing enamel or cause destruction of the ameloblasts, the subjacent odontoblasts have been observed to produce a reparative type of dentin. The irregular dentin bridges the gap where there is no enamel covering to aid in protecting the pulp from further injury.

DILACERATION

The condition referred to as dilaceration occasionally occurs after the intrusion or displacement of an anterior primary tooth. The developed portion of the tooth is twisted or bent on itself, and in this new position growth of the tooth progresses. Cases have been observed in which the crown of a permanent tooth or a portion of it develops at an acute angle to the remainder of the tooth (Fig. 27-23). Kilpatrick and colleagues reported a dilacerated root of a primary central incisor in a 6-year-old boy.[37] The tooth was necrotic, the root had not resorbed, and the apex of the root was exposed in the labial sulcus and was associated with a draining sinus. No specific history of trauma could be confirmed, but the child was prone to accidents. The authors speculate that this unusual dilaceration may have been due to injury soon after initial eruption of the tooth.

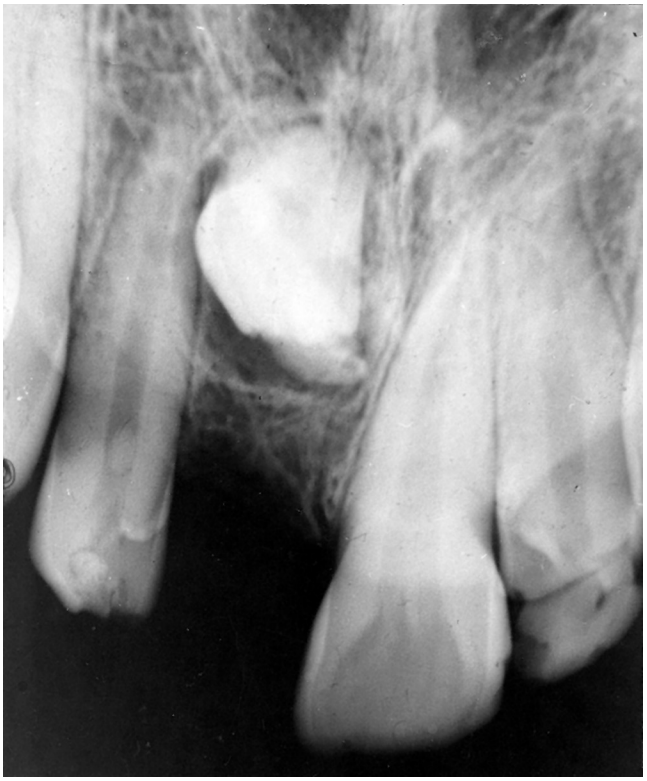

Figure 27-22 Radiograph of malformed central incisor. This condition can be traced to a severe trauma to the primary teeth.

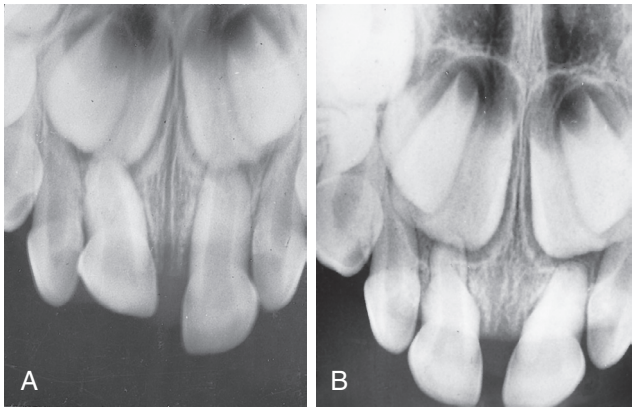

Figure 27-23 **A,** The degree of intrusion of the primary tooth. Damage to the permanent teeth often results from an injury of this type. **B,** Radiograph obtained 8 months after the injury shows that the injured tooth has re-erupted. The pulp has retained its vitality, although there is evidence of partial obliteration of the pulp canal. External root resorption has occurred on the adjacent central incisor.

DISPLACEMENT OF PRIMARY AND PERMANENT ANTERIOR TEETH (LUXATION)

INTRUSION AND EXTRUSION OF TEETH

The displacement of anterior primary and permanent teeth presents a challenge in diagnosis and treatment for the



Figure 27-24 Radiograph of intruded primary central incisor with its root apex lying labial to the permanent central incisor.

dentist. Relatively few studies have been reported that can be used as a guide for the treatment of injuries of this type.

Primary Teeth

Intrusion by forceful impaction of maxillary anterior primary teeth is a common occurrence in children during the first 3 years of life. Frequent falls and striking of the teeth on hard objects may force the teeth into the alveolar process to the extent that the entire clinical crown becomes buried in bone and soft tissue. Although there is a difference of opinion regarding treatment of injuries of this type, it is generally agreed that immediate attention should be given to soft-tissue damage. Intruded primary teeth should be observed; with few exceptions, no attempt should be made to reposition them after the accident. Most injuries of this type occur at an age when it would be difficult to construct a splint or a retaining appliance to stabilize the repositioned teeth.

Normally, the developing permanent incisor tooth buds lie lingual to the roots of the primary central incisors. Therefore when an intrusive displacement occurs, the primary tooth usually remains labial to the developing permanent tooth (Fig. 27-24). If the intruded primary tooth is found to be in a lingual or encroaching relationship to the developing permanent tooth, it should be removed. Such a relationship may be confirmed from a lateral radiograph of the anterior segment.

The examination should be carried out as previously described, and radiographs should be made to detect evidence of root fracture, fracture of the alveolar bone, and damage to permanent teeth. However, predicting whether the permanent successors will show evidence of interrupted growth and development is impossible unless actual encroachment of their space can be seen radiographically.

Primary anterior teeth intruded as a result of a blow may often re-erupt within 3 to 4 weeks after the injury. In a study of the results of 248 traumatic episodes to primary incisors, Ravn reported 88 cases of intrusion.[38] Of these teeth, four were extracted within 2 weeks because of infection and four did not re-erupt and were extracted several months later, but the remaining 80 teeth fully re-erupted within 6 months. Incipient re-eruption was observed 14 days after the injury in a few instances. These teeth may even retain their vitality and later undergo normal resorption and be replaced on schedule by their permanent successors. During the first 6 months after the injury, however, the dentist often observes one or more of the reactions of the pulp and supporting tissues that have been mentioned previously in this chapter, the most common of which is pulpal necrosis. Even after re-eruption, a necrotic pulp can be treated if the tooth is sound in the alveolus and no pathologic root resorption is evident.

Primary teeth that are displaced but not intruded should be repositioned by the dentist or parent as soon as possible after the accident, to prevent interference with occlusion. The prognosis for severely loosened primary teeth is poor. Frequently the teeth remain mobile and undergo rapid root resorption.

Skieller observed 60 children treated for looseness of one or more young teeth.[39] Loosened teeth were divided into 3 groups: those with spontaneous re-eruption, those with impaction, and those with dislocation with extrusion. He concluded that the immediate and future prognosis for the pulp was more favorable if root formation was still incomplete at the time of the accident. Root resorption, which was observed in impaction cases. Teeth with complete root formation seemed to undergo resorption more frequently than those with incomplete root formation. However, when resorption did occur, it was more extensive and progressed more rapidly in teeth with incomplete root development.

Permanent Teeth

Intruded permanent teeth apparently have a poorer prognosis than similarly injured primary teeth. The tendency for the injury to be followed by rapid root resorption, pulpal necrosis, or ankylosis is greater.

The treatment for a permanent tooth with a closed root end, and intruded less than 3 mm, is to allow the tooth to erupt without intervention. If no movement is evident after 2 to 4 weeks, the tooth may be repositioned either orthodontically or surgically before ankylosis can take place. If the tooth is intruded 7 mm or more, the tooth is repositioned surgically and stabilized for 4 to 8 weeks by means of a flexible splint. In most instances the pulp will become necrotic with intrusive injuries in teeth with complete root formation. Root canal treatment should be initiated, with calcium hydroxide as a temporary canal-filling material, 2 to 3 weeks after stabilization.[5]

The treatment for an intruded permanent tooth with incomplete root formation is to allow it to erupt spontaneously. If no movement is seen within a few weeks, orthodontic repositioning should begin. If the tooth is intruded 7 mm or more, the tooth can be repositioned surgically and stabilized by means of a flexible splint. Endodontic therapy is often required, however, and the tooth should be monitored closely while a decision on endodontic therapy is pending.[5]

Recently Alkhalifa and Alazemi conducted a literature review to assess the current strength of evidence of factors important in choice of treatment for intrusive luxation of permanent teeth.[40] Only cohort studies comparing spontaneous eruption and surgical and orthodontic extrusion were assessed. Of the 117 studies identified, only three

Dentlearn.ir

were suitable for inclusion in their analysis; these studies were not meta-analyzed because of methodological and clinical heterogeneity. The authors concluded that, given that infection can be controlled by endodontic therapy, it appears that spontaneous eruption results in the fewest complications in immature teeth, regardless of the degree of intrusion. There appear to be no significant differences between surgical and orthodontic extrusion in terms of adverse outcomes. Spontaneous eruption had a low failure rate of 5% to 12%. They believe that guidelines for treatment are currently not based on strong evidence.

Wang and associates evaluated 603 teeth with uncomplicated crown fractures followed for 6 months or longer, 104 of which suffered luxation at the same time. The frequency of pulpal necrosis in teeth with complete root development was higher than in those with incomplete root development. Teeth with uncomplicated crown fractures with luxation and crown-fractured teeth with intrusion had a higher incidence of pulpal necrosis than any other types of concurrent luxation. The incidence of pulpal necrosis within 3 months was significantly higher than in other time periods evaluated. They concluded that a concurrent luxation injury and complete root development are important risk factors of pulpal necrosis with uncomplicated crown fractures.[41]

Tronstad and associates have reported on the management of severely intruded mature maxillary central incisors in an 11-year-old patient in whom spontaneous re-eruption occurred.[42] Rather than repositioning the teeth to gain endodontic access, they performed a palatal gingivectomy and endodontic treatment 10 days after the injury, while the teeth remained in their intruded position. Eight weeks after the injury, the teeth had re-erupted naturally and were judged to be near their original position. Similar management of severely intruded immature central incisors has been reported by Shapira and colleagues.[43] In these cases the palatal gingivectomies and endodontic treatment were performed 8 to 10 weeks after injury, when periapical rarefactions and root resorption were noted radiographically. Accelerated spontaneous re-eruption of all treated teeth was noted soon after the gingivectomies and calcium hydroxide endodontic treatments were performed. Complete re-eruption of the teeth and apparent periapical and periodontal healing had occurred 2 to 3 months after the surgical intervention.

It seems that both treatment approaches to the treatment of severely intruded permanent teeth (early repositioning or waiting for spontaneous re-eruption) have demonstrated reasonably successful results. However, the affected teeth seem to benefit by early calcium hydroxide endodontic therapy with either treatment approach. The decision to reposition mechanically or hope for spontaneous re-eruption of intruded permanent teeth remains a matter of clinical judgment that may be based on several conditions associated with the particular case.

The extrusive luxation of a permanent tooth usually results in pulpal necrosis. The immediate treatment involves the careful repositioning of the tooth and stabilization following the technique described later in this chapter. If mature repositioned teeth do not respond to pulp vitality tests within 2 to 3 weeks after being repositioned, endodontic treatment should be undertaken before there is evidence of root resorption, which often occurs after severe injuries of this type. The need for endodontic intervention is virtually certain in cases of significant extrusion (more than 2 mm) of mature teeth. With extruded immature teeth, the clinician should monitor the situation frequently and be prepared to intervene with endodontic therapy, as described later, if conditions warrant.[5]

AVULSION AND REPLANTATION

Replantation is the technique in which a tooth, usually one in the anterior region, is reinserted into the alveolus after its loss or displacement by accidental means. There are few reports in the literature of this technique's proving successful for indefinite periods of time. For example, Barry reports on functioning teeth that were replanted 42 years earlier.[44] However, slow or even rapid root resorption often occurs with even the most precise and careful technique. Replantation of permanent teeth continues to be practiced and recommended, however, because prolonged retention is also achieved in many cases, especially when replantation occurs soon after the accident. The replanted tooth serves as a space maintainer and often guides adjacent teeth into their proper position in the arch, a function that is important during the transitional dentition period. The replantation procedure also has psychological value. It gives the unfortunate child and parents hope for success; even though they are told of the possibility of eventual loss of the tooth, the early result often appears favorable and softens the emotional blow of the accident (Figs. 27-25 and 27-26).

The success of the replantation procedure is undoubtedly related to the length of time that elapses between the loss of the tooth and its replacement in the socket. The condition of the tooth and particularly the condition of the periodontal ligament tissue remaining on the root surface are also important factors that influence the success of replantation. There have been reports that immediate replacement of a permanent tooth occasionally results in the maintenance of vitality and indefinite retention. However, replantation should generally be viewed as a temporary measure. Under favorable conditions, many replanted teeth are retained for 5 or 10 years and a few for a lifetime. Others, however, fail soon after replantation.

Camp reports that the tooth most commonly avulsed in both the primary and the permanent dentition is a maxillary central incisor.[45] Most often, an avulsion injury involves only a single tooth. Avulsion injuries are three times more frequent in boys than in girls and occur most commonly in children from 7 to 9 years of age, when permanent incisors are erupting. Andreasen suggests that the loosely structured periodontal ligament surrounding the erupting teeth favors complete avulsion.[46]

The sooner a tooth can be replanted in its socket after avulsion, the better the prognosis will be for retention without root resorption. Andreasen and Hjørting-Hansen reported a follow-up study of 110 replanted teeth. Of those replanted within 30 minutes, 90% showed no discernible evidence of resorption 2 or more years later.[47] However, 95% of the teeth replanted more than 2 hours after the injury showed root resorption. If the tooth has been out of the mouth for under 30 minutes, the prognosis is therefore

Dentlearn.ir

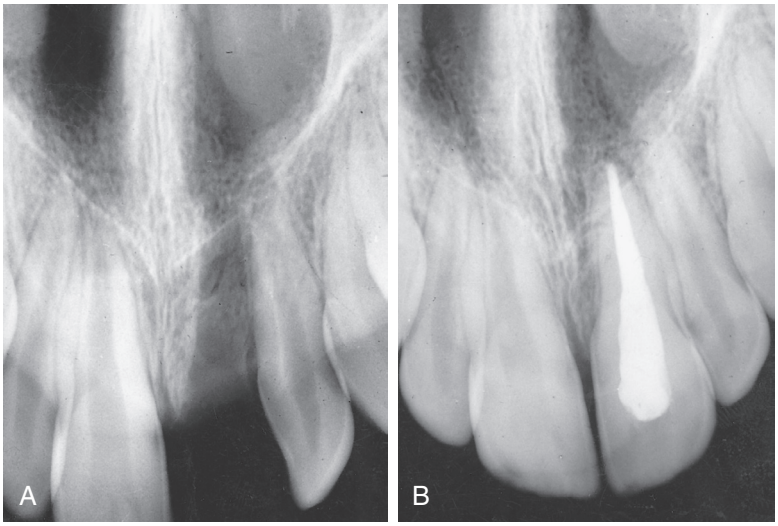

Figure 27-25 **A,** Radiograph of a patient who lost a central incisor as the result of trauma. Replantation was performed. **B,** After the replantation procedure, peripheral root resorption is evident along the mesial surface.

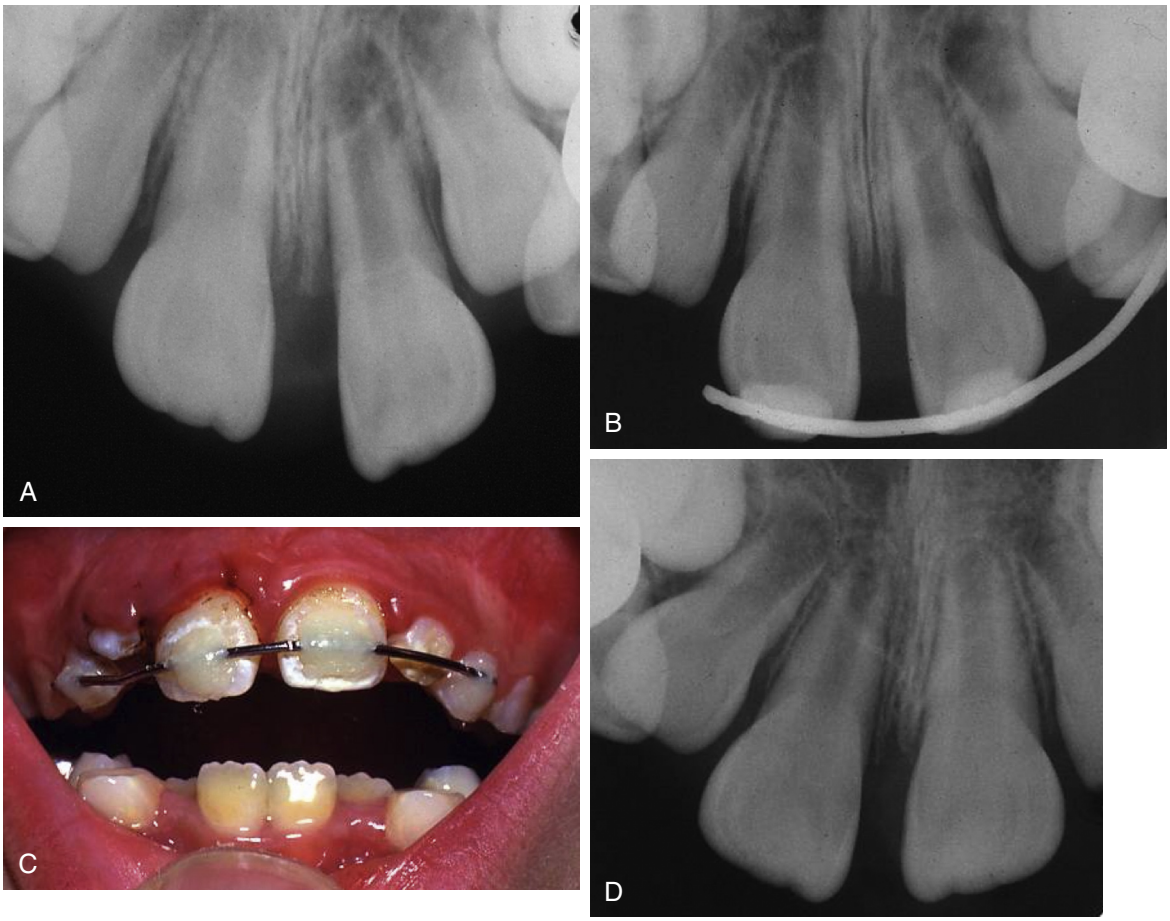

Figure 27-26 **A,** Radiograph of an avulsed maxillary right central incisor, with incomplete root development, that was positioned into the canal immediately upon arrival at the office. The patient was seen within 20 minutes after tooth avulsion. Note the degree to which the tooth was repositioned to approximate its original position. Gentle pressure was exerted to place the apex of the root in the ideal position. **B,** Radiograph of the avulsed central incisor showing that it is now at the desired position and has been stabilized with a section of 0.028-inch stainless steel wire. Note that at least one nontraumatized tooth, on either side of the avulsed incisor, was used to anchor the splint. The splint will remain in place for at least 7 to 10 days. **C,** Splint in place at the end of the initial appointment. **D,** Radiograph at the conclusion of 10 days of splint therapy. The incisor tested vital to both electric and cold pulp-testing. The incisor, to this date, has received periodic evaluation and has not required follow-up pulp therapy.

more favorable. Also, if the apical end of the tooth is incompletely developed at the time of the injury, there is a greater chance of regaining pulp vitality after replantation. If the apex is closed, the dentist should proceed with a pulpectomy a few days after the replantation, even if the extraoral time for the tooth was brief.

If a parent calls to report that a tooth has been avulsed, and it can be determined that the injury is without other oral, neurologic, or higher-priority physical complications, the dentist may instruct the parent to do the following (primary teeth should not be replanted)[5]:

1. Keep the patient calm.
2. Find the tooth and pick it up by the crown (the white part). Avoid touching the root.
3. If the tooth is dirty, wash it briefly (10 seconds) under cold running water and reposition it. Try to encourage the patient/parent to replant the tooth. Bite on a handkerchief to hold the tooth in position.
4. If repositioning is not possible, place the tooth in a suitable storage medium (see below).
5. Seek emergency dental treatment immediately, unless the patient was knocked unconscious. If the child was unconscious for a period of time, first seek emergency medical evaluation for a concussion.

If the parent cannot or will not replant it, the tooth must be kept moist during the trip to the dental office. Allowing the avulsed tooth to dehydrate before replantation is damaging to a favorable prognosis. Hanks' buffered saline, isotonic saline, and pasteurized bovine milk may be the most favorable known storage media. Although tap water has been a commonly recommended storage solution (and its use would be preferable to dehydration of the tooth), it is hypotonic, and its use leads to rapid cell lysis and increased inflammation on replantation.

The patient should receive immediate attention after arriving at the dental office. If the tooth has not already been replanted, the dentist should make every effort to minimize the additional time that the tooth is out of the socket. The patient's general status should be quickly assessed to confirm that there are no higher-priority injuries.

If an evaluation of the socket area shows no evidence of alveolar fracture or severe soft-tissue injury, the tooth is intact, and only a few minutes have elapsed since the injury, the dentist should replant the tooth immediately. Under the conditions just described, every effort should be directed toward preserving a viable periodontal ligament. Trope correctly asserts that treatment should be directed at avoiding or minimizing the resultant inflammation that occurs as a direct result of the two main consequences of tooth avulsion: attachment damage and pulpal infection.[48] If the tooth was cleanly avulsed, it can probably be replanted without local anesthetic, and obtaining the initial radiograph can also be delayed until the tooth is replaced in the socket and held with finger pressure. The minutes saved may contribute to a more successful replantation. If a clot is present in the socket, it will be displaced as the tooth is repositioned; the socket walls should not be scraped with an instrument. If the tooth does not slip back into position with relative ease when finger pressure is used, local anesthesia and a radiographic evaluation are indicated. Local anesthetic should also be administered when fractured and displaced alveolar bone must be repositioned before the tooth is replanted. Soft-tissue suturing may be delayed until the tooth has been replaced in the socket; however, the suturing should be performed to control hemorrhage before the tooth is stabilized with a bonded splint. Splinting techniques are discussed in the next section of this chapter.

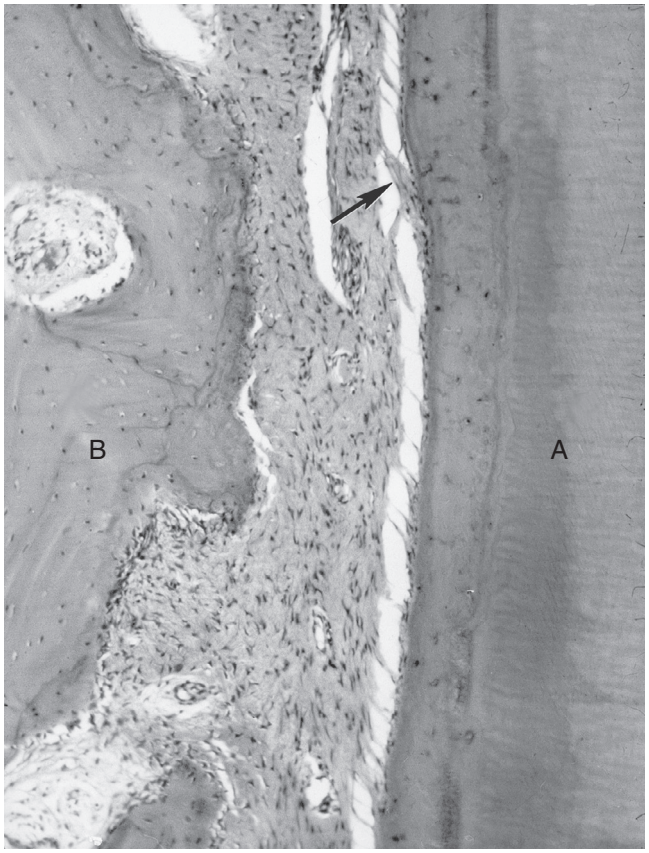

Figure 27-27 Microscopic section of a tooth replanted with the periodontal ligament intact. The reattachment of the periodontal fibers is illustrated by their crossing the tear in the periodontal ligament. **A,** Tooth. **B,** Alveolar bone. (Courtesy Dr. Philip Sherman Jr.)

Sherman studied the mechanism by which the replanted tooth becomes secured in the alveolus.[49] Intentional replantation was performed on 25 incisors in dogs and monkeys. The root canals were hermetically sealed with gutta-percha, and the teeth were splinted for 1 month. Subsequent microscopic examination under fluorescent and incandescent light revealed deposition of secondary cementum and new alveolar bone, which entrapped the periodontal fibers (Fig. 27-27).

The preservation of an intact and viable periodontal ligament is the most important factor in achieving healing without root resorption. Delicate handling of the tooth, storage in an appropriate moist environment, quick replantation, and appropriate stabilization are all important in preserving the periodontal ligament. Undesirable periodontal ligament reactions may result in replacement resorption (ankylosis) or inflammatory resorption of the root. Either reaction may cause eventual loss of the tooth unless the resorption can be controlled. Use of an enamel matrix derivative (Emdogain; Biora, Chicago, IL, and

Dentlearn.ir

Malmö, Sweden) has been shown to increase the incidence of healed periodontal ligament when this gel is applied to the root surface of the avulsed tooth and/or inserted directly into the alveolar socket before implantation. It appears to aid in preventing or retarding resorption and ankylosis.

Stabilization of Replanted Teeth

After replantation of a tooth that has been avulsed, a splint is required to stabilize it during at least the first week of healing. Camp[45] has stated that an acceptable splint should meet the following criteria:

1. It should be easy to fabricate directly in the mouth, without lengthy laboratory procedures.
2. It should be able to be placed passively without causing forces on the teeth.
3. It should not touch the gingival tissues, causing gingival irritation.
4. It should not interfere with normal occlusion.
5. It should be easily cleaned and allow for proper oral hygiene.
6. It should not traumatize the teeth or gingiva during application.
7. It should allow an approach for endodontic therapy.
8. It should be easy to remove.

The splint should also allow mobility of the replanted tooth that is comparable with the normal mobility of a tooth. Rigid stabilization seems to stimulate replacement resorption of the root. Hurst has demonstrated that rigid stabilization of a replanted tooth is detrimental to proper healing of the periodontal ligament.[50]

The bonded resin and wire splint satisfies all the criteria just described. It can be used in most situations requiring the stabilization of one or more teeth if sufficient sound teeth remain for anchorage. Rectangular or round orthodontic wire is bent to approximate the arch configuration along the midportion of the labial surfaces of the teeth to be incorporated into the splint. At least one sound tooth on each side of the tooth to be stabilized is included. The size of the wire is not too critical, but rectangular wire should be at least 0.016 × 0.022 inch and round wire at least 0.018 inch. If three or four teeth must be stabilized, a stiffer wire (e.g., 0.028-inch round wire) is required. If round wire is used, a right-angle bend should be made near each end of the wire to prevent rotation of the wire in the resin. A 20- to 30-pound-test monofilament nylon line is an acceptable substitute for wire in the splint.

If the labial enamel surfaces to be etched are not plaque-free, they should be cleaned with a pumice slurry, rinsed, thoroughly dried, and isolated with cotton rolls. The enamel surfaces are etched with a phosphoric acid etchant; the gel form is convenient. The enamel surfaces are thoroughly washed and dried again. The wire is then attached to the abutment teeth by the placement of increments of the resin material over the wire and onto the etched enamel. The resin should completely surround a segment of the wire, but it should not encroach on the proximal contacts or embrasures. The replanted tooth is then held in position while resin is used to bond it to the wire. The resin may be lightly finished if necessary after polymerization. The splint is easily removed (usually 7 to 10 days later) by cutting through the resin with a bur to uncover the wire. The remaining resin may then be removed with conventional finishing instruments. If the splint is used to stabilize lower teeth, it may be necessary to affix the wire to the lingual surfaces if placing it on the labial surfaces will interfere with natural occlusion. Because lingual surfaces are more likely to be contaminated with saliva during the procedure, however, labial placement is preferred whenever possible.

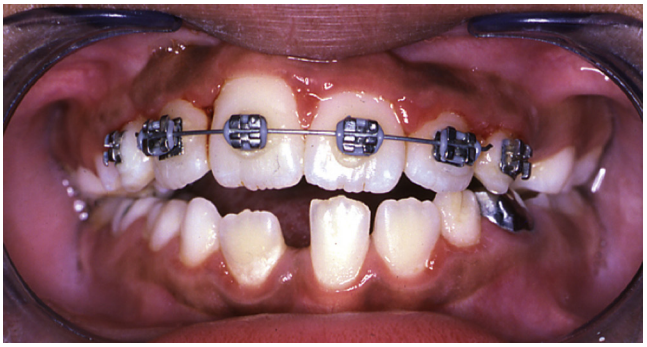

Figure 27-28 Bonded brackets and archwire splint.

Direct-bonded orthodontic brackets may also be placed on the teeth, and a light labial archwire bent to conform accurately to the natural curvature of the arch is then ligated to the brackets. The brackets are properly aligned on the archwire and bonded to the abutment teeth first. The avulsed tooth is then ideally positioned, and additional bonding material is placed, if necessary, to fill any remaining small space between the tooth and the bracket before being bonded to the splint. If performed properly, this technique results in an excellent splint (Fig. 27-28). However, it requires much more accurate and precise wire bending than the bonded resin and wire technique (without brackets) to achieve a passive appliance.

If the patient has mental disabilities or immature behavior and does not tolerate foreign objects in the mouth well, or if there are insufficient abutment teeth available for the bonded resin and wire splint, the suture and bonded resin splint advocated by Camp[45] may be an acceptable alternative (Fig. 27-29). The titanium trauma splint has been developed by von Arx and colleagues to ease the application and removal of the splint and to increase comfort for the patient.[51]

In general, stabilization for replanted teeth without other complications is required for 7 to 14 days. The periodontal ligament fibers should have healed sufficiently after the first week to allow the splint to be removed. However, the patient should be advised not to bite directly on the replanted tooth for 3 to 4 weeks after the injury and then gradually to begin to return to normal use of the tooth. During this time, food may be cut into bite-size pieces and chewed carefully with unaffected teeth. The patient should maintain good oral hygiene by brushing and flossing normally and using chlorhexidine mouthrinses.

We recommend that systemic antibiotic therapy begin immediately and continue for at least a week following replantation. If the apex is closed, extending the antibiotic therapy until the pulp is extirpated seems to be a good way to determine the duration of antibiotic coverage. Research by Sae-Lim and associates has shown that antibiotic therapy is effective in preventing the development of external inflammatory root resorption of replanted teeth in which the pulps were not extirpated.[52] This finding

Dentlearn.ir

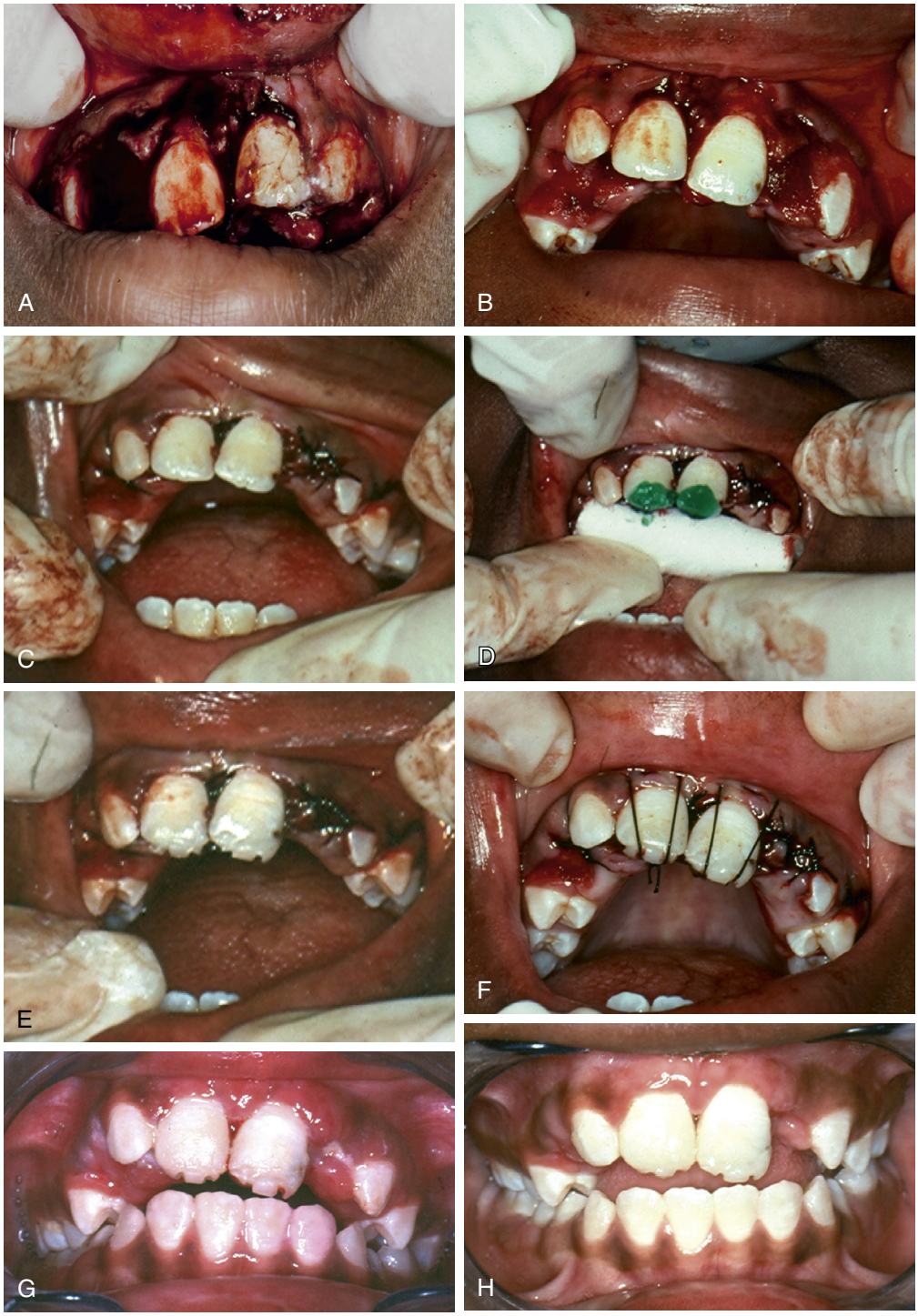

Figure 27-29 Suture and bonded resin splint. **A,** The maxillary central incisors as seen at the initial presentation at the office. The maxillary left central incisor was avulsed and placed in its socket by the parent (approximately 30 minutes after being avulsed) after being instructed to do so by the front desk staff on the way to the office. **B** and **C,** The area has been initially cleansed, and suturing has been accomplished to reapproximate the lacerated gingival tissue. There are not sufficient teeth to provide adequate anchorage adjacent to the replanted maxillary central incisors. **D,** The incisal edges of the maxillary central incisors are etched, per manufacturer's instructions, before resin placement. **E,** Retention grooves have been created in the resin on the incisal edges of the maxillary central incisors. **F,** A suture is placed over each tooth. Starting at the labial tissue, each suture crosses the incisal edge, enters and exits the lingual tissue, recrosses the incisal edge, and reenters the labial tissue. The ends are then tied. Care is taken to ensure that no contact with the opposing occlusion is present. **G** and **H,** Clinical presentation at 7 (sutures removed) and 21 days after initial replantation. Both teeth are stable in their respective sockets, with minimal mobility, and gingival tissue health is improved. Pulp testing demonstrated necrosis in both maxillary central incisors, and root canal therapy was scheduled.

suggests that antibiotic therapy may also be helpful in those cases in which the pulps of immature replanted teeth are allowed to remain while revitalization remains a possibility. Additional studies in this area are indicated.

Krasner and Rankow have published detailed recommendations for replanting a tooth based on its status as judged by the clinician's determination of the physiologic condition of the root periodontal ligament cells, the development of the root apex, and the length of extraoral time.[53] Their recommendations recognize 10 different categories of avulsed teeth and detail a specific treatment regimen for each category. A modified version of Guidelines for the Management of Avulsed Permanent Teeth from the International Association of Dental Traumatology is shown in Box 27-1.[54] Of course, the dentist should confirm at the time of replantation that the patient is adequately immunized against tetanus.

Endodontic Management of Replanted Teeth

All replanted permanent teeth with complete apical root development should undergo a pulpectomy soon after replantation regardless of the length of time the tooth was out of the mouth. Even though a few reports of revitalization exist, the chances for revitalization are remote at best. Moreover, adverse reactions are virtually certain if degenerating pulp tissue is allowed to remain in the canals for more than a few days. The risk-benefit ratio for the patient favors pulpal extirpation.

Because replantation should be done as soon as possible after the injury, the dentist should not take time to extirpate the pulp before replantation. The pulp should be extirpated before the splint is removed, however, and preferably within 1 week after the injury. A sterile, dry cotton pellet or one dampened with CMCP and blotted on sterile gauze may be sealed in the pulp chamber after debridement and irrigation. The canal should be filled approximately 2 weeks after the injury. When the canal is filled, calcium hydroxide paste is the material of choice. However, Trope suggests that the pulp contents be removed at the emergency visit and a tetracycline-corticosteroid combination (Ledermix; Sigma Pharmaceuticals Pty Lid., Croydon, Victoria, Australia) be placed in the root canal.[48] He believes that this combination decreases the inflammatory response after replantation to allow for more favorable healing than in those teeth that do not receive the medicament.

Root canal treatment should be initiated 7 to 10 days after replantation. Early extirpation of the pulp may help to control the early onset of inflammatory root resorption.[54] Filling the root canal with calcium hydroxide also controls and may even arrest external inflammatory root resorption. If the calcium hydroxide is placed in the canal too soon (before adequate healing of the periodontal ligament), however, it may stimulate replacement root resorption. Andreasen suggested that 2 weeks after replantation is the ideal time to fill the canal with calcium hydroxide. The use of calcium hydroxide as a root-canal–filling material was described previously in the discussion of apexification.

If the avulsed permanent tooth has immature root formation with an open apex, the chances of pulpal revitalization after replantation improve considerably, especially if replantation occurs within 30 minutes after avulsion. If the avulsed tooth has been cared for properly, there is a small chance for revitalization even if the tooth is replanted within 1 hour after the injury. However, many teeth do not revitalize. Those that do respond favorably may still require root canal treatment several months later. During the time beyond 1 week that the pulp tissue is allowed to remain, evaluation of the tooth is recommended at weekly intervals until favorable signs of healing without pulpal pathosis are conclusive (vitality tests are unreliable) or until a decision is made to extirpate the pulp. The pulp should be extirpated when the first signs of degeneration appear.

Rubber dam isolation is always desirable when pulp therapy is performed. It can usually be used even during the pulp extirpation procedure, while several teeth are splinted together. Instead of separate holes in the rubber dam for each tooth, a slit is made so that the rubber can be placed over all teeth in the splinted segment. This does not afford ideal isolation, but it is generally better than the use of cotton rolls. In addition, the rubber dam helps prevent the swallowing or aspiration of foreign objects during treatment. If small endodontic instruments are used without rubber dam protection, they should be secured with a length of dental floss to facilitate retrieval in the unlikely event that they are dropped in the patient's mouth.

The calcium hydroxide material used to fill the root canal should be replaced every 3 to 6 months until a decision is made to fill the canal with gutta-percha. The optimum duration of the calcium hydroxide treatment is unknown, but generally calcium hydroxide should be kept in the canal for at least 6 months or until root end closure (apical plug) occurs beyond 1 year. In cases in which an adjacent tooth is still unerupted, calcium hydroxide treatment is recommended until eruption of the adjacent tooth.[55] It is believed that eruption may stimulate or accelerate the resorptive process in a nearby replanted root.

MANAGEMENT OF ROOT FRACTURES

Root fracture of primary teeth is relatively uncommon because the more pliable alveolar bone allows for displacement of the tooth. When root fracture does occur, it should be treated in the same manner as recommended for permanent teeth; however, the prognosis is less favorable. The pulp in a permanent tooth with a fractured root has a better chance to recover.

Root fractures that occur in the apical half of the tooth are more likely to undergo repair (Fig. 27-30). Fractures in the apical third are often repaired without treatment. In fact, many apparently are undetected until evidence of a calcified repair is seen radiographically sometime after the injury.

Andreasen[56] has described four tissue reactions after root fracture: (1) healing with calcified tissue, which is characterized by a uniting callus of hard tissue that may consist of dentin, osteodentin, or cementum; (2) healing with interposition of connective tissue, in which the fractured root surfaces are covered by cementum with connective tissue fibers joining the two fragments; (3) healing with interposition of bone and connective tissue, in which a bony bridge and connective tissue are positioned between the fragments; and (4) interposition of granulation tissue.

The last is the least favorable form of attempted repair, and the fracture will not heal spontaneously. The teeth

Dentlearn.ir

Box 27-1

Categories for Treatment of Avulsed Teeth

1. Closed apex, tooth replanted prior to the patient's arrival at the dental office

Treatment

- Leave the tooth in place.
- Clean the area with water spray, saline, or chlorhexidine.
- Suture gingival lacerations if present.
- Verify normal position of the replanted tooth both clinically and radiographically.
- Apply a flexible splint for up to 2 weeks.
- Administer systemic antibiotics. Tetracycline is the first choice (Doxycycline 2x per day for 7 days at appropriate dose for patient age and weight). The risk of discoloration of permanent teeth must be considered before systemic administration of tetracycline in young patients. (In many countries tetracycline is not recommended for patients under 12 years of age.) In young patients, Phenoxymethyl Penicillin (Pen V) or amoxicillin, at an appropriate dose for age and weight, is an alternative to tetracycline.
- If the avulsed tooth has been in contact with soil and if tetanus coverage is uncertain, refer to physician for a tetanus booster.
- Initiate root canal treatment 7-10 days after replantation and before splint removal.

Patient instructions

- Avoid participation in contact sports.
- Eat only soft food for up to 2 weeks.
- Brush teeth with a soft toothbrush after each meal.
- Use a chlorhexidine (0.1%) mouthrinse twice a day for 1 week.

Follow-up

- Splint removal and clinical and radiographic control after 2 weeks.
- Root canal treatment 7-10 days after replantation.
- Clinical and radiographic control after 4 weeks, 3 months, 6 months, 1 year, and then yearly thereafter.

2. Closed apex, extraoral dry time less than 60 minutes: The tooth has been kept in physiologic storage media or osmolality-balanced media (milk, saline, saliva, or Hanks' Balanced Salt Solution) and/or stored dry for less than 60 minutes

Treatment

- Clean the area with water spray, saline, or chlorhexidine.
- Re-implant the tooth in the socket.
- Suture gingival lacerations if present.
- Verify normal position of the replanted tooth both clinically and radiographically.
- Apply a flexible splint for up to 2 weeks.
- Administer systemic antibiotics (see previous comments).
- If the avulsed tooth has been in contact with soil and if tetanus coverage is uncertain, refer to physician for a tetanus booster.
- Initiate root canal treatment 7-10 days after replantation and before splint removal.

Patient instructions (see previous comments)

Follow-up (see previous comments)

3. Closed apex, extraoral dry time greater than 60 minutes, suggesting non-viable cells

Delayed replantation has a poor long-term prognosis. The periodontal ligament will be necrotic and cannot be expected to heal. The goal in delayed replantation is, in addition to restoring the tooth for aesthetic, functional, and psychological reasons, to maintain alveolar bone contour. However, the expected eventual outcome is ankylosis and resorption of the root, and the tooth will be lost eventually.

Treatment

- Clean the area with water spray, saline, or chlorhexidine.
- Re-implant the tooth in the socket.
- Suture gingival lacerations if present.
- Verify normal position of the replanted tooth both clinically and radiographically.
- Apply a flexible splint for up to 2 weeks.
- Administer systemic antibiotics (see above).
- If the avulsed tooth has been in contact with soil and if tetanus coverage is uncertain, refer to physician for a tetanus booster.
- Initiate root canal treatment 7-10 days after replantation and before splint removal.

To slow osseous replacement of the tooth, treatment of the root surface with fluoride prior to replantation has been suggested (2% sodium fluoride solution for 20 minutes).

Patient instructions (see previous comments)

Follow-up (see previous comments)

Ankylosis is unavoidable after delayed replantation and must be taken into consideration. In children and adolescents, ankylosis is frequently associated with infraposition. Careful follow-up is required and good communication is necessary to assure the patient and guardian of this likely outcome. Decoronation may be necessary when infraposition (>1 mm) is seen. For more detailed information on this procedure, the reader is referred to textbooks.

1. Open apex, tooth replanted prior to the patient's arrival at the dental office or clinic

Treatment

- Leave the tooth in place.
- Clean the area with water spray, saline, or chlorhexidine.
- Suture gingival laceration if present.
- Verify normal position of the replanted tooth both clinically and radiographically.
- Apply a flexible splint for up to 1-2 weeks.
- Administer systemic antibiotics (see previous comments).
- If the avulsed tooth has been in contact with soil and if tetanus coverage is uncertain, refer to physician for a tetanus booster.
- The goal for replanting still-developing (immature) teeth in children is to allow for possible revascularization of the tooth pulp. If that does not occur, root canal treatment is recommended.

Patient instructions (see previous comments)

Follow-up (see previous comments)

Box 27-1

Categories for Treatment of Avulsed Teeth—cont'd

2. Open apex, extraoral dry time less than 60 minutes. The tooth has been kept in physiologic storage media or osmolality-balanced media (milk, saline, saliva, or Hanks' Balanced Salt Solution) and/or stored dry for less than 60 minutes

Treatment

- Clean the root surface and apical foramen with a stream of saline.
- Topical application of antibiotics has been shown to enhance chances for revascularization of the pulp and can be considered if available (minocycline or doxycycline 1 mg per 20 mL saline for 5-minute soak).
- Administer local anesthesia.
- Examine the alveolar socket. If there is a fracture of the socket wall, reposition it with a suitable instrument.
- Irrigate the socket with saline.
- Replant the tooth slowly with slight digital pressure.
- Suture gingival lacerations, especially in the cervical area.
- Verify normal position of the replanted tooth clinically and radiographically.
- Apply a flexible splint for up to 2 weeks.
- Administer systemic antibiotics (see previous comments).
- If the avulsed tooth has been in contact with soil and if tetanus coverage is uncertain, refer to physician for a tetanus booster.

Patient instructions (see previous comments)

Follow-up (see previous comments)

The goal for replanting still-developing (immature) teeth in children is to allow for possible revascularization of the pulp space. The risk of infection-related root resorption should be weighed against the chances of revascularization. Such resorption is very rapid in children. If revascularization does not occur, root canal treatment may be recommended.

3. Open apex, extraoral dry time greater than 60 minutes, suggesting non-viable cells

Delayed replantation has a poor long-term prognosis. The periodontal ligament will be necrotic and is not expected to heal. The goal in delayed replantation is to restore the tooth to the dentition for aesthetic, functional, and psychological reasons and to maintain alveolar contour. The eventual outcome will be ankylosis and resorption of the root.

Treatment

- Remove attached non-viable soft tissue with gauze.
- Root canal treatment can be carried out prior to replantation or later.
- Administer local anesthesia.
- Irrigate the socket with saline.
- Examine the alveolar socket. If there is a fracture of the socket wall, reposition it with a suitable instrument.
- Replant the tooth slowly with slight digital pressure.
- Suture gingival lacerations if present.
- Verify normal position of the replanted tooth clinically and radiographically.
- Stabilize the tooth for 4 weeks using a flexible splint.
- Administer systemic antibiotics (see previous comments).
- If the avulsed tooth has been in contact with soil or if tetanus coverage is uncertain, refer to physician for evaluation of the need for a tetanus booster.

To slow osseous replacement of the tooth, treatment of the root surface with fluoride prior to replantation has been suggested (2% sodium fluoride solution for 20 minutes).

Patient instructions (see previous comments)

Follow-up (see previous comments)

Ankylosis after delayed replantation (see previous comments)

dentaltraumaguide.org

usually present unfavorable symptoms that may be accompanied by fistulas resulting from necrosis of the coronal portion and also sometimes the apical portion of the pulp. These teeth require follow-up endodontic treatment or extraction.

Gross separation of the root fragments invariably causes inflammation in the area and subsequent resorption of the approximating fractured surfaces. For repair to take place, the fragments must be maintained in apposition. Therefore splinting is usually necessary, particularly if the coronal fragment is mobile.

Although a relatively long stabilization period (3 months) has been previously recommended for teeth with fractured roots, Cvek and colleagues have cast doubts on the efficacy of long-term splinting and the types of splints used for root fracture healing.[57,58] Previously, a longer stabilization period seemed necessary to encourage a more favorable type of healing of calcified tissue; however, their study showed no significant difference in the frequency of healing when short periods (under 60 days) and long periods (60 to 90 days) of splinting were compared. They found that hard-tissue healing also took place in teeth that were not even splinted. A comparison between nonsplinted and splinted teeth showed no difference in frequency of healing. They suggest that optimal positioning of dislocated fragments significantly increases the frequency of healing, particularly in mature teeth. Their study showed that, in immature teeth, healing took place even after suboptimal repositioning of dislocated coronal fragments and persistent diastases between the fragments after splinting. They conclude by suggesting that teeth with no or slight loosening of the fragment may not require splinting.

In addition, there is general agreement that splints for root fractures should be more rigid than the splints used for stabilization after other types of displacement injuries. Application of a more rigid splint is also believed to enhance the opportunity for calcified tissue repair. Therefore the use of heavier wires is recommended (0.032 to 0.036 inch) when one is stabilizing teeth with fractured roots.

Dentlearn.ir

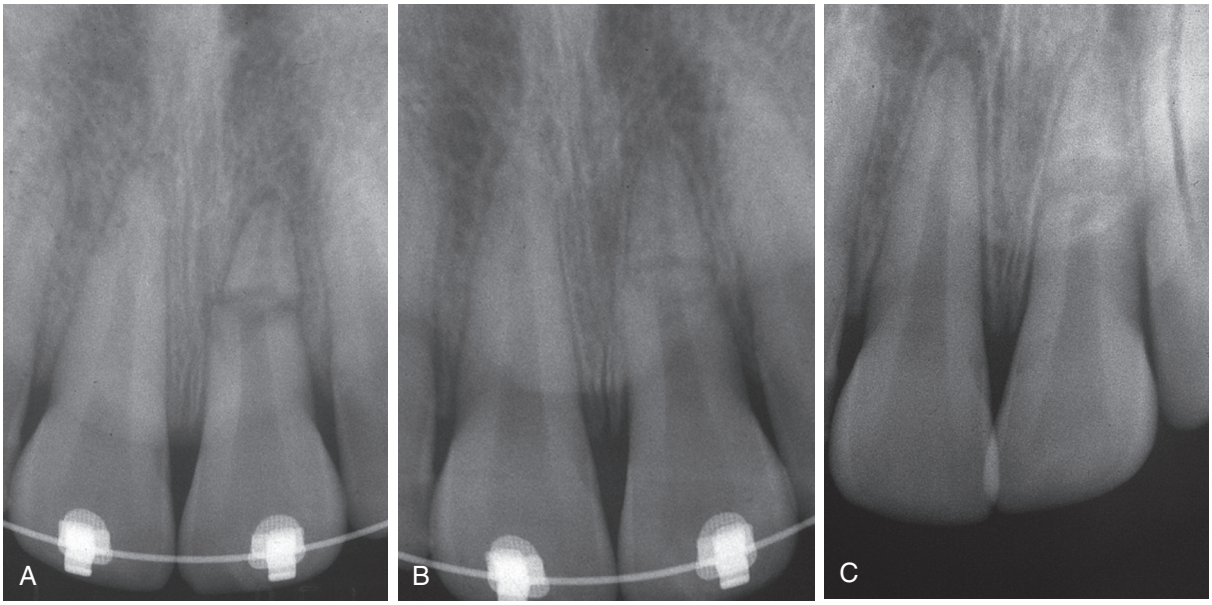

Figure 27-30 **A,** Root fracture is evident in the apical one third of the maxillary left central incisor. A splint was placed the day of the fracture. The patient reported that both teeth received trauma (via a baseball to the area), although only the root of the maxillary left central incisor was fractured. **B,** One month after initial splint placement. Both central incisors responded favorably to pulp testing, and the splint was removed. Periodic evaluation and pulp testing were maintained. **C,** More than 2 years had elapsed when this radiograph revealed a normal periapical appearance to the maxillary left central incisor with the fractured root. Pulp testing for the incisor was normal. The patient complained of pain associated with the maxillary right central incisor (see developing periapical lesion) and was referred for endodontic evaluation.

The occlusion should be adjusted so that the injured tooth is not further traumatized during normal masticatory function. Follow-up radiographs should be obtained and pulp tests performed at frequent intervals during the first 6 months after the injury.

OTHER DISPLACEMENT INJURIES OF TEETH REQUIRING STABILIZATION

Teeth subjected to less severe luxation injuries may also benefit from stabilization with a bonded resin and wire splint during the recovery period. The severity of the injury will help determine the length of time the splint should remain in place. Splinting times may vary from 1 to 2 weeks, for teeth that have been discernibly loosened (subluxation), to 4 to 6 weeks, for teeth that have been laterally displaced, fracturing the alveolar process. As with all tooth injuries, frequent periodic evaluation is required for at least the first 6 months to afford the dentist the opportunity for early intervention if adverse sequelae develop; after this, evaluation at regular recall appointments should continue.

Nearly all significantly displaced teeth with closed apices and many with open apices will require follow-up endodontic therapy. As with many of the other injuries already discussed, calcium hydroxide paste is the currently recommended material for initial canal filling, and the canal should be recleaned and refilled with calcium hydroxide periodically if signs or symptoms warrant retreatment. This current recommendation of using calcium hydroxide may change in the relatively near future. Placement of a permanent gutta-percha filling should be delayed for at least 1 year (arbitrarily determined), and the calcium hydroxide should be replaced at least once (again, arbitrarily determined) during this time. If the injured tooth had an open apex when endodontic therapy was initiated, the calcium hydroxide filling material should be used until the apexification process is complete or at least 1 year has elapsed, whichever is longer.

MANAGEMENT OF ORAL BURNS

As a result of secondary wound healing and scar contracture, burns involving the perioral and intraoral tissues can cause various degrees of microstomia. A common cause of oral burns is electrical trauma. The most frequently encountered electrical injury to children is a burn about the mouth. These burns occur most often in children between 6 months and 3 years of age and are equally common among boys and girls.

Oral electrical burns occur when (1) the child places the female end of a "live" extension cord into the mouth, (2) the child places the female end of a "live" appliance cord (e.g., that for a hot plate, shaver, or portable radio) into the mouth, or (3) the child sucks or chews on exposed or poorly insulated electrical wires.

How does the burn occur? One plausible theory is that an electric arc is produced between a source of the current, such as the female end of an extension cord, and oral tissues. The electrolyte-rich saliva provides a short circuit between the cord terminals and the mouth, which results in the arc phenomenon. This type of burn characteristically involves intense heat that causes coagulation tissue necrosis.

NATURE OF THE INJURY

The clinical appearance of electrical burns is variable and depends on several factors: (1) the degree and duration of contact, (2) the source and magnitude of electric current, (3) the state of grounding, and (4) the relative degree of resistance at the point of contact. The wound may be superficial, involving only the vermilion border of one or both lips, or it may be a very destructive, full-thickness, third-degree burn. The more serious burns generally involve portions of the upper and lower lips and the commissure. Damage with more serious burns may extend intraorally to the tongue, labial vestibule, floor of the mouth, or buccal mucosa. There have also been reports of damage to hard tissue, such as the mandible and the primary and permanent teeth.

With third-degree burns, subcutaneous tissues may be damaged. The tissue destruction may be much more extensive than is initially evident. Because nerves are frequently damaged, the patient will probably have paresthesia or anesthesia. Therefore pain is generally not a significant problem. Hemorrhage is usually inconsequential because blood vessels are cauterized when the injury is sustained. However, spontaneous arterial bleeding may occur anytime during the first 3 weeks of healing. The hemorrhage may be caused by the rupture of blood vessel walls weakened by the passage of current. Bleeding can also occur with sloughing of necrotic tissue that overlies regenerating granulation tissue.

The clinical appearance of an electrical burn involving the lips and commissures is characteristic of a wound caused by intense, localized heat, perhaps as high as 3000°C. Necrosis, in which there has been heat-induced coagulation of protein, liquefaction of fats, and vaporization of tissue fluids, is evident.

During the first few days after the accident, the center of the lesion is generally composed of grayish or yellowish tissue that may be depressed relative to a slightly elevated, narrow, erythematous margin of tissue that surrounds it (Fig. 27-31).

Within a few hours after the injury, there may be a great increase in edema. The margins of the wound may become ill-defined and the lips protuberant. The patient may drool uncontrollably because of loss of sensation. In 7 to 10 days, the edema begins to subside. The delineation between the central nonviable tissue and the surrounding viable tissue becomes more apparent. The necrotic tissue, known as *eschar*, becomes charred or crusty in appearance and begins to separate from the surrounding viable tissue (Fig. 27-32). The eschar sloughs off 1 to 3 weeks after the burn incident. Healing occurs by secondary intention as granulation tissue proliferates and matures. Two or three months after the accident, the wound becomes indurated as a result of fibrous tissue formation. For an additional 6 months, the immature fibrotic scar tissue may bind the lips, alveolar ridges, and other involved structures. If such tissue is not treated, its contraction results in unaesthetic and functionally debilitating microstomia. The scar tissue softens as it matures, and by 9 months to 1 year after the injury, the potential for tissue contraction is greatly decreased. The duration of the healing process and the selected course of treatment depend on the extent and severity of tissue destruction. Because of the variable nature of burn injuries, surgery or appliance therapy may be used or no treatment may be needed.



Figure 27-31 Appearance of injury to the upper lip and commissure 5 days after electrical burn. (Courtesy Dr. Theodore R. Lynch.)



Figure 27-32 Appearance of injury to the lower lip and commissure 10 days after electrical burn. The dark lesion on the lower lip is an eschar. (Courtesy Dr. Theodore R. Lynch.)

TREATMENT

Assessing the general physical status of a patient who has sustained an electrical burn to the mouth is the first priority. Subsequently, the extent of the burn is carefully evaluated and local measures are initiated, such as control of minor hemorrhage or conservative debridement of nonviable tissue.

The immunization status of the patient must be ascertained, and tetanus toxoid or depot triple antigen (diphtheria-pertussis-tetanus vaccine) administered when appropriate. Many physicians prescribe a broad-spectrum antibiotic as prophylaxis. However, it may not be necessary or prudent to prescribe antibiotics in the absence of infection.

The parents should be informed of the possibility of spontaneous arterial hemorrhage that can occur during the first 3 weeks. They should be instructed to place firm pressure, with gauze, on the bleeding area for 10 minutes. If bleeding persists, they should take the child to the

Dentlearn.ir

emergency department. Usually, hemorrhage is not a significant problem and does not warrant prophylactic hospitalization except for the most severe and extensive injuries.

The surgical management of burn injuries to the mouth, especially with regard to the time when such surgery should be performed, is controversial. Initially, no surgical intervention is generally warranted. Instead, the treatment of choice is the use of a prosthetic appliance. The primary functions of such an appliance are to prevent contracture of healing tissue and to serve as a framework on which a more normal-appearing commissure may be created and preserved after completion of the healing process. Many patients at James Whitcomb Riley Hospital for Children have been successfully treated with these appliances. Moreover, surgical procedures have not been needed in cases with good patient compliance in appliance use.

The major components of the burn appliance are illustrated in Figure 27-33. The appliance is removed when the patient eats, when the teeth and appliance are cleaned, or when modifications of the wings are necessary. The appliance is a static base with wings extending laterally to provide contact with both commissures. If symmetry relative to the midline is to be maintained during the healing process, the wings must come into contact with the commissures equidistant from the midline and must exert essentially equal pressure at these points.

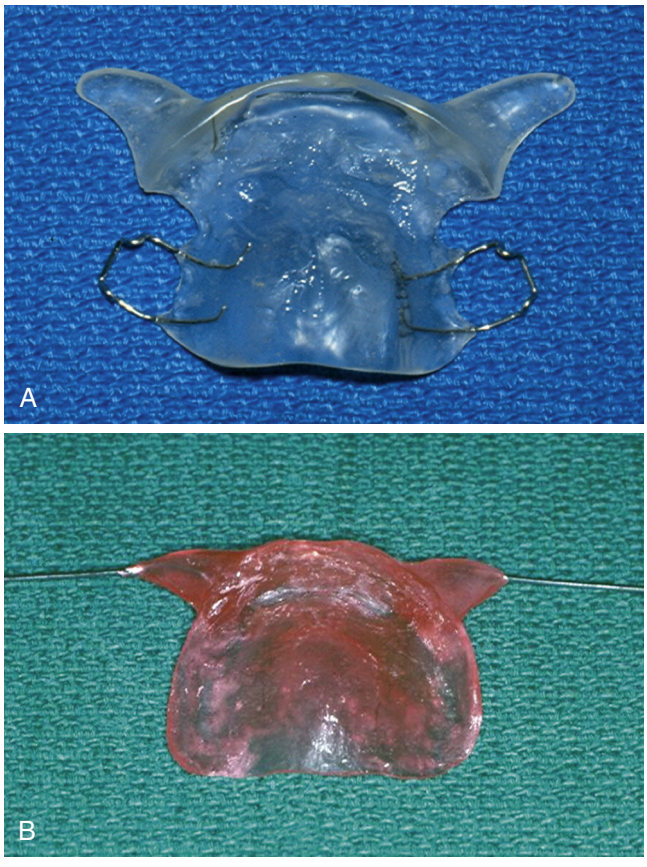

Figure 27-33 **A,** Example of a burn appliance designed for intraoral retention. **B,** Example of a burn appliance designed for intraoral and extraoral retention in combination with headgear.

The shape and location of the wings are important not only in preventing contracture or cohesion of the lips during healing but also in shaping the affected commissure to duplicate the unaffected side. Each wing is contoured so that it is thickest in its occlusocervical dimension on the labial aspect. It is tapered as thinly as possible at the point of contact with the commissure (Fig. 27-34). The wings should be just large enough to maintain the correct shape of the commissure. Wings of the proper size will look more pleasing during wear and will enhance acceptance and compliance by the child and parent.

If compliance is a problem with an acrylic appliance, a modified fixed appliance can be constructed and ligated in the mouth. Bands are adapted on the upper second primary molars, and an impression is made. Headgear tubes are welded onto the bands, and a Nance appliance is constructed from a 0.036- or 0.040-inch wire. If the Nance button is not used, the wire is contoured along the gingival portion of the teeth.

After the stabilizing framework is made, the outer portion of the appliance is formed. The anterior arch form is established with a 0.045-inch wire. Horizontal loops are placed in the area approximating the location of the commissures, as determined by clinical measurements. The wire is continued posteriorly, and omega loops are placed mesial to the headgear tubes. Adjustments are made in the acrylic in one or both of the omega loops to achieve the correct fit. With the omega loops used as tiebacks, the appliance is ligated in the mouth. The patient should be evaluated as often as needed during the first month so that necessary adjustments can be made. The patient should be seen at least once a month thereafter.

Ideally, the patient with an oral electrical burn should be seen by the dentist between the fifth and tenth days after the accident. The initial appointment is probably the most crucial to the success or failure of treatment with the burn appliance. Parental apprehension and feelings of guilt are often high, and the trust and confidence of both the parents and the child must be acquired as soon as possible. They should be told in detail what they can expect from the dental services offered and what is expected of them. The parents and the child should be shown pictures from previous cases. This not only demonstrates the appearance and purpose of the appliance but also emphasizes that they are not the only ones who have experienced the physical and psychological trauma associated with such an accident. Pictures of patients who did not

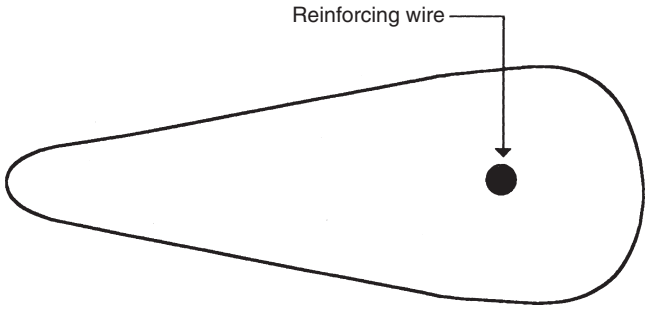

Figure 27-34 Cross-sectional view of the commissure wing of the burn appliance.

Dentlearn.ir

have an appliance or who did not wear their appliance as instructed are also shown. The impact of such illustrative materials is dramatic.

After the consultation session, the initial data are recorded, photographs are taken, and alginate impressions are obtained for fabrication of the appliance. The appliance is generally delivered between the tenth and fourteenth days after the injury. At the delivery appointment and at each subsequent appointment, the information and instructions given in the initial consultation session are reinforced. Constant encouragement and positive reinforcement are important psychological aids in enhancing compliance.

After delivery of the appliance, the patient is seen as often as needed during the first week, but at least once during that time. The patient is checked again at 4 and 8 weeks after appliance delivery. During this period, most of the major modifications to the wings and other components of the appliance are made, and the patient's compliance is closely monitored. Once the appliance is properly modified and the patient is wearing the appliance as instructed, the appointments can be spaced out over 4- to 6-week intervals. The appliance should be worn 24 hours a day for 9 to 12 months except when the patient is eating and when the appliance is being cleaned (Fig. 27-35).



Figure 27-35 **A,** Patient the day of the oral burn. There is considerable tissue damage with accompanying swelling at the patient's left lower lip, extending from the midline to the commissure. **B,** Properly fitted burn appliance in place (see Fig. 27-39A for specific appliance type used). **C,** Six-month result of appliance usage. Note the contour of the patient's left commissure. **D,** Nine-month result of appliance usage. Note that, at maximum opening, there is symmetry of the perioral area without noticeable constriction at the left commissure. **E,** One year after the oral burn and optimal appliance usage.

Dentlearn.ir



Figure 27-36 Burn patient who did not wear the appliance as recommended, shown 10 months after the injury. Surgical correction will be considerably more difficult in this patient.

The burn appliance may not eliminate the need for minor surgical revisions of the lips or surrounding cutaneous tissues. Its purpose is to obviate the necessity for more difficult surgical procedures because good results are hard to achieve and maintain when one is surgically restoring the shape and location of the oral commissure. The appliance can prevent asymmetry of the commissures resulting from tissue cohesion and scar contracture. It can provide a more normal-appearing commissure after healing. The successful use of this appliance ultimately depends on patient compliance (Fig. 27-36).

Infants or toddlers who do not have primary molars that can be used for intraoral anchorage will not be able to retain the burn appliance without extraoral stabilization. Figure 27-37 illustrates a headgear type of extraoral anchorage apparatus. It is made of durable cloth, such as denim lined with gingham, and provides a static base from which elastic material extends to the wings of the burn appliance. A well-fitted bonnet may also be used.

Patients with burns to the mouth and who did not have access to appliance therapy or were noncompliant in wearing the burn appliance may have tissue cohesion, contraction, and deformation as a result of healing. Such patients may require a commissurotomy to reestablish the original dimensions and symmetry of the mouth. Unfortunately, with healing of the commissurotomy there is again a tendency for wound contraction and distortion. Therefore it may be necessary for the patient to undergo more than one such surgical procedure unless surgery is followed by appliance therapy.

Clinical management of the burn appliance after a commissurotomy differs from management of the appliance after a burn injury. First, the appliance must be delivered by the time the sutures are removed. By the second week after surgery, there may already be a decrease in the lateral extension of the primary incision as a result of wound healing. Second, the total time the patient needs to wear the appliance may be less than 1 year, depending on the clinical course of the healing process. The patient still wears the appliance 24 hours a day except when eating and when the appliance is being cleaned.

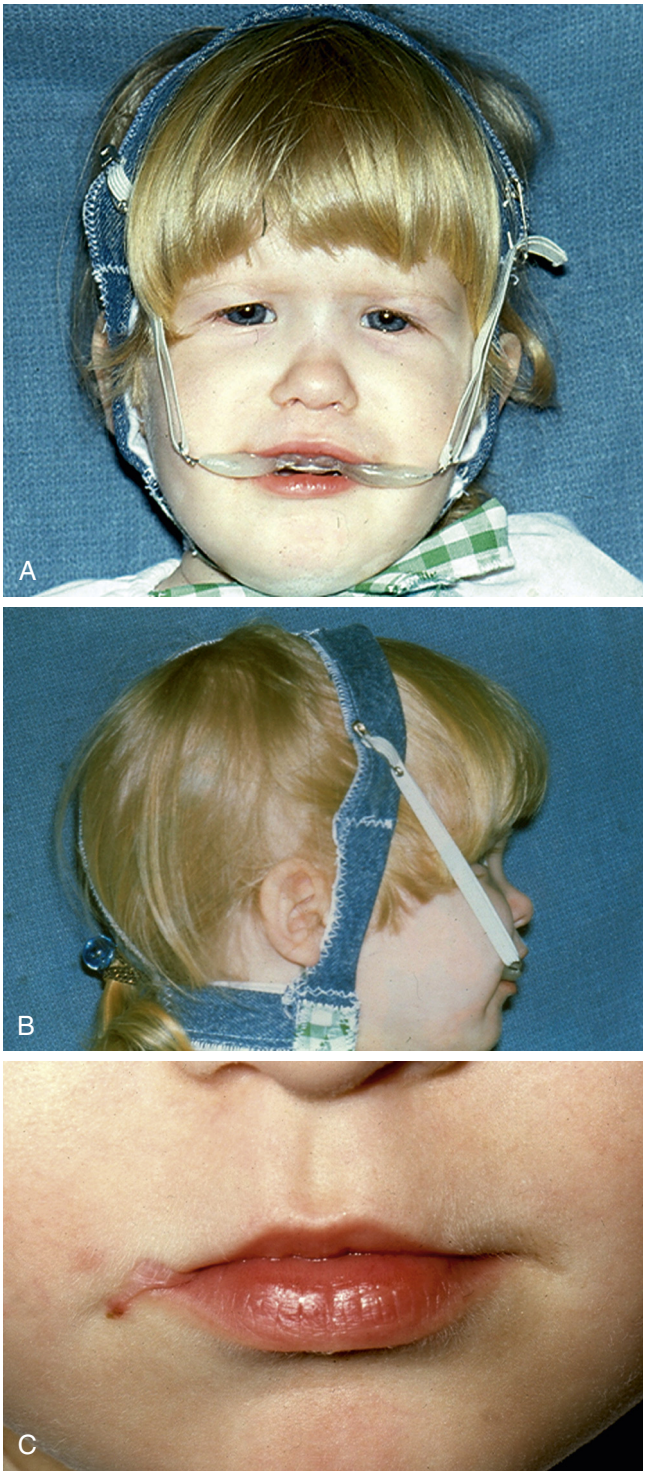

Figure 27-37 **A** and **B,** Properly fitted burn appliance with headgear to enhance stability and retention of the appliance. **C,** Nine-month result with appliance therapy.

TRAUMA PREVENTION

Dental practitioners should be proud that we are a prevention-oriented profession. Prevention is especially predominant in dentistry for children. We strive to prevent dental caries, periodontal disease, malocclusion, and

Dentlearn.ir

anxiety about dental care. If disease is present, our treatment becomes part of an overall prevention plan designed to halt the progress of disease and prevent its recurrence. The success of the prevention plan, provided that there is parent and patient cooperation, is reasonably predictable.

Unfortunately, our ability to prevent injuries to oral structures is limited. Living and growing carry a high risk of trauma. A child will not learn to walk without falling, and few children reach 4 years of age without having received a blow to the mouth. We cannot totally prevent trauma. Moreover, the results of treatment for trauma are often less predictable than those of other types of dental treatment.

On the brighter side, there are preventive measures that have been proved to reduce the prevalence of traumatic episodes in certain environmental situations. For example, because the prevalence of fractured incisors is higher among those with protrusive anterior teeth, many dentists are recommending early reduction of excessive protrusion to reduce the susceptibility of such teeth to injury. The use of car safety seats and restraining belts has prevented many injuries to infants and young children. The protective mouthguard described in Chapter 24 has prevented or reduced the severity of countless injuries to the teeth of youngsters participating in organized athletic activities; active youngsters should be encouraged to wear their mouthguards during high-risk unsupervised athletic activities as well.

Parents should be reminded that accessible "live" electric cords are potentially dangerous, especially to small children who still use their mouths to evaluate their environment. In addition, anticipatory guidance and education are necessary to advise our patients regarding the negative health effects of intraoral and perioral body piercing. Possible problems that can occur include scar tissue formation, fracture of the dentition, allergic reactions, and bacterial endocarditis in susceptible patients. When we have the opportunity to save a child from pain and suffering, an ounce of prevention is worth a pound of cure.

REFERENCES

1. Davis MJ, Vogel L: Neurological assessment of the child with head trauma, *J Dent Child* 62:93–96, 1995.
2. Davis MJ: Orofacial trauma management. Patient assessment and documentation, *N Y State Dent J* 61(7):42–46, 1995.
3. Rusmah M: Traumatized anterior teeth in children: a 24-month follow-up study, *Aust Dent J* 35:430–433, 1990.
4. Andreasen JO, et al.: Effect of treatment delay upon pulp and periodontal healing of traumatic dental injuries—a review article, *Dent Traumatol* 18(3):116–128, 2002.
5. Diangelis AJ, et al.: International Association of Dental Traumatology guidelines for the management of traumatic injuries: 1. Fractures and luxations of permanent teeth, *Dent Traumatol* 28:2–12, 2012.
6. Vilela Maia EA, et al.: Tooth fragment reattachment: Fundamentials of technique and two case reports, *Quintessence Int* 34:99–107, 2003.
7. Macedo GV: Reattachment of anterior teeth fragments: A conservative approach, *J Esthet Restor Dent* 20(1):5–18, 2008.
8. Farik B, et al.: Fractured teeth bonded with dentin adhesives with and without unfilled resin, *Dent Traumatol* 18:66–69, 2002.
9. Kanca J: Replacement of a fractured incisor fragment over pulpal exposure: a long-term case report, *Quintessence Int* 27:829–832, 1996.
10. Ludlow JB, LaTurno SA: Traumatic fracture—one-visit endodontic treatment and dentinal bonding reattachment of coronal fragment: report of a case, *J Am Dent Assoc* 110: 341–343, 1985.
11. Cvek M: A clinical report on partial pulpotomy and capping with calcium hydroxide in permanent incisors with complicated crown fractures, *J Endod* 4:232–237, 1978.
12. Fong CD, Davis MJ: Partial pulpotomy for immature permanent teeth, its present and future, *Pediatr Dent* 24:29–32, 2002.
13. American Academy of Pediatric Dentistry: Guidelines on Pulp Therapy for Primary and Immature Permanent Teeth, *Pediatric Dent* 34:222–229, 2012.
14. Frank AL: Therapy for the divergent pulpless tooth by continued apical formation, *J Am Dent Assoc* 72:87–93, 1966.
15. Weine FS: *Endodontic therapy*, ed 6, St. Louis, 2004, Mosby, 528–529.
16. Giuliani V, et al.: The use of MTA in teeth with necrotic pulps and open apices, *Dent Traumatol* 18:217–221, 2002.
17. Murray PE, Garcia-Godoy F, Hargreaves KM: Regenerative endodontics: a review of current status and a call for action, *J Endod* 33:377–390, 2007.
18. Nygaard-Østby B: The role of the blood clot in endodontic therapy. An experimental histologic study, *Acta Odontol Scand* 19:324–353, 1961.
19. Nygaard-Østby B, Hjørtdal O: Tissue formation in the root canal following pulp removal, *Scand J Dent Res* 79:333–349, 1971.
20. Iwaya SI, Ikawa M, Kubota M: Revascularization of an immature permanent tooth with apical periodontitis and sinus tract, *Dent Traumatol* 17:185–187, 2001.
21. Nakashima M, Akamine A: The application of tissue engineering to regeneration of pulp and dentin in endodontics, *J Endod* 31:711–718, 2005.
22. Hargreaves K, Law A: Regenerative endodontics. In Hargreaves K, Cohen S, editors: *Cohen's pathways of the pulp*, ed 10, St. Louis, 2010, Mosby Elsevier, pp 602–620.
23. Diogenes A, Henry MA, Teixeira FB, Hargreaves KM: An update on clinical regenerative endodontics, *Endodontic Topics* 28:2–23, 2013.
24. Yassen GH, Chu TM, Eckert G, Platt JA: Effect of medicaments used in endodontic regeneration technique on the chemical structure of human immature radicular dentin: an in vitro study, *J Endod* 39:269–273, 2013.
25. Hoshino E, Kurihara-Ando N, Sato I, et al.: In-vitro antibacterial susceptibility of bacteria taken from infected root dentine to a mixture of ciprofloxacin, metronidazole and minocycline, *Int Endod J* 29:125–130, 1996.
26. Reynolds K, Johnson JD, Cohenca N: Pulp revascularization of necrotic bilateral bicuspids using a modified novel technique to eliminate potential coronal discolouration: a case report, *Int Endod J* 42:84–92, 2009.
27. Ruparel NB, et al.: Direct effect of intracanal medicaments on survival of stem cells of the apical papilla, *J Endod* 38: 1372–1375, 2012.
28. Cehreli ZC, et al.: Regenerative endodontic treatment (revascularization) of immature necrotic molars medicated with calcium hydroxide: a case series, *J Endod* 37:1327–1330, 2011.
29. American Association of Endodontists: Considerations for

clinical-resources/regenerative-endodontics/considerations-for-regenerative-procedures.aspx. Accessed December 29, 2013.

30. Geisler TM: Clinical considerations for regenerative endodontic procedures, *Dent Clin North Am* 56:603–626, 2012.
31. Croll TP, et al.: Traumatically injured primary incisors: a clinical and histological study, *J Dent Child* 54:401–422, 1987.
32. Holan G, Fuks AB: The diagnostic value of coronal dark-gray discoloration in primary teeth following traumatic injuries, *Pediatr Dent* 18:224–227, 1996.

sorption, *Oral Surg* 60:231–233, 1985.
34. Mummery JH: Some further cases of chronic perforating hyperplasia of the pulp, the so-called "pink spot," *Br Dent J* 47:801–811, 1926.
35. Andreasen JO, et al.: The effect of traumatic injuries to the primary teeth on their permanent successors, *Scand J Dent Res* 79:219–283, 1971.
36. Cutright DE: The reaction of permanent tooth buds to injury, *Oral Surg* 32:832–839, 1971.
37. Kilpatrick NM, et al.: Dilaceration of a primary tooth, *Int J Paediatr Dent* 1:151–153, 1991.
38. Ravn JJ: Sequelae of acute mechanical traumata in the primary dentition, *J Dent Child* 35:281–289, 1968.
39. Skieller V: The prognosis for young teeth loosened after mechanical injuries, *Acta Odontol Scand* 18:171–181, 1960.
40. Alkhalifa JD, Alazemi AA: Intrusive luxation of permanent teeth: a systematic review of factors important for treatment decision-making, *Dent Traumatol* 30:169–175, 2014.
41. Wang C, et al.: Analysis of pulp prognosis in 603 permanent teeth with uncomplicated crown fracture with or without luxation, *Dent Traumatol* 30(5):333–337, 2014.
42. Tronstad L, et al.: Surgical access for endodontic treatment of intruded teeth, *Endod Dent Traumatol* 2:75–78, 1986.
43. Shapira J, et al.: Reeruption of completely intruded immature permanent incisors, *Endod Dent Traumatol* 2:113–116, 1986.
44. Barry GN: Replanted teeth still functioning after 42 years: report of a case, *J Am Dent Assoc* 92:412–413, 1976.
45. Camp JH: Replantation of teeth following trauma. In McDonald RE, et al.: *Current therapy in dentistry*, vol 7. St. Louis, 1980, Mosby.
46. Andreasen JO: Effect of extra-alveolar period and storage media upon periodontal and pulpal healing after replantation of mature permanent incisors in monkeys, *Int J Oral Surg* 1:43–53, 1981.
47. Andreasen JO, Hjørting-Hansen E: Replantation of teeth. I. Radiographic and clinical study of 110 human teeth replanted after accidental loss, *Acta Odontol Scand* 24:263–286, 1966.
48. Trope M: Clinical management of the avulsed tooth: present strategies and future directions, *Int Endod J* 18:1–11, 2002.
49. Sherman P Jr: *A histologic study of intentional replantation of teeth in dogs and monkeys*, Master's thesis. Indianapolis, 1967, Indiana University School of Dentistry.
50. Hurst RV: Regeneration of periodontal and transseptal fibers after autografts in rhesus monkeys: a qualitative approach, *J Dent Res* 51:1183–1192, 1972.
51. von Arx T, et al.: Splinting of traumatized teeth with a new device: TTS (titanium trauma splint), *Dent Traumatol* 17: 180–184, 2001.
52. Sae-Lim V, et al.: Effect of systemic tetracycline and amoxicillin on inflammatory root resorption of replanted dogs' teeth, *Endod Dent Traumatol* 14:216–220, 1998.
53. Krasner P, Rankow HJ: New philosophy for the treatment of avulsed teeth, *Oral Surg Oral Med Oral Pathol Oral Radiol Endod* 9:616–623, 1995.
54. Andersson L, et al.: International Association of Dental Traumatology (IADT), *Dent Traumatol* 28:88–96, 2012.
55. Waterhouse PJ, et al.: Pediatric endodontics: Endodontic treatment for the primary and young permanent dentition. In Cohen S, Hargreaves KM, editors: *Pathways of the pulp*, ed 10, St. Louis, 2010, Mosby, pp 808–857.
56. Andreasen FM, Andreasen JO, Cvek M: Root fractures. In Andreasen JO, Andreasen FM, Andersson L, editors: *Textbook and color atlas of traumatic injuries to the teeth,* ed 4, 337-371, Blackwell, 2007, Oxford.
57. Cvek M, Andreasen JO, Borum MK: Healing of 208 intra alveolar root fractures in patients age 7-17 years, *Dent Traumatol* 17:53–62, 2001.
58. Cvek M, Mejàre I, Andreasen JO: Healing and prognosis of teeth with intraalveolar fractures involving the cervical part of the root, *Dent Traumatol* 18:27–65, 2002.

SUGGESTED READINGS

Jones JE, Cooper MD: Tooth avulsion: a protocol for improved success, *Contemp Oral Hygiene* 2(4):40–43, 2002.

Martins-Junior PA, et al.: Replantation of avulsed primary teeth: a systematic review, *Int J Paediatr Dent* 24:77–83, 2014.

Palin WE, et al.: Perioral electrical injury in a pediatric population, *J Oral Med* 42:17–21, 1987.

Sadove AM, et al.: Appliance therapy for perioral electrical burns: a conservative approach, *J Burn Care Rehabil* 9:391–395, 1988.

Taylor LB, Walker J: A review of selected microstomia prevention appliances, *Pediatr Dent* 19(6):413–418, 1997.

CHAPTER 28

Tumors of the Oral Soft Tissues and Cysts and Tumors of Bone

▲ John S. McDonald

For additional resources, please visit the evolve website.

CHAPTER OUTLINE

BENIGN TUMORS OF THE ORAL SOFT TISSUES
- Squamous Papilloma, Verruca Vulgaris, and Condyloma Acuminatum
- Fibroma
- Pyogenic Granuloma, Peripheral Ossifying Fibroma, Peripheral Odontogenic Fibroma (Who Type), and Peripheral Giant Cell Granuloma
- Neurofibroma and Neurofibromatosis (Von Recklinghausen Disease)
- Hemangioma
- Lymphangioma
- Congenital Epulis (Gingival Granular Cell Lesion) of the Newborn
- Mucocele
- Ranula

BENIGN TUMORS OF BONE
- Benign Fibro-Osseous Lesions of the Jaws
- Fibrous Dysplasia
- Cemento-Ossifying Fibroma
- Juvenile Ossifying Fibroma
- Central Giant Cell Granuloma

ODONTOGENIC CYSTS
- Primordial Cyst
- Dentigerous Cyst
- Eruption Cyst or Eruption Hematoma
- Odontogenic Keratocyst (Keratocystic Odontogenic Tumor)
- Nevoid Basal Carcinoma (Gorlin) Syndrome

ODONTOGENIC TUMORS
- Ameloblastoma
- Adenomatoid Odontogenic Tumor
- Odontogenic Myxoma
- Ameloblastic Fibroma
- Ameloblastic Fibro-Odontoma
- Odontoma

MALIGNANT TUMORS
- Fibroblastic Tumors and Fibrosarcoma in Infancy and Childhood
- Rhabdomyosarcoma
- Osteogenic Sarcoma
- Ewing's Sarcoma
- Langerhans Cell Histiocytosis (Histiocytosis X)

Too often, dental practitioners see their responsibility to the patient as beginning and ending with the care and maintenance of the teeth and the periodontium. Physicians do not give oral health the attention it deserves because, for the most part, they do not receive education and training from this perspective. This leaves the responsibility to the dental practitioner to monitor and help maintain the overall health and well-being of the patient, as evidenced in the orofacial and head and neck structures that are so obviously within their purview. Even so, it remains easy to focus strictly on the dental needs of the patient and remain oblivious to, among other things, subtle or even not so subtle lumps, bumps, swellings, or changes in texture or color that may signify the presence of a reactive or a hamartomatous overgrowth of tissue, or a benign or malignant disease. These disorders occur within the oral and maxillofacial region too often for the dentist to take the attitude that they happen only in someone else's patients.

This chapter provides an overview of some of the more frequently encountered cysts and tumors in the soft tissues and bone of the oral and maxillofacial region in the

BENIGN TUMORS OF THE ORAL SOFT TISSUES

SQUAMOUS PAPILLOMA, VERRUCA VULGARIS, AND CONDYLOMA ACUMINATUM

The squamous papilloma is a relatively common, benign neoplasm that arises from the surface epithelium. It is typically an exophytic lesion whose surface may vary from cauliflower-like to finger-like in appearance, and although it is generally a pedunculated lesion, it may arise from a sessile base. While the average age of occurrence is in the fourth decade of life, nearly 20% of cases have been noted to occur before 20 years of age.[1,2] The most common sites of occurrence appear to be the palatal complex, dorsal and lateral tongue borders, and lips, followed by the gingiva and buccal mucosa. This lesion can, however, also occur on the floor of the mouth, retromolar pad, and alveolar ridges.

Oral verruca vulgaris, or oral warts, are exophytic papillomatous lesions clinically indistinguishable from oral squamous papillomas. Like their skin counterpart, the common wart (verruca vulgaris), they are a viral disorder associated with the human papillomavirus (HPV) and may be spread

Dentlearn.ir



Figure 28-1 **A,** Verruca vulgaris on the anterior tip of the tongue. This is an example of autoinoculation from finger-sucking. **B,** Notice the wart on this patient's finger from which he inoculated his tongue. (Courtesy Dr. Mark L. Bernstein.)

to the oral cavity in children through autoinoculation (Fig. 28-1); vertically (i.e., periconceptually around fertilization), prenatally (during pregnancy), and perinatally (during birth and within 28 days afterward); horizontally (as among family members possibly later in childhood) and through sexual contact (i.e., sexual abuse).[5,6] Skin types of HPV-2, 4, and 57 have been found in oral wart lesions.[5,7]

Although the histopathologic differences between squamous papilloma and verruca vulgaris are subtle, these lesions are distinguishable from one another. Histologically, the papilloma is seen as a proliferation of the spinous cell layer in a papillary pattern, often with hyperkeratosis, acanthosis, and basilar hyperplasia. Mitotic figures may be prominent. The supporting fibrous connective tissue stroma often contains prominent numbers of small blood vessels as well as an inflammatory cell infiltrate. HPV DNA may, however, be commonly seen in squamous cell papillomas (13 of 19 {68%} in one study), most commonly types 6 and 11, or both.[8]

The presence of papillomatosis, often with convergence of rete ridges centrally, hyperkeratosis, a coarse keratohyalin granular cell layer, and vacuolated cells with pyknotic nuclei (koilocytes), may be used to differentiate verruca vulgaris from a squamous papilloma. Hence, from the foregoing discussion, both squamous papilloma and verruca vulgaris should probably be considered benign, virus-induced epithelial hyperplasias, and the identification of HPV does not appear to offer any diagnostic advantage because the histopathologic features alone allow for differentiation of one from the other.[9]

Condyloma acuminatum (Fig. 28-2), or venereal warts, are another type of HPV DNA infection that may be found in children and adolescents. As with squamous cell papillomas, the most prevalent virus types found are HPV 6 and 11.[7] They occur more frequently on the buccal or labial mucosa, soft palate, and tongue or lingual frenum and often appear as a nontender exophytic mass with short blunted papillary projections and a sessile base. While usually considered to be sexually transmitted, they can be spread by autoinoculation and vertical transmission from the mother, as discussed above for verruca vulgaris.

Treatment of oral squamous papilloma, verruca vulgaris, or condyloma acuminatum is best accomplished by complete surgical excision of the lesion, including the base.

FIBROMA

Fibroma is the most common benign soft-tissue tumor found in the oral cavity. It is characteristically a dome-shaped lesion with a sessile base and a smooth surface that is usually the color of the surrounding mucosa. It may vary from firm to flaccid in texture and most commonly occurs in sites predisposed to irritation or trauma, such as the buccal mucosa, lip, tongue, gingiva, and hard palate. It may occur at any age. Sometimes termed focal fibrous hyperplasia, a fibroma occurring in the oral cavity is reactive, being basically either a reactive type of fibrous hyperplasia or, in some cases, a healed pyogenic granuloma that has undergone sclerosis.

Histologically, the fibroma is a dome-shaped lesion composed of a fibrous connective tissue stroma that may vary from loose and delicate to quite dense in its appearance, with an overlying layer of stratified squamous epithelium. Treatment consists of simple surgical excision. There is little propensity for recurrence.

PYOGENIC GRANULOMA, PERIPHERAL OSSIFYING FIBROMA, PERIPHERAL ODONTOGENIC FIBROMA (WHO TYPE), AND PERIPHERAL GIANT CELL GRANULOMA

Pyogenic Granuloma

Pyogenic granuloma is a relatively common soft-tissue tumor that arises from the fibrous connective tissue of the skin or mucous membranes. Originally believed to be a botryomycotic infection, it is now known to be a reactive inflammatory process in which an exuberant fibrovascular proliferation of the connective tissue occurs secondary to some low-grade, chronic irritation.

Clinically, pyogenic granuloma is a raised lesion on either a sessile or a pedunculated base. Its surface may have a smooth, lobulated, or, occasionally, warty appearance that is erythematous and often ulcerated (Fig. 28-3). Depending on the age of the lesion, the texture varies from

Dentlearn.ir

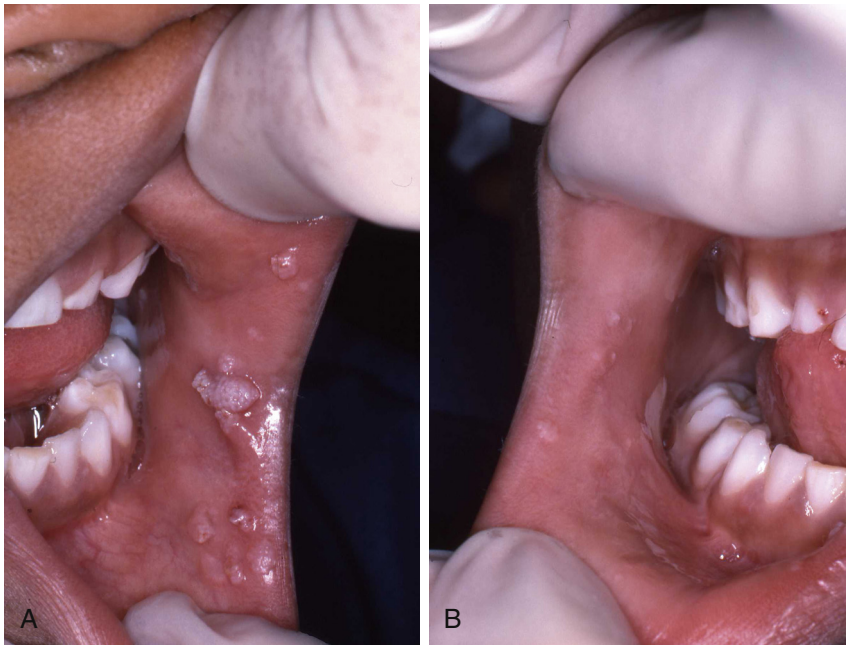

Figure 28-2 A 4-year-old male patient seen on routine new-patient examination with multiple dome-shaped lesions having cauliflower-like surface and sessile base. Biopsy showed them to be oral condyloma acuminatum.

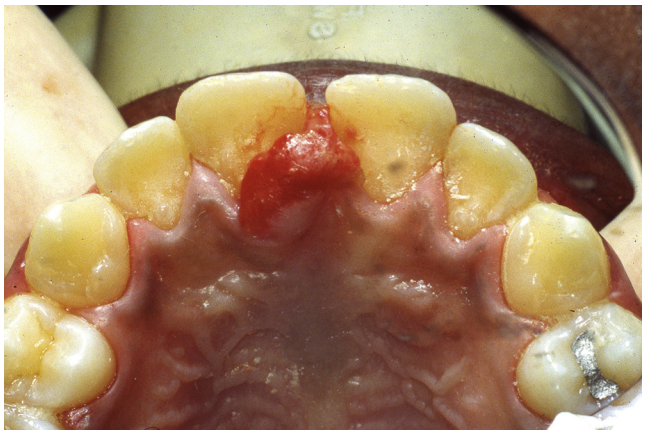

Figure 28-3 Pyogenic granuloma arising from the interdental papilla between the maxillary central incisors. The surface is lobulated with erythema and ulceration. There was poor oral hygiene with heavy accumulation of plaque on the lingual surfaces of the teeth.

soft to firm and is suggestive of an ulcerated fibroma. Because of the pronounced vascularity of these lesions, they often bleed easily when probed. A review of pyogenic granulomas of the oral cavity revealed a 65% to 70% incidence of occurrence on the gingiva, most commonly the maxillary anterior labial gingiva, followed by the lips, tongue, buccal mucosa, palate, mucolabial or mucobuccal fold, and alveolar mucosa of edentulous areas.[10] In this series, 27% of 46 patients were younger than 20 years of age. Another review of 38 cases reported an age range of 5 to 75 years (mean age, 33 years), with the most frequent site of occurrence also being on the gingiva (74%).[10,11]

Histologically, the pyogenic granuloma presents as a remarkable proliferation of plump fibroblasts and endothelial cells with the formation of prominent numbers of thin-walled, endothelium-lined vascular channels. A polymorphous inflammatory cell infiltrate is present, and the overlying surface epithelium is often ulcerated. Treatment consists of surgical excision, with care being taken to completely remove any local irritant that may still be present that would predispose to recurrence of the lesion.

In addition to an ulcerated fibroma, which in fact may itself be a nearly healed or sclerosed pyogenic granuloma, both peripheral ossifying fibroma and peripheral giant cell granuloma must be considered in the differential diagnosis of pyogenic granuloma, because these lesions are clinically indistinguishable.

Peripheral Ossifying Fibroma

Peripheral ossifying fibroma is a benign reactive lesion believed to be of periodontal ligament origin that occurs exclusively on the gingiva. In the largest series of cases, 50% of the lesions were noted to occur in individuals between 5 and 25 years of age, with the peak incidence at 13 years.[12] The lesions were almost equally divided between maxilla and mandible, with more than 80% of the lesions in both jaws occurring anterior to the molar area.

Histologically, peripheral ossifying fibroma demonstrates a proliferation of plump fibroblasts in a characteristic stroma of delicate, interlacing collagen fibrils. Osteoid and calcified material varying from dystrophic calcification to spicules of lamellar bone may be found in the lesion. The surface epithelium is often ulcerated. Although simple surgical excision is the treatment of choice, recurrences are not uncommon and were reported in two studies in 16% and 20% of cases, respectively.[12,13] In a more recent study of 134 cases of peripheral ossifying fibroma in patients aged 1 to 19 years, the overall

recurrence rate was 8%. However, this was thought to represent the minimum rate of recurrence, in that no attempt was made to determine how many patients with or without recurrent lesions were followed clinically and, if so, for how long.[14]

Peripheral Odontogenic Fibroma (WHO type)

Previously, the terms peripheral ossifying fibroma and peripheral odontogenic fibroma were used synonymously, which introduced considerable confusion into the literature. To clarify the confusion, *peripheral odontogenic fibroma* (World Health Organization [WHO] type) was proposed to denote the rare peripheral counterpart of the central odontogenic fibroma (WHO type), and *peripheral ossifying fibroma* was proposed to be retained and used to denote the relatively common reactive gingival lesion.[15] Clinically, peripheral odontogenic fibroma (WHO type) must be considered in the differential diagnosis of dome-shaped or nodular, usually nonulcerated, growths on the gingiva.

Peripheral odontogenic fibroma (WHO type) is a rare odontogenic tumor characterized by a fibrous or fibromyxomatous stroma containing varying numbers of islands and strands of odontogenic epithelium. Cementum-like, bone-like, or dentinoid material may be present. Its age at presentation is strikingly similar to that of the peripheral ossifying fibroma. Even though treatment consists of local surgical excision, in one study recurrence was noted in 7 of 18 cases for which follow-up information was obtained.[16]

Peripheral Giant Cell Granuloma

Peripheral giant cell granuloma, like the peripheral ossifying fibroma, is a lesion unique to the oral cavity, occurring only on the gingiva. Unlike peripheral ossifying fibroma, however, it may occur on the alveolar mucosa of edentulous areas. Like pyogenic granuloma and peripheral ossifying fibroma, peripheral giant cell granuloma may represent an unusual response to tissue injury. It is distinguishable from pyogenic granuloma and peripheral ossifying fibroma only on the basis of its unique histomorphology, which is essentially identical to that of central giant cell granuloma (discussed later in this chapter). In a review of 720 cases, 33% were seen in patients younger than 20 years of age, which concurs with the findings of another study in which 33 of 97 cases (34%) occurred in individuals between 5 and 15 years of age.[17,18] There is a nearly 2:1 predilection of females to males, with the mandible being involved more often than the maxilla. Although it develops in soft tissue, resorption of the subjacent alveolar bone may occur. Also, while rare, cervical root resorption may be seen in association with a peripheral giant cell granuloma.[19]

The peripheral giant cell granuloma is best treated by complete surgical excision, with care taken to excise it at its base. Little tendency for recurrence has been noted.

NEUROFIBROMA AND NEUROFIBROMATOSIS (VON RECKLINGHAUSEN DISEASE)

Neurofibroma is a benign neural neoplasm of Schwann cell origin, several clinical forms of which are recognized. The solitary neurofibroma may present in the skin or oral mucous membranes as a soft tumor with a sessile or pedunculated base. Some neurofibromas are diffuse, presenting as a soft, nonspecific tissue mass or swelling. The presence of either solitary or diffuse neurofibromas does not in itself herald the diagnosis of neurofibromatosis. However, the presence of a third form, plexiform neurofibroma, is considered to be diagnostic of neurofibromatosis. Plexiform neurofibroma differs from either the solitary or diffuse forms in that it remains confined to the perineurium, presenting as a tortuous, fusiform enlargement of the nerve.

As familial cancer syndromes, there are three recognized forms of neurofibromatosis—neurofibromatosis type 1 (NF1), neurofibromatosis type 2 (NF2), and schwannomatosis—with the most prominent common denominator of all three being the appearance of Schwann cell–initiated tumorigenesis of the peripheral nervous system.[20] Because of its relative comparative frequency of occurrence and frequency of oral and cutaneous manifestations potentially evident to the dental practitioner, only NF-1 will be discussed in this chapter.

NF1, known as *von Recklinghausen disease*, is a relatively common disorder showing autosomal-dominant inheritance with complete penetrance, variable clinical expressivity and pleiotropy, and age-dependent expression of clinical manifestations. It occurs in approximately 1 in 3000 live births, with an equal gender predilection. The *NF1* gene is carried on chromosome 17 and has tumor-suppressor function, with the tumor-suppressing properties of neurofibromin (the NF1 gene product) being impaired or lost due to mutation in the gene. It is said to be the most common single-gene disorder to affect the human nervous system. The criterion for diagnosis is the presence of two or more of the following features: six or more café-au-lait spots (1.5 cm or larger in postpubertal individuals, 0.5 cm or larger in prepubertal individuals), two or more neurofibromas of any type or one or more plexiform neurofibromas, freckling in the axillary or inguinal region, optic glioma, two or more pigmented iris hamartomas or Lisch nodules, dysplasia of the sphenoid bone or dysplasia or thinning of long bone cortex with or without pseudoarthrosis, and a first-degree relative with NF1.

As previously noted, the *NF1* gene is a tumor-suppressor gene, and thus patients with NF1 are at increased risk of developing benign and malignant tumors. Neurofibromatosis is a progressive condition, with different presentations occurring at specific times and some complications worsening over time. While cutaneous or dermal neurofibromas are considered one of the characteristic features of this disorder and may appear in childhood, they more commonly develop in teenagers or adults. Although malignant peripheral nerve sheath tumors may be noted in pediatric patients with NF1, they usually develop in adulthood and are heralded by the presence of pain or rapid growth arising in a plexiform or deep nodular neurofibroma.[21]

Intraorally, neurofibromas may present as nodular lesions on either a sessile or pedunculated base, often

Dentlearn.ir

with a normal, pink mucosal color (Fig. 28-4); as a diffuse, ill-defined swelling with a firm to doughy consistency; or as a diffuse, noncompressible mass. They are most frequently found on the tongue and buccal mucosa but occasionally present as intraosseous lesions, which occur most commonly in the posterior mandible (Fig. 28-5).

The most common radiographic findings include an increase in bone density, enlarged mandibular foramen, lateral bowing of the mandibular ramus, increase in dimensions of the coronoid notch, and decrease in the mandibular angle.[22] Computed tomographic scans may reveal findings such as enlargement of the mandibular foramen and concavity of the medial surface of the ramus.

A great deal of histomorphologic variability may be noted, from relatively circumscribed but nonencapsulated solitary neurofibromas to diffuse and plexiform neurofibromas. Diffuse neurofibromas are characterized by infiltrative growth pattern along connective tissue planes and its Wagner and Meissner tactile corpuscles. Plexiform neurofibromas are characterized by fascicles of neoplastic Schwann cells and collagen within a myxoid matrix that is confined to the perineurium. Mast cells are common findings within neurofibromas.

Solitary lesions are best treated by simple surgical excision and show little propensity for recurrence. Surgical excision of diffuse neurofibromas is difficult because of their diffuse, infiltrating nature. Plexiform neurofibromas are also difficult to treat in that they have a tendency to grow along the course of a nerve, which results in frequent recurrences. It has been noted that (1) children younger than 10 years of age, (2) children with plexiform neurofibromas in the head, face, and neck, and (3) those with tumors that cannot be almost completely removed are at particular risk for progression of their disease.[23]

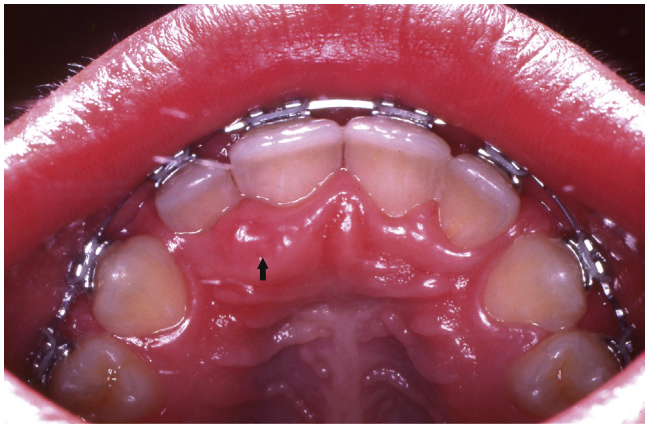

Figure 28-4 A 14-year-old boy undergoing orthodontic therapy was referred for evaluation of gingival hyperplasia on the lingual surfaces of the maxillary incisors and a firm swelling on the palatal side of tooth number 9 that was found after biopsy to be a neurofibroma *(arrow)*.

HEMANGIOMA

Vascular anomalies are commonly encountered lesions of childhood and may be divided into hemangiomas and vascular malformations.[24] Hemangiomas are differentiated from vascular malformations since they demonstrate proliferative activity, whereas vascular malformations grow commensurately with the child.[25] The hemangioma is a common, benign, vasoformative tumor that frequently occurs in the head and neck in children. It is generally believed to be hamartomatous rather than neoplastic in nature. Most hemangiomas are either present at birth or develop within the first year of life. It is believed that even those lesions that do not appear until adult life may have been present but not clinically evident until they began to enlarge.

Hemangiomas arising in the oral soft tissues most commonly affect the tongue, lips, and buccal mucosa. Clinically, they may be flat or raised and may vary from deep red to blue. Their histologic classification is based on the size of the vascular spaces. A capillary hemangioma is the most common type and is composed of many tiny capillaries with a pronounced endothelial cell proliferation. The cellular or juvenile hemangioma consists principally of a proliferation of endothelial cells with only small numbers of discernible capillaries. A cavernous hemangioma is characterized by large, blood-filled sinusoidal spaces lined by endothelial cells and supported by a fibrous stroma. Hemangiomas may also occur centrally within the mandible or maxilla.

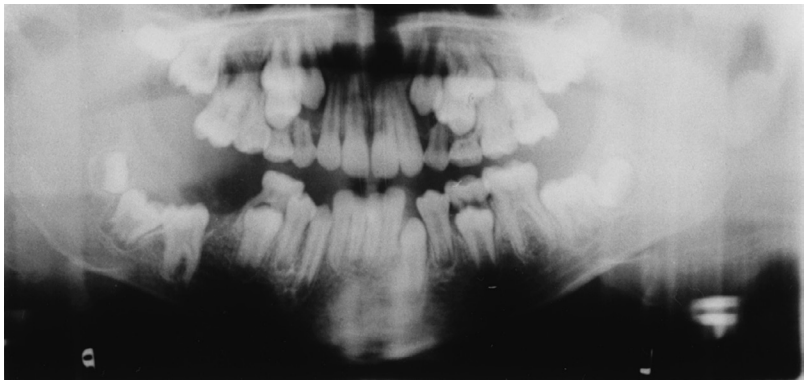

Figure 28-5 Neurofibroma involving the molar region and ramus of the right mandible in a child with neurofibromatosis. (Courtesy Dr. Robin Cotton.)

Dentlearn.ir

Vascular malformations most frequently involve the skin but also may affect visceral organs or bone. They may be categorized as fast-flow lesions and slow-flow lesions.[26] Fast-flow lesions include arterial malformations, arteriovenous malformations, and arteriovenous fistulas. Slow-flow lesions include capillary, lymphatic, and venous malformations. Vascular malformations of the mandible (i.e., arteriovenous malformations or central hemangioma of the mandible, as they are sometimes called) are potentially dangerous in that a biopsy or simple event such as a tooth extraction may lead to a catastrophic hemorrhage, possibly leading to death.[27] These lesions may be asymptomatic, picked up only as incidental radiographic findings, or they may cause pain and swelling. They are typically well-circumscribed radiolucent lesions with no characteristic radiographic pattern to denote their underlying nature. Occasionally, loose or displaced teeth may be seen. Arteriovenous malformations bear a radiographic similarity to any number of other relatively well-circumscribed unilocular or multilocular radiolucent lesions in the jaws. Therefore it is advisable to aspirate such lesions with a needle before surgery or dental extraction, to avoid the possibility of severe blood loss or exsanguination caused by the inability to control the resultant profuse bleeding. The treatment for hemangiomas varies with the type, location, and size of the lesion involved. Many lesions spontaneously involute with age, especially those that are noted early and cease growing during the first year of life. Others require no treatment because of their small size and innocuous nature.

LYMPHANGIOMA

Lymphangiomas are relatively rare benign congenital tumors of the lymphatic system. Even though the embryologic events leading to their development remain unclear, they are thought to arise as a benign hamartomatous proliferation of sequestered lymphatic rests. Forming along tissue planes or penetrating adjacent tissue, they become canalized and, in the congenital absence of venous drainage, accumulate fluid. The head and neck region is most commonly involved, with up to two thirds of cases being present at birth and as many as 90% being present by the second year of life; a small number may not be manifest for a number of years.[28]

illary lymphangiomas, cavernous lymphangiomas, and cystic hygroma. Capillary lymphangioma is typically composed of a proliferation of thin-walled, endothelium-lined

lymphangioma is characterized by the presence of dilated

of erythrocytes. Cystic hygroma is a macroscopic form of the cavernous lymphangioma, with large sinusoidal spaces lined with a single layer of endothelial cells that form multilocular cystic masses of varying sizes. Lymphangiomas of the oral soft tissues occur most commonly on the tongue, lips, and buccal mucosa. They are often elevated and nodular in appearance and may have the same color as the surrounding mucosa. Treatment is generally not indicated for small oral mucosal lymphangiomas; partial or complete spontaneous involution is occasionally noted.

Although cystic hygromas may be found in the oral cavity in sites such as the tongue, they most frequently appear as a mass in the neck, occasionally extending into the mediastinum. Most commonly presenting as a slow-growing asymptomatic soft-tissue mass, however, they may undergo sudden enlargement in the presence of

ry tract infection. Large cystic hygromas may encroach on the airway and esophagus, leading to difficulty in swallowing and even airway obstruction.

CONGENITAL EPULIS (GINGIVAL GRANULAR CELL LESION) OF THE NEWBORN

Congenital epulis of the newborn is a rare lesion of uncertain histogenesis that occurs exclusively in newborn infants, chiefly on the maxillary anterior alveolar ridge and less commonly on the mandibular anterior alveolar ridge. Although usually solitary lesions, they may be multiple, most often affecting both the maxilla and mandible, although rare simultaneous occurrence of lesions on the maxillary anterior alveolar ridge and tongue have been reported. Clinically, the lesion presents at birth as a pink, smooth to lobulated, pedunculated mass that may vary in size from a few millimeters to more than 7 cm in diameter. More than 90% of cases occur in girls (Fig. 28-6).

While typically considered to be a lesion of uncertain histogenesis, immunohistochemical studies have revealed strong and diffuse cytoplasmic staining for neuron-specific enolase and vimentin, which suggests that the congenital epulis may be derived from uncommitted nerve-related mesenchymal cells.[29]

Although histologic similarities to the granular cell tumor have long been noted, the epithelium over the congenital epulis is generally thin without rete ridge formation, whereas the granular cell tumor is characterized by pseudoepitheliomatous hyperplasia of the overlying epithelium. Distinct differences are obvious on both ultrastructural and immunohistochemical evaluation; one differentiating factor between the congenital epulis and granular cell tumors is the absence of S100 in the former and its presence in the latter lesion.[30]



Figure 28-6 Congenital epulis of the newborn. (Courtesy Dr. Robin Cotton.)

Dentlearn.ir

Although the clinical presence of congenital epulis may frighten parents, it ceases to grow following birth and is entirely benign, with some cases undergoing spontaneous involution. The usual treatment is simple surgical excision, with care taken not to interfere with the developing dentition. As there have been some reports of spontaneous regression of lesions treated conservatively (i.e., nonsurgical management), it has been concluded that, in lesions less than 2 cm in its largest dimension, where there is no interference with respiration or feeding, that nonsurgical management to avoid general anesthesia in a neonate, for a benign lesion which will not recur, should be considered.[31] There is no propensity for recurrence with excision, even in those cases in which the lesion is incompletely removed.

MUCOCELE

Mucocele, or mucus retention phenomenon as it is often called, is a salivary gland lesion of traumatic origin that forms when the main duct of a minor salivary gland is torn, with subsequent extravasation of mucus into the fibrous connective tissue so that a cystlike cavity is produced. The wall of this cavity is formed by compressed bundles of collagen fibrils, and its lumen contains inspissated mucin.

Mucoceles are noted to occur most commonly on the lower lip, with the floor of the mouth and buccal mucosa being the next most frequent sites of involvement. Mucoceles are only rarely seen on the upper lip, retromolar pad, or palate. Although they may occur at any age, including at birth, they tend to be noted most frequently in the second and third decades of life. No obvious gender predilection is noted.

A mucocele may be located either in the superficial mucosa, where it is typically seen as a fluid-filled vesicle or blister (Fig. 28-7), or deep within the connective tissue, where it is seen as a fluctuant nodule with the overlying mucosa normal in color. There may be spontaneous drainage of the inspissated mucin with temporary resolution, especially in superficial lesions, and subsequent recurrence as the mucous saliva continues to drain into the connective tissue at the site of the torn duct. Fibrosis may be observed over the surface of a long-standing lesion where chronic periodic drainage has taken place.

Treatment is by surgical excision, with removal of the involved accessory salivary gland. Marsupialization will only result in recurrence.



Figure 28-7 Mucocele on the lower lip. Notice the small white area of fibrosis where the mucocele has spontaneously drained with healing on the roof of the lesion, only to have the mucocele recur.

RANULA

Ranula is the clinical term for a mucocele occurring on the floor of the mouth after trauma to components of the sublingual glands. Two varieties of ranula exist: cystic (mucus retention cyst) and pseudocystic (mucus retention phenomenon or mucocele). In the cystic type, there is partial obstruction of the distal end of a sublingual gland duct that results in a small epithelial lined cyst usually less than 1 cm in diameter. However, the pseudocystic type, which is more common, forms as a result of extravasation of mucus into the fibrous connective tissue after a tear in a sublingual gland duct and, as in the case of a mucocele, arises as a result of the escape of mucus into the adjacent connective tissue. The clinical term *plunging ranula* is used when extravasated mucus dissects through the mylohyoid muscle and along the fascial planes of the neck, producing a swelling evident in the floor of the mouth.

Ranulas are typically slowly enlarging, fluctuant masses occurring on one side of the midline of the floor of the mouth and are so named because of their resemblance to the bloated underside of a frog's belly (Fig. 28-8). Lesions are usually treated by marsupialization, with occasional recurrence being noted. Chronic recurrence may require excision of the entire involved gland.

BENIGN TUMORS OF BONE

BENIGN FIBRO-OSSEOUS LESIONS OF THE JAWS

Benign fibro-osseous lesions of the jaws comprise a di-

tor, the replacement of normal bone architecture by a benign fibrocellular stroma containing varying amounts of mineralized material, including woven bone, lamellar bone, and curvilinear trabeculae or spherical calcifications. The mineralized material may histologically

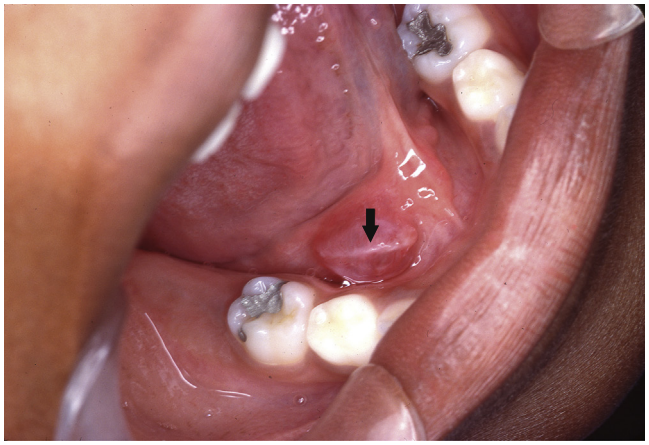

Figure 28-8 Ranula on the floor of the mouth *(arrow)*.

Dentlearn.ir

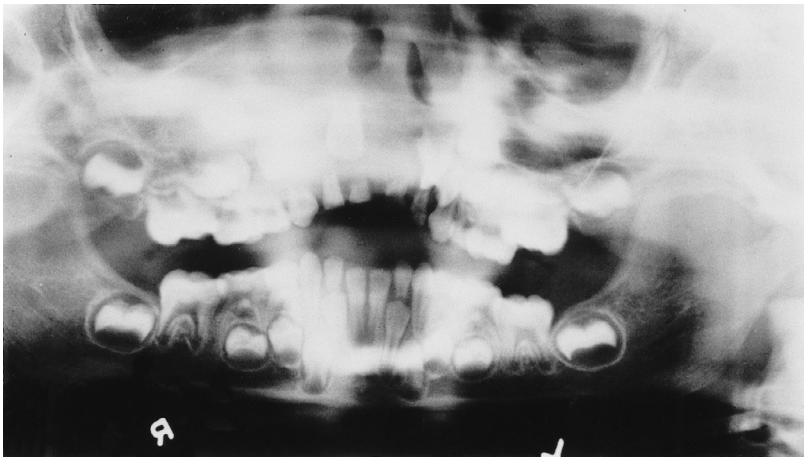

Figure 28-9 Panelipse radiograph of a child with fibrous dysplasia showing a uniformly radiodense lesion crossing the midline with poorly defined borders blending into the surrounding bone. Notice the displacement of the developing teeth.

resemble bone and/or cementum. Because of the similar histomorphology of these lesions, diagnosis is best made on the basis of distinguishing clinical and radiographic

cludes fibrous dysplasia (considered a developmental

the collective term cemento-osseous dysplasia, and cemento-ossifying fibroma, which is a benign neoplasm. Because of the frequency of occurrence of fibrous dysplasia and cemento-ossifying fibroma of bone in the jaws of children and the relative lack of occurrence of the

to the commonality of the histopathologic features of these disorders, a definitive diagnosis of any of them is dependent on evaluation of a combination of the clinical, histopathologic, and imaging features taken together, not just the microscopic features alone.[32]

FIBROUS DYSPLASIA

Fibrous dysplasia of the jaws is a distinct clinicopathologic entity that is generally considered to be a nonneoplastic developmental lesion of bone. One of the disease entities included in the spectrum of benign fibro-osseous lesions of the jaws, it is distinguished from the others by its clinical and radiographic features. In the child and adolescent, it has most often been confused with the cemento-ossifying fibroma, which is a benign neoplasm believed to be of periodontal ligament origin. Fibrous dysplasia is caused by a somatic activating mutation of the alpha subunit of the G protein receptor (Gs-alpha) that ultimately results in abnormalities of osteoblast differentiation and therefore abnormal bone.

The two forms of fibrous dysplasia are (1) the relatively rare polyostotic form of the disease and (2) the considerably more common monostotic fibrous dysplasia. A severe form of polyostotic fibrous dysplasia called McCune-Albright syndrome is associated with café-au-lait macules on the skin and a variety of endocrine disorders, most commonly precocious puberty, but also including Cushing's syndrome, hyperthyroidism, growth hormone excess, etc.

Monostotic fibrous dysplasia tends to develop early in life, with lesions being detected late in the first and early in the second decades.[32] It is seen with approximately equal frequency in males and females, with the maxilla being involved more frequently than the mandible. Maxillary involvement can be an especially serious form of the disease, frequently involving contiguous bones across suture lines, including the maxillary sinus, floor of the orbit, sphenoid bone, base of the skull, and occiput. This form of the disease has been called craniofacial fibrous dysplasia and is not truly monostotic in its nature.

The most common clinical manifestation is a painless swelling of the jaws characterized by a smooth, uniform, fusiform expansion of the involved alveolar ridge. Obliteration of the mucobuccal or mucolabial fold is a common feature, with the overlying mucosa being normal in appearance. When the maxilla is involved, elevation of the eye may be noted.

Radiographically, maxillary lesions most often show a ground-glass appearance of the bone, whereas mandibular lesions usually show either a ground-glass or a mixed radiolucent-radiopaque appearance (Fig. 28-9). Their borders are typically poorly defined, except for the anterior portion of some maxillary lesions, which may appear to be well-circumscribed. Divergence of roots may be noted, and in children in whom developing permanent teeth are present, there may be displacement of teeth with noneruption (see Fig. 28-9). Other potential distinguishing radiographic findings include superior displacement of the mandibular canal and a fingerprint bone pattern as well as displacement of the maxillary sinus cortex, alteration of the lamina dura because of the abnormal bone pattern, and narrowing of the periodontal ligament space.[33]

Histologically, there is a benign fibrous stroma with bony trabeculae varying in appearance from woven to lamellar, proportionate to the relative maturity of the lesion.

Monostotic fibrous dysplasia of the jaws is typically a slow-growing, painless, progressive enlargement of bone whose growth pattern often stabilizes with time as maturation in skeletal growth is reached. Conservative therapy is indicated because of the benign nature of this lesion and because surgically the margins are ill-defined and blend into the surrounding normal bone. Surgery, chiefly in the form of osseous recontouring, should be considered only when there is functional or significant

Dentlearn.ir

cosmetic deformity and then usually only after stabilization of the disease process. Because this is a benign lesion of bone, radiation therapy is contraindicated because of the possibility of development of a postradiation sarcoma in the area. In symptomatic cases in which pain control and disease stabilization are needed, bisphosphonates have been used, resulting in pain relief and, in a number of patients, disease stabilization as well.[34,35] Little, however, is known about the long-term skeletal effects of childhood bisphosphonate use, and it has been recommended that its use be limited to experienced pediatric units.[34]

CEMENTO-OSSIFYING FIBROMA

Cemento-ossifying fibroma is a benign neoplasm of bone

odontogenic tumors under the broad category of benign fibro-osseous lesions of the jaws. As with other benign fibro-osseous lesions, it is characterized histologically by a benign fibrocellular stroma, with formation of variable amounts of woven-appearing bone, lamellar bone, and spherical to annular to amorphous cementum-like calcifications. Although it was traditionally considered to be an odontogenic neoplasm of periodontal ligament origin affecting the tooth-bearing areas of the jaws, the occurrence of histologically identical neoplasms in the temporal, frontal, ethmoid, and sphenoid bones leaves this concept in doubt. Although there is a predilection for occurrence in the third and fourth decades of life, cemento-ossifying fibroma is found with some frequency in patients younger than 20 years of age. The mandible is involved more often than the maxilla, with the molar and premolar regions of the mandible being the most common sites of occurrence.

Cemento-ossifying fibroma may be entirely asymptomatic, being discovered on routine radiographic examination, or may present as a painless expansion of bone. Radiographically, it is a well-circumscribed lesion, often with a well-demarcated sclerotic border (Fig. 28-10). Beyond this, the radiographic features are quite variable.[36] It most frequently presents as a unilocular radiolucency with or without radiopaque foci, which may be superimposed over teeth, be interposed between contiguous teeth, or reside in edentulous regions. Aggressively expansile lesions, with or without radiopaque foci, and multilocular expansile lesions may also be noted. Tooth displacement or divergence of roots of teeth and/or root resorption may be seen with varing degrees of frequency, with tooth displacement or root divergence being reported in 17% to 33% of cases and root resorption being seen between 11% and 44% of the time.[36,37] Cortical thinning and bony expansion with clinical deformity have been reported in as many as 91% of cases.

Initial treatment is by enucleation or curettage where possible, with the frequency of recurrence varying from 0% to 28%.[36,38]

JUVENILE OSSIFYING FIBROMA

The term *juvenile ossifying fibroma* (JOF), also known as juvenile active ossifying fibroma and juvenile aggressive



Figure 28-10 Ossifying fibroma in a 10-year-old boy. The radiograph shows a well-circumscribed, expansile, radiolucent lesion with thinning of the inferior cortical plate of bone. (Courtesy Dr. Mark L. Bernstein.)

ossifying fibroma, encompasses two distinct clinicopathologic variants of ossifying fibroma involving the craniofacial bones: trabecular JOF (TrJOF) and psammomatoid JOF (PsJOF).

The majority of cases of TrJOF occur in children and adolescents. Both maxilla and mandible may be involved, with the maxilla being involved slightly more frequently.[32] Occurrence in extragnathic locations is extremely rare.[32] The reported mean age ranges from 8.5 to 12 years (range, 2 to 12 years).[39] The growth of TrJOF has been characterized as painless, progressive, and sometimes rapid expansion of the affected area.[32,39] Radiographically, they may show a mixed radiolucent radiopaque appearance and are expansile, fairly well-defined, and may present with cortical thinning and perforation.

PsJOF occurs predominantly in the sinonasal and orbital bones in children, with a mean age range of 16 to 33 years (range, 3 months to 72 years).[32,39] Clinically, it presents as bony expansion of the orbital or nasal bones or sinuses, and radiographically, it is seen as a round, well-defined, sometimes corticated, osteolytic lesion with cystic appearance.[32]

Aggressive growth was noted to occur in some cases of both types of tumors, with a high recurrence rate after excision (30% to 56%). This has been postulated as likely due to incomplete excision caused by the infiltrative nature of the tumor borders.[39] Even with this, it has been proposed that, despite their similarities in biologic behavior, differences in histologic and clinical presentation as well as sites of occurrence between PsJOF and TrJOF warrant their separation into two distinct clinicopathologic entities.[39]

CENTRAL GIANT CELL GRANULOMA

First described in 1953 as giant-cell reparative granuloma, the central giant cell granuloma (CGCG) of the jaws

Dentlearn.ir

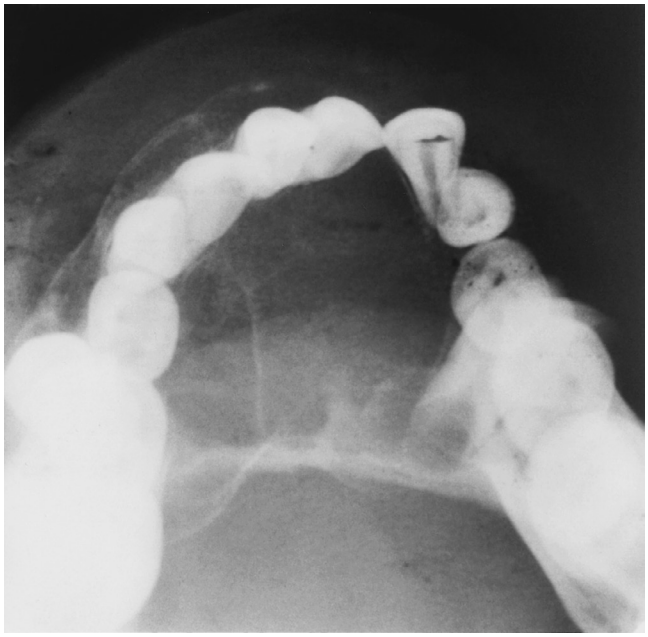

Figure 28-11 Central giant cell granuloma involving the anterior mandible presenting radiographically as a multilocular, radiolucent lesion with expansion and thinning of the cortical plates. Notice also the faint trabeculation within the lesion.

is a relatively uncommon benign lesion of bone.[40] It occurs most commonly during the first 30 years of life, with more than 60% of lesions noted before 20 years of age and nearly 50% occurring in patients younger than 16 years of age. CGCG occurs more often in females than in males. It may be found in either jaw, but the mandible is involved twice as often as the maxilla. Although it was traditionally accepted that the majority of lesions occur anterior to the first permanent molar, a study of 80 cases of CGCG found that nearly 50% of cases occurred in the molar, ramus, and tuberosity regions.[41] Usually asymptomatic, CGCG may present with aggressive growth, pain, and swelling. Radiographically, CGCG may vary from a unilocular radiolucency to a multilocular expansile bone-destructive lesion with displacement and noneruption of teeth, root resorption, and cortical perforation (Fig. 28-11). Histologically, CGCG is composed of a few to many monocyte-derived multinucleated giant cells in a fibrous connective tissue stroma of ovoid to spindle shape, probably fibroblast-related, mesenchymal cells, and round monocyte-macrophages. Prominent numbers of extravasated red blood cells with associated hemosiderin pigment are often scattered throughout the fibrous connective tissue. Varying amounts of osteoid and bony trabeculae are also noted.

The pathogenesis of CGCG of the jaws remains un-

both reactive and neoplastic disease. There is also considerable discussion in the literature as to its relationship to giant cell tumor of bone. It has been suggested by several authors that CGCG and giant cell tumor of other bones represent a spectrum of a single disease process, with the differences in clinical behavior partially accounted for by differences in age distribution and by the site of occurrence, among other factors.[42,43,44]

As originally described, CGCG was a rather indolent process that yielded readily to therapy, with the therapeutic procedure of choice being surgical curettage.[40] It was subsequently reported that there is a range of biologic behavior of CGCGs, from quiescent to aggressive, expansile bone-destructive lesions.[45] Lesions in CGCG

sive, based on their clinical presentation. Nonaggressive lesions have a slow, asymptomatic growth without perforation of the cortical plate of bone or root resorption. Features of aggressive lesions may include rapid growth, expansion and/or perforation of the cortical plate of bone with soft-tissue extension, pain, and root resorption.[41,43-45] It has also been suggested that younger age at presentation may be associated with more aggressive behavior. In one series, for example,[43] recurrence developed in 5 of the 25 patients for whom follow-up information was available, with the average age of these 5 patients being 11 years compared with an average age of 29 years for patients without recurrence. In a study of 31 cases of CGCG of the jaws in 29 patients, seven lesions demonstrated cortical perforation and soft-tissue extension.[44] Lesions recurred in five cases, all of which showed microscopically confirmed cortical perforation at the time of first occurrence.

Surgical curettage is the most commonly used therapy for CGCG, although in aggressive cases resection may be indicated. Although alternative treatments to surgical curettage have been suggested, including injections of corticosteroid, calcitonin, and interferon (INF-α) as well as some others, a Cochrane review did not identify evidence from randomized controlled trials to support their use.[46,47] Radiation therapy is contraindicated.

ODONTOGENIC CYSTS

Odontogenic cysts are so named because it is believed that they are derived from epithelium that arose from the dental lamina during odontogenesis. They may be developmental or inflammatory in origin. Even though the pathogenesis of the developmental types of odontogenic cysts is not clearly understood, it is known that inflammatory cysts such as the periapical cyst (apical periodontal cyst, radicular cyst) result from proliferation of epithelial rests of Malassez secondary to inflammation from pulpal necrosis of an associated tooth.[48]

Because of their relative potential for occurrence in the pediatric dental population, four types of developmental odontogenic cysts—primordial cyst, dentigerous cyst, eruption cyst, and odontogenic keratocyst (OKC, aka keratocystic odontogenic tumor or KOT)—are discussed in this chapter. Odontogenic keratocyst (OKC/KOT) is also discussed in relation to the nevoid basal cell carcinoma syndrome (Gorlin syndrome).

PRIMORDIAL CYST

Traditionally, primordial cyst was considered to be an uncommon type of odontogenic cyst, formed by cystic

Dentlearn.ir

degeneration of the enamel organ (primordium) before the formation of enamel or dentin. Primordial cysts are usually asymptomatic and are most likely to be found on routine radiographic examination. Although they begin to evolve when the enamel organ is developing before the formation of the enamel or dentin, they may not be noticed or become clinically evident for many years.

Radiographically, the primordial cyst may be a well-circumscribed, unilocular- or multilocular-appearing radiolucent lesion in a location where a permanent tooth failed to develop and where none has been extracted. Such cysts are more commonly found in the third molar region, but they may occur in any location where a permanent tooth would have formed.

Although more typically lined by nonkeratinizing, stratified squamous odontogenic cyst-lining epithelium with a fibrous connective tissue wall, primordial cyst may present as a histologically distinct type of odontogenic cyst, the odontogenic keratocyst. In one large series of cases, 60 of 135 (44.4%) primordial cysts were histologically odontogenic keratocysts.[49] Some authors have concluded that all primordial cysts are odontogenic keratocysts and use the two terms synonymously. However, if one takes into consideration that, in the study cited here, in which greater than 55% of cysts that clinically and radiographically fit the traditional criteria for a primordial cyst were not histologically odontogenic keratocysts, the concept that the two terms are synonymous ignores the histologic evidence to the contrary.

Appropriate treatment for the primordial cyst is surgical removal unless an extremely large bone-destructive lesion is present, in which case cystotomy with placement of a polyethylene drain followed by cystectomy when the cyst has reached a manageable size is the treatment of choice. If the lesion is found histologically to be an odontogenic keratocyst, the chance for recurrence is high (see later in this chapter).

DENTIGEROUS CYST

Dentigerous cyst, the most common type of odontogenic cyst, is found in association with the crown of an impacted, embedded, or otherwise unerupted tooth. The incidence of dentigerous cysts is reportedly 1.44 per 100 unerupted teeth.[50] Even though the dentigerous cyst is considered to be a developmental type of odontogenic cyst, it has been speculated that some may have an inflammatory origin from a source such as periapical inflammation from a nonvital deciduous tooth.[51] Typically, dentigerous cysts are asymptomatic and found on routine radiographic examination, appearing as a well-defined unilocular or multilocular radiolucent lesion. The lesion may vary in size from one in which the differentiation from an enlarged dental follicle is somewhat arbitrary (a pericoronal radiolucency of 2.5 mm or greater from the crown of the tooth has been generally accepted as differentiating a dentigerous cyst from a dental follicle)[48] to a large, bone-destructive lesion that may resorb the roots of primary teeth, cause the divergence of or completely displace permanent teeth, and produce large areas of bone destruction in either the mandible or the maxilla (Fig. 28-12).

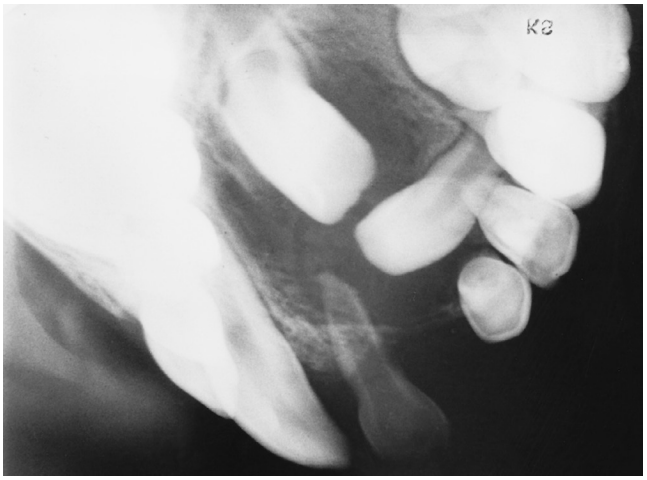

Figure 28-12 A dentigerous cyst in an 8-year-old girl associated with the developing maxillary central incisor with bone destruction and expansion, as well as displacement of the lateral incisor.

In addition to its potential for bone destruction and because of the multipotential nature of this epithelium derived from the dental lamina, several entities may arise in or be associated with the wall of a dentigerous cyst. For example, 8.5% of cysts that clinically appear as dentigerous cysts have been found histologically to be odontogenic keratocysts.[49] Although relatively uncommon in children and adolescents, it is believed that the majority of dentigerous cysts, with 50% to 80% of cases of cystic ameloblastoma appearing radiographically as dentigerous cysts.[53-55] It has been concluded, based on histopathologic features, that these ameloblastomatous changes occurred in a preexisting cyst rather than representing cystic degeneration of a solid tumor.[54] Mucus-secreting cells and, more significantly, mucoepidermoid carcinoma may also arise in the wall of a dentigerous cyst.

The treatment of choice for dentigerous cysts is surgical removal. Large bone-destructive lesions, however, are best treated initially by cystotomy and the placement of a polyethylene drain in the lesion, which facilitates shrinkage with healing around the periphery to the point where the lesion becomes amenable to more simple surgical removal. Because of the potential for occurrence of an odontogenic keratocyst or the development of an ameloblastoma or, more rarely, mucoepidermoid carcinoma, all such lesions, when removed, should be submitted for histopathologic evaluation.

ERUPTION CYST OR ERUPTION HEMATOMA

An eruption cyst or eruption hematoma is a type of dentigerous cyst associated with an erupting primary or permanent tooth in its soft-tissue phase after erupting through bone. The lesion is usually a translucent, smooth, painless swelling over the erupting tooth. If bleeding occurs into the cystic space, it may appear blue to blue-black and is then called an *eruption hematoma*. In most cases no treatment is indicated because the tooth usually erupts into the oral cavity undelayed and in a normal fashion.

Dentlearn.ir

ODONTOGENIC KERATOCYST (KERATOCYSTIC ODONTOGENIC TUMOR)

The odontogenic keratocyst is a distinct clinicopathologic entity with a clearly identifiable histologic appearance. Clinically it is characterized by a high rate of recurrence after treatment and by the potential to become an aggressive, bone-destructive lesion. In a review of 312 cases, the peak incidence was found to be in the second and third decades of life, with 17% occurring before 20 years of age (only two cases were noted in children younger than 10 years of age).[49] The mandible is involved twice as frequently as the maxilla, with the most common site of origin being the mandibular third molar region and ramus of the mandible, followed by the maxillary third molar region, mandibular first and second molar area, maxillary canine area, and mandibular premolar region. Half of the patients were symptomatic, with swelling and drainage being the most common clinical findings.

Radiographically, odontogenic keratocyst may be a unilocular or multilocular lesion, almost always with a well-defined sclerotic border (Fig. 28-13). Tooth displacement, particularly of unerupted teeth, root resorption, root divergence, and extrusion of erupted teeth may be seen. Although radiographic evaluation typically includes a panoramic radiograph, in the case of large lesions, especially those in the maxilla, computed tomography studies should be performed preoperatively to accurately define margins and soft-tissue extension that may be present.

The histologic appearance is pathognomonic. The lesion has a thin, generally uniform lining epithelium, usually 6 to 10 cells thick, with palisading and hyperchromasia of the basal layer of cells and a corrugated parakeratin layer. Often parakeratotic squames are shed into the lumen of the cyst cavity.

Occasionally, a cyst is lined by orthokeratin with a subjacent granular cell layer. These cysts have been termed *orthokeratinized odontogenic cysts* and should be differentiated clinically from odontogenic keratocyst, because orthokeratinized odontogenic cysts show little clinical aggressiveness and rarely recur.[56]

There is no uniform agreement as to the most appropriate method of treatment of odontogenic keratocysts. Recommendations vary from enucleation, with or without adjunctive therapy such as application of Carnoy solution, to marsupialization or decompression, to marginal or segmental resection. This is partly because of their variable clinical presentation, which includes differences in size and the multilocular nature of many odontogenic keratocysts, and partly because of their benign nature coupled with the high frequency of recurrence. A review of 22 reports citing 1592 cases of odontogenic keratocysts revealed a recurrence rate varying from 3% to 62% and an average rate of recurrence of 30.8%.[57] Seventy percent of recurrences have been shown to take place within 5 years of treatment.[58] Although these lesions should be surgically excised, enucleation is difficult because the cyst lining is often extremely thin and friable, and disruption of the epithelial lining in the resected specimen may be a primary determinant of recurrence.[59] It has been shown that odontogenic keratocysts that are completely enucleated recur significantly less often than those removed piecemeal.[60] Enucleation followed by the application of Carnoy solution and decompression followed by enucleation have been associated with low recurrence rates and resulted in significantly less morbidity than resection.[61] Alternatively, the radiograph in Figure 28-14 shows a large odontogenic keratocyst in which decompression was performed with placement of a



Figure 28-13 An odontogenic keratocyst in a 9-year-old girl involving the angle and ramus of the left mandible with displacement of the developing second and third molar teeth. (Courtesy Dr. Steven Reubel.)

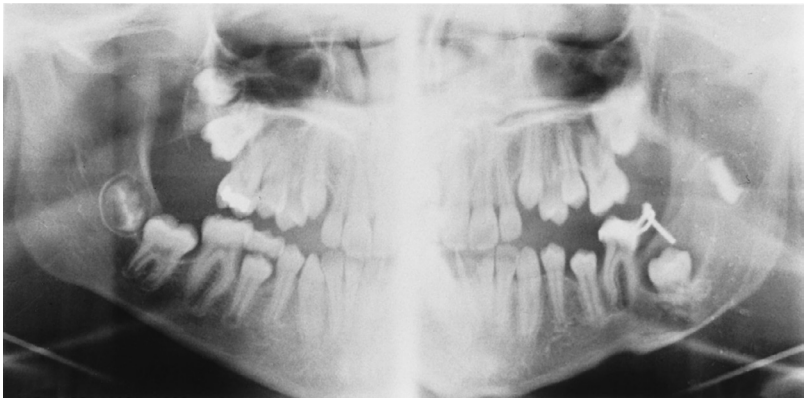

Figure 28-14 Same patient as in Figure 28-12, 9 months after marsupialization and placement of a drain. Notice the shrinkage of the cyst with bone fill in the area. Notice also inferior displacement of the inferior alveolar nerve. (Courtesy Dr. Steven Reubel.)

Dentlearn.ir

polyethylene drain, followed by cystectomy as the lesion became more surgically manageable.

Hence, as pointed out in a recent systematic review of the recurrence rate for OKCs as related to treatment modalities, there is currently no high-quality evidence available to evaluate recurrence rates relative to treatment types, leaving the most optimal treatment type in doubt.[62]

Patients with documented or suspected nevoid basal cell carcinoma syndrome have a higher rate of recurrence than patients without the syndrome.[60,63]

NEVOID BASAL CARCINOMA (GORLIN) SYNDROME

Nevoid basal carcinoma syndrome is a trait with autosomal-dominant inheritance with complete penetrance and remarkably variable expressivity.[64] It is caused by a mutation of the patched (*PTCH1*) gene, which is thought to be crucial for proper embryonic development and for tumor suppression. Traditionally characterized by a symptom complex of multiple basal cell carcinomas of the skin, odontogenic keratocysts, and rib abnormalities (bifid, fused, or splayed ribs), a variety of other abnormalities may accompany this disorder. Patients may have characteristic facies with cranial enlargement, frontal and parietal bossing with overdevelopment of the supraorbital ridges, hypertelorism, and a broad nasal root and mild mandibular prognathism. Calcification of the falx cerebri is evident radiographically in the majority of adult patients. In addition to the basal cell carcinomas, palmar and plantar pits and epidermal cysts of the skin are commonly seen. Congenital malformations such as cleft lip and cleft palate and polydactyly or syndactyly may be present. Spina bifida occulta of the cervical or thoracic vertebrae may occur, and marfanoid habitus may be seen. A variety of benign and malignant neoplasms have been reported to occur, including medulloblastoma, meningioma, ovarian fibroma, and fetal rhabdomyoma.[64] Neurologic abnormalities, including cognitive disabilities, may be noted, and some patients may be hyporesponsive to parathyroid hormone. Because of the association of the odontogenic keratocyst with the basal cell nevus syndrome, all patients with single or multiple odontogenic keratocysts should be evaluated medically with this condition in mind. This is especially true when an odontogenic keratocyst is found in a young patient because the median age of appearance is younger in syndromic than in nonsyndromic patients.[64] Also, as previously stated, there is an apparent increase in the rate of recurrence of odontogenic keratocysts in patients with the syndrome.

ODONTOGENIC TUMORS

The odontogenic tumors are so named because of their presumed origin from the tissues derived from the developing odontogenic elements—that is, epithelium ultimately derived developmentally from the dental lamina and/or ectomesenchymally derived mesenchymal cells. The word tumor is used in its broadest sense, which here includes neoplastic and hamartomatous processes.

AMELOBLASTOMA

Ameloblastoma, the most common odontogenic neoplasm, is an aggressive, benign odontogenic neoplasm of ectodermal origin. Usually an asymptomatic lesion, its initial presentation may be facial swelling. It may present with symptoms of pain and occasionally with lip/facial numbness. Ameloblastoma may be discovered on routine radiographic evaluation or may show features such as bony expansion, mobility, or divergence of teeth. The average age of patients with ameloblastoma is approximately 36 years, with more than 80% of the lesions occuring in the mandible and more than 70% occurring in the molar-ramus area.

At first glance, with the average age of occurrence of ameloblastomas in the fourth decade of life, the discussion of this entity in a pediatric context would not appear to be particularly relevant to this chapter. In 1977 however, the unicystic ameloblastoma was described, which was thought to be a prognostically distinct entity.[65] In the 20 patients studied, the average age was 21 years, with half of patients being younger than 20 years. Clinically and radiographically, the lesions were described as having the features of a nonneoplastic cyst, with the majority mimicking dentigerous cysts. A critical review of 193 cases of unicystic ameloblastoma in the literature found that the mean age at the time of diagnosis of unicystic ameloblastoma was most closely related to one clinical feature: the presence of an impacted tooth. Cases associated with an impacted tooth have been termed the dentigerous type and those not associated with an impacted tooth the nondentigerous type. The mean age at diagnosis of the dentigerous variant was 16.5 years, whereas that of the nondentigerous type was 35.2 years.[66] A review of the literature of ameloblastoma in children in Western societies from 1970, when the histologic criteria for ameloblastoma were well-defined,[67] through 2001 revealed the average age of occurrence to be 14.3 years.[68] There is a strong predilection for mandibular involvement, particularly in the molar-ramus region.[68,69,70] Of interest is that when literature from Africa was reviewed, while the average ages (i.e., 14.7 years) were essentially identical to those in Western countries, unicystic ameloblastoma accounted for only 19.5% of cases, and there was an increased frequency of occurrence in the mandibular symphysis (44.2%). A similar trend has been reported in children and adolescents in one report from China: the average age of occurrence (14.8 years) was again essentially identical, with a strong predilection for occurrence in the mandible (96.6%), and historically the solid type predominated over the unicystic type (63% vs 37%).[71]

Radiographically, ameloblastomas may present as either unilocular or multilocular radiolucent lesions, with or without bony expansion. Cystic-appearing spaces may be compartmentalized by separate, distinct septa of bone. Unicystic ameloblastoma occurs almost exclusively in the mandible, predominantly in the posterior part. Although most commonly found in association with the crowns of impacted teeth, unicystic ameloblastomas may be seen in interradicular, periapical, or edentulous regions.

Histologically, they are distinguished by their resemblance to the enamel organ. Regardless of age or location,

Dentlearn.ir

ameloblastomas demonstrate, singly or in combination, a variety of distinct histologic patterns. They are frequently characterized by discrete islands of neoplastic odontogenic epithelium with a peripheral layer of columnar to cuboidal epithelial cells that are palisaded in their appearance, with polarization of the nuclei away from the basement membrane. The central portions of these islands of neoplastic odontogenic epithelium are composed of cells that resemble the stellate reticulum. In some lesions these central areas may take on an acanthomatous or granular appearance. The plexiform pattern is the one most frequently encountered and is characterized by a rearrangement of tumor cells as a network of interconnecting strands of cells. An important histologic finding in the unicystic form, other than the observation of ameloblastic change in the cyst lining itself, is the presence of a significant luminal and/or mural component characterized by a proliferation of ameloblastic odontogenic epithelium into the lumen of the cyst, the fibrous cyst wall, or both. Mural invasion of the cyst wall portends a higher risk of recurrence for this lesion.

Therapy is by surgical removal, the method of which varies according to the location and clinical and radiographic extent of the lesion. Although a recurrence rate of 55% to 90% has been found for ameloblastomas of all types that have been treated by curettage, it has been believed that the cystic form, the type found most commonly in children, potentially carried a lower potential for recurrence.[55,69] More recent studies, however, have shown significant potential for recurrence after conservative treatment, not dissimilar to that of conventional ameloblastoma, with the recommendation being made for more aggressive therapy than has been recommended in the past.[72]

ADENOMATOID ODONTOGENIC TUMOR

Adenomatoid odontogenic tumor (AOT) is a benign, probably hamartomatous, epithelial tumor that occurs in two intraosseous forms (follicular and extrafollicular) as well as a peripheral variant. It has also been known as adenoameloblastoma, which is misleading because it behaves clinically in a distinctly different fashion than does ameloblastoma.

Several large clinical and epidemiologic reviews of AOT three variants based on clinical and radiologic findings. Two of these are central or intraosseous variants. The first is the follicular (dentigerous) type, in which the tumor is found in association with the crown of an impacted tooth, with the most likely provisional diagnosis being that of a dentigerous cyst. The second and less commonly reported intraosseous variant is the extrafollicular type, in which there is no association with the crown of an impacted tooth and with the most likely provisional diagnosis being that of a residual, radicular, globulomaxillary, or lateral periodontal cyst, depending upon its location. The third variant is the peripheral or extraosseous variant, which may appear clinically as a fibroma. Approximately 98% of AOTs are reported as being the intrabony or central type, with the follicular variant accounting for 71%. Although most often asymptomatic, the tumor frequently causes a painless swelling exhibiting slow but progressive growth.

AOTs occur most commonly in the second decade of life. Nearly 70% of patients are younger than 20 years of age, and more than 50% of cases occur in the teenage years. Females are involved twice as often as males, and the intraosseous lesions have been noted to occur nearly twice as frequently in the maxilla as in the mandible, with a noticeable predilection for occurrence in the canine and incisor regions. The rare peripheral type is found almost entirely in the anterior maxillary region. While it presents as a peripheral lesion, there has been agreement from the beginning that it is an erupted AOT, forming when an associated tooth erupts into the gingiva, allowing for its soft-tissue presentation.[76-79]

The most common radiographic finding is that of a unilocular radiolucent lesion, which, as previously stated, may appear radiographically as a dentigerous cyst (Fig. 28-15) or as a residual, radicular, globulomaxillary, or lateral periodontal cyst, depending on its location. Radiopacities of varying size and density are often present. Because these are space-occupying lesions, divergence of roots and displacement of teeth may be noted.

Histologically, AOT is composed of neoplastic odontogenic epithelium with a distinct histologic appearance: an encapsulated proliferation of swirling strands of spindle-shaped or polygonal epithelial cells within which are nodules of duct-like or rosette-like structures composed of a row of definite cuboidal to columnar epithelial cells; these may be empty or may contain variable amounts of an amorphous eosinophilic material, which may become calcified in some areas.

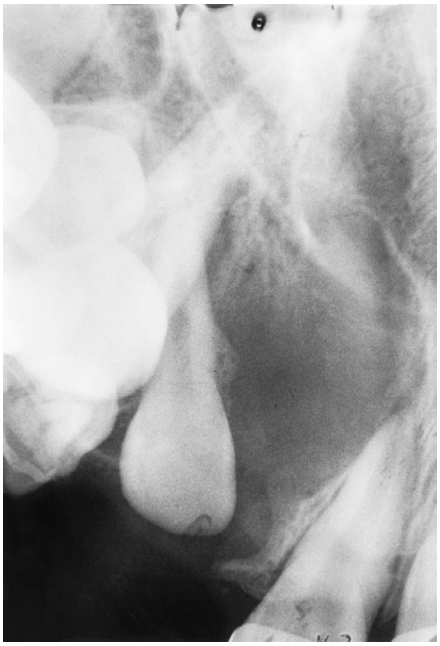

Figure 28-15 Adenomatoid odontogenic tumor in a 12-year-old girl presenting as an expansile radiolucent lesion in the right maxilla associated with the lateral incisor. The lesion was curetted, and the lateral incisor was allowed to erupt and was orthodontically moved into proper alignment. (Courtesy Dr. Dan J. Crocker.)

Dentlearn.ir

Because these lesions are, in almost all cases, well-encapsulated and show an identical benign biologic behavior, conservative surgical enucleation and curettage is the treatment of choice. There is no propensity for recurrence.

ODONTOGENIC MYXOMA

Odontogenic myxoma is an uncommon benign mesodermal neoplasm of the jaws, thought to arise from odontogenic ectomesenchyme or undifferentiated mesenchymal cells in the periodontal ligament. In one large review,[80] two thirds of the cases involved the mandible and one third involved the maxilla, with the molar and premolar region being the most common site of occurrence. Although the majority of cases were diagnosed in the second to fourth decades of life, 33% of the cases were in patients 20 years of age or younger (7% in patients younger than 10 years and 26% in the second decade of life).

Clinically, odontogenic myxomas are usually painless, slow-growing lesions that can attain considerable size before manifesting noticeable signs and symptoms such as swelling or mobility and divergence of teeth. Several cases have been reported as occurring in association with impacted or missing teeth, while some cases have been noted to occur in non–tooth-bearing areas, such as the ramus and condyle.

Radiographically, odontogenic myxomas may be unilocular or multilocular lesions that may cause expansion, thinning, and destruction of the cortical plates of bone and displacement of teeth. Multilocular lesions often exhibit a mottled, soap-bubble, or honeycomb appearance. There is no universal agreement regarding the relative frequency of presentation as a unilocular versus a multilocular radiographic appearance. In an analysis of 10 cases of odontogenic myxoma in childhood, the most frequent radiographic finding was a unilocular lesion with cortical expansion and tooth displacement.[81] In a review of cases in 55% of cases, with a significant correlation between the size of the lesion and its locularity being noted.[80] Perhaps the frequency of unilocular lesions in pediatric cases can be accounted for based on a smaller lesional size in childhood cases, with larger lesions more likely being multilocular.[80,81] Because of the variable nature of the radiographic appearance of odontogenic myxomas, the differential diagnosis should include odontogenic lesions such as dentigerous cyst, odontogenic keratocyst, and ameloblastoma, as well as nonodontogenic lesions such as CGCG, central hemangioma, traumatic bone cyst, and aneurysmal bone cyst.

Histologically, odontogenic myxoma is made up of stellate to spindle-shaped cells with delicate fibrillar interlacing processes, which produce a loose myxoid appearance. Occasional nests of inactive odontogenic epithelium may be noted, interspersed within this fibromyxoid stroma.

A potentially major diagnostic pitfall lies in the fact that the dental papilla from a developing tooth appears nearly identical histologically to the stroma of an odontogenic myxoma, and the two can be confused, causing misdiagnosis. One distinguishing characteristic is the presence of the peripheral layer of odontoblasts in the dental papilla, if visible in the tissue sections available on the slide.

The appropriate treatment for odontogenic myxoma is still a matter of debate and is certainly dependent on its size and location. The preferred treatment is complete surgical excision, which may prove difficult because of infiltration and expansion of the tumor into bone and the absence of a true capsule. Treatment is complicated by the understandable reluctance to perform wide surgical excision of a benign lesion, especially in a child. Periodic follow-up to check for recurrence is important. In the series of 10 cases of childhood odontogenic myxoma previously discussed, two patients experienced recurrence within the first year after surgery.[81]

AMELOBLASTIC FIBROMA

Ameloblastic fibroma is a true mixed neoplasm of odontogenic origin characterized by the proliferation of both odontogenic epithelium and mesenchymal tissue without the formation of enamel or dentin. It is generally believed to be less aggressive than ameloblastoma. In a review of the largest series of cases to date, the average age of occurrence was shown to be 15.9 years, with a male-to-female ratio of 1.26:1.[82]

The lesion occurs in the mandible in approximately 75% of cases, with a predilection for the mandibular second primary molar or second premolar-first molar region.[82,83] Its initial clinical presentation is most often swelling; however, it is not uncommonly asymptomatic, being found on routine radiographic examination. Radiographically, it may be a unilocular or multilocular radiolucent lesion, usually with well-defined, often sclerotic borders, and may be found in association with unerupted or displaced teeth.

Ameloblastic fibroma has a characteristic histologic appearance, with strands of cuboidal to columnar epithelial cells and islands with peripheral columnar epithelial cells surrounding loosely arranged epithelial cells resembling stellate reticulum, which proliferate along with a primitive-appearing mesenchymal component that resembles the developing dental papilla.

There is a rare peripheral ameloblastic fibroma.[79] Also, malignant transformation of ameloblastic fibroma into ameloblastic fibrosarcoma has been reported and reviewed.[82]

Treatment is by surgical removal that is complete but conservative compared with that advocated for ameloblastoma. At one time, simple surgical excision was advocated because there was believed to be little chance for recurrence. Recent evidence, however, indicates that the recurrence rate is higher than originally suspected. In a recent review of published studies with well-documented follow-up data, an overall recurrence rate of 33.3% was noted.[82] Hence, somewhat more aggressive surgical therapy with long-term clinical follow-up is indicated than was previously recommended.

AMELOBLASTIC FIBRO-ODONTOMA

Ameloblastic fibro-odontoma (AFO) has been defined as "a lesion similar to ameloblastic fibroma, but also

Dentlearn.ir

showing inductive changes that lead to the formation of both dentin and enamel."[84] It should be stressed, however, that they are separate tumors and that ameloblastic fibromas do not develop into AFOs or that the latter will arise in the former.[83] The average age of occurrence has been reported as 9.4 years, with the majority of cases occurring in the mandible (59.5%).[85] Although typically described as a painless, slow-growing, and expanding lesion, it can show rapid growth.[85] It most often presents radiographically as a well-circumscribed, unilocular, mixed-density, radiolucent-radiopaque lesion associated with displaced or unerupted teeth, the clinical manifestations of which commonly lead to its diagnosis.[84,85] Size may vary from lesions evident only microscopically to a large mass of up to 6 cm or more in its greatest dimension.

Histologically, the epithelial and mesenchymal components are those of an ameloblastic fibroma, with the formation of osteodentin or dentin-like material and enamel matrix.

While it is generally agreed that AFO is a hamartomatous lesion that is a stage preceding the development of a complex odontoma,[84,86] it has been argued that, from a neoplasm. This is because of, among other reasons, its potential for continued and even rapid growth with potential for local destruction, as well as the fact that malignant transformation of an AFO to an ameloblastic fibro-odontosarcoma has been reported.[85] While the overall biologic behavior of AFOs has been shown over time to be fairly innocuous, the largest review to date has shown a recurrence rate of 7.4%, with these recurrences attributed to inadequate surgical removal at the time of the initial treatment.[85] Hence, conservative surgical removal with extraction of associated teeth has been recommended.

ODONTOMA

Odontomas are mixed odontogenic tumors in which both the epithelial and mesenchymal components have undergone functional differentiation to the point that both enamel and dentin are formed. The most common of the odontogenic tumors, odontomas are believed to be hamartomatous rather than neoplastic. WHO has classified odontomas into two types depending on their degree of morphodifferentiation. The *compound odontoma* is a lesion in which all the dental tissues are represented in an orderly fashion so that there is at least superficial anatomic resemblance to teeth. In a *complex odontoma*, on the other hand, although all the dental tissues are represented, they are formed in such a rudimentary fashion that there is little or no morphologic similarity to normal tooth formation (Fig. 28-16).

A review of 149 cases indicated that compound odontomas have a propensity for occurrence in the canine and incisor region, being found more often in the maxilla than in the mandible, whereas complex odontomas show a predilection for occurrence in the posterior jaws.[88] Compound odontomas have been reported as having a mean age of occurrence of 14.8 years compared with 20.3 years for complex odontomas, possibly because the odontogenic tissue in the anterior jaws, where the compound odontoma predominantly occurs, has finished its differentiation earlier than tissues in the posterior part of the jaw.[86]

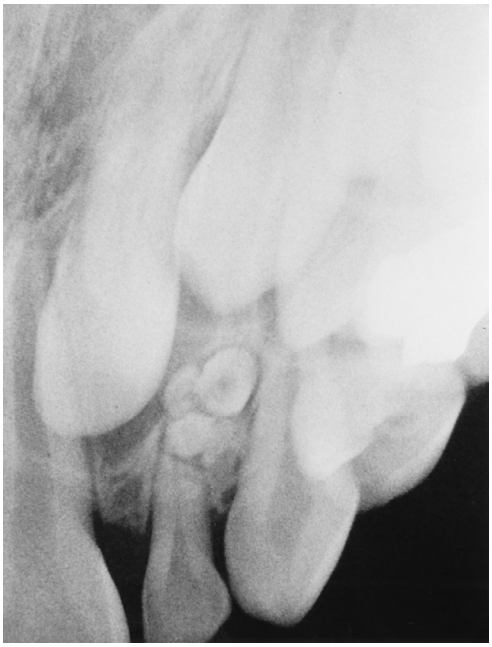

Figure 28-16 Complex composite odontoma delaying eruption of the lateral incisor.

It has been argued that, because the radiographic and histologic distinction between the compound and complex odontomas is poorly defined and because no appreciable clinical difference separates them, differentiation between these two types cannot be justified given the obliquity of the diagnostic criteria.[89] Others take exception to this concept, holding the view that complex and compound odontomas are pathogenetically different.[84] Those who take exception argue that complex odontomas are the terminal stage in the series of hamartomatous lesions (termed the developing complex odontoma line), including ameloblastic fibro-dentinoma, AFO, and the hamartomatous type of ameloblastic fibroma. They also argue that ameloblastic fibromas occurring after the age of 20 years represent a benign neoplasm, whereas those occurring during childhood (i.e., during the tooth-development period) are likely to be non-neoplastic hamartomatous lesions. They believe that compound odontoma represents a malformation with a high degree of histomorphologic differentiation similar to the process producing supernumerary teeth, "multiple schizodontia," or locally conditioned hyperactivity of the dental lamina.

Although odontomas are usually asymptomatic, they may be the cause of noneruption or impaction of teeth and retained primary teeth (see Fig. 28-15). In one study, for instance, odontomas were found to be in association with an unerupted tooth in 48% of cases and in conjunction with a dentigerous cyst in 28% of cases.[89]

Odontomas are most commonly found on routine radiographic examination, presenting as an irregular radi-

Dentlearn.ir

opaque mass or as small, tooth-like structures with the most frequent presenting symptom being lack of eruption of a permanent tooth or bony expansion or swelling. The recommended treatment for an odontoma is conservative surgical excision, with care taken to remove the surrounding soft tissue. No propensity for recurrence has been noted.

Finally, the occurrence of the, albeit rare, ameloblastic odontoma (odontoameloblastoma) should be mentioned. These are reported to occur in an age range similar to that of standard odontomas, with the location, clinically aggressive growth, and recurrence rate seen for conventional ameloblastomas.[89]

MALIGNANT TUMORS

FIBROBLASTIC TUMORS AND FIBROSARCOMA IN INFANCY AND CHILDHOOD

Desmoid-type Fibromatosis

Desmoid-type fibromatosis (DF), also known as aggressive fibromatosis or desmoid tumors, are fibroblastic-myofibroblastic tumors of intermediate prognosis that are locally aggressive in behavior with a tendency for recurrence; and although they do not metastasize, they can kill by local infiltration and extension into vital structures. The head and neck region has been reported as a common site of involvement for these lesions, with DFs occurring there known as fibromatosis, extra-abdominal fibromatoses, or extra-abdominal desmoid tumors. They most commonly present as a painless mass involving the cheek, tongue, or submandibular region, with erosion of bone being a frequent finding in lesions arising in soft-tissue adjacent to the jaws.[91] In one large study of DF occurring in the oral and paraoral region, 74% of cases occurred in the first decade of life.[91]

Histologically, DF is characterized by a proliferation of spindle-shaped or oval bland and uniform cells that are arranged in streaming fascicles with varying amounts of collagen. Cellular pleomorphism and nuclear hyperchromatism are not noted, and mitoses are essentially absent. Immunostaining confirms their fibroblastic-myofibroblastic nature.

When DFs occur in bone, they are still termed desmoplastic fibromas or aggressive fibromatosis, with the mandible being the most common site of involvement.[92] Microscopically, there is nothing to differentiate desmoplastic fibroma of bone from DF occurring in the soft tissues. The radiographic findings are variable, ranging from unilocular to multilocular with borders that may vary from ill-defined to well-demarcated. Whereas magnetic resonance imaging may be valuable in surgical planning, computed tomography is best for demonstrating perforation of the cortical plate.[92] Because of the locally aggressive nature of DF, complete surgical excision with a generous margin of normal tissue has been reported as the treatment of choice, with recurrence being dependent on the adequacy of initial treatment.

Relative to treatment of DF occurring in the soft tissues, aggressive surgery has traditionally been the mainstay of therapy, with procedures producing significant loss of function and morbidity without being curative in many cases.[93] This is reported to have led to more recent strategies that have included various systemic therapies and even a "wait and see" strategy following clinical and radiological assessment.[93]

Fibrosarcoma

Fibrosarcoma is a malignant neoplasm of fibroblastic and myofibroblastic differentiation. Congenital and infantile fibrosarcoma (IFS) is a relatively rare tumor that usually is manifest in the first year of life, especially in the first 3 months, and almost always before 4 years of age.[94] Compared with DF, it is generally more cellular in appearance, with increased mitotic activity, and radiographically, it may be more destructively expansile.[94] IFS, as with DF, is

sis.[93] It rarely metastasizes and has a very good prognosis. While surgery has been the traditional mainstay of treatment for IFS, currently, after initial biopsy, neoadjuvant chemotherapy is used, after which delayed conservative resection may be performed. If complete remission is noted following chemotherapy, then the patient may be spared surgery.[95] Due to the young age of the patients, radiation is not an option.[93]

RHABDOMYOSARCOMA

Rhabdomyosarcoma (RMS) is a malignant neoplasm derived from primitive mesenchymal tissue destined to form striated skeletal muscle.[96,97] It is the most common soft-tissue sarcoma in children, accounting for more than half of all such lesions occurring in childhood. It is one of the small, round, blue-cell tumors of childhood, which include neoplasms such as neuroblastoma, Ewing's sarcoma, and lymphoma.[97] There are two key age ranges for the occurrence of RMS in children—from 2 to 6 years of age and in adolescence—with the early peak due primarily to occurrences in the head and neck region and genitourinary tract and the peak during adolescence due to tumors of the testes and adjacent structures.[98]

Three general histologic subtypes of RMS are recognized: embryonal and its botryoid variant, alveolar, and pleomorphic. The embryonal subtype accounts for most cases of RMS in infancy and childhood.[97] The most common clinical finding is a mass occurring in any region of the head and neck where striated muscle or its mesenchymal progenitor cells exist. There are three primary sites of involvement for RMS in the head and neck in children: the eyelid and orbit, parameningeal sites, and remaining head and neck sites, including the oral cavity.[87] The parameningeal sites include the pterygopalatine and infratemporal fossas, nasal cavity, nasopharynx, paranasal sinuses, and middle ear and mastoid. Although there is not good consensus about site predilection within the oral cavity, the soft palate and tonsillar region, tongue, and cheek seem to be most frequently involved, with the gingiva and floor of mouth being unusual locations.[100,101] Typically, a rapidly growing, often nonulcerated soft-tissue mass, RMS typically metastasizes by hematogenous routes to lungs, bone, and brain but may also disseminate via the lymphatics or direct extension.

Dentlearn.ir

RMS arising in the head and neck region are characterized by a wide variation in survival rate, which is dependent on the site, with orbital lesions having the highest survival rates of any site in the body and parameningeal tumors having a worse prognosis.[102] The high survival rate in patients with orbital lesions is likely because they present with less advanced disease compared with the insidious presentation of parameningeal primaries, which more typically present with advanced-stage disease.[102] Even though age, anatomic subsite, and resectability were not shown to correlate with survival, the extent of disease, including tumor size, invasiveness, nodal metastases, and distant disease at presentation, was significantly associated with mortality.[102] Children 11 years of age or younger with a tumor 5 cm or smaller have been shown to have the best survival, whereas patients older than 11 years with a tumor larger than 5 cm had the worst survival outcome.[103] Treatment considerations include risk-guided therapy based on the chance of a cure with a specific treatment approach and taking into consideration both near- and long-term side effects of the various therapeutic modalities. In general, then, all patients will likely receive chemotherapy along with a local treatment strategy such as surgery, radiation therapy, or both.[97]

OSTEOGENIC SARCOMA

Osteogenic sarcoma (OS) is an uncommon, highly malignant, primary neoplasm of bone with a soft-tissue counterpart with a similar histomorphology. Its peak age of occurrence is the second decade of life, with the modal age of incidence being 16 years for girls and 18 for boys.[104] The most common site of involvement is the distal femur, followed by the proximal tibia and proximal humerus.

OS of the jaws (OSJ) accounts for approximately 6.5% of all cases of OS, with the average age of onset being 10 to 20 years later than for skeletal lesions.[105] The mandible seems to be involved more often than the maxilla.[105,106] Swelling with or without pain is the most frequently described early symptom, although paresthesia/anesthesia and loosening of the teeth may be noted. In a clinicopathologic study of 22 cases of OS of the head and neck in a pediatric population ranging from 1 to 18 years (mean age, 12.2 years), the primary symptoms were painless swelling occasionally associated with pain or tenderness. In a few cases there was associated malocclusion and loosening or loss of teeth.[107] The average duration of symptoms was 5.9 months. Nineteen cases (86%) occurred in the mandible, two cases in the sphenoid sinus, and one in the maxilla.

The radiographic findings are typically those of a poorly defined, bone-destructive lesion suggestive of malignancy. Radiographically, it may be osteoblastic or osteolytic or may have a mixed radiographic appearance. One study reported that most of the lesions on the maxilla were osteoblastic, whereas most of those on the mandible were osteolytic.[108] A frequently described radiographic feature is a "sun-ray" appearance, with delicate, hair-like osteophytes radiating in a sunburst fashion away from the peripheral surface of the lesion. This has been reported to occur in as few as 10% and as many as 55% of cases.[105,109] An additional radiographic finding in early OSJ is symmetric widening of the periodontal ligament space around one or more of the teeth in the area of the lesion.

Histologically, OS is characterized by the production of tumor osteoid forming a malignant stroma that often histologically into osteoblastic, chondroblastic, or fibroblastic subtypes according to the dominant histologic pattern. There is no agreement, however, as to whether the histologic subtype has any significant bearing on the patient's prognosis.

The primary treatment modality for OSJ should always be radical surgery, with the single most important factor in curative therapy being its amenability to radical resection with clear margins.[105] Overall, chemotherapy has not been shown to be as effective in OSJ as in extragnathic sites for two reasons: first, even though almost all patients with OS of the long bones have at least microscopic metastatic disease at the time of diagnosis, the incidence of metastatic disease to be no higher than 18%[98]; and second, OSJs tend to be better differentiated than those involving the long bones, which may be partially responsible for the better prognosis for patients with osteosarcoma of the jaws.[108,110] Even so, it is still recommended that patients with primary osteosarcoma of the jaws should be treated with multi-agent chemotherapy in addition to complete surgical excision, with free surgical margins being absolutely essential.[111]

EWING'S SARCOMA

After osteosarcoma, the Ewing's sarcoma (ES) family of tumors (ES along with peripheral primitive neuroectodermal tumor [pPNET]) is the second most common primary malignancy of bone in children and adolescents. Ewing's sarcoma of bone and soft tissue, as well as pPNET, are small round-cell tumors, the genetic hallmarks of which are a translocation of chromosomes 11 and 22, t(11;22)(q24;q12),[112-114] and, in most cases, overexpression of the MIC2 gene surface marker,[100] which differentiates them from the majority of other small round-cell tumors.

The histologic and electron microscopic features of ES and pPNET, as well as expression of the antigen of the *MIC2* gene, provide the basis for characterizing them as neuroectodermally derived neoplasms.[115,116]

Approximately 4% of primary cases of ES arising in bone arise in the bones of the head and neck, with the skull being the most frequent site of involvement and the mandible being the most commonly involved gnathic bone.[117] A review of 105 cases showed the average age at diagnosis to be 15.9 years, with an age range of 2 to 44 years at presentation.[118] There was a slight predilection for occurrence in males, with a male-to-female ratio of 1.5:1. The mandible was involved more than twice as often as the maxilla, with a predilection of 4:1 for occurrence in the posterior aspect of the jaws over other regions.

A histopathologically identical extraskeletal form of ES has been identified.[119] In a series of 130 patients with ES of soft tissue in childhood, 18% of cases involved the head and neck. Patients with soft-tissue or extraskeletal ES were compared with patients with pPNET.[120] There were no significant differences in patient age, gender, tumor

Dentlearn.ir

location, or stage at presentation between patients with ES and those with pPNET of the soft tissue.

Localized swelling and pain are the most frequent complaints at the time of presentation, although paresthesia and tooth mobility may also be presenting symptoms. The soft tissue overlying the lesion may be erythematous and warm to the touch, and thus more suggestive of an inflammatory process than a neoplasm (Fig. 28-17). In addition, the patient may have fever, elevated erythrocyte sedimentation rate, increased serum lactic dehydrogenase level, anemia, and leukocytosis.

The radiographic features are those of a diffuse bone-destructive lesion, appearing as an irregular, somewhat mottled, radiolucent lesion that may resemble an osteomyelitis (Fig. 28-18). Although reduplication or lamination of the periosteum has been considered a common radiologic sign of ES of long bones, this has been shown not to be a common feature of this disease in the jaw bones; however, sun-ray spicules of periosteal bone may be seen as previously described for osteogenic sarcoma.[118] Computed tomography and, in particular, magnetic resonance imaging are invaluable in further delineating the extent of disease not readily visible on plain radiographs.[121,122]

Histologically, ES appears as sheets of cells with small, dark-staining nuclei and poorly defined cytoplasmic outlines. Mitotic figures are prominent, and necrosis is a common feature. Sheets of cells may be separated by vascular connective tissue septa. The presence of intracytoplasmic glycogen and positive results on periodic acid–Schiff staining are essential findings unless there is documented gly-

antigen along with the use of molecular techniques to detect the t(11;22) (q24;q12) translocation have generally improved the clinician's ability to diagnose these tumors.

In the past, ES as a whole has been associated with an almost uniformly poor prognosis, with nearly all patients having micrometastatic disease at the time of diagnosis. The prognosis for ES in the head and neck, however, has been noted to be significantly better than that for ES

Study of patients who had been followed in the study for more than 3 years, 80% were alive and well without known progressive, recurrent or metastatic disease. Of the 10 patients who had survived 5 years or longer, none had subsequently died; and of the 5 who had died, none had gnathic involvement.

Chemotherapy is the cornerstone of treatment for ES and is usually applied in a neoadjuvant fashion.[122] Therapy consists of systemic multiagent chemotherapy along with local control, which may consist of surgery, radiation therapy, or a combination of the two, depending on the age of the patient, location of the primary tumor, and functional consequences of therapy. When surgery is employed, the goal should be complete tumor removal, avoiding marginal resection.[122] Because of the potential for post-radiation sarcomas, particularly bone sarcoma in the field of radiation treatment, the importance of local control of the disease with surgery and safe local control with radiation is now emphasized. Patients with clinically detectable metastases at the time of diagnosis and those with relapse after initial therapy have a significantly poorer prognosis.



Figure 28-17 Photograph of a 6-year-old boy with Ewing's sarcoma who had a 1-month history of swelling on the left side of his face. Clinically, there was swelling with mucosal ulceration in the mucobuccal fold in the first molar area. (Courtesy Drs. Richard L. Miller and William Epstein.)

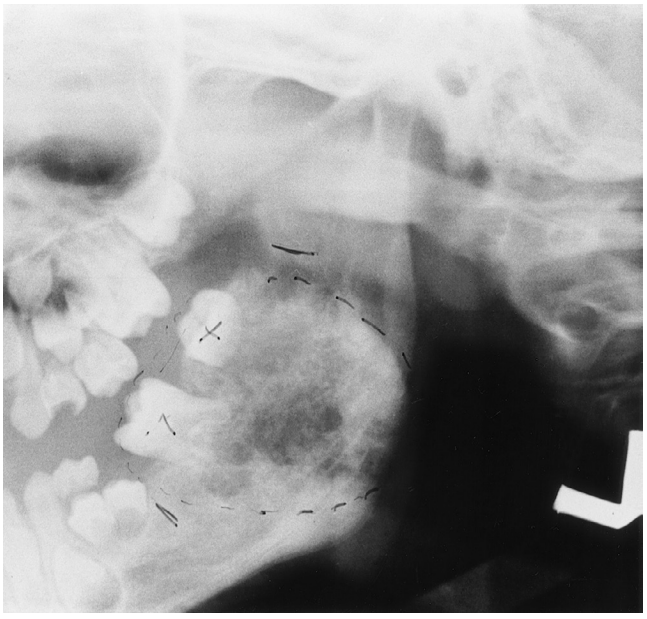

Figure 28-18 Radiograph of the same patient as in Figure 28-16 with Ewing's sarcoma involving the left angle of the mandible. Notice the mottled radiolucent appearance. (Courtesy Drs. Richard L. Miller and William Epstein.)

LANGERHANS CELL HISTIOCYTOSIS (HISTIOCYTOSIS X)

Langerhans cell histiocytosis (LCH) is the current designation replacing the term histiocytosis X that was introduced by Lichtenstein in 1953 as a unifying designation for several previous eponyms, including Letterer-Siwe dis-

Dentlearn.ir

ease, Hand-Schüller-Christian disease, and eosinophilic granuloma (LCH of bone).[123] Prior to this, the three clinical entities that comprise this nosologic category were described and categorized over a period of nearly 50 years.[124] Histiocytosis X was renamed LCH in 1987.[125] While its etiology and pathogenesis remain obscure, the one common denominator is the Langerhans cell, a bone marrow–derived, antigen-presenting dendritic cell. Langerhans cells reside in the skin, thymus, and mucosal epithelium, including the oropharynx and nasopharynx, esophagus, bronchi, and cervix, and are said to be the most potent antigen-presenting cells in the body.[126]

Histologically, LCH is characterized by the presence of uniform sheets of large round Langerhans histiocytes, which have been shown to be immature dendritic cells and not histiocytes at all, with a homogenous pink cytoplasm when stained with hematoxylin and eosin. These Langerhans cell histiocytes are interspersed with variable numbers of eosinophils, lymphocytes, plasma cells, and multinucleated giant cells, particularly in lesions of bone. Langerhans cells are characterized ultrastructurally by the presence of Langerhans or Birbeck granules, rod-shaped organelles that may have a vesicular portion imparting the so-called "tennis racquet appearance" under the electron microscope. LCH can now be identified on the basis of immunoreactivity to cell-surface markers such as CD-ia and, more specifically, CD-207 (Langerin), which differentiates it from other dendritic disorders.[127,128]

The clinical manifestations of LCH are variable and, as previously noted, were historically divided into distinct entities. The term Letterer-Siwe disease (now better termed *acute disseminated histiocytosis*) has been used as a moniker for an acute fulminating proliferative disorder involving Langerhans histiocytes that chiefly affects infants and children younger than 3 years of age. It is often characterized initially by the development of a scaly erythematous skin rash initially most prominent on the trunk but progressing to involve the scalp and extremities (Fig. 28-19). This is accompanied by a persistent low-grade fever, anemia, thrombocytopenia, hepatosplenomegaly, and lymphadenopathy.

Bony involvement, indistinguishable from that found in chronic disseminated histiocytosis (Hand-Schüller-Christian disease) and eosinophilic granuloma of bone, may be noted (Fig. 28-20). Oral lesions with swelling, pain, ulceration, gingival inflammation and necrosis, and destruction of alveolar bone with premature exfoliation of the teeth may be an early manifestation of this form of the disease. Although multiagent chemotherapy may result in regression of the disease in some cases, patients with this form of the disease have a relatively poor prognosis.

Hand-Schüller-Christian disease (now better termed *chronic disseminated histiocytosis*) has been used to describe the chronic disseminated form of LCH, which is characterized by the development of multifocal eosinophilic granulomas of bone, lymphadenopathy, and visceral involvement, especially hepatosplenomegaly (Fig. 28-21). The classic clinical triad that has often been described for this disease is the occurrence of punched-out–appearing radiolucent defects in membranous bones, exophthalmos, and diabetes insipidus. Chronic otitis media is also a frequent finding. Although usually diagnosed early in the first decade of life, chronic disseminated histiocytosis has been reported to occur as late as the sixth decade.[129] The treatment varies according to the extent of the disease, with surgical curettage or radiation therapy being used to treat focal disease. Multiagent chemotherapy has been relatively successful in long-term control of disseminated disease.

Eosinophilic granuloma (LCH of bone) is the most common and also least severe form of LCH. It is characterized by single or multiple usually well-defined radiolucent bony lesions, most often accompanied by pain



Figure 28-19 Characteristic erythematous scaly skin rash in a 5½-month-old infant with Letterer-Siwe disease.

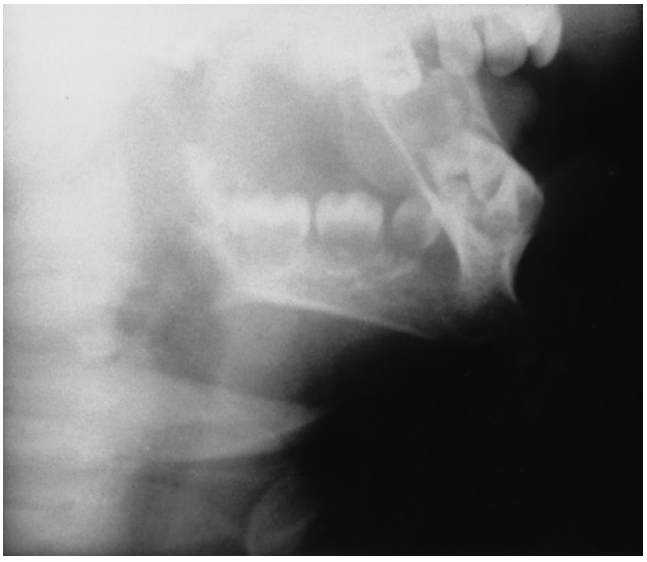

Figure 28-20 Diffuse destruction of maxillary and mandibular alveolar bone around the developing primary teeth in the same patient as in Figure 28-18. Notice also destruction of the left angle and ramus of the mandible.

Dentlearn.ir



Figure 28-21 Radiograph of a 12-month-old girl with Hand-Schüller-Christian disease. There is an expansile, radiolucent lesion in the right body of the mandible as well as destruction of the greater wing of the sphenoid and supraorbital rim on the left.

and swelling. Older children and young adults most commonly display this form of the disease. In addition to the mandible and skull, the femur, humerus, ribs, and pelvis are also frequently involved. The maxilla is involved less frequently than the mandible, with the midposterior mandible being the most common site of occurrence. Skin and visceral involvement such as that described for the acute and chronic disseminated forms of the disease are absent. Several options exist for patients with eosinophilic granuloma. After confirmation of the diagnosis by biopsy, the lesion may be left alone for observation, it may be surgically curetted or excised, intralesional injections of corticosteroids may be given, or low-dose radiotherapy may be used. In one series of 41 lesions in 25 patients, treatment varied from excisional biopsy to curettage and peripheral ostectomy as the only surgical treatment, followed by low-dose radiotherapy. Three lesions (7.3%) in three patients (12%) recurred.[130]

REFERENCES

1. Abbey LM, Page DG, Sawyer DR: The clinical and histopathologic features of a series of 464 oral squamous cell papillomas, *Oral Surg* 49:419–428, 1980.
2. Greer RO, Goldman HM: Oral papillomas: clinicopathologic evaluation and retrospective examination for dyskeratosis in 110 lesions, *Oral Surg* 38:435–440, 1974.
3. Praetorius F: HPV-associated diseases of oral mucosa, *Clin Dermatol* 15:399–413, 1997.
4. Syrjänen S: Human papillomavirus infections and oral tumors, *Med Microbiol Immunol* 192(3):123–128, 2003.
5. Syrjänen S: Current concepts on human papillomavirus infections in children, *APMIS* 118:494–509, 2010.
6. Rautava J, Syrjänen S: Human papillomavirus infections in the oral mucosa, *J Am Dent Assoc* 142(8):905–914, 2011.
7. Castro TP, Filbo IB: Prevalence of human papillomavirus (HPV) in oral cavity and oropharynx, *Braz J Otorhinolaryngol* 723(2):272–282, 2006.
8. Ward KA et al.: Detection of human papilloma virus DNA sequences in oral squamous cell papillomas by the polymerase chain reaction, *Oral Surg Oral Med Oral Pathol Oral Radiol Endod* 80:63–66, 1995.
9. Eversole LR, Laipis PJ: Oral squamous papillomas: detection of HPV DNA by in situ hybridization, *Oral Surg Oral Med Oral Pathol* 65:545–550, 1988.
10. Angelopoulos AP: Pyogenic granuloma of the oral cavity: statistical analysis of its clinical features, *J Oral Surg* 29:840–847, 1971.
11. Lawoyin JO, Arotiba JT, Dosumu OO: Oral pyogenic granuloma: a review of 38 cases from Ibadan, Nigeria, *Br J Oral Maxillofac Surg* 35:185–189, 1997.
12. Cundiff EJ: Peripheral ossifying fibroma: a review of 365 cases, master's thesis, Bloomington, IN, 1972, Indiana University. Cited in Shafer WG, Hine MK, Levy BM: *Textbook of oral pathology*, ed 4, Philadelphia, 1983, WB Saunders.
13. Eversole LR, Rovin S: Reactive lesions of the gingiva, *J Oral Pathol* 1:30–38, 1972.
14. Cuisia ZE, Brannon RB: Peripheral ossifying fibroma—a clinical evaluation of 134 pediatric cases, *Pediatr Dent* 23(3):245–248, 2001.
15. Gardner DG: The peripheral odontogenic fibroma: an attempt at clarification, *Oral Surg Oral Med Oral Pathol* 54:40–48, 1982.
16. Daley TD, Wysocki GP: Peripheral odontogenic fibroma, *Oral Surg Oral Med Oral Pathol* 78(3):329–336, 1994.
17. Giansanti JS, Waldron CA: Peripheral giant cell granuloma: review of 720 cases, *J Oral Surg* 27:787–791, 1969.
18. Andersen L, Fejerskov O, Philipsen HP: Oral giant cell granulomas: a clinical and histological study of 129 new cases, *Acta Pathol Microbiol Scand* 5(Sec 81):606–616, 1973.
19. Nedir R, Lombardi T, Samson J: Recurrent peripheral giant cell granuloma associated with cervical resorption, *J Periodontol* 68:381–384, 1997.
20. McClatchey AI: Neurofibromatosis, *Annu Rev Pathol* 2: 191–216, 2007.
21. Hersh JH: American Academy of Pediatrics Committee on Genetics: Health supervision for children with neurofibromatosis, *Pediatrics* 121(3):633–642, 2008.
22. Lee L, Yan YH, Pharoah MJ: Radiographic features of the mandible in neurofibromatosis: a report of 10 cases and review of the literature, *Oral Surg Oral Med Oral Pathol Oral Radiol Endod* 81:361–367, 1996.
23. Needle MN et al.: Prognostic signs in the surgical management of plexiform neurofibroma: The Children's Hospital of Philadelphia experience, 1974-1994, *J Pediatr* 131:678–682, 1997.
24. Robertson RL et al.: Head and neck vascular anomalies of childhood, *Neuroimaging Clin North Am* 9(1):115–132, 1999.
25. Mulliken JB, Glowacki J: Hemangiomas and vascular malformation in infants and children: a classification based on endothelial characteristics, *Plast Reconstr Surg* 69(3):412–422, 1982.
26. Arneja JS, Gosain AK: Vascular malformations, *Plast Reconstr Surg* 122(6):1982–1984, 2008.
27. Lamberg MA, Tasanen A, Jääskeläinen J: Fatality from central hemangioma of the mandible, *J Oral Surg* 37(8):578–584, 1979.
28. Hancock BJ et al.: Complications of lymphangiomas in children, *J Pediatr Surg* 27(2):220–226, 1992.

29. Ugras W et al.: Immunohistochemical study on histogenesis of congenital epulis and review of the literature, *Pathol Int* 47:627–632, 1997.
30. Kaiserling E, Ruck P, Xiao JC: Congenital epulis and granular cell tumor: a histologic and immunohistochemical study, *Oral Surg Oral Med Oral Pathol Oral Radiol Endod* 80(6):687–697, 1995.
31. Ritwik P, Brannon RB, Musselman R: Spontaneous regression of congenital epulis: a case report and review of the literature, *J Med Case Rep* 4:331–334, 2010.
32. Eversole R, Su L, El Mofty S: Benign fibro-osseous lesions of the craniofacial complex. A review, *Head Neck Pathol* 2:177–202, 2008.
33. Petrikowski CG et al.: Radiographic differentiation of osteogenic sarcoma, osteomyelitis, and fibrous dysplasia of the jaws, *Oral Surg Oral Med Oral Pathol Oral Radiol Endod* 80:744–750, 1995.
34. Mäkitie AA, Törnwall J, Mäkitie O: Bisphosphonate treatment in craniofacial fibrous dysplasia—a case report and review of the literature, *Clin Rheumatol* 27(6):809–812, 2008.
35. Landesberg R et al.: Alternative indications for bisphosphonate therapy, *J Oral Maxillofac Surg* 67(Suppl 1):27–34, 2009.
36. Eversole LR, Leider AS, Nelson K: Ossifying fibroma: a clinicopathologic study of sixty-four cases, *Oral Surg Oral Med Oral Pathol* 60:505–511, 1985.
37. Sciubba JJ, Younai F: Ossifying fibroma of the mandible and maxilla: review of 18 cases, *J Oral Pathol Med* 18:315–321, 1989.
38. Waldron CA: Fibro-osseous lesions of the jaws, *J Oral Surg* 28:58–64, 1970.
39. El-Mofty S: Psammomatoid and trabecular juvenile ossifying fibroma of the craniofacial skeleton: two distinct clinicopathologic entities, *Oral Surg Oral Med Oral Pathol Oral Radiol Endod* 93:296–304, 2002.
40. Jaffe HL: Giant-cell reparative granuloma, traumatic bone cyst, and fibrous (fibro-osseous) dysplasia of the jawbones, *Oral Surg Oral Med Oral Pathol* 6(1):159–175, 1953.
41. Kaffe I et al.: Radiologic features of central giant cell granuloma of the jaws, *Oral Surg Oral Med Oral Pathol Oral Radiol Endod* 81:720–726, 1996.
42. Waldron CA, Shafer WG: The central giant cell reparative granuloma of the jaws: an analysis of 38 cases, *Am J Clin Pathol* 45:437–447, 1966.
43. Auclair PL et al.: A clinical and histomorphologic comparison of the central giant cell granuloma and the giant cell tumor, *Oral Surg Oral Med Oral Pathol* 66:197–208, 1988.
44. Whitaker SB, Waldron CA: Central giant cell lesions of the jaw. A clinical, radiologic, and histopathologic study, *Oral Surg Oral Med Oral Pathol* 75(2):199–208, 1993.
45. Chuong R et al.: Central giant cell lesions of the jaw: a clinicopathologic study, *Oral Maxillofac Surg* 44(9):708–713, 1986.
46. de Lange J, van den Akker HP, van den Berg H: Central giant cell granuloma of the jaw: a review of the literature with emphasis on therapy options, *Oral Med Oral Pathol Oral Radiol Endod* 104(5):603–615, 2007.
47. Suarez-Roa MDL et al.: Interventions for central giant cell granuloma (CGCG) of the jaws, *Cochrane Database Syst Rev* 4:CD007404, 2009.
48. Browne RM: The pathogenesis of odontogenic cysts: a review, *J Oral Pathol* 4(1):31–46, 1975.
49. Brannon RB: The odontogenic keratocyst: a clinicopathologic study of 312 cases. Part I. Clinical features, *Oral Surg* 42:54–72, 1976.
50. Mourshed F: A roentgenographic study of dentigerous

Med Oral Pathol 18:47–53, 1964.

51. Benn A, Altini M: Dentigerous cysts of inflammatory origin. A clinicopathologic study, *Oral Surg Oral Med Oral Pathol Oral Radiol Endod* 81(2):203–209, 1996.
52. Mourshed F: A roentgenographic study of dentigerous cysts. II. Role of roentgenograms in detecting dentigerous cyst in the early stages, *Oral Surg Oral Med Oral Pathol* 18:54–61, 1964.
53. McMillan MD, Smillie AC: Ameloblastomas associated with dentigerous cysts, *Oral Surg* 51:489–496, 1981.
54. Leider AS, Eversole LR, Barkin ME: Cystic ameloblastoma, *Oral Surg* 60:624–630, 1985.
55. Gardner DG, Corio RL: Plexiform unicystic ameloblastoma: a variant of ameloblastoma with a low recurrence rate after enucleation, *Cancer* 53:1730–1735, 1984.
56. Wright JM: The odontogenic keratocyst: orthokeratinized variant, *Oral Surg Oral Med Oral Pathol* 51(6):609–618, 1981.
57. Eyre J, Zakrzewska JM: The conservative management of large odontogenic keratocysts, *Br J Oral Maxillofac Surg* 23:195–203, 1985.
58. Woolgar JA, Rippin JW, Browne RM: A comparative study of the clinical and histological features of recurrent and non-recurrent odontogenic keratocysts, *J Oral Pathol* 16:124–128, 1987.
59. Anand VK, Arrowood JP, Krolls SO: Malignant potential of the odontogenic keratocyst, *Otolaryngol Head Neck Surg* 111:124–129, 1994.
60. Forsell K, Forsell H, Kahnberg KE: Recurrence of keratocysts in a long-term follow-up study, *Int J Oral Surg* 17:25–28, 1988.
61. Blanas N et al.: Systematic review of the treatment and prognosis of the odontogenic keratocyst, *Oral Surg Oral Med Oral Pathol Oral Radiol Endod* 90:553–558, 2000.
62. Kaczmarzyk T, Mojsa I, Stypulkowska J: A systematic review of the recurrence rate for keratocystic odontogenic tumor in relation to treatment modalities, *Int J Oral Maxillofac Surg* 41:756–767, 2012.
63. Meara JG et al.: The odontogenic keratocyst: a 20-year clinicopathologic review, *Laryngoscope* 108:280–283, 1998.
64. Gorlin RJ: Nevoid basal cell carcinoma (Gorlin) syndrome, *Genet Med* 6(6):530–539, 2004.
65. Robinson L, Martinez MG: Unicystic ameloblastoma: a prognostically distinct entity, *Cancer* 40:2278–2285, 1977.
66. Philipsen HP, Reichert PA: Unicystic ameloblastoma. A review of 193 cases from the literature, *Oral Oncol* 34:317–325, 1998.
67. Vickers RA, Gorlin RJ: Ameloblastoma: delineation of early histopathologic features of neoplasia, *Cancer* 26:699–710, 1970.
68. Ord RA et al.: Ameloblastoma in children, *J Oral Maxillofac Surg* 60:762–770, 2002.
69. Kahn MA: Ameloblastoma in young persons: a clinicopathologic analysis and etiologic investigation, *Oral Surg Oral Med Oral Pathol* 67:706–715, 1989.
70. Rosenstein T et al.: Cystic ameloblastoma—behavior and treatment of 21 cases, *J Oral Maxillofac Surg* 59:1311–1318, 2001.
71. Zhang J et al.: Ameloblastoma in children and adolescents, *Br J Oral Maxillofac Surg* 48:549–554, 2010.
72. Ghandhi D et al.: Ameloblastoma: a surgeon's dilemma, *J Oral Maxillofac Surg* 64(7):1010–1014, 2006.
73. Philipsen HP, Reichart PA: Adenomatoid odontogenic tumor: facts and figures, *Oral Oncol* 35:125–131, 1998.
74. Philipsen HP et al.: Adenomatoid odontogenic tumor: biologic profile based on 499 cases, *J Oral Pathol Med* 20:149–158, 1991.
75. Philipsen HP et al.: An updated clinical and epidemiological profile of the adenomatoid odontogenic tumour: a collaborative retrospective study, *J Oral Pathol Med* 36(7):383–393, 2007.

76. Abrams AM, Melrose RJ, Howell FV: Adenoameloblastoma; a clinicopathologic study of ten new cases, *Cancer* 22:175–185, 1968.
77. Courtney RM, Kerr DA: The odontogenic adenomatoid tumor. A comprehensive study of twenty new cases, *Oral Surg Oral Med Oral Pathol* 39:424–435, 1975.
78. Ide F et al.: Rare peripheral odontogenic tumors: report of 5 cases and comprehensive review of the literature, *Oral Surg Oral Med Oral Pathol Oral Radiol Endod* 106(4):e22–e28, 2008.
79. Ide F et al.: Development and growth of adenomatoid odontogenic tumor related to formation and eruption of teeth, *Head and Neck Pathol* 5:123–132, 2011.
80. Kaffe I, Naor H, Buchner A: Clinical and radiological features of odontogenic myxoma of the jaws, *Dentomaxillofac Radiol* 26:203–299, 1997.
81. Keszler A, Dominguez FV, Giannunzio G: Myxoma in childhood: an analysis of 10 cases, *J Oral Maxillofac Surg* 53:518–521, 1995.
82. Chen Y, Wang JM, Li TJ: Ameloblastic fibroma: a review of published studies with special reference to its nature and biological behavior, *Oral Oncol* 43(10):960–969, 2007.
83. Tomich CE: Benign mixed odontogenic tumors, *Sem Diagnostic Pathol* 16(4):308–316, 1999.
84. Philipsen HP, Reichart PA, Praetorius F: Mixed odontogenic tumours and odontomas: considerations on interrelationship. Review of the literature and presentation of 134 new cases of odontomas, *Oral Oncol* 33:86–99, 1997.
85. Boxberger NR, Brannon RB, Fowler CB: Ameloblastic fibro-odontoma: A clinicopathologic study of 12 cases, *J Clin Padiatr Dent* 35(4):397–404, 2011.
86. Slootweg PJ: An analysis of the interrelationship of the mixed odontogenic tumors—ameloblastic fibroma, ameloblastic fibro-odontoma and the odontomas, *Oral Surg* 51:266–276, 1981.
87. Takeda Y: Ameloblastic fibroma and related lesions: current pathologic concept, *Oral Oncol* 35:535–540, 1999.
88. Budnick SD: Complex and compound odontomas, *Oral Surg Oral Med Oral Pathol* 42:501–506, 1976.
89. Kaugars GE, Miller ME, Abbey LM: Odontomas, *Oral Surg Oral Med Oral Pathol* 67:172–176, 1989.
90. Kaugars GE: Ameloblastic odontoma (odonto-ameloblastoma), *Oral Surg Oral Med Oral Pathol* 71:371–373, 1991.
91. Fowler CB, Hartman KS, Brannon RB: Fibromatosis of the oral and paraoral region, *Oral Surg Oral Med Oral Pathol* 77(4):373–386, 1994.
92. Said-Al-Naief N et al.: Desmoplastic fibroma of the jaw: a case report and review of literature, *Oral Surg Oral Med Oral Pathol Oral Radiol Endod* 101(1):82–94, 2006.
93. Ferrari A et al.: Fibroblastic tumors of intermediate malignancy in childhood, *Expert Rev Anticancer Ther* 13(2):225–236, 2013.
94. Fisher C: Fibromatosis and fibrosarcoma in infancy and childhood, *Eur J Cancer* 32A:2094–2100, 1996.
95. Orbach D et al.: Infantile fibrosarcoma: management based on the European experience, *J Clin Oncol* 28(2):313–323, 2010.
96. Hicks J, Flaitz C: Rhabdomyosarcoma of the head and neck in children, *Oral Oncol* 38:450–459, 2007.
97. Paulino AC, Okcu MF: Rhabdomyosarcoma, *Curr Probl Cancer* 32:7–34, 2008.
98. Miller RW, Calager NA: Fatal rhabdomyosarcoma among children in the United States, 1960-69, *Cancer* 34(6): 1897–1900, 1974.
99. Sutow WW et al.: Three-year relapse-free survival rates in childhood rhabdomyosarcoma of the head and neck: report

    49(11):2217–2221, 1982.
100. Bras J, Batsakis JC, Luna MA: Rhabdomyosarcoma of the oral soft tissues, *Oral Surg Oral Med Oral Pathol* 64(5):585–596, 1987.
101. Peters E et al.: Rhabdomyosarcoma of the oral and paraoral region, *Cancer* 63(5):963–966, 1989.
102. Kraus DH et al.: Pediatric rhabdomyosarcoma of the head and neck, *Am J Surg* 174:556–560, 1997.
103. Simon JH et al.: Prognostic factors in head and neck rhabdomyosarcoma, *Head Neck* 24:468–473, 2002.
104. Meyers PA, Gorlick R: Osteosarcoma, *Pediatr Clin North Am* 44:973–989, 1997.
105. Fernandes R et al.: Osteogenic sarcoma of the jaw: a 10-year experience, *J Oral Maxillofac Surg* 65(7):1286–1291, 2007.
106. Garrington GE et al.: Osteosarcoma of the jaws: analysis of 56 cases, *Cancer* 20:377–391, 1967.
107. Gadwal SR et al.: Primary osteosarcoma of the head and neck in pediatric patients: clinical pathologic study of 22 cases with a review of the literature, *Cancer* 91:598–605, 2001.
108. Clark JL et al.: Osteosarcoma of the jaw, *Cancer* 51: 2311–2316, 1983.
109. August M, Magennis P, Dewitt D: Osteogenic sarcoma of the jaws: factors influencing prognosis, *Int J Oral Maxillofac Surg* 26(3):198–204, 1997.
110. Mardinger O et al.: Osteosarcoma of the jaw: The Chaim Shebe Medical Center experience, *Oral Surg Oral Med Oral Pathol Oral Radiol Endod* 91:445–451, 2001.
111. Thiele OC et al.: Interdisciplinary combined treatment of craniofacial osteosarcoma with neoadjuvant and adjuvant chemotherapy and excision of the tumour; a retrospective study, *Br J Oral Maxillofac Surg* 46(7):356–533, 2008.
112. Turc-Carel C et al.: Chromosomal translocations in Ewing's sarcoma, *C R Seances Acad Sci III* 296(23):1101–1103, 1983.
113. Turc-Carel C et al.: Chromosome study of Ewing's sarcoma (ES) cell lines. Consistency of a reciprocal translocation t(11;22)(q24;q12), *Cancer Genet Cytogenet* 12(1):1–19, 1984.
114. Whang-Peng J et al.: Chromosome translocation in peripheral neuroepithelioma, *N Engl J Med* 311(9):584–585, 1984.
115. Ambros IM et al.: MIC2 is a specific marker for Ewing's sarcoma and peripheral primitive neuroectodermal tumors. Evidence for a common histogenesis of Ewing's sarcoma and peripheral primitive neuroectodermal tumors from MIC2 expression and specific chromosome aberration, *Cancer* 67(7):1886–1893, 1991.
116. Lombart-Bosch A et al.: Histology, immunohistochemis-

    bone, *Semin Diagn Pathol* 13:153–170, 1996.
117. Siegal GP et al.: Primary Ewing's sarcoma involving the head and neck, *Cancer* 60:2829–2840, 1987.
118. Wood RE et al.: Ewing's tumor of the jaw, *Oral Surg Oral Med Oral Pathol* 69:120–127, 1990.
119. Raney RB et al.: Ewing's sarcoma of soft tissues in child-

    Study, 1972-1991, *J Clin Oncol* 15:574–582, 1997.
120. Siebenrock KA et al.: Comparison of soft tissue Ewing's sarcoma and peripheral neuroectodermal tumor, *Clin Orthop* 329:288–299, 1996.
121. Eggli KD et al.: Ewing's sarcoma, *Radiol Clin North Am* 31:325–337, 1993.
122. Bielack SS, Carrle D: State-of-the-art approach in selective curable tumors: bone sarcoma, *Ann Oncol* 19(Suppl 7): 155–160, 2008.
123. Lichtenstein L: Histiocytosis X: integration of eosinophilic granuloma of bone, Letterer-Siwe disease and Schüller-Christian disease as related manifestations of a single nosologic entity, *Arch Pathol* 56:84–102, 1953.

124. Badalian-Very G et al.: Pathogenesis of Langerhans cell histiocytosis, *Annu Rev Pathol Mech Dis* 8:1–20, 2013.

dromes in children, *Lancet* 1(8526):208–209, 1987.
126. Lam KY: Langerhans' cell histiocytosis (histiocytosis X), *Postgrad Med J* 73:391–394, 1997.
127. Valladeau J et al.: Langerin, a novel C-type lectin specific to Langerhans cells, is an endocytic receptor that induces the formation of Birbeck granules, *Immunity* 12(1):71–81, 2000.
128. Hicks J, Flaitz CM: Langerhans cell histiocytosis: current insights in a molecular age with emphasis on clinical oral and maxillofacial pathology practice, *Oral Surg Oral Med Oral Pathol Oral Radiol Endod* 100(Suppl 2):42–66, 2005.
129. McDonald JS et al.: Histiocytosis X: a clinical presentation, *J Oral Pathol* 9:342–349, 1980.
130. Ardekian L et al.: Clinical and radiographic features of eosinophilic granuloma in the jaws, review of 41 lesions treated by surgery and low-dose radiotherapy, *Oral Surg Oral Med Oral Pathol Oral Radiol Endod* 87:238–242, 1999.

CHAPTER 29

Oral Surgery for the Pediatric Patient

▲ **Elie M. Ferneini** and **Jeffrey D. Bennett**

For additional resources, please visit the evolve website.

CHAPTER OUTLINE

SIMPLE EXODONTIA
IMPACTED TEETH
Impacted Third Molars
Impacted Teeth Other than Third Molars
ASSOCIATED HARD-TISSUE LESIONS
Odontoma
Odontogenic Cysts
SOFT-TISSUE PROCEDURES
Mucoceles and Ranulas
Fibroma and Pyogenic Granuloma
INFECTION OF THE HEAD AND NECK REGION
Fracture of the Mandible
SUMMARY

Office-based pediatric oral surgical procedures include dentoalveolar surgery (primarily consisting of exodontia), intraoral soft-tissue procedures (e.g., frenectomy), medical and surgical management of odontogenic infections, and intraoral surgical procedures involving the alveolar ridge (e.g., enucleation of an odontoma). The basic principles used in the management of these surgical conditions are essentially identical to those used by the pediatric dentist in the management of the various other dental diagnoses encountered.

The initial step in patient management is a diagnosis, which is developed through a process involving history taking, physical examination, and imaging. Once the decision to perform surgery is made, the practitioner should visualize the various steps and their sequence, as well as the potential complications and their management, before administering local anesthetic.

The pediatric patient's ability to cooperate must be considered. Depending on the patient's age, systemic health, and planned surgery, the practitioner may consider using nitrous oxide inhalational sedation, oral sedation, intramuscular sedation, intravenous sedation, or a combination of these modalities. Regardless of the route of agent administration or the selection of pharmacologic agent, the primary consideration in sedating a pediatric patient is the depth of sedation achieved. Oral sedation and nitrous oxide are the agents most commonly used in the pediatric dental office. Nitrous oxide is advantageous in that it can be titrated, achieving both rapid onset and recovery. The practitioner must be aware that nitrous oxide when combined with an oral agent (e.g., benzodiazepine or chloral hydrate) can potentiate the effect of the oral agent, producing a more profound depth of sedation and at times producing a depth of sedation equal to that of general anesthesia.[1] In fact, oral sedation is frequently used in pediatric oral surgery. A recent study showed adequate anxiolysis and sedative effects of both oral midazolam and oral diazepam. However, intravenous midazolam produced more sedation.[2]

General principles that apply to both the adult and pediatric patient include profound anesthesia, aseptic technique, visibility, and surgical site stability. Achieving profound anesthesia depends on the clinician's knowledge of the anatomy of the second and third divisions of the trigeminal nerve. This is discussed in Chapter 15.

Most office-based oral surgical procedures do not dictate adherence to sterile technique but require a clean technique. The clean technique requires that the dentist scrubs his or her hands with an antiseptic soap. The hands may be dried using a nonsterile disposable towel. The hands are then gloved. The dentist does not need to wear a sterile gown but should wear a gown covering his or her arms. A mask and eye protection are also used by the dentist. The gown, mask, and eye protection are as much for the protection of the dentist as they are for the protection of the patient. The perioral region and oral cavity do not need to be decontaminated for a clean technique. However, only sterile water or sterile saline should be used for irrigating a surgical wound. Surgical drills that are self-irrigating can accommodate the use of sterile irrigating solutions. Last, the dentist may opt to drape the patient and place protective eyewear on the patient. Draping and eyewear maintain sterility in the sterile surgical field and protect the patient from soiling of clothes or from having debris or a suture injury to the eye. The clean technique strives to achieve the basic premise of a sterile technique, which is to prevent any organism from the surgical staff, other patient, instrumentation, or equipment from contaminating the patient.

Adequate visibility is required for all dental procedures. For oral surgical procedures this entails adequate access, adequate light, and a good suction to create a debris-free surgical field. Adequate access requires appropriate mouth-opening. Opening the patient's mouth and maintaining its opening can be facilitated with a bite block (Fig. 29-1) or a Molt mouth prop. A small bite block may be used and the degree of mouth-opening varied by its

Dentlearn.ir



Figure 29-1 Two views of a bite block.



Figure 29-2 Austin retractor.



Figure 29-3 Minnesota retractor.

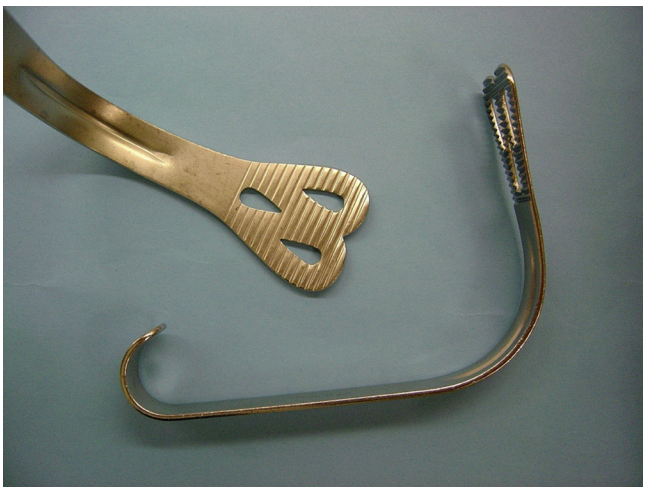

Figure 29-4 Weider "sweetheart" retractor.

placement in the mouth. For maximal mouth-opening, the bite block is placed more posteriorly. A piece of floss may be attached to the bite block. The knot securing the floss to the bite block must be secure so that it does not loosen. If the bite block is displaced into the pharynx, the floss attached to the bite block extends out of the mouth, assisting in retrieval of the bite block. The Molt mouth prop has a ratchet-type action and can be used to assist in opening the patient's mouth. This can be beneficial in the management of the uncooperative patient. Excessive force could be applied with the Molt mouth prop, causing iatrogenic injury, such as displacement of teeth or injury to the temporomandibular joint. In addition to keeping the mouth open for the surgical procedure, the bite block stabilizes the mandible. When a mandibular tooth is extracted, use of the bite block minimizes mandibular movement and the resultant transmission of excessive forces to the temporomandibular joint.

Adequate access also requires appropriate retraction. Commonly used retractors in oral surgery include the Austin retractor (Fig. 29-2), the Minnesota retractor (Fig. 29-3), and the Weider retractor (Fig. 29-4). The Austin and Minnesota retractors are usually used to retract the cheek and surgical flaps. Tongue retraction is usually performed with a Weider retractor, which is a heart-shaped retractor with a serrated edge. Retraction of the tongue with the Weider retractor is best achieved by placement of the lateral aspect of the retractor firmly against the alveolus. Gauze or sponge packing may be placed just medial to the retractor. This packing provides a barrier between the surgical site and the pharynx, preventing the tooth, surgical debris, or irrigating solution from potentially being swallowed, aspirated, or irritating the pharynx. If the tongue is retracted medially, the pharyngeal barrier is displaced medially, opening up a passage between the mouth and the pharynx, with potential stimulation of the gag reflex. Care must also be taken not to position the retractor too far posteriorly into the pharynx, which also stimulates the gag reflex. Retraction may be performed either by the dentist, using his or her nondominant hand, or by the assistant.

Adequate visibility depends on the establishment of a debris-free surgical field. This requires a good surgical assistant using high-speed surgical suction. The surgical tray should have a Fraser suction tip (Fig. 29-5), which is available in various sizes. The Fraser tip has an opening in the handle that allows for regulation of the suction power. The operator of the suction places his or her thumb over the hole in the handle when the suction is

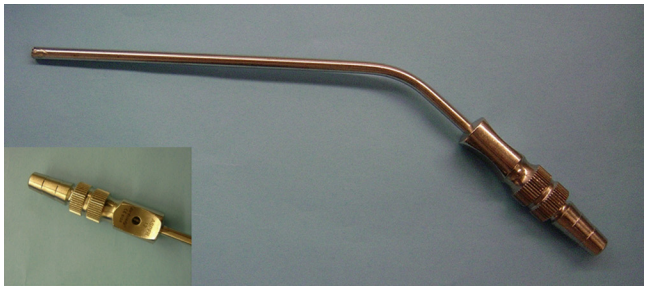

Figure 29-5 Fraser suction tip.



Figure 29-6 Yankauer or tonsillar suction.

placed on bone and maximal suction power is desired. When less suction power is desired (e.g., when suctioning soft tissue), the operator leaves the opening in the handle open, which decreases the suction power. The practitioner should also have a Yankauer or tonsillar suction device available (Fig. 29-6). This suction removes significant quantities of debris and, with its blunt tip, can be passed blindly down the throat.

SIMPLE EXODONTIA

Indications for extractions for children are much the same as those for adult patients: nonrestorable caries, apical disease, fractures of crowns or roots, prolonged retention of primary teeth because of improper root resorption or ankylosis, impacted teeth, and supernumerary teeth. The dentist must have an understanding of the growth and development of the pediatric patient, to assess and diagnose the situations that will be encountered. For example, the dentist should know the eruption patterns of the primary and permanent teeth. Delayed eruption, especially when asymmetric, is frequently an indication of an abnormality.

Radiographic surveys of teeth to be extracted are of prime importance. The dentist should observe the size and contour of the primary roots, the amount and type of resorption, the relation of the roots to the succedaneous teeth, and the extent of disease (Fig. 29-7).

Simple exodontia in the pediatric patient requires minimal modification from that used in the adult. Concepts that may dictate slight modification include the following: (1) the dentist must be cognizant of the proximity of the deciduous tooth to the succedaneous tooth and (2) the roots on primary teeth with nonresorbed roots will be long, slender, and potentially divergent.

The patient must be positioned appropriately for the surgical procedure. For the extraction of a maxillary tooth, the patient is positioned in the dental chair such that the maxillary occlusal plane is at an angle between 60° and 90° to the floor. For the extraction of a mandibular tooth, the patient is positioned in the dental chair such that the mandibular occlusal plane is parallel to the floor. The height of the chair should be such that the patient's mouth is at or slightly below the level of the dentist's elbow. The elbow of the surgeon's dominant arm should be against his/her body. When surgery is performed in the dental office in a dental chair (compared with in the operating room on an operating room bed), the patient is usually semisupine rather than completely supine. Patients are generally more reclined for extractions of maxillary teeth. There is an advantage for the sedated patient to be positioned more upright and not fully supine. The pediatric patient's ribs are angled more horizontally relative to the vertebral column and the accessory muscles are less developed, resulting in less effective thoracic expansion and a greater dependence on diaphragmatic breathing. Diaphragmatic breathing is compromised when the patient is supine; thus maintaining a more upright position is respiratorily favorable, especially in the sedated patient.

The basic details are eloquently illustrated in more detail in the sixth edition of *Contemporary Oral and Maxillofacial Surgery*.[3] The first step in extracting a tooth is to separate the soft-tissue attachment from the cervical aspect of the tooth. This is most commonly achieved with a #9 Molt elevator (Fig. 29-8). The Molt elevator is a dual-ended instrument with one end sharply pointed and is used to initiate the separation of the soft-tissue attachment from the tooth. The sharp pointed end of this instrument is placed interproximally on the mesial aspect of the papillae. The concave aspect of the instrument faces the tooth. Using a twisting motion, the dentist elevates the papillae. The tip of the elevator is then slid through the sulcus along the crest of the alveolar bone, completely separating the buccal soft-tissue attachment from the tooth. The same can be done on the lingual or palatal aspect of the tooth. If a flap is reflected, the broad, rounded end of the instrument may be used in a pushing (concave aspect of instrument against bone) or a pulling motion (instrument more perpendicular to bone with the concave aspect of the instrument facing the direction of movement) to reflect a full-thickness mucoperiosteal flap.

Extracting a tooth is an exercise in administering a controlled force in a slow and deliberate fashion to expand the alveolus and disrupt the periodontal ligaments, such that the tooth can be atraumatically removed from the jaw. The second step in extracting a tooth is to use a dental elevator to luxate the tooth. A straight elevator (Fig. 29-9) is most commonly used; it has a concave blade that is placed toward the tooth being luxated. The blades are available in various sizes, and their edges may be serrated to better grasp the tooth. The separation and reflection of the dental papillae facilitate placement of the elevator such that it rests on the alveolus. The elevator is initially inserted perpendicular to the tooth in the axial plane, and

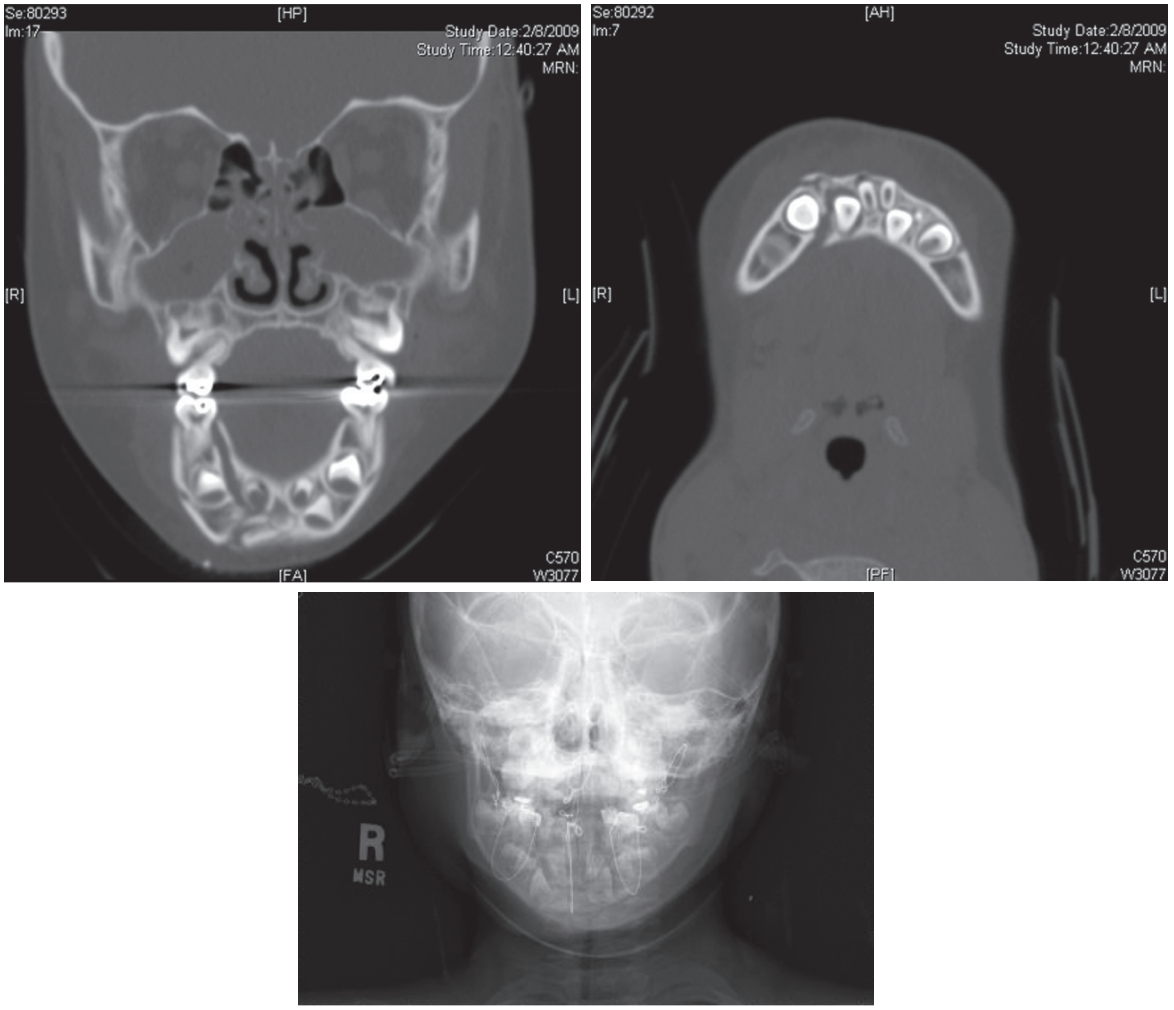

Figure 29-7 Proximity of succedaneous teeth to roots of deciduous teeth.



Figure 29-8 #9 Molt elevator.

either parallel to or with the blade of the elevator angled toward the alveolar crest up to 45° from the alveolar crest in the coronal plane. The elevator is then turned such that the portion of the blade resting on the alveolus acts as a fulcrum and the coronal portion of the blade rotates toward the tooth being extracted. This action expands the alveolus, disrupts the periodontal ligament, and establishes initial mobility of the root. The degree of mobility need not be great to achieve benefit from an elevator. Indeed, only limited movement can be achieved when there are adjacent teeth. Excessive force can fracture the tooth being extracted, converting a simple, closed extraction into an open extraction, or damage adjacent teeth or restorations. The straight elevator may, in selected situations, be used as a wedge. In this situation once a space has been created between the bone surrounding the tooth socket and the tooth, the elevator is "wedged" between the alveolar bone and the tooth. Wedging the elevator inferiorly expands the alveolus, which facilitates extracting the tooth with forceps. Alternatively, as the elevator is "wedged" apically into the space between the bone and the tooth, the tooth is displaced coronally.

The last step in extracting a tooth is to remove the tooth with forceps, which must be appropriately selected. Several forceps are available in smaller sizes for the pediatric patient (Fig. 29-10). The basic principles in selecting forceps are as follows:

1. The beaks of the forceps should adapt to the root surface of the tooth.
2. The beaks of the forceps, when positioned and engaging the tooth, should be parallel to the long axis of the tooth.
3. The size of the beaks of the forceps should be small enough not to engage the adjacent teeth during luxation and removal of the tooth. The beaks of the forceps should be placed under the separated and reflected soft tissue and the tooth firmly engaged.

The first force applied by the dentist when using forceps is apically directed. The apically directed force positions the center of rotation as close to the root apex of the tooth as possible. The more apical the center of rotation and the

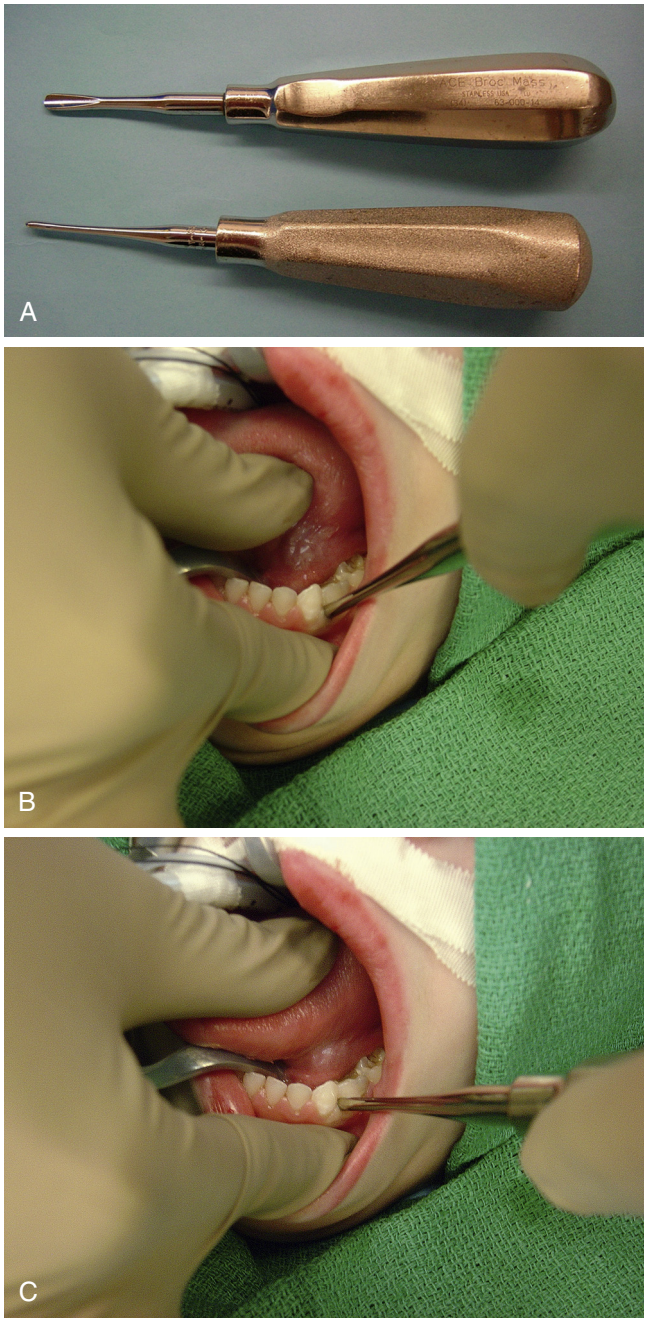

Figure 29-9 **A,** Straight elevator. The straight elevator can be placed at 45° to the occlusal plane, **B,** or parallel to the occlusal plane, **C**.

closer it is to the apex of the tooth, the less the apical third of the root is subjected to translational movement, and the less likely an apical third root fracture will occur. The apically directed force also disrupts the periodontal ligaments. With this force maintained, the tooth is luxated toward the buccal and lingual/palatal aspects. Luxation is slow. Movement is in one direction and then stopped, and the alveolus is allowed to expand before movement begins in the opposite direction. With each deliberate movement, the force is increased, expanding the alveolus. Rapid, jerky movements are ineffective and not recommended.



Figure 29-10 The armamentarium for exodontic procedures in pediatric patients is much the same as that for adults, even though all anatomic structures are smaller. Several forceps for primary teeth offer some convenience; however, they are not necessary to perform any of the extractions. Large adult forceps, such as the "cowhorn" forceps, are contraindicated in the pediatric patient.

Rotational forces may be applied for selected roots that are conical (anterior teeth, cuspids, mandibular premolars, maxillary second premolars). The dentist's opposite hand may be placed such that the index finger or thumb is positioned on either the buccal and/or lingual/palatal aspect of the alveolus and he/she can feel the expansion of the alveolus. Finally, once the alveolus is sufficiently expanded and the periodontal ligament disrupted, slight coronal tractional forces are applied and the tooth is removed.

In general, deciduous anterior teeth should be luxated to the labial aspect during the extraction procedure because of the lingual position of the permanent teeth and posterior teeth should be luxated with buccal and lingual pressures. However, the dentist may know the direction of least resistance and may deliver the tooth based on the individual situation. Although they are rare, the dentist must know when the roots of the deciduous molars are configured such that they could engage the succedaneous tooth and possibly cause the succedaneous tooth to be extracted with the deciduous tooth. If this is recognized radiographically or during the extraction, then sectioning the deciduous tooth with a surgical handpiece may be indicated.

A traditional dental drill should not be used for surgical procedures. The surgical drill must vent its air away from the surgical field. If a drill vents its air toward the surgical site, there is significant risk for development of air emphysema or an air embolism. Air emphysema is the result of air being forced into the tissue planes under the periosteal flap. This can cause a significant dissection of the tissue planes, resulting in crepitus and swelling and potentially causing airway problems. When the dentist is drilling on bone, air could be forced into the vascular

stream and cause an embolus in more distant and vital organs.

A root tip from a primary tooth may fracture during the procedure; the dentist should attempt to remove it. Proper use of an elevator will ideally have loosened the root of the tooth, which facilitates root tip removal. However, if the dentist thinks that the attempt to remove the root tip poses a significant risk to the adjacent or succedaneous tooth, then the residual root tip should be left in the bone. Usually these root tips do not cause adverse sequelae. They may eventually resorb or migrate toward the gingiva and become exposed with the eruption of the permanent tooth. A posttreatment radiograph should be obtained, and the child's parent should be informed. Informing the parent before the extraction and obtaining a written consent listing the various potential complications avoid having to present the complication as an unlikely and unexpected sequela of surgery and the perception of "poor-quality" treatment.

A primary tooth may be submerged or ankylosed. Ankylosed teeth may be slightly out of occlusion (Fig. 29-11) or they may be completely within the alveolar process yet show evidence of having once been in the mouth. A submerged tooth may have nonresorbed divergent roots or may have all or nearly all the root resorbed. Despite having the root significantly resorbed, the tooth may show no signs of mobility when pressure or leverage is applied and exhibit a solid sound on percussion. These teeth may be virtually welded to the surrounding bone. The radiographic and clinical examination may not entirely predict the considerable difference in the degree of ankylosis and what difficulties may be encountered in the removal of the tooth. The basic principles pertaining to extraction are followed. A tooth with nonresorbed divergent roots in which the potential for a root fracture is high and the path of draw is inadequate may be best extracted if the tooth is sectioned. If luxation is not accomplished with reasonable forceps pressure when the ankylosed tooth is extracted, a surgical approach is required.

One such technique for surgical removal of an ankylosed tooth entails (1) the use of a bur to remove bone around the tooth judiciously and conservatively until it can be removed or (2) the use of a bur to carefully "drill away" the tooth. Frequently the difference between tooth structure and bone cannot be determined clinically. Care must be taken to minimize excessive bone removal and avoid injury to another tooth. An intraoperative or postoperative radiograph may be indicated to assess the situation. The dentist may decide to leave a portion of the residual root, which is rarely associated with any adverse sequelae.



Figure 29-11 Ankylosed tooth.

IMPACTED TEETH

An impacted tooth is one that fails to erupt. This may be secondary to insufficient space in the dental arch (e.g., dental crowding or aberrant tooth development), mechanical obstruction secondary to a pathologic lesion (e.g., odontoma), a supernumerary tooth, or malposed tooth germs. Failure of a tooth to erupt may also be associated with genetic abnormalities.

IMPACTED THIRD MOLARS

The extraction of third molars is the most common surgical procedure in dentistry. It is therefore critical for the pediatric dentist to understand the standard of care for the treatment of the impacted third molars. Refer to *Contemporary Oral and Maxillofacial Surgery* for a review of surgical principles and techniques for extracting third molars. There are multiple reasons for extracting a third molar; however, the primary reason for the pediatric dentist to refer the patient to a surgeon for the extraction of an impacted third molar is to limit the progression of periodontal disease. Even though Ash and colleagues raised this issue almost 50 years ago, the concept of prophylactically extracting third molars to prevent disease versus extracting them when pathology develops remains controversial.[4]

The extraction of third molars in the young patient, however, is not necessarily deemed as preventive. Several publications from the Oral and Maxillofacial Surgery Foundation's and American Association of Oral and Maxillofacial Surgeons' jointly sponsored Third Molar Clinical Trials have demonstrated that "absence of symptoms does not indicate absence of disease or pathology." Analysis of data from these studies has "demonstrated that periodontal pathology initiates in the mandibular third molar region" and spreads throughout the mouth.[5,6] Additionally, caries in erupted third molars increases in prevalence with increasing age. Recent literature has also demonstrated an association of periodontal disease with systemic manifestations, further supporting the indications for extracting third molars. One controversial issue regarding mandibular third molars is the issue of their influence on anterior crowding of mandibular teeth, especially after orthodontic therapy. Multiple studies have been reported that support both sides of this controversy. Even though it is likely that third molars have a role in the etiology of crowding, it may not be clinically significant.[7]

If it is advantageous to extract third molars, the timing of this procedure should be such that it is performed with the intent to optimize health and minimize potential risks and complications. Optimal bone healing with improvement of intrabony defects on second molars adjacent to

Dentlearn.ir

third molars has been shown to occur when surgery is performed in individuals younger than 25 years of age.[8] Risks associated with surgery, such as alveolar osteitis, injury to the inferior alveolar nerve, and oroantral communication, have also been demonstrated to be higher in individuals 25 years of age and older.[9] Health-related Quality of Life indicators are also better for younger individuals.[10]

Case 1: Impacted Third Molars

A healthy 18-year-old male was referred to our office for consultation regarding his third molars. For the past few weeks, he had been experiencing increased discomfort in the posterior mandible bilaterally. An intraoral examination revealed the oral soft tissue to be free of any lesions with no evidence of acute infection. The mandibular third molars were impacted with insufficient room for functional eruption. The overlying operculum appeared slightly inflamed with evidence of food debris and periodontal pockets of 6 mm on the distal of the left second molar. The right mandibular second molar and maxillary third molars were also impacted. Oral hygiene was fair. A panoramic radiograph revealed four impacted third molars and an impacted right mandibular second molar (Fig. 29-12, *A*). Cone-beam imaging revealed a three-dimensional location of the right mandibular second and third molars (see Fig. 29-12, *B*). The patient underwent surgical extraction of his impacted third molars under IV sedation. A clinical photograph (see Fig. 29-12, *C*) revealed the right mandibular second molar after the extraction of the right mandibular third molar. A postoperative panoramic radiograph was obtained to demonstrate the integrity of the right mandibular second molar (see Fig. 29-12, *D*).

IMPACTED TEETH OTHER THAN THIRD MOLARS

The most commonly impacted tooth is the third molar. Whereas any tooth can be impacted, other commonly impacted teeth seen by the dentist include (in this frequency) the maxillary canine, second premolar, mandibular second molar, and maxillary incisors. Rare is the impaction or failure to erupt of a deciduous tooth. The latter is commonly associated with pathology, such as an odontoma or supernumerary tooth. Commonly impacted supernumerary teeth managed by the pediatric dentist include the mesiodens and supernumerary mandibular premolars.

The prevalence of impaction of the permanent maxillary canine is up to 2% (Fig. 29-13). Eight percent of the time, the impaction occurs bilaterally. The occurrence of an impacted canine is greater in female patients and has a predilection of occurrence in individuals with a familial history.[11] The impacted maxillary canine is labially positioned 15% of the time and palatally positioned 85% of the time. Arch length deficiency probably contributes to the impaction of the labially positioned canine, whereas it may not be a contributing factor with the palatally positioned canine.[12]

Most commonly, the second premolar is reported as the next most frequently impacted tooth. The mandibular

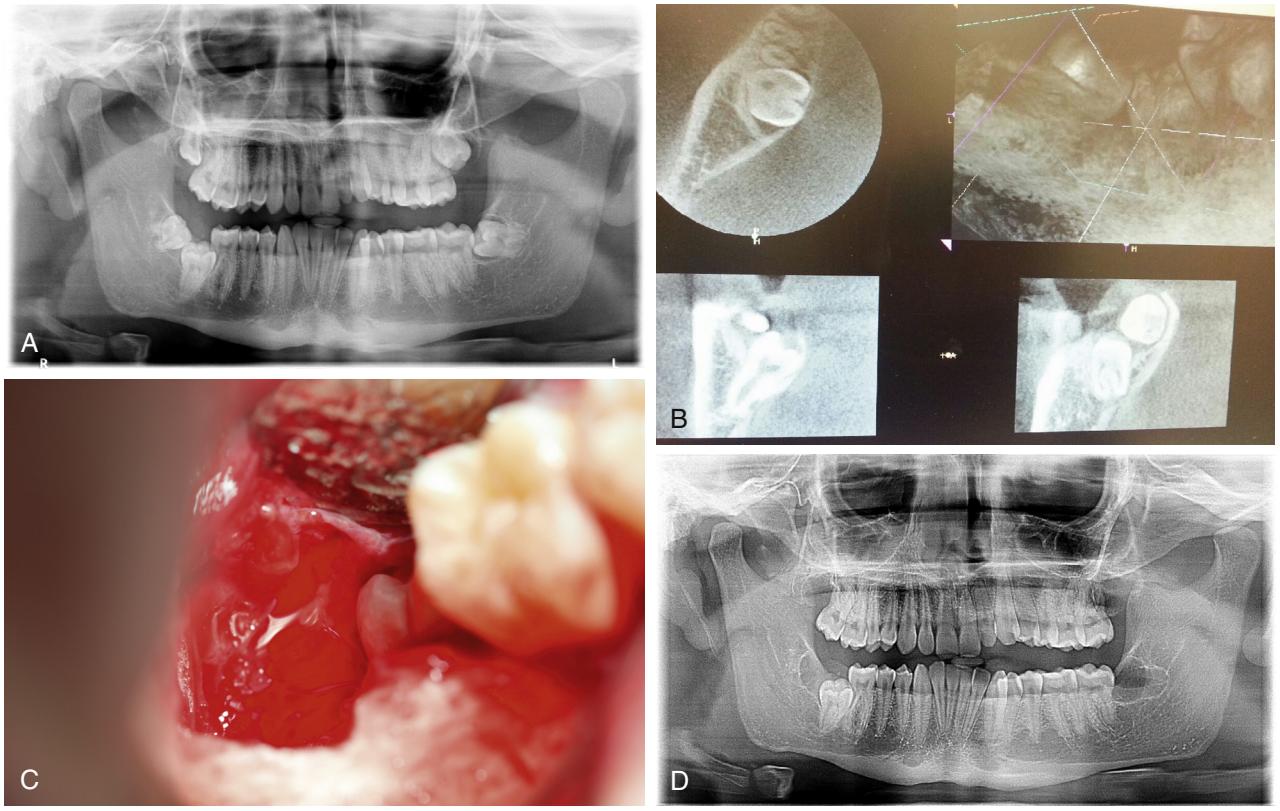

Figure 29-12 **A,** Panoramic x-ray showing impacted third molars and a right mandibular second molar. **B,** Cone-beam imaging showing a 3-dimensional view of the impacted right mandibular second and third molars. **C,** A clinical photograph showing the right mandibular second molar after extraction of the third molar. **D,** Postoperative panoramic x-ray.

Dentlearn.ir

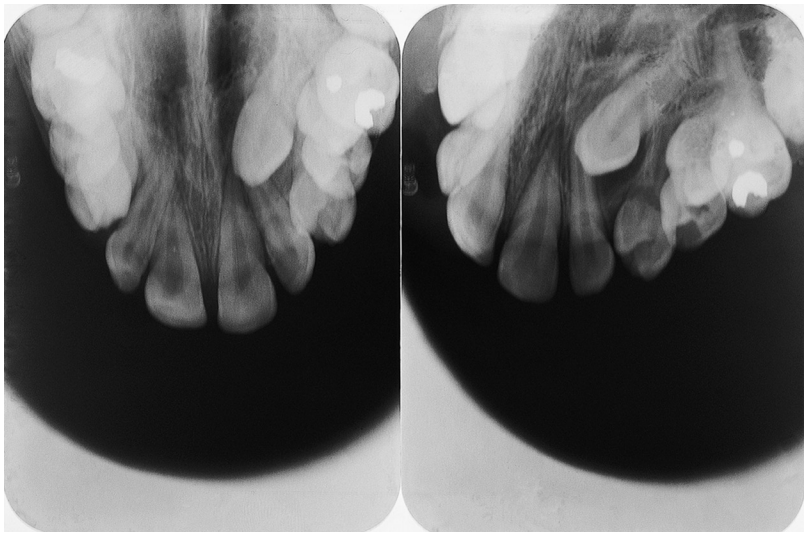

Figure 29-13 Impacted cuspid.

premolar is more commonly impacted than the maxillary premolar. The location of the impacted mandibular premolar is usually lingual or midalveolus, and that of the maxillary premolar is palatal. Kaban and Troulis, however, reported the maxillary incisors as the tooth impacted most frequently after the maxillary canine.[13] They believe that the frequency of impaction of the maxillary incisors is most likely secondary to injury, infection, or loss of the deciduous incisors. If the deciduous incisors are lost prematurely, a dense, hyperplastic, fibrous tissue may form over the alveolus, which impedes eruption and contributes to the impaction of the permanent maxillary incisors.

Ideally, early recognition of an altered eruption pattern and, if possible, interceptive serial extractions of deciduous teeth and/or orthodontics can facilitate eruption. However, regardless of early recognition, a tooth may become impacted. Once an altered eruption pattern is recognized, the dentist must perform a clinical and radiographic examination. Palpation of the buccal, lingual, or palatal aspect may reveal a bulge, suggesting the location of the impacted tooth. When the tooth is not palpable, radiographic imaging is indicated to determine the location of the impacted tooth. Several radiographic techniques can be used to locate an impacted tooth. These are discussed in Chapter 2. Cone-beam technology has played an important role in locating an impacted tooth.[14,15]

Management of an impacted tooth may include (1) observation, (2) extraction of the impacted tooth, (3) surgical exposure and assisted eruption, (4) surgical uprighting, or (5) autotransplantation. Several factors need to be taken into consideration in deciding the management of the impacted tooth. These include the age and health of the patient, potential pathology associated with the impacted tooth, location and angulation of the impacted tooth, benefit of surgery, frequency and severity of the risks of surgery, risks and consequences of no surgical intervention, and economic consequences of surgical versus nonsurgical intervention and the quality of life associated with each of these decisions.

This chapter does not discuss the treatment planning decisions pertaining to whether to perform an extraction versus a surgical exposure or surgical uprighting. If the decision is made to surgically expose the tooth and facilitate eruption, care must be coordinated between/among the appropriate dental colleagues. The first step is to create and ensure that there is adequate space to accommodate the eruption of the impacted tooth. Surgical exposure should not be performed until adequate space is obtained. For example, if a premolar is to be extracted to establish space for the exposure and eruption of a canine, the orthodontic appliances should be in place before the extraction of the premolar tooth. Although it is likely that orthodontic tooth movement may not be initiated until after the premolar tooth is extracted, the application of orthodontic appliances establishes a commitment by the patient to the planned treatment before the irreversible extraction of the premolar tooth.

Surgical Exposure

The ideal time for surgical intervention to expose an impacted tooth is when the root of the impacted tooth is almost completely formed and the apex is not yet closed. Exposure of a palatally impacted tooth is frequently accomplished by making a sulcular incision between the palatal tissue and teeth and reflection of a full-thickness mucoperiosteal flap. The anterior and posterior extent of the mucoperiosteal flap depends on the access required. Frequently, a prominence or bulge is evident where the impacted tooth's crown lies. The bone overlying this bulge may be thin and easily removed with a curette or periosteal elevator. For thicker bone, a surgical handpiece with bur and copious irrigation or a chisel is used to remove bone in a controlled manner, with care taken not to damage the tooth. Bone is removed to expose enough of the palatal surface of the tooth's crown so that an orthodontic bracket can be attached to aid in eruption. Depending on the impaction and path of eruption, additional bone may be removed to facilitate eruption. The exposed den-

tal follicle is removed with a curette. Care must be exercised to maintain the integrity of bone around the crestal margins of the adjacent teeth. Additionally, an impacted tooth may be close to the roots of the adjacent teeth, and care must be exercised not to damage or devitalize these adjacent roots. The mucoperiosteal flap is repositioned into its original position, and the soft tissue overlying the impacted tooth's crown is excised, exposing the crown and orthodontic bracket. The gold chain attached to the orthodontic bracket is passed through this window of soft tissue and frequently secured to the orthodontic arch wire with silk suture. The palatal mucoperiosteal flap is anatomically aligned and secured with a resorbable suture. The soft-tissue window overlying the crown of the impacted tooth can be left open or packed with a periodontal dressing for approximately 4 days. If the tooth is deeply impacted within the palate, no overlying tissue may be excised and the gold chain is brought through the soft tissue at the crestal margin, frequently corresponding with the incision.

When a labially impacted canine is exposed, a critical component of the surgical outcome is the maintenance of a cervical margin of attached mucosa on the erupted impacted tooth. Two surgical techniques exist: (1) apical positioned flap and (2) closed technique. The apical positioned flap technique consists of a horizontal crestal incision that is made in the edentulous region with two vertical releasing incisions on the mesial and distal aspects of this edentulous region. The flap is reflected and the tooth is exposed, with bone removed to the cervical margin as necessary. The bracket is attached and the flap is repositioned apical to the bracket, ideally at the level of the cervical margin of the tooth. The premise of the apical positioned flap is to maintain a collar of attached gingiva that will advance coronally as the tooth erupts (Fig. 29-14). The closed technique consists of a crestal-sulcular incision with or without a vertical release that allows for the development of a full-thickness mucoperiosteal flap. The tooth is exposed, removing necessary bone, and a bracket is attached. The gold chain attached to the bracket is attached to the orthodontic arch bar, generally with silk suture, and the flap is closed with resorbable suture. The gold chain generally exits the wound through the crestal incision. The closed technique can be used for all labially impacted canines; however, it is indicated for high impactions or midalveolar impactions when the apical positioned flap is contraindicated. There may also be a disadvantage with the apical positioned flap technique in that it can contribute to increased crown length and intrusive relapse.[16] These basic principles are used for surgical exposure of most impacted teeth. With cone-beam technology becoming more readily available, root resorption of adjacent teeth is observed due to maxillary canine impaction.[17]

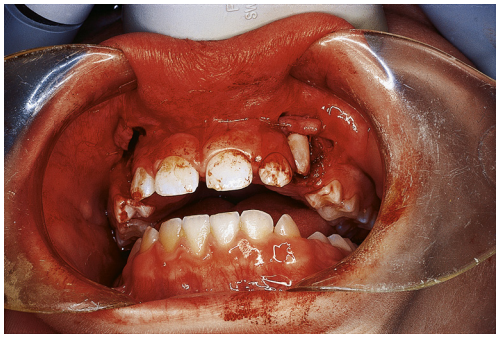

Figure 29-14 Apically positioned flap.

Case 2: Impacted Maxillary Canine

A healthy 14-year-old male was referred to our office by his orthodontist for exposure and bracketing of his impacted right and left maxillary canines. Orthodontic treatment had begun a year previously, and sufficient arch space accommodated the guided eruption of the impacted canine. An intraoral examination revealed that orthodontic bands, brackets, and arch wires were in place. Retained primary maxillary canines were present (Fig. 29-15, *A*). The gingival and palatal tissue appeared healthy with no notable periodontal defects. A panoramic radiograph revealed impacted right and left maxillary canines and retained primary maxillary canines (see Fig. 29-15, *B*). Cone-beam imaging revealed the palatal location of both impacted canines (see Fig. 29-15, *C*). The patient underwent surgical extraction of his maxillary primary canines and exposure and bracket placement of his impacted maxillary canines under nitrous oxide sedation (see Fig. 29-15, *D*).

Surgical Uprighting

Surgical uprighting is a technique that has most commonly been used for bringing an impacted mandibular second molar into occlusion (Fig. 29-16).[18] The optimal time for performing the procedure is when the root is two-thirds formed and the apex is open. The tooth should have a mesial inclination not exceeding 90° and should be neither labially nor lingually inclined, for optimal results.[19] Excessive mesial inclination has an increased risk for devascularizing the tooth. In this situation the surgical procedure would be more consistent with an autotransplantation than a surgical uprighting. Excessive labial or lingual inclination is associated with diminished crestal bone on the respective surface, compromising initial stability and ultimate bone height on that respective surface of the tooth.

The surgical technique entails the making of a sulcular incision that extends from the mesial of the first molar to the distal buccal of the second molar. The incision is then extended distally along the alveolar crest angling into the buccal sulcus along the external oblique ridge. A full-thickness mucoperiosteal flap is reflected. Adequate space must be created distal to the impacted second molar tooth. Prophylactic removal of the third molar is commonly performed. Using a surgical drill with a bur, the dentist may find it necessary to remove bone on the distal aspect of the second molar to the level of its greatest concavity. This ensures that there is adequate space into which the impacted second molar can move. An elevator is then used to elevate and reposition the tooth. The repositioned tooth should be slightly out of occlusion. Most frequently, the surgically uprighted tooth is stable in its new position and requires no additional stabilization. If the tooth is mobile, it should be splinted with an

Dentlearn.ir

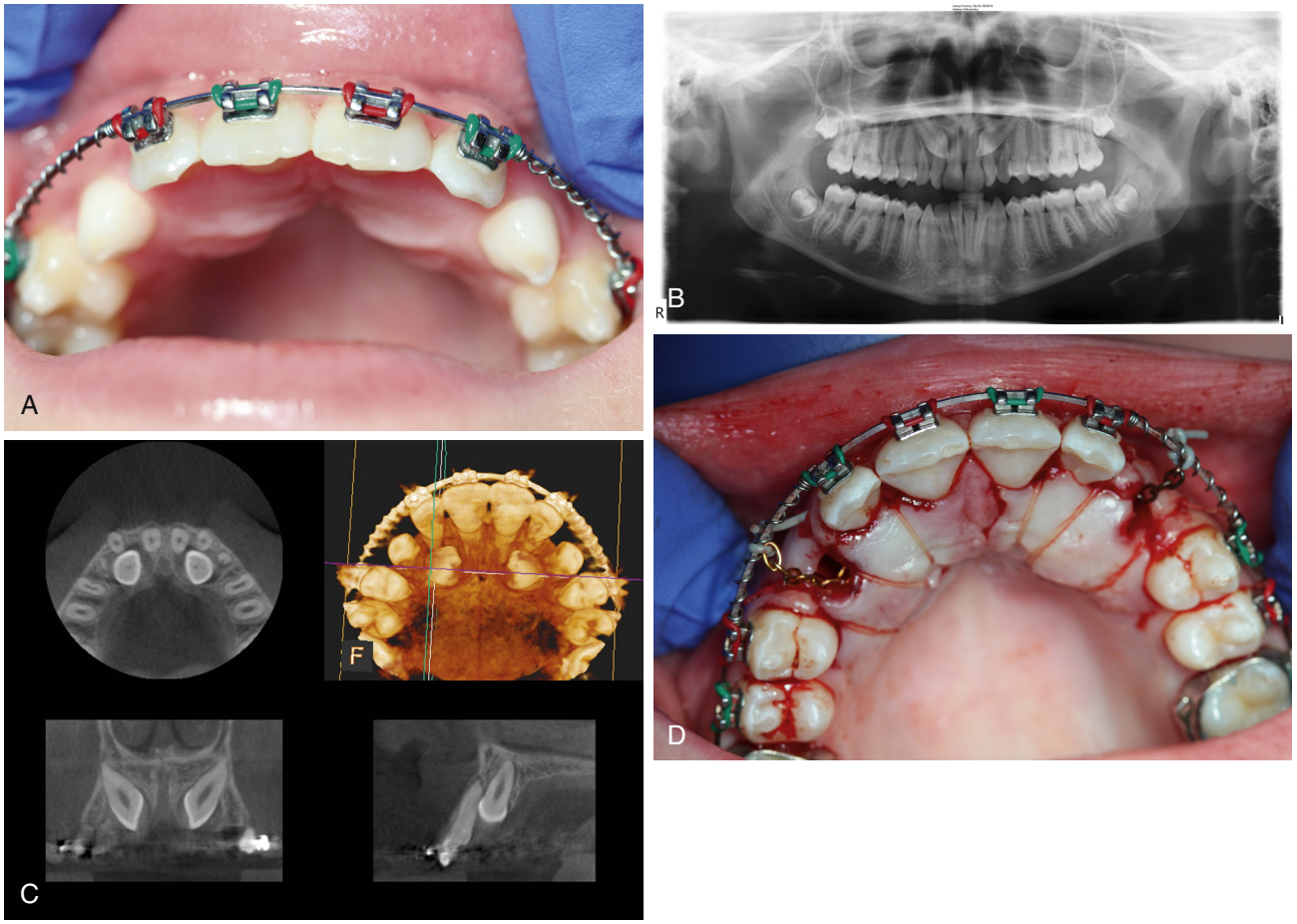

Figure 29-15 **A,** Preoperative photograph showing the retained primary maxillary canines. **B,** Panoramic x-ray showing the impacted maxillary canines. **C,** Cone-beam imaging showing the palatal location of the impacted maxillary canines. **D,** Postoperative clinical photograph.



Figure 29-16 Mesially impacted mandibular second molar.

orthodontic arch wire for approximately 2 weeks. The mucoperiosteal flap is approximated into position, accommodating the newly uprighted tooth, and sutured. Antibiotics are generally prescribed for the first week. Prophylactic endodontic therapy is generally not required.

Case 3: Surgical Uprighting

A healthy 17-year-old female patient was referred to our office for consultation regarding her third molars and impacted mandibular right second molar. Orthodontic treatment had been completed 6 months previously. An intraoral examination revealed the oral soft tissue to be free of any lesions, with no evidence of acute infection. The mandibular third molars were impacted, with insufficient room for functional eruption. The overlying operculum appeared slightly inflamed with no evidence of food debris, and periodontal pockets of 4 mm existed on the distal of the mandibular second molars. The right mandibular second molar was also mesially impacted (Fig. 29-17, *A*). Additionally, the maxillary third molars were impacted. Oral hygiene was fair. A panoramic radiograph revealed four impacted third molars and an impacted right mandibular second molar (see Fig. 29-17, *B*). The patient underwent surgical extraction of her impacted third molars and uprighting of her right mandibular second

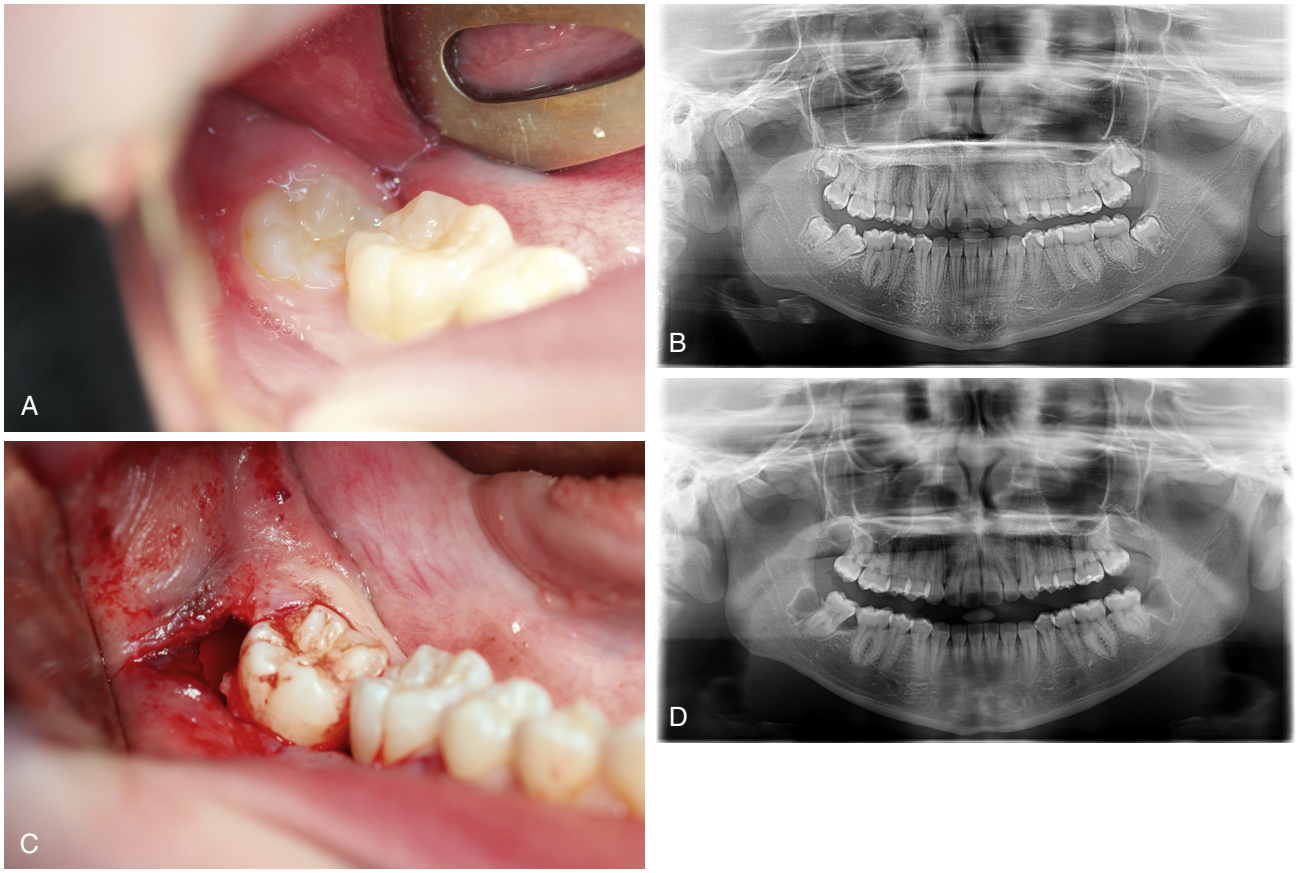

Figure 29-17 **A,** Preoperative clinical photograph showing the mesially impacted right mandibular second molar. **B,** Panoramic x-ray showing four impacted wisdom teeth and the mesially impacted right mandibular second molar. **C,** Intraoperative photograph after extraction of the right mandibular third molar and surgical uprighting of the right mandibular second molar. **D,** Postoperative panoramic x-ray.

molar under IV sedation. An intraoperative clinical photograph (see Fig. 29-17, *C*) showed the right mandibular second molar after the extraction of the right mandibular third molar and surgical uprighting of the right mandibular second molar. A postoperative panoramic radiograph was obtained (see Fig. 29-17, *D*).

Extraction of Impacted Teeth Other Than Third Molars

The extraction of a non–third molar impacted tooth entails many of the techniques described pertaining to the exposure of the impacted tooth. However, a few critical points may differ. The supernumerary impacted tooth or the unerupted succedaneous tooth that is scheduled to be extracted may be deeply impacted. Complications associated with extraction may include injury to adjacent tooth roots or vital structures, such as the inferior alveolar nerve. Localization of the deeply impacted tooth may be achieved with cone-beam computed tomography (CT). The cone-beam CT may provide a better image, demonstrating the exact location of the tooth and its proximity to adjacent roots and vital structure, and may also be beneficial for localizing teeth that will be exposed. The technique cannot be considered standard of care at this time and probably should not become standard of care for many impacted teeth that are readily palpable.

A full-thickness mucoperiosteal envelope flap is created with or without a vertical release. If a vertical release is used to facilitate access, the vertical releasing incision should be made away from the planned extraction. Usually the crown of the tooth is exposed. When the impacted tooth is extracted, the objective is to minimize the amount of bone removal. To facilitate extraction of the tooth with minimal bone removal, the tooth may be sectioned such that the crown and root are removed separately.

ASSOCIATED HARD-TISSUE LESIONS

ODONTOMA

Odontomas are the most frequently occurring odontogenic tumors seen in pediatric patients (Fig. 29-18). They are frequently discovered when the patient presents for evaluation of an unerupted tooth or incidentally during routine radiographic examination. There are two types of odontomas: compound and complex. A compound odontoma represents multiple toothlike structures. A complex odontoma has irregularly shaped masses of enamel with no anatomic resemblance to a tooth. Treatment for an odontoma involves simple enucleation and curettage.

Enucleation is usually carried out intraorally. A mucoperiosteal flap of sufficient size is elevated to expose



Figure 29-18 Odontoma.

the tumor. If required, the overlying bone is removed by means of a round or tapered fissure bur. The odontoma is well-encapsulated and can be curetted from the surrounding bone. The specimen is sent for biopsy. The surgical site is irrigated with normal saline, and the wound is reapproximated with resorbable sutures.

ODONTOGENIC CYSTS

The dentigerous cyst is the most common odontogenic cyst in the pediatric population. It is usually associated with an unerupted permanent tooth or with a supernumerary tooth. Traumatic cysts are also common, especially in active young patients. They are usually unilateral and solitary. Appropriate imaging should be obtained when the dentist suspects a cyst or lesion in the pediatric patient. A biopsy is preferable before definitive surgery. However, if a general anesthetic is required to manage the pediatric patient for a lesion in which the dentist is most confident about the diagnosis, it is usually preferable to perform the definitive procedure and obtain histological evaluation on this specimen with the intent that only one general anesthetic will be necessary. Aspiration is always advised before biopsy to rule out a vascular lesion.

The initial step in managing a cystic lesion is to aspirate the wound. Aspiration of the cystic cavity assists the dentist with differential diagnosis and allows the dentist to rule out a vascular lesion. The treatment of a dentigerous cyst involves complete enucleation of the cyst and its epithelial lining. If an impacted third molar is involved with the cyst, removal of the tooth is indicated. Otherwise, an effort should be made to save the involved permanent tooth to help preserve the integrity of the dental arch. Although a dentigerous cyst is a benign cyst lined by squamous epithelium, this epithelium has a potential to undergo neoplastic change (e.g., ameloblastoma). Postoperative observation should continue until the permanent tooth has erupted and complete healing has occurred.

An eruption cyst is a cystlike lesion caused by eruption trauma of either primary or permanent teeth. Usually seen in erupting molar areas, it usually resolves spontaneously when the involved tooth penetrates the gingival tissue.

Case 4: Traumatic Bone Cyst

A 15-year-old male patient was referred for evaluation of a lesion on his right mandible. The patient's medical history was significant for Burkitt's lymphoma and CMT (Charcot-Marie-Tooth disease). The patient had been in orthodontic treatment for a year. The radiolucency was found as an incidental finding on a panoramic radiograph. An intraoral examination revealed a normal examination with no soft-tissue lesions or buccolingual expansion. The right mandibular first and second molars had normal vitality tests. The panoramic radiograph revealed a unilocular radiolucent lesion between the roots of the right mandibular first and second molars (Fig. 29-19, *A*). A maxillofacial CT scan revealed a 1.4 × 1 cm lucent area in the right mandible below the first and second molars. An incisional biopsy was performed with the patient under nitrous oxide sedation. A bony window was created to provide access to the lesion (see Fig. 29-19, *B*), and 1-mL of serosanguineous fluid was aspirated from the empty cavity (see Fig. 29-19, *C*). Upon examination and biopsy findings, the lesion was determined to be consistent with a traumatic bone cyst.

SOFT-TISSUE PROCEDURES

The pediatric dentist is frequently involved in the management of several minor intraoral soft-tissue lesions. This section discusses commonly seen soft-tissue pathologic conditions: mucocele, ranula, fibroma, and pyogenic granuloma. Lingual and labial frenectomies are discussed in Chapters 13 and 3, respectively.

MUCOCELES AND RANULAS

A mucocele or mucous retention cyst is a benign pathologic lesion resulting from the extravasation of saliva from an injured minor salivary gland. The collection of extravasated fluid develops a fibrous wall around itself, forming a pseudocyst. The lesion can fluctuate in size, depending on its fluid-filled state. A decrease in lesion size is frequently associated with a history of drainage of a thick viscous fluid. The lesion is nonpainful, soft, doughy, and fluctuant to palpation. Clinically, the overlying mucosa may have the same coloration as the lower lip or have a bluish hue. Lesions of longer duration may appear firmer and fibrotic and be difficult to distinguish from a fibroma. A mucocele most likely results secondary to a traumatic event that, in most situations, goes unrecognized. The lower lip is the most common location.

The basic premise in excising a mucocele is to remove the fibrous capsule and any associated minor salivary glands. For a lesion within the lip, the lip is frequently everted and stretched. This stabilizes the lesion. A Kazanjian retractor can be used to isolate and stabilize the lesion. An elliptical incision (staying within the confines of the lesion) is made in the lip perpendicular to the fibers of

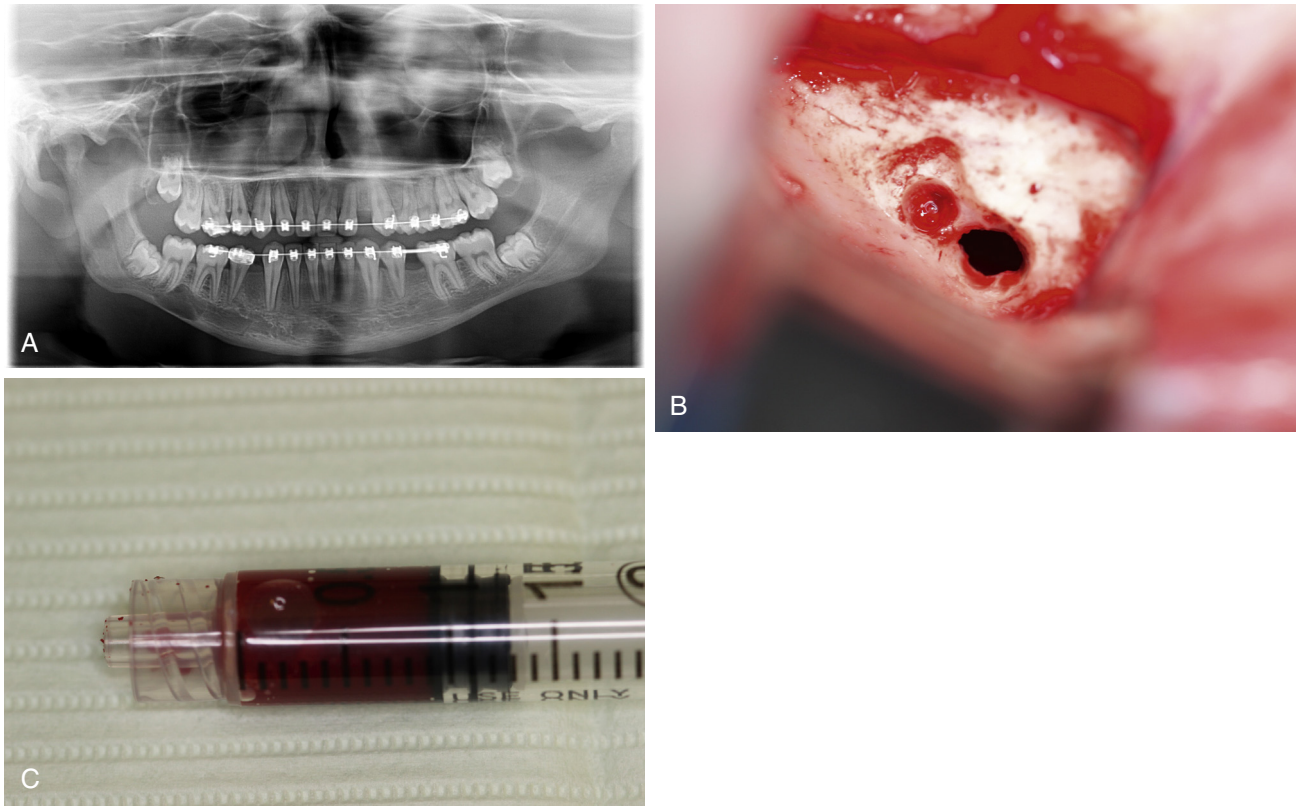

Figure 29-19 **A,** Panoramic x-ray showing a unilocular radiolucent lesion between the roots of the right mandibular first and second molars. **B,** Intraoperative photograph showing the surgical access to the lesion. **C,** 1cc of serosanguinous fluid aspirated from the lesion.

the orbicularis oris muscle. By a combination of sharp and blunt dissection, the fibrous capsule of the lesion is separated from the surrounding tissue. If done properly, the mucocele can be removed intact. All minor salivary glands surrounding the lesion and within the surgical field should be removed. Removal of the surrounding minor salivary glands minimizes the potential for recurrence. Hemostasis is controlled and closure is accomplished with a 4-0 resorbable suture. The lip is a prominent area, and it may be challenging for the smaller child to not disturb the wound during healing. The suture knots should be buried, and an extra suture to ensure integrity of the closure may prevent the wound from dehiscing (Fig. 29-20).

A ranula is a mucous retention cyst that occurs in the floor of the mouth and is associated with the sublingual gland. A ranula in a young pediatric patient needs to be differentiated from a lymphatic malformation. A ranula may be managed by marsupialization or excision of the sublingual gland. Many surgeons initially manage a ranula with marsupialization and perform an excision of a sublingual gland secondarily if the ranula recurs, although some surgeons think that there is a high incidence of recurrence with marsupialization and choose excision of the sublingual gland as their primary surgical intervention. The first step before either of the two procedures is performed is identification and cannulation of the ipsilateral submandibular duct. The mucosa overlying the lesion is then excised. With marsupialization, the lining of the pseudocyst cavity is then sutured to the overlying mucosa of the floor of the mouth. A Penrose drain may be sutured in place to maintain the definitive communication between the pseudocyst and oral cavity. If the intent is to excise the sublingual gland, once the overlying mucosa is excised, blunt dissection is used to identify and isolate the sublingual gland. Extraoral pressure elevating the floor of the mouth can facilitate this process. Anterior traction of the gland may also facilitate dissection. The lingual nerve and submandibular duct, which are in close proximity to the deep surface of the sublingual gland, should be identified before definitive excision, to minimize iatrogenic injury. The wound is loosely closed.

Case 5: Mucocele

A healthy 11-year-old male patient was referred to our office for consultation regarding a right lower lip lesion that had been present for 6 months. The patient, a hockey player, reported a history of repeated trauma to his lower lip. An intraoral examination revealed a nonpainful, soft, fluctuant lesion on his right lower lip. The lesion measured 5 × 5 mm (Fig. 29-21, *A*). An excisional biopsy was performed with the patient under nitrous oxide sedation (see Fig. 29-21, *B*). The specimen was consistent with a mucocele (see Fig. 29-21, *C*).

FIBROMA AND PYOGENIC GRANULOMA

The pediatric patient may present with other soft-tissue lesions. Common lesions found in the pediatric patient include both the fibroma and the pyogenic granuloma.

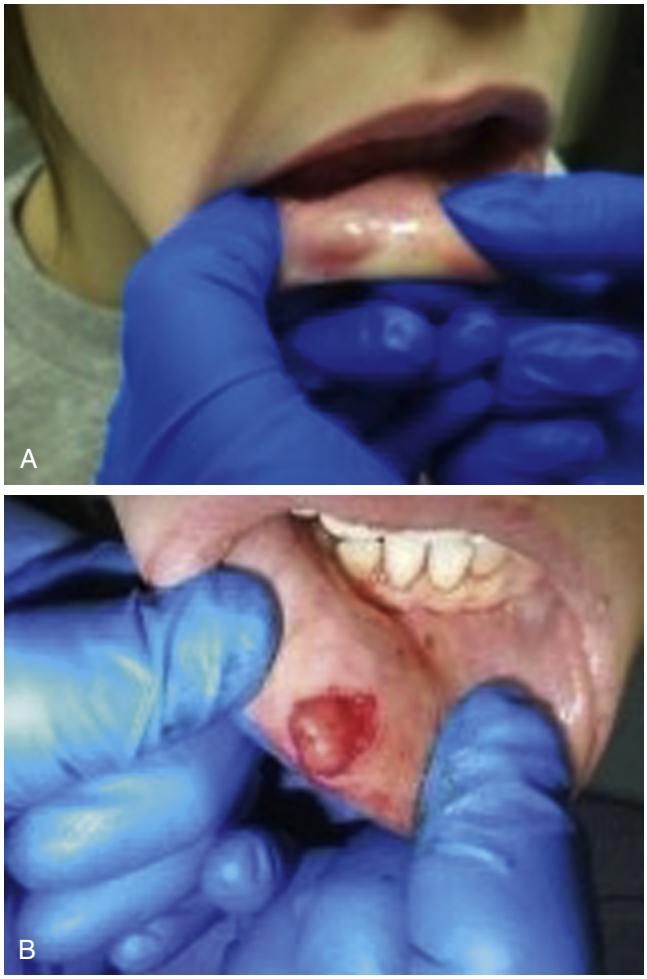

Figure 29-20 Mucocele and stages of surgical excision. **A,** An elliptical incision made with a combination of blunt and sharp dissection. **B,** The mucocele sac is separated from the surrounding mucosa.

Oral pathology is discussed elsewhere in this text. If the lesion is small, it may be excised completely, and the specimen submitted for histological evaluation. This can usually be accomplished by an elliptical incision made within normal tissue around the lesion. The depth of the dissection is determined by the appearance and feel of the lesion. Minor modifications to this basic technique are dependent on the differential diagnosis. For example, removal of interproximal tissue and scaling of teeth may be indicated when a pyogenic granuloma is excised, to ensure complete removal and minimize recurrence.

INFECTION OF THE HEAD AND NECK REGION

This section focuses on infections of odontogenic etiology. However, whereas the etiology of head and neck infections may be odontogenic, the etiology may also be secondary to sinus, salivary gland, skin, or middle ear conditions. Defining the etiology is critical to the management of the infection because the infection may persist and potentially worsen if the cause is not removed and the appropriate antibiotic is not selected based on the etiology. Infections can progress rapidly in both the pediatric patient and the adult patient; however, the pediatric patient is especially susceptible to becoming rapidly dehydrated and systemically ill from what may appear to be a relatively minor infection.

This discussion provides a protocol for the management of the pediatric patient with a head and neck infection. Similar to cardiopulmonary resuscitation (CPR)/basic life support (BLS), which provides an algorithm and a sequence for managing the airway, breathing, and circulation, this section provides a logical sequence for assessing and treating the patient. An experienced individual can assess the situation and perform CPR simultaneously; likewise, the experienced dentist may perform several of these assessments and interventions simultaneously.

The first step in managing the pediatric patient with a head and neck infection is to obtain a history, including details about both the patient's present illness and the patient's past medical and surgical history. The history of the present illness must include: (1) onset; (2) rate of progression; (3) history of preceding odontogenic pain, upper respiratory infection, sinus pain, otitis media; (4) airway compromise (dysphagia, dyspnea, change in voice); (5) trismus; and (6) ophthalmic complaints (e.g., photophobia, changes in visual acuity). It may be difficult to elicit a complete history from a younger patient when neither the patient nor the parent is able to provide a history of preceding odontogenic pain. The dentist must obtain a complete past medical history. In the management of a patient with an infection, it is important to identify diseases that compromise the immune system (e.g., diabetes) and the patient's ability to withstand stress (e.g., congenital heart disease). The latter is important because a severe infection can impose severe physiologic stress on the patient, whose ability to respond to the infection may be dependent on his or her systemic reserve.

The second step in managing the pediatric patient with a head and neck infection is to examine the patient. The clinical examination includes visual inspection, identifying the: (1) patient's respiratory compromise, distress, or lack of distress; (2) involved swelling and the severity thereof; (3) palpation of the tissues to discern their tenderness and consistency (cellulitic or fluctuant); (4) assessment of maximal mouth-opening; and (5) examination of the dentition. The radiographic examination may consist of a periapical or panoramic radiograph, which can be obtained in the office. The panoramic radiograph is a good screening radiograph. A periapical radiograph may provide more discerning information; however, this may be difficult to obtain if the child's head and neck are swollen. Severe fascial space infections require a CT scan with contrast to delineate the full involvement of the infection. A differential diagnosis is developed from the history and examination.

The dentist must be knowledgeable about the anatomic spaces of the head and neck and the routes in which infection can spread. The routes of dissemination of an infection are dependent on the position of the roots of the teeth relative to anatomic considerations, such as muscles,

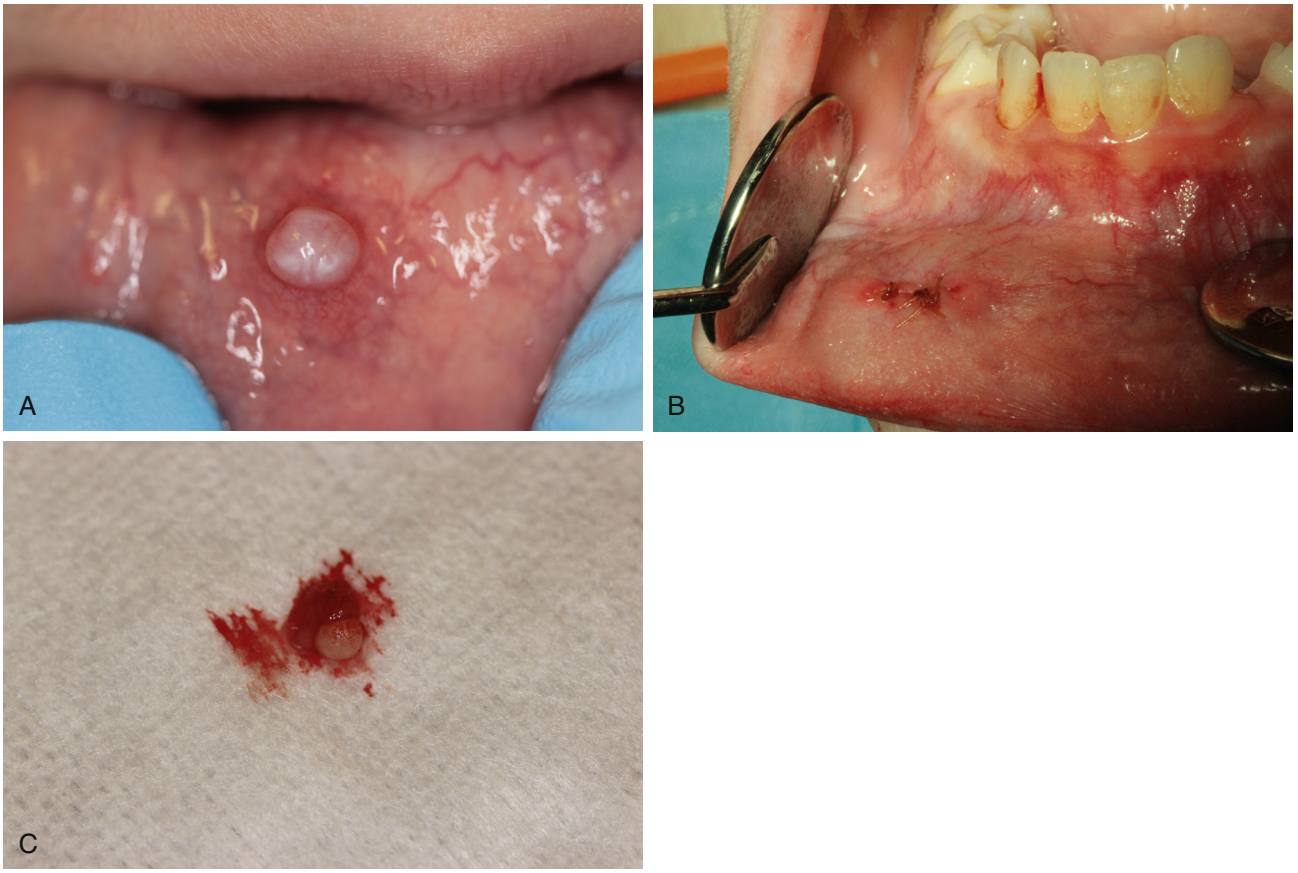

Figure 29-21 **A,** Clinical photograph of a right lower lip lesion. **B,** Postoperative clinical photograph. **C,** Surgical specimen.

maxillary sinus, and root angulation relative to their respective jaws. For example, a vestibular space infection is the result of an infection dissecting through the lateral maxillary or mandibular bone and perforating the buccal bone inferior (maxilla) or superior (mandible) to the buccinator muscle attachment. The maxillary teeth can result in a canine space infection, which can extend and ultimately involve the periorbital tissues. The proximity of the maxillary teeth to the maxillary sinus can produce maxillary sinusitis. Posterior spread of a maxillary infection can involve the infratemporal space and spread directly into the orbital tissues through the inferior orbital fissure. Mandibular molar infections can spread above or below the mylohyoid muscle, resulting in a sublingual space or submandibular space infection, respectively. An infection of the sublingual space displaces the tongue superiorly and posteriorly. Posteriorly, a mandibular infection may spread either lateral to the ramus or medial to the ramus, resulting in either a submasseteric space or a pterygomandibular and/or lateral pharyngeal space infection, respectively. The submasseteric space, the pterygomandibular space, and the infratemporal space comprise the masticator space. Infections of the masticator space result in trismus. Infections of the sublingual, submandibular, submental, and masticator space can compromise airway integrity. Although rare, infections of the head and neck may have hematogenous spread via the valveless veins of the face and cause central neurologic infections.

The third step in managing the pediatric patient with a head and neck infection is to develop a plan of intervention, beginning with an assessment of the airway. Urgent airway intervention may be indicated based on the involved fascial spaces, their severity, the patient's signs and symptoms, and the progression of the infection. Managing a patient with a compromised airway requires a team approach between the surgeon (capable of performing a tracheostomy, if necessary) and the anesthesiologist. This is a challenging situation in an adult, in whom the induction of a sedative state or general anesthetic may worsen an already compromised airway. In situations where the airway is compromised, the adult patient may be fiberoptically intubated with minimal sedation. The fearful pediatric patient lacks the ability to cooperate, necessitating a more profound depth of sedation, which potentially makes airway management more challenging and dangerous.

Once the airway is assessed and controlled, the practitioner must continue with the interventional plan development. The components of intervention include (1) determining whether the infection should be treated in an outpatient or inpatient setting, (2) establishing the appropriate antibiotics to use, and (3) undertaking surgery (incision and drainage and removal of the etiology). Indications for admitting a pediatric patient to the hospital include fever (temperature <101.5°F), lymphadenopathy, elevated white blood cell count (WBC), poor oral intake,

dehydration, involved fascial spaces, associated findings (e.g., dysphagia), and the appearance of being ill (i.e., looking sick). The latter item should not be disregarded; this is one situation in which the general appearance of the patient provides significant guidance.

Odontogenic infections are polymicrobial. There is a significant increase in resistance to antibiotics that has developed over the past couple of decades, especially to beta-lactamase–producing organisms. The antibiotic for a less severe odontogenic infection that is to be managed in an outpatient setting is penicillin VK (25 to 50 mg/kg per day in divided doses every 6 to 8 hours) or clindamycin (10 to 20 mg/kg per day in divided doses every 6 hours).[20] Because of the increase in beta-lactamase–producing organisms, the first-line antibiotics for infections requiring hospitalization are intravenous ampicillin-sulbactam (Unisyn) or intravenous clindamycin. Hospitalization facilitates supportive care, such as providing hydration, nutritional support, and fever management.

Surgery includes incision and drainage and removal of the source of infection (which may involve pulpectomy or extraction). In our opinion, if hospitalization is required, the offending tooth should be extracted. The following are basic principles for performing an incision and drainage. If the patient is not going to have a general anesthetic, the site must be anesthetized with local anesthesia. Regional block anesthesia without infiltrating the infective site is recommended. A Gram stain and culture and sensitivity (C&S) test are indicated for all fascial space infections (not including a vestibular space infection), immunocompromised patients, or infections that have failed multiple courses of antibiotic treatment. Ideally, the dentist obtains an aspirate for a Gram stain and C&S before making the incision and drainage. Before the infection is incised, a needle on a syringe is inserted into the wound and its contents aspirated. The aspirate is submitted for Gram stain and C&S. When a vestibular space infection is drained, an incision is made, frequently centered within the swelling. The incision is carried through the mucosa down and through the periosteum. The dentist must have knowledge of the anatomy to avoid vital structures, such as the mental nerve and facial artery. A small hemostat (mosquito) is inserted with the beaks closed. Blunt dissection is performed with the beaks closed. The beaks are opened and withdrawn. The hemostat beaks are never closed blindly when the instrument is in the wound, to prevent injury to vital structures. A Penrose drain may be placed into the incision and drainage site and secured with a nonresorbable suture for a few days. The drain keeps the wound open and patent, facilitating irrigation (if necessary) and spontaneous drainage of the wound and preventing a recurrent collection from developing. Refer to a surgical text for more detailed information pertaining to draining fascial spaces.[20]

FRACTURE OF THE MANDIBLE

The pediatric dentist may encounter pediatric patients who have suffered a traumatic event and injured the soft and/or hard tissue of the face. These injuries can include soft-tissue lacerations, dentoalveolar injuries, and facial fractures of the maxilla, mandible, nose, and cheek. Probably the most common injury that the pediatric dentist sees is the dentoalveolar injury, which includes intrusion and avulsion of teeth, crown and tooth fractures, and alveolar fractures. Diagnosis and assessment of these injuries are discussed elsewhere.[21] The mandibular fracture is the most common skeletal injury that occurs in the pediatric patient with a mandibular fracture may initially present to the pediatric dentist, who must be able to recognize the injury and make the appropriate referral.

When assessing a patient who presents with a facial injury, the treating doctor must recognize that the patient can have associated injuries. A history of the events contributing to the event and a comprehensive physical evaluation are important and must be completed. The treating doctor must also be cognizant that the force required to cause a facial fracture is directed to the head and neck, and could result in neurologic or cervical injury. Understanding the mechanism of injury may present some insight. The doctor should inquire as to loss of consciousness or symptoms suggestive of neurologic injury (e.g., dizziness, lightheadedness, amnesia of the event, nausea and vomiting). In the awake adult individual, cervical trauma is assessed frequently by clinical examination and the patient's ability to relate whether or not neck pain is present. In the younger patient who cannot reliably relate whether or not neck pain is present, radiographic assessment may be indicated. The pediatric dentist must be cognizant that the pediatric patient may sustain cervical injuries, as well as other injuries secondary to the mechanism of injury, and manage the patient to minimize those potential adverse consequences. For example, if there is any question that the patient has sustained a cervical injury, the patient should be supinely positioned and EMS contacted for transportation to the emergency department.

The first step in assessing the patient who presents with a facial injury is to obtain a comprehensive history. The younger patient may be less able to provide reliable answers. These questions include:

1. "Where does it hurt?" "What makes it hurt?"
2. "Can you open your mouth?" (Does the patient have any limitation of jaw movement? Is the bite different?)
3. "Do you have any loose teeth?"
4. "Do your lips feel different?" "Are your lips numb?"

The answers to these questions may reveal the patient's diagnosis. A patient may complain of pain in the temporomandibular joint, suggestive of a hemarthrosis or a condylar fracture. On clinical examination the patient may have a chin abrasion or laceration. The force of a blunt trauma to the region of the chin that results in an abrasion or laceration may be transmitted to the condylar region. Thus a chin abrasion or laceration in a patient complaining of pain in the temporomandibular joint may support the suspicion of an injury to the joint. Alternatively, a patient who presents with a chin abrasion or laceration secondary to blunt force should be assessed for pain in the joint that may be suggestive of a condylar fracture.

Bony or muscular injury can result in limited mobility of the jaw because of pain, bony mechanical obstruction,

Dentlearn.ir

joint or soft-tissue swelling, or muscular inflammation or irritability. A unilateral condylar injury may result in deviation to the ipsilateral side with opening in the occlusion secondary to the action of the contralateral lateral pterygoid muscle.

Fractures of the mandible can result in a malocclusion. Unilateral condylar fractures usually result in an ipsilateral premature bite. Bilateral condylar fractures may result in bilateral shortened rami with a resultant anterior open bite and mandibular retrognathia. A hemarthrosis of the condyle may result in an ipsilateral posterior open bite secondary to the joint swelling and inferior displacement of the rami. Because of the elasticity of the pediatric mandible, a fracture may not always result in displacement and a resultant malocclusion. The practitioner must be diligent and assess for tenderness of the region, which may be an indication of an injury. Hemorrhage into the tissue associated with the fracture may result in localized ecchymosis in the buccal or lingual vestibule. A fracture may result in gingival tearing. The findings may be more subtle, with slight evidence of sulcular blood along the teeth adjacent to the fracture. Teeth adjacent to the fracture may be loose. This must be distinguished from an avulsive type of injury, an alveolar fracture, or the normal resorptive pattern present in a mixed dentition. Palpation of the mandible may identify a step along the inferior border. Bimanual palpation may demonstrate segmental mobility or elicit discomfort.

The bony canal of the inferior alveolar nerve traverses the rami and the body of the mandible. A mandibular fracture may result in hemorrhage into the canal with a resultant compressive type injury, or the nerve may sustain a contusion, a stretching-type lesion, or a partial or complete transection. Paresthesia occurs as a result of the nerve injury. In most situations in which the fracture segments are not grossly displaced, the paresthesia is transient and recovery occurs over the next several weeks to months. Pediatric patients are less able to report various symptoms and may not be able to express that they are paresthetic.

Radiographic examination of the mandible in the office usually includes a panoramic radiograph. This image is useful and reliable in visualizing the entire mandible, including the condyles, rami, angle, body, and symphysis. Radiographic assessment ideally should occur in two planes. A condylar/subcondylar fracture may not always be recognized on a panoramic radiograph. Additionally, the panoramic radiograph does not demonstrate the lateral/medial displacement of the fracture segments in the coronal plane, as demonstrated on a Towne's view. A fracture that is not clearly visualized on the panoramic radiograph may be identified on the Towne's view. The symphysis may be outside the ideal trough of the panoramic radiograph, and a nondisplaced or greenstick fracture may not be clearly seen on a panoramic image. A mandibular occlusal radiograph at 90° to the mandible should be obtained when a mandibular symphyseal fracture is suspected and is not seen on a Panorex. For the patient who presents to the emergency department, CT imaging is becoming more regularly used and is replacing more traditional flat-plane imaging. The CT scan provides images in the axial, coronal, and sagittal views. Three-dimensional reconstruction is also available and should be requested. It is important to have all of these images available because a fracture may be easily visible and recognized on only one of them.

The discussion of managing the pediatric patient focuses on the patient with a mixed dentition. Treatment of a mandibular fracture includes reduction of the fractured segments, reestablishment of a stable occlusion, and stabilization of the fractured segments. Fractures in pediatric patients can heal rapidly, and treatment should ideally be initiated within the first days after injury. If for various medical conditions or associated injuries fracture reduction is not initiated within the first few days, the bony segments may begin to heal and reduction may become difficult, if not impossible. One advantage in managing pediatric patients with mixed dentition is that minor malocclusions usually self-correct with growth.

sular or extracapsular. A pediatric patient who has sustained an intracapsular fracture or injury is at increased risk of ankylosis or growth disturbance. Treatment is frequently dictated by the degree of malocclusion and jaw opening/function. If the occlusion is grossly normal, the fracture may be managed with a blenderized diet, analgesics if necessary, and observation. Physiotherapy to ensure symmetric opening may be indicated. If the pediatric patient has a malocclusion or significant pain, a short period of 7 to 10 days of maxillomandibular fixation may be warranted. The risk of rami shortening and an anterior open bite is a concern in a patient who has sustained a bilateral condylar fracture, and the practitioner may more readily consider a period of maxillomandibular fixation. The use of guiding elastics for a period of 1 to 2 weeks after the release of maxillomandibular fixation may be beneficial to facilitate symmetric opening. Open reduction and fixation, even for a displaced condylar fracture in the pediatric patient, are rarely indicated. Slight malocclusions usually self-correct with growth.

Management of a nondisplaced body or symphysis fracture may also be achieved with a blenderized diet and observation. When maxillomandibular fixation is required (for either a nondisplaced or displaced fracture), the patient is frequently placed in fixation for a period of approximately 3 weeks. An alternative to maxillomandibular fixation for a body or symphysis fracture is the placement of a lingual splint, which is secured to the teeth with either circumdental or circumandibular wires. The advantage of the splint is that it does not require the patient's jaws to be wired closed. This facilitates respiratory care and nutritional support in the seriously injured patient. A disadvantage of a lingual splint is that it may require a separate anesthetic to take the impression necessary to make the splint. If the patient is having multiple injuries managed during the same operation, the dental surgical team may take the maxillary and mandibular impression at the beginning of the operation, fabricate the splint, and have it ready to be placed before termination of the anesthetic. Angle fractures or fractures posterior to the teeth require maxillomandibular fixation for 3 weeks.

Dentlearn.ir

in managing the pediatric patient. Care must be taken to avoid succedaneous developing teeth. The authors have rarely found it necessary to perform an ORIF of a pediatric mandibular fracture. Slight malocclusions usually self-correct with growth.

Maxillomandibular fixation is traditionally achieved by ligation of an arch bar to the teeth in each arch with circumdental wires placed around the cervical collars of the teeth. The shape and shortness of the deciduous teeth may make this difficult at times. The arch bar provides hooks (with the opening apically positioned) that can be used to secure wires or elastics to achieve either tight maxillomandibular fixation with absolute lack of movement or to place elastics that allow for limited function and guide the patient's opening and occlusion. If the patient's dentition does not facilitate circumdental wiring, the practitioner may opt to use skeletal wiring either alone or in combination with circumdental wiring. Skeletal fixation consists of circumandibular wires, piriform wires, and zygomatic buttress wires. A circumandibular wire is placed around the mandible. The wire is inserted extraorally using a Keith needle or an awl. The inferior border of the mandible is palpated, and the first end of the wire is passed along the lingual aspect of the mandible and enters the mouth in the lingual vestibule adjacent to the mandible. Care must be taken to pass the wire along the lingual surface of the mandible; if the wire is passed too far medially, it may injure various structures, such as Warthin's duct. The other end of the wire is passed through the same extraoral puncture site in the skin inferior to the border of the mandible. This end of the wire is passed buccally and enters the mouth in the depth of the vestibule just adjacent to the buccal surface of the mandible. Each wire end is grabbed individually, and the wire is sawed back and forth until the inferior aspect of the looped wire passes through the soft tissue and lies firmly against the inferior aspect of the mandible. The pediatric mandibular cortex is thin, and aggressive sawing action can result in pulling the wire through the mandible, resulting in a new fracture. Piriform and buttress wires are inserted via an incision made over the respective site, creating a hole through which a wire can pass with a bur. The practitioner must be cognizant of where the developing tooth buds are.

This discussion focuses on the management of the mandibular fracture in the pediatric patient with mixed dentition. Patients with permanent dentition have less capacity for the bone to adapt and remodel.

SUMMARY

This chapter outlines basic principles used in the management of basic oral and maxillofacial surgical procedures. Many of the principles discussed can be used in various aspects of dental practice.

REFERENCES

1. Litman RS et al.: Breathing patterns and levels of consciousness in children during administration of nitrous oxide after oral midazolam premedication, *J Oral Maxillofac Surg* 55:1372–1377, 1995.
2. Tyagi P et al.: Sedative effects of oral midazolam, intravenous midazolam and oral diazepam in the dental treatment of children, *J Clin Pediatr Dent* 37(3):301–305, 2013.
3. Hupp JR: Principles of routine exodontia. In Hupp JR, Ellis E III, Tucker MR, editors: *Contemporary oral and maxillofacial surgery*, ed 6, Philadelphia, 2014, Mosby/Elsevier, pp 88–118.
4. Ash MM et al.: A study of periodontal hazards of third molars, *J Periodontol* 33:208, 1962.
5. Blakey GH et al.: Changes in third molar and non-third molar periodontal pathology over time, *J Oral Maxillofac Surg* 65:1577–1583, 2007.
6. Blakey GH et al.: Progression of periodontal disease in the second/third molar region in subjects with asymptomatic third molars, *J Oral Maxillofac Surg* 64:189–193, 2006.
7. Sidlauskas A, Trakiniene G: Effect of the lower third molars on the lower dental arch crowding, *Stomatologija* 8(3):80–84, 2006.
8. Kugelberg CF et al.: Periodontal healing after impacted lower third molar surgery in adolescents and adults. A prospective study, *Int J Oral Maxillofac Surg* 20:18, 1991.
9. Chipasco M et al.: Germectomy or delayed removal of mandibular third molars: the relationship between age and incidence of complications, *J Oral Maxillofac Surg* 53:418–422, 1995.
10. Pogrel MA: What is the effect of timing of removal on the incidence and severity of complications? *J Oral Maxillofac Surg* 70(9 Suppl 1):S37–S40, 2012.
11. Park JH, Srisurapol T, Tai K: Impacted maxillary canines: diagnosis and management, *Dent Today* 31(9):62, 64–66, 2012.
12. Jacoby H: The etiology of maxillary canine impaction, *Am J Orthod* 84:125–132, 1983.
13. Kaban LB, Troulis MJ: Dentoalveolar surgery. In Kaban LB, Troulis MJ, editors: *Pediatric oral and maxillofacial surgery*, Philadelphia, 2004, WB Saunders, p 131.
14. Alqerban A et al.: Pre-surgical treatment planning of maxillary canine impactions using panoramic vs cone beam CT imaging, *Dentomaxillofac Radiol* 42(9):20130157, 2013.
15. Rossini G et al.: Localization of impacted maxillary canines using cone beam computed tomography. Review of the literature, *Ann Stomatol (Roma)* 3(1):14–18, 2012.
16. Kokich VG: Surgical and orthodontic management of impacted maxillary canines, *Am J Orthod Dentofac Orthop* 126:3, 2004.
17. Yan B et al.: Maxillary canine impaction increases root resorption risk of adjacent teeth: a problem of physical proximity, *Am J Orthod Dentofacial Orthop* 142(6):750–757, 2012.
18. Boynton T, Lieblich SE: Surgical uprighting of second molars, *Atlas Oral Maxillofac Surg Clin North Am* 21(2):235–237, 2013.
19. Pogrel MA: The surgical uprighting of mandibular second molars, *Am J Orthod Dentofac Orthop* 108:180–183, 1995.
20. Topazian RG et al.: *Oral and maxillofacial infections*, ed 4, Philadelphia, 2002, WB Saunders.
21. Fonseca RJ et al.: *Oral and maxillofacial trauma*, ed 4, Philadelphia, 2013, WB Saunders, pp 248–292.

CHAPTER 30

The Child in Context of the Family, Community, and Society

▲ **Burton L. Edelstein** and **Karen M. Yoder**

For additional resources, please visit the evolve website.

CHAPTER OUTLINE

CONCEPTUAL FRAMEWORK FOR PEDIATRIC ORAL HEALTH
CHILDREN'S ORAL HEALTH AND DENTAL CARE
Disease Burden and Caries Consequences
Dental Care Utilization and Governmental Impacts
THE STRUCTURE OF DENTAL PUBLIC HEALTH AND ITS ROLE IN CHILDREN'S ORAL HEALTH
COMMUNITY ORAL HEALTH PROGRAMS WITH IMPACT ON CHILDREN'S ORAL HEALTH
CONCLUSIONS

CONCEPTUAL FRAMEWORK FOR PEDIATRIC ORAL HEALTH

Children are, by nature, dependent. They are significantly influenced by others in their lives. They live and function within the larger contexts of their families, communities, and societies, and their oral health is significantly influenced by each of these layers-of-life. In fact, their oral health risks and their oral health status are influenced more by the genes they inherit, the social and cultural environment in their lives, the physical characteristics of their community, and most of all the health behaviors they learn and adopt than by the totality of care provided by dental professionals. Yet the dental professional is the reliable source of technical information on oral health promotion through prevention and risk mitigation and the only professional capable of treating oral and dental pathology.

For the clinician who cares for children, these facts suggest three essential courses of action to promote a child's oral health: (1) the dentist must address each child and family with a keen awareness of the opportunities and constraints that affect the child's oral health; (2) the dentist must recognize the provision of dental care as a single component among multiple factors affecting each child's oral health and recognize that what happens day-to-day outside the dental operatory is most critical; and (3) the dentist must actively engage as a recognized resource for oral health information who can influence what happens on a daily basis. While the dental professional is the oral health expert, the holistic approach to oral health promotion arising out of these actions recognizes that others, including dieticians, social workers, health educators, and community health workers, have special knowledge skills and capacities to work with children and families in ways that complement clinical dental care. These "helping professionals" hold the keys to family-level and community-level interventions that set the stage for salutary health behaviors. They are more specifically trained to influence health behaviors than are dental professionals. If the central goal of pediatric dental care is sustained positive oral health for all children, then a collaborative approach that targets social and behavioral as well as clinical determinants of oral health is essential.

From a societal perspective, professionals and community leaders of all types assume responsibility not only for

for a single child but for children in general. For example, dental societies support public education campaigns and engage with policymakers to support the development and funding of health programs for children. Individual den-

children, for example, volunteering as the oral health consultant to a Head Start Program or engaging with a commu-

special needs program, early intervention program, youth

This shift from thinking of individual children as "patients" to thinking about the oral health of all children is inherent to a shift from "clinical thinking" to "population thinking" or "public health thinking." Just as clinical dentistry utilizes standard approaches to assessing individual children's oral health status through complete examination, providing needed services through clinical care, and ensuring oral health promotion through ongoing preventive care, so too does population-oriented public health dentistry conduct surveillance to assess population health, attend to the adequacy and availability of dental care delivery systems to provide care, and conduct oral health promotion activities that maximize the totality of a society's oral health.

Dentlearn.ir

Of particular interest to readers of this volume is that pediatric dentistry and public health dentistry share common origins. This is because society, most often through its governmental structures, has long attended to the needs and interests of vulnerable populations, whether those populations are made vulnerable by social or physical liabilities or dependencies that result from age or special needs. Pioneers in community dentistry who were motivated by concern for children's oral health include photography giant George Eastman, who developed school-based dental programs at the turn of the twentieth century; Alfred Fones, who founded the dental hygiene profession's first school in 1913; and the American Academy of Pediatric Dentistry founders, who created an organization with a mission that today affirms its commitment to "advocate policies, guidelines and programs that promote optimal oral health and oral health care for infants and children through adolescence, including those with special healthcare needs."

Just as the range of potential interventions for clinicians is wide, so too is the range of potential interventions for dentists who commit their work to improving all children's oral health. At the family level, oral and general health behaviors and environmental conditions, including the availability and use of fluoridated water, are key oral health determinants. At the community level, the availability of oral and general health educational programs, school-based and school-linked dental sealant programs, school nutrition and "junk food" policies, and even school-based dental care programs exemplify oral

of children rather than individual children. At the societal level, governmental policies on licensure regulate the availability of the dental workforce (including dentists, hygienists, advanced practice dental personnel, and dental therapists), policies on coverage and insurance (e.g., in the United States through public insurance programs such as Medicaid and the Children's Health Insurance Program [CHIP] and through private insurance acquired from employers) and Affordable Care Act Marketplaces influence the availability of care, health reform that is moving toward value-based purchasing and outcomes-assessed incentives influences health care organization and financing, and fluoridation policies have an impact on disease burden. Questions of who can provide what components of care with what financing under what conditions and to which children are the "mega" systems questions of public health and public policy that directly affect the practice of dentistry for children. These questions are consequential to children and to the dental professionals who care for them as they influence the epidemiology of disease, the availability of care, and the options for advancing children's oral health and dental care.

Conceptually, pediatric dentistry and public health dentistry share a unique niche within the spectrum of dental disciplines. They are the only two recognized specialties of dentistry that are essentially holistic in nature. Unlike other recognized areas of dental specialization that attend to a particular issue (e.g., periodontics and endodontics), a set of clinical techniques (e.g., orthodontics, prosthodontics, and oral and maxillofacial surgery), or to a diagnostic domain (e.g., oral pathology and oral radiology), both pediatric dentistry and public health dentistry are defined by those they serve—that is, children and entire populations, respectively. For this reason, the required knowledge and skill sets needed for effective management of their target population's oral health are broad.

Care of children requires a working knowledge of all dental disciplines, with a particular application to patients who are simultaneously growing and developing. Care of populations similarly requires a working knowledge of all core public health disciplines. Epidemiology is the study of disease prevalence and distribution, correlates across

ties in clinical dentistry. Biostatistics is the discipline of measurement whose theories and techniques are used for describing, analyzing, and interpreting health data; it is analogous to skills used to interpret clinical data. Environmental health is the branch of public health that deals with all aspects of the natural, built, and social environment as it affects human health; it is analogous to the clinician's assessment of individual children's home conditions that affect oral health behaviors, care-seeking, compliance, and health outcomes. Nutrition is the study of foods and nutrients and their effect on health; it plays the same role in population health as it does in individual health. The public health discipline of health policy and management deals broadly with the conditions under which oral health is obtained and care if provided across populations by dealing with issues as wide ranging as care-financing, health care workforce, safety-net health facilities, systems of care, resource allocations, and governmental and professional regulations; it is analogous to the wide range of issues with which clinical dentists deal in managing their practices. Just as in dentistry, children and families have their own unique holistic niche within public health in the disciplines of *maternal and child health* (MCH)—the field that deals with children, including those with special health care needs, in the context of their parents, families, communities, and societies. As dentistry for children utilizes all of the clinical disciplines, so too does MCH utilize all of the disciplines of public health to focus attention on children's health. The essential need for both pediatric dentistry and MCH was well stated by child health leader Grace Abbott in the 1930s when she asserted that "children are not pocket editions of adults" but need to be attended to with special consideration of their vulnerabilities and served through an approach that is "not merely an adaptation of the program for adults."

With this perspective, it is clear that public health dentistry is of direct relevance to the daily practice of dental care for children. This chapter describes many of the opportunities, options, resources, and possibilities available to the dental professions to assess, improve, promote, and manage the oral health of our children.

A quote attributed to the classical Roman poet Virgil—"As the twig is bent, the tree inclines"—provides a paradigm for public health's concern for children and their oral health. After following a cohort of 980 people from birth to the age of 26 years, researchers noted that "adult oral health is predicted by not only childhood socioeconomic advantage or disadvantage, but also

Dentlearn.ir

by oral health in childhood."[1] Research techniques in MCH, including "social determinants of health," "life-course studies," and "common determinants of health modeling," all suggest that conditions affecting children play out consequentially throughout life. This is particularly true of oral health because having childhood caries, particularly early childhood caries (ECC), is the strongest indicator of lifelong caries risk. This is because the presence of ECC signifies the presence of a well-established caries process that remains quite stable as the primary teeth exfoliate and are replaced by permanent teeth, and as periodontal diseases cause recession that exposes root surfaces to caries as children age into adulthood and senescence. Similarly, genetic, environmental, behavioral, and even psychological factors strongly affect periodontal health, dental development, occlusion, the occurrence and effects of trauma, susceptibility to soft-tissue lesions, and every other aspect of a child's oral health.

CHILDREN'S ORAL HEALTH AND DENTAL CARE

While professional dental care is an essential component of oral health attainment and maintenance, its contribution is relatively modest compared with those of other oral health determinants. One effort to model the relative importance of various determinants of general health suggests that only about 10% of health status can be explained by access to health care. The remaining 90% can be attributed primarily to health behaviors and secondarily to environmental and hereditary factors.[2] Such conceptual modeling has been applied to children's oral health status to clarify the relative importance of various oral health determinants. The model shown in Figure 30-1 lists the "use of dental care" as only one of six "child-level" factors influencing oral health along with eight "family-level influences."[3] An analogous approach to explaining oral health disparities in children considers four levels of influence: (1) macro factors as wide ranging as the natural environment and dental care systems that are available to children; (2) community factors that include the social/cultural environment and availability of dental services; (3) interpersonal factors involving social stressors, integration, and support; and (4) individual factors of biology, health behaviors, care-seeking behaviors, and psychological considerations.[4]

Such models help clinicians understand the range of factors that they can, and cannot, manage or influence in seeking to help each child and each child's family attain and maintain excellent oral health. The technical content of clinical care is entirely within the scope of the clinical dental practitioner. However, key approaches to children's dental care, such as anticipatory guidance, primary prevention through modification

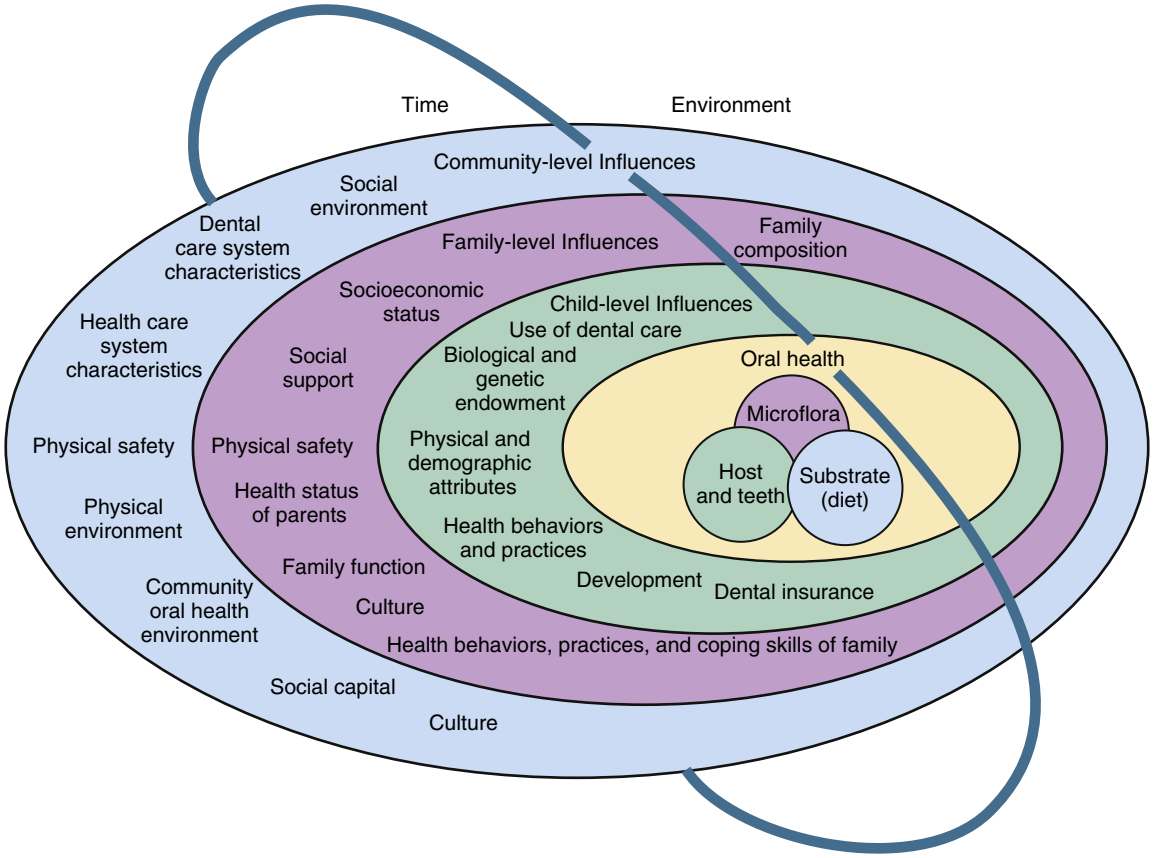

Figure 30-1 The promotion of children's oral health through family, community, and society-wide population-level interventions, including governmental interventions. (Reproduced with permission from *Pediatrics* 120:510-520, 2007.)

Dentlearn.ir

of health behaviors, disease suppression through individually tailored disease management protocols, and encouraging compliance with professional recommendations, move the clinician away from the biological sciences and their technical correlates and into the realms of social and behavioral sciences and their roles in health education and health promotion. These "soft science" disciplines have equal relevance for the oral health of individuals and populations. The dentist who seeks to improve children's oral health must therefore rely equally on clinical and public health interventions that are based on both hard and soft science.

DISEASE BURDEN AND CARIES CONSEQUENCES

The term *disease burden* implies the volume and distribution of disease within a population and its consequences in terms of morbidity and mortality. Dental caries remains highly prevalent worldwide. In the United States and other countries, it is the most prevalent chronic illness in childhood. It is disproportionately a disease of poverty, minority, and social disadvantage. In the United States, for example, the Centers for Disease Control and Prevention (CDC) reports profound disparities in both oral health status and dental care by income,[5] which correlates with age, income, race, and parental education.[6] In 2002 the U.S. Surgeon General's Report, *Oral Health in America*, predicted that epidemiologic and demographic trends would drive childhood caries experience higher and would lead to additional stress on the dental delivery system that attends to poor and low-income children.[7] Since that time, disease burden and inequities in its distribution have indeed increased among young children. More U.S. children were born each year since 2007 than at the peak of the baby boom, with further growth among minority, poor, and single-parent families, whose children also experience higher caries rates and lower treatment rates. While caries experience among older children has declined, caries experience among 2- to 5-year-olds is at a record level of 28%, suggesting additional future stress on dental care capacity. Possible explanations for the reported increasing disease burden among young children include greater access to care that skews epidemiologic surveys and nonclinical factors including demographic changes, lesser availability of fluoride exposure because of increased use of nonfluoridated bottled water, changes in parenting styles and practices, and temporary changes in dietary practices.

Not only is childhood caries the most common chronic disease of U.S. children,[8] but also it is consequential at many levels—from mild dysfunction to death. A morbidity/mortality pyramid constructed for ECC and its consequences includes a wide base representing the high prevalence of dysfunctions related to intermittent pain and infection. These include difficulties children encounter in daily functions of eating, sleeping, and attending to learning. With greater distraction from more intense dental pain, additional disruptions such as lost school time occur along with family-level disruptions in lost work as parents seek care for their affected child and increases in family stress resulting from the child's complaints and dysfunctions. In the aggregate, these family-level disruptions result in lost productivity and performance and take a societal toll that is of concern to public policymakers. More severe impairment from ECC further disrupts normal childhood functions, whereas the natural sequelae of cavities, including localized and generalized infections, constitute acute illness requiring intensive pharmacologic and surgical management. Such infections occasionally extend to adjacent and distant vital structures, leading to critical impairment, avoidable uses of the emergency room, hospitalization, and occasional death both from disease itself and from failed sedative management.

DENTAL CARE UTILIZATION AND GOVERNMENTAL IMPACTS

Dental service rates continue to be highest for children from higher-income families who enjoy higher levels of private dental insurance and ready availability of dental care. Children from poor and low-income U.S. families are insured under publicly funded programs (Medicaid and CHIP) that are not as widely accepted by private dentists as are commercial plans, but are widely accepted by "safety net" providers such as health centers, dental training programs, hospital dental services, and Medicaid-specific private pediatric dental management networks.[9] As a reflection of expanding dental coverage,[10] utilization of dental services by children, including poor and low-income children, has increased steadily since 2000 even as utilization by adults has steadily declined.[11]

Because government provides dental coverage through Medicaid and CHIP to roughly half of U.S. children at some time during the year, it maintains a strong interest in efficient and cost-effective pediatric dental care. In an effort to enhance the cost-effectiveness of U.S. health care, the federal Centers for Medicare and Medicaid Services seeks to achieve the triple aim of (1) improved population health outcomes, (2) lower cost, and (3) positive patient experience. Applied to pediatric oral health, this orientation supports expanded attention to prevention and disease control through medical management rather than surgical repair. Fundamental to this triple aim endeavor are the development and implementation of value-based rather than volume-based payment mechanisms. Such payment mechanisms are promoting novel reorganization of health care delivery in medicine that is anticipated to extend to dental care.[12]

Envisioned is a future U.S. oral health care delivery system in which "everyone has the ability to be free from active oral disease and to maintain good oral health."[13] In moving toward this vision, numerous changes in oral health care delivery and financing are anticipated that include the following: greater use of quality improvement and outcomes-based accountability measures to demonstrate value as measured by health outcomes per unit cost; expanded integration of dental care with medical, educational, and social service personnel and systems; and an increased emphasis on prevention and disease management targeted to subpopulations that experience higher rates of oral diseases, such as children from poor and low-income families. The death in 2007 of one such child, 12-year-old Deamonte Driver, near Washington,

Dentlearn.ir

DC, garnered national attention and led to extensive Congressional investigations of the oral health and dental care of socially disadvantaged children. Greater policymaker attention to public health strategies for improving children's oral health included attention to insurance coverage for dental services, workforce competency and capacity, safety-net adequacy, and promotion of dental prevention through community water fluoridation (CWF) and school-based sealant programs and through proposed public education campaigns. These federal efforts are mirrored in a host of state oral health planning efforts that are evidenced in the oral health plans that have been developed by most states.[14] These plans, like all governmental efforts, focus mainly on children and other vulnerable populations. Common public health interventions called for by these plans include all those mentioned above. Congressional interests as well call for greater surveillance, engagement of nondental health professionals in promoting early care for children's oral health, building partnerships and coalitions with others concerned with child health and welfare, developing case management and disease management systems in communities, and reducing tobacco initiation and prevalence.[15] Many of these proposed public-level interventions mirror American Academy of Pediatric Dentistry policies that call for engagement of medical practitioners in oral health promotion, early establishment of dental care in a "dental home," and maximal use of anticipatory guidance based on risk assessment.[16] Similarly, the Federal Maternal and Child Health Bureau, CDC, the National Institutes of Health, Head Start, the United States Department of Agriculture Food and Nutrition Service, the Department of Defense, and other federal agencies have long promoted population-level interventions that hold promise to improve children's oral health.

THE STRUCTURE OF DENTAL PUBLIC HEALTH AND ITS ROLE IN CHILDREN'S ORAL HEALTH

The public health infrastructure consists of the agencies, institutions, and people who are charged with the *assessment* of the status of conditions related to oral health, *policy development* to ensure science-based prioritization of resources, and the *assurance* of adequate systems for the provision of essential public health services. A wide range of entities, both governmental and nongovernmental, comprises the public health system, including educational institutions, local, state, territorial, and tribal health departments, federal departments and agencies, hospitals, health centers, laboratories, other health care providers, and dedicated voluntary organizations. Funding for public health comes from discretionary funding by government at all levels, grants from foundations, reimbursement from insurance companies, and a variety of patient and regulatory fees.[8]

At the federal level in the United States, the Department of Health and Human Services' oral health endeavors seek to improve the nation's oral health through coordinated activities across its many agencies. Among these activities relevant to children's oral health are Head Start's involvement in securing dental providers for young children, the National Institutes of Health's research support for ECC control through pharmacological and behavioral interventions, the Centers for Medicare and Medicaid Services' promotion of dental access through coverage, the Health Resources and Services Administration's support for training dentists, funding health centers, and supporting MCH program, the Indian Health Service's effort to prevent ECC through interdisciplinary programs, CDC support for state-level oral health programs and fluoridation surveillance programs, and the Office of Minority Health's promotion of cultural competency in oral health training.

The foundation for current public health roles was delineated by the Institute of Medicine in its landmark 1988 publication, *The Future of Public Health,* which identified public health's core functions as assessment, policy development, and assurance.[17] Assessment activities include surveillance of disease, health care structures, and health care capacities, as exemplified by the CDC's state-based Oral Health Surveillance System that monitors the population burden of oral disease, utilization of the oral health care delivery systems, and status of community water fluoridation. Policy development leverages public and legislative, regulatory, and programmatic capacities to improve the public's health, as exemplified by Congress' expansion of dental coverage for children and the American Academy of Pediatric Dentistry's promulgation of clinical policies and guidelines for care of children. Assurance programs focus on the capacity needed to address those needs discovered through assessment and to implement standards promulgated through policy development. Examples include programs to enhance competencies and capacities of the dental workforce and delivery systems. A second Institute of Medicine report, *The Future of Public Health in the 21st Century,* expands on these roles by identifying six activities inherent in public health practice that can be applied to advancing the oral health of children: policy making, financing, public health protection, collecting and disseminating information about health and health care delivery systems, capacity building for population health, and direct management of services.[18]

Dental Public Health, one of nine recognized dental specialties, and its certification body, the American Board of Dental Public Health, define dental public health as, "the science and art of preventing and controlling dental disease and promoting dental health through organized community efforts. It is that form of dental practice that serves the community as the patient rather than the individual. It is concerned with the dental education of the public, with applied dental research, and with the admin-

prevention and control of dental disease on a community basis." Board certification requires ten specified competencies beyond clinical dentistry needed to develop and administer programs that ensure the oral health of children and adults[19] (Box 30-1).

Dental public health personnel and programs have been guided since 1979 by Healthy People National Health objectives, with the goals of increasing quality and years of healthy life and eliminating health disparities.

Dentlearn.ir

Box 30-1

Dental Public Health Competencies

Dental public health professionals must be competent in the following skills:

- Plan oral health programs for populations
- Select interventions and strategies for the prevention and control of oral diseases and promotion of oral health
- Implement, manage, and develop resources for oral health programs for populations
- Incorporate ethical standards into oral health programs and activities
- Evaluate and monitor dental care delivery systems
- Design and understand the use of surveillance systems to monitor oral health
- Advocate for, implement, and evaluate public health policy legislation and regulations to protect and promote the public's oral health
- Critique and synthesize scientific literature
- Design and conduct population-based studies to answer oral and public health questions

(Adapted from Dental Public Health Competencies. Journal of Public Health Dentistry, [1998] 58: 121–122. doi: 10.1111/j.1752-7325.1998.tb02541.x)

Box 30-2

Healthy People 2020: Oral Health Objectives Targeting Children

OH-1 Reduce the proportion of children who have dental caries experience in their primary or permanent teeth

OH-2 Reduce the proportion of children and adolescents with untreated dental decay

OH-7 Increase the proportion of children, adolescents, and adults who used the oral health care system in the past year

OH-9 Increase the proportion of school-based health centers with an oral health component

OH-12 Increase the proportion of children and adolescents who have received dental sealants on their molar teeth

OH-13 Increase the proportion of the U.S. population served by community water systems with optimally fluoridated water

OH-15 (Developmental) Increase the number of States and the District of Columbia that have a system for recording infants and children with cleft lips and cleft palates to craniofacial anomaly rehabilitative teams

topicsobjectives2020 (accessed 25th Feb, 2014).

The objectives, which include a series of measures to guide oral health and dental care, are specific, science-based, measurable, time-defined, attainable, and relevant to the populations' health and well-being. They are reassessed and redefined every 10 years based on scientific advances and environmental changes[20] (Box 30-2).

COMMUNITY ORAL HEALTH PROGRAMS WITH IMPACT ON CHILDREN'S ORAL HEALTH

Healthy People Oral Health objectives have helped shape innovative programs aimed at improving access to care and the overall oral health of children. Among the most effective population-level interventions and programs relevant to children's oral health are community water fluoridation, school-affiliated sealant programs, and application of fluoride varnish by pediatricians, family physicians, and pediatric nurse practitioners.

Although there is some naturally occurring fluoride in the United States, adjusting the fluoride concentration to the optimal level for caries prevention is a highly effective method of preventing and controlling dental caries. Community water fluoridation began in 1942 and by 2012 reached 74.6% of the U.S. population being served by public water systems (over 210 million residents) and approaching the Healthy People 2020 objectives of 79.6%. To overcome challenges facing fluoridation, public health professionals and oral health advocates will need to enhance their promotion of fluoridation and build community-based partnerships to advocate at the local and state levels for necessary equipment, personnel training, and maintenance.

School-based and school-linked sealant programs address the most common permanent tooth caries occurrence in children by applying dental sealants to the occlusal surfaces of permanent molars. School-based services are delivered on-site at schools using portable equipment or a self-contained mobile dental clinic, whereas school-linked programs are affiliated with nearby public or private dental office sites. Most sealant programs are publicly funded and target populations of low-income children with limited access to comprehensive dental care. The utility of sealants as a public health measure is substantiated by their effectiveness in both preventing cavities and arresting caries progression in noncavitated teeth[21] and their appropriateness for school-affiliated delivery. For this reason, the percentage of third-grade children with a dental sealant on a permanent molar has been a key annually reported state-level oral health measure adopted by both the Maternal and Child Health Bureau and the Centers for Medicare and Medicaid Services.

Almost all state Medicaid and CHIP programs train and finance pediatric primary care medical providers to counsel families about caries prevention in the form of fluoride varnish applied to the primary teeth of young enrolled children and refer children to a dentist for ongoing oral health supervision.[22] These and other programs and services that advance the oral health of child populations were initiated by individuals joining together to make a difference. The adage "it takes a village to raise a child" could be rephrased to "it takes a coalition to promote oral health." Effective pediatric oral health coalitions involve many players, including health and healing professionals, child and health advocates, community organizations that serve children's and families' interests, policymakers of various types, and health care organizations. One growing manifestation of interprofessional collaboration around pediatric oral

health, both in the United States and internationally, is the movement promoting interprofessional education, which promotes collegiality, cooperation, and familiarity with the strengths that each profession can offer to the health care of individuals and communities. In affluent countries, sufficient resources exist to enable each profession to have its own curriculum, faculty, and licensing bodies, thus separating and polarizing the various professions. In the United States, the Institute of Medicine's report, *Improving Access to Oral Health Care for Vulnerable and Underserved Populations*, recommends developing a core set of oral health competencies for nondental health care professionals, integrating these competencies into accreditation requirements, and requiring graduates to demonstrate oral health competency.[23] Similarly, the Federal Health Resources and Services Administration promotes integration of oral health within primary medical care practice and has specified associated core clinical competencies.[24] The Society of Teachers of Family Medicine has developed the national "Smiles for Life" interdisciplinary oral health curriculum that is endorsed by sixteen professional societies. Specific to children, the Bright Futures consortium has developed a series of guidelines for use by all health care practitioners who treat children to promote children's oral health and dental care.[25]

Developing coalitions for action requires a skill set not typically taught in health professions schools. Recognizing this, Community Campus Partnerships for Health (CCPH), founded in 1997, builds coalitions between academic institutions and community agencies to promote health equity and social justice.[26] CCPH's collaborative intervention model is comprised of four components: guiding principles of partnership, quality processes, meaningful outcomes, and transformative experiences. Guiding principles of partnership that are useful in a variety of coalition settings are as follows:

1. The partnership forms to serve a specific purpose and may take on new goals over time.
2. The partnership agrees upon mission, values, goals, measurable outcomes, and processes for accountability.
3. The relationship among partners in the partnership is characterized by mutual trust, respect, genuineness, and commitment.
4. The partnership builds upon identified strengths and assets but also works to address needs and increase capacity of all partners.
5. The partnership balances power among partners and enables resources among partners to be shared.
6. Partners make clear and open communication an ongoing priority in the partnership by striving to understand each other's needs and self-interests, and by developing a common language.
7. Principles and processes for the partnership are established with the input and agreement of all partners, especially for decision making and conflict resolution.
8. There is feedback among all stakeholders in the partnership, with the goal of continuously improving the partnership and its outcomes.
9. Partners share the benefits of the partnership's accomplishments.
10. Partnerships can dissolve, and when they do, they need to plan a process for closure.
11. Partnerships consider the nature of the environment within which they exist as a principle of their design, evaluation, and sustainability.
12. The partnership values multiple kinds of knowledge and life experiences.

CCPH describes "quality processes" as honest, respectful, and ethical commitments to mutual goals and shared credit. "Meaningful outcomes" refers to valid goals that hold promise to improve the public's health, and "transformative experiences" includes heightened political consciousness regarding the problem needing attention, evolving policies to address and resolve the problem, community capacity building, and generating knowledge. Taken together, these principled activities seek to enhance social justice and improve community health.

CONCLUSIONS

Public health and pediatric dentistry share common concerns, goals, and interventions. Both recognize that children's oral health must be promoted and ensured through policies and programs that affect children within the contexts of their families, communities, and society. Effective collaborations between clinicians who care for the individual children and public health authorities who care for populations of children are essential if the oral disease burden among children is to be reduced and children's health and welfare are to be assured. A Workshop on Children and Oral Health, sponsored by the U.S. Surgeon General, developed a set of recommendations for improving children's oral health.[27] Distilled from expert perspectives offered by many different disciplines, they are as follows:

1. Start early in children's lives and involve all who come in contact with young children and their families.
2. Ensure the availability of the needed competencies of all who work to improve children's oral health.
3. Be accountable for children's oral health outcomes and for resources committed to oral health programs to ensure that efforts are most effective and worthwhile.
4. Take public action through health education, public policy formulation, removal of barriers to oral health and dental care, and enhancement of the social environment to promote oral health.
5. Maximize the utility of science, both biological and behavioral science, to ensure efficiency and effectiveness.
6. Fix public programs when they fail to meet their objectives by ensuring sufficient resources, management, and accountability.
7. Grow an adequate workforce of health professionals, child care workers, nutritionists, behaviorists, and others who can promote children's oral health and well-being.
8. Empower families and enhance their capabilities and opportunities to ensure their children's oral health.

These eight approaches (Fig. 30-2) are synergistic and cross clinical and public health domains. Effective dentistry

Dentlearn.ir

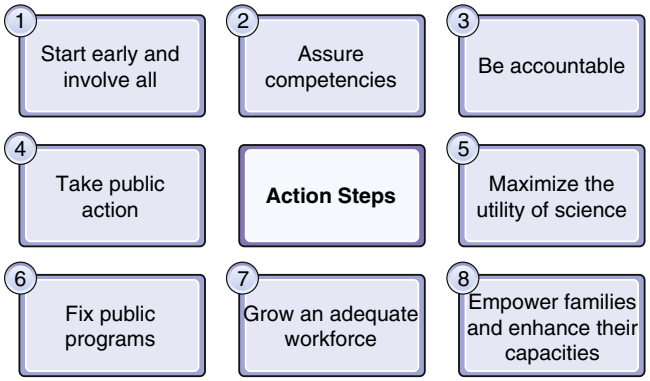

Figure 30-2 Healthy People objectives are established every decade by the U.S. Department of Health and Human Services to communicate science-based high-priority health issues. Benchmarks are established to enable monitoring progress toward goals over time. Oral Health Objectives are one of the 42 topic areas. (Data from Edelstein BL: Forward to the background papers from the U.S. Surgeon General's Workshop on Children and Oral Health. *Amb Pediatr* 2(2):139-140, 2002.)

for children requires that all concerned with children's

dations. The resulting improvement in children's oral health will secure a future in which oral health disparities are eradicated, oral health is ensured, and oral function is guaranteed for all children (see Box 30-1).

REFERENCES

1. Thomson WM, et al.: Socioeconomic inequalities in oral health in childhood and adulthood in a birth cohort, *Community Dent Oral Epidemiol* 32:345–353, 2004.
2. McGinnnis JM, Williams-Russo P, Knickman JR: The case for more active policy attention to health promotion, *Health Affairs* 21(2):78, 2002.
3. Fisher-Owens SA, et al.: Influences on children's oral health: a conceptual model, *Pediatrics* 120:e510–e520, 2007.
4. Patrick DL, et al.: Reducing oral health disparities: a focus on social and cultural determinants, *BMC Oral Health* 6(Suppl 1):S4–S21, 2006.
5. Dye BA, Li X, Thorton-Evans G: Oral health disparities as determined by selected healthy people 2020 oral health objectives for the United States, 2009-2010, *NCHS Data Brief* 104:1–8, 2012.
6. Edelstein BL, Chinn CH: Update on disparities in oral health and access to dental care for America's children, *Acad Pediatr* 9:415–419, 2009.
7. Oral Health in America: *Report of the U.S. Surgeon General*, 2002.
8. Casamassimo PS, et al.: Beyond the dmft: the human and economic costs of early childhood caries, *J Am Dent Assoc* 140:650–657, 2009.
9. Edelstein B: Dental visits for Medicaid children: analysis and policy recommendations, *Children's Dental Health Project*, June 2012.
10. Mandal M, et al.: Changes in state policies related to oral health in the United States, 2002-2009, *J Public Health Dent* 74(4):266–275, 2014.
11. Vujicic M, Nasseh K: A decade in dental care utilization among adults and children (2001-2010), *Health Serv Res* 49:460–480, 2014.
12. Edelstein BL: The roles of federal legislation and evolving health care systems in promoting medical-dental collaboration, *J Calif Dent Assoc* 42(1):19–23, 2014.
13. National Oral Health Quality Improvement Committee: Vision for the US Oral Health System for 2023. Dentaquest Insti-

    org/sites/default/files/DQI_QI_OralHealthSystemVision Statement.pdf
14. Children's Dental Health Project: *State Oral Health Plan Comparison Tool*, Washington, DC, 2014, Children's Dental Health

    -state-oral-health-plan-comparison-tool.
15. Edelstein BL: Federal supports for state oral health plans, *J Public Health Dent* 72:S54–S59, 2012.
16. American Academy of Pediatric Dentistry: 2013-14 Definitions, Oral Health Policies, and Clinical Guidelines. Avail-

17. Institute of Medicine (IOM): *The future of public health*, Washington, DC, The National Academy of Sciences.
18. Institute of Medicine (IOM): *The future of public health in the 21st century*, Washington, DC, 2002, The National Academy of Sciences.
19. American Dental Association, Commission on Dental Accreditation and Licensure: Definitions of recognized dental

    .healthypeoplegov/hp2020.
21. Beauchamp J, et al.: Evidence-based clinical recommendations for the use of pit and fissure sealants: a report of the American Dental Association Council on Scientific Affairs, *J Am Dent Assoc* 139(3):257–268, 2008.
22. American Academy of Pediatrics: *State medicaid payment for caries prevention by non-dental professionals*, June 2013. http://

    pdf.
23. IOM (Institute of Medicine) and NRC (National Research Council): *Improving access to oral health care for vulnerable and underserved populations*, Washington, DC, 2011, The National Academies Press.
24. Health Resources and Services Administration: *Integration of oral health and primary care practice*, US Department of Health

    publichealth/clinical/oralhealth/rimarycare/integration oforalhealth.pdf.
25. Casamassimo P, Holt K, editors: *Bright futures in practice: pocket guide*, Washington, DC, 2004, National Maternal and Child Oral Health Resource Center.
26. CCPH Board of Directors: *Position statement on authentic partnerships*. Community-Campus Partnerships for Health, 2013.

    Conference/ConferenceChildrenOralHealth.

CHAPTER 31

Practice Management

▲ Julie Weir

For additional resources, please visit the evolve website.

CHAPTER OUTLINE

THE FIVE PARTS OF A SUCCESSFUL DENTAL PRACTICE
DOCTOR'S VISION FOR THE PRACTICE
MISSION STATEMENTS: PRACTICE AND TEAM
FISCAL MANAGEMENT
Business Plan
Monitor Goal Numbers
Monitoring Schedule
Setting a Budget
Reports That Should be Monitored Regularly
Fees
Accounts Payable
Retirement Planning
TEAM DYNAMICS
Doctor Leadership
Employee Management
SYSTEMS
New-Patient Appointment
Effective Scheduling
Surgical Referrals
Managing Collections
Managing Insurance
Treatment Tracking

Dental Office Technology
Compliance
Clinical Organization
Inventory Control

It is important that practitioners have a thorough understanding of what it takes to operate a successful private pediatric dental practice. In addition to excellent clinical dentistry and behavior management skills, strong leadership, business, and practice management knowledge are also necessary. Now more than ever, a dental practice must run like a business because of decreasing profit margins due to increased competition and lower managed care reimbursement.

An owner-doctor should feel confident in handling the following challenges:

- Be able to handle multiple business issues while also spending most of the business hours "on the line" making the product. A dentist must also be the Chief Executive Officer (CEO), Chief Financial Officer (CFO), Chief Operating Officer (COO), Chief Information Officer (CIO), and run the Human Resources department.
- Engage, motivate, and lead the staff to buy into the doctor's vision and help the doctor create the type of practice he/she desires.
- Create loyal relationships with parents and children so they stay in the practice long-term and accept and complete the treatment plans that are presented.
- Successfully go out into the community and meet other health care providers, creating loyal referring relationships.
- Address poor job performance issues in a timely manner directly with the staff member to keep practice systems running efficiently and smoothly.
- Make tough decisions that are for the greater good of the team and practice but may not be popular with all staff members.

Limited leadership and business skills are taught in dental school and the average dental student is unable to assimilate this information without hands-on application, which is not usually available in school. Therefore the dental practitioner must acquire these skills through books, continuing education programs, trade journals, newsletters, and good advisors: accounting, legal, marketing, and practice management. The wise doctor who desires financial success will start educating him/herself about leadership, business principles, and practice management systems early on and surround him/herself with experts who can help shorten the learning curve and increase profits more quickly. It is beyond the scope of this chapter to give detailed steps for each practice management area; however, it aims to create an awareness of what should be in place in a practice to establish a framework for success.

THE FIVE PARTS OF A SUCCESSFUL DENTAL PRACTICE

It can be overwhelming to understand what must be in place to create a successful practice. Think of it as building a structure with the doctor as the architect. First, the architect has to create a set of plans, so others will know what the structure will look like and how to build it. The doctor's Vision and the practice's Mission Statements are the "plan" for the practice.

All structures need to be built on a strong foundation. The foundation of a dental practice rests on three strong pillars: fiscal management, team dynamics, and systems. If a doctor successfully builds these five practice parts and consistently works to keep them strong, the practice will take form and be prosperous (Fig. 31-1). Jim Collins, in his book

Dentlearn.ir



Figure 31-1 Building a successful dental practice: the five parts that go together. (©Julie Weir & Associates Management Consulting.)

Good to Great, wrote, "The real path to greatness, it turns out, requires simplicity and diligence. It requires clarity, not instant illumination. It demands each of us to focus on what is vital—and to eliminate all of the extraneous distractions."[1]

PART 1: DOCTOR'S VISION FOR THE PRACTICE

A doctor should define what is in his/her head and heart about the practice to be created and then share that vision with team members. A vision cannot be realized until it is shared. When all team members are working toward a common vision and goal, the probability of success greatly increases. The team's energy becomes synergistic.

PART 2: MISSION STATEMENTS: PRACTICE AND TEAM

Each day, team members serve two customers: the parent/patient and each other, including the doctor. Therefore it is necessary for the team to create two Mission Statements, one for each customer they serve:

1. Patient Mission Statement (for serving patients)
2. Team Mission Statement (for serving each other)

The two Mission Statements express what the team is working to achieve and serve as leadership accountability tools. Each mission statement sets the standard of performance for team members.

PART 3: FISCAL MANAGEMENT

Fiscal management concerns the way in which the finances of a business are managed and includes goal setting, accounts receivable (money owed to the practice), accounts payable (money owed by the practice), budgeting, fee structure, and monitoring methods.

BUSINESS PLAN

A doctor should have a strong understanding of the business numbers in his/her practice. Every practice should have an Annual Business Plan with goals that meet the practice's and doctor's financial needs. Monitoring these goals on a daily and monthly basis will show if any goal number is not being met. This indicates exactly where a doctor and team need to focus their actions for the practice to be financially successful. These goal numbers should also be used as a benchmark of performance and accountability for the employee who is in charge of

the system that produces the numbers. Calculating the practice break-even point, goals, and budget can be outsourced if desired.

A Business Plan should identify the following numbers:

- **Break-Even Point (BEP) =** total dollars needed to meet overhead expenses, capital improvements, new equipment, raises, inflation adjustment, loan payments, doctor salary, and retirement contributions. Typically, practitioners will work with their accountant or practice management consultant to calculate the BEP.
- **Monthly Collection Goal =** BEP total ÷ 12 months
- **Collection Ratio =** previous year's collection ÷ previous year's production = collection ratio %
- **Monthly Production Goal =** monthly collection goal ÷ practice collection ratio
- **Producer Work Days/Month Goal** defines the average number of "restorative," "recare," "hospital," and "ortho" work days per month. There can be four different areas of productivity in pediatric dentistry (restorative, recare, ortho, and hospital or in-office general anesthesia [GA]) that should be monitored separately.
  - Procedures for one "doctor" work day are typically scheduled in two columns.
  - Procedures for one "recare" work day are scheduled in one column. A good benchmark is that for every pediatric "doctor" work day, there should be at least two "recare" work days scheduled (two columns). At least 13 recare appointments are completed per day in each column.
  - If a doctor who sees patients 4 days per week × 4 weeks per month (i.e., 16 doctor days per month) schedules two columns of recare every day, then there would be 32 recare work days per month. If a doctor does orthodontics, hospital, and/or GA dentistry, then the average number of orthodontic, hospital, and/or GA work days per month should also be determined.
- **Daily Production Goals for Each Producer =** the amount of production that the doctor should complete each day in restorative work and the amount of production that the hygienist/coronal polishing assistant should complete in each recare column.
  - The daily production by each producer can be monitored separately by the use of different producer codes.
  - The producer's (doctor, recare, orthodontics, hospital, and/or GA) work days per month multiplied by the producer's daily production goal must equal the Monthly Production Goal.
  - Practice recare should continue to grow until it becomes 50% to 75% of the total practice production, depending upon the decay level of the patient population.
  - All procedures performed on the recare patient or in the recare chairs should be included in the recare production total to accurately reflect the level of productivity generated from recare patients: recare examination, prophylaxis, radiographs, fluoride treatments, and sealants.
- **Daily Scheduling Goals for Each Producer =** the producer's daily production goal ÷ 95%.

Example of calculations for practice goals:

- For illustration purposes, the example in Box 31-1 BEP of $1,147,776.
- Notice that in this example, when the BEP is calculated, the practice's new desired BEP requires a 17% increase over the previous year's total collections. [($1,147,776 – $975,000) ÷ $975,000 = 17%].
- At this point the doctor must either take action to achieve this 17% growth through marketing for more new patients, if there are unfilled appointments in the schedule, or increase efficiency with the current schedule, facility, and staff to produce the 17% increase in collections.
- If the doctor is unable to meet the 17% increase in collections, then adjustments must be made to the practice's financial needs by decreasing expenses or income expectations.

Box 31-1

Goals

Annual Break-Even Point $1,147,776 ÷ 12 = Monthly Collection Goal $95,648

Previous Year's Annual Collection $975,000 ÷ Previous Year's Annual Production $994,898 = 98% Collection Ratio

Monthly Collection Goal $95,648 ÷ Practice Collection Ratio 98% = Monthly Production Goal $97,600

Average Restorative Work Days/Month 16 × Daily Restorative Production Goal $2700 = $43,200 Restorative Monthly Production Goal

Average Recare Work Days/Month 32 × Daily Recare Production Goal $1550 = $49,600 Recare Monthly Production Goal

Average Hospital Work Days/Month 1 × Daily Hospital Production Goal $5000 = $5000 Hospital Monthly Production Goal

The three Monthly Producer Production Goals above should equal the Total Monthly Production Goal $97,600

MONITOR GOAL NUMBERS

Monitoring practice goal numbers is a system that should be a part of every practice. The universal law of business is that people pay attention to what gets measured. The purpose of monitoring is to *measure and improve*. Some goal numbers are monitored on a daily basis so that immediate actions can be taken for improvement. Other numbers are not as time-sensitive and are reviewed on a monthly basis. Numerous goal-monitoring tools are available in the marketplace, or a doctor can track goals in an Excel spreadsheet.

Meeting the practice goals month to month can vary depending on the time of the year, so monthly totals should also be tracked on a year-to-date basis. Goal numbers should

Dentlearn.ir

be discussed monthly as a team, and if any goal is not met, the team can decide what they can do differently to help the practice meet that particular goal number. A team can easily increase production by 10% when using a goal-monitoring system because of a better team focus on the end result.

MONITORING SCHEDULE

There are various monitoring tools available in the marketplace in addition to dental software reports that a team can use to monitor important practice numbers and statistics.

Daily

- Production vs. Goal for each producer
  - Average restorative production per day—$2500 to $6500 Usual and Customary Rate (UCR) fee, depending on the fee level and the use of expanded-function assistants
  - Average recare production per column—$1800 to $2200 UCR fee, depending on the fee level
- Month-to-date production vs. goal for each producer and the total practice
- Show rate of patients: number of patients who appeared for their appointment/number of patients scheduled
- Treatment acceptance ratio: case acceptance/case presentations = 80% to 90%

Monthly

- Total practice production
- Total producer production (doctor, recare, hospital, orthodontics)
- Average daily producer production
- Producer work days (doctor, recare, hospital, orthodontics)
- Total practice collections
- Collection ratio: 96% to 98% of collectable fees, depending upon how much charitable dentistry is performed
- Show rate of patients: 95% show rate is preferred
- Accounts receivable total: 1:1 ratio of total accounts receivable : monthly production
- Total of accounts receivable in 61+ days: not more than 18% to 25%
- Collection at time of service: 35% to 45%
- Adjustments to production: 2% to 4%
- Adjustments to collection: insurance/patient refunds and insufficient funds checks = less than 1%
- New patients: from 55 to 65+ new patients/month are needed to maintain and grow an average one-doctor pediatric dental practice. Count only Current Dental Terminology (CDT) code # DO150 (Comprehensive Oral Examination).
- Percent of patients in recare: goal is 75%

Quarterly

- Overhead expenses from the Profit and Loss Statement against budget amounts

Yearly

Do a comparative analysis of all goal numbers to see if there is a decrease or increase and if the practice is growing correctly. A dental practice should grow 2% to 4% *above* the national inflation rate each year to stay even, and higher than this to experience true practice growth. The costs of dental supplies and services can be greater than those for regular consumer products.

SETTING A BUDGET

There are two ways to increase profitability in any practice: earn more or spend less. Control of expenses (savings) is one of the most underused yet valuable tools to increase profitability. Unspent dollars can go directly to the bottom line in the form of profit. The most effective way to save is to control spending through budgeting.

- Create an Annual Overhead Budget by taking the practice BEP amount and multiplying it by the following expense category percentages. Then, divide that number by 12 to get the monthly budget amount for each category. Budgets should be tracked at the end of each fiscal quarter to see if expenses are in line and to make adjustments in a timely manner.
  - Miscellaneous, 4% to 6%: advertising, business insurance, property taxes, misc.
  - Office, 3%: bank charges, credit card fees, billing and collections, office supplies, postage, printing
  - Professional development, 1%: dues and subscriptions, staff continuing education
  - Dental supplies: 4% to 6% (if practice has limited reduced-fee patients), 7% to 10% (if practice has a high volume of reduced-fee patients)
  - Lab, .25% (will be higher if there is a large volume of ortho)
  - Facilities, 8% to 10%: rent, repairs, janitorial, laundry, telephone, utilities
  - Professional advisors, 2% to 4%: legal, consulting, accounting, payroll service
  - Labor, 18% to 24%
  - Staff benefits, 2% to 3%
  - Staff payroll tax, 2%
  - Owner benefits, 1% to 3%: payroll tax, auto, continuing education, travel, dining, retirement, insurance
  - Owner income, 30% to 48%
  - Equipment, depreciation, and debt service, 3% to 10%
  - Associate doctor wages, 5% to 10%

REPORTS THAT SHOULD BE MONITORED REGULARLY

Using the reports in the dental software can help the practice operate more efficiently. Following are some of the major reports your office manager (OM)/front desk coordinator should be completing and the doctor should be reviewing.

- **Day Sheet:** Printed daily and reviewed to make sure that all services are included and have been billed correctly to the insurance company. Practice revenue is lost when additional procedures completed on the patient are not communicated to the front desk staff before the patient checks out.

Dentlearn.ir

- **Daily Deposit Report:** Your bank account should reflect the same amounts on the daily deposit slip. Often, with electronic funds transfers, it is hard to track whether the money that was deposited into your bank account was entered into patient accounts in your software. Make sure each day that your bank account deposits match the amounts on your previous daily deposit slip. That means that all EFT payments, credit card charges, checks, cash, and CareCredit payments need to be entered into the software the day they are received. The doctor should go online, log on to the bank account in the morning, and let the staff know what EFT payments arrived and if the credit card amounts that were settled the evening before match.
- **Unpaid Claims Report:** The Unpaid Claims report should be completed weekly to ensure that claims are paid in a timely manner or resubmitted for payment with corrected information, if necessary. Some offices lose thousands of dollars each year on claims that the insurance carrier denied because they were not submitted within the time limit for payment.
- **Procedures Not Attached to Insurance Claims:** This report will show all procedures that were never submitted to insurance for payment. This report should be reviewed at the end of each day. These procedures should be submitted for payment immediately.
- **Secondary Insurance Report:** Many offices also lose money by not submitting the secondary claims. Even if the primary insurance company paid 100%, you still should submit to the secondary insurance. In some cases where the primary is a PPO and the secondary is a traditional indemnity, there is a possibility for additional payment on those services up to your UCR fees.
- **Unscheduled Treatment Plans, Broken Appointments, and Past Due Recare Reports:** Don't let your patients get lost! This is untapped potential revenue to quickly fill your schedule and create production. These reports should be printed monthly, and your OM should assign a team member who will be accountable for working these reports and tracking the results.
- **New-Patient Referral Report:** Review monthly with the marketing team and decide on appropriate marketing actions to take place in the next month.

FEES

Fees should be reviewed annually and, if necessary, raised at least by the inflation rate to generate an adequate margin of profit. Most patients expect, accept, and may not even notice small adjustments in fees. Problems arise when a dentist who is reluctant to increase fees does not do so for several years and then must implement a significant increase. A hiatus in raising fees while costs of operations continue to increase means lower profits. If this pattern is allowed to continue, a practice can have significant financial difficulties that force a fee increase of 20% to 30% or more in one year. Because most patients will notice and complain about such a large increase, it is better to raise fees gradually year to year to adjust for inflation and to cover increases in expenditures.

Fee increases should not be announced to patients; an increase simply becomes effective on a certain date. The dentist and staff who take pride in the quality of their care and services will seldom feel defensive about fee increases, and that feeling will be imparted to patients and parents. Most people are willing to pay for care that they value and services that exceed the norm. When customer service expectations are met and exceeded, fees are never an issue. When expectations fall short, fees are always an issue. To support a well-deserved fee, excellent customer service is paramount.

Staff members should be informed why regular fee increases are necessary. With no concept of overhead costs, the staff may assume that all fee increases go directly into the dentist's pocket, which is not true. Explain that the fee increases are there to keep up with the increasing costs of supplies, services, and updating equipment.

The following factors must be considered when fees are set:

- Professional fees in the area, although collusion with other dental practices is illegal
- Level of desired fees for the practice (high, mid-, or low range) and the type of patient the doctor desires to treat
- Cost of operations
- Profit after debt service

Fee increases or fee cuts have significant impact on practice income and profit, as demonstrated in Figures 31-2, 31-3, and 31-4.

ACCOUNTS PAYABLE

Accounts payable is the total amount of money the practice owes for goods and services received. Bills should be paid no more frequently than twice a month after statements are checked against invoices.

An *invoice* is an itemized list of goods received with each supply shipment, and a *statement* is a summary of all invoices for that month. Paying accounts regularly from statements rather than from invoices can help avoid mistakes, such as paying the same bill twice, and ensure that the practice maintains an excellent credit rating.

Utilize a well-organized Chart of Accounts in an accounting software program to track expense categories and an overhead budget.

Profit Margin	5% Fee Increase	10% Fee Increase	15% Fee Increase	20% Fee Increase
20%	25%	50%	75%	100%
25%	20%	40%	60%	80%
30%	16.6%	33%	50%	66.6%
35%	14.3%	28.6%	42.9%	57.2%
40%	12.5%	25%	37.5%	50%
45%	11.1%	22.2%	33.3%	44.4%
50%	10%	20%	30%	40%

Figure 31-2 Increase in net income related to fee increase.

Dentlearn.ir

Profit Margin	Fee Increase	% Loss of Production
25%	5%	17%
25%	10%	29%
25%	20%	45%
30%	5%	14%
30%	10%	25%
30%	20%	40%
35%	5%	13%
35%	10%	22%
35%	20%	36%
40%	5%	11%
40%	10%	20%
40%	20%	33%

Figure 31-3 Percent loss of production related to fee increase to maintain profitability.

Profit Margin	Fee Cut	% Production Increase Required
25%	10%	67%
25%	20%	400%
25%	30%	not realistic
30%	10%	50%
30%	20%	200%
30%	30%	not realistic
35%	10%	40%
35%	20%	133%
35%	30%	600%
40%	10%	33%
40%	20%	100%
40%	30%	300%

Figure 31-4 Fee decrease related to increase in production to maintain profitability.

RETIREMENT PLANNING

The time for a dentist to begin planning retirement is the day he/she begins to practice because the only financial benefits he/she can count on in retirement will be what he/she has saved and Social Security. Monies from a practice sale can be unpredictable depending on the timing of the sale and the state of the economy.

A financial advisor can help the dentist choose from among many plans with various tax benefits, such as an individual retirement account (IRA), a 401K, pension plan, pension and/or profit-sharing plan, and so on. The earlier one begins, the greater the accumulation of wealth at retirement, due in large measure to compound interest. Compound interest is the concept of adding accumulated interest to the principal.[2] The rule of 72, a simple way of illustrating the growth potential of compound interest, is a useful tool for calculating an approximation of the time needed to retain an investment before it doubles in value. You can find an example of the rule online.[3]

PART 4: TEAM DYNAMICS

DOCTOR LEADERSHIP

Many doctors do not understand the power their leadership actions have on their level of stress, job satisfaction, and practice profits. *At whatever point a doctor stops being a leader by not performing important leadership actions, he/she will lower his/her profitability potential*. Anyone can be a great leader, regardless of personality type, if he/she consistently and successfully carries out the following leadership actions:

- Define Practice Vision
- Provide Strong Fiscal Management
- Monitor Practice Goals and Budget

Assume the Leadership Role

All teams need a leader or they will not know where to go or what to do. A doctor can delegate some leadership responsibilities but cannot abdicate the leadership role. In the book *The Leadership Challenge* by Kouzes & Posner,[4] leadership is defined as:

- A process ordinary people use to bring forth the best from themselves and others
- A set of distinct practices that leaders exhibit when they're doing their best
- An understandable and a universal process

The authors also go on to say that success depends on your ability to lead people:

- To set and communicate a clear direction,
- To motivate,
- To provide coaching and feedback so that they will succeed in their goals

A strong commitment to good leadership is an essential ingredient for practice success.

Constantly Evaluate if Things Can Be Done Better. Do Not Settle for the *Status Quo*

Strive to improve efficiency, systems, and staff. There will always be new and better technology and systems.

Have Excellent Advisors, Mentors, and a Support System

- Advisors include an accountant, attorney, banker, insurance advisor, practice management consultant, computer/technology expert, and investment counselor/retirement planner.
- Good mentors are invaluable and usually free. Find successful professionals who would be willing to share their knowledge. Create a support system with colleagues with whom you can meet regularly for lunch or call for advice.

has a variety of publications pertinent to practice management issues. Of particular interest is *Frequently Asked Legal Questions,* available through ADA Member Services.[5]

Lead by Example and Create a Healthy Business Culture

A doctor is in control of the "business culture" or environment in which he/she and the team will work on a daily basis. It can be a healthy environment that is fun and productive or a dysfunctional environment that is stressful and less productive. A doctor's behavior sets the standard and defines this culture; therefore he/she must hold him/herself to high standards and never behave in ways that would not be tolerated from an employee.

Dentlearn.ir

Healthy Business Culture
- Open and honest communication; team members give feedback to each other.
- Expressing a different opinion is not feared. A discussion between parties can take place and a solution or compromise can be reached.
- Employees are not afraid to take risks and try new things. They are not fearful of severe admonition, but are comfortable in taking ownership of the mistake and learning from it.
- Employees praise and support each other.
- Gossip is not tolerated.
- Problem employees are held accountable in a timely manner to improve their behavior, or they are removed.
- Problem patients/parents are removed from the practice.
  - Each state and/or Dental Board has certain laws that govern the dismissal and/or transfer of a patient, including charging for radiographs and records. The dentist must weigh the advantages and disadvantages of his or her actions and responses in each individual case and seek legal advice if necessary. Everything should be documented, because any notes written into a patient's chart could, in case of a lawsuit, be read aloud in court. A dentist or staff member should never argue with or belittle a patient or parent. In addition to concerns regarding the doctor/patient relationship, such actions can lead to negative public relations, may well cause the patient to leave the practice, or could trigger a lawsuit.

Be "People Smart": Understand People's Different Behavioral Traits and Strengths

Managing staff effectively and with low stress is one of the biggest challenges doctors face.

Being "People Smart" is a powerful leadership tool that helps a doctor be a better leader, manager, and employer by understanding:
- That people possess different mixtures of behavioral traits and how this affects their job performance
- A person's strengths and limitations to be able to hire and coach correctly
- Each person's motivators that will empower him/her to be more productive and experience greater job satisfaction.

After extensive research, Professional DynaMetric Pro-

top-of-the-line behavioral assessment solutions for businesses, has defined the four behavior traits as *Dominance* (take charge), *Extroversion* (people), *Pace* (patience), and *Conformity* (systems). Each trait has high and low behavioral intensities. One of these four high traits will be a person's strongest and will dictate 50% to 70% of his/her natural behavior and responses. It is almost like people come from four different "planets," each "planet" with its own natural way of behaving and communicating.

After learning about the four "planets" and work style approaches, a doctor has a better insight as to why employees function the way they do.

High Dominance (Take Charge Trait)
- Can take charge, likes to accomplish goals, and is comfortable with risks
- Communication style is short and to the point, can often be interpreted as blunt

Low Dominance
- Does not want to be in charge, looks for strong leadership
- Agreeable

High Extroversion (People Trait)
- Outgoing, enthusiastic, motivating, prefers to interact with people, and makes others feel welcomed and comfortable
- Communication style is persuasive and enjoys talking

Low Extroversion
- Does not mind working alone
- Quiet with people he/she does not know

High Pace (Patience Trait)
- Focuses on work output. Prefers routines and working on one thing at a time, does not like changes
- Communication style is warm and friendly and is careful to avoid confrontation

Low Pace
- Likes change and fast pace
- Can easily multi-task

High Conformity (Systems Trait)
- Prefers structured and standard operating procedures, concerned with accuracy
- Communication style is guarded, cautious, and exacting

Low Conformity
- Can see the big picture and does not need a pre-set structure in which to work
- Independent, wants to live by his/her own rules

Work-Style Approaches

There are three ways people approach getting a job done. Many times doctors do not understand why their employees wait to be told what to do. This can easily be explained by understanding the three work style approaches. It is wise to hire a person with a Thrust work style for the leadership positions in your office.

Thrust
- An inner drive to push quickly to get the job done
- Initiates and completes a project or task

Ste-Nacity
- A coined word of Professional DynaMetric Programs (PDP), from steadfast and tenacious
- An inner drive that gets the job done in a steady, persistent manner
- Initiates and completes a project or task

Allegiance
- Looks to an outer-directed source (supervisor) to be told what needs to be done
- Supports completing a project or task, rarely initiates

Hold Employees Accountable

Many doctors find it difficult to talk to an employee about poor job performance issues, such as skill level, attitude, tardiness, absenteeism, and/or teamwork. Most doctors either avoid this necessary leadership skill or do it poorly

Dentlearn.ir

because it feels confrontational, and they simply do not have a format to follow, thus missing a valuable coaching opportunity with their employees.

When a doctor does not hold employees accountable for proper job performance and attitudes, it becomes demoralizing, and the good workers will lose respect for the doctor. Team morale and productivity drop, and eventually the good workers get frustrated and leave for other jobs. Eventually, this causes the team to "dumb down" to the manipulative, low-functioning employees with bad attitudes and poor work ethics, which makes coming to work each day a nightmare of endless problems. However, when employees are promptly held accountable for proper job performance, the doctor's reward will be an enjoyable, high-functioning team that supports the practice vision, and everyone looks forward to coming to work each day.

Motivate with Praise, Appreciation, and Recognition

- Encourage employee development and growth. Know what each employee's goals and motivators are and try to create them in the workplace.
- Make employees feel that they are part of the team and that they matter and make a positive difference.
- Give recognition and a praise/strength compliment for a job well done at least once a week to each employee.

Hold Regular Meetings

Clear and consistent communication is the only tool a team has to improve how its members work together. Therefore teams should meet regularly to discuss the status of the practice—what is working, what is not working, and how they are going to fix it—resulting in increased productivity and reduced stress.

Meetings should take place in the office and not in a restaurant over lunch. It is more difficult to discuss confidential practice information (production and collection status) and/or address staff issues in a public atmosphere.

Types of Meetings to Hold

- Morning meetings
  - Set the tone and level of productivity for the day.
  - Help the team focus on how to get through the day's schedule with reduced stress and increased production by exchanging important team and patient information relating to the schedule (Fig. 31-5).
- Monthly team meetings
  - Discuss work patterns between departments and team members.

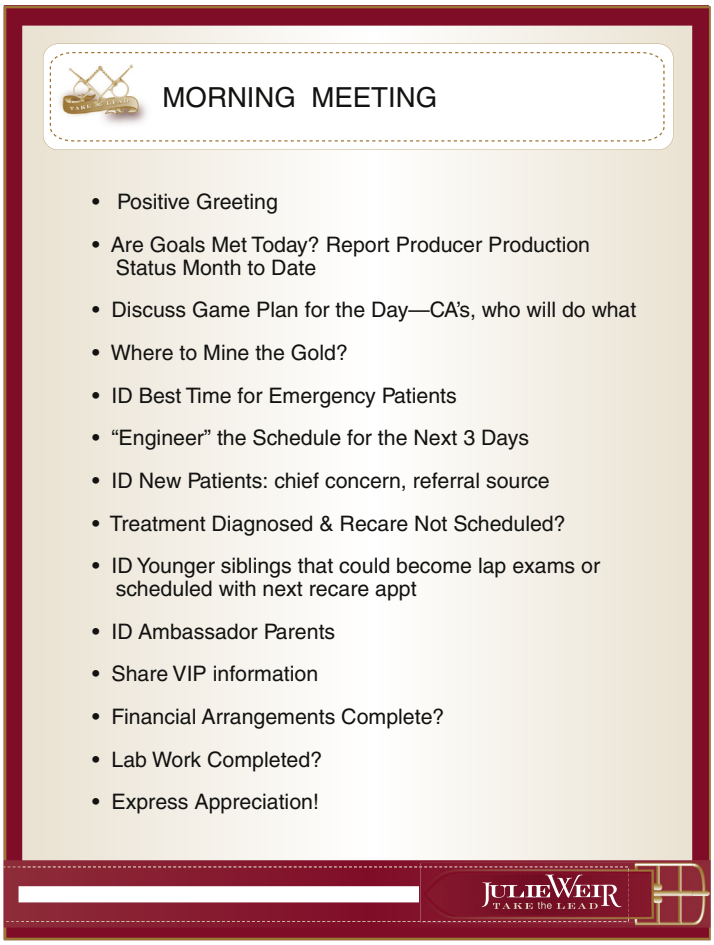

Figure 31-5 Morning meeting agenda. (©Julie Weir & Associates Management Consulting.)

Dentlearn.ir

  - Practice monitors are discussed to see if goals are met and problem-solve what new actions will be taken if they are not.
  - Educate team members on any new information pertaining to the practice specifically or pediatric dentistry generally.
- Quarterly department meetings
  - There can be up to four departments in a pediatric dental office: front desk, restorative assistants, recare, and management (if there is an OM and/or more than one doctor). Each department meets quarterly with the doctor and OM to discuss and problem-solve department-specific issues, job duties, and system changes.
- Monthly marketing meeting
  - To evaluate marketing efforts and decide on new actions.

Celebrate Success

It is important to recognize the team's efforts and celebrate achieving milestones and goals. Celebration activities can be a dinner or lunch or a surprise shopping afternoon (doctor gives everyone a cash amount that he/she must spend on him/herself or return the unspent money at the end of the afternoon).

EMPLOYEE MANAGEMENT

Personnel Needs

A personable, professional staff is vitally important for practice success. The dentist must invest time, effort, and money to hire, train, and retain quality individuals who can be developed into a high-performing team. A team of committed professionals, working together, focused on the patients and the practice, can make the difference between an excellent and a mediocre practice. Therefore staff development is a sound investment in any practice.

Before becoming an employer, the dentist must be aware of state and federal regulations concerning hiring, employment policies, including Occupational Safety and Health Administration (OSHA) requirements, employee records maintenance and retention, employee discipline and dismissal, and so on. All employment applications, other forms and tests used in the hiring process, and employment policies described in the office manual should be reviewed by an attorney who is familiar with state and federal laws.

Initially, the new practitioner may need to hire only one or two staff members. If only one individual is hired at first, a second employee should be added when patient flow increases to the point where this person can no longer assist at the chair and handle the business desk (e.g., collect fees, make appointments, answer the telephone by the third ring, prepare and mail statements on time, and pursue broken appointments). When the dentist treats recare patients more than 8 hours per week, a hygienist or coronal polishing assistant, depending on the state practice act, should be hired. Many dentists will eventually make the first person who helped them open their practice their OM. This is not wise, since many times these people do not exhibit the leadership skills necessary to manage a successful dental practice. Be sure that the person you hire to manage your investment is good with numbers and people.

Office Manual

An Office Manual should be completed before employees are hired so that there is no confusion about the rules the employees are expected to follow and the benefits they will receive. An Office Manual outlines the duties, obligations, and mutual expectations of the employee and employer and clarifies office policies, employment procedures, benefits, training methods, and office paperwork. Each employee should read the manual and sign a form attesting to the fact that he/she has read and agreed to the policies, to prevent misunderstandings. This document should be placed in the employee's file. The manual should be updated as policies and benefits change in the practice, along with documentation confirming that employees have read the updated version. Prototypes of office manuals are available in electronic versions to assist in the process and can be customized to the practice and the state's labor laws. The attorney for the practice should review the manual before it is implemented.

Personnel Records

Personnel records are important documents, charting the history of the employee-employer relationship, just as a patient's chart is a documentation of the patient-dentist relationship. If a problem arises with an employee (e.g., a charge of wrongful dismissal in case of termination), the record will serve as proof that the dentist correctly discharged employer responsibilities.

Personnel records for all employees should be identical in locked files, and maintained for the duration of employment plus at least 30 years following an auxiliary's departure. Employee medical records (see below) must be maintained in individual locked files separate from other personnel records for the duration of employment plus 30 years and include all appropriate forms with pertinent data.

A comprehensive employee record could include the following:

- Employee's name, address, telephone number, and Social Security number
- Completed job application, résumé, and interviewing notes
- Authorization for a background check and reference checks
- Offer of employment
- Employment tests given as part of the hiring process
- Date of employment, wage and benefits information
- Licenses or certifications
- Federal and state income tax and Employment Eligibility Verification; W-4 and I-9 forms
- Spouse's name, employer, and telephone number
- Person to contact in case of emergency
- Training records, including dates of training, contents of the session, and the name and qualifications of the trainer for OSHA training and cardiopulmonary resuscitation training
- Logs of unsafe incidents

Dentlearn.ir

- Employee medical records, including injury or exposure to harmful substances, and record of hepatitis inoculation, or signed and dated refusal of the vaccine, must be maintained in separate locked files
- Performance appraisal forms and notes from one-on-one discussions, signed and dated by the employee and the dentist; verbal and written requests for performance changes
- Absentee records
- CE course records
- Record of termination, including last date of employment, and the employee's letter of resignation or notes from the dismissal conversation if the employee was fired

Standard Operating Procedures (SOP) Manual

The SOP Manual defines each important task, including what it is and how to do it, that takes place in the practice so that the task can be successfully repeated by others. This becomes a good training tool with new staff or a reference if a staff member leaves and the task must be completed.

Interviewing, Hiring, and Training

Jim Collins' quote from *Good to Great*[1] is famous and powerful in its logic: "Get the right people on the bus, the wrong people off the bus, and the right people in the right seats." Successful entrepreneurs find the right people by following an organized systematic approach for hiring. Many wrong hires occur because important steps are left out. Statistics show that it costs a business a minimum of one and a half times an employee's annual salary when an employee has to be replaced. Therefore it is imperative to do the best job possible when hiring.

Improve your chances of hiring the right person by following these steps:

Create a Job Description

- Identify the specific job duties and traits/strengths needed for the job to be performed effectively. Use behavioral assessment surveys to help put the right person in the right job by picking the candidate with the right strengths.

Write an Effective Ad

- Realize that the best workers may often already be working for someone else, but they may not be satisfied. Rather than placing the standard ad that is worded like everyone else's, write an ad that includes motivators for the type of person you would like to hire.

Have Applicants E-mail Their Résumés to Your Office

- Having applicants e-mail their résumés allows you to prescreen applicants and provides an indication of their ability to follow directions.

Narrow Your List of Applicants through Telephone Interviews to Save Time

- Applicants can look good on paper, but they can have poor interpersonal and verbal skills, manners, etc.
- Review job requirements and the applicants' skills and experiences.
- Discuss their salary and benefits requirements, geographic location, and available work hours to see if they are compatible.

Interview

- To maximize efficiency, a well-trained staff member, preferably your OM, may conduct the initial interview. If the candidate is promising, employment tests, a tour of the office, an introduction to other staff members, and a brief conversation with the dentist should be a part of the first interview.
- Ask the applicant to complete the following:
  - Employment application
  - Behavioral assessment survey (trait profiling)
  - Release to undergo a background check
  - Release to check references
- Show him/her a written job description and discuss the duties.
- Prepare a list of interviewing questions.
  - These questions should explore the following traits: initiative, organization, conscientiousness, effective communication, ability to work well with others, technical or business training and experience, and ability to apply previous training and experience to the job. If questions are skillfully posed, an applicant's answers will indicate strengths or weaknesses in these areas.
  - The interviewer should talk less than 25% of the time. The purpose of the interview is to understand the applicant and his or her potential for the job. Excessive talking by the interviewer limits the time and opportunity that the applicant has to tell about personal abilities and experiences.
  - Do not help the interviewee answer questions. Let pauses happen. The applicant may be thinking during the silences, and the interviewer can see how well and quickly the person responds.
  - Ask open-ended questions. Do not ask questions that can be answered with "yes" or "no." If the interviewee begins answering "yes" or "no," ask him or her to explain or expand on the answer.
  - Never argue with an applicant. Maintain poise and remember that you, the interviewer, are in control.

Hire Based on Behavioral Strengths and Traits, Not Just Skills. This is one of the most important guidelines when a new employee is hired. You can train a new employee for specific job skills, but it is very difficult to change someone's "personality" if it is not the right match for the position available.

- Ask applicants who pass the initial interview to take a behavioral assessment survey so you can determine if they have the strengths and traits needed to be successful in the job. The Professional DynaMetric Programs has very informative surveys and hiring

Check References

- Checking references is absolutely essential. Many people know how to "package" themselves to cover up past problems. While employers might be willing to confirm employment dates only, you can often determine their overall satisfaction with the employee by their tone of voice and other comments.

Dentlearn.ir

- If the applicant has worked in a dental office, be sure to speak with the doctor. Describe your perceptions and observations of the applicant to determine if they are correct. Ask the doctor if there is anything else he/she would like to share with you. One of the most effective questions to ask the previous employer is: "If you had a position open up in your office, would you rehire this person?" This almost always provides a strong indication of the employer's level of satisfaction with the employee.
- Always have signed permission to call references. Never call an applicant's current employer unless he/she has given permission. Not only could it cost an applicant his/her job, it is also illegal.

Perform a Background Check

- If the applicant's references are positive, be sure to complete a federal criminal background check. Embezzlers move around from office to office.

Conduct Working Interview

- Ask the applicant to come in for a half-day working interview.
- Observing the applicant in the office will provide an indicator of the applicant's current skills, ability to work with others, ability to follow directions, speed of work, and adaptability to your unique work environment.

Lunch Out and the Doctor Pays

- If the working interview goes well, suggest that the applicant have lunch with the team members with whom they would be working most closely, to get to know each other better. The doctor should pay for this lunch but not attend. Ask the staff to observe and give feedback on the applicant's politeness, manners, and personality outside the office. They should also assess the applicant's interest in the job itself, not just the paycheck and benefits.

Ask the Team's Opinion about Hiring the Applicant

- Is the team comfortable with this person and willing to let him/her into the "dental family"? No matter how qualified the applicant, there will be problems in the office, and the new hire will eventually leave if the team is unsupportive of him/her.

Proper Certification

- Make verification a condition for employment. It is not uncommon to find dentists using assistants who had indicated they were licensed to take x-rays but who actually are not.

Offering the Applicant a Position

- If the applicant is to be hired, the dentist should offer the job using the term *full-time* or *part-time* employment and should avoid using the word *permanent,* either orally or in writing. Use of the term *permanent* denotes continuous work with a contractual understanding, regardless of problems that might develop later. If dismissal should become necessary, the employee might claim wrongful dismissal if promised permanent employment.
- If the applicant will not be hired following the first or second interview, he or she may be told at that time or notified within 1 week of either interview. If an applicant is rejected, maintain all applications, test forms, and other paperwork for at least 1 year in case a complaint concerning unfair hiring practices is filed by the rejected applicant.
- If testing is part of the application and interviewing process, testing must be standardized, that is, all applicants must be given identical tests.

Orientation and Training. In *The One Minute Manager,* a book long-favored by business managers, Blanchard and Johnson wrote, "Most companies spend 50% to 70% of their money on people's salaries, and yet spend less than 1% of their budget to train their people. Most companies, in fact, spend more time and money on maintaining their buildings and equipment than they do on maintaining and developing people."[7] A new employee must be made to feel welcome and a part of the team. Orientation on the first day of employment and a written training schedule to be followed the first 6 to 8 weeks should be part of this process.

Orientation. A training/benefits waiting period may be the first 60 to 90 days of employment, during which time the dentist determines whether there is a match between office needs and a new employee's skills and personal style. Use of the term *training/benefits waiting period* rather than *probationary* or *trial period* denotes the importance of performance to the new employee, emphasizing that this is considered a time to work diligently, to strive to learn as much as possible.

- Ask the employee to read the Office Manual and sign a statement that he/she has read and agrees with the office policies.
- Review salary and benefits package.
- Share and discuss the practice's Patient and Team Mission Statements, what they mean, and how to "live" them in the office.
- Communicate your "practice culture"—who is in charge of what, to whom the new employee reports, attitudes and communication (those expected and those that are not), as well as your practice philosophy and beliefs.
- Review the written job description.
- Create a list of duties in which the new employee must be proficient. Mark the duties off as the employee demonstrates acceptable ability.
- Introduce the new employee to all team members.

Encourage Team Relationships

- Arrange to have different staff members who will be working closely with the new employee go to lunch with him/her.

Training Method: TELL-SHOW-DO. Much of the responsibility for training new employees can be delegated to current staff. A well-trained veteran staff member may become a Training Coordinator, available to instruct the new employee, answer questions, and check progress. Although one person may efficiently coordinate training, all other team members and the dentist should also be involved in the process.

- What do you know about this?
- What are your strengths and weaknesses?
- How can I best teach you?
- How do you like to learn something new?

Dentlearn.ir

- Tell them what the "importance" of each function is and how it fits into the "big picture."
- Tell them the "benchmark" of acceptable performance for each job function they have.
- Ask them to role-play as much as possible. They will not "own" the new behavior until they have done it themselves a number of times.

Regular Coaching. Conduct a 5- to 10-minute debriefing with the employee at the end of each day for the first 2 weeks (every other day is sufficient for weeks 3 and 4). Finally, the supervisor should conduct a 30-day review.

- Tell him/her the following:
  - What he/she did well that day
  - What he/she needs to do differently and how
  - Where his/her focus should be the next day
- Ask him/her the following:
  - What was your biggest struggle today?
  - What would you like me to help you with tomorrow?
  - What did you learn today that affected you the most?

Job Descriptions

- Office Manager
- Front Desk Systems Coordinator
- Clinical Coordinator
- Front Desk Staff
- Clinical Assistant
- Flow Coordinator
- Sterilization Assistant
- Hygienist
- Hygiene Assistant

Office Manager. The doctor of a small practice can perform many of the employee management and business administrative duties. Once a staff reaches a level of 5 to 6 or more employees or has more than one location, a doctor should consider having an OM. Sometimes the same person can function as the OM and the Front Desk Coordinator. A good OM has the mindset that he/she is an extension of the doctor and is vested in the success of the practice. Doctors should realize they are putting their financial security and future in the hands of their OM; therefore this person must be strong and effective to help run the practice efficiently. The following outlines may be edited to fit the need of any office. See Figure 31-6 for a schedule of front office tasks.

General Duties

- Represent office and doctor
- Make sure the facility presents well and is in working order
- Help the doctor with administrative duties
- Handle patient/parent issues and complaints
- Order necessary front office supplies
- Make sure that computer backup is done daily
- Oversee that bills are paid in a timely manner
- Answer parents' or patients' questions concerning office procedures, financial matters, etc.
- Maintain office calendar
- Work to free the dentist from administrative details
- Handle correspondence for the dentist when requested

Systems Management

- Understand all of the goal numbers of the practice and how to monitor them
- Work toward meeting production goals; monitor total practice and individual producers
- Work toward meeting collection goals
- Work toward meeting new-patient goals
- Oversee the daily and monthly production monitor
- Oversee all front desk systems and hold the appropriate front desk staff accountable for the performance of each system
- Oversee the clinical manager
- Step in as a front desk staff member when needed
- Communicate the status of practice operations with the doctor weekly
- Oversee that month-end reports are run
- Make sure that each month is closed out in the practice management software
- Print end-of-year reports
- Oversee that deposits are made daily

Employee Management

- Hold employees accountable for proper job performance and appearance
- Manage staff requests for time off
- Enforce office policies
- Maintain a file for each employee
- Maintain updated personnel/office manual
- Give verbal praise and appreciation to employees
- Encourage employees' growth and development
- Conduct timely performance reviews of employees
- Maintain appropriate staffing coverage
- Manage new hires and exiting employees
- Oversee employee time cards and payroll
- Administer and interpret employee benefits

Leadership Duties

- Show leadership behavior
- Support doctor leadership
- Exhibit professional behavior
- Set appropriate example for employees to follow
- Keep stress level low in office
- Keep morale high in office
- Direct the "morning meeting," a brief meeting to plan the day

Coordinators. If the practice is large enough, it can also have a Clinical Coordinator and a Business Coordinator. A Coordinator is an experienced staff member who also shows leadership skills and enjoys using her or his initiative. The following outlines may be edited to fit the needs of any office.

Front Desk Systems Coordinator Duties

- Overall, coordinate the business desk; oversee scheduling, collections, insurance, customer service, running and working reports
- Meet regularly with the doctor and OM
- Suggest business area staffing needs
- Help evaluate business staff performance
- Help monitor practice statistics
- Monitor daily deposits

Clinical Coordinator Duties

- Overall, coordinate clinical area
- Meet regularly with the doctor and OM
- Suggest clinical staffing needs
- Help evaluate clinical staff performance

Dentlearn.ir

Front Office Tasks

Basic Tasks

Answering the phones	Greeting patients	Checking patient eligibility	Reviewing patient paperwork
Oversee office equipment/supplies	Scheduling next appointments	Checking out patients	Entering patient insurance
Sorting the mail	Cleaning the office	Manage telephone greetings; Change the voicemail message when needed	

Daily Tasks

Balancing deposit	Sending out claims	Entering insurance payments	Processing CareCredit
Sending out new-patient packets	Sending out thank you notes to new patients	Sending out thank you notes to the patients who have referred patients	Sending out thank you notes for online reviews
Settling the credit card machine	Pre-authorizations for insurance	Answer e-mails	Confirm patients
Adjust the schedule accordingly	Checking for EFT payments	Checking patient communication software reports/marking patients confirmed	Daily Monitor
Track treatment diagnosed			

Weekly Tasks

Check outstanding claims	Send out statements	Collection calls	Collection letters
Call on unscheduled treatment plans	Call past due recare patients	Check supplies	Enter new-patient paperwork
Scan in paperwork	Office walk-through inspection		

Monthly Tasks

Month-end reports	Purge magazines	Send out recare cards	Patient purge
Patient credit report and letters	Enter and update PPO fee schedules	Monthly Team Meeting	

Figure 31-6 Front office tasks. (©Julie Weir & Associates Management Consulting.)

- Coordinate office-wide OSHA training
- Direct and maintain clinical staff work schedules
- Assign collateral duties to clinical staff
- Help schedulers with scheduling questions
- Direct flow of patients through the clinical area
- Make certain that all systems are consistent, e.g., data entry, paperwork, laboratory delivery, etc.
- Help plan and maintain clinical area budget
- Supervise clinical supply inventory and ordering

Front Desk Staff Duties

Patient Management

- Greet each patient, preferably by name
- Answer phone by third ring
- Check messages, return calls
- Announce patients to back office
- Tell patients that the practice always welcomes new patients
- Promote the practice outside of the office, as appropriate

Scheduling

- Schedule to goal, fill openings, and keep the schedule productive
- Confirm all patients' appointments 2 days in advance
- Review patients' charts (Electronic Health Records [EHR]) as necessary the day before their appointment
- Print schedule for next day and 3 days out for the morning meeting; write the producer production totals on each schedule
- Enter treatment plans, discuss with patient, secure financing, sign consent form(s), and schedule appointment(s)

Collections

- Collect all estimated portions, deductibles, and fees
- Verify insurance benefits for patients and send predeterminations, as needed
- File claims with insurance
- Follow up with outstanding insurance and accounts
- Post all payments received
- Process statements

Treatment Tracking of Recare and Unfinished Restorative Work

- Manage the patient communication software (PCS), e.g., Lighthouse

- Make phone calls to parents of children who are due for recare visits and keep the overdue recare report current
- Ensure that the PCS mails the recare postcards to those who are due for an appointment but for whom there are no e-mail addresses
- Make phone calls to parents of children who have an unfinished treatment plan and keep the report current

Miscellaneous

- Pull and file charts
- Check patients in/out
- Note changes to patients in computer and chart
- Inactivate charts as needed
- Keep the front office, waiting room, and bathroom in order
- Close out the preceding day (deposit, day sheet, credit cards)
- Initiate computer backup

Monthly Duties

- Generate billing statements
- Print month-end reports, production/collection, referral
- Close out the month in the computer

Clinical Assistant Duties

- Patient care
- Chart review
- Set up rooms for procedure
- Seat patient and prepare patient for treatment
- Assist dentist during any procedures
- Provide patient education and postoperative instruction
- Dismiss patient to front desk
- Take x-rays
- Follow infection control procedures
- Perform basic sterilizing techniques for instruments
- Sterilize treatment room after use
- Stock treatment rooms with supplies
- Pour and trim models
- Perform lab work
- Maintain equipment
- Assist other team members, if time allows
- Tell patients that the practice always welcomes new patients
- Promote the practice outside of the office, as appropriate

Flow Coordinator Duties. A flow coordinator is a clinical assistant who also watches the overall schedule and directs the doctor and other assistants to keep the schedule flowing on time.

Sterilization Assistant

- Turns over chairs and sterilizes instruments
- Provides backup for the restorative and hygiene assistants

Dental Hygienist Duties

- Provides patient care: prophylaxis, radiographs, fluoride treatments, sealants, impressions
- Reviews radiographs, teeth, and soft tissue for decay and anomalies and informs the doctor of findings
- Charts results
- Reviews charts
- Sets up room for procedure
- Seats patient and prepares patient for treatment
- Assists dentist during examinations
- Provides patient education
- Dismisses patient to front desk
- Follows infection control procedures
- Performs basic sterilizing techniques for instruments
- Sterilizes treatment room after use
- Stocks treatment rooms with supplies
- Maintains equipment
- Assists other team members, if time allows
- Assists front desk with the recare system as needed, if time allows
- Tells patients that the practice always welcomes new patients
- Promotes the practice outside of the office, as appropriate

Hygiene Assistant Duties. A hygiene assistant assists the hygienist and/or coronal polishing assistant with the flow of recare patients. For every two columns of recare scheduled for 30-minute appointments, one hygiene assistant is needed to help keep the schedule on time.

- Greets parent
- Confirms medical history and treatment
- Takes radiographs
- Seats patient
- Turns over chairs and instruments
- Assists doctor with examination and charting
- Works to educate patient
- Escorts parent/patient to front desk

Performance Reviews. A well-done performance review is a powerful leadership tool for the doctor and a great learning experience for the employee. Team members must know what they are expected to do, how to do it, and what the criteria are for an acceptable or, better yet, outstanding job performance. Employees want to feel that their presence is valued and contributes a positive difference that is recognized.

The following steps will make the performance review a positive learning experience:

- Set aside one day a year for all annual reviews instead of trying to do a review on each employee's employment anniversary.
- Treat the review like any other important business meeting. Set aside at least 45 minutes. Do not reschedule this meeting; this is a significant event on your employee's calendar.
- Prepare for the meeting ahead of time. An evaluation form is completed, and talking points are prepared by the doctor on the following:
  - Employee accomplishments since the last review
  - Employee strengths that the doctor appreciates
  - New duties and levels of job performance
- Two weeks before the review date, the employee is given the review form for self-evaluation of his/her performance and then returns the form to the doctor 1 week prior to review. This advance information gives the doctor time to understand the employee's view of his/her level of performance and helps the doctor prepare their discussion points and coaching for improvement.
- It is also beneficial to use a form that asks the employee to identify goals and challenges for the next year. Discussing the staff member's opinion of his or her own performance often makes the appraisal more

Dentlearn.ir

meaningful. Each job should have understandable benchmarks of acceptable performance, which must be communicated to the employee. For example, the person in charge of collections should be collecting 98% or more of collectable fees with an "accounts receivable to collectable fees" ratio of 1:1, and not more than 18% to 25% of the accounts receivable should be over 90 days. If any one of these criteria is not being met, then the employee will know exactly where to concentrate his/her efforts to improve. Benchmarks can also be set for scheduling to goal, working recare and unfinished treatment plans reports, and clinical performance.

- Job skills and work performance should be reviewed separately from salary. A conversation that combines performance review with news of a raise interferes with the staff member's concentration. An employee may be so interested in hearing about a salary increase that setting goals for performance improvement is relegated to a secondary level of importance.
- It should be clearly communicated to employees that annual raises and/or bonuses are given for making themselves more valuable to the practice through improved skills and a motivated attitude, not for just being there another year.
- During periods of economic difficulty, instead of annual raises, quarterly bonuses can be tied to increased practice performance over the previous year, or monthly bonuses on a 3-month rolling average.

Coach to Improve Performance

1. Ask yourself: As their leader, have I provided the appropriate training, time, and tools for them to perform adequately? If not, provide these items and see if the desired job performance is achieved.
2. Speak directly to the employee. Do *not* complain to other employees about the poor performer. This is gossip and destructive to the team.
3. Tell them what they are doing well or what you value in their performance. People listen better when they feel that the appraiser recognizes their strengths rather than only their deficiencies. Use the term *opportunities for growth* rather than weaknesses when discussing areas to be improved
4. Tell them specifically what you want done differently.
5. Tell them specifically how you want it done differently.
   - Most people respond best when asked to concentrate on no more than three or four areas for development.
6. Ask them, "Is this something you think you can do?"
   - If they answer no, ask them why.
   - The dentist may offer to help the employee improve in certain areas through additional training and CE courses, thereby giving the staff member a sense of support.
7. Ask them, "Is this something you want to do?"
   - If they answer no, ask them why. Determine if you are dealing with insubordination or lack of motivation in seeing the importance of the task.
8. Establish a time frame for improvements; between 1 and 3 months is usually appropriate. The dentist and the staff member should meet frequently in the interim to assess improvements.
9. If the behavior/job performance is strongly lacking (e.g., consistently arriving late, abusing

   or unable to perform at required skill levels), tell the employee:
   - He/she needs to know that his/her job is in jeopardy and that he/she is on probation until job performance improves.
   - If the requested change does not take place, he/she will be terminated.
   - Your goal is to help every employee reach his/her full potential, but it is up to the individual to choose to be successful in your practice.
10. *Document all conversation*s, including dates, times, and information exchanged at all meetings with employees, when job performance is discussed. This is important for reference in the event the employee is terminated.

Dismissal

Dismissal of an employee is one of the most difficult tasks a dentist may face. There are, however, processes that can make a dismissal less stressful. Dismissal usually happens because of incompetence in job performance or unacceptable behavior such as patient abuse, sabotage, theft, harassment, or substance abuse on the premises. Problems often arise when an employee loses interest and therefore effectiveness and/or efficiency in her or his responsibilities. Behavior and performance problems must be addressed; simply ignoring the situation will not make it go away. The dentist and staff member should discuss the problems and ways they can be rectified. If the ten steps outlined in the previous section "Coach to Improve Performance" have been gone through and the employee will not or cannot improve behavior or achieve required skill levels, dismissal will be necessary.

- Prepare a document stating that the employee is being terminated and why. Check with an employment attorney to be sure you are following your state's labor laws. After this statement is explained, the employee and the dentist should sign and date the statement, and it should be retained in that individual's personnel file.
- If an employee refuses to sign and date notes from any discussion, the dentist should so note on the statement and sign and date the document him/herself. Such a note is an acceptable record that the discussion occurred.
- It is important for a dentist to avoid a wrongful termination lawsuit, which is why documentation of all meetings with the employee is important, even more so if the employee is in one of the following protected classes of employees:
  - Race
  - Religion
  - Age (40 years and over)
  - Pregnancy

Dentlearn.ir

  - Disability
  - Sexual orientation
- It is best to seek advice from a lawyer versed in labor relations if the dentist is unclear about the proper way to discipline or dismiss an employee. It is much less costly to pay an attorney than to be involved in a wrongful dismissal lawsuit with a disgruntled employee.
- In most states, no notice is necessary for dismissal related to unlawful behavior such as stealing, patient mistreatment, or deliberate property damage. The staff member committing such actions can be dismissed immediately if such actions can be proved indisputably. It should be clearly stated in the office manual that such conduct will not be tolerated and will result in immediate dismissal.
- A dismissed employee should always leave immediately after the termination conversation. The dentist may pay severance wages, but payment is not mandatory in all states. (The dentist should check with an attorney about state law and write the policy in the office manual.) It is unwise for an employee who was fired to remain on the job. The dismissed person may sabotage the practice, even unconsciously, and bother other staff members with the details of termination. Thus a dentist may pay a penalty for being kind-hearted enough to let a fired employee keep working until he or she finds another job.
- The dismissed employee should be given his/her final paycheck, return office keys, and be accompanied by the OM as he/she collects his/her belongings. The best safeguard is to change locks and all passwords.

Wages, Raises, and Benefits

Fair salaries and good benefits are necessary to avoid job dissatisfaction; however, salary and benefits do not necessarily motivate an employee to perform better. Motivated staff members are most often those to whom responsibility is delegated. Their personal and professional growth is encouraged and recognized by the dentist. They are appreciated and told how valuable they are to the office, the dentist, and the patients. In short, motivated staff members are recognized for the contributions they make to the practice, and money is only one way appreciation is shown.

There must be a balance among managing payroll costs, sharing practice income and profits equitably with staff members, and maintaining careful control of expenses. Team members should understand that their actions have a direct impact on their raises and benefits. Increased productivity creates additional profits the doctor can share, and reduced productivity will delay raises and benefits.

- Hourly wages should be commensurate with community wage scales. The dentist should survey similar jobs in other practices in the area to determine minimum and maximum pay ranges. It is financially more prudent to pay employees hourly rather than pay them a salary.
- Wages and benefits should be reviewed yearly. Raises are based on merit (positive behavior and increased skills), increases in cost of living (inflation), and the overall economic status of the practice. If the practice has had increased profitability and raises are neglected, good employees may quit.
- The relative worth of each position—including business positions (e.g., receptionist, scheduling coordinator, patient accounts coordinator) and clinical positions (e.g., clinical assistant, hygienist, sterilization/laboratory assistant)—to the practice is determined based on answers to the following questions:
  1. How long would it take to find a replacement?
  2. Are there specific certification, education, or training requirements?
  3. What is the value of longevity in this position?
  4. How skilled is a certain individual?

  The more competent, valuable, and difficult to replace the employee is, the higher the wage should be.

Employees receive more than wages; net pay is only one part of a total compensation package. Although higher take-home pay with fewer benefits may attract some employees, fair wages with expanded benefits generally help retain team members. Each employee should be given an annual total compensation statement listing gross wages, employer-paid taxes, and the dollar value of benefits such as vacation, personal leave, insurance, uniform allowance, and free or reduced-cost dental care. Receiving an actual statement of wages and benefits lets employees perceive their full value.

PART 5: SYSTEMS

NEW-PATIENT APPOINTMENT

The first impression that sets the foundation for a long-term relationship with parents and patients is established at the new-patient appointment. The website is typically the parent's first contact with the office, and the telephone is the first contact with a team member. Therefore it is paramount that the website be well done and that the telephone is answered by a friendly and helpful person who is great at building relationships quickly. The office must be represented as organized and knowledgeable. Speaking highly of the doctor and staff will instill trust and confidence in the parent about your practice and give parents the impression that they are making a good decision to bring their child to your practice for dental care. Always remember that the parents chose your office over other offices in the area, and if they are not treated well, they will go elsewhere.

Initial Telephone Call

- Gather information from the parent using a New Patient Information form (Fig. 31-7).
- Refer the parent to your website for more information about the practice and ask them to complete the New Patient forms prior to their visit. Many software programs can be set up for this information to download automatically into your dental software.
- Schedule the new patient within 1 week of the call—block time in your schedule for new patients.
- Send the parent an e-mail with the links to your website and the New Patient paperwork. This is a marketing opportunity to thank him/her for scheduling and let him/her know that you are looking forward to seeing him/her. Customer service tip: Always make it easy for the parent to do business with you.

Dentlearn.ir

Thank you for calling [dental office]. This is [your name]. How may I help you?
Parent states he or she is calling to make an appt. May I ask your name … and the name of your child?
When did we see your child last?

Parent's Name _____ Today's Date _____

Who may we thank for referring you? Get the specifics.

Patient's Name _____ Age _____ Date of Birth _____

Tell me a little about [child's name] favorite interest, sport, toy, pet, or color.

Any medical or dental concerns?

Prior dental experiences?

Patient's Address

Home Phone _____ Work Phone _____ Cell Phone _____

E-mail Address

For your convenience we will confirm your appointment by text, e-mail, or both. Which would you prefer? T E B

Will we be helping you file insurance? Y N - Enter Insurance info on the back.

If pt indicates dental problems, ask the five questions

What area is bothering pt? _____

How long has this been bothering pt? _____

Sensitive to hot or cold or pressure? _____

Does it keep pt up at night? _____

Is there any swelling? _____

When was your last cleaning? _____

Now that we have collected all of your information, let's see when we can reserve an appointment for [child's name]. We have an appointment available on [date] at [time] or [date] at [time]. If parent objects, ask for his or her concern so you can overcome the objection. I understand [objection]. We have reserved time for our new patients at [indicate times] because this allows the doctor the appropriate amount of time to evaluate your child, and we find that children do best at these times. I have [date] at [time] or [date] at [time] available.

[Patient Name] is going to love [Dr. Name] and our entire staff. Our office is decorated [describe theme], and we have great toys and games. You're welcome to come early so [patient name] can play before his/her scheduled appt. He/She will have a great experience. Thank you for choosing our office. We'll take great care of [patient name].

Please visit our website at [website] and complete the registration paperwork. It would be ideal if you could do so within the next 24 hours. By completing the registration online, you won't need to do any paperwork when you arrive. Everything will be completed and we can see [patient] without delay.

We look forward to meeting you and [child's name] on [date] at [time]. You will receive an electronic confirmation by [text, e-mail]. Simply click the Confirm option and the appointment will be confirmed. May I ask a favor? If for any reason you need

will look forward to meeting you. Is there anything else we can help you with?

Figure 31-7 New-patient information. (©Julie Weir & Associates Management Consulting.)

Before the New-Patient Appointment

- Verify eligibility and dental insurance coverage, if needed, and ensure that the New Patient paperwork has been received.

New-Patient Appointment in the Office

- New-patient appointments should always run on time.
- From the moment the new patient walks in the door, your staff should be on target for excellent customer service. Team members should smile and make sure they connect with the patient and parents. Remember, people don't care how much you know until they know how much you care.
- The greeter should rise to greet the parent/patient and introduce him/herself with an outstretched arm to shake their hands. Let the parent/patient know you are glad that they chose your office.
- A well-trained team member should escort new-patient arrivals to a conference room or the operatory. At this time the staff person should review with parents the child's health history and the anticipated treatment to be performed that day, recording pertinent notes for the dentist.
- The dentist should be introduced by the staff member who interviewed the new patient and parents. After a short conversation addressed mainly to the patient, the dentist should again review the health history with the parents, reading notes made by the staff member during the interview. This routine provides two opportunities to ensure that the health history has been correctly completed and that the review with parents is documented. If the initial conversation occurred in a conference room, the dentist should leave while the team member prepares to take the child to the operatory. In this way, if the child is upset, the dentist, who must gain the child's full cooperation during the dental examination, is not involved.
- The pass-off of the child from person to person should be very positive. "Ann, I would like you to meet Billy. Billy, you are so lucky, you get to see my friend Ann today. And you know what? She is going to get your teeth sparkling clean! You will love her!" At check-out: "Wow, Ann did a fabulous job cleaning your teeth!"
- In many offices, parents accompany their child to the operatory. Sometimes this can be a distraction for the child; however, the presence of parents in the operatory is a reality in many pediatric dental offices in today's litigious society. The dentist can, however, wisely limit the number of adults accompanying each patient to the operatory and also forbid their use of cell phones.
- At some point during the first appointment, an assistant or hygienist should give home care instructions utilizing a Tell-Show-Do method. The staff member should also impart information about recommendations if fluoride is not in the child's drinking water, healthy snacks, bottle habits (if appropriate), and the importance of maintaining regular preventive visits.
- After the examination the dentist should present the case to the parents, who usually want answers to the following questions: What is wrong? Can it be fixed? How much will it cost?
  - The practitioner should answer "What is wrong and how it can be fixed?" when presenting the treatment plan, using language that the parent can understand. Do not use excessive clinical terminology, which only intimidates and confuses the parent.
  - The front desk staff will answer the question, "How much will it cost?"
  - When explaining treatment, always tie the treatment to the benefits that will result, any motivators that the parent has shared, and the consequences of no treatment.

    ment to help the parent understand.
  - The doctor should close the case by asking the parent, "Mrs. Jones, If you do not have any other questions, is this the treatment plan you would like me to complete for Johnny?" If the parent has questions or objections, the doctor is the best person to address the parent's concerns and not put this burden on the front desk staff to close the case.
  - The dentist may wish to rehearse case presentations with staff members, seeking their critique and suggestions.
- The patient and parents are then escorted to a check-out area. The next appointment is usually scheduled before the fee is collected.
- A written treatment plan is presented to the parent.
  - The parent is told the total cost and his/her estimated portion that will be due at the appointment.
  - The patient/parent signs or initials the treatment

- After check-out, a staff member should express thanks to the parents for choosing the office and let them know that if any of their friends would enjoy the same experience, new patients are always welcome.
- The child and parents should leave the office feeling that the dentist and staff are extraordinarily caring, thorough, skilled, and efficient. The lasting impression should make both the parents and the child look forward to their next visit and eager to recommend the practice to other family members and friends.

Forms

Forms for the pediatric patient need to take into consideration the circumstances of multiple parents, multiple e-mail addresses, and dual insurance as well as multiple mailing addresses. Consider adding a section for a list of people authorized to bring the patient to appointments.

Many companies have designed forms for purchase to use in the dental office. It is always advised that forms be reviewed by your liability insurance lawyer to ensure state and federal compliance. Often, organizations such as AAPD, ADA, and your liability insurance company can

Dentlearn.ir

There are also companies that can integrate your forms into your website for parents to complete online.

List of patient forms required for the dental office:

- Medical history
- Patient demographics/information form
- HIPAA compliance forms
- Perpetual release for photos and patient reviews
- Financial Policy Form
- Appointment Policy
- Consent for treatment/nitrous oxide use
- Oral sedation form
- Hospital forms

EFFECTIVE SCHEDULING

Offices are more efficient and productive when there is a proactive approach to scheduling the "ideal day" by using block scheduling and daily restorative and recare producer goals. Block scheduling controls the work pace and productivity level of the day, in contrast to a day in which appointments are haphazardly scheduled, which causes stress and chaos.

The telephone connects patients to the practice, and it must be answered in a cheerful and professional manner. The attitude of the appointment secretary can give a positive impression, making scheduling a pleasant experience, or create a negative one, resulting in no appointment being made. The appointment secretary should listen carefully to each parent or patient and try to be accommodating while offering choices of appointment times that work with the block scheduling.

Since most offices have multiple people scheduling patients, it is essential that the block schedule be easy to follow and that blocks be clearly labeled for appointment types. Many software systems have the ability to set up block scheduling and producer goal monitoring.

Consider the following when scheduling:

- Not all procedures should be scheduled for the same amount of time. Consider qualifying each treatment appointment as either a simple or complex appointment, giving each one a specific amount of time for its respective category and alternating them in the schedule.
- Schedule to meet producer goals for restorative, recare, and Hospital/GA.
- Monitor the number of doctor and recare work days each month to meet the monthly production goal.

Schedule morning appointments for more complex treatments to accommodate patient behaviors.

- Allow for uninterrupted time with the doctor when sedation is involved.
- Block enough appointments for new patients.
- Accommodate short time slots for lap examinations, consultations, and postoperative appointments.
- Leave slots available for urgent procedures once your appointment schedule is at capacity.

If a patient fails to keep an appointment, a staff member should telephone the parents within 10 minutes. If unsuccessful, call again within 24 hours. If the parents cannot be reached by telephone, a message, perhaps by e-mail or, failing that, by regular mail, should be sent asking them to contact the office. If the appointment cannot be rescheduled, the patient must be listed or flagged in the computer. At the end of each month, a broken appointment list can be printed so that patients with failed appointments can be re-contacted.

Efficiency must be maximized in the scheduling of patients with low-reimbursement plans, or providing care to these patients may become cost-prohibitive. Consider the following:

- Schedule during the hardest times of the day to fill (if the plan allows the doctor to dictate appointment time). Normally this is between 10:00 AM and 2:00 PM.
- Understand the volume required. Typically a procedure must be done 3 to 5 times more often to get the same dollar out as one full-fee procedure.
- Delegate as much as possible to dental staff, within the constraints of state law.
- Track new patients in Lower Fee Plans separately from Private Pay patients. Put limits by age or number/month on Lower Fee Plan patients if necessary.
- Have a strict "no-show, short cancel" policy. Dismiss at first or second no-show.
- Have parents sign an appointment policy form. These polices can be different from those for Private Pay patients.

SURGICAL REFERRALS

Some pediatric dentists have instituted a section of their practice entitled Surgical Referrals, indicating care for patients who need dental treatment and meet American Academy of Pediatric Dentistry Guidelines for General Anesthesia. This particular program is one in which a patient is treated under GA and then sent back to the referring doctor, mimicking the approach frequently used by some other specialties such as oral surgery.

These patients may be seen for an initial examination by the pediatric dentist, treated in the proper setting while under GA, seen for at least one postoperative visit, and, if appropriate, returned to the referring doctor.

MANAGING COLLECTIONS

Prevention is the key to successful collections. A clearly stated financial policy (Fig. 31-8), presented to parents in a professional manner, and insurance plan information correctly entered into the practice management software will prevent uncollected balances. In offices that accept the assignment of insurance or allow patients to pay dental fees on a payment plan, 1 month's gross production is the recommended guideline for total accounts receivable. When the accounts receivable total is more than 1 month's production, cash flow suffers and many accounts become uncollectible.

Collect Accurate Insurance Information for Patients with Insurance Coverage

- Insurance company's name, telephone number, and plan number
- Employer's name, telephone number, and contact person
- Deductible requirements and amount
- Maximum annual and lifetime benefits

Dentlearn.ir

Financial Policy

We are pleased to welcome you to our practice. Our desire is to provide you with the highest quality dental care in a caring and enjoyable atmosphere. ***It is our policy to make definite financial arrangements with you before any treatment starts.*** Below is an explanation of our payment procedures. If you have any questions, please do not hesitate to ask.

1. Payment for services is due at the time services are rendered. We accept cash, checks, and credit cards.
2. For new-patient emergency visits we require payment in full at the time of the appointment.
3. reimbursement or you may assign the payment to our office and we will file the insurance for you.
4. Our office will file your insurance claim a maximum of **two times** per appointment.
5. **If the claim is not paid by your insurance carrier within sixty days, you will be responsible for the full balance and further insurance appeal becomes your responsibility.** We will be happy to provide you with a claim form so that you can follow up on your insurance claims personally.
6. You must provide the office with a dental insurance card with the proper mailing address of the insurance company, or provide a dental claim form, which is provided by the employer. If one of these documents is not available at the time of the appointment, you will be responsible for payment of all fees and we will provide you with a claim form for you to submit for reimbursement.
7. If insurance benefits are assigned to the doctor, you will be responsible for paying your deductible and co-payments at the time of service. **You are responsible for paying all charges not covered by your insurance company.** Your insurance benefits are a contract between you and your employer. The amount of coverage you will receive will depend on the quality of the plan purchased by your employer, not the fees of the doctor.
8. **The office cannot carry balances longer than 60 days,** regardless if the insurance payment is still pending. A $5.00 monthly re-billing charge will be added to your account if it is not paid within 60 days, regardless of balance amount.
9. After 60 days, we will inform you of the delinquent account by letter and if no action is taken to clear the account, this office will be required to employ a collection service to collect payment. The responsible party agrees to pay all reasonable, related collection fees.
10. There will be a $30.00 service charge for all returned checks.
11. **The parent or guardian who brings the child for his or her initial visit is responsible for payment independent of what a divorce decree or custody arrangement may state. Reimbursement must be made between the divorced parents. We will not intervene.**

AUTHORIZATION

I have read & accept the above Financial Policy, understand it, & agree to the terms set forth regarding payment.

Signature of Responsible Party	**Date**

Figure 31-8 Financial policy. (©Julie Weir & Associates Management Consulting.)

- Pre-estimate requirements
- Percent or scheduled amount paid on various procedures, including preventive and orthodontic treatment
- Any exclusions

Collect All Patient Payments, Deductibles, and Co-Payments at the Time of Service

- Train parents to pay their portion at the time of service by presenting accurate treatment plans and informing the parents of their co-payment amount that will be due before the parents schedule the next appointment.
- When parents do not pay on the day of treatment, a statement with an envelope addressed to the office should be presented at check-out.

Preparing Deposits

Daily deposits should be compared with the reports generated from the software system. To prevent embezzlement, the staff member preparing deposits should be different from the one who is entering payments into the system. Further, the doctor should take the office deposit to the bank.

Sending Statements

Every software system has the capacity to either send statements directly or integrate with a vendor that offers electronic billing services, which is typically more cost-effective by saving the cost of postage, staff labor, and envelopes. What once took 2 hours can be done in less than 5 minutes and pays for itself.



Figure 31-9 Value of a dollar when not collected.

- Send statements daily after posting payments. Select all accounts with a balance and to which statements have not been sent within the preceding 21 days. This will also cover all balances after insurance payments have been posted. This is much easier than processing individual statements each time a balance is left after a claim has been paid. The due date for payments should be in 14 days.
- An account on which no payment has been made for 30 to 60 days may be considered overdue. Sending an e-mail reminder is an effective way to contact patients when they are not responding to the traditional statements. The value of a dollar greatly diminishes over time (Fig. 31-9).
- If there is no response or payment by 90 days, the account may be forwarded for outside collection action after the dentist reviews the account and gives approval.
- Laws concerning collection techniques and the do's and don'ts for collecting overdue accounts vary from state to state. Therefore the dentist must make certain that his or her patient accounts coordinator is well-trained in the legalities of pursuing delinquent accounts in that state.
- Have a signed financial policy that allows you to collect all legal fees, interest, and collection agency fees from the patient.
- Consider using a pre-collect service, before a collection agency, which charges a flat fee per account. The accounts can then be transferred to a collection agency if payment is not recouped. Collection agencies typically charge about 50% of the balance for their collection fee.
- Once an account is sent to collections, write off the account balance and dismiss the patient from the practice. The account balance should be written off with a code reflecting that it was sent to a collection agency.
- Send the patient a dismissal that includes the availability of emergency care for 30 days, to avoid accusations of patient abandonment.

Remove any scheduled appointments of the dismissed patient and his/her family members, and inactivate these patients in your system. If the patient's treatment is incomplete or the patient has an appliance or prosthetic device, the dentist should seek legal counsel before designating the patient's chart as inactive and sending the account for outside collection action. An attorney can best advise on patient abandonment issues so that potential legal problems are avoided.

Follow all state debt collection laws regarding phone calls, written communication, and e-mails in attempts to collect the bad debt. It is essential that you document all collection activity. Make sure that every letter, every phone call, and every e-mail are documented in your dental software. You want to be able to prove that you took every measure possible to collect payment before sending the account to collections.

Accounts Receivable Report

- Print monthly and review all accounts with balances past 30 days.
- Take the appropriate action to collect the balance:
  - Resubmit to the insurance company for payment
  - Send the parent a statement
  - Call the parent
  - Send the account to collection

MANAGING INSURANCE

The acceptance of insurance assignment can be a good marketing tool because it attracts patients to the office. Parents are more likely to accept treatment for their child if they have additional financial assistance. However, to maintain healthy accounts receivable, it is essential to take a proactive approach with dental insurance by obtaining the patient's dental benefit coverage before he/she arrives for the appointment.

Steps for Effective Insurance Management

Practice management software programs are set up to calculate the patient's correct insurance coverage through the use of a Coverage Table and a Payment Table for each insurance plan when these tables are used correctly and consistently by the front desk staff.

The Coverage Table contains information on the insurance plan's deductible, maximum, and percentage of coverage for preventive, restorative, etc. The Payment Table, when utilized correctly, allows the software to build a history of the actual payment amounts received from the insurance plan for each procedure. This creates a more accurate estimate of insurance coverage for the parent instead of relying only on the insurance plan's stated percent of coverage for a procedure.

1. Sign up for online management of insurance companies. Most insurance companies allow you to check patient eligibility, check claim status, and submit claims online through their websites.
2. Understand the latest CDT (Current Dental Terminology) codes. The ADA's current handbook

   .org/.[8] Periodically review the insurance company's fee schedules to understand the codes for benefits covered and the reimbursement levels, to maximize your coding and coverage.
3. Collect insurance information on the phone during

   dental benefits card when new patients arrive in your office.
4. Contact the dental insurance company to confirm eligibility and use a detailed form for collecting information on insurance benefits coverage (Fig. 31-10).

Dentlearn.ir

INSURANCE VERIFICATION

Patient Name | DOB | Relationship

Name of Insured | ID # or SS # (as it appears on card)

Employer | Insured's DOB

Name of Insurance Company | Insurance Company Phone Number

Address of Insurance Company

Insurance Rep | Effective Date | Benefit Year - Renewal Month

Yearly Max		Max Used		Ind Deduct		Deduct Met?	
Preventive %		Basic %		Major %		Family Deduct	

	Elig/Cov		Benefit Category					
Procedure	Y	N	Prev	Basic	Maj	Freq/Lim	Date of Last?	Comments
Comp Rxam D0150								
Per Exam D0120								
Infant Exam D0145								
Child Prophy D1120								
Adult Prophy D1110								
Fluoride D1206								
2 BWX D0272								
4 BWX D0274								
Psno F0330								
BW/Pano Bundle as D0210								
Sealants D1351								
Sealants D1352								
Endo D3000								
Space Maintainers D1515								
Night Guard D9940								
SS Crowns								
Ortho								
Post Comp D2391/2/3								
In Off Sedation D9240								
Nitrous D9230								
Hospital Case D9420								
Waiting Periods								
Non-Duplication?								

Figure 31-10 Insurance benefits. (©Julie Weir & Associates Management Consulting.)

5. Enter the patient's insurance information into the dental software. Benefits are based on the employer/

   guarantors have Delta Dental and they work for different companies, their benefits will be different.)
6. Attach a fee schedule to the Coverage Table for each In-Network plan. This will provide accurate estimates and will minimize time-consuming adjustments, refunds, and billing statements.
7. Attach a fee schedule to an employer only for PPO programs. Attaching a fee schedule will ensure that your accounts receivable numbers reflect the actual amount that you will receive from the services rendered, and it will also create accurate treatment plans and patient estimates.
8. The provider must submit a claim for all procedures performed, regardless of coverage for those procedures. Always submit claims with your full fees so the insurance company will have a record of the full fee amount for the procedures. This will also be reflected on the Explanation of Benefits.
9. Once the appointment is "set complete," an insurance claim should be generated by the software system and batched. After the providers have reviewed daily services and deemed them accurate, send the batched claims electronically for payment. The insurance company will review the claim and send a payment. You can track the progress of the claims online through most insurance websites.
10. When the insurance claim is received, check to see what the insurance company paid, what the patient portion should be, and what the patient was charged. Do not make adjustments based on the explanation of benefits without checking to see how much the patient was charged. For instance: The patient's account shows a cleaning for $75, a new-patient exam for $75, and an FMX for $100, for a total of $250. If the payment comes back and the insurance paid $200, stating that the patient portion for this claim is $0, then you know you have to "adjust off" the $50. If the company paid $200 and states that the patient portion is $25, then the adjustment would be $25.
11. Enter the insurance payments by each procedure instead of entering the bulk insurance payment for the total claim. This way the software "learns" the true coverage and the Payment Table will then override the Coverage Table as it builds this information and then be able to produce more accurate co-payment amounts on treatment plans. The Payment Table must be updated each time after insurance payments are entered.
12. Send preauthorizations for dental treatment to insurance companies only when the insurance company requires it or when services are expected to be over $2000.
13. Each week, generate an Outstanding Insurance Claims Report so that overdue claims can be pursued. The insurance coordinator should call the insurance company to inquire about payment and carry out needed actions for payment to be received.

It is important to help the parents understand that they, not the doctor, have the contract with the insurance company, and that the parents can call their insurance company at any time to discuss what their patient portion should be. Sometimes you will have to politely remind them that the insurance company, not the dental office, determines their patient portion.

Coordination of Benefits

When a patient has more than one dental insurance that can be utilized, a coordination of benefits must take place. Which insurance is primary and which secondary must be determined. Medicaid will almost always process as secondary insurance.

When checking insurance benefits, ask what the coordination of benefits is for the plan. There are some options: Nonduplication of Benefits, Birthday Rule, and Biological Benefits. Send all claims out at UCR when the patient has dual insurance.

The office is not obligated to submit secondary claims if the doctor is not a provider with the secondary company.

Dental Insurance Fraud

Insurance fraud can result in criminal prosecution of the dentist, even if he/she was not aware of how claims from the office were being submitted by his/her staff. You can submit only for completed procedures and only for the fee that is charged to the patient.

The dentist should not discount or disregard the portion of fees not paid by an insurance company (i.e., the patient's co-payment). Doing so may constitute insurance fraud, because the dentist has misrepresented actual charges. For example, if a fee for a procedure is $100 and an insurance company pays only $80, do not submit a claim for the full $100 fee if $80 has been accepted as payment in full. Submit the $100 claim only if the parent is expected to pay the $20 that is not covered.

Different Types of Dental Insurance Programs

Most insurance companies provide some preventive and basic coverage, but the insurance coverage depends on the plan purchased by the employer or the individual.

Indemnity Plans

- Indemnity plans are considered "fee for service" plans where most of the UCR fee is covered. These plans require filing claims and may require the patients to accept assignment of benefits and receive payment directly from the insurance, which means that they will have to pay for all the services in your office in full. The advantage of an indemnity plan is that the policyholders are not typically restricted as to which dental care providers they can use.
- Almost all indemnity plans have a deductible.

Managed Care

- Dental benefit organizations fit under the umbrella term *managed care,* which is an insurance industry term for a system that curbs expenditures in benefit plans by cutting reimbursement levels and transferring financial risk to those providing care (in this case, the dentist).

Dentlearn.ir

- In managed care, it is the payment methods rather than the actual dental treatment modalities that are different. Each managed care system has a specific mechanism of payment for treatment, usually accompanied by some form of utilization review. Dentists who participate in managed care organizations surrender control of their fees for that part of their patient population enrolled in the managed care organization.
- The two most widely used types of dental managed care are the preferred provider organization (PPO, EPO, DPOs) and capitation contract dentistry (CCD, HMO, DMO). A PPO is a network of private practitioners who contract with a plan to provide specific services to a particular patient population at reduced fees. Patients enrolled in a certain PPO must choose a dentist from the organization's list of providers. In CCD plans the dentist contracts with a plan to provide specific services to enrollees in return for a monthly capitation amount, whether or not the enrollees-patients actually make and keep appointments. In other words the dental office receives a monthly lump capitation payment based on the enrolled number of patients eligible for treatment in that office.
- Dentists must weigh many issues, options, and fiscal matters regarding managed care. The ADA has a comprehensive array of resources to help dentists understand and analyze the positive and negative aspects of managed care. Among the services offered is contract analysis, which is available from the ADA through individual state dental societies. Any dentist who is considering signing a contract with a dental benefit organization is well advised to consult with the ADA and his or her own attorney, financial advisor, and management consultant.
- Being a managed care provider will help direct new patients to the practice. However, the doctor will be treating these patients at a fee schedule that is typically 20% to 60% lower than the doctor's full fee. This can be a good way to get new patients and start cash flowing. It is better to make fifty cents on the dollar than zero to help pay overhead costs when the practice opens. A doctor can always decrease his/her managed care involvement as the practice grows. The fee discount of a PPO plan can be viewed as a marketing expense to bring in new patients.

Medicaid and Federally Funded Programs

- These fees are typically 40% to 60% of a doctor's full fee.
- Practitioners must decide how much dental service their practice can provide for public assistance patients. The positive for doing so is the personal and professional satisfaction of knowing that you, the dentist, have cared for some of the neediest patients in your community and have met some of your moral and ethical obligations as a professional. The negative for doing so is that many states' program reimbursement levels fall short of covering the actual cost of dentistry delivered to these patients. In this case the dentist loses money on the services rendered to every public assistance patient he or she treats. Some pediatric dentists solve this quandary by treating a limited number of these patients by setting limits on the age of patients they will treat, the age they "graduate" from the practice, or the number of such patients seen per day.
- Medicaid (known by other titles in some states) is a state-administered program in which each state sets its own guidelines regarding eligibility and services, including reimbursement rates. The wise practitioner investigates his or her state program thoroughly before deciding to become a public assistance provider. One might begin seeking information at a variety of websites available through the U.S. Department of Health and Human Services.

TREATMENT TRACKING

Treatment Plan Acceptance

Tracking diagnosed treatment on a daily basis has many advantages. Patients who are seen today should always have a future recare and/or restorative appointment. When a patient leaves without a future appointment, extra time and money must be spent to bring that patient back. By tracking who presented the cases and who assisted, the doctor can determine if there is a pattern for which patients accept or do not accept treatment.

What to Track at the End of the Day

- Number of patients who have another appointment scheduled after today's visit
- Number of treatment plans diagnosed
- Number of treatment plans scheduled
- Number of treatment plans not scheduled; who presented the treatment plan and who assisted with the patient. Training should be provided for treatment acceptance.

Actions

- Assign a staff member to stay in contact with the parents who did not schedule restorative treatment, to keep the importance of completing treatment fresh in their minds.
- Make the doctor aware of patients who did not schedule their restorative treatment, especially if it is a complex case or care has been neglected.
- Determine if case acceptance is 75% or higher.

Unscheduled Treatment

Each software system will have reports for tracking unscheduled treatment.

1) Once a month, run an unscheduled treatment plan report with your software. Work to schedule patients from this report regularly throughout the month.
2) Go through the report and delete any treatment that is no longer necessary or has previously been completed. Often, if treatment changes from the original treatment plan, the old treatment may possibly stay on the report.

Dentlearn.ir

3) Contact parents to discuss the importance of returning for treatment. Communicate possible consequences of not scheduling treatment and the advantages of completing treatment.
4) Document all attempts to contact the parent.
5) Document all conversations with the parents regarding a child's past due treatment.
6) Once the treatment diagnosis is 6 months old, schedule the patient to come back for continuing care.
7) Make no more than three attempts by telephone or text to contact the parent over the course of 2 months. If a parent does not respond and schedule an appointment to complete treatment, send a letter explaining the dental consequences of not completing treatment or not having periodic adjustments and examination of an appliance or orthodontic treatment. Such letters should be mailed to the patient's last known address with a Certificate of Mailing (PS Form 3817), which can be obtained from the U.S.

   in the patient's chart with the Certificate of Mailing attached, to prove that the letter was mailed and that the dentist's professional responsibility was fulfilled. A Certificate of Mailing adds nominal cost to first-class postage.

Recare

The foundation of any successful dental practice is the recare system. The recare system provides a constant source of recare and restorative appointments that safeguards children's oral health and emphasizes the fact that the dentist and staff care a great deal about them. The term *recare* is preferable to the frequently used word *recall*. *Recare* denotes ongoing, continuous attention, whereas *recall* suggests an occasional check for problems (e.g., the recall of an automobile for the replacement of faulty parts).

The most effective and efficient recare systems that retain the most patients are those in which the next recare appointment is scheduled 6 months in advance at the conclusion of the present appointment. A reminder postcard, e-mail, or text message should be sent 4 weeks before the appointment. Dental software systems and patient communication software are essential for helping to manage these messages. Run the unscheduled recare report once a month with your software. Send reminders by text messages and/or postcards to patients without appointments that are past due, now due, and coming due. Place reminder phone calls to those who do not respond.

There are two types of preappointed recare systems: *preselected* and *preassigned*. When implementing either system, the appointment secretary should emphasize to parents and patients that the preappointed recare system is for their convenience and is more likely to allow them to choose an appointment 6 months hence at the time that they prefer.

In preselected systems, at check-out, the parent chooses the next recare appointment. In 5 months, a notification with the day, date, and time is generated and mailed or an e-mail message is sent.

In preassigned systems the patient is automatically assigned a date and time for the next appointment. The appointment may be at approximately the same time as the present visit or it may alternate to be during or after school. Again, in 5 months an appointment reminder is sent by mail, e-mail, or text. This method is especially helpful in a busy practice because it speeds the check-out process.

For either a preselected or preassigned system, the appointment date is entered into the computer so that notifications can be generated when needed. If the recare appointment must be changed for any reason, such as a change in the dentist's schedule, rescheduling should be done by telephone.

On receipt of the recare card, parents who find the time inconvenient usually call to reschedule. A confirmation telephone call should be made 2 days before the appointment. The staff person calling to confirm should be prepared to reschedule appointments if changes are requested.

Flexibility to accommodate appointment changes initiated by the office can be built into the preappointed system by leaving 1 or 2 days unscheduled toward the end of each month. If the time is not needed for changed appointments, it may be booked 1 or 2 weeks ahead with regular restorative appointments, new examinations, and rescheduled appointments initiated by patients.

Checking Recare System Effectiveness

The recare program is the life-support system for any practice. The recognized minimum goal is for at least 8 of 10 active patients to return regularly at the prescribed frequency for hygiene appointments (i.e., 80% effectiveness). The effectiveness of the recare system should be checked at least quarterly.

Accuracy of the check depends on a close count of patients who have been seen in the previous 18 months (active patients), except those whose treatments could

Terminology [CDT] code No. DO140) and who are not enrolled as regular patients.

The following example illustrates a quick, easy way to check the effectiveness of a recare system:

- 4000 active patients ÷ 6 months (recare frequency) = 667 recare appointments per month for a 100% effective system
- Actual average for 3 months = 300 recare appointments per month
- 300 actual ÷ 667 potential = a 45% effective system
- Goal = 80% or more of active patients returning for regular recare appointments
- 4000 active patients × 0.80 = 3200 patients
- 3200 patients ÷ 6 months (recare frequency) = 533 recare appointments per month as 80% goal
- (533 recares per month as 80% goal = 300 recares per month actual average) = 233 additional recares per month
- 233 × $155 average recare fee (child with and without BWX and fluoride) = $36,115 per month increased production

Dentlearn.ir

- $36,115 per month production × 12 months = $433,380 of additional income generated from current patients—plus better care and service to patients

After the current effectiveness rate is determined, the dentist and staff can work toward the goal of 80% of active patients returning regularly for recare. Problems with the system should be listed and analyzed, and ways to improve the system must be planned and implemented. Many practitioners find that 60% or more of restorative and orthodontic treatment needs is diagnosed during hygiene examinations, which reinforces the importance of an effective recare system in any office.

Purging Charts and Reactivating Patients

It is important to purge patients' charts at least once a year, preferably in September or October. As defined by the American Dental Association, an active dental patient of record is any individual in either of the following two categories: Category I - patients of record who have had dental service(s) provided by the dentist in the past twelve (12) months; or Category II - patients of record who have had dental service(s) provided by the dentist in the past twenty-four (24) months, but not within the past twelve (12) months. An inactive patient is any individual who has become a patient of record and has not received any dental services(s) by the dentists in the past twenty-four (24) months.

The appointment secretary can run a report of patients who have not been seen during that year and telephone or e-mail the parents to stress the importance of regular hygiene appointments. Parents of children with incomplete treatment should be informed of the treatment yet to be rendered and the importance of completing it. Parents with dental insurance should be reminded that benefits for that year will be lost unless they schedule an appointment for their child before year's end. Many people will schedule an appointment to avoid losing insurance benefits. Individuals who refuse to reschedule should be contacted once more, and so noted in the patient chart, before their charts are placed in the inactive file. It costs the practice five times as much to attract a new patient as it does to keep an existing one. Practices need to invest time and effort in patient retention and reactivation.

Some state laws specify a minimum period after the last treatment date that dental records must be maintained. Regardless of the statutory requirement, it is best to maintain records for as long as possible but certainly no less than 10 years from the last treatment date for adults and up to age 28 for patients treated when they were children. Charts should be kept as evidence against malpractice claims and to answer medical or dental questions that may arise in later years. If storage becomes a problem, records can be scanned into digital files. Such records are admissible in most state courts. Of course, a proper backup system for storage of inactive charts must be maintained if the office has only computerized charts.

For additional information regarding patient records, pdfs/dentalpractice_dental_records.pdf. Steps for reactivation include:

- Print a list of patients who have not been seen for 12 or 18 months.
- Document all efforts to contact the parent.
- Place phone calls during times when you expect the phone to be answered.
- Leave a message: "I am calling about your child's dental health."
- Follow up the phone message with an e-mail if the call is not returned.
- Send letters via U.S. mail only after all other attempts have been unproductive.
- If at any time during this process the parent states that the family has gone elsewhere for dental treatment, ask if there was anything that your office could have done differently, since you are striving to provide excellent customer service. Document reasons for their voluntary release from the practice in their ledger, and let the patients know that you will welcome them back into the office at any time.
- Once a patient has gone more than 24 months without an appointment or the contact information is no longer valid, the patient should be placed on inactive status.

Parents "buy" three "products" in a pediatric dental "store": procedures and information to help prevent dental disease, procedures to treat dental disease, and the dental team. There are two avenues through which these

The extent as to where and how external marketing activities will occur depends on the doctor's desire and the available mix of full-fee, PPO, and Medicaid patients for the practice.

The doctor should create a marketing team that will

forts 12 months a year to ensure a continuous stream of new patients. The goal is to build a "marketing machine" of regularly repeated activities that results in an increased awareness of the importance of all children having a dental home by age 1 and what a pediatric dentist can offer to infants and children vs. a general dentist. Marketing expenses should be built into the budget and should be 1% to 5%, depending on the number of unfilled appointments in the schedule. New patients should be counted by CDT code 0150 Comprehensive Exam, and a doctor who sees patients 4 days a week should strive for 55 to 75 new patients per month, depending on the level of decay in the community.

Practice Branding, Website, and Social Media

- Practice branding should reflect the identity of the practice. A logo starts the branding process and should be carried out in all things related to the practice: office décor, uniforms, business cards, stationery,

  It is important that the branding be easily recognizable by parents and communicates that the practice delivers specialized dentistry for children.

Dentlearn.ir

Monthly Marketing Meeting

- Hold a monthly marketing meeting between the doctor and staff members who are assigned to the marketing team and are responsible for executing marketing actions. This meeting creates your monthly marketing action plan.
- Each month, print a new-patient referral report and examine it to determine the following:
  - Who is referring—parents, pediatricians, general dentists, or obstetricians?
  - How should they be acknowledged?
  - What marketing actions are working? What are not?
  - What new marketing actions should be carried out in the next month?
- Thank referral sources
  - All referral sources should be acknowledged with appreciation. (Always check your state's Dental Practice Act to be sure you are in compliance. Some states do not allow a referral gift to be given.)
  - Parents can be thanked with a handwritten note and a $5 gift card.
  - Health care offices can be thanked with a box of treats or a variety of small gifts for staff members. These can be dropped off monthly, bimonthly, or quarterly, depending upon the number of referrals sent.

that are focused on exceeding expectations and creating loyal relationships with the parent and child so they will come in for regular preventive appointments, accept treatment plans, and refer friends and family. Existing families should be your biggest referral source, due to your excellent customer service.

Prevention of Dental Disease

- Provide as much patient education as possible! The amount of patient education a parent/patient receives makes the difference between a "satisfied" parent/patient and a "highly satisfied" parent/patient. Parents are willing to pay more for services when they feel they have also received excellent preventive and postoperative education.
- Educate the caregiver on how to prevent and reduce early childhood caries (ECC) through providing information about proper brushing and flossing, healthy diet and snacks, fluoride, and preventive visits.
- Provide educational materials
  - Give written material to the parent that reinforces caries prevention, Oral Hygiene Instructions, and/or postoperative instructions.
  - Have pictures and models of the different dental procedures so parents can better understand what is being recommended and how it will benefit their child.
  - Utilize technology to educate caregivers. The Baby Infant Oral Health Program website is an excellent resource that educates caregivers, team members, and expectant mothers about the prevention of

Dental Team

Parents typically have a choice of pediatric dental practices where they can seek treatment for their child. Most often their choice is based on who will be providing the care. Parents must **T**rust, **L**ike, and have **C**onfidence in the team before they will "buy" a treatment plan; therefore the most important "product" in the dental office is the team that provides the TLC. Each staff member is just as important a "product" as the doctor. A great doctor can be tarnished by a front desk staff member who is rude or a clinical staff member who is rough and insensitive.

- The appearance of the team should reflect excellence; uniforms should look clean and crisp.
- Staff hair, makeup, and jewelry should be appropriate.
- Use good eye contact, smile as you shake the parent's hand, and introduce yourself along with your position in the office.
- Ask the parent and child about themselves, their dental concerns, interests, hobbies, sports. Show genuine interest in them.
- Find something on which to compliment them. Make them feel good about themselves.
- Listen well. Do not interrupt. Be empathetic, friendly, and polite.
- Laugh and have fun. People remember how you make them feel more than what you say.
- Make a personal note about the child and date it in the chart so this topic can be discussed at the next visit by anyone in the office.
- Review the personal notes before seeing the child.
- Send handwritten personal notes/cards to patients to welcome them to the practice or compliment them on being a good patient. Have a pleasant and educational "on hold" message.
- Ask for referrals. After a parent compliments the practice, say, "Thank you for appreciating what we do here. We are always welcoming new patients to the practice. If you know any families who would also enjoy this type of practice for their children, please tell them about us. We would enjoy helping them."
- Offer more flexible financial options for payment.
- Become a preferred provider on higher-paying insurance plans.
- Increase the number of new Medicaid patients to fill open time.

Facility

- The appearance of the facility should reflect excellence. Parents judge the quality of your clinical excellence on everything they see, touch, and hear. If the office looks out of date and shabby, with stained carpet and paint-chipped walls, then parents will think that the clinical dentistry is behind the times and of poor quality and will have concerns about infection control.
- Create a good flow for check-in and check-out so that bottlenecks do not occur. Typically there is one check-in station and two check-out stations, separated for private financial conversations.

Dentlearn.ir

- Create a comfortable area for parents, play areas with electronic games and special toys for young patients, and perhaps a separate area for teenage patients.
- Keep the facility up to date by redecorating every 5 years.

External Marketing

External marketing involves activities outside of the office to create an awareness of and need for your services. The AAPD has created a number of marketing programs for use by its members that can be found on the AAPD website.

Marketing to Health Care Professionals

- Pediatricians should be your second top referral source after parents of existing patients. Other referring health care professionals are general practitioner physicians, general practitioner dentists, obstetricians, and school nurses.
- Educate health care professionals and their staffs about the importance of a child having a dental home by age one and what a pediatric dentist can offer. This can be done by offering to conduct "lunch and learn" sessions in their office. Be aware that it is not just the physician who refers; parents ask nurses and front desk staff where to take their child for dental care. Therefore it is just as important to educate the staff of referring offices as well as the physician.

Dental Health Education Programs

Dental health education programs are a wonderful way to speak directly to children. They can be scheduled in public and private schools, day care centers and homes, vacation Bible schools, and summer day camps. Alterna-

field trip. Follow the tips below:

- The program will be more memorable if you include a staff member dressed as a tooth fairy, mascot, super hero, or popular fictional movie character. The costumed character you choose should become part of your practice "branding." Have a picture of your mascot on your website and in your reception room.
- Make your program interactive with the children. The more children interact with the information you share, the more they will remember.
- Include a letter to the parents in the child's goody bag that has the following information: who you are, information about the presentation, what the child learned, information about ECC, and a "call to action" about the importance of having preventive visits and a dental home by age one.
- Your mascot can also be in a booth at health fairs, especially health fairs for expectant mothers and mothers of newborns.

Website and Social Media

- Most parents now use the Internet or a mobile device to search for a children's dentist instead of the Yellow Pages in the phone book. Make your website mobile-optimized and own multiple domain names that parents might use to find you/your practice name.
- Utilize a reputation management company that can also boost your search engine optimization to help you stay competitive.
- Set up your Google Places Page with information that exactly matches what is on your website name, phone, and address. Google Maps gets its information from your Google Places Page.

User-Friendly Website

- Meet the dentist: video clip of the doctor introducing him/herself and talking about his/her practice philosophy. Discuss your practice's unique qualities and why families love you.
- Meet the team: video clip of staff members talking about the practice and why they like working there.
- Testimonials: video clip of satisfied parents and patients.
- Include pictures of your office.
- Provide your location, including a Google Maps link.
- List the insurance plans with which you have contracts.
- Get information on dental topics.
- Be able to fill out New Patient Information forms online.

Social Media

Social media are an inexpensive way to help maintain relationships and foster loyalty with your current patient base. They can also greatly expand your reach to new patients. There are several choices of social media to promote your practice:

when they are not in your office.

- LinkedIn—the "professional" connection with colleagues and other business people.
- Blogging—the "educational" connection for you to share your professional knowledge and current thoughts regarding topics in the industry.

sion in real time.

- Pinterest— the "social bookmarking" site where users collect and share photos of their favorite events, interests, and hobbies.
- Manage your online reputation by interacting with parents/patients as you see fit and posting information that you feel is important.
- Have policies in your Employee Policy Manual related to social media that address the following issues:
  - Use of practice equipment and services

    tion
  - Protection of patient information
  - Use of the Internet to harass co-workers
  - Prohibition against criticizing patients and vendors
- Ensure that staff members understand the detrimental effects of negative comments about their workplace on social media sites. There is little privacy on the Internet.

Dentlearn.ir

- Monitor doctor rating sites by setting up a Google

cated staff and doctor time to sustain a consistent presence and monitor content. Set aside 10 minutes a day to update and review your social media sites.

DENTAL OFFICE TECHNOLOGY

Dental offices are increasingly using technology because it is efficient, because parents like the convenience, and because practice management software systems are vital and give the doctor and OM good business information.

- Basic technology for the front desk includes: dental practice management software system, patient communication software, scanners, printers, multiple computers, and multi-line phone systems. Invest in a software system that allows for electronic statements and electronic claims submission and clinical charting.
- Regular cloud and mirror backup systems are imperative to ensure that data are not lost.
- Limits to staff access levels in the systems need to be adjusted to avoid changes in settings.
- Chartless offices require the use of scanners and digital radiography; they are also more efficient and cost-effective.
- Advanced technology for clinical teams would include Isolight, Diagnodent, Digital Radiography, Waterlase, and much more.

COMPLIANCE

Pediatric dental practices should make compliance standards a top priority and must provide training to the staff to ensure that compliance standards are followed and that mandatory forms are signed by each parent or guardian. The main categories for compliance standards are as follows:

1. Infection control—Centers for Disease Control and Prevention: Sterilization processes and routine spore-testing.

   guidelines/index.htm[10]
2. HIPAA Compliance: HIPAA Privacy Rule gives patients some rights over their dental records, billing ledgers, and other health information.

   .org/checklist.htm[11]
3. Patient Records Compliance: Check your state's Dental Practice Act for information on record-keeping requirements in your state.

   pdfs/dentalpractice_dental_records.pdf [9]
4. OSHA Compliance: Follow all OSHA and state regulations. Maintain records of all training and all required documentation, including sports testing, sharps disposal, as well as CPR training.

   3187.html[12]
5. Many states require that labor laws be posted. Additional postings specifically for the dental office may be required in your state, such as pay date postings, what to do in case of injury on the job, etc. Check with your state Labor Board for compliance requirements.
6. Be sure that you are in compliance with parents' signing informed consents for treatment. The AAPD web-

   Informed Consents.
7. Keep your credentials current.
   - Declarations pages from the insurance companies, CPR cards, DEA license, dental license, and certifications all must be kept current, and there are penalties if these expire.
8. Stay compliant with insurance company contracts.
   - Insurance companies often send reminders for updated paperwork.
   - Immediately update any doctor provider changes for credentialing with contracted insurance companies. Insurance companies will not pay for work performed by a doctor who is not credentialed.

CLINICAL ORGANIZATION

- Clinical supplies stored in cabinets and carts should be identical in each room so that materials can be found quickly; this ensures efficiency.
- It is less expensive to maintain and service equipment than to replace it. Review all service manuals and follow the manufacturer's recommendations for service. Place notes on the schedule when service is due and document all service in a maintenance logbook (Fig. 31-11).
- Ensure that handpieces are oiled and maintained according to the recommendations.

INVENTORY CONTROL

A well-organized inventory system will keep you from running out of necessary supplies and materials or being oversupplied and thus tying up excess cash.

- Create a list of all the materials used in the office and where these supplies are ordered. All items that are used in the practice should be assessed once a year, catalogued, and included in the systems manual.
- Work with your dental supply company to create a barcode scanner or a tag system for reordering supplies. Inventory control involves communication among all team members; it is not one person's responsibility to report supplies that are running low.
- Store dental materials in ideal conditions. Failure to store products as per the manufacturer's recommended conditions may lead to having to throw out materials and/or procedure failures/redos.
- A front desk staff member should be in charge of front office supplies, and a dental assistant should be in charge of clinical supplies.
- Each should work within the practice's monthly front office and clinical supply budget. Ask for the best deals possible and keep a log of supply orders.

ACKNOWLEDGMENTS

I am grateful to Lilly Cortes-Pona and Brenda McNulty for their excellent contributions of practice management knowledge in this chapter.

Dentlearn.ir

Clinical Maintenance Checklist

Daily	
☐ Compressors turned on AM off PM	☐ Turn vacuum on AM off PM
☐ Turn water lines on AM off PM	☐ Check fluid levels in sterilizer—always before a cycle
☐ Open nitrous and O2 tanks	☐ Fill ultrasonic/drain at end of the day
☐ Refill water bottles on all units	☐ Back up computer hard drives
☐ Clean out/change as needed vacuum traps and run vacuum system cleaner through all lines	☐ Purge water lines by blowing air through them at the end of the night
Weekly	
☐ Spore test sterilizer	☐ Clean outside and inside of the sterilizer
☐ Check traps on all dental units	☐ Check o-rings for wear and replace as needed
☐ Lubricate vacuum valves	☐ Clean ultrasonic
☐ Wipe down light reflectors and shields	☐ Check oil on oil-lubricated compressors and drain compressor tank
☐ Empty and clean out water bottles on all units	☐ Clean out boiling chamber of water distiller
Monthly	
☐ If using plaster trap clean and check	☐ Check AED battery and emergency supplies such as med kit
☐ Lubricate joints on equipment	☐ Check all filters
Quarterly	
☐ Check filters on compressor	☐ Check filter on vacuum
☐ Check and/or change compressor oil	☐ Check tubing on the units and N20
☐ Clean model trimmer wheel	☐ Check traps on model trimmer and drain lines
☐ Check hydraulic fluid on the chairs	☐ Check battery backup systems on all computers
☐ Check smoke alarms	☐ Verify computer backup
Yearly	
☐ At least yearly change the oil in the compressor	☐ Change sterilizer gaskets
☐ Conduct staff OSHA training	☐ CPR (every 2 years if AHA)
☐ Check for worn cords	☐ Check equipment for leaks
☐ Conduct emergency drills	☐ Check AED for expired pads or battery
☐ Have x-ray equipment inspected, calibrated, and certified	☐

LOGBOOKS:

☐ X-ray calibration and recertification of equipment logbook	☐ Fire extinguisher replenishment and fire inspections logbook
☐ Sharps and red bag contaminates disposal log	☐ Spore testing and documentation of sterilization equipment maintenance log
☐ MSDS logbook	☐ Dosimeter results log
☐ Staff training logbook	☐ Water line testing log
☐ Oil changing in the compressor log	☐ Other state required mandated logs

Figure 31-11 Clinical maintenance checklist.

REFERENCES

1. Collins J: *Good to great*, New York, NY, 2001, William Collins.
2. Parker JF: *Do the right thing*, Upper Saddle River, NJ, 2008, Pearson Education Inc.
3. *The Rule of 72: double your money, reduce your debt*. Available
4. Kouzes JM, Posner BW: *The leadership challenge*, San Francisco, 1995, Jossey-Bass Inc.
5. American Dental Association. Member Services. Available at:

   ence librarians at the ADA Library, 312-440-2653.
7. Blanchard K, Johnson S: *The one minute manager*, New York, 2003, Harper Collins.
9. *American Dental Association Council on Dental Practice*, http

   practice_dental_records.pdf, 2007.

   .gov/oralhealth/infectioncontrol/guidelines/index.htm.
11. U.S. Department of Health and Human Services. HIPAA Pri-

    hipaa.

    osha.gov/Publications/OSHA3187/osha3187.html.

A

AAPD. *see* American Academy of Pediatric Dentistry (AAPD)
ABO. *see* American Board of Orthodontics (ABO)
Abortion, spontaneous, 90–91
Abscess, alveolar, 40, 40f–41f
  after pulp therapy, 239
Absolute neutrophil count (ANC), 557
Abuse. *see* Child abuse and neglect
Acatalasia, 48
Accounts payable. *see* Practice management
Acetaminophen, for postoperative pain, 284t
Achondroplastic dwarfism, eruption of teeth and, 368, 371f
Acid-etch technique, 212, 213f
Acquired and developmental disturbances, of teeth, 39–79
  agenesis of teeth, 61–64
    anodontia, 61–62, 62f
    ectodermal dysplasias, 64, 65f–66f
    hypodontia, 62–63
      and cancer, 63–64
      and palatally displaced canines, 63
  alveolar abscess, 40, 40f–41f
  amelogenesis imperfecta, 59–61, 60f
  cellulitis, 40–41, 41f
  dentin defects, 56–59
    dentinogenesis imperfecta, 56–59, 56f–58f
    dysplasia, 59
  early exfoliation, 43–48
    acrodynia, 48
    cherubism (familial fibrous dysplasia), 45–48, 46f–47f
    cyclic neutropenia (cyclic hematopoiesis), 48
    hypophosphatasia, 44–45
    hypophosphatemia, 48
  enamel and dentin aplasia, 61, 61f
  enamel hypoplasia, 49–54, 49f
    allergies and, 50–51
    from brain injury and neurologic defects, 50
    cleft lip and palate and, 51
    fluoride and, 53–54
    ionizing radiation and chemotherapy, 52, 53f
    lead poisoning (plumbism) and, 51
    local infection and trauma, 51, 51f–52f
    microabrasion and, 54, 54f
    molar-incisor hypomineralization and, 52–53
    nephrotic syndrome and, 50
Acquired and developmental disturbances, of teeth *(Continued)*
    from nutritional deficiencies, 49–50, 50f
    from rubella embryopathy, 52, 53f
    treatment of, 53
  labial frenum, abnormal, 73–74, 73f–74f
    frenectomy, 73–74, 74f–75f
  micrognathia, 68–69, 69f
  pigmentation of teeth, 65–68
    bleaching of intrinsic tooth, 68, 68f
    in cystic fibrosis, 67
    in hyperbilirubinemia, 65–66, 67f
    in porphyria, 66–67
    in tetracycline therapy, 67–68, 67f
  pre-eruptive "caries," 54–56, 54f–55f
  taurodontism, 56, 56f
  teeth anomalies, 41–43
    dens invaginatus (dens in dente), 43, 44f–45f
    fusion of teeth, 42, 43f
    gemination, 42–43, 43f
    odontoma, 41, 42f
  tongue anomalies, 69–73
    ankyloglossia, 70, 70f
    black hairy tongue, 72, 72f
    coated tongue, 71–72, 72f
    fissured tongue and geographic tongue, 71, 71f
    indentation of margin, 72
    macroglossia, 70
    median rhomboid glossitis, 72
    trauma, tongue piercing, 72–73, 73f
    white strawberry tongue, 72
Acquired immunodeficiency syndrome (AIDS), 549–551
Acrodynia, 48
  and periodontitis, 259
Active listening, 298
Acyanotic congenital heart disease, 536
Acyclovir (Zovirax), for herpes simplex virus infection, 246–247
ADA. *see* American Dental Association (ADA)
"Addictive" foods, 152
Adenomatoid odontogenic tumor, 616–617, 616f
Adhesives, dental, 212–214
Adolescents
  dental caries. *see* Caries, dental
  diet sodas and sports/energy drinks for, 151
  healthy eating in, 150
  home oral hygiene for, 135
  meal replacement shakes and smoothies for, 151
Adolescents *(Continued)*
  occlusion, development of. *see* Occlusion, developing
  pain control. *see* Anesthesia, local, and pain control for child and adolescent
  prosthodontic treatment of. *see* Prosthodontic treatment of adolescent patient
  substance abuse, 14
Aesthetics
  facial, 408–414, 409f
    frontal view, 409–411, 409f–412f
    profile view, 411–414, 412f–413f
  orthodontics for, 467–468
Agranulocytosis, and periodontitis, 259
AIDS. *see* Acquired immunodeficiency syndrome (AIDS)
Airway management, in sedation, 319–320, 320f
Airway obstruction, in cleft lip and palate, 488, 488f
Albright hereditary osteodystrophy, 368–372
Alginate impression, 485
Alleles, 92
Allergies
  and enamel hypoplasia, 50–51
  and gingivitis, 245
Alloys
  high-copper, 215
  and mercury ratio, 215
  selection of, 215
Amalgam, 214–218
  in bonded restorations, 217
  in marginal breakdown and bulk fracture, 216–217, 216f
  in restorative dentistry, 191, 192f
  silver, in restorations, 186
Amalgamators, mechanical, 216, 216f
Ameloblastoma, 615–616
Amelogenesis. *see* Enamel, hypoplasia
Amelogenesis imperfecta, 59–61, 60f, 95
American Academy of Child and Adolescent Psychiatry, 14
American Academy of Pediatric Dentistry (AAPD)
  alternative restorative treatment, 201–202
  anesthesia guidelines, 671
  Behavior Guidance for the Pediatric Dental Patient Reference Manual 2014-15, 520
  behavior management, 286
  caries risk assessment, 163–164, 164t–165t
  in cleft lip and palate, 489–490
  early childhood caries, 158

Note: Page numbers followed by "b", "f" and "t" indicate boxes, figures and tables respectively.

Dentlearn.ir

American Academy of Pediatric Dentistry *(Continued)*
gingivitis and periodontal disease, 243
guidelines for
pediatric care, 2t
in performing moderate sedation, 325
pit and fissure sealants, 178
preoperative dietary instructions, 322
special health care needs, 513
American Association of Oral and Maxillofacial Surgeons, 632
American Board of Orthodontics (ABO), 467
American Board of Pediatric Dentistry, parenting styles and dental practice, 294
American Cleft Palate-Craniofacial Association, 480, 489
American Dental Association (ADA)
pit and fissure sealants, 178
Toothbrush Acceptance Program Guidelines of, 125
American Journal of Orthodontics, 468
American Society of Anesthesiologists, physical status classification system, 321, 321b
Americans with Disabilities Act, 514
Amicar, 544
ε-Aminocaproic acid, 544
Amoxicillin, for periodontitis, 258–259
Analgesia, for hemophilia, 545
Analgesics, 284, 284t
Analog film, 20–21
direct, 20, 20t
indirect, 20–21, 20f
Anesthesia
continuum of, 303–305, 304f
general
see also Hospital dental services
topical fluorides in, 169–170
local, and pain control for child and adolescent, 274–285
complications after, 282–283
toxicity, 282–283, 283t
trauma to soft tissue, 283, 283f
by conventional injection, 275
dental anesthesia
analgesics, 284, 284t
reversal of, 283–284
for hemophilia, 545
jet injection, 275
of mandibular teeth and soft tissue, 275–277
conduction anesthesia (Gow-Gates mandibular block technique), 277, 277f
conventional mandibular block, 275–276, 276f
infiltration anesthesia, for mandibular primary molars, 276–277
infiltration for mandibular incisors, 277
lingual nerve block, 276
long buccal nerve block, 276, 276f
Anesthesia *(Continued)*
maxillary permanent molars, 279–280
maxillary primary and permanent incisors and canines, 278
local infiltration (supraperiosteal technique), 278, 278f
maxillary primary molars and premolars, 278–279, 279f
palatal tissues, 280
greater (anterior) palatine injection, 280, 280f–281f
nasopalatine nerve block, 280, 280f
supplemental injection techniques, 281–282
computer-controlled local anesthetic delivery system, 282
infraorbital nerve block, 281
intraosseous, interseptal, and intrapulpal injections, 282
mental nerve block, 281
periodontal ligament injection, 281–282
topical anesthetics, 274–275
local, sedation and, 318, 318f–319f
Aneuploidy, 91t
Angles of growth. *see* Cephalometrics
Angular cheilitis, 550
Anhidrotic ectodermal dysplasia, 64
Ankyloglossia (tongue-tie), 70, 70f
Ankylosis, 582–584
see also Tooth (teeth), ankylosed
Anodontia, 61–62, 62f
Anorexia nervosa, 148–149
Anterior mandibular occlusal technique, in bitewing radiography, 27, 30f
Anterior maxillary occlusal technique, in bitewing radiography, 26, 28f–29f
Anterior nasal spine, 394
Antibiotic, prophylaxis, in hemophilia, 547
Anticipatory guidance, 1
Antidiuretic hormone, 542–543
Antifibrinolytic agents, for hemophilia, 544–545
dosages of, 544–545
side effects of, 545
Antihistamines, for sedation, 310–311
diphenhydramine (Benadryl), 311
hydroxyzine (Atarax, Vistaril), 310
promethazine (Phenergan), 310–311
Antiseptic agents, for plaque control, 129–132, 130f–131f
Antiviral medication, for herpes simplex virus infection, 246–247
Anxiety
dental, 291
parental, 292
Apert syndrome, 96
Apexification, 573–576, 575f, 577f
Aphthasol, 249
Aphthous ulcer, recurrent, 248
A point, in cephalometrics, 394
Appliances, dental
and caries, 162
in cleft lip and palate, 484–490
for early tooth loss, 422–423
Appointments. *see* Practice management
Apposition, 81, 81f
Arch, teeth arrangement in, 162
Aromatase, 103
Articaine, 277
Articulare, 394
Ascorbic acid deficiency gingivitis, 256, 256f
ASD. *see* Autism spectrum disorder (ASD)
Asthma, 531–532
Astringedent, 234
Asymmetric tonic neck reflex, 530
Atraumatic Restorative Treatment (ART), 201
Attending, 298
Attitude, in dental team, 296
Audiologist, in cleft lip and palate, 484
Autism spectrum disorder (ASD), 528–529
Autograft, free gingival, 266–268, 267f–268f
Autoimmune disorders, 551
Autosomal-dominant inheritance, 93, 93f
Autosomal-recessive inheritance, 93–94, 94f
Autosomes, 90
Aversive conditioning, 299–300
Avulsion, of injured tooth, 588–593, 589f–590f
treatment of, 594b–595b
Awareness, of dental problem, 292
Azidothymidine (AZT), 550

B

Bacterial infections, in HIV infection, 551
Basic life support (BLS), 640
Basion, 394
Basion-nasion plane, 395
Battered child syndrome, 110
Beanbag dental chair insert, 522, 524f
Behavior
in child abuse, 113
nonpharmacologic management of, 286–302
age-related psychological traits and skills, 287b
parents, 294
pediatric dental patients, 286–294
cooperative behavior classification in, 292–293
developmental milestones in, 287, 288t–290t
functional inquiry in, 293–294, 293b
general problems with, 292
intellectual development in, 291
medical experiences, 292
parental anxiety, 292
questionnaire in, 293
toxic stress, 292
treatment triangle, 286, 287f
variables influencing, 291–292
pharmacologic management of, 303–327, 304f
anatomic and physiologic differences in, 305–306
airway, 306, 306f
body size and composition, 306

Dentlearn.ir

Behavior *(Continued)*
cardiovascular system, 305–306, 306t
central nervous system, 305
respiratory system, 306
definition of, 303–305
documentation of, 320–321
drugs and agents used for sedation, 309
antihistamines, 310–311
benzodiazepine agonists and antagonists, 311–312
hypnotics, 313–314
nitrous oxide, 309–310, 314–316
opioid agonists and antagonists, 312–313
facilities and equipment for, 319–320
fundamental concepts of, 305–314
monitoring of, 322–324, 323f–324f
intraoperative, 322–324
postoperative, 324
patient selection and preparation in, 321–322
indications for, 321
informed consent, 321–322
instructions to parents in, 322
preoperative evaluation of, 321
routes of drug administration, 305–306, 308f
enteral, 307
inhalational, 307, 318
intramuscular, 307
intravenous, 307–308
rectal, 309
submucosal and subcutaneous, 307
sedation, 303, 304f
combination of methods and agents in, 318–319
continuum of, 303–305, 304f
intravenous, 305
oral, 305, 318–319
strategies of dental team, 294–301
aversive conditioning in, 299–300
behavior shaping in, 298–299, 299f
communicating with children in, 297–298
guidance of child, 295–297
limitations in, 301
parent-child separation in, 300–301
preappointment behavior modification, 295, 296f
reinforcements, tangible, 301
retraining in, 299
scheduling in, 300
Benadryl, for herpes simplex virus infection, 246
Benzodiazepine agonists and antagonists, for sedation, 311–312
diazepam (Valium), 311, 318
flumazenil (Romazicon), 312
midazolam (Versed), 311–312
Bethesda units (BU), 543–544
Binge-eating disorder, 150
Biofilm, infection control in dental office, 16
Biostatistics, 646
Bisecting angle technique, in periapical radiography, 23, 26f
Bisphenol A-glycidyldimethacrylate (bis-GMA) resin, 208
Bisphosphonate, eruption of teeth and, 372
Bite block, 627–628, 628f
Bite marks, in child abuse, 115–116, 115f
Bitewing radiography, 23–27, 27f
Black hairy tongue, 72, 72f
Bleaching, of intrinsic tooth discoloration, 68, 68f
Bleeding disorders. *see* Hemophilia
Blindness, 534
Bloch-Sulzberger syndrome, 368–372
BLS. *see* Basic life support (BLS)
Bluegrass appliance, 440, 441f
Blue light-emitting diodes, 210–211
Blunderbuss canal, 572
BMI. *see* Body mass index (BMI)
Board certification competencies, 650b
Body mass index (BMI)
obesity and, 145
standards for children, 146t
Bohn nodules, 356–357
Bone
benign tumors of. *see* Tumors, benign, of bone
endochondral formation of, 378
freeze-dried, for pulp capping, 235
lesions in leukemia, 555
on nonerupted tooth, 422
Bone grafting, of alveolar cleft defects, 488–489
primary, 489
secondary, 490–493, 494f–496f
Bone marrow transplantation, 558–559
Bottle feeding, dental caries and, 158
B point, in cephalometrics, 394
Brachyfacial pattern, 404, 405f
Brain injury, and enamel hypoplasia, 50
Brain tumors, 560
Brass ligature, for ectopic eruption, 456
Breakfast, nutritious, 150
Bronchopulmonary dysplasia, 532
Bruises, in child abuse, 112–115
Bruxism, 435, 437f
in cerebral palsy, 530
BU. *see* Bethesda units (BU)
Bulimia, 149–150
Burns
in child abuse, 112–113, 113f
oral
management of, 596–600, 598f–600f
nature of injury, 597, 597f
Butacaine sulfate, in pain control, 275

C

Calcification, of teeth, 81, 349, 350t
of anterior primary teeth, 81
dystrophic, 580–581, 580f–581f
of posterior teeth and first permanent molar, 81–82
Calcium, dietary, 144
Calcium hydroxide
liner, in pulp therapy, 224–226
pulpotomy, 572
Calcium phosphate ceramics, for pulp capping, 235
Calculus, 271–272
Caloric intake, 140
Cancer
and hypodontia, 63–64
obesity and, 145
Candida albicans, 550
Candidiasis
acute, 250, 250f
in leukemia, 557–558
Candidosis, 250, 250f
Canines
eruption guidance for, 459–461, 460f
congenitally missing teeth in, 464–467, 466f
diastemas in, 462, 463f
supernumerary teeth in, 462–464, 463f–465f
mandibular, 83
maxillary, 82
impacted, 635
palatally displaced, and hypodontia, 63
primary, early loss of, 424–425, 426f
primary and permanent, anesthesia for, 278
Canker sore, 248–249, 248f
Capitation contract dentistry (CCD), 676
Capnography, 323–324, 325f
Capping materials, 233–236
calcium hydroxide, 233–234, 234f
dentin-bonding agents, 235
ferric sulfate, 234–235
formalin, 234, 235f
mineral trioxide aggregate, 235
summary of, 236, 237f, 237t
zinc oxide-eugenol, 233
Carbohydrates, fermentable, 165–166
Caries, dental
activity tests for, 172
anatomic characteristics of teeth and, 162
antimicrobial agents for, 166–171
chlorhexidine, 172
povidone-iodine, 172
thymol, 172
xylitol, 172
appliances and restorations presence and, 162
bottle feeding and, 158
in cerebral palsy, 530
control of, 164–171
active lesions, 164–165
dentist's role in, 155, 173
fermentable carbohydrate intake, 165–166
oral hygiene procedures, 166
deep, indirect pulp treatment of, 224–226, 224f–226f
see also Pulp therapy
diagnostic tools for, 171–172
digital imaging fiberoptic transillumination, 171–172
infrared laser fluorescence (DIAGNOdent), 171, 171f
quantitative light fluorescence, 172
in early childhood, 158–159, 159f–160f

Dentlearn.ir

Caries, dental *(Continued)*
early detection of, 162–163
etiology of, 156–157, 157f
fluoride uses, 166–171
combined therapies, 170
communal water fluoridation, 167–168
in dental office, topical, 168–169, 169f
in dietary supplements, 170
fluoride-containing dentifrices, 168, 168f
for fluorosis, 170–171
in general anesthesia patient, topical, 169–170
home-use mouthrinses, toothpastes, and gels, 170
over-the-counter mouthrinses and gels, 170
genetics and, 98–99
hereditary factors of, 162
incidence of, 156
nursing, 158–159
pre-eruptive, 54–56, 54f–55f
in preschool children, 157–158
preventive therapies for, 172
chlorhexidine and thymol, 172
povidone-iodine, 172
xylitol, 172
in primary teeth. *see* Primary teeth; cavity preparation in
rampant, 158, 159f, 164
restorative dentistry for, 194–196
see also Restorative dentistry
risk assessment, 163–164, 164t–165t
AAPD policy statement, 158
saliva and, 159–161
deficiency of, 160–161, 161f
flow reduction of, 161
viscosity of, 161
in school children, 158
sealants, pit and fissure, 178
socioeconomic status and, 161–162
teeth arrangement in arch, 162
treatment of, 221–242
vaccine, 172
Caries-Risk Assessment Tool (CAT), 516
Carriers, of hemophilia, 543
Cartilage, growth of, 378
Cartoons, on toothbrushes, 121, 121f
CAT. *see* Caries-Risk Assessment Tool (CAT)
Cavities. *see* Caries, dental
CCD. *see* Capitation contract dentistry (CCD)
CCPH. *see* Community Campus Partnerships for Health (CCPH)
CDC. *see* Centers for Disease Control and Prevention (CDC)
Cell differentiation, 89–90
Cellulitis, 40–41, 41f
Cements
luting
glass-ionomer, 219
polycarboxylate, 219
zinc phosphate, 218
resins, 219–220
Cements *(Continued)*
tetracalcium phosphate, for pulp capping, 235
zinc oxide-eugenol, 164–165
Centers for Disease Control and Prevention (CDC), 648
Central papillary atrophy, of tongue, 72
Cephalometrics, 390–414, 391f
Angle classification of occlusion in, 406–408, 407f–408f
anteroposterior interarch discrepancies in, 403–404, 403f–404f
computerized, 402
dentofacial measurements in, summary of lateral, 413f
directions of growth in, 401–402, 402f
for facial aesthetics, 408–414, 409f
frontal view, 409–411, 409f–412f
profile view, 411–414, 412f–413f
in facial types, 404
frontal assessment in, 400–401, 401f
interpretation of, 395
lateral assessment in, 396–400
mandibular dental, 398–399, 398f
mandibular skeletal, 397–398, 397f–398f
maxillary dental, 396–397, 396f–397f
maxillary skeletal, 396, 396f
soft tissue, 400, 400f
vertical, 399, 399f
radiographic technique in, 391–393, 392f
frontal (posteroanterior) film, 392–393, 393f
lateral head film, 391–392, 392f
reference lines, angles and planes in, 395, 395f
reference points for lateral tracing in, 394–395, 394f
tracing technique in, 393–394, 393f–394f
vertical arch discrepancies in, 405
Cerebral palsy, 529–531
and enamel hypoplasia, 50
CF point, 395
CGH. *see* Comparative genomic hybridization (CGH)
Charters method, of toothbrushing, 127
Chédiak-Higashi syndrome, 48
and periodontitis, 100, 259
Cheiloplasty, in cleft lip and palate, 488
Chemically cured sealant, 181
Chemotherapy
and enamel hypoplasia, 52, 53f
for plaque control, 129–132, 130b
antiseptic agents, 129–132, 130f–131f
enzymes, 132
plaque attachment interference agents, 132
plaque-modifying agents, 132
sugar substitutes, 132
Cherubism (familial fibrous dysplasia), 45–48, 46f–47f
Chewing gum
for caries prevention, 172
for plaque control, 132
Child abuse and neglect, 110–119
definition of, 110–112
documentation of, 117
emotional or psychological abuse, 111, 111t
evaluation of, 113–116, 114f–116f
communication with patient in, 114
history-taking in, 113–114
physical examination in, 114–116, 115f
indicators of, 112–113
behavioral, 113
physical, 112–113, 113f
legal requirements in, 118
management of, 116–118
medical, 111–112
neglect, 111
obligation of dentist in, 118
parental concerns in, 117–118
physical abuse, 110, 111t
reporting of, 117
sexual abuse, 111, 111t
statistics of, 112
treatment of, 116–117
victims of, 112
Child protective service agencies, 117–118
Children
criteria for exposing of, to ionizing radiation, 30–32, 36t–37t
diet sodas and sports/energy drinks for, 151
fruit drinks and juices for, 151
healthy eating in, 150
ideal dinner plate for, 150
meal replacement shakes and smoothies for, 151
oral health and dental care, 647–649, 647f
community oral health programs with impact on, 650–651
conceptual framework for, 645–647
disease burden and caries consequences, 648
structure of dental public health and role in, 649–650, 650b
utilization and government impacts, 648–649
unhealthy eating in, 150
vegetarian diet for, 150
Children's Health Insurance Program (CHIP), 646
CHIP. *see* Children's Health Insurance Program (CHIP)
Chloral hydrate, 313–314, 319
Chlorhexidine
as oral antimicrobial agent, 172
for plaque control, 251–252
Chondrocranium, 378
Chondroectodermal dysplasia, 368–372
Christ-Siemens-Touraine syndrome, 64
Christmas disease, 540
Chromosomal microarray (CMA), 90–91
Chromosomes, 90–91
aberrations in, 91t
in leukemia, 553
Ciprofloxacin, pigmentation of teeth, 68

Dentlearn.ir

Claims, insurance, 657
Clamps, in restorations, 187–188, 187f–189f
Classification
  Angle system, of occlusion, 406–408, 407f–408f
  of children's cooperative behavior, 292–293
  of cleft lip and palate, 479, 480f
Cleft lip and palate (CLP), 479–497
  classification of, 479, 480f
  and enamel hypoplasia, 51
  genetics of, 104–105
  multidisciplinary team, 479–480
    dental specialties, 481–483, 481f–482f
    medical and allied health specialties, 483–484
  multifactorial inheritance in, 97, 97f
  oral health risk factors of, 490t
  sequencing of treatment in, 484–497
  stage I (infant appliance stage: birth to 18 months of age), 484–490
    airway obstruction, 488, 488f
    bone grafting of alveolar cleft, 488–489
    cheiloplasty, 488
    maxillary orthopedics, 488, 489f
    obturator therapy, 486, 486f
    palatoplasty, 489
    presurgical orthopedics, 486–488, 487f
  stage II (primary dentition stage: 18 months to 5 years of age), 490, 491f
  stage III (late primary or early mixed dentition stage: 6 to 10 or 11 years of age), 490–494, 492f–493f
    alveolar cleft bone graft, 490–493, 494f–496f
    facial aesthetics, 493–494, 496f
  stage IV (permanent dentition stage: 12 to 18 years of age), 494–497
Cleidocranial dysplasia, eruption of teeth and, 365–367, 365f–366f
Clinical deviation, 391
Clinical genetics, 87–109
  and craniofacial, oral, and dental conditions, 98–99
    cleft lip and palate, 104–105
    dental caries and, 98–99
    external apical root resorption, 104
    malocclusion and, 101–103
    periodontal disease and, 99–101
  review of genetic principles, 87–89
    autosomal-dominant inheritance, 93, 93f
    autosomal-recessive inheritance, 93–94, 94f
    cell differentiation and developmental biology, 89–90
    developmental biology of enamel, 92–93
    hereditary traits in families, 91–92
    multifactorial inheritance, 96–98
      in human diseases, 97–98
    X-linked dominant, 94, 94f
Clinical genetics *(Continued)*
    X-linked or sex-linked inheritance, 94–95
    X-linked recessive, 95, 95f
Clotrimazole, for acute candidiasis, 250
Clotting factor, 543
CMA. *see* Chromosomal microarray (CMA)
Cocaine, in pain control, 275
Codeine
  in postoperative care unit, 342
  for postoperative pain, 284t
Coffin-Lowry syndrome, 48
Colds, foods for prevention of, 151
Communal water fluoridation, 167–168
Communication, with children, by dental team, 297–298
  active listening in, 298
  appropriate responses in, 298
  communicator, establishment of, 297
  establishment of, 297
  message clarity in, 297
  multisensory, 298
  problem ownership in, 298
  voice control in, 297–298
  word substitutes in, 297b
Community Campus Partnerships for Health (CCPH), 651
Community oral health, 645–652
  programs with impact on children's oral health, 650–651
Comparative genomic hybridization (CGH), 90–91
Computed tomography (CT)
  medical, 29–30
  for oral surgery, 637
Computer-controlled local anesthetic delivery system, 282
Computerized cephalometric diagnosis, 402
Condensation, of amalgam, 216
Conditioning, aversive, 299–300
Condylion, 394
Condyloma acuminatum, 604, 605f
Cone beam computed tomography, 29, 34f
Congenital anomalies. *see* Cleft lip and palate (CLP); Down syndrome (trisomy 21 syndrome)
Consanguineous mating, 94
Contemporary Oral and Maxillofacial Surgery, 629, 632
Cosmetic surgery, in cleft lip and palate, 495–497
Cranial nerve, in tooth trauma, 566
Craniofacial fibrous dysplasia, 610
Craniofacial growth
  basic concepts of, 379–380, 380f
  principles of, 377–379, 377f–379f
Craniosynostosis syndromes, 96
Crenation, 72
Crossbite. *see* Occlusion, developing.
Crouzon syndrome, 96, 484
Crowns
  all-ceramic and metal-ceramic, for single teeth, 498–499, 499f–500f
  cosmetic zirconia, 200–201, 201f
  fracture, 566, 571f–572f
  stainless steel, 197–199, 197f
CT. *see* Computed tomography (CT)
Cyanotic congenital heart disease, 536, 536f
Cyclic neutropenia (cyclic hematopoiesis), 48
Cyklokapron, 544
Cystic fibrosis, 533
  and pigmentation of teeth, 67
Cysts
  dental lamina, 356–357, 358f
  eruption, 354, 355f
  eruption hematoma, 613
  odontogenic, 612–615, 638
    dentigerous, 613, 613f
    eruption, 613
    keratocyst, 614–615, 614f
    nevoid basal carcinoma (Gorlin) syndrome, 615
    primordial, 612–613
  traumatic bone, 638, 639f

D

DDAVP. *see* Desmopressin acetate (DDAVP)
Deep bite, 405, 406f
de Lange syndrome, 368–372
Deletion, chromosomal, 91t
Delmopinol, 132
Denavir, 247
Dens invaginatus (dens in dente), 43, 44f–45f
Dental arch
  growth of. *see* Face and dental arch growth
  pattern, 385–388
    compensations in development of, 387
    environmental factors on, 388
    ideal, 385
    maintenance of, 387, 387t
    similar stage sequencing in, 385
    tooth size/arch size ratio in, 386
Dental disease, in hemophilia, 545
Dental health education programs, 680
Dental insurance, 675
  different types of, 675–676
Dental lamina, 80
Dental materials, 206–220
  alloy selection, 215
  amalgam, 214–218
  bonded amalgam restorations, 217
  for cavity preparation treatment, 207
  cements, 218–220
    glass-ionomer, 219
    luting, 218–220
    polycarboxylate, 219
    resin, 219–220
    zinc oxide-eugenol, 218
    zinc phosphate, 218
  ceramics, 218
  condensation, 216
  high-copper alloys, 215
  marginal breakdown and bulk fracture, 216–217, 216f
  mechanical amalgamators, 216, 216f
  mercury/alloy ratio in, 215
  mercury toxicity in, 217–218

Dentlearn.ir

Dental materials *(Continued)*
moisture of, 216
regulatory considerations for, 206
resins, restorative, 208–214
acid-etch technique, 212, 213f
conventional composites, 208–209, 208f–209f, 208t
dental adhesives, 212–214
dentin bonding, 212–214
enamel bonding, 212
hybrid composites, 209–210
inlays, 212
light-cured composites, 210–211, 211f
microfilled composites, 209, 209f
posterior composite restoration, 211–212
for restorations, temporary and permanent, 207–208
tooth-restoration interface, 206–207
trituration, 215
Dental midline, 400
Dental office
accessibility for SHCN, 514, 515f
oral hygiene programs in, 135
technology, 681
topical fluorides in, 168–169, 169f
Dental public health, 648–649
Dental pulp, calcific metamorphosis of, 580–581, 580f–581f
Dental specialties, in cleft lip and palate, 481–483, 481f–482f
Dental team
behavior guidance, 295–297
attitude of team in, 296
flexibility in, 297
organization in, 296
positive approach to, 296
tolerance in, 297
truthfulness in, 296
strategies of, in behavior management, 294–301
aversive conditioning in, 299–300
behavior shaping, 298–299, 299f
communicating with children in, 297–298
gift, giving of, 301
limitations in, 301
parent-child separation in, 300–301
preappointment behavior modification in, 295, 296f
reinforcements, tangible, 301
retraining in, 299
scheduling in, 300
Dentifrices
fluoride-containing, 168, 168f
plaque control and, 125–126, 125f
Dentin, inherited defects of
dentinogenesis imperfecta (hereditary opalescent dentin), 56–59, 56f–58f
dysplasia, 59
Dentinogenesis imperfecta, 96
Dento-alveolar trauma, radiographic exposures in, 32
Dentofacial Orthopedics, 468
Dentures
for early tooth loss, 423–424
fixed partial, 500–503
complete crown retainers, 502–503
pontics, 503
resin-bonded retainers, 500–502, 501f–504f
to jaw midlines, 400
removable partial, 503–505, 505f
Desmopressin acetate (DDAVP), 542–543
Development
chronologic ages and, 287, 287b
in medical/dental history, 3, 4f
milestones in, 287, 288t–290t
of occlusion. *see* Occlusion, developing
physical, 287
poverty and, 286–287
of primary teeth. *see* Primary teeth, development and morphology of
visual-motor skill mastery and, 128–129
Developmental biology, 89–90
of enamel, 92–93
Diabetes mellitus
genetics and, 97
juvenile, premature exfoliation, 48
obesity and, 145
and periodontitis, 259
Diastemas, in eruption guidance for canines, 462, 463f
Diazepam (Valium), 311
Diet, fluoride supplements in, 170
Dietary intake patterns, 139–141
eating out, 141
meal pattern and frequency, 141
portion sizes, 141
Diffusion hypoxia, 315
DIFOTI. *see* Digital imaging fiberoptic transillumination (DIFOTI)
Digit sucking, 437–440, 437f, 439f–441f
Digital imaging, in dental care, 402
Digital imaging fiberoptic transillumination (DIFOTI), 171–172
Dilaceration, 586, 586f
Diphenhydramine, 311
for herpes simplex virus infection, 246
Diplegia, 529
Direct film, in radiography, 20, 20t
Direct pulp cap, vital pulp exposures treatment of, 569–572, 572f
Direction, of growth, 375
Disclosing agents, 126–127, 126f
Disease burden, 648
and caries consequences, 648
Dismissal, of employee, 667–668
Distal shoe appliances, 430, 431f
Disto-occlusion, 403
DNA, test kit for aggressive periodontitis, 259
Documentation
of child abuse and neglect, 117
for nitrous oxide sedation, 315–316
for sedation, 320–321
Dolichofacial pattern, 404, 405f
Double-mask scavenger breathing circuit, 314, 315f
Down syndrome (trisomy 21 syndrome), 90, 90f, 527
eruption of teeth in, 362–365, 365f
and periodontitis, 259
premature exfoliation, 48
Dyclonine, in pain control, 275
Dyclonine hydrochloride, for herpes simplex virus infection, 246

E

Early childhood caries (ECC), 646–647
Eating disorders, 148–150
ECC. *see* Early childhood caries (ECC)
Ecchymoses, in leukemia, 555, 555f
Ectodermal dysplasias, 64, 65f–66f
Ectopic eruption, 355
Ehlers-Danlos syndrome, 100
premature exfoliation, 48
Elastics
for crossbite, 449, 449f
for ectopic eruption, 456
Electric pulp testing, 223
Electrical trauma, 596
Elephantiasis gingivae, 253
Ellis-van Creveld syndrome, 368–372
Emergency dental treatment, 16
of fractured teeth without pulp exposure, 568–569
fragment restoration, 568–569, 570f
temporary bonded resin restoration, 569, 571f
in hemophilia, 547
of soft-tissue injury, 568
Emotional abuse, 111, 111t
Emotions, dental caries and, 158
Employee management, 661–668, 665f
Enamel
developmental biology of, 92–93
hypoplasia, 49–54, 49f
allergy-related, 50–51
from brain injury and neurologic defects, 50
cleft lip and palate, 51
fluoride and, 53–54
ionizing radiation and chemotherapy, 52, 53f
lead poisoning (plumbism) and, 51
local infection and trauma, 51, 51f–52f
microabrasion and, 54, 54f
molar-incisor hypomineralization and, 52–53
nephrotic syndrome and, 50
from nutritional deficiencies, 49–50, 50f
from rubella embryopathy, 52, 53f
treatment of, 53
hypoplasia of, 93
Endocarditis, infective, 536
Endocrine system, and gingivitis, 252–253, 252f
Endogenous opioid system (EOS), 312
Environmental factors, on dental arch pattern, 388
Environmental health, 646
Enzymes, in plaque control, 132
EOS. *see* Endogenous opioid system (EOS)

Dentlearn.ir

Epigenetics, 96
Epistasis, 96
Epstein pearls, 356–357
Epulis of newborn, congenital, 608–609, 608f
Equilibration, selective, 452
Equipment
  for nitrous oxide sedation, 314, 315f–316f
  for sedation, 319–320
  for SHCN patients, 514–515, 515f
Eruption gingivitis, 244, 244f
Eruption of teeth, 349–374
  Bohn nodules in, 356–357
  chronologic development and, 349–352, 350t
    molecular mechanisms in, 351, 351f
    premature loss of primary molars in, 351–352
    sequence variations in, 352, 352f
  delayed, diagnostic algorithm for, 372f
  dental lamina cysts in, 356–357, 358f
  Epstein pearls in, 356–357
  local and systemic factors in, 357–372
    achondroplastic dwarfism in, 368, 371f
    ankylosed teeth, 357–360, 359f–361f
      permanent teeth, 360–362, 363f–364f
      of primary molars with no permanent successors, 360, 362f
    cleidocranial dysplasia, 365–367, 365f–366f
    hypopituitarism in, 367, 370f
    hypothyroidism in, 367, 368f–369f
    other causes, 368–372
    trisomy 21 syndrome in, 362–365, 365f
  mandibular permanent incisors, 352–354, 353f
  natal and neonatal, 355–356, 356f–358f
  problems and guidance in, 454–467
    ectopic, of first permanent molars, 455–458, 455f–457f
    in lower incisor segment, 458, 459f
    in mandibular canine and premolar segment, 459–461, 460f
    in maxillary canine and premolar segment, 461–467, 461f
  teething and difficult eruption, 354–355
    ectopic, 355
    hematoma in, 354, 355f
    sequestrum in, 355, 355f
Erythematous (atrophic) lesion, 550
Etching, in pit and fissure sealants, 179
Ethnic factors
  in cleft lip and palate, 105
  in dental arch pattern, 385
  malocclusions and, 102
Ethyl aminobenzoate, in pain control, 275
Euphemisms, 297, 297b
Ewing's sarcoma, 620–621, 621f
Examination
  of mouth, 1–16, 2t
    biofilm, 16
    clinical examination, 5, 8f–9f
    diagnostic method, 3
    early examination, 11
    emergency treatment, 1, 16
    infant dental care, 12–13, 13f
    infection control, 15–16
    medical and dental history, 3–5, 4f
    parental contact, 1–3
    radiographic examination, 11
    substance abuse, 13–14
    suicidal tendencies, 14–15
    temporomandibular evaluation, 5–11, 9f–10f
    uniform dental recording, 11
  physical, in child abuse, 114–116, 115f
Exfoliation, early, 43–48
  acrodynia, 48
  cherubism (familial fibrous dysplasia), 45–48, 46f–47f
  cyclic neutropenia (cyclic hematopoiesis), 48
  hypophosphatasia, 44–45
  hypophosphatemia, 48
Exodontia, simple, 629–632, 630f–631f
Expansion appliances, 472
Extraction, of impacted teeth other than third molars, 637
Extraoral radiography, 29–30
  cephalometric imaging, 29
  cone beam computed tomography, 29, 34f
  magnetic resonance imaging, 30, 35f
  medical computed tomography, 29–30
  oblique lateral radiography, 29, 33f
  panoramic imaging, 29, 32f
  ultrasound imaging, 30, 35f
Eye contact, 298

F

Face and dental arch growth, 375–389
  craniofacial pattern in, 380–381
  dental arch pattern, 385–388
    compensations in development of, 387
    environmental factors on, 388
    ideal, 385
    maintenance of, 387, 387t
    similar stage sequencing in, 385
    tooth size/arch size ratio in, 386
  nature of, 375–380, 376f
    basic concepts in, 376–377, 377f
    craniofacial growth in, 377–380, 377f–379f
  occlusion
    consistency in pattern development of, 383
    ideal static pattern in, 383–384
    maintenance of, 384–385
    opposing first molars in, 383, 384t
    primary dentition terminus in, 383, 384f
  patterns of
    consistency in maturation, 381, 381f
Face and dental arch growth *(Continued)*
    dentofacial, ideal paradigms for, 380–381
    frontal, ideal, 381, 381f
    maintenance of, 382
    profile, ideal, 381–382, 383f
    and somatic growth, 382–383, 383f
Facial axis, 395
Facial plane, 395
Factor VIII deficiency. *see* Hemophilia
Factor XI deficiency. *see* Hemophilia
Failure to thrive, 142–145
Famciclovir, for herpes simplex virus infection, 247
Familial fibrous dysplasia (cherubism), 45–48, 46f–47f
Fat, dietary
  harmful, 151
  healthful, 151
FDA. *see* Food and Drug Administration (FDA)
Fear/anxiety, dental, 291
  dental behavior management and, 291
Federally funded programs, 676
Fédération Dentaire Internationale's Special Committee on Uniform Dental Recording, 11
Feeding disorders, 148–150
Fees. *see* Practice management
Fentanyl (Sublimaze), 313
Feracrylum, for pulp capping, 235
Ferric sulfate, for pulp capping, 234–235
Fetal alcohol spectrum disorder (FASD), 528
Fiberoptic transillumination, digital imaging, 171–172
Fibrinolysins, in cellulitis, 41
Fibroma, 604, 639–640
  ameloblastic, 617
  cemento-ossifying, 611, 611f
  juvenile ossifying, 611
  peripheral odontogenic (WHO type), 605–606
  peripheral ossifying, 605–606
Fibromatosis, 619
Fibrosarcoma, 619
Fibrous dysplasia, 610–611, 610f
  and periodontitis, 259
Fillers, of resins, 208, 208f
First-pass effect, 307
Fiscal management, 654–658
  accounts payable, 657
  budget setting, 656
  business plan, 654–655, 655b
  fees, 657, 657f–658f
  monitor goal numbers, 655–656
  monitoring reports regularly, 656–657
  monitoring schedule, 656
Fissured tongue, 71
Fixed transpalatal wires, with springs, 448–449, 448f
Flexibility, of dental team, 297
Floss/flossing
  in leukemia, 557
  in plaque control, 123–124, 123f–124f, 128, 128f, 166
Flu, foods for prevention of, 151

Dentlearn.ir

Fluconazole, for acute candidiasis, 250
Flumazenil (Romazicon), 312
Fluorescence
  infrared laser (DIAGNOdent), 171, 171f
  quantitative light, 172
Fluorides
  in communal water, 167–168
  in dentifrices, 125, 168, 168f
  in dietary supplements, 170
  and enamel hypoplasia, 53–54
  in home-use mouthrinses, toothpastes, and gels, 170
  in over-the-counter mouthrinses and gels, 170
  for SHCN patients, 519
  topical
    in dental office, 168–169, 169f
    in general anesthesia, 169–170
Folic acid, neural tube defects and, 105
Food allergies, 151
Food and Drug Administration (FDA), in food and nutrition labeling practices, 150
Food insecurity, 141–142
Food security, definition of, 142
Food Stamp Program, 142
Formocresol, 229, 234, 235f
Formulas, infant, dental caries and, 158–159
Fractures
see also Trauma, to teeth and supporting tissues
  in child abuse, 112–115
  of mandible, 642–644
Fragile X syndrome, 528
Frankfort horizontal plane (FH), 395
Frankl behavior rating scale, 293
Fraser suction tip, 629f
FRC. *see* Functional reserve capacity (FRC)
Frenum
  abnormalities, 264, 264f
    frenotomy and frenectomy, 264–265
  in hemophilia, 545–546
  labial, 73–74, 73f–74f
Frontometaphyseal dysplasia, 368–372
Functional inquiry, 293–294, 293b
Functional reserve capacity (FRC), 306
Fungal infection, in HIV infection, 550
Fusion of teeth, 42, 43f
The Future of Public Health, 649

G

Gardner syndrome, 368–372
Gels
  over-the-counter fluoride, 170
  prescription home-use fluoride, 170
Gemination, 42–43, 43f
Gender differences, in tooth eruption, 351
Gene expression
  in amelogenesis imperfecta, 60
  in dentin anomalies, 56–57
  epigenetics, 96
  expressivity, 96
  in hypodontia, 62–63
  penetrance, 96
  regulation of, 89
  variation in, 96
General Anesthesia Spinal (GAS) study, 305
Genetic conditions, salivary flow and, 161
Genetic lesions, and gingivitis, 253, 253f
Genome, 87
  sequencing, cost of, 88–89, 89f
Genotype, 87
Geographic tongue, 71, 71f
Giant cell granuloma, central, 611–612, 612f
GIC. *see* Glass-ionomer cement (GIC)
Gift, giving of, 301
Gingicaine, 275
Gingival granular cell lesion, 608–609, 608f
Gingivitis, 243–273
  acute, 245–250
    bacterial infections, 250
    candidiasis (thrush, candidosis, moniliasis), 250, 250f
    herpes simplex virus infection, 245–248, 246f–248f
    necrotizing ulcerative (Vincent infection), 249, 250f
    recurrent aphthous ulcer (canker sore), 248–249, 248f
  allergy and, 245
  chlorhexidine, for plaque control, 251–252
  chronic nonspecific, 250–251, 251f
  definition of, 243–244
  dental plaque-induced, 244–245, 245f
  eruption, 244, 244f
  gingival inflammation, 245
  HIV infection and, 551
  by systemic factors, 252–256
    ascorbic acid deficiency, 256, 256f
    endocrine system, 252–253, 252f
    genetic lesions, 253, 253f
    phenytoin-induced overgrowth, 254–256, 254f
Gingivoperiosteoplasty (GPP), 486
Glass-ionomer cement (GIC), 219
  resin-modified, 219
  as sealant, 177–178
Glass-ionomer material, 164–165
Glossitis, median rhomboid, 72
Gluten, 152
Gnathion, 394
Goltz syndrome, 368–372
Gonion, 394
Government, dental care utilization and, 648–649
Gow-Gates mandibular block technique, of anesthesia, 277, 277f
GPP. *see* Gingivoperiosteoplasty (GPP)
Graft-*versus*-host disease (GVHD), 558–559
Granulomas
  central giant cell, 611–612, 612f
  eosinophilic, 622–623
  peripheral giant cell, 606
  pyogenic, 604, 605f
Growth hormone receptor, malocclusions and, 102
Growth of face and dental arches. *see* Face and dental arch growth
Guidance, anticipatory, 1
Günther disease, 66
GVHD. *see* Graft-*versus*-host disease (GVHD)

H

Haim-Munk syndrome, periodontal disease and, 101
Hajdu-Cheney syndrome, 48
Halothane, 337
Halterman appliance, 457–458, 457f
Hand hygiene, infection control in dental office, 15
Hand-over-mouth exercise (HOME), 299–300
Hand-Schüller-Christian disease, 249, 621–623, 623f
Haplotype blocks, 98
Hawley-type appliance, 440, 440f, 447–448, 447f
Hawthorne effect, 124
Head
  infection of region of, 640–644
  inspection and palpation of, 5
Headgear, extraoral, 472
Healthy People 2010, 146
  oral health objectives targeting children, 650b
Healthy People 2020, 139, 139t
Healthy People objectives, 652f
Hearing loss (deafness), 533–534, 533t
Heart disease
  acquired
    infective endocarditis, 536, 537b–538b
    rheumatic fever, 536
  cardiac surgery patients, 537
  congenital, 535–537, 536f
  obesity and, 146
Hemangioma, 607–608
Hematoma, eruption, 354, 355f
Hematopoiesis, cyclic, 48
Hematopoietic stem cell transplantation, 558–560
  admission and nursing interventions of, 560, 560b
  graft-*versus*-host disease, 559
  oral complications of, 558–559
  pretransplantation preparation in, 559
  remission phase of, 560
Hemiplegia, 529
Hemophilia, 540–547
  antifibrinolytic agents for, 544–545
  complications of, 543–544
  dental management of, 545–547
    antibiotic prophylaxis, 547
    dental disease, 545
    emergencies, 547
    oral surgery, 546–547
    orthodontic treatment, 547
    periodontal therapy, 545–546
    pulpal therapy, 546
    restorative procedures, 546
    surgical complications, 547

Dentlearn.ir

Hemophilia *(Continued)*
hemostasis disorders, 540–541, 541f–542f
pain control for, 545
procoagulant classification of, 541–542
risks to dental staff, 544
treatment of, 542–544
von Willebrand disease, 543
women with bleeding disorders, 543
Hemophilia A, treatment of, 542–543
Hemophilia B, treatment of, 543
Hemorrhage

pulpal, 226–227, 227f
Hepatitis. *see* Viral hepatitis
Hereditary factors, dental caries and, 162
Hereditary gingival fibromatosis (HGF), 253, 253f
Hereditary opalescent dentin, 56–59, 56f–58f
Heritability, 91
Herpes simplex virus (HSV) infection, 245–248, 246f–248f, 550–551
Herpes zoster (shingles), 551
HGF. *see* Hereditary gingival fibromatosis (HGF)
High-copper alloys, 215
Hiring, of personnel, 662–664
Histiocytosis X, 621–623, 623f
and periodontitis, 259
Histodifferentiation, of tooth, 81
HIV. *see* Human immunodeficiency virus (HIV)
"Hollywood" bridge, 424, 426f
Home dental care, for SHCN patients, 516–518, 517f–518f
Home oral hygiene
fluoride mouthrinses, toothpastes, gels, 170
mechanical and chemotherapeutic, 120–137
plaque control. *see* Plaque, control of
Homologue chromosome, 90
Horizontal scrubbing method, of toothbrushing, 127
Hormone, for tooth eruption, 351
Hospital dental services, 328–348
abbreviations commonly used in, 335b–336b
admission, 334, 334f, 335b
general anesthesia
end time-out protocol, 341–342
indication for, 329
inhalation, 336–337, 336f
medical history and physical examination, 331–334, 332f–333f, 333b–334b
perioral cleaning, draping, and placement of pharyngeal throat pack, 337–339, 340f–344f
postanesthesia care unit, 342
postoperative care, 342–344, 345f, 346b, 347f
preparation of child, time-out protocol in, 337, 338f–340f
operating room protocol, 335–336
Hospital dental services *(Continued)*
outpatient *versus* inpatient surgery, 330–331, 331t
restorative dentistry in operating room, 339–341, 344f
staff privileges, 328–329
Hospitalization
in medical/dental history, 3
psychological effects of, 329–330
HSV. *see* Herpes simplex virus (HSV) infection
Human genome project, 87
Human immunodeficiency virus (HIV), 550–551
in hemophilia, 544
Humphrey appliance, 456–457
Hunter syndrome, 368–372
Hurricaine, 275
Hutchinson-Gilford syndrome, 368–372
Hyaluronidase, in cellulitis, 41
Hybrid glass ionomers, 219
Hydrocephalus, genetics and, 97
Hydrocodone, for postoperative pain, 284t
Hydroxyzine, 310
Hyperbilirubinemia, teeth discoloration in, 65–66, 67f
Hyperemia, pulpal, 579–580
Hyperpituitarism, premature exfoliation, 48
Hyperplastic lesion, 550
Hypertension, genetics and, 97
Hyperthyroidism, premature exfoliation, 48
Hypnosis, in hemophilia, 545
Hypnotics, 313–314
Hypocalcification, 49
disorders
autosomal-dominant inheritance and, 93
genetics of, 93
of injured permanent tooth buds, 585–586, 586f
Hypodontia, 62–63
and cancer, 63–64
and malocclusion, 101–102
and palatally displaced canines, 63
Hypomaturation, genetics of, 93–95
Hypophosphatasia, 44–45
and periodontitis, 259
Hypophosphatemia, 48
see also Rickets
familial, 368–372
Hypopituitarism, 367, 370f
Hypoplasia
of enamel. *see* Enamel, hypoplasia
of injured permanent tooth buds, 585–586, 586f
Hypothyroidism, eruption of teeth and, 367
congenital, 367, 368f
juvenile, 367, 369f
Hypoxia, diffusion, 315
Hyrax appliance, 452, 453f, 454

I

Ibuprofen, for postoperative pain, 284t
Idiopathic lesions, in HIV infection, 551
IL-1β, root resorption and, 104
Image receptors, in radiography, 20–23
analog film, 20–21
image-viewing conditions, 22–23, 23f–24f
photo-stimulable phosphor storage plates, 21, 21f–22f
solid-state sensors, 21, 22f
Image-viewing conditions, of radiographic image receptors, 22–23, 23f–24f
Immune disorders, salivary flow and, 161
Impacted teeth, 632–637
other than third molars
surgical exposure and, 634–635, 635f–636f
surgical uprighting, 635–637, 636f–637f
Impetigo, 5, 9f
Implant prostheses, for adolescent, 506–507, 507f–508f
before growth completion, 507, 509f–510f
for orthodontic anchorage, 507
Incisors
eruption guidance for, 458, 459f
mandibular, infiltration anesthesia for, 277
mandibular central, 82
mandibular lateral, 82
maxillary central, 82–84, 82f–83f
maxillary lateral, 82
permanent mandibular, lingual eruption of, 352–354, 353f
primary, early loss of, 423–424, 424f–426f
primary and permanent, anesthesia for, 278
Incontinentia pigmenti syndrome, 368–372
Indemnity plans, 675
Indirect film, in radiography, 20–21, 20f
Infants
birth to 18 months of age, cleft lip and palate, 484–490
airway obstruction, 488, 488f
bone grafting, 488–489
cheiloplasty, 488
maxillary orthopedics, 488, 489f
obturator, 485–486, 485f–486f
palatoplasty, 489
presurgical orthopedics, 486–488, 487f
dental care, 12–13, 13f
home oral hygiene for, 133, 133f
low-fluoride dentifrice for, 126
natal and neonatal teeth in, 355, 356f–358f
Infections
control in dental office, 15–16
and enamel hypoplasia, 51, 51f–52f
of head and neck region, 640–644
herpes simplex virus, 245–248, 246f–248f
in HIV infection, 550–551
Informed consent, 300
for sedation, 321–322
Infraocclusion, 357

Dentlearn.ir

Inhalation anesthetics, properties of, 336–337, 336f
Inheritance
  autosomal-dominant, 93, 93f
  autosomal-recessive, 93–94, 94f
  multifactorial, 96–98
    in human diseases, 97–98
  X-linked or sex-linked, 94–95
    dominant, 94, 94f
    recessive, 95, 95f
Injection techniques. *see* Anesthesia, local
Inlays, resin, 212
Instruments, infection control in dental office, 15
Insurance
see also Practice management
  dental, 675
Intact dental occlusion, 481–482
Intellectual disability, 291, 522–527
  in cerebral palsy, 530
  classification of, 527t
  dental treatment of patient with, 525–527
Intelligence quotient (IQ), 291
  tests for, 291
Interim therapeutic restorative technique, 201
International Association of Dental Traumatology, 563
Interviewing, of personnel, 662–664
Intraoral radiography, 23–29
  bitewing, 23–27, 27f
  oblique occlusal, 27, 29f, 31f
  periapical, 23
Intravenous sedation, 305
Inventory control, 681
Ionizing radiation
  criteria for exposing of children to, 30–32, 36t–37t
  and enamel hypoplasia, 52, 53f
IQ. *see* Intelligence quotient (IQ)
Iron, dietary, 143
Iron-deficiency anemia, 143
Irrigators, oral, 127
Isolation, pit and fissure sealants, 179
Isolite system, 188–189, 189f

J

Jaw, fibro-osseous lesions of, 609–610
Jet injection, of local anesthesia, 275
Joint contractures, in cerebral palsy, 530
Justification principle, of radiation protection, 17

K

Kaopectate, for herpes simplex virus infection, 246
Kaposi sarcoma, 551
Karyotype, 90, 90f
Kawasaki disease, tongue anomalies, 72
Keratocyst, odontogenic, 614–615, 614f
KRI paste, 231
Kwashiorkor, 142

L

Labial Edgewise archwires, 448–449
Langerhans cell histiocytosis, 621–623
Laser Doppler flowmeter, pulp blood flow, 223
Lasers, for periodontal disease, 268–269
Latex allergy, spina bifida and, 531
Lead apron, 19, 20f
Lead poisoning, and enamel hypoplasia, 51
Leadership, doctor, 658–661, 660f
Learning disabilities, 527–528
Ledermix, 593
Leeway space, 386–387, 417
Legal requirements, in child abuse and neglect, 118
Lesch-Nyhan syndrome, 263–264
Letterer-Siwe disease, 622, 622f
Leukemia, 551–558, 552t, 554t
  dental management of, 555–558, 556t–558t
  oral manifestations of, 554–555, 555f–556f
  and periodontitis, 259
  premature exfoliation, 48
Leukocyte adhesion deficiency, and periodontitis, 100, 259
Lice, head, 5, 8f
Lidocaine
  for herpes simplex virus infection, 246
  in pain control, 275
Life cycle of tooth, 80–81, 81f
Life expectancy
  comparison of, 138t
  obesity and, 146
Light
  composites cured by, 210–211, 211f
  sealants cured by, 177, 180f, 181
Limitation principle, of radiation protection, 17
Lingual holding arch, 431, 431f
Listening, active, 298
Listerine Antiseptic, 249
Localized juvenile periodontitis, 257–258, 258f
Ludwig's angina, 41
Luxation. *see* Trauma
Lymphangioma, 608
Lymphoma, non-Hodgkin, 551
Lyonization, 95
Lysine, for herpes simplex virus infection, 247–248

M

MAC. *see* Minimum alveolar concentration (MAC)
Macroglossia, 70
Magnetic resonance imaging (MRI), 30, 35f
Magnitude, of growth, 375
Malnutrition, 141–142
  chronic, 141
Malocclusions
  in cerebral palsy, 530
  genetics of, 101–103
  and gingivitis, 251
Maltreatment. *see* Child abuse and neglect
Managed care, 675–676
Mandible
  cephalometric assessment of, 397–398
  eruption guidance for, 459–461, 460f
  fracture of, 642–644
  growth and development of, 506
Mandibular plane, 395
Mandibular teeth
see also Canines; Incisors; Molars
  anesthesia for, 275–277
    conduction anesthesia (Gow-Gates mandibular block technique), 277, 277f
    conventional mandibular block, 275–276, 276f
    infiltration anesthesia, for mandibular primary molars, 276–277
    infiltration for mandibular incisors, 277
    lingual nerve block, 276
    long buccal nerve block, 276, 276f
Marketing, in practice management
  external, 680

Maroteaux-Lamy mucopolysaccharidosis, 368–372
"Maryland" bridge, 219–220
Maternal and child health (MCH), 646
Maxilla
  cephalometric assessment of, 396
  growth and development of, 506
Maxillary obturators, 484–485
Maxillary teeth
see also Canines; Incisors; Molars
  anesthesia for
    permanent molars, 279–280
    primary and permanent incisors and canines, 278
    primary molars and premolars, 278–279, 279f
Maxillomandibular cephalometric assessment, 400
Maxillomandibular fixation, 644
McCune-Albright syndrome, 610
MCH. *see* Maternal and child health (MCH)
Meal, pattern and frequency of, 141
Mean-change-expansion scheme, 382
Mediated generalization, 297
Medicaid, 648, 650–651, 676
  coverage for dental caries, 161–162
Medical and allied health specialties, for cleft lip and palate management, 483–484
Medical/dental history, preliminary, 3–5, 4f
Medical geneticist, in cleft lip and palate management, 484
Medical history, before general anesthesia, 331–334, 332f–333f, 333b–334b
Medical waste, infection control in dental office, 15–16
Medically compromised patient, management of, 540–562
Mental retardation, 522
  and calculus, 271
  and enamel hypoplasia, 50

Dentlearn.ir

Menton, 394
Meperidine (Demerol), 313
Mercury
  alloy ratio, 215
  toxicity of, 217–218
Meridol, for plaque control, 252
Mesial molar shift, 416–417, 416f
Mesio-occlusion, 403–404
Mesofacial pattern, 404, 405f
Metronidazole, for periodontitis, 258–259
Microabrasion, of enamel, 54, 54f
Microdeletions, 90–91
Micrognathia, 68–69, 69f
Microleakage, of dental material, 206–207
  resins, 211
Microorganisms
  dental caries and, 156
  role in dental disease, 121
Microporosities, 179
Microsomia, hemifacial, 484
Midazolam (Versed), 311–312
Milk, human, dental caries and, 158
Miller-Dieker syndrome, 368–372
Mineral trioxide aggregates for pulp capping, 235, 572
Minimal alveolar concentration, 336–337
Minimal residual disease (MRD), 553
Minimum alveolar concentration (MAC), 309, 309t
Mixed dentition
  occlusion, development of. *see* Occlusion, developing.
  space analysis, 386
  tooth size/arch size, 386
Mobility, tooth, 222
Modified Stillman method, of toothbrushing, 127–128
Moisture, in amalgam, 216
Molars
  early loss of, infiltration anesthesia for, 276–277
  first permanent
    development and calcification of, 81–82
    ectopic eruption of, 455–458, 455f–457f
  loss of
    first, 425–428, 427f–428f
    multiple, 432, 433f–434f
    permanent, 433–435, 435f–436f
    second, 428–432, 429f–432f
  mandibular first, 84
  mandibular second, 84
  maxillary first, 83, 83f–84f
  maxillary second, 83–84, 83f, 85f
  permanent
    cavity preparation, interim restoration for hypoplastic, 197
    interim restoration for hypoplastic, 197
  primary
    ankylosis of, with no permanent successors, 360, 362f
    premature loss of, 351–352
  third, impacted, 632–633, 633f
  variations in sequence of eruption of, 352, 352f
Molt elevator, 630f
Molt Mouth Prop, 520–521
Mongolism, 362
Moniliasis, 250, 250f
Monitoring of sedation, 322–324, 323f–324f
  intraoperative, 322–324
  for nitrous oxide sedation, 315–316
  postoperative, 324
Monogenic traits, 91
Monoplegia, 529
Monosomy, 90
Morphodifferentiation, of tooth, 81
Morphology
see also Primary teeth, development and morphology of
  primary tooth pulp chamber, 84–86
  primary *vs*. permanent teeth, 84, 85b
Mosaicism, germinal, 93
Mouth
  examination of, 1–16, 2t
    biofilm, 16
    clinical examination, 5, 8f–9f
    diagnostic method, 3
    early examination, 11
    emergency treatment, 1, 16
    infant dental care, 12–13, 13f
    infection control, 15–16
    medical and dental history, 3–5, 4f
    parental contact, 1–3
    radiographic examination, 11
    substance abuse, 13–14
    suicidal tendencies, 14–15
    temporomandibular evaluation, 5–11, 9f–10f
    uniform dental recording, 11
  physical abuse injuries to, 110
Mouthguards, protective, 508–511, 511f
Mouthrinses
  over-the-counter fluoride, 170
  prescription home-use fluoride, 170
MRD. *see* Minimal residual disease (MRD)
Mucoceles, 609, 609f, 638–639, 640f–641f
Mucus retention phenomenon, 609
Multifactorial inheritance, 96–98
  in human diseases, 97–98
Multifactorial-threshold model, 97, 97f
Mumps, salivary flow and, 161
Munchausen syndrome by proxy, 111–112
Mutans streptococci (MS), dental caries and, 156
Myelomeningocele, 531
Myosin, gene expression in malocclusions, 102
MyPlate Food Guidance System, 139, 140f
Myxoma, odontogenic, 617

N

Naloxone (Narcan), 313
Nance appliance, 432, 432f
Nasal spine, posterior, 394–395
Nasion, 394
Nasoalveolar molding (NAM) appliance, 486–488
Nasopalatine nerve block, 280, 280f
National Institute of Health Consensus Panel, pit and fissure sealants, 177
National School Lunch Program (NSLP), 140
Neck
  infection of region of, 640–644
  inspection and palpation of, 5
Necrosis, pulpal, 582, 583f
Necrotizing ulcerative gingivitis, 249, 250f
Needles, for anesthesia injections, 275
Neglect. *see* Child abuse and neglect
Neon colors, on toothbrushes, 121, 121f
Neoplasms, in HIV infection, 551
Nephrocalcinosis syndrome, 95
Nephrotic syndrome, and enamel hypoplasia, 50
Nerve blocks
  greater (anterior) palatine injection, 280, 280f–281f
  inferior alveolar, 275–276, 276f
  infraorbital, 281
  lingual, 276
  long buccal, 276, 276f
  mental, 281
  nasopalatine, 280, 280f
Neuroblastoma, 560
Neurofibroma, 606–607, 607f
Neurofibromatosis, 606–607, 607f
Neurologic defects, and enamel hypoplasia, 50
Neutropenias
  cyclic, 48
  and periodontitis, 259
Nevoid basal carcinoma syndrome, 615
Nitrous oxide, 309–310, 316f, 627
  administration of, 314–316
    equipment for, 314, 315f–316f
    monitoring and documentation in, 315–316
    objectives of, 314
    technique in, 314–315
  adverse effects of, 309–310
  delivery system for, 320f
  mechanism of, 309
  occupational exposure to, recommendations for minimizing, 310b
  oxygen and, inhalational sedation with, 318
  pharmacokinetics of, 309
  toxicity of, 310
Normeperidine, 313
Nursing, dental caries and, 158–159
Nutritional considerations, for pediatric dental patient, 138–154
  dietary intake patterns, 139–141
    eating out, 141
    meal pattern and frequency, 141
    portion sizes, 141
  feeding and eating disorders, 148–150
    anorexia nervosa, 148–149
    binge-eating disorder, 150
    bulimia, 149–150
  issues in, 150–152
  life expectancy comparison, 138, 138t

Dentlearn.ir

Nutritional considerations, for pediatric dental patient *(Continued)*
malnutrition and food insecurity, 141–142
MyPlate Food Guidance System, 139, 140f
pediatric overnutrition, 145–148
overweight and obesity, 145
pediatric undernutrition, 142–145
calcium, 144
iron, 143
vitamin B_{12}, 145
vitamin D, 144–145
zinc, 143–144, 143b
Nutritional deficiencies, and enamel hypoplasia, 49–50, 50f

O

Obesity
dietary intake patterns and, 140
overweight and, 145
pharmacologic management of behavior and, 306
Oblique lateral radiography, 29, 33f
Oblique occlusal radiography, 27, 29f, 31f
Obstructive sleep apnea, and orthodontics, 467
Obturator, in cleft lip and palate, 485–486, 485f–486f
Occlusal interferences, in pit and fissure sealants, 181
Occlusal plane, 395
Occlusion
Angle classification of, 406–408, 407f–408f
developing, management of, 415–478
crossbite in, anterior, 443–449, 444f
fixed transpalatal wires with springs for, 448–449, 448f
lower inclined plane in, 446–447, 446f
palatal-spring appliances for, 447–448, 447f
tongue blade/popsicle stick therapy for, 445, 445f
crossbite in, posterior, 449–454, 449f–451f
maxillary expansion for, 452–454, 453f
selective equilibration for, 452
early loss of teeth, and space maintenance in, 418–435, 421f
assessment of, 418–423, 423f
first primary molar loss, 425–428, 427f–428f
multiple primary molar loss, 432, 433f–434f
permanent molar loss, 433–435, 435f–436f
primary canine loss, 424–425, 426f
primary incisors loss, 423–424, 424f–426f
second primary molar loss, 428–432, 429f–432f
specific strategies for, 423–435
eruption problems and guidance in, 454–467
Occlusion *(Continued)*
ectopic, of first permanent molars, 455–458, 455f–457f
in lower incisor segment, 458, 459f
in mandibular canine and premolar segment, 459–461, 460f
in maxillary canine and premolar segment, 461–467, 461f
obstructive sleep apnea and, 467
oral habits in children and, 435–443
bruxism in, 435, 437f
digit sucking in, 437–440, 437f, 439f–441f
tongue-thrust swallowing in, 440–443, 443f
orthodontics for, 467–476
in early permanent dentition, 473–476, 475f–476f
in mid- to late mixed dentition, 471–473, 473f–474f
in primary to mid-mixed dentition, 468–471, 469f–472f
timing of interventions for, 415–418
considerations in, 417–418, 419f–420f
leeway space in, 417
mesial molar shift in, 416–417, 416f
primate spaces in, 415–416
growth and pattern of, 383–385, 384f, 384t
Occupational Safety and Health Administration (OSHA)
operating room protocol, 335
personnel needs, 661
Odontogenesis imperfecta, 61
Odontoma, 41, 42f, 618–619, 618f
ameloblastic fibro-, 618
surgery for, 637–638, 638f
Okeson's *Management of Temporomandibular Disorders and Occlusion*, 5
Oligodontia. *see* Hypodontia
Omnibus Budget Reconciliation Act, 519
The One Minute Manager, 663
Open bite, 405, 406f

(ORIF), 643–644
Open Wide mouth prop, 520–521
Opioids, 312, 313f
agonists and antagonists, 312–313
fentanyl (Sublimaze), 313
meperidine (Demerol), 313
naloxone (Narcan), 313
ventilatory response to hypercarbia, effects on, 312–313
Optimization principle, of radiation protection, 17–18, 18t
Oral and maxillofacial surgeon, in cleft lip and palate management, 482
Oral cleanliness, and periodontal disease, 269–270
Oral examination record, 5, 6f–7f
Oral hairy leukoplakia (HL), 551
Oral hygiene
and gingivitis, 255
in plaque reduction, 166
for SHCN patients, 516
Oral squamous cell carcinomas, 551
Oral surgery, 627–644
exodontia, simple, 629–632, 630f–631f
fibroma, 639–640
granuloma, pyogenic, 639–640
hard-tissue lesions
cysts, 638
odontoma, 637–638, 638f
for hemophilia, 546–547
impacted teeth
other than third molars, 633–637, 634f
third molars, 632–633, 633f
infection of head and neck region, 640–644
mandible fracture, 642–644
office-based, 627
outpatient *versus* inpatient, 330–331, 331t
soft-tissue procedures, 638–640
mucoceles, 638–639, 640f–641f
ranulas, 638–639
Oral warts, 550
OraVerse, 283–284
Orbitale, 394
Organization, in dental team, 296
Orientation, of personnel, 663

fixation (ORIF)
Oropharyngeal candidal infections, 550
Orthodontics
appliances
caries and, 162
for developing occlusion. *see* Occlusion, developing
for occlusion, 467–476
in early permanent dentition, 473–476, 475f–476f
in mid- to late mixed dentition, 471–473, 473f–474f
in primary to mid-mixed dentition, 468–471, 469f–472f
Orthodontist, in cleft lip and palate management, 482
Orthognathism, 406
OSHA. *see* Occupational Safety and Health Administration (OSHA)
Osteoarthritis, obesity and, 146
Osteoporosis, 144
Osteosarcoma, 560
Otolaryngologist, in cleft lip and palate management, 484
Overdentures, 505, 506f
Overnutrition, pediatric, 145–148
Oxygen, sedation. *see* Nitrous oxide, oxygen and, inhalational sedation with
Oxyhemoglobin dissociation curve, 323, 324f

P

Pacifier, and periodontitis, 261–263
Padded tongue blades, 520–521

Dentlearn.ir

Pain
control
see also Anesthesia, local, and pain control for child and adolescent
for hemophilia, 545
in previous health care visits, 292
in pulpal inflammation, 221
Palatal crib appliance, 438–439, 439f
Palatal plane, 395
Palatal-spring appliances, 447–448, 447f
Palatal tissues, anesthesia for, 280
greater (anterior) palatine injection, 280, 280f–281f
nasopalatine nerve block, 280, 280f
Palatoplasty, 489
PANDA. *see* Pediatric Anesthesia and Neurodevelopment Assessment study (PANDA)
Panoramic imaging, 29, 32f
Papilloma, squamous, 603–604, 604f
Papillon-Lefèvre syndrome, 48, 101, 259
Papoose board, 316–317, 317f, 522, 523f, 529
Paralleling technique, in periapical radiography, 23, 25f
Paraplegia, 529
Parents
child behavior and, 294, 301
contact with dental office, 1–3
instructions for sedation, 322
Patient care coordinator, in cleft lip and palate management, 483
Patient discharge, for sedation
criteria for, 317b
instruction after, 317b
Patient selection, for sedation, 321–322
indications for, 321
informed consent, 321–322
instructions to parents in, 322
preoperative evaluation of, 321
Patient systems. *see* Practice management
Pattern of growth
facial, 381–383, 381f, 383f
of occlusion, 383–385, 384f, 384t
Pedi-Wrap, 522, 524f, 529
Pediatric Anesthesia and Neurodevelopment Assessment study (PANDA), 305
Pediatric condition falsification, 111–112
Pediatric dentist, in cleft lip and palate management, 481–482
Pediatrician, in cleft lip and palate management, 483–484
Pedigree, genetic, 92, 92f
Penciclovir (Denavir), for herpes simplex virus infection, 247
Penetrance, genetic, 96
Periadenitis mucosa necrotica recurrens, 248
Periapical radiography, 23
Peridex, 251
Periodontal disease, 243–273
calculus and, 271–272
in cerebral palsy, 530
in children, 256–259
early onset/aggressive periodontitis, 257
Periodontal disease *(Continued)*
extrinsic stains and deposits on teeth, 270–271
free gingival autograft, 266–268, 267f–268f
generalized aggressive, 257, 257f
genetics and, 99–101
aggressive (early-onset), 101, 101f
lasers for, 268–269
localized aggressive, 257–258, 258f
mandibular frenectomy and vestibular depth increase, techniques for, 265–266
complete denudation, 265
periosteum retention, 265
vestibular incision, 265–266, 265f–266f
oral cleanliness and, 269–270
plaque control record, 269–270, 269f
screening and recording, 270
and systemic disease, 259–269
frenum attachment, 264, 264f
gingival recession, 260
Papillon-Lefèvre syndrome, 259–260, 259f–262f
premature bone loss in primary dentition, 259
self-mutilation, 260–264, 263f
Periodontal ligament injection, 281–282
Periodontal therapy, for hemophilia, 545–546
Periodontitis
early onset/aggressive, 257
treatment of, 258–259
generalized aggressive, 257, 257f
in HIV infection, 551
localized aggressive, 257–258, 258f
and systemic disease, 259–269
frenum attachment, 264, 264f
gingival recession, 260
Papillon-Lefèvre syndrome, 259–260, 259f–262f
premature bone loss in primary dentition, 259
self-mutilation, 260–264, 263f
PerioGard, 251
Peri-Press syringe, 281
Permanent dentition, in cleft lip and palate, 494–497
Permanent teeth
ankylosed, 360–362, 363f–364f
anterior, cosmetic procedures for, 202–204
bonded composite veneer, 202, 202f–203f
bonded laminate veneer, 202–204, 203f–204f
in cleft lip and palate, 481
congenital absence of, 422
displacement of anterior teeth (luxation), 586–596
avulsion and replantation, 588–593, 589f–590f
intrusion and extrusion, 587–588
eruption of. *see* Eruption of teeth
eruption times for, 385
Permanent teeth *(Continued)*
occlusion, development of. *see* Occlusion, developing
pulpotomy for, 228, 229f
surgical procedures for. *see* Oral surgery
trauma effects on tooth buds, 585–586, 585f–586f
dentin production, 586
dilaceration, 586, 586f
hypocalcification and hypoplasia, 585–586, 586f
Peroxyl, 244
Petechiae, in leukemia, 555, 555f
PFAPA (periodic fever, aphthous stomatitis, pharyngitis, adenitis), 248
Pfeiffer syndrome, 96
Pharmacokinetics, of nitrous oxide, 309
Pharyngeal throat pack, 337–339, 340f–344f
Phenotype, 87
Phenylketonuria, 93
Phenytoin, gingival overgrowth induced by, 254–256, 254f
Philadelphia chromosome, 553
Phosphoric acid, for etching, 179
Phosphorus, dietary, 143
Photoplethysmography, pulp blood flow, 223, 223f
Photo-stimulable phosphor storage plates, 21, 21f–22f
Physical abuse, 110, 111t
indicators of, 112–113, 113f
Physical activity, and dietary guidelines, 147
Physical examination
see also Mouth, examination of
before general anesthesia, 331–334, 332f–333f, 333b–334b
Piercing of tongue, 72–73, 73f
Pigmentation of teeth, 65–68
bleaching, 68, 68f
in cystic fibrosis, 67
in hyperbilirubinemia, 65–66, 67f
in porphyria, 66–67
in tetracycline therapy, 67–68, 67f
Pin-index yoke system, 314, 316f
Pit-and-fissure sealants, 177–184
clinical trials of, 177–178
preventive resin restoration in, 181–184, 182f–183f
rationale for use of, 178
for SHCN patients, 519
technique, 179–181, 180f
application, 181
cleaning, 179
etching, 179
isolation, 179
occlusal interferences, 181
reevaluation, 181
washing, 181
tooth selection for, 178–179
Planes. *see* Cephalometrics
Plaque
chlorhexidine effects, 251–252
control of
age-specific
adolescents, 135

Dentlearn.ir

Plaque *(Continued)*
infants, 133, 133f
prenatal counseling, 133
preschoolers, 134, 134f
school-aged children, 134–135
toddlers, 133–134, 134f
chemotherapeutic, 129–132, 130b
antiseptic agents, 129–132, 130f–131f
enzymes, 132
plaque attachment interference agents, 132
plaque-modifying agents, 132
sugar substitutes, 132
in-office oral hygiene programs, 135
mechanical methods, 121–129
dentifrices, 125–126, 125f
disclosing agents, 126–127, 126f
floss, 123–124, 123f–124f
manual toothbrush, 121–123, 121f–123f
other devices, 127
powered or electric, 124
techniques in, 127–128
time considerations in, 129
visual-motor skill mastery, 128–129
formation of, microbial aspects of, 121
gingivitis induced by, 244–245, 245f
in SHCN patients, 517f, 518
Plaque-modifying agents, 132
Plastic and reconstructive surgeon, in cleft lip and palate management, 484
Pogonion, 394
Policy development, dental public health and, 649
Polycarboxylate cement, 219
Polygenic traits, 91
Polymorphisms, single nucleotide, 87, 88f
Pontics, 503
Popsicle stick therapy, 445, 445f
Porion, 394
Porphyria, and pigmentation of teeth, 66–67
Porphyromonas-like species, 258
Postanesthesia care unit, 342
Posterior maxillary occlusal technique, in bitewing radiography, 26–27
Postoperative care, 342–344, 345f, 346b, 347f
Postural extension, 530
Potency, of anesthetics, 336–337
Poverty
development and, 286–287
dietary intake patterns and, 140
malnutrition and, 141
Povidone-iodine, as oral antimicrobial agent, 172
PPO. *see* Preferred provider organization (PPO)
Practice management, 653–682
doctor's vision for, 654
employee management, 661–668, 665f
coach to improved performance, 667
dismissal of employee, 667–668
Practice management *(Continued)*
interviewing, hiring, and training, 662–664
job descriptions, 664–667
leadership duties, 664
office manual, 661
orientation and training, 663
performance review, 666–667
personnel needs, 661
personnel records, 661–662
standard operating procedures manual, 662
systems management, 664
wages, raises, and benefits, 668
fiscal management, 654–658
accounts payable, 657
budget setting, 656
business plan, 654–655, 655b
fees, 657, 657f–658f
monitor goal numbers, 655–656
monitoring reports regularly, 656–657
monitoring schedule, 656
retirement planning, 658
mission statement, 654
successful dental practice, 653–654, 654f
systems, 668–681
clinical organization, 681, 682f
collection management, 671–673, 672f–673f
compliance, 681
dental office technology, 681
effective scheduling, 671
external marketing, 680
initial telephone call, 668
insurance management, 673–676, 674f
inventory control, 681
managed care, 675–676
new-patient appointment, 668–671, 669f
surgical referrals, 671
treatment tracking, 676–678
team dynamics, 658–668, 660f
Preferred provider organization (PPO), 676
Prenatal counseling, 133
Preschoolers
dental caries in, 157–158
home oral hygiene for, 134, 134f
nutrition, 140
President's Committee on Mental Retardation, 522
Prevotella intermedia, 252
Primary bone grafting, 489
Primary dentition
in cleft lip and palate, 490, 491f
eruption of, sequence of, 385
terminus, occlusion of, 383, 384f, 384t. *see also* Occlusion, developing
Primary teeth
see also specific tooth
ankylosis of molars, with no permanent successors, 360, 362f
Primary teeth *(Continued)*
anterior, proximal incisal caries in, 194–196, 194f–196f
cavity preparation in, 189–190, 190f
class I cavity
deep-seated, 190–191
pit or fissure, 190
in very young child, 190
class II cavity, 191–193, 191f–192f
aesthetic materials, 192–193
amalgam, 191, 192f
dentin involvement, 191
resin infiltrate, 193
small lesions, 191, 191f–192f
class III cavity, 193, 193f
modified, 193–194, 193f–194f
development and morphology of, 80–86
early development and calcification
of anterior primary teeth, 81
of posterior teeth and first permanent molar, 81–82
histodifferentiation and morphodifferentiation (Bell stage), 81, 81f
life cycle of tooth, 80–81, 81f
initiation (bud stage), 80
proliferation (cap stage), 80–81, 81f
mandibular canine, 83
mandibular central incisor, 82
mandibular first molar, 84
mandibular lateral incisor, 82
mandibular second molar, 84
maxillary canine, 82
maxillary central incisor, 82–84, 82f–83f
maxillary first molar, 83, 83f–84f
maxillary lateral incisor, 82
maxillary second molar, 83–84
primary and permanent teeth, 84, 85b
primary tooth pulp chamber, 84–86
displacement of anterior teeth (luxation)
avulsion and replantation, 588–593, 589f–590f
intrusion and extrusion, 587, 587f
pulp treatment exfoliation or over-retention of, 239–240, 240f
pulpotomy for, 229–230, 230f
root fracture of, 593, 596f
Primate spaces, 415–416
Primordium, 80
Progeria syndrome, 48, 368–372
Prognathism, 407, 408f
Promethazine, 310–311
Prosthetic therapy, advantages of, 484
Prosthodontic treatment of adolescent patient, 498–512
fixed partial dentures, 500–503
complete crown retainers, 502–503
pontics, 503
resin-bonded retainers, 500–502, 501f–504f
implant prostheses, 506–507, 507f–508f

Dentlearn.ir

Prosthodontic treatment of adolescent patient *(Continued)*
before growth completion, 507, 509f–510f
for orthodontic anchorage, 507
mouthguards, protective, 508–511, 511f
overdentures, 505, 506f
recare program, 507–508
removable partial dentures, 503–505, 505f
restoration of single malformed, discolored, or fractured teeth, 498–500
crowns, 498–499, 499f–500f
pulpal involvement, 499–500
Prosthodontist, in cleft lip and palate management, 482–483, 483f
Protrusion, 407
Pseudohypophosphatasia, 45
Pseudomembranous lesion, 550
Psychiatrist, in cleft lip and palate management, 484
Psychological effects of hospitalization, 329–330
Psychologist, in cleft lip and palate management, 484
Pterygoid vertical plane, 395
Pterygomaxillary fissure, 394
Pt point, 395
Puberty, gingivitis, 252, 252f
Pulp cap, direct, vital pulp exposures treatment of, 569–572, 572f
Pulp chamber, primary, 84–86
Pulp therapy, 232, 233f
capping materials for, 233–236
calcium hydroxide, 233–234, 234f
experiments, 235
ferric sulfate, 234–235
formalin, 234, 235f
mineral trioxide aggregate, 235
zinc oxide-eugenol, 233
of deep caries, indirect pulp treatment, 224–226, 224f–226f
diagnostic aids for
clinical signs and symptoms, 222
pain, 221–222
physical condition of patient, 223–224
pulp testing, 223, 223f
radiographic interpretation, 222, 222f–223f
failure after, 236–239, 238f
alveolar abscess, 239
nonvital, with irreversible pulpitis or necrotic pulp, 230–232
pulpectomy, 230–232, 230f–233f
primary teeth exfoliation or over-retention, 239–240, 240f
prognosis of, 224
restoration of involved tooth, 232–233
techniques of, 227–230
direct pulp capping, 227–228, 227f
pulpotomy, 228–230, 228f
for permanent teeth, 228, 229f
for primary teeth, 229–230, 230f
Pulp therapy *(Continued)*
vital pulp exposure, 226–227
size and pulpal hemorrhage, 226–227, 227f
Pulpal involvement, for single teeth, 499–500
Pulpal therapy
for hemophilia, 546
for leukemia, 556
Pulpectomy, 230–232, 230f–233f
Pulpotomy, vital pulp exposures treatment of, 572, 573f–574f
Pulse oximetry, 323

Q

Quad-helix appliance, 451f, 454
Quadriplegia, 529
Quantitative transmission disequilibrium test, 98
Quartz-tungsten-halogen lamp, 210–211
Quiet room, 319

R

Radiographic techniques, 17–38
in cephalometrics, 391–393, 392f
frontal (posteroanterior) film, 392–393, 393f
lateral head film, 391–392, 392f
extraoral, 29–30
guidelines for prescribing, 36t–37t
image receptors, 20–23
analog film, 20–21
image-viewing conditions, 22–23, 23f–24f
photo-stimulable phosphor storage plates, 21, 21f–22f
solid-state sensors, 21, 22f
interpretation of radiographs, 32–35
intraoral, 23–29
localization, 27–29, 31f
protection from, 17–20
basics of, 17–18, 18t
dental staff, 18–19, 19f
patient, 19–20, 19f–20f
safety for, 17–20
selection criteria and examinations, 30–32
Radiography
in children, 11
of pulp, 222, 222f–223f
of SHCN patients, 515, 515f–516f
Rainbow Stabilizing System, 522, 524f
Rampant dental caries, 158, 159f
Ranulas, 609, 609f, 638–639
Reactive airway disease, 531–532
Recare program, for adolescent, 507–508
Recare system, 677
Recording, dental
examination of, 5, 6f–7f
uniform, 11
Records, personnel, 661–662
Rectangular collimation, 19, 19f
Recurrent herpes labialis (RHL), 247, 247f
for herpes simplex virus infection, 247
Reference points, for lateral tracing in cephalometrics, 394–395
Regenerative endodontic procedures (REPs), 576–579, 578f
Replantation, of injured tooth, 588–593, 589f–590f
Reporting, of child abuse, 117
REPs. *see* Regenerative endodontic procedures (REPs)
Resins
cements, 219–220
preventive restoration, 181–184, 182f–183f
in restoration of primary anterior teeth, 194, 194f
restorative, 208–214
conventional composites, 208–209, 208f–209f, 208t
dental adhesives, 212–214
dentin bonding, 212–214
enamel bonding, 212
hybrid composites, 209–210
inlays, 212
light-cured composites, 210–211, 211f
microfilled composites, 209, 209f
posterior composite restoration, 211–212
Resorption
after pulp therapy, 237–239, 239f
external, 582, 582f
Respiratory diseases
asthma, 531–532
bronchopulmonary dysplasia, 532
cystic fibrosis, 533
Restoration
after vital pulp therapy, 232–233
of fractured teeth, 584–585
aesthetic bonded composite resin, 584–585, 584f–585f
in prosthodontic treatment of adolescent, 498–500
temporary and permanent, 207–208
Restorative dentistry, 185–205
see also Trauma, to teeth and supporting tissues
AAPD guidelines for, 185
alternative treatment in, 201–202
cavity preparation in primary teeth, 189–190, 190f
class I cavity, 190
class II cavity, 191–193, 191f–192f
class III cavity, 193, 193f–194f
clamp selection for, 187–188, 187f–189f
common materials for, 185–186
controversies in pediatric, 204–205
laser use, 204
minimalist approach, 204–205, 204f
cosmetic procedures for permanent anterior teeth, 202–204
bonded composite veneer, 202, 202f–203f
bonded laminate veneer, 202–204, 203f–204f
crowns, stainless steel, for posterior teeth, 197–199, 197f
contouring of, 199, 200f

Dentlearn.ir

Restorative dentistry *(Continued)*
size selection, 199, 199f
tooth preparation, 198–199, 198f
Isolite system in, 188–189, 189f
maintenance of clean field in, 186–188
morphologic considerations in, 189
in operating room, 339–341, 344f
proximal incisal caries in primary anterior teeth, 194–196
aesthetic resin restoration, 194, 194f
direct resin crowns, 196, 196f
stainless steel crowns, 195–196, 195f
rubber dam placement, 187, 187f
in young permanent teeth, 196–197
Retainers
complete crown, 502–503
resin-bonded, 500–502, 501f–504f
Retention scheme, 474
Retirement planning, 658
Retractors, for oral surgery, 628, 628f
Retraining, in behavior management, 299
Retrognathism, 407, 407f
Retrusion, 407
Rhabdomyosarcoma, 560, 619–620
Rheumatic fever, 536
RHL. *see* Recurrent herpes labialis (RHL)
Rickets
familial or X-linked hypophosphatemic, or vitamin D-resistant, 48
vitamin D deficiency, 145
Ringworm infection, 5, 8f
Roll method, of toothbrushing, 127
Root canal therapy, pulpotomy, 572
Root resorption, external apical, 104
Rubber bite blocks, 521
Rubber dam
in hemophilia, 546
isolation, 593
placement of, 187, 187f
Rubella embryopathy, and enamel hypoplasia, 52, 53f

S

Saliva, 159–161
deficiency of, 160–161, 161f
flow reduction of, 161
viscosity of, 161
Salt intake, health impact of high, 147–148
Sarcoma, osteogenic, 620
SCA. *see* Sickle cell anemia (SCA)
Scheduling of appointment, 300
School Breakfast Program (SBP), 140
School children
dental caries in, 158
home oral hygiene for, 134–135
nutrition, 141
Scleroderma, and periodontitis, 259
Scorbutic gingivitis, 256, 256f
Sealants
see also Pit-and-fissure sealants
cariostatic properties of, 177
chemically cured, 181
cured by light, 177, 180f, 181
effectiveness of, 178
glass-ionomer cement as, 177–178
recommendations for use of, 178
Sedation
combination of methods and agents in, 318–319
conscious, 305
continuum of, 303–305, 304f
deep, 304
documentation of, 320–321
drugs and agents used for, 309
antihistamines, 310–311
diphenhydramine (Benadryl), 311
hydroxyzine, 310
promethazine, 310–311
benzodiazepine agonists and antagonists, 311–312
diazepam (Valium), 311
flumazenil (Romazicon), 312
midazolam (Versed), 311–312
hypnotics, 313–314
chloral hydrate, 313–314, 319
nitrous oxide and, 309–310, 316f
adverse effects of, 309–310
equipment for, 314, 315f–316f
mechanism of, 309
monitoring and documentation in, 315–316
objectives of, 314
occupational exposure to, recommendations for minimizing, 310b
pharmacokinetics of, 309
technique for, 314–315
toxicity of, 310
opioid agonists and antagonists, 312–313
fentanyl (Sublimaze), 313
meperidine (Demerol), 313
naloxone (Narcan), 313
oral, 305, 318–319
enteral technique, 316–317
facilities and equipment for, 319–320
general anesthesia and, 304–305, 320t
intravenous, 305
levels of, 320t
minimal, 304
moderate, 304
monitoring of, 322–324, 323f–324f
intraoperative, 322–324
patient discharge for
criteria for, 317b
instruction after, 317b
Seizure disorders, in cerebral palsy, 530
Self-mutilation, 260–264, 263f
Sella-Nasion plane (SN), 395
Sella turcica, 394
Sensitivity, pulpal inflammation, 222
Sensory deficits or dysfunctions, in cerebral palsy, 530
Septocaine, 277
Sequestrum, eruption, 355, 355f
Sevoflurane, 337
Sexual abuse, 111, 111t
SHCN. *see* Special health care needs (SHCN)
Sickle cell anemia (SCA), 548–549
Single nucleotide polymorphisms, 87, 88f
Singleton-Merten syndrome, 48
Sjögren syndrome, 161
"Snow-capped teeth," 95
Social media, practice management, 680–681
Social worker, in cleft lip and palate management, 484
Socialization, of children, 287–291
Society of Teachers of Family Medicine, 650–651
Socioeconomic status, dental caries and, 161–162
Soft tissues
anesthesia for, 275–277
benign tumors, 603–609
congenital epulis of newborn, 608–609, 608f
fibroma, 604
peripheral odontogenic (WHO type), 605–606
peripheral ossifying, 605–606
granulomas
peripheral giant cell, 606
pyogenic, 604, 605f
hemangioma, 607–608
lymphangioma, 608
mucocele, 609, 609f
neurofibroma, 606–607, 607f
ranula, 609, 609f
squamous papilloma, 603–604, 604f
verruca vulgaris, 603–604, 604f
von Recklinghausen disease, 606–607, 607f
cephalometric assessment of, 400, 400f
complications of anesthesia, 283, 283f
surgical procedures for, 638–640
Software programs, for digital imaging, 402
Solid-state sensors, 21, 22f
Space analysis, mixed dentition, 386
Space maintainers
caries and, 162
fixed, 432, 432f
Space maintenance, in developing occlusion, early loss of teeth and, 418–435, 421f
assessment of, 418–423, 423f
canines, 424–425, 426f
first primary molar loss, 425–428, 427f–428f
incisors, 423–424, 424f–426f
multiple primary molar loss, 432, 433f–434f
permanent molar loss, 433–435, 435f–436f
second primary molar loss, 428–432, 429f–432f
specific strategies for, 423–435
Special health care needs (SHCN), 513–539
autism spectrum disorder, 528–529
cerebral palsy, 529–531
dental access, 514–515, 514t, 515f
during dental treatment, 519–522
Down syndrome, 527
fetal alcohol spectrum disorder, 528
first dental visit, 515
fragile X syndrome, 528
hearing loss, 533–534, 533t

Dentlearn.ir

Special health care needs *(Continued)*
heart disease, 535–537
acquired
infective endocarditis, 536, 537b–538b
rheumatic fever, 536
cardiac surgery patients, 537
congenital, 535–536, 536f
dental management, 537
intellectual disability, 522–527, 527t
learning disabilities, 527–528
preventive dentistry, 516–519
diet and nutrition, 518–519
fluoride exposure, 519
home dental care, 516–518, 517f–518f
professional supervision, 519
restorations, 519
protective stabilization, 519–522, 520f–521f, 523f–526f
radiographic examination, 515, 515f–516f
respiratory diseases
asthma, 531–532
bronchopulmonary dysplasia, 532
cystic fibrosis, 533
spina bifida and latex allergy, 531
visual impairment, 534–535
Special-needs patients, radiographic exposures in, 32
Speech disorders, in cerebral palsy, 530
Speech pathologist, in cleft lip and palate management, 484
Spina bifida
genetics and, 97
and latex allergy, 531
Splints for root fractures, 595, 596f
Stabilization, for SHCN patients, 519–522, 520f–521f, 523f–526f
Stainless steel
alloy in restorations, 185–186
crowns
for posterior teeth, 197–199, 197f
for primary anterior teeth, 195–196, 195f
Stains and deposits on teeth, extrinsic, 270–271
black stain, 271, 271f
green stain, 270, 271f
orange stain, 270, 271f
removal of, 271
stannous fluoride application, 271
Standard operating procedures (SOP) manual, 662
Startle reflex, 530
Statistics, of child abuse and neglect, 112
Stethoscope, pretracheal, 323f
Stimulus generalization, 299
Stomatitis, aphthous recurrent, 248
Strangulation marks, 115, 115f
Streptococcus mutans, dental caries and, 11, 99
Streptococcus sanguis, 248–249
Streptococcus sobrinus, 156
Substance abuse, 13–14
etiologic factors, 14
specific substance and frequency of use, 14
Suction tip, Fraser, 629f
Sugar substitutes, in plaque control, 132
Suicide tendencies, in children and adolescents, 14–15
Supernumerary teeth, 462–464, 463f–465f
in cleft lip and palate, 481
Supplemental Nutrition Assistance Program, 142
Surgery. *see* Oral surgery
Sutton disease, 248
Swallowing, tongue-thrust, 440–443, 443f
Syrijet Mark II, 275
Syringes, for periodontal ligament injection, 281
Systems. *see* Practice management

T

Taurodontism, 56, 56f
in amelogenesis imperfecta, 60
Tay-Sachs disease, 93
TDO. *see* Trichodento-osseous syndrome (TDO)
Team dynamics, 658–668
Teething, and difficult eruption, 354–355
ectopic, 355
hematoma in, 354, 355f
sequestrum in, 355, 355f
Tell-show-do, 299, 299f
behavior shaping and, 299
Temporomandibular disorders, 5, 9f
Tetracaine, in pain control, 275
Tetracycline therapy, and pigmentation of teeth, 67–68, 67f
Thrush, 250, 250f
Thumb sucking, 437, 437f, 439f–441f
Thymol, as oral antimicrobial agent, 172
Time considerations, for oral hygiene, 129
Time-out protocol
in anesthetic preparation of the child, 337, 338f–340f
end of, 341–342
Timing of interventions. *see* Occlusion, developing
Tobacco smoking, by adolescents, 14
Toddlers, home oral hygiene for, 133–134, 134f
Tolerance, of dentist, 297
Tongue
anomalies of, 69–73
ankyloglossia, 70, 70f
black hairy, 72, 72f
coated, 71–72, 72f
fissured tongue and geographic tongue, 71, 71f
indentation of margin, 72
macroglossia, 70
median rhomboid glossitis, 72
tongue piercing in, 72–73, 73f
trauma, 72–73
white strawberry, 72
scrapers, 127
Tongue blades, 445, 445f, 520–521
Tongue-thrust swallowing, 440–443, 443f
Tonic labyrinthine reflex, 530
Tooth (teeth)
agenesis of, 61–64
anodontia, 61–62, 62f
ectodermal dysplasias, 64, 65f–66f
hypodontia (oligodontia), 62–63
and cancer, 63–64
and palatally displaced canines, 63
ankylosed, 357–360, 359f–361f, 632, 632f
permanent teeth, 360–362, 363f–364f
of primary molars with no permanent successors, 360, 362f
in cleft lip and palate, 481
congenitally missing, 464–467, 466f
developmental anomalies of, 41–43
eruption of teeth. *see* Eruption of teeth
fractured, restoration of, 584–585
pigmentation of, 65–68
bleaching, 68, 68f
in cystic fibrosis, 67
in hyperbilirubinemia, 65–66, 67f
in porphyria, 66–67
in tetracycline therapy, 67–68, 67f
posterior, stainless steel crowns for, 197–199, 197f
contouring of, 199, 200f
size selection of, 199, 199f
tooth preparation, 198–199, 198f
reattachment of, fragment restoration, 568–569, 570f
replanted
endodontic management of, 593
stabilization of, 591–593, 591f–592f
selection of, for sealing, 178–179
single malformed, discolored, or fractured, in adolescent, 498–500
size and arch size of, 386
stains and deposits on, 270–271
surgery procedures for. *see* Oral surgery
trauma effects
ankylosis, 582–584
calcification, dystrophic, 580–581, 580f–581f
external resorption, 582, 582f
pulpal hyperemia, 579–580
pulpal necrosis, 582, 583f
Toothbrush/toothbrushing
in leukemia, 556–557
manual, 121–123, 121f–123f
in plaque reduction, 166
powered or electric, 124
for SHCN patients, 516, 518f
techniques for, 127–128, 127f
Tooth-charting systems, 11
Toothpaste, fluoridated, 168
Topical rinses, for aphthous ulcers, 249
Topicale, 275
Toxicity
of local anesthesia, 282–283, 283t
of mercury, 217–218
of nitrous oxide sedation, 310
Training, of personnel, 662–664
Tramadol, for postoperative pain, 284t
Tranexamic acid, 544–545
Translocation, chromosomal, 91t

Dentlearn.ir

Transpalatal bar, 432, 432f
Transpalatal wires, with springs, fixed, 448–449, 448f
Transplantation of stem cells. *see* Hematopoietic stem cell transplantation
Trauma
  and aphthous ulcers, 249
  in cerebral palsy, 530
  and enamel hypoplasia, 51, 51f–52f
  to teeth and supporting tissues, 563–602
    clinical examination of, 566–567, 567f
    displacement of anterior teeth (luxation), 586–596
      avulsion and replantation, 588–593, 589f–590f
      intrusion and extrusion, 586–588
    emergency treatment of
      of fractured teeth without pulp exposure, 568–569
      soft-tissue injury, 568
      temporary bonded resin restoration, 569, 571f
    fractured roots, 593–596
    history and examination of, 563–568, 564f–565f
    oral burns, 596–600, 599f
    other displacement injuries requiring stabilization, 596
    permanent tooth buds, 585–586, 585f–586f
      dilaceration, 586, 586f
      hypocalcification and hypoplasia, 585–586, 586f
      reparative dentin production, 586
    prevention of, 600–601
    radiographic examination of, 567–568, 567f
    reaction tooth, 579–584
      ankylosis, 582–584
      calcification, 580–581, 580f–581f
      external resorption, 582, 582f
      hemorrhage, 580, 580f

      581–582, 581f
      pulpal hyperemia, 579–580
      pulpal necrosis, 582, 583f
    restoration of fractured, 584–585
    vital pulp exposures treatment, 569–573
    see also Pulp therapy
  to tongue, 72–73, 73f
Traumatic bone cyst, 638, 639f
Treacher-Collins syndrome, 484
Triangle, pediatric dentistry treatment, 286, 287f
Triangular sheet technique, 522, 524f
Trichodento-osseous syndrome (TDO), 60
Trisomy, 90, 90f
Trisomy 21 syndrome. *see* Down syndrome
Trituration, 215
Truthfulness, in dental team, 296
Tumors
  benign
    of bone
      cemento-ossifying fibroma, 611, 611f
      central giant cell granuloma, 611–612, 612f
      fibro-osseous lesions of jaw, 609–610
      fibrous dysplasia, 610–611, 610f
      juvenile ossifying fibroma, 611
    of oral soft tissues, 603–609
      congenital epulis of newborn, 608–609, 608f
      fibroma, 604
      granulomas, 604, 605f
      hemangioma, 607–608
      lymphangioma, 608
      mucocele, 609, 609f
      neurofibroma and neurofibromatosis (von Recklinghausen disease), 606–607, 607f
      ranula, 609, 609f
      squamous papilloma, verruca vulgaris, and condyloma acuminatum, 603–604, 604f
  malignant, 619–623
    Ewing's sarcoma, 620–621, 621f
    fibromatosis and fibrosarcoma, 619
    Langerhans cell histiocytosis (histiocytosis X), 621–623, 622f
    osteogenic sarcoma, 620
    rhabdomyosarcoma, 619–620
  odontogenic, 615–619
    adenomatoid, 616–617, 616f
    ameloblastic fibroma, 617
    ameloblastic fibro-odontoma, 618
    ameloblastoma, 615–616
    myxoma, 617
    odontoma, 618–619, 618f
  solid, 560
Turner syndrome, 90
Turner tooth, 51, 586
Twin studies
  for cleft lip and palate, 104
  for dental caries, 99
  in nature-nurture argument, 98
  for periodontal disease, 100

U

Ulcerative lesions, in leukemia, 557
Ultrasound imaging, 30, 35f
Undernutrition, pediatric, 142–145
Unerupted tooth, 54, 55f
Uniform Federal Accessibility Standards, 514
Urea peroxide, for plaque control, 132
Urethane dimethacrylate resin, 208

V

Vaccine, for caries, 172
Valacyclovir, for herpes simplex virus infection, 247
Varnishes, fluoride-containing, 168
Vegetarians, vitamin B_{12} deficiency in, 145
Velocity, of growth, 375
Veneers
  composite, 202, 202f–203f
  laminate, 202–204, 203f–204f
  resin and ceramic, 219–220
Verruca vulgaris, 603–604, 604f
Vertical arch discrepancies, 405
Videotapes, for behavior modification, 295
Vincent infection, 249, 250f
Vineland Adaptive Behavior Scales, 291
Viral hepatitis, 547–549
Viral infection, in HIV infection, 550–551
Visual impairment, 534–535
Vital pulp exposures, treatment of
  direct pulp cap, 569–572, 572f
  pulpectomy with endodontic treatment, 572–573
  pulpotomy, 572, 573f–574f
  regenerative endodontic procedures, 576–579, 578f
  root growth stimulation and apical repair after pulpal necrosis (apexification), 573–576, 575f, 577f
Vitamin A, 143
Vitamin B_{12}, 145
Vitamin D, 144–145
Vitamin supplements, for children, 151
Vitapex, 231–232
Voice control, 297–298
von Recklinghausen disease, 606–607, 607f
von Willebrand disease (VWD), 540–541, 543

W

Wages, in practice management, 668
W-arch appliance, 451f, 454
Wechsler intelligence scales, 291
Weider retractor, 628, 628f
White strawberry tongue, 72
Wilms' tumor, 560
Witkop syndrome, 64
Wrapped tongue blades, 520–521

X

X-linked or sex-linked inheritance, 94–95
  dominant, 94, 94f
  recessive, 95, 95f
Xylitol, as oral antimicrobial agent, 172

Y

Yankauer or tonsillar suction, 629f
Y chromosome, 94

Z

Zinc, dietary, 143–144, 143b
Zinc oxide-eugenol, 218
  cement, 164–165
  for pulp capping, 233
  in pulpotomy, 230
Zinc phosphate cement, 218
Zirconia crowns, 200–201, 201f
Zovirax, 246–247
Zygosity, 98

Dentlearn.ir